

M0016565: Human skeletal remains showing trephining

Publication/Creation

1958

Persistent URL

<https://wellcomecollection.org/works/z2n7u9v4>

License and attribution

Conditions of use: it is possible this item is protected by copyright and/or related rights. You are free to use this item in any way that is permitted by the copyright and related rights legislation that applies to your use. For other uses you need to obtain permission from the rights-holder(s).



Wellcome Collection
183 Euston Road
London NW1 2BE UK
T +44 (0)20 7611 8722
E library@wellcomecollection.org
<https://wellcomecollection.org>

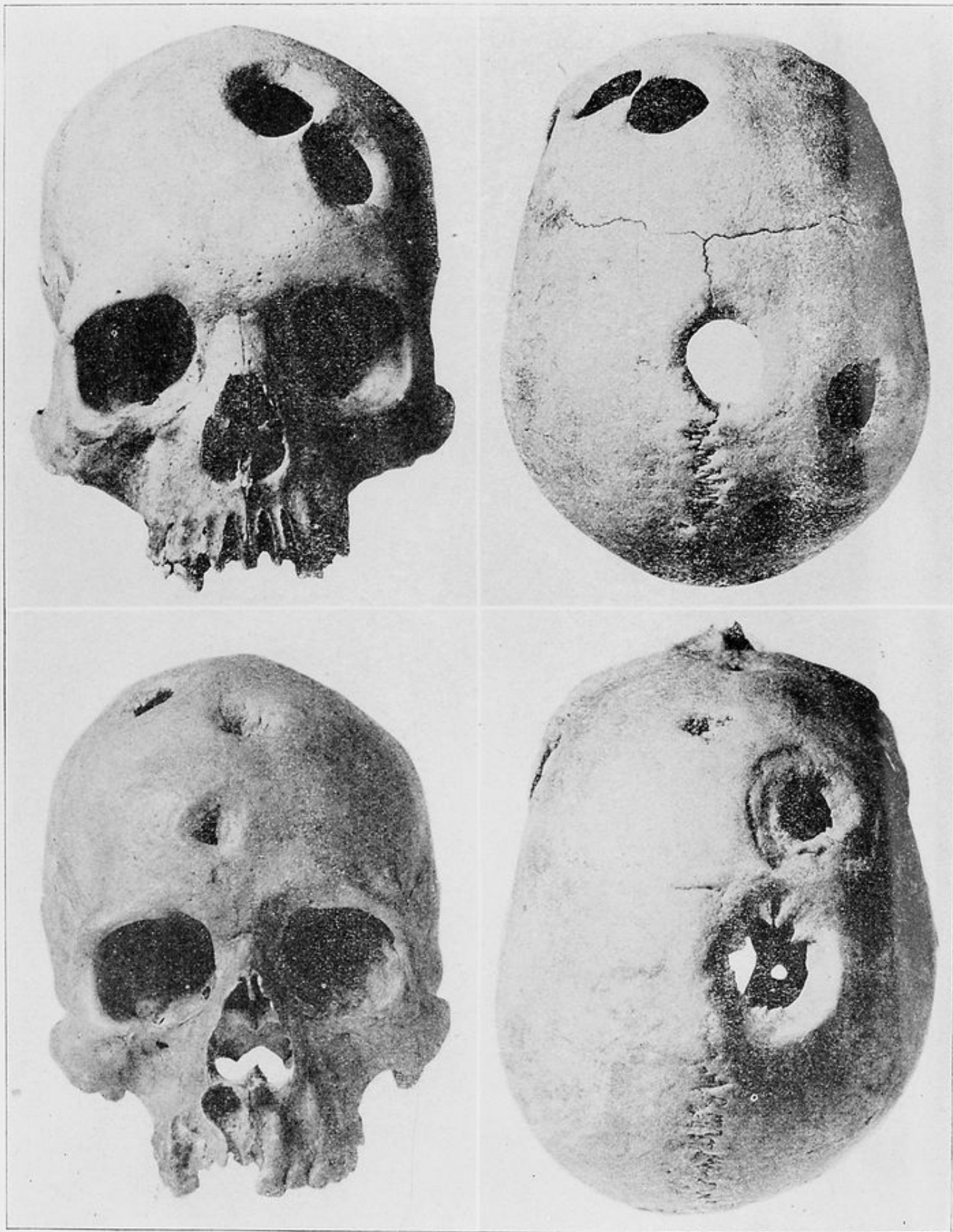


PLATE NO. XXI—*Left upper*, Patallaeta. Cranium of an adult male with five circular trepanations of which the margins had all healed (Cat. no. 628). Frontal aspect. *Right upper*, Vertical aspect of No. 1. *Left lower*, Huata. Cranium of an adult male with trepanations and depressed fractures, all of which had healed (Cat. no. 877). Frontal aspect. *Right lower*, Upper aspect of No. 3.