

M0013466: Diagram made from x-ray of a patient diagnosed with tuberculosis.

Publication/Creation

June 1954

Persistent URL

<https://wellcomecollection.org/works/x8jjqe7e>

License and attribution

Conditions of use: it is possible this item is protected by copyright and/or related rights. You are free to use this item in any way that is permitted by the copyright and related rights legislation that applies to your use. For other uses you need to obtain permission from the rights-holder(s).



Wellcome Collection
183 Euston Road
London NW1 2BE UK
T +44 (0)20 7611 8722
E library@wellcomecollection.org
<https://wellcomecollection.org>

John H
Tuberculosis

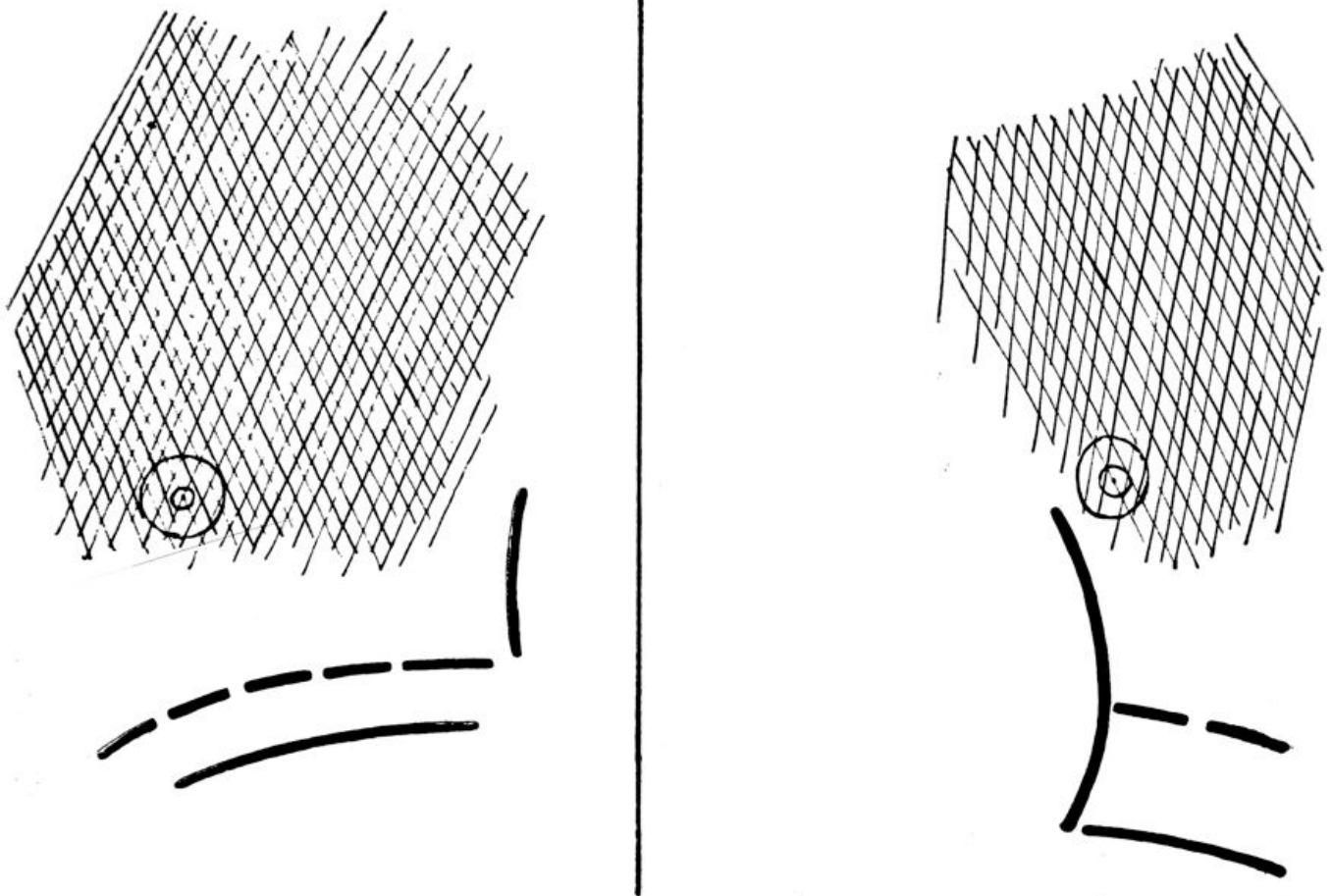


FIG. 93. John H. January 3, 1900. Tuberculosis. X-ray examination with screen showed darkened lungs, but apices and bases less affected than physical signs indicated. Autopsy confirmed X-ray examination. Excursion of diaphragm shortened on both sides. See Fig. 80 for half-tone of a radiograph of lung. (One-third life size.)