

**M0012131: Reproduction of a diagram showing the superficial facial musculature from Theodore H. Bast's The anatomy of the rhesus monkey, 1933**

**Publication/Creation**

1951

**Persistent URL**

<https://wellcomecollection.org/works/u87kzmb7>

**License and attribution**

Conditions of use: it is possible this item is protected by copyright and/or related rights. You are free to use this item in any way that is permitted by the copyright and related rights legislation that applies to your use. For other uses you need to obtain permission from the rights-holder(s).

# ANATOMY OF THE RHESUS MONKEY

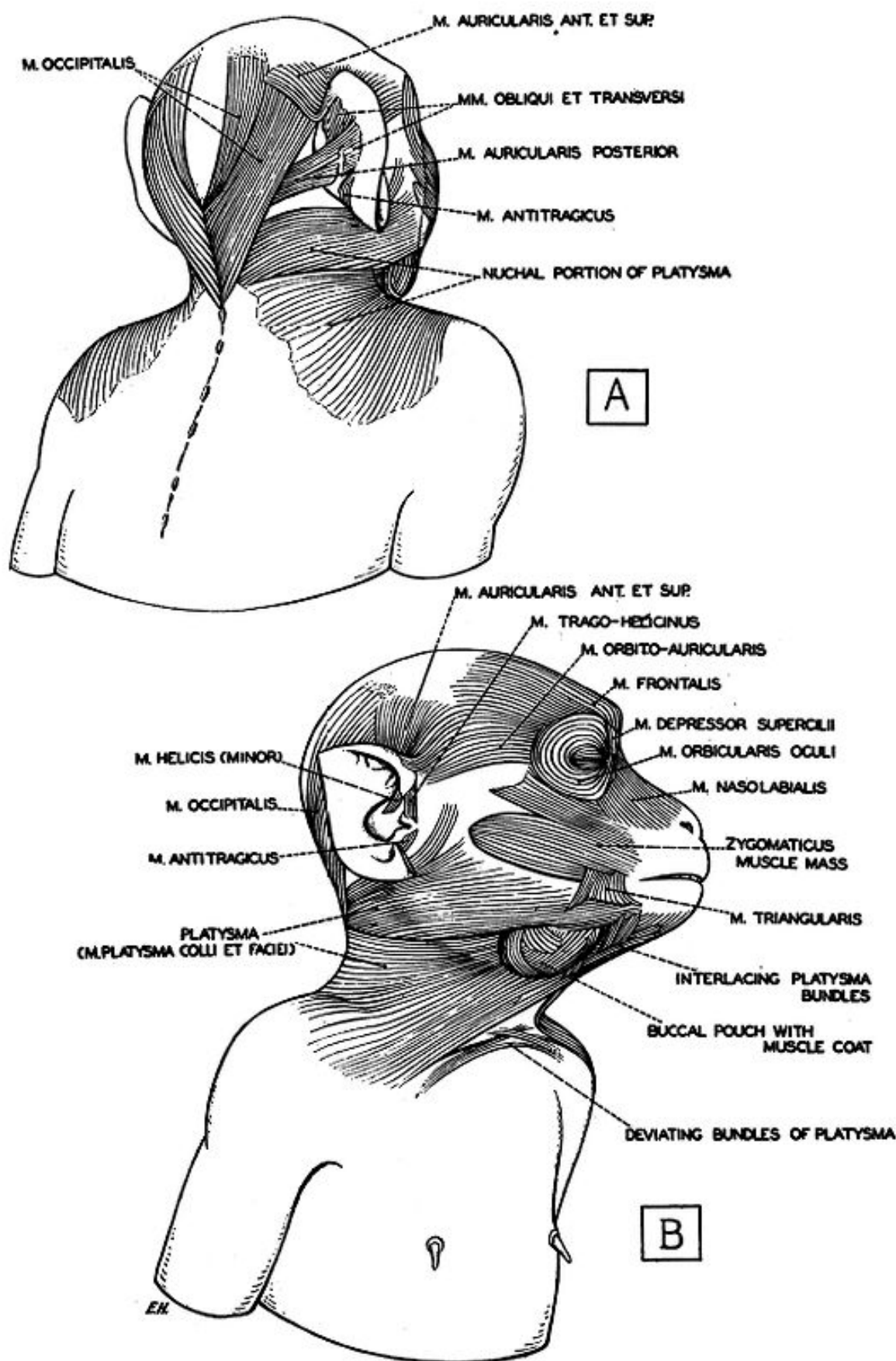


FIG. 53. The superficial facial musculature. (Drawn by E. Huber.)

A, posterior view, to show the postauriculo-occipital muscle group in genetic relation with its matrix, the nuchal portion of the platysma.

B, side view, to show the general arrangement of the superficial facial musculature. (1) M. platysma colli et faciei and postauriculo-occipital musculature, of which are seen the m. occipitalis, the posterior section of the m. auricularis ant. et sup., and two of the intrinsic ear muscles, the m. helicis and the m. antitragicus. (2) The rest of the muscles of the anterior part of the cranial vault and face, and of the buccal pouch, representing derivatives of the sphincter colli profundus (see further fig. 54, A and B).