

M0012124: Reproduction of a diagram showing the superficial or extrinsic back muscles from Theodore H. Bast's The anatomy of the rhesus monkey, 1933

Publication/Creation

1951

Persistent URL

<https://wellcomecollection.org/works/dkgxk6vj>

License and attribution

Conditions of use: it is possible this item is protected by copyright and/or related rights. You are free to use this item in any way that is permitted by the copyright and related rights legislation that applies to your use. For other uses you need to obtain permission from the rights-holder(s).



Wellcome Collection
183 Euston Road
London NW1 2BE UK
T +44 (0)20 7611 8722
E library@wellcomecollection.org
<https://wellcomecollection.org>

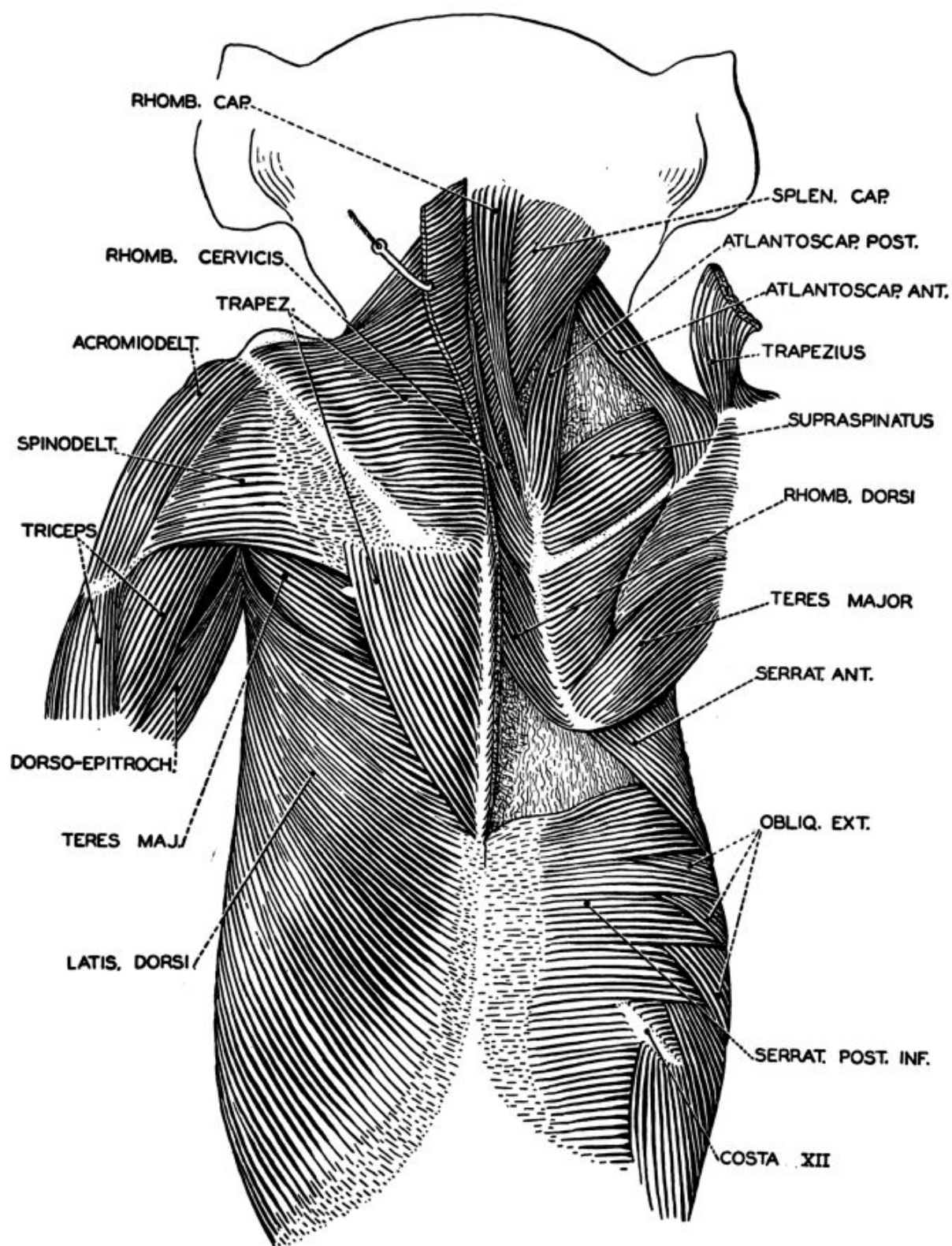


FIG. 40. The superficial or extrinsic back muscles. On the right side, the trapezius and latissimus dorsi muscles have been removed, exposing the deeper extrinsic back musculature.