

**M0011458: Wellcome Historical Medical Museum display: microscope slides prepared by a histologist in 1850**

**Publication/Creation**

1950

**Persistent URL**

<https://wellcomecollection.org/works/tg3v3sj2>

**License and attribution**

You have permission to make copies of this work under a Creative Commons, Attribution license.

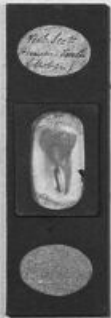This licence permits unrestricted use, distribution, and reproduction in any medium, provided the original author and source are credited. See the Legal Code for further information.

Image source should be attributed as specified in the full catalogue record. If no source is given the image should be attributed to Wellcome Collection.

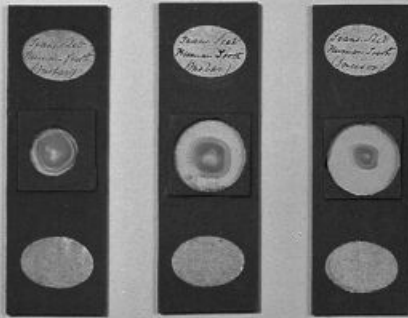


Wellcome Collection  
183 Euston Road  
London NW1 2BE UK  
T +44 (0)20 7611 8722  
E [library@wellcomecollection.org](mailto:library@wellcomecollection.org)  
<https://wellcomecollection.org>

SLIDES PREPARED BY A HISTOLOGIST IN 1850



VERTICAL SECTION  
OF A HUMAN TOOTH (MOLAR)



TRANSVERSE SECTIONS OF HUMAN TEETH  
(MOLAR AND INCISOR)



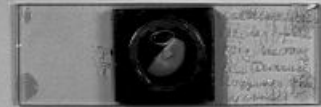
VERTICAL SECTION  
OF A HUMAN TOOTH (CANINE)



SECTION OF THE LUNG OF A BIRD  
(ROOK)



THE EYE-BALL OF THE RAT



CARTILAGE FROM THE LEG OF THE PIG  
SHOWING THE LOOPINGS OF THE TERMINAL  
VESSELS.



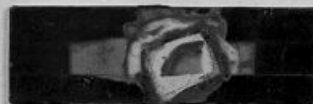SYNOVIAL SHEATH OF A TENDON



VILLI OF HUMAN INTESTINE



SKIN OF THE FROG



SECTION OF KIDNEY OF KITTEN  
(INJECTED)



TRANSVERSE SECTION  
OF VOLUNTARY MUSCLE (DOG)



INJECTED MUSCLE