

**Elements of the general and minute anatomy of man and the mammalia, chiefly after original researches / To which are added notes and an appendix, comprising researches on the anatomy of the blood, chyle, lymph, thymous fluid, tubercle, &c.;, by George Gulliver. Atlas containing 34 plates.**

### **Contributors**

Gerber, Fr.  
Gulliver, George, 1804-1882

### **Publication/Creation**

London : H. Baillière, 1842.

### **Persistent URL**

<https://wellcomecollection.org/works/en7px95d>


### **License and attribution**

This work has been identified as being free of known restrictions under copyright law, including all related and neighbouring rights and is being made available under the Creative Commons, Public Domain Mark.

You can copy, modify, distribute and perform the work, even for commercial purposes, without asking permission.



Wellcome Collection  
183 Euston Road  
London NW1 2BE UK  
T +44 (0)20 7611 8722  
E [library@wellcomecollection.org](mailto:library@wellcomecollection.org)  
<https://wellcomecollection.org>



Accession n<sup>o</sup> 9320

Class. 611.

Loc. Basil



Bath  
Public Reference  
Library.

Presented by

Alfred Jones.

of Bath.

1915.

NEW YORK

11 BAILLIEN, 210 REGENT STREET

ATLAS ANATOMIQUE DE L'ORGANISME DE L'HOMME ADON  
BY J. CH. CHENIERE

Publication of the *Atlas Anatomique de l'Organisme de l'Homme* by J. Ch. Chenier, M.D., Paris, 1821. This work is a valuable addition to the anatomical literature, and is highly recommended to all who are interested in the study of the human body.

Paris, 1821. 1 vol. 8vo. with 100 plates. Price 10 fr.

ODONTOGRAPHY

Of the structure of the human teeth, and of the diseases to which they are subject, and of the means of preventing and curing them.

BY BERNARD DENT, F.R.S.

This work is a valuable addition to the anatomical literature, and is highly recommended to all who are interested in the study of the human body.

# ELEMENTS

OF

## GENERAL ANATOMY.

ILLUSTRATIONS OF CUTANEOUS DISEASE

A series of illustrations of the diseases of the skin, and of the means of preventing and curing them.

By J. C. CHENIER, M.D., Paris, 1821.

This work is a valuable addition to the anatomical literature, and is highly recommended to all who are interested in the study of the human body.

ELEMENTS OF MEDICINE.

By J. C. CHENIER, M.D., Paris, 1821.

THE PRINCIPLES OF SURGERY.

By J. C. CHENIER, M.D., Paris, 1821.

## NEW PUBLICATIONS,

TO BE HAD OF

H. BAILLIERE, 219, REGENT STREET.

### ATLAS ILLUSTRATIVE OF THE ANATOMY OF THE HUMAN BODY,

BY J. CRUVEILHIER,

Professor of Anatomy to the Faculty of Medicine, Paris.

Drawn from nature by E. BEAU. With Descriptions by C. BONAMY, M.D.

This ATLAS will consist altogether of 200 Plates, small 4to. Each Number containing 4 Plates with Descriptions, will appear regularly in Monthly Parts, from Nov. 1, 1841, till the completion of the Work. Price 2s. 6d. Plain; 5s. Coloured.

Parts I. and II. royal 8vo., with 100 beautifully engraved Plates, with text.

Price £1. 11s. 6d. each,

### ODONTOGRAPHY,

Or description of the Microscopic Structure of the Teeth in various existing and extinct Species of Vertebrate Animals.

BY RICHARD OWEN, ESQ., F. R. S.

Corresponding Member of the Academy of Sciences of Paris, Berlin, &c. &c.

This splendid work will be published in Three Parts, each part containing 50 plates with their descriptions. It will be completed in May, 1842, and will form One Volume of letter-press, and an Atlas royal 8vo. of 150 Plates, engraved by Mr. L. Aldous, and Mr. Dinkel.

*A few copies are printed in 4to., and the Plates, proofs on India paper, Price 2l. 12s. 6d. each Part.*

### A GENERAL INTRODUCTION TO THE

### NATURAL HISTORY OF MAMMIFEROUS ANIMALS,

With a particular View of the PHYSICAL HISTORY OF MAN, and the more closely allied Genera of the order QUADRUMÆNA, or MONKIES.

BY W. C. L. MARTIN.

Illustrated with 296 Anatomical, Osteological and other Engravings on wood, and 12 full Plate Representations of Animals, drawn by W. Harvey.

1 vol. 8vo. 1841. 16s.

### ILLUSTRATIONS OF CUTANEOUS DISEASE,

A series of delineations of the Affections of the Skin, in their more interesting and frequent forms; with a practical summary of their symptoms, diagnosis and treatment, including appropriate formulæ.

BY ROBERT WILLIS, M.D.

Licentiate to the Royal College of Physicians, and Physician to the Royal Infirmary for Children.

THE DRAWINGS ARE AFTER NATURE, AND LITHOGRAPHED BY ARCH. HENNING.

These Illustrations are comprised in 94 Plates, folio, the drawings are originals, carefully coloured. Complete Twenty-four Numbers.

Bound in cloth, lettered. Price £6.

### ELEMENTS OF MEDICINE.

MORBID POISONS.

BY R. WILLIAMS, M.D., TRIN. COL. CAMBRIDGE,

Fellow of the Royal College of Physicians, Senior Physician of St. Thomas's Hospital, and President of the Royal Medical and Chirurgical Society, London.

1836-41. 2 vols. 8vo. £1. 8s. 6d.

The Second Volume may be had separately. 1841. 18s.

### THE PRINCIPLES OF SURGERY,

BY JAMES SYME,

Professor of Clinical Surgery to the University of Edinburgh, and Surgeon in ordinary to the Queen.

Third Edition, much enlarged, and illustrated with Plates, and many wood-cuts in the text. 1 vol. 8vo. 1842.

ELEMENTS  
OF THE  
GENERAL AND MINUTE  
ANATOMY  
OF  
MAN AND THE MAMMALIA,  
CHIEFLY AFTER ORIGINAL RESEARCHES.

BY  
FR. GERBER,

PROSECTOR IN THE UNIVERSITY OF BERN.



TO WHICH ARE ADDED

NOTES AND AN APPENDIX,

COMPRISING OBSERVATIONS ON THE BLOOD, CHYLE, LYMPH, THYMOUS  
FLUID, TUBERCULAR MATTER, EPITHELIAL CORPUSCLES, &c. &c.

BY  
GEORGE GULLIVER, F.R.S.

ATLAS

CONTAINING THIRTY-FOUR PLATES, ENGRAVED.

---

LONDON:  
HIPPOLYTE BAILLIERE, 219, REGENT STREET,

FOREIGN BOOKSELLER TO THE ROYAL SOCIETY, AND TO  
THE ROYAL COLLEGE OF SURGEONS.

PARIS: J. B. BAILLIERE, RUE DE L'ECOLE DE MEDICINE.  
LEIPSIG: T. O. WEIGEL.

---

M.DCCC.XLII.

5400



## ADVERTISEMENT.

---

THESE Figures illustrative of my ELEMENTS OF GENERAL ANATOMY I have, with a few exceptions, drawn from Nature with my own hand. I do not pretend that they have won anything as works of art from this ; but I had no choice ; and I believe them to be faithful. Their great defect, in my own eyes, is a want of the natural delicacy which the structures represented possess,—a delicacy, indeed, which no human hand can hope to emulate. However ready to acknowledge their want of artistic merit, then, I can nevertheless say that they are the product of many an hour that would else have been an hour of relaxation.

A few repetitions, in consequence mainly of the introduction of the Table of TERMINOLOGY, will have to be pardoned. I thought it well to present a general and comprehensive view of the elementary forms of the component parts of animals, to show their affinities, and to trace the passage, by gradual evolution, into more highly organized forms, and finally, the essence of their complete metamorphosis first, and then of their degeneration till they are felt

as no longer serviceable to the organism in its totality.

With regard to the means of research and observation at my command, I have, through the kindness of the owners, had the use, for longer or shorter periods, of the following microscopes:—

1. An instrument by Schiek and Pistor, the property of Professor Valentin; an admirable instrument, well known and celebrated among microscopic observers.

2. An instrument by Plössel, belonging to Dr. Seiler.

3. A microscope by Chevallier of Paris, the property of Dr. Baswitz.

4. An English microscope, name of the maker unknown to me, the property of M. Von Werdt-Steiger.

All these instruments, except the last, are achromatic; one of them is, in addition, provided with a screw micrometer and cross wires; and two with sets of double glass micrometers, the one having the line divided into 30, the other having it divided into 60 parts. Some of my older observations, and among my more recent ones, those having reference to the structure of the nerves, were made with my own microscope, which is one of the better non-achromatic old-fashioned instruments. The compressor and the double knife I found at times of essential service. Among chemical reagents, solutions of common salt, of caustic potash, of carbonate of potash, and of sal ammoniac, as also acetic

acid, oil of turpentine, sulphuric ether and alcohol, were frequently employed.

The true dimensions of the microscopic objects, and their apparent magnitudes as indicated in the Figures, were determined by the simplest and most certain methods, either by means of the screw micrometer, or of one of the glass micrometers placed under the eye-piece. To use the latter conveniently and assuredly, I fell upon the following plan: I placed in the focus of the eye-glass one of the glass plates having the line divided into 30 parts, and in the focus of the instrument at large one of the glass plates having the line divided into 60 parts; I then determined with the greatest nicety the number of degrees upon the under (60 to the line) plate which were comprised within a single degree of the upper (30 to the line) plate. Suppose these under the lowest power—eye-piece No. 1, object-piece No. 1—to amount to  $5^\circ$ , then one degree of the upper micrometer measures,  $\frac{6}{30}$ , or 1-12th of a line; an object, therefore, that measured  $3^\circ$  in length of the upper micrometer, would have an absolute length of 3-12ths or 1-4th of a line. With higher powers, of course many degrees of the upper micrometer are included in one of the lower, for instance, 30 in 1. The true length of an object which measured  $1^\circ$  of the upper micrometer would then be  $\frac{1}{30} \times 60 = \frac{1}{1800}$ th of a line; did it measure  $5^\circ$ , it would then be  $\frac{5}{30} \times 60 = \frac{5}{1800} = \frac{1}{360}$  of a line; and so on. By means of a Table constructed upon these data, all dimensions are readily ascertained with celerity and precision.

I take the present opportunity of publicly expressing my thanks for the readiness with which the friends I have mentioned favoured me with the use of their costly instruments; my more particular acknowledgments, however, are due to my honoured colleague Valentin; ever ready to oblige, ever actively engaged himself, and ever glad to aid research in all within the sphere of his influence—may he long continue to adorn the school upon which he now sheds so bright a lustre!

FR. GERBER.

BERN, 1840.

# GENERAL ANATOMY.

## SKETCH

OF A

### SYSTEMATIC TERMINOLOGY IN REFERENCE TO GENERAL ANATOMY;

OR,

AN ATTEMPT TO DESIGNATE APPROPRIATELY, AND TO  
DIVIDE SYSTEMATICALLY, THE ELEMENTARY CONSTIT-  
UENTS OF ANIMALS, INCLUDING A PARTICULAR EX-  
PLANATION OF THE FIGURES FROM FIG. 164 TO 238.

I. UNORGANIZED CONSTITUENTS, THE FORMS OF WHICH  
DEPEND ON GENERAL PHYSICAL AND CHEMICAL FORCES.

1. *Liquid with the globular form.*

GUTTULA, a drop, a globule. Figs. 164—168; the ob-  
jects seen by transmitted light.

Fig. 164. A flattened round drop, adhering to the port-  
object, in this instance a plate of glass.

— 165. An elliptical-shaped drop, under the same cir-  
cumstances.

— 166. A free globular drop, its lowest point in the  
focus of the microscope.

— 167. A similar drop, its centre in the focus.

— 168. A similar drop, its highest point in the focus.

— 169. A drop of the same description seen by reflected  
light falling laterally.

PLATES.

*b*

*Example.*—Oil or fat-globule:

In milk. Fig. 22.

In chyle. — 23 B.

In sebaceous matter of the skin. Fig. 31 e.

(Bubbles of air in a liquid might with propriety be referred to this head.)

2. *Solid; a. Crystalline.* These are generally objects having a regular figure bounded by flat surfaces, and rectilinear edges and angles.

CRYSTALLI, crystals. Fig. 170—176.

Fig. 170. A four-sided table.

— 171. A cubical crystal.

— 172. A lozenge or rhomboidal horny plate, such as in disturbance of the cerebral functions is often seen formed in the choroid plexus of the horse.

— 173. A three-sided prism.

— 174. A six-sided prism pointed at one end.

— 175. A three-sided pyramid.

— 176. Acicular crystals.

*Examples.*—In fluids:

In the fluid of the allantois. Fig. 30 B.

In the sebaceous matter of the skin (crystals of stearine, horse.) Fig. 31 d.

In solids:

In firm exudation. Fig. 30 A.

——— *b. Non-crystalline, globular or rounded.*

GLAREA, gravel, grit, sediment. Hard globules and granules.

Fig. 177. Gravelly globules.

— 178 Gravelly granules.

— 179 Mulberry-like gravel.

*Examples.*—The urinary sediments and grit of the Solidungula. Fig. 29.

The grit of the choroid plexus of the brain.

The grit of the pineal gland.

II. IMPERFECTLY ORGANIZED, AMORPHOUS, TRANSPARENT, SOLID, HOMOGENEOUS SUBSTANCES, WHICH GENERALLY CONTAIN CELLS, NUCLEI, OR CANALS.

SUBSTANTIA VITREA S. HYALINA, vitreous or hyaline substance.

a. Not including cells or nuclei:

Pulp of the navel string.

Fibrine at the moment of its coagulating.

The crystalline lens.

b. Including cells. Fig. 216.

*Examples.*—Hyaline substance of the cellular cartilages. Fig. 53 B, fig. 57 A.

Hyaline substance of reticulate cartilages. Fig. 59.

c. Including nuclei or nucleoli.

*Example.*—Cartilage of bone. Fig. 60 and 61 a.

d. Including canals or tubuli.

*Example.*—Cartilage of the teeth—hyaline substance of the tubular structure. Fig. 68 k.

III. HIGHLY ORGANIZED ANIMAL STRUCTURES. SIMPLE AND COMPOUND ORGANIC ELEMENTS OF THE ANIMAL BODY, THE FORMS OF WHICH ARE THE EFFECTS OF THE ORGANIZING FORCE (THE FORMATIVE VITAL POWER.) Fig. 180—207.

1. Simple or elementary constituents; not susceptible of subdivision into dissimilarly organized parts.

A. Plates or flat formations. Fig. 180—186.

a. Simple.

*aa.* More minute, with rounded boundaries.

SQUAMÆ S. SQUAMULÆ, plates or scales. Horny cells without nuclei.

Fig. 180. Six-sided plate or scale.

— 181. Eight-sided plate or scale.

— 182. Elliptical plate or scale.

Three, four, and five-sided squamæ.

*Example*.—Horny plates of the horn of the ox. Fig. 34.

Scales from the conjunctiva (horse.) Fig. 41 a.

*b b.* Larger, with various, not predominating linear boundaries.

LAMINULÆ. Fig. 183.

*Example*.—Large cells without nuclei.

*c c.* Long, linear.

FILA TÆNIOFORMIA S. TÆNIOLÆ. *a.* Simple band-like or flat fibre. Fig. 184.

*Example*. The flattened fibre, of elastic tissue. Figs. 54—56.

The involving, spiral fibre of the primary voluntary muscular fasciculus in the dog. Fig. 29, 2 b, 3 b, 4 c.

*b.* Compound flat fibrous formations, made up of several flat fibres.

FIBRA SQUAMOSA, squamous fibre. *Fibra tæniolaris*, flat fibre. Allineated squamæ, or squamæ hanging together in a line. Fig. 185.

*Example*.—Fibrous horn. Fig. 34 B.

FUNICULUS TÆNIOLARIS. Flat filamentous cord;—parallel flat filaments bound together.

*Example*.—Fig. 79, 3 b.

FUNICULUS FIBRO-SQUAMOSUS. Fibro-squamous cord: parallel squamous fibres bound together.

*Example*.—Fig. 34 B.

MEMBRANA S. CUTICULA SQUAMEA SIMPLEX. Simple or unilamellar membrane,—squamæ arranged superficially. Fig. 186.

*Example*.—Fig. 41 b.

MEMBRANA SQUAMOSA COMPOSITA. Compound or multilamellar membrane,—superficially arranged squamæ, one layer lying over another.

*Example.*—Fig. 41, c, and 40 e, f.

The flat filamentous bundle.

The flat fibrous bundle.

The flat filamentous membrane.

The flat fibrous tissue, and so on, vide fig. 194 to 201.

B. Rounded homogeneous soft solids.

a. Simple, peripheral.

GRANULA, granules; aggregated granules. Small, soft, rounded, simple formations. Fig. 187—192.

*Examples.*—Lymph granules. Fig. 7 b, fig. 23 B, b. Granules of the cyst-corpuscle (multigranular pus-corpuscle.) Fig. 9 c.

Attached granules. Fig. 10 upon c, d, and l.

Fibrinous granules. Fig. 23 A.

Granules of coagulated milk. Fig. 23 A.

Mucus-granules. Fig. 25 A, d and B. fig. 48 D.

Seminal granules. Fig. 26 A.

Pigmentary granules. Fig. 32, l. and fig. 39 d.

Ganglionic granules (ganglionic cells.) Fig. 89. 2, 3, 4. fig. 89, 1 and 7.

Granules of the granular muscles of organic life (?) Fig. 74.

Granules of the fibres of the muscles of animal life (?) Fig. 82.

GLOBULI, globules. Smooth, spherical granules. Fig. 188.

*Example.*—Seminal globules. Fig. 26 A.

b. Compound, consisting of many granules stuck together. Fig. 189—192.

CORPUSCULA GRANULOSA s. GRANULATA, granular or granulated corpuscles. Aggregation corpuscles; rounded corpuscles having no nucleus, made up of granules. Fig. 190.

*Examples.*—Cyst-corpuscle (multigranular pus-corpuscle.) Fig. 9 c, fig. 10 e, f, l.

Mucus-corpuscle. Fig. 25 B.

Corpuscle of the Graafian vesicle (?) Fig. 27 b, fig. 28 a.

Pigmentary corpuscle. Fig. 32, 1 a.

FIBRA GRANULOSA S. GRANULATA. Granular fibre. A fibre consisting of simple granules arranged in lines. Fig. 189.

*Example.*—The fibre of the granular muscles. Fig. 74 a, and fig. 82 A. B.

MEMBRANA GRANULOSA. Granular membrane. Granules arranged in the same plane. Fig. 192.

*Example.*—The inner lamina of the retina.

c. Simple, rounded, central, productive granules (germ granules.)

NUCLEOLUS, nucleolus. (Kernchen, G.) Central grain. A simple granule included in a nucleus (cell-germ.) Fig. 193.

*Examples.*—Nucleus (properly nucleolus) of the blood corpuscle. Fig. 1 b, fig. 2 c, fig. 205, 1 b.

Nucleolus of the true, healthy, reproductive or seven granular pus corpuscle. Fig. 9 b, fig. 10 g, fig. 205, 3.

Nucleus (properly nucleolus) of the exudation corpuscle. Fig. 9 a, fig. 10 i, fig. 205, 2.

Nucleoli of cells generally. Fig. 215 e, fig. 217 b, fig. 220 b, fig. 226 c.

Nucleolus of the cartilage-cell. Fig. 217 b.

NUCLEUS, nucleus or kernel. (Kern. G.) A simple central grain, granule, or globule, without a nucleolus, surrounded immediately by a cell. Fig. 202 a, b.

*Examples.*—Nucleus of the epithelial-cell. Fig. 25 A, in a, a, a. The white point in the pigmentary cells of the choroid coat of the eye. Fig. 32, 2 and 3 b; fig. 33.

Nucleus of the cartilage cell. Fig. 59 b, b, b, fig. 217 a.

Nucleus of the bone-cell or bone-corpuscle. Fig. 61 a, fig. 62 a, fig. 63 a, fig. 68 d, fig. 70 a.

Nuclei of cell and ciliary corpuscles. Fig. 48 g.

**NUCLEUS GRANULOSUS**, granular nucleus. A nucleus composed of granules; probably a granular nuclear corpuscle, as that of the true pus corpuscle. Fig. 217 g, fig. 218 a, b, c, fig. 223 b.

*Example.*—Common, perhaps constant, in cartilage cells. Fig. 57 c. In the cell-fibres of the sheaths of nerves and vessels. Fig. 102 at d.

C. Cylindrical, simple, linear formations.

a. **FILA ROTUNDA S. CYLINDRICA**. Simple rounded filament. Fig. 194.

*Example.*—Fibre of cellular substance. Fig. 19 b, fig. 73 c.

Fibre of tendon. Fig. 51 +.

Fibre of ligament. Fig. 52.

Fibre of one variety of cartilage. Fig. 53 A, a.

Fibre of contractile tissue. Fig. 73 b.

b. Compound, round, filamentous formations—compounds of many round filaments.

**FASCICULUS FILORUM**. A bundle of filaments—a cylindrical filamentous cord. Fig. 195.

**FUNICULUS FILORUM**. A round filamentous cord. Round filaments connected parallel to the length of the cord. Fig. 196.

*Examples.*—Cord of the filaments of cellular substance. Fig. 19.

Cord of tendinous filaments. Fig. 51 b, c.

Cord of ligamentous filaments. Fig. 52.

Cord of cartilaginous filaments. Fig. 53 A.

Cord of contractile filaments. Fig. 73 a, a, a.

**MEMBRANA FILORUM**. A filamentous membrane. A membrane composed of filaments lying parallel to each other. Fig. 200.

*Example.*—Serous membrane. Fig. 49 A.

**CONTEXTUS FILORUM**. A filamentous tissue. A structure composed of filaments. Fig. 197.

*Example.*—Tissue of cellular substance. Fig. 49 B.

Tissue of contractile filaments. Fig. 75, at b. and c.

RETE FILORUM. A filamentous net. Fig. 198, fig. 225 (?)

*Example.*—Elastic tissue (?) Fig. 54 a.

FILORUM IMPLICATIO REGULARIS. A grating of filaments. Fig. 199.

*Example.*—Fig. 76 A (?)

CONTEXTUS FASCICULOSO-FILOSUS. A tissue of filamentous fasciculi. Fig. 201.

2. More highly organized proximate or compound constituent parts, in which dissimilar structures are distinguishable.

A. Binary. Composed of two simple elements.

a. Uniform structureless substances, forming simple investing covers.

$\alpha$ . Rounded.

VESICULA S. BULLULA SIMPLEX S. PRIMITIVA. A simple vesicle. An unnucleated cell. A simple hollow globule, or globular cuticle including structureless substances, fig. 208; heaped together, fig. 209. Including serum:

The serous vesicle, which occurs every where in the moist cellular substance.

Including fat:

The fat vesicle; occurs universally in the adipose cellular substance.

*Example.*—Round fat vesicles. Fig. 31 a, b, c.

Crowded (multilocular) fat vesicle. Fig. 71 and 72 b, and fig 94 s.

$\alpha$ .  $\beta$ . Transition of the simple vesicle into the simple hollow fibre (simple vessel.)

VESICULA PEDUNCULATA SIMPLEX. Pedunculated simple vesicle. Fig. 208.

*Example.*—The vesicle of the epithelial corpuscle (?) for example, of the intestinal villus. Fig. 240 c, d, and fig. 241 b.

Vesicle of the sebaceous glands. Fig. 42 n, o, p, fig. 43 e, fig. 44 e, fig. 45 e.

Vesicle of the sudoriparous glands. Fig. 43 i, i.

Vesicle of the Meibomian glands. Fig. 158 c.

$\beta$  Elongated, siliquose, simple, hollow envelope, with uniform contents.

VASA SIMPLICIA. Simple vessels with homogeneous contents. Fig. 213.

*Example.* The most delicate peripheral or efferent lymphatic vessels. Fig. 108; a, a, in fig. 113; fig. 141.

The excretory ducts of the cutaneous glands: viz.

Of the sebaceous glands. Fig. 36 e, f, fig. 37 a, a, fig. 40 g, h, fig. 42 d, d, fig. 43 f f, fig. 44 c, fig. 45 d, c, fig. 160, fig. 161, fig. 239 d, e, f.

Of the sudoriparous glands. Fig. 43 k, k.

The sheaths of the hairs. Fig. 42 c, fig. 43 and 45 c.

The tubuli of the ivory in the teeth. Fig. 68 f, i, k, l.

Horny tubes, with simple solid contents:

*Pili*, hairs. Fig. 42 k, l, m, fig. 43 h, fig. 45 f, fig. 94 r.

Soft moveable hairs:

CILIA VIBRATORIA. Vibratile cilia.

Of the ciliary cells. Fig. 221 d, fig. 222 c.

Of the ciliary corpuscles. Fig. 48 d.

Of the ciliary cellular fibres. Fig. 223 at a, and fig. 224 at b.

b. Organized simple formations; simple, including envelopes:

$\alpha$ . Rounded.

NUCLEUS NUCLEOLATUS. Nucleolated nucleus. (Schachtelkern, G.) A nucleus with an included nucleolus. Figs. 204—206.

*Example.*—Blood corpuscles. Fig. 1—6, fig. 10, a, b.

Lymph-corpuscles. Fig. 7, fig. 4 a.

Exudation corpuscles. Fig. 9 a, fig. 10 i, k.

Ichor corpuscles. Fig. 9 d, fig. 10 c, d.

CELLULÆ NUCLEATÆ. Nucleated cells. (Kernzellen, G.) Simple cells without nucleoli. Figs. 214, 216, 227.

*Example.*—Simple epithelial cells. Nucleated cells of the epidermis and epithelium. Fig. 25 A, a, a, a, fig. 47, fig. 103 b, b, b.

Pigmentary cells of the choroid coat of the eye, fig. 32, 2, 3.

Bone cells. Fig. 86 b, b'.

Nucleated cells in cellular cartilage. Fig. 57 b, c, fig. 58; and mingled with nucleolo-nucleated cells, and binucleated cells. Fig. 217 a.

Nucleated cells in reticulate cartilage. Fig. 59 b, b.

Compound nucleated-cellular formations.

FIBRÆ CELLULOSO-NUCLEATÆ. Cellulo-nucleated fibres. Fig. 218, fig. 219.

*Example.*—In the second stage of the secondary fibrous organization. Fig. 17.

The cellulo-nucleated fibres of the nervous sheaths. Fig. 102 c, c, fig. 103 c, d, e.

The cellulo-nucleated fibres of the vascular sheaths. Fig. 103 d, d.

MEMBRANA CELLULOSO-NUCLEATA S. EPITHELIUM CELLULOSO-NUCLEATUM. Cellulo-nucleated membrane or epithelium. Fig. 214, fig. 215 a.

*Example.*—Outer skin (epithelium) of the mucous membranes, ex. gr. Of the allantois. Fig. 103 b, b, b.

Of the conjunctiva. Fig. 47 and farther,

Of the choroidea. Fig. 32, 2, and fig. 33.

B. Ternary, organized constituent parts. Parts with three different elementary constituents.

1. Simple coverings, including contents of two dissimilar kinds.

a. Rounded, with organized contents:

CELLULÆ NUCLEO-NUCLEOLATÆ. Nucleo-nucleolated cells. (Schachtelzellen, G.) Cells with included nucleolated nuclei. Fig. 215 at c, fig. 217 b, c, fig. 220, fig. 226.

*Example.*—Ganglionic cells, ganglionic globules. Fig. 89, 2, 3, 4.

Nucleo-nucleolated cells (encased cells) of cartilage.

Nucleo-nucleolated cells of the external indusiæ (epidermis, epithelium.) Fig. 226 a, b, c.

b. Elongated, with contents of two kinds, partly organized.

VASA SIMPLICIA CONTENTO DUPLICI USA. Simple vessels, with contents of a twofold nature. Corpuscles suspended in a fluid.

*Example.* The capillary bloodvessels. Fig. 6 A, b, b, b, fig. 20, fig. 21 c, d, e, fig. 132—135, fig. 136 c, c, fig. 137—152, fig. 153, fig. 155 c.

Canals of the bones—the most delicate bloodvessels of the bones. Fig. 61 b, c, fig. 62 b, fig. 68 e.

2. Bitunicated canals with homogeneous contents.

a. With a simple cellular external coat.

All the finer secretory canals furnished with a mucous membrane (VASA SECRETORIA CAPILLARIA, the capillary secretory canals.)

*Example.*—The tubuli of the kidney.

The finest subdivisions of the biliary ducts.

The finest subdivisions of the salivary ducts. Fig. 156 and 157.

The finest subdivisions of the lachrymal ducts.

The finest subdivisions of the Meibomian ducts. Fig. 158.

The finest subdivisions of the prostatic ducts.

The finest subdivisions of the Cowper's glands, and so on.

b. With a ciliate epithelium or external coat.

FIBRÆ PRIMATIVÆ NERVORUM. Primary fibres of the nerves. Fig. 88, 4; a. Neurelema, or immediate investing coat; b, Ciliate external coat; b, b, The coagulated contents.

C. Quaternary, compounded, organized constituents. Parts made up of four simple but different elements.

1. Bitunicated, with contents of two descriptions.

a. Rounded.

OVUM, OVULUM. The primary egg before fecundation.

(Eichen, Eibläschen, G.) Fig. 27. Made up of the double envelope or covering. *c.* The vitelline membrane, and *d.* the exochorion or zona pellucida, which include *e.* the vitellus or yolk, and *f.* the germinal vesicle.

a b. Transition from the rounded to the elongated form.

VESICULÆ PEDUNCULATÆ COMPOSITÆ. Pedunculated, compound vesicles.

*Example.*—The pulmonary vesicle or vesicles. Fig. 159 (Cover:—the mucous membrane, and cellular epithelium; Contents—a muco-aqueous fluid and air.)

b. Elongated.

VASA COMPOSITA. Compound vessels. Vessels having two tunics, and contents of two different descriptions.

*Example.*—The central or efferent lymphatic vessels. Fig. 108 b, e, f.

The venous lymph-ducts. Fig. 110 a, 111 b, e, 112 b, c.

The interglandular lymphatics. Fig. 109 a.

(Cover:—A muscular fibrous tunic, and a serous tunic; Contents—Lymph-corpuscles and lymph-fluids.)

The bloodvessels:

The veins. Fig. 14—120, fig. 136 d. (Cover:—An organic, muscular, fibrous coat, and a serous coat; Contents—Blood-corpuscles and blood-fluid or liquor sanguinis.)

The arteries. (Cover:—An elastic tissue, or coat, and a serous coat.) Contents—Same as the veins.)

The excretory ducts of such glands as the

Salivary glands,

The liver,

The testes,

The lachrymal glands,

The mammary glands, &c. which are lined throughout with a mucous membrane, and of which the cover or bounding parietes consist of this membrane with a super-composed cellular epithelium, and the contents are mucous corpuscles and granules, oil-globules, or watery fluid, &c.

# EXPLANATIONS

OF THE

## PLATES.

---

Fig. 1—21. Blood.

— 1—14. Blood-corpuscles, globules or discs.

— 1—6. Blood corpuscles of vertebrate animals.

— 1. Blood corpuscles of the fish, (the barbel, *Cyprinus barba*.)

*a.* The capsule (nucleus); *b.* the nucleus (nucleolus.)

Fig. 2. Blood-corpuscles of the reptile (newt or triton) magnified 450 diameters.

Fig. 3. Blood-corpuscle of the bird (pigeon) magnified 450 diameters.

Fig. 4. Blood corpuscle of the mammal (horse) magnified 450 diameters.

*a.* A lymph globule; *b.* two blood-corpuscles standing on their edges.

Fig. 5. Blood corpuscle of man, magnified 530 diameters.

— 6. Blood corpuscles of the newt in the capillary vessels, magnified 35 diameters.

*a.* Final subdivisions of the arteries; *b b b.* Capillaries with single rows of blood-corpuscles; *c.* Passage into the first divisions of the veins. The arrows indicate the course of the blood in the capillaries.

## B. Sections of blood-corpuscles.

1. Section of a meniscus-shaped blood-corpuscle of the spider.

2. Section of a blood-corpuscle of the frog with elliptical nucleus (nucleolus) rising above the general level of the corpuscle.

3. Section of a dried blood-corpuscle of the pigeon. In the middle a round nucleus is perceived, in the circumference of which the nucleus has sunk in. The other two eminences are formed by the periphery of the nucleus, which rises in the guise of a ring above the capsule.

4. Section of a blood-corpuscle of a mammal.

Fig. 7. Lymph-globules of a mammal (horse) magnified 450 diameters, from the pale lake-coloured lymph of the thoracic duct.

*a.* Lymph-globule, clearer and smaller than the blood-globule (vide fig. 4.)

*b.* Lymph-granules, produced by the coagulation of the lymph. *c.* Lymph-globule resting on its edge.

Fig. 8. Columns of blood-corpuscles of a mammal (horse) in apposition by their flat surfaces, magnified 450 diameters.

*a.* Columns. *b.* Single blood-corpuscles resting on their edges. *c.* Single blood-corpuscles lying flat.

Fig. 9. and 10. Nuclear and granular corpuscles of different kinds.

Fig. 9. Corpuscles of blood (blood-corpuscles) of coagulable lymph (exudation-globules,) of pus, (pus-globules,) of cysts, (cyst-globules,) of ichor, (ichor-globules,) magnified 450 diameters.

*a.* Exudation-globules, which arise when the fibrine of transuded blood or lymph (plasma, liquor sanguinis) coagulates in contact with the living tissues.\* Out of the body, or after death, instead of proper exudation-globules, granules are formed (*vide* fig. 15 *b.*) At first exuda-

\* But without forming cells, as happens with regard to the layer that is immediately in contact with the living tissues.

tion globules look extremely like blood-globules, they then split or divide into six or seven pieces, and undergo transformation into pus-globules.

*b.* Pus-globules, (true pus-globules, seven granular, productive pus-globules,) of which laudable or productive pus almost entirely consists. In the true pus-globule six or seven granules surround the smaller and rounded nucleus, which in some of the globules appears to be farther subdivided into from two to four granules.

*c.* Cyst-globules; unnucleated, highly granular pus-globules, often much larger than the nuclei of these last. These cyst-globules are encountered in close cavities, the products of morbid action—in cysts—and are generally mingled with crystals, &c.

*d.* Ichor-globules. These are met with in the discharge from ulcers, in the matter of glanders, &c. They appear to be altered blood and exudation-globules, which are incapable of forming either granulations (cells) or pus.

Fig. 10. Corpuscles of blood, pus, coagulable lymph, and ichor, magnified 1300 diameters.

*a.* A blood-globule of a mammal (horse) seen on its flat surface.

*b.* The same seen from the edge.

*c.* Ichor-globule (glanders) with attached granules.

*d.* The same seen from the edge.

*e.* The flat highly granular cyst-globule.

*f.* The same seen from the edge.

*g.* The flat, true pus-globule, (the seven granular, laudable, or productive pus-globule,) the variety with quadrigranular nucleus.

*h.* The same standing on the edge.

*i.* Exudation-globule, which has become fissured, and is about to change into a pus-globule.

*k.* The same standing on its edge.

*l.* The rounded cyst-globule, (multigranular, round pus-globule,) with adhering granules. The cyst-globule is generally much larger than any of the other globules. Cyst-

globules are encountered most frequently in the cysts of glandular structures ; for example, in those of the thyroid body. (See fig. 9 *c*.)

Fig. 11—14. Peculiarities presented by blood coagulating out of the body.

Fig. 11. Blood received into a cup, coagulating. The blood-globules are equally distributed through the coagulating plasma, or liquor sanguinis.

Fig. 12. The same blood completely set or coagulated.

*a a*. The serum, which has transuded, and now completely surrounds the coagulum.

*b*. The coagulum or cruor. The blood-globules are surrounded by coagulated fibrine.

Fig. 13. Blood mixed with sugar, coagulating. The coagulation being delayed, as it is in this instance, the blood-globules, which are specifically heavier than any other constituent of the blood, sink towards the bottom, and a clear layer of fibrine, *b*, is formed on the upper part of the coagulum, *c*. \*

Fig. 14. The same blood completely set.

*a a*. Serum. *b*. Layer of pure fibrine (buffy coat, inflammatory crust.) *c*. The precipitated blood-globules, now occupying a smaller space, and, with the smaller quantity of fibrine with which they are mingled, forming a very deep-coloured coagulum.

Fig. 15 A. Coagulated fibrine in strings, procured by switching a quantity of freshly let blood with a rod.

*a*. The rod. *b b*. Club-shaped masses. *c*. Filiform and *d*. Looped fibres.

B. Granular fibrine, which has set out of the body. Magnified 100 diameters.

Fig. 16—21. Fibrine which has set under the influence of the vital power ; organization of the same.

\* The formation of the buffy coat depends on something more than this. It often does not appear on blood that coagulates slowly ; and, on the contrary, it is thick on that which sets within the usual time. Very recently it has been maintained that the buffy coat is connected in every instance with a diminution in the specific gravity of the blood.—ED.

Fig. 16. Plan figure; progress of organization in the fibrine composing coagulable lymph, (exudation of the liquor sanguinis without admixture of blood-globules,) deposited on serous and synovial membranes, &c.

*a.* Fluid fibrine in the form of drops. *b.* A piece of consolidated but still amorphous fibrine.

*c.* Exudation corpuscles (fig. 9 *a.*) not sufficiently magnified to bring the nuclei into view—*first stage of the organization.* *d.* Associated cell-bundles, more highly magnified than in fig. 102 *c d*, 103 *d d*, and figs. 218 and 219—*first stage of the fibrillation.* *e.* Associated cylindrical fasciculi—*second stage of fibrillation.* *f.* Divided or disgregated cylindrical fasciculi as they appear in the fibrils of cellular membrane, of sinews, &c.—*complete fibrillate organization.*

Fig. 17. Secondary organization in coagulable lymph. Loops and lancet-shaped leaflets—exudation villi formed of aggregated cell-fasciculi (as in fig. 102 *c.*) The liquor sanguinis (coagulable lymph) has exuded upon a portion of inflamed peritoneum. The organization has here passed the first and has reached the second stage, or the commencement of fibrillation. A specimen of secondary organization in false membranes. From a mammal (the horse.)

Fig. 18. Second stage of fibrillation in a mass of exudation from the peritoneum—aggregated cylindrical fibrillation.

Fig. 19. Secondary round fibrils (fibril of cellular membrane, and transformation of this into the fibril of sinew.)

*a.* Bundles and strings of the fibrils of cellular membrane.

*b.* Strings of the fibrils and single fibrils of sinew.

Fig. 20. Secondary formation of bloodvessels in villi of coagulable lymph.

Fig. 21. A portion of another leaf-like villus of exudation, with the bloodvessels more highly magnified.

*a.* Artery running into the middle of the mass.

*b.* Vein lying near it.

- c.* Capillaries of the vein.
- d.* Capillaries of the artery.
- e.* Capillaries or intermediate vessels forming the peripheral vascular rete.

Fig. 22—26. Secretions from the blood with organized constituent elements, and unorganized precipitates.

Fig. 22. Healthy milk, magnified 450 times (from the cow.)

Fig. 23 A. Abnormal milk: slimy, imperfectly coagulated, reddish-coloured milk, (from a cow which had died of the poll-evil,) magnified 200 times.

*a.* Milk-globules connected together by a thick fluid.

*b.* Scattered milk-granules.

B. Milky chyle from the mesenteric lacteals of a dog which had been fed upon horse-flesh.

*a.* Oil-drops.

*b.* Lymph-granules.

Fig. 24. Detached epithelial corpuscles (epidermic cylinders) of the bile of man and different animals. With these figures compare fig. 46, and also fig. 48. The objects are here seen under a better microscope than those of fig. 48, but they are without ciliæ.

*a.* In the bile of the human subject.

*b.* In the bile of the horse.

*c.* In the bile of the ox.

*d.* In the bile of the hog.

*e.* In the bile of the dog.

Fig. 25. Mucus.

A. From the mucous plug of the cervix uteri, magnified 450 diameters.

*a.* Epithelial cells from the epithelium of the mucous membrane of the cervix uteri.

*b.* Perfectly horny scales.

*c.* An epithelial body with ciliæ.

B. Mucous corpuscles and granules, magnified 100 diameters.

Fig. 26. Seminal fluid of different vertebrata.

A. Seminal animalcules or spermatozoa, and seminal granules of man and the mammalia.

a. Of man.

b. Of the bear (this observed by the best microscope resembles fig. 231.) The tails of the spermatozoa were not perceived in this instance.

c. Of the common mouse.

B. Spermatozoa (in packets or nests) and seminal granules in birds.

a. The spermatozoa.

b. Seminal granules including nuclei.

c. Cysts full of young spermatozoa.

Fig. 27 and 28. Contents of the ovary in the unimpregnated state.

Fig. 27. Magnified view of the Graafian vesicle or follicle (of the cow.)

a a. The membrane of the Graafian vesicle.

b. The granular follicular corpuscles.

c—g. The ovum.

c. The outer covering of the ovum—*Exochorion*, or *Zona pellucida*.

d. The inner investment of the ovum—*Endochorion*, or vitelline membrane.

e. The finely granular vitellus or yolk.

f. The germinal vesicle.

g. The germinal spot.

Fig. 28. Graafian vesicles from the ovary of a foetal calf of four months.

a. Substance of the ovary—*Stroma*.

a'. An isolated vesicle covered by the ovarian stroma.

a". and a"". Smaller Graafian vesicles projecting from the surface of the ovarian stroma.

When the ovarian stroma is removed, the ovum, with its germinal vesicle and spot, is brought into view.

Fig. 29, 30. Crystalline deposits in various fluids.

Fig. 29 A. Yellowish-gray precipitate—gravel from the bladder of a male ass.

*a.* A globule split by pressure into three pieces.

B. Globular precipitate—gravel from the pelvis of the kidney of the horse? (Pferdewallachen, G.) The globules are smaller and fewer in number.

*a.* An agglomerated heap of deposit.

Fig. 30 A. Crystals of sulphate of lime in fibrine after exudation of coagulable lymph into the thoracic cavity of the horse.

*a a.* A linear rank of these crystals. Magnified 120 diameters.

*b.* Various clusters of the same crystals. Magnified 400 diameters.

B. Crystals from the fluid of the allantois of the horse.

Fig. 31. Fat of the horse. Magnified 50 diameters.

*a.* Fat vesicle from the pappy layer of fat within the spinal canal.

*b.* Fat vesicle from the cavity of the orbit.

*c.* Vesicle with transparent oily fat—elain vesicle.

*d.* Crystalline fat—tallow, stearine; and

*e.* Globular drop of viscid brown elain, both from the prepuce of a horse? (Pferdewallachen, G.)

Fig. 32 and 33. Black pigmentary matter.

— 32, 1. Pigmentary corpuscles and pigmentary granules.

*a.* A pigmentary corpuscle entire.

*b.* A pigmentary body, resolved into its constituent parts.

*c.* Pigmentary granules.

2, 3. Pigmentary cells of the choriod coat, of the ox's eye.

2, *a.* Meshes of the intercellular rete, after the removal of the pigmentary cells, under a power of 170.

3. A single pigmentary cell—a nucleated pigmentary corpuscle, magnified about 400 diameters.

*a.* The lamellation of the layers, which cover one another like steps.

*b.* The clear nucleus of the cell.

4. Different other forms of the pigmentum nigrum.

*a.* Elongated.

*b.* Radiated.

*c.* Asteroid.

*d.* Reticulated.

} Pigmentum nigrum.

Fig. 33. A portion of the tunica choroidea or vascular tunic of the ox's eye, magnified 56 times.

*a a a.* Veins of this tunic, covered by a single layer of pigmentary cells.

*b.* Arborizations of the veins in the neighbourhood of the ciliary ligament, covered with pointed and reticulated pigment.

*c.* Thick pigment in the vascular meshes.

Fig. 34—45. Horny tissue.

— 34 Elementary parts of horn. Slice of the horn of the ox, of the greatest possible delicacy. Magnified 400 diameters. (With this compare the horn of the foetal ox, in the cells of which nuclei and nucleoli are still apparent, fig. 226.)

A. Elementary plates or lamellæ of the transparent, colourless, hyaline horn.—Cells transformed to horn, the nuclei of which have disappeared.

B. Plates arranged in rows or bundles,—fibrous horny tissue.

Fig. 35. A thin layer, cut parallel with the axis from the tip of the horn of an ox. Magnified 100 diameters.

*a a.* Clear hyaline horn.

*b b.* Deep brown pigmentary spots, which occur in the coloured parts of streaked horn.

*c.* Vascular canal, in the middle of the tip of the horn.

Fig. 36—39. Horny tissue of the horse's hoof.

— 36. A perpendicular slice from the upper part of the posterior wall of the hoof. Magnified 15 diameters.

*a.* A part of the crown edge (Krohnrinne, G.) of the hoof.

- b.* Several vascular cones.
- c.* Colourless, glassy horn.
- d.* Ducts of sebaceous glands, running between the cones for the bloodvessels.
- e.* The spirally twisted or corkscrew-like expansions of these ducts. The turns all go to the right like the threads of a common male screw.

*f.* The narrower part of the sebaceous duct in the firm horn, as it traverses the entire length of the horny crust of the hinder part of the hoof to open finally upon the plantar aspect of the bearing edge.

Fig. 37. A perpendicular slice of the lower part of the anterior wall of a horse's hoof. Magnified 40 diameters.

*a a.* Two twisted sebaceous canals, filled with brown sebaceous matter.

*b b b.* Smaller pigmentary spots which surround the canals.

*c c c.* Larger pigmentary spots, surrounding a middle one composed of smaller streaks.

Fig. 38. A horizontal transverse slice of the wall of the same hoof, cut from near the bearing edge; magnified 40 diameters.

*a a a.* The inferior ends of the spirally twisted sebaceous canals.

*++.* Their external openings. The other references as in Fig. 37.

Fig. 39. A thinner slice of the same hoof from the same situation, magnified 80 diameters.

The spiral canals here form but a quarter of a turn. The pigmentary spots appear as translucent, elongated, pigmentary granules.

- a.* Sebaceous canals.
- b.* Tubular shaped smaller pigmentary granules disposed around these.
- c.* Larger pigmentary granules, enclosing the smaller ones.
- d.* Pigmentary granules, beyond the pigmentary tubuli.

Fig. 40. Section of the integument of the palm of the human hand.

- a.* Corium, or cutis vera—true skin.
- b.* More compact stratum of this upon which
- c d.* The papillæ, or papillary body—the vasculo-nervous cones—are seated.
- c.* Nearest rank of tactile papillæ.
- d.* Next rank in order of the same.
- e.* Horny epidermis or cuticle, composed of numerous superimposed sinuous layers of horny squamæ.
- f.* The sinuous projections of the epidermis, formed by the most external of the horny layers of which the tissue consists.
- g h i.* The spirally twisted excretory ducts of the sebaceous glands.
- g.* In the corion.
- h.* In the cuticle.
- i.* Their external openings.

Fig. 41. Horny epithelium, from the conjunctiva covering the cornea of the eye, as a continuation of the general tegumentary cuticle, magnified 150 diameters (horse.)

- a.* Single scales.
- b.* Simple lamina of the epithelium.
- c.* Double lamina of the same.

Fig. 42. A hair with its associated sebaceous glands, from the vicinity of the crown of the hoof, magnified about 25 diameters (horse.)

- a a.* Corium.
- b.* Horny cuticle.
- b.* Malpighian pigmentary layer.
- c c c.* Hair follicles, hair-sheaths.
- c.* Their funnel-shaped outer openings.
- d d.* Excretory ducts of the sebaceous glands.
- e e.* Secreting pulp of the hair and its sheath.
- f f.* Part of the pulp which immediately secretes the root of the hair.
- g.* Thickening of the still clear portion of the root of the hair.

- h.* Root of the hair.
- i.* Its cavity filled with vessels, nerves, and cellular substance.
- k l m.* The hairs, prolongations of the roots.
- n n.* The mulberry-like sebaceous glands.
- o.* Union of the pediculated vesicles of the gland to form the excretory duct.
- p.* External surface of the vesicles.

Fig. 43. Sebaceous and sudoriparous glands (prepuce of the stallion) magnified about 12 diameters.

- a a.* Epidermis.
- b.* Infundibuliform depression of the same.
- c c.* Sheaths of hairs.
- d d.* Pulps of hairs in their sheaths.
- e e.* Sebaceous glands.
- f f.* Their excretory ducts.
- g.* Root of hair.
- h.* Delicate hair.
- i.* Sudoriparous glands.
- k.* Their excretory ducts.

Fig. 44. Section of the integument of the scrotum, magnified 8 diameters (horse.)

- a a.* The globular cutaneous papillæ, covered with the dark coloured cuticle.
- b b.* Infundibuliform inversion of the cuticle.
- c.* Excretory duct of a sebaceous gland.
- d.* The particular ducts of the several glomeruli composing the gland.
- e.* The sebaceous gland, filled with brown coloured secretion.

Fig. 45. Section of the labium, magnified about 8 times (mare.)

- a.* The papillæ covered with cuticle.
- b.* The infundibuliform inversion of the cuticle.
- c.* The excretory ducts of the sebaceous glands.
- d.* The secondary divisions of these.
- e.* The appendices or vesicles of the sebaceous glands, filled with sebaceous matter.

*f.* Fine hairs.

Fig. 46—48. Epithelial corpuscles and ciliary corpuscles.

— 46. Section of the mucous membrane of the trachea, magnified 100 diameters (horse.)

*a b c.* The ciliary epithelium.

*a.* The ciliary corpuscles.

*b.* Ciliæ attached to the crown of the same.

*c.* Thick superficies of the mucous membrane, formed of elastic membrane, upon which the ciliary corpuscles, and ciliary cellular fibrils, are implanted by means of their pedicles.

*d.* Single detached ciliary epithelial corpuscles magnified 125 times. Among these are to be distinguished cylinder or roller-shaped ciliary corpuscles, bell-shaped corpuscles, cup-shaped corpuscles, and bicellular corpuscles, the latter with pedicles at either extremity.

Fig. 47. Villi of the conjunctiva, from the inner aspect of the upper eye-lid (horse.)

*a a.* Two villi.

*b b.* Spaces betwixt these.

*c.* The cells of the cellular epithelium, or the coronary edges of the epithelial corpuscles.

*d.* The nuclei of the corpuscles.

Fig 48. Ciliary corpuscles and their constituent parts.

A. A bell-shaped ciliary corpuscle seen from the side, and magnified about 400 diameters.

*a.* The ciliary crown.

*b.* The ciliary papilla.

*c.* The coronal pit.

*d.* The ciliæ.

*e.* The coronal globule (coronal nucleus.)

*f.* The body.

*g.* The nucleus.

*h.* The pedicle by which the corpuscle is attached to the mucous membrane.

B. A ciliary corpuscle viewed from the coronal aspect.

*a a.* The ciliary corona.

*b.* Papillæ.

- c.* Coronal depression.
- d.* Section of the ciliary processes (ciliæ.)
- e.* Globule.

C C. Globules that have been detached, and have fallen out, lying in the midst of

D. Extremely minute mucus-granules.

Fig. 49. The most delicate cellular membrane and elastic fibres, magnified 150 diameters.

A. Compact serous membrane, formed of a simple lamina of sinuous fibrils of cellular tissue lying parallel to one another.

B. Cellular membranous tissue of the finest transparent serous membrane.

C. The very delicate sinuous elastic filaments, composing the elastic tissue in the fibrous tunic of the smallest bronchial ramifications (horse.)

Fig. 50. A portion of the great omentum, to show the reticulate structure of the serous membrane in this part, magnified 150 diameters. The membrane consists of an interlacement of

- a.* Cellular membranous fasciculi or ropes, and
- b.* Of cellular membranous filaments.

Fig. 51. Sinew, tendon,—sinewy tissue, magnified 150 diameters.

*a.* Connection of sinew with muscle.

1. Delicate sinewy fibrils, which are united with the conical shaped extremities of the primary muscular bundles, 2.

*b.* Sinuous tendinous bundle, or cord.

+. Lacerated and corrugated sinewy fibrils.

*c.* Tendinous bundle, shortened and lying in alternate loops.

Fig. 52. Bundle from a ligament (one of the lateral ligaments of the knee-joint) magnified 120 diameters (horse.)

Fig. 53. Cartilaginous tissue.

A. Fibro-cartilage, from an inter-articular cartilage of the knee-joint, magnified 120 diameters (horse.)

*a.* A layer of parallel fibres.

*b.* A layer of other fibres crossing the former at right angles.

B. Cellular-cartilage of the septum narium, magnified 200 diameters (horse.)

*a.* The rounded cartilage-cells scattered through the hyaline matter.

*b.* The compressed and elongated cartilage-cells in the vicinity of the mucous membrane.

Fig. 54—56. Elastic tissue.

— 54 Reticulate elastic tissue of the ligamentum nuchæ magnified 200 diameters (horse.)

*a.* Loosened elastic tissue with the meshes opened.

*b.* Elastic tissue in its natural condition, the meshes close.—Elastic tissue, its fibres disposed in lines and layers parallel to one another.

Fig. 55. Elastic tissue from the middle fibrous coat of the aorta, magnified 300 diameters. Elastic tissue, its fibres intertangled (ox.)

Fig. 56. Elastic tissue from the eye-ball of the ox, magnified 200 diameters.

1. From the ciliary ligament.

2. From the choroid coat in the vicinity of the ciliary ligament and in the iris.

Fig. 57—59. Cartilaginous tissue.

— 57 Cellular cartilage from the septum narium, magnified 560 diameters (horse.)

*a.* Hyaline cartilage,—vitreous cartilaginous matter.

*b d.* Cartilage-cells with granular nuclei.

*b.* Cell.

*c.* Nucleus.

*d.* Long-shaped cartilage-cell.

Fig. 58. Transverse section of a costal cartilage in the first stage of ossification, magnified 160 diameters (dog.)

A. Cells disposed in groups, uninclosed; at

*a.* They are imperfectly inclosed by an indistinctly limited area; at

B. On the contrary, the cells, pressed together, are

completely surrounded by a distinct area; as yet, however, there is no deposition of earthy matter apparent.

Fig. 59. Reticular cartilage from the arched portion of the concha of the ear, magnified 300 diameters (horse.)

*a.* The fibres of the intercellular net-work, corresponding to elastic tissue, and also of similar origin.

*b.* Cartilage cells—cartilage-corpuscles.

Fig. 60. Costal cartilage, the ossification begun, from the neighbourhood of the transverse slice represented in fig. 58, magnified 160 diameters.

1, 1. The reticular cells formed by the bony matter just deposited.

*a.* The osseous cartilage (hyaline substance.)

*b.* Osseous corpuscles (nuclei of the bone-cells.)

*c.* Fat-vesicles occupying the place of the cartilaginous substance which has been removed.

Fig. 61—70. Elementary parts of bone.

— 61 A perpendicular section from the middle of the femur, magnified 12 diameters (horse, 4 years old.)

*a.* Ossific cartilage, with scattered bone-corpuscles.

*b.* Canals—medullary, or for vessels.

*c.* Anastomoses, or communications of these with one another.

Fig. 62. A portion of the same section magnified 50 diameters.

*a.* Ossific cartilage, with included bone-corpuscles.

*b.* Medullary canals.

*c.* Transverse communicating branches of these.

Fig. 63. Transverse section from the humerus, magnified 15 diameters (young horse.)

*a a a.* Vascular canals running parallel with the medullary cavity.

*b b.* Perpendicular medullary canaliculi, transversely divided.

*c.* Anastomotic vessels betwixt the perpendicular and transverse vessels of the bone in medullary canals.

Fig. 64. A portion of the same section magnified 50 diameters.

- a.* Perpendicular canaliculi.
- b.* Transverse canaliculi.
- c c.* Branches of communication between them.

Fig. 65. A very small portion of the same section magnified 100 diameters.

- a.* Transversely arranged rank of osseous corpuscles.
- b. to c.* Osseous corpuscles arranged concentrically to the transversely divided medullary canaliculus *c.*
- d.* Transverse canaliculus.

Fig. 66. Section of the outer table of the human skull, magnified 15 diameters. The medullary canaliculi form a rete.

Fig. 67. Transverse section of the rubbing surface of a grinder from the upper jaw of the full-grown horse, magnified one-third.

*a' a'.* Bony substance of the outer aspect of the tooth.

- a.* The inner portion of the bony substance—cortical substance.
- b.* Vitreous substance, or enamel.
- c.* Ivory or substance of the tooth.
- d.* Brown middle streak of pigment.
- e.* Inner layer of the vitreous substance.
- f.* Inner layer of the bony substance.
- g.* Deep brown depression, not yet filled up by the inner bony substance.

Fig. 68. The portion of the tooth inclosed by the oblong *h.* in fig. 67 magnified 36 diameters.

- a b.* External bony or cortical substance.
- a.* External margin of the tooth.
- b.* Connection of the external bony substance, with the enamel. The surface of the bony substance which is united with the enamel is covered with hemispherical points (*b' b'*) which are sunk amidst the enamel and inclose bony corpuscles; these are the bony cells with their nuclei which penetrate the enamel.
- b'.* Connection of the internal bony substance with the internal enamel.

*c c c.* More compact layers of bony substance, in which the bony cells with their nuclei,—the bone-corpuscles, lie in compressed rows.

*d.* Bone-corpuscles.

*e.* Osseous canaliculi.

*f g h h.* External layer of enamel.

*f h.* The margin of the external deposit of enamel.

*f.* The suture or line of union between the substance of the tooth, or tubular substance, broken through, interrupted by the branched periphery of the tooth-tubulus *i*.

*n.* Crack in the vitreous substance—an effect of the drying of the tooth.

*k k l.* Substance—tubular substance of the tooth.

*k.* The bent tubuli branch, to pass over into the enamel at *i f g* and *n*.

*l.* Section of the central mass of the substance of the tooth.

*m.* Inner margin and inner suture.

*b' m.* Internal deposit of enamel.

*b' o e' n.* Internal bony substance.

*e' e' e'.* Vascular canals.

*o* and *n.* Bone-corpuscles.

Fig. 69. Cartilage in process of ossification, magnified 250 diameters.

A. Cartilage with regularly disseminated corpuscles,—cellular-cartilage.

B. The corpuscles, with the commencement of ossification are forced into groups, between which the hyaline cartilage is transformed to bone-cartilage.

C. The groups of cartilage-corpuscles are completely inclosed by bone-cartilage.

D. The cartilage-corpuscles are rendered less transparent by the process of resolution that is going on; at the same time the bone-corpuscles make their appearance in the bone-cartilage.

E. The cartilage-corpuscles are dissolved and partially removed.

F. The cartilage-corpuscles have disappeared; have been absorbed.

*a.* In spongy bones, cells filled with fat remain (Fig. 60, 1.)

*b.* In compact bones the cells are reduced to minute canals by the growth of the bony matter, or they disappear entirely.

Fig. 70. Bone-corpuscles magnified 450 diameters.

*a a.* The bone-corpuscles—nuclei of the bone-cells.

*b.* The vessels of the bony cells (canaliculi calicophori, Müller) which by their inosculations form a rete.

Fig. 71—73. Contractile tissue.

— 71. Contractile tissue of the corium, seen from the inner aspect, and magnified about 8 diameters (hog.)

*a.* The filaments of contractile tissue crossing each other, and surrounding

*b.* The roots of the bristles, which are covered with fat.\*

*c.* The bristles seen arising in threes together.

*d.* Divided cæca or appendices of the sebaceous ducts.

*e.* Divided vessels and nerves.

*f.* Pigmentary deposits.

Fig. 72. A portion of integument from another part of the body of the same animal, magnified about 12 diameters.

*a a.* The interlacing filaments of the contractile tissue.

*b.* Fat cells of the roots of the bristles.

*c.* Bulbs of the bristles.

Fig. 73. Contractile tissue of the dartos, from under the common integument of the scrotum of the ram.

*a.* Strings of contractile tissue: strings composed of numerous simple filaments.

*b.* Single filaments of the same.

\* Among several of the lower animals the contractile tissue may be seen in certain situations passing in threads from the root of one hair to another, by which the power is acquired of raising the bristles, mane, or hair on end.

*c.* Filaments of cellular tissue.

Fig. 74—86. Elementary parts of muscles.

— 74. Granular muscle of the *organic* life, from the muscular tunic of the uterus, magnified 80 diameters (cow.)

A. A primary bundle.

B. A bundle resolved into its several elements by means of alternately spirting water upon it, and gentle pressure between two plates of glass.

*a.* The filaments which serve as the basis of the tissue (filaments of cellular tissue and vessels.)

*b.* The attached muscular granules, in uninjured bundles, arranged in rows like strings of beads.

Fig. 75. Filamentous muscle of the *organic* life.

A. Primary bundles and ropes of filamentous organic muscle, magnified 80 diameters (longitudinal fibres of the colon, horse.)

*a a a.* Bundles.

*b.* A rope or string of muscular fibres teased out.

B. A bundle of sinuous primary fibres teased out.

C. Puckered or crisped primary muscular fibres.

D. A grating of rigid muscle of the *animal* life, (*a.* from the lingualis, *b.* from the myloglossus,) after the action of oil of turpentine. In these bundles neither transverse streaking nor longitudinal fibrillation is distinguishable.

Fig. 76 A. A grating of organic primary muscular filaments. A very thin slice from the muscular tunic of a piece of small intestine that had lain for a short time in brine (sheep.)

*a.* Longitudinal layer.

*b.* Transverse layer.

B. Two organic primary muscular bundles, intermediate betwixt the granular and filamentous structure, or compounded of the two (from one of the longitudinal muscular bands of the colon, horse.)

Fig. 77—86. Elements of the muscles of voluntary motion, or of the *animal* life.

Fig. 77. Simple layer of a primary bundle of a muscle of voluntary motion (long head of the *triceps brachialis*, horse.)

Fig. 78. A primary muscular bundle, magnified 200 diameters (same animal.)

*a.* Primary bundle with wrinkled boundary line and complete striæ.

*b.* Primary bundle with the sheath removed in parts, or in which the granules of the primary filaments in some places only appear transversely arranged in rows near to one another: in other places they appear co-ordinated lengthwise, rather than transversely, so that in these the bundles seem to be streaked longitudinally.

*c.* Primary bundle with the sheath torn longitudinally, or with an interruption of the transverse striæ in the direction of the long axis.

Fig. 79. Primary bundle of a muscle of voluntary motion, magnified 200 diameters.

1. Bundle which has been stripped off from a larger mass of muscle.

*a.* Transverse striæ, or transversely streaked sheath.

*b.* Sharp torn edge of the same.

*c.* Primary filaments, presenting the appearance of a series of adhering hemispheres.

2, 3, 4. Primary bundles of a voluntary muscle as I have occasionally observed them when they were examined in the recent state.

2, *a.* Primary fibres.

*b b b.* Spiral sheath of flat filaments.

3, *a.* Primary fibres.

*b.* The spirally convoluted flat filaments, united five or six together, form broader spiral bands.

4, *a.* Primary fibres, which at

*b.* Are lacerated.

*c.* Spiral sheath composed of several flat filaments connected together.

*d.* Lacerated spiral filaments.

Fig. 80. Primary muscular bundles, the sheaths having been burst by the compressor (rabbit.) \*

*a a.* Two compressed layers of primary fasciculi, from which the longitudinally streaked bundles *b*, that scarcely show any trace of transverse streaking, have been squeezed out.

*c c.* Isolated bundles.

*d.* A part where the fasciculi are still connected and included in their sheaths.

Fig. 81. Three portions of primary bundles of voluntary muscles (horse) magnified 200 diameters.

1. A bundle, with nipple-shaped torn extremities, which is only partially occupied with transverse striæ.

2. A fasciculus without transverse striæ, the primary filaments slightly sinuous, and the torn extremities conical.

3. A bundle with notched torn extremities, without particular transverse striæ, but with broad darker transverse bands, as if depending upon some partial separation of the primary filaments.

Fig. 82. Two short pieces of primary fasciculi of voluntary muscles magnified 300 diameters; also three primary filaments of the same pieces magnified 700 diameters (horse.)

A. A piece at one end of which the moniliform primary filaments are seen forming a kind of tuft. The diameter of the component globules is greater in the direction of the length of the filaments than of their breadth; the filaments and the fasciculi therefore appear elongated. As in this passive state, or state of relaxation, the primary filaments tend to part from one another, the bundle they compose appears longitudinally streaked.

B. A portion of a muscular bundle in the moment of active contraction. Here the transverse diameter of the globules increases at the expense of the long diameter: and

\* Although I do not maintain that the transverse striæ of the muscles of animal life depend on the presence of a wrinkled sheath, still I am by no means satisfied that a sheath of this description does not exist.

thus and because the globules approximate more closely and stand in regular transversely arranged ranks, the fasciculus appears shortened, transversely streaked, and increased in diameter.

C 1. A primary fibre in a state of relaxation.

2. A primary fibre in a state of contraction.

3. A primary fibre, which, as often happens, appears shortly sinuous, or even twisted like a cord, rather than composed of globules connected with one another in rows.

Fig. 83. Structures met with in the voluntary muscles, whose office, and relations to the surrounding tissues, are not yet known, magnified 150 diameters.

3, 3. Two primary muscular fasciculi from the masseter muscle of the horse.

1, 2. Two other fasciculi lying near to these and parallel with them, filled apparently with convoluted filaments, the sheaths, which between *b* and *b* were accidentally injured.

*a a.* Gelatinous external covering.

*b b.* A part where this has been accidentally removed.

*c.* A finer inner envelope, which having escaped injury still surrounds the fasciculus 1, completely. The corresponding fine membrane having been lacerated in fasciculus 2, its contents have escaped.

*d.* The convoluted fibres or filaments, of which from eight to ten are contained in each fasciculus, protruding from their sheath.\*

Fig. 84. Primary muscular fasciculus, from the heart (dog.)

*a a.* Fasciculi which divide into two.

*b b.* Parts of fasciculi transversely streaked.

Fig. 85. Muscular fasciculi from the bladder (dog.)

— 86. Muscular tissue from the tongue (hog.)

\* I have found enigmatical fasciculi of the same description, although less distinctly, in the lips and tongue of the full-grown horse. I have not met with them elsewhere.

Unable to display this page

D. A vorticella which, after having been closed, is expanding the body and erecting the pedicle. \*

*a.* The body now of a globular form.

*b.* The half expanded crown.

1. The muscle.

2. The erectile vessel.

E. An agglomeration of granules to which the pedicles are attached.

Fig. 88—90. Constituent elements of nerves.

— 88. 1, 2. Two primary fibrils of a spinal nerve examined in the body of an animal just dead.

*a.* The investing membrane pinched in at intervals. In the living animal the fibrils are perfectly cylindrical.

*b.* The still transparent fluid contents.

3. A nervous fibril examined some short time after the death of the animal, immediately before the consolidation of the contents. The fibril is more irregularly sinuous.

4. A primary nervous fibril more highly magnified.

*a.* Nervous tunic (nervous tubulus.)

*a'.* Presumed ciliary epithelium.

*b.* The cone-shaped ciliæ.

5. The ciliæ more highly magnified.

6. Highly magnified primary nervous fibril.

*a.* Tubulus.

*b.* The consolidated contents.

7. A delicate nervous fasciculus in its sheath.

*a.* The sinuously disposed fasciculus.

*b.* The cylindrical sheath.

8. A nervous fasciculus, the sheath of which exhibits sinuosities also.

*a.* The fasciculus.

*b.* The sheath.

9. A delicate nervous cord highly magnified, consisting of four primary fibrils; the particular sheaths of the several fibrils are conspicuous.

\* In this process the body of course makes as many revolutions upon its axis as the muscle of the pedicle is twisted times around the erectile vessel.

10. A cylindrical nervous fasciculus.

11. Sections of nerves.

*a.* Section of a cylindrical nervous fasciculus.

*b.* Section of a nervous cord consisting of a single layer of fasciculi.

*c.* Section of a cord made up of three layers.

*d.* Section of a pyriform fasciculus.

Fig. 89. Minuter elements of the nervous system.

1. Cerebral medullary granules or globules.

2—6. Ganglionic cells, globules or corpuscles.

2. An egg-shaped ganglionic globule.

*a.* The nucleus.

*b.* The nucleolus.

3. A ganglionic cell, nearly globular.

*a.* The nucleus.

*b.* The nucleolus.

4. A pear-shaped ganglionic globule.

5. Two ganglionic cells with their sheaths and bond of connexion (cellular tissue.)

*a.* The bond of connexion.

*a' a'.* The sheaths of the cells.

*b.* The ganglionic corpuscles.

6. A ganglionic cell, surrounded by its filamentous sheath.

7. Root of a cerebral nerve.

*a.* The nervous roots, connected with which are numerous medullary globules, approaching each other.

8. Root of a spinal nerve.

*a b.* The portion of the root which lies within the spinal cord.

*a c.* The root after it has passed from the spinal cord.

*c.* Point at which the root passes through the dura mater of the cord.

*c—8.* The root beyond the sheath of the cord.

Fig. 90. Final expansions in the dermis, of nerves of sensation. Peripheral nervous plexuses (with or without ganglionic cells?) (hog.)

1. Simple plexiform expansion of a nervous cord.
  - a.* The nervous cord.
  - b.* The cord resolved by the separation of its component fibrils.
  - c.* Fibrils spreading widely from the rest.
  - d.* Part from which primary fibrils depart, and where others from neighbouring fasciculi are received.
  - f.* A new cord formed by the reassembled nervous fibrils.
2. Two nervous plexuses or expansions from the same cord.
  - a.* The nervous fasciculus.
  - b b.* The two plexiform expansions proceeding from it.
  - c.* Single fibrils.
  - d.* Plexus formed by fibrils proceeding from and fibrils approaching the great plexus.
  - e.* A terminal loop.

Fig. 91—102. Peripheral distribution of nerves of voluntary motion, and of common sensation.

Fig. 91. A portion of the transversus abdominis muscle with the inosculations and loopings of several muscular branches of nerves (rabbit.)

- a a a.* Primary fasciculi of the muscle.
- b b b.* Three terminal branches of muscular nerves.
- c.* Division of one of these branches into ramusculi, each consisting of four or five primary fibrils.
- d.* Most delicate twigs consisting of no more than two primary fibrils, and continuations of these into
- e e e e.* Twigs consisting of single primary fibrils forming terminal loopings.
- f f f.* Terminal loops which pass over into other nervous twigs betwixt the muscular fasciculi.
- g.* Two associated primary fibrils, one of which, after joining the middle nervous cord *b'*, soon quits this in company with another primary fibril, and enters deeply among the muscular fasciculi at *h*; whilst the other, after running for some way by the side of a terminal loop at *i i*, parts

company with it, runs isolatedly at *k*, then joins two primary fibrils of the right hand cord at *l*, is associated at *m* with one of these only, separating from which, it finally forms the terminal loop *n*, and is re-associated with the middle cord *b'*.

Fig. 92—101. Peripheral relations and mode of distribution of the nerves of sensation.

Fig. 92. A thin perpendicular slice from the integument of the lip, dried and steeped in oil of turpentine (hog.)

*a a a*. Fine cords and fasciculi of the labial branches of the nervus trigeminus.

*b b b*. Simple nervous fibrils, which, without forming proper loops, pass from one fasciculus to another.

*c c c*. Terminal loops within the substance of the dermis.

*d d d*. Terminal loops reaching near to the surface.

*e*. Tactile convoluted terminal loops, forming the papillæ or papillary bodies of the skin.

*f*. A larger tactile papilla formed of the convoluted terminal loops of several cords.

*g g*. The external surface of the dermis in contact with the epidermis.

Fig. 93. The tactile nerves of the extremity of the human thumb.

*a a a*. Three terminal cords of the nervus volaris pollicis of the median nerve.

*b b*. Simple primary fibrils in the terminal plexus within the skin.

*c c c*. Simple bows or knots of terminal loopings between the papillæ.

*d d d*. Three papillæ, the nervous fibrils entering into their constitution convoluted and in the fashion of rosettes.\*

\* In injected preparations the arteries present very nearly the same appearance, so that I have often found it requisite to look narrowly with a view to distinguish whether I had nerves or arteries before me.

Fig. 94. Section of a portion of the integument of the neck (hog.)

*a a.* Outer surface of the skin, darkened by a fine pigmentary deposit.

*b.* Depression where a bristle issues, and the ducts of sebaceous and sudoriparous glands terminate.

*c c c c.* Cutaneous nervous cords.

*e e.* Nerves of the secreting pulps of bristles.

*d d.* Loops of nervous fasciculi.

*e.* Terminal plexus under the cuticle.

*f.* A cord resolved into fibrils (perhaps a peripheral ganglion, of which many are encountered in the skin\*) vide fig. 90.

*g g g.* Anastomotic fibrils—fibrils passing from one fasciculus to another.

*h h.* Terminal loops that surround the bristles.

*i.* Duct of a sebaceous gland.

*k.* Expansion in the course of the same where a secreting crypt has been cut away.

*l.* Union of the sebaceous follicle with the sheath of the bristle.

*m.* Sebaceous follicle,—simple sebaceous crypt.

*n.* Duct of a sudoriparous gland.

*o o.* Portions of the secreting follicles of two bristles.

*p.* Cavities of the same.

*q q.* Sections of the roots of the two bristles.

*r.* Bristle.

*s.* Fat in the nidus of the bristles.

Fig. 95. Peripheral plexiform distribution of the nerves in a portion of the skin of the neck, seen from the outer or epidermic aspect (hog.)

*a a a.* Nervous twigs and terminal fasciculi, which traverse the skin slantingly and form the terminal plexus.

*b b b.* Meshes of the terminal plexuses.

\* I must say, however, that I have never seen ganglionic globules in these plexuses.

*c c c.* Triangular spaces betwixt the meshes.

Fig. 96—101. Different forms of the peripheral terminations of nerves of sensation (nerves of touch.)

Fig. 96. Simple terminal loops of cutaneous nerves seen from the surface of the skin.

Fig. 97. Simple terminal loops of nerves of the skin, each of which is formed of the final branches of different fasciculi.

Fig. 98. Four simple tactile loops, three of which are formed by two different fasciculi, whilst the fourth, (that to the right hand) is formed from one fasciculus only.

Fig. 99. A convoluted nervous or tactile papilla, formed of two, or more properly of only one terminal fibril returning on itself.

Fig. 100. A fusiform tactile papilla from the lip of the horse. A primary nervous fibril by several turns or convolutions, forms a spindle-shaped knot, and then proceeds onwards in the same direction.

Fig. 101. A rosette-like compound tactile nervous papilla seen from the surface. Several slightly convoluted terminal loops lying in the same plane form concentric circles, in the centre of which a larger hemispherical convoluted papilla like that represented in fig. 99, stands somewhat raised above the general level.

Fig. 102. Soft nervous envelope.

*a.* A portion of a nervous fasciculus.

*b.* A small blood-vessel accompanying the same, filled with blood-corpuscles.

*c c.* The delicate sheath or envelope of the nervous fasciculus consisting of cellular fibres.

*d.* An isolated portion of one of these cellular fibres, more highly magnified to show the granular nucleus.

Fig. 103. A piece of the allantois seen from the external surface (sheep.)

*a a.* A blood-vessel containing a number of altered blood-globules, over and in the vicinity of which the cellulo-membranous sheath, freed from its epithelial endu-

sium, is so separated, that its component fibres with their cells and nuclei are distinctly to be seen.

*b b b.* Superficial rete of epithelial cells under which the allantoic membrane composed in the manner just stated extends. The nuclei of the epithelial cells are only inserted in a part of the figure to the left. Each cell, however, is to be understood as having had its nucleus.

*c.* Altered blood-globules.

*d d.* A few of the cellulo-membranous fibres which formed the outer sheath of the vessel. These run parallel with its axis, and present the same appearance as those which form the outer sheath of the finer nervous fasciculi and cords (vide fig. 102, *c c.*)

Fig. 104. Is a half plan figure to show the way in which the finer nervous fasciculi mutually interchange the most delicate fasciculi and primary fibrils. The cord *a* unites at *c* with a portion of the cord *b*, and gives delicate fasciculi and a simple fibril to the cord *d d* proceeding from *b*. (Valentin.)

Fig. 105. Tuft of terminal loops of the nerve of sensation from the pulp of a grinding tooth of the sheep. (Valentin, On the course and terminations of the Nerves, fig. 31.)

*a a.* Nervous cords.

*b.* Single nervous fibrils.

*c.* Terminal loopings of these.

*d.* Terminal loopings of the cords *a a*.

Fig. 106. Plexus of a nerve of sensation in the skin, (hog.)

*a.* Delicate nervous cord.

*b b.* Simple nervous fibrils.

*c.* Transverse and longitudinal sections, generally of fibres of the cellular membrane which accompany the ultimate divisions of the nervous filaments, occasionally of the nervous filaments themselves.

These delicate fibrils compose an independent rete within the meshes of the nervous plexus.

Fig. 107. The second dorsal ganglion of the sympathetic

nerve very highly magnified (mouse.) (Valentin, op. cit. fig. 44.

*a b.* Anterior and posterior cord of the sympathetic nerve, which connect the first and the third dorsal ganglia with this the middle one.

*c c c c.* Delicate cordlets which pass either to the viscera or to join the second dorsal nerve.

*d.* Ganglionic globules or cells.

*e.* Nervous fibrils coursing round the ganglion.

Fig. 108—113. Lymphatic vessels.

— 108. Lymphatic vessels and lymphatic glands from the spermatic cord of the horse, magnified 8 diameters.

*A. A.* The lymphatic glands.

*a a a.* Peripheral, efferent larger lymphatic vessels.

*b b.* An efferent or central lymphatic vessel.

*c c'.* Superficial network of delicate lymphatics, which serves in part to connect the small flat gland *d* with the efferent vessel *b*.

*d.* A very small, loose, semiglandular plexus of lymphatic vessels.

*e.* Extensive lymphatic network, formed of the vessels of the gland and the parts immediately adjacent.

*f.* Larger lymphatic vessels passing over and near to the gland, the numerous valves of which are obvious.

*g.* Delicate efferent lymphatics.

Fig. 109. The inferior cervical lymphatic gland of the horse, of the natural size.

*a.* The inferior portion of the connecting vessel of the cervical gland—the *tracheal canal* of Gurlt.

*b.* Larger trilobular } cervical gland, the vessels of

*c.* Smaller inferior } which are imperfectly injected.

Fig. 110—112. Transit of lymphatics into veins, magnified 1 diameter.

Fig. 110. Termination of a large lymphatic vessel in a vein from the iliac mesentery of the horse.

*a.* The lymphatic vessel, which was proceeding back towards the intestine from a mesenteric gland (an anasto-

motie vessel between the lymphatic and proper venous systems.)

*b.* Two semilunar valves at the point of communication, extremely like the ileo-cæcal valve of the human subject in structure.

*c.* A mesenteric vein.

Fig. 111. A piece of a mesenteric vein laid open, in which lymphatics are ending (to save space, two of these are represented close together.)

*a.* Mesenteric vein.

*b.* Lymphatic vessel.

*c.* The common cavity of the two semilunar valves represented as shut or in contact.

*d.* The free edges of the valves.

*e.* End of the lymphatic within the vein.

*f g h.* Opening of a lymphatic within a vein, the valves open.

*f.* The valvular pit or depression—the space between the valves and parietes of the vessel.

*g.* The free edge of one of the valves.

*h.* The cavity of the lymphatic vessel.\*

Fig. 112. A more complete valve between a lymphatic and a vein (after A. Meckel, in Meckel's Archiv. 1828.)

*a.* A piece of a mesenteric vein of the horse seen from within.

*b.* A lymphatic vessel approaching the vein *a*.

*c.* The continuation of the lymphatic within the vein, by which a peculiar valve is formed, a structure, however, which is also encountered between vein and vein (vide fig. 114 and 116.)

*d d.* Two opposed semilunar valves, lying in contact with the parietes of the vein.

\* The valve that guards the orifice of the thoracic duct where it enters the axillary vein is precisely of the kind here figured. So is the ilio-cælic valve of the human intestine, and the valves of the veins in general (vide figs. 116 and 117.)

*e.* The orifice of the lymphatic vessel within the vein.

Fig. 113. Mode of origin of a lymphatic or lacteal vessel at the extremity and within the substance of an intestinal villus, from the human subject, 16 years of age, after Krause in Müller's Archiv. 1837, Fol. 1.

The delicate incipient vessels, which in all probability are not completely distended, proceed here immediately, and then after they have formed a simple rete by anastomosing together, into the central vessel. It is probable that the lacteals have generally the same peripheral distribution as the veins, that they commence at every point in festoons and delicate reticulations.

Fig. 114—120. Structure of veins.

— 114—116. One half of a vein from the neck of the horse slit longitudinally in two, of the natural size, but somewhat shortened in the drawing, so that the valves are brought closer together than they are in nature.

Fig. 114. The vessel with the valves open, and the cavity free, as they are when the blood is flowing regularly towards the heart, or when the pressure in the branches is greater than it is in the trunk.

- a.* Superior, and
- b.* Inferior divided extremity of the vein.
- c.* Branch entering the larger vein laterally.
- d.* The valve guarding the entrant orifice of this branch, open.
- e.* The valve guarding the entrant orifice of a branch entering the larger vein from behind—the valve open.
- f f.* Two bisected semilunar valves of the venous trunk, in contact with the inner parietes of the vessel.
- g.* An uninjured semilunar valve, applied to the inner wall of the trunk which it guards.
- h.* The outer coats of the vein.
- i.* The inner serous tunic which forms the valves.

Fig. 115. The upper portion of fig. 114, seen from below.

- a.* The vaulted external aspect.
- b.* The external membranous tunic of the vein.
- c.* The internal serous tunic.
- d.* The valvular pit between the vein and the valve.
- e.* The free edge of one of the valves.

Fig. 116. A perpendicular section of the same venous trunk, the valves represented as closed.

- a.* The upper end of the portion of vein represented.
- b.* The under end of the same.
- c.* Orifice of a lateral entrant branch.
- d.* Perpendicular section of the valve which guards it, closed.

*e.* The closed valve of the branch which enters from behind.

*ff.* Section of the two semilunar valves of the venous trunk raised from the internal walls of the vessel, or closed.

*g.* The untouched semilunar valve of the trunk, placed at right angles to the pair of valves *ff* raised, or closed.

The arrows by the side of figs. 114 and 115, show the current of the blood in reference to the action of the valves.

Fig. 117. The valves *ff* of fig. 116 seen from below.

- a.* The outer circle of the vein.
- b.* The external tunic.
- c.* The internal serous tunic.
- d.* The bulging or cavity of one of the semilunar valves.

Fig. 118—120. Erectile veins from organs susceptible of erection.

Fig. 118. Commencement of the vein of the dorsum of the penis, one half the natural size. The anastomotic branches are in contact by their sides, but they all proceed in the direction of the trunk, towards which they are tending (horse.)

Fig. 119. A convoluted venous mass of the natural size from the under side of the bulbis urethræ (dog.)

The several veins, without dividing into branches here,

form transversely convoluted masses, which are not unlike the convolutions of the small intestines, or of the brain.

Fig. 120. Erectile venous mass from the human spleen, magnified one-half. The preparation made by corrosion.

*a.* A vein.

*b.* Rounded vesicular venous cavities.

*c.* Pyriform and apparently blind vesicles forming the beginning of the vein. Many branches and pedicles of vesicles are broken off.

Fig. 121—152. Structure of arteries.

— 121. A wax model of the three semilunar valves at the root of the aorta—reduced one-third in size (colt.)

*a.* Aorta beyond the valves.

*b b b.* Sides of the aorta vaulted outwards in the situation of the three valves.

*c.* Notch where the valve is attached to the aorta.

*d.* Imprint of the sacculus of the valve.

*f.* Sulcus where the free edges of the two neighbouring valves come into contact when they are closed.

*e.* Situation or impression of the three corpora Arantii, lying in the axis of the aorta, the valves being closed.

Fig. 122—135. Peripheral or terminal arborizations of the arteries.

Fig. 122. Bifurcate or dichotomous terminal subdivision of an arterial twig, where the last divisions of the proper arteries pass into the capillary arches, or retia, and the incipient branches of the veins.

Fig. 123. Polychotomous or pecteniform terminal subdivisions of an arterial twig.

Fig. 124. and 125. Penicillate terminal sub-divisions of arterial twigs.

Fig. 126. Pomoid or globular terminal sub-division.

— 127. Asteroid terminal sub-division.

— 128. Capituloid terminal sub-division.

— 129. Penniform terminal sub-division.

— 130. Palmiform terminal sub-division.

Fig. 131—134. Peripheral transition loops or festoons,—arterial capillary festoons.

Fig. 131. The most simple form of this mode of termination.

Fig. 132. A more complex form of the same mode of termination.

Fig. 133. Another and yet more complex form of the same mode of termination.

Fig. 134. Apparent terminal loops or nooses, each minute twig returning into itself.

Fig. 135. Tassel-like terminations of an artery (from the foetal placenta of the horse.)

Fig. 136. The vessels of two intestinal villi, magnified 160 diameters (colon of the horse.)

*a*. A delicate arterial twig of the intestinal tunics.

*b b b*. Bifurcate subdivisions of the same at the bases of villi.

*c c c*. Distribution of the finest arterial twigs at the edges of the villi. They form a delicate rete in the villi with the vein which courses along the centre of each villus. The veins of the two villi represented are seen united in the common branch *d*.

Fig. 137—152. Peripheral relations of the blood-vessels of different tissues of the human body, after Berres's microscopical observations. The same forms are shown by my preparations to occur among the mammalia.

Fig. 137. The simple arterial loop or noose. This distribution is particularly met with at the points of the fingers and toes, under the nails, on the Schneiderian membrane, on the surface of the tongue, and in the mucous membrane of the mouth.

Fig. 138. Palm-formed arterial distribution, common in mucous membranes. From the tongue of a young subject.

Fig. 139. Complex, fasciculate and anastomatic distribution. Tongue of a child.

Fig. 140. The vascular rete of the salivary glands, which lies over the arborescent arterial plexus of these organs,

and forms the intermediate vascular net-work of their two orders of vessels.

Fig. 141. The rectangular linear arterial plexus from the muscular coat of the small intestine of a child. Lieberkühn.

Fig. 142. The comb-like linear arterial plexus of the muscles of animal life. From a child. Berres.

Fig. 143. The linear arterial erectile plexus. Iris of a child. Berres.

Fig. 144. The mesentery (of a frog?) with the arcuate dendritic vascular plexus. Berres.

Fig. 145. The membrana Ruyschiana of the eye of a new-born child with the simple vascular rete. Berres.

Fig. 146. The enveloping vascular retia of the nuclei of the thyroid body of a new-born child. Berres.

Fig. 147. The festooned vascular rete of the mucous membrane of the colon of an adult. Berres.

Fig. 148. The pulmonary cells with the vascular plexus. Barth.

Fig. 149. The deep lying twigs of the arborescent ex-centric arterial retia. Berres.

Fig. 150. The membrana Ruyschiana of the eye of a new-born child, with the simple vascular rete. Berres.

Fig. 151. The clubbed pampiniform arterial plexus, with its intermediate vascular rete, from the supra-renal capsule of a child. Berres.

Fig. 152. The intermediate loops of the asteriform arterial rete of the renal granules. Berres.

Fig. 153 and 154. Malpighian bodies of the kidneys.

— 153. To the left. The first division and sub-division of excentric asteroid arterial plexus of the renal granules (acini.) Barth.

To the right. The entire renal granule (acinus) together with the origins of the tubuli uriniferi and of the renal veins. Barth.

Fig. 154. The imperfectly conical lappets formed by the several cortical uriniferous tubuli, with the blood-vessels

and glomeruli injected : from the kidney of an adult, after Krause in Müller's Archiv. 1837, Taf. I. fig. 3.

Fig. 155. Imperfectly filled arteriæ helicinæ—convoluted or tendril-like arteries, from the penis of the human subject, after Müller, in Archiv. 1838, Taf. V.

Fig. 156—161. Structure of glands.

— 156. Beginning of the excretory duct of a salivary gland (the parotid of a foal one year old.)

Fig. 157. One of the tufts of the above more highly magnified.

*a a.* Salivary vessel (a branch of the excretory duct.)

*b b.* The pediculated secretory vesicles—the peripheral blind extremities of the excretory duct.

*c c.* Twigs of blood-vessels.

Fig. 158. Two entire, and portions of two other Meibomian glands seen from the inside of the eyelid (foetal calf of 5 months.)

*a.* The excretory duct.

*b.* The orifice of this on the inner aspect of the edge of the eye-lid.

*c.* The secreting vesiculi.

Fig. 159. Pulmonary vesicles (horse.)

*a.* One of the most delicate bronchial twigs.

*b.* The pulmonary vesicles.

Fig. 160 and 161. Bilocular sebaceous glands (skin of the sow.)

Fig. 160. A globular, closely convoluted sebaceous gland.

Fig. 161. The same with its convolutions unfolded.

— 162. Nervi nervorum, particular primary nervous festoons of the nervous fasciculi (addition to the structure of nerves.)

*a a.* A delicate nervous fasciculus, highly magnified.

*b b.* A primary fibril which at *c.* forms a somewhat sinuous terminal loop, and at *d.* plunges in between two of the constituent primary fibrils.

*efg*. A terminal loop which turns round more abruptly.

*h*. A third terminal fibril, whose course is indicated by the letters *k, l, m, n*.

Fig. 163. A delicate soft fasciculus of the sympathetic.

*aaaa*. Four primary fibrils, separated by delicate fibres of the general investing sheath.

*bb*. Two primary fibrils lying deeper, and scarcely to be distinguished.

*ccc*. Delicate cellular fibrils between the nervous fibrils.

*dd*. Stronger investing cellular fibres.

*ee*. Still stronger and more condensed external sheath of cellular fibrils (perhaps tubuli of cellular tissue surrounding one another concentrically.)

Fig. 164—238. Figures having reference to the Terminology.

A. Drops in their various relations to the bodies with which they are in contact and the magnifying power.

Fig. 164. Flat, spread out, round-shaped drop.

— 165. Flat, spread out, elliptical drop.

— 166. A spherical drop, the most remote point of which is in the focus of the magnifier or microscope.

Fig. 167. The same drop removed till its centre is in the focus of the magnifier.

Fig. 168. The same drop the upper point of which is now in the focus,—the nearest point of the surface of the drop is at focal distance from the magnifying power.

Fig. 169. Drops illuminated from the side and from above, in a less consistent medium.

B. Crystals.

Fig. 170. A flat or short four-sided pyramid, with truncated apex.

Fig. 171. A cubical crystal.

— 172. Rhomboidal tables.

— 173. Three-sided prism.

— 174. Six-sided prism.

— 175. A three-sided pyramid.

Fig. 176. Acicular crystals.

C. Grit, gravel, amorphous deposits.

Fig. 177. Globular gravel.

— 178. Granular gravel.

— 179. Mulberry-like gravel.

D. Flat formations.

Fig. 180. Six-sided  
— 181. Eight-sided } scale.  
— 182. Elliptical }

— 183. Lamina, or lamella.

— 184. Flat fibre.

— 185. Squamous fibre.

— 186. Simple or unilamellar squamous membrane.

E. Granules, and granular formations.

Fig. 187. Granules.

— 188. Globules.

— 189. Granular band or fibre.

— 190. Granular corpuscle.

— 191. Granular fibrous bundle.

— 192. Granular membrane.

F. Nuclei, nucleoli, and round fibrous formations.

Fig. 193. Nucleoli in cells (*a*.) Nucleolus in nucleus (*b*.)

— 194. Cylindrical or round fibres, fibrils, filaments.

— 195. A bundle or fasciculus of fibres.

— 196. A fibrous cord (a smaller collection of fibres than a fasciculus.)

Fig. 197. A fibrous tissue.

— 198. A fibrous net or rete.

— 199. A fibrous grating.

— 200. A fibrous membrane.

— 201. A fibrous fascicular tissue.

G. Nuclei and nucleolated nuclei.

Fig. 202. A nucleus in an elongated rounded cell. *b*.  
Nucleus in a six-sided cell.

Fig. 203. Nuclear or nucleolar fibre.

— 204. Nucleolated nucleus in the cell.

— 205. 1. Blood-corpuscles or globules. *a* Nucleus  
(investment, envelope.) *b* Nucleolus (nucleus.)

2. Exudation-corpuscle or globule, previously to its transformation into a pus-globule.

3. Pus-globule or corpuscle.

Fig. 206. Exudation membrane.

— 207. Granular nucleus within a cell.

H. Vesicles and hollow fibres.

Fig. 208. Round and pediculated vesicles.

— 209. An acervulus, small cluster or heap of vesicles.

— 210. Hollow fibre (primary fibre of nerve.)

— 211. Hollow fibrous cord (most delicate nervous cord.)

Fig. 212. Hollow fibrous plexus (peripheral nervous plexus.)

Fig. 213. Hollow fibrous rete or net (capillary net or rete.)

I. Cellular formations.

Fig. 214. Nucleated cellular membrane, with intercellular rete.

*a.* A binucleated cell.

*b.* Uninucleated cells.

Fig. 215. Nucleated cellular membrane without intercellular rete.

*a.* Sectional line.

*b.* Row of nucleated cells.

*c.* Row of cells—cells whose nuclei contain nucleoli.

*d.* The cells divided in the line *a*, which in the section appear like a cellular fibre.

Fig. 216. Newly formed globular nucleated cells.

*a.* One of these isolated, with an excentric nucleus.

*b.* Nucleo-nucleated or incased cells of recent formation.

Fig. 217. Cartilaginous cells.

*a.* Elongated nucleated cell, with elongated nucleus.

*b.* Rounded nucleo-nucleated cell.

Fig. 218. Cells that tend to separate in lines, and formation of cellular fibres.

Fig. 219. Metamorphosis of cellular fibres into round threads.

*a.* Cellular fibres with granular nuclei and delicate produced connecting filaments.

*b.* Shrunk cells with connecting fibres.

*c.* Cell with three connecting fibres.

*d.* Cellular fibres with granular nuclei, which are connected by peculiar filaments that run through the inter-cellular fibres.

Fig. 220. Irregularly quadrilateral granular or granulated cell with three granular incased nuclei, two of which lie partly over one another. (A variety as regards the number and position of the nuclei.)

Fig. 221. Ciliary or ciliated cellular membrane.

*a.* Crown or circle of ciliæ.

*b.* Basis or roots of more distant ciliæ.

*c.* Nucleus of the ciliary cells.

*d.* The ciliæ.

Fig. 222. An isolated ciliary cell.

*a.* The cell.

*b.* The ciliary basis.

*c.* Ciliæ.

*d.* Nucleus.

Fig. 223. A four-celled ciliary cellular fibre.

*a.* Ciliary corona.

*b.* (above.) One of the granular nuclei, *b.* (below.)

The cell connected with the membrane.

Fig. 224. Ciliary cellular fibres in connexion, and as they appear on the surface of a section of the ciliary fibrous membrane.

*a.* Uppermost nucleus (ciliary nucleus.)

*b c.* Rank of ciliæ.

Fig. 225. Formation of elastic tissue out of the inter-cellular rete.

*a.* Intercellular rete with included nucleated cells.

*b.* Transition into

*c.* Elastic tissue.

Fig. 226. Horn-cells in the foetus, before their conversion into horn, still furnished with nuclei and nucleoli. (Valentin.)

Fig. 227 and 228. Change of the young cell into a scale, in section. In *a—e*, the nucleus is still recognizable. In *f*, the formed scale, it has disappeared.

K. Living animals in the living mammal now as constituent elements, and again as adventitious parasites.

Fig. 229 and 230. *Cysticercus cellulosæ*.

— 229. *Cysticercus cellulosæ* of the natural size.

*a.* Head.

*b.* Neck.

*c.* Caudal vesicle.

Fig. 230. Head, neck, and part of the body of the *cysticercus* highly magnified.

*a.* Point of the mouth.

*b.* The double circle of hooklets.

*c c.* Suctory papillæ.

*d.* Neck.

*e.* A part of the body.

Fig. 231—234. Seminal animalcules and seminal corpuscles from the epididymis (guinea-pig.)

Fig. 231. A seminal animalcule very highly magnified, seen from the abdominal aspect.

*a a.* The rounded margin of the flat spoon-shaped body.

*b.* Internal vesiculi (probably botryoidal stomach.)

*c.* Two globular organs (internal organs of generation? ovaries?)

*d.* Oral aperture on the oral papillæ.

*e.* Genital and anal orifice on the posterior papillæ.

+ Notch between the body and the tail.

*f.* Caudal papillæ.

*g.* Tail.

*h.* Imperfect loop or coil which the tail generally forms when not in use.

Fig. 232. A seminal animalcule less highly magnified, seen from the side. Great part of the tail is left out.

Fig. 233. Five seminal animalcules in apposition, packed like table spoons one within the hollow of the other.

Fig. 234. A seminal corpuscle and three isolated seminal globules.

Fig. 235 and 236. Entozoon from the folds of the conjunctiva of the eye of the horse (*Filaria papillosa*.)

Fig. 235. The entozoon of the natural size.

— 236. The same magnified 6 diameters.

*a.* Oral aperture.

*b.* Top of the œsophagus.

*c.* The intestine lying in coils.

*d d.* Part at which the animal was accidentally injured, and through which the intestine has protruded.

*e.* Anus.

*f.* The conical shaped point of the tail.

*g g.* The ovaries.

*h h.* The genital orifices.

Fig. 237. Ovum of an entozoon from the intestines of the horse, highly magnified.

Fig. 238. *Acarus scabiei*—magnified.

— 239. Development of the sebaceous glands of the skin from the palm of the human foetus (Valentin.)

Supplement to the formation of the glands.

*a.* Round inversion of the epidermis.

*b.* The inversion advancing, a pediculated vesicle is formed.

*c.* The pediculated vesicle begins to turn round spirally like a corkscrew.

*d.* The follicle divides into two lappets. The excretory duct makes a complete spiral turn.

*e.* The two glands are completely divided, the elementary vesicles more numerous and more distinct. The excretory duct now makes three spiral turns.

*f.* The gland nearly perfectly evolved, consists of numerous elementary vesicles, which form botryoidal clusters, each vesicle connected by its duct with another, and all ending in one common efferent canal, which now makes four spiral turns between its origin and its termination on the surface.

Fig. 240. Several vesicular shaped pediculated epithelial cellular corpuscles from an intestinal villus (horse.) Addition to the lymphatics.

*a.* Epithelial corpuscles, which lie near the middle of the villus.

*b.* Epithelial corpuscles from the edge of the villus.

*c.* An epithelial vesicle seen from the side opposite to that to which the pedicle is attached.

*d.* Pediculated epithelial vesicles seen from the side.

Fig. 241. Peripheral vesicular reservoir (?) as the beginning of a lacteal vessel in the extremity of the villus, with the epithelial vesicles, the cellular investments of which have been omitted in the Drawing. This is an appearance that is frequently met with, but one the significance of which is still doubtful. In other villi these collecting vesicles rather compose peripheral retes.

*a.* Collecting vesicle, passing inferiorly into a rete of lymphatic vessels.

*b.* Absorbing epithelial vesicles?

Fig. 242. A magnified section of the epithelium and a portion of the mucous membrane of the root of the tongue of the horse prepared by boiling and maceration in oil of turpentine. Addition to the nerves.

*a.* The terminal festoons of the nerves upon the outer aspect of the integument, mucous membrane.

*b.* Scattered terminal loops penetrating the epithelium.

*c.* Several of them cut through slantingly.

*d.* Filamentous papillæ, upon the free surface of the tongue.

FIGURES ILLUSTRATIVE OF MR. GULLIVER'S OBSERVATIONS.

To avoid ambiguity it may be proper to mention, that I have employed the term *granules* to designate extremely minute particles, seldom above  $\frac{1}{100000}$ th of an inch in diameter, and the majority of them gradually diminishing in size until they become only just perceptible by the aid of the deepest magnifying powers. The larger granules are generally more or less globular, though often irregular in shape; but a great proportion of them are too minute to admit of their form being distinctly recognized even by the best instruments. It would be difficult, for instance, to determine the form of the particles composing the granular ground in Figs. 249 and 279. The phrase *granular matter* is applied to a shapeless assemblage of these granules, whether of the larger kind, of the larger and smaller mixed, or of the smallest of all. This granular matter frequently pervades a hyaline matrix; but it may be contained in cells, when of course it presents a more regular outline; indeed the very minute granules probably often coalesce, so as to form a great part of various corpuscles or globules. In the notes at pages 56 and 57, I find that the globules of the chyle and thymous fluid have been inadvertently spoken of as *granules* or *granular particles*, expressions which must not be understood in the sense as explained above, and in which these terms will be subsequently used. But as the chyle-globules and other analogous corpuscles have been termed granules by many anatomists, especially on the continent, I have, for the sake of perspicuity, named the peculiar base of the chyle the *molecular base*, as will be more fully explained in the Appendix.

G. G.

Fig. 243. Portion of opaque, white coloured, coagulated lymph, magnified about 380 diameters, from a case of

traumatic inflammation of the peritoneum of the horse. The lymph was very friable, and had only been a few days effused. It is composed of globules, smaller molecules, and granular matter in a hyaline matrix. In the lower part of the figure the granules and molecules are shown as floating in serous fluid from the clot. (See page 29; also fig. 272.)

Fig. 244. Portion of fibrine exhibiting an appearance of fibrils. Magnified nearly 700 diameters. From the heart of a child about 24 hours after death.

Fig. 245. Another portion of the same clot as in Fig. 244, similarly magnified, and showing a faint appearance of globules between the fibrils.

Fig. 246. Corpuscles in fibrine, obtained by whipping, from the blood of a horse. About the centre a corpuscle is shown, though obscurely, composed of a congeries of minute spherules, as mentioned in the note p. 34, and Appendix, p. 21. Magnified 700 diameters.

Fig. 247. Fibrine from the same blood as Fig. 246. The fibrine was boiled, and the corpuscles and fibrils are shown in a very thin slice. A cluster of the corpuscles is seen, though not very prominently, in the upper part of the figure. Magnified 700 diameters.

Fig. 248. The corpuscles rendered more distinct, and their nuclei shown, by the aid of acetic acid. The fibrine was obtained from the same blood as in Figs. 246 and 247. Magnified 700 diameters.

Fig. 249. Corpuscles in a clot of fibrinè from the heart of a child, aged two months. The corpuscles have a corrugated appearance, and the intervening matter is very minutely granular. Magnified 800 diameters.

Fig. 250. Nuclei shown by soaking the fibrine for a while in sulphurous acid. The matrix has a finely granular appearance. From the fibrine of a horse, four days before death from inflammatory fever following an injury.

Fig. 251. Very distinct nuclei and faint envelopes, exposed by acetic acid, in fibrine from the venous blood of the horse. This and Fig. 250. were both made from bri ne in which it was difficult to distinguish the nuclei

or corpuscles till the acids were used. Both Figures were drawn with the camera lucida and a magnifying power of 800 diameters.

(The figures 243 to 251 are spoken of more fully in the note at p. 29, et seq. and in Sect. 5 of the observations on the blood-corpuscles of Mammiferous Animals in the Appendix.)

Figs. 252—255 exhibit the structure of *tubercle* made up chiefly of irregular corpuscles and cells, with oblong and circular nuclei. A very minutely granular matter is situated between the corpuscles and cells, which indeed it often seems to pervade. Fig. 252. is from a small crude tubercle of the lung, about as big as a hemp seed: the envelopes are very faint, and the nuclei of small size. Fig. 253. is from a similar tubercle which was situated immediately beneath the pulmonary pleura; the envelopes are obscured by the granular matter, while the nuclei are of large size and distinctly marked. Fig. 254. is from a small tubercle obtained from the peritoneal coat of the small intestine; the envelopes are here also very faintly seen, but the nuclei are perfectly distinct, and some of these inclose nucleoli. Fig. 255. shows very distinct cells, and nuclei containing spherical molecules in their substance, as appears also to be the case in some of the nuclei of fig. 254. In the lower part of fig. 255 an aggregation of similar molecules forms an oval corpuscle almost as large as a cell.

All the figures were made from portions magnified 800 diameters; and in Figs. 252—254. the tubercular matter was of the common yellowish opaque kind, and obtained from a man, aged 26, who died of pulmonary phthisis; he had also numerous tubercles in the mesentery, in the omentum, and on the surface of the intestines. Fig. 255. was taken from a very minute tubercle from the surface of the ovary. The tubercular matter was paler than that which formed the subjects of Figs. 252—254, but still quite opaque. It was obtained from a woman, aged 48, who died of general dropsy connected with valvular disease of the heart. There was much fluid in the belly, and the

peritoneum was throughout studded with tubercular accretions. The lungs contained only two or three small tubercles, none of which were in the active state.

Fig. 256. exhibits the structure of some whitish flaky matter from an enlarged ovarian cyst. Some distinct cells of large size are seen inclosing numerous minute spherules. Near to the top of the Figure these are aggregated into a corpuscle destitute of any envelope, close above which corpuscle is a cell nearly empty, and oval in shape. Many of the minute spherules seem to contain a still more minute nucleus. The cells are contained in a matrix, composed of oval nucleated corpuscles, of much smaller size, fainter, and quite distinct in character from the large circular cells. From the same woman as the tubercle shown in Fig. 255. Magnified 800 diameters.

Fig 257. Very singular baton-like bodies, mostly furnished with knobs at their extremities. There are also numerous minute spherules, and a flattened prismatic crystal; besides three large globular cysts, with extremely delicate parietes, but destitute, as far as could be observed, of nuclei or granules. The curious bodies first mentioned are perhaps crystals: Mr. Siddall showed me some similar bodies in the bile of a rabbit. The minute spherules exhibited remarkably vivid molecular motions. The drawing was made from some yellowish matter, not unlike thickened pus, or tubercle, obtained from a small tumor in the choroid plexus of a man who died of pulmonary phthisis. Magnified 800 diameters.

Fig. 258. Pus from a chronic abscess in a scrofulous child affected with hip disease and ulceration of the vertebræ. This pus is seen to be made up chiefly of minute spherules with granular matter, and the globules are fewer and less distinct than in healthy pus. They seem to be destitute of the two or three nuclei contained in healthy pus globules, though mostly containing minute spherules of a granular matter. This scrofulous pus is also peculiar, as being quite unaffected by several reagents which act instantly on common pus. Acetic acid neither affected the

minute spherules nor the globules of this scrofulous matter, and the action of caustic alkalies on the globules was very faint. As neither acetic nor sulphurous acid would act on the globules, of course no regular nuclei could be seen, and the pus was instantly coagulated by these acids, and therefore immiscible with them. Like healthy pus, this scrofulous matter was creamy and homogeneous, and readily miscible with water. A quantity of the pus dried and heated on paper produced no greasy stain; and a bottle full of the matter was kept for a month, the temperature being about 55°, at the end of which time there was no putrefaction, and the particles had not subsided in the least, so that there was no supernatant serum. Magnified 800 diameters. (See Notes, p. 92 and 95.)

Figs. 259—260. Globules of pus, showing the remarkable manner in which they swell out, on the addition of water. In both figures the globules are magnified 800 times in diameter. Fig. 259. exhibits them without water. Fig. 260. after the addition of water. Perfectly fresh pus shows the phenomenon best, for after the matter has been kept some time, the change either does not take place, or is comparatively slight. The Drawing was made from gonorrhoeal matter immediately after it was taken from the urethra. In the upper part of the fig. the nuclei of two of the globules are very distinctly seen.

Fig. 261. *Pus-cells*, and their contents. On the right, near to the margin, is a congeries of pus molecules, or nucleoli, without any envelopes. A pus cell, *a*, is seen to enclose the pus globules as *nucleated nuclei*. Another cell, *b*, encloses an aggregation of molecules, or nucleoli. The pus cells are about  $\frac{1}{1146}$ th of an inch in diameter. Several corpuscles, one of which is marked *c*, have much the size and appearance of pus globules, but, on comparison with the cells, give the idea of the latter, with their contents, in progress of growth or evolution. Magnified 800 diameters.

Fig. 262. Abnormal pus. Only six or seven regular pus globules, one of which is marked *a*, are present. The rest

Unable to display this page

cles, and the minute spherules of the blood, magnified 800 diameters. Some of the angular particles are star-shaped. From a sucking kitten immediately after death. (See Appendix, pp. 10 and 23.)

Fig. 269. Pus-like globules in the blood of a horse. There are five of these globules, which differ remarkably from the blood discs. The blood was taken from the animal while he was suffering from inflammatory fever. (See Appendix, p. 20—21.) Magnified 800 diameters.

Fig. 270. Corpuscles and minute spherules in tubercle, magnified 800 diameters. The corpuscles exhibited no change when treated with acetic acid; they are very irregular in form, and in this respect differ from the cells and nuclei shown in figures 252--255. From a portion of the common kind of crude tubercle, obtained from the lung of a woman aged 33, who died of pulmonary phthisis.

Fig. 271. Fragment of tubercular matter, magnified 800 diameters. It was obtained from the kidney of a man aged 80, who died of pericarditis. This tubercular matter appears to be void of regular structure, being composed of shapeless fragments, and a granular matter formed of minute spherules very variable in size.

Fig. 272. A bit of false membrane, magnified 800 diameters. Numerous corpuscles are seen, more or less globular, and having the character of primary cells; the intervening texture is formed of most delicate fibrils. As is generally observable in effused clots of lymph, several minute opaque granules are scattered throughout the tissue. The Drawing was made from a flake of the common whitish kind of false membrane, formed on the serous surface of the lung in a man aged 51, who died of phthisis and pleuropneumonia. In this case the structure of the effused matter seems to be further advanced than in the coagulated lymph depicted in Fig. 243.

Fig. 273. Vesicular corpuscles in some crude tubercular matter obtained from the pancreas of the patas. (*Cercopithecus ruber*, Geoff.) The smaller tubercular deposits so common in the thoracic and abdominal viscera of the quad-

rumana are frequently composed chiefly of this vesicular structure, and it may sometimes be seen in the minute tubercular accretions of the human subject, especially in those of the omentum.

Figs. 274 to 287 illustrate the anatomy of the chyle and of the lymphatic and thymous juices. All the figures, except 275, are magnified about 800 diameters.

Fig. 274. Plan of the molecular base of the chyle. The scale represents micrometer divisions of  $\frac{1}{4000}$ th of an inch; and as from six to nine of the molecules are required to extend across one space, it may be inferred that their diameter is from  $\frac{1}{36000}$ th to  $\frac{1}{24000}$ th of an inch. It is obvious, however, that the result of any method of estimating the size of particles so extremely minute can merely be considered as an approximation to the truth; for it is perhaps questionable whether either the form or the magnitude of such objects can be satisfactorily determined. When examined, however, under the most favourable circumstances, the molecules have a spherical appearance; and quite as minute particles as these may be recognized in the most delicate granular matter, as in the ground of Fig. 279.

Fig. 275. Chyle from the peripheral lacteals in the mesentery of a kitten. There are six chyle globules, magnified fully 800 diameters, and the molecular base, which is magnified about 700 diameters, occupies the entire field.

Fig. 276. Chyle from a peripheral lacteal of a bitch. The molecular base as usual pervades the whole field, and five blood-smooth discs are contained in it. A few of the blood discs were observed in many trials, made with the greatest care to prevent the admission of blood to the chyle; but no chyle globules were present, although they were ascertained to be numerous in the chyle of a large central lacteal. The animal was fed plentifully, five hours before death, on boiled cow's paunch; and the lacteals were well distended with chyle.

Fig. 277. Chyle from a prick of a lacteal of a mesenteric gland of a puppy. The globules are very numerous, and

the effect of the molecular base is well depicted. It was obtained from the animal three hours after he had been fed with potatoes and boiled meat.

Fig. 278. Chyle from a prick of a turgid lacteal in a mesenteric gland of the same bitch as mentioned at Fig. 276. The chyle was very rich and white, and the molecular base accordingly appears richer than in Fig. 277, and the chyle globules are extremely numerous.

Fig. 279. Juice from the lymphatic gland of the ham of the same puppy as the chyle delineated in Fig. 277. The examination in both cases was made with the same glasses, and the two Figures give a faithful representation of the difference between the most minutely granular matter and the molecular base of the chyle. The globules in both figures appear to be identical, but in Fig. 279, the base in which they are contained is merely granular, and in Fig. 277 it is the characteristic molecular ground of the chyle.

Fig. 280. Lymphatic juice from an absorbent gland of the ham of a young bitch. In this instance, as is frequently the case, the fluid is pervaded merely by the globules, and a few much smaller spherical particles, which seem like nuclei of the former. But the action of acetic acid did not render the nucleated appearance clearer; and is here rather more distinctly represented than it was seen in the object under the microscope.

Fig. 281. Clot from the chyle of the thoracic duct of the same bitch as the lymphatic juice represented in the preceding Figure (280.) The clot contains numerous globules in a hyaline matrix, apparently pervaded by extremely delicate fibrils. The chyle was kept two hours in a glass tube, when the clot was removed with a needle and washed in water, so as to be in great part deprived of its opacity, before examination. As is generally the case, the globules of the clot appeared more irregular in size and shape than those of the fluid chyle; but this character is not well preserved in the Figure.

Fig. 282. Spherules of the whitish substratum resulting

from the mixture of æther with chyle: these appear more delicate and pellucid than oily spherules.

Fig. 283. Chyle globules treated with dilute muriatic acid. Most of them are somewhat enlarged, and exhibit an appearance of nuclei contained in transparent envelopes, probably from changes produced by the acid on the surface of the globules.

Fig. 284. Thymous fluid from the same puppy as the chyle Fig. 277, and the lymphatic juice Fig. 279. This thymous fluid is as usual rich in globules; and a few oil-like spherules are present. But it is totally destitute of the peculiar molecular base of the chyle, and a comparison with Fig. 277 will at once show the difference in question.

Fig. 285. Thymous fluid from a young ass.

Fig. 286. The same from a young dromedary. The globules are seen to be similar in shape to those of animals with circular blood discs. It will be recollected that the blood corpuscles of the dromedary are oval.

Fig. 287. Thymous globules of the same dromedary treated with acetic acid, by which they are rendered a little smaller, smoother on the surface, more distinct and translucent; the appearance of nuclei is more clearly seen than is usually the case after mixing acetic acid with thymous globules.

Figs. 288—291. Corpuscles in the muscular fibre of the heart, and in the mitral valve, magnified 800 diameters. The corpuscles may sometimes be seen, though rather indistinctly, without the aid of reagents. Acetic acid was used to render the corpuscles distinct for the drawings.

Mr. Bowman (Phil. Trans. part ii. 1840) has depicted similar corpuscles in the fibre of voluntary muscle, and Dr. Baly in the flat bands of some of the muscular fibres of organic life, (Translation of Müller's Physiology, part ii. plate 2. Fig. 9. ;) but he does not mention the heart. The primary fascicles or bands of this organ are often so intimately connected, that it is difficult to see them distinctly; but they are sometimes tolerably well defined, often appearing flattened, occasionally nearly or quite cylindrical. I

have given measurements of them, in some mammals, in the note at p. 237.

In mammals the corpuscles vary in diameter from  $\frac{1}{6000}$ th to  $\frac{1}{4000}$ th of an inch; in the newt they are considerably larger. They are very irregular in shape, being sometimes rounded, often either oval or spear-shaped, and frequently still more elongated.

They may be found in a great variety of tissues. Mr. Bowman has seen the corpuscles in the coats of the capillary blood-vessels, in the sheath of nerve, and in the substance of tendon, and I have repeatedly observed corpuscles, either much resembling those depicted in Fig. 288, or more elongated, in parts too numerous to particularize. I may mention, however, the bag-like portion of the pericardium, the peritoneum, semilunar valves of the arteries, the coats of veins, and of the seminal tubes, and the dura mater. By the aid of the aqueous solution of sulphurous acid and the acetic acid, the corpuscles may generally be brought into view: they are supposed to be the remains of the cells, from which the tissues were originally formed.

Fig. 288. Corpuscles in the tissue of the mitral valve: they are more numerous than in the muscular tissue of the heart.

Fig. 289. Corpuscles in the tissue of the auricle.

Fig. 290. Corpuscles in the tissue of the ventricle. This and Figs. 288 and 289 are from the hedgehog.

Fig. 291. Corpuscles, of much larger size than the preceding, in the fibre of the ventricle of a water newt. (Triton Bibronii, Bell.)

Fig. 292, Epithelial corpuscles, magnified 800 diameters, from the gullet of a newt, (Triton Bibronii, Bell,) to show their large size in this reptile. They are generally more or less oval, often round: the elliptical form also occurs frequently in nuclei of the cells of mammiferous animals. In the note at p. 42, I have noticed that the epithelial corpuscles of the frog do not exceed in size those of man. In another examination these corpuscles were found to be slightly larger than in man, but having no sort of relation

to the great difference in size between the human and batrachian blood corpuscles. The lymph globules of the musk deer too are nearly or quite of the same size as those of man. In the water newt, however, the large size of the epithelial corpuscles, as well as of the colourless globules of the blood, is remarkable in connection with the magnitude of the blood discs of this reptile. From recent measurements I find the average length of its blood corpuscles to be  $\frac{1}{848}$ th, and the breadth  $\frac{1}{1311}$ th of an inch, linear. The diameter of the white globules of the newt's blood varies from  $\frac{1}{3000}$ th to  $\frac{1}{1300}$ th, and that of the epithelial corpuscles from  $\frac{1}{2900}$ th to  $\frac{1}{888}$ th of an inch.

Fig. 293. The same epithelial corpuscles after having been treated with acetic acid. They are only rendered rather smaller, and more distinct at their edges.

Fig. 294. Blood discs of a very young water newt, (*Triton Bibronii*, Bell) apparently in progress of formation from the colourless globules. A perfect blood corpuscle is shown (*a*) with its usual oval nucleus; all the other corpuscles represented in the figure were nearly or quite colourless, and their round nuclei are exactly like the colourless globules of the blood. In some the envelopes are forming evenly around the nuclei (*b*, *b*.) In others the corpuscles, though smaller than the regular discs, are oval in consequence of the envelope extending principally in opposite directions (*c*, *c*.) In none of these has the nucleus assumed its elliptical figure; but in one (*d*) this change would seem to be commencing. Occasionally the envelope was seen to begin in a crescentic form, arising from a part only of the circumference of the globule; but of this no delineation is given.

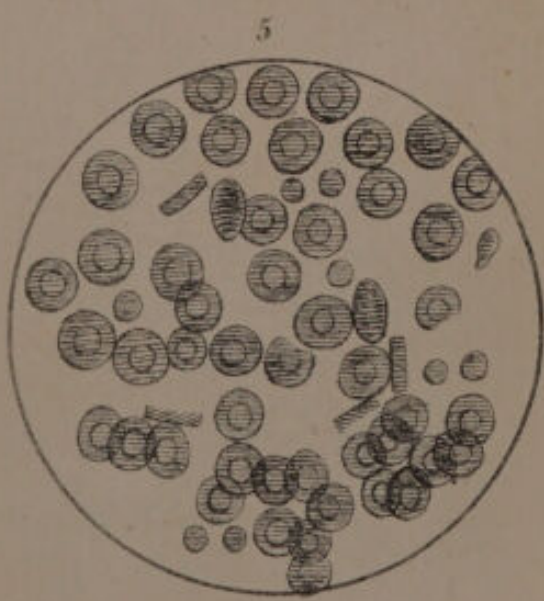
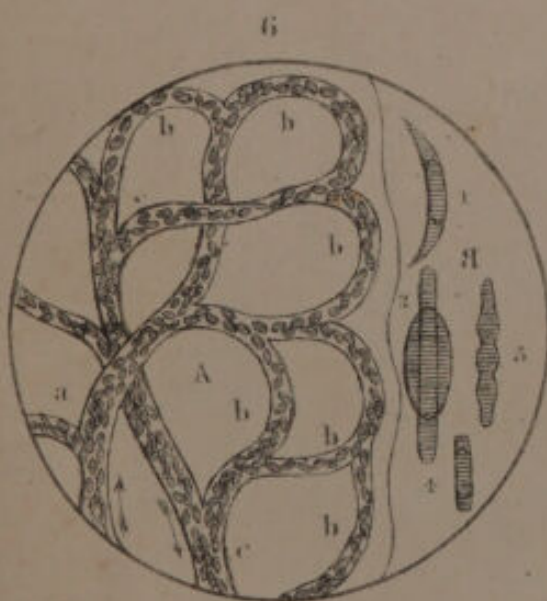
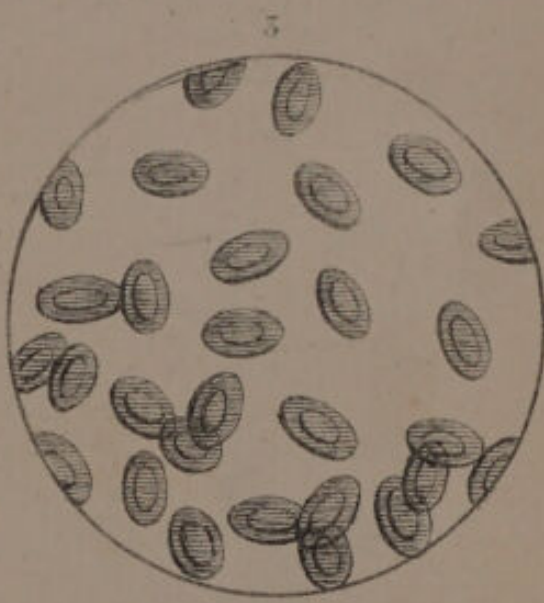
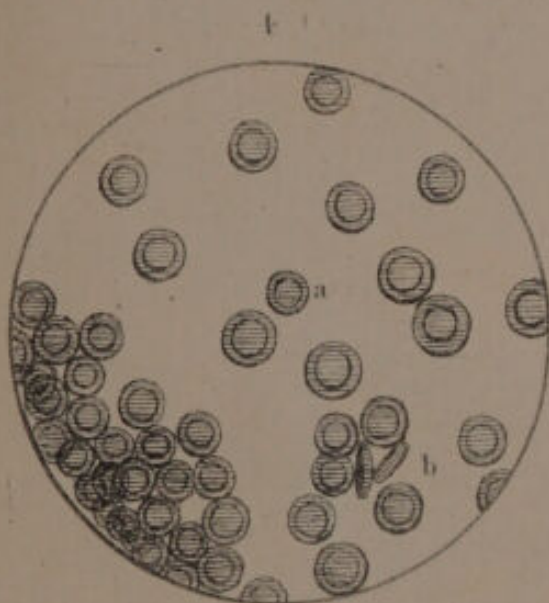
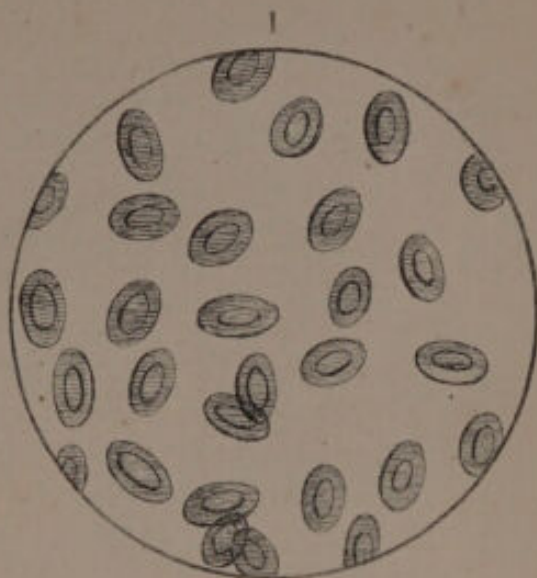
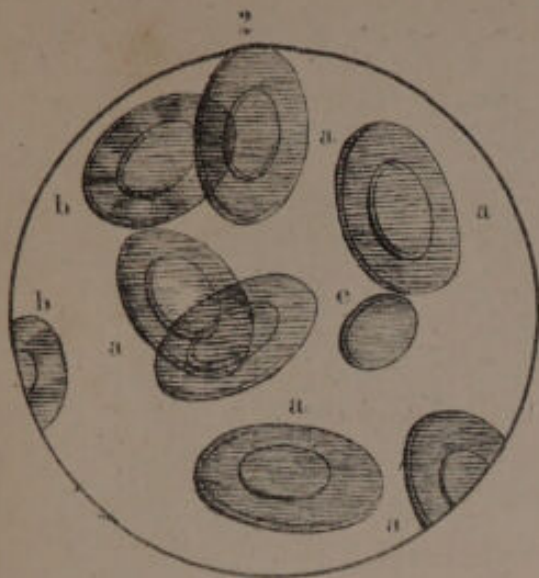
In the blood of the newt, oval cysts full of granular matter are sometimes present (*e*.) They are generally as large, frequently larger, than the blood corpuscles.


As formerly mentioned (Appendix p. 24,) my observations on the formation of the corpuscles in the blood of birds were entirely negative. But in young reptiles of the genera *Triton* and *Lissotriton*, the blood corpuscles may be seen in the various states above described. Since the

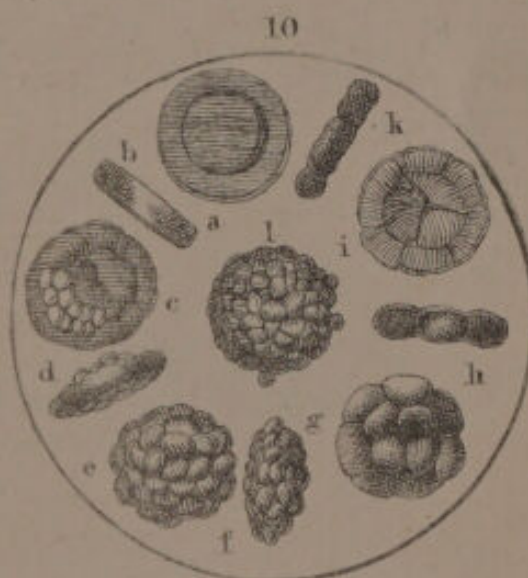
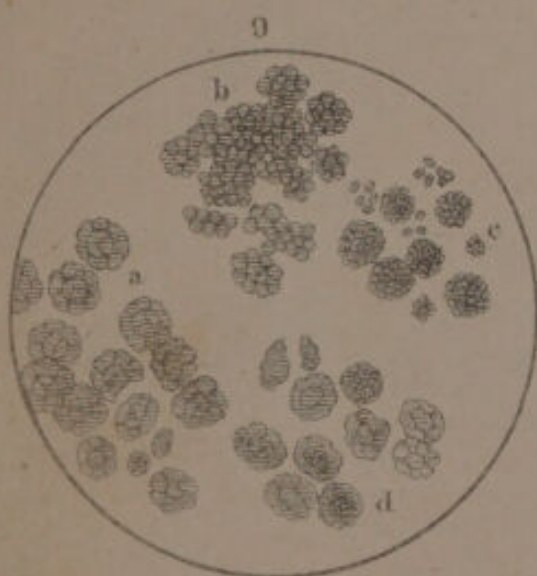
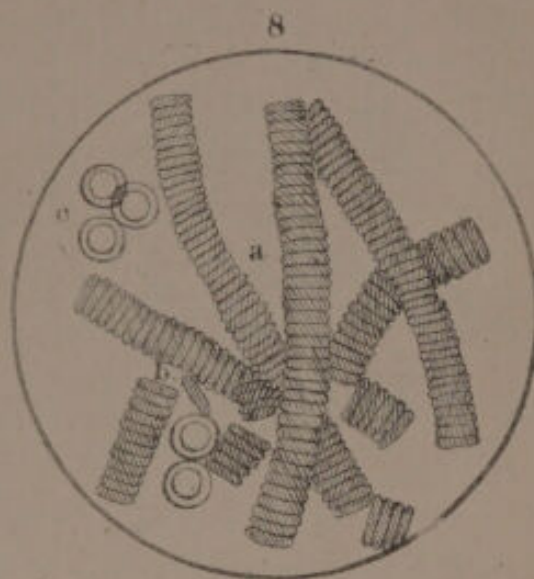
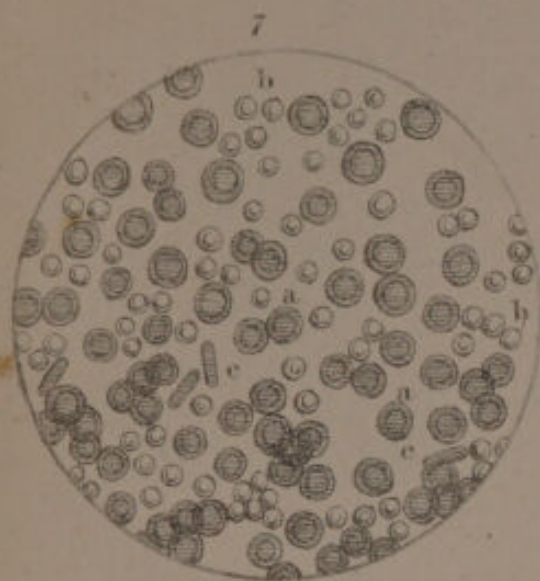drawing was executed, I find that similar results have been obtained by Wagner (*Physiology by Willis*, part ii.) and Nasse (*Unters. zur Physiol.* 11, s. 138.) The latter describes the capsule as growing by offsets from opposite sides of the globule, while the former has always seen the envelope formed evenly around the globule. My own observations tend to reconcile this slight discrepancy, by showing that the evolution of the vesicle may take place in the manner described by both these eminent physiologists.


G. G.

END OF EXPLANATION OF PLATES.

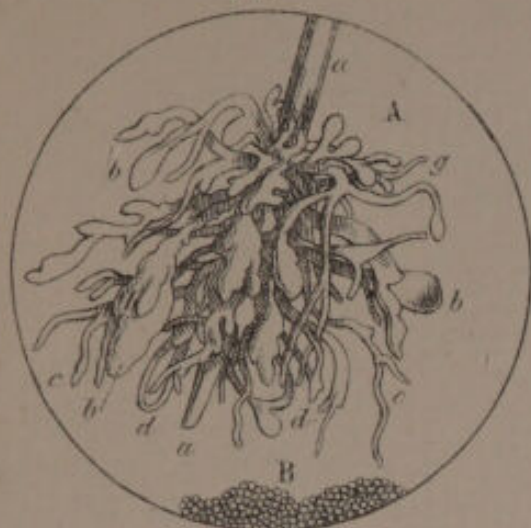








F15



F16



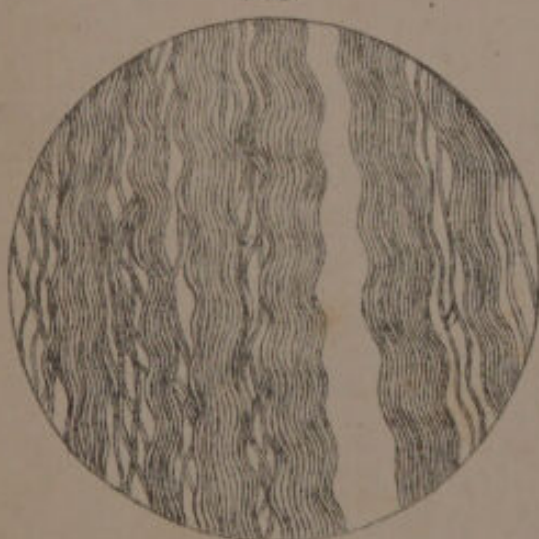F17



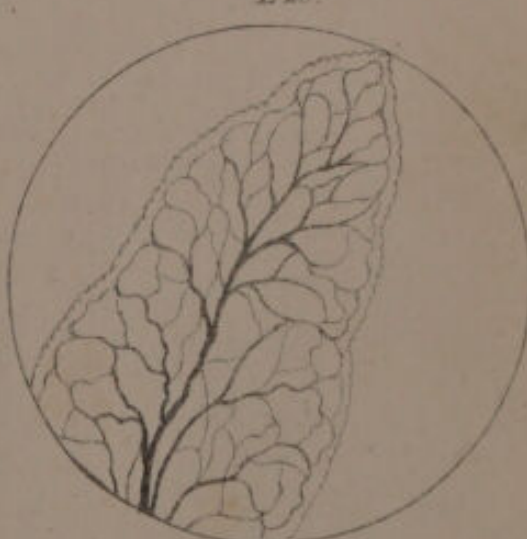
F18



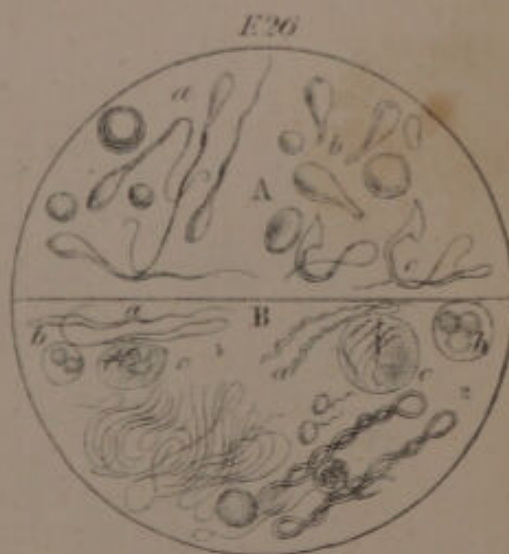
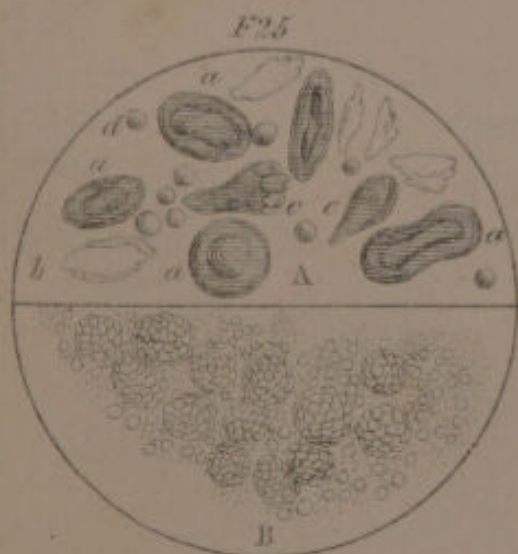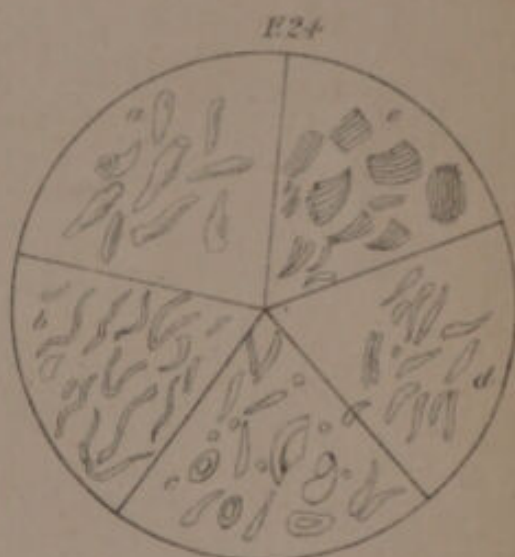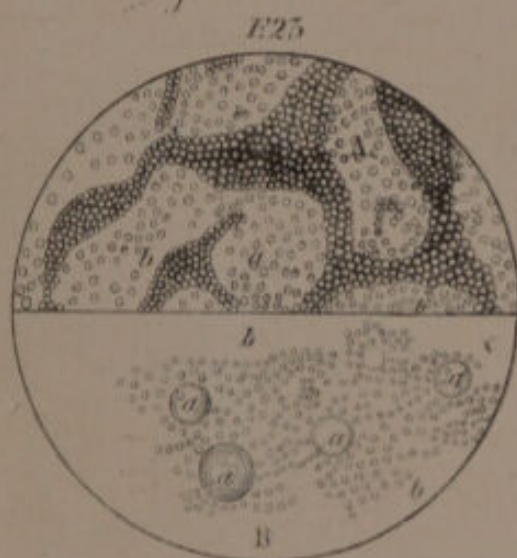
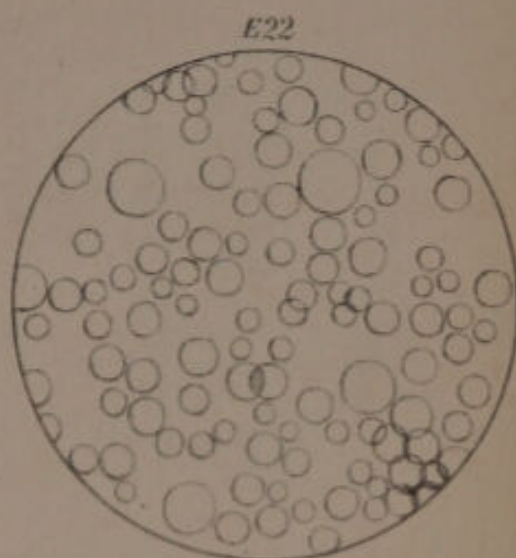
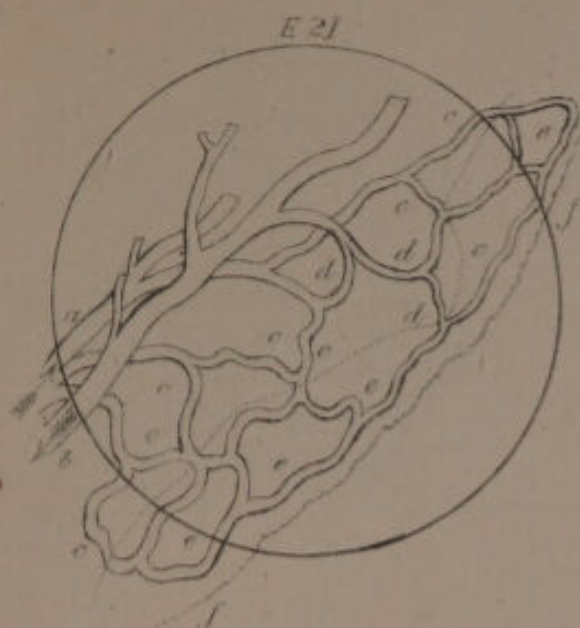
F19




F20

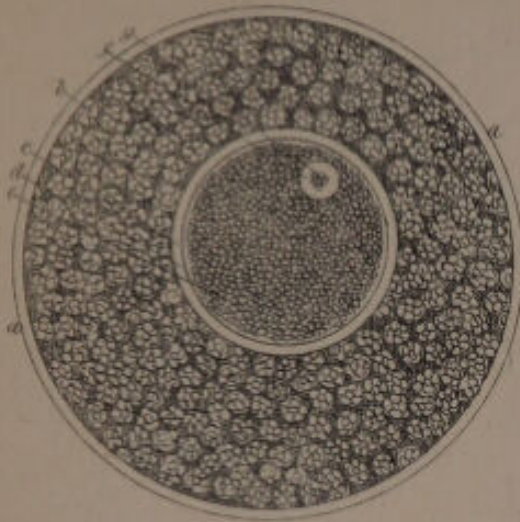




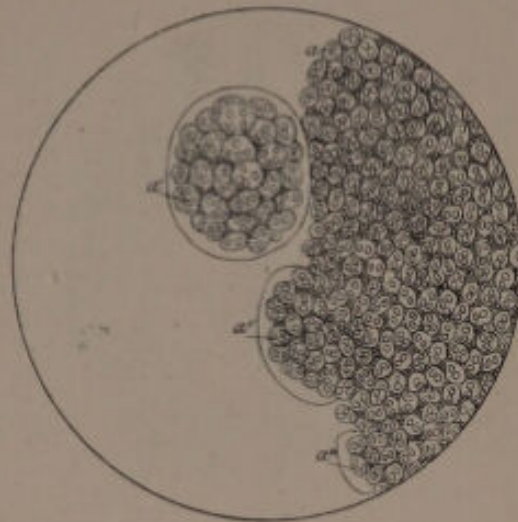




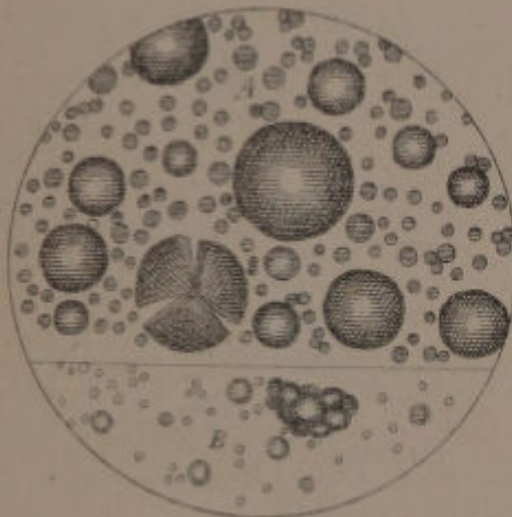
F. 27.



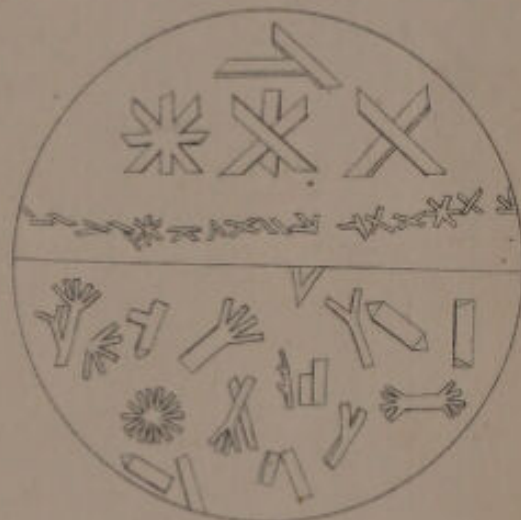
F. 28.



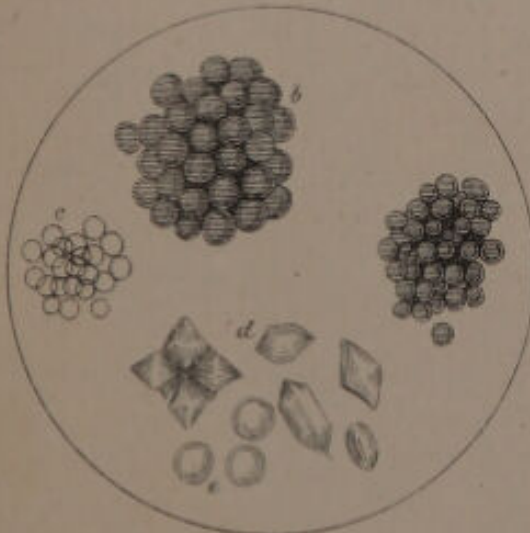
F. 29.




F. 30.




F. 31.



F. 32.

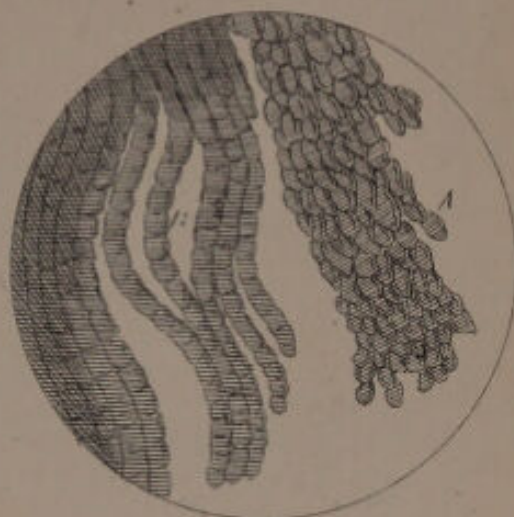




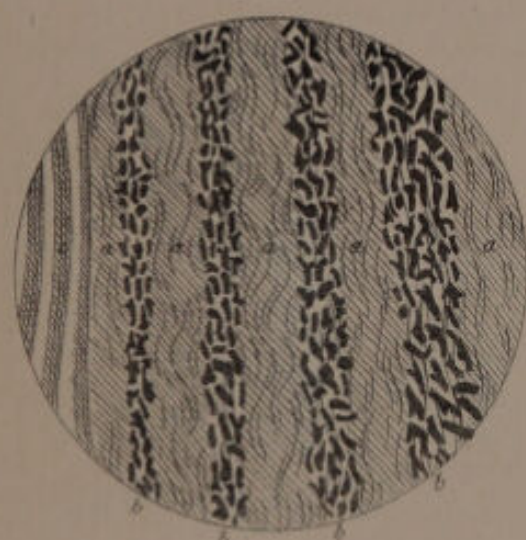
F. 33




F. 34



F. 35



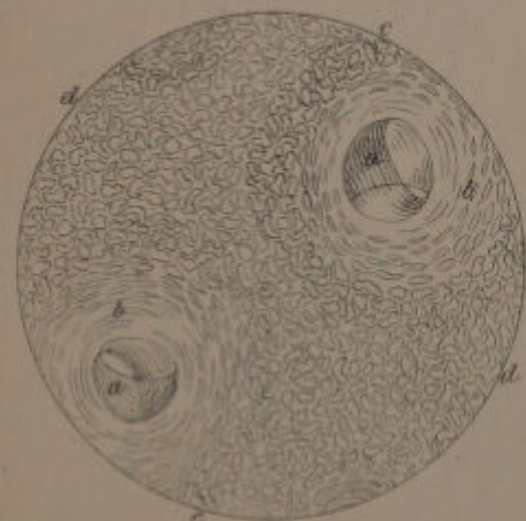
F. 36



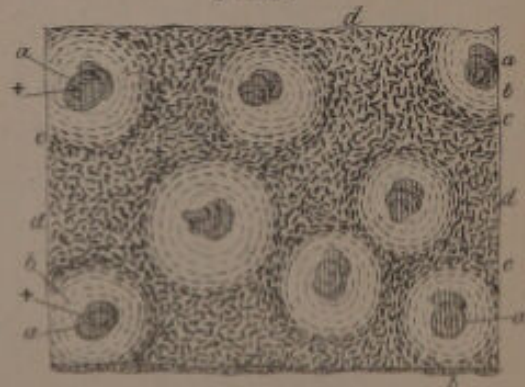
F. 37




F. 39



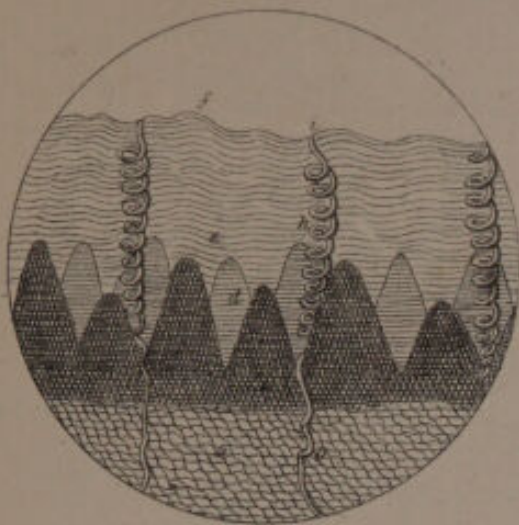
F. 38



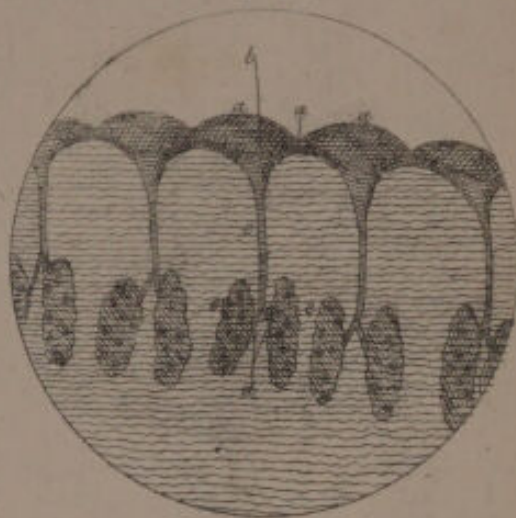


GERBER'S GENERAL ANATOMY.

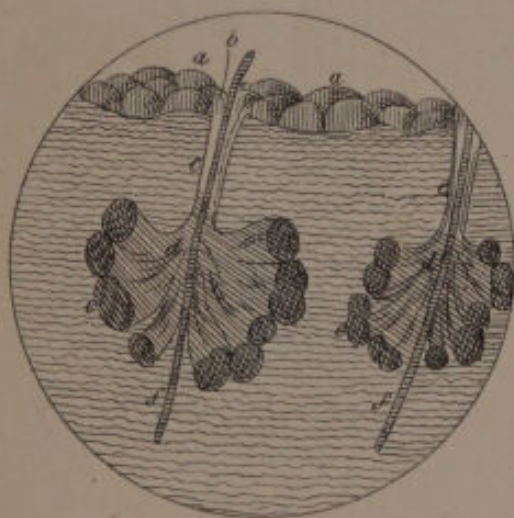F. 40.




F. 44.



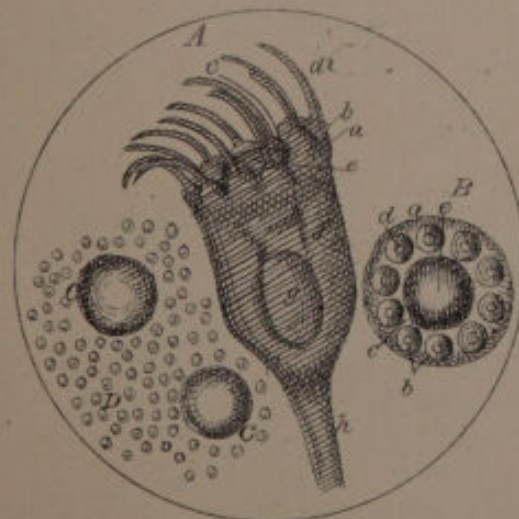
F. 45.



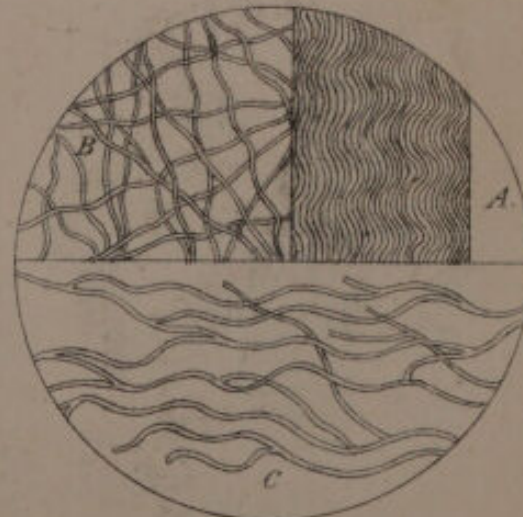
F. 47.



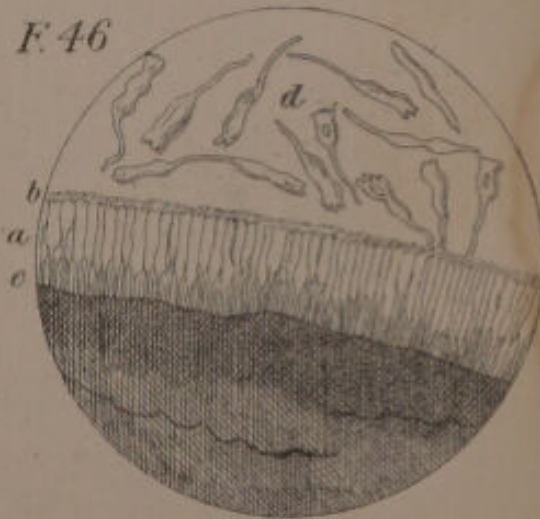
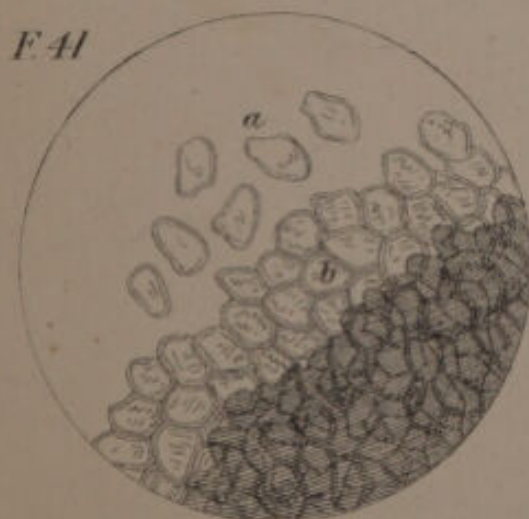
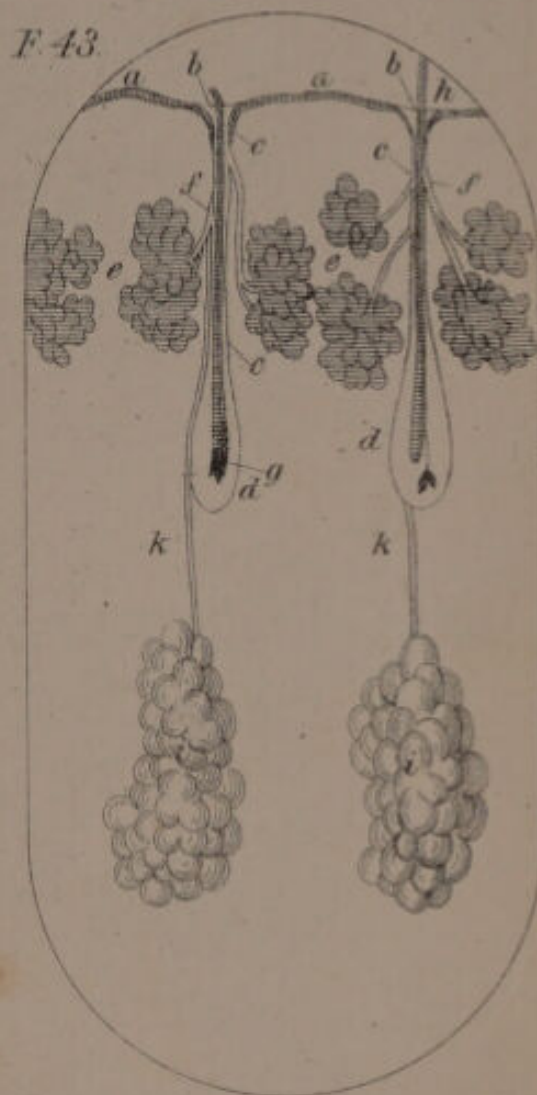
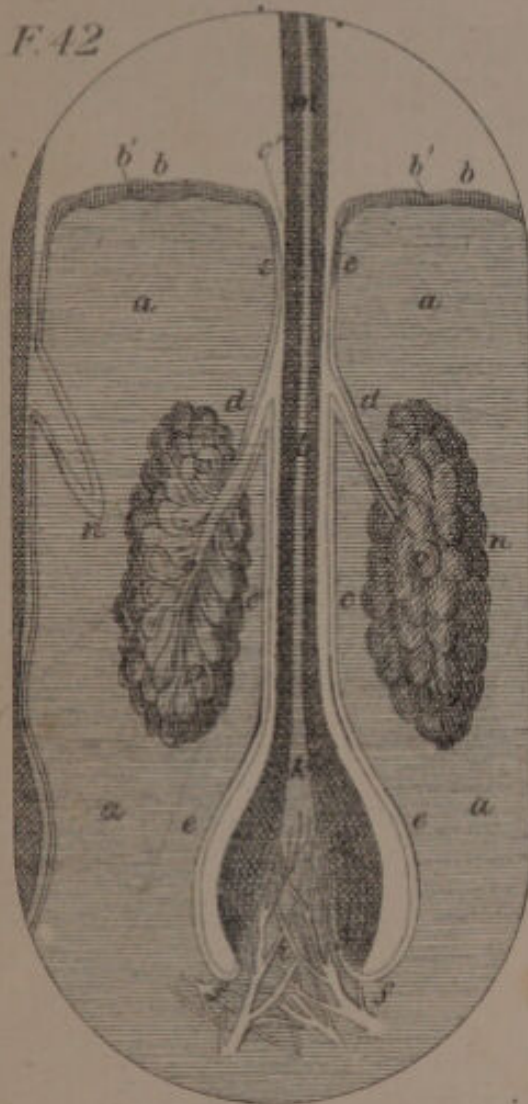
F. 48.



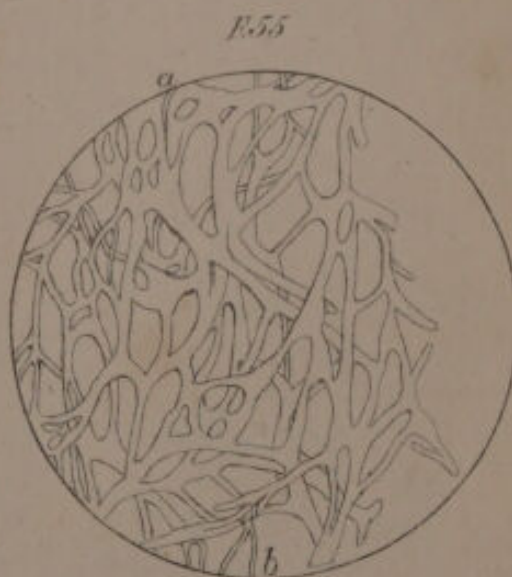
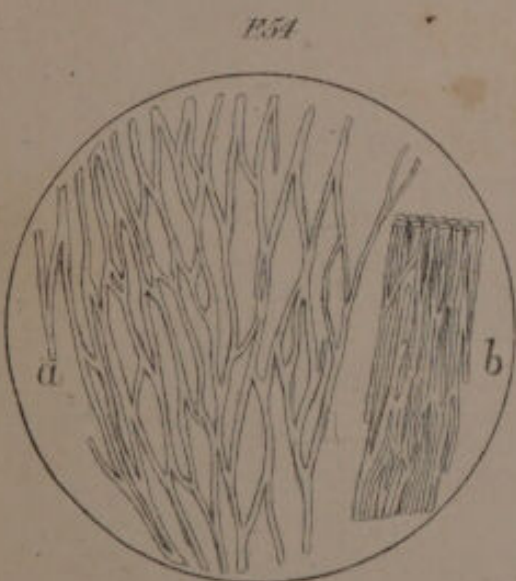
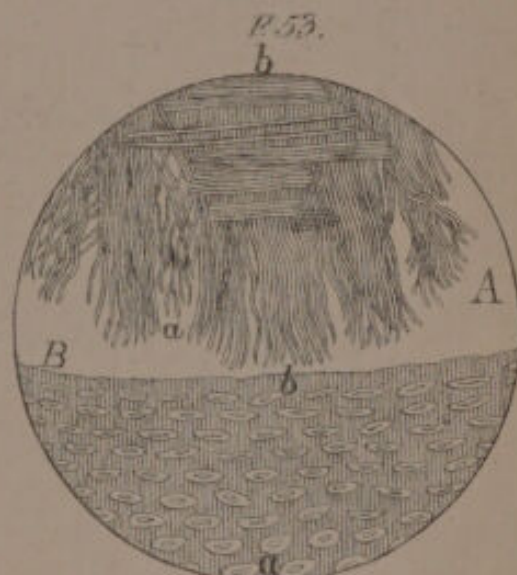
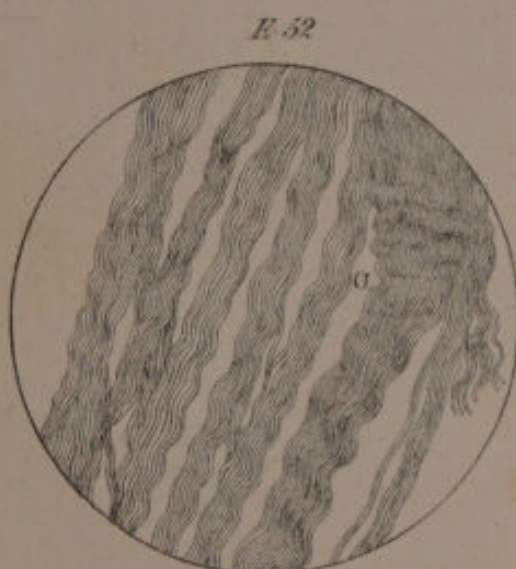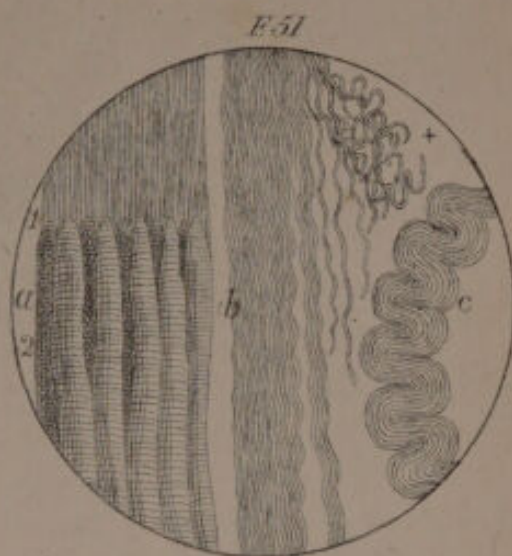
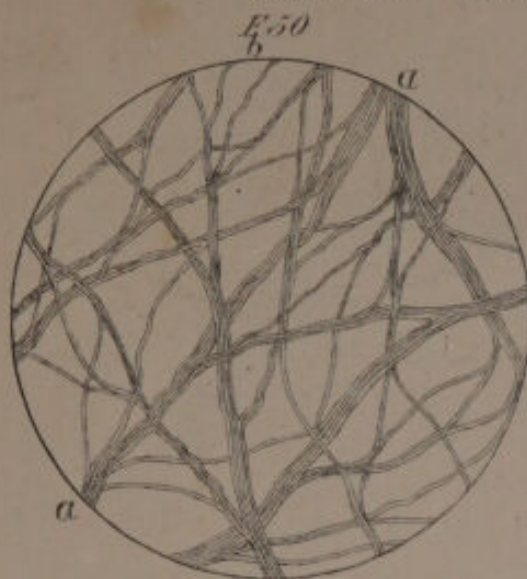
F. 49.






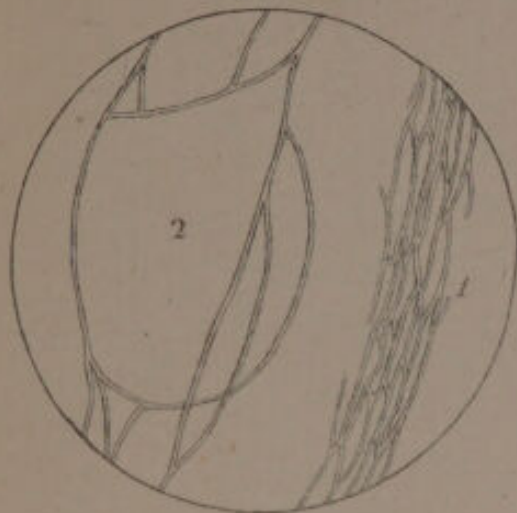



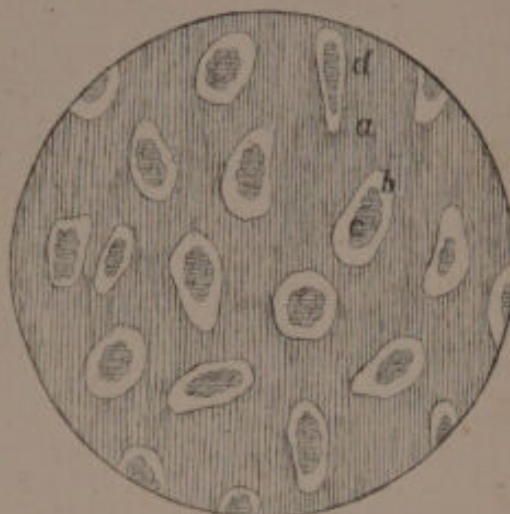




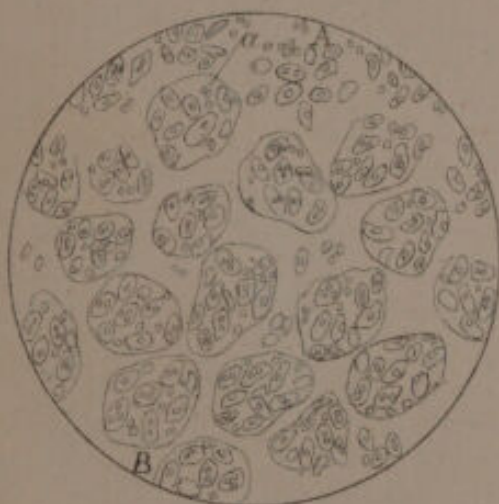
E56



E57



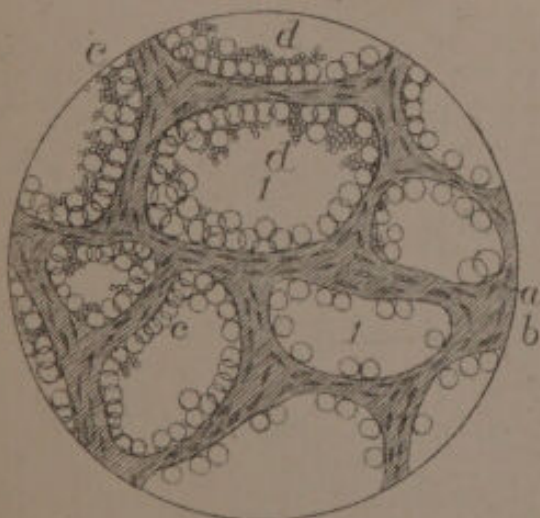
E58



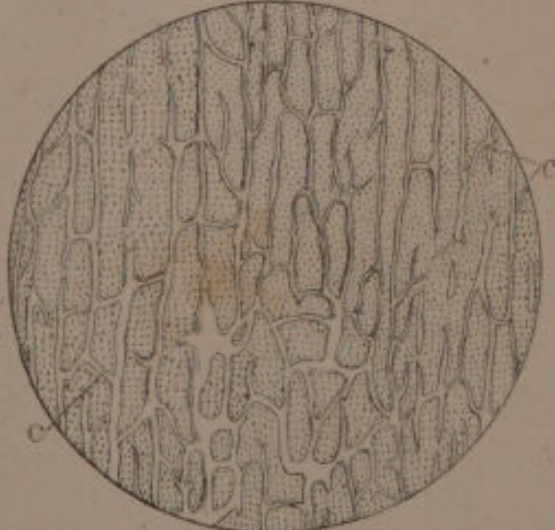
E59




E60

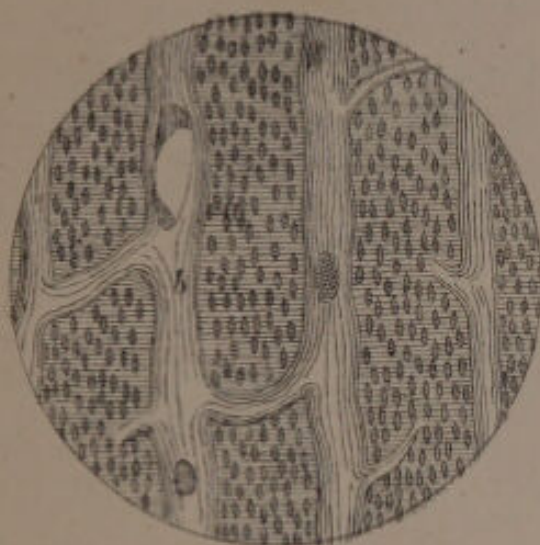


E61

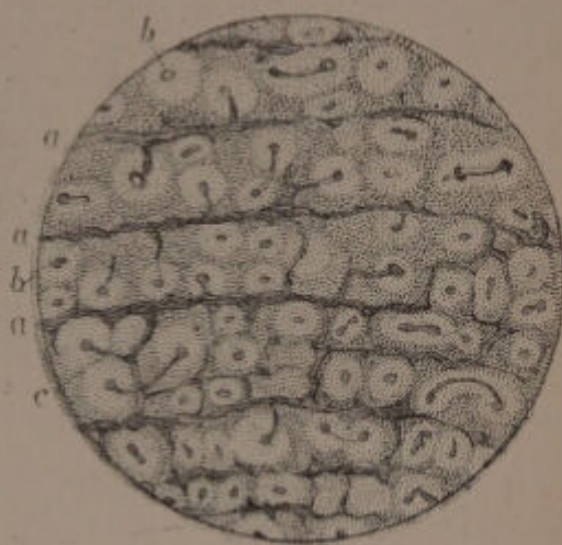



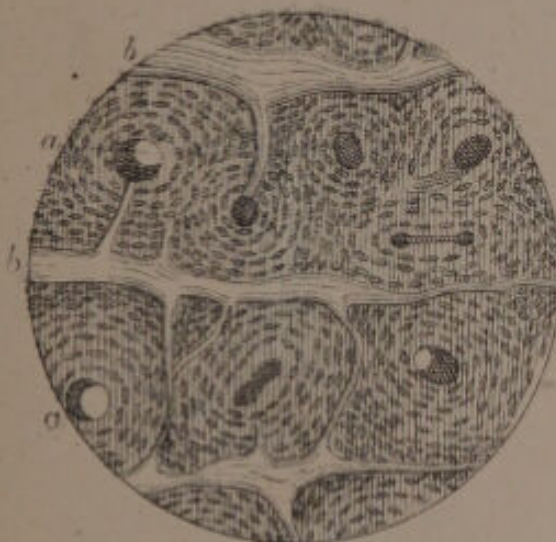
F. 62.




F. 63.



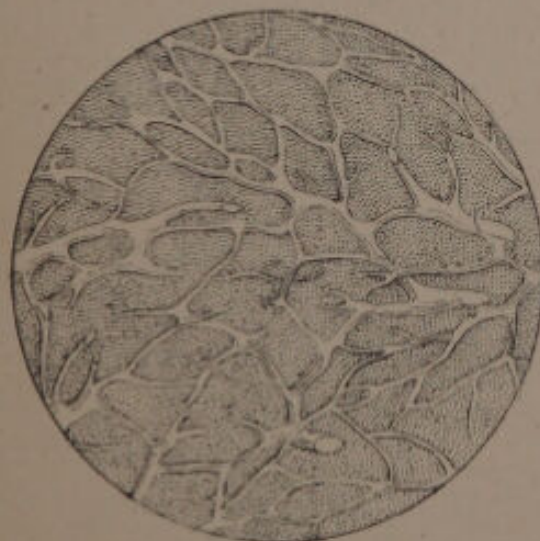F. 64.



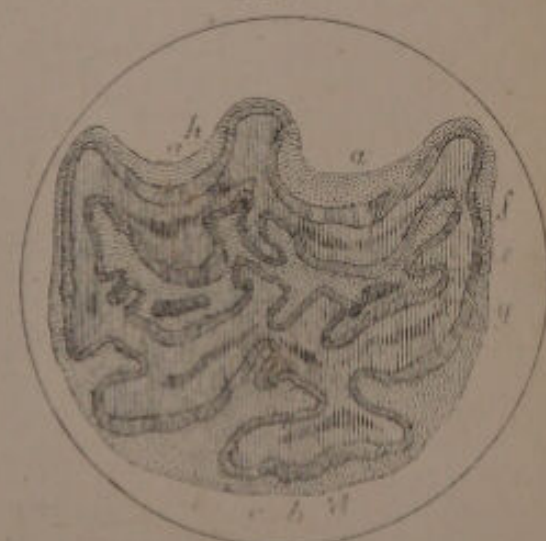
F. 65.




F. 66.



F. 67.

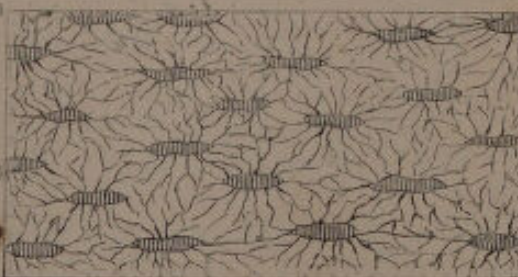
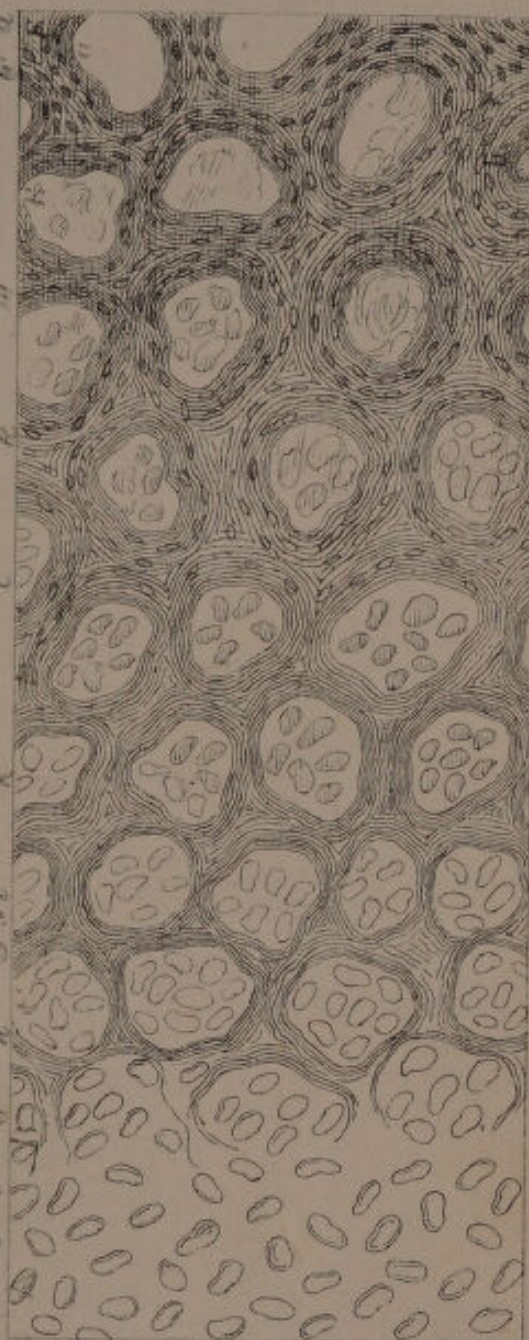




F 68.




F 69.

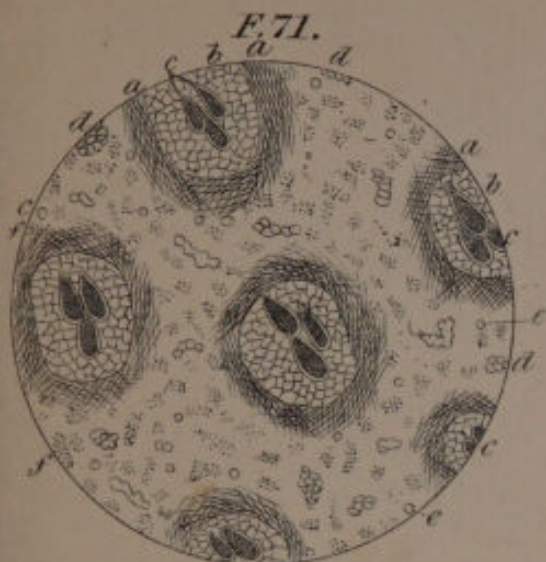


F 70.

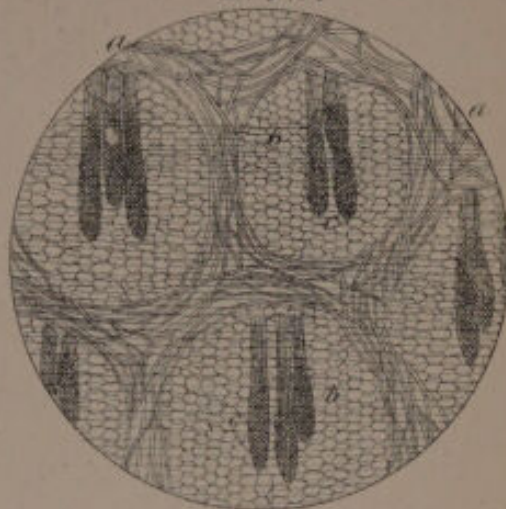
Schäfer, Zinn.



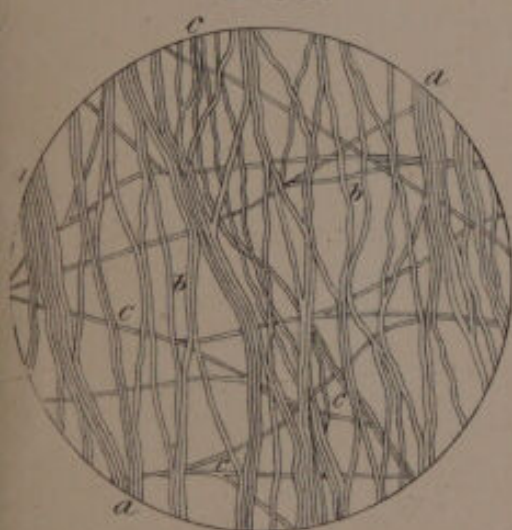
F. 71.



F. 72.



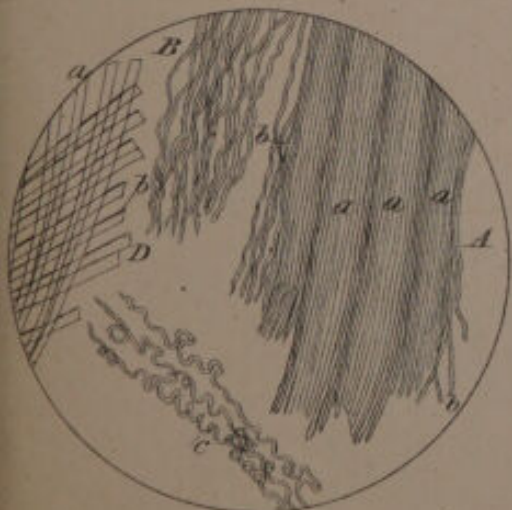
F. 73.



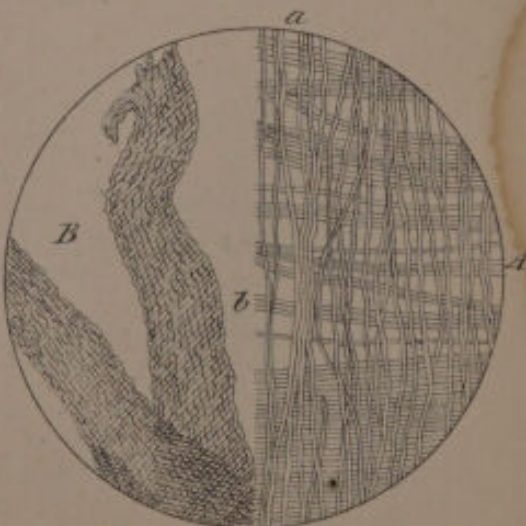F. 74.



F. 75.

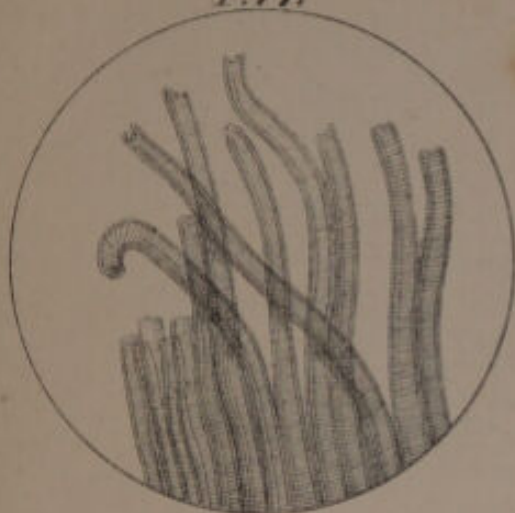


F. 76.

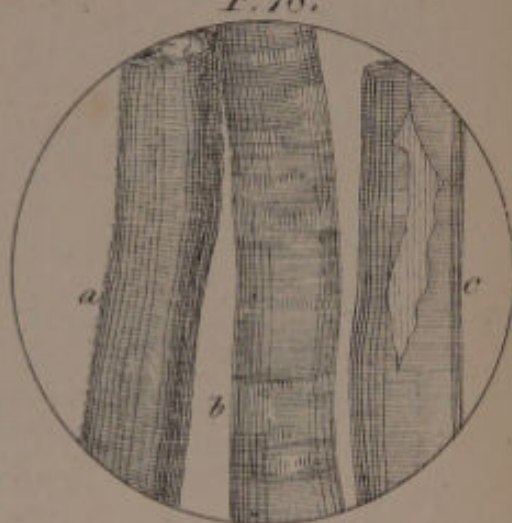




F. 77.



F. 78.



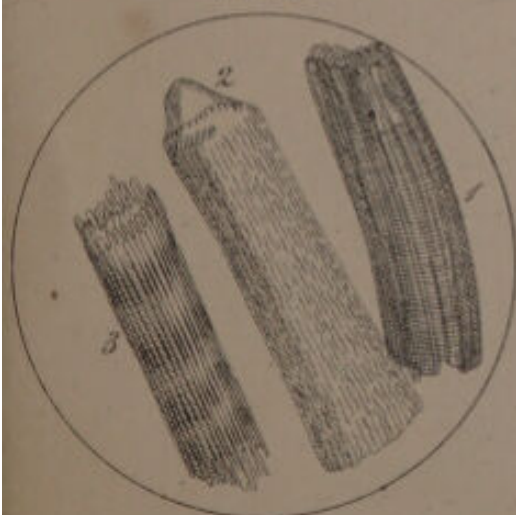
F. 79.



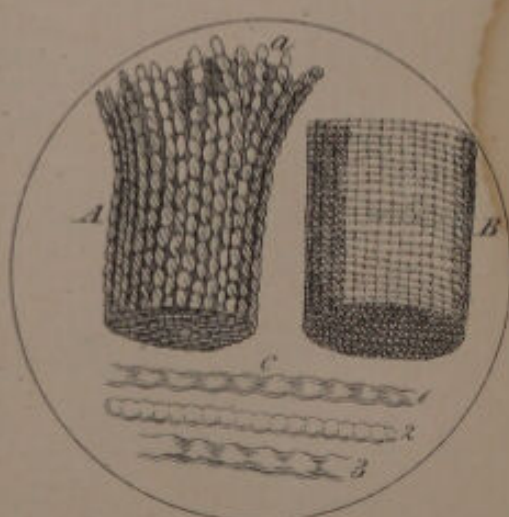
F. 80.




F. 81.

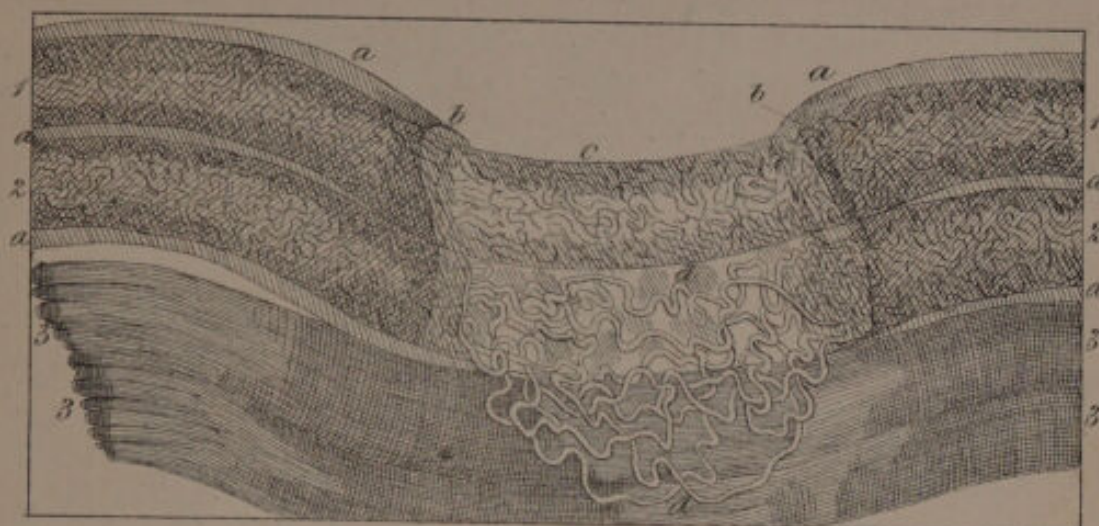


F. 82.

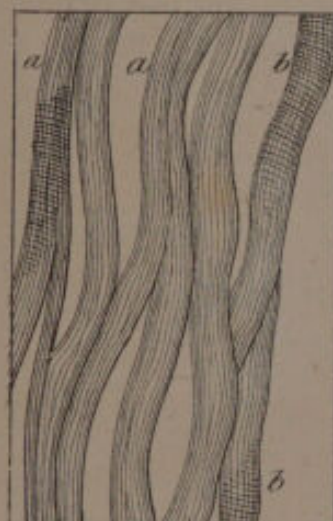



F. 83.



F. 84.



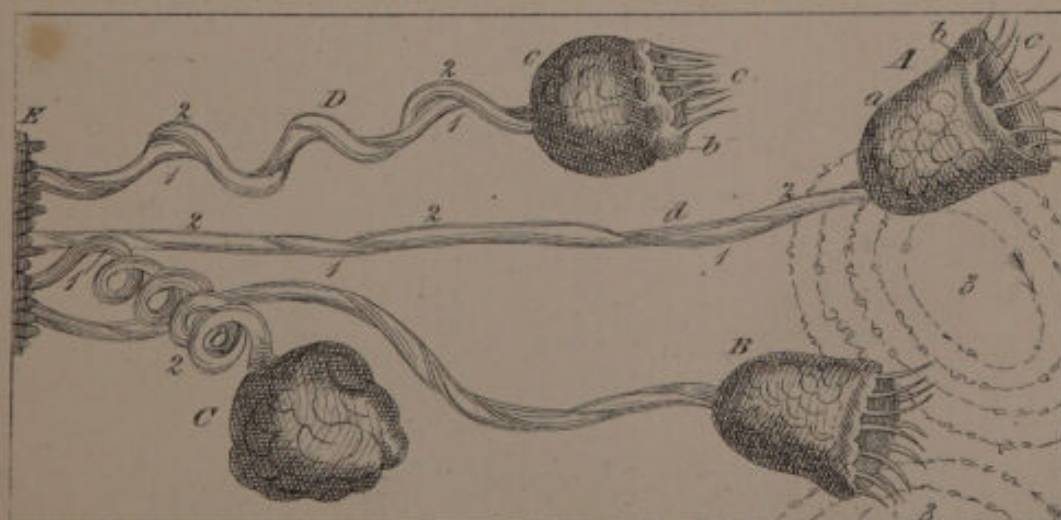
F. 85.




F. 86.



F. 87.

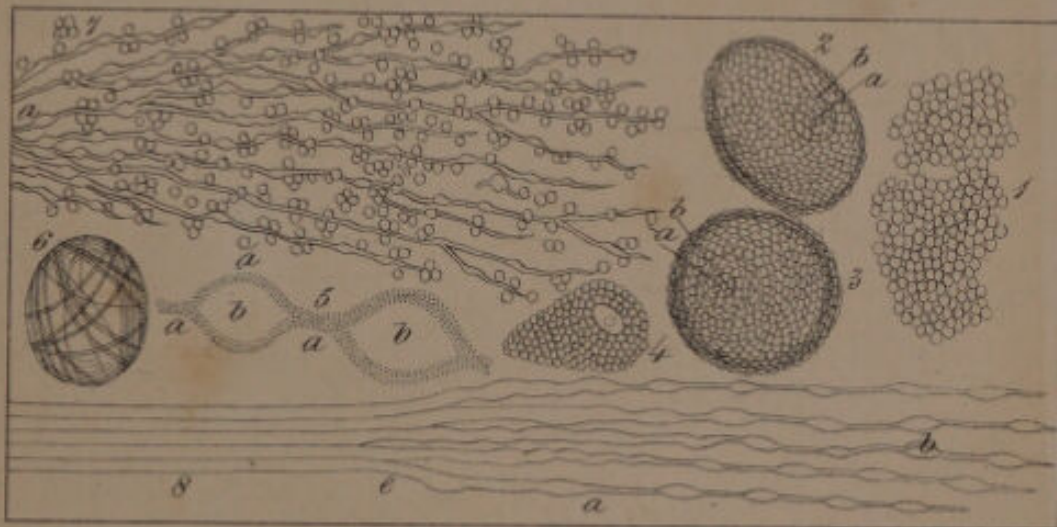




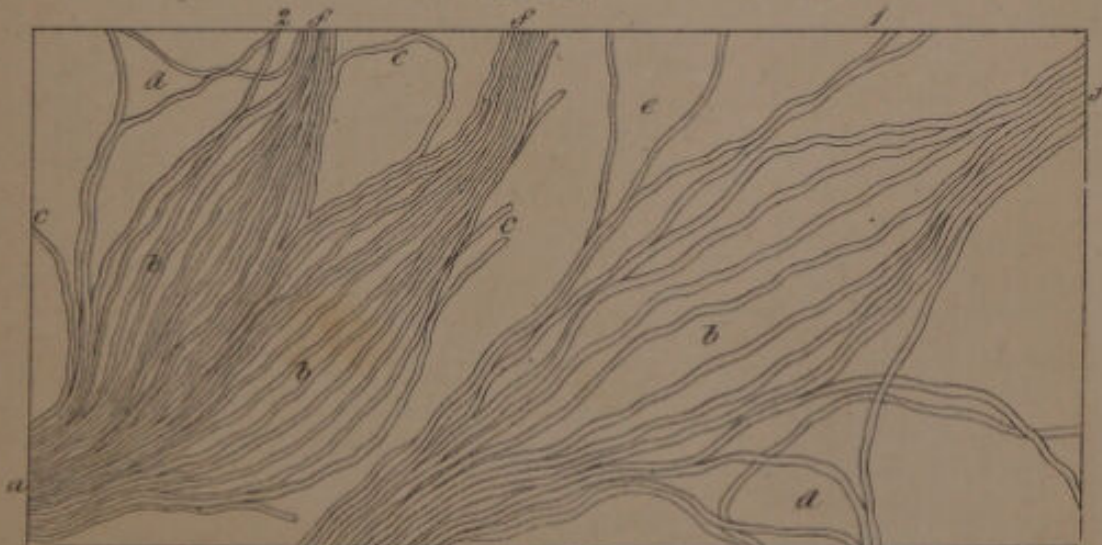
F. 88.




F. 89.



F. 90.






F. 91.

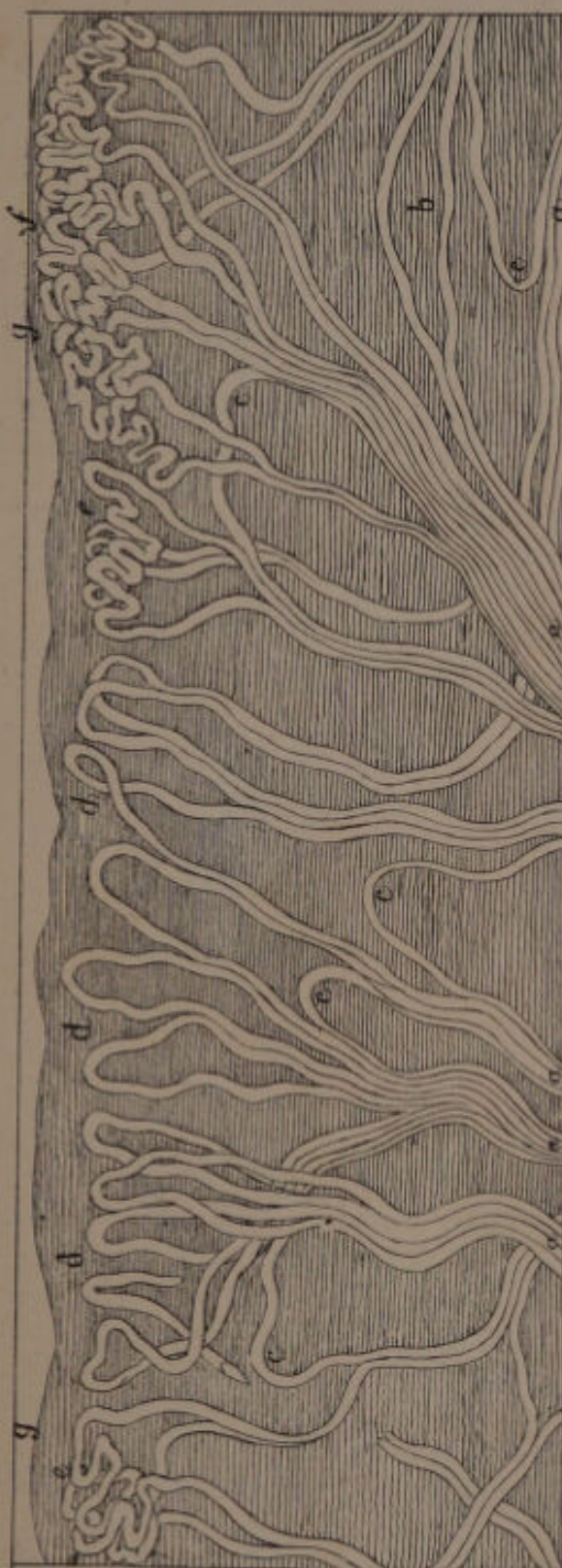

*Modell. Linc.*

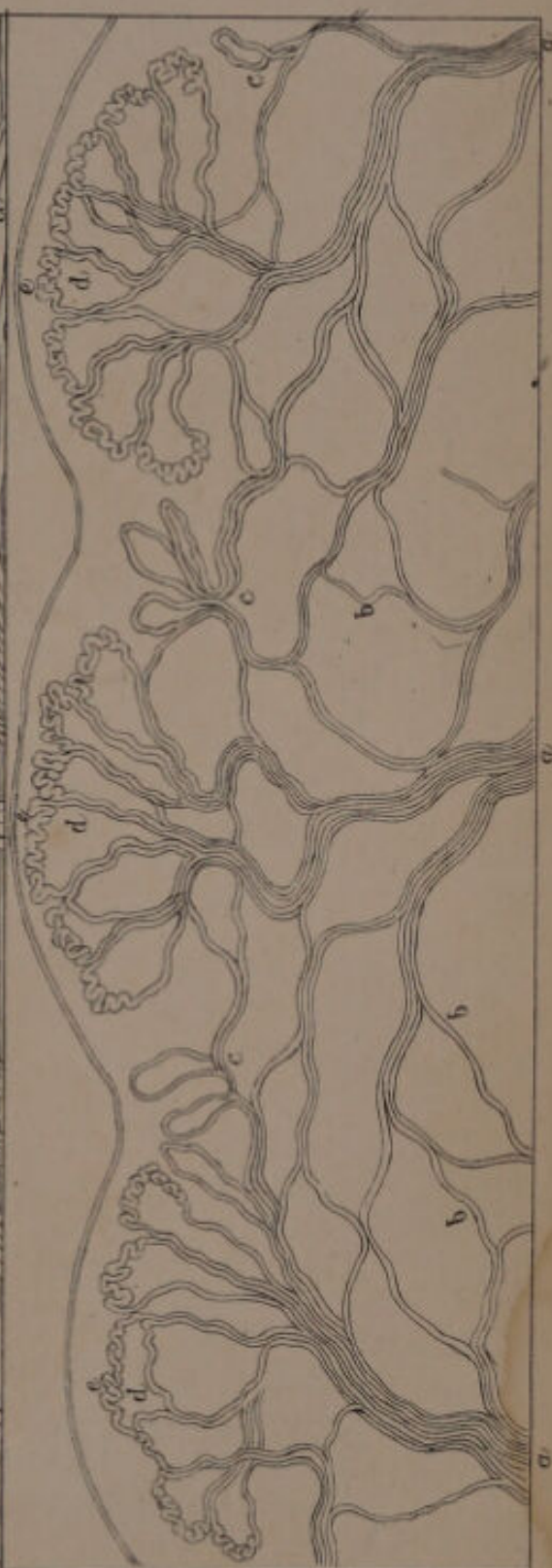*J. Süsser, del.*




F. 92.



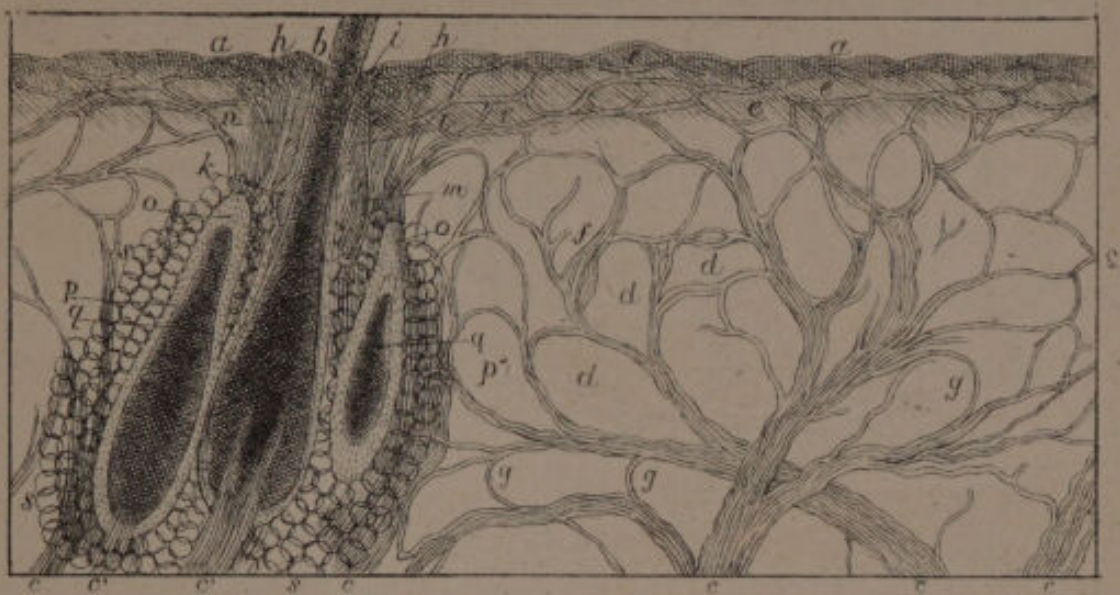F. 95.



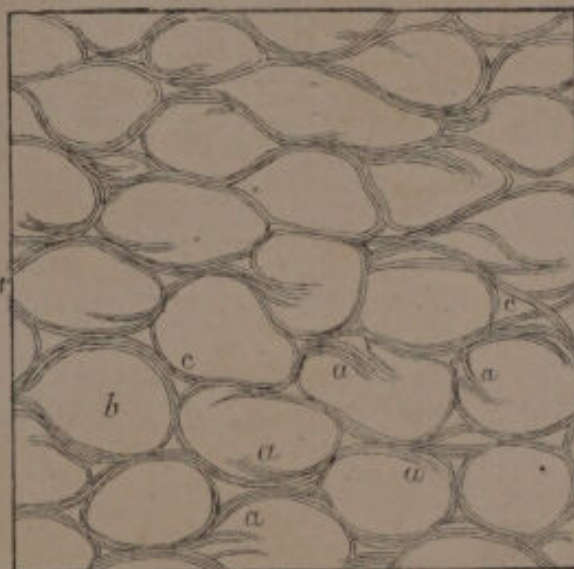
*Modell. 20.00*



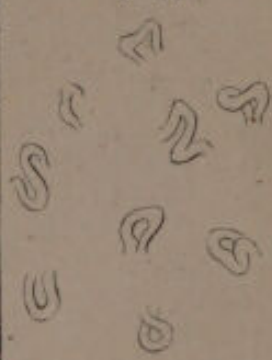F. 94.



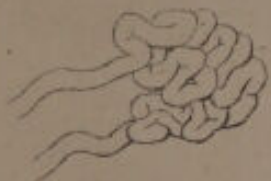F. 95.



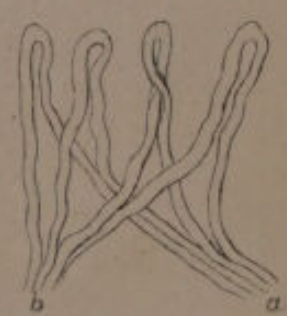
F. 96.



F. 99.



F. 97.



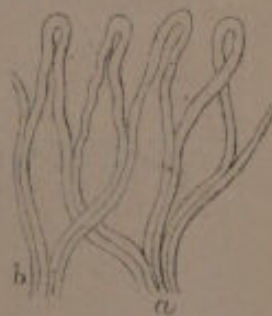
F. 100.



F. 102.




F. 98.



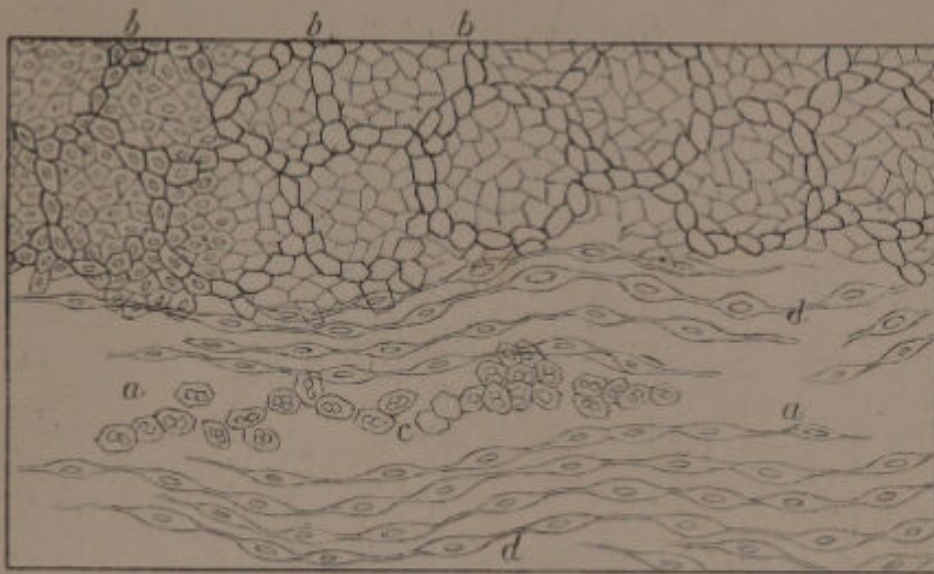
F. 101.



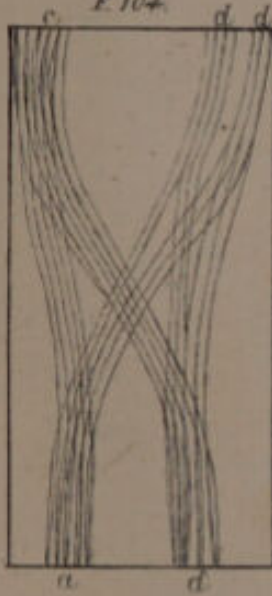
Anatom. Atlas



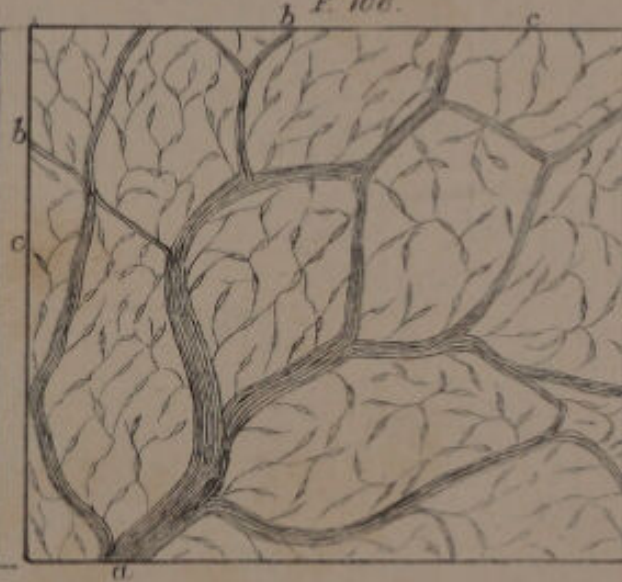
F. 103.




F. 104.



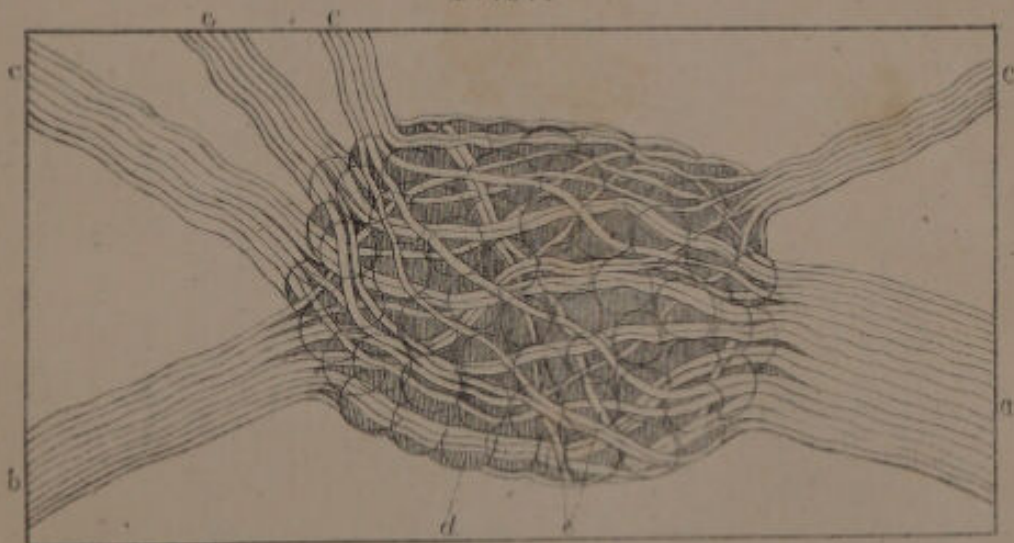
F. 106.



F. 105.




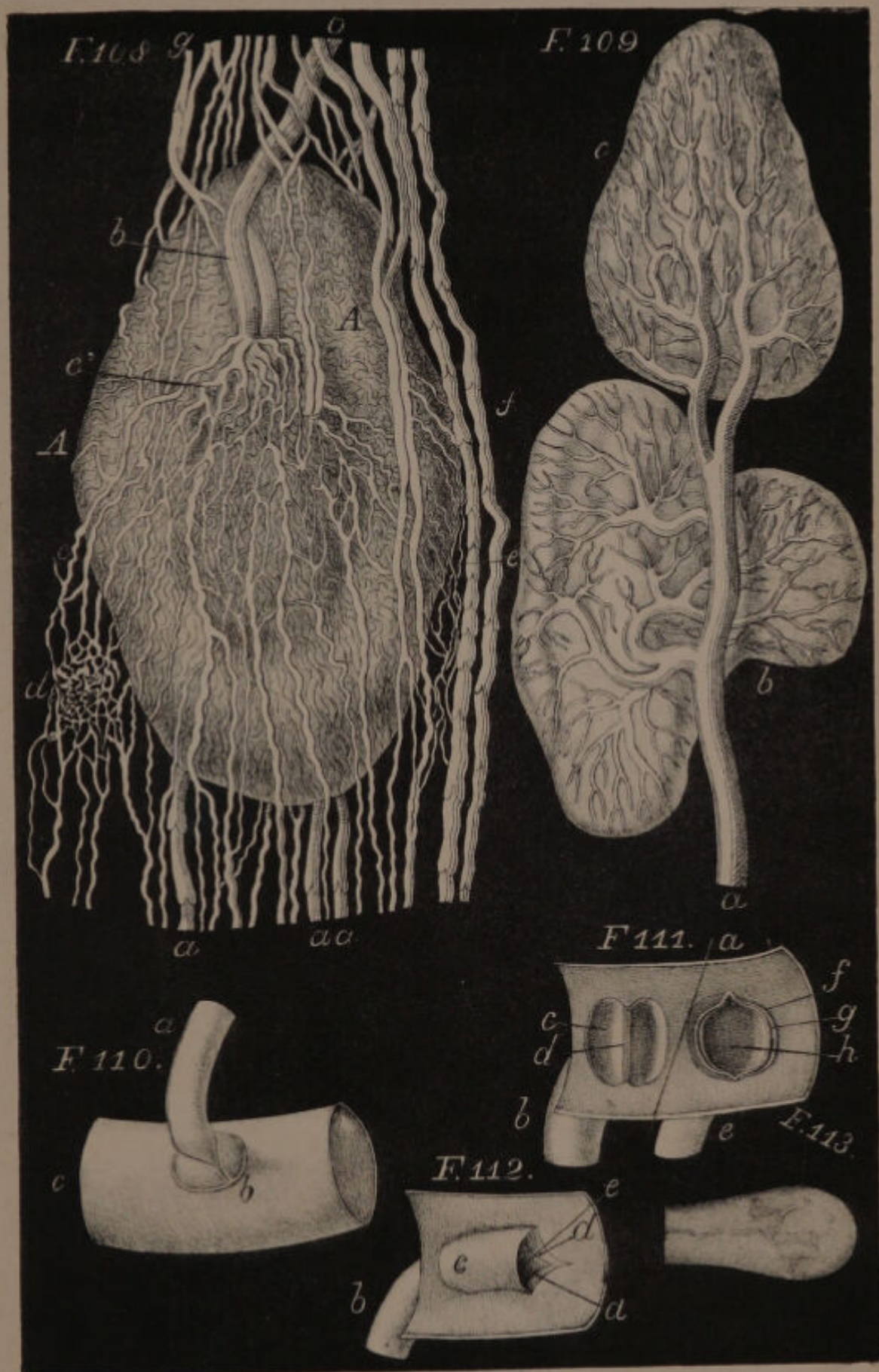
F. 107.



Modellir: Linceo.

Published by H. Bailliere, 219, Regent Street, 1841.

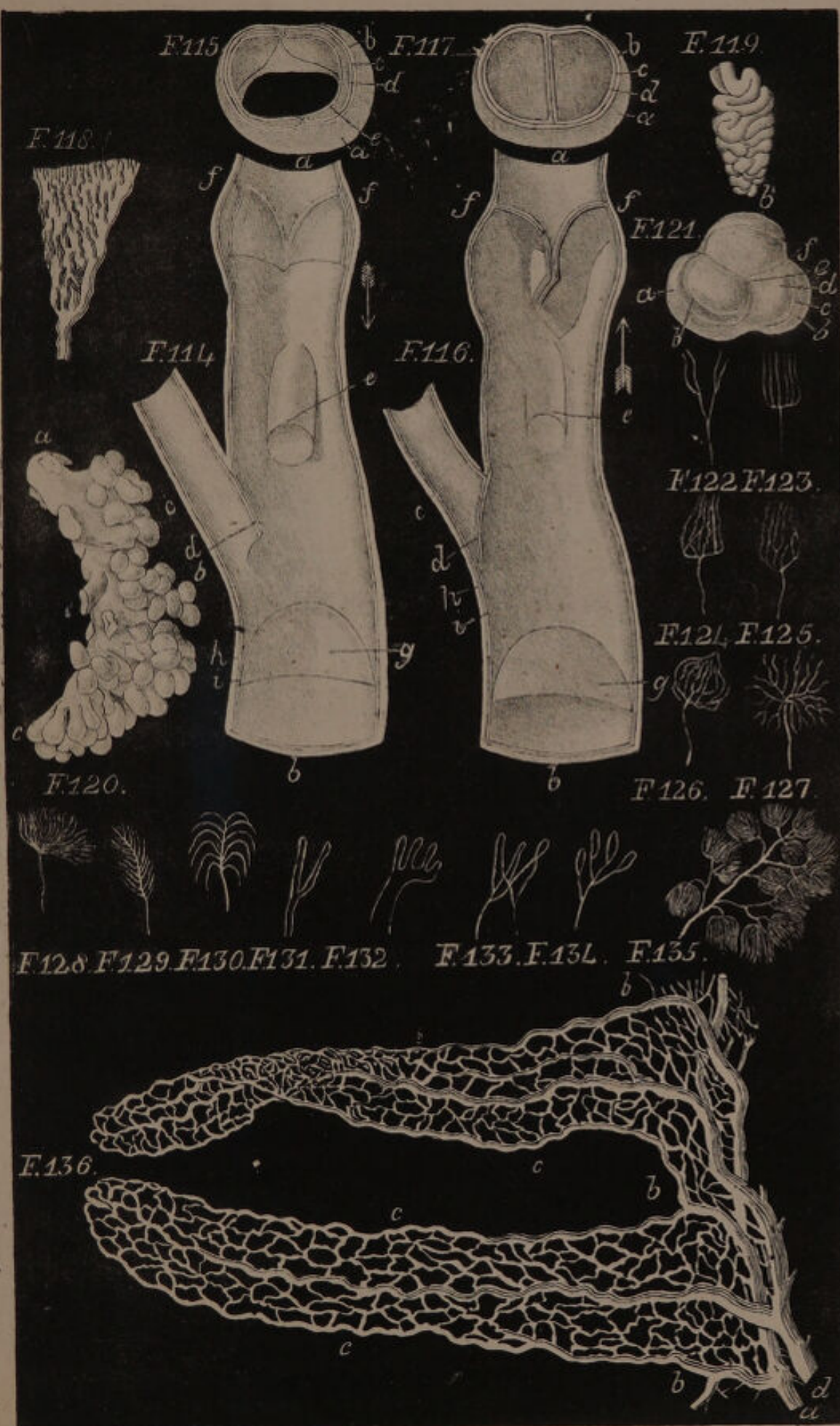




Modell. von

Stadell del.







F.137.



F.138.



F.139.



F.140.



F.141.



F.142.



F.143.



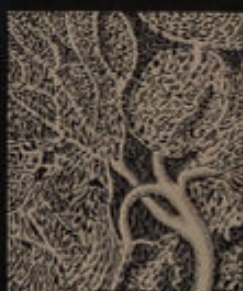F.144.



F.145.



F.146.



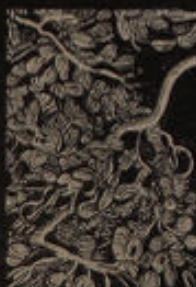F.147.



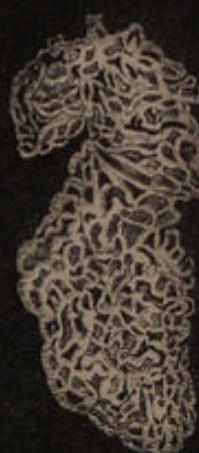F.148.



F.149.



F.150.




F.151.



F.152.

*Leon Albinus Zinn.*

*Abraham Zinn.*





F. 153.



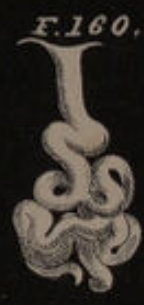F. 154.



F. 156.



F. 155.



F. 160.



F. 161.



F. 159.

F. 158.



F. 157.




F. 240.



F. 239.



F. 242.



F. 162.

F. 163.

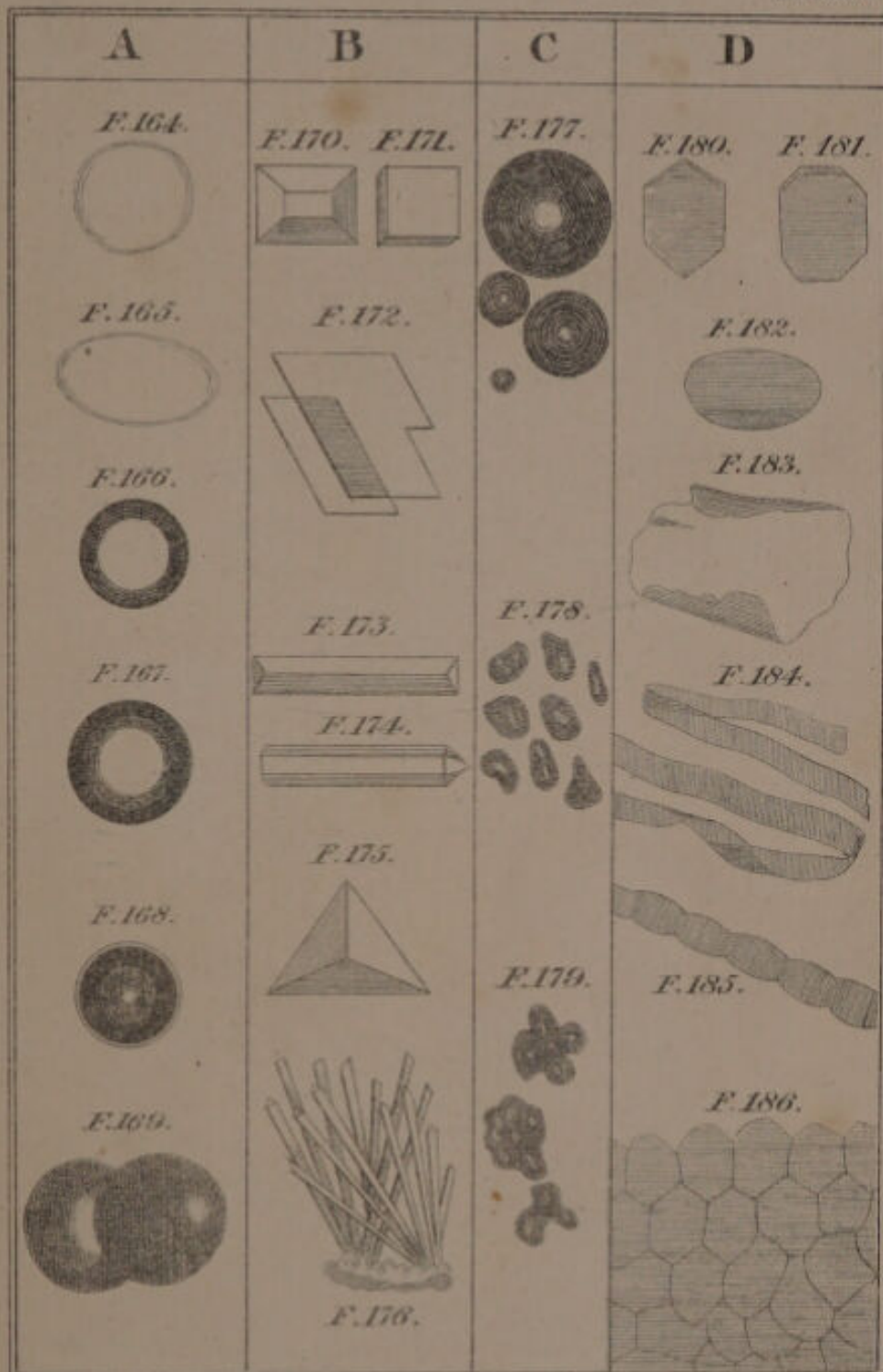


F. 249.


F. 250.

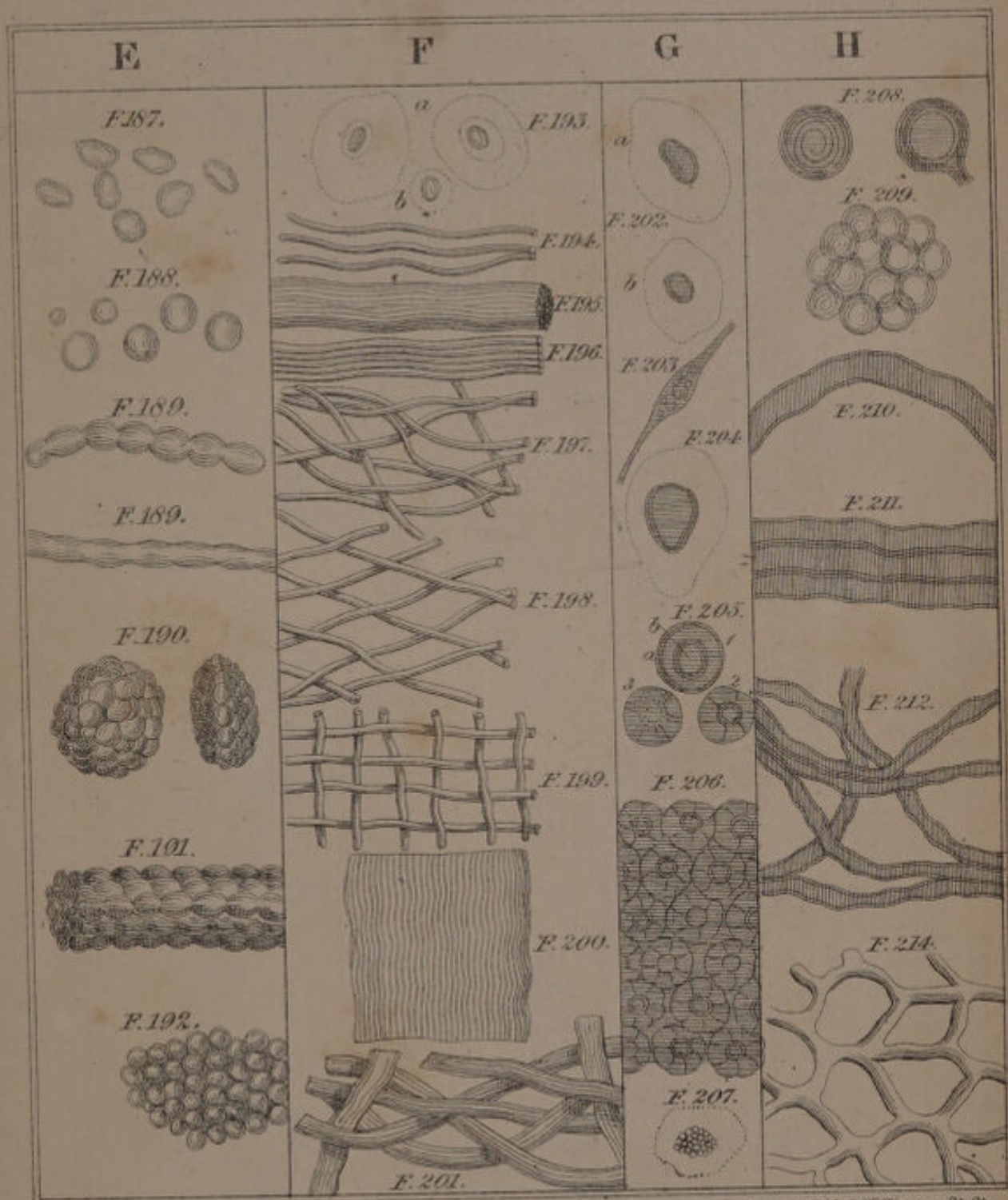
F. 251.






Middleby, lith. 3 Wellington St. Strand.






London: J. B. Baillière, 218, Regent St. 1841.





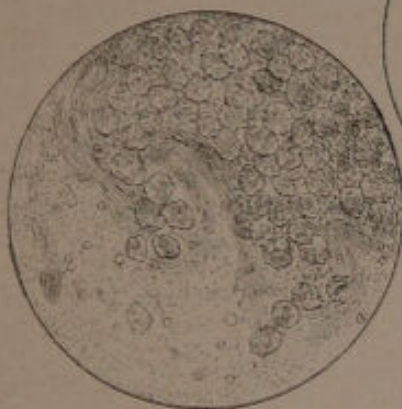
Madeley, lith. 3. Wellington-St. Strand



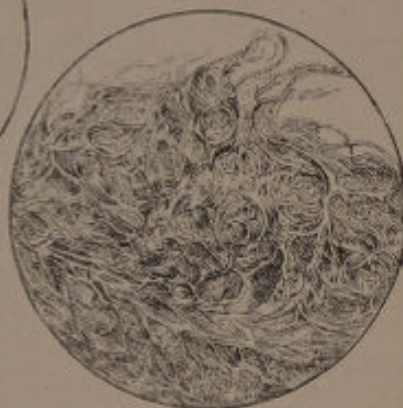
F. 244.



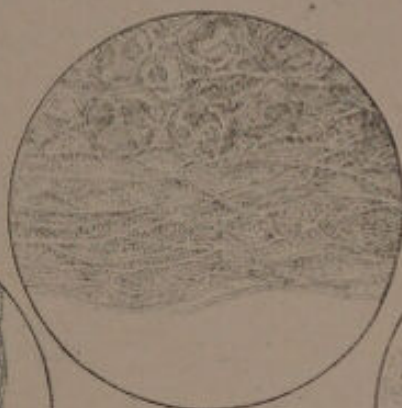F. 243.



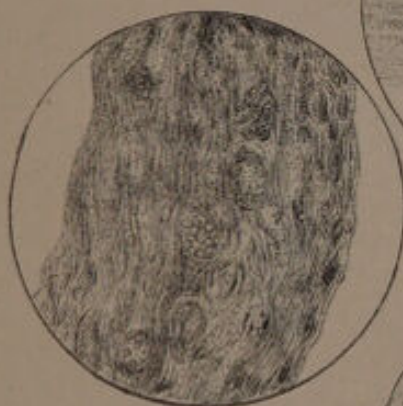
F. 245.



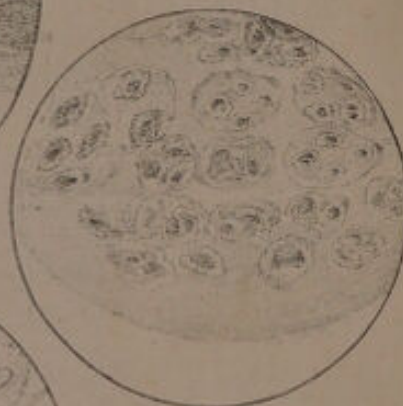F. 247.



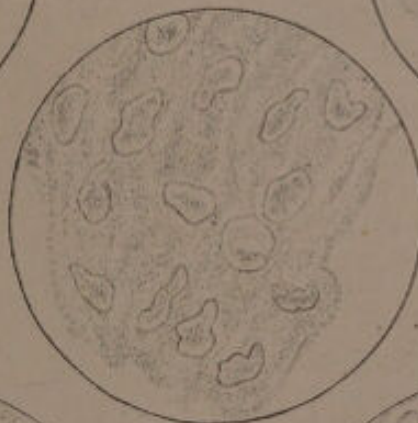F. 246.



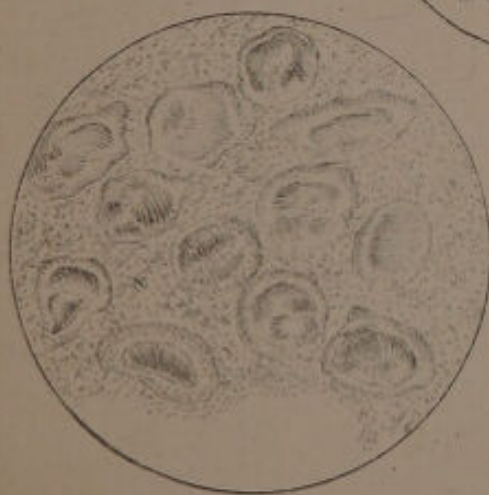F. 248.



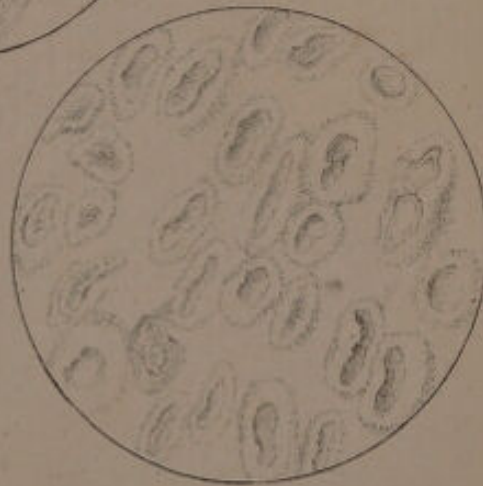
F. 250.



F. 249.

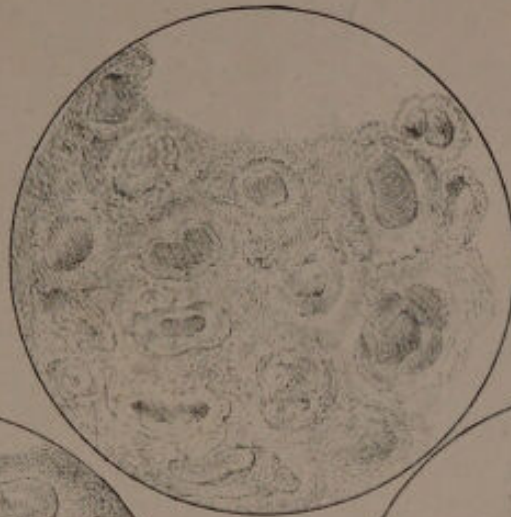


F. 251.

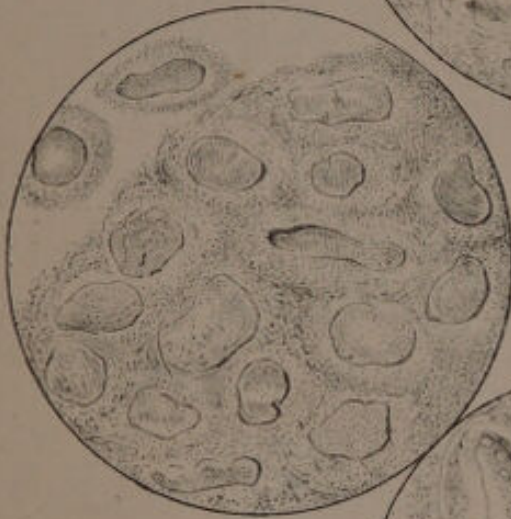



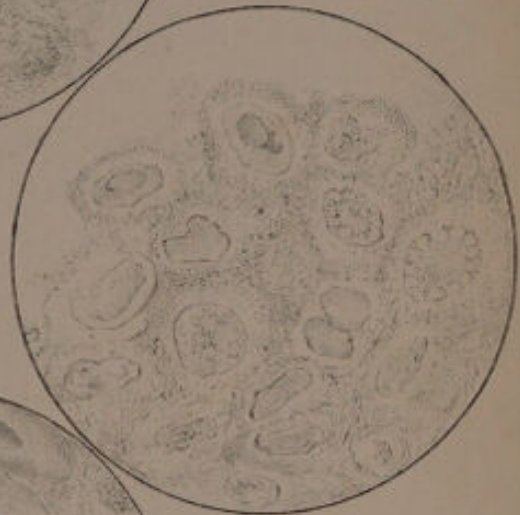F. 252.



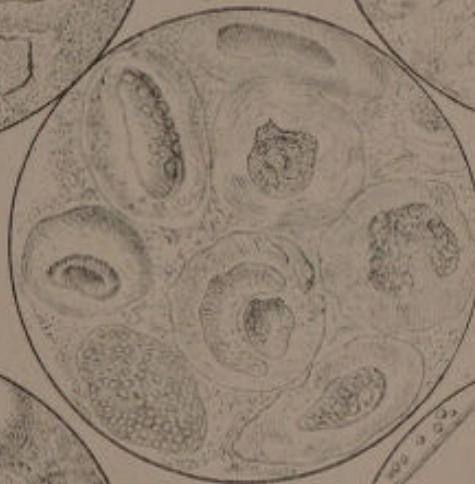
F. 255.



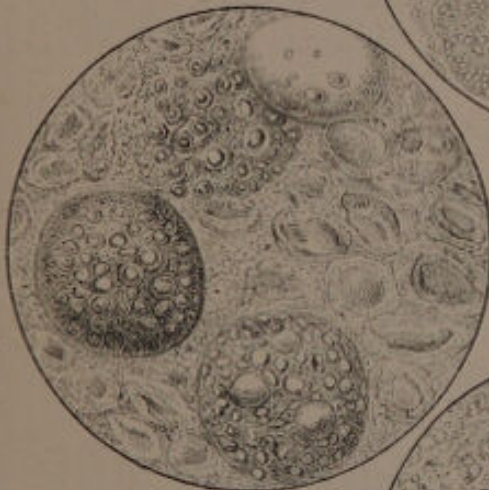
F. 254.



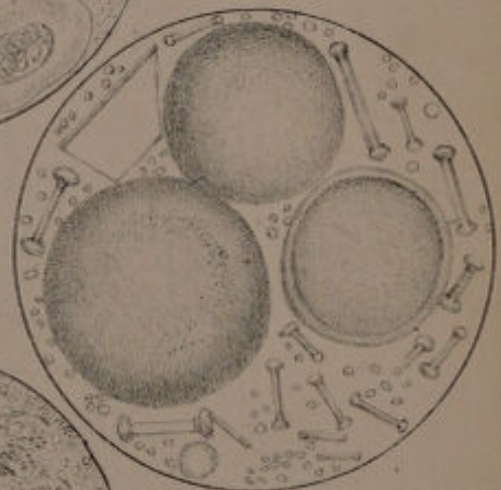
F. 256.



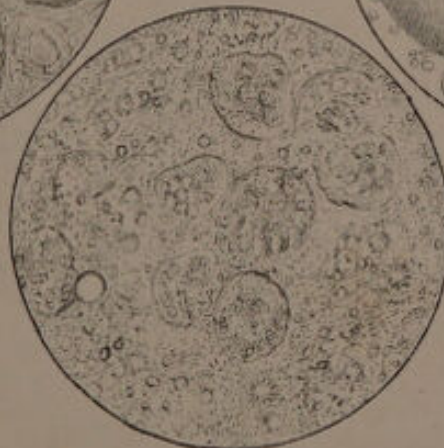F. 258.




F. 257.



F. 256.

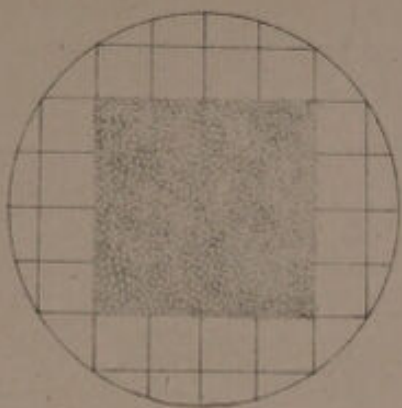




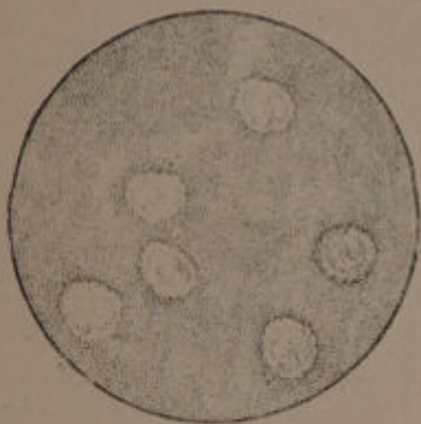
Unable to display this page

Unable to display this page

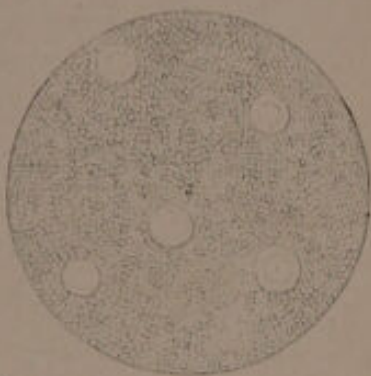
F. 274.



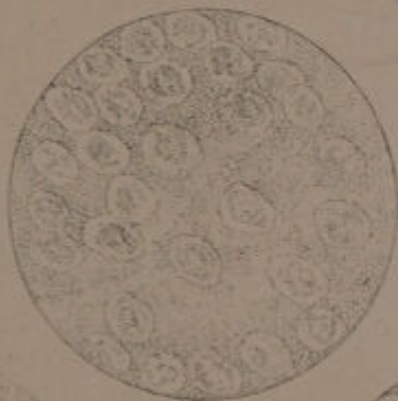
F. 275.



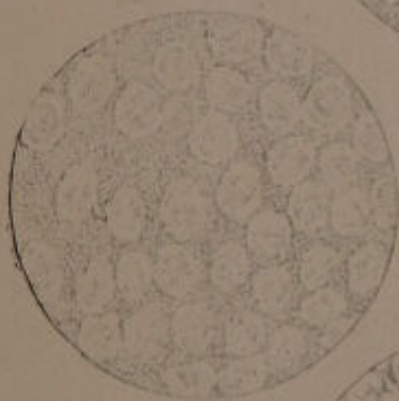
F. 276.



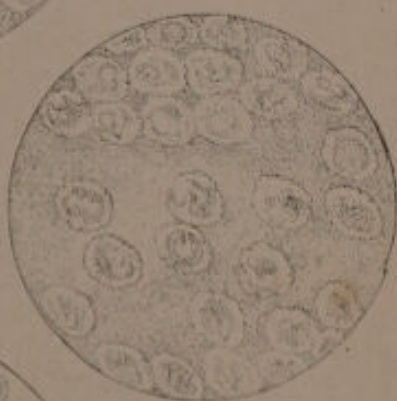F. 277.



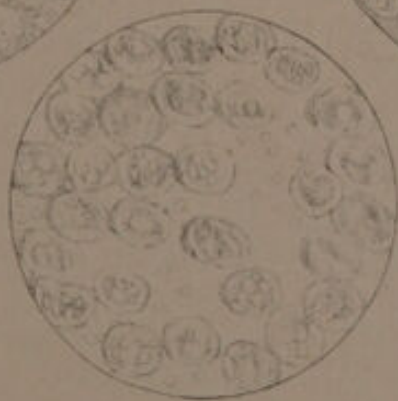F. 278.



F. 279.




F. 280.

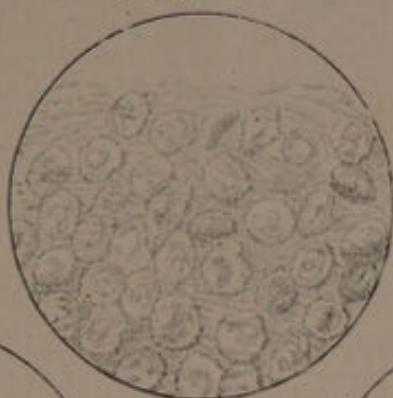


*Madley, Engr.*

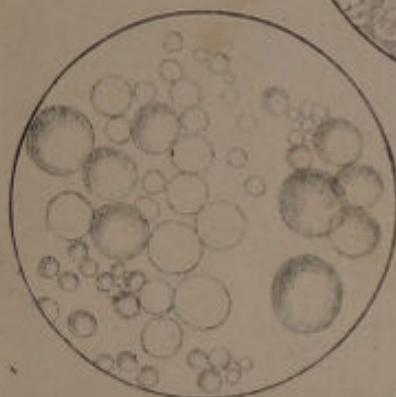
*J. Sadler, Sc.*



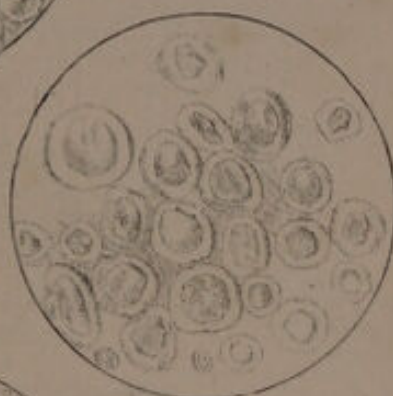F. 281.



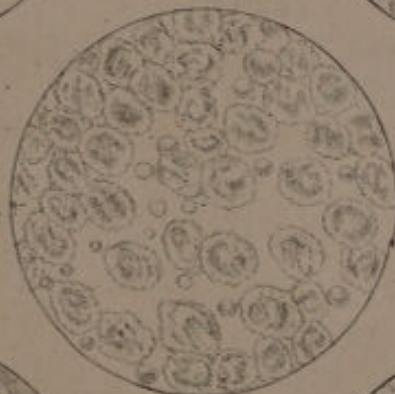
F. 282.



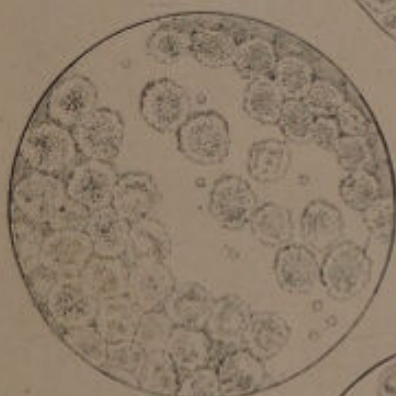
F. 283.



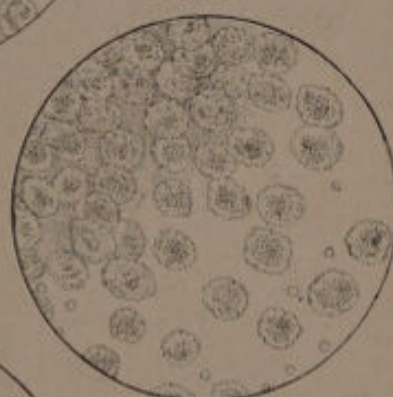
F. 284.



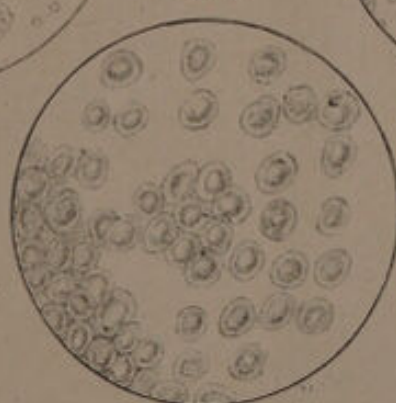
F. 285.



F. 286.



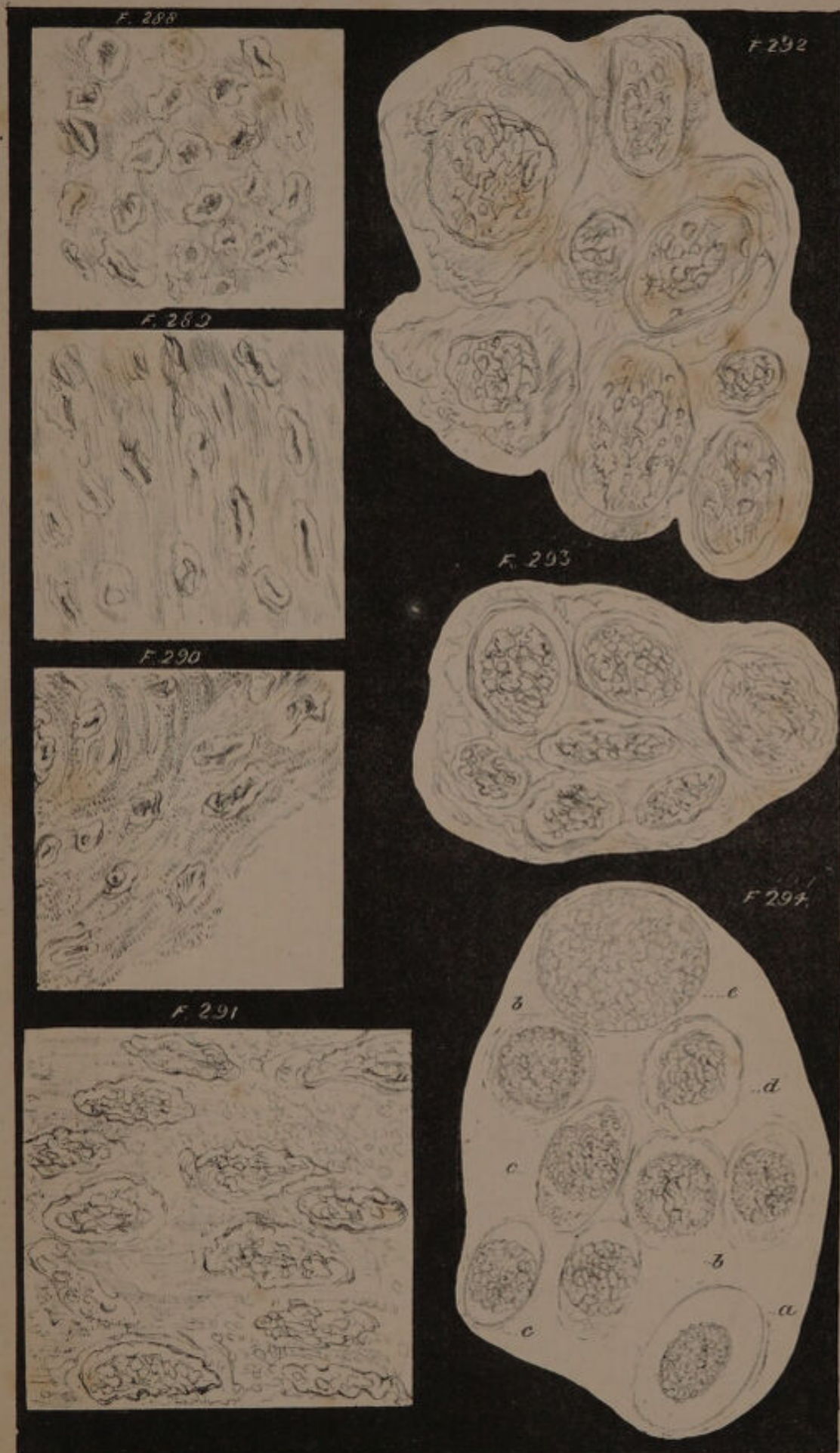F. 287.



*Handley. Pinx.*


*J. Siddall. del.*







Maddox lines

Siddall, del.







L L

