

**M0007803: Wound after removal of mamma and axillary glands, from
Cheyne: Antiseptic Surgery (1882)**

Publication/Creation

1941

Persistent URL

<https://wellcomecollection.org/works/ved4zy6v>

License and attribution

This work has been identified as being free of known restrictions under copyright law, including all related and neighbouring rights and is being made available under the Creative Commons, Public Domain Mark.

You can copy, modify, distribute and perform the work, even for commercial purposes, without asking permission.



Wellcome Collection
183 Euston Road
London NW1 2BE UK
T +44 (0)20 7611 8722
E library@wellcomecollection.org
<https://wellcomecollection.org>

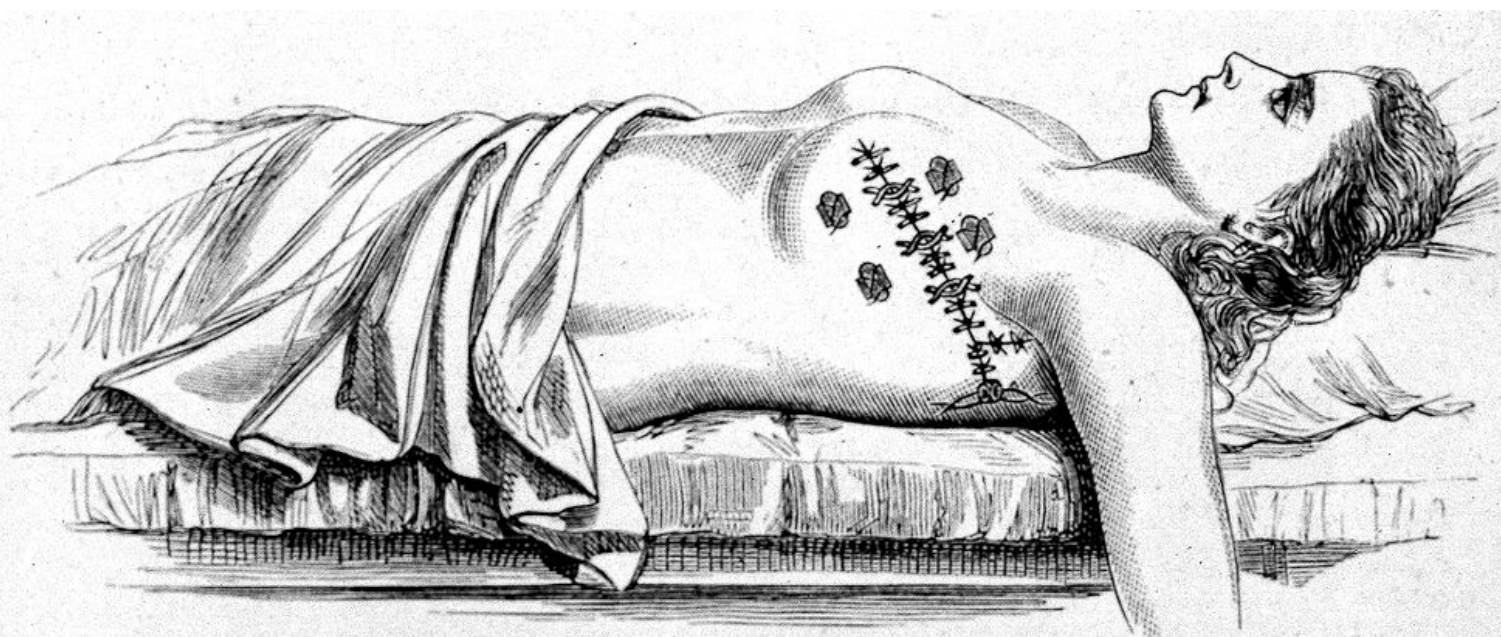


FIG. 35.—WOUND AFTER REMOVAL OF MAMMA AND AXILLARY GLANDS,
STITCHED.

To show the three kinds of stitches. The button stitches will be at once recognised ; the thick stitches, of which three are represented, are the stitches of relaxation ; and the remainder are the stitches of coaptation.