

**M0007814: Abscess dressing from behind, from Cheyne: Antiseptic Surgery (1882) / M0007815: Lumbar abscess dressing from behind, from Cheyne: Antiseptic Surgery (1882)**

**Publication/Creation**

1941

**Persistent URL**

<https://wellcomecollection.org/works/rg2v3srq>

**License and attribution**

This work has been identified as being free of known restrictions under copyright law, including all related and neighbouring rights and is being made available under the Creative Commons, Public Domain Mark.

You can copy, modify, distribute and perform the work, even for commercial purposes, without asking permission.



Wellcome Collection  
183 Euston Road  
London NW1 2BE UK  
T +44 (0)20 7611 8722  
E [library@wellcomecollection.org](mailto:library@wellcomecollection.org)  
<https://wellcomecollection.org>

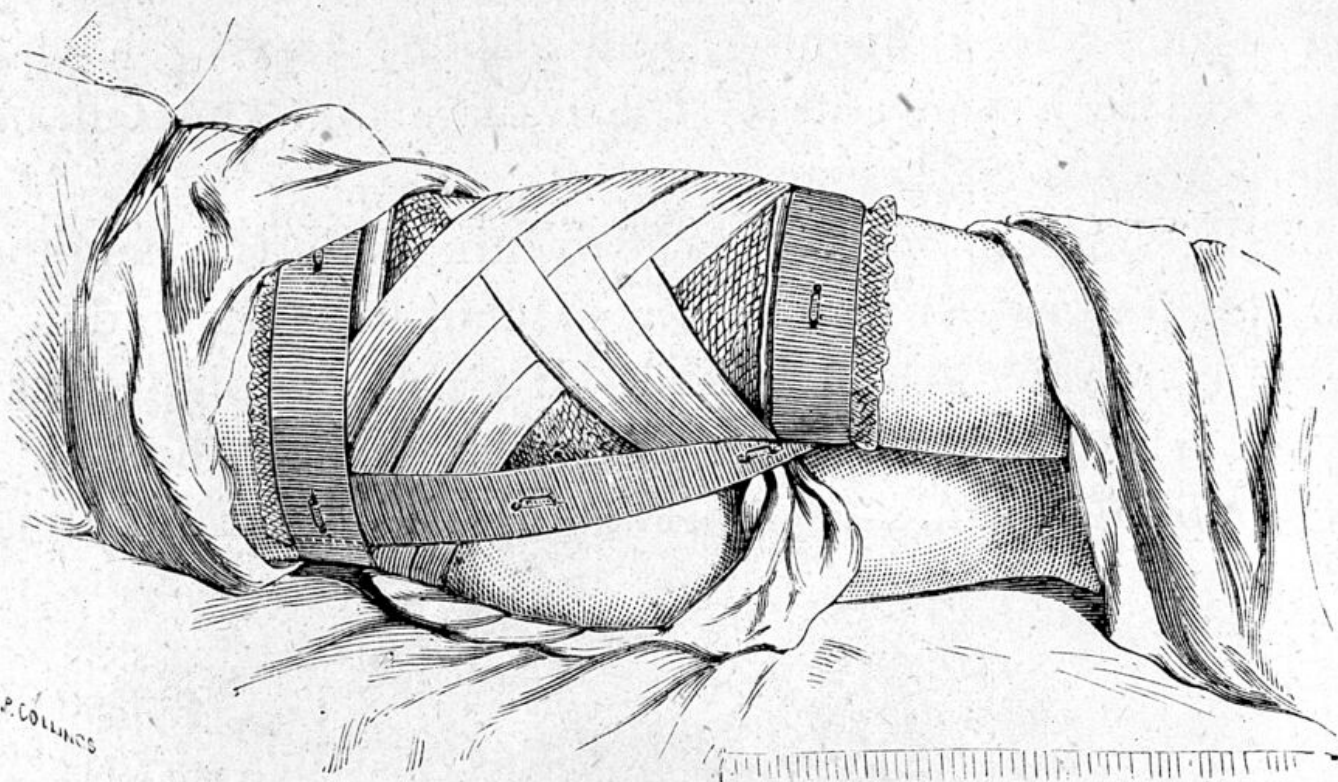


FIG. 48.—PSOAS ABSCESS DRESSING (FIG. 47), SEEN FROM BEHIND.

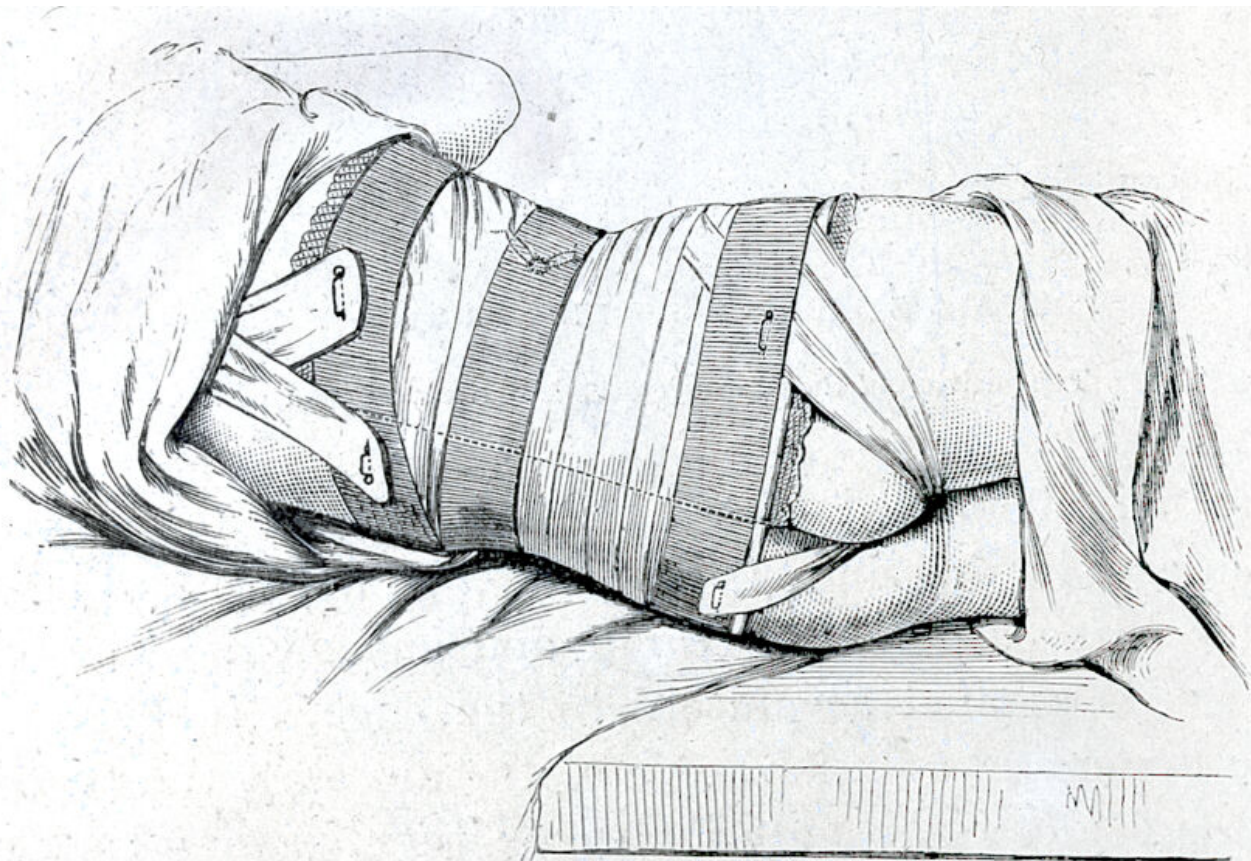


FIG. 49.—DRESSING IN A CASE OF LUMBAR ABSCESS, SEEN FROM BEHIND.

The position of the drainage tube is indicated by dotted lines; the vertical dotted lines at the middle of the back indicate the edge of the dressing.