

M0009240: Incisor of a camel from the pliocene of the snake creek beds of Nebraska showing in the cleft dentine a possible instance of dental caries, from Moodie: Paleopathology

Publication/Creation

September 1945

Persistent URL

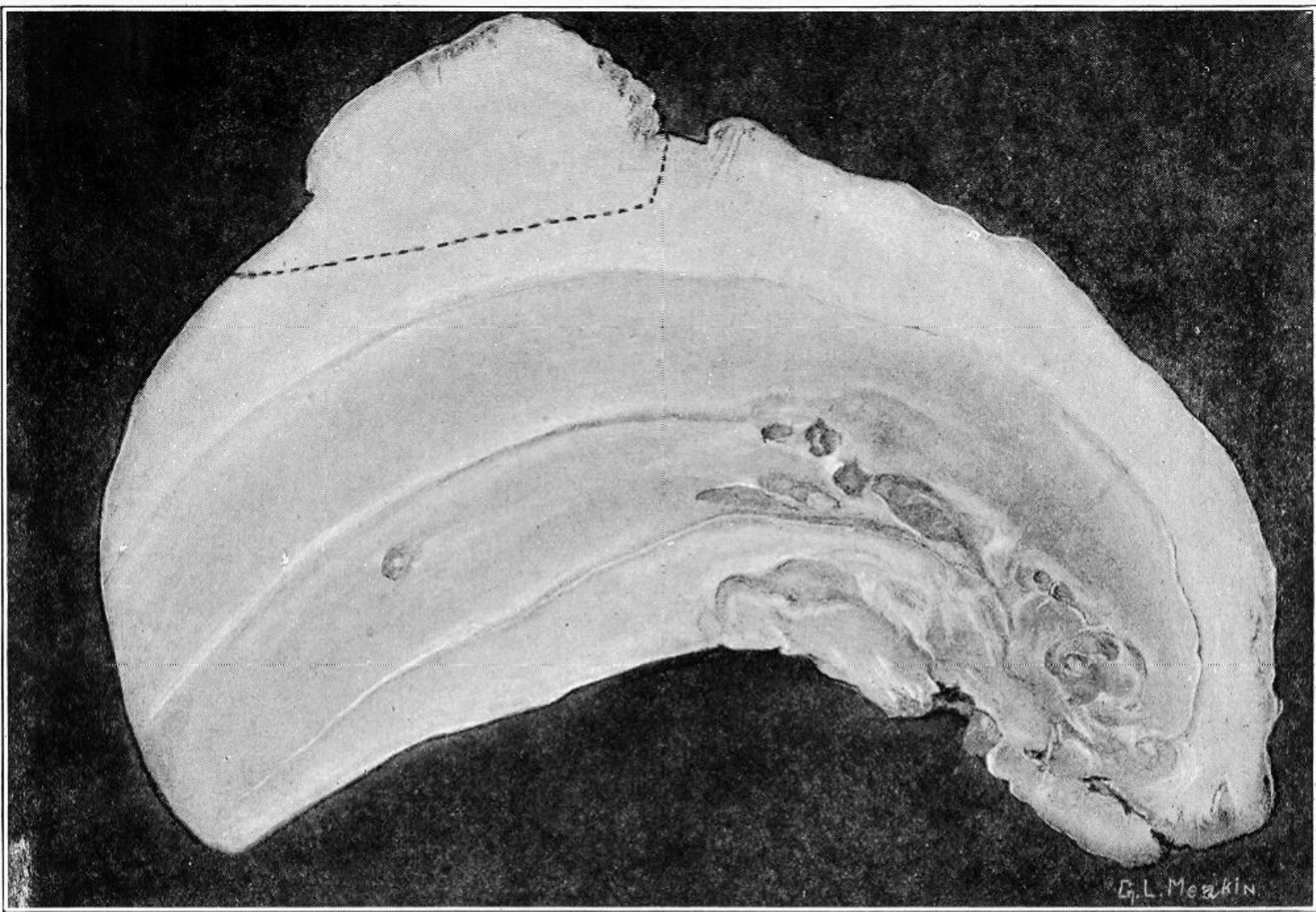
<https://wellcomecollection.org/works/amph2jf5>

License and attribution

Conditions of use: it is possible this item is protected by copyright and/or related rights. You are free to use this item in any way that is permitted by the copyright and related rights legislation that applies to your use. For other uses you need to obtain permission from the rights-holder(s).



Wellcome Collection
183 Euston Road
London NW1 2BE UK
T +44 (0)20 7611 8722
E library@wellcomecollection.org
<https://wellcomecollection.org>



E. L. Meakin