

M0005581: Illustrations of 13 mouths showing tooth extractions

Publication/Creation

August 1938

Persistent URL

<https://wellcomecollection.org/works/pvpk6bjx>

License and attribution

Wellcome Library; GB.

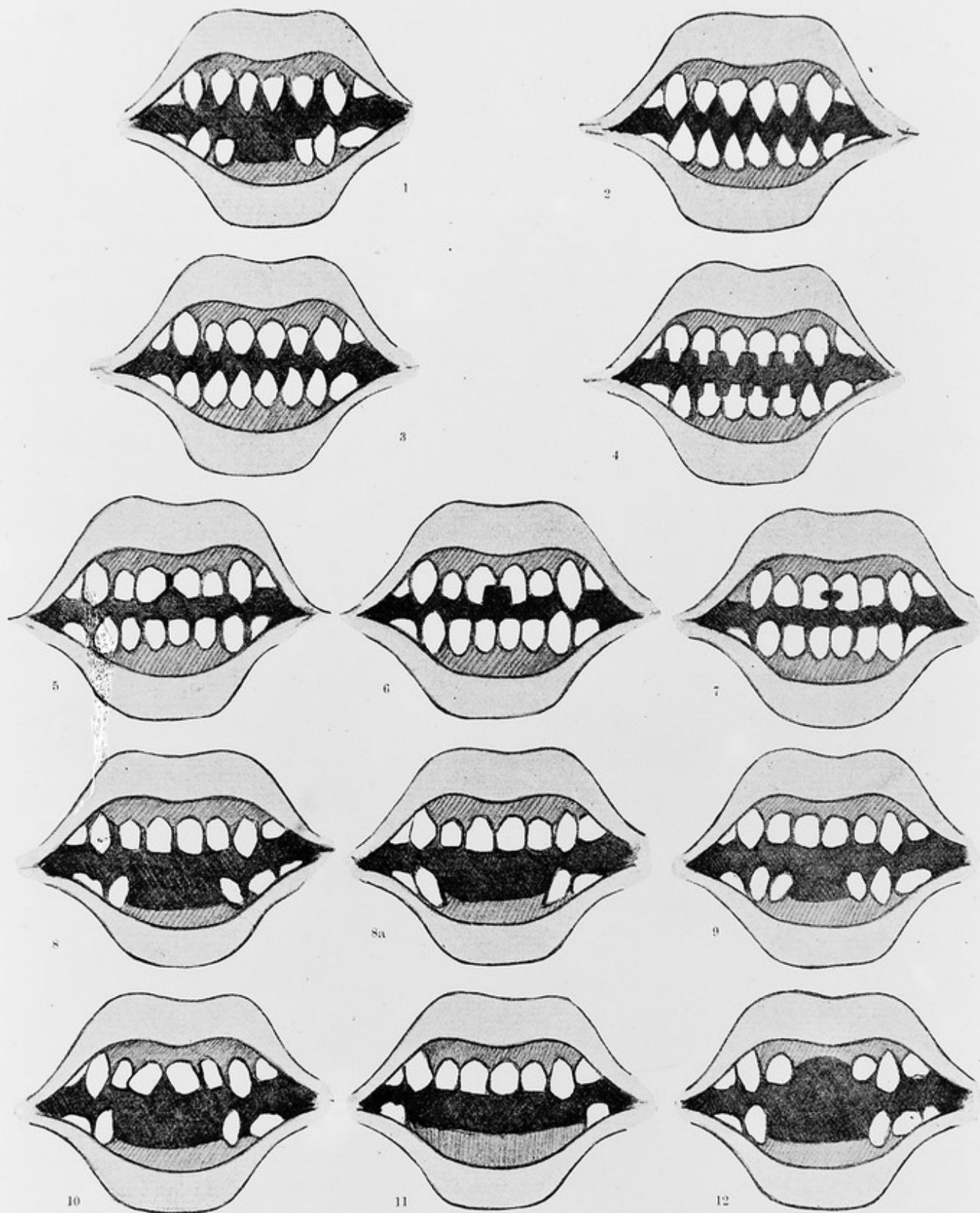
You have permission to make copies of this work under a Creative Commons, Attribution license.

This licence permits unrestricted use, distribution, and reproduction in any medium, provided the original author and source are credited. See the Legal Code for further information.

Image source should be attributed as specified in the full catalogue record. If no source is given the image should be attributed to Wellcome Collection.



Wellcome Collection
183 Euston Road
London NW1 2BE UK
T +44 (0)20 7611 8722
E library@wellcomecollection.org
<https://wellcomecollection.org>



H. G. ANDERSON

EXTRACTION AND MUTILATION OF TEETH

1. Extraction of lower and pointing of upper incisors. (Nyam-nyam).
- 2, 3 and 4. Sharpening and pointing of incisors and two lower canines. Various designs in use by the Zandeh Nyam-nyam.
- 5, 6 and 7. Sharpening and notching of central upper incisors by the Avungara (or Royal House).
- 8, 8a and 9. Removal of all or only the central lower incisors, with alterations in direction of the unopposed teeth. (Gebelawi Nyam-nyam, Makrakka, Bagaro and Gour).
10. Extraction of four lower, with separation of upper central incisors. (Bakka).
11. Extraction of four lower incisors and two lower canines. (Gour).
12. Extraction of four lower and two upper incisors. (Gour).