

M0004099: Page from Chyurgia Albucasim, Albucasis (Surgical Treatise, Al Zahrawi)

Publication/Creation

14 December 1934

Persistent URL

<https://wellcomecollection.org/works/g4zungnj>

License and attribution

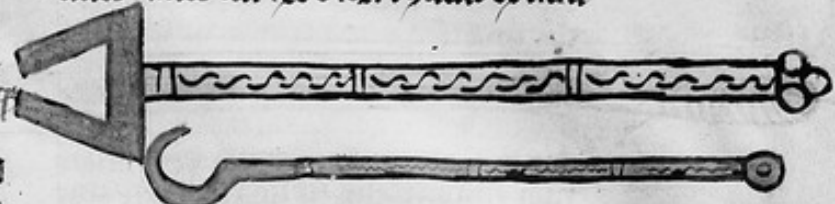
Conditions of use: it is possible this item is protected by copyright and/or related rights. You are free to use this item in any way that is permitted by the copyright and related rights legislation that applies to your use. For other uses you need to obtain permission from the rights-holder(s).



Wellcome Collection
183 Euston Road
London NW1 2BE UK
T +44 (0)20 7611 8722
E library@wellcomecollection.org
<https://wellcomecollection.org>

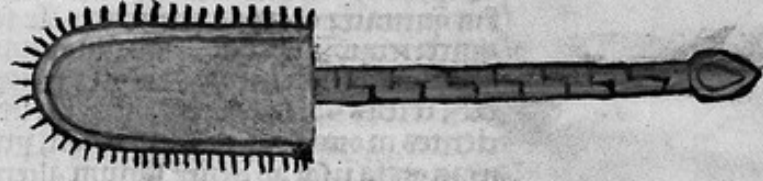
tere tē ad ex cegi ⁊ imple cū eo locū ⁊
sino. caucica ipm sino ⁊ fert t cegi. foz
foz capū sūbūm qbz mouet tēns imp
mis sine lōraz extremitatū breuima
nubūz crosi ut non duplicentur qm
cum es super dentem.

Et iam uuaat cū hēc instrumto habente ⁊
duos ramos cui hēc ē fōz. ⁊ galus ex istru



Sint sicut uides crossoz manubrioꝝ
dōn qn stngis cum eis nō tēnt. ipas nō
duplicentur breuium extremitatum.
Et sūz ex fero into aut ex faules tēcē
facti directaz extremitatūz. Et in eoz
extremitatibz sint dentes quoz quidaz
ingēdiant in qōdā ⁊ stngant ⁊ stēcē te
centi fortis. Et qnqz sunt extremitates
sic fōz ous auis que nominat cōna
et sunt fortis ⁊ stricois. Caplm cōssi
mū pmi te eradicaatē tēncū ⁊ extrac
tiō ossium mandibulaz fractaz.

ntic ⁊ sciamtis que pēsse ⁊ in rasiōe ten
tum. Et iā sit uuaatū q hēc instrumto
q assimilāt incō mag' cui hēc ē format
angulate extremitatis tōte in qē qōdam
ēsticūdis ut nō frangat. Et sic nō bibitū.
Et scias q instrumta tēncūm sē mltā ⁊
silitē reliq instrumta nō ⁊ putantē. Et arti
fer putens sūbūl marte sua inuēit p se
ipm instrumtū sū mltō q significat ei o
patō regnes ipē. Qn ex egnibz sūt ad qō
nō dūerūt antiq instrumtū p dūsi
tatem sūz eaz. Si autē frangitū os et
mātibulā aut ex alis ossibz ous aū pu
trefit tē pcutare sup ipm in loco suo qō
q pūcē ei ex instrumtis ⁊ forticibz. Et
ti inēctūe radiciū. Et uuaatē ⁊ gēsticū
forma est hēc




Quando remanet ap eradicaatē tēncū
qui frangit ad tē op ut pōas sup locum
cotum. ⁊ butiro die uno aut duobz die
bz tōnz mollificēt locus. sēctūte in tōmi
te ad illuz algēti aut fozipes qz exte
mitates assimilantē auis que nomi
natur cōna. forma fozapis.

Sit in eo qōdam ēsticūdis paulatū ul'te
neat ut stngat cum eo os nō ul' fugiat
euadat tōnz egēdiat os. Et restaura locū
cum medicanis pūcētibz ad illō. Si au
tē in osse est pūcēdo pua. tē tate ipm a
pūctēdie sua ⁊ sua ingēdie. Et cura ipm
donec sanet. Caplm cōssimū sū m tē
sēctūra tēncūm eminentium sup




Sint extremitates eoz sicut luna tēnt
aut sic altēskilfegi. Sig nō obedir tē
ad extum ⁊ istis forticibz. tē op ut car
ues radicez. ⁊ tētegas carnem totam
⁊ inēctūas instrumtū palanea atali
parua cui forma est hēc. Sit breuis

Quando dentes eminet alios:
Qnō stil' cū sūz sūū nēz. feda sit pūllō
forma ⁊ pūpue qn accidit illō in mulli
eibz ⁊ puellis. Op g' ut ⁊ scātēs. Mā si tēnc
ē natus p' tēncem aliū ⁊ nō locat ul' est
possibil' ei serratā. nō limatā ipm. tē era
dica ipm. Et sic anēz us ⁊ tēncē alio tūc
in tate ipm qūsto instrumto cui hēc ē forma.



extremitatis esse pūp. Et nō sit inbibitū
ut nō frangat. Sig egēditē radice pūllō ē
tōnū. Et sino uuaatē qūstis instrumtis
aliis qz forme sūt iste fōz pmi tangu
late extremitatis in qua ē qōdaz ēsticūto.



forma tangu late subtilis.

Et sicut rostro puo. Et sit ex ferro into a
cūte extremitatis ualce. Et sit inasiotua
qūpm inactis in diebz mltis p' dūncē

