

M0003446: X-ray of skull / M0003446EA: "Humerus, Radius and Ulna from Skeleton No. 8" Quincy, Illinois

Publication/Creation

15 March 1933

Persistent URL

<https://wellcomecollection.org/works/pb4pgdzu>

License and attribution

Conditions of use: it is possible this item is protected by copyright and/or related rights. You are free to use this item in any way that is permitted by the copyright and related rights legislation that applies to your use. For other uses you need to obtain permission from the rights-holder(s).



Wellcome Collection
183 Euston Road
London NW1 2BE UK
T +44 (0)20 7611 8722
E library@wellcomecollection.org
<https://wellcomecollection.org>

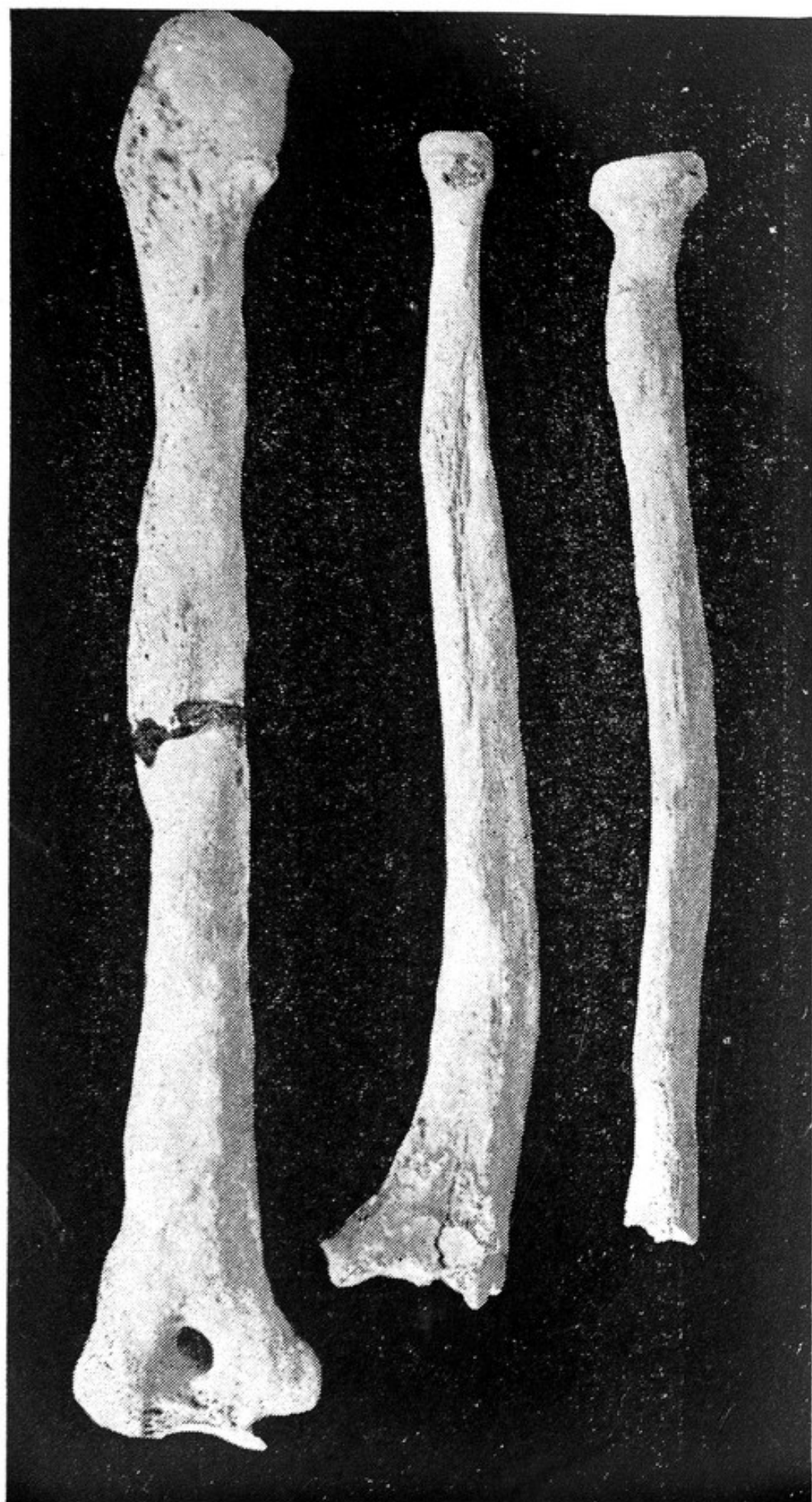

FIG. 6. HUMERUS, RADIUS AND ULNA FROM SKELETON No. 8 (QUINCY, ILL.) SHOWING THE HYPEROSTOTIC CHANGES DESCRIBED IN THE TEXT.

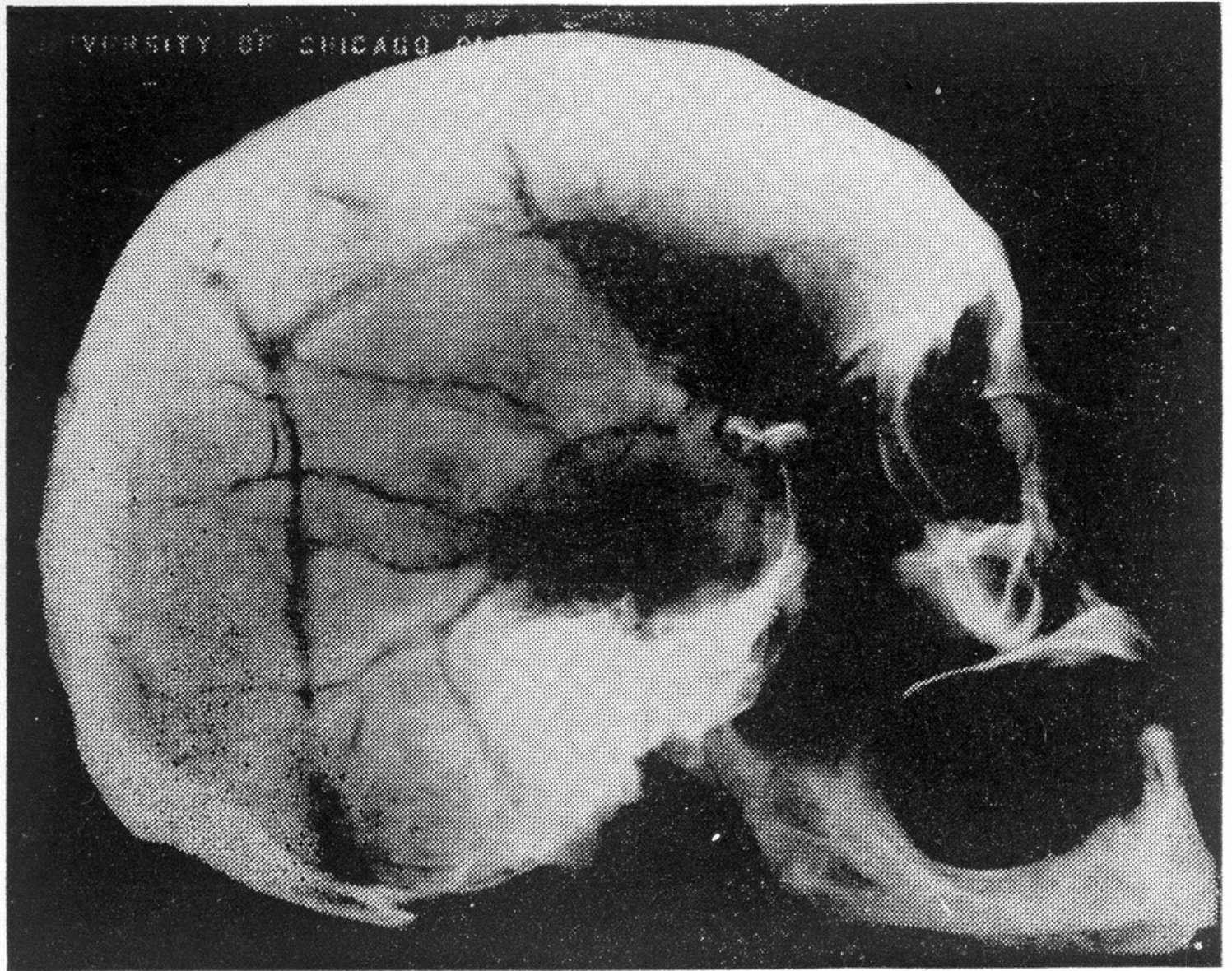


FIG. 5. ROENTGENOGRAM OF SKULL W. 3. THE ENTIRE CALVARIUM APPEARS DENSELY SCLEROTIC. THE DEPRESSIONS NOTED GROSSLY ARE HERE BARELY VISIBLE.