

M0002833: Microscopic view of Scurvy in an infant

Publication/Creation

03 March 1932

Persistent URL

<https://wellcomecollection.org/works/awyk68vr>

License and attribution

Conditions of use: it is possible this item is protected by copyright and/or related rights. You are free to use this item in any way that is permitted by the copyright and related rights legislation that applies to your use. For other uses you need to obtain permission from the rights-holder(s).



Wellcome Collection
183 Euston Road
London NW1 2BE UK
T +44 (0)20 7611 8722
E library@wellcomecollection.org
<https://wellcomecollection.org>

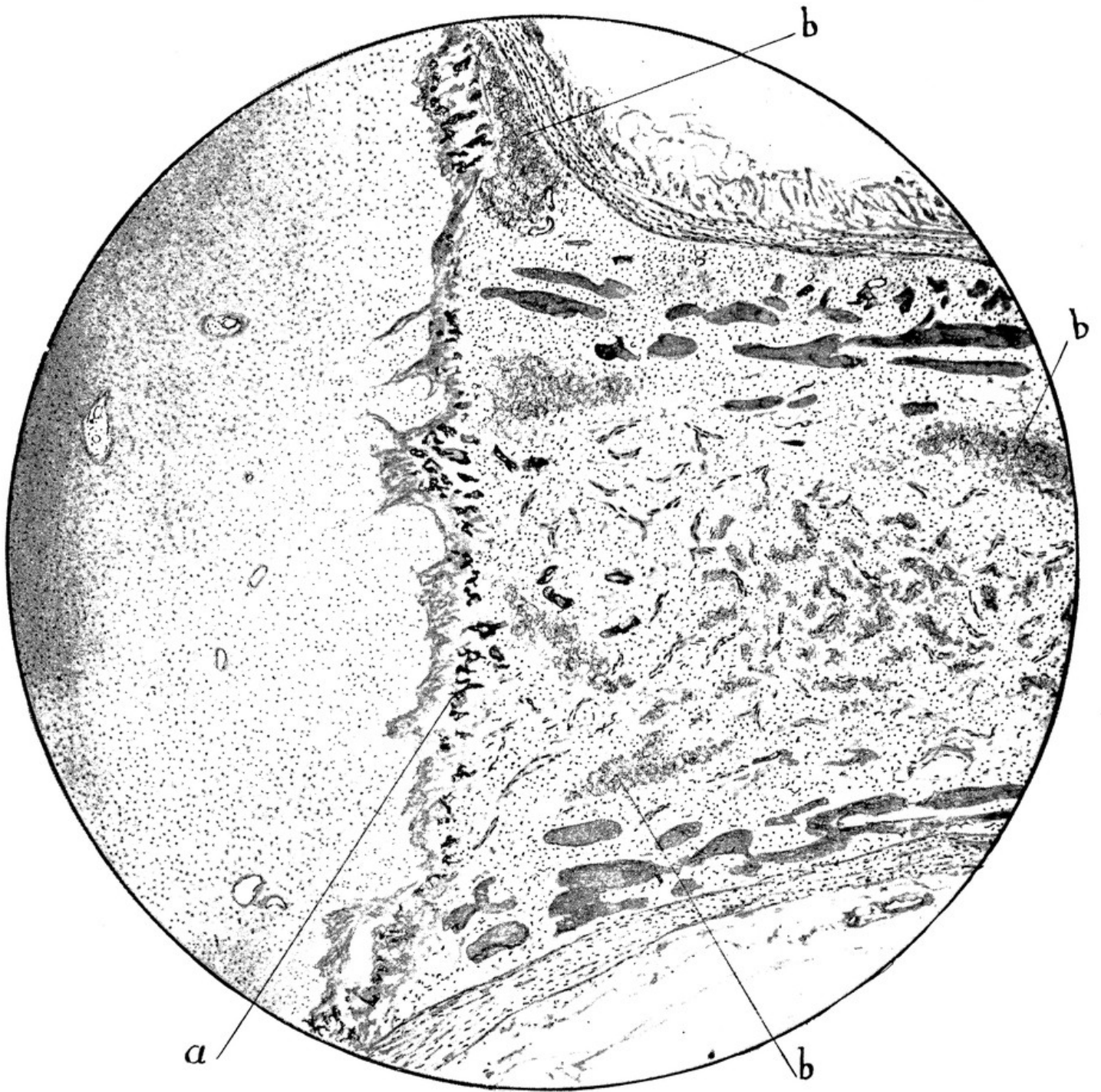


FIG. 5.—Infantile scurvy. Epiphyseal junction of lower end of femur: (a) calcified cartilage at "Truemmerfeld"; (b) hemorrhage in the fibrous marrow (Gernest-mark). Bone cortex and trabeculae abnormally thin. McCallums' Text Book of Pathology. W. B. Saunders Co.