

**Observations on fungus hæmatodes or soft cancer, in several of the most important organs of the human body: containing also a comparative view of the structure of fungus hæmatodes and cancer. With cases and dissections / By James Wardrop.**

**Contributors**

Wardrop, James, 1782-1869.

**Publication/Creation**

Edinburgh : Printed by G. Ramsay and company, for A. Constable and company; [etc., etc.], 1809.

**Persistent URL**

<https://wellcomecollection.org/works/gea7b6ud>

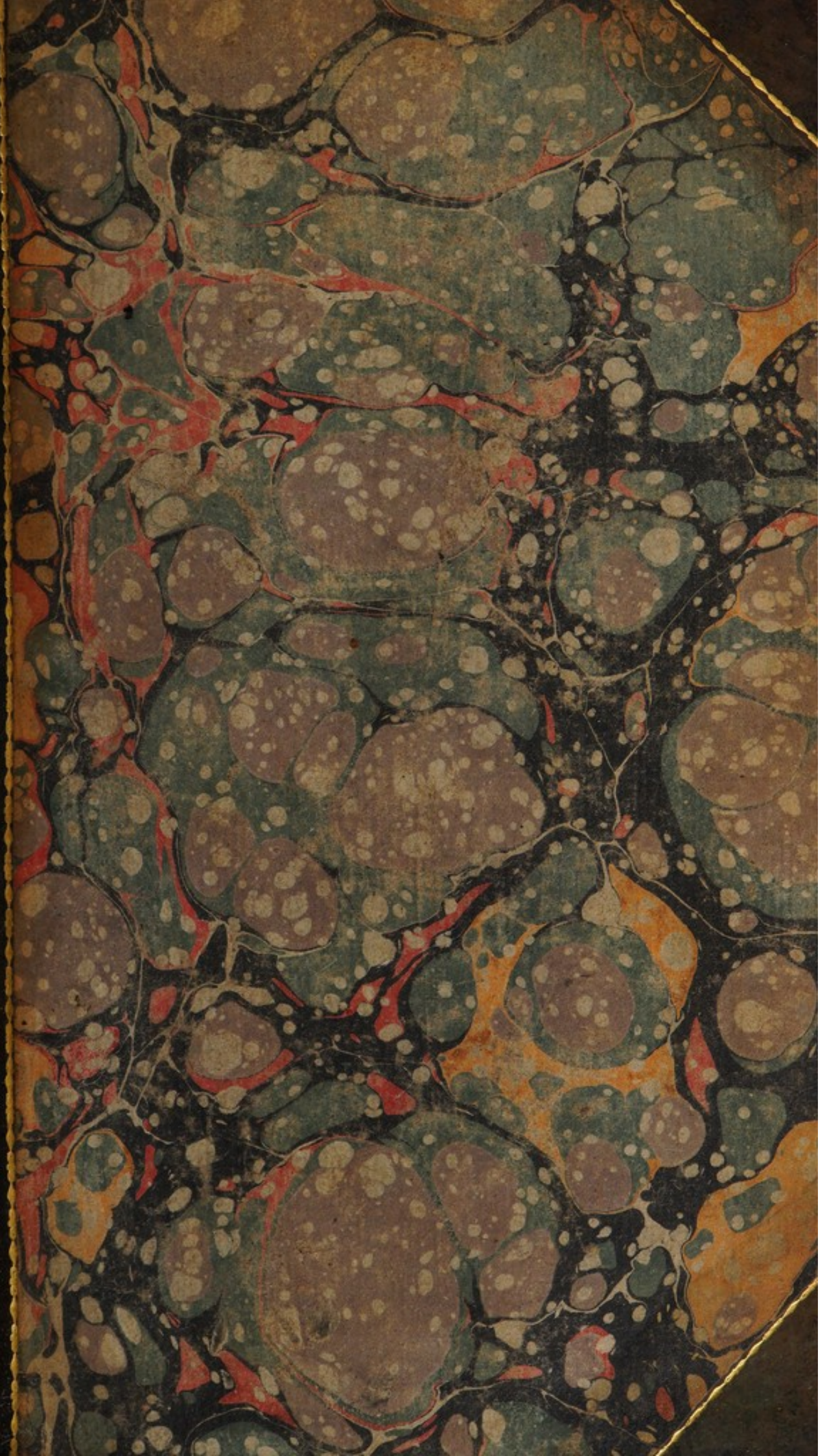
**License and attribution**

This work has been identified as being free of known restrictions under copyright law, including all related and neighbouring rights and is being made available under the Creative Commons, Public Domain Mark.

You can copy, modify, distribute and perform the work, even for commercial purposes, without asking permission.



Wellcome Collection  
183 Euston Road  
London NW1 2BE UK  
T +44 (0)20 7611 8722  
E [library@wellcomecollection.org](mailto:library@wellcomecollection.org)  
<https://wellcomecollection.org>





EPB/B

54507/B


F. XIV. c


19

7/6







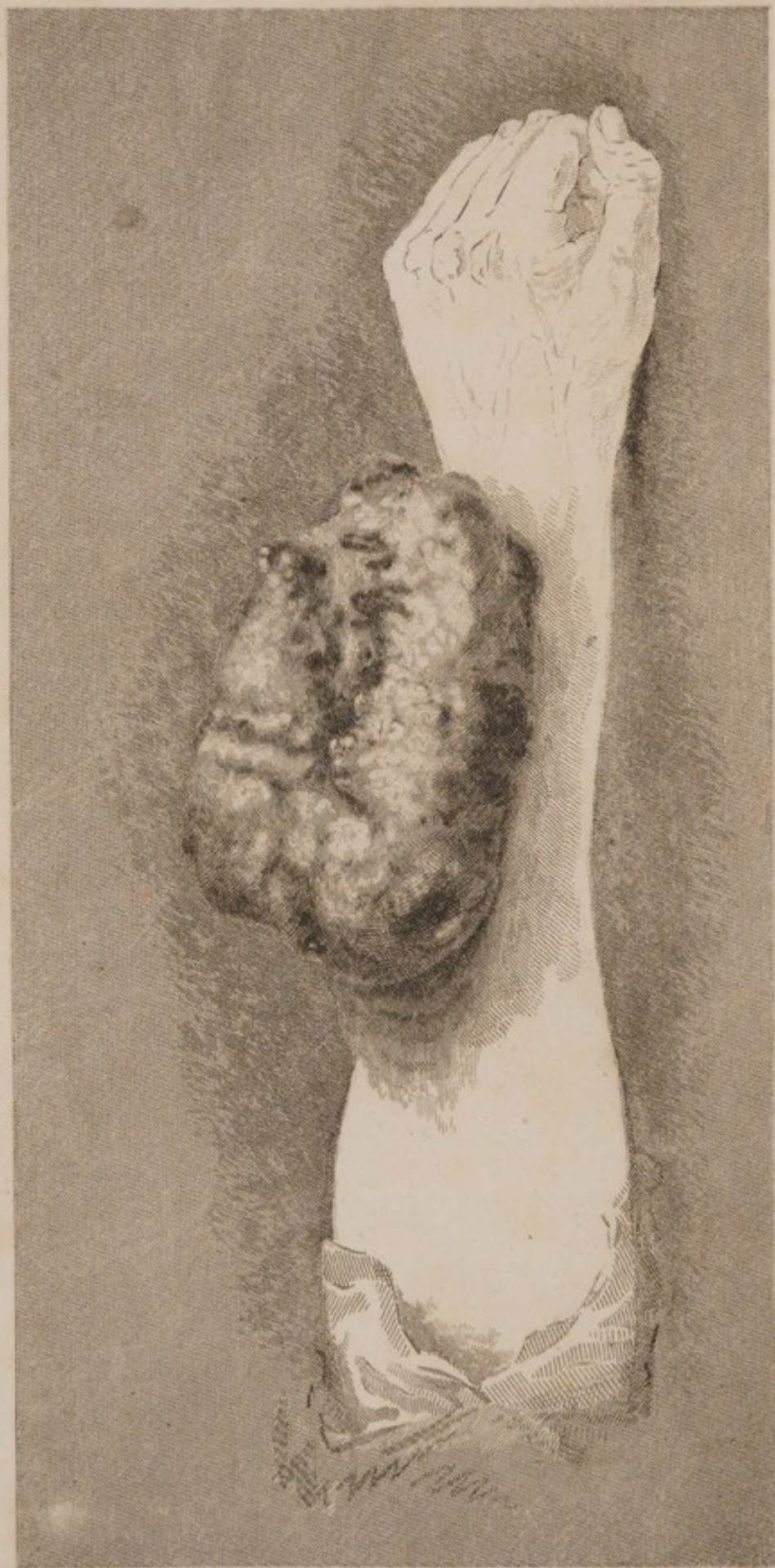












FUNGUS HÆMOTADES OF THE ARM.




50761

OBSERVATIONS  
ON  
FUNGUS HÆMATODES  
OR  
SOFT CANCER,  
IN SEVERAL OF  
THE MOST IMPORTANT ORGANS  
OF THE  
HUMAN BODY:


CONTAINING ALSO A COMPARATIVE VIEW OF THE STRUCTURE OF  
FUNGUS HÆMATODES AND CANCER.

WITH CASES AND DISSECTIONS.



BY  
JAMES WARDROP, F.R.S.E.

FELLOW OF THE ROYAL COLLEGE OF SURGEONS, AND ONE OF THE SURGEONS  
OF THE PUBLIC DISPENSARY OF EDINBURGH.



ILLUSTRATED BY PLATES.

EDINBURGH:

*Printed by George Ramsay and Company,*  
FOR ARCHIBALD CONSTABLE AND COMPANY, EDINBURGH; AND  
CONSTABLE, HUNTER, PARK, AND HUNTER,  
LONDON.

1809.



OBSERVATIONS  
ON  
FUNGUS HÆMATODES  
OR  
MARTIN'S SOFT CANCER  
IN A REPORT OF  
THE MOST IMPORTANT ORGANS  
OF THE  
HUMAN BODY

CONTAINING ALSO A GENERAL VIEW OF THE SYSTEMS OF  
THESE ORGANISMS AND THEIR  
WITH CASES AND DISSECTIONS

BY  
JAMES WARDROPE, F.R.S.E.  
MEDICAL OFFICER OF GENERAL HOSPITAL, AND ONE OF THE PHYSICIANS  
OF THE GREAT DISPENSARY OF EDINBURGH

EDINBURGH  
Printed by George Thomson and Company  
THE SCOTLAND DISPENSARY AND GENERAL DISPENSARY, 200  
CORNHILL, EDINBURGH.



TO

**MATTHEW BAILLIE, M. D. F. R. S.**

FELLOW OF THE ROYAL COLLEGE OF PHYSICIANS OF LONDON,

&c. &c. &c.

DEAR SIR,

*THE advantages which the science of Medicine has derived from your valuable work on the Morbid Anatomy of the Human Body, induce me to lay the following observations before the public under the patronage of your name.*

*Impressed with the opinion that inquiries, conducted in the manner you have so successfully pursued, afford the surest means of ascertaining the true nature of diseases, and lead to the best criterion for distinguishing them from each other, I have endeavoured to follow the path which you have pointed out, and attempted, by dissection, to distinguish Cancer from one of those diseases with which it has been generally confounded.*



*Allow me to entertain the hope, that these observations will not be uninteresting to one who contributed to institute a society for investigating the nature and cure of Cancer; and it will give me sincere pleasure, should the following account of a disease, perhaps the most afflicting to which the human race is subject, be considered as a satisfactory answer to one of the most important queries proposed by that laudable institution.*

*I am,*

*With sincere regard,*

*Dear Sir,*

*your much obliged,*

*and obedient servant,*

**JAMES WARDROP.**

EDINBURGH, }  
July 1809. }

PREFACE.

---

---

AN outline of the following Observations was read nearly two years ago before the Chirurgical Society of Edinburgh, an institution formed by the members of the Royal College of Surgeons, for the purpose of promoting medical and surgical knowledge. The subject having thus become one of general conversation among his medical friends, the author was enabled to add many important facts to his original observations; and it acquired such importance as to induce him to lay the result of his inquiries before the public in the present form.



An accurate investigation of the history and morbid appearances of Fungus Hæmatodes and Cancer, is, perhaps, as interesting a subject as can come within the sphere of medical inquiry, and is the only sure path in which we can set out to explore the nature of these diseases, or from which we can expect to discover rational principles for their treatment.

On the following observations one remark may be made,—that they are not an attempt to recommend to the public a remedy for a disease which has been generally, the author may almost say universally, found to be incurable ; on the contrary, of the numerous cases which he has detailed, and referred to in the various parts of the work, there is scarcely one where the disease has not proved fatal. It has been a severe reproach on medical men, that they have seldom brought before the public an account of cases,

the termination of which has been unfavourable; and that they have generally contented themselves with selecting a few extraordinary cures, with the view either of recommending some favourite remedy, or of adding to their own professional reputation. Such a practice is attended with the worst effects in the science of medicine. Practitioners are thus deceived in forming their opinions, and in the employment of particular modes of treatment recommended by others; and future inquirers are prevented from deriving that assistance and information which the experience and observation of those who have preceded them might have otherwise afforded. The author, therefore, hopes that this work will not prove less useful, by bringing before the public the discussion of a subject, where the present state of the practice of medicine can avail little, than by attempting, in an ostentatious display of suc-



cessful cases, to recommend a favourite remedy.

Aware that what he has done by no means exhausts the subject of the present observations, the author will feel gratified if his endeavours shall have the effect of directing the attention of the medical profession to similar inquiries ;—convinced that it is chiefly by these that we can expect the improvement of an art, which so deeply involves the comfort and happiness of mankind.

# CONTENTS.

## CHAP. I.

General Observations on Fungus Hæmatodes, . . . Page 1

## CHAP. II.

Of Fungus Hæmatodes of the Eye-ball,	10
1.—External Appearances of the Disease,	ib.
2.—Appearances on Dissection,	14
3.—History of the Disease,	25
Case I. . . . .	30
II. . . . .	35
III. . . . .	41
IV. . . . .	43
V. . . . .	44
VI. and VII. . . . .	46
VIII. . . . .	47
IX. and X. . . . .	50
XI. . . . .	55
XII. . . . .	59
XIII. . . . .	62
XIV. . . . .	63
XV. . . . .	66
XVI. . . . .	74
XVII. . . . .	81
4.—Concluding Observations,	86



5.—Of the Treatment of the Fungus Hæmatodes of  
the Eye-ball, - - - Page 90

6.—Observations on the Mode of Extirpating the  
Eye-ball, - - - 93

### CHAP. III.

Of Fungus Hæmatodes in the Extremities, - 99

1.—External Appearances of the Disease, - ib:

2.—Appearances on Dissection, - 105

Case XVIII. - - - 110

XIX. - - - 113

XX. - - - 115

3.—Of the Treatment of Fungus Hæmatodes in the  
Extremities, - - - 122

### CHAP. IV.

Of Fungus Hæmatodes in the Testicle, - 124

1.—External appearances of the disease, - ib.

2.—Appearances on Dissection, - 130

Case XXI. - - - 134

XXII. - - - 136

XXIII. - - - 139

XXIV. - - - 140

XXV. - - - 141

3.—Of the Treatment of Fungus Hæmatodes in the  
Testicle, - - - 144

### CHAP. V.

Of Fungus Hæmatodes in the Liver, - 147

1.—Appearances on Dissection, - ib.

### CHAP. VI.

Of Fungus Hæmatodes in the Spleen, - 155

Case XXVI. - - - 157

CONTENTS.

xiii

CHAP. VII.

Of Fungus Hæmatodes in the Kidney, - Page 162

CHAP. VIII.

Of Fungus Hæmatodes in the Lungs, - - 165

CHAP. IX.

Of Fungus Hæmatodes in the Uterus, - - 167

CHAP. X.

Of Fungus Hæmatodes in the Ovarium, - - 170

CHAP. XI.

Of Fungus Hæmatodes in the Female Breast, - 173

CHAP. XII.

Comparative View of the Structure of Fungus Hæmatodes  
and Cancer, - - - 178

1.—Analogy between Fungus Hæmatodes and Can-  
cer, &c. - - - ib.

2.—Of the Structure and Appearances in Scirrhus  
and in Fungus Hæmatodes, - - 181

3.—Of the Texture in which Fungus Hæmatodes ori-  
ginates, - - - 191

Explanation of the Plates, - - - 199



Page 152	CHAP. VII.	Of Fungus Hematodes in the Kidney.
163	CHAP. VIII.	Of Fungus Hematodes in the Esophagus.
167	CHAP. IX.	Of Fungus Hematodes in the Uterus.
170	CHAP. X.	Of Fungus Hematodes in the Ovary.
173	CHAP. XI.	Of Fungus Hematodes in the Female Breast.
	CHAP. XII.	Comparative View of the Structure of Fungus Hematodes and Cancer.
178		1.—Analogy between Fungus Hematodes and Cancer.
181		2.—Of the Structure and Appearance in Sections and in Fungus Hematodes.
181		3.—Of the Texture in which Fungus Hematodes originate.
182		Explanation of the Plates.

## CHAP. I.

---

### GENERAL OBSERVATIONS ON FUNGUS HÆMATODES.

THE disease which is the subject of the following observations, in whatever organs of the body it may have been known to occur, has been generally classed and treated as a *cancerous* affection. Though, in its history, it has some analogy to cancer, yet its symptoms, and the appearances on dissection, are so different from those of cancer, that it cannot be considered as a disease arising from the same morbid alteration of structure\*. The

\* The terms *scirrhus* and *cancer* are used in the following pages as expressive of *two* stages of the same morbid affection, the first expressing what has been called the *occult*, and the latter the open or *ulcerated* state of the disease.



occurrence of fungus hæmatodes is by no means unusual; the symptoms with which it is attended, and the appearances on dissection, are very striking, and very different from those of any other disease; from all which, as well as from its destructive and fatal effects, it must appear somewhat unaccountable, that it should have been so long overlooked by pathological inquirers.

Mr John Burns, of Glasgow \*, is the first person who has given a detailed account of this morbid change of structure. He has described it under the name of *spongoid inflammation*; but he has mentioned it only as appearing in the inferior extremities of the body, and in the upper part of the shoulder.

Mr Hey, of Leeds †, afterwards described several cases of a disease, to which he gave the name of *fungus hæmatodes*, occurring in the superior and inferior extremities, and also in the female breast. Some of these

\* Dissertations on Inflammation, by John Burns, 1800.

† Practical Observations in Surgery, London, 1803.

cases were very analogous to the spongoid inflammation of Mr Burns, though Mr Hey does not appear, from his writings, to have been acquainted with Mr Burns's observations until his own were published.

Mr Abernethy, in his ingenious Essay on Tumors, gives an account of a disease, under the name of *medullary sarcoma*\*, the appearances of which are also quite analogous to the spongoid inflammation of Mr Burns, and to some of the cases of the fungus hæmatodes of Mr Hey. The description of this morbid change of structure, given by Mr Abernethy, is illustrated by two cases, in one of which the disease appeared in the inferior extremities, and in the other the testicle was affected; Mr Abernethy, however, though he does not mention its occurrence in any other particular organ, remarks, that "tumors of a similar structure have been found to exist in various parts of the same subject."

\* Surgical Observations, &c. 1804.



The disease has also been called by some authors, and in some schools of surgery, *soft cancer*.

Though the observations of these respectable authors have, no doubt, contributed to draw the attention of pathologists to this very interesting subject, yet they have left much to be done, and they may only be considered as having paved the way for future inquirers. None of these authors seems to have compared his observations with those of the others; each has affixed a different name to the disease which he has described; and this multiplicity of names has proved a very considerable barrier to the advancement of our investigations. Mr Hey, indeed, I much suspect, has described, under the name of fungus hæmatodes, cases of disease which are not analogous to one another; and since his publication, the term has been applied by many to all those diseases which were not cancerous, but which had some resemblance to it, from their formidable appearance and fatal effects.

In the following observations, therefore, it has been my great object to point out the anatomical structure of the fungus hæmatodes, and to fix precise limits to the import of the name—to bring under one general view a considerable number of facts, the greater part of which have fallen under my own notice, along with others which have been communicated to me by my medical friends, or which are to be found insulated, and not arranged, in the works of different authors—and also, to describe the disease in particular organs, where it has not been hitherto known to exist. “Souvent,” says Lænnec, “une seule observation nouvelle peut servir à en lier, ou éclaircir une multitude d’autres, et utiliser ainsi une foule de faitês, perdus pour la science à raison de leur isolement \*”.

The disease first excited my particular attention, from having had an opportunity of observing an example of it, in its early stage,

\* Vide Note sur l'Anatomie Pathologique par R. T. H. Lænnec, Journal de Chirurgie, &c. tom. ix.



affecting the eye-ball, and of tracing its whole progress, to its fatal termination. Its first symptoms appeared to me quite anomalous, and did not correspond with the description of any disease in that organ which I had either before seen or had found described by any author. But towards its termination, when a large fungous mass grew out from the eye-ball, I suspected it might be an example of the disease commonly considered as a cancerous affection of that organ, examples of which I had before seen in this advanced stage. The appearances on the dissection of this case, the age of the patient, and observations on similar cases, which, afterwards came under my notice, convinced me that the disease was of a nature quite different from cancer, and that it had a great analogy to the disease which had received the names of spongoid inflammation, fungus hæmatodes, and medullary sarcoma, in some other parts of the body. Future observations on the appearances and termination of the disease, not only in the eye-ball,



but also in different organs of the body, have satisfied me of the truth of these remarks, and have convinced me, that a great number of those cases which have been described and classed among cancerous affections in various organs, have no analogy in their structure to cancer, do not admit of the same mode of treatment, and therefore ought to be considered as of a different and distinct nature.

It is therefore proposed, in the following pages, to describe the appearances, and point out the character of fungus hæmatodes, in some of the most important organs of the human body. As these may be more easily traced, and more distinctly and satisfactorily seen during their whole progress in the eye, than in any other part, I shall first give a description of the disease in that organ ; it will be next examined in the superior and inferior extremities, in the testicle, mamma, uterus and ovarium, liver, spleen, lungs, and thyroid gland, in all of which parts its existence has been ascertained. Having done this, some general views of the change of



structure in fungus hæmatodes will be pointed out, and a comparison made between it and the cancerous structure ; the texture or textures in which it originates will also become an object of investigation ; and, afterwards, such practical conclusions will be drawn from a review of all the facts in the history of the disease as our *data* appear to warrant.

I have already mentioned the obscurity which has been thrown on this subject by the introduction of different names. However difficult it may be to choose names for diseases, such as can convey an accurate idea of the nature of the complaint, yet it is of the utmost importance to specify, in a precise manner, the exact meaning, and to limit the signification of every name. In the present instance, were I to choose a name, none of those which I have mentioned appears to me to be altogether eligible. The words *spongoid* inflammation, would lead us to conceive that the disease was a species of which inflammation was the genus ; *soft cancer*, for the

same reason, would make the disease appear to be a species of the genus of cancer ; and the term *medullary* sarcoma is certainly ambiguous, and only expresses one of the characters of the tumor. Nor can the term *fungus hæmatodes* be employed without objection ; but as it points out some of the leading characters of the disease, and as it is already in use, I shall adopt it in preference to any of the others.



## CHAP. II.

### OF THE FUNGUS HÆMATODES OF THE EYE-BALL.

#### 1.—*External Appearances of the Disease.*

THE first appearances of the fungus hæmatodes, when it attacks the eye, are observed in the posterior chamber. The pupil becomes dilated and immoveable, and, instead of having its natural deep black colour, it has a dark amber, and in some cases a greenish hue, giving to the eye very much that appearance which is observed in the sound eye of the sheep, the cat, and in many of the lower animals. As the progress of the disease advances, the colour becomes more remark-

able; and it is soon discovered to be produced from a solid substance, which is forming at the bottom of the eye, and gradually approaching towards the cornea.

The surface of this substance is generally rugged and unequal, and not unlike what may be supposed to arise from a quantity of effused lymph. In some cases, red vessels can be seen running across the opake body, but these are not the vessels which nourish it, but the ramifications of the central artery of the retina lying above it. During the progress of the disease, the new formed substance gradually fills up the whole of the posterior chamber; its surface advances so as to arrive at the same plane with the iris, and has the appearance of an amber or brown-coloured mass. In this stage of the disease, I have known two cases which were mistaken for cataracts, and in one of them an experienced surgeon attempted to couch it. When the disease advances still further, the form of the eye-ball begins to alter, acquiring an irregular, knobbed appearance; at the



same time the sclerotic coat loses its natural pearly white colour, and becomes of a dark blue or livid hue. The tumor, by its continued growth, finally occupies the whole anterior chamber; and, in some cases, a quantity of purulent matter collects between it and the cornea. At last the cornea ulcerates, and a *fungous* tumor shoots out from the portion of the diseased substance, contiguous to the ulcerated cornea; and, in other cases, the tumor pushes itself through the sclerotic coat.

This fungus is very rapid in its growth, and, before the disease arrives at a fatal termination, it often acquires a very great bulk. When it is small, it has a good deal of the appearance of the softer kinds of polypi which grow from mucous membranes. It is generally of a dark red, or purple colour. Its surface is irregular, and often covered with coagulated blood.

The substance of this fungus is very readily torn; and when a portion of it is separated, or if it be slightly scratched, it bleeds pro-

fusely. In other cases, the tumor is of a firmer texture, and if, as sometimes happens, instead of coming through the cornea, it burst through the sclerotic coat, it then pushes before it the conjunctiva, and thus derives a mucous covering. When the tumor becomes very large, portions of the most prominent parts begin to lose their vitality, and separate in sloughs, which have a very fetid and offensive smell, and are accompanied with the discharge of an acrid sanies.

The absorbent glands become also affected during the progress of the disease; they swell and inflame, and sometimes grow to an enormous size\*. In some cases the swelling of the glands commences at a very early period, whilst in others they are not affected until the disease is far advanced. Most commonly those glands swell which lie in the immediate neighbourhood of the parotid gland, or lower jaw. In two cases, I found a small hardened gland close to the

\* See Plate I.



optic nerve ; in a third case, glands were found near the nose, and on the superciliæ ; and, in another case, a diseased gland was found adhering to the os malæ, within the margin of the orbit.

2.—*Appearances on Dissection.*

ON dissection it is found, that not only the contents of the eye-ball, but that the optic nerve, and in many cases the brain itself, are all involved in the disease, exhibiting some very remarkable alterations in structure.

The retina becomes so completely changed, that in no instance could I detect any remains of its natural appearance ; and a tumor is formed in the posterior chamber, extending from the entrance of the optic nerve, forwards, in such a manner as to displace and promote an absorption of the vitreous, crystalline, and aqueous humours. When this new formed substance is small, I have seen, in some

cases, the choroid coat pushed before it, appearing like an irregular shaped bag, containing vitreous humour, the quantity of the humour varying according to the bulk of the new formed substance. In some cases where a *fungus* has been thrown out exterior to the cavity of the eye-ball, the choroid coat cannot be distinguished, either on account of its being intermixed with the general diseased mass, or from its having been altogether absorbed. In some cases, the choroid coat is found in its natural situation, having no attachment, or apparent connexion with the tumor contained within it. I have also observed the choroid coat remaining unchanged in one part of the globe of the eye, whilst at another part it was displaced, and the tumor adhered firmly to the sclerotic coat. The choroid coat has generally a redder colour than natural, and, in some instances, portions of it are increased to five or six times the natural thickness. Little alteration is ever to be perceived in the structure of the sclerotic coat;



neither its thickness nor vascularity is ever sensibly changed, though, in many instances, the new formed substance has been found closely and inseparably adhering to it. The humours of the eye disappear as the bulk of the morbid growth increases; and when it has burst through the sclerotic coat or cornea, they are generally altogether destroyed.

The morbid growth itself has, in almost every instance, more or less of the appearance of *medullary matter*. It is chiefly composed of an opaque, whitish, homogeneous substance, having the same degree of pulpy softness and tenacity with brain. Like brain, it becomes a soft pulp when exposed for a short time to the open air, mixes readily with cold water, and dissolves in it, and it becomes firmer and harder when boiled, or when immersed in alcohol or acids. When the softer parts are washed away in water, or when the mass is forcibly compressed, the more firm and solid parts remain. These consist of a filamentous substance, resembling

cellular membrane, which varies in its quantity and in the closeness of its texture\*.

The consistence of the tumor varies, to a certain extent, in different cases, and in different parts of the same tumor, being in some not much firmer than common custard, whereas in others it is more firm than the most solid parts of a fresh brain.

Bony matter has also been found in some of the tumors, and this generally appeared in the form of small gritty particles.

The colour of the tumor is subject to considerable variety; most commonly, it has exactly the colour, as well as the consistence of brain; sometimes a portion of it is redder, and has more of a fleshy appearance, and sometimes another portion resembles a clot of blood. I have also seen it of a dark brown colour, and, in one instance, both the tumor within the cavity of the eye-ball, and that exterior to it, were tinged of a deep black colour, only a few greyish-coloured

\* See Case I.



streaks being interspersed through the dark mass. In this case the dark colour was so remarkable, that I bestowed great pains, in order to discover, if possible, the cause of such a singular appearance; and, from all that I could observe, I at first conceived that it was produced in consequence of a morbid secretion of the black pigment. By an accurate comparison of the two substances, when viewed through a microscope, they appeared quite analogous. They soiled the fingers or paper of the same dark-brown colour as the black pigment, and communicated to water the same tinge. After the tumor was macerated for some time in water, a great part of the colouring matter was dissolved, and the solid substance which remained was similar, both in its general appearance and texture, to the tumors in the other cases, or to a piece of brain. On the death of the patient, however, all these hypothetical speculations were overturned, as an examination of the body after death showed that the liver was

also affected with the same disease, the tuberculous masses which were formed in it being composed chiefly of the same dark brown medullary matter \*. In a case mentioned by Mr Ford, in the first volume of the London Medical Communications, which seems to be an example of the disease which we are now considering, "the tumors of the eye were converted into a black gelatinous substance," which was, in all probability, very analogous, if not similar, to the matter which composed the tumor in the case above alluded to †.

The morbid alterations which take place in the *optic nerve* deserve to be particularly taken notice of.

In some cases, the nerve retains its natural form, becoming thicker, much firmer and harder than natural, of a brownish ash-colour, and losing that tubular appearance which is observed in the healthy nerve with the naked eye ‡. In other examples of the

\* See Case XVI.

† See Case XII.

‡ See Case I.



disease, the optic nerve, besides being altered in its structure, is split into one or more pieces, the morbid growth filling up the intervening spaces, surrounding the different portions of the nerve, and forming one connected mass with the contents of the eye-ball. The divided portions of the nerve lose entirely their natural structure and colour, becoming soft and pulpy, and sometimes of a deep yellow hue\*. In some cases the nerve has a flesh colour, and more of the texture of sound liver. In many no distinction can be made between the *neurilema* and medullary portions †; whilst in others changes take place in the one which are not observed in the other ‡. In the case formerly mentioned §, [where the contents of the eye-ball and exter-

\* See Case III.

† See Case XVI.

‡ Reil, who is one of the latest authors who has accurately described the intimate structure of the nerves, has distinguished two parts of which they are composed; 1st, the *neurilema*, or membrane which contains the medullary matter; and, 2d, the medullary matter itself, or *medulla*.

§ See Case XVI.

nal tumor had a very remarkable dark appearance, the neurilema remained unchanged, but the medullary portion of the optic nerve had the same dark-brown colour, as far up as the nerve had been divided, in the extirpation of the eye-ball. After the patient's death, which was nearly five months after the operation had been performed, it was found, on dissection, that the same singular black appearance extended along the medullary portion of the optic nerve, to beyond the union of the two nerves ; and what is an important fact to the physiologist, this case proved, in a very striking manner, that the optic nerves do not decussate each other. The nerve of the *right* eye arose from the right side of the brain, and was healthy all the way to where it formed the retina, whereas the *left* optic nerve was black, from the place where it had been divided during the operation of extirpating the eye-ball, to beyond the union of the two nerves.

Most of the foregoing observations were made from the examination of eyes which



had been extirpated during life, in hopes of stopping the progress of the disease; opportunities are seldom met with of examining the optic nerve within the cranium in its early stages. I have already mentioned that the disease appears to begin in the retina; at least the retina has been found changed in its structure, in all those cases where the optic nerves were diseased, and also in others where the disease had not extended to them. There is only one case with which I have become acquainted where neither the retina nor optic nerve appeared to be changed in its structure\*. In one eye of this patient, the retina was completely changed, and in the other a "whitish curdly substance" was found occupying part of the place of the vitreous humour, lying contiguous to the sound retina.

When the optic nerve is diseased, the alteration in its structure generally extends as far up as its junction with the nerve from the opposite side. In many cases it extends further.

\* See Case XI.

the thalamus being converted into an irregular soft pulpy mass, some parts of which resemble natural brain; others are mixed with blood; and large cavities filled with blood are occasionally found between it and the adjacent part of the brain, or in the substance of the tumor itself.

In some cases, too, the membranes of the brain have appeared altered from the natural structure. In one instance\*, there appeared, on the external surface of the *dura mater*, two dark red coloured spots; and two spots similar to them were also observed in the corresponding portions of the *pericranium*. Between the *tunica arachnoides* and *pia mater* there were numerous white spots, scattered in a very irregular manner over almost the whole surface of the brain, which, when cut into, were found to be small bags, or abscesses, containing a viscid white fluid like cream. An appearance somewhat simi-

\* See Case II.



lar to this is taken notice of in the case related by Mr Ford \*.

WHEN any of the *absorbent glands* are enlarged, they are found converted into a substance, resembling, in every respect, that which composed the tumor of the eyeball and brain; and the medullary-looking matter is contained in a distinct capsule of firm cellular membrane. In some cases, the glands ulcerate before death, and form a very unhealthy sloughy ulcer †, but most frequently the patient dies before the skin covering them is destroyed. When ulceration of the skin takes place in a primary tumor of this kind in the extremities of the body, a fungous mass is soon formed, projecting through the ulcer. I have never observed, however, in any case, a fungus arise from a contaminated absorbent gland, after the skin covering it had ulcerated.

\* See Case XII.

† Plate I. fig. 1.

3.—*History of the Disease.*

ONE of the most striking features of this disease is the early period of life at which it occurs; for in a list of twenty-four cases, which have come to my knowledge, twenty of them were under twelve years of age. In illustration of this important fact, it may be proper to mention, in this place, an observation of the celebrated M. Dessault, that “one third of the patients on whom he operated at the Hotel Dieu, for *carcinoma* of the eye, were under twelve years of age\*.” “Le carcinome de l’œil attaque tous les sexes, se manifeste à tous les âges; cependant il semble plus que les autres tumeurs de cette nature s’attacher à l’enfance. L’observation l’a démontré à l’Hôtel Dieu, où plus du tiers des malades qu’y a opérés Dessault étoient au dessous de 12 ans.” In the account which Bichât has given in Dessault’s works, in the

\* Vide *Oeuvres Chirurgicales de Dessault*, par Xav. Bichât, tom. ii. Paris, 1801.



chapter relating to carcinoma of the eye, he has not attempted to point out any difference of the disease in children and in adults, but has given an account of the most striking symptoms attending the true *cancerous* affection of the organ; neither does he make any observations on the relative success of the operations at these different periods of life.

The early period of life at which this disease most frequently prevails, is a striking proof of its dissimilarity to cancer, for cancer is, for the most part, confined to those advanced in years.

When the fungus hæmatodes takes place in children, they are generally found to have entirely lost the sight of the affected eye, before it is remarked by the parents. In a great proportion of the cases, however, the history of which I have been able to collect, the patient had received a blow, which brought on inflammation; and after the inflammation continued, in some only a few days, the coloured substance became perceptible at the bottom of the eye. In those cases

where the eye receives no injury from external violence, a little fulness merely of the vessels of the white of the eye is the first symptom perceived; and the iris is sometimes full of vessels, and changes in its colour, whilst, at the same time, the pupil is much dilated, and immoveable. The child seldom complains of much pain, but sometimes appears languid and feverish.

When the disease attacks those advanced in life, it commonly begins without any apparent cause, though I believe, that in them it also sometimes takes place after a blow on the eye. As in children, it begins with a slight redness of the white of the eye, and, at the same time, the patient sees objects indistinctly. This redness and indistinctness in vision increase slowly; and the patient at last begins to complain of an uneasy aching pain in the head, which often becomes most agonizing, particularly during the night, and it seldom suffers any diminution until the eye bursts, and the humours are discharged.



In most cases only one eye has been affected with the disease. In the cases mentioned by Mr Ware \*, by Mr Hey †, and in that of Mr Saunders ‡, a short time before death a discolouration appeared in the second eye; but in none of those cases was there any mark of disease found in the optic nerve after death. In Mr Saunders's case, the retina was converted into a diseased mass, though the nerve remained sound; but in that by Mr Ware and Mr Hey, the retina is particularly mentioned as having been observed quite sound. From this a very important practical conclusion may be deduced, viz. that if the disease originate in the retina, or in some part of the posterior chamber, and be confined to it alone, in its first stages, an early extirpation of the diseased eye might save the life of the patient.

From the account which has now been given of the symptoms, morbid appearances, and history of the Fungus Hæmatodes in

\* See Case XV.

† See Case XI.

‡ See Case VIII.

the eye-ball, a general knowledge may be obtained of that very remarkable change of structure in this organ. In order, however, to explain more fully the peculiar nature of this disease, and to illustrate some of the most striking facts relating to its history, I shall mention, in detail, some of the most important cases which have come within my own observation, and extract and refer to the works of others, for an account of some cases, which, though they have been considered as cancerous affections of the eye, appear to me to be examples of the same disease.



CASE I.

THIS patient was a female child, about three years of age, whose parents said, that, fourteen days before I saw her, she had got a blow on the left eye, but that, previous to the accident, the eye had appeared sore and painful.

On examining the eye, it was slightly inflamed, and had the peculiar expression of a blind eye. But what appeared remarkable, was, that the pupil was much dilated, and that behind it, and at the very bottom of the posterior chamber, there was a tawny, yellow-coloured flaky-looking mass, the surface of which was unequal, and formed into folds, and a large blood-vessel, which I supposed to be the central artery of the retina, was seen running across the pupil. The anterior chamber had lost its natural transparency, apparently from the aqueous humour being slightly tinged with blood. The child appeared to be in good health, but occasionally complained of pain in the eye, which was considered as no more than what could be readily accounted for, from its apparent degree of inflammation. The case appeared to me so unusual, that I was much at a loss to form even a conjecture of its nature; I thought it, however, not improbable, that the same appearances might have been produced from an effusion of lymph at the bottom of the posterior chamber. With a view of alleviating the inflammatory symptoms, opiates were employed as an external application,



and they produced the desired effect. The inflammation, however, soon afterwards returned, and the child complained of so much pain, that leeches and fomentations were thought necessary. The symptoms, however, continued to suffer but slight alterations, and in eight months, from the first appearance of the disease, I made the following report. "The brown-coloured body which appeared at the bottom of the posterior chamber, has gradually moved forwards, and has now come upon the same plane with the iris. It has all the appearance of a layer of lymph. The eye-ball appears enlarged, and is irregularly tumefied; the sclerotic coat has lost its shining, pearly white appearance, and is of a dark blue colour; the pupil is so much dilated that the iris is contracted to a narrow band. She complains of a constant uneasiness and pain in her eye, with an inability to move about and amuse herself."

From this period, the eye-ball increased in bulk, and in a few weeks the iris and the brown-coloured mass came in contact with the transparent cornea. In other four months the tumor became so big that the eye-lid could not cover it. It had a very irregular form, and no line of division could be perceived between the cornea and sclerotic coat, except by a number of varicose vessels which covered the sclerotica, and terminated by a kind of ring of anastomoses at the circumference of the cornea; at this time, also, a small spot of purulent matter was observed behind the cornea, the cornea ulcerated, and in a few days a small tumor rose out from the ulceration. The tumor had a great disposition to bleed, and, from the effusion of coagulated blood, the upper eye-lid and ball of the eye were kept always glued together.

The disease now began to assume such a formidable appearance, that it was thought advisable to remove the eye-ball, as the only chance of saving the child. This I per-



formed in the usual manner, and nothing particular occurred during the operation.

*Dissection of the Eye-ball.*

The eye-ball was afterwards carefully dissected. Its shape was of a cylindrical form, but the surface irregular; the whole anterior chamber was destroyed, and occupied by a soft fungous mass, having no defined structure\*.

The optic nerve (*a*) was remarkably firm and hard, and of a cineritious colour, much darker than natural. It was also evidently increased in size, though it retained its round form. On one side of it, and lying close upon the eye-ball, adhering to it firmly, there was a hard mass, of the bulk of a garden pea, which was apparently an enlarged lymphatic gland (*b*). An incision was made through the sclerotic coat, which was not altered in its structure, and was as readily separated from the choroid coat as in the natural state. The choroid coat was not of its usual dark brown colour, but had more a mixture of red; a change which took place, probably, on account of an increased vascularity. I next attempted to separate the choroid coat from the retina, but found that it adhered to a solid substance, on the surface of which I could distinguish nothing like the nervous expansion. A vertical section was now made through the eye-ball, so as to divide it and the optic nerve into two equal portions. It then appeared that the posterior chamber, instead of containing its humours, was completely filled with a solid mass, which had very much the general appearance of a portion of brain. Some parts were pulpy, and easily washed away in water, leaving behind a filamentous substance, like loose cellular membrane. On tearing the mass, some parts were much harder and firmer than

\* See Plate II. fig. 3.



thers, and towards one part of it there was a great quantity of particles of a gritty osseous matter (*c*). All that part of the tumor which occupied the posterior chamber, had very much of the general character of medullary matter; but the portion anterior to it, which formed the external fungus, had more the appearance of a soft mucous polypus, and was as easily torn as a piece of jelly. The optic nerve appeared of one uniform, firm texture, and the division between the neurilema and medullary portions of it could not be detected. The sclerotic coat had, throughout, its natural thickness and structure (*dddd*).

---

There was a considerable degree of swelling of both eye-lids, and a discharge of matter from the cavity of the orbit after the operation; but in about three weeks the swelling abated, the discharge stopped, and the child's health was much improved. About six weeks after the operation, she complained suddenly of a pain in the orbit, and on the following day, there was an evident elevation of the eye-lids. The swelling of these gradually increased, and the tumor contained within the orbit soon became so large as to project beyond them.

About this period, also, a small glandular swelling appeared on the cheek, immediately opposite to the ear, and two smaller ones underneath the lower jaw, on the same side\*.

The tumor of the orbit, and the glandular swelling, gradually afterwards increased in size, her general health failed, and, about six months after the operation, she died, being for some time before her death in a state of stupor, speaking none, and expressing no signs of pain.

\* See Plate I. fig. 2.



At the time of her death the tumor of the orbit was about the bulk of a goose-egg; two-thirds of it was covered by the upper eye-lid, much distended, and the other part of it was an irregular shaped mass, of a dark colour, and so fetid as to resemble a piece of corrupted flesh\*. The tumor anterior to the ear was much swollen, and the integuments discoloured. The glands under the jaw had also acquired a very considerable bulk.

With the assistance of Dr Barclay, a careful dissection was made of the brain, and contents of both orbits.

*Dissection after Death.*

On laying open the lateral ventricles of the brain, from four to five ounces of a transparent colourless fluid flowed out. The posterior portions of the optic thalami had their natural appearance; but at the place where the optic nerves unite in the *sella turcica*, a tumor was formed about the bulk of a chesnut. This tumor was nearly globular, its surface a little unequal, but smooth, and its colour rather more yellow than common medullary matter. On removing a delicate transparent membrane, which surrounded the tumor, the parts within were found to be a pulpy-looking matter, of a very white colour, and of an equal consistence. It turned rapidly softer by being exposed to the air, and was readily dissolved in water. Nothing resembling nerve could be found in it; although the optic nerves were seen entering it at one extremity, and passing out at the other, to go into the *foramina optica*. At the place where the nerve of the left side had been divided, in removing the brain, a similar matter seemed to have issued from the divided extremity. Having sawn off the orbiter plate of the frontal bone, the contents of the orbit were removed. The

\* See Plate I. fig. 2.

optic nerve could be traced a little way, and suddenly expanded, forming, as it were, the nucleus of a mass of diseased structure, composed of muscles, blood, adipose substance, and a number of rounded masses, which had a pretty firm, cellular, external covering, but contained a substance exactly resembling that of the tumor in the *sella turcica*, and in the posterior chamber of the eye-ball.

The tumor on the cheek, anterior to the ear, had no adhesion to the integuments, or parts surrounding it, and had every external character of an enlarged lymphatic gland. An incision was made into its substance, and it was found to contain a pulpy matter, similar in every respect to that of the tumor of the brain. One of the glands below the lower jaw was carefully dissected out. When removed, it had all the general appearances of a common enlarged gland; but when its external covering of firm cellular membrane was cut into, the substance of the tumor was found to be composed of a matter exactly resembling that which was found in the other swellings.

---

## CASE II.

IN the second case, which I had an opportunity of seeing, the disease appeared also in a girl of about twenty months old; and, during its whole progress, the symptoms very much resembled those which were observed in the former patient. There was the same brown or yellowish colour observed in the bottom of the posterior chamber, accompanied with a great dilatation of the pupil, and total want of vision. Although the opake body could



be observed to be gradually approaching the iris, as the disease advanced, yet it existed seven months before the eye-ball began to be altered in its shape. At last, it became so large that the eye-lids could scarcely cover it; the conjunctiva became inflamed, and formed into a fold at the inferior eye-lid; the anterior chamber became of a dark yellow colour, and the opaque body approached very close to the cornea, having the same deep yellow tinge as when it was first observed.

The failure in the operation of extirpating the eye-ball in the former case, after the cornea had ulcerated, and a fungous tumor grown from it, suggested the idea of performing the operation at a more early period of the disease. Accordingly I extirpated the eye-ball. The operation was performed in the manner recommended by M. Dessault \*, by dividing, in the first place, the connection of the two tarsi at the external angle of the eye, so as to liberate the eye-lids, and facilitate the extirpation. After removing the ball, along with a firm mass adhering to the optic nerve, I could trace a continuation of this substance with my finger, passing through the optic foramen into the cavity of the cranium; so that no further attempt was made to remove any more of the diseased parts.

*Dissection of the Eye-ball.*

There was a quantity of aqueous humour, tinged of a pale yellow colour, discharged through an opening made in the cornea by a ligature which was passed through it, in order to facilitate the extirpation of the diseased eye. The eye-ball, after it was removed, did not appear to be much altered in its general form. A fleshy looking mass, about

\* Vide Oeuvres Chirurgicales de Dessault.

the bulk of the last joint of the little finger, so completely surrounded the optic nerve, and adhered so firmly to it, and to the adjacent part of the sclerotic coat, that it could not be removed, so that the nerve could be traced passing into the eye-ball. An incision was made through the eye-ball, and through the mass inclosing the nerve, dividing them into two equal portions \*. A small quantity of a humour, resembling vitreous, flowed out, whilst the incision was made. This section shewed the optic nerve (*aa*) and tumor (*b*) to be distinct from each other, from a difference in their colour. The nerve was a little larger and firmer than natural, had changed its colour, and was converted into a dull, flesh-coloured substance, having none of the characters of a healthy nerve (*aa*). After the nerve entered the sclerotic coat, nothing like retina could be distinguished, but it seemed to swell out, and form a mass resembling that which surrounded it externally. This mass filled the posterior chamber in such a manner, that the choroid coat was pushed from its natural situation towards the anterior chamber, in the form of an irregular shaped bag (*ccc*). The section of the tumor represented it to be composed as if of two lobes (*dd*), separated from one another by a fibrous band, which extended from the central part of the optic nerve, and terminated in the choroid coat; and it was probable that this was the blood-vessels, or central artery of the retina. Besides the two distinct lobes, thinner portions of the tumor (*eee*) extended forwards on each side, as far as the cornea, so that the choroid coat was inclosed within the diseased mass, as in a bag. The tumor could be separated from the sclerotic coat (*ff*) at every part, except near the entrance of the optic nerve. There it adhered to it so firmly that it could not be dissected from it without being torn. The different parts of the mass

\* See Plate II. fig. 1.



much resembled common medullary matter, intersected in an irregular manner with cellular fibres, which rendered it rather firmer, and less easily divided than brain.

---

The swelling and inflammation soon abated after the operation, but in ten days she had several violent convulsions. These never returned, but in a few days there was an evident tumor formed within the orbit. Twenty-five days after the operation, she died, having had violent symptoms of deranged functions of the brain. The orbit had gradually become filled with a tumor which distended the eye-lids, but did not project beyond them. Her strength and flesh gradually wasted, and, for some days before her death, she was observed not to see distinctly with the left eye.

*Dissection after Death.*

The parts were examined after death; and I am indebted to Dr Thomson for his able assistance in the dissection, and in drawing up the following account of it.

On removing the scalp, a number of white spots appeared on the surface of the cranium, some of them nearly the breadth of a sixpence, and all of them of a circular form. Two were of a deep red colour, and were rough and unequal to the touch; the pericranium covering them was thicker than natural, and more easily separable from the bone. On the external surface of the dura mater there were two dark red-coloured spots, corresponding to those observed on the external surface of the cranium. They were formed by a spongy-looking substance, which was a little elevated above the surface of the dura mater, and appeared to be organized lymph. On removing the dura mater, an effusion of a serous fluid was found to have taken place between the tunica arachnoides and pia mater.

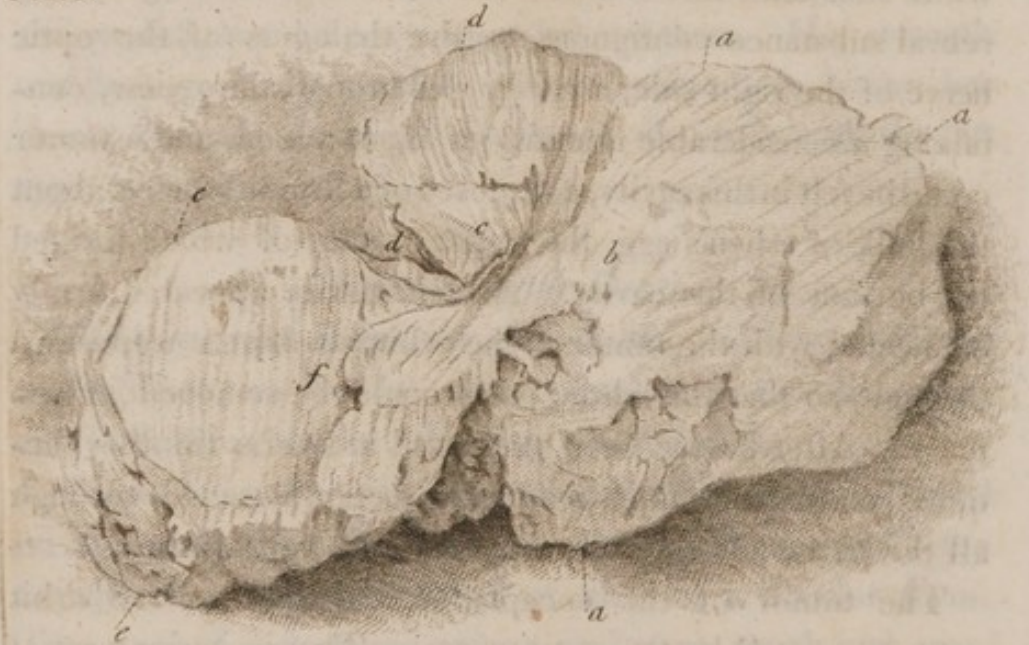In the same space, and scattered in an irregular manner over almost the whole surface of the brain, there were numerous white spots, varying from the size of a pin's head to that of a large pea. When cut into, they were found to be small bags, or abscesses, containing a viscid white fluid, somewhat like cream. The lateral ventricles contained a little more water than usual.

The *plexus choroides* was much thickened, and that part of it which is vascular, and has been regarded as hydatids, was considerably swelled, and converted into a greyish white substance like *brain*. On removing some of the cerebral substance contiguous to the thalamus of the optic nerve of the right side, a cavity was brought into view, containing a considerable quantity of black blood, and a tumor could be felt in this cavity, composed of a firm substance, about the bulk of a hen's egg, the upper surface of which formed the bottom of the cavity. As this tumor appeared firmly connected with the tumor in the orbit, the bones were sawn through, so that the whole parts could be removed in one mass. After having been preserved in spirits till they acquired consistency, a perpendicular section was made through all the parts, and the following were the appearances.

The tumor of the encephalon and that in the orbit were connected by the optic nerve. The posterior part of the tumor was soft, and resembled, in every respect, common brain, but the rest of it consisted of a reddish, and apparently very vascular mass, of a firm, but equal consistence, so that, on a superficial examination, it very much resembled *liver*. Nothing resembling nerve could be distinguished in any part of the mass, until it approached the optic foramen, at which point there was a kind of very indistinct collection of the nervous fibres going to form the nerve. The nerve emerged from the tumor



rather larger than natural, but not very remarkably changed in structure; and that portion of it which passed through the bony canal seemed to have been prevented from growing larger, from the resistance of the bone. The tumor contained in the orbit was of a rounded form, about the bulk of an eye-ball, and resembled the firmer portion of the other tumor. The optic nerve could be traced a little way into the tumor contained in the orbit, and terminated abruptly at that part where it had been divided in the operation of extirpating the eye-ball, being as it were the centre of the diseased mass.



In the above sketch, which Mr Russell was obliging enough to make for me, the different parts displayed in the section of the tumors are detailed with much accuracy and precision. *a* Is the posterior part of the tumor of the encephalon, which was soft, and its edge rugged. At *b* there was something like nervous fibres, and at *c* the nerve appears of a larger size than natural, and that portion between *c* and *d* passed through the osseous canal. *e* Is the tumor contained within the orbit; and the optic nerve is seen passing into its substance, and terminating (*f*) where it had been divided when the eye-ball was extirpated.



### CASE III.

---

THE patient, the subject of this case, was under the care of Dr Brown, one of the surgeons of the Royal Infirmary of Edinburgh, and, with his permission, I am now enabled to lay it before the public. It illustrates, in a striking manner, the remarkable features of this formidable disease, and more particularly, the changes in the structure of the optic nerve.

The girl was two years of age, and the father, a very intelligent man, gave the following history of the complaint.

Nine months ago, the right eye was accidentally perceived to have lost its natural colour, and to have that greenish tinge observed in the eyes of cattle. During three months it underwent no change, unless that the green colour became more apparent. Soon after this, the whole anterior chamber lost its natural transparency, and became so turbid, that the different parts contained in it could not be distinguished. During five months, the turbid state of the anterior chamber continued, and the eye-ball became in some degree swollen; at last, some purulent matter appeared in the anterior part of it, and was discharged by an ulceration of the cornea. After this took place, a tumor began to grow through the ulcerated surface, and the eye-ball lost all its natural form. The tumor gradually became so large as to project a considerable way beyond the margin of the cavity of the orbit, and spread open both the eye-lids. It had an irregular form, being composed of several rounded masses, separable



a little way from one another, and adhering to one central nucleus. The surface of the different parts was smooth, except in those places which were covered with coagulated blood. There was a discharge of a thin fetid sanies, and it bled on the slightest friction. No vestige of the eye-ball could be traced. The child was fretful and complaining, but its general health had not suffered much. As the extirpation of the eye-ball was resorted to as affording the best chance of a cure, the operation was performed by Dr Brown. In extirpating the tumor, it was found to be connected with the optic and sphenoidal holes, by a firm mass, and this was cut off in order to remove the eye-ball.

*Dissection of the Eye-ball.*

Nothing could be seen resembling the natural structure of the eye, by an external examination of the diseased mass. The sclerotic coat and optic nerve were completely enveloped by a tumor, about one inch in diameter, having a firm resisting feel, and an irregular knobbed shape; and, on examining the part of the tumor where it had been cut through during the operation, a portion of it had some resemblance to the optic nerve. An incision was made through the whole mass, so as to divide it and the nerve into equal portions\*. This section shewed an imperfect outline of the sclerotic coat (*aaaa*), the tumor growing from the whole of its internal surface, and the large mass exterior to it, and surrounding the optic nerve. The nerve was completely imbedded in the mass of tumor. It appeared to be split into two parts, the tumor within the eye-ball and that exterior to it being joined with one another, and forming, as it were, one mass, separating the two portions of nerve. One of the

\* See Plate II. fig. 2.

parts of the nerve adhered to the sclerotic coat (*b*), and the other appeared detached from it, and was, as far as could be observed, completely enveloped in the tumor (*c*); the external tunic of the nerve was of a white colour, and adhered firmly to the diseased mass; the internal part of the nerve consisted of a soft porous substance, like some of the *fungi*, and it was, throughout, of a yellow colour, in some parts paler, and in others, of a deep gall-stone hue. Every part of the tumor had a *medullary* appearance, and adhered all round both to the external and internal surfaces of the sclerotic coat.

---

Five days after the operation, a considerable degree of redness and swelling appeared over the parotid gland, which subsided by the application of leeches. Dr Brown informed me, that some weeks afterwards, the tumor had again begun to grow from the orbit, and the swelling on the cheek to enlarge, soon after which the child died, and, as this happened at a distance from town, no opportunity was had to inspect the brain.

---

#### CASE IV.

THIS patient was under the care of Mr Astley Cooper, who had the politeness to send to me the drawing of it, from which the first figure in Plate I. is copied. It is a very striking example of the enormous size the absorbent lymphatic glands sometimes acquire in this complaint. The disease had advanced so far before the girl was put under Mr Cooper's care, that no attempt could have been made to remove the diseased part with any chance



of relief. The disease was therefore allowed to proceed uninterrupted; and before the patient's death, the tumor that is seen in the drawing growing out of the orbit, and the prodigious mass of glands over the lower jaw, were in a complete state of mortification. This prevented Mr Cooper from examining the parts satisfactorily after death; but from the diseased state of the brain, and particularly of the optic thalami, and also from the external appearances, there can be little doubt of the true nature of the disease, and of its analogy to the other cases.

---


### CASE V.

THIS case was communicated to me, as a singular instance of disease, by Mr Smith, surgeon at Appin, in Argyllshire, and affords another striking instance of the fungus hæmatodes of the eye-ball. Mr Smith's own words give a clear and very distinct account of the case. "The disease had gone on to a great extent before I saw it; but I shall relate what I could learn of its history. The patient was a boy about the age of eight or nine years. The disease made its appearance towards the beginning of August 1805, with an inflammation in the eye, and a violent pain in the head, and particularly in the forehead of the same side of the affected eye. Perhaps it is proper to mention, that at this period the most of the poor people in the neighbourhood had a degree of ophthalmia among them. As the parent of the child was poor, no medical assistance was at this time called for, and he applied a blister to the temple, and a solution of the acetite

of lead to the eye. By these means the inflammation abated, but the pain in the forehead and eye continued as violent as ever. It was observed, too, that the eye was beginning to swell, and, on looking at the pupil, a white speck appeared at a distance behind it. The eye now began to swell rapidly, and to be forced out of its socket. The child was seized with frequent startings at night, a total want of sleep, an inclination to vomit in the course of the day, and an aversion to all animal food. It was at this period, towards the latter end of September, that I was called to see him. I found him greatly emaciated, with the eye completely forced out of the orbit. The appearance which it had was that of a large ulcerated tumor of a livid colour, covering one half of the cheek, discharging a sanies, having a fetid smell. I ordered bark, opium, port wine, and dressed the eye with common ointment, mixed with a little of the red oxide of quicksilver. The tumor increased daily, till at last it covered the whole cheek, and extended over the chin. In this state it was supported by a bandage, but if the bandage at any time came off, it was attended with most excruciating pain. As Mr ——— seemed a good deal interested, I desired that another medical gentleman should be called in; which being done, I suggested the necessity of having it extirpated. To this, however, the parent would not consent, and the unfortunate child *died* early in November, in great misery. The size of the tumor, as far as I recollect, was from ten to eleven inches in circumference."



## CASE VI. AND VII.



Mr JOHN BURNS, of Glasgow, whom I have already mentioned as being the first person who has given a detailed description of the disease in the extremities, has been so obliging as to favour me with the history of two cases of the disease in the eye-ball, which appear to be quite analogous to those already mentioned.

CASE I.—“The patient was a girl of eleven years of age. The disease first began with enlargement of the anterior part of the eye, an increased discharge of tears, and sensibility to light. Very soon the eye became red and painful, the cornea more prominent, with a discharge of fetid matter from the surface.

“For some months there was little change, but at last the eye was perceived to enlarge. Then the cornea gave way; and in this case, from the bloody lymph discharged, the eye shrunk for a little, but very soon the fungus shot forth, and then, for the first time, the pain became considerable, and a great quantity of very fetid matter was daily discharged. The health gradually suffered, and both the surgeons and the patient, being tired of unsuccessful applications, agreed to extirpate the tumor. The operation was accordingly done, but the lacrymal gland was left in the orbit, though for what purpose I cannot tell. Every thing went on well for a time, and the girl left the place, but I believe died some time after, though in what manner I did not learn.’

CASE II.—“The second case was a boy six years of age. In infancy something like a speck was observed in the cornea, and very soon the ball of the eye began to swell, but without much pain, although it occasioned loss of sight. About half a-year before the operation of extirpating the eye was performed, the swelling increased, burst, and yielded a fungus, and very soon the eye resembled a cauliflower. An adhesion took place between the eye-ball and the palpebræ. The eye was cut out, and the patient to all appearance cured in three weeks, the other eye being sound and strong. But in two years after this he returned to town with a large fungous ulcer on the temple, which had begun at the outer canthus of the eye, and this at last carried him off.”

---

### CASE VIII.

THE following case was communicated to me by Mr Saunders, Demonstrator of Anatomy at St Thomas's Hospital, and surgeon to the City Dispensary for the diseases of the eyes. It contains an accurate account of the history and appearance of the fungus hæmatodes on dissection, in its advanced stage in one eye, and at a more early period in the other

#### *Case of Master E. L.*

At the age of nine months the disease commenced in the left eye, which, when I first saw him, although not inflamed, was vascular, and a little enlarged. The iris, in particular, was full of red vessels, and the pupil was very large and



fixed. The retina appeared like a concave silver plate, in the posterior part of the eye. This eye was blind, but he suffered little or no pain, and was, in other respects, in good health. At the age of fifteen months, the right eye was attacked, and exhibited similar appearances. The left eye was now much changed; the crystalline lens had dropped from its situation, and lay in an opaque state at the inferior part of the vitreous humour. About three months before his death, the left eye, which had been for some time very irritable, suddenly enlarged, and began to protrude beyond the eye-lids in the form of a red mass, which ultimately acquired the size of a large apple. About a fortnight before his dissolution, he fell into a state of stupor, with occasional screaming. He soon became frequently convulsed, and died in one of these fits. I examined the right eye a few days before his death, and observed, that what had previously exhibited the appearance of a concave metallic plate, in the situation of the retina, had advanced, and apparently occupied, every part behind the iris. It seemed to touch the iris, and the eye gave the appearance of a white cataract with a dilated pupil. This was, however, a deception, as it only occupied the space of the vitreous humour; the crystalline lens being in its natural situation, and transparent.

*Dissection after Death.*

The tumor of the left eye being cut in various directions, was found to consist of a hard fibrous vascular mass. None of the original parts of the organ could be distinguished. The head being opened, it was ascertained that the disease had extended in the course of the left optic nerve to the ganglion, the whole of which was converted into a bloody tumor, too soft to analyse by the knife, and which melted, as it were, under the touch, although the examination was made shortly after death. The ventricles were unnaturally



large, and full of water; the ganglion was altogether diseased, being converted into the tumor already mentioned; but the left optic nerve was sound, from the ganglion to its thalamus; and the right optic nerve was sound in each side of the ganglion.

---

In addition to the cases which have been already given, I think it proper to take notice of some others, recorded by different authors; and although the authors alluded to seem to be unacquainted with the peculiar nature of the disease, they have yet described the cases accurately. As those cases not only illustrate the most striking features in the history of the disease, but lead to important practical conclusions, I shall quote some of them at considerable length, more particularly such as are in works not easily accessible, or which are scattered among descriptions of other diseases.

The first two cases were put into my hands by Mr Wishart, who had the politeness to extract them from the *Ophthalmologische Bibliothek*, a German periodical work. They are entitled, "A Descrip-



tion of a remarkable Morbid Change of the Eye-ball, and of the Organic Structure connected with it, by M. Schmidt, of Vienna."

---

### CASE IX. AND X.

THE principal features in the histories of the cases are as follows:

The one individual was a girl, two years old, (a soldier's child), the other a boy about five years of age, the son of the Manager of the Porcelain Manufactory in Vienna. Both of the children were *scrofulous*, and had a tendency to rickets. In both, the change began about the beginning of the winter 1801, in the form of an ophthalmia.

I had not an opportunity of observing the course of the ophthalmia; nor did I see the children till after the exophthalmy, or swelling of the eyes, had taken place.

The exophthalmy was accompanied by constant restlessness, want of sleep, loss of appetite, dry warm skin, quick, small pulse, continual pain of the one half of the head, the stools sometimes scanty and sometimes copious.

All the coats of the protruding eye-ball were enormously swelled, and of a dark red colour, the cornea destroyed, the iris covered with a layer of purulent matter, and the eye-ball as hard to the touch as a billiard-ball. The humours were, by degrees, discharged; the crystalline lens in both cases fell out; and the vitreous humour gradually disappeared. But the tumor of the coats of the eye increased the more in proportion as the humours were evacuated. The upper and under eye-lids were so completely displaced by



the pressure of the flesh-like mass, into which the coats of the eye was converted, that neither of them could be discovered.

The soldier's child had been left to itself till the above-mentioned period. The boy was attended by physicians, one of whom, when the exophthalmia was just forming, made a puncture into the eye, with the intention of evacuating the contained fluid, or pus. After the incision, the change went on more rapidly, and acquired a more enormous bulk than it ever attained in the soldier's child.

It was evident, that the progressive enlargement of the eyes, and conversion into *sarcomas*, was in the inverse proportion to the nourishment of the body of both children. The more the sarcoma increased, the more remarkable was the wasting of the body. The boy, in whom the mass acquired so great a bulk, was, however, much better attended to, in respect to diet and nursing, than the soldier's child.

In both children the question arose, whether the diseased eyes should be extirpated or not? In both, an operation was contraindicated by the high degree of direct debility of the vital powers, as it could not have been performed without a considerable loss of blood. In both it was to be apprehended, that the loss of three or four ounces of blood might bring on convulsions during the operation, which might instantly terminate fatally.

In both cases escharotics were employed. But these remedies were evidently hurtful. At first the *cosmean* powder was tried. It only attacked the sarcomatous excrescences superficially, and the reproduction was much more luxuriant. I then employed a mixture of unslacked lime, nitrate of silver, and soap, in form of an ointment, and applied it partially to the tumor. This mixture penetrated deep. But the more of the tumor I destroyed, the more disproportionably it shot out from the bottom. I say, the more



disproportionably luxuriant was the growth, as, in fact, I never could destroy in a given time as much of the mass, as, in the same time, the root of the mass sent forth anew. It was just as if it had been a polypus which was wounded, for these grow the more luxuriantly the more they are wounded.

As the debility of the soldier's child approached the highest pitch, and local applications completely laid aside, the increase of the tumor stopped, and, instead of the change being always progressive, it now began to be regressive. The dark red fleshy mass began to turn blackish and scurfy on the surface, and at the same time to decay and fall off piece-meal. As one of these decayed layers fell off, another decayed and again came away; and thus it went on, till the orbit was almost completely empty. At the back of it lay a small knot, drawn together, which was the remains of the sclerotic coat. In this state the child died, completely exhausted.

The boy lived six weeks longer than the little girl. In his case also the reproduction stopped as soon as the debility of the living principle reached a certain point. But as the debility became still more considerable, there began, in several parts of the excrescence, a similar destruction or corruption, and the change then became regressive. The mass, however, had lost very little of its bulk, when the boy slipped off, with symptoms of very great debility.

#### *Dissection after Death.*

After death the bodies of both the children were carefully dissected by Mr Abendroth, when the following circumstances were remarked:

There were no eye-lashes on the eye-lids. Both cartilages of the lids were melted into skin; the eye-lids quite



shrivelled into folds ; the orbicularis and levator muscles of the upper eye-lid were quite destroyed ; the lacrymal canal quite gone ; a small remains of the puncta. No caruncle or lacrymal gland.

On opening the orbit from behind, there was no trace of any muscle of the eye, nor of the numerous nerves which enter that cavity. There were also no remains of the veins or arteries.

The most interesting phenomena that presented themselves, were the remains of the sclerotic coat, which was contracted into a knob, still connected with the sheath in which the optic nerve runs. But, on opening carefully this sheath, and following the nerve to the knot of the eye, there was scarcely any vestige of nerve to be found. A small quantity of a nearly fluid gelatinous mass was contained in it, which was still more pappy than the first pair of nerves commonly is. The brain, however, was in a natural state, and even the thalamus of the optic nerve showed not the smallest deviation from the natural structure.

In the five year old boy the skin of the upper and under eye-lids was so intermixed, in every direction, with the circumference of the excrescence, and expanded over its surface, that it was easy to perceive the striving of the sound skin to incase the whole tumor.

The *tarsus* in both eye-lids dissolved into skin. But, as the skin was very much expanded, a thin irregular little raised strip appeared, on which, however, there could be discovered no vestige of eye-lashes. The entrance to the lacrymal canal was marked by a pointed pit.

At the upper part of the growth a black firm lump was attached, the remains of the eye-ball, which was nothing but the contracted half dried sclerotic coat.

Around the remains of the sclerotic coat were several



small pits, arising from the falling off of small decayed pieces of the excrescence ; a few scales were still coming away.

The conjunctiva at the nasal and temporal angles presented an interesting appearance, near the commissure. It was converted into a lardy mass, about half an inch thick, and was intimately connected with the general mass.

On opening the orbit from behind, the most attractive appearances were observed.

The whole orbit was filled by the root of the excrescence, and all the parts of the organic structure were so confused and blended together, that even the most skilful anatomist could merely imagine vestiges of the natural structure.

The muscles of the eye were all changed into a firm, horny cellular membrane.

In this horny substance red radiated streaks were perceived.

Neither blood-vessel nor nerve could be recognised. The red radiated streaks were situated exactly in the place where the first branch of the fifth pair, the *oculomotores*, the *abducens*, the *trochleator* ramify.

The abundant cellular substance which lies between the muscles of the eye-ball and of the upper eye-lid, and in the orbit in general, was evidently converted into a bacony mass, extending from within outwards.

The conjunctiva of the eye-ball and the lacrymal gland were converted into a similar mass.

The *optic* nerve here also presented the most interesting phenomena.

On examining the mass from above downwards, and from behind forwards, towards the shrunk knot of the sclerotica, I found this nerve passing through the mass, and in continuity with the remains of the sclerotic coat ; but it was only as large as a fine thread. But when we reflect that the sclerotic coat, which covered the mass externally, was at least two inches and an half removed from the optic foramen,

we may easily conceive what an unusual length this nerve must have assumed, in order to be equally spun out from its usual thickness to so extraordinary a thinness and length. The optic nerve began to become thin as it entered the optic foramen. Within the base of the cranium it had its ordinary size. The thalamus also was unchanged.

---

### CASE XI.

A DESCRIPTION of this case is given by Mr Hayes, in the 3d volume of the London Medical Observations and Inquiries, published in 1767. The following is an abstract of it :

The disease appeared in a girl fifteen months old, and its first symptom was a peculiar colour in the eye, when turned in particular directions, more discernible in the evening and when the light was not strong. The eye afterwards became inflamed, and, what was peculiar in this case, after the inflammatory symptoms abated, the eye-ball diminished more than one half of its natural bulk. After remaining of this small size for ten months, it began to enlarge ; and about this time the other eye began to assume the same peculiar colour behind the pupil which the first one had. It was now proposed to empty the *left*, which was the first affected, with the view of discharging the collected humours, and saving the *right*. After making the incision of the cornea as for extraction, and not being able to see any lens or vitreous humour, the whole cavity was



found filled with a fleshy substance. “ This discovery immediately pointed out to us our error, and the true nature of the case, viz. that it was of a *cancerous* nature.” The whole contents of the orbit were removed; and on dissecting the eye “ we found not the least remains of the humours, nor of any of the coats, but the sclerotica. This was filled in every part, except in the anterior chamber, with a *steatomatous* kind of substance, and a loose spongy flesh, whose fibres had no particular direction. There was likewise a considerable quantity of calcareous earth lodged in different parts of it.” Some months after the operation, the right eye began to increase in bulk, and at last a large fungus grew out from it, pushing before it the two eye-lids. The child now began to vomit her food, was seized with giddiness in her head, and convulsions, and she lost the use of her lower extremities. At last she died, retaining her memory and judgment perfect till within a few hours of her death. The disease in this case lasted during three years.

*Dissection after Death.*

“ Upon opening the head with Mr Hunter, the following appearances were observed. We found more water in the left ventricle than in the right; on raising the anterior lobes of the cerebrum, the right appeared quite sound, but the left was red, and some extravasated blood lay on the orbital process of that side. We then cut off the right lobe, and laid bare the optic nerve of that side, which we found, in all appearance, perfectly sound; but the left lobe, which was found diseased in its substance, adhered to the optic nerve, internal carotid artery, infundibulum, and the glandula pituitaria, so that we were not able to distinguish any separation of these parts. We, therefore, took out all these parts, with the optic nerves, the right eye, and the tumor in the orbit of the left side, whole and joined toge-



ther. Mr Hunter then inverted them, and examined the optic nerves on their under surfaces; that on the right seemed perfectly sound, through its whole length, but, on the left, what was the optic nerve could not be distinguished from the substance of the anterior lobe and glandula pituitari, which adhere there. He then cut into the tumor, that had lain in the orbital foramen, to see if he could trace it on to the brain, but he could not find any appearance of a nerve: he afterwards began at the union of the optic nerves, to try if it could be traced from thence to the foramen, but it could hardly be said that there was any continuation of it from this part.

“ We observed, that the disease in the nerve had proceeded no farther, towards the brain, than the union of the two nerves; but it had gone so close to that union, as to appear just as if no nerve had ever been given off at that part: both nerves seemed sound before and at their union. The thalami were likewise sound. The tumor, which was in the left orbit, had an external covering, everywhere, of about one-eighth of an inch thick, and, within that, was a brownish substance, that seemed to have no direction of fibres, and appeared as if glandular; yet it was not so smooth, or solid in texture, but more spongy or loose. Mr Hunter observed, *that he had always found this sort of texture in scirrhus testicles, breasts, &c. when not of the gristly kind, such as often arise in wens, white-swelling, or from the remains of inflammation.*

“ The optic nerve of the right eye seemed quite sound through its whole length; the eye-ball, when cleared of the muscles, cellular membrane, &c. had just the common appearance. Mr Hunter took off the upper part of the sclerotica, choroides, and retina, with as much of the vitreous humour as was contained in this section, and, by that means, exposed the cavity of the eye.



“ We found the coats and retina perfectly sound, and the crystalline humour, in its place, firm and transparent ; but in place of part of the vitreous humour, was a whitish curdly substance, which lay in the posterior and outer part of the cavity, and had pushed the vitreous, that remained, to the anterior and inner part of it. Whether this whitish curdly substance had been formed on the outside of the vitreous humour, and had pushed it to the inside, or whether this substance was produced in the humour itself, which was wasted in proportion as that matter was formed, is not very easily determined ; but the latter seems most probable ; for it appeared as if the vitreous humour was continued into this substance, or, as it were, entangled in it. This substance was as much detached from the retina, as the vitreous is in common.

“ I should not have attempted offering a case of this sort to the public, it having been so unsuccessfully treated, and so little understood, had not the dissection rendered the appearances more intelligible, and pointed out the immediate seat of the disease. If this could have been known, and the eye emptied, before the coats were at all affected, might not the life of the child have been preserved ? for, by the dissection of the right eye, the disease appears to have arose in the vitreous humour only, and to have been confined to this part several months, while the other parts of the eye remained, in all appearance, perfectly sound : and is it not possible that the coats of the eye might again have been filled with some kind of aqueous humour, which might have restored an imperfect vision \*?”

\* Medical Observations and Inquiries, vol. iii. p. 133-137.

## CASE XII.

THIS case is very fully described by Mr E. Ford, in the first volume of the London Medical Communications, entitled, "A case of *Proptosis*."

A girl, three years of age, born of healthy parents, was brought to me with a proptosis of the left eye. "The tumor projected to a considerable distance from the edge of the orbit, was covered with a hard dry crust, and discharged a fetid corrosive matter. The right eye was perfectly free from disease. The patient had no headach, was very lively, and appeared in every other respect to enjoy a good state of health.

"The parents informed me, that about a year before she had been affected with a scabby eruption on her head, which soon yielded to a saturnine application, and that, within a month after the disappearance of the eruption, an inflammation and swelling had taken place in the left eye, for which she had been under the care of different empirics; that the tumor had continued to enlarge, till the sight of that eye was totally lost; and that one day, after slipping down, it burst, and discharged a quantity of sanious matter.

"From the nature of the complaint it seemed obvious, that a total extirpation of the diseased eye was the only resource left; and, from the account given of its progress, there was no reason to form an unfavourable prognostic.



Accordingly the operation was performed in the presence of Dr Duncan of Edinburgh, and several other gentlemen. Upon removing the cellular membrane, in which the eye is enveloped, we discovered a small *scirrhous* tumor at the bottom of the orbit, surrounding the optic nerve. This was entirely removed, together with a large portion of the nerve itself.

“ The operation was performed without any considerable hemorrhage, and the eye-lids, not being diseased, were preserved.

“ Upon macerating the tumor in water, great part of the spongy substance, which had made so large a prominence in the face, dissolved. The optic nerve was harder than common, and of a cineritious colour. The humours of the eye were converted into a black gelatinous substance, but its coats had not undergone much alteration.

“ For some time after the operation, the patient was free from pain, the wound looked well, discharged a thick matter, and the cavity filled up with red granulations. It was observed, however, that she did not acquire strength. She became paler and more emaciated, and, at the end of the third week, was suddenly and totally deprived of the sight of her remaining eye.

“ There was no inflammation on the surface of this eye ; the cornea, and the crystalline humour were free from any defect, but the pupil was very much dilated, and the iris incapable of motion, so as to exhibit the appearance of a *gutta serena*.

“ Various means of relief were attempted, without effect. The patient languished, in a very emaciated state, with frequent vomitings and convulsions, and died on the 20th of October 1781, two months after the operation.



*Dissection after Death.*

“ The membranes of the brain were in a healthy state. The lateral venticles contained an ounce and a half of a serous fluid, the greatest part of which was in the left ventricle. There was no morbid appearance in the corpus callosum, plexus choroides, or fornix; but, on removing the roots of the latter, we observed that the interior part of the thalami of the optic nerves was of a greyish colour, and much firmer than usual.

“ The upper part of the brain was now removed, and under the anterior lobes we found a swelling, larger than a hen's egg, formed by an enlargement of the thalami on the left side; and, upon raising this substance from the cranium, we discovered the cause which had so suddenly deprived the patient of the sight of her right eye.

“ This swelling, which seemed to have begun on the left side, having gradually increased in bulk, had at length pressed upon the right optic nerve. The compression had been so violent, that the nerve was removed from its natural situation, as it were, and bent against the clinoid process of the *os sphenoides* so forcibly, that the portion of the nerve between this process, and the foramen opticum, was diminished one-half of its usual size, while the portion nearer the brain retained its usual appearance. The disease extended backwards almost to the medulla oblongata, comprehending the pituitary gland. The cerebellum, and all the other parts of the encephalon, were in a sound state, as were likewise the coats and humours of the right eye.

“ From the bulk of this tumor, and from the morbid appearance of the left optic nerve, at the time of the operation, may it not be concluded, that the disease had existed in the left side of the brain, previous to any affection of the right eye? If this be allowed, does not this circum-



stance tend to weaken an opinion which Cheselden and others have supported, that the nerve of each eye arises wholly from the opposite side of the brain \*?"

### CASE XIII.

SCARPA, in the preface to his work on the Diseases of the Eyes says, " that I have not entered into a description of the *cancer* of the eye, since I have never met with more than two instances of this disease, these only serving to establish a fact already sufficiently known, viz. the inefficacy of extirpating the eye-ball whenever the cancerous diathesis has, in the smallest degree, extended beyond the ball itself or its appendages. The first of these cases occurred in a boy thirteen years of age, in other respects strong and healthy, in whom, besides the eye-ball being *scirrhous*, and projecting out of the orbit, there was a tubercle of the same nature, situated between the internal angle of the eye-brow and the root of the nose. I extirpated the eye, and removed every part within the orbit which was indurated or diseased, in the most careful manner, together with the tubercle situated between the supercilium and root of the nose : every thing went on well, and the wound was completely healed. Two months after the child returned home, two new indurated tubercles appeared in the cellular membrane of the supercilium of that side, towards the temples, and a fungus afterwards grew from the bottom of the orbit.

\* Medical Communications, vol. i. p. 95-100.

This unfortunate child was then seized with a constant pain in the head, and afterwards with slow fever and general convulsions, which shortly terminated fatally."

The other patient on whom Scarpa operated was a man 50 years of age; and the description he gives of the case makes it probable that it was a true cancerous affection. But the history and symptoms of the disease in the first case, the age of the patient, and the consequences of the operation, prove, I think, beyond a doubt, that it was a disease in every respect analogous to that which I have so fully detailed. The only circumstance which is particularly worthy of remark in the progress of it, was the situation of the swelled gland on the eye-brow; for in most of the other cases the glands affected were those lying over the parotid or under the jaw.

---

#### CASE XIV.

THE case, of which the following is an abstract, is recorded by Mr John Rodman of Paisley, in the 11th volume of the Medical and Physical Journal.

The girl was twelve years of age. While amusing herself she struck her forehead against a wall, by which she was stunned. On the 5th day after this accident, she felt a pain in the forehead, over the left eye. This pain increased, inflammation succeeded, and the eye-ball enlarged. Common cataplasms were applied to the eye, the vessels of the adnata were divided, the cornea was opened with a lancet, and a small quantity of pus was discharged, along with the



aqueous humour. Twelve months from the first appearance of the disease, it had made great progress, the pulse was 130, and remarkably feeble; the face and lips had scarcely a tinge of blood, and the body was much emaciated. Though she took considerable quantities of laudanum, she had not been known to enjoy sleep for several months. The tumor hung down even below the chin, and covered great part of the mouth, being of a conical form,  $7\frac{1}{2}$  inches long, and its base 11 inches in circumference. The palpebræ were so much distended as wholly to cover the tumor, and there was a foul ulcer between the ciliæ, from which frequent alarming hæmorrhagies took place. In this stage the tumor was extirpated, and for some weeks her health improved, and she was relieved from pain. Towards the end of the seventh week from the operation, a small livid fungous tumor appeared at the internal angle of the orbit, where a deficiency of bone was discovered during the operation. "Ten days after the appearance of this tumor, the surface of the sore changed for the worse; her pulse quickened, and her appetite diminished. The sight of the right eye gradually failed, till she became blind. Diarrhœa ensued, and she died in the eleventh week after the operation. Being sensible of approaching dissolution, the day before death she remarked, with a considerable degree of gratitude, that she suffered more pain in one day, before the operation, than she had ever done since."

*Dissection twenty-four hours after Death.*

Having exposed the contents of the cranium, no mark of disease could be discovered; but, upon pressing behind the diseased orbit, a large hard body was felt. After cutting up the dura mater, and removing the brain, which



seemed free from disease, this body was found lying between the orbit and dura mater, and adhered to it by means of slender vascular filaments. It was of a white colour, very irregular, extending as far back as the sella turcica, and considerably to the right of the *crista galli*. Its surface was hard, like a body approaching to ossification, but, towards the base of the cranium, it had a gelatinous appearance, whiter and more consistent than pus. The livid tumor, observed on the seventh week after the operation, which I attempted to destroy by caustic, was a branch from the internal tumor. Another branch had forced itself into the left nostril, some time before death, which in every respect resembled a very firm *polypus*.

On the left side there did not remain the smallest vestige of the optic, nor any nerve, to the seventh. The right optic nerve was preternaturally enlarged, and surrounded by the internal tumor, from the sella turcica forward. After all the diseased substance was extracted, a most extraordinary deficiency of bone was observed. The left orbitar process of the frontal, malar, and maxillary bones were consumed, except at the external canthus, where a small portion of the two first bones remained carious and thickened. The os unguis, with the whole left side of the sphenoid and ethmoid bones were wanting; indeed, every portion of bone which had been in contact with the tumor was either softened or destroyed. A probe passed freely through the body of the sphenoid bone into the nostrils and palate. Another tumor, which had appeared for some weeks, extended before death from above the superciliary ridge to the apex of the nose; it was an inch and a half broad, and near an inch deep. The bones with which it was connected were also softened, and, though it resembled the firmest



part of the internal tumor in colour and consistence, they were totally unconnected.

December 19th 1804.

---

### CASE XV.

MR WARE gives a very accurate account of an example of Fungus Hæmatodes in the eye\*, where, after relating a curious dissection of a disease in a man's eye, in which the retina was formed into a cone, from the collection of a fluid between it and the choroid coat, he adds;

“ I do not remember in any author to have met with the description of a case in which the immediate cause of blindness was similar to that which has just been related; and I recollect only one instance in which the appearance on dissection bore a resemblance to it. This was in the case of a young lady, about six years old, who gradually lost the sight of the left eye, in consequence of the formation of a white substance in the posterior part of the vitreous humour. The whiteness was perceptible through the pupil in some particular positions of the head, but not in all. It continued without producing any other change in the appearance of the eye for many months. At length the eye began to enlarge, soon after which its natural shape was destroyed, and the tumor assumed a *carcinomatous* appearance. When the tumor had advanced thus far, it was thought advisable to extirpate it,

\* Observations relative to the Eye, &c.



and the operation was performed with great accuracy and care. But, notwithstanding this, in the course of a few weeks, the tumor discovered a tendency to regenerate, and in a short time it grew again to its former size, being now accompanied with an enlargement of the left parotid, and of many other glands on that side of the face and neck. An appearance was now also discovered in the pupil of the *right* eye, similar to that which had been perceived at the beginning of the disorder in the pupil of the *left* eye. But here it advanced no further, than to be perceptible as a white substance in the posterior part of the vitreous humour, and this only in particular positions of the head. The young lady *died*, having previously suffered most violent pain in the whole head, and particularly on the left side.

*Dissection after Death.*

“ On opening the head, a thick sanious fluid was found collected between the cranium and *dura mater*, not only on the inside of the left orbital process of the os frontis (which process was carious, and its surface much jagged), but also on the inside of the os occipitis, a little inclined to the right side, where it occupied a space nearly as large as a crown-piece. The bone here was also discovered to be very rough and jagged, and it appeared to be indented by the pressure of the confined matter. The quantity of water collected in the ventricles of the brain was considerably greater than is usually found, and several small hydatids were observed on the *plexus choroides*. The cavity of the left orbit was filled with the excrescence above described. The right eye did not appear to be enlarged, but, on cutting through its tunics, almost the whole space usually occupied by the vitreous humour was found to be filled with a *steatomatous* substance, which, in general, was



of a white colour, but in some few places was red and bloody. When this substance was removed, a white smooth tumor was discovered behind it, perfectly distinct from the steatomatous substance above mentioned, and appearing to be a morbid alteration in the retina. The choroid coat had very little of the *nigrum pigmentum* spread over its surface. The crystalline humour, as well as its capsule, was perfectly transparent; and the optic nerve, and every other part connected with the eye, appeared to be in a sound state.

“ In this case, notwithstanding the morbid change above described in the retina, and in the vitreous humour, it is remarkable, that the eye preserved a considerable degree of sight, even till the time of the young lady’s death.”

---

M. Gendron in his *Traité sur les Maladies des Yeux*, Vol. II. p. 405, slightly hints at a disease existing in the eye different from cancer, and alludes to a particular case of a fungous tumor in the eye of a child. “ The cancerous poison,” says he, “ is not the only one which can occasion that elevation of the membranes of the eyes; a *scrofulous* humour may also cause it. I have seen a child, in whom the globe of the eye projected out of the orbit more than two fingers’ breadth, and this young child had a well marked scrofulous habit.”



M. Luis \* quotes a case mentioned by Paaw, of a child three years of age, “ in whom the left eye escaped out of its cavity, and acquired the bulk of three fists. The disease had not been observed till a few months before the child’s death. On opening the cranium, a *fungous* tumor was discovered, the base of which adhered to the *dura mater* upon the orbit, without the brain being changed.”

In the same memoir M. Luis quotes the following case :

“ On the 8th of July 1737, my father,” says M. Hoin, “ called a consultation of all the principal surgeons of Dijon, at the house established for the sick poor, in order to examine the case of Christian Sordeau, aged *three* years. The globe of the left eye was pushed forwards, and had acquired the bulk of a goose-egg. The pain was very violent, and it had only been fifteen days since the globe of the eye had begun to enlarge, although the child had totally lost the sight of both eyes, from an obscurity of the cornea, which followed an obstinate ophthalmia. There was reason to believe, that this disease was produced by the action of a *scrofulous* virus, because the child had a num-

\* Vide Memoires sur Plusieurs Maladies du Globe de l’Œil, par M. Luis, dans les Memoires de l’Academie de Chirurgie, Tom. V.



ber of swelled glands on the neck, particularly on the left side, where there was one which extended from the larynx to behind the ear. Notwithstanding the fever which tormented the child, it was agreed upon to extirpate the prodigious eye. My father performed the operation immediately, and the child was cured nineteen days after the operation."

In the case alluded to by M. Gendron, and in those of Messrs Paaw and Hoin, there is much reason to suspect, that they were examples of the disease of which we have been speaking. The ages of the patients, and the general appearance of the tumors, make this opinion probable; and though M. Hoin's patient is said to have been cured in nineteen days, yet, from the unsuccessful results of all the other cases, there is every reason to fear that the disease ultimately returned, and proved fatal.

Heister has also given a drawing of a case of *fungus of the eye* in his surgery, and refers to his "Observations," &c. for a history of the case; but his account of it is extremely short and inconclusive.

I have also become acquainted with a considerable number of other cases, which have come under the care of several of my medical friends. But their history and termination are so analogous to those already mentioned, that I think it unnecessary to give them in detail.

One of these was under the care of Dr Thomson some years ago. He was struck with the greenish colour at the bottom of the eye; and when the eye enlarged, and apparently contained an increased quantity of humours, he made an opening in the cornea to discharge them; but besides aqueous humour, a quantity of a thick whitish matter, resembling custard, came out, and soon afterwards a fungous mass grew from the eye-ball, which destroyed the child.

Two cases have also come under the care of Mr George Bell. In one of these a very large tumor protruded from the orbit, and it was thought advisable to extirpate it. I had an opportunity of seeing the operation per-



formed by Mr Bell, and all the diseased parts were completely removed. "Every thing went on well for several weeks, and there seemed a tolerable prospect of a cure being effected, as the edges of the wound healed, and the discharge from the bottom of the orbit was good, and reduced to a very trifling quantity. These favourable appearances, however, were not of long duration, as a fungous growth soon began to appear in the orbit, and increased with prodigious rapidity, baffling the power of every escharotic I durst venture to apply to it. A second operation was performed nearly with the same success; for after the parts had assumed a healing appearance, and matters had gone on favourably for some weeks, they began to degenerate, and the disease soon terminated fatally." In the other case no operation was performed; and though now near two years have elapsed since Mr Bell first saw the child, the disease has not yet terminated fatally.

It may be remarked, that all the cases which have been yet mentioned, have occurred in children; the disease, however, as I before took notice, though most frequent in them, is not confined alone to the early periods of life. I have been able to learn of only a few cases of the disease in the adult, and two of these have come under my own observation\*.

In those advanced in life, the morbid growth appears to be liable to more variation in its structure than in children, though it may be observed, in the cases which follow, that the same general character belongs to all. The chief part of the diseased mass presents the *medullary* appearance noticed in children; there is the same tendency in the disease to contaminate the adjacent absorbent lymphatic glands; and the termination of the disease is equally fatal.

\* See Cases XVI. and XVII.



### CASE XVI.

---

THIS patient was under the care of Mr Allan Burns, surgeon in Glasgow, with whom I had an opportunity of examining the eye, and of dissecting the parts after they were removed. As the case is extremely interesting, affording an example of Fungus Hæmatodes, not only in the globe of the eye, but also in the *liver*, Mr Burns has been so obliging as to allow me to publish the following account of it.

“ The female whose eye you assisted me in extirpating, was about 41 years of age. She had always been of a delicate habit of body, and of a sallow complexion, but had never observed any affection of her eyes till two years and a half ago. About that time she began to see less distinctly than usual with her left eye; and on looking at the organ, a milkiness was seen behind the pupil. This opacity of the lens gradually increased for four months, when she became completely blind of that eye. After having been blind for about two months, the eye became very much inflamed, without any obvious cause. By bleeding with leeches, &c the inflammation abated, but the redness and pain never entirely left the eye. From what I have been able to learn, the opacity of the lens could not be so decidedly ascertained after this attack, owing to the turbidity of the anterior chamber. The further progress of this case was not traced till within the last six months. At the beginning of that period, a tumor began to protrude from the lower side of the



sclerotic coat, just behind the attachment of the lucid cornea. When I examined the eye, about four months ago, it appeared that the cornea was more prominent than usual, and I could neither distinguish with accuracy the iris nor crystalline lens. The appearances impressed me with the idea, that a fungus was lodged behind the cornea, ready to protrude as soon as the cornea gave way; and in regard to the tumor attached to the lower side of the sclerotic coat, it at that time seemed to contain a dark-coloured transparent fluid, which I thought was a part of the aqueous humour, which had escaped from the eye-ball, by a rupture of the proper coats of that organ. This cyst was about the size of a musket ball, and was formed by a distention of that part of the tunica conjunctiva which covers the sclerotic coat; and over the surface of the sac a number of red vessels were seen running in every direction. The pain was intense and lancinating; her sleep was interrupted; and, besides being affected with hysteria and pain in the back, she was in some degree hectic. When I saw this patient four months afterwards, matters were in a much worse state than formerly; her health was now completely broken; she had confirmed hectic fever, and was often attacked with paroxysms of hysteria. She was much reduced, and exceedingly weak, and had not been out of bed for two months. On examining the eye, it was found that the cyst, which formerly was not larger than a musket ball, had now become as large as a pigeon's egg, forming a solid fungous mass, which could be with difficulty raised, so as to uncover the under eye-lid. The cornea was now flat, and hid beneath the upper eye-lid; and, from the body of the large fungus, two small fungi protruded. Towards the temporal angle of the under eye-lid, there was a hard tumor, situated underneath the integuments, which adhered firmly to the cheek-bone."



Mr Burns extirpated the globe of the eye with much care and accuracy, but the tumor which adhered to the cheek-bone could not be completely removed, the bone itself being found diseased and carious.

*Dissection of the Eye-ball.*

When dividing the eye-ball and optic nerve, a great quantity of a thick viscid matter, having a very dark brown colour, covered the knife. The eye-ball and tumor seemed at first sight entirely composed of a similar dark-coloured matter. This singular looking substance was of the consistence of thick oil-paint, though not so clammy or oleaginous. It soiled the fingers of a dark brown or amber colour. It was readily dissolved in water, and both Mr Burns and I were struck with its resemblance to the *pigmentum nigrum*; but we were much at a loss how to account for the formation of such a large quantity of that substance. I kept the eye-ball in water for twenty-four hours, so that a great quantity of the black matter was dissolved, leaving the solid parts of the mass more distinct. The cornea (*a a*)\* appeared sound, and the crystalline lens behind it was of an amber colour.

The sclerotic coat, at that part which corresponded to the malar portion of the orbit, was ruptured by the edges of the tumor, and the torn edges were separated about a quarter of an inch from one another (*b b*). At the same place the sclerotic coat was split into two layers, a small quantity of the dark-coloured substance being interposed between them.

I could not distinctly trace any remains of the iris, but the choroid coat (*c c*) appeared much more vascular than natural; and at one part it was five or six times its natural thickness.

\* See Plate III. fig. 1.



At the place where the sclerotic coat was ruptured, the choroid coat insensibly terminated in a white pulpy substance, composing part of the diseased mass (*d*).

The contents of the eye-ball were chiefly composed of a medullary-looking pulpy substance, variously tinged in different places by the dark brown colouring matter. The tumor, projecting beyond the sclerotic coat, appeared to be composed of a similar structure, and from the maceration numerous white striæ, and in some places spots, appeared throughout the substance of the diseased mass (*eee*). The tumor exterior to the eye-ball was covered with a thick mucous membrane, except at the two small prominent parts where it had been ulcerated; and this covering had probably been derived from the tumor pushing before it, during its growth, the conjunctiva which lies over the sclerotic coat.

The *optic* nerve was of its natural size; but, by examining its section, it was found that the medullary part of it had a black appearance, exactly resembling the tumor in the eye-ball, whilst the *neurilema* (*ff*) was of its natural colour, and apparently healthy. I could not detect any remains of the retina.

The following account of the result of this case was communicated to me by Mr Burns.

“ This woman, although much reduced by a hectic, and emaciated to a great degree at the time of the operation, soon appeared to recover. She gained flesh and strength; her appetite was restored; the pains in her back and loins left her; she slept well, and was able to walk about. The orbit even discharged good pus, in moderate quantity, and was at last filled up with a soft substance, which, although dark in colour, skinned over. At this stage, when she her-



self and her friends considered her recovery certain, the weather became cold and damp; the pain soon recurred about her back; she lost her appetite, and was unable to walk, from exquisite pains in the loins. After she was confined to bed, she became rapidly worse. The pains increased in severity, insomuch that she could obtain no sleep, except from the use of opium. The lower eye-lid was protruded by an elastic fungus, which also began to project from between the palpebræ. The disease in the orbit gave her no uneasiness, her whole complaint being seated in the back and loins. The pain there was so excruciating, so gnawing, and occasionally so much increased in intensity, that she screamed from agony. She could neither turn in bed, nor permit herself to be turned; for, on every motion, she felt as if many sharp instruments were pushed into her back. In this deplorable condition, she lingered for two or three months; the tumor below the orbit all the while increasing in size, and the pain in the loins in no degree remitted. When I saw her, three weeks before her death, she was a hideous picture of disease; she was emaciated to the last degree, and the tumor below the orbit was as large as a pullet's egg. Its surface was unequal; the most prominent parts of it were covered with livid integuments; and the swelling conveyed to the fingers the impression, as if it contained a fluid. From between the palpebræ, a very small fungus protruded, which was covered with a crust of bloody-looking matter. She had, however, little or no pain either in the orbit or in the head; and the vision of the other eye remained unimpaired. From this time to her death, she sunk gradually; and the tumor enlarging, became more discoloured on its surface, and more irregular; but the fungus between the eye-lids did not alter. About 24 hours previous to her death, she became suddenly comatose."



*Dissection after Death.*

“ The *liver* contained some tumors of a similar consistence with the contents of the eye-ball. There was also a cyst in the substance of the liver, filled with a great quantity of grumous-looking purulent matter.

Above the kidneys, there were similar tumors, of pretty considerable size; and the uterus was of a cartilaginous density. The urinary bladder was enormously distended, with a turbid bloody-looking fluid; but otherwise, in so far as this viscus was examined, its structure appeared healthy.

By making a vertical section of the orbit, and the fungus it contained, we found the tumor entirely arising from the *antrum maxillare*, which was burst open both above and in front. The fungus also projected beyond the lower spongy bone and investing membrane of the nose into the nostril. The tumor proceeding from the antrum was, on its outer surface, studded over with small knobs, of a dark livid colour. Internally, this tumor was made up of a soft substance, of an ink-colour, intersected by membranous slips, intermixed with a greyish-looking substance, and ragged fragments of bone. The anterior wall of the antrum was destroyed at the upper part, and the floor of the orbit was elevated, so as merely to have the periosteum and a thin layer of fat between it and the orbital plate of the frontal bone. The fungus was exterior to the orbit, although, from the destruction of the periosteum attached to the lower and exterior margin of the orbit, it was not allowed to protrude from between the eye-lids. This portion of the periosteum was in part destroyed by disease, and in part, in consequence of the removal of a carious portion of the bone, when the operation of extirpating the eye was performed.

With regard to the *optic* nerve, it was expected, that its extremity would have been joined and connected with the



fungus. Between them, however, the periosteum of the floor of the orbit was interposed. The nerve itself was of its natural size, but of a black colour where it passed through the optic foramen. From this point, to near where it had been divided at the extirpation of the eye-ball, it was nearly in a similar state; its coats had only a slight connection with the diseased substance of the nerve. Exterior to them, there was considerable matting and induration of the muscles. The nerve, at its termination, formed a sharp point, and its sheath was attached to the thickened periosteum of the floor of the orbit, which was pushed up in contact with it, by the fungus from the antrum. The optic nerve within the cranium was as thick as the little-finger, and as dark in colour as that portion of it within the orbit. The junction of the nerves was so much enlarged, that it formed a tumor into the third ventricle.

As, from the dark colour of the diseased parts, this was a favourable case for ascertaining whether the optic nerves decussate each other, or merely come in contact, I examined carefully the state of these parts. I found the dark colour extending beyond the point where the nerves join; but this change of colour was confined to the *left* side, or that of the affected eye. On the *right* side, the nerve was of its natural size and colour, and was merely attached to the black diseased parts by cellular shreds. This dissection, therefore, clearly proved, that the nerves did not, in this individual, cross each other. I would be, however, inclined to believe, from what I saw, that the optic nerves were joined to each other, by interposed nervous substance common to both. The left optic thalamus was of natural structure, but about a third larger than the opposite one. The third, fourth, ophthalmic branch of the fifth, and sixth pairs, were all healthy."

## CASE XVII.

---

THIS patient was under the care of Mr Renton, surgeon at Pennyquick. I was present at the operation, and Mr R. was so obliging as to give me the parts afterwards for dissection. In several points of view, this case is extremely interesting; for though, in the history of the disease, and in many of its general characters, it resembles Fungus Hæmatodes, yet, in some particulars, it differs considerably from all the other cases, and in nothing more than its fortunate termination.

A woman, at fifty-eight years of age, had a tumor of the right eye, of such a bulk, as not only to fill up completely the cavity of the orbit, but to project an inch and a half beyond the superciliary ridge. It pressed forwards the conjunctiva of the eye-lids, and completely effaced any remains of an eye-ball. The tumor was of an irregular knobbed form, and appeared as if composed of two principal parts. One of these filled up the orbit, and was covered by the eye-lids, and their extended conjunctiva. The other part projected beyond the former. Its surface was more irregular; it had a dark purple colour; a thin skin could be traced covering it, except on two or three parts, where ulceration had taken place; and the ulcerated parts discharged a thin sanies, and sometimes blood. The whole mass had a soft elastic feel, though no distinct fluctuation could be perceived.



This woman had been seized with a violent inflammation in the eye, *ten* years before, accompanied by a great degree of fever, and pain in her head. These symptoms continued, with unremitting violence, during three months, at which time the eye burst, and the pain in her head abated. After that period, the eye was occasionally attacked with inflammation, but it seldom lasted long. At last, the eye-ball appeared flattened, and the cornea opake. No change had taken place till fourteen months before I saw her. At that time, Mr Renton observed a tumor arise on the cornea of the collapsed eye-ball, about the bulk of a garden-pea, which tumor had gradually increased in bulk. During its increase, she was frequently seized with severe febrile paroxysms; and, after each attack, an evident enlargement took place. Some portions of the swelling mortified, and sloughed off; and this process was always followed by a profuse hæmorrhagy.

Mr Renton, with Dr Thomson's assistance, extirpated the whole contents of the orbit. After freely dividing the eye-lids at their junction at the temporal angle of the eye, and dissecting back the integuments to the bony edge of the orbit, a curved knife was thrust down between the orbit and the tumor, and carried round it, close to the bone. When an attempt was made to turn out the diseased mass with the fingers, it was bruised, and broke through near the bottom of the orbit, a very considerable quantity of a dark-brown coloured *pulpy* matter being squeezed out in removing it.

A few pieces of the morbid mass which remained were afterwards taken away, and the whole contents of the orbit were completely removed.

*Dissection of the Eye-ball.*

A horizontal section of the tumor being made \*, so

\* See Plate III. fig. 3.

as to divide it into two equal parts, it appeared to be composed of a substance a good deal firmer than brain, but, like brain, it became softer when exposed to the air, and was readily mixed with water. Its colour was of an iron-gray, or cineritious gray colour, intermixed with septæ of a paler hue. The septæ (*a a a a*) were not very numerous, and they converged to a point which corresponded to the place where the exterior tumor, and tumor contained within the orbit, were united. The septæ, though not of a very firm consistence, were rather more so than the other parts of the mass.

Some parts of the tumor had much the appearance of a clot of blood.

Nothing like optic nerve, or any of the coats of the eye-ball, could be detected; nor were there any remains of the muscles of the eye-ball or lacrymal gland.

---

The woman recovered rapidly, after the operation; the orbit was filled up with healthy granulations, and her general health, in a very few weeks, was completely established.

Ten months have now elapsed since the operation was performed, and Mr Renton informs me she remains in perfect health.

---

From the external appearance of the tumor, in this case, the *medullary* looking substance of which it was composed, the disposition of the part to throw out a *fungus*, and the fungus to mortify and slough away, there are, I think,



sufficient grounds to consider it as an example of Fungus Hæmatodes. On the other hand, the appearances on dissection were certainly different from those of every other case of the disease which has come under my observation. The organization of every part composing the globe of the eye was destroyed, whereas, in the other cases, all the parts except the retina could be easily distinguished. The success attending the operation is also an important fact; but time alone can prove whether it shall be considered as a radical cure, or as affording merely a temporary relief. These observations are not, however, sufficient to warrant us in denying the analogy of this case to fungus hæmatodes. The present state of our knowledge is yet too circumscribed, to be able to speak with decision and certainty in all cases; but from what we know, I think it cannot be denied, that it more resembles *fungus hæmatodes* than any other disease with which we are acquainted.

There is a very accurate account of a case, extremely similar to that last mentioned, re-

corded in the third volume of the *Edinburgh Medical and Surgical Journal*, by Mr Mead, surgeon at Hadleigh. As this work is in the hands of most medical men, I think it unnecessary to make any long abstract of the case. I may only remark, that the patient, who was a man 58 years of age, received a violent blow on his left eye, which brought on great inflammation, loss of sight, and, in a year afterwards, the eye burst. During two years after this took place, he remained without pain; but he was afterwards attacked with excruciating torture, which prevented him from having an hour's sleep during months. For several years, he had many slight attacks of pain; and in the tenth year from the time the eye was first affected, it became inflamed, painful, and swelled, and, at the time of the operation, it had acquired the bulk of a middle-sized lemon. The tumor was punctured, being supposed to contain a fluid; but nothing but blood escaped. Mr Mead then extirpated the tumor. "All the fat of the orbit was found to be absorbed; the muscles,



coats, and humours of the eye were one confused mass of disease, connected extensively by morbid adhesions to the periosteum : in short, the whole orbit was literally crammed with a confused mass of disease."

He lived a year from the time of the operation; and, excepting one week, he applied himself to various branches of agricultural labour, till within five days of his death.

#### 4.—*Concluding Observations.*

In the relation of the cases, some may accuse me of too great minuteness, and of having described at full length more of them than was necessary. But on a subject which is, in many respects, new, and which lays open an extensive field, yet unexplored, I hope that, by an accurate detail of all the cases with which I have been able to become acquainted, though they do not now appear of importance, yet they may afterwards prove useful, by establishing some new pathological or practical doctrine.

After the fungus hæmatodes has been described in the different organs of the body, we shall be prepared to enter fully into a comparative view of the alterations in structure which take place in this disease and in *cancer*, and thus to point out the precise characters of both. I may, however, observe here, that I much suspect whether *cancer* ever affects the globe of the eye in its *primary* form ; at least, I have never met with an example of this kind. I have had repeated opportunities of observing a cancerous sore beginning on the integuments of the eye-lid or tarsi, and spreading along the conjunctiva, till it reached the globe of the eye, the structure of which it ultimately destroyed, and contaminated the neighbouring absorbent glands ; but I have never been able to obtain an accurate account of a single case, where any of the coats or contents of the eye-ball were the primary seat of cancer \*.

\* Fig. 2. plate III. is a representation of a section of a scirrhous tumor situated between the under eye-lid and globe of the



The cases which I have already mentioned, have been generally, if not always, considered as examples of cancer in the eye; and I have had an opportunity of seeing other diseases of this organ, at a time when my attention was not particularly directed to the investigation of the present subject, which were, perhaps, neither of the nature of *fungus hæmatodes* nor *cancer*. I am led to form this opinion from the final result of the cases; and from thinking it highly probable, from analogy, that when the eye bursts, tumors may arise from its internal parts, resembling more some kinds of *polypi*, than either *fungus hæmatodes* or *cancer*. There are several cases of tumors of this kind described and delineated by Beer; and, in the works of Fabricius Hildanus, there is a very accurate account of a case, which was successfully extirpated, in which a prodigious tumor grew from the eye-ball. A very remarkable case, very analogous to that given by Fab.

eye. It is given in order to contrast the structure of scirrhus and *fungus hæmatodes*. See explanation of the plate.

Hildanus, I had an opportunity of seeing, ten years ago, under the care of Dr Wardrop.

A gentleman, who resided in England, consulted many respectable surgeons about a very large excrescence which grew from the eye-ball ; but as they supposed it to be of a *cancerous* nature, and as the disease had extended far, they declined making an attempt to remove the diseased parts. When he came to Edinburgh, a very large excrescence was found projecting from the orbit, and extending beyond its bony margin. As Dr Wardrop was assured, from a careful examination of the parts, that the whole diseased mass was within the reach of the knife, and doubtful of its cancerous nature, he undertook to extirpate it. The operation was accordingly performed, and, the eye-lids being excoriated, they were also taken away along with the tumor. The parts healed in the most rapid manner, and the gentleman returned home to England in a month after the operation. A short time ago, Dr W. heard that the disease had not returned. No account was



taken of this case ; but Dr Wardrop particularly remembers, that the optic nerve was found quite sound.

5.—*Of the Treatment of the Fungus Hæmatodes of the Eye-ball.*

FUNGUS Hæmatodes, like cancer, has, as far as I know, resisted the power of all external and internal medicines.

The extirpation of Fungus Hæmatodes in the eye-ball has been also unsuccessful ; for, in all those cases in which I have removed the eye-ball, and in those, the history of which I have been able to learn, where the operation has been resorted to, it has been attended with the same unfortunate failure, excepting in one doubtful case\* ; and even in this, as only ten months have elapsed since it was performed, we cannot speak of its effects with certainty. In whatever texture of the organ the disease originates, it appears ex-

\* Vide Case XVII.

tremely probable, that we are ignorant of its existence before the *retina* has become affected; and that, in many cases where the disease does not appear to have proceeded far, judging from the external symptoms, not only the retina, but also the optic nerve, is altered in structure. From the effect of the operation, therefore, in those cases with which we are acquainted, and from what we know of the change which takes place in the optic nerve and retina, we should be led to desist entirely from attempting the extirpation of the eye-ball. But as we know of no instance of the operation being performed at a very early period of the disease, or in any case where the optic nerve was found in a healthy state, there is still room to hope for success under such circumstances. It is an experiment, at all events, which well merits trial; and were I in any case to be assured of the existence of the disease in the early stage, I would have no hesitation in urging the performance of the operation. Past ex-



perience proves the impropriety of attempting any operation, when the disease has advanced so far that the posterior chamber is filled with the diseased growth. An operation at this period has, in many instances\*, alleviated the patient's sufferings, but I have no hesitation in saying, that it has, also, in many cases, hastened the patient's death. The want of success in the treatment of what has been generally called *cancer* of the eye, by extirpating the disease, has been long and very generally remarked by surgeons; and I have little doubt, but that opinion has arisen from the fungus hæmatodes being classed among cancerous diseases, and operated on as such. The benefit which is to be expected by the use of internal medicines, or by external applications, can alone be determined by experience. Our present knowledge does not even give us room to form a conjecture from any analogous reasoning, or encourage us to expect, that the exhibition of any medicine will impede its pro-

\* See Cases XV, XVI, XVII, &c.

gress, or eradicate it from the affected organ. It is, at least, one step, however, in the advancement of medicine, that we have pointed out the line of distinction between Fungus Hæmatodes and Cancer, so that all attempts in the cure of the one may not be confounded with that of the other; for there is much reason to suspect, that a want of accuracy in the discrimination of diseases, leads often to very erroneous conclusions in adopting a mode of cure. Thus, diseases *resembling* cancer, have been considered as such, and successfully treated by some, whilst the same remedy, employed by others, in true cancerous cases, has proved altogether inefficacious.

6.—*Observations on the Mode of Extirpating the Eye-Ball.*

THOUGH the eye may be removed by a very simple piece of dissection, yet there are several circumstances which merit the attention of the surgeon, both with the view of



facilitating the operation, and of insuring its success.

When the globe of the eye is not so much swollen as to protrude beyond the eye-lids, and when the cornea remains sound, it is difficult to get hold of it with sufficient firmness to dissect it out speedily ; it is, therefore, necessary to pass a ligature through the cornea or sclerotic coat, so that it can be held firm, and easily pulled out, as quickly as the parts connecting it to the orbit are divided.

The operation is most easily performed with a common scalpel, and the surgeon should begin with dividing the conjunctiva all round the eye-ball. The eye-lids are then easily dissected back, and the scalpel may be afterwards thrust down to the bottom of the orbit, close and parallel to the bone, and carried, as if sawing the parts, round the whole orbit. The eye-ball now becomes very loose ; and by pulling it outwards, the optic nerve, or any other parts left undivided, may be readily cut through. The branch of the ophthal-

mic artery, which goes to the eye-ball, and supplies the muscles, is necessarily divided in this operation; but the principal trunk or *nasal* branch should be saved. It lies close upon the bone after it enters the foramen lacerum; and it runs along the nasal side of the orbit, till its exit near the nasal suture, where it inosculates with the artery from the opposite side, and is distributed on the parts about the root of the nose.

In all cases where it is necessary to remove the eye-ball, it is also advisable to take out the lacrymal gland, as the lacrymal apparatus becomes useless after the eye-ball is destroyed. This gland, and any portions of the muscles which may remain, may be easily dissected out after the eye-ball has been removed.

The ophthalmic artery generally bleeds profusely when first divided; but I have never met with any case where it was necessary to tie the artery with a ligature. A moderate and well applied pressure most effectually prevents all risk of hæmorrhagy. The pressure should be made, by placing a com-



press of caddis, not broader than the nail of the little finger, directly on the orifice of the bleeding vessel, any blood being previously cleared out of the orbit: a larger compress may be put above the first, and so on, using compresses larger and larger, in succession, until they reach the plane of the orbit, and moderately fill up the cavity. The eye-lids may then be spread over the compresses, and afterwards a pledget of ointment and compress of linen laid above them, and the whole moderately pressed upon by a double circular roller, put round the head.

But in most cases, where this operation is necessary, the eye-ball has altogether lost its form, and becomes much larger, having a fungous tumor growing out of it, and projecting beyond the eye-lids. In such a case, it is extremely difficult to dissect out the eye-ball, without injuring and cutting the edges of the eye-lids. To obviate this difficulty, Mr Dessault adopted a very ingenious, though simple, improvement in the operation \*. It

\* Vide *Oeuvres Chirurgicales du Dessault*, Tom. II.

consists in making an incision through the integuments, at the temporal angle of the eye, not less than half an inch long, so as to disunite the *tarsi*, and thus liberate the two eye-lids: this he made the first step of the operation. In adopting this mode of operating, I have experienced the greatest advantages; it accelerates the operation, and renders every part of it more simple and more easily accomplished.

The future dissection may be made with a common scalpel, unless the tumor be so large as completely to fill the orbit. When this happens, there is an advantage in using a knife a little curved; for, with such an instrument, the point can be easily turned, so as to divide the part of the tumor at the bottom of the orbit, a step in the operation which is not easily managed with a straight instrument.

In some cases, the tumor exterior to the eye-lids is very large. In a case of this kind, on which Dr Wardrop operated, the operation was much accelerated, by first dissect-



ing off the external tumor, which was done with a single stroke of the knife, and afterwards removing the contents of the orbit.

In some cases, the eye-lids are diseased; this occurs only in cases of a true cancerous nature, the cancerous ichor excoriating and ulcerating the skin. In all those cases, the whole of the diseased skin should be removed along with the cancerous tumor in the orbit, and no attempt should be made to save skin, or any other part which has been exposed to the smallest risk of contamination.

Fungus Hæmatodes has been found to take place in these parts of the body during all the different periods of life, though it appears to occur during the early periods, less frequently in the latter.

### CHAP. III.

#### OF THE FUNGUS HÆMATODES IN THE EXTREMITIES.

##### 1.—*External Appearances of the Disease.*

EVERY part of the upper and lower extremities seems to be liable to be affected with Fungus Hæmatodes. It has been met with contiguous to the ankle and knee-joints, on the shin-bones, on the calf of the leg, on different parts of the thigh, in the groin, and on the hip-joint. It has been also observed about the wrist, in the fore-arm, in the arm, and over the elbow and shoulder-joints\*.

\* Hey's Practical Observations, &c.

†



Fungus Hæmatodes has been found to take place in these parts of the body during all the different periods of life, though it appears to occur, during the early periods, less frequently in them than in the eye-ball. It is generally first perceived in the extremities in the form of a small tumor, which is moveable underneath the common integuments. The tumor has a smooth and equal surface, and feels firm, though it has not the degree of hardness of a *scirrhus* tumor of the same size. In some cases, the tumor at its commencement is much deeper seated, and its degree of hardness and equality of surface cannot be so distinctly felt.

Tumors of this kind have been known to succeed a blow, so that at their commencement they could not be distinguished from the adjacent injured parts.

The progress of this species of tumor is slow; and it has, in many cases, remained during two or three years before it acquired the size of a hen's-egg. As it increases in bulk, it advances, like most other swellings,

towards the surface of the body ; the integuments covering it become thinner ; at last they adhere to it, are discoloured, and ulcerate.

When the swelling is of considerable size, it has commonly a soft and very elastic feel ; and I have known several cases, where a sense of fluctuation was so striking, that a lancet was plunged into the tumors, in order to discharge the supposed contained fluid. In one of those cases, where the tumor surrounded the knee-joint, an attempt was made by a surgeon to discharge the contents, but no fluid was found. Another surgeon, who was present, being still more decided in his opinion as to the presence of a fluid, made an incision much deeper, but with the same success. A fungous tumor afterwards arose from both the openings, hectic fever came on, and the patient soon died. Indeed, in whatever part of the body this disease occurs, and becomes an object of external examination, this deception of the presence of a fluid is very re-



markable. It is particularly so in the testicle; for, in four cases of Fungus Hæmatodes in that organ, which have come to my knowledge, the tumor was punctured for a Hydrocele.

When the skin covering the tumor ulcerates, there is generally an oozing of bloody sanies in place of a purulent fluid; and in a few hours after the ulcerative process has commenced, a *fungus* begins to rise, which rapidly increases in bulk.

The appearance of this fungus may be considered as one of the most striking and diagnostic characters of the Fungus Hæmatodes. It has not the regular smooth surface of the fungus of the eye-ball, for, in general, the conjunctiva forms the external covering when the eye is the seat of the disease. In the extremities, it is generally of a rounded form; it has an unequal ragged surface, giving the tumor a raspberry or cauliflower appearance, and clotted blood often adheres to it. It is of a dark red colour, is easily torn, and bleeds on the smallest fric-

tion. It has generally a very narrow neck, and in some cases spreads out so much as completely to cover the edge of the ulcerated integuments. During the process of ulceration, the skin covering the whole tumor does not become uniformly thin, and of a dark-red colour, as takes place during the formation of a common abscess. This change takes place in one particular part, and is accurately circumscribed, so that the integuments continue thick and unaltered, contiguous to the part where the fungus has burst through them \*. When the fungus acquires a very large size, the most prominent parts begin to lose their life, and slough away, rendering the discharge which always accompanies the disease extremely fetid, and often a considerable hæmorrhagy takes place.

The *absorbent* glands are contaminated during the progress of the disease, and those glands swell which are in the course of the circulation. Sometimes this happens early,

\* Vide Mr Hey's Practical Observations, &c. page 284.



and when the *primary* tumor has only acquired a small bulk.

At other times, the swelling of the glands does not appear until the skin covering the original tumor has ulcerated ; and, in some cases, the fungus which arises through the ulcerated integuments, acquires a large size before any of the glands become affected.

As in most other diseases, the kind and the degree of pain which the patient suffers are extremely various. When the tumor is small, it generally gives little uneasiness ; as it increases, it becomes more tender to the touch ; and when it is situated in the vicinity of a joint, or a part exposed to much friction, it sooner becomes troublesome and inconvenient. In some cases it has a frequent sharp stinging pain darting through it ; and when the disease is far advanced, it is generally attended with acute pain.

Before the disease advances to a fatal termination, the swelling of the glands, and the number which are affected, are often

prodigious, particularly in the inferior extremities ; for here the glands, along the course of the iliac vessels and aorta, all contribute to form one formidable diseased mass within the abdomen.

2.—*Appearances on Dissection.*

The appearances on dissection of Fungus Hæmatodes in the superior and inferior extremities, much resemble those changes of structure which are seen in the eye-ball. The primary tumor exhibits the true *medullary* appearance in its internal structure. The limits of the tumor are, in general, accurately defined, when it has not attained a very large size. It commonly consists of distinct portions or lobes, separated from one another by thin membranous intersections, and an indistinct kind of sac or capsule is formed, surrounding the whole tumor. When the tumor acquires a very large size, the neighbouring muscles become involved in the diseased mass, and I have seen bundles of muscular fibres interspersed in various parts



of the tumor ; its form then becomes very irregular, and its limits cannot be accurately ascertained.

The colour of the tumor, when small, is generally of a pale gray, or brownish red hue ; but when it is large, the different portions which are separated from one another by capsules, assume very different appearances, the general mass being thus composed of a number of parts, differing in colour and in structure. Some of these are of the colour and consistence of brain ; some are of a deep yellow colour, and some of them have the colour and consistence of the boiled yolk of an egg : some portions are of a dark red colour, like masses of coagulated blood, and others more resemble *liver*. Sometimes portions of it are of a dark red colour, and cavities are found between the different portions, containing blood, or a thin bloody serum.

The *absorbent* lymphatic glands, which are affected during the progress of the disease, are converted into a matter resembling, in

every respect, the structure of the *primary* tumor.

In Plate IV. there is a drawing of the external appearance of a tumor of this kind in the fore-arm ; and in Plate V. there is a section of the same case, which shews distinctly the peculiar structure of this species of tumor. The patient, from whom these drawings were taken, was under the care of Dr Brown ; and it is from his politeness I had an opportunity of dissecting the tumor, and of laying the case before the public.

The patient was a woman forty-seven years of age. About three years before she came under Dr Brown's care, she perceived a small tumor, the bulk of a common garden-pea, underneath the skin of the back of the fore-arm, a little above the wrist, which was quite moveable. It increased gradually to the size of a hen's egg, in which state it continued for two years. After this period, it increased rapidly, and she was advised to get it removed. The operation was performed, and the wound



healed up, excepting a spot about the size of a shilling, which was suddenly affected with a violent stinging pain. The surface of this ulcer began to be elevated above the surface of the adjacent skin, and increased after that time, so as to attain the size of the tumor represented in the plate.

The amputation of the arm above the elbow joint being thought the only safe mode of practice, the operation was performed, and the wound healed by suppuration.

I examined the structure of the tumor, by making a perpendicular section through it, leaving one portion attached to the *radius*, the other to the *ulna*; the former of these is represented, in Plate V. The whole mass resembled, in a very remarkable degree, a portion of *brain*, in colour, consistence, and every external character; and as the arm was injected with coloured size, many vessels could be traced throughout the substance of the tumor, being a strong proof of its organization. It became also, like brain, softer by exposure to the air, and readily mixed

with water. It appeared to be composed of several distinct portions, separated from one another by thin membranous partitions. One of these portions, larger and more distinctly circumscribed than the others, formed the part of the tumor nearest the elbow, and had several small cavities in its substance, containing a fluid tinged deeply with blood. The other portions were smaller, more irregular in shape, and extended in a direction from the bone to the external surface of the tumor. The blood-vessels which were injected were also observed taking a similar course, though they were not numerous. In one place, the tumor adhered slightly to the periosteum, but did not appear to have formed with it any remarkable vascular connection. The integuments which covered the base of the tumor could be readily dissected from it, the different portions being enveloped in a firm membranous capsule.

In Chap. I. I took particular notice of the changes which were observed in the struc-



ture of the optic nerve, when Fungus Hæmatodes appears in the eye-ball. An examination of the *nerves* in other parts of the body affected with the disease is an object of considerable importance. I am enabled to add one important fact on this part of the subject, and for which I am in a particular manner indebted to Dr Monro senior. As the case is also a strong illustration of the most striking characters of the disease, I hope the following extracts, taken from Dr Monro's notes, will not be unacceptable.

---

### CASE XVIII.

“ A lady, twenty-seven years of age, in the year 1798, observed a swelling on the anterior part of the right fore-arm, the origin of which she could attribute to no cause, except that she had been bled some months before by an ignorant person, and had been accustomed to ride a hard-trotting horse. The swelling gradually increased, and at last attained the size of a goose-egg, and it was accompanied by a pain, as

if exposed to a burning flame, which stretched from the point of her fingers up to the wrist. There was an obscure fluctuation in the tumor, but no pulsation, and the fore-finger was benumbed.

“ On the 17th of June 1801 the tumor was opened, and two or three ounces of a bloody water were discharged, which was inclosed in a thick, fatty, membranous cyst. After the water was evacuated, there was a soft substance observed in the bottom of the cyst, like clotted blood. The tumor was afterwards extirpated, and the radial nerve was incorporated with the back of the cyst, so that the cyst could not be extracted without cutting it.

“ The sore healed in about a month, and she continued well till March 1802, when the tumor returned, and increased rapidly to a great size, and from which a *fungus* grew out. The arm was amputated in October 1802, and the radial nerve being examined, both above and below, the tumor was found connected to it by threads like nerves, and the under part of the nerve was as large as the upper.

“ In January 1804 she was seized with shivering and pain in her head. Soon thereafter a tumor appeared over her left eye, which was about the size of a chesnut, extremely painful to the touch, and the left *eye-ball* seemed enlarged and protruded. On opening the head after the patient's death, the brain was found in a fungous state; and the tumor, on being cut, resembled *medullary* matter.”

---

In several cases of Fungus Hæmatodes of the eye-ball, it was observed, that, before the patient's death, other organs of the body also became affected with the disease. The same



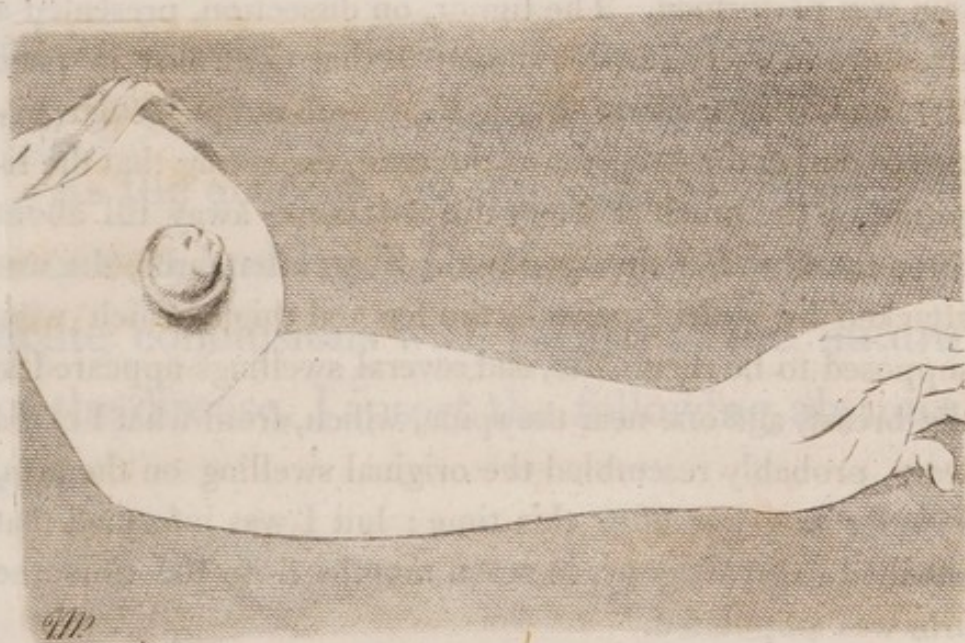
thing takes place when Fungus Hæmatodes appears in the extremities. In a case, afterwards to be related, where a large Fungus Hæmatodes formed on the hip-joint, the same disease was found, on dissection, to have appeared in the *kidney*. In the foregoing case (Case XVIII.), the brain was affected, the primary disease having appeared in the forearm. In the fifth volume of the London Medical Journal, there is a case described by Mr Dease of Dublin, in which the disease began in the hand, and, on dissection, "the liver was found to have a small *steatoma* on its convex surface."

A very interesting case of Fungus Hæmatodes, beginning in the arm, and afterwards attacking the *mamma*, was under the care of Mr George Bell, some years ago, with an account of which he has been so obliging as to favour me. As this case, also, shews well the general form of this species of tumor, and the appearance of the fungus arising after the integuments have ulcerated, I have ad-

ded to Mr Bell's account of the case an outline taken from a cast of the diseased arm.

### CASE XIX.

---



“ Two years ago, a swelling appeared on the arm of a lady, about fifty years of age, near the insertion of the tendon of the biceps muscle. It increased gradually and uniformly from that time, impeding, as it became larger, the motion of the joint ; and although at all times uneasy, yet it did not give her any great pain. Five weeks before she came to Edinburgh, the tumor became suddenly more painful, acquiring, at the same time, a considerable increase of



bulk. The gentleman who then attended her, suspecting that suppuration was about to take place, applied emollient poultices, and, at the end of a fortnight, the most prominent part of the tumor burst, and discharged a quantity of thin, bloody, ichorous matter. The discharge continued, and became very offensive to the smell; the pain increased, the swelling enlarged, and a *fungous* excrescence appeared at the opening from which the matter had been discharged. She became feverish, restless, and uneasy; and the case being considered *cancerous*, she came to Edinburgh. The amputation of the arm being thought necessary, the operation was performed. The tumor, on dissection, presented a structure in every respect similar to that described in page 107, and delineated in Plate V. Nothing particular occurred during the progress of the cure, excepting that the ligature on the brachial artery did not come away till about three months after the operation. Soon afterwards, she was attacked by violent pains in the leg and thigh, which were supposed to be rheumatic, and several swellings appeared in the breast, and one near the spine, which, from what I could learn, probably resembled the original swelling on the arm. I never saw her after this time; but I was informed that she died in great agony, in seven months from the time the arm was amputated."

---

Fungus Hæmatodes takes place, perhaps, more frequently in the extremities than in any other part of the body. It has been already mentioned \*, that Mr John Burns first

\* See General Observations, page 2.

published a general description of this disease in these parts: there are, however, some cases of fungus hæmatodes described in works published prior to that of Mr Burns; but it seems evident that the nature of the disease was not understood.

An account of one of these is given by Dr Monro, in the edition of his works published by his son, entitled, "*An Anomalous Tumor of the Leg unsuccessfully treated.*"

As the account of the case is extremely accurate, and leads Dr M. to draw some very acute conclusions with regard to the nature of the disease, I insert the following abstract of it.

### CASE XX.

---

A TUMOR appeared on the outside of a woman's leg, forty-six years of age, attended by excruciating pain, hectic paroxysms, and night sweats. Dr M. believing the tumor to contain a fluid, an opening was made into it. "Not one drop of pus was discharged, only two or three ounces of mucus dropped out." When the dressings were remov-



ed, the day after, “ a *fungus* appeared at the orifice, which resembled the flabby *tunica cellulosa*, so often to be seen in the back, and other depending parts of those that die of tedious lingering diseases. I cut off some of this fungus, put gentle escharotics on the remains of it, and dressed the rest of the wound with suppurants. On the second day, the fungus came out much larger, and violently stretched the aperture of the teguments and tendinous aponeurosis, by which a gangrene was begun all round the edges. I cut off the fungus, enlarged the orifice considerably, and dressed it up with antiseptics and suppurants, in the common way. In two days, the gangrened parts fell off, and, the aperture being now very large, I dissected from between the two bones of the leg near a pound of flabby substance. After having cut as deep as I durst, without risking the opening of the large arteries, I thrust a probe through that soft fatty substance, till I felt it and saw it striking against the skin of the opposite part of the leg.

Expecting, therefore, no success from this method, I resolved to perform the amputation as soon as the fever and diarrhœa, which were now come on, were abated ; but neither were stopped by any medicines given, and in a few days the patient died.

The skin of all the leg appeared, after death, sound ; but the *tunica cellulosa* and muscles were all degenerated into that pappy substance which had appeared as a fungus, and I could not distinguish one muscle from another, though I was at pains to dissect them.

The periosteum was everywhere separated from both tibia and fibula. Between it and the bones, an acrid dark brown liquor was contained, and the surfaces of the bones were rough and yellow.

I had occasion, soon after, to see a leg affected with just such another sort of tumor ; but it was opened sooner, be-

fore any other bad symptoms had come on. It would not cure with either external or internal medicines, and the patient would not allow amputation, so that it was palliated, till both surgeon and patient wearied of each other."

Having finished his account of the case, he makes the following very pertinent queries:—

"Pray, gentlemen, under what class of tumor is this to be reckoned? Is it akin to the windy swellings of the joints, or to what the French call the *fatty tumors*?"

"If you know the species of tumor, what is the pathognomic sign by which it is to be distinguished from *erysipelas-œdematodes*, or the slow phlegmons; for I am much afraid of falling into some such mistake as the former, unless you will explain the difference to me?"

---

Mr Pott, in his surgical works, when treating of the diseases of the extremities which require amputation, makes the following observations:

"There is," says he, "another kind of complaint affecting the leg, removable (as far as my experience goes) by amputation only, which is one reason why I mention it in this place, and to which I might add another reason, which is, that it either derives



its origin from a bursten artery, or at least is accompanied by it.

“ I know no *name* to give it, or under what *class* to range it, but will describe it in the best manner I can.

“ It has its seat in the middle of the calf of the leg, or rather more towards its upper part, under the gastrocnemius and soleus muscles. It begins by a small, hard, deep-seated swelling, sometimes very painful, sometimes but little so, and only hindering the patient's exercise. It does not alter the natural colour of the skin, at least until it has attained a considerable size. It enlarges gradually, does not soften as it enlarges, but continues, through the greatest part of it, incompressibly hard; and when it is got to a large size, it seems to contain a fluid, which may be felt towards the bottom, or resting, as it were, on the back part of the bones. If an opening be made for the discharge of this fluid, it must be made very deep, and through a *strangely distempered mass*. This fluid is generally small in quantity, and con-

sists of a sanies, mixed with grumous blood. The discharge of it produces very little diminution of the tumor; and, in a few cases which I have seen, very high symptoms of irritation and inflammation come on, and, advancing with great rapidity, and most exquisite pain, very soon destroy the patient, either by the fever, which is high and unremitting, or by a mortification of the whole leg.

“ If amputation has not been performed, and the patient dies after the tumor has been freely opened, the mortified and putrid state of the parts prevent all satisfactory examination; but if the limb be removed, without any previous operation, (and which, as far as my experience goes, is the only way of preserving the patient's life,) the arteria tibialis postica will be found to be enlarged, distempered, and burst; the muscles of the calf of the leg to have been converted into a *strangely morbid mass*, and the posterior part of both the tibia and the fibula more or less carious\*.”

Whether this disease, described by Mr

\* See Pott's Works, Vol. iii.



Pott, is to be considered as Fungus Hæmatodes, or a disease of the arteries, may be by some disputed. The description appears to me to accord more with that of fungus hæmatodes, than with any other morbid alteration of structure with which we are acquainted; at the same time, it is so imperfect, saying nothing more of the structure of the tumor, than that "it is a strange distempered mass," that we cannot draw from it any satisfactory conclusion.

The same remarks will also apply to two cases mentioned by Mr Freer \*; for in neither of them is there to be found, in the account of the dissection of the tumor, any of those appearances which I have attempted to point out as characteristic of Fungus Hæmatodes.

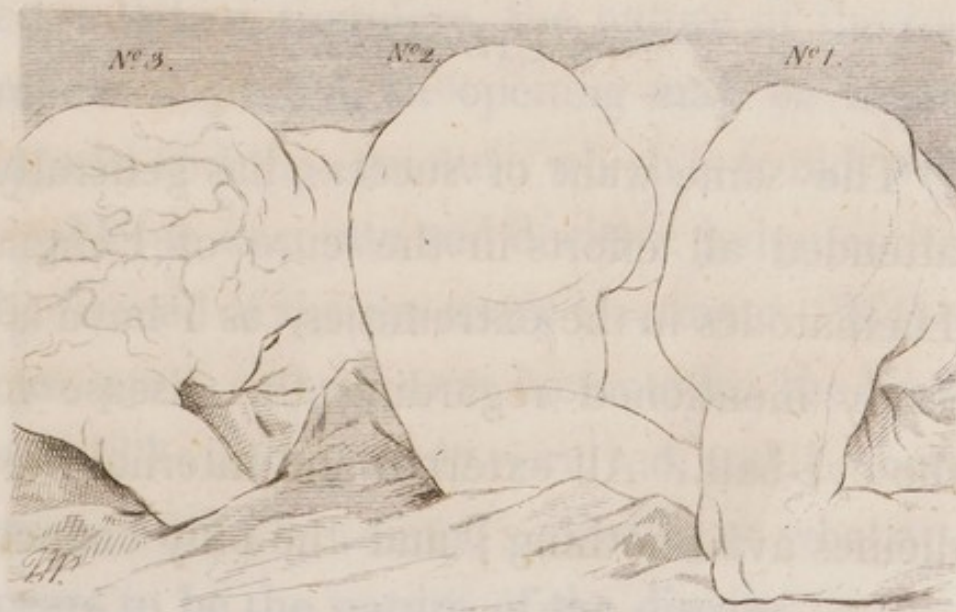It has been already noticed, that a case of fungus hæmatodes in the hand † is described, in the fifth volume of the London Medical Journal, by Mr Dease, and quoted

\* See Observations on Aneurism, p. 25. Birmingham, 1807.

† See Page 112.

by Mr Burns. Mr Burns has also given an account of four cases which came under his own immediate observation. In three of these, the disease took place in the inferior extremities, and in the other, it appeared on the upper part of the shoulder. Mr Hey has mentioned two cases of the disease in the superior, and three in the inferior extremities. Mr Abernethy has also given the account of a case on the thigh of a boy, twelve years of age.

In the Collection of the *Ecole de Medicine* at Paris, there are drawings of three cases of a disease in the shoulder-joint, called by the French *Carcinome Sanglante*, from which I took the annexed outlines.





Though I could not get any particular account of the cases, the great resemblance which these sketches have to the drawing given by Mr Hey, and to a case of fungus hæmatodes of the shoulder I had an opportunity of seeing, under the care of Mr Astley Cooper, leave little room to doubt but that they are representations of the true fungus hæmatodes.

The outlines give a good idea of the general form of the tumor when it appears in that part of the body, No. 1. shewing it when small, and Nos. 2. and 3. in its successive stages.

### 3.—*Of the Treatment of Fungus Hæmatodes in the Extremities.*

The same want of success has generally attended all efforts in the cure of Fungus Hæmatodes in the extremities, as I have already mentioned regarding this disease in the eye-ball. All external and internal medicines avail nothing ; and the only chance

of saving the patient's life, is by an early removal of the whole limb. In a considerable number of cases, which have come within my knowledge, and in many of the cases which have been recorded by Dr Monro, Mr Burns, Mr Hey, &c. an attempt was made to cure the disease by removing the tumor alone. But in every one of these, the practice was unsuccessful, the disease afterwards returning at the place where the tumor was removed, in the neighbouring absorbent glands, or in some other organ of the body. From the event of these cases, we would be warranted in urging the removal of the whole limb, as soon as the true nature of the case is perfectly ascertained. When, therefore, the nature of the tumor is suspected, an opening may be made into it, and the structure which is found, will enable an accurate and decisive judgment to be formed of the necessary treatment. If the case prove to be fungus hæmatodes, the limb should be immediately removed, and if otherwise, it must be treated according to what appears to be the nature of the disease.



## CHAP. IV.

### OF THE FUNGUS HÆMATODES IN THE TESTICLE.

---

#### 1.—*External Appearances of the Disease.*

THIS disease of the testicle was first described, and is also delineated, by Dr Baillie, in his *Morbid Anatomy*, under the name of the *pulpy testicle* \*. “The testicle,” says he, “is sometimes much enlarged, and converted into a uniform pulpy matter, in which its natural structure is entirely lost. This sort of change has been sometimes mistaken for scirrhus, but it is very different from what is called scirrhus in other parts of the body, and what is also

\* See the *Morbid Anatomy of some of the most important parts of the Human Body*, p. 350, 1807.

found in the testicle itself." Notwithstanding the accurate description given by Dr Baillie, there are still many facts, both in the history of Fungus Hæmatodes of the testicle, and in the appearances of the tumor on dissection, which merit investigation.

The disease is found, in some cases, to begin in the body of the testicle; in others, its origin has been remarked by a tumor forming in the *epididymis*. The progress of the disease is very slow, and, as the swelling of the gland increases, the tumor retains an oval or globular form, and it becomes difficult, if not impossible, to distinguish the body of the testicle and epididymis from one another. The pain attending the disease is generally so trifling as to excite little alarm, and there is no inequality or hardness in the gland, or any change in the structure of the scrotum.

When the testicle has increased considerably in bulk, it becomes remarkable for its softness and elasticity, and produces the sensation of containing a fluid. In relating the



symptoms of Fungus Hæmatodes in the extremities \*, it has been particularly noticed, that a sense of fluctuation is one of the striking characters of this species of tumor, in all those parts of the body where it could be examined externally. It is, perhaps, even more so in the Testicle than in any other organ; and an accurate diagnosis between Fungus Hæmatodes of the testicle and *hydrocele* is a great desideratum in the practice of surgery. The proportion of cases of this disease which have been treated as hydrocele by experienced and judicious surgeons is almost incredible. Four cases where this took place have come within my own observation. In Dr Monro's collection of morbid preparations, there is one of a testicle where this mistake happened. In the collection of Dr Jeffrey of Glasgow, there is also an example of the disease preserved where the same accident took place.

The want of transparency in the tumor is one appearance in the fungus hæmatodes of the testicle which might be expected to lead

\* See page 110.

to an accurate diagnosis between it and hydrocele; but as there are many collections of water in the vaginal coat of a dark colour, and sometimes even of blood, and as the vaginal coat is often very much thickened, this cannot be always regarded as a diagnostic symptom. The fungus hæmatodes of the testicle, when of considerable bulk, though resembling many of the more frequent varieties of hydrocele in shape, yet, on inquiry, will not be found to have had a similar progress. In hydrocele, the water begins to collect at the bottom of the scrotum, and the testicle may be generally distinguished at the posterior part, until the tumor has acquired a very large size; whereas, in fungus hæmatodes, the disease commences in the body of the testicle, or in the epididymis, and the whole gland gradually enlarges. The tumor, too, in hydrocele, is accurately circumscribed towards the ring, whereas, in the fungus hæmatodes, there is a gradual swelling or fulness, extending up from the testicle along the spermatic cord. In those cases of Fungus Hæ-



matodes which I have seen, it was difficult to distinguish accurately the nature of the change in the spermatic cord, though, in all of them, a particular kind of fulness was perceptible, very different from the unyielding hardness of a scirrhus affection of this part of the body. Besides the want of transparency in the tumor, its progress, and the state of the spermatic cord, the comparative weight of it to what a hydrocele of an equal bulk would be, ought also to be taken into consideration, in judging of the nature of the disease.

The softness and elasticity of the swelling does not remain in all cases after it has acquired a great bulk, for, when large, it often becomes in some places hard, in others very soft, as if soon going to burst. The veins of the scrotum also become varicose, and the skin discoloured. The absorbent glands become contaminated in the groin of the same side with the affected testicle; and a case of this disease is given by Mr Abernethy\*,

\* See Observations on Tumors, page 52.



where the glands in both groins swelled. Generally, before the disease proves fatal, the glands along the course of the spermatic cord, within the abdomen, swell, and form, in many cases, a very large mass of disease, surrounding the great artery and vein.

In no case have I ever been able to learn, that the integuments of the scrotum have given way, and a fungus grown from the diseased testicle. From the history of this disease in other organs, we would have expected this change to have also taken place in the testicle; but the irritation and fever created by the extent of the glandular affection which takes place, as well as the state of the testicle itself, seems to put an end to the patient's sufferings before such a change as ulceration and the production of a fungus could take place.

Fungus Hæmatodes affects the testicle, as well as most other organs of the body, more frequently in early life. A case of it was under the care of Mr Cline, of a boy five years of age; and in those cases, with the particu-



lars of which I have become acquainted, most of the patients have been under thirty years of age.

In many of the cases, the disease has been supposed to originate from a blow, or some kind of injury, in others, to have been connected with, or to have succeeded a venereal affection. But, in the investigation of the history of diseases, we are too apt to attempt to find out their exciting causes, and to attribute them to fortuitous events. In cancerous and scrofulous affections, this mode of reasoning is very common, though there can be little doubt but that both these diseases make their appearance without any exciting cause, the nature of which we are able to trace.

## 2.—*Appearances on Dissection.*

The appearances on dissection of Fungus Hæmatodes in the testicle, are very similar to those which have been observed to take place when the disease appears in the extremities of the body, or in the eye-ball. Fungus Hæmatodes in the testicle presents, per-

haps, more variety in its appearances than when it affects the eye-ball, but this probably arises, not from any specific difference in the diseased process, but from that variation in structure which is observed in the healthy state of the different organs; the phenomena of the same disease being always found to vary more or less, in every texture in which the disease takes place, though there are always some leading and prominent features, which give the peculiar character to the disease, in the organ it happens to be developed.

The pulpy or *medullary* appearance, so remarkable in other parts affected with Fungus Hæmatodes, is also the striking character of fungus hæmatodes in the testicle. The medullary-looking matter is generally of a pale brownish colour, at other times more of a red. Sometimes the whole gland is converted into one mass of this nature, having very much the same appearance throughout, whilst, at other times, it is composed of parts varying in consistence, in colour, and in texture, and separated from



each other by thin cellular sheaths. Some of these subdivisions of the morbid mass are much softer than fresh brain, and have more the consistence of custard, but they never seem to degenerate into a puriform fluid; other parts have the degree of firmness of common polypi, or of liver, whilst some portions have been found cartilaginous, having *spiculæ* of bone formed in the cartilage.

When the gland is immersed in water, a great proportion of these substances readily mix with it, and there remains a loose cellular-looking tissue, in which the pulpy matter had been deposited. In one case (Case XXII.) the analogy to the Fungus Hæmatodes in the eye was very remarkably illustrated; for, on making an opening into the vaginal coat, where it had formed a circumscribed tumor from adhesions to the albuginea, a *fungous* tumor, larger than two field beans, covered by the albuginea, was observed to have risen out of the body of the testicle, resembling in structure and colour the fungus from the eye-ball.

In most cases the vaginal coat and albuginea form strong adhesions; in others they remain separated, the intervening space being generally filled with a fluid.

The *absorbent glands* which are contaminated when the testicle is affected, exhibit the same appearances on dissection as what have been already noticed when the primary disease is seated in other parts.

In those cases which I have had an opportunity of dissecting, I have never been able to detect any change in the structure of the *spermatic cord*, or been able satisfactorily to account for the peculiar fulness which I have observed to take place in it during life. From the appearances, however, which were observed by Mr Cooper in the dissection of the cord in Case XXV. it is not improbable that the swelling may arise from a diseased state of the absorbent vessels.

---

With the view of still further illustrating this important subject, I shall add an account of five cases of *Fungus Hæmatodes* in the tes-



ticle, all of which afford striking examples of the disease.

### CASE XXI.

THIS case, with an account of which I have been obligingly favoured by Mr Newbigging, one of the surgeons of the Royal Infirmary of Edinburgh, affords an example where Fungus Hæmatodes appeared, not only in the testicle and the absorbent glands, but also where the Liver, Lungs, and Kidneys seemed to be affected with the same disease.

“ The circumstances of the case of pulpy testicle appear from some notes I have upon it to have been as follows :

“ A man, about twenty-eight years of age, had a swelling of the left side of the scrotum, the size of a goose-egg, which had been forming for nine months. As, from its shape, the sensation it communicated on pressure, and its being attended with no pain, it was believed, by many surgeons who examined it, to be a *hydrocele*, it was determined to perform the operation for the cure of that disease.

“ However, in attempting the operation, the testicle was found diseased, only a small quantity of water having collected in the cavity of the vaginal coat. It was therefore thought necessary to remove the testicle, which was done in the usual manner.

“ Almost the whole wound healed by adhesion, and it was completely cicatrized in three weeks. About this time, the patient was affected with pectoral complaints, accompanied with hæmoptysis, and a tumor, the bulk of a large fist, also formed over the upper lumbar vertebræ, the nature of which could not be accurately ascertained by any external examination, the only remarkable symptom with which it was attended, being a very strong pulsation communicated from the aorta. He soon died, with all the symptoms of hectic fever.

“ On examining the testicle after extirpation, it exhibited the following structure : It was elastic, though soft, and of a dark brownish colour. A number of small sacs, containing a transparent, and somewhat glairy fluid, were in various parts of its substance, and a small quantity of coagulated lymph was found in the cellular membrane, betwixt the vaginal coat and scrotum.

“ On opening the abdomen after death, the spermatic cord of the affected testicle appeared indurated, and several swelled glands were observed adjacent to it, and stretching in a chain to the very large mass of disease, which had been felt during life through the abdominal parietes. This mass seemed to be chiefly composed of a cluster of diseased glands. It was soft when cut into, had a dark-brown colour, and in some parts of it was formed a quantity of thickened grumous blood. This tumor surrounded the aorta and vena cava, the coats of the latter being evidently diseased, and its canal apparently somewhat lessened.



“ In the *liver*, there were many tubercles, containing a thick blackish fluid.

“ In the pelvis of the *kidney*, a quantity of purulent matter was formed.

“ The *lungs* were tuberculous, some of the tubercles being also filled with a thick blackish fluid.”

---

## CASE XXII.

FOR this, and the following case, I am in a particular manner indebted to Dr Thomson, and by the assistance of his notes, I have been enabled to give a fuller account of the dissection of the diseased parts, than I would otherwise have been able to do.

This patient, who was twenty-five years of age, had observed, three years and a half before his death, a tumor in the scrotum, the bulk of a small bean, which appeared to him to be attached to the right Testicle. He attributed its origin to a syphilitic affection in the form of bubo, which he had had eighteen months before. In two years and a half from

the appearance of this small tumor, the testicle had acquired the bulk of an orange, but of an oval form; it was hard and very painful when pressed upon, and its surface was equal. The spermatic cord was also somewhat hardened and enlarged, and he felt a dull gnawing pain extending up its course. At this period he took a small quantity of mercury for several weeks, and solutions of the acetite of lead were applied to the scrotum with little or no benefit. Blisters were also applied to the scrotum, but the testicle always continued to increase in bulk. At last, after having complained of pain in the belly for several days, a tumor was felt in the right side of the umbilicus; it was of a rounded form; gave a sense of fluctuation when pressed upon, and was painful to the touch. The swelling of the testicle and tumor in the belly continued both to enlarge and to give excruciating pain, till at last, after having brought on symptoms of hectic fever, he died.

*Appearances on Dissection.*

I had an opportunity of carefully examining the diseased parts with Dr Thomson, and the various appearances which were observed, rendered the dissection extremely interesting. The testicle, when removed from the scrotum, appeared to be an oval shaped body, about eight inches in its longest and five inches in its shortest diameter, and weighed four pounds. It was soft and elastic, and seemed in some parts to contain a fluid.

By dividing the testicle in several different parts, it was found to be composed of distinct portions or lobes, which differed from one another in colour and in structure. The number of them could not be ascertained, as one section exhibited four or five principal divisions, and another section made it appear to be composed of many more. These larger divisions were separated from one another by firm



cellular capsules, and their layers were detached from the capsules, forming numerous subdivisions of each of the lobes. The whole mass presented a spongy structure, formed of cells, which varied from an almost imperceptible size to such as would admit the last joint of the little finger. Some of these cells were filled with a serous looking fluid; others with a fluid tinged with blood, and others with coagulated blood.

On comparing the structure of the lobes with one another one of them resembled very much a portion of *brain*, both in colour and consistence, and it was observed that a *fungous tumor*, about the bulk of two field beans, had arisen from this lobe, and pushed forwards the albuginea. Another lobe had a more chalky whiteness, and, on pressing it, a fluid resembling medullary matter, mixed with water, oozed out from innumerable small cells. A third lobe appeared more vascular, of a darker colour, and of a more fibrous structure. A fourth lobe was variously intersected with cellular membrane, by which cells were formed, some of them filled with a fluid, some with a yellowish substance, resembling in colour and consistence the boiled yolk of egg, and others with cartilage, some parts of which were converted into bone. Nothing like sound structure could be perceived in any part of the mass. The vaginal coat adhered almost to every part of the albuginea, and, where no adhesion had taken place, cavities were formed, filled with fluid, in one of which the *fungous tumor* above mentioned was contained.

The tumor in the cavity of the abdomen presented a very extensive mass of disease, surrounding portions of the mesentery and intestines, and involving the large vascular trunks. No very material difference could be perceived in the structure of this tumor from that of the testicle, except that the cells were much larger, the texture more fibrous, and the

whole mass much looser. When cut into, it had more of a honeycomb appearance; in some places it felt harder than even the testicle; and, in several points, *ossification* could be distinguished.

Two tubercles of a similar nature to the disease in the testicle and abdomen were found in the *liver*.

---

### CASE XXIII.

“A YOUNG man, about eighteen years of age, had a considerable swelling in the right side of the scrotum, which was of a uniform shape, very soft to the touch, and seemed to include the *epididymis* as well as the body of the testicle. The spermatic cord, as it passed from the testicle to the abdomen, appeared to be but little enlarged.

“After a ligature was applied to the spermatic vessels, the testicle was dissected out in the usual manner, and the wound continued for several days to have a healthy appearance. On the sixth day after the operation, he complained of a pain in his belly, which was aggravated on pressure. This pain was, at no time, very severe, but he had one or two hectic paroxysms, and died on the tenth day.

“On opening the belly, I found the spermatic cord sound within as well as without the abdominal ring, but there was a considerable enlargement of the lymphatic glands, lying along the fore and lateral parts of the lumbar vertebræ. The glands, when cut into, were of a uniform white colour, and soft consistence, some of them having acquired the bulk of a small fist.”



## CASE XXIV.

---

THIS case, which was under the care of Dr Wardrop several years ago, affords a good example of fungus hæmatodes in the Testicle. It also shows the danger in mistaking the disease for *hydrocele*, and the little advantage to be expected from extirpating the testicle.

A patient, thirty-three years of age, had a swelling of the right testicle the bulk of two large fists, and of a very globular form. Its surface was equal and smooth, and it felt hard and tense. The pain which attended it was compared by the patient to the pricking of pins, which sometimes darted with violence along the spermatic cord and across the loins. The cord, as far as the external abdominal ring, was enlarged, hard, and painful on pressure. The scrotum was of a deep purple colour, the veins on its surface varicose, and at the inferior part of it there was some degree of œdema. On the middle and anterior part of the scrotum there was a small opening, which allowed a probe to pass upwards about an inch under the skin, and from which there issued a copious discharge of purulent matter. This swelling had commenced eight months before, without any known cause, except severe bodily exertion. At the end of five months it had only attained the size of a hen's-egg. After this period, the increase was very rapid, and it continued so for three weeks.

Ten days before he came under Dr Wardrop's care, a surgeon who attended him, conceiving the swelling to be a

*hydrocele*, plunged a trocar into it; but after two attempts, which gave him little pain, nothing came away but a large quantity of blood mixed with water. The bulk of the swelling was very little diminished by the operation. Matter formed round the opening made by the trocar, and continued to be discharged through it. The testicle was extirpated, as affording the only hopes of saving this patient's life.

For a few days the febrile symptoms appeared to be alleviated, but they soon returned, and he died in twelve days after the operation.

The testicle weighed two pounds; the vaginal coat and albuginea were firmly adhering to one another, and the gland was converted into a soft pulpy mass, in various parts mixed with blood, none of the natural structure remaining. On opening the abdomen, a chain of swelled glands were seen stretching from the internal abdominal ring to a large diseased mass which was situated on the lumbar vertebræ. This mass seemed to be altogether composed of diseased glands, the whole of which, as well as those along the cord being converted into a *pulpy* matter, parts of which were as soft as cream, others being firmer than brain.

---

### CASE XXV.

MR ASTLEY COOPER, in an ingenious paper in the *Medical Records and Researches*, entitled, "Three instances of obstruction of the thoracic duct, with some experi-



ments, showing the effects of tying that vessel," has given a description of one case of a disease in the testicle and absorbent glands of the belly, which appears to me to be an example of Fungus Hæmatodes. I shall extract those parts of it which appear most important for our present purpose.

A labouring man, twenty-two years of age, was admitted into St Thomas's Hospital. "The account which he gave of his complaint was, that about five months before he had been attacked with a pain in the testis of the right side, which soon after swelled, and had continued to the present time gradually enlarging; and that, seven weeks previous to his admission, he had observed a tumor in the abdomen, on the same side of the umbilicus. The testis, at the time he became an hospital patient, was of considerable size, but preserved its natural figure, being flattened on its sides, and round on its fore-part; its substance felt *pulpy*, yet not sufficiently soft to give the sensation of fluctuation; the spermatic cord was somewhat enlarged. The tumor in the abdomen, though small when he first observed it, now was at least four inches in diameter, and although it was not, in the beginning, attended with uneasiness, it now occasioned very considerable pain. His general health, however, had not suffered, for he seemed equal to any labour, and his countenance exhibited no marks of disease." A fortnight after his admission into the hospital, he complained of great pain in the abdomen, extending in a line from the testicle to the tumor. He lost his health and strength, his pulse became quick and feeble, his skin hot, continual thirst, restlessness, loss of appetite, and disordered bowels. He also complained of a disagreeable sensation of distention in the upper part of the abdomen, after taking a small quantity of food, which continued for several hours. These symptoms, along with vomiting, all increased, and, in little more than ten weeks from his admission into the hospital, he died.



*Appearances on Dissection after Death.*

“ On making an incision into the enlarged testicle, a *pulpy* mass appeared, composed of broken coagulable lymph, and of a blood-coloured serum.

“ The *absorbents* of the spermatic cord were very considerably enlarged, their coats thickened, and small tumors appeared at irregular distances, arising from a diseased and enlarged state of their valves. These vessels were entirely impervious, and contained matter similar to that found in the testicle, which adhered firmly to their internal surfaces. The small glands on the loins, which receive the absorbents of the testicle and cord, by their enlargement and union formed a tumor on the lumbar vertebræ, weighing nine pounds and a half.

“ On opening the tumor, it exhibited a similar appearance to the testicle, and there could be no doubt of the disease being of the same nature.

“ The appearance of the *thoracic duct* was much altered, its coats were thickened and opake, and it was rounder than usual, bearing more resemblance to a nerve than to the principal trunk of the absorbent system.

“ The *receptaculum chyli* was filled with matter of the same kind with that found in the tumor, in the absorbents of the spermatic cord, and in the body of the testicle. It adhered with firmness to the inner coat of the vessel, which was thickened, opake, and irregular.

“ The *thoracic duct* had undergone a similar change; for, in its cavity a substance was contained resembling that in the other diseased parts, by which the tube was rendered impervious. Opposite to the curvature of the aorta, the vessel was lost in a swelling as large as a moderate sized walnut, differing, in no respect, excepting in bulk, from the swelling in the abdomen. Above this tumor, the duct ap-



peared in a healthy state, and terminated, as usual, in the vein.

“ This disease in the testicle was, I believe, *truly cancerous*. The great pain with which it was accompanied, and the rapid progress it made by absorption, are proofs of the truth of this opinion. And, as the appearance of the duct was the same, I believe that this part also was affected by *cancer*.”

In relating the above case, Mr Cooper's object was to prove that the absorbent vessels possess the same powers as the arteries and veins—that though their canal be obliterated, yet the circulation of the chyle continues by means of collateral branches. Thus a minute investigation of the diseased structure, which might, under particular circumstances, produce an obstruction of the thoracic duct, became an object of secondary importance. It therefore appears to me, that, from the testicle and gland, in this case, presenting the pulpy or medullary appearance, the disease ought rather to be considered a case of Fungus Hæmatodes than of Cancer.

### 3.—*Of the Treatment of Fungus Hæmatodes in the Testicle.*

Of the treatment of this disease in the testicle, little requires to be said; for I have never become acquainted with an account of a single case that has been relieved, either by internal medicines, or by the extirpation of the diseased testicle. In all the cases which I have known, where an ope-

ration was performed, the patient died in a few weeks afterwards; and there could be little doubt, that their death was much accelerated by it. From the difficulty of detecting the disease in its early stages, an operation, I believe, has been resorted to in those cases only where it had made considerable progress, and when either the absorbent glands in the groin, or those within the cavity of the abdomen, had been contaminated. There is, therefore, still room to hope, if a diagnosis, sufficiently accurate, could be established between this disease in its early stage, and other diseases of the testicle, that the life of the patient might be saved by extirpation. These observations naturally lead us to conclude, that, in any case where the presence of fungus hæmatodes in the testicle is suspected, the safe and prudent practice would be to open the vaginal coat, and if the appearances warrant the removal of the gland, to proceed immediately to the operation; or otherwise, if the disease



be of a more favourable nature, as a *hydrocele*, it should be treated according to the usual mode employed in such cases.

## CHAP. V.

---

### OF THE FUNGUS HÆMATODES IN THE LIVER.

#### 1.—*Appearances on Dissection.*

WHEN the liver is affected with fungus hæmatodes, a pulpy mass is formed in its substance, which, when exposed to the air, soon becomes very soft, and when macerated in water, the softer parts mix with it readily, and are washed away, a firmer part remaining, which has the appearance of a delicate fibrous, or rather cellular structure. The colour of the tumor varies in different parts, being in some nearly white, or of a pale yellow, resembling *brain*, and in others



more vascular, having a light red colour. In one case \* the tumors had a very remarkable brown colour, mixed in irregular patches among the whiter parts, but, by maceration in water, the brown colouring-matter was washed away.

Tumors of this kind are generally formed near the surface of the liver, and as they increase in bulk they always proceed towards it. When they reach the surface, they form a prominent tumor, which at last destroys the thin peritoneal covering derived from the liver, and throws out a *fungus*, analogous in appearance and texture to what has been already described in the eye-ball and extremities. In some cases, instead of the tumor advancing towards the surface, and producing a fungus externally, cavities are formed in the substance of the liver, into which one or more fungous masses protrude.

The number of tumors which appear in a liver affected with fungus hæmatodes is different in different cases. Sometimes there is

\* See Case XVI. and Plate VI. fig. 2.

only one, sometimes two, and sometimes three or four have been found in the same patient. Their size is also very various, but I have never seen any of them larger than a hen's egg.

The limits of the tumor are always readily perceived, though it is never inclosed in any distinct capsule; for the sound liver contiguous to the diseased portion seems gradually to degenerate into the same structure as that of the tumor, and appears to be inseparably connected with it.

As far as I know, no author has given a description of fungus hæmatodes in the Liver. Dr Baillie, to whose works medical men will always refer, as the ground-work of all pathological inquiries, has described and delineated a species of *tubercle* in this organ, of which he gives the following description; and it appears to me to have a greater resemblance to fungus hæmatodes than to any other disease.

“ I have also seen,” says he, “ in the liver, a number of soft tumors, about the size of a



walnut. They were principally seated on the surface of the liver, and consisted of a smooth, soft, brownish matter. This is a very rare appearance of disease. Such tumors would be by some considered as *scrofulous*; but there is no strong evidence in support of their opinion, and there is certainly no resemblance between this sort of tumor, and either a scrofulous tubercle of the lungs, or a scrofulous absorbent gland. *About its real nature, nothing is satisfactorily ascertained.*"

I have never known the liver to be affected with fungus hæmatodes in any individual in whom the same disease had not first appeared in some other organ. In the case mentioned by Mr Dease, formerly quoted \*, the *steatoma* which was observed in the liver was, in all probability, a tumor of the same kind as that which had originally appeared on the wrist. In Case XVI. where the disease was first observed in the eye-ball, the liver was similarly affected;

\* See page 112.

and in Cases XXI. and XXII. the liver was found diseased where the testicle had been the primary seat of the disease.

Our knowledge of this disease in the liver is yet too limited to be able to point out the symptoms by which it may be distinguished in the living body, from the various other diseases of this organ. It is probable that it is attended with more or less pain; and the excruciating agony which Mr Burns's patient complained of in the back and loins, may have arisen from the disease, which was found after death to have affected her liver\*.

Nor can we even indulge any sanguine expectations of being soon able to find out for it any remedy. The impossibility of detecting the disease in this organ, in its early stages, and its having appeared as a secondary affection in all the cases with which we are acquainted, affords little room to hope for the discovery of any successful mode of treatment.

\* See Case XVI.



In addition to the general observations on the appearances of fungus hæmatodes in the Liver, I shall transcribe the notes taken from the dissection of two cases of this disease.

*Appearances of the Liver on Dissection in Case XXII.*

There were two tumors on the liver, one on the small and the other on the large lobe, and, except the portions of liver converted into these tumors, all the rest of the organ appeared sound.

One of the tumors appeared externally to be an oblong shaped mass, two inches in length, not unlike a piece of coagulated blood in colour, and a little elevated above the natural surface of the liver. It was covered by a thin layer of very vascular lymph, which extended over the edge of the tumor in the form of a thin floating border. The tumor felt pulpy and soft, and a section being made through the middle of it, it seemed of an oval form, and its limits distinctly circumscribed, though it was not inclosed in any kind of sac or capsule; for the sound liver, contiguous to the diseased portion, seemed as if it was gradually degenerating, and converted into the common diseased mass. The tumor was composed of a soft pulpy substance, a great quantity of the softer parts of which escaped while dividing the mass, and these were exactly similar in consistence and in colour to a portion of *brain* which has become soft from incipient putrefaction. I washed the tumor in water, and a great quantity of this white pulpy matter dissolved in it, leaving the firmer parts of the mass more distinct. These were of a bright red colour, and were interspersed and mixed, in various ways, by the white soft parts, so as to produce a variegated appearance.

The redness was most remarkable towards the part of the tumor which was nearest to the surface of the liver, and this appeared to be produced, not only from the greater vascularity at that part, but from the effusion of small quantities of blood. When put in water, the firmer portions of the tumor separated into a great number of filamentous parts, which extended in a direction towards the surface of the liver, this being probably the direction of the blood-vessels.

The second tumor projected a considerable way beyond the natural surface of the liver, forming a circumscribed fungous mass, the surface of which was not quite smooth, apparently from the effusion of thin layers of coagulated lymph. It was about the bulk of a chesnut; in some parts its colour was livid, in others blue, and in some parts there were streaks of a bright red. It was very soft, and extremely delicate to the touch; for whenever any portion of the external surface was rubbed off, a quantity of thin *medullary* looking matter oozed out. The portion of it which was in the substance of the liver, resembled that of the other tumor, only being rather less firm.

*Dissection of the Liver in Case XVI.*

Two tumors were found in the liver of this patient, both of which were seen on its surface; one of them being about one inch diameter, and the other three quarters of an inch\*. The latter (*a*) was considerably elevated above the surface of the liver, and was of a grayish hue, mottled with black blotches. On making a section of it, it appeared to be of a rounded form. It was composed of a pulpy mass, like

\* See Plate VI. fig. 2.



firm *brain* in consistence. Some parts were of a white, and the others of a dark-brown or black colour, the same as observed in the eye-ball. The larger tumor (*b*) presented appearances quite analogous. There was an intervening portion of sound liver between the tumors. The tumors were not inclosed in cysts, but were immediately connected with the sound liver, the line of division between the sound and diseased portions being distinctly marked. "There was also a cyst in the substance of the liver, filled with a great quantity of grumous-looking purulent matter\*."

The representation given in Plate VI. fig. 2. which is taken from the liver in this case, shows well the general appearance of this species of tumor when the liver is affected with fungus hæmatodes.

\* See Page 79.

## CHAP. VI.

### OF THE FUNGUS HÆMATODES IN THE SPLEEN.

---

IN a patient who died of a disease in the testicle, which had all the appearances of Fungus Hæmatodes, the spleen was felt enormously enlarged, through the abdominal parietes, and was very probably affected with the same disease ; but this fact could not be ascertained, permission not being obtained to open the body.

I have had an opportunity of seeing the spleen affected with this disease in only one case, the preparation and an accurate account of which was sent to me by Mr G. Monteath, then house-surgeon to the Royal Infirmary of Glasgow.



In this patient, there were soft pulpy tumors in each groin, and a very large mass of swelled glands had formed in the abdomen, which was connected at one part with the Spleen.

The spleen was much enlarged, weighing two pounds and a half. Every part of it was studded over with white tuberculous masses, which slightly elevated its external surface, and, on making a section of it, a number of rounded and oval-shaped masses, most of them about the bulk of chesnuts, and some of them smaller, were seen in every part of the organ, and so close to one another as to leave only small portions of sound spleen between them. These tubercles were of a uniform white colour, and consisted of a white pulpy matter, resembling *brain*, which appeared to be inseparably connected with the sound structure. As this case affords an excellent example, not only of the disease in the spleen, but also in the inferior extremities, I shall give an account of it in Mr Monteath's own words.

## CASE XXVI.

“ *March 28th 1808.*

“ J. F. aged twenty-three years, a tailor, had a tumor the size of two fists, of an oblong shape, lying along the course of Poupart's ligament, upon the top of the left thigh. It was pretty hard, but elastic, and softer in some parts than in others. No fluctuation, however, could be detected. It was firmly attached by its posterior surface to the neighbouring parts. This tumor had begun three years before, without any known cause ; it constantly and gradually increased in size, and gave him unremitted dull pain. The thigh and leg of that side were much swelled by œdema, and felt so rigid as to render him a little lame.

“ Three weeks before this, a tumor began to form in the right groin, which is at present the length of the little finger, and an inch in diameter, having a knotty glandular feel. It is similar, he says, to what the other was at its commencement.

“ A very small opening was made into the large tumor, with the view of ascertaining its contents. A probe was introduced into the opening, and was easily made to pass in all directions through the tumor, without feeling almost any resistance, or giving any pain. Nothing but thin venous-looking blood issued, which came in considerable quantity, by a constant slow stream, without jets, and without diminishing in the least the size of the tumor. The wound was closed, and healed by the twisted suture. Four days after this he became affected with feverish symptoms, which increased to an alarming degree, attended with a diffused erysipelatous-looking inflammation over *both* tumors, spreading



along the lower part of the abdominal integuments, and upper part of the left thigh. By using diaphoretics, acid drinks, and by the exhibition of purgatives, these symptoms were nearly subdued in seven days, that is, by the 12th of June, when it was observed that both tumors had become remarkably diminished in size, and doughy to the feel, having lost all their elasticity; the œdema of the thigh had also much diminished. Having suffered much in his general health by this attack, he was now allowed wine, with bark in small doses. The tumor burst in two places, and discharged a small quantity of pus. Both the openings, however, healed in three weeks, without any particular treatment. A poultice was now kept constantly applied to the large tumor. About the middle of July, the tumors began again to increase in size, and resumed their elasticity. At this time, a considerable fulness and hardness was observed in the abdomen, along the course of the left psoas muscle. He was now much confined to bed, his pulse kept about 100, and he had considerable nocturnal sweats. By the 10th of August the tumors had become considerably enlarged; the integuments over the large one were reddish, and in some parts of the tumor, there was a sense as if of fluctuation. A seton was passed longitudinally across the tumor, but without giving exit to a drop of pus, though a large probe could, as at the time when formerly opened, be easily pushed, without almost meeting any resistance, through every part of the tumor, and without giving any considerable uneasiness. About six ounces of blood were discharged from the two openings in a few minutes; the discharge, however, was stopped by the application of caddis to the wounds. The whole cord was daily covered with laudable pus, but the tumor becoming much larger and more tender, and his health rapidly declining, it was removed ten days after being inserted. The pain of the tumor now became more urgent,



darting up into the abdomen, and much hardness and fullness could be felt about the umbilicus and epigastric regions. About the 23d of August a dark-coloured ulceration took place on several parts of the surface of the tumor. These ulcerated parts, and the two former openings made by the seton, increased considerably in size, and shewed the contents of the tumor to be in a sloughy state. He was now seized with singultus and retching, and upon the 2d of September, after having been for many hours in a torpid speechless state, he died.

*“ Dissection after Death.*

“ The tumor of left groin being cut into, its substance, in general, had a white fatty appearance, and was very soft; in some places, however, it had more the appearance and feel of the cineritious part of the *brain*. In some of the cavities formed by the ulceration and sphacelation, there was lodged a small quantity of thin dark-coloured fetid fluid. On laying open the abdomen, the tumor was found to extend up along the inner edge of the psoas muscle to the spine. The contents of the small tumor of opposite groin were exactly similar to those of the left groin, and from it there was a continuation of the same matter, beneath Poupart's ligament, and up along the psoas, to meet the tumor from the opposite side, upon the lumbar vertebræ. The united tumor at this part was very large, and proceeded along the spine, near to the stomach, where part of it ended in the Pancreas, which had become somewhat assimilated to it. Another portion of it terminated in the spleen, *which was very large, weighing two and a half pounds*, and was almost totally converted into the same *medullary*-looking matter with the tumor. The tumor, where lying over the upper lumbar vertebræ, was of an enormous size, and tuberculated upon its surface. The inguinal, iliac, and lum-



bar glands were all involved in the tumor; some even of the detached mesenteric glands were enlarged and changed in texture. The aorta passed through the centre of the tumor, but when it was cut open, its coats, &c. seemed free from disease. The iliac and commencement of the femoral arteries were also completely included in the tumor, and the ureters passed through it in their course to the bladder. The tumor adhered very firmly to the spine, which did not appear diseased, and, proceeding down along the psoas muscles, it gave off considerable detachments, which entered the pelvis, and nearly filled up that cavity. The tumor within the abdomen being cut out, independent of the spleen, weighed six pounds, and at least three pounds remained in the pelvis and groins, which could not be conveniently removed. The liver and stomach were natural, also the kidneys, except that they were very soft. Some of the folds of the intestines had formed adhesions to each other. The cavity of the bladder was diminished, from the pressure of the tumor. There were several extensive adhesions of the pleuræ, but otherwise the thoracic viscera were natural. The structure and appearance of the tumor in the abdomen was exactly like to that of the groins, and in some parts of it collections of a cream-coloured fluid were found."

---

The spleen is more rarely found diseased than most of the other organs of the body; and it would appear, that in the foregoing case, it had become contaminated with Fungus Hæmatodes, in consequence of its adhesion to the morbid mass of glands in the ab-

domen. Fungus Hæmatodes of the spleen has, as far as I know, never been described in any account of the morbid anatomy of that organ.



## CHAP. VII.

### OF THE FUNGUS HÆMATODES IN THE KIDNEY.

---

IN a patient of Mr Allan Burns, where a very large fungus hæmatodes had formed over the hip-joint, the Kidneys were also found altered in structure ; and I have little doubt, from the appearances, that they were affected by the same disease.

The tumor of the hip-joint presented all the striking characters of fungus hæmatodes, and resembled so much a section of the testicle in Case XXII., that a gentleman, well accustomed to examine morbid parts, mistook the one for the other.

When the contents of the abdomen were examined after death, one of the Kidneys appeared rather larger than natural.

On its convex margin were observed three prominences, of a whitish colour, about the breadth of the nail of the fore-finger, and there were also several light-coloured spots on different parts of its surface, of a small size. The kidney being divided into two equal portions, the diseased masses were cut into. One of these sections is represented in Plate VI. fig. 1. The three large white portions (*aaa*) were nearly equal to one another in size, each being of a very irregular shape, and some sections showing them to be five or six irregular-sided masses.

The limits of the tumors were readily distinguished from the sound structure, the colour of the former being of a gray, that of the latter, of its natural brick-red. On examining the tumors, however, with a magnifying glass, they did not appear to have any distinct capsule; but the diseased portions seemed to be closely and inseparably connected with the sound liver, by an intimate intertexture of the two structures. Every part of the tumors had the same light-gray colour, but



variously interspersed with florid red streaks, which were produced by the ramifications of blood-vessels. They had also, throughout, the same degree of firmness, being rather softer than the sound kidney, and not giving that gritty sensation to the edge of the knife, which is observed in the healthy organ. In no part, however, was the disease so soft, or of the same consistence as brain. The other kidney presented similar appearances.

The morbid alterations of structure observed in the kidneys, would not perhaps be alone sufficient to warrant us in considering this case as an example of fungus hæmatodes. But a tumor, indisputably of this nature, being observed in the hip-joint, and in many other cases several organs of the same individual having been affected with this disease,—these circumstances, along with the diseased appearances of the kidneys, are strong grounds for considering it as an instance of fungus hæmatodes.

of these tumors, I did not find any of them in a state of suppuration. They were commonly as large as a gooseberry, and were chiefly placed on the surface of the

## CHAP. VIII.

### OF THE FUNGUS HÆMATODES IN THE LUNGS.

Examining this disease in the lungs; but there is little doubt, not only from the accurate account quoted from Dr Baillie's work, but from the lungs suffering in several cases

DR BAILLIE has remarked a species of *tubercle* in the lungs, which, both from the description and delineation he has given, appears to me to have a great analogy to *fungus hæmatodes* \*.

“ I have seen another sort of tubercle,” says he, “ in the lungs, which I believe to be very rare. It consists of a soft tumor, formed of a light-brown smooth substance. This is not contained in any proper capsule, but adheres immediately to the common structure of the lungs. In cutting through sever-

\* See *Morbid Anatomy*, page 71, and plate.



ral of these tumors, I did not find any of them in a state of suppuration. They were commonly as large as a gooseberry, and were chiefly placed on the surface of the lungs; some, however, were scattered through their substance, of a smaller size."

I have never had an opportunity of examining this disease in the lungs; but there is little doubt, not only from the accurate account quoted from Dr Baillie's work, but from the lungs suffering, in several cases, where other organs of the same individual were affected with fungus hæmatodes, particularly in Case XXI., that they are subject to this disease.

Of its symptoms in these organs, and of its diagnosis from the various other species of *tubercles* with which they are so often affected, nothing is at present known; it is, however, a subject which well merits future investigation.

CHAP. IX.

OF THE FUNGUS HÆMATODES IN THE UTERUS.

---

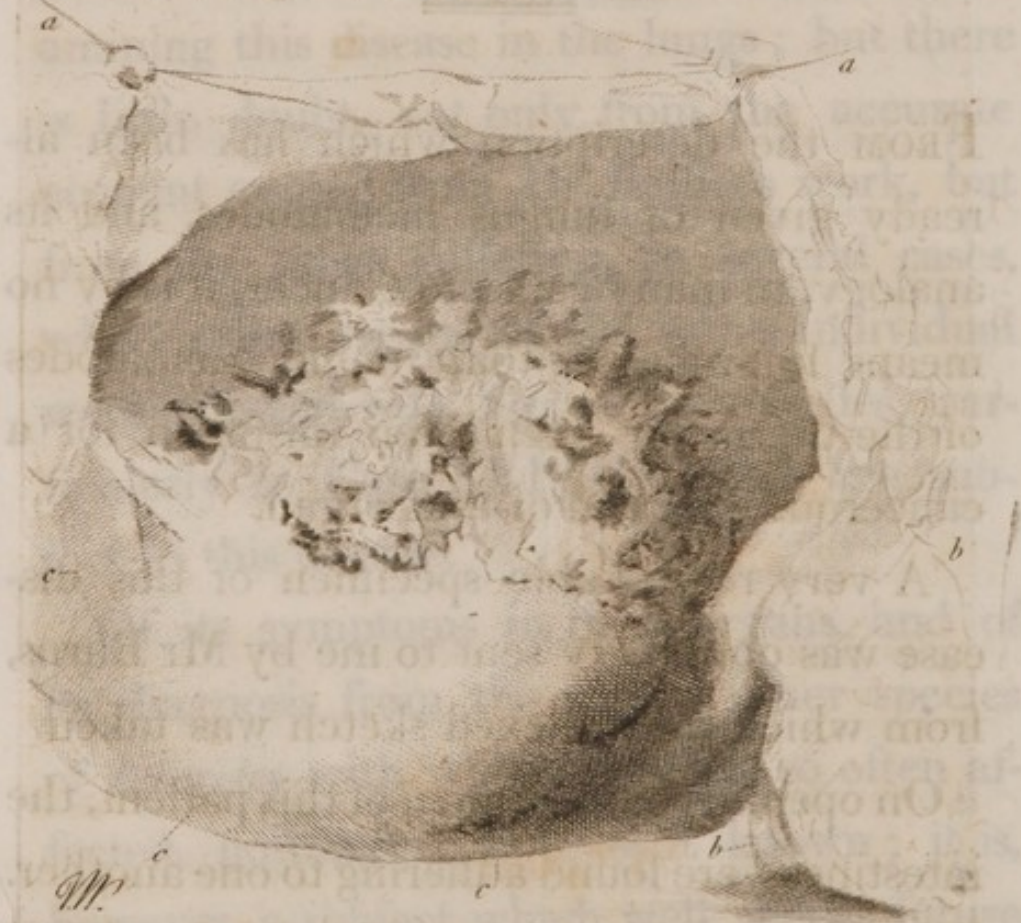FROM the description which has been already given of fungus hæmatodes, and its analogy, in many cases, to Cancer, it is by no means improbable, that fungus hæmatodes of the uterus has been often mistaken for a cancerous affection of that organ.

A very remarkable specimen of this disease was obligingly sent to me by Mr Burns, from which the annexed sketch was taken.

On opening the abdomen of this patient, the intestines were found adhering to one another. The *uterus* was as large as the fist, hard and ragged about the os uteri; and, by the extent of the ulceration, the whole anterior part of the vagina, and the posterior part of the bladder were destroyed. The bladder and



vagina were thus formed into one cavity; and what remained of the former was considerably thickened. From the body of the uterus, a dark-coloured soft and spongy *fungus* protruded into the cavity of the abdomen, which resembled, in a striking manner, the fungus from the other organs affected with this disease.



The sketch represents this tumor of the uterus, viewing it from the abdomen. (*aa*) Are two threads which are attached to the peritonæum, and suspend the preparation; (*bb*) is one of the fallopian tubes;

and (*ccc*) is the fundus of the uterus much enlarged, and with the fungus growing from it. The history which Mr Burns gave me of this case was, "that the woman's health was much impaired, having well-marked hectic fever. She suffered constant pain about the back and pelvis, and there was an incessant fetid discharge from the vagina, which excoriated the external parts, when allowed to remain for any length of time in contact with them. She had also been weakened from repeated hæmorrhagies from the uterine system.

"On examination, the os uteri was felt indurated and prolapsed, and its margins ragged. When the finger was gently pressed on the orifice of the womb, she complained of pain, which was also brought on by going to stool. Six months before she had perceived any swelling in the pelvis, or discharge of matter from the vagina, she was much debilitated by a severe attack of menorrhagia. After this, she never recovered her health; and, from the time the local affection became evident, she sunk rapidly."



## CHAP. X.

### OF THE FUNGUS HÆMATODES IN THE OVARIUM.

---

IT may be remarked, that, in the account given of fungus hæmatodes in the testicle, liver, and lungs, I have quoted a description of a disease in these organs from Dr Baillie's *Morbid Anatomy*, to which he had affixed no name; and though, in that valuable work, no analogy is mentioned between the disease in these different organs, yet the peculiar appearances of that morbid alteration of structure did not escape the notice of that accurate observer.

Fungus Hæmatodes will probably be seldom met with in the ovaria. Dr Baillie re-

marks \*, that “ the ovaria are sometimes very much enlarged, and converted into a *pulpy* matter of a smooth uniform texture, and cells are often formed in a part of this substance which contain a fluid.” It appears to me by no means improbable, that this description is taken from ovaria affected with fungus hæmatodes. I have only seen one diseased ovarium, which I suspected to be of this kind. The ovarium was swelled to an enormous size, being a rounded shaped mass, about nine inches in diameter. The peritonæum which covered it was nowhere ulcerated, and its surface, though smooth, was not entirely equal. On dividing it through the middle, it appeared to be composed of a variety of different lobes, divided from one another by thin cellular capsules †. All these portions differed from one another in colour and in texture, one of them (*a*) resembling *brain*, another (*b*) being much firmer, and more vascular, and a

\* See Morbid Anatomy, page 388.

† See Plate VI. fig. 3. and explanation.



third (c) having little tenacity, and of a light-orange colour; and, in many places, cavities containing blood were placed among these lobes,

cases alluded to, had not fungous tumors arisen from the uterus and being aware at the same time, that a very considerable difference may arise in the appearance of

CHAP. XI.

OF THE FUNGUS HÆMATODES IN THE FEMALE BREAST.

---

IN the description which Mr Hey has given of Fungus Hæmatodes, three cases are mentioned where the female breast is said to have been affected by it. In none of these cases, however, nor in two others which I carefully dissected, and which appeared to be very analogous to those mentioned by Mr Hey, was there that *medullary* structure in any part of the tumor which has been found to be a constant appearance in fungus hæmatodes, in all the other organs where it has been met with. I would, therefore, be led to doubt of the nature of the disease in the



cases alluded to, had not fungous tumors arisen from the cicatrix, and being aware, at the same time, that a very considerable difference may arise in the appearances of this disease in the different organs, the natural structure of the mamma being as unlike that of the sound eye-ball or liver, as the same disease in these organs.

The tumors of the mamma, in the cases which I examined, had an unequal tuberculat-ed appearance externally, when the integuments covering them were removed. By dividing them, they appeared to be composed of several smaller masses, which differed from one another in structure. They had, however, one general character, which Mr Hey has mentioned in his cases—that the whole divided surface was covered, immediately after being cut through, with a transparent glairy fluid, which exuded from numerous small cells interspersed everywhere through the tumor. Maceration in water did not dissolve any part of the mass. The lobules were separated from one another by

firm membranous intersections, which formed to some of them nearly a complete capsule. The lobules themselves were different from one another in colour and consistence, giving the whole tumor a firm and elastic feel. Some of them were of a pale gray colour, interspersed with spots of a light brown; others were of a light purple shade. All of them had a firm and very elastic feel, and in some of them there were portions resembling very much, in texture, a piece of softened glue or firm jelly. In one of the cases, the tumor did not appear to be formed in the gland of the mamma, it being seen of its natural structure displaced by the tumor, and the lactiferous tubes passing into it.

The appearances in these two cases, and in those mentioned by Mr Hey, may not be considered by some as the generic characters of fungus hæmatodes; and there are strong grounds for doubt on this subject. There is, however, sufficient reason to consider them as perfectly different from a *scir-*



*rhous* affection of the mamma, having none of the predominant features of that disease. I am led also to doubt of the nature of these cases, not only from their dissimilarity to fungus hæmatodes in the other organs where the existence of that disease has been ascertained, but from having dissected tumors on other parts of the body, distinctly different from fungus hæmatodes, when it takes place in these parts, the appearances of which were extremely analogous to the affection of the mamma which has now been described.

---

I formerly took notice, that, besides the eye-ball, the superior and inferior extremities, the testicle, liver, spleen, kidney, lungs, uterus, ovarium, and mamma, there were other parts of the body where fungus hæmatodes had been met with. On the authority of Mr Allan Burns, I mentioned that the *thyroid gland* had been found affected with it, two cases of this kind having come within his observation. There have also been cases where this disease appeared in the *neck*;

and I have been informed, by an intelligent surgeon, that he observed a disease resembling fungus hæmatodes appear in the *fauces* of a young girl, which soon proved fatal.

It is extremely probable, that fungus hæmatodes will be found in many of the other organs of the body, when this subject becomes one of more general investigation, though, at the same time, it is reasonable to expect, from what we know of the history of other diseases, that some organs are much more liable to be affected by it than others.



177  
IN THE FEMALE BREAST.  
and I have been informed, by an intelligent  
surgeon, that he observed a disease resembling  
fungus hæmatodes appear in the vagina of a  
young girl, which soon proved fatal.  
It is extremely rare, but fungus hæ-  
matodes will be found in many of the other  
COMPARATIVE VIEW OF THE STRUCTURE OF  
FUNGUS HÆMATODES AND CANCER.

---

1.—*Analogy between Fungus Hæmatodes and  
Cancer, &c.*

FROM the account that has been given of the history and symptoms of Fungus Hæmatodes in several organs of the body, and from the appearances of the disease which are observed on dissection, there are, I think, sufficient grounds to consider it as a morbid change of structure, specifically distinct, and in every point of view different from *cancer*, or any other disease described in nosological systems. The structures of the two tumors

have little analogy to each other, nor are their external symptoms similar; the periods of life at which the diseases take place are different; and some organs are attacked with the one, which have never been observed to be affected with the other.

These differences are found on an accurate examination of the diseases; but when superficially examined, some analogy may be observed between them, which has probably been the cause of their being so long confounded with one another, and classed as one and the same disease.

The progress of both fungus hæmatodes and cancer is generally slow. When ulceration has taken place, neither of them discharges purulent matter, but a thin fetid ichor; and occasionally they bleed profusely. They both sometimes assume a fungous appearance, and, during their progress, contaminate the absorbent glands, which are in the course of circulation; they are also equally destructive, communicating the disease to the neighbouring parts, what-



ever the nature of these may be, whether cellular membrane, skin, muscle, periosteum or bone. Both diseases, too, frequently affect several organs of an individual at the same time. This fact is well known in the history of Cancer, and has been already observed to take place in Fungus Hæmatodes.

Cases of fungus hæmatodes have been also considered by some authors as scrofulous affections. It may be, however, remarked, besides the peculiarity of constitution which is observed to accompany Scrofula and not fungus hæmatodes, the suppuration, and ulceration, which take place in the former, and the formation of a fungus, in the latter; the universal fatality of the one, and the comparative trifling danger of the other—besides these differences in the two diseases, the structure of the two tumors will be found, on accurate examination, to be essentially different; for, instead of the light-yellow, pulpy, tenacious matter which composes fungus hæmatodes, the scrofulous tumor is in-

variably found to be composed of a curdy matter, of a greenish colour, which is gradually converted into a purulent matter.

2.—*General view of the Structure and Appearances in Scirrhus and in Fungus Hæmatodes.*

It has been mentioned, that the structure and symptoms of Fungus Hæmatodes and Cancer are essentially different from one another, even though some slight analogy may be traced between them. I shall now attempt to give a general description of these two morbid alterations of structure, with a view of pointing out these differences, and of affixing precise and definite characters to the names.

The *scirrhus* tumor, from its commencement, is a hard, firm, and incompressible mass, which, by a minute examination, will be found to be composed of two distinct and very different substances. The one is hard



and fibrous, the other more soft, and apparently inorganic.

The *fibrous* substance composes the chief part of the scirrhus mass, and consists of septæ, which are opake, and commonly of a paler colour than the soft part. These septæ are very unequal in their length, breadth, and thickness, and disposed in various directions, so as to form sometimes a solid mass, and at other times a greater or lesser number of irregular cavities, which contain the soft part.

The *soft* or inorganic part is sometimes semi-transparent, of a bluish colour, and resembling, in consistence, softened glue. In other cases it is more opake, softer, somewhat oleaginous, and more resembling cream in colour and consistence.

The proportion and mode of distribution of these two substances, are very different in scirrhus affections of the same and of different organs, and give that great variety which may be observed by examining a number of tumors of this kind. In some, the fibrous

part is most conspicuous, and is condensed into a very solid form, having the appearance of a nucleus, from which septæ come off in all directions, and giving a section of the tumor a radiated appearance. This is perhaps the most usual form of the disease. In some, the tumor is very irregularly shaped, and nearly a uniform hard mass, in which scarcely any defined structure can be traced. In some, the fibrous part has a cellular appearance, the cells being filled with the soft pulpy matter, which can be readily pressed out with the finger. In others, it has cysts formed in it of various dimensions, which generally contain a bloody or dark chocolate-coloured fluid, and have sometimes a fungous tumor growing within them. It occasionally happens, too, that parts of scirrhus tumors acquire a great degree of hardness, being converted into a substance resembling cartilage, in which bony depositions are sometimes formed.

When scirrhus tumors are formed in the substance of a gland, their limits cannot be



accurately determined, the two structures being apparently inseparably connected. At other times they condense the cellular membrane which is in their immediate vicinity, and acquire a more circumscribed appearance\*.

Scirrhus tumors change from the state now described to that of suppuration and ulceration. The hard fibrous substance is transformed into a thin ichorous matter, and the dissolution generally begins at the centre of the morbid mass, and extends towards that part of it which is nearest to the surface of the body, or to some of the natural openings. When ulceration has taken place, the tumor does not increase in bulk, but is destroyed by the process of ulceration; and as the disease extends, and the ulcerative process goes on, new organs become involved, and the disease proves fatal, by the extent of parts which it destroys,

\* This appearance in scirrhus tumors has been remarked by Mr Abernethy in his Surgical Observations, page 68.

and the universal irritation which such a process creates throughout the system.

It sometimes happens, when the skin covering a scirrhus tumor has ulcerated, that a fungus arises from it, forming a tumor of a cauliflower appearance, and of a very hard, firm texture; but this is by no means the progress in all cases, and if the disease be allowed to proceed, the fungus and original tumor are finally destroyed. It has been observed of some cancerous sores, that, from having been very malignant and painful, they suddenly assume a more healthy appearance at one particular part, and begin to cicatrize. Mr Everard Home \* considers the formation of a thin skin on the edge of a cancerous ulcer as one of the most unequivocal symptoms of the disease. This change, however, in the cases to which I allude, is merely a delusion, for always sooner or later

\* Observations on Cancer, connected with Histories of the Disease. London, 1805.



the ulcerative process is renewed, and goes on without interruption.

*Fungus Hæmatodes* presents, on dissection, a very different series of phenomena from the scirrhus tumor. When it appears in the external parts of the body, and has not yet acquired a considerable bulk, instead of being hard and unyielding, it is soft and elastic, and has an equal surface, giving, in most cases, more or less a sense of obscure fluctuation. Its form, when taken out of the body, is determined and accurately circumscribed, having generally a distinct covering of condensed cellular membrane. In place of the hard fibrous-looking substance, the principal component part of scirrhus tumors, the morbid growth in fungus hæmatodes consists of a soft pulpy matter, which mixes readily with water, and is hardened by acids and boiling in water. It has been also compared, by all who have attempted to describe it, to *medullary* matter in colour and consistence. When the skin or covering of fungus hæmato-

des has been eroded by the progress of the disease, instead of the morbid growth being destroyed by ulceration, a fungus arises from it, and the tumor seems only to increase more rapidly in bulk. If the fungus hæmatodes is not interrupted in its progress, both the original tumor and the fungous mass growing from it attain a larger size; and the fungus, instead of having a firm texture, like that which sometimes arises from the cancerous ulcer, is a dark-red, or purple-coloured mass, of an irregular shape, and of a soft texture, is easily torn, and bleeds profusely when slightly injured.

---

Cancer seems to be confined to very few organs of the body, and to a few textures; whereas Fungus Hæmatodes has been detected in parts where no true scirrhus structure has been ever met with. Cancer is found in the skin, in the mucous membranes lining the nose, mouth, fauces, stomach, intestinal canal, and bladder. It affects the



lymphatic glands\*, the salivary glands, the mamma, uterus, ovarium, and testicle. But fungus hæmatodes, though it has not been met with in all these parts in its primary form, yet it has been described in the liver, spleen, kidney, and lungs, organs where the scirrhus structure has never been demonstrated.

It is also a striking fact in the history of cancer, that it is nearly altogether confined to those advanced in life. There may be a few exceptions to this general observation, but the instances are extremely rare in which the true scirrhus structure has been met with in any of the parts already mentioned,

\* One of the Queries of the Society for Investigating the Nature and Cure of Cancer was, "Are the *lymphatic* glands ever affected *primarily* in this disease?"

There are few cases of cancer which, if allowed to follow their natural progress, do not ultimately contaminate the lymphatic glands; but if my observations are accurate, I have met with two cases of primary affection of lymphatic glands. In one, a very large scirrhus tumor of a lymphatic gland appeared in the axilla, and advanced to ulceration, no disease being in any of the adjacent organs; and I have also extirpated a scirrhus gland under the clavicle when the mamma was not affected. Similar cases to the latter have occurred to Mr Abernethy, but I believe they are rarely met with.

in people below the age of twenty-five or thirty\*. Fungus hæmatodes, on the contrary, may be rather considered as a disease of early life. In twenty-four cases of it in the eye-ball, only four of them were adults, the others being children from one to twelve years of age; and in a considerable proportion of the cases where it attacked the extremities, the patients were under the age of puberty.

Both fungus hæmatodes and cancer have been found to affect several organs of the same individual, and this might lead us to suspect that these diseases were not *local*. If we were to judge from the final event of the cases of fungus hæmatodes which have been mentioned, there might be reason to believe that a constitutional taint had originally ex-

\* I had an opportunity of seeing an example of a true cancerous sore in a girl about twelve years of age, and it is the only case of the kind which has come to my knowledge. It appeared on the lower part of the abdomen, and begun in the form of a black wart on the skin. The wart ulcerated, and the surrounding skin was gradually destroyed, so as to form an immense ulcer, having all the characters of a true cancerous sore, which at last destroyed the child.



isted ; but when, at the same time, we consider the great progress of the disease in those cases, before an attempt was made to extirpate the affected part, it becomes impossible, from the present extent of our knowledge, to determine whether the disease is, from its origin, merely local, or whether it is originally connected with a constitutional affection. There is one circumstance which, if proved, would enable us to speak with more certainty on this part of the subject, which is, to ascertain whether fungus hæmatodes is formed in a part, the natural structure of which has been previously changed. If this be the case, the *local* nature of fungus hæmatodes becomes probable ; and in many of the cases of this disease which have been recorded, the affected organ had either been exposed to, or had received some injury.

The locality of *cancer* has engaged the attention of many celebrated authors, and, from what is known of the history of this disease, and of the success attending the extirpation

of primary cancerous tumors, there seem sufficient grounds to consider it as a local affection.

3.—*Of the Texture in which Fungus Hæmatodes originates.*

Thus far an attempt has been made to point out the most striking characters of Fungus Hæmatodes; and some of those appearances have been also taken notice of which are subject to variation, or which arise from the difference in the natural structure of the organ which is affected by the disease. The next object which naturally suggests itself is, to inquire in what particular system or *texture* of the organs does this morbid change originate? Whether does it arise in the vascular, absorbent, cellular, or nervous texture? This question, from the present state of our knowledge, would lead to a discussion a good deal speculative. There are



some facts, however, relating to it, which ought to be brought together, as they are not only interesting to the pathologist, but may lead to some very important practical conclusions.

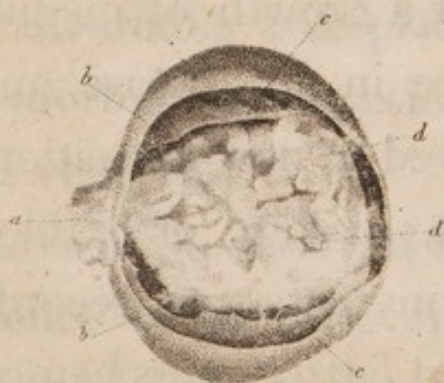It appears certain, that in all those cases in which the disease affected the eye-ball, we were ignorant of its existence before either the *optic nerve* or *retina* were changed. In all of the cases, an alteration in the structure of the retina, and an imperfection in the exercise of its functions, were the first symptoms of the disease; and in those cases where the disease advanced further, no remains of the retina could be detected, and the structure of the optic nerve itself was changed, even in some as far as its thalamus. In one case\* the optic nerve, besides its alteration in structure, was split into different portions by the tumor, which latter seemed to be formed in its internal structure. In another case †, the medullary portion of the

\* See Case III.

† See Case XVI.

nerve was changed, and the disease extended just to that place where it loses its *neurilema*, and becomes altogether medullary. In other cases \*, the neurilema and medullary portions were equally changed.

By a section of the right eye, in Case VIII. a drawing of which Mr Astley Cooper was so obliging as to send to me, the origin of the disease in the *retina* is so beautifully and so satisfactorily illustrated, that I have added the annexed plate, accurately copied from the drawing.



(a) Is the optic nerve, which was apparently in a sound state ; (bb) is the sclerotic coat ; (cc) the choroid coat, which was observed in this case to be unusually thin ; and (dd)

\* See Case I.



is the diseased mass into which the *retina* had degenerated, connected only with the optic nerve, and floating in the posterior chamber. The only thing which the plate does not display was a glairy and opaque fluid, which lay between the choroid and sclerotic coats in considerable quantity.

Were we, therefore, to attempt to draw any general inference from observations on fungus hæmatodes in the eye-ball alone, we should be apt to conclude that the disease consists in a morbid change of the *nerve* itself; and that a growth of medullary matter takes place in this disease, analogous to what is observed in new formations of bony matter, of fat, of skin, or of blood-vessels. There are many cases on record, of enormous bony and fatty tumors being formed in various parts of the body; and those cases of large fungi which grow from wounds, and some species of polypi, may perhaps be considered as a mere increase of blood-vessels.

On the other hand, there are circumstances which would rather lead us to sus-



pect that this disease does not arise from the accidental formation of a substance analogous to any of the natural textures of the animal economy, but that it is a morbid matter *sui generis*. When either bone, cartilage, fat, cellular membrane, or skin, are formed in a situation where it did not formerly exist, it is seldom followed by any bad consequences. From its bulk or situation, it may deprive a joint of its motions, or disturb the functions of an organ; but its formation is not followed by any of those evils which invariably take place in the formation of a morbid matter, as in cancer, scrofula, or lues venerea.

The changes to be observed in the nerves, in consequence of disease, are extremely rare, and scarcely can the most skilful anatomist detect alterations in their structure after death, which during life were the source of agonizing complaints. In two cases of the *Tic Douloureux*, M. Dessault, after much patient dissection, could find no deviation



from the natural structure in the nerves of the face; nor can any disease be observed in the nerves of a paralytic limb\*. From these observations, we should not expect to find the nervous system undergoing such very remarkable changes as take place in fungus hæmatodes, and particularly in those cases where prodigious swellings are formed on the extremities of the body.

But it is extremely difficult to bring forward on this part of the subject any thing conclusive. It remains, therefore, an object of most interesting inquiry, if, in other parts of the body which are affected with this disease, besides the optic nerve and retina, any change in the structure of the nerves of the organ can be detected. In this investigation, the peculiarity in the natural structure of the different nerves ought not to be overlooked; for it is by no means improbable, that the greater proportion of medullary matter in the optic nerve, the canals in

\* Vide Bichât, Anatomie Generale.



which it is contained being larger, and more closely united than in other nerves ; its having one general neurilematic covering, and an artery passing along its axis, leaving branches in its tract, instead of having, like other nerves, vessels penetrating its sides from the neighbouring vascular trunks ;— these peculiarities, in the natural structure of the optic nerve, may perhaps lead to an explanation of some of the peculiar phenomena of Fungus Hæmatodes in this organ ; and the same mode of inquiry may also lead to a successful investigation of this subject in other parts of the body.





## EXPLANATION

OF THE

## PLATES.

---

### PLATE I.

THE two busts which are given in this plate are intended to illustrate the external appearances of Fungus Hæmatodes in the eye-ball. In Mr Cooper's case, a tumor, which was of a livid colour, is seen occupying the right orbit, and a very large tumor projects from below the under jaw, which was entirely composed of diseased lymphatic glands. The surface of the tumor in the orbit, though unequal, is yet smooth; and, on the surface of the enlarged gland, extensive ulceration had taken place.—(See Case IV. p. 43.)

In the other figure there is a representation of the fungus which grew from the orbit after the extirpation of the eye-ball in Case I. It shews the enormous size of such swellings. One half of it is covered by the upper eye-lid, much distended, and the other presents a very ragged dark-coloured fetid mass. There are also three glands of very considerable bulk on the cheek of the same side.



## PLATE II.

This plate is intended to illustrate the appearances of Fungus Hæmatodes of the eye-ball on dissection.

*Fig. 1.* represents the appearances on dissection in Case II. where the disease had not proceeded so far as to alter the natural form of the eye-ball. The engraving was taken from a very accurate drawing, which Mr Russell was so obliging as make for me. (*aa*) Is the optic nerve, enveloped in the diseased mass (*b*), both of which were easily distinguished from one another by a difference in their colour, and being also separated by the neurilematic envelope of the nerve. The posterior chamber is filled with a tumor, intimately connected with, and apparently a continuation of, the medullary matter (*d d e e e*). The choroid coat is pushed forwards, and partly surrounded by the morbid mass, and is seen in the form of an irregular-shaped bag (*cc*). The tumor could be separated from the sclerotic coat (*ff*) at every part, except near the entrance of the optic nerve, and there it adhered to it so firmly that it could not be dissected from it without being torn.

*Fig. 2.* represents a section of the eye-ball in Case III. taken also from a drawing of Mr Russell's. (*aaaa*) Is an imperfect outline of the sclerotic coat; and a tumor is seen growing from the whole of its internal surface, and also exterior to it, surrounding the optic nerve. The nerve was completely imbedded in the mass of tumor, and appeared to be split into two portions (*bc*), which were of a yellow colour. One of the portions of nerve (*b*) adhered to the sclerotic coat, and the other (*c*) appeared detached from it, and was, as far as could be observed, completely enveloped in the tumor. The neurilema and medulla of the nerve remained distinct from each other in both portions; the external surface of the former adhering firmly to the diseased mass, and the latter was converted into a soft porous substance, of the



consistence, and of the same shade of colour of the yolk of egg. Every part of the tumor had a soft medullary appearance, and adhered firmly all round both to the external and internal surfaces of the sclerotic coat.

*Fig. 3.* represents the section of the eye-ball in Case I. taken from a drawing of Mr Syme's, one half of the eye-ball being kept in outline, and the other highly finished. The whole anterior chamber is destroyed, being filled with a soft spongy mass, having no defined structure. (*a*) Is the optic nerve, retaining its round form, but remarkably firm and hard, and no distinction can be perceived between the neurilema and medullary portions of it. (*b*) Is a diseased lymphatic gland, seen in outline, lying on the sclerotic coat, close to the optic nerve. The posterior chamber was completely filled with a solid mass, which had very much the general appearance of brain. Some parts of the mass were firmer than others; and at (*c*) there were a number of particles of a gritty chalky-looking matter. The edge of the sclerotic coat (*d d d d*) is seen of its natural thickness and structure.

### PLATE III.

This plate is also intended to illustrate the appearances of *Fungus Hæmatodes* in the eye-ball, and to compare its structure with that of *scirrhus*.

*Fig. 1.* shows the appearances of the eye-ball on dissection in Case XVI. where the disease appeared in an adult. In this case the morbid mass was remarkable for the dark-colouring matter with which it was mixed. (*aa*) Is the cornea quite sound; (*bb*) are the lacerated edges of the sclerotic coat, which are also split into two layers, a small quantity of the dark-colouring matter being interposed between them. (*cc*) Is the choroid coat, which was much more vascular



than natural; in some places of five or six times its natural thickness, and insensibly terminating in the white pulpy substance at (*d*); and (*eeee*) are white spots, which appeared in different parts of the tumor, after being macerated in water. The optic nerve was of its natural size, but by its section it appeared that the central or medullary part of it had a dark appearance, resembling the morbid structure in the eye-ball, whilst the neurilema, (*ff*), was of its natural pale colour, and apparently healthy. (*g*) Is an enlarged lymphatic gland, also converted into a dark brown-coloured matter.

*Fig. 2.* represents the section of a scirrhus tumor, situated between the eye-ball and malar plate of the orbit. In this case the whole contents of the orbit were removed by an operation, and, after being kept some time in spirits, the vertical section was made of them, which is represented in the drawing. (*aa*) Is the upper tarsus, from which the *cilia* are growing out, and, from the scirrhus tumor being placed between the eye-ball and under eye-lid, the latter is displaced by the tumor, and seen at (*b*). (*ccc*) Mark the boundaries of the scirrhus mass, in the formation of which there are two distinct substances to be distinguished. The one is of an undefined texture, and the other appears in the form of firm fibrous-looking laminæ, dividing the former part into many portions.—(See p. 181.) (*d*) Is the crystalline lens, and (*e*) the vitreous humour *in situ*; and (*fff*) is the fat which was contained in the orbit.

*Fig. 3.* This figure represents the section of the contents of the orbit described in Case XVII. In this instance, nothing like any of the sound structure of the eye-ball could be detected. The morbid mass was composed of a structure a good deal firmer than brain, but, like brain, it became softer a short time after being exposed to the air, and readily mixed with water. Its colour was of an iron-gray, or eimeritious gray colour, intermixed with septæ (*aaaa*) of a



paler hue. The septæ, which were extremely irregular in appearance, all converged to a point (*b*), which corresponded to the place where the exterior tumor and tumor contained within the orbit were united. At (*c*) there was a cavity in the tumor filled with grumous blood, and between (*d*) and (*e*) is the anterior portion of the tumor, covered with the extended conjunctiva. (*ff*) Is the posterior portion of the tumor, which was lacerated and torn during the operation.

## PLATE IV.

In this plate is seen the external appearances of a Fungus Hæmatodes in the arm, which was described in page 107. The tumor had acquired an enormous bulk, and all the prominent part was one fungous mass, covered with a thin fœtid sanies. Some parts of the tumor was of a dark-red colour, others yellow, and some quite putrid. It was soft, and easily injured, bleeding profusely when any part of it was destroyed. The general appearance, form, and bulk of the tumor are well seen in the plate.

## PLATE V.

This plate represents a section of the tumor in the arm in Plate IV. and was selected in order to show what may be considered as the most usual appearances in the structure of Fungus Hæmatodes. The appearances on the dissection of this case are particularly alluded to in p. 108. The tumor was extremely like brain, and appeared composed of several distinct portions, separated from one another by thin membranous partitions. The portion of the tumor attached to the radius is represented in the plate, and the head of that



bone is seen at the under corner. A portion of the tumor may be observed larger and more circumscribed than the others, and of a rounded form, in the substance of which were several small cavities, which contained a fluid tinged deeply with blood.

### PLATE VI.

In this plate are represented the alterations of structure which take place in the Kidney, in the Liver, and in the Ovary, when affected with Fungus Hæmatodes.

*Fig. 1.* shows the section of the kidney, which is described in p. 162. (*aaa*) Represents the three tumors which were observed prominent on its external surface, and (*b*) is the ureter. These tumors were of a pale white colour, rather softer than the sound structure, but so intimately connected with it, that a distinct line of division could not be perceived between them.

*Fig. 2.* This drawing was made from the liver in Case XVI. and mentioned in p. 153. Only one of the tumors is minutely detailed, the other I have kept in outline. The figure represents a section of a portion of the large lobe of the liver. (*a*) Is that part of the smallest tumor which appeared externally covered by the peritonæum, and (*b*) is the larger tumor. Both of these had the consistence of a piece of fresh brain, but, in place of being of the same light colour, they were variegated in a very singular manner with a dark-brown matter. This peculiar appearance was observed on the external part of the tumor shining through its peritoneal covering, as well as in the cut surface.

*Fig. 3.* In this figure I have drawn a general outline of the Ovary, and detailed the structure of only one portion of it. In this case, which is mentioned in p. 170, the ova-



rium had become so enlarged as to measure nine inches in diameter ; and the section of it showed it to be composed of a variety of different structures, very analogous to what has been observed in some cases of Fungus Hæmatodes in the extremities, and testicle. All the different portions of the tumor differed from one another in colour and in texture, and were separated by thin capsules, formed of condensed cellular membrane. The portion marked (*a*) resembled brain. (*b*) Was much more firm and more vascular. (*c*) Had little tenacity, and was more like the boiled yolk of egg in colour and consistence ; and between the portions, cavities containing blood were formed (*dd*).



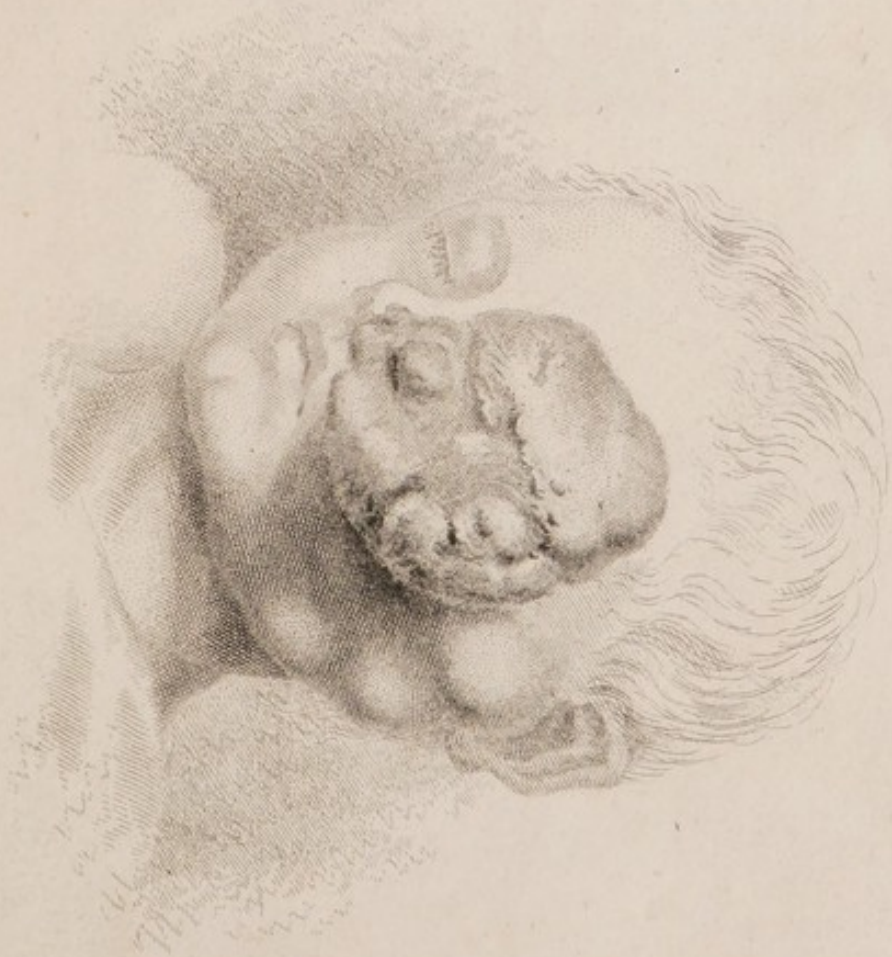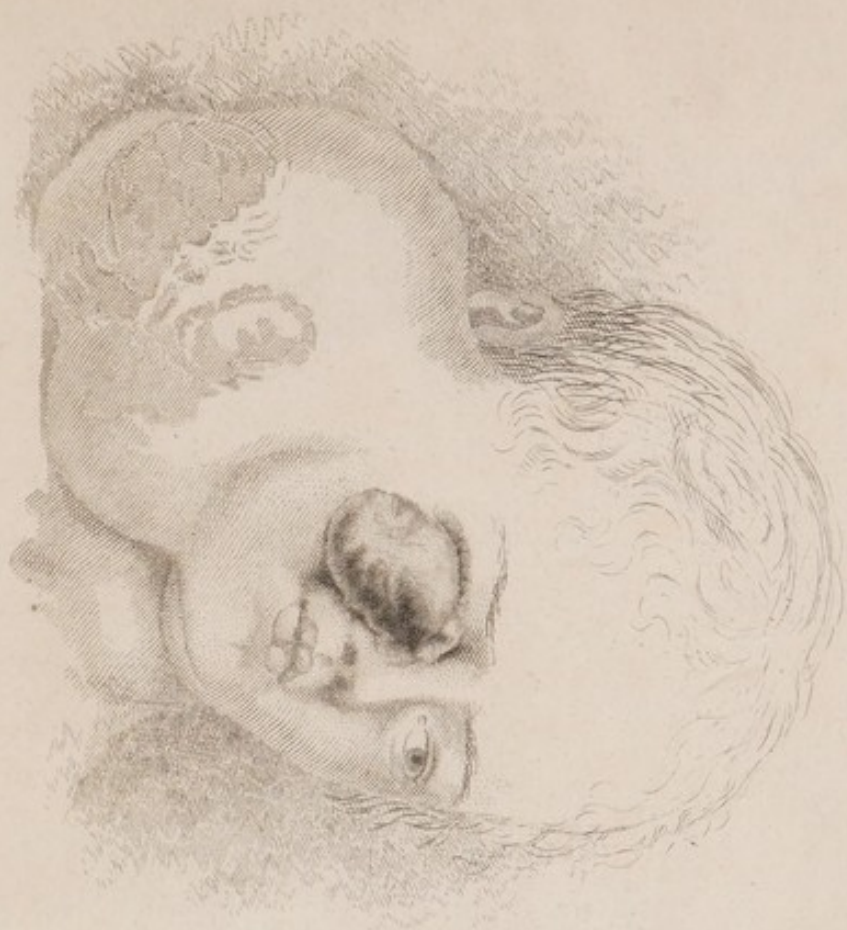from the blood as well as by the bile which  
 in the liver, and the action of it, and it is to be  
 seen of a variety of animal functions, very much  
 which has been observed in some cases of this  
 in the stomach, and testicle. All the different parts  
 of the liver differ from one another in colour and in  
 size, and were separated by the capsule, to each of  
 which, whether membrane, the portion marked (a),  
 essential part, (a) was much more than and more  
 the (c) the liver, and was more like the  
 folk of the in colour, and non-vascular, and  
 portion, which containing blood was (b).

The liver is a large, soft, and  
 is situated in the right  
 side of the abdomen, and  
 is covered by a capsule  
 of fibrous texture, which  
 is continuous with the  
 capsule of the gall bladder.

The liver is divided into  
 two lobes, the right and  
 the left, by the falciform  
 ligament, which is  
 attached to the anterior  
 surface of the liver, and  
 is continuous with the  
 peritoneum. The right  
 lobe is larger than the  
 left, and is divided into  
 four segments by the  
 gall bladder, which is  
 situated in the right  
 lobe, and is connected  
 to the liver by the  
 gall bladder duct, which  
 is continuous with the  
 common bile duct.

The liver is supplied with  
 blood by the hepatic  
 artery, which is  
 situated in the  
 falciform ligament, and  
 is continuous with  
 the abdominal aorta.

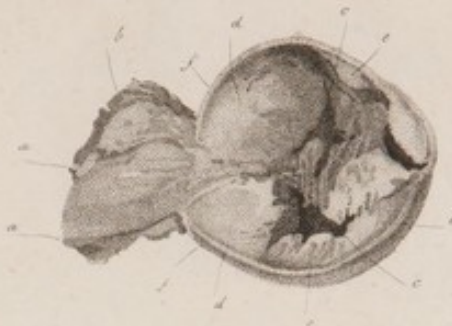The Spongy Membranes of the Eye ball.



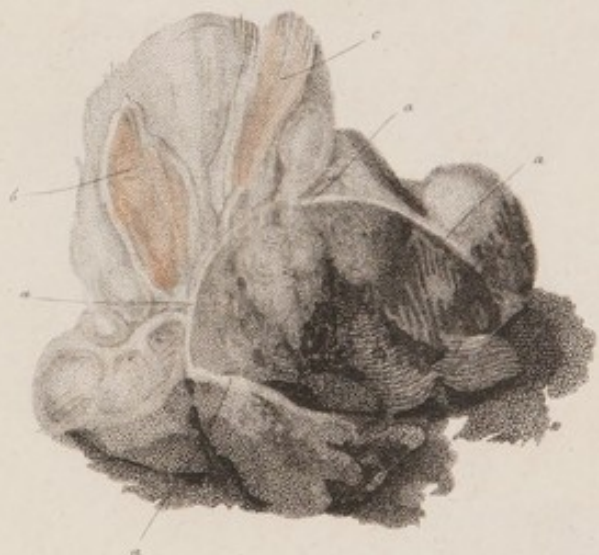

Manuscript of the

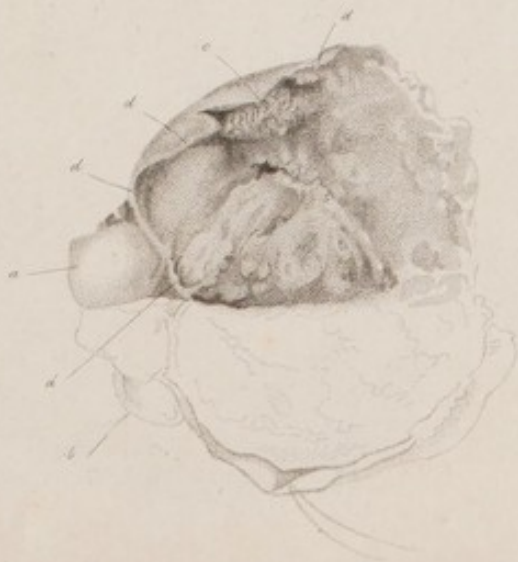*Dissection of the FUNGUS HEMATODES of the Eye-ball Case 2*




*Dissection of the Eye-ball Case 3*



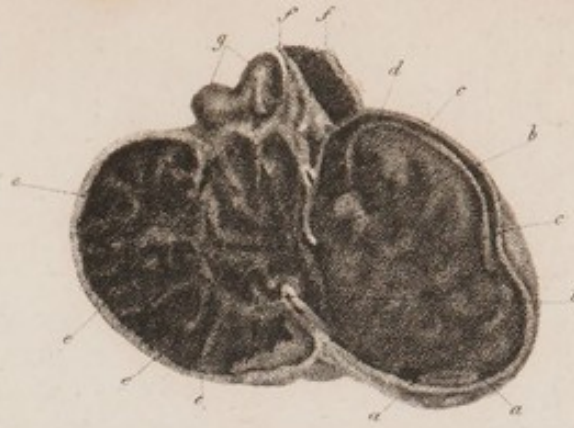
*Dissection of the Eye-ball Case 1*



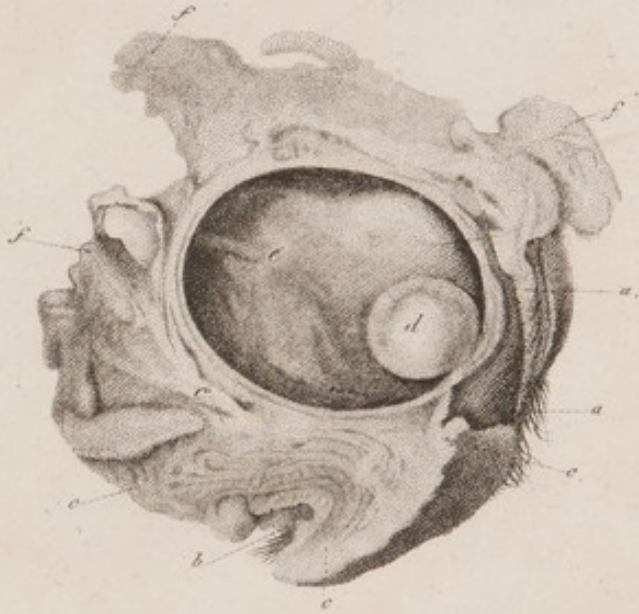




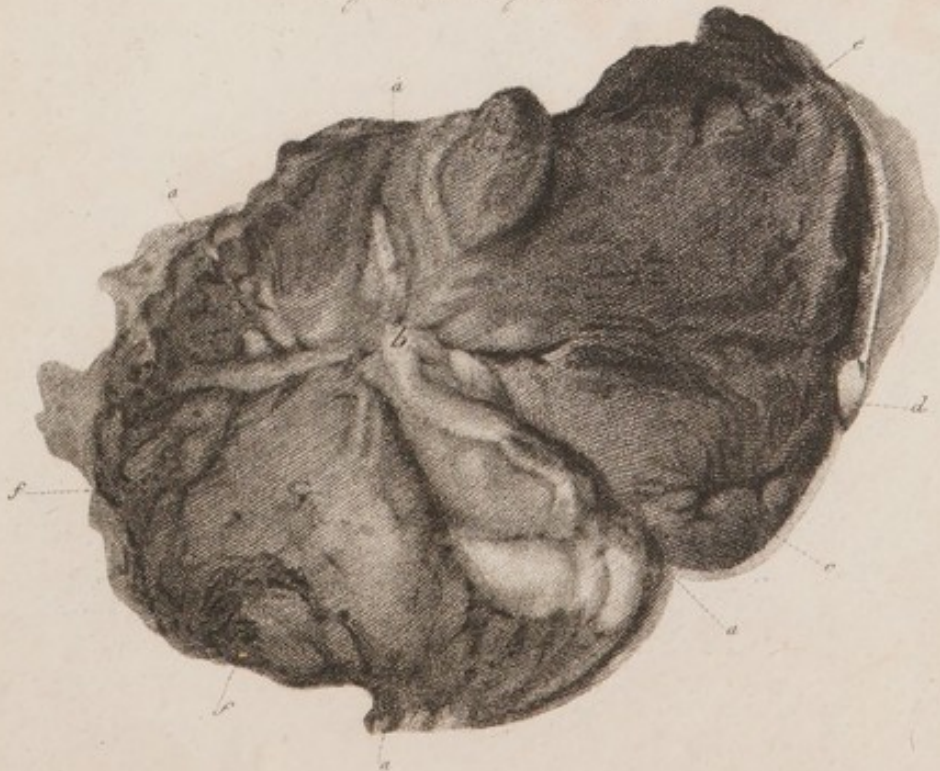*Dissection of a FUNGUS HEMATODES of the Eye ball*




*Section of a Sarcous Tumor between the Eye ball & under Eye lid*



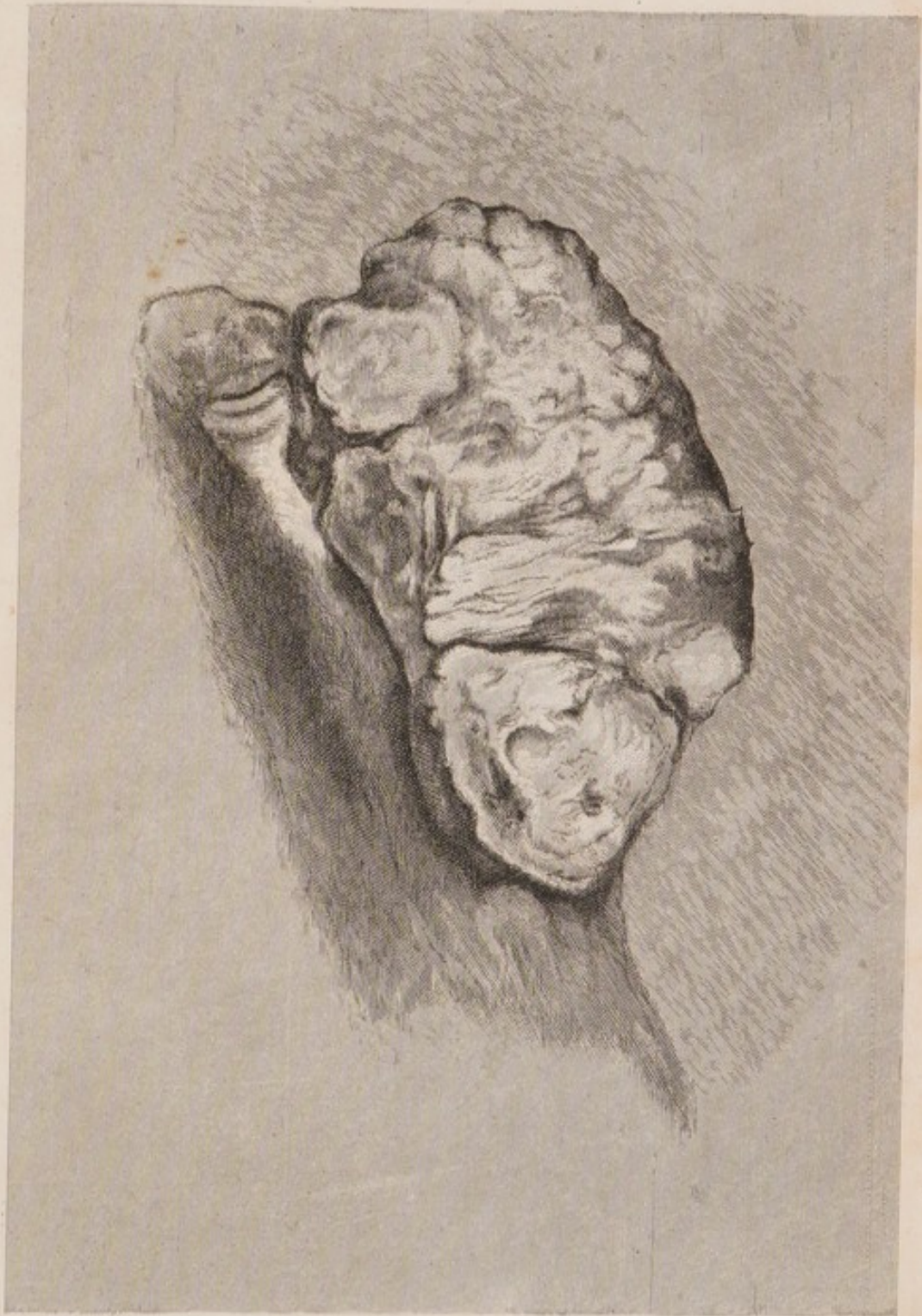*Dissection of the Eye ball. Case 17.*








FUNGUS HEMIATODES OF THE ARM



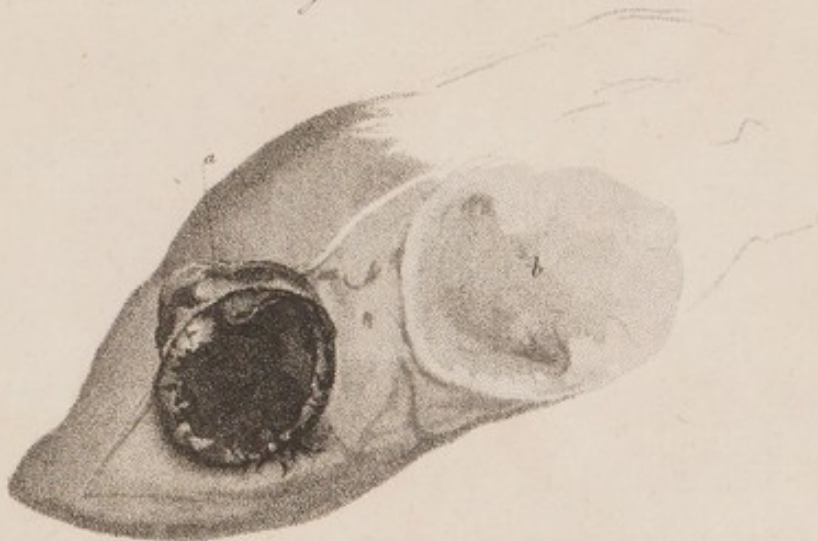



*Dissection of a FUNGUS HEMATODES in the Kidney*



*Fungus Hematodes in the Liver*



*Fungus Hematodes in the Ovarium*





