

Anatomia uteri humani gravidi tabulis illustrata ... The anatomy of the human gravid uterus exhibited in figures / [William Hunter].

Contributors

Hunter, William, 1718-1783.

Publication/Creation

[Place of publication not identified] : [publisher not identified], [1824?]

Persistent URL

<https://wellcomecollection.org/works/jnxngaem>


License and attribution

This work has been identified as being free of known restrictions under copyright law, including all related and neighbouring rights and is being made available under the Creative Commons, Public Domain Mark.

You can copy, modify, distribute and perform the work, even for commercial purposes, without asking permission.



Wellcome Collection
183 Euston Road
London NW1 2BE UK
T +44 (0)20 7611 8722
E library@wellcomecollection.org
<https://wellcomecollection.org>



[F. 439]

D. IX.

18/R

Variant = LeFam 18.4 ?? (collotype edition)

Deduction - milled

Plates on wove paper, with arabic numerals in top left corner


Compared with KCMC copy 4/5/71

These plates are watermarked J. Whitman / Turkey Mill / 1824

The copy #535

PCPS plate copy in cover bound

Note watermarked in KCMC copy



A N A T O M I A
UTERI HUMANI GRAVIDI
TABULIS ILLUSTRATA,

AUCTORE

GULIELMO HUNTER,

SERENISSIMAE REGINAE CHARLOTTAE MEDICO EXTRAORDINARIO,
IN ACADEMIA REGALI ANATOMIAE PROFESSORE,
ET SOCIETATUM, REGIAE ET ANTIQUARIAE, SOCIO.

BIRMINGHAMIAE EXCUDEBAT JOANNES BASKERVILLE, MDCCLXXIV.

LONDINI PROSTANT APUD S. BAKER, T. CADELL, D. WILSON, G. NICOL, ET J. MURRAY.



T H E A N A T O M Y
O F T H E
H U M A N G R A V I D U T E R U S
E X H I B I T E D I N F I G U R E S.

B Y

W I L L I A M H U N T E R.

PHYSICIAN EXTRAORDINARY TO THE QUEEN, PROFESSOR OF
ANATOMY IN THE ROYAL ACADEMY, AND FELLOW OF THE
ROYAL AND ANTIQUARIAN SOCIETIES.

PRINTED AT BIRMINGHAM BY JOHN BASKERVILLE, 1774.

SOLD IN LONDON BY S. BAKER AND G. LEIGH, in York-Street; T. CADELL in the Strand; D. WILSON AND G. NICOL,
OPPOSITE York-Buildings; AND J. MURRAY, in Fleet-Street.

STATE OF MICHIGAN

OFFICE OF THE REGISTER

DEPARTMENT OF LAND AND NATURAL RESOURCES

1913

EXHIBIT NO. 1000

AGREEMENT IN RE OF CHARLOTTE MARY WILSON

AND HER HUSBAND JOHN WILSON

TO SELL AND CONVEY TO THE STATE OF MICHIGAN

CERTAIN REAL ESTATE

IN THE COUNTY OF WASHTENAW

TO HAVE EFFECT FROM THE DATE HEREIN

THE STATE OF MICHIGAN

OF THE

REGISTER

EXHIBITED



WILLIAM H. WILSON

REGISTERED TO THE STATE OF MICHIGAN

IN THE COUNTY OF WASHTENAW

TO HAVE EFFECT FROM THE DATE

HEREIN

TO HAVE EFFECT FROM THE DATE

HEREIN

PRO O E M I U M.

QUOD omnes fere homines, in studiis scientiarum versati, diu multumque desiderarunt, linguam scilicet per univcrsum terrarum orbem cognitam atque perceptam, id nobis ex parte aliqua suppeditat tabularum ænearum sculptura, ad veras rerum formas exhibendas adprime accommodata. Imo hujusce artificii ea est utilitas, ut in nature explicatione sæpenumero plus valeat quam quævis verborum copia, aut vis dicendi. Quodcumque enim oculo fideli inde subjicitur (speçtet modo aliquis argumenti haud ignarus) animo confestim arripitur, memorieque alte impressum haud profus excidit. Lentior sermone mora, et vis hebetior.

Proinde ex quo tempore hoc artificium usibus hominum communiter intervivit, via brevior faciliorque patefacta est ad inventa quælibet tum divulganda, tum conservanda; et rerum simul naturalium cognitio, ab exiguis profecta initiis, paulatim eo usque increvit, ut seculi hujusce, omnium ornatissimi, summum fere ornamentum jam tandem extiterit.

Cæterarum artium incrementa, æquis saltem passibus, comitata est anatomia. Etenim non pauci recentiorum, viri excellentis ingenii atque judicii, labore plurimo, nec minori solertia, corporis humani tum fabricam tum œconomiam pervestigarunt. Ex his plurimi artem hanc graphicam ancillantem sibi adhibuerunt; præcipuisque inde reperiis suis feliciter illustratis, effecerunt, ut ars anatomica, hominum generi, si qua alia, utilis et fructuosa, intellectu simul facilius fieret, simul cultu jucundior.

Restabat tamen pars una humani corporis, eaque sive structurae suæ perlegantis, sive muneris officiique ratione, primas tenens, a disciplinae hujus professoribus non satis explorata. Restabat scilicet uterus humanus. Absit vero, ut viris hisce egregiis vitio detur, quod rem quasi neglectam habuerint, cujus penitus perspicienda copia rara erat et infrequens. Paucissimis enim contigerit necesse est, ut tot cadavera fecerint, quot ad conditionem uteri gravidæ, variis temporibus variam, pervestigandam, nedum demonstrandam, sufficerent. De aliis itaque silendum, ubi laudare nefas. Quod ad auctorem attinet, anno ille primum MDCCLII. felici usus est occasione id in humano corpore explorandi, quod in brutis jam olim quæsierat. Mulier quædam, graviditatis suæ mensibus prope exactis, repentinam obierat mortem. Cadaver, adhuc integrum, cultro subiectum est. Operi favit tempestas. Cera, vasis rite injecta, voto respondit. Repertus est pictor, vir ille in suo genere adprime solers. Partes fingula, multis coram ædificantibus, exploratæ sunt atque excusatæ, ut omnino rei veritas firma satis auctoritate comprobari posset atque stabiliri.

Sub his auspiciis, aliquot mensium spatio decurso, decem primæ tabulae perfecte delineatæ fuerant; partes ipse identidem publice exposuit; et ea quæ de singulis animadversa fuerant ac notata, palam dicta. Auctoris inde animus subit, se rem disciplinæ hujusce fautoribus haud ingratorum futurum, si historiam uteri gravidæ anatomiam ederet, his decem tabulis illuminatam. Consilium placuit. Opus in manus artificum, maxima laude florentium, traditum est; et pecunia collatitia a plurimis pro more representata.

Alterum interea cadaver in manus incidit, quod quidem, cœli licet tempestas minus jam anatomie amica esset, haud nullo in pretio habendum fuit; quandoquidem huic acceptæ referuntur figure aliquot, ab hoc instituto haud alienæ, dignæque adeo vise, quæ operi, supplementi loco, adjicerentur. Dum autem super his operam navabat sculptor, en tertium cadaver, quam opportune! Etenim illud non modo quædam, prius obscura, luci dedit, sed novis etiam figuris adornandis materiam aptissimam subministravit.

Cum auctor huic se accingebat negotio, animo destinavit decem tabulas, modo dictas, in lucem proferre. pactum quasi aliquod fundamentum, cui alia plura, de hac parte anatomie, postea adjicere ac superstruere sperabat, si quando per otium ipsi liceret hanc rem altius investigare.

P R E F A C E.

THE art of engraving supplies us, upon many occasions, with what has been the great desideratum of the lovers of science, an universal language. Nay, it conveys clearer ideas of most natural objects, than words can express; makes stronger impressions upon the mind; and to every person conversant with the subject, gives an immediate comprehension of what it represents.

From the time when this art came more generally into use, it has been much more easy both to communicate and to preserve discoveries and improvements; and natural knowledge has been gradually rising, till it is at length become the distinguishing characteristic of the most enlightened age of the world.

Anatomy has, at least, kept pace in improvement with the other branches of natural knowledge. Many of the moderns, through much labour and patience, as well as ingenuity and judgment, have thrown considerable lights upon the structure and operations of the human body; and they have particularly by engravings, made the study of that art, in which humanity is so much interested, both more easy and pleasant. Most of the principal parts of anatomy have, in this manner, been successfully illustrated.

One part however, and that the most curious, and certainly not the least important of all, the pregnant womb, had not been treated by anatomists with proportionable success. Let it not, however, be objected to them, that they neglected what in fact it was rarely in their power to cultivate. Few, or none of the anatomists, had met with a sufficient number of subjects, either for investigating, or for demonstrating the principal circumstances of uterogestation in the human species. But let what cannot be praised, in others, be passed over in silence. With respect to the present undertaking, in the year 1751 the author met with the first favourable opportunity of examining, in the human species, what before he had been studying in brutes. A woman died suddenly, when very near the end of her pregnancy; the body was procured before any sensible putrefaction had begun; the season of the year was favourable to dissection; the injection of the blood-vessels proved successful; a very able painter, in this way, was found; every part was examined in the most public manner, and the truth was thereby well authenticated.

In the course of some months, the drawings of the first ten plates were finished, and from time to time the subject was publicly exhibited, with such remarks as had occurred in the examination of the several parts. Many lovers of this study approved of the author's proposal to publish the anatomy of the gravid uterus, illustrated by those ten plates: the work was immediately put into the hands of our best artists; and subscriptions were received.

In the mean time a second subject was procured; which, though the weather happened to be very unfavourable, afforded a few supplemental figures, of importance enough to be taken into the work. And before the engravings were finished, a third subject occurred very opportunely, which cleared up some difficulties, and furnished some useful additional figures.

The original plan having been only to publish the first ten plates, as a ground-work for further improvements in this branch of anatomy, to be added whenever good opportunities should be offered, the author now began to entertain hopes of being able to give a much more complete work. He foretold that

P R O O E M I U M.

velligare. Jam vero majora quædam animo complecti, et etiam spem fovere ausus est, fore ut opus aliquod exædificare posset, quod ad perfectionem abolitionemque propius perveniret. Prævidit enim, in hac urbe, tanta hominum multitudine referta, annorum aliquot spatio, occasionem omnia ea quæ ad gravidum uterum pertinent, observandi viro, hoc agenti, haud fortasse defuturam; unde sibi facultas dari posset aliquod quasi systēma condere, variasque illas mutationes, singulis graviditatis mēsis proprias, figuris exprimere. Ejusmodi fere est hoc opus; quod, longo tempore promissum, tandem aliquando in medium prodit. Ut id sane ad exitum perducere posset, moras trahere necesse fuit, præter opinionem diuturnas. Quoties autem auctor secum reputat hæc moras operi minime infructuosas fuisse, abunde sentit, quo se consoletur.

Quod autem hoc argumentum illustrandi uni alicui mortali tam pulchra occasio toties obtigerit, in causa fuerunt tum varii casus, tum amicorum multorum gratissima subsidia. Tabularum harum ultima e manu artificis vix excefferat, cum datum fuit delineare embryonem mole minorem, quam quem antea vidisse auctori unquam contigerat; et haud ita pridem *conceptus* in tuba fallopiana, res hæc animadversione egregie digna, figurarum numerum adauxit. Hæc figuræ, et si qua alia, ejusdem argumenti, occurrunt, vel in tabula his adjicienda, vel cum uteri gravidæ descriptione anatomica, quam auctor secum meditatur, data occasione, in publicum aliquando proferentur. Hactenus quidem ipsi id otii non concessum est, quod ad hanc operis partem absolvendam esset satis. Quod si casu aliquo improviso impeditus fuerit, quo minus id, quod cupiat, possit exsequi, persuasum sibi habet, haud defuturum aliquem, huic muneri obeundo parem. Multi enim sunt, qui auctorem de his rebus publice differentem sæpe sæpius audierint; multi quos ille opinionis ac sententiæ suæ participes fecerit.

FIGURARUM fere anatomicarum duplex est et diversa ratio. Ab altera simplex rei imago, qualis oculo visa est, talis delineatur. Altera, una cum visis, etiam excogitata exhibet; nec tam ad oculum artificis, quam ad ingenium memoriæque accommodatur. Prioris generis exempla apud Bidloo extant; posterioris apud Eustachium.

Fieri non potest, quin figura ista, quæ fit ex fideli naturæ imitatione, et ex rei unius contemplatione enascitur, in quibusdam sæpe partibus indistincta aut minus perfecta esse videatur. Altera autem, ex ingenio nata, quæ autem non fit, nisi per laborem, et observationem et experientiam multiplicem, id uno intuitu videndum exhibet, quod fortasse non nisi ex rerum varietate colligendum fuerat. Porro hæc est ea, quæ et meliorem ordinem, et compendium facilius, et majorem perspicacitatem admittit. Alteram quidem contemplans oculos, elegantia ac concinnitate naturæ oblectatur: in altera, geometrici cujusdam diagrammatis, accurati quidem exactique, sed nudæ, sed inornatæ similitudinem agnoscit. Illa rem quamlibet spectatori, tanquam præsentem, subjicit, et dat *percipere*: hæc tantummodo describentis vice fungitur, remque delineatam in animi conspectu ponit. Prior autem posteriori in hoc præstat maxime, quod ea, quæ revera visa sunt, exhibens, speciem quandam veritatis præ se fert; et fit propemodum æque nescia fallere, ac illud ipsum quod assimilatur.

De hoc opere, quod naturæ ipsius speciem proponit, alii fortasse aliud judicium ferent. Nisi enim auctorem fallat vana spes sua atque opinio, multi sunt apud quos ille nec censetur operam inutilem posuisse, nec inepte erogasse pecuniam; apud quos scilicet figurarum magnitudo, elegantia, ac varietas aliqua in laude ponentur. Contra, non deerunt, quibus magna pars sumptus supervacanea omnino atque infructuosa fuisse videbitur. Contentent scilicet operis hujus utilitatem ad plures potuisse pertingere, si figuræ omnes in formam archiorem contractæ fuissent; si sculptura manu minus delicata fuisset elaborata; si aliquot etiam figuræ, utpote aliis non abimiles, omnino omisissæ.

Cum autem figuræ, de quibus agitur, ea mente atque consilio fingi soleant, ut ab iis, quantum fieri potest, explicetur tam vera natura partium (nempe earum habitudo et structura) quam forma externa, positura, ac nexus; magnitudo illis aliqua concedatur necesse est; aliter enim partes, ut aiunt, *componentes* haud satis distincte delineari possunt. Quod si magnitudo rei propria sculpturæ quodammodo apta sit ac conveniens, ea ipsa, utpote quæ observatu dignissima est, haud dubio eligenda est præcipue. His de causis figuræ omnes, quotquot hic proferantur, ad justum naturæ modum perfectæ sunt, paucis tantum exceptis, quæ in formam naturali angustiores coguntur,

P R E F A C E.

that, in the course of some years, by diligence he might procure in this great city, so many opportunities of studying the gravid uterus, as to be enabled to make up a tolerable system; and to exhibit, by figures, all the principal changes that happen in the nine months of utero-gestation. Such is the work which, at length, is offered to the public. The execution of it has indeed taken up more time, than what was at first expell'd: but it gives the author no small satisfaction to reflect, that the delay of publication has contributed not a little to the value of the work.

That one person should have had so many opportunities of illustrating this subject, has been owing to fortunate circumstances, as well as to the assistance of many friends. Even since the last plate was finished, he had an opportunity of making a drawing of a younger embryo than he had before seen; and he has likewise made some figures from a very curious case, which he lately met with, namely a conception in the fallopian tube. These, and whatever may hereafter occur, he will offer to the public upon some future occasion; probably in the way of a supplemental plate, or with the anatomical description of the gravid uterus, which he proposes to publish at full length. He has not hitherto had leisure to finish that part of the work. But if he should be prevented from doing it, by any unforeseen accident, it will be in the power of many gentlemen of the profession to do it for him, as he has constantly explained his observations on this subject in his public lectures.

ANATOMICAL figures are made in two very different ways; one is the simple portrait, in which the object is represented exactly as it was seen; the other is a representation of the object under such circumstances as were not actually seen, but conceived in the imagination. Bidloo has given us specimens of the first kind; Eustachius of the latter.

That figure which is a close representation of nature, and which is singled from a view of one subject, will often be, unavoidably, somewhat indistinct or defective in some parts: the other, being a figure of fancy, made up perhaps from a variety of studies after NATURE, may exhibit in one view, what could only be seen in several objects; and it admits of a better arrangement, of abridgement, and of greater precision. The one may have the elegance and harmony of the natural object; the other has commonly the hardness of a geometrical diagram: the one shows the object, or gives perception; the other only describes, or gives an idea of it. A very essential advantage of the first is, that as it represents what was actually seen, it carries the mark of truth, and becomes almost as infallible as the object itself.

With regard to this work, which is a faithful representation of what was actually seen, the judgement of the public will probably be divided. Many will approve of the labour and expence which have been bestowed upon it, and commend the largeness, elegance, and variety of the figures. Others will think that a great part of the expence might have been spared, and the work thereby rendered of more general use, if the figures had been made to a smaller scale, if the engraving had been less finished, and if some of the figures, which are very similar to others, had been omitted.

Anatomical figures being intended to shew, as much as possible, the true nature, that is, the peculiar habit and composition of parts, as well as the outward form, situation and connection of them, should certainly be large; otherwise the smaller component parts can not be distinctly represented; and if the natural size of the object be tolerably fit for an engraving, that must be of all others the very best, as it has the advantage of shewing such an important circumstance. Upon these considerations, all the figures in this work were made of the natural size, except a few which were reduced in size, and one or two of minute objects which, on that account, were magnified.

For

coguntur, nec non una atque altera ex rebus minutissimis, quas auctor idcirco ampliandas curavit.

Isdem etiam de causis constat hujuscemodi figuris deberi accuratorem quandam atque elegantiam. Profecto in pictura saepe fit, ut oculi levissima adumbratione oblectentur; maxime ubi vel ipsum tabulae argumentum adeo pervulgatum est, ut vis imaginandi facile excitetur, id, quodcumque defuerit, statim adimpletura (sicuti iis in tabulis, ubi hominum effigies, aut aliae res, pariter notae, exhibentur) vel ubi partes rerum minores aciem pene oculorum fugiunt, ut ea in tabula chorographica, quae, propter distantiam foam, parum cernuntur. Sed in anatomia, ut et in rei naturalis historia, argumentum tabulae spectatori vel omnino esse incognitum ponitur, vel non satis exploratum; partemque minimam, pariter cum majoribus, studium diligentiamque requirit. Operam quidem dare, ut summa arte elaborentur eae figurarum partes, per quas nihil, aut parum exprimitur, nisi quod prius sit expressum, hominis esset vehementer et opera sua et pecunia abutentis. Harum igitur figurarum pars maxima ultra mediocritatem perfecta est; aliquot summa expositione atque artificio ornata; levia, vel ea quae prius fuerant aliqua ex parte illustrata, leviter tacta; ea vero quae secunda vice profertur, lineis fere exterioribus adumbrata.

Cuiuslibet homini, cui iudicium sit paulo severius, in proclivi erit id auctori vitio dare, quod opus hoc haud satis iusto ordine procefferit, nec formam preflam satis atque concinnam induat. Quod si ille difficultates, quotquot auctorem circumvenerint, contemplatione fuerit complexus, conamina haecce, qualiacumque sint, animo magis aequo excipiet. In plurimis aliis operibus, ad rem anatomicam quae spectant, veniam sibi haud facile impetrat vel defectus aliqua ex parte, vel materies confuse permistae disposita. Quivis enim, si modo laborem pati decreverit, primum quidem exercitatione et experientia intimam argumenti sui cognitionem adipisci poterit; deinde autem operis cuiusdam, perfecti undique omnibusque numeris absoluti, formam atque imaginem animo effingere; et denique ex variorum cadaverum contemplatione rem institutam pro arbitrio suo ad exitum perducere.

Humani autem corporis uterum gravidum otiose fecare paucis datum est. Pauci sunt, quibus, in omni vite spatio, nisi semel, aut etiam fortassis iterum hoc fuerit indultum. Ponamus quidem talem occasionem, faustam omnino atque felicem, cultori cuiuspiam anatomie esse oblatam; necesse est ut continuo et sine mora de ratione illi instituti fixum aliquod certumque destinet; et uno eodemque tempore duo consilia, inter se non bene convenientia, prosequatur. Primum enim, ut ipse rem penitus perspectam habeat, cadaver sua manu fecerit necesse est; ita tamen instituenda est investigatio, ut artifice simul adstanti, praecipuas partes commodè delineandi plena sit copia. Proinde vix fieri potest, quin consilium, optime susceptum, immutari oporteat, variisque rebus accommodari quae de improviso et praeter expectationem possint occurrere. Ut autem id rite perfici possit, opus est longi temporis mora; partes interea aeri externo, inter pingendum, expositae plurimum detrimenti capient; praecipue si vir talis negotio obeundo praesit cui cure est, ne scilicet quidpiam, aut ex memoria de promptu, ipsi rei veritati inducatur, et ut nihil ibi locum habeat, nisi quod ex naturae ipsius observatione, re alia nulla intercedente, arripit fuerit.

Si auctor tot opportunitates, hanc ornandi provinciam, sibi prospexisset futuras, quot ipsi bona sua fortuna indulserit, figuras ille quidem aliquas emendatione reddere potuisset; alias aliis melius accommodare, et ita earum seriem in minorem numerum cogere. Figuras quidem nonnullas, jam delineatas, duasque tabulas, a sculptore prorsus perfectas, apud se prudens detinuit; ne operis scilicet moles atque impendium plus aequo crescerent. Et profectio plures, eadem ratione inductus, detinuit, nisi ipsi mentem subiisset, longum fortasse fore tempus, priusquam aliquod figurarum systema, hoc suo minus imperfectum, in lucem sit exiturum. Potius igitur duxit culpae in periculum incurere, eo quod rem nimis copiose, quam quod parcius ac negligenter tractaverit.

Operi, nimiae iam magnitudinis, nimique sumptus, internam foetus anatomiam adicere, supervacaneum fore visum est; praefertim cum alio isto munere sunt functi; et cuiuslibet, id qui de integro meditatur, haec omnia cognoscendi atque tractandi haud facile defutura est occasio.

For the reason already given it should seem obvious that anatomical figures ought to be likewise well finished. In many subjects of painting, indeed, the slight manner of producing an effect, without labour, is very agreeable; particularly when, either the subject is so well known, that a mere hint is enough to the imagination, which easily supplies all that is wanting; as, in designs where human figures, and other well known objects are introduced; or, when the smaller parts of objects are not to be seen distinctly, as the objects, especially the more distant ones, in a landscape. But in anatomy, as in natural history, the subject is supposed to be new, or only imperfectly known; and the smaller parts are to be studied with care, as well as the larger masses. In those parts of anatomical figures, indeed, which are mere repetitions, or nearly so, the labour and expence of finishing may well be saved. Accordingly in this work the greater part is tolerably well finished, some very highly and delicately; matters of less moment, or approaching to repetitions are executed in a slight manner; and what is merely a repetition, is commonly put down in bare out-lines.

Any judicious person, who examines this work with care, will naturally think that the plan might have been more regular and more compact: but it is presumed that he will be less dissatisfied with the authors best endeavours when he shall consider the difficulties which lie in the way, and render the subject almost unmanageable. In many other works of anatomy, imperfections, and particularly a want of method, are not readily excused. For, if the author will but take the pains, he may first of all make himself master of his subject by repeated dissections and experiments; he may, at his leisure, lay down a studied plan for a complete and regular work; and with his own convenience he may execute his plan from a variety of dead bodies.

But, opportunities of dissecting the human pregnant uterus at leisure, very rarely occur. Indeed, to most anatomists, if they have happened at all, it has been but once or twice in their whole lives. Upon such occasions therefore, even when attended with the most favourable circumstances, the anatomist must fix upon a plan, without loss of time, and at once carry on two schemes which are hardly compatible; that is to say, he must dissect for his own information, in the first place, and yet conduct the inquiry so as to have good drawings made of the principal appearances: and it is more than probable that he must alter any plan that he might have proposed, and adapt it to a variety of circumstances in the subject that could not be foreseen; and much time must be lost, and the parts must be considerably injured by long exposure to the air before the painter; especially if the work be conducted by an anatomist who will not allow the artist to paint from memory or imagination, but only from immediate observation.

If the author could have foreseen the numerous opportunities which have fallen to his share, he might have easily improved some of the figures; and by adapting them better to one another he might have completed the series in a smaller number. He has actually kept back several drawings which had been made, and two plates which had been engraved, that the work might not be overcharged; and would have withheld more, for that reason, if he had not thought that it would probably be long before a more perfect system of figures would be offered to the public. This consideration induced him to risk the being censured rather for having done too much, than too little.

In a work which was already become too large and expensive, it was thought proper to omit the internal anatomy of the child, especially as that part has been executed by others, and opportunities of studying it may be easily procured.

P R O O E M I U M.

In artem typographicam sumptus, major solito factus est, non quidem solum ob elegantiam, qua opera celeberrimi artificis *Joannis Baskerville* ornantur omnia; sed præcipue chartæ, quæ ille utitur, atramentique ratione habita. Talis est enim chartæ hujusce levor, atramentumque tam cito arefcit, ut folia, literis licet plenissima, tabulæ cuiusque interpositæ nitorem integrum atque illesum conservatura sint.

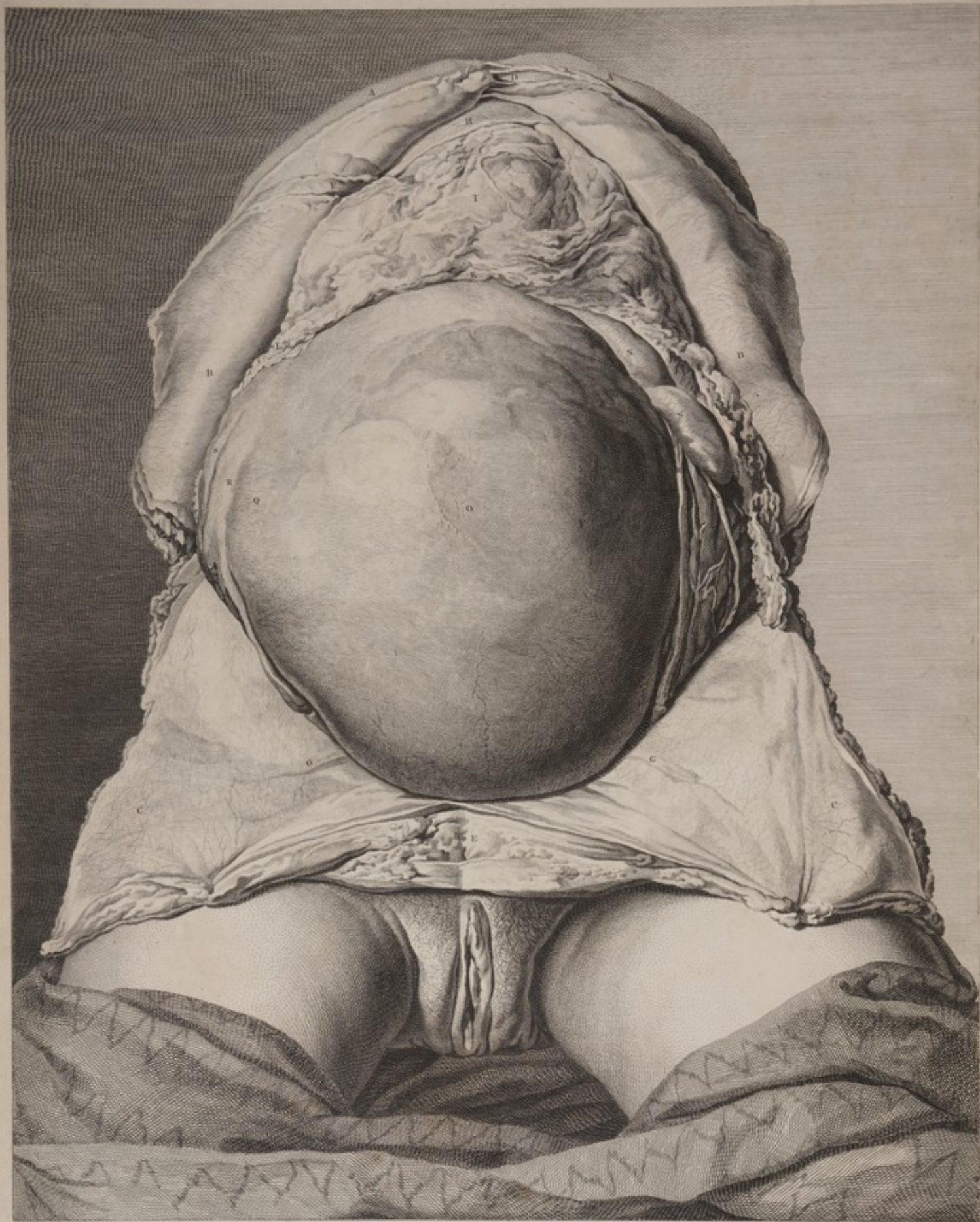Ad summam, si auctori ea laus fuerit concessa, quod, in hac primaria parte humani corporis illustranda, neque operæ suæ, neque impensarum, neque temporis rationem habuerit, voti sane fit compos, nec aliud gratiæ sibi apponi postulat. Harum autem laudum in partem plurimum merito suo evocandus est frater auctoris solertissimus *Joannes Hunter*; nam in plurimis cadaveribus secandis partem ille laborum sustinuit: cujus quidem viri acumen et diligentia in hujusmodi perveffigationibus adeo omnium fermone celebrantur, ut de illo si fileretur adjutore, operis ipsius pretio atque exillimationi parum effet consultum. Artificibus etiam singulis, quorum ingenii atque induftriæ monumenta hic extant, gratias agit quas habet maximas; præ cæteris autem viro optimo ac peritiffimo artifice *Roberto Strange*, non modo quod is manu sua tabularum harum duas tanquam æternitati consecravit, sed etiam quod, ab incepto operis usque ad exitum, auctorem amicitia stabili atque incorrupta dignatus, vel consilium vel auxilium expetenti haud unquam defuerit.

P R E F A C E.

The additional expenfe of Mr. Baskerville's art was not incurred for the sake of elegance alone; but principally for the advantage of his paper and ink, which render a leaf of his Press-Work an excellent preservative of the plates between which it is placed.

If it be allowed that the author has spared neither labour, nor time, nor expenfe in improving an important part of anatomy, this is all the merit which he can claim. In most of the dissections he was assisted by his brother Mr. John Hunter, whose accuracy in anatomical researches is so well known, that to omit this opportunity of thanking him for that assistance, would be in some measure to disregard the future reputation of the work itself. He owes likewise much to the ingenious artists who made the drawings and engravings; and particularly to Mr. Strange, not only for having by his hand secured a sort of immortality to two of the plates, but for having given his advice and assistance in every part with a steady and disinterested friendship.





T. J. Rousset del. F. S. Leijonh. sculp.
 TAB. I. Praem priores Tabula Mulierem exhibent, nono ferè graviditatis Mense occunte subitè morte extinctam, Arteria a venis ceri diversi coloris injecta distincte erant. In hac primò contenta. Abdominis, integumentis decussatim incisis et reflexis, sub conspectum veniant. Rescindendum ut ita, ac clivi situ, ostender, ut superior Trunci pars haud paulò esset clatior, et Viscera inde abdominalia clarius contemplanda obicerentur.

TABULA I.

DECEM priores tabulae mulierem exhibent, nono fere graviditatis mense exeunte, ann. 1750, subita morte extinctam. Arteriae a venis, cera diversi coloris injecta, distinctae erant. In hac prima, contenta abdominis, integumentis decussatim incisus et reflexis, sub conspectum veniunt. Resupinatum est acclivi situ cadaver, ut superior trunci pars haud paulo effect elatior, et viscera inde abdominis clarius contemplanda objicerentur.

Femora et pudenda, utpote partes externae, eam, quam caetera, notationem non desiderant. Pudenda vero, in hoc cadavere, ut ex figura concipi potest, aqua inter cutim intumuerunt.

- AA** Pars anterior thoracis infra mammas, qua truncus erat transverse discissus, figuram a parte superiori terminans.
- BB** Integumentis, musculis, et peritoneo decussatim incisus, eorum anguli duo superiores in marginem thoracis cartilagineosum reflexi.
- CC** Eorundem anguli duo inferiores, in inguen, femur, et ossis ilium spinam anteriorem, utriusque reclinati. In angulis illis, ad marginem inferiorem medio femori oppositum, observare licet partem rugosam et tensam, qua filum adhibitum fuit, ea mente, ut, angulo detracto, uterus et partes vicinæ manifestius apparent.
- D** Incisionis longitudinalis, ad scrobiculum cordis a mucrone cartilaginis ensiformis ductae, extremitas superior.
- E** Ejusdem incisionis, ad symphylin ossium pubis, extremitas inferior.
- F** Hepatis ligamentum falciforme, super faciem internam musculorum abdominis, ad illius visceris fissuram, magnum inter lobum et parvum, protensum.
- GG** Arteria et vena epigastrica, in utriusque musculorum angulis inferioribus trans peritoneum sese projicientes.
- H** Hepatis lobus sinister, in parte summa regionis epigastricae situs, illius in superficie, arteriae quaedam parvae, ex substantia illius glandulosa exeuntes, et in peritoneum quo vestitur diffuse, delineantur.
- I** Omentum in regione epigastrica situm, intestinis tenuibus incumbens. Vasa quamvis cera vivido coloris impleta, ob partis adhaerentem vix potuerunt.
- K** Omenti pars inferior et media, ab utero antea elevata, quae in plicaturas multas quam minimas contracta jacuit et compressa.
- L** Omentum a latere dextro, post partem eam uteri, qua incipit tuba dextra, descendens.
- M** Omentum quod in latere sinistro ante tubam fallopianam, &c. descenderat, scotum positum, quo partes eae in conspectum prodirent.
- NN** Duo intestinorum tenuium gyri, quorum utriusque, maxime antica inferior, omenti parte praedicta tecli fuerant.
- O** Uterus, regionem totam umbilicalem et hypogastricam possidens. Superficies ejus vasorum ramulis tenuibus inextensa: horum pleraque venae. Multa sanguine solummodo impleta, cadavere diutius asservato, paulatim exaruerunt. Situs uteri paulo obliquus, et ad latus dextrum. Umbilicus parte qua stat haec litera aliquanto altior fuit. Forma uteri quodammodo irregularis; aliae ejus partes aliis eminentiores. Id ex eo oritur, partim quod visceribus vicinis incumbens, praefertim ad fundum, se ad eorum formam finxerat: partim etiam quod contenta ejus formam irregularem praese tolerant.
- P** Tumor ad latus sinistrum uteri, in ea scilicet parte cui media placenta interne adhaerebat.
- Q** Uteri tumor in latere dextro, ubi foetus nates jacebat, ubi etiam foetum per substantiam ejus satis distincte tactu sentire licuit. Undique circum hanc partem uterus aliquanto depressus, et faculi instar aqua repleti, tactum afficiebat.
- RR** Ligamenta rotunda. Sinistrum, propter uteri situm obliquum, dextro longius. Exitus amborum, angulis inferioribus integumentorum &c. filo deductis, in conspectum veniebat. Quae strictura ibi videtur, nihil aliud est, quam peritonei in forma thecae duplicatio et protrusio, ea ligamenta per paululum spatii sequens, quaeque ab eo peritonei processu, funem spermaticum canis vel tauri comitante, gradu tantum distat.
- SS** Tubae fallopianae. In latere dextro, solum fere tubae principium cernere licet, parte reliqua post uterum descendente. In latere sinistro, tubae media pars sola in conspectum venit; tegitur enim ejus principium intestino ibi posito; sinemque ejus, vel fimbrias, vasa spermatica occultant. Ea vasa, in latere sinistro, satis aperte conspiciuntur; spatium illud totum inter ligamentum rotundum et tubam occupant; vas parvum arteria; magnum ei adhaerens vena. Utraque ad uteri latus, in peritonei duplicatione illa, quae ligamentum latum appellatur, procedunt.

PLATE I.

THE first ten plates were made from the dissection of a woman, who died suddenly, in the end of her ninth month of pregnancy, in the year 1750. The arteries and the veins were injected with wax of different colours.

This plate represents the object, as it appeared when the abdomen was opened by a crucial incision, and the four angles of the containing parts turned outwards; the subject lying on its back, but so that the upper part of the trunk was considerably higher than the rest.

The thighs and pudenda require no explanation: the latter of these were edematous in the subject, as they appear in this figure.

- AA** The forepart of the chest, just below the breasts, where the trunk was cut through, and which therefore terminates the figure above.
- BB** The two upper angles of the integuments, muscles, and peritoneum, turned back over the cartilaginous margin of the chest.
- CC** The two inferior angles, turned down over the groin, thigh, and anterior spine of the os ilium, on each side. In each of these, at its lower edge and opposite to the middle of the thigh, a part may be observed to be stretched and puckered, where a thread was fixed, which pulled the flap down, in order more fully to expose the womb and adjacent parts.
- D** The upper end of the longitudinal incision, at the pit of the stomach, beginning just at the point of the ensiform cartilage.
- E** The lower end of the same incision carried down to the symphysis of the ossa pubis.
- F** The umbilical or falciform ligament of the liver, which runs upwards, on the inside of the abdominal muscles, to the fissure between the great and the small lobe of that viscus.
- GG** The epigastric artery and vein, projecting through the peritoneum, upon each of the lower angles of the muscles.
- H** The small lobe of the liver, situated in the highest part of the epigastric region. Upon its surface are represented some small arteries, which emerge from the glandular substance, and are diffused in the peritoneum that covers it.
- I** The omentum, spread over the small intestines in the epigastric region. The vessels of this part, tho' injected, were hardly visible, being obscured by fat.
- K** The lower and middle part of the omentum, which had been pushed up by the womb, and lay in numerous small folds pressed together.
- L** The omentum, in the right side, passing a little way down behind that part of the womb from which the right tube begins.
- M** The omentum, in the left side, which came down before the fallopian tube, &c. and which was thrown a little aside, that those parts might be seen.
- NN** Two turns of the small intestines; both of which, but especially the lower, were covered by the above-mentioned part of the omentum.
- O** The womb, possessing all the umbilical and hypogastric regions. Its surface is interspersed with a number of small vessels, the greatest part of which are veins. They were filled with blood only, and therefore gradually disappeared after the subject had been preserved some time. Its situation is a little oblique, and towards the right side. The navel was a little higher than the part upon which this letter is placed. The form of the womb is a little irregular, at some places projecting more than at others. This seemed partly owing to its being moulded upon the neighbouring bowels, particularly at its fundus; and partly to its contents; whence,
- P** A swelling towards the left side of the womb, where the middle of the placenta adhered; and
- Q** A swelling on the right side of the womb, where the buttocks of the child lay; and where the child could be felt, pretty distinctly, through its substance. All around this part the womb was somewhat depressed, and felt like a bag of water.
- RR** The round ligaments. The left is longer than the right, because of the oblique situation of the womb. The exit of each was brought to view by drawing down the lower angles of the integuments, &c. with threads; and the appearance of a stricture there, was occasioned by a sheath-like doubling and protrusion of the peritoneum attending those ligaments some little way; which differed only in degree from that process of the peritoneum, which accompanies the spermatic rope in a dog, or bull.
- SS** The fallopian tubes. In the right side, little more than the beginning of the tube is seen, the rest running down behind the womb. Of the left tube the middle part only is exposed; its beginning at the womb being concealed by the gut which lies upon that part, and the end or fimbriae being covered by the spermatic vessels. Those vessels are pretty distinctly seen in the left side: they fill up all the space between the round ligament and the tube; the small vessel is the artery, and the great, to which that clings, is the vein: both of them are passing up to the side of the womb, in that doubling of the peritoneum called, the broad ligament.

TABULA II.

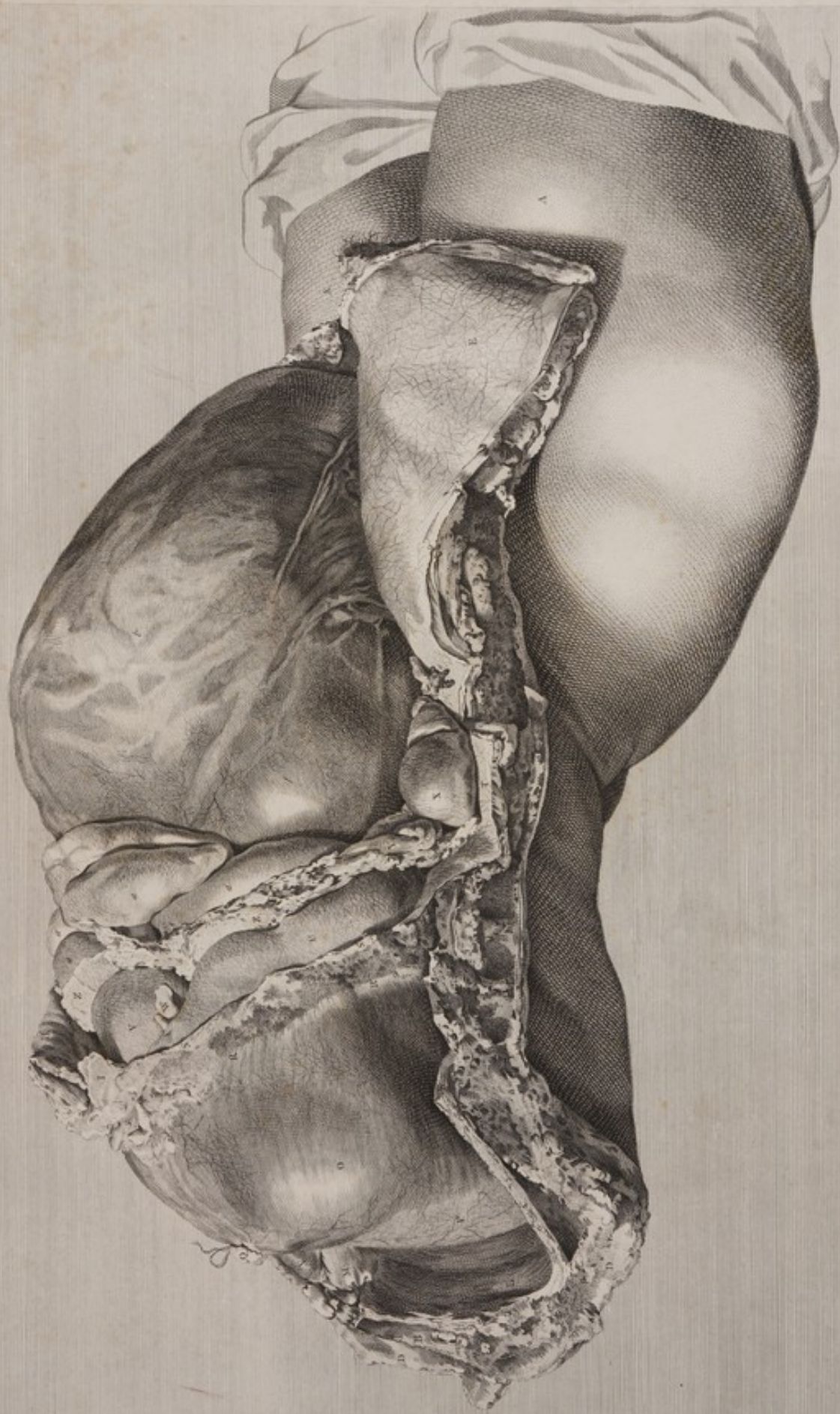PLATE II.

CONSPECTUS viscerum abdominis a latere dextro, partibus continentibus thoracis et hypochondrii, ac maxima omenti parte sublatis.

- AA* Femora, ubi transverse scissa, linteo cooperta.
B Spina, supra diaphragma, transverse discissa.
C Costae octavae pars.
DD Integumenta et muscoli, ad partem thoracis posteriorem, eo loco quo negligenter se junctus erat truncus, rescissa.
E Musculorum abdominis angulus inferior, in seatur, ut in precedente figura, devolutus.
F Montis, ut dicitur, veneris pars, una cum musculis abdominis, devoluta.
G Ad sinistrum latus pars huic respondens.
H Thoracis margo, ad latus scrobiculi cordis sinistrum, peritoneo et musculis inversis, testus.
I Cartilago mucronata.
KK Costae inferiores, partisque caeterae continentes sectione longitudinali se junctae, adeo ut, in qua sectionem et scrobiculum cordis interjacerent remotis, viscera hypochondrii dextri sese videntia offerrent.
L Pars ima atque posterior cavi dextri thoracis.
M Aorta descendens, eo loco, quo cadaver transverse discissum fuerat, deligata; nec non, colorata cera impleta.
N Oesophagus ibidem deligatus.
O Superficies superior convexa diaphragmatis; quod, pleura testum, in situ suo naturali manet.
P Diaphragmatis centri tendinosa pars quae in dextro latere sita est.
Q Venae caeve inferioris truncus, juxta diaphragmatis superficiem superiorem deligatus.
RR Pleurae sectae margo, loco quo reflexa de superficie superiori diaphragmatis, faciem internam costarum contegebat.
SS Peritonei secti margo, loco quo scilicet a superficie diaphragmatis inferiori, membranae investientis more, ad faciem internam musculorum abdominis cursum tenebat.
 Superficies inter margines pleurae (*RR*) et peritonei (*SS*) connexio est diaphragmatis ex facie interna costarum disrupta.
T Facies interna muscoli transversii peritoneo testata.
U Hepatis lobus magnus, vel dexter: in cuius crepidine, ex adverso literae *U*, exiguum videre est fossulam, quam vesicula fellis figurae suae aptaverat, faciei internae hepatis hic loci apposita.
V Hepatis lobus parvus, in hypochondrium sinistrum sese extendens.
W Ligamentum hepatis falciforme, seu venae umbilicalis reliquiae, loco quo fissuram hepatis intrat, rescissum.
X Colon ex caeco ad hepar sursum transiens.
YY Colon, cum appendicibus suis adiposis, sinistrorsum currens, hepar inter et intestina tenuia.
ZZ Omenti principium vel radix, quod ex intervallo hepatis et intestinorum tenuium nascitur.
aaaa Illorum intestinorum tenuium gyri aliqui, omento paulo infra marginem hepatis excisso, in conspectum veniunt.
b Uterus. In facie ejus externa, venas, aliquantulum obscurius, notare licet. Haec, cum cadaver primum apertum posui, cera etiam impletae, colore tantum distinguebantur. Tempore autem quo tabula haec erat delineata, venae, parte jam arefacta, sese magis projiciebant, ut in figura quodammodo se videntia offerant.
c Ligamentum rotundum in inguen descendens.
d Tuba fallopiana, juxta faciem internam ossis ilium retrorsum currens.
e Tubae extremitas fimbriata, pone latus uteri jacens, hic paululum educta, nempe ut conspicatur. Ligamentum rotundum inter et tubam, vasa spermatica, praesertim vena, conspiciuntur, ad partem uteri anteriorem, cui placenta adhaerebat, praecipue tendentia.
f Uteri angulus prominens, loco quo fetus natus, utero nondum adaptato, tactu sentire licebat.
 N. B. Costis nothis lateris dextri remotis, illae quae ad latus erant sinistrum, ex vi resiliendi, marginem thoracis (*H*) et exinde cartilagineum ensiformem elevaverunt; unde facies ejus anterior in dextrum latus oblique tendebat.
 Figura hac nondum delineata uterum observavi sensum subdidisse; quapropter ope quam minime cannulae, uterum, spiritu vinoso injiciendo, in pristinam figuram restituere conatus sum.

A View of the same object from the right side, after the upper abdominal flap, and the containing parts of the right hypochondrium had been removed, that the whole mass of the abdominal viscera might appear in its natural situation, the subject lying on its back.


- AA* The thighs, covered with a cloth where they had been cut through.
B The back-bone cut through above the diaphragm.
C Part of the eighth rib.
DD The integuments and muscles at the back part of the chest, cut rudely through in severing the trunk at that place.
E The inferior flap of the abdominal muscles, &c. turned down over the thigh, as in the preceding figure.
F Part of the mons veneris turned aside with the abdominal muscles.
G The respective part of the left side.
H The margin of the chest at the left side of the scrobiculus cordis, covered by the peritoneum and muscles, which are turned over it.
I The ensiform cartilage.
KK The lower ribs and other containing parts, cut down longitudinally, by which means all the parts, between this section and the scrobiculus cordis were removed, that the viscera of the right hypochondrium might be exposed to view.
L The posterior and lower part of the right cavity of the chest.
M The trunk of the descending aorta, tied up where it was cut, and filled with injection.
N The oesophagus, tied up at the same place.
O The upper convex surface of the diaphragm, which remains, covered by the pleura; in its natural situation.
P That part of the centrum tendinosum of the diaphragm which is in the right side.
Q The trunk of the lower cava tied, close to the upper surface of the diaphragm.
RR The cut edge of the pleura, where it was reflected, from the upper surface of the diaphragm, to line the inside of the ribs.
SS The cut edge of the peritoneum, where it was continued as an investing membrane, from the inferior surface of the diaphragm, to the inside of the abdominal muscles.
 The surface which is seen between the edge of the pleura (*RR*) and that of the peritoneum (*SS*) is the attachment of the diaphragm cut off from the inside of the ribs.
T The inside of the transversus muscle covered with the peritoneum.
U The great, or right lobe of the liver; at the lower edge of which, over against the letter *U*, there is a small notch formed by the concave bed of the gall bladder, which lies upon the inside of the liver at this place.
V The small lobe of the liver, which stretches over into the left hypochondrium, and is therefore seen in perspective.
W The falciform ligament, or remains of the umbilical vein, cut off as it enters the fissure of the liver.
X The colon passing up from the caecum to the liver.
YY The colon with its appendiculae adiposae running towards the left side, between the liver and small guts.
ZZ The beginning or root of the omentum, coming downwards from the interstice of the liver and small guts.
aaaa Some turns of those small intestines brought to view by cutting off the omentum a little below the edge of the liver.
b The womb. Upon its surface we can trace, though obscurely, its veins. These, though injected, were distinguishable only by their colour when the subject was first opened: But when this drawing was made, the part, having been some time in the air, had become a little dry, and the veins projected, as they appear in the figure.
c The round ligament running down to its passage into the groin.
d The fallopian tube running backwards on the inside of the os ilium.
e The fimbriated end of the tube, lying behind the side of the womb; but drawn a little out, that it might be seen.
 Between the round ligament and the tube, are seen the spermatic vessels, especially the vein, which go closely, or by their largest branches, to the forepart of the womb where the placenta adhered.
f The prominent corner of the womb, where the buttocks or loins of the child were distinctly felt before the part was opened.
 N. B. The false ribs of the right side having been removed, those of the left side, by their elasticity raised up the margin of the chest (*H*) and consequently the ensiform cartilage; the anterior surface of which was thereby turned obliquely to the right side.
 Just before this figure was made, I had observed that the womb had insensibly subsided, and therefore by the cannula of a very small trocar I injected some spirits to raise it up, as nearly as I could guess, to the figure it had when the abdomen was first opened.



TAB. II. *Conspiculus viscerum abdominalium a latere dextro, partibus continentibus Thoracis, et Hypochondrii.*
ac maximè eminenti parte sublatis.

W. Cheselden sculp.

W. Cheselden sculp.







Tab. III.

TAB. III. Visent eadem abdominalia a sinistro latere, una cum Diaphragmate uti superius. Facile apparet in delineanda huc figura, conjecturam oculi fusse a parte lateris superiori obliqui dextram, alterius quippe partem sinistram vici interchubabat.

J. G. de Graaf delin.

TABULA III.

PARTIS trunci inferioris prospectus; oculo scilicet a parte finistri lateris superiori, oblique deorsum ita collineato, ut universa viscerum compages, una cum diaphragmate, in situ suo naturali appareret.

- A** Femur finistrum. Uteri prominentia femur dextrum oculo subtrahit.
- B** Clunus finistra.
- C** Integumentorum et muscutorum abdominis, lateris finistri, angulus inferior in inguen et femur inversus.
- D** Integumentorum et muscutorum abdominis sectio transversa.
- EE** Partium abdominis continentium sectio longitudinalis, ab ilium osse sursum ducta. Hac sectione, angulus superior partium continentium omnino auferitur, ut viscera hypochondri finistri in conspectu ponantur.
- FF** Partium thoracis continentium posteriorum sectio transversa.
- G** Vertebrae transversae scissae.
- H** Medulla spinalis.
- II** Cavorum thoracis partes inferiores posticae, quae, pulmonibus sublatis, vacuae conspici possunt.
- KK** Diaphragma superficiem convexam hepatis complectens.
- L** Cartilago mucronata, diaphragmati adhuc adherens.
- M** Diaphragmatis ad latus dextrum convexitas magna: quae in hoc cadavere, parte huic consentanea in latere sinistro elatior comparuit. Ibi etiam vasa nonnulla conspiciuntur; quorum majora, venae scilicet plurenicae, cera impleta sunt a vena cava; hinc altius extantia.
- N** Diaphragmatis superficies, qua pericardio annectitur, quaeque cor sustinet.
- O** Vena cava, ubi per diaphragma transit, deligata.
- P** Oesophagus supra diaphragma deligatus. Hunc cera injecta, dum per arterias fluebat, materia colorante amissa, in ventriculum transiens, implevit.
- Q** Aorta, eodem modo, ubi corporis truncus transverse fuerat scissus, supra diaphragma, deligata.
- Oesophagus et aorta, una cum spinæ prominentia, cavum fatum magnum in diaphragmatis parte postica et superiori efficiunt.
- RSTU** Diaphragma in hypochondrio sinistro recisum. Ex parte posteriori, labia (**TU**) ejusdem fissurae in diaphragmate mutuo recedunt; et ex parte anteriori, anguli (**RS**) inversi sunt, nempe ut viscera hypochondri finistri in conspectum veniant.
- V** Hepatis extremitas finistra.
- W** Ventriculi extremitas finistra.
- XX** Lienis margo anterior denticulatus.
- a** Hepatis lobus dexter.
- b** Ligamentum falciforme, fissuram hepatis intrans.
- c** Hepatis lobi finistri ea pars quae in regione epigastrica sedem habet.
- dddd** Omenti radix dextrosum de ventriculo et colo, hepar inter et intestina tenuia, descendens.
- eeff** Omenti radix in hypochondrio sinistro ita disposita, ut cavum suum exhibeat. Ea pars, quae marsupii omenti anteriorem partem facit (**ee**), quaeque de ventriculo descendit, ventriculo jam et hepati incumbit replicata: omenti autem pars posterior, quae colo connectitur (**ff**) ante intestina tenuia in proprio manet situ.
- gg** Omenti radix, ventriculum inter et lienem.
- kk** Omenti pars ad latus finistrum, in situ suo naturali, tenuia inter intestina et peritoneum faciem internam transversalis abdominis integens.
- iiii** Intestinelorum tenuium gyri multo inferiores et frequentiores hac in parte, quam eorum, quae in latere dextro jacent; partim propter obliquitatem uteri, praecipue autem quod in latere dextro hepatis moles minus spatii intestinis permittit.
- k** Uterus. Tempore quo figura haec delineabatur, pars uteri superior arescere coeperat, unde vasa infarcta, magis conspicua sese exhibebant: minorum pleraque arteriae sunt; majora omnia venae.
- l** Ligamentum rotundum.
- m** Tuba.
- n** Arteriae spermaticae ramus magnus, trans ligamentum latum ad uterum repens.
- oo** Ramorum, venae scilicet spermaticae, majorum fasciculus, per ligamentum latum ad uterum ascendendum.

PLATE III.

A View, from the left side and downwards, of the lower part of the trunk; so prepared, as to show the whole mass of the bowels, with the diaphragm, in their natural situation.

- A** The left thigh. The right thigh is covered from our view by the projection of the womb.
- B** The left buttock.
- C** The lower flap of the integuments and abdominal muscles on the left side, turned down over the groin and thigh.
- DD** The section of the integuments and muscles, made by the transverse incision of the belly.
- EE** A longitudinal section of the containing parts of the belly, carried upwards from the os ilium, or posterior extremity of the transverse incision, parallel to the spine; whereby the upper flap of the containing parts is entirely removed, to show the viscera of the left hypochondrium.
- FF** A transverse section of the posterior containing parts of the chest.
- G** The body of the vertebra cut through.
- H** The spinal marrow.
- II** The lower posterior parts of the cavities of the chest, which are seen empty, the lungs being removed.
- KK** The diaphragm, embracing the convex surface of the liver.
- L** The ensiform cartilage left adhering to the diaphragm.
- M** The great convexity of the diaphragm in the right side, which in this subject was much higher than the analogous part in the left. Upon this part, some vessels are seen: the larger are the phrenic veins, which were filled with wax from the cava, and are therefore prominent.
- N** The surface of the diaphragm, where the pericardium is united with it, and upon which the heart rests.
- O** The venæ cava tied, as it passes through the diaphragm.
- P** The oesophagus, tied above the diaphragm. It was filled by the injection, which passed without the red colour, from the arteries into the stomach.
- Q** The aorta, in the same manner tied above the diaphragm, where the trunk of the body was cut through.
- The oesophagus and aorta, as well as the projection of the spine, make a considerable notch upon the upper posterior part of the diaphragm.
- RSTU** The diaphragm, slit up in the left hypochondrium. At the posterior part, the lips of the fissure in the diaphragm (**TU**) recede from each other; and forwards, the corners (**RS**) are inverted, to show the viscera in the left hypochondrium: viz.,
- V** The left extremity of the liver;
- WW** The left, or great extremity of the stomach; and
- XX** The spleen: its anterior edge indented.
- a** The right, or great lobe of the liver.
- b** The falciform ligament, entering the fissure of the liver.
- c** That part of the small lobe of the liver which lies in the epigastric region.
- dddd** The root of the omentum towards the right side, coming down from the stomach and colon, between the liver and the small intestines.
- eeff** The root of the omentum in the left hypochondrium, so disposed as to show its cavity. What makes the anterior part of the pouch of the omentum (**ee**) which comes down from the bottom of the stomach, is turned up over the stomach and liver: and the posterior part of the omentum (**ff**) which is fixed to the colon is left, in its natural situation, before the small intestines.
- gg** The root of the omentum, between the stomach and spleen.
- hh** Part of the omentum in the left side, in its natural situation, between the small intestines and the peritoneum which lines the transversalis muscle.
- iiii** The convolutions of the small intestines, which are considerably lower and in greater quantity in this side than in the right; partly because of the obliquity of the womb, but chiefly because in that side the liver comes low down, and leaves little space for intestines.
- k** The womb: which had begun to dry at its upper part when this figure was taken; so that the injected vessels began to appear more remarkably. The smaller are chiefly arteries; the larger are all veins.
- l** The round ligament.
- m** The tube.
- n** A large branch of the spermatic artery going across the broad ligament to the womb.
- oo** A group of large veins from the spermatic, mounting in the broad ligament to the womb.

T A B U L A I V.

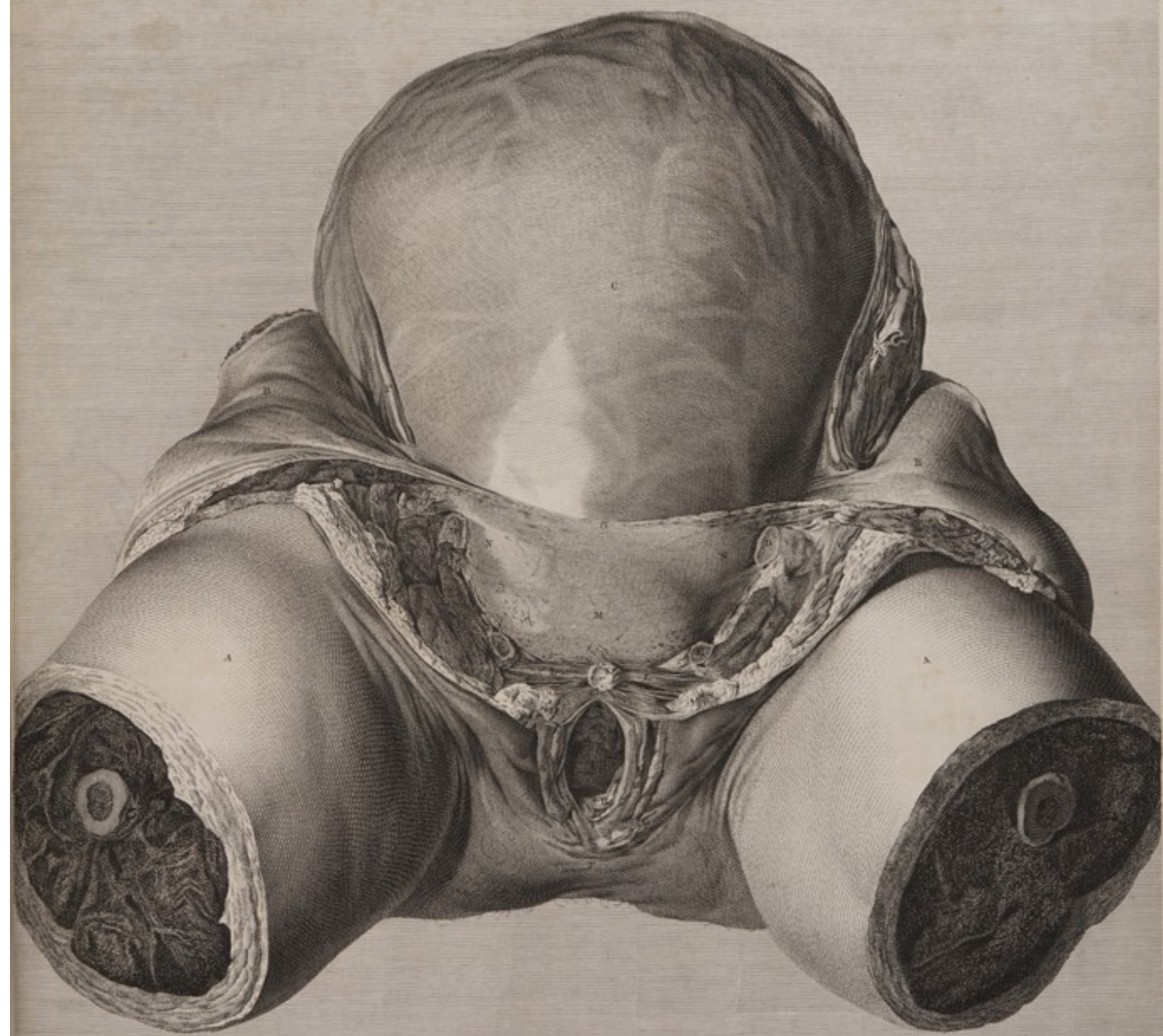
UTERUS, et contenta pelvis a parte anteriori: ossa pubis, cum integumentis, et superiori pudendorum parte, omnino fuerant abscissa, quo cervix uteri, et vesica simul urinaria ei praetensa, oculo incidereant.

- AA Femora transverse abscissa.
- BB Musculorum abdominis, et peritonci, anguli inferiores, in latera reflexi.
- C Uterus; cujus in tota superficie, perque substantiam, vasa cetera impleta, et exinde prominentia, conspiciuntur.
- DD Os pubis utrinque supra foramen magnum ischii resectum.
- EE Ischii processus parvus, eo in loco ubi ossi pubis committitur resectus.
- F Perinaeum.
- GG Labia pudendi: horum pars superior, nymphae etiam, et clitoridis extremas, abscinduntur.
- HH Caruncula myrtiformis insignis.
- I Vagina. In parte huius introitus inferiore (nigriore scilicet in hac tabula), vaginae cavum, tam retrosum quam sursum ducens, representatur. Ad litteram (I) conspiciuntur vaginae pars superior et anterior, quae cum vesica urinaria et urethra connectitur, quaeque a visceribus incumbentibus deprimitur. Ad punctum etiam orificii huiusmodi, fusci, ovati, superius, urethrae extremitas prominens, meatusque urinarii orificium conspiciuntur.
- K Clitoridis corpus transverse discissum: in medio, duas arteriolas fere contiguas, scilicet in utroque corpore cavernoso unam, cernere licet.
- LL Clitoridis crura et erectores. Haec, ossibus pubis quibus annectuntur sublatis, magis horizonti ad libellam, quam in situ suo naturali, respondentia jacent. Sejunctione autem ossium pelvis, nempe ut contenta ejus melius possint conspici, extenduntur.
- M Vesicae urinariae pars superior, simul utero, pone sito, et caput fetus continenti, simul ossibus pubis unitis, eam exadversum ambientibus, compressa.
- NN Peritoneum reflexum, telaque cellulosa, latera integens pelvis, et ei uteri parti quam ossa pubis amplectuntur, circumjacent.
- O Ex peritoneo et tela cellulosa resectis, margo, eo loco ubi de vesica urinaria ad faciem internam musculorum abdominis tegendam, supra ossa pubis, ascendunt.
- PP Ligamenta rotunda, abdominis intra cavum.
- QQ Ligamenta rotunda, eo in loco ubi ex abdomine recedentia sese in montis veneris lateribus sensim reconduunt.
- RR Musculi femoris, ossibus pubis exorti, resecti.

P L A T E I V.


A Fore-view of the womb, and of the contents of the pelvis; the ossa pubis, with the muscles and integuments which cover them, being removed.

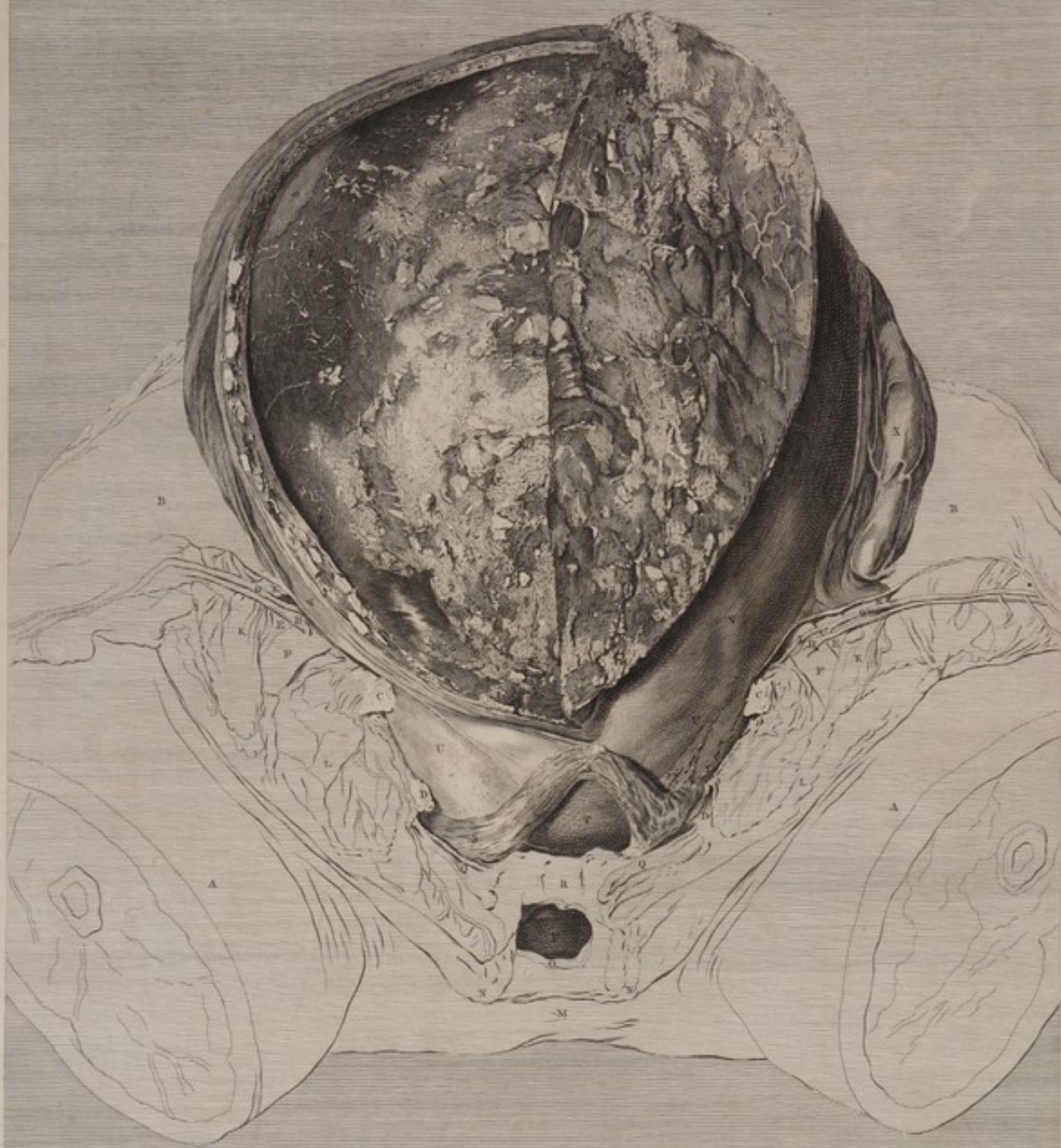- AA The thighs cut through.
- BB The lower angles, or flaps of the abdominal muscles and peritoneum turned aside.
- C The womb. All over its surface the injected vessels are seen projecting through its substance.
- DD The os pubis of each side cut through, above the foramen magnum ischii.
- EE The small branch of the ischium which joins the os pubis, cut through.
- F The perinaeum.
- GG The labia pudendi. The upper part of those, the nymphae and the extremity of the clitoris are cut off.
- H A large caruncula myrtiformis.
- I The vagina. At the lower part of this passage, the deeper black part of the surface, in this figure, represents the cavity of the vagina leading backwards as well as upwards: and where this letter (I) stands, is seen the upper or anterior part of the vagina which is united to the bladder and urethra, and which is pressed downwards by the viscera that lie over it. At the upper point of this dark oval orifice, the tuberosity of the urethra is seen, with the orifice of the meatus urinarius.
- K The body of the clitoris cut through; in the middle of which two small arteries are seen almost contiguous, viz. one in each corpus cavernosum.
- LL The crura and erectores clitoridis. These lie more horizontally than in the natural state, the ossa pubis, &c. which suspend them, being removed: and they are stretched or lengthened, from the bones of the pelvis being drawn a little asunder that the contents might be better seen.
- M The upper part of the bladder, which was compressed between the womb containing the child's head, which lay behind it, and the united ossa pubis which had embraced it forwards.
- NN The reflected peritoneum and cellular membrane, which lines the sides of the pelvis, surrounding that part of the womb which was embraced by the ossa pubis.
- O The cut edge of the peritoneum and cellular membrane, where these ascend from the bladder to line the abdominal muscles above the ossa pubis.
- PP The round ligaments within the cavity of the abdomen.
- QQ The round ligaments after they have passed out of the abdomen, where they are insensibly lost in the sides of the mons veneris.
- RR The muscles of the thigh, which spring from the ossa pubis, cut through.



TAB. IV. Uterus, et contenta Pelvis a parte anteriori, ossa pubis, cum integumentis, et superiori pudendorum parte, omnino fuerant abscessa, quò cervix uteri, et vesica simul urinaria ei protensa in visum incurrerent.







J. G. Weyland del.

J. Hunter sculp.

TAB. V. Uteri pars anterior et dextra, cuti manu ab adherentibus secundinis separata, et in sinistram partem reflexa. Ad hoc factum est consilio, ut pars membranae deciduae ac Placenta, cum vasis circumdanti omni repleta, et superficies uteri, cui adhererant, interna eadem exponerentur. Partes lineis designatis proximè sequens tabula scilicet integras.

TABULA V.

PLATE V.

- U**TERI pars anterior et dextra, cauta manu ab adherentibus secundinis separata, et in sinistrum latus reflexa. Id eo factum est consilio, ut pars membranæ deciduæ ac placentæ, cum vasîs carundem cera repletis, et superficies uteri cui adhererant interna, oculis exponerentur. Partes læcis designatas proxime sequens tabula exhibet integras. Priorem autem hæc habet locum linearum de sequenti tabula explanatio, ne literæ insculptæ nimis illam obscurarent.
- AA** Femorum superiora.
- BB** De angulis inferioribus partium continentium abdominis, quod superest, in ossa ilium reflexum. Anguli utrinque, peritoneo vasîs distinctio integritur; quod vero, ex parte, præsertim in latere sinistro, ad cursum vasorum epigastricorum retegendum, excindebatur.
- CC** Ossa pubis supra foramina ischium transverse scissa.
- DD** Ischium processus ascendentes transverse scissis.
- Ossa hæc pelvis, symphysi pubis sublata, laxa evaserunt; et in latere sinistro, ad descensum uteri in cavum pelvis magis illustrandum, extrorsum fuerunt evulsa.
- EE** Arterie inguinales.
- FF** Venæ inguinales.
- GG** Arterie epigastricæ.
- HH** Venæ epigastricæ.
- I** Arteria obturatoria sinistra lateris, epigastricæ scilicet ramus.
- KKK** Ligamenta rotunda ex abdomine ad exteriora vasorum epigastricorum descenduntia.
- LL** Scotio integumentorum et muscûlorum, in utroque inguine, facta nimirum, dum partes pelvis anteriores continentibus amovebantur.
- M** Perinæum.
- NN** Labiorum pudendi partes imæ.
- O** Hymenis reliquæ.
- P** Vagina.
- QQ** Clitoridis crura.
- R** Urethra ex parte superiori in longum diffusa et expansa.
- SSSS** Vesica urinaria, anteriorem inferioris extremitatis uteri portionem ambiens.
- T** Vesicæ urinariæ cavum, partem ejus anteriorem ab urethra sursum incidendo, oculis subiectum.
- UU** Uteri extremitas parva vel inferior, in cavo pelvis posita. Ea pars quæ circumdata fuerat margine pelvis, satis evidenter contracta fuit: quam super uterus statim eminentior evasit, quippe partes quæ facilius cedunt cum ibi amplectebantur.
- VVV** Uteri facies exterior.
- X** Vasorum spermaticorum in latere sinistro chorus.
- YY** Uteri substantia, ad dextrum latus, ab fundo penitus dissecta. In hac sectione vasa resecta occurrunt; quod autem ad figuram attinet inordinata, quippe cera friabili adimpleta. Venæ coloris sunt lucidioris ac grandes; exiliores arteriæ, atque fuscae; fundum versus uteri utraque minores quam in parte inferiori, ubi a lateribus uteri ad placentam transibant. Uteri crassitudo cum magnitudine vasorum his in locis proportionis legem quodammodo servat.
- ZZ** Decidua, sive membrana exterior, ramulis venarum ab facie interna uteri ad eam transeuntium distincta.
- a** Hic decidua vasîs resecta et opaca, cauta manu sublata fuit. Nulla hic loci, vel in chorio, vel in amnio, venarum, ex injectione ceræ, species fuit. Altera enim pars per alteram adeo perlucebat, ut fetus cutem distincte cernere liceret.
- bb** Externæ superficiei placentæ portio, hic cera extra venas uteri effusa, illic venis ipsis cera impletis, a facie interna uteri ad eam transeuntibus interflucta.
- c** Arteria cera rubri coloris impleta, quæ ab utero abrupta fuit, et, semel circumvolata, in placentam se immisit.
- dd** Ejus partis uteri, quæ deciduam (ZZ) antea obtexerat, facies interna. In hac superficie venæ quæ per deciduam ramos suos dissuderunt, abrupte conspiciuntur.
- ee** Ejus partis uteri quæ placentam (bb) obtexerat facies interna. Hac quidem superficies cera extra vasa effusa specimen præ se tulit. Quæ autem aspectu primo, extra vasa effusa videbatur, re vera, venarum complanatarum, cum anastomosis frequentioribus, ex utero ad placentam peroblique transeuntium, cera adimpletarum, species fuit. Cujus quod sequitur sit specimen.
- f** In substantia uteri vena.
- g** Eiusdem venæ in placentam continuatio.
- h** Uteri facies interna hic cavata, et venæ dimidium, quæ cursu peroblique transibat, formans.

- T**HE first view of the opened womb. Its substance is cut through on the right side and turned to the left; by which means part of the decidua and of the placenta, as well as the inside of that portion of the womb, are exposed in the injected state. All the parts represented in out-lines are seen finished in the next plate. The explanation is given here, that the other might not be obscured with engraved letters.
- AA** The upper part of the thighs.
- BB** Part of the lower corners of the containing parts of the abdomen turned down over the ossa ilium. They are covered by the vascular peritoneum; which (in the left side especially) was partly cut away, to show the course of the epigastric vessels.
- CC** The ossa pubis cut through above the foramina ischium.
- DD** The ascending processes of the ischia cut through. These bones of the pelvis became loose, from the loss of the symphysis at the pubes; and on the left side they were drawn outwards, to show more fully the descent of the womb into the cavity of the pelvis.
- EE** The inguinal arteries.
- FF** The inguinal veins.
- GG** The epigastric arteries.
- HH** The epigastric veins.
- I** The obturator artery of the left side, a branch of the epigastric.
- KKK** The round ligaments descending from the abdomen upon the outside of the epigastric vessels.
- LL** The section of the integuments and muscles in each groin, which was made in removing the anterior containing parts of the pelvis.
- M** The perinæum.
- NN** The lower extremities of the labia pudendi.
- O** The remains of the hymen.
- P** The vagina.
- QQ** The crura clitoridis.
- R** The urethra slit on its upper part, through its whole length, and spread out.
- SSSS** The bladder spread round the forepart of the lower end of the womb.
- T** The cavity of the bladder exposed by an incision through its forepart from the urethra upwards.
- UU** The small or lower extremity of the womb, lodged in the cavity of the pelvis. There was a manifest constriction upon that part of it which was surrounded by the brim of the pelvis; above which the womb swelled out immediately, being there embraced by more yielding parts.
- VVV** The outside of the body and fundus of the womb.
- X** The cluster of spermatic vessels of the left side.
- YY** The substance of the womb cut quite through, from the fundus downwards on the right side. In this section the cut vessels bear an irregular figure, which was occasioned by the crumbling of the wax with which they were filled. The veins are of a light colour, and large; the arteries dark, and small in proportion. At the upper part of the womb, both of them are small in comparison with what they are lower down, where they were passing from the sides of the womb to the placenta: and the thickness of the womb bears some proportion to the size of its vessels in these different places.
- ZZ** The external membrane, or decidua, full of small branching veins which passed into it from the internal surface of the womb.
- a** At this place the vascular and opaque decidua was carefully removed: there was no appearance of injected veins upon the chorion, or in the amnion; both of which were so transparent, that the child's skin could be seen distinctly through them.
- bb** A portion of the external surface of the placenta, interspersed partly with extravasated wax, from the venal system of the womb, and partly with injected veins, passing into it from the interior surface of the womb.
- c** An artery filled with red wax, which was broken off from the womb. It made one circumvolution, and plunged into the placenta.
- dd** The inner surface of that part of the womb which was in contact with the decidua (ZZ). Upon this surface the veins are seen broken off, which dispersed their branches through the decidua.
- ee** The inside of that part of the womb which covered the placenta (bb). Upon this surface there was indeed some extravasated wax. But the greatest part of what seemed, at first sight, to be extravasation, proved to be injected veins, of a flattened figure with numerous anastomoses, passing from the womb to the placenta in a very slanting direction. The following instance may serve as a specimen.
- f** A vein in the substance of the uterus.
- g** The same vein continued into the placenta.
- h** The inner surface of the womb hollowed, and forming half of the vein, which passed here in a very slanting direction.

TABULA VI.

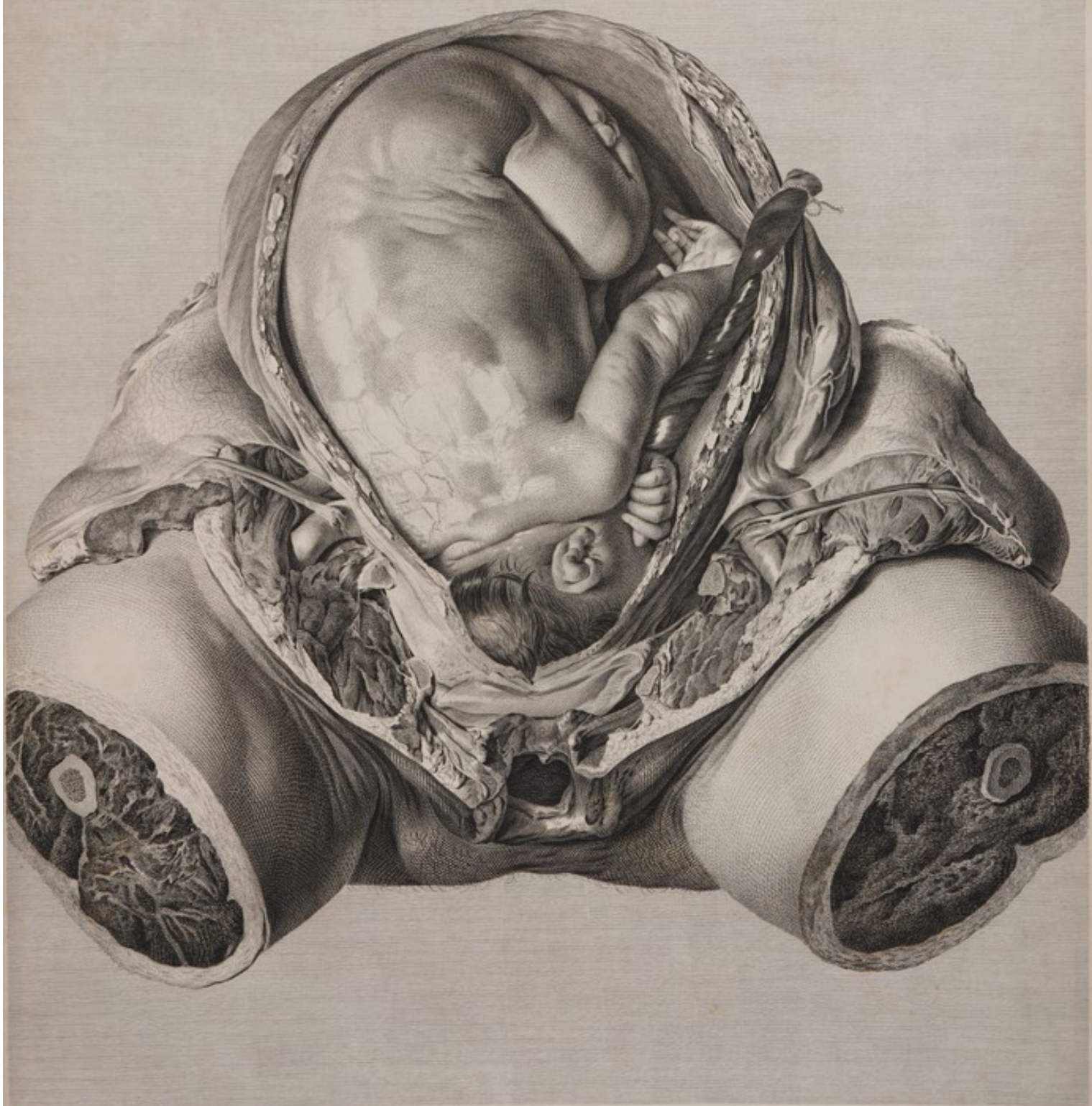FŒTUS in utero prout a natura positus.

Omnes hujus figuræ partes, utero et iis quæ in eo continentur exceptis, eadem fere sunt cum iis, quæ, in tabula præcedenti lineis exterioribus, literisque jamjam explanatæ sunt. In hoc tantum discrepant, nimirum hic vesicæ urinariæ pars superior omnino sublata est, ad fœtus caput in parte uteri inferiori exhibendum. Uteri et secundarum pars anterior, una cum placenta, omnino sublata est. Funis umbilicalis est dissectus, deligatus, et in marginem uteri resecti sinistrorsum reflexus. Ad fundum uteri membranæ investientes etiam in marginem uteri quo melius possint conspici inversæ sunt. Caput fœtus in uteri parte inferiori, in pelvis scilicet cavo, ponitur; corpus ejus præcipue in latere dextro jacet. Positio obliqua, vel ad lineam diagonalem appropinquans; unde partes posteriores antrosum sunt et ad matris latus dextrum; partes anteriores retrorsum et ad latus sinistrum versæ. Pes dexter inter femur sinistrum et tibiam occurrit. Corpus, uti infantibus denuo utero exclusis plerumque fit, mucro albo pinguiusculo sedatum: scilicet hic mucus, ad dorsi partem superiorem, ex rugis in corpore fœtus, motuque suo lineis interfecta, oculis subijcitur. Representatur quoque pars eodem modo quo primum occurrebat, ne quidem vel digiti articulo deturbato, partem aliquam magis illustrandi, aut tabulam elegantiorum reddendi gratia.

PLATE VI

THIS represents the child in the womb, in its natural situation.

All the parts of this figure, except the womb, and its contents, are nearly the same as those represented by out-lines in the fifth plate, where they are lettered and explained. The only difference is, that here all the upper part of the bladder is cut away, in order to shew the situation of the child's head in the lower part of the womb. All the forepart, both of the womb and of the secundines, (which included the placenta) is removed. The navel-string is cut, tied, and turned to the left side, over the edge of the womb. At the fundus the investing membranes are likewise turned over the edge of the womb, that they might be more apparent. The head of the child is lodged in the lower part of the womb, or in the cavity of the pelvis; and its body lies principally in the right side. Its position is diagonal or oblique: so that its posterior parts are turned forwards and to the right side of the mother, and its foreparts are directed backwards and to the left side. Its right foot appears between its left thigh and leg. Its body was covered with a white, greasy mucus, which is commonly seen on children at their birth. This is represented at the upper part of its back, where it was interstred with lines, from the wrinkles and motion of the child's body. Every part is represented just as it was found; not so much as one joint of a finger having been moved to shew any part more distinctly, or to give a more picturesque effect.



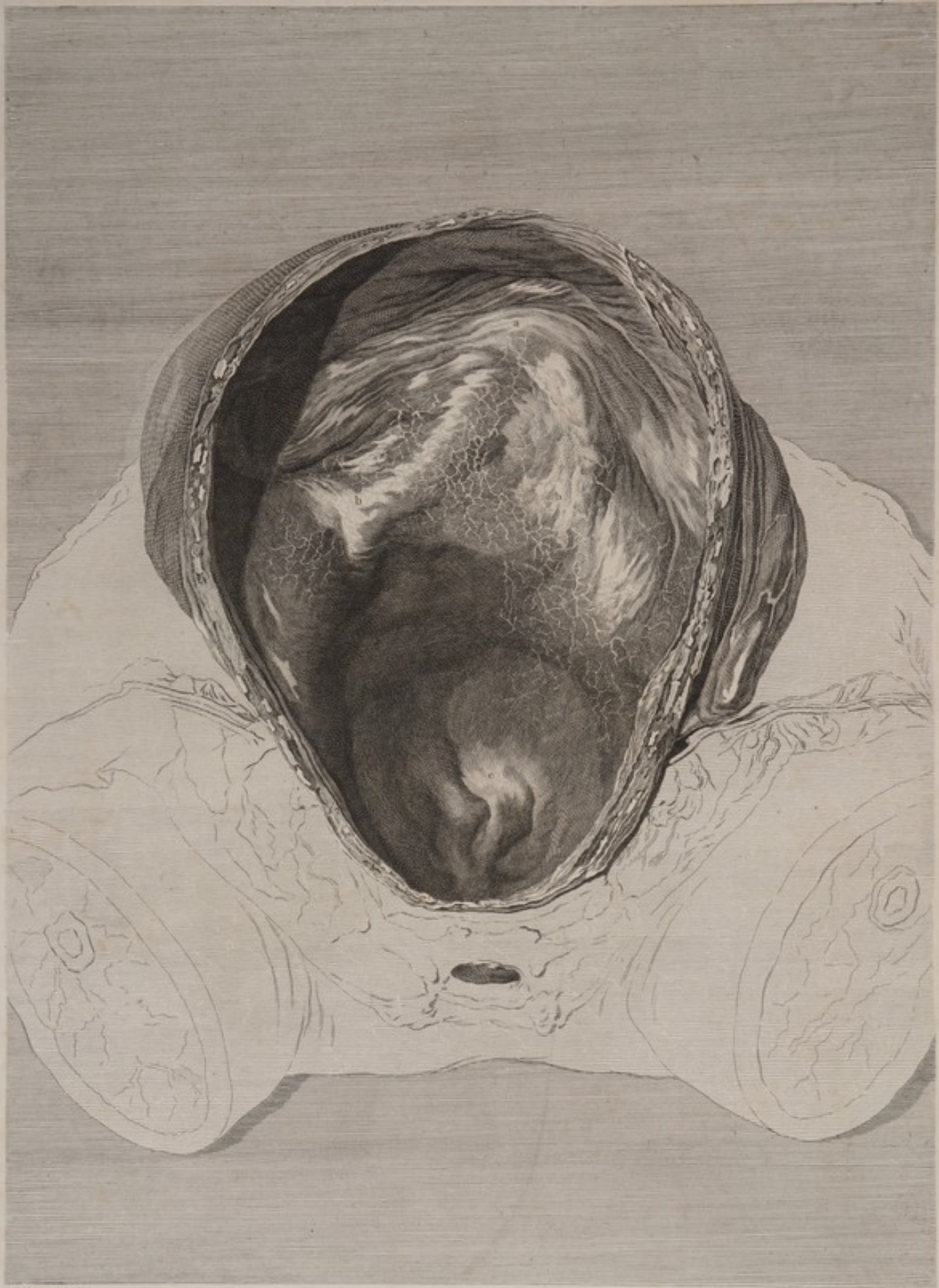J. S. Reynolds delin.

L. Strange sculp.

TAB. VI. *Fœtus in utero, prout a naturâ positus, rescissis omnino parte uteri anteriori,
ac Placentâ, ei adhærente.*







W. H. Edwards delin.

J. C. Bennett sculp.

TAB. VII. *Sublato foetu, paries uteri conspicitur intimus et posticus, membranis, suis adhuc vestitus.*
Partes laevis adumbrate praecedenti tabula. se ad placentam dedere.

T A B U L A VII.

SUBLATO foetu, paries uteri conspicitur intimus et posticus, membranis suis adhuc vestitus. Partes lineis adumbrate in praecedenti tabula se ad plenum dedere.

- A** Partis uteri projectio versus interna. Haec nata est a spina, valis magnis, et praecipue ex aorta, quae hic loci in arterias duas iliacas se dividit. Pars projecta, cadaveris situ supinato adacta, superiorem et posticam uteri partem in cava duo lateralia retrorsum dividit. Cavum dextrum, propter obliquitatem hujus uteri, sinistro majus fuit, et maximam foetus partem continuit.
- BB** Partes duae eodem modo projectae, scilicet ob projectionem muscutorum psoae, vasorumque iliacorum. Obliqua haec juga, uteri cava superiora lateralia ab inferiore azygo, in pelve posita, fecerunt; in parte hujus ima posteriore oculis subijcitur.
- C** Os tinctae, paulo ad latus dextrum versus. Uterus in statu laxo, rugoso, uti foetu vacuus apparebat, representatur. Partes totus internus membranis suis vestitus. Per eas venae cera impletae, tales quales in hac figura, distincte se videndas exhibuerunt.

P L A T E VII.

A Fore-view of the cavity of the womb, as it appeared when the child was taken out, and the investing membranes left adhering. The parts which are expressed by out-lines are nearly the same as in plate V. and VI. the first of which may be consulted for the explanation.

- A** An internal projection of the womb, occasioned by the spine and great vessels, especially the aorta which divides at this place into the two iliac arteries. This projection, which is increased by the supine position of the subject, divides the upper part of the womb backwards into two lateral cavities. The right cavity, from the obliquity of the womb in this case, was larger than the left, and contained the greatest part of the child.
- BB** Two similar projections occasioned, in the same manner, by the projection of the psoae muscles, and of the iliac vessels. These oblique ridges divide the upper lateral cavities of the womb, from the azygos lower cavity which is situated in the pelvis; at the lower posterior part of which is seen
- C** The os tinctae, in this case a little on the right side. The womb is represented in the loose rugous state, as it appeared when empty; and its whole internal surface is covered by the membranes. Through these the injected veins were distinctly seen, as they appear in this figure.

T A B U L A VIII.

PARTES proxime post gravidum uterum sitæ; utero ipso sede sua amoto, et in pudenda devoluto. Ossa pubis &c. prius fuerant abscissa, ut in tabula quarta.

Femora, partetque cæteras lineis adumbratas, in tabula quinta jam jam explanata, cernere licet.

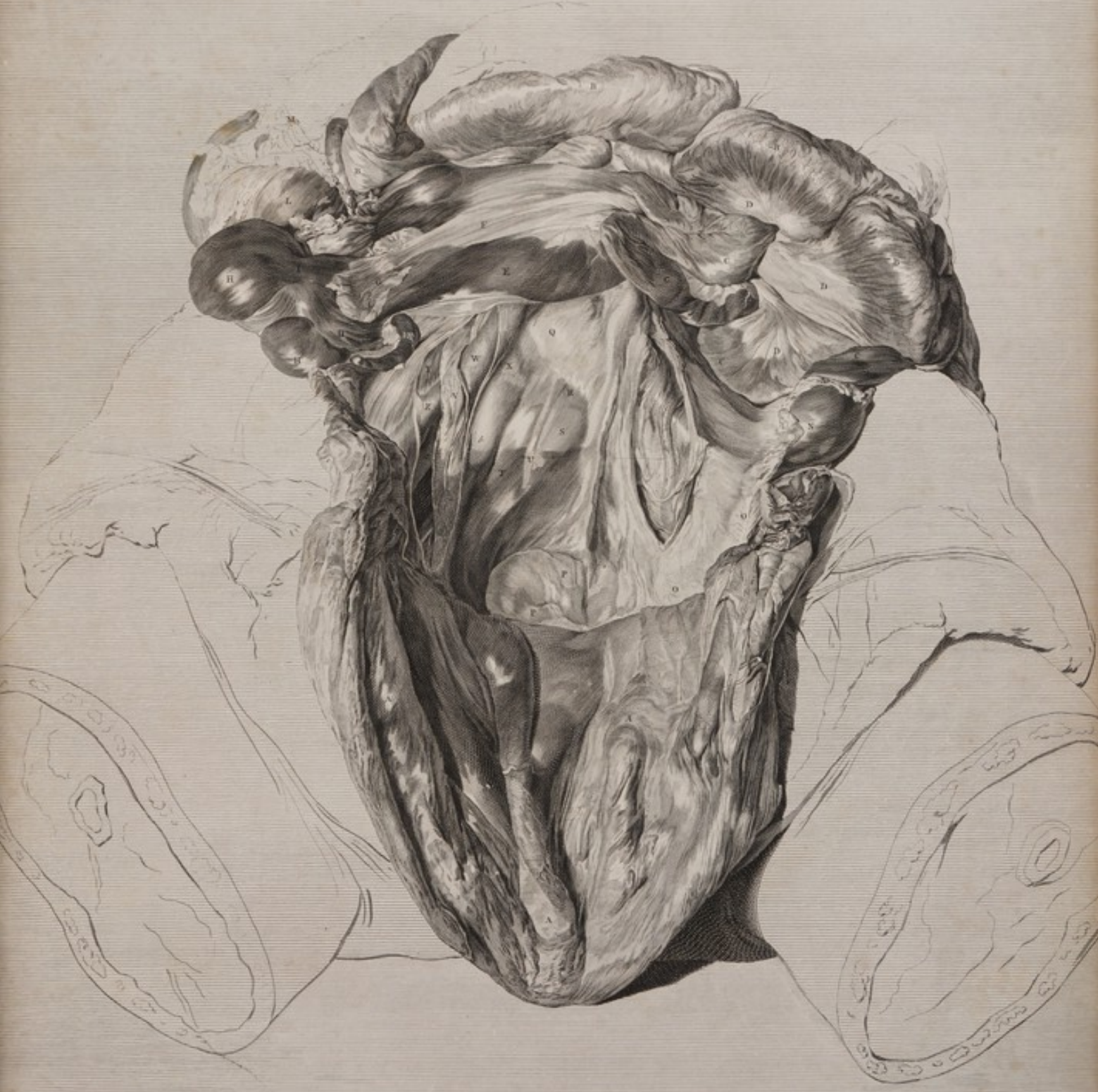- AAA** Uterus.
BBBB Intestina tenuia quæ fundo uteri arcte circumjacebant.
CCCC Intestinorum tenuium (cum mesenterio **DDD**) gyri, qui, post uterum, in latere sinistro, spinam inter et os ilium, supraque partem oblique prominentem, e musculo scilicet psoa et vasis iliæ formatam, jacebant.
E Intestini ilei pars inferior, (cujus mesenterium **F**) uterum inter et furcam aortæ decurrens ad
G Terminationem suam in cæco.
HHH Cæcum in cellas corrugatum propter ligamenta carnea per longitudinem ejus tendentia.
I Cæci ligamentum arterius.
K Appendix cæci vermiformis.
L Cæcum in colon continuatum.
M Colon cum omento, loco in quo sursum et sinistrorsum sub hepar ascendit, lineis adumbratum.
N Sinistri lateris colon, post intestina tenuia in faciem internam ossis ilium descendens.
OO Colon vasa iliaca transiens, et in pelvis cavum decurrens rectum continuo appellatum. Id suspensum cernitur de parte extrema mesocoli, supra vasa iliaca sinistra expansi. Hoc in loco intestinum coarctatum fuit, et adipe involutum.
PP In cavo sacri, intestini recti priores gyri.
Q Trunci venæ cavæ extremitas, quæ hic in iliacas se dividit.
R Vertebrae lumborum infimæ facies anterior.
S Substantia, ligamenti natura prædita, vertebrae inter proximè distantem et sacri partem summam.
T Ossis sacri summi facies anterior.
U Vena sacra.
 Partes quæ literis **Q, R, S, T, U**, notantur, per peritoneum illis incumbens conspiciuntur.
V Ureter dexter vasa iliaca transiens, et in pelvis latus decurrens.
W Arteriae dextræ iliacæ truncus.
X Venæ dextræ iliacæ truncus.
Y Psoas dexter.
Z Arteria iliaca externa.
a Vena iliaca externa.
 Ut partes, quæ literis **V, W, X, Z** et **a** notantur, in conspectum venirent, peritoneum illas obtegens fuerat percissum, membranaque cellulosa quæ circumjacebat cultro anatomico sublata.
b Vena iliaca interna.
c Ureter sinister per membranam cellulosam post peritoneum, et ante arteriam iliacam, ad pelvium transiens. Quo hic in conspectum prodiret, peritoneum et mesocoli pars inferior fuerant percissa, paululum etiam membranæ cellulosæ sublatum.
dd Vasa spermatica dextri lateris post cæcum, peritoneo testæ, descendentia.
ee Eadem vasa ad terminum superiorem ligamenti lati, in uterum, tubam, et ovarium se diffundentia.
ff Tubæ dextræ pars.
g Ovarii dextri pars.
h Sinistri lateris vasa spermatica.
i Tuba sinistra.
k Ovarium sinistrum.

P L A T E VIII.

A View of the parts which lay immediately behind the womb, and which were in contact with it. They were brought to view by turning down the empty womb over the pudendum; the ossa pubis, &c. having been removed, as in the preceding figures.

The thighs and other parts expressed by out-lines, are nearly in the same state as in plate V. where the explanation is given.


- AAA** The womb.
BBBB The small intestines which lay around, and in contact with the upper part of the womb.
CCCC Those turns of the small intestines (and **DDD** the mesentery) which lay behind the womb in the left side, between the spine and os ilium, and above the oblique ridge formed by the psoas and iliac vessels.
E The lower part of the intestine ileon, and (**F**) its mesentery. It passed between the womb and the bifurcation of the aorta to
G Its termination in the cæcum, where it was covered externally with an appendicula epiploica.
HHH The cæcum, corrugated into cells by its longitudinal fleshy bands, or ligaments.
I The anterior band or ligament of the cæcum.
K The appendix cæci vermiformis.
L The continuation of the cæcum into the colon.
M The colon and omentum represented in out-lines, where this intestine mounts upwards, and to the left, under the liver.
N The colon in the left side, coming down, from behind the small intestines, upon the inside of the os ilium.
OO The colon passing over the iliac vessels into the cavity of the pelvis, where its continuation is called rectum. It is here suspended by the extremity of the mesocolon which is expanded over the left iliac vessels. At this part the gut was contracted, and involved in fat.
PP The first turns of the rectum in the hollow of the sacrum.
Q The extremity of the trunk of the vena cava, which divides at this place into the iliac veins.
R The forepart of the lowest vertebra of the loins.
S The ligamentous substance between the last mentioned vertebra and the upper part of the sacrum.
T The forepart of the uppermost bone of the sacrum.
U The vena sacra.
 The parts which are marked **Q, R, S, T, U**, are seen through the peritoneum that covers them.
V The right ureter, passing over the iliac vessels into the side of the pelvis.
W The common trunk of the right iliac artery.
X The common trunk of the right iliac vein.
Y The right psoas muscle.
Z The external iliac artery.
a The external iliac vein.
 The parts marked **V, W, X, Z**, and **a**, were brought to view by slitting the peritoneum which covered them, and dissecting away the cellular membrane at that place.
b The internal iliac vein.
c The left ureter passing in the cellular membrane behind the peritoneum, and before the iliac artery, to the pelvis. This was brought to view, by making a long slit in the peritoneum, and lower part of the mesocolon, and taking away a small quantity of the cellular membrane.
dd The spermatic vessels of the right side, coming down from behind the cæcum and covered by the peritoneum.
ee The same vessels at the upper end of the broad ligament, diffusing themselves into the womb, tube, and ovary.
ff Part of the right tube.
g Part of the right ovary.
h The spermatic vessels of the left side.
i The left tube.
k The left ovary.



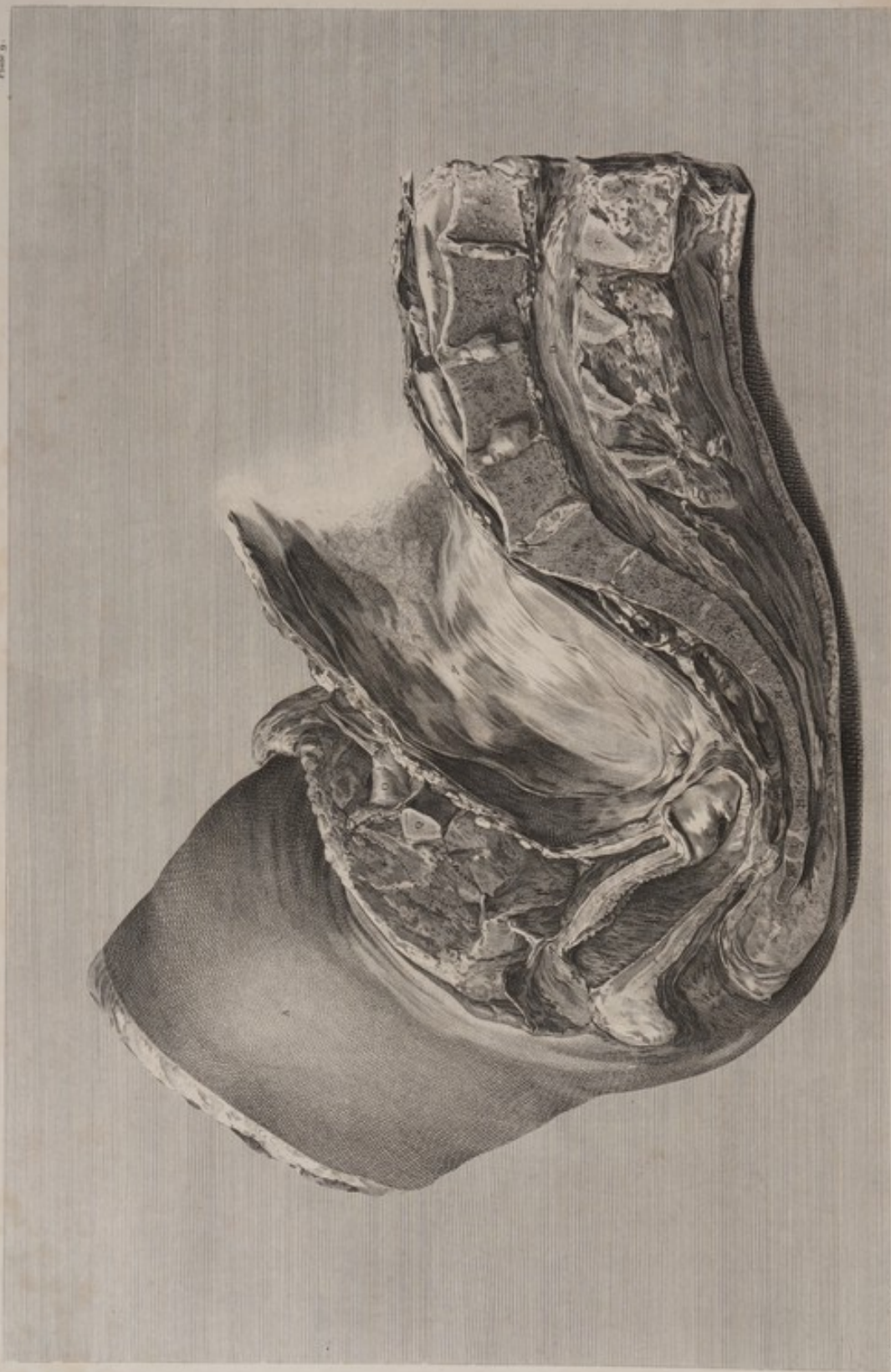TAB. VIII. *Partes immutatae post introductum uterum site, utero ipso sale sua amoto, et in pudenda devoluta. Ova pubis, &c. prius fuerunt abscissa. Confer TAB. IV.*

W. Cheselden delin.

C. Weyling sculp.







TAB. IX. Truncus et rectrix per omniaque spinae dorsae, hinc supra respiciuntur pectoris, quaeque costarum, cum visus naturalis, cum aliquot et finitima dextra et sinistrae parte.
 Quae hinc depicta circa pectoris, ad obliquissimas, praesentibus tabulis, immittitur et multum abstrahit, supplebit Tabulae 22.^a

T A B U L A IX.

P L A T E IX.

PELVIS a latere ad plenum conspecta, una cum contentis ejus, partibusque contiguis; per medium scilicet divisa, ut ossium flexura, et situs partium internarum oculo facilius exhiberi possent. Imperfecta est hæc figura ad pubem, extrorsum pariter atque introrsum. Partes quæ hic deficiunt, cultro separate sunt, dum cadaver ad aliquas tabularum præcedentium pingendas parabatur. Defectum autem abunde supplebit tab. XXII, in hunc finem delineata.

- A** Femur dextrum a parte interiori.
- BBBB** Lumborum vertebræ quatuor inferiores. Has inter cernitur substantia ligamentosa, extans, inæqualis, circa medium præsertim ubi mollissima est, et facile tumescit, si quando secta fuerit, et in aqua macerata.
- CCCC** Vertebrarum earundem processus spinales.
- D** Vertebrarum lumborum canal, in quo reliquæ quedam caudæ equinæ, obscure licet, conspiciuntur.
- EE** Musculorum lumbos extendentium partes inferiores.
- F** Lumborum membrana adiposa et cutis.
- GGG** Sacri ossa tria superiora.
- HH** Sacri ossa duo inferiora, primumque coccygis, firmiter coalita.
- I** Coccygis os secundum, quod, ope mediæ cartilaginis, ad primum facile movetur.
- K** Coccygis ossa duo inferiora in unum coalita, parique ad secundum mobilitate prædita.
- L** Sacri spina. — **M** Sacri canal.
- N** Musculorum abdominis et intestinentorum anguli inferioris pars, in ossis ilium spinam reflexa.
- O** Vena inguinalis magna epigastricam emittens, quam etiam arteria ejusdem nominis comitatur.
- P** Femoris muscoli, ex osse pubis orti, qui que in osse eo se jungendo fuerant percissi.
- Q** Os pubis supra foramen magnum disscissum.
- R** Idem os, ubi ramo parvo ischii committitur, disscissum. In loco quo litera **P** occurrit, lineis punctis adumbrata representatur partis ejus ossis pubis, quæ abscissa fuerat, figura. Nota * iidem lineis adumbratam symphyin ostendit.
- S** Pars carnea anum inter et os coccygis.
- T** Anus omnino apertus.
- U** Recti pars inferior hac sectione exposita. In hac figura videtur, intestinum idem ab ano sursum progrediens oculo dum perqueris, id se retrorsum deflexisse, nempe ut ad faciem internam ossis coccygis veniret.
- V** Hic rectum ad latus sinistrum se deflexit, solamque membranam suam cellulosam in hac sectione cernere licebat.
- WW** Rectum sectione apertum, ubi ante coccygis os primum, sacrique ossa tria inferiora, decurrebat.
- X** Hic rectum omnino in latere dextro jacebat, nec id aperuit scissura.
- Y** Rectum disscissum, ubi de latere dextro ad os secundum sacri decurrebat, et in flexuram colli signoidem cursum suum tenebat.
- Z** Vena cava. — **a** Arteria iliaca dextra.
- b** In hoc loco vena iliaca sinistra fuerat disscissa; cera autem, quæ injecta fuerat, utpote friata, jam delapsa, vena hæud satis clare se in conspectum dedit.
- c** Perineæ sectio.
- d** Labii dextri, ad partem inferiorem, facies interna.
- e** Nymphae dextræ, ad partem inferiorem, facies interna.
- f** Coarctatio, hymenisve reliquæ, ubi incipit vagina.
- g** Meatus urinarii extremitas. — **h** Vaginae cavum.
- i** In hoc loco vagina et rectum sunt coalita. Rectum vagina densius.
- k** Vaginae pars anterior, cum urethra et vesica urinaria conjuncta.
- ll** Os uteri in vagina, ad os coccygis vergens. Quamvis in hoc cadavere fundus uteri dextrorsum inclinatus fuerat, os uteri tamen adeo ad dextrum se tenebat, ut cultrum anatomicum has partes secantem fugerit.
- mm** Ad os tinxæ, uteri et vaginae substantia coalita.
- nn** Uteri in duas partes æquales secti marginis posterior.
- oo** Uteri secti pars anterior. Sectio hæc nequaquam per medium uteri se habebat, sed ad latus dextrum hæud paululum; etenim ut figuræ præcedentes commodè possent delineari, cadaver hoc modo necesse habuit disponere.
- p** Os uteri intus. — **q** Uteri partes internæ membranæ suis velitis. Fundus uteri in hac figura non representatur: tum quoniam id a proposita ratione alienum duxi, tum quoniam uterus adeo flaccidus et tener tunc temporis erat, ut in situ suo naturali, ad arbitrium et usum pictoris, minime potuerit retineri. Membrane, tempore quo tabula hæc delineabatur, ipse se ab utero sepe prorsus sejunxerant. In parte superiori, decidua, ubi se ab utero receperat, venulis abundavit; juxta os uteri, vix ullum horum vasorum vestigium apparuit.
- r** Meatus urinæ.
- s** Vesicæ urinariæ pars inferior, uteri cervicem inter et vaginae partem superiorem sita. Omnis vesicæ portio post symphyin pubis sita jamdudum abscissa fuerat. Melius autem mihi visum est, figuram vel curtam dare, quam aliquod ingenio excogitatum pingere.

A Full side-view of the pelvis with its contents, and adjacent parts, cut down through the middle, to show the turns of the bones, and the situation of the internal parts. This figure is imperfect at the pubes, both externally and internally; the defective parts having been cut away, in preparing the subject for some of the preceding figures. But what is wanting in these, may be seen in plate XXII, which was intended as a supplement to this.

- A** The inside of the right thigh.
- BBBB** The bodies of the four lowermost lumbar vertebræ. Between these the ligamentous substances are represented prominent, and unequal, especially near the centre, where they are softest and most disposed to swell when soaked in water, and cut through.
- CCCC** The spinal processes of the same vertebræ.
- D** The canal of the lumbar vertebræ in which some remains of the cauda equina is indistinctly seen.
- EE** The lower part of the extending muscles of the loins.
- F** The adipose membrane and skin of the loins.
- GGG** The three superior component bones of the os sacrum.
- HH** The two lowermost bones of the sacrum, and the first of the coccyx, firmly ankylosed.
- I** The second bone of the coccyx, moveable on the first by means of an intermediate cartilage.
- K** The two last bones of the coccyx grown into one, and moveable on the second bone by the intervention of a cartilage.
- L** The spine of the sacrum. — **M** The spinal canal in the sacrum.
- N** Part of the lower flap of the abdominal muscles and integuments, turned over the spine of the os ilium.
- O** The great inguinal vein, sending off the epigastric, which is accompanied with the artery of the same name.
- P** The muscles of the thigh which arose from the os pubis, and which were cut through when that bone was removed.
- Q** The os pubis cut through above the foramen magnum.
- R** The same bone cut through at its conjunction with the small branch of the ischium. Where the letter **V** stands, is represented, in dotted out-lines, the figure of that part of the os pubis which was cut off, and the mark * is upon the symphysis in the same out-lines.
- S** The fleshy part between the os coccygis and the anus.
- T** The anus considerably opened.
- U** The lower part of the rectum laid open by the section. In tracing the gut from the anus upwards, we see from this figure that it takes a bend backwards, to get at the inside of the os coccygis.
- V** Here the rectum made a turn to the left side, and its surrounding cellular membrane only was seen in the section.
- WW** The rectum laid open by the section, where it runs before the first bone of the coccyx, and the three lowermost pieces of the sacrum.
- X** Here the rectum lay intirely in the right side, and was not opened by the section.
- Y** The rectum cut through, by the section, where it passed from the right side, across the second bone of the sacrum, and was continued into the sigmoid flexure of the colon.
- Z** The vena cava. — **a** The right iliac artery.
- b** Here the left iliac vein was cut through: but the brittle wax with which it was filled had fallen out, and the vein was seen indistinctly.
- c** The section of the perineum.
- d** The inside of the lower part of the right labium.
- e** The inside of the lower part of the right nymphæ.
- f** The stricture at the beginning of the vagina, or remains of the hymen.
- g** The extremity of the meatus urinarius. — **h** The cavity of the vagina.
- i** The compound substance of the vagina and rectum, the latter of which is considerably the thickest.
- k** The forepart of the vagina united with the urethra and bladder.
- ll** The mouth of the womb in the vagina, directed towards the os coccygis. Though the bottom of the womb, in this case, was directed towards the right side, its mouth lay so much on the right side, that it was not touched in making the middle section of all the parts.
- mm** The substance of the womb and vagina blended, at the os tinxæ.
- nn** The edge of the ligamented womb backwards.
- oo** The edge of the womb forwards. This section was not in the middle, but considerably on the right side. It had been made to prepare the subject for some of the preceding figures.
- p** The mouth of the womb internally.
- q** The inside of the womb lined with the membranes. The bottom of the womb is not represented in this figure; both because it was not very material here, and because it was become so flaccid and tender, that it could not be well kept out, in its natural situation, before the painter. The membranes were almost entirely separated from the womb, of themselves, when this figure was made. In the upper part the decidua was full of small veins, even where it parted off itself from the womb; but near the mouth of the womb, hardly any such vessels appeared.
- r** The meatus urinæ.
- s** The lower part of the bladder, placed between the neck of the womb and the upper part of the vagina. The upper part of the bladder, which was situated behind the symphysis of the pubes, had been cut away before this section was made; and we chos to leave the figure imperfect, rather than venture to delineate from fancy.

TABULA X.

FIG. I.

UTERI pars anterior et externa, prout se videndam præbuit, omnino siccata, exhibens faciem vasorum uterinorum, qualem illa præ se ferunt, eo loci ubi placenta utero adhæret.

Venæ cæra flava impletæ, ab arteriis, magnitudine, colore lucidiori, anatomosis pluribus, facile dignoscuntur. Arteriæ enim, minores, pauciores, flexuosæ, coloris magis luridi hic loci sunt. Arteriæ omnes convolutæ; pauciores autem videbantur, quia multi earum ramuli, cæra flava, venis prius injecta, impleti fuerint. Hujus exemplum unum est ad literam A.

Venas profundius sitas, per uterum siccatum cernere non licuit; indistinctæ igitur, nulloque ordine, ita uti visæ sunt, delineantur.

FIG. II.

Facies interna placentiæ, cujus vasa per funiculum umbilicalem cæra sunt repleta.

A Cannula ænea in arteriarum alteram umbilicalem inserta, per quam utraque arteria cæra viridi implebatur.

B In vena cannula, per quam cæra cærulea illi injecta fuit.

CC Amnion, in parte quadam placentiæ, laxum relictum.

DD Placentiæ, qua amnion sublatum est, superficies intima chorion productio cooperta. Hoc in loco rami primi vasorum umbilicalem conspicuntur. Arteriæ colore lucidiori facile possunt dignosci.

Hic arteriæ quidem lucidiores, ut in figura, apparebant; tunicis scilicet earum pellucidis colorem cære injectæ viridem lucidorem transmittentibus: In funiculo autem umbilicali aliter se res habet; quippe vena, in medio posita, undique glutinosa funiculi substantia fuit intercepta; unde cæra cærulea ad livorem propius accedens visa est.

E Decidua pars in margine placentiæ relicta, inque faciem ejus internam reflexa; nempe ut superficies ejus exterior, utero quæ adhæserat, vasis parvulis (cæra flava per venas uteri impletis) referta, possit exhiberi.

Placenta cæra flava ubique turgida, quæ substantiam ejus cellulofam adeo implevit, ut in facie interna ubique per chorion transluceret. Cæra ubique quasi in grana abiit, quod inde cava naturalia impleverat, indicium certum exhibens, se cum placenta, vasis effusa implevisset, in massas majores, irregulares formatas, se ad conspectum dedisset. Cæra in hanc spongiosam, five cellulofam partem, injecta, placentiæ crassitudo naturali duplo major evaserat.

FIG. III.

Mulieris, die secundo post partum extinctæ, uteri superficiem internam pars.

Decem his tabulis jam delineatis, eas statim in lucem edere proposui; et simul hanc tertiam figuram, quasi supplementum, addere, utpote solum quod tunc temporis potui. Discrimen exhibet inter superficiem uteri (A, B, C) cui membrana adhæserant, et superficiem (D, E, F) cui placenta se immiserat; illam quidem levem et unius formæ; hanc autem orificiis magnis venarum refertam. Ubi primum hæc orificia sub examen venerant, omnia grumis coagulati sanguinis referta comperi, in cavum uteri nonnihil extantibus. Utero vero aliquamdiu in aqua macerato, coagula hæc magis albida evaserunt; nonnulla exciderunt; et aliqua etiam extracta sunt, ut venarum orificia clarius monstrari possent. Ita se res habuit, cum figura hæc delineabatur.

PLATE X.

FIG. I.

A View of the outside of the forepart of the womb, as it appeared when quite dry; exhibiting a specimen of the uterine vessels, at the part where the placenta adhered.

The veins were filled with yellow wax, and are readily distinguished by the largeness, light colour, and frequent anatomoses, from the arteries, which are here smaller, less numerous, serpentine, and of a darker colour. The arteries were all convoluted; but they did not appear to be so numerous, because many of the branches were filled with the yellow wax, which had been thrown into the veins. This is seen, in one instance, at the letter A.

The deeper-seated veins could not be distinctly seen through the dried substance of the womb, and are therefore represented with the same obscurity and confusion which appeared in the object itself.

FIG. II.

The inside of the placenta, which was injected by the umbilical vessels after it was taken out of the womb.

A A brass-pipe tied into one of the umbilical arteries, by which the two arteries were filled with green wax.

B A pipe in the vein, by which it was filled with blue wax.

CC The amnion left loose upon one part of the placenta.

DD The internal surface of the placenta, where the amnion was removed, covered by a continuation of the chorion: upon this are seen the first branches of the umbilical vessels. The arteries are sufficiently distinguishable by their lighter colour.

They appeared so from being filled with a lighter coloured green wax, and from the transparency of their coats: but on the navel-string it was the contrary; because the vein, being the most central, was covered with a greater thickness of the gelatinous substance of the string, and therefore did not allow the darker-coloured blue wax to be so well seen.

E Part of the decidua left at the edge, and turned over the inside of the placenta, so as to show its outer surface (which had adhered to the womb) full of small vessels, injected with yellow wax from the uterine veins.

The body of the placenta was uniformly filled with the yellow wax. This had so completely filled all the cellular substance of the placenta that upon the inside it appeared every where through the chorion. And the wax was every where manifestly granulated; so that it had plainly filled natural cavities: for if it had filled the substance of the placenta by common extravasation, it would have formed itself into irregular and large masses. From this injection of the spongy or cellular part, the placenta had acquired at least double its natural thickness.

FIG. III.

A portion of the internal surface of the womb, from a woman who died two days after delivery.

When these ten plates were finished, I intended to have published them immediately; and this third figure was added, as the only supplement which I could give at that time. It shows the difference between the surface of the womb (A, B, C,) where the membranes had adhered, and that surface (D, E, F,) to which the placenta had been fixed. The first was much more smooth and uniform; the latter was full of large venous orifices. At the first examination, all these orifices were found filled up with plugs of coagulated blood, which projected some way into the cavity of the womb. The part being steeped some time in water, they became whiter, and many of them fell out, or were pulled out, to show the orifices of the veins more clearly. In this state the drawing was made.

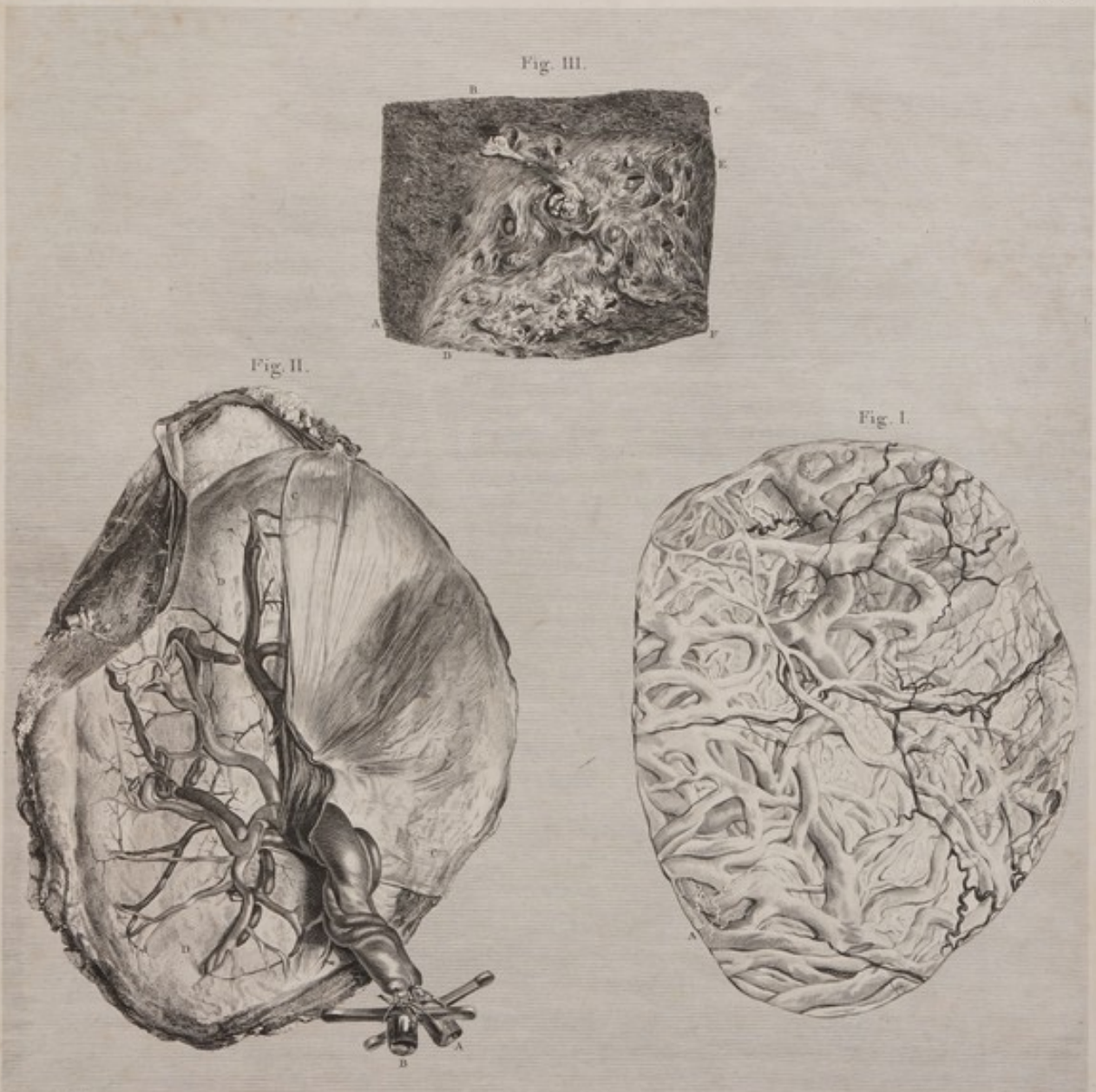


Fig. III.

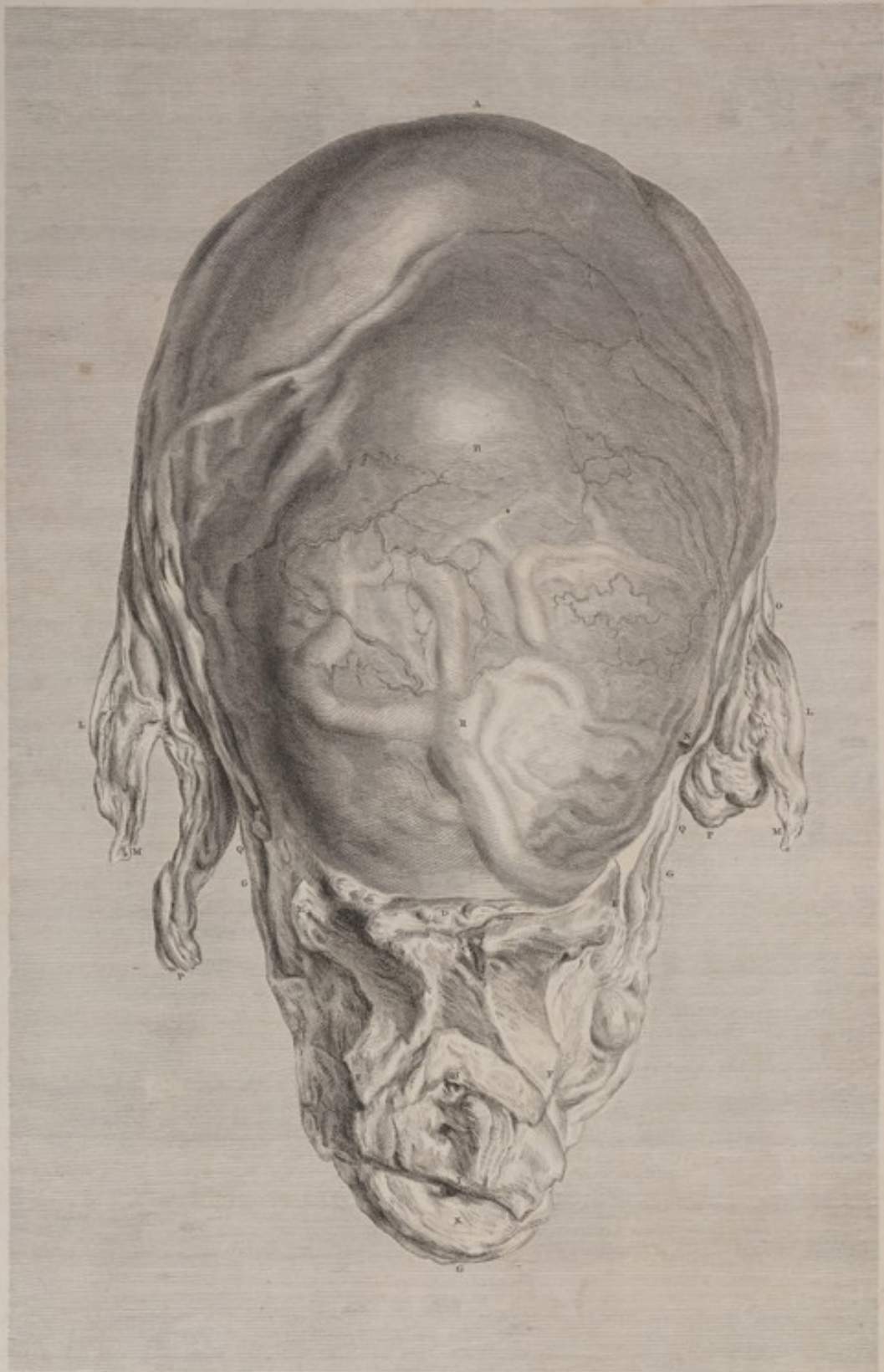
Fig. II.

Fig. I.

J. F. Borelli delin.
 TAB. X. Fig. I. Uteri pars anterior et externa, prout se præbuit omnino siccata, exhibens faciem vasorum uterinorum, qualem præ se
 ferunt in loco, ubi Placenta utero adhæret. Fig. II. Facies interna Placenta, cujus vasa per funiculum umbilicalem cerni sunt repleta.
F. C. Gaubius sculp.
 Fig. III. Ab alia muliere biduo post partum extinctâ, exhibet partem superficiem internam uteri.







J. S. Weyland sculp.

F. - Habesius sculp.

TAB. XI. ab alia muliere, nono graviditatis mense haemorrhagia uterina e medio sublata. Conspicitur uterus, et ossa pubis juxta naturam sita. Vasa injecta cera turgida, quaeque ad partem inferiorem et cervicem uteri digresserunt esse amplissima, arguant. Placentam parti illi adhæsisse.

TABULA XI.

- A** B alia muliere, nono graviditatis mense hæmorrhagia uterina e medio sublata. Conspicitur uterus, et ossa pubis juxta naturam sita. Vasa, injecta cera, turgida; quæque ad partem inferiorem et cervicem uteri dignoscuntur esse amplissima, arguunt placentam parti illi adhæsisse.
- A** Fundi uteri pars media et summa.
- B** Uteri pars quæ scilicet in cadavere fuit ex adverso umbilici.
- C** Symphysis ossium pubis.
- D** Membrana adiposa ad fundum vesicæ urinariæ.
- EE** Os pubis utrinque, ad locum fere quo ossi ilium committitur, percissum.
- FF** Utriusque ossis ischiâ ramus parvus, ad locum quo ossi pubis adjungitur, percissus.
- GGG** Contenta pelvis omnia, antrosum ossibus pubis obtecta.
- H** Infra hanc literam meatus urinarii orificium.
- I** Ab hac litera sursum ad meatum urinarium vaginæ principium; infraque hanc literam aditus ad rectum.
- K** Strato intimo ani sphincteris circumtectus.
Labia pudendi, perinæum et anus hîc non habent locum; in sita enim suo relicta erant in cadavere, quippe illud externe mutilum et deforme reddere non liceret.
- LL** Tubæ.
- MM** Fimbriæ.
- NN** Ligamenta rotunda.
- O** Ovarii pars.
- PP** Vasorum spermaticorum utrinque ad uterum ascendentium fasciculus.
- QQ** Vasa hypogastrica, in latere uteri, ad conjunctionem cum spermaticis ascendentia.
- R** Uteri venæ magnæ in loco cui placenta interne adhærebat.

PLATE XI.

- FROM** a second subject, viz. a woman who died of a flooding in the ninth month of pregnancy. It represents a fore-view of the womb, with the ossa pubis in the natural situation. The situation of the large vessels, which were injected, shews, that the placenta was attached forwards, and to the lower part of the womb.
- A** The middle and highest part of the bottom of the womb.
- B** That part of the womb which, as it lay in the dead body, was directly opposite to the navel.
- C** The symphysis of the ossa pubis.
- D** The adipose membrane upon the fundus of the bladder.
- EE** The os pubis of each side, cut through near its union with the os ilium.
- FF** The small branch of each os ischiâ, cut through near its conjunction with the os pubis.
- GGG** The whole contents of the pelvis covered forwards by the ossa pubis.
- H** Immediately below this letter is seen the orifice of the meatus urinarius.
- I** From this letter upwards to the meatus urinarius is seen the beginning of the vagina; and immediately below this letter **A** is seen the passage into the rectum, surrounded by
- K** The inner stratum of the sphincter ani.
The Labia, perinæum and anus were left in the body, that it might not be disfigured outwardly.
- LL** The tubes.
- MM** The fimbriæ.
- NN** The round ligaments.
- O** Part of the ovarium.
- PP** The group of spermatic vessels, on each side, approaching the womb.
- QQ** The hypogastric vessels mounting upon the sides of the womb to join the spermatic.
- R** The great veins of the womb in that place to which, internally, the placenta was attached.

T A B U L A XII.

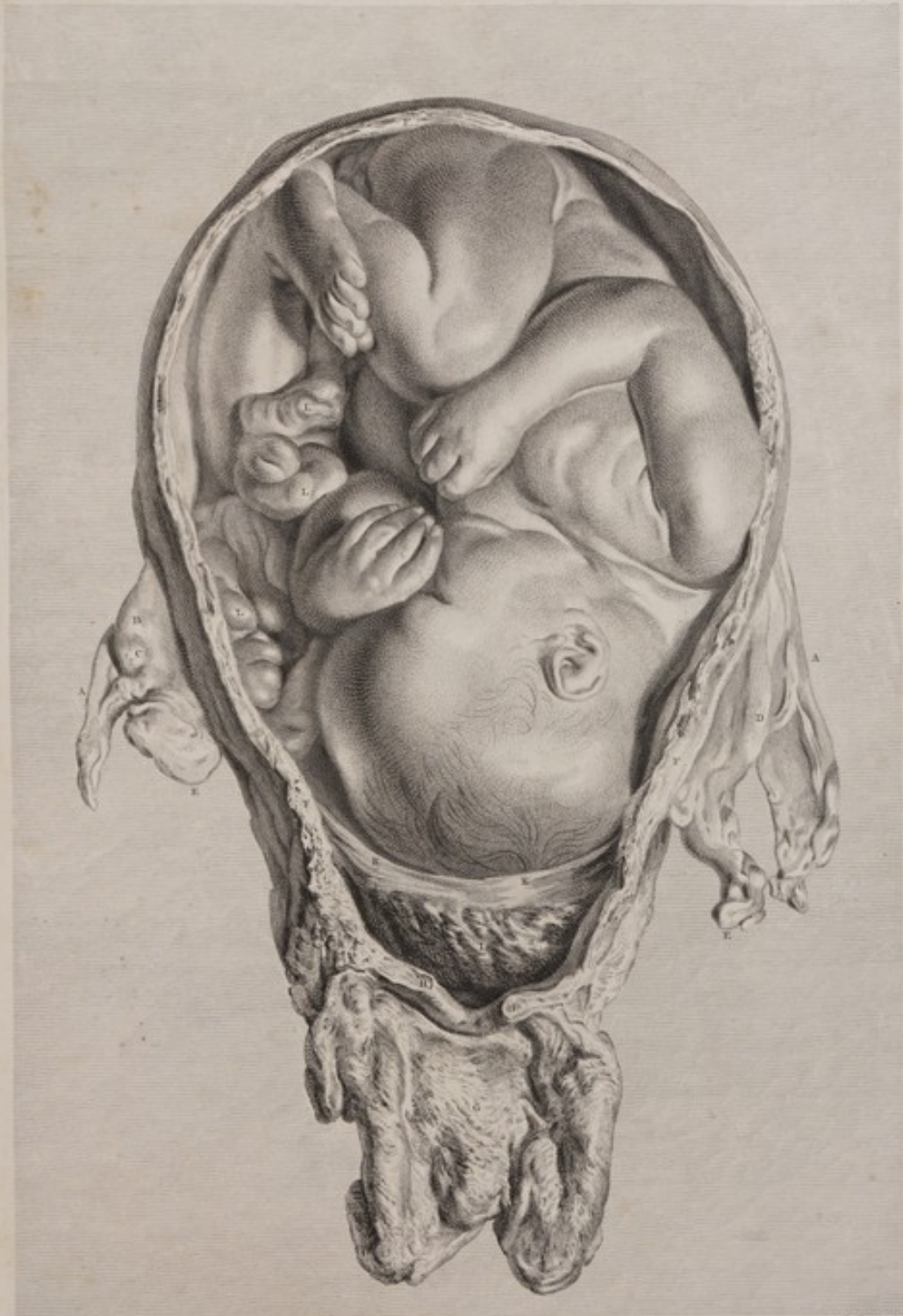A B eadem, qua præcedens, muliere, exhibet apertum plane a parte postica uterum cum vagina, quo situs fœtus, partique inferior placentæ, sub fœtus capite, indicarentur. Placenta scilicet orificio uteri interno accreverat, eoque sub finem graviditatis dilatato, separata est: unde hæmorrhagia, et mors.

- AA** Tubæ fallopianæ.
B Ovarium sinistrum; cujus ad extremitatem inferiorem videre est
C Corpus luteum extans.
D Ovarium dextrum.
E Vasorum spermaticorum ad uterum ascendentium fasciculus.
FFF Substantiæ uteri sectio.
G Vaginæ per incisionem apertæ et expansæ facies interna.
HH Os uteri.
I Placentæ partis inferioris facies externa, in lobos partita, quæ quondam cervici et ori uteri interne adhæserat: tempore autem parturienti instanti, partium illarum dilatatione scjuncta fuerat, unde necessario hæmorrhagia.
KK Membranæ de margine placentæ exeuntes, capitique fœtus partem inferiorem amplectentes, percissæ. Spatium, quod inter cervicis uteri partem interiorem, et secundas, vacuum occurrit, in cadavere sanguine coagulato refertum comperi.
 Situs partelque fœtus explanatione non egent.

P L A T E XII.

FROM the same subject, a view of the womb and vagina fully opened on the back part, to shew the situation of the child, and of the lower part of the placenta at the inside of the mouth of the womb, under the child's head, and detached from the womb; the occasion of the fatal hæmorrhage.

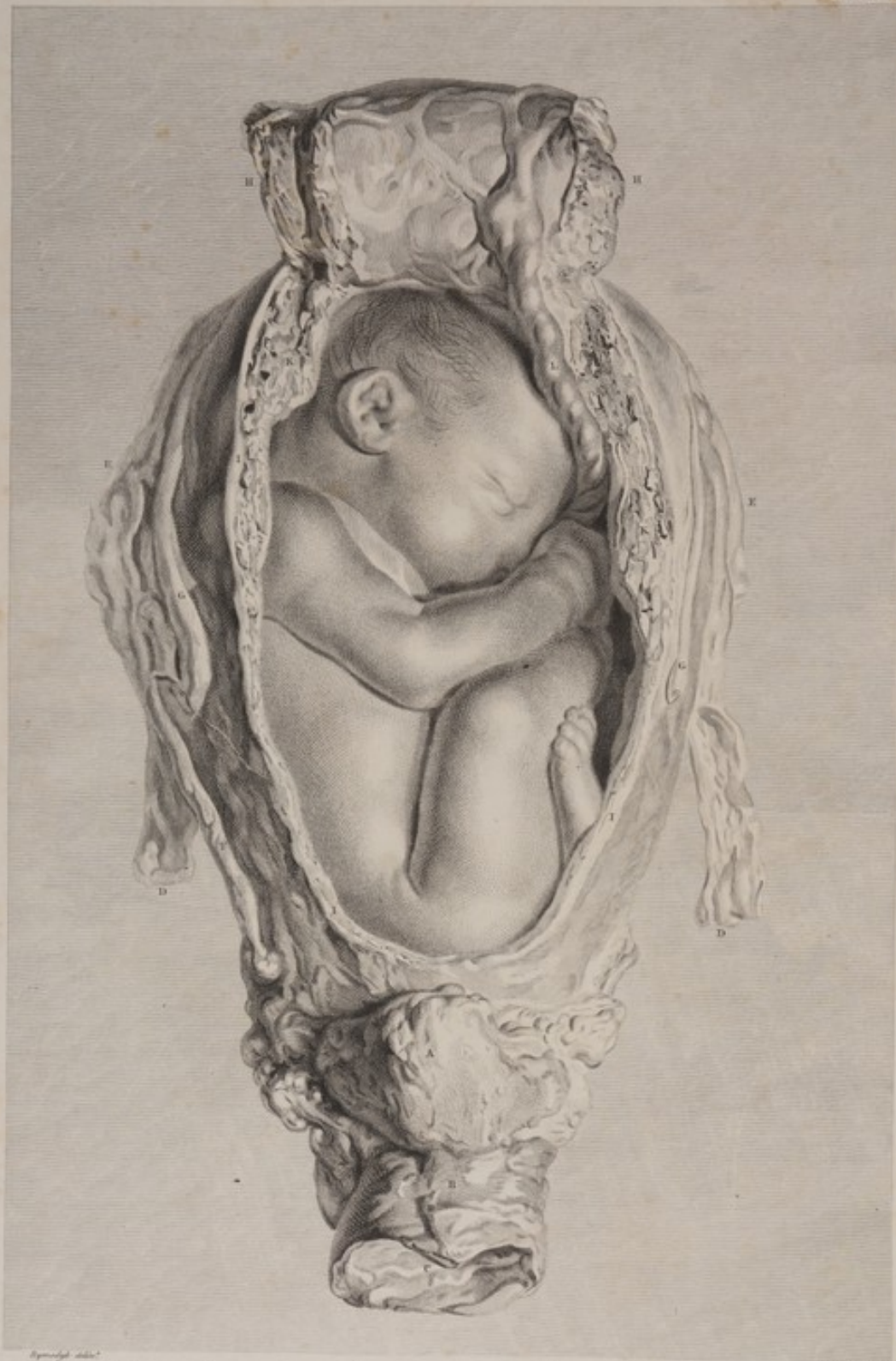- AA** The fallopian tubes.
B The left ovarium, at the lower end of which is seen
C The projecting corpus luteum.
D The right ovarium.
E The group of spermatic vessels approaching the sides of the womb.
FFF The section of the substance of the womb.
G The inside of the vagina, which is laid open by a longitudinal incision, and spread out.
HH The mouth of the womb.
I The external lobulated surface of the lower part of the placenta; which had originally stuck to the inside of the neck and mouth of the womb; but as parturition approached, the dilatation of these parts occasioned a separation, which was necessarily followed by an hæmorrhage.
KK The membranes cut through where they were coming out from the border of the placenta, and enclosing the most depending part of the child's head. The vacant space which is seen between the inside of the neck of the womb, and the secundines, was full of clotted blood in the dead body. The situation, and the several parts of the child require no explanation.



TAB. XII. ab eadem, quæ præcedens, muliere, exhibet apertum planè a parte postici uterum cum vagina, quò situs Fetus, partusque inferior Placentæ sub Fetus capite indicarentur. Placentæ scilicet orificio utero interno accreverit, æque sub finem graviditatis dilatato, fatali inde divisione separata est.







Figurae Tabulae *Michael Anspach*
 TAB. XIII. A tertio cadavere, nono graviditatis mense. Aperto Utero (Vagina et Vesica urinaria integra) incisis scilicet, una cum anteriori Uteri pariete, secundinis, et adherentibus, et in fundum Uteri reclinatis, situs Fetus (qui hic erectus est) conspicitur. Vasa Uteri cœci erant repleta.

T A B U L A XIII.

A Tertio cadavere, nono graviditatis mense. Uteri conspectus ab anteriori, cum vagina et vesica urinaria. Pariete hujus anteriori, cum secundis ei adherentibus, inciso, et in fundum ejus reclinato, situs foetus erecti conspicitur. Vasa uteri, cera prius injecta, turgida fuerunt.

- A** Vesica urinaria in situ suo naturali, respectu habito ad uterum.
B Vaginae pars superior et externa, quae sub symphyfi ossium pubis jacet, quaeque ibi cum urethra connectitur.
C Vaginae cavum in conspectu positum, cum labia partesque aliae externae fuerant abscissae, quo specimen hoc e cadavere eximiretur.
DD Vasa spermatica, ad uteri latera ascendentia.
EE Tubae: quarum extremitates, seu fimbriae, sub racemo vasorum spermaticorum, occultantur.
F In uteri latere dextro, vena magna, ab anastomosi venarum, hypogastricae scilicet et spermaticae, ortum suum ducens.
GG Ligamenta rotunda.
HH Uteri pars anterior, cum portione placentae quae ei adhaerebat, incisa, et in fundum uteri reclinata, ut foetus in conspectum prodiret.
III Uteri substantiae, et membranarum investientium, sectio.
KK Eadem sectio per placentae substantiam ducta, quae uteri parti anteriori in latere dextro adhaerebat. Ex figura inversa latus dextrum sinistrum fit.
L Funis umbilici, a foetu ad placentam tranfrens.

P L A T E XIII.

FROM a third subject, in the ninth month of pregnancy. A fore-view of the womb (with the vagina and vesica urinaria) in which all the inclosing parts were cut through, and turned up, to shew the situation of the child, with its head upwards. The vessels of the womb had been previously injected.

- A** The bladder, in its natural situation with respect to the womb.
B The upper and external part of the vagina, which lies under the symphysis of the ossa pubis, and where the urethra is united with it.
C The cavity of the vagina exposed, where the labia and other external parts had been cut off, in taking this part from the dead body.
DD The spermatic vessels, passing up towards the sides of the womb.
EE The tubes, of which the extremities, or fimbriae, are concealed behind the group of spermatic vessels.
F The great vein on the right side of the womb, formed by the anastomosing hypogastric and spermatic veins.
GG The round ligaments.
HH The forepart of the womb, with that part of the placenta which adhered to it, cut up, and turned back over the fundus of the womb, to bring the child to view.
III The section of the substance of the womb, and of the investing membranes.
KK The same section carried through the substance of the placenta, which, in this case, was fixed to the forepart and right side (which is the left in this inverted figure) of the womb.
L The navel-string passing from the child to the placenta.

TABULA XIV.

A Quarto cadavere, nono itidem graviditatis mense. Fasciculi fibrarum muscularium, in parte interna uteri, triplici figura exhibentur.

Hac parte uteri per aliquot dies in aqua macerata, decidua jam tenera ablergebatur.

F I G. I.

Uteri inverfi, et in latus paululum reclinati, facies posterior interna.

- A* Uteri os relaxatum; supra quod, paulo obscurius licet, cervicis rugæ, ramorum adinstar dispositæ, cernuntur.
- BB* Uteri pars angusta, margine pelvis antea circumcincta.
- CC* Seta in orificio utriusque tubæ; quam circum fasciculi fibrarum ad musculos pertinentium, in orbem, eodem centro terminatos, se disponunt.
- D* Hic fasciculi, in orbem dispositi, uterum cingunt.
- E* Uteri fundi pars media, qua ordines hi duo fibrarum, tubas cingentium, inter se coeunt, sive se invicem contingunt.
- F* Interstitium triangulare, tres inter ordines fibrarum prædictarum, ubi mutuo inter se coeunt, diversumque ordinem et cursum tenent.

F I G. II.

Ejusdem uteri, forma minuta, conspectus a latere.

- A* Uteri os.
- B* Seta in orificio tubæ.
- C* Fibrarum, sine ordine dispositarum, stratum, faciem internam fasciculorum, qui in circulum flectuntur, obtegentes.

F I G. III.

Ejusdem uteri partis anterioris facies interna.

- A* Os uteri; supra quod rugæ anteriores, in ramos abeantes, se in conspectum dant.
- B* Superfici cui placenta adhaererat pars media, ubi fibræ fascias sine ullo ordine formabant; quas inter, venarum orificia, in placente partem spongiosam cursum tenentium, passim occurrunt. Ad cervicem uteri, fibræ musculosæ, in fasciculos collectæ, nulle conspiciuntur.

PLATE XIV.

FROM a fourth subject, at nine months. This shews the disposition of the muscular fasciculi on the inside of the womb, in three different views.

The part was steeped in water some days, whereby the decidua was made tender, and then brushed off.

F I G. I.

The inner surface of the posterior part of the womb, turned a little to one side.

- A* The relaxed mouth of the womb, over which are faintly seen the branching rugæ of the neck of the womb.
- BB* The narrow part of the womb, which was embraced by the brim of the pelvis.
- CC* A bristle put into the orifice of each tube, round which the fasciculi of muscular fibres are ranged into concentric circles.
- D* The fasciculi going circularly round the body of the womb.
- E* The middle of the fundus of the womb, where the two orders of circular fibres, which surround the tubes, meet, or become reciprocally tangents.
- F* The triangular interstice between the three orders of circular fibres, where they are all blended, and take a variety of directions.

F I G. II.

A side-view of the same womb, in miniature.

- A* The mouth of the womb.
- B* A bristle in the orifice of the tube.
- C* An irregular stratum of fibres, upon the inside of the circular fasciculi.

F I G. III.


The inner surface of the anterior part of the same womb.

- A* The mouth of the womb: over which are seen the anterior branching rugæ.
- B* The centre of the surface to which the placenta adhered, where the fibres formed irregular, interwoven bands; in the interstices of which were the orifices of the veins which went into the spongy part of the placenta. At the cervix no distinct muscular fibres appear on the internal surface of the womb.



TAB. XIV. A quarto Cadavere, nono itidem graviditatis mense. Fasciculi fibrarum muscularium, in parte interna uteri, triplici figura exhibentur.







J. J. Weyland delin. J. W. Blomstedt sculp.
 TAB. XV. *Il quinto Cadavere, nove d'anni gestationis, mense. Systema arteriosum Uteri quintuplici figurae aspersum. Fig. I. Truncus Uteri in loco, quo praesertim loco Placenta adheserat. Fig. II. Arteriae partem Uteri anteriorem perreplantes. Fig. III. Eodem per partem posticam distributae. Fig. IV. Eodem Truncum pervariantes. Fig. V. Corpus Luteum in Ovario per medium divisum, & Fallopiana, Subo.*

T A B U L A X V.

A Quinto cadavere, nono etiam gestationis mense, systema arteriosum uteri quintuplici figura expressum.

Mulier hæc, post partum neustiquam dischilem, in animi deliquium incidit, causa quidem adsistentes latente; horis autem duabus a partu nondum lapsis, illam mors abstulit. Arterix cetera rubri coloris impletæ.

F I G. I.

- Facies uteri inversi, quo præsertim loco placenta adhæserat.
- A** Pars media superficiei, cui placenta adhæserat, in fundi parte posita, et paulo ad latus sinistrum flexa.
- B B** Arterix convolutæ quampurimæ, quarum extremitates, quo loco per deciduam ad placentam decurrerant, ruptæ sunt.
- C C** Orificia venarum uteri (vulgo sinus appellata) quæ per deciduam ad placentam decurrerant: hæc multo plura quam quæ in figura representantur; minora præsertim innumera. Ex venarum illarum cursu, uteri scilicet superficiei parallelè, aere non prius inflato, orificia vix possunt conspici. Earum igitur statu dilatarum maxima pars delineatur, nimirum ut umbris inferis, magis conspicuè evaderent, et cursus etiam eorum obliquus, nec non orificia ramorum inter se coeuntium, in conspectum venirent.
- D** Uteri superficiei pars cui membranz adhæserat. Vasa hujus partis, omnia quam minima. Pars etiam ipsa levior, quam ea cui Placenta se immiserat. Faciei deciduæ externæ perfectam quandam similitudinem præ se ferebat.
- E** Uteri internæ lamellæ pars, cultro anatomico sublata, et reclinata, ea mente, ut conspiceretur.
- F** Uteri fibrarum fasciculi, quorum maxima pars circulos conficiunt.
- G** Oris uteri dilatati margo, vesiculis glutinosi distinctus.
- H** Cervicis uteri, ad partem posticam, rugæ pennatz, quæ vulgo valvulæ appellantur.
- I** Vaginz inversæ pars.

F I G. II.

Arterix partem uteri ejusdem anteriorem præsertantes. Uteri facies externa jam siccata fuerat, et inde pellucida adeo facta, ut arterix in conspectum distinctè venirent, pariter ac si in superficiei externa dispersæ fuissent. Uterus hic duodecim fuit pollices longus: unde facile patebit, quantum mole contrahatur in hac figura; quantum etiam in figura tertia et quarta, quæ ad eandem normam delineantur. Pars hæc dum arefcebatur, in longitudinem quam latitudinem magis dilata fuit; quapropter uterus, in hac, et in figura proxime sequenti, longior est quam ex natura.

- A** Peritonæi resecti margo, eo loci, quo, ab utero ad vesicam urinariam reflexitur.
- B B** Tubæ.
- C** Ovarium sinistrum. — **D** Ovarium dextrum. Vid. fig. V.
- E E** Ligamenta rotunda; quorum in sinistro est arteria magna flexuosa, ab ramo spermaticæ, per anastomosin conjunctæ cum hypogastricæ, transmissa: in dextro aliquot sunt minores.
- F** Truncus arteriæ sinistræ hypogastricæ, ad cervicem uteri latus ascendens.
- G** Truncus arteriæ sinistræ spermaticæ, in ligamenti lati duplicationem transeuntis.

Arteriarum distributionem in utero explanare haud opus est. Cursus enim earum flexuosus, anastomoseque pærimæ, per se satis patent.

F I G. III.

- Eundem exhibet uterum a parte postica visum.
- B B** **C** **D** **E E**. Vid. fig. II. — **F** Arteria hypogastricæ dextra.
- G G** Arterix spermaticæ ad ligamenta lata excurrentes.
- H H** In ea parte uteri cui placenta adhæserat arterix flexuosæ confertæ. Si arterias in hac figura, cum iis in figura præcedenti conferamus, eas multo majores, magisque convolutas esse, in latere eo uteri, cui placenta adhæserat, cernere licebit. In utero gravido, cursus sanguinis maxime in placentam dirigitur.

F I G. IV.

- Fundum exhibet uteri, parte postica farsum versa.
- B B** Tubæ. — **D** Ovarium sinistrum.
- C** Ovarium dextrum. — **H H** Vid. fig. III.

F I G. V.

- Ovarium dextrum et tuba ejusdem uteri.
- A** Tuba. — **B** Tubæ ligamentum, mesenterio quodammodo respondens.
- C C** Tubæ orificium externum, fimbriis folia referentibus circumdatum.
- D** Fimbriæ a latere utroque orificii tubæ, per ligamentum, ad ovarii extremitatem externam, continuatæ.
- E E** Ovario jam aperto, arterix flexuosæ, per substantiam ejus sparæ, conspiciuntur.
- F F** Hac in parte corpus luteum, per medium divisum, in ovarii substantia cernitur. Nulla conspiciuntur vasa in centro, quod colore est albido. Circa centrum illud undiqueque, substantia ejus vasculis abundat.

P L A T E X V.

FIVE figures, from a fifth subject at the full time, to explain the arterial system of the pregnant womb.

This woman, immediately after a natural labour, grew faint, as was said, without an apparent cause; and died within the space of two hours. The arteries were injected with red wax.

F I G. I.

- The womb, inverted.
- A** The centre of the surface to which the placenta had been fixed; which was at the back-part of the fundus, and a little on the left side.
- B B** Innumerable convoluted arteries, with broken extremities, where they had passed through the decidua into the placenta.
- C C C** The orifices of these uterine veins, commonly called sinuses, which had passed through the decidua to the placenta. These orifices were much more numerous than they are represented in this figure. The smaller especially were innumerable. The passage, or direction of these veins, was almost parallel to the surface of the womb; so that their orifices were scarce perceptible, without being inflated. Most of them are represented in that state; both that they may be distinguished, by having a little flange, and that their oblique direction, and the orifices of their communications, or anastomosing branches, may be seen.
- D** Part of the surface of the womb where the membranes had adhered. This was furnished with very small vessels only; and was much smoother than that part to which the placenta had adhered. In every respect it was like the outer surface of the decidua.
- E** Part of the inner lamella of the womb, raised by dissection, and turned to one side, to show
- F** The fasciculated fibres of the womb, most of which, at this place, were nearly circular.
- G** The border, formed by the dilated mouth of the womb, and studded with gelatinous vesicles.
- H** The branching rugæ commonly called valves, at the posterior part of the neck of the womb.
- I** Part of the inverted vagina.

F I G. II.

A fore-view of the outside of the same womb, after it was dried, and become so transparent, that the arteries could be seen distinctly, as if they had been dispersed on its outer surface. The os uteri was twelve inches long; from which it will be understood, how much the foetus is reduced, in this, as well as in the third and fourth figures, which are delineated to the same proportion. In drying, the preparation was unavoidably more stretched in its length, than in its width; whence in this, and in the following figure, the womb is more oblong, than it is naturally.

- A** The edge of the cut peritonæum, where it was reflected from the womb to the bladder.
 - B B** The tubes. — **C** The left ovary.
 - D** The right ovary. See fig. V.
 - E E** The round ligaments. In the left there is one large serpentine artery, sent down from an anastomosing branch of the spermatic and of the hypogastric; in the right there are several small arteries.
 - F** The trunk of the left hypogastric artery, mounting upon the side of the neck of the womb.
 - G** The trunk of the left spermatic artery, passing into the duplication of the broad ligament.
- The distribution of the arteries upon the womb requires no explanation. Their serpentine course, and frequent anastomoses are apparent.

F I G. III.

- A back-view of the same subject. **B B** **C** **D** **E E**. See fig. II.
 - F** The right hypogastric artery.
 - G G** The spermatic arteries passing into the broad ligaments.
 - H H** The crowded serpentine arteries in that part of the womb where the placenta adhered.
- By comparing the arteries in this figure, with those in the preceding, we see that they are much larger, and more convoluted, in that side of the womb to which the placenta is fixed; the great current of blood being towards the placenta.

F I G. IV.

- A full view of the fundus of the same womb, the back part being upwards.
- B B** The tubes. — **D** The left ovary.
- C** The right ovary. — **H H** See fig. III.

F I G. V.

- The right ovary and tube of the same womb.
- A** The tube. — **B** The ligament of the tube, analogous to the mesentery.
- C C** The external orifice of the tube, surrounded by foliage-like fimbriæ.
- D** The fimbriæ continued from each side of the orifice of the tube, all along the ligament, between that and the outer end of the ovary.
- E E** The ovary cut open, with serpentine arteries interspersed through its substance.
- F F** Here, in the substance of the ovary, the corpus luteum is seen, split through the middle. No vessels appear at its centre, which is of a white complexion; but all around that centre, its substance is very vascular.

T A B U L A XVI.

A Sexto cadavere, oſtavo menſe, uterus a latere dextro viſus, atque ita injecta cera preparatus, et ſcalpello anatomico denudatus, ut vaſorum ad eum accessus, eorumque primæ ramificationes quam clariffime appareant. A parte poſtica, adhuc peritoneo levi coopertus eſt uterus. In parte autem anteriori, qua placenta interne adharebat, ſtratum externum uteri ſubſtantie cultro anatomico ſublatum fuit.

AA Cervicis uteri, nullo modo dilatati, facies exterior. Os uteri literæ inferiori *A* oppoſitum; ab qua parte deorſum, pars vaginæ, adipe teſta, relinquitur.

BB In uteri ſuperficie ſtriſtura, ubi margine pelvis antea fuit circumdatus.

CC Tuba; poſt quam ovarium obliteſcebat.

DD Ligamentum rotundum, cultro anatomico diſſectum; nimirum ut vena, ex parte inferiore tortuoſa, binæque arteriæ convolutæ, ex vaſis ſpermaticis omnes ortum diſcentes, in conſpectum venirent.

E Arteria hypogaſtrica.

F Vena hypogaſtrica.

Vaſa hæc ramos quam plurimos ad vaginam dimittunt, et per latus uteri aſcendunt, nimirum ut per anastoſin cum ſpermaticis ſuis propriis cœcant. Partem utriuſque trunci, adminiſtratione inſuſoria neceſſario deſtructam, ingenium pictoris ſupplevit.

G Arteria ſpermatica.

H Vena ſpermatica.

Vaſa hæc dum ad uterum accedunt, ramos quam plurimos, antroſum ad tubam, et retroſum ad ovarium mittunt; deinde, ad uteri latus adventantia, per anastoſin cum hypogaſtricis cœcunt. Rami præcipui utriuſque, hic, ad fundi uteri partem anteriorem, cui placenta adharebat, curſum tenent.

II Peritonei, poſticam uteri ſuperficiem tegentis, margo.

P L A T E XVI.

FROM a ſixth ſubject, at eight months. A full view, from the right ſide, of the womb, ſo injected and diſſected, as to ſhew the approach, and firſt general branchings of the uterine veſſels. The back-part of the womb is ſtill covered by the ſmooth peritonæum; but at the fore-part, to which the placenta adhered internally, the outer ſtratum of the ſubſtance of the womb was removed by diſſection.

AA The outside of the neck of the womb, which was not in the leaſt dilated. The os uteri was oppoſite to the lower letter *A*; from which downwards, there is a part of the vagina left, covered with fat.

BB A ſtriſture on the womb, where it was ſurrounded by the brim of the pelvis.

CC The tube; behind which the ovary lay concealed.

DD The round ligament diſſected, to ſhew a vein in its middle (twiſted at the inferior part) and two convoluted arteries; all from the ſpermatic veſſels.

E The hypogaſtric artery.

F The hypogaſtric vein.

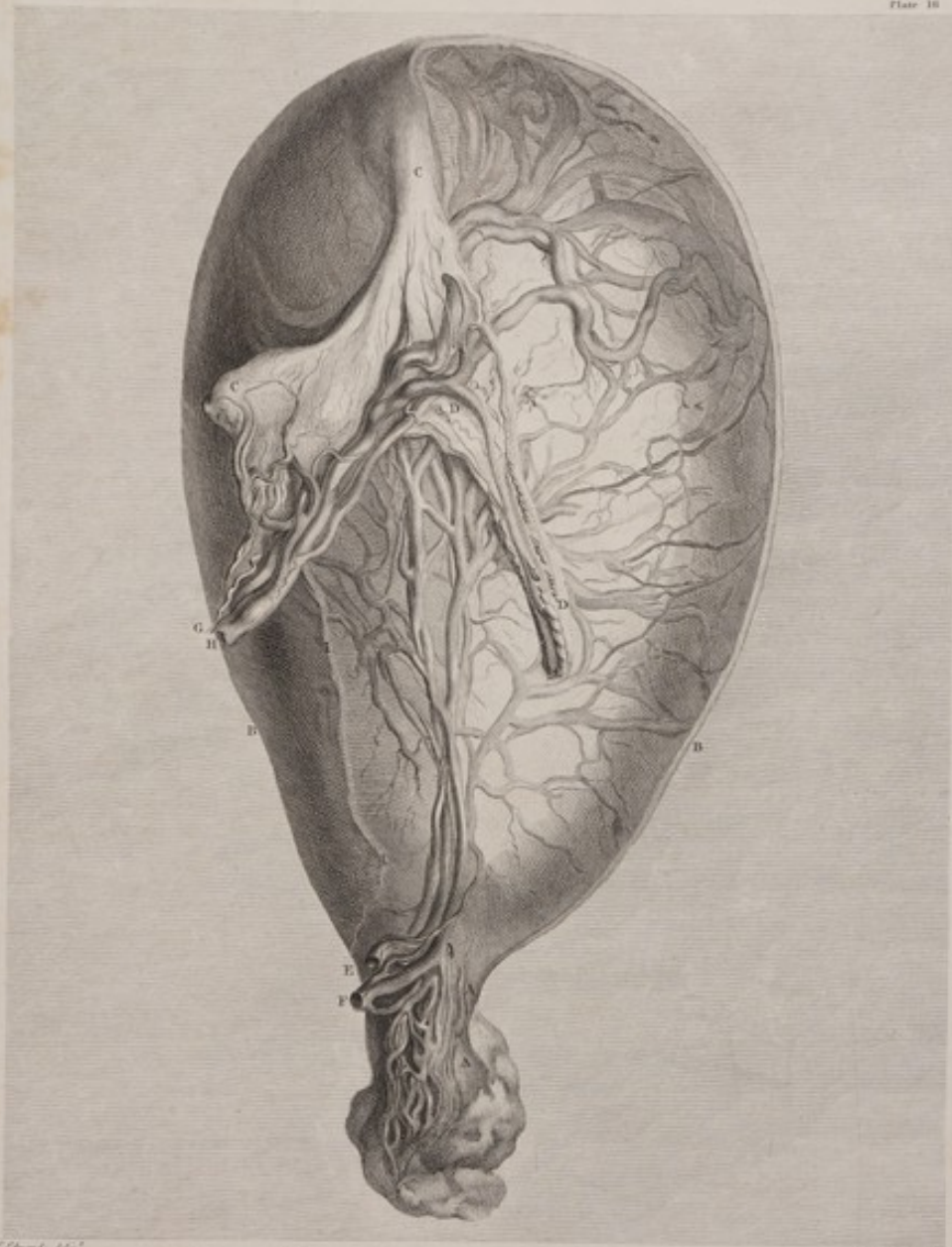
Theſe veſſels ſend down numerous branches to the vagina, and mount upon the ſide of the womb, to anastoſe with the reſpective ſpermatics. By fixing pipes, for the injection, and tying up theſe veſſels, a part of each trunk was loſt, and then ſupplied by fancy.

G The ſpermatic artery.

H The ſpermatic vein.

Theſe veſſels, in their approach to the womb, ſend up numerous branches, forwards to the tube, and backwards to the ovary; then, paſſing to the ſide of the fundus uteri, they anastoſe with the hypogaſtric. The principal branches of both, in this caſe, go to the fore-part of the fundus uteri, where the placenta was attached.


II The edge of the peritonæum which covers the poſterior ſurface of the womb.



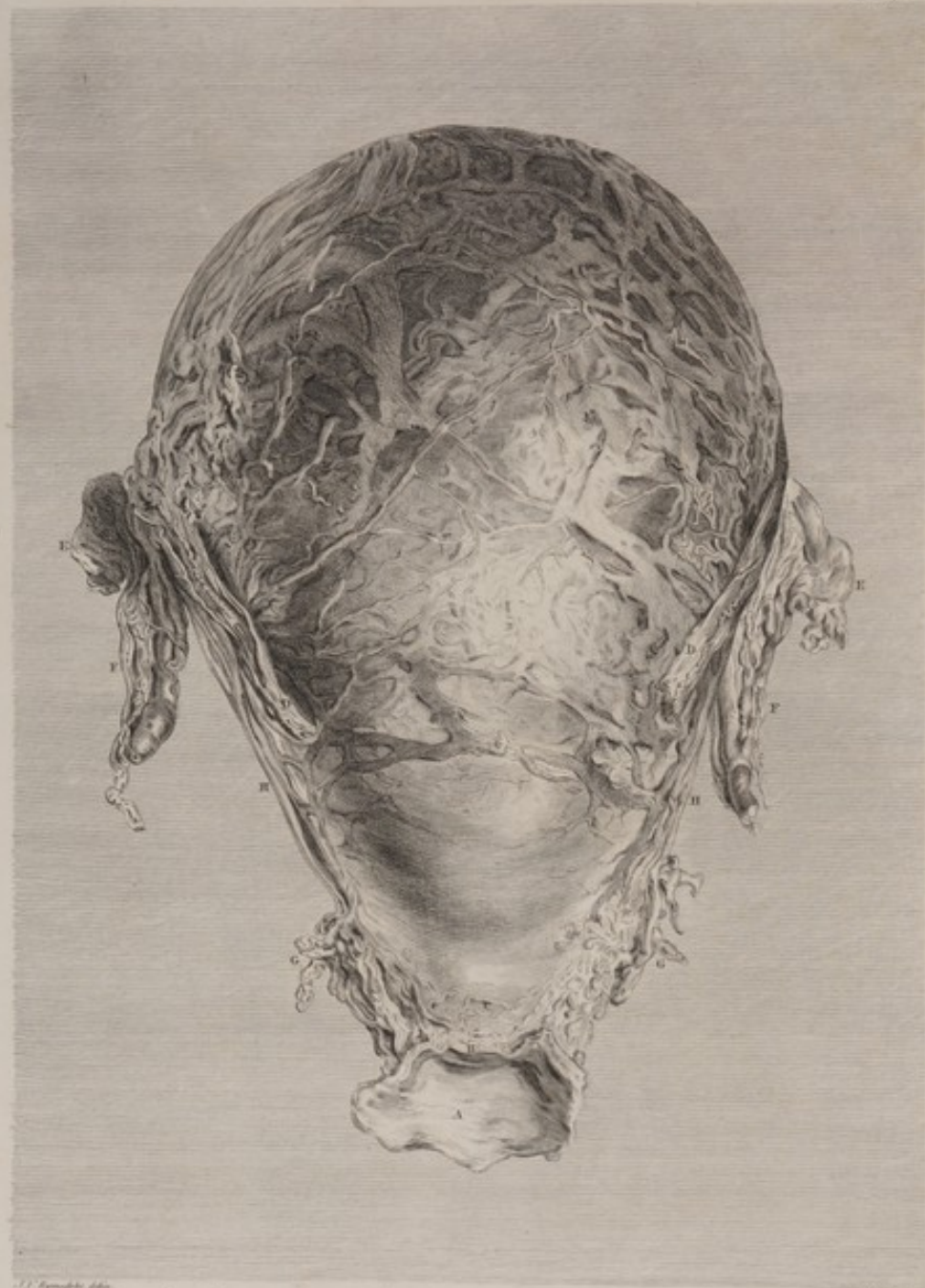
C. Goussier delin.

M. Goussier sculp.

T A B. XVI. A sexto Cadavere, octavo mense. Alterus a latere dextro visus, atque da
 injecta cera preparatus, et scalpello anatomico denudatus, ut vasorum ad cum accessus,
 eorumque primae ramificationes quam clarissime apparerent.







*TAB. XVII. Idem Uterus a fronte. Primo sive externo strato sublato, vasorum am-
 pliorum distributio, eorumque versus Placentam (quae hic parti anteriori et fundo Uteri adhaerebat)
 progressus melius conspiciuntur.*

T A B U L A XVII.

IDEM uterus a fronte. Primo, five extimo substantiæ strato sublato, vasorum distributio majorum, eorumque versus placentam (quæ hic parti anteriori et fundo uteri adhaerebat) progressus, melius conspiciuntur.

- A* Vaginæ extremitas summa, incisione aperta.
B Uteri orificium contractum.
C Uteri cervix nondum dilatata.
DD Ligamenta rotunda.
EE Tubæ: ovariis pone absconditis.
FF Fasciculus vasorum spermaticorum, ad latus uteri ascendentium.
GG Fasciculus vasorum hypogastricorum, ad latus cervicis uterij accedentium.
HH Trunci vasorum spermaticorum et hypogastricorum, ex anastomosi communes, ad uteri latera decurrentium. In fundi parte anteriori, arteriæ et venæ, cursum versus placentam tenentes, conspiciuntur: vasa minora, rotundiora, magisque convoluta, arteriæ sunt; majora, et planiora, venæ.

P L A T E XVII.

FROM the same subject. A direct fore-view of the womb, after the outer stratum of its substance had been dissected off, to shew the distribution of the larger uterine vessels in their way to the placenta; which, in this case, adhered to the fore-part and fundus of the womb.

- A* The upper extremity of the vagina laid open.
B The orifice of the womb, contracted.
C The neck of the womb, not stretched.
DD The round ligaments.
EE The tubes: the ovaries being concealed behind them.
FF The group of spermatic vessels, mounting up towards the sides of the fundus of the womb.
GG The group of hypogastric vessels, coming to the side of the neck of the womb.
HH The common, or anastomosing trunks of the spermatic and hypogastric vessels, running along the sides of the womb. On all the fore-part of the fundus are seen the arteries and veins, passing towards the placenta: the smaller, rounder, and convoluted vessels are the arteries; the larger and flattened vessels are the veins.

TABULA XVIII.

EJUSDEM uteri fundus, eodem modo preparatus, ut amplissimorum vasorum, venarum præsertim, placentaë ex adverso objectarum, crebraë inter se commissuræ contemplandæ proflarent.

- AA* Sectio per fundum uteri transverse ducta; inter
AAB Uteri parietem posteriorem, in statu suo naturali, (scilicet, peritonæo levi coopertum) et
AAC Uteri parietem anteriorem, ubi stratum substantiæ ejus extimum sublatum est, ut vasa, ex adverso placentaë sita, conspici possent. Vasa majora et planiora, ut in figura præcedenti, venæ sunt.
DD Tubæ. Post, sive infra eas, ovaria illiusmodi situm habebant, qui illa conspici non sineret.
EE Ligamenta rotunda, deorsum, paulo ante tubas, cursum tenentia.

In hoc cadavere, uteri paries anteriori tumidior fuit; ita ut si uterus a vertice deorsum per tubas transmissus fuisset, pars anterior, altera major existisset. Re vera tamen, inter eas discrimen haud tantum fuit, quantum in hac tabula videtur; quippe uterus, paulo oblique oculo se offerens, plus superficiei anterioris, quam posterioris, exhibebat.

PLATE XVIII.

FROM the same subject. The very fundus, or upper part of the womb, which was previously dissected to shew in the preceding figure as well as in this, the plexus of large vessels, especially the veins, opposite to the placenta.

- AA* The transverse section across the fundus of the womb, between
AAB The posterior side of the womb left in its natural state; that is, covered with the smooth peritonæum, and
AAC The anterior side of the womb at its fundus, the outer stratum of its substance being removed, to shew the vessels opposite to the placenta. The larger and more flattened vessels, as in the preceding figure, are veins.
DD The tubes. The ovaries lay behind; that is, below them in this attitude, and farther from the eye of the spectator, so as to be hidden.
EE The round ligaments, going downwards, a little before the tubes. In this case, the anterior side of the womb made a greater swelling, or was more stretched than the posterior; so that if the womb had been vertically cut down through the two tubes, the anterior portion would have been larger than the other. Yet the difference was not so considerable, as may be imagined from a view of this figure, because the object was placed a little obliquely to the eye, which thence took in more of the anterior, than of the posterior surface.



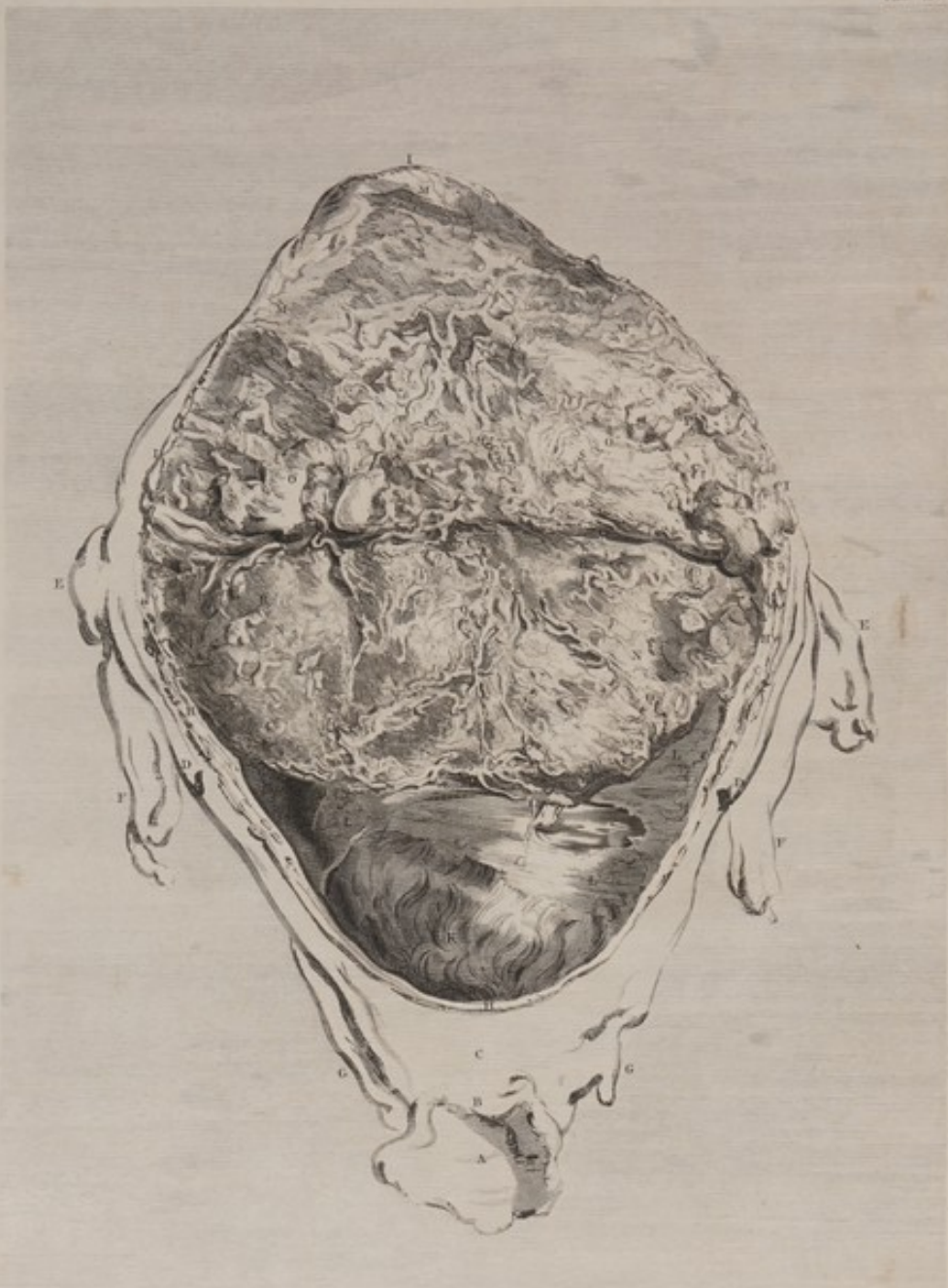J. V. Pignatelli delin.

Blond sculpit.

TAB. XVIII. Eisdem Uteri Fundus, eodem modo preparatus, ut amplissimorum vasorum,
 Venarum praesertim Placentae ex adverso obiectarum, frequentes inter se commissurae
 contemplanda praearent.







J. Van Swinderen delin. *J. Fongom. sculp.*
TAB. XIX. *Uterum Uterus, ejus facie anteriori incisa et in Fundum revoluta illius secundina per*
quas caput Fetus, obscurus licet, videtur. Hic igitur visui sese offert cum Superficie externa Placentae
sed dimidiata, tum parvi Superfici interna uteri, ei respondens, una cum vasis quae inter Uterum et
Placentam intercedunt. Partes Uteri externae solis linearum ductibus expressae sunt.

T A B U L A XIX.

IDEM uterus; ejus facie anteriori incisa et in fundum revoluta, illeis secundis, per quas caput foetus, obscurius licet, cernitur. Hic igitur visui sese offert cum superficies externa placentæ, dimidiatæ quidem, tum pars superficiei internæ uteri, ei respondens, una cum vasibus quæ inter uterum et placentam intercedunt. Partes uteri exteriores lineis solummodo expressæ sunt.

- A* Vaginae extremitas superior incisione aperta.
B Uteri orificium contractum.
C Uteri cervix nondum dilatata.
DD Ligamenta rotunda.
EE Tubæ; ovaria, pone iis sita, oculum fugiunt.
FF Vasa spermatica.
GG Vasa hypogastrica.
HHH Uteri substantia incisa.
III Uteri paries anterior a secundis separatus, et supra fundum uteri reflexus.
K Chorion, amnion tegens. Per membranas illas pellucidas foetus caput conspicitur.
LLL Decidua, qua uteri parieti intimo adhaerebat. Vasa quædam parva, in eam ex utero transmissa, conspiciuntur.
MMM Uteri superficies interna, parti huic deciduæ respondens.
NN Superficies externa partis illius placentæ quæ ab utero avulsa fuit.
OO Superficies uteri interior huic respondens.
PP In uteri superficie interna arteriæ convolutæ, quæ ad placentam antea transierant, jam vero disruptæ, dum uterus a placentâ separabatur.
QQ Arteriæ in placentæ superficie illis respondentes.
RR Venæ ex placentæ substantia excurrentes; in ea scilicet parte superficiei ejus disruptæ, quæ ad uterum transibant.
SS Venæ in facie uteri interna, venis proxime dictis respondentes.
T In angulo, superficiem externam placentæ inter et superficiem internam inverfam uteri, arteria convoluta, ab utero in placentam continuata, conspicitur.
V Vena, arteriam proxime dictam juxta posita, et illi respondens, ex placentâ in uterum continuata.

P L A T E XIX.

FROM the same subject. A fore-view of the womb. Its substance is cut through and turned up over the fundus, to show a part of the membranes, through which the child's head is obscurely seen, and about half of the placenta; together with the corresponding internal surface of the womb, and the vessels passing between the womb and the placenta. The external parts of the womb are represented in out-lines only.

- A* The upper extremity of the vagina laid open.
B The orifice of the womb, contracted.
C The neck of the womb, not stretched.
DD The round ligaments.
EE The tubes; the ovaries concealed behind them.
FF The spermatic vessels.
GG The hypogastric vessels.
HHH The substance of the womb, cut through.
III The fore-part of the womb raised up from the secundines, and turned over the fundus.
K The chorion covering the amnion; through which transparent membranes the child's head is seen.
LLL The decidua where it adhered to the inner surface of the womb, in which are seen some small vessels sent into it from the womb.
MMM The corresponding inner surface of the womb.
NN The outer surface of that part of the placenta from which the womb was separated.
OO The corresponding internal surface of the womb.
PP Convoluted arteries upon the inner surface of the womb, which had passed to the placenta, and were broken through in separating the womb.
QQ The corresponding arteries on the surface of the placenta.
RR Veins emerging from the substance of the placenta, and broken through at its surface, where they were passing into the womb.
SS The corresponding veins on the inside of the womb.
T In the angle between the outer surface of the placenta, and the inverted inner surface of the womb, is here seen a convoluted artery, continued from the womb into the placenta.
V A corresponding vein, near that artery, continued from the placenta to the womb.

TABULA XX.

IDEM denuo uterus, sed omnino apertus, ut foetum in situ naturali ostendat. Circa fundum quaquaversus substantia tam placentae quam uteri incisa conspicitur.

Uteri partes exteriores, lineis leviter adumbratae, eadem sunt, quae in praecedenti figura, et in tabula decima septima ad plenum sunt expressae.

AAA Utero per medium diviso, dimidii inferioris substantiae sectio, ad eam partem scilicet qua membranae adhaerebant.

BBB Uteri dimidii superioris substantiae sectio, ad partem qua placenta adhaerebat.

CCC Placentae sectio; illius cava spongiosa cera flava, ex uteri arteriis, et cera rubra, ex venis impleta sunt.

DDD Gyri nonnulli funis umbilicalis, brachia inter et crura foetus positi.

EE Sectioni uteri superimposita funis umbilicalis extremitas, ad partem illam placentae, quae foetum preaecebat, excisa.

Foetus iconem explanare supervacaneum foret.

PLATE XX.

FROM the same subject. A fore-view of the womb, fully opened, to show the child in its natural situation. All around, at the fundus, the substance of the placenta, as well as that of the womb itself, is seen cut through.

The external parts of the womb, slightly sketched in out-lines, are the same as in the preceding plate, and were fully expressed in plate XVII.

AAA The section of the substance of the lower half of the womb, where the membranous part of the secundines adhered.

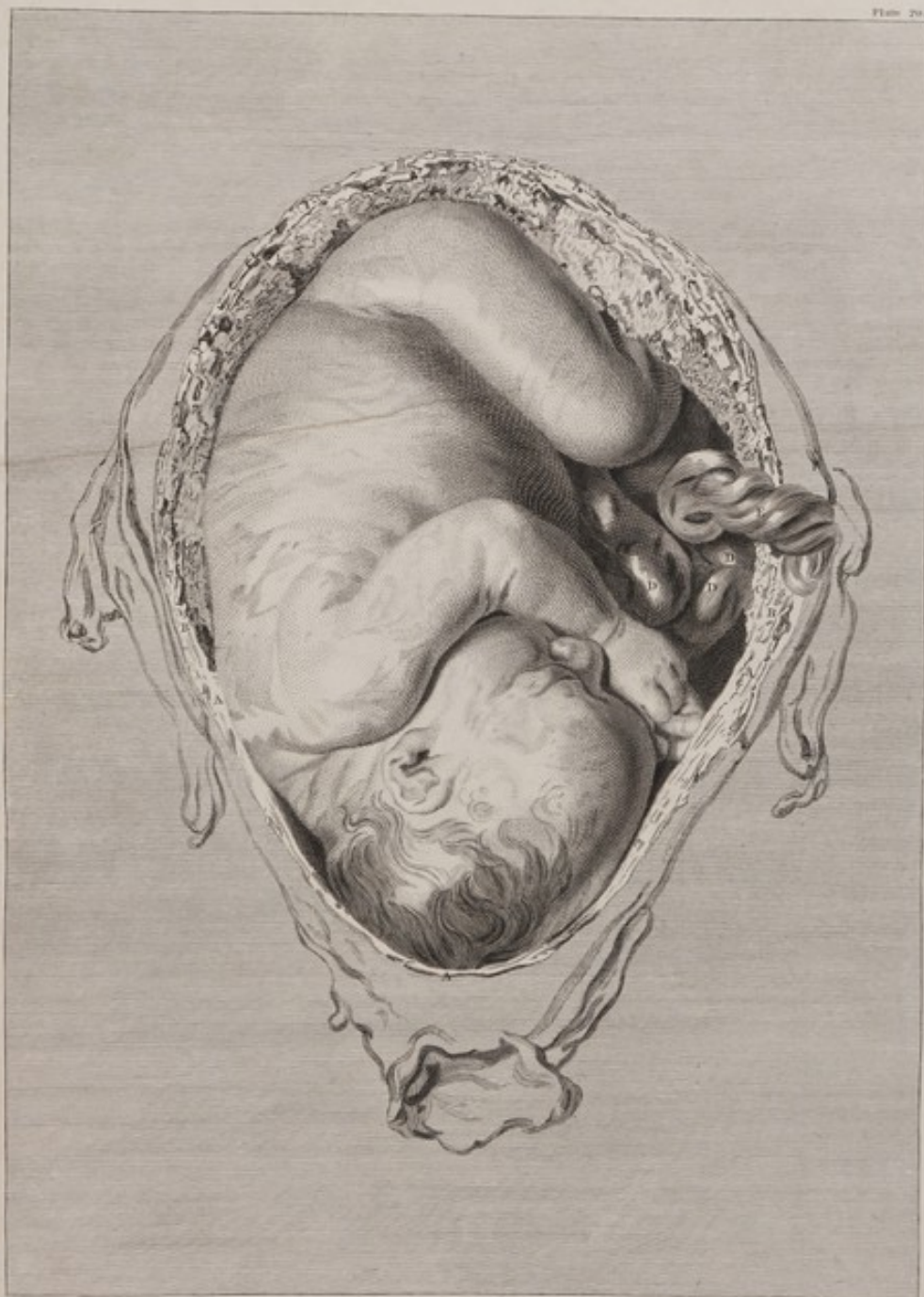BBB The section of the substance of the upper part of the womb, where the placenta adhered.

CCC The section of the placenta: the spongy cavities of which contained both some of the yellow wax, from the arteries of the womb, and of the red wax, from the veins.

DDD Some turns of the navel-string, lying between the arms and the legs of the child.

EE The end of the navel-string laid over the section of the womb. It was cut off from its attachment at that part of the placenta which lay before the child.

The parts of the child require no explanation.



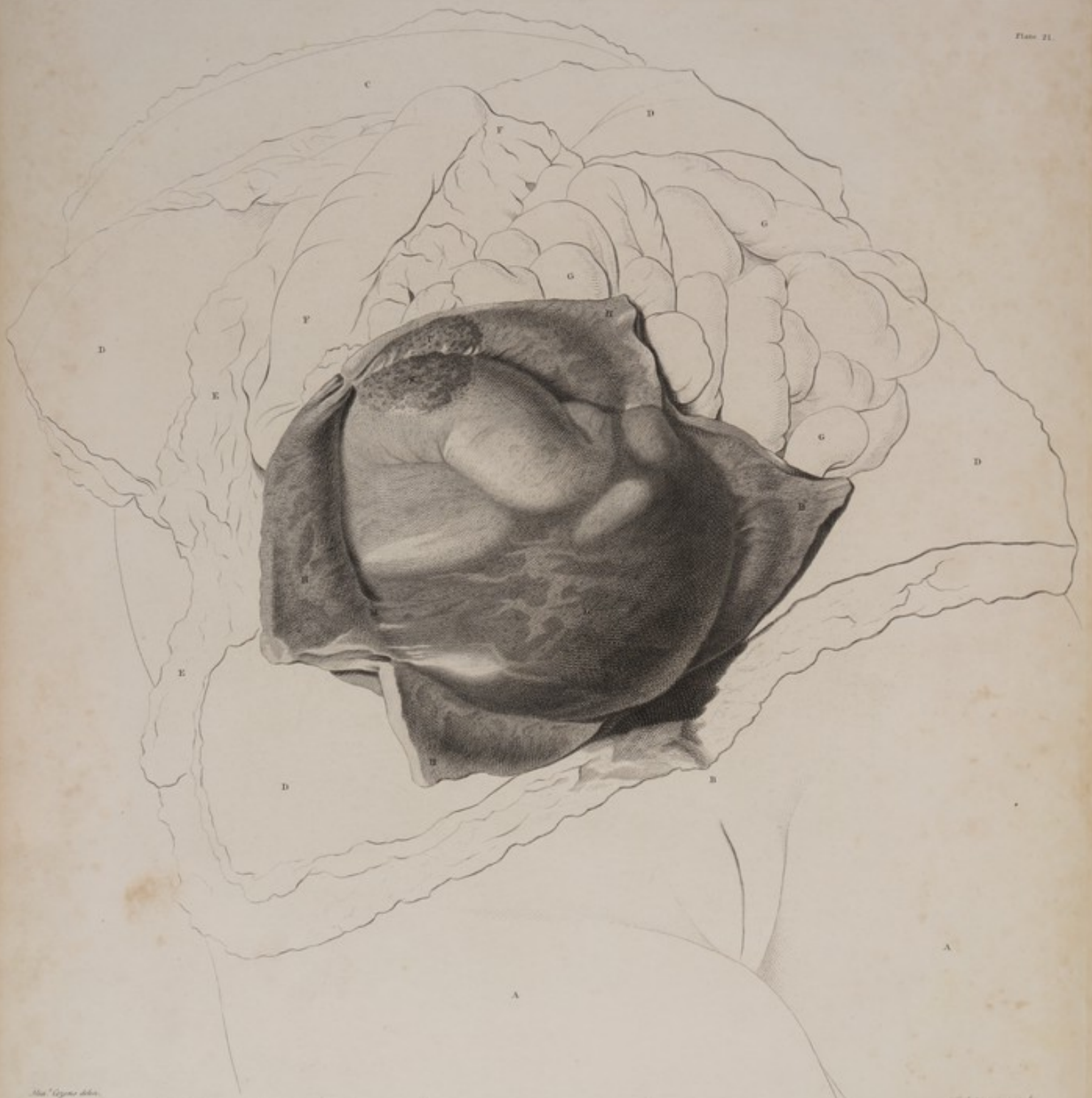J. J. Wandelaar del.

J. B. de Meijer sculp.

TAB. XX. Idem denuo Uterus, sed omnino apertus, ut Factum in situ naturali ostendat. Circa Fundum quaquaversus substantia tam Placentae quam Uteri, incisa conspicitur.







Tab. XXXI. del. G. G. G.

Fig. 1. del. G. G. G.

TAB. XXI. A. Septimo cadavere, Septimo graviditatis mense. Aperto cruciformi incisione Utero, & reclinatis rite cornibus, per membranas Fœtum continentes Fœtus ipse aquis immans conspicitur. Reliquæ partes nudis lineis distincte sunt.

T A B U L A XXI.

A Septimo cadavere, septimo graviditatis mense. Aperto cruciformi incisione utero, et reclinatis rite cornubus, per membranas foetum continentes, foetus ipse aquis innatans conspicitur. Reliquae partes nudis lineis distinctae sunt.

- AA* Femora.
B Mons veneris, ad partem qua abdominis incisio longitudinalis definit.
C Scrobiculus cordis, qua abdominis incisio incipit.
DDDD Partium continentium abdominis anguli quatuor reflexi, ut viscera plene paterent.
EE Omentum, in latere dextro abdominis.
FF Colon, ad latus sinistrum abdominis transiens.
GGG Intestina tenuia, uteri latus sinistrum versus, quorum gyri nonnulli, tempore quo cadaver primo apertum fuit, ante uterum jacebant.
HHHH Uteri, cruciformi incisione aperti, anguli quatuor, a secundis subtus positus liberati et reflexi, ut contenta ejus in conspectum prodirent.
I Uteri superficiei intimae pars exigua, cui placenta adhaeserat, minus quidem complanata, magis autem sanguine imbuta quam pars illa quae membranis vestita fuerat.
K Lobi parvi placentae superficiei parti proxime dictae respondens.
L Membranae liquorem amnii continentes, quae ad partem uteri inferiorem, propter cadaveris declivem situm, foetus partes superiores e conspectu fere tollunt; ad fundum autem uteri subsidentes, foetus partes satis distincte in conspectu locant.
M In hoc angulo, uterum inter et secundas, pictor id exprimere voluit, quod in cadavere satis manifestum fuit, scilicet, uteri et secundarum substantiam inter se mutuo continuatam: dum autem hanc partem separabamus, tenera illa internectens membrana, decidua, in duas lamellas abiit; quarum haec utero, illa chorion adhaerebat.

P L A T E XXI.

FROM a seventh subjell, at seven months. The womb opened by a crucial incision, and the four corners carefully separated, and turned aside from the secundines, so as to shew the child, and waters, through the enclosing membranes.
The adjacent parts of the subjell are represented in out-lines.

- AA* The thighs.
B The mons veneris, where the longitudinal incision of the abdomen terminates.
C The pit of the stomach, where the longitudinal incision of the abdomen begins.
DDDD The four angles of the containing parts of the abdomen, inverted, to expose the bowels.
EE The omentum, in the right side of the abdomen.
FF The colon passing towards the left side of the abdomen.
GGG The small intestines on the left side of the womb; some turns of which, when the body was first opened, lay before the womb.
HHHH The four angles of the womb, (which was opened by a crucial incision) separated from the subjacent secundines, and inverted, to expose the contents.
I A small part of the inner surface of the womb to which the placenta had adhered, more unequal and more bloody than what had been lined by the membranes.
K The corresponding surface of a small lobe, or extremity of the placenta.
L The membranes containing the liquor amnii, which, at the lower part of the womb, from the declivity of the object, cover the upper parts of the child from our view: and towards the fundus uteri collapse so as to shew the parts of the foetus not indistinctly.
M In this angle between the womb and secundines, the artist endeavoured to express what was very apparent in the object, viz. the continuity of the substance of the womb and of the secundines; in parting which, the tender connecting medium, the decidua, separated into two layers, one of which clung to the womb, and the other to the chorion.

TABULA XXII.

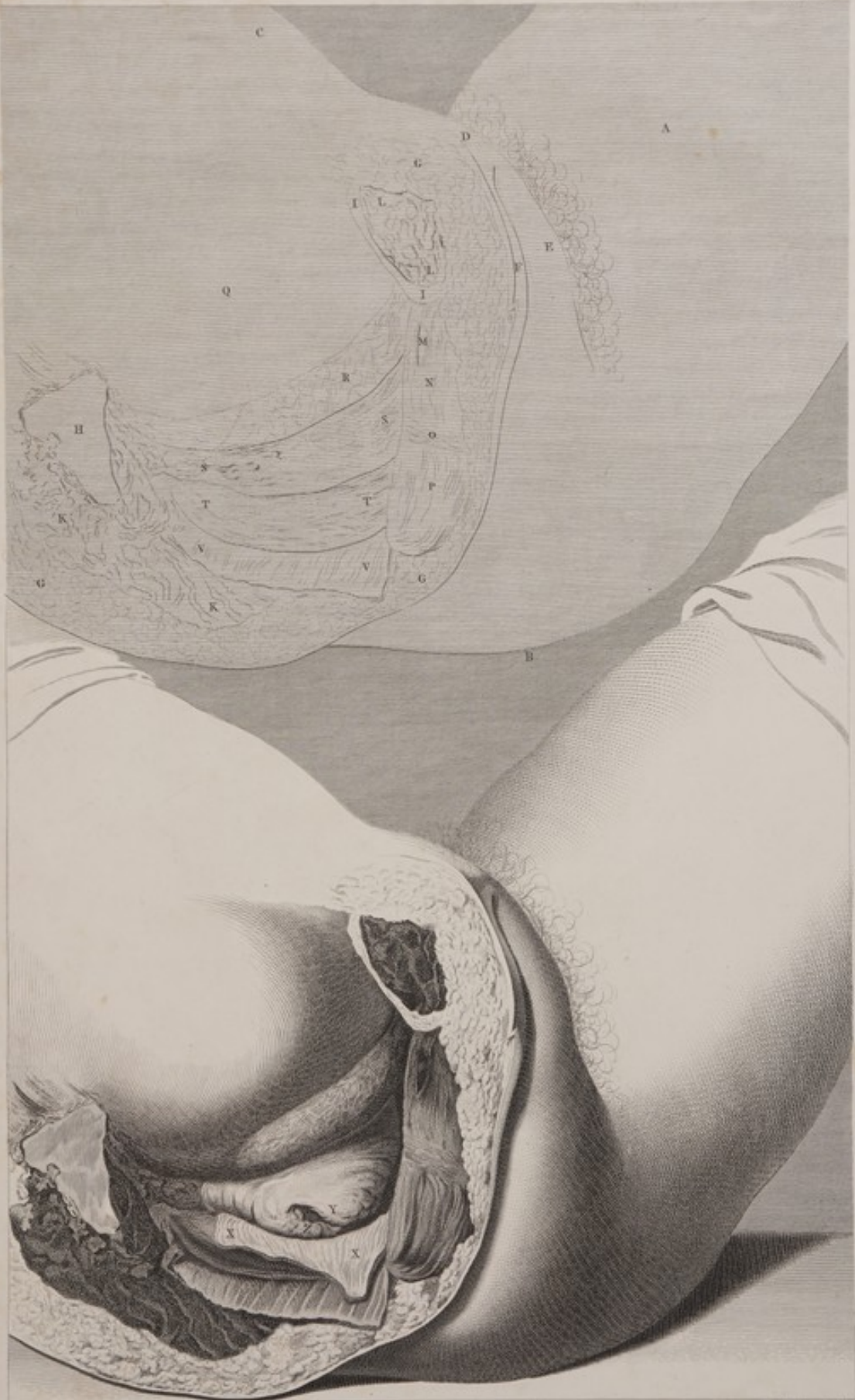
IDEM cadaver. Contenta pelvis, quo situ disposita sunt, ex duplici patet figura: in altera, lineis nudis expressa, vaginam integram vides; in altera, magis elaborata, dextro vaginæ latere dissecto et devolato, os uteri in conspectum prodit.

- A* Femoris sinistri facies interna.
B Nates sinistra.
C Abdominis pars anterior.
D Mons veneris.
E Labium sinistrum.
F Labii dextri pars.
GGG Cutis et membranae adiposæ sectio, eo consilio facta, ut in latere dextro, partes continentes pelvis removerentur.
H Ollis sacri superficies cartilaginea, qua ossi ilium dextro commissa fuerat.
II Os Pubis dextrum, prope symphylin, transverse scissum.
KK In pelvis parte postica, musculi externi secti.
LL Musculi in facie ossis pubis externa etiam secti.
M Clitoridis crus dextrum, ubi ischio, quod hic sublatum est, connectebatur.
N Vaginæ sphincter.
O Musculus transversalis perinæi.
P Ani sphincter.
Q Tumor ex utero in cavi pelvis parte superiori.
R Vesica urinaria, fere vacua, parte anteriori uteri et latere superiori vaginæ compressa.
SS Lateralis sequentes ad lineas adumbratas spectant.
SS Vaginæ facies externa situ suo naturali vesicam urinariam inter et
TT Rectum.
VV Musculi, levator ani scilicet et coccygeus lateris dextri, cultro anatomico a pelvis contentis separati, et in superficiem recisam devoluti.
XX Lateralis sequentes ad figuram magis elaboratam spectant.
XX Totius vaginæ substantia ex uteri cervice et vesica urinaria excisa et in rectum devoluta, ut os uteri in conspectum prodiret.
Y Oris uteri labium anterius.
Z Eiusdem labium posterius.
Z Vagina ad hunc modum aperta, os uteri, nimirum adnunculo suo jam a latere sublato, dextrorsum propendebat.

PLATE XXII.

FROM the same subject, shewing the situation of the contents of the pelvis. In the figure which is expressed by out-lines, the vagina is whole; but in the more finished figure, its right side is cut out, and turned down to shew the mouth of the womb.

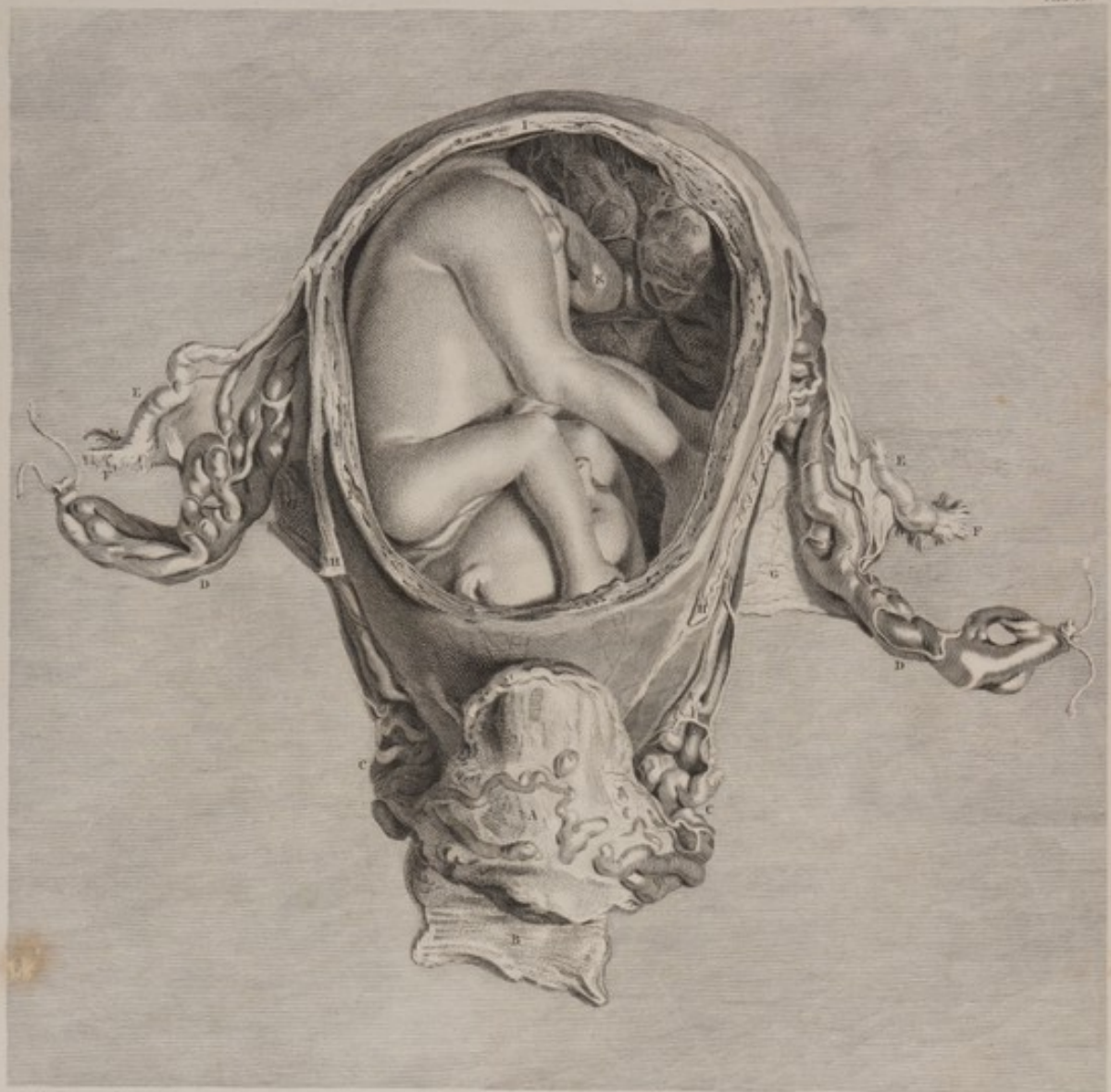- A* The inside of the left thigh.
B The left nates.
C The anterior part of the abdomen.
D The mons veneris.
E The left labium.
F Part of the right labium.
GGG The section of the skin and adipose substance, which was made to remove the containing parts, on the right side of the pelvis.
H The cartilaginous surface of the sacrum, by which it was joined to the right os ilium.
II The right os pubis, cut through near the symphysis.
KK The external muscles, on the back part of the pelvis, cut through.
LL The muscles which lie on the outside of the os pubis, cut through.
M The right crus clitoridis, where it was fixed to the ischium, which is removed.
N The sphincter vaginæ.
O The transverse muscle of the perineum.
P The sphincter ani.
Q The swelling formed by the womb, in the upper part of the cavity of the pelvis.
R The bladder, almost empty, compressed between the anterior part of the womb and the upper side of the vagina.
SS The following letters refer only to the figure of out-lines, viz.
SS The outside of the vagina in its natural situation between the bladder and rectum.
TT The rectum.
VV The levator ani and coccygens muscles of the right side, by dissection turned down from the contents of the pelvis over the cut surface.
XX The following letters relate only to the more finished figure, viz.
XX The whole substance of the vagina, in the right side, cut from the neck of the womb and bladder, and turned down over the rectum, to shew the orifice of the womb.
Y The anterior lip of the orifice.
Z The posterior lip of the same.
Z When the vagina was thus opened, the lateral support being removed, the os uteri pushed out towards the right side.



W. Cheselden delin.
 TAB. XXII. *Idem* Cadaver. Contenta Pelvis, quo siti disposita sunt, ex duplici patet figura:
In illa elaboratione, dextro Vagina latere dissecto & devoluto, Os Uteri in conspectum prodit.
J. Wandelaar sculp.







J. V. Wandelaar del.

M. Wandelaar sculp.

TAB. XXIII. Octavum Cadaver, Sexto Gestationis mense. Uteri ac membranarum parte anteriori sublata, exhibetur Fœtus cum parte Placentæ et Funiculi umbilicalis..
 Uteri Vasa aërâ impleta erant.

TABULA XXIII.

OCTAVUM cadaver, sexto gestationis mense. Uteri ac membranarum parte anteriori sublata, exhibetur foetus cum parte placentæ et funiculi umbilicalis. Uteri vasa cera impleta fuerant.

- A* Vesica urinaria, respectu habito ad uterum, in situ suo naturali; modice distenditur, et ramis quibusdam majoribus venarum hypogastricarum circumtegitur.
- B* Vaginæ partis posticæ facies interna.
- CC* Vasa hypogastrica ad cervicem uteri decurrentia et ramos ad vesicam urinariam et vaginam transmittentia.
- DD* Vasa spermatica, duplicationem ligamenti lati intrantia.
- EE* Tubæ.
- FF* Fimbriæ.
- GG* Ligamenti lati lamella posterior: anterior cultro anatomico sublata fuerat, ut vasa spermatica, ad fundum uteri ascendentia, oculo plenius occurrerent.
- HH* Ligamenta rotunda. In sinistro, arteria præcipua, convoluta, a spermatica descendens conspicitur.
- III* Uteri substantiæ totius et membranarum sectio, qua uteri et secundarum paries anterior, ad eorum contenta exhibenda, sublatus fuerat.
- K* Funis umbilicalis, prope locum ubi in placenta definit. Placenta uteri parti posticæ, versus fundum, adharebat. Funis umbilicalis, primo deorsum, super humerum sinistrum, deinde sursum, pone corpus infantis, ad finem suum in placenta transibat.

PLATE XXIII.

FROM the eighth subjell, at six months. A fore-view of the womb, which was injected; the anterior part, both of the womb and of the membranes, having been cut away, and the liquor amnii taken out to shew the foetus, with a part of the placenta and of the navel-string.

- A* The bladder, in its situation with respect to the womb. It is moderately distended, and is covered with some large branches of the hypogastric veins.
- B* The inside of the posterior part of the vagina.
- CC* The hypogastric vessels, going into the neck of the womb, and sending branches to the bladder and vagina.
- DD* The spermatic vessels, going into the duplicature of the broad ligament.
- EE* The tubes.
- FF* The fimbriæ.
- GG* The posterior lamella of the broad ligament: the anterior had been removed by dissection, to give a clearer view of the spermatic vessels, in their ascent to the fundus of the womb.
- HH* The round ligaments. In the left is seen a large convoluted artery, coming down from the spermatic.
- III* The section of the whole substance of the womb, and of the membranes, by which the forepart of the womb and of the secundines was removed, to expose their contents.
- K* The navel-string, near its termination in the placenta. The placenta adhered to the posterior part of the womb, towards the fundus. The navel-string passed first downwards, over the left shoulder, and then upwards, behind the body of the child, to its termination at the placenta.

TABULA XXIV.

A B eodem cadavere.

FIG. I.

Placenta uteri fundo et parti posticæ adhærens; substantia ejus spongiosa, injecta per vasa uterina cera, turgescit.

Pleraque partes lineis adumbratæ, in tabula præcedenti ad plenum sunt expositæ.

- A Vesica urinaria.
- B Vagina.
- CC Vasa hypogastrica.
- DD Vasa spermatica.
- EE Tube.
- FF Fimbriæ.
- GG Ligamenta lata.
- HH Ligamenta rotunda.
- III Uteri et membranarum sectio.
- K Funis umbilicalis.
- LL Placenta utero adhærens.

Nulla pars cere, in vasa uterina injectæ, ad ramos vasorum ilorum quæ funem umbilicalem constituunt, transierat; vasa illa sanguinem solummodo continentia, obscure designata erant, ubi ex fune umbilicali in faciem internam placente se immittebant. Cellule autem in placente parte spongiosa, omnes eodem modo cera, vel cœrulea in venas uteri injecta, vel rubra in arterias infusa, turgescerant. Hanc rem indicat figura secunda.

M Membranæ ex margine placente exsurgentes, et uterum undique investientes.

Placente margo hic paulo elatior est, et magis conspicuus, substantia ejus spongiosa cera distensa.

FIG. II.

Portio aliqua placente transverse secta, ut substantia ejus spongiosa apparet, ejusdemque cera adimpletæ crassitudo.

- A Placente superficies interna.
- B Placente superficies externa.
- C Membranarum portiuncula, ex margine placente, cera injecta turgescens, et in figuram rotundiorum adacta, exiens.

Ceræ cœruleæ, primum per venas uteri injectæ, maxima pars ad superficiem ejus internam propulsa fuerat; ceræque rubra, postea per arterias injecta, in partibus exterioribus rellabat; per totam autem ejus substantiam, colores hi duo plus minusve commixti sunt.

FIG. III.

Arterias exhibet illius partis membranæ deciduæ, quæ parietem uteri anteriorem investiverat.

FIG. IV.

Venæ ejusdem partis deciduæ.

Figure hæ duæ separatim, aliqua ne fieret confusio, delineatæ sunt.

PLATE XXIV.

FROM the same subject.

FIG. I.

The placenta, adhering to the fundus and back-part of the womb: its spongy substance is filled by the injection of the uterine vessels.

Most of the parts in out-lines were more fully represented and explained in the preceding plate.

- A The urinary bladder.
- B The vagina.
- CC The hypogastric vessels.
- DD The spermatic vessels.
- EE The tubes.
- FF The fimbriæ.
- GG The broad ligaments.
- HH The round ligaments.
- III The section of the womb and membranes.
- K The navel-string.
- LL The placenta, adhering to the womb.

None of the wax, injected into the vessels of the womb, had passed into the branches of those vessels which compose the navel-string; and as they contained only some blood, they were not distinctly marked, where they spread, from the navel-string, over the internal surface of the placenta. But the cells, or interstices in the spongy part of the placenta, were universally loaded with wax; either the blue, which was injected into the veins of the womb, or the red, which was thrown into the arteries. This is illustrated by Fig. II.

M The membranes, coming out from the edge of the placenta, and investing the womb all around.

The edge of the placenta, in this case, was much more elevated and distinct, its spongy substance being distended.

FIG. II.

A section of half of the placenta, principally to shew what thickness it had acquired, by its spongy cavities being filled with wax.

- A Its internal surface.
- B Its external surface.
- C A small portion of the membranes, going off from the edge of the placenta, which was thickened, and rounded, by the injected wax.

Most of the blue wax, which was first injected by the veins of the womb, was driven on towards the internal surface; and the red wax, which was afterwards injected by the arteries, was lodged principally in the outer parts; but the two colours were, more or less, blended through the whole.

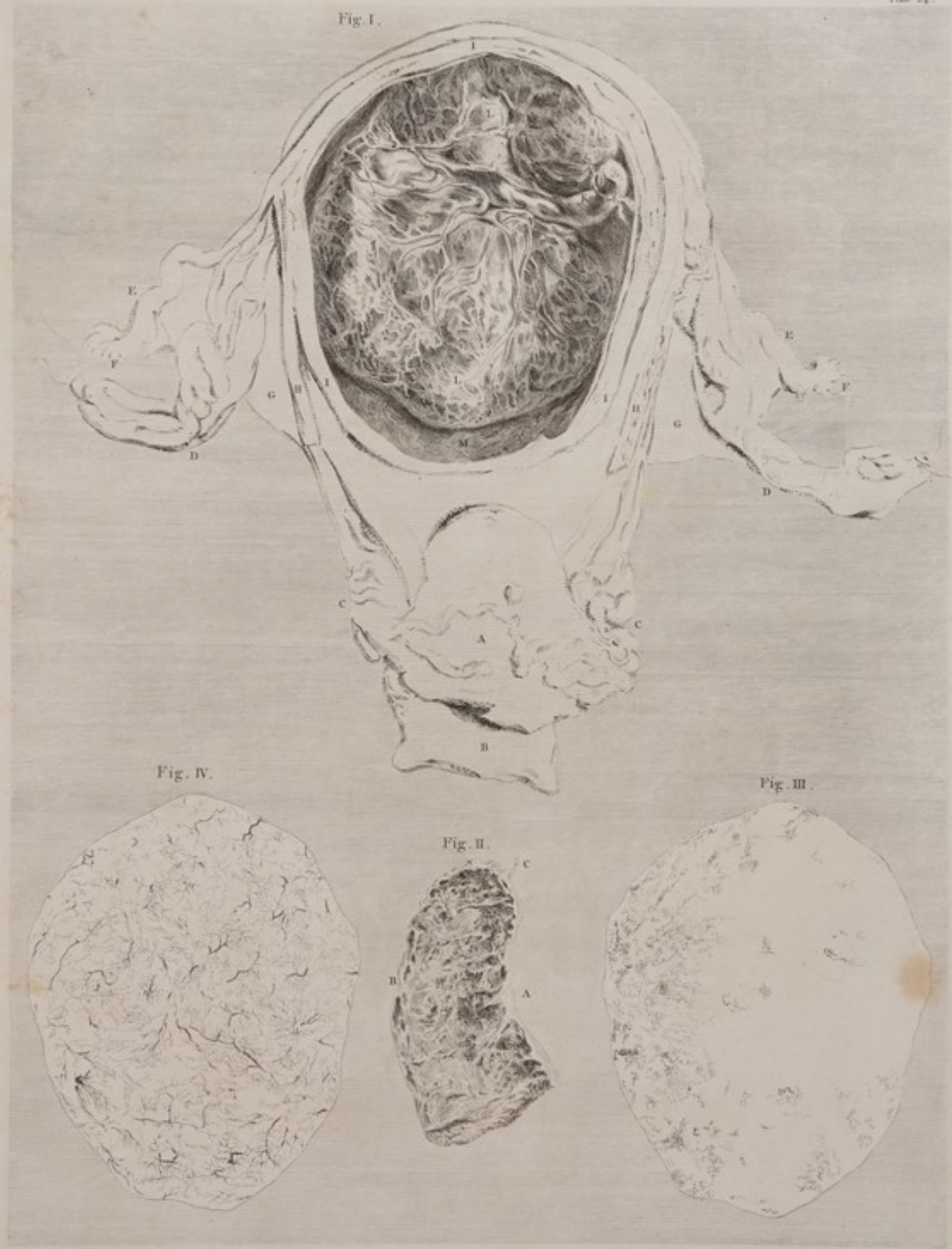FIG. III.

The decidua, from the fore-part of the same womb, with the convoluted uterine arteries, which are dispersed through it.


FIG. IV.

The same part of the decidua, with the uterine veins, which ramify through it.

These two figures were drawn separately, to avoid confusion.



TAB. XXIV. . Ab eodem Cadavere. Fig. I. Placenta Trāndo et postice Uteri parti adhaerescens, Substantia quae spongiosa inspecta per vasa uterina vera turpescit. Fig. II. Pectus aliqua Placenta transversim secta, ut substantia quae spongiosa apparet, epistempque vni adimpleto crepatis. Fig. III. . Insitit . Arterias. Fig. IV. Venas illius partis membranae Dividit, quae parietem Uteri anteriorem investierent.







TAB. XXV. *Ænium cadaver quinto mense. Apertus omnino Uterus, ac Fetus inde exemptus, quo subtilius
 judicium feratur de Fœtu ipso, de partibus ejus scæm invicem comparatis et dimensis, nec non de conditione
 Cervicis Uterinæ quæ sub hoc tempus obtinet.*

J. V. Wandelaar del.

Wandelaar sculp.

T A B U L A XXV.

NONUM cadaver, quinto menſe. Apertus omnino uterus, ac foetus inde exemptus; quo ſubtilius iudicium feratur de foetu ipſo, de partibus ejus ſecum invicem comparatis et dimenſis, nec non de conditione cervicis uterinae quae ſub hoc tempore obtinet.

Foetus ipſe, funiſque umbilicalis illuſtratione non egent.

- AAA** Vulnus per membranas factum, quo foetus eximiretur; unde interna faciei placentae pars, circa finem funis umbilicalis, cernitur.
- BBB** Amnion et chorion collapſa, et decidua reflexa (quae nondum ceperat deciduae ipſi adhaereſcere) externe cooperta.
- CC** Tubae.
- DD** Ligamenta lata.
Literas ſequentes alteri figurae ſeparatim inſculptas invenies.
- E** Decidua, omnem illam partem uteri, quam placenta non occupaverat, inveſtiens.
- FFFF** Subſtantia cervicis uteri, ab altero latere ad alterum ſecta.
- G** Pars ſuperior, anguſtior, et laevior introitus cervicis uteri, ubi decidua manifeſte continuata fuit in membranam ejus internam.
- H** Pars inferior, latior, et rugoſa, ejuſdem.
- I** Facies interna poſterioris labii oris uterini, veſiculis, glutine repletis, bullata.
- K** Facies interna vicinae partis vaginae.
- LL** Portiunculae hae duae membranarum fluitantium, exhibent, imperfeſte quidem, partes duas cuticulae vaginae inveſtientis, quae in cadavere, de quo agitur, diſtincte admodum, ſeparabatur uſque ad ipſam oris uteri prominentiam.

P L A T E XXV.

FROM the ninth ſubjeſt, in the fifth month. The womb fully opened, and the fetus taken out; to ſhow the exall dimensions and proportions of the child, and the ſtate of the cervix uteri at this period of utero-gestation.

The child and its Navel-ſtring require no explanation.

- AAA** The opening made in the membranes for the extraction of the child, through which is ſeen the inſide of the placenta around the termination of the navel-ſtring.
- BBB** The collapsed amnion and chorion, covered externally with the decidua reflexa, which had not as yet contracted an adheſion to the decidua.
- CC** The tubes.
- DD** The broad ligaments.
The following letters are engraved on a ſeparate figure in out-lines.
- E** The decidua, lining that part of the womb where the placenta did not adhere to it.
- FFFF** The ſection, from ſide to ſide, of the ſubſtance of the cervix uteri.
- G** The upper, narrower, and ſmaller part of the paſſage in the cervix uteri, where the decidua was evidently continued down into the inner membrane of that paſſage.
- H** The lower, wider, and rugous part of that paſſage.
- I** The inſide of the poſterior lip of the os uteri, ſtudded with ſmall bags of jelly.
- K** The inſide of the adjacent part of the vagina.
- LL** The two ſmall pieces of floating membranes, repreſent, though very imperfeſtly, two portions of the cuticular lining of the vagina; which, in this ſubjeſt, was ſeparated diſtinctly and evidently as far up as the projeſtion of the os uteri.

TABULA XXVI.

DECIMUM cadaver, quinto graviditatis menſe. Exhibetur ſtatus uteri retroverſi.

F I G. I.

Apertum cruciali incifione abdomen, contractiori autem forma exhibitum, cum veſica urinaria præter morem diſtenta.

- A* Inciſio longitudinalis a ſcrobiculo cordis incipiens:
- B* Qua ad montem veneris delinens.
- CC* Partium continentium anguli ſuperiores, ſuper hypochoondria reflexi.
- DD* Anguli inferiores utriusque, ſupra ſpinam oſſis ilium reflexi.
- E* Veſica urinaria, ita urina ſanguinolenta diſtenta, ut fundus ejus ad dimidium ſpatiū, umbilicum inter et ſcrobiculum cordis, porrigeretur.

F I G. II.

Veſica urinaria, forma pariter minori, per medium diviſa, et ad imam partem aperta, ut ſitus oris uterini, hæc præter naturam ſurſum ſpectantis, appareat.

- AA* Pars dimidia veſicæ ſuper ſpinam oſſis ilium utrinque reflexa.
 - B* Inciſionis, a vertice ductæ, qua veſica urina aperta fuit, finis anterior.
 - C* Unus recti intellini circuitus, qui in conſpectum prodiit ad ejuſdem finem poſteriorem.
- Duas inter hæc literas *B, C*, veſicæ pars ima tumore, qui univerſum pelvim occupavit, elevata fuit: hæc quoque, facta cruciali incifione parva, inter et paulo ante fines ureterum, os uteri in conſpectum venit, pone ſitum, ut in hæc figura, et paulo elatius quam pars ſuperior ſymphyleos oſſium pubis.

F I G. III.

Contenta pelvis omnia a parte poſtica; inter quæ, uterus retroverſus maximum locum habet.

- A* Rectum, ubi in cavum pelvis tranſibat, deligatum.
- BBB* Margines poſteriores ſectiōnis veſicæ a vertice ductæ.
- CC* Rectum, uterum inter et oſſa, ſacrum et coccygis, compreſſum.
- DD* Peritoneum, quod, ad ſiniſtrum recti intellini latus, pelvim inveſtiverat, ope catheteris, hanc partem inter et uterum immiſi, elevatum.
- EEE* Pars peritonei, parti modo deſcriptæ reſpondens, ad dextrum recti intellini latus, pericæſta, et margo ejus *F* ſepoſitus.
- G* Uteri facies anterior, retroſum verſa.
- H* Tuba aſcendens ab uteri fundo, qui ſcilicet ad partem pelvis inferam devoluta fuerat.
- I* Ovarium ante tubam poſitum.

F I G. IV.

Uteri portione, ac deciduæ parte ſublatis, fetus per pellucidas membranas, chorion nempe et amnion, conſpicitur.

- A* Os uteri ſurſum verſum. Circum undique conſpiciuntur partium vaginæ contiguarum interiora.
 - BB* Uteri ſubſtantia diviſa.
 - C* Facies externa partis alicujus deciduæ. Membrana hæc denſa, opaca, et arteriis parvis, injeſta ab utero cera impletis, abundavit.
 - D* Facies interna alius partis membranæ ejuſdem. Qua parte ablata fuerat decidua, per chorion pellucidum et amnion conſpicitur fetus, cujus caput dependet, et collum ſine umbilicali circum-cingitur.
- Lineæ albæ ſuper chorio leviter adumbratæ, vaſorum tenuium, quæ inde in deciduam tranſeunt, reliquiis reſequentant.
- Cum hæc tabula delinebatur, liquor amnii ſanguine exudante infectus fuerat. Membrantarum autem pellucidarum facies convexa figuram ſatis diſtinctam, forma quidem contractam, ſeneſtra, lucem admittentis, dedit.
- Tubarum et ovariorum figuram huicce tabule inferere ſupervacaneum duxi.

PLATE XXVI.

FROM the tenth ſubject, in the fifth month, ſhewing the circumſtances of a retroverted womb.

F I G. I.

Shows, in miniature, the abdomen fully opened by a crucial incifion, and the bladder enormously diſtended.

- A* The beginning of the longitudinal incifion at the pit of the ſtomach.
- B* Its termination in the mons veneris.
- CC* The upper angles of the containing parts, turned over the hypochoondria.
- DD* The lower angles; each turned over the ſpine of the os ilium.
- E* The bladder, ſo diſtended with bloody urine, that its fundus reached half way between the navel and the pit of the ſtomach.

F I G. II.

Drawn in miniature to the ſame ſcale, ſhews the bladder cut down through its middle, and opened, at its lower part, to ſhew the ſituation of the os uteri.

- AA* Half of the bladder, on each ſide, turned over the ſpine of the os ilium.
 - B* The anterior extremity of the vertical incifion by which the bladder was opened.
 - C* One turn of the rectum which was ſeen at the poſterior end of the ſame incifion.
- Between theſe two letters, *B, C*, the depending part of the bladder was raiſed up by a tumor which poſſeſſed the whole cavity of the pelvis: and here, a ſmall crucial incifion having been made, between, and a little before the ends of the ureters, the os uteri was ſeen, as in this figure, ſituated behind, and a little higher than the upper part of the ſymphyleos of the oſſa pubis.

F I G. III.

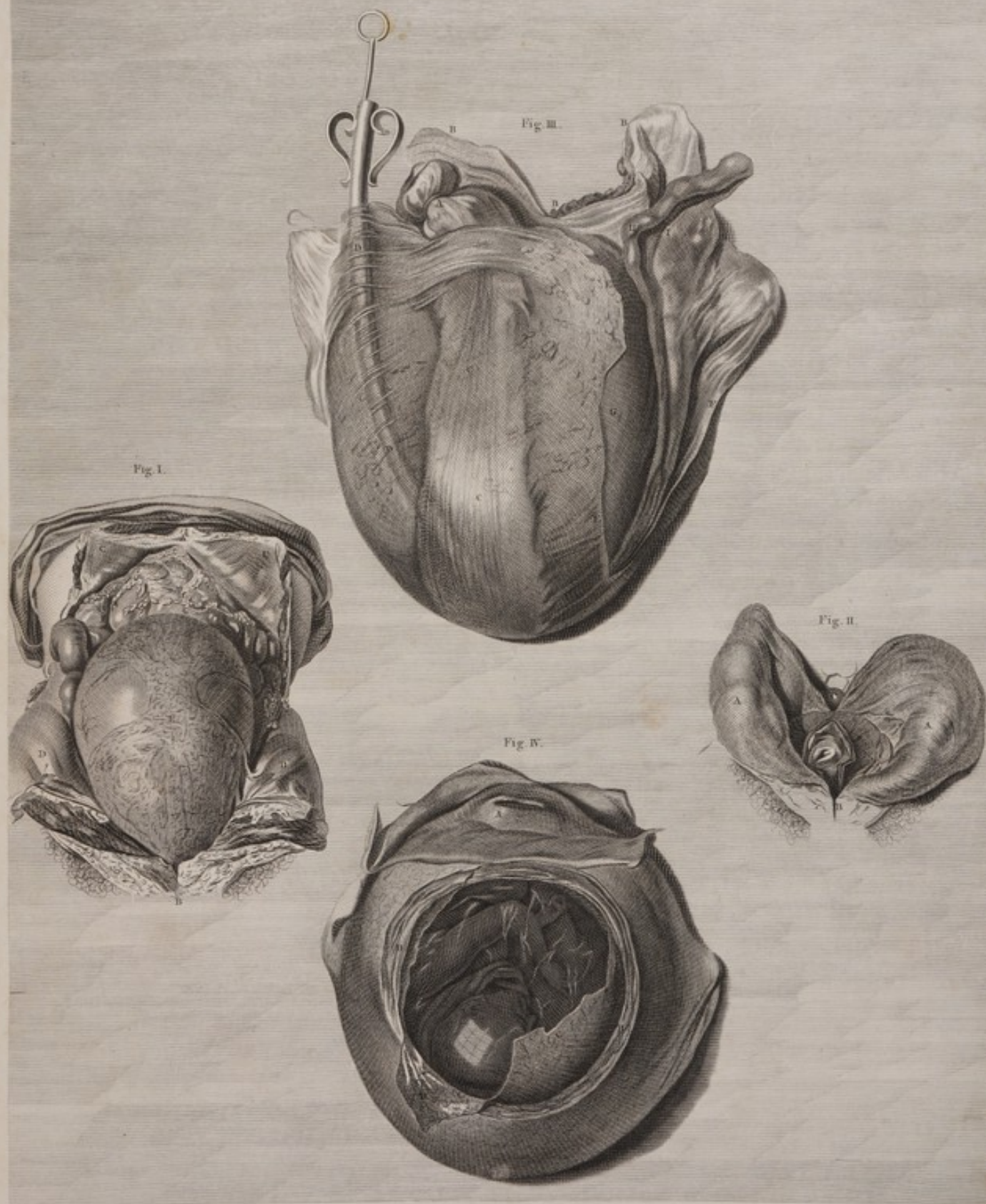
A back-view of the whole contents of the pelvis, conſiſting principally of the retroverted womb.

- A* The rectum tied, where it paſſed down into the cavity of the pelvis.
- BBB* The poſterior edges of the vertical ſectiōn of the bladder.
- C* The rectum, where it was preſſed and flattened, between the womb and the ſacrum and os coccygis.
- DD* The peritoneum, which lined the pelvis on the left ſide of the rectum, raiſed up by a large catheter, introduced between it and the womb.
- EEF* The correſponding part of the peritoneum on the right ſide of the rectum, ſit down, and the edge *F* turned off.
- G* The anterior ſurface of the womb, turned backwards.
- H* The tube, coming up from the fundus uteri, which was turned down, into the lower part of the cavity of the pelvis.
- I* The ovarium, placed before the tube.

F I G. IV.

The womb opened, to ſhew the ſecundines and their contents.

- A* The os uteri, turned upwards. All around it, is ſeen the inſide of the adjacent parts of the vagina.
 - B* The ſubſtance of the womb, cut through.
 - C* The external ſurface of part of the decidua. This membrane was thick and opaque, and full of ſmall arteries, which were injeſted from the womb.
 - D* The internal ſurface of another part of the ſame membrane. Where the decidua was removed, through the transparent chorion, and amnion, is ſeen the fetus, with its head depending, and the funis round its neck.
- The white, looſe lines on the chorion are the remains of the filamentous veſſels, which paſſi from it into the decidua.
- The liquor amnii was become bloody, by tranſudation, when this figure was drawn; and the convex ſurface of the transparent membranes, reflected a diſtant miniature picture, of the window which gave light.
- It was thought unneceſſary to introduce the tubes and ovaria.



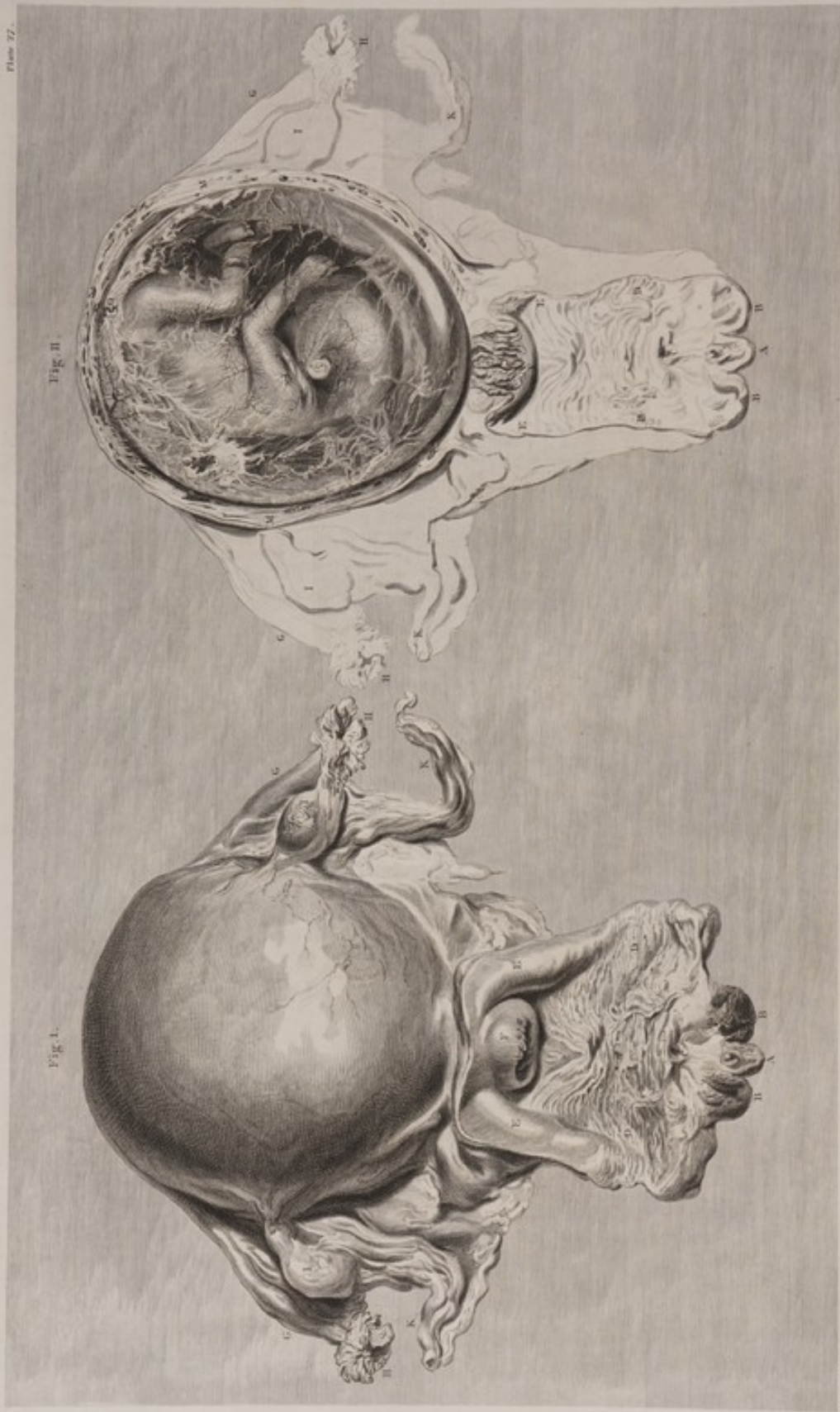
TAB. XXVI. Decimum cadaver, quinto graviditatis mense. Exhibetur status Uteri retroversi. Fig. I. Apertum decussata incisione. Abdomen, sed contractiori formâ exhibitum, cum Vesicâ Urinariâ præter morem distentâ. Fig. II. Vesicâ Urinariâ formâ pariter minutori, per maliam divisa et ad imam partem aperta, ut situs Oris Uterini hic præter naturam sursum spectantis appareret. Fig. III. Contenta Pelvis omnia a parte posticâ. Fig. IV. Uteri portione ac Deciduo parte sublatis, Fœtus per pellucidâs membranas, Chorion nempe et Amnion, conspicitur.

J. S. de Graaf delin.

Blomart sculp.







TAB. XVIII. *Uterinum Cadaver, mense quinto incante. Fig. I. Uterus cum appendicibus suis à tergo situs; Vagina secundum longitudinem incisa, Cervix et Oris uterini status apparet. Fig. II. Uterus eodem modo aperto, membranae Deciduae, Placentae, Chorion involutions, cornutum, et Cervix Unaque alteri facies interna.*

T A B U L A XXVII.

UNDECIMUM cadaver, mense quinto ineunte. Duæ figuræ. Arteriæ et venæ cera diverſi coloris impletæ ſunt.

F I G. I.

Uterus a tergo viſus, una cum vagina eo conſiſio incifa, ut ſtatus cervicis oriſque uteri oculo objiciretur.

- A Clitoris.
- BB Nymphae.
- C Proxime hanc ſupra literam, oriſcium urethrae conſpicitur.
- DD Vaginae pars extrema inferior, rugis aſpera.
- EE Ejuſdem pars extrema ſuperior, altera levior, præcipue a parte poſtica.
- F Uteri oriſcium, in terminum vaginae ſuperiorem ſe projiciens.
- GG Tubæ.
- HH Fimbriae.
- II Ovaria.
- KK Vaſorum ſpermatiorum faſciculus, per ligamenta lata, ad ovaria, tubas, et fundum uteri aſcendentium.

F I G. II.

Utero omnino aperto, membrana decidua reflexa, chorio ſuper extenſa (per quas membranas foetum videas) et cervicis oriſque uterini facies interna apparent.

- A, BB, C, DD, EE, F, GG, H, II, KK, vide fig. I.
 - L Cervicis uteri facies interna rugoſa, per gluten pellucidum cernitur.
 - MM Subſtantia tam uteri quam deciduae perſciſſa.
 - NN Decidua reflexa, membranas pellucidas inveſtiens, alba, opaca, ſtriata, diſſectu adeo tenuata, ut in locis plurimis ſere pellucida videretur: deciduae, quæ hanc obtegebat, adhæreſcere nondum cœperat.
 - O Arteria convoluta, per deciduam reflexam, a margine placente excurrans.
 - P Vena huic ſimilis.
- Vaſa foetus ſub cute repentiæ, ſanguine adeo diſtincte adimpleta ſunt, ut proſecto vaſorum cadaveris, cera injecta turgentium, imaginem præ ſe ferrent.
- Funis umbilicalis pars altera foetus collum ambibat, talem ſiſtrum altera.

P L A T E XXVII.

TWO figures from the eleventh ſubject, in the beginning of the fifth month. The arteries and veins were injected with wax of different colours.

F I G. I.

A back-view of the womb, with the vagina ſlit up to ſhew the ſtate of the cervix and os uteri.

- A The clitoris.
- BB The nymphae.
- C Immediately over this letter is the oriſce of the urethra.
- DD The lower end of the vagina, which is rugous.
- EE The upper end, which is more ſmooth, eſpecially behind.
- F The oriſce of the womb, projecting into the upper end of the vagina.
- GG The tubes.
- HH The fimbriae.
- II The ovaries.
- KK The bundle of ſpermativ veſſels, paſſing up, in the broad ligaments, to the ovaries, tubes, and fundus of the womb.

F I G. II.

The ſame womb fully opened, ſhewing the decidua reflexa upon the chorion, (through which the child appears,) and the inſide of the neck and oriſce of the womb.

- A, BB, C, DD, EE, F, GG, HH, II, KK, ſee fig. I.
 - L The rugous inſide of the neck of the womb, ſeen through the transparent cement.
 - MM The ſubſtance, both of the womb and of the decidua, cut through.
 - NN The decidua reflexa, covering the transparent membranes, in white and opaque ſtrix. It was become ſo thin, by extenſion, as to be rendered almoſt transparent in many places. It had not as yet contracted an adheſion with the decidua which covered it.
 - O A convoluted artery, branching through the decidua reflexa, from the edge of the placenta.
 - P A vein of the ſame kind.
- The cutaneous veſſels of the child were as diſtinctly filled with blood, as if they had been injected.
- One turn of the navel-ſtring was round the child's neck, and another was twiſted round the left ankle.

TABULA XXVIII.

FIG. I.

IDEM uterus quem exhibet figura secunda tabule præcedentis, sed inversus (i. e. fundo decliviori); ut, contentis suo pondere a cervice fundum versus devolutis, margo placente clarius distinguatur; ac decidua, quæ ibidem ab interno uteri pariete in externam chorii superficiem reflexa, nomen deciduæ reflexe assumit, melius conspiciatur.

- Partes lineis adumbrate in tabula præcedenti modo expofite sunt atque explanate: scilicet *A, BB, C, DD, EE, F, GG, HH, II, et KK*, in figura prima; atque *L et MM* in figura secunda.
- NNN* Decidua crassa, faciem internam uteri, ubi placenta non adhærebat, involvens.
- OOO* Placentæ margo, ubi lamina interna deciduæ a facie interna uteri, ad faciem membranarum externam, inflexa fuit atque continuata; quo in loco efficit
- PP* Deciduam reflexam, eo magis attenuatam, quo longius a margine placente distat.
- Q* Hic patuit, deciduam non eodem modo, quo cæteræ membrane, trans aditum in cervice uteri se porrexisse; sed per paululum spatii intra hunc aditum, more involvens membranæ, esse continuatam; tandemque sensim evanuisse, aut cum glutine illo, quod vice cæmenti fungitur, esse confusam.

FIG. II.

Ejusdem uteri facies interna, qualis apparuit, placenta jam separata.

- A, BB, C, DD, EE, F, GG, HH, II, KK*, Vide tabule præcedentis figuram primam.
- L, MM*, Vide ejusdem tabule figuram secundam.
- NNN* Pars deciduæ, undique circa placente marginem, etiamnum utero intus adhærens.
- O* Centrum superficiæ orbiculatæ, in uteri parte anteriori, cui placenta hoc in cadavere adhærebat. Hæc arteriis venisque abundabat, quæ scilicet utero ac placente communes fuerant, quasque necessario perrupi, duas has partes dum separabam. Arteriæ quidem parvæ erant, convolutæ, colorisque magis lucidi, ut ad literam *P*; venæ autem perrupte speciem macularum fulcarum, vel foraminum, magnitudinis haud exiguæ, præ se ferebant, ut ad literam *Q*.
- Linea inæqualis quæ superficiem hanc scabram, cui placenta adhærebat, ambit, extremum marginem placente a membranâ abscisse designat; eadem etiam indicat locum quo deciduæ lamina interna reflexa fuerat, circum undique, in faciem chorii externam.

PLATE XXVIII.

FIG. I.

THE womb, from the same subject, turned upside down, that the weight of its contents might carry them towards the fundus; to show the border of the placenta, where the decidua is reflected from the inside of the womb, to the outside of the chorion, at which last place it makes the decidua reflexa.

The parts represented in out-lines were seen and explained in the preceding plate, viz. *A, BB, C, DD, EE, F, GG, HH, II, and KK*, in the first figure, and *L, MM*, in the second.

- NNN* The thick decidua, lining the inside of the womb, where the placenta was not attached.
- OOO* The edge of the placenta, where the inner layer of the decidua was continued, by inflexion, from the inside of the womb to the outside of the membranes; at which last place it constitutes
- PP* The decidua reflexa, which becomes thinner, in proportion as it is farther distant from the edge of the placenta.
- Q* Here it was evident that the decidua was not, like the other membranes, extended across the passage in the neck of the womb, but was continued a little way down that passage, and there insensibly lost, or blended with the glutinous cement.

FIG. II.

The inside of the same womb, after the placenta had been separated.


- A, BB, C, DD, EE, F, GG, HH, II, KK*, See the first figure of the preceding plate.
- L, MM*, See the second figure of the preceding plate.
- NNN* Part of the decidua all around the edge of the placenta, left adhering to the inside of the womb.
- O* The centre of the circular surface at the forepart of the womb, to which the placenta, in this case, adhered. It was full of arteries and veins, which had passed between the womb and placenta, and which we broke through in separating these two parts: the arteries were small, and convoluted, and of a lighter colour, as at the letter *P*; the broken veins had the appearance of dark spots, or holes, of some considerable size, as at the letter *Q*.
- The irregular line, which surrounds this rough surface to which the placenta adhered, points out the extreme border of the placenta, which was cut off from the membranes, and where the inner layer of the decidua, all around, was reflected upon the outer surface of the chorion.

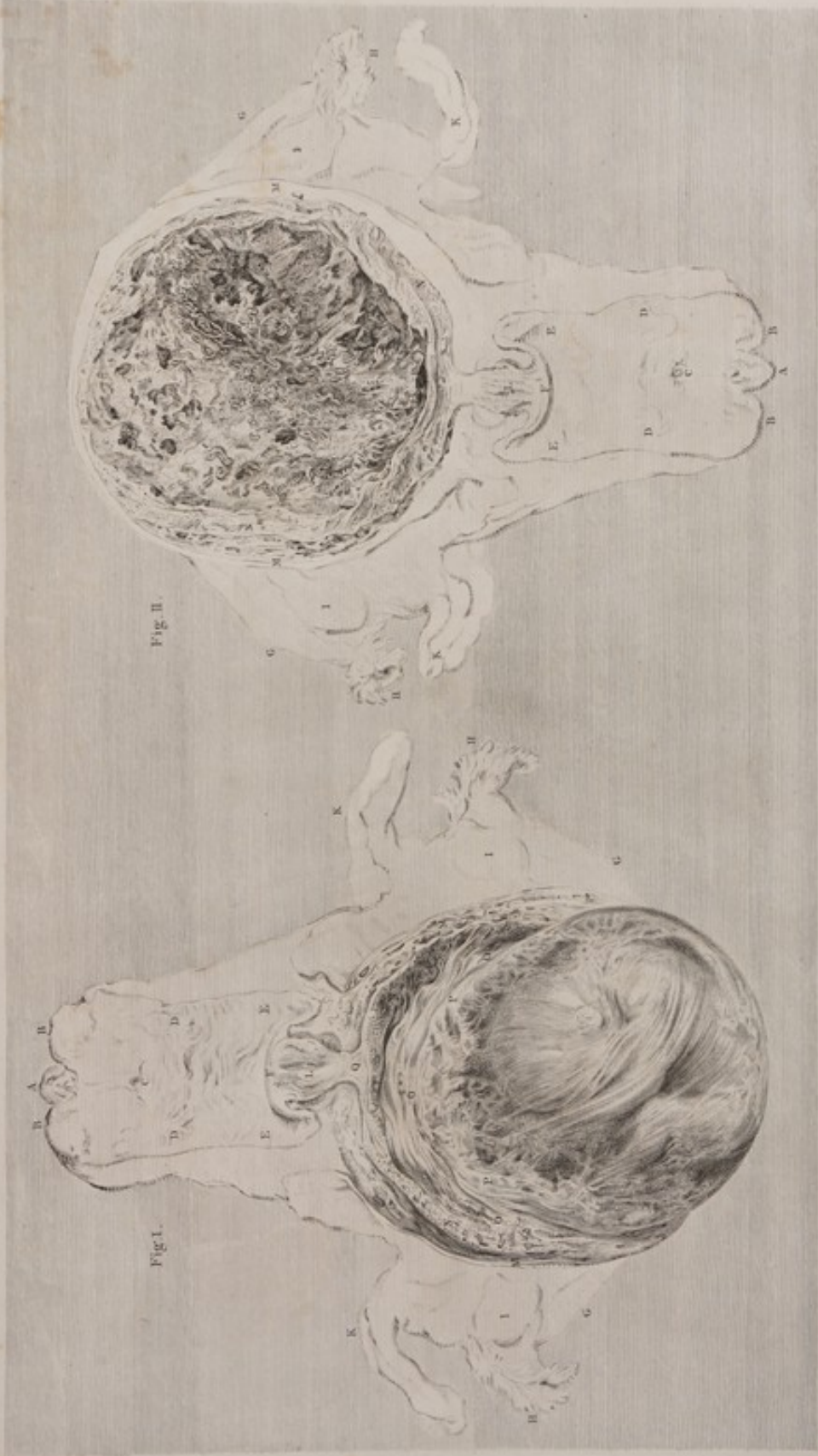

Fig. II.

Fig. I.

T. A. B. XVIII. Fig. I. Schem. Uteri quem catheter figuræ secunda. Tubula præcedentis, sed inversus (i.e. fundo dextriviro) ut contentis, suo pondere a Cervice præcedentem vasculis dextriviro, utroque. Placenta clarius distinguitur, ut præcedat, quæ ibidem ab interno Uteri pariete in æternam chorii, oppositum reflectit, nonnem præcedat. Reflexæ asperit, molis conspicitur. Fig. II. Fœtus quædam uteri interna, præcedat. Placenta, ut ostendat. Sicut illa irregularis asperit et iniqualem, asperitiam circumscriptens, æternam indicat. Placenta limitis, ubi præcedat ab Utero circumscriptus in chorion fuerat reflectit.







T. C. Campbell delin.
T. C. Campbell sculp.
 TAB. XXIX. Quinque figuras exhibet, quarum tres priores ex eodem sunt Cadavere. Fig. I. Ovarium
 illud exemptum. Fig. II. Pars Dextrae utero adhibita amplificata. Fig. III. Ovarium cum Corpore luteo.
 Fig. IV. Pars Illa et Placenta cum membranis. Fig. V. Pars membranarum nono mense.

TABULA XXIX.

TRES figurae ad idem exemplar depictae; quibus adjiciuntur duae aliae, tanquam appendices.

FIG. I.

Ovum utero exemptum, faciem placentae externam representans, laciniisque marginem ejus undique ambientes, membranae scilicet deciduae reflexae dilaceratae reliquias. Haec figura cum figura secunda praecedentis tabulae congruit, faciem ovi exhibens, quod isti utero intus adhaererat.

AAA Decidua reflexa, undique a margine placentae, ad chorion intendendum, exiens.

BB Limbus, marginem placentae circum-ambiens, ortus scilicet ex sectione deciduae reflexae, ubi illa separata fuit a decidua, aut, si ita loqui mavis, a facie uteri interna.

Circulus, limbo isto circumdatus, faciem externam placentae exhibet, quae utero adcreverat. Has partes dum separabamus, arteriae venaeque plurimae dilaceratae sunt, quarum pars altera utero adnexa est, altera placentae. Arteriae quidem, ut in figura praecedenti, parvae, convolutae, et colore sunt lucidiori, ut ad literas CCC; venas autem maculae laevae ac fuscae representant, ut ad literam D.

FIG. II.

Partis membranae deciduae facies interna, ope vitri optici amplior visa, ut textura ejus propria, cribrum haud male referens, explicari posset.

FIG. III.

Ovarium, corpusque luteum percussa. Corpus luteum, etiam ad hoc temporis, cavatum esse manifeste apparuit.

FIG. IV.

Figura addita.

Pars aliqua membranae deciduae, pertinentis ad partum legitimum, mensibus scilicet novem rite exactis.

FIG. V.

Alia figura addita.

Portio aliqua uteri et secundarum, nono mense, ita disposita, ut earum partium strata diversa distincte conspiciantur. Arteriis cera rubra, venis flava est injecta.

AAA Uteri substantia discissa.

BB Placenta ei adhaerens, prope marginem percissa.

CC Decidua ea in parte utero adhaerens.

DD Decidua in illa parte ab uteri facie interna elevata, chorioque adhaerens.

E Chorion, supra faciem internam placentae continuatum, ubi separari non potest.

F Amnion elevatum a chorio, cui non, nisi per gluten aliquod molliissimum, adhaesit.

PLATE XXIX.

THREE figures from the same subject, and two supplemental.

FIG. I.

The ovum taken out of the womb, shewing the external surface of the placenta, and the ragged edge all round, where the decidua reflexa was torn through. This figure corresponds with the second figure in the preceding plate, shewing the surface of the ovum which was attached to the inside of that womb.

AAA The decidua reflexa going off, all round, from the edge of the placenta, to cover the chorion.

BBB The edge, formed all round the brim or border of the placenta, by cutting the decidua reflexa where it came off from the decidua, or, in other words, from the inside of the womb.

The round surface, enclosed by that edge, is the outer surface of the placenta, which had adhered to the womb. In separating those two parts, many arteries and veins were torn through, one part of each remaining with the womb, and the other with the placenta. The arteries, as in the preceding figure, are small, convoluted, and of a lighter colour, as at the letters CCC; the veins make broad dark spots, as at the letter D.

FIG. II.

The internal surface of a portion of the decidua, considerably magnified, to shew its peculiar cribriforme or lace-like appearance.

FIG. III.

The ovarium and corpus luteum cut through; the latter of these, even at this time, had an apparent cavity.

FIG. IV.

A supplemental figure.

A portion of the decidua, from a common delivery at nine months; its vessels filled with red blood.

FIG. V.

Another supplemental figure.

Part of the womb and secundines, at nine months, so disposed as to exhibit distinctly the different strata of those parts. The arteries had been injected with red wax; the veins with yellow.

AAA The substance of the womb cut through.

BBB The adhering placenta cut through, near its edge.

CC The decidua, at that part left adhering to the inside of the womb.

DD The decidua, at this part raised from the inside of the womb, and adhering to the chorion.

E The chorion, which is continued upwards over the inside of the placenta, where it cannot be separated.

F The amnion, raised up from the chorion, to which it adhered by a tender jelly only.

T A B U L A XXX.

A Duodecimo cadavere, quarto mense decurrente. Uterus a parte antica apertus, vasis cœra repletis. Præcipue hic notanda occurrunt, superficies placentæ externa; vasa ex utero se immergentia in placentam; cervicis uteri externa, qualis facies, fit, et, respectu ad vesicam urinariam urethramque habito, quem situm obtineat.

Placentæ superficies, sectione uteri substantiæ circumdata, adeo refert præcedentem, scilicet fig. I. ut explanatione minime indigeat.

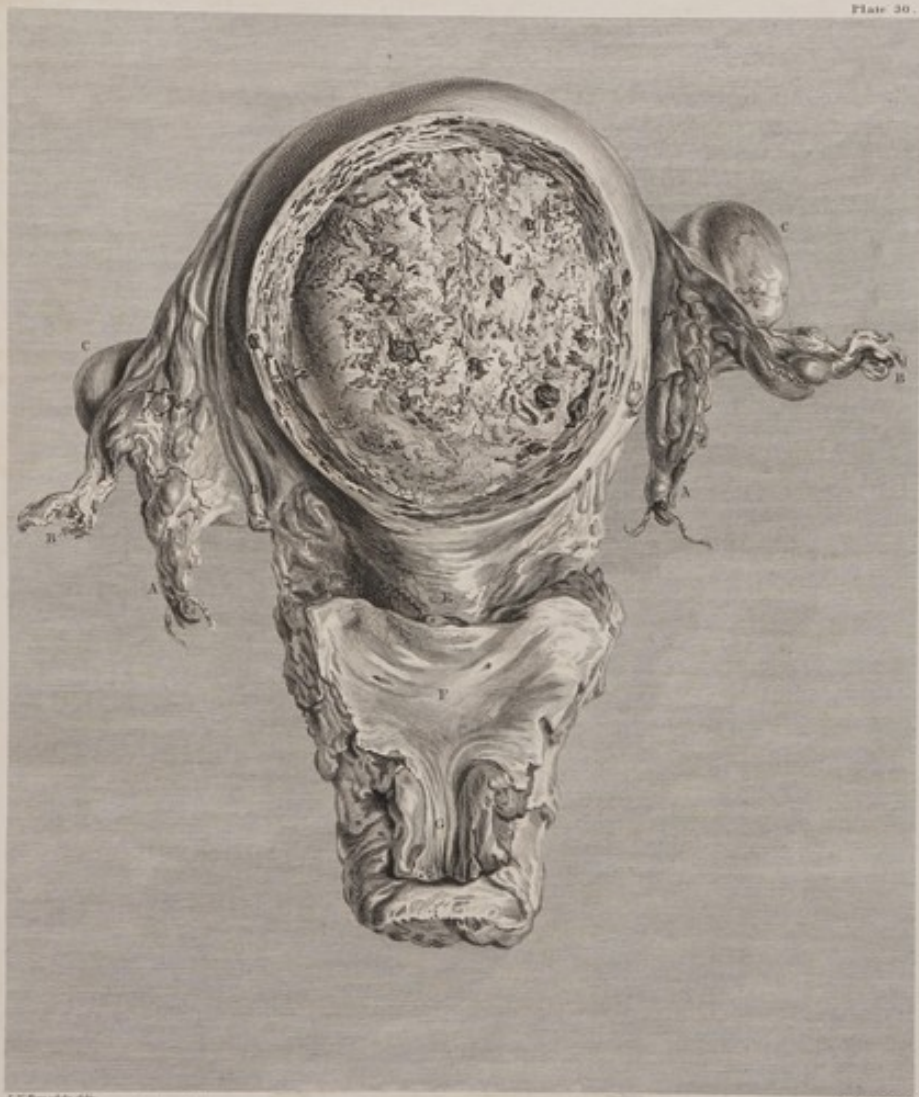- AA Vasa spermatica.
- BB Fimbriæ, sive tubarum partes extremæ.
- CC Ovaria. Horum finistrum corpore luteo nonnihil auctum fuit.
- DD Ligamenta rotunda.
- E Cervix uteri contracta.
- F Facies interna portionis istius vesicæ, quæ vaginæ subiecta adheret. Utroque in latere, et hæc litera paulo superius, cernitur orificium urethræ.
- G Urethra universa omnino aperta.

P L A T E XXX.

FROM the twelfth subject, in the fourth month, shews the injected womb, opened on its fore part, to give a full view of the external surface of the placenta, with the vessels passing into it from the womb. It shews likewise the state of the cervix uteri externally, and its relation to the bladder and urethra.

The surface of the placenta, surrounded by the section of the substance of the womb, is so much like that of the first figure in the preceding plate, that it requires no explanation.

- AA The spermatic vessels.
- BB The fimbriæ, or ends of the tubes.
- CC The ovaria. The left was enlarged by the corpus luteum.
- DD The round ligaments.
- E The cervix uteri, in a contracted state.
- F The inside of that portion of the bladder which adheres to the subjacent vagina. On each side, and a little higher than this letter, is seen the orifice of the ureter.
- G The urethra opened in its whole length.



TAB. XXX. A dissectione Cadaveri, quarto mense decurrente: Uterus a parte antica apertus, vasis cœni repletus. Præcipue hic notanda occurrunt, superficies Placentæ externa; Vasa in Placentam ex Utero se immergentia; Cervix uteri externa: ita ut, quælibet ad, respectu ad Vesicam Urinariam Uræthramque habito, quæ situm obtineat.






Fig. I.

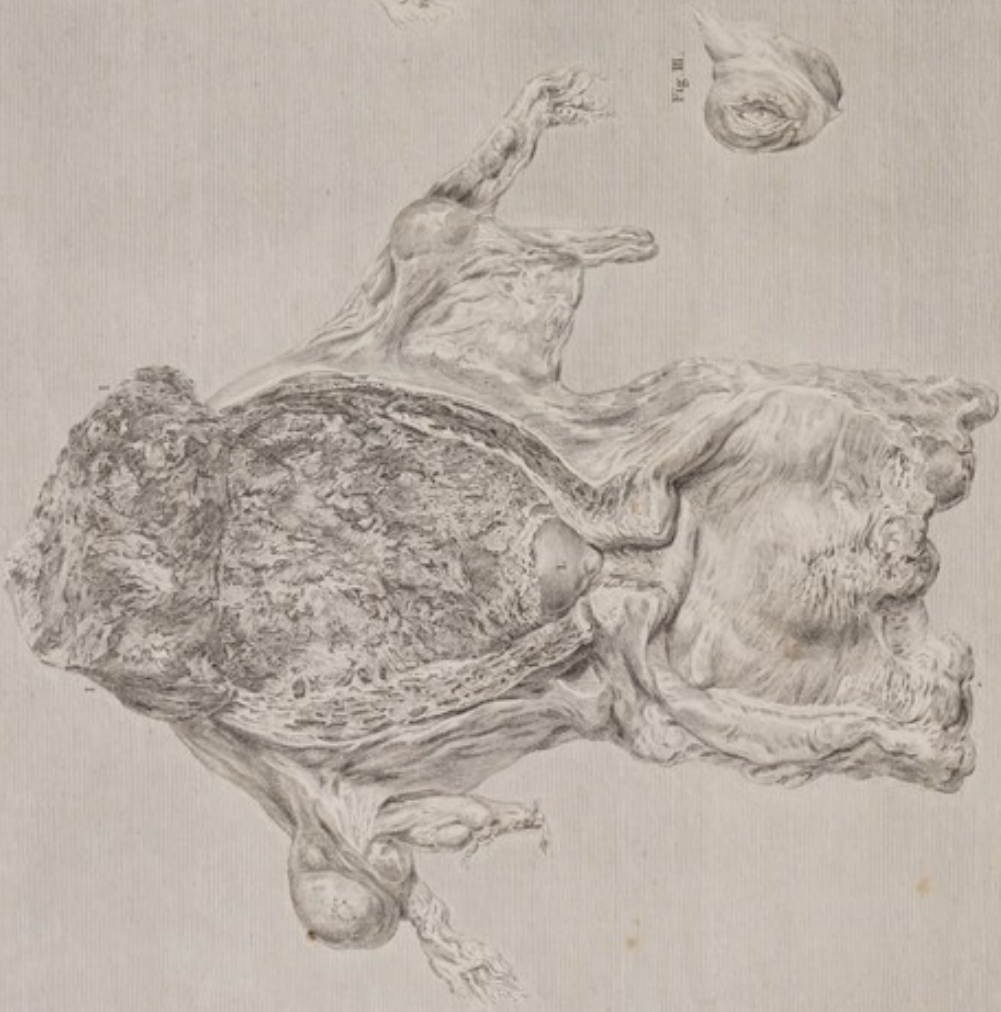

Fig. II.

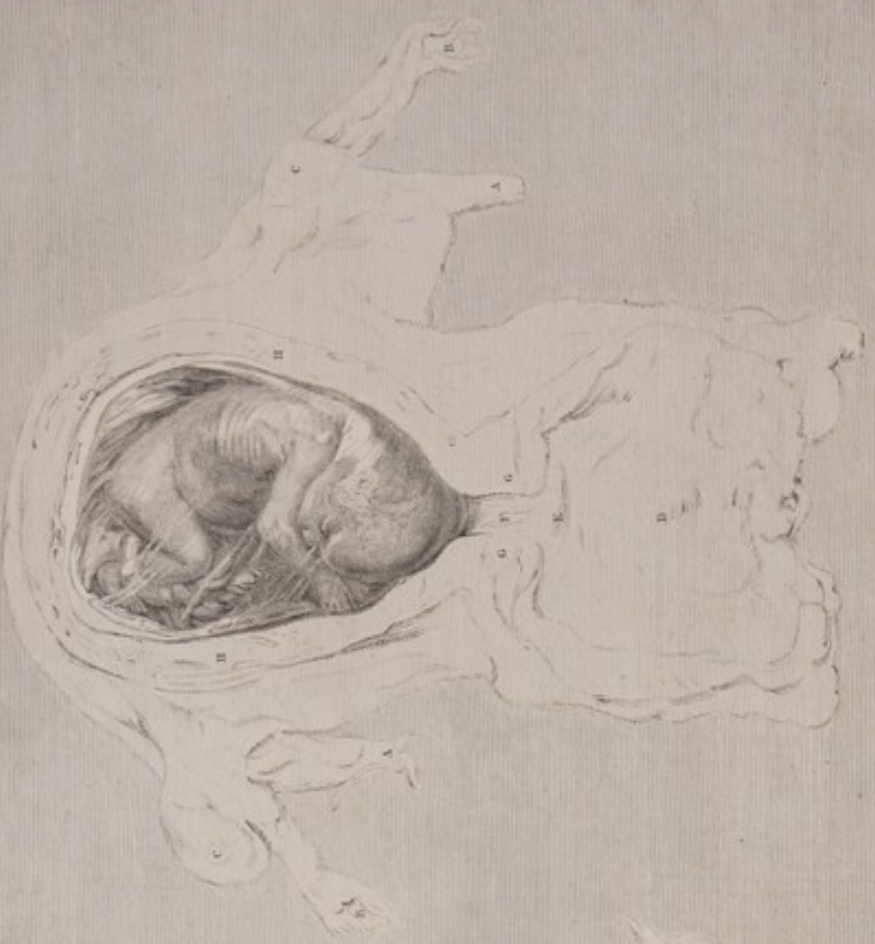

Fig. III.



J. J. Wandelaar del.

M. J. Wandelaar sculp.

TAB. XXXI. *Tres figure ab eodem Cadavere. Fig. I. Uterus a parte posteriori dissectus, et Funic Membranae Divulsa externa, ac status Cervicis uterinae visui exponitur.*

Fig. II. Parte posteriori Uteri membranisque Divulsa sublati. Fœtus ipse per pellucidam membranam apparet. Fig. III. Ovarium apertum corporis Lutei cavum ostendit.

T A B U L A XXXI.

TRES figuræ ab eodem cadavere.

F I G. I.

Uterus a parte postica ita apertus, ut facies membranæ deciduæ externa, ac flatus cervicis uterinæ visui exponantur.

Literas tabulæ huic explanandæ accommodatas omnes præter

II, K et L, in figura secunda videas.

- AA Vasa spermatica.
- BB Fimbriæ.
- CC Ovaria.
- D Vagina univërfa, quæ in longum extenditur, omnino aperta.
- E Os uteri in vaginam se protendens.
- F Via rugosa, per cervicem uteri ducens, unde gluten illud consolidans jam exciderat.
- GG Sectio substantiæ cervicis uteri.
- HH Sectio substantiæ uteri, unde
- II Pars posterior totius substantiæ uteri de decidua sublata et in fundum uteri revoluta cernitur.
- K Decidua, adhuc membranis adhærens, superficiem suam scabram externam exhibens, unde uterus fuerat separatus. Membrana hæc vasis, cera impletis, venis maxima de parte, abundavit. Plurimis autem in locis, cera, vasis effusa, hæc visu indistincta reddiderunt.
- L Membranæ pellucidæ, amnion scilicet et chorion, decidua reflexa tenuissima et pellucida obteçta, in aditum cervicis uteri, ubi decidua ipsa deficit, viam sibi facientes.

F I G. II.

Idem uterus; postquam scilicet inversa pars uteri fuerat abscissa, et decidua ablata, ea mente ut fœtus, in liquore amnii natans, per pellucas membranas appareret.

Decidua reflexa hic adeo tenuis fuit, ut, nisi ad marginem placentæ, vix percipi posset.

Fœtus, cujus crura fune umbilicali circum-vincta sunt, per se fati est manifestus.

F I G. III.

Corpus luteum ovario in sinistro percussum, ut appareat quale sit ejus cavum, sub hoc tempus gestationis. Qualem se habeat cicatricula illa, in externa facie corporis lutei ovarii sinistri, ibi cernitur, ubi stat litera C, in figuris prima et secunda.

P L A T E XXXI.

THREE figures, from the same subject.

F I G. I.

A back-view of the womb, so opened as to expose the outer surface of the decidua, and to shew the state of the neck of the womb.

The letters for explanation, except II, K, and L, are seen in fig. II.

- AA The spermatic vessels.
- BB The fimbriæ.
- CC The ovaries.
- D The vagina laid open in its whole length.
- E The os uteri protuberating into the vagina.
- F The rugous passage through the neck of the womb, from which the viscus cement had, by this time, fallen out.
- GG The section of the substance of the cervix uteri.
- HH The section of the substance of the womb; whence
- II The posterior part of the whole substance of the womb, raised up from the decidua, and turned over the fundus of the womb.
- K The decidua left upon the membranes, shewing its scabrous outer surface from which the womb was separated. It was crowded with injected vessels, especially veins; and in many places the wax was extravasated, which occasioned indistinctness.
- L The transparent membranes, viz. amnion and chorion, covered with a very thin and transparent decidua reflexa, pushing down into the passage of the cervix uteri, where the decidua is wanting.

F I G. II.

The same object, after the inverted portion of the womb had been cut off, and the decidua removed, to shew the fœtus, in the liquor amnii, through the transparent membranes.

The decidua reflexa in this subject was so thin, that it was scarcely perceptible, except near the edge of the placenta.

The fœtus, with the navel-string round its legs, requires no explanation.

F I G. III.

The corpus luteum, in the left ovary, cut through, to shew its cavity at this period. The appearance of the cicatricula, upon the outside of the corpus luteum in the left ovary, is seen where the letter C stands in the first and second figures.

T A B U L A XXXII.

FIGURÆ duæ, a decimo tertio cadavere, tertio mense profus exacto.

F I G. I.

Uterus a parte antica apertus, unde fœtus cervicisque uteri status in conspectum procedunt.

- AA Ligamenta lata.
 - BB Ligamenta rotunda.
 - CC Tubæ.
 - DD Fimbriæ.
 - EE Ovaria.
 - F Vagina omnino aperta.
 - G Oris uterini labium posterius.
 - HH Via per cervicem uterinam.
 - III Sectio substantiæ uteri, portione quadam ovali excisa, ut contenta ejus sub examen venirent.
 - K Membrana percussa.
 - L Faciei internæ uteri pars.
 - M Pars ista deciduæ, quæ inde separata fuit. Prope hanc literam cernitur foramen quoddam, (locus nimirum ubi decidua deest) viæ quæ per cervicem uteri ducit, exadversum situm.
 - N Decidua reflexa, nec non chorion et amnion, percussa.
 - O Placenta parti posteriori uteri adhærens.
- Fœtus, cum collo fune umbilicali bis circumdato, abunde patet.

F I G. II.

Uteri, placentæ et membranarum secundum longitudinem sectio, cum fœtu juxta sito, funiculo autem umbilicali nondum diducto.

- AA Vaginæ facies interna.
- BB Os uteri percissum.
- CC Cervix uteri percussa.
- DE Via quæ per cervicem ducit, cujus, in parte posteriori E, rugæ penniformes conspiciuntur.
- FFFF Sectio fundi uteri, ubi conceptus sedem habebat.
- GG Sectio placentæ, quæ retrosum adhæserat, ubi uterus, de quo agitur, præter morem crassus visus est.
- HH Placentæ superficies interna, amnio et chorio obsecta.
- I Uteri superficiei interioris pars.
- K Pars parva deciduæ, inde separata.
- LL Decidua facies interna, sive cavum ipsam inter et deciduam reflexam.
- M Angulus prope marginem placentæ, ubi decidua lamella interior super chorion reflectitur, nempe ad deciduam reflexam faciendam.
- N Decidua reflexæ facies externa; sive cavum, membranam illam inter et deciduam.
- O Margines secti decidua reflexæ et chorii, quæ inter se intus connectuntur.
- P Margo amnii fœtus.

P L A T E XXXII.

TWO figures from the thirteenth subject, at full three months.

F I G. I.

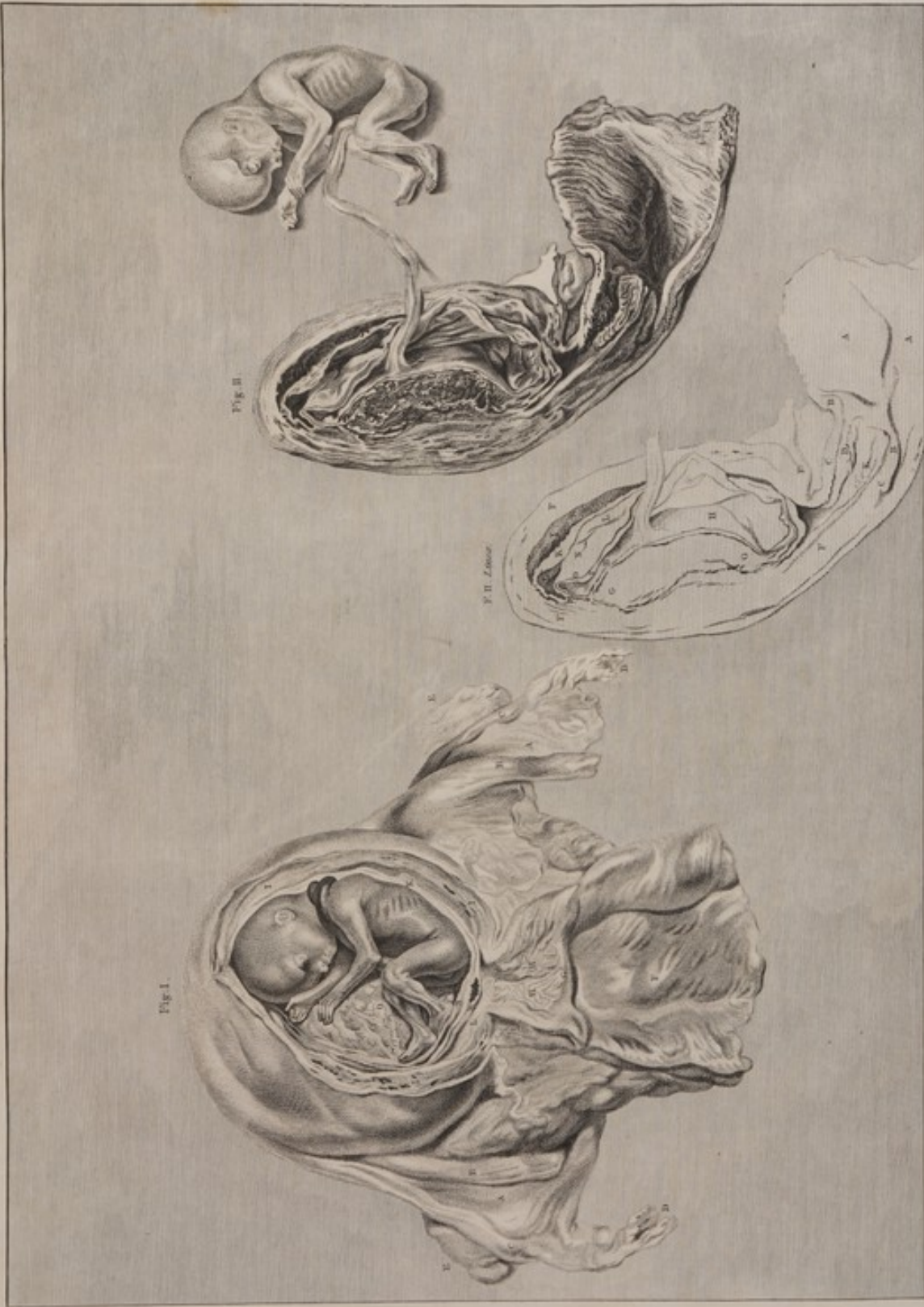A fore-view of the womb opened, to shew the child, and the state of the cervix uteri.

- AA The broad ligaments.
- BB The round ligaments.
- CC The tubes.
- DD The fimbriæ.
- EE The ovaries.
- F The vagina laid open.
- G The posterior lip of the os uteri.
- HH The passage through the cervix uteri.
- III The section of the substance of the womb, where an oval piece was taken out to shew its contents.
- K The membranes cut through.
- L Part of the internal surface of the womb.
- M That part of the decidua which was separated from it. Near this letter is the hole, or deficiency of the decidua opposite to the passage through the cervix uteri.
- N The decidua reflexa, chorion and amnion cut through.
- O The placenta, adhering to the posterior part of the womb. The fœtus, with two turns of the navel-string round its neck, requires no explanation.

F I G. II.


A longitudinal section of the womb, placenta and membranes; with the child near it, but still attached by the navel-string.

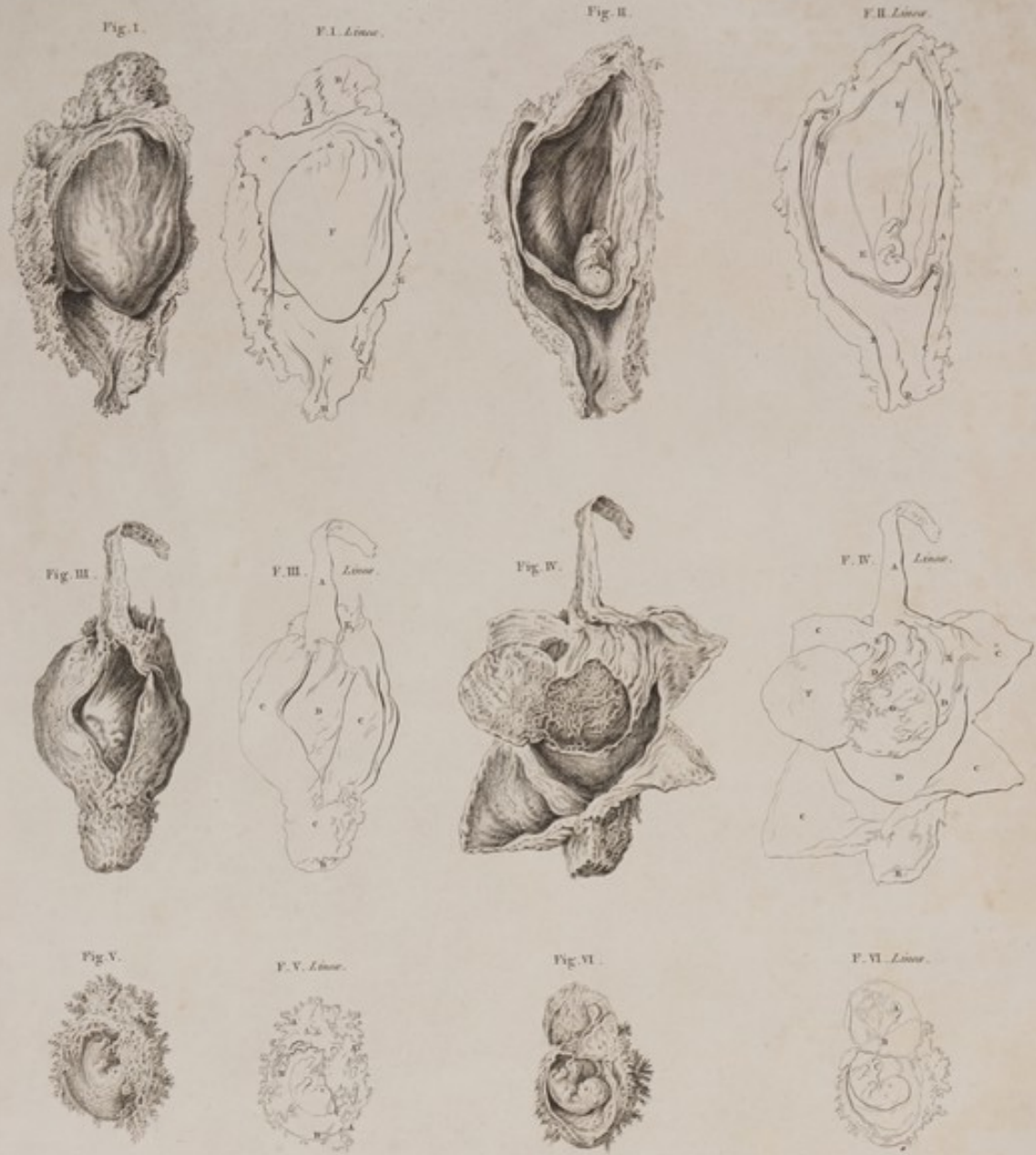- AA The inside of the vagina.
- BB The os uteri cut through.
- CC The cervix uteri cut through.
- DE The passage through the cervix; in the posterior part of which E, the penniform rugæ are conspicuous.
- FFFF The section of the fundus uteri, in which the conception was lodged.
- GG The section of the placenta, which adhered backwards, where this womb was remarkably thick.
- HH The internal surface of the placenta, covered with the amnion and chorion.
- I Part of the inner surface of the womb.
- K A small part of the decidua separated from that inside of the womb.
- LL The internal surface of the decidua; or the cavity between the decidua and decidua reflexa.
- M The angle, near the edge of the placenta, where the inner layer of the decidua is turned over the chorion to form the decidua reflexa.
- N The outside of the decidua reflexa; or the cavity between that membrane and the decidua.
- O The cut edges of the decidua reflexa and chorion, which are intimately connected.
- P The cut edge of the amnion.



TAB. XXXII. *Quae a decimo tertio Calavero figure, tertio mense elapso. Fig. I. Uterus a parte anteriori postfactus, Fœtum cum Cervice Uterinâ contemplandum aspectu. Fig. II. Idem Uterus secundum longitudinem cum Placentâ et membranis, divisione, adspicente etiam Fœtu, ac per funiculum umbilicalem adspicente.*







Tab. XXXIII. Ova tria abortu perditâ, sex figuris expressa. Fig. I. Conceptus novem circiter hebdomadarum, à parte que tota membrana est oculis aspectâ. Fig. II. Ejusdem setiv secundum longitudinem. Fig. III. Conceptus alter post octo feri hebdomadas. Fig. IV. Idem conceptus ad exitum paulo curvatus reversus. Fig. V. Chorion nudum, i. e. ab ambiente Decidua expulsum. Fig. VI. Idem conceptus apertus.

TABULA XXXIII.

OVA tria abortiva, sex figuris expressa.

F I G. I.

Ovum nonæ circiter hebdomadæ abortivum, ab ista scilicet parte que membranacea est adspectum. Decidua lacerata est, et aliquantulum revoluta, ut decidua reflexa lævis et opaca in conspectum prodiret.

- AA Decidua ab utero separate facies externa scabra.
- B Facies externa portiunculæ cujusdam placenta, cujus reliqua pars federa suam exadversum habebat.
- CCCC Decidua facies interna cribriformis, quæ primis mensibus graviditatis membranis inclusis non adhærescit.
- DDDD Decidua margo laceratus, qui in marginem *EEE* membranæ ejusdem cursum suum tenuerat.
- F Decidua reflexa per faciem externam chorii diffusâ.
- GG Angulus partis reflexæ, ad marginem scilicet placenta, ubi lamella interior decidua in chorion reflectitur, simili fere modo quo lamella interior pericardii reflectitur ad superficiem externam cordis obtegendam.
- H Extrema pars decidua ad cervicem uteri.

F I G. II.

Ejusdem sectio a vertice ad inam usque.

- AAA Sectio placenta, quam superficiem superiori et posteriori uteri adhæsisse supponendam est.
- BB Decidua partis anterioris sectio.
- CC Decidua partis posterioris sectio.
- D Pars extrema decidua ad cervicem uteri.
- EE Amnii cavum, in quo fixus, ope funiculi tenuissimi umbilicali, a facie interna placenta suspenditur.
- F Sectio trium membrarum, scilicet amnii, chorii et decidua reflexæ, que non solum sunt contigua, sed et sibi invicem adhærescunt.
- GG Angulus ad marginem placenta, ubi lamella interior decidua in faciem externam chorii reflectitur.
- H Hic tres istæ membranæ paululum sejunguntur, ut situs earum, respectu habito ad placenta, manifestus appareat.

F I G. III.

Ovum octo circiter hebdomadarum abortivum. Pars quædam exigua decidua excissa est, et fusum reflexa, ut cavum inter eam et cæteras membranas cerneretur.

- A Decidua pars exigua excissa.
- B Conceptus pars ubi deest decidua, exadversum scilicet aditum per uteri cervicem ducenti.
- CCC Decidua superficies externa.
- D Decidua reflexa obtogens chorion et amnion, quæ membranæ se protendentes cavum decidua adimplent.
- E Partis superioris placenta facies externa.

F I G. IV.

Idem ovum, decidua jam incisione decussatim aperta, angulis quatuor revolutis deciduaque reflexa portione rotunda cultro sublata et devoluta, nempe ut vascula in superficie externa chorii in conspectum prodirent.

- A, B. Vide fig. III.
- CCCC Facies interna quatuor angulorum in quos decidua cruciali incisione fuerat divisa.
- DDD Decidua reflexa cæteras membranas investiens.
- EE Angulus ad placenta marginem, ubi lamella interior decidua protenditur supra faciem externam chorii, nomenque decidua reflexæ obtinet.
- F Decidua reflexa portio rotunda, ex facie externa chorii cultro anatomico sublata et devoluta.
- G Chorion cum vasculis suis hirsutis expositum. Vasa ista decidua reflexæ arcu adhaerebant, et eorum nonnulla una cum membrana illa abscissa sunt.

F I G. V.

Ovum eodem fere tempore abortu separatum, constans ex chorio solo, cum vasculis et contentis ejus; quippe decidua, vel pars secundarum uterina, in utero remanebat.

- AAA Vasorum hirsutorum rami majores et frequentiores, ex quadam parte superficiem externam chorii emergentes, et cum decidua, vel parte uterina, ad placenta consociandam se commiscuentes.
- BB Chorii ea portio quæ postea membrana uniformis et pellucida evadit; vasculis paucioribus, subtilioribus, fluitantibus, quæ in decidua reflexa evanescent, abundat: per eam conspicitur embryo.
- C Vescula umbilicalis in facie externa amnii per chorion conspecta: filum exalbida (reliqua arteria et vena) ab ea ad umbilicum embryonis transit.

F I G. VI.

Idem ovum apertum. Membranæ antica parti insidentibus a placenta abscissis et reflexis, distincte conspicitur embryo.

- A Vescula umbilicalis, ex qua
- BB Reliquæ arteria et vena, holoalbo similes, ad umbilicum embryonis transeunt. Intestinorum gyri quidam in principio funis umbilicalis includuntur.

PLATE XXXIII.

SIX figures of three different abortions.

F I G. I.

An abortion, of about nine weeks, seen on that side which is membranous. The decidua is torn, and turned somewhat aside, to show the smooth and opaque decidua reflexa.

- AA The rough, external surface of the decidua, which exfoliated from the womb.
- B The outside of a small portion of the placenta, the rest of which was situated on the back-part of this object.
- CCCC The internal cribriform surface of the decidua, which, in the first months of pregnancy, does not adhere to the membranes which it encloses.
- DDDD The lacerated edge of the decidua which had been continued into the edge *EEE* of the same membrane.
- F The decidua reflexa spread over the outside of the chorion.
- GG The angle of reflection at the edge of the placenta, where the inner layer of the decidua is turned over the chorion; much in the same manner as the inner lamella of the pericardium is reflected, to cover the outer surface of the heart.
- H The termination of the decidua at the cervix uteri.

F I G. II.

A vertical section of the same.

- AAA The section of the placenta; which, we must suppose, had adhered to the upper and back-part of the womb.
- BB The section of the anterior portion of the decidua.
- CC The section of the posterior portion of the decidua.
- D The termination of the decidua at the cervix uteri.
- EE The cavity of the amnion, in which the embryo hangs by a slender navel string, from the inside of the placenta.
- F The section of the three membranes, which are not only contiguous, but adhere to one another, viz. the amnion, the chorion and the decidua reflexa.
- GG The angle, at the edge of the placenta where the inner layer of the decidua is reflected over the outside of the chorion.
- H Here these three membranes are a little separated, to show their course at the placenta.

F I G. III.

An abortion of about eight weeks. A small slip of the decidua is cut out, and turned up, to show the cavity between it and the other membranes.

- A The cut slip of the decidua.
- B The part of the conception where there is no decidua; viz. opposite to the passage through the cervix uteri.
- CCC The external surface of the decidua.
- D The decidua reflexa covering the chorion and amnion, which project and fill up the cavity of the decidua.
- F The outside of the upper part of the placenta.

F I G. IV.

The same, when the decidua had been opened by a crucial incision, and the four angles had been turned off, and then a round piece of the decidua reflexa dissected off, and turned to one side, to show the loose vessels on the outside of the chorion.

- A, B. See fig. III.
- CCCC The inside of the four angles or flaps into which the decidua was reduced by a crucial incision.
- DDD The decidua reflexa, covering the other membranes.
- EE The angle, at the edge of the placenta where the interior lamella of the decidua is continued over the inside of the chorion, forming the decidua reflexa.
- F A round portion of the decidua reflexa dissected from the outside of the chorion and turned aside.
- G The chorion, with its shaggy vessels, laid bare. These vessels adhered firmly to the decidua reflexa, and parts of them were cut off with that membrane.

F I G. V.

An abortion of the same age, consisting of the chorion only, with its vessels and contents; that is, without the decidua, or uterine part of the secundines.

- AAA The larger and more crowded branches of the shaggy vessels which shoot from the external surface of one part of the chorion, to mix with the decidua, or uterine part, to form the placenta.
- BB That portion of the chorion which afterwards becomes the uniform transparent membrane. It is covered with fewer and more delicate floating vessels, which lose themselves in the decidua reflexa. The embryo is seen through it.
- C The vesicula umbilicalis on the outside of the amnion, seen through the chorion; with a whitish thread, (the remains of an artery and vein) leading from it, towards the navel of the embryo.

F I G. VI.

The same opened. The membranes, which were at the fore-part, being cut from the placenta, and turned up, the embryo is distinctly seen.

- A The vesicula umbilicalis, from which B, the remains of an artery and vein, in the form of a white thread, pass to C, the navel of the embryo, with some turns of the intestines lodged in the beginning of the navel string.

T A B U L A XXXIV.

F I G. I.

OVUM, scilicet chorion, cum omnibus ejus contentis, quintam, ut licet conjicere, circiter hebdomadam. Literæ, antea usitatz, ad dignoscendas partes, minime desiderantur. Macule quæ maxime fuscæ sunt, sanguinis coagulati reliquias parvas repræsentant. In medio, globi instar, conspicitur amnion, per quod fetus indistincte apparet. Ovum ipsum haud paululum mole sua complanatum expansumque fuit, coram pictore in patella dum jacebat.

F I G. II.

Idem ovum præparatum, magna satis parte chorii abscissa, amnioque cum fetu incluso, ut partes circa umbilicum ejus conspicerentur, in latius reflexo, vitri optici ope, ut partes minores magis distincte possent conspici, amplificatum fuit. Vasa hirsuta fluitantia, ex facie externa chorii excusata, per se satis patent.

A A Spatium inter chorion et amnion. Hoc repletum erat gelatina tenera, adeo pellucida ut vix cerni posset; unde arteriæ venæque ramosa, sanguine rubro impleta, in facie interna placenta distincte per eam conspiciantur.

B Amnion liquore pellucido colorisque experte, purissima veluti aqua fontana, distendebatur; per quem fetus partes minores apparebant.

C Vescula umbilicalis humore distensa: neque amnio illa, neque chorio connexa fuit; gelatina autem tenera circumdata, umbilico fetus per arteriam et venam, quasi per pediculum, adnexa; quibus quidem vas tanta inter se vicinitate fuit, ut vas unum sanguine rubro impletum, et ramos in vesiculam umbilicalem folam emittens, videretur. Caput fetus trunco ejus longius fuit; brachia et crura non nisi per paululum emicuerant; viscera abdominis nondum fuerant velita; pars eorum magis fusca hepar fuit: fune umbilici nondum orto, factus faciei internæ chorio et amni, quæ eo loci contigua erant, medio abdomine, adnectebatur.

F I G. III.

Ovum integrum, quartæ hebdomadæ, ut licet conjicere. Ovi pars superior, latior et plana, sacculus fuit, textura tenera, per deciduam folam formatus: hinc ad angulos superiores foramen dentatum utrinque fuit, ubi tubus intrasse conjicere licebat; et ad ovi partem inferiorem portio crassa angulataque ex membranis omnibus contentisque eorum consistit.

F I G. IV.

Ejusdem ovi, sectione a vertice ad imam ducta aperti, facies interna. Ovum totum adhuc fundi uteri formam triangularem retinebat.

Pars lata superior, deciduæ faciem internam levissimam, cribro similem, ostendit; et pars angusta inferior, omnium membranarum sectionem cavumque in conspectu ponit. Fetus primordia omnino soluta fuerant. Amnion a chorio sejanctum fuerat, et in cavo ejus fluitabat. Ex duobus ab eodem centro circulis albis, interior est chorii sectio; cujus in facie externa stratum spongiosum, cui vasa ex chorio se immittunt, cernitur; circulus albus exterior, ad partem inferiorem, deciduam, placentam obtegens, et ad partem superiorem deciduam reflexam repræsentat.

F I G. V.

Ovum integrum tertiam circiter hebdomadam.

A A Seta in cavum ovi trajecta per foramen ad utrumque angulum superiorem, quod scilicet tubæ fallopiæ extremitatem esse conjicere licet.

B B Eadem seta per foramen majus excusata ad angulum inferiorem, quod cervici uteri exadversum esse ponimus.

C Hydatis, molis admodum exigue, per deciduam sese projiciens, et filamenta gracilia ramosa ex superficie sua emittens: chorion esse, vix dubitandum.

F I G. VI.

Idem ovum, maxima parte partium anterioris excissa.

A A, B B, C. Vide fig. V.
Manifestum est deciduam, hæc in ovo, membranam fuisse densam, sextuæ glutinose, quæ toti cavo triangulari fundi uteri, tanquam vestimentum, adhaeserat; consistat etiam tubus in facie ejus interna fuisse terminatus; chorion inter duplicem ejus membranam situm fuisse, vel substantiam ejus circumdatum; parique passis cum incremento chorii, procedente uteri gestatione, cavum deciduæ contractasse, lamellam ejus interiorem (sive deciduam reflexam) distendens, donec tandem, delecto cavo, lamella illa interna faciei interiori deciduæ fuisse contigua. Progressus hæc, de quo agitur, mutationis planius intelligitur, si proximæ his figuræ inter se conferantur, ordine earum inverso, primo scilicet nonam, deinde octavam, et postremo sextam.

F I G. VII.

Scimus ovi æqualem scilicet animo licet conspici: in utero atque proventoria, ubi chorion, decidua reflexa, obtectum, per plurimum spatium in cavum deciduæ porrigitur.

A A Decidua sectio, ubi certo temporis progressu, lamellam externam duplici membrana, spongiosam vel notham chorion vulgo dicitur, constitit.

B In hoc loco, decidua partem placenta, uterinam distam constitit.

C Amnion cavum. — **D** Cavum, vel spatium, amnion inter et chorion.

E Cavum deciduæ, vel spatium membranam illam inter et deciduam reflexam.

F F Tubus in faciem internam deciduæ sese aperientes.

G Cervix uteri nullam partem ovi continens.

F I G. VIII, et IX.

Dux hæc figuræ, in hoc fere solo ab ultima differunt; nimirum chorii in deciduæ cavum projectio eo minor est, quo ovum atque minus.

P L A T E XXXIV.

F I G. I.

A Conception, viz. the chorion with all its contents, supposed to be about five weeks. The parts will be understood without letters of reference. Some of the darkest spots represent the little remnants of clotted blood. In the middle the amnion is seen like a round ball, through which the fetus appears indistinctly. The whole object was considerably flattened and spread out, by its own weight, as it lay in a little dish before the painter.

F I G. II.

The same conception, prepared by cutting away a considerable part of the chorion, and turning aside the amnion with the enclosed fetus, that the parts about the navel might be seen. It is considerably magnified, to show the small parts more distinctly.

The flabby floating vessels, which shoot from the outer surface of the chorion, require no explanation.

A A The space between the chorion and amnion. This was filled with a tender jelly, so transparent as to be almost invisible; whence, the branching arteries and veins, filled with red blood, upon the inside of the placenta, were distinctly seen through it.

B The amnion distended with a liquor as transparent and void of colour as the clearest water; through which the minute parts of the fetus were distinctly seen.

C The vesicula umbilicalis, distended with a fluid. It was neither attached to the amnion nor the chorion; surrounded with the tender jelly; connected, as by a pedicle, to the navel of the fetus by an artery and a vein; which lay so close together, as to appear like one vessel filled with red blood, and dispersing its branches on the vesicula umbilicalis alone.

The head of the fetus was longer than the trunk; the arms and legs had shot out but a little way: the abdominal viscera were not covered: the darker part of these was the red liver: there being no navel-string, the fetus was attached at its abdomen to the inside of the amnion and of the chorion, which were contiguous at that place.

F I G. III.

An entire conception supposed to be in the fourth week. The broad and flat upper part of the object was a bag of a tender texture, formed of the decidua only, with a ragged perforation at each of the two upper angles, where the tubes were supposed to have entered; and the thick and narrow portion, at the lower part of the object, consisted of all the membranes and their contents.

F I G. IV.

The inside of the same object, laid open by a vertical section. The whole conception retained still the triangular shape of the fundus uteri. The broad upper part shows the smoother and cribrate internal surface of the decidua; and the narrow part below shows the section and cavity of all the membranes. The rudiments of the fetus were dissolved. The amnion had separated from, and lay loose in the cavity of the chorion. Of the two, concentric, white circles, the interior is the section of the chorion; upon the outside of which is seen the stratum of spongy substance into which the vessels shoot from the chorion. The outer white circle represents, at its lower part, the decidua covering the placenta; and, at its upper part, the decidua reflexa.

F I G. V.

A complete conception, of about three weeks.

A A A bristle passed into the cavity of the conception, through a hole at each of the upper angles, which was supposed to be the termination of the fallopiian tube.

B B The same bristles coming out through a larger hole at the lower angle, supposed to be opposite to the cervix uteri.

C A small hydatide, projecting through the substance of the decidua, which had slender branching filaments shooting from the surface, supposed to be the chorion.

F I G. VI.

The same conception, after a considerable portion, by its fore part had been cut out.

A A, B B, C. See fig. V.
It plainly appears that, the decidua, in this case, was a thick membrane (of a glutinous texture) which had lined and adhered to the whole triangular cavity of the fundus uteri; that, the tubes terminated on its internal surface; that, the chorion was lodged in its duplicature, or was surrounded with its substance; and that, in proportion as the chorion would have been extended, in the progress of gestation, it would have encroached upon the cavity of the decidua, stretching its interior lamella (or decidua reflexa) till at length the cavity being obliterated, that interior lamella would have come into contact with the inside of the decidua. This progressive change will be more clearly understood by comparing the three following figures in the inverted order, viz. IX, VIII, and VII.

F I G. VII.

The more advanced state of a supposed conception in the womb; when the chorion, covered by the decidua reflexa, is stretched a great way out into the cavity of the decidua.

A A The section of the decidua where, in proof of time, it would constitute the external lamella of the double membrane which has been commonly named the spongy or false chorion.

B Here the decidua constitutes the uterine part of the placenta.

C The cavity of the amnion. — **D** The cavity or space between the amnion and chorion.

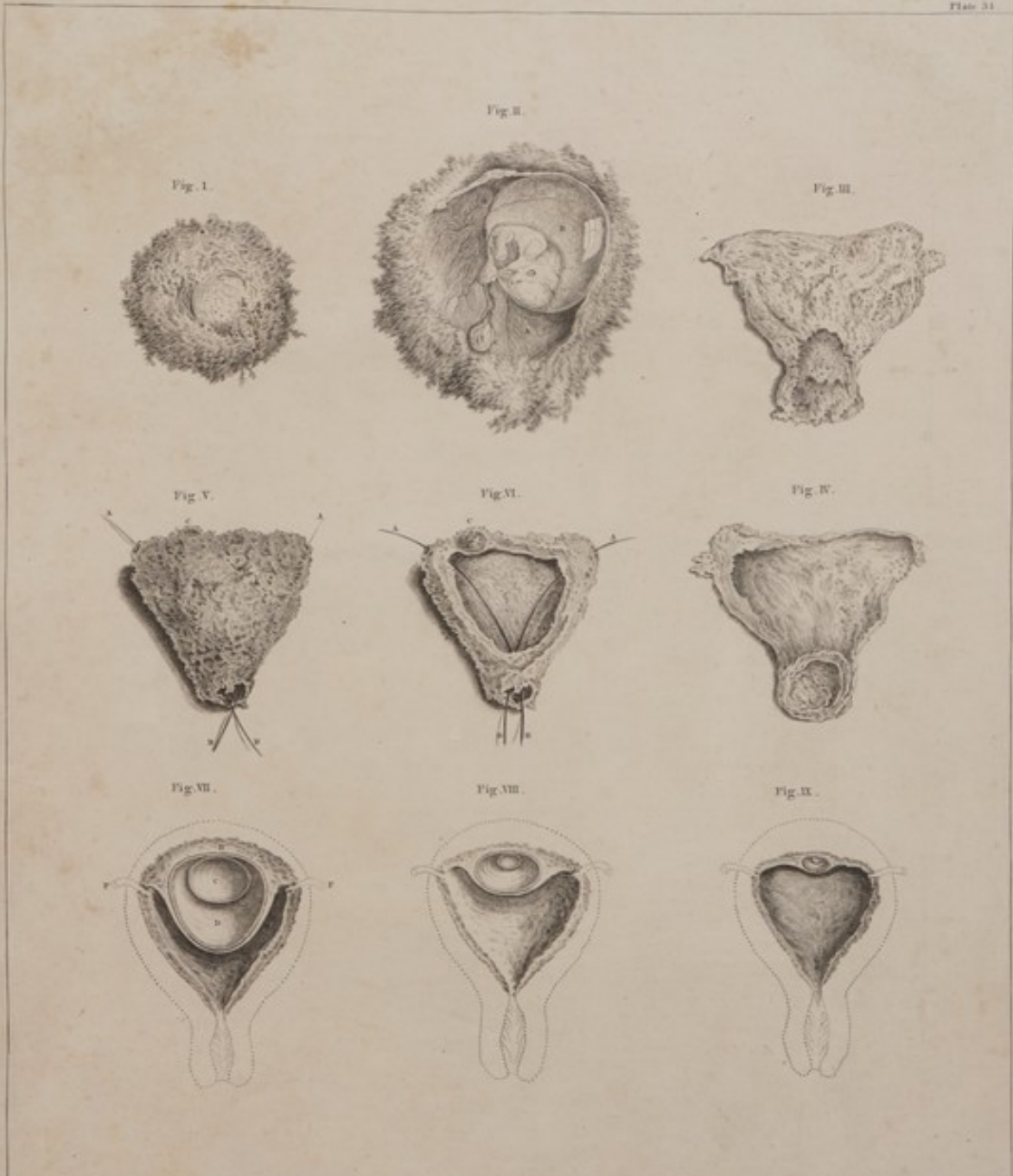E The cavity of the decidua, or the space between that membrane and the decidua reflexa.

F F The tubes, opening upon the inside of the decidua.

G The cervix uteri, containing no part of the conception.

F I G. VIII, and IX.

These two figures differ from the preceding almost in this respect alone, that the projection of the chorion into the cavity of the decidua is less in proportion as the conception is younger.



TAB. XXXIV. Fig. I. Conceptus, quinta circiter hebdomade, nempe Chorion cum omnibus suis contentis. Fig. II. Idem conceptus, circumscripto amplificato, Chori parte anteriori avulso, et Amnio Embryonem continente in latus reflexo. Fig. III. Conceptus integer, quarta circiter hebdomade. Fig. IV. Partes ejusdem interioris, sectione a vertice ad imam ducta, patefacte. Fig. V. Conceptus integer, circa tertiam hebdomadem. Fig. VI. Idem parte anteriori sublata. Fig. VII. VIII. IX. Figurae Quaedam fictae Uteri, in gravidis, secundum longitudinem dissecti, ut ejus diversus, in primis graviditatis hebdomadis, status, qualis mihi videbatur, innotesceret.

10

3
T

2

1/11/18 1867 to 1/11/18

