

Bone and joint studies. 1 / by Leonard W. Ely, and John Francis Cowan.

Contributors

Ely, Leonard W.
Cowan, John Francis.

Publication/Creation

Stanford : Published by the University, 1916.

Persistent URL

<https://wellcomecollection.org/works/qafngum3>

License and attribution

This work has been identified as being free of known restrictions under copyright law, including all related and neighbouring rights and is being made available under the Creative Commons, Public Domain Mark.

You can copy, modify, distribute and perform the work, even for commercial purposes, without asking permission.



Wellcome Collection
183 Euston Road
London NW1 2BE UK
T +44 (0)20 7611 8722
E library@wellcomecollection.org
<https://wellcomecollection.org>

2.B

LELAND STANFORD JUNIOR UNIVERSITY PUBLICATIONS
UNIVERSITY SERIES

Bone and Joint Studies

I

BY

LEONARD W. ELY

Associate Professor of Surgery (Orthopedics)

AND

JOHN FRANCIS COWAN

Assistant Professor of Surgery

(From the Laboratory of Surgical Pathology, Stanford Medical School)

STANFORD UNIVERSITY, CALIFORNIA
PUBLISHED BY THE UNIVERSITY
1916

2

UNIVERSITY SERIES

- INHERITANCE IN SILKWORMS, I. Vernon Lyman Kellogg, Professor of Entomology. 89 pp., 4 plates. 1908. Price \$1.00.
- THE OPISTHOBRANCHIATE MOLLUSCA OF THE BRANNER-AGASSIZ EXPEDITION TO BRAZIL. Frank Mace McFarland, Professor of Histology. 105 pp., 19 plates. 1909. Price, \$1.00.
- A STUDY OF THE NORMAL CONSTITUENTS OF THE POTABLE WATER OF THE SAN FRANCISCO PENINSULA. John Pearce Mitchell, Assistant Professor of Chemistry. 70 pp., 1 map. 1910. Price, 50c.
- SYNOPSIS OF THE TRUE CRABS (BRACHYURA) OF MONTEREY BAY, CALIFORNIA. Frank Walter Weymouth. 64 pp., 14 plates. 1910. Price, 50c.
- THE OSTEOLOGY OF CERTAIN SCOMBROID FISHES. Edwin Chapin Starks, Assistant Professor of Zoology. 49 pp., 2 plates, 1 text figure. 1911. Price, 50c.
- A PHYSICAL THEORY OF ELECTRIFICATION. Fernando Sanford, Professor of Physics. 69 pp., 2 plates. 1911. Price, 50c.
- THE MATZKE MEMORIAL VOLUME. Papers by John Ernst Matzke, late Professor of Romanic Languages, and Thirteen Colleagues. 162 pp. 1911. Price, \$1.00.
- DAS HISTORISCHE PRÄSENS IN DER ÄLTEREN DEUTSCHEN SPRACHE. Bruno Boezinger, Assistant Professor of Germanic Languages. 91 pp. 1912. Price, 50c.
- THE EFFECT OF A STRICTLY VEGETABLE DIET ON THE SPONTANEOUS ACTIVITY, THE RATE OF GROWTH, AND THE LONGEVITY OF THE ALBINO RAT. James Rollin Slonaker, Assistant Professor of Physiology. 36 pp., 1 plate, 15 text figures. 1912. Price, 50c.
- CATALOGUE DE TOUS LES LIVRES DE FEU M. CHAPELAIN. (Bibliothèque Nationale, Fonds Français, Nouv. Acq., No. 318.) Colbert Searles, Associate Professor of Romanic Languages. 119 pp., 2 plates. 1912. Price, 75c.
- THE DUDLEY MEMORIAL VOLUME. Papers by William Russel Dudley, late Professor of Botany, and Several Colleagues. 137 pp., 12 text figures, 9 plates. 1913. Price, \$1.00.
- THE FISHES OF THE STANFORD EXPEDITION TO BRAZIL. Edwin Chapin Starks, Assistant Professor of Zoology. 77 pp., 15 plates. 1913. Price, 75c.

(Continued on third page of cover.)



22900271329

Med
K29599

LELAND STANFORD JUNIOR UNIVERSITY PUBLICATIONS
UNIVERSITY SERIES

Bone and Joint Studies

I

BY

LEONARD W. ELY

Associate Professor of Surgery (Orthopedics)

AND

JOHN FRANCIS COWAN

Assistant Professor of Surgery

(From the Laboratory of Surgical Pathology, Stanford Medical School)

STANFORD UNIVERSITY, CALIFORNIA
PUBLISHED BY THE UNIVERSITY
1916


STANFORD UNIVERSITY
PRESS

31388444

WELLCOME INSTITUTE LIBRARY	
Coll.	welMOMec
Cell	
No.	WE

CONTENTS

	PAGE
Experimental Resection of the Dog's Knee-Joint	
. (Ely and Cowan)	5
Reaction of the Tissues of the Knee-Joint of the Rabbit to Injury	
. (Ely and Cowan)	39
1. Incision, Scraping and Burning the Cartilage of the Patella	
or of the Femur	39
2. Removal of a Wide Piece of Cartilage from the Intercon-	
dylar Groove of the Femur	82
3. Removal of Cartilage, and Boring through the Subjacent	
Buttress	101
Regeneration of Bone Marrow (Ely)	110
A Study of One Hundred Dry Bones Sawn in the Laboratory	
. (Ely)	114
A Study of the Sterno-Clavicular Joint (Ely)	121

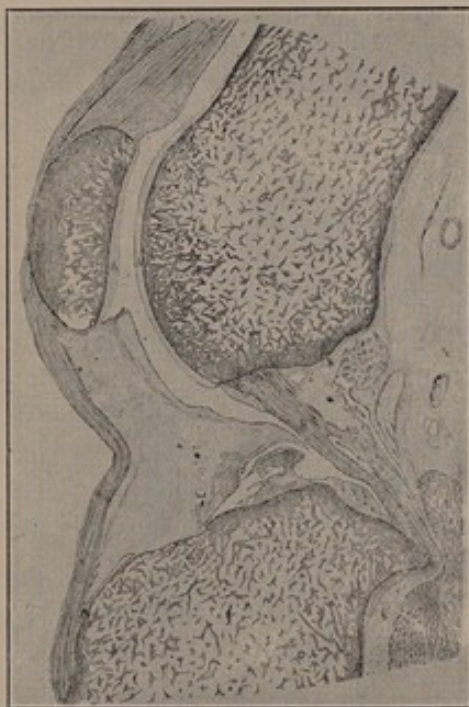


EXPERIMENTAL RESECTION OF THE DOG'S KNEE-JOINT

By LEONARD W. ELY and JOHN FRANCIS COWAN

Illustrations by FRANK BLAISDELL

On the assumption that resection of the dog's knee would result in bony union, this work was undertaken primarily with the idea of studying the histological changes in the bone and marrow following the bony union. This assumption apparently is at the base of most of the work which has been done in experimental arthroplasty. When it be-



Sagittal section of normal knee of dog.

came clear that bony union did not always result, our study was directed to the changes that took place.

Our material consisted of twenty-one dogs. Most of the dogs appeared young. Dog 6 was old. The first dog died under the anaesthetic, probably by suffocation from regurgitated food. Dog 9 was lost. Before the operation the animals, after the first one, received a hyper-

dermic injection of morphine. They were anaesthetized with ether. The skin about the knee was shaved, cleansed with soap and water, mercuric bichloride 1-1000, and alcohol. The wound was sutured in layers, usually with catgut. A plaster of Paris dressing was finally applied.

In many of the operations a piece of bone was implanted in the muscles of the thigh. The results of this bone implantation will be reported at another time.

After death the joint was examined in gross; then an antero-posterior section was made through it. The material was fixed in alcohol, or Orth's fluid, decalcified, usually in 5% nitric acid, run up through the alcohols, imbedded in celloidin, and stained with haematoxylin and eosin and by the van Gieson stain.

Dog 2, 2 years.

Nov. 10, 1913. Resection of right knee-joint.

OPERATION.—Incision curved, convexity downward, through the *ligamentum patellae*. The flaps were reflected and the joint was opened. The articular surface of the condyles was removed, and about one-eighth inch of the articular extremity of the tibia,—that is, a very small piece from each bone. Chromic sutures for the *ligamentum patellae* and capsule. Silk sutures for the integument. Dressing, gauze pads. Limb enveloped with absorbent cotton and bandaged. Plaster spica applied.

Dec. 20. Abdomen large. It is evident that the bitch is pregnant. Plaster removed therefore. Wound healed. Considerable motion is present between the fragments.

Jan. 4, 1914. Gave birth to five puppies.

Jan. 22. In good condition. Bitch has fairly good use of operated leg, though she favors it.

Mar. 18. Uses leg well. Fairly good motion antero-posteriorly.

July 9. Uses leg well. About 20° of motion.

Sept. 16. Uses leg well. About 20° of motion.

Nov. 20. Uses leg well. About 15° of motion. No lateral mobility.

May 4/15. Little if any motion.

Nov. 11. Dog uses limb fairly well. The operated joint seems larger than the other, and possesses a few degrees of motion. It is in about the normal attitude. Killed by gas.

AUTOPSY.—Joint has about 25° motion. Joint removed.

Sagittal section made with a saw. Bones are bound together by fibrous tissue (with a small joint cavity), and in this fibrous tissue there

are transverse clefts, one anteriorly and the other posteriorly. The convex lower end of the femur is received snugly into the concave upper end of the tibia, and motion in flexion is limited by the impinging of the femur against the posterior projection on the tibia, and extension is limited by the tight posterior ligament. The ends of the bones are somewhat sclerosed. A new articular surface for the patella has formed on the anterior surface of the femur. This is soft but smooth, and has the appearance of fibrous tissue. An incision on the lateral aspect of the joint shows that the thickening here is due to a pad of tissue which appears to be fibro-cartilage. Specimen into 80% alcohol.

HISTOLOGY.—A joint is present between the two bones. Each bone has at its end a small bare area, near the anterior portion of the joint. The rest of their extremities is covered by fibrous tissue and by fibro-cartilage. These tissues have cartilage at most of their surface. Long fingers or villi of cartilage protrude into the joint. The end of each bone is hollowed out to a limited extent and the excavation is filled by fibrous tissue. The cartilage on the anterior aspect of the lower end of the femur is fairly well preserved, but its surface is villous and irregular. It articulates with the patellar tendon, and the joint surface of this tendon is lined by villous cartilage, evidently the result of a change of the synovial membrane into cartilage. The tissue preserves the outlines of a villous synovial membrane, and is continuous above with synovial membrane, but it contains many cartilage cells in a delicate fibrous matrix, and has not the internal structure of a synovial membrane.

The cartilage of the patella is becoming delicately fibrillated at its surface. Its distal portion is replaced entirely by fibrous tissue, and this fibrous tissue is continuous at its lower portion with distinct synovial membrane. In other words, the synovial membrane is substituting the cartilage,—the exact opposite of what is transpiring in the patellar tendon, where the femur articulates with it. At one place on the anterior aspect of the femur, blood-vessels are pushing up through the buttress of bone, and the overlying cartilage is becoming fibrous in its whole thickness. Fibrous tissue is replacing the more superficial half of the proximal portion of the femoral cartilage, whose surface has the appearance of a synovial membrane.

The hollow in the end of each bone is, as said above, filled with fibrous tissue; and that in the tibia contains, in its part next the bone, fragments of bone trabeculae undergoing absorption. Evidently the bone has been hollowed out, and the hollow filled by fibrous tissue. Cartilage cells are seen in the fibrous tissue. The cartilage between the two

bones, like that on the posterior surface of the patellar tendon, has the internal structure of cartilage, but the outline of a villous synovial membrane.

The marrow of both bones is mostly fatty, with fibrous marrow at the extreme end. The bone trabeculae are thickened. The marrow of the patella is fatty.

SUMMARY.—Removal of small pieces of bone. Plaster of Paris for 40 days. Duration of experiment, 2 years.

Result.—Bones bound together posteriorly by fibrous tissue. The joint persists anteriorly. The ends of the bones are partly bare, but are mostly covered by cartilage, which was evidently produced from synovial membrane. The joint has a range of motion of about 25° (compare with joint 7).

Dog 3, Lost.

Dog 4, 122 days.

Nov. 14/13. Resection of right knee-joint. Preparation for operation as usual.

OPERATION.—Resection of right knee, removing only small portions of bone, as for dog 2. Wound sutured in layers with catgut. Plaster of Paris spica applied.

Dec. 2. Animal has gnawed the plaster about the ankle; as a result the dressing is looser, and the limb has considerable movement inside of it.

Dec. 6. The plaster has slipped back, and must be retained by a bandage.

Jan. 22/14. Plaster removed. Wound healed. Rather free motion between the bones.

Apr. 16. Dog has been ailing for past 48 hours, is very weak, has cough, nasal discharge and conjunctivitis. Uses leg fairly well in walking, though rather stiffly. About 30° of motion is present in the joint. Animal chloroformed. There appears to be some bone production about the joint, but there is no ankylosis—simply a restricted motion. Joint removed and put into Orth's fluid; later into alcohol.

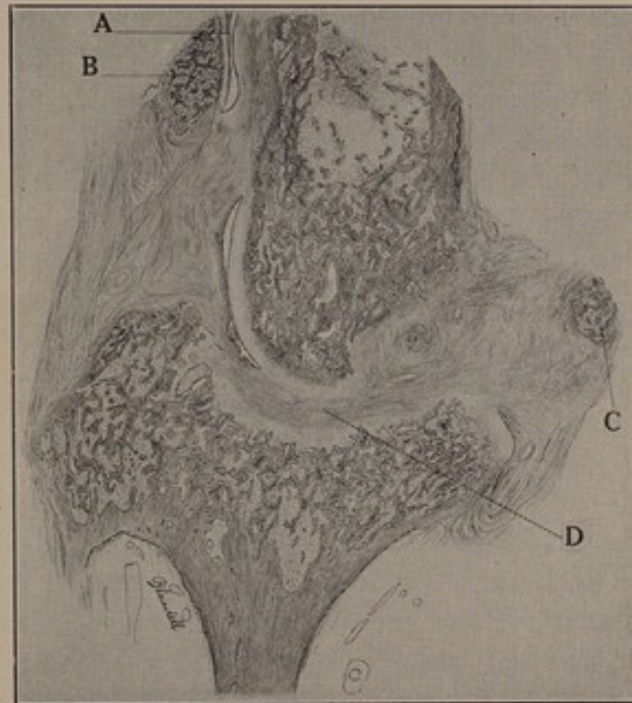
Aug. 6. Sagittal section (anterior-posterior) of joint made with hack-saw. The ends of the bones are compact and are tightly united by fibrous tissue; but anteriorly and posteriorly there is a transverse slit in the fibrous tissue. A tongue of fibrous tissue appears to have extended up into the femur. The fibrous tissue appears continuous with the periosteum. The synovial cavity beneath the patella is preserved.

A section of the joint was made about $\frac{3}{16}$ inch thick. On the other side of the section, that is, $\frac{3}{16}$ of an inch away from the area just described, the tongue of fibrous tissue in the femur has disappeared, and the femur appears larger antero-posteriorly.

HISTOLOGY.—The irregularly convex end of the femur is received into the concave end of the tibia, and the ends of the bones are united by fibrous tissue, in which are clefts.

The trabeculae in the ends of both bones are thickened.

The concavity on the upper end of the tibia seems to be the result chiefly of a rarefying osteitis which has consumed most of the bone



A, Fibrous tissue over roughened patellar cartilage. *B*, Patella. *C*, Sesamoid bone. *D*, Fibrous tissue and fibro-cartilage.

trabeculae in the center of the head of the bone. A few trabeculae here show typical Howship's lacunae. The bone and marrow here are replaced by fibrous tissue, and this fibrous tissue extends down among the trabeculae of the bone beneath. The concavity is made deeper by a large projection of new-formed bone anteriorly, and by a smaller one posteriorly. In the marrow of the posterior process (lymphoid in character), and in the fibrous tissue just posterior to the anterior process, are islands of cartilage.

Posterior to the lower end of the femur, and connected with it by fibrous tissue, is a small piece of bone. It is surrounded by fibrous tissue, and contains a small island of cartilage at its extreme posterior part. It is probably a sesamoid bone. Apparently osseomucin is being deposited in the fibrous tissue about the bone island. The cartilage on the anterior surface of the femur is still present, but is overlaid by fibrous tissue, and its surface is irregular in places. It faces the fibrous tissue of the patellar tendon. A slit is present between these two, and the tissue at their surface has the appearance of a synovial membrane. The patella probably has been displaced upward by the operation, and articulates with the periosteum-covered femur. Its cartilage is still present, though its surface is irregular, and it is being replaced in its superficial portion by fibrous tissue.

SUMMARY.—Removal of small pieces of each bone. Immobilization, not very thorough, for 69 days. Duration of experiment, 122 days.

This appears to be a case of the formation of a new joint by the tying of the bone ends together by fibrous tissue. Clefts have formed in the fibrous tissue. The end of the tibia has been hollowed out to receive the convex end of the femur. This hollow has been deepened by the production of new bone, anteriorly and posteriorly, on the tibia.

Dog 5, 21 months.

Nov. 17/13. Resection of right knee-joint.

OPERATION.—Incision curved, convexity downward, running below patella. Flap retracted, joint opened. Tips of condyles removed and about one-eighth inch from head of the tibia,—that is, very little bone. Deep chromicized catgut and superficial silk sutures. Plaster spica.

Nov. 19. Spica has slipped; removed; new spica. Wound in good condition.

Nov. 20. During night the spica slipped off entirely. In spite of this fact the dog does not appear to suffer and the wound is not injured. New spica.

Nov. 23. Spica came off; renewed. Swelling better. Wound looks good.

Nov. 28. During night the spica came off. Wound is completely closed by first intention. All swelling has disappeared. Leg in excellent condition.

Dec. 1. New plaster dressing, running up around neck.

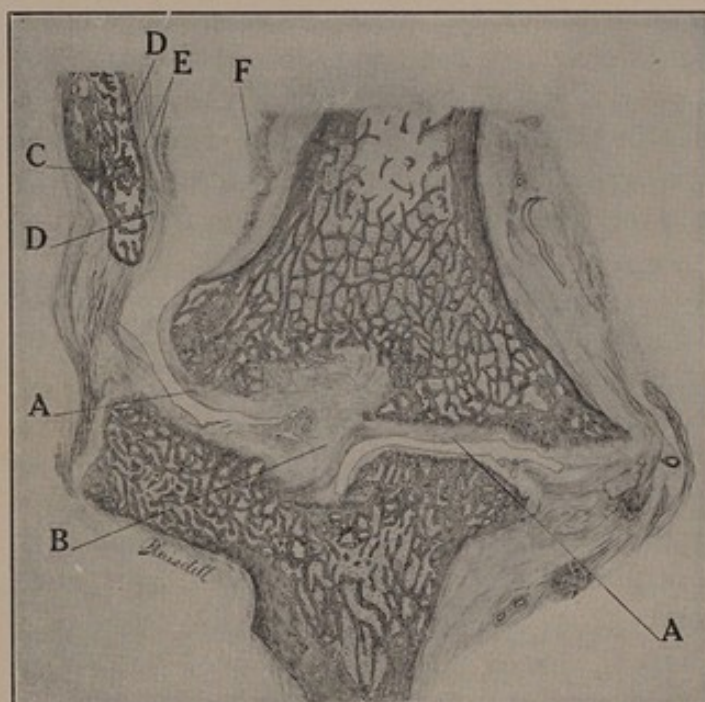
Dec. 6. The spica has a tendency to slip backward. Held in place by applying bandage about neck.

Jan. 22/14. Dog in excellent condition. Plaster broken; removed. Bones evidently united fairly firmly with fibrous tissue. Some motion is present between them. The dog can use the leg for bearing weight.

Nov. 20. Uses leg a little. About 10° or 15° of motion; no lateral motion.

May 4/15. Apparently firm ankylosis.

Aug. 13. Dog uses the leg well. Killed by illuminating gas. Joint removed. There are about 5° to 10° of motion in it. No lateral motion.



A, Fibro-cartilage. B, Intra-articular ligament. C, Patella. D, Articular cartilage. E, Fibrous tissue. F, Synovial membrane.

Patella freely movable. Sagittal section into alcohol. There is no evidence of union between the bones, except by a fibrous cord midway of the joint. Anterior and posterior to this are joint cavities. The obstruction to flexion and extension is caused by the tightness of this band and by the flattening off of the contiguous surfaces of the femur and tibia. They fit very tightly together.

HISTOLOGY.—The microscopic findings confirm the macroscopic. The two bones are held tightly together by an intra-articular ligament, and their opposing surfaces, covered by fibro-cartilage and fibrous tissue, are practically plane surfaces. In places the surface is covered by a film of

degenerated tissue. The cartilage cells are found mostly close to the bone. A well developed joint cavity, divided by the intra-articular ligament into two compartments, is present. The anterior pouch is continuous with that on the anterior surface of the lower end of the femur. Posterior to the posterior slit the bones are bound together by fibrous tissue and fibro-cartilage. A synovial membrane with well marked villi covers the periosteum on the anterior surface of the lower end of the femur, but does not extend in between the tibia and femur. The cartilage on the posterior surface of the patella is covered by fibrous tissue, possessing also a synovial lining in places. The cartilage has been replaced at the periphery and at the center by fibrous tissue. The bone of the patella stains poorly, and is degenerating. The marrow is fatty. The bone trabeculae in the extreme ends of the femur and tibia are quite thick, and stain well. The marrow here is fatty. Farther away from the joint the trabeculae stain poorly, and seem to be undergoing absorption.

SUMMARY.—Removal of small pieces of bone. Immobilization for over 2 months. In this specimen, after 21 months, we find a process which, as far as the joint itself is concerned, apparently has run its course. The head of each bone is covered by fibro-cartilage, and a well-marked joint is present. No adhesions have formed between the bone ends. No ankylosis is present. The limitation of motion is due simply to the tight apposition of the flattened and broadened bone ends. The bone is dense in the end of the tibia and of the femur, and is disappearing in the patella.

Dog 6, 462 days.

Nov. 19/13. Resection of right knee. Operation as in previous cases, removing a rather small amount of bone. Plaster spica.

Nov. 22. Spica entirely off the body and badly gnawed on the leg. Later the animal had completely torn the spica and dressings off the wound. New spica applied. At one point the skin margins of wound are separated for about one-half inch. Slight discharge, reddish and slightly purulent.

Nov. 23. Spica gnawed off. Slight discharge from wound. Wound to be left uncovered so that animal may lick it. The knee is in flexion.

Nov. 26. Wound gaping a little at middle; no swelling, very little discharge; condition satisfactory.

Dec. 1. Skin-wound about same. Considerable serous fluid from the wound. Knee region slightly swollen.

Jan. 22/14. Wound healed a couple of weeks ago. Animal in good condition, but will not use operated leg.

Mar. 18. Animal uses leg. Some motion between bones.

July 9. A useful, movable joint of good stability is present.

Sept. 16. Good range of motion. Useful, painless joint.

Feb. 24/15. Animal in health, uses leg well. Wound is healed. Killed by blow on back of head and ether. Knee in semiflexion. Range of motion between about 115° and 65° ,—that is, 50° .

Feb. 24. Joint removed and sawed sagittally. No bony union. Fibrous union between femur and tibia. Upper end of tibia cupped. In mass of fibrous tissue there are one or two small cavities. A joint is present between patella and condyles. Ends of bones seem to be quite dense; condyles fit into a slight concavity in the upper end of the tibia.

HISTOLOGY.—The bones are tied together by dense fibrous tissue, in which are two or three small clefts. The femoro-patellar joint is in good condition, except that the synovia is encroaching on the patellar cartilage from the side, and is somewhat villous and thickened, and in one place fibrous tissue is pushing up through the cartilage of the femur (Type I), at the surface to meet the synovial membrane, extending in from the side.

The cartilage on the posterior portion of the femur, spared by the saw, is, except for some irregularity of structure and some surface degeneration, fairly normal; but as it approaches the fibrous tissue binding together the two bones (femur and tibia) it becomes fibrillated. Under the fibrous tissue on the end of the femur runs a buttress of bone, pierced by small channels containing blood-vessels.

The fibrous tissue over the end of the tibia contains many groups of cartilage cells. The buttress of bone is not as well marked as on the femur, and in one area about 5 mm. in diameter does not exist. The fibrous tissue here seems to be pushing down into the head of the tibia, and so forming a cavity in it.

The marrow in both bones is fatty, with a little lymphoid. Synovial membrane is seen anteriorly and posteriorly, but there is none in the uniting fibrous tissue.

SUMMARY.—Removal of rather small amount of bone. Ineffectual immobilization for a few days. Duration of experiment, 462 days.

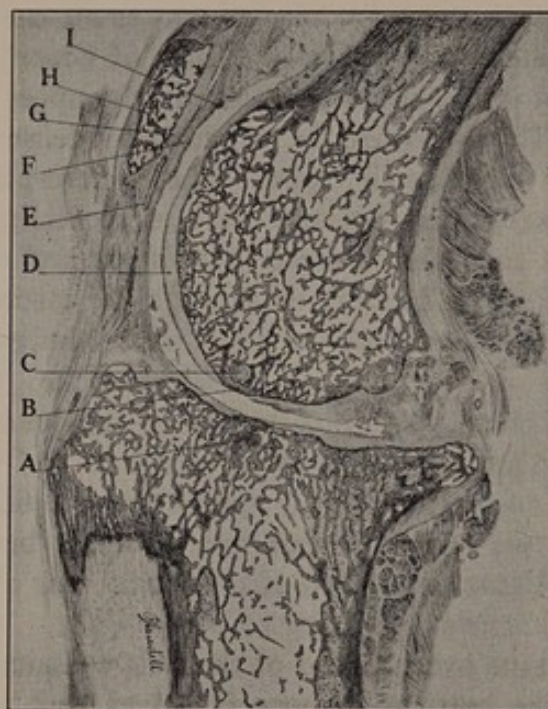
Result.—The bones are bound loosely together by fibrous tissue, in which no synovial cavities are seen. The process seems to be practically at an end, without prospect of any firmer union than at present exists.

Dog 7, 23 months.

Nov. 21/13. Resection of right knee-joint.

Operation as in previous cases. Greatest thickness of piece of condyles removed, 7 mm.; greatest thickness of articular end of tibia resected, 5 mm.—small pieces. Deep chromicized and superficial plain catgut sutures. Plaster spica applied.

Feb. 27/14. Galled by plaster. Plaster removed. Good firm union of bones; no apparent motion with use of moderate force.



A, Fibro-cartilage in tibia. *B*, Bare bone. *C*, Fibro-cartilage in femur.
D, Articular cartilage. *E*, Synovial pocket. *F*, Fibrous tissue
 over patellar cartilage. *G*, Patellar cartilage. *H*, Patella.
I, Synovial membrane.

Mar. 18. Uses leg. Very little motion.

Nov. 20. Very little motion, no lateral motion.

May 4/15. Very stiff. Apparently firm ankylosis.

Oct. 4. In health. Animal killed by illuminating gas. The knee possesses about 20° motion in flexion and extension. No lateral motion possible.

Joint excised and sawed sagittally.

No adhesions between bone ends are present, no attempt at bony union. A well marked joint cavity is present between the two bones, and the only obstruction to motion is by the capsular ligaments. The femur is convex, rounded off, smooth, cartilage-like, and fits into concavity in the tibia, which is also smooth and cartilage-like.

Ends of bones appear denser than normal.

HISTOLOGY.—A distinct joint is present between the two bones, and their ends evidently have been so remodeled that they fit well to each other. The lower end of the femur in gross is smoothly convex, and the upper end of the tibia is concave. The tibia seems bigger antero-posteriorly than normal.

The ends of the bones are seen to be bare over a small portion of their extent. The bare bone of the tibia is very rough, of the femur rather smooth. Over the rest of their articular ends they are covered by fibrous tissue, which in turn is overlaid by a layer of rough, shaggy, villous fibro-cartilage. The cartilage on the anterior aspect of the lower end of the femur is preserved, and in good condition, except that it is becoming fibrillated at its surface. From its surface also spring more finger-like processes, one of them very long. This cartilage on the anterior aspect of the femur articulates with the fibrous tissue of the patellar tendon and with the patella, which is mostly covered by synovial membrane. Clefts in the fibrous tissue are lined also with synovial membrane.

The patellar articular cartilage is present. The surface, irregular in places, is overlaid by fibrous tissue, to which it is tightly adherent over a portion of its extent. The exact limit of the two cannot always be defined. At the surface of the fibrous tissue, where it articulates with the cartilage of the femur, is a small patch of synovial tissue, and another one at the extreme proximal end of the crural pouch.

Immediately beneath the bare area at the end of each bone, in the marrow, is a small area of fibrous tissue containing cartilage cells. The marrow in each bone is mostly fatty. There is no sign of active bone production. The process apparently is finished.

SUMMARY.—Removal of small pieces of bone. Immobilization for 98 days. Duration of experiment, 23 months.

Result.—Formation of new joint. The bone ends are lined for most of their extent by fibro-cartilage. Presumably, from the villous appearance of the fibro-cartilage, it has been produced by a spreading in of the synovial membrane. Remnants of a synovial membrane persist in the capsule. Activity in the reparative process apparently is ended.

Dog 8, 432 days.

Dec. 1/13. Usual preparation. Resection of right knee. Removal of 9.5 mm. of tuberosities of tibia and 16.5 of lower end of femur. *Removal of patella and its burial in gluteal muscles.* Deep sutures of chromicized catgut, and superficial sutures of silk. Catgut and silk in wound in gluteal muscle. Plaster of Paris spica applied.

Jan. 22/14. Plaster filthy. Pressure sores. Plaster removed. Rather firm union, with large bony callus. Very little motion present.

Mar. 18. Animal doing well. She uses leg. Firm union present.

July 9. No motion at site of operation.

Feb. 13/15. Dog killed by ether anaesthesia. Very little movement in joint. Wound healed. Joint removed; sawed sagittally and placed in 80% alcohol.

Feb. 19. Sagittal section of knee shows firm bony union of femur and tibia. The bone in the vicinity seems denser than normal, and there is a well marked tendency to the formation of two strips of dense bone prolonging the cortical bone above and below. The marrow is yellow except in a few small patches, where it is red.

HISTOLOGY.—The bones are united by bone, and this bony union does not extend clear across the specimen but across only about its central third. On one side of the slide extending in from the anterior aspect is a plug of fibrous tissue and fibro-cartilage, binding together the ends of the bones. On the other side is another plug of fibrous tissue and fibro-cartilage streaming in from the posterior aspect, and tying the ends of the bones together. In places where the uniting tissue joins the bone, especially in the posterior plug, a layer of cartilage is present, which is undergoing ossification. The bony union is represented by rather dense bone, continuous with trabeculae above and below,—that is, in the femur and tibia. Here and there in the band of dense bone are groups of cartilage cells, whose capsules are frayed and indistinct. At the anterior extremity of the posterior plug, a bundle of fibrous tissue runs from it into the marrow. There is no sign of bone condensation at the cortex. The marrow is mostly fatty. Here and there small areas of lymphoid marrow are seen. Many giant cells are seen in the area of bony union, especially that part of it composed of cartilage. There are a few also at the anterior extremity of the posterior plug of fibro-cartilage.

Many of the marrow spaces contain quantities of bone detritus, bits of necrotic bone, some of which can be seen connecting with the trabeculae; that is, the trabeculae seem to be breaking up into fragments, but not by any action of fibrous tissue or of osteoclasts.

SUMMARY.—Removal of rather large pieces of bone. Immobilization for 54 days. Duration of experiment, 432 days.

Result.—Bony union between a portion of the bones; fibro-cartilaginous union, evidently becoming bony, between the rest.

Dog 9, 98 days.

Dec. 15/13. Usual preparation. Resection of right knee. Removal of 20.5 mm. of femur, 14 mm. of tibia (a very large amount). Deep sutures of chromicized catgut, superficial sutures of silk. Plaster of Paris spica applied.

Dec. 27. Plaster has been chewed up so as to be of no use. Remnants removed. Wound healed per primam. Bones freely movable. Silk removed. New plaster spica applied.

Dec. 29. Plaster chewed off again. Removed.

Jan. 22/14. Animal uses operated leg somewhat, though favoring it.

Mar. 18. Free motion.

Mar. 23. Chloroformed. No sign of any infection. Wound healed and hair grown over it. The joint possesses a range of motion of about 90° and is fairly firm when extended. In flexion it is wobbly. Joint removed.

Apr. 24. Bones removed from acid. The soft parts have been detached so that the bones fell apart. Section cut from tibia and femur for further decalcification. Material lost.

Dog 10, 208 days.

Dec. 15/13. Small bitch. Usual preparation. Resection of right knee, removing 20 mm. from femur, 11.5 from tibia (large pieces for this sized dog). Suture as usual; plaster spica.

Jan. 22/14. Plaster removed; it was of very little use. There appears to be a production of callus on the lower end of the femur, but the tibia is very loose and wobbly. What union there may be is very unstable. Stitches removed. Wound healed.

Mar. 18. Animal uses leg a little. The operated joint is quite wobbly.

July 9. Genu recurvatum. Freely movable, laterally and antero-posteriorly.

July 11. Dog died suddenly this morning.

AUTOPSY.—Lungs engorged. Pneumonia in stage of red hepatization—rather extensive. Joint removed.

Aug. 6. Femur seems displaced somewhat laterally. Joint sawn sagittally. The ends of the bones are apparently denser than normal, and are bound together by fibrous tissue, in which there are two partial transverse slits, like partial joints. The synovial cavity under the patella has disappeared except at its distal part, where one of the slits is. The cartilage is present anteriorly over the femur.

HISTOLOGY.—The ends of the bones are tied loosely together by fibrous tissue, in which are many clefts, some lined by a synovial membrane. On the anterior aspect of the lower end of the femur is a large knob, and another on the posterior. These knobs are composed of bone, fibro-cartilage and fibrous tissue. Vessels are pushing into the fibrous tissue and the fibro-cartilage from the marrow beneath, and are converting them into bone. Many thick trabeculae have been formed in the end of the femur, and the end of the bone is covered by fibrous tissue, with a synovial surface shutting off communication between joint and marrow. A depression exists between the two knobs on the end of the bone, and lying in this depression are masses of connective tissue—villi—for the most part covered by a synovial membrane, and smaller masses of hyaline fibrous tissue in which are many cartilage cells, single and in irregular groups. The marrow of the femur is a mixture of lymphoid, and fatty.

The head of the tibia has been subluxated backward, and articulates with the knob on the posterior aspect of the femur, to which it is tied by fibrous tissue. On account of a lateral displacement of the two bones, the head of the tibia appears in the slide only as a thin piece of bone. The trabeculae in the patella are scant, and take the eosin stain very poorly. They are evidently being consumed. The marrow is largely fatty. Fibrous tissue has grown in over the cartilage at its proximal portion, obliterating the joint in this region. The joint is also largely filled by fibrous tissue. The surface of the patellar cartilage is rough, and in one place in the section a communication exists between the marrow and the fibrous tissue covering the cartilage. The limits of the encroaching fibrous tissue and those of the cartilage cannot be exactly defined.

SUMMARY.—Removal of large pieces of bone. Ineffectual immobilization for 5 weeks. Duration of experiment, 208 days. A joint exists in this case, without any tendency to obliteration. The fibrous union is a loose one. The lower end of the femur forms the cup (the only instance in our series), by means of the production of new bone and cartilage. It is covered by fibrous tissue, with a synovial lining. A

synovial covering also is present on the fibrous villi in the joint, and some of these villi are transforming into cartilage.

Dog 12, 14 days.

Rather small young bitch.

Jan. 28/14. Resection of right knee. Removal from femur of 22.5 mm., from tibia of 8.5 mm. Patella into gluteal muscles. Wound suture same as in preceding experiments. Plaster spica applied.

Feb. 4. Plaster galls; removed. Ugly sore under opposite thigh.

Feb. 5. Operation wound healed.

Feb. 11. Dog has been ailing for 48 hours. Now looks worse.

Feb. 12. Dog died last night. Blood-streaked saliva before death.

AUTOPSY.—The operation wound is almost healed, and shows no sign of infection. There is no fluid in the joint, which is movable in flexion and extension. Joint not opened, put into Orth's fluid.

The abdominal cavity was full of a haemorrhagic exudate, and multiple haemorrhages were found in peritoneum. The lungs were the seat of multiple haemorrhages also. The liver was reddened and seemed roughened.

Feb. 23. Material put into 10% nitric acid solution.

Mar. 25. Joint cut sagittally with a knife. The bones are rather firmly united by fibrous tissue at their circumference. The head of the femur is subluxated laterally on the tibia. The ends of the bones are covered by loose fibrous tissue, but are not united. No adhesions are present. A piece of cartilage can be seen on the posterior portion of the head of the tibia. Two sagittal sections made, and put back into 10% HNO_3 .

HISTOLOGY.—A joint cavity is plainly seen between the two bones. The end of the femur is covered by fibrin, the end of the tibia partly so. Fibrin lines also the soft parts of the joint, and beneath it is fibrous tissue with very fine collagen fibrils. Nothing that looks like synovial membrane can be seen.

Femur.—The bone ends are very straight, as cut by the saw. A few remnants of necrotic cartilage lie beneath the fibrin. The marrow is packed with cells, and near the joint is undergoing fibrosis. Here, near the joint, the trabeculae are extremely irregular in their arrangement, and in their staining. Either they are undergoing necrosis, or bone production through the medium of fibrous tissue is taking place. Rarefying osteitis is going on at the side of the bone near the line of section, with osteoclasts in Howship's lacunae. One side of the cortex

(that on the side opposite to the rarefying area) presents a peculiar appearance. A layer of dense bone, which we take for the original cortex, is overlaid by a layer of spongy bone with the staining qualities noticed in some of the trabeculae in the bone end. This layer of spongy bone, when followed toward the joint, contains near the line of section large irregular areas of cartilage which appear to be ossifying. Communications exist between the marrow of the spongy and the dense areas. The marrow in the former is fibrous and oedematous, in the latter lymphoid. We regard the spongy layer as new periosteal bone.

Tibia.—The joint end is lined in places by fibrin, in places by necrotic material. The tissue beneath the former is fibrous, beneath the latter, bone. The trabeculae near the joint are numerous and are irregular in their staining reaction. They are evidently degenerating.

SUMMARY.—Removal of large pieces of bone. Immobilization for one week. Duration of experiment, 14 days.

Result.—Free motion between the bones, and a cavity between them lined by fibrin. Beginning periosteal bone formation to remodel the end of the femur.

Dog 13, 88 days.

Jan. 29/14. Resection of right knee. Removal of 20 mm. from femur and 12.5 mm. from tibia. Patella buried in glutei. Suture as usual. Plaster spica applied.

Feb. 28. Plaster removed.

Mar. 18. Apparently firm union.

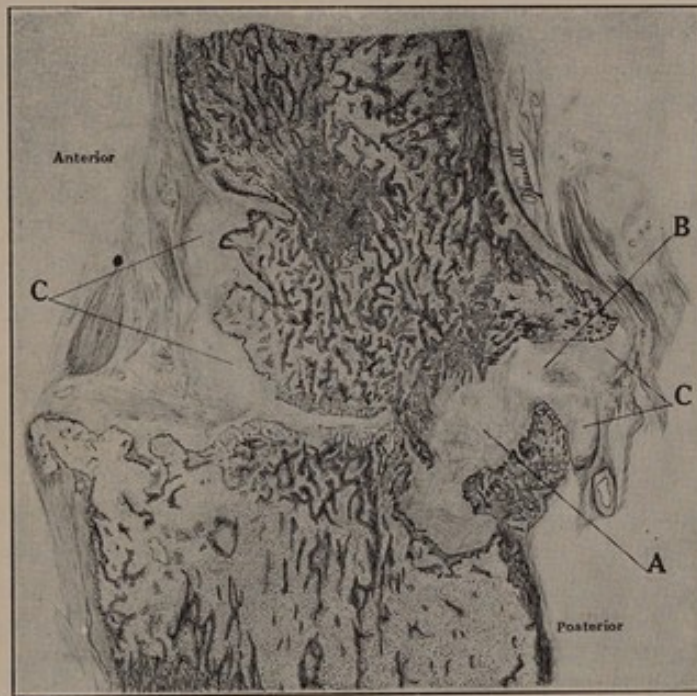
Apr. 27. Dog died last night of an epizootic that has affected most of the dogs.

AUTOPSY.—Apparently firm bony ankylosis, with production of new bone. The lungs are consolidated and hyperaemic through much of their extent. Adhesions in the left pleura are present. *Pneumonia.* Joint removed in toto, with about 3 cm. of bone on each side. No sign is present of any infection whatever. Apparently complete firm ankylosis. Red marrow in the shaft of both bones. (At line of section there was the beginning of a central canal.)

Aug. 10. Joint sawn sagittally. The bones are tightly united, giving the impression of bony union, but a fine line of division can be made out. The bones are very dense in structure, but at two or three places there are areas of soft tissue, near the joint line.

Dec. 15/15. Review of specimen. The blocked section shows a fine line of cartilage running across between the two bones, but one side of the joint left in alcohol shows an actual bony union between the two.

HISTOLOGY.—On the anterior aspect of the lower end of the femur is a layer of cartilage, which extends in between the femur and tibia, and unites the bones firmly for about half the line of their junction. At the posterior extremity of this thin band of cartilage is a small area where the trabeculae pass from one bone to the other (bony union). Vessels are pushing into the cartilage from both bones, and the cartilage is undergoing ossification. Posterior to this bony band of union, the tibia



A, Dense fibrous tissue. B, Fibro-cartilage. C, Cartilage.

and femur are united by dense fibrous tissue. Posterior to this, the uniting tissue is composed of fibrous tissue and fibro-cartilage. At the posterior part of the line of junction are two fairly large areas of hyaline cartilage separated by a layer of fibro-cartilage. These are immediately beneath the posterior ligament. Ossification of these areas of cartilage is going on from above and below. In the middle of the area next the femur are several capillaries, giving an appearance identical with that seen in the early stages of ossification in the epiphysis,—by tufts of blood-vessels pushing in from the marrow beneath and starting an ossific center in the cartilage. This same phenomenon is present in the cartilage on the anterior aspect of the femur.

The bone trabeculae in both bones are irregular in their arrangement, and extremely so in their staining. Their cells also stain very poorly or not at all. Many of the trabeculae near the line of junction are composed largely of cartilage ossifying at its margin. Islands of cartilage can also be seen in the marrow. The marrow is largely lymphoid, but near the line of junction it is mostly fibrous. Areas of a hyaline substance are abundant in the marrow. So-called osteoclasts in Howship's lacunae can be seen here and there.

SUMMARY.—Removal of large pieces of bone. Immobilization for 30 days. Duration of experiment, 88 days.

Result.—Bony union, through the medium of fibrous tissue and cartilage.

Dog 14, 117 days.

Feb. 3/14. Resection of right knee. Removal of 20.75 mm. from femur and 9.5 mm. from tibia. Patella into glutei. Usual suturing. Plaster spica applied.

Feb. 21. On account of excoriation, plaster removed. Wound healed except at its outer end, where it is granulating.

Mar. 18. Doing well. Uses leg a little. Free motion.

June 1. Animal died yesterday; she had been ailing for a couple of days.

AUTOPSY.—The incision has healed completely. The knee is freely movable. Cause of death not discovered. The lungs seem very dry. Knee and patella removed and put into 80% alcohol.

Aug. 8. Joint sawn sagittally. The end of the femur is received into a cup-shaped surface of the tibia. Both bones seem eburnated. There is a well defined joint cavity, and no fibrous connection between the cut surface of the bones, but some loose fibrous tissue on these surfaces.

HISTOLOGY.—A joint is present between the two bones. The trabeculae in the end of the femur are much thickened, and are arranged irregularly. The marrow near the joint is fibrous, at a little greater distance it is lymphoid, and the trabeculae are more sparse. The trabeculae in the head of the tibia are increased in number and thickness.

The ends of both bones are rough, and are partly covered by fibrous tissue. Synovial membrane covers part of this fibrous tissue. Especially over the head of the tibia the extension inward is marked. No articular cartilage is present. A synovial membrane, thickened and villous, lines the capsule. Much of the synovial membrane is covered by a material which looks like fibrin. In a fibrous plug going down into the head of

the tibia are a few cartilage cells. In some of the villi also groups of cartilage cells are seen.

SUMMARY.—Removal of a large amount of bone. Immobilization for 18 days. Duration of experiment, 117 days.

Result.—Formation of a new joint, but without the formation of a new articular cartilage. Synovial membrane lines the capsule.

Dog 15, 240 days.

Feb. 5/14. Resection of right knee. Removal of 21 mm. from femur, 7.75 from tibia. Patella buried in glutei muscles. Usual suturing and plaster spica.

Mar. 19. Plaster filthy; removed. Considerable motion is present.

July 9. Free motion.

Sept. 16. Moderate amount of motion.

Oct. 1. Killed with ether. The joint possesses free motion in arc of 90° and moves smoothly.

Oct. 3. Sagittal section through joint. There is a small joint cavity divided into compartments by fibrous tissue on the lateral and medial aspect of the former joint; but throughout the middle portion of the union and including the section saved, no cavity can be seen and the bones are united by dense fibrous tissue. Bone ends are dense, and marrow is present in the shaft of the tibia and femur. The end of each bone is concave.

HISTOLOGY.—The bones are bound loosely together by a thick band of dense fibrous tissue in bundles, with rifts and spaces in it. Some of the spaces contain detritus, others are lined by synovial membrane, with a marked villous proliferation. The fibrous bundles run in all directions, some directly between the two bones, others in from the periosteum to the end of either bone, where they merge into the bony tissue itself, and pass also into the marrow spaces. The upper end of the tibia is hollowed out, although the femur does not fit into it, and the fibrous tissue fills most of the space between the two layers of cortical bone. There is little bone here in the hollowed-out area, but farther away from the joint thick trabeculae abound (shutting off the marrow canal from the end of the bone). From these thick trabeculae slender trabeculae run toward the joint, in the fibrous tissue. Apparently they are being replaced by fibrous tissue. Here and there can be seen giant cells in Howship's lacunae.

The marrow is lymphoid, except for the fibrous marrow in the ends of both bones.

A large synovial cavity is present posterior to the line of junction of the bones, and another anterior to the lower end of the femur. The latter is probably the remains of the quadriceps pouch. A third fairly large cavity is present in the fibrous tissue between the two bones near the posterior portion.

SUMMARY.—Removal of large pieces of bone. Immobilization by plaster of Paris for 42 days. Duration of experiment, 240 days.

Result.—Loose fibrous ankylosis with persistence of synovial cavities, and no indication of the conversion of this ankylosis into bone.

Dog 16, 97 days.

Feb. 16/14. Resection of right knee. Removal of 20 mm. from the femur and 17 mm. from the tibia. Patella into glutei. Plaster spica applied.

Apr. 11. Plaster removed. It was foul about the site of operation, where the skin was red and granulating.

May 25. Dog has been sick for some time. He was stricken with paralysis two days ago, and died yesterday.

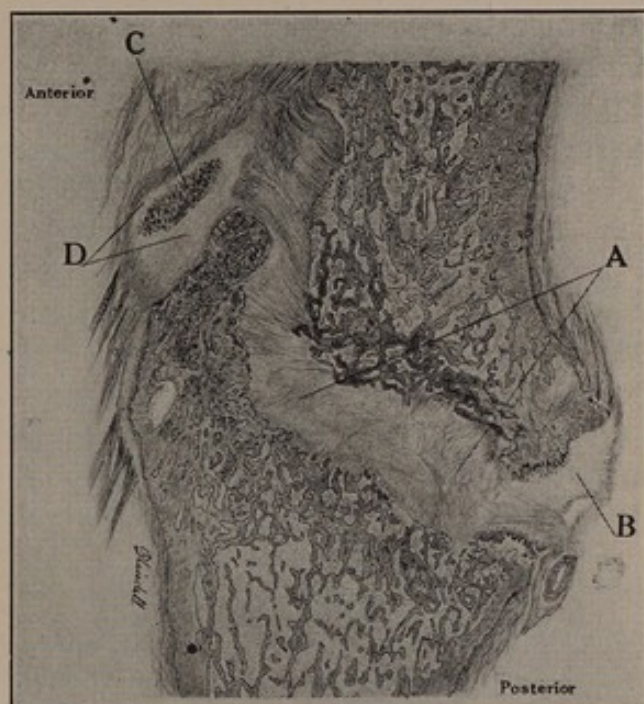
AUTOPSY.—Right lung pale. Contains what is probably an old organized pneumonia in two or three small areas. Embolus in left lung. Organized thrombus in heart.

Knee appears firmly ankylosed, with bony proliferation. Wound has completely healed. Sections from lung show pneumonia and organized emboli.

Aug. 10. Joint sawn sagittally. The ends of the bones are tightly united, in fact so tightly that in one place the union appears bony. The ends of the bones seem very dense.

HISTOLOGY.—The bones are bound together tightly by dense fibrous tissue in the middle of the section, without any rifts, and containing a few cartilage cells here and there. There is no suggestion of a joint cavity anywhere. The union is very firm. Anteriorly and posteriorly fibro-cartilage binds the bones together, and appears to be undergoing ossification where it meets the bones. Anteriorly the tibia is developing a spur of bone up in front of the femur, out of fibro-cartilage; that is, a mass of fibro-cartilage in front of the lower end of the femur is undergoing ossification from the bone in the tibia below. It is also being ossified from the femur posteriorly, and shows in its interior a typical picture of endochondral ossification, as in an epiphysis. This makes the union very firm. The bone trabeculae at the end of each bone are quite

abundant, and form a well marked transverse layer, more or less toothed. The uniting fibrous tissue merges into these teeth of bone. The marrow in the immediate vicinity of the operated area is fibrous and oedematous, in other situations it is lymphoid. A small wedge of fibrous cartilage is



A, Dense fibrous tissue. *B*, Fibro-cartilage. *C*, Bone. *D*, Cartilage.

present between the bones posteriorly, and is being ossified from the marrow of each bone. A small sesamoid bone behind the line of junction of the bones has been caught by the microtome.

SUMMARY.—Removal of large pieces of bone. Immobilization by plaster for about 8 weeks. Duration of experiment, 97 days.

Result.—Firm union by fibrous tissue and by fibro-cartilage. This fibrous tissue and fibro-cartilage are being converted into bone. The indications are that the union eventually would have been bony.

Dog 17, 347 days.

Feb. 28/14. Resection of right knee. Removal of 22 mm. from the femur (an enormous piece for a dog of this size, and almost reaching the medullary canal. A good layer of dense cortex is present at point of section), and 7 mm. from tibia. Patella buried in thigh muscles. Plaster spica applied.

Mar. 10. The plaster has been so badly gnawed that it is of no use; removed. Wound healed. Much motion at knee.

July 9. About 20° of motion.

Sept. 16. Very little motion.

Feb. 10/15. Uses leg fairly well. About 30° of motion in joint. Killed by chloroform. Line of incision over anterior aspect of joint seen. Knee-joint removed. Sectioned longitudinally.

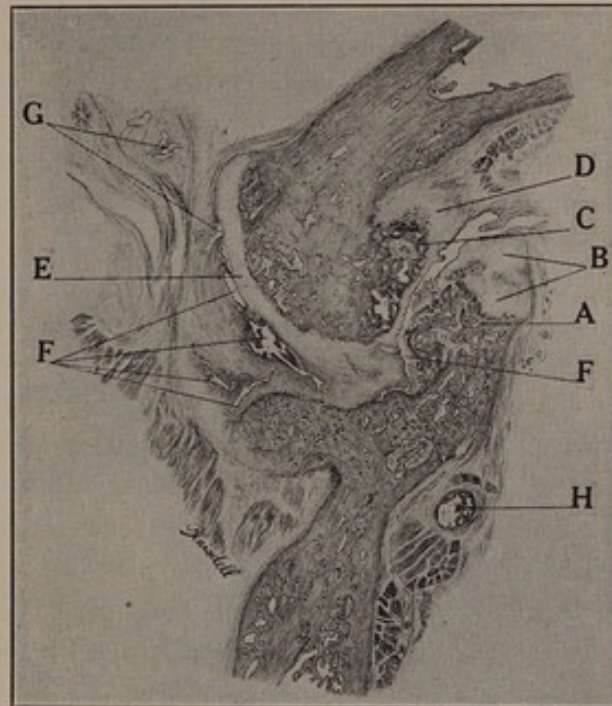
The femur is received into an actual cavity of the tibia, a hollowing out of the upper surface of the tibia. There are indications of a joint in places, and the bones are united by fibrous tissue. The ends of the bones are eburnated, and are very dense. Sawing done with considerable difficulty.

HISTOLOGY.—The end of the femur is received into a cup-shaped cavity in the tibia, as above, and the ends of both bones are covered with cartilage and fibro-cartilage. There is a distinct slit between the bones anteriorly, and another posteriorly, but in the center the bones are joined by fibro-cartilage and cartilage. At the margin of the section the connecting tissue is fibrous. Several other irregularly transverse rifts are also present.

The posterior slit begins behind the posterior aspect of the lower end of the femur, between it and the tongue-like process on the tibia, passes obliquely downward and forward, and then turns and runs at right angles transversely about half-way across the joint. There is a tendency in some of the slides toward a shutting off of the lumen of this slit by strands of degenerated fibrous tissue and small tongues of cartilage where it changes its direction, but the two arms in other slides are seen to communicate. The longitudinal arm is lined by cartilage, with a homogeneous or delicately fibrous basement substance. The cartilage cells stain well, have distinct capsules, and are arranged in groups. In places the cells are not cartilage cells, but are typical fibroblasts. The surface of the cartilage is not regular, as is customary with joint cartilage, but has a contour like that of villous synovial membrane, with finger-like processes, which have been cut at various angles. In many places a film of degenerated cartilage lines the slits. There are one or two villi also which look like typical synovial villi, and contain a few cartilage cells. The layer of cartilage is irregular also in its thickness and in its structure, and is not backed up by a buttress of bone as is the normal joint cartilage, but by irregular bone trabeculae, containing fibrous tissue in their meshes. It is for the most part hard to tell where bone shades off

into cartilage. In other words, the deeper portion of the cartilage is undergoing transformation into bone.

The anterior slit, very irregular in outline, is lined by the peculiar degenerated fibrous tissue, containing very few cells. Many villi are



A, Spur on tibia. *B*, Cartilage capping the spur. *C*, New bone in femur. *D*, Cartilage capping this bone. *E*, New articular cartilage. *F*, "Bursal cavities." *G*, Synovial cavities. *H*, Sesamoid bone.

present, composed of fibrous tissue, with a few cartilage cells. In the extreme anterior portion of the specimen, anterior to the end of the femur, is a small typical synovial cavity.

A marked thickening has taken place in the trabeculae of both bones. The marrow in the immediate vicinity of the joint is fibrous, farther away it is lymphoid.

SUMMARY.—Removal of large amount of bone. Plaster of Paris for a few days only. Duration of experiment, 347 days. The convex end of the femur is received into a concavity of the tibia. The concavity is formed by anterior and posterior tongues of bone in the tibia. The bones are united by cartilage and by fibro-cartilage, and at the periphery by fibrous tissue. Slits of greater or less size are present in the cartilage and fibro-cartilage. These slits are lined by villous and irregular cartil-

age, some of it necrotic, and evidently produced from synovial membrane. Some evidences are present of the transformation of the deeper portion of the cartilage into bone. No ankylosis is present.

Dog 18, 317 days.

Mar. 9/14. Resection of right knee by mortise method, removing 20 mm. from femur and 15 mm. from tibia. Patella into glutei. Plaster spica applied.

Apr. 18. Plaster removed. Slight movement in joint.

July 9. Practically no motion.

Nov. 20. Very stiff. Uses leg very clumsily.

Jan. 20/15. Well nourished, healthy animal, killed by blow on head. Used leg well, but knee-joint is ankylosed. Joint removed and sawed sagittally. Apparently bony union in places.

HISTOLOGY.—The convex lower end of the femur is firmly united to the concave upper end of the tibia by a thick layer of fibrous tissue, fibro-cartilage and cartilage. In this tissue are small transverse clefts. The fibers of the fibrous tissue and of the fibro-cartilage run generally transversely near the joint circumference, but in the center they run from bone to bone. The tibia and femur are not united anywhere by bone, but in certain areas the fibro-cartilage is undergoing ossification by blood-vessels extending from the marrow of each bone. The uniting tissue is continuous with the tissue in the marrow spaces, and also attaches firmly to the bony trabeculae. The bone trabeculae are thickened. The marrow is mostly lymphoid.

The posterior cortex of the femur spreads out as it nears the joint. The trabeculae springing from it are arranged in fan-shape, as are those springing normally from the medial cortex of the femur, and running up to the femoral head. These trabeculae and the cortex support the weight of the body, and are arranged generally in a distinct longitudinal direction. Anterior to them in the specimen, this regular arrangement is absent. The marrow here is full of fragments of dead bone, evidently being destroyed by the marrow, but no sign of "osteoclasia" (giant cells and Howship's lacunae) is present.

SUMMARY.—From this operation, done with a special endeavor, by mortising the bones, to secure close apposition and no motion, and thus to attain a firm ankylosis, fibrous and fibro-cartilaginous union is present after 317 days. A few transverse slits persist in the fibrous tissue, but these have no synovial membrane. The limb had been immobilized with plaster of Paris for 40 days.

Dog 19, 40 days.

Mar. 12/14. Resection of right knee, removing 27.5 mm. from femur, 14.5 from tibia. The periosteum was united carefully by deep stitches, holding the bones rather firmer than usual. Patella into glutei. Plaster spica applied.

Apr. 21. Plaster removed.

Apr. 22. Animal died during the night.

AUTOPSY.—Knee freely movable. Excellent joint. Patella and knee removed, and placed in alcohol.

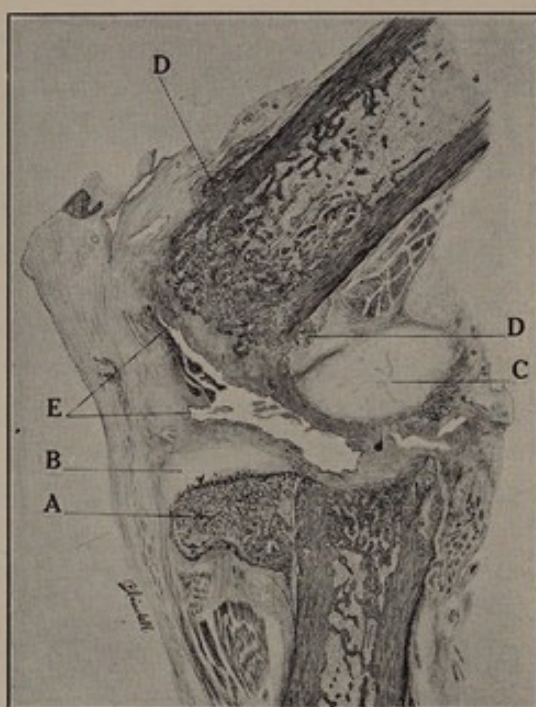
Aug. 11. Bones sawn sagittally. A well defined joint-like slit is present between their ends, lined with what appears to be delicate new connective tissue. No eburnation or sclerosing of the bone ends is present. On the lateral aspects of the ends of the bones cartilage is present, but not in the section removed for study. The tibia is subluxated backward on the femur, and apparently a large production of new fibrous tissue has occurred behind the lower end of the femur.

HISTOLOGY.—The tibia and femur articulate at an angle of about 130° , and a joint cavity is present between them. The tibia is subluxated backward on the femur, and the architecture of its articular extremity is being re-formed in the following manner:

Anteriorly a large projection or shelf has been formed which juts out at right angles with the shaft. (In the lateral portions of the specimen, which have not been cut for sections, this shelf consists of cartilage.) This shelf is composed of bone and cartilage, the cartilage toward the joint. At the junction of the bone with the cartilage, blood-vessels may be seen pushing up from the marrow of the former into the latter, and the picture is typical of endochondral ossification. The cartilage is new, and not the remains of any articular cartilage, and is separated from the joint by a thick mass of fibrous tissue, covered near the circumference by a synovial membrane, and villous nearer the middle, but without the peculiar cells of a synovia at the surface.

Posteriorly between the two bones,—that is, in their re-entrant angle, between the posterior surface of the head of the tibia and the posterior cortex of the lower portion of the femur,—is another large mass of cartilage. This cartilage is united to the head of the tibia by dense bands of fibrous tissue, in which, close to the tibia, are some bony trabeculae, with Howship's lacunae. Among these bands are ramifications of the joint cavity or separate joint cavities. These are lined by synovial membrane. The cartilage is united to the cortical bone on the

posterior surface of the lower portion of the femur, partly by fibrous tissue, and partly by spongy bone springing from the cortex. The cartilage where it impinges on the femur is undergoing ossification—typical endochondral bone formation—and blood-vessels can be seen in it, giving an identical picture with that seen in beginning ossification of an epi-



A, Spur on tibia. *B*, Cartilage over spur, being ossified from the bone marrow beneath. *C*, Cartilage posterior to lower end of femur. *D*, New spongy bone on femur. *E*, Pockets lined by synovial membrane.

physis. The lowermost part of the cortex is being rearranged in its architecture to open up a communication between the spongy bone within and that without. In other words, ossification of the first mass of cartilage described is taking place from the tibia; of the second mass, mostly from the femur.

The ends of both bones are covered by fibrous tissue, having prolongations running down into the marrow. No articular cartilage is present anywhere. The joint is lined in places, especially near the circumference, by synovial membrane. It contains large masses of fibrin, which is becoming organized, and some of which lies spread out on the surface.

The marrow is lymphoid and fatty in both bones.

SUMMARY.—Removal of large pieces of bone. In this case, after 40 days, with immobilization for 39 days, by the production of new cartilage, and the subsequent ossification of this cartilage, the ends of the bones are changed in their structure and outline, and are adapting themselves to the new mechanical conditions. A new synovial membrane is forming, but no articular cartilage. A joint is present, allowing excellent motion, but no articular cartilage has formed.

Dog 20, 304 days.

Mar. 17/14. Resection of right knee, removing about 5 mm. from the condyles and about 4 mm. from tibia. Patella left in place. The crucial ligaments were not divided. The semilunars were dissected out partly. The joint locked rather firmly in extension. Piece of tuberosity of tibia buried in the gluteal muscles.

July 9. Very little motion—antero-posterior—with crepitus.

Sept. 6. A few degrees of antero-posterior motion.

Nov. 20. Uses leg well. About 30° of motion in joint. No lateral motion.

Jan. 15/15. Killed by chloroform.

AUTOPSY.—Well nourished, healthy looking animal. Uses leg well. The knee is in the attitude of slight flexion. Range of motion about 30°. Nothing remarkable in scar at site of old wound. Patella freely movable, and quadriceps pouch is apparently intact.

Joint sawed sagittally. Apparently a joint cavity has persisted in the posterior part, but in this area the cartilage appears to have disappeared from the end of the femur. On the anterior portion of the condyles cartilage is present, and here also there is a small joint cavity apparently not connected with the other. Fibrous bands run from the cartilage on the femur to the head of the tibia. No cartilage can be distinguished at the line of section on the head of the tibia. The bone is extremely dense at the articular ends,—in fact, eburnated. The quadriceps pouch is divided off into compartments by fibrous bands. Both the cartilaginous surface of the patella and that on the front of the femur are covered by fibrous tissue. No indication of bony union is seen in any place.

HISTOLOGY.—A large slit is present between the two bones, divided roughly into two compartments, anterior and posterior, by bands of fibrous tissue. The ends of the bones are irregular, and are covered over a portion of their surface by cartilage, over a portion by fibro-cartilage, and over a portion by fibrous tissue. Over a small portion of

the surface of the tibia bare bone presents. The cartilage at its free surface is irregular, and is in tatters. Some of these tatters contain cartilage cells. The cartilage, in other words, looks like that of Type II arthritis ("arthritis deformans"). Areas of cartilage are seen, with cells in groups. The synovial membrane is present in the capsular portions of the joint cavity, thickened in its lymphoid elements. Anteriorly it is encroaching on the femoral cartilage, especially at its surface. The head of the tibia anteriorly is covered by fibrous tissue containing a few cartilage cells, which is much frayed out. The ends of the bones contain fatty marrow.

The joint between the patella and femur is lined throughout most of its extent by thickened, lymphoid, villous synovial membrane, which has encroached so greatly upon the cartilages as to cover most of their free surface. Where the cartilage is not encroached upon, its surface shows a tendency to tattering.

SUMMARY.—In this case very little bone was removed from the femur and tibia. Duration of plaster immobilization was not stated, but as all the dogs were put up in plaster, immobilization must have been attempted at least. After 304 days about 30° of motion is present. The bones are bound together by fibrous tissue, and are separated by a cleft whose walls present the characteristics of a joint cavity, namely cartilage and synovial membrane.

Dog 21, 255 days.

Mar. 19/14. Resection of right knee. Removal of 7 mm. from condyles of femur, and about 3 mm. from tuberosities of tibia. Patella left in. Operation as in 20. Piece of the head of the tibia buried in glutei. Plaster of Paris spica applied.

Apr. 3. Plaster of Paris removed, as it failed to immobilize the limb. The lower part had been entirely gnawed away.

July 9. Joint practically stiff.

Sept. 16. Dog was sick several months ago. Since then she has had a coarse tremor, a muscular twitching—asleep and awake. She has an opacity of the cornea. The joint is practically stiff, and a trifle sensitive when it is moved.

Nov. 20. Animal killed by chloroform anaesthesia. Well nourished and in good physical condition. Wounds healed per primum. Joint shows about 20° motion. Piece of bone in glutei found and removed. Patella is movable on the condyles. Sagittal section of knee-joint. Dense fibrous union is present. The ends of the bones for about 6 mm. are very dense and hard. In places between the bone ends there are

small spaces (two very small cavities), and a small area of softening in the dense bone of upper end of tibia.

HISTOLOGY.—The bone ends are united by fibrous tissue. The trabeculae near the line of junction are extremely thick and numerous, and the marrow about them is largely fibrous; farther away it is lymphoid. Between the two bones is dense fibrous tissue, with two or three clefts in it, but with nothing that resembles a synovial membrane, except in the anterior portion, near the region where the articular cartilage remains. (*Note*.—The cartilage was not removed completely at operation.) The femoro-patellar joint is in a good state of preservation. It is shut off below from the operated area by a band which passes from the fibrous tissue in front of the line of section backward and upward to the articular cartilage on the front of the femur, thus making a complete joint cavity. This band of fibrous tissue, on its joint side, is apparently being invested with a synovial membrane by an extension of the synovial membrane lining the posterior surface of the patellar tendon below the patella. Following the femoral cartilage downward, one sees below the band described another small cavity, lined on one side by the femoral cartilage with more or less fibrillated surface, and on the other by synovial membrane. Tracing down still further, one sees the cartilage change to fibro-cartilage. At its surface are two or three cavities, containing bone detritus. This fibro-cartilage then merges into fibrous tissue between the tibia and femur. Blood-vessels are pushing up into this fibrous tissue from the bone beneath it, giving one the impression that the fibrous tissue is being converted into bone.

In the head of the tibia is a rather large excavation filled with organizing blood-clot and lined by fibrous tissue, continuous with that on the anterior aspect of the joint. The excavation is surrounded by bone whose trabeculae are very thick, and whose marrow is fibrous. It is to be observed that the fibers of the tissue which binds the bones together do not pass directly across from bone to bone, but pass into the joint cleft from the periphery and then into one bone or the other. In other words, ankylosis is being brought about by bands of fibrous tissue between each bone and the capsule.

In the tibia head near the excavation, at the outer margin of the area of dense bone noted above, is an island of cartilage connected on one side by a narrow isthmus with a bone trabecula, and in various places about its periphery with the fibrous tissue in the marrow. Here and there at its periphery it is becoming ossified. It contains areas of marrow, about which also ossification is going on. In the neighborhood,

and in fact all about the extreme end of the bone, new bone is being formed on the trabeculae through the medium of fibrous tissue. In one or two places this bone, which we consider new-forming, presents the typical appearance of what is known as rarefying osteitis,—Howship's lacunae, osteoclasts, etc. Farther from the joint the marrow contains bone detritus, and the trabeculae are normal in density. Between this area and the one described above, with dense bone and fibrous marrow, the marrow is lymphoid, and, near the periphery, fatty.

In the end of the femur is a sharp, deep excavation, partly filled by fibrous tissue, and containing cavities, some lined by synovial membrane.

SUMMARY.—Removal of small amount of bone. Immobilization ineffectual. Duration of experiment, 8 months. The sclerosed ends of the bones are bound together by fibrous tissue and by fibro-cartilage, containing clefts. Each bone contains a small cavity in its end, filled or partly filled by fibrous tissue continuous with the periosteum. Neither bone is hollowed out to receive the other, nor is there any flattening out of their apposed surfaces to prevent motion. No evidence is present of any building up of bone about the periphery of either bone.

Dog 22, 47 days.

Mar. 23/14. Resection of right knee. Removal of 3.5 mm. from the femoral condyles, and 3 mm. from the tibial tuberosities, doing all with chisel, and extending the denudation all over the front of the condyles and in intercondyloid notch. Patella left in place. One condylar piece buried in the glutei.

Apr. 4. Plaster removed, as it had been entirely gnawed away below operation wound.

May 9. The dog had been ailing for some time, but grew better. This morning she seems sick again—rapid respiration and groaning. Killed by chloroform anaesthesia.

AUTOPSY.—Panniculus on abdomen well developed. Lungs show wide areas of consolidation, as of a new process engrafted on an old. Areas of engorgement. In other places the bronchi exude pus. Intestines empty, stomach also.

Knee possesses about 20° of motion; removed. Red marrow in shaft of femur.

Aug. 11. Bones sawn sagittally. The marrow canals (red marrow) come down almost to the epiphyseal lines (still present) in both

bones. The bone ends are tied together by fibrous tissue, but there is no joint cleft. Ordinary spongy bone (not sclerosed) in bone ends. Patella is not adherent.

HISTOLOGY.—The bones are tied together by fibrous tissue, in which are clefts. Some of these clefts are lined by a tissue identical with synovial membrane. The articular cartilage is present posterior to the end of the tibia,—that is, on the posterior surface of the epiphysis,—but nowhere else on this bone. Synovial membrane is pushing over its surface.

In the anterior and posterior portions of the epiphysis of the tibia, bone and marrow exist. The marrow is lymphoid, and its cells show a marked tendency to gather along the margins of the trabeculae. In the middle of the epiphysis the bone and marrow have practically disappeared, and their place is taken by fibrous tissue in which are a few small fragments of bone trabeculae which have lost their bone cells. The floor of this area is formed by the epiphyseal cartilage; anterior to this area, between it and the bone in the anterior portion of the epiphysis, is a mass of tissue, transitional between fibrous tissue and cartilage, and containing islands of new-formed cartilage. Lime-salts are being deposited in the islands of cartilage next the bone.

Posterior to the area, between it and the bone in the posterior part of the epiphysis, is a smaller area of cartilage.

The lower end of the femur is covered by fibrous tissue in which are a few stray islands of cartilage. It is convex, rounded off, and applied to the fibrous area in the tibial epiphysis.

A joint is present between the femur and patella, and the synovial membrane is spreading in over their cartilages, and has formed a layer of fibrous tissue over them near their circumference, tapering off toward the center.

SUMMARY.—Very little bone removed. Partial immobilization only for 12 days. Duration of experiment, 47 days.

From the persistence of bone anteriorly and posteriorly in the tibial epiphysis, with its disappearance in the middle, and from the presence of cartilage anterior and posterior to the middle area, and from the persistence of the epiphyseal line at its base, it appears probable that a new socket is being formed for the end of the femur in the head of the tibia, which socket eventually would have been lined by cartilage. Apparently the medullary canal has extended in both bones toward the joint. The bones are united by fibrous tissue containing clefts, some lined by fibrous tissue.

SUMMARY

Dog	Amount of Bone Removed	Immobilization	Duration of Experiment	Result
		Days, unless otherwise noted		
2	Small	40	2 yrs.	Joint cavity present, and bone ends partly covered by new-formed cartilage. Synovial membrane present. 25° of motion.
4	Small	69	122	Head of tibia hollowed out. Ends of bones tied together by fibrous tissue, allowing about 30° motion.
5	Small	60	21 mos.	Heads of bones covered by fibro-cartilage. A well-marked joint cavity is present. Motion limited by flattening of bone ends.
6	Small	3	462	Ends of bones bound loosely together by fibrous tissue. About 50° of motion.
7	Small	98	23 mos.	New joint formation. Ends of bones almost covered by fibro-cartilage. Synovial membrane in capsule.
8	Large	54	432	Bony union.
9	Large	35	98	About 90° of motion. No histological examination.
10	Large	38	208	The bones are united loosely by fibrous tissue, in which are clefts, some lined by synovial membrane. Free motion.
12	Large	7	14	Free motion. Cavity between bones lined by fibrin.
13	Large	30	88	Bony union.
14	Large	18	117	Formation of new joint, but without articular cartilage. Synovial membrane lines the capsule. Free motion.
15	Large	42	240	Loose fibrous ankylosis, with persistence of synovial cavities.
16	Large	8 wks.	97	Firm union by fibrous tissue and fibro-cartilage.
17	Large	Few	347	Convex end of femur received into concavity of tibia. Bones united by fibrous tissue, fibro-cartilage and cartilage. A few degrees of motion persist.
18	Large	40	317	Bones united by fibro-cartilage and cartilage.
19	Large	39	40	Joint is present, but no articular cartilage. Motion is rather free.
20	Small	?	304	Joint with cartilage and synovial membrane is present, allowing about 30° of motion.
21	Small	Few	8 mos.	Ends of bones united by fibrous tissue, allowing about 20° of motion.
22	Small	12	47	Ends of bones united by fibrous tissue, containing fat. About 20° of motion possible.

CONCLUSION

It is seen from a study of our sections and histories that our results fall roughly into four groups:

1. Bony union—two cases.
2. Firm fibrous, fibro-cartilaginous, and cartilaginous union.
3. Loose fibrous union, with or without synovial cavities.
4. The formation of a new joint, with a joint cavity, and a covering of the bone ends by cartilage.

In a good proportion of cases, the head of the tibia is broadened antero-posteriorly and made concave to receive the convex end of the femur. The broadening is accomplished by means of new bone, made from cartilage and from fibro-cartilage. The concavity may be increased by the absorption of the bone trabeculae in the middle. The concavity may be deepened also by the production upward of tongues of bone anteriorly and posteriorly on the tibia.

It is impossible to tell from our cases just what factors influence the result. Length of time, amount of bone removed, and duration of immobilization do not seem to constitute the deciding factor in the persistence of motion, though it may be said that if much bone be removed, a true joint with articular cartilage will not form, and that if little bone be removed, bony ankylosis will not ensue.

In some cases the new joint appears to have been formed by the spreading in of the synovial membrane over the ends of the bones. This synovial membrane later was transformed into cartilage.

The transformation of synovial membrane into cartilage in the capsule has been noted; *e. g.* dog 2.

The replacement of cartilage by fibrous tissue, with or without synovial membrane at its surface, has also been noted.

Our results confirm the contention of various other writers, that cartilage and synovial membrane are similar tissues, and that each may replace the other.

New articular cartilage, then, may form on the ends of denuded bones. The problem in producing a new joint is to ascertain what the conditions are which cause it to form.

If motion persists after a dog's knee is resected, as it does in the majority of cases, whether by loose fibrous union or by the formation of a true joint, then the results of experimental arthroplasties by the interposition of various tissues, must be thrown out, as a case of *non sequitur*.

These results cannot be utilized as applying to human joints. If a human knee be resected, by whatever method, ankylosis will result almost invariably. Whether the interposition of any substance will prevent this is another question, not to be decided by results obtained from simple resections of dogs' knees.

The thickening of the trabeculae in the ends of the bones in our cases was often a marked phenomenon. This thickening, this eburnation, may be the deciding factor against an ankylosis. Eburnation in the human subject is known to be a factor, at least, in the production of pseudoarthrosis; and in those forms of arthritis characterized by eburnation of the bone ends, Type 2, union of the bone ends never takes place. The result is much the same in this form of arthritis as that which is well shown in our dog 5.

Certain of our cases (*e. g.*, Nos. 2, 5 and 7), in which a new joint was formed, present a marked resemblance to cases of arthritis of Type II, *i. e.*, to the German arthritis deformans, the English osteoarthritis, Goldthwait's hypertrophic arthritis, Nichols and Richardson's degenerative form. The main features of the process are the same, namely, eburnation of the bone ends, with splitting up and fibrillation of the cartilage basement substance, and the peculiar arrangement and form of the cartilage cells. Weichselbaum* noted these changes in an examination of two old resected human elbows. He assumed that the joint which had formed after the resection had been damaged by a supervening ("später aufgetretene") arthritis deformans.

The marrow about the region of the resection often takes on a fibrous or fatty character. Usually it is exclusively fatty and fibrous.

In those of our cases where the patella was left, its cartilage was overlaid and partly replaced by fibrous tissue,—continuous with synovial membrane, and often covered by it. The cartilage was also perforated, and the fibrous tissue at its surface communicated through the perforation with the fibrous tissue in the interior of the bone. The joint evidently was being obliterated in this manner. The bone trabeculae in the patella also tend to disappear.

In one or two instances cartilage appeared in the patellar ligament, where it articulated with the condyles of the femur under changed conditions.

* Weichselbaum, A.: "Anatomische Untersuchung von drei geheilten Gelenkresectionen." *Archiv für klinische Chirurgie*, 1874, XVI, 248. This peculiar conception of these changes by the Germans, as an etiological, pathological and clinical entity, crops up constantly in their research work on joints.

REACTION OF THE TISSUES OF THE KNEE-JOINT OF THE RABBIT TO INJURY

By LEONARD W. ELY and JOHN FRANCIS COWAN

I

INCISING, SCRAPING AND BURNING THE CARTILAGE OF THE PATELLA OR OF THE FEMUR.

The following series of experiments was undertaken to determine the effect of an injury to the joint tissues of rabbits, and to observe the processes of repair in them, especially to observe the reaction and the repair of the articular cartilage.

Very little experimental work has been done until quite recently upon the joint cartilage.* Many experiments have been done upon the cartilages of the ribs, but these have a perichondrium. A perichondrium does not exist in the articular cartilage, except in foetal life and shortly afterward. Hence results predicated on experiments upon rib cartilage

*Archangelsky: "Regeneration des hyalinen Knorpels." *Centralblatt für die medicinischen Wissenschaften*, 1868, VI, 658.

Experiments on dogs (what cartilages the author does not say).

1. Die Narbe in dem verwundeten Knorpel besteht anfänglich aus Bindegewebe, welches sich vom Perichondrium ausbildet und in der Regel an zelligen Elementen reich ist.

2. Nach Verlauf einiger Zeit geht dieses narbige Bindegewebe allmählich in Knorpel über, indem von vornherein die Bindegewebskörperchen mit doppelt contourirten Kapseln umbilden, so dass man zuerst einen Faserknorpel vor sich hat, und später bildet sich aus diesem letztern der wahre hyaline Knorpel, welcher den Raum der Wunde einnimmt.

3. Die knorpligen Ränder der Wunde nehmen keinen Antheil bei der Bildung der Narbe in einem verwundeten Knorpel und zeigen dabei weder progressive noch regressive Veränderungen.

Redfern: "On the Healing of Wounds in Articular Cartilages." *Monthly Journal of Medical Science*, London, 1851, XIII, 201.

Operations on dogs' knees.

Conclusions:

1. Wounds in articular cartilages heal perfectly by the formation of fibrous tissue out of the cut surfaces.

2. The fibrous cicatrix consists of white and yellow fibers, which are formed out of the intercellular substance of the cartilage, and out of the nuclei of its cells, respectively.

are not applicable to the joint cartilage. Axhausen (*Archiv für klinische Chirurgie*, 1912, XCIX, 519), from experiments upon dogs and rabbits, stated that lesions typical of "arthritis deformans" followed injury to the cartilage by an electric needle, namely a "dissecting" inflammation in the marrow, and the formation of "Randexostosen" (lipping) at the circumference of the cartilage of the injured bone and of that of the other bones of the articulation. He affirmed, in other words, that a small localized injury to a joint cartilage set in motion a pathological process involving not only the cartilage but also the synovia, the marrow, and the bone. It is to be noted that an injury of the cartilage by an electric needle would likely involve the marrow beneath, and therefore in our experiments we chose methods of injury which could be regulated more exactly.

Three sets of experiments comprise our series:

1. Making a circular incision through the cartilage on the posterior surface of the patella, or through that in the intercondylar groove on the anterior aspect of the femur.
2. Gouging out a small piece of the cartilage on the under surface of the patella.
3. Burning a small area of cartilage on the anterior surface of the intercondylar groove of the femur with an actual cautery.

In all three sets we endeavored to wound only the cartilage, though we occasionally damaged the synovial membrane by accident, and sometimes burned through the buttress of bone beneath the cartilage.

The animals employed were rabbits. All operations were done under ether anaesthesia, and with aseptic precautions. Only two or three infections took place. Extreme care was used to damage the joint tissues as little as possible by rough handling. At various intervals up to 360 days the animals were killed, and the gross appearances of the joint tissues were noted.

The parts of the joint to be studied were removed, fixed with Orth's fluid or alcohol, and the bones were decalcified in 5% nitric acid. The material was run up through the alcohols and imbedded in celloidin. The sections, mostly 20 microns thick, were stained in haematoxylin and eosin, and by the van Gieson method.

Rabbit 1, 270 days.

Dec. 8/13. An incision was made about 3 cm. long on the lateral aspect of the right knee, curved, with convexity backward. Another

incision was made with another knife, opening up the knee-joint. The patella was drawn medially, exposing the condyles of the femur.

With the point of the scalpel, the cartilage over the front of the inner condyle was incised in a circle, whose diameter was about 3 mm. The attempt was made to run the point of the knife down to the bone. The wound was sutured up with two layers of catgut, and collodion was applied.

Sept. 4/14. Rabbit was sacrificed by blow on back of the neck. An abscess is present on right side of the chest, with thick, creamy contents. The joint was then opened by a medial incision. The synovia looks succulent and thickened. The old incision on the condyle can be identified as a slight irregularity in surface. A transverse section of the femur through operated site was put into Orth's fluid.

HISTOLOGY.—Sections of femur. In a number of these, one cut can be distinguished. It is closed throughout most of its depth, and a partial "lid" has been formed for it (a teat-like process) by the border nearest the periphery. While the sides of the cut are in close apposition, no union has taken place between them. The cut goes down into the buttress underneath. The rest of the cartilage is normal. No signs of lipping are present. Marrow is largely fatty, especially at the sides of the bone, but normal.

Rabbit 2, 270 days.

Dec. 8/13. Incision and preliminaries as in 1. The cartilage was removed with a gouge over an area of 3 mm. in diameter, from the inner condyle down to the bone. Wound sutured in two layers with catgut. Collodion.

Sept. 4/14. Rabbit killed. Ulceration of right side of face, in front and below the eye.

Wound healed *per primam*. No signs of incision; right knee-joint removed. Joint opened; articular surface of femur appears normal. No sign of injury; no lipping. On the posterior surface of patella, however, there is an irregular rounded, depressed area, 3 mm. in diameter, the surface of which is roughened. Patella—depressed area removed and placed in Orth's fluid.

Sept. 6. Specimen washed and placed in 5% HNO_3 .

HISTOLOGY.—The hole is partly filled by pigmented material. The sides of the hole are rather rounded off, and are formed by cartilage, de-

generated at the extreme border of the area, and with the fibers turned down to make the rounding off. The bone, immediately beneath the gouged area, is necrotic. The marrow is mostly fatty; in one area directly beneath the injury it is fibrous and oedematous.

(The results of the examination of this case indicate that the description of the operation was faulty. Evidently the patella was injured, not the femur.)

Rabbit 3, 311 days.

Dec. 12/13. Incision as before. Patella drawn aside and turned over. From its under-surface a piece of cartilage about 3 mm. in diameter was removed, exposing the bone.

Suture, and collodion dressing as in 1 and 2.

Oct. 19/14. Animal died last night. Autopsy to-day. Wound healed completely. Mass palpable on lateral aspect. Joint opened from above. The patella shows a slight irregularity at site of operation, but its surface is fairly smooth. The cartilage apparently has re-formed. Lateral to the patella and connected with it, is a white, smooth mass of cartilaginous material, measuring 8 x 15 mm., with long diameter longitudinally. It is a thin shell. Its surface is irregular. The lateral condylar ridge is irregular and eroded, and the lateral aspect of the condyle is irregular and eroded also. The synovial membrane is slightly injected, and seems to extend over the new cartilaginous shell. No lipping of the cartilage, but rather erosion. Tibia normal. The internal genitals, uterus and tubes, are large sacs full of the thick, cheesy matter so often found in these rabbits—pus infection.

HISTOLOGY.—Patella and cartilage plate. Wounded area identified. It is empty in places (that is, in certain sections), in other places it contains pieces of necrotic cartilage. The cartilage near the border of the injury shows evidences of degeneration. The bone buttress appears to be thickened. The marrow is normal lymphoid. The trabeculae are thickened by the production of new bone from fibrous tissue.

At one side, the cartilage and bone shade into the "cartilaginous plate" noted above. This is composed of fibrous tissue and of fibrocartilaginous tissue—a transitional tissue, as Professor Ophüls describes it. Some of it is typically fibrous, some has cells with typical capsules.

The lateral condylar ridge is covered by cartilage with few cells. On its lateral aspect it is, so to speak, eaten out, and in the deepest part

of the excavation is a mass of fibrous tissue, which evidently is undergoing transformation into bone. Farther away from the joint line again—that is, on the far side, adjoining the excavation—a “hook” of bone has been built up. Underneath the layer of bone at the surface in this region the marrow is fibrous and oedematous, and in various spots elsewhere in the end of the bone, mixed in with the prevailing lymphoid marrow, are small areas of fibrous marrow.

Some sections show the production of new, live cartilage.

Rabbit 4, 346 days.

Dec. 12/13. Same operation as in 3, namely, scraping off of cartilage from under surface of patella.

Nov. 22/14. Rabbit died.

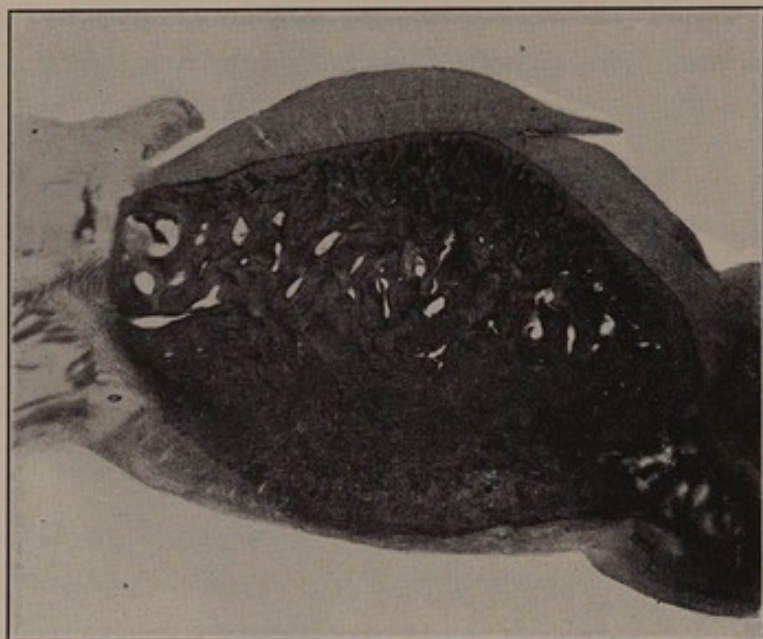
Nov. 23. Autopsy.

Knee from outside is apparently normal, movement free; no sign of operation. Joint opened from above. No sign of active inflammation can be seen in the joint. Wound in cartilage of patella can be identified as a slight irregularity in the surface; under magnifying-glass this irregularity appears to be slightly depressed. The tissue which has filled in the wound appears to be cartilage.

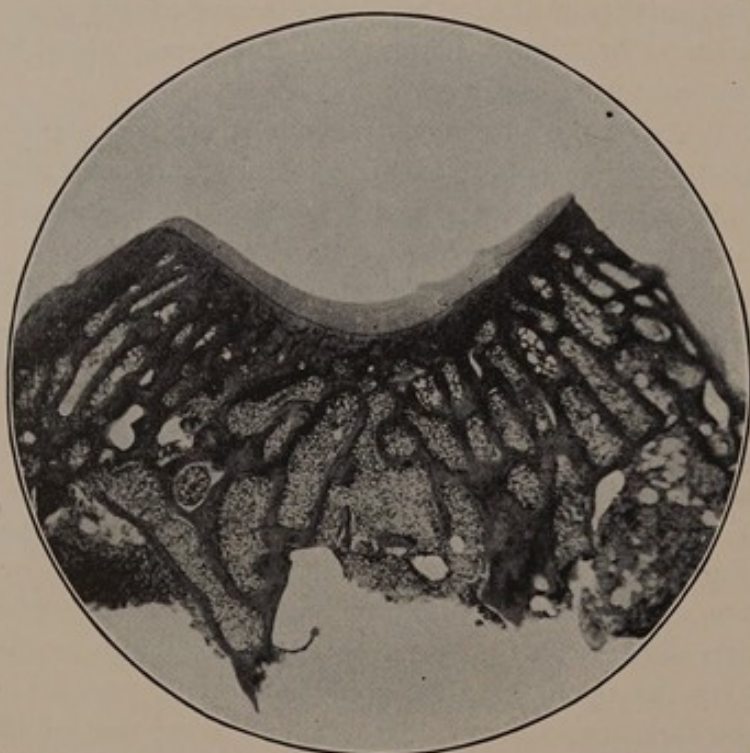
The cartilage on the anterior intercondylar space is slightly irregular over an area approximately the same as that of the wound in the patellar cartilage. An erosion of the medial aspect of the medial condyle is present.

AUTOPSY.—Left kidney greatly enlarged, somewhat irregular, somewhat mottled. Right kidney similar in appearance. Liver evidently sclerotic. Spleen apparently smaller than normal. Tubercles in left lung. Right lung normal.

HISTOLOGY.—*Patella*.—Two cuts of the cartilage can be seen in cross-section. One is very faint, is closed in at the surface by a pressing together of the two sides, and does not extend down to the bone. It runs practically perpendicular to the surface. The other is deeper, in some sections extends down into the bone, and has an oblique course (except at its deepest part). Its pointed cartilaginous border forms a sort of lid for the opening. The point is directed towards the nearest border of the cartilage,—that is, it is attached to the part of the cartilage included in the circular cut. It contains few cells.



Rabbit 4—Low-power photomicrograph showing regeneration of cartilage over wounded area. Note long, projecting teat of new cartilage.



Rabbit 4—Low-power photomicrograph, showing rifts in cartilage of unwounded femur.

Bone is dense. Very little marrow present. Some of the marrow is lymphoid.

Condyle.—Two cuts appear in the cartilage nearer the medial eminence. They are oblique, and on the more medial one the overlapping border is nearer the periphery and is much the longer. Its tip has very few cells. The rest of the cartilage is practically normal. The bone buttress possibly is a trifle thicker than normal. The marrow is lymphoid. On the medial side the cartilage ends suddenly, and is not prolonged over the condylar eminence as normally. The side of the medial condyle is eroded, and the bone below it is bare but for a very thin, incomplete strand of fibrous tissue.

This case shows formation of new cartilage at site of injury.

Rabbit 5, 6 days.

Dec. 17/13. Incision as before. Right patella drawn aside, turned half over, and a circular incision about 3 mm. in diameter made through the cartilage on its under surface.

Dec. 23. The rabbit, after ailing a few days, died to-day. Autopsy did not reveal cause of death. The knee-joints appeared normal, except for a slight injection of the synovia about the margins of the patella on the operated side. Patella removed for examination, and placed in Orth's fluid.

HISTOLOGY.—The cut can be identified easily in the slides. In some, the cartilage has closed over at the joint surface, leaving the gap below. Cartilage stains with eosin. At the periphery its cells are packed without definite arrangement, but toward the center they are arranged in columns, perpendicular to the surface deep in, but superficially without this arrangement.

The vessels of the marrow are engorged, and haemorrhages are evident in the marrow. In places the cut in the cartilage opens up the marrow. Not much lymphoid marrow is present.

Slight injection of the synovial blood-vessels is evident.

Rabbit 6, 31 days.

Dec. 17/13. Incision and operation as in rabbit 5.

Jan. 17/14. Killed by blow on back of neck.

The wound was entirely healed, and the fur had grown over site of operation. On opening the joint it was found normal to gross inspection—no signs of inflammation whatever. On close inspection the line of incision in the patellar cartilage could be distinguished, and running out from it thin, faint cracks could be seen in the cartilage. The cartilage within the incision was whiter than that outside. It lacked the purplish tinge of the latter. Patella into Orth's fluid.

HISTOLOGY.—Cut recognized through cartilage. Bone torn in cutting. Hence more slides to be done.

(Later), Other slides. The cuts (3) can be easily recognized. Their sides are separated. There is no healing over at the surface, but in two of them one border has a tendency to lap over the other at the surface. The bone is so badly torn by the microtome that nothing can be said about its structure. The cartilage shows little if any degeneration. The synovia is congested.

Rabbit 7.

Lost some time after operation.

Rabbit 8, 8 days.

Dec. 18/13. Duplicate of previous operations of incising cartilage of right patella in a circle of 3 mm. in diameter.

Dec. 26. Rabbit died.

Dec. 27. *Post-mortem*.—Cause of death not ascertained. The wound was evidently healing normally. The synovia showed no signs of inflammation. No fluid in joint. Cartilage irregular where it was incised. Patella put into Orth's fluid.

HISTOLOGY.—Cuts recognized; they are filled with detritus. The surface of the cartilage presents several small rifts, which we regard as artifacts. The cartilage appears normal otherwise. Synovia oedematous.

The marrow is missing from the interior of bone, and the trabeculae seem to have been torn away also.

(Later), Other slides. In some of these, the circular cut has evidently been caught near the periphery by the knife, so that the two cuts are close together. In these the cartilage looks as if it had been squeezed out. It lies in two ribbons out on the surface. The cartilage here at the

injured area has lost its columnar arrangement entirely, and is degenerated in places. It consists almost exclusively of basement substance.

In other slides the two cuts are wide apart. The lateral borders here overlap the central.

The fixing is poor, and details are not sharp. The bone is torn. The marrow is congested.

Rabbit 10, 31 days.

Dec. 19/13. Duplicate of previous operations of gouging out 3 mm. of cartilage from under surface of right patella. The cartilage appeared slightly abnormal, as if it had been injured.

Jan. 19/14. Rabbit killed. Wound healed completely; its site could not be determined. Joint synovia normal to gross inspection. Area of cartilage destruction plainly visible. Both patellae into Orth's fluid. Material lost.

Rabbit 11, 104 days.

Dec. 19/13. Duplicate of previous operations of incising cartilage of patella of right knee in a circle 3 mm. in diameter. Subsequent course uneventful. Wound healed.

Apr. 3/14. Death yesterday.

AUTOPSY.—Fur has not grown out completely, but there is no sign of the operation wound.

Right knee swollen, fluctuating, flexed, and limited in motion. Lump about the size of a bean can be felt in it. Thigh is drawn up toward body. When skin was removed, a marked injection of the vessels on anterior surface of thigh was evident. The lumps could be seen to be yellowish masses, apparently discrete. Joint opened. It is full of cheesy yellow material. The cartilages are roughened. A large part of the joint surface of the patella has been eroded. The lower portion of it presents as bare bone.

Nothing worthy of note in the viscera.

Infection. Not examined microscopically.

Rabbit 12, 278 days.

Dec. 22/13. Duplicate of previous operations of a circular incision through cartilage of right patella, 3 mm. in diameter.

Sept. 26/14. Rabbit has a sausage-shaped irregular mass about 20 cm. along under skin of back. It is soft and fluctuating.

Incision.—The mass was encapsulated, and for a large part of its extent the dissection was carried out without breaking through this. Then it broke. The cavity ran up under the skin almost to the neck (from the tail). The capsule posteriorly was thick, anteriorly (near the neck) it was very thin. The contents were like Camembert cheese. Wound sewn up. Rabbit died about fifteen minutes after removal from table.

AUTOPSY.—The incision in the cartilage is easily recognized. The cartilage within the incision is white in contrast to the pink color of that outside. Otherwise the joint is absolutely normal in appearance.

HISTOLOGY.—The exact lines of incision cannot be determined. The cartilage, presumably at about the site of incision, is fissured in a number of places, and is more or less irregular in structure, though still preserving a columnar appearance. The fissures for the most part run down to bone. The subjacent bone shows small blood-vessels in the marrow spaces.

The overlapping border of a certain number of the cuts points toward one margin, and that of the other cuts toward the other; roughly they point toward their nearest joint margin. The overlapping border is the central one.

Marrow is a mixture of lymphoid and fatty.

Rabbit 13, 149 days.

Dec. 22/13. Duplicate of previous operation of gouging out a piece of cartilage 3 mm. in diameter from the under surface of patella.

May 20/14. Killed by a blow behind neck. The animal has a peculiar horny condition of his untagged ear.

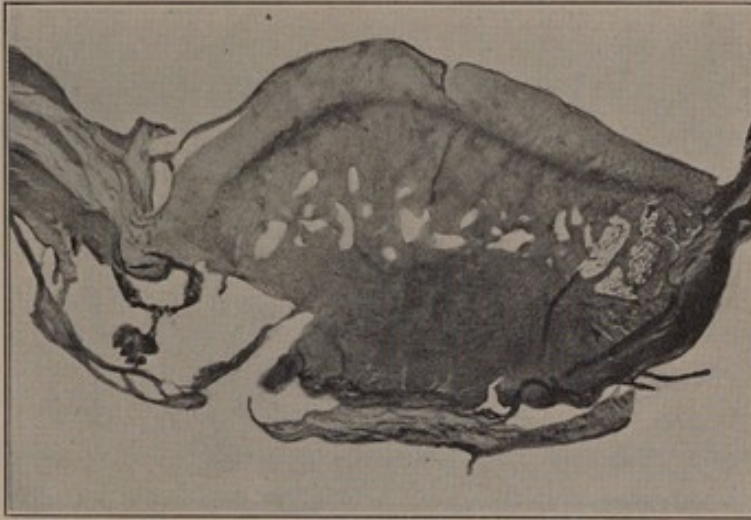
AUTOPSY.—The ear condition was due to "mites," which had built up a structure like a hornet's nest.

The knee wound has healed completely, leaving no trace in the joint. Joint put into alcohol.

Examination of Joint, Aug. 13. Joint laid open by an incision medial to the patella. Cartilage of patella is somewhat irregular. An irregular depression in the form of a ring can be made out, but inside this ring the cartilage seems to have regenerated. Rest of joint appears normal. No lipping or signs of "arthritis deformans."

HISTOLOGY.—On one side of the section the synovia has grown over the unwounded cartilage in the shape of a fibrous band, right up to

the border of the wounded area. It is attached to the cartilage at the border of the wounded area, and for some distance from it, but toward the periphery it is lifted away. At or about the place where the fibrous band ends, the structure of the cartilage becomes extremely irregular. The cells are arranged in groups instead of in columns, and are rather



Low-power photomicrograph showing regeneration of cartilage, probably by means of the spreading inward of the synovial membrane in the form of a band.

few in number. Then comes a small gap or rift in the cartilage, not reaching down to the bone; and still farther away from the fibrous band, at a distance corresponding to the usual width of the cartilage wound another small slit is seen. We have here a *regeneration* of cartilage, probably by means of the synovial membrane spreading in from the side.

Rabbit 14, Lost.

Rabbit 15, 3 days.

Dec. 23/13. Burn as usual. 3 mm. in diameter, with actual cautery through cartilage on under surface of patella. The cautery slipped, probably damaging synovia. One of the *testes* was greatly enlarged, and hanging down in a covering of what looked like thick, dirty skin. It was ligated, tied off, and put into Orth's fluid.

Dec. 26. Died.

AUTOPSY.—Did not show cause of death. The wound was evidently healing well. The synovia of the entire joint showed a violent reaction—it was injected with blood. No fluid in the joint or evidence of sepsis. The burnt hole in the cartilage was evident. Patella put into Orth's fluid.

HISTOLOGY.—Burnt area in cartilage identified. In one or two of the slides a thin scale of deeply pigmented material occupies part of the hole. The burn goes down almost to the bone beneath, but a small layer of cartilage is left, whose structure is practically obliterated. The marrow shows congestion. The cartilage at the side of the burn, where it is not destroyed absolutely, is degenerated, and does not stain properly.

The synovia is injected and oedematous. In two or three slides the burn is at the periphery of the patella, so as to injure the synovia, which is thickened and oedematous. The bone of the patella has been torn so badly in cutting that little can be told about it. (Later), More slides show the same.

Rabbit 16, 360 days.

Jan. 5/14. Right knee. Incision as before. With actual cautery at very dull red-heat, a hole about 3 mm. in diameter was burned in the articular cartilage between the condylar ridges, anteriorly. Suture, and dressing with collodion.

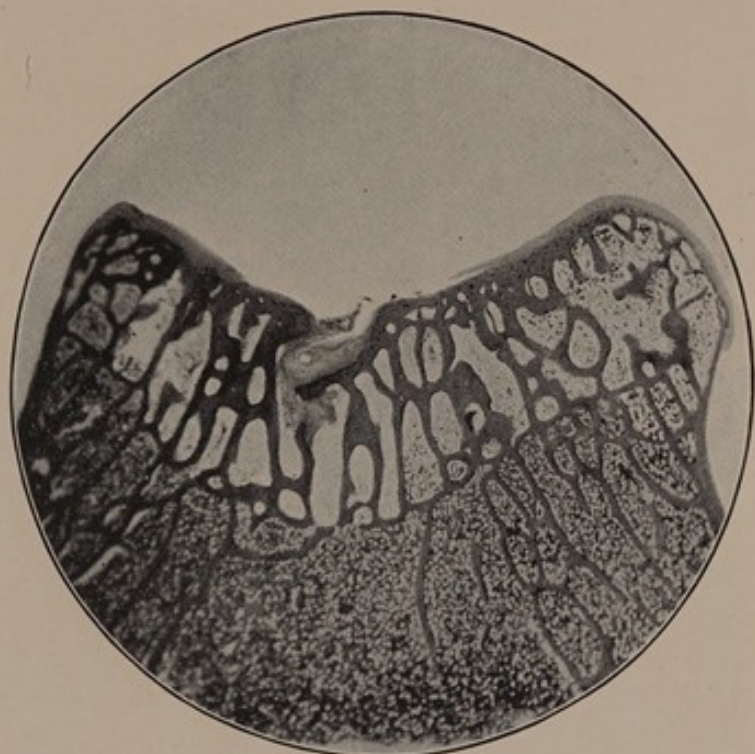
Dec. 31. Apparently in perfect health. Killed by blow on neck.

Joint from outside appears perfectly normal. Movements normal. Joint opened from above. Burned area identified. It is slightly depressed and roughened and has a small pigmented area in its center with a faint halo surrounding it. In other respects the joint appears perfectly normal. No lipping of cartilage or of bone. Synovia is not injected nor thickened. Cross-section with wounded area put into 80% alcohol.

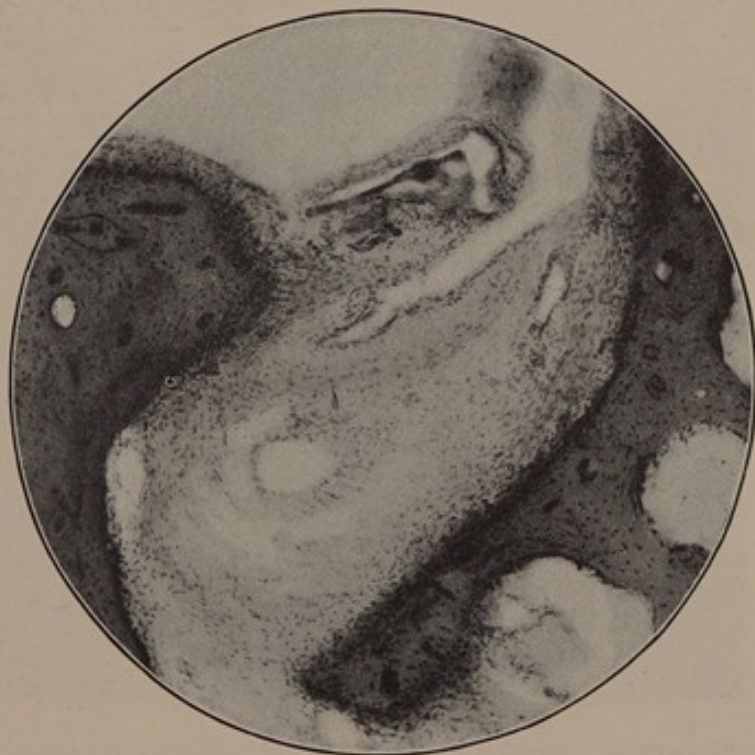HISTOLOGY.—Burned area identified. The cartilage is absent there, and the bone is bare. In the center is a hole through the bone. The "halo" is caused by dead cartilage.

The various slides present various pictures of the tissues in and about the hole. In one the bone buttress looks like a trap-door turned down. In others a bony layer has formed across at a lower level. Again in others there is no bony layer between the joint cavity and the marrow.

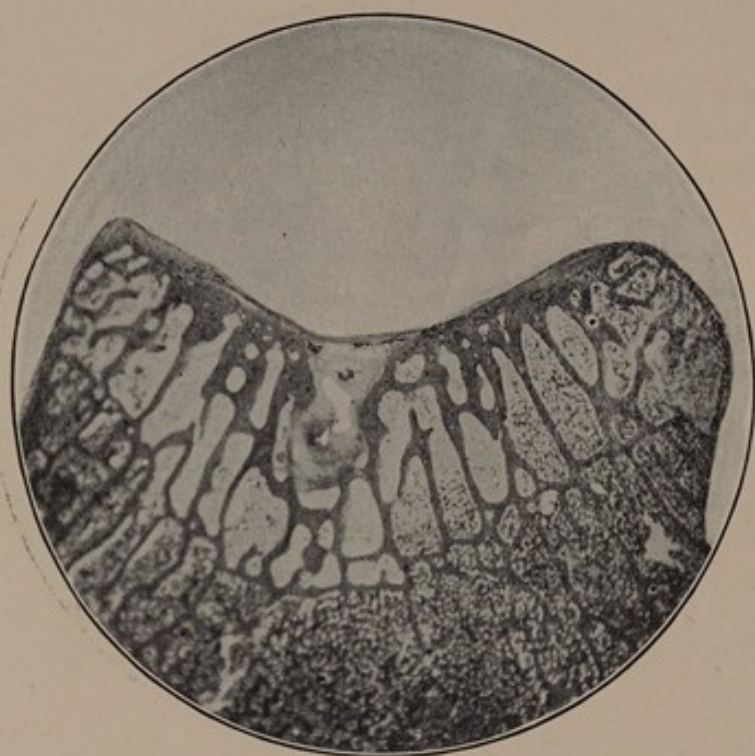
The hole is plugged almost to the joint surface by fibrous tissue with spaces in it, which apparently are communications with the joint—prolongation of the joint cavity—cut across. This fibrous tissue can be seen undergoing transformation into bone, as if to shut off the marrow from the joint; and according to the place at which the microtome knife



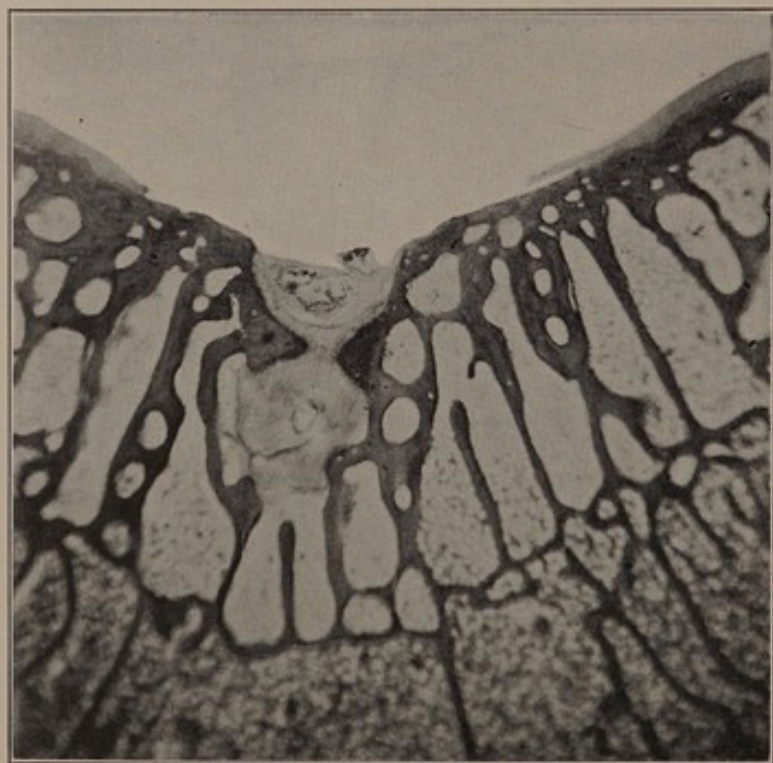
Low-power photomicrograph showing absence of cartilage at site of burn. The cautery penetrated the bony buttress, and the hole is plugged, in this picture, almost to the surface, by fibrous tissue. A new bony buttress is forming at an angle. The cartilage has not regenerated.



High-power picture of the preceding.

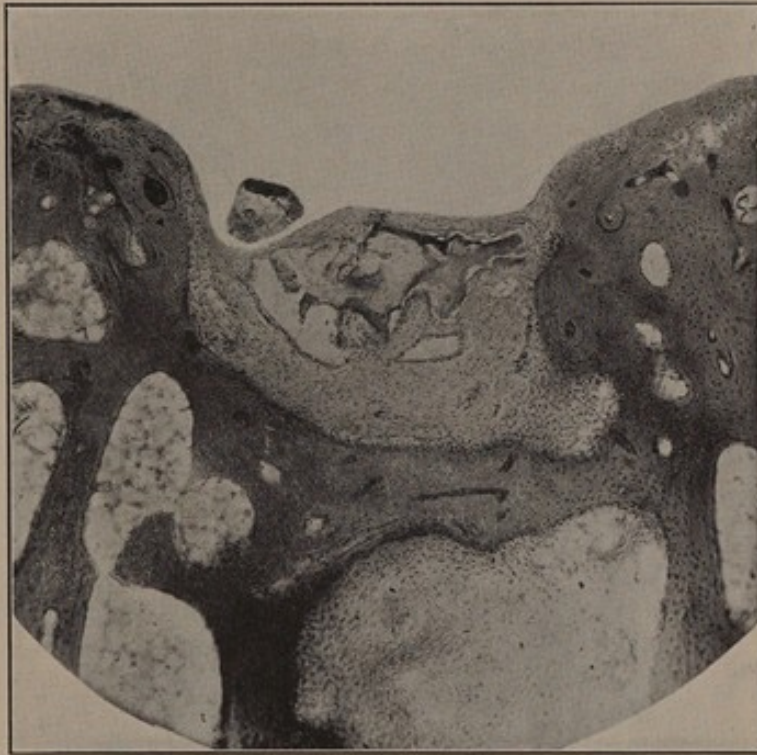


Low-power photomicrograph. A section taken at a different place, showing absence of bony buttress.



Photomicrograph, somewhat higher power, of another slide, showing new buttress, somewhat more advanced in the process of formation.

has passed, one sees a trap-door of bone, a complete layer at a lower level than the surface, or no bony obstruction at all. In other words, the hole evidently was first plugged by fibrous tissue to stop the communication of joint and marrow, and this is now undergoing transformation into bone.



Low-power photomicrograph. In this slide the new buttress of bone, at a lower level, is complete.

Small collections of pigment are enclosed in the fibrous tissue plugging the mouth of the hole.

So far from any thickening of the trabeculae (as for instance in rabbit 4), the trabeculae look to be of normal thickness, or, in one area, rather fewer and thinner than usual. The marrow is largely fatty near the cartilage, lymphoid deeper in. No evidence of lipping of cartilage or bone.

The only living cartilage is over the condylar eminences. No tendency to spreading in of synovia can be seen.

In none of our slides have we found any giant cells "eating up" the pigment.

Rabbit 17, 241 days.

Jan. 5/14. Duplicate of 16; burning of a hole about 2 mm. in diameter in the articular cartilage of the intercondylar region in front of femur. Actual cautery at dull red-heat. Suture, and collodion dressing.

Sept. 3. Rabbit has a large abscess under chin in neck. Killed. Wound completely healed. Joint removed. It is apparently perfectly normal. No Randexostosen. Slightly anaemic. Opened by lateral incision. The burned spot on the femur appears as a non-pigmented depression about 2 mm. in diameter, apparently running down to bone. Its base is rough. About this area is an areola, slightly depressed, about 5 mm. in diameter.

HISTOLOGY.—The wounded area in the cartilage had been lost by careless cutting.

Rabbit 18, 4 months.

Jan. 6/14. Duplicate of 16 and 17. Burning. Rabbit died about four months after operation.

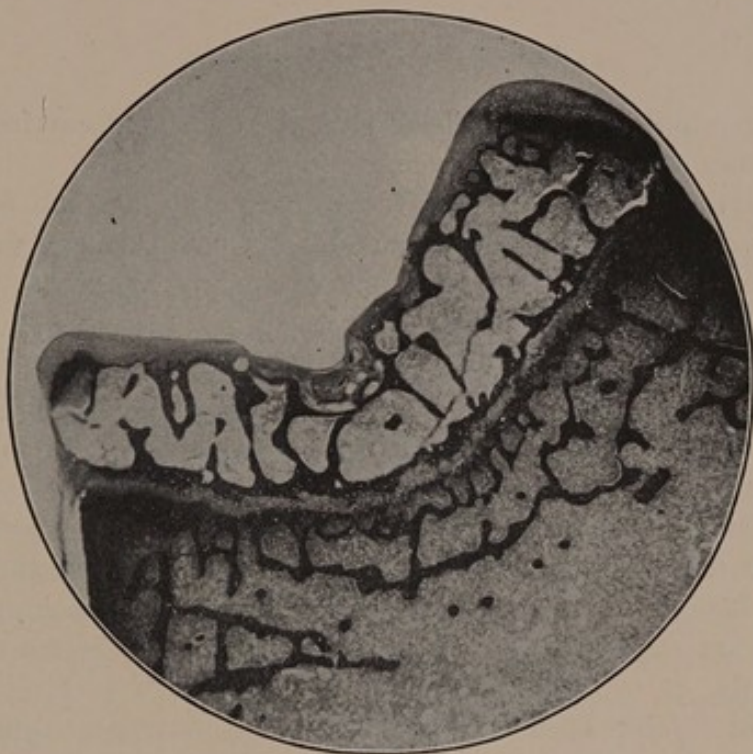
The joint is apparently normal. The thigh is drawn up against the abdomen, and in the groin and on the anterior aspect of the lower end of the femur are soft fluctuating swellings about the size of pigeon's eggs. On the inner aspect of the knee is what appears to have been a third of these collections, but it has evidently ruptured, and now is half filled with a yellow cheesy material. The joint itself seems freely movable. These collections of purulent material are connected by strands; in one of these strands there is a cheesy lymph node. There are other smaller lymph-nodes filled with similar material. A section of the larger masses shows a greenish-yellow material like over-ripe Camembert cheese.

Right knee-joint removed and put into 80% alcohol.

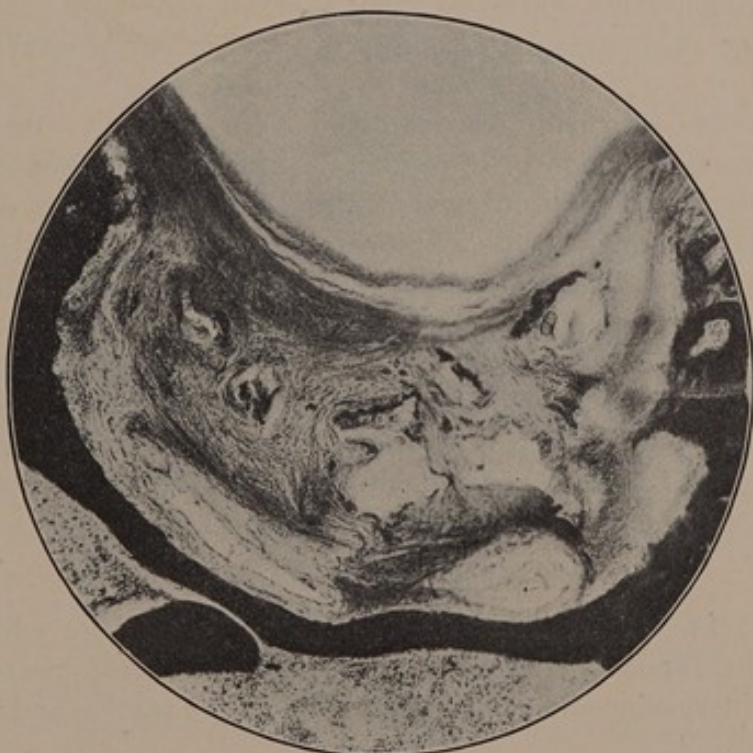
AUTOPSY shows a jelly-like substance in pericardium and an extensive right pneumonia.

Aug. 26. Joint opened. The wounded area is manifest as a depressed area, surrounded by a faint halo. Center, 2 mm. in diameter, is roughened and depressed. Halo surrounding this—5 mm. in diameter—smooth and slightly depressed. Placed in 5% HNO_3 .

HISTOLOGY.—The burn in the cartilage is manifest as a depressed area, partly filled with fibrous tissue in which are seen some irregular spaces, and some areas containing pigment and detritus. Two or three blood-vessels can be distinguished in the fibrous tissue. The buttress of bone immediately beneath the cartilage is also gone, and the depression goes much below it; but underneath the burned area a new buttress of



Low-power photomicrograph. The cautery has penetrated the bony buttress. The injured area is manifest as a depression partly filled by fibrous tissue. Note new buttress formed at a lower level. No regeneration of cartilage.



High-power photomicrograph, showing masses of pigment and detritus in the new fibrous tissue.

bone has been built, at a lower level than the other, but continuous with it, as if to shut off the marrow from the joint.

The cartilage over the rest of the joint looks normal, except for small degenerated areas. No evidence of any new cartilage production. The marrow is normal. No evidence of lipping or of "arthritis deformans."

Rabbit 19, 225 days.

Jan. 6/14. Duplicate of 16, 17, 18 (burning hole through cartilage between condylar ridges of femur).

Aug. 22. Rabbit died last night.

AUTOPSY.—Fur has grown over joint. No sign of any lesion of joint. Skin removed; no sign of incision. Joint removed and put into formalin. It presents no sign of abnormality, prior to opening.

Lungs are engorged. Apparently the animal died in the first stage of pneumonia.

Aug. 24. Joint opened, through incision in capsule medially to patella. Circular depression, 3 mm. in diameter, extending across trochlear surface from external ridge. In center of this is a black pigmented spot about 1 mm. in diameter, apparently covered by cartilage. This area is slightly roughened. Patella, even where it plays over roughened surface of femur, shows no abnormality.

Aug. 26. Cross-section through trochlear surface at level of burned area.

HISTOLOGY.—Burned area identified. Its cartilage and most of its bone buttress are gone. It contains a little detritus, and is covered over by a pigmented strip of burned cartilage. In the hole is a group of cartilage cells, staining well. The necrotic covering extends over most of the burn, but at its side an area of fibrous marrow can be seen communicating directly with the joint. The cartilage which remains beyond the limits of the actual burn is dead. In the bone, immediately under part of the degenerated cartilage, are short columns of cartilage cells arranged almost perpendicularly to the surface. The marrow shows two or three areas of fibrosis immediately beneath the burned area. Otherwise it seems to be much more fatty than normal.

Rabbit 20, 59 days.

Jan. 14/14. Duplicate of 17 (burning the cartilage with cautery point). The exposure was clumsy, and the joint tissues were injured. Also the cautery slipped, burning downward on the patella, and wounding synovia.

Mar. 10. Animal died last night after giving birth to a litter of rabbits.

AUTOPSY.—Exudate in pericardium. Right pleural cavity full of purulent exudate; left pleura same. Consolidation of both lungs. Fibrinous exudate on visceral pleura.

Right knee-joint operation. Wound is healed completely. Joint opened by transverse incision. It presents no signs of inflammation, except possibly a slight injection of the synovial membrane near its line of reflection to the cartilage. The burned area of cartilage appears as a black ellipse, about 3×1 mm., with its long diameter transverse (running between the two condyles). Lower end of femur removed and put in Orth's solution.

HISTOLOGY.—The cartilage has been destroyed at site of injury. A thin layer of structureless, irregular, pigmented (brown to black—van Gieson, and H. & E.) material takes its place partly. Beneath this the various slides show different pictures.

1. Under most of the area is bone, some living and some dead, the living and dead side by side. Beneath the center of the area, however, there is an area partly filled by a mass of cartilage. The rest of the area is vacant toward the joint from the mass of cartilage. This mass of cartilage is continuous on its deeper aspect with bone, as if it were forming bone. The layer of bone beneath the burn in this slide is rather thin in most places. The marrow beneath the burn is fibrous and oedematous in character.

2. Other slides show no traces of the space half-filled by a mass of cartilage, or a thinning of the bone, but rather a thickening of the bone, some living and some dead. The deep surface of this bone shows evident new bone formation by fibrous tissue in marrow. The dense bone contains a few marrow areas near the surface. Not so much oedematous fibrous marrow is present in these slides as in the first set. The marrow areas near the surface contain cells that look like cartilage cells, and they are surrounded in places by new formed bone.

3. Other slides show very little bone under burned area, and that in the form of trabeculae, some living and some dead, among which are fibrous marrow and small groups of cartilage cells.

All the cartilage is eosinophilic.

There are absolutely no signs of any change in the joint or marrow or bone at a distance from the site of the injury.

The unwounded cartilage looks normal. Its cells are arranged in columns perpendicular to the surface, except near the surface, where the columnar arrangement ceases.

Rabbit 21, 6 days.

Jan. 14/14. Duplicate of preceding. Hole about 2 mm. in diameter burned in cartilage of femur. The rabbit seems sick. Its breathing is rapid, and its reflexes exaggerated.

Jan. 17. Angora rabbit ill, losing flesh fast. On picking it up, and putting it down, its head moves from side to side as in paralysis agitans.

Jan. 20. Died.

AUTOPSY, Jan. 21. Wound shows no sign of infection. Knee opened. Joint dry. Synovia injected. Burnt hole apparent in cartilage of femur. Otherwise cartilage appears normal. Section of femur including the hole was removed and placed in alcohol.

HISTOLOGY.—The burn goes down into the marrow through the subjacent bone. The edges of the cartilage, dead, protrude over the opening. Practically no reaction has taken place in the tissues. The marrow near the joint is mostly fatty; deeper in, it is more lymphoid.

Rabbit 22, 345 days.

Jan. 19/14. Duplicate of preceding operations of burning cartilage of femur.

Dec. 30. Killed by blow on head. Well nourished, healthy looking. Knee-joint on examination appears to be normal. Movement free. Joint opened from above. Burned area identified. It is slightly depressed and slightly roughened, but is not pigmented. Examination reveals nothing abnormal in joint. Outside of burned area there is a second rounded smooth area, an areola.

HISTOLOGY, Mar. 12/15. The burned area is easily recognized as bare bone, with a thin layer of necrotic cartilage over it in places, but with no attempt at covering over by new tissue. This bone is fairly smooth and regular. At the sides the second smooth area noted above is seen to consist of degenerated cartilage, so that except for a short distance on one side, on the tip of the condylar ridge, no live cartilage can be seen between the condylar ridges. The bone beneath is quite dense, the trabeculae are numerous and thick. New bone is evidently being deposited on the old and degenerated trabeculae, but all take the stain about the same. The marrow is largely fatty, in areas lymphoid. The new bone on the trabeculae is evidently being formed from fibrous tissue.

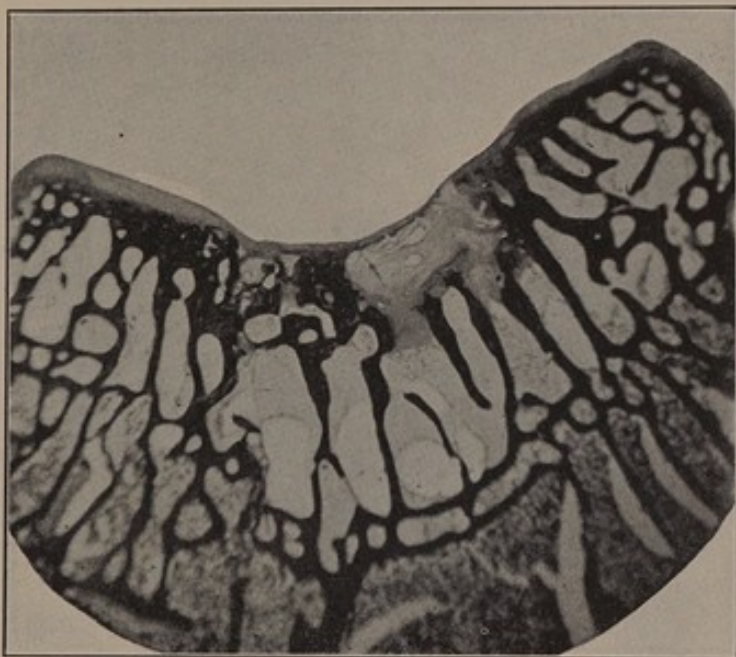
Rabbit 23, 320 days.

Jan. 19/14. Duplicate of preceding operations of burning hole in cartilage of femur. The operation was clumsy, the cautery slipped twice, and burned the synovial membrane.

Dec. 5. Rabbit runs without lameness. It has, however, a wound on right ankle, from which pressure forced out a cheesy material. Animal killed by blow on back of neck.

Wound has healed completely.

Joint opened from above. It is perfectly normal, except for the

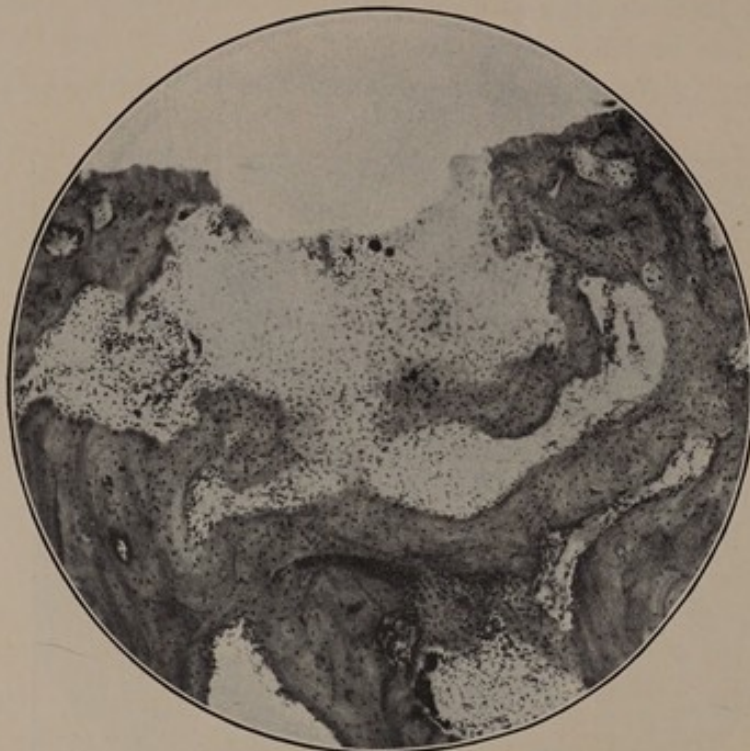

Low-power photomicrograph. The cartilage has not regenerated. It is absent at the burned area. The bony buttress is represented by a strip of necrotic bone. Underneath this is a mass of fibrous tissue which is undergoing ossification in its deeper portion. At the sides of the denuded area structureless, degenerated cartilage begins and extends up to the condylar eminences. Over the eminences alone is healthy cartilage seen.

wound in the femur, which can be identified easily as a roughened depression. (In sawing, the saw slipped and injured the medial condyle.)

HISTOLOGY.—No sign of "border exostoses." Burned area clearly identified as an area in which the cartilage is absent and bare bone is at the surface, fairly smooth over most of its extent. Toward the sides of the joint, the cartilage is still present, but degenerated. No live cartilage until the condylar eminences are reached. At about the center of the burned area, covered over mostly by a thin layer of bone, is a collection of fibrous tissue,—that is, in the spongy bone. In places it is very dense,

in places thinner, and seems to be undergoing a transformation into bone. (This looks as if the cautery had gone down into the bone.)



High-power photomicrograph from another section, without the strip of necrotic bone. This shows the buttress of bone formed at a lower level, and the conversion of the fibrous tissue into bone.

The bone trabeculae appear quite thick under the burned area. For a short distance under the cartilage the marrow is fatty, further toward the shaft it is lymphoid.

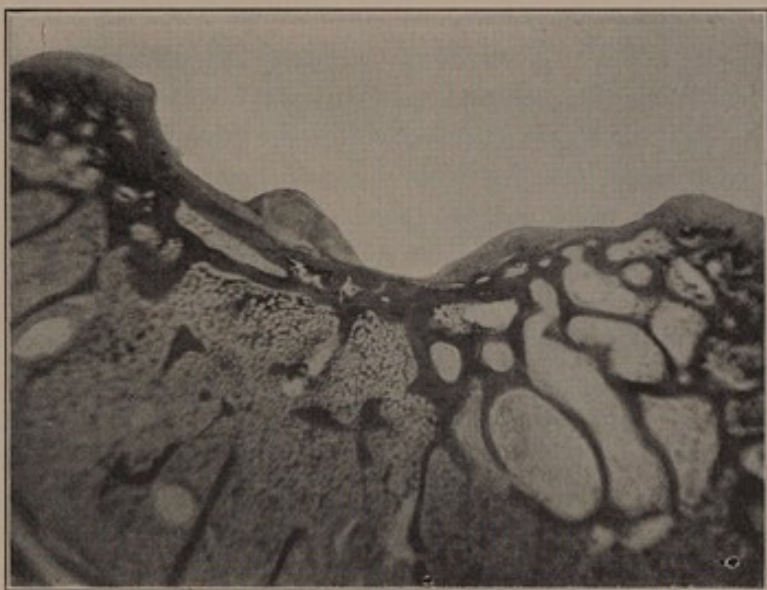
Young rabbit.

Rabbit 24, 298 days.

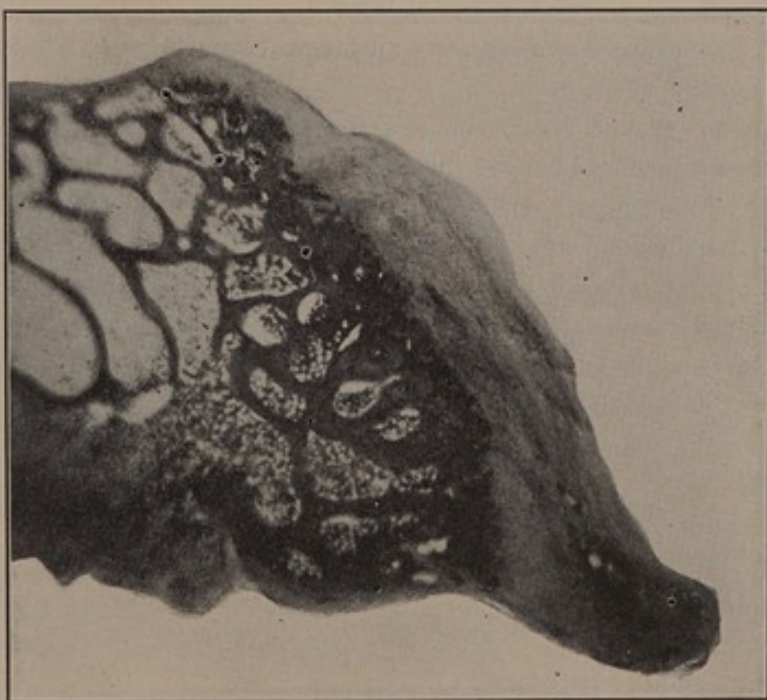
Jan. 22/14. Duplicate of preceding operations of burning a hole in the cartilage of the lower end of the femur. Suture with catgut.

Nov. 16. Rabbit killed by blow on back of neck. No sign of operation. Joint is perfectly movable, but feels broader from side to side.

Joint opened from above. Patella has been dislocated medially—accounting for the broadened joint. The patella has formed on the femur an articulating cartilaginous-like surface covered with firm tissue. Between the condylar ridges is a depressed area, corresponding to burn. It is covered by white, fibrous tissue. From this area to the synovia lateral to the patella is a strong, firm, glistening, grayish band of fibrous tissue. From the lateral aspect of lateral condyle to the synovia are sim-



Low-power photomicrograph of femur at site of burn. The cartilage is absent in the intercondylar groove, and fibrous tissue covers the bone. The exact location of the burn cannot be determined.



High-power photomicrograph, showing the fibro-cartilage formed on the medial aspect of the femur for the new articulation with the patella.

ilar but finer bands. The synovia appears thickened, but not injected. The tissue directly over the burn (that is, on under surface of quadriceps aponeurosis) just lateral to the adhesion is thickened, white, glistening, and firm; it appears cartilaginous (new forming patella?).

A, Section through burned area.

B, New articulating surface on medial aspect of medial condyle.

C, Cartilaginous tissue over burn.

(All into alcohol.)

HISTOLOGY.—*A*. Between the two condylar ridges the cartilage is absent. The layer of bone is covered by fibrous tissue, varying in thickness, but at no place very thick. Some of this fibrous tissue looks at its surface like synovial membrane. There is no collection of pigment, and the exact spot of burning cannot be identified. The fibrous tissue is continuous at the sides with cartilage, which covers the medial and lateral condylar eminences. Upon what is evidently the medial aspect is a *thick layer of fibro-cartilage*.

The marrow in the bone ends is a mixture of fatty and lymphoid. New bone is forming in it.

B. *New cartilage has been formed over the new articular surface*, on the medial aspect of the bone, whose cells are arranged in irregular groups, rather than in the columnar normal manner. Its superficial layer is almost devoid of cells.

A large synovial villus is seen over the new articulating surface, which is becoming converted into cartilage. The passage from synovia to cartilage is so gradual that the transition is hard to establish. The bone trabeculae under the new articulation are thickened, and the marrow in places is fibrous, and is being converted into bone.

C. Dense fibrous tissue and muscle. No cartilage.

This case shows the transition of synovial membrane into cartilage.

Rabbit 25, Lost.

Young rabbit.

Jan. 23/14. Duplicate of preceding operations of burning hole in cartilage of femur. Catgut.

Rabbit lost.

Rabbit 26, 19 days.

Young rabbit. Infected.

Jan. 23/14. Duplicate of preceding operations of burning hole in cartilage on front of lower joint surface of femur. Poorly done. The cautery slipped and singed soft parts.

Feb. 11. Rabbit ailing. The right knee is drawn tightly up against the body, and cannot be pulled down. The wound is infected and discharges thick, cheesy pus. Animal killed by blows on back of neck, and an immediate autopsy done. Even after death the knee was held tightly to the body, and ordinary force could not straighten it. Skin removed from thigh, knee and groin, also from portion of abdomen. Great distension of the blood-vessels between the knee and groin, and in the groin. Cheesy masses along the vessels and in the groin. The knee was literally tied to the abdomen by the inflamed tissues. When these were divided the knee could be brought down. Knee-joint greatly distended—tissues outside it succulent. Knee-joint opened by transverse incision. It was filled with cheesy matter. The cartilages were practically normal in most of their extent. The site of the burn could be identified, and upward from this the cartilages seemed damaged, not so much eroded as "coated." The general autopsy revealed nothing of note.

A, Piece of femur with the burned cartilage area into Orth's fluid.

B, Femur into Orth's fluid.

C, Tibia and patella into Orth's fluid.

D, Soft parts of joint, and cheesy mass from groin, into Orth's fluid.

A. The cartilage over the femur has disappeared, except near the circumference, where it is degenerated or dead. The buttress bone layer has disappeared almost throughout. The marrow of the epiphysis is fibrous, but contains a few polymorphonuclears. The trabeculae show "Randapposition" and productive ostitis. Some rarefying ostitis.

In a few places the marrow appears to be bursting through the degenerating cartilage. Fibrous tissue lies beneath the cartilage. The marrow of the metaphysis shows a dense infiltration, mostly by polymorphonuclears, with a few plasma cells and a few eosinophiles; also many giant cells. The trabeculae are small and scant. The synovial membrane is thickened, and infiltrated with polymorphonuclears and endothelial leucocytes mostly. It has also areas of necrosis. The epiphyseal line seems normal.

B. Congested blood-vessels in marrow—polymorphonuclears and giant cells in great numbers.

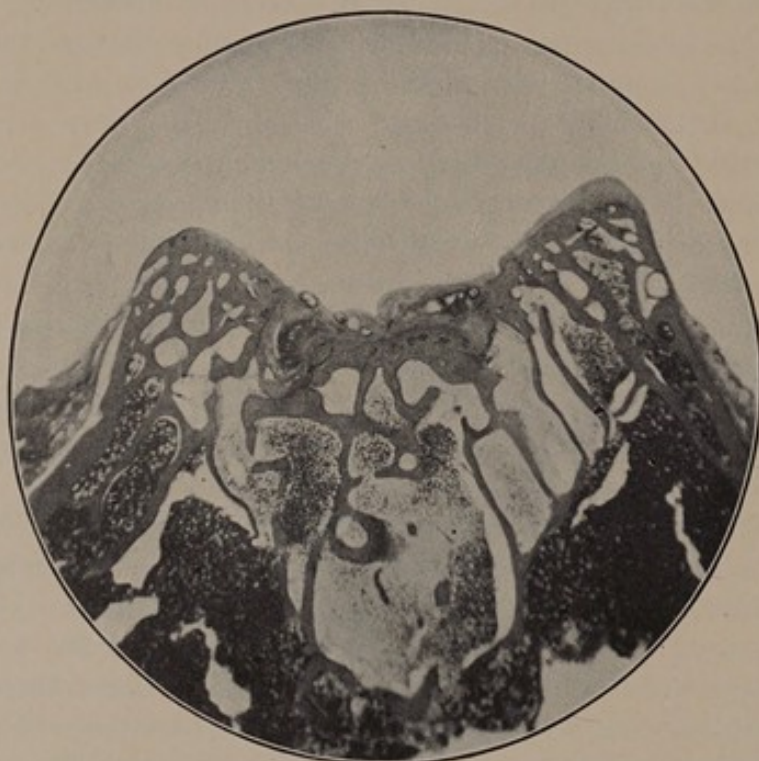C. Patella. Cartilage degenerating at the surface. Marrow fairly normal. Much productive ostitis.

Young rabbit. **Rabbit 27, 255 days.**

Jan. 26/14. Duplicate of preceding operations of burning hole 2 or 3 mm. in diameter in the cartilage on anterior surface of lower end of femur.

Oct. 8. Rabbit in perfect health. Uses leg well. No evidence of limp. Wound has healed.

Rabbit killed by blow on back of neck. The wound in capsule cannot be distinguished. Joint opened by medial incision. It is apparently perfectly normal in most of its extent. Wound in cartilage identified.



Low-power photomicrograph. The wounded area is filled with fibrous tissue. Cartilage is absent over most of the joint surface. No regeneration of cartilage has occurred. In spite of the severe trauma here, no evidence is present of "border exostoses" or of "arthritis deformans."

It feels rough, as the handle of the scalpel is passed over it. Under a magnifying-glass the hole appears to be filling up irregularly with cartilage.

HISTOLOGY.—Wound in cartilage identified. It is filled with dense fibrous tissue. Encapsulated in this are a few small pieces of pigmented material (burned matter). At one spot beneath the fibrous tissue the bone buttress is absent, and the fibrous tissue communicates with the marrow. The marrow, under the burned area and throughout at the extreme end, is fatty, except for a small area at one side of the section, where there is a little lymphoid marrow. Deeper in, the marrow is

lymphoid. At one side of the burned area the cartilage persists as an irregular, thin layer. It has lost its regular cellular arrangement. The cells, mostly without their capsules, are generally seen as irregular groups, with deeply staining nuclei. In places the cartilage is without cells. The layer of cartilage tapers down toward the hole, and ceases at about the margin of the burned area.

On the other side of the burned area, immediately adjacent to it, the cartilage is very thin, and presents the same appearance as on the side just described. It then becomes a layer of cartilaginous basement substance, gradually increasing in thickness toward the periphery, where there is a sharp line of demarcation between it and comparatively normal cartilage. Here the cells have deeply staining nuclei, are mostly without capsules, and have no regular columnar arrangement. The cell arrangement in columns is not present in any part of the section.

On the first side described the synovial membrane has undergone a fibrous proliferation. On the other side there is a slight lymphoid proliferation at the surface, with fat below it.

The fibrous tissue filling in the hole is villous at its surface, and has much the appearance of synovial membrane.

Young rabbit. **Rabbit 28, 198 days.**

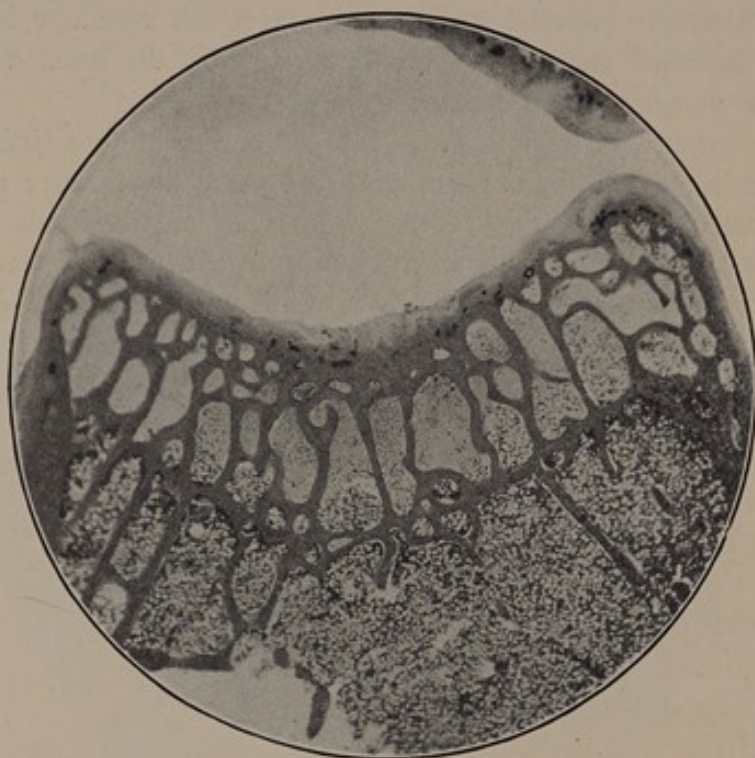
Jan. 26/14. Duplicate of preceding. Burning hole, 2 to 3 mm. in diameter, with cautery at dull heat, in cartilage on anterior surface of lower end of femur.

Aug. 12. Killed. Joint opened through lateral aspect. No trace of original wound of soft parts. From the outside, the joint appears normal. Original burn in cartilage of the femur can be identified as a slight pigmented depression about 2 mm. in diameter. This is in the center of a shallower depression measuring 5 mm. in diameter. The central area is slightly irregular, and light brown in color. The outer depression is round and smooth, opalescent.

On the medial aspect of the medial condyle at a slightly lower level than the burn (distal to it) and anterior to the reflection of the synovial membrane (in a pocket of it) is a small irregular protuberance apparently covered with cartilage. This exostosis is not on the articulating surface, but posterior to it. Cartilage of tibia normal.

HISTOLOGY.—Burned area identified. It is almost level with the surrounding cartilage, its surface is irregular, and it is filled with cartilage, whose cells are grouped irregularly. It contains small masses of pigment. The cartilage shades into subjacent bone without a sharp

line of demarcation. The cartilage over the rest of the articulating surface is largely degenerated, especially in its more superficial portion. There is no normal cartilage on the articular surface—no columnar ar-



Low-power photomicrograph showing regeneration of cartilage over burned area.

range. Over the side of the condyle the cartilage looks normal. There is no sign of any exostosis. The marrow near the cartilage contains much fat and little lymphoid tissue. *Apparent regeneration of cartilage.*

Rabbit 29, Lost.

Young rabbit.

Jan. 27/14. Duplicate of preceding operations of burning hole in anterior surface on front of cartilage of condyles of femur.

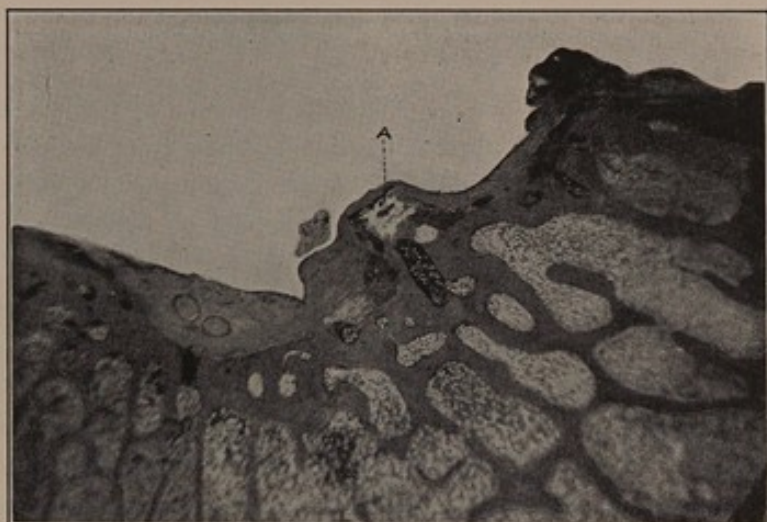
Lost.

Rabbit 30, 127 days.

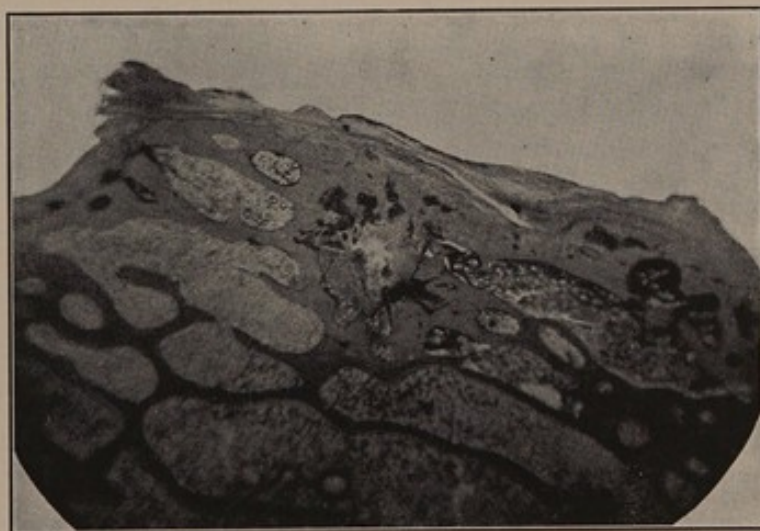* Young rabbit.

Jan. 27/14. Duplicate of preceding operations of burning hole, about 2 mm. in diameter, in cartilage on front of lower end of femur. Cautey slipped and seared cartilage in neighborhood.

June 5. The joint is in flexion, and cannot be fully extended, though motion up to a certain degree of extension is free. Flexion is free. The operated knee is enlarged.



Low-power photomicrograph. The center of the burned area shows a small projection or teat (A). This is composed of fibrous tissue and bone. The bone injured at operation evidently has become encapsulated and is manifest by collections of black and brown pigment. Oedematous fibrous tissue containing blood-vessels extends inward on either side across the joint surface, evidently a prolongation of the synovia. The cartilage has disappeared from the joint surface, except in a small area over the tip of the lateral condyle. Here the cartilage cells have lost their columnar arrangement. There is no evidence of regeneration of cartilage.



New cartilage on medial aspect of femur, for articulation with the dislocated patella.

Killed by blow on neck. The wound has healed completely, leaving no trace. The quadriceps apparatus has slipped over the internal condyle, and this condition is evidently responsible for the limitation of extension. The patella was over the medial aspect of the femur.

Joint into 80% alcohol.

A swelling on the right side of the jaw proved to be a multilocular cyst. On opening it, a parasite identified under the microscope as a species of tapeworm was revealed inside.

Examination of Joint, Aug. 12. Joint opened by incision on the lateral aspect, reflecting the extensor apparatus to the medial side. On opening the joint the cartilage appeared irregular in texture, surface and color, but was not eroded. The patella seems to be making a new articular surface for itself on the medial aspect of the medial condyle. The site of the burn is covered with what appears to be a plug of new fibrous tissue, and this plug extends upward in the intercondylar notch to the upper portion of the joint.

On removing the plug of tissue over site of burn an excavation of about 5 mm. in diameter is revealed, occupying the entire space between the condyles. The surface of depression is roughened. The cartilage seems to have been eroded. Above this is a firm, whitish, fibrous mass overlying cartilage. The bearing surface of the medial condyle and that of the tuberosity show what appear to be beginning erosions.

HISTOLOGY.—The burned area (manifest by the collections of black and brown pigment) is occupied by a small projection or teat between the condyles. This is composed of bone in its deeper portion. Above this (superficial) are spaces containing traces of necrotic bone. The outline of the stellate bone cells can be made out. The bone injured at operation evidently has become encapsulated. Above this necrotic tissue is the pigmented area described above. Covering this is a smooth band of dense fibrous tissue, which can be traced on either side clear across the joint surface, becoming thinner and less dense toward the periphery. It expands on either side into an oedematous fibrous tissue, containing many blood-vessels. A synovial membrane covers this fibrous tissue. We interpret the teat as a collection of necrotic material in a fibrous capsule, much of which capsule is undergoing ossification. The cartilage has disappeared entirely from the joint surface, except in a small area over the tip of the lateral condyle. This is losing in places its columnar arrangement, is covered over by fibrous tissue, and is evidently ossifying from below. The marrow is pushing up into it. We regard the change at site of injury as the result of the action of the synovial membrane spreading in from the periphery. The whole con-

tour of the medial condyle is changed. Instead of being approximately a straight line, it bulges out and forms a convexity.

On the medial aspect of the specimen, a new articulation is forming. The bone is covered in places by cartilage, in places by fibro-cartilage, and these again are covered by fibrous tissue, and in some places by synovial membrane. Between this area and the tip of the condyle, beneath the surface of the bone, there is a rather large, irregular area of new-formed cartilage, which is apparently undergoing ossification. The marrow is densely cellular in the vicinity, and is pushing through the layer of cortical bone. This pushing through exists all along down the side of the condyle.

The marrow throughout the specimen is lymphoid.

The synovial membrane is villous, and the structure of the villi is fibrous, with a layer of cells on the surface. The new intercondylar synovia is oedematous.

The structure of the synovial membrane is much the same as in "arthritis deformans."

Rabbit 35, 47 days.

Young rabbit.

Feb. 19/14. Duplicate of former operations of *gouging* out a circular area about 2 or 3 mm. in diameter from the under surface of right patella. Wound sutured in two layers. Collodion.

Apr. 7. Died.

AUTOPSY, Apr. 8.—Joint appears absolutely normal. The wound has completely healed. On posterior and lateral portion of the thigh there is a collection of cheesy material, communicating with the surface and running upward over the spine down into the lateral portion of the opposite thigh. About this encapsulated cheesy material the veins are injected. Operated knee-joint opened by transverse incision; the synovia is possibly a trifle injected, but otherwise the joint generally appears normal. The operation wound on patella shows as a slightly depressed light-brown scar. Patella removed for observation and placed in Orth's fluid. The right lung seems injected. At the lower margin of the left lung is a brownish, discolored area. Cause of death probably pneumonia.

HISTOLOGY.—The wound in the cartilage is filled with fibrin which has become partly organized into fibrous tissue. Near one side of this tissue cartilage cells can be seen, and there is also a large nest of cartilage below the tissue, whose matrix is basophilic. The cartilage bordering on the hole at the side presents areas of basement substance with few cells, and on one side its cells are proliferating. There is a thin layer of bluish cartilage beneath the wound in some of the slides—zone

of provisional calcification. The marrow is lymphoid, and somewhat engorged. This is evidently a case of *new forming cartilage*.

Rabbit 36.

Young rabbit.

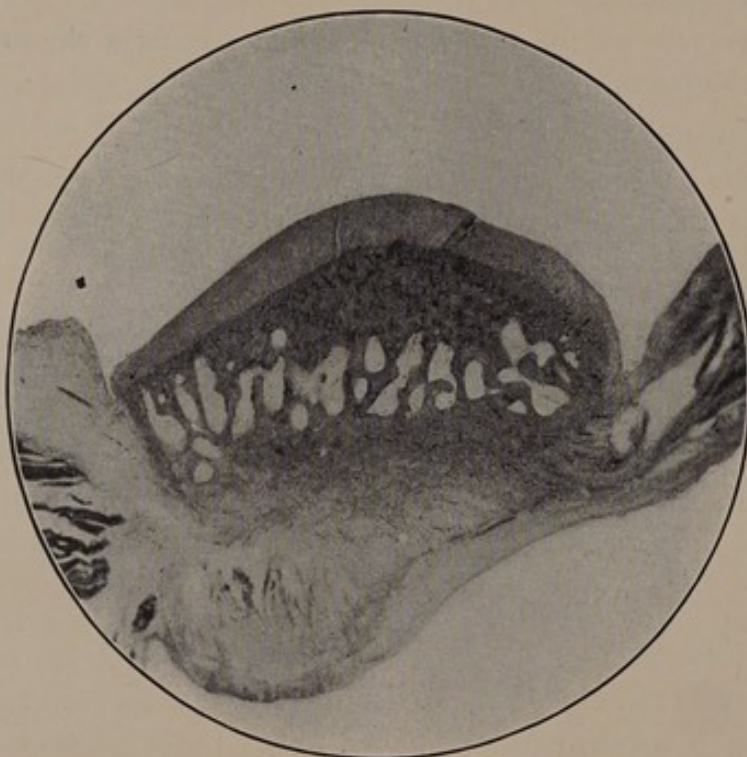Feb. 19/14. Duplicate of former operations of making a circular incision about 2 or 3 mm. in diameter through the cartilage on under surface of right patella.

Oct. 7. Rabbit lost.

Rabbit 37, 138 days.

Young rabbit.

Feb. 23/14. Duplicate of operation of making circular incision 2 mm. in diameter through the cartilage on the posterior surface of the right patella. Wound sutured with chromicised catgut in two layers. Collodion.



Low-power photomicrograph. The incisions are seen to extend through the cartilage. One remains open, another appears closed at the surface and is open throughout the rest of its extent, while a third is closed throughout its whole depth. The closure is by simple apposition of the edges, and not by any active process of cartilage regeneration. The joint otherwise is normal.

July 11. Rabbit killed by blow on back of neck. Joint apparently perfectly normal. It was removed with about 3 cm. each of femur and tibia. Red marrow in femur shaft.

Joint opened. Apparently perfectly normal except for a slight injection of the synovia in the quadriceps pouch, medially, where it passed to the cartilage. The incision of patella could not be distinguished with the naked eye. The cartilage appeared perfectly normal; under a magnifying-glass it appeared superficially fissured. There were no "Randexostosen," nor any signs of abnormality about the joint.

HISTOLOGY.—The cartilage throughout most of its extent appears normal. In the various sections can be seen fissures in it, perpendicular to the surface,—in some one, in some two, and in some three. One fissure (a deep one) shows the surface of the cartilage on one side slightly higher than on the other, and has its mouth plugged by what appears to be chondro-mucin, containing a few small areas of cartilage cells. Another fissure reaches only about half-way through the cartilage, and has an open mouth. Another deep one seems to have been healed near the surface by a fusion of its walls, but is open deeper in. Marrow fatty throughout. Synovia normal. No exostoses.

The overlapping borders are the circumferential ones, that is, the cuts point toward the middle of the patella.

Rabbit 38, 235 days.

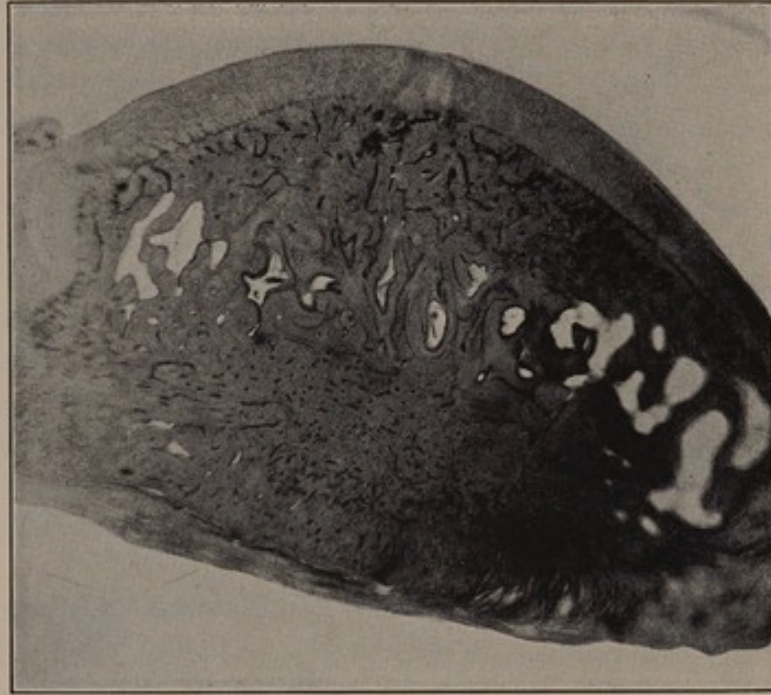
Young rabbit.

Feb. 23/14. Duplicate of operation of gouging out a circular piece of cartilage about 2 mm. in diameter from the posterior surface of the patella. Wound sutured with chromicised catgut in two layers. Colloidion.

Oct. 16. Rabbit, in perfect health, killed by blow on back of head. The incision has healed completely and cannot be distinguished. Joint opened by incision from above. Site of wound in patella can be barely distinguished by a slight irregularity in the cartilage, an irregularity which is not perceptible when the handle of the scalpel is passed over it. Joint otherwise is normal. No Randexostosen. No evidences of inflammation in the synovial membrane.

HISTOLOGY.—The sections presumably have been taken rather high up on the wounded area, or rather low down, for the changed area in the cartilage is narrower than the actual wound. Cartilage, whose structure is irregular, has filled up the gouged area. The columnar arrangement of the cells is absent, and the ratio of cells and basement substance

varies in different parts of the new cartilage. Superficially the cartilage has degenerated. There is a slit about the middle of the new-formed cartilage, perpendicular to the surface, but not reaching it. The new



Low-power photomicrograph, showing production of new cartilage at site of injury.

cartilage is thicker through than the normal cartilage. The thickening is at the expense of the subjacent buttress, giving the latter a gouged-out appearance.

This specimen is evidently an example of the production of new cartilage to fill the gap left by the gouge.

Rabbit 39, 116 days.

Young rabbit.

Feb. 26/14. Repetition of operation of gouging out a piece of cartilage from posterior surface of patella of right knee. Slightly more than usual was gouged—3 mm.,—and the gouge slipped upward, wounding the cartilage beyond. Suture and collodion.

June 22. Animal died at 2:10 p.m.

AUTOPSY at 3 p.m. Right knee normal. *Left knee* enlarged and patella displaced medially. Marked thickening of the lateral condyle of femur. The medial condyle is prominent and thickened, but less than the lateral. Deformity of limb not noticeable until skin is removed or upon palpation. Abdominal viscera and brain normal. Heart relaxed and distended with blood. Middle lobe of right lung dark-red in color, and preserved in 80% alcohol. Left lung with fine rounded haemorrhagic spots not over 3 mm. in diameter. Numerous whitish areas, not over 1 mm. in diameter, are observed scattered over external surface of lung.

Specimen of knee-joint preserved in alcohol.

Left knee-joint opened through a lateral incision. The patella is luxated medially, and rests against the medial aspect of the medial condyle. Behind the patella is a mass of bone apparently built up by nature as a resting place for the patella. *This is not the operated joint.*

Right knee-joint laid open by a medial incision at side of the patella. Entire joint, save the operated patella, seems normal. The patella presents near its center an irregular depression, apparently not as large as the gouged area. It appears as if the cartilage has regenerated and covered the gouged area.

HISTOLOGY.—Marrow is fibrous. The sections have been taken off evidently at a wrong level. A small piece of cartilage is present at one side of one slide, whose cells are proliferating.

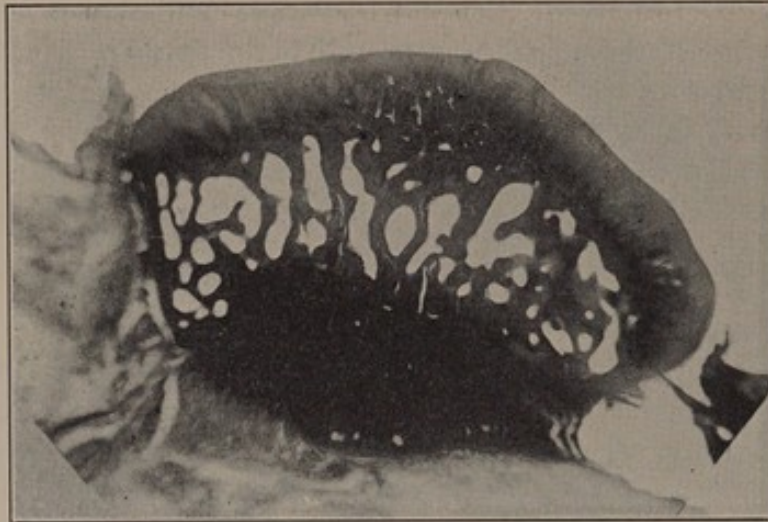
Rabbit 40, 204 days.

Mar. 5/14. Repetition of gouging operation from under surface of patella.

Sept. 25. Killed by blow on back of neck. Joint opened by medial incision. The operation wound was healed without visible evidences of its location. The wound was identified in the patella, smaller than when operated. Otherwise the joint tissues were normal.

HISTOLOGY.—The hole is filled up with cartilage, reaching almost to the level of the surrounding cartilage. The cartilage itself, however, is about half the normal thickness, the deep portion being filled by bone—the thickened buttress. There is no distinct line of demarcation between cartilage and bone, such as is seen in the rest of the specimen. At about the "area" of demarcation are a number of small marrow spaces containing injected blood-vessels. The cartilage itself (in the hole) shows a tendency toward a columnar arrangement of its cells. Between the wounded and the surrounding cartilage is a small area of chondro-

mucin, broader at the surface than deeper in. Close to it on the unwounded area the cartilage cells are proliferating. The bone beneath



Low-power photomicrograph, showing production of new cartilage over wounded area. Note thickness of bone buttress under it.

the injury* is denser than elsewhere. The marrow throughout the bone is practically all fatty. The synovia looks normal.

This is an example of regenerated cartilage.

Rabbit 41, 60 days.

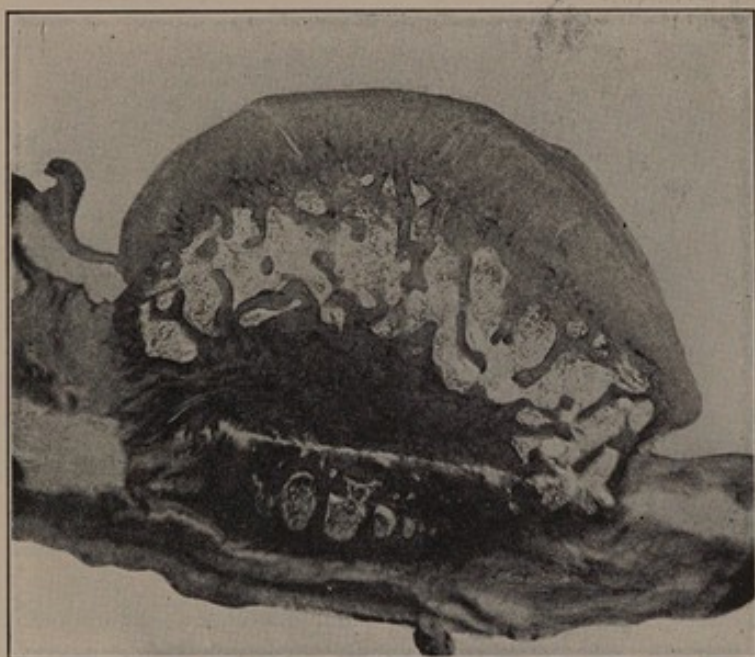
Mar. 5/14. Repetition of circular incision through cartilage on posterior surface of patella. The animal struggled a great deal while being prepared, and may have wrenched his leg.

May 5. Rabbit (in perfect health) killed by blow behind neck. Wound healed completely. The end of the femur seems enlarged, but the enlargement may be only apparent, due to the displacement of the patella inward with its tendon. Joints (knees) into 80% alcohol.

Joint examined Aug. 13. Joint opened by a lateral incision.

Patella dislocated medially and resting against medial aspect of medial condyle, on which it has made an articular surface, apparently covered with cartilage. Cartilage on surface of patella fairly smooth, but with an irregular, faint, curved depression.

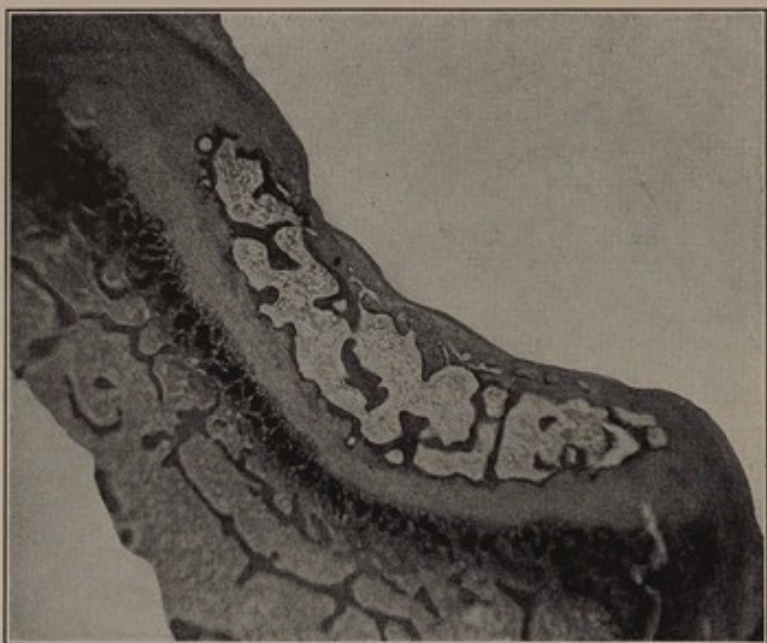
At upper portion of joint (between the condylar eminences at their upper extremities) is an irregular erosion of the cartilage about 2 x 3



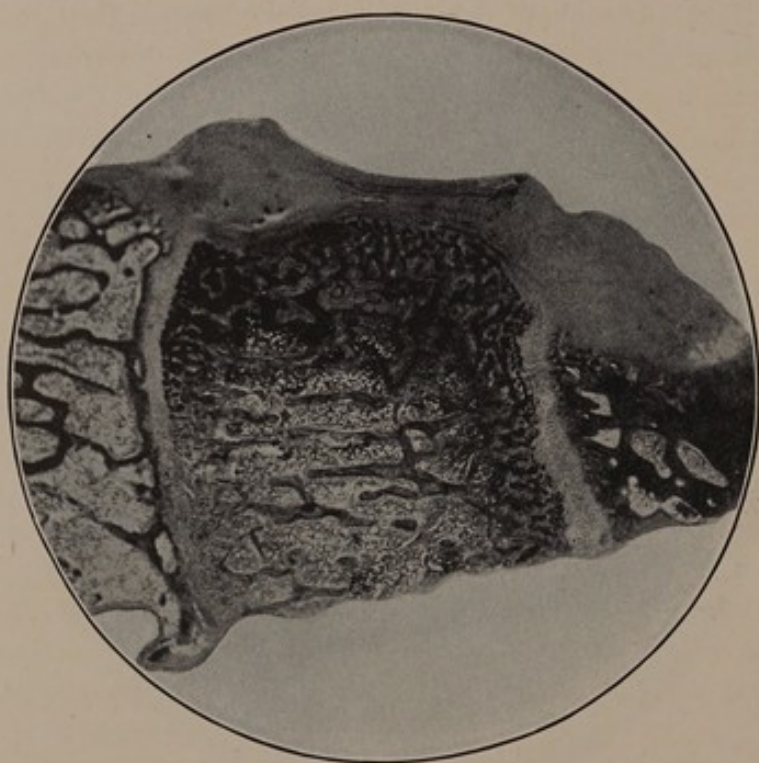
Low-power photomicrograph. The incision to the left remains open. The incision to the right, at the joint level is closed by fibrous tissue, which is continuous with the synovia. The deeper portion of the incision remains open.



High-power photomicrograph of the closed-in incision.



Low-power photomicrograph of the "eroded" area on the intercondylar notch. Note irregularity of the cartilage. The synovial membrane is creeping in over its surface.



Low-power photomicrograph showing the new articulation of the patella on the medial aspect of the femur.

mm. No border exostoses except about new place of articulation for patella.

A, Patella through injured area; *B*, Injured (eroded) area in upper part of femoral trochlea; *C*, New articular surface on medial aspect of femur.

HISTOLOGY.—*C*. The cartilage over the end of the femur is perhaps slightly thin, and fibrillated in places on its free surface. It is continuous at about the level of the epiphyseal cartilage with fibrous tissue, representing the new articular surface. At the level of a second epiphyseal cartilage layer in the specimen, this fibrous tissue changes to fibro-cartilage, which seems to be proceeding from this second epiphyseal line.

B. A thin layer of cartilage (about half normal thickness) with irregular, wavy surface, covers the bone. This is perforated by the marrow below, which is sending prolongations up into it, and communicates with a thin layer of fibrous tissue on the surface, which looks like synovia. Where the marrow pushes up into the cartilage it is evidently building bone, for it is often surrounded by a layer of bone, and there is in the deep portion bone formation. The superficial layer of cells of the fibrous tissue at the surface of the cartilage looks like synovia, with which it is continuous at the edge of the cartilage. On both condylar ridges the cartilage is fibro-cartilage.

This slide shows a distinctly different type of disease from that described by Axhausen. Marrow is lymphoid.

A. In some slides two cuts can be identified, in others only one. *One cut* is present in all. It runs from the surface of the cartilage to the bone, and has the usual shape,—that is, at first, at an angle with the surface, and then perpendicularly. The rounded margin of the cartilage is, as usual, nearer the circumference.

The other side rises to a higher level, and at the tip contains few cells, and much basement substance. The synovia on this side is markedly proliferated, and seems to be extending out over the cartilage, but not extending as much as on the other side. A small strand of fibrous tissue runs from the bottom of the slit, through the bone, to the subjacent marrow.

The other cut. In those sections in which this is visible, it is of a greater or lesser length, but in all it is closed over at the joint surface. The overlapping border here is the one nearest the center also. The margin away from the circumference contains few cells, and much basement substance. It is prolonged upwards, passes over the cut to close

it in, and is covered above by a layer of fibrous tissue, which passes in from the synovia over the surface, and is continued for some distance beyond the cut. At one spot the fibrous tissue at the surface is thrown into folds or villi, like those of a synovial membrane. In one section there is, at the site of the cut, close to the surface, what appears to be a small area of calcification.

The cartilage between this slit and the circumference presents peculiar features. Superficial to the layer of cartilage is a narrow area (strip) in which are large quantities of fibroblasts (some of them in pairs) surrounded by a homogeneous substance which is continuous with the columns of chondro-mucin in the cartilage below. This substance stains deeper as it approaches the cartilage below. The whole layer gives the impression of fibrous tissue being converted into cartilage. This layer is quite apparent near the cut, but shades off, and disappears near the circumference.

Above this layer is fibrous tissue in a fairly thick layer, which looks like synovial membrane, and is continuous with the synovial membrane at the side. The arrangement of the cells throughout the cartilage is columnar.

The junction of cartilage and subjacent bone is not in a regular line as usual, but is very irregular, and not clearly defined. Bone and cartilage shade into each other and are prolonged into each other. In places under the entire extent of the cartilage, the marrow is pushing up through in small fingers.

Marrow throughout is lymphoid.

This case again shows the change of synovial membrane into cartilage, wrought by pressure upon it.

Rabbit 42, 27 days.

Mar. 13/14. Repetition of *cauterizing* a 3 mm. area in cartilage, intracondylar, on anterior surface of femur. The burning was poorly done, searing cartilage above spot of intended damage. Cautery at dull red-heat.

Apr. 9. Died.

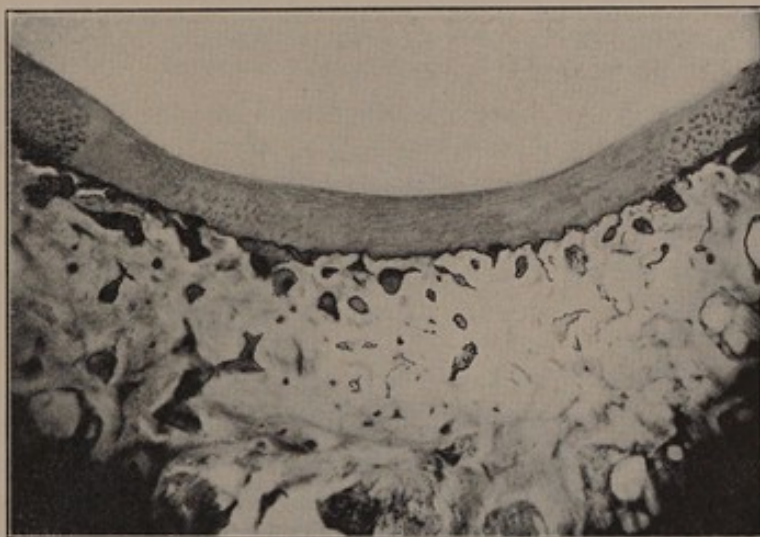
AUTOPSY, Apr. 11.—This rabbit, like most of the others which have died, evidently had a severe diarrhoea.

The operation wound had healed completely. Joint opened. Wound in cartilage identified. The joint appears quite normal except for a slight injection of the synovia near its line of reflection.

No cause of death found in abdomen or chest.

Lower end of femur into HNO_3 , 5; alcohol (95%), 95.

HISTOLOGY.—The cartilage over both condylar ridges is normal. The groove between them where the cartilage was burned, is occupied by a layer of hyaline material, making the contour of the intercondylar



The area of the burned cartilage between the condylar eminences is occupied by a homogeneous layer of hyaline material.

groove normal. This hyaline material has at its middle, below the surface, a broad group of cells which stain poorly, and evidently are degenerating. Directly beneath this group of cells, fibroblasts can be seen making their way into the hyaline material from the marrow below.

Rabbit 43, 24 days.

Mar. 13/14. Repetition of cauterizing operation by dull-red actual cautery, on anterior intercondylar surface of femur.

Apr. 6. Death.

The thigh is drawn up slightly, and complete extension is not possible in knee. Otherwise knee appears quite normal. There is a large open wound on external aspect of lower part of right thigh, laying bare the bone, but apparently not involving the joint. The operation wound has healed.

The joint was opened by transverse incision. The synovia appeared normal, and the other joint tissues, except for the following peculiarities. The patella was displaced inward and was forming a new hollow of articulation on the medial aspect of the medial condyle—as if it had not been replaced after the operation. Below it (distal) is an erosion of

cartilage, whose borders are quite regular. The site of the burn on the femur is evident by a reddened, depressed area whose borders are rather sloping and smooth, and larger than the original burn, giving an appearance similar to that of a healing leg ulcer.

Whole lower end of femur into Orth's solution.

Cause of death not apparent from autopsy. Probably death was caused by the thigh wound.

HISTOLOGY.—Site of burn identified as a shallow depression, going down to the subjacent bone buttress, and partially filled with new fibrous tissue which communicates with marrow below. The fibrous tissue runs out on the surface of the cartilage for some distance, and underneath it the cartilage is degenerated in places. The marrow is hyperaemic, but otherwise normal. No evidence of border exostoses.

CONCLUSION

A cut in the cartilage of the patella may persist indefinitely, or it may be closed in, usually at or near the surface. When closed in partially or completely, the closing in is usually not by a repair, a union, an active process, but simply by a pressing together of the sides of the cut.

A cut in the cartilage of the patella occasions no change in cartilage at a distance, or in the bone beneath, or in the synovia, in the majority of instances. In a few cases where the cut was near the periphery, the synovia spread in over the cartilage apparently in an effort to repair the damage, and in one case (rabbit 41) actually did close in the cut at the surface. Otherwise the synovia was not affected.

Usually the cut runs obliquely near the surface, then turns and runs more perpendicularly, following the known direction of the fibers of the basement substance of the cartilage.

A small hole gouged out of the patellar cartilage usually fills up with new cartilage. In one of our cases the active agent in this process seems to be the synovial membrane which spreads in from the side; in the others the active agent in the production of the new cartilage cannot be determined, but the cartilage appears to be formed from a plug of fibrous tissue which fills in the hole (*vide* rabbit 35).

In some cases the bone trabeculae have been thickened under the site of the injury. In one the bony buttress was markedly thickened under the injured cartilage, and helped to fill up the defect in it.

A hole burned in the cartilage of the intercondylar groove on the front of the femur persists indefinitely, and rarely fills in (*vide* rabbit 28). A gap almost always remains, whose base is formed by bare bone.

If the burn goes through the subjacent bone, the hole becomes plugged with fibrous tissue, which later turns to bone, and shuts off the marrow from the joint cavity; but the bony layer is below the level of the original bone. Cartilage may appear in the fibrous tissue in the marrow, and take part in the bone formation.

The cartilage around the margin of the burn loses its cells and persists, even after 360 days, as a depressed area, or halo, over which the synovia never extends.

The marrow immediately beneath the burn sometimes becomes fatty in a small area. No constant change has been determined in the marrow.

In only one or two instances in the three sets of experiments were any adhesions formed in the joint, and those only in the burn cases.

Synovial membrane, when exposed to pressure between two bones, transforms into cartilage, usually fibro-cartilage. This is plainly seen in several cases, in which luxation of the patella took place, and new cartilage formed on the side of the condyle.

In one or two of our animals, in which the patella was permanently dislocated, a rudimentary patella of fibrous tissue formed in the quadriceps tendon, at a spot corresponding to the former location of the original patella.

In one or two instances a fibro-cartilaginous plate formed on the side of the patella, but we attribute this to injury done at the time of the operation to the synovial membrane in the immediate vicinity of the bone. The incision was made in some cases very close to the border of the patella.

In none of the three series was any constant change noted in the bone, cartilage or synovial membrane at a distance from the site of operation. No "arthritis deformans," no "Randexostosen," no lipping was observed. Where general joint changes were observed they were often of an entirely different type than those of what Axhausen considers arthritis deformans.

The power of regeneration of cartilage which has been scraped off, as compared with that of cartilage which has been burned off, is noticeable. One might infer that the smaller regenerative power of the latter was due to the damage to the subjacent bone and marrow, but a later series of experiments contradicts this.

The so-called osteoclasts, giant cells in Howship's lacunae, generally considered as an evidence of rarefying osteitis, were conspicuous by their absence, and, basing our opinion on this series, as well as upon other experimental and pathological work, we are sceptical of the correctness of this interpretation of the role of these cells.

II.

REMOVAL OF A WIDE PIECE OF CARTILAGE FROM THE INTERCONDYLAR GROOVE OF THE FEMUR.

As a sequel to the former series of experiments on rabbits' cartilage the following series was undertaken, to determine more definitely:

1. The reaction of the joint tissues to cartilage injury.
2. Whether or not cartilage was regenerated after its removal.

We were interested also to find out the truth of Axhausen's conclusions that an injury to the joint cartilage caused the production of "border exostoses" (Randexostosen) and the phenomena of "arthritis deformans."

In the majority of cases, young rabbits were taken. The animals were anaesthetized with ether, the skin over the right knee was shaved and disinfected with soap and water, alcohol, and bichloride of mercury. The incision was a longitudinal one, medial to the patella. The patella was drawn aside, and the cartilage was removed with a scalpel, from the intercondylar region, over an area about 5 x 10 mm., with the long diameter longitudinally. This included all the cartilage between the condylar ridges for a distance of 1 cm., and part of the cartilage also from the condylar eminences. Care was observed to damage the other joint tissues as little as possible. The capsule was then sutured carefully, and the wound was dressed with collodion. The animals died or were killed at intervals from 5 to 258 days after operation.

The bone sections were fixed and dehydrated for the most part in alcohol, decalcified with 5% or 10% nitric acid, washed for a very short time in water, run up through the alcohols and ether, imbedded in celloidin, and stained with haematoxylin and eosin and by the van Gieson method.

Rabbit 51, 59 days.

Beginning a series in which the cartilage was scraped away between the two condylar ridges on the front of the femur, with a scalpel.

Aug. 13/14. Right knee. Usual preparation.

Incision through muscle medially to patella. Patella drawn laterally. Cartilage down to bone scraped away over area of about 4 x 7 mm., long diameter longitudinally, from front of femur, between the condylar eminences. Wound sutured in two layers. Catgut, collodion.

Oct. 12. Rabbit died yesterday.

AUTOPSY.—The knee was surrounded by a lobulated, obscurely fluctuating mass. This was dissected off as carefully as possible, but was punctured several times. It contained the cheesy material so common in rabbits (pus infection). The collection evidently came from the knee. The joint was full of the same material. The cartilages were roughened and the joint was badly disorganized. Lower end of femur and patella into alcohol.

Oct. 19. Section of femur into HNO_3 , 10%. Patella also.

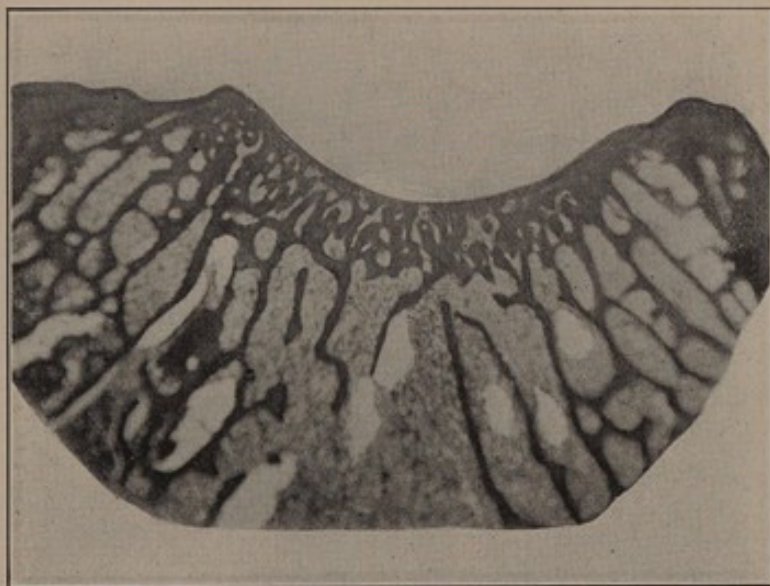
HISTOLOGY.—Typical acute osteomyelitis and synovitis.

Rabbit 52, 258 days.

Aug. 13/14. The rabbit was rather young. Usual preparation. Right knee.

Incision through muscle medially to patella. Patella drawn laterally. Cartilage scraped away over area of about 4 x 8 mm. (long diameter longitudinally) from in front of femur, taking off everything between the two lateral eminences. Wound sutured with catgut in two layers. Collodion.

Apr. 28/15. Adult healthy rabbit, killed by blow on back of neck. Freely movable joint, opened from above. Denuded area recognized



Low-power photomicrograph showing bare bone all across the intercondylar groove. One of the few examples of "border exostoses" in our series.

as a slightly roughened, depressed area, with bottom composed of bone. There is a small "gouging out" of the medial condylar ridge at about the lower level of the denuded area. Below this the ridge appears somewhat broadened. Patella normal. Synovia somewhat thickened and villous.

A, Cross-section of denuded area. *C*, Thickened synovia.

HISTOLOGY.—*A*. The denuded area is manifest as bare bone, immediately under which the marrow is fibrous. The cartilage on the condylar eminences is irregular in its structure. Over one of the eminences fibrous tissue, continuous with the synovia, seems to be spreading. This lateral eminence is decidedly broader than the other, and the breadth is caused by bone formation, on the tip of the lateral aspect of the condyle, apparently made from fibrous tissue. There is no sign of new formation of cartilage over the denuded area between the ridges.

B. The synovial membrane in places is very fatty, in others it consists of dense fibrous tissue. It is villous, but at the surface it has a normal appearance, with a thin sprinkling of cells.

Rabbit 53, 48 days.

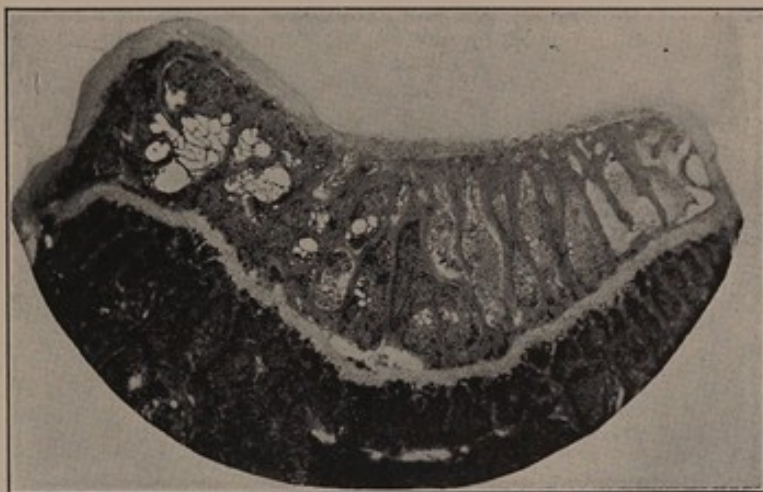Aug. 13/14. Usual preparation.

Incision through muscle medially to right patella. Patella displaced laterally. Cartilage scraped away over area of about 4 x 9 mm., long diameter longitudinally, with scalpel, from the groove on the front of the femur. Wound sutured in two layers with catgut. Colloidion.

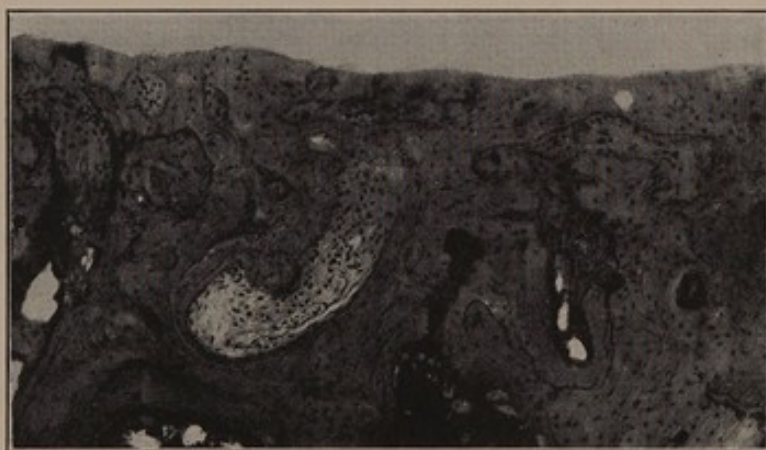
Oct. 1. Rabbit died last night.

AUTOPSY.—External wound healed, and not identified. The situation of the wound in the capsule could be told by a small irregularity, an accumulation of what appeared to be fat. The wound in the capsule had not healed smoothly,—in other words, the apposition was not nice. Joint opened. The synovia is injected. The wound in the cartilage is identified easily. *At the side of the patella*, immediately adjacent to the capsular wound, is a small spur, looking as if it corresponded to the poorly united wound in the capsule.

HISTOLOGY.—*Patella*.—The spur is seen to consist of bone whose trabeculae are continuous with those of the patella. This bone is covered by a layer of fibrous tissue, whose deeper portion appears to be undergoing transformation into cartilage. The fibrous tissue is covered



Low-power photomicrograph. Femur: The surface shows bare bone, with new osteoid tissue. No formation of new cartilage. The bone trabeculae beneath are thickened, and the marrow spaces are filled, to a great extent, by fibrous tissue, which is undergoing transformation into bone. The marrow is hyperaemic. The cartilage over the condylar ridges is normal, and the step between it and the wounded area has been smoothly rounded off. No evidence of "Randexostosen." No evidence of "arthritis deformans."



High-power photomicrograph of joint surface.

partly by synovial membrane, and is continuous with the cartilage of the patella, the line of demarcation being abrupt.

Femur.—Denuded area recognized. Its surface shows bare bone, and no formation of new cartilage. The bone trabeculae beneath are thickened and the marrow spaces filled up to a great extent by fibrous tissue, undergoing transformation into bone. Farther from the joint the marrow is engorged with blood and contains much fibrinous exudate.

The cartilage over one condylar ridge is normal, and the step between it and the wounded area has been smoothly but sharply rounded off. From the other condylar ridge the cartilage has been removed, and no sign of regeneration is observed, though possibly the synovia extends a little farther up the side of the ridge than usual. No evidence of any "border exostoses." The synovial membrane is thickened and oedematous. The epiphyseal cartilage is present.

Rabbit 54, 172 days.

Aug. 14/14. Rather young animal. Usual preparation.

Incision through muscle just medially to patella. Patella displaced laterally. Cartilage scraped away with scalpel from the intercondylar groove on front of femur, its entire width, about 5 x 10 mm., long diameter longitudinally. Wound sutured in two layers with chromic catgut. Collodion.

Feb. 2/15. Rabbit died.

Feb. 3. Joint laid open from above. Denuded area identified as a slightly depressed, roughened area not covered by cartilage. The synovia is injected. There are no "border exostoses."

HISTOLOGY.—The cartilage over one condylar eminence is present, but is thinner than normal and is irregular in structure. Over the other condyle the cartilage is mostly absent. The synovial membrane extends well up the side of both ridges. The denuded area is still bare of cartilage, except occasionally for small areas of transitional tissue (bone and cartilage) lying in the bone, flush with the surface. No sign of any new cartilage production between the ridges, except for one or two small pieces. The synovial membrane is creeping up the side of the condyles in the form of a perichondrium.

The synovial membrane is normal. The marrow near the joint is oedematous lymphoid, and somewhat engorged. Deeper in, the marrow is lymphoid, and the engorgement is much greater. No epiphyseal line is present. The trabeculae are about normal in number and thickness.

Rabbit 55, 220 days.

Aug. 14/14. Rather young animal. Usual preparation.

Usual incision through muscle just medially to patella. Patella displaced laterally. Cartilage scraped away with scalpel from the intercondylar groove on front of femur, entire width, about 5 x 10 mm., long diameter longitudinally. Wound sutured with chromic catgut in two layers. Collodion.

Mar. 23/15. Rabbit died last night.

AUTOPSY.—Hair has grown over wound. Joint apparently normal. Joint opened from above. Wound in cartilage identified. It feels rough to the handle of the scalpel, and appears to be bare bone with small islands of cartilage. The condylar ridges are roughened and irregular, and there is a large erosion on the medial condyle. The head of the tibia is normal. Patella on each side, where it articulates with the condylar ridges, has a cartilaginous or bony prolongation, as if caused by the rough surface of the condylar ridges. The marrow in the femur is haemorrhagic.

A, Femur with operated area. *B*, Patella.

HISTOLOGY.—*B*. On one side of the patella the cartilaginous prolongation noted in the gross inspection is hardly distinguishable, except that the fibrous joint capsule is very thick, and appears to be undergoing transformation into cartilage in one area. The other side of the patella is continued to form a spur of bone well covered by cartilage, and this again by fibrous tissue. The spur has been built up apparently in the fibrous capsule at the side of the bone, for the cartilage over the bone in the spur does not border on the joint, except at the base of the spur. The marrow in the spur is engorged. The line of demarcation between the new cartilage and the old is very sharp and distinct. This patella presents a "border exostosis" of Axhausen, but no signs of arthritis deformans.

A. The cartilage is present over the condylar ridges, but is irregular in the arrangement of its cells. The synovial membrane is creeping up the side of the ridges to form a distinct perichondrium. The cells of the cartilage are grouped, and certain areas contain no cells. The operated area presents a strip of fairly new cartilage at its middle, and on each side of this a strip of bare bone. The new cartilage seems to have developed at the expense of the subjacent bone,—that is, its surface is nearly on the level of the adjacent bare bone. The trabeculae under the new cartilage are thickened. Fragments of necrotic bone caught in the meshes of fibrin lie in the joint.

The marrow is engorged, the blood sinuses are greatly distended. The synovial membrane appears possibly a trifle thickened.

No epiphyseal line is present.

Rabbit 57, 100 days.

Aug. 14/14. Rather young animal. Right knee.

Usual incision through muscle just medially to patella. Patella displaced laterally. Cartilage scraped away with scalpel from the intercondylar groove on the front of the femur. Area of denudation about 5 x 10 mm., with its long diameter directed longitudinally. Wound sutured with chromic catgut in two layers. Collodion.

Nov. 22. Rabbit died.

AUTOPSY.—The joint from the outside is apparently normal. Joint opened from above. The synovial membrane apparently has undergone a villous change. The denuded area of femur identified. Its surface is still rough. On the medial aspect of the medial condyle is what appears to be an erosion—a loss of substance in the bone.

A, Denuded area.

HISTOLOGY.—The denuded area does not extend clear across the intercondylar groove, but on one side the bone is covered by cartilage continuous with the condylar cartilage for a distance of at least one-third that between the condyles. For some distance from the condyle, this cartilage looks fairly normal; then it suddenly changes its structure, and becomes markedly irregular in outline. Its cells are arranged in groups of various sizes, separated by masses of basement substance. Its surface is indented. This thin, irregular layer gradually ceases, and the bone is bare for some distance. The other condyle is mostly bare. The removed cartilage has not been replaced here, and up the side of this condyle the synovia is extending.

Beneath the wounded area the bone trabeculae are thickened.

The synovia appears normal, and there are no evidences of extensive bone and cartilage changes set in play by the injury other than the thickening of the trabeculae.

The epiphyseal line is present.

This is an example of regeneration of a part of the destroyed cartilage.

Rabbit 58, 252 days.

Aug. 17/14. Rather young animal. Right knee.

Incision along medial side of patella and tendon. Joint opened.

Patella displaced laterally. Entire cartilage removed from trochlear surface of femur between the condylar ridges. Capsule sutured with chromic, skin with plain gut. Collodion.

AUTOPSY.—Apr. 26/15. Healthy rabbit, killed by blow on back of head. Joint normal. Movements free. Joint opened from above.

Denuded area identified. It is slightly depressed and is slightly rough to handle of scalpel. Medial condylar ridge at the level of the injury has been (apparently) eaten away so as to give a concave appearance to ridge when viewed from in front. Below this loss the condylar ridge is more prominent (border exostosis?).

Patella, articular surface normal. What appears to be the development of new cartilage has taken place at the sides of the patella over the condylar ridges, better marked over the medial than over the lateral condyle. The synovial membrane is normal.

A, Section through femur in region of erosion—80% alcohol.

B, Section through femur in region of exostosis—80% alcohol.

C, Patella.

HISTOLOGY.—B. The cartilage over the lateral eminence is thin, and apparently is being transformed into bone. The medial eminence is broader than normal, and is prolonged medially so as to give the effect of the exostosis noted in the gross examination. It is covered with cartilage, some normal, some apparently undergoing ossification. This cartilage varies in thickness, but has, over the end of the bone, a fairly smooth surface. Over the exostosis at the side it presents several teats. This exostosis resembles those found in "arthritis deformans" possibly, but the remainder of the joint surface presents an entirely different appearance.

The denuded area shows partly as bare bone, partly as bone covered over by a thin layer of fibrous tissue, which apparently is being transformed into bone, partly by a tissue transitional between bone and cartilage. No new growth of cartilage has taken place on the denuded area. The cartilage cells were probably in cartilage left by the gouge. The marrow is somewhat fatty near the joint, at about the middle of the specimen, lymphoid elsewhere.

A. Both eminences are covered by a thin layer of cartilage, whose cells have the arrangement in large groups, so frequently seen in these cases. The space between them shows bare bone, and a tissue transitional between cartilage and fibrous tissue. Close to the medial condyle a large cavity is present in the joint end, lined by fibrous tissue, backed up by bone trabeculae. A bulging out of the medial aspect of the em-

inence gives it the "hook" appearance noted above. The synovial membrane extends very far up the side of each condylar eminence. The appearance of this slide is more characteristic of Type I* than of Type II. No epiphyseal cartilage is present.

C. On one side of the patella the cartilage is prolonged in a triangular mass which tapers slowly to a pointed extremity. The capsule in the vicinity seems to be undergoing transformation into cartilage. On the other side (evidently the medial) the patella is prolonged into a distinct bony and cartilaginous spur. The cartilage over the spur has a decidedly irregular surface. Streamers or tatters run from it. Its cells are arranged in large groups, and as the end of the spur is approached the cartilaginous layer at the surface shades into fibrous tissue, and the dividing line between the bone and fibrous tissue at the spur end is hard to establish. Apparently the spur has been formed, and was being formed by the change of the capsule at the side of the patella, into bone and cartilage. This appears to be a typical "border exostosis," as described by Axhausen.

Rabbit 59, 165 days.

Aug. 17/14. Rather young animal. Right knee.

Incision along medial side of patella and tendon. Joint opened. Patella displaced laterally. Entire cartilage removed from trochlear surface of the femur, between the condylar ridges, with scalpel. Ligament sutured with chromicized catgut. Skin sutured with plain gut. Collodion.

Jan. 30/15. Rabbit died last night. Joint from outside appears normal.

AUTOPSY.—Joint opened from above. Wounded area identified. It is somewhat rough, and at its lower portion is a small deeper excavation about 2 x 3 mm. in diameter (*A*). In the upper part of the joint on the front of the femur and contiguous with the damaged area is a deep excavation through the cartilage down into spongy bone beneath (*B*). This excavation (*B*) lies directly under the patella when the leg is in

* By Type I we mean the hypertrophied synovial membrane, the atrophic changes in the bone, and the erosion and perforation of the cartilage, such as are ordinarily found in tuberculosis, gonorrheal joints, pus joints and the chronic arthritides variously known as "infectious" chronic arthritis, atrophic arthritis (Goldthwait), rheumatoid arthritis (English), and the proliferative form (Nichols and Richardson). The appearance of this joint indicates that changes of both types may be found in one joint.

full extension. The patella (*C*) appears to be broader than normal, and to be provided at its borders with "border exostoses," though this is not certain, and can only be determined under the microscope. Head of the tibia is normal. *D*, Denuded area between excavations.

The rabbit is in very poor condition. It is emaciated, and its intestines are almost empty. The liver presents many small nodules. The wall of the stomach near the pylorus is thickened and hard. Remnants of epiphyseal line are present.

HISTOLOGY, *D*. The cartilage over one condylar eminence has changed almost entirely to fibrous connective tissue. Over the other eminence the cartilage is present, but the cells are arranged in irregular groups, and on the lateral aspect of the eminence the change to fibrous connective tissue is manifest,—that is, the synovia is creeping over the eminence, in the form of a perichondrium. The denuded area shows two small strips of bare bone, and between them a rather extensive strip of cartilage, fairly normal, except that it is rather thin. This cartilage apparently is new cartilage grown over part of the site of operation.

C. The surface of the patellar cartilage is somewhat rough. The cartilage appears to be degenerating. Areas of basement substance without cells are seen with an arrangement perpendicular to the surface, and these give the cartilage a striated appearance. The marrow is lymphoid. The synovia is normal. There is no distinct evidence of the spurs mentioned in the gross inspection, but the cartilage on one side of the slide is a little knob-like.

B. The cartilage is absent from the entire joint surface, including the condylar ridges, and has been replaced by fibrous tissue. Synovial membrane covers the ridges. Underneath the fibrous tissue is a layer of bone, and no communication exists between the joint cavity and the marrow, except that the fibrous tissue covering the bone is continuous with the marrow tissue. The whole bone end is gouged out, throwing the two condylar ridges into great prominence; but two small elevations are present on the intercondylar surface, whose summits probably represent the level of the original joint line. In the joint cavity, over the denuded area and by the side of the condyle, are collections of small fragments of bone enmeshed in fibrous tissue, having the appearance of synovial membrane at the surface. The connection of some of the collections with the synovial membrane can be demonstrated. The marrow is engorged and lymphoid.

The synovia is thickened, engorged and villous, and the fibrous tissue over the joint is evidently the result of its extension inward.

A. The cartilage over the condylar eminences is present, but its cells over one eminence show a decided tendency to arrangement in large groups. Over the other eminence the cartilage is thinned and is partly replaced by fibrous tissue. A deep cleft is present in one cartilage (the first), going down to the bone. The joint surface between the condyles is extremely irregular, and is composed mostly of cartilage of varying thickness. The excavation noted in the gross inspection is fairly deep. Its bottom is composed of a thin layer of bone covered by a tissue which appears transitional between bone and cartilage. At one side of the excavation is a small elevation covered by cartilage, and beside this another smaller excavation lined by degenerating cartilage. The sub-cartilaginous layer of bone is rather thin all across the specimen, and the trabeculae are thin and scant. The marrow is lymphoid. Remnants of the epiphyseal line are present. Very little cartilage is present on the side of the condyles.

This appears to be an example of new production of cartilage, with a type of joint changes quite different from those of "arthritis deformans."

Rabbit 60, 82 days.

Aug. 17/14. Rather young rabbit. Right knee.

Incision along medial side of patella and tendon. Joint opened. Patella displaced laterally. Entire cartilage removed (by knife) from trochlear surface of femur between the condylar ridges (area 5 x 10 mm.). Aponeurosis sutured with chromicized gut; skin sutured with plain gut. Collodion.

Nov. 7. Animal in convulsions. Killed.

AUTOPSY held on Nov. 7 at 2 p.m. Observations: Discharge of a purulent mucus from nose. A rounded swelling was present in the occipital region at the base of the skull. This swelling was formed by a collection of cheesy pus-like material. The vessels of the brain were engorged, and the pus-like material had begun to work its way onward along the vertebral arteries, especially on the right side. Joint put into 80% alcohol.

Nov. 12. Examination of joint. Joint opened from above. Denuded area roughened. No other evidences of joint abnormality.

HISTOLOGY.—The injured area is without cartilage, except for two or three very small pieces, which look as if they had been left behind by the knife. The marrow in the immediate vicinity of the joint consists largely of fibrous tissue, which is undergoing transformation into bone, making the bone trabeculae much thicker than normal, so that

the bone is quite dense near the joint. Beneath the fibrous marrow the marrow is quite fatty. The cartilage over the condylar eminences is irregular in structure, and has not regenerated where it was removed. It presents the usual appearance of grouping of cells where it is present. The epiphyseal line is present.

Rabbit 61, 5 days.

Aug. 17/14. Rather young animal. Right knee.

Incision along medial side of patella and tendon. Joint opened. Patella displaced laterally. Entire cartilage removed with scalpel from trochlea of femur between the condylar eminences, area 5 x 10 mm. Wound sutured in two layers. Collodion.

Aug. 22. Died.

AUTOPSY, Aug. 24. The wound is evidently infected. Thigh is drawn up against abdomen in flexion. Leg flexed on thigh. Superficial veins over anterior and medial aspect of thigh and leg are injected. Some injection also of lateral veins. Beneath the fascia on anterior and medial aspect of thigh is a yellowish, purulent exudate. Over the muscle are flakes of fibrin. The vessels of the underlying muscles are injected. The knee-joint is apparently not involved. Joint removed. Cause of death could not be determined; probably septicaemia.

Aug. 24. Joint opened by lateral incision. It contains no exudate. The synovia is injected and succulent. Small blood-clot along line of incision on medial aspect. Joint put in formaldehyde solution, 3%.

Aug. 26. Transverse section of bone, made through denuded area on trochlear surface of femur. Specimen placed in 5% HNO_3 .

HISTOLOGY.—The cartilage has been scraped off almost entirely from ridge to ridge. Here and there are fragments of it still clinging to the bed. The marrow immediately underneath has undergone a fibrous change. All the marrow is deeply congested. The condylar eminences are also badly damaged as to their cartilage, and at the side of the bone the cartilage has a distinct perichondrium, which is continuous with the synovial membrane. Epiphyseal cartilage present.

Rabbit 62, 38 days.

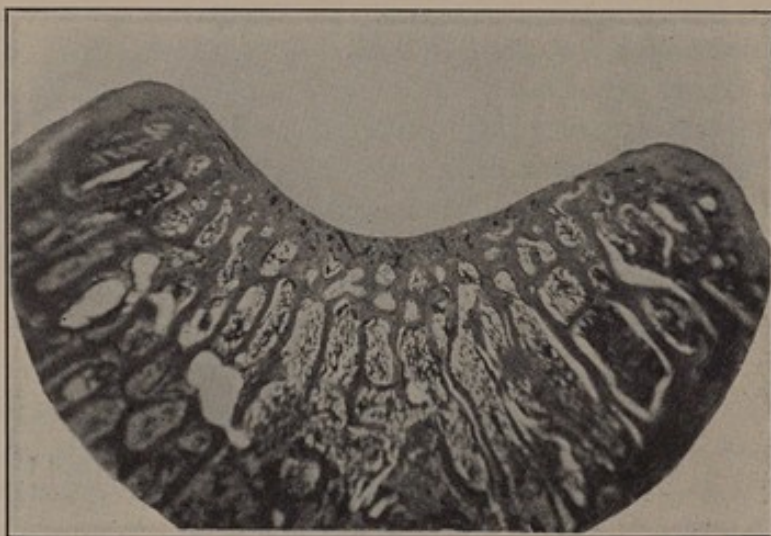
Aug. 17/14. Rather young animal. Right knee.

Incision along medial side of patella and tendon. Joint opened. Patella displaced laterally. Entire cartilage removed with scalpel from trochlea of femur between the condylar eminences, 5 x 10 mm. (long diameter longitudinally). Wound sutured with two layers of catgut. Collodion.

Sept. 24. Killed by blow on back of neck. Animal used legs normally. Wound healed. Over the site of incision in capsule is a mass of what appears to be fat (*A*). On attempting to dissect it away, the capsule was opened.

Joint opened from the lateral aspect. It presents a normal appearance. The synovia is pale and glistening. One or two small pieces of what appear to be cartilage were found loose in the joint (*B*).

The denuded intercondylar area was identified. It is rough to the handle of the scalpel. Cross-section of femur at site of denuding, so



Low-power photomicrograph.

that any section cannot fail to include the damaged area (*C*). All put into alcohol.

HISTOLOGY.—*A*. The section shows well-encapsulated areas of leucocytes, endothelial, lymphocytic, and a few polymorphs. Several giant cells. The fibrous tissue about the aggregations is very dense.

C. A thin layer of osteoid tissue of about one-half the normal thickness covers the operated area. In it, and in the bone directly beneath it, are engorged blood-vessels. The cells in this layer have a tendency to the usual columnar arrangement of cartilage, but there is more intercellular substance than normal. The condylar eminences have been damaged also, and on the lateral aspect of the condyles the synovial membrane is creeping over, forming a distinct perichondrium. This fibrous perichondrium contains blood-vessels. The marrow is lymphoid.

B. Small pieces of cartilage, which stain well. One of them is at-

tached to what appears to be thickened synovial membrane. The epiphyseal cartilage is present.

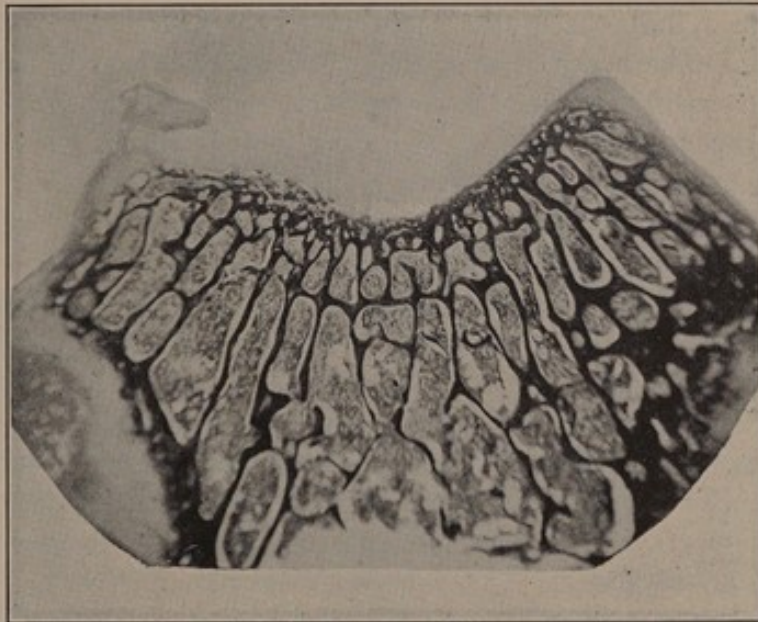
Rabbit 63, 5 days.

Aug. 18/14. Half-grown rabbit.

Right knee. Medial incision. Joint opened. Patella displaced laterally. Cartilage removed (with knife) from trochlear surface between ridges of condyles (1 x .5 cm.). Aponeurosis sutured with plain gut, the skin also. Collodion.

Aug. 23. Died.

AUTOPSY, Aug. 24. Knee looks normal. Wound is clean. The skin over the anterior and medial aspect of the joint shows extravasation



Low-power photomicrograph, showing the appearance of the wounded region shortly after injury.

of blood. About line of incision into joint, the vessels are injected. Joint appears normal—removed. Evidences of peritonitis. An exudate is present over the liver, and in the pelvis.

Aug. 24. Joint opened by lateral incision. It contains no exudate. The synovial membrane is slightly injected and succulent. Joint put into formalin, 3%.

Aug. 26. Transverse section made with saw through denuded area on trochlear surface of femur. Specimen placed in 5% HNO_3 .

HISTOLOGY.—The cartilage has been thoroughly scraped from the bone between condylar eminences, the debris lying partly at site of the wound. The cartilage has been partly scraped off also from the eminences, and the synovial membrane is creeping over the cartilage at the side of the eminences, forming a perichondrium. The marrow is very much engorged.

Rabbit 64, 237 days.

Aug. 17/14. Half-grown white rabbit.

Right knee; medial incision. Joint opened. Patella displaced laterally. Cartilage removed (with knife) from trochlear surface between intercondylar ridges, area 5 x 8 mm. Aponeurosis sutured with plain gut, the skin also. Collodion.

Apr. 15/15. The rabbit died last night. The joint apparently is normal to external observation, and is freely movable. Joint opened from above. The synovial membrane is slightly injected. The wound in the cartilage is identified. It feels rough when the handle of the scalpel is passed across it. Otherwise the joint is normal. There are no "border exostoses."

A, Cross-section of femur at site of injury.

B, *Ligamenta alaria*.

Diagnosis. Cause of death, pneumonia—probably tuberculous.

HISTOLOGY.—A thin, irregular layer of cartilage is present between the condylar ridges. It is irregular both in structure and in outline. In places it contains approximately the normal number of cells, in places very few. There is no sign of any spreading across of synovial membrane, nor of its creeping up the side of the condyles. Nothing abnormal appears in the bone or marrow except that the trabeculae are somewhat thickened. The marrow is lymphoid.

B. The synovial membrane is thick and villous. The villi are composed mostly of fat and of fibrous tissue, and are without increase of lymphoid elements. One very small, short remnant of epiphyseal line is present on one side of the femur.

Rabbit 65, 139 days.

Aug. 18/14. Half-grown rabbit.

Right knee. Denudation, as in preceding cases.

Jan. 7/15. Full-grown, healthy rabbit, killed by blow on head. Joint apparently normal. Motion normal. No sign of former incision.

Joint opened from above. The denuded area can be recognized easily. It is rough, and apparently bony. At its upper portion is a

small, deeper excavation about 3 mm. in diameter, whose bottom is also apparently bony. Slightly distal to this there is a depression on the lateral condylar ridge. Low down, the medial condylar ridge is very sharp. This sharpness is apparently caused by an excavation of its medial aspect. The synovial membrane looks normal. No sign of any "border exostoses."

A, Cross-section including deeper depression, and depression of lateral condylar ridge.

B, Cross-section lower down, including sharp medial condylar ridge.

HISTOLOGY.—*B*. The cartilage has been torn off, evidently by the saw, so that no reliable conclusion can be reached.

A. The joint surface is very irregular, with a rather deep depression at the middle. The cartilage is absent, except over the condylar ridges and for a short distance from them. It is thin, irregular in its structure, and provided with a perichondrium over the eminences, and shades off toward the middle into a thin layer of fibrous tissue. The fibrous tissue is backed up by a thin layer of bone, but the normal bone buttress is absent. Numerous capillaries are seen directly under the surface. One condylar eminence is thickened by the production of cartilage on its lateral aspect, in the shape of an ecchondrosis or teat, covered by a tissue transitional between cartilage and fibrous tissue. This has apparently been built up by a creeping of the synovial membrane over the side of the eminence.

The bone trabeculae are thin and sparse. The marrow near the joint is fatty; that on the shaft side of the thin strip of bone which evidently was the epiphyseal line, is lymphoid. The epiphyseal cartilage is not present.

While the small teat of cartilage might be termed a "border exostosis," the changes in the bone and cartilage are distinctly not those of the human arthritis deformans.

Rabbit 66, 253 days.

Aug. 18/14. Half-grown rabbit. Right knee. Denudation as in previous cases.

Apr. 28/15. Healthy adult rabbit. Joint freely movable. Killed by blow on back of neck. Operation wound cannot be distinguished. Joint opened from above. Denuded area recognized as a rough, depressed area between the condylar ridges. Its floor is apparently bone. A small, rounded tubercle, apparently covered by cartilage, is present on the medial ridge, at about the level of the middle of the denuded

area. Synovia and patella normal. A cartilaginous plaque is present in the synovial membrane over the site of the newly developed tubercle,—that is, facing it. No other “border exostoses.”

A, Section of femur through wound and tubercle.

B, Plaque.

HISTOLOGY.—*A*. The cartilage is absent over the denuded area, except for a thin, irregular stretch near its middle. The cartilage over the undenuded ridges does not cease suddenly, abruptly, but thins slowly toward the mid-line. Over one eminence it is fibro-cartilaginous. The “tubercle” over the medial ridge, noted above, consists of an irregular mass of fibro-cartilage, attached by a pedicle to the summit of the condylar eminence. The lateral condylar ridge is squared off and flattened. It has the angular contour occasionally noticed in these specimens, rather than the normal rounded outline. Its lateral border, well away from the joint line, is excavated for a considerable distance, and in this excavation is a good-sized blood-vessel. The marrow is perhaps more fatty than usual.

B. Dense fibrous tissue—no sign of cartilage. Here and there can be seen small pieces of bone lying in collections, enmeshed in fibrin. The synovial membrane looks normal. In other words, small loose fragments of bone exist in the joint without causing inflammation.

The ecchondrosis on the condyle in this case apparently was caused by the creeping in of the synovial membrane.

Rabbit 67, 204 days.

Aug. 18/14. Half-grown rabbit.

Right knee. Denudation as in previous cases.

Mar. 10/15. Rabbit killed by blow on the head. Wound healed. Hair has grown over it. Joint freely movable. Joint opened from above. Denuded area is hard to identify with the eye, but to the handle of the scalpel it feels decidedly rough. The surface is at the same level as the surrounding cartilage. No evidence of “border exostoses” is present. Small excavation of medial ridge just above condyle can be seen. The joint structure is otherwise normal.

HISTOLOGY.—The cartilage over the two eminences is present, though one side is thinner than the other, and the arrangement of the cells in both is very irregular. The denuded area has at its surface a tissue transitional between bone and cartilage. There is no evidence of the formation between the condylar eminences of new cartilage. The tissue looks like the bone which ordinarily underlies the joint cartilage.

Apparently there has been practically no change since the operation, except a shading off of the border of the denudation, and possibly the re-formation of cartilage over the condylar eminences. A thick layer of cartilage is continued over the lateral aspect of one condyle much thicker and to a greater distance than normal. The marrow is lymphoid. No epiphyseal line.

Rabbit 68, 12 days.

Aug. 18/14. Half-grown rabbit. Right knee. Denudation as in previous cases.

Right knee. Medial incision. Joint opened. Patella displaced laterally. Cartilage removed (with knife) from the trochlear surface of the femur between the ridges. Area of denudation 6 x 10 mm.

Aponeurosis sutured with plain gut, the skin also. Collodion.

Aug. 30. Rabbit died.

AUTOPSY.—Wound healed. Everything clean. Joint removed. Opened by longitudinal medial incision. Synovial membrane is injected and succulent. Denuded area identified. Transverse section, taking in the denuded area, put into Orth's fluid.

HISTOLOGY.—The bone between the eminences is laid bare, and the marrow in the immediate vicinity, under the wound, is composed largely of fibrous tissue, with here and there islands of cartilage cells, and occasionally small islands in the marrow, directly beneath the joint. Deeper in, the marrow is haemorrhagic. At one side of the wound on the surface is a small mass composed of detritus, and small pieces of bone and cartilage, some of them dead. There is another similar collection on the side of the condyle,—that is, in the recess of the joint, and attached to the fibrous tissue under it. The synovial membrane is creeping up over the side of the condyles, having the appearance of a regular perichondrium. The cartilage is present over the very tip of the eminences, but does not run far out on the joint. The epiphyseal line is present.

CONCLUSION

1. In a small proportion of cases new cartilage forms across the injured area.

2. In a certain proportion, cartilage forms over part of the area.

The source of production of the new cartilage in classes 1 and 2 cannot be determined with certainty, but the evidence points to the conclusion that the cartilage production is by the spreading inward of the synovial membrane in the form of a perichondrium.

3. In a large proportion the space between the condylar eminences remains bare.

4. In most cases new cartilage forms over the condylar eminences. Apparently this new cartilage is formed by the "perichondrium,"—that is, by the spreading in of the synovial membrane. This new cartilage is more irregular in its structure than is normal cartilage and is peculiar in the collection of the cells into large groups.

5. In a few of the joints changes were noted corresponding to those of the German "arthritis deformans" (Axhausen's Randexostosen); but in the great majority these changes did not take place.

6. In a few, changes were noted of a type entirely different to those of the German arthritis deformans, namely, Ely's Type I, Nichols and Richardson's proliferative form, Goldthwait's atrophic arthritis, etc.

7. In the great majority, the joint changes were localized to the area of injury. In other words, no general joint changes were set in motion.

8. Function was not disturbed by cartilage injury.

9. The marrow in some cases was fibrous, in others fatty.

10. Loose fragments of bone in the joint tend to become enmeshed in fibrin and to produce no other joint changes.

11. If a wound is made in the capsule immediately adjacent to its line of junction with the bone, bone and cartilage may be deposited in the resulting scar, by extension from the adjacent bone and cartilage.

In one or two cases the hypertrophic bone changes observed in the patella possibly were caused by the clumsy sewing up of the wound in the immediate vicinity, thereby damaging the synovial membrane. This circumstance indicates that perhaps the extensive changes noted by Axhausen in his experiments were due to faulty technique, and to the widespread damage done by his electro-cautery.

One of the most important of the conclusions drawn from this and from the two preceding series is that cartilage can be formed by synovial membrane, especially when exposed to pressure. When not exposed to pressure the synovial membrane does not undergo this change.

The engorgement of the marrow in those animals dying of inter-current disease is quite marked.

III

REMOVAL OF CARTILAGE, AND BORING THROUGH THE
SUBJACENT BUTTRESS

In this series of experiments the cartilage was removed from a wide area of the intercondylar groove on the anterior aspect of the lower end of the right femur of the rabbit and partly also from the condylar eminences. This area was approximately 5 x 10 mm., with the long diameter longitudinal, about the same size as in the preceding series. In addition a hole about 1.5 mm. in diameter was bored at about the center of the denuded area through the subjacent bone buttress into the marrow. The operations were done under general anaesthesia, with the technique described in the last series. The fixing, decalcification, imbedding, and staining were as in the previous series.

Rabbit 69, 138 days.

Half-grown rabbit.

Aug. 19/14. Medial incision alongside of patella and tendon. Joint opened. Synovial membrane is thickened and injected. Patella displaced laterally, and cartilage removed with a knife from trochlear surface of femur. Hole about 1.5 mm. in diameter made into marrow in center of denuded area of femur with awl. Patella replaced. Aponeurosis and skin sutured with plain gut. Collodion.

Jan. 7/15. Full-grown, healthy rabbit, killed by blow on back of neck. The joint appears normal. Motion normal. Joint opened from above. The synovia appears decidedly thickened and injected. The denuded area is easily recognized. It is rough, and its base seems to consist of bone covered by fibrous tissue. The bored area is still deeper, and its floor is similar. Alongside it there is a deep indentation of the lateral condylar ridge as if it had been eaten away.

The condyles of the femur (that is, the condyles proper) are somewhat roughened. There seems to be a little lipping of the medial tuberosity of the tibia, as compared with that of the opposite side.

A, Cross-section of condylar ridges, with deep hole and irregularity of condylar ridge.

B, Cross-section of condyles proper,—that is, facing the tibia.

C, Cross-section of tibia.

HISTOLOGY.—*A.* No normal cartilage is present on the entire joint surface. The surface is very irregular. Over one condylar eminence (the medial?) the cartilage is irregular in structure and outline. The cells show a marked tendency to grouping, and at one spot at about the apex of the eminence, is a small hook-like process consisting of chondro-mucin with a few cells. On the medial aspect of this medial condyle the cartilage is continued for some distance, and is covered by fibrous tissue and synovial membrane. In other words, the synovial membrane is creeping up over the condyle in the form of a perichondrium. The other condylar eminence is gone, and the marrow is exposed to the joint. This marrow is partly fibrous. The lateral aspect consists of bare spongy bone and marrow, and is not covered by capsule or periosteum.

A new-formed, irregular layer of cartilage covers the bone between the condylar eminences. Its surface is more or less wavy, and most of its cells have no capsules, and are irregular in shape and size. The transition between the cartilage and the subjacent bone is a gradual one. The marrow is mostly fatty. The location of the bored hole cannot be distinguished. The bony buttress near the joint is increased in thickness. The epiphyseal line is present.

B. The surface of the cartilage of the condyles presents several small elevations. The cells are flattened out and are without capsules. In places, small filaments of cartilage are partly torn loose and resemble fibrous tissue.

C. The cartilage over one tuberosity is thin, and its cells are gathered in irregular groups. The cartilage over the other is thicker (probably about normal) and its cells are arranged more regularly, in columns. At the margin of this latter tuberosity (presumably the medial) the bone is thickened. The cartilage is also thickened, and is covered by a mass of fibrous tissue, all three—bone, cartilage and fibrous tissue—making a little knob.

This is evidently a case of new formation of cartilage, and of extensive general joint changes following the injury.

Rabbit 70, 240 days.

Half-grown rabbit.

Aug. 19/14. Operation the same as on rabbit 69. Denuded area about 6 x 10 mm. Hole about 2 mm. in diameter.

Apr. 26/15. Healthy rabbit. Killed by blow on head. Joint normal in external appearance. Movement free. Joint opened from above. Wounded area identified. It is decidedly rough in places, fairly smooth

in other places, and depressed. The lateral ridge at the level of the wound has suffered a slight loss of substance, forming a slight concavity. Cross-section of femur including irregularity of condylar ridge into 80% alcohol. Synovial membrane normal.

HISTOLOGY.—The eroded lateral condylar ridge is much lower than normal, and consists of bone, bare in places, and in other places covered with a thin layer of fibrous tissue. Where the hole was bored through the bone, a fairly thick layer of cartilage is present, whose cells are somewhat irregular in their grouping and arrangement, but which otherwise is fairly normal. The bone under this whole (punctured) area is thicker than normal, and the marrow is lymphoid. The rest of the denuded joint surface is covered by thin cartilage, the outline of which is irregular. This is underlaid by a very thin buttress of bone, and the bone trabeculae beneath it are thin and sparse. The marrow is fatty. The summit of the medial condylar ridge is covered with cartilage, the cells of which are arranged in somewhat large groups, and stain very deeply with haematoxylin. There are large areas of basement substance without cells in this cartilage. The synovia is decidedly thickened, and this thickening consists of fibrous tissue. The cellular layer at the surface is not thickened.

This experiment shows a development of new cartilage.

Rabbit 71, 92 days.

Half-grown rabbit.

Aug. 19/14. Same operation as in 69. Denuded area about 6 x 10 mm. Hole 2 mm. in diameter.

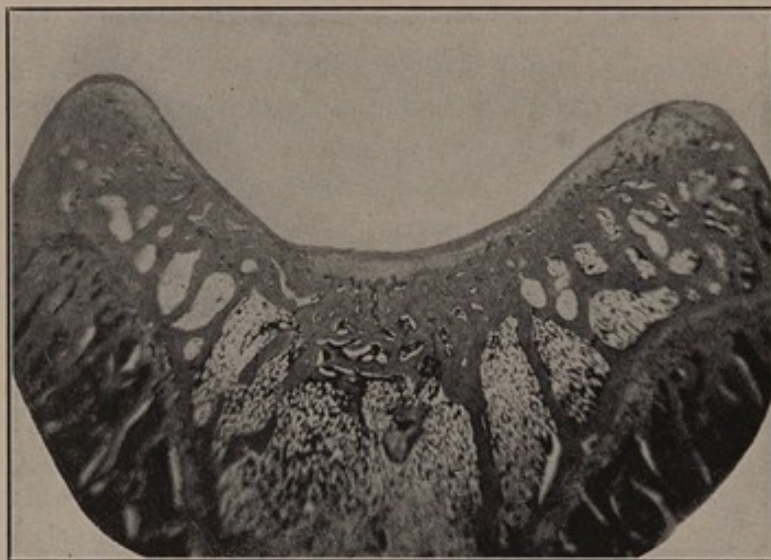Nov. 19. Animal killed by blow on back of neck. Function of the operated joint is perfect. The operation wound is healed completely. Joint opened from above. Denuded area identified. It is rough to the feel of a blunt instrument passed over it. The position of the hole punched through the bone is identified. It is filled up with a white glistening substance which is smoother than the denuded area and looks like cartilage. There is an excavated area on the medial aspect of the medial condyle, and this excavation extends over to the intercondylar groove. The synovia appears thickened. There are no "border exostoses."

A, Section including the site of original hole into marrow.

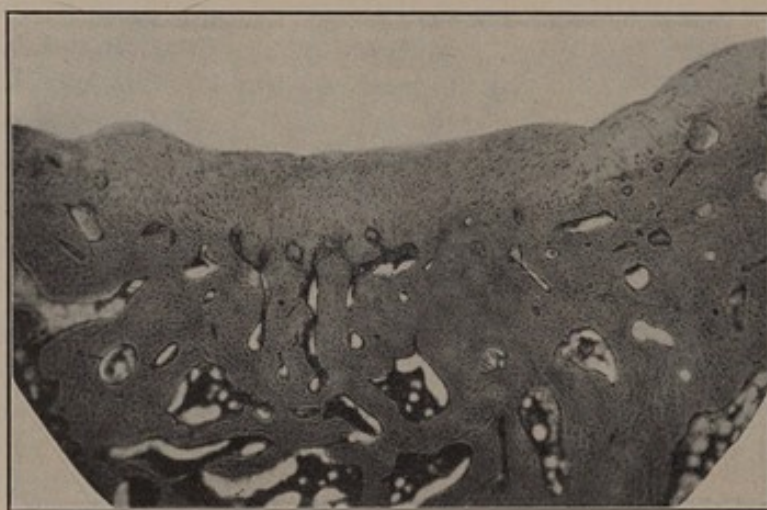B, Excavation on medial condyle.

C, Capsule.

A, B and C into 80% alcohol.



Low-power photomicrograph showing new cartilage formed over part of the denuded area. This picture is taken from another section than the one described.



High-power photomicrograph of the new cartilage.

HISTOLOGY.—*B.* The "*excoriation*" was evidently caused by the splitting off at operation of the side of the condyle, which was torn partly off, turned over, and lies proximal to its normal position. Its former bed has been filled in with fibrous tissue.

A. The denuded area cannot be identified exactly. Part of its surface is bony and part cartilage. Starting from one condyle, one sees a strip of cartilage of approximately normal thickness, of decidedly ir-

regular structure. The cells show arrangement in groups. This layer tapers off, until at about one-fourth of the distance across the joint the bony buttress is exposed for a very short distance. Then comes a small island of cartilage, whose cells are arranged in groups of varying sizes. Then comes a small notch exposing the bone, then a strip of tissue for about one-fifth of the joint, not quite as thick as normal cartilage. This is a transitional tissue, resembling bone and cartilage. It passes into a small thin strip of cartilage of irregular structure, which appears to be undergoing ossification. Then comes a small depressed area of denuded bone. Then a strip of cartilage running up to the condylar eminence, whose structure is similar to that covering the other condyle, but which is shorter than it. There is no sign of the hole punched through the bone. In the place where the puncture should be, the bone trabeculae are thickened and numerous, and in the marrow below this again are irregular islands of cartilage, apparently transforming into bone. In one section the cartilage cells can be traced almost up to the joint from these islands.

Other slides show a somewhat different picture. The condylar eminences show a rift more or less complete, running almost parallel to the surface; and the connection of the layer next the surface with the synovial membrane creeping up the side of the condyle, is evident. The arrangement of the cartilage cells in the condyles is in irregular groups, separated by areas of basement substance. The arrangement in the overlying layer just mentioned is different from that of the layer beneath it. In the overlying layer the cells are more closely packed, and are arranged generally parallel to the surface. They look like the cells in the fibrous tissue at the side of the condyle. The epiphyseal line is present, though thin and irregular.

C. The synovial membrane is thickened by the production of fibrous tissue, and is villous. The villi are composed largely of fibrous tissue. Not much cellular infiltration is present.

This is an example of new cartilage formation. The new cartilage over the condyles has evidently been formed by the synovia creeping up over the site of the condyle, in the form of a perichondrium. Presumably the new-formed cartilage adjoining one of the eminences has been formed in the same manner.

Rabbit 72, 250 days.

Half-grown rabbit.

Aug. 19/14. Right knee. Medial incision alongside of patella and tendon. Joint opened. Patella displaced laterally. Cartilage removed

with knife from trochlear surface of femur between the ridges, area about 6 x 10 cm. Hole about 2 mm. in diameter made with awl into spongy bone below. Patella replaced. Aponeurosis sutured with plain gut, the skin also. Collodion.

AUTOPSY, Apr. 26/15. Healthy rabbit, killed by blow on back of head. Joint apparently normal, movements free. Joint opened from above. The gouged area is somewhat depressed, and is rough to the handle of the scalpel. Beginning at about the middle of the injured area and extending distally for a short distance, the medial condylar ridge is eaten away. Cross-section of femur, including gouged area and area eaten away. Synovia normal.

HISTOLOGY, Sept. 1. The cartilage on the lateral condylar ridge is normal as to thickness, but is irregular in its structure and cell distribution. The creeping over it of the synovial membrane can be distinguished plainly. The cells in places are abundant, and in places absent. The cartilage then becomes gradually thinner. Its free surface is fairly smooth. Passing along, we come to the place where the puncture was made. Here the cartilage is somewhat thicker. The thickening is partly at the expense of the subjacent bone. Adjacent to this is a short stretch of bare bone, and then a thin, irregular stretch of cartilage over the medial condylar ridge. The synovial membrane is thickened.

The medial condylar ridge is flattened, and angular instead of curved. The marrow is somewhat fatty in areas, but is mostly lymphoid. The bone trabeculae beneath the puncture are somewhat thickened.

The formation of new cartilage on one eminence by the synovial membrane spreading in, is evident.

Rabbit 73, 252 days.

Half-grown rabbit.

Aug. 19/14. Right knee. Operation same as in the four preceding experiments. Area denuded about 6 x 10 mm. Hole in femur about 2 mm.

Apr. 28/15. Adult healthy rabbit, killed by blow on back of neck. Joint freely movable, and scar not recognized. Joint opened from above. Wounded area identified as a slightly depressed, partly smooth, and partly rough area. Cartilage appears to have formed at its lower portion. No border exostoses are seen.

A, Upper or bare portion.

B, Lower, or portion with apparent cartilage formation. Patella and synovia normal.

HISTOLOGY.—*B*. Cartilage stretches across from condyle to condyle, except over one very small area, where there is bare bone. This is at one side of the presumable drill-hole. The other side is shown in some slides by a notch or depression running down through the cartilage to the bone. In other slides this notch is not present. The cartilage over the drill-hole is of about normal thickness, but appears more fibrous than normal. The bone trabeculae and buttress under it are decidedly thickened. None of the cartilage is normal. It all shows the irregularity of structure so often noted. Apparently it is all new-formed. The synovia can be seen spreading in up to the apex of one condyle. Near the apex of this condyle the articular cartilage sends an offshoot for a short distance into the marrow below it, where it terminates in a strand of fibrous tissue. The deep portion of this cartilage is transforming into bone. The marrow near the joint is fatty. Deeper in, it is lymphoid.

We interpret this as a walling off of the joint from the marrow by new bone, and a production of new articular cartilage throughout, part at least by the synovia.

A. The buttress of bone is much thinner than in *B*. Some of the slides show a thin, irregular strip of cartilage over it, with bare bone at one area; others a thin layer of fibrous tissue looking like synovial membrane, or of bare bone, with very little cartilage,—that is, over the puncture. The cartilage over the condyles is present, but of irregular structure. Over one eminence it is of normal thickness, over the other thinner.

Rabbit 74, 203 days.

Half-grown rabbit.

Aug. 19/14. Right knee. Operation same as in preceding cases. Area of denudation and hole, the same.

Mar. 10/15. Full-grown, healthy rabbit, killed by blow on head. Scar not seen. Joint apparently normal. Movements normal. Joint opened from above. The exact limits of the original area of denudation cannot be defined. An irregular depressed area somewhat larger than the bored hole is present at the site of injury. The bottom of this area apparently consists of bone. A shallow groove from which cartilage is absent extends outward over the lateral ridge. The posterior surface of the patella, which lies directly over the defined area, is slightly roughened. Otherwise the joint appears normal—no “border exostoses.” Specimen *A*, transverse section removed from wounded area. Placed in 80% alcohol.

HISTOLOGY.—One condylar eminence is covered by cartilage, which shows the usual arrangement of its cells in large groups separated by basement structure, the other is covered by fibro-cartilage. No distinction between the denuded and the punctured areas can be made. Between the two eminences is an excavation, which begins quite sharply on each side. It presents no cartilage, but a thin layer of fibrous tissue, whose surface looks like that of synovial membrane. Underneath the fibrous tissue is bone, and through small apertures in this bony wall the fibrous tissue communicates with the marrow. At the side of one eminence the creeping up of the synovia can be distinctly seen. The marrow itself appears normal lymphoid. The synovia is normal.

Apparently the formation of new cartilage over both eminences has been by synovial membrane. In other words, the synovial membrane over both eminences, where it has been exposed to pressure, has transformed into cartilage. In the excavation between the eminences, where the synovial membrane has not been exposed to pressure, it has retained its structure.

CONCLUSIONS

If the cartilage be removed from the intercondylar groove on the front of the rabbit's femur, and more or less from the condylar eminences, and if in addition a hole be bored through the bone buttress into the marrow, new cartilage will be formed over the entire joint surface or over the greater portion of it. This new cartilage is formed, at least to a large extent, by the synovial membrane, spreading in from the circumference. In those cases where, on account of irregularity of the surface, the synovia is not exposed to pressure, it may retain its structure and may not transform into cartilage.

Whether or not the tissue from the marrow takes part in the formation of new cartilage, it is impossible to say. As these cases show a production of cartilage more nearly complete than the cases of the previous series, this question may be answered tentatively in the affirmative. In fact, the whole process of plugging up the hole with bone and cartilage, in this series, seems to have been through the activity of the marrow.

The new cartilage is always irregular in structure, and usually in outline. It may be partly fibro-cartilage. The hole bored through into the marrow always becomes closed off by bone, and the bone trabeculae are thickened. The new-formed cartilage, it may be noted, has much the same appearance as has the cartilage in "arthritis deformans."

As a rule the joint changes are confined to the area of injury. The marrow is usually fatty in whole or in part. In one or two instances the injury was followed by a marked destructive process in the bone at the site of the injury. Function remains perfect in these joints.

Ossification through the medium of islands of cartilage in the marrow of the epiphysis was noted once. This intracartilaginous ossification is seen in "arthritis deformans"—that is, in arthritis of Type II.

An injury of the joint cartilage, then, accompanied by an injury of the subjacent bone and marrow, sufficient to cause their actual destruction, is often followed by a repair of these tissues more or less complete,—an actual regeneration of them. The new cartilage looks like that found in what the Germans call "arthritis deformans." In other words what Axhausen regarded as a disease produced by his electric needle was actually the result of the process of repair.

REGENERATION OF BONE MARROW

By LEONARD W. ELY

The following series of experiments was done to ascertain if the marrow regenerated completely after it had been removed from the shaft of a long bone. Rabbits were employed. Under ether anaesthesia, and after shaving and disinfection of the skin, a trephine opening was made in the cortex of the right tibia, either through the antero-medial aspect or through the crest. A small scoop was inserted into the opening, and as much of the marrow as could be reached was removed. In the earlier cases a long piece of the cortex was removed, but this weakened the bone. The wound was sutured, and dressed with collodion. At varying intervals thereafter the animals were sacrificed. By a combination of sawing and splitting, the marrow cylinder was removed, fixed in Zenker's fluid, dehydrated in alcohol, mounted in paraffin, and stained with haematoxylin and eosin, and with methyl blue and eosin.

Rabbit 114.

Sept. 30/15. Ether, customary shaving and skin disinfection.

Incision over the front of right tibia (middle third), separating periosteum. With cutting forceps, the cortex of the anterior surface of the tibia was nicked at two points about 2 cm. apart, and then with the scalpel the anterior cortex of the bone was removed, exposing marrow. The marrow was removed with a scoop. The wound was sewed up with two layers of catgut. Collodion dressing and plaster of Paris applied.

Oct. 21. Killed on account of infection of compound fracture. Material thrown away.

Rabbit 115, 77 days.

Almost full-grown animal.

Sept. 30/15. Preparation as in rabbit 114; incision as before. Removal of about 2 cm. of anterior portion of cortex of right tibia. Removal of marrow 2 cm. in extent from interior of the shaft. The wound was sewed up with two layers of catgut and dressed with collodion.

Oct. 4. Leg broken. Plaster of Paris applied.

Oct. 21. Foot swollen. Plaster removed.

Dec. 16. Rabbit, in health, killed by blow on back of head. The tibia has healed with considerable callus and angular deformity. Sawn longitudinally. The marrow canal is patent throughout, but the cylinder of marrow is adherent in the region of the fracture. Below the fracture it is yellow, above lymphoid. Marrow into Zenker's fluid.

HISTOLOGY.—The marrow of the upper portion is a mixture of lymphoid and fatty, with lymphoid at the periphery and the fatty generally at the center in a band which varies in width, growing wider from above downward. Then comes an area exclusively lymphoid at about the middle of the cylinder. The lower portion is practically all fatty, with a little lymphoid at the periphery. At the lower end the lymphoid at the periphery ceases entirely.

Rabbit 116.

Oct. 13/15. Adult rabbit. Usual skin disinfection. A trephine opening was made with cutting bone forceps through crest of the right tibia. By accident the whole anterior cortex of lower part of the bone was broken. With a scoop practically all the marrow was removed. Wound sewed with catgut, two layers. Collodion and plaster of Paris dressing.

Oct. 26. Rabbit died.

AUTOPSY, Oct. 27. One fragment of bone nearly through skin. On section, bone end found surrounded by cheesy pus. Specimen thrown away.

Rabbit 117, 61 days.

Oct. 13/15. Full-grown rabbit. Duplicate of preceding operations. Incision over the subcutaneous portion of right tibia about its middle. With a drill the cortex on the subcutaneous surface of tibia was bored through, and the hole was enlarged with bites of the cutting forceps. The marrow was removed by a scoop practically from the entire canal of the tibia. The wound was sewed up with catgut in two layers. Collodion.

Dec. 13. Rabbit killed by blow on back of head. He is full-grown. The wound has healed and the hair has grown over it. No sign of infection. Tibia removed. It is rough at the seat of operation, and has one or two holes in its cortex into which a pin-point can enter. Tibia sawn longitudinally. There is not the same division into red and yellow marrow of the upper and lower ends, as noted in 122, etc., either in right or left tibia.

HISTOLOGY.—The marrow from the operated tibia contains areas of lymphoid and of fatty marrow. It differs from the marrow of the other

tibia chiefly in its lesser content of lymphoid elements. The marrow of the unoperated side is practically exclusively lymphoid.

Rabbit 119, 49 days.

Oct. 21/15. Young animal. Operation as on animal 117.

Dec. 9. Full-grown rabbit, in health, killed by blow on back of head. Tibia removed. The bone is thickened and rough at site of operation. Tibia sawn longitudinally. The marrow in the upper portion is deeper in color than in the lower, but the difference is not as marked as in one or two of the other animals. The marrow of the other tibia was also removed for comparison. Its upper portion is of deeper red than that of the operated tibia.

HISTOLOGY.—The upper portion of the cylinder of the operated side (about three-fifths) is dense lymphoid, with one small area of fatty in the neighborhood of a fair-sized arteriole. The lower portion is fatty, with a little lymphoid at the periphery.

Normal tibia. The upper part of the cylinder consists of a mixture of lymphoid and fatty marrow. In a general way one side of the film (about one-half) is lymphoid, the other side fatty. This specimen does not show the tendency of the lymphoid elements to collect at the periphery, leaving the center fatty. The lower portion (about two-fifths) of the specimen consists mostly of fatty marrow, but with some lymphoid elements, especially at the periphery.

The marrow of the operated tibia differs from the other in containing more lymphoid elements.

Rabbit 120, 49 days.

Oct. 21/15. Rather young animal. Operation as on rabbits 117 and 119.

Dec. 9. Animal killed by blow on back of neck. The rabbit is full-grown. The wound is healed completely, and the hair has grown over it. Tibia removed. The hole is closed by bone, which is thickened at site of the operation. Bone sawn lengthwise. The marrow is red above, but mottled. Below it is paler. Marrow into Zenker's fluid.

HISTOLOGY.—In this specimen the upper or lymphoid part can be distinguished from the lower or fatty, though the line of division is not sharp. The lymphoid elements of the former show a marked tendency to grouping at the periphery.

Rabbit 121, 36 days.

Oct. 28/15. Rather young animal. Repetition of previous operation of removal of marrow from right tibia.

Dec. 3. Animal killed by blow on the back of the neck. The rabbit is larger than when operated. The wound is healed completely. Tibia removed. It is thickened over site of operation and the opening will just admit the shaft of a pin. Bone sawn lengthwise and marrow removed. The upper two-thirds is lymphoid, including that portion in the neighborhood of the trephine opening. The lower third is fatty. This marrow, red above and yellow below, is not abnormal. The normal tibia has the same condition.

HISTOLOGY.—A similar difference as to the quality of the upper and lower portions of the cylinder is present as in rabbit 122, but the change is not so sharp nor so pronounced. Lymphoid islands are seen in the lower, fatty portion. The grouping of the lymphoid elements at the periphery of the upper part is not marked. Myeloplaxes are fairly abundant.

Rabbit 122, 36 days.

Oct. 28/15. Full-grown rabbit. Repetition of former operations of removing marrow from inside of right tibia, through trephine opening.

Dec. 3. Rabbit is pregnant. Killed by blow on back of neck. The rabbit evidently was only partly grown, for it is much larger than at time of operation. About the site of the trephine opening the bone is roughened and thickened, and the hole is closed.

Bone sawn lengthwise. The marrow looks normal; lymphoid in the upper three-fifths of the shaft, and fatty below. Under the trephine opening and for some distance below it the marrow is lymphoid.

HISTOLOGY.—The larger, upper portion of the marrow cylinder shows a mixture of lymphoid and fatty marrow, with a general tendency of the lymphoid elements to gather at the periphery, while the marrow at the center is more fatty. The change from this marrow of the upper three-fifths to that of the lower two-fifths is rather sudden. In the lower portion the marrow is fatty. Blood sinuses abound in the upper portion, growing scarce, and finally cease in the lower portion. Myeloplaxes with their "basket" nuclei are seen with fair frequency in the upper portion.

CONCLUSION

If the marrow be removed from the shaft of the rabbit's tibia, it will quickly regenerate, without any trace of the operation. Possibly the lymphoid element is less than normal in the operated marrow.

The peculiar division of the marrow into lymphoid above and fatty below is noteworthy.

A STUDY OF ONE HUNDRED DRY BONES SAWN IN THE LABORATORY

By LEONARD W. ELY

The following study was undertaken to determine whether a routine examination of many bones would reveal a departure from the normal in the structure of a considerable number, and if so, what the changes would be.

The material was furnished, by courtesy of Professor Meyer, from the anatomical department of Stanford University. Old, dry bones were sawn into slices about 5 mm. in thickness, with a band-saw. The ends of the bones received particular attention. The results, of course, were not as satisfactory as if fresh material had been at hand, but, as will be seen, a number of interesting facts were brought out.

To Professor Meyer my thanks are due for his aid in my investigation.

Bone 1. Tibia. Negative.

Bone 2. Femur. Old cavity in the head of the bone, about 5 mm. from the lower portion of the joint line. The cavity itself is about 5 mm. in diameter, has irregular walls, and is filled with a plug of marrow.

Bone 3. Tibia. Negative.

Bone 4. Tibia. Negative.

Bone 5. Femur. Lower extremity presents well marked lesions of Type II arthritis. At about the location of the crucial ligaments in the intercondylar notch, the bone is decidedly thickened, and directly beneath the thickened bone is a cavity about 8 x 12 mm. in diameter, whose walls are rough, but not thickened. The walls, while rough, are nevertheless too smooth to permit the assumption that the cavity was formed post-mortem.

Bone 6. Tibia. The articular surface of the inner tuberosity is somewhat rough, and presents a small bony nodule near its center. Nothing of note appears on sawing.

Bone 7. Right Tibia. Negative.

Bone 8. Left Tibia. Negative.

Bone 9. Left Tibia. Nothing worthy of note.

Bone 10. Left Femur. The bone seems denser than normal, both above and below.

Bone 11. Left Femur. Nothing worthy of note.

- Bone 12. Lower end of Left Femur. Nothing worthy of note.
- Bone 13. Left Tibia. Nothing worthy of note.
- Bone 14. Upper end of Left Tibia. Tuberosities present slight changes of Type II arthritis; slight lipping. The bone in the tuberosities seems a trifle dense on sawing.
- Bone 15. Lower end of Left Femur. Very slight lipping of the condyles. The bone in the condyles is rather dense.
- Bone 16. Lower end of Right Femur. The condyles show slight changes of arthritis of Type II, namely, slight lipping, and small, wart-like exostoses on their articular surface.
- Bone 17. Lower end of Right Femur. Well marked lipping of condyles. Nothing of note on sawing.
- Bone 18. Lower end of Left Femur. Very slight lipping of the condyles.
- Bone 19. Right Femur. Nothing of note.
- Bone 20. Right Tibia. Nothing of note.
- Bone 21. Right Femur, upper end. Well marked changes of Type II arthritis. Lipping and bony outgrowth on the articular surface.
- Bone 22. Upper end of Left Femur. Very slight lipping of articular surface. Nothing of note on sawing.
- Bone 23. Upper end of Left Femur. Nothing of note.
- Bone 24. Upper end of Right Tibia. Nothing of note.
- Bone 25. Upper end of Right Tibia. Slight lipping of tuberosities. Nothing of note on sawing.
- Bone 26. Upper end of Right Humerus. Slight changes of Type II arthritis—irregularity of joint surfaces and lipping.
- Bone 27. Upper end of Left Femur. Nothing of note.
- Bone 28. Lower end of Left Humerus. Nothing of note.
- Bone 29. Upper end of Left Ulna. Nothing of note.
- Bone 30. Lower end of Right Femur. Moderate lipping of condyles. Nothing of note on sawing.
- Bone 31. Upper end of Right Tibia. Nothing of note.
- Bone 32. Lower end of Left Femur. Very slight lipping of condyles.
- Bone 33. Right Scapula. Nothing of note.
- Bone 34. Lower end of Right Humerus. Nothing of note.
- Bone 35. Right Os Innominatum. Nothing of note.
- Bone 36. Lower end of Right Femur. Nothing of note.
- Bone 37. Half of a lumbar vertebra. Nothing of note.
- Bone 38. Head of Femur. Nothing of note.

Bone 39. Lower end of Fibula. Nothing of note.
Bone 40. Lower end of Humerus. Nothing of note.
Bone 41. Lower end of Humerus. Nothing of note.
Bone 42. Lower end of Humerus. Nothing of note.
Bone 43. Lower end of Humerus. Small irregular cavity in the trochlea about 2 x 5 mm. in diameter. Walls are irregular, but not thickened.

Bone 44. Upper and Lower ends of Fibula. Nothing.

Bone 45. Upper end of Radius. Nothing of note.

Bone 46. Upper end of Fibula. Nothing of note.

Bone 47. Upper end of Fibula. Nothing of note.

Bone 48. Lower end of Fibula. Nothing of note.

Bone 49. Acetabulum. Nothing of note.

Bone 50. Humerus. Well marked changes of Type II arthritis in the upper joint, very slight in the lower. There is a large cavity in the head, approximately 1 cm. in diameter, with irregular but not thickened walls. It is located about 1 cm. from the joint line. The central marrow canal extends very high in the bone.

Nothing to see in the lower end.

Bone 51. Humerus. Well marked lipping in the upper joint. When the first slice, about 5 mm. thick, was sawn from the greater tuberosity, a small cavity about 5 mm. in diameter was discovered immediately beneath the cortical layer. The next section revealed the connection of this small cavity with a large cavity in the head of the humerus, located about 1 cm. from the joint line. This cavity has irregular walls, not thickened, and communicates with the central medullary canal. It is, therefore, an extension of the central medullary canal upward, to within 1 cm. of the joint.

Lower end of bone,—nothing.

Bone 52. Humerus. Slight lipping of the upper joint. Lower joint practically normal. The greater tuberosity contains a cavity about 1.5 cm. in diameter, the walls of which are comparatively smooth and regular, giving the cavity a spherical shape. The walls seem somewhat thickened. Another much smaller cavity, not communicating with the first, is present about 5 mm. medially to it. The central marrow canal does not extend higher than normal.

Lower extremity of bone,—nothing.

Bone 53. Humerus. Slight lipping of the upper joint. The central marrow canal extends up to within about 2 cm. of the shoulder joint, and in places even nearer to the joint than this. The bone trabeculae are very scant and are easily broken through.

Lower end,—nothing.

Bone 54. Humerus. Upper joint, slight lipping. Marrow canal extends upward to within about 2 cm. of the shoulder joint.

Lower end: The bone in the trochlea is soft, and breaks down easily, but this may possibly be from the age of the specimen.

Bone 55. Humerus. Practically normal.

Bone 56. Humerus. Upper end shows lipping and eburnation. Lower end possibly very slight lipping. Marrow canal extends to within about 1.5 cm. of the shoulder joint. An irregular communicating cavity carries it still nearer,—that is, to about 1 cm. from the joint.

Lower end of bone,—nothing.

Bone 57. Humerus. Upper end very slight lipping, lower end normal. Small irregular cavities in upper end of bone.

Bone 58. Humerus. Upper joint shows lipping. Lower end negative. Upper end of the bone contains a cavity under the great trochanter, with irregular, unthickened walls, not communicating with the marrow canal.

Lower end of bone negative.

Bone 59. Humerus. Very slight lipping of upper joint surface. On sawing, a cavity is found, about 1 cm. in diameter, fairly regular, directly under the trochanter, and within about 5 mm. of the joint. Central medullary canal does not extend upward higher than normal.

Lower end normal.

Bone 60. Humerus. Slight lipping of upper joint. Marrow canal extends up to within about 2 cm. of shoulder joint. A large cavity, not communicating directly with the marrow canal, about 1 cm. in diameter, occupies the great trochanter.

Bone 61. Tibia. Nothing of note.

Bone 62. Tibia. Nothing of note.

Bone 63. Tibia. Nothing of note.

Bone 64. Tibia. Both ends mouse-eaten, so that changes in joint surface cannot be determined. Upper end contains rarefied area about 1 x 1.5 cm., which has not reached stage of cavity formation.

Lower end negative.

Bone 65. Tibia. Negative.

Bone 66. Tibia. Negative.

Bone 67. Tibia. Negative.

Bone 68. Tibia. Negative.

Bone 69. Tibia. Negative.

Bone 70. Tibia. Upper end negative.

Lower end: Marrow canal comes down to within about 3 cm. of joint.

Bone 71. Tibia. Negative.

Bone 72. Tibia. Upper joint shows slight lipping. Nothing seen on sawing.

Lower end negative.

Bone 73. Upper end of Tibia. Negative.

Bone 74. Upper end of Tibia. Negative.

Bone 75. Tibia. Negative.

Bone 76. Tibia. Negative.

Bone 77. Tibia. The joint surfaces are too badly damaged to determine whether changes existed in them. Large cavity 2 cm. in diameter and about 1 cm. from joint, in head of tibia, from which the trabeculae are almost entirely absent. This cavity has no distinct wall, and appears to be simply caused by almost complete absorption of the bone trabeculae.

Lower end of bone: The marrow canal extends somewhat further than usual. The bone is evidently from a fairly young person, for the epiphyseal line is still distinctly visible.

Bone 78. Tibia. Negative.

Bone 79. Femur. Upper end: Moderate amount of lipping. Trabeculae in the neck of the bone are rather scanty, and break down easily on sawing, but there is no actual cavity.

Lower end: Lipping of joint margin. Area 5 mm. in diameter in the external condyle, in which the bone trabeculae are very scant and around which the bone is denser, as if to wall it off.

Bone 80. Femur. Nothing of note on gross inspection. One notes on sawing that the bone trabeculae of the head of the bone in its under portion, immediately adjacent to the joint, are very scant, as compared with those in the rest of the head.

Lower extremity: The internal condyle has been eaten away by mice. The external condyle shows lipping. Large cavity in bone about 5 cm. from the joint; but whether or not this is a post-mortem change, is impossible to say.

Bone 81. Femur. Upper end. Nothing of note. One notices on sawing the same scantiness of the trabeculae in the lower portion of the head near the joint as was observed in the last specimen.

Bone 82. Femur. Upper end: Slight lipping about margin of joint and bony excrescences on the great trochanter. One exostosis at summit of trochanter amounts to a small "spur." Well marked cavity about 1 cm. in diameter is present in the neck, and the marrow canal

extends somewhat higher than usual. One notices the same area of comparative rarefaction in the lower portion of the head noted previously. Lateral to it the dense lines of trabeculae spring from the cortex of the inner side of the shaft (or the under surface of the neck), and pass radiating upward to the joint. These are the trabeculae corresponding to the lines of strain. In other words, this area of spongy bone lies in a protected area just medially to the dense bone, just described. In this protected area there is little else but marrow.

Lower extremity: Moderate lipping. On sawing, nothing of note.

Bone 83. Femur. Upper extremity: Bony roughening on trochanter. One notes the same scarcity of trabeculae on the under portion of the head already mentioned.

Lower extremity: Mouse-eaten.

Bone 84. Femur. Negative.

Bone 85. Femur. Upper end: Breaks in cutting.

Lower end: Marked lipping.

Marked difference in density of the two condyles. Lateral condyle much denser than medial.

Bone 86. Femur. Upper end: Same rarefied area of trabeculae in head of bone before mentioned. The neck shows a well marked *calcar femorale*.

Lower end: Very slight lipping. Nothing worthy of note, on sawing.

Bone 87. Femur. Upper end: Mouse-eaten around head. The neck contains a cavity about 2 cm. in diameter, communicating with another smaller cavity below the great trochanter, and also with the central canal, which extends very high.

Lower end: Negative.

Bone 88. Femur. Upper end: Usual rarefied area is seen in lower portion of the head, another in the upper outer portion, and a third just above the attachment of the ligamentum teres. Wherever these rarefied areas are seen the bone over them is perforated for the entrance of blood-vessels.

Lower end: Marked lipping. Nothing of note on sawing.

Bone 89. Femur. Negative.

Bone 90. Femur. Slight lipping of head. Marked exostosis on greater trochanter. Neck contains cavity about 1 cm. in diameter, just above the *calcar femorale*. Same rarefied areas in upper and lower portion of head before noted.

Lower end: Negative.

Bone 91. Femur. Negative.

Bone 92. Femur. Upper end: Usual rarefaction of under portion of head is present. Area of rarefaction in neck, not amounting to a cavity, about 1 cm. in diameter.

Bone 93. Tibia. Upper end negative.

Lower extremity presents very small exostosis. Nothing on sawing.

Bone 94. Tibia. Negative.

Bone 95. Femur. Negative.

Bone 96. Acetabulum. Nothing of note.

Bone 97. Tibia. Negative.

Bone 98. Tibia. Negative.

Bone 99. Humerus. Negative.

Bone 100. Humerus. Negative.

Many of the specimens were in a poor state of preservation, and were badly broken or mouse-eaten, especially about the joint margins, so that their original condition could not be determined. It is possible, however, to draw a few definite conclusions from the material.

1. Changes peculiar to arthritis of Type II * (lipping of joint margin, exostoses about joint, eburnation) are very common.

2. Cavities in the bone near the joint are also very common. These cavities may be separate, they may communicate with the central marrow canal, or they may be merely extensions of the marrow canal to the vicinity of the joint. Usually the cavities possessed no definite, thickened wall. They seemed to have been caused by a more or less complete absorption of the bone trabeculae.

3. A certain connection seems to exist between 1 and 2. Cavities are most common in those bone ends which show changes of Type II arthritis. In the head of the humerus especially, when these changes are present, one can be fairly sure that sawing will reveal cavity formation.

4. The presence of an area of marrow with very little bone, in the under part of the head of the femur, explains the well known predilection of tuberculosis for this area as a starting place in hip-joint tuberculosis.

5. The head of the femur contains three small areas in which bone is scanty,—the one just mentioned, another about the insertion of the *ligamentum teres*, and a third in its upper part just lateral to the joint margin.

*Type II Arthritis is a synonym for Nichols and Richardson's degenerative form, Goldthwait's hypertrophic form, the English osteo-arthritis, the German arthritis deformans, etc.

A STUDY OF THE STERNO-CLAVICULAR JOINT

By LEONARD W. ELY

The material for this study was gained at autopsies conducted at Lane Hospital and at the San Francisco Hospital by the pathological department of Stanford University, and I take this opportunity to thank Dr. William Ophüls, professor of pathology, for his courtesy in supplying the material, as well as for his help in elucidating certain difficult problems which presented themselves.

The sterno-clavicular joint was chosen, because, although it presented a less promising field for study, it could be removed without mutilation. The joint was removed, and was sawn through antero-posteriorly. The quality of the marrow was noted, whether red or yellow, and any gross abnormalities. In many instances—invariably, in the later stages of the investigation—if the joint presented any evidence of abnormality, a section was taken from it, fixed in alcohol, decalcified in 5% nitric acid, run up through the alcohols, mounted in celloidin, and was stained with haematoxylin and eosin, and by the van Gieson method.

My material consists of ninety-one joints. The table contains certain facts about the cases gleaned from the autopsy records.

NOTES ON SPECIAL CASES

XVII, 58. The cartilages are somewhat roughened,—that is, as if they were blistered—but there are no erosions visible. Red marrow predominates in both bone ends. In the clavicle an area of yellow marrow is seen, which in one place approaches the cartilage near its periphery, but in another section is about 1 cm. removed from it. In the sternum a strip of yellow marrow runs down at one side of the section almost to the joint cartilage.

HISTOLOGY.—The blisters can be identified as small irregularities, small projections, on the surface of the cartilage. The margin of the cartilage is composed of a strand of dense fibrous tissue. The bone and marrow beneath the cartilage appear normal.

XVII, 73. The marrow in the two bone ends is red and yellow in about equal parts, with the red predominating slightly. The joint appears normal, and the condition of the cartilage does not reflect the quality of the marrow.

CASE No.	SEX AND AGE	OCCUPATION	DURATION OF DISEASE	BLOOD COUNT		CAUSE OF DEATH	JOINT	MARROW	ABNORMALITY IN BONE OR CARTILAGE
				RED	WHITE				
XVII, 52	M 23	Dishwasher	4,000,000	14,000	Tuberculosis of intestines, liver, spleen, periton- cum, kidneys, lungs, lymph nodes, etc.
58	M 62	Attorney	3 wks., 1 day	Broncho-pneumonia. Cholecystitis. Cholecystotomy. Old pulmonary tuberculosis healed.	Cartilage slightly roughened.	Red and yellow in both, red predominates.	No
59	M 55	Broncho-pneumonia. Pyonephrosis. Nephrectomy.	Normal	Mixed in both, red predominates.	No
60	M 52	Engineer	4,000,000	3,300 to 10,000	Endocarditis, aortic insufficiency, splenic enlarge- ment, nephritis. (Healed pulmonary tubercu- losis.)	Normal	Red in both.	No
63	M 44	Electrician	1 yr.	Hgb. 5,000,000	60% 12,800	Carcinoma of stomach. Carcinoma metastasis. Broncho-pneumonia.	Normal	Red predominates in both, some yellow in both.	No
69	M 50	Broncho-pneumonia, cholelithiasis, nephritis. (Healed tuberculosis of bronchial lymph nodes.)	Normal (Rather thin cartilage.)	Both red.	No
70	M 70	Carcinoma of prostate, with metastasis in blad- der, liver, pleura, lungs. Pyelitis, pyelonephri- tis, colitis, broncho-pneumonia, etc.	Both yellow.	No
73	M 48	Teamster	8 mos.	Carcinoma of pancreas, with metastasis in liver, lymph nodes, etc. Ulcer of stomach. Hepatic cirrhosis.	Red and yellow, red slightly more.	No
68	F 28	Domestic	1 yr.	2,700,000	14,000	Cystitis. Pyelitis. Lues(?). Nephritis. Broncho-pneumonia.	Normal	Red.	No
75	M	Lues of spinal cord. Fibro-sarcoma of left leg, with metastasis. Tuberculosis of lymph nodes (peri-bronchial). Emphysema. Broncho-pneu- monia.	Thin cartilages, otherwise normal	Red, a thin streak of yellow in clavicle.	No
80	M 32	Cook	2 yrs.	5,000,000	22,400	Diabetes. Tuberculosis of lungs. Pneumonia.	Normal	Red.	No

89	F 29	Housewife Social worker	4,000,000	Tuberculosis of peritoneum.	Normal	Red in both, a streak of yellow in sternum.	No
95	M 62	Laborer	Senility. Emphysema. Broncho-pneumonia, gan- grene of lung. Pleurisy. Colitis (acute).	Roughened and thin cartilage.	Red and yellow mixed.	No
99	M 49	Furrier	Cystitis, chronic. Pyelitis, chronic. Lues (?) Abscess of kidney. Nephritis.	Normal	Red, some yellow.	Yes
91	M 32	Dentist	6 mos.	Dementia praecox. Broncho-pneumonia.	Normal	Red.	No
92	M 46	Laborer	7 wks.	Broncho-pneumonia. Gangrene of lung. Carcinoma of stomach. Metastatic carcinomata.	Normal	Red and yellow equal.	No
97	F 16	1 mo.	37,000	Vincent's angina. Pharyngitis (pseudo-membranous). Enteritis Laryngitis Vaginitis Broncho-pneumonia.	Normal	Red.	Yes
98	M 37	Laborer	6 mos.	4,550,000	5,700	Sarcoma of testis. Sarcoma of lymph nodes (metastatic). Metastatic sarcoma of left kidney. Broncho-pneumonia.	Normal	Red in both, but a streak of yellow in clavicle.	No
106	M 48	Cook	6 mos.	3,370,000	6,800	Carcinoma of larynx. Old tuberculosis of lung (healed). Broncho-pneumonia.	Normal	Red in both, but a triangle of yellow in sternum.	No
121	M 82	1 day	Broncho-pneumonia following fracture of femur. Taenia saginata.	Normal	Yellow in sternum, red and yellow in clavicle.	Yes
122	M 64	Laborer	7 days	14,000	Lobar pneumonia.	Normal	Red.	No
127	M 48	Cook	1 yr.	Carcinoma of stomach. Carcinoma metastasis. Acute peritonitis, following operation. Emphysema of lungs. Endocarditis. Broncho-pneumonia.	Normal	Red.	No
133	M 63	Waiter	4,500,000	14-15,000	Aneurysm of aorta. Arteriosclerosis. Lues. Chronic pleurisy. Emphysema. Cholelithiasis.	Normal	Mostly red, a little yellow in both bones.	No

CASE No.	SEX AND AGE	OCCUPATION	DURATION OF DISEASE	BLOOD COUNT		CAUSE OF DEATH	JOINT	MARROW	ABNORMALITY IN BONE OR CARTILAGE
				RED	WHITE				
XVII, 134	M 36	Laborer	2 yrs.	Pulmonary tuberculosis.	Normal	Red.	No
135	F 52	Housewife	15 yrs.	3,200,000	14,800	Lues of aorta, and valves with regurgitation. Hydrothorax.	Normal	Red in both, in clavicle yellow begins about 1 cm. from joint.	No
137	M 37	Wood-chopper	2 mos.	Carcinoma of liver. Carcinoma metastasis. Cirrhosis of liver. Acute nephritis.	Normal, but unusual in structure.	Red in both.	No
139	F	Septic abortion. Peritonitis. Oedema of lungs. Goitre, adenomatous. Aerogenes capsulatus infection.	Normal	Red.	No
145	M 30	Laborer	Old healed tuberculosis of lung. Chronic pleurisy. Thrombosis of heart. Embolism of pulmonary artery. Chronic nephritis.	Normal	Red.
146	M	5 days.	Incarcerated hernia. Acute peritonitis. Chronic pericarditis. Broncho-pneumonia. Arteriosclerosis. Carcinoma of prostate. Acute pleurisy.	Normal	Yellow except for a small streak under cartilage and at sides in both bones.	No
147	M 28	Kitchen helper	Tuberculosis of lungs, chronic, healed. Tuberculosis of adrenals. Addison's disease. Bronchitis, acute.	Normal, but unusual in structure.	Red.	No
148	F 36	Housewife	1 mo.	3,000,000	5,000	Carcinoma of bronchus. Metastatic carcinoma of lymph nodes, thyroid gland, liver, kidney, etc. Abscess of left lung.	Normal	Pale red.	No
149	M 24	Box-maker	4 mos.	3,100,000	39,600	Acute bronchitis. Tuberculosis of intestine, lymph nodes, spleen, etc. Chronic endocarditis, nephritis and myocarditis.	Normal	Red in both predominates, but some yellow is present.	Yes

153	M 57	Miner	4,400,000	18,100	Bronchiectasis. Embolism of pulmonary artery. Infected infarct of lung. Chronic suppurative pleurisy. Thrombosis of heart. Necrosis of liver.	Normal	Red and yellow in clavicle, red in sternum.	No
155	M 41	Lead worker	3,000,000	15,000	Carcinoma of stomach. Metastatic carcinomata. Acute cholangitis. Abscess of liver. Collibacillosis. Acute pleurisy. Broncho-pneumonia.	Thin cartilage over clavicle.	Red.	No
156	F 43	7 mos.	Arteriosclerosis. Acute nephritis. Acute hepatitis. Broncho-pneumonia.	Normal	Yellow predominating in both.	No
157	M 71	Laborer	2 wks.	4,500,000	6,200	Arteriosclerosis. Chronic splenitis. Chronic hepatitis. Pulmonary emphysema. Hydrothorax and ascites.	Normal	Red and yellow in about equal parts.	No
161	M 38	Real estate	2½ yrs.	Lymphosarcoma of mediastinum. Metastatic lymphosarcomata.	Normal	Red.	No
164	M 61	Cook	20 ?	3,500,000	14,600	Gout. Arteriosclerosis. Broncho-pneumonia. Chronic pleurisy.	Normal	Red.	No
167	M 44	Laborer	2 mos.	2,400,000	44,000	Carcinoma of gall bladder.	Thin cartilage over clavicle.	Red.	Yes
169	M 49	Laborer	Tabes. Bronchiectasis. Abscess of kidney. Pyelitis, cystitis. Broncho-pneumonia.	Normal	Red.	No
171	M 64	Leprosy. Broncho-pneumonia. Arteriosclerosis. Cholelithiasis.	Normal	Red in clavicle, red near the joint, yellow further in, in sternum.	No
174	F 50	3 mos.	1,600,000	15,000	Carcinoma of pancreas. Metastatic carcinomata. Abscess of liver.	Normal	Red.	No
175	M 47	Contractor	1 mo.	Gangrene of lung. Carcinoma.	Normal	Red.	Yes
179	M 67	Laborer	4,000,000	11,000	Arteriosclerosis. Ascites. Hydropericardium. Hydrothorax.	Normal	Red.	Yes
XVIII, 2	M 48	Salesman	1 yr.	1,024,000	6,000	Pernicious anaemia.	Normal	Red.	No

CASE No.	SEX AND AGE	OCCUPATION	DURATION OF DISEASE	BLOOD COUNT		CAUSE OF DEATH	JOINT	MARROW	ABNORMALITY IN BONE OR CARTILAGE
				RED	WHITE				
XVIII, 4	M 37	Butcher	Syphiloma of brain. Broncho-pneumonia. Parenchymatous goitre.	Normal	Red in sternum, little marrow of any kind can be seen in clavicle.	Yes
10	M 45	Laborer	6 wks.	Chronic ulcer of stomach, with perforation of splenic artery. Emphysema. Chronic pleurisy.	Normal	Pale red.	No
13	M 50	Farmer	Malaria. Otitis media, acuta. Operation, mastoid. Septicaemia.	Normal	Red.	No
15	M 64	Salesman	10-12,000	Tuberculosis of lungs, healed, chronic; of adrenals, kidney, bladder, testis, vas deferens. Addison's disease.	Normal	Red with a little yellow.	Yes
18	M 40	Solicitor	10,000	Syphilis of meninges, cerebral. Syphiloma of brain. Broncho-pneumonia. Syphilis of aorta.	Normal	Red and yellow in both.	Yes
23	F 65	Intestinal obstruction. Broncho-pneumonia.	Normal	Red.	No
25	M 2	Diphtheria. Broncho-pneumonia.	Normal	Red.	No
32	M 48	Kitchen helper	Syphilis of aorta. Syphilis of skin. Aneurysm of arch of aorta.	Normal	Yes
31	F 30	1,064,000	50,000	Haemorrhage into peritoneum. Abscess of pelvis. Anaemia, secondary progressive.	Normal	Red.	No
43	Diphtheria. Broncho-pneumonia.	Normal	Red.	No
44	F 35	Prostitute	21,000	Tabes dorsalis. Pelvic peritonitis, chronic. Cystitis, acute. Pyelitis, acute. Endocarditis, chronic.	Normal	Red in sternum, mixed in clavicle.	Yes
45	M 28	Laborer	4,000,000	Endocarditis, chronic. Aortic regurgitation. Aortitis, chronic ulcerative. Broncho-pneumonia.	Normal	Red.	No

46	M 60?	10 dys.	24,000	Cellulitis. Septicaemia. Endocarditis. Erysipelas.	Normal	A little yellow in clavicle. Red.	No
50	F 59	Carcinoma of sigmoid flexure. Endocarditis, chronic. Pericarditis. Emphysema.	Normal	Red.	No
56	M ..	Teamster	Bronchitis, acute. Broncho-pneumonia. Alcoholism, acute (?). Pellagra, acute (?).	Normal	Red and yellow.	Yes
57	M 62	Laborer	Arteriosclerosis, general. Embolism of pulmonary artery with infarcts in lung.	Normal	Red and yellow.	Yes
58	M 79	4,900,000	21,200	Endocarditis, chronic. Pericarditis, acute. Broncho-pneumonia. Pleurisy, serofibrinous. Septicaemia. Arteriosclerosis of aorta.	Normal	Red.	No
60	M 37	Laborer	Sarcoma of liver, primary. Embolism. Metastatic sarcomata. Peritoncneum, haemorrhage into.	Normal	Red and yellow, yellow most.	Yes
?	Tonsillitis, pseudo-membranous. Stomatitis " " Pharyngitis " " Nephritis, chronic.	Abnormal	Red.	Yes
70	M 53	Laundry- man	Glossitis. Tonsillitis. Broncho-pneumonia.	Normal	Red and yellow.	Yes
71	M 9	School	5 dys.	Carcinoma of bronchus. Metastatic carcinoma of brain.	Normal	Pale red.	Yes
72	M 39	Plumber	1½ yrs.	14,000	Tuberculosis of lung, chronic; of prostate, men- inges, kidneys.	Normal	Red, with small amount of yellow.	Yes
75	M 42	Domestic	4-5 yrs.	5,500	Asthma. Broncho-pneumonia. Nephritis, chronic. Tuberculosis of mesenteric glands, healed.	Normal	Deep red.	No
76	M 42	4,600,000	7,800	Arteriosclerosis, general and cardiac hypertrophy. Arteriosclerosis, local, of coronary. Thrombosis of right auricle.	Normal	Red in both.	No
77	F 70	13,000	Embolism of pulmonary artery. Aneurysm of heart.	Normal	Red predominates, but yellow in both.	No
78	M 61	Laborer	3 wks.	20,000	Nephritis, chronic. Arteriosclerosis. Gout. Embolism of pulmonary artery with haemorrhagic infarction of lung.	Normal	Red in both.	No

CASE No.	SEX AND AGE	OCCUPATION	DURATION OF DISEASE	BLOOD COUNT		CAUSE OF DEATH	JOINT	MARROW	ABNORMALITY IN BONE OR CARTILAGE
				RED	WHITE				
XVIII, 83	M 20	Janitor	Tuberculosis of lymph nodes, peribronchial. Tuberculosis of cerebro-spinal meninges. Cystitis, acute.	Normal	Red.	No
84	M 64	Bedmaker	Endocarditis, chronic. Broncho-pneumonia. Pleurisy.	Normal	Red and yellow in both.	No
85	M 22	Waiter	7 mos.	Tuberculosis of lungs, chronic; of intestines, lymph glands. Pleurisy, chronic.	Normal	Red in sternum, red and yellow in clavicle.	No
86	M 64	Long-shoreman	Tuberculosis of lungs, chronic, healed. Emphysema of lungs. Nephritis, chronic. Arteriosclerosis, general. Pleurisy, chronic.	Normal	Red and yellow in both.	Yes
87	M 50	Painter	1 mo.	3,280,000	22,600	Cirrhosis of liver. Broncho-pneumonia. Endocarditis, acute, pulmonary.	Normal	Red and yellow.	No
90	M 50	Miner	12 yrs.	Carcinoma. Operation, enucleation of eye. Carcinoma, metastasis. Meningitis, acute. Tuberculosis of lungs. Broncho-pneumonia. Syphilis of aorta, healed.	Normal	Red in clavicle, red and yellow in sternum.	No
92	M 33	Bookkeeper	Operation, appendectomy, drainage of liver abscess. Pneumonia, lobar. Dysentery, entabnetic (?). Abscess of liver, healed.	Normal	Red.	No
99	M ?	3 mos.	Broncho-pneumonia. Pellagra (?). Dysentery, ulcerative.	Normal	Red in clavicle, red and yellow in sternum.	No
100	M 70	Tuberculosis of lungs, healed; of lymph nodes, of mesenteric nodes, chronic; of retroperitoneal, intestine, meninges; acute general.	Normal	Red.	Yes

101	M 26	Chronic osteomyelitis of lumbar spine. Abscess. Psoas. Sup. nephritis. Multiple abscesses of lungs. Bronchiectasis. Amyloid of spleen.	Normal	Red.	No
103	M 50	Peddler	5 mos.	10,800	Carcinoma of bile duct, hepatic duct. Streptococcal cholangitis. Cirrhosis. Carcinoma of oesophagus. Bronchitis, acute. Broncho-pneumonia.	Abnormal	Red and yellow.	Yes
105	M 6	Diphtheria. Tracheotomy, pressure necrosis. Trachea, perforation of. Cellulitis of neck. Broncho-pneumonia. Trichiasis.	Normal	Red.	No
106	F 27	Housewife	3 wks.	10-15,000	Nephritis, glomerular, subacute. Cystitis, acute. Erysipelas. Broncho-pneumonia.	Normal	Red.	No
107	F 3	Diphtheria. Angina Ludovici. Septicaemia; endocarditis, acute. Infarcts of kidney. Infarct of spleen. Broncho-pneumonia. Tuberculosis of peribronchial lymph nodes, healed.	Normal	Red.	No
112	F 64	27 yrs.	Operation, myomectomy. Arteriosclerosis, general. Nephritis, arteriosclerosis, chronic. Broncho-pneumonia, terminal.	Normal	Red in sternum, red and yellow in clavicle.	Yes
114	M 38	Tabes dorsalis. Broncho-pneumonia.	Normal	Red.	No
115	F 25	Cyst. of broad ligament. Peritonitis, acute, general. Peritoneum, haemorrhage into. Abscess of liver, healed. Mole, pigmented.	Normal	Red.	No
117	F 45	Housewife	Tabes dorsalis. Chronic cystitis. Pyelitis, chronic. Pyelonephritis, acute. Bladder, perforation of. Peritonitis. Salvarsan, ill effects of. Arsenical poisoning, acute. Colitis, ulcerative.	Normal	Red.	No
119	M 36	9 mos.	Endocarditis, chronic. Pneumonia, lobar. Tuberculosis of lungs, healed. Infarction of kidney, old.	Normal	Red.	No
120		Normal	Red.	No

XVII, 75. At one side of the joint the clavicular cartilage is rather rough, and looks degenerated and thin. On the other side it is rather thick. Where the thin cartilage begins, there the interarticular cartilage is split across so that it can be lifted off. A similar condition is present over the cartilage of the sternum. The marrow of both bones is red, except for a thin streak of yellow down one side of the clavicle.

XVII, 95. The cartilage over the end of the clavicle is thin and roughened. The marrow in this bone is about an equal mixture of red and yellow. In the sternum the red predominates.

XVII, 99. The joint is perfectly normal, the cartilages are intact. A section shows the following very peculiar condition of the bone: On one side of the section the marrow in both bones is almost entirely red. At one spot in the clavicle is a small area of yellow marrow. Near it is a small cavity about 3 mm. in diameter, and shaftwards from this the bone is soft and pulpy. On the other side of the section the yellow area is much larger, and a bar of dense bone on the shaft side runs partly across the clavicle about 1.5 cm. from the joint. The bone on the shaft side of this bar is pulpy. One fragment of the clavicle from which the section was taken shows the other half of the cavity with a pulpy area about it. The other fragment shows a yellow streak of bone and marrow.

HISTOLOGY.—The cavity in the bone is easily identified. It is lined by marrow and has no distinct fibrous wall. Throughout the slide, and especially in the pulpy portion, engorged blood-sinuses form a prominent feature. The pulpy part contains but a few scattered trabeculae.

XVII, 98. Red marrow in both bones, except for a streak of yellow running down one side of sawn surface of clavicle.

XVII, 106. Red marrow in both bones, except for a triangle of yellow just below the cartilage under the periosteum of the sternum.

XVII, 121. The interarticular fibro-cartilage has disappeared except for a "glenoid" ligament about the circumference. The cartilages are thin, but the joint surfaces are normal. Yellow marrow in sternum, red and yellow patches in clavicle. In the clavicle, about 8 mm. from the cartilage, the bone has undergone softening, and the marrow is pulpy in an area approximately 1 cm. in diameter.

HISTOLOGY.—The cartilages present the characteristic features of an arthritis of Type II—the gathering of the cells in groups, the peculiar fibrillation of the basement substance, the tattering of the cartilage, and its bizarre appearance. Underneath the cartilage is an irregular layer of osteoid tissue. The subjacent marrow is partly lymphoid and partly

fatty. The lymphoid marrow contains many engorged blood-vessels and blood-sinuses. In the sternum, immediately beneath the level of the cartilage but not completely covered by it, is a "focus" of dense fibrous tissue fairly well surrounded by bone trabeculae, and communicating with the joint. There is another "focus" about 1 mm. from the first, away from the joint, which may be an irregular prolongation of it, caught at an angle by the knife. There are also two or three small "foci" in the clavicle near the cartilage, and strands of fibrous tissue deep in the marrow. The pulpy area mentioned above consists of fatty and lymphoid marrow, engorged with blood, and containing only a few small bone trabeculae.

XVII, 133. This joint presents indications of an interarticular ligament between the clavicle and the interarticular fibro-cartilage. Red marrow throughout, except for a small mass of yellow in the anterior portion of the clavicle, and a smaller one in the anterior portion of the sternum.

XVII, 146. Yellow marrow throughout, except for a streak of red about 3 mm. broad, directly under the clavicular cartilage and under the bone along one side, and another thinner streak on the sides and end of sternum.

HISTOLOGY.—The areas of red marrow mentioned in the gross inspection can be identified easily. In them can be seen many blood-sinuses filled with blood. These sinuses have no well defined vessel-wall, but look like currents of blood washing through the marrow.

XVII, 149. Red marrow predominates, but yellow is present in both bones. The section of the clavicle at autopsy went through what appears to be a fibrous "focus," filling in a large part of the space between the layers of cortical bone. The "focus" is mostly in the posterior portion of the clavicle, and has perforated the shell of bone there, communicating thus with the outside.

XVII, 155. Red marrow in both. The cartilage over the clavicle is very thin, and this thinness in one place is so marked as to amount almost to an erosion. The bone looks normal.

XVII, 167. Red marrow throughout. The cartilage of the clavicle is very thin and slightly eroded. Only a trace of interarticular fibro-cartilage is present. About 1.5 cm. from the cartilage is a cavity in the bone, through which the autopsy cut has gone. This cavity is filled with a deep red, semifluid material, which looks like red marrow. The cortex is much thickened about this cavity, but no actual bony wall separates it from the spongy bone jointwards.

HISTOLOGY.—The cartilage varies in its thickness. Over one half it is very thin, over the other of about normal thickness. Its thin part resembles hyaline cartilage more than fibro-cartilage. "Fingers" of marrow are pushing up into it. The trabeculae stain irregularly, and seem to be undergoing absorption, but not by osteoclasts. They cease almost entirely about 1 cm. from the joint.

XVII, 175. Normal joint. Red marrow in both bones. In the clavicle are reddish, irregular, rather firm areas of what appears to be fibrous tissue, from which all bone has disappeared. In the sternum at about 1 cm. from the joint begins an area of yellowish, fairly tough fibrous tissue, which takes up the entire space between the layers of cortical bone. It also contains no bone.

HISTOLOGY.—Well-marked carcinoma. The nodules are composed of fibrous tissue and epithelial cells, and infiltrate the surrounding healthy marrow.

XVII, 179. Normal joint. Red marrow in both bones. In this, as in the preceding specimen, the spongy bone of the clavicle at a distance of about 1 cm. from the joint disappears, and is replaced by a soft pulpy mass of what appears to be yellow marrow, filling the entire area between the layers of cortical bone.

HISTOLOGY.—Pulpy area identified. It consists of densely packed marrow cells, of "myxomatous" marrow, and of a few small trabeculae.

XVIII, 4. The bone in the clavicle seems much denser than normal. The marrow canal is filled with bone only slightly less dense than the thick cortical bone. There is little else but dense bone in the clavicle—just a little dense, spongy bone in the immediate vicinity of the joint and in small patches elsewhere. The cortex is enormously thickened, and bulges out at one spot about 2 cm. distant from the joint. The sternum contains red marrow. The joint is normal.

HISTOLOGY.—There is a great increase of bone throughout the clavicle. The trabeculae are enormously thickened. Very little of a cortex with its regular arrangement exists. The cortex is formed by the thick trabeculae, among many of which the fibrous tissue passes down from the periosteum into the marrow. The marrow is mostly fibrous. The bulging of the cortex noted macroscopically consists of dense fibrous tissue replacing the cortex, and the bone and marrow beneath it. The marrow of the sternum is lymphoid.

XVIII, 15. Red marrow throughout, except for a small transverse band of yellow in the clavicle about 1 cm. from the joint, and a small patch of yellow in the sternum a short distance from the joint

near the cortex. There is also a patch of red pulp in the sternum about 1 cm. from the joint.

HISTOLOGY.—The pulp is seen to consist of lymphoid marrow with a few small trabeculae.

XVIII, 18. Joint appears normal. The marrow in the sternum is in two longitudinal bands, red and yellow, the red the broader. In the posterior part of the clavicle the red marrow appears as a triangular area beneath the cartilage. The rest of the marrow is yellow. Beginning at a spot about 1 cm. from the joint-line the posterior cortex of the clavicle is replaced by a dense, soft tissue of the consistency of felt.

HISTOLOGY.—On one side of the section the cortex is very thin near the joint, and is broken through at intervals, so that the periosteum communicates with the marrow. At a short distance from the joint the bone cortex ceases entirely, and the fibrous tissue of the periosteum streams into the marrow (or the reverse). The cortex does not begin again for a distance of about 2 cm. from the joint. All about the fibrous tissue the bone trabeculae are greatly thickened. In the fibrous tissue is a small area of calcified, necrotic material. The cartilage shows a marked variation in thickness. One half is thin, the other thick. The thin cartilage covers bone with fatty marrow, the thick cartilage bone with lymphoid marrow.

The specimen appears to be an example of an old infectious process in the bone, with destruction of the cortex, and a production of fibrous tissue in the marrow. Possibly the process is traumatic, and the necrotic material has been carried in from the outside.

XVIII, 32. The marrow is mostly red. The clavicle contains a patch of yellow marrow about 5 mm. in diameter, about 1 cm. from the joint. Between this patch and the joint the bone trabeculae seem scant, and are replaced by areas of soft, red material. Shaftward the bone seems thickened.

HISTOLOGY.—The area of yellow mentioned in the gross examination consists of yellow marrow, with small, scanty bone trabeculae; the red area, of lymphoid marrow with few trabeculae, and of yellow marrow greatly engorged. In places the bone trabeculae are thickened, and to some of these trabeculae masses of fibrous connective tissue are attached, in which calcification is going on. Running along the margin of other trabeculae are bundles of connective tissue partly ossified. Ossification seems to be proceeding, in other words, through the medium of fibrous connective tissue. There is no evidence of new formation of bone by osteoblasts. The cortex is re-enforced in places by small masses

of bone on its inner aspect, which show a marked affinity for haematoxylin.

No. 54 (autopsy number unknown). Normal joint. Very red marrow. Section shows a thickening of the bone beginning about 1.5 cm. from the joint-line, on the anterior aspect. On one side of the section the thickening shows as an increase of the cortex, on the other as a diffuse thickening of the spongy bone.

HISTOLOGY.—The joint is not normal. Tracing in from one side of the joint, we find a rather thin cartilage, with almost the appearance of hyaline cartilage, covered by a layer of fibrous tissue, which evidently has spread in from the circumference. Then comes a short, depressed area of cartilage, covered by fibrous tissue. Adjacent to this is an excavation in the end of the bone, filled with fibrous tissue and fibro-cartilage. At the far side of this again, a thick layer of fibro-cartilage begins, and continues to the other side of the joint. The diffuse thickening of the bone noted in the macroscopical examination is caused by a large number of thick trabeculae, enclosing lymphoid marrow. In this marrow are many large, engorged blood-vessels. The marrow is mostly lymphoid, and is markedly engorged.

XVIII, 44. Red marrow in the sternum. In the clavicle the marrow near the joint is red, farther away it is red and yellow in patches. Beginning about 1 cm. from the joint is a patch, about 5 mm. in circumference, of yellow marrow, in which the trabeculae seem very scanty, and the bone soft.

HISTOLOGY.—The microscopic appearance confirms the macroscopic. No definite disease is evident. The marrow is mostly fatty, and the scanty small trabeculae appear to be undergoing absorption, but not by osteoclasts.

XVIII, 57. The joint is normal. Red marrow predominates, but yellow areas appear in both bones. In the clavicle the spongy bone ceases at a distance of about 1 cm. from the cartilage, and the entire space within the shell of dense bone is filled with a reddish pulp.

HISTOLOGY.—The areas of fatty and of lymphoid marrow are evident. The pulpy area is seen to consist of fatty and lymphoid marrow, with very few, small trabeculae. The cartilage is irregular in its structure and in its staining. Its cells are arranged in groups, and its free border is "tattered"—as in Type II chronic arthritis.

XVIII, 56. Red and yellow marrow is mixed in the two bones, about equally as to area. The joint appears free from disease, but is peculiar in construction. Instead of the usual shape of the end of the

clavicle, and an interarticular fibro-cartilage with a joint cavity on either side of it, the end of the clavicle is deeply concave, and is filled with fibrous tissue in the concavity. This fibrous tissue represents the clavicular joint and the fibro-cartilage; that is, there is but one joint cavity. About 5 mm. from the deepest part of the clavicular end the bone trabeculae seem to be sparse, and the spongy bone is mere pulp.

The microscopical examination confirms the macroscopical.

XVIII, 60. Red and yellow marrow mixed in both bones, yellow predominating. The cortex of the clavicle is very thick.

HISTOLOGY.—The section of the sternum shows well the impossibility of drawing a sharp line of distinction between marrow and periosteum. On the outside of the cortex, but beneath the fibrous tissue of the periosteum, are small pockets of marrow.

No. 60 (autopsy number unknown). Red marrow throughout. The clavicle is greatly increased in size, out of all proportion to the sternal piece. Both cartilages seem thin. That over the clavicle is rough, and somewhat eroded at its center.

HISTOLOGY.—Sternum. At one side of the section, granulation tissue is pushing its way under the cartilage. Nearer the center, granulation tissue is pushing up through the cartilage from the subjacent marrow. The cartilage varies in thickness, and is more or less irregular in outline. A few vessels with thickened walls are present in the marrow.

Clavicle. The marrow is lymphoid, but contains here and there islands of fibrous tissue, some of which apparently is being transformed into bone. The line of demarcation between the bone trabeculae and the fibrous tissue is shown by a moderately thin line of calcification. Underneath the cartilage the marrow is fibrous, and pushing up into the cartilage from below at fairly regular intervals are small "fingers" of new connective tissue, some of which contain typical myeloplaxes.

XVIII, 70. Normal joint. Yellow and red marrow in about equal proportions in both bones. Where yellow marrow is, there the bone is soft.

HISTOLOGY.—The red and yellow marrow are very "patchy" in their arrangement. Where the yellow is, there generally the bone trabeculae are few in number. This section shows well the error of a sharp division between marrow and periosteum. Here and there on the *outside* of the cortex are small depressions or "pockets" containing marrow.

XVIII, 71. The specimen is a child's joint, normal. The marrow is pale red in both bones. Near the joint the marrow of the clavicle is of a deeper red. Immediately under the clavicular cartilage, near the side

of the section, is a soft, red, pulpy area, about 3 mm. in diameter, without bone.

HISTOLOGY.—The marrow throughout most of the section is largely of a "fibro-myxomatous" character. The softened area, mentioned above, is seen to consist of fibrous and fibro-cartilaginous tissue. Many typical osteoclasts can be seen in their Howship's lacunae. The cortex in places is not a real layer of dense bone, but consists of lamellae with a somewhat longitudinal arrangement.

XVIII, 72. Normal joint. Red marrow in sternum. Red marrow in the clavicle near the joint, but at a distance of about 1 cm. from the joint the red changes to yellow, and farther still from the joint a softening appears.

HISTOLOGY.—The marrow at the site of the softening noted above appears normal, but the bone trabeculae have disappeared from it.

XVIII, 85. Red marrow in sternum, and in the clavicle with the exception of a patch of yellow about 2 cm. from the joint. The cortex on one side of the clavicular section is thickened, and presents a slight bulge at one spot. The joint is normal, but the deep surface of the clavicular cartilage is irregular.

HISTOLOGY.—The cortex on one side of the section is markedly thickened, beginning at a point about 3 cm. from the joint-line. In one place, over the bony thickening, the periosteum is absent, and its place is taken by cartilage, whose cells are arranged in large groups. Ossification evidently is taking place in the deep portion of this cartilage, and apparently this is the method of bone production which is responsible for the bony thickening, for cartilage cells can be distinguished over the entire exostosis, at times under the fibrous periosteum, at times in it. The deeper cells of the articular cartilage are in large groups, which stain deeply with haematoxylin. The cartilage looks like that of arthritis of Type II, and apparently is undergoing ossification in its deep portion. Its under aspect is extremely irregular. The trabeculae in the vicinity contain cartilage cells, and even at a distance from the joint, islands of cartilage can be seen in the marrow. This evidently is a case of endochondral ossification, within and without the bone.

XVIII, 86. The joint is normal, but the cartilage on the clavicle is very thin. Red and yellow marrow in the sternum, the yellow predominating. The marrow in the clavicle is red. In the clavicle, about 2 cm. from the cartilage, is a paler area, running up to the line of post-mortem section, where it is yellow. In places this area contains bone, but for the most part it is pulp. The cortex on one side is thickened. (The section was completely decalcified in four days.)

HISTOLOGY.—The pulpy area in the clavicle consists of fatty marrow, from which the bone has practically disappeared. The marrow near the joint is normal lymphoid, and here the trabeculae are normal in size and in number.

XVIII, 100. Normal joint. Deep red marrow throughout both bones. In the clavicle at a distance of about 1 cm. from the joint, the bone trabeculae practically cease, and the whole shaft is filled with a pulp-like mass. The same condition to a lesser extent is present in the sternum, but nearer the joint. The bone cuts very easily. The specimen decalcified in forty-eight hours.

HISTOLOGY.—Clavicle. The marrow shows a very early stage of tubercle formation. Small typical tubercles are scattered here and there, some of them beginning to coalesce. *They are located in otherwise apparently normal lymphoid marrow* near the joint, not in the pulpy area farther away, described above. The bone trabeculae in their vicinity are normal, the joint also. The pulpy areas consist of lymphoid and of fatty marrow, from which the trabeculae have almost disappeared. The marrow contains perhaps a superabundance of endothelial leucocytes. The sternum also contains a very small focus directly under the cartilage, in the lymphoid marrow—aggregated tubercles, with beginning cheesy degeneration,—and one some distance from the joint, also in lymphoid marrow. The marrow is exclusively lymphoid, except for a small area of fatty marrow at a distance from the joint. Slides stained by the Ziehl method show tubercle bacilli.

XVIII, 103. Red marrow predominates in both bones, but some yellow is present. The cartilage over the sternum is thin and irregular.

HISTOLOGY.—The thin and irregular sternal cartilage is manifest. The marrow directly beneath it is engorged with blood, and in places is pushing up "fingers" into the cartilage.

XVIII, 112. The joint is normal. The marrow in the sternum is red, in the clavicle red and yellow. From one area in the clavicle, about 5 mm. in diameter, the bone trabeculae have almost disappeared, and the marrow is so much pulp.

HISTOLOGY.—The area of pulp is seen to consist of yellow marrow, in which are a very few small bone trabeculae. On one side of the section the layer of cortical bone is extremely thin; in fact for a short distance it ceases entirely. The periosteum over this thin cortical bone is normal near the joint, but becomes much thicker farther away, so as to form a thick mass of fibrous tissue. Many cartilage cells are seen in the periosteum, so that in places it is fibro-cartilage.

CONCLUSION

1. The marrow of the bones entering into the formation of the sterno-clavicular joint is of the red or lymphoid variety, as a rule. In the majority of cases each bone end contains red marrow exclusively. Frequently a mixture of red and yellow marrow is seen. Very rarely does either bone contain yellow marrow exclusively.

2. Age does not seem to affect the quality of the marrow, nor does the nature or duration of the disease which caused death.

3. The disappearance or partial disappearance of the trabeculae in areas of the spongy bone is a frequent phenomenon, even when no morbid process can be discovered in the neighborhood. *Note:* On account of the absence of stress and strain in this region, the bone absorption causes no physical signs in life, but in other regions, *e. g.*, the femoral neck, it might cause a bending of the bone.

4. Areas of fibrous tissue occur quite often in apparently normal marrow. In other words, localized "ostitis fibrosa" is not a rare process.

5. Pockets of marrow may now and then be distinguished on the outside of the cortex, communicating with the marrow on the inside. This marrow, then, is "periosteum." Again, in other specimens, bundles of fibrous tissue can be seen passing in from the periosteum through the cortex. The periosteum, therefore, may be said to become marrow. In other words a sharp distinction between marrow and periosteum is not always easy to draw. This fact is of interest in the present controversy over the bone-forming function of the marrow.

6. The role of the so-called "osteoclast" in destructive processes perhaps has been exaggerated.

7. Increase in size of the trabeculae, and the production of new trabeculae, in our specimens usually took place by the ossification of fibrous tissue in the marrow.

8. Thinning and roughening of the cartilage is seen occasionally in apparently normal specimens.

9. Specimen XVIII, 100, shows well that tuberculosis affects the lymphoid, not the fatty marrow, and that the disease may exist in the marrow without involving the joint.

10. A curious phenomenon, observed in two or three specimens, is the presence of cartilage cells in the periosteum without any signs of

fracture. This also is of importance in regard to the bone-forming function of the periosteum.

II. Finally: Various processes involving the marrow, cartilage, bone and periosteum, and at least verging on the pathological, may exist in the bone ends of this articulation without causing any symptoms or physical signs.



THE HISTORY OF THE

REIGN OF KING CHARLES THE FIRST

BY JOHN BURNET

OF THE UNIVERSITY OF OXFORD

IN TWO VOLUMES

LONDON

- THE BIRDS OF THE LATIN POETS. Ernest Whitney Martin, Associate Professor of Greek. 260 pp. 1914. Price, \$1.00.
- ACCELERATION IN THE DEVELOPMENT OF THE FOSSIL CEPHALOPODA. James Perrin Smith, Professor of Paleontology. 30 pp., 15 plates. 1914. Price, 75c.
- A MORPHOLOGICAL STUDY OF SOME MEMBERS OF THE GENUS PALLAVICINIA. Douglas Houghton Campbell, Professor of Botany, and Florence Williams. 44 pp., 23 text figures. 1914. Price, 50c.
- THE EVOLUTION OF BRAZIL COMPARED WITH THAT OF SPANISH AND ANGLO-SAXON AMERICA. Manuel de Oliveira Lima, Minister of Brazil to Belgium. 160 pp. 1914. Price, \$1.00.
- THE HEMOLYMPH NODES OF THE SHEEP. Arthur William Meyer, Professor of Anatomy. 74 pp., 1 plate, 4 colored plates. 1914. Price, \$1.00.
- AN INTRODUCTION TO THE STUDY OF THE ENDOCRINE GLANDS AND INTERNAL SECRETIONS. (Lane Medical Lectures.) Sir Edward Schäfer, Regius Professor of Physiology in the University of Edinburgh. 94 pp. 1914. Price, 75c.
- THE PRONOUN OF ADDRESS IN ENGLISH LITERATURE OF THE THIRTEENTH CENTURY. Arthur Garfield Kennedy, Instructor in English Philology. 91 pp. 1915. Price, \$1.00.
- THE ANOPLURA AND MALLOPHAGA OF NORTH AMERICAN MAMMALS. Vernon Lyman Kellogg, Professor of Entomology, and Gordon Floyd Ferris. 74 pp., 18 text figures, 8 plates. 1915. Price, 75c.
- THE FLÜGEL MEMORIAL VOLUME. Papers by Ewald Flügel, late Professor of English Philology, his Colleagues and Students. 232 pp. 1916. Price, \$1.50.
- THE SESAMOID ARTICULAR: A BONE IN THE MANDIBLE OF FISHES. Edwin Chapin Starks, Assistant Professor of Zoology. 40 pp., 15 text figures. 1916. Price, 50c.
- A STUDY OF GERMAN VERBS COMPOUNDED WITH AUS, EIN, ETC. AS CONTRASTED WITH THOSE COMPOUNDED WITH HERAUS, HINAUS, HEREIN, HINEIN, ETC. Charles Reining. 142 pp. 1916. Price, \$1.00.
- THE PATHOLOGY OF NEPHRITIS. William Ophüls, Professor of Pathology. 103 pp., 64 text figures and plates. 1916. Price, \$1.00.
- BONE AND JOINT STUDIES, I. Leonard W. Ely, Associate Professor of Surgery, and John Francis Cowan, Assistant Professor of Surgery. 139 pp., 41 text figures and plates. 1916. Price, \$1.00.

