

**Diseases of the mouth : for physicians, dentists, medical and dental students / Tr. and edited by John Bethune Stein.**

**Contributors**

Zinsser, Ferdinand, 1865-  
Stein, John Bethune.

**Publication/Creation**

New York : Rebman, [1912]

**Persistent URL**

<https://wellcomecollection.org/works/hu4rmha2>

**License and attribution**

This work has been identified as being free of known restrictions under copyright law, including all related and neighbouring rights and is being made available under the Creative Commons, Public Domain Mark.

You can copy, modify, distribute and perform the work, even for commercial purposes, without asking permission.



Wellcome Collection  
183 Euston Road  
London NW1 2BE UK  
T +44 (0)20 7611 8722  
E [library@wellcomecollection.org](mailto:library@wellcomecollection.org)  
<https://wellcomecollection.org>

DISEASES  
OF THE MOUTH

ZINSSER STEIN




30p net  
or



22101915148

Med  
K32483





DISEASES  
OF  
THE MOUTH  
SYPHILIS AND SIMILAR DISEASES

FOR  
PHYSICIANS, DENTISTS, MEDICAL  
AND DENTAL STUDENTS

BY  
PROF. DR. F. ZINSSER

DIRECTOR OF THE DEPARTMENT OF DERMATOLOGY AT THE CITY  
HOSPITAL, LINDENBURG; DOZENT AT THE ACADEMY  
FOR PRACTICAL MEDICINE, COLOGNE

TRANSLATED AND EDITED

BY  
JOHN BETHUNE STEIN, M.D.

PROFESSOR OF PHYSIOLOGY AT THE NEW YORK COLLEGE OF DENTISTRY,  
LATE INSTRUCTOR IN GENITO-URINARY DISEASES AT THE COLLEGE  
OF PHYSICIANS AND SURGEONS (MEDICAL DEPARTMENT OF  
COLUMBIA UNIVERSITY), NEW YORK CITY

*WITH 52 COLORED AND 21 BLACK AND WHITE ILLUSTRATIONS*



LONDON  
REBMAN LIMITED  
129 SHAFTESBURY AVENUE, W. C.

[1912 ?]

4 780 694


*All rights reserved*



WELLCOME INSTITUTE LIBRARY	
Coll.	weIMOmec
Call	
No.	WI

TO  
HERRN GEH. MEDIZINALRAT  
PROF. DR. EDMUND LESSER





## **AUTHOR'S PREFACE**

Some lectures and demonstrations which I instituted some years ago suggested my writing this work. It has been proved that there exists a need for lucid and detailed instruction in the diagnosis of syphilis and similar diseases of the mouth of which no account has been taken in spite of its great importance.

This circumstance depends probably upon the fact that the clinical material belonging to this domain of medicine is, as a rule, very much scattered; appearing not only in the dermatological clinic but also in the clinics of laryngology, surgery, internal medicine, pediatrics and dentistry, and making it difficult to obtain a general view of the subject. This difficulty is especially marked in the dental curriculum, where the few hours devoted to the clinical demonstration of syphilis make it necessary to resort at times to charts in order to more fully present the subject.

Of course, physicians, dentists, medical and dental students lose much because of this scattering of clinical material. Even if it was possible to attend the clinics and polyclinics regularly and for a long time in order to obtain some experience in this domain of medicine a comprehensive view of it would be wanting.

By the interest with which experienced physicians have studied our collection of moulages of diseases of the mouth, I am convinced that there exists



a need for a composite pictorial representation of this subject.

In the introduction I have endeavored to give a short review of the course of syphilis and to describe in a few words the diseases of the mouth resembling syphilis, especially in reference to their differential diagnosis.

It would by far exceed the limits of this book if I should describe in detail the clinical manifestations of these diseases, which frequently appear only as partial manifestations of general diseases.

This book is intended to be an illustrated aid in study and diagnosis. For a more detailed study the text books of medicine, surgery, pediatrics, laryngology and dermatology are necessary.

The therapeutic side has not been taken up, because in syphilis, as in the other mentioned diseases of the mouth, the therapy is usually not only local but also general; consequently, its discussion would lead us too far.

Although pictorial representations are but poor substitutes for clinical observations, I hope the present book will fulfil its task in helping the study and diagnosis of syphilis and similar diseases of the mouth.

DR. ZINSSER.

*Cologne on Rhein.*



## EDITOR'S PREFACE

Some years since, while visiting the museum at the Hospital of Saint Louis, in Paris, I was much impressed by the teaching value of the moulages collected there, to the number of several thousand.

In the few moulages—showing typical primary, secondary, and tertiary lesions of the buccal cavity—which I then brought to this country, considerable interest was shown, not only by specialists in syphilis but also by general practitioners, dentists, and of course students. It was chiefly because of the favorable manner in which these moulages were received that I later, with permission of the authorities in Paris, had autochrome lantern slides made of some of the moulages at the museum of the Hospital of Saint Louis, showing various diseases of the buccal cavity, including hypoplasia of the teeth of syphilitic origin.

The keen interest shown in these lantern slides and in my remarks thereon at the several meetings of physicians and dentists where they were exhibited, manifest unmistakably a desire on the part of members of both professions in this country for a further and more complete exposition of the nature and diagnosis of the diseases to which these pictures relate, in the light of present-day scientific knowledge.

The recent advancement in the study of the nature, diagnosis, and treatment of syphilis is so great that a statement of it amounts to a revelation, and *Professor Zinsser's* "Syphilis and Similar Dis-

eases of the Mouth" is abreast of the foremost expositions of modern medical science. I am confident, therefore, that this edition will be appreciated by English-speaking physicians and dentists, who should find the work of considerable practical value.

In the translating and editing of his work, I have of course, endeavored to give a clear and accurate reproduction of *Professor Zinsser's* views, which I have supplemented by the addition of some matter chiefly relating to the Spirochætæ, the *Wassermann* reaction, luetin (*Noguchi*), etc., and I have inserted four drawings made for me by one of my students, *Mr. Francis Ovary*.

JOHN BETHUNE STEIN.


*New York City.*



## TABLE OF CONTENTS

	PAGE
INTRODUCTION . . . . .	1
THE PRIMARY LESION OF SYPHILIS . . . . .	12
SECONDARY SYPHILIS . . . . .	20
TERTIARY SYPHILIS . . . . .	28
HEREDOSYPHILIS . . . . .	34
DISEASES SIMILAR TO THE LESIONS OF SECONDARY SYPHILIS	
OF THE MOUTH . . . . .	45
DISEASES SIMILAR TO THE LESIONS OF TERTIARY SYPHILIS	
OF THE MOUTH . . . . .	59
INDEX . . . . .	263





## LIST OF ILLUSTRATIONS

FIG.		PAGE
1.	Chancre of the Upper Lip (Chancrous Erosion) .	71
2.	Two Chancres of the Lower Lip . . . . .	75
3.	Chancre of the Tongue . . . . .	79
4.	Syphilitic Erythema of the Mucous Membrane of the Mouth . . . . .	83
5.	Erosive Mucous Patches of the Lower Lip and Condylomata Lata of the Naso-Labial Folds .	87
6.	Erosive Mucous Patches of the Upper Lip and Tongue . . . . .	91
7.	Hypertrophied Mucous Patches of the Tongue and Lips . . . . .	95
8.	Papulo-Ulcerated Syphilide of the Lips and Tongue (Ulcerated Mucous Patches) . . .	95
9.	Ulcerated Syphilide of the Lips (Ulcerated Mu- cous Patches). . . . .	99
10.	An Ulcerated Annular Syphilide of the Lower Lip Resembling a Serpiginous Ulcer . . . . .	103
11.	Opaline Mucous Patches of the Tongue . . .	107
12.	Papulo-Ulcerated Syphilide of the Tongue . .	107
13.	Glossitis Syphilitica (Syphilitic Glossitis). . .	113
14.	Ulcerated Mucous Patches of the Tongue . .	113
15.	Angina Syphilitica (Syphilitic Angina) . . .	117
16.	Papules of the Soft Palate and Uvula . . .	121
17.	Annular Syphilide of the Mucous Membrane of the Soft Palate, Uvula, and Pillars of the Fauces	125



FIG.	PAGE
18. Hypertrophied Mucous Patch of the Soft Palate and Uvula . . . . .	129
19. Angina Ulcerosa (Ulcerated Syphilitic Angina).	133
20. Circinate Mucous Patches About the Mouth and Nose . . . . .	137
21. Gummatous Ulcers of the Mucous Membrane of the Hard Palate . . . . .	141
22. Tertiary Syphilis, Perforation of the Hard Palate, Periostitis of the Processus Alveolaris . . . .	145
23. Gummatous Destruction of the Soft Palate . .	149
24. Ulceration of the Fauces in Malignant Syphilis .	153
25. Malignant Syphilis of the Fauces . . . .	157
26. Syphilis Hereditaria (Heredosyphilis). . . .	161
27. Syphilis Hereditaria Tarda (Late Heredosyphilis)	165
28. Syphilis Hereditaria Tarda (Late Heredosyphi- lis). Gumma of the Tongue . . . . .	169
29. Syphilis Hereditaria Tarda (Late Heredosyphi- lis). Gummatous Perforation of the Hard Palate and Heredosyphilitic Teeth . . . .	169
30. Stomatitis Mercurialis (Mercurial Stomatitis) .	175
31. Stomatitis Mercurialis (Mercurial Stomatitis with Ulcerations on the Border of the Tongue) .	175
32. Angina Mercurialis (Mercurial Angina) . . .	179
33. Antipyrin (Salipyrin) Exanthem of the Tongue	185
34. Lichen Ruber Planus of the Buccal Mucous Mem- brane . . . . .	185
35. Erythema Exudativum Multiforme of the Mucous Membrane of the Mouth (Idiopathic Poly- morphous Erythema) . . . . .	189
36. Herpes Labialis (Herpes of the Lip) . . . .	193
37. Aphthous Ulcer (Aphthous Stomatitis) . . . .	197
38. Angina Follicularis Catarrhalis (Follicular Tonsil- litis). . . . .	197



FIG.	PAGE
39. Angina Syphilitica et Angina Follicularis Catarrhalis (Syphilitic Angina and Follicular Tonsillitis) . . . . .	201
40. Diphtheria . . . . .	201
41. <i>Plaut-Vincent</i> Angina (Ulcerated Angina Resembling a Chancre of the Tonsil) . . . .	205
42. Angina Ulcerosa Traumatica (Ulcerated Traumatic Angina). ( <i>Plaut-Vincent</i> Angina?) . .	209
43. Angina Mycotica (Mycotic Angina) . . . .	213
44. Lingua Geographica (The Geographical Tongue)	219
45. Lingua Geographica (The Geographical Tongue)	219
46. Leukoplakia Linguae (Leukoplakia of the Tongue)	223
47. Tuberculosis of the Mucous Membrane of the Hard Palate . . . . .	223
48. Tuberculosis of the Mucous Membrane of the Fauces, Soft Palate, and Uvula . . . .	227
49. A Tubercular Ulcer of the Lower Lip . . . .	231
50. Carcinoma of the Tongue . . . . .	235
51. Tumor of the Tongue. Gumma? . . . .	235
52, 53. <i>Hutchinson</i> Teeth . . . . .	239
54, 55, 56, 57. Heredosyphilitic Teeth . . . .	239
58, 59, 60, 61. Heredosyphilitic Teeth . . . .	243
62. Heredosyphilitic Teeth . . . . .	243
63, 64, 65, 66. Heredosyphilitic Teeth . . . .	249
67. Heredosyphilitic Teeth . . . . .	249
68. <i>Treponema Pallidum</i> ( <i>Spirochæta Pallida</i> ). The Specimen was Obtained from a Mucous Patch of the Lip . . . . .	253
69. <i>Spirochæta Buccalis</i> and <i>Spirochæta Dentium</i> ( <i>Treponema Microdentium</i> ). The Specimen was Obtained from a Healthy Mouth . . . .	253

FIG.		PAGE
70.	Treponema Pallidum, Pus Cells, Erythrocytes, and Cocci . . . . .	257
71.	Treponema Microdentium (Spirochæta Dentium), Treponema Macrodentium ("Medium Form" of <i>Hoffmann</i> and <i>von Prowazek</i> ), Spirochæta Buc- calis . . . . .	257
72.	Spirochæta of <i>Vincent</i> and Bacillus Fusiformis of <i>Vincent</i> , Pus Cells . . . . .	261
73.	The Chronology of the Calcification of the Teeth	261



## Introduction

Syphilis is a chronic infectious disease caused by a specific microorganism, the *treponema pallidum* (*spirochæta pallida*). The primary lesion of syphilis or chancre (initial lesion, primary sclerosis) develops at that point on the body which serves as a port of entrance for this microorganism. The infection spreads through the whole organism, rapidly by the blood and slowly by the lymphatics.

In the secondary period of syphilis, the manifestations of the disease may appear in any organ of the body. Occasionally they are ushered in with fever, swelling of the spleen, and general systemic disturbances, which syndrome may run a chronic course for about a year. It is possible for syphilis, during the secondary period, to run an exceptionally light course, to confine itself to a single transitory and scarcely observable erythema, which occasionally may even fail to appear or may escape observation. Regularly, in the course of the first months and years following more or less intense general manifestations of the disease, general or local expressions of syphilis alternate with latent periods, when no symptoms appear. Gradually the disease subsides, not to reappear; usually under the influence of treatment; seldom without it. In a certain number of cases it may reappear, after a more or less long latent period, in the form of tertiary syphilis, or ripen in the worst form as a parasyphilosis.

In contrast to the secondary period, tertiary syphilis is to be looked upon more as a local rather than as a constitutional disease. It is usually a local flaming up of the disease in a place where, for years, the



causal agent has been preserved and remains dormant. Tertiary syphilitic lesions are mostly solitary or sporadic.

What tertiary syphilis loses in extensiveness it richly gains in intensiveness. It distinguishes itself by the development of neoplasms of inflammatory origin, which quickly grow and extend. The embryonic cells of this syphilitic inflammation may undergo either a fibrous transformation or a rapid necrobiosis. This necrobiosis or necrosis of the neoplasm compromises not only the function of the organ involved, but may menace the life of the patient. The interim between the beginning of the secondary period and the occurrence of tertiary lesions varies greatly. There are cases where tertiary manifestations appear synchronously or alternately with secondary lesions. One may be apparently healthy for years before the appearance of tertiary lesions. The tertiary period begins most often about five or six years after the primary lesion. But cases have been reported with latent periods of fifteen, twenty, thirty, and even fifty and sixty years' duration after the infection.

The cause of the appearance of late tertiary syphilitic manifestations in one case and not in another is unknown. The only thing that one can say with any degree of security is, that the frequency of the late manifestations of syphilis is directly dependent upon the thoroughness of the treatment in the secondary period. The more energetic the treatment so much less frequently the appearance of tertiary lesions and vice versa. [Treatment should be begun as soon as the diagnosis of the chancre has been made.—TR.]

Of still greater significance than the tertiary syphilides are the so-called post-syphilitic manifestations, or parasyphiloses; that is, such pathological conditions which if not of a specific syphilitic character are due to or occasioned by the syphilitic infection.



Among these are tabes, dementia paralytica, many cases of arteriosclerosis, aneurysm, amyloid degeneration, etc. By the presence of these sequelæ it is possible to determine the intensity of the early syphilitic treatment.

No disease plays such a rôle in transmitting itself to posterity as syphilis. It is not a question of inheriting the disease, but a direct infection of the embryo or foetus exclusively by the syphilitic mother.

At any time during pregnancy the disease can be transmitted to the embryo or foetus. With an early infection or with severe syphilitic involvement of the placenta the foetus dies and abortion takes place. This occurs for the most part during the third to the sixth month of pregnancy. No other cause interrupts pregnancy so often as syphilis. If the foetus survives the syphilis in utero, it comes into the world afflicted with the disease; the manifestations showing themselves more or less soon after the infection. It is obvious that a severe chronic infection of the newborn endangers its life and often leads to such severe damage that the traces of it are never entirely removed.

A peculiar characteristic of syphilis is the numerous phases and various manifestations of the disease during the sometime long period of the duration. Even if syphilis spares no organ and its manifestations occur in all possible parts of the body, it has, however, a special predilection for certain parts. The most frequent point of infection is about the genitals, because coitus—entirely in a mechanical way—favors the transmission of syphilis, and the infections of the mouth, which are comparatively frequent, are also mechanically brought about by direct or indirect contact.

The secondary manifestations of syphilis have a predilection for the skin and mucous membranes. The acute eruption usually distributes itself over the entire body, but most intensely on predisposed



places, and in cases of later relapses, almost exclusively on such. In order to understand the localization of syphilitic manifestations it is important to know that secondary and tertiary syphilis establish themselves with predilection and intensity on such spots as have been determined by irritation and injury. We often see condylomata lata on places where the skin is rubbed and macerated by the sweat; as, the buttocks, about the external genitalia, under the breasts and between the toes. The eruption is most pronounced on those places which are irritated by the pressure of suspenders, garters and belts, and secondary and tertiary periostitis occurs on those bones, tibia, clavicle and bones of the skull, which being directly under the skin are most frequently subjected to trauma.

For this same reason secondary syphilis has an especial predilection for the mouth, as the mucous membrane of the mouth and tongue is continually irritated by eating, drinking, biting, smoking, unequal surface quality of the teeth, and tartar, etc. Foreign bodies and many different kinds of microorganisms may lodge upon the tonsils, thus leading to inflammation. The lips are often chapped, and there may be slight injuries to the epithelium. As no other mucous membrane of the body is subjected to as much trauma as that of the mouth, the manifestations of syphilis occur in and about this locality more frequently than upon any other part of the body.

Tertiary syphilitic lesions of the mouth are comparatively frequent. The mucous membrane, however, is not so often involved as the underlying tissue, viz., the muscle and bone. Destruction of the soft palate, perforation of the hard palate, and necrosis of the roof of the mouth are not infrequent sequelæ of tertiary syphilis.

Heredosyphilis makes itself evident in the mouth and its adnexa, not only in the early but also in the late forms of syphilis, as tertiary lesions, leading at



times to considerable destruction of the bones. Deformities of the teeth following heredosyphilis are of quite frequent occurrence, and of great importance.

Leukoplakia buccalis is a post-syphilitic lesion.

We are therefore able to observe in the mouth all stages of syphilis and to a certain extent study in the syphilitic oral manifestations a paradigm of the entire course of syphilis.

As the mouth and its adnexa are especially exposed to irritation, trauma, and infection, a large number of diseases other than syphilis may involve these localities, such as catarrh, the various forms of angina, thrush, diphtheria, etc. Many acute or chronic infectious diseases cause or complicate lesions of the mouth and pharynx, and with some skin diseases the eruption sometimes invades the buccopharyngeal mucous membrane. Consequently the differential diagnosis of such conditions is very important and often difficult.

As the clinical picture of syphilis varies greatly, and as syphilis of the mouth may resemble many other diseases occurring in this locality, a diagnosis cannot be made by considering the clinical manifestations alone: to them must be added a thorough examination of the entire body, a consideration of the anamnesis and course of the disease, accompanied by bacteriological, microscopical, serological examination and sometimes even inoculation experiments.

The causal agent of syphilis is the *Treponema Pallidum* (*Spirochæta Pallida*) (Figs. 68 and 70), discovered by *Schaudinn* in 1905. It is pale, has an average length of about ten to twenty microns; its thickness is only .25 of a micron. It has no undulating membrane; is circular in transverse section, and has finely pointed ends. The spiral or corkscrewlike form is constantly maintained by the spirochæta, both while resting or moving. The turns of the spirals are deep, regular, close together, and vary from six to twelve and may even be twenty-six in number. It



is markedly elastic and not easily deformed. [In vitro its vitality is not great, and its movements cease in five or six hours at room temperature. It is difficult to stain and is colored red by *Giemsa*.—Tr.]

The *treponema pallidum* moves by rotation around its long axis, comparatively slowly, at times forward, sometimes it stops and may move in the opposite direction. There are also undulating, flexion and extension movements. [The movement of the other spirochætæ, except the *treponema microdentium* (*spirochæta dentium*), is for the most part sinuous or snakelike, and there is also a tendency to lengthen their spirals during rest.—Tr.]

The *treponema pallidum* has been found in the chancre and adenopathies accompanying the same; in secondary manifestations (mucous patches, papules roseola, etc.), and in the blood of the general circulation. [The *treponema pallidum* has not been found in the semen; but during the secondary period of the disease this secretion has been proved infectious. Tertiary syphilis is said to be, clinically, not infectious; however, the causal agent has been encountered in papular tertiary lesions and gummata. Apes which have been inoculated with fragments of gummata and the blood from persons having tertiary syphilis contracted the disease. It has also been found in the aorta in syphilitic aortitis. In the lesions of heredosyphilis the pallidum is found in greatest numbers, and may also be encountered in any organ. It is found in the placenta, and may be found even within the ovocytes. It is almost always present in the mucus from the mouth, tonsils, pharynx and nose of heredosyphilitics.

Syphilis has been produced in the ape by inoculating it with the nasal mucus from a syphilitic man. In 1903, *Roux* and *Metchinkoff* demonstrated that anthropoid apes are susceptible to syphilis. It is, however, not so easily generalized in animals as in man. A syphilitic keratitis and orchitis can be pro-



duced in a rabbit, a keratitis in a guinea-pig, and the cat, dog and sheep can be infected through the cornea. Syphilis has also been produced in a two days' old mouse by a subcutaneous inoculation of syphilitic material.—Tr.]

The *treponema pallidum* is not easy to find in the lesions of malignant or tertiary syphilis. [The microorganisms are probably encapsulated in some lymph node or old diseased spot, and thus escape detection. It is difficult to find them in latent syphilis; but their presence has been proved in this period of the disease in the fluid obtained by puncturing a lymph ganglion. It is very difficult and only possible to find the *treponema pallidum* in the blood when there is some general manifestation of the disease.—Tr.]

The *treponema pallidum* has been successfully cultivated, and its specificity has been demonstrated in that it has fulfilled all the conditions of *Koch's* law.

The *Spirochæta Refringens* is found in smegma and in ulcerated lesions of the skin and may be associated with the *treponema pallidum* in syphilitic lesions, but is usually met with on the surfaces of the lesion and not in the deeper part where the *treponema pallidum* is found. The *spirochæta refringens* is thicker and longer than the *treponema pallidum*, and when alive very refringent and presents a number of flat, irregular open curves; its movement being more rapid than that of the *pallidum* and not easy to follow under the microscope. It is easy to stain and colors blue with Giemsa, and can be readily distinguished from the *treponema pallidum*.

[Two species of *spirochætæ* have been demonstrated in ulcerated cancers, viz.: The *Spirochæta Micro-girata* and the *Spirochæta Loewenthalii*, which differ markedly from the *treponema pallidum*.—Tr.]

In a tropical disease, *Frambesia* (Yaws, Pian),



a spirochæta is found—*Spirochæta Pertenuis* or *Pallidula* (*Castallani*) or *Treponema Pertenuis*—which in morphology and in its staining properties with *Giemsa* cannot be distinguished from the *treponema pallidum*.

Three forms of spirochætæ are very often found in the healthy mouth, viz.: the *Spirochæta Buccalis* (*Cohn*, 1875), *Spirochæta Dentium* (*Koch*, 1877) (*Treponema Microdentium*) [and the "Medium Form" of *Hoffmann* and *von Prowazek* (*Treponema Macrodentium*).—Tr.] The *Spirochæta Buccalis* (Figs. 69 and 71) is thick and bulky, with elongated irregular curves, and in movement and appearance resembles the spirochæta refringens. The spirochæta buccalis and "medium form" (Fig. 71) are frequently found in the mucus about the tonsils and pharynx, and in great numbers in ulcerative stomatitis.

The *Treponema Microdentium* (*Spirochæta Dentium*) (Figs. 69 and 71), is found in the mouth, especially at the margins of the gums and in the cavities of carious teeth, and is more likely to be mistaken for the *treponema pallidum* than any other microorganism. The spiral form, as in the *treponema pallidum*, persists in this microorganism, even during rest. [It moves by rotating around its long axis and has no flexion movements. It further resembles the *treponema pallidum* by being pale with little refringence, with its spirals close together, very regular, but the curves are not so high as the *pallidum*. Its average length is about four to ten microns. It has been successfully cultivated. *Noguchi* has found that the *treponema microdentium* grown upon his medium produces an odor, whereas the cultures of the *treponema pallidum* on the same medium are odorless. This organism is more easily stained than the *treponema pallidum*.—Tr.]

[The *Spirochæta* of *Vincent*, associated with the *Bacillus Fusiformis* of *Vincent* (Fig. 72) in *Plaut-*



*Vincent* angina, has the characteristics of the spirochæta buccalis, and may be confused with it. It is chiefly found in the mouth, and may possibly be a saprophytic microorganism in that locality.—Tr.] It stains blue with *Giemsa*.

In the differential diagnosis of the spirochætæ of the mouth, the greatest caution is required, because of their close resemblance to one another. A smear may be made from the exudate of the suspected lesion and stained, or the method of *Burri* (India ink method) may be used to find the microorganism. The best method for determining the presence of the *treponema pallidum* or other spirochætæ is by means of the *dark-field microscope* (*dunkelfeld-* or *ultra-microscope*), which permits the study of not only the form but the refringence and movements of the living organism.

Formerly, it was necessary to watch the further course of the separate symptoms of syphilis until a positive diagnosis of syphilis could be made; thereby losing much valuable time before treatment was commenced. To-day, however, by proving the presence of the *treponema pallidum*, a diagnosis can at once be made and the disease immediately treated.

The *Sero-reaction of Wassermann* is at times an important aid in detecting syphilis. The reaction depends upon the fact that in the body the living causal agents of a given disease produce or incite the cells of the body to produce a substance, which is known as the immune body, or antibody. These exceptionally delicate and labile substances have not been analyzed, but through a biological reaction their presence influences the capability of the blood serum to dissolve the erythrocytes of another animal species.

The serodiagnosis of syphilis introduced into the practice of medicine by v. *Wassermann*, *Neisser* and *Bruck*, in 1905, is the application to syphilis of a method for the deviation of the complement [discov-



ered by *Jules Bordet* and *Octave Gengou*, in 1901. Widal calls it the "reaction of fixation."—Tr.] The non-syphilitic gives, with very few exceptions, a negative reaction. The reaction may be positive in the following diseases, viz.: (1) in leprosy and some tropical diseases, (2) in the last stages of tuberculosis and carcinoma, (3) during the febrile movement of some systemic diseases. Scarlatina occasionally gives a positive reaction, which does not last long. All these diseases are easy to differentiate from syphilis, or do not occur among us. In manifest syphilis the reaction is almost always positive. The reaction is usually not positive until the seventh week after the appearance of the chancre, although it has been found positive four to six weeks after the infection. With the occurrence of the general manifestations the reaction becomes positive in 95 per cent. of the cases. In tertiary syphilis the reaction is positive in 80 per cent. of the cases. From the reaction, especially if it be positive, conclusions can be drawn for diagnosis. In long-standing latent syphilis the number of positive reactions are much fewer. Latent syphilis often gives a weak reaction; 30 per cent. incomplete, 20 per cent. positive, and 50 per cent. negative. Untreated cases of latent syphilis are more likely to give a positive reaction than well-treated cases where the reaction when positive is weak. Time and experience will show the value of the reaction in long-standing latent syphilis. Are cases of long-standing latent syphilis giving a negative reaction cured? Are those giving a positive reaction uncured? Is the positive reaction in such cases a sign of complete immunity following the disease? The positive reaction indicates the necessity for continuation of treatment. The serum of the patient should be examined at frequent intervals during the course of whatever treatment is employed, in order to ascertain how the treatment affects an important symptom of the disease, viz.: the deflection of the complement. The



grave post-syphilitic diseases—tabes and dementia paralytica—occurring after a long latent period of the disease almost invariably give a positive reaction.

The *Wassermann* reaction, while being a very valuable means for supporting our diagnosis in cases where we are in doubt as to whether the manifestations of a disease are or are not syphilitic, does not prove the tumor we have before us is a syphilitic neoplasm, or carcinoma, as it is to be remembered that a man having a chronic or latent syphilis may also be afflicted with some other disease. In doubtful cases a positive *Wassermann* favors a diagnosis of syphilis and influences the treatment.

Too much reliance should not be placed upon the *Wassermann* reaction alone; its great value in diagnosis is found when taken in conjunction with the clinical picture, anamnesis, etc.

A single *Wassermann* test showing a negative reaction has no diagnostic worth. It is only good for the time when it is made. In general, we can say that the positive *Wassermann* reaction has, in the diagnosis of syphilis, the same value as a positive syphilitic anamnesis.

[*Noguchi* claims that *luetin* (*Noguchi*) produces a cutaneous reaction in syphilitic and parasymphilitic patients, which is most constant and severe in the tertiary and hereditary affections, 100 per cent. of manifest tertiary affection, 94 per cent. of latent tertiary affection, 96 per cent. of hereditary affection. This test, in conjunction with the *Wassermann*, may facilitate the diagnosis in difficult and obscure cases.—TR.]



## The Primary Lesion of Syphilis

Extra genital chancres constitute about 8% to 9% of the entire number of primary syphilitic lesions, and 75% of these are situated on the head. *Fournier*, in his well-known statistics, states, that of 1,124 extragenital primary lesions, 849 were upon the head. Of these, 567 were upon the lip; 75 on the tongue; 69 on the tonsils; 11 on the gums; and 1 on the mucous membrane of the cheek.

The fairly frequent occurrence of a **primary lesion** in or about the mouth is not remarkable when we consider how easily an injury, such as a scratch or break of the skin or mucous membrane, can happen to these structures. The following are some of the conditions which predispose these parts to infection, viz.: small tears and fissures, excoriations of the lips, the habit of chewing the lip, chapped lips which are cracked or where the underlying epithelium is exposed, eczema of the lips (especially if mouth washes are used which continually irritate them). Injury to the tongue by biting or by a sharp tooth, etc.

In order to contract syphilis it is necessary that the port of entrance for the *treponema pallidum* must come in contact with either the exudate of a chancre or mucous patch or with some material containing the *treponema pallidum*. Aside from this, the disease is contracted by perverse sexual relations, as coitus per os, cunnilingus, etc. Not infrequently syphilis is caused by a kiss, for the causal agent of syphilis has a predilection for the mucous membrane of the mouth, and this is especially marked during the secondary



period of the disease. These lesions of the mouth are frequently so insignificant that they are not noticed, yet they are extremely infectious, as the *treponema pallidum* is found in them and passes into the saliva in great numbers. The danger of promiscuous kissing is obvious, and wherever it obtains the relative number of tongue and lip chancres increases, and among some peoples and in some localities the chancres of the lips are seen very often. In Cologne, every year during the carnival time, the number of primary lesions in the mouth is especially great.

Another mode of directly transmitting syphilis to or by the mouth is through nursing, viz.: a wet nurse with a chancre of the lip or tongue, etc., may infect the child or a heredosyphilitic child may infect the wet nurse. The parts in and about the mouth are especially exposed to the indirect transmission of syphilis through the general use of eating and drinking utensils, cigar holders, pipes, wind musical instruments, etc., for the *treponema pallidum* can remain alive outside of the body for days when it is in a moist medium. Among the large number of isolated cases of primary syphilis of the mouth where the way of contracting the disease was not at the time determined, the formerly endemic indirect buccal transmission of syphilis among glass-blowers may be mentioned, when tubes were passed from one worker to the other. Surgical and dental instruments play an important rôle in the indirect transmission of syphilis, but to-day no scientific physician, surgeon, or dentist would use an instrument which had not been properly sterilized.

It is difficult to explain the comparative frequency of a chancre upon the tonsil. The tonsils are very much less subjected to trauma than either the lips, the tongue or cheeks, and the direct transmission of the causal agent, from mouth to mouth and thus to tonsils, or by touching them with instruments, etc., is certainly very seldom. For these reasons it is highly



probable that the tonsils are prone to the syphilitic infection, and that the *treponemata pallida*, gaining entrance to the mouth either directly or indirectly, stick to the tonsils and perhaps remain alive there for some time in the lacunæ, and even pass through the uninjured mucous membrane.

The prognosis of the extragenital chancre has been considered especially unfavorable. In general this is not correct. Often the extragenital chancre is not recognized, and early treatment is thus omitted which favors the development of serious lesions. It has been asserted, but not proved, that primary lesions upon the head afford the easy transit of especially great numbers of *treponemata* to the brain, and thus favor the occurrence of cerebral manifestations.

Between the time of the infection and the occurrence of the first manifestation or the initial lesion, there is a latent period, or period of incubation, of two, three, and four weeks.

On the lips the chancre appears at first as a flat, not shining *erosion* about the size of a lentil, which is elevated very little or not at all above the surface of the surrounding mucous membrane (*Chancrous erosion*, Fig. 1). It gives a distinctly hard (sclerosis or induration) cartilaginous feel to the touch which, in the absence of other syphilitic manifestations, is characteristic of syphilis. The erosion has no covering, especially if the patient has licked it considerably, but it may have a thin fibrinous membrane. On pressure there exudes from the surface of the chancre an abundant clear yellow serum in which numerous *treponemata pallida* are easily found. This small erosion increases in size until it may have a diameter of 2 centimetres. The induration always present in this form of chancre is slight and superficial. This type of chancre is almost always painless, and this, accompanied by the fact that it occasions scarcely any inconvenience and is often not noticed by the syphi-



litic, makes him a menace and favors the spreading of the disease.

Both genital and extragenital chancres may be either the erosive type or a *papular*, elevated or even a *hypertrophied chancre* (Fig. 2). We have then a tumor with a cartilaginouslike hardness, the surface of which is either entirely covered with epithelium or eroded. It may be covered with a fibrinous membrane, crusts or with a covering resembling bark. The centre of the primary lesion on the lip often undergoes suppuration, so that an *ulcerated chancre* is found which has craterlike edges, an uneven base covered with a milky pellicle and pus, or pus mixed with blood or with rupiallike crusts or with crusts resembling oyster shells.

The ulcer is surrounded by an intensely indurated tissue, yet the induration is often much less than in non-ulcerated lesions. The development of the ulcerated chancre is in many cases the result of a mixed infection. The entire lip is seldom infiltrated, yet when the lesion is situated upon the upper lip there may be a snoutlike or elephantiasic thickening.

The lip chancre, as well as an initial lesion elsewhere, always involves the neighboring lymph nodes or ganglia, so that an adenopathy of the submaxillary and submental lymph ganglia follows. The lymph nodes are swollen and a lateral position of the chancre determines a unilateral involvement.

There takes place unilateral enlargement of several ganglia determined by that side, on the right or left of the median line, of the lip upon which the chancre is situated. The lymph ganglia or nodes are painless and are freely movable. Occasionally, through a mixed infection (more often with a primary lesion of the buccal cavity), they undergo suppuration, break down and even rupture through the skin. The suppuration of these neighboring lymph nodes does not, however, indicate that the previous diagnosis of chancre was incorrect.



The primary lesion on the lips is usually single and has a predilection for the middle of the vermillion, where cracks, fissures, etc., are most often seen. The solitary appearance of the chancre is generally a peculiarity of the syphilitic infection and is explained by the fact that a chancre, as it develops, confers to the entire body and especially its environs such a grade of immunity that it is difficult to produce an autoinoculation. The chancroid, however, is always autoinoculable. The widely prevalent view that the chancre is always invariably solitary is far from being correct, for by simultaneously infecting several points it is possible to cause the development of several chancres at the same time (Fig. 2). More than one initial lesion may also appear if the autoinoculation takes place at a very early period in the disease before sufficient syphilitic antibodies are formed, or if the autoinoculation is very intense, *e.g.*, on an opposing surface which is continually coming in contact with the infectious material. Thus it is that occasionally on a point on the upper or lower lip corresponding to an already developed chancre we see another appear.

On the tongue, as on the lip, the initial lesion may appear as an erosion, a papular erosion, or in an ulcerated form. The flat chancrous erosion of the tongue can appear in its lightest form solely as a flat, faintly shining spot denuded of papillæ. Induration is only determined by palpation. In most cases the infiltration raises the primary lesion above the level of the tongue (Fig. 3). The erosion is not coated with anything, there is no pus, nor very little blood, but on pressure a clear serum exudes, containing numerous spirochætæ.

The primary lesion can develop occasionally in the deeper parts of the tongue, so that only a hard swelling of a part of the tongue, *e.g.*, the tip of the tongue, without any change in the mucous membrane, is observed. The initial lesion of the tongue rarely



causes any subjective trouble. The disturbance is purely mechanical, as it may interfere with eating and speaking. The ulcerated primary lesion of the tongue is very rare. It can lead to destruction of the tongue, but, as a rule, it does not spread to any great extent. There is little pus, and the ulcer is covered with a milky pellicle. The tip or side of the tongue is the seat of predilection of the chancre, and the sub-maxillary lymph nodes are always involved.

On the gums, cheeks, and palate the initial lesion is but seldom seen, but it appears oftener upon the tonsils.

As mentioned above, it is not easy to explain the infection of the tonsils, and while the chancre of the lip and tongue have distinct characteristics, that of the tonsil has none. It may appear upon the tonsil in the erosive, papular, or ulcerated form, but the induration is not especially marked and the whole process is more diffuse, less sharply marked off and therefore not so easy to define. The diagnosis is difficult. Sometimes, however, the tonsil is pale and protrudes markedly and exhibits a cartilaginous hardness, which can be proved on palpation. From the erosion or ulceration of the surface of the tonsil not much can be determined, and there is very little congestion of the surrounding parts. The chancre of the tonsil may appear as a tonsillitis, with great congestion and œdema of the entire throat. With the ulcerated form of tonsillar chancre there is often a marked inflammatory reaction. The ulceration, which can be markedly anfractuouse, is covered with pus and bleeds more profusely than any other form of chancre.

The primary lesion of the tonsil is sometimes difficult to diagnose from diphtheria, carcinoma, tuberculosis of the tonsil, or a severe tonsillitis, except where the tonsillitis is bilateral. A primary lesion of the tonsil can occasion considerable uneasiness, pain and difficulty in swallowing. It produces an adenopathy



of the submaxillary ganglia and the ganglia at the angle of the mandible.

The diagnosis of an initial lesion upon the lip and tongue is easy, especially if its course, the behavior of the neighboring lymph nodes and other allied conditions are considered. The small chancreous erosion may escape unobserved or be regarded as a harmless erosion. Palpation of the lesion, however, quickly determines its specific nature. A large elevated papular chancre is not likely to be confused with any other lesion.

At times secondary manifestations, a mucous patch or ulceration, can be mistaken for a primary lesion. It is very difficult to differentiate them, even if they are present simultaneously. The presence of treponemata and a positive *Wassermann* reaction are of no help in the differential diagnosis. The conditions of the lymph nodes are not of much help, in diagnosis, when both a chancre of the lip and mucous patches on the tongue are present at the same time.

The chancre may be but slightly indurated, while there is considerable infiltration of the mucous patch. At times a differential diagnosis is impossible. A gumma can at times simulate a primary lesion and vice versa. But the adenopathy, the presence of spirochætæ in the lesion and other symptoms of the disease assist in the diagnosis. The differential diagnosis of carcinoma, tuberculosis, and syphilis will be later considered.

The confusing of the chancre with any other mouth lesion is unlikely. Furuncles on the lip last only a few days, are very painful, soon suppurate, and are often accompanied by a painful adenitis. Tonsillar abscess and catarrhal or ulcerated angina run a different course. There is a febrile onset, great pain and difficulty in swallowing, and they are usually bilateral and heal quicker. But it must not be forgotten that an initial lesion can at times assume

the aspect of a unilateral angina and may be accompanied at the time of the secondary manifestations with a low fever. It is also possible to mistake a case of the *Plaut-Vincent* angina for a primary lesion (Fig. 41).

The chancroid or soft chancre is rarely found in the mouth, and when it does appear it is usually by autoinoculation of a lesion somewhere else on the body. It is not always easy to distinguish by sight a chancroid from an ulcerated chancre. The chancroid, however, is distinguished by its rapid growth, absence of induration, undermined edges, irregular base with pus and blood exudating, pain, and the neighboring adenitis, which may or may not be accompanied by a suppurative periadenitis; and, finally, the presence of the causal agent, viz., the *Ducrey-Krefting* Streptobacillus.



## Secondary Syphilis

Four to six weeks after the occurrence of the primary lesion the secondary manifestations usually occur. With their appearance the **secondary period** of the disease begins. The causal agent of the disease has now traversed the entire body by way of the blood and lymph, and a general systemic infection of the organism results. At this period the syphilis affects all the organs (even the viscera and nervous system), and particularly the skin and dermo-papillary mucous membrane (visible mucous membranes), which, like the skin, are derived from the ectoderm and have nearly the same histological characteristics. [Included among the dermo-papillary mucous membranes are those of the lips, mouth, tongue, pharynx, larynx, nose and eyelids.

The manifestations upon the skin and the mucous membranes are known as cutaneous and mucous syphilides; the latter are also commonly called mucous patches. The mucous syphilides are moist and usually contain the *treponema pallidum* in great numbers. The cutaneous syphilides are dry lesions. Mucous patches may also occur upon the skin, where, having become eroded or ulcerated, they are known as condylomata lata. Mucous patches are absent in mucous membranes of entodermic origin. This is a striking example of the fact that syphilis has a predilection for tissues derived from certain embryonal cells. The pathological differences in the mucous membranes, derived respectively from the ectoderm and entoderm, correspond with embryological differentiation.—Tr.]



The skin eruption or exanthem may be represented in varying frequency by any of the following types of syphilides, viz.:

1. As very pale rose-colored spots (erythema or roseola), which are usually of ephemeral duration and often escape detection except by a careful observer.

2. The roseola may be more intense; last longer, with some very slight infiltration.

3. Small or large papules.

4. Small or large pustules.

5. The ulcerated syphilide—the larger pustules forming small ulcers, which leave scars on healing.

As in the skin, so may the secondary manifestations appear in the mucous membrane. With the first general or systemic manifestation of the disease lesions of the mucous membrane of the mouth are rarely absent, and in the later course of the secondary period they are extremely frequent.

It often happens that after the eruption has disappeared, with the exception of the mouth lesions, there are no syphilitic manifestations. These mouth lesions give no, or at times extremely little, evidence of their presence, and as they are particularly infectious the importance of recognizing them is evident. Corresponding to the time of the appearance of the roseola, simple *erythematous spots* (Fig. 4) appear upon the mucous membrane of the mouth. These spots, oftentimes very ephemeral, may be large, small, round, oval, or not infrequently confluent. The only perceptible change in that part of the mucous membrane where they are situated is the hyperæmia. These spots can be regarded as symptoms of syphilis, only through the fact that their appearance is synchronous with that of a secondary syphilide and that they react to antisiphilitic treatment.

A simple hyperæmia of the isthmus of the fauces—resembling an angina—with sharp lines of demar-



cation from the non-erythematous mucous membrane, is sometimes seen.

By far the most frequently occurring type of syphilis of the mouth is the *erosive syphilide* (Fig. 5), which is a round or oval superficial erosion seldom larger than 2 cm in diameter. Its surface is faintly shining, very little roughened, and either slightly redder than the surrounding mucous membrane, above which it is rarely raised, or a slight glistening gray. There is a sharp line of demarcation between the lesion and the healthy mucous membrane, and inflammatory reaction is usually absent.

If inflammatory reaction takes place in this form of syphilide, it then becomes denser, more or less raised above the surrounding mucous membrane, and can be detected by the palpating finger. This represents the true "*mucous patch*" (Fig. 6). (*Papel* of the Germans, and *plaque muqueuse* of the French.)

The surfaces of the various mucous patches differ greatly in appearance. With the flat form we have either a slight erosion of the mucous membrane or a thin yellow fibrinous coating, or the epithelium, remaining intact and becoming thicker and cloudy, gives the lesion a gray appearance. This sometimes becomes whitish, yellowish or bluish, somewhat like an opal, and hence the name *opaline mucous patch* (Fig. 11) (*Plaques Opalines*).

The mucous patch may become raised and hypertrophied (*hypertrophied mucous patch*) (Fig. 7), the epithelium usually increasing in thickness. The color of its surface is a more pronounced gray or dirty yellow or sometimes distinctly white (*Diphtheroid*).

While the flat mucous patches have for the most part a smooth, faintly shining surface, the hypertrophied ones are rough, granular, or anfractuous. The inflammatory reaction can vary greatly. The mucous patch may rise precipitously or gradually from the normal surrounding mucous membrane. It



may be surrounded by a slight inflammatory zone of mucous membrane, or it may be situated in the midst of an actively congested, inflamed and swollen membrane. As a rule, the line of demarcation between the zone of inflammation and the normal membrane is extremely sharp.

In severe, neglected or untreated cases the mucous patches of the mouth, as of the skin, may often undergo ulceration (*ulcerated mucous patches*) (Figs. 8 and 9). All stages are met with from that of a small, superficial, insignificant ulcer to a severe, inveterate, ulcerating process, with extensive destruction of the submucous tissue. Neglected oral hygiene, smoking, chewing, surface inequalities of the teeth, or a badly fitting denture, etc., play a prominent part in causing these ulcerated mucous patches. A direct mixed infection of the mucous patch will sometimes cause them.

As a rule, the ulcers appearing during the secondary period of syphilis lie in an acutely inflamed area and are surrounded by an extensive inflammatory zone. They may be round, flat, funnel-shaped, hollowed-out or irregular in form, with an anfractuous base covered with pus or fibrin. The ulcerated mucous patches can give rise to considerable pain, particularly if they are situated in such places as are exposed to mechanical irritation. It is comparatively easy to find the *treponema pallidum* in the erosive and hypertrophied type of mucous patch, while in the ulcerated form it is often very difficult.

True serpiginous ulcers (healing from the centre) of the mucous membrane of the mouth are rare, yet an annular syphilide occasionally ulcerates and thus simulates a serpiginous ulceration (Fig. 10).

On account of certain histological peculiarities of the tongue (viz., the poorly developed submucosa and as a result the scarcely movable mucosa on the upper surface and base of this organ, absence of glands in the mucosa and the presence of epithelial



papillæ and lymphoid tissue), the aspect of syphilides of the mucous membrane of the tongue often differs essentially from that of syphilides of the mucous membrane of the rest of the mouth. Sometimes the papillæ are especially pronounced, and then the patches stick up from the mucous membrane as rough gray spots. Sometimes, on account of the syphilitic inflammatory process, the papillæ have disappeared, resulting in smooth reddish spots, between which there is either a normal or coated spot of mucous membrane (*alopecia of the tongue*). If the syphilitic infiltrate or mucous patch attacks an otherwise normal tongue, except that it has deep furrows, the furrowing becomes especially striking in appearance as star or V-shaped rhagades (Fig. 13).

Very frequently in the early stages of secondary syphilis a deep interstitial inflammatory process tends to involve the tongue, especially if mucous patches, more often ulcerated ones, have existed for a long time upon the mucous membrane of the organ. Thus early in the disease there is a *diffuse glossitis*, which gradually passes into a chronic condition (Fig. 12), and can lead to permanent changes in the tongue (*chronic interstitial glossitis*, or *sclerosis of the tongue*). The "smooth atrophy" of the base of the tongue, which has for some time been considered as an important point in the diagnosis of syphilis, is caused by the chronic inflammation of the tongue.

The different configurations of the syphilides which are seen upon the skin may be encountered upon the mucous membrane of the mouth. Most often round or oval foci are seen, by the confluence of which bow-shaped patches are formed. The extension of each individual focus is usually not very great, but with the hypertrophic types may be quite extensive. The pronounced ring or garland form of syphilide—the so-called *orbicular, annular or circinate syphilide* (Figs. 10 and 17)—is not often seen



in the mouth. The favorite seat for the circinate syphilide is about the lips (Fig. 20).

The syphilis of the isthmus of the fauces, or so-called *syphilitic angina* (*Angina syphilitica*, *Syphilitic sore throat*), is the most frequent appearing form of mouth syphilis seen in the secondary period of this disease. It differs in appearance according to the situation and kind and intensity of the congestion. The tonsils are not always involved. The condition and size of the tonsils may remain normal, and they may even disappear between the thickened pillars of the fauces or they may be so congested, swollen and inflamed that they nearly come in contact and almost occlude the fauces. Cases where the tonsils alone are involved are rare. Mucous patches in the form of plugs can lie directly in the openings of the follicles, so that the appearance of the tonsils resembles that of a follicular tonsillitis. These isolated mucous patches soon run together, and the process almost always tends to extend and involve the pillars of the fauces. It is this localization of this lesion upon the faucial pillars which distinguishes the syphilitic from the follicular angina or ordinary follicular tonsillitis. Very often a patch is seen on the edge of the anterior pillars of the fauces which extends backward and involves the tonsils or upward and forward in an arched manner until it even involves part of the hard palate. Sometimes a mucous patch is found in the pocket between the tonsil and the anterior pillar of the fauces, and thus be confined entirely to the posterior surface of the pillar or appear as a small projecting point, or it may become apparent only when the pillar is lifted off from the tonsil with an instrument. The patches can appear as isolated small foci, which may be few or many, or they can become confluent and quickly involve other parts by peripheral extension. In the mildest form of angina the mucous membrane is only a little thickened and has a soft, grayish tone, as if



it were covered over with milk or been painted with a solution of silver nitrate (Figs. 15 and 16).

In mucous patches which have undergone hypertrophy and considerable infiltration, the color becomes markedly yellow or distinctly white (Fig. 18). In such a case the syphilitic angina resembles diphtheria, especially if the surrounding mucous membrane is congested, œdematous, and intensely inflamed, which often happens to the loose submucous tissue of the soft palate and uvula.

Small flat lesions of the mucous membrane with a grayish papular border are quite frequent. They have a predilection for the free borders of the soft palate, which has thereby an eaten-out appearance. Large hypertrophied mucous patches of long standing, which are inclined to form small central ulcerations, together with large bow-shaped lesions, may appear. Finally, there sometimes develops on the fauces large, deeply penetrating ulcerations of the submucous tissue, which may lead to the formation of scars (Fig. 19).

The multiplicity of syphilitic manifestations upon the mucous membrane of the mouth during the secondary period of the disease make their diagnosis particularly difficult. Naturally, there are cases where the experienced physician does not doubt for a moment that he is dealing with a case of syphilis; nevertheless, he should always act with the greatest caution, and search for every possible aid in diagnosis. He should examine the entire body for evidences of the disease. As already stated, a seat of predilection of secondary syphilides (*circinate*) is on the skin surrounding the mouth (Fig. 20). With subjects having especially well-developed sebaceous glands infiltration of the nasolabial folds may develop, which often appears either as a disfigurement of a dull bluish-red color or as a light infiltrate or as a more or less thickened mucous patch—*Condyloma Latum* (Fig. 5). The furrow between the chin

and lower lip, which contains numerous sebaceous glands, is also often the seat of mucous patches.

The consideration of the anamnesis, the observation of the course of the disease, the influence of treatment and the result of the *Wassermann* reaction help in confirming a diagnosis. While the final and most important evidence of the disease is the presence of the *treponema pallidum* in the lesion.



## Tertiary Syphilis

The syphilitic lesions in the mouth accompanying the tertiary period of the disease are frequent, but have no such predilection for this cavity as have the secondary manifestations. The lips, tongue, hard and soft palate, the tonsils as well as the bones forming the mouth can all be attacked. Doubtless the injuries, irritations, etc., to which the mouth is continually subjected can act as they did for the secondary lesions as stimuli for the production of the tertiary.

**Tertiary syphilis** in the mouth, as in the skin, appears in many forms. Lesions occur in the mouth as papules, and as small or large nodules. These may form numerous *small, flat*, and often *reticulated ulcers* (Fig. 21), which gradually extend over a considerable surface. Sometimes they heal from the centre and sometimes otherwise. These nodules, instead of undergoing a necrobiosis and forming ulcers, can become sclerosed and cause the formation of flat, reticulated cicatrices—*tertiary papular syphilide*. Tertiary syphilis of the mouth appears chiefly in the form of this tertiary papular syphilide, if the process starts in the mucous membrane.

More often the tertiary syphilitic process begins in the submucous tissue, leading to the formation of gummata, which undergo a more or less rapid development and necrobiosis.

In general, the syphilitic neoplasms in the mouth show no special tendency to extend. Yet, like gummatus processes of the skin, those of the lips, tongue, and especially about the soft palate and



fauces, may become large tumors, which quickly undergo necrosis and form extensive ulcers. These ulcers, embedded in a firmly infiltrated area, have irregular or arched borders, and often undermine the inflamed congested mucous membrane and thus extend to appear at the surface at some distant point. The floor of the ulcer is very uneven, bleeds easily, and is covered with pus or a viscid non-offensive smelling serous exudate. The gumma, as a rule, is painless, and especially characteristic is its rapid development, its continuous marked tendency to extend and to involve in the coagulation necrosis process, all tissues within reach. This is especially true of gummatous ulcers originating in the musculature of the soft palate, which often in a short time bring about considerable destruction. In a few days necrosis and perforation of the entire soft palate and uvula may take place. The ulcer may even extend to the posterior pharyngeal wall and the nasopharynx. With such a lesion of the soft palate there is usually an accompanying acute inflammatory process, congestion and œdema.

The gummatous processes in the lips and tongue run a less violent course, as the tissues are denser, so there is a correspondingly slower development and necrosis of the gumma and a less active inflammatory reaction. In these localities the opportunity is afforded to observe the gradual growth of the gummatous nodes, their central softening and rupture.

The tertiary syphilitic processes of the mouth often have their origin in the underlying bone or periosteum. The mandible, or, as more often occurs, the hard palate or bones of the nose, may be involved. The destruction of the periosteum leads without exception to a necrosis of the bone to which it was attached. As this process of destruction is not painful, and as it frequently takes place in parts which cannot be easily seen, it often happens that various-sized pieces of necrotic bone are discharged before



the patient is aware that anything is the matter. The first symptom is redness and a slight doughy swelling of the mucous membrane, then at a circumscribed spot a pustule forms, and from this there later exudes a creamy, viscid pus. The rough surfaces of the denuded bones can be easily detected by a probe, and if an immediate, energetic treatment is not afforded, a large ulcer, followed by sequestra, quickly develops, which leads to inoperable bony defects and perforation of the hard palate (Fig. 22). In cases which are severe and extensive the entire palate and all the nasal bones may be destroyed, so that the oral and nasal cavities become one. Even if the gummatous inflammatory process is limited in its destruction and healing takes place, characteristic defects and cicatrices result.

The healing of a gummatous ulcer in soft tissue results in peculiar radiating cicatrices, which strangely distort the non-involved tissue. Juxta-imposed ulcerated surfaces may become united.

The soft palate may be united to the posterior pharyngeal wall (Fig. 23), while respiration is effected through a perforation in the palate. Small perforations of the hard or soft palate may close spontaneously, while the larger remain open and cause disturbances in speaking and eating until they are closed either by operation or prosthesis.

Aside from the papular, gummatous, and ulcerated tertiary processes in the mouth, which are only distinguished from those of the skin by their position and not by their behavior, there may appear other tertiary syphilitic manifestations which have more the character of visceral syphilis. Instead of the syphilitic neoplasm undergoing sclerosis or necrobiosis and thereby becoming a gumma, the two processes may combine, forming a sclerogummatous tissue. This is the usual type of syphilitic neoplasia found in the interstitial tissue of the viscera.

The lips, which are seldom involved in this man-



ner, are thickened, infiltrated, and fibrous. Sometimes they are covered with superficial ulcerations. They have an elephantiasic or snoutlike appearance. [This hypertrophic syphiloma of the lips is sometimes called *syphilitic leontiasis*.—Tr.]

Interstitial tertiary syphilitic lesions of the tongue are comparatively frequent. As the infiltrate is superficial or deep, so is a single part or the entire tongue affected; thus producing different clinical pictures.

With a diffuse infiltration the entire tongue assumes a peculiar dense, rigid condition. It feels hard; cannot be moved; its surface has a faint lustre; radiating furrows traverse the organ, and the papillæ have disappeared (*Sclerosis of the Tongue*). More often the added retraction and atrophy of the infiltration lead to a lobulated condition of the surface (*Lingua Lobata*).

With a superficial infiltration the lobes are smaller and the furrows shallower. Deeper processes may lead to deeper furrows, to the formation of large lobes and to an appearance of the tongue as if a part of it has been ligated. The mucous membrane in such conditions show no, or scarcely any, change.

The sclerosis of the tongue and the consecutive atrophy both in the superficial and deeper part can be either diffuse or circumscribed. When the sclerosis is peripherally situated, the tongue assumes a crumpled-up, serrated form, and when central, a more or less concave appearance.

The sclerosed areas may occasionally become ulcerated, especially if the sharp edge of a tooth injured the furrows of the tongue or when the tongue is subject to some other form of injury. These ulcerations, which are to be distinguished from ulcerated gummata, if they persist, may sometimes become carcinomatous. These deep lesions of the tongue come to the physician when the retraction and atrophy have already set in. They are extremely re-



bellious to treatment, and in this and through their extremely slow development they distinguish themselves from true gummatous processes.

The striking fact that severe and extensive tertiary syphilitic lesions—neoplasms and ulcerations—never involve the adjacent lymph ganglia, is a most important diagnostic point.

The mouth manifestations of *malignant syphilis* are worthy of especial mention. It is not clear under what conditions this form of syphilis makes its appearance and a discussion of this subject cannot be taken up in this work. Alcoholism, a depraved general nutrition or some cachexia may act as predisposing factors. These factors surely do not apply in every case. In a number of cases of syphilis soon after the infection, the disease appears in a form which differs entirely from the clinical picture as usually seen in the secondary period of syphilis. Either the lesions are of a very grave character or there is a marked resistance on the part of the disease to treatment.

In malignant syphilis exceptionally severe ulcers of the skin and mucous membranes appear even when the disease has not reached the tertiary period with its characteristic gummatous neoplasia. These ulcers extend rapidly with great resulting destruction, not only deeply, but also over the surface of the body.

These ulcerations of malignant syphilis are similar to those observed in tertiary syphilis in respect to their extent and the destruction caused by them.

Through the confluence of neighboring lesions (shaped like the figure 8), large ulcers are formed which bleed easily, and their walls slope precipitously. The floor of the skin ulcers is, as a rule, light red, while that of the ulcers involving the mucous membrane usually has a very adherent yellowish-gray coating. In the mouth these malignant ulcers appear by predilection upon the soft palate. Here extensive



inoperable defects can be produced in a few days, either by the entire destruction of the velum palati or of the uvula or perforation of the soft palate (Figs. 24 and 25). Destruction of bone occurs more frequently with malignant than with tertiary syphilis, and the destructive process, which can scarcely be distinguished from the manifestations of tertiary syphilis, begins either in the periosteum or the bone itself. Malignant syphilis runs a more rapid course than tertiary syphilis, so rapid that it never takes the form of a gummatous neoplasm. It appears, in contradistinction to tertiary syphilis, in various situations: thus, bone lesions in different parts of the body occur synchronously with skin and mucous membrane manifestations. The skin lesion has partly the character of a papular syphilide of the secondary period and partly that of the tertiary syphilitic ulcer. The hard palate is sometimes destroyed in cases of malignant lues. Usually the perforation of the palate is concomitant with the destruction of the bones of the nose.



## Hereditosyphilis

Hereditosyphilis and acquired syphilis are identical. The infection in the former, however, takes place in utero by the mother. The *treponema pallidum* is transferred exclusively via the placenta to the embryo or foetus.

The syphilitic child does not always show obvious symptoms of the disease at birth. They can develop later. The lesions of hereditosyphilis and those of acquired secondary syphilis are essentially the same, but their nature and the localities where they are found in the child and adults bodies are not so, as the child's organization differs from that of the adult. The metabolism and circulation of the blood of the foetus differ from the metabolism and circulation in a child or adult. In the foetus the special functional activity of certain organs and the rapid growth and development of tissues cause an increased blood supply to given regions and bring about local conditions which will perhaps later on permit of a reaction of certain tissues of the body to special kinds of external stimuli and injury. Where these regions and conditions are, there the *treponema pallidum* lodges. In utero the skin and mucous membrane are not vigorously attacked by the *treponema pallidum*, although it has a predilection for these organs. The foetal syphilis involves however the liver, spleen, lung, epiphyses of joints, etc., but not the skin and mucous membranes; because they are not subjected to any special irritation in utero. After birth, on account of the different forms of injury, irritation, etc., mucous and cutaneous lesions appear and on account of the



weak or slight reactive powers of the tissues they are particularly intense.

Mucous patches are found in the mouth upon the mucous membrane covering the bones, gums, cheeks and tongue, upon the lips and especially about the angles of the mouth. In the two latter situations they are frequently hypertrophied, so that the lips become infiltrated and the mucous patches on the lips and about the angles of the mouth cracked, ulcerated and painful by the more or less continuous crying of the child. When these lesions heal, scars remain through life as stigmata of hereditary syphilis.

The diagnosis of syphilitic lesions in the mouth (Figs. 26 and 27) of the newborn is not always easy. The characteristic mucous patch declares itself as a slightly hypertrophied portion of the mucous membrane with a whitish surface, surrounded by an erythematous areolar. These lesions often lose their characteristic appearance quite early, and in cases where they become eroded, soft, and possibly ulcerated, and the *treponema pallidum* cannot be found, a guarded diagnosis must be made. However, the earliest and most constant symptom of heredosyphilis is coryza and the *treponema pallidum* while easily found in the serous discharge is more difficult to find in the later purulent and bloody discharge.

Aside from the clinical manifestations, the following points must naturally be taken into consideration in the diagnosis of syphilis, viz.: The history of the case and family should be studied. Have the father, mother, sisters or brothers ever had syphilis? How often, if ever, has the mother aborted? How many children in the family have died? Have any of the children had snuffles or an eruption soon after birth? Did any of the children become blind in early life or have difficulty in hearing at that time? Is the *Wassermann* reaction positive not only of the child but also of the father and mother?

The differential diagnosis of mucous patches,



syphilitic ulcerations and other mouth lesions, diphtheria, parasitic stomatitis, etc., will be considered later.

Hereditary as well as acquired syphilis may have a tertiary period in which the lesions are not only the same but follow the same course. The lesions of *Late Heredosyphilis* (*Lues Hereditaria Tarda*) in the mouth, etc., consist of sclerotic and necrotic gummatous infiltrations of the tongue, lips, hard and soft palate, and nose, which may lead to destruction of the soft palate and cartilages of the nose and perforation of the hard palate (Figs. 28 and 29).

These late manifestations of syphilis usually appear a number of years after (3 to 20 years) birth, and sometimes they are the only symptoms of heredosyphilis observed.

The severe, intrauterine infection of the foetus has naturally a marked influence upon its development, so that aside from the manifest lesions of syphilis and their direct local sequelæ the heredosyphilitic child shows, as a rule, the evidences of a severely perverted metabolism in a blighted development or so-called *developmental hypoplasia*.

In the course of time this general hypoplasia may be overcome, but it always leaves its mark, and thus there remains with these heredosyphilitics a number of permanent changes in the organism which are partly the sequence of the local syphilitic process and partly the result of the severe damage inflicted upon the entire organism. The stigmata upon the teeth may be classed as one of the results of the damage to the entire organism, and in order to understand these it is necessary to know something of the process of calcification of the teeth (Fig. 73).

If the tooth is completely developed (calcification completed) naturally no systemic disease can alter its structure. If, however, the dental-germ is injured before the period of calcification is completed, it may lead to a substantial disturbance in the normal pro-



cess of calcification and thus to a deformity of the tooth.

The formation of dentin begins at the apex of the dentinal papilla and extends during the course of several months to its base. This process, begun before birth, continues for some time. The formation of the dentin cap does not appear in all teeth at the same time. In deciduous teeth it begins in the 5th month of foetal life, and in the six-year molar in the 6th or 7th month of foetal life. At birth the development of the dentin for the deciduous teeth is finished. Of the permanent teeth at birth only the 6-year molar has a dentin cap.

The dentin cap appears for the incisor teeth during the first and second months after birth.

Later, in the course of the first year of life, the dentin cap appears for the cuspids and still later for the bicuspid.

The dentin cap for the 2d molars begins in the third year and for the last molars in the twelfth year.

One is thus able, by studying the changes in the crown of a tooth to determine with considerable exactness at what time damage was done the tooth germ. Deformities of the deciduous incisor teeth indicate some disturbance during the first months of foetal life.

Degenerative changes of the morsal surface of a six-year molar prove the presence of disturbances in the tooth germ shortly before birth, and on the morsal margin of the incisor teeth during the first year after birth. If the morsal margin of a tooth is normal and the deformity is on the crown nearer the gingival margin, then the time when the disturbance affected the tooth is still later. As extensive as the changes are along the tooth extending from its morsal to its gingival margin, by just so long a time has the damaging process lasted. Injury with repeated re-



missions leads to parallel changes on different levels or heights, along the surface of the crown.

It is highly probable that the hypoplasia of the teeth in heredosyphilis is not of a specific nature—caused by the syphilis itself—but is a sequela of the grave systemic disease of the foetus.

This is shown by the fact that the alterations in the teeth appear symmetrically, always involving the teeth of the same period of calcification, exactly at the same time and to the same extent. If the disturbance was the sequence of a local syphilitic process in the tooth germ or in its neighborhood, then the hypoplasia would appear in an unsymmetrical manner, involving teeth of different periods of calcification.

The occasional finding of the *treponema pallidum* in the tooth germ of a heredosyphilitic foetus does not seem to alter this view.

It is possible, however, but not proved, that the hypoplasia of the teeth, as well as that in the epiphyses of bones may be caused by the specific systemic infection.

The evidence that the defective calcification is due to syphilis is found in the fact that the developmental hypoplasia begins before birth, and in the fact that syphilis is the only disease of a grave and continuous character which attacks the foetus before birth or even in the earliest months after birth and leads to such a marked disturbance in the general metabolism. It is well known that syphilis is the only known intra-uterine infectious disease. Of course, occasionally, a grave disease of the mother, e.g., typhoid fever can cause death of the foetus and abortion. In the pathology of pregnancy intrauterine syphilis appears as the chief cause of abortion. Acute infectious diseases or chronic disease of the mother as tuberculosis, and alcoholism will naturally influence the nutrition and development of the foetus. But experience teaches that these secondary indirect injuries to the foetus do not so interfere with its development as to lead



to hypoplasia. Tuberculosis, rachitis and other grave diseases do not usually exist in the child at birth and infectious diseases generally come later. Even the gastroenteritis occurring during the first months after birth does not occasion such devastation that one can attribute any developmental hypoplasia to it. Deformed teeth have not been observed in children who have suffered from gastroenteritis.

Some months after birth in addition to syphilis other diseases, especially rachitis and tuberculosis can doubtless affect the calcification of the teeth but their stigmata correspond to the time when the damage is done and they are found in other places on the teeth. The development of the enamel on the morsal surfaces of the crowns of the first molar, incisor and cuspid teeth is not affected, but hypoplasia may be seen anywhere on the surface of the crown of the teeth extending from just above their morsal to their gingival margin. Traces of injury through syphilis can be seen at these points, but we cannot distinguish them from those due to rachitis, etc., as they are not at all characteristic.

The view that anomalies in tooth structure are due to syphilis is supported by the fact that other traces of heredosyphilis are often seen with them, such as deformities, swellings on bones, saddle nose, radiating scars about the mouth, difficulty in hearing, a positive *Wassermann* reaction; or in a case of active late heredosyphilis, a tumor on a bone or in the pharynx or an interstitial keratitis.

Usually an interstitial keratitis and otitis are combined with the deformed teeth, constituting the *Hutchinson triad*, which is an important symptom in the diagnosis of heredosyphilis. Here the positive *Wassermann* reaction is also an important adjunct in diagnosis. The stigmata of course will still persist even if the disease has long since run its course and the *Wassermann* reaction has become negative. Occasionally, while seeking a trace of syphilis by the



*Wassermann* reaction, the reaction proving positive, the teeth were examined and characteristic defects were discovered on them. The positive *Wassermann* reaction of the blood of the father and mother has been supported by finding tooth hypoplasia in the mouth of their child.

The more carefully the cases are studied so much more often is syphilis seen as the etiological factor of developmental hypoplasia of the teeth, and even if the proof is lacking in some cases (and we cannot deny that occasionally another cause may come into play) heredosyphilis appears to be the only cause.

The severe protracted general infection of the foetus or newborn child must have a marked influence upon the young enamel cells during the time they are forming the enamel. The slightest injury at this time even of very short duration causes an irreparable defect in the enamel. However, during periods of remission of the damaging process the development of the enamel continues. Thus ridges and depressions are formed upon the tooth corresponding respectively to periods of remissions and exacerbations of the disease. The disturbance shows itself either in the enamel not forming at all or in the forming an uneven humped-up layer of enamel differing in thickness and of diminished resistance, in place of the smooth symmetrical layer. At the affected part, the tooth becomes rough and brittle and in particular situations the enamel is wanting and the dentin lies exposed. The lesion has the appearance of an erosion. The changes are not from a loss of substance but from a defective growth and development. At first, little by little, the places of diminished resistance through chewing become worn away and then there appears a true erosion. This wearing away does not take place if the defect is on the crown nearer the gingival border of the tooth where most of the parallel ridges and depressions can persist during life.

The most frequently seen, best known, and the



first described of these imperfectly developed teeth where the so-called *Hutchinson teeth* (Figs. 27, 52, 53, 54 and 56) in which the defect is seen at the morsal margin of the two upper central incisors ("the test teeth"). Usually the teeth are narrower at the gingival and morsal margins of the crown and are thus oval in shape, or they gradually narrow from the gingival to morsal margin and are peg-shaped. The middle of the facial surface of the crown is often arched forward and the lower end of the tooth gradually runs to a sharp point. This deformity is best seen from the side.

The length and the intensity of the injury determines the defect. It can be indicated by only a small rough spot on the morsal margin of the tooth or by a small notch which may also extend to the middle of the tooth. In marked cases it is seen as a crescentic shaped cut-out portion of the morsal margin which by the wearing away of the tooth becomes gradually deeper. The surface of the cut-out portion is uneven (humped up) and of a brownish-yellow color differing markedly from the normal enamel of the rest of the tooth. The pointed corners of the incisors being gradually worn away disappear, leaving only short incisor teeth; so that typical *Hutchinson teeth* have usually disappeared in middle aged syphilitic subjects.

If the damaging process to the two upper central incisors extends over a long period, then, as a rule, the upper lateral incisors and all the lower incisors are affected and the morsal edges of the canines also show a rough surface. In such a case not only is there an hypoplasia of the morsal edge of the incisors as indicated by the crescent-shaped notches, but the hypoplasia may even involve one-quarter to one-third (Figs. 58 and 62) of that part of the tooth nearer the gingival margin. The original *Hutchinson teeth* are caused by syphilis in the first weeks or months after birth, i.e., at the period when the heredosyphilis is



at its worst in extrauterine life, and when it most often runs a lethal course.

That more frequent but less known form of hypoplasia of the morsal surface of the first molar dates from the last months of intrauterine life (Figs. 53, 56, 57, 60, 61 and 62). The morsal end of the crown is atrophied, the morsal surface has an irregular rough surface with spicules and craterlike elevations and in place of the smooth white surface, an amorphous dirty grayish-yellow mass is seen. The extent of the degeneration is determined by the duration and time of the inception of the disturbance. It may be confined to the extreme ends of the cusps so that they appear as if they were worn away by sand, or it can attack one-quarter to one-third of the crown. This part of the crown with its diminished diameters rests upon the normal stumplike part of the tooth (Figs. 60 and 61) as a kind of atrophied and irregularly shaped tooth. These defective morsal surfaces have only a limited existence. They wear away and a yellow or brownish-yellow depression takes the place of the protuberance, which is surrounded by a white border of dentin. It is quite striking how this anomaly always involves the four first molars in the same way and at the same time.

These eroded areas naturally form a favorable ground for caries of the tooth, and thus it is that these four teeth either at once undergo caries or go entirely to pieces, while the rest of the teeth are in good condition; or on one or more of the first molars there is degeneration of the morsal surfaces and on the remaining caries (always a central caries involving that part of the tooth immediately underlying the eroded portion). The first molar teeth have an especial predilection for caries; their early calcification appears less resistant to caries than the rest of the permanent teeth. The symmetrical central caries of the four first molars is a very suspicious sign, and the



hypoplasia of the morsal surfaces of these teeth is distinctly pathognomonic.

Of 48 cases where these lesions were seen, 16 were without doubt heredosyphilitics; 18 were very suspicious, as the patients had either *Hutchinson's* teeth, or syphilitic parents or heredosyphilitic brothers or sisters. In 6 cases syphilis could not be excluded entirely and only in 8 cases was there no absolute proof of heredosyphilis.

An hypoplasia similar to that on the first molars is occasionally seen on other teeth, viz.: on the lower incisors where sometimes the atrophied pointed end resembling a clove is implanted upon the base of the crown (Fig. 59).

In how far the numerous other irregularities in shape and position of the teeth (sharklike teeth, abnormally formed, twisted teeth, obliquely placed teeth, asymmetrical teeth, microdentism, the absence of a single tooth or groups of teeth, the persistence of the deciduous teeth) can be connected with syphilis is doubtful. Yet, it is striking how these deformities appear synchronously with the other signs of heredosyphilis and especially with true syphilitic teeth.

As already mentioned the hypoplastic defects of the teeth arising at a later period in the course of heredosyphilis appear in a form which cannot be distinguished, without further studying the cause, from that produced by rickets. Teeth with pits, depressions, holes, parallel furrows crossing the crown and irregularly formed crowns may be caused by rachitis. But rickets is not to be regarded as the only cause, especially if accompanying changes appear, such as hypoplasia of the morsal surface of the first molars which must have begun shortly before birth.

What has been said of changes in the teeth occasioned by heredosyphilis refers to the permanent teeth. Very rarely are such disturbances seen in the deciduous teeth. Disturbances of calcification of the



deciduous teeth in heredosyphilis are not often observed.

Hypoplasia of the deciduous teeth is not to be distinguished from that of the permanent teeth, the crescentic notches being seen most often upon the incisor teeth.



## Diseases Similar to the Lesions of Secondary Syphilis of the Mouth

Traumatic changes in the mucous membrane of the mouth resembling syphilis can be produced in many ways, viz.: by mechanical injury, or corrosive substances and burning, and appear as if the mucous membrane had been painted with a weak solution of silver nitrate and thus give somewhat the picture of mucous patches of the mouth. Among all the forms of mechanical injury to which the mouth is subjected biting is the most frequent, and ulcers may be caused by the sharp borders of carious or fractured teeth. There is sometimes found on the mucous membrane of the cheeks quite a dense chronic infiltration with a grayish-white cicatricial surface, which may ulcerate. Faulty articulation by oft-repeated biting of this surface causes and maintains this condition. Such a lesion is especially difficult to diagnose from a mucous patch, since the syphilitic process has a predilection for this locality. In such cases repeated observations and all adjunct diagnostic means are necessary for a diagnosis.

*Injuries to the Frenum Linguae* are frequently seen in children soon after the eruption of the lower incisor teeth and especially in those who are suffering from whooping-cough. In this disease the tongue is more or less protruded on account of the coughing and choking, and the ulcers found on its under surface are continually irritated and kept open by the sharp teeth. These sublingual ulcers, on account of their persisting, refractory character, may be mistaken for syphilis.



The apparent cause of these ulcers and the absence of any other suspicious syphilitic lesion on the body excludes a diagnosis of syphilis, even if the diagnosis of syphilis is made by the father himself who was formerly syphilitic.

*The Ulcers of the Palate—the So-Called "Bednar's Aphthæ"*—of the nursing child are probably caused by the sucking of rubber nipples or the excessive cleaning of the mouth. These ulcers might be syphilitic. But their characteristic localization upon the raphé of the hard palate and the absence of other signs of syphilis makes such a diagnosis improbable.

Although the clinical manifestations of *Stomatitis Mercurialis* (*Mercurial Stomatitis*) are generally very characteristic, yet it is occasionally very difficult to diagnose it from syphilis. The reason for this is that papules and ulcerations caused by the mercury may appear in the mouth, and mercurial intoxication occurs almost exclusively in those who have taken mercurial treatment, i.e., in syphilitic subjects. If the syphilitic attempts to treat himself, and there are apparent indications justifying the treatment, the mercurial ulcerations may be mistaken for stubborn syphilides which are kept up by the continued mercurial treatment.

The typical mercurial stomatitis (Figs. 30 and 31) with its diffuse redness and swelling of the mucous membrane, the profuse salivation, the ulcerations covered with pus upon the gums, the swelling of the tongue, the deep often sloughing ulcers made by indentations of the teeth upon the edges of the tongue and the mucous membrane of the cheeks, together with the abominable fœtor, is not easily mistaken or forgotten. But if the lesions occur only in one or more spots determined by trauma, it is not easy to decide whether we are dealing with syphilitic ulcerations or a localized mercurial stomatitis. Such spots are most often seen either in the angle of the mandible, where the mucous membrane of the cheek oppo-



site the last molars is pinched and bruised, or on the gum over a partially erupted wisdom tooth. Both the mercurial and syphilitic ulcerations have a predilection for these localities and if there are no especially distinguishing features to support the diagnosis, it cannot be made. Mercurial poisoning may lead to extensive ulcerations in the region of the tonsils and lower part of the soft palate. The ulcerations are covered with a white necrotic membrane and cannot be distinguished from diphtheria, especially if there is only a single spot and the other manifestations of mercurial poisoning are absent or very slight (Fig. 32).

The other toxic causes of lesions in the mouth which may resemble syphilis are all such drugs which can occasion upon the skin the so-called *Medicamentous Eruptions*. Medicamentous eruptions of the mucous membrane of the mouth are much less frequent and more insignificant than those of the skin.

*Potassium iodide* and other alkaline iodides almost always cause the formation of more or less pronounced pustules in the skin. A light, diffuse catarrhal reddening is seen accompanying the iodic coryza.

With the administration of *balsamics* no oral manifestations are observed.

The use of *phenacetin*, *antipyrin* and *antipyrin-containing drugs*, e.g., pyramidon, migranin, salipyrin, etc. (Fig. 33) causes an eruption of the oral mucous membrane which may be not unlike that of syphilis. It is not unlike that of erysipelas. It is not difficult to diagnose the erythema occasioned by any of these drugs. Sometimes protracted circumscribed infiltrates arise and the upper layers of the epithelium, especially of the tongue and cheeks, desquamate in spots, thus occasioning an error in diagnosis. The medicamentous exanthem often occurs upon the genitalia so that the genital affection appears to confirm the diagnosis of syphilis of the mouth. However, the



sudden appearance of the mouth lesion, as a rule, synchronous with the eruption upon the other parts of the body, together with the history of the case permits of an exclusion of the diagnosis of syphilis.

The participation of the mucous membrane of the mouth in acute infectious diseases, *Scarlatina*, *Measles*, *Varicella*, etc., will at least give some slight occasion for confusing lesions of these diseases which may appear in this locality with those of syphilis.

A single efflorescence of the mucous membrane, e.g., in varicella, and the scarlatina angina may occasionally resemble a syphilitic erosion or mucous patch. The entire picture and course of these diseases do not permit of confusion. There are some lesions of the mucous membrane of the mouth which occur as part manifestations of *Chronic* or *Acute Skin Diseases* and may be very difficult to diagnose as they may be confined entirely to the mouth.

*Eczema* and *Psoriasis* do not involve the mucous membranes.

*Lichen Ruber Planus* (Fig. 34) occurs comparatively often in the mucous membrane of the mouth, and its efflorescence is like that of the skin. There are many miliary flattened, often umbilicated, grayish papules of a horny character, which do not undergo pustular transformation, with no inflammatory border. In protracted cases the papules may coalesce forming patches which may be of a ring or arched shape; they may even resemble a mosaic. Their seat of predilection is the mucous membrane at the middle of the cheek, the lips and tongue. So long as it is evident that the patches are made up of papules or that a single typical isolated papule can be seen at the periphery of the patch the diagnosis is not difficult. The appearance of lichen ruber on the skin at the time of its occurrence in the mouth will also indicate the nature of the disease. If the lichen ruber appears on the mucous membrane of the mouth alone in the form of large gray patches, as they may be seen upon



the tongue; or possibly as an atypical single manifestation upon the glans penis; it is extremely difficult for even an experienced observer to make a differential diagnosis. The diagnosis is further complicated by the slow development of the disease, its chronic course and the absence of any considerable subjective symptom. This disease, which undergoes less and slower changes than syphilis, should be carefully studied. It never attacks the mucous membrane of the soft palate or tonsils and does not react to either local or general antisyphilitic treatment. The result of the *Wassermann* reaction is not decisive. The presence of the *treponema pallidum* in the lesions is conclusive.

*Pemphigus* occasionally attacks the mouth. The entire mucous membrane becomes covered with bullæ. Some of the bullæ may rupture, forming easily bleeding excoriations bordered by epithelial débris and covered with a fibrinous membrane. Some bullæ may subside without rupturing. The suddenly occurring and quickly healing excoriations scarcely ever appear confined to the mouth but form, as a rule, a part of the manifestation of a severe general pemphigus and therefore the disease is not likely to be confused with syphilis. The involvement of the mucous membrane of the mouth in pemphigus is an unfavorable prognostic symptom.

In *Dermatitis Herpetiformis* the mucous membrane of the mouth is often attacked in a similar manner.

The mucous membrane of the mouth may be affected by *Erythema Multiforme Exsudativum* (Fig. 35). (*Idiopathic Polymorphous Erythema*.) This first appears as an erythema, which is followed by the formation of bullæ. These bullæ develop more slowly, are not so superficial, and do not rupture so easily as those of pemphigus, and often contain blood, which can coagulate. Sometimes they lead to lesions covered with layers of adherent yellowish fibrin which



on removal cause bleeding of the eroded membrane. The clinical appearance of erythema multiforme exsudativum distinguishes itself in many details from the syphilitic affections of the mouth. When the disease is fully developed the lesions are characteristic; while in the beginning and decline it lacks individuality and can be easily mistaken. The presence of similar spots, at the same time, on other parts of the body facilitates diagnosis. Still the erythema exsudativum also occurs isolated upon different places of the mucous membrane of the mouth.

*Purpura Hæmorrhagica* of the mouth might possibly resemble syphilis. The hemorrhages into the mucous membrane, however, are easy to recognize as such. They appear by predilection on the gums, when on the hard or soft palate they develop into bluish-red, mostly serrated, sharply marked off spots. Their sudden non-protruding appearance in the mucous membrane and gradual resorption with the well-known changes in color characterize them as hemorrhages into the mucous membrane.

*Herpes Facialis* (Fig. 36) is usually found on the lips. From here it extends to the mouth or it may attack the mouth alone. The flat ulcers resemble mucous patches of the mouth. Their formation from groups of vesicles and the polycyclic form of the eruption precludes any doubt as to their being syphilitic.

In buccal *Herpes Zoster* the eruption is located in a definite nerve region and is accompanied by neuralgic pain and swelling of the adjoining lymph nodes.

The *Aphthous Ulcers* of the mouth in *Stomatitis Aphthosa* (*Stomatitis Maculo-Fibrinosa*, *Aphthous Stomatitis*) (Fig. 37) may be confused with syphilis and may also be a cause for alarm in patients who are suffering from latent syphilis. In most cases it is not difficult to make a differential diagnosis. The aphthous ulcer appears suddenly, either singly or in groups, as a superficial flat, hollowed out erosion.



The surrounding mucous membrane is red, inflamed and a little raised. The edge of the erosion is sharp, sometimes it is marked off by a very narrow bright red border. The patch is covered with a bright yellow fibrinous membrane, which after 1 or 2 days as it loosens and detaches itself from the ulcer becomes grayish. The process runs its course in 4 or 5 days. The aphthous spots appear either alone or in groups, at the same time or in sequence, so that different stages can occasionally be observed in their development. They are usually situated on the mucous membrane of the lips, cheeks, gums and frenum linguæ. The single patches have a definite size when they appear, which is maintained until they disappear. They have but little tendency to peripheral growth, but neighboring spots may undergo confluence in the form of a figure 8. Pain, which is a very characteristic symptom of this disease, especially if the lesions are extensive, makes the eating of solid food impossible. This is a most important symptom in distinguishing these aphthous patches from syphilitic mucous patches. The latter, however, do not appear so suddenly; are grayish-white; not so highly colored, have less signs of inflammation, run a chronic course; and have a tendency to peripheral growth. There are cases where the differential diagnosis of an aphthous ulcer from a mucous patch solely by the clinical signs is simply impossible, and there are also cases where aphthous ulcers appear in subjects with latent syphilis. In any of such cases the finding of the treponema pallidum in the lesion determines the diagnosis.

The lesions of *Thrush* (*Parasitic-Mycotic Stomatitis*), which usually appear in nursing children, are not easily confused with syphilis. The irregular white membranes in the form of dots, stripes, or several of these connected together and growing and extending rapidly over a congested mucous membrane cannot be mistaken. The presence of the *oïdum albicans* in the



lesions, which is not difficult to find, confirms the diagnosis. It is comparatively seldom that a form of *Angina Follicularis* (Fig. 38) (*Follicular Tonsillitis*) suggests syphilis, as the fever, acute inflammation, congestion, swelling and the localization of "plugs" in the openings of the follicles are distinguishing features. It has been stated that there are cases in which the syphilitic mucous patches can localize about the follicular openings, the syphilitic angina taking a course similar to that of the follicular angina. The follicular stage of the syphilitic angina passes quickly, the mucous patches run together, appear in other places or extend and involve even the arch of the palate. The two pictures are very different. But, it must not be forgotten that occasionally both forms of angina appear at the same time (Fig. 39).

Under some conditions it is difficult to make a differential diagnosis between a syphilitic angina and a mild case of *diphtheria* (Fig. 40). The differences are marked in pronounced cases. In diphtheria there is the acute onset, fever, active inflammatory reaction, the white rapidly extending false membrane, the great pain and difficulty in swallowing, etc. In the syphilitic angina the course is chronic, there is slight inflammatory reaction and the gray false membrane either does not extend or does so but slowly. But there are cases where a severe papular syphilitic angina resembles a moderate diphtheria. A mild syphilitic angina can appear diphtheroid if the false membrane is particularly white, and if fever and severe general symptoms are present. Sometimes a true case of diphtheria occurs without especially high fever or noticeable subjective disturbances. In all such cases a false diagnosis may be made if we rely on the clinical picture alone. [The presence of the *Klebs-Löffler* bacillus in the lesion determines the diagnosis in these obscure cases.—Tr.] It has been stated above, that a mercurial stomatitis can occasionally resemble a diphtheritic or syphilitic angina.



*Stomatitis Ulcerosa* or *Stomacace* (*Ulcerative Stomatitis*), appears mostly in enfeebled individuals, especially children who have been debilitated by some such disease as measles or typhoid fever, etc. Sometimes it is epidemic. The clinical picture closely resembles that of mercurial stomatitis.

Generally the process in ulcerative stomatitis is less diffuse than in mercurial stomatitis. The gums are less and the mucous membrane of the cheeks more often involved. Severe pain accompanies a marked swelling and redness of the mucous membrane. The latter quickly changing to a bluish color. Flat bullæ are formed which rupture after a short time forming ulcers with a dirty grayish yellowish necrotic membrane, which goes to pieces and produces a most offensive odor. The ulcers may form without passing through the bullous stage. The ulcers extend not only superficially but deeply. The lymph ganglia are swollen, painfully inflamed and may suppurate. Fever is present and the patients are quickly debilitated not because they are unable to take food on account of the pain it occasions, but on account of a septic pneumonia or general sepsis which may take a lethal course.

From the ulcerated stomatitis on the mucous membrane of the cheek there can develop a fulminating gangrene of the cheek, the so-called *Noma* (*Cancrum Oris*, *Gangrenous Stomatitis*). It is not known whether ulcerated stomatitis has a determined etiology. The bacteriological side of this question is not clear. The numerous spirochætæ found in ulcerated stomatitis have not been differentiated from those frequently found in the healthy mouth, e.g., the spirochæta buccalis, etc.

*Plaut* and *Vincent* described an angina appearing sometimes in a diphtheroid and oftentimes in an ulcerated form. Large spirochætæ and fusiform bacilli were constantly found in these lesions (Fig. 72). The synchronous appearance of lesion and microor-



ganisms is regarded as characteristic of the *Plaut-Vincent Angina*. While the severe ulcerative stomatitis can scarcely be confused with any form of syphilis, the mild and sometimes very chronic course of the *Plaut-Vincent* angina can resemble an ulcerated syphilitic process and make the differential diagnosis extremely difficult.

The finding of the *treponema pallidum* in the lesion will render the decision for syphilis. On the other hand, the presence of coarse thick spirochætæ associated with fusiform bacilli has no great diagnostic worth in favor of the *Plaut-Vincent* angina, as such a finding can occur in ulcerated syphilis of the mouth.

The *Plaut-Vincent* disease and allied conditions, such as an ulcerative angina may resemble a chancre of the tonsil. The fact that it runs a slow course, gives relatively little trouble, and causes an involvement of the sub-maxillary lymph nodes may make the diagnosis difficult (Fig. 41).

There may appear in the mouth persistent ulcerative processes resulting from *Trauma* which not only in their clinical picture but also in their course very closely resemble syphilitic ulcerations. They must be studied closely for some time before a diagnosis can be made (Fig. 42).

It is easy to distinguish from syphilis the severe inflammatory diseases of the mouth such as the *Foot and Mouth Disease* in man and *Those Stomatites the Causal Agent of Which is Unknown*, because, like the ulcerative stomatitis, they are very active and take a rapid course.

The colonization of *Fungi* and the *Leptothrix Buccalis* can produce an extremely stubborn form of angina, which on account of its chronicity and slight inflammatory reaction may very well be taken for syphilis. The masses of fungi are situated like plugs in the openings of the follicles of the tonsils.

After the plugs have persisted for some time



they become hard owing to the presence of substances other than the fungi, viz.: epithelial débris and calcareous matter and may project more than a millimetre from the orifices of the follicles (Fig. 43). The microscope will easily prove the presence of the fungus.

*Lingua Geographica* (*The Geographical Tongue*) (Fig. 44). The nature and cause of this very peculiar condition of the mucous membrane of the tongue is not clear. The tongue itself may not be changed at all. In most cases it is however a little thicker and shows the imprint of the teeth on its edges. Many folds and furrows, the latter more or less deep, traverse the surface of the tongue which gives it a flattened form or at the edges a pulled out and fringed appearance (*Lingua plicata*).

The most important and characteristic symptom is a peculiar thickening of the epithelium. These thickened epithelial spots as they spread assume ring and bow-shaped forms which have a more or less bright red, sometimes remarkably smooth centre (Fig. 45). The bow-shaped forms are raised a little above the normal mucous membrane, have a gray or yellowish-gray color and are often covered with epithelial débris, which loosely adheres to the mucous membrane. The uninvolved part of the mucous membrane of the tongue can have a perfectly normal appearance, although it is usually slightly coated and the filiform papillæ are especially well developed.

Rapid change is particularly characteristic of this condition. The configuration of the tongue can change from day to day. Sometimes the rings grow, sometimes they disappear entirely, leaving an apparently normal mucous membrane. But the aspect of the tongue is never normal, on some part of its mucous membrane new points and rings are reappearing. It is not known what these changes are or what causes them.

Not even a rapidly developing herpes tonsurans



or an annular syphilide—at best only pemphigoid and erythematous lesions—can pass through such and so many changes in a few days as are to be seen upon the geographical tongue. Therefore the geographical tongue is sometimes designated "*Annulus migrans*" or "*Wandering Rash*." The condition exists at birth and lasts during life. Sometimes it shows itself but slightly, at others it appears in its severest form. It usually gives no trouble and there are many who have no presentiment of the condition of their tongue. Some are sensitive to mechanical stimulation (cannot eat hard bread, nuts, etc.) and are inclined to develop glossitis, which however is transitory. The cause of the condition is unknown. It has been attributed to an exudative diathesis and has been looked upon as a manifestation of scrofula. Against these surmises we have the facts that, it has been seen immediately after birth and that it remains throughout life in spite of all kinds of therapy.

The geographical tongue is surely not syphilitic, but it resembles very much those changes which are caused by an annular syphilide of the mucous membrane and on superficial inspection may be easily mistaken for an annular syphilide. If there are discrete spots (about 5 mm. in diameter) or small bow-formed areas where the epithelium is thickened, the diagnosis becomes difficult and can only be made by repeated examinations and availing one's self of all accessory means [*Wassermann* reaction, dark-field-microscope, etc.—Tr.] of diagnosis. Syphilis and a geographical tongue can be present at the same time and with such an occurrence the difficulty of a differential diagnosis is obvious.

Although there is no doubt but that *Leukoplakia Buccalis* is not exclusively a syphilitic lesion, nevertheless there is also no doubt that syphilis in a great measure predetermines conditions for its occurrence, and that an especially high percentage of those who suffer from leukoplakia are syphilitic.



The predisposing factors are: chronic irritation of the mucous membrane of the mouth, especially smoking and chewing, excessive use of strong alcoholic drinks and highly seasoned foods, etc.

Leukoplakia buccalis (Fig. 46) is a chronic thickening and cornification of the epithelium of the mucous membrane. So that the mucous membrane is covered with a callous or rindlike membrane. Both leukoplakia buccalis and lingualis are sometimes called psoriasis buccalis and lingualis, which is incorrect, as psoriasis never attacks the mouth. Leukoplakia buccalis usually appears as several discrete light bluish-gray spots, which in time coalesce, forming larger spots, and in extreme cases the entire tongue is involved. The gums usually escape or are attacked last of all. The first spots which are very thin and soft, and permit the red color of the underlying mucous membrane to shine through, have a predilection for the dorsum of the tongue and the middle of the cheek. In the course of time they become firm and sometimes cornified.

If the spots grow they show in most cases a marked off surface or area with more or less deep furrows and even cracks. It is remarkable how little trouble is caused by a very extensive and also intensive leukoplakia. Before the patient is aware of its presence it can have extended considerably.

The course is distinctly chronic: very gradually and unnoticed very small spots of leukoplakia develop the larger discrete ones.

The process may stop at any time. Sometimes the disease consists of only small patches in the cheeks, but it usually extends to some extent. The extension and intensity of the process need not be in proportion. Small spots can gradually form very marked thickenings of the mucous membrane which are callous and cracked, while the conjoined lesions of the mucous membrane of the tongue and cheeks may consist



of only a soft gray translucent thickening of the epithelium.

It is not customary, even under the influence of therapeutic measures, for a leukoplakia spot to disappear. Leukoplakia has a special meaning in that it creates a certain local predisposition to carcinoma. Many cases of carcinoma of the tongue have been seen developing from a leukoplakia. This transit however from leukoplakia to carcinoma is not so frequent as generally believed. Cases of severe leukoplakia with crevices and ulcerations which have been under observation for a period of years have shown no signs of becoming carcinomatous. All harsh therapeutic measures are contraindicated.

The diagnosis of leukoplakia is easy in typical cases, but fresh spots can so resemble syphilitic mucous patches that it is impossible to diagnose them. Occasionally, in old syphilitic cases, there can appear on the border of the tongue isolated quite firm, sometimes cornified gray leukoplakialike plaques which can be extremely stubborn to treatment. The *treponema pallidum* should be looked for in the lesion and a *Wassermann* reaction or luetin test, preferably both, should be made. If all are negative then a diagnosis by palliative therapeutics must be resorted to.

Lichen ruber planus may at the first glance resemble leukoplakia, but by a careful examination one will never miss seeing the little primary nodules and the fine reticular formation.



## Diseases Similar to the Lesions of Tertiary Syphilis of the Mouth

The destructive and grave alterations occasioned by tertiary syphilis are exceedingly characteristic. Tuberculosis and carcinoma may appear in a form which very closely resembles syphilis, thus making a differential diagnosis very difficult. *Tuberculosis* of the mouth can appear in very many forms. It is almost always possible to observe either the insignificant isolated spots or severe extensive processes developing from the characteristic initial tubercular lesion.

In the mouth there is a single tubercle or a number of them may appear at the same time. The tubercle grows more or less slowly, disintegrates, undergoing coagulation necrosis, ulcerates and discharges a little caseous pus.

The differential diagnosis must at times be made between lupus and other tubercular processes not only of the skin but of the mucous membrane of the mouth. The difference between lupus and other tubercular processes in the mouth is not marked. A characteristic skin lupus, occurring in conjunction with a suspected lupus of the mouth, will assist in diagnosing the latter. In the mucous membrane the lupus nodules are not so characteristic as in the skin. They have not the same color or consistence; the secondary peculiarities—desquamation and hyperkeratosis—are lacking; and the lupus nodules in the mucous membrane ulcerate much sooner.

The first lupus nodules or tubercles give no trouble, their appearance is scarcely noticed. Some-



times it is only by accident that they come to the physician's attention, when they are searched for in the mouth of a subject having lupus of the skin or mucous membrane of the nose.

The mildest and most primitive form in which tuberculosis is likely to occur in the mouth is the ulcerated miliary tubercle or tubercle granulum. Each ulcer develops in a tubercular infiltrate, which is so inconspicuous and produces so little disturbance that it may not be observed or is recognized only when the disintegration and formation of the ulcer begins.

The tubercular nature of even the smallest ulcers is at once determined by seeing them originating from the miliary tubercles. The form of the tubercular ulcer is irregular, with undermined edges and a finely granular uneven floor covered with yellow or greenish-yellow pus. The form of the ulcers changes according to their position and the anatomical structures beneath them. On the mucous membrane of the lips and cheeks their form is round or oval and they are more inclined to a superficial extension. Ulcers of the soft palate extend deeply into the tissues and those on the tongue are long, indented and cleftlike.

The tubercular tissue in which the ulcers lie, forms around them a sort of reddened wall which is slightly raised above the adjoining mucous membrane. These primary tubercles and ulcerations grow slowly but steadily, and if appropriate treatment does not stop them more tubercles and a diffuse tubercular inflammation (diffuse tubercle) develop in their neighborhood.

The tubercular process then extends either superficially, deeply or in both directions. The diffuse tubercle extending deeply into the tissue may form ulcers resembling those of a gumma or carcinoma or it may extend and form a superficial tuberculosis of the mucous membrane which corresponds more with the clinical picture of a tertiary papular syphilide (Fig. 47).



The so-called tubercular tissue is not always inclined to undergo disintegration. There may be a very extensive tubercular infiltration of the mucous membrane in which only small or large typical ulcers are seen.

The tubercular tissue on the mucous membrane of the palate can assume a very characteristic appearance, viz.: the dark bluish-red colored surface of the mucous membrane acquires a peculiar velvety condition which is due to the presence of a large number of exceedingly delicate miliary tubercles. Such a condition is liable to be mistaken for lupus (Fig. 48).

The bones are also attacked in tuberculosis as well as in syphilis, but the tubercular process contrary to the syphilitic starts from the surface and travels inward, so that the corresponding changes in the bones are superficial erosions which do not lead immediately to the formation of sequestra.

The tubercular ulcers of the mouth in progressive phthisis are especially grave. They correspond to those tubercular ulcerations which are found so often in the respiratory and intestinal tract of patients with phthisis and are characterized by their rapid development, great destruction and the very acute pain they occasion.

These ulcers, when on the tongue and lips, cause in a short time extensive defects, although there is little tubercular infiltration. The pus-covered floor and characteristic border clearly demonstrate their tubercular nature (Fig. 49).

Although pronounced peculiarities exist in tubercular lesions of the mouth, there are a number of cases of tuberculosis of this cavity which are very difficult to distinguish from syphilis; therefore, besides the simple clinical consideration of the lesion, all other allied conditions must be studied and recourse had to all available diagnostic measures. Tubercular processes, if they have undergone any extension, often have involved the neighboring lymph



nodes, while in secondary and tertiary syphilis the lymph nodes are never so affected. The never-failing adenitis follows the chancre usually within a week or two, i.e., at a time which plays no part in the tubercular process.

Generally the period within which the syphilitic and tubercular processes develop and act their part forms a remarkable distinction between the two often similar diseases. Alterations and destructions which take tuberculosis months or even years to bring about, can be accomplished by syphilis in a few weeks and even sometimes in a few days. Pain is often another differential characteristic. Small tubercular ulcers may be quite painful; whereas serious, extensive syphilitic ulcers will elicit only an insignificant local complaint. The result of therapeutic measures may enable us to make a diagnosis. The administration of potassium iodide or mercury usually has some favorable effect upon the syphilitic process, while tubercular processes are not usually influenced. If the diagnosis by *palliative medication* (*diagnosis ex juvantibus*) is at all doubtful, great caution should be exercised as it must be remembered that syphilis can be very refractory at times to treatment and that the administration of potassium iodide might occasion a transitory change in the appearance of tubercular processes.

The *diagnosis ex juvantibus* no longer plays the rôle it did and for this we are indebted to the *Wassermann* reaction and the detection by means of the microscope, especially the dark-field-microscope, of the *treponema pallidum*. Occasionally the *diagnosis ex juvantibus* is made in a doubtful affection, for example, a tumor of the tongue, which is not affected by antisyphilitic treatment, although the patient's serum gives a positive *Wassermann* reaction. A careful microscopic examination before prescribing antisyphilitic treatment might have determined the presence of the *treponema pallidum*, the tubercle



bacillus, or carcinoma cells in the lesion. In such a case we are dealing with a syphilitic individual and a non-syphilitic affection of the tongue, possibly a tuberculous or cancerous tumor of that organ.

[The *tuberculin reaction*, the *ophthalmic reaction* of *Calmette* and *Wolff-Eisner*, the *cuti-reaction* of *von Pirquet*, or the *intradermic reaction* of *Martoux* are of use in detecting tuberculosis. All these reactions indicate the presence of tuberculosis, not always its localization.—Tr.]

The general reaction with tuberculin indicates as little for a local tubercular process as the *Wassermann* does for a local syphilitic process. However, by comparing the positive result of the one with the negative result of the other, important diagnostic information may be obtained.

[In conjunction with the *Wassermann* reaction, the luetin cutaneous reaction, which is said to be most constant and severe in tertiary affections, may be used.—Tr.]

A local tuberculin reaction however indicates tuberculosis, but it is not always so distinct in the mucous membrane of the mouth, as elsewhere in the body [e.g., about the arytenoid cartilages in suspected tuberculosis of the larynx. The presence of the causal agent of the disease in the lesion is decisive.—Tr.]

It is difficult to find the tubercle bacillus in tubercular lesions of the mouth. The microscopic examination of and inoculation experiments with the material taken from tubercular ulcers (except those of phthisis), especially lupus, do not always prove the presence or absence of the tubercle bacilli as they may be very few and thus either escape observation or not being present in the material used for the inoculation experiments give a negative result. But in tubercular ulcers of phthisis tubercle bacilli are always easy to find. The presence of the *treponema pallidum* is proof positive of syphilis. The differential diagnosis



of syphilis and tuberculosis from the clinical signs alone is usually not difficult, and cases are rare where a biopsy or a microscopical examination are necessary.

The differential diagnosis between *carcinoma* and syphilis is sometimes of the greatest importance in order to ascertain whether or not an operation shall be undertaken to save the patient's life, or again to determine if the lesion may be removed in a short time by suitable general treatment instead of by a dangerous and mutilative operation. These two diseases have so many features in common that every diagnostic measure must be resorted to in order to differentiate them, and the diagnosis is made at times solely through a biopsy.

*Carcinoma* (Fig. 50) can at any stage resemble a syphilitic manifestation, and, like syphilis, shows a predilection for the lip, tongue, and tonsils. In the earliest stage it appears as an insignificant infiltrate, a small ulcer or little wart with nothing characteristic about it. It grows very slowly at first; for months it undergoes no appreciable change and causes no inconvenience. As it grows its surface becomes eroded, the epidermis desquamating completely, and a surrounding surface, resembling a rampart, which bleeds easily and has an edge as hard as cartilage, gradually rises above the surrounding tissues. The erosion becomes a penetrating ulcer, the infiltrate spreads in every direction, and the neighboring lymph nodes begin to be involved. The floor of the ulcer is covered with yellow, greenish or grayish yellow pus or with a dirty, bloody mass. Very often one perceives on the surface of the ulcer, especially the edges, small gray bodies, the epithelial pearls, which can be pressed from the tissue. Often, through extensive ulceration, the process loses its tumor characteristic. The degeneration is such a marked feature that at times there remains of the original neoplasm only a firm, slightly raised edge.



At other times the neoplastic tissue, instead of undergoing degenerative changes, tends to increase, and as a result large irregular tumors are formed, with a surface which bleeds easily, is uneven, granular, and covered with pus or sanious material. The sad, final picture of carcinoma is well known; the terrible destruction, the metastases, the cachexia and death.

The differential diagnosis of carcinoma and chancre is not easy; consequently, it is most important to avail one's self of all possible means of diagnosis. Carcinoma can resemble a *primary syphilitic* lesion not only in its initial stages, when there is only a slight infiltration, but also when it becomes eroded or indurated or even ulcerated.

The facts, that carcinoma is usually a disease occurring after middle life, that the chancre is usually contracted earlier in life, and that their predilection for localizing themselves is different, are not important points in diagnosis. However, it is well to remember that, on the lip, the usual situation of a chancre is at the centre, of carcinoma toward the side; that a chancre is rarely seen upon the base or under surface of the tongue, and that a chancre on the gums, cheeks or palate is less frequent than carcinoma.

The difference in the clinical picture and course of these two diseases is very important so long as the epidermis is intact; the character of the periphery of the lesion is especially noteworthy in diagnosis. The eroded surface of the chancre is flat, smooth, faintly shining, and exudes a clear serum, while the rough, uneven surface of the eroded carcinoma bleeds easily and pus exudes. In the event of ulceration the surface of the chancre is not so uneven, corroded and anfractuous as in carcinoma, and the bleeding and exudation of pus is less, but there is a greater exudate of serum. The ulcerated chancre never has a sanious exudate, which always appears early in carcinoma,



as evidenced by the bad taste in the mouth and the foetor. The primary lesion never extends, there is no limit to the extension of carcinoma. The epithelial pearls in the border of the tumor are pathognomonic of carcinoma. The pain, which is almost always absent, in even very extensive primary lesions, occurs in the earliest stages of carcinoma and is very severe. The course of the two diseases is very striking. The chancre grows quickly. It would take at least several months for a carcinoma to acquire the size, a small erosion does in two or three weeks. The adenopathy of the adjoining lymph ganglia occurs very early with the initial lesion; it takes but a few days to develop, and is never absent. A carcinoma can exist for a long time before any metastasis in the neighboring lymph nodes is noticed. Finally, the secondary manifestations of syphilis never fail with the primary lesion, although occasionally they may be very indistinct and thus overlooked.

The *Wassermann* reaction remains negative up to about the seventh week after the appearance of the chancre. It is usually easy to find the *treponema pallidum* in the exudate from the chancre, unless the chancre is ulcerated. In ulcerated chancres where there is an exudation of pus it is sometimes difficult to find the causal agent.

The lesions of secondary syphilis of the mouth, especially when they are ulcerated, can occasionally resemble carcinoma, but they develop faster and have not the characteristic firm base of the latter. The syphilitic lesions are multiple, the carcinoma always single. Other manifestations of syphilis accompanying the lesion under question help the diagnosis. Ulcerated lesions of malignant syphilis are seldom single, and the diagnosis is sometimes difficult, in that it is not easy to find the *treponema pallidum* in these lesions.

The *treponemata pallida* have been found in gummata, but as there are so few of them in these lesions



it is difficult to find them. This is especially unfortunate, as a number of diagnostic features which are present in the primary and secondary manifestations of syphilis are wanting in the gumma, therefore the differential diagnosis of gumma and carcinoma, which is most important, is sometimes very difficult. A study of the course of the two processes is helpful in making a differential diagnosis. The gumma can grow very fast, but may at times develop slowly. It, however, develops much more slowly than the chancre. An involvement of the neighboring lymph nodes is always absent with the gumma, but is always an early pathognomonic sign with the initial lesion. The gumma can extend and produce as much destruction as carcinoma, but here the absence of adenopathy with the gumma is a help in diagnosis. The serous exudate is absent on the eroded and ulcerated surfaces of the carcinoma and gumma. Where no secondary manifestations follow the suspected primary lesion the diagnosis of carcinoma is favored.

The gumma usually gives a positive *Wassermann* reaction, but there are tertiary processes where the reaction may be negative, and it is possible that a subject with latent syphilis giving a positive *Wassermann* reaction can also be afflicted with carcinoma. [*Noguchi's* luetin reaction can be used in conjunction with the *Wassermann* reaction in diagnosing tertiary syphilitic lesions.—Tr.] In cases where there seems to be danger in waiting even a week to determine the condition, a biopsy should be made to find out the nature of the disease.








PLATE I

**Figure 1.—Chancre of the Upper Lip  
(Chancrous Erosion)**

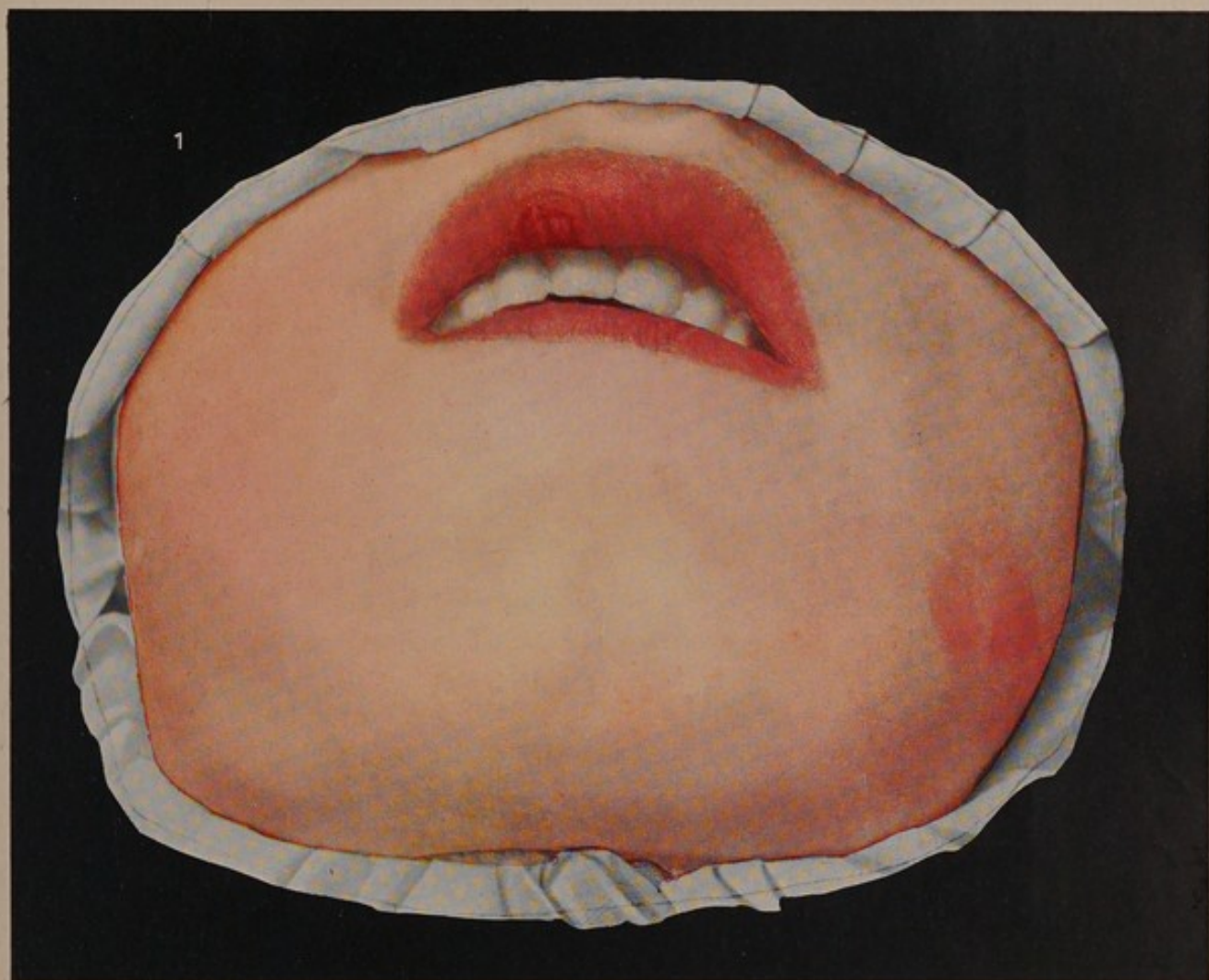


**Figure 1.—Chancre of the Upper Lip  
(Chancrous Erosion).**

On the right side of the upper lip there was an eroded spot about 1 cm in diameter. Its surface had a faint lustre, was darker than the surrounding normal mucous membrane, and upon pressure a clear serum exuded. The induration at the base of the erosion was of small extent and depth, and on palpation it felt almost as hard as cartilage. The right submaxillary ganglia were swollen, but not painful, and were movable under the skin. In the exudate from the chancre numerous *treponemata pallida* were found.

The patient, who was twenty years old, also had a syphilitic angina and a light roseola. The *Wassermann* reaction was positive.












PLATE II

**Figure 2.—Two Chancres of the Lower Lip**



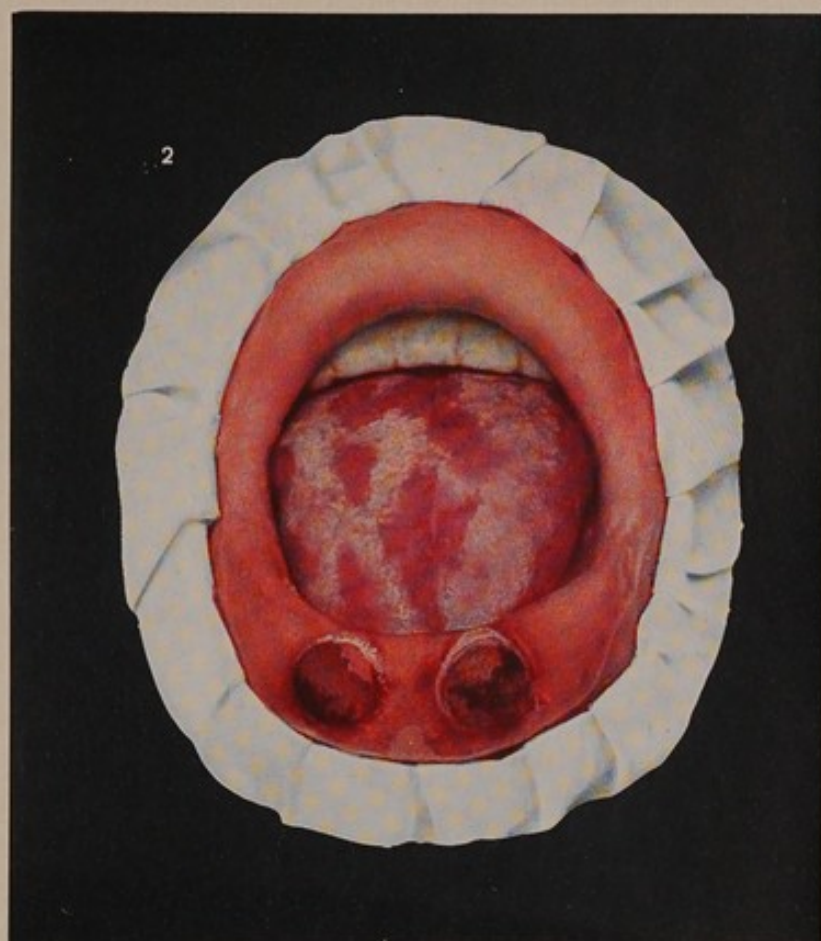
## **Figure 2.—Two Chancres of the Lower Lip**

On either side of the median line there was a round elevated, eroded, partly ulcerated chancre with an encrusted surface. When the crusts were detached a bloody serum exuded in which numerous *treponemata pallida* were found. Marked adenopathy of the submaxillary lymph nodes on each side. The tongue was coated and there were a number of elliptical, sometimes confluent spots—mucous patches of the tongue—with a smooth surface.

The patient, a young woman, having chapped lips was infected by a kiss during the carnival in Cologne. She also had a miliary syphilide, a syphilitic angina, general adenopathy, condylomata lata about the genitals, an impetigo capitis and psoriasis palmaris et plantaris.

*The Wassermann reaction was positive.*












PLATE III

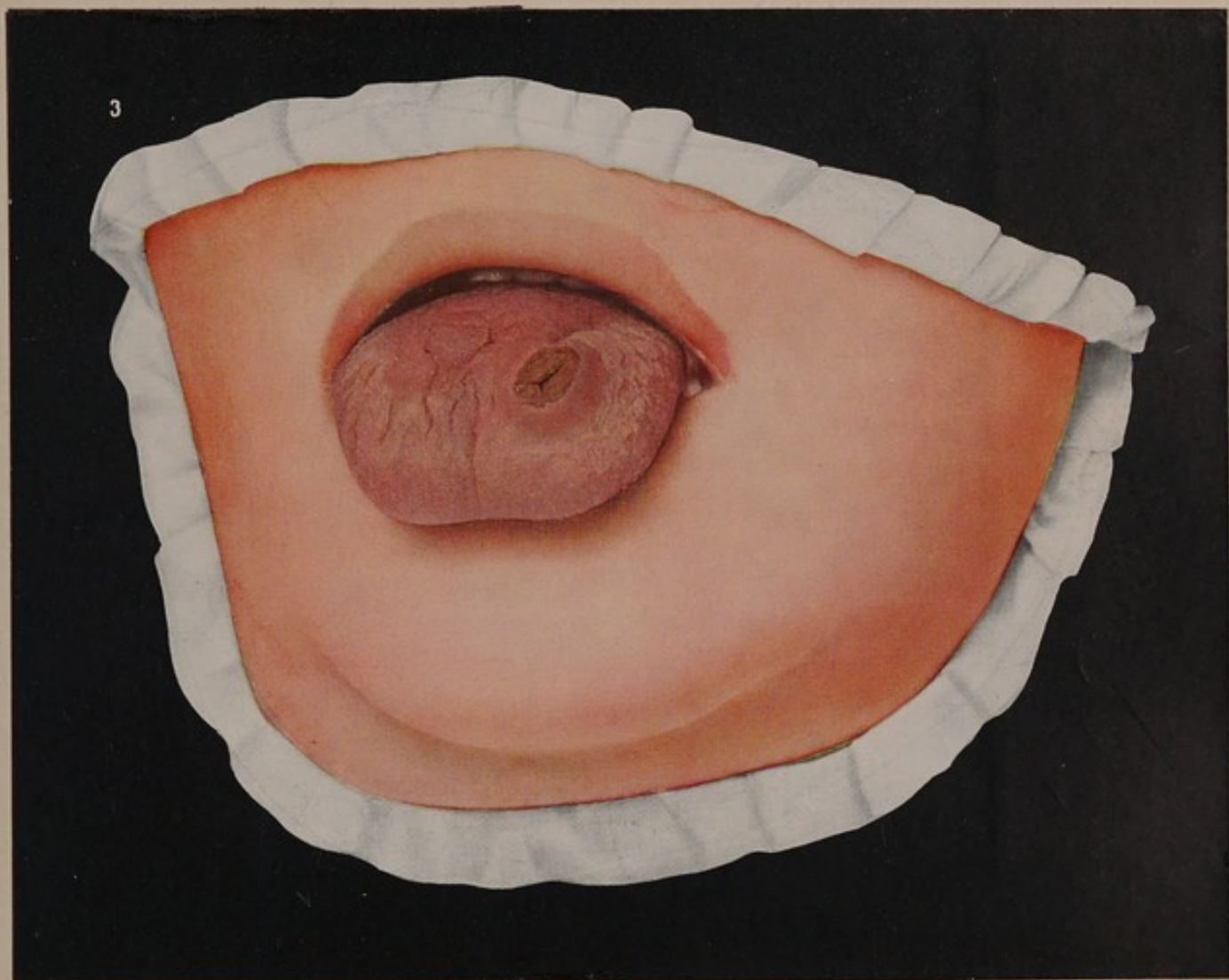
**Figure 3.—Chancre of the Tongue**



### Figure 3.—Chancre of the Tongue

On the left side of the tongue there was an elliptical tumor about 1.5 cm long and 1 cm wide, which involved the musculature. It felt firm and gradually merged with the surrounding normal tissue. Its brownish red surface was eroded and there was a furrow running through it. The surrounding tissue was not congested. The submaxillary lymph nodes on both sides were involved. On pressure serum exuded from the lesion, in which *treponemata pallida* were found. The patient did not know how he acquired the lesion, but stated he had sexual intercourse eight weeks previously. Besides a slight syphilitic angina there were no other signs of syphilis. The *Wassermann* reaction was positive.












PLATE IV

**Figure 4.—Syphilitic Erythema of the  
Mucous Membrane of the Mouth**



**Figure 4.—Syphilitic Erythema of the  
Mucous Membrane of the Mouth**

Red spots, with darker borders, somewhat annular in form, are seen on the mucous membrane of both sides of the upper lip. They are not eroded and are not characteristic of syphilis. They may correspond to the roseola on the skin, and are the mildest form of lesion involving the buccal mucous membrane in the secondary period of syphilis. The lesions pictured accompanied the secondary manifestations following a chancre on the finger and disappeared in a few days, after the disease had been treated by inunctions of mercury.



Plate IV. Fig. 4

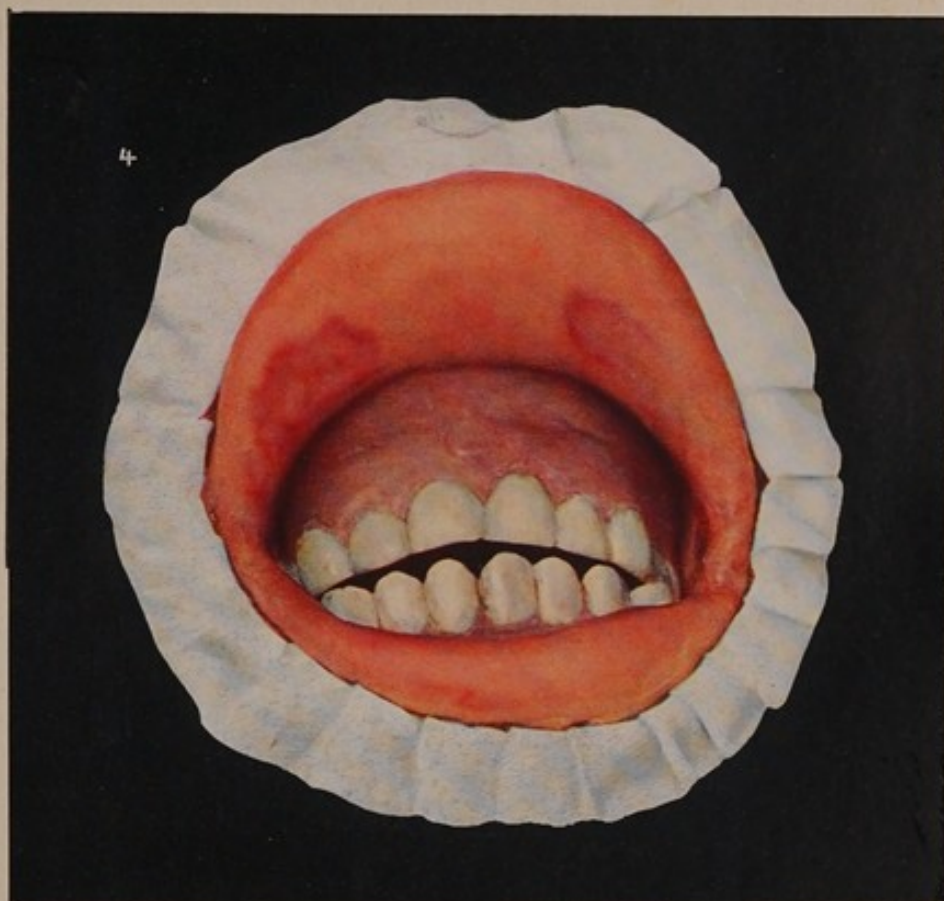








PLATE V

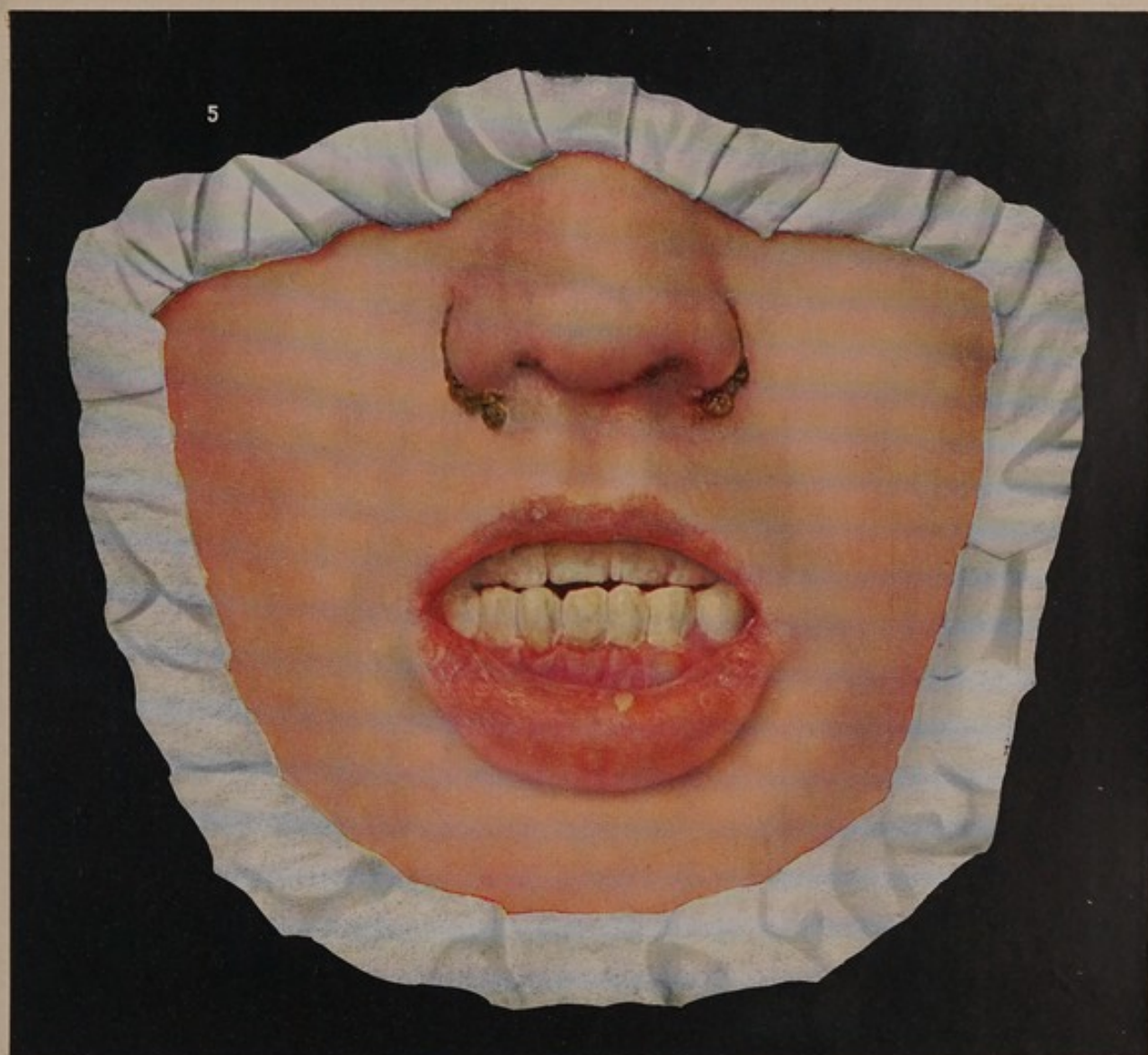
**Figure 5.—Erosive Mucous Patches of the  
Lower Lip and Condylomata Lata of the  
Naso-Labial Folds**

**Figure 5.—Erosive Mucous Patches of the  
Lower Lip and Condylomata Lata of the  
Naso-Labial Folds**

On the vermillion of the lower lip is a small red spot beginning to erode at the centre. Behind it, on the mucous membrane of the lip, is a small eroded papule covered with a layer of yellowish fibrin. Neither is absolutely characteristic of syphilis. The yellow erosion resembles greatly an aphthous ulcer of the mouth, but there is no pain or surrounding inflammatory reaction. The diagnosis of these papules (mucous patches), when they are the only manifestations in a relapsing syphilis, is most important, as the patient often does not know he has them. The *treponema pallidum* was easily found in them.

In this case, however, other manifestations showed themselves, e.g., condylomata lata in the naso-labial folds, which are well developed, ulcerated, and encrusted. A slight congestion and insignificant infiltration of the skin in this region is suspicious, but it is not to be forgotten that a similar infiltrate may occur with seborrhœa.










PLATE VI

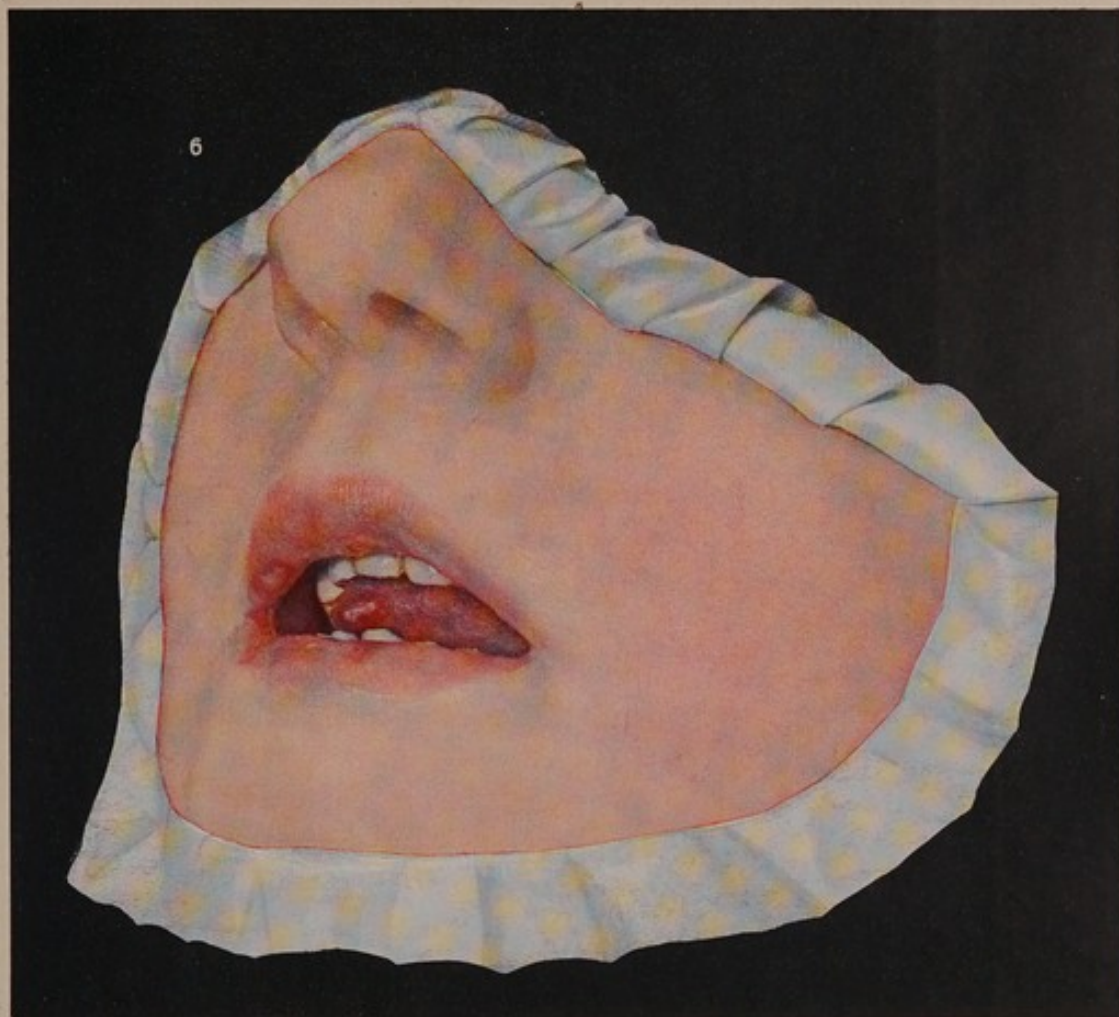
**Figure 6.—Erosive Mucous Patches of the  
Upper Lip and Tongue**

**Figure 6.—Erosive Mucous Patches of the  
Upper Lip and Tongue**

A slightly elevated eroded mucous patch was seen upon the right side of the upper lip and on the tip of the tongue. Accompanying them was a roseola, syphilitic angina, impetigo capitis, and condylomata lata about the genitals. Spirochætæ were found in them and the *Wassermann* reaction was positive.

Alone, these lesions are not characteristic of syphilis, and might be mistaken for a superficial burn, corrosion, or bite.










PLATE VII

**Figure 7.—Hypertrophied Mucous Patches  
of the Tongue and Lips**

**Figure 8.—Papulo-Ulcerated Syphilide of  
the Lips and Tongue (Ulcerated Mucous  
Patches)**

### **Figure 7.—Hypertrophied Mucous Patches of the Tongue and Lips**

On the mucous membrane of the tongue and lower lip are raised, irregular, bow-shaped, tumorlike, circumscribed mucous patches, and passing through them here and there are deep ulcerated furrows. Their surfaces are white or yellowish-gray and in some places there is a thickening of the epithelium.

These lesions were the only symptoms of syphilis which was contracted seven years previously and which had been insufficiently treated. Eating and speaking were but slightly affected.

During a little more than a year the lesions gradually developed into their present condition. The patient was sixty years old. Prompt improvement followed antisyphilitic treatment.

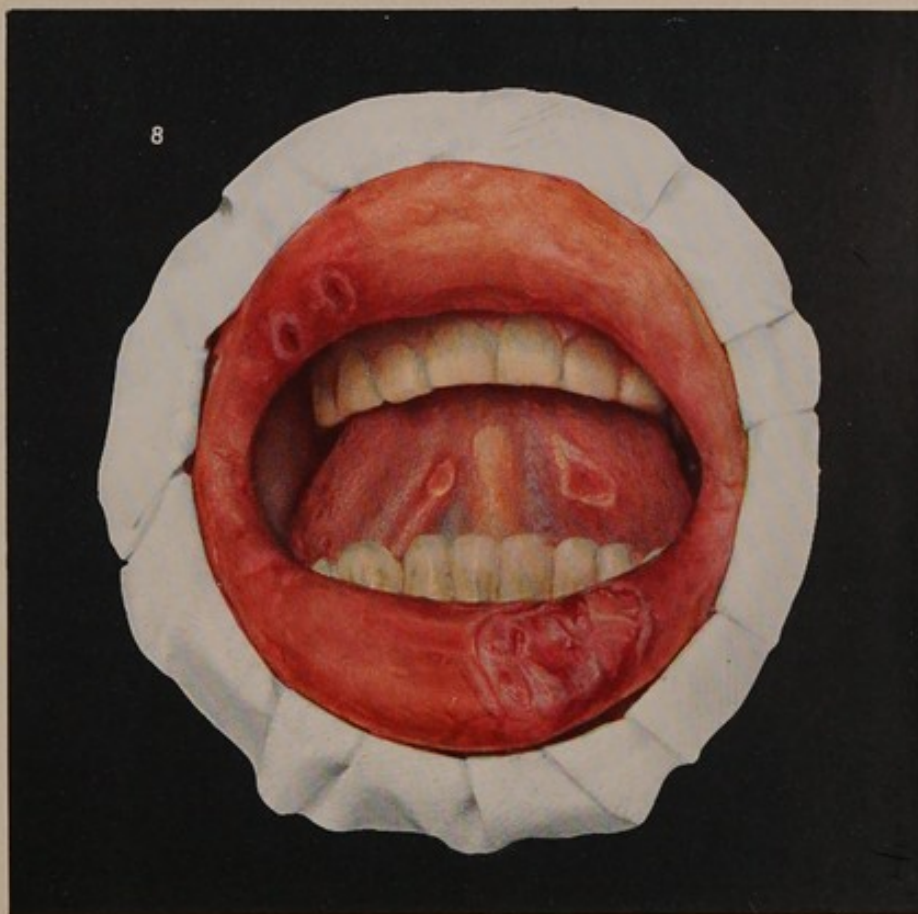
### **Figure 8.—Papulo-Ulcerated Syphilide of the Lips and Tongue (Ulcerated Mucous Patches)**

On the left side of the lower lip is an elliptical raised gray mucous patch, with bow-shaped ulcerated edges and on its surface are ulcerated furrows. On the upper lip are two ulcerated excoriations with a gray border. On either side of the frenum of the tongue is a flat elliptical ulceration with a yellowish-gray coating.

The patient, a waiter, twenty-eight years old, had syphilis for nine months. The only treatment received consisted of potassium iodide internally and local treatment of the lesions. There was also an indurated scar on his penis, general adenopathy and a syphilitic angina. The *Wassermann* reaction was positive.

Under inunctions and painting of the lesions with bichloride of mercury (2%) the manifestations disappeared.




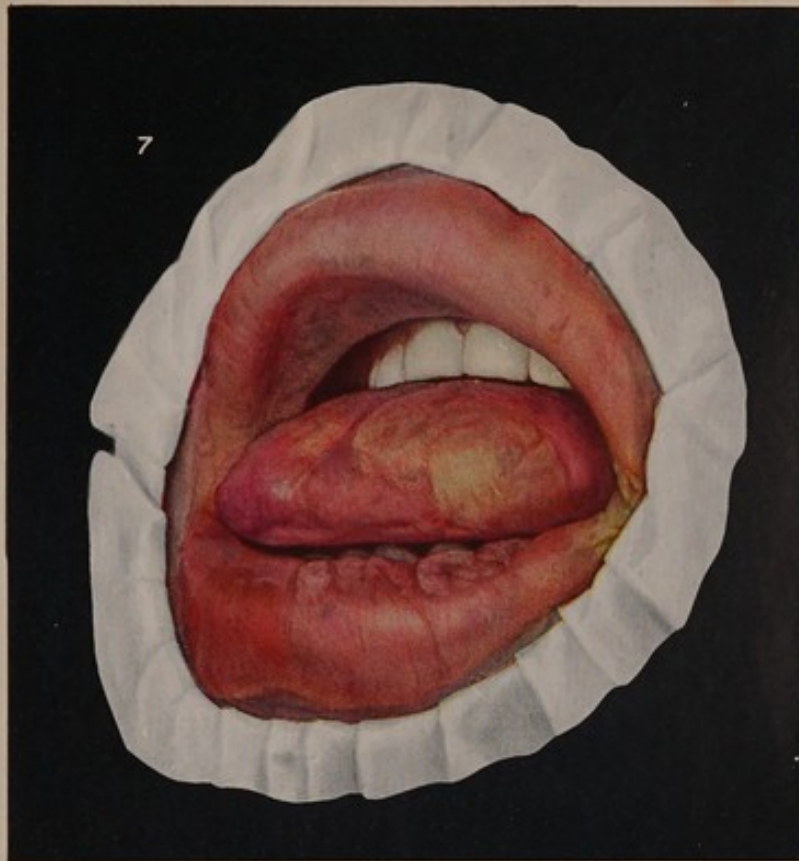





PLATE VIII

**Figure 9.—Ulcerated Syphilide of the Lips  
(Ulcerated Mucous Patches)**

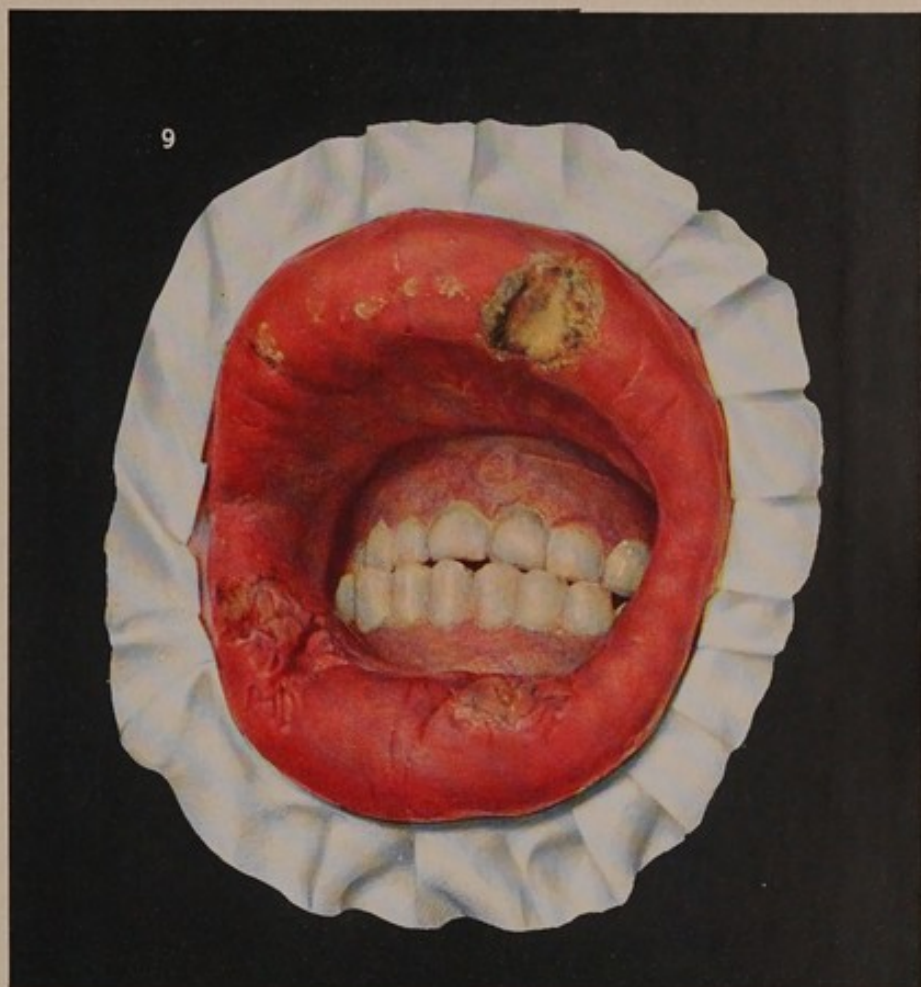
**Figure 9.—Ulcerated Syphilide of the Lips  
(Ulcerated Mucous Patches)**

The upper and lower lips are inflamed and swollen. On the actively congested mucous membrane are several ulcerations. On the left side of the upper lip is an ulcer with a concave floor covered with an adherent yellow coating and with dried somewhat hemorrhagic crusts on its border.

On the lower lip near the right angle of the mouth the mucous membrane is puffed up and covered with a slight grayish coating. Irregular, hollowed out and furrowlike ulcers cross it. The ulcers are painful. On the mucous membrane of the gums (above) there is seen a flat ring-shaped mucous patch.

The patient had syphilis for four years, which had been insufficiently and irregularly treated. The ulcers in the mouth existed about four weeks. They might possibly be mistaken for tuberculosis, but their short duration, their gray borders and the presence of a characteristic syphilitic angina indicated syphilis. The margins of these ulcers do not show the finely serrated or cutout borders which are to be observed in tubercular ulcerations. The tongue of this patient is shown in Fig. 13.










PLATE IX

**Figure 10.—An Ulcerated Annular Syphilide  
of the Lower Lip Resembling a Serpigi-  
nous Ulcer**

**Figure 10.—An Ulcerated Annular Syphilide  
of the Lower Lip Resembling a Serpigi-  
nous Ulcer**

On the vermillion of the lower lip is a ring-shaped ulcer, having a transverse diameter of about 2 to 3 cm. The ulcer is quite narrow, comparatively deep, with precipitous walls and its floor is covered with pus. In addition to this lesion there was a suspicious angina, a leukoderma colli and a positive *Wassermann* reaction. (The annular ulcer does not develop into a serpiginous ulcer by peripheral growth, as the centre is not made up of scar tissue, but it is thought that the border of a papular infiltrate has undergone ulceration.)



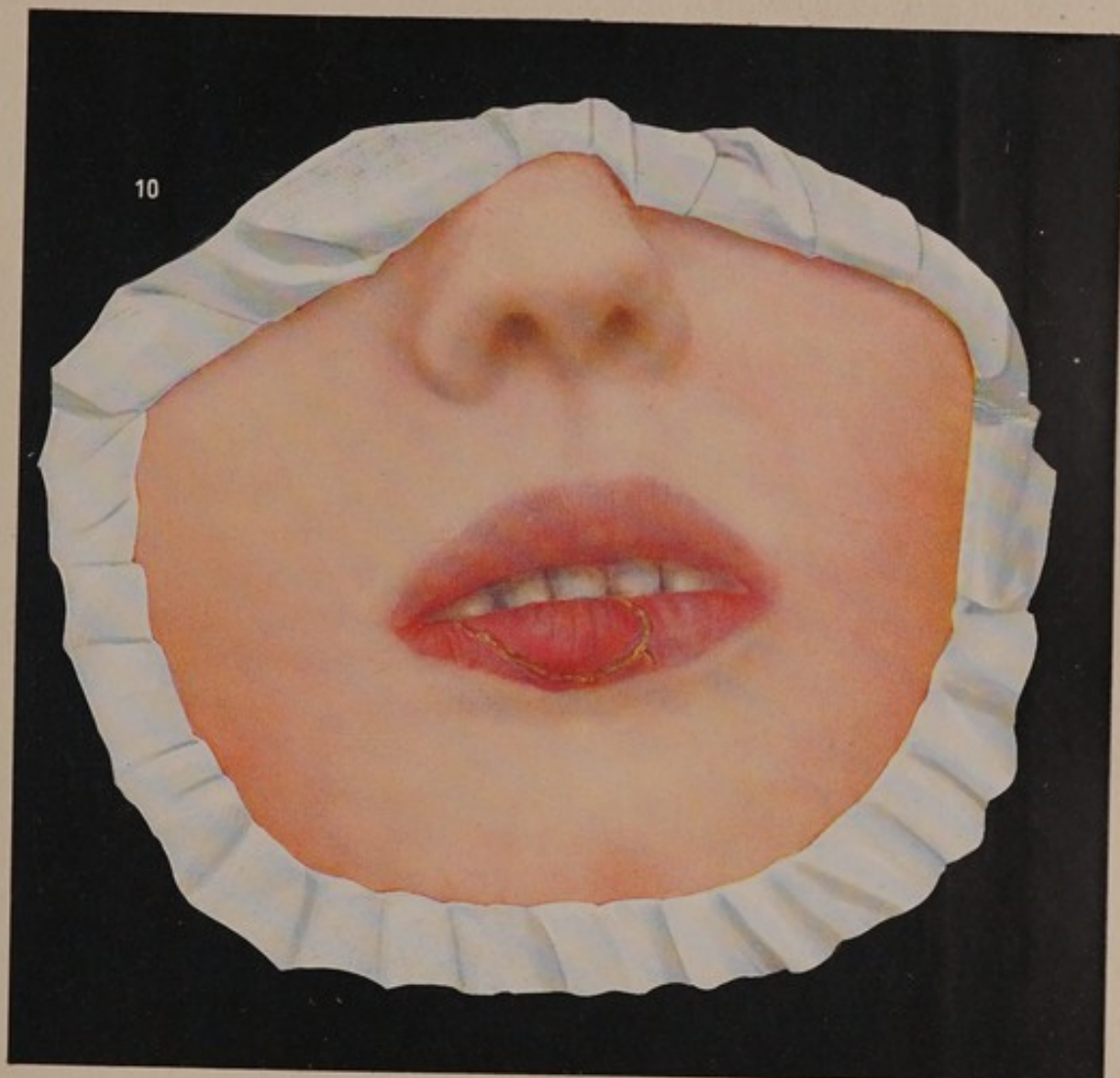






PLATE X

**Fig. 11.—Opaline Mucous Patches of the  
Tongue**

**Fig. 12.—Papulo-Ulcerated Syphilide of the  
Tongue**

### **Figure 11.—Opaline Mucous Patches of the Tongue**

To the right of the tip of the tongue is a slightly elevated mucous patch with a soft gray covering, as if it had been painted with a weak solution of silver nitrate. On the base of the tongue is a circular, raised, rampartlike mucous patch with a depression in its centre and surrounded by a shallow groove.

Syphilis had been contracted eight weeks previously. The genital chancre was still present, together with an ulcerated syphilide of the skin, a syphilitic angina, and an alopecia diffusa.

### **Figure 12.—Papulo-Ulcerated Syphilide of the Tongue**

This case shows a marked superficial and parenchymatous involvement of the tongue. The entire tongue is swollen and congested. The mucous membrane is smooth, excepting where the numerous irregular flat mucous patches and ulcers are situated. The ulcers are round, except on the tip of the tongue where they have run together and become shaped like the figure 8. The preexisting furrows of the tongue have become especially marked by the infiltration.

The patient, who was twenty-five years old, through deficient treatment, found himself in this condition after the disease had existed for one year. In addition to these lesions there was an extensive deeply ulcerated syphilide of the skin and a syphilitic angina.

Under *Zittman* and calomel injections the local manifestations of the disease and the general condition of the patient rapidly became better.



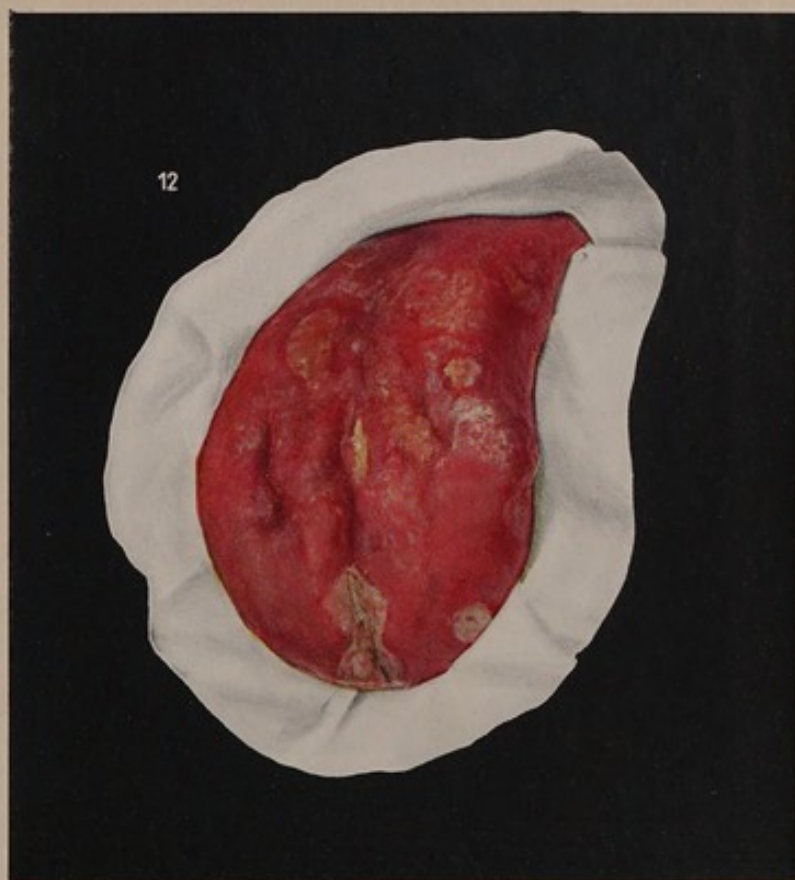
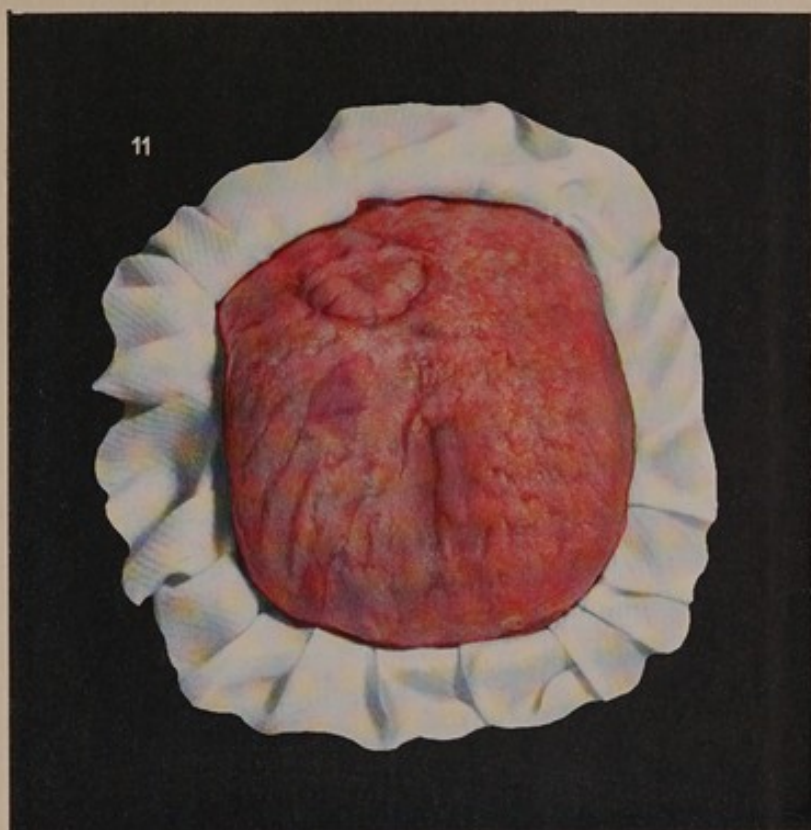







PLATE XI

**Fig. 13.—Glossitis Syphilitica (Syphilitic  
Glossitis)**

**Fig. 14.—Ulcerated Mucous Patches of  
the Tongue**





**Figure 13.—Glossitis Syphilitica (Syphilitic Glossitis)**

The entire tongue is infiltrated and swollen, and its movement is hindered. The hypertrophied papillæ give the surface a rough appearance. In the middle of the tongue, embedded in an especially firm infiltrated tissue, are several star and V-shaped furrows about 1 cm deep. They are not the result of ulcerations, but are the original furrows of the tongue which through the parenchymatous infiltration have become marked.

This case must be looked upon as a deep papular infiltrate passing into a chronic parenchymatous and interstitial inflammation with final atrophy of the tongue. Such cases do not appear in the secondary period of syphilis, but in syphilis of long standing and in neglected cases. This case was of four years' duration, and had received insufficient treatment. Compare Fig. 9.

**Figure 14.—Ulcerated Mucous Patches of the Tongue**

The entire tongue is intensely red and swollen. The right half of the tongue is almost covered with mucous patches, more or less deeply ulcerated and covered with yellow fibrinous membranes. The lesion nearest the tip of the tongue is undergoing central softening and is about to rupture. On the left

side of the tongue is a typical, faintly shining, smooth mucous patch.

The patient was twenty-four years old, and in addition to the above lesions had a chancre of the anus, condylomata about the genitals, a macular eruption, and mucous patches of the mucous membrane of the cheeks.

These deep ulcers of the tongue occurred in the early secondary period of syphilis, eight to ten weeks after the chancre. This is not usual, and this case is to be looked upon as having somewhat the character of a malignant syphilis.

Some months after the disappearance of the first manifestations of the disease, which was obtained by mercurial inunctions, the patient returned with a relapse indicated chiefly by a severe rupial syphilide.



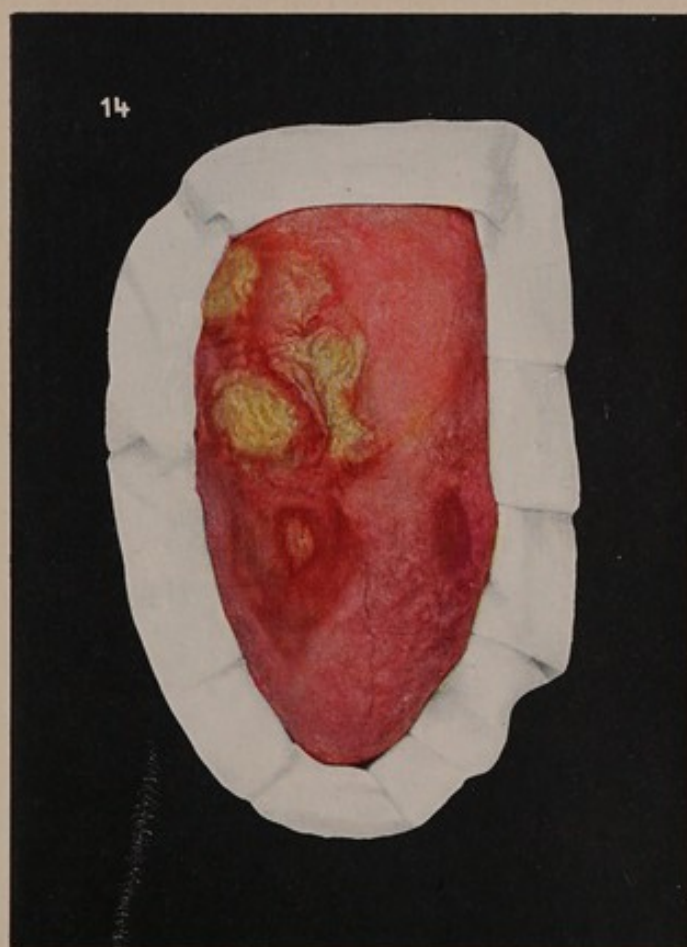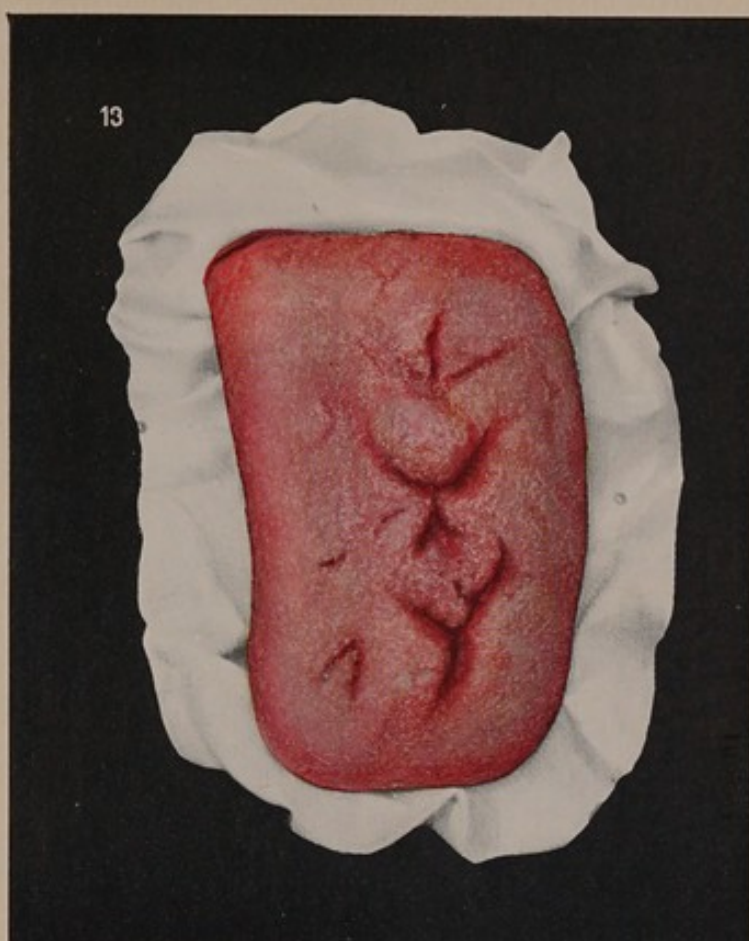






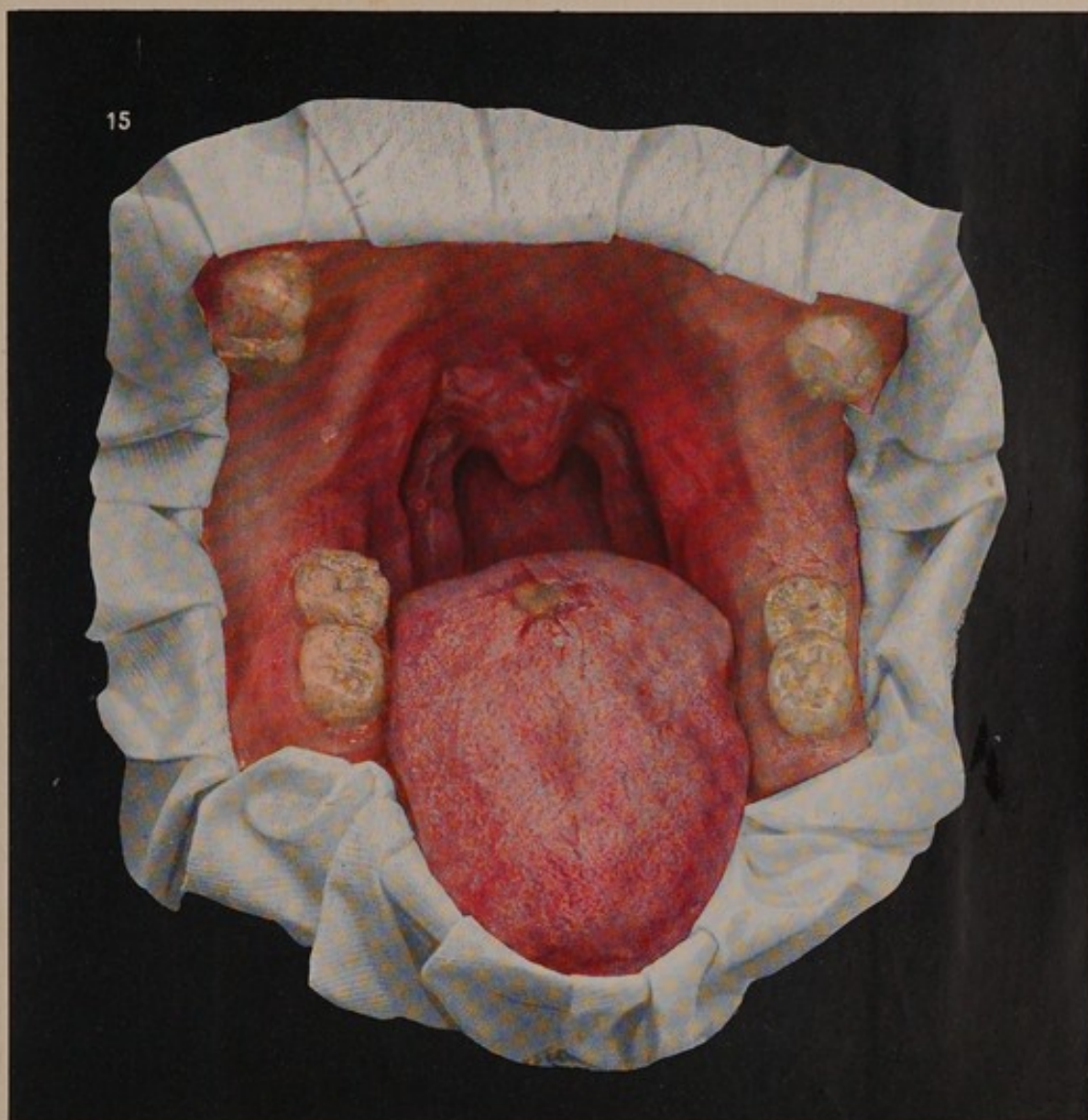
PLATE XII

**Fig. 15.—Angina Syphilitica (Syphilitic Angina)**

**Figure 15.—Angina Syphilitica (Syphilitic Angina)**

In this case there is to be seen on the reddened, oedematous and swollen mucous membrane of the isthmus of the fauces, soft palate, and uvula, a number of shining soft gray, bow-formed or round mucous patches which look somewhat as if milk had been poured on the surface of the mucous membrane. This is a mild form of syphilitic angina, and when examined in an unfavorable light might be mistaken for a simple catarrhal angina. On the middle of the tongue is a flat, round or somewhat star-shaped ulceration.










PLATE XIII

**Fig. 16.—Papules of the Soft Palate and  
Uvula**

**Figure 16.—Papules of the Soft Palate  
and Uvula**

On the mucous membrane of the soft palate and uvula is a slightly raised bluish-gray-red papular infiltrate, which causes a thickening of the free border of these structures. There is also a soft darker red border separating this infiltrate from the surrounding normal tissue. The tonsils are not swollen and cannot be seen. This is a mild form of papular angina. The patient, who was in his eighth week after infection, had condylomata lata on his scrotum, and his chancre had not disappeared.

These manifestations in the mouth quickly disappeared after inunctions were begun.



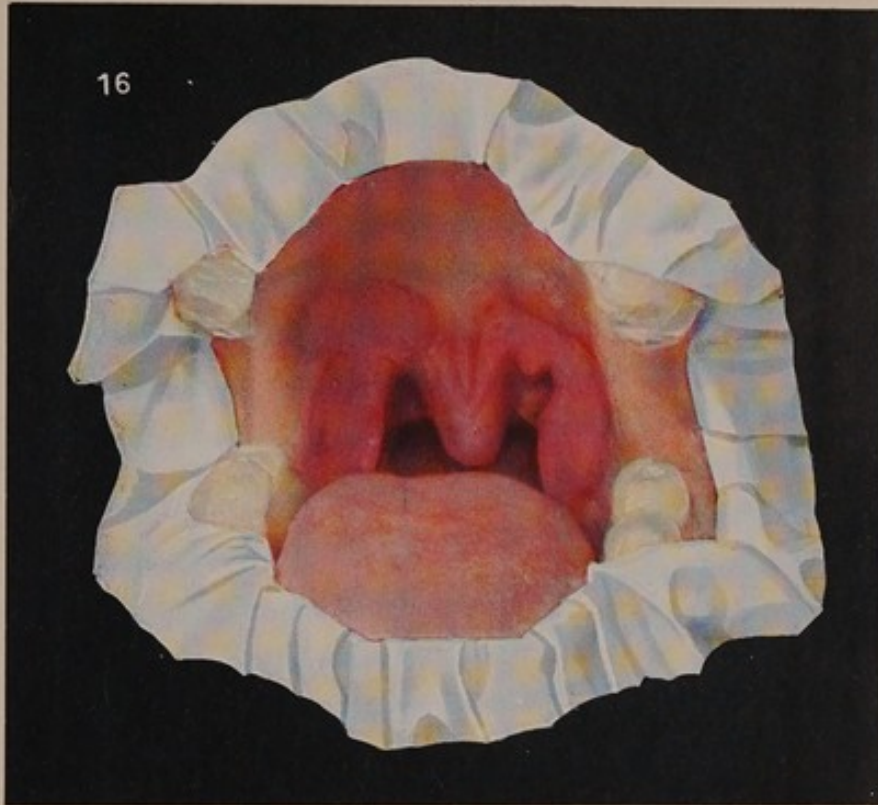






PLATE XIV

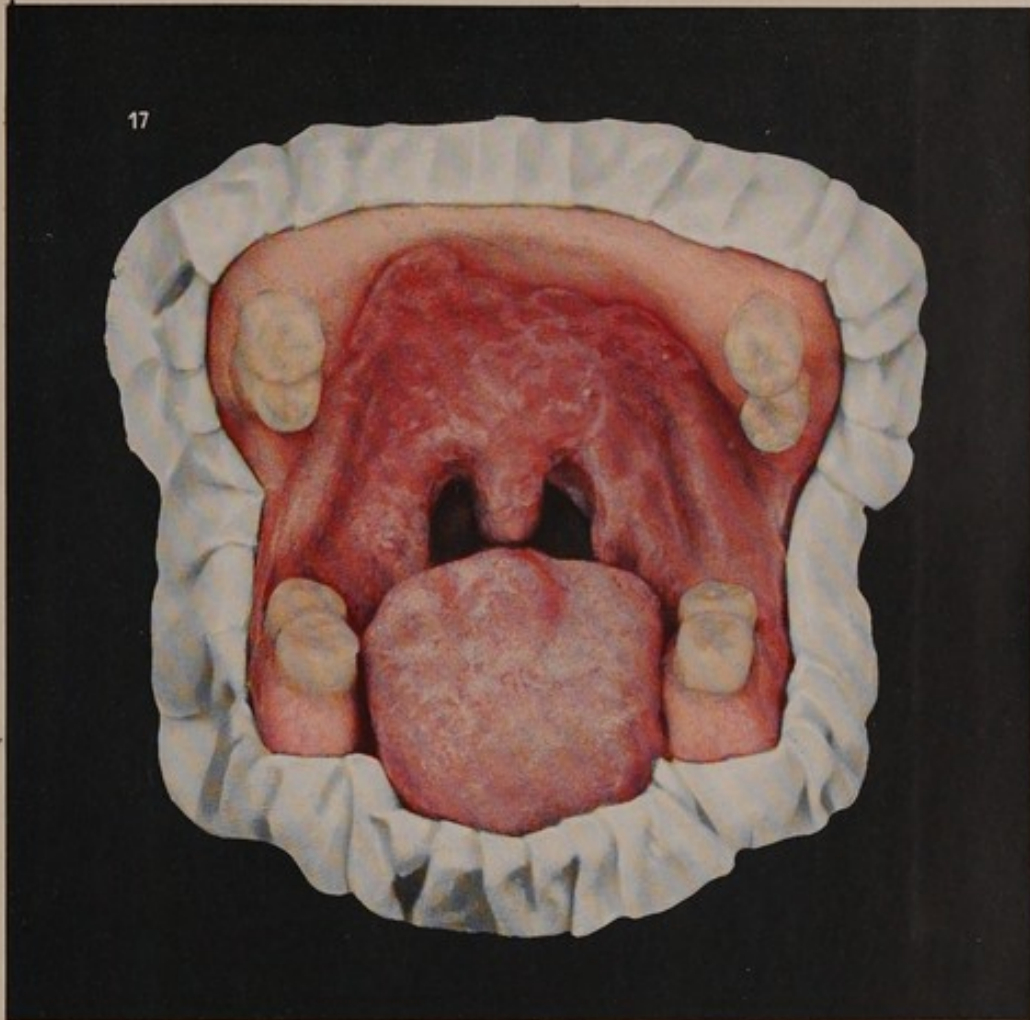
**Fig. 17.—Annular Syphilide of the Mucous  
Membrane of the Soft Palate, Uvula and  
Pillars of the Fauces**

**Figure 17.—Annular Syphilide of the Mucous Membrane of the Soft Palate, Uvula and Pillars of the Fauces**

The mucous membrane of the soft palate, uvula and pillars of the fauces is quite red and covered with numerous ring-formed gray mucous patches which tend to run together, forming a network. There are also some gray mucous patches on the tongue. There is a very red, narrow border which forms quite a sharp line of demarcation between the healthy and diseased mucous membrane. The tonsils are not involved.

This manifestation existed some months, with very slight skin manifestations, following a chancre of the upper lip. The case had been insufficiently treated.










PLATE XV

**Fig. 18.—Hypertrophied Mucous Patch of  
the Soft Palate and Uvula**

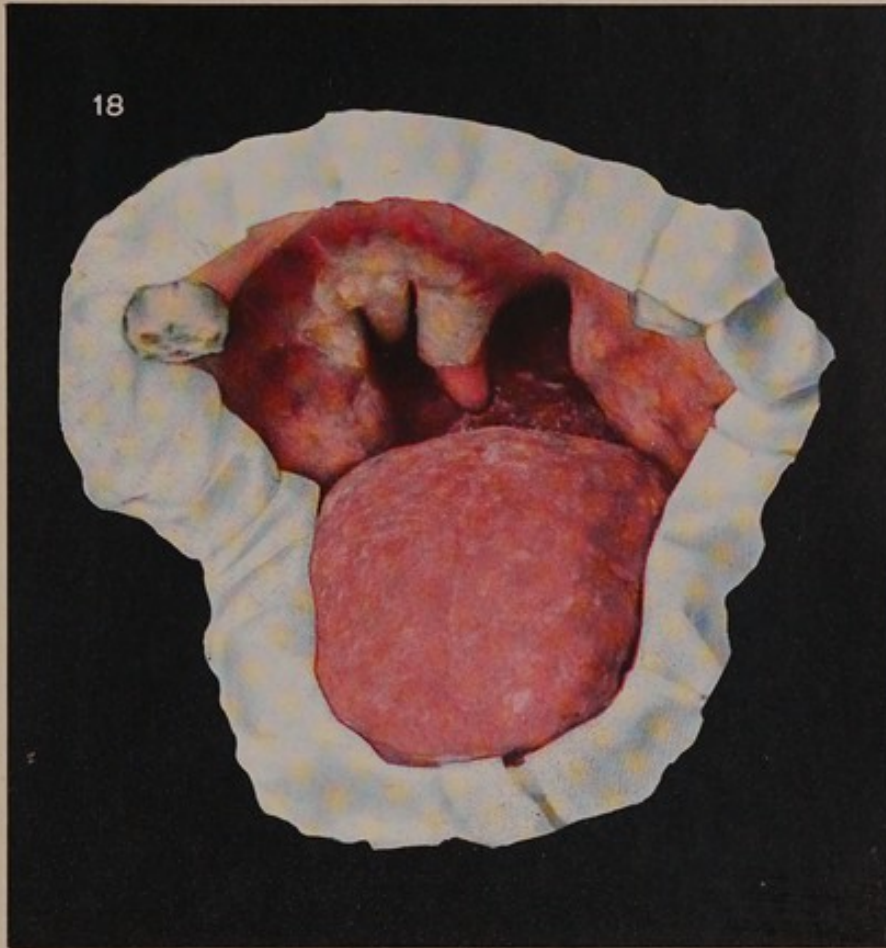
**Figure 18.—Hypertrophied Mucous Patch  
of the Soft Palate and Uvula**

A markedly hypertrophied mucous patch involves the base of the uvula, the edge of the velum palati and the right anterior pillar of the fauces. This appears as a white tumor upon an actively congested mucous membrane.

The lesion extended over the enlarged tonsil to the right posterior pillar of the fauces (not shown in the plate).

The patient at this time was thirty years old, the disease had been contracted eight months previously, and about sixteen inunctions of mercury had been given. A leucoderma colli was present and the *Wassermann* reaction was positive.










PLATE XVI

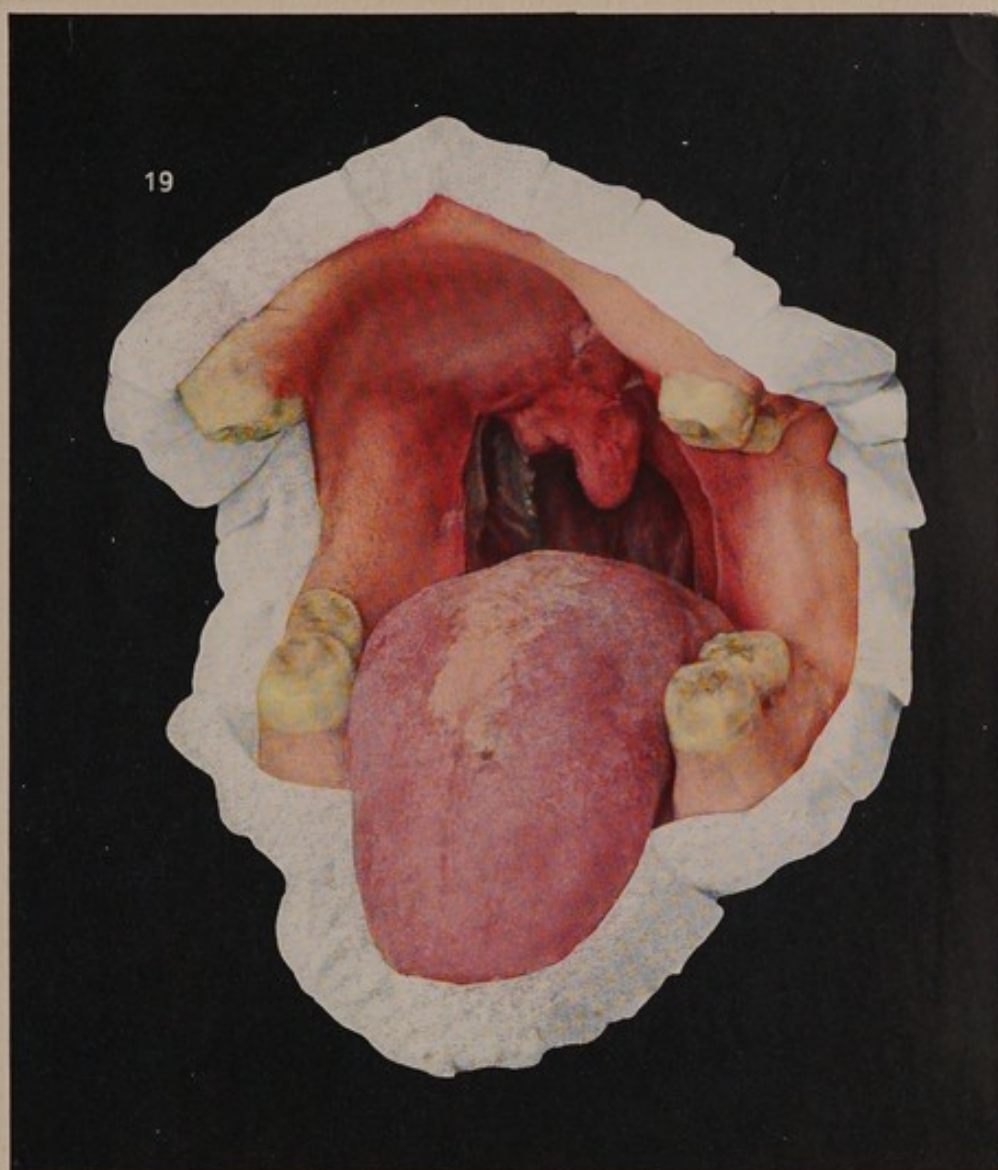
**Figure 19.—Angina Ulcerosa (Ulcerated  
Syphilitic Angina)**

**Figure 19.—Angina Ulcerosa (Ulcerated Syphilitic Angina)**

Congestion and œdema of the mucous membrane of the fauces, and especially of the uvula, are to be seen. In the middle of the soft palate, above the uvula, there are small flat ulcerations with a grayish coating. The mucous membrane, to the right of the uvula, is puffed up and at the right, between the anterior and posterior pillars of the fauces, is a flat ulcer covered with a dirty grayish-yellow membrane, which extends to the posterior pharyngeal wall. The edges of the anterior and posterior pillars of the fauces have been destroyed by the ulcerative process.

The patient, who had contracted syphilis three years before, had taken insufficient treatment. In addition to the ulcerated angina a pustular syphilide was present, and the *Wassermann* reaction was positive.










PLATE XVII

**Figure 20.—Circinate Mucous Patches  
About the Mouth and Nose**

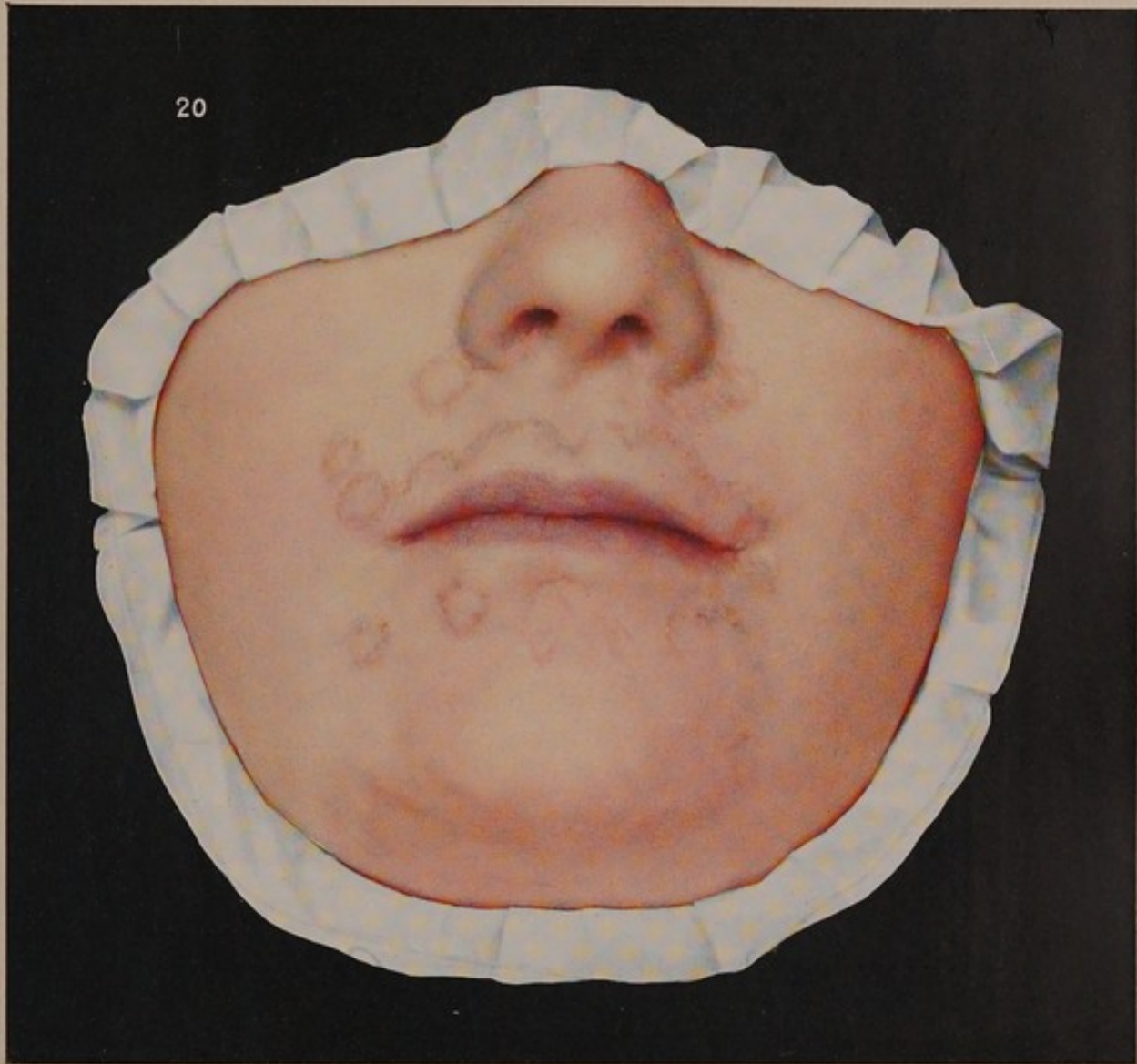
### **Figure 20.—Circinate Mucous Patches About the Mouth and Nose**

About the mouth is a group of slightly raised brownish-red-colored, ring and garland-formed mucous patches with slightly desquamating surfaces. Their situation about the mouth is characteristic of syphilis and an important sign in its diagnosis. The circinate mucous patch has a special predilection for this locality.

Sometimes a differential diagnosis must be made between this affection and herpes tonsurans. The almost uniform size of the rings, the slight desquamation and the relatively firm infiltration help to distinguish this affection from herpes tonsurans. In herpes tonsurans the fungi and in these mucous patches the *treponemata pallida* are easily found.

In this case there were condylomata about the genitals and a papulo-squamous eruption.










PLATE XVIII

**Figure 21.—Gummatous Ulcers of the  
Mucous Membrane of the Hard Palate**

### **Figure 21.—Gummatous Ulcers of the Mucous Membrane of the Hard Palate**

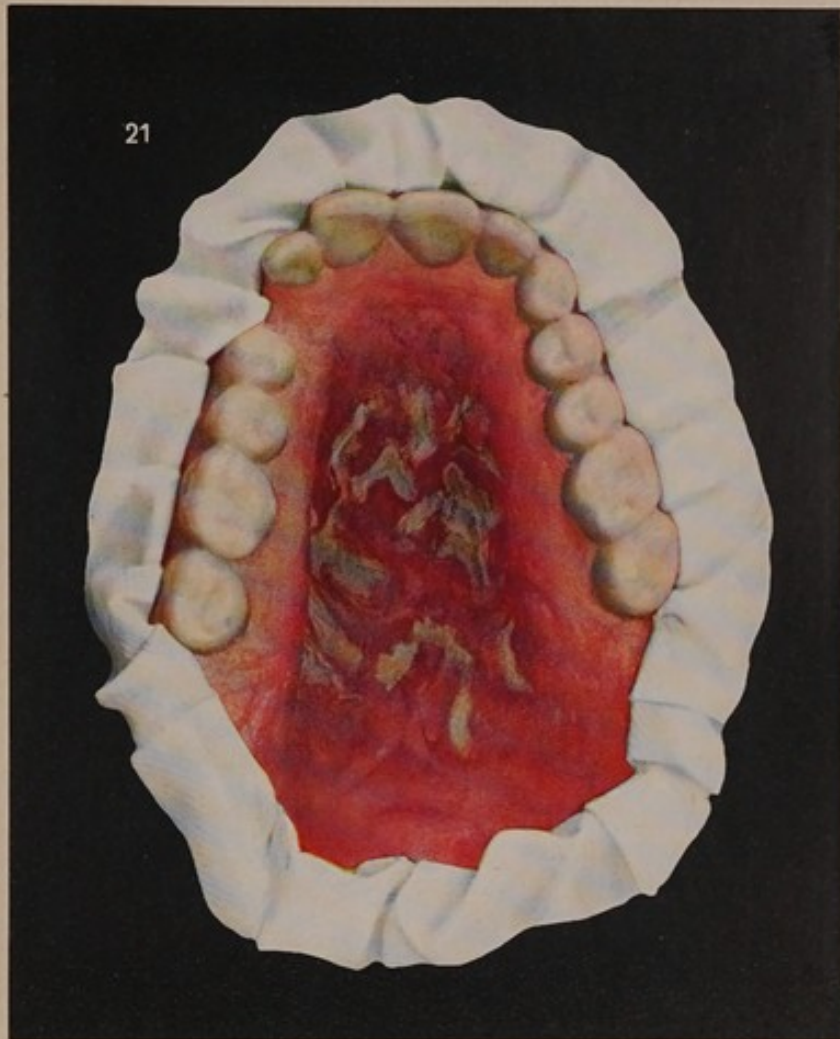
The entire mucous membrane of the hard palate is actively inflamed, œdematous, swollen and dark red in color. Upon it are seen numerous long, bow-shaped superficial ulcers covered with a grayish-yellow membrane. In places the ulcers run together and form a reticulated ulcer. The ulcers have resulted from a central necrosis of protruding infiltrates.

Eighteen years since, the patient had a chancre and bubo; had received some inunctions, but since then had taken no treatment. These ulcers developed within four months before the existence of the condition, seen in the picture, and a sequestrum had issued from his nose within a week before the picture was taken. The *Wassermann* reaction was positive.

Notwithstanding the involvement of the bones of the nose in this case, these ulcers originated in the mucous membrane and not from the periosteum or bone. The appearance of these ulcers resemble somewhat tubercular ulcers of the mucous membrane.

The tubercular ulcers are, however, more hollowed out and serrated with sharper and more precipitous walls and are accompanied by evidence of necrosis of the tubercles—some of which, still intact, may perhaps be seen surrounding the ulcers. Tubercular ulcers never reach such an extension in four months. Compare Fig. 47.










PLATE XIX

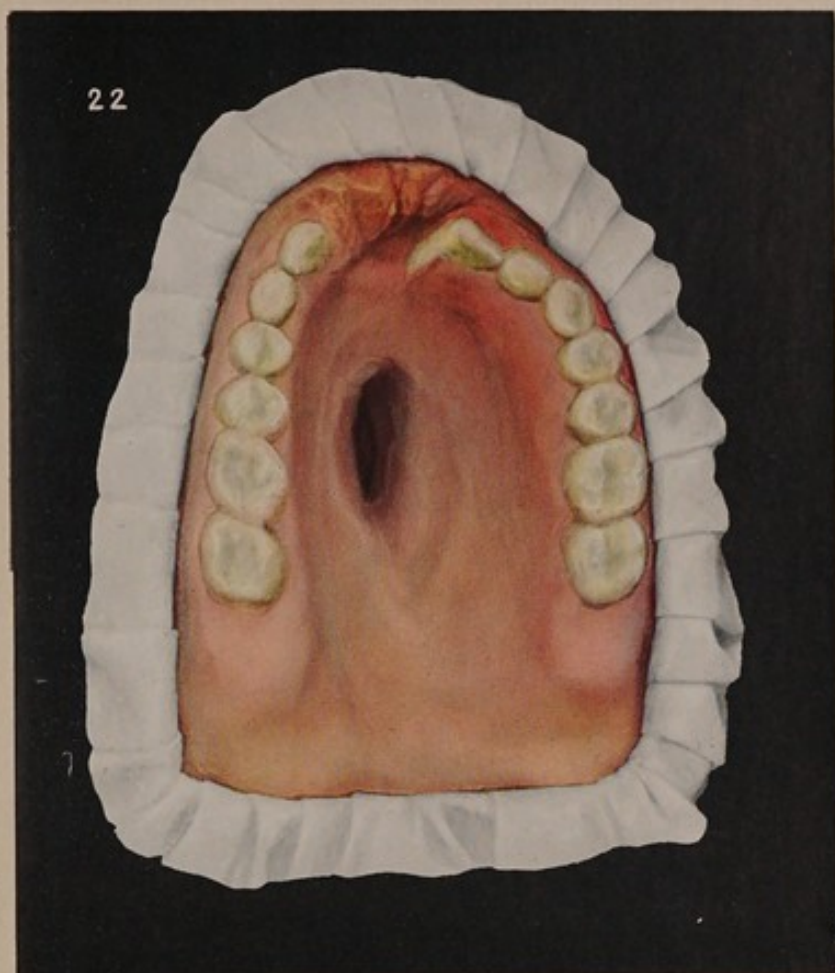
**Figure 22.—Tertiary Syphilis, Perforation  
of the Hard Palate, Periostitis of the  
Processus Alveolaris**

**Figure 22.—Tertiary Syphilis, Perforation  
of the Hard Palate, Periostitis of the  
Processus Alveolaris**

The patient, thirty-two years old, had contracted syphilis ten years previously. She had received inadequate treatment and had aborted several times. In the eighth year of the disease there was swelling of the hard palate followed by perforation. An extensive gummatous destruction of the bones of the nose, perforation of the hard palate and ozæna caused her to seek treatment.

Under an energetic treatment with potassium iodide and mercury these manifestations subsided. Six months later there appeared a new lesion of the nose, and a periostitis of the alveolar process of the maxillary bones, which led to the formation of a sequestrum containing three incisor teeth. The *Wassermann* reaction was positive. The plate shows the condition after some treatment with mercury, potassium iodide, *Zittman* and 0.3 salvarsan.










PLATE XX

**Figure 23.—Gummatous Destruction of the  
Soft Palate**

### Figure 23.—Gummatous Destruction of the Soft Palate

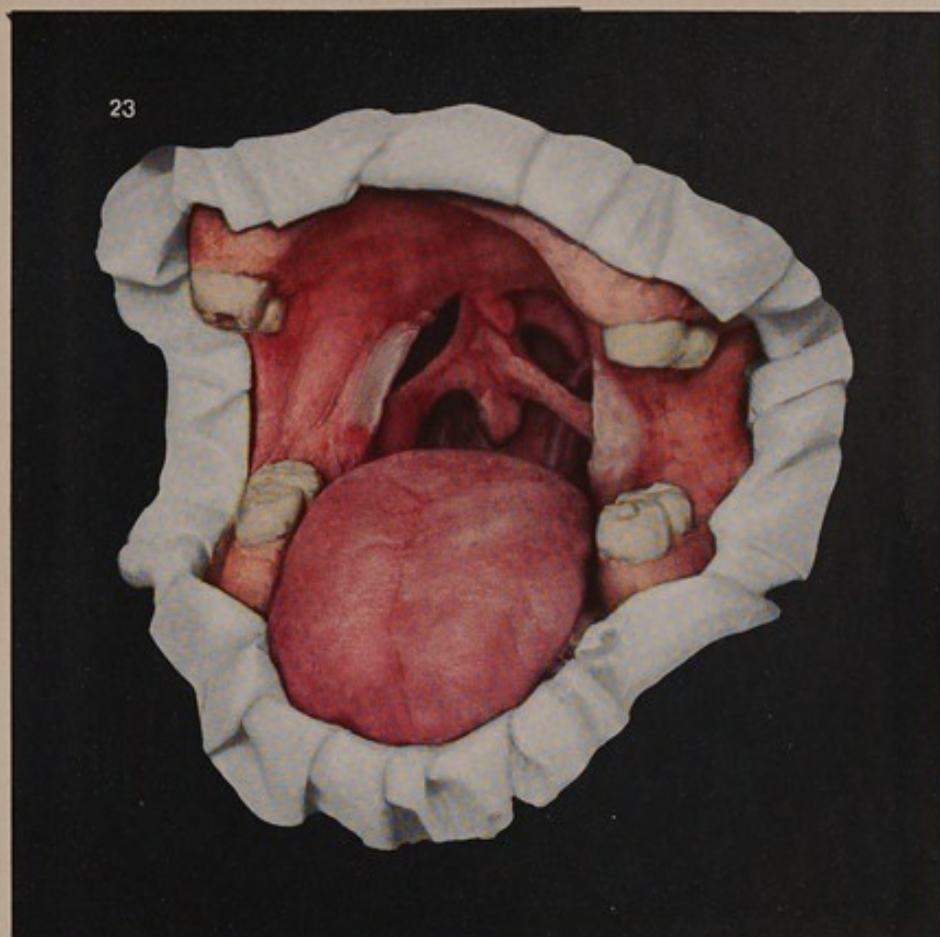
The soft palate on either side of the raphé is entirely destroyed. Only the uvula and lower part of the anterior pillars of the fauces remain intact. Through the perforation the posterior pharyngeal wall can be seen, from which a band of connective tissue extends to the remaining part of the posterior surface of the soft palate. On the free borders of the perforations, mother-of-pearl colored cicatrices are seen. Scars are also to be observed on the posterior wall of the pharynx. The inflammatory process has ceased.

The patient, a woman thirty-five years old, had an inflammation of the throat nine years previously which healed after inunctions were administered. Since then no treatment was taken.

For several years a large ulcer existed on the thigh. Six weeks previous to the condition as seen in the plate there was difficulty in swallowing. At the time the patient entered the hospital she was much run down, and on the left thigh there were a deep gummatous ulcer, as large as the palms of two hands, and several small gummata. The soft palate on both sides was perforated. The borders of the perforations were ulcerated and ulcers also existed on the posterior wall of the pharynx. All of the ulcers had a dirty grayish covering. The *Wassermann* reaction was positive.

After an intramuscular, and intravenous injection of salvarsan the throat ulcerations healed entirely within three weeks, while the gummata of the skin diminished greatly in size within six weeks. The patient gained 16 pounds. The plate shows the condition of the soft palate, etc., when the patient left the hospital. Speaking and swallowing were not interfered with.










PLATE XXI

**Figure 24.—Ulceration of the Fauces in  
Malignant Syphilis**

### **Figure 24.—Ulceration of the Fauces in Malignant Syphilis**

The entire left anterior and posterior pillars of the fauces, almost all of the uvula and the left tonsil are ulcerated, so that there is a deep destruction of the mucous and submucous tissue. The floor of the ulcer is covered with a markedly adherent white diphtheroid necrotic membrane. The wall of the ulcer is precipitous. The surrounding mucous membrane, to a considerable distance from the ulcer, is actively congested, œdematous, and swollen. To the left of the large ulcer is a small one having a sharp border and tending to unite with the large one. The patient, a woman fifty-one years old, had eight to ten weeks previously a chancre of the lower lip with a submaxillary adenitis. At the time when the ulceration of the fauces occurred there were no skin manifestations, but there was a periosteal gumma of the right tibia. The *Wassermann* reaction was positive.

The ulcer had much the appearance of a gumma rapidly undergoing necrosis, which, in conjunction with the presence of the periosteal gumma of the tibia and its occurrence in the first weeks after infection, is especially characteristic of malignant syphilis. The age of the patient may be looked upon as predisposing to the malignant course of the disease. Local treatment of the ulcers with bichloride of mercury in glycerine (2%) and inunctions of mercury caused a rapid disappearance of the lesions.



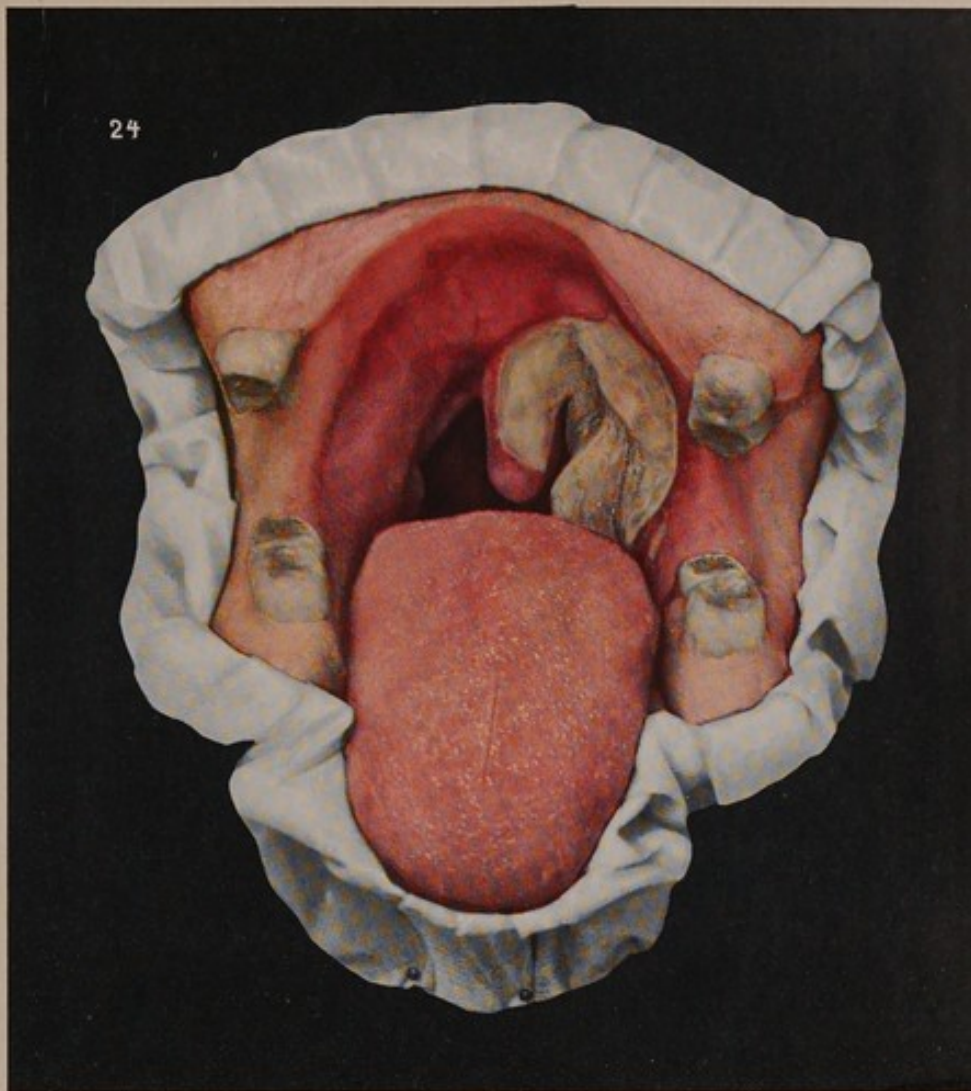






PLATE XXII

**Figure 25.—Malignant Syphilis of the  
Fauces**

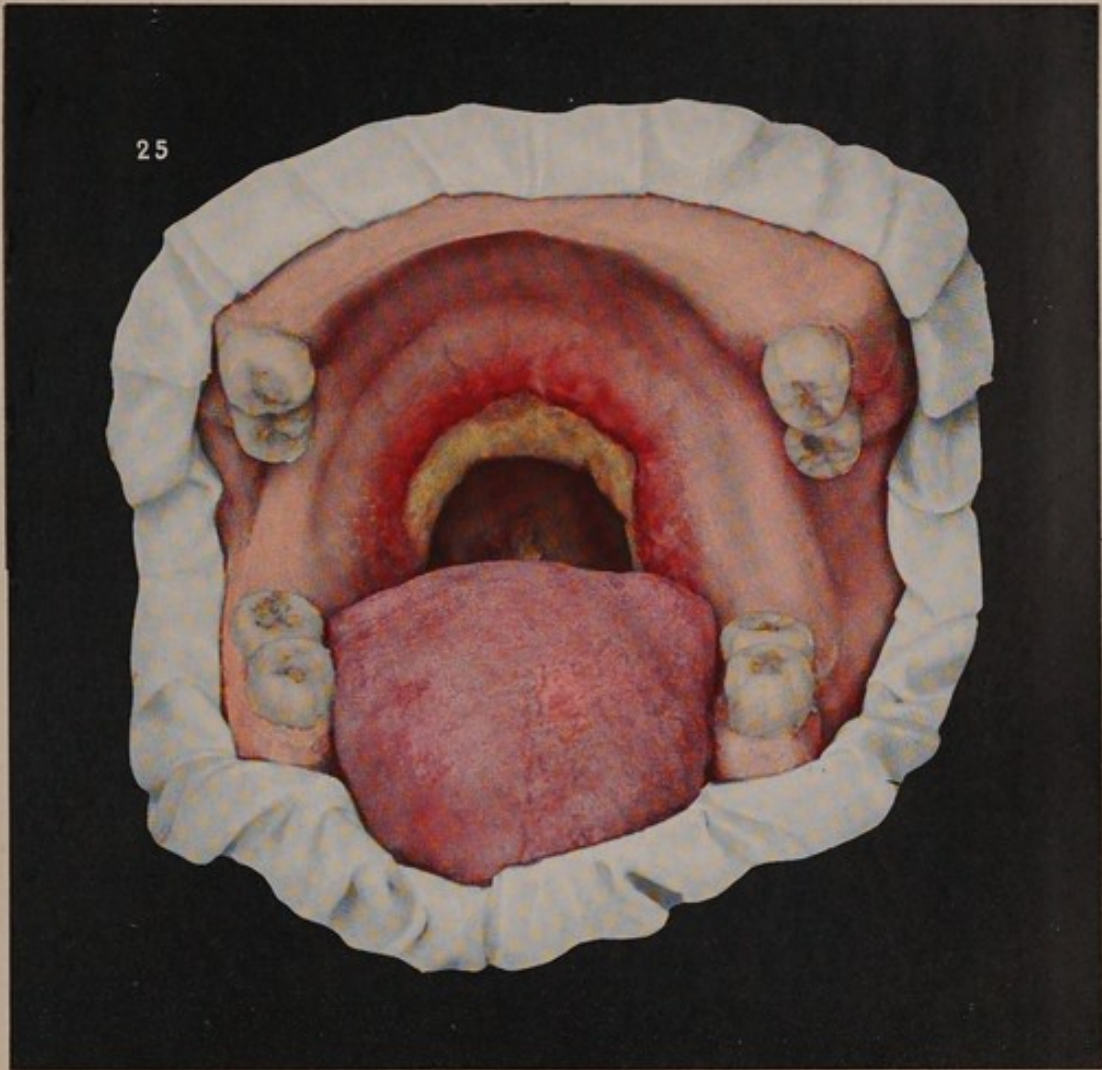
### **Figure 25.—Malignant Syphilis of the Fauces**

The entire soft palate, the uvula and anterior and posterior pillars of the fauces have been destroyed by a syphilitic ulcer. On the edge of the lesion is a large ulcer, with precipitous walls surrounded by a not very extensive bright red border. The floor of the ulcer is covered with a strikingly yellow adherent membrane, but there is no œdematous swelling. On the posterior pharyngeal wall similar ulcers can be seen.

The destructive process has probably been going on for several weeks, but the patient could make no definite statement regarding his condition.

Syphilis had been acquired about six months previously. Inunctions had been given for four or five weeks without much result, when a macular eruption and the ulcerated angina appeared. Under potassium iodide and biniodide of mercury improvement took place. Some months later the patient returned in the present condition. There were several deep ulcerated syphilides on the skin and one on the skull which reached the periosteum. The marked destructive changes which took place in the first year of the disease designate the case as one of malignant syphilis.










PLATE XXIII

**Figure 26.—Syphilis Hereditaria  
(Heredosyphilis)**

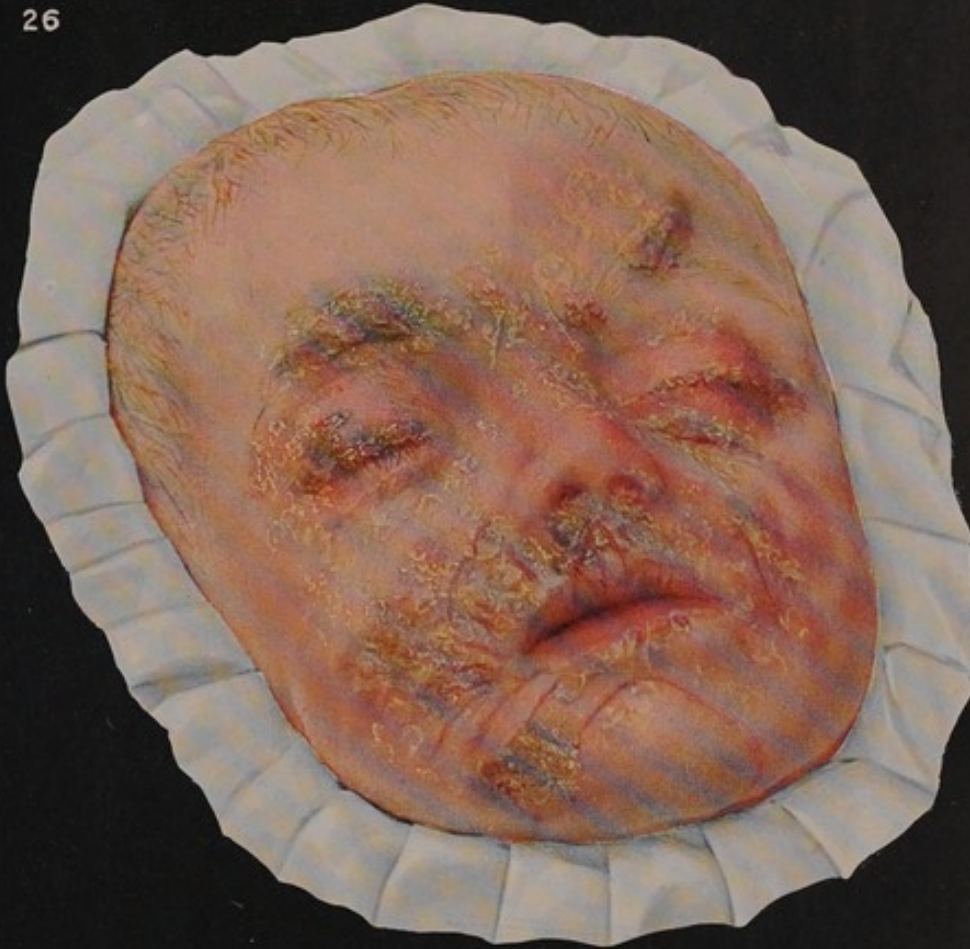**Figure 26.—Syphilis Hereditaria  
(Heredosyphilis)**

In this case a severe papular syphilide of the entire face is seen, especially about the anterior nares and the mouth. The syphilitic infiltrate is particularly dense and deep. Radiating furrows are seen, which will later on form radiating scars, characteristic of heredosyphilis. In one of the mucous patches about the angle of the jaw *treponemata pallida* were found.

This child was born of a syphilitic mother, who had early secondary manifestations of the disease. Four weeks after birth there appeared an eruption on the body of the child followed by that on the face. Aside from the presence of the *treponema pallidum* in the lesions and otherwise characteristic syphilitic changes, the eruption is not likely to be confused with any other disease. Eczema might be thought of were it not that in eczema we do not find the individual papules and vesicles, and there is no marked formation of crusts. The penetrating character of the infiltrate and the formation of the radiating fissures are against a diagnosis of eczema.



26



—



PLATE XXIV

**Figure 27.—Syphilis Hereditaria Tarda  
(Late Heredосyphilis)**

**Figure 27.—Syphilis Hereditaria Tarda  
(Late Heredosyphilis)**

This is a typical case showing the entire stigmata of heredosyphilis. This case shows, besides the well-known *Hutchinson triad* (parenchymatous keratitis, otitis and *Hutchinson* teeth), a marked protrusion of the frontal protuberances, saddle nose and radiating scars about the mouth. The radiating scars in the vermillion and skin, which have come from the deep fissures in the syphilitic infiltrate, are pathognomonic of heredosyphilis. (Compare Fig. 26.)



27

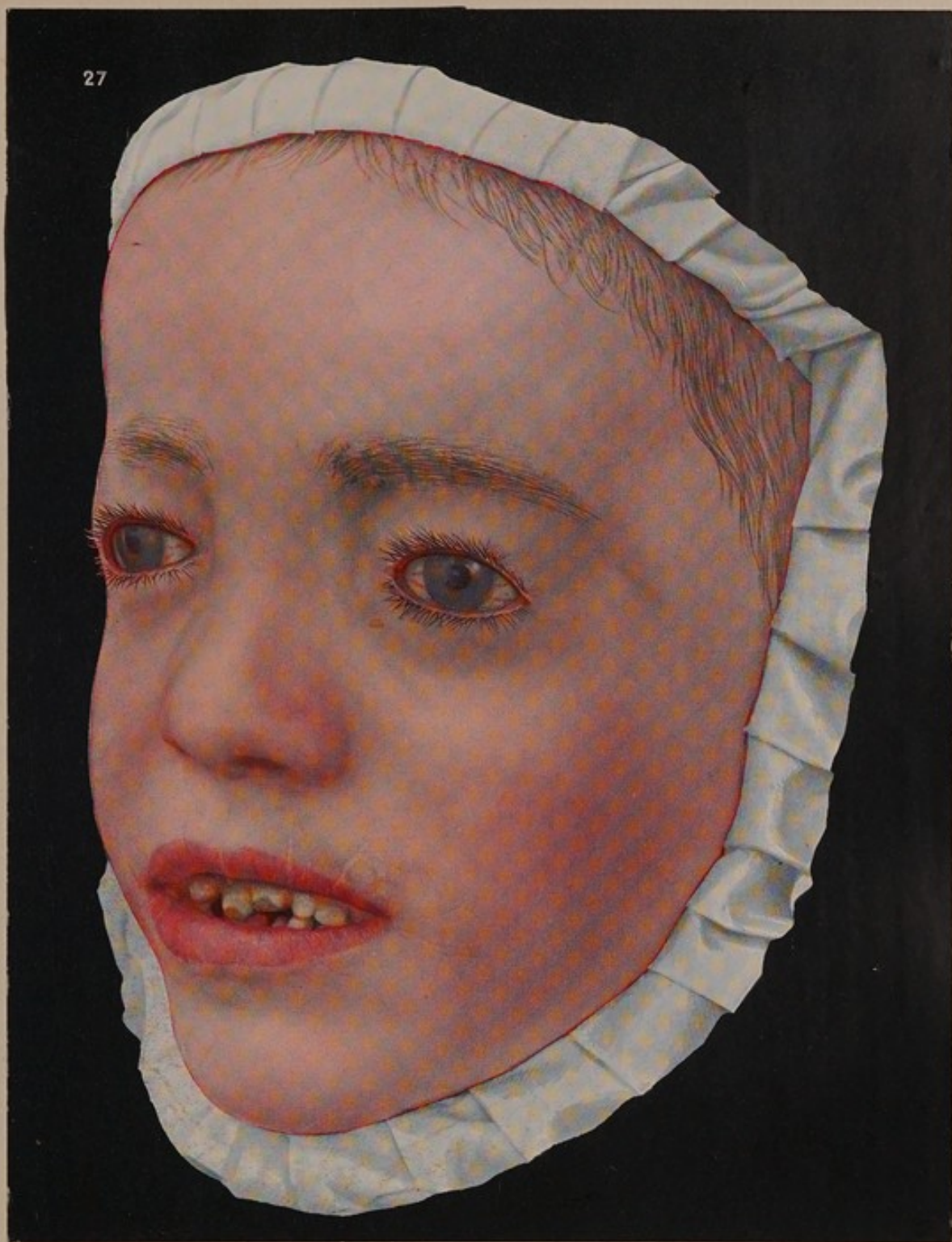






PLATE XXV

**Figure 28.—Syphilis Hereditaria Tarda (Late Heredosyphilis). Gumma of the Tongue**

**Figure 29.—Syphilis Hereditaria Tarda (Late Heredosyphilis). Gummatous Perforation of the Hard Palate and Heredosyphilitic Teeth**

**Figure 28.—Syphilis Hereditaria Tarda (Late Heredosyphilis). Gumma of the Tongue**

In the middle of the tongue, extending almost through its entire length, is a deep linear scar with a number of radiating scars. The patient, sixteen years old, who denied ever having contracted syphilis, was admitted to the hospital for gonorrhœa. On the root of the nose was a typical gummatous ulcer about 2.5 cm in diameter, which had existed for about two months. Two years previously he had ulcers on the tongue, all but one of which had healed completely. The *Wassermann* reaction was positive.

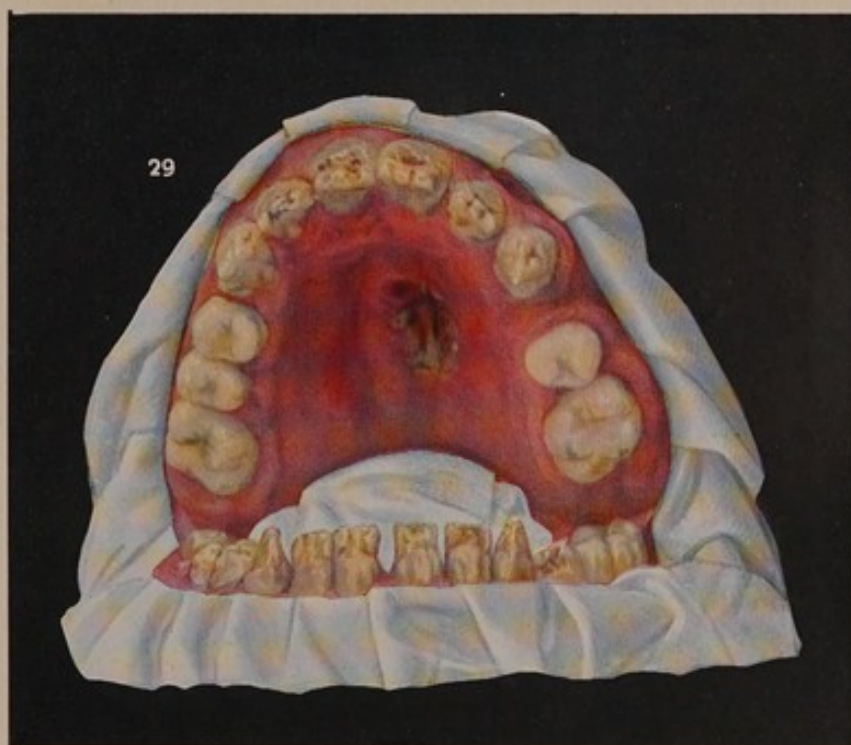
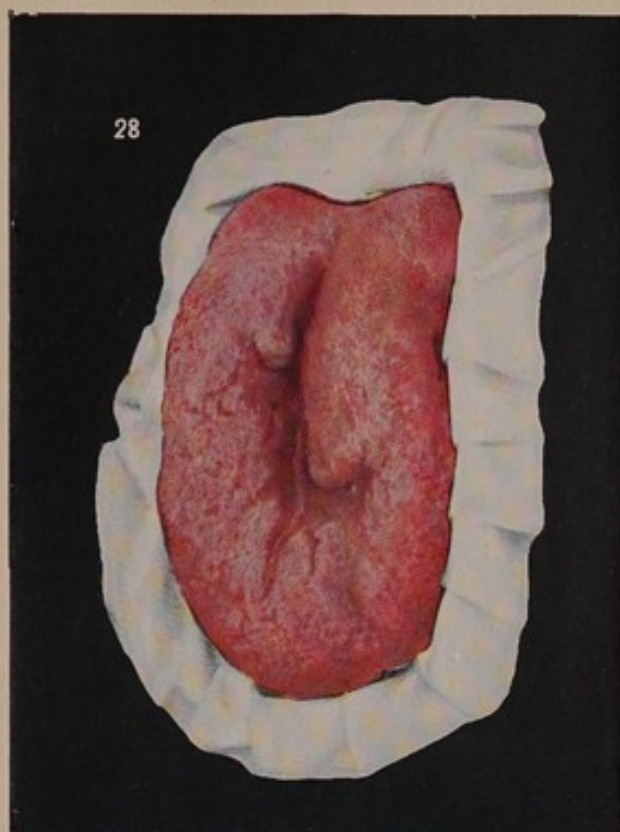
Since the other stigmata of heredosyphilis are absent and the family history is negative regarding syphilis, the diagnosis of syphilis acquired in early life might be made, but the diagnosis of heredosyphilis is probably the correct one in this case.

**Figure 29.—Syphilis Hereditaria Tarda (Late Heredosyphilis). Gummatous Perforation of the Hard Palate and Heredosyphilitic Teeth**

On the hard palate is a deep perforating ulcer covered with pus and with a dirty membrane and having a foul smelling exudate. The bones of the nose have become necrosed. Sequestra have been discharged from the nose and there is ozæna. The ulcer developed within two months. The *Wassermann* reaction was positive.

The patient was thirteen years old, had a parenchymatous keratitis, but there was no family history of syphilis. The teeth are seen better in Fig. 67.










PLATE XXVI

**Figure 30.—Stomatitis Mercurialis (Mercurial Stomatitis)**

**Figure 31.—Stomatitis Mercurialis. Mercurial Stomatitis with Ulcerations on the Border of the Tongue**

*[Faint, illegible handwriting]*



**Figure 30.—Stomatitis Mercurialis (Mercurial Stomatitis)**

This is a case of a severe general ulcerated stomatitis. The mucous membrane of the entire mouth is very red and swollen. The gums are necrotic and covered with a yellowish membrane containing pus. Pus can be pressed out of the alveoli for the teeth. The tongue is greatly swollen, and hollowed-out ulcers, covered with pus, are to be seen along its edge at points opposite the teeth.

The mucous membrane of the lips is very much swollen and ulcers caused by pressure from the teeth are seen. There was marked salivation and fœtor.


**Figure 31.—Stomatitis Mercurialis. Mercurial Stomatitis with Ulcerations on the Border of the Tongue**

A woman, twenty-six years old, with early syphilis, syphilitic angina, psoriasis palmaris and a severe mercurial stomatitis, was admitted to the hospital. For fourteen days she had taken inunctions, without taking any care of her mouth. The entire mucous membrane of the mouth was inflamed and the tongue was coated. On the edge of the tongue were several hollowed-out ulcers with very red borders and covered with yellowish-gray adherent necrotic membranes. These ulcers corresponded to the adjacent teeth and might be regarded as decubital ulcers.

As there are signs of early syphilis present these

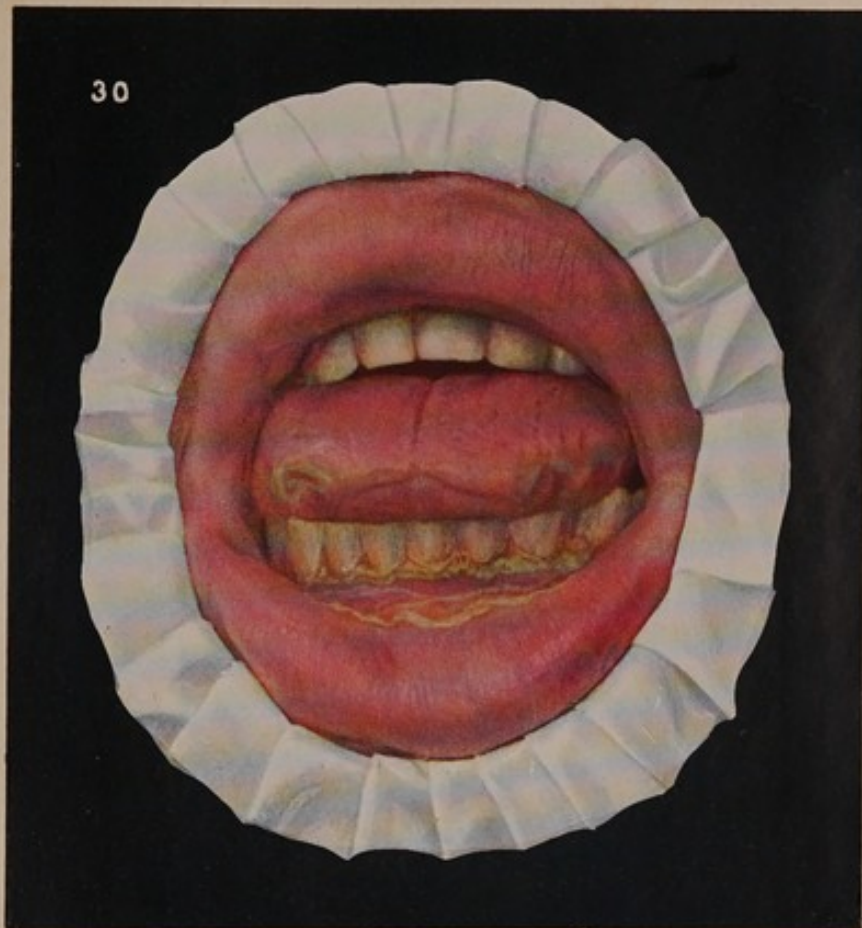
11

ulcerations might be falsely diagnosed as those of secondary syphilis, but the number and regular arrangement, together with their smooth floors covered with necrotic membranes, distinguish them from the ulcers of secondary syphilis. In secondary syphilis the floor of the ulcer is irregular and anfractuous, and has a grayish border. The flat form of the pictured ulcers and their number preclude also a diagnosis of gumma. The ulcers healed under simple treatment.





30



31



*[Faint, illegible handwriting]*



PLATE XXVII

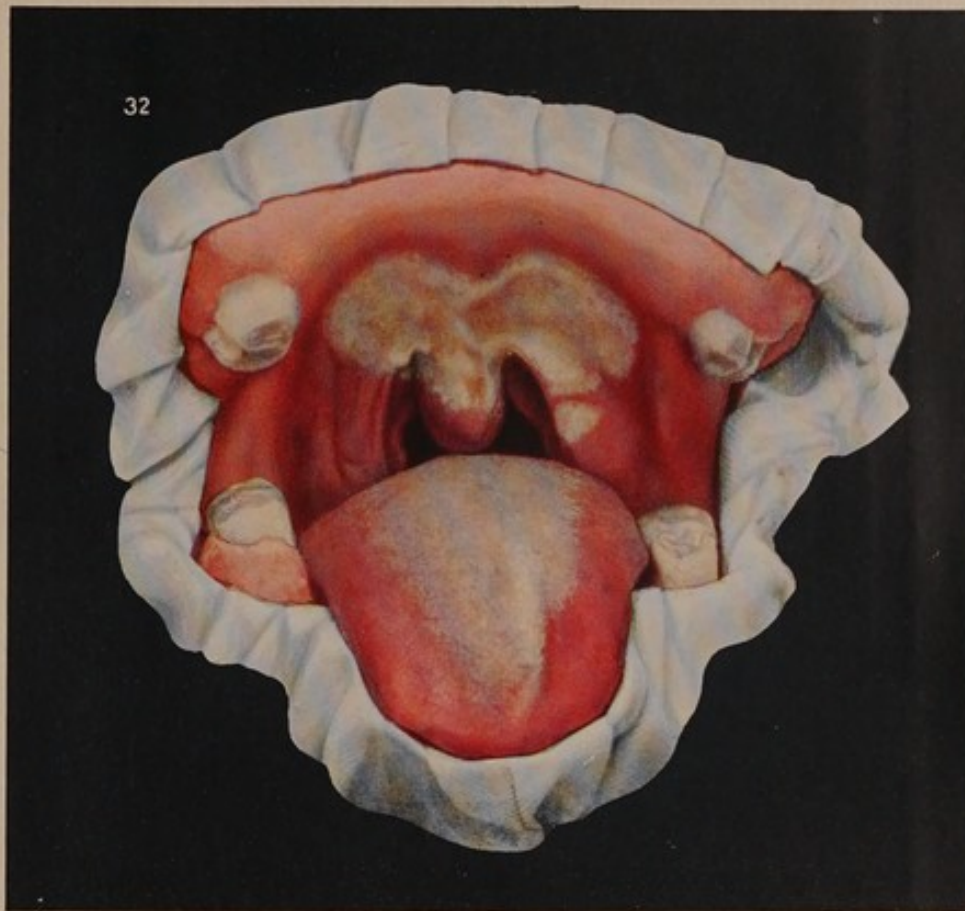
**Figure 32.—Angina Mercurialis (Mercurial  
Angina)**

**Figure 32.—Angina Mercurialis (Mercurial Angina)**

A syphilitic young woman was given several injections of mercury, whereupon an acute severe inflammation of the throat followed. The mucous membrane of the fauces became intensely red, œdematous and swollen. On the soft palate and uvula was an extensive white necrotic adherent membrane giving the appearance of a severe diphtheria. The tongue was badly coated and the mucous membrane of the entire mouth red. Salivation was present. On the gums, the usual place of predilection for mercurial stomatitis, there was no membrane or ulceration. The temperature was only slightly raised.

The patient deceived her parents and physicians about her having taken mercury. The diagnosis of diphtheria was made and the patient was sent to the department for infectious diseases in the hospital. The slight fever and the good general condition of the patient did not agree with the severe local manifestations. The *Klebs-Löffler* bacillus was sought for again, but not found. Later on distinct swelling of the border of the gums appeared, which indicated the mercurial poisoning. From the appearance of the lesion the first diagnosis (diphtheria) was justified.





Handwritten text, mostly illegible due to fading and bleed-through from the reverse side. The text appears to be organized into several lines or paragraphs, with some words and phrases being more legible than others. The handwriting is cursive and somewhat slanted.



PLATE XXVIII

**Figure 33.—Antipyrin (Salipyrin) Exanthem  
of the Tongue**

**Figure 34.—Lichen Ruber Planus of the  
Buccal Mucous Membrane**

THE HISTORY OF THE  
CITY OF BOSTON  
FROM THE FIRST SETTLEMENT  
TO THE PRESENT TIME  
IN TWO VOLUMES  
BY NATHANIEL BENTLEY  
VOL. II.  
BOSTON: PUBLISHED BY  
J. B. ALLEN, 1825.



**Figure 33.—Antipyrin (Salipyrin) Exanthem  
of the Tongue**

An old man, several hours after taking 0.5 gram of salipyrin, developed a severe inflammation of the mouth. There was a marked burning sensation and congestion and swelling of the mucous membrane. The tongue was swollen and its surface became rough: bullæ, which soon ruptured, formed upon the lips and gums.

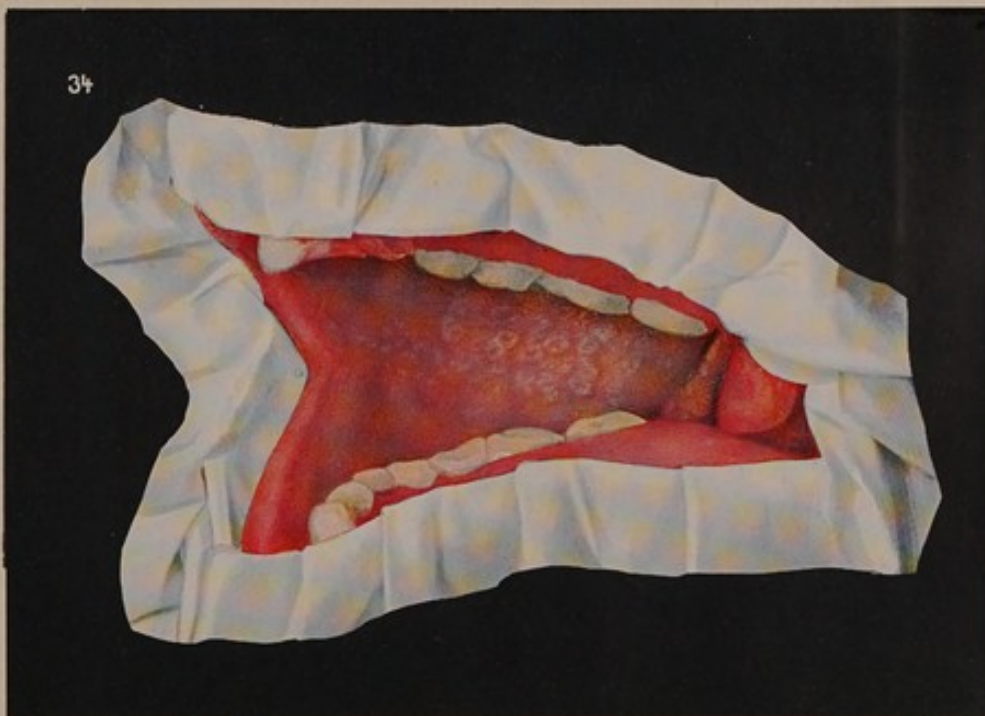
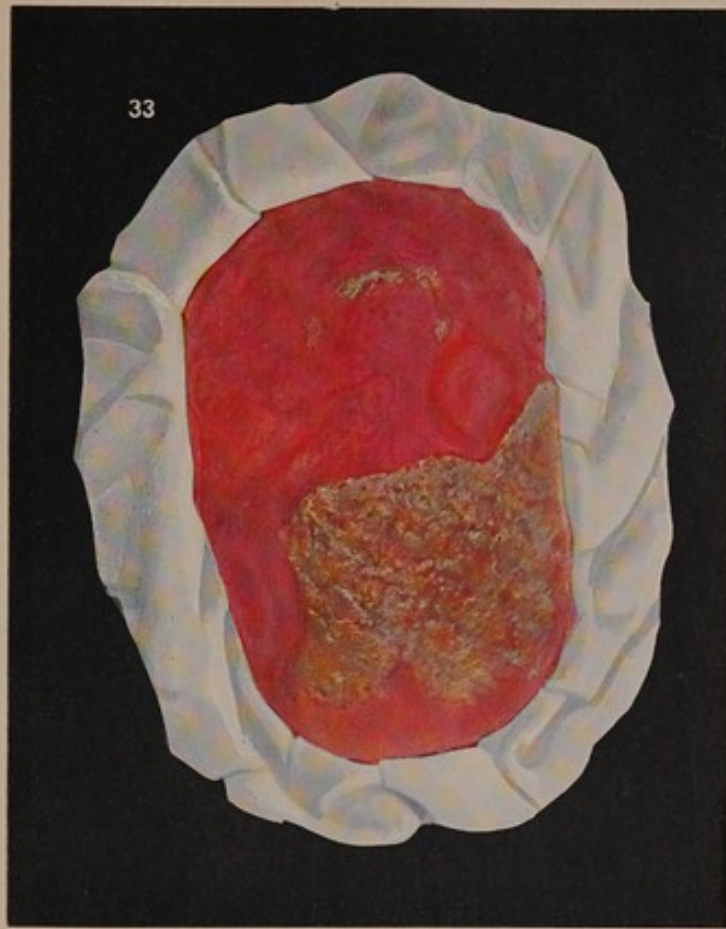
The mucous membrane of the tongue fell to pieces, especially on the base of the tongue, which was denuded of epithelium. The anterior part of the tongue was markedly coated. After using camomile tea as a mouth wash, healing began in a few days. The patient said that some years previously, after taking antipyrin, he developed bullæ in his mouth, but the attack was not so severe as this one. The sudden appearance directly after taking the drug, the spontaneous healing and the previous occurrence of similar manifestations after the administration of antipyrin indicate a medicamentous exanthem.

**Figure 34.—Lichen Ruber Planus of the  
Buccal Mucous Membrane**

On the mucous membrane of the cheeks, a number of mother-of-pearl gray papules are seen. They are umbilicated and ringlike, with a diameter of about 2 or 3 mm. The rings coalesce here and there, shaping themselves like the figure 8. Near the angle of the

mandible the papules are the largest, and they gradually diminish in size to the angle of the mouth where they become little dots. In this case the diagnosis was easy, both on account of the characteristic form of the lesion, and because there was also a typical lichen ruber on the body. In similar cases the papules may coalesce, forming patches which greatly resemble mucous patches, or they may be more umbilicated and thus form greater efflorescences of less characteristic appearance. If there is no accompanying eruption on the skin it may be difficult to make a diagnosis, owing partly to the fact that efflorescences on the mucous membrane are far more refractory to arsenic than are those of the skin.










PLATE XXIX

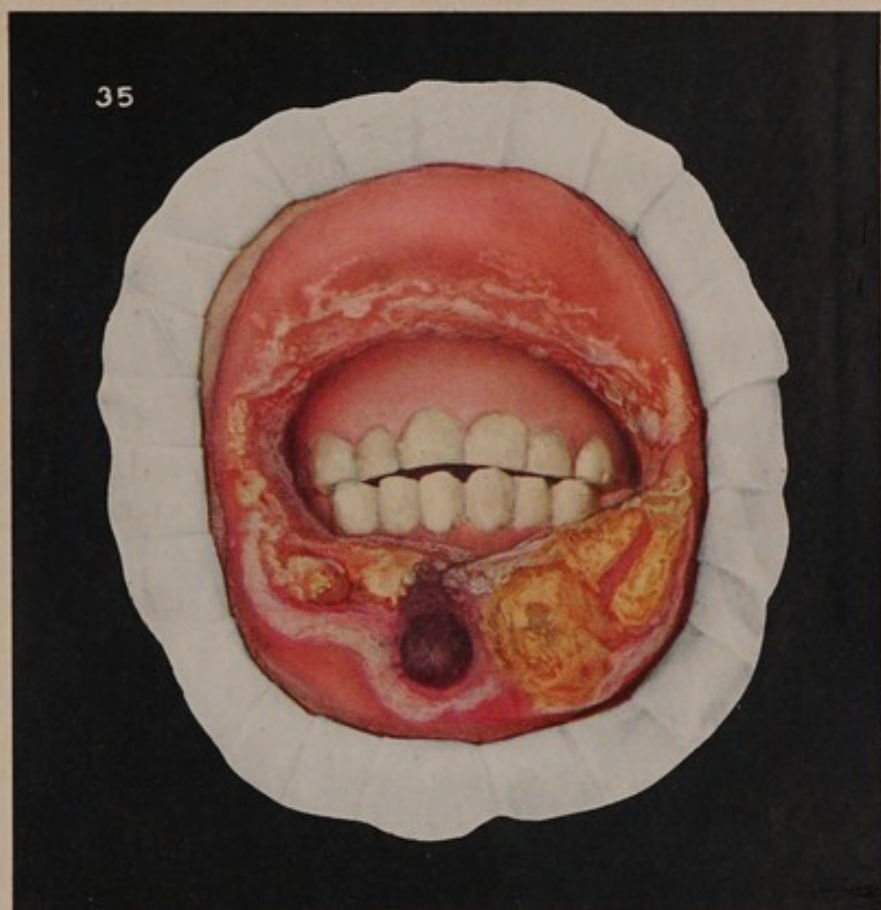
**Figure 35.—Erythema Exudativum Multi-  
forme of the Mucous Membrane of the  
Mouth. (Idiopathic Polymorphous Ery-  
thema)**

**Figure 35.—Erythema Exudativum Multiforme of the Mucous Membrane of the Mouth. (Idiopathic Polymorphous Erythema)**

Some days after the occurrence of a typical erythema multiforme exudativum upon the hands and feet of a man thirty years old, a similar eruption appeared upon the mucous membrane of the lips and cheeks. Large bullæ developed upon the lower lip, which ruptured soon after their contents had coagulated. Only one in the centre of the lower lip maintained its bloody contents. The mucous membrane was covered with crusty, yellowish, markedly adherent fibrinous membranes. When these were removed the excoriated surfaces bled easily. On the mucous membrane of the upper lip and cheek large bullæ did not form, but small excoriations are seen surrounded by pieces of epithelial débris. Here the process has passed the climax. The surrounding inflammatory reaction is slight. The diseased part is quite sharply marked off from the sound tissue by a zone of loosened epithelium. The affection is very painful, and the patient can only take fluids.

Syphilis can scarcely be confused with it. The sudden appearance of the eruption on the mucous membrane and the synchronous appearance of a typical erythema multiforme exudativum on the extremities make the correct diagnosis. So extensive and intensive an involvement of the mucous membrane as is seen here does not often occur. One is reminded of an antipyrin exanthem when examining these lesions.





*[Faint, illegible handwriting]*



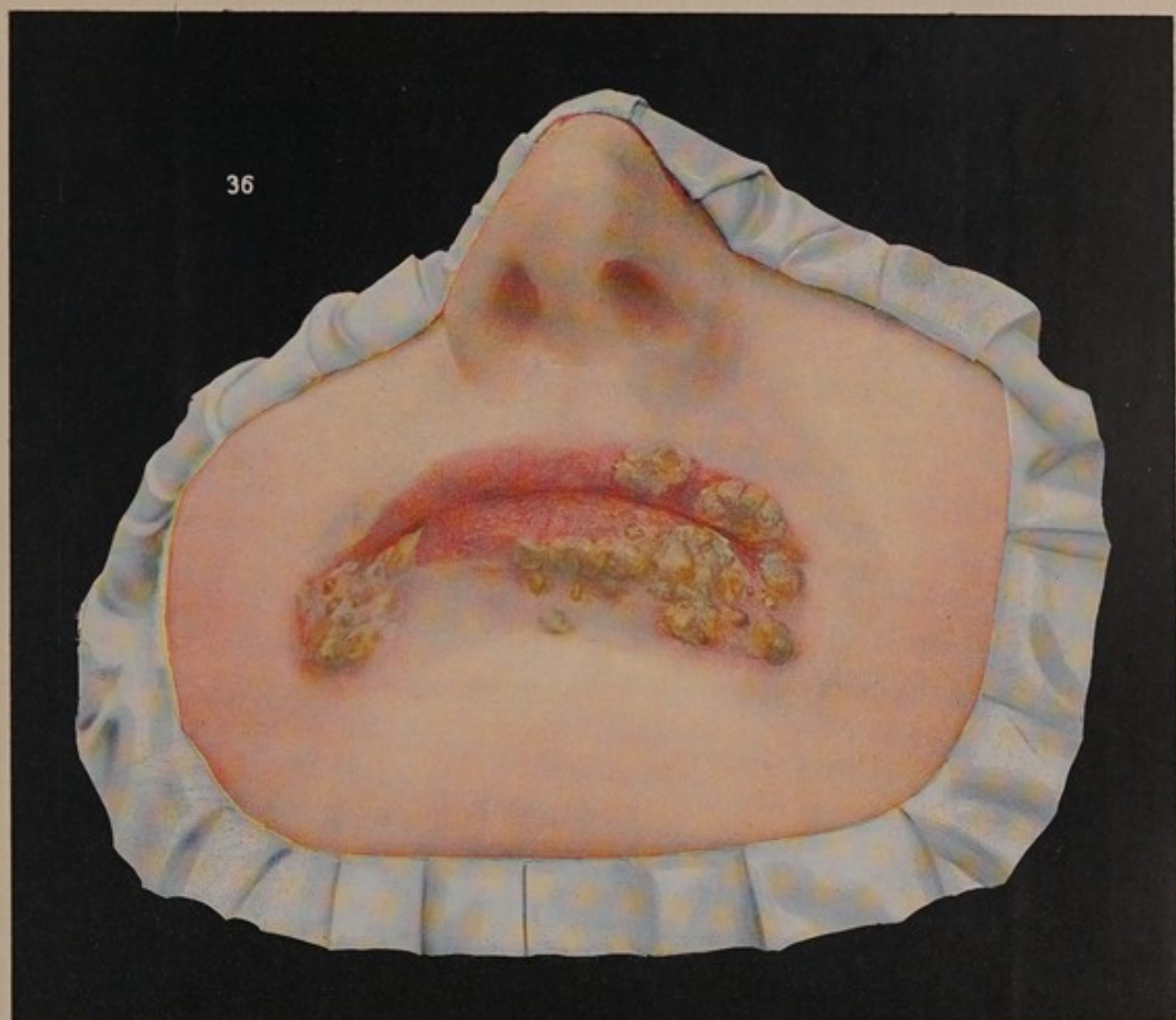PLATE XXX

**Figure 36.—Herpes Labialis (Herpes of  
the Lip)**

**Figure 36.—Herpes Labialis (Herpes of the Lip)**

This patient had syphilis and was given an intravenous injection of salvarsan. He reacted the same evening with a high fever. Next morning the herpes appeared. On the vermillion and the bordering skin a group of small vesicles appeared which partly coalesced. The contents of the vesicles, at first clear, quickly coagulated. The surrounding skin was slightly congested. In this case these manifestations, characteristic of herpes, cannot easily be mistaken for the characteristic manifestations of syphilis. One can perceive in the plate the way the herpes began at the arched borders of the lesion. When the herpes exists only as a single group of small vesicles on the vermillion or mucous membrane (especially in its last stage when the vesicles have ruptured and the coagulated contents are discharged) it may resemble an eroded mucous patch. It is not always easy to diagnose herpes, close examination and study of the case are frequently necessary.





*[Faint, illegible handwriting]*



PLATE XXXI

**Figure 37.—Aphthous Ulcer (Aphthous Stomatitis)**

**Figure 38.—Angina Follicularis Catarrhalis (Follicular Tonsillitis)**

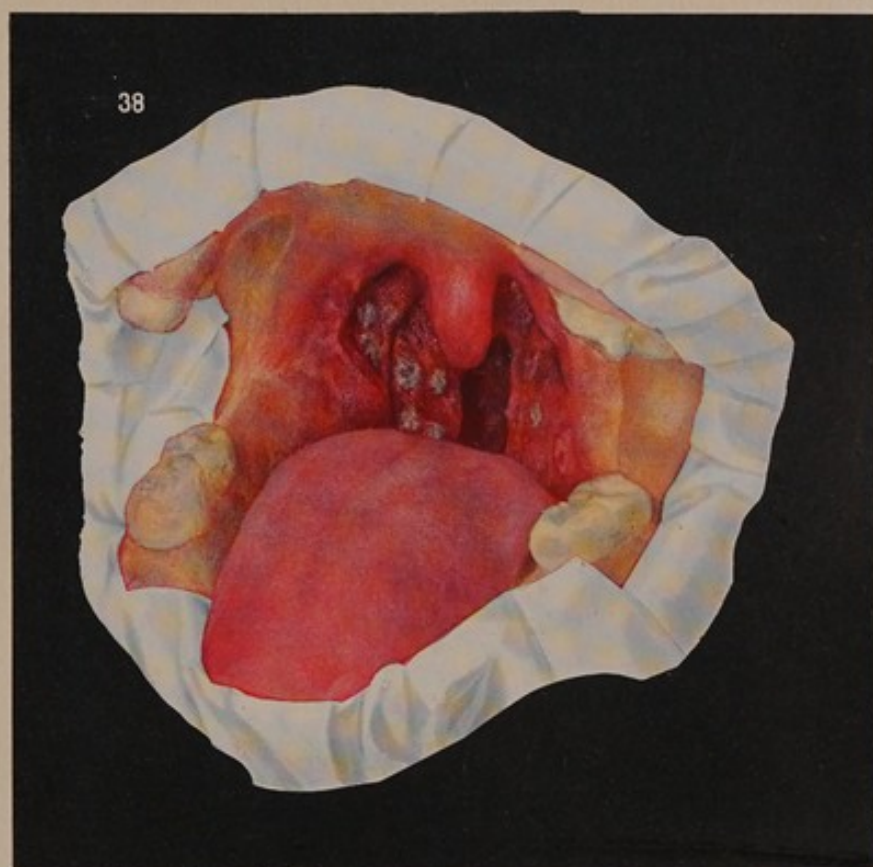
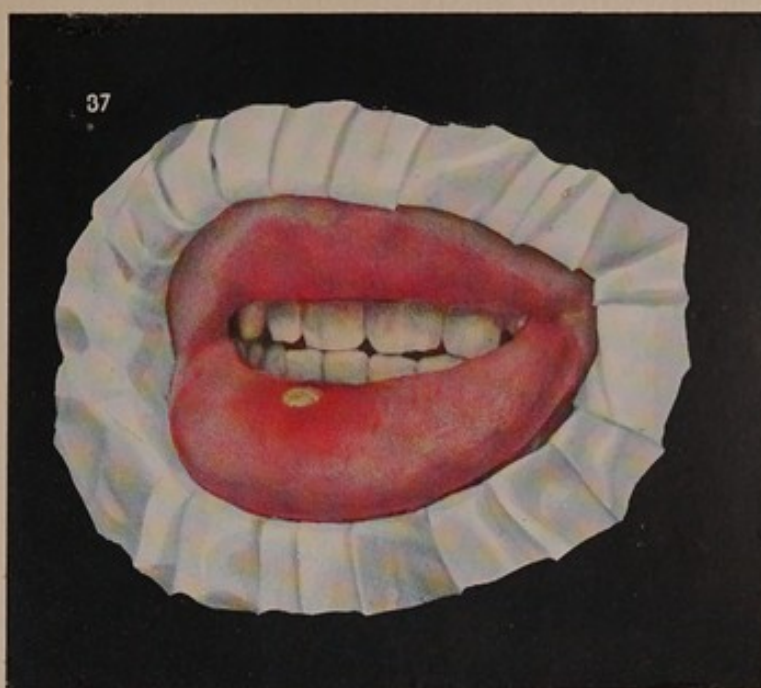
**Figure 37.—Aphthous Ulcer (Aphthous Stomatitis)**

On the middle of the lower lip is a flat hollowed-out little ulcer with a yellowish-white covering and an acutely inflamed border. It was very painful and had a sudden onset. The sudden onset, the pain and the active inflammatory reaction existing together disfavor a diagnosis of syphilis, but when the pain and inflammatory reaction are absent, it is difficult to diagnose this lesion from an erosive mucous patch. Aphthous ulcers of the mouth occasionally occur in syphilitics. The finding of the *treponema pallidum* in the lesion, which is always easy in erosive mucous patches, makes the diagnosis.

**Figure 38.—Angina Follicularis Catarrhalis (Follicular Tonsillitis)**

In this case there is an acute inflammation of the isthmus of the fauces accompanied with fever. There is much congestion and swelling so that the isthmus of the fauces is narrowed. The tonsils are also swollen. Projecting from the lacunæ of the tonsils are to be seen the yellowish white plugs which contain pus cells.










PLATE XXXII

**Figure 39.—Angina Syphilitica et Angina  
Follicularis Catarrhalis (Syphilitic An-  
gina and Follicular Tonsillitis)**

**Figure 40.—Diphtheria**

**Figure 39.—Angina Syphilitica et Angina Follicularis Catarrhalis (Syphilitic Angina and Follicular Tonsillitis)**

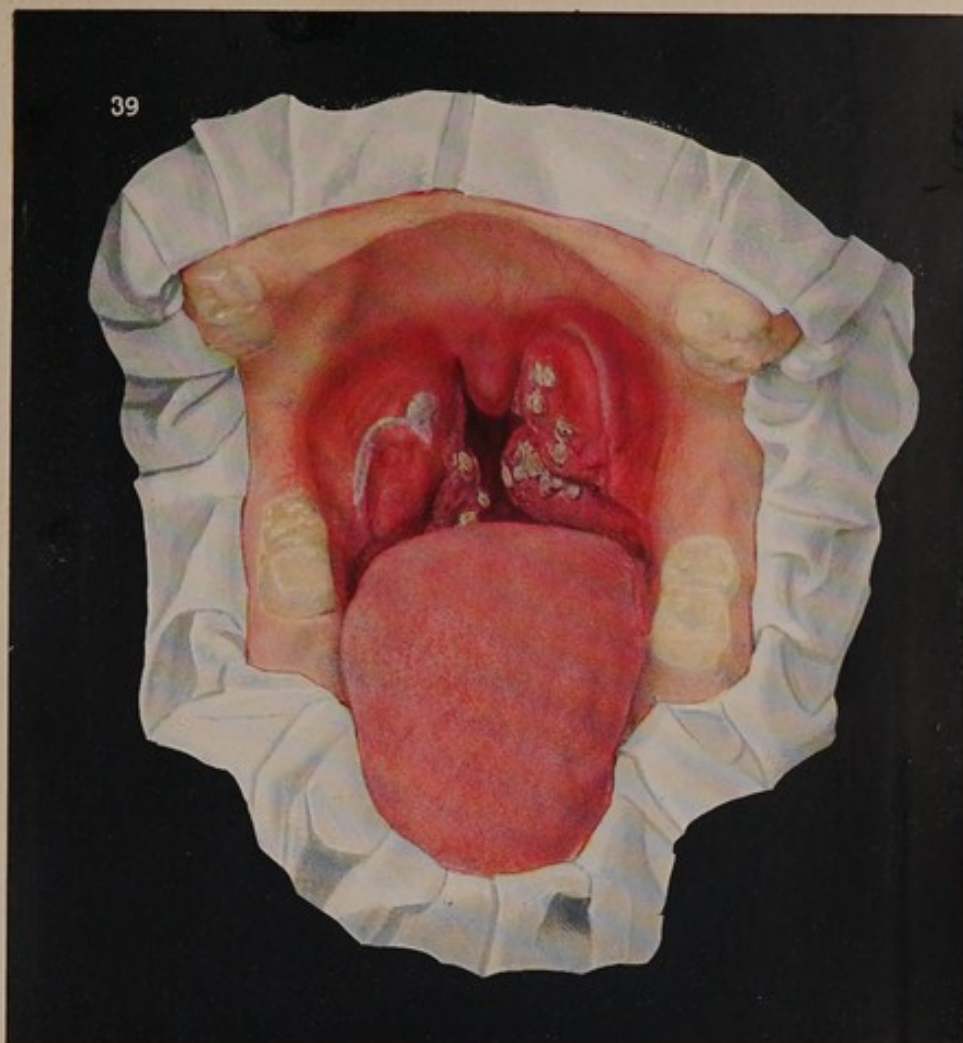
The patient was being treated for secondary syphilis. The manifestations were a chancre of the right labium majus, a papulo-squamous syphilide, impetigo capitis, and a syphilitic angina. Shortly after the beginning of the treatment there occurred a severe inflammation of the fauces, the tonsils became swollen and the follicles were filled with plugs containing pus, accompanied by fever and difficulty in swallowing. The easily seen gray mucous patchlike edge of the syphilitic angina persisted after the angina follicularis had healed.

**Figure 40.—Diphtheria**

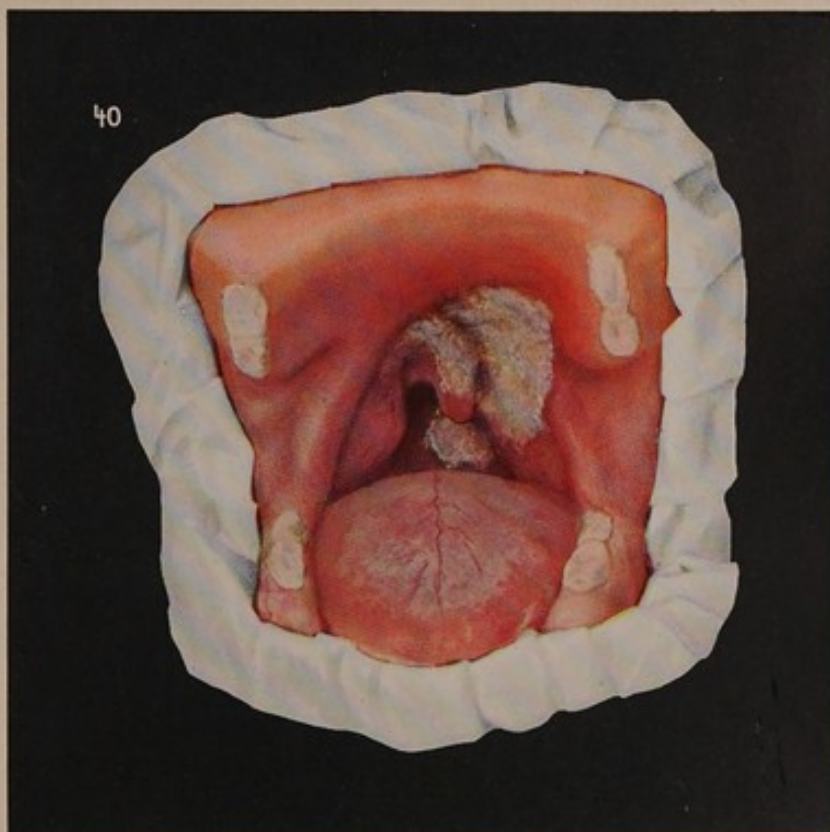
There is an active inflammation. The tonsils are but slightly swollen. A grayish-white, markedly adherent membrane lies on the left anterior and posterior pillars of the fauces, left tonsil, left half of the soft palate and uvula, and extends to the posterior pharyngeal wall. There is not much coating of the tongue. In this case the constitutional symptoms were very slight. There was no high fever. The diagnosis of diphtheria was based on the sharp line of demarcation between the white markedly adherent membrane and the surrounding red actively inflamed mucous membrane, on the fact that the lesion developed in two days and finally upon the conclusive evidence, viz.: the *Klebs-Löffler* bacilli in the lesion.




39



40







## PLATE XXXIII

### **Figure 41.—Plaut-Vincent Angina (Ulcerated Angina Resembling a Chancre of the Tonsil)**

This very instructive case is one of a young man, eighteen years old, who came to the hospital with an inflamed throat. About three or four weeks previously he had attended a masked ball and became very intimate with an unknown young woman whom he kissed a great deal. When he came under observation the lesion was a characteristic chancre of the tonsil. The right tonsil was swollen, but the surrounding mucous membrane was not especially congested.

There was not much pain, and on palpation the lesion was quite firm.

On the side and anterior surface of the tonsil there was an elliptical ulcer with arched-shaped borders about 2 cm long and 1 cm wide. Its hollowed-out floor was covered by a greenish-yellow, markedly adherent, fibrinous membrane. At the angle of the mandible on the right side there were two movable indolent lymph ganglia, one of which was about the size of an almond and the other a little smaller. There was little doubt but that the lesion was a chancre. Before giving an injection of salvarsan, as no secondary manifestations of the disease had appeared, the *treponemata pallida* were sought in the lesion, but none were found, though the effort to find them was continued for several days. However, a large number of thick spirilla were detected, and in a

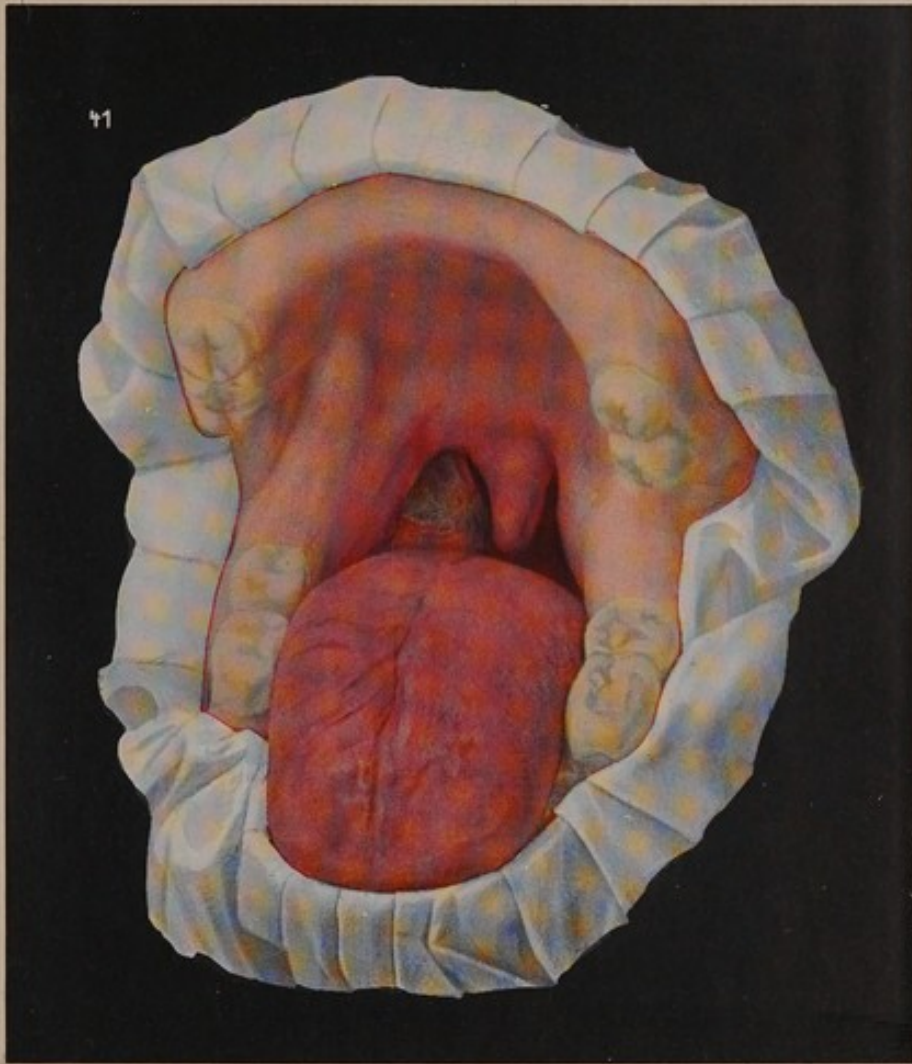


stained specimen numerous fusiform bacilli were also discovered.

As the *treponema pallidum* was not found on the ulcer the submaxillary lymph nodes were punctured daily for several days and their aspirated fluid carefully examined, but with negative result. Local treatment was begun, which consisted of gargling the throat with weak hydrogen peroxide and painting the lesion with 30% hydrogen peroxide. After a few days the ulcer became clean and healed; the tonsil became softer and the swelling disappeared; the submaxillary lymph nodes diminished in size, and after fourteen days there was no trace of the disease, excepting a slight swelling of the lymph nodes. The patient was kept under regular observation for several weeks. There was no manifestation of syphilis, and the *Wassermann* reaction which was at first negative remained so.

This is a case of a non-specific ulcer of the tonsil, which, in view of the microscopic findings, viz.: spirilla and fusiform bacilli, is to be classed in the *Plaut-Vincent* angina group. This case, in which nobody believed the lesion to be anything other than a chancre of the tonsil, shows how careful one must be in making a diagnosis, even when aided by the findings of the dark-field-microscope, as it occasionally happens that the *spirochæta dentium* (*treponema microdentium*) and especially "the medium form" (*treponema macrodentium*) may be found, and these are often difficult to distinguish morphologically from the *treponema pallidum*.









## PLATE XXXIV

### **Figure 42.—Angina Ulcerosa Traumatica (Ulcerated Traumatic Angina). (Plaut- Vincent Angina?)**

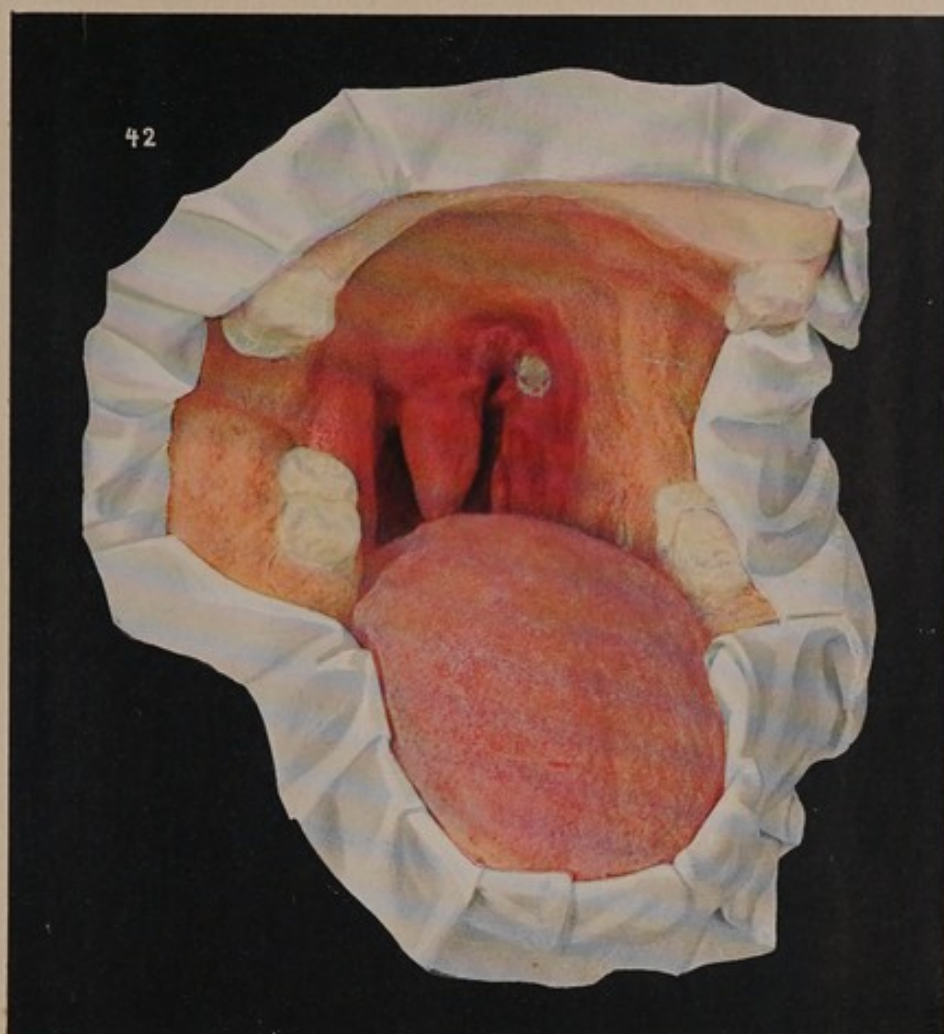
A man in good health, forty-two years old, who emphatically denied ever having had syphilis, had a foreign body stick into the soft palate near the uvula. A small pustule developed. After some days a physician removed the foreign body from this pustule. The resulting small ulcer did not heal, but gradually increased in size, so that in about four weeks it had a diameter of about 6 mm, and as a crescentic ulcer involved the upper part of the left anterior pillar of the fauces. When the patient came under our observation, the ulcer had almost completely healed, excepting the serpiginous part which had extended to the left pillar of the fauces, where there was seen a hollowed-out ulcer about the size of a lentil with a yellowish-white floor. The scar felt quite firm. The surrounding mucous membrane was red, oedematous, and swollen. There was but slight pain and little difficulty in swallowing.

The diagnosis swung at first between gumma and chancre. Against tuberculosis, aside from the form of the ulcer and the absence of tubercles, was its occurrence and partial healing within four weeks. The absence of adenopathy precluded the diagnosis of chancre, although a suspicious eruption occurred which was found to be a medicamentous acne caused

by taking potassium iodide. The treponema pallidum was not found in the lesion, although there were a number of coarse thick spirilla present. The fusiform bacillus was absent. The *Wassermann* was negative, hence the diagnosis of gumma was not made. An energetic treatment with potassium iodide had no effect. The possibility of actinomycosis was not excluded. When one part healed, other small ulcerations slowly extended along the left anterior pillar of the fauces. Diligent gargling with camomile tea and 2% hydrogen peroxide had no effect. After four weeks, when the lesion was rubbed several times a day with 30% of hydrogen peroxide, the process quickly came to a standstill. The patient remained for some time under observation. No secondary manifestations of syphilis or relapsing of ulcerations were seen. The *Wassermann* reaction remained negative. Carcinoma was thought of, but the healing and the entire course of the disease excluded such a diagnosis.

This case was an ulcero-serpiginous inflammation of the mucous membrane of the fauces of traumatic origin, which is to be classed among the *Plaut-Vincent* angina group, although the spirilla and fusiform bacilli could not be found in the lesion.










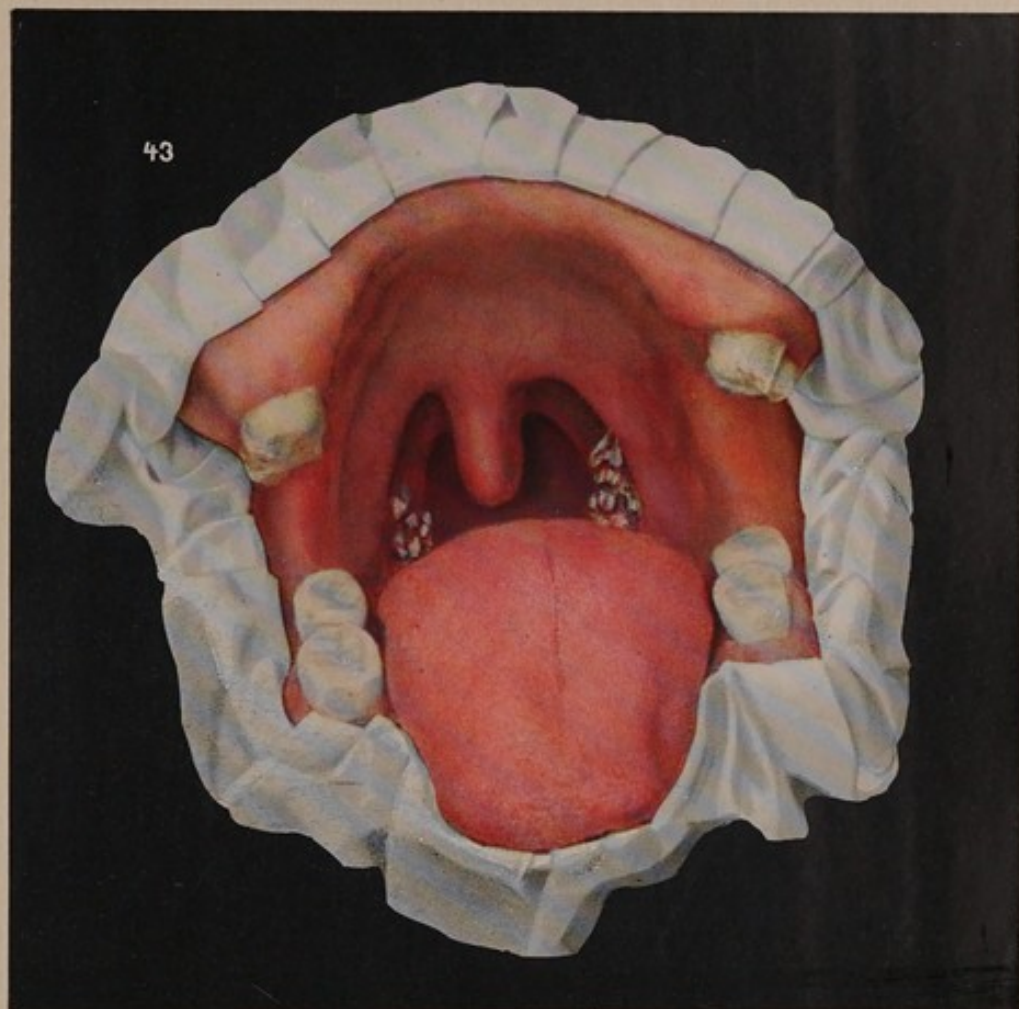
PLATE XXXV

**Figure 43.—Angina Mycotica (Mycotic  
Angina)**

**Figure 43.—Angina Mycotica (Mycotic Angina)**

The mucous membrane of the fauces is neither red nor swollen. In the follicles of the tonsils which are not enlarged, yellowish-white keratogenous plugs are seen extending several millimetres above the mucous membrane. The plugs can be squeezed out of the follicles and appear by microscopic examination to be composed of masses of epithelium, calcareous material, and threads of fungi (*Leptothrix Buccalis*).











PLATE XXXVI

**Figure 44.—Lingua Geographica (The Geographical Tongue)**

**Figure 45.—Lingua Geographica (The Geographical Tongue)**





**Figure 44.—Lingua Geographica (The Geographical Tongue)**

The entire tongue is somewhat coated. The epithelium is thickened and arranged in the form of bows and garlands. There is no swelling or pain. The differential diagnosis of this condition from an annular syphilide of the tongue was not easy, and therefore the fact that the patient had, six weeks before, a not very characteristic ulcer in the coronary sulcus was of considerable importance. No *treponemata pallida* were found, the *Wassermann* reaction was negative and there was an inflammatory adenitis in the left inguinal region.

As the patient insisted he had had these white bows on his tongue from childhood, and as in the course of the further observation no manifestations of secondary syphilis appeared, the diagnosis of syphilis was excluded.

**Figure 45.—Lingua Geographica (The Geographical Tongue)**

This is a form of lingua geographica which very greatly resembles a papular syphilide of the mucous membrane of the tongue. On the tongue are to be seen round and elliptical, quite smooth bluish-red spots, surrounded by a narrow darker red border which is also surrounded by a whitish border of thickened epithelium. There is no infiltration, the mucous membrane of the rest of the tongue being normal.

Without great care the efflorescence cannot be dis-

tinguished from smooth mucous patches of the tongue.

In this case the diagnosis was especially difficult as the patient also had syphilis. This affection of the tongue, however, had existed since childhood and was not affected by the inunctions of mercury, which the patient had taken. The appearance of the tongue rapidly changed, so that in a few days the form and arrangement of the spots were entirely altered.



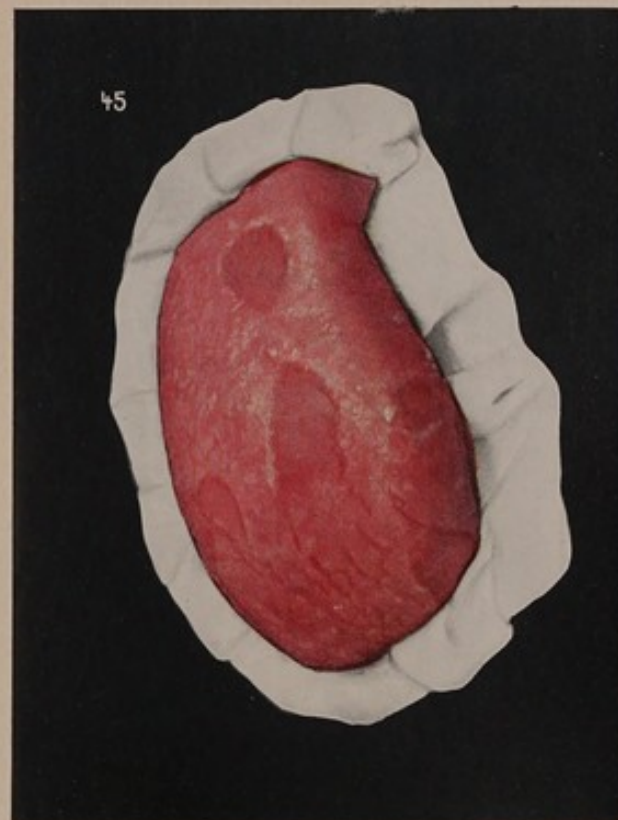
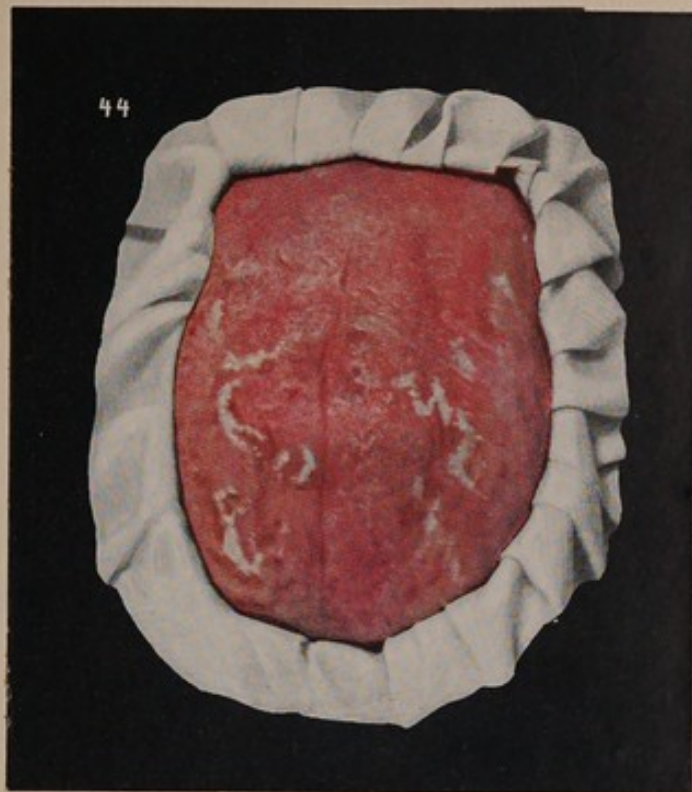





PLATE XXXVII

**Figure 46.—Leukoplakia Linguae (Leukoplakia of the Tongue)**

**Figure 47.—Tuberculosis of the Mucous Membrane of the Hard Palate**

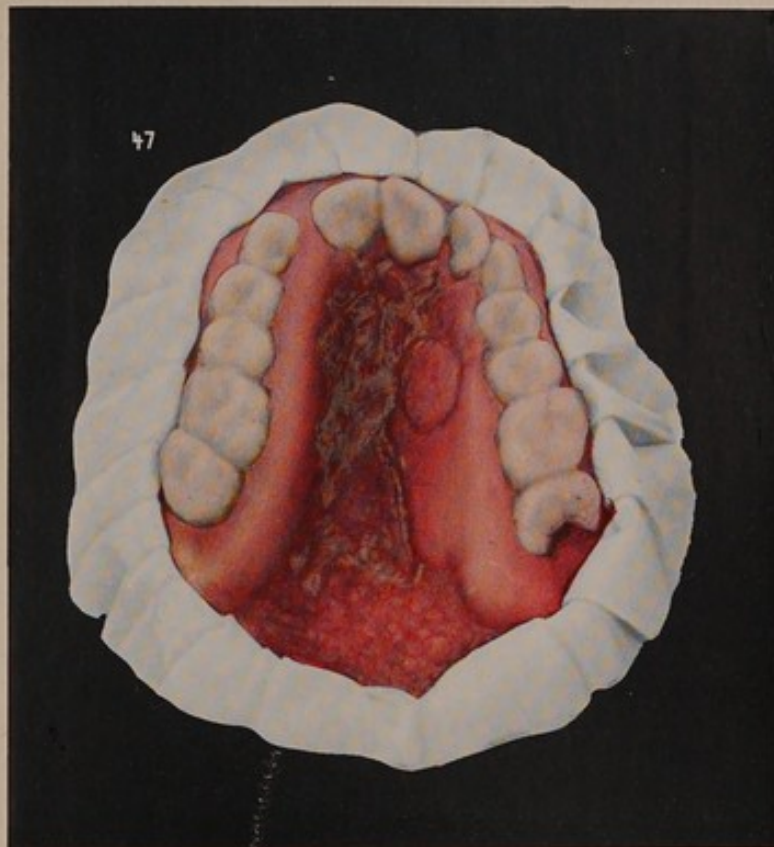
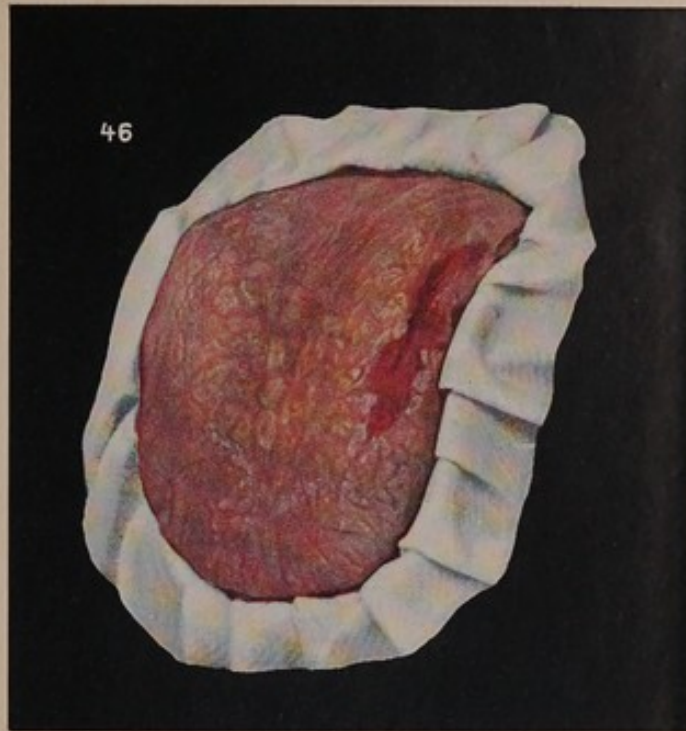
**Figure 46.—Leukoplakia Linguae (Leukoplakia of the Tongue)**

In a man, seventy years of age, who had syphilis in his youth, the mucous membrane of the entire mouth was altered, becoming thickened and callous-like, and of a dull gray appearance, permitting the red of the underlying tissue barely to show itself and feeling dry and hard. The entire surface of the tongue was divided into small fields by numerous fine furrows arranged in a reticular manner. In separated localities the thickening of the epithelium led to the formation of a horny layer, especially on the cheeks. On the left border of the tongue, opposite some sharp stumps of teeth, a sort of ulceration occurred, but there was no pus and the lesion was covered with epithelium. This lesion may be the beginning of carcinoma of the tongue, as it has been observed for over a year, and no change has taken place in it.

**Figure 47.—Tuberculosis of the Mucous Membrane of the Hard Palate**

In this case the diseased mucous membrane is intensely congested, with a rough, granular surface which has hollowed-out small irregular and in part reticular ulcers with precipitous borders scattered over it. The floor of the ulcers is covered with a greenish-yellow pus and their form makes clear their origin from miliary tubercles. The mucous membrane of the soft palate is thickly covered with tubercles somewhat resembling sago. Tubercle bacilli were not found in the pus. The patient suffered from a severe lupus of the face and mucous membrane of the nose, which extended to the naso-pharynx.










PLATE XXXVIII

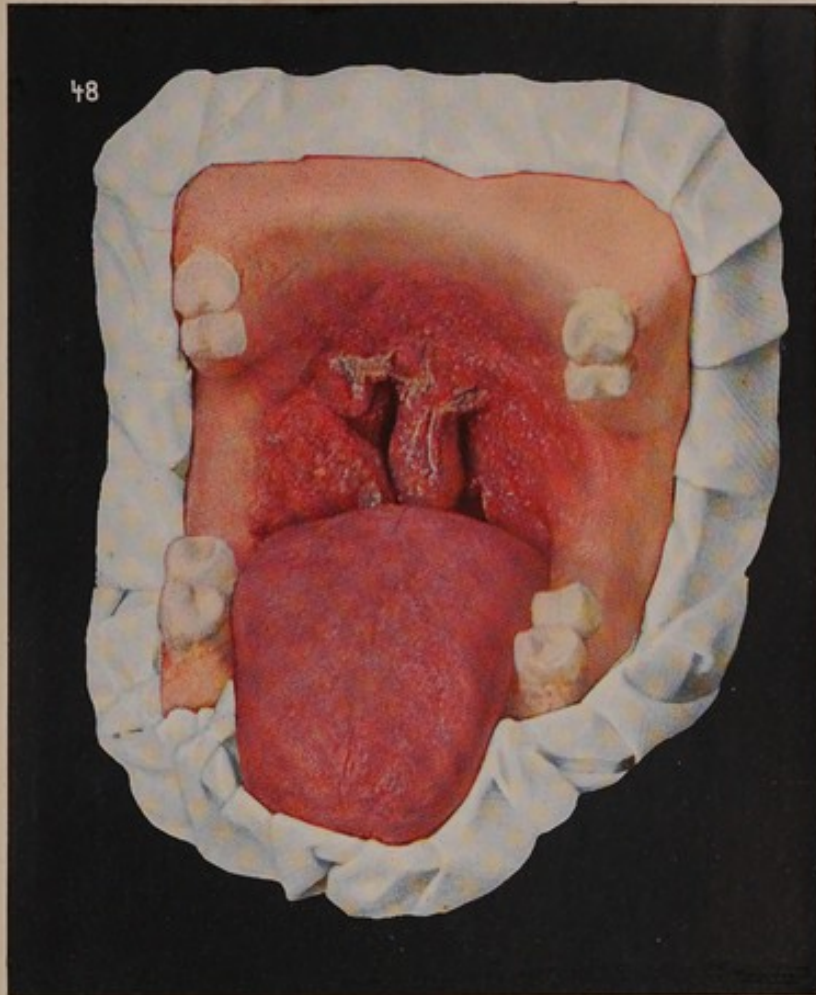
**Figure 48.—Tuberculosis of the Mucous  
Membrane of the Fauces, Soft Palate,  
and Uvula**

**Figure 48.—Tuberculosis of the Mucous Membrane of the Fauces, Soft Palate, and Uvula**

The entire mucous membrane of the fauces, soft palate, and uvula is much congested, œdematous, and swollen. The surface of the mucous membrane is finely granular or velvetlike. On the uvula and soft palate there are several small, hollowed-out ulcerations with undermined edges. It can be seen that these ulcers arise from the confluence of numerous miliary tubercles. The ulcers are covered with yellowish-white pus. The process gradually extends over the normal mucous membrane. Tubercle bacilli were not found in the pus, but an extirpated portion of the mucous membrane, which was rubbed up with normal saline solution and injected into the peritoneal cavity of a guinea-pig, produced tuberculosis in the animal.

The patient is a weak anæmic child, six years old, and suffers also from a pannus serophulosus of both eyes and an eczema of the scalp.










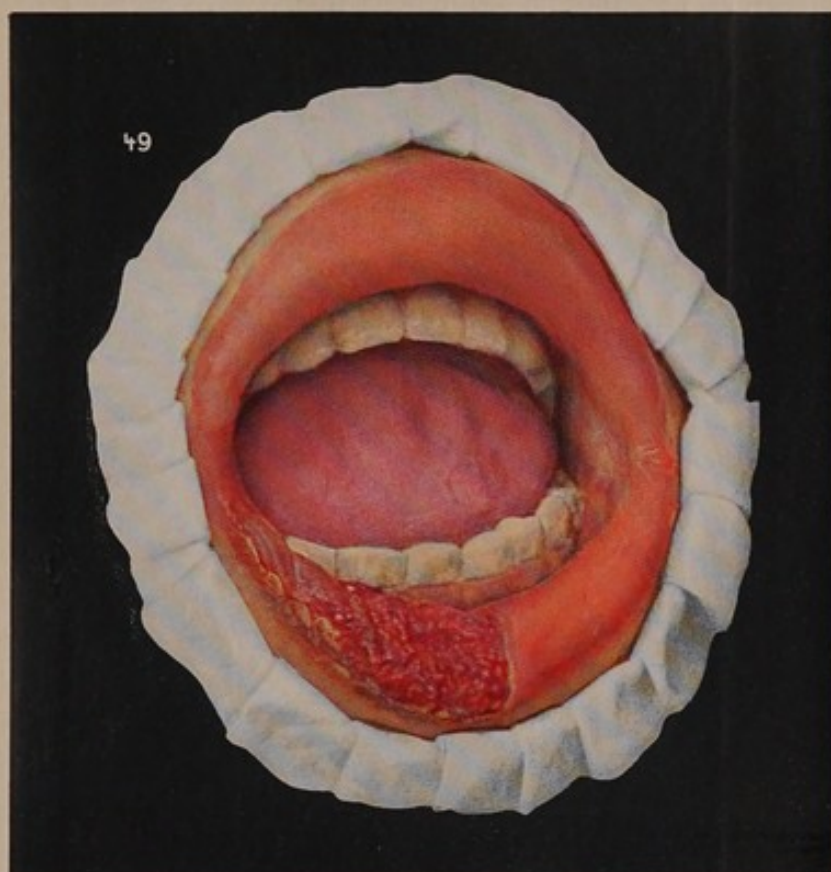
PLATE XXXIX


**Figure 49.—A Tubercular Ulcer of the  
Lower Lip**

**Figure 49.—A Tubercular Ulcer of the  
Lower Lip**

In this case a deep, painful ulcer is seen on the lower lip of a moribund phthisical patient. It has existed less than four months. It involved the right half of the lower lip and extended to the gums and the mucous membrane of the right cheek. The floor of the ulcer is granular and humped up, and in the hollows and furrows a small amount of yellow pus is seen which contained tubercle bacilli. Separating the normal mucous membrane on the left side of the lip from the ulcer is a precipitous border which in some places is 2 or 3 mm high.









## PLATE XL

### **Figure 50.—Carcinoma of the Tongue**

### **Figure 51.—Tumor of the Tongue. Gumma?**

#### **Figure 50.—Carcinoma of the Tongue**

On the left side of the tongue is a tumor about 2 cm in diameter. The border of the tumor is precipitous and rampartlike, and extends 2 or 3 mm above its level. It is as hard as cartilage and forms a sharp line of demarcation between the normal tissue and the tumor. The ulcerated humped up surface of the tumor is flattened or somewhat concave, is covered with tenacious pus and bleeds easily. The tumor, which is situated opposite a sharp tooth, gradually developed from a small ulcer during the course of three months. It is quite painful. No involvement of the adjacent lymph nodes was seen. Even without a negative *Wassermann* and the absence of the *treponema pallidum* in the lesion a diagnosis of carcinoma can be made. The compactness of the rampartlike border was too great for a chancre, and besides there would be evidence, at this time, of the involvement of the adjoining lymph nodes and of the secondary syphilitic manifestations. The development was too slow and the breaking down too slight, and the tumor itself, and especially its border, too hard for it to be mistaken for a gumma. Tuberculosis was to be thought of, but the tubercle granula were absent. A biopsy confirmed the diagnosis.

#### **Figure 51.—Tumor of the Tongue. Gumma?**

A man, thirty years of age, came under observation who had a tumor of the tongue situated to the right of its median line. It consisted of two nodes situated one beside the other, each being about the size of a hazel nut. The tumor gradually, in the



course of some weeks, developed. There was quite a sharp line of demarcation between it and the surrounding normal tissue. It was firm and painless. There was a distinct central softening in both nodes, which in the course of a few days approached the surface, and finally a grayish-yellow color appeared over the spot. The patient said that ten years previously he had had a chancroid which quickly healed after applying iodoform, and following which there were no secondary manifestations of syphilis. The *Wassermann* reaction was and continued to be negative. The lymph nodes in the neck were slightly swollen. On puncturing the tumors, a greenish, viscid, gelatinous mass was obtained, but the tumor could still be distinctly felt. Under small doses of potassium iodide the tumor very quickly disappeared without leaving a scar. It is very doubtful if this was a gumma of the tongue. The appearance of the tumor, the way in which it developed, and, finally, the central softening, favor the diagnosis of gumma. The exceptionally rapid and spontaneous healing after the administration of the potassium iodide is striking. That the *Wassermann* reaction continued negative proves nothing, even if it gives weight to a diagnosis excluding syphilis.

A malignant tumor, carcinoma, or sarcoma could not run such a course. It was not an abscess, as there was no pain and the softened spot did not contain pure pus, but cell detritus.

Actinomycosis was thought of, but the microscopic examination did not prove the presence of the actinomyces. Echinococcosis was thought of, as the patient had a dog which he had repeatedly treated for tape worms. But here proof was lacking. It must be clearly understood that in the beginning this tumor was not a cystic tumor, but that it was a compact tumor, which underwent softening at the centre. That is why it cannot be a retention cyst.

In this case where the lesion closely resembles a gumma, the diagnosis must be left open on account of insufficient proof.



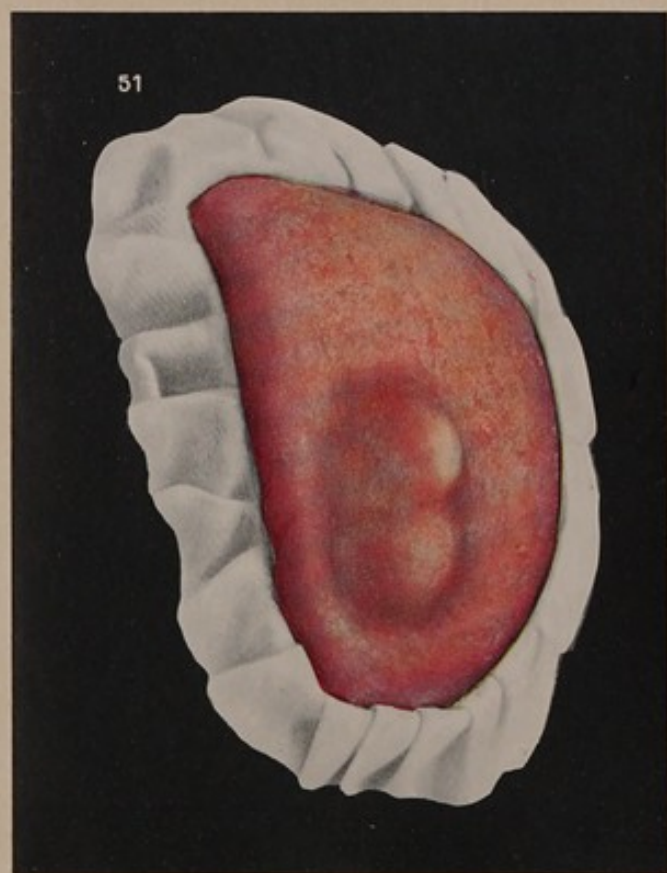
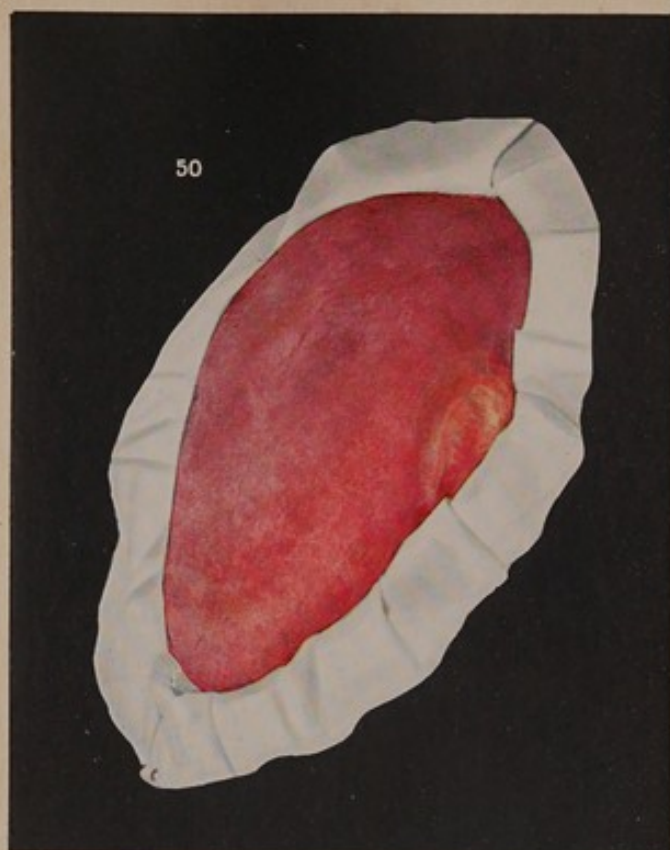






PLATE XLI

**Figures 52, 53.—Hutchinson Teeth**

**Figures 54-57.—Herodossyphilitic Teeth**

### **Figures 52, 53.—Hutchinson Teeth**

The two upper central incisor teeth, which are oval in shape, have a deep notching of their morsal margin; otherwise the teeth are perfectly smooth and normal. The left upper lateral incisor tooth is round and pointed. A central caries of the two upper first molars (which evidently resulted from the hypoplasia of the morsal surface of the teeth) is also seen.

The teeth are those of a girl sixteen years old who has heredosyphilis and a parenchymatous keratitis.

The lower first molars were completely destroyed.

### **Figures 54-57.—Herodosyphilitic Teeth**

In this case the teeth of a ten-year-old girl show a high grade of disturbance during the period of calcification. The two upper central incisor teeth are well-marked *Hutchinson* teeth, each with its characteristic, crescentic notch. These two teeth are broad, but narrow toward the morsal, and gingival margins and their outer edges are pointed. The two upper lateral incisor teeth have eroded morsal margins. The two upper canine teeth are misplaced and have sharp-pointed eroded tips.

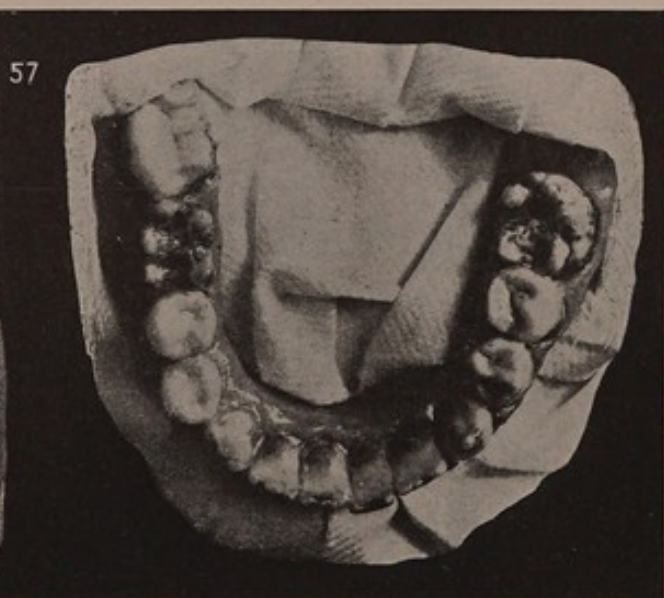
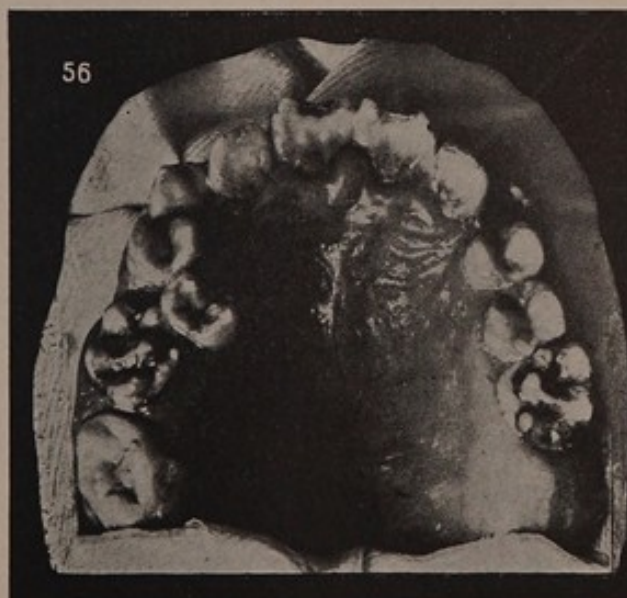
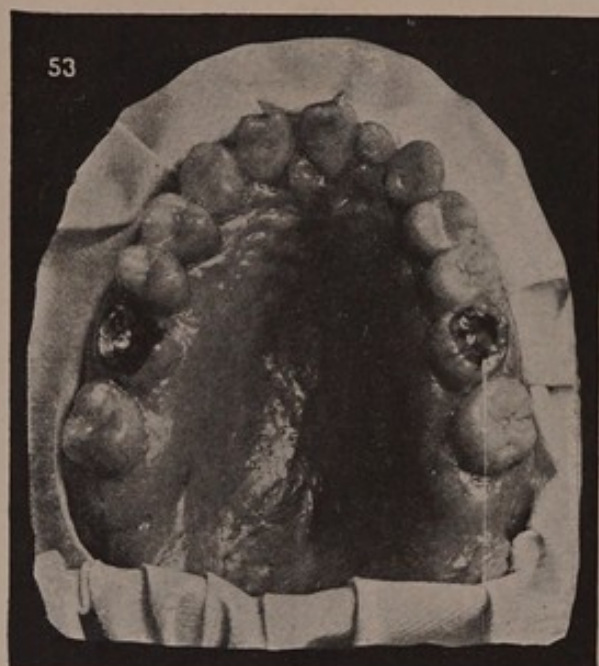
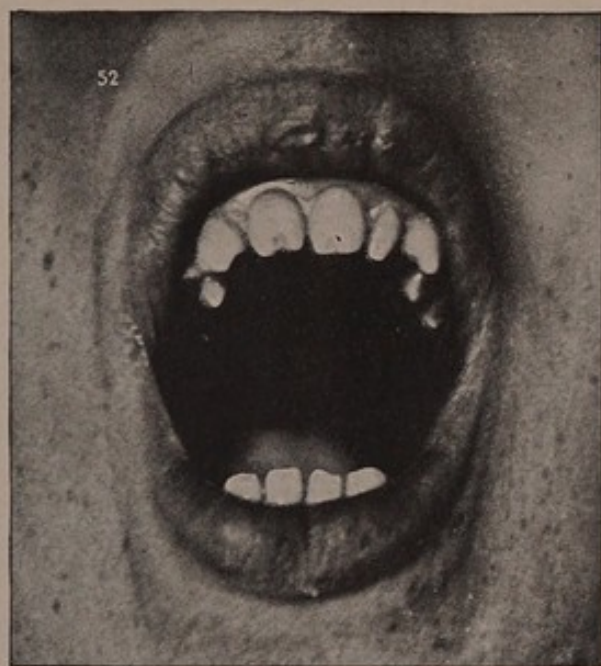
The four lower incisor teeth show a superficial hypoplasia, extending from the middle of the crown to the morsal margin. The lower canine teeth are eroded at their tips.

The morsal surfaces of the entire four first molars are distinctly eroded. Instead of the normal smooth cusps there are numerous irregular, wrinkled, granular points.

In striking contrast to the teeth with the developmental hypoplasia, notice the smooth normal morsal surfaces of the cuspid, bicuspid, and other molar teeth.



Plate XLI. Figs. 52, 53, 54, 55, 56, 57



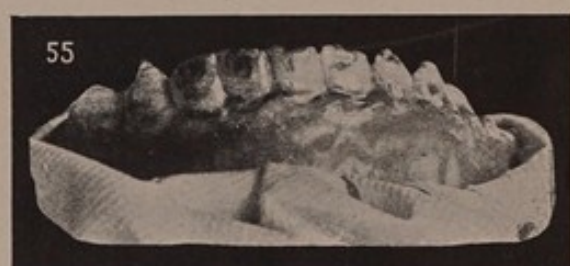




PLATE XLII

**Figures 58-61.—Herodossyphilitic Teeth**

**Figure 62.—Heredossyphilitic Teeth**

### **Figures 58-61.—Herodosyphilitic Teeth**

This case also demonstrates a high grade of hypoplasia, especially of the two upper central incisor teeth. The entire distal third is diminished in size in all directions, and the hypoplastic, amorphous portion of each of these teeth, without any enamel, rests upon the normal part of the teeth as a base. This condition resembles the notching of the *Hutchinson* teeth, with the difference that here the disturbance to the calcification process lasted longer. The upper lateral incisor teeth are a little worn away at the morsal margins. The upper and lower canine and the lower incisor teeth show a high grade of hypoplasia toward their morsal margins. The hypoplasia, on the morsal surfaces of the four first molar teeth, is especially marked. Here the dirty yellow humped-up morsal surface of the teeth is situated upon the remaining normal part of the tooth.

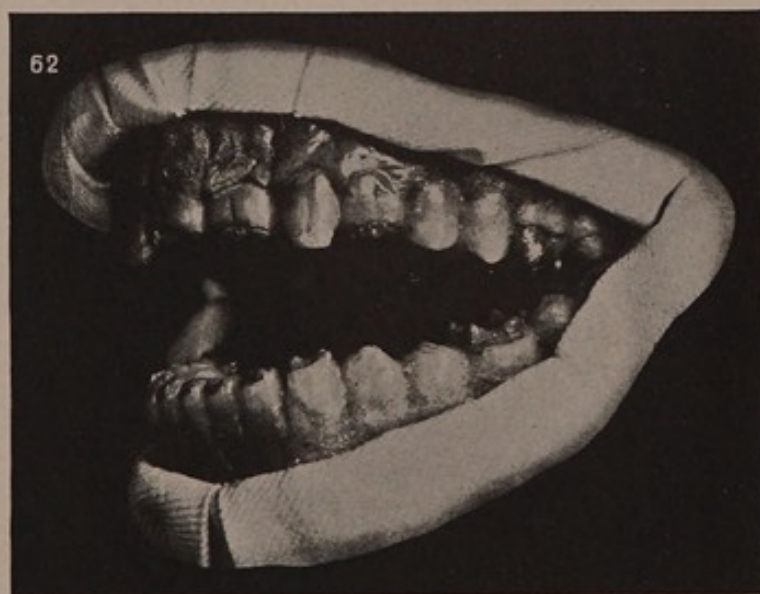
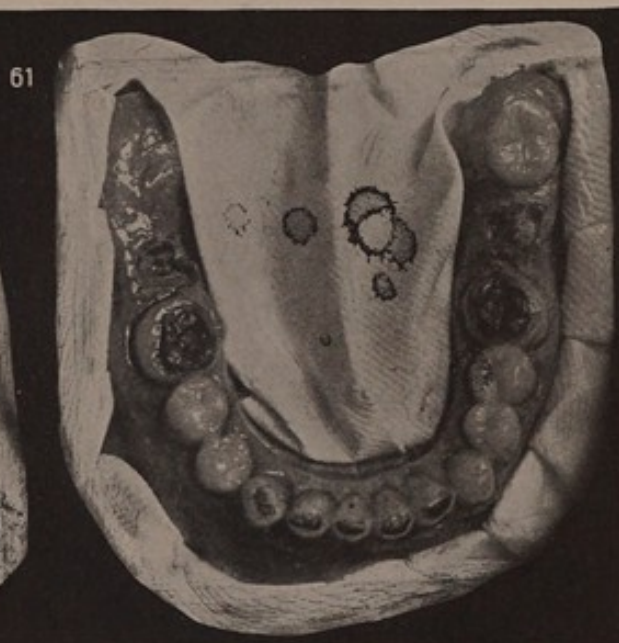
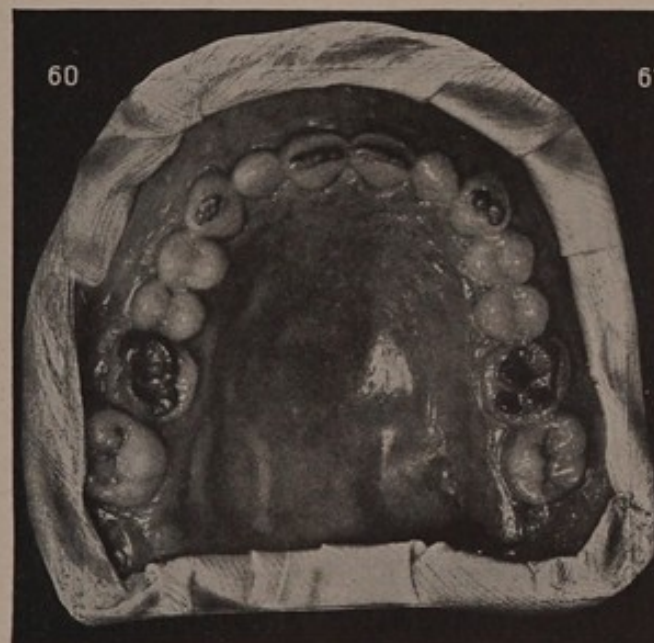
The cuspid, bicuspid, and the other molar teeth, so far as they are preserved, are perfectly developed.

### **Figure 62.—Heredosyphilitic Teeth**

Shows an especially marked hypoplasia of the morsal surfaces of the first molar teeth.



Plate XLII. Figs. 58, 59, 60, 61, 62




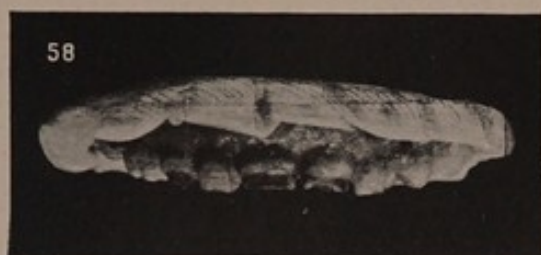




PLATE XLIII

**Figures 63-66.—Heredosyphilitic Teeth**

**Figure 67.—Heredosyphilitic Teeth**





### **Figures 63-66.—Heredosyphilitic Teeth**

Erosions in the form of pits are seen upon the two upper central and all the lower incisor teeth, upon both the morsal margins and the facial surfaces of the crowns. All four canine teeth show a hypoplasia of their tips, which appear as if they were separated from the rest of the tooth by a flat furrow. The upper first molar teeth also have an encircling furrow, which is the line of demarcation between the hypoplasia of the morsal surfaces and the remaining normal portion of the teeth. One of the lower molars is missing, and but little of the other is left. The condition of the first molars, which must be attributed to the damage done before birth, was probably caused by heredosyphilis, which is also to be regarded as the cause of the erosions in the form of pits and hollows.

The patient probably had heredosyphilis. A sister had *Hutchinson* teeth and a parenchymatous keratitis.

### **Figure 67.—Heredosyphilitic Teeth**

On the facial surfaces of all the upper and lower incisor and canine teeth are several furrows and cup-like erosions, and all their morsal margins are notched in several places. All the first molars are missing, except the right lower one, in which there is a central caries, apparently following a developmental hypoplasia of the morsal surface. The cuspid and bicus-

pid teeth show on their surfaces slight erosions and transverse furrows.

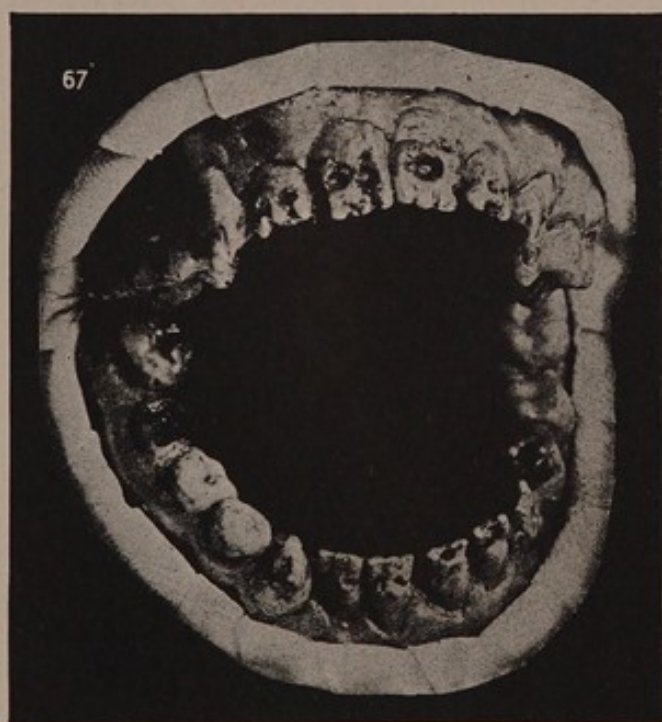
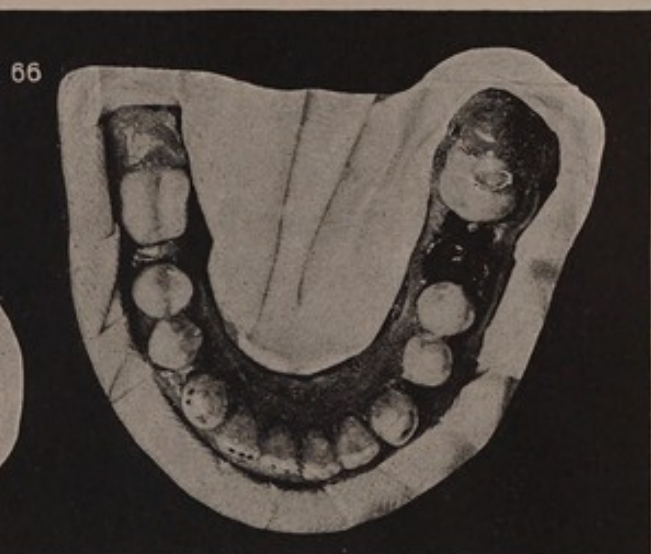
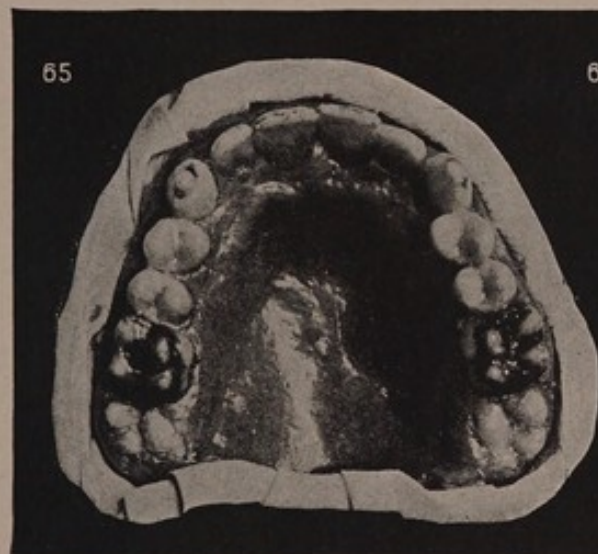
This is the result of a condition existing before birth and continuing to the end of the first or part of the second year of life.

The history of this case is very instructive. The patient, a boy, twelve years old, had been treated a year and a half for a parenchymatous keratitis. The diagnosis of syphilis was not made, and antisyphilitic treatment was not energetically applied, because the keratitis did not react well to mercury; the *Wassermann* reaction was negative, there were no other symptoms of heredosyphilis, and the condition of the teeth was attributed by me, at that time, to rachitis.

A year later the boy returned with a severe syphilitic perforation of the hard palate (compare Fig. 29) and a positive *Wassermann* reaction. If the hypoplasia of the right lower first molar had been recognized as a sign of heredosyphilis and energetic antisyphilitic treatment resorted to, the patient would have been spared the severe disfigurement.



Plate XLIII. Figs. 63, 64, 65, 66, 67




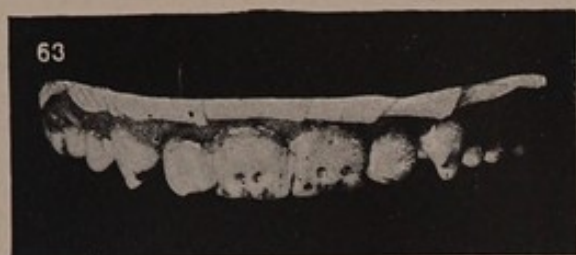



PLATE XLIV

**Figure 68.—Treponema Pallidum (Spirochaeta Pallida). The Specimen was Obtained from a Mucous Patch of the Lip**

**Figure 69.—Spirochaeta Buccalis and Spirochaeta Dentium (Treponema Microdentium). The Specimen was Obtained from a Healthy Mouth**

**Figure 68.—Treponema Pallidum (Spirochaeta Pallida). The Specimen was Obtained from a Mucous Patch of the Lip**

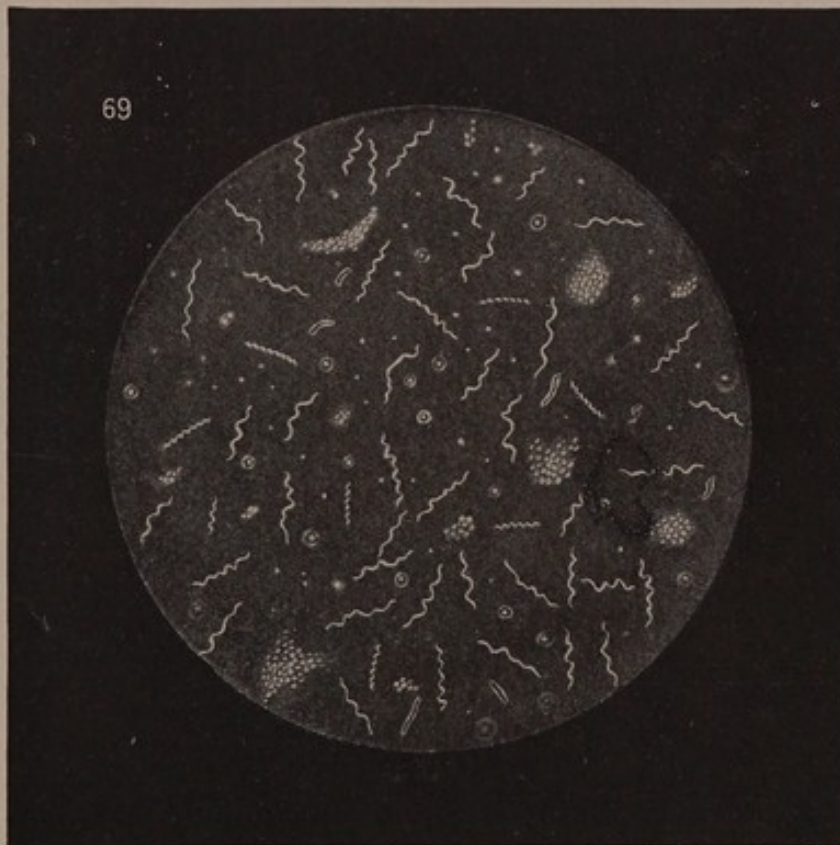
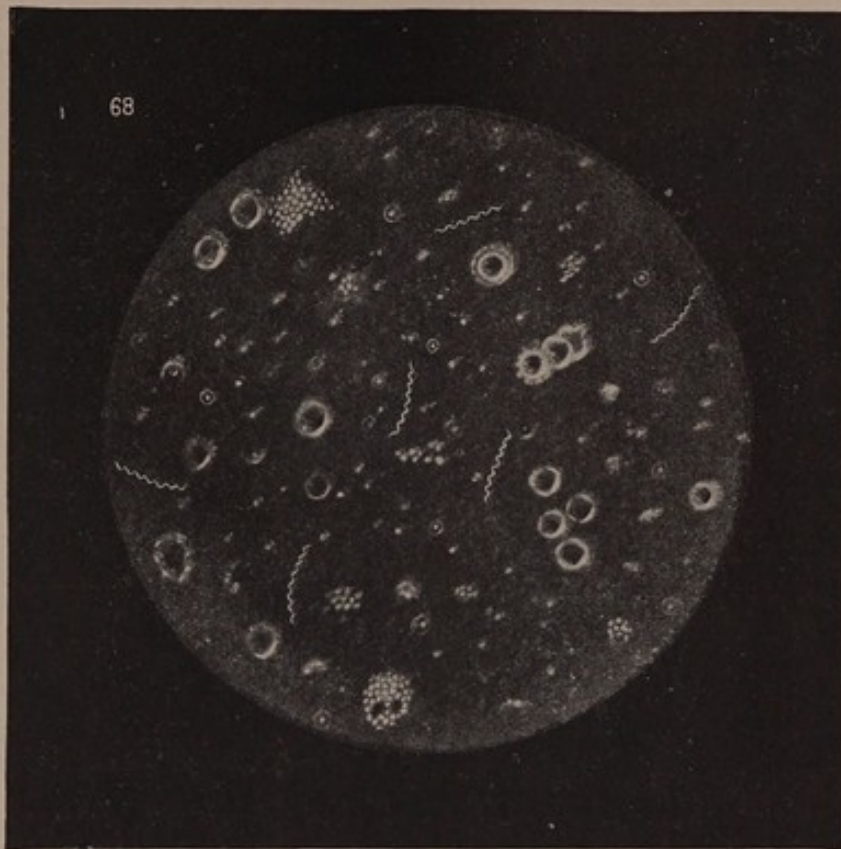
Six treponemata pallida are seen in the dark field. They are shown here as straight or slightly curved spirilla, with pointed ends, and having seven to eight turns. They move slowly by rotating about their axes. There are also flexion and extension movements.

**Figure 69.—Spirochaeta Buccalis and Spirochaeta Dentium (Treponema Microdentium). The Specimen was Obtained from a Healthy Mouth**

The Spirochæta Buccalis is thicker than the pallida, and has irregular turns and an active snakelike or flagellating movement.

The Spirochæta Dentium is finer than the pallida, and its very regular windings are closer and its curves steeper than those of the pallida. The Spirochæta Dentium moves about its long axis, and its movement is not so rapid as the spirochæta buccalis.











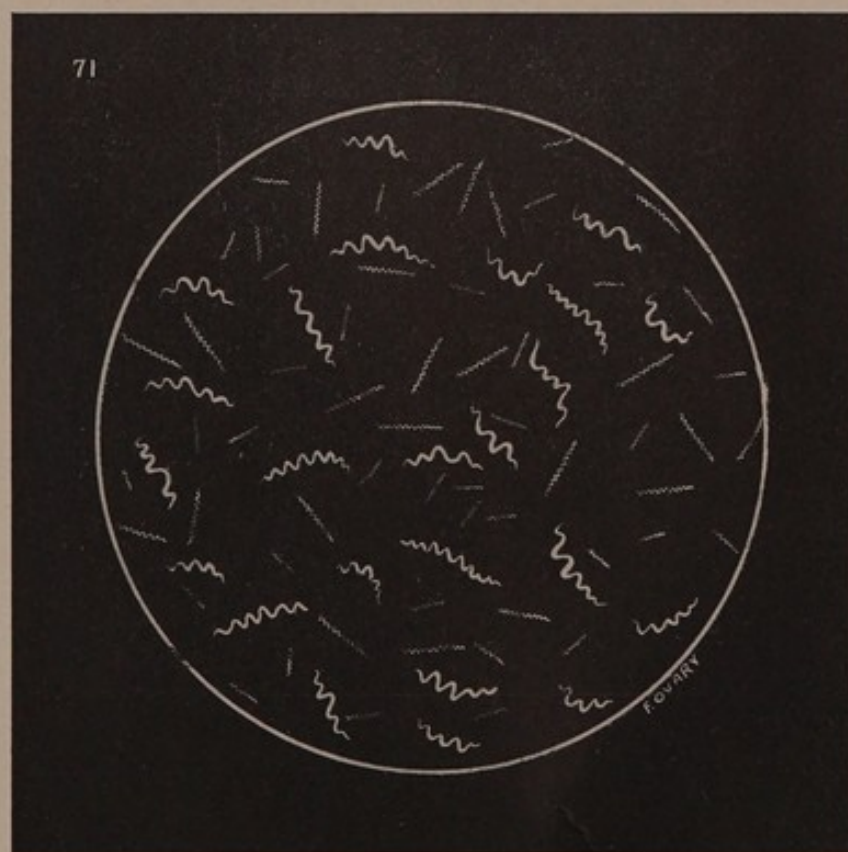
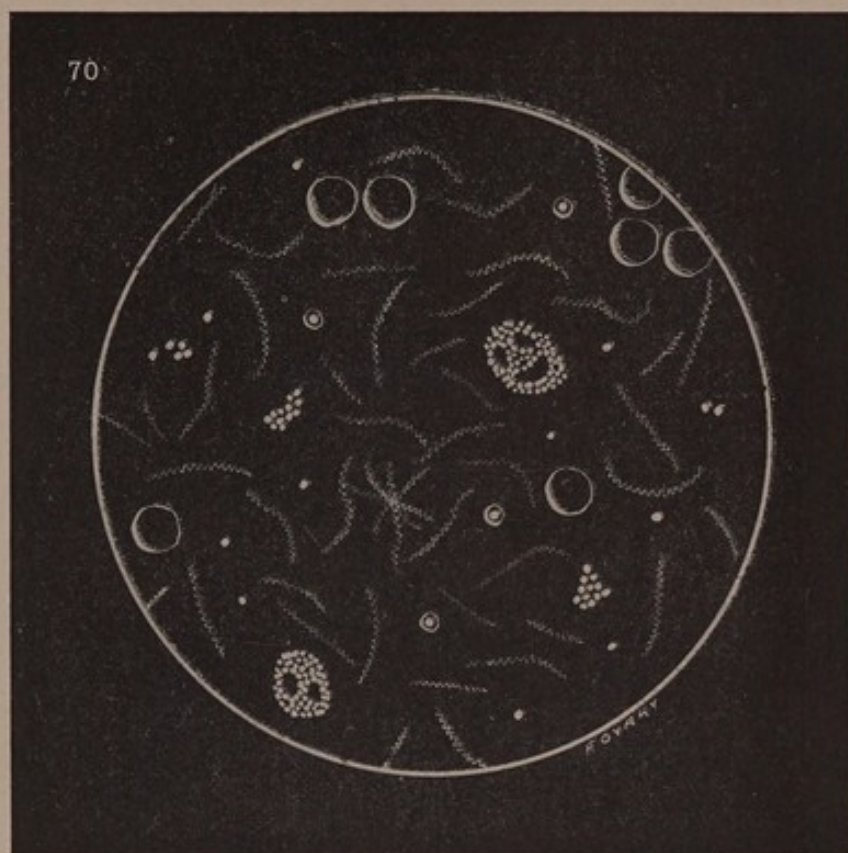
PLATE XLV

**Figure 70.—Treponema Pallidum, Pus Cells,  
Erythrocytes, and Cocci**

**Figure 71.—Treponema Microdentium (Spirochaeta Dentium), Treponema Macro-  
dentium ("Medium Form" of Hoffmann  
and von Prowazek), Spirochaeta Buc-  
calis**












PLATE XLVI

**Figure 72.—Spirochaeta of Vincent and Bacillus Fusiformis of Vincent, Pus Cells**

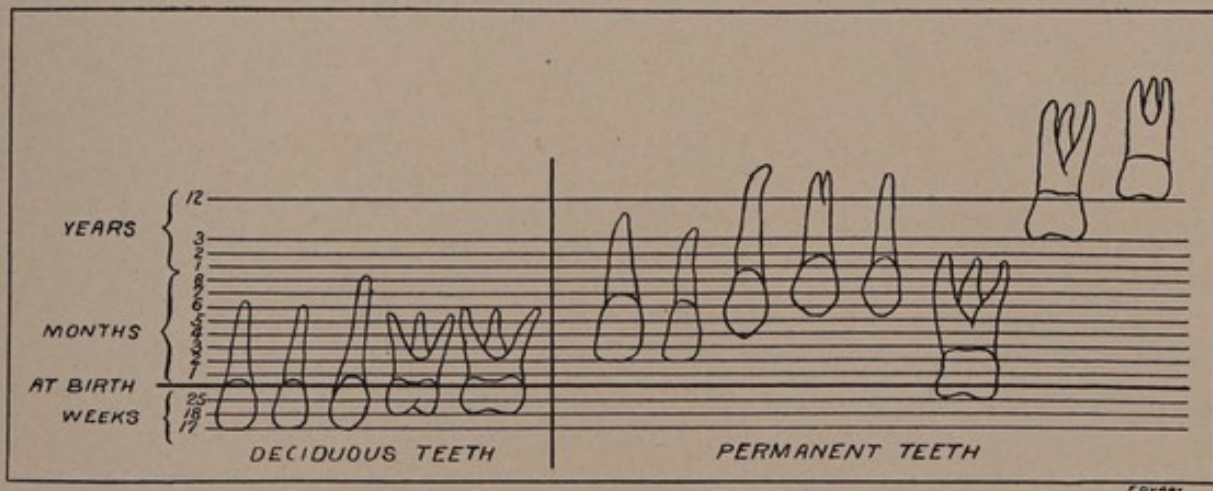
**Figure 73.—The Chronology of the Calcification of the Teeth**





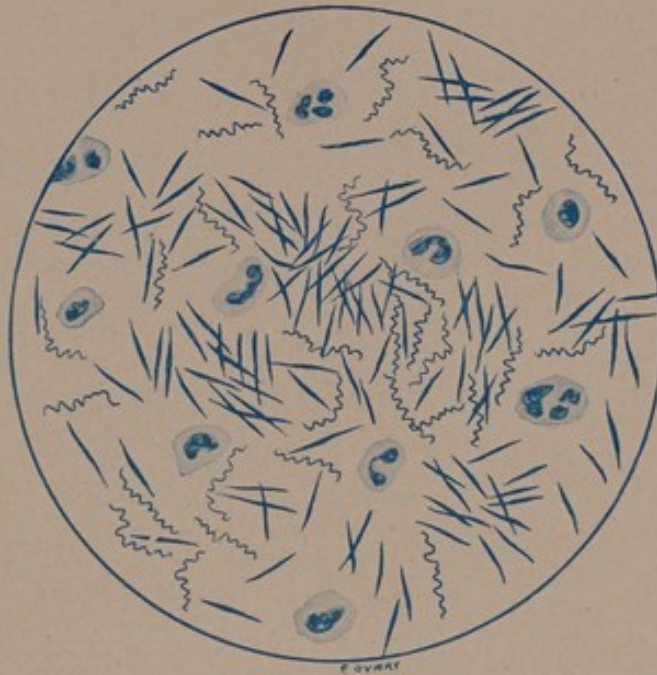

FIG. 72




THE CHRONOLOGY OF THE CALCIFICATION OF THE TEETH

FIG. 73





## **INDEX**





## INDEX

- Abscess, catarrhal, 18  
     tonsillar, 18  
 Alcoholism, 32, 38  
 Alopecia, 24, 102, 106  
 Amyloid degeneration, 3  
 Aneurism, 3  
 Angina, 5, 18, 106  
     follicularis, 52, 196, 200  
     mercurialis, 178  
     mycotica, 212  
     *Plaut-Vincent*, 8, 19, 53, 203, 207  
     syphilitic, 25, 116, 132, 200  
     traumatic, 207  
     ulcerosa, 132, 203, 207  
 Annulus migrans, 56  
 Antipyrin, 47  
     exanthem, 183  
 Arteriosclerosis, 3  
 Atrophy, smooth, 24  
  
 Bacillus fusiformis of *Vincent*, 8, 259  
 Balsamics, 47  
*Bednar's* aphthæ, 46  
 Bony defects, 30  
 Buccal mucous membrane, lichen of, 183  
*Burri*, method of, 9  
  
 Cachexia, 32  
*Calmette*, ophthalmic reaction of, 63  
 Cancrum oris, 53  
 Carcinoma, 10, 59, 64, 233  
 Caries, 42  
 Chancre, 1  
     extragenital, 15  
     genital, 15  
     hypertrophied, 15  
     on cheeks, 17  
     on gums, 17  
     on lip, 14, 70, 74  
     on palate, 17  
     on tongue, 15, 78  
     on tonsils, 17  
     papular, 15  
     soft, 19  
     ulcerated, 15  
 Chancroid, 16, 19  
 Cheeks, chancre on, 17  
 Condylomata lata, 4, 20, 26, 86  
 Coryza, 35  
 Cuti-reaction, 63  
  
 Dark-field microscope, 9  
 Deflection of the complement, 10  
 Dementia paralytica, 3, 10  
 Dentin cap, 37  
 Dentin, formation of, 37  
 Dermatitis herpetiformis, 49  
 Diagnosis ex juvantibus, 62  
 Diphtheria, 5, 36, 200  
 Diseases similar to lesions of secondary syphilis of the mouth, 45  
 Diseases similar to lesions of tertiary syphilis of the mouth, 59  
*Ducrey-Krefting* streptobacillus, 19  
 Dunkelfeld microscope, 9  
  
 Ectoderm, 20  
 Eczema, 48  
 Embryo, infection of, 3  
 Embryonic cells, 2  
 Entoderm, 20  
 Erosions, chancrous, 14, 70  
 Eruptions, medicamentous, 47  
 Erythema, idiopathic polymorphous, 49  
     multiforme exudativum, 49, 188  
     syphilitic of the mouth, 82  
 Erythematous spots, 21  
 Exanthem, 21

- Fauces, annular syphilide of, 124  
 malignant syphilis of, 156  
 tuberculosis of, 226  
 ulceration of, 152
- Fœtus, infection of, 3
- Foot and mouth disease, 54
- Frambesia, 7
- Frenum linguæ, 45
- Fungi, 54
- Furuncles on lip, 18
- Gastroenteritis, 39
- Geographical tongue, 55, 216
- Giemsa* stain, 9
- Glossitis, chronic interstitial, 24  
 diffuse, 24  
 syphilitic, 111
- Gumma, 6, 168, 232
- Gums, chancre on, 17
- Hard palate, 30, 140, 144, 168, 220
- Heredosyphilis, 4, 34, 160  
 late, 36, 164, 168
- Heredosyphilitic child, 13
- Herpes facialis, 50
- Herpes labialis, 192
- Hutchinson* teeth, 41, 238
- Hutchinson* triad, 39
- Hyperæmia of the isthmus, 21
- Hypoplasia, developmental, 36
- India ink method, 9
- Intradermic reaction, 63
- Introduction, i
- Keratitis, 6
- Klebs-Loeffler* bacillus, 52, 200
- Latent syphilis, 10
- Leontiasis, 31
- Leprosy, 10
- Leptothrix buccalis, 54
- Lesion, initial, 1  
 primary, 1, 12, 16  
 secondary, 2  
 tertiary, 2, 6
- Leukoderma colli, 102
- Leukoplakia buccalis, 5, 56
- Leukoplakia linguæ, 222
- Lichen ruber planus, 48, 183
- Lingua geographica, 55, 217
- Lingua lobata, 31
- Lingua plicata, 55
- Lip, annular syphilide on, 102  
 chancre on, 14, 70, 74  
 chapped, 12  
 eczema of, 12  
 erosive mucous patches on, 86, 90  
 furuncles on, 18  
 herpes of, 192  
 hypertrophied mucous patches on, 94  
 papulo-ulcerated syphilide of, 94  
 tubercular ulcer of, 230  
 ulcerated syphilide of, 98
- Lues hereditaria tarda, 36
- Luetin, 11
- Martoux'* intradermic reaction, 63
- Measles, 48
- Medication, palliative, 62
- Mercurial stomatitis, 46
- Microdentism, 43
- Microscope, 9
- Migranin, 47
- Mouth, circinate mucous patches of, 136  
 erythema multiforme of, 188  
 syphilitic erythema of, 82
- Mucous patches, 6, 20, 35, 86, 90, 94, 98, 106, 111, 128, 136  
 hypertrophied, 22  
 opaline, 22  
 ulcerated, 23
- Naso-labial folds, condylomata lata of, 86
- Necrobiosis, 2
- Necrosis, 2
- Neoplasia, 30
- Nochugi* luetin reaction, 11, 67
- Noma, 53
- Nose, circinate mucous patches of, 136
- Ophthalmic reaction, 63
- Orchitis, 6
- Palate, 30, 33  
 chancre on, 17  
 ulcers on, 46
- Palate, hard, gummatous ulcers of, 140  
 perforation of, 30, 144, 168  
 tuberculosis of, 220



- Palate, soft, annular syphilide of, 124  
     gummatous destruction of, 148  
     hypertrophied mucous patch of, 128  
     mucous patches of, 120  
     tuberculosis of, 226  
 Papules, 6, 120  
 Parasyphilosis, 2  
 Pemphigus, 49  
 Periostitis, 4, 144  
 Phenacetin, 47  
 Pian, 7  
*Pirquet*, cuti-reaction of, 63  
 Plaque muqueuse, 22  
 Plaque opaline, 22  
 Point of infection, 3  
 Post-syphilitic diseases, 10  
     manifestations, 2  
 Processus alveolaris, periostitis of, 144  
 Psoriasis, 48  
 Purpura hemorrhagica, 50  
 Pyramidon, 47  
  
 Rachitis, 39  
 Reaction of fixation, 9  
 Roseola, 6  
  
 Salipyrin, 47  
     exanthem, 183  
 Scarlatina, 10, 48  
 Sclerosis of the tongue, 24, 31  
     primary, 1  
 Secondary period, 1  
 Sero-reaction, 9  
 Skin diseases, 48  
 Soft palate, 33  
 Spirochæta buccalis, 8, 252, 255  
 Spirochæta *Castallani*, 8  
 Spirochæta dentium, 6, 8, 252  
 Spirochæta *Loewenthalii*, 7  
 Spirochæta microgirata, 7  
 Spirochæta of *Vincent*, 8, 259  
 Spirochæta pallida, 1, 252  
 Spirochæta pallidula, 7  
 Spirochæta pertenuis, 7  
 Spirochæta refringens, 7  
 Stomacace, 53  
 Stomatitis, 36  
     aphthous, 50, 196  
     gangrenous, 53  
     maculo-fibrosa, 50  
     Stomatitis, mercurial, 46, 173  
         parasitic-myotic, 51  
         ulcerative, 53  
 Syphilide, annular, 24, 98, 102, 124  
     circinate, 24, 26  
     cutaneous, 20, 106  
     erosive, 22  
     mucous, 20  
     orbicular, 24  
     papular, 28, 60, 106  
     tertiary, 2  
 Syphilis, congenital, 34  
     hereditary, 4, 34, 160, 164  
     intrauterine, 38  
     latent, 10, 36, 164, 168  
     malignant, 32, 152, 156  
     primary, 12  
     secondary, 20, 66  
     tertiary, 28, 144  
     transmission of, 13  
 Systemic diseases, 10  
  
 Tabes, 3, 10  
 Teeth, absence of, 43  
     asymmetrical, 43  
     chronology of the calcification of the, 259  
     heredosyphilitic, 168, 242, 247  
     sharklike, 43  
     twisted, 43  
 Tertiary period, 1  
 Test teeth, 41  
 Throat, syphilitic sore of, 25  
 Thrush, 5, 51  
 Tongue, antipyrin exanthem of, 183  
     carcinoma of, 233  
     chancre on, 15, 78  
     erosive mucous patches of, 90  
     geographical, 55, 216  
     gumma of, 168  
     hypertrophied mucous patches of, 94  
     leukoplakia of, 220  
     opaline mucous patches of, 106  
     papulo-ulcerated syphilide of, 94, 106  
     ulcerated mucous patches of, 111  
     tumor of, 233  
 Tonsillitis, follicular, 52, 196, 200  
 Tonsils, chancre on, 17, 203

- Trauma, 54  
Treponema macrodentium, 8, 255  
    medium form, 8  
Treponema microdentium, 6, 7,  
    252, 255  
Treponema pallidum, 1, 5, 20, 35,  
    38, 66, 252, 255  
Treponema pertenue, 8  
Tropical diseases, 10  
Tubercular ulcers of the mouth,  
    60  
Tuberculin reaction, 63  
Tuberculosis, 10, 38, 222, 226  
    of the mouth, 59  
Typhoid fever, 38  
  
Ulcer, aphthous, 50, 196  
    reticulated, 28  
  
Ulcer, serpiginous, 102  
    tubercular, 230  
Ultra-microscope, 9  
Uvula, annular syphilide of, 124  
    hypertrophied mucous patches  
        of, 120, 128  
    tuberculosis of, 226  
  
Varicella, 48  
  
Wandering rash, 56  
Wassermann reaction, 9  
Wet nurse, 13  
Wolff-Eisner, ophthalmic reaction  
    of, 63  
  
Yaws, 7



## LIST OF AUTHORS

Bordet, 9	Neisser, 9
Bruck, 9	Nochugi, 11, 67
Burri, 9	
	Metchnikoff, 6
Calmette, 63	
Castallani, 8	Pirquet, 63
Cohn, 8	Plaut-Vincent, 19, 53
	Prowaczek, 8
Ducrey-Krefting, 19	
	Roux, 6
Fournier, 12	
	Schaudinn, 5
Gengou, 9	
	Vincent, 8
Hoffmann, 8	
Hutchinson, 39, 41, 43, 164	Wassermann, 9
	Widal, 9
Klebs-Loeffler, 52	Wolff-Eisner, 63
Koch, 7, 8	
	Zittmann, 106, 144
Martoux, 63	



