

Bilharziosis / by Frank Cole Madden.

Contributors

Madden, Frank Cole.

Publication/Creation

London ; New York : Cassell, 1907.

Persistent URL

<https://wellcomecollection.org/works/e69m2ahk>

License and attribution

This work has been identified as being free of known restrictions under copyright law, including all related and neighbouring rights and is being made available under the Creative Commons, Public Domain Mark.

You can copy, modify, distribute and perform the work, even for commercial purposes, without asking permission.



Wellcome Collection
183 Euston Road
London NW1 2BE UK
T +44 (0)20 7611 8722
E library@wellcomecollection.org
<https://wellcomecollection.org>

With the Author's Compliments

Price 3s. 6d. net

BILHARZIOSIS

By

FRANK COLE MADDEN

M.D., F.R.C.S.

Not to be thrown away.

CASELL AND COMPANY, LIMITED

London, Paris, New York, Toronto & Melbourne

MCMVII

All Rights Reserved

13593



22200184160

Med
K28345

BILHARZIOSIS

BY THE SAME AUTHOR.

THE PRACTICAL
NURSING OF INFANTS
AND CHILDREN.

"Should find a place on every nurse's bookshelf. The latest methods of treatment are fully explained, rendering the work a really invaluable guide."—*Dublin Medical Journal*.

3s. 6d.

CASELL & COMPANY, LIMITED, London,
Paris, New York, Toronto and Melbourne.



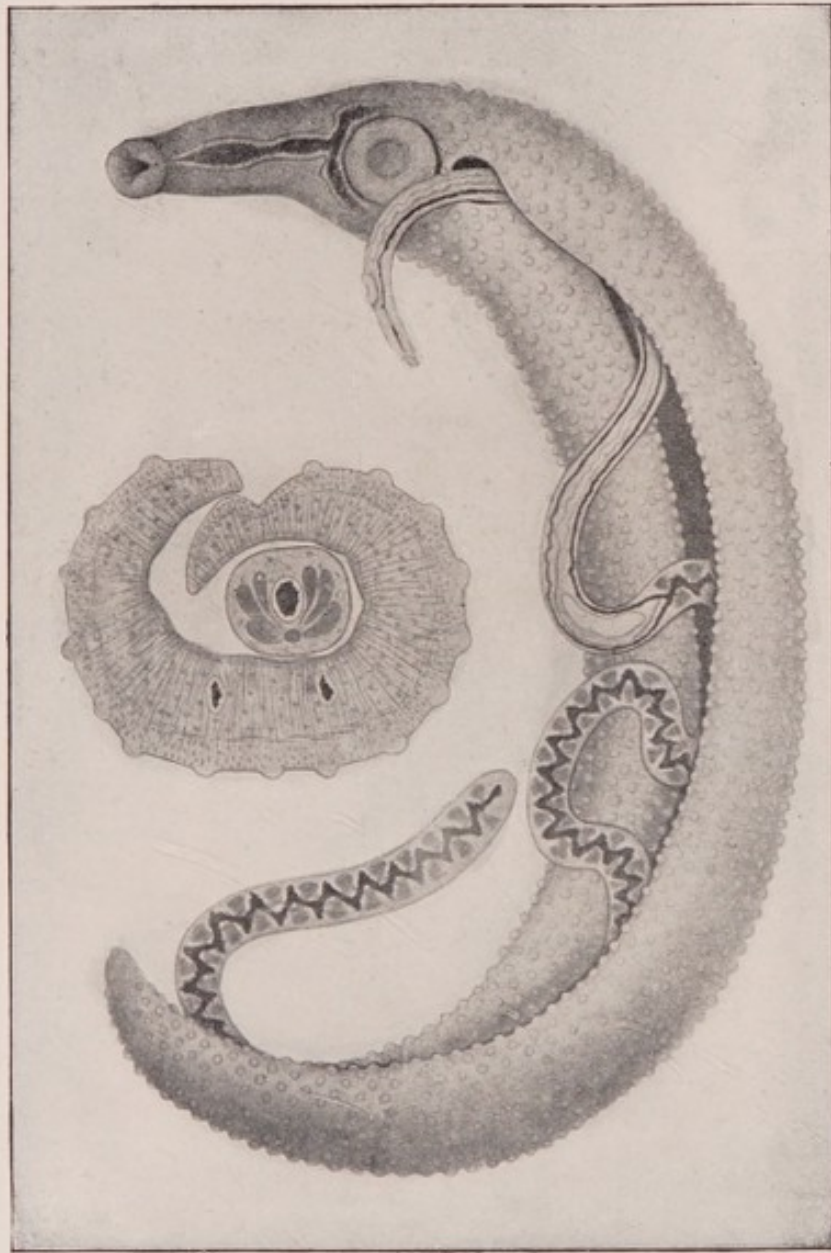


Fig. 1.—The bilharzia worm (*Schistosomum hematobium*). To the right is a coupled pair of worms, the female lodged in the gynecophoric canal of the male. To the left is seen a cross-section of a pair, to show the mode of formation of the gynecophoric canal, in which a single cross-section of the female worm is visible. Both figures semi-diagrammatic.

(Photograph of a drawing by Professor Looss, figured in Mense's "Handbuch der Tropen-krankheiten," Vol. 1.)

83562

BILHARZIOSIS

BY

FRANK COLE MADDEN

M.D.MELB., F.R.C.S.ENG.

PROFESSOR OF SURGERY EGYPTIAN GOVERNMENT SCHOOL OF MEDICINE, SENIOR
SURGEON KASR-EL-AINY HOSPITAL, CAIRO

ILLUSTRATED

CASELL AND COMPANY, LIMITED

LONDON, PARIS, NEW YORK, TORONTO AND MELBOURNE

MCMVII

ALL RIGHTS RESERVED

13593

RESEARCH

LIBRARY

11287 292

WELLCOME INSTITUTE LIBRARY	
Call No.	welMOrnec
Call	
No.	WC

PREFACE.

IN this monograph I have endeavoured to give a *résumé* of the present state of our knowledge of Bilharziosis; and, in doing so, have naturally had to draw largely upon the work and experience of others in the same field. To these observers I wish here, at the outset, freely and frankly to acknowledge my great indebtedness.

I am especially beholden to my friend and colleague, Professor Looss, who has taken infinite pains in providing me with an abstract of that portion of his article in Mense's "Handbuch der Tropenkrankheiten" which deals with the life-history and mode of infection of the *Bilharzia* worm.

Again, much of the pathological description of the disease is the result of a study of specimens in the Pathological Museum of the School of Medicine in Cairo, prepared by Professor W. St. Clair Symmers, formerly Professor of Pathology in this School, now Musgrave Professor of Pathology in Queen's College, Belfast. For his kindness in revising an earlier manuscript of mine on the subject and allowing me to avail myself so fully of the

material at his disposal, I am deeply grateful; but I must accept all responsibility for any inaccuracies that may appear in the text.

In the clinical paragraphs I have included much of the work published by my former colleague, Mr. Frank Milton, in various papers, in my endeavour to make this side of the picture as complete as possible; and, throughout the whole monograph, I have avoided the discussion of controversial points, upon which much work is still to be done, and have tried to approach the subject from the standpoint of a practical surgeon.

I am also indebted to Dr. H. P. Keatinge, the Director of the School, for his ready assent to the publication of photographs of specimens and cases from the School collections; and, finally, to my friend and colleague, Professor A. R. Ferguson, the present Professor of Pathology in the School of Medicine, for so carefully revising with me the whole manuscript, I take this opportunity of expressing my sincerest thanks.

Cairo, 1907.

CONTENTS.

	I.		
THE PARASITE		PAGE	9
	II.		
THE PATHOLOGICAL CHANGES PRODUCED BY BILHARZIA			18
	III.		
BILHARZIOSIS OF THE URINARY SYSTEM			30
	IV.		
BILHARZIOSIS OF THE INTESTINAL TRACT			64
	V.		
BILHARZIOSIS OF THE FEMALE GENERATIVE ORGANS			73
	VI.		
BILHARZIOSIS OF THE SKIN AND SUBCUTANEOUS TISSUES			75

LIST OF ILLUSTRATIONS.

Fig. 1.—The bilharzia worm	<i>Frontispiece</i>
„ 2.—Section of bilharzial tissue in the meso- rectum	<i>To face page 10</i>
„ 3.—A bilharzia ovum in the urine	„ „ 10
„ 4.—Section of bilharzial cirrhosis of the liver	„ „ 12
„ 5.—Free-swimming bilharzial miracidium	„ „ 12
„ 6.—Section of portion of a bilharzial papilloma	„ „ 18
„ 7.—The mucus membrane in early bilharziosis of the bladder	„ „ 18
„ 8.—More advanced bilharziosis of the bladder	„ „ 22
„ 9.—Bilharzial papillomata in the large intestine	„ „ 22
„ 10.—Ulceration of the large intestine (“bilhar- zial dysentery”)	„ „ 27
„ 11.—Extreme case of bilharziosis of the bladder	„ „ 27
„ 12.—Section of “bilharzial scirrhus” of the bladder	„ „ 29
„ 13.—Advanced bilharziosis of the bladder	„ „ 36
„ 14.—Bilharziosis of the penis and scrotum in a young boy	„ „ 57
„ 15.—Bilharziosis of the penis in a boy of nine	„ „ 59
„ 16.—Bilharziosis of the sigmoid flexure and meso-sigmoid	„ „ 68
„ 17.—Bilharzial papillomata protruded from the anus	„ „ 68
„ 18.—Bilharzial papillomata of the vulva grow- ing from the left labium majus	„ „ 73
„ 19.—Smaller papillomatous mass growing from right labium majus in same case	„ „ 74
„ 20.—Bilharziosis of the vulva and vaginal orifice	<i>To follow Fig. 19</i>
„ 21.—Bilharzial papilloma growing from pos- terior lip of cervix uteri	<i>To face page 76</i>
„ 22.—Scarring left after operations on bilharzial sinuses	„ „ 76
„ 23.—Epithelioma around anus originating on site of old bilharzial disease	„ „ 76
„ 24.—Epithelioma of the penis, scrotum, and inguinal glands secondary to old bilharziosis	<i>To follow Fig. 23</i>

BILHARZIOSIS.

I.

THE PARASITE.

THE pathological conditions included in the term bilharziosis are produced by the presence of the bilharzia worm, *Schistosomum hæmatobium*, in the human body.

Geographical distribution.—The bilharzia worm is endemic in Egypt, and also, to a more limited extent, in South Africa. Endemic centres appear to exist in Syria, the Soudan and Uganda, Madagascar, Mauritius, Réunion, China, Cyprus, and the West Indies; and sporadic cases of bilharziosis, probably contracted in one or other of these centres, have been reported in many other countries, for instance, in England and Australia, among the troops who have recently returned from South Africa.

Description and life-history.—The worm belongs to the group of the Trematodes, but is distinguished from the majority of this group by having male and female separate individuals.

The male worm, to the naked eye, is about 1 cm. long, milky-white in colour, cylindrical in shape with tapering extremities. Microscopically, its body is seen to be thickly studded with minute warty projections, each tipped with short stout bristles. Two suckers,

one behind the other, are seen on the under surface of the body, near the anterior extremity. Under the microscope it will also be seen that the body of the worm is not cylindrical, but thin and flattened, and that the lateral margins of the body are folded towards the ventral surface to form a long open canal—the gynecophoric canal—in which the female lies during the period of sexual activity.

The female worm is much longer and thinner than the male and is often found lying within the gynecophoric canal, generally with part of the anterior and posterior extremities protruding. She can, however, completely withdraw herself into the canal. (Figs. 1 and 2.)

The most common habitat of the worm is the portal vein and its tributaries within the liver.

Here the worms are small, often very small, are not yet sexually active, and the male and female occur separately, not coupled. Exceptionally, however, coupled pairs of worms may be met with in this situation.

The worms are also found in the mesenteric veins and their larger tributaries. Here they are larger than those found in the portal vein and mostly occur as coupled pairs. They are sexually mature, but the female does not contain many ova.

The other common habitat of the worm is the vessels of the submucous tissue of the bladder and rectum and, to some extent, also, of other parts of the intestinal tract.

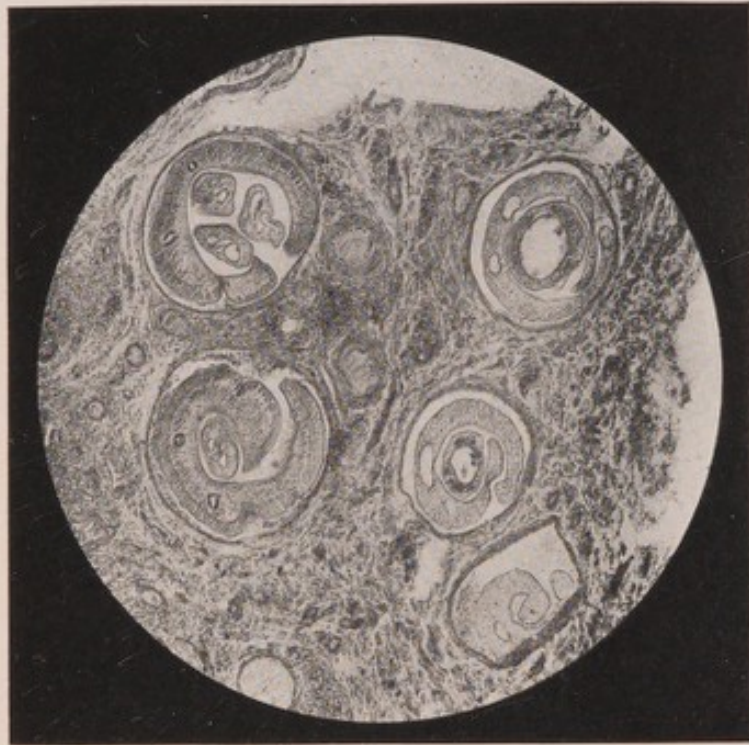



Fig. 2.—Photo-micrograph of section of bilharzial tissue in the meso-rectum (see Fig. 16), showing several coupled pairs of worms *in situ*. To the left and above, the female has been so much coiled up that three cross-sections of it have been made. Below and to the right no female is present.

(From a preparation by Professor Looss, figured in Meuse's "Handbuch der Tropen-krankheiten," Vol. 1.)

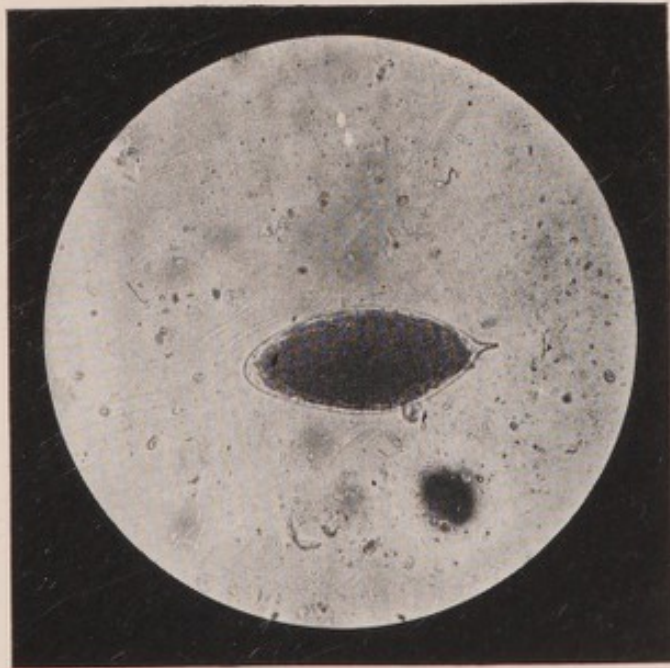

Fig. 3.—A bilharzia ovum, with calcified contents, in the urine. The shell and its end spine are particularly well seen.

(From a photo-micrograph in the Photographic Album of the School of Medicine, Cairo.)



Worms found in these situations are fully developed, physically and sexually, they nearly always occur in coupled pairs, and the uterus of the female is distended with ova.

Exceptionally, worms may be found in the vessels of other organs of the body, notably the lungs (Symmers).

From these observations it would appear that the worms travel from the liver in the veins of the portal system generally, to the vessels in the submucous tissue of the bladder and rectum and other parts of the intestine. Some even escape into systemic veins, by way of their communications with the portal system, and may thus reach the lungs or other organs even more distant.

It will be noted that the course of the worms is against the blood stream. This mode of progression is probably effected by strong muscular movements on the part of the male worm, which carries the female, lodged in its gynecophoric canal, with it.

The *ova* are of a blunt spindle shape, about 0.16 mm. long on an average. They are encased in a thin yellowish shell. Two forms of ova are to be distinguished. The most common (normal) ovum has a terminal spine, which may vary in size within narrow limits in different ova, or even be entirely absent. The second (abnormal) ovum presents a large lateral spine, which varies considerably in size and position. These lateral-spined ova are usually seen in small numbers in the uterus of young females and are

commonly found in the liver, and, more rarely, in the lungs. (Figs. 3 and 4.)

The ova are laid into the blood and the laying begins when the female is still in the liver. The ova, being thus free in the blood-stream, are washed away through the larger vessels until they reach a smaller capillary than they can traverse, and here they become impacted. Thus, the ova that are laid when the worms are still in the portal vein, or in the larger veins of the portal system, may be washed back into the liver and become fixed there; or may even pass through this organ and reach the pulmonary or the systemic circulation. In the latter case they are ultimately infarcted in the smaller capillaries of distant tissues or viscera.

When the ova are laid in the smaller vessels, as, for instance, in those of the submucous tissue of the bladder or rectum, the capillaries may become completely packed with ova, to such an extent that the walls of the vessels burst and the ova pass into the substance of the organ and become fixed there. By the muscular movements of the viscus, aided also by their peculiarly penetrating shape, the ova slowly travel in the organ; and some approach the surface of the mucous membrane and are eventually extruded and passed with the urine or fæces. This movement of the ova in the tissues is comparable with the wandering of a needle, which has penetrated the skin and lies loose in the subcutaneous tissues.

In the exceptional cases in which worms are found

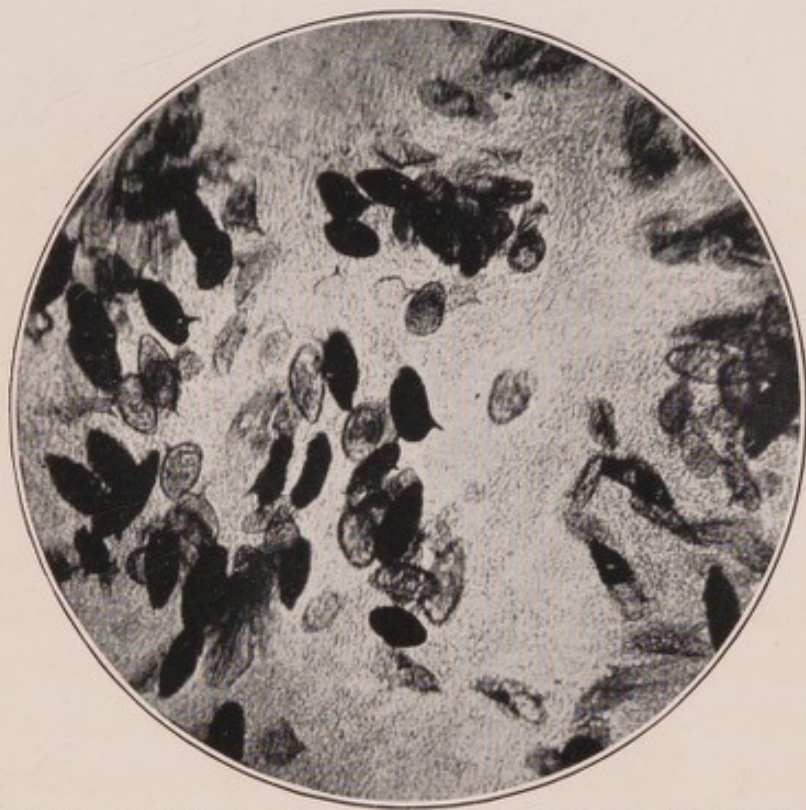


Fig. 4.—Section of bilharzial cirrhosis of the liver, showing many lateral-spined ova.

(From a specimen, prepared by Professor Symmers, in the Pathological Museum of the School of Medicine, Cairo. Photo-micrograph by Mr. F. S. Willmore.)

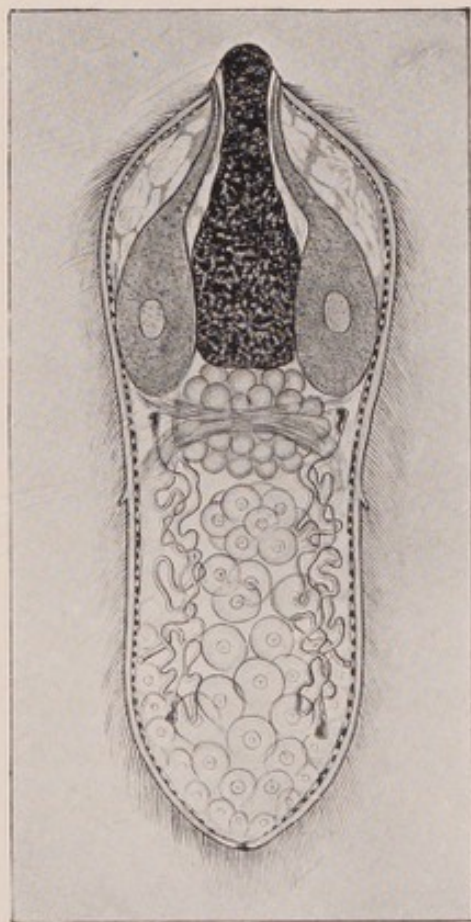


Fig. 5.—The free-swimming bilharzial miracidium. Semi-diagrammatic.

(From a wall-diagram drawn by Professor Looss, and figured in Mense's "Handbuch der Tropen-krankheiten," Vol. 1.)



in the systemic circulation, the ova are passed directly into the circulating blood and are thus directly carried to unusual seats.

At the time of its formation in the female the impregnated ovum contains an unsegmented egg-cell and a number of yolk-cells. It is then much smaller than the ova found in the tissues, increasing in size as the process of development goes on within it. By the time the ovum is passed in the urine or fæces it contains a fully developed embryo or *miracidium*. If such ova get into water, or if water be added to the urine or fæces, the miracidium hatches out in a few minutes and swims actively about by means of its cilia. In urine and in almost any other fluid, except water, the miracidium dies in about 24 hours without hatching out; and even in water, once it has hatched out, it cannot be kept alive for longer than 24 to 48 hours. (Fig. 5.)

Many ova die during development, and their contents become granular and finally calcified. Microscopically, such ova present a blackened opaque appearance. (See Figs. 3 and 4.) These calcified ova, indeed all ova, will vary in size according to their stage of development.

Further Development.—The complete cycle of development of the bilharzia worm is still unknown. From analogy with other Trematodes it seemed reasonable to infer that, in order to become a young worm, the miracidium must pass through a further stage of development in some intermediary

host. No intermediary host has ever yet been discovered. Looss, working under the most favourable conditions, in the very midst of bilharziosis in Egypt, has utterly failed to find any intermediary host, or to induce any species of animal or plant life to harbour the miracidium. He is, therefore, of opinion that man himself acts as the intermediary host.

Two **modes of infection** are possible on this hypothesis.

1. By the *mouth*, being introduced through the medium of the drinking water.

In this connection, Looss has shown that free-swimming bilharzia miracidia are killed in a 1 in 1000 watery solution of hydrochloric acid, almost instantaneously, and in less than three minutes in a 1 in 2000 solution. For this reason, infection through the stomach, the secretion of which contains a stronger solution of hydrochloric acid, is practically impossible.

2. By the *skin*, by penetration. Looss holds the view that the miracidia probably penetrate the skin, find their way to some resting place, probably the liver, and there pass through a sporocystic stage; the final outcome of which is young worms of both sexes, similar in appearance to those found in the veins of the liver. The presence of certain so-called germinal cells in the body of the miracidium indicate conclusively that there must be a sporocystic stage in the cycle of development.

In support of this infection-by-skin theory, it has been noted that, in the *country* districts of Egypt, it

is the agricultural labourer, or fellah, who works all day in the wet irrigated fields, who is most commonly affected: and that it is the scavengers, street sweepers, gardeners, and small children (who love to go about bare-footed in the puddles and wet), who are especially subject to bilharziosis, among the *town dwellers*. In the country, the whole agricultural population drink plain unfiltered Nile water; but in the towns the water is treated by filtration and supplied by Water Companies. In spite of the supposed protection against infection thus afforded, certain classes of the town-dwellers *do* become subject to bilharziosis; and, as has just been pointed out, the classes most affected are made up of individuals whose habits, in other respects, are similar to those of the agricultural labourer.

Any small puddle may become defiled with the urine or fæces of a patient suffering from bilharziosis; and, in a very short time, the water or mud is alive with miracidia, which may become applied to the bare feet, legs, or hands, penetrate the skin and so lead to infection. In this way, too, constant re-infections may occur and a cure is almost impossible.

Children who contract bilharziosis during the bare-foot period of their existence may grow out of their disease in a few years' time; for re-infection does not occur, owing to their altered habits and indoor occupations. It has frequently been noted, also, that when a patient suffering from bilharziosis leaves the

country in which he contracted it he may eventually be completely cured.

It is a remarkable fact that, of the cases of bilharziosis treated at Kasr-el-Ainy Hospital, Cairo, which drains all parts of Egypt, except Alexandria, nearly 90 per cent. come from Cairo and the country to the north of Cairo. This is the only part of Egypt now perennially irrigated, and comprises the rich agricultural lands of the Delta; whereas the country to the south is entirely inundated during the rise of the Nile and, after its subsidence, receives only just sufficient water for the purposes of cultivation. Thus in the north the fields are practically always under water; while in the south the supply is strictly limited and the northern wet sodden condition of the ground does not prevail (Milton).

Of a total of 1,346 cases of bilharziosis admitted for treatment in the hospital, during a certain term of years, about 94 per cent. were males; and the greater number of cases occurred between the ages of 15 and 45. It was remarkable that the proportion of female cases to male was as 1 to 9, under the age of 15 years; but above that age, when the girls marry and begin to lead more of an indoor life, it was as 1 to 20, a very significant fact in view of what has already been stated regarding the mode of probable infection (Milton).

Further, Talaat has shown that bilharziosis in *women* is common among the poorer agricultural population, all of whom work in the fields with the men.

It is much less frequent in the better classes and in those who are mainly occupied with domestic duties. In the towns, the disease is altogether less common than in the country and is only met with in women whose work brings them in contact with wet soil or mud, and in children, and it is quite unknown among the better classes.

It is well recognised that almost every Egyptian of the agricultural class, in Lower Egypt at all events, has had bilharzial hæmaturia at one time or another. A careful investigation of a series of 100 consecutive admissions to the hospital, irrespective of their disease, showed that 35 of them had bilharzia ova in the urine; but only 2 of this number complained of symptoms of bilharziosis (Milton).

A great many cases must eventually recover without symptoms at any time sufficiently serious to call for medical treatment; the severe cases being found among those whose occupation renders them particularly liable to repeated re-infections and in whom, sooner or later, septic infection supervenes.

II.

THE PATHOLOGICAL CHANGES PRODUCED BY BILHARZIA.

THE pathological effects of Bilharzia are due, primarily, to the deposit of the ova in the tissues. These ova soon excite a small-celled infiltration around them, as is the case with any foreign body, and to such an extent may this infiltration proceed that, at times, the true structure of the affected parts is almost completely replaced by ova, leucocytes and young connective tissue cells. (Fig. 6.)

The pathological manifestations may be divided somewhat arbitrarily into two classes of lesions, the hypertrophic and the atrophic. In the former occurs a marked proliferation of cells, especially epithelial cells, leading, particularly, to the formation of papillomatous growths: whereas, in the atrophic form, the principal change is due to the presence of what may be called bilharzial granulation tissue. This becomes fibrillar, and, in fact, goes through all the various changes of inflammatory granulation tissue of more acute origin; the final result being a peculiar white dense contracting fibrous tissue, a true scar tissue, which may contain very few ova in its substance. The hypertrophic form is especially found in connec-

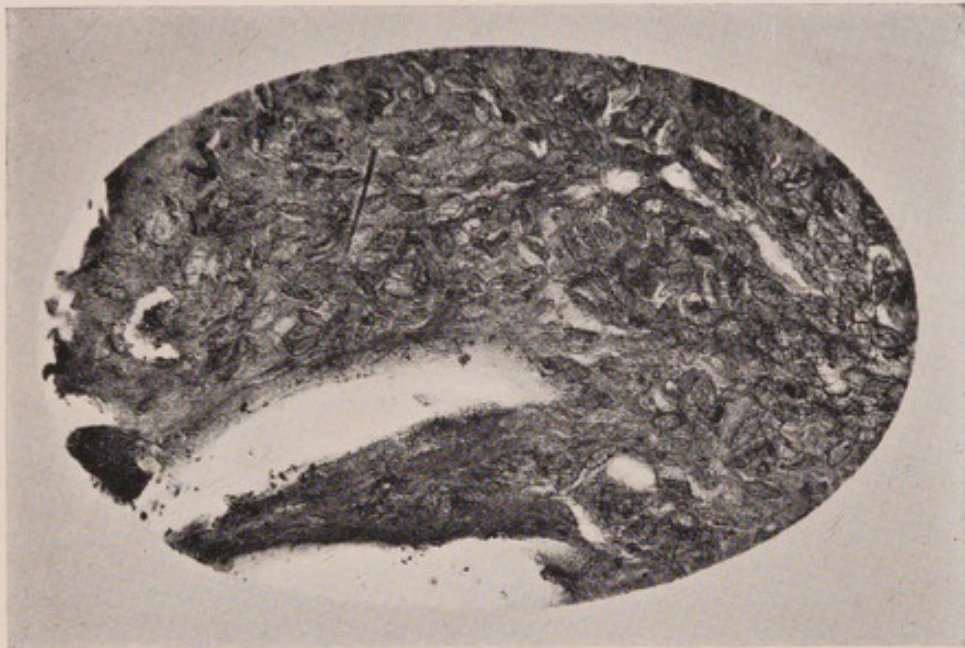

Fig. 6.—Section of portion of a bilharzial papilloma, showing the enormous crowding of the tissues with ova.

(From a specimen, prepared by Professor Symmers, in the Pathological Museum of the School of Medicine, Cairo. Photo-micrograph by Mr. F. S. Willmore.)

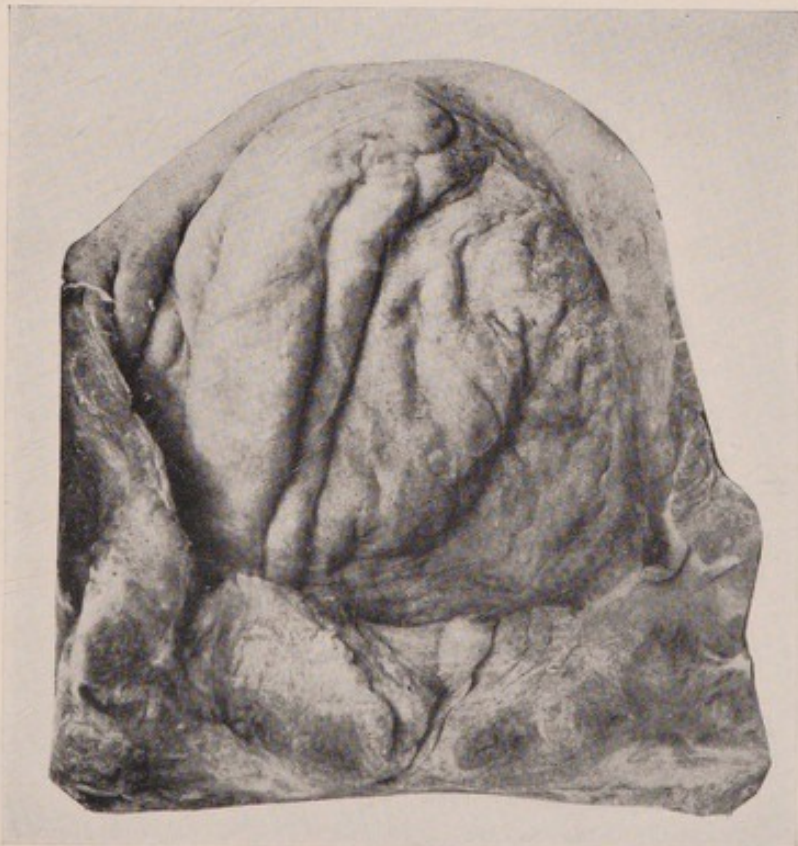

Fig. 7.—General swelling and infiltration of the mucous membrane in early bilharziosis of the bladder.

(From a specimen, prepared by Professor Symmers, in the Pathological Museum of the School of Medicine, Cairo.)



tion with bilharziosis of viscera lined by mucous membrane; the atrophic being more usual in the disease as it affects the connective tissues, either of the subcutaneous area or of the viscera. In certain cases the two forms may be seen side by side in the same viscus.

CERTAIN PATHOLOGICAL APPEARANCES COMMON TO BILHARZIOSIS OF VISCERA LINED BY MUCOUS MEMBRANES.

The changes about to be described may be found in any part of the genito-urinary tract from the pelvis of the kidney to the meatus of the urethra; from just beyond the duodenum, along the whole length of the intestinal tract, to the anus; and from the vaginal orifice to the internal opening of the cervical canal of the uterus.

General swelling and infiltration of the mucous membrane.—One of the earliest manifestations of bilharziosis of mucous membranes is a characteristic velvety swelling of the whole thickness of the membrane. The surface is dark-red in colour and has the appearance of a "thick pile velvet"; its superficial layers are coated with a viscid tenacious mucus and, but for this protection, they would be easily rubbed off on the least friction. The mucous membrane strips off easily from the deeper structures, and is so much swollen and thickened as to be thrown into folds. It often has a very fine brownish-yellow powdery appearance in its substance, sometimes throughout its whole extent, but, usually, more marked in some parts

than in others, and is very vascular throughout its whole thickness. It looks almost as if wet sea-sand had been scattered throughout the deeper parts of the mucous membrane. It is easy to understand that any squeezing of this soft, friable, vascular mucous membrane by the muscular walls behind it, as in the act of expelling urine or fæces, may lead to a rubbing away of the surface in certain parts and the occurrence of hæmorrhage from the eroded area. (Fig. 7.)

In some cases, scattered irregularly over the surface and sown, as it were, on the softened mucous membrane, are crops of small, friable papillomata, like large granules, or forming elevated ridges of swollen tissue. This condition is best seen in the rectum, and especially well when a portion of the mucous membrane is prolapsed during defæcation.

The change in the mucous membrane must take a considerable time to develop; for, with it, the rest of the wall of the viscus is usually much thickened, by hypertrophy of the muscular layer and the formation of bilharzial fibrous tissue throughout it.

If a snip of this infiltrated mucous membrane be taken and a smear made on a slide, bilharzia ova will be found. A section of the wall of the affected viscus shows the mucous membrane swollen, thickly infiltrated throughout with leucocytes, and crowded with ova. These are densely packed in the deeper parts of the epithelium and in the subjacent tissue, the basement membrane being perforated at certain points. In most places, at this early stage, the epithelial lining of the

mucous membrane is intact, but the ova may be seen pushing right up to it, and they soon cause a necrotic melting away of the surface cells. By the excessive crowding of the tissues with ova and cells the parts, in spite of their vascularity, begin to lose their vitality and a molecular disintegration takes place. As this process involves the epithelial layer the eggs are shed, together with small round cells, degenerated epithelial cells and blood corpuscles. By the crowding of the ova behind, those in front are gradually pushed towards the surface and are shed in a continuous stream as soon as the least erosion occurs.

Looss has prepared a series of sections which show that the ova may even escape from the surface of a mucous membrane the epithelial layer of which is quite intact. The ova are seen lying between the epithelial cells and in all stages of their passage through the epithelial lining.

The fine capillaries and veins immediately beneath the epithelial lining, and the loose connective tissue in which they occur, are also filled with ova; while in the deeper submucous tissue coupled pairs of worms are found in the vessels. In the muscular coat there may be collections of ova with an occasional couple of worms at some distance from them. The further appearances vary with the duration of the disease; and on this will also depend the amount of small-celled infiltration and young fibrous tissue that will be present.

Sandy patches.—Another comparatively early change, characteristic of bilharziosis of mucous mem-

branes, is the occurrence of brownish-yellow sandy patches, showing apparently through the membrane, which, over these areas, is thickened and dry. The patch appears to be made up of very fine grains, not unlike powdered sulphur, which are irregularly grouped together into small heaps at certain points. At a later stage the whole mucous membrane, of the bladder particularly, may be so altered, in colour and structure, that a regular calcified lining, which gives a characteristic gritty feeling on examination with a sound, is formed. The walls of the affected viscus will generally be found much thickened, partly from muscular hypertrophy, but also from the deposit of bilharzial fibrous tissue throughout the various layers. (Fig. 8.)

On cutting into such a sandy patch it will be found hard, thickened, and gritty, and the tissue easily turns the edge of the razor used in cutting the sections. On microscopical examination, the appearances are very similar to those described in the preceding change; except that there is much more hard thickening of all the parts concerned and the majority of the ova in and under the epithelial layer are calcified. Deeper in the section in the submucous tissue the blood-vessels, especially the veins, will be seen dilated and varicose, and pairs of worms will be found within their lumen. Looss has pointed out that in the immediate neighbourhood of the worms no free ova are found, and from the position of the worms in certain serial sections, he suggests that the female stretches out her thin attenuated body along the ultimate radicles of the submucous

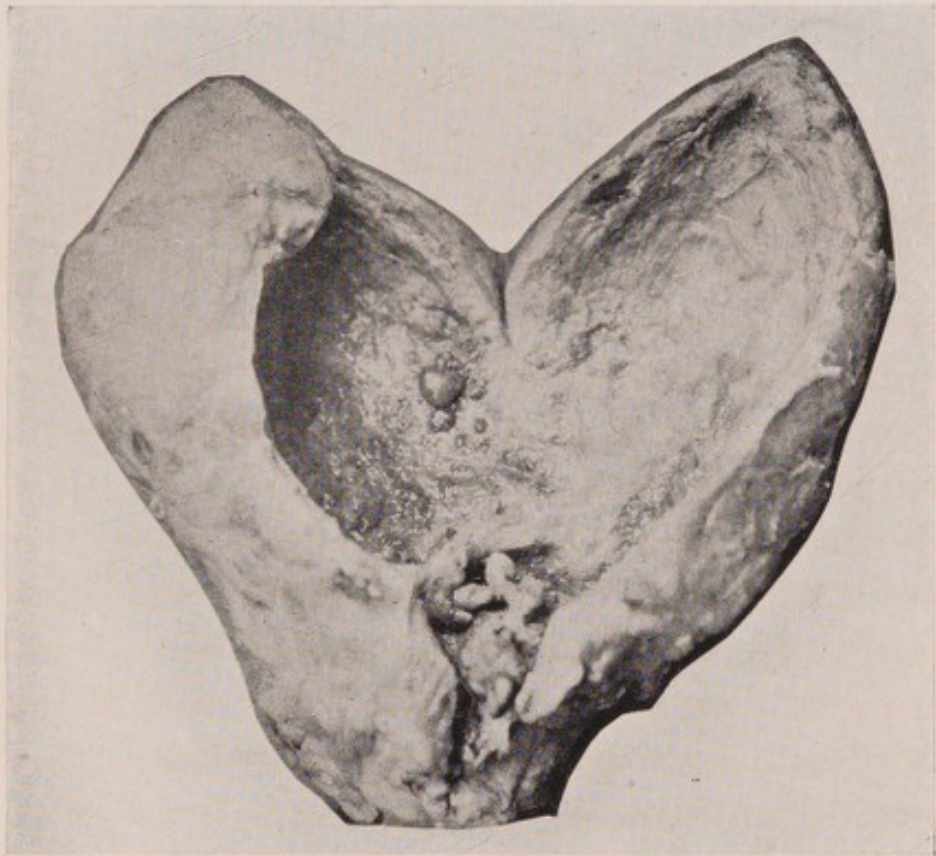

Fig. 8.—More advanced bilharziosis of the bladder, with much sandy change and considerable thickening of the coats of the viscus. Some small papillomata are seen on the posterior wall.

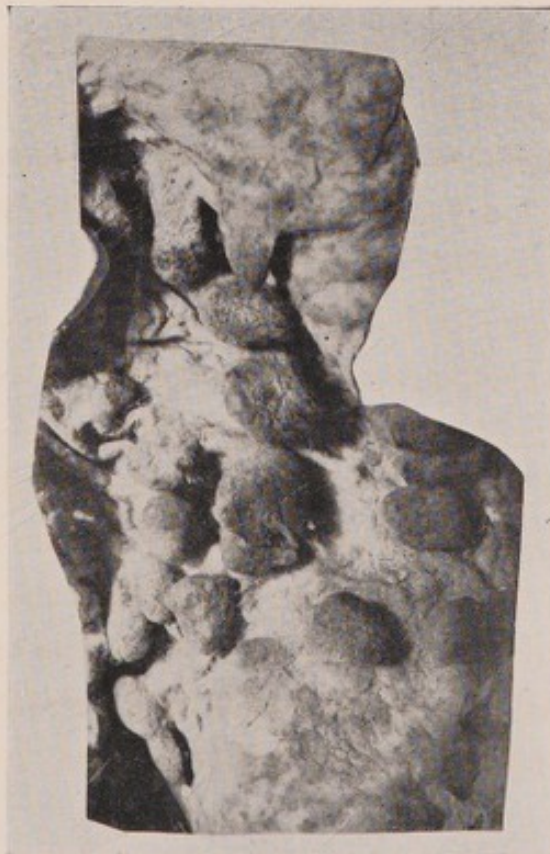

Fig. 9.—Bilharzial papillomata in the large intestine.
(From specimens, prepared by Professor Symmers, in the Pathological
Museum of the School of Medicine, Cairo.)



capillaries. Having stretched herself to her fullest extent, she deposits her mature ova and then withdraws into the gynecophoric canal of the male, of which she has retained hold throughout this stretching and depositing process. The ova thus set free in a very fine capillary remain where they have been placed, the tissues between them and the withdrawing worm closing in again; thus, a considerable interval is left between the depositor and her deposit.

Patchy hyperæmia.—The early sandy patches are usually associated with some hyperæmia of the mucous membrane beyond their margins; but this hyperæmia may sometimes occur, independently of any other change, as quite the earliest manifestation in the bilharzial series. This is altogether different from the general vascularity of the mucous membrane already noticed. In these hyperæmic areas the mucous membrane is thickened and infiltrated with ova, as in other early manifestations, and around them and in them are irregular extravasations of blood.

Bilharzial vesicles.—In some cases of bilharziosis of mucous membranes rounded globules, containing a clear or, sometimes, a turbid fluid are seen, like small blisters on the epithelial surface. These globules, which are superficially covered by stretched and flattened epithelial cells, suggest that they have their origin in small retention cysts. They resemble closely the small mucous cysts seen in the buccal mucous membrane, and probably have a similar pathology.

The formation of papillomata.—In certain cases the principal change is one of proliferation of epithelium. Small warty outgrowths may be seen arranged quite irregularly over the mucous membrane, sometimes surrounded by a zone of hyperæmia, which varies considerably in size and colour, or in the midst of a sandy patch. These outgrowths have the structure of an ordinary papilloma, the central very vascular core of loose connective tissue being directly continuous with the submucous tissue, in which, at the extreme base of the papilloma, a coupled pair of worms may sometimes be found. The core itself is infiltrated with leucocytes, in which lymphocytes predominate, and numbers of ova are scattered irregularly throughout it. It will be noticed that in certain places the ova come right up to the epithelial covering of the papilloma. In some parts the epithelium has the appearance of being scooped out from below; while in other sections the surface epithelium is entirely missing and the ova are seen streaming out from the broken surface. The epithelium, often very delicate, as the fine filaments of the papillomata are so thin, is very easily shed, and thus early permits of secondary bacterial invasion.

The papillomata, which are of all conceivable shapes and sizes, are of a dark-red colour, fairly firm in consistence, but have a velvety friable surface; but, as the disease progresses and the surface epithelium undergoes necrosis, they become granular and shaggy and bleed very readily on the least fric-

tion. In the blood thus discharged ova and granular *débris*, consisting of leucocytes, degenerated epithelial cells, connective tissue cells and red blood corpuscles are found. Later, the papillomatous change becomes more and more marked and there is no limit to the diversity of form or size of the individual outgrowths. Very often a bunch of papillomata seems to sprout from a raised plateau of thickened mucous membrane, and these papillomata have a rather bulbous appearance at their extremities. All forms may give off secondary extremely minute papillæ. Leuckart writes: "One may find on the mucous membrane of the bladder single or grouped excrescences, not unlike condylomata, with or without pedicles, which may present manifold variations of shape and may be as large as a bean. On section, the mucous membrane is thickened and the submucous connective tissue hypertrophied. Both are pervaded by a rich network of capillaries, the vessels being sometimes dilated, and here and there changed into rather large cavities, which often contain full-grown specimens of the bilharzia. In the parenchyma of the excrescences, which is formed chiefly of the submucous tissue, numerous eggs are found." (Fig. 9.)

Sessile masses.—In other specimens the papillomatous formation is not so marked; but irregular hummocks, involving often a considerable extent of the mucous membrane, are met with. These masses form irregular raised prominences, which may encroach upon the cavity of the viscus to a large extent

and sometimes almost fill it. They are very vascular and have the structure of loose fibrous tissue covered with a thickened mucous membrane, which is infiltrated with ova, and, at first, they are covered with epithelium. Later, on the surface of the elevations small pits and finally ulcers may form, the surface epithelium having necrosed, exposing a richly vascular and highly cellular granulation tissue. The whole viscus affected with this change is always very much thickened, and many of the earlier, more superficial, changes are present in what remains of the mucous membrane. Papillomata and sessile masses often occur side by side in the same organ.

Ulceration.—Sometimes small pits may be found in the mucous membrane without any papillomatous or sessile changes. These may be scattered over the surface, perhaps in the midst of a sandy patch, or, sometimes as the principal lesion in a thickened, infiltrated bladder. Then, again, ulcers may be the second stage of the vesicular formation already mentioned, the vesicle bursting and a minute necrosis of the tissue taking place, owing to the obstructed blood supply caused by the presence of ova and small celled infiltration; in other cases crevices form at the base of papillomata or over a sandy patch and ultimately form ulcers. At a later stage of the disease larger and more definite ulcers may form, especially in the intestine. They are produced by the separation of a papilloma from its base. A distinct ring of necrosing tissue is seen round the pedicle, and the



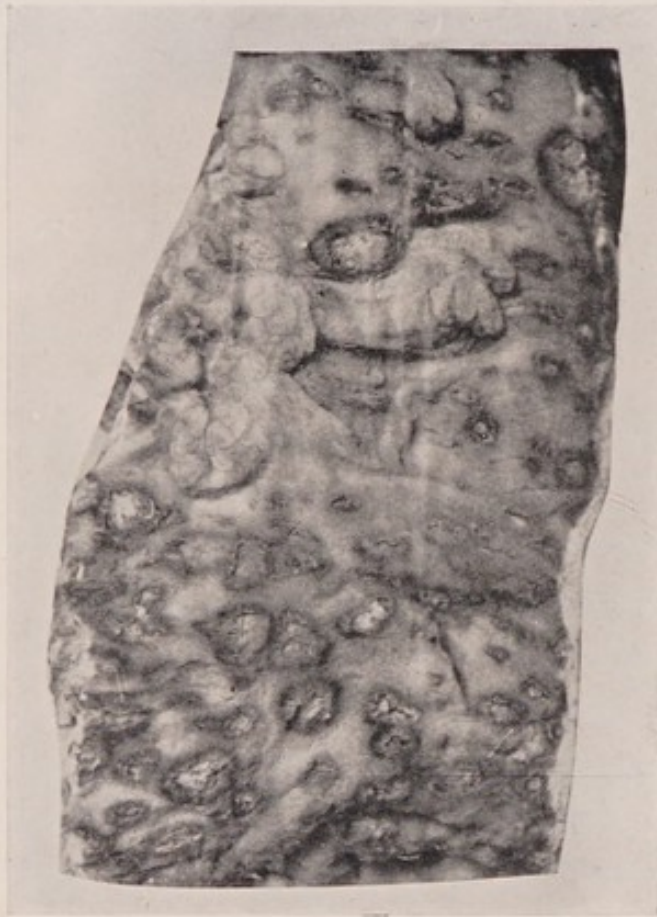


Fig. 10.—Ulceration of the large intestine, resulting from the sloughing off of bilharzial papillomata ("bilharzial dysentery").

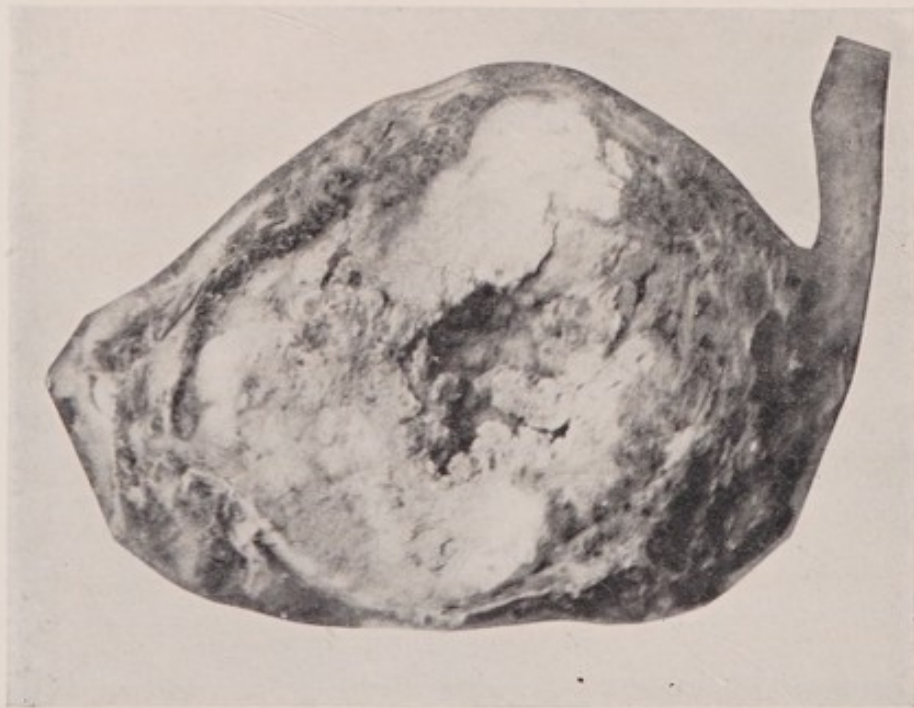

Fig. 11.—Extreme case of bilharziosis of the bladder with formation of much dense scirrhous-like tissue. The cavity of the bladder is almost non-existent.

(From specimens, prepared by Professor Symmers, in the Pathological Museum of the School of Medicine, Cairo.)

various appearances of papilloma, commencing necrosis, partial separation and finally complete separation, with the formation of deeply-punched-out, gumma-like ulcers, can be studied in good specimens. It is this condition of late ulceration in the large intestine which is most commonly responsible for "bilharzial dysentery." (Fig. 10.)

Another form of ulceration is met with in the atrophic types of bilharziosis. This finds its best illustration in bilharziosis of the skin and subcutaneous tissue, in connection with which it will be again referred to.

The condition of the structures deep to the mucous membrane varies considerably. In the early stages the bilharzial change seems to affect mainly the mucous and submucous coats, with but little infiltration of the muscular coats; but, later, the whole organ is infiltrated. The change deep to the submucous coat is, as elsewhere, due to an infiltration of small cells and ova, and is best understood by considering it the formation of a (bilharzial) granulation tissue, which goes through all the changes common to that tissue. The tissue thus formed varies considerably in density and extent.

Thus in most of the specimens of sandy patches and of infiltration of the mucous membrane, in fact in all the changes already described, there has been some thickening of the visceral walls, either local or general. In many cases this thickening would appear to be one of the earliest effects produced by bilharzia;

and many of the so-called early changes occur in an organ already much thickened by an infiltration not only of the mucous membrane but of all the layers of the wall of the viscus deep to that structure. Even hyperæmic patches are often seen on the internal surface of a thickened bladder, and must then be only a manifestation of an increase in an irritation which has already been going on for some considerable time. In fact, one can best judge of the chronicity of a bilharzial infection in a hollow organ by the thickness of the walls of the viscus and the degree of fibrous transformation of its surrounding tissues.

Sometimes a very hard indurated fibrous mass is produced in the muscular and deeper structures of the affected viscus; and eventually the whole essential structure of the parts is completely destroyed. In such cases very little of the mucous membrane remains. In certain cases a mass of bilharzial granulation tissue appears to spread inwards and makes the cavity of the organ much smaller, in much the same way that a bone with congenital syphilitic changes, by becoming harder, denser, and thicker in all directions, eventually almost, if not completely, obliterates the central medullary canal of the bone. The analogy is a good one, as the bilharzial fibrous tissue is often a true sclerosis. Very few ova are found in this hard tissue. (Fig. 11.) Sometimes the structure of this mass resembles that of a scirrhus cancer with ova lying in between the columns of epithelial cells, but



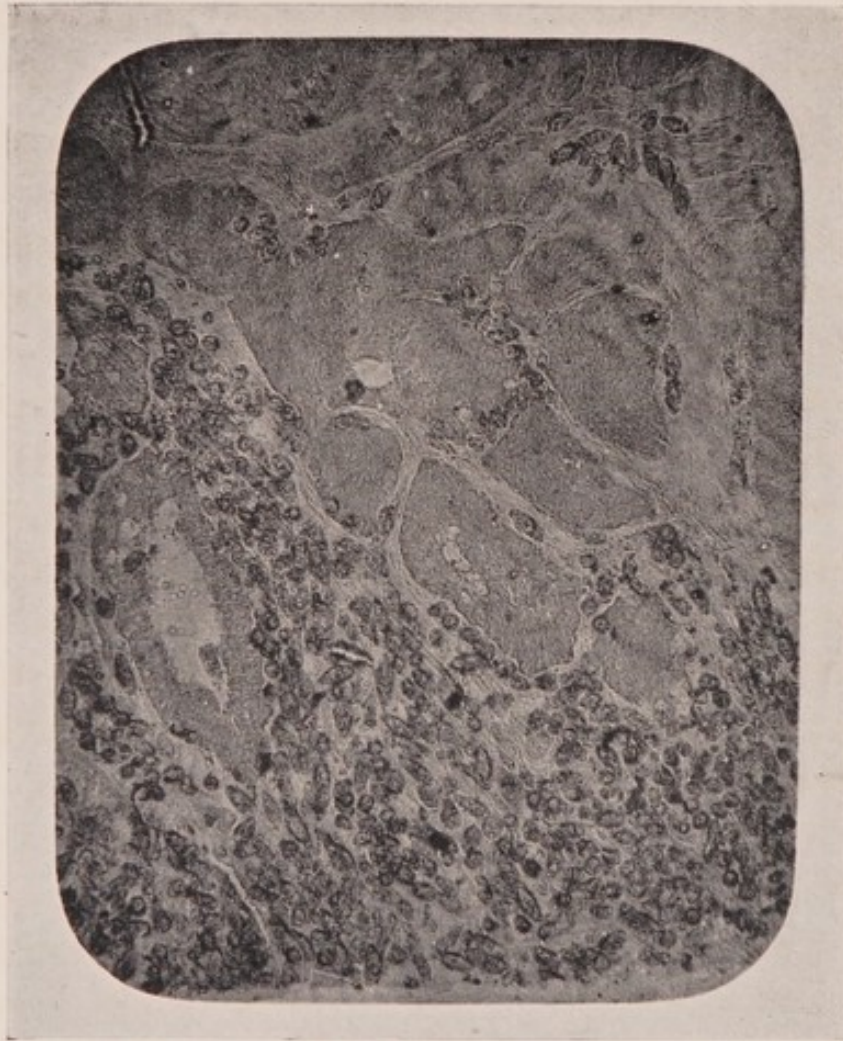

Fig. 12.—Section of the so-called bilharzial scirrhosis of the bladder. Numbers of ova are seen lying in between groups of epithelial cells.

(From a specimen, prepared by Professor Symmers, in the Pathological Museum of the School of Medicine, Cairo. Photo-micrograph by Mr. F. S. Willmore.)

opinion is still divided as to the true significance of this apparently cancerous appearance. (Fig. 12.)

A special condition in which the connective tissue of the meso-cæcum, meso-colon, and meso-rectum is densely infiltrated, is seen in certain cases of bilharziosis of the large bowel, and will be referred to in a later section.

The extreme variety in the pathological manifestations, and their great diversity of form, is probably to be explained by repeated re-infection, to which the patients must be constantly subject, living, as they do, always amidst the same unfavourable conditions. Indeed short of a complete exile from Egypt the affected person, usually an agricultural labourer, can hardly get away from the risk of re-infection. The multiplicity of the lesions, due to a new beginning being constantly made in the series of pathological changes, is thus not difficult to understand.

III.

BILHARZIOSIS OF THE URINARY SYSTEM.

A VARIETY of interstitial nephritis of bilharzial origin has been described, and bilharzia ova have been found in the substance of the kidneys by Kartulis and others. Papillomatous growths occur in the pelvis of the kidney; and both the hypertrophic and the atrophic forms of the disease are met with in the ureters; but the bladder is by far the most common seat of bilharziosis. It is probable that the disease here, as in other organs, is only one of the local manifestations of bilharziosis, and not a centre from which extension takes place, by contact or proximity of tissue, to other parts of the urinary tract in communication with it. Infection of a part by bilharzia is due to a centrifugal distribution, the centre being the blood in the portal vein and its tributaries, and there is no local propagation of the worms in the tissues. Each manifestation is due to the local effect of certain couples, or colonies of couples, and the effects are limited by the extent of surface or area over which each couple is able to disseminate its ova. Large areas of disease are due to the combined action of many couples working side by side, each taking charge of a particular area for destruction.

Bilharziosis of the bladder.—The general swelling and infiltration of the mucous membrane, described in some detail in the preceding section, is probably the earliest manifestation we know and recognise, and this condition is seen at its best in the bladder. Photographs and drawings fail to give an adequate idea of this very characteristic appearance with its wet sea-sand scattered about in the substance of the swollen membrane, and, it may be, thickly infiltrating the whole of the prostate. (Fig. 7.) In the fresh state such a surface is thinly coated with a peculiarly tenacious mucus, in which ova may be found, and which appears to be a great protection to the membrane. Were the surface bereft of this slippery mucus and dry, it would be very friable and easily abraded by the least friction. As it is, it is not until the sandy change becomes marked that the surface of the mucous membrane becomes dry, harsh, and thickened. This may occur to such an extent that the internal lining of the bladder comes to resemble a cyst wall which has undergone an almost general calcification. The surface has then the appearance of being coated with much *dry* sun-baked sand, as opposed to the earlier appearance of *wet* sea-sand, which is definitely deep within the substance of the mucous membrane. (Fig. 8.)

Another change is a patchy hyperæmia associated with minute extravasations, either as an independent manifestation, or in an already thickened and infiltrated mucous membrane. This may be confined to

the region of the trigone or scattered irregularly over the posterior surface of the bladder. On these hyperæmic patches in the substance of a swollen mucous membrane, or as quite distinct lesions in themselves, may be larger or smaller dry sulphury sandy patches. These have the general characters already described and map out definite areas, which are irregularly distributed over the surface of the bladder upon thickened patches of the mucous membrane. As the disease progresses, larger and larger areas become affected, and as adjoining patches unite, the thickened internal lining of the organ becomes hard and on section grates under the knife, not only from the presence of calcified ova in the mucous membrane, but also from the granular phosphatic deposit which has occurred on its surface. At the same time the associated thickening increases and soon involves all the coats of the bladder, until the viscus resembles a calcified cyst, with thickened walls. "As the patches increase in size, they also increase in thickness, owing to the overgrowth of the surrounding tissue, due to the irritation of the presence of the eggs, and also to the fact that Nature, striving to undo the mischief she has permitted for the sake of the propagation of the bilharzia species, tries to render the eggs harmless within the host by enveloping them in fibrous tissue and isolating them, as she does to foreign bodies embedded in living tissue elsewhere." (Milton.)

Sometimes a row of bilharzial vesicles makes a border round the trigone, or a few tiny warty projec-

tions occur in the same situation, with or without the so-called earlier manifestations. As has already been pointed out, these changes frequently occur in an already much thickened and generally hyperæmic bladder; and before the sandy patches have had time to develop, considerable general infiltration of the whole thickness of the bladder with ova and small round cells has been going on. The calcification of the ova, which is the principal change in the sandy patch, takes at least a year to develop.

From the early stages in the pathological changes above described onwards, the different forms of bilharzial lesions are very much mixed; and it is difficult to present the progress of the disease in anything like regular order. In almost every infected bladder all or many of the different manifestations are to be found, in greater or less degree, but the principal change is that of marked epithelial proliferation and the formation of papillomata. The papillomata, the general structure of which has already been described, occur in many shapes, from the fine villous form to the large bulbous-ended variety. It is not at all unusual to find a bunch of fine papillomata sprouting from a small raised plateau of thickened mucous membrane. Even at this early stage, there is much more firmness about a bilharzial papilloma than in an ordinary soft fibrous or myxomatous polypus. The bilharzial papillomata are, however, very friable and bleed readily in advanced cases; and, at times, become so soft as to form large shaggy masses, with a fleecy surface, growing in

clusters from the wall of the bladder. The papillomata have a special predilection for the trigone and the posterior surface generally; but after a time they are seen widely distributed over the mucous membrane. So profuse may be the growth of papillomata that almost the whole cavity of the bladder may be filled with them, and as concurrently there is an increase in the thickness of the bladder wall, the actual reservoir space becomes very small indeed. In other cases, sessile masses, not unlike condylomata, but much firmer and extensive, form the prominent features of the bilharzial changes. These elevations are of various sizes and shapes and are usually associated with considerable papillomatous formation also. They consist of a loose fibrous tissue foundation, capped with much thickened infiltrated mucous membrane. Their structure is thus similar microscopically to a papilloma and they undergo exactly the same secondary changes.

Another change, which must begin very early, is thickening of the coats of the bladder from the irritation of the bilharzia worms and their ova. This involves all the coats of the bladder, and the organ is to all appearances like an hypertrophied organ resulting from some chronic obstruction to the outflow of urine. There is some true hypertrophy of the muscular coat from overwork, due to the increased frequency of micturition, the obstruction to the outflow, and the straining entailed in emptying the bladder, but quite as much, if not more, of the thickening is due to the

formation of bilharzial granulation tissue and its subsequent transformation into fibrous tissue. The prostate is often found infiltrated, as are also the vesiculæ seminales, which, in advanced cases, are almost lost in a fibrous mass, that is welding the base of the bladder to the surrounding connective tissue. There is not usually much enlargement of the prostate, as here the atrophic form of the disease is most commonly found, and contraction, rather than proliferation of the new tissue, is the rule. In later stages, any true prostatic symptoms that may be present are masked by the presence of cystitis, stone, etc.

Probably the most usual condition of the bladder in severe bilharziosis is as follows:—The bladder internally is thickly infiltrated with extensive patches of dry sandy change, so that portions of the wall are almost entirely converted into a calcified plate; or it is filled with papillomata of various sizes and shapes, very irregularly distributed throughout the mucous membrane. The walls of the bladder are much thickened and infiltrated, and the cavity is considerably contracted. From this thickening and the presence of the papillomatous masses the actual urine space is very small, and the cavity is often eccentrically placed. “Owing also to the calcification of the bladder wall the effect of muscular contraction is largely lost, and the bladder is more like a dilatation in a firm-walled tube than a cavity in a contractile organ” (Milton). The prostate is infiltrated throughout with calcified ova, and may be somewhat enlarged. The urine

collects in the depressions between the papillomatous masses and decomposition readily occurs, so that the surface of the masses and the mucous membrane generally may be thickly coated with phosphates; and, owing to obstruction at their orifices, the ureters become dilated and hydronephrosis with all its consecutive and, later, septic consequences soon results.

Other cases are seen with enormous thickening, deep to the mucous membrane, extending throughout all the coats of the bladder. This has a section like caseous tissue, or may be quite fleshy, like sarcoma. In some instances there is only a very narrow slit left as a representative of the bladder cavity. What remains of the mucous membrane is dark, ragged, and degenerated, and shows the remains of papillomata. (Fig. 13.)

Another fairly common change of the same kind consists in the formation of an exceedingly soft mass of tissue, often with the consistence and colour of softened brain matter. This, which usually springs from a considerable area of the mucous surface, may almost completely occupy the cavity of the viscus. It is not uncommon to find that the remainder of the cavity is filled with recent blood clot and fragments of necrosed tissue from the surface of the mass.

As the thickening of the bladder proceeds, it comes to be felt as a hard mass above the pubis, and it may increase to such an extent as to reach almost to the umbilicus, with or without infiltration of the abdominal wall. In other cases the thickening is not so much of

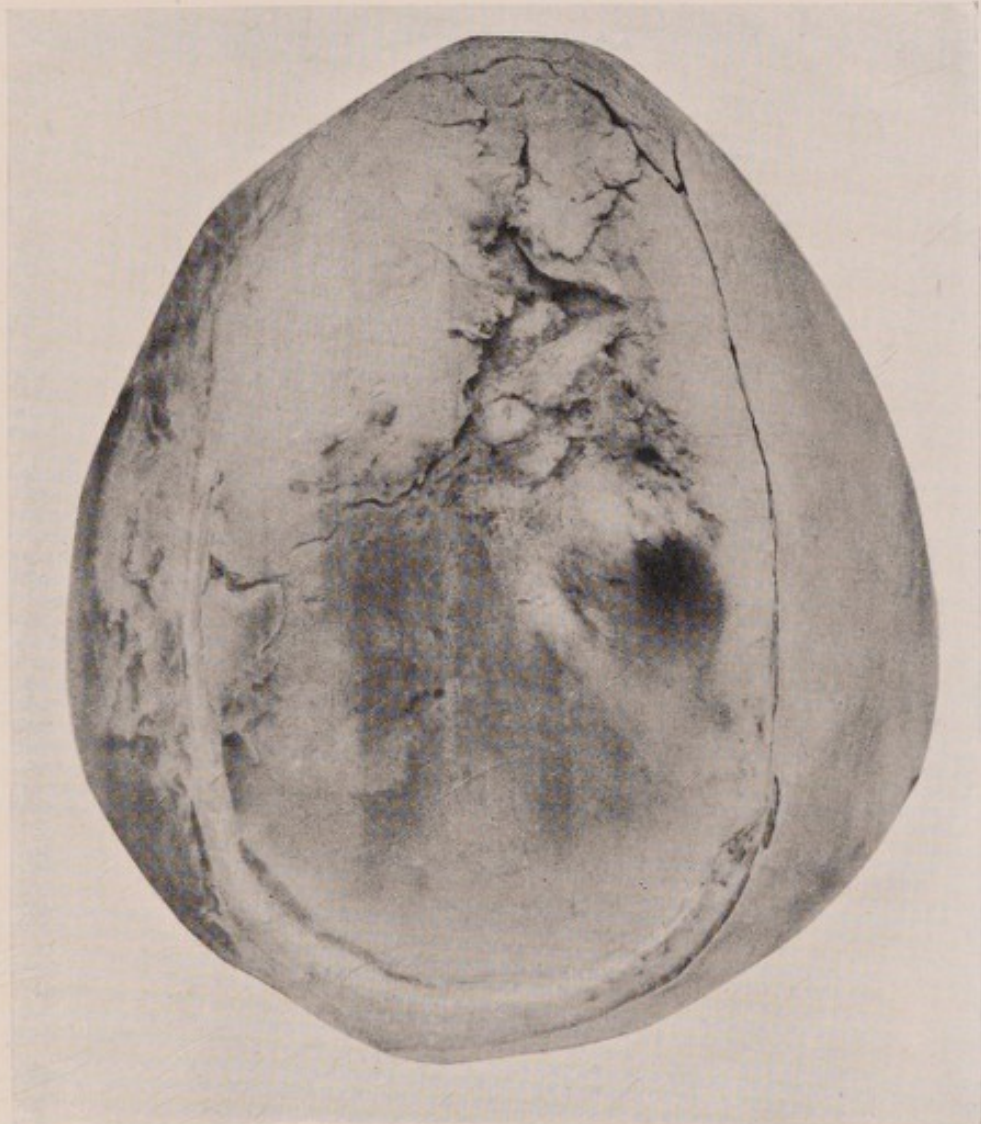

Fig. 13.—Advanced bilharziosis of the bladder. The narrow crescentic area below and to the left represents all that remains of the cavity of the viscus.

(From a specimen, prepared by Professor Symmers, in the Pathological Museum of the School of Medicine, Cairo.)



the bladder itself, but involves all the loose connective tissue round it and the adjacent organs. The most usual site of this change is anteriorly, whence it extends into the structures of the abdominal wall. The following case illustrates this condition very well: The patient was a young woman, who gave a four months' history of a tumour in the lower part of the abdomen, associated with painful micturition for some time preceding the appearance of the swelling. A lump was found above the pubis, extending upwards almost to the umbilicus and laterally to each semilunar line. The mass was of stony hardness, and running into its substance were two unhealthy-looking sinuses, which did not, so far as could be made out, communicate with the bladder. There was not the least tenderness on examination or pain, the only inconvenient symptom being marked frequency of micturition, which was explained by the discovery of a large stone in the bladder. The vagina, uterus and urethra were quite healthy, and the urine contained no ova. An incision was made in the middle line through the hard mass and exposed the wall of the bladder, which was thickened with bilharzial tissue, especially at the apex. The bladder was opened and a large ovoid stone removed. The bulk of the tumour was in front of the bladder, and the sinuses ran down through the mass to a space full of soft degenerated bilharzial tissue, just above the apex of the viscus. The whole thickness of the abdominal wall was infiltrated with the growth, in which, except for a few

fibres of the rectus muscle, nothing but a fibrous structure could be made out.

Microscopically the growth consisted of firm white fibrous tissue, in which no ova could be found. The opening in the bladder gradually closed, and, though the tumour remained as before, considerable relief was experienced by the removal of the stone.

There is still considerable discussion as to the nature of these hard masses produced by bilharzia. Some would have one believe that they are all cancerous, the exciting cause of the malignant change being bilharzia ova; but, certainly, most of them are simply masses of dense fibrous tissue, practically scar tissue, the density being specially marked owing to the essentially chronic nature of the inflammatory process. There are, however, cases of apparently typical scirrhous cancers in connection with bilharzial changes in the bladder, and, in such, microscopic section shows the ova, often in very large numbers, lying between the masses of cancer cells. (See Fig. 12.) Clinically there is very little to help in the differential diagnosis of these bilharzial fibrous masses from those really cancerous, though sometimes a secondary enlargement of neighbouring glands and the extreme rapidity of growth are in favour of cancer. "The co-existence of carcinoma and bilharzia is generally regarded as fairly common, but, I think, it does not in reality occur so frequently as some writers would lead one to expect." (Milton.)

Occasionally sinuous fistulous tracks, lined with

bilharzial granulation tissue, form in the hard masses, whether carcinomatous or not, and, communicating by means of a narrow opening with the bladder below, discharge a small amount of filthy urine, pus and granular *débris* on the skin surface. These fistulæ in the midst of hard tissue are specially found in the suprapubic region, sometimes opening at the umbilicus, or in the perinæum. In the umbilical fistulæ a track runs down between the muscles of the anterior wall of the abdomen and the peritoneum, and ends in a soft degenerated mass round the upper part of the bladder, but without, apparently, opening into it. This degenerated mass is found in the prevesical and lateral vesical spaces, while the bladder walls are thickened and severely affected with bilharzia, but there is no direct communication between the lesions within and without the bladder. It seems as if these cases begin as a bilharzial infiltration of the loose connective tissue round the bladder in front, which ultimately makes for the umbilicus along the urachus in the lines of least resistance.

Rarely, an enormous proliferating mass may burst through the walls of the bladder and present in the peritoneal cavity where, once leakage of urine has taken place, fatal peritonitis rapidly ensues.

The secondary backworking effects of bilharziosis of the bladder on the **ureters** and **kidneys** are in no way different from those produced by any other obstruction to the outflow of urine; indeed, the dilatation of the ureters and the pelvis of the kidney,

due often to blocking of the vesical orifice of the ureter, may almost be considered the natural consequences of bilharziosis of the bladder, since so much obstruction to the outflow of urine is offered by the many lesions in that viscus. Further, the ureter itself is not unfrequently the seat of bilharzial changes, papillomata and a general infiltration of the mucous membrane being the most common lesions, and thus, quite apart from any assistance rendered by the bladder, considerable hydronephrotic changes may be produced. One never finds these mechanical changes in ureters and kidneys without also a septic infection, arising from the condition into which the bladder passes after the onset of cystitis. A rapidly spreading septic inflammation is soon developed and extends not only to the ureters and the pelvis of the kidneys, but also into the substance of the latter organ, with all the severest accompaniments of the worst type of septic surgical kidney. "When it happens, as is so frequently the case, that the contents of the bladder are represented by a collection of decomposing organic tissue and stinking urine, the step to a septic inflammation of ureters and kidneys, from simple dilatation of the ureters and hydronephrosis, is easily taken." (Milton.) On the other hand, severe symptoms may sometimes be produced by apparently insignificant manifestations. Thus one has seen an autopsy on a case of marked double hydronephrosis in which the causal lesions were two small bilharzial papillomata at the vesical openings of both ureters.

The very frequent association of bilharziosis of the bladder and of the urethra will be again referred to.

Early symptoms of bilharziosis of the bladder.—The very earliest pathological manifestations of bilharziosis do not appear to give rise to any symptoms for a considerable time; but, as the infiltration and swelling of the mucous membrane progress, the softening of the surface layers of the epithelium increases, probably from the irritation of the urine, as well as from the gradual molecular disintegration due to the bilharzial process, and a centre of irritation is produced; and that, usually, in the naturally most sensitive portion of the bladder, the trigone. This will give rise to some increased frequency in micturition and, perhaps, a feeling of heat in the perinæum or the rectum, or along the course of the urethra. Further, in the attempt to get rid of the irritant, that is, to expel the urine from the irritated trigone, an increased straining occurs at the end of the act of micturition. If a small piece of the swollen vascular mucous membrane becomes nipped between the contracted muscular bands of the wall of the bladder, some hæmaturia may be present, especially at the end of micturition. “The amount of blood lost is, as a rule, insignificant, and would probably never be noticed by the patient if it were mixed with the urine as it is passed; but the peculiarity of this hæmorrhage is that the few drops of blood which are lost are voided, either with the last few drops of urine, or else escape from the urethra after the act of micturition is alto-

gether finished ; whereby the attention of the patient is caught by the marked difference in the appearance of the last part of the evacuated fluid. In a large number of cases hæmaturia begins without any subjective symptoms ; but, as a rule, soon after the patient notices the loss of blood, he begins to complain of pricking or scalding in the urethra during micturition, together with a sense of pain or weight in the perinæum." (Milton.) This state of irritation, much of which may be due to an early infiltration of the prostate, with occasional hæmaturia, may persist for a long time before any more definitely characteristic symptoms appear ; indeed, many cases go no further than this for several years.

The signs above noted may be so slight that the possibility of bilharzia as a cause may not have been considered. Nothing can be made out on abdominal examination except, perhaps, some tenderness on deep pressure just above the symphysis pubis. Examination with a finger in the rectum and a sound in the bladder may disclose distinct thickening of the bladder wall and, perhaps, some enlargement of the prostate, which may also be tender. On introducing the sound it usually passes without difficulty, but there may be considerable pain as the point of the instrument enters the bladder. The mucous membrane may feel soft and swollen but, at this early stage, no roughness of the wall will be felt except, at times, posteriorly where the mucous membrane is thrown into ridges and feels harder than in other situations.

Early papillomata or warty projections are difficult to feel with the sound, but a bunch of them may sometimes be made out in the region of the trigone. On the withdrawal of the sound a small quantity of blood may escape from the urethra or be passed with the next urine.

If there are other symptoms pointing to the possibility of bilharziosis these local signs may be discovered when one is on the look-out for them, but they are often so indefinite that they may very easily be missed in an ordinary routine examination of the bladder. The urine is acid and clear, except at the very end of micturition, when some thick tenacious mucus may be passed with it. Repeated examinations, especially of the deposit of the whole day's urine (if necessary, after centrifugalising the deposit), may reveal the presence of ova, which at once confirms the diagnosis. The ova are much more likely to be found if hæmaturia is present, especially if the last few drops of urine are examined. Obviously if there is hæmaturia the urine will contain a small amount of albumen and blood corpuscles.

Certain cases, even when there is an early formation of papillomata, present no symptoms whatever except painless hæmaturia, varying in amount and coming somewhat irregularly, especially with the last squeeze.

In these early stages, the general health does not suffer to any appreciable extent; but after a time the constant hæmorrhage, insignificant in amount though

it may be, gives rise by its persistence to anæmia, with all its usual accompaniments. In all anæmias in Egypt the presence of ankylostoma must also be suspected and search made accordingly for ova in the fæces.

It is not at all uncommon to find ankylostoma and bilharziosis associated in the same patient.

In a somewhat more severe case the symptoms will present an aggravation of those already described, but are still, mainly, irregular hæmaturia and some increased frequency of micturition. The urine will continue to be acid, fairly clear at most times but containing blood and mucus at the end of micturition. To examine such urine for ova the whole quantity passed in the twenty-four hours should be taken and allowed to settle in a conical glass. The supernatant fluid is drawn off, as soon as a good deposit has formed, and a small quantity of the residue taken off in a pipette and placed on a slide. The specimen will contain, besides the usual constituents, blood corpuscles, epithelial cells, small round cells, connective tissue cells, amorphous masses and granular *débris*, pus cells and ova. The ova have the spine at the end, and contain either living or dead miracidia. Often the contents of the ova are a granular *débris* or a calcified mass. (See Fig. 3.) The ova which contain living miracidia are clear and more or less transparent and with high powers the structure of the miracidia may be clearly made out.

Ova are sometimes found in the spermatic fluid

(Lortet and Vialleton), especially in cases in which the vesiculæ seminales are affected.

Sooner or later the urine becomes decomposed, as will be readily understood when the condition of the bladder is recalled, and all the symptoms of acute cystitis set in. There is nothing to distinguish this form of cystitis from any other except the almost constant hæmaturia and the presence of bilharzia ova in the urine. Once cystitis has started the patient is practically never free of it, though after a time the acuteness of the condition passes off and a steady chronic form persists. The urine will now be alkaline, turbid, offensive, dark-brown in colour from the blood in it, and will contain mucus, pus, albumin, phosphates, granular *débris*, epithelial cells, blood corpuscles and ova, the latter in great numbers. At a late stage the ever-present symptoms of cystitis and the almost constant micturition, from the irritation within and the small size of the cavity of the bladder, the pain and scalding in the urethra during the passage of urine, the pain above the pubis, in the perinæum and in the rectum, the latter often with a great deal of tenesmus, soon make the patient's life an absolute misery to himself. He gets very little rest at night and it is difficult to imagine even an Egyptian allowing this condition to go on without any attempt at treatment, yet such is constantly the case.

The bladder condition may become at any time still further aggravated by the deposit of phosphates on the abraded mucous membrane or on the ragged

tops of papillomata or sessile masses. The whole interior of the bladder may be thickly crusted with these phosphatic masses, which go on increasing as the cystitis persists and the urine is always alkaline. Pieces of these incrustations may break off and form the nucleus of phosphatic stones, thereby greatly increasing the patient's misery. These stones are a frequent accompaniment of bilharziosis of the bladder, and are formed in exactly the same way as a stone forms on any other foreign body in this organ. A great many stones are, however, met with in bilharzial bladders which consist of uric acid or oxalate of lime, with, sometimes, alternating layers of phosphates. Such stones must form originally in acid urine, that is, before it has become alkaline and there has been any deposit of phosphates. Renal colic is comparatively uncommon in Egypt, and it would seem probable that many uric acid stones form in the bladder on a nucleus of bilharzial ova or, more probably, upon a small piece of a papilloma, in a bladder in which the urine is still acid, the occasional layer of phosphates being formed when a mild attack of cystitis has supervened and subsequently yielded to treatment. The average Egyptian pays so little attention to the comparatively severe symptoms of bilharziosis and the cystitis with it that, as soon as the stone is removed, he will never consent to remain in hospital for further treatment of the original bladder condition.

The conditions found on abdominal, rectal, or

combined examination, and also with the sound, will vary with the pathological changes within the viscus and in its immediate neighbourhood. Many of the grosser lesions, such as tumour masses, sandy patches, concretions, and stones, can be felt with a sound, and the extent and contour of the bladder cavity and the thickness of the walls determined. Especially must a careful search be made for stone, the presence of which may be the cause of the marked severity of the symptoms. Considerable difficulty in the introduction of the sound may sometimes be experienced, owing to the implication of the urethra in the bilharzial process, and the presence of stricture, which occurs in one variety of urinary fistula.

In certain cases there may be an almost constant oozing of blood from the shaggy surface of degenerated papillomata, and the urine may be almost entirely blood, altered by decomposition. This may clot in large masses in the bladder, giving rise to acute retention, with very severe pain, for which the only possible treatment is removal of the masses of necrotic tumour and blood clot piecemeal, through a perinæal opening—usually a Cock's puncture—and afterwards washing out the bladder with very hot water and inserting large drainage tubes. It is quite impossible to wash out the bladder in this condition through any catheter passed by the urethra. Masses of degenerated tissue and thick dark clotted blood have to be evacuated and free drainage must be provided to give any hope of relief. Retention of urine

may also occur from the blocking of the urethral orifice by papillomata, phosphatic concretions, stone, granular *débris* and the like.

The **last stage** in an advanced bilharziosis of the bladder is somewhat as follows: The patient is usually a man, though a few very severe cases are met with in women, and he is very weak and anæmic, thin and haggard, and absolutely miserable. He has constant micturition and dribbling, with pain in the penis and deep down in the perinæum near the rectum. He very often carries his scrotum in his hand in an attempt to relieve the pain. The history is usually absolutely untrustworthy, the native mind having no idea of the duration of time. On examining the penis, the meatus will be wet and there is a constant slight dribbling going on. On passing water a very small quantity is voided and there is much pain, especially at the completion of the act, followed by a slight temporary relief. The urine varies in appearance, but is usually very offensive, dark-red and turbid, and, on standing, deposits phosphates, *débris*, blood, and ova. On examining the abdomen a hard mass may be felt in the suprapubic region. This lump is usually not in the least tender, is very irregular and stony, and may extend upwards as far as the umbilicus and to any extent laterally. One or both kidneys will be found enlarged and tender, and the ureters may be felt much dilated through the unusually thin abdominal wall. The whole course of the urethra may be hardened or, on the other hand, it may be quite

unaffected. On rectal examination the bladder will be felt firm and contracted, or simply as a thick hard mass; and bimanually, with the other hand on the abdomen, the great thickening of and around the bladder will be well appreciated. On introducing the sound, it can often just be passed beyond the neck of the bladder, and then only with severe pain, into a very much contracted cavity. Masses of bilharzial tissue may be felt, crusted with concretions, but, in many cases, such is the contraction of the space within the bladder that beyond feeling that the end of the sound is free within a small cavity, very little else can be made out.

The usual treatment and fate of these advanced cases is that a perinæal opening into the bladder is made to relieve the incessant pain. The incision, passing through a very hard mass, opens, at what seems to be a great distance from the skin surface, into a very small cavity, which is at first difficult to recognise as that of the bladder. On introducing the finger and dilating up the wound great masses of degenerated tissue are found, coated with phosphates, and almost completely filling what remains of the bladder cavity. Large pieces of concretions or structureless "pinkish cream-cheese" come away. The bladder walls, when they can be made out at all, are greatly thickened and all the surroundings are much indurated. A lot of decomposing blood clot may also be evacuated, mixed with very offensive urine. If there is room a drainage tube is introduced into the

bladder and stitched to the edges of the wound (which is itself closed by suture), and the urine drained into a vessel at the side of the bed by syphon action. The patient has great relief for two or three days after operation; then he starts a diarrhoea, which nothing will stop, and one can see him visibly melting away. His temperature goes up and stays up and becomes typically septic. His anæmia and weakness are extreme, and in about a fortnight he dies from sheer exhaustion, with great emaciation and the severest possible symptoms of septic kidneys, or with uræmia. The condition is really quite hopeless from the first; but, for a day or two after operation, so great is the relief afforded that the unwary surgeon is inclined to congratulate himself on his opportune interference.

Treatment of bilharziosis of the bladder.—

Our first duty, in connection with the treatment of this awful disease, is candidly to admit that there is nothing yet known that has any effect whatever upon the actual cause of the trouble, the bilharzia worm itself. And, taking into consideration the early pathology and habitat of the worm, it is difficult to see how we can expect to kill the invader in the blood without doing fatal damage to the whole organism at the same time. There is this to be said, however, that there are certainly many instances of spontaneous cure of the disease, hæmaturia and the bladder irritability lasting for a varying period and then disappearing, never to recur. This fortunate ending can only be expected to happen if the patient is re-

moved from the possibility of re-infection; and can never occur among the ordinary rank and file of the sufferers from this disease, namely the agricultural labourers of Egypt. Even though a patient exiles himself entirely from Egypt, cases are reported in which ova have continued to be passed in the urine for several years afterwards. What it is that leads to the death of the worm within the body we do not know; but it is comforting, to some extent, to realise that this happy result *does* sometimes occur, though, even after the death of the worms, symptoms may persist for a long time, until all the ova are eliminated from the body in the urine or fæces or encapsuled.

In the earliest clinical stages of the disease, when some slight irritability and painless and temporary hæmaturia are present, very good results frequently follow the administration of the liquid extract of male fern, given regularly in fifteen minim (1.0) doses, three times a day, in capsule. A long course of male fern and washing out the bladder with increasingly strong solutions of nitrate of silver, starting with a 1 in 10,000 solution, or with a four per cent. solution of quinine, has sometimes a good effect in checking the hæmaturia and relieving the irritation. Boracic acid in five grain (0.30) cachets three times a day, or irrigations of the bladder with adrenalin in normal saline solution, may also prove of service.

One also gives full directions as to diet, but it must be admitted that, even if such are carried

out, very little benefit is likely to result. As the disease progresses and cystitis sets in (in hospital practice one rarely sees a case before this has happened), considerable, if only temporary, benefit may result from strict anti-cystitic treatment. The diet consists of milk and milky foods generally, vegetable soups and farinaceous food of all kinds, meat being avoided. The best diluent and cleanser is plain water, which may be given in large quantity. Barley water and Vichy water (Source Célestins) are also largely used and, medicinally, the changes must be rung on salol, urotropine, benzoic acid and the benzoates and boracic acid, in appropriate doses. Better than any of these, however, is the time-honoured buchu and hyoscyamus mixture, usually made up with bicarbonate or acetate of potassium, fifteen grains (1.0); tincture of hyoscyamus, half-a-drachm or more (2.5); glycerine or syrup of orange, half-a-drachm (2.5); and infusion of buchu to the fluid ounce (25.0). This mixture is given four times a day for an extended period.

Except to give a certain amount of relief, by clearing the bladder of accumulated *débris* and decomposing urine, washing-out the bladder accomplishes little; and, even in the earliest stages, it cannot be looked upon as exerting any local curative or inhibitory effect on the disease. For this mechanical washing out of the viscus, plain sterilised water, or boracic or quinine solution, may be used.

From this stage onwards, treatment must be

entirely symptomatic; and, later, the question of the advisability of drainage of the bladder has to be considered. In general, it may be said that in all cases the drainage opening, if any, must be made in the perinæum and not in the suprapubic region; and, further, before it is decided upon at all, a careful examination must be made for stone, which, in spite of the already awful condition of the bladder, may and does give rise to a great aggravation of the symptoms. After the removal of the stone, immense relief usually follows and the patient considers he is cured of all the symptoms worth worrying about. Drainage must be undertaken when the urine is very foul and there is evidence of early septic absorption, the operation being either a Cock's puncture or a median perinæal cystotomy, followed by prolonged washing-out of the bladder and the introduction of a drainage tube, through which the washing may be continued for some time, until the urgency of the symptoms disappears, after which the wound is allowed slowly to close of itself. Sometimes a fistula is left which, though acting to some extent as a safety valve, distinctly adds to the patient's discomfort. Drainage is imperatively called for in all cases of acute retention, either from blocking of the urethral orifice by stone, concretion, growth or *débris*, or from clotted blood, as already described. The presence of a drainage opening adds a very considerable risk in all these cases, as septic infection very readily sets in in such a filthy bladder and goes very rapidly

upwards to the kidneys. In cases of hæmorrhage the injection of very hot water or adrenalin solutions may be of temporary service.

All stones should be treated, as far as possible, by lithotripsy; and, in spite of the extensive changes in the bladder, the results of this operation, *quâ* operation and as a reliever of symptoms, are remarkably good. It might almost be stated as a golden rule that no stone in a bilharzial bladder should ever be treated by a cutting operation, unless the condition of the bladder is such as to call for drainage, or the pain is so severe and constant as to require the bladder to be put at rest, by providing a free artificial outlet for the urine. Further, if a cutting operation is done, it must be in the perinæum and not in the suprapubic region. It seems almost as if the further you keep away from the kidneys with the knife the better the immediate result and the prognosis for the future.

It must always be remembered that the true cause of death even from a very early stage in the proceedings, lies in the ureters and kidneys; moreover a fatal result in cases of stone after a cutting operation and, for that matter, after lithotrities, rare as they are, is almost always to be ascribed to the condition of the kidneys and ureters and the septic complications already present there at the time of the operation.

Some temporary relief may be obtained in severe cases by such palliative measures as hot fomentations to the abdomen, morphia and belladonna suppositories,

hot baths, passing urine with the penis immersed in a cup of hot water, etc., but all of these are only confessions of failure to cope with the disease in anything like a satisfactory manner.

For cancer associated with bilharziosis, and the fibrous indurations in and surrounding the bladder, nothing can be done; though some relief may be afforded by hypodermic injections of morphine for the pain, and a temporary respite from the awful irritation and constant micturition may be obtained by perinæal drainage. These measures are unfortunately only adopted in our endeavour to give the patient a more comfortable death.

Bilharziosis of the urethra.—The male urethra is very frequently the seat of bilharziosis, and is far more often affected than the female urethra. When the disease *does* occur in the female it is usually part of a general involvement of the bladder, instead of being a separate local manifestation, as is the case in the male canal.

Occasionally small elevations, resembling a urethral caruncle, but containing bilharzia ova, are met with at the orifice of the female urethra; and, quite recently, a case came for operation in which there was a papillomatous mass—with much general infiltration of the mucous membrane—which was attached by a loose pedicle to the base of the bladder and had protruded from the urethral orifice of a small girl, forming a mass the size of a large walnut. The tumour had all the typical bilharzial characters.

Symptoms.—The symptoms of early bilharziosis of the male urethra are usually localised pain in the perinæum and a hard, tender lump at the seat of the pain. There is a certain amount of difficulty in passing urine, and this symptom may be so marked that many cases are sent into hospital as impacted stone in the urethra. On careful examination with the sound it will be found that, though there is often some little difficulty in passing the instrument beyond the lump in the perinæum, it goes fairly easily, with a little coaxing, into the bladder; and, except for some roughness at the thickening, no stone is to be felt. The point of the sound may catch in the wall of a small thick-walled cavity in passing, and the grating thus produced may be easily mistaken for the rubbing against a stone impacted in this situation. As the disease advances the lump becomes larger and softer and approaches the skin surface in the posterior part of the scrotum, or just behind it, with all the symptoms of a subacute periurethral abscess. Eventually this leads to a thinning of the skin and a discharge of thick offensive pus and granular *débris*, and, very soon, a slight leakage of urine from the opening during the act of micturition. In this way a urinary fistula is produced and will persist indefinitely unless radical treatment is adopted. On cutting down in such a case one opens into a thick-walled cavity, which has a small connection with the urethra and is filled with pus, granular *débris*, and a few drops of urine. The granular tissue will contain ova; the walls of the urethra above



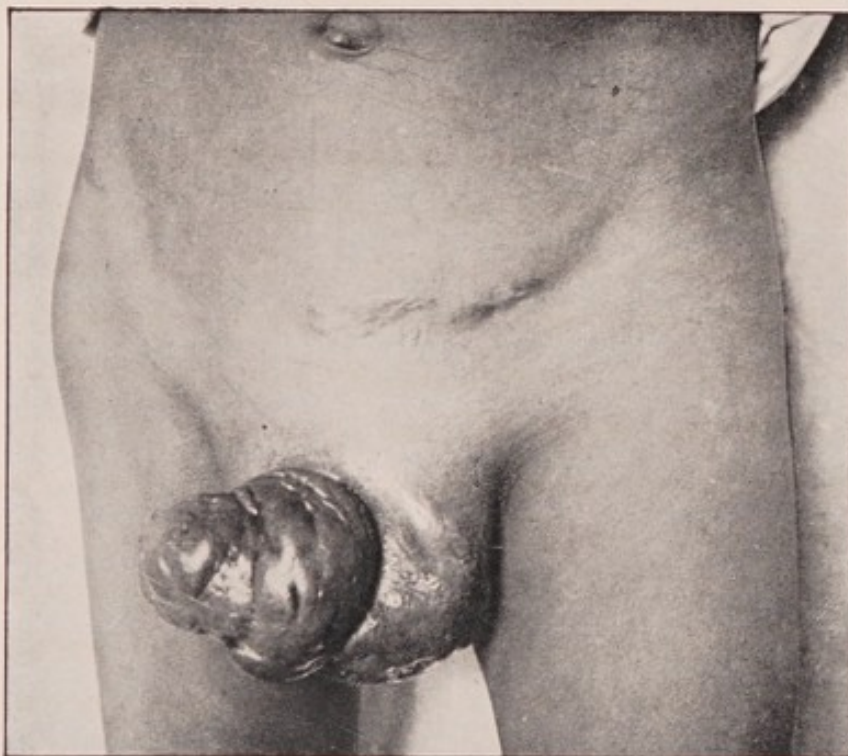


Fig. 14.—Bilharziosis of the penis and scrotum in a young boy. The glans penis and the prepuce, indeed the whole penis is in a condition of false elephantiasis, and riddled with sinuses, as is also the scrotum. The sinuses are really fistulæ in connection with extensive bilharziosis of the urethra. Old bilharzial sinuses are also seen in the left iliac region.

(Photograph of a case in the Author's wards in Kasr-el-Ainy Hospital, Cairo.)

and below the fistula will be thickened and its mucous membrane softened and infiltrated with bilharzial granulation tissue.

Treatment.—The treatment of such a case consists in the complete removal of all the infiltrated tissue right up to the level of the urethra, while the urethral edges of the fistula must be well scraped with a sharp spoon and all the granular tissue removed. If there is any stricture of urethra an external urethrotomy must be performed also. The wound is carefully plugged with gauze and allowed to granulate up from the bottom, a full-sized catheter being passed at short intervals while the healing process is going on.

In the majority of cases a **fistula** has already formed before any treatment is sought, and these cases present every degree of severity, from a single perinæal fistula, usually to one side of the middle line, just behind the scrotum, with little, if any, surrounding inflammation, to the formation of a hard indurated tissue, occupying the whole perinæum and surroundings and riddled with fistulous openings in various directions. The skin of the scrotum is often hardened and swollen with firm œdema, and the fistulous track can be felt coming up from the urethra, as a firm column of almost stony hardness. The urethra is also thickened and hard and may be much narrowed in its anterior part and the meatus much contracted. The fistula discharges pus, granular *débris* and urine, and there may be considerable eczema around the opening. There may also be a thin purulent discharge

from the meatus, which may easily be mistaken for that of chronic gonorrhœa. On passing a sound it usually enters the bladder easily, though in some cases, owing to the destruction of a portion of the urethra by the disease, an absolutely impermeable stricture may be present. The fistulous track runs in the substance of a very hard fibrous tissue which is directly continuous with a much thickened urethra, the bilharzial change in which extends for any length along it. The fibrous sheath is lined internally with soft bilharzial tissue, which extends up to the base of the ulceration forming the urethral end of the fistula. Ova are to be found in this soft tissue, and sometimes worms may be seen in open spaces beside the fibrous sheath of the fistulæ and in the periurethral tissue.

From the preceding, comparatively mild, cases all grades of severity are met with. The penis, the scrotum, the skin, and soft parts of the perinæum and the buttocks, and even the suprapubic region, may all be individually or collectively riddled with fistulæ, having the characters just described, the intervening soft parts being transformed into masses of scar tissue. The fistulæ branch in all directions, each separate branch often opening at a considerable distance from the original, "but it will be noticed that all the fistulæ arise from a very short length of the urethra, namely, that portion between the posterior margin of the scrotum and the bulb." (Milton.) It is not so common to find fistulæ arising from the penile urethra,



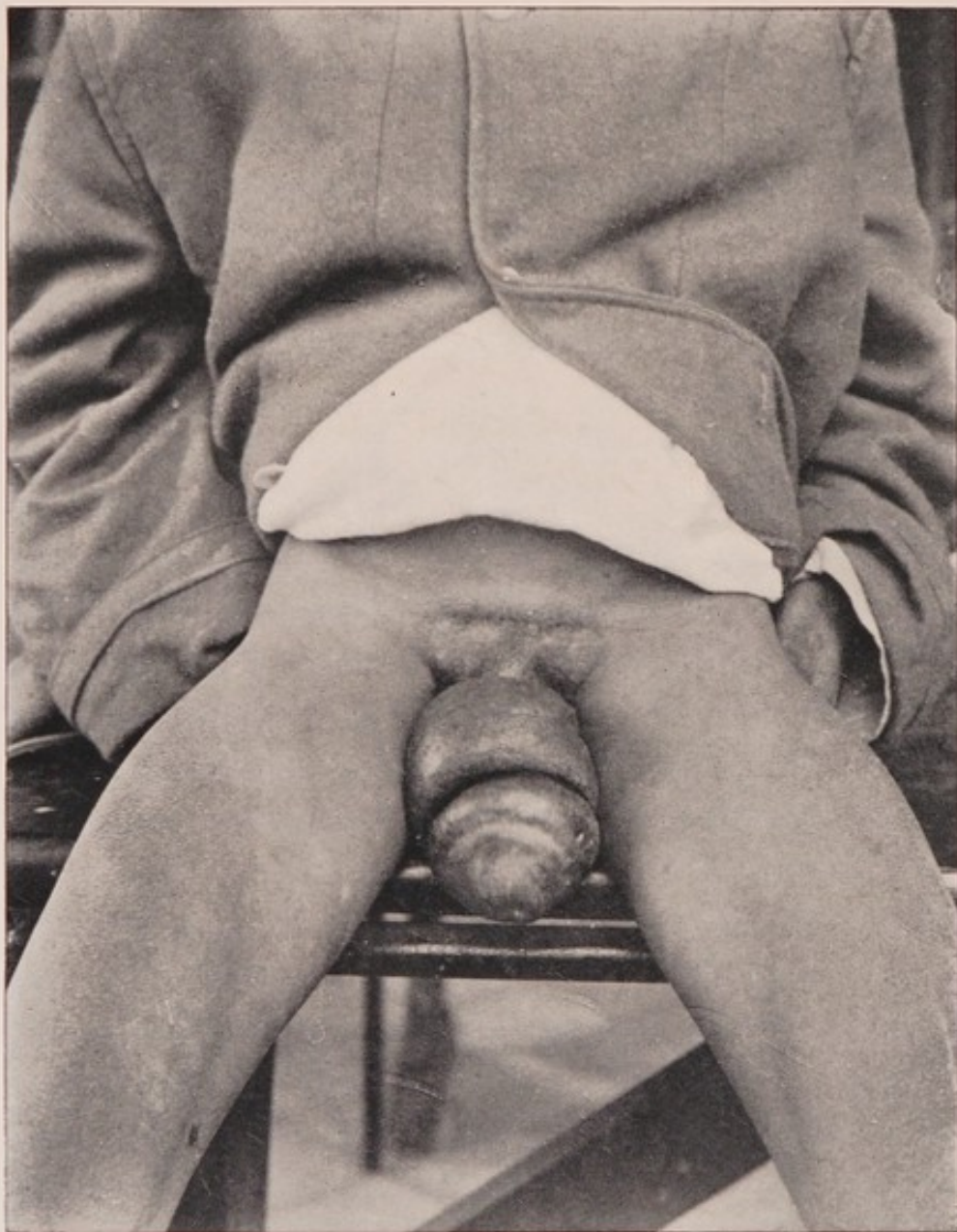

Fig. 15.—Bilharziosis of the penis in a boy of nine. The false elephantiasis of the glans, prepuce, and skin of the penis generally is well seen, but there are no sinuses or bilharziosis of the urethra in this case. (It may sometimes be difficult to diagnose this condition from filarial elephantiasis, but the comparative freedom of the glans in filarial invasion is an important feature.)

(Photograph of a case under the care of Mr. O. W. Richards in Kasr-el-Ainy Hospital, Cairo.)

but, when they do so, there is usually considerable destruction of the urethra in its anterior part, and the prepuce, skin of the penis, and the organ generally often becomes transformed into a mass of false elephantiasis, a condition which is also seen in the scrotum in the case of fistulæ traversing this structure. (Figs. 14 and 15.)

In some instances the glans penis is much infiltrated and may be extensively destroyed by ulceration, and, although the urethra is also affected, it seems that the deposit originated in the tissues of the glans itself.

No hope of cure can be expected in bilharzial urethral fistulæ unless the whole affected tissue is removed. Very extensive operations are often necessary to effect this, and half-measures are useless. The fistulæ must be followed up in their whole length and they and their surrounding fibrous tissue, however extensive it may be, freely excised. Large portions of the scrotum may require removal, as well as portions of the skin and subcutaneous tissues of the perinæal, gluteal, ischio-rectal and suprapubic regions. To dissect out certain tracts the scrotum may require to be split in half. The testicles are almost never affected, though fistulous tracks burrow in all directions in the scrotal tissues. If penile fistulæ are present they must be just as radically excised, and, in all cases, after the urethra itself has been freely scraped, the wounds must be made as clean as possible and tightly plugged with gauze, to allow them

to granulate up from the bottom and from the level of the urethra.

The treatment of the urethra varies with the condition. In some cases the mass of fibrous tissue seems to be closely incorporated with the urethral walls and an external urethrotomy must be done through this mass into the urethra and any stricture freely divided in the incision. In other cases the fistula can be traced in between the corpus spongiosum and the corpora cavernosa to the side of the urethra, where it opens laterally or even in the roof. This mass of tissue must be removed right up to the canal and the ragged opening into the urethra well scraped with a spoon and all the soft bilharzial tissue removed. Three or four days after the operation a full-sized catheter is passed and then every few days until healing is complete. The large open wounds often take a considerable time to heal, but with careful packing and proper attention the result of these cases is usually very satisfactory, though repeated operations are often necessary. Sometimes an operation, similar to that for the complete removal of an elephantiasis of the scrotum, has to be performed; and in this case it is often advisable to place a drainage tube in the bladder through the urethral incision for some days to prevent any infiltration of the new scrotal wound with urine. When the urethra is very much destroyed, and there is difficulty in finding any track at all, once the remains of the canal have been found a large catheter must be tied in the bladder for a few days.

In nearly all cases of bilharziosis of the urethra the bladder is affected with the disease, and the ultimate prognosis of the case must depend upon the bladder, ureter and kidney condition rather than upon that of the urethra.

In his "Three Lectures on Bilharzia," Milton divides these urinary fistulæ into *roof* and *floor* fistulæ as follows: "By far the greater number of these fistulæ take their origin from the roof, or pubic side, of the urethra; those coming from the floor, or perinæal side, being quite the exception. The floor fistulæ, though usually found in the urethra just in front of the bulb, are not so strictly confined to this part as the roof fistulæ and are fairly frequent in the penile urethra. It is very rare to find the corpora cavernosa infiltrated with bilharzial tissue, all fistulous tracks running in the corpus spongiosum, or between it and the adjacent corpus cavernosum. The roof fistulæ are probably formed originally by the destruction of a portion of the urethral wall by bilharzial deposit, which extends into the substance of the corpus spongiosum and then into the space between this structure and the corpus cavernosum on one side or the other. It is thus directed towards the perinæum, where it eventually arrives at the skin and opens externally, to one side of the middle line, and the fistula is complete.

"The amount of inflammation involved in the formation of a roof fistula is very small, in marked contrast to that occurring with floor fistulæ. In the latter variety the destruction of tissue occurs on the perinæal

side of the urethra with the formation of an ulcer, which, being in a dependent position, acts as a trap, catching and retaining the decomposing matter from the bladder. A septic inflammation is set up in this ulcer trap and a periurethral abscess formed, with gradually increasing surrounding fibrous induration, owing to the constant irritation. This fibrous tissue becomes firmer and firmer, until it is almost of stony hardness, and gradually approaches the surface of the perinæum, bearing in its centre a gradually elongated pouch, constantly filled with pus, urine and decomposing matter. The urethra in front of the ulcer becomes thickened by irritation of the discharges of the filthy cavity into its lumen. The result is that the whole urethra, from the site of the fistula even to the meatus, is narrowed and, not uncommonly, there may be complete obliteration of the canal by cicatricial tissue, due to the final healing of long-continued ulceration of the urethra, set up and maintained by the discharge from the fistula abscess. In roof fistula there is no obstruction of the urethra at all."

The pathological conditions met with in the urethra are mainly those of general infiltration of the mucous membrane and ulceration. Not unfrequently small raised grape-like projections may occur on the mucous surface, but there is an absence of any extensive papillomatous change.

Reference will be made later to other forms of fistulæ, due to bilharziosis, in the region of the perinæum, which sometimes secondarily acquire a com-

munication with the urethra; and there are certain other cases, in which there is a deposit of bilharzial tissue in the form of a hard lump in the corpus spongiosum, or even in the corpora cavernosa, which can sometimes be completely removed by operation and which is then seen to have no connection with the urethral canal. Sometimes, again, an external sinus leads down to a hard mass of similar characters, but without any urethral communication. The structure of these masses is typical bilharzial tissue, and they are due to the presence of a pair or a small colony of worms and their ova in the venous spaces of the erectile tissue; and, though it is probable that they will eventually open into the urethra, at this stage the mucous membrane of the canal is entirely unaffected.

IV.

BILHARZIOSIS OF THE INTESTINAL TRACT.

As might be expected, from the extensive distribution of the bilharzia worm and its ova in the portal circulation, the intestines may be severely affected; and, next to the bladder and urethra, the lower part of the intestinal tract, especially the rectum, is the most frequent seat of the disease.

Ova have been found in the muscular wall of the stomach, the condition being later verified *post-mortem* (Goebel), but not in the mucous membrane, and bilharzial manifestations may be found in any part of the mucous membrane of the intestinal tract, from the ileum to the anus.

Three main sets of lesions may occur in the intestines. The *first* consists in the formation of much redundant mucous membrane, due to its general infiltration, and of papillomatous and sessile masses. In the *second* of the series, ulceration is the most prominent feature; while in the *third* the most striking change is a very marked induration and thickening of the connective tissue between the layers of the peritoneal attachments of the gut.

In every part of the tract liable to infection, the only part apparently free being the stomach and duo-

denum, papillomata, usually definitely pedunculated, and of varying sizes and shapes, are the most common manifestations. In some cases they are but sparsely scattered over the surface of a vascular infiltrated mucous membrane, but in others very thickly studded throughout it; and towards the lower part of the sigmoid flexure and in the rectum large pendulous masses, dragging with them a good deal of lax mucous membrane, occur and may be extruded from the anus on slight straining.

The papillomata in the intestine present no special local characteristics, but in some situations, particularly in the descending colon, they are extremely liable to slough off at their base. A dark ring of necrosis is seen round the pedicle, which gradually deepens until separation takes place at this line, leaving a raw surface, which remains as an ulcer with rather ragged edges and an excavated base. There may be considerable general thickening of the coats of the bowel in the neighbourhood of these ulcers, but there is no local induration at their base. In some specimens all stages in the separation of the papilloma and the formation of an ulcer may be seen. When a large area of the mucous membrane of the gut is studded with ulcers of this nature, both from its appearance and the symptoms it produces, it well merits the name of "bilharzial dysentery" which has been given to it. (See Fig. 10.)

Another pathological change consists in a great thickening of all the coats of the gut with extensive dense fibrous tissue formation between the layers of

the peritoneal attachments. This condition is most commonly seen in the meso-cæcum, transverse meso-colon, meso-sigmoid and the meso-rectum, but it is not confined to these situations. Within the thickened gut, the calibre of which is much diminished by papillomata and sessile masses, a lot of thick mucus is present ; and it is difficult to see how the fæces can pass the affected section, and yet one has never seen a case of intestinal obstruction due to this bilharzial change. It may be that the mucus acts as a lubricant and so allows masses of fæces to slip past the narrowed portions of the gut.

The clinical aspects of this condition are very well exhibited by the case of a young man who gave an indefinite history of colicky pains in the abdomen and the passage of blood and mucus in the motions for nearly two years. Ova were found in the fæces and small papillomatous growths in the rectum. Above the umbilicus, in the middle line of the abdomen, was a curved hard tumour, dull on percussion, freely movable and somewhat tender. Both liver and spleen were enlarged. On opening the abdomen a soft nodule, the size of an almond, was cut through on the anterior parietal peritoneum, and similar masses were found in the omentum. The mesenteric glands were enlarged, but were much firmer in consistence than the nodules. The transverse colon was found to contain a large hard tumour within its lumen ; and, on making an incision into the gut, a fleshy mass with a smooth undulating surface, firmly incorporated with the wall of the colon at

its meso-colic attachment and extending for some six inches or more along it, was found. In this case there was not much thickening or fixation of the meso-colon; but in the case of another patient with a tumour, in the same situation, the induration between the layers of the peritoneal attachment was much more marked. Similar conditions have been found about the cæcum and the sigmoid, and in these situations the appendices epiploicæ, in addition to the peritoneal folds, were the seat of a firm bilharzial infiltration. The lumen of the gut was filled with innumerable papillomata, or much constricted in its calibre by elongated sessile masses, and externally masses of varying size and firmness were scattered over the serous surface. The appendix may be found firmly matted to the cæcum and its surroundings, or independently the seat of a bilharzial process. The mesenteric glands in the neighbourhood of these massive lesions in and around the gut are swollen and infiltrated, and there is generally also an ulceration in other parts of the tract, the main symptoms being those of dysentery, the presence of the mass and of ova in the fæces and other symptoms of the general infection confirming the bilharzial nature of the condition. (Fig. 16.)

All the cases of this nature I have hitherto diagnosed have been treated by an exploratory laparotomy and then by a simple enterotomy over the site of the mass in the bowel. Through this opening pieces of papillomata have been removed and the diagnosis

thus confirmed, and then the small incision has been sutured and the abdomen closed. In every case the result of this procedure has been most satisfactory; the dysenteric symptoms have completely disappeared and the tumours appreciably diminished in size. Why they should do so one cannot imagine but the fact deserves to be mentioned, as when one remembers the very general involvement of the other portions of the intestinal tract in these cases, no severe operation, such as excision of the affected portion of the gut, can ever be justified.

Many of the changes already described as common to mucous membranes in general are well seen in the intestine and especially in the **rectum**; "but the changes which are most marked and most fully developed are those which make for an increase of growth rather than the changes that bring about necrosis; and thus the disease develops on different lines from those followed in the bladder, where necrosis is more marked. Thus the hard indurated patches common in the bladder are never found in the rectum; but, instead, the mucous membrane becomes hypertrophied and excessively vascular, the surface layers are deeply injected and readily bleed when handled, and the appearance of the surface resembles rich red velvet. After a time, the elements of the mucous membrane, probably owing in part to their excessive nutrition, take on abnormal growth, with thickening of the structure and general increase in bulk, and with excessive local overgrowth, which takes the form of

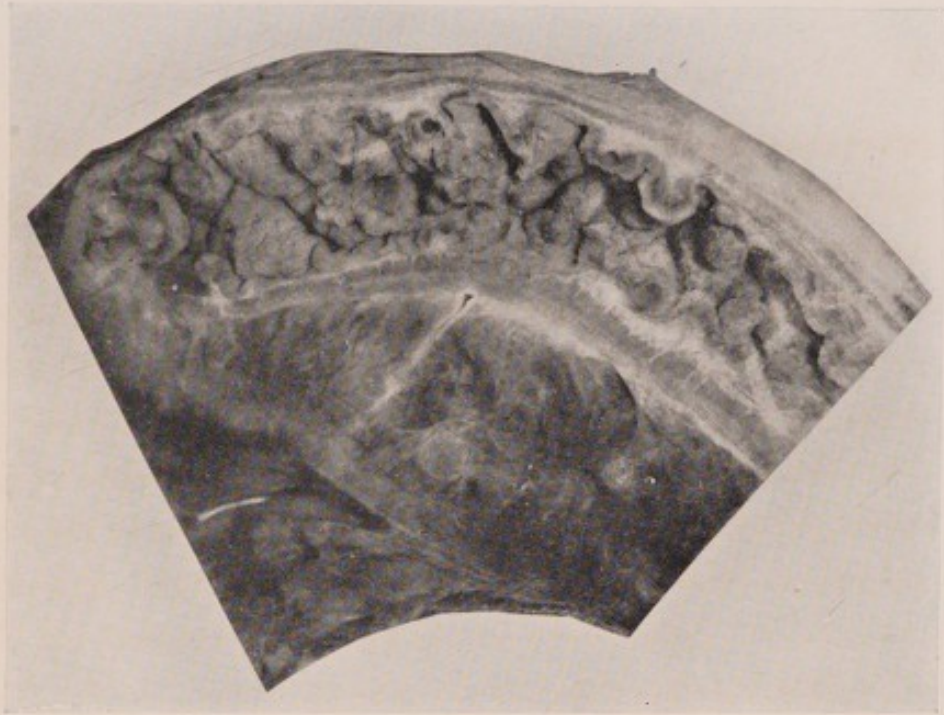


Fig. 16.—Bilharziosis of the sigmoid flexure and meso-sigmoid. The processes of submucous tissue running up into the papillomata are well seen, and also the filling of the lumen of the gut with masses of bilharzial growth, and the great thickening of all the coats of the bowel. The meso-sigmoid is enormously thickened and infiltrated with bilharzial tissue, in which many coupled worms are to be found. (See Fig. 2.)

(From a specimen, prepared by Professor Symmers, in the Pathological Museum of the School of Medicine, Cairo.)

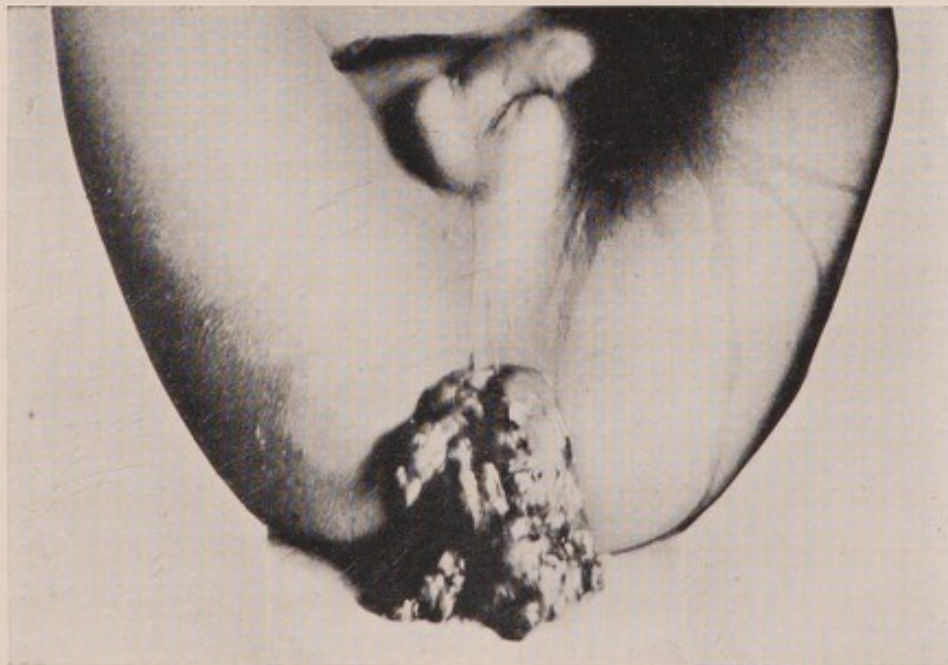

Fig. 17.—Two enormous masses of bilharzial papillomata protruded from the anus of a boy of twelve. They were removed with considerable temporary relief.

(Photograph of a case in the Author's wards in Kasr-el-Ainy Hospital, Cairo.)



polypoid adenomatous tumours. Near the anus these polypoid tumours bear some resemblance to ordinary hæmorrhoids, but within the gut, and especially beyond the internal sphincter, they differ materially from these latter. In the first place, in a given area they are infinitely more numerous than piles ever are; and, instead of being rounded and smooth like hæmorrhoids, their surface is velvety, from thickening of the mucous membrane itself, and the outline is broken up in all directions by the formation of secondary polypi, growing from their own surface and branching in all directions, until the larger and fully-developed tumours bear a great resemblance to red branching coral. These tumours extend high up in the rectum beyond the reach of the finger, and this is so invariably the case that it would suggest the idea that the affection of the rectum begins from above, in the neighbourhood of the sigmoid flexure, and proceeds downwards." (Milton.) As in other parts of the intestinal tract, stricture of bilharzial origin is never found in the rectum.

In the lower part of the rectum, the most common seat of intestinal bilharziosis, the symptoms are those of tenesmus, with an irritative diarrhœa and the passage of thick glairy mucus and blood. Very often mucus and blood are passed without any fæcal matter at all, and the straining may be almost continuous, and the tenesmus very severe, especially if pendulous masses are protruded from the anus and caught by the sphincter during defæcation. This also increases

the bleeding, and gives rise to very great pain. On examination the anus is usually somewhat patulous, and, on slight straining, a polypoid mass, and with it a good deal of lax swollen mucous membrane, may be protruded. The papillomata have the usual bilharzial characters, and bleed readily on digital examination. A large number of polypi of various sizes and forms may be felt round the anus and as far up the rectum as the finger can reach. On removing the finger thick pieces of mucus are discharged. The microscopical examination of this mucus and blood reveals the presence of ova. (Fig. 17.)

At a later stage of the disease there may be a complete prolapse of first a ring of thickened and swollen mucous membrane, perhaps bearing on its surface many ranges of sessile and papillomatous masses, and, in extreme cases, a large part of the rectum may be almost constantly prolapsed.

It sometimes happens that fistulæ form in connection with bilharziosis of the rectum. They cause considerable destruction of the parts round the anus and buttocks or may even extend to the perinæum. The mode of their formation is very similar to that described in the case of urethral fistulæ, and the treatment must follow the same lines.


Treatment.—The treatment of bilharziosis of the intestinal tract resolves itself into that of bilharzial dysentery and of rectal bilharziosis. The “dysentery” must be treated with all the various drugs and the strict *régime* of a case of true dysenteric diarrhœa, and in

some cases large injections of astringent lotions may be of service. Reference has already been made to the good effect of an exploratory laparotomy and of enterotomy when the dysentery is complicated with tumours of bilharzial origin. The treatment of bilharziosis of the rectum must be almost entirely palliative and symptomatic. The severe tenesmus may sometimes be temporarily relieved by stretching the sphincter ani under an anæsthetic, and, at the same time, a strong astringent lotion—sulphate or chloride of zinc, for example—may be injected into the rectum, or the actual cautery may be applied in longitudinal lines all round the lumen of the gut. Protruding masses must be cut off, after ligaturing their pedicles. In other cases a deep ring of lax and prolapsed mucous membrane may be excised, like an extensive Whitehead's operation, or an excision of a portion of the whole thickness of the rectum may even be justifiable and be attended with very good results. At best, however, any treatment gives but temporary relief; the dysenteric symptoms persist in making the patient's life a perfect misery to himself, even if the tenesmus and other distressing symptoms in the lower portion of the intestine are relieved.

Reference has already been made to the occurrence of bilharzial deposits in the peritoneum, omentum and mesenteric glands, and ova have also been found in the pancreas. Bilharzial abscess of the liver also occurs, and Kartulis and Symmers have described a periportal cirrhosis of the liver with, in addition, thickened

patches of bilharzial fibrous tissue on the surface of the organ. Similar patches have been demonstrated on the spleen, but so far no cases of ova in the substance of the spleen have been reported. The ova have also been found in gall-stones and in the pancreas (Symmers); and, among extra-abdominal sites, they have been discovered in the fine capillaries of the walls of the alveoli of the lungs and even giving rise to a form of chronic interstitial pneumonia. (Chaker.)

The blood in the hæmoptysis due to this condition contains ova. Griesinger has also reported the presence of ova in the blood circulating through the heart.



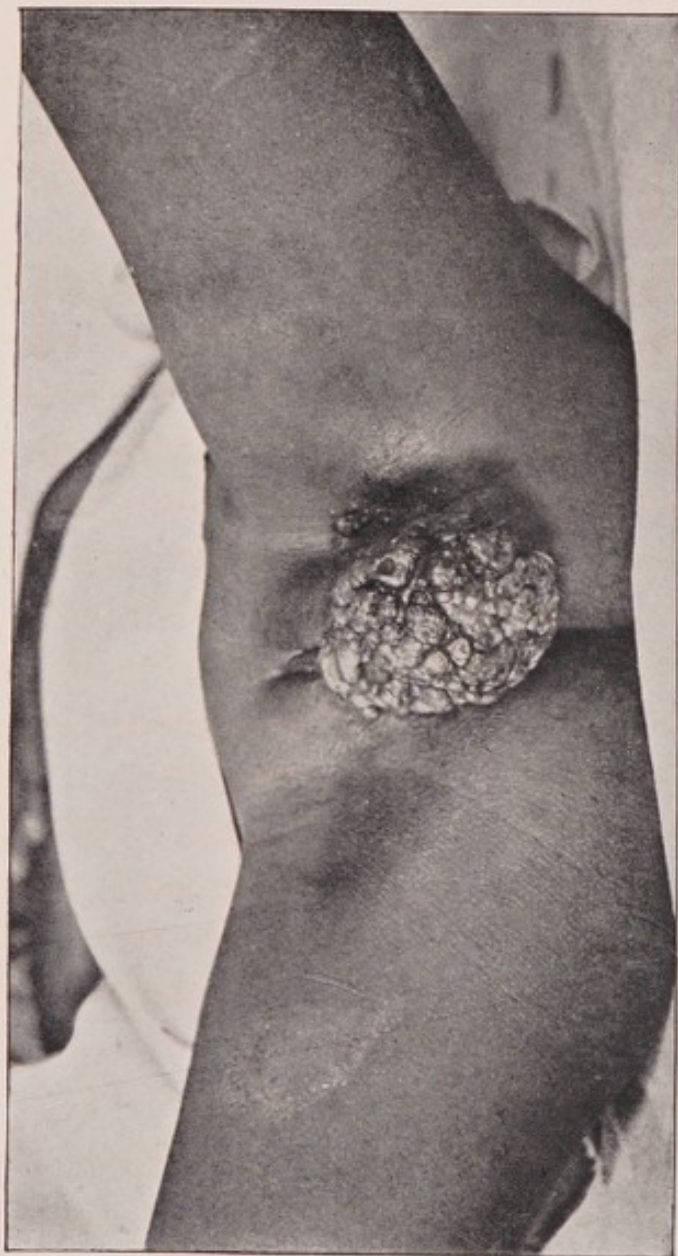


Fig. 18.—Bilharzial papillomata of the vulva growing from the left labium majus. There was also a bilharzial infiltration of the skin near the upper edge of the mass.

(Photograph of a patient in the Author's wards in Kasr-el-Ainy Hospital, Cairo. This case was figured and described in the second volume of the Records of the School of Medicine, Cairo, 1904.)

V.

BILHARZIOSIS OF THE FEMALE GENERATIVE ORGANS.

IN the general invasion of the body by the bilharzia worm the female generative organs do not escape; and here all the changes common to bilharziosis of mucous membranes may occur. In my own personal experience cases involving all parts of the tract from the vulva to the internal os uteri have been met with.

On the **vulva**, papillomatous masses, much resembling venereal warts at first sight, are most common. A bilharzial infiltration of the skin around the vaginal orifice may be associated with these masses. Or an area of crumbling ulceration, involving a triangular space including the upper edge of the hymen and the vestibule, and even extending into the clitoris and destroying it, may occur and cause considerable destruction of tissue in this situation. The urethral orifice may be completely surrounded by such an ulceration. Sometimes the ulceration takes on an excessive growth at the edges, and may easily be mistaken for epithelioma. (Figs. 18, 19, 20.)

Within the **vagina**, the general infiltration of the mucous membrane with wet sea-sand deposits and much redundancy of the membrane is the most usual

change, though ranges of papillomatous outgrowths may also be found. A certain proportion of cases present signs of ulceration and, in rare instances, a vesico-vaginal fistula is formed by extension of a marked bilharziosis of the bladder through the anterior vaginal wall.

Firm polypoid excrescences are not unfrequently found on the **cervix uteri**, their pedicles sometimes extending within the cervical canal nearly to the internal os. In most of these cases there is some infiltration of the mucous membrane of the vagina, often only quite high up in the fornices, which gives one a clue to the diagnosis, for at first sight early epitheliomatous growths may be suspected. (Fig. 21.)

Small fibro-adenomatous tumours, containing bilharzia ova, may also occur on the cervix; but, so far, no evidence of infiltration of the mucous membrane of the uterus itself is forthcoming, though several suspected scrapings have been examined.

Whenever possible these various manifestations must be treated by excision, scraping, or removal as the case demands.

Symmers has noted the occurrence of a mass of fibrous tissue involving the ovary and the upper edge of the broad ligament in a young child. Microscopical examination disclosed the presence of bilharzia ova.

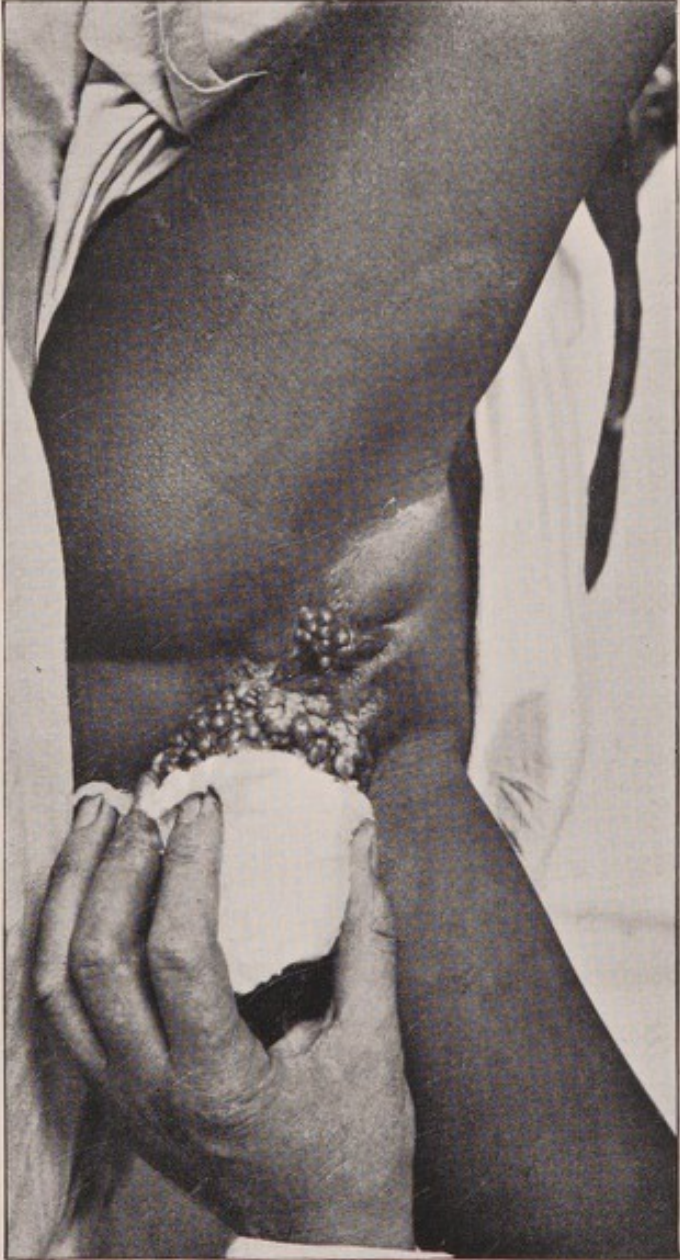


Fig. 19.—Same case as the preceding figure, showing a smaller papillomatous mass growing from the right labium majus.



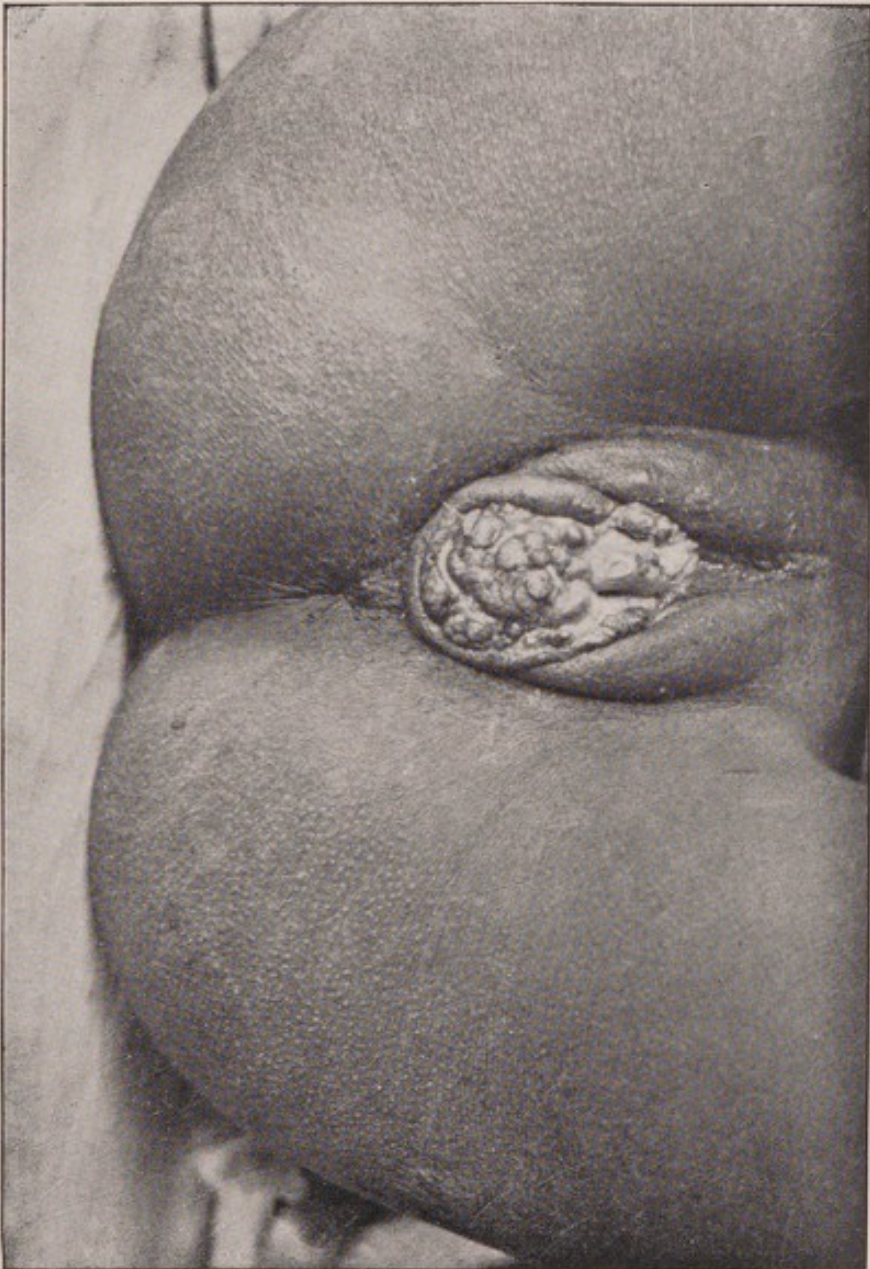



Fig. 20.—Billharziosis of the vulva and vaginal orifice. Professor Ferguson was unable to find ova in the specimens he prepared from this case; but, to the Author's mind, it is so typically billharzial, clinically, that he has ventured to include the photograph here, in the hope that ova will eventually be found in a further series of sections, and so confirm the clinical diagnosis.
(Photograph of a case under the care of Mr. O. W. Richards in Kasr-el-Ainy Hospital, Cairo.)



VI.

BILHARZIOSIS OF THE SKIN AND SUBCUTANEOUS TISSUES.

CERTAIN sinuses form in the region of the perinæum, over the sacrum and coccyx, and in the suprapubic region particularly, which have, primarily at any rate, no connection with bladder, urethra, or rectum. These arise from the deposit of a mass of bilharzial tissue in the subcutaneous connective tissue. They grow slowly, much like a tuberculous deposit, and eventually reach the skin, soften it, burst and discharge a thick pus and granular *débris*, and persist as sinuses lined with unhealthy granulations and discharging a thin sero-pus. From the original sinus branches may be given off in all directions, and these eventually open at adjacent points on the skin surface, or sometimes at some considerable distance. A large area of skin may thus become riddled with discharging sinuses, the track of the sinus consisting of firm fibrous tubes sharply marked off from the surrounding tissues. Each track is lined with bilharzial granulation tissue, in which ova are found. The sinus when split up usually ends quite abruptly in a rounded cul-de-sac or in a mass of granular tissue, and does not communicate with any viscus or cavity in close proximity to it. In severe cases the intervening tissue becomes in-

filtrated also, and is gradually converted into a hard scar tissue, the openings of the various sinuses being surrounded by prominent buttons of granulation tissue.

The only possible treatment of these cases is to dissect out the whole track completely, cutting wide of the thick fibrous tissue tubes through healthy tissue. In most situations where these sinuses occur, such a radical operation is not possible, in which case the sinuses must be freely laid open and very thoroughly scraped with a sharp spoon, until every vestige of granular tissue is removed, and the wound then plugged and allowed to heal from the bottom. Many operations may be required, as each new track must be opened up as it forms, and, in the end, a large area may be transformed into a mass of scar tissue extending over a considerable area. (Fig. 22.)

Sometimes these independent sinuses acquire a secondary connection with adjoining cavities, more often with the rectum than with either bladder or urethra, in which case they lose all their individuality and become bilharzial fistulæ of the more ordinary type, though there may not be any affection of the viscus with which they communicate.

On the skin surface one sometimes sees patches, made up of a number of small rounded elevations closely packed together, on a darkly pigmented base; and, again, a peculiar form of ulceration may be present. "A few small discrete infiltrated spots of dark colour, raised above the level of the skin, may

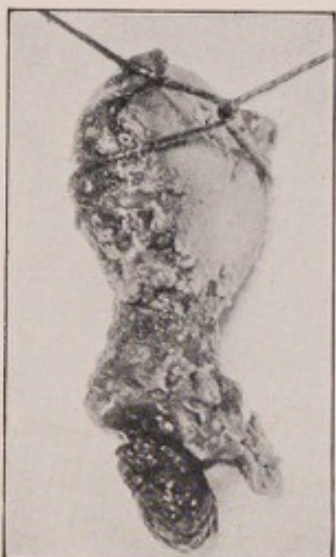


Fig. 21.

Fig. 21.—Bilharzial papilloma growing from the posterior lip of the cervix uteri. The case was diagnosed epithelioma, and vaginal hysterectomy was performed.

(Photograph of the uterus removed by the Author in Kasr-el-Ainy Hospital, Cairo. The case was figured and described in the second volume of the Records of the School of Medicine, Cairo, 1904.)

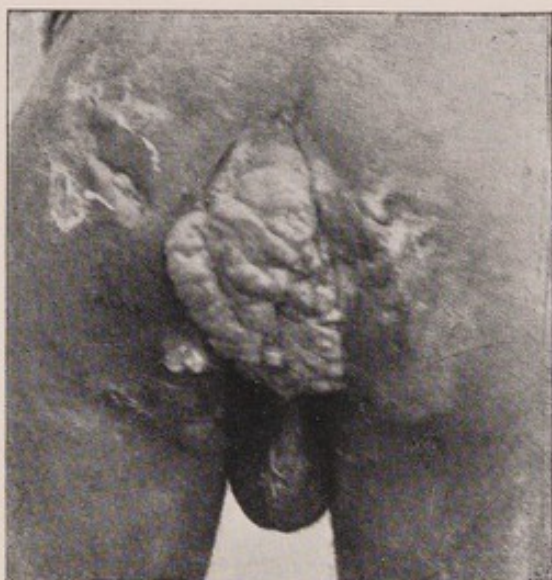

Fig. 23.

Fig. 23.—Epithelioma around the anus originating on the site of old extensive bilharzial disease in and around the lower end of the rectum. Scars of old bilharzial sinuses are seen scattered throughout the surrounding skin.


(Photograph of a case in the Author's wards in Kasr-el-Ainy Hospital, Cairo.)

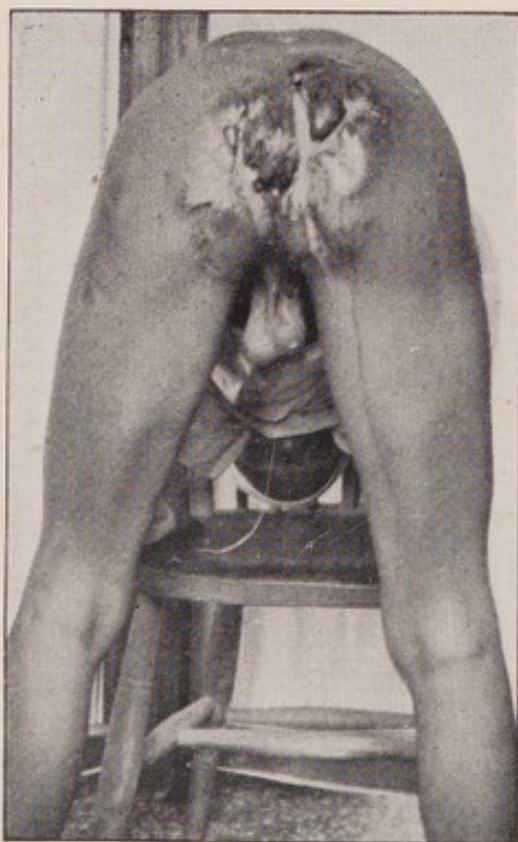

Fig. 22.

Fig. 22.—Extensive scarring left after multiple operations on bilharzial sinuses, originating in the subcutaneous tissue. The whole area was riddled with sinuses which had no connection with either rectum or urethra.

(Photograph of a case in the Author's wards in Kasr-el-Ainy Hospital, Cairo.)



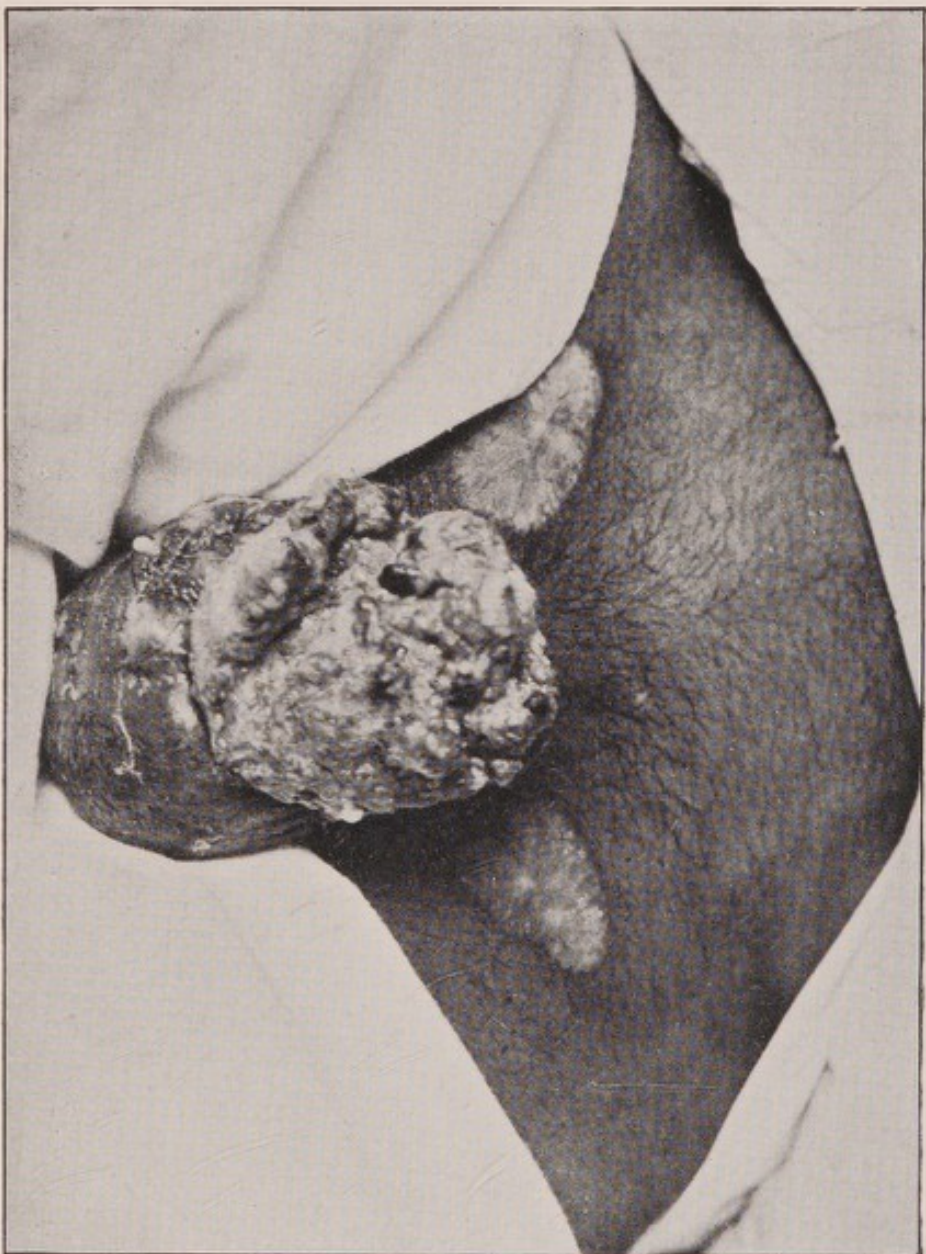


Fig. 24.—Epithelioma of the penis, scrotum, and inguinal glands, secondary to old bilharziosis of the urethra and bilharzial infiltration and ulceration of the penis. A complete removal of the malignant growth was effected, but the patient died two days later from shock.

(Photograph of a case in the Author's wards in Kasr-el-Ainy Hospital, Cairo.)



occur. These spread and run together, and having reached a certain size, break down and form ulcers, which spread in an irregular way and very slowly. The surrounding skin is healthy, though there may be outlying bilharzial papules. The edges of the ulcer are irregular, crenated and sinuous, and they show no sign of healing, though there may be scar tissue around them from pre-existing bilharzia. The ulcer is somewhat raised, and its base is irregular, and the discharge is scanty and serous. It is quite painless and, on scraping, one finds a gelatinous bilharzial tissue coated with feeble granulations. This granular tissue burrows into healthy tissues and forms little pockets below and beyond the borders of the ulcer." (Milton.) The only satisfactory treatment is complete excision or vigorous scraping, as before explained.


In certain situations, particularly around the anus and on the site of ulceration of the glans penis, an epithelioma sometimes develops. The structure of such growths is that usually associated with epithelioma; but bilharzia ova are freely distributed throughout the section. (Kartulis.) As in the case of bilharziosis with scirrhus cancer (page 38), the true significance of this association is not yet properly determined. (Figs. 23 and 24.)

The treatment of such cases resolves itself into that of epithelioma.

BIBLIOGRAPHY.

A very complete bibliography of bilharziosis has been compiled by Looss in Mense's "Handbuch der Tropen-krankheiten," and since that publication a series of articles has appeared in the Transactions of the Egyptian Medical Congress 1902. Papers on interesting cases by W. H. Clayton-Greene in the *Lancet* of December 17th, 1904, P. G. Stock in the *Lancet* of September 29th, 1906, E. C. Freeman in the Journal of the Royal Army Medical Corps, page 145, vol. for 1905, and a most interesting and instructive article on "A remarkable case of Bilharziosis," by Professor Symmers, in the "Studies in Pathology," written by Alumni to celebrate the Quatercentenary of the University of Aberdeen, 1906, may also be mentioned.





PRINTED BY
CASSELL & COMPANY, LIMITED, LA BELLE SAUVAGE,
LONDON, E.C.

MANUALS FOR STUDENTS AND PRACTITIONERS OF MEDICINE

Published by *CASSELL & COMPANY, Limited.*

TUMOURS, INNOCENT AND MALIGNANT: Their Clinical Characters and Appropriate Treatment. By **J. Bland-Sutton, F.R.C.S.**, Surgeon to and member of the Cancer Investigation Committee of the Middlesex Hospital, &c. With 355 Engravings. *New and Enlarged Edition.* 21s. net.

"A work which must have entailed on its author the expenditure of infinite labour and patience, and which there can be little question will rank high among works of its class."—*The Lancet.*

SURGICAL DISEASES OF THE OVARIES AND FALLOPIAN TUBES, including Tubal Pregnancy. By **J. Bland-Sutton, F.R.C.S.** With 146 Illustrations. 10s. 6d.

TROPICAL DISEASES: A Manual of the Diseases of Warm Climates. By **Sir Patrick Manson, K.C.M.G., M.D., LL.D. Aberd., F.R.C.P., F.R.S.**, Foreign Associate of the Académie de Médecine (France), Physician to the Seamen's Hospital Society, Lecturer on Tropical Diseases at St. George's Hospital and Charing Cross Hospital Medical Schools, Lecturer in the London School of Tropical Medicine, Medical Adviser to the Colonial Office and Crown Agents for the Colonies. With 5 Coloured Plates and about 250 Illustrations in the Text. *New, Revised and Enlarged Edition, 16th Thousand. In preparation.*

"It is a good book, conceived and written in a scientific spirit and well up to date. . . . It strikes us as sound and judicious in regard to the general dietetic and therapeutical treatment of the maladies which it describes. The volume is of a handy size and admirably illustrated."—*The Lancet.*

CLINICAL METHODS: A Guide to the Practical Study of Medicine. By **Robert Hutchison, M.D., F.R.C.P.**, Assistant Physician to the London Hospital and to the Hospital for Sick Children, Great Ormond Street, and **Harry Rainy, M.A., M.D., F.R.C.P. Edin., F.R.S.E.**, Hon. Sec. of and Examiner to the Royal College of Physicians, Edinburgh; Examiner in Medicine and Clinical Medicine St. Andrews University, &c. With 9 Coloured Plates and upwards of 150 Illustrations. *Revised Edition. 21st Thousand.* 10s. 6d.

S.S. 5.07.

Manuals for Students and Practitioners of Medicine (contd.).

MATERIA MEDICA & THERAPEUTICS :

An Introduction to the Rational Treatment of Disease. By **J. Mitchell Bruce, M.A., LL.D. Aberd., M.D., F.R.C.P.**, Consulting Physician to Charing Cross Hospital and to the Hospital for Consumption, Brompton, &c. *Enlarged Edition*. Revised throughout, and containing the Indian and Colonial Addendum to the British Pharmacopœia. 47th Thousand. **7s. 6d.**

The present edition of this work has been subjected to thorough revision and brought up to the level of the latest knowledge. An entirely new Part has been added, which contains an account of the *Materia Medica and Therapeutics* of the drugs in the Indian and Colonial Addendum to the British Pharmacopœia.

DISEASES OF THE SKIN :

An Outline of the Principles and Practice of Dermatology. By **Malcolm Morris**, Consulting Surgeon to the Skin Department, St. Mary's Hospital; Surgeon to the Skin Department of the Seamen's Hospital; Lecturer on Dermatology in the London School of Clinical Medicine. With 2 Coloured Plates, 36 Plain Plates, and Numerous Illustrations. 11th Thousand. **10s. 6d.**

RINGWORM IN THE LIGHT OF RECENT

RESEARCH : Pathology — Treatment — Prophylaxis. By **Malcolm Morris**. With 22 Micro-photographs and a Coloured Plate. **7s. 6d.**

A MANUAL OF MEDICAL TREATMENT, or

Clinical Therapeutics. By **I. Burney Yeo, M.D., F.R.C.P.**, Emeritus Professor of Medicine in King's College, London, Consulting Physician to King's College Hospital. With Illustrations. Two Vols. 20th Thousand. **21s. net.**

"It is a book from which the most skilled therapist has something to learn, a book which the more ordinary physician, no matter how frequently he appeals to it, will surely find a true guide, philosopher and friend . . . likely to remain for some time to come the standard work on the subject in the English language."
—*The Medical Press and Circular*.

THE THERAPEUTICS OF MINERAL

SPRINGS AND CLIMATES. By **I. Burney Yeo, M.D., F.R.C.P.** **12s. 6d. net.**

"The author furnishes the medical profession with a very complete guide to the therapeutics of mineral springs and climates. The application of mineral springs to the treatment of various maladies is succinctly treated under the various diseases."—*The Lancet*.

FOOD IN HEALTH AND DISEASE. By

I. Burney Yeo, M.D., F.R.C.P. **10s. 6d.**

HYGIENE AND PUBLIC HEALTH. By **B.**

Arthur Whitelegge, C.B., M.D., B.Sc. Lond., F.R.C.P., D.P.H. Camb., late Lecturer on Public Health at the Charing Cross Hospital Medical School, and **George Newman, M.D., D.P.H., F.R.S.E.**, Medical Officer of Health for the Borough of Finsbury. Illustrated. *Revised and Enlarged Edition*. 12th Thousand. **7s. 6d.**

Manuals for Students and Practitioners of Medicine (*contd.*).

A MANUAL OF CHEMISTRY: Inorganic and Organic, covering the Synopses of the Conjoint Board and the Society of Apothecaries. By **Arthur P. Luff, M.D., B.Sc. Lond., F.R.C.P.**, Physician to St. Mary's Hospital, and **Frederic James M. Page, B.Sc. Lond., F.I.C.**, Lecturer on Chemistry and Physics to the London Hospital Medical College, Examiner in Chemistry and Physics to the Society of Apothecaries, London. With 43 Illustrations. *Revised Edition. 12th Thousand. 7s 6d.*

"No other work covers quite the same ground, or is so adapted to the requirements of the medical student."—*Medical Review.*

ELEMENTS OF PHYSICS FOR MEDICAL STUDENTS. By **Frederic James M. Page, B.Sc. Lond., F.I.C.**, Lecturer on Physics and Chemistry to the London Hospital Medical College; Examiner in Physics and Chemistry to the Society of Apothecaries, London. With Coloured Frontispiece and 230 Figures in the Text. *5s.*

ELEMENTS OF SURGICAL DIAGNOSIS:
A Manual for the Wards. By **A. Pearce Gould, M.S. Lond., F.R.C.S.**, Surgeon to the Middlesex Hospital, Member of the Court of Examiners and of the Council of the Royal College of Surgeons, Member of the Senate of the University of London. *Enlarged Edition. 12th Thousand. 9s.*

"We strongly recommend the careful study of this little manual to every student of surgery."—*Dublin Journal of Medical Science.*

DISEASES OF WOMEN: A Clinical Guide to their Diagnosis and Treatment. By **George Ernest Herman, M.B. Lond., F.R.C.P., F.R.C.S.**, Consulting Obstetric Physician to the London Hospital, late Examiner in Midwifery to the Universities of Oxford, Cambridge, London, &c. *New and Revised Edition. 11th Thousand. With upwards of 265 Illustrations. 25s.*

DIFFICULT LABOUR: A Guide to its Management for Students and Practitioners. By **G. Ernest Herman, M.B. Lond., F.R.C.P.** With 165 Illustrations. *Revised Edition. 15th Thousand. 12s. 6d.*

"The book is well arranged and profusely illustrated with excellent diagrams. It is a decided acquisition to the literature of midwifery, and we have pleasure in recommending it to all interested in the subject."—*Glasgow Medical Journal.*

FIRST LINES IN MIDWIFERY: A Guide to Attendance on Natural Labour for Medical Students and Midwives. By **G. Ernest Herman, M.B. Lond., F.R.C.P.** With 81 Illustrations. *New and Revised Edition, with a Supplementary Chapter containing the Rules of the Central Midwives Board, with Comments. 22nd Thousand. 5s.*

Manuals for Students and Practitioners of Medicine (*contd.*).

A MANUAL OF OPERATIVE SURGERY.

By **Sir Frederick Treves, Bart., G.C.V.O., C.B., F.R.C.S., LL.D.**, Sergeant-Surgeon to H.M. the King, and **Jonathan Hutchinson, Jun., F.R.C.S.**, Surgeon to the London Hospital. *New Edition in preparation.*

THE STUDENT'S HANDBOOK OF SURGICAL OPERATIONS.

By **Sir Frederick Treves, Bart.** Revised by the Author and **Jonathan Hutchinson, Jun., F.R.C.S.** With 120 Illustrations. *17th Thousand. 7s. 6d.*

SURGICAL APPLIED ANATOMY.

By **Sir Frederick Treves, Bart., G.C.V.O., C.B., &c.** Revised by the Author with the assistance of **Arthur Keith, M.D., F.R.C.S.** With 80 Illustrations. *32nd Thousand. 9s.*

INTESTINAL OBSTRUCTION: Its Varieties,

with their Pathology, Diagnosis, and Treatment. By **Sir Frederick Treves, Bart., G.C.V.O., C.B., &c.** *Illustrated. 10s. 6d.*

SYPHILIS.

By **Jonathan Hutchinson, F.R.S., F.R.C.S.**, Consulting Surgeon to the London Hospital and to the Royal London Ophthalmic Hospital. With 8 Chromo Plates. *10th Thousand. 9s.*

INSANITY AND ALLIED NEUROSES, PRACTICAL AND CLINICAL.

By **George H. Savage, M.D., F.R.C.P.**, late Medical Superintendent and Resident Physician to Bethlem Royal Hospital and Lecturer on Mental Diseases at Guy's Hospital, and **Edwin Goodall, M.D. Lond., B.S., F.R.C.P.**, Medical Superintendent of Cardiff City Asylum. *New and Revised Edition.* With 6 Coloured Plates and about 40 Illustrations in the Text. *12s. 6d. In preparation.*

DISEASES OF THE JOINTS AND SPINE.

By **Howard Marsh, F.R.C.S.**, Professor of Surgery in the University of Cambridge, Consulting Surgeon to St. Bartholomew's Hospital and to the Hospital for Sick Children, Great Ormond Street, Honorary Member of the Medical Society of New York. With 79 Illustrations. *12s. 6d.*

DISEASES OF THE EAR.

By **A. Marmaduke Sheild, M.B. Cantab., F.R.C.S. Eng.**, Surgeon to St. George's Hospital, late Aural Surgeon to Charing Cross Hospital. With 4 Coloured Plates and 34 Woodcut Illustrations. *10s. 6d.*

A HANDBOOK FOR MIDWIVES AND MATERNITY NURSES.

With a Section on the Principles of Infant Feeding. By **Comyns Berkeley, B.A., M.B., M.R.C.P. Lond.**, Assistant Obstetric Physician at the Middlesex Hospital, Lecturer on Midwifery at the Middlesex Hospital Medical School, Senior Physician to Out-Patients at the Chelsea Hospital for Women, Examiner in Midwifery to the Central Midwives Board and to the Society of Apothecaries, London. With 58 Illustrations. *5s.*

Manuals for Students and Practitioners of Medicine (*contd.*).

DISEASES OF THE TONGUE. By **H. T. Butlin, F.R.C.S., D.C.L.**, Consulting Surgeon and Lecturer on Clinical Surgery, St Bartholomew's Hospital, and **Walter G. Spencer, M.S., M.B. Lond., F.R.C.S.**, Surgeon to Westminster Hospital. With 8 Coloured Plates and 36 other Engravings. **10s. 6d.**

ORTHOPÆDIC SURGERY: A Text-book of the Pathology and Treatment of Deformities. By **J. Jackson Clarke, M.B. Lond., F.R.C.S.**, Surgeon to the North-West London and City Orthopædic Hospitals, Member of the Council of the British Orthopædic Society. With upwards of 300 Illustrations. **10s. 6d.**

SURGICAL DISEASES OF THE KIDNEY AND URETER, including Injuries, Malformations, and Misplacements. By **Henry Morris, M.A., M.B. Lond.**, President of the Royal College of Surgeons. With 2 Coloured Plates and upwards of 200 Illustrations. Two Vols. **42s. net.**

ON THE ORIGIN AND PROGRESS OF RENAL SURGERY, with Special Reference to Stone in the Kidney and Ureter; and to the Surgical Treatment of Calculous Anuria. Being the Hunterian Lectures for 1898, together with a Critical Examination of Subparietal Injuries of the Ureter. By **Henry Morris, M.A., M.B. Lond.**, President of the Royal College of Surgeons, &c. &c. With 28 Illustrations. **6s.**

SURGICAL DISEASES OF CHILDREN. By **Edmund Owen, M.B., F.R.C.S.**, Surgeon-in-Chief to the French Hospital, London, Consulting Surgeon to the Hospital for Sick Children, Great Ormond Street, and to St. Mary's Hospital. With 5 Chromo Plates and 120 Engravings. **21s.**

MEDICAL DISEASES OF INFANCY AND CHILDHOOD. By **Dawson Williams, M.D. Lond., F.R.C.P.**, Fellow of University College, London, Consulting Physician to the East London Hospital for Children. With 18 Full-page Plates and numerous Illustrations. **10s. 6d.**

GOUT: ITS PATHOLOGY, FORMS, DIAGNOSIS, AND TREATMENT. Founded on the Goulstonian Lectures on "The Chemistry and Pathology of Gout," delivered by the Author before the Royal College of Physicians of London in 1897. By **Arthur P. Luff, M.D., B.Sc. Lond., F.R.C.P.**, Physician at St. Mary's Hospital. *Third Edition, Revised and much Enlarged.* **10s. 6d. net.**

ELEMENTS OF HISTOLOGY. By **E. Klein, M.D., F.R.S.**, Lecturer on Advanced Bacteriology in the Medical School of St. Bartholomew's Hospital, London, and **J. S. Edkins, M.A., M.B.**, Lecturer and Demonstrator of Anatomy and Physiology in the Medical School of St. Bartholomew's Hospital. With nearly 300 Illustrations. **7s. 6d.**

Manuals for Students and Practitioners of Medicine (*contd.*).

MANUAL OF MILITARY OPHTHAL-

MOLOGY for the Use of Medical Officers of the Home, Indian, and Colonial Services. By **M. T. Yarr, F.R.C.S.I.**, Lieut.-Col. Royal Army Medical Corps, Fellow Medical Society of London, &c. With numerous Illustrations and Diagrams. **6s.**

SUBMUCOUS EXCISION OF DEVIATIONS AND SPURS OF THE NASAL SEPTUM.

With a Report of the first 30 Operations. By **St. Clair Thomson, M.D., F.R.C.P., F.R.C.S.** **1s.** net.

THE CEREBRO-SPINAL FLUID: Its Spontaneous Escape from the Nose.

By **St. Clair Thomson, M.D., F.R.C.P., F.R.C.S.,** &c. **5s.**

ORAL SEPSIS AS A CAUSE OF SEPTIC GASTRITIS, TOXIC NEURITIS, and other Septic

Conditions, with Illustrative Cases. By **W. Hunter, M.D., F.R.C.P.,** Physician to the London Fever Hospital, &c. **3s. 6d.**

CLINICAL PAPERS ON SURGICAL SUBJECTS.

By **Herbert W. Page, M.A., M.C. Cantab., F.R.C.S. Eng.** **5s.**

A GUIDE TO THE INSTRUMENTS AND APPLIANCES REQUIRED IN VARIOUS OPERATIONS.

By **A. W. Mayo Robson, F.R.C.S.** Cloth, **2s. 6d.**

MEDICAL HANDBOOK OF LIFE ASSURANCE

for the Use of Medical and other Officers of Companies. By **James Edward Pollock, M.D., F.R.C.P.,** President of the Life Assurance Medical Officers' Association, and **James Chisholm, F.I.A. Lond.,** General Manager and Actuary of the Imperial Life Insurance Company. **7s. 6d.**

INCOMPATIBILITY AND SOME OF ITS LESSONS.

By **Walter G. Smith, M.D.,** Ex-President Royal College of Physicians, Ireland, &c. **1s.**

Enlarged Series, in Monthly Parts, price 2s. net, of the

ANNALS OF SURGERY.

A Monthly Review of Surgical Science and Practice. Edited by **W. H. A. Jacobson, M.Ch.** (of London); **L. S. Pilcher, A.M., M.D.** (of Brooklyn, U.S.A.); **William MacEwen, M.D.** (of Glasgow); **J. William White, M.D.** (of Philadelphia, U.S.A.). A subscription of **24s.**, paid in advance, will secure the Journal being sent post free for one year.

THE OTHER SIDE OF THE LANTERN.

By **Sir Frederick Treves, Bart., G.C.V.O., C.B., LL.D.** With 40 Full-page Plates, from Photographs by the Author. *Popular Edition, 6s. net.*

**NEW SERIES
OF MEDICAL TEXT-BOOKS
ON MODERN
METHODS OF TREATMENT.**

The literature dealing with modern methods of treatment is already considerable, but it is scattered through a number of periodicals, British and Foreign, and it is thus to a large extent inaccessible to the general body of the medical profession. This Series consists of monographs, in which all the available evidence is critically reviewed by writers whose practical experience enables them to form a judicial estimate of the value of the methods described. Among the works in preparation are volumes devoted to treatment by light and X-rays and by electricity, and another on minor surgery. The first three volumes are

SERUMS, VACCINES, AND TOXINES IN TREATMENT AND DIAGNOSIS. By **Wm. Cecil Bosanquet, M.A., M.D. Oxon., F.R.C.P. Lond.,** Assistant Physician to Charing Cross Hospital. *7s. 6d.*

THE OPEN-AIR TREATMENT OF PULMONARY TUBERCULOSIS. By **F. W. Burton-Fanning, M.D. Cantab.,** Physician to the Norfolk and Norwich Hospital; Honorary Visiting Physician to the Kelling Open-Air Sanatorium. *5s.*

ORGANOTHERAPY; OR, TREATMENT BY MEANS OF PREPARATIONS OF VARIOUS ORGANS. By **H. Batty Shaw, M.D. Lond., F.R.C.P.,** Lecturer in Therapeutics, University College, London, and Assistant Physician to University College Hospital and the Hospital for Consumption and Diseases of the Chest, Brompton. *6s.*

Other Volumes in Preparation.

NURSING HANDBOOKS, &c.

THE CARE AND MANAGEMENT OF DELICATE CHILDREN. By **Dr. Percy G. Lewis**, Honorary Medical Officer to the Victoria Hospital and Surgeon to St. Andrew's Convalescent Home, Folkestone. *3s. 6d.*

COOKERY FOR COMMON AILMENTS. By **A Fellow of the Royal College of Physicians** and **Phyllis Browne**. Paper covers, *1s. net*; cloth, *1s. 6d. net*.

HANDBOOK OF NURSING for the Home and for the Hospital. By **Catherine J. Wood**, formerly Lady Superintendent of the Hospital for Sick Children, Great Ormond Street. *Twenty-second Thousand. 1s. 6d.*; cloth, *2s.*

THE PRACTICAL NURSING OF INFANTS AND CHILDREN. By **Frank Cole Madden, M.B., B.S. Melb., F.R.C.S.**, Professor of Surgery in the Egyptian Government School of Medicine, Cairo. *3s. 6d.*

ADVICE TO WOMEN ON THE CARE OF their Health, Before, During, and After Confinement. By **Florence Stacpoole**, *Diplômée* of the London Obstetrical Society, etc. etc. Paper covers, *1s. net*; cloth, *1s. 6d. net*.

OUR SICK, AND HOW TO TAKE CARE OF THEM; or, Plain Teaching on Sick Nursing at Home. By **Florence Stacpoole**. Paper covers, *1s. net*; or cloth, *1s. 6d. net*.

AMBULANCE WORK AND NURSING. A Handbook on First Aid to the Injured. With a Section on Nursing. Containing Numerous Illustrations from Photographs and Drawings. *Cheap Edition. 6s.*

Cassell & Company's COMPLETE CATALOGUE, containing particulars of upwards of One Thousand Volumes, including Bibles and Religious Works, Illustrated and Fine-Art Volumes, Children's Books, Dictionaries, Educational Works, History, Natural History, Household and Domestic Treatises, Science, Travels, &c., together with a Synopsis of their numerous Illustrated Serial Publications, sent post free on application.

CASSELL & COMPANY, LIMITED, Ludgate Hill, London,
Paris, New York. Toronto & Melbourne.



