

Principles and technique of crowns and bridges / by J.F. Hovestadt.

Contributors

Hovestadt, J. F. (Julius Frank)

Publication/Creation

London : Henry Kimpton, [1915], ©1915.

Persistent URL

<https://wellcomecollection.org/works/v5j6seen>

License and attribution

This work has been identified as being free of known restrictions under copyright law, including all related and neighbouring rights and is being made available under the Creative Commons, Public Domain Mark.

You can copy, modify, distribute and perform the work, even for commercial purposes, without asking permission.



Wellcome Collection
183 Euston Road
London NW1 2BE UK
T +44 (0)20 7611 8722
E library@wellcomecollection.org
<https://wellcomecollection.org>

PRINCIPLES AND TECHNIQUE
OF
CROWNS AND BRIDGES

▼
HOVESTADT

22/11/22




22101904695

Med
K48991

Frank Young 1920.







PRINCIPLES AND TECHNIQUE OF CROWNS AND BRIDGES

BY

J. F. HOVESTADT, D.M.D.

Instructor in Crown and Bridge Work, Harvard Dental School, Harvard
University; former Vice-President of the Massachusetts Dental Hygiene
Council; Member Harvard Odontological Society;
Member National Dental Association, etc.

WITH 226 ILLUSTRATIONS

LONDON

HENRY KIMPTON

263 HIGH HOLBORN, W.C.

AND 40 AND 42 UNIVERSITY AVENUE, GLASGOW

1915



24 438 360

*(The right of reproduction of the original illustrations is
strictly reserved.)*

All rights reserved. 1915.



WELLCOME INSTITUTE LIBRARY	
Coll.	weIMOmec
Call	
No.	WU

CONTENTS

I. INTRODUCTION	Page 9
II. EXAMINATION AND STUDY OF CROWN AND BRIDGE CASES . .	11
III. CLASSIFICATION OF CROWN AND BRIDGE CASES	13
A. AS TO HEALTH AND PATHOLOGICAL CONDITIONS OF THE TEETH AND MOUTH	13
1. Septic roots	13
2. Acid mouth and erosion	15
3. Pyorrhoeatic condition	15
4. Absorption of tissue	18
B. AS TO OCCLUSION	20
1. Normal occlusion	20
2. Sufficient occlusion	20
3. Mal-occlusion	21
a. Lack of contact points	22
b. Teeth tipped forward	22
c. Teeth elongated	24
d. Temporary teeth retained	26
e. Closed bite	27
f. Maxillary and mandibular } pro- tusion	29
g. Wandering teeth	30
h. Irregularly arranged teeth	33

IV. PRELIMINARY TREATMENT OF THE MOUTH AND TEETH	Page 37
1. Prophylactic treatment	37
2. Exodontia	37
3. Pyorrhoea treatment	37
4. Devitalization of healthy teeth	37
5. Treatment of teeth with pathological pulps	38
a. Treatment from root canals	38
b. Treatment from alveolar side, surgically	42
6. Building up of decayed and broken-down teeth	43
V. ORAL ANAESTHESIA	44
A. INSTRUMENTARIUM	44
B. DRUGS	47
C. PREPARING OF SOLUTION	47
1. For normal cases	48
2. For deep anaemia	48
3. For abnormal cases	48
D. PREPARING OF PLACE FOR INSERTION OF THE NEEDLE	49
E. INFILTRATION METHOD	49
1. Injection in buccal and labial side of maxillary teeth	51
2. Injection on labial side of lower incisors	52
3. Injection on palatal and lingual sides	52
F. CONDUCTIVE METHOD	54
1. Pterygo-mandibular injection	54
2. Buccinator injection	57
3. Zygomatic injection	57
4. Infra-orbital injection	58
5. Incisive injection	58
6. Post palatine injection	59
G. AFTER-EFFECTS	59
PULP REMOVAL: PRESSURE ANAESTHESIA	59
TREATMENT FOR HYPERSENSITIVE DENTIN	60

VI. GENERAL TECHNICAL MANIPULATION	Page
1. Selecting shade	61
2. Taking bite	61
3. Taking impression	61
4. Mounting a Crown and Bridge case on articulator	63
5. Selecting of teeth	64
6. Grinding of teeth	64
7. Backing of teeth	65
8. Reinforcing or backings	66
9. To prevent cracking of facing	67
10. Soldering bridge in sections	69
11. Casting	70
12. Polishing	72
13. Gold plating	73
14. Fitting bridges in mouth and wearing them	74
15. Cementing	75
16. Final adjustment of occlusion	76
17. Instruction to patients	76
18. Care of bridges	77
 VII. SINGLE CROWNS	 78
ALL PORCELAIN CROWNS	78
Crown I	1. Jacket crown 78
	2. Detached post crown 81
Crown II	Detached carved crown 81
Crown III	Detached stock crown 82
PORCELAIN CROWN WITH METAL BASE	88
Crown IV	1. Porcelain baked crown with platinum base 88
Crown V	2. Porcelain crown with cast base 89
	<i>Direct Method</i> 89
	<i>Indirect Method</i> 90

		Page
	BANDED CROWNS	92
	I. BASE FOR BANDED CROWNS	93
	<i>Direct Method</i>	93
Crown VI	1. Soldered caps	93
Crown VII	2. Burnished caps	95
	<i>Indirect Method</i>	96
Crown VIII	3. Swaged caps	96
	II. SUPPLIES FOR BANDED CROWNS	97
Crown VIa VIIa VIIIa	a. With facings	97
Crown VIb VIIb VIIIb	b. With detached post crowns	98
Crown VIc VIIc VIIIc	c. With Goslee teeth	100
Crown VId VIId VIId	d. With Steele teeth	101
	ALL-METAL CROWNS	102
Crown IX	1. Open-faced crowns—glove fit	102
Crown XI	3. Two-piece all-metal crowns	105
XIa	a. With swaged cusps	106
XIb	b. With cast cusps	107
Crown XII	4. Seamless pressed crowns	108
Crown XIII	5. Seamless swaged crowns	113
Crown XIV	6. Crowns with porcelain facing	118

	Page
VIII. FIXED BRIDGES	119
A. ABUTMENTS FOR FIXED BRIDGE- WORK	119
A. INLAY ABUTMENTS	119
Abutment I 1. Inlays with posts or M. O. D. inlays .	119
B. BANDED CROWN ABUTMENTS . .	122
I. BASE FOR BANDED ABUTMENTS . . .	122
Abutment II 1. Soldered caps	122
Abutment III 2. Burnished caps	122
Abutment IV 3. Swaged caps	122
II. SUPPLIES FOR BANDED ABUTMENTS . .	122
Abutment IIa-IIIa-IVa a. With facing	122
Abutment IIb-IIIb-IVb b. With detached post crown .	122
Abutment IIc-IIIc-IVc c. With Goslee tooth	122
Abutment IId-IIId-IVd d. With Steele tooth	122
C. ALL-METAL ABUTMENTS	123
Abutment V 1. Half crown with post	123
Abutment VI 2. Staple	124
Abutment VII 3. Open-faced, glove fit	126
Abutment VIII 4. Open-faced, other methods	126
Abutment IX 5. Two-piece all-metal crown	
Swaged cusps	126
Cast cusps	126
Abutment X 6. Seamless pressed crown	126
Abutment XI 7. Seamless swaged crown	126
Abutment XII 8. Crown with porcelain facing	126
B. SUPPLIES FOR BRIDGEWORK	126
Supply I 1. Cast supplies	127
Supply II 2. Facings with double backings	128
Supply III 3. Facing with backings and swaged cusps	128
Supply IV 4. Detached post crowns	130
Supply V 5. Steele facings	130
Supply VI 6. Steele posterior	131
Supply VII 7. Goslee teeth	134
Supply VIII 8. Evslin interchangeable teeth	136

		Page
	C. ASSEMBLING BRIDGES	137
Bridge I	1. Sanitary bridges	137
Bridge II	<i>a</i> With gold chewing surface	137
	<i>b</i> With porcelain chewing surface	138
Bridge III	2. Self-cleansing bridges	138
Bridge IV	3. Saddle bridges	140
	With continuous saddles	140
Bridge V	With porcelain saddles	142
	With individual saddles	143
Bridge VI	4. Extension bridges	144
Bridge VII	5. Interlocking two-piece bridges	144
	Dove-tail attachment	144
IX. REMOVABLE BRIDGES		145
	A. Gilmore attachments	145
	General description of technique	145
	Preparing caps and posts	145
	Fitting platinized gold wire	147
Bridge I	1. Full bridges	156
Bridge II	2. Short bridges	158
Bridge III	3. Partial bridges with vault bar	158
Bridge IV	4. Partial bridges with lingual bar	160
Bridge V	5. Extension bridges	160
Bridge VI	B. Removable bridges with Roach attach- ment	168
Bridge VII	C. Removable bridges with Morgan attach- ment	169
X. REPAIR OF CROWNS AND BRIDGES		174
	1. For temporal use	174
	2. For permanent use	177
	Ash repair outfit	178
	Steele repair outfit	179
	Bryant bridge repair tools	180
	Another method	180
	Mineral stains	182
	Special instruments	182
XI. PRACTICAL CASES		185

I. INTRODUCTION

IT is the author's aim to give in this book a practical, systematic and condensed description of the technique of Crown and Bridge work.

The book is specially written for the student, and the practitioner, who has had little experience in this branch of our profession, to help him restore the vital function and characteristic beauty of the masticating apparatus.

Realizing the great importance which so often is overlooked, to make a careful study of a mouth, so as to be able to follow a definite plan of restoration, the author has tried to make the less experienced reader acquainted with mal-occlusion resulting from the loss of teeth, which have not been replaced, and mal-occlusion in the adult resulting from other reasons. Also the condition of the teeth, to serve as abutments, should receive close attention. As it would be unwise to build a beautiful new house on an unsafe foundation, so it would be condemnable to use unhealthy teeth or roots, as abutments for a bridge. The author therefore will also bring close attention to such conditions, and point out the importance of making careful examinations of such teeth, which should be extracted if they do not yield to treatment.

Bridgework as a rule requires the most extensive reduction of the shape of the teeth and if, after careful study, it is found necessary to devitalize a tooth, one can accomplish this in no other way with such ease, with so little pain, and so much saving of time, as with the aid of "Local Anaesthesia," the importance of which has not yet been sufficiently recognized, and therefore a very condensed chapter on "Local Anaesthesia," an extract from Dr. K. H. Thoma's book "Oral Anaesthesia," has been added by special arrangement with my esteemed friend and co-worker.

Crown and fixed bridge work will then receive our attention. The technique is given in step form, with illustrations to make it as simple as possible to follow, one after the other,

the steps of construction. The author considers well-constructed fixed bridgework the best known replacement, as it is closest to what nature intended us to have. However, the cases must be properly selected. Removable bridges help us in many cases to overcome conditions, which are unfavorable, and impractical for fixed bridges, and these render it possible in many cases to give the patient a satisfactory and comfortable appliance, especially when it would be almost impossible to get a good result with a plate.

The author's experience is based upon twenty-seven years of practical work, conducting his own laboratory, as well as directing the work for other practitioners, consisting chiefly of metal and porcelain work. During this long period of private practice and seven years of teaching in the Crown and Bridge Department of Harvard Dental School, the different methods have been given the most careful tests. The principal aim is to give the inexperienced a reliable guide, and it is the author's sincere hope and wish that the reader may benefit humanity, through knowledge received from this book, and receive in return the appreciation of his patients.

II. EXAMINATION AND STUDY OF CROWN AND BRIDGE CASES

It is of greatest value that the entire mouth should be studied when a case presents itself for Crown and Bridge work. Too many men let themselves be influenced by patients desir-



FIG. 1. These two cases show the result of work done without the help of Radiographs.

ing to improve their appearance, and therefore asking for replacement of some particular teeth only, disregarding conditions in the masticating region, which are of much greater importance. It is the dentist's duty to point out the double

advantage of restoring the normal occlusion. Not only should *hopeless* teeth be extracted, sufficient roots treated, cavities filled, but the posterior teeth should be replaced first of all, to give the patient the possibility to masticate and in this fashion improve his general health. Beside the improvement of health and efficiency, we have another reason which is very closely associated with the operator's success. If teeth are only restored by bridges in parts of the mouth, while spaces remain in others, we get abnormal pressure, and abnormal force applied upon the artificial appliances, shortening the time of service of their abutments. A dentist is therefore more than justified to refuse treatment, if the patient does not commit himself to the operator's advice.

Models

As in orthodontia so in Crown and Bridge work, it is most satisfactory to study a mouth with the aid of plaster models. It is not only much easier to study the conditions on models, but these will be a help to consult and advise the patient. Finally they will be a record of the primary condition of the mouth.

Radiographs

The teeth to be used for abutments, should be carefully studied. The condition of the pulp, direction of the roots, number of roots and canals, and in devitalized or septic teeth the condition of the apex should be ascertained. In pyorrhoeatic cases, we should know how much of the process has been absorbed. All this is easily done by radiographs, which give us a good idea beforehand how strong the fundamentals are upon which we base our work.

III. CLASSIFICATION OF CROWN AND BRIDGE CASES

We can classify a mouth in two ways:

- (a) Pathological conditions of the teeth and mouth.
- (b) In regard to occlusion.

A. PATHOLOGICAL CONDITIONS OF THE TEETH AND MOUTH

Patients needing bridgework have usually brought about the loss of teeth by negligence of their mouth, and we therefore frequently find their teeth in very bad condition.

1. Septic Roots

Often we find diseased teeth, and we have to decide just what teeth should be saved, and what teeth should be extracted. To decide this question, we must consider that a tooth has a relative value. If there are plenty of good abutments, we will condemn a tooth, with a chronic alveolar abscess, which has given trouble from time to time, but in case of scarcity, it would be important to treat this tooth, even if it involves a long and tedious process. For example, it might be of practical value to save even one root of a tooth, if it is healthy, to be used as an abutment, as the palatal root of an upper, or the mesial or distal root of a lower molar. (Figure 2.) These surrounded by healthy tissue, give in most cases as equally good service as any single rooted teeth. We should, however, be careful in our diagnosis and treatment. Cause and result of treatment should be ascertained by the X-ray, and teeth which do not yield to treatment should be extracted. (See Figure 3.)

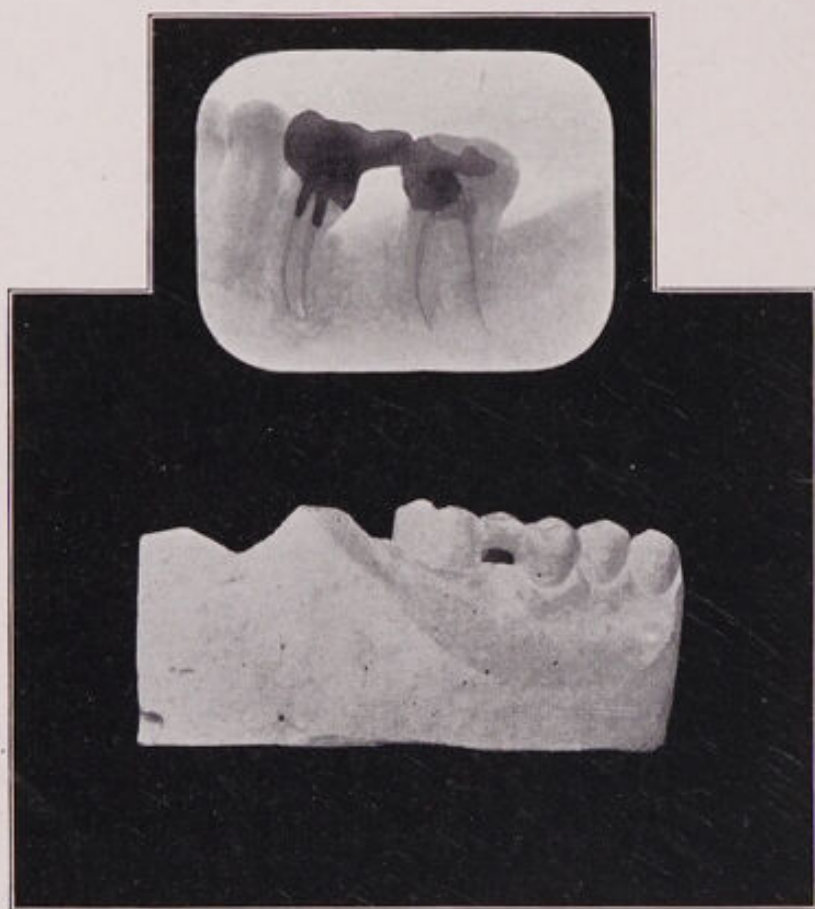


FIG. 2. Mesial root of an inferior six-year molar, used as an abutment. The distal root of this six-year molar was amputated on account of chronic abscess. Above, radiograph; below, model of the case.

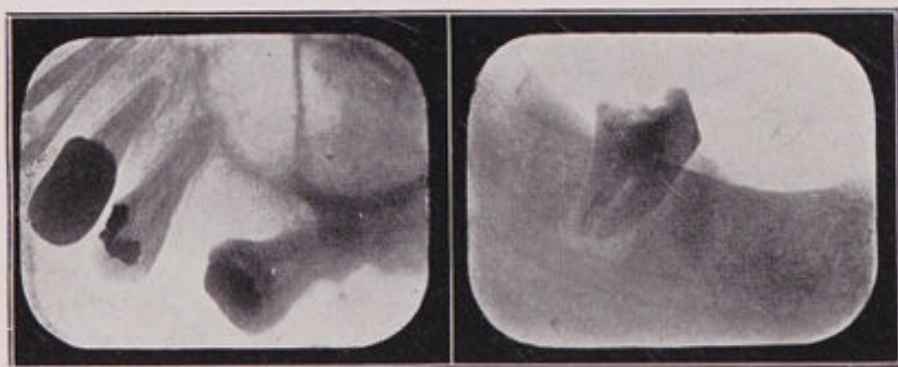


FIG. 3. Pathological conditions of the teeth. Radiographs of teeth and roots which had to be extracted on account of chronic abscesses and failure of root canal treatment.

If roots or teeth are hopeless on account of their pathological conditions or on account of their position or direction, we decide on their removal. (See Figure 3.)

2. Acid Mouth and Erosion Certain crowns (and inlay abutments) are contra-indicated in an acid mouth; these are half crowns with post, open-faced, and staple crowns. It is important to have all abutments extending under the gum, to eliminate as far as possible further attack of decay and the dissolving of the cement, which is used for setting.

3. Pyorrhoeatic Condition A great many of the cases which we examine have pyorrhoeatic teeth, and these are the most difficult ones to diagnose and prognose. Some teeth usually have to be sacrificed, others can be treated in the regular way, and still others may

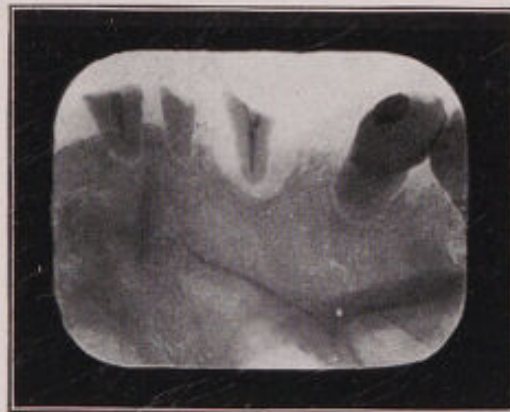

FIG. 4. Pathological conditions of the mouth. Radiograph showing absorption of the alveolar process, caused by pyorrhoea alveolaris.

be found sound. Radiographs give us a good idea of the amount of absorption that has taken place in the alveolar process, and which teeth are strong enough for bridge abutments. (Figure 4.)

When treating pyorrhoeatic teeth, the first and most important is correction of the occlusion. Many teeth will tighten in a surprisingly short time, if the strike is relieved to give them a chance to rest and recuperate. It is advisable in many cases to devitalize pyorrhoeatic teeth, and if they are to serve as abutments to cut them off. By extirpating the pulp of such a tooth, we increase the circulation in the alveolo-dental mem-

brane, which then receives the entire supply of the dental vessels. Cutting these teeth off, even with the gum, will improve the condition for two reasons: first, it gives the teeth the important surgical rest; and second, if used as abutments for the bar in removable bridges, it decreases the lever action.

The next step to decide upon is, what appliance should be used. For pyorrhoea cases are recommended:

- (a) Bridges without bands.
- (b) Bridge splints.
- (c) Removable bridges.

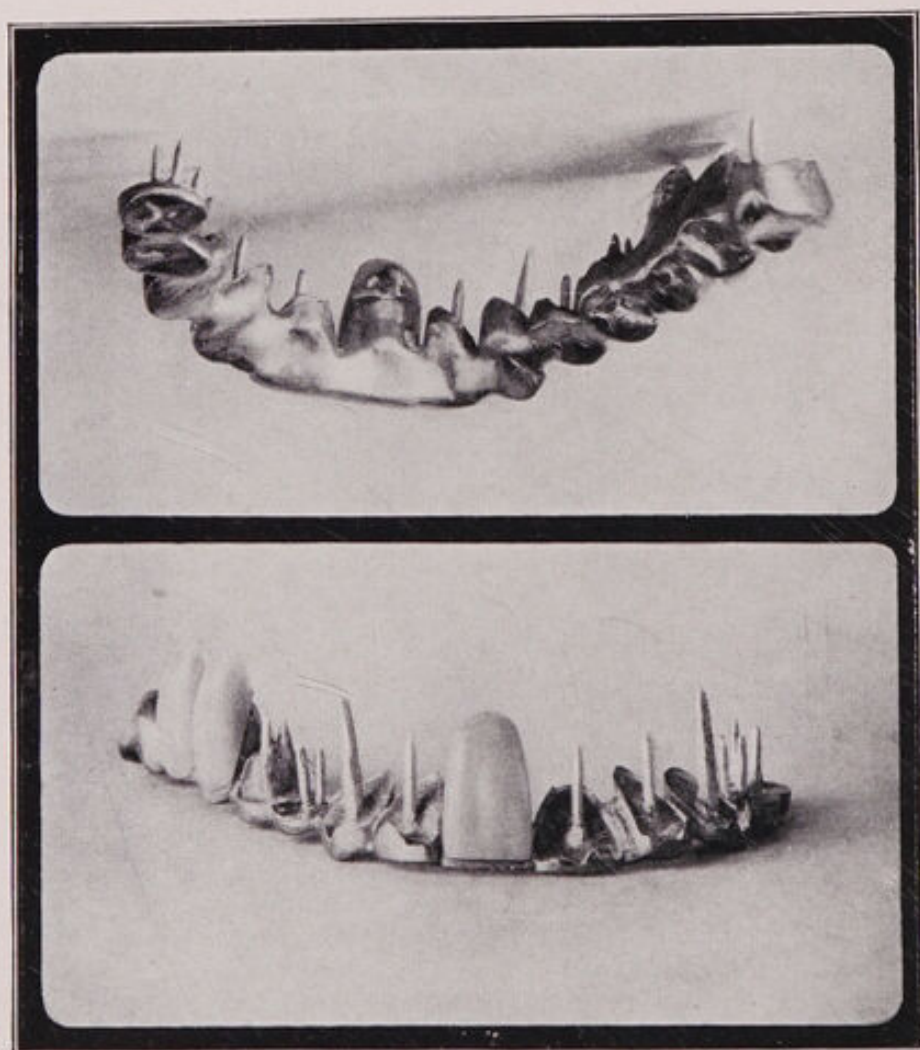


FIG. 5. Pyorrhoeatic condition. Bridge splint.

(a) Bridges without bands. If there is but little absorption of the process with large and persistent pockets, or if bridges have to be made before the teeth can be cured, it is

advisable to construct them in a manner which does not interfere with the scaling and curetting. Therefore use abutments without bands, such as inlays, half crowns, bandless crowns, etc.

(b) Bridge splints. These are used if mastication causes abnormal stress on the teeth, or on wandering teeth. The process and gum has receded, and the free part of the tooth is out of proportion to the part that retains the tooth in the

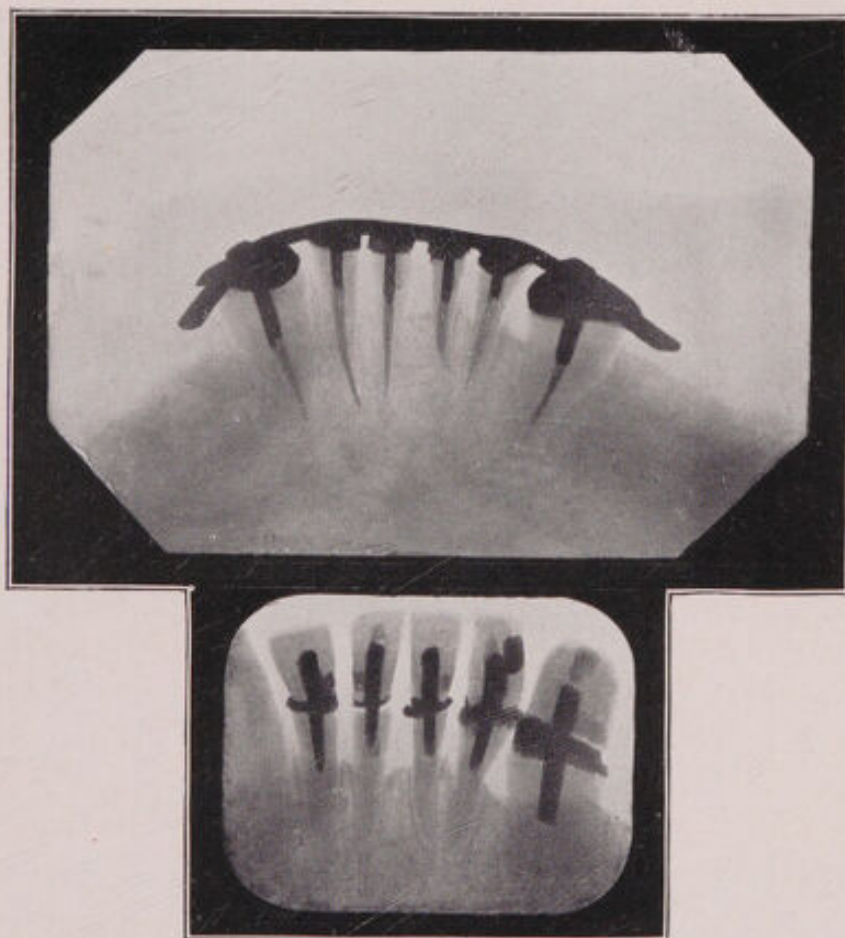


FIG. 6. Pyorrhoeatic condition. Lower picture shows the condition before the treatment; a great deal of tissue has been absorbed, and the lever action on the part of the tooth extending out of the gum is great. Upper picture shows the roots cut flush with the gum and connected with a bar, which also acts to hold a removable bridge.

socket, the lever action on the teeth in mastication has to be counteracted, the teeth have to receive a support to put them at rest, which is brought about by fixing them together with an appliance called a splint. Missing teeth can be replaced by adding them to the appliance. (Figure 5.) It is, however,

important to keep in mind that a splint is not a cure for pyorrhoea, but only a device to do two things:

1. Assist the healing process, allowing new bone to form, by giving the teeth a surgical rest. It may be used only as a temporary appliance.
2. To hold very badly affected teeth in place and prevent them from getting worse. These splints usually preserve the teeth for a number of years. A splint of that sort is called a bridge splint. It should, however, be so constructed that it does not interfere with prophylactic treatment by the patient, and pyorrhoea treatment by the operator, which should be continued at regular intervals. (Figure 5.)

(c) Removable bridges. If a great amount of tissue has been absorbed, which we find necessary to fill in, or where there are but a few abutments, we find the most satisfactory restoration in a suitable removable bridge. (Figure 6.)

The teeth are cut off flush with the gum, which does away with the lever action, and gives the remaining end of the root a much better chance. The roots are capped and held in their position, this again strengthens them, while the stress of mastication is partly taken up by the saddle support on the gum. These appliances also have the advantage that the patient can take them out, and clean them, and what is of still greater importance there is easy access to the roots for prophylactic treatment.

4. Absorption of the Tissue

A great amount of tissue may be lost in some cases, which on the lower jaw is of no great consequence, as the teeth do not show very much; but in the upper jaw, and especially in front of the mouth the tissue has to be replaced. To avoid ungainly long teeth we use saddles, replacing gum as well as teeth. Gum teeth can be used, or the bridge can be made in platinum, with continuous gum. (Figures 7, 8, 9.) Often the gum over one tooth only needs to be restored; this can be accomplished by baking pink porcelain on a long plain tooth. In cases of much absorption, the restoration can be accomplished more satisfactorily with removable bridges, especially from the sanitary point of view.

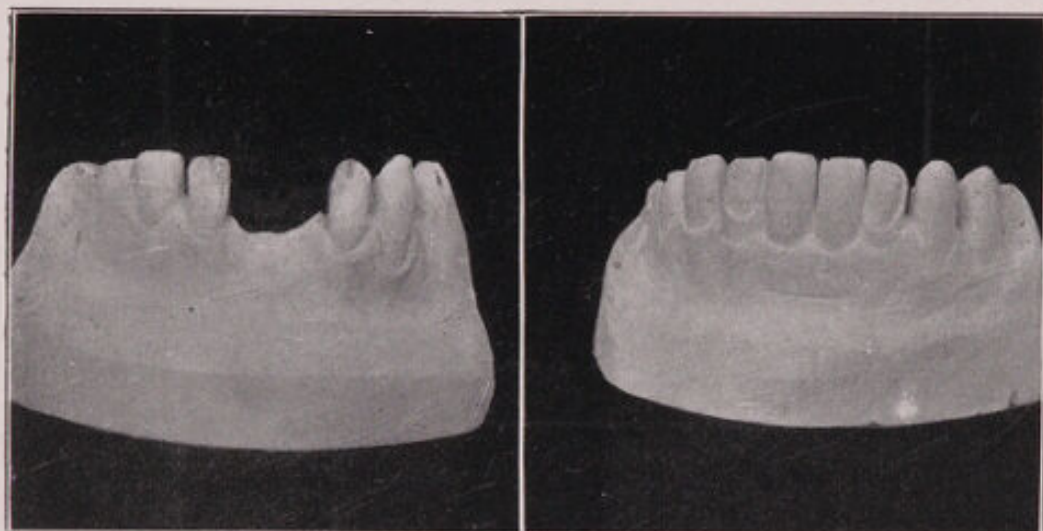
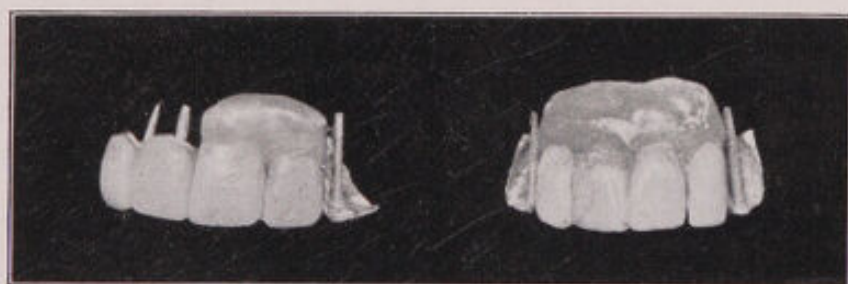


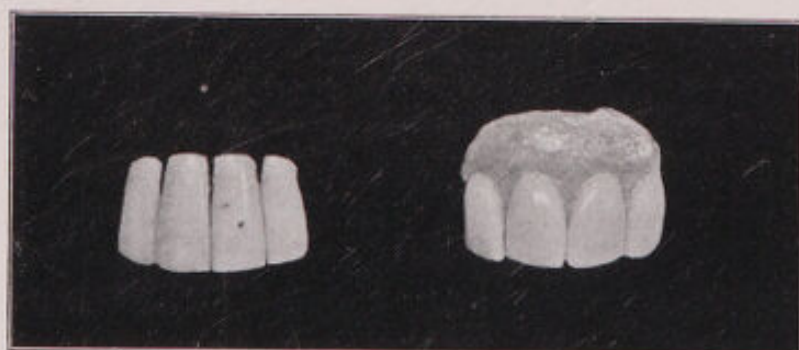FIG. 7. Absorption of tissue. Model shows the absorption of tissue which has taken place on account of pyorrhoeatic conditions, and the replacement with a gum block.



A

B

FIG. 8. Absorption of tissue. Models show two bridges constructed to restore the absorbed tissue.



A

B

FIG. 9. Absorption of tissue. A shows the length of teeth which would have to be used for a bridge without gum. B shows the gum block of the same case.

B. AS TO OCCLUSION

Mal-occlusion is a very frequent complication in crown and bridge work. Therefore it is very important to study such a case with the aid of models.

1. Normal Occlusion

In a case with normal occlusion there is, strictly taken, no tooth missing. However, we will put under this head all the cases which need but restoration of a certain number of teeth to give normal occlusion. These are among the most common cases of crowns or bridges. (Figure 10.)

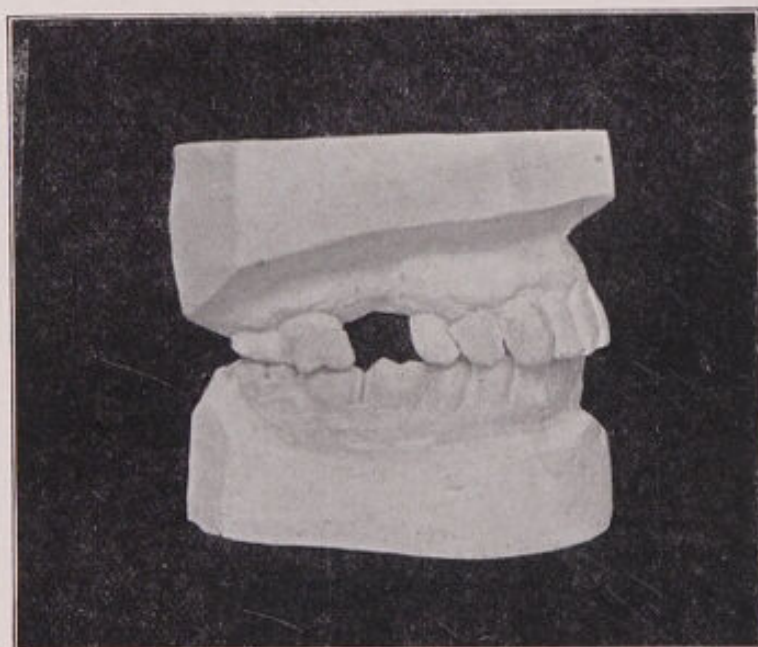


FIG. 10. Bridge case with normal occlusion. Upper six-year molar missing.

2. Sufficient Occlusion

Sufficient occlusion is a very convenient term for which we are indebted to Dr. Eugene Smith, of Harvard Dental School. The occlusion is not normal, but the patient finds it sufficient, because restoration to normal occlusion would involve changes out of proportion to the result, on account of technical difficulties.

In this class come cases of edge to edge bite, of over-bite of the lower molars and bicuspid, and some cases of mandibular, or maxillary protrusion. (See Figure 11.)

3. Mal-occlusion

Mal-occlusion in the adult can come from neglect of treatment for orthodontia in childhood, or can be acquired in late life as "closed bite" from loss of teeth or wear; as "protrusion" of the maxillary incisors, caused by pressure from the lower ones; or as "tipping" or "elongation" of teeth on account of spaces, etc. We will subdivide these and consider them separately.

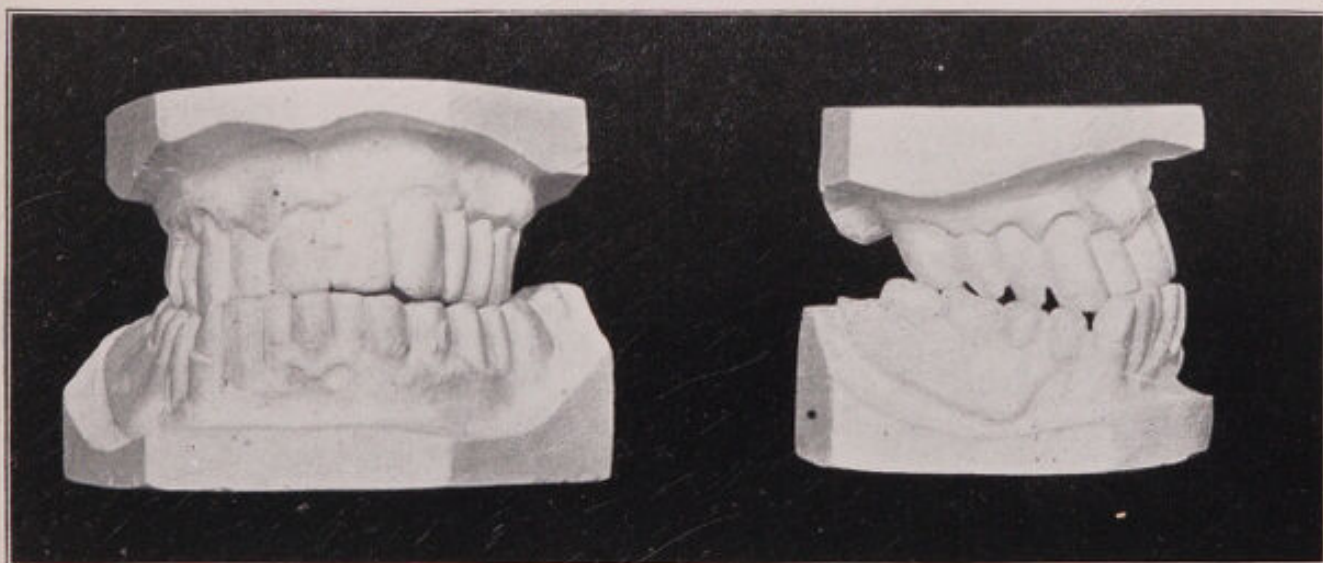


FIG. 11. Sufficient occlusion, edge to edge bite of the incisors, and over-bite of the lower bicusps and molars.

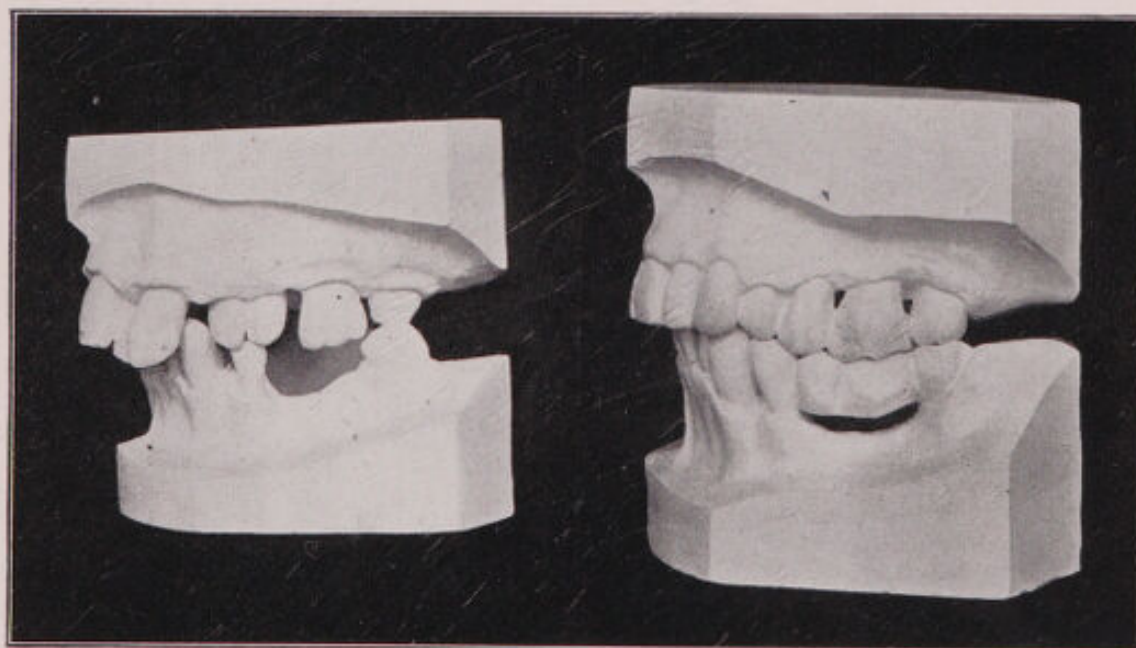


FIG. 12. Mal-occlusion. Spaces mesially and distally of the upper molar. The contact points have been restored by a hand-carved porcelain crown with cast base.

(a) **Lack of contact points.** Teeth have the tendency to move forward if a space occurs from extraction (see Figure 12), but the contact point is not always restored entirely, and the space left is frequently a great source of trouble. But spaces between teeth are not necessarily directly due to the loss of a tooth. The teeth posterior to an extracted tooth move forward, but the tooth anterior to the space often moves back on account of force from the occlusion of the antagonist (Figure 13.) Small spaces also occur from supra-numerous (Figure 14) peg-shaped teeth, and from insufficient restoration

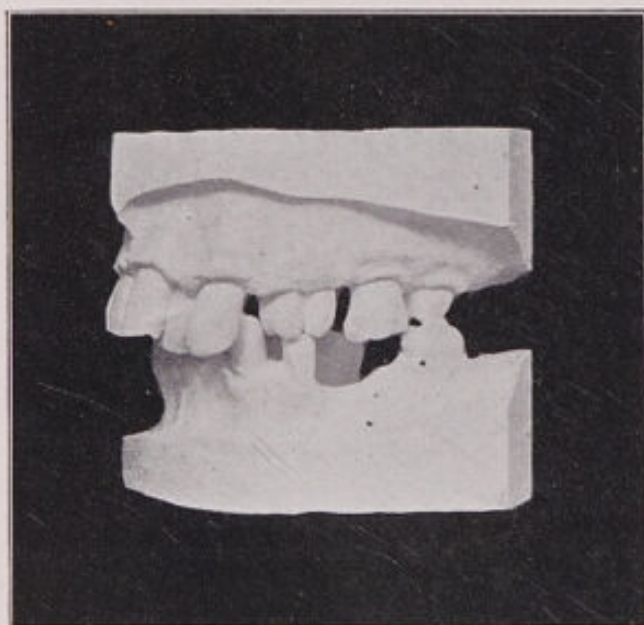


FIG. 13. Mal-occlusion. Space between the upper cuspid and bicuspid. The latter as well as the lower first bicuspid, has been forced back.

of fillings and decay. Spaces of that nature ought to be filled in, either by contour fillings, inlays (Figure 15) with special extensions, crowns with large contour (Figure 16), or if the space is next to an abutment, the latter has to be constructed to restore the contact point.

(b) **Teeth tipped forward.** (Figure 17.) Teeth which have tipped towards the space, or have been pushed out of vertical direction by force of a faulty bite, complicate bridge-work considerably. In some cases they can be ground suffi-

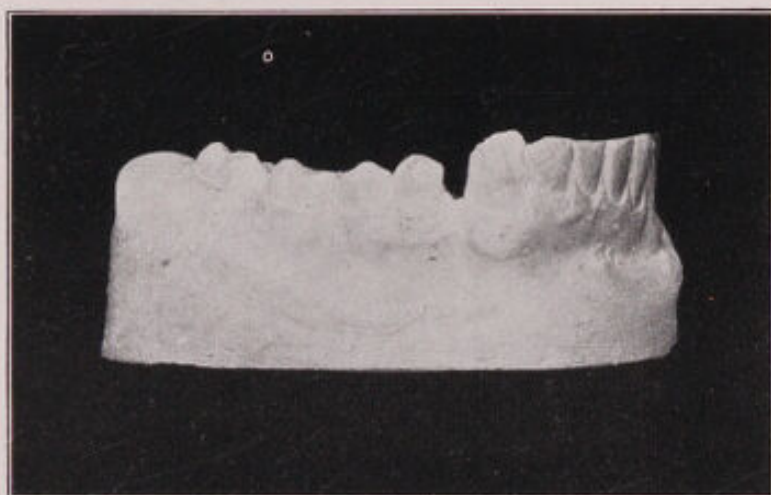


FIG. 14. Mal-occlusion. Space between the lower cuspid and first bicuspid, caused by a supra-numerous tooth, which was not extracted in time.

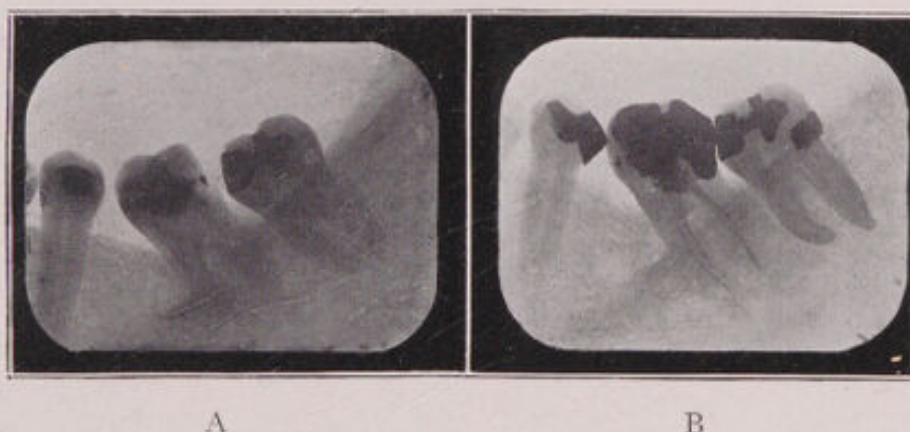


FIG. 15. Mal-occlusion. A, space between the six-year molar and second bicuspid caused by the extraction of the first molar. Space between the second and third molar caused by decay. B shows the same case with all the contact points restored.

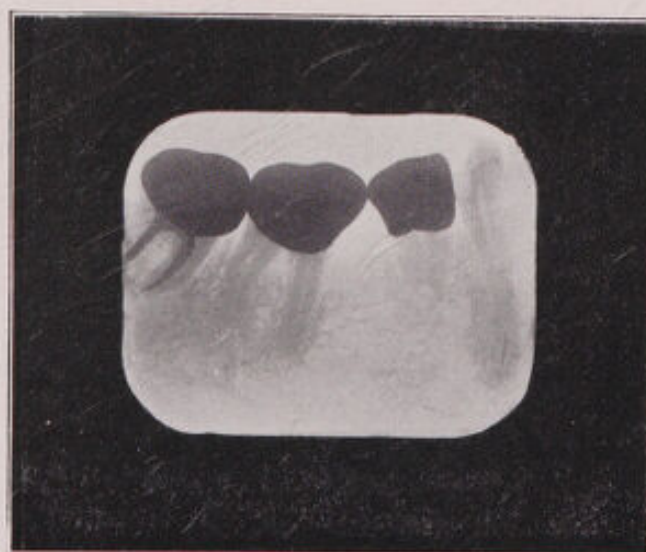


FIG. 16. Mal-occlusion. The space between the lower twelve-year molar and the second bicuspid was filled with gold crowns, sufficiently built out to get the contact point.

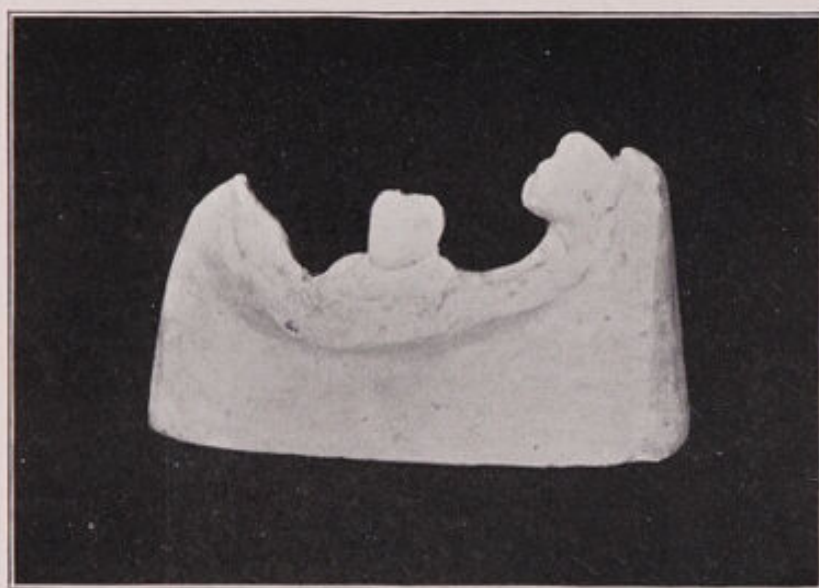


FIG. 17. Mal-occlusion. The molar is tipped forward, so as to render the making of an ordinary bridge impossible.

ciently to bring them in line, but in extreme cases it is most always necessary to use special constructions, as:

1. Two-piece bridges with interlocking device. (See Figure 18.)
2. Inlays with post for abutments. (See Figure 19.)
3. Removable bridges.

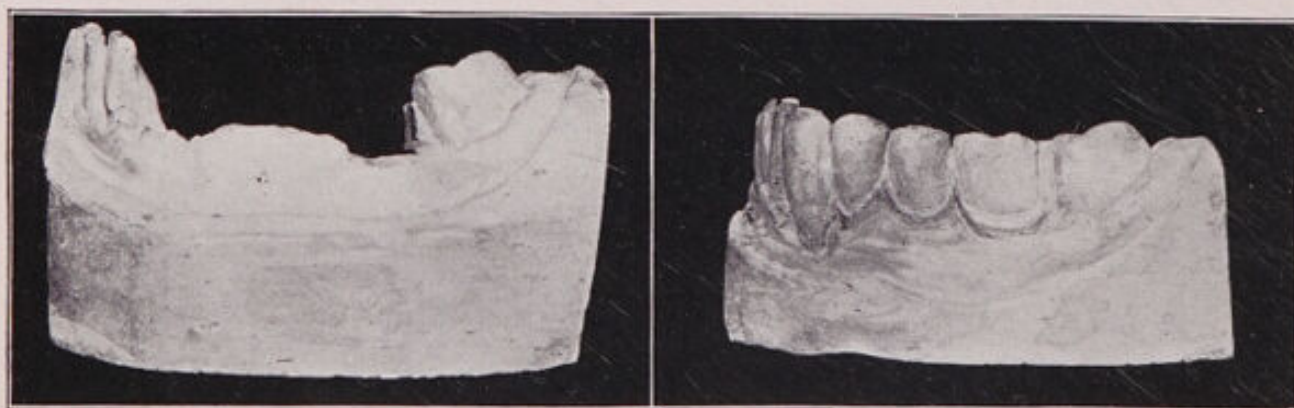


FIG. 18. Mal-occlusion. Bridge with interlocking device to overcome the tipping of the tooth. For construction see Fig. 170.

(c) Teeth elongated. Teeth which do not occlude, usually elongate, that is, they grow down from the maxilla, or up from the mandible. (Figure 20.) These have to be restored to normal length, either for looks or to get proper masticating

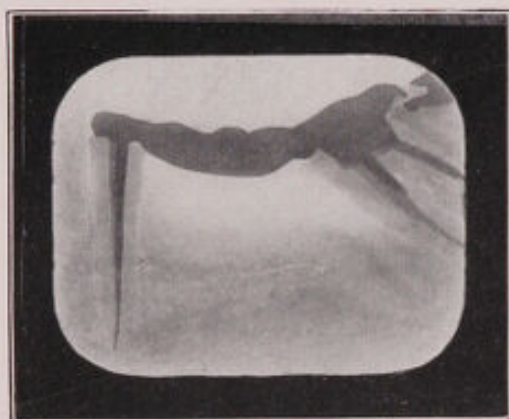


FIG. 19. Mal-occlusion. Bridge with inlay abutments,—one way to overcome the difficulty of tipping teeth.

occlusion, if the space opposite is bridged. When they are ground down, and if the contact points are not lost, they can be filled with a well-carved inlay to replace the occlusal surface. If the contact points are lost, as in teeth with narrow necks, it is best to crown the tooth with a suitable crown, or to cut a mesial-occlusal-distal cavity for an extension inlay.

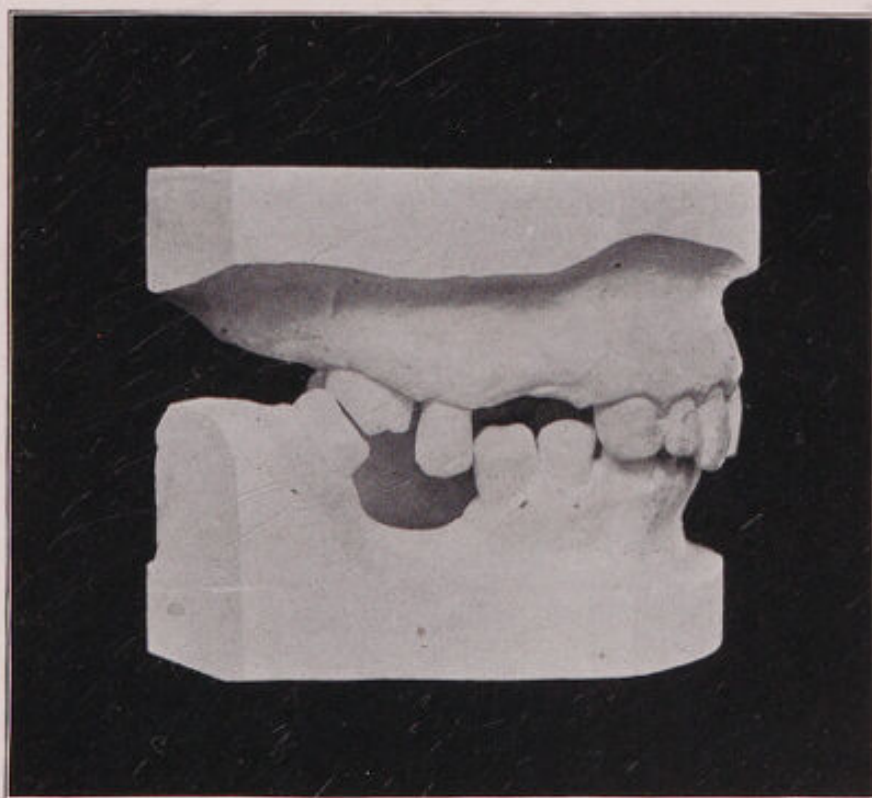


FIG. 20. Mal-occlusion. The upper bicuspid has elongated on account of the loss of the lower teeth. The bite has closed, making the condition worse.

(d) Temporary teeth retained. Very often we find retained temporary teeth in persons of advanced age, and the question arises whether they should be used as abutments. A radiograph will give the desired information. (Figure 21.)

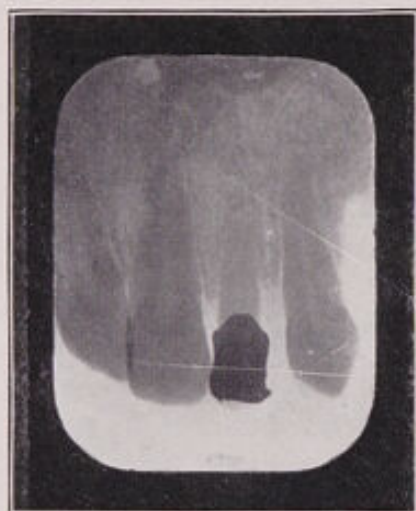

FIG. 21. The right lateral incisor is a temporary tooth. The X-ray shows that the root is perfectly healthy, and strong for an abutment. The X-ray also ascertains the absence of a permanent lateral incisor.

If the root is strong, firm and no absorption at the apex, there is no reason why it should not be a good abutment. But if we find the tooth partly absorbed (Figure 22), or if there is



FIG. 22. Radiograph showing absorption of the roots of two temporary teeth, the central and lateral incisors. The cuspid has a strong, healthy root with no absorption. Be careful not to attempt to crown a tooth, when you encounter a large opening and bleeding in the root canal.

an impacted permanent tooth (Figure 23), these conditions should be carefully considered. A temporary root on which absorption has started is hopeless. If the corresponding per-

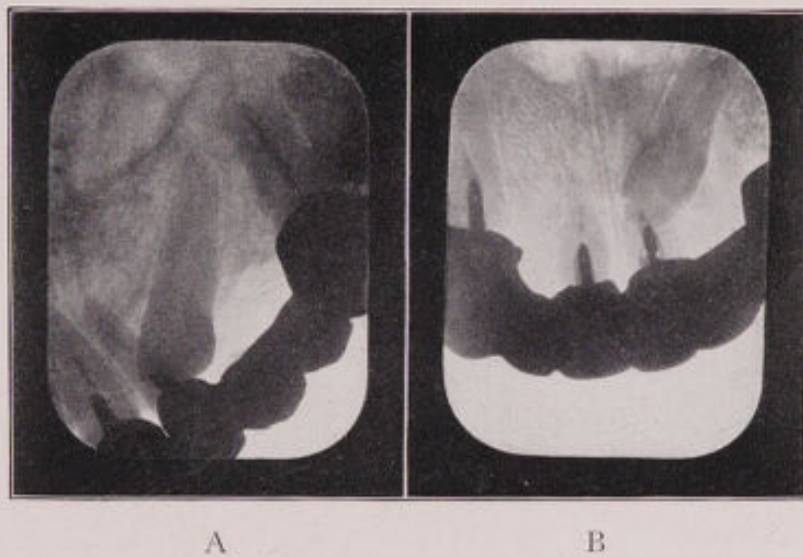


FIG. 23. Showing unerupted cuspids under bridges, illustrating the importance of radiographic examination before constructing bridges.

manent tooth is impacted and ill-placed while the temporary root stays, and no sign of absorption is shown in the radiograph, we may remove the permanent tooth and use the temporary root. If there is a good chance for the permanent tooth to come down in good line, we may hasten its coming to the surface by extracting the temporary root and making space for the permanent tooth by cutting away overhanging bone and keeping the space open.

(e) Closed bite. The bite may be closed from the loss of the back teeth, and the wearing down of the front teeth. The

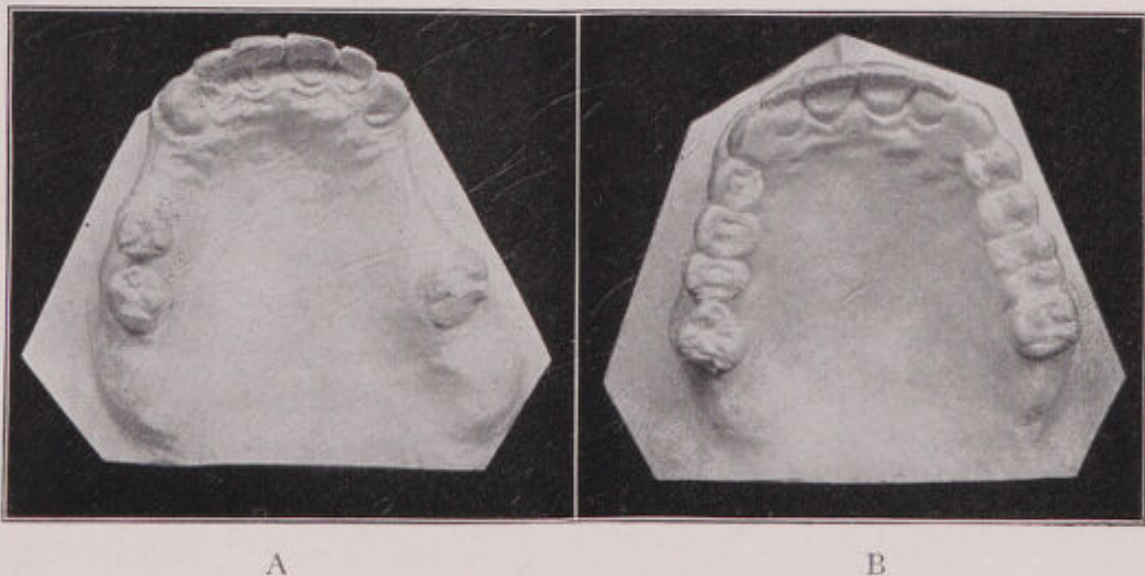
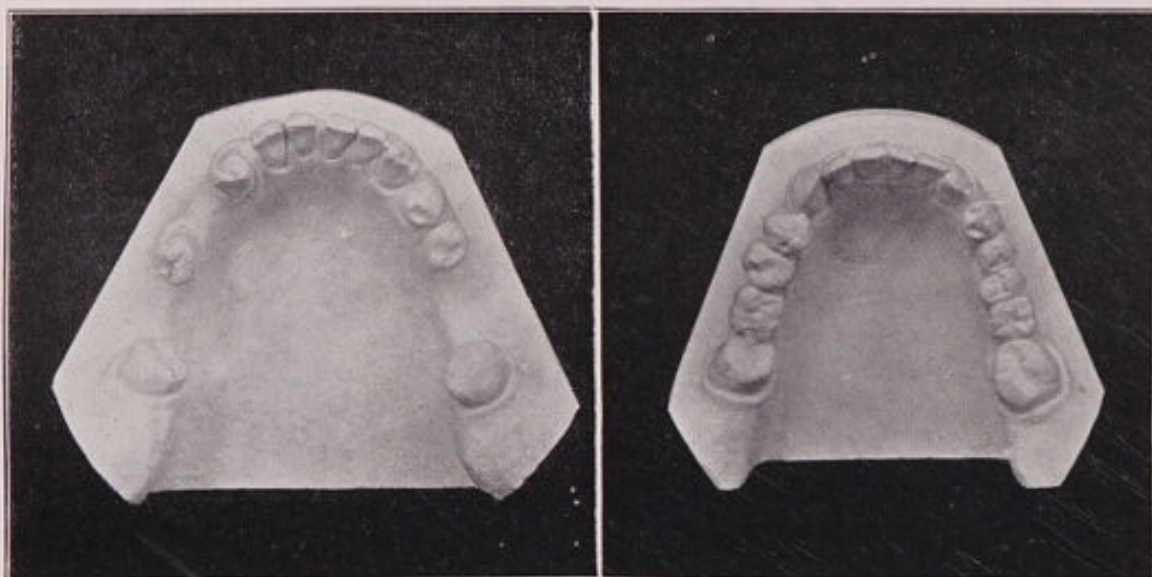


FIG. 24. Mal-occlusion closed bite. The bite has closed to such an extent, the upper incisors have worn down so much, that the pulps were visible on the palatal side. A before, B after repairing the incisors with inlays and the sides with bridges.

upper incisors are worn on the cutting edge, or on the palatal surface (Figure 24), or are pushed out. If abrasion is the cause, the remedy consists in elongating the molars and bicuspids with so-called shoes or with bridgework (Figures 24, 25, 26,



A

B

FIG. 25. Mal-occlusion closed bite, the lower jaw. A before, B after treatment, filling the spaces with bridgework.

27 and 28). In some cases filling of the incisors at the palatal surface or gold inlays containing iridio-platinum is sufficient.

However, loss of teeth and cavities more frequently produce this condition. The bite can be opened with bridgework or a plate.

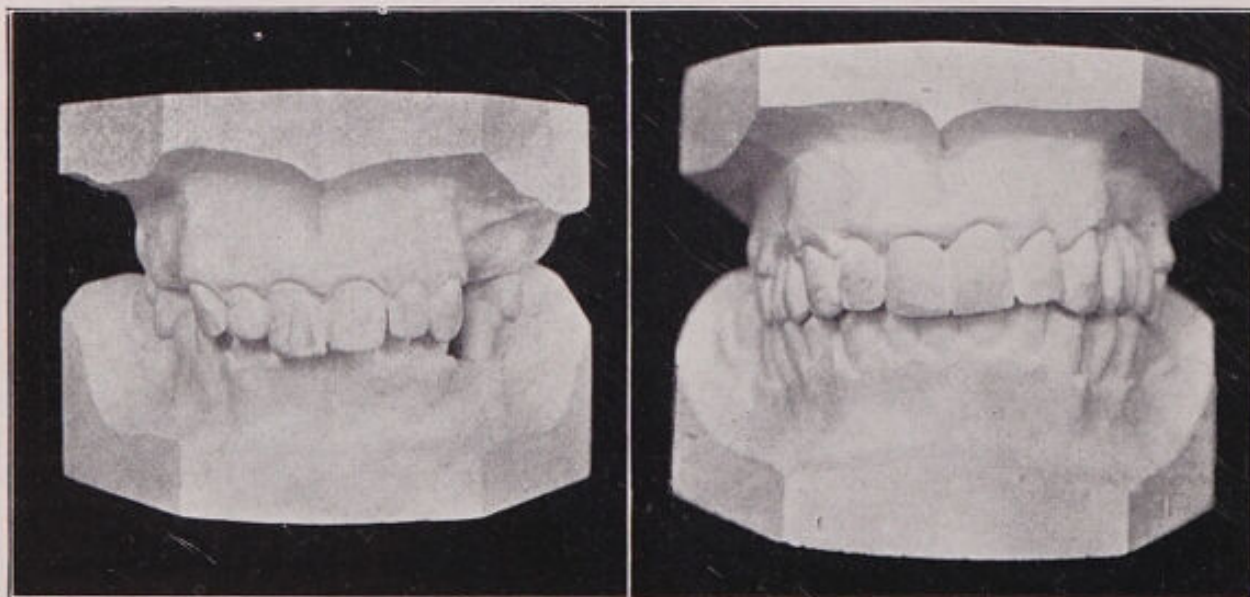


FIG. 26. Mal-occlusion, closed bite. Front view, before and after treatment.

(f) **Maxillary and mandibular protrusion.** (Figures 29 and 30.) It is often desirable not only to adjust occlusion to improve mastication, but moreover to restore beauty and harmony of the face. If after a certain age orthodontia has ceased to be applicable, cases of protrusion with irregularities of the front teeth can be corrected by bridgework in a more radical manner. The irregular teeth can be cut off and porcelain

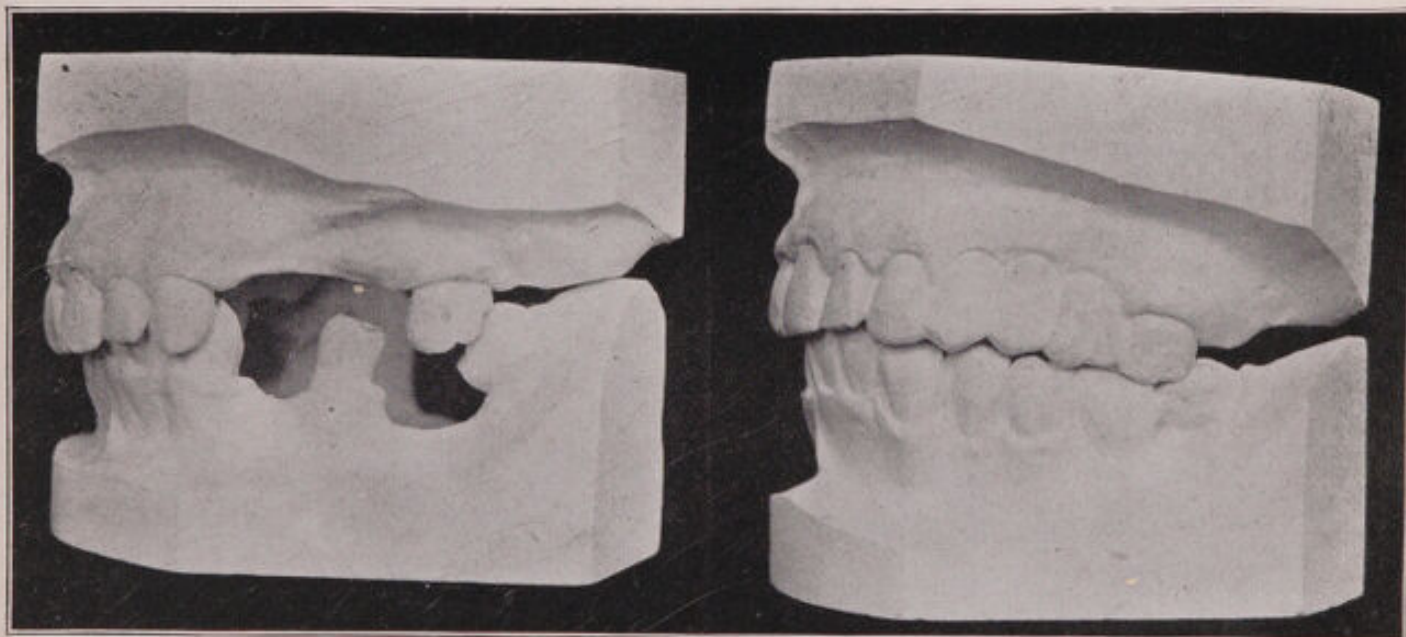


FIG. 27. Mal-occlusion, closed bite. These views of the left side show conditions before and after restoration, with bridgework to open the bite.

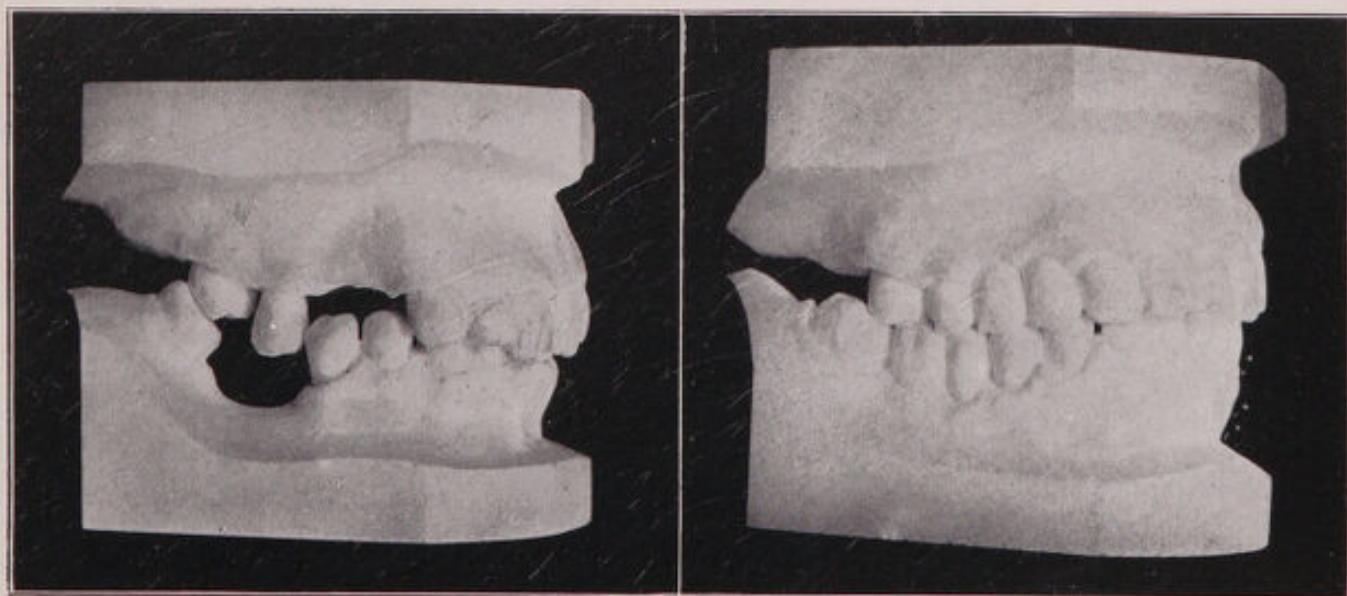


FIG. 28. Mal-occlusion, closed bite. The right side of the same case (Figs. 24-28), same mouth, before and after treatment.

crowns fitted at a different angle. In Figure 31 four teeth were replaced by a bridge of three teeth to get a better appearance and occlusion.

(g) **Wandering teeth.** With this term we mean teeth which have been forced out of line either singly, or in groups, by mal-

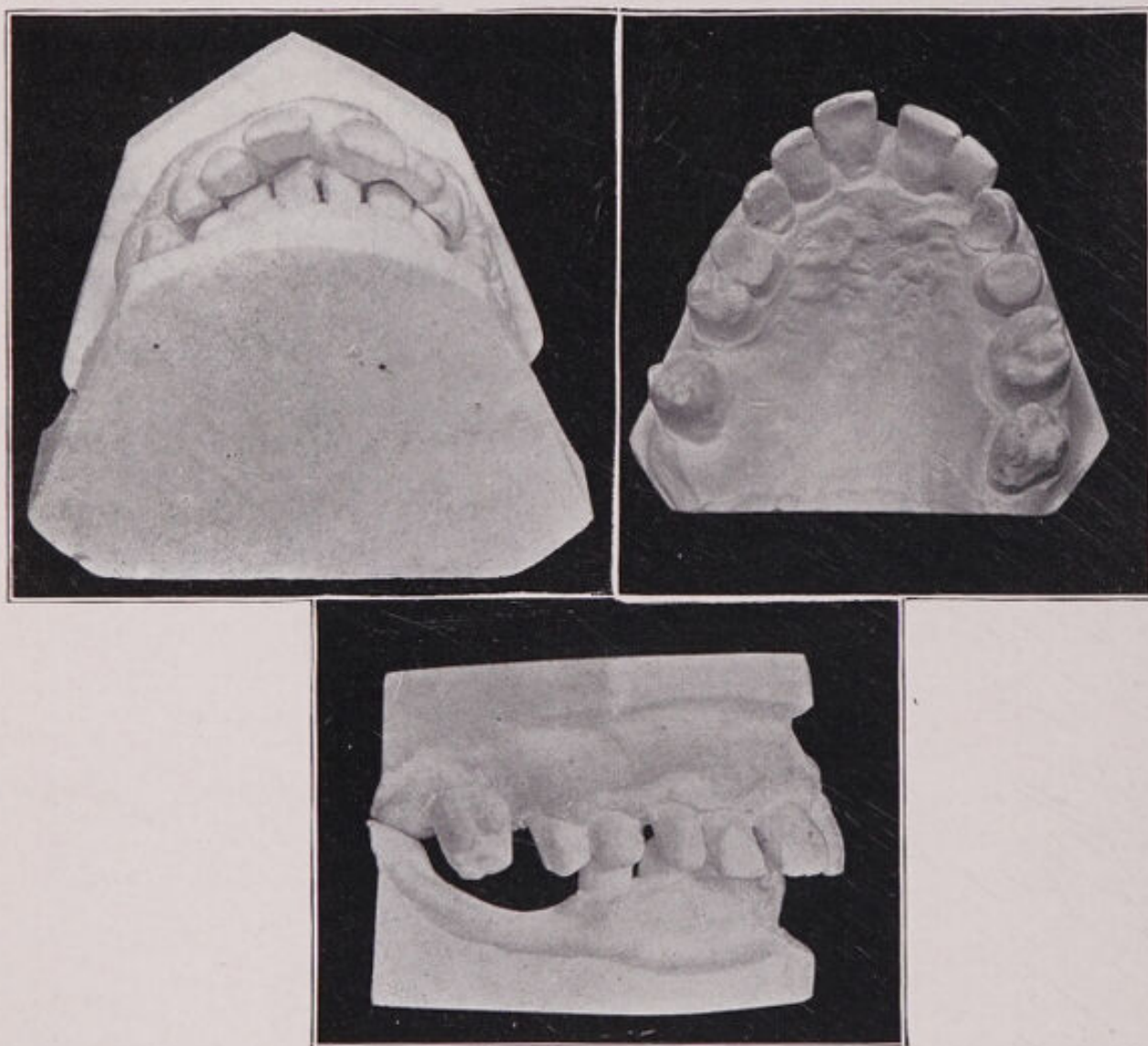


FIG. 29. Mal-occlusion. The incisors have been pushed out on account of the closing bite. Models show the loss of the teeth in the upper and lower jaw, causing this condition. (See construction of bridges for this case. Figs. 202-211.)

occlusion, and it is characteristic that they keep getting worse, moving further and further, pressed usually by a closing bite. (Figure 32.)

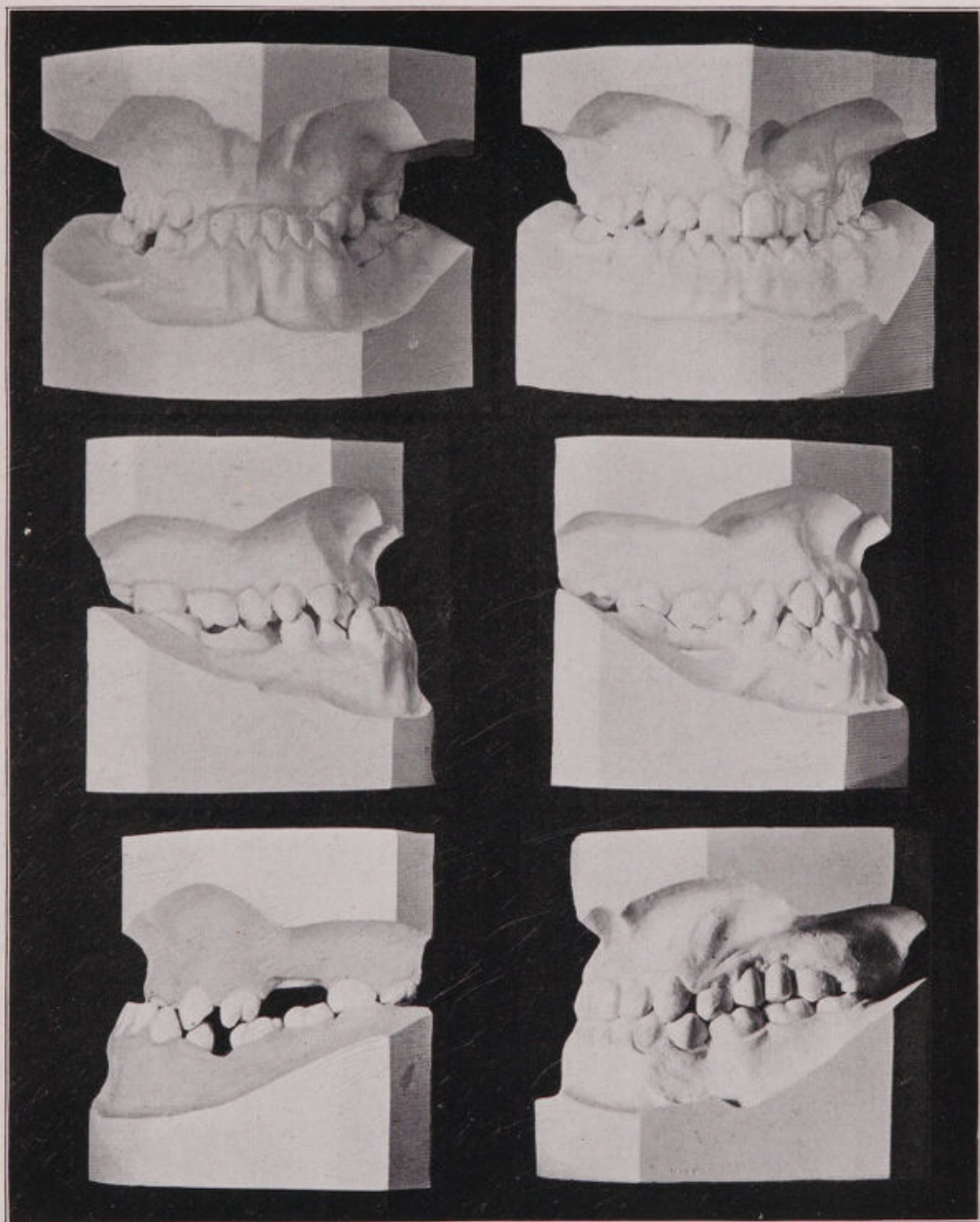
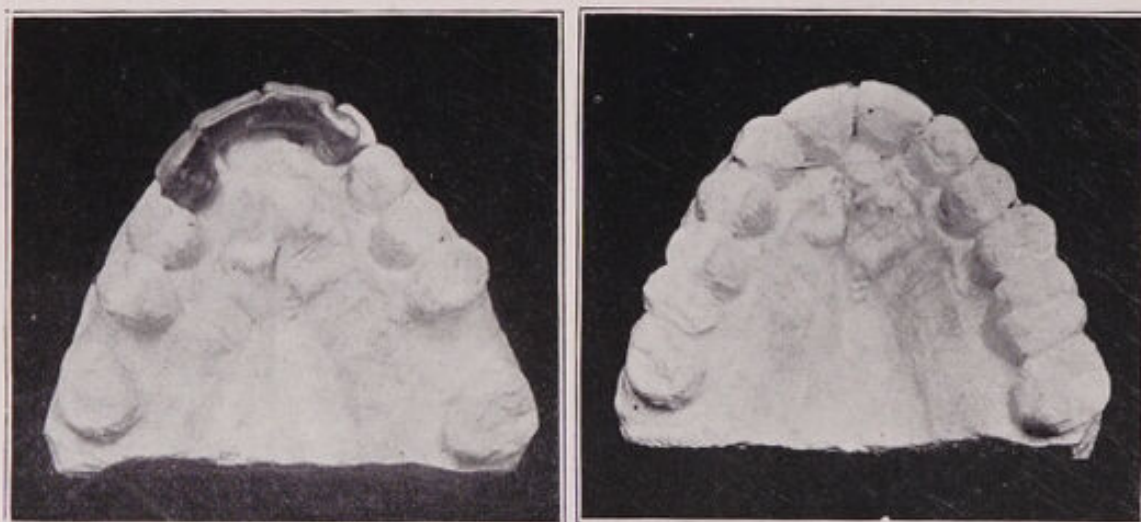

FIG. 30. Mal-occlusion, mandibular protrusion. Harvard Dental School case. Before and after treatment in the Orthodontia and Crown and Bridge Departments.

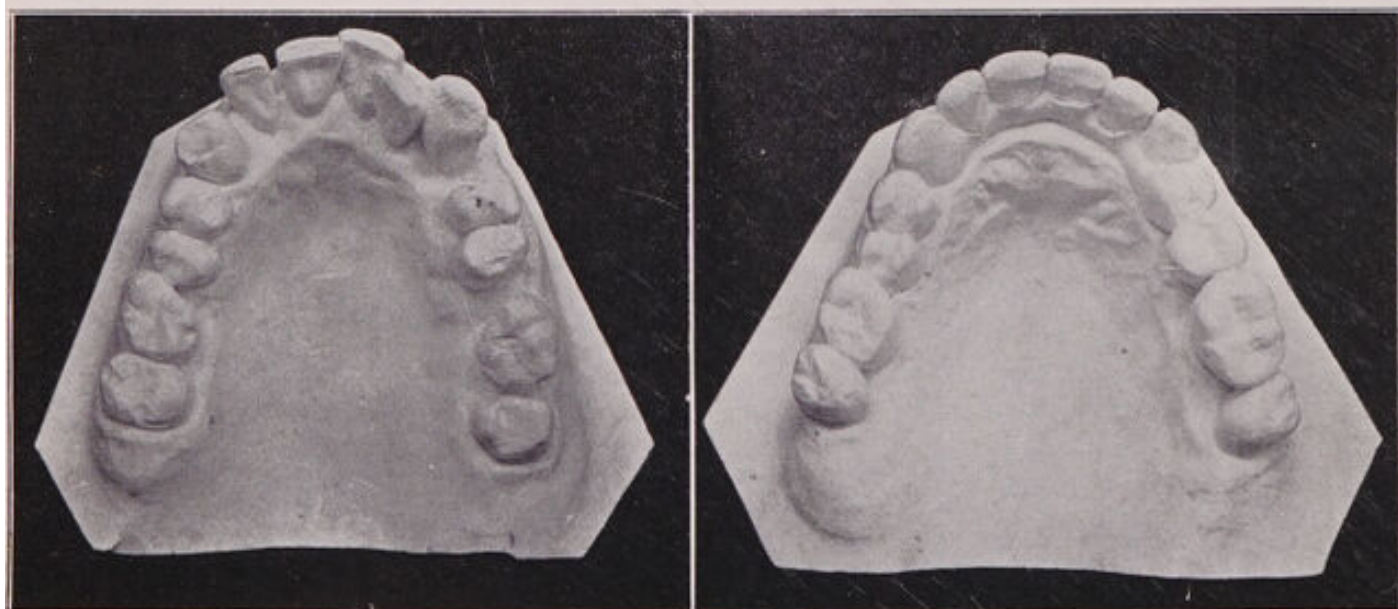
In these cases single crowns are contra-indicated; such teeth have to be connected. Usually the roots have taken an oblique direction, and have to be cut flush with the gum; a bridge is then constructed with crowns extending down vertically, or the trouble is overcome by a removable bridge. (Figure 33.)



A

B

FIG. 31. Mal-occlusion, maxillary protrusion. Model A, before; model B, after treatment.



A

B

FIG. 32. Mal-occlusion, the upper incisors are projecting. A shows condition before; B, after treatment.

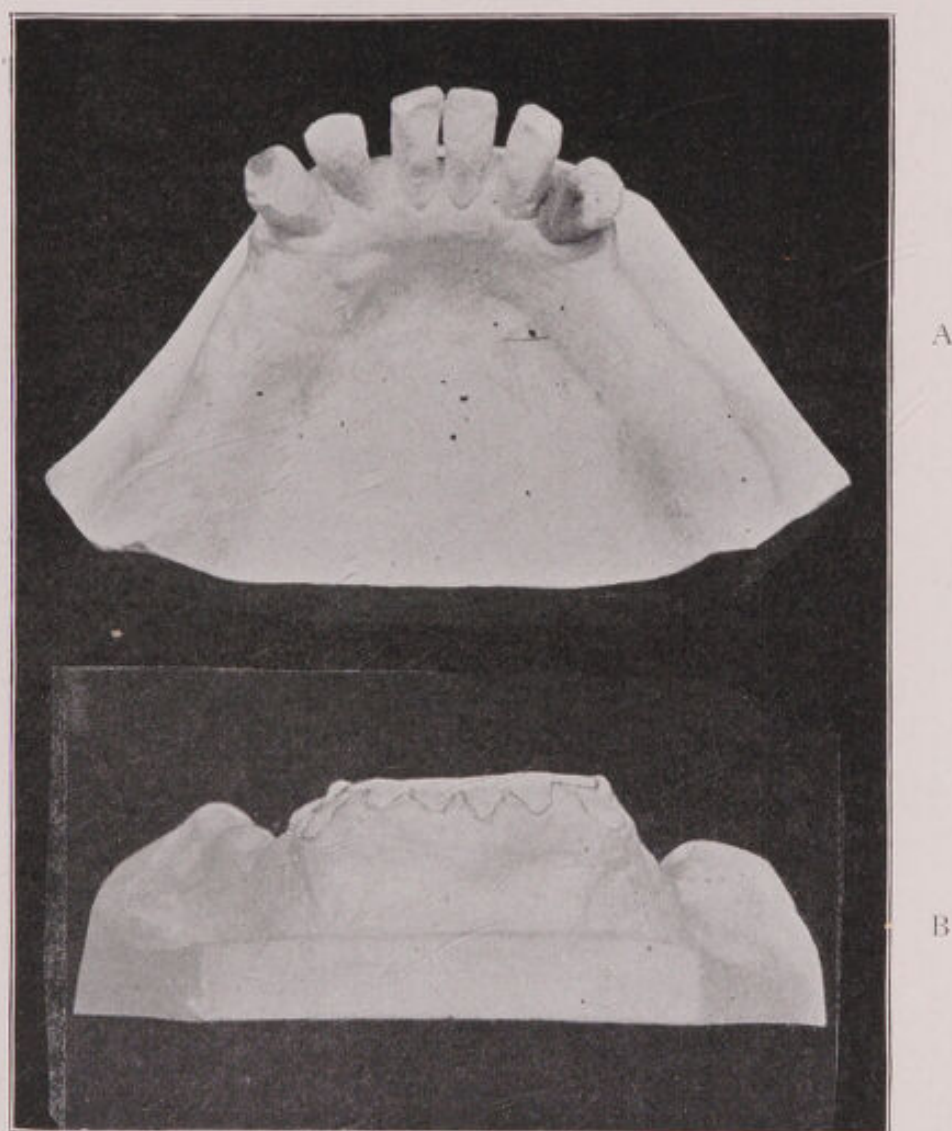


FIG. 33. Mal-occlusion, wandering teeth. A shows case before treatment; the teeth have the tendency to move and are extending in all directions. B shows teeth cut off at the gingival margin, and connected with a wire, which holds them together, and also serves as abutment for a removable bridge. (See construction Fig. 219-221.)

Often it occurs that the maxilla seems to separate, producing a space between the central incisors, especially if we have bridges on either side involving the centrals on each side. Cases of that sort can be drawn together and fixed with a staple, or a vault bar to the bridge. If spreading is prognosed, in mouths with otherwise normal conditions, this can be corrected by inserting a staple. (Figure 34.)

(h) Irregularly arranged teeth. Regulating irregularities for sake of appearance is a task the bridge specialist is often

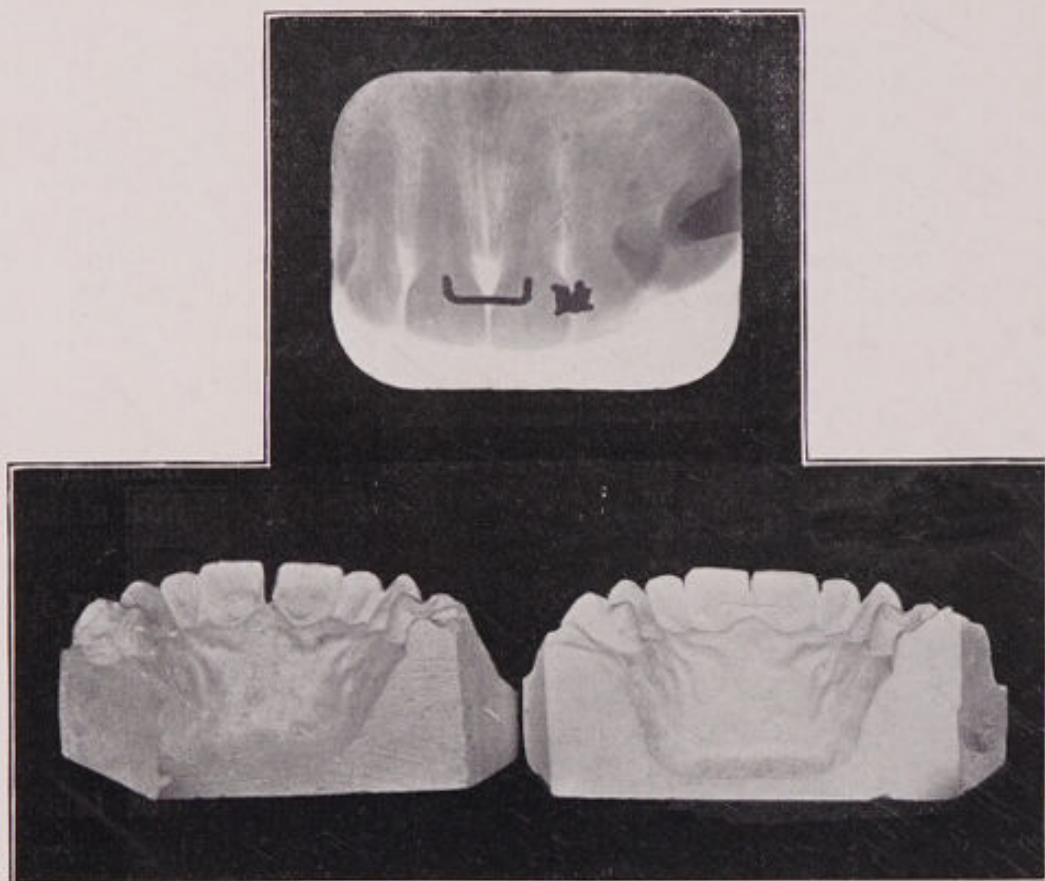


FIG. 34. Mal-occlusion. Spreading of the two central incisors. Case treated fifteen years ago. Radiograph showing condition today with perfectly normal pulps. The holes for the platinum staple wire were drilled between the enamel wall and pulp chamber.

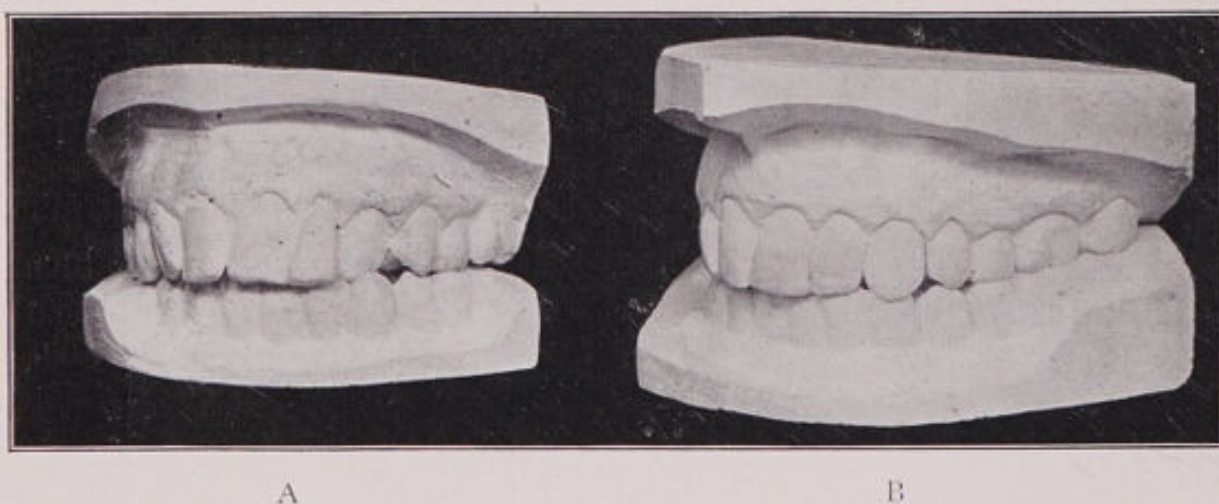


FIG. 35. Mal-occlusion. A shows the position of the upper lateral, and cuspid. The lateral protrudes, the cuspid occludes lingually, and is twisted. B shows two Davis crowns in good occlusion, which have been attached to the roots.

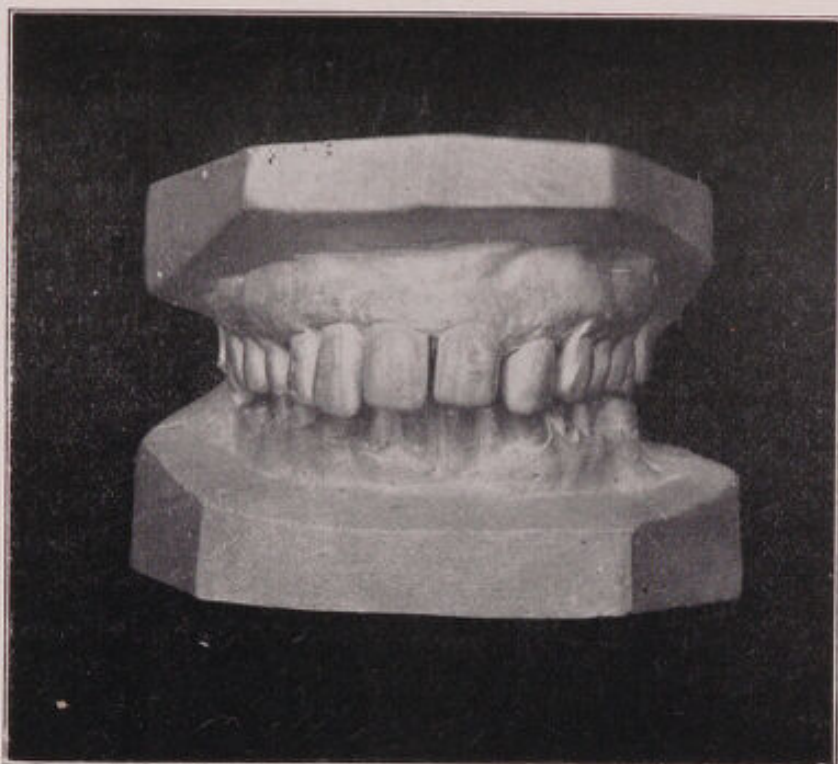
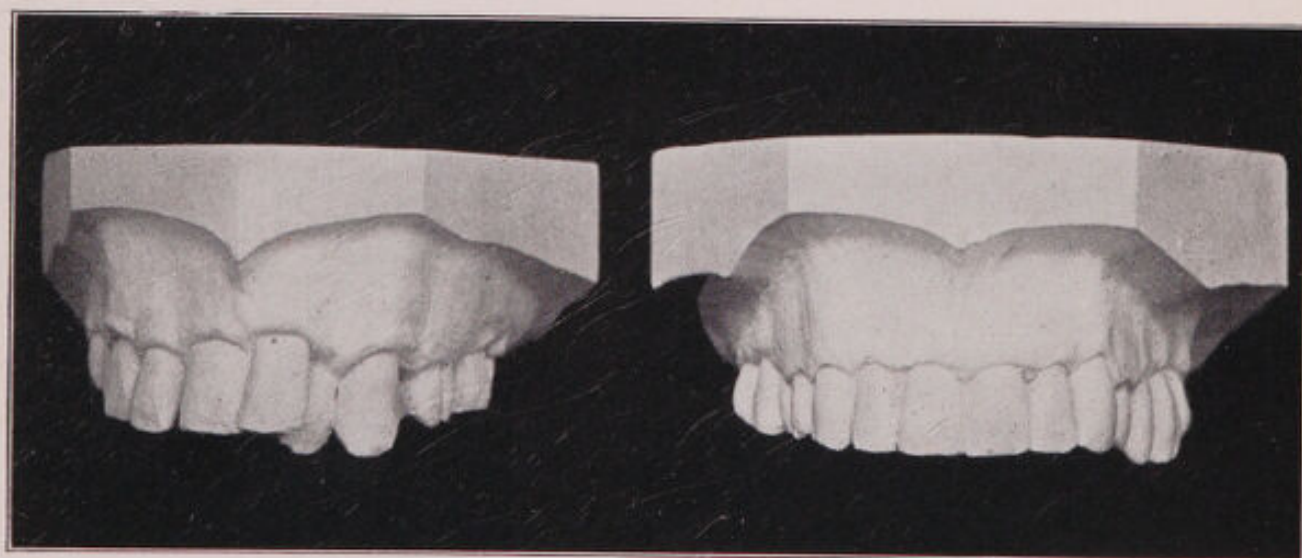


FIG. 36. Mal-occlusion. The one lateral incisor is absent, the front teeth are of irregular length, and have the tendency to move upward, on account of pyorrhoeatic condition. Fig. 9A shows four teeth which would fill the space for this case, which occurred after the absorption of the process. Fig. 9B is a gum block carved for this case. Fig. 8B shows the finished bridge with half-crowns and posts for abutments.



A

B

FIG. 37. Mal-occlusion. The case with very irregular teeth as shown in A, replaced by a bridge. In Figure B the same result might have been obtained with porcelain crowns, but the case was a pyorrhoeatic one, and two teeth had to be extracted, and the further moving of the teeth prevented by a bridge.

confronted with. As a rule the teeth in question are the incisors and cuspids. The crowns of twisted, protruding or retruding teeth can be replaced by porcelain crowns with normal and artistic appearance. (Figure 35). If the whole set of incisors has to be changed, we have a more difficult problem. As a rule there is lack of space for four incisors lined up in normal position, and it is hard to decide whether three incisors give a more artistic appearance than four very narrow ones. Each case is a study in itself and must be left to the good judgment of the operator. (See practical cases Figures 36 and 37.)

IV. PRELIMINARY TREATMENT OF THE MOUTH AND TEETH

Before starting with bridgework the mouth should be put in general good condition. Sources of infection should be eliminated.

1. Prophylactic Treatment First of all the teeth should be scaled and cleaned and polished, which also gives us an opportunity to select the right shade of the teeth.

2. Exodontia The next thing is to extract all roots and teeth which have been decided upon as worthless.

3. Pyorrhoea Treatment If there are pyorrhoeatic teeth, these should be treated; scaling and in some cases devitalizing is indicated. If they are to serve as abutments, they should be cut down at once to receive surgical rest. If all or most of the teeth are affected, a temporary splint might be applied until the treatment has sufficiently progressed. In some cases temporary plates are advisable to relieve the strain from the affected teeth.

4. Devitalization of Healthy Teeth It is a much discussed question among crown and bridge workers, whether a tooth should be devitalized previous to crowning in all cases. There are well-known writers who advocate devitalization in every case for various reasons. And there are also a great many other practitioners who can prove that pulps do live under crowns (see Figure 38), and think that it is not justifiable to remove a healthy pulp and take the chance of not even being able to thoroughly fill the root canals. Therefore the author

leaves it to the operator to choose the wisest course and be governed by the condition he is working under, and not by any law of one method only.

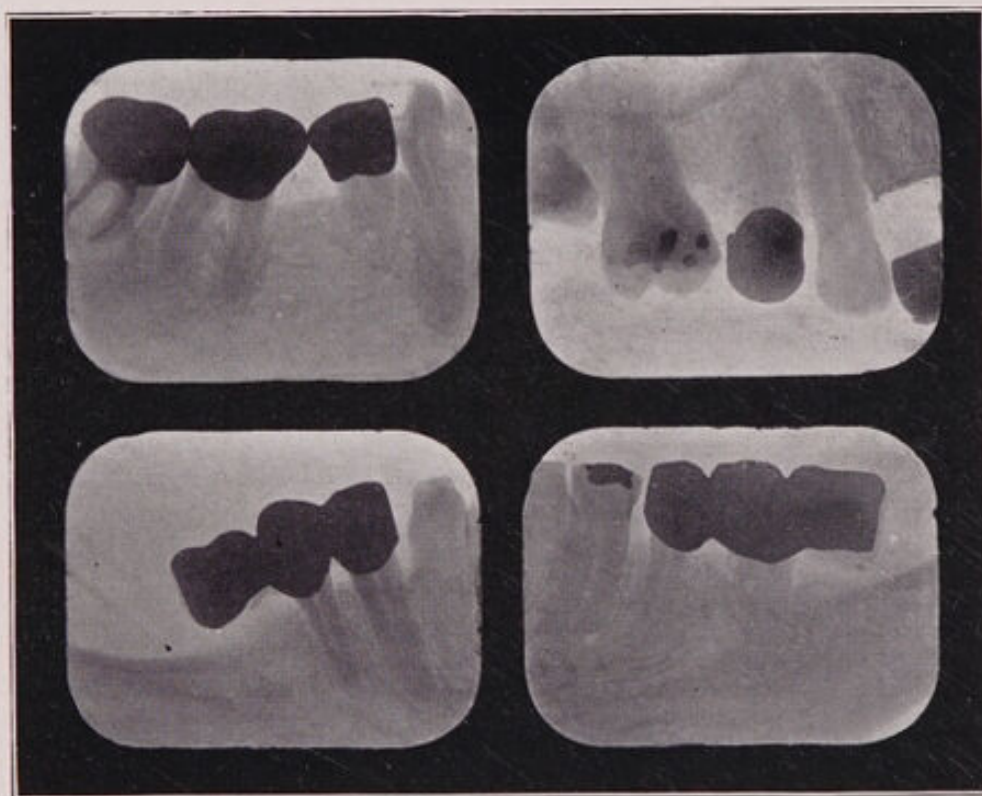


FIG. 38. Radiographs showing cases where teeth have been crowned without devitalizing the pulps. The lower radiograph shows a right and left lower, one tooth extension bridge, both bridges in same mouth. The upper are bridges with live pulps in healthy condition, after fifteen years. Left lower radiograph shows a gold crown over tooth with live pulp, after twelve years. Right lower, gold crowns of teeth with live pulps after twenty-three years.

5. Treatment of Teeth with Pathological Pulp

The pulps of all the teeth involved in crown and bridge work should be examined as to their vitality. All the teeth with pathological pulps as well as devitalized teeth should be examined with the aid of radiographs.

These should be carefully studied, and usually we can determine whether the tooth can be treated from the root canals, or whether surgical treatment is indicated.

(a) Treatment from root canals. Cases of pulpitis, acute alveolar abscesses, and sometimes chronic abscesses can be treated from the pulp chamber. The complete opening of the root canals is the most difficult part of this operation, and

failures in this, as well as in the proper filling of the canals, give rise to the most condemnable conditions. There is much more trouble coming from insufficient root treatment than from the percentage of normal pulps dying under crowns. Chronic alveolar abscesses derived from improperly treated roots are today the commonest source of most serious trouble. (Figures 39 and 40.)

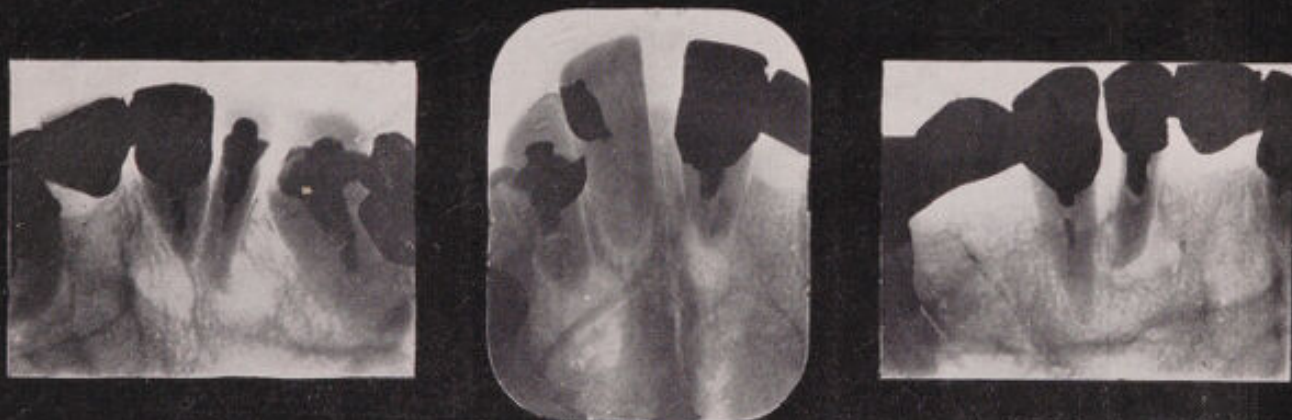

FIG. 39. Radiographs showing chronic abscesses on the roots of upper teeth, which have been used as abutments, the root canals not having been properly filled.

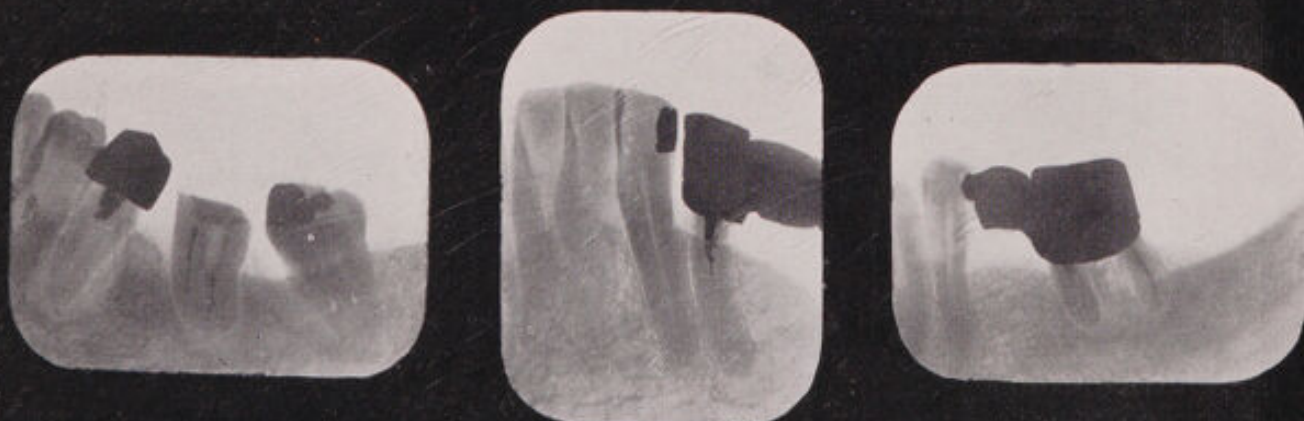

FIG. 40. Radiographs showing chronic abscesses on the roots of lower teeth, which have been used as abutments for bridgework, and the root canals of which have not been properly treated and filled.

It is of the greatest importance that teeth used for bridge abutments should be treated with the utmost care, and it is next to malpractice to neglect intentionally the application of any means which modern science makes available to reach the very best results. Large numbers of radiographs are sometimes necessary to open root canals, a process which requires patience and time more than anything else. (Figure 41.) After sterilizing the inside of the tooth with one of the well-known methods, we come to the filling, and the careful filling

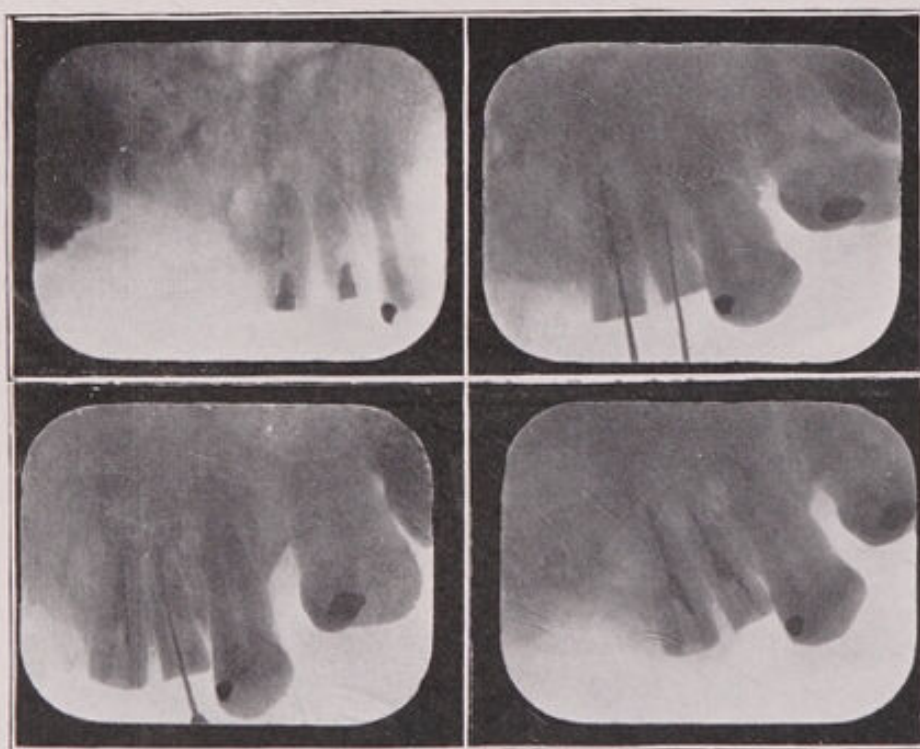


FIG. 41. Series of radiographs showing treatment and filling of root canals of teeth to be used as bridge abutments.

of root canals, is of equal importance as the opening up. It is evident that the better a canal is opened the easier it is to fill it. A proper root filling should extend through the apical foramen, and should be so condensed that it fits its outline closely. This also should be ascertained with the radiograph. The pain caused when the root canal cone is pushed through the foramen is not a safe guide for root canal fillings. If a canal is not properly cleaned, there is sometimes similar sensation produced, when the point passes in the apical part of the root. Figure 42 shows such a case. The operator in this

case was very careful, and intended to do his very best to fill the canal properly. The patient felt the root canal filling penetrating through the apex, and saw the results in the radiograph taken five years later.

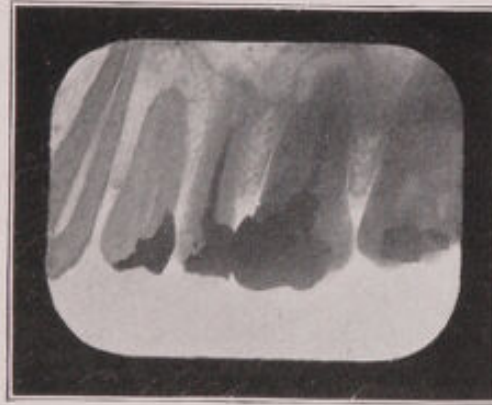

FIG. 42. Radiograph of second bicuspid and first molar with chronic abscesses, cyst in the latter. When the root canal of the second bicuspid was filled, the patient felt the gutta-percha point penetrate through the apex. See the result to show that the sense of pain, produced by the gutta-percha point, is not a sure guide.

Chronic alveolar abscesses are not so easily treated. Exostosis, granulum, or cyst frequently complicate cases of long standing. Medical treatments from the root canal do not always give satisfactory results on account of bent roots, calcified canals, open foramina in young teeth, and branching root

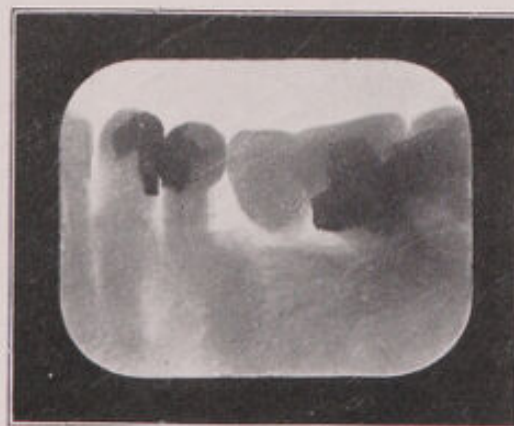


FIG. 43. Showing bent root of a lower second bicuspid.

canals. Figure 43 shows a radiograph of a badly bent root, which could not be properly filled. Figure 45 and Figure 46 show radiographs of teeth with calcified pulps, normal pulps,

open apices, and abnormal branching of the root canal. Zinc electrolysis is the best treatment for alveolar abscesses known at the present date, and should be the routine treatment of all these cases. If there are complications there is usually, however, only surgical treatment left to be resorted to.

(b) Treatment from alveolar side surgically. In cases where chronic abscesses do not yield to treatment, in cases of

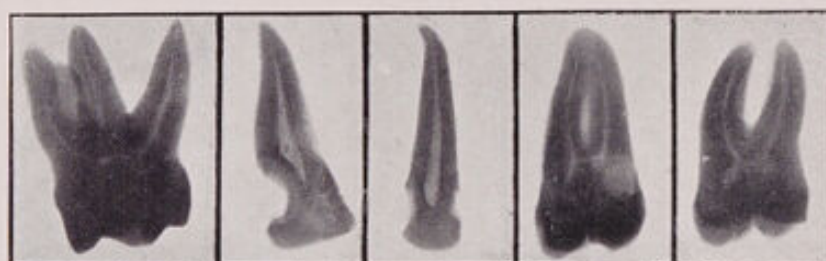


FIG. 44. Radiographs of receded pulps, and constricted chambers, as found in advanced age.

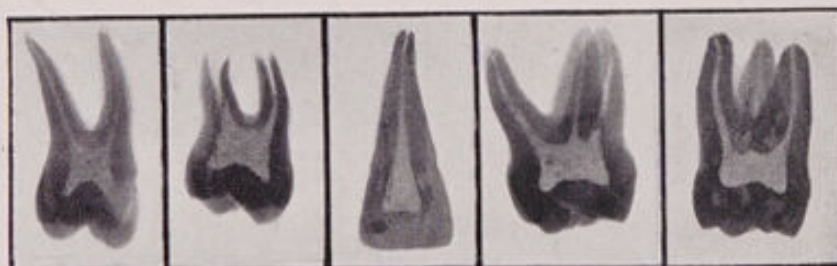


FIG. 45. Radiographs showing large pulp chambers, such as found in young teeth.

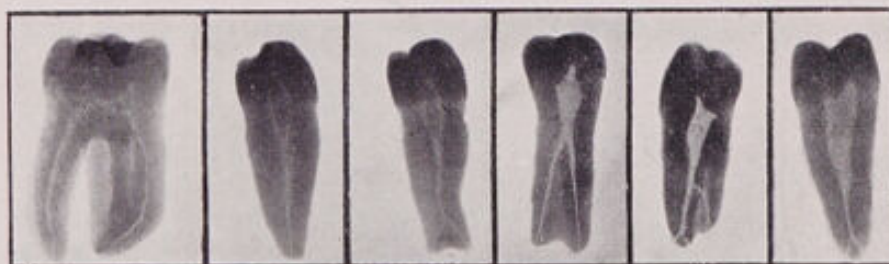

FIG. 46. Radiographs showing abnormal branching of root canals.

complications on the outside of the root, a radical operation is necessary. Either the tooth has to be extracted and the socket curetted, or if practical, the apex of the root which, in such cases is always gangrenous, should be amputated. This can be performed on almost all teeth; the single-rooted ones, how-

ever, are the easier. In amputating the buccal root of the upper bicuspid, we must take care not to injure the antrum, and in the lower bicuspid, the mental nerve. The two last mandibular molars are the hardest ones on account of their position.

6. BUILDING UP OF DECAYED AND BROKEN-DOWN TEETH

If the teeth which serve as abutments are decayed, this decay should be carefully removed, and the cavity filled with suitable material, as cement and amalgam. Should the decay, however, have progressed to such an extent as to render the tooth frail, or should the crown be broken down entirely, it can be built up in the following manner:

1. After removing all decay and treating and filling the root canals, fit post of sufficient length into same. The best posts are those with a thread, they hold better in the canals, and give better attachment to the amalgam.

2. Cement the posts into the canals.

3. Select a seamless band of copper, or other suitable metal, and fit it over the root and trim to allow closing of the teeth and sufficient space for the top of the crown.

4. Sterilize and dry the tooth, and fill the band with amalgam. The patient is discharged, and the band removed at a later sitting. This gives a good abutment for an all-metal crown.

V. ORAL ANAESTHESIA

In crown and bridge work we perform the most radical dental operations, operations which under certain conditions would be almost impossible to perform without an anaesthetic. To devitalize a tooth without cavity or to prepare a tooth for a crown, in a frightened patient, with very sensitive teeth, is sometimes, to say the least, a very tedious task. The grinding is frequently, on account of the patient's attitude, not performed completely, resulting in an ill-fitting crown. There are more failures in bridge work, resulting from not being radical enough than from any other cause; and the reason why the work is done in too conservative a manner is in most cases due to pain, on account of the unwillingness of the patient to permit these most necessary operations.

The importance to relieve pain then is two-fold: it decreases the strain on the patient and it gives the dentist a chance to perform his work more thoroughly.

There is no doubt that local anaesthesia has proved its superiority over general anaesthesia for our work. Local anaesthesia gives us plenty of time; there is nothing to abstract our attention, we have the coöperation of the patient, and can therefore concentrate our mind on one thing: perfect work.

Local anaesthesia is based upon thorough knowledge of the oral anatomy, exact technique, and scrupulous asepsis. Referring for detail information to Thoma's book on "Oral Anaesthesia," this chapter will describe only the instrumentarium, drugs and technique, as specially applied to crown and bridge work.

A. INSTRUMENTARIUM

1. Use two Fischer syringes, one mounted in a short hub with a 26 mm., the other in a long hub with a 45 mm., iridio-platinum needle. I prefer iridio-platinum needles because they simplify matters, in that they do not need to be boiled before



Fig. 47. Bottle for Ringer solution. Jar with tight-fitting cover filled with absolute alcohol. Syringes and dissolving cups are placed on a nickel-plated stand and kept in the jar. Glass tray with cover to keep drugs and reserve needles.

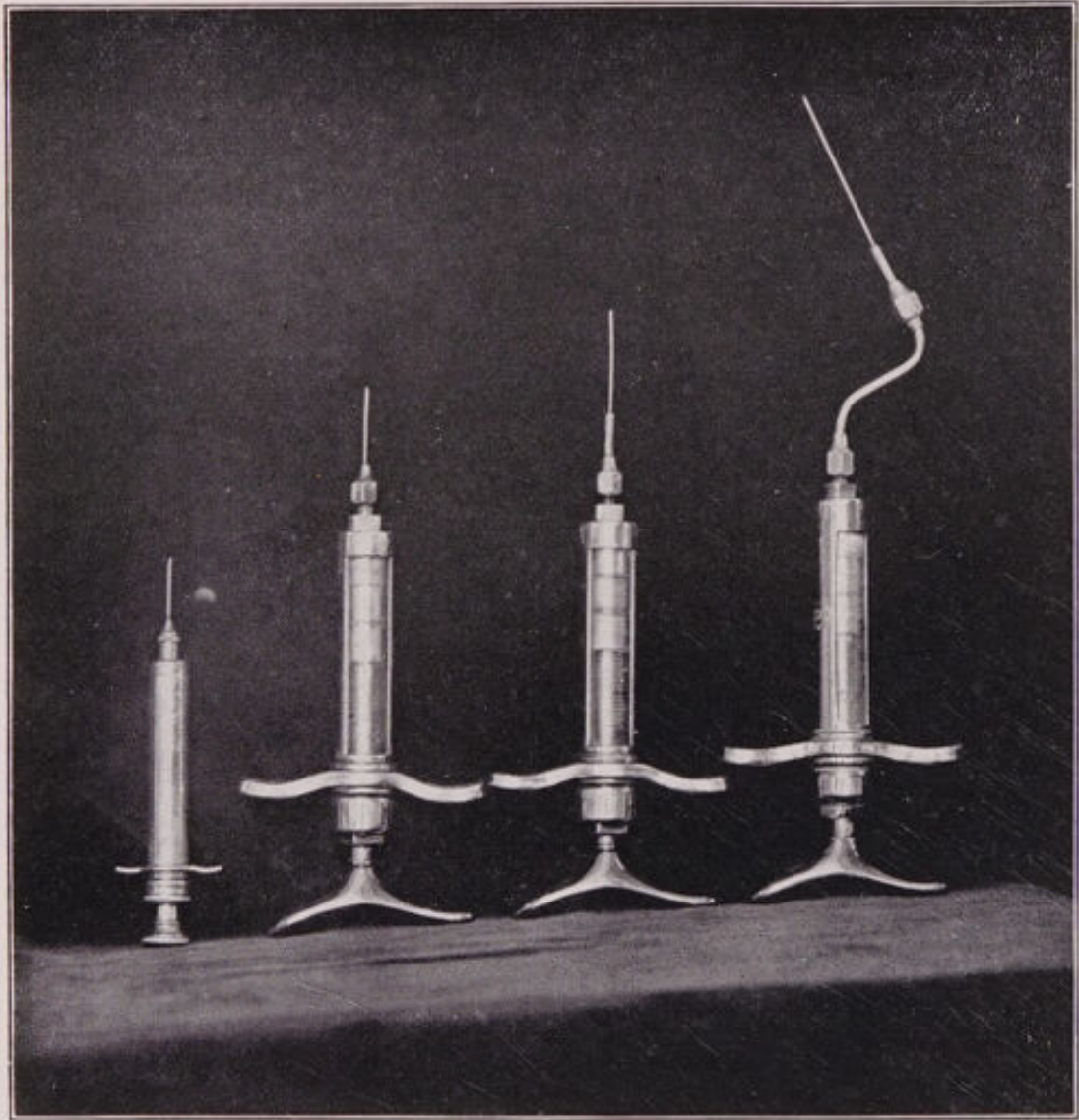


FIG. 48. Syringes. The small syringes with 27-gauge platinum needle for mucous anaesthesia, previous to injecting with the large syringe. The next syringe is Fischer's syringe mounted with the short needle. The third is mounted with the 45 mm. long needle, and the last one is mounted with the bayonet piece and a 60 mm. long needle.




FIG. 49. Large and small dissolving cups.

use, can be used again, and therefore can always be mounted on the syringe ready for use. They do not break. If steel needles, which often show specks of rust and oxide, are used, one has to boil them and should only use them once.

2. One glass jar, filled with absolute alcohol, containing nickel-plated stand for syringes and porcelain cups.

3. One bottle, double corked, for physiological salt solution.

4. One small porcelain dissolving cup, graduated from 1 to 3 cc., and,

5. One large cup graduated up to 10 cc. These are used to measure and cook the solutions, to dissolve the tablets and fill the syringe.

6. One glass tray, with cover, to keep tablets and reserve needles.

7. Alcohol lamp.

B. DRUGS

Physiological salt solution. Instead of using normal salt solution to dissolve the Novocain tablets, I use and recommend a solution containing also calcium chloride and potassium chloride. This is called Ringer solution, made from Ringer tablets.* They contain:

Sodium chloride	0.050	gram
Calcium chloride	0.004	"
Potassium chloride	0.002	"

Dissolve 10 tablets in 100 c.c. of pure distilled water, and sterilize.

NOVOCAIN L = SUPRARENIN SYNTHETIC

E Tablets* containing Novocain	0.02	gram.
L-suprarenin synthetic	0.000,05	"
F Tablets* containing Novocain	0.05	"

C. PREPARING OF THE SOLUTION

Remove the stand from the jar, and wash the cup and syringe in distilled water, to remove all traces of alcohol. Then fill the cup with Ringer solution to the mark and boil

* Farbwerke Hoechst Co., 111 Hudson St., New York.

this solution over the flame for a few seconds. Add the tablets, as required, and draw it through the flame till they are dissolved. The syringe then is filled from the cup and the needle sterilized in the flame. Use the following solution:

In normal cases of extirpating pulps, preparing teeth to receive crowns or for extraction the bleeding should be only little decreased. It is therefore important to use but a small amount of suprarenin. This does not shorten the time of anaesthesia, as experience has proven. Use:

1 E tablet }
 plus } to 3.5 c.c. of Ringer solution. This gives
 1 F tablet }

Novocain	2%
Suprarenin	0.000,015 gram to 1 c.c.

For deep anaemia as required in cases of different extraction, or amputation of the apex of a root, use: 1 E tablet to each 1 c.c. of Ringer solution. This gives:

Novocain	2%
Suprarenin	0.000,05 gram to 1 c.c.

For abnormal cases, arteriosclerosis, cardiac disorders, hysteria, it is advisable to decrease the amount of suprarenin used:

1 E tablet }
 2 F tablets } to 5 c.c. Ringer solution.
 gives

Novocain	2%
Suprarenin	0.000,009 to 1 c.c.

However, I want to call attention to the fact that the second and third solutions are very seldom used, and that therefore the preparation of the solution is much simpler than it appears.

The tablets are sterile, in tubes of twenty. Always replace the rubber stopper at once, otherwise the drugs will be deteriorated from the influence of air, light and moisture.

REQUIREMENTS OF A SOLUTION PREPARED FROM TABLETS

1. It should be immediately used after it has been prepared.

2. The solution should not come in contact with anything, except the porcelain cup and the syringe.

It should not be left longer than absolutely necessary in the dissolving cup nor in the syringe. The solution is very sensitive, being affected and chemically changed by air, heat, light, and especially alkalies.

3. The tablets should not be touched with hands nor instruments and the tube should be closed immediately after use, with the rubber stopper. The tablets are chemically changed by air, light and especially moisture.

4. The tablets should be white; sometimes the uppermost one discolours from chemical changes caused by improper handling of the tube.

5. The solution gained from the tablets should be clear as water.

If it shows any light pink color, it should be discarded.

D. PREPARING OF PLACE FOR INSERTION OF THE NEEDLE

An unclean mouth should first be sprayed out with an antiseptic solution, then hold the lip away from the gum, and with a short roll wipe all the mucus from the field of operation. Then with a little bit of cotton dipped in campho-phenique, or tincture of iodine, equal parts, sterilize and anaesthetize the part where the needle is to be inserted. In very sensitive patients I use a small hypodermic syringe, with a very fine and sharp platinum needle and inject a few drops of novocain solution previous to the injection.

E. INFILTRATION METHOD

This method depends upon diffusion of the solution through the pores of the bone, thus reaching the dental nerve before it enters the tooth. The number of pores is different over different teeth, and in the upper jaw different from the lower. (Figure 50.) Moreover, the density of the bone varies greatly

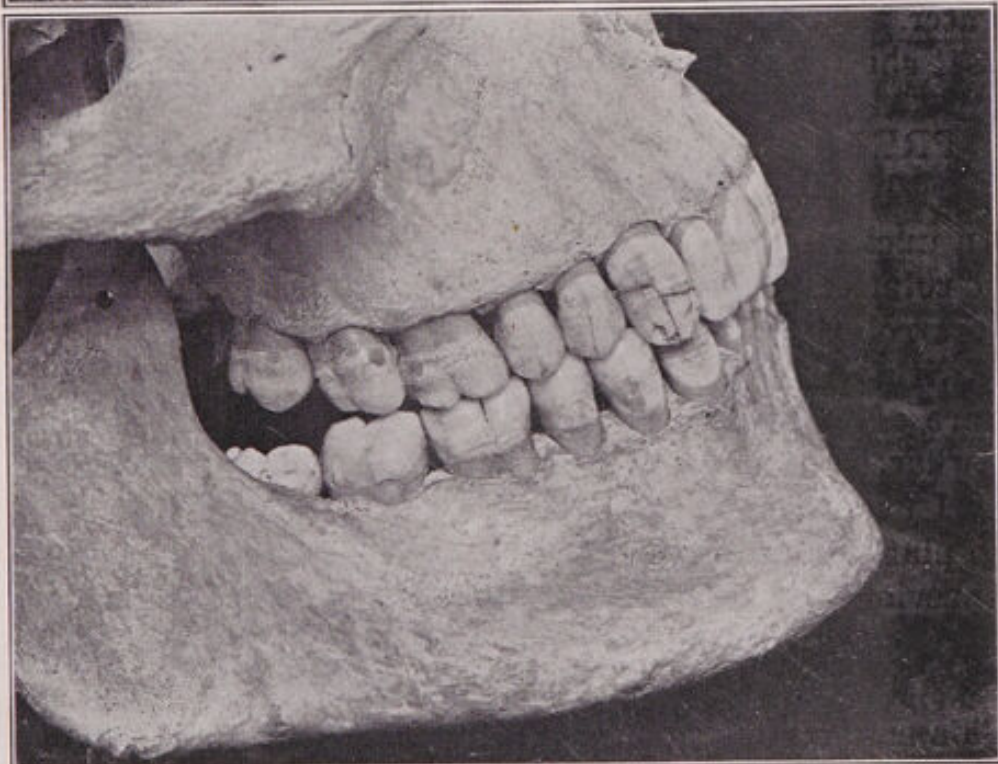
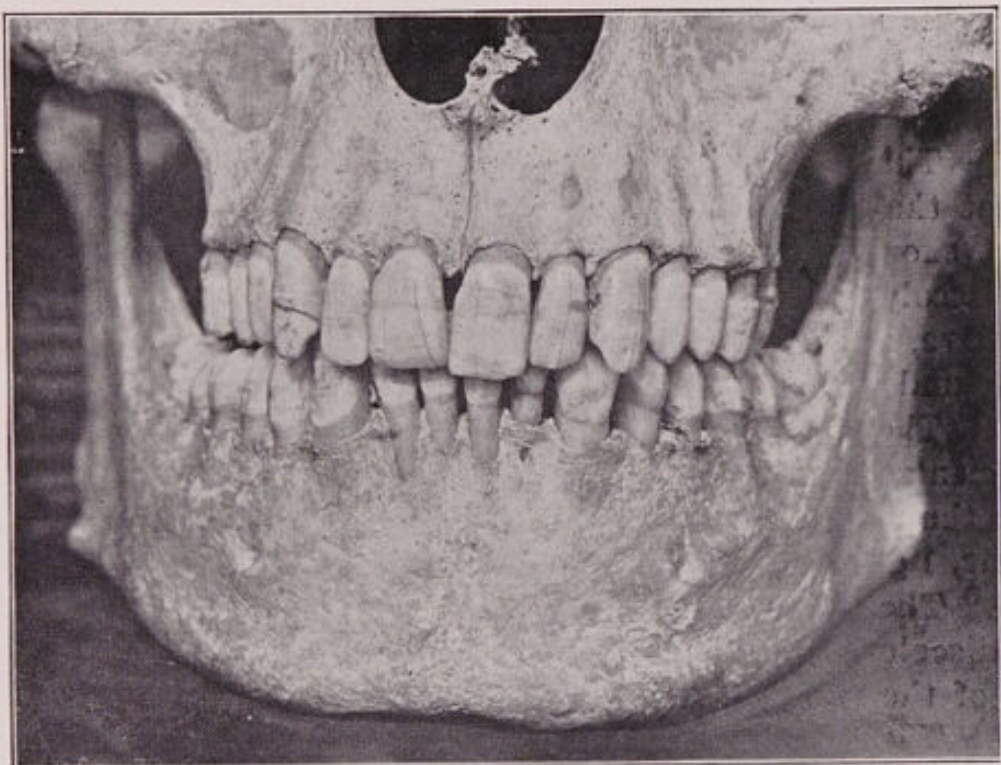


FIG. 50. Skulls showing the small foramina in the alveolar process of the maxilla, and in the incisor region of the mandible.

in different individuals. Without exception this method can be used for any teeth in the upper jaw. The lower jaw is porous only in the mental fossa, while in the region of the back teeth the bone is very dense. The infiltration method, therefore, is not advisable for the lower jaw, except for the four incisors.

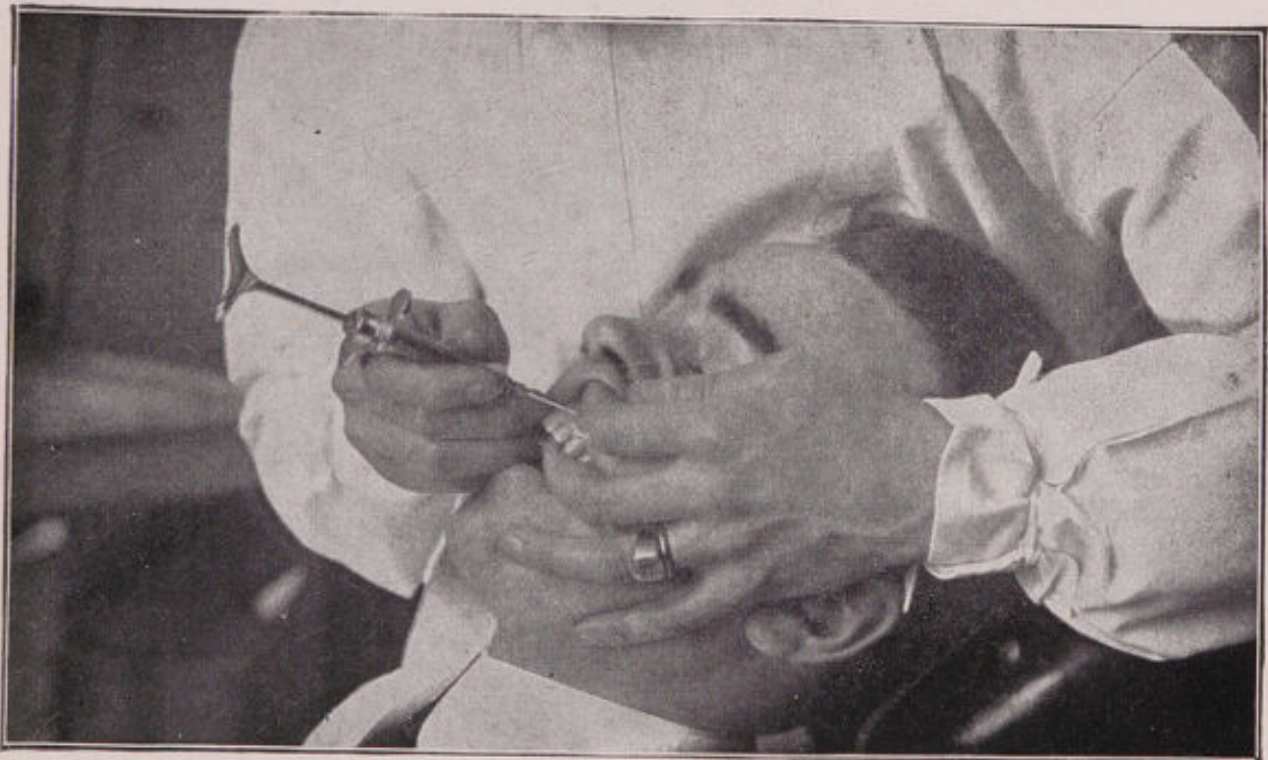

FIG. 51. Position of the operator when injecting for an upper tooth, by the infiltration method.

1. Injection in Buccal and Labial Side of Maxillary Teeth

The point of insertion on the labial and buccal side, is halfway between the gum margin and apex of the root. The needle is pushed, opening directed toward the bone, down to the periosteum. Where a drop or two is injected, and after this has taken effect, push the needle slowly and carefully upwards, if necessary, injecting as you go along, till you are opposite the apex of the root. Here I inject slowly and evenly, moving the syringe slightly back and forth, to avoid injecting into a small vein. In this manner a depot of 1 to 1.5 c.c. is deposited in the submucous tissue between mucous membrane and

bone. Little force is needed to inject. After five to eight minutes, anaesthesia occurs in the tooth injected for, sufficient to extirpate the pulp without pain.

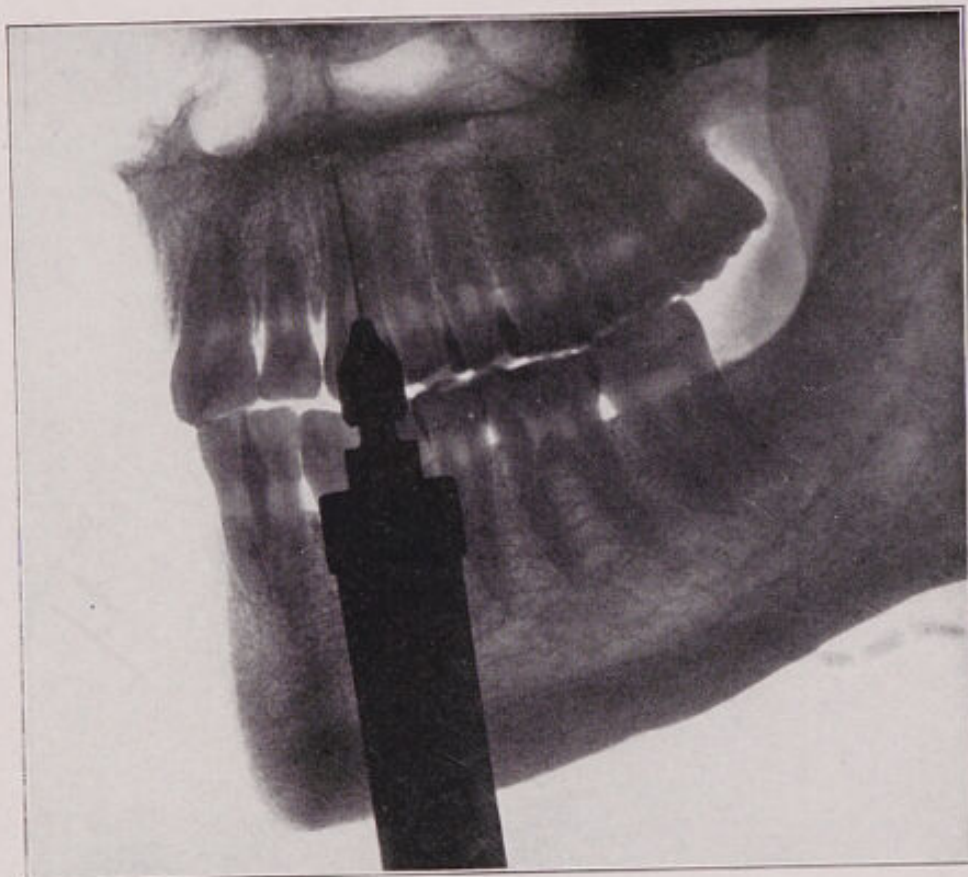


FIG. 52. Radiograph showing the infiltration method for an upper cuspid.

Here the procedure is very much like in the maxilla, often, however, it is easier to insert the needle over the tooth next to the one we wish to anaesthetize, pushing it obliquely toward the apex of the tooth in question.

2. Injection on Labial Side of Lower Incisors

3. Injection on Palatal and Lingual Sides

The palatal gum of the maxilla is supplied by the anterior naso-palatine nerves, therefore for surgical operation, an additional injection to produce anaesthesia of the soft parts is required. The same is true for the lingual gum, in the mandible, which is supplied by the lingual nerve. For these injections we start at the gingival margin, push the needle down parallel with the process, and inject

0.25 c.c. again into the part which takes up the solution the easiest: the submucous tissue.

The anaesthesia lasts more than one hour, and the injection can be repeated, if necessary. Massage of the injected area quickens the result.

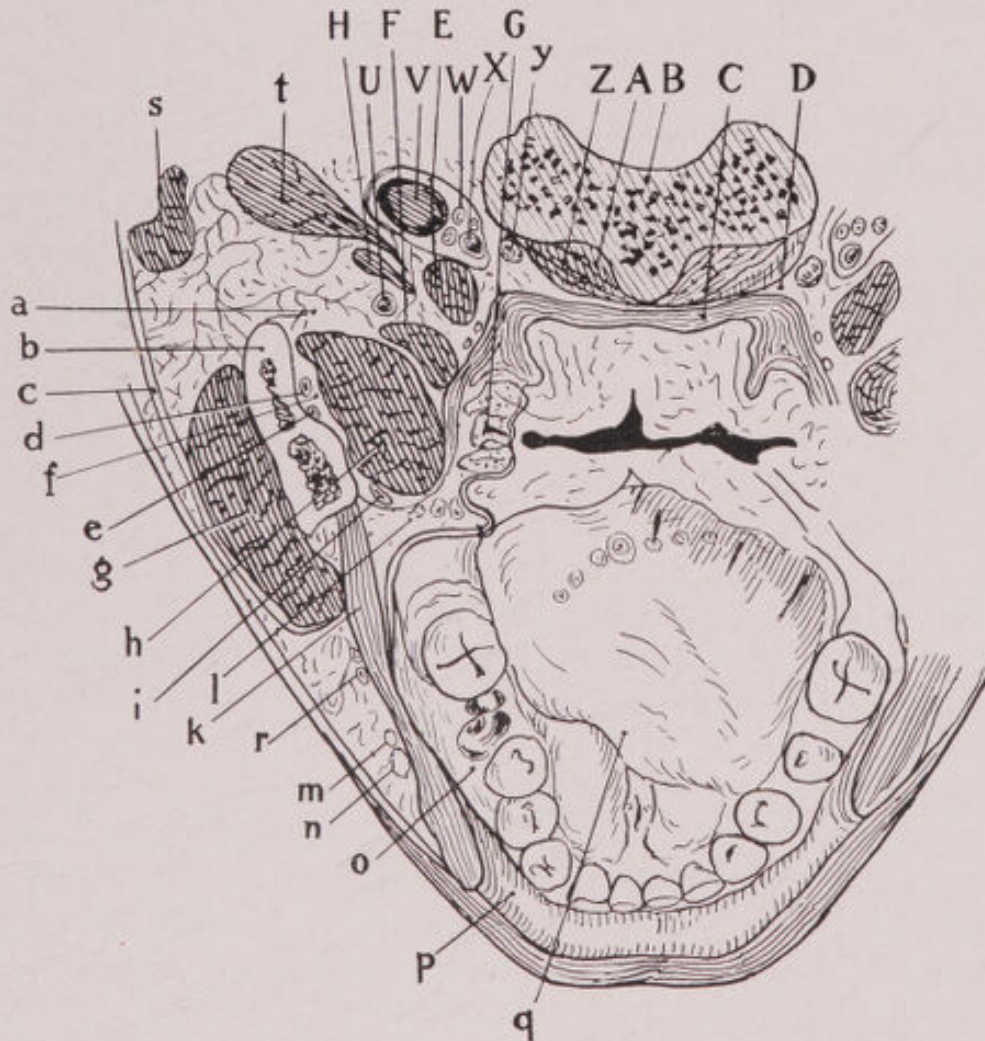


FIG. 53. Horizontal section through human head in the plane in which mandibular conductive anaesthesia is best accomplished. a. Glandula parotis; b. Ramus mandibulae; c. Fascia parotideomasseterica; d. Nervus alveolaris inf.; e. A. and V. alveolaris inf.; f. Spatium pterygomandibulare; g. M. masseter; h. M. pterygoid int.; i. Nervus lingualis; k. M. buccinator; l. Glandulae palatinae; m. Art. maxillaris externa; n. Glandulae buccalis; o. Gingiva; p. Labium inferius; q. Lingua; r. Glandulae buccalis; s. M. masseter; t. M. Diagastricus; u. Art. carotis externa; v. Vena jugularis interna; w. N. vagus, glossopharyngeus and hypoglossus; x. Art. carotis interna; y. Ganglion cervicale superior; z. M. longus capitis.

A. M. rectus capitis anterior; B. Epistropheus; C. M. constrictor pharyngis superior; D. Fascia praevertebralis; E. M. stylopharyngeus; F. M. styloglossus; G. Tonsilla palatina; H. M. stylohyoideus.

F. CONDUCTIVE METHOD

To anaesthetize the molars and bicuspid in the mandible, and if the infiltration method is contra-indicated, on account of septic conditions, we resort to the conductive anaesthesia. For surgical operations, we often use both combined, to get extensive anaesthesia combined with anaemia.

In this method the conductivity of the main trunk of the nerve supplying the teeth and tissues in the oral cavity is intercepted or blocked at a convenient point, while in mucous anaesthesia, the drug acts on the peripheral nerves.

1. Pterygo-Mandibular Injection

Palpate the post-molar triangle with tip of index finger on the left, with the tip of the thumb on the right side; with the other finger fixing the jaw. Prepare place of insertion as described above, place syringe (mounted with 45 mm. needle) between cuspid and first bicuspid of opposite side, and insert it in the mucous membrane 1 c.m. over the last molar, and try to feel with the needle the internal oblique line. Then slide it a little more medially, and push it forward, keeping in close contact with the ramus. This may necessitate a different direction of the syringe according to the angle of the ramus to the median line, which varies.

After the insertion of the needle inject a small quantity. Now comes the distinction in dental and surgical anaesthesia. The lingual nerve lies anterior and medially of the alveolar nerve, one third to halfway between the alveolar nerve and the mucous membrane. Therefore, by depositing one-third of the solution when the needle is one third to halfway in, we will anaesthetize the lingual nerve, the rest being deposited into the pterygo-mandibular space, through which the alveolar nerve and vessels pass, that is, when the needle is inserted to its full extent, by slow and even pressure, while moving the syringe slightly back and forth.

If you want anaesthesia of the alveolar nerve only, we do not inject until the needle is inserted to its full extent, so avoiding anaesthesia of the lingual nerve, depositing 1.5 c.c. at the alveolar nerve. This gives anaesthesia of one half of the mandible, but on account of anastomosis of the nerve from

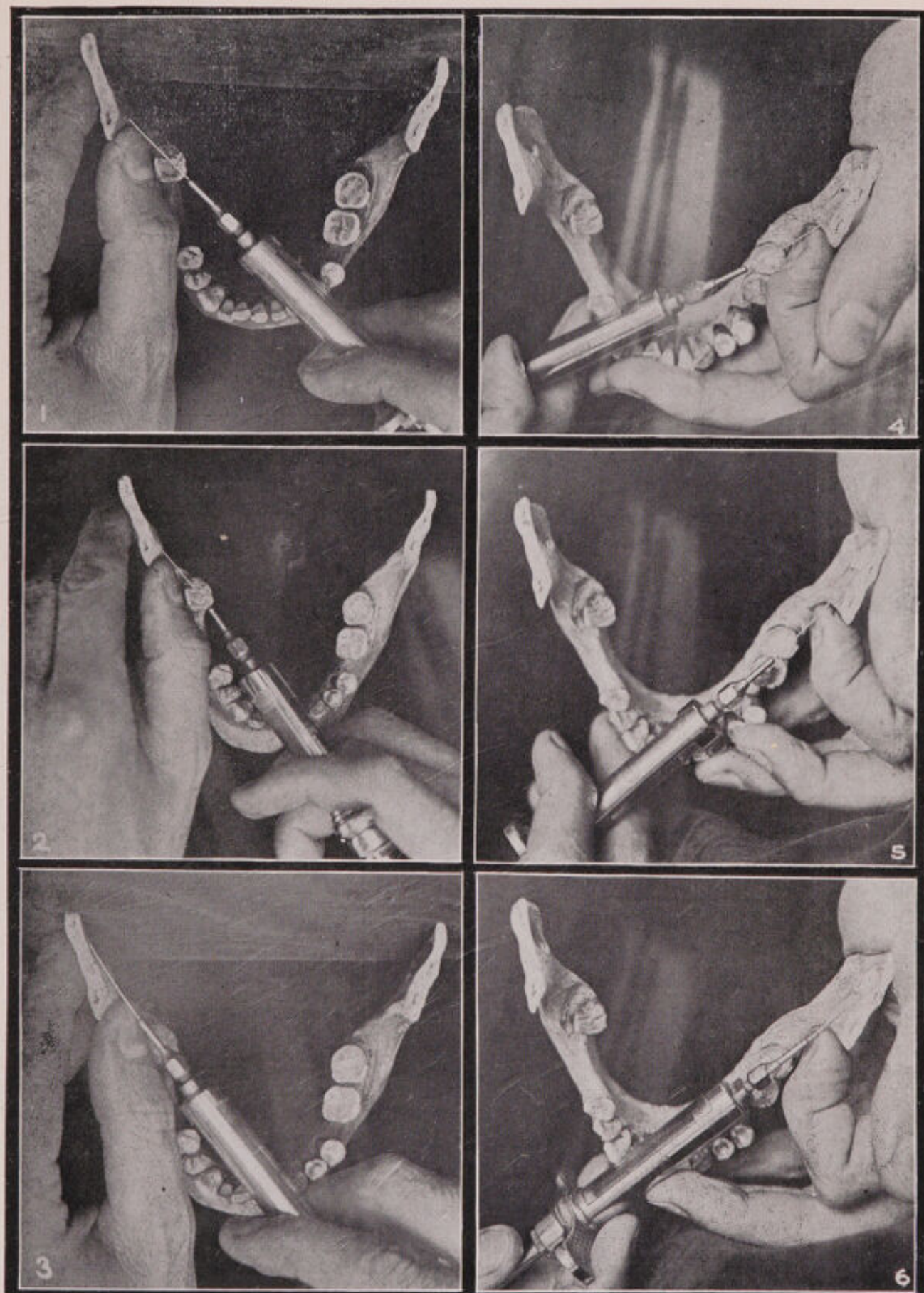


FIG. 54. Technique of inserting the needle for the pterygo-mandibular injection. 1, 2 and 3 on the right side; 4, 5 and 6 on the left side; 1 and 4, feeling of the internal oblique line; adjusting position of 2 and 5, the syringe parallel with the ramus; 3 and 6, reaching the pterygo-mandibular space.

the other side in the median line, the incisor teeth remain often slightly sensitive. Usually an exposure can be made, however, and then the nerve can be anaesthetized easily by pressure anaesthesia. To get complete anaesthesia of this part, an additional injection into the mental fossa is required.

The pterygo-mandibular injection is the least painful, and most ideal, as the injection is made at a place distant from the field of operation. The first sign of success occurs in a few

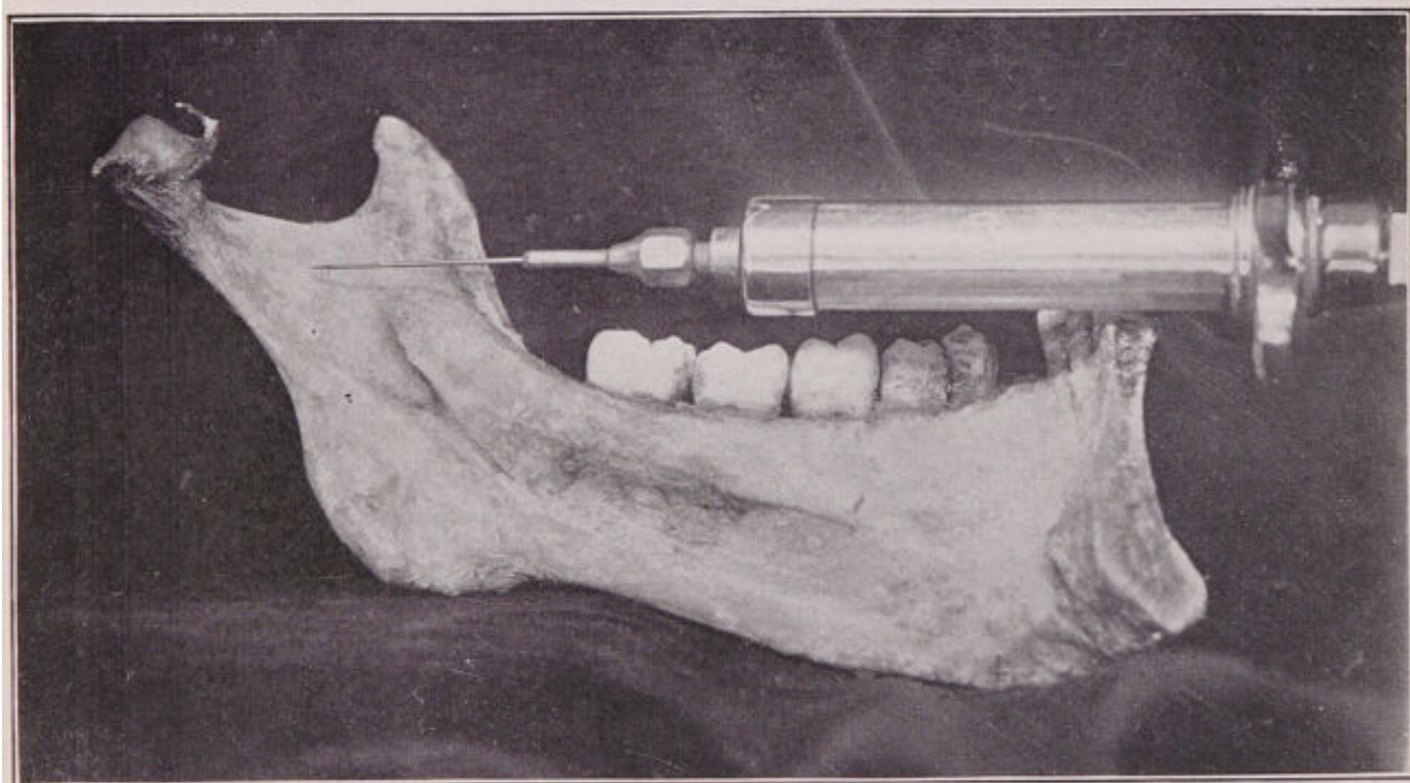


FIG. 55. Sulcus mandibularis with needle, which is inserted one centimeter over the occlusal surface.

minutes, when the patient complains of numbness of the lip, and if the lingual nerve has been anaesthetized, of the tongue.

The anaesthesia starts in the median line of the lips, and works backwards. It occurs in fifteen and twenty minutes, is the deepest between thirty and forty minutes, but lasts one hour. For longer anaesthesia inject two syringes full or 4 c.c. at once. After one hour the anaesthesia decreases gradually, and normal sensation occurs in from thirty to sixty minutes.

2. Buccinator Injection

To anaesthetize the buccal part of the gum of the first and second molar in the lower jaw, supplied by the buccinator nerve, we inject directly into the mucous membrane supplied by it.

3. Zygomatic Injection

Sometimes the maxillary first and second molar cannot be anaesthetized by the infiltration method on account of the root of the zygomatic process, thickening the bone over their roots. In these cases as well as when the teeth are in severe pathological condition, the zygomatic injection is recommended. (Figure 56.)

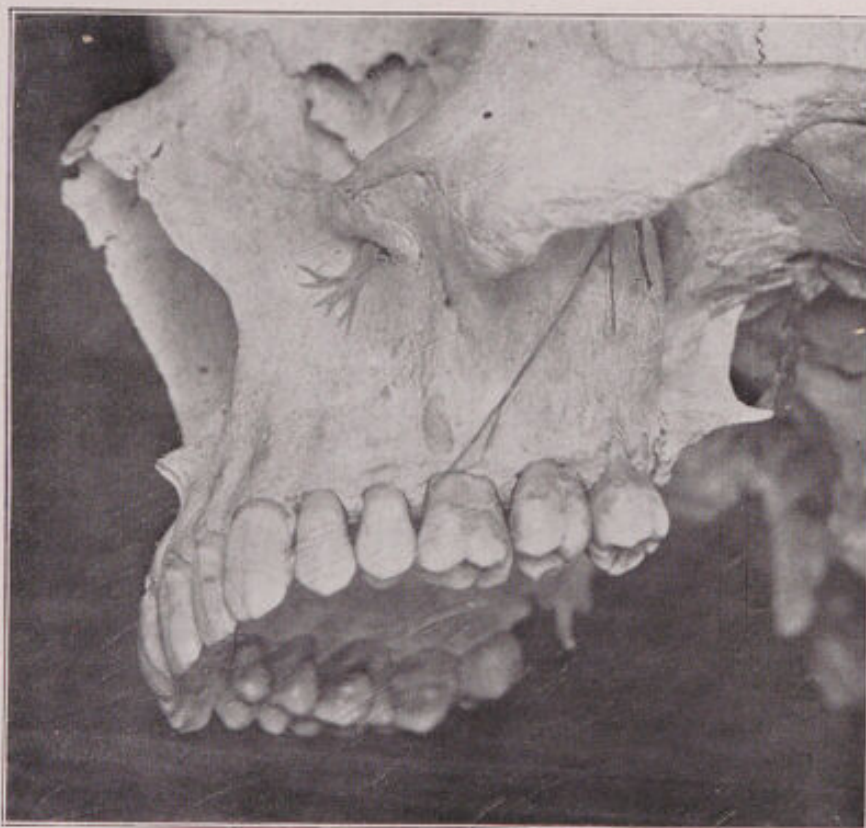

FIG. 56. Photograph showing the posterior superior alveolar branches, which enter small foramina to supply the three molar teeth. An extra branch supplies the gum.

Palpitate the zygomatic process of the maxilla, preparing the place of insertion, which is distal to the first molar as above, and sliding the long needle upward, backward, and inward, depositing the solution while injecting. In this manner the two

posterior superior alveolar nerves are crossed by the direction of the needle, which produces anaesthesia in the three molars and buccal part of the gum. Inject 2 c.c. Anaesthesia occurs in ten minutes and lasts one hour.

4. Infra-orbital Injection

This injection is only used in severe cases to avoid injecting into pus areas. Palpitate the infra-orbital foramen, and place the tip of one finger over it. With another finger retract the lip, and prepare the place for insertion of the needle. Start high in the canine fossa, between cuspid and first bicuspid, and push the needle along the bone till felt under the finger tip. While compressing the soft tissue with the finger tip, inject slowly, forcing the solution into the foramen. Use 1 c.c. Anaesthesia occurs in ten minutes in the cuspid and incisors of the respective sides.

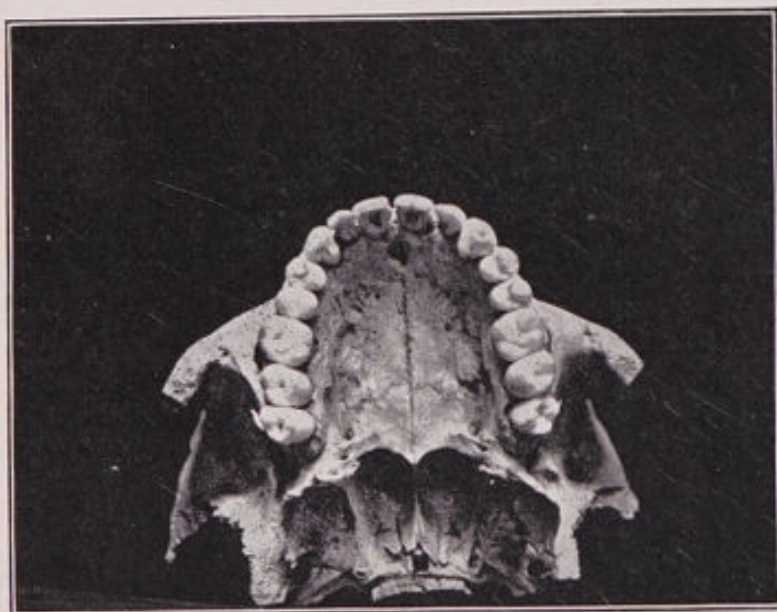


FIG. 57. Palate of an adult. Note location of incisive and palatal foramina.

5. Incisive Injection

If anaesthesia of the first part of the palate and palatal gum is desired, we insert the needle in the median line, between the two upper central incisors. Push it along the bone and you cannot fail to get into the incisive foramen. A few drops produce anaesthesia in five minutes.

6. Post Palatine Injection

To get anaesthesia of the posterior palatal part of the gum, the needle is inserted over the inferior part of the third molar (in children, over the last molar present), working slightly upward and backward. A few drops are sufficient. If more than 0.3 c.c. is injected, anaesthesia of the soft palate occurs, which is undesirable.

G. AFTER-EFFECTS

If there are after-effects, they come from unclean instruments, deteriorated drugs, false technique, injecting into pathological tissue, injecting into muscle tissue, or from too large percentage of suprarenin.

They are swelling which disappears without treatment, and pain which can come from above sources, or from injection during or after the operation. Such an injection is also invited by too great anaemia, produced by too large percentage of suprarenin. Pain is relieved by cold applications, and administering of aspirin and trigenin.

I have used local anaesthesia in children, and in adults up to eighty, in patients who collapsed from cocain, and who have been warned not to have another injection, and I have repeatedly used it on patients with severe heart and pulmonary disorders of all kinds. In these cases you can, to go entirely safe, *decrease* the amount of suprarenin. If you are perfect in the technique and eliminate any danger of infection, you have, however, little to fear of ill- or after-effects. Anyone that is beginning to use local anaesthesia, should start with a simple case, such as an upper bicuspid or incisor, and gradually, as he gets the results and confidence, take more difficult cases.

PULP REMOVAL: PRESSURE ANAESTHESIA

Apply the rubber dam and cut an opening directly over the pulp. This is not such a painful operation if one takes time and uses sharp new burs. Enter a tooth if possible where there is no decay; if entering a tooth through carious dentin it is best to remove all decay before forcing the cocain into the pulp chamber: this is to avoid infection. If possible obtain an exposure, place the cocain into the opening and moisten. With

a ball of soft vulcanite rubber force the cocain into the tooth. This should be done first with a slight pressure, which must be gradually increased to a considerable force.

Specially prepared cocain or novocain tablets are most convenient to handle.

After the pulp has been anaesthetized, open the pulp chamber or root canal entrance, remove the pulp, wash the canal with alcohol, dry and fill permanently at the same sitting.

TREATMENT FOR HYPERSENSITIVE DENTIN

We are indebted to Dr. J. P. Buckley for giving us a safe and reliable remedy for hypersensitive dentin. It consists of:

Neothessin $(\text{CH}_3)_2\text{N} (\text{C}_7\text{H}_{11}) (\text{C}_2\text{H}_5). \text{OCO} (\text{C}_6\text{H}_5), \text{HCl}$.

Trioxymethylene $(\text{CH}_2\text{O})_3$

Thymol $\text{C}_6\text{H}_3 (\text{CH}_3) (\text{OH}) (\text{C}_3\text{H}_7)$

This desensitizing paste may be used with perfect safety in *all cases* of hypersensitive dentin *where the pulp is not diseased*.

In cases where we do not want to make a Novocain injection in order to enter a sensitive tooth, the desensitizing paste will make the operation painless.

When entering a tooth through a decayed spot for the purpose of enlarging the cavity for an inlay, or to make an exposure of the pulp for the removal of same, it is not necessary to remove any of the sensitive decayed dentin in order that the desensitizing paste can do its work.

All that is necessary in order to obtain the desired result is to dry the cavity and the surrounding tooth surface, place the paste over the carious dentin and seal same with a good sticky cement. The paste should remain twenty-four to forty-eight hours. No harm will follow if the paste should remain in the tooth longer.

If the paste has been sealed hermetically the result obtained is most pleasing; it is as painless as when working on a pulpless tooth.

For very large cavity preparations, such as for inlay abutments, it may be necessary to make a second application of the paste.

VI. GENERAL TECHNICAL MANIPULATION

1. SELECTING OF SHADES

First of all the teeth should be cleansed and polished, then compare them with the shade guide. The teeth of the shade guide have to be moistened so as to get the same condition as in the mouth. It is well to have the artificial teeth rather a little darker than lighter, because darker teeth don't stand out as light ones do. The natural teeth also have the tendency to darken with age. The cuspids as a rule are darker than the rest of the teeth, especially do they show a great deal of yellow on the neck. If metal backings are used on the teeth, try the selected tooth with the backing. To make sure of the right color effect, this should be done before grinding.

2. TAKING BITE FOR CROWN AND BRIDGE CASES

When bands or abutments are in place, press a roll of soft wax against the opposite tooth or teeth.

This roll of wax must be long enough to *extend over the teeth adjoining* the crowns or the abutments for the bridge. (Figure 94.)

Have the patient bite into the soft wax, and then tell him to press the tongue against the wax. Press the wax at the same time on the buccal surface against the teeth with the finger; make sure that the patient gives the correct bite by watching the opposite side.

When cold, remove carefully.

3. TAKING OF IMPRESSION FOR CROWNS AND BRIDGE CASES

First of all make sure that the band, or the bridge abutments, are in their proper position. In removing the wax bite the abutments are sometimes pulled out of their position, and

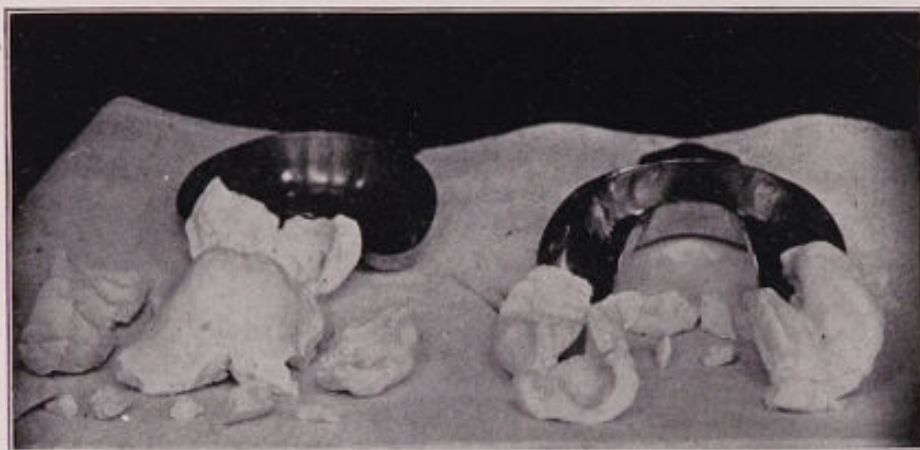


FIG. 58. Plaster impressions after washing trays and broken pieces with hot water.

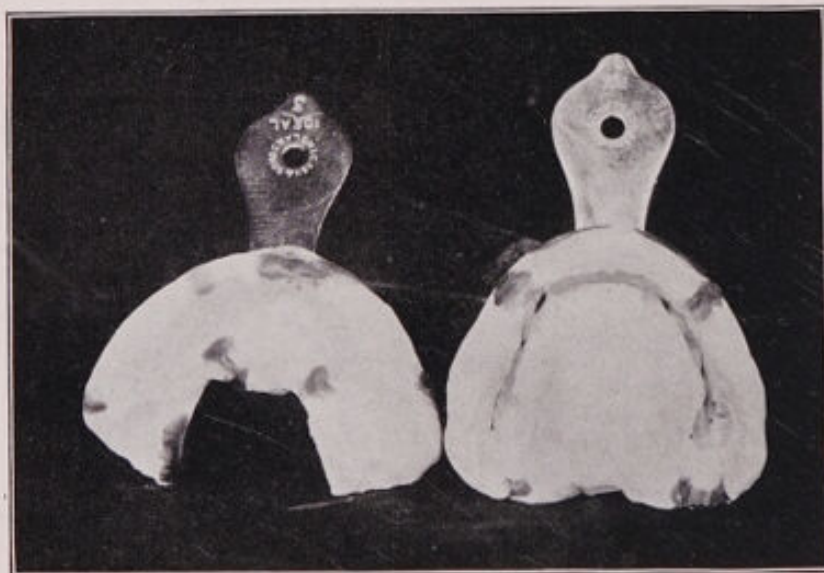


FIG. 59. Plaster impressions after pieces are put back in place, and held there with sticky wax.

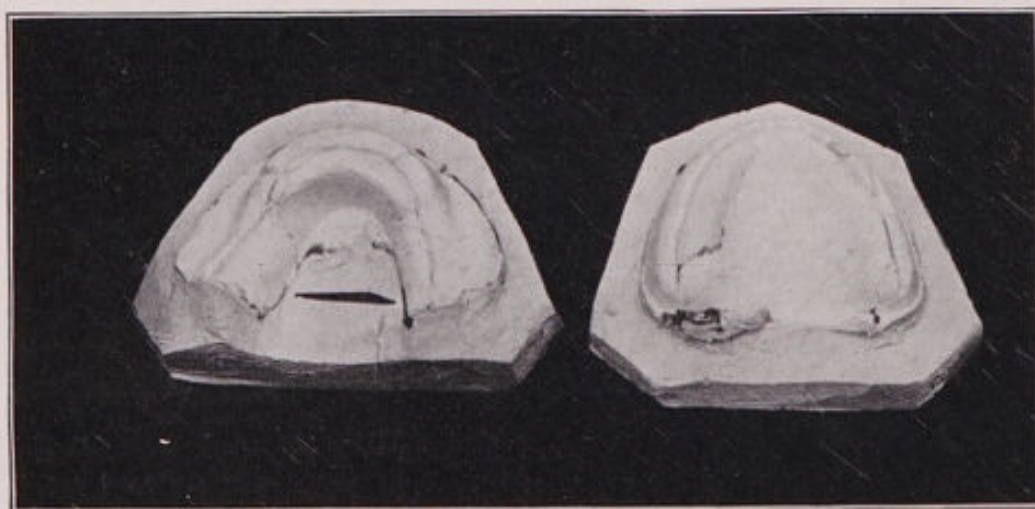


FIG. 60. Plaster impressions after casting, showing how the impression was cut in the mouth, lengthwise over the ridge, and vertically in the cuspid regions.

care must be taken to get them back in their proper places before taking the impression.

Select an impression tray of proper size.

Take a plaster impression of the bridge space and the teeth adjoining the abutments.

For large bridges, take impression of entire upper and lower jaws. The broken pieces of a plaster impression and the tray should be thoroughly washed by running hot water over them, to insure proper replacement of all the pieces. (See Figures 58, 59, 60.)

Before placing crown abutments back into the plaster impression, make sure that the crowns are filled in with solder to reinforce the grinding surface, and that all flux is boiled out in acid.

Place the abutments carefully in their places, also the broken plaster pieces, using sticky wax to hold them there. (Figure 204.)

Varnish impression carefully.

Fit pins or staples into the crowns, to prevent them from breaking off the plaster model.

Pour impression with plaster and Portland, plaster and pumice, or some other good investment material.

4. MOUNTING CROWN AND BRIDGE CASES ON ARTICULATOR

For large cases impressions of the entire upper and lower jaw should be taken, and the case is to be mounted on an *anatomical* articulator, using the face bow to get the right bite. (Figure 61.)

Small cases should also be mounted on *anatomical* crown and bridge articulators.

In placing the wax bite on the model, procured from the impression, care should be taken to cut away, with a warm spatula, all wax, which would interfere with the proper seating.

The models are fastened to the articulators with plaster.

After the plaster has set, soften the wax in warm water before opening the articulator.

Protect occluding plaster teeth with tin-foil.

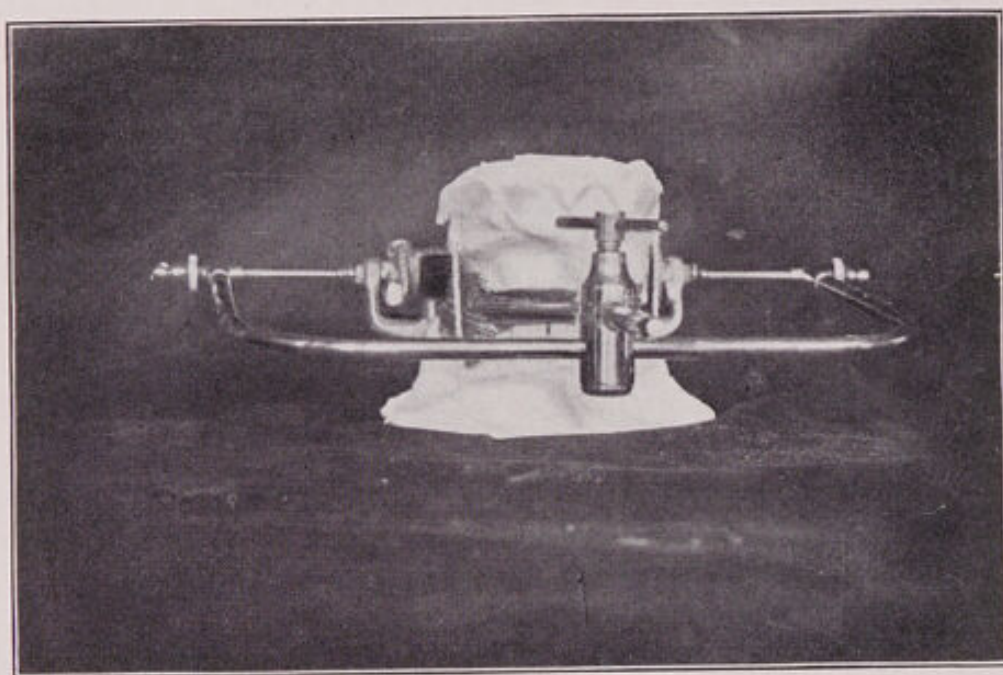


FIG. 61. Case mounted on anatomical articulator by means of a face bow.

5. SELECTION OF TEETH

Select the teeth according to the length of the bite, the width of the abutments to restore the normal fullness of the face and other conditions caused by the loss of teeth, such as a long or short lip, etc. Be sure that the color is satisfactory before grinding the teeth to place. With facings it is advisable to place a gold backing on one or two teeth, and try them in the mouth, as very often the backing changes the color.

6. GRINDING OF TEETH

No matter what type of tooth is used, it is best in all cases to rough-grind the teeth into position first, and try them in the mouth in wax. Rearrange the teeth in wax, if necessary. (Figure 207.) Then only grind the occlusion. When facings are used, allow between the bite about 24 gauge thickness for backings of same. For box teeth such as Davis or Goslee type teeth, allow for thickness of box on gum, or saddle. (Figures 148 and 208.)

To Enlarge Holes in Porcelain Crowns

Very often we find it necessary to enlarge the hole in a detachable porcelain crown to make it line up with the post

in the root. This is best accomplished with an S. S. White Number 1 Diamond Point, or with carborundum points. In either case use plenty of water and do not press too long and too hard at one place, as this will spoil the cutters or stones.

7. BACKING OF TEETH

When teeth are perfectly ground and waxed to position to the abutments, and the spaces on to the model, varnish or shellac the front of the plaster model, and pour a plaster core or jacket over same. (Figures 65 and 208.) Boil out the wax and observe whether the distance between the teeth and the abutments, between the saddle or the gum, is sufficient for the gold backing, or box, and reinforcement of the same, to get sufficient strength. If the distance is not right, now is the time to correct it, by grinding away from the back of the tooth. This is the place to give strength to the backing or the box. (Figure 208.) Now remove the teeth from the core and swage the backing or the box. Cut the first backing of sufficient length to reach from the cutting edge to the gum line. When the teeth are in the core on the model, we can cut and fit all the backings correctly, where they should reach. This makes the soldering simple and gives more strength. The first backing should be 24 karat 31 gauge. Anneal the gold, punch holes first and swage backing to the tooth. (Figure 62.) Do extend, but do not have backing bent over the




FIG. 62. A, Facing with single; B, Facing with double backings.

cutting edge. Many facings are weakened or cracked, when swaging the backings. When swaging, make sure to have the facing well supported in the cup of the swager, from the cutting edge to the labial cervical margin. Examine the facing for defects closely before soldering.

8. REINFORCING OF BACKINGS

Cut a backing out of 26-gauge 18-karat gold plate to extend from the pins to the cutting edge over the first backing of pure gold. Do not attempt to swage this second 18-karat backing on thin or narrow teeth, as these facings are liable to crack. Bend 18-karat backing in such cases approximately with pliers. Remove both backings from the tooth and unite them by flowing 18-karat solder in between so it will show at all edges. (Figure 63.) Boil in sulphuric acid 20%. Replace backings to the

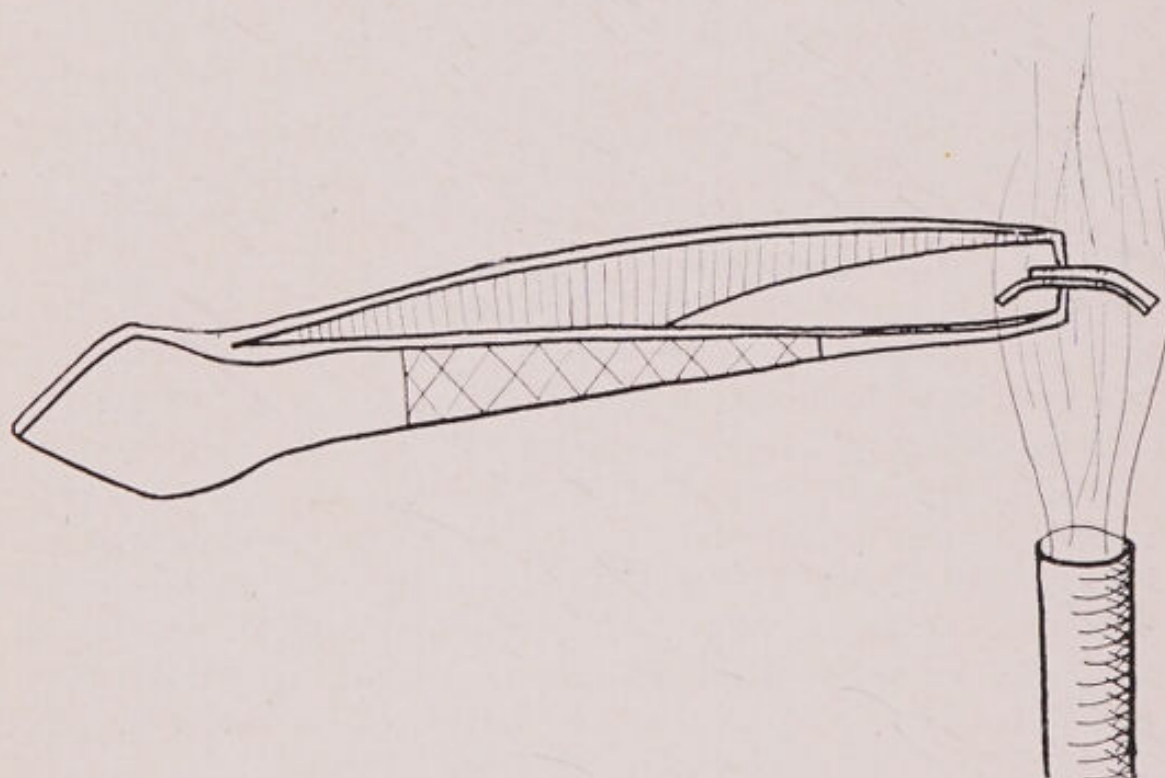


FIG. 63. Soldering the two backings in the flame.

facings and burnish it around the pins with a hollow burnisher. Do not cut or split the pins. After soldering the backing to the pins, either in sections or in one soldering with the abutments, file the backing at a right angle to the level of the facing.

It is advisable to reinforce Goslee or similar tooth boxes also with 18-karat 26-gauge plate, to strengthen the backing over the pin (Figure 139B) at arrow-point B, and to prevent polishing through at the weakest point of the box at arrow-point A. If the box is not reinforced, at B the post with the thin backing often breaks away, and at the point A the solder

does not always cover sufficiently to prevent a hole to be polished through. The 18-karat extension backing prevents both of these events. This same reinforcement is also useful when using a Davis type crown as an abutment. (Figure 139E).

The Goslee platinum or gold post with shoulder will also prevent the post from breaking away from the box. Other useful suggestions in box construction for Goslee teeth are furnished by the dealers of these teeth.

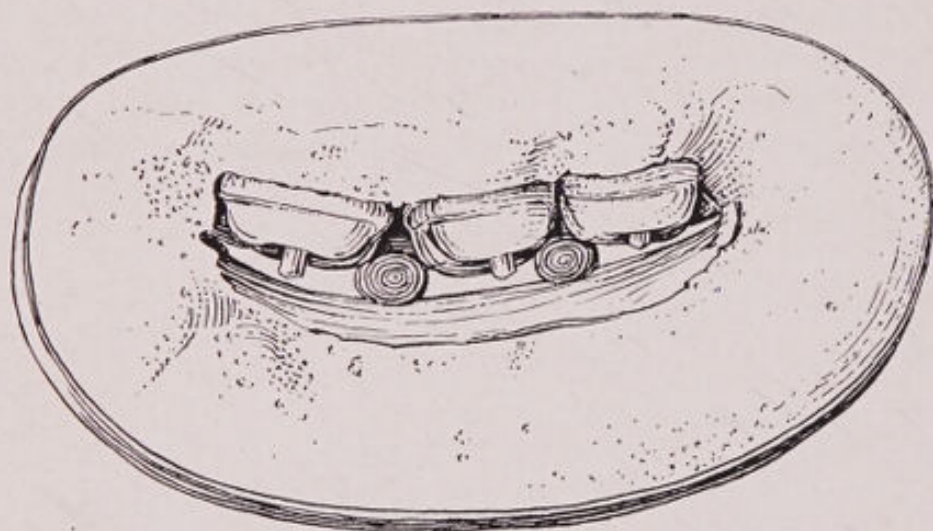
The most commonly used gold solders in bridgework are the 22-karat, 20-karat, and 18-karat. The higher karat gold is used to prevent discoloration of the joints of bands, and all metal crowns, and also to prevent reflowing. For example, use a higher karat gold solder for the soldering in constructing abutments, and the lower karat (18- or 20-karat as a rule) to unite the abutments and dummies.

9. TO PREVENT THE CRACKING OF FACING

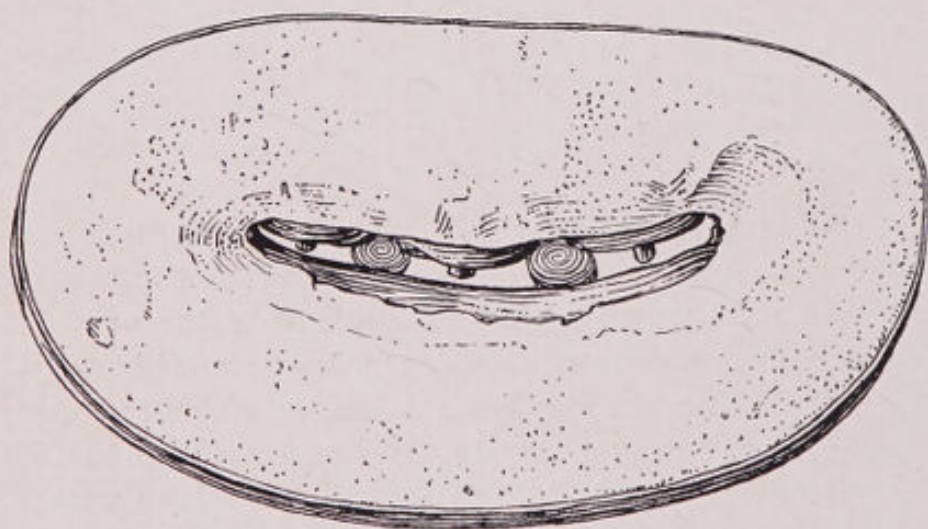
When setting up a bridge case with facings, allow small spaces between the teeth, so that they do not touch each other; this allows for expansion of the porcelain caused by the heating of the case, and when soldering. Take an iron or german silver band about $\frac{1}{2}$ inch high and invest the bridge into this (Figure 208).

Have the investment of small size and expose by cutting away the investment, the surface to be soldered as much as possible. Remove all wax by pouring boiling water over it. *Do not burn the wax out* over the flame, because this will make the gold surface unclean. Examine the invested bridge once more before heating, to see if any part of the porcelain is exposed, where the backing should extend; cover this place with a thin piece of platinum or pure gold plate. Gold-foil is also very useful to cover such exposed places; be sure to pack the foil thick enough, so that it will not burn away under the flame when soldering. Large spaces such as between tooth boxes and saddles are best packed with Alexander gold; this gold will pack in like wax, and suck up the solder. Tooth boxes on saddles are best invested, and soldered, leaving both the front and back open. (Figure 64.) This enables us to solder from both sides. Large backings for gum blocks to be soldered to

gold plates or saddles are also best invested in the same way. Heat the case over a suitable flame slowly, so that the porcelain will not crack. Always let the bridge cool slowly after soldering, for the same reason.



A



B

FIG. 64. Showing a Goslee tooth saddle bridge invested ready to solder. Figure A shows the back of bridge, Figure B the front of bridge open from both sides, and partly packed with Alexander gold. This kind of investment permits perfect soldering on both sides.

When ready for soldering, first test if the case is dried out and hot enough to solder by sprinkling powdered borax on the metal surface. If the borax puffs, or boils up, the case is ready, otherwise heat longer; add the borax, and also solder,

and place the case on the soldering block so that the soldering does not interfere with the laws of gravity. The solder will flow downwards and also towards the hottest part, therefore tip the investment accordingly, and apply the heat where you want the solder to flow. A poker, such as a broken excavator, will also help to lead or push the solder when melted to the right place and is very helpful. Keep sprinkling dry borax during soldering to the bridge and solder as needed. Soldering fluids should not be used on a hot case for two reasons: first, if used on backings with facings, the moisture and cold may crack the facing. Secondly, applying a fluid to hot metal with a brush, the end of the brush will burn, and leave a carbon deposit that will prevent good soldering. In soldering gold bands, put the soldering fluid on the surface when the metal is cold, then place the solder and melt in the open flame, or with blow-pipe.

10. SOLDERING BRIDGE IN SECTIONS

To overcome contractions on bridges, it is necessary to solder the dummies in sections, then replace these soldered sections on the abutments and unite the whole. (Figure 65.)

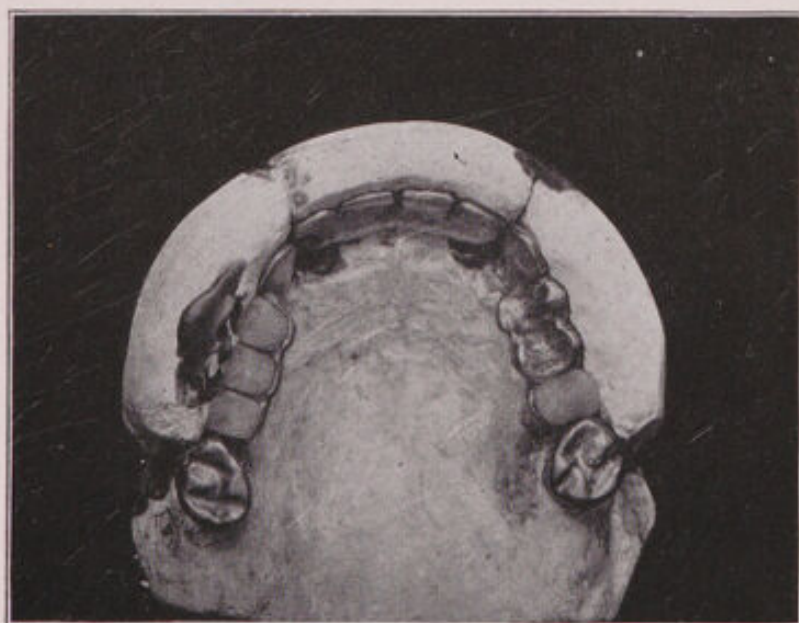


FIG. 65. Showing a full upper bridge. The teeth have been soldered together in three sections to prevent contraction. Case is ready for final assembling and soldering to the bridge abutments.

11. CASTING

The introduction of pressure casting by Taggart, has so revolutionized many methods of operative dentistry, crowns and bridgework, that we may call its introduction the most remarkable period of modern dentistry. In crown and bridge work, we can now use inlays with posts, as abutments, cast vault and sub-lingual bars, cusps to crowns, dummies for sanitary bridges, saddles for saddle bridges, etc., etc.

Though perfect results can be obtained with small and medium sized pieces, it is not practical to undertake too complicated and large castings. For example, it would not be advisable to cast too many dummies to the abutments, because these would be drawn out of position by contraction. Experience and good judgment must guide the selection of the method. Like with all new inventions, we can only find its real usefulness by experiments. So also in the casting process, the pendulum swung over to one side; first everything that we formerly would solder, had to be cast: small and large pieces of bridgework, with and without teeth, upper and lower, full, and partial gold plates, with or without teeth, clasp, bars, boxes, saddles, dummies, crowns, etc.,—everything had to be tried and tested before the pendulum swung back the other way, and we are now satisfied that, after all, swaged crowns, swaged cusps, swaged plates and teeth soldered to same, are still superior to casting in many cases, with the exception of small cases, such as the casting of single crowns, tooth boxes, saddles, sanitary bridge supplies, vault and sub-lingual bars, inlays, etc. I prefer to swage and solder all large pieces as of old.

To get perfect results we have to watch carefully all the small details connected with the making of the wax pattern, the investing, setting, drying and heating of the case, and this is of greater importance than the use of any special make of casting machine. Beautiful results can be obtained with the simplest as well as the most expensive casting machine, and whether using vacuum, steam, centrifugal power or gas pressure. A paper reviewing the pressure casting, compiled from the recent "American Literature" has been read before Section V at the Sixth International Dental Congress, London, 1914, and a report of this can be found in the "Items of Interest,"

Volume XXXVI, No. 10, October, 1914. A report of Dr. Ottolengin's "Review on Casting" is to be found in the "Items of Interest," Volume XXXVI, No. 11, November, 1914.

TECHNIQUE

Wax form

The wax form is either carved on the anatomical articulated model, or in cases of inlays, by the direct (from the mouth), or preferably by the indirect method. In the latter case an amalgam die is made.

Taggart's wax, also Kerr's blue wax, is recommended. When carving, special pains should be taken to reproduce nature as far as possible. All the cusps, grooves, fissures, and sulci should be imitated from extracted teeth, or a good plaster model of perfect teeth. Not only should the casting be carved to occlude properly, it should also *allow normal lateral motion*, as produced in mastication. The carved piece is then smoothed with alcohol, and a sprue wire, of the size of an ordinary pin, is placed in the most bulky part. Place the sprue wire into the hole in the sprue and hold it with wax.

Investing

The process of investing the wax is very important, and all small points should be carefully observed to get the most perfect results.

Taggart's special investment compound is highly commendable. Use it as follows:

Fill the large cup of the balance scale that comes with the box with loose powder and scrape off level with a straight plaster spatula. Place the weighing device on the fulcrum and with a water syringe fill the small cup until it exactly balances; cover the powder and pour the water into a clean plaster bowl, now add the powder. Spatulate for one minute, then jar and rotate the bowl for two minutes more. On account of the fluid condition of this mixture this prolonged manipulation permits all the air and gas bubbles to come to the surface. The inlay should then first be painted with the investment material, and the balance is poured into the ring in such a manner as to permit it to trickle down the inside of the ring. Do not hurry the work; there is a period of at least eight minutes during which the material is workable.

Let the investment harden for about twenty minutes, and then place it over a small flame, heating it up slowly. As soon as the wax has burnt out, cast, or let the flask cool and cast later. The twenty minutes heat gives a better surface than if heated too long, and casting in a cold flask prevents feathers on the casting.

Gold

Use coin gold for inlay abutments, or platinized gold, adding $2\frac{1}{2}\%$ platinum to the pure gold. Use 18 or 20-karat gold for parts of bridgework. Better still are gold alloys, after Weinstein's formula.

1. SOFT ALLOYS FOR INLAYS, ETC.

(Melt by nitrous oxide or ordinary blow-pipe)

Pure gold	60-90 parts
Plate Number 2.....	10-40 parts
according to hardness desired.	

2. HARD ALLOYS FOR BRIDGEWORK

(For nitrous oxide blow-pipe)

Pure gold	80.0 parts
" platinum rhod.....	8.5 "
" palladium	3.5 "
" silver	2.0 "
" copper	6.0 "

(For gas and air blow-pipe)

Pure gold	80.5 parts
" platinum rhod.	6.5 "
" palladium	2.5 "
" silver	2.5 "
" copper	8.0 "
100.0	

12. POLISHING OF CROWNS AND BRIDGES

In order to attain the highest finish on a crown or bridge, care and patience must be used in properly filing, stoning and sand-papering before applying felt cones and brushes for the final polish. No matter how smooth your soldering appears, all soldered surfaces should be stoned. In spite of boiling in

acid, some borax and also a skin-like porous covering of these surfaces is not always removed by the acid. Carborundum stones in the dental engine or lathe attachments are the handiest in reducing gold and getting smooth surfaces. While rubber carborundum wheels are best to use for the inter-dental spaces, between crowns and near cutting edges, sand-paper disks on a mandrel are also of great help.

Before polishing, always stone and finish the deep fissures and the inter-dental spaces first. These inter-dental or so-called wash spaces can be reached best by applying pumice and water, or triplex rubbed on twine. Hold these with the left hand, and with the right hand work the bridge against the twine in a quick up-and-down motion, until the desired result is obtained. Now polish the large surfaces with pointed or flat felt cones, pumice and water, triplex, or other polish; then go over the entire bridge with a brush wheel until all the scratches are removed. Wash all the pumice off and apply whiting or rouge with a soft brush or polishing wheel, then wash bridge again with warm water, and gold plate same.

13. GOLD PLATING OF CROWNS AND BRIDGES

It is of great importance to gold plate soldered crowns, also all bridges. The deep fissures, the soldered joints, such as between the crowns and the dummies, and the gold in the inter-dental spaces show the first effect of oxidation in the mouth. Large surfaces and especially masticating surfaces are kept bright in polish and color through the constant rubbing and friction caused by the masticating and cleaning process. When a bridge is properly gold plated with 24-karat gold plate, we have a piece of work which is of uniform color, and the plating will protect all the deep fissures and soldered joints from discoloration and oxidation for many years. There are various plating outfits offered for sale on the market. However, it is very simple and easy to make your own apparatus, which will do good service. Here is one I have used for many years. (Figure 66.)

Use the following solution in the jar:

Chloride of gold.....	30 gram
Cyanide of potassium.....	60 "
Water	8 ounces

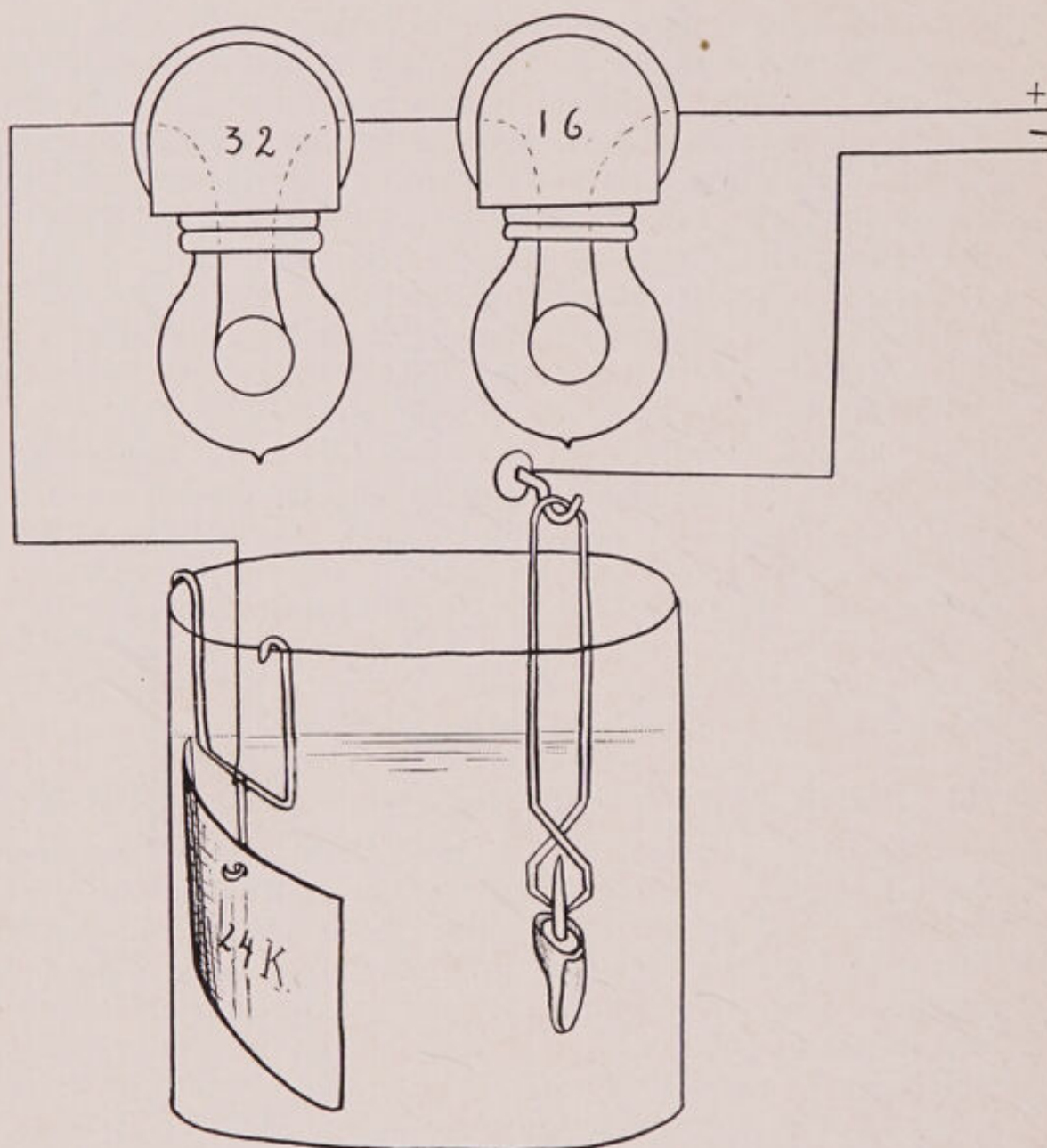


FIG. 66. Gold-plating outfit, of simple construction, for 110-volt direct current, using a 110-volt 16-candle power lamp and one 220-volt 32-candle power lamp to reduce the current. (See page 73.)

14. FITTING OF BRIDGES IN THE MOUTH AND WEARING THEM FOR A DAY OR TWO

In fitting large bridges we often find that the finished bridge will not go in its proper place, or as we may term it, is not seated. This may be due to some carelessness in putting the abutments in their proper places in the plaster impression, or it may be caused by a broken off abutment on the plaster

model, and when this abutment was not put back in the exact position, where it belonged. Another cause may be that the bridge has contracted in the final soldering. (See Figure 65.)

If it should be necessary to refit the bridge, cut some of the abutments off, place them in the mouth, take another bite, and impression, and resolder. But these mechanical defects of the bridge abovementioned, are not the only causes that may prevent a bridge from going into its proper place. One of the commonest causes is the side shifting or moving of the teeth or roots, to which the abutments have been fitted; in such cases it is advisable to let the patient wear the bridge uncemented for several hours, or even twenty-four hours, during which time the teeth will readjust themselves to the bridge. If the teeth or root canals have not been lined up to prevent the bridge from getting into place, it is best to start all over again and use more care. Figure 201 shows an instrument of great value for such cases.

15. CEMENTING OF CROWNS AND BRIDGES

Never try to cement a crown or bridge until the same has been tried and is correctly seated. Make sure that the apical end of the roots are correctly filled. It is important to know the working qualities of the crown and bridge cement used, its color effect and especially its setting period. Dry the abutments of the bridge, and wherever there is a saddle or deep inter-dental space, coat these places with a thin film of vaseline. (The vaseline will prevent the lodging of cement at these places after the bridge has been cemented.) Paint the gum around abutments with camphor phenol, or a 20% solution Novocain, and dry all roots and teeth which are used for abutments by wiping them off first with alcohol and then applying warm air with chip blower or compressed air. This overcomes the pain so often caused by the cement. Place cotton rolls and napkins around the teeth to be crowned. After the assistant has mixed the cement and is filling in the different crowns, the operator should, with a suitable instrument, fill cement in the root canals which are to receive post crowns. Do not mix the cement too thick, fill the crowns even full, as this will prevent the arresting of air, and act as a lubricant to slide the crowns into place. The bridge must be held into place until

the cement is set. If the operator cannot hold the bridge in position with one hand while he burnishes the metal caps to place with the other hand, before the cement sets, an assistant should hold the bridge.

Color of cement important

The color of cement is of great importance when open-faced, staple, half crowns, with post or inlay abutments are used. If a brown or gray cement is used in such cases, it will often change the color of the tooth. To prevent this, a light yellow cement is preferable, which will sustain the natural color of the tooth.

16. FINAL ADJUSTING OF OCCLUSION

The correct occlusion of a crown or bridge is most important, as the comfort, the service, and life of the crown or bridge depends on this to a great extent.

Have the patient bite in the various ways which the movements of the lower jaw permit; ascertain the hard striking places by the use of carbon paper; grind them carefully with a suitable stone. Be sure to clear the cuspids of the lateral bite, as these are the ones that are most severely affected. In a general way follow the directions for adjusting the bite of a crown or bridge as you would for setting up teeth on an anatomical articulator.

17. INSTRUCTION TO PATIENTS

Patients frequently experience more or less difficulties with new bridges, especially if they have been without teeth for a long time. If large bridges are put into a patient's mouth, they feel, as they often express it, "all teeth." The tongue which was used to a large space, taking up the room of the lost teeth and extending even into the vestibulum oris, finds itself suddenly restricted to the cavum oris proper. It often takes several weeks before the tongue gets used to its new environments.

Mastication is another feature which has to be considered. If many of the molars and bicuspids have been missing, the patient either masticated with the front teeth, or swallowed

the food unchewed. Both habits have to be corrected. The patient ought to be instructed to use the bridge and to masticate each mouthful of food properly. In the beginning this may trouble them, as they may not have used that side and the teeth for a long time. But gradually the need is supplied by nature, the circulation will increase in the alveolo-dental membrane and the tissues surrounding the teeth will be strengthened until they are all able to fulfill their requirements. It is of great importance that the occlusion should be adjusted for proper masticating antagonism. *Anatomical articulators* should be used *for the construction of all bridges*, and the teeth should be readjusted in the mouth before and after the bridge is set.

18. CARE OF BRIDGES

Bridges should be properly cared for by the patient, and should receive regular attention by the dentist. Fixed bridges can be cleaned with the toothbrush, dental floss and cleaning tape, in combination with a proper tooth paste. Removable bridges are easy to keep clean, that is, the bridge itself; the abutments and gum, however, should not be neglected, and receive careful brushing. Brushing of the gum is important to stimulate the blood circulation. Massaging the gums around removable bridge abutments with cotton rolls in a Kuroris holder is highly recommended.

VII. SINGLE CROWNS

Whenever there is a crown of a tooth missing or badly decayed, with its root in good condition, or with a root which yields to treatment so as not to be a source of infection, it is safe to crown, providing the bite is favorable. There are different types of crowns which can be used to replace such a tooth, and they are made for different conditions. The type of crown which comes nearest to the ideal condition, without taking a chance as to its practical value, should be selected. The ideal crown has the following qualities:

- Clean surface.
- Not irritating the gum.
- Esthetic appearance.
- Restoring occlusion.
- Restoring contact points.

ALL PORCELAIN CROWNS

These are the most ideal crowns. Porcelain is the cleanest material and gives the best effect. If properly fitted, porcelain crowns are most favorably received by the gum.

TYPES OF ALL PORCELAIN CROWNS

1. Jacket crowns.
2. Detached post crowns.
 - Hand-carved crowns.
 - Stock crowns.

1. JACKET CROWNS

Crown I.

This crown can be used for a devitalized tooth, as well as for a tooth with a live pulp; it encloses the part of the tooth extending over the gum like a jacket, therefore the name.


Its use is largely to restore malformed, peg-shaped, pitted, or eroded teeth, but can be used to replace almost any tooth in the mouth, if tooth or root is rightly trimmed and built up.

Preparing of tooth

To prepare the tooth for a jacket crown, cut down the tooth to procure a cone-shape with shoulder, as shown in Figure 67A, I, and B, III.

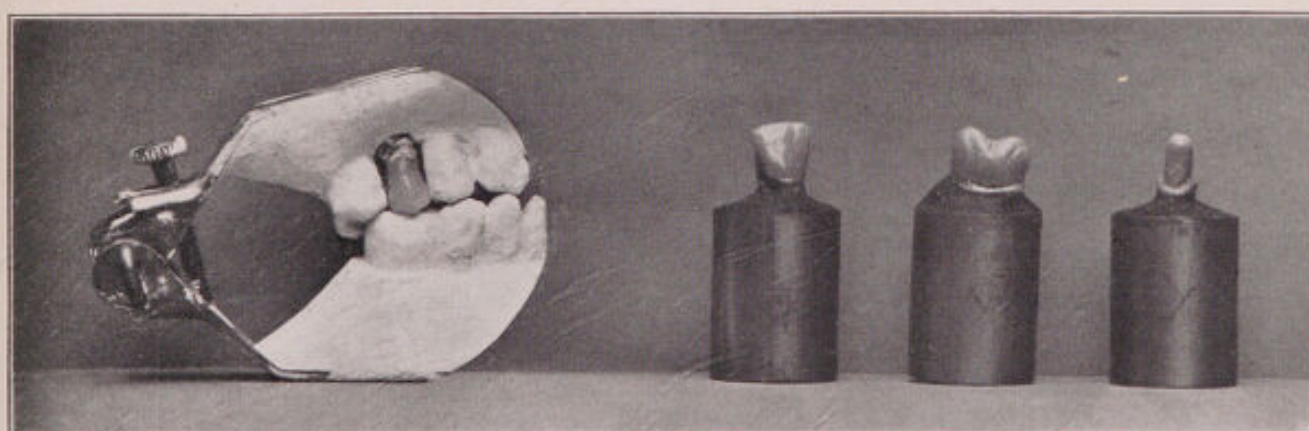
The mesial and distal sides of the tooth are best reduced with a wet rubber carborundum disk stone.

The front and back with small stones, well wetted, cutting little at a time.



(A) I II III IV V

FIG. 67A.



(B) I II III

FIG. 67B.

The groove is cut with a sharp square-end plain fissure bur.

To cut this groove well under the gum margin, steady the bur and handpiece by resting the thumb on the adjoining teeth, and apply steady pressure to overcome the vibration.

Impression of tooth

Fit a seamless copper band loosely around the prepared tooth, heat the end of a Kerr impression stick, and press this into the band against the tooth.

Chill and withdraw carefully.

Making of die

Pack the impression with amalgam, forming a cone-shaped extension. (Figure 67A. I.)

When hard, remove the impression compound and trim the end of the die cone-shape as per Figure 67A. I. This is best accomplished with a sandpaper wheel on the lathe. Oil the die (the cone-shaped extension).

Take another impression, also a wax bite of the prepared tooth and the adjoining teeth, and place the amalgam die in the impression of the prepared tooth and make an articulated model.

Take a piece of 1-1000 platinum foil, cut and shape it like Figure 67C, I, II.

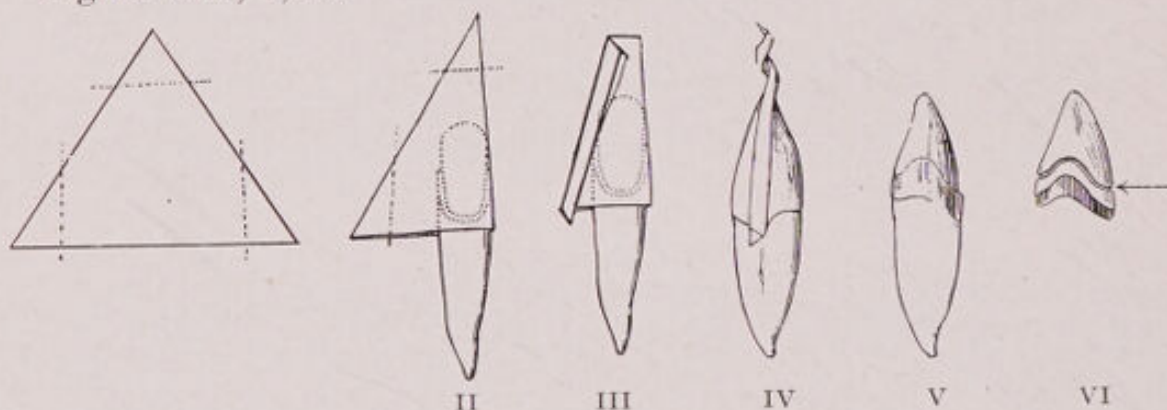


FIG. 67C. Steps for jacket crown.

Trim excess of foil to allow fold to be double lapped.

Make a matrix with a *double folded lap* to the mesial or distal side of the tooth. (Figure 67C, III.) Use long-nosed cotton pliers to fold the foil.

This double lapped joint does not need to be soldered and will permit perfect forming of the foil to the die.

Twist the upper end of the foil (Figure 67C, IV), cut off excess but allow enough for closing of top.

Form the foil with finger pressure to the die, burnish edges with gold burnishers.

For the groove use a fine ball burnisher, getting a perfect adaptation to the groove, edge and sides. (Figure 67C, V.)

Remove foil matrix from die.

Trim the overhanging edge to $\frac{1}{2}$ overhanging length.

Replace matrix to die, and reburnish to same.

If a change in trimming of the tooth was necessary, the matrix can now be reburnished directly on the tooth in the mouth.

Porcelain to matrix

Build *body porcelain* to cover the whole matrix to desired shape of crown. Do this with the matrix on the die; try the crown on model for desired shape.

Remove die from the model and with a fine knife or the pointed end of a thin cement spatula, cut a deep groove in the porcelain clear around the base of the crown, down to the matrix. (Figure 67C, VI.)

This cut should be made before the porcelain is dry.

This cut is the most important step of the whole operation.

This cut will prevent the pulling away of the matrix from the lower edge of the crown, when baking the porcelain.

Now remove the matrix with the porcelain from the die.

Set the matrix (covered with the *body porcelain*) on a small tray of silex and bake.

After the first bake, the line (Figure 67C, VI) will show much shrinkage of the porcelain.

Fill in this line with *body porcelain* first, then add the *enamel porcelain* for final shape and color.

Try again on model and when built up satisfactorily, set crown on a tray with silex and give the crown the final backing.

Remove the foil by pulling the edges towards the centre of crown.

Setting of jacket crown

Use a creamy mixture of cement, forcing the crown with a rotary pressure of the finger to place.

Hold crown for five minutes.

Do not allow the patient to bite on the crown until after the cementing.

To my mind this is the most esthetic, the strongest, in fact the most beautiful crown that can be made.

2. DETACHED POST CROWNS

Crown II.

HAND-CARVED CROWNS

The best in appearance is the hand-carved crown. It usually does not need much fitting to the tooth or root. All the small details of the adjoining teeth can be imitated and splen-

did results be obtained in shape, in color effect and natural appearance. The technique is as follows:

Root preparation

Grind the root as for a post crown.

Fit post into position and with this take an impression, and bite, and make a model with tail to articulate.

Shellac the model.

Making of crown

Use special high-fusing porcelain, and mix first the *body* porcelain (with water) to a putty-like consistency, and pack it into the space on the model, articulate and carve the outside. Disarticulate and carve the inside roughly. After it has dried, remove it, and biscuit it in an electric furnace.

The crown has now the consistency of soft chalk, and can be carved easily to receive the desired shape. However, it should be left long enough to allow for shrinking in the final baking. A hole is drilled with a round bur to receive the post. The body gives the color of the neck of the crown.

Now add the *enamel* porcelain very thick at the cutting edge and at the sides, thinner at the labial or buccal surface, and little at the neck; dry carefully, and bake up to the given degree to get the desired glaze. Such a crown is very easily fitted in the mouth and needs very little grinding. The principle of fitting is the same as for the stock crown.

STOCK CROWNS

Crown III.

Post crowns if properly selected and fitted give very good and satisfactory results.

Selection of teeth

Take impression and bite, also shade. Make model and select a suitable crown, one that is of good color and will *cover the base* of the root. The crown should be sufficiently long to permit of some grinding, and also *wide enough* to have a firm *approximal contact* with the adjoining teeth. If a crown after being ground is too short, too narrow, or if it does not cover the entire part of the root, this can easily be

remedied by baking some porcelain on. Porcelain, as well as mineral stains, can be used to advantage to change the shape, color and effect of a crown. Small details of the adjoining teeth can be imitated. Staining the cutting edge and the neck to give a natural appearance is a common need and should be more practiced.

METHOD A: WITH ROOT FILES

Root preparation

Reduce the root to the level of gum margin with fissure burs, root facer and stones.

Select a root file of suitable size, as wide as the space will allow, and file the root end below the gum margin, filing in labio-palatal direction. (Figure 68.)

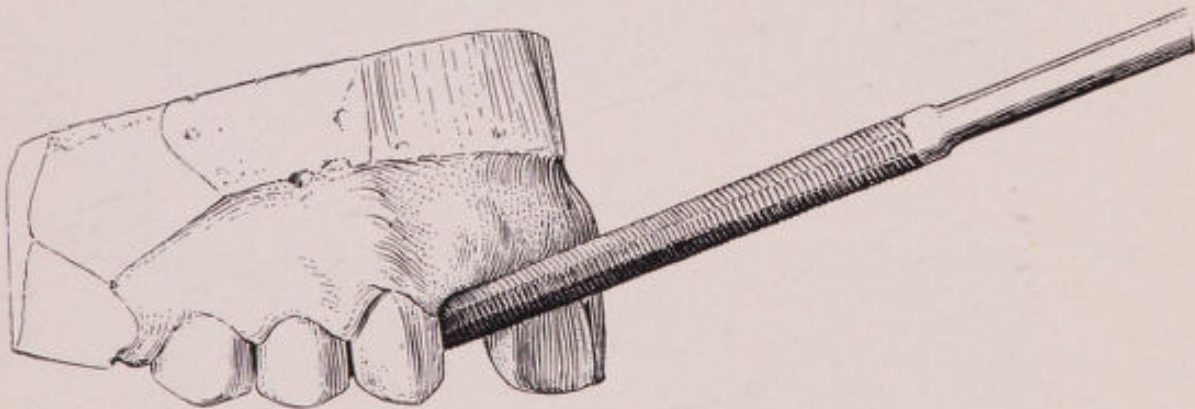


FIG. 68. File methods for root preparation.

It is important to keep the file in the centre of the root and not file to one side. To accomplish this, it is of importance that the operator take a good position by the chair. Figure 69 shows the position for filing those roots which are the hardest to reach with a root file.

Fitting of post into canal

Open and enlarge the root canal first with Kerr broaches, then follow this up with Gates Glidden canal drills, if necessary.

Fill the apex of the canal so that it is sealed tightly.

Enlarge the upper part of the canal with a Davis root reamer.

Use a post corresponding in size to that of the reamer.

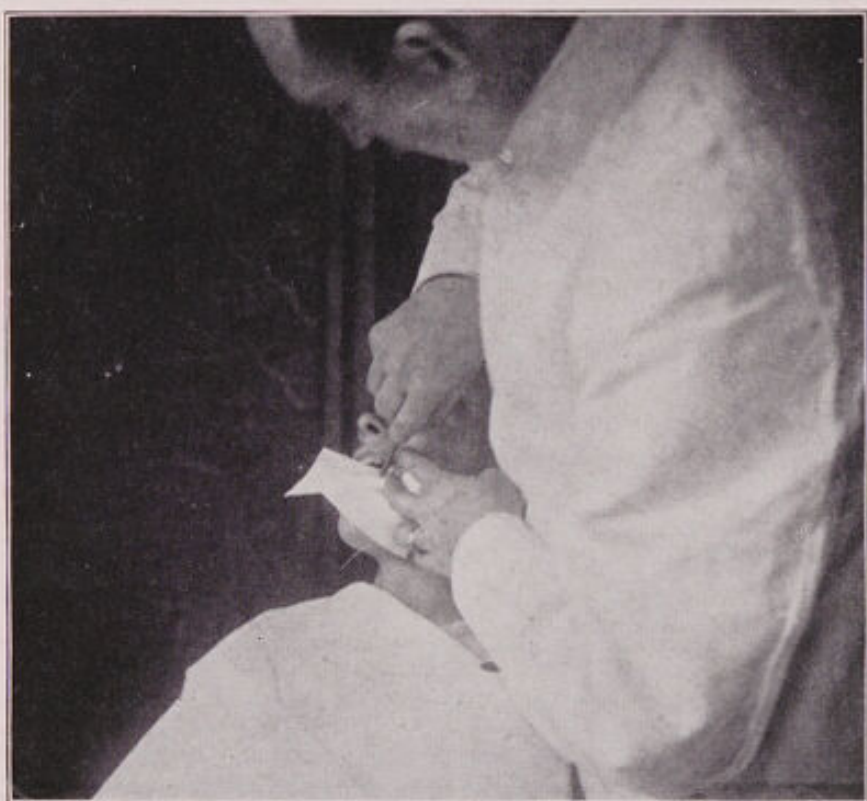

FIG. 69A. Position of operator filing a left upper bicuspid root.

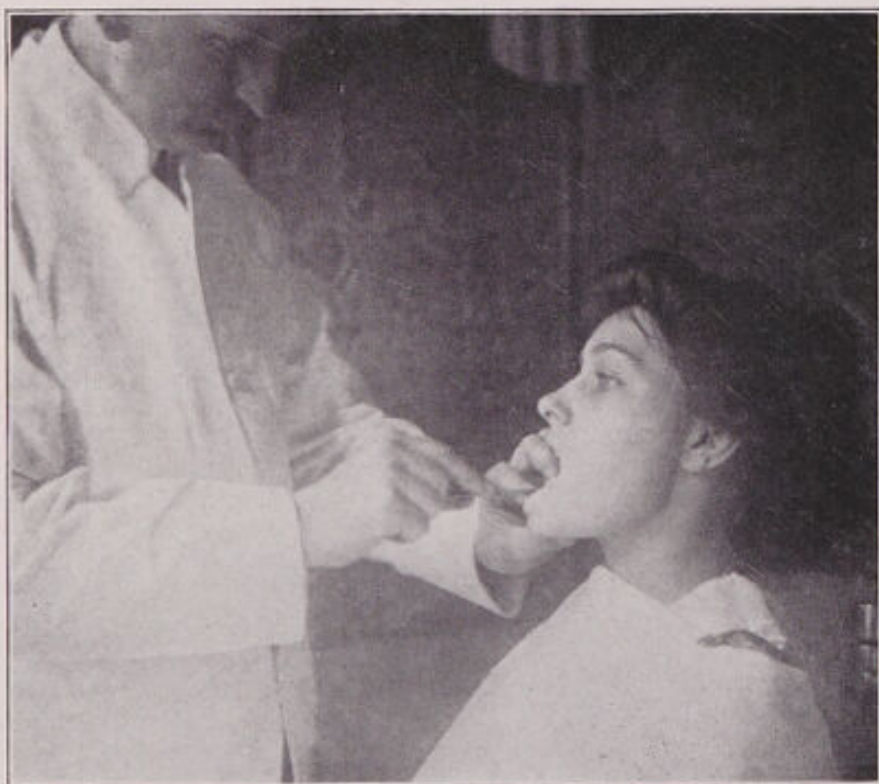

FIG. 69B. A lower incisor root.

If the post is not in the right line to fit into the slot of the crown, use an offset centre post. Be sure to have a post large enough to fill the canal, leaving no play. (Figure 73.)

Grinding of crown

Select a detached post crown of suitable color, one that will cover the root end and is sufficiently long to permit of some grinding and wide enough to have firm approximal contact.

Rough grind the porcelain crown to get the right labio-lingual and mesio-distal position.

To get a perfect joint, grind the crown to a groove filed in a toothbrush handle with a file of the same size as the one used in preparing the root end. (Figure 71.) This can be done with a dental lathe stone.

When a perfect joint is obtained, grind off any edge of the crown that may overhang the root end with the aid of gutta-percha. This remaining gutta-percha also prevents the cement from washing out between the joint of crown and root. The thinner the gutta-percha is pressed when forced into place, the better the result. This thin layer of gutta-percha undergoes in the mouth a hardening process, becomes in years as a fibrous mass, and will not deteriorate.

Fitting of gutta-percha base

Take a piece of pink base plate gutta-percha and cut it approximately to the size of the base of the crown. (Figure 70.)

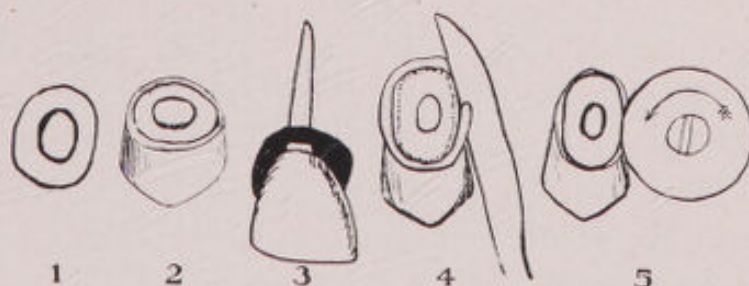


FIG. 70. Detached post crown with gutta-percha washer.

Punch a large hole in the centre, now moisten base of the crown with chloro-percha, warm the piece of gutta-percha and seal it to the base of the crown by pressing moistened finger

against it. (Figure 70; 1, 2.) Now heat over the flame, and press the crown over the root with the post in position. Let it cool, and then remove crown. The gutta-percha on the crown now shows the outline of the root. Trim the gutta-percha with a hot knife, and grind the crown to the outline of the root with a stone running from the gutta-percha base toward the crown. (Figure 70; 4, 5.) The outline of the crown now fits the outline of the root exactly. The gutta-percha has been thinned out by pressing on to the root and this thin layer is left on the crown and will prevent the dissolving of the cement.

When post and crown are both fitted, dry all parts well, cement the post into the crown and to the root with one mix of cement, leaving the gutta-percha in place between crown and root end.

METHOD B: WITH ROOT FACER, AND STONES

Root preparation

Reduce the root to the level of the gum margin with a fissure bur or stones or both. Then cut the labial and palatal portion of the root with Roach root facer, till they extend under

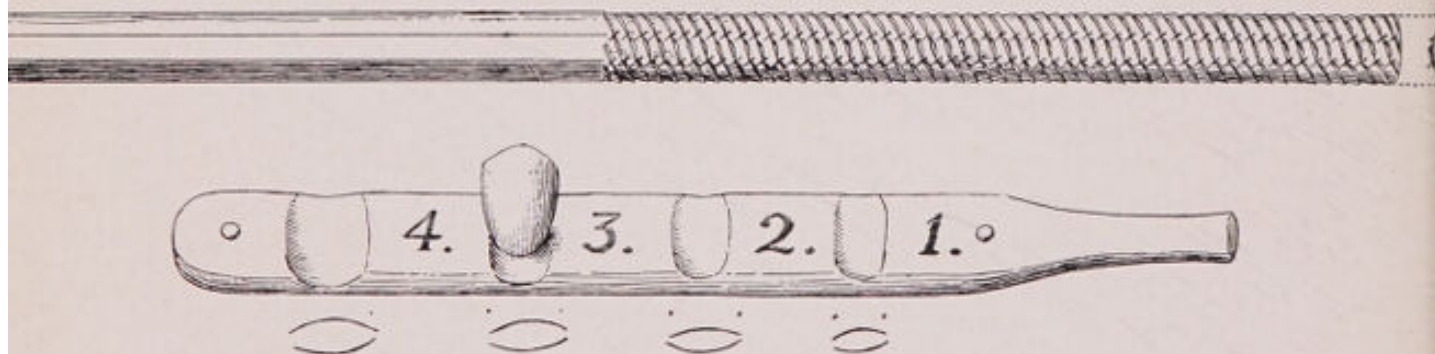


FIG. 71. Showing a root file, also a toothbrush handle with root-file grooves. A tooth has been fitted to groove No. 3.

the gum. This will leave the top of the root in the shape of an obtuse angle seen labro-palatally, with the longer side of the angle on the palatal side. (Figure 72.)

Fitting post into canal

Open the root canal with a Kerr broach and Gates Glidden canal drill, if necessary.

Fill the apex of the canal so that it is sealed tightly.

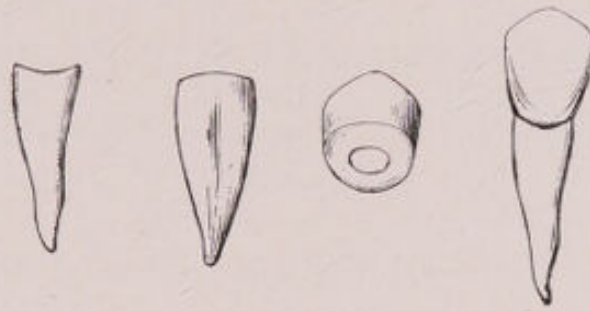


FIG. 72. Root preparation for detached post crown.

Enlarge the upper part of the canal with Davis root reamer.

Use a post corresponding in size to that of the reamer. There are posts of different metals and sizes, straight and offset centre posts, the latter for crowns where the root canal and the hole in the crown do not line up (Figure 73), split posts

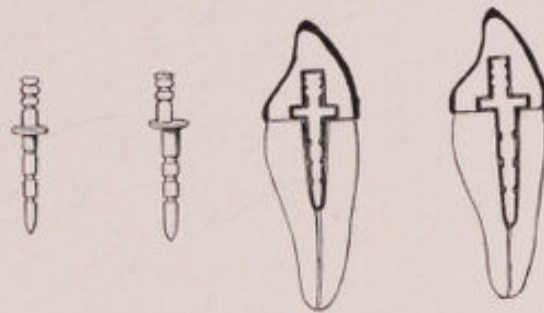


FIG. 73. Showing a straight and an offset centre post, such as used in detached post crowns.

for upper first bicuspid. Platinum posts may be enlarged by casting to same, or a strip of plate or wire wound around the posts and soldered. It is most important to have the post fill the canal.

Grinding of crown

Grind the crown to fit the end of the prepared root, using articulating paper between crown and root end as a guide, or use the gutta-percha method described in Method A.

Fit the post and cement the crown as described in Method A.

B. PORCELAIN CROWNS WITH METAL BASE

1. Porcelain baked crown with platinum base.
2. Porcelain crown with cast base.

1. PORCELAIN BAKED CROWN WITH PLATINUM BASE

Crown IV.

A porcelain baked crown can be constructed from a facing or rubber tooth, with platinum pins soldered and baked to platinum cap and post. (Figure 74.)

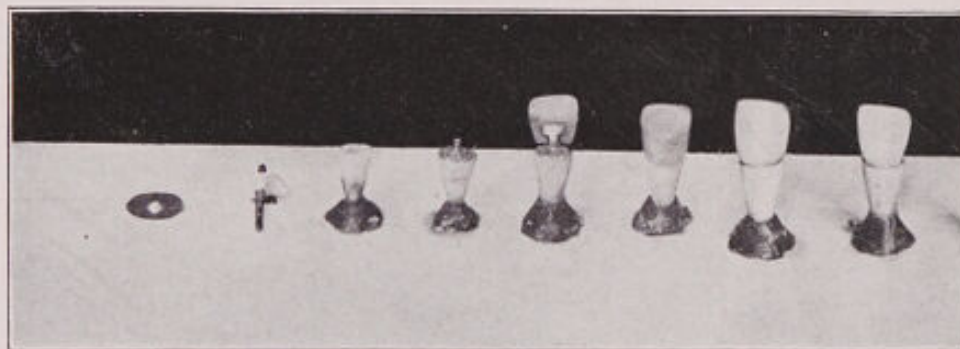


FIG. 74. Steps of making porcelain baked crown, using platinum base.

Root preparation

Prepare root as for Crown III, A or B.

Fitting of post into canal and making of cap

Fit an iridio-platinum post into root canal of same size as root reamer used.

Remove post and fit a cap of platinum plate (32-gauge) over ground surface of root, as following:

Punch a hole in the platinum plate over the opening of the root canal, and push the previously fitted post through the plate into position; leave the post projecting over the plate, withdraw and catch with platinum solder or 24-karat gold plate or foil. Replace to root and burnish the plate well over the edges of the root, holding it in place with a suitable instrument, and pressing the metal with a shoe-shaped gold plugger on to the root, trimming and conforming the cap until perfectly seated.

Making of crown

Take a wax bite and plaster impression with the cap and post in position. Cast the impression with cap and post, using plaster and Portland, or other suitable investment.

Grind a facing to the articulated model.

Bend the pins of the facing to the platinum post.

Wax the facing to the cap and post and invest.

Boil the wax out and heat it carefully.

Solder the facing and the cap to the post with platinum solder or pure gold plate.

When cool, remove the plaster and fill in with medium or high fusing porcelain the back of the soldered facing and cap.

Keep tapping to bring the moisture to the surface until perfectly dry. Set the crown on a broken clay pipe-stem and bake.

Bake it with a slow heat up to fusing point and again cool down slowly.

Add more porcelain if necessary, and bake again until the required shape is obtained.

Cementing of Crown

Cement to the root in ordinary manner.

2. PORCELAIN CROWN WITH CAST BASE

If the root is decayed under the gum line, and a band is impossible or undesirable, a cast base will often meet the requirements to obtain good results by the direct or indirect methods.

Direct Method. (Figure 75.)

Root preparation

Remove all decay from the root and reduce it with burs, stones and root facers, till it extends slightly under the gum margin.

Open the canal with a Kerr broach and Gates Glidden canal drill and enlarge it with a root reamer.

Fitting of post and making of crown

Fit an iridio-platinum post as high toward the apex as possible.

Rough grind a detachable post crown of suitable size, and color, so that it will fit close to the labial portion of root end, leaving a V-shaped space between crown and root end on the palatal side. (Figure 75.)

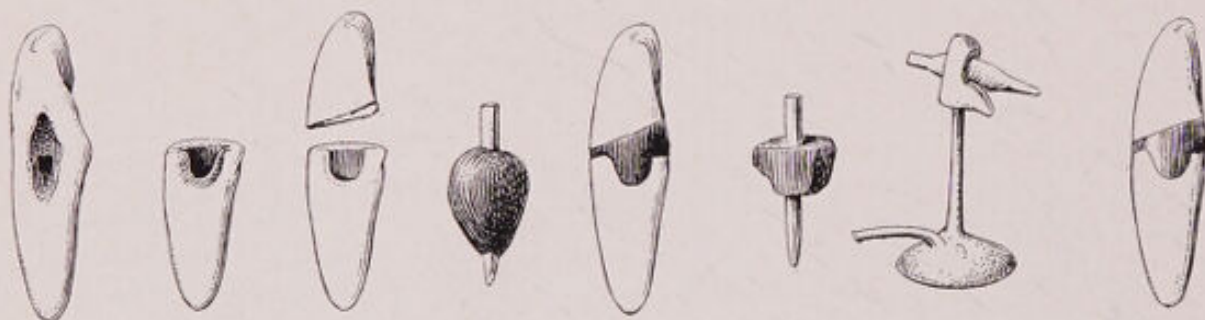


FIG. 75. Porcelain crown with cast base. *Direct Method.*

Vaseline the base of the porcelain crown.

Warm the post and form inlay wax around it.

While wax is soft press the post and wax into the canal and press the vaselined porcelain crown into position.

With a warmed instrument trim the excess wax so that it will be flush with the sides of the root and crown; when the wax is chilled carefully remove from the root, first the crown, and then the post with wax attached to it.

Attach sprue wire to the thick palatal part of the wax.

Invest and cast with 22-karat gold to the post.

Remove any imperfection from casting and fit crown to casting and to root end.

Cement porcelain crown to base and polish.

Cementing of Crown

Cement then the crown to the root in the usual manner.

Indirect Method. (Figure 76.)

Root preparation and fitting of post

Prepare root as for direct method.

Fitting of post

Fit post as for direct method, then cover the fitted post with a thin film of wax or paraffine, and press it into the root canal.

Impression

Select a copper band of suitable size and fit it over the prepared root. Take an impression of the root by forcing a Kerr modelling compound stick, the end of which has been softened into the band.

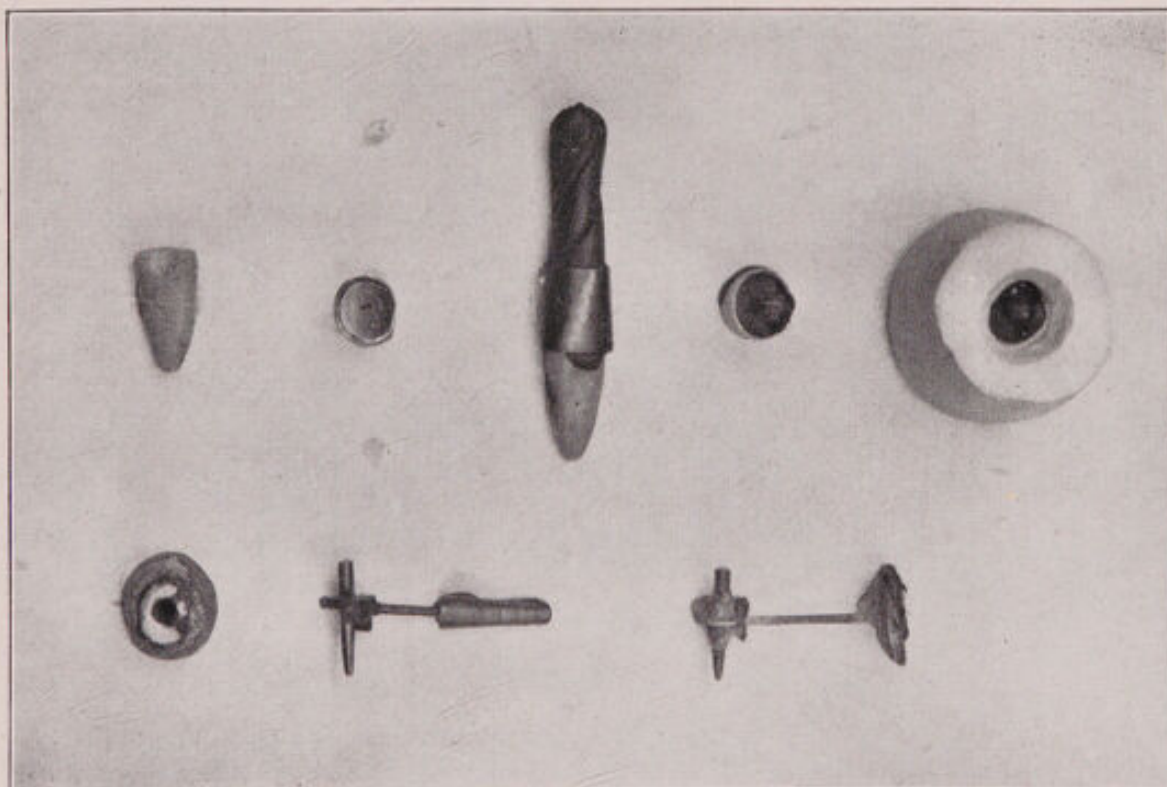


FIG. 76. Porcelain crown with cast base. *Indirect method.*

Take an impression of the adjoining teeth, and a bite to make an articulated model.

Trim and shape the die cone-shape and place it into the impression, same as placing a crown abutment back into the impression, then make an articulated model, from which the die can be removed.

Making of crown

Select a porcelain crown of suitable color. Shape it to fit at the labial or buccal part of the neck, also to be in contact

with the adjoining teeth, and to occlude properly. Grind the porcelain crown at the palatal side so that there is a large V-shaped space between the root and the base of the crown.

Remove the post from the amalgam die, vaseline the die as well as the base of the porcelain crown.

Take some inlay wax which has been heated previously, and stick the post to same, then place it over the die, pressing the porcelain crown in position while the wax is soft.

Let the wax cool and remove the die and crown from the model. Take a warmed instrument and trim the wax flush with the model and the crown.

Place a sprue wire into the lingual part of the wax where it is thickest. Remove the porcelain crown and then draw the wax with the post from the die.

Invest and continue as for the direct method.

C. BANDED CROWNS

These are a step removed from the ideal, as a band, even if fitted very accurately, is irritating to the gum and therefore more or less objectionable. For bridge abutments this is, however, very often required to get strength, and it has its obvious advantages for weak roots. Platinum is the ideal metal for root bands and caps.

I. BASE FOR BANDED CROWNS

Direct Method

1. Soldered caps.
2. Burnished caps.

Indirect Method

3. Swaged caps.

II. SUPPLIES FOR BANDED CROWNS

- A. Banded crown with facing.
- B. Banded crown with detached post crown.
- C. Banded crown with Goslee tooth.
- D. Banded crown with Steele tooth.

I. BASE FOR BANDED CROWNS

Direct Method

1. SOLDERED CAP

Root preparation

Remove all decay from the root. Grind the labial portion down below the gum margin while the palatal portion may be left longer.

Cut the sides of the root parallel, removing all enamel by the use of enamel cleavers, knife edge stones, Evans' fissure burs, or all combined.

Open the root canal with Kerr broaches and Gates Glidden drills and enlarge with Davis root reamer.

Making of cap

Measure circumference of the root below the gum margin with a wire in dentimeter. (Figure 77.) Use platinum plate or cut a strip of 22-karat 30-gauge gold plate with sides parallel of the length of the wire. File the ends so that they form a perfect joint when bent to a band. (Figure 77.)

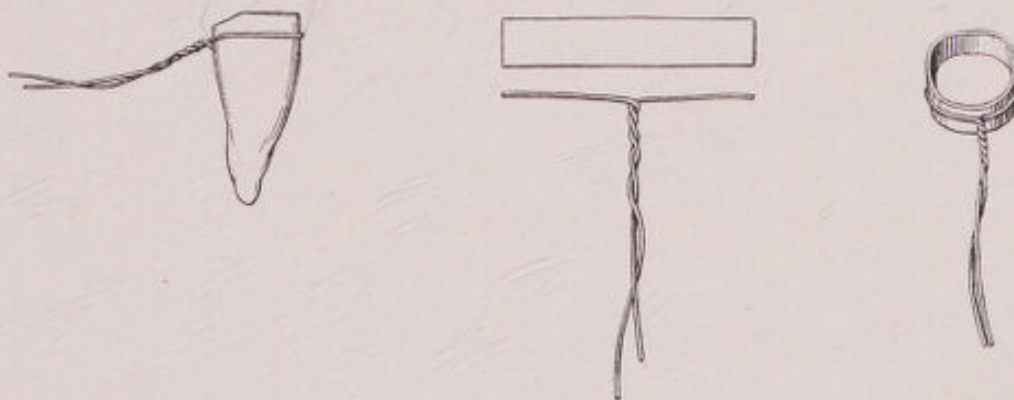


FIG. 77. Steps for making of band for soldered cap.

Bind around this band an iron binding wire to hold the joint together while soldering. Put wet flux outside of the joint and a small piece of 22-karat solder on inside. Hold it in the flame and flow the solder, uniting the joint. Fit the band on root, trimming the cervical edge parallel to the margin of gum and filing it to a bevelled edge. See that it extends slightly under the gum margin.

Trim the top of the band so that it is flush with the top of the root.

Burnish a piece of 34-gauge 22-karat silver alloy gold plate over the top of the root and band. Remove band and fit the burnished piece to place, soldering it with 22-karat solder. (Figure 78.) Trim the overhanging edges. Cut a hole

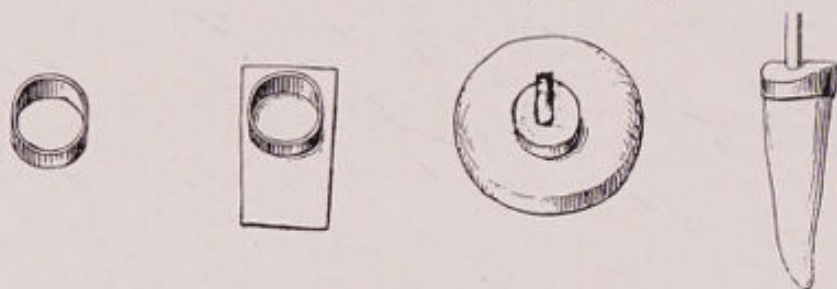


FIG. 78. Fitting of top to band and soldering post.

through the top, opposite the root canal, with Dr. Hovestadt's special punch (Figure 79) and burnish well into the root

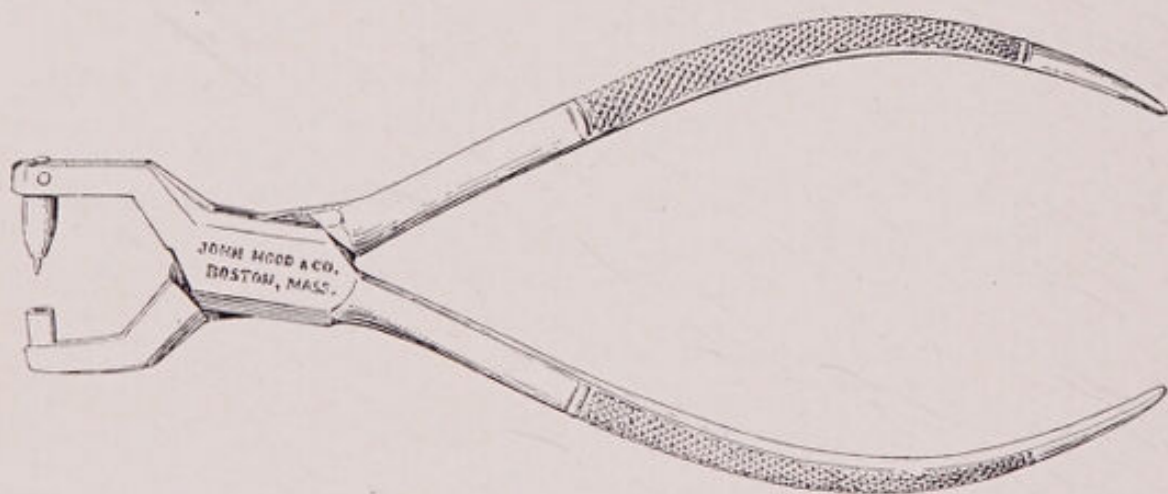


FIG. 79. Dr. Hovestadt's special plate punch.

canal. Push the iridio-platinum post through the cap into the root canal, allowing a short piece of the post to extend from cap. (Figure 80.)

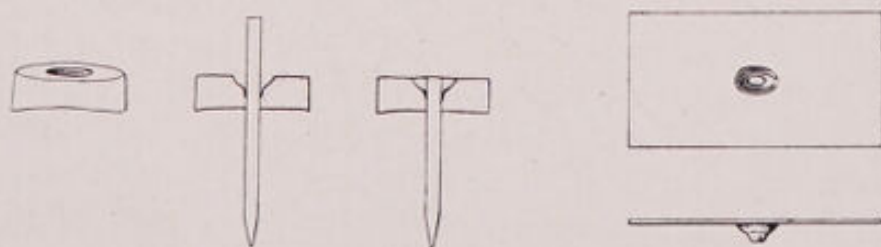

FIG. 80. Showing the use of the plate punch.

Take a small plaster impression to secure the relation of the cap and post.

Remove cap and post and fit into place in the impression. Make small model of impression material. When sufficiently hard break the impression away and solder with 22-karat solder. Sticky wax or Kerr impression sticks may be used instead of plaster impression by heating the end of the stick and pressing it against the extending post and cap. Chill and withdraw. Invest and solder as above. (Figure 78.)

Flow solder first on the post then draw it to the cap; otherwise it would flow over the cap only. *Platinum plate and posts for all kinds of bases in crownwork cannot be surpassed and give the best satisfaction.*

2. BURNISHED CAP (Crown VII)

Root preparation

Cut the root level to the gum line, then bevel all sides of it below the gum, leaving the centre around the root canal opening high. (Figure 74.)

Making of cap

These caps can be made of platinum plate 34 gauge, or 32-gauge pure gold plate.

Take a piece of sufficient size to cover the top of the root and punch a hole through its centre with special punch. (Figure 81.) Place this over the root, and push a previously



FIG. 81. Hand-burnished top with post. (Finished crown.)

prepared good fitting post through the hole into the root canal. Flow a little sticky wax connecting post and plate (small cotton pellets saturated with sticky wax are very practical for this purpose) and withdraw from the root. Invest and solder the post to the plate. To determine the exact outline of the root and to trim the plate or cap accordingly,

take a piece of temporary stopping, press it flat and punch a hole through the middle and lay this over the back of the plate. Heat all and press it on the root, chill and withdraw it. Trim the plate according to the outline of root on the temporary stopping. Then remove the temporary stopping and return the cap to the root, holding the cap in position with a suitable instrument with the left hand, and with the right hand form the plate to the shape of the root by working with a cerated instrument from the post towards the periphery. A shoe-shaped gold plugger is very good for this purpose. Hand or automatic mallets are also very practical to drive the plate to place. The old hand mallet and shoe plugger is, however, preferable to any other method when fitting a platinum plate to the root. Hold the plate in position with the left hand, the right holding the long plugger; the assistant is to deliver two blows at each position of the shoe-point. A cerated instrument lays the metal down smoother and quicker than a smooth flat instrument or burnisher, which will thin out and wrinkle the metal. Remove the burnished cap and trim the edges smooth.

Indirect Method

3. SWAGED CAPS

Root preparation

Prepare the root, removing all decay, and trim it slightly below the gum margin, leaving its centre high. (Figure 82.)



FIG. 82. Steps showing the making of swaged root caps (or coping).

Making of cap

Fit an iridio-platinum post into the root canal as high toward apex of the root as possible.

Remove post and fit a copper band loosely around root.

Shape a Kerr impression compound stick to fit the inside of the band; soften the end of the stick and press it into the copper band on the root. (Figure 82.)

Chill and remove the compound and band and cast a plaster model of the root end.

After the plaster has hardened, remove the compound, lengthen the outline of the root end on plaster model by trimming the plaster.

Powder and press this plaster model of the root into soft moldine, pour Melotte's metal into the impression thus gained. (Figure 82.)

Swage on this metal die a 32- or 34-gauge platinum plate to form a cap or coping. (Figure 82.)

Trim and fit the coping to the root in mouth.

Remove and punch hole through coping with Dr. Hovestadt's special punch.

Place the coping back to the root and force the fitted post through the hole in the coping into the root canal. (Figure 82.)

Dry the coping and the end of the post and place cotton pellet saturated with sticky wax over them to secure the relations of the two.

Withdraw the coping and post carefully from the root and invest.

Solder the post to the coping with a small piece of platinum solder or pure gold. Boil in acid. The swaged cap or coping is now ready to receive its mount.

II. SUPPLIES FOR BANDED CROWNS**A. BANDED CROWN WITH FACING (Richmond)**

Crown VI_A, Crown VII_A, Crown VIII_A

Making of model

After the cap and post are made, by any of the Methods VI, VII, VIII, place the cap on the root. Take a wax bite and plaster impression and stick the cap and post in place into the impression.

Make an articulated model, using an anatomical crown and bridge articulator.

Making of crown

Grind a suitable facing to fit the cap and bite, allowing a space of 24 gauge between it and the occluding teeth. Bevel the back of the cutting edge of the facing.

Make double gold backing and attach them to the facing. (Figures 62, 63.)

Wax facing to cap and post and invest.

Boil the wax out and heat it slowly. Solder with 18- or 20-karat solder. When cool, remove the investment, boil in acid and polish. (See Figure 83.)



FIG. 83. Banded crown with facing.

B. BANDED DETACHED POST CROWN

Crown VI_B, Crown VII_B, Crown VIII_B

Making of model

Fit a cap after Methods VI, VII or VIII, but let the post extend above cap far enough to retain a detachable post crown.

Take a bite and impression with cap and post in place.

Make an articulated model.

Grinding of crown to cap and post

Select a proper sized detached post crown. Rough grind the crown as nearly perfect to the gold cap as possible, then fit

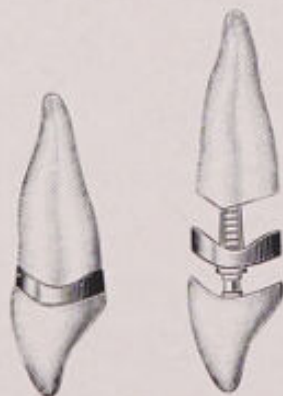


FIG. 84. Soldered cap with detached post crown.

it accurately by rubbing the ground base of the porcelain crown on the gold cap; a black mark similar to a carbon paper mark will be found where the porcelain needs more grinding. Repeat this until the whole surface shows the mark from the metal surface. Also see that the bite is ground correctly.

It is advisable to try the crown at this stage to verify it.

Cement the crown on the cap and post, polish and set. (Figure 84.)

Swaged box for crown

Another method of fitting a crown to the cap and post is to cut off the extending post flush with the cap, make a box with post for the crown, and solder the box to the root cap and post. Have a V-shaped space towards the palatal side of the crown, and bevel the back and sides of the crown to fit close in front only to the cap.

Swage a 35-gauge 24-karat gold box to crown (Figure 85), and solder a post through the box to fit the slot of the crown.



FIG. 85. Swaged cap and swaged box with detached post crown.

Wax the box into place, remove the crown and paint the inside of the box with anti-flux.

Invest and solder.

Boil in acid stone and polish.

Cement crown into the box.

C. BANDED CROWN WITH GOSLEE TOOTH*Crown VIc, Crown VIIc, Crown VIIIc***Making of model**

Make cap VI, VII, or VIII.

Take impression with cap in place, and make model as in B above.

Backing of Goslee tooth

When properly ground, mount the Goslee tooth into softened modelling compound in the swaging ring, leaving that part over which the box is to be swaged, exposed. (Figure 139D.)

Swage a box of 35-gauge 24-karat gold.

Trim the overhanging edges of the gold away.

Punch a hole in the gold opposite the slot in the Goslee tooth.

Fit a suitable-sized iridio-platinum post through gold backing into the slot.

Stick the box and post together with sticky wax.

Withdraw the tooth.

Paint the inside of the box with anti-flux, invest and solder with 22-karat solder.

NOTE.—It is sometimes advisable to reinforce the gold box by soldering a piece of 20-gauge platinized gold or iridio-platinum wire around the palatal rim of the box to prevent the box from changing shape while soldering. (Figure 139H.)

Making of crown

Wax the box with tooth to the cap on the model, remove tooth and invest.

Solder the box to the cap.

Fit and cement the tooth into the box.

Polish and cement onto the root. (Figure 86.)



FIG. 86. Banded crown with Goslee tooth.

D. BANDED CROWN WITH STEELE TOOTH

Crown VIb, Crown VIIb, Crown VIIIb

Making of model

As for C.

Backing Steele tooth

Grind Steele tooth to fit the cap and bite. (Figure 87A.)

Fit the Steele backing to the tooth, cutting away any overhanging edges, except at the incising edge, leave that longer than the facing, wax, invest and solder. (Figure 87 B and C.)



FIG. 87. Banded crowns with Steele facings.

When Steele posteriors are used it is necessary after grinding the tooth to fit the cap and bite, to burnish a piece of 35-gauge 24-karat gold over that part of the tooth which is not covered, having it extend slightly under the Steele backing. Solder the extended piece in open flame as Figure 132, or wax the burnished piece to the Steele backing with sticky wax. Remove it from the tooth. Paint the inside of the backing with Steele anti-flux. Invest and solder the two pieces together.

Replace backing on tooth and see that it fits. (Figures 132 and 134.) To make full box for the Steele posteriors, see Figure 134.

Making of crown

Wax the backing to the cap with sticky wax.

Remove Steele tooth and paint the inside of backing with Steele anti-flux. (Figures 127 and 128.) Invest in a small amount of investment.

Solder the backing or box to the base with 18- or 20-karat solder, restoring the natural tooth form as much as possible.

Cement the porcelain to the metal, finish and polish. (Figure 87.)

D. ALL METAL CROWNS

These crowns are the least desirable ones, as they have not only the disadvantage of extending under the gum in most cases, but also are not esthetic. If they do not serve for bridge abutments, they can be avoided almost entirely. Gold inlays with posts, porcelain crowns with metal bases, and banded post crowns can frequently be used instead. In very badly decayed vital or split teeth, and in the back of the mouth they, however, frequently find their place. Some of the different types of all-metal crowns are:

1. Open-faced crowns, glove fit.
2. Open-faced crowns, other methods.
3. Two-piece crown.
 - (a) With swaged cusps.
 - (b) With cast cusps.
4. Seamless pressed crown.
5. Seamless swaged crown.

1. OPEN-FACED CROWN, GLOVE FIT (Crown IX)

The use of open-faced crowns as bridge abutments is of great value in some cases, especially on the lower front teeth. (Figure 7.)

Preparing of tooth

Remove all contour on the back as well as on the sides of the tooth to be crowned, being careful not to remove the enamel from the labial surface. (Figures 88A and B.)

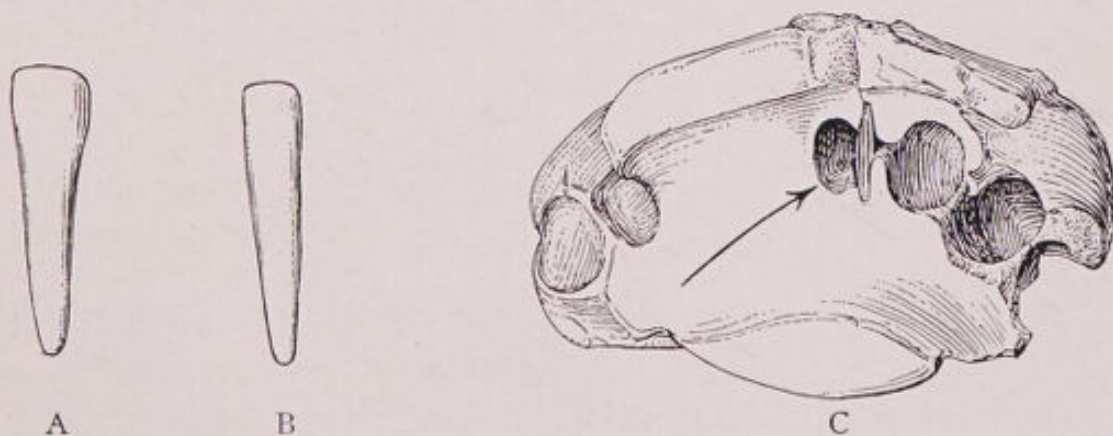


FIG. 88. Steps for seamless open-face crown (glove fit).

Grind the occluding portion of an *upper* incisor, for an open-face crown, so that a space equal to 24-gauge is left between it and the occluding tooth or teeth.

Do not shorten the labial part of the cutting edge of a lower incisor, but bevel the lingual side; this will decrease the showing of gold and also prevent the crown from sliding down on the tooth.

Measure the circumference of tooth at the gum margin with a wire placed in the dentimeter. (Figure 90A.)

Making of model

Take a plaster impression of the prepared tooth and pour into this fusible metal, plunging a broken excavator into it, before it hardens. (Figure 89.)



FIG. 89. Die with handle. Dotted line at neck shows overhang, which has been filed away.

Withdraw the handle with the attached fusible metal tooth from the impression, and file with a rubber file enough from the neck of the metal die to reproduce the shape of the root, which extends under the gum margin. Leave no shoulder on the die. (Figure 89.) Note dotted line.

Making of crown

Select a 22-karat gold shell of sufficient length, the circumference of which must be the same as the wire measurement. (Figure 90B.) (Compare size by fitting each over a mandrel.)

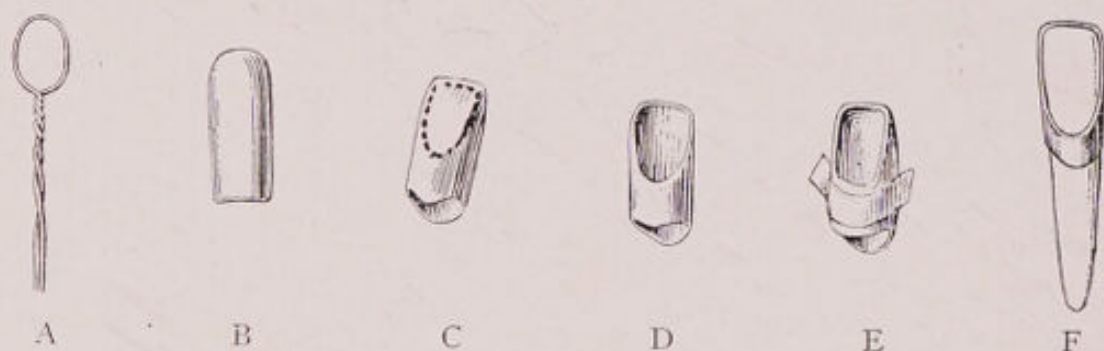


FIG. 90. Steps continued for open-face crown (glove fit).

Anneal the gold shell, paint the inside with whiting and drive the die into the shell gently on a wooden block. When the outline of the cutting edge shows, then drive the sides over the metal tooth, using a small contouring hammer. First tap gently and then with increasing force, always striking the highest points of the shell, until it is finally driven to a glove fit on the metal tooth, and, if necessary, swage it in a small crown and bridge swager. Do not thin out the gold by hammering unnecessarily where it fits close to the die. Support the shell on the die by the pressure of the forefinger of the left hand, the dummy holding the handle and pressing the crown firm against the finger; this will prevent the shell from changing its position at the start. Pull the crown from metal die or boil the die out of the crown in water.

Thoroughly clean the inside of the shell so that none of the fusible metal remains. Put in nitrous acid for a few minutes, if necessary.

Anneal and trim crown to proper length to fit the tooth. When the crown is placed on the tooth in the mouth, mark the area to be cut out for the open face or window. (Figure 90C.)

Remove the crown from the tooth and with a thin metal saw, cut out the marked portion (so-called window.) (Figure 90D.)

Put the crown back on tooth and burnish it to place.

Remove again, contour and reinforce the labial portion with 20-karat gold plate, using 20- or 22-karat solder. (Figure 90E.)

NOTE.—Use light yellow cement for setting open-faced crowns. Bicuspids or molar crowns are constructed as Crown XII or XIII, a window being cut at the buccal side to give a better appearance. Sometimes such a window can be cut in a gold crown if the buccal side of the tooth is decayed, and the buccal side then filled in with porcelain cement of proper color.

3. TWO-PIECE ALL-METAL CROWN (Crown XI)

Root preparation

Cut away all contour from the tooth. Cut the sides of tooth parallel to each other until they are reduced to the size of that part of the neck as far under the gum as the crown is intended to reach. Grind the occluding portion of the tooth enough to allow room for gold cusps with reinforcement. (Figure 91.)

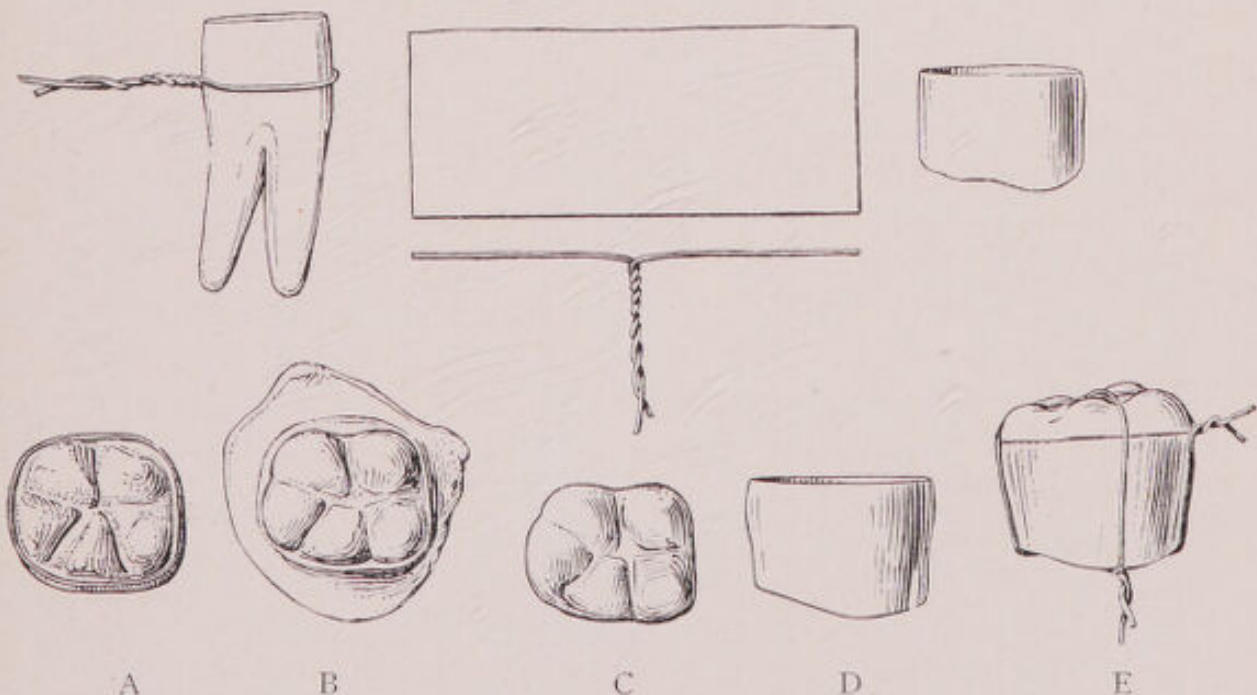


FIG. 91. Steps for two-piece all-metal crown, swaged cusps.

Fitting band

Measure the circumference of the prepared root at the cervical margin with a wire in the dentimeter.

Cut the wire opposite the twist. Cut a strip of 22-karat 30-gauge gold plate the same length as the wire. Have sides parallel and file the ends so that they form a perfect joint when bent to form a band. Bend strip to a band and bind it together with iron binding wire. Solder with borax placed on the outside, a small piece of solder on the inside of the band. (Figure 91.)

Stretch the occlusal end of the band by hammering it on an anvil, to give it sufficient contour to replace the natural shape of the tooth.

Fit the band to the circumference of the root, testing the fit with a smooth broach. Trim the cervical border so that it will at no part penetrate more than $\frac{1}{32}$ inch under the gum. Contour the upper part of the band, so restoring the contact points with the neighboring teeth if there are any.

Cut the occlusal end of the band flat.

A. WITH SWAGED CUSPS (Crown XIa)**Making of the cusps**

Take wax bite and plaster impression with fitted band in position on the tooth. (Figure 94.) See that the band in the impression is in its right place, run a film of wax on the inside of the band and make articulated models, using an *anatomical* crown and bridge articulator.

Remove the wax. Varnish the occluding teeth and burnish thick tin-foil over them.

With a film of sticky wax attach a small block of carving wax over the band. Soften it and press the occluding teeth into it. Carve the cusps, sulci and grooves as closely resembling a corresponding natural tooth as the occlusion will permit. (Figure 95.)

Leave the edge of the band exposed. (Figure 91A.)

Take an impression of the cusps and half the width of the band, with moldine. Cast a Melotte's metal die (Figure 91B) and swage cusps over it, using a piece of 22-karat 30-gauge plate gold. (Figure 91C.) Trim this to fit the occlusion and

the edge of the band (with no overlap). (Figure 91C and D.) Reinforce the cusps and solder the top to the band (Figure 91E) in the Bunsen flame, or by investing and soldering.

NOTE.—If the crown is to be used for a bridge abutment, do not finish it down, boil it very carefully in acid to remove all flux from inside, and try it in the mouth.

B. WITH CAST CUSPS (Crown XIb)

Prepare the tooth for this crown as XI. (Figure 92.)

Cut the band down to the level of the occluding surface of the tooth. Solder a 34-gauge pure gold plate top over it. (Figure 93A.)

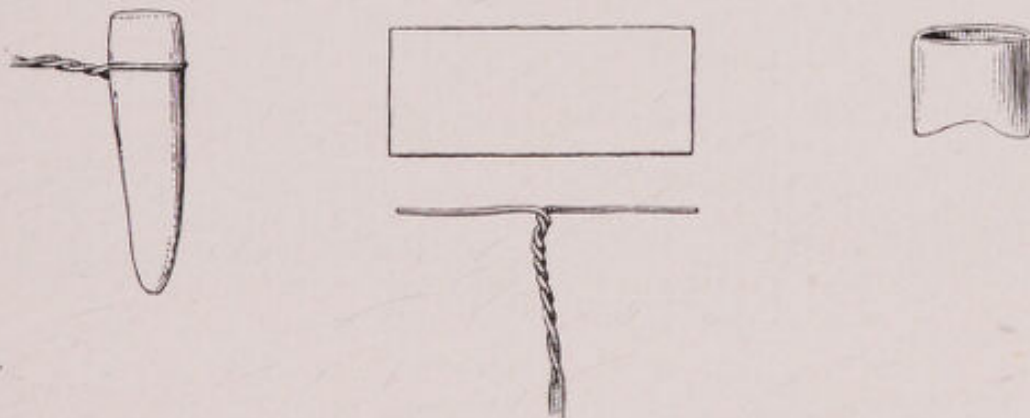


FIG. 92. Steps for two-piece all-metal crown, cast cusps.

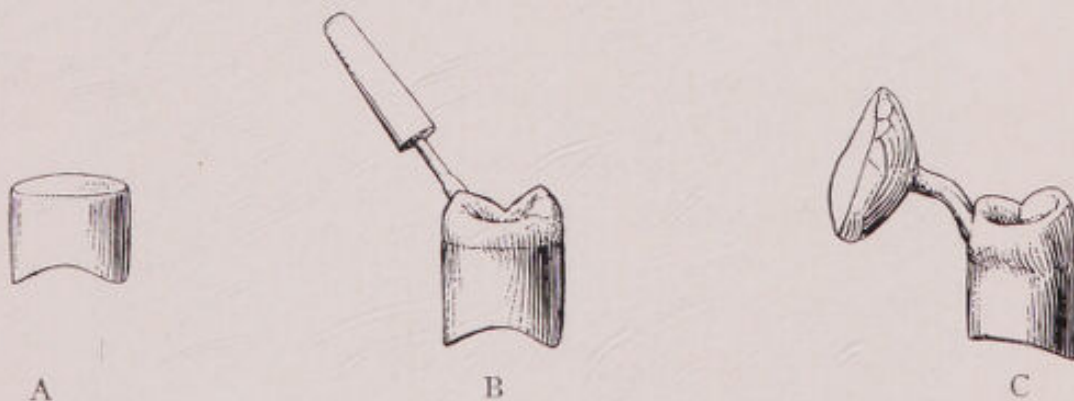


FIG. 93. Steps continued from Figure 92.

Place it on tooth and take a bite and impression, make a model and mount it on an *anatomical* crown and bridge articulator as described for Crown XI.

Soften inlay wax and press it on the top of the band, closing the occluding teeth on it.

Carve cusps as nearly as possible like a corresponding natural tooth, restoring contour and approximal contact. (Figure 93B.)

Remove the crown from the model, place a sprue wire in the thickest part of the wax. Invest and cast with 22-karat gold. (Figure 93C.)

4. SEAMLESS PRESSED CROWN (Crown XII)

Preparing of tooth

Prepare tooth as for Crown XI.

Fit seamless copper band over the prepared tooth. (Figure 94.)

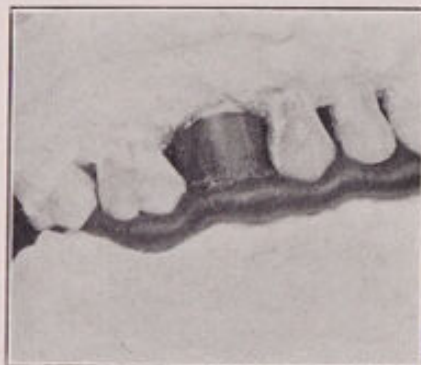


FIG. 94. Taking bite with copper band in position.

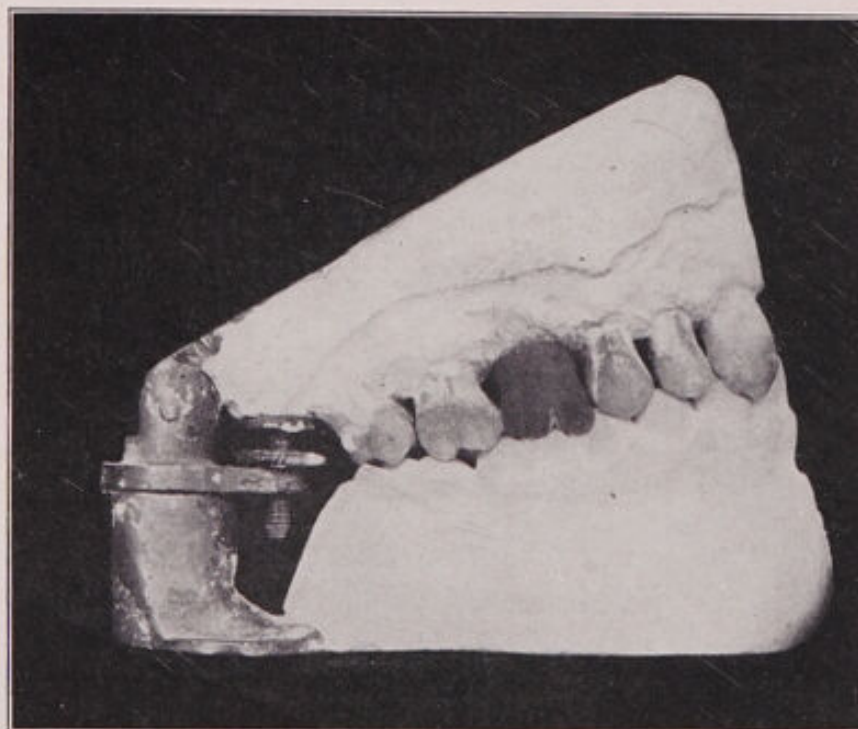


FIG. 95. Crown contoured to copper band.

Take plaster impression and wax bite.

Make a model, remove the copper band, build out and carve the tooth in wax. (Figure 95.) Place a strip of thin plate mesially and distally of tooth.

Take an impression in moldine with a split tray. (Figure 96.) Cut the moldine in halves with a knife, open the tray,

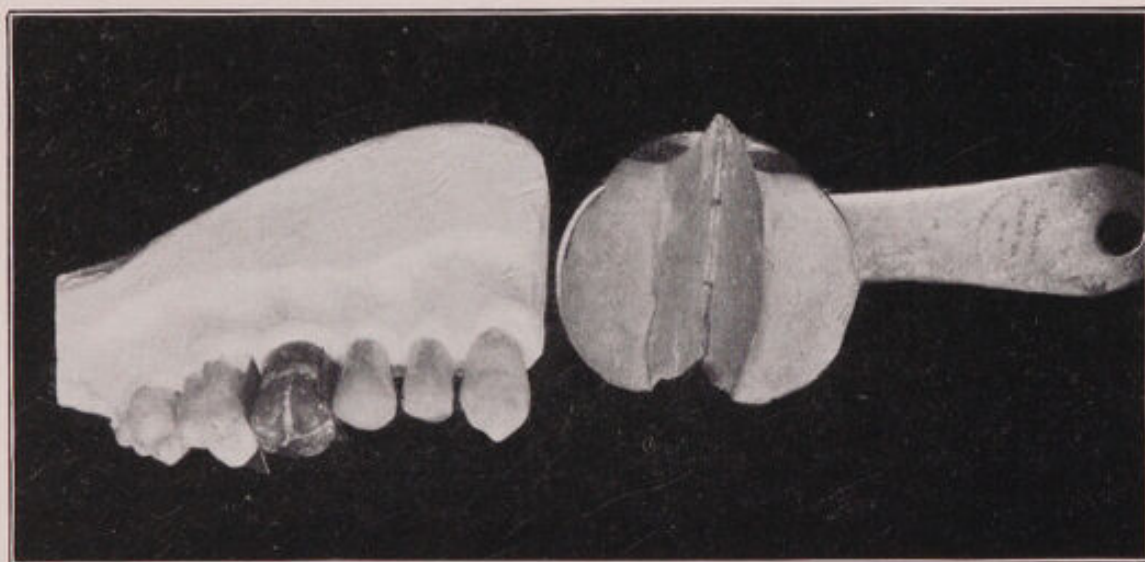


FIG. 96. Showing split tray with moldine to take impression of crown.

powder both halves, and close it upon the crown from both sides. (Figure 97.) Reopen it, withdraw and close. (Figure 98.) Build up with moldine around the impression of the waxed tooth.

Pour Melotte's metal into the impression.




FIG. 97. Split tray in position.



FIG. 98. Tray after removal and closed.

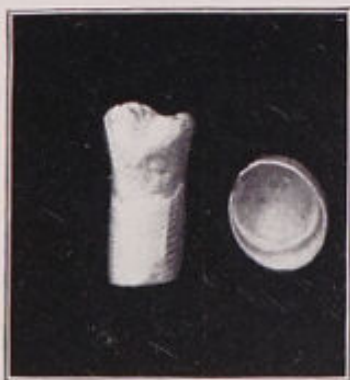

FIG. 99. Metal die and shell.

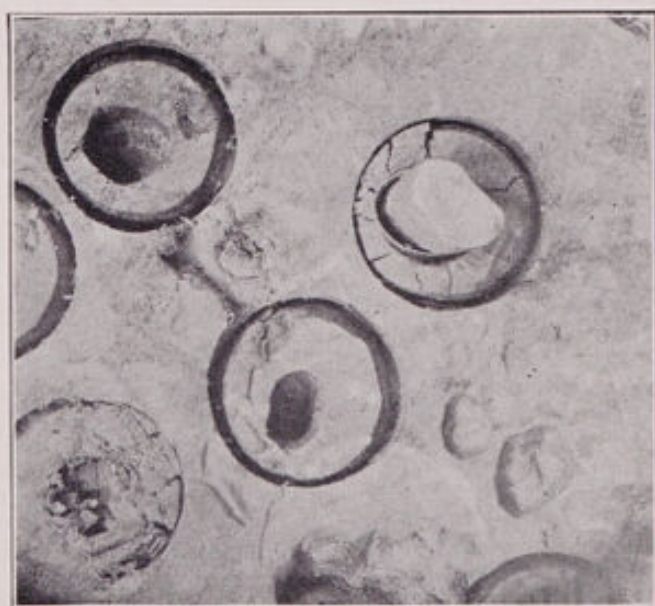


FIG. 100. Wooden block showing imprints of metal die and swager.

Trim the die, file away all overhang at the neck, just leaving a thin outline of gum line. (Figure 99.) Then place a gold shell over it, and drive it into a wooden block as following:

First drive the die into the wood without the shell, then paint the inside of shell with whiting to prevent metal from sticking to gold.

Then place the shell over the die, and gradually shape it with small contour hammer. Now drive the die or shell gently into the wood to about the depth of the shell. (Figure 100).

Place the swager over the die and drive it into the wood. (Figure 101.)

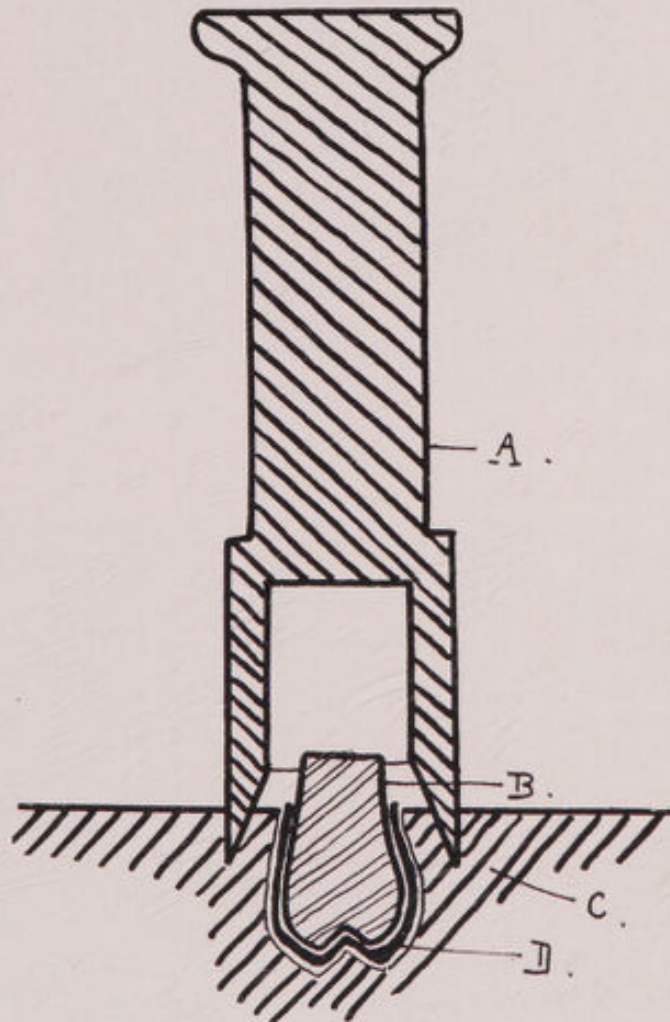


FIG. 101. A, Swager; B, Die; C, Wood block; D, Gold shell.

Take out the die and tap the wrinkles out gently. (Figure 102.)

Repeat the swaging and tapping several times until the shell fits absolutely tight, without showing wrinkles.




FIG. 102. Swaging of crown over die into wood block. Note outline of cervical margin of crown on the die.

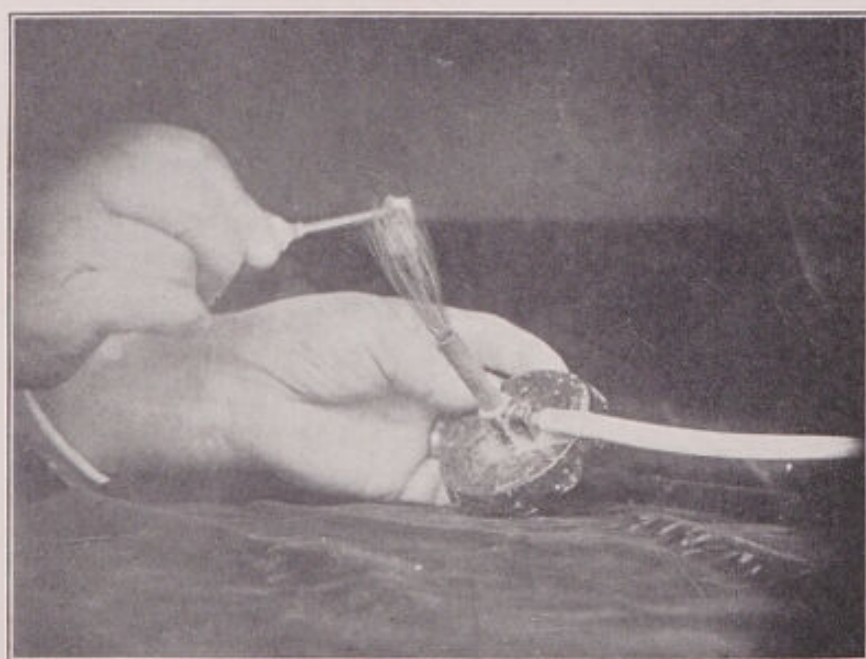


FIG. 103. Melting out the metal from the crown.

Hold the crown between a pair of pliers over the flame to melt out the metal. (Figure 103.)

Then quickly drop the crown into 50% nitric acid and let it remain there for a few minutes.

Trim the gold crown to fit the gum margin, as shown by line on crown. (Figure 102.)

Reinforce crown with solder.

Stone and polish.

This method has the advantage that the crown is thickened by the process instead of being thinned out as in swaging into a die. (Figure 104.)

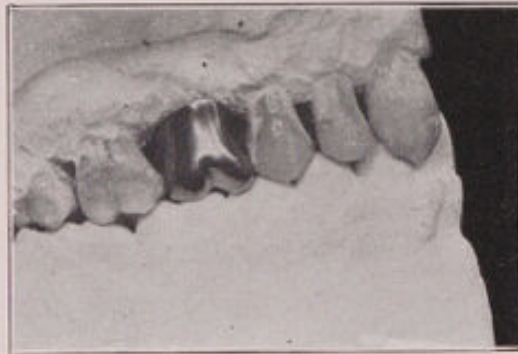

FIG. 104. Finished crown.

5. SEAMLESS SWAGED CROWN (Bridge method) Crown XIII

Preparing of tooth

As for Crown XI.

Making of crown

Measure the circumference of the prepared tooth at the cervix with wire. Select a copper band of the same circumference as wire (by mandrel) and of sufficient length. Fit it over the prepared tooth and trim the cervical edge to the outline of the gum.

Cut occlusal end short enough to clear the bite.

Approximately contour the band by pressing with suitable instruments against the adjoining teeth. Take a wax bite of the copper band and occluding teeth, a plaster impression (Figure 105), and mount the whole on anatomical crown and bridge articulator as in the case of Crowns XI and XII. (Figure 106.)

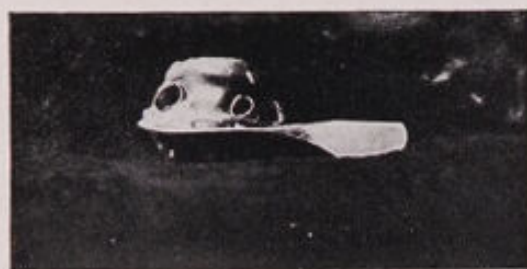

FIG. 105. Seamless all-metal crown. Bridge method. Impression with bands.

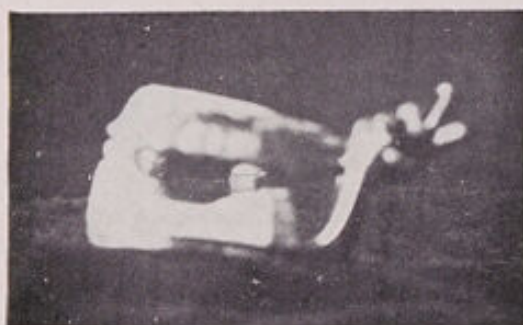

FIG. 106. Bands on articulated model.

With Bridge's carving wax build suitable cusps and contour over the copper band. (Figure 107.)

Remove contoured band with cusps from the model, and place it on a flat piece of moldine or mudola, having same projecting into the band. (Figure 108.)



FIG. 107. Crowns contoured and articulated.



FIG. 108. Ready to cast.

Place Bridge's casting ring over it and pour with fusible metal. (Figure 109.)




FIG. 109. Casting to die.

Have the surface of the fusible metal flush with the cervical edge of the copper band, either by cutting the fusible metal or adding more with a hot spatula, as may be needed to get the outline of the gum. (Figure 110.)

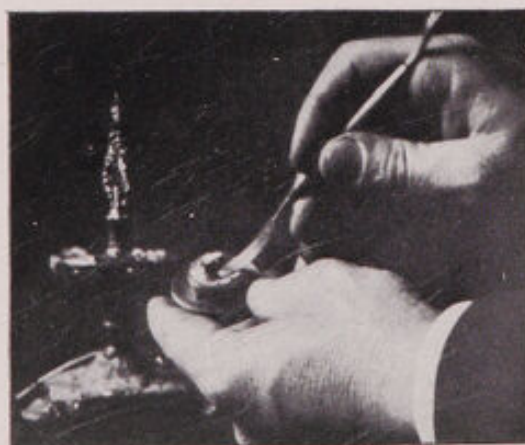

FIG. 110. Building fusible metal to edge of bands.

Knock the fusible metal from casting ring (Figure 111) and split it; remove the copper band and carving wax. (Figure 112.)

Place the two halves of metal back into the casting ring. Place a seamless 22-karat gold shell into the metal die.




FIG. 111. Knocking off metal from ring.




FIG. 112. Splitting of die.

Have the shell of as large a size as will fit into the die. Use bridge swager using vulcanite rubber instead of wax (Figure 113), or:

Fill shell one-third with lead shot and drive it gently into the metal die, using a mandrel of smaller size than the shell.

Add more shot and pound until the desired contour is obtained.

Cut the cervical edge of shell to the edge of the metal die, so as to get the proper length of the crown. (Figure 114.) Remove and cut the crown to the proper length (Figure 115).

Take the crown out of the die and by gently tapping its sides remove all lead shot. Boil in nitric acid to remove the lead and particles of die.

Reinforce the cusps with solder after it is fitted. Then polish.




FIG. 113. Pressing of seamless shell.

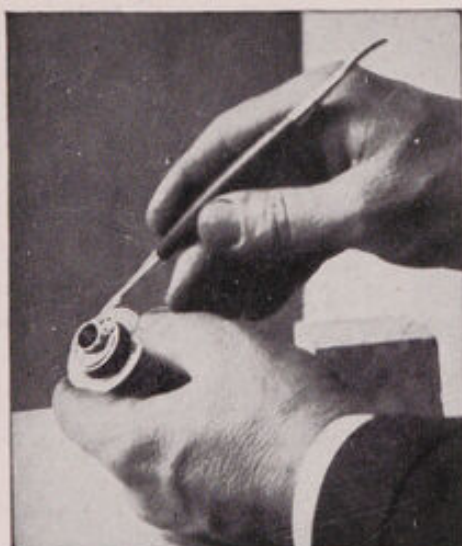

FIG. 114 shows marking of swaged crown to conform to cervical margin as determined by trial band.

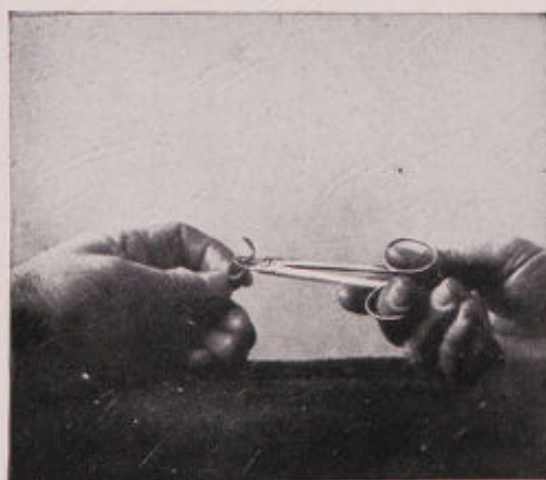


FIG. 115 shows the curved scissors so desirable for trimming crowns and bands, also how to trim a band where marked.

6. GOLD CROWNS WITH PORCELAIN FACING (Crown XIV)

Preparing of root

Prepare root as for Crown XI, but cut away more of the buccal side to allow for the facing.

Making of crown

Fit the gold crown in one of the usual ways, try it in the mouth and outline an opening for the porcelain tooth. (Figure 116.)

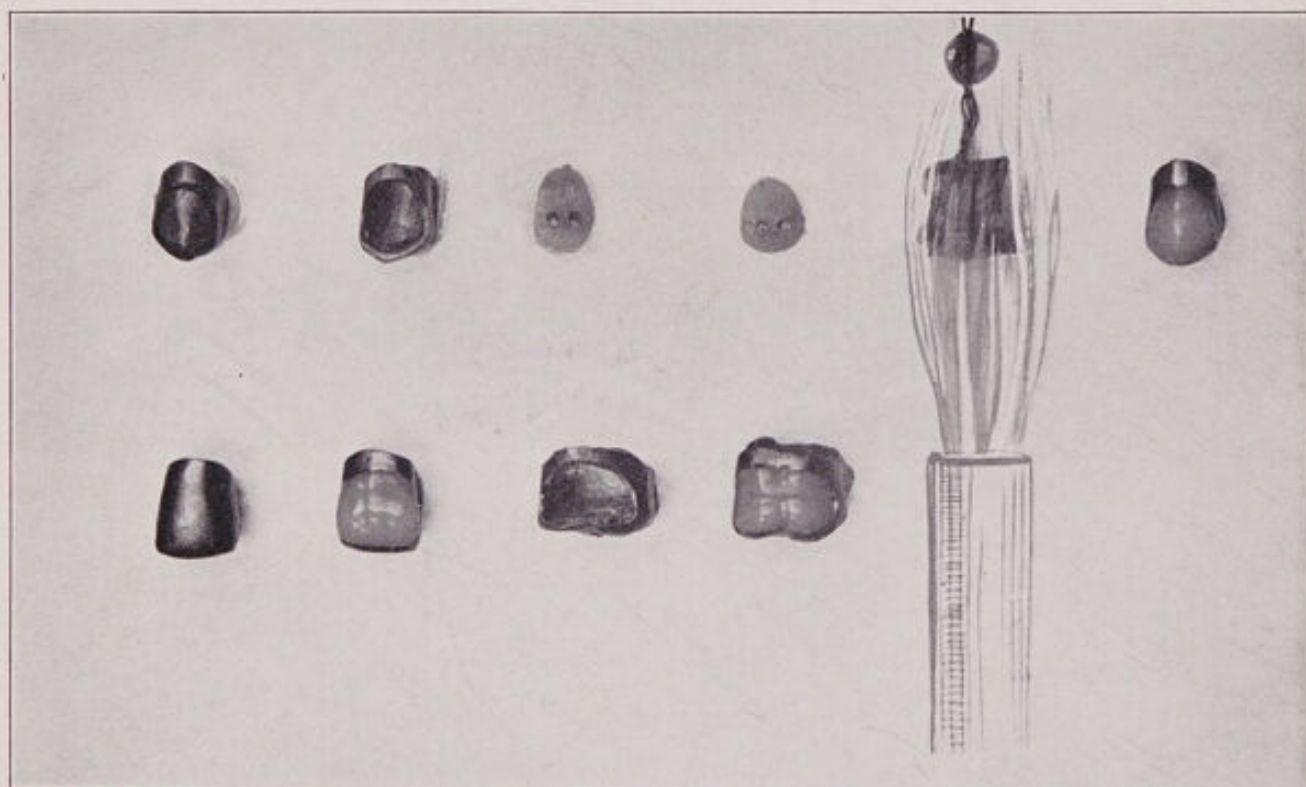


FIG. 116. Steps for crowns with porcelain facing.

Remove the crown from the tooth and cut the window according to the outline. For this use a saw or knife-edged rubber carborundum stone.

Select a thin facing and bevel the sides from the pins toward edges (Figure 116), until reduced to fit the window or opening in crown. Back the facing with 36- to 38-gauge pure gold, file the gold flush to edges, and allow no overhanging of the backing.

Wire it to place (Figure 116), place borax and solder in the inside of the crown and solder in the open flame. There is little danger of cracking the facing if the crown is heated and cooled slowly. It is well to hold the crown with the facing towards the flame, as the facing requires the most heat for soldering.

Finish and polish.

VIII. FIXED BRIDGES

The ideal replacement of lost teeth is by the fixed bridge-work, but only if suitable conditions favor such replacements. If the teeth and roots, which are to serve as abutments, are in a healthy condition, or if they can be put in such a condition by treatment, if the occlusion and the distance between the gum and the antagonizing teeth is of sufficient width, then a fixed bridge will be found most satisfactory indeed.

A. ABUTMENTS FOR FIXED BRIDGES

Bridge abutments should be selected according to their practical value and strength, technical conditions, prophylactic and esthetic properties. It is of greatest importance to select the right kind of abutments, and a careful study should be made of the prevalent conditions. Here at the *start* is the opportunity for the operator to show his ability and foresight, which will lead to success. The lasting quality of a bridge depends greatly upon the choice of the abutments. It would be unwise to use open-faced, staple or half-shell crowns with posts in a mouth with acid conditions, because these would not last very long, the cement would dissolve and the teeth decay at the exposed surfaces. In a close bite we should not use Goslee teeth, Steele posterior or Davis crowns, as they could not be made strong enough. In pyorrhoeatic conditions, bands under the gums should be avoided, and the foremost thought in constructing the bridge, should be the possibility of prophylactic treatment of the abutments and the adjoining teeth. Some of the bridge abutments have already been described in the previous chapter on single crowns; they will therefore only be referred to here, while abutments which have not yet been spoken of, will be described in detail.

INLAY ABUTMENTS

1. INLAY WITH POSTS AND M. O. D. INLAYS (Abutment I)

Inlays for bridge abutments should be cast with platinized gold. They should invariably have posts in the pulp canals

with the possible exception of M. O. D. cavities (mesial, occlusal, and distal cavities).

All cavities for inlay abutments should be sufficiently cut so that the gold extends well towards the buccal and lingual

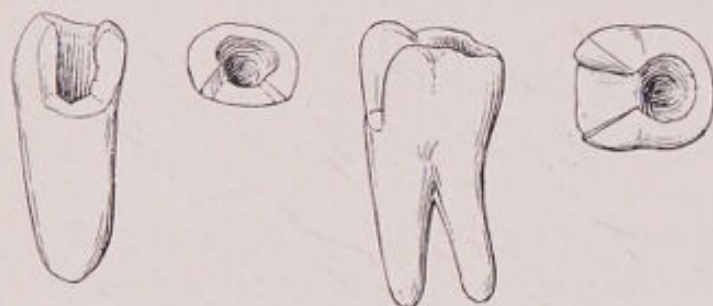


FIG. 117. Tooth preparations for inlay abutments.

surface, this gives the patient a chance to keep the margins clean. The cervical margin of the inlay should extend below the gum.

Impression

Inlays can be made by the direct, but preferably by the indirect method. In the latter method we take an impression with a small tray, a seamless copper or aluminum band. Fill

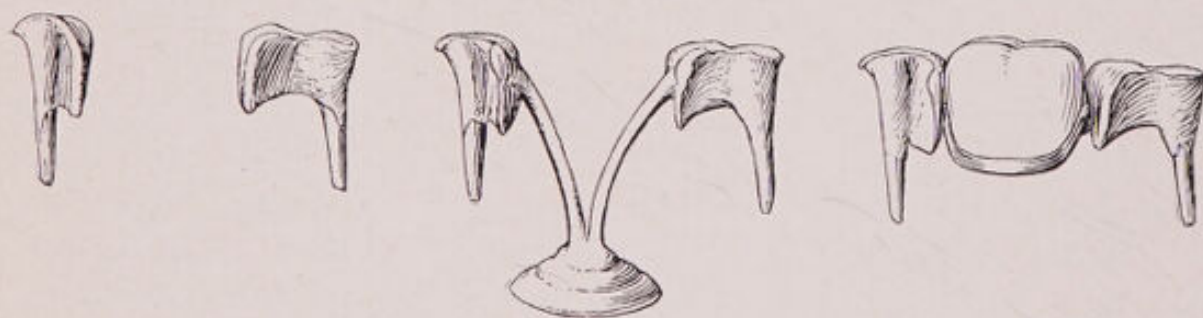

FIG. 118. Steps for bridge with inlay abutments.

it with Kerr's modelling compound (stick form), and press it over the tooth or place the ring over the tooth, pressing the softened end of the modelling compound stick into it. Let it cool.

The wax pattern is then roughly shaped in the mouth, by letting the patient bite into it, and also perform slight lateral masticating movements. Take also a wax bite of cavity, and the adjoining teeth in case an articulated model is wanted.

For Taggart's wax use the following method:

Mount the pieces of wax on long pins that are stuck into a large round piece of cork to fit the top of a water glass. The glass is filled with hot water. The heat of the water may be tested by holding a piece of wax in same, and should not be quite as hot as to turn the wax pale. The pieces of wax mounted on the pins of the cork are allowed for a few minutes in the hot water, and may then be found just right to press into the tooth cavity or metal die.

Kerr's blue inlay wax is commendable, and can be softened in the flame. Good results can be obtained, if handled carefully.

Making of die

The impression in the seamless band is invested in plaster and when plaster is hard, filled with silver and tin amalgam, carefully packing it into all the grooves and corners. If there is a post in the inlay this should be withdrawn with the impression. Cover the end of the post, extending out of the impression, with a thin film of wax so that it can be removed from the amalgam die later.

After the amalgam has hardened, the modelling compound should be softened in moderately warm water and removed. The die is now trimmed best with a sandpaper wheel on the lathe. In case we want to carve the wax on a model, trim the distal and mesial ends of the die cone-shaped, so as to be able to remove it from the model, then place it into the plaster impression taken for this purpose from the mouth. Make an articulated model from the metal die and bite.

Carving inlay

The wax pattern is now placed into the die. Sometimes it has to be slightly warmed first, but not enough to lose its form, nor press it out of shape. After it gets hard, carve it with special carving knives, reproducing all the cusps, grooves, fissures and sulci, which are best copied from a good selection of extracted teeth, or a good model taken from a mouth of perfect teeth. After carving the wax, Taggart recommends smoothing the surface by the aid of alcohol or chloroform.

Place a sprue wire, which is to be of the size of a common pin (but a large one will do), into the greatest bulk of the

wax. Remove the wax from the model carefully, and with a very fine camel's hair brush remove all fatty substances by painting the whole surface with alcohol; this makes it easier for the investment to stick.

Place the sprue wire on the sprue, fixing it with wax if necessary.

Investing

Proceed as described in chapter on casting.

Cast

Cast as described in the chapter on casting. It is best to use every time new gold as it is seriously affected by every remelting.

B. BANDED CROWN ABUTMENTS

I. BASE FOR BANDED ABUTMENTS

1. SOLDERED CAP (Abutment II)

See Crown VI.

2. BURNISHED CAPS (Abutment III)

See Crown VII.

3. SWAGED CAPS (Abutment IV)

See Crown VIII.

II. SUPPLIES FOR BANDED ABUTMENTS

A. WITH FACING (Abutment II_A, III_A, IV_A)

See Crown VI_A, VII_A, VIII_A.

B. WITH DETACHED POST CROWN (Abutment II_B, III_B, IV_B)

See Crown VI_B, VII_B, VIII_B.

C. WITH GOSLEE TOOTH (Abutment II_C, III_C, IV_C)

See Crown VI_C, VII_C, VIII_C.

D. WITH STEELE TOOTH (Abutment II_D, III_D, IV_D)

See Crown VI_D, VII_D, VIII_D.

C. ALL METAL ABUTMENTS (Abutment V)

1. HALF CROWN WITH POST

Preparing of tooth

Remove pulp under rubber dam by opening the tooth on the palatal side, near cutting edge, so as to get in straight line with the root canals, and fill the apex of the root canal carefully.

Enlarge the canal and fit an iridio-platinum post into same.

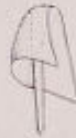

FIG. 119. Half crown with post.

Remove the post, reduce the tooth to clear the bite of the opposing teeth, have a 24-gauge space to allow for gold plate and reinforcement of the crown.

Cut away the approximate contour of the tooth on the side where the dummy is to be attached; this may be mesially, distally, or on both sides.

Remove all contour on that surface of tooth to be covered.

Making of die

Take plaster impression of the prepared tooth without the post.

Remove the plaster impression, bank both sides of the impression of the tooth with moldine, and flow low fusing metal into it.

Pull the metal from the impression, and file the neck of the metal tooth on the palatal and approximal side, to reproduce the shape of the root under gum margin, so as to allow the gold backing to extend slightly below the gum.

Making of crown

Swage a 24-karat 30-gauge gold backing over the back of tooth.

Trim and fit the swaged backing to tooth in the mouth.

Force the iridio-platinum post through the backing into canal opening, allowing the post to extend a little through backing. Flow sticky wax over backing and post, remove carefully, invest and solder, or take a plaster impression.

Remove backing and post carefully from the tooth, place them into their place in the impression, and cast a model.

Solder the post to the backing and flow solder, evenly, over the palatal surface, but not on the mesial and distal wings. This is to allow for the burnishing into place at the time of cementing. Be sure to use a light yellow cement for the setting of the half crowns with post, to bring out the natural color of the tooth.

2. STAPLE CROWN (Abutment VI)

Preparing of tooth

Grind the occluding portion of tooth so that a space equal to 24 gauge is left between the occluding tooth or teeth.

With thin safeside carborundum disc cut enough contour from the mesial and distal surfaces of the tooth to allow a 30 gauge gold plate to pass between the adjoining tooth.

Remove all contour from palatal side of the tooth. Then cut a horizontal groove for the staple. This groove should be started well toward the cutting edge of incisors and through the occlusal fissure in bicuspid. (In most cases this groove is best started with a thin carborundum disc.)

For mesial and distal grooves use a round bur (size S. S. White $\frac{1}{2}$).

The grooves can be enlarged with a fissure bur to 18 gauge.

NOTE.—Extreme care must be taken to have mesial and distal grooves parallel to each other and with the long axis of the tooth.

Fitting staple

Measure the length of mesial groove with 18-gauge iridio-platinum wire.

Mark the wire at point where mesial and horizontal grooves meet, and bend it at the point marked.

Hold the wire into the horizontal groove with the bent end in the mesial groove and mark the wire, for the length of horizontal groove.

Bend at the mark.

Measure with plain wire the length of distal groove, and mark the length on the platinum wire.

Cut the wire at that mark and file the ends square.

By adjusting and bending, fit the staple accurately, and see that it fits firmly.

Making of crown

Place staple into position and take a plaster impression of the tooth.

Remove the plaster impression and place the staple wire into the impression.

Flow low fusing metal into it.

Pull the metal from impression and file the neck of the metal tooth to reproduce the shape of the root slightly under the gum margin. The staple is now in the metal die.

Swage backing of 30-gauge 24-karat gold plate over the back of tooth (metal die).

Have the gold backing cover the tooth, from cutting edge to below the gum line, and extend it mesially and distally beyond staple wire.

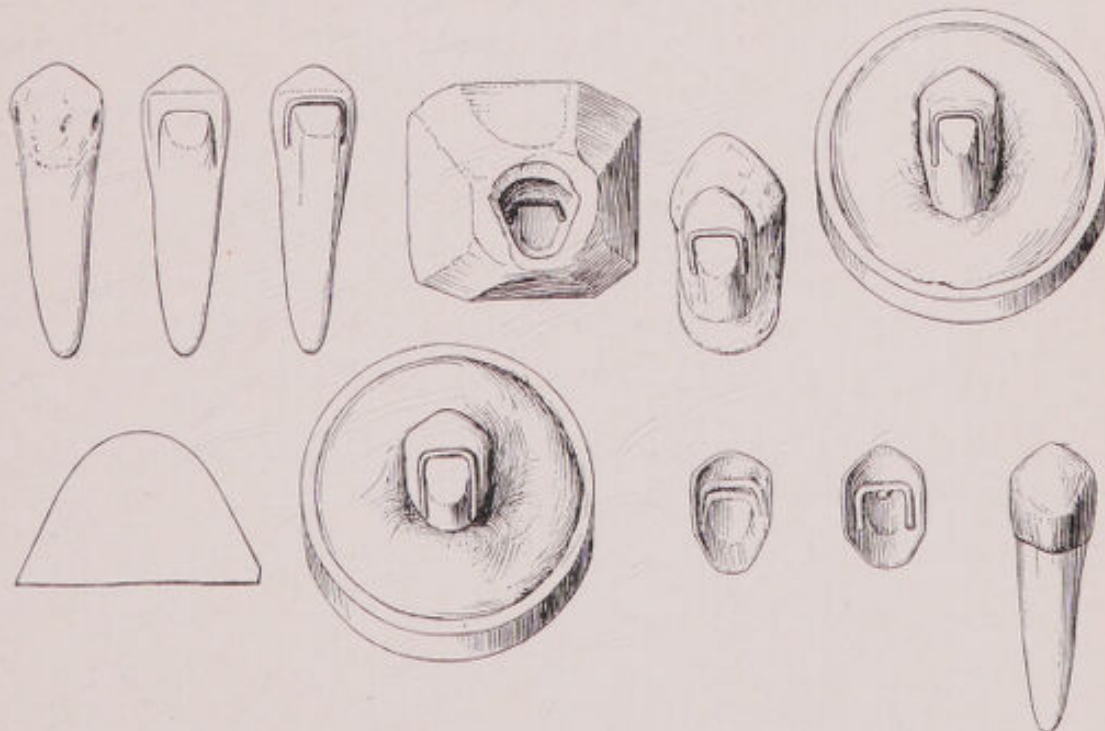


FIG. 120. Steps for making of staple crowns.

Remove the backing and leave it in nitric acid for a few minutes. Force or melt the staple out of the die, and place it in the groove of the swaged backing. Catch it at one point with 22-karat solder, and fit the crown on tooth in the mouth, by pressing against the staple of crown to force it to place; burnish the whole surface. Remove and complete the soldering of the staple. Boil in sulphuric acid, trim and place it on the tooth, take wax bite and impression for the bridge. (See steps, Figure 120.)

NOTE.—When soldering dummies to a staple crown, flow the gold solder well over the backing, the palatal surface of the staple crown, except at the mesial and distal wings, which should remain soft so that they can be burnished.

Use light yellow cement for the setting of staple crowns, and burnish the wings, when cementing, to get close adaption on mesial and distal parts.

3. OPEN-FACED CROWN, GLOVE FIT (Abutment VII)

See Crown IX.

4. OPEN-FACED CROWN, OTHER METHOD (Abutment VIII)

See Crown X.

5. TWO-PIECE ALL-METAL CROWN (Abutment IX)

See Crown XIA-XIB (swaged and cast cusps).

6. SEAMLESS PRESSED CROWN (Abutment X)

See Crown XII.

7. SEAMLESS SWAGED CROWN (Abutment XI)

See Crown XIII.

8. CROWN WITH PORCELAIN FACING (Abutment XII)

See Crown XIV.

B. SUPPLIES FOR BRIDGEWORK

There are different ways of supplying the lost teeth. The best supply is the one that has a porcelain chewing surface, but with a close bite, gold is advisable to give the desired strength.

1. CAST SUPPLIES (Supply I)

Make articulated plaster models, with abutments in place, and press softened inlay wax between them. (Figure 121.) Occlude the articulator so as to get imprint of the occluding

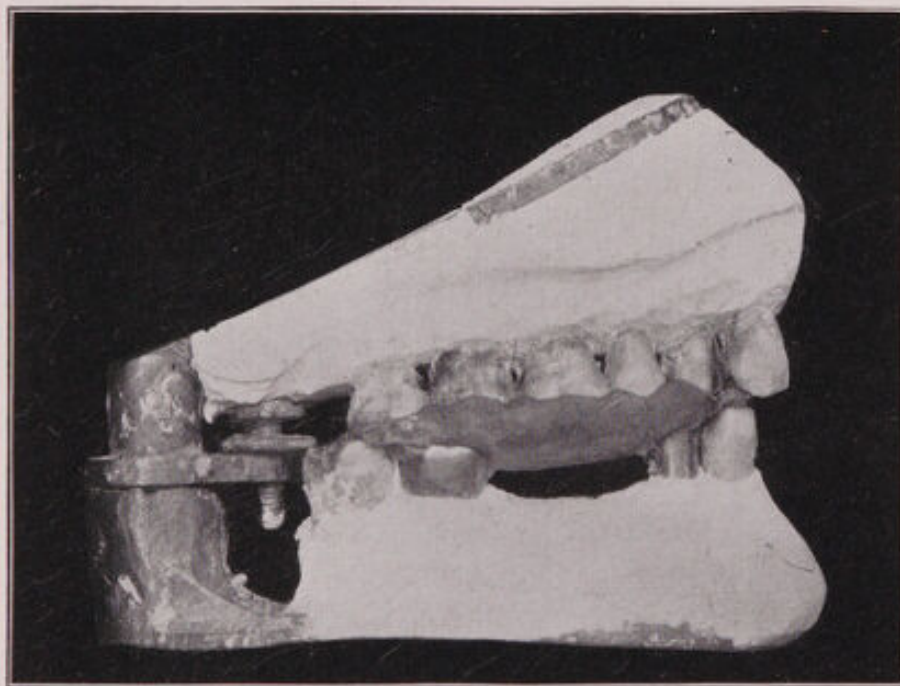


FIG. 121. Model on articulator for cast supplies.

cusps, the teeth occluding opposite. Make also masticating motions. When cold carve the wax as nearly like the cusps of natural teeth as occlusion will permit.

Slant the wax on the under side, so as to form a bevel toward center, or a V-shape in cross section.

Remove wax from the model, insert a sprue wire, invest and cast with 20-karat gold. (Figure 122.)

Stone or file casting and wax it to the bridge abutments.

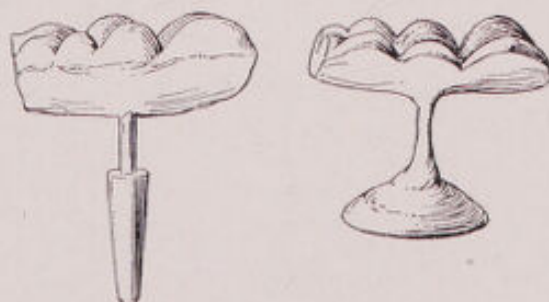

FIG. 122. Supplies before and after casting.

2. FACINGS WITH DOUBLE BACKINGS (Supply II)

Bevel back of cutting edge of facing.

Cut out 31-gauge 24-karat backing to extend from the ridge lap and beyond the cutting edge. Anneal, punch holes for pins and burnish it on the facing. Then insert in modelling compound and swage, but do not have backing bent over cutting edge.

Cut a 26-gauge 18-karat backing to extend from below pins to over cutting edge. Punch holes. Burnish and swage this in place over the first backing. Do not swage second 24-gauge

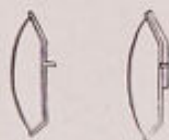

FIG. 123. Facings with single and double backings.

backing on thin or narrow teeth, as the facing is liable to crack. Bend such a backing approximately to fit, and fill the space between the two backings with solder.

Remove backings and unite them by flowing solder between them so that this will show at all edges. (Figure 63.)

Boil in 20% sulphuric acid.

Replace the backings on the facing and burnish it around the pins with a hollow burnisher. Do not cut or split the pins.

File to an approximate finish; then wax the facings to the abutments.

Remove the model from the articulator, cut surplus plaster off and invest in a good investment, so that nothing is exposed except the backing and metal of the abutments. A small investment ring is often very advantageous to hold the case together.

Cut the investment to get free opening to the parts to be soldered.

Heat slowly over the flame and solder.

3. FACINGS WITH SWAGED CUSPS (Supply III)

Grind suitable facing to fit the gum and the bite, leaving a space of 24 gauge between edge and occluding teeth.

Bevel the cutting edge of facing on the back side.

Swage 31-gauge pure gold backing to the facing, allowing it to extend $\frac{1}{2}$ of an inch over the cutting edge. Wax the backing to the pins and the whole on the articulated model, using sticky wax.

Build cusps with pink base plate, wax and occlude to get the imprint of the opposite teeth, then carve the occlusal surface as nearly as possible to natural shape.

Chill the wax cusps and take an impression of them in moldine.

Flow a Melotte's metal die. Make a counter die if necessary.

Swage the cusps of 22- or 24-karat, 31-gauge gold plate, place gold plate over the die, using a small swager if possible.

Drop in nitric acid for a few minutes to remove Melotte's metal.

Trim the gold cusps to the proper size. Place them on the wax cusps on the model and settle them to place with a hot spatula, trying the occluding bite. (Figure 124A.)



FIG. 124. Facings with swaged cusps. A, normal; B, for close bite.

When the case is all set up, add investment to the model to hold the cusps and backed facing in position. Invest in a metal ring. Boil the wax out. Dry. Heat up and solder, filling the space between palatal edge of cusps and cervical edge of the backings first, then connect the individual dummies, and the dummies to the abutments.

Fill all level with solder.

Let cool slowly, cover the case to prevent draft from touching it.

File the cutting edge of the metal in a continuous line with or at an obtuse angle to the labial surface of the facing, so that the occluding teeth will not strike the facing.

NOTE.—In very close bites, use double backing, attaching cusps to a part of the backing beyond the cutting edge. (Figure 124B.)

4. DETACHED POST CROWNS IN BOX (Supply IV)

Grind the porcelain crown, which can be hand-carved, or a stock crown to occlude and fit the gum at the labial or buccal side. Leave space enough for the thickness of the box and its reinforcement.

Swage a box and fit a post as described in crown VIB or VIC. (Figure 139A and D.)

To add strength to the box and post, solder a piece of 18- or 20-karat 28-gauge gold plate over the base of the box. (Figure 139B.)

Wax the boxes with teeth to the abutments and remove the teeth before investing.

Paint the inside of the boxes with anti-flux, cut the model from the articulator, and extend the investment to fill the boxes.

Solder with 18- or 20-karat solder to get about the natural shape of the teeth.

5. STEELE FACINGS (Supply IV)

Steele facings may be used to advantage as supplies instead of pin facings, in bridgework.

Grind Steele facing to fit the gum and bite. Do not bevel the tip of facing as is done with pin facings. (Figure 125.)



FIG. 125. Bridge with supplies of anterior Steele teeth.

Fit a Steele backing to the ground facing, trim off overhanging edges of the backing, except at the incising edge, where the backing should be left longer than the facing. (Figure 129.) Wax, invest and solder.

When the bridge is finished, do not file the backing flat at the end of the facing, but use the file in a line continuous with the labial bevel of the facing.

Do not cement the Steele facings to the backings until the bridge has been tried in the mouth and is found to be perfect.

Cement them to the bridge before cementing the latter into the mouth, using a right color cement.

NOTE.—Be sure in all cases to wash the bridge well; *leave no acid* on bridge backings or tooth boxes, as otherwise a cemented tooth (the cement) will be affected by same and drop off.




FIG. 126. Steps for making of Steele anteriors crown.

6. STEELE POSTERIORES (Supply VI)

In using Steele posteriors as supplies in bridgework, first grind the tooth to fit gum and bite.

Place Steele backing in place on the tooth. Burnish or swage a piece of 35-gauge 24-karat gold over the back part of the tooth not covered by the Steele backings, and allow it to extend slightly under the edge and sides (Figure 132 of the lat-



FIG. 127. Steele Anti-flux. Indispensable in crown and bridge work.

ter). Wax the 24-karat gold extension to the Steele backing with sticky wax and remove it from the tooth. Paint the inside of backing and extension with Steele anti-flux. (Figures 127 and 128.) Invest and solder them together, or hold in

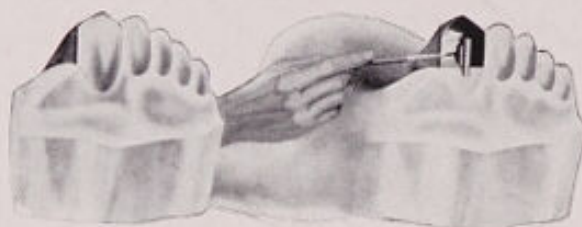

FIG. 128. Painting of backing with Steele Anti-flux.

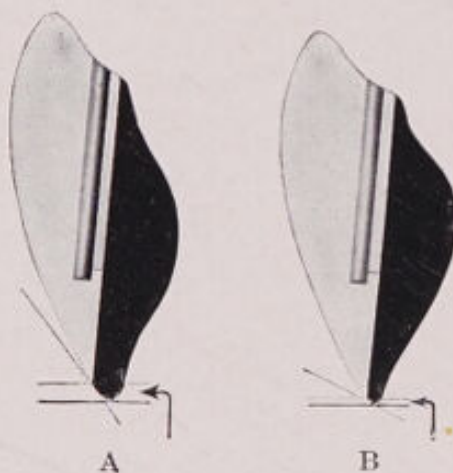


FIG. 129. (Oblique line) right and (arrow point) wrong way of filing backings.

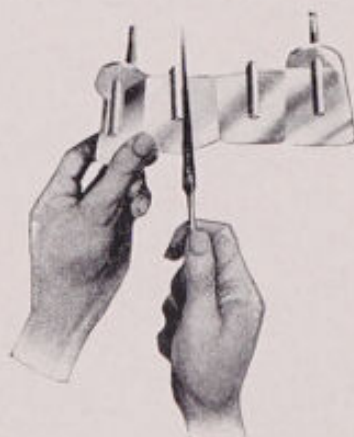


FIG. 130. Filing to remove obstructions.

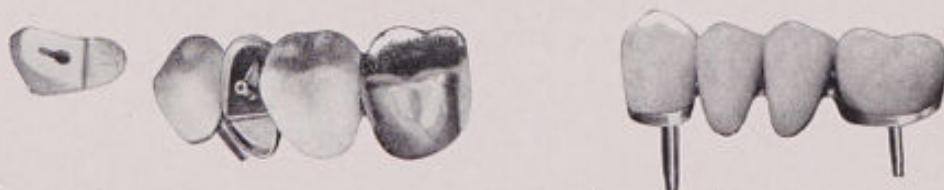

FIG. 131. Bridges with Steele posteriors.

place and solder in open flame. (Figure 132.) Place backing and extension back on the tooth, and burnish it to accurate fit. To make a box, use a common leather or ticket punch and punch hole in a 24-karat gold plate, solder plate to backing (Figure 134). Swage to Steele posterior or as per Figure 139D.

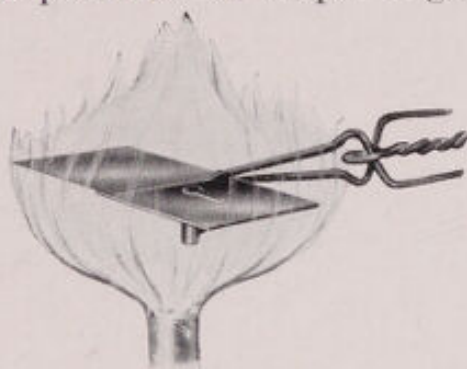


FIG. 132. Soldering extension to backing.

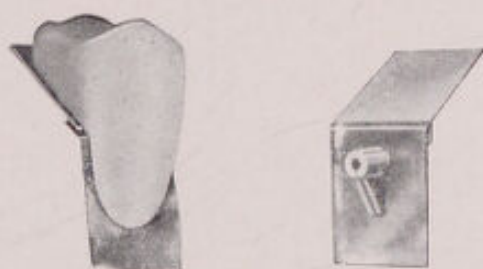


FIG. 133. Fitting to tooth.

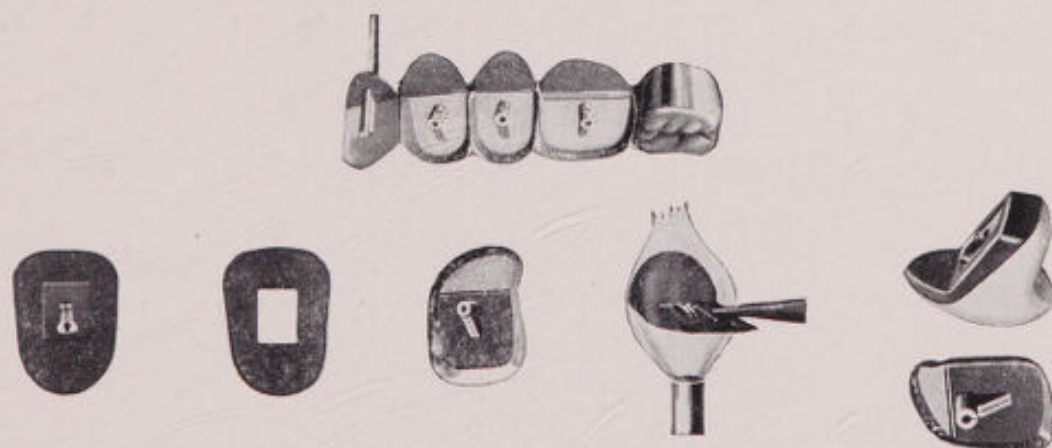


FIG. 134. Steps for making of box of Steele posterior.



FIG. 135. Above bridge with short teeth, and short gold crown abutments; this has no wash spaces, and its weakest point is where the Steele posterior molar joins the gold crown.

Place backed tooth in position on the model in its proper relation to the abutments. Wax backings to the abutments. Remove teeth from backings. Paint inside of backings with Steele anti-flux. Invest and solder the dummies and abutments together.

NOTE.—To obtain strength and wash space in close bite cases when the Steele posterior fits close to the gum margin and the abutment, leave a V-shaped space between Steele tooth and gum margin. (Figure 136.) Burnish or swage the Steele



FIG. 136. Steele posterior molar with slice cut from the distal side; this will overcome the weak place next to its abutment, as shown in case above.

backing over the bevelled surface and proceed as above. Base metal posts and backings as these will not stand the soldering and acid.

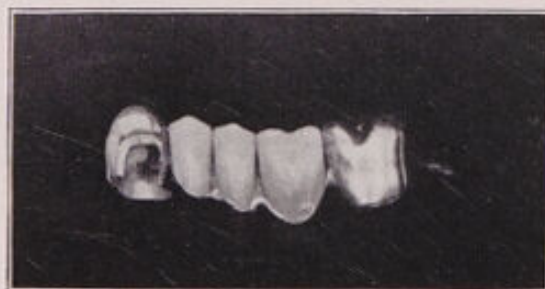


FIG. 137. Notice the wash space and freedom of the festoon next to crown abutments and dummies. This is very important and should be provided for in all fixed bridges.

7. GOSLEE TOOTH (Supply VII)

Goslee teeth can be used as dummies with or without saddle, as the case may call for.

Grind Goslee tooth to fit the bite and the gum, leaving sufficient space between gum and Goslee tooth for thickness of box, as described for crown VIC.

To swage a box for a Goslee tooth, invest the tooth in modelling compound as shown by centre (Figure 139D.)

Swage 35-gauge pure gold box.

Solder a post to the box and reinforce same. (Figure 139B.)

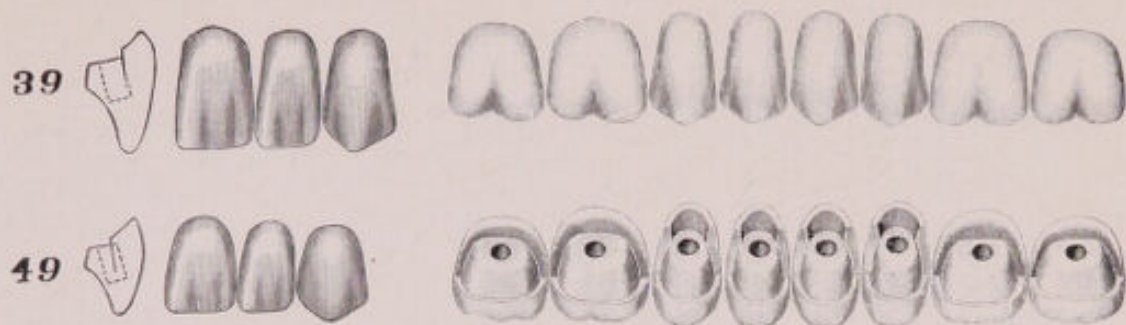


FIG. 138. Anterior and posterior Goslee teeth.




FIG. 139. Steps to show making of boxes for Goslee teeth, or other porcelain crown.

C. ASSEMBLING BRIDGES

Bridge I

1. SANITARY BRIDGES

a. Sanitary bridges with gold chewing surfaces

After the supply is cast, it is waxed to the abutments. (Figures 121-122.)

Fill the space between the supply and gum with investment. (Figure 143.)

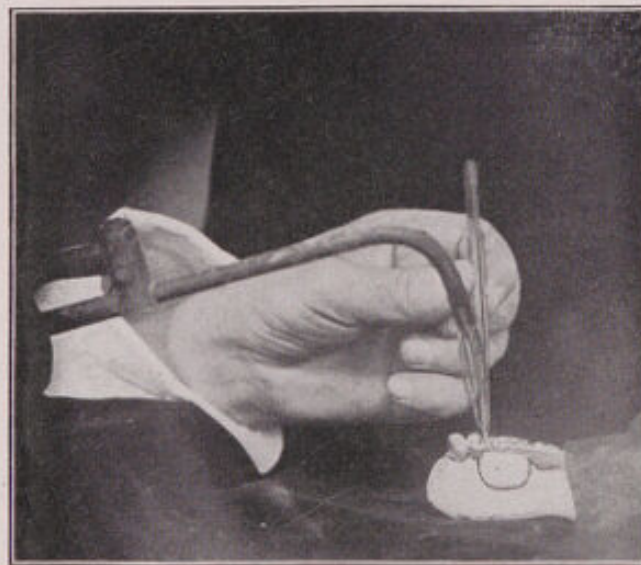


FIG. 143. Soldering of casting to all metal abutments.

Remove the model from the articulator, trim it to small size and heat it slowly.

Solder from the occlusal surface with 18- or 20-karat solder, stone and polish.



FIG. 144. Top view of sanitary bridge.



FIG. 145. Sanitary bridge with gold casting.

b. Sanitary bridges with porcelain chewing surfaces.**Bridge IV.**

If there is sufficient space between the teeth of the opposite jaw and the gum, use detached post crowns, or other porcelain boxed teeth, to get a porcelain chewing surface, which masticate better and give a better appearance. This is especially important for orators or singers. These porcelain crowns should be trimmed down sufficiently, however, so as not to take up too much space. The gold underneath is again V-shaped, so that it can be easily kept clean from both sides.

Make a model with the abutments and grind the detached post crowns or diatoric teeth to get a good occlusion. Then shorten them at the lower part, but not enough to weaken the crown.

Proceed as described for supply IV.

After the bridge is invested and heated up, flow 18- or 20-karat solder over the boxes. Sometimes, especially if the bridge is long, it needs to be reinforced with a strip of 18- or 20-karat plate gold placed over the boxes. The boxes could also be waxed together, cast and then soldered to the abutments.

Stone grind and polish. (Figure 146.)

2. SELF CLEANING BRIDGES (Bridge III)

Fit supplies and wax them in the correct position on the articulated model.

Make a plaster core around supplies and abutments.

Boil out the wax, study and mark the teeth for length of backings.

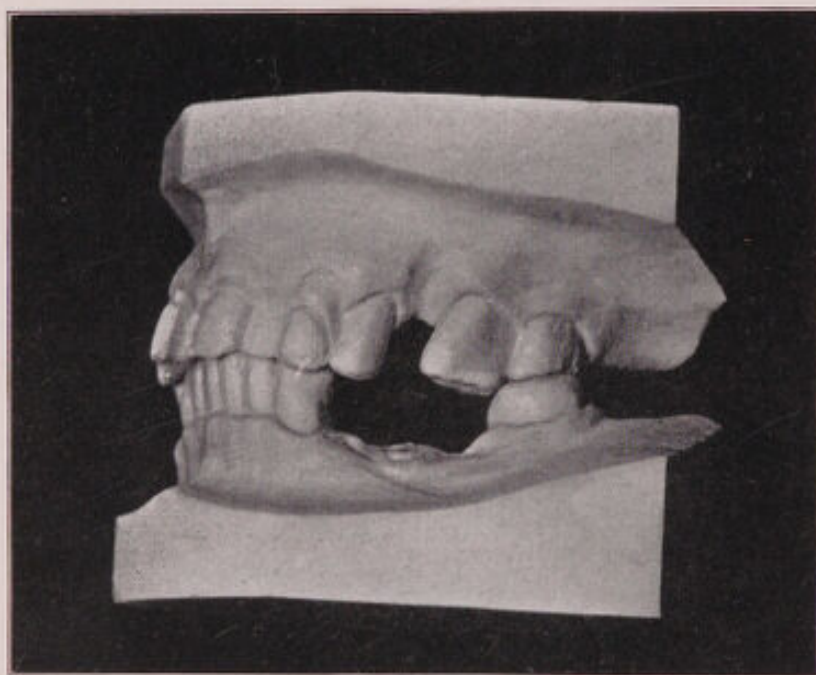
Remove supplies from the core and fit the backings or boxes.

Backings must reach to the gum line. Test this by placing the supplies with backings on the model with cores. (Figure 65.)

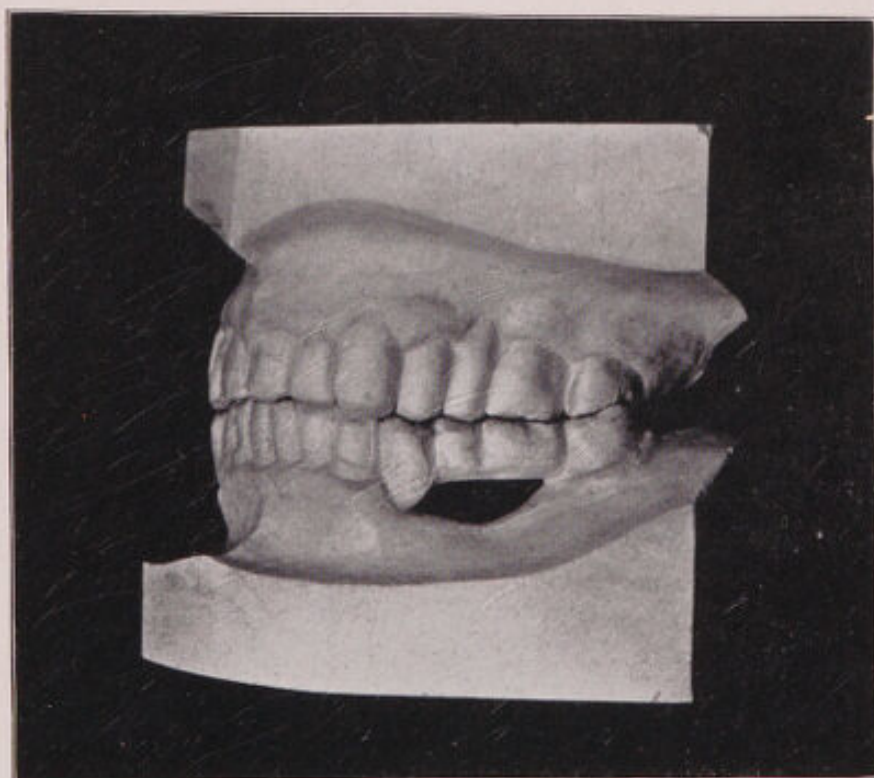
Boxes must clear the gum line sufficiently to allow for their reinforcement, which is not less than 24 gauge.

Place cores on the models and supplies into same, wax the supplies together (not more than four in a section, use a wire in the wax for stiffener. (Figure 208.)

Remove this waxed section, from the core, invest and solder (or cast). (Figure 209.)



Before.



After.

FIG. 146. Sanitary bridge with porcelain chewing surface.

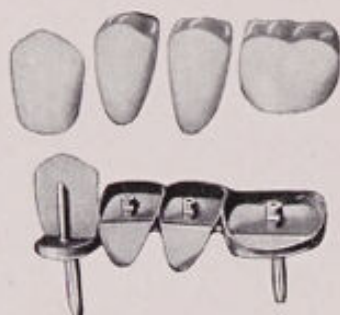


FIG. 147. Self-cleansing bridge showing wash spaces.

Boil the soldered section and replace it in the core on the model.

Wax soldered dummies or sections to the abutments.

Remove the cores, invest the whole bridge on the model in plaster and Portland cement, or other investment.

Solder the supplies to the abutments as shown in Figure 65.

Cool, boil in acid, stone and polish.

3. SADDLE BRIDGES (Bridge IV)

Continuous saddle

Outline the area on the model to be covered by the saddle. (Figure 148.)

Swage or cast the saddle. Swaged saddles can be made of gold, but are better of platinum 32-gauge. The latter are the cleanest. Cast saddles are made by pressing thin casting wax over the model, and trimming it to the outline. Put sprue into the center, and paint with inlay investment. After this has hardened, remove it from the model, invest and cast. Thin platinum saddles can be stiffened by gold casting to same.

Place the saddle on the model.

Follow steps as for bridge II.

Backings and boxes may rest on the saddle. (Figure 150.)

Place supplies on the model with cores. (Figure 149.)

Wax supplies to the saddle.

Remove core from the supplies and model.

Remove teeth from the boxes, and paint the inside of the boxes with Steele anti-flux.

Remove saddle with waxed boxes from model. Cast with 20-karat gold.

Invest and solder. (Figure 150.)

Boil in acid, and rough stone this section.

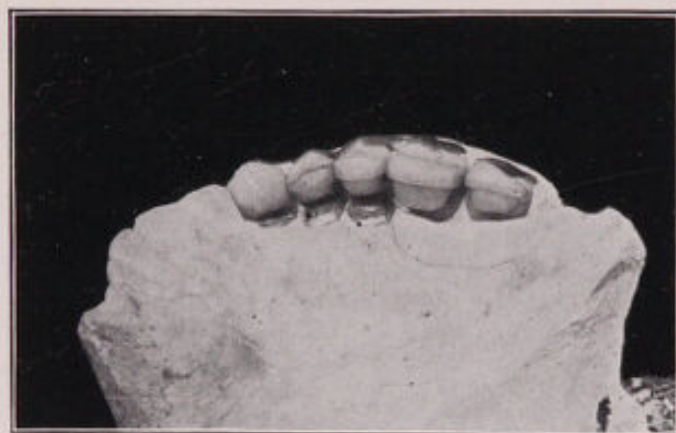

FIG. 148. Saddle bridge. Teeth in core before boxing.

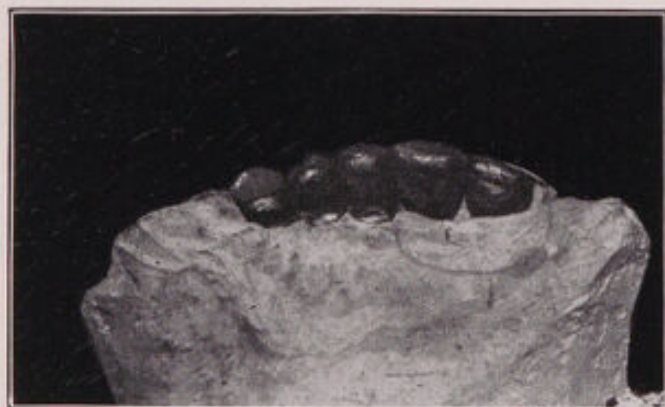

FIG. 149. Saddle bridge. Teeth boxed.

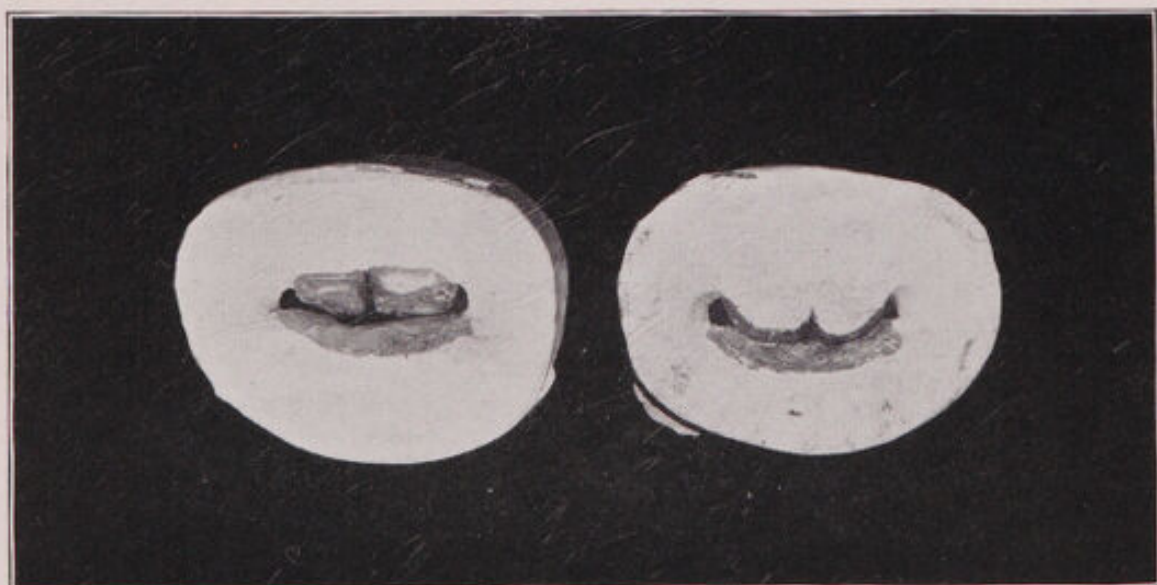


FIG. 150. Saddle and boxes invested ready for solder; investment opens from front and back.

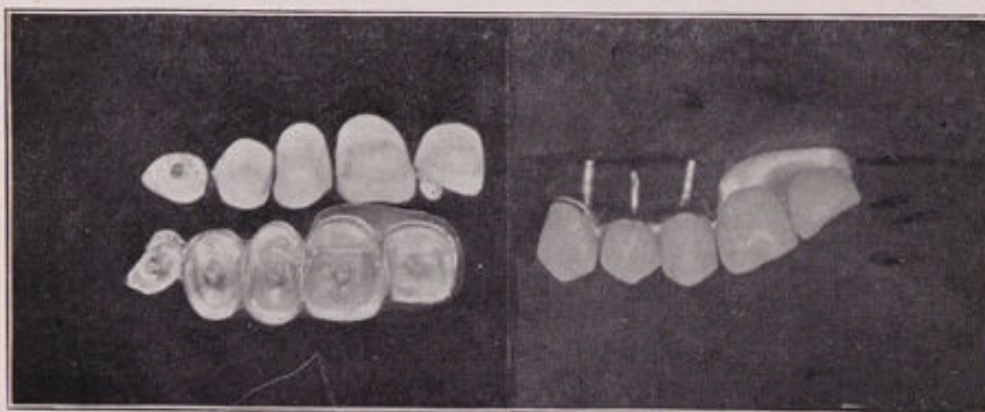


FIG. 151. Saddle bridge, before and after cementing of supplies.

Place back on to model, and wax it to the abutments.

Invest the whole bridge on the model, in a ring with plaster and Portland cement.

Boil the wax out, solder, boil in sulphuric acid, stone and polish. Care should be taken to allow sufficient space between the abutments and the saddle for the faustum of the gum.

Porcelain saddles

If there is a great deal of absorption of tissue, saddle bridges sometimes necessitate the showing of gold to avoid too long teeth. This can be overcome by the use of gum blocks, either

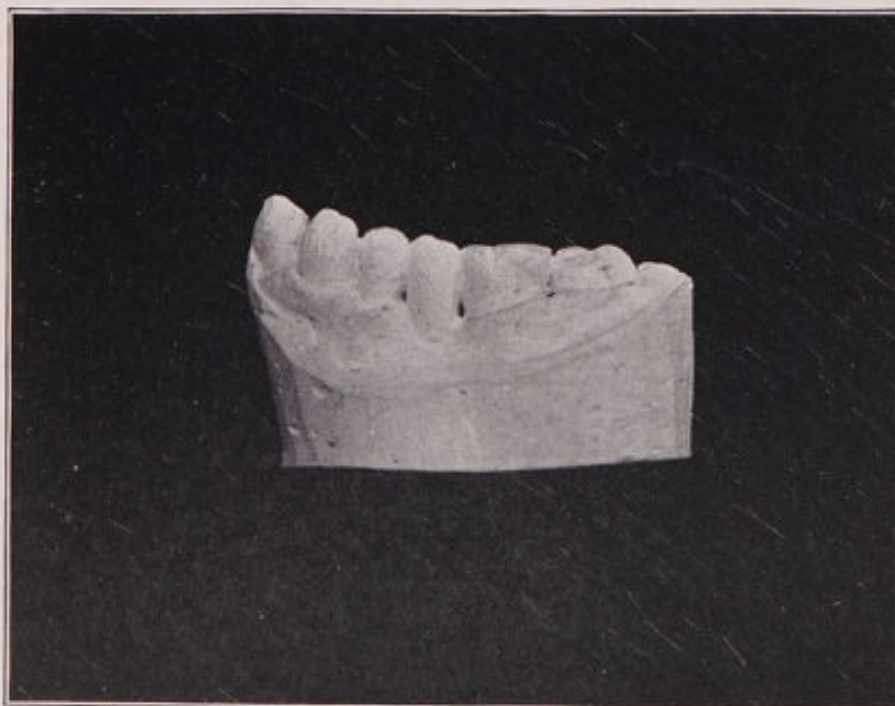

FIG. 152 shows a banded porcelain molar crown, and bicuspid dummy. The slotted porcelain crown and dummy were carved in one piece and cemented to metal base on molar roots.

baked and soldered to the saddle, or still better by entire gum blocks with porcelain saddles. These are attached to both abutments by bars extending from bridge abutments and being

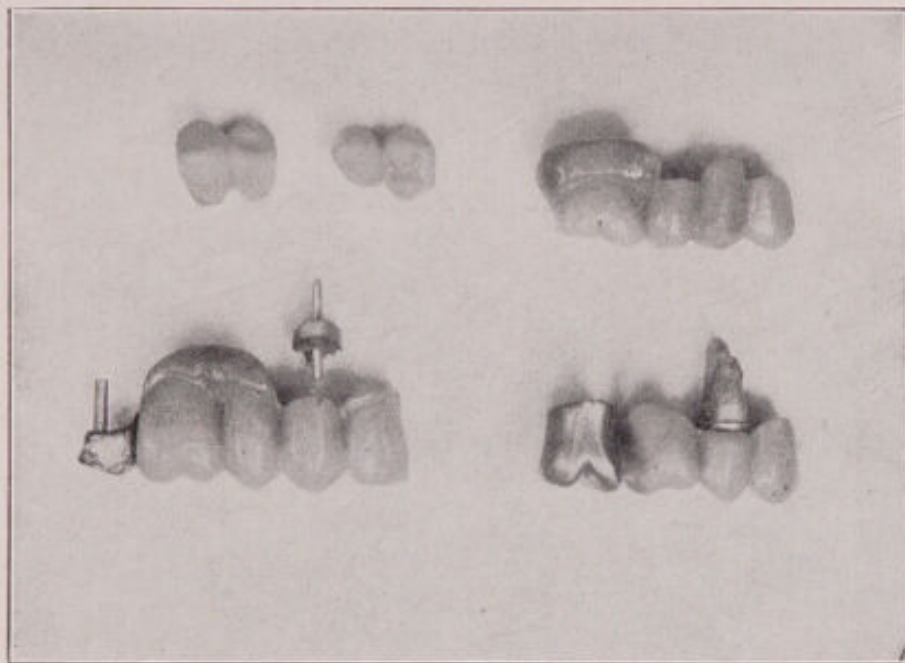

FIG. 153. Hand-carved porcelain blocks with porcelain saddles.

cemented into the block. They are very clean and give excellent effect. (Figures 152 and 153.) Follow general instruction as for making single hand-carved crown.

Individual saddles

When planning to use a saddle, make a thorough examination of the ridge which is to be covered by the same. It is almost always necessary to carve the plaster model to allow the saddle to set firmly on to the ridge, without having an opening at any place except next to the abutments.

Individual saddles are most practical for dummies, which are carried by abutments at each end, such as from cuspid to molar bridge, or bicuspid to molar bridge.

These individual saddles permit wash spaces between each crown and dummy, which is of great advantage in the cleaning, also to the feeling to the tongue, as it is more natural, is the nearest restoration to nature of the missing teeth. (Figure 139C.)

Continuous saddles are more practical for extension bridges, such as shown in Figures 151 and 210. These continuous sad-

dles are also used to cover a larger surface, but this all depends on the strength of the abutments, the bite and the ridge. In all cases the platinum saddle is preferable to the gold, be it for a cast or a soldered bridge. Platinum or porcelain saddles are less irritating, and have proven cleaner than gold saddles, in all practical cases.

4. EXTENSION BRIDGES (Bridge VI)

Fixed extension bridges are always saddle bridges. The force of mastication should be taken up by the alveolar ridge, to a great extent, and not so much by the abutments. The further away we can remove this pressure from the abutments the longer will these last.

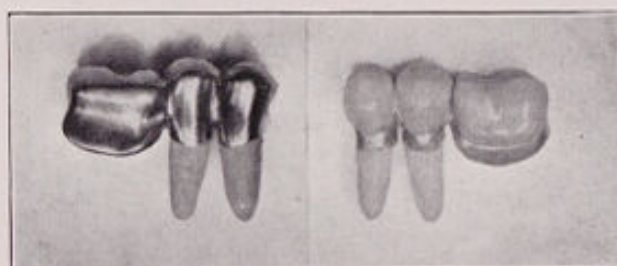


FIG. 154. Extension bridge from front and back; note space for festoon, to allow for gum between crown and saddle.

The construction of these bridges is similar to the foregoing ones, being usually saddle bridges, with abutments only on one side. (Figures 154 and 151.)

(Bridge VII)

Interlocking bridges

Whenever it is impossible to line up or bring into parallel lines the teeth, and roots, which are used for bridge abutments, one can use an interlocking device, by which the difficulty of fixed bridges is overcome. Various devices such as the Morgan attachment, the Roach attachment, the split-bar attachment, and many others, are offered for sale by the dental depots, and all of them have their place in this line of work.

See description of these appliances. (Figures 184-191.)

If the dentist does not care to use any of these appliances, but prefers to make his own, he can easily accomplish this in the following manner. Make a dove-tail, or tube attachment, either by bending double plates and reinforcing same with solder, or by the casting process. Care must be taken in all cases to set these attachments at a right angle or in parallel line with the fixed abutment. (Figures 17 and 18.)

IX. REMOVABLE BRIDGES

Removable bridges are the next step to the fixed bridges for the replacement of lost teeth. If the abutments are not strong enough to support the new teeth, for fixed bridges, then use the alveolar process to support the appliances. These bridges, if well constructed, and in the right place, are very useful, although they are not as ideal as fixed bridges; nevertheless, they are far superior to a plate. Dr. Pieso's, Dr. Ash's, and other removable bridge systems have been described so often in the past, that I will content myself with the later and less known systems, such as the Gilmore, Roach, and Morgan types.

A. REMOVABLE BRIDGES WITH GILMORE ATTACHMENT

GENERAL DESCRIPTION OF TECHNIQUE

PREPARING CAPS AND POST FOR GILMORE ATTACHMENTS

The Gilmore attachment is a V-shaped clasp (Figure 183). This clasp is fastened to the removable bridge saddle (or plate), and is engaged to a 14-gauge platinized gold wire, which is soldered to a crown, cap or inlay. This wire can be extended from a single abutment, or the wire can be soldered to two or more abutments, and as many attachments used as to the size of the bridge.

Great care must be taken in the preparation of such roots, and teeth to be used, *if they are to be connected by the gold wire*; the posts in the root canals and the gold crowns or inlays must be parallel to one another. (See Figure 159.) The bridge meter is of great value in this work. (Figure 201.) With a single extension no such care is necessary.

It is advisable to *start with a simple case*, such as a removable bridge between a cuspid and molar, or bicuspid and molar

with crowns. After making the crowns in the usual manner, take a wax bite and a plaster impression of the crowns in place and of the tooth space.

Before placing the crowns back into the plaster impression, line the inside of the crowns with a thin film of wax, so that when the model is made, the crowns can be warmed and pulled off.

Make an articulated model, warm the crowns and pull them from the model, boil off the wax and place them back on to the model.

Fit a 14-gauge platinum wire from crown to crown, bending the end of the wire upward. (Figure 183, B and C.) The wire should lay on top of the ridge, if possible.

Wax the wire to the crowns, remove all from the model, invest and solder wire to the crowns.

Place the gold frame back onto the plaster model.

Now proceed with making a cast or swaged saddle.

Another simple case to start with, would be to solder an extension wire to the lower bicuspid crowns. (See cases Figures 179, 182, 183B and C.)

Solder the gold wire (14-gauge) to the crowns, take bite and impression in plaster.

Make a partial lower gold bar denture, gold or rubber saddles with a Gilmore attachment at each end. In setting the crowns with the wire extension, it is best to place the crowns with the wire in the attachment on the denture and then *cement the crowns with the denture to place.*

In using roots for abutments it is well to *build the root caps to the level of the gum*, as otherwise the gums will fold over the root caps, and it is hard to care for them by the patient and dentist.

The wire can extend to one side of a root cap, but I have had my best results by *soldering the wire across the root cap*, extending mesially and distally with an attachment at each end. (Figures 170, 171.)

For the construction of large frames and to finish the bridge such as shown in Figures 173, 174, *with one plaster impression* (with the abutments in place) do as follows:

**FITTING PLATINIZED GOLD WIRE TO THE ABUTMENTS FOR
GILMORE ATTACHMENT**

Place abutments in position on roots or teeth.

Take wax bite and plaster impression as for a rubber plate.
(Figure 155.)

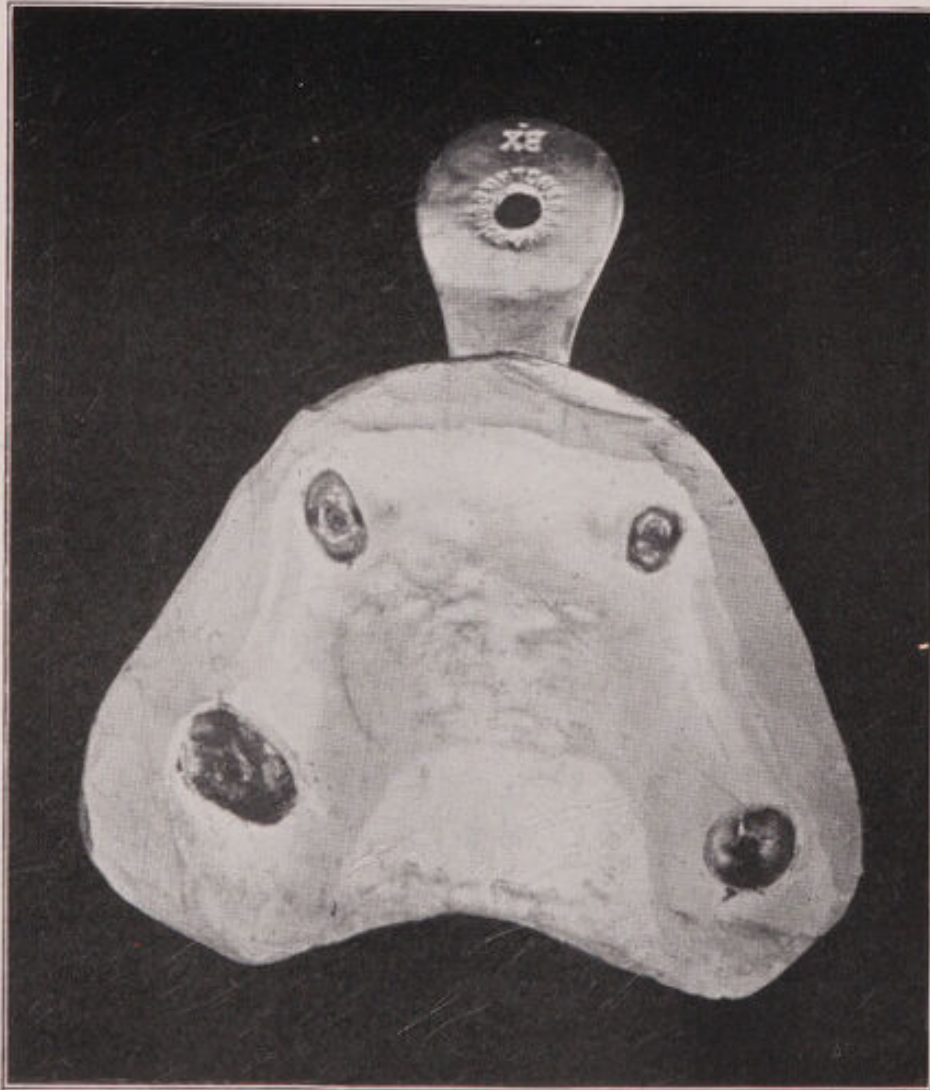


FIG. 155. Plaster impression of four abutments.

Before placing the abutments in the plaster impression, flow a thin film of wax over the posts and inside of the bands and crowns, so that they can be removed later from the plaster model.

Make a plaster model. (Figure 156.)

Mount model, and bite on an anatomical articulator.

Remove the wax bite. Shellac or varnish plaster model, and take a plaster impression of the model with the abutments in place. This is for a large case only.

NOTE.—Care must be taken to fill with wax all undercuts on the model, so as not to break the model when removing the plaster impression from it.

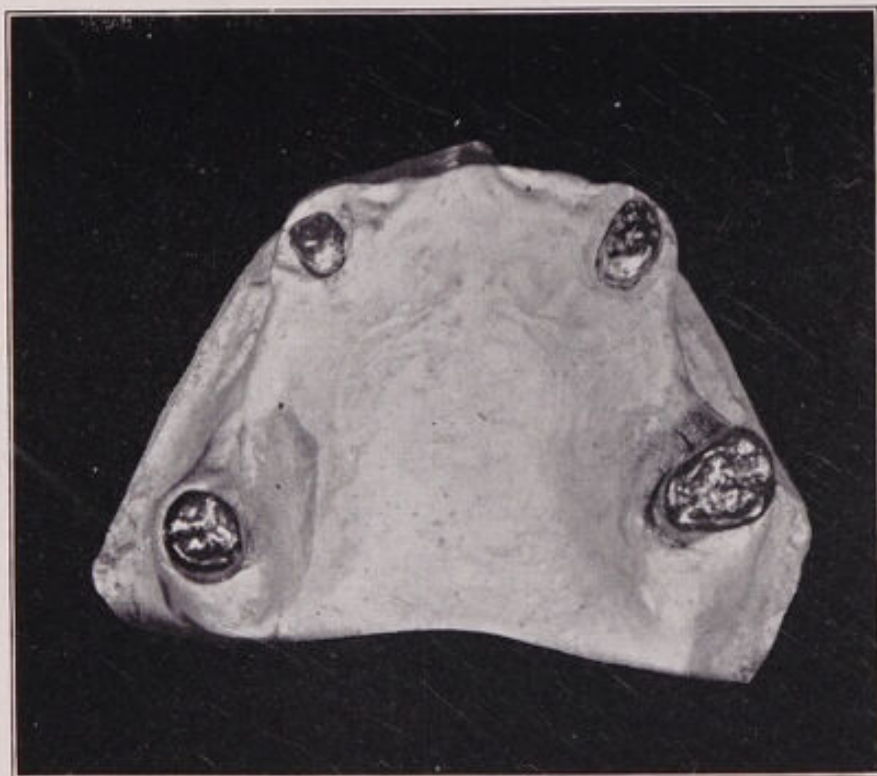


FIG. 156. Plaster model with four abutments.

Remove the plaster impression; heat and remove the abutments from model (Figure 157) and place the abutments in their positions, in the *new* plaster impression, making them secure by flowing a little sticky wax around their edges. Make this, the second model, of plaster and Portland cement or other good investment.

To this model fit a round 14-gauge 18-karat platinized gold wire over the center of the root-abutment, and over the ridge of the gum, so that it barely touches the model between the abutments.

If the posterior abutment is a crown, bend the wire so that it will fit upright on the center of its mesial surface. (Figures 185B and C.)

Fasten the gold wire to the model with binding wire, and solder the wire to the abutments with 18-karat solder.

Boil the framework in acid and place it on the first original *plaster* model. (Figure 157.) Figure 158 shows finished

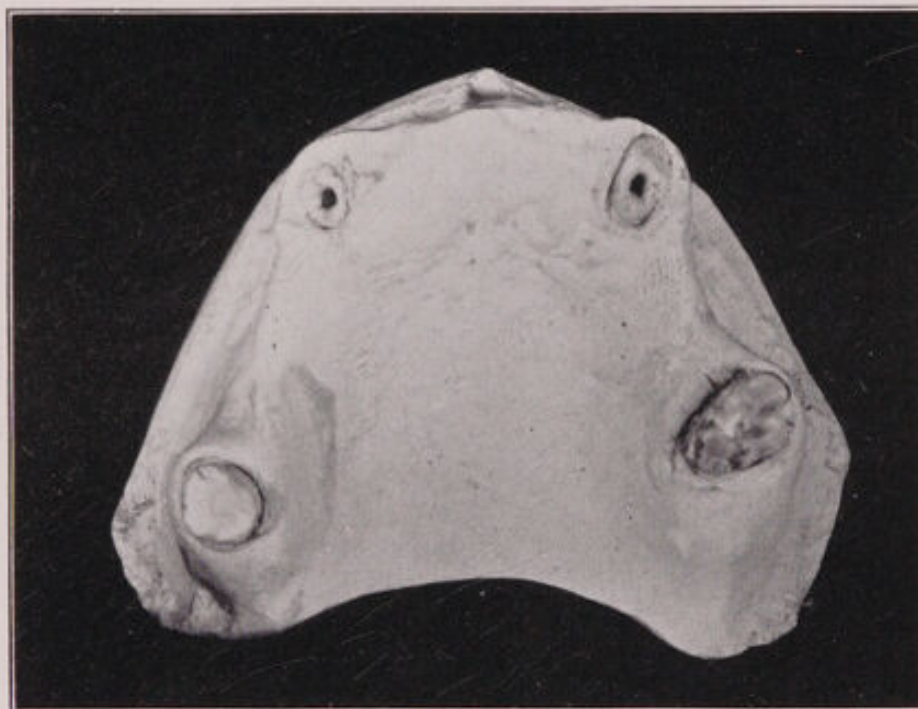


FIG. 157. Abutments removed from model to solder wire frame.



FIG. 158. Finished frame in position.

frame. In small cases the gold wire could be fastened to the abutments of the original model with sticky wax; taken off the model, invested, and soldered.

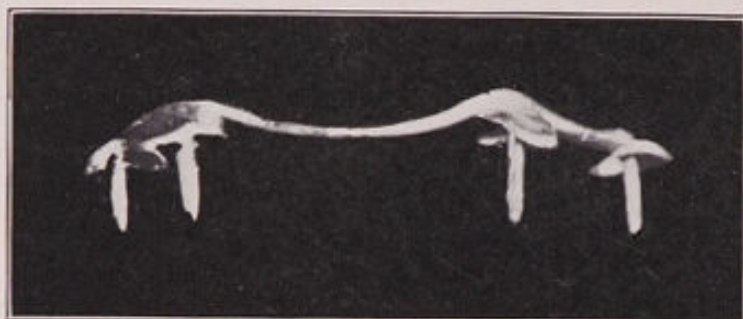


FIG. 159. Finished frame for another case.

Making of bridge proper

Place a plain opened Gilmore attachment (Figure 183, No. 5) (*i.e.*, without any extension) over the wire where desired, and make a swaged or cast saddle to cover the framework, the attachment and as much of the gum ridge as you wish to cover. (Figure 183H.)

Making of cast saddles

Place a plain *open* dummy attachment over the wire (Figure 183, No. 5); slightly oil or vaseline all the territory to be covered by the model wax. On removing the wax it will be found to bear an imprint of the attachment and bar, which features are reproduced in the casting, indicating the position the attachment should occupy in the completed case. The object in using *open* attachments is to prevent the metal from being in absolute contact with the free wings of the attachment, after the gold attachment has been soldered in position, and also to create a channel on each side of the clasp, so that it can be adjusted for tension.

In partial, and full cases as well, I would like to point out the importance of placing the clasps or attachments "straight" on the wire, for if the attachment is tilted to one side, the plate or saddle to which it is fastened will spring up from the wire during mastication.

When the extension wires run parallel to one another (Figure 182), the denture will slide back, and leave a space to the adjoining teeth. This is overcome by soldering a knob at the end of each extension wire, and set the attachment close to this knob.

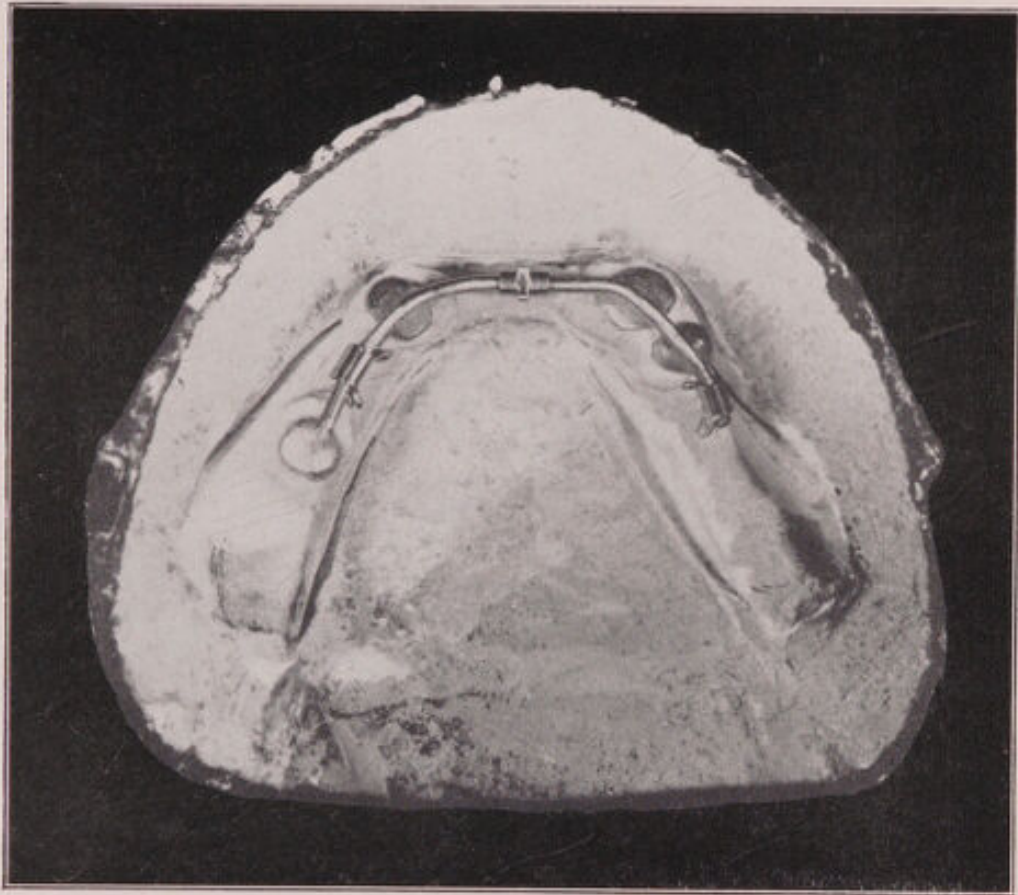


FIG. 160. Frame and Gilmore Attachments in position on flaked model. Before packing with rubber, tinfoil the whole case, open the attachments, and cement them over the tinfoil to place.

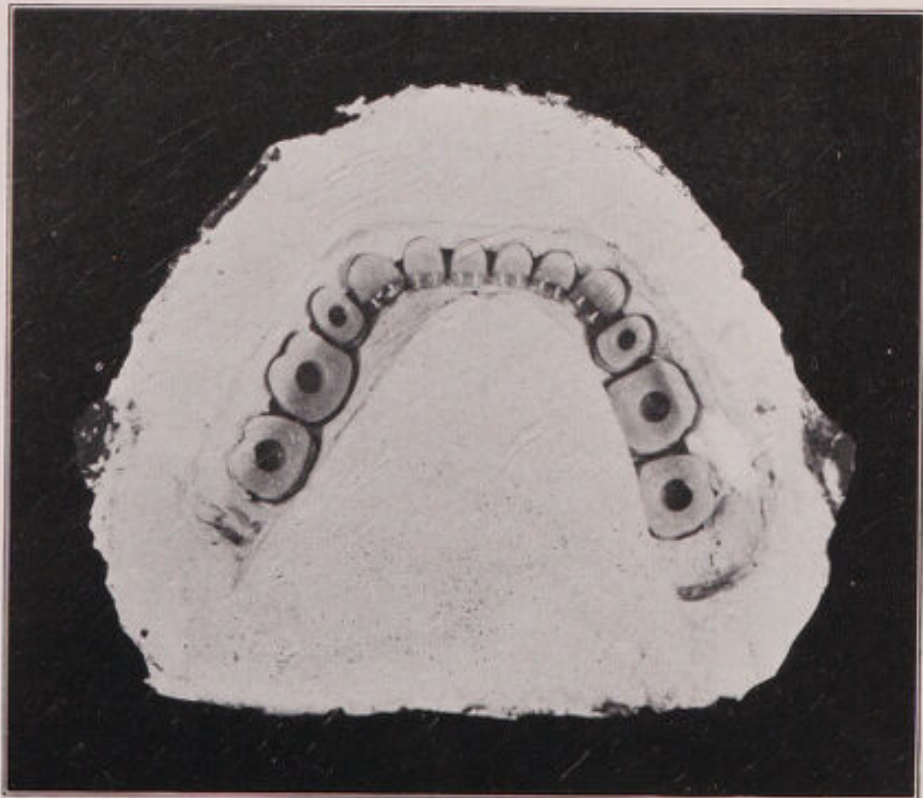


FIG. 161. Other half of flask.

This knob can be produced by heating the end of the gold wire until it melts, and forms a thickened round end.

A gold color soldered to the end of the wire will also answer the same purpose.

Whenever the extension wires are spread, as in Figure 179, no trouble of sliding of the denture will be experienced.

For one side dentures (see Figure 180), I have found this loop extension with two attachments very practical.

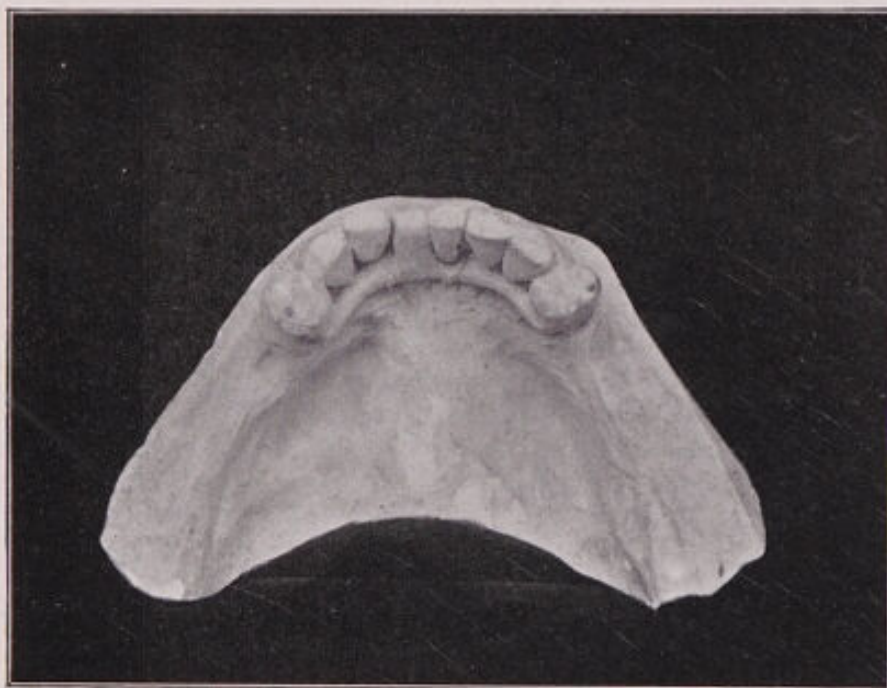

FIG. 162. A full lower Gilmore denture. Case before treatment.

Cut a slot through the saddle over the center of the position of the attachments.

Fit attachment No. 6, Figure 183 (with the pin through the slot in the saddle).

Open the attachment slightly to allow it to slip on and off the wire easily, then paint the sides of the attachments with Steele anti-flux. Place it in position in the saddle, and wax the extension to its outer surface with sticky wax.

Invest the inside of the saddle and the clasps. Remove the sticky wax and solder the clasp extensions to the saddle with 18-karat solder from the occlusal side.

NOTE.—Great care must be taken to have the attachment in a vertical axis. Gilmore attachments must all be parallel

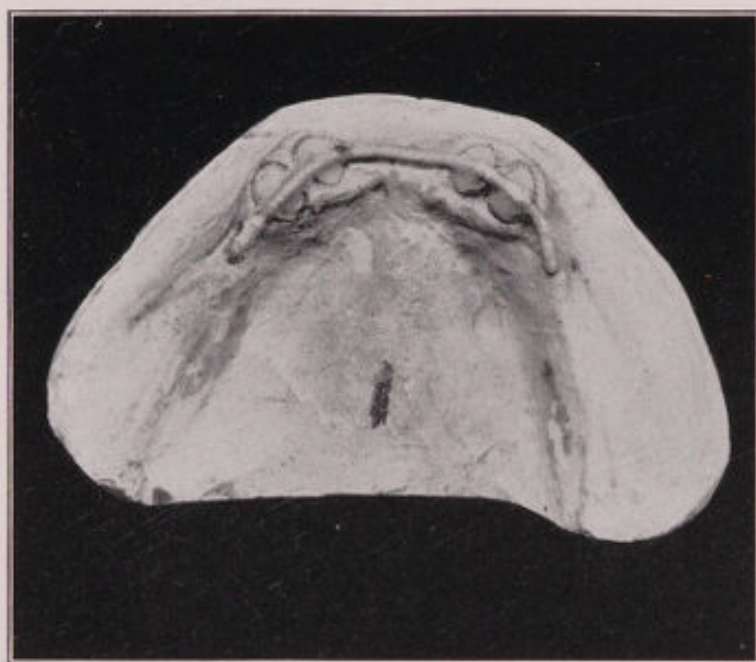

FIG. 163. A full lower Gilmore denture after treatment. Finished frame on model.

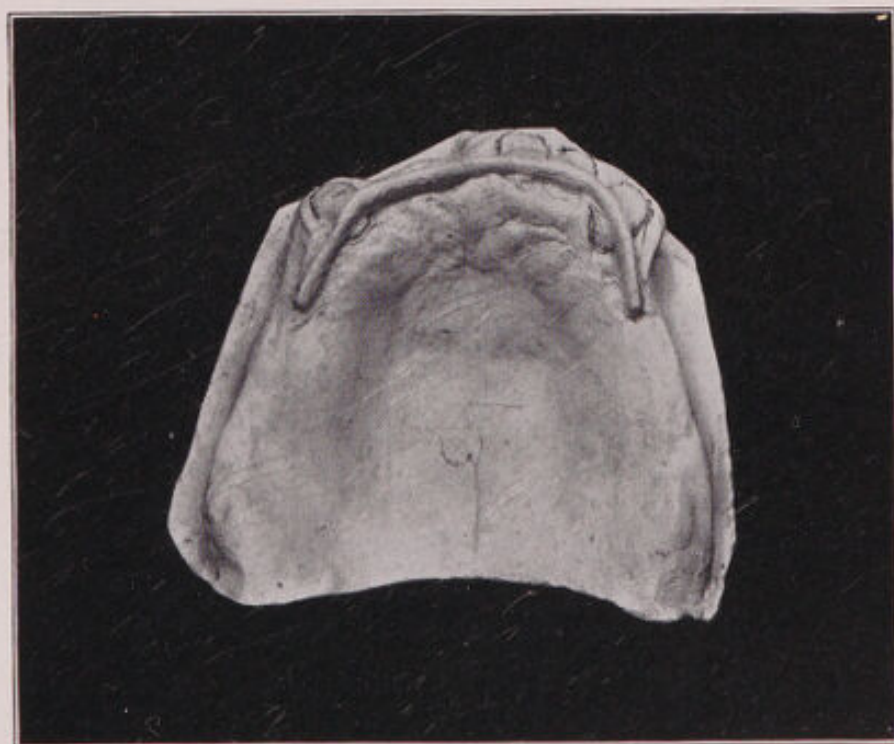


FIG. 164. Full upper Gilmore denture. Frame finished to show abutments and gold wire on model.

to each other, as a slight tilting of the attachments will make it very difficult to seat and remove the saddle.

Place the swaged or cast saddle with attachments on the articulated model.

Grind all supplies into position and wax them to the saddle.

Follow steps as for ordinary saddle bridges. (See bridge IV.)

Place supplies into the core on the model.

Backings and boxes may rest on saddle or plate.

Wax supplies to the saddle.

Remove saddle with the supplies from the model.



FIG. 165. Another full lower Gilmore case. Finished frame on model.

Paint the Gilmore clasps in back of saddle with Steele's anti-flux.

Invest the whole into a ring or band.

Boil the wax out, heat carefully and solder.

Boil in acid, stone and polish. Now close the open attachment to fit the wire soldered to the abutments. This is done by placing a piece of a wire inside of the clasp and applying pressure with flat-nose pliers. Splendid results have been obtained with this attachment in small and large cases alike.

Roots slanted

If the roots are slanted, one is not able to use a fixed framework, and then one has to devise variations as required for spe-

cial cases. Such a case is shown in Figure 220. To the cuspid caps is soldered a loop allowing the caps and posts to swing in position of the slanting cuspid roots; the other four caps are soldered to the gold wire.

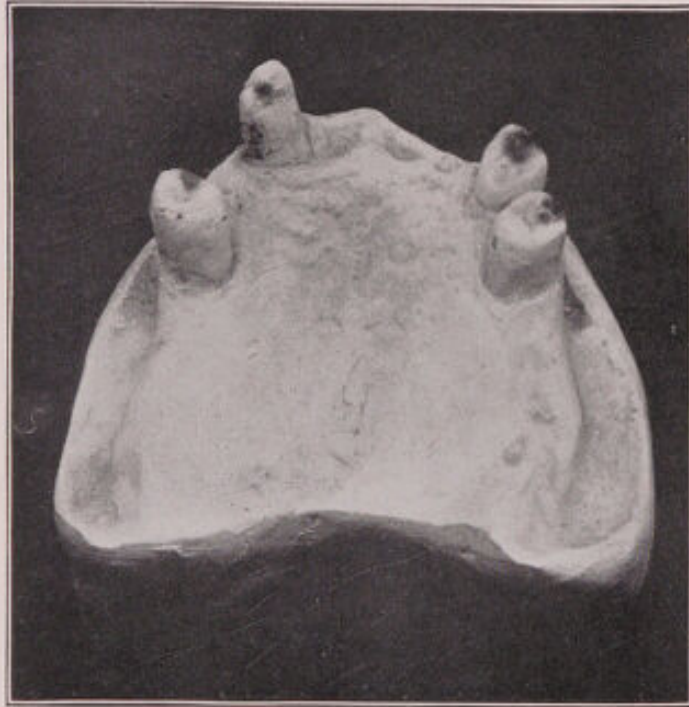

FIG. 166. Full upper Gilmore denture. Case before treatment.

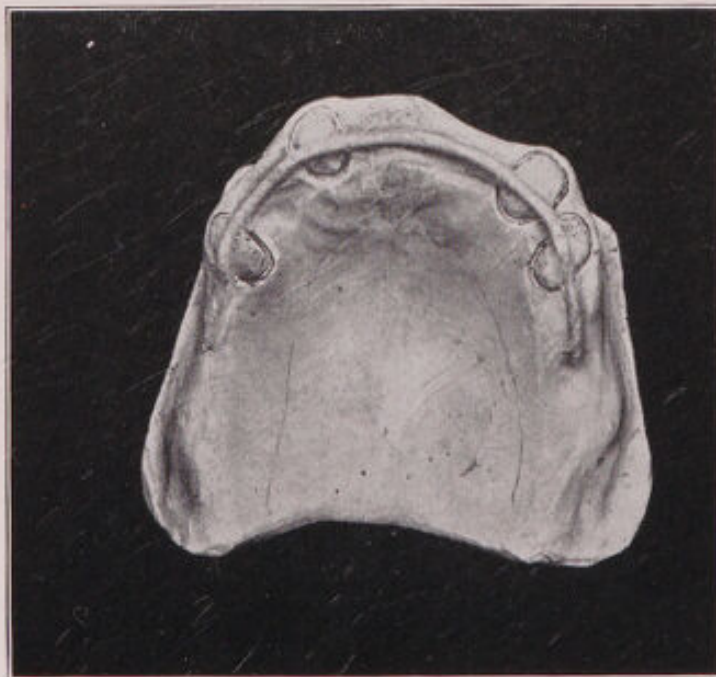

FIG. 167. Same case with finished frame in position.

Material

These bridges can be made in various ways, as for temporary bridges, by using rubber. Also, if the patient cannot afford gold, other material, such as rubber or combinations of gold saddle with rubber attachments, can be used. The different combinations are:—

1. Rubber.
2. Gold saddle with hand-carved teeth, detached post crowns, Goslee or Steele tooth and similar teeth.

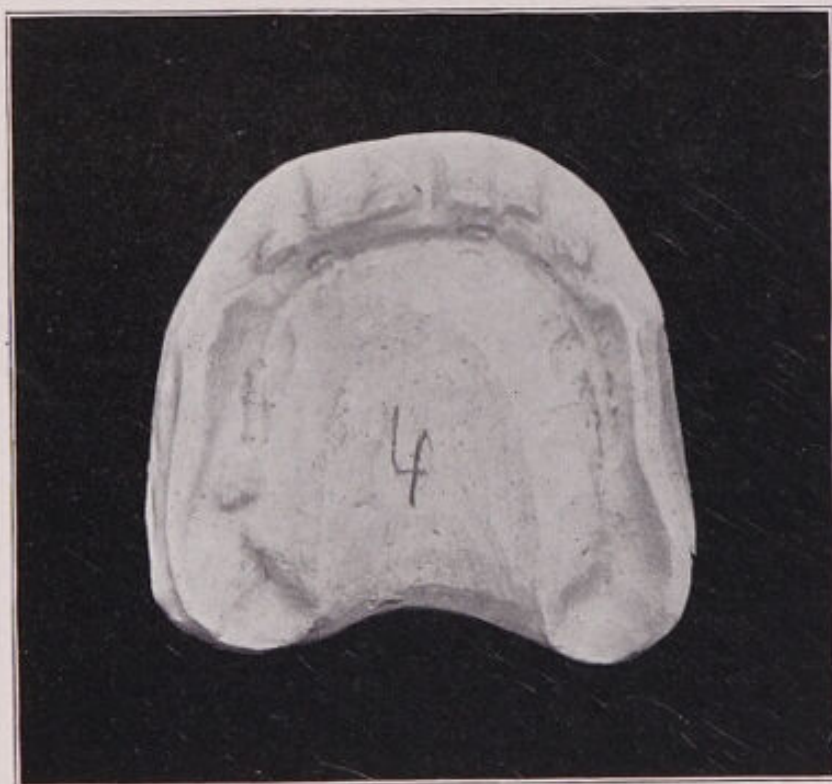

FIG. 168. A plaster model of the back of finished denture.

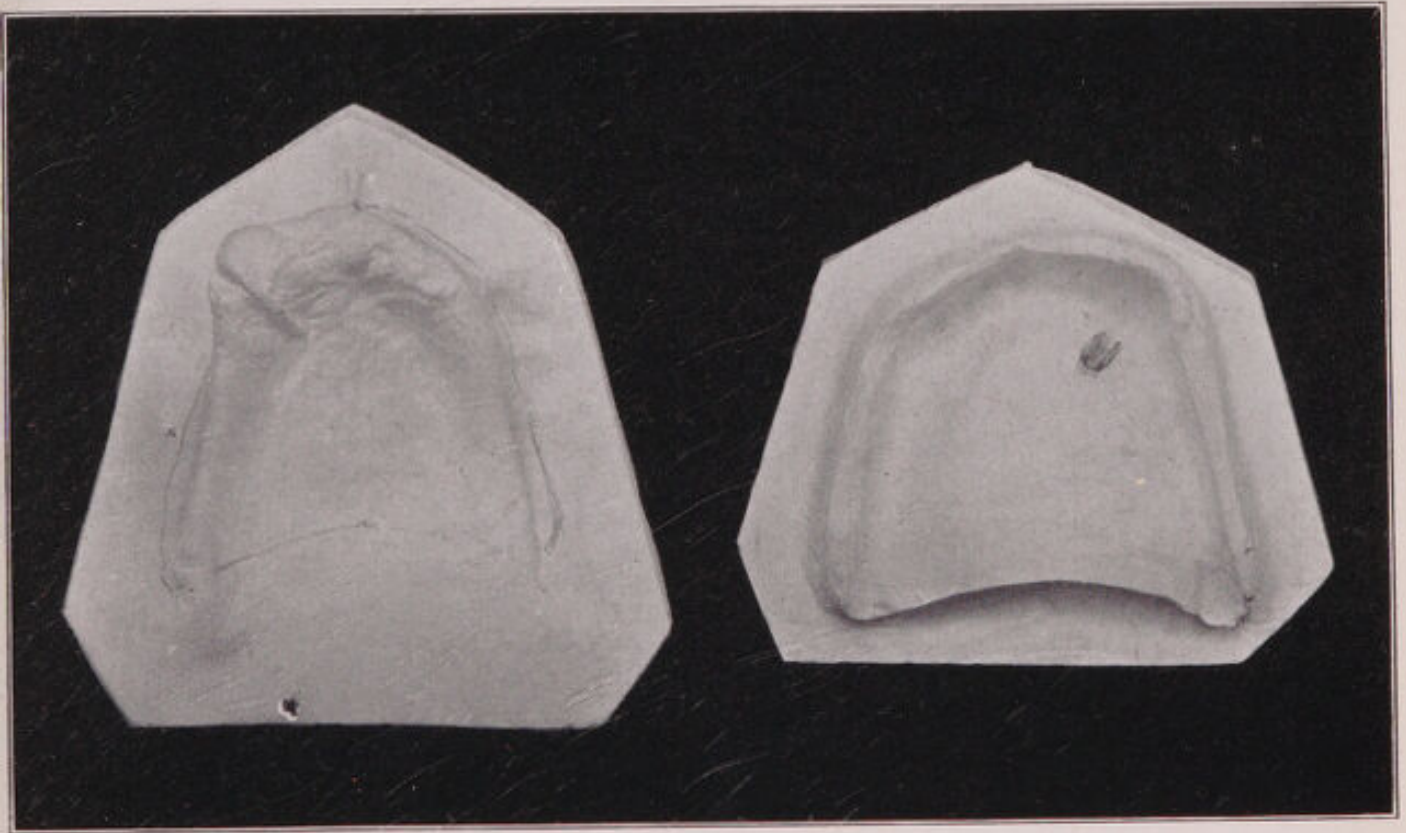
3. Platinum saddle with crowns, Goslee or Steele teeth, hand-carved teeth or detached post crowns, or others.
4. Platinum saddle with gum blocks.
5. Platinum saddle with teeth soldered on, or continuous gum baked on.

Different kinds of bridges with Gilmore attachments as shown (Figures 158 to 182.)

1. FULL BRIDGES (Removable Bridge I)

Very frequently there are only a few roots or teeth left in the mouth, and as they would be too weak to serve as abutments

for a fixed bridge, they could be utilized, when in healthy condition, for the retaining of a removable bridge. The principle of the removable bridge is to bring most of the stress of mastication on the alveolar process and gum, so as to prevent the attachments from being forced out of place by the force of the bite, the tongue, cheeks, lips, etc. It is, of course, of greatest importance to set the teeth up for anatomical articulation, so that mastication does not strain the attachments, on account of faulty occlusion.



CASE: Figure 169. This patient, 73 years of age, had but one good upper cuspid tooth, but a complete lower set of her own teeth. She had a very flat palate, and had never worn a plate of any kind. Gilmore attachment was made as follows: The upper cuspid was cut off, and a swaged platinum cap with a platinum post was fitted to the root. To this cap and post a 14-gauge platinum gold wire was soldered; this wire was pointed toward the center of the palate. A Gilmore attachment was fitted almost to the end of the wire, and over this a thin 20-karat gold plate of 36 gauge was swaged, also having a gold mesh wire soldered on the surface. (This is known as a Perfection gold plate.) To this the clasp was soldered, and a full upper set of 14 teeth were vulcanized to the plate. The patient could wear the plate with comfort from the first day, and as yet the root shows no sign of loosening. If later the root should give way, the patient no doubt would then find no difficulty in wearing a plate that was dependent wholly upon suction.

One can utilize even one strong single root for this purpose. (Figures 169 and 171.) Two or more are of course of greater advantage (Figures 170, 165, 163, etc.), and insure longer service. It is advisable to make a full plate with the attachment to any weak supports, as narrow ridge, or skeleton plates, bring too much pressure on the abutments. (This refers to full cases.) The illustrations show various practical cases that have proven very satisfactory.

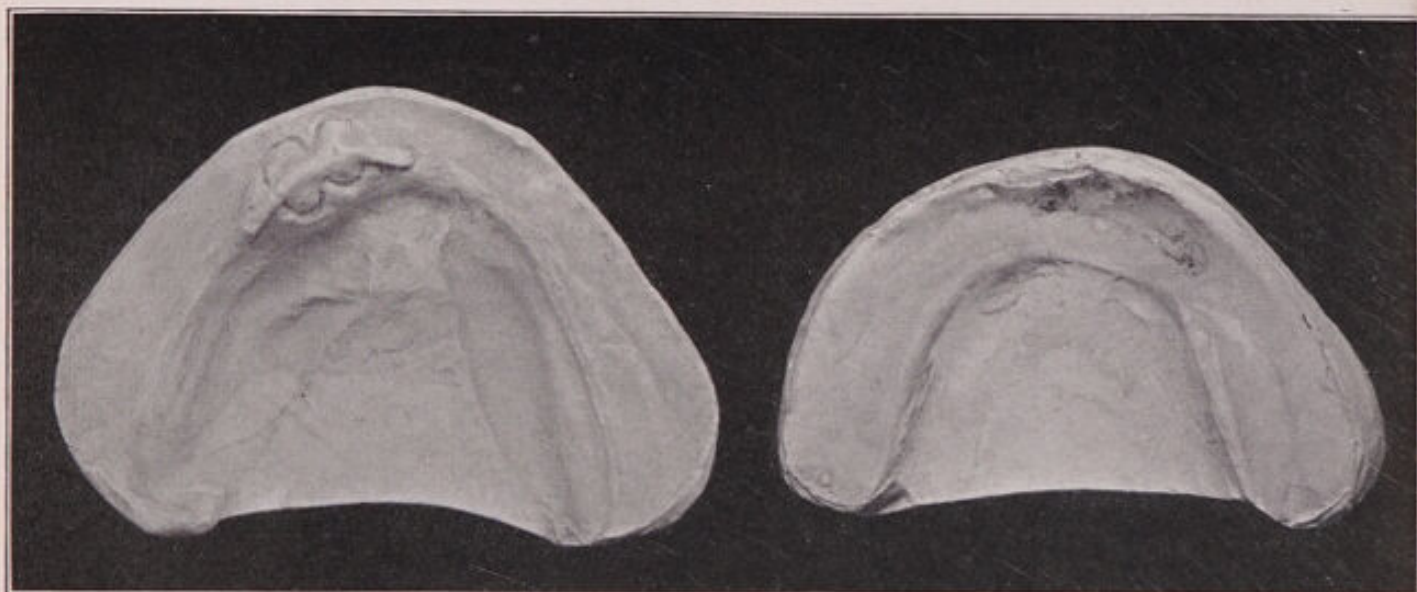

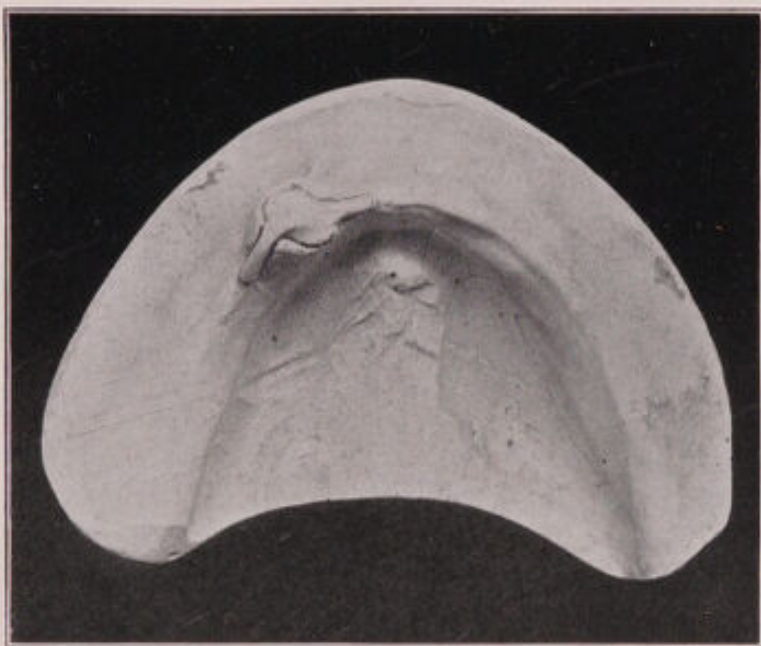
FIG. 170. Full lower with two roots and two Gilmore attachments.

2. PARTIAL BRIDGES (Removable Bridge II)

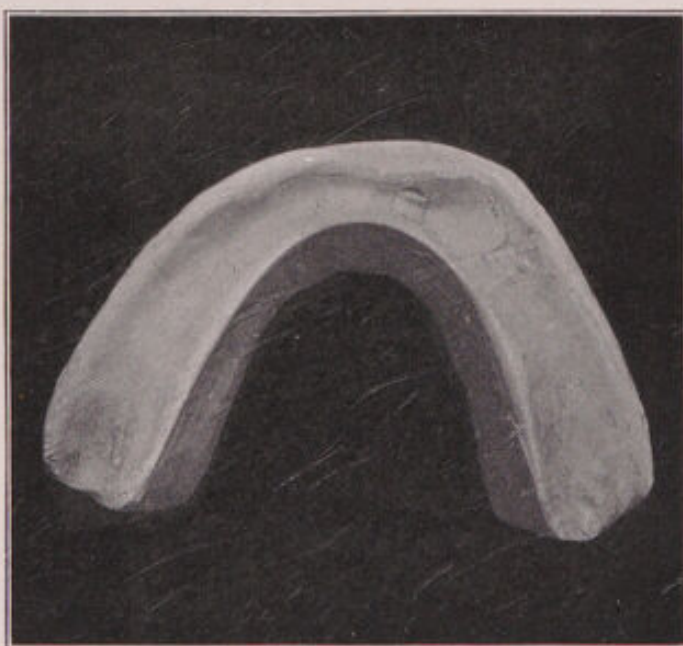
For partial removable bridges, gold crowns, banded porcelain crowns, and inlays are of the most frequent abutments used. These small bridges can be made by different methods, and some of these methods are here described.

3. PARTIAL BRIDGES WITH VAULT BAR (Removable Bridge III)

If a number of teeth on both sides of the mouth are to be supplied, it is of advantage to connect them with a vault bar to prevent lateral stress. This bar is closely adapted to the palate. Take a strip of pure gold 30 gauge and burnish it on the model, from one saddle to the other. This is then reinforced with an oval bar of platinized gold, and soldered to the strip of pure gold and also to the saddles of the two lateral parts of the bridge. The vault bar should be so constructed



A



B

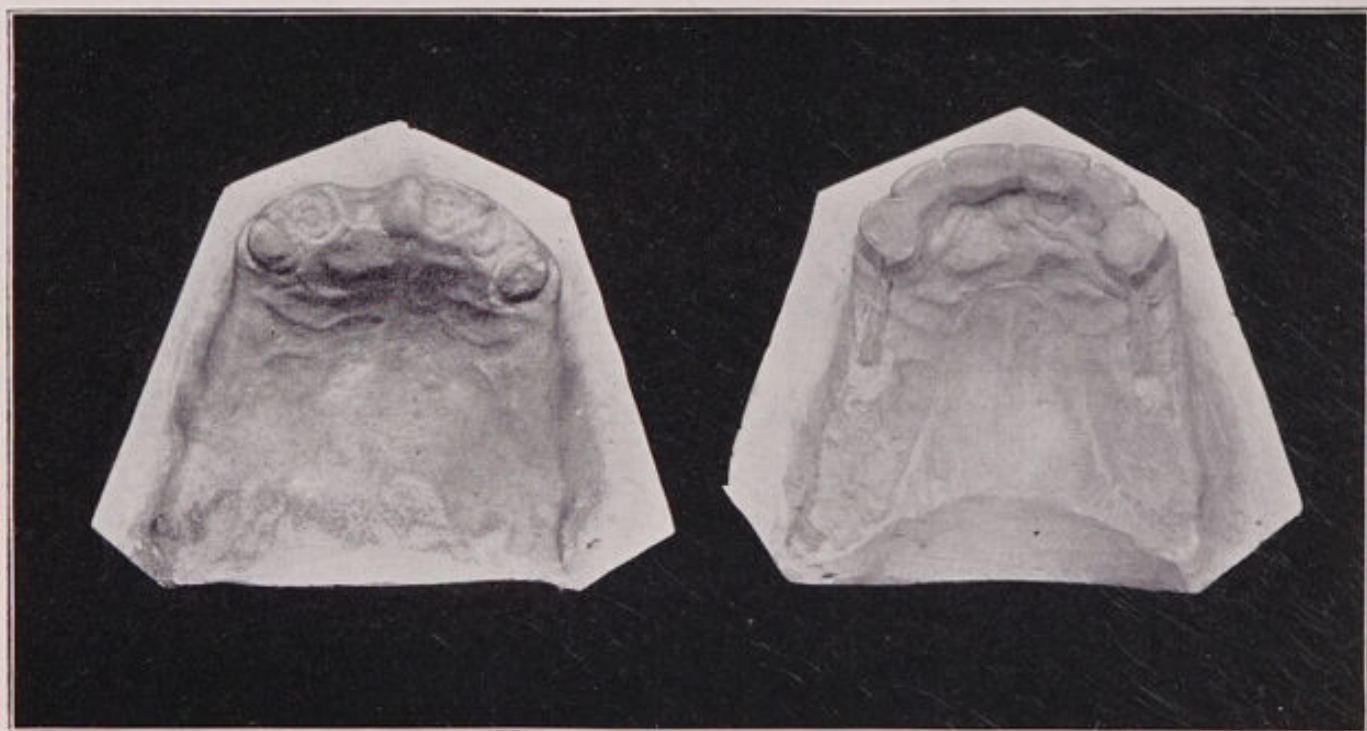
FIG. 171. Full lower with one root using two Gilmore attachments. This was a case one could not expect too much from as far as the lasting of this one root was concerned, but time has proved it to be satisfactory beyond all expectations. It helped the patient, an old lady, to get accustomed to the plate.

that it does not interfere with the movements of the tongue in speaking. As a rule, it should be as far back as possible.

Cast bars of clasping gold are good for such cases.

4. PARTIAL BRIDGE WITH LINGUAL BAR (Removable Bridge IV)

The above is also true for removable bridges for the mandible. The two halves are connected with a bar extending along the lingual part of the gum of the front teeth.



A

B

FIG. 172. Anterior fixed and posterior removable bridge with Gilmore attachments. A, shows the roots before treatment. B, anterior bridge with wire extensions in place.

5. EXTENSION BRIDGES FOR ONE SIDE (Removable Bridge V)

If teeth are missing on one side of the jaw only, either in the maxilla or mandible, we can use an extension bridge. The Gilmore wire is only connected on one side to the abutments, and extends out over the gum. This wire can also be bent in a loop, so as to give attachments for two clasps laterally. This prevents motion. (Figures 180 and 181.)

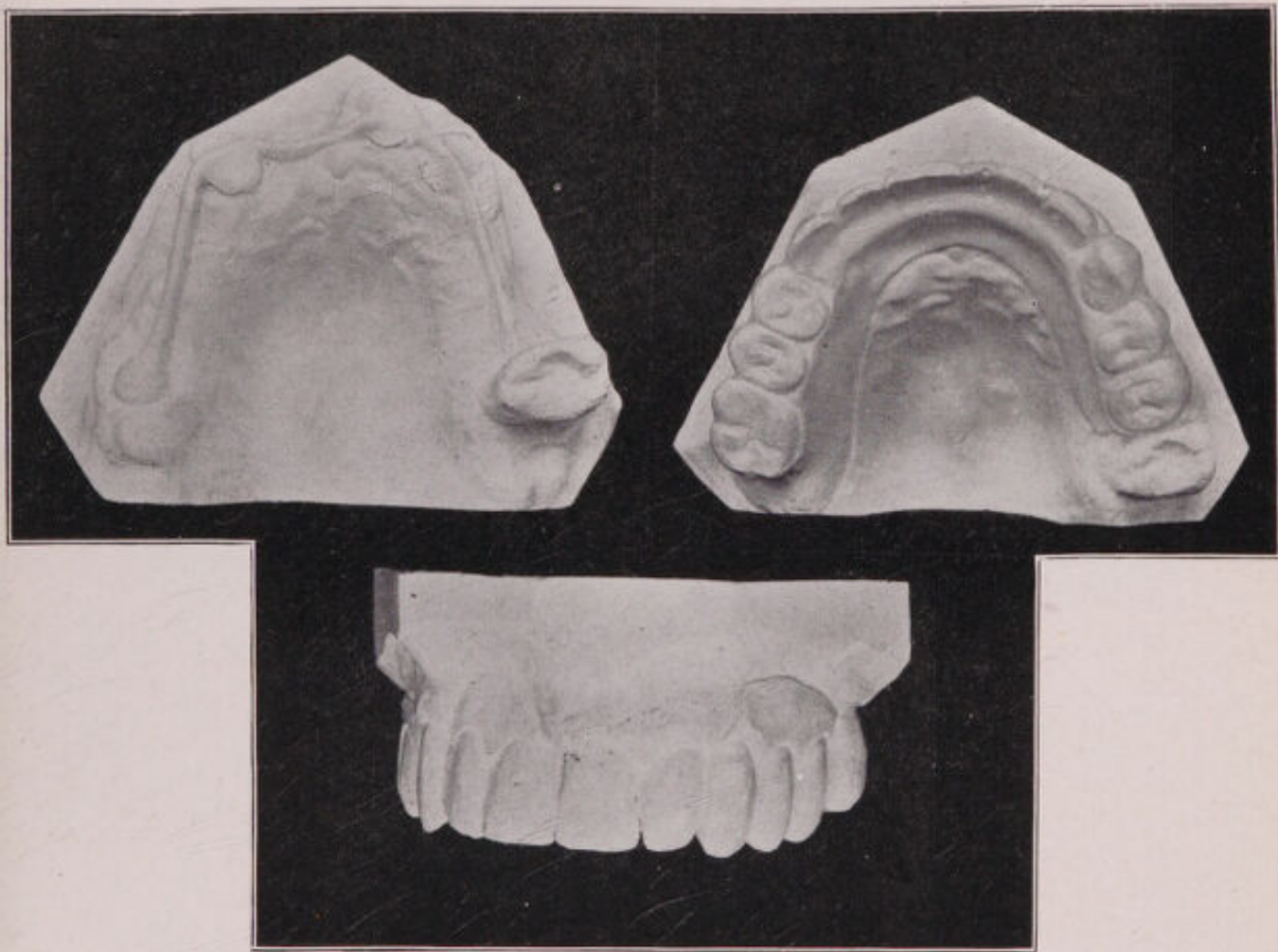
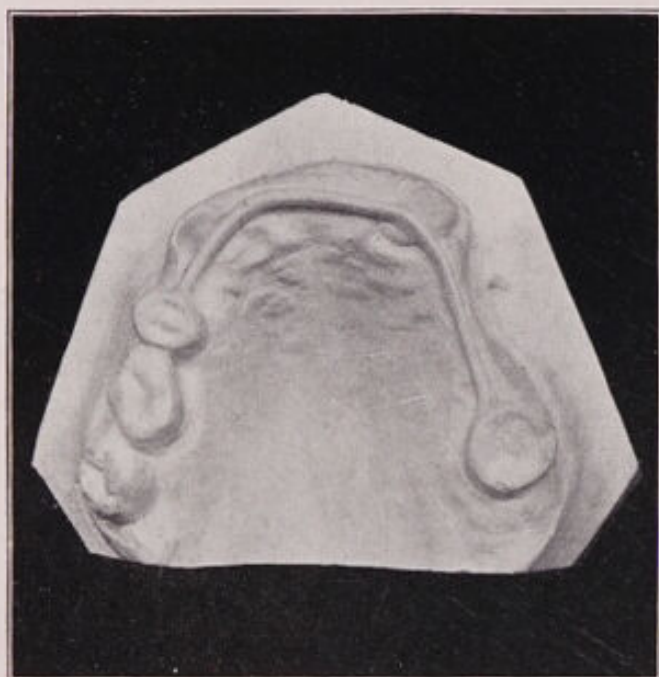

FIG. 173. Partial removable bridges with three Gilmore clasps used in this case, one between cuspid and central, and one between the cuspids and molars on each side. A swaged saddle of platinum with hand-carved teeth soldered to it.



A



B

FIG. 174. Removable partial bridge. In this case the lost teeth were restored with a removable bridge. Gilmore attachment wire was soldered on the right upper bicuspid abutment and both cuspid roots, and left upper molar. Ten teeth, some with porcelain gum, were soldered to a swaged platinum plate, having three Gilmore attachments, one between the cuspid root caps and two between cuspid and molar on left side.

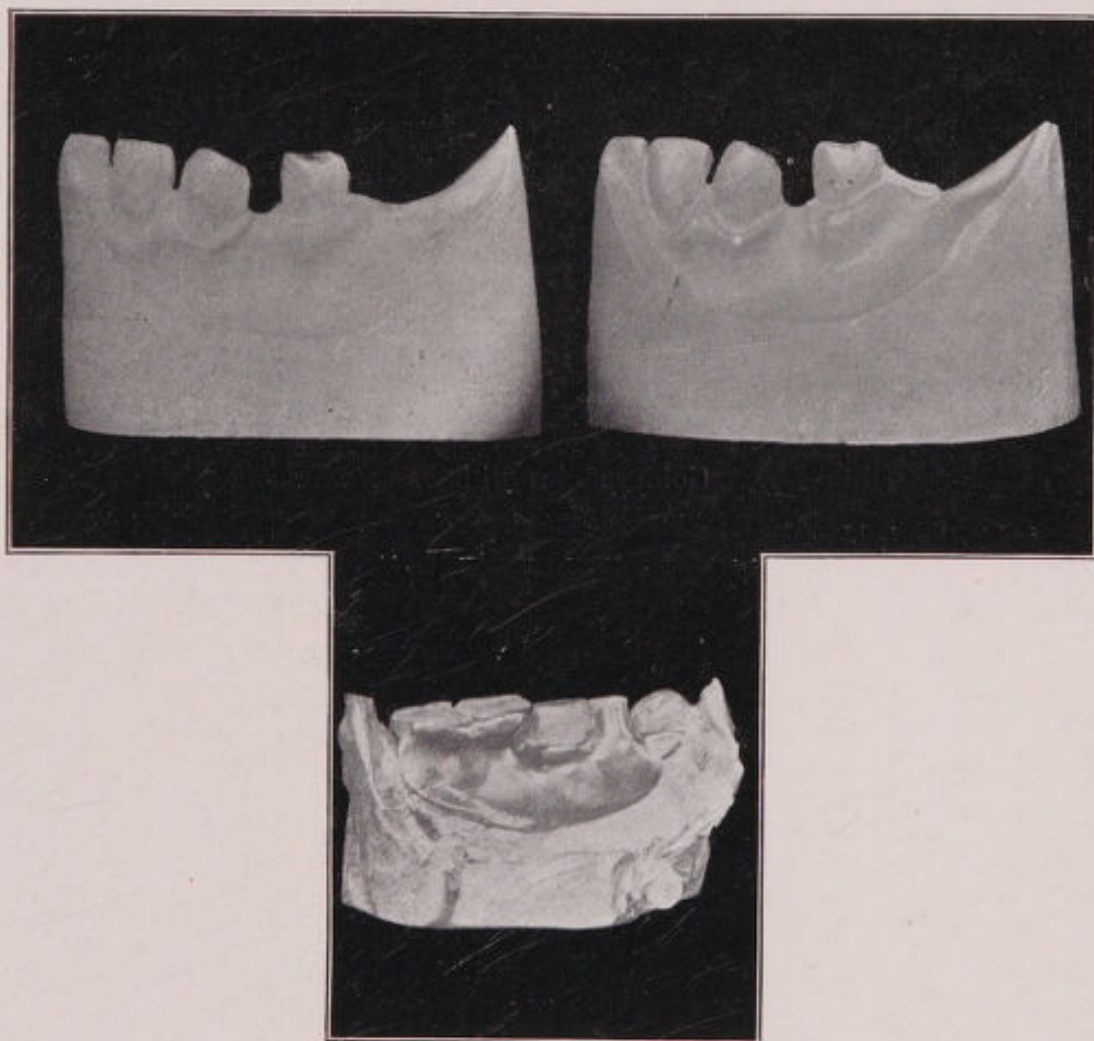
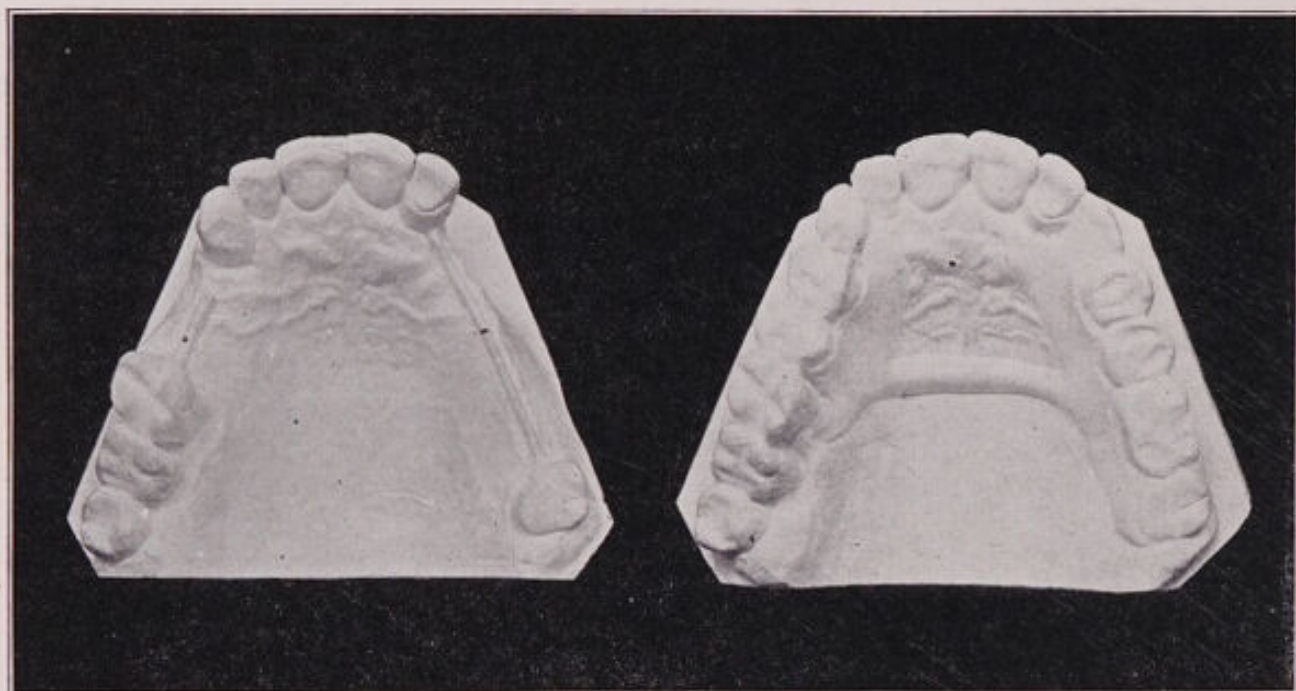

FIG. 175. Partial lower removable gold denture held with one Gilmore attachment to second bicuspid gold crown.



A

B

FIG. 176. Removable bridge with vault bar. In this case the anchorage was obtained by crowns to the lateral and molar of the left side and by gold inlays with posts on two molars of the right side (Figure A). Gold saddles with vault wire and hand-carved teeth with porcelain gum were used. Three attachments, one on the right side, and two on the left side, held the bridge securely.

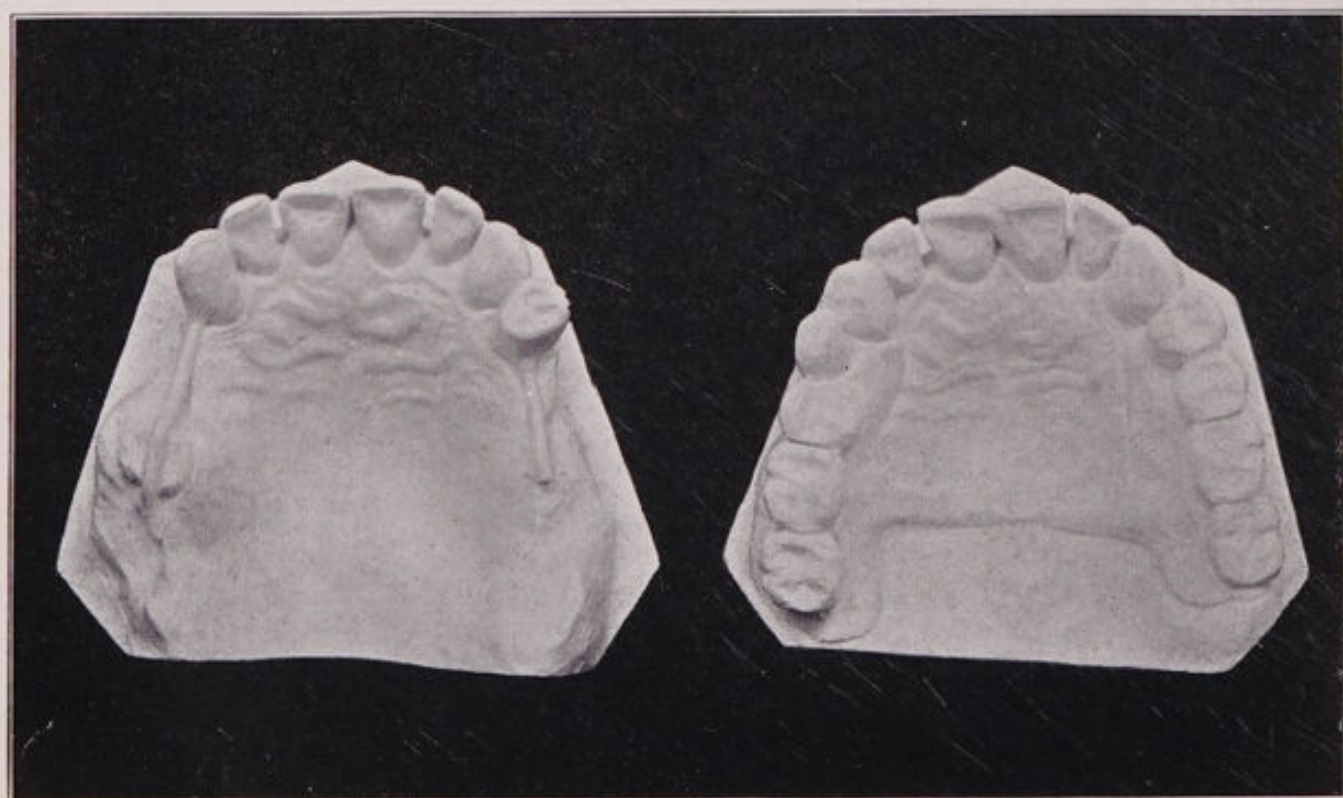


FIG. 177. Removable bridge held by three Gilmore attachments.

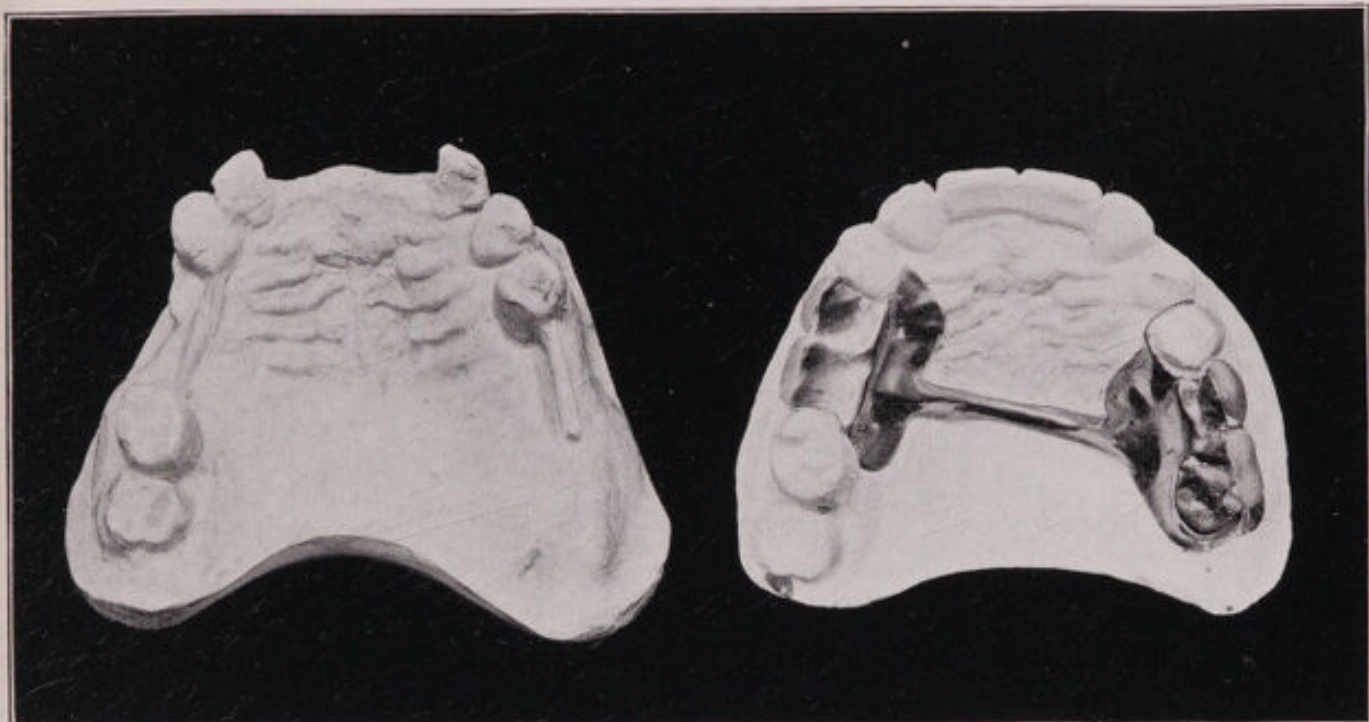


FIG. 178. Partial removable bridge with vault bar, two Gilmore attachments.

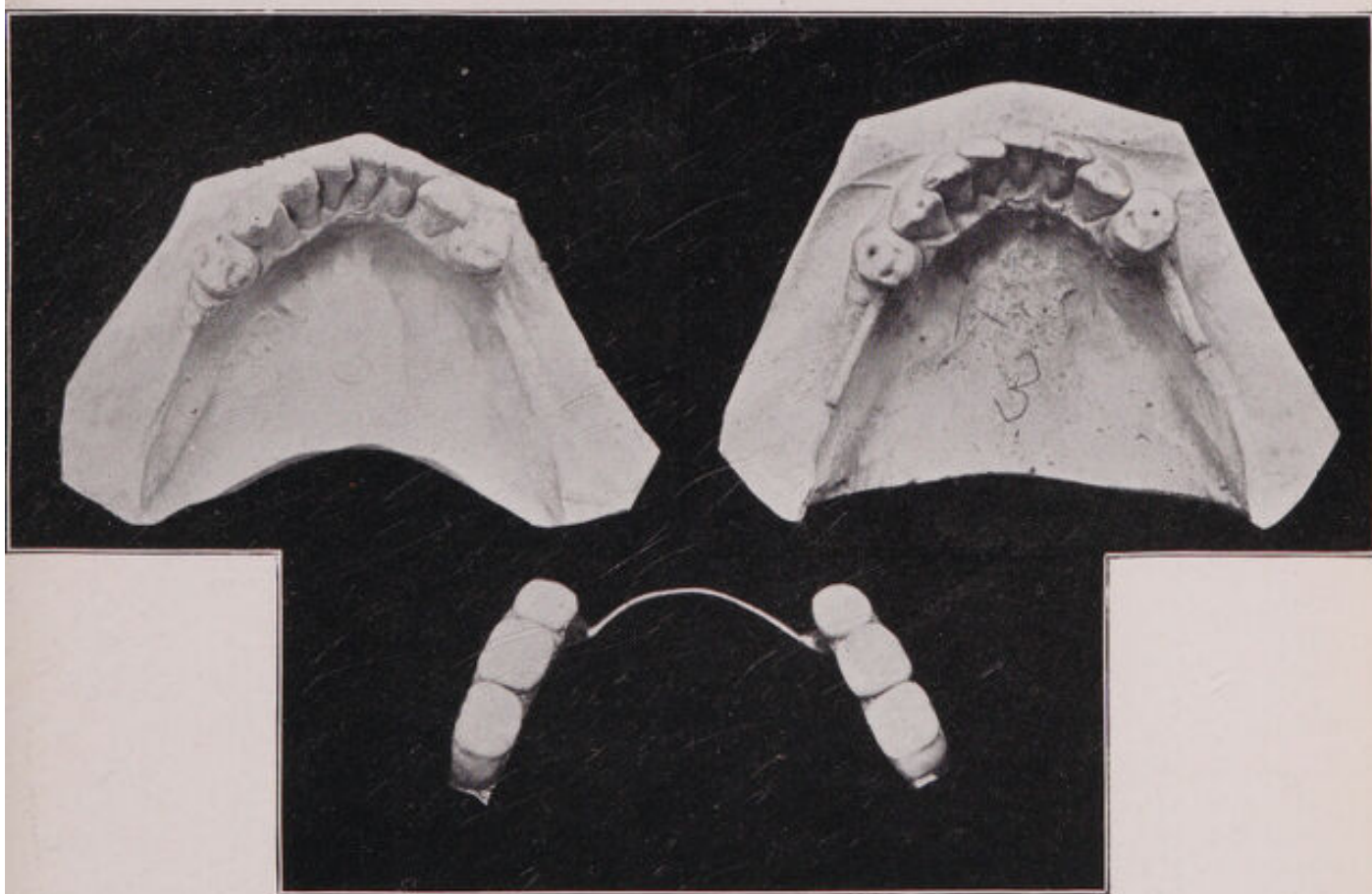


FIG. 179. Partial removable bridge with lingual bar and two Gilmore attachments. Extension wires are soldered to bicuspid, banded crowns with Steele posterior supplies. The bridge is made in gold with hand-carved gum blocks.

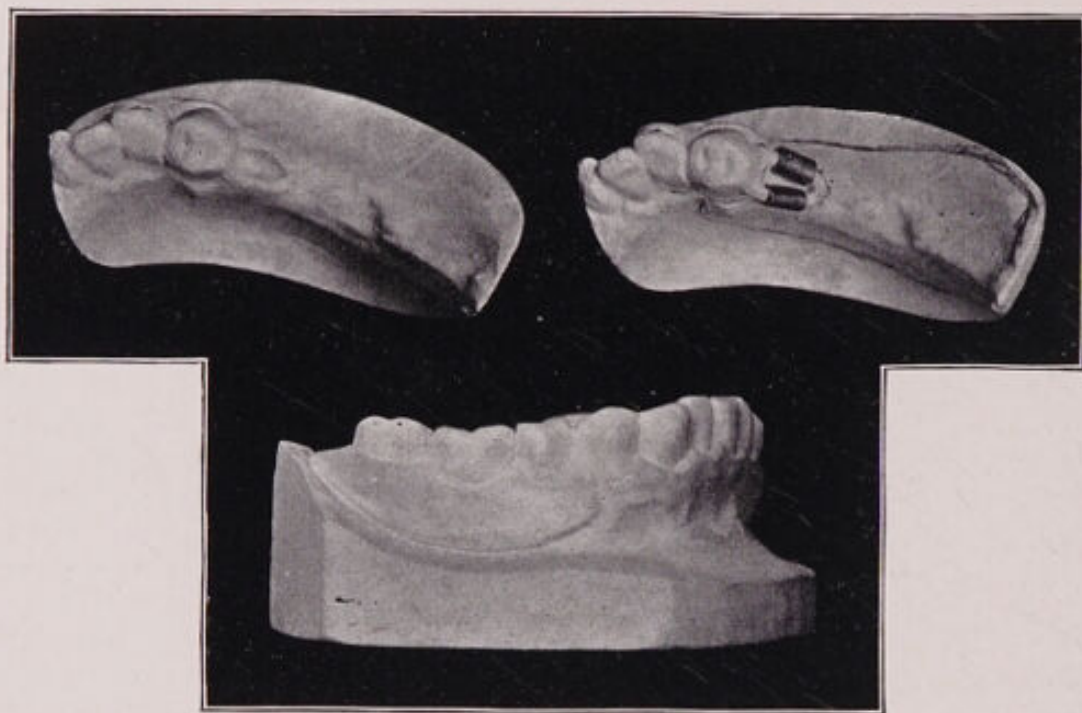


FIG. 180. Removable extension bridge for one side. Case showing a removable extension saddle bridge. A loop was soldered to an all-metal bicuspid crown, which was connected to an inlay with post in the cuspid. Two Gilmore attachments were placed one on each side of the looped wire, and over this a cast gold saddle was made, and the teeth were mounted to the saddle, as shown. A double attachment on a looped wire has a great advantage over a single wire, as the looped wire prevents the backward sliding of the saddle, gives more firmness to the bridge, and most of all it affords great strength where it is needed, next to the crown.

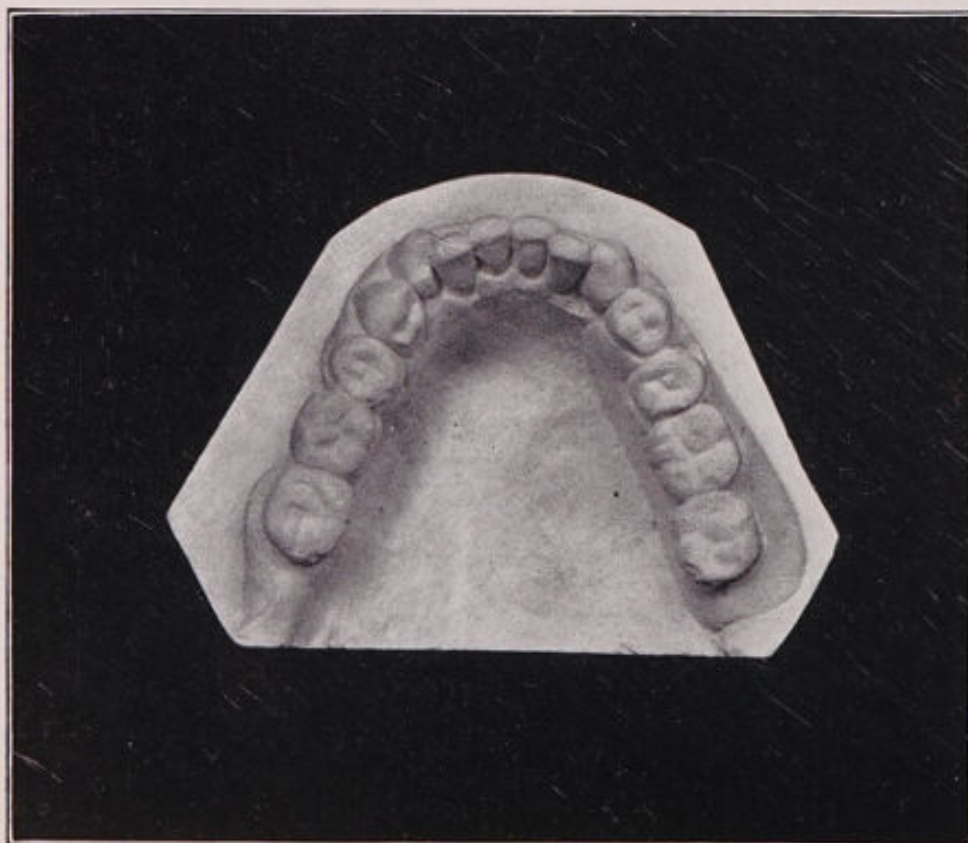

FIG. 181. Top view of finished case No. 180.

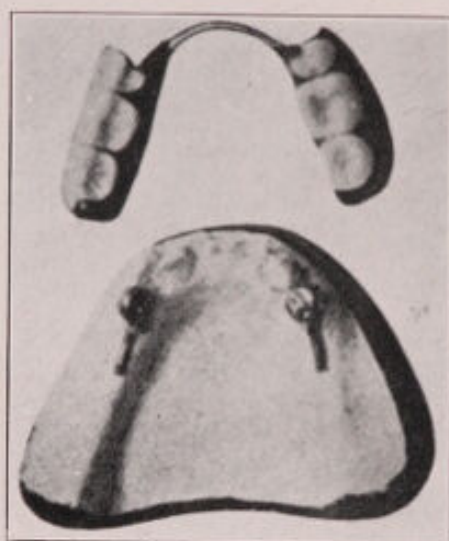



FIG. 182. When extension wires run parallel, as in this case, then the denture with the Gilmore attachments is liable to slide back. This should be taken in consideration when soldering the wires to the crowns, soldering a collar or knob to the end of the wire, and placing the attachments close to same, will overcome all back sliding of the denture.



No. 3

No. 4

No. 5

No. 6

FIG. 183. Different styles of Gilmore Adjustable Attachments. No. 3, No. 4, No. 5 and No. 6 are made of a special clasp gold. B C shows 14-gauge clasp gold wire soldered to gold crown. H shows No. 6 attachment soldered to saddle bridge. No. 3 and No. 4 are also made in special white metal and are intended for rubber work only and are sold as style No. 1 and No. 2.

B. REMOVABLE BRIDGES WITH ROACH ATTACHMENTS

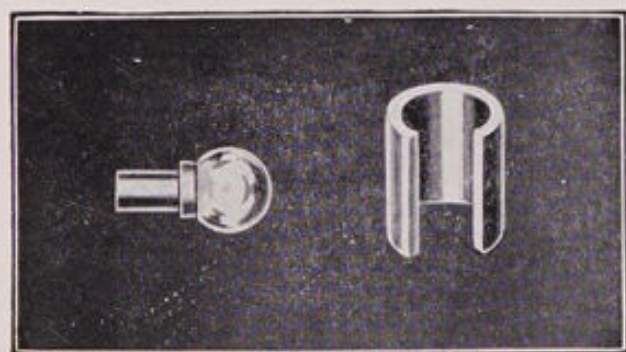
Removable Bridge VI

The Roach attachments are constructed on the ball and socket principle, which eliminates leverage and obviates paralleling, thus making its use very simple and efficient.

1. FITTING THE ATTACHMENTS TO THE ABUTMENT

Fitting to gold crowns

Make the crown and adjust it in the mouth; mark the location for the ball about $\frac{3}{8}$ of an inch from the gum lingually, so that the attachments will line up with the lingual surface of the teeth; remove the crown from the mouth, drill a hole of the size of the stem on the ball at the point marked; cut the stem short so that it will not project inside of the crown, and solder



A, Solid ball.

B, Tube.

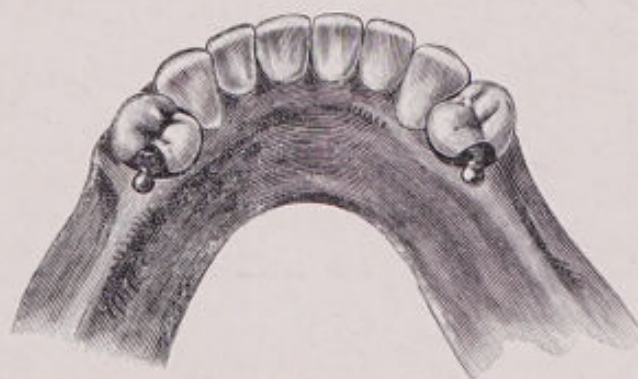


FIG. 184. Roach attachments for removable bridges.

it to place. The stem also may be cut off to the shoulder and the ball soldered to the crown without drilling a hole. (Figure 184.)

In some cases it is advantageous to take an impression of the crown in position and locate the attachment on the crown after the model is cast.

Fitting to banded porcelain crowns

Construct caps, adjust them in the mouth and mark the location for the ball, so that it may be waxed to place, invested and soldered simultaneously with the facing.

Fitting to inlays

After a wax pattern is secured, warm the ball and imbed the stem into the wax, try it again into the cavity to verify the fit of wax and the proper location of ball, invest and cast. The melted gold will unite with the stem of the ball and will need no soldering. The inlay may also be completed, the stem cut off, and the ball soldered to the inlay.

2. TAKING IMPRESSION FOR BRIDGE

The abutment with the ball attached should now be placed in the mouth, take an impression, and form model, making sure that the abutment is securely held in place.

3. ASSEMBLING OF THE BRIDGE WITH ROACH ATTACHMENT

Construct the saddle bridge in usual manner, placing the tube over the ball. The tubes are soldered to the bridge.

One side of the tube should be left uncovered for the purpose of tightening.

Tighten attachment by compressing tube with pliers, placing an end of a match or piece of wire in the tube to prevent closing it too much.

NOTE.—Open tubes slightly to facilitate removal during construction.

C. REMOVABLE BRIDGE WITH MORGAN ATTACHMENT

Removable Bridge VII

Another means of anchoring bridges is with the Morgan attachment. The originator claims that he has tried this attachment out thoroughly in hundreds of cases.

Making of the abutments

All the different abutments suitable for fixed bridges can be used. The attachment consists of a two-winged curved piece (Figure 185A), into which fits a two-armed anchor (Figure 185B). The curved piece is called a keeper, and is to be sold-




FIG. 185. Morgan attachments for removable bridge.

ered to the gold crown abutment, banded crown or inlay abutment. The other piece is called the anchor, and its head is curved to fit into the keeper with a cap soldered on the top, the shank passes out between the wings of the keeper, and furnishes anchorage in the gold, or other material of which the denture is made.

The abutments are made in the usual manner: place them in the mouth, take impression and bite, and make articulated model. If you wish to avoid taking a second impression and making a second cast, flow a thin coating of wax inside the crown, before pouring the plaster cast, then by heating the crowns sufficiently to melt the wax, these can be slipped off and on at will, and the one impression and cast will do the entire work.

To adjust a keeper to each of the abutments, and to have both perfectly parallel to each other, the originator constructed a jig. (Figure 186.)




FIG. 186. Jig for Morgan attachments.

Fasten the plaster model to the base of the jig by means of the thumbscrews.

Slip the keepers over the forks of the jig, being careful that they are put on evenly, as can be told by sighting past the edge of both to see if the edges are in line with each other.

Loosen the thumbscrew on the upright bar, and lower the keeper to the place beside the abutments.

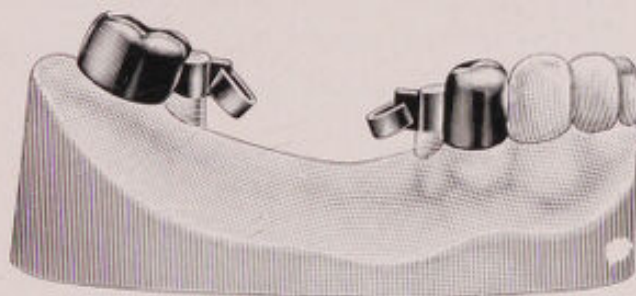


FIG. 187. Morgan attachments soldered to all-metal crowns.

Wax them in place with sticky wax and when cold raise the guide forks out of the keepers. Loosen the thumbscrews and remove the model.

Now remove the crowns from the cast, and wax them so that no plaster can come between the keeper and the crown.

Invest with that end of the crown upwards, which makes it most convenient for soldering. Make sure that the investment holds the parts in place, and that the curved slot in the keeper is thoroughly filled with investment. Cut the investment away

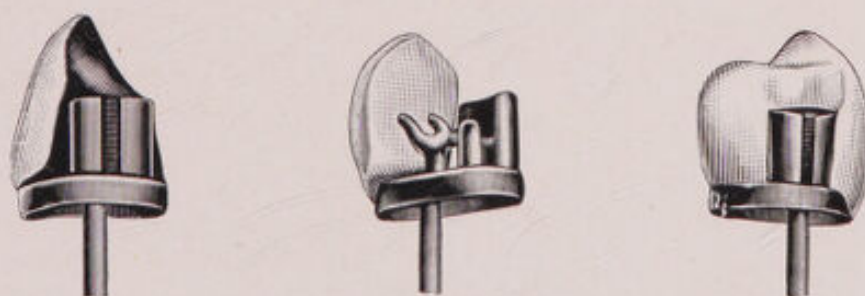

FIG. 188. Morgan attachments used on various crowns.

to give free access to soldering, boil the wax out and solder. Should the keeper stand away from the crown at one end, fill the space with gold-foil, so as to assure a strong joint when you solder.

After having the keeper soldered to the abutments, fit them in the mouth, and take impression and bite for a new articulated model; but if you have saved your first cast by using a wax coating in the abutments, replace the abutments to the plaster model.

Making of the supply

As described for Gilmore bridges, one can use different materials to supply the lost teeth: rubber facings, detached post crowns, Steele teeth, Goslee teeth, and others.

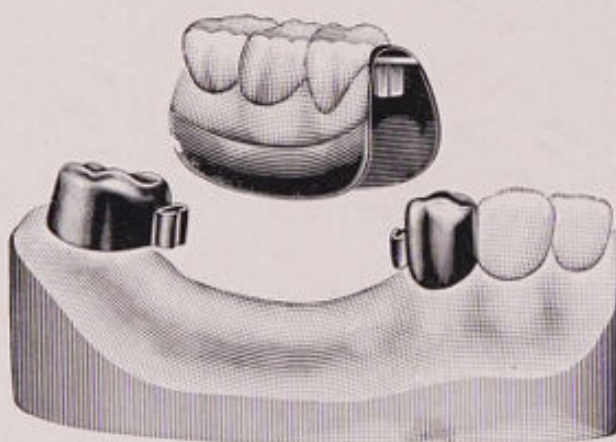


FIG. 189. Finished case of Figure 187.

Slip the anchor over the keepers, slipping the metal loop which comes with the attachment over the anchor's shank. Bend the latter down so as to keep it as much out of the way as

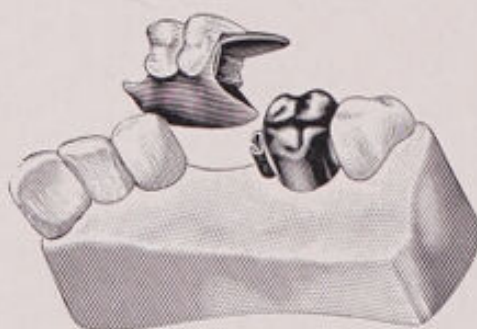


FIG. 190. Saddle with single Morgan attachment.

possible, when you are setting up the teeth. The loop is furnished with the attachments, and allows for stronger connection of the anchor with the supplies.

When all the supplies are waxed up, solder the bridge in ordinary manner, making sure to get a good junction between the anchor-loop and the gold of the bridge. In case of a saddle

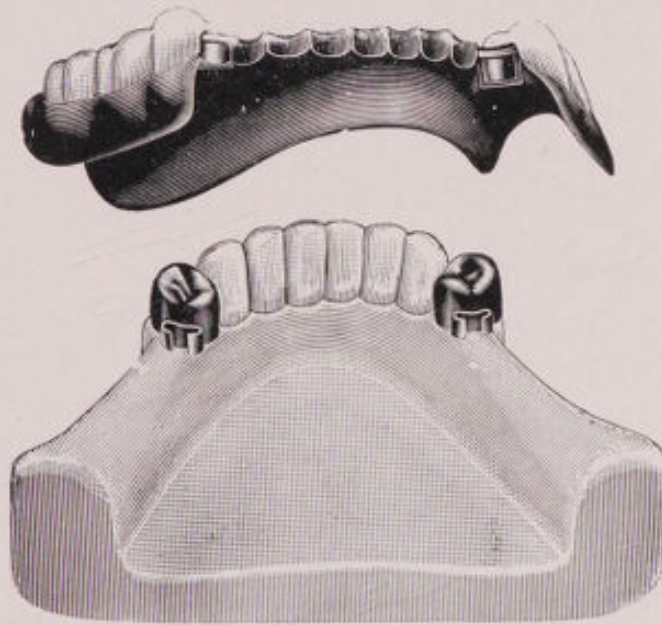


FIG. 191. Lower denture with Morgan attachments.

bridge, the anchor and loop can also be soldered to the saddle first. The illustrations show some practical cases. (Figures 189, 190, 191.)

X. REPAIR OF CROWNS AND BRIDGES

1. FOR TEMPORARY USE

Crowns and bridges which have been taken off can be repaired for temporary use, while the new bridge is under construction. There is no need for the patient to go without the crown or bridge teeth, as it is a simple matter to fix old bridges so that they will fill the spaces and spare the patient objectionable appearance. For example: when crowning an incisor or bicuspid tooth, we can cut the tooth off close to the gum, with a small cross-cut fissure bur, then prepare the root for whatever crown we intend to use. Instead of sending the patient home toothless, fit a temporary tooth or crown, such as shown in Figure 192, or use the tooth that was cut off, by first removing all decay, then drilling a hole for a german silver post. Cement post into the crown, and press into place while the cement is still soft. With the same cement fill up all imperfections of the tooth to be used. When the cement is set, remove the tooth with post and sandpaper the edges (Figure 192). Now dry

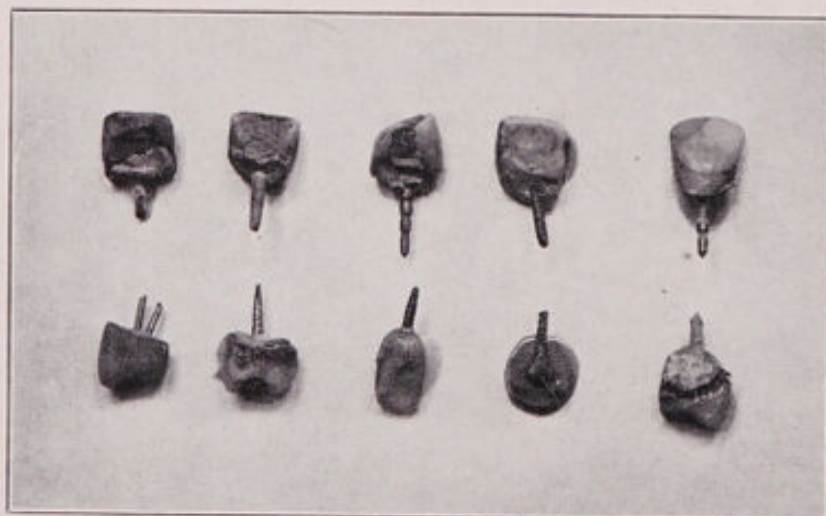


FIG. 192. Temporary crowns.

the root, put in the dressing, or fill the apex of the root, and then set the crown with temporary stopping or soft gutta-percha.

This temporary tooth or crown will keep the gum from growing over the root, which would happen if the root would not be protected with a covering. If for any reason a tooth or crown cannot be used temporarily, a covering can be constructed of german silver by cutting a plate the size of root almost any gauge (from 26 to 36 gauge), whatever is at hand, and soldering a post through it. Set this with gutta-percha.

A gutta-percha plug can also be used for this purpose, as follows: Shape a piece of pink base plate gutta-percha (cone shape), dry the root and force it into the canal with a suitable instrument. When the point is firmly held in the canal, press an extending ball over the whole surface of the tooth. In regard to replacing old bridges for temporary wear, see Figures 193 and 194. The post of the cuspid crown was cut off through

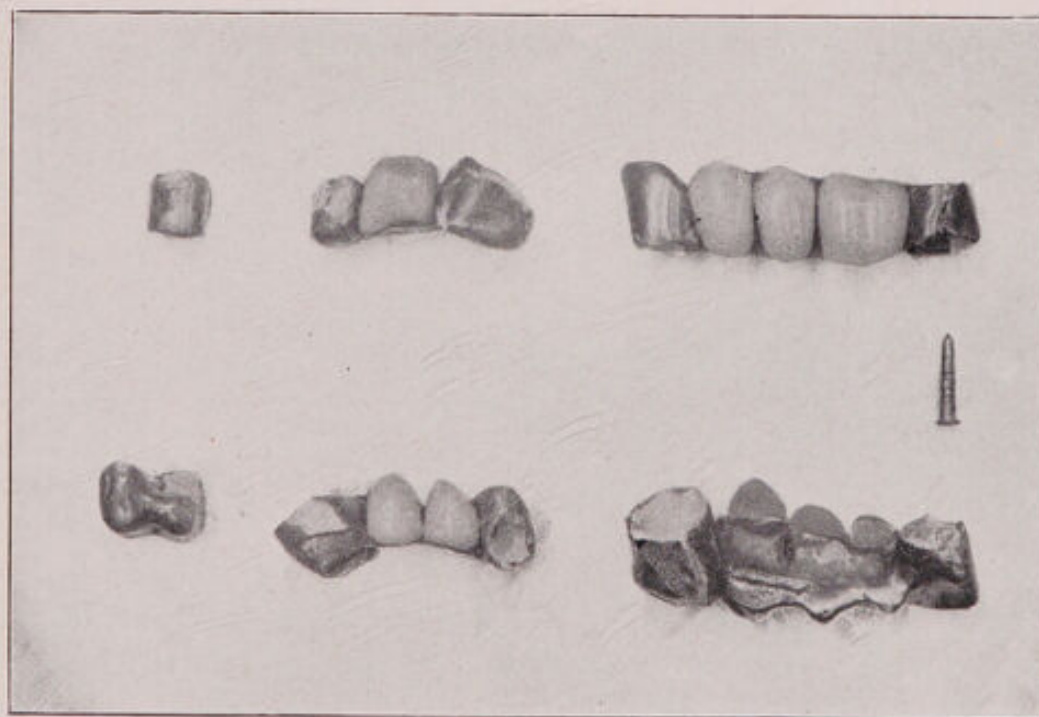


FIG. 193. Old crowns and bridges after they have been taken off.

the band from the labial side. The gold crown was split open from the palatal side, and after the cuspid and molar roots were prepared for the new crowns, the old bridge, after boiling

it in acid, and a new post with a shoulder, is cemented in the cap without necessitating the drilling of a hole into the gold. While the cement was still soft, the bridge was placed into the position on the root. After the cement had set, the bridge was removed, all surplus cement taken away, and after drying the cuspid and molar roots the bridge was set with temporary stopping. (The split of the molar crown was only drawn together, and burnished, but not soldered.) Figure 194 shows two gold

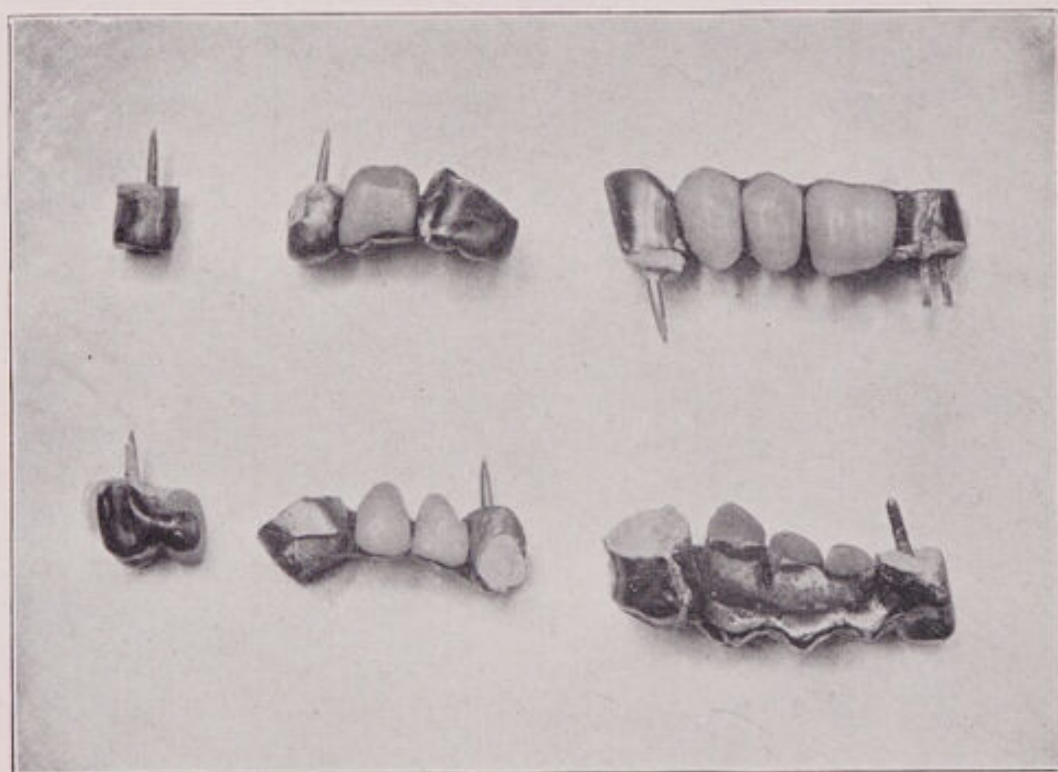


FIG. 194. Old bridges with posts cemented into crowns and used temporarily till new bridges were constructed. These bridges were set with temporary stopping.

crowns with cemented pins, both teeth having been cut off. It was set with temporary stopping, with post cemented in bicuspid gold crowns, and used temporarily to protect the roots, during the construction of new bridge.

Very often a broken post of a Richmond crown can be replaced without soldering, by drilling a hole into the bulk of gold, and cementing a new post into same instead of soldering. The principle is the same as with a detached post crown.

2. REPAIR OF CROWNS AND BRIDGES FOR PERMANENT USE

Before removing a crown or bridge consider whether you are going to use it only for a temporary appliance, till the new bridge is made, or whether you want to repair it for permanent use. In the latter case you want to be careful when cutting the crowns, so as to make the repair as easy as possible. All metal crowns are best cut on the buccal side, while banded post crowns can be removed easily, if we cut from the lingual side into the cap, using a new small round bur. In this fashion, we cut off the post from the cap and also remove part of the cement. After removing the bridge, we repair the all-metal crowns by burnishing them in place, waxing a piece of platinum foil in the inside. After investing, flow solder over the cut part. For banded crowns, fit a new post, which extends through sufficiently far to get the relation, wax it in place with sticky wax, or take a plaster impression. Invest and solder. To cut the buccal side of a gold crown, try your wedge cutter. It does it better than most crown slitters.

To extract a broken post from the root of the tooth, one can use the S. S. White's post extractor, or the Giant post puller, or

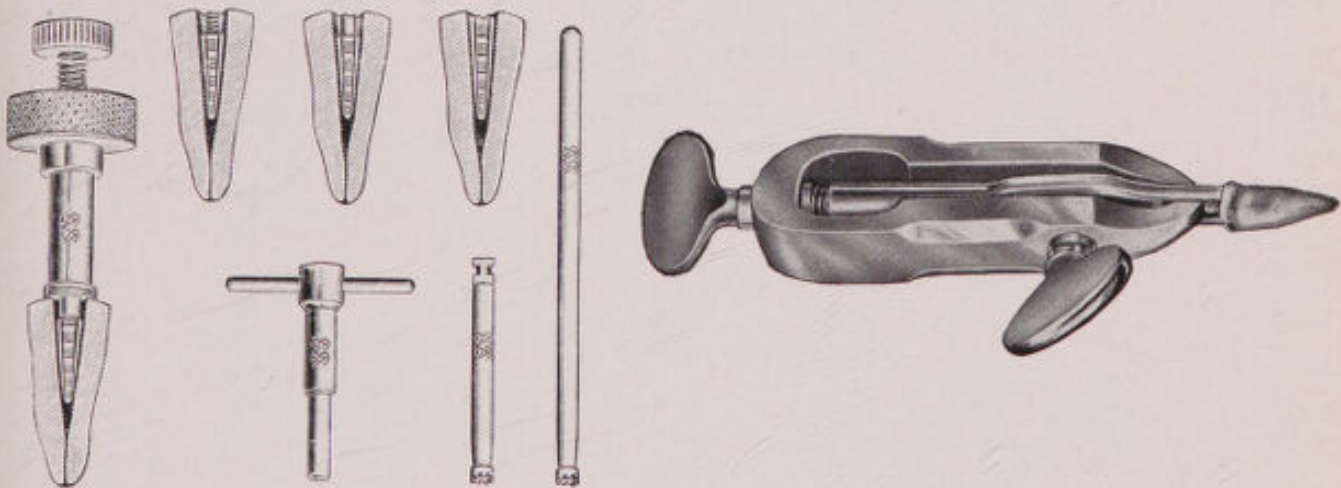


FIG. 195. S. S. White's and the Giant post pullers.

similar device. With a small round bur cut around the post till there is sufficient space to take hold of it with one of the described instruments. A post can also be removed by drilling with a new No. $\frac{1}{2}$ round bur, around the post downwards, along side of post, stay in close contact with the post, drilling part

of the post, there is no danger in perforating the root. Should the post be at one side of the root, one can easily drill down on the other, finally pushing it to the side, in the newly drilled hole, and then removing it.

Broken Steele, Goslee teeth or facings can often be replaced without taking the bridge off. To repair facings we have the following methods:

1. Ash's repair outfit.
2. Steele repair outfit.
3. Bryant repair outfit.
4. Another method.

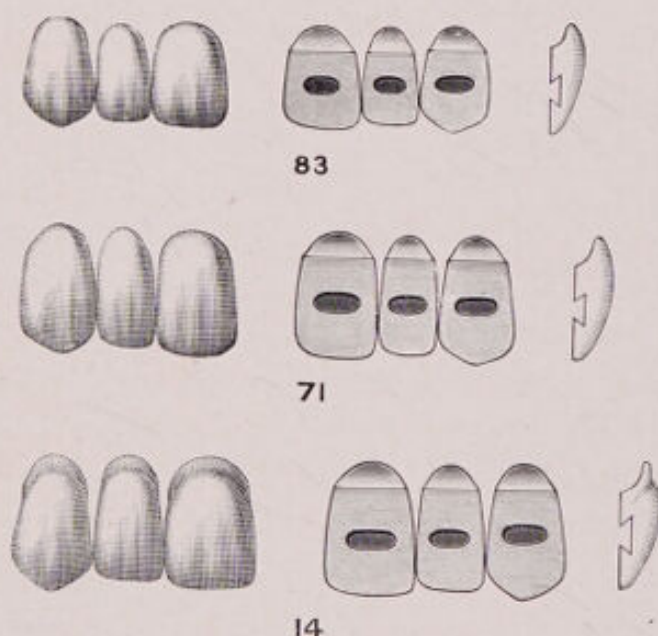


FIG. 196. Ash repair facings.

1. ASH'S REPAIR FACINGS

a. If a pin facing is broken and both pins (cross pins) are left in the backing, simply cement a repair facing on as described below.

b. If one pin is broken, the other remaining in the backing, cut off the standing pin, grind the backing flat with a small carborundum point, drill a hole in the centre of the backing with the Ash repair outfit, remove the burred edge formed by the drill, with the countersinking tool, tap the hole with the small tap, follow on with the large tap, again clear away the burred

edge with the countersinking tool, fix the Ash stud selected in holder, and screw it into position right up to the shoulder.

Select a repair facing of the same size as the broken-off tooth, remove all traces of wax from it, grind it to place, thoroughly cleanse it; mix crown and bridge cement to a thin creamy consistency, smear the backing and the back of the facing with it, also fill up the undercuts in the oval cavity of the facing, press the facing to place, hold it firmly in position for four or five minutes, then trim away excess of cement, and coat the exposed edge with varnish. (Figure 196.)

2. STEELE REPAIR OUTFIT

Cut off the projecting pins, and stone the bridge to a flat surface. Two holes are drilled and threaded to receive the screws provided for the purpose. (Figure 197B.) A Steele's



FIG. 197A. Steele repair outfit.

interchangeable tooth facing is then placed in position over the heads of the screws, which engage the hole and slot in the facing. When cemented, all fluids are excluded, which renders it thoroughly sanitary. (See Figure 197B.)

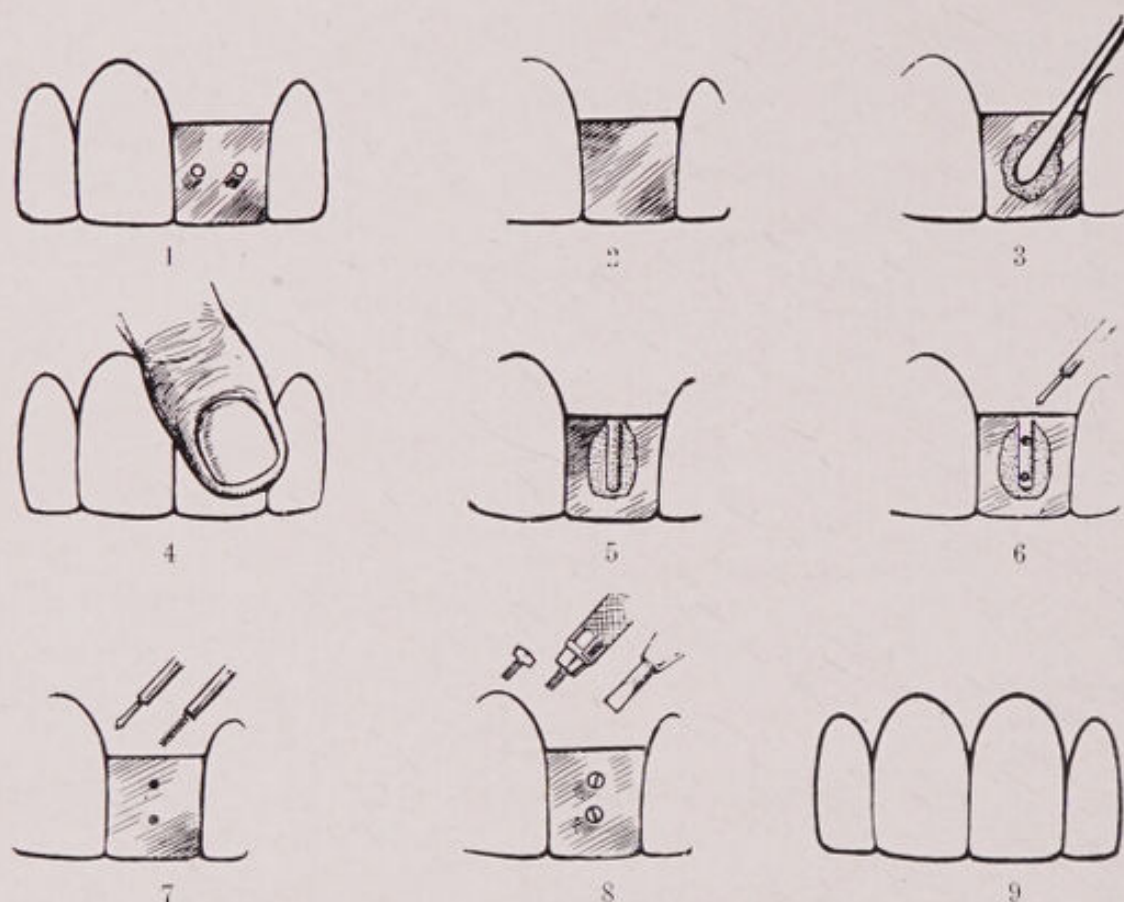


FIG. 197B. Different steps to repair a broken pin facing.

3. BRYANT REPAIR OUTFIT

This method is also very good. The repaired tooth is fastened to the bridge by means of threaded nuts. The method is very simple, and gives a strong result. (Figures 198A, 198B.)




FIG. 198A.

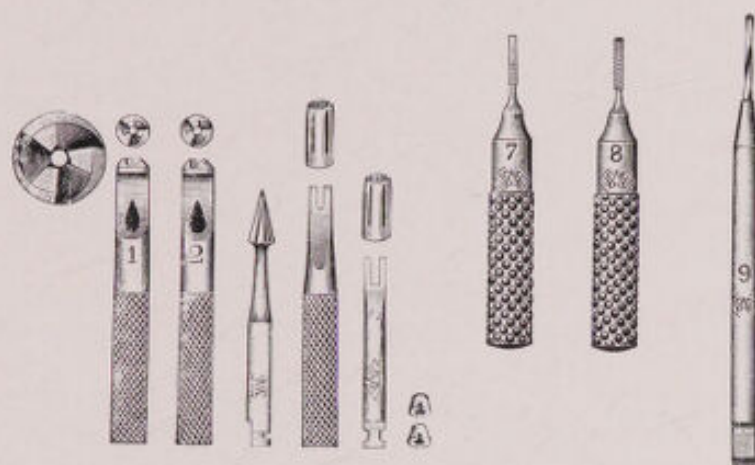


FIG. 198B. Bryant repair outfit.

4. ANOTHER METHOD

Cut pins even with backing. Select a *long pin facing* of proper size, flow a thin layer of wax over surface of the backing.

Press facing in right position on to the wax against the backing.

Drill the holes through the backings, as shown by the imprint of the pins on the wax.

Grind the facing to the backing, or take an impression, make a cement model and grind facing to that.

If the backing is thick enough, as it is often the case in cuspids, Richmond crowns, bicuspid and molar dummies, the cementing of the pins and facing to the backing is sufficient to secure a good hold.

In case of a thin gold backing and close bite, the position of the pins to the bite must be taken into consideration. The pins when extending through the backing must be below or clear the bite.

Grind and cement the facing into place, turn the pins over on the other side, using a pair of flat plate pliers.

If the pins are far enough apart, it is best to have them meet ends to ends.

Stone the pins, dry both pins, and gold surface around them, and build amalgam into and around the pins.

The mercury will amalgamate perfectly with the gold.

When hard, stone and polish.

MINERAL STAINS

To get the effect of rhachitic-hypoplastic, smokers', and other teeth, grind teeth first to desired shape, then use the S. S. White or Ash stains. Mix the stains with oil and turpentine, and apply the paint to the tooth with a fine brush. As the color does not change in the firing, it is best to paint and match the teeth in the mouth, when the patient is present. (Figure 199.)

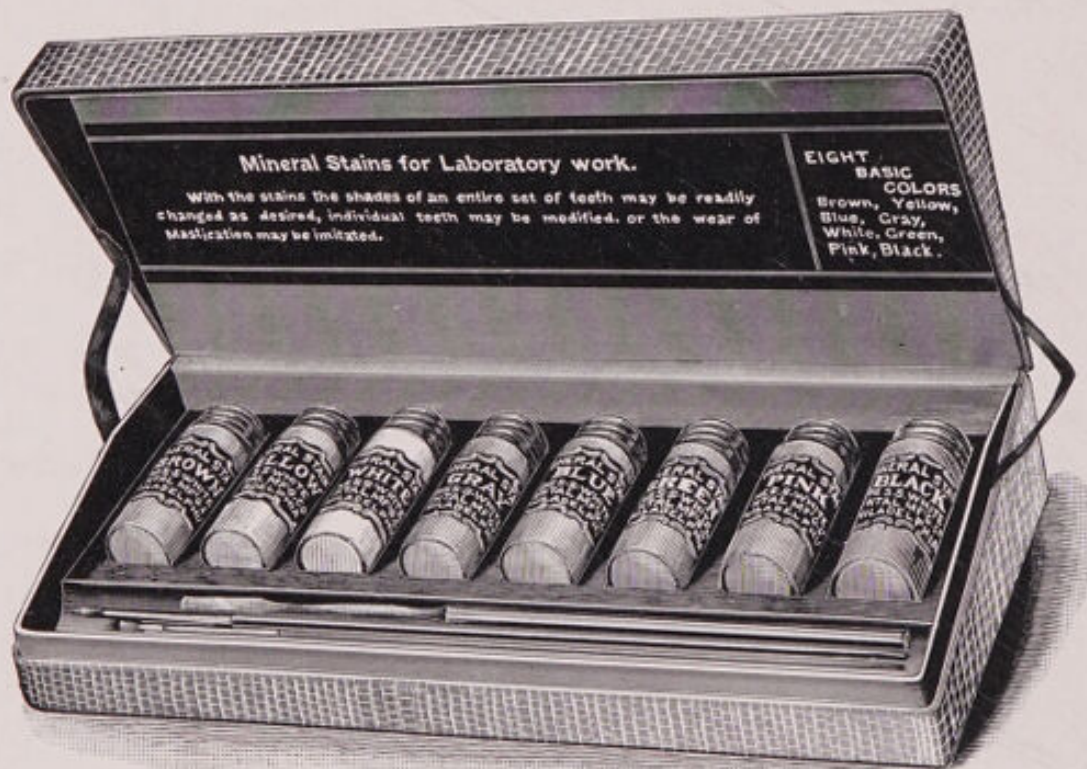


FIG. 199. Mineral stains and stained teeth.

SPECIAL INSTRUMENTS

1. BRIDGE METER

This instrument is used for measuring distances, and is indispensable for paralleling root canals and lining up of teeth.

Many bridges are built and could not be set, because the teeth or roots were incorrectly prepared for the abutments.

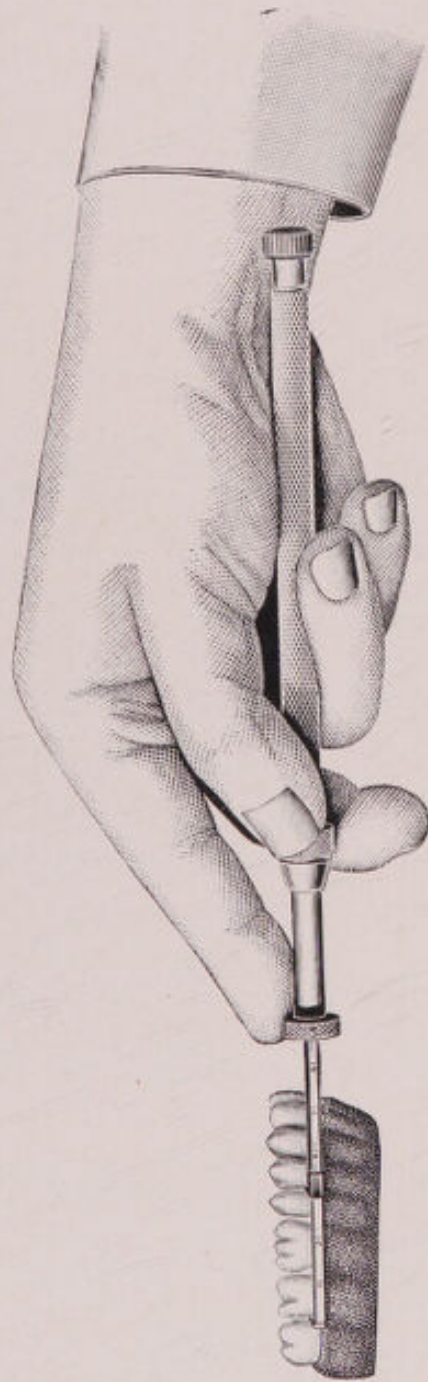


FIG. 200. Measuring of distance with the bridge meter.

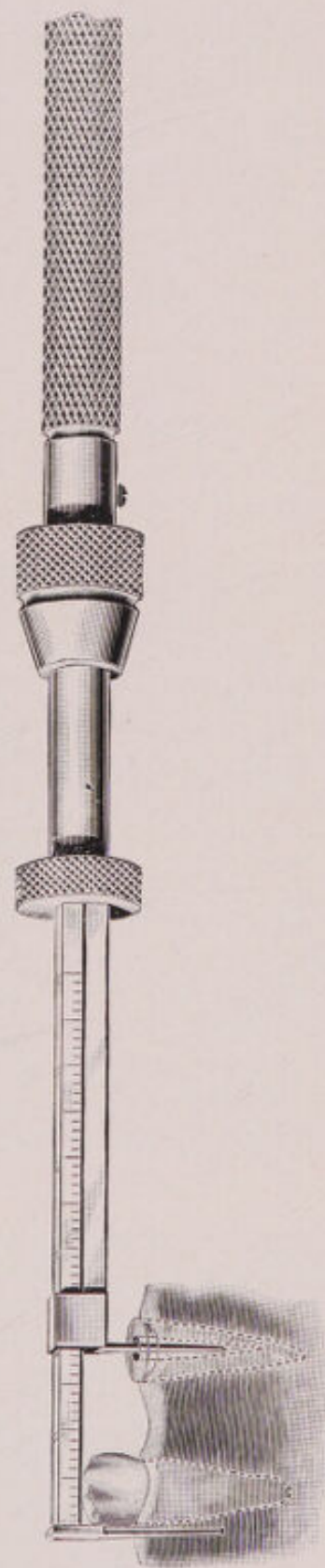


FIG. 201. Parallelism obtained with the Eyslin bridge meter.

Very seldom we find two or more teeth or roots in the mouth stand parallel to one another, to permit a bridge with good fitting crowns to slide in place rightly.

This instrument is of great value for measuring the distances of tooth spaces, also length and thicknesses of teeth in the mouth, as well as on the work model, for lining up of interlocking devices on fixed or removable bridges, and in many other cases.

XI. PRACTICAL CASES

CASE I

To correct mal-occlusion in the adult with bridgework is a more difficult problem than the treatment of same in orthodontia in the early age, and while in the latter, normal occlusion can almost always be obtained, we usually have to be satisfied in bridgework by getting sufficient occlusion.

Figure 202 shows condition of the mouth. Figure 203 is radiographs of the roots. It was decided to extract the two upper central incisors, right lateral and the right upper molar.

Figures 202 to 211 show steps for making of bridge.

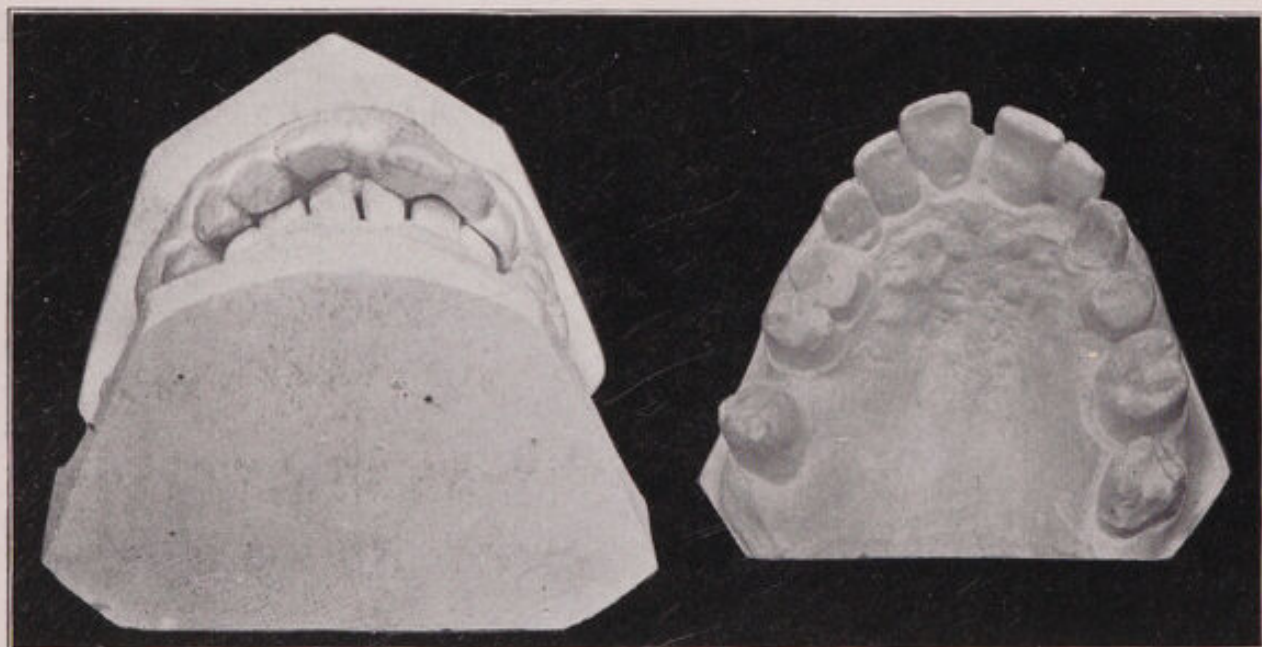


FIG. 202.

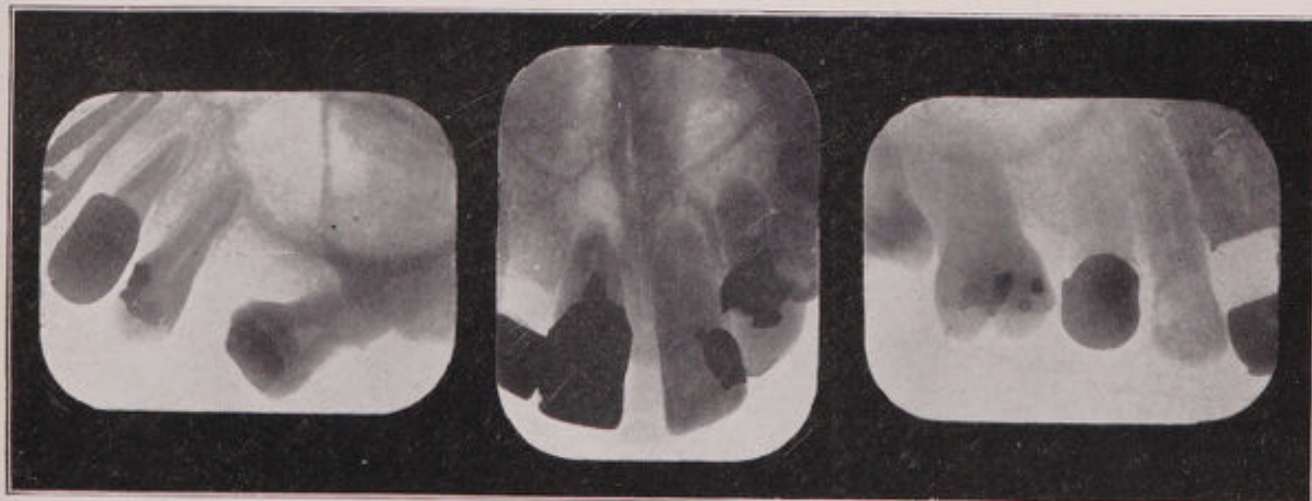


FIG. 203.

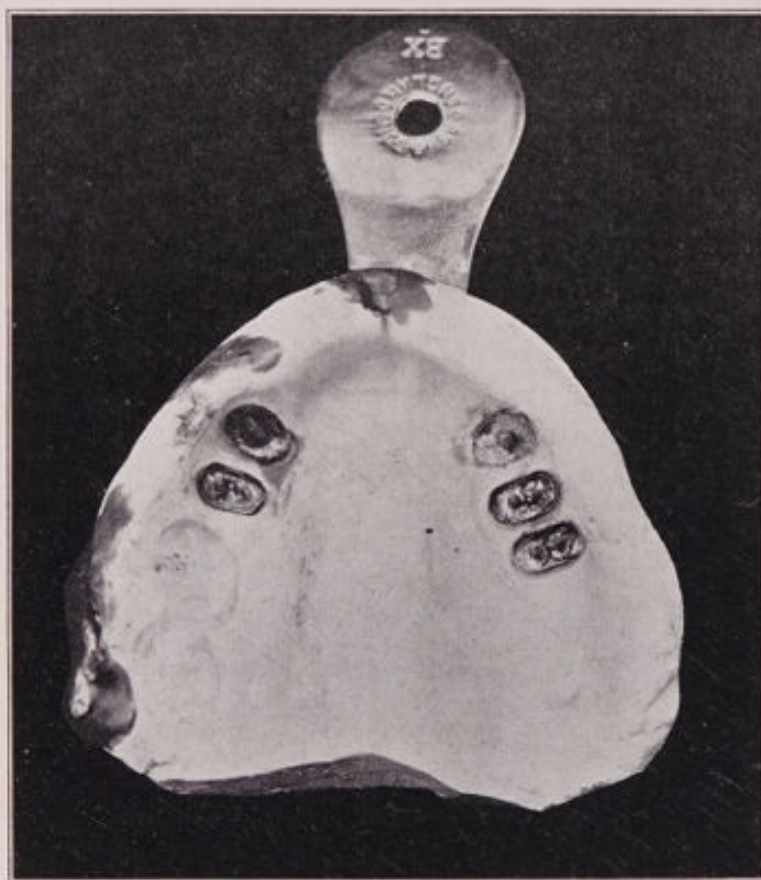


FIG. 204.

Figure 204 shows the impression of the abutments.

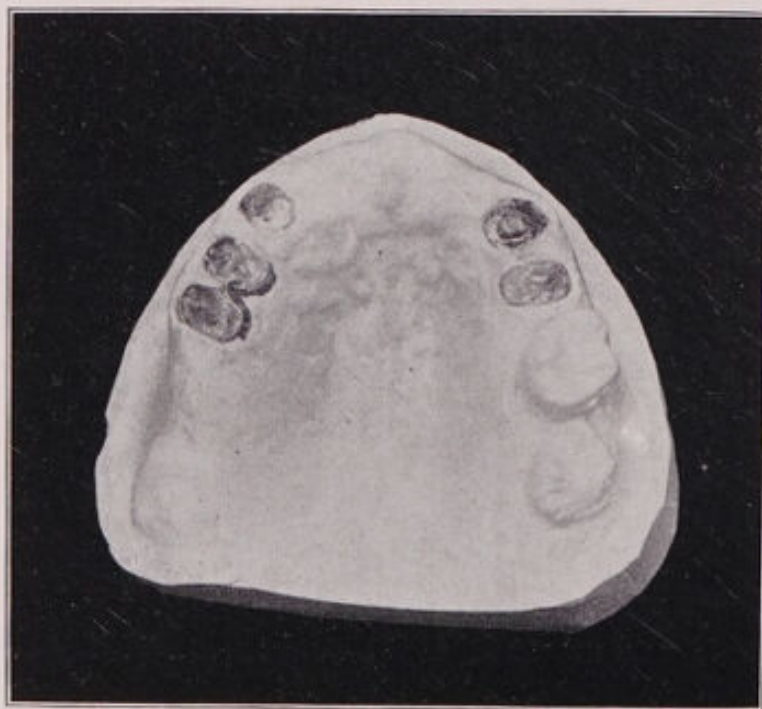


FIG. 205.

Figure 205 is the plaster model with the abutments in place.




FIG. 206.

Figure 206 shows the articulated models with face bow relation.

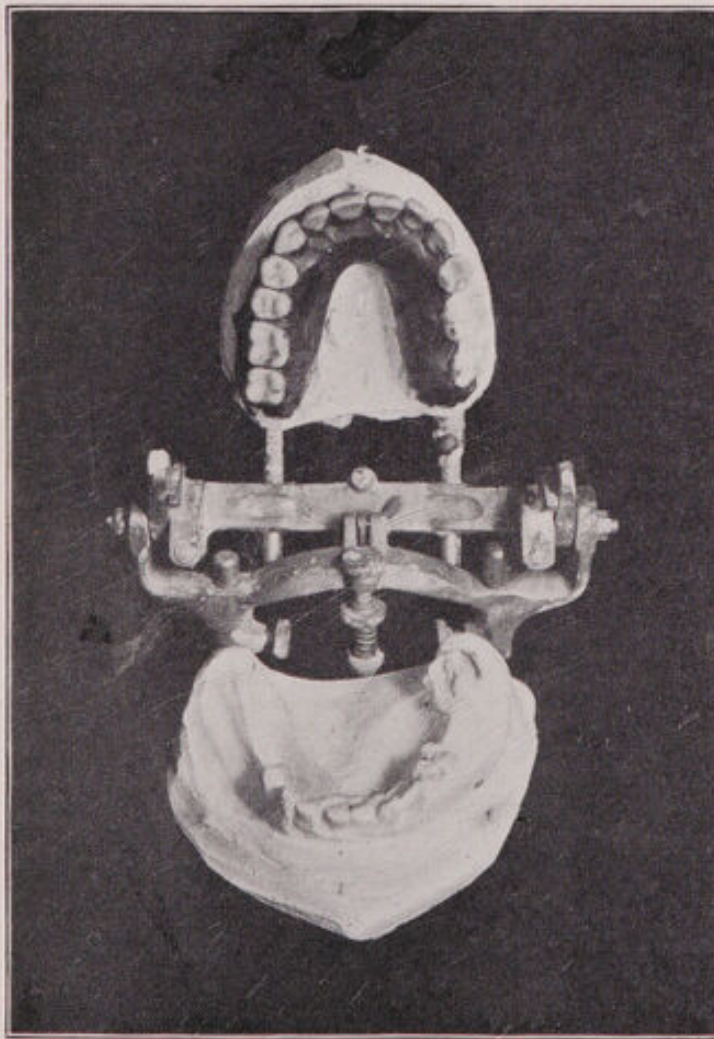
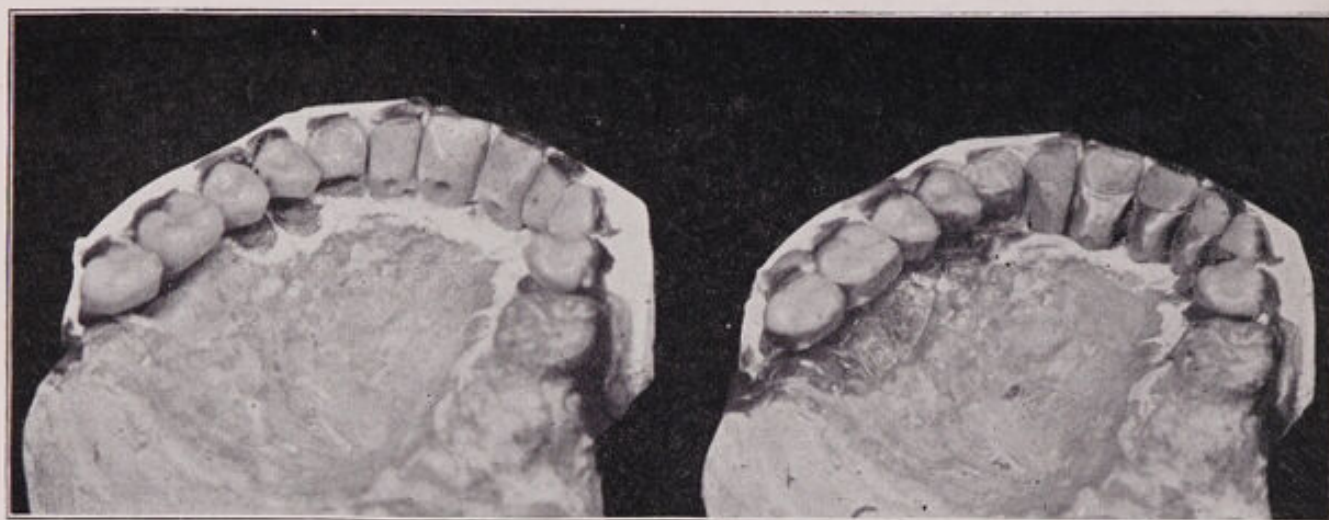

FIG. 207. Bridge teeth waxed for trial.

Figure 207, detached post crowns, ground in position and ready for trial in wax.



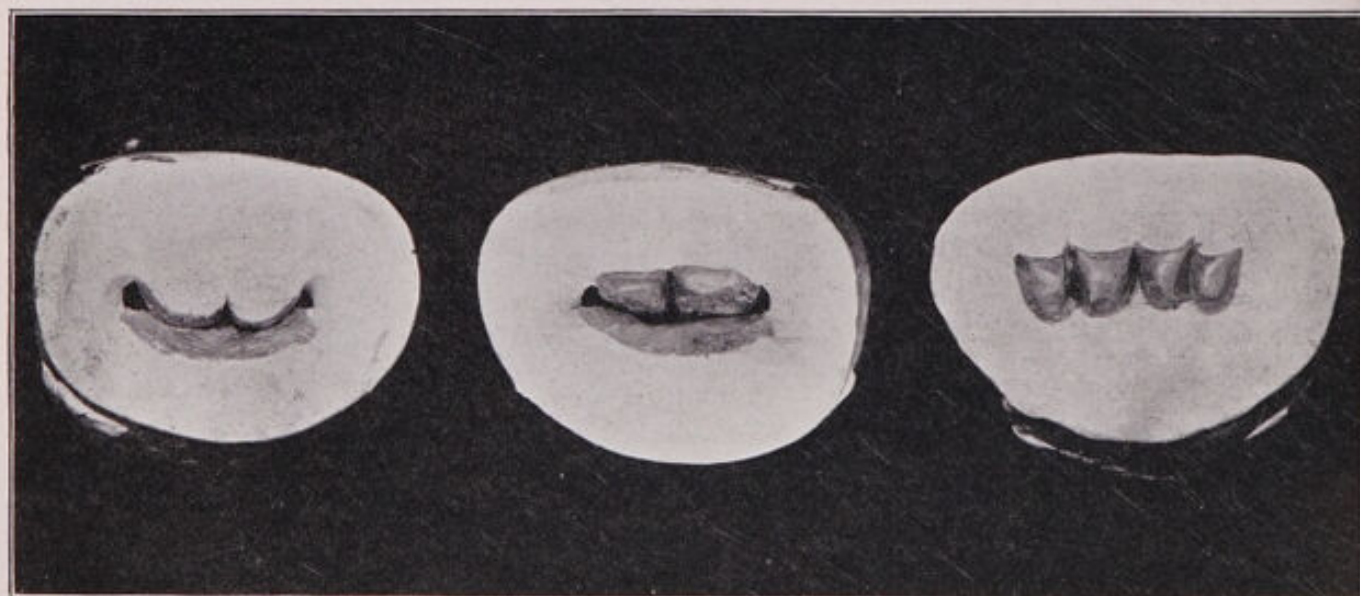A

B

FIG. 208. A, showing teeth in plaster core on the model. B, showing teeth boxed, ready to be soldered in sections of two and four.

Figure 208A shows the crowns held in plaster core, ready for backing.

Figure 208B shows the crowns boxed, with swaged platinum saddle on the molars in position.



A

B

C

FIG. 209. Sections of tooth boxes, invested and ready for soldering.

Figure 209A, invested saddle from front; B from back; C invested section of cast boxes of front teeth ready to solder.

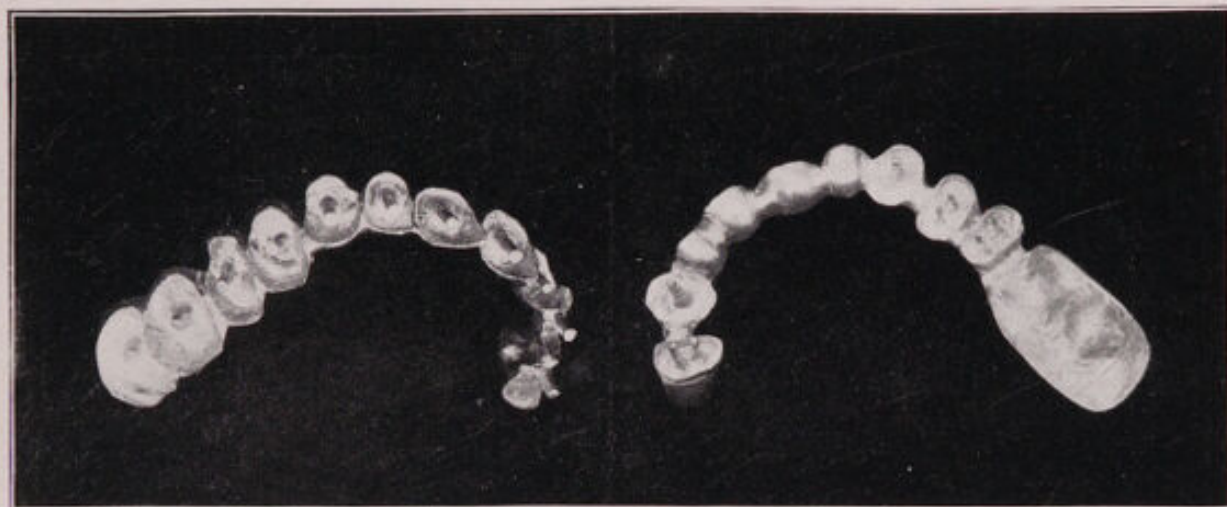

FIG. 210. Sections united to abutments.

Figure 210, soldered bridge, top and bottom view.

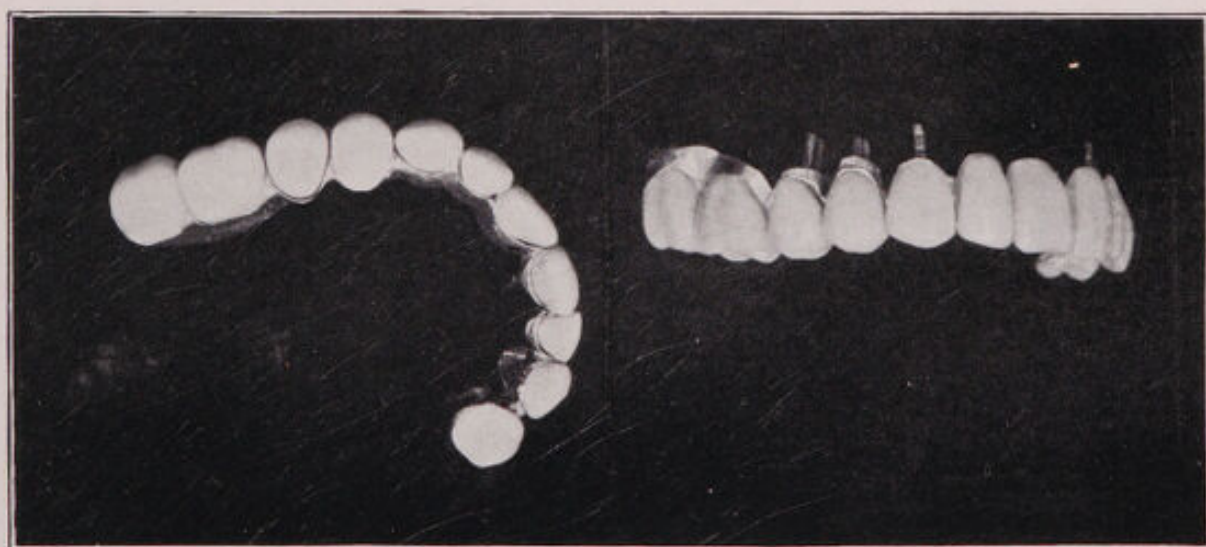

FIG. 211. Finished fixed bridge with teeth cemented into boxes.

Figure 211, finished bridge, teeth cemented.

CASE II

Case II, a school case, shows the mouth of a young girl of 18 years, with only six permanent teeth, the four six-year molars

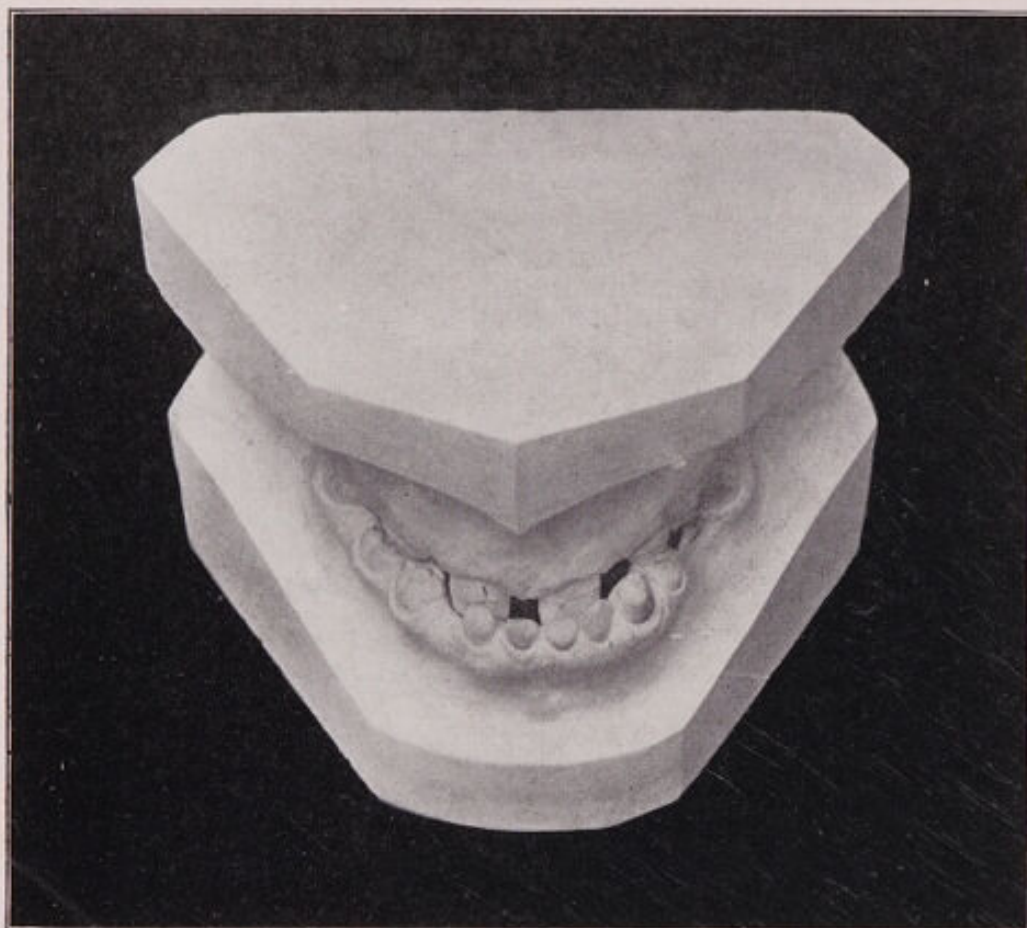


FIG. 212. Harvard Dental School case, before treatment.

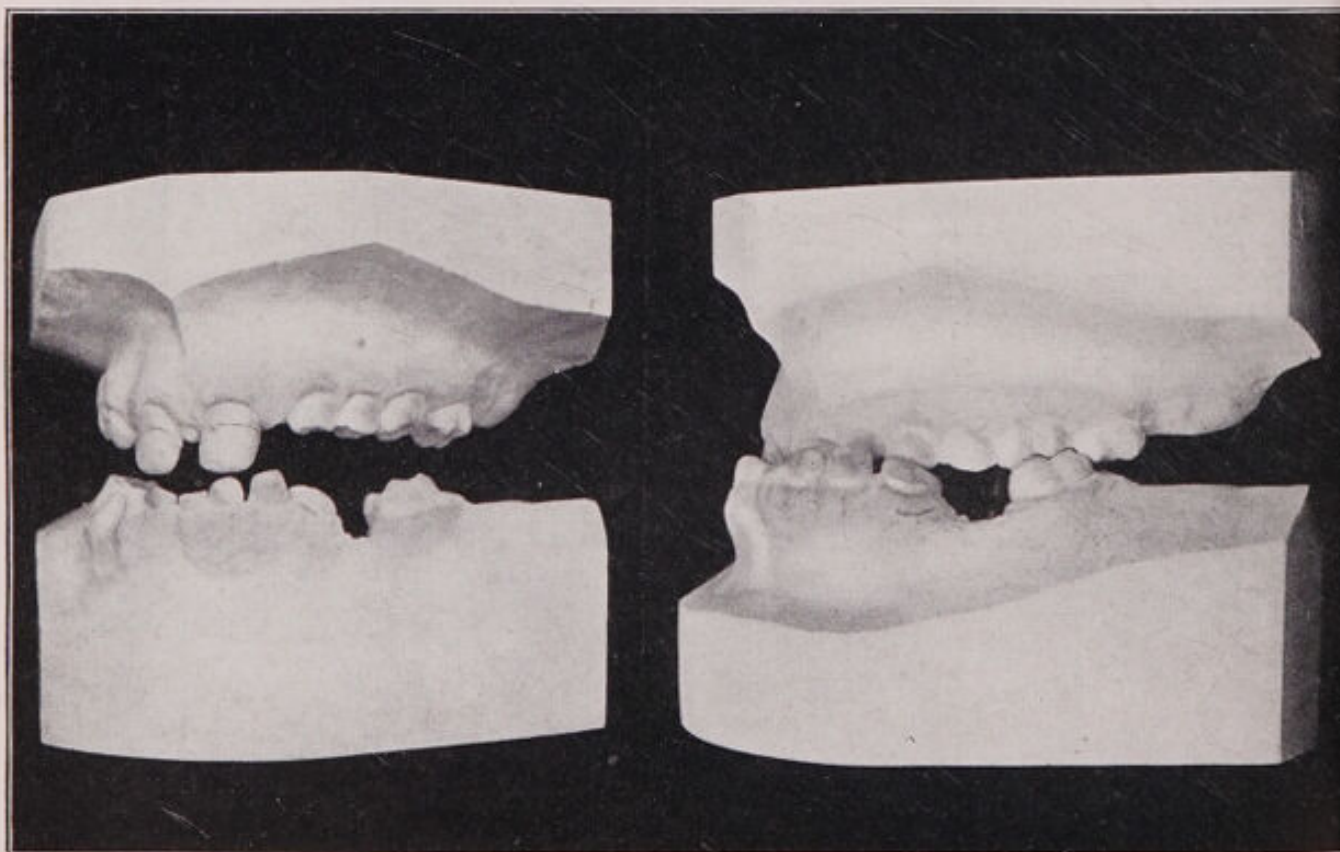


FIG. 213. Same case, before treatment.

and two upper central incisors. Figures 212 and 213 show the case before treatment.

Radiographs revealed absence of permanent teeth beneath the temporary teeth in both jaws. (Figure 214.) Radiographs

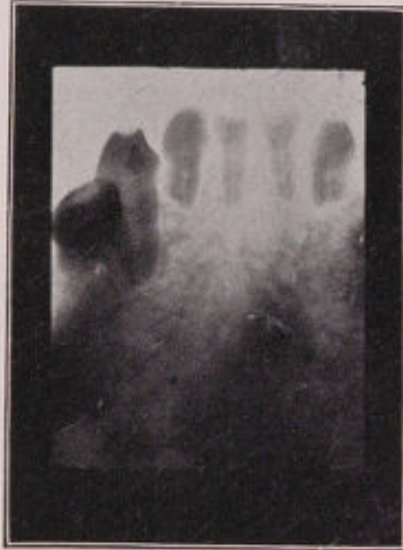

FIG. 214.

show absorption of roots of temporary teeth, with the exception of the cuspid; same condition on the other side of the mouth.

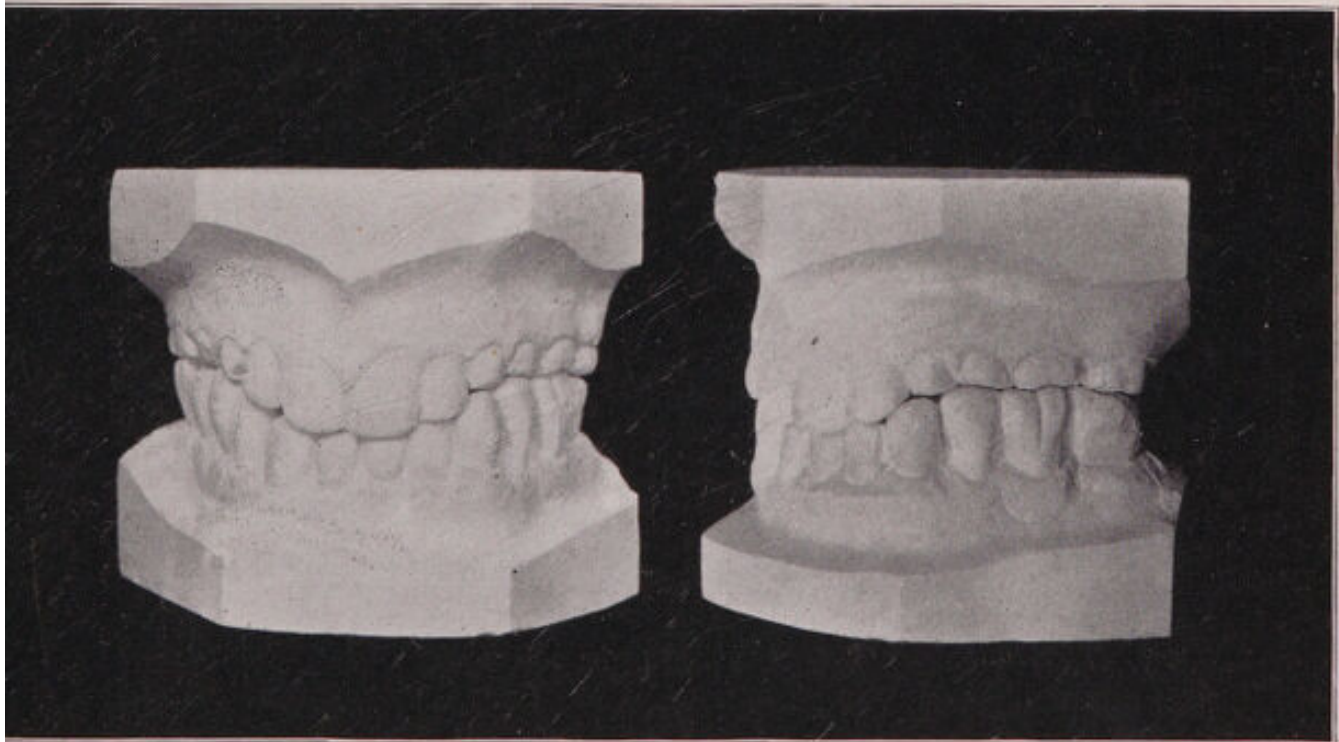


FIG. 215. After treatment.

Figure 215 shows finished case. Upper and lower fixed bridges were constructed. In the upper jaw the centrals were pushed forward and drawn together, and two laterals attached to same, leaving the temporary cuspids and molars untouched.

CASE III

A pyorrhoea case, with fixed bridgework: A, before treatment; B, after treatment. (Figure 216.)

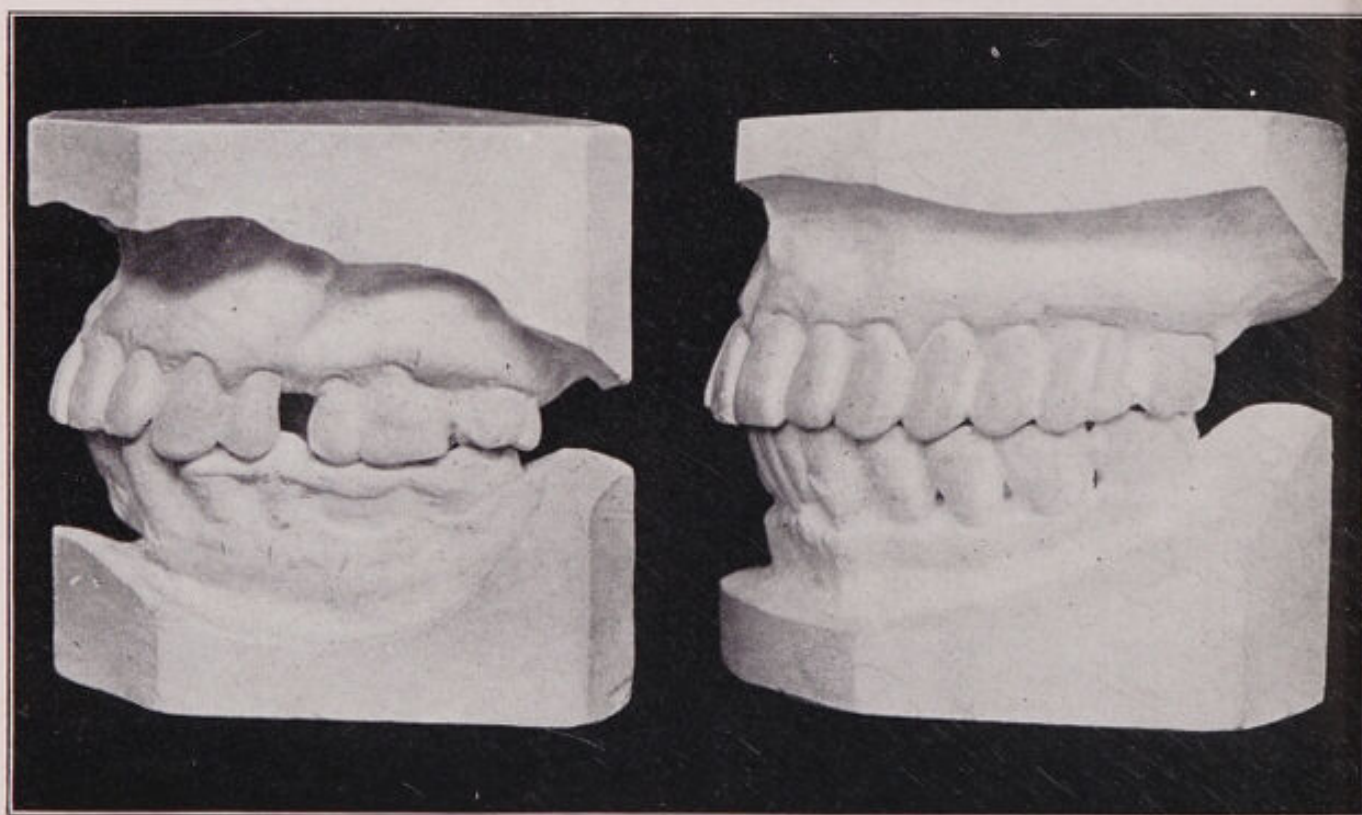
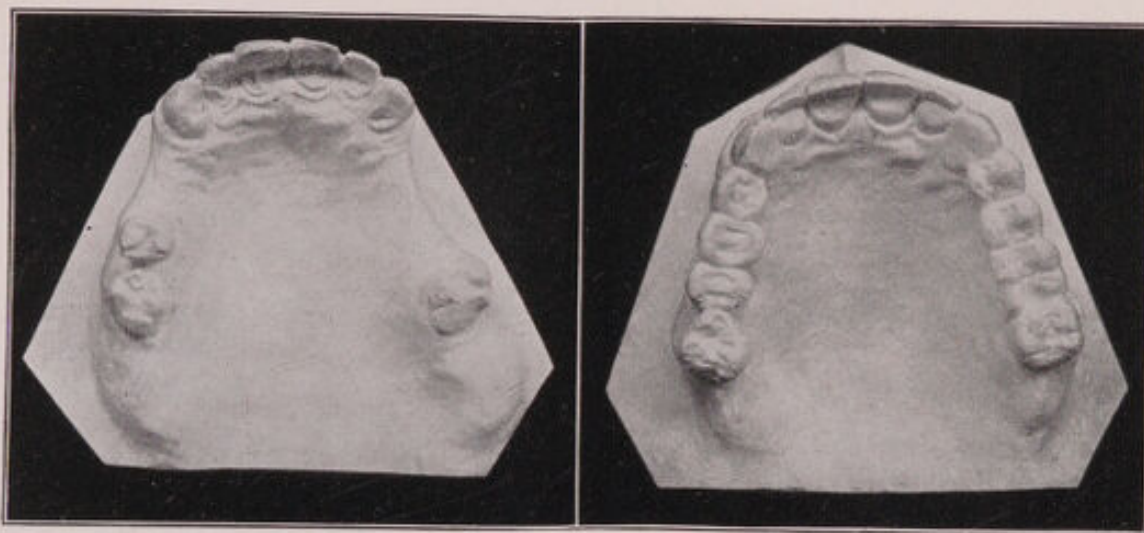


FIG. 216. Pyorrhoea case, before and after treatment.

CASE IV

Patient presented a closed bite, as shown in Figure 217A and 219A. The incisors were worn down on the palatal side. This was remedied by raising the bite with fixed bridges. (Figures 217B and 219B. The incisors received gold inlays without removing the pulps. Radiograph (Figure 218) shows the condition of the pulps after seven years.



A B
FIG. 217. Before and after treatment.

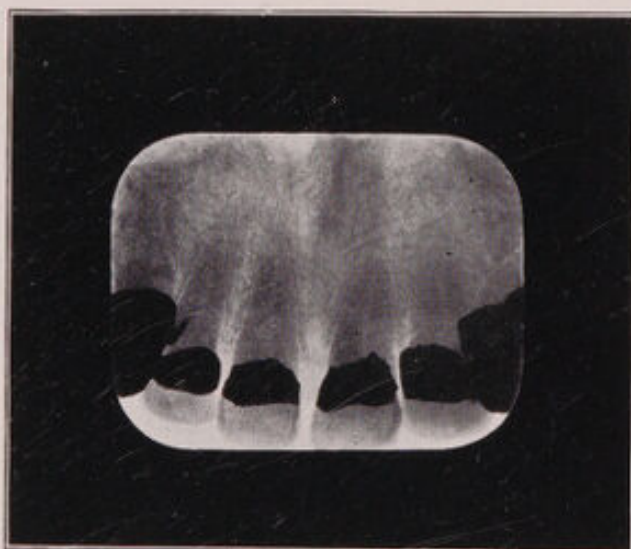
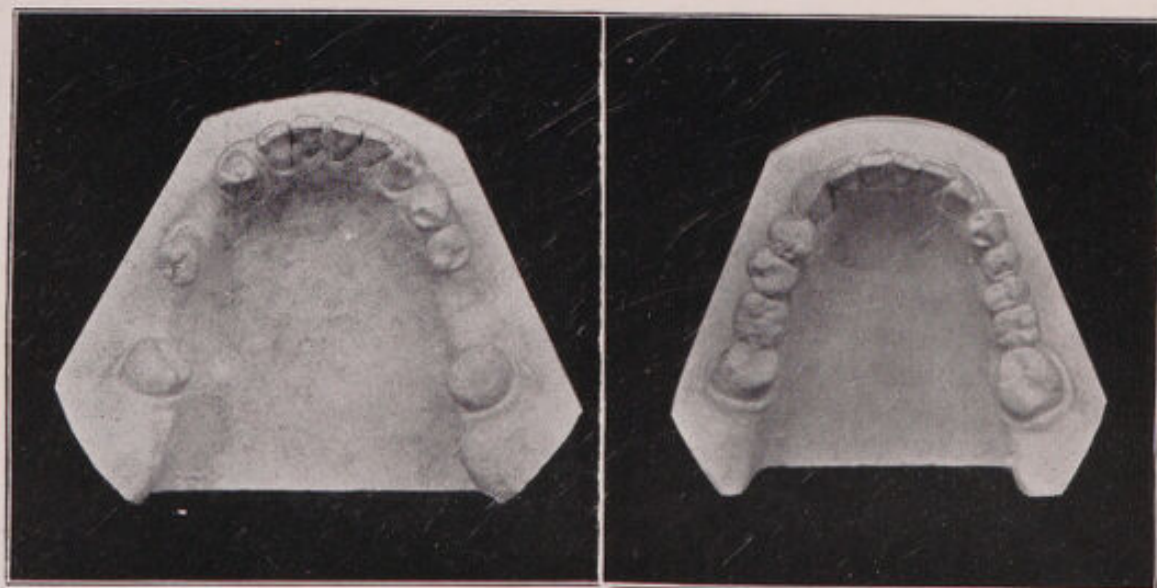


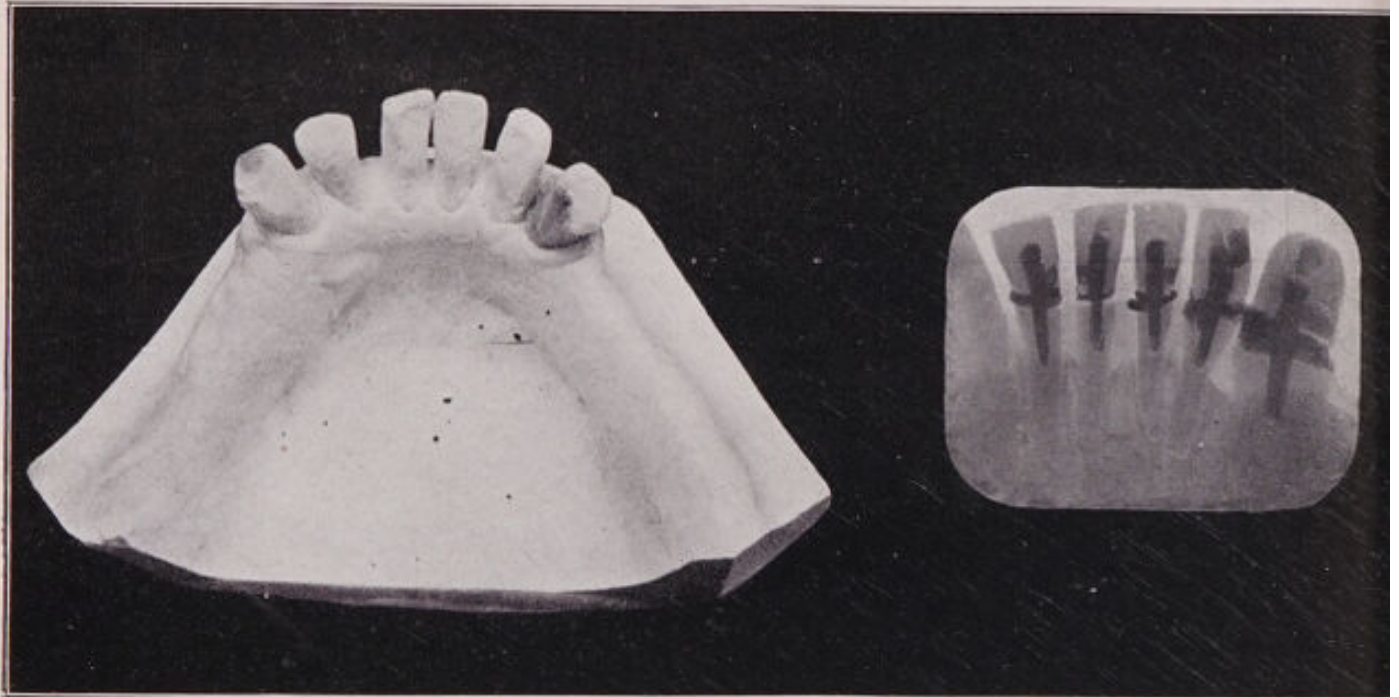
FIG. 218. Cast inlays for Fig. 217.



A B
FIG. 219. Before and after treatment.

CASE V

The patient's lower teeth were protruding (Figure 220A). Radiograph (Figure 220B) shows direction of roots.



A

B

FIG. 220. Before treatment; model and radiograph.

Figure 221 shows the frame with platinum caps and posts. The centrals and lateral caps were soldered to the wire, while the two cuspids were fastened by a loop to permit the swinging of caps and posts towards the median line to accommodate the angle of their roots.




FIG. 221. Bridge frame.

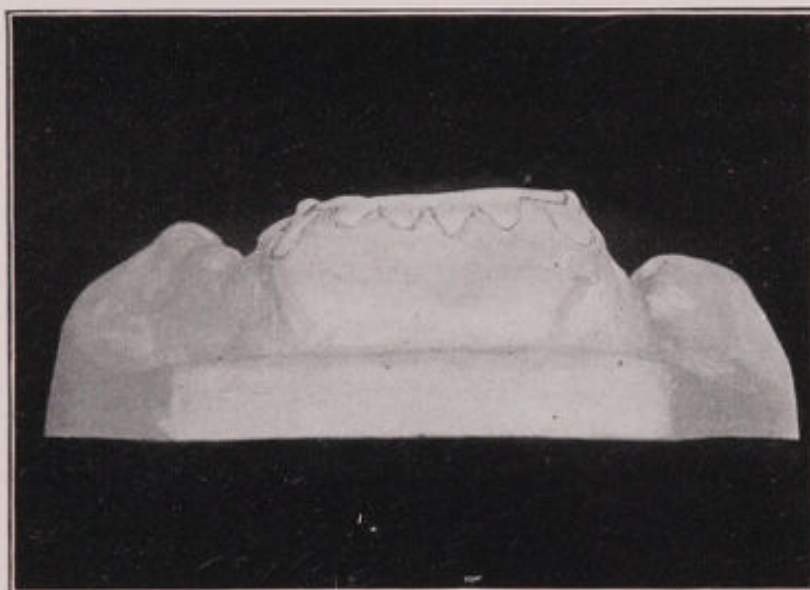

FIG. 222A.

Figure 222A shows the frame on the model, Figure 222B radiograph of frame on the roots.

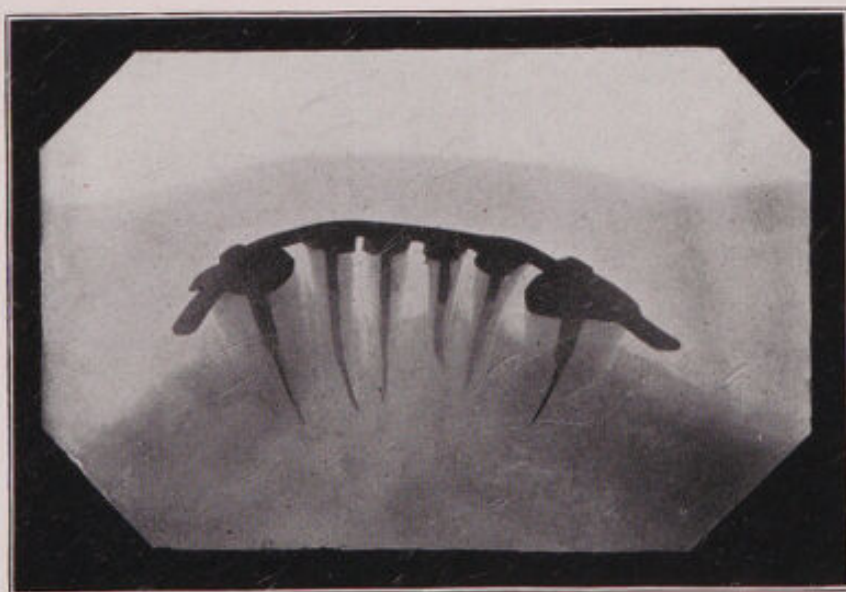


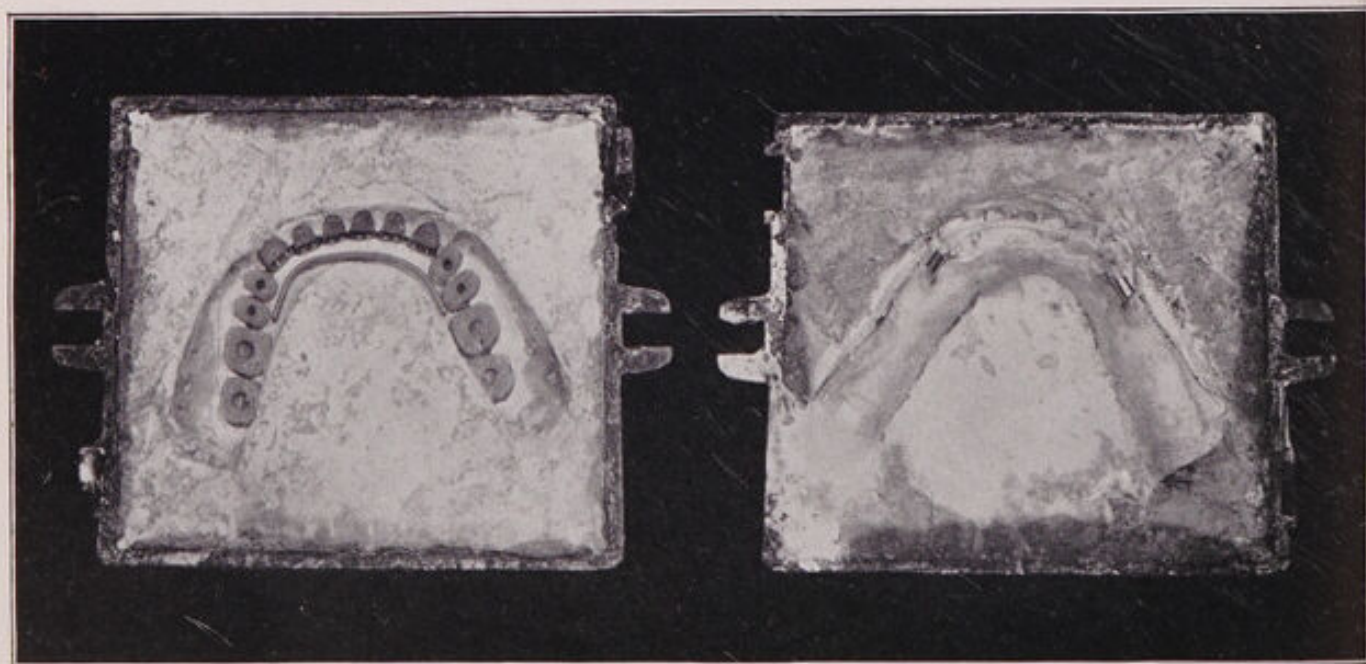FIG. 222B.

Figure 223 shows upright position of the artificial teeth.




FIG. 223. Cases like this in rubber must be strengthened from bicuspid to bicuspid as otherwise the plate will break easily. The gold frame takes up much space and weakens such a plate in front.

Figure 224, the case flaked.



A

B

FIG. 224. A, Gold bar in place to strengthen plate. B, Attachments in place.

NOTE.—There are two Gilmore attachments behind the cuspids in 224B, and the strong platinized gold bar in the other half of the flask (Figure 224A). This gold bar is necessary, as rubber plates of this type are weak in front.

CASE VI

Two crowns to show how to overcome a wide space of the median line.

A, showing the front; B, the back of two central crowns (a practical case). These crowns, one a Richmond, the other a banded porcelain crown, filled the big space that was between the central roots, and gave satisfaction to the patients for many years.




FIG. 225. Extra wide crowns to fill space of median line.

CASE VII

PORCELAIN ROOT DUMMIES

Supplies with porcelain roots give good satisfaction to the patient and operator. Figure 226 shows right side superior

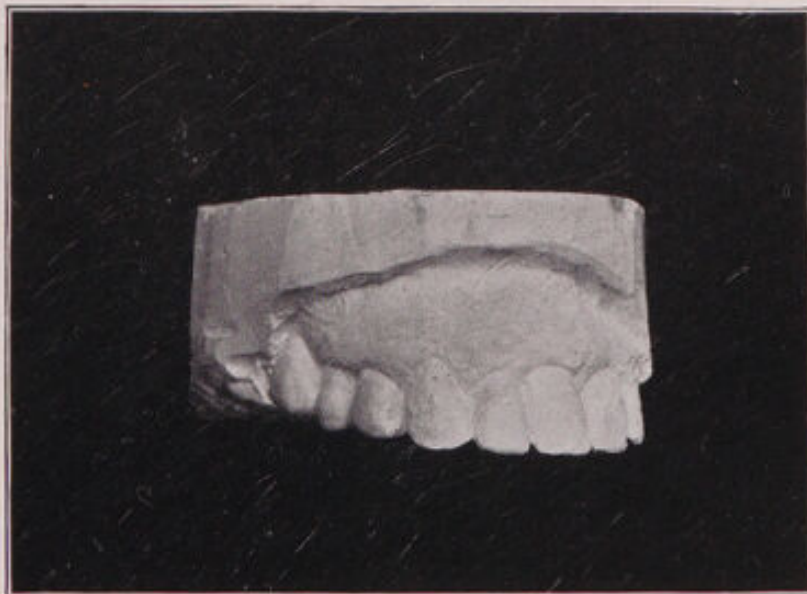


FIG. 226. Model showing effect of lateral tooth dummy with porcelain root after six years.

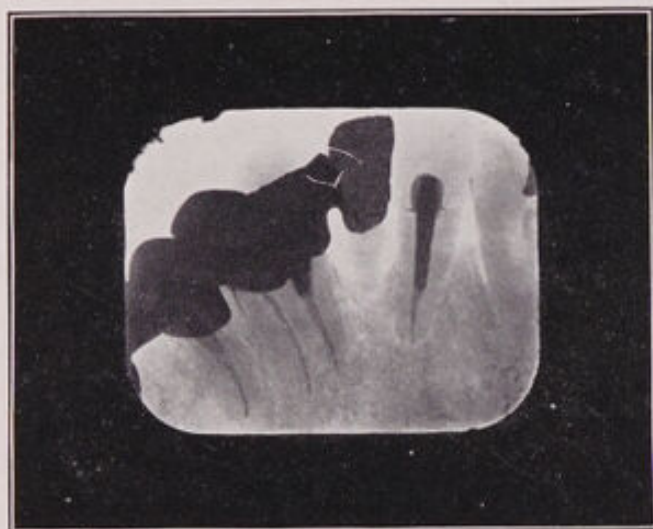

FIG. 227. Radiograph of same case.

bridge; the bicuspid and cuspid roots carry Richmond crowns, with lateral dummy attached. The lateral dummy with a porcelain root shows after six years no irritation, or absorption of gum, as shown in Figures 226 and 227. The operation is as follows:

Take a radiograph of the teeth involved in the bridge.

Take a plaster impression and bite.

Make an articulated model.

Cut away the plaster tooth and carve (with the aid of the radiograph) the depth of the root in the model.

Shellac model, carve a facing or slotted tooth with root, (Figure 228), using high fusing porcelain body.

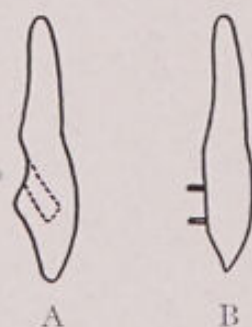


FIG. 228. A, slotted porcelain tooth with root. B, pin facing with root.

Finish the abutments next to the tooth or teeth that are to be extracted, and to be replaced with porcelain root dummies first.

Then take a wax bite and plaster impression.

Now extract the bad tooth, and place it, with the abutments, into the plaster impression.

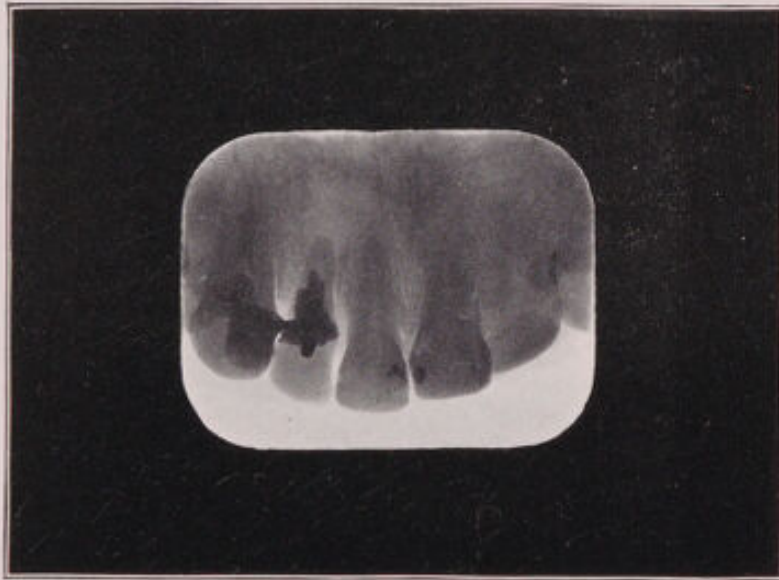

FIG. 229. Fractured lateral root and crown.

In case of a split root often caused by a post crown (Figure 226), put this post crown back on to the extracted split root, and put this with the bridge abutments back into the plaster impression.

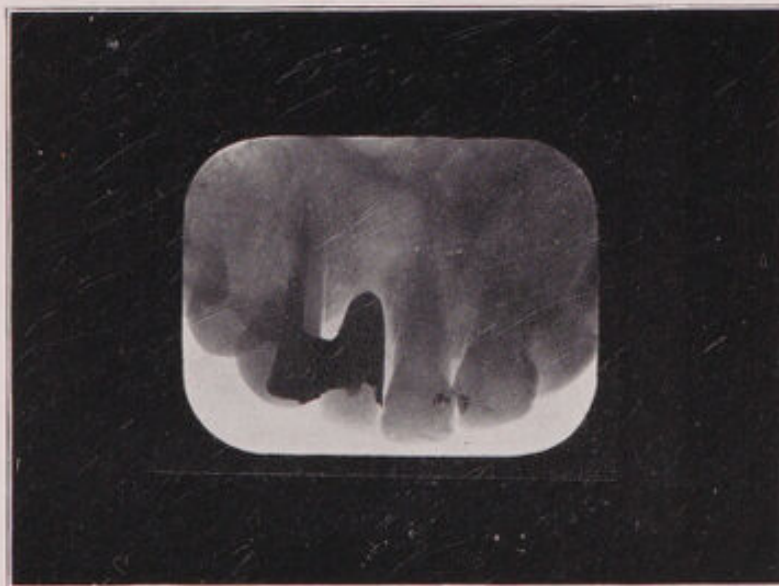

FIG. 230. Gold inlay, with post carrying lateral dummy with porcelain root as per Figure 223A.

Make articulated model.

Remove from the model the extracted tooth or split root.

Fit into the socket a hand-carved porcelain root dummy. (Figure 228.)

Fit a gold backing to facing (Figure 228A), or gold box with post to slotted tooth (Figure 228B); wax same to the abutments.

Invest, solder and finish in the usual way.

The bridge should be finished and set the same day when the root is extracted, as this will facilitate the placing of the porcelain root. The porcelain is received very favorably by the tissue, and therefore no inflammation and absorption is experienced.

CASE VIII

FULL UPPER—FIXED BRIDGE

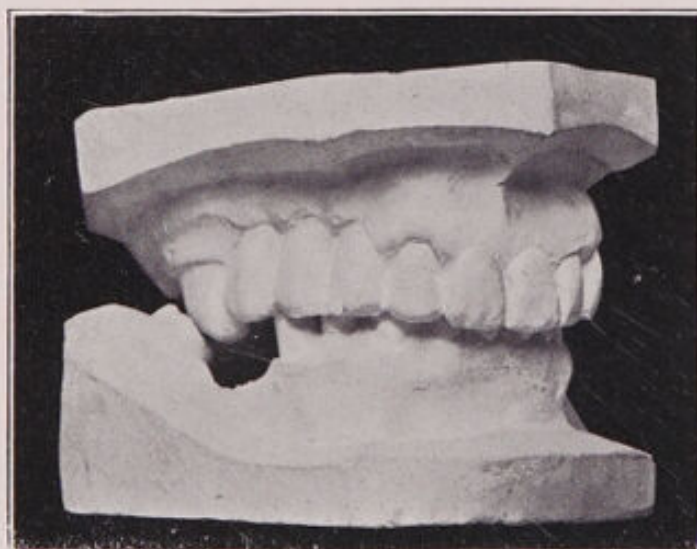


FIG. 231. Crown and Bridge Case VIII, before treatment. Showing a closed bite due to poor bridge construction. These bridges were made without chewing surfaces (see Fig. 232), allowing the bite to close, forcing the bridges apart and thereby loosening the bridge abutments.

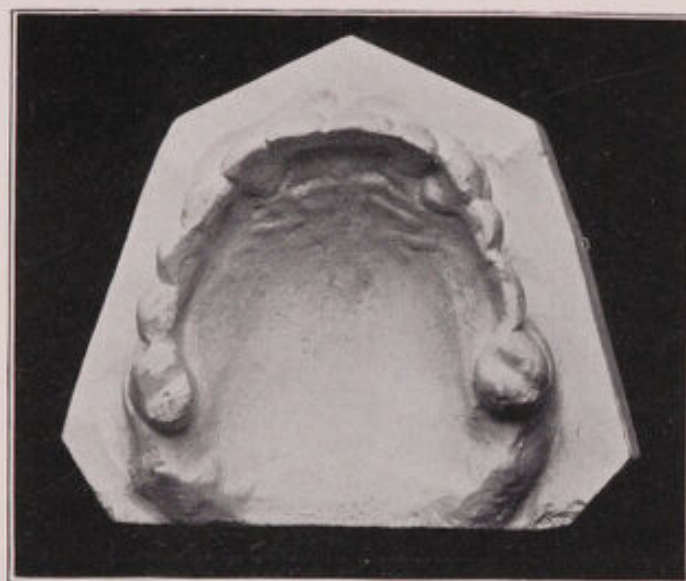


FIG. 232. Crown and Bridge Case VIII, before treatment.

The left superior bridge is supported by the cuspid and molar. The right superior bridge by the two laterals and molar.

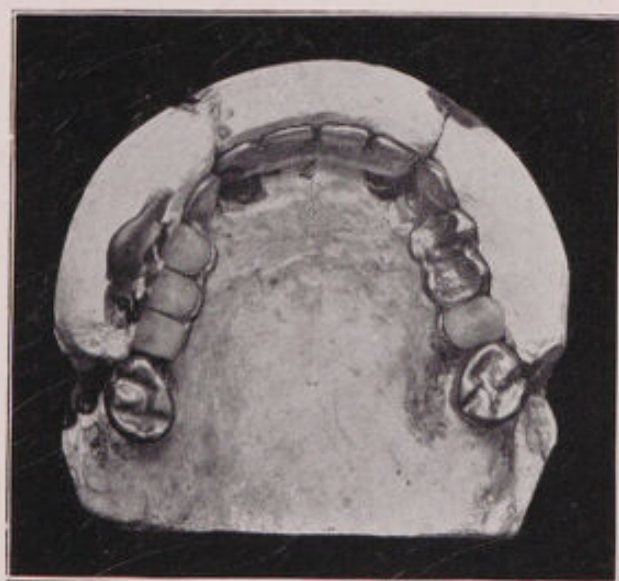


FIG. 233. Crown and Bridge Case VIII, after treatment.

Showing the new bridge with raised bite under construction. At this stage the bridge is shown ready for the final assembling of the three parts: lateral to lateral and cuspid to molar for each side. When soldered to the three root caps with posts and the two all-metal molar crowns this will complete a full upper fixed bridge. Facings and Steele Posteriors in gold boxes were used for dummies with two close bite gold cusps on the left bicuspid. These cusps had to be used to overcome the close bite in that region, and were constructed as shown in Fig. 124B.

CASE IX
FIXED BRIDGES

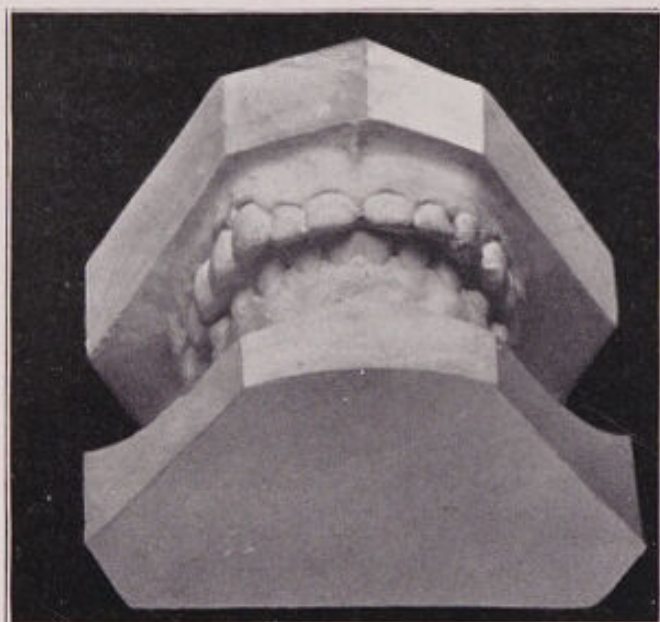


FIG. 234. Crown and Bridge Case IX, before treatment.

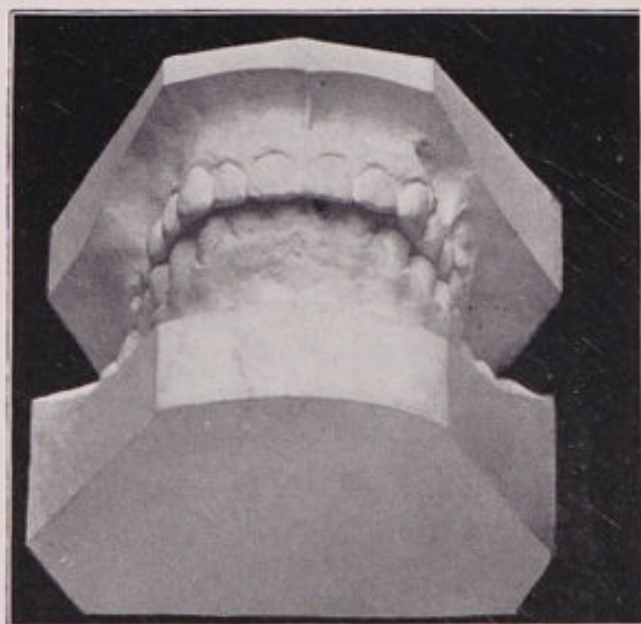


FIG. 235. Crown and Bridge Case IX, after treatment.

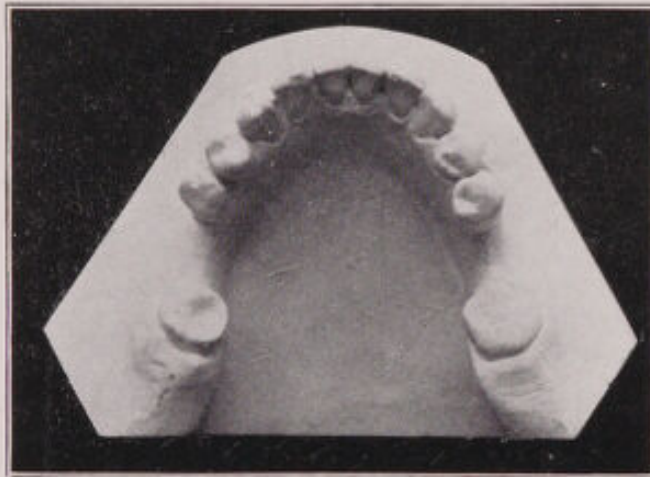


FIG. 236. Crown and Bridge Case IX.
Showing the lower, before treatment.

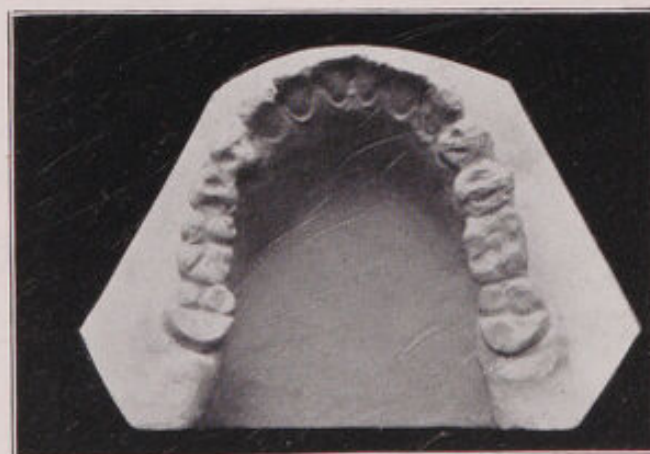


FIG. 237. Crown and Bridge Case IX.
Showing the lower, after treatment, with two sanitary bridges.

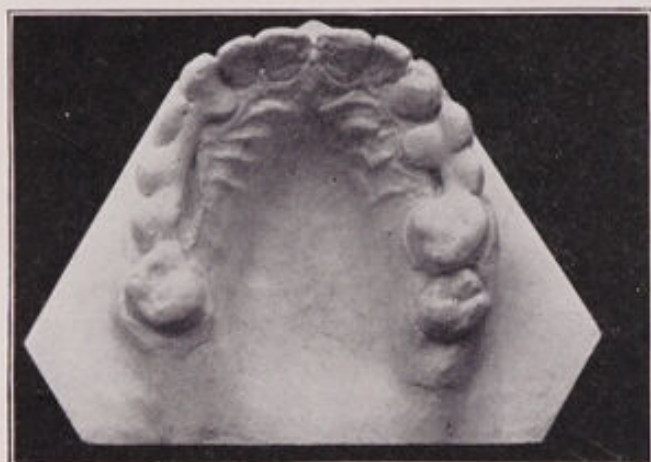

FIG. 238. Crown and Bridge Case IX.
Showing the upper, before treatment.



FIG. 239. Crown and Bridge Case IX.
Showing the upper after treatment, with four anterior porcelain crowns and
two cuspid to molar self-cleansing bridges.

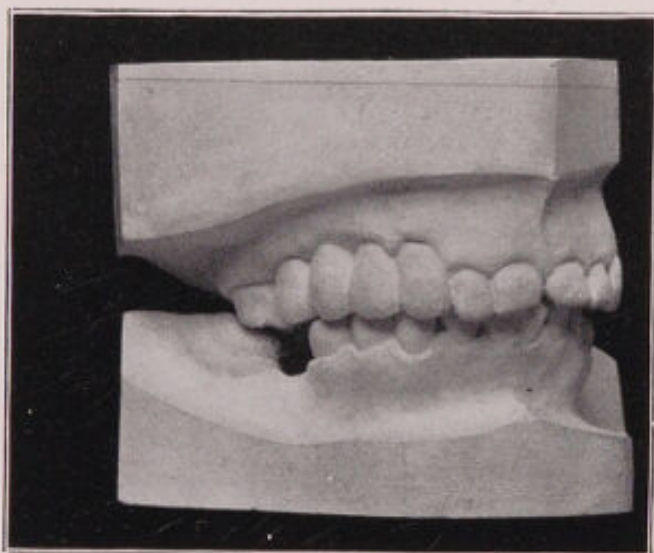


FIG. 240. Crown and Bridge Case IX, before treatment.

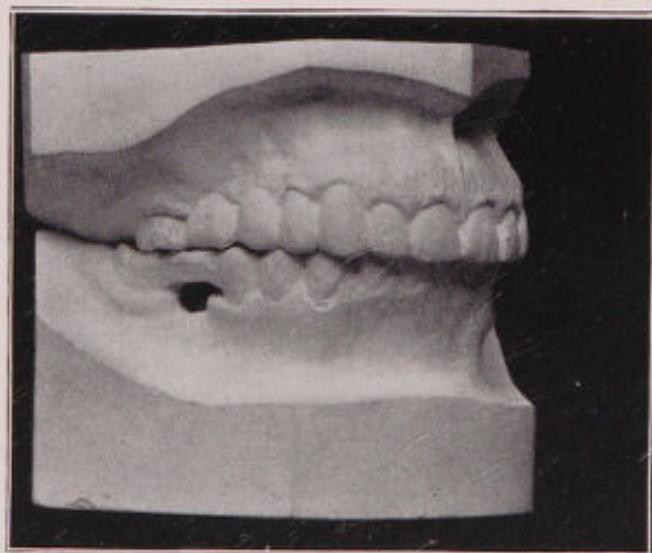


FIG. 241. Crown and Bridge Case IX, after treatment.

CASE X
FIXED BRIDGES

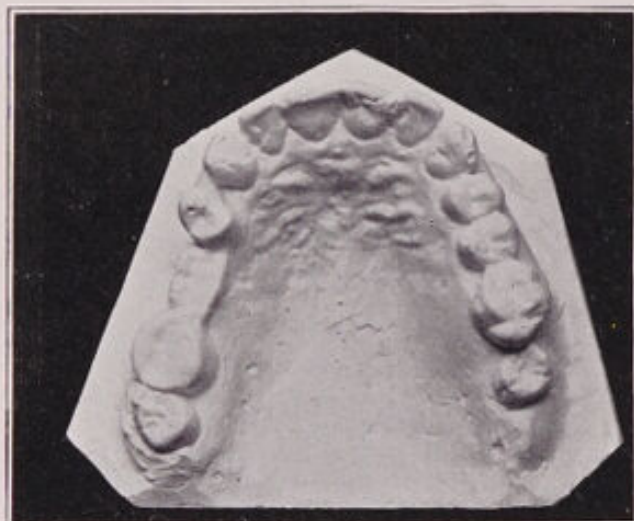

FIG. 242. Crown and Bridge Case X, before treatment.

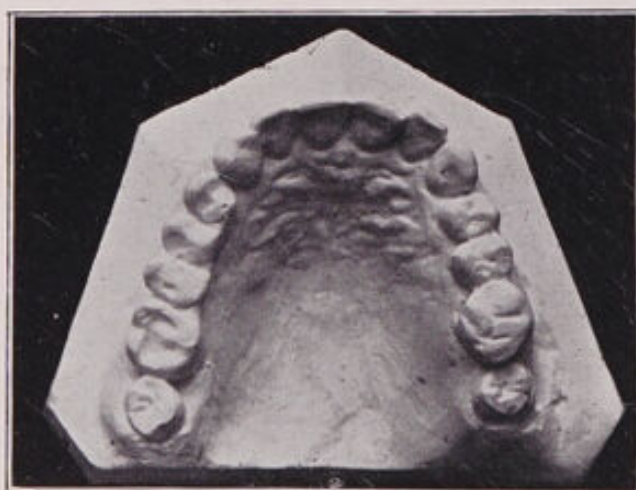

FIG. 243. Crown and Bridge Case X, after treatment.

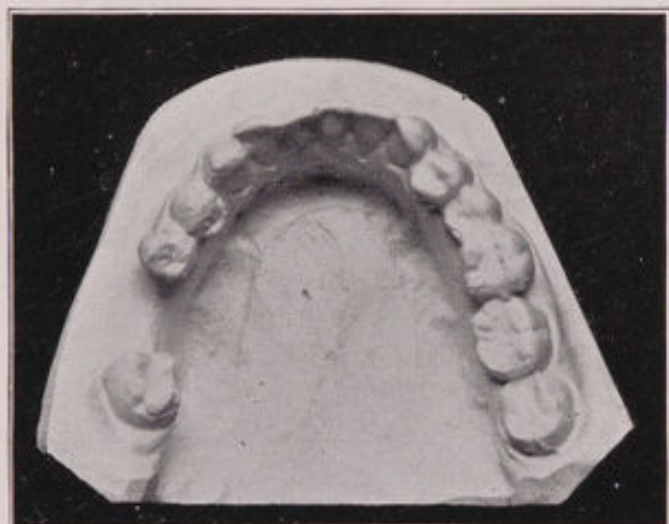

FIG. 244. Crown and Bridge Case X, before treatment.

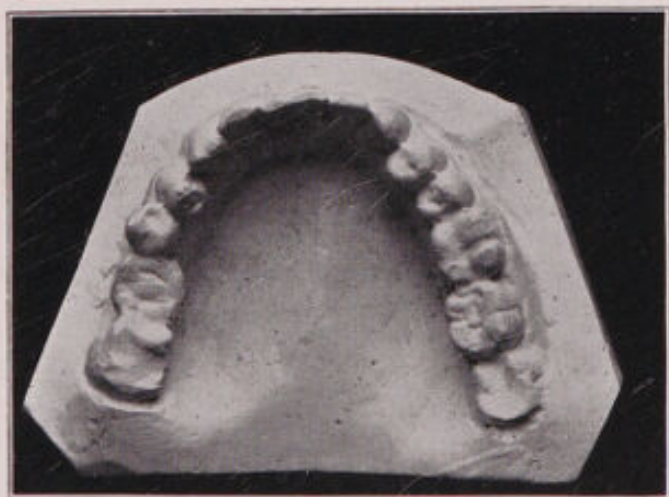


FIG. 245. Crown and Bridge Case X, after treatment.

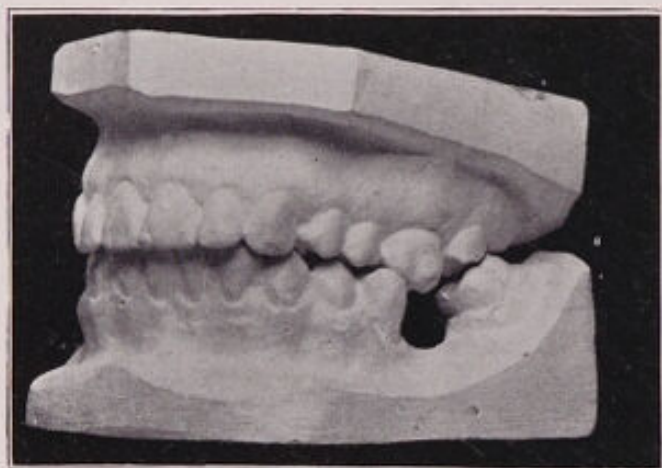


FIG. 246. Crown and Bridge Case X, before treatment.

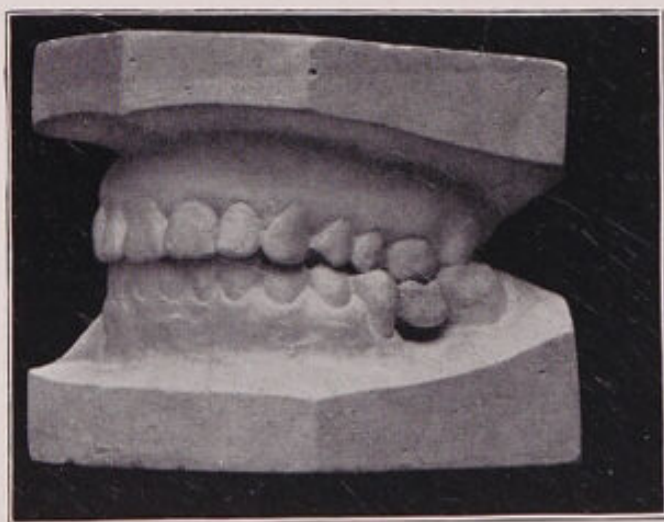


FIG. 247. Crown and Bridge Case X, after treatment.

Showing lower sanitary bridge with porcelain tooth dummy in box, carried by a biscuspid and molar gold inlay with post abutments.

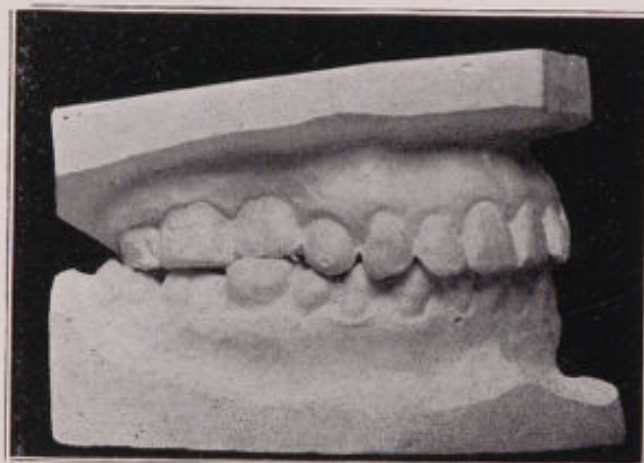


FIG. 248. Crown and Bridge Case X, before treatment.

Showing a molar dummy carried by an all-metal bicuspid and molar crown. The dummy is short and sets in to accommodate the elongated lower six-year molar. Compare this with Fig. 242.

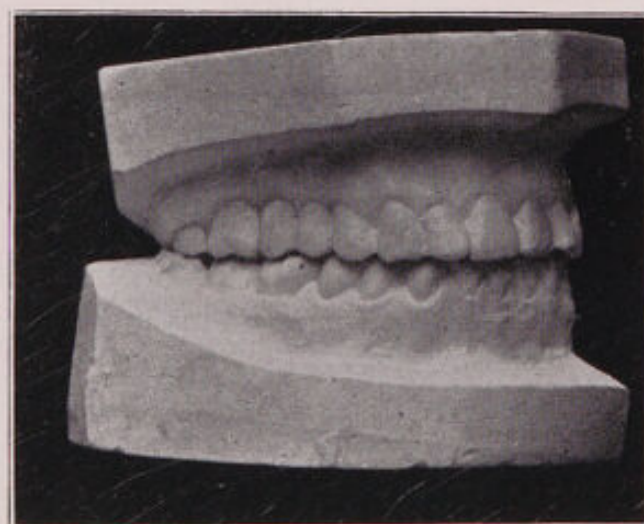


FIG. 249. Crown and Bridge Case X, after treatment.

The lower six-year molar cut down and finished on top with a porcelain inlay. The upper bridge is constructed of three Davis bicuspid crown type porcelain teeth, carried by the first bicuspid root with a platinum cap and post and an all-metal molar crown. The mesial corner of the cuspid is built out with porcelain.

CASE XI
FIXED BRIDGES

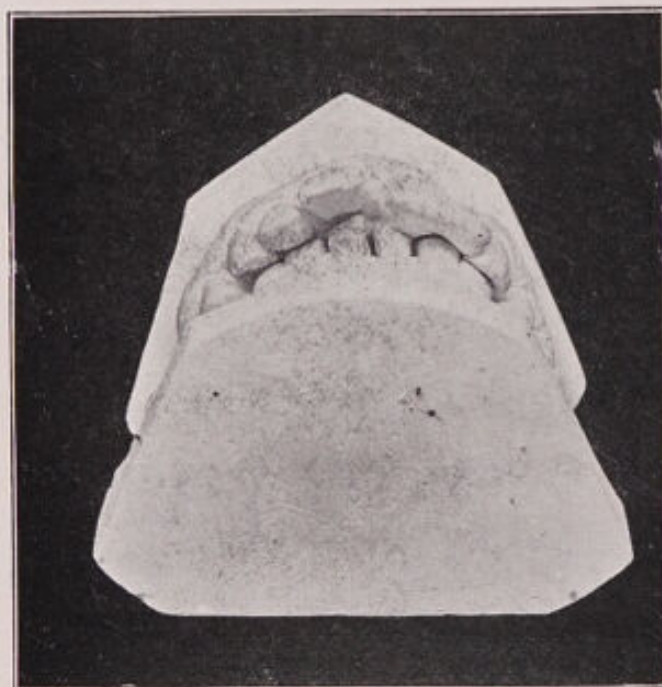


FIG. 250. Crown and Bridge Case XI, before treatment.
Showing close bite.

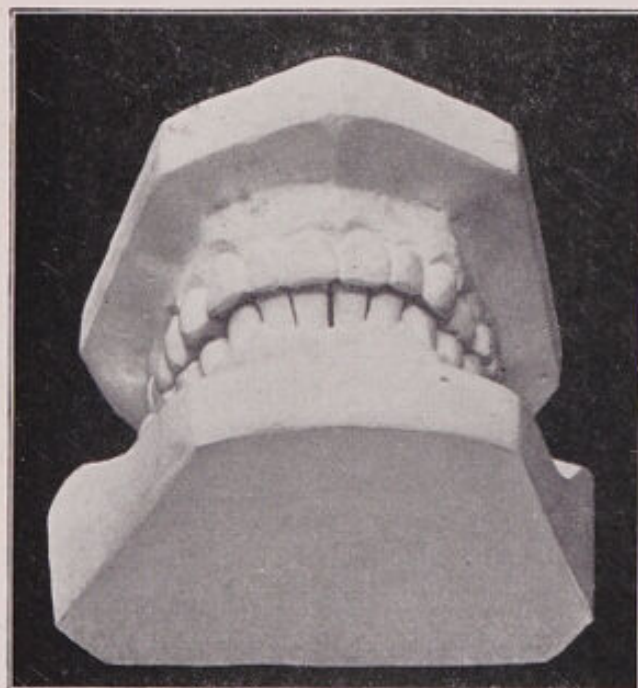


FIG. 251. Crown and Bridge Case XI, after treatment.
Showing raised bite.

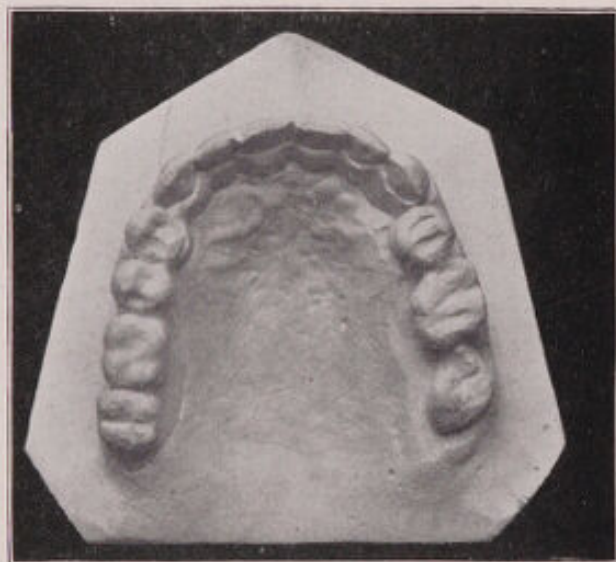

FIG. 252. Crown and Bridge Case XI, after treatment.
Showing bridge in place.

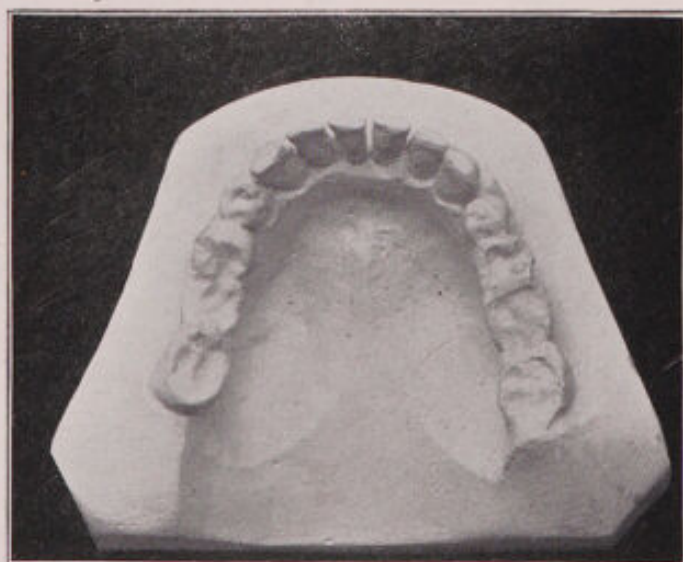


FIG. 253. Crown and Bridge Case XI, after treatment.
Showing bridge in place.

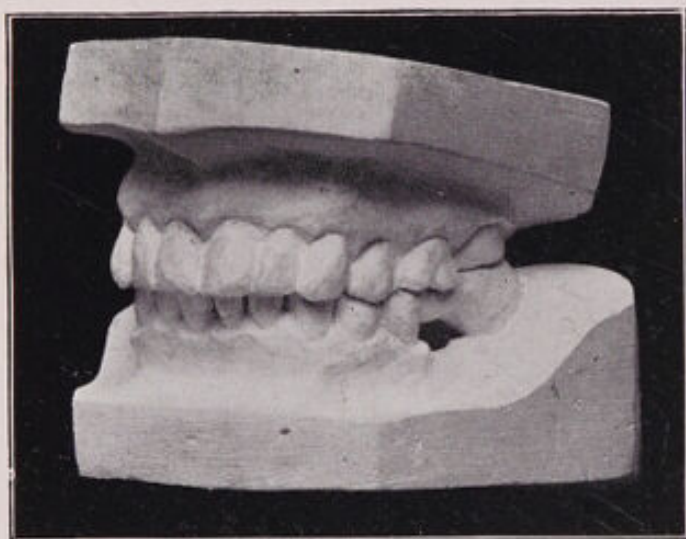


FIG. 254. Crown and Bridge Case XI, after treatment.
Finished case.

CASE XII
FIXED BRIDGES

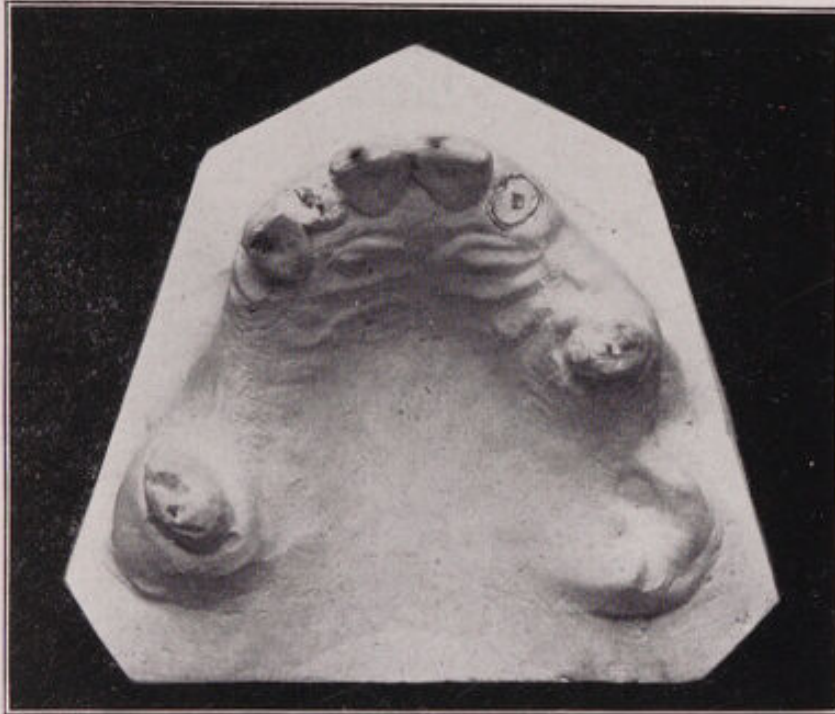


FIG. 255. Crown and Bridge Case XII, before treatment.

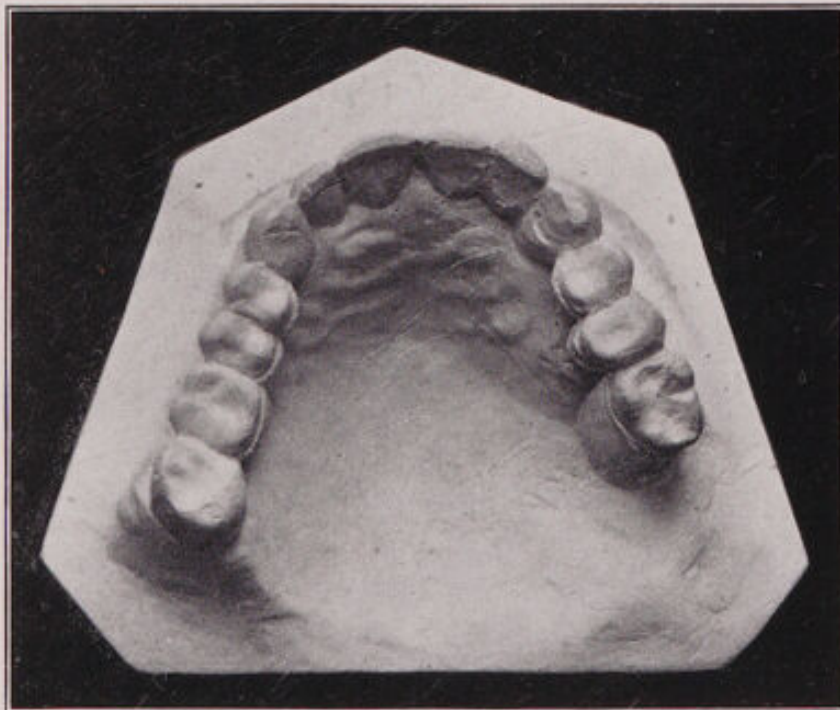


FIG. 256. Crown and Bridge Case XII, after treatment.
Showing bridges with porcelain teeth in boxes in place.

CASE XIII

FIXED UPPER AND REMOVABLE LOWER BRIDGES

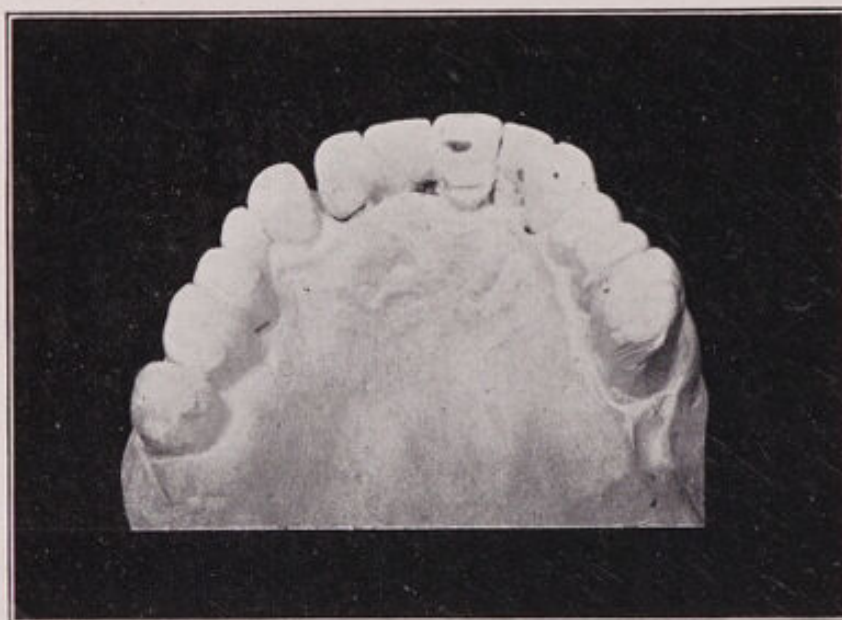


FIG. 257. Crown and Bridge Case XIII, before treatment.
The central and laterals are badly affected by pyorrhoea.

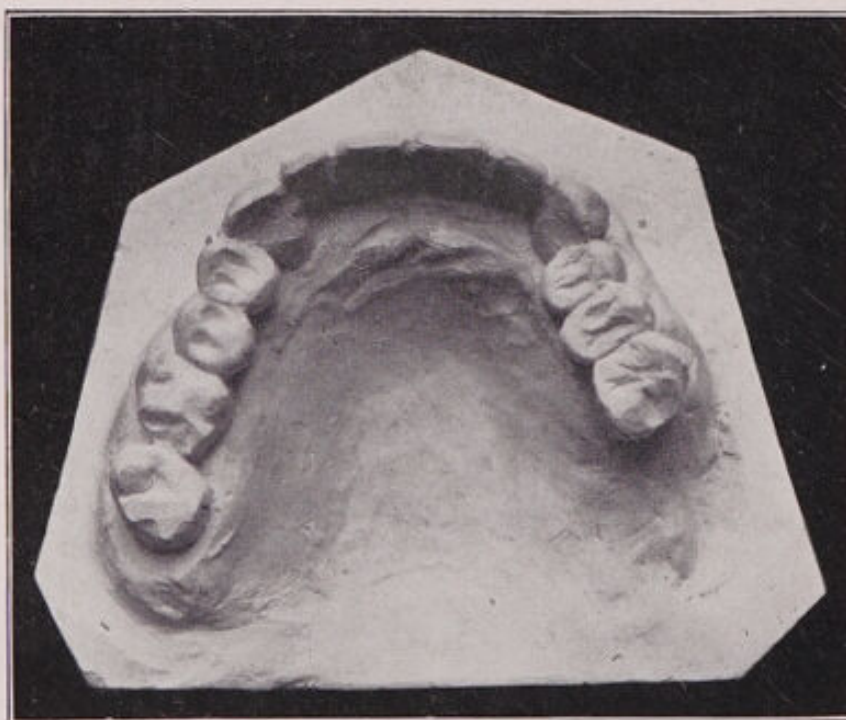


FIG. 258. Crown and Bridge Case XIII, after treatment.
With a fixed bridge in place.

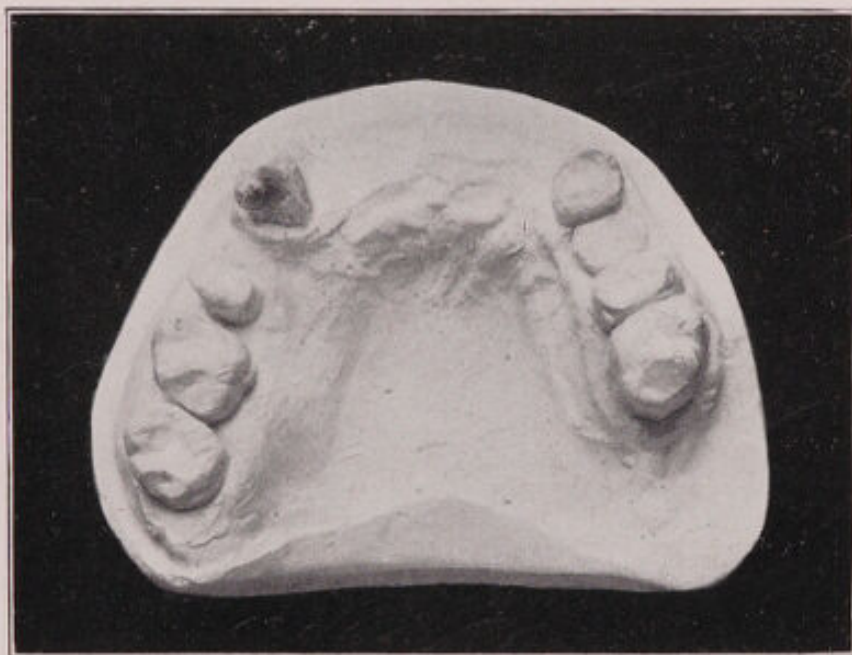

FIG. 259. Crown and Bridge Case XIII,
Note the amount of tissue lost on the labial side between the cuspids.

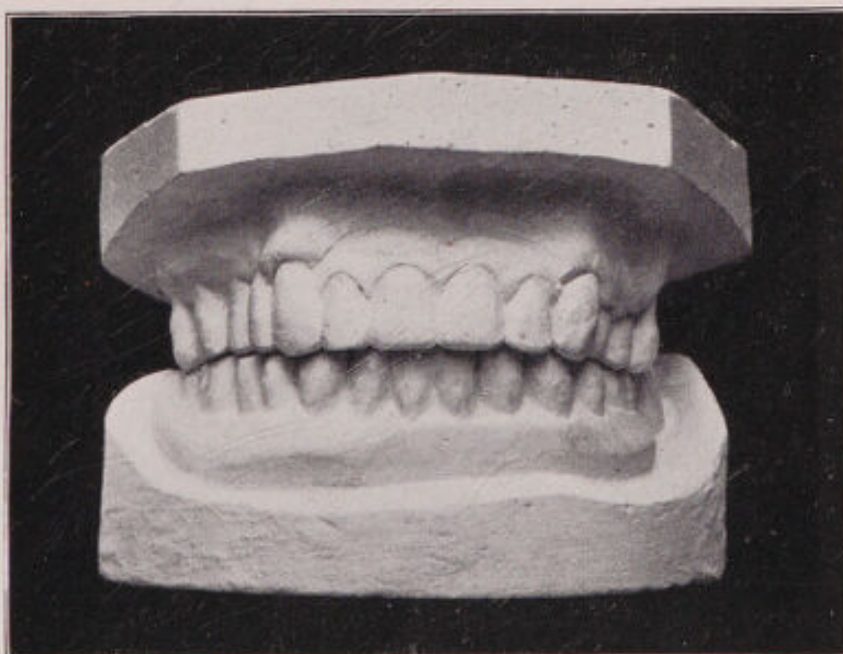


FIG. 260. Crown and Bridge Case XIII.
The lost tissue between the cuspids has been replaced by two porcelain gum
blocks (stock teeth) with double backings soldered to the adjoining Richmond
crowns.

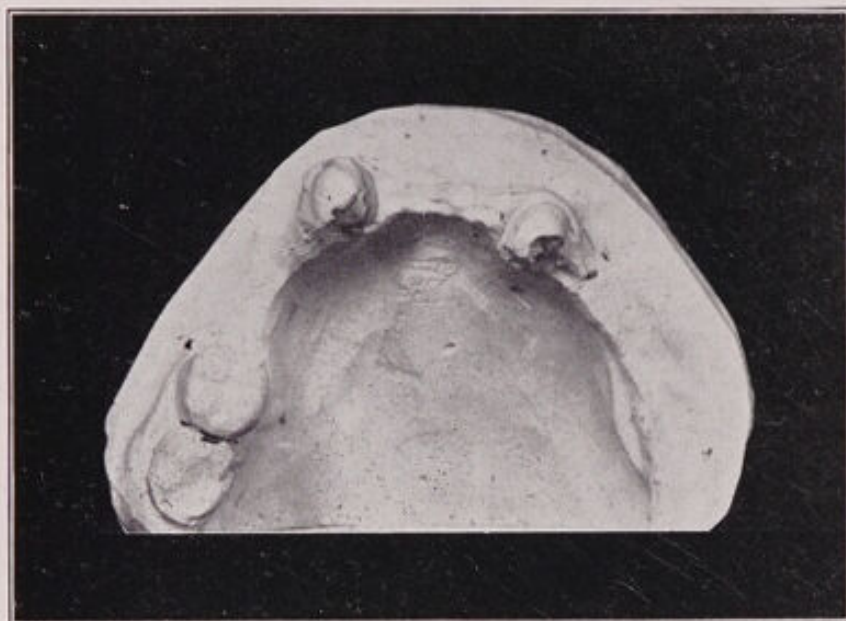


FIG. 261. Crown and Bridge Case XIII, before treatment.
The last lower molar on the left side was badly abscessed.

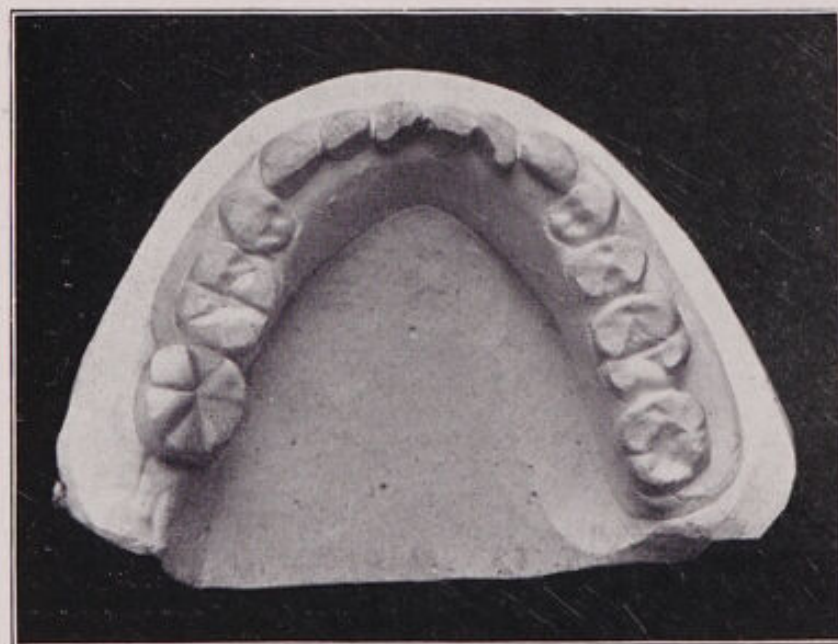


FIG. 262. Crown and Bridge Case XIII, after treatment.
Showing removable bridge in place.

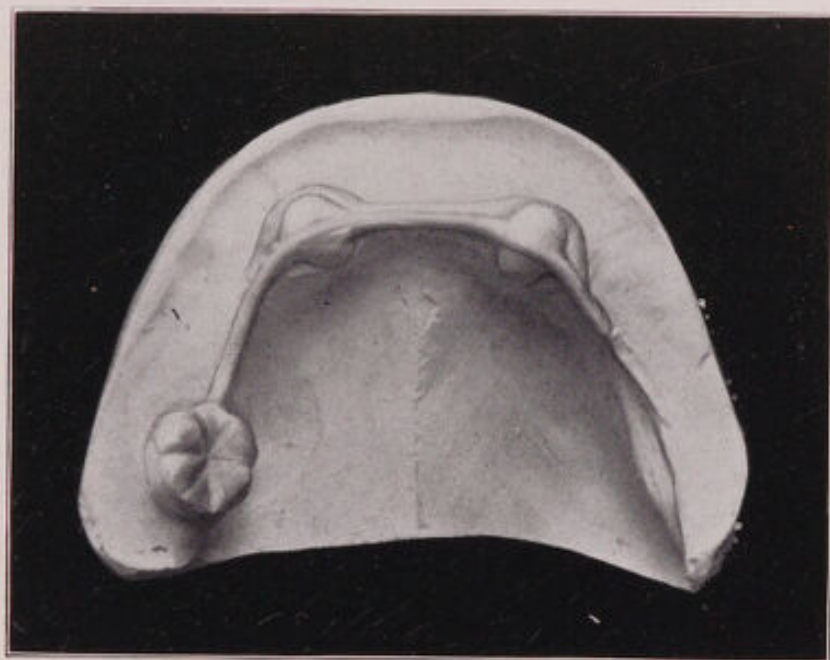


FIG. 263. Crown and Bridge Case XIII.
Showing gold frame in place.

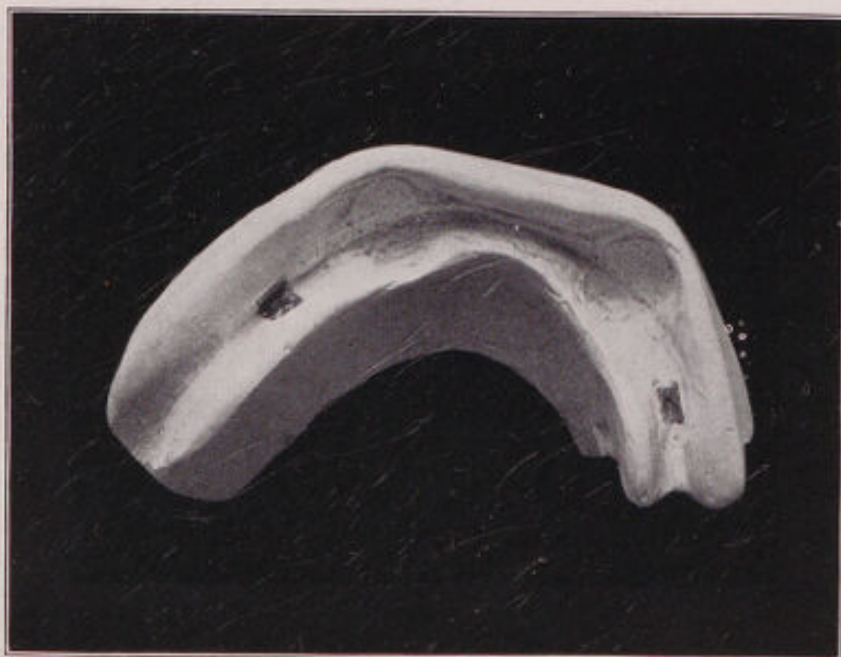

FIG. 264. Crown and Bridge Case XIII.
Showing under side of the removable lower bridge with two Gilmore attachments in place.

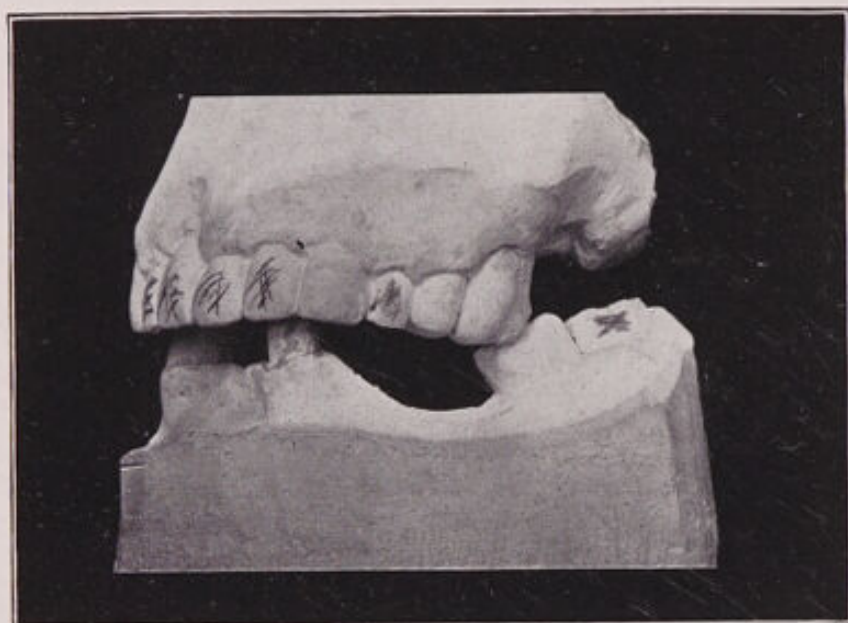

FIG. 265. Crown and Bridge Case XIII, before treatment.
Pencil marks on model show teeth to be extracted.

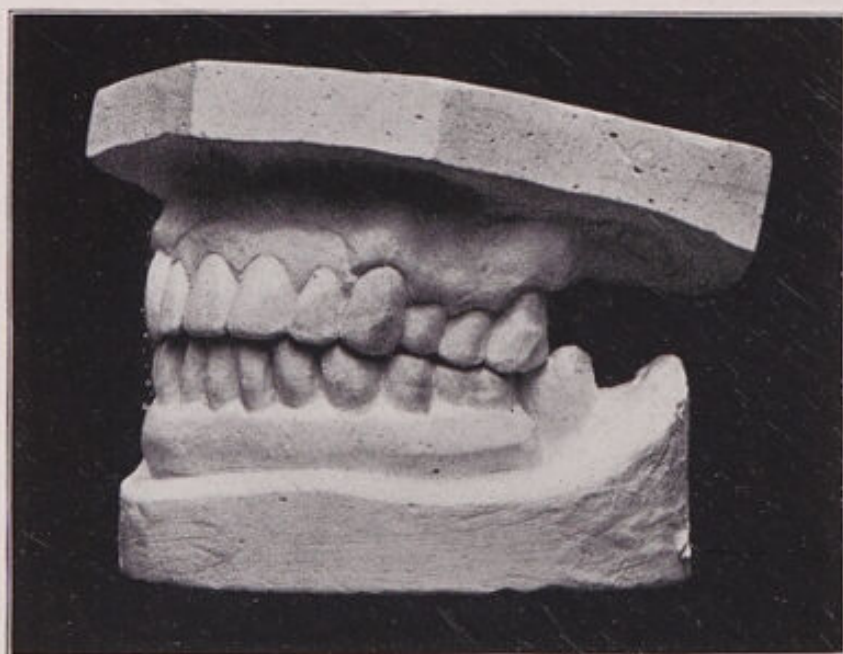



FIG 266. Crown and Bridge Case XIII, after treatment.
With the upper fixed bridge and lower removable bridge in place.



INDEX

A

- Acid mouth, 15
- Adjustments, 76
- Advice, operator's, 12
- After-effects, 59
- All-porcelain crowns, 78
- Anaemia (deep), 48
- Anaesthesia, Oral, 44
- Ash's bridge system, 145
- Ash repair facings, 178
 - outfit, 178
- Attachment, dove-tail, 144
 - Gilmore, 146
 - Morgan, 169
 - Roach, 168

B

- BACKING of teeth, 64
- Banded crown abutments, 122
- Banded crowns, 92
- Base for banded abutments, 122
 - crowns, 93
- Box for Goslee tooth, 99
- Bridge cases, classification, 13
 - case on articulator, 63
 - extensions, 144
 - gold chewing surface, 138
 - Goslee teeth, 136
 - individual saddles, 143
 - interlocking, 144
 - porcelain saddle, 142
 - repairs, 174, 180
 - sanitary, 137
 - self-cleansing, 138
 - study of cases, 11
 - with continuous saddle, 140
- Bridgework, abutments for fixed, 119
 - supplies, 126

Bridges, assembling, 137

- extension, 160
- fixed, 119
- full, 156
- Morgan attachments, 169
- removable, 144-218
- removable, with Gilmore at-
tachments, 145
- Roach attachments, 168
- short, 158
- with lingual bar, 160
- with vault bar, 158
- Building up decayed or broken down
teeth, 43
- Burnished caps, banded abutments, 122
 - banded crowns, 95

C

- CARE of bridges, 77
- Cases, normal and abnormal, 48
- Cast cusps, 107-126
- Casting, 70
- Cast supplies, 127
- Cementing, 75
- Cement for setting crown, 124, 126
- Chewing surface, gold, 137
 - porcelain, 138
- Classification, 13
- Closed bite, 27
- Conductive method, 54
- Crowns, all metal, 102
 - detached post, 81
 - hand carved, 81
 - half, with post, 123
 - jacket, 78
 - open-face (glove fit), 102
 - porcelain, backed with plati-
num base, 88
 - porcelain, with burnished cap,
direct method, 95

- Crowns, porcelain, with cast base, 89
 cast base, direct method, 89
 cast base, indirect method, 90
 detached post crowns, 98
 facings, 97
 Goslee teeth, 100
 soldered cap, direct method, 93
 Steele teeth, 101
 swaged cap, indirect method, 96
- Crowns, seamless pressed, 108
 cast cusps, 107
 Evslin teeth, 136
 facing soldered in, 118
 Morgan attachments, 171
 Roach attachments, 168
 seamless swaged, 113
 staple, 124
 stock, 82
 swaged cusps, 106
 temporary, 174
 to fill wide space of median line, 197
 two-piece, 105
 two-piece, all metal, 105
- Cusps, swaged, 126
- D**
- DEEP anaemia, 48
Dentin, treatment for hypersensitive, 60
Detached post crown, 81-130
Devitalization, 37
Direct method, burnished caps, 93
 cast base, 89
 soldered caps, 93
- Double backings, 128
Dovetail attachment, 144
Drugs, 41
Dummies, supplies for bridgework, 126-197
- E**
- EFFECTS, after-, 59
Evslin teeth, 136
 bridge meter, 183
- Examination, 11
Exodontia, 37
Extension bridges, 144-160
- F**
- FACE, harmony of the, 29
Facings, 67, 97-118, 126
Fear, 59
File method for root preparation, 83
Files, root, 86
Fillings, contour, 22
Final adjusting crowns and bridges, 76
Fischer syringes, 44
Fitting gutta-percha base, 85
Fixed bridges, 119, 185, 189, 192, 194, 197, 200, 202, 206, 210
Foundation, 9
Forced out of line, 30
Fractured root, 199
- G**
- Gold, 72
Gold, Alexander, 68
 backings, 66
Gold casting, 70
 crowns, 102-113
 filling contour, 22
 foil, 67
 plate, 93
 plating, 73
 plating outfit, 74
 platinized wire, 147
 solder, 67
Grinding porcelain teeth, 64, 187
Gum blocks, 19, 215
Gutta-percha base, 85
- H**
- Harvard Dental School cases, 31, 189
Heat the case, 68
Hypersensitive dentin, 60
- I**
- Inlay abutments, 119
 M.O.D., 119
 with posts, 119

Injection, Buccinator, 57
 labial side of lower incisors, 52
 infra-orbital, 58
 incisive, 58
 palatal and lingual sides, 52
 post palatine, 59
 Pterygo-mandibular, 54
 side of maxillary teeth, 51
 Zygomatic, 57
 Instruction to patients, 76
 Instrumentarium, 44
 Inter-locking two-piece bridges, 114
 Introduction, 9
 Irregular teeth, 33

J

Jacket crown, 78
 Jar for syringe, 45
 Jaw, lower, 51

K

Knowledge received, 10

L

Lack of contact points, 22
 Lateral, porcelain dummy with root, 198
 Local anaesthesia, 44

M

Mal-occlusion, 21
 Mandibular protrusion, 29
 Manipulation, general, 61
 Maxillary injection, 51
 protrusion, 29
 Metal abutments, 123
 Method facing repairs, another, 182
 Methods, direct, 89, 93
 indirect, 89, 96
 Mineral stains, 182
 Models, 12
 Mouths, treatment of, 37
 Morgan attachments, 169
 Mounting crown and bridge case on articulator, 63

N

Needle, 49
 Neothetin, 60
 Nerve, Buccinator, 57
 Nerves, posterior superior alveolar, 58
 Normal occlusion, 20
 Novocain, 47

O

Occlusion, 20
 Open-face crown, 102
 Oral anaesthesia, 44

P

Pathological conditions, 13
 Pieso's, 145
 Plating bridges with pure gold, 73
 Platinum plate, 88
 post, half-crown, 123
 saddle, 144
 staple, 124
 Polishing, 72
 Porcelain crowns, 78, 90
 Position of operator, 84
 Posterior Goslee teeth, 135
 Steele teeth, 131
 Post fitting to root, 83
 with inlays, 119, 120
 Post-palatine injection, 59
 Posts, Davis straight and offset centre, 87
 Preliminary treatment, 37
 Preparing for insertion, 49
 Prophylactic treatment, 37
 Pterygo-mandibular injection, 54
 Pulp removal, 52, 59
 Pyorrhoeatic conditions, 15
 Pyorrhoea treatment, 37

R

Replaceable crowns, Goslee, 135
 facings, 101, 136
 Removable bridge, 145
 Gilmore attachment, 145-160, 214-218
 Roach attachments, 168

Removable bridge, Morgan attach-
ments, 169

Repair bridges, 174, 180
facings, Ash, 179

Richmond crown, 93, 97

Root, impression of, 96
preparation, 93
porcelain, 198

S

Saddle bridges, 140

with continuous saddle, 140
extension with saddle, 144
with individual saddle, 143
with porcelain saddle, 142
with removable saddle, 145,
169

Sanitary bridges, 137

Seamless crowns, 102
pressed, 108
swaged, 113

Self-cleansing bridges, 138

Selecting teeth, 64
shade, 61

Septic roots, 13

Soldering, 69

Soldering bridge in sections, 69

Soldered caps, 93

Special instruments, 182

Split root, 199

Staple crown, 124

Steele posterior, 131

Steele repair outfit, 179

Steele teeth, 101

Supplies for banded crowns, 97

Swaged caps, 96

Swaged cusps, 106

Syringes, 46

T

Tablets of Novocain, 47

Taggart wax, 120

Taking bite, 61
impression, 61

Technical manipulation, 61

Teeth, condition of, 13
elongated, 24
Evslin, 136
Goslee, 100
irregularly arranged, 33
Steele, 101
tipped forward, 22
temporary retained, 26
treatment of, 37
wandering, 30

Treatment for hypersensitive dentine,
60

U

Use of Amalgam, 43

Antiflux, 131
bridge meter, 183
bridge repair tools, 180
stains, 182
swager, 111, 134

V

Vulcanite rubber, 60

W

Wax, Taggart's, Kerr's, 120

Window or open-face crown, 104

With cast cusps, 107
detached post crown, 98, 122
facings, 97, 122
gold chewing surface, 137
Goslee teeth, 100, 122
porcelain chewing surface, 138
Steele teeth, 101, 122
swaged cusps, 106



LIST OF ILLUSTRATIONS

FIG.		PAGE
1.	Radiographs showing perforation of roots with posts extending through same	11
2.	Model and radiograph of distal root of a six-year molar carrying a crown with extension	14
3.	Radiograph showing pathological conditions of the teeth	14
4.	Radiograph showing pyorrhoeatic conditions of the roots	15
5.	Bridge splint	16
6.	Radiograph of bridge splint in place	17
7.	Lower bridge of two open-face crowns with gum block	19
8.	Two bridges with gum blocks	19
9.	Plain and gum teeth	19
10.	Bridge case with normal occlusion	20
11.	Two models showing sufficient occlusion	21
12.	Mal-occlusion. Before and after treatment	21
13.	Mal-occlusion. Model	22
14.	Mal-occlusion. Model	23
15.	Radiographs showing lack of contact points. Before and after treatment	23
16.	Radiograph showing contact points restored by crowns	23
17.	Mal-occlusion. Molar tipped forward	24
18.	Mal-occlusion. Bridge with inter-locking device	24
19.	Mal-occlusion. Bridge with inlay abutments	25
20.	Mal-occlusion. Upper bicuspid is elongated caused by loss of lower teeth	25
21.	Radiograph. Right lateral incisor a temporary tooth	26
22.	Radiograph showing absorption of the roots of two temporary teeth	26
23.	Showing unerupted cuspids under bridges	27
24.	Mal-occlusion, closed bite. Bite has closed to such an extent, the upper incisors have worn down	27

FIG.		PAGE
25.	Mal-occlusion, closed bite, lower jaw. Before and after treatment	28
26.	Mal-occlusion, closed bite. Front view	28
27.	Mal-occlusion, closed bite. Left side views show conditions before and after restoration	29
28.	Mal-occlusion, closed bite. Right side of same case	29
29.	Mal-occlusion. Incisors pushed out on account of closing bite . .	30
30.	Mal-occlusion, mandibular protrusion	31
31.	Mal-occlusion, maxillary protrusion	32
32.	Mal-occlusion, upper incisors are projecting	32
33.	Mal-occlusion, wandering teeth	33
34.	Mal-occlusion. Spreading of the two central incisors	34
35.	Mal-occlusion. A shows the position of the upper lateral and cuspid	34
36.	Mal-occlusion. One lateral incisor absent, front teeth of irregular length	35
37.	Mal-occlusion. Case with very irregular teeth	35
38.	Radiographs showing cases where teeth have been crowned without devitalizing the pulps	38
39.	Radiographs showing chronic abscesses on roots of upper teeth, used as abutments, root canals not having been properly filled . . .	39
40.	Radiographs showing chronic abscesses on roots of lower teeth	39
41.	Series of radiographs showing treatment and filling of root canals of teeth to be used as bridge abutments	40
42.	Radiograph of second bicuspid and first molar with chronic abscesses	41
43.	Showing bent root of a lower second bicuspid	41
44.	Radiographs of receded pulps and constricted chambers, found in advanced age	42
45.	Radiographs showing large pulp chambers, found in young teeth .	42
46.	Radiographs showing abnormal branching of root canals	42
47.	Instruments for local anaesthesia	45
48.	Syringes	46
49.	Large and small dissolving cups	46
50.	Skulls showing the small foramina in the alveolar process . . .	50
51.	Position of the operator when injecting	51
52.	Radiograph showing the infiltration method for an upper cuspid .	52

FIG.	PAGE
53. Horizontal section through human head	53
54. Technique of inserting needle for pterygo-mandibular injection . .	55
55. Sulcus mandibularis with needle	56
56. Photograph showing posterior superior alveolar branches	57
57. Palate of an adult	58
58. Plaster impressions after washing trays and broken pieces with hot water	62
59. Plaster impressions after pieces are put back in place and held by sticky wax	62
60. Plaster impressions after casting, showing how impression was cut in mouth	62
61. Case mounted on anatomical articulator by means of a face bow . .	64
62. Facings with single and double backings	65
63. Soldering two backings in the flame	66
64. Showing a Goslee tooth saddle bridge invested ready to solder . .	68
65. Showing a full upper bridge	69
66. Gold-plating outfit of simple construction	74
67A, 67B, 67C. Steps for jacket crown	80
68. File methods for root preparation	83
69A, 69B. Position of operator filing a left upper bicuspid root and a lower incisor root	84
70. Detached post crown with gutta-percha washer	85
71. A root file, also a toothbrush handle with root-file grooves . . .	86
72. Root preparation for detached post crown	87
73. Shows straight and offset centre post	87
74. Steps for making porcelain baked crown, platinum base	88
75. Porcelain crown with cast base. Direct method	90
76. Porcelain crown with cast base. Indirect method	91
77. Steps for making band for soldered cap	93
78. Fitting of top to band and soldering post	94
79. Dr. Hovestadt's special plate punch	94
80. Shows the use of plate punch	94
81. Hand burnished top with post. Finished crown	95
82. Steps showing the making of swaged root caps	96

FIG.	PAGE
83. Banded crown with facing	98
84. Soldered cap with detached post crown	98
85. Swaged cap and box with detached post crown	99
86. Banded crown with Goslee tooth	100
87. Banded crowns with Steele facings	101
88. Steps for seamless open-face crowns (glove fit)	102
89. Die with handle	103
90. Steps continued for open-face crown (glove fit)	104
91. Steps for two-piece all-metal crown, swaged cusps	105
92. Steps for two-piece all-metal crown, cast cusps	107
93. Steps continued from Figure 92	107
94. Taking bite with copper band in position	108
95. Crown contoured to copper band	108
96. Shows split tray with moldine to take impression of crown	109
97. Split tray in position	109
98. Tray after removal and closed	110
99. Metal die and shell	110
100. Wooden blocks showing imprints of metal die and swager	110
101. Diagram of swager	111
102. Swaging of crown over die into wood block	112
103. Melting out the metal from the crown	112
104. Finished crown	113
105. Seamless all-metal crown. Bridge method. Impression with bands	114
106. Bands on articulated model	114
107. Crowns contoured and articulated	114
108. Ready to cast	114
109. Casting to die	115
110. Building fusible metal to edge of bands	115
111. Knocking off metal from ring	116
112. Splitting of die	116
113. Pressing of seamless shell	117
114. Shows marking of swaged crown to conform to cervical margin, determined by trial band	117

FIG.		PAGE
115.	Shows curved scissors for trimming crowns and bands	117
116.	Steps for crowns with porcelain facing	118
117.	Tooth preparations for inlay abutments	120
118.	Steps for bridge with inlay abutments	120
119.	Half-crown with post	123
120.	Steps for making staple crowns	125
121.	Model on articulator for cast supplies	127
122.	Supplies before and after casting	127
123.	Facings with single and double backings	128
124.	Facings with swaged cusps	129
125.	Bridge with supplies of anterior Steele teeth	130
126.	Steps for making Steele anterior crown	131
127.	Steele anti-flux	131
128.	Painting of backing with Steele anti-flux	132
129.	Right and wrong way of filing backings	132
130.	Filing to remove obstructions	132
131.	Bridges with Steele posteriors	132
132.	Soldering extension to backing	133
133.	Fitting to tooth	133
134.	Steps for making box for Steele posteriors	133
135.	Bridge with short teeth and short gold crown abutments	133
136.	Steele posterior molar with slice cut from the distal side	134
137.	Bridge with wash space and freedom of festoon next to crown abutments and dummies	134
138.	Anterior and posterior Goslee teeth	135
139.	Steps to show making of boxes for Goslee teeth, or other porcelain crowns	135
140.	Anterior Goslee bridge	136
141.	Posterior Goslee bridge	136
142.	Evslin interchangeable teeth for crown and bridge work	136
143.	Soldering of casting to all metal abutments	137
144.	Top view of sanitary bridge	137
145.	Sanitary bridge with gold casting	137

FIG.	PAGE
146. Sanitary bridge with porcelain chewing surface	138
147. Self-cleansing bridge showing wash spaces	140
148. Saddle bridge. Teeth in core before boxing	141
149. Saddle bridge. Teeth boxed	141
150. Saddle and boxes invested ready for solder	141
151. Saddle bridge, before and after cementing supplies	142
152. Shows a banded porcelain molar crown and bicuspid dummy	142
153. Hand-carved porcelain blocks with porcelain saddles	143
154. Extension bridge from front and back	144
155. Plaster impression of four abutments	147
156. Plaster model with four abutments	148
157. Abutments removed from model to solder wire frame	149
158. Finished frame in position	149
159. Finished frame for another case	150
160. Frame and Gilmore Attachments in position on flaked model	151
161. Other half of flask	151
162. A full lower Gilmore denture	152
163. A full lower Gilmore denture after treatment	153
164. Full upper Gilmore denture	153
165. Another full lower Gilmore case. Finished frame on model	154
166. Full upper Gilmore denture. Case before treatment	155
167. Same case with finished frame in position	155
168. A plaster model of back of finished denture	156
169. Case of a patient seventy-three years of age	157
170. Full lower, with two roots and two Gilmore attachments	158
171. Full lower, with one root, using two Gilmore attachments	158
172. Anterior fixed and posterior removable bridge with Gilmore attachments	160
173. Partial removable bridges with three Gilmore clasps	161
174. Removable partial bridge	162
175. Partial lower removable gold denture held with one Gilmore attachment	163
176. Removable bridge with vault bar	164

FIG.	PAGE
177. Removable bridge held by three Gilmore attachments	164
178. Partial removable bridge with vault bar, two Gilmore attachments	165
179. Partial removable bridge with lingual bar and two Gilmore attachments	165
180. Removable extension bridge for one side	166
181. Top view of finished case No. 180	166
182. Model with extension wires running parallel; in this case the denture with Gilmore attachments is liable to slide back	167
183. Different styles of Gilmore Adjustable Attachments	167
184. Roach attachments for removable bridges	168
185. Morgan attachments for removable bridges	170
186. Jig for Morgan attachments	170
187. Morgan attachments soldered to all-metal crowns	171
188. Morgan attachments used on various crowns	171
189. Finished case of Figure 187	172
190. Saddle with single Morgan attachments	172
191. Lower denture with Morgan attachments	173
192. Temporary crowns	174
193. Old crowns and bridges after they have been taken off	175
194. Old bridges with posts cemented into crowns and used temporarily	176
195. S. S. White's and the Giant post pullers	177
196. Ash repair facings	178
197A. Steele repair outfit	179
197B. Different steps to repair a broken pin facing	180
198A, 198B. Bryant repair outfit	180, 181
199. Mineral stains and stained teeth	182
200. Measuring distance with bridge meter	183
201. Parallelism obtained with the Evslin bridge meter	183
202. Shows condition of mouth	185
203. Radiographs of the roots	185
204. Shows impression of abutments	186
205. Plaster model with abutments in place	186
206. Articulated models with face bow relation	187

FIG.	PAGE
207. Bridge teeth waxed for trial	187
208A. Shows crowns held in plaster core	188
208B. Shows crowns boxed	188
209. Sections of tooth boxes invested and ready for soldering	188
210. Sections united to abutments	189
211. Finished fixed bridge with teeth cemented into boxes	189
212, 213. Harvard Dental School case, before treatment	190
214. Radiograph revealing absence of permanent teeth, same case	191
215. Same case, after treatment	191
216. Pyorrhoeca case, before and after treatment	192
217. Same case, presenting a closed bite. Bite was raised with fixed bridges	192
218. Cast inlays for same case	193
219. Same case, before and after treatment	193
220. Protruding lower teeth, before treatment; model and radiograph	194
221. Bridge frame, same case	194
222A, 222B. Shows frame on model and radiograph of frame on roots	195
223. Shows upright position of artificial teeth	196
224. The case flaked	196
225. Extra wide crowns to fill space of median line	197
226. Model showing effect of lateral tooth dummy with porcelain root after six years	197
227. Radiograph of same case	198
228. Slotted porcelain tooth with root and pin facing with root	198
229. Fractured lateral root and crown	199
230. Gold inlay, with post carrying lateral dummy with porcelain root	199
231. Crown and Bridge Case VIII, before treatment, showing a closed bite due to poor bridge construction	200
232. Case VIII, before treatment	201
233. Same case, after treatment	201
234. Case IX, before treatment	202
235. Case IX, after treatment	202
236. Case IX, showing lower	203

FIG.		PAGE
237.	Case IX, showing lower, after treatment; two sanitary bridges . . .	203
238.	Case IX, showing upper, before treatment	204
239.	Case IX, after treatment	204
240.	Case IX, before treatment	205
241.	Case IX, after treatment	205
242.	Case X, before treatment	206
243.	Case X, after treatment	206
244.	Case X, before treatment	207
245.	Case X, after treatment	207
246.	Case X, before treatment	208
247.	Case X, after treatment	208
248.	Case X, before treatment	209
249.	Case X, after treatment	209
250.	Case XI, before treatment, showing close bite	210
251.	Case XI, after treatment, showing raised bite	210
252.	Case XI, showing bridge in place	211
253.	Case XI, showing bridge in place	211
254.	Case XI, finished	212
255.	Case XII, before treatment	213
256.	Case XII, after treatment	213
257.	Case XIII, before treatment	214
258.	Case XIII, after treatment	214
259.	Case XIII	215
260.	Case XIII	215
261.	Case XIII, before treatment	216
262.	Case XIII, after treatment	216
263.	Case XIII	217
264.	Case XIII	217
265.	Case XIII, before treatment	218
266.	Case XIII, after treatment	218

