

## **Dental anatomy note book ... / by Douglas Gabell.**

### **Contributors**

Gabell, Douglas (Douglas Phillimore)

### **Publication/Creation**

London : Ash, 1909.

### **Persistent URL**

<https://wellcomecollection.org/works/h48nq5pp>

### **License and attribution**

This work has been identified as being free of known restrictions under copyright law, including all related and neighbouring rights and is being made available under the Creative Commons, Public Domain Mark.

You can copy, modify, distribute and perform the work, even for commercial purposes, without asking permission.



Wellcome Collection  
183 Euston Road  
London NW1 2BE UK  
T +44 (0)20 7611 8722  
E [library@wellcomecollection.org](mailto:library@wellcomecollection.org)  
<https://wellcomecollection.org>

DENTAL ANATOMY  
NOTE BOOK

DOUGLAS GABELL

DEPARTMENT OF


NOTES BOOK

LONGMAN GROUP



22102168970

Med  
K48869



# DENTAL ANATOMY

## NOTE BOOK

*FOR USE IN CONJUNCTION WITH TOMES' "DENTAL ANATOMY,"*  
*THE SOUTH KENSINGTON MUSEUM,*  
*AND*  
*PERSONAL INSTRUCTION.*

BY  
DOUGLAS GABELL, M.R.C.S., L.R.C.P., L.D.S.,

SURGEON AT THE ROYAL DENTAL HOSPITAL OF LONDON, AND  
EXAMINER AT VICTORIA UNIVERSITY OF MANCHESTER.

FOURTH EDITION.

LONDON :  
CLAUDIUS ASH, SONS & CO., LIMITED,  
5 TO 12, BROAD STREET, GOLDEN SQUARE, W.

1909.

14 631 143

7327

LONDON :  
PRINTED BY WILLIAM CLOWES AND SONS, LIMITED,  
DUKE STREET, STAMFORD STREET, S.E., AND GREAT WINDMILL STREET, W.

WELLCOME INSTITUTE LIBRARY	
Coll.	welMOMec
Call	
No.	WU

## PREFACE TO THE THIRD EDITION.

---

IN this edition the size of the page has been reduced to more comfortable dimensions, and it is hoped that sufficient room has still been left for the making of notes and the insertion of diagrams by the student himself.

The portion dealing with Reptiles and Mammals has been more systematised, and the most modern classification adopted. As this is indicated mainly by the type, it is hoped that it may prove helpful without adding unnecessary complication.

The rest of the book has been revised, but no great alteration made.

The book is still only to be regarded as a **Note Book**, and not as a treatise on Dental Anatomy, and the student is urged to make diligent use of the microscope, illustrations, museums, and lectures for the proper appreciation of the subject and its utility.

DOUGLAS GABELL.

9, PORTLAND PLACE.

*May, 1903.*

## PREFACE TO THE THIRD EDITION

LONDON

THE first edition of this book was published in 1891, and the second in 1896. The present edition is the result of a revision of the second edition, and is published in 1901.

The present edition is the result of a revision of the second edition, and is published in 1901. The revision has been made in accordance with the suggestions of the many readers who have written to the author, and has been made in accordance with the suggestions of the many readers who have written to the author.

The present edition is the result of a revision of the second edition, and is published in 1901. The revision has been made in accordance with the suggestions of the many readers who have written to the author, and has been made in accordance with the suggestions of the many readers who have written to the author.

THE AUTHOR

LONDON

# DENTAL ANATOMY.

---

## Enamel

Is very hard, brittle, bluish-white, and semi-translucent,  
And composed of **Calcified Prisms** in a **Calcified Matrix**.

### Chemical Composition.

Organic Matter,	. . .	(mucin ?)	. . . . .	None.
Salts,	. . . . .	{ Calcium phosphate Calcium carbonate Calcium fluoride Magnesium phosphate }	. . .	95 %
Water,	. . . . .	(chemically combined with salts)		5 %

## The Matrix

Is very small in amount, absolutely calcified, but is more easily dissolved by acids than the prisms.

## The Prisms

Are long hexagonal varicose rods, solid, and absolutely calcified, but the centre is usually more easily dissolved by acids than the external part.

The enamel prisms of the:—

**Eel** are indistinguishable from the matrix.

**Manatee** are straight.

**Sciuridæ** are lamellate, thus:—

**Beaver** are lamellate and flexuous, thus:—

**Porcupine** are lamellate and spiral.

**Leporidæ** show no lamellæ, only flexuous prisms.

**Muridæ** are serrated and lamellate.

**Man** are straight or slightly flexuous.

# DENTAL ANATOMY

Chapter I

The study of dental anatomy is essential for the dentist to understand the structure and function of the teeth and the oral cavity.

The Teeth	
Incisors	Cutters
Canines	Pointers
Pre-molars	Grinders
Molars	Grinders
Wisdom Teeth	Third Molars

The teeth are divided into two main groups: the upper teeth (maxilla) and the lower teeth (mandible).

The upper teeth are further divided into the incisors, canines, and premolars, while the lower teeth are divided into the incisors, canines, premolars, and molars.

The teeth are also divided into the deciduous teeth (baby teeth) and the permanent teeth (adult teeth). The deciduous teeth are the first set of teeth that a child has, while the permanent teeth are the second set of teeth that a child has.

The **Transverse Striæ** of prisms are due to either:—

1. Varicosity of the prisms.
2. Intermittent calcification.
3. Decussation of the prisms.
4. Boedecker's "thorns."
- or 5. The action of acids (balsam).

In all **Marsupials** (bar the **Wombat**), some **Rodents** (**Jerboa**), some **Insectivora** (**Soricidæ**), **Hyrax**, and some **Fishes** (**Barbel**, **Porbeagle Shark**), the central portions of the prisms remain **Uncalcified**, *i.e.*, **Tubular Enamel**.

Sometimes this happens at the inner parts of the enamel only, sometimes at the outer part (**Sargus**); often this condition is irregularly distributed.

Learn to recognise and explain:—

- "Brown striæ of Retzius."
- "Schreger's lines."
- "Tomes' lines."
- "Pigment in the enamel."
- "Irregular fissures near the dentine."

#### Distribution of Enamel.

Absent from . . . . .	Edentata, Narwal, some Cetaceans, Reptiles, and Fish.
Tip only in . . . . .	Hake, Eel, Elephant's tusk.
Front or sides only of tooth in {	Rodents' incisors.
	Canines of Suinæ, Iguanodon.
All over crown in . . . . .	Man and most Mammalia.

Learn how to prepare sections to show:—

Enamel prisms, transverse striæ, striæ of Retzius, Schreger's lines.

The following table shows the results of the  
analysis of the data  
in the following table  
The results of the analysis  
are shown in the following table

The following table shows the results of the  
analysis of the data  
in the following table  
The results of the analysis  
are shown in the following table

The following table shows the results of the  
analysis of the data  
in the following table  
The results of the analysis  
are shown in the following table

The following table shows the results of the  
analysis of the data  
in the following table  
The results of the analysis  
are shown in the following table

The following table shows the results of the  
analysis of the data  
in the following table  
The results of the analysis  
are shown in the following table

The following table shows the results of the  
analysis of the data  
in the following table  
The results of the analysis  
are shown in the following table

## Dentine.

Dentine is only formed under an enamel organ, and cannot be formed without one.

### Varieties.

Hard (unvascular), **Plici-dentine**, **Vaso-dentine**, and **Osteo-dentine**.

### Hard Dentine

Is hard, elastic, yellowish and semi-translucent, and composed of **Calcified Matrix**, permeated by **Tubes** containing **Fibrils**.

### Chemical Composition (dried dentine).

Organic Matter, . . .	{ Collagen } . . . . .	20 %
	{ Elastin }	
Salts, . . . . .	{ Calcium phosphate Calcium carbonate Calcium fluoride Magnesium phosphate }	72 %
Water, . . . . .	(chemically combined with salts)	8 %

Fresh dentine also contains 10% **FREE** water.

### The Matrix

Is collagen impregnated with salts. When decalcified a very faint fibrous structure is apparent.

### The Tubes (Sheaths of Neumann)

Run at right angles to the surface of the pulp, and  
Decrease in diameter as they near the periphery;  
Those at the neck of the tooth have a large flexuous **Primary Curve**.  
Some, in the root especially, have many small spiral **Secondary Curves**.

Many small lateral branches are given off, and

The tubes terminate:—In forked extremities,  
in loops with each other,  
in the granular layer of **Tomes**,  
in fissures in the enamel,  
or by anastomosing with the canaliculi in  
the cementum.

The tubes are said to be composed of **Elastin** and lime salts, and resist the action of acids and alkalies.

1. The first part of the paper is devoted to a general discussion of the problem of the origin of life. It is shown that the problem is one of the most important and interesting in the history of science. The author discusses the various theories of the origin of life, and shows that the most probable one is the theory of spontaneous generation. This theory is based on the fact that life is everywhere, and that it is impossible to find a place where it does not exist. The author also discusses the question of the origin of the first living organisms, and shows that the most probable one is the theory of the origin of life from non-living matter. This theory is based on the fact that the elements of life are everywhere, and that it is impossible to find a place where they do not exist. The author also discusses the question of the origin of the first living organisms, and shows that the most probable one is the theory of the origin of life from non-living matter. This theory is based on the fact that the elements of life are everywhere, and that it is impossible to find a place where they do not exist.

### The Fibrils

Are soft, sentient, branched processes of the odontoblasts.

Proofs = stretching and contraction.

Functions are nutritive and sentient.

Learn to recognise and explain:—

“Schreger’s lines.”

“Owen’s lines.”

“Interglobular spaces.”

“Granular layer of Tomes.”

Learn how to prepare sections to show:—

Owen’s lines, interglobular spaces, Schreger’s lines, granular layer, sheath of Neumann, dentinal fibril, fibrous matrix.

1870

For the purpose of the present investigation, the following facts have been ascertained:

1. The first of the series of experiments was conducted in the year 1868, and the results were as follows:

2. The second of the series of experiments was conducted in the year 1869, and the results were as follows:

### Plici-Dentine.

The pulp is more or less folded. No cementum intervenes.

Plici-dentine occurs in **Varanus**, **Lepidosteus**, **Labyrinthodon**, **Myliobates**, **Orycteropus** (Cape ant-eater), and **Pristis** (dermal spines). The last three might be regarded as fused simple teeth.

### Vaso-Dentine.

The dentinal tubes and fibrils are replaced by **Canals** containing **Capillary** blood-vessels.

The **Matrix** is often laminated, and in its outer part a fibrous structure is often visible.

Vaso-Dentine is **softer** than hard dentine.

In the **Hake**, **Chætodonts**, and **Ostracion** there are no dentinal fibrils.

In the **Flounder**, **Megatherium**, **Iguanodon**, **Odontostomus**, and **Haddock** there are both capillaries and fibrils.

In the **Lotella** there are neither.

**Sargus** and **Manatee** show the remains of a vascular system.

Vascular canals are rarely found in **Human** dentine.

### Osteo-Dentine.

Calcification takes place in the substance of, as well as on the surface of, the pulp.

There is usually an outer layer of fine tube dentine, then irregular trabeculae of dentine containing **Canaliculi** and sometimes **Lacunæ**, and between the trabeculae are spaces filled with pulp tissue and lined with flattened cells;

Osteo-dentine occurs in **Pike** and **Lamna**.

**Note the gradations between—**

Hard, Plici- (both sorts), Vaso-, Osteo- Dentine and Bone.

### Secondary Dentine

May be of any of the varieties above mentioned, or structureless, or irregular.

It occurs very readily in elephants' tusks and whales' teeth,

And normally in the pulps of persistent growing teeth;

Also in any pulp as a pathological condition.

**Learn how to prepare sections to show:—**

Plici-, vaso-, or osteo- dentines (*a*) with; (*b*) without soft parts.

1870-1871

The first of these is the fact that the  
the first of these is the fact that the  
the first of these is the fact that the

1872-1873

The second of these is the fact that the  
the second of these is the fact that the  
the second of these is the fact that the

1874-1875

The third of these is the fact that the  
the third of these is the fact that the  
the third of these is the fact that the

1876-1877

The fourth of these is the fact that the  
the fourth of these is the fact that the  
the fourth of these is the fact that the

1878-1879

The fifth of these is the fact that the  
the fifth of these is the fact that the  
the fifth of these is the fact that the

1880-1881

The sixth of these is the fact that the  
the sixth of these is the fact that the  
the sixth of these is the fact that the

1882-1883

The seventh of these is the fact that the  
the seventh of these is the fact that the  
the seventh of these is the fact that the

## **Pulp.**

Composed of **Matrix, Cells, Fibrous Tissue, Vessels and Nerves.**

### **Functions.**

**Formative; Nutritive; Nervous.**

### **The Matrix**

Is plentiful, soft and jelly-like.

### **The Cells.**

The **central** cells are numerous, round, and have fine processes.

The **odontoblasts** (*membrana eboris*) form a complete surface layer; they are large elongated granular cells and send out processes: 1, into the **Dentine** (dentinal fibril), 2, laterally (not certainly proved), and 3, towards the pulp (very small).

In old age the odontoblasts become smaller and more oval.

### **The Vessels.**

Numerous arteries, capillaries and veins, but no lymphatics.

### **The Nerves.**

Three or four **medullated** nerves enter the apical foramen; they soon lose their sheaths and form a plexus near the surface of the pulp (plexus of Raschkow). The nerves probably terminate as fine varicose filaments between the odontoblast cells. Other views are that they join the dentinal fibrils, or run with them, or that they join the pulp processes of the odontoblasts.

### **The Fibrous Tissue**

Is very faint, and continuous with that in the matrix of the dentine. In old age it increases and the cells disappear.

Learn to recognise and explain:—

“**Basal layer of Weil.**”

“**Odontoblasts.**”

Learn how to prepare sections to show:—

Odontoblasts, pulp tissue in situ, nerve trunks, nerve endings.



## Cementum

Consists of a **Calcified Matrix** containing **Lacunæ**, **Canaliculi** and sometimes blood-vessels.

### Chemical Composition.

Almost the same as bone.

### The Matrix.

If thin, is **structureless** or granular.

If thick, it is **laminated** and contains **lacunæ**.

Sharpey's fibres are imperfectly calcified periosteal fibres enclosed in the matrix.

Learn to recognise and explain:—

“Sharpey's fibres.”

“Intercemental lines of Salter.”

### The Lacunæ

Are not usually present in thin cementum.

They are more irregular in size and shape than bone lacunæ.

The canaliculi are abundant, especially towards the surface.

Each lacuna is filled with a **Cement Corpuscle**.

Learn to recognise and explain:—

“Encapsuled lacunæ.”

### The Blood-Vessels

Occur in thick cementum only, and do not form Haversian systems.

### Distribution.


Cementum is rare in Fishes and Reptiles.

It covers the root in all Mammalian teeth and the crowns of some.

It is the most **external** dental tissue.

Learn how to prepare sections to show:—

Sharpey's fibres, intercemental lines of Salter, lacunæ and encapsuled lacunæ.



### Nasmyth's Membrane

Is a thin layer of **hardened epithelial cells** (derived from the enamel organ), covering the enamel, and having on its inner surface a thin, structureless membrane.

Learn how to prepare sections to show:—

Nasmyth's membrane in situ, also its structure.

### Gum

Is composed of **stratified epithelium** covering broad **papillæ**, which contain numerous **blood-vessels** and **lymphatics** and a few **nerves**, bound together by much firm **fibrous tissue**, the latter blending with the periosteum of the alveolus. It also contains mucous gland.

It is hard, dense, firmly adhered to the bone, very vascular and only slightly sentient.

A thickening of the epithelium at the necks of the teeth is called the "Gingival organ."

Learn to recognise and explain:—


"Glands of Serres."

"Pockets" round the teeth.

"Health line."

Learn how to prepare sections to show:—

Gum in situ, nerves, glands of Serres.



## Alveolo-Dental Membrane

Is composed of bundles of **white fibrous tissue** containing **blood-vessels, lymphatics, nerves, and cells** between the meshes.

It serves to fix the teeth, to prevent shock and damage to the nerves, and to nourish the cementum.

### The Fibres

Are non-elastic, and run **obliquely** from the bone to the tooth.

The ends of these fibres become imbedded in the hard tissues to form

**"Sharpey's fibres."**

The fibres are most numerous and strong at the neck of the tooth.

### The Blood-Vessels

Are very numerous and derived from the bone, gum and apical vessels.

They form a capillary network close to the cementum.

Lymphatics are plentiful and most visible near the apex.

### The Nerves

Are derived from the gum and apical nerves, and render the membrane highly sensitive.

### The Cells

Are found between the fibres, especially near the cementum (cementoblasts).

Nests of epithelial cells are also often found, which are remnants of the **Epithelial sheath of Hertwig**, and form the so-called

**"Glands of Serres."**

The alveolo-dental membrane is thickest near the neck and apex.

In old age it becomes thinner.

Learn how to prepare sections to show:—

Periosteum in situ, glands of Serres, blood-vessels.

# THE HISTORY OF THE

... of the ...

## THE HISTORY OF THE

... of the ...

... of the ...

## THE HISTORY OF THE

... of the ...

... of the ...

## THE HISTORY OF THE

... of the ...

... of the ...

... of the ...

... of the ...

... of the ...

... of the ...

... of the ...

... of the ...

... of the ...

... of the ...

... of the ...

... of the ...

... of the ...

## Development of the Teeth.

### In Fish.

In the Elasmobranch fish there is a continuous growing **tooth band**, **enamel buds**, and **dentine papillæ**, but no follicle, and the enamel organ is very simple in structure.

In Teleost fish there is no tooth band or follicle, and each simple enamel bud and **dentine papilla** is developed *de novo*.

### In Reptiles

There is a continuous growing **tooth band**, **enamel buds**, and **dentine papillæ**, the whole being enclosed in a fibrous sac, a sort of common follicle, forming the "**area of tooth development**."

### In Mammalia (*e.g.*, Human)

There is a **tooth band** of limited growth, only two sets of **enamel buds** and **dentine papillæ**, each tooth having its own follicle.

Confining our description for convenience to the lower jaw, at the:—

#### 6th week


An ingrowth of epithelium occurs all round the margin of the jaw.

#### 7th week

This ingrowth divides into two bands, an outer vertical "**labio-dental strand**" (lippenfurche), and an inner more horizontal "**dental lamina**" (zahnleiste); a groove "**dental furrow**" appears at the origin of the latter from the surface. Calcification of the bone starts.

#### 9th week

Ten enlargements, "**enamel buds**," appear near the free end of the dental lamina.



**10th week**

Eight thickenings of the mesoblast appear against the under surface of the enamel buds, "**dentine papillæ**." The enamel buds have become club shaped.

**11½th week**

Two more dentine papillæ appear, *i.e.*, ten "**tooth germs**" are now formed.

The central cells of the lippenfurchen atrophy to form the labio-dental sulcus.

**14th week**

The enamel buds for the incisors develop into "**enamel organs**." The bone commences to grow up round the developing teeth. The dental lamina extends backwards free from the gum.

**17th week**

Another enamel bud (for the six-year-old molar) appears with its corresponding dentine papilla. The dental lamina is beginning to **become fenestrated** at the front of the mouth.

**20th week**


Calcification starts in the milk incisors.

**24th week**

Enamel buds and dentine papillæ for the permanent incisors and canines appear. Calcification commences in the temporary canines and molars.

**29th week**

The enamel bud for the 1st bicuspid appears.



**33rd week**

The enamel bud for the 2nd bicuspid appears.

**At Birth**

The dental lamina is cribriform in front, but whole at the back of the mouth.

The necks of the enamel organs of the incisors have gone; those of the molars are whole.

The teeth are calcified thus:—

The germs of the permanent incisors and canines are visible to the naked eye; those of the bicuspids and 2nd and 3rd molars are not yet visible.


The crypts are incomplete, and the permanent and temporary teeth are in a common loculus.

**Temporary Dentition.**

	Central.	Lateral.	Canine.	1st Molar.	2nd Molar.
Enamel buds appear	9th week.	9th week.	9th week.	9th week.	9th week.
Calcification starts	20th week.	20th week.	24th week.	24th week.	24th week.
Condition at birth	1 (crown).	$\frac{1}{2}$	$\frac{1}{2}$	$\frac{1}{2}$	$\frac{1}{2}$
Eruption occurs	6th month.	9th month.	18th month.	14th month.	26th month.
Calcification ends	3rd year.	3½th year.	4½th year.	5th year.	6th year.
Absorption starts	4th year.	5th year.	9th year.	7th year.	8th year.

**Permanent Dentition.**

	I <sub>1</sub> .	I <sub>2</sub> .	C.	B <sub>1</sub> .	B <sub>2</sub> .	M <sub>1</sub> .	M <sub>2</sub> .	M <sub>3</sub> .
Enamel bud appears	24th wk.	24th wk.	24th wk.	29th wk.	33rd wk.	17th wk.	4th mth.	3rd yr.
Calcification starts	1st mth.	2nd mth.	6th mth.	1½th yr.	2nd yr.	At birth.	2nd yr.	12th yr.
Condition at 6 years	1 (crown).	$\frac{1}{2}$	1	$\frac{1}{2}$	$\frac{1}{2}$	$\frac{1}{2}$ (root).	$\frac{1}{2}$ (crown).	—
Eruption occurs	7th yr.	8th yr.	11th yr.	10th yr.	11th yr.	7th yr.	13th yr.	24th yr.
Calcification ends	10th yr.	10th yr.	11th yr.	13th yr.	13th yr.	9th yr.	16th yr.	?



### Enamel Organ.

The enamel bud is composed of cubical epithelial cells, and is at first only a thickening of the lower end of the tooth band; it then becomes club shaped, and then bell shaped, growing out on the **labial** side of the tooth band. Next, as it increases in size and encloses the dentine papilla, it becomes differentiated into four layers: the **External Epithelium**, composed of oval cells; the **Stellate Reticulum**, composed of large degenerate oval cells, with stellate intercellular tissue; the **Stratum Intermedium**, composed of one or two layers of oval cells; and the **Internal Epithelium**, composed of large, long, granular, columnar cells, with the nucleus at the outer end.

The function of the

**Internal epithelium** (ameloblasts) is to form enamel,

**Stratum intermedium** is to recruit the internal epithelium,

**Stellate reticulum** is to act as a packing material,

**External epithelium** is to form Nasmyth's membrane.

The enamel organ only becomes thus specialised where it is going to produce enamel. It is continued on as a thin layer of oval cells, so as to invest the whole of the roots of the tooth; this continuation is called the "**Epithelial Sheath of Hertwig.**"

### Dentine Papilla.

The dentine papilla is at first only a thickening of the mesoblast in front of the enamel bud, but presently the surface cells develop into columnar cells (odontoblasts), smaller and less regular than the ameloblasts, but still well marked off from the underlying round cells of the rest of the papilla, which is well supplied with blood-vessels and nerves.

### Dental Follicle or sac.

The follicle at first appears as a thickening of the mesoblast cells outside the enamel organ and continuous below with the dentine papilla. At first it is composed of very loosely packed cells, but later on it becomes differentiated into an **outer** firm fibrous layer and an **inner** very vascular, more cellular layer; little processes from the latter project into the enamel organ a short way. The **functions** of the outer layer are to protect the developing tooth, and later on to form the dental periosteum; those of the inner layer are to nourish the enamel organ and eventually to form the cementum.

When a very thick layer of cementum has to be formed, the inner layer of the follicle becomes **cartilaginous** before calcification takes place. This cartilage is called the "**Cement organ.**"

A **small foramen** exists behind the necks of the temporary teeth, for the transmission of a small artery and a little fibrous tissue from the gum to the follicle of the permanent tooth.

The first thing I noticed when I stepped out of the car was the cold. It was a sharp contrast to the warm blanket of the car's interior. I shivered slightly, but then I remembered that this was just the beginning. The air was crisp and clean, a welcome change from the stuffy atmosphere of the city. I took a deep breath, feeling the cool air fill my lungs. The sun was shining brightly, casting long shadows on the pavement. I looked up at the sky, feeling a sense of peace and tranquility. The world was so beautiful, and I was so lucky to be here.

I walked towards the park, feeling a sense of purpose. The path was wide and open, leading me towards the heart of the city. I saw many people walking, some alone and some in groups. They were all going about their day, living their lives. I felt a sense of connection to them, a sense of being part of something bigger than myself. The trees were tall and leafy, providing a natural canopy over the path. The birds were singing, their voices filling the air. It was a beautiful scene, and I was so grateful to be here.

I continued walking, feeling a sense of joy and freedom. The path led me to a small pond, where I saw many children playing. They were laughing and running, their voices echoing through the air. I watched them for a moment, feeling a sense of nostalgia. I remembered the days of my childhood, the days of carefree play and discovery. It was a beautiful memory, and I was so glad to see it in the eyes of these children.

I walked towards the lake, feeling a sense of awe and wonder. The water was calm and still, reflecting the sky and the surrounding trees. I saw many people sitting on the grass, some reading books and some talking. They were all enjoying the peaceful atmosphere. I felt a sense of calm and serenity, a sense of being in the right place at the right time. The sun was setting, casting a warm glow over the scene. It was a beautiful moment, and I was so lucky to be here.

I walked towards the city, feeling a sense of excitement and anticipation. The lights were on, and the city was alive. I saw many people walking, some alone and some in groups. They were all going about their day, living their lives. I felt a sense of connection to them, a sense of being part of something bigger than myself. The city was so beautiful, and I was so lucky to be here.

**Calcification** = impregnation with lime salts.

May take place :—

1. By the deposit of lime salts in the substance of the formative organ. (**Conversion.**)
2. By the formative organ shedding out organic matter and lime salts. (**Excretion.**)

If lime salts are precipitated from a watery solution, they come down as an amorphous powder, but if albumen is added to the water, they come down as round bodies with concentric markings, combined with some very insoluble form of albumen; these round bodies are **calcospherites**, and the insoluble albuminous material is **calcoglobulin**. Calcoglobulin is also formed on the surface of calcospherites.

For calcification to take place, Woodhead believes that there is required :—

1. A devitalised albuminoid tissue.
2. A layer of formed material covering it.
3. A layer of proliferating cells.

The lime salts precipitated from the blood by the latter dialyse through the second, and are deposited in the first.

## Enamel.

### Facts.

Large granular Ameloblast cells, with nuclei at their outer end, exist.

In the corners of these cells, Fibrils appear (Osteogenic fibres).

The corners become tougher (calcoglobulin, "membrane").

Lime salts are deposited in the corners (the middle soft part is 'Tomes' process).

All these changes spread inwards and upwards.

(In **Marsupials** the centre of the prisms remain uncalcified).

### Theories.

Cells grow at nucleus end and become impregnated with lime salts at the other end (**Conversion** theory).

Cells grow at inner end, and the new part becomes impregnated.

Cells do not grow, but excrete matter from the inner end, which becomes impregnated (**Excretion** theory).



**Dentine.****Facts.**

Odontoblasts with large nuclei and rounded ends, imbedded in a slightly fibrous matrix, exist.

Toughening of the matrix occurs, then a deposit of calcospherites. The Odontoblasts move off, but leave strips behind them (Dentinal fibrils).

The toughness follows and surrounds the fibrils (Sheath of Neumann).

Lime salts are deposited in between the fibrils (Dentine matrix).

**Theories.**

Odontoblasts form matrix, sheath, and fibrils.

Odontoblasts secrete a fibrous matrix, which become calcified, and themselves form the fibrils.

**Odontoblasts form fibrils; and Intercellular substance forms matrix and sheath (Mummery).**

**Vaso-Dentine.****Fact.**

The fibrous matrix is better seen.

**Theory.**

Same as before, but the Odontoblasts move away completely, and the Capillaries do not.

**Osteo-Dentine.****Fact.**

Calcification occurs on the surface and in the substance of the pulp also.

**Theory.**

Same as for Ossification in membranous bone.

**Cementum.****Facts.**

A fibro-cellular membrane exists and becomes impregnated with lime salts.

When a very thick mass of cementum is formed, the fibrous membrane becomes cartilaginous before calcification occurs (Cement organ).

**Theory.**

Cementoblasts form both Matrix and Lacunæ.

...the ...  
...the ...  
...the ...  
...the ...  
...the ...

...the ...  
...the ...  
...the ...  
...the ...  
...the ...

...the ...  
...the ...  
...the ...  
...the ...  
...the ...

...the ...  
...the ...  
...the ...  
...the ...  
...the ...

...the ...  
...the ...  
...the ...  
...the ...  
...the ...

...the ...  
...the ...  
...the ...  
...the ...  
...the ...

## Development of the Jaws.

**Learn** the development of the head and the centres of ossification of the jaws.

Condition of the jaws :—

### Before birth.

Same shape as at birth, but smaller.

### At birth.

The lower jaw is in two halves.

The coronoid process rises at angle of  $45^\circ$  from the anterior margin of the crypt of  $M_1$ .

The condyle is level with the alveolus.

The symphysis is flat behind, there is no chin, and the lower border of the jaw is convex.

The crypts are open, incomplete, and packed.

The malar process is opposite the second temporary molar.

The antrum is a mere depression. (Teeth up against orbit.)

The teeth are calcified thus :—

### Eight months.

The halves of the lower jaw are uniting.

The coronoid process is farther back, the condyle is rising.

The symphysis bulges behind, there is a chin, the lower border of the jaw is concave.

The crypts in front have closed and reopened; at the back are almost complete.

The antrum extends  $\frac{2}{3}$  across the orbit.

The teeth are calcified thus :—

$\frac{1}{2}$  root,  $\frac{1}{3}$  root,  $\frac{2}{3}$  crown, all crown, all crown, cusps united.

### Adult age.

The coronoid process rises at a right angle from behind the wisdom tooth.

The condyle stands high above the alveolus.

The sockets are all regularly arranged.

The malar process is opposite the first permanent molar.

The antrum forms a wide space between the teeth and the orbit.

# Journal of the Year

Journal of the Year  
The Journal of the Year  
The Journal of the Year

The Journal of the Year

The Journal of the Year

The Journal of the Year

The Journal of the Year

The Journal of the Year

The Journal of the Year

The Journal of the Year

The Journal of the Year

The Journal of the Year

The Journal of the Year

The Journal of the Year

The Journal of the Year

The Journal of the Year

The Journal of the Year

The Journal of the Year

The Journal of the Year

The Journal of the Year

The Journal of the Year

The Journal of the Year

The Journal of the Year

The Journal of the Year

The Journal of the Year

The Journal of the Year

The Journal of the Year

The Journal of the Year

The Journal of the Year

The Journal of the Year

The Journal of the Year

The Journal of the Year

**Old age.**

The alveolus has all gone.  
 The angle has been much absorbed.  
 The chin is protruded. (Closure of bite.)

**Growth takes place**

At all sutures (till united).  
 Beneath the periosteum.  
 In the sub-articular cartilage.

The **alveolar** portion grows, is absorbed, and grows again exactly as it is required by the **teeth**.

The **basal** portion steadily grows according to the **muscular** development, and so becomes a little wasted in old age.

The **ascending ramus** grows more rapidly than the basal portion, to provide room for the teeth. (Depth of bite and of antrum.)

**The Lower Jaw increases in length by growth:—**

1. Beneath the periosteum behind the ascending ramus.
2. In the sub-articular cartilage of the oblique set ramus.
3. Beneath the periosteum in front of the jaw.

**The Lower Jaw increases in width by:—**

1. Elongation of the jaw (continuance of arch).
2. Sub-periosteal growth on outer side of jaw.
3. Growth between the halves. (Mainly intra-uterine.)



## Eruption of the Teeth.

### Facts.

Large multinucleated cells appear on the under side of the roof and front wall of the bony crypts.

The roof of the crypt is absorbed away, and more than enough room made for the tooth to pass out.

The soft tissues disappear and the tooth moves up.

The alveolus closes in around the neck of the tooth and both grow up together.

### Theories.

No fully satisfactory theory is at present known, but the following have been suggested.

That the eruption of teeth is due to:—

1. **The elongation of the roots**, but some teeth move farther than the length of their roots.
2. **The enamel of the tooth acting as a foreign body**, but the teeth of the sloth, which have no enamel, erupt.
3. **The blood pressure**, but why do they stop, or the alligator's teeth move sideways?
4. **Enamel being an epithelial structure** and therefore tending to return to the surface, but glands and nerves do not erupt.
5. **Growth of the alveolus**, but the crocodile's teeth erupt without any change of the socket.
6. **A movement of the tissues, à la shark**, but this is only begging the question.

### Times of Eruption of the Temporary Teeth.

Lower centrals . . .	about 6th mth.,	take 10 days,	then a rest of 2 mths.
Upper incisors . . .	„ 9th „	„ 1 mth.	„ „ 2 „
L. laterals and 1st molars „	12th „	„ 2½ mths.	„ „ 3 „
Canines . . . . .	„ 18th „	„ 2 mths.	„ „ 5 „
2nd molars . . . . .	„ 26th „	„ 3 mths.	

Struma and syphilis accelerate, and rickets retard the eruption.



### Condition of the Jaws at the age of Six Years.

The temporary teeth are fully calcified, spaced, partly absorbed, and vertical in direction.

There is a wide space behind the last temporary molar.

The permanent teeth are packed, partly calcified, obliquely directed, and placed behind or between the roots of the temporary teeth.

Learn the direction and position of each tooth.

Room for the Permanent Teeth is made by:—

1. The elongation of the jaw backwards.
2. The oblique direction of the erupting teeth.
3. The thickening of the jaw by sub-periosteal growth externally.
4. The smaller antero-posterior diameter of the bicuspid than of the temporary molars.

Absorption of the Temporary Teeth is caused by an "absorbent organ," not by direct pressure.

Learn to recognise and explain:—

"Giant cells."

"Howship's lacunæ."

### Times of Eruption of the Permanent Teeth.

	I <sub>1</sub> .	I <sub>2</sub> .	C.	B <sub>1</sub> .	B <sub>2</sub> .	M <sub>1</sub> .	M <sub>2</sub> .	M <sub>3</sub> .
Upper . . .	7 $\frac{1}{4}$	8 $\frac{3}{4}$	11 $\frac{3}{4}$	10 $\frac{1}{4}$	11 $\frac{1}{4}$	7 $\frac{1}{2}$	12 $\frac{3}{4}$	24 years.
Lower . . .	7 $\frac{1}{4}$	8 $\frac{1}{4}$	10 $\frac{3}{4}$	10 $\frac{3}{4}$	11 $\frac{1}{4}$	7	12 $\frac{1}{2}$	24 years.

Girls cut their canines and 2nd molars earlier than boys.

Rich children cut their teeth earlier than poor children.

...of the ...  
...  
...  
...  
...

...  
...  
...  
...  
...  
...  
...  
...  
...

...  
...  
...  
...  
...  
...  
...  
...  
...

...  
...  
...  
...  
...  
...  
...  
...  
...

## The Attachment of Teeth

Is by :—Membrane, hinge, anchylosis, or socket.

### By Fibrous Membrane.

The teeth are imbedded in a fibrous membrane which revolves over the jaw, *e.g.*, **Sharks** and **Rays**.

Or the teeth are bound down to a pedestal of bone by an annular ligament, *e.g.*, **Sargus**.

### By a Hinge.

(a) **Elastic**. The hinge itself is elastic and pushes up the tooth, *e.g.* :—**Lophius** (angler). **Hake** (merlucius). **Odontostomus**. **Bathysaurus**.

(b) **Non-Elastic**. The tooth is erected by elastic fibres in the pulp cavity, *e.g.* :—

**Pike** (*esox*).

The hinge is composed of uncalcified dentine matrix.

### By Anchylosis.

The teeth are fixed to the jawbone by "**Bone of Attachment**," which is probably formed from the periosteum of the jaw, *e.g.* :—

**Pike** and **Python**.

**Eel**, **Chameleon**. (**Acrodont**, *i.e.*, on a pedestal of bone.)

**Frog**, **Iguanodon**, **Varanus**. (**Pleurodont**, *i.e.*, to an external parapet of bone.)

**Haddock**.

**Mackerel**.

### By Socket (*gomphosis*).

The teeth are bound to the walls of a socket by a fibrous membrane, *e.g.* :—

**Mammals**. Also the **File-fish**, **Lepidosteus**, **Baracuda Pike**, the **Dermal Spines** of the **Pristis**.

**Crocodile**. (The same socket serves throughout life ; only the teeth change.)

The Attachment of Tenth

is not, however, a mere matter of style

to which we must

be true, and which we must not

be true, and which we must not

be true, and which we must not

be true, and which we must not

be true, and which we must not

be true, and which we must not

be true, and which we must not

be true, and which we must not

be true, and which we must not

be true, and which we must not

be true, and which we must not

be true, and which we must not

be true, and which we must not

be true, and which we must not

be true, and which we must not

be true, and which we must not

be true, and which we must not

be true, and which we must not

be true, and which we must not

be true, and which we must not

be true, and which we must not

be true, and which we must not

be true, and which we must not

be true, and which we must not

be true, and which we must not

be true, and which we must not

be true, and which we must not

be true, and which we must not

be true, and which we must not

be true, and which we must not

be true, and which we must not

be true, and which we must not

be true, and which we must not

be true, and which we must not

be true, and which we must not

be true, and which we must not

be true, and which we must not

## Pisces.

**Morphology.** (*Morphology* is the science of structure and form.)

### Distribution.

The teeth of fishes are very widely placed.

On the margin of the jaws only in **sharks** and **rays**.

All over the mouth and pharynx in **Teleost** fishes.

Some fishes are edentulous:—

**Pipe-fish, hippocampus, adult sturgeon.**

### Homology.

The case contains diagrams to show that **Dermal Spines** and **teeth** have the same origin and structure.

### Structure.

The teeth of fishes vary greatly in structure.

**Horny teeth** consist of hardened epithelium only, *e.g.*, **Lampreys**.

**Calcified teeth** consist of:—

Dentine	{	Fine tube dentine	<b>Charcarias</b> and others.
		Plici-dentine	<b>Lepidosteus</b> .
		Vaso-dentine	<b>Hake, flounder.</b>
		Osteo-dentine	<b>Lamna, pike.</b>
Enamel	{	Tips only	<b>Eel, hake, chætodonts.</b>
		Thin layer	<b>Sharks, pike.</b>

Sometimes the enamel is tubular, *e.g.*, **Porbeagle shark**.

**Cementum** is rare.

“**Bone of attachment**” occurs in the **eel, hake, &c.**

12/1/19

Received of the Treasurer of the University of California the sum of \$100.00

for the year 1919

The sum of \$100.00 is the amount of the subscription for the year 1919 of the University of California. The sum of \$100.00 is the amount of the subscription for the year 1919 of the University of California.

Witness my hand and seal this 1st day of January 1920

Attest: The Treasurer of the University of California

12/1/19

The sum of \$100.00 is the amount of the subscription for the year 1919 of the University of California. The sum of \$100.00 is the amount of the subscription for the year 1919 of the University of California.

University of California	12/1/19
12/1/19	12/1/19
12/1/19	12/1/19
12/1/19	12/1/19
12/1/19	12/1/19
12/1/19	12/1/19
12/1/19	12/1/19
12/1/19	12/1/19
12/1/19	12/1/19
12/1/19	12/1/19

The sum of \$100.00 is the amount of the subscription for the year 1919 of the University of California.

12/1/19

The sum of \$100.00 is the amount of the subscription for the year 1919 of the University of California.

### Mode of Attachment.

The teeth of fishes vary greatly in their mode of attachment.  
Attachment by socket is rare (*see p. 20*).

### Forms.

The teeth of fishes are homodont; the actual form varies.

Cones are very common . . . . **Pike.**

Slender rods . Chætodonts	{	Dents en velours.
		„ „ brosse.
		„ „ cardes.

Flat plates . . . All the rays.

A few are heterodont (**Anarchus lupus**).

The **Raia clavata** shows sexual differences.

### Succession.

All fishes are polyphyodont and have either:—

Several rows at a time . **Raia maculata.**

One row at a time . . **Carcharias lamna.**

Irregular succession . . the **Teleost** fishes.

Vertical succession . . **Baracuda pike.**

Fused vertical succession **Porcupine fish.**

### Function.

The teeth of fishes are for prehension mainly.

## Notes of Observations

The main body of the text is very faint and illegible.

## Summary

The summary section is also very faint and illegible.

## References

The references section is very faint and illegible.

The references section is very faint and illegible.

The references section is very faint and illegible.

## Appendix

The appendix section is very faint and illegible.

The appendix section is very faint and illegible.

## Conclusion

The conclusion section is very faint and illegible.

The conclusion section is very faint and illegible.

The conclusion section is very faint and illegible.

The conclusion section is very faint and illegible.

The conclusion section is very faint and illegible.

The conclusion section is very faint and illegible.

The conclusion section is very faint and illegible.

## References

The references section is very faint and illegible.

The references section is very faint and illegible.

## Pisces.

### Leptocardii.

*Amphyxus* has no jaw and no teeth.

### Cyclostomata

Have numerous conical horny teeth.

*Lamprey* has horny teeth, vertical succession.

*Myxine* (hag-fish) has rudimentary calcified teeth under the horny functional teeth.

### Palæichthyes.

Teeth round the margin of the jaws.

Homodont, numerous.

Enamel and various kinds of dentine.

Attached to a revolving membrane.

Polyphyodont.

Prehension. Diet, piscivorous.

### Sharks.

Teeth are usually triangular blades.

Thin enamel; osteo, or fine tube dentine.

*Cestracion* is heterodont.

### Rays.

Teeth are flattened to form a tessellated pavement.

Thin enamel and plici-dentine.

*Myliobates*, *Ætobates*, *Rhyncobates* are normal.

*Pristis* has a normal mouth and also socketed, persistent growing, plici-dentine, *dermal spines* on its rostrum.

*Raia clavata* shows a sexual difference in the teeth.

Placed

Leptocarpus

Leptocarpus

Cyclotoma

Cyclotoma

Cyclotoma

Cyclotoma

Cyclotoma

Polysiphonia

Polysiphonia

Polysiphonia

Polysiphonia

Polysiphonia

Polysiphonia

Blatta

Blatta

Blatta

Blatta

Blatta

Blatta

Blatta

Blatta

Blatta

Blatta

Blatta

**Ganoids.**

<b>Lepidosiren</b>	{	Have grooved teeth composed of fused super-imposed plates of enamel, and a few teeth on the vomer.
<b>Ceradotus forsteri</b>		

**Sturgeon** is edentulous when adult; the sterlet has teeth.

**Polyodon** has many minute teeth.

**Teleostei.**

Teeth widely distributed on mouth and throat.

Homodont, haplodont, numerous.

Enamel, fine tube, vaso- or osteo- dentine.

Every kind of attachment.

Polyphyodont.

Prehension. Piscivorous diet.

**Pike** has osteo-dentine, a non-elastic hinge to most of its teeth, and a few anchylosed teeth.

**Lophius** has vaso-dentine, elastic hinged and anchylosed teeth.

**Wolf-fish** is heterodont. Diet, shell-fish.

**Gymnodont** fish have fused vertical succession; pharyngeal teeth.


**Sargus** has tubular enamel, vertical succession; remains of vascular canals in the dentine.

**Pipe-fish** and **Hippocampus** are edentulous.

**Carp** have edentulous mouths, but pharyngeal teeth.

**File-fish** and **Baracuda pike** have socketed teeth.

**Wrasse** has vertical succession of front teeth, and the pharyngeal

teeth move thus 

1870

1871

1872

1873

1874

1875

1876

1877

1878

**Amphibia** (*ἀμφίβιος* = *living a double life*). (Batrachia.)

1. Teeth on the premaxillary, maxillary vomer and mandibular bones.
2. Homodont, simple cones (haplodont).
3. Structure is hard dentine and a thin layer of enamel.
4. The attachment is by ankylosis.
5. The succession is polyphyodont.
6. The diet is principally worms, insects, and crustacea.

**Stegocephali** (*στέγειν*, *cover* + *κεφαλή*, *head*). (Labyrinthodontia.)

Labyrinthodon has plici-dentine.

**Lissamphibia** (*λίσσος*, *smooth* + *ἀμφίβιος*, *amphibia*).

**Urodela** (Tailed amphibia).

**Salamandridæ.**

Salamandria (Salamanders).

*S. maculosa* (Fire salamander) has two cusps to its teeth.

Triton (*molge*), newts or tritons.

*T. cristata* has two cusps to its teeth.

**Anura** (Tailless amphibia).

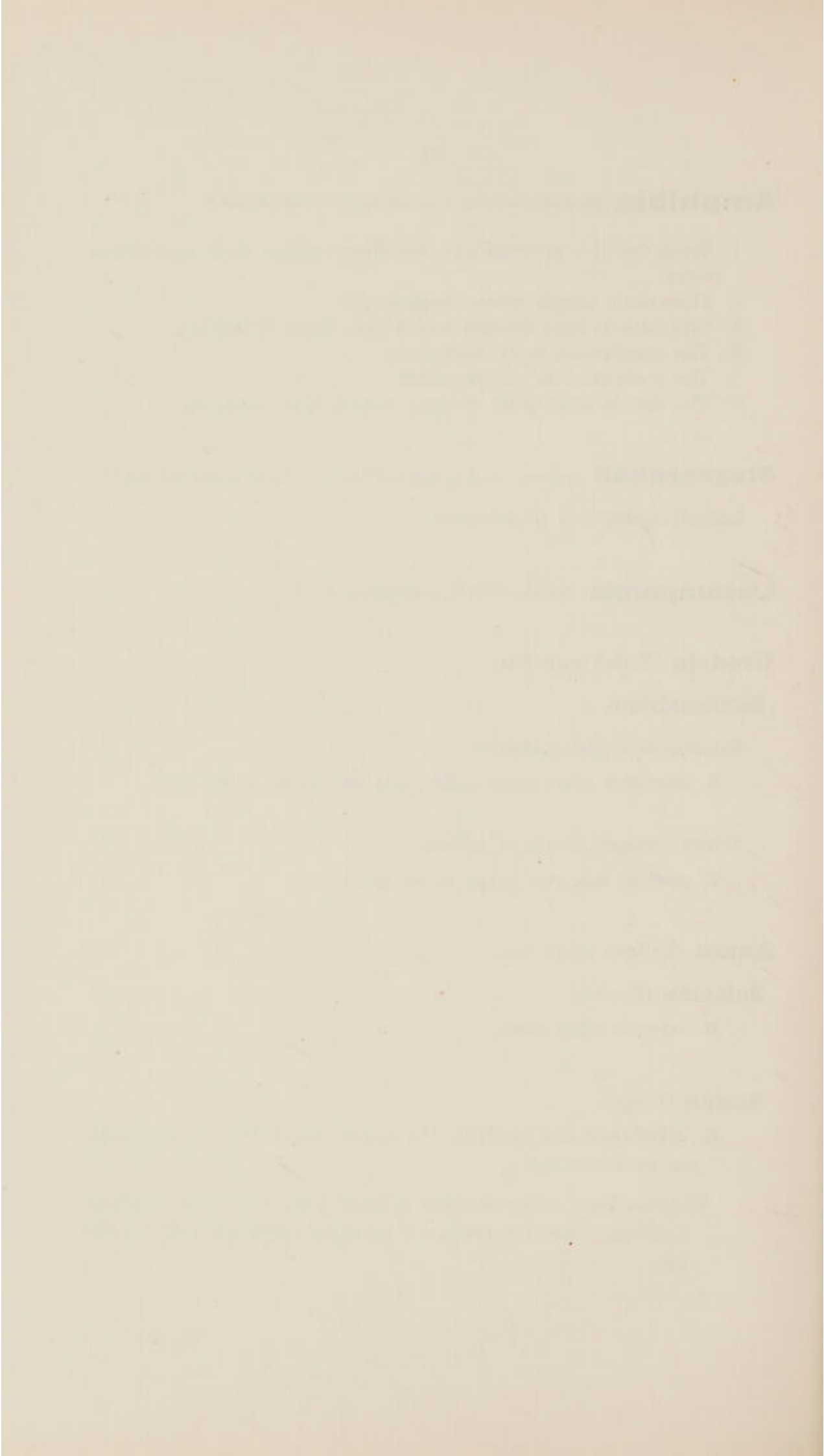
**Bufonidæ** (Toads).

*B. asper* is edentulous.

**Ranidæ** (Frogs).

*R. catesbiana* has teeth in the upper jaw only. A few teeth are on the vomer.

*Tadpoles* have horny sheaths to their jaws, and rows of horny hooklets, each composed of a single hardened cell, on the lips.



## **Reptilia** (*reptile, a creeping animal*).

Cold-blooded vertebrates which breathe by lungs and have a median occipital condyle.

1. One row of teeth in the upper jaw, and one in the lower jaw.  
Occasionally palatal teeth also.
2. Homodont, usually haplodont, and numerous.
3. Enamel, fine tube dentine, and sometimes cementum.
4. Socketed or anchylosed.
5. Polyphyodont.
6. Prehension.

## **Prosauria** (*πρό, before, + σαύρα, a lizard*).

Mostly extinct primitive reptiles.

## **Rhynchocephali** (*ῥύγχος, snout, + κεφαλή, head*).

*Sphenodon punctatus* (Hatteria, Tuatera), New Zealand.

Two rows above, one row below.

Homodont, haplodont.

The two upper front teeth are large, soon wear out the lower and then bite on the bare bone.

Enamel and dentine.

Anchylosed (acrodont).

Monophyodont.

Carnivorous.

*Hyperodapedon gordonii*, an extinct member of this group.

## **Theromorpha** (*θήρ, a wild beast, + μορφή, form*).

Extinct reptiles; probably ancestors of the mammalia.

**Pareiasauri** had homodont, numerous, socketed teeth.

## **Theriodontia** (*θήπιον, a wild beast, + ὀδούς, a tooth*).

Heterodont, monophyodont, socketed teeth.

*Empedias molaris* is heterodont.

*Gomphognathus* is like a carnivorous mammal.


*Cynognathus* also has a characteristic carnivorous dentition.

## **Anomodontia** (*ἀνομος, irregular, + ὀδούς, a tooth*).

*Dicynodon* has only two tusk-like canines.

## **Placodontia** (*πλάξ, a tablet, + ὀδούς, a tooth*).

<i>Placodus gigas</i>	} {	Have chisel-shaped incisors and blunt-topped molars. Diet, molluscs.
<i>Cynamodus laticeps</i>		



**Chelonia** (*χελώνη, a tortoise*).

Reptiles with a bony shell and horn-covered jaws.

Edentulous.

Horny plates covering a more or less ridged bony jaw.

Herbivorous or carnivorous.

**Chelone imbricata** (Hawk's-bill turtle) has sharp-edged bony plates, and is carnivorous.

**Trionyx** (Soft-shelled turtle) is also carnivorous.

**Testudo tabulata** (Brazilian tortoise) is herbivorous.

**Chelone mydas** (Green turtle) is herbivorous.

**Dinosauria** (*δεινός, mighty, + σαύρα, a lizard*).

Teeth round the margin of the jaws.

Homodont, flattened, serrated plates.

Enamel and dentine.

Socketed.

Polyphyodont, sometimes only one functional set.

Herbivorous or carnivorous.

**Megalosaurus bucklandi** is carnivorous.

**Iguanodon mantelli** is herbivorous and monophyodont.

The enamel, hard dentine and vaso-dentine are so disposed as to produce a good grinding surface by their uneven wear.

**Crocodylia.**

Teeth on premaxilla, maxilla and mandible.

Homodont, haplodont, numerous.

Enamel, fine tube dentine, cementum.

Socketed.

Polyphyodont. Vertical succession.

Carnivorous.

**Gavialis gangeticus** (*gharial, Hindustani for fish-eater*).

Has a long, narrow snout, slender recurved teeth, and is entirely piscivorous.

**Crocodylus palustris** (Mugger).

Jaws rather broad.

**Alligator.**

Jaws very broad.

In both the latter the teeth at the corner of the jaws, and again towards the back of the mouth, are larger than at other parts, producing a crude imitation of the canines and sectorial teeth of carnivorous mammals. Both are carnivorous.

Christina, Maria, and  
Anna, who were born and  
baptized in the  
Church of St. John the Baptist  
in the year 1780.  
The same year, Maria and Anna  
were married to each other  
in the Church of St. John the Baptist  
in the year 1780.

Christina, Maria, and  
Anna, who were born and  
baptized in the  
Church of St. John the Baptist  
in the year 1780.  
The same year, Maria and Anna  
were married to each other  
in the Church of St. John the Baptist  
in the year 1780.

Christina, Maria, and  
Anna, who were born and  
baptized in the  
Church of St. John the Baptist  
in the year 1780.  
The same year, Maria and Anna  
were married to each other  
in the Church of St. John the Baptist  
in the year 1780.

Christina, Maria, and  
Anna, who were born and  
baptized in the  
Church of St. John the Baptist  
in the year 1780.  
The same year, Maria and Anna  
were married to each other  
in the Church of St. John the Baptist  
in the year 1780.

**Ichthyosauria** (*ἰχθύς, a fish, + σαῦρος, a lizard*). (Aquatic reptiles.)

Teeth round the margin of the jaws.

Homodont, haplodont, with open roots.

Ridges of enamel over dentine.

Incomplete sockets. (Open grooves.)

Polyphyodont.

*Ichthyosaurus communis* shows the incomplete sockets.

**Pterosauria** (*πτερόν, a wing, + σαῦρος, a lizard*). (Flying reptiles.)

Some have teeth all along the margin of the jaws, some only part of the way, and some are edentulous. Horny plates probably covered the edentulous parts of the jaw.

**Sauria** (*σαῦρα, a lizard*).**Lacertilia** (*lacertus, a lizard*). (Lizards.)

Saurians which have the right and left halves of the mandibles connected by a sutural symphysis.

Teeth round the margin of the jaws.

Homodont, haplodont.

Enamel and dentine.

Anchylosis (acrodont and pleurodont).

Polyphyodont.

Mainly carnivorous and insectivorous.

**Iguanidæ** are pleurodont, have vascular canals in their dentine, and the teeth are flattened and serrated. Herbivorous and insectivorous.

**Varanidæ** are pleurodont, and have the pulp at the base of the teeth folded to form plicid-dentine.

**Chameleodontidæ** are acrodont, have no teeth on the premaxilla, and the teeth are flattened, triconodont and monophyodont.

**Heloderma** has grooved teeth for the conveyance of poisonous saliva; the teeth are pleurodont and recurved.



**Ophidia** (*ὄφις, a serpent, + εἶδος, form*). (Snakes.)

Saurians which have the right and left halves of the lower jaw united by an elastic ligament.

**Boidæ.** (Non-poisonous.)

Two rows of teeth (the outer on the maxillary and the inner on the palatine and pterygoid bones) in the upper jaw and one row on the mandible. Egg teeth occur on the premaxillæ.

Homodont, haplodont, recurved, numerous teeth.

Enamel and dentine.

Anchylosed.

Polyphyodont.

For prehension only.

The **pythons** and **boas**.

**Colubridæ.****A-glypha** (*ἀ, without, + γλύφειν, cut out*).

All the teeth are solid and not grooved; non-poisonous.

**Dasypeltis** has few teeth, and crushes eggs against its pharyngeal vertebrae.

**Opistho-glypha** (*ὀπισθεν, behind, + γλυφή, carving*).

One or more of the posterior maxillary teeth are slightly grooved; slightly poisonous.

The **Whip** and **Tree** snakes.

**Protero-glypha** (*πρότερος, fore, + γλυφή, carving*).

The anterior maxillary teeth are grooved or perforated; very poisonous.


The **Cobra**, **Hydrophis**, and **Craik**.

**Viperidæ**

Have a poison fang with a complete tube, and the maxillary bone is hinged to the skull.

The **Puff-adder**, **Rattlesnake**, and **Viper**.

The maxillary teeth of snakes become *fewer* in number as they become more specialised in the higher order of snakes.



The *poison tube* is evolved by the formation of an open groove, which becomes deeper until the edges overlap and finally completely fuse together, except at the upper and lower ends.

The *maxillary bone* also becomes shorter and at last (in the viperidæ) movable.

The maxilla, hinged above to the prefrontal bone, is rotated by the forward pressure, on its lower part, of the *transverse* bone, which is pushed by the *pterygoid* bone, and the latter by the *quadrate* bone. The *spheno-pterygoid* is the chief muscle for thus erecting the poison fang. The *digastric* is the principal muscle for opening the mouth and compressing the poison gland.

The successional teeth of snakes lie *horizontally* and not vertically.

Two rows of tooth germs are present to replace each poison fang in the viperidæ.

## Birds.

All recent birds are **edentulous**, and have the jaws covered with **horny plates** of various patterns.

**Odontopteryx** had bony prominences below the horny plates.

**Archæopteryx** had teeth.

Many fossil birds with homodont, haplodont, polyphyodont, more or less completely socketed teeth, have been found in America, *e.g.*, **Ichthyornis** and **Hesperornis**.

Notice the "**egg-tooth**" shown in the chick at the far end of the case; egg-teeth also occur in **snakes** and **lizards**.



## INTRODUCTION.

---

It is certain that the many existing species of animals are derived from fewer primitive species.

Each successive generation has a strong **hereditary** resemblance to the preceding generation, but there will always be *variations* among individuals of the same generation.

When these variations are of advantage to the animals in their struggle for existence, they will lead to the survival of these fitter animals (**natural selection**), and so to the perpetuation and improvement of the variations by heredity.

Conversely, useless organs will tend to become rudimentary or disappear.

Male animals with teeth suitable for fighting are able to drive away less well-provided males, obtain possession of the females, and propagate their own peculiarity ; so, by **sexual selection**, these fighting teeth are developed.

It has also been observed that variation in one organ is sometimes associated with variation in another related organ ; thus, early castration may prevent development of teeth used only for sexual warfare ; also, abnormalities of the skin sometimes accompany abnormalities of the teeth. This influence is known as correlation of growth or **concomitant variation**.

Thus, the influence of heredity, natural selection, sexual selection, and concomitant variation will tend to produce animals having a strong family resemblance, but exactly adapted to the circumstances (*environment*) under which they have to live.

These circumstances are so varied and changeable, and the ways of meeting them are so numerous, and their influences come into action at such different times, that there now exist, or have existed, a vast number of different species, and it is only occasionally that we are able to clearly trace the steps by which any particular organ has arrived at its present shape and structure.



In tracing out the **homologies** (*resemblances*) among teeth and allied structures, there is great difficulty and difference of opinion as to details.

The covering of the outside of the body and inside of the mouth is composed of epiblast and mesoblast.

These layers are at various places raised into papillæ, and these papillæ may develop into hairs, scales, feathers, nails, whalebone, horny plates, or teeth, and hence they all are said to be **homologous** (*i.e.*, resemble each other) **in origin**.

Sometimes it is the epiblast that is chiefly concerned, as in hairs, whalebone, nails, horny plates, and the enamel of the teeth. Sometimes both layers are equally concerned, as in scales, dermal spines, and teeth; each group is thus more closely homologous.

The hardening of these structures is sometimes affected by the chemical alteration of the albuminous cells (keratinisation), as in hairs, whalebone, nails, and horny plates; at other times by their impregnation with lime salts (calcification), as in dermal spines and teeth. Each of these groups respectively is **homologous** (resemble each other) **in structure** also.

According to the **Tritubercular Theory**, the following are the changes brought about by natural selection, etc.:—

- a. Soft papillæ.
- b. Calcification of papillæ to form teeth.
  1. Simple conical (**Haplodont**) teeth.
  2. The development of subsidiary cusps (**Protodont** teeth).
  3. The formation of an anterior and posterior small cusp on each side of the principal cusp (**Triconodont** tooth).
  4. The placing of the cusps in the position of a triangle instead of a straight line (**Tritubercular** tooth).

The principal cusp is called the *Protocone*, the anterior small one the *Paracone*, and the posterior one the *Metacone*. In the lower jaw the cusps are called protoconid, paraconid, metaconid. In the upper jaw the principal cusp is placed internally, in the lower jaw externally in the tritubercular stage.

From this generalised (tritubercular) form different requirements have led to different ways of modification, such as:—

1. The **addition of cusps**. In the lower carnassial tooth of the **dog**, in which the paraconid, protoconid, and metaconid are united to form the blade, a small heel (hypoconid) is added. In the **bear** an entaconid is also added.



2. The addition and suppression of cusps. In the lower carnassial tooth of the **tiger** the metaconid is gone (hence there are only two cusps to the blade), and a heel hypoconid is added. In the **seals**, **edentata**, and **cetacea** the teeth have become more simple.

3. The elevation of the cingulum. In the **insectivora** the cingulum is raised both on the outer and inner side to form extra cusps. In the **suina** the cingulum is raised distally to form new cusps, and in the **mastodons** and **elephants** this is still more marked.

4. The folding of the tissues. As seen in the "mark" on the incisors of the **horse**, and in the grooves on the sides of **rodents'** molars.

5. The suppression of tissues. As seen in the partial covering of enamel on the incisors of **rodents**, the canines of **suina**, and its entire absence from **edentata**.

6. The addition of tissues. In the persistent growing teeth of the **sloths** the pulp cavities are filled up with secondary dentine of a different type. On the long cusped teeth of **ruminants** the cementum is continued over the crown.

7. The lengthening of cusps. As seen in the hypsodont teeth of **ruminants**, and still more in the persistent growing teeth of **rodents**.

In the molars of the **horse** we have examples of an addition and lengthening of cusps, elevation of the cingulum externally, bending of the ridges to an oblique direction, and thickening of the cementum.

The tritubercular theory is supported by the common occurrence of tritubercular teeth in extinct animals, their reappearance in degenerate dentitions, and our ability to trace indications of the three primary cusps in modern teeth. But many people do not accept the theory *in toto* because:—

1. The earliest known mammals had multitubercular teeth.
2. Authorities differ in the identification of cusps in many cases.
3. It places the growth of the cingulum in a very secondary place.
4. The order of the calcification does not always agree with the accepted order of importance of the cusps.

There is an alternative theory that accounts for the modern multicuspid tooth, by supposing that it is formed by the **fusion** of several primitive simple conical teeth.



The functions which teeth are called upon to perform are:—

**Prehension** of food, as in the **pike**, **python**, **garial**, etc.

**Comminution** of food, as in the **tiger**, **elephant**, **rays**, etc.

**Combat**, as in the **tiger**, **pig**, **narwal**, etc.

**Locomotion**, as in the **walrus**.

**Anchorage**, as in the **dinothereium**.

**Transport**, as in the **elephant**, **beaver**, etc.

**Speech**, as in **man**.

Comminution may be effected by a scissors-like action, as shown in the **sectorial teeth** of the carnivorous **felidæ**, or by a **grinding** action, as in the herbivorous **elephants**. Mammalian teeth usually have the crown and root of about the same length, and are called **brachyodont** (*e.g.*, man, pig), but teeth which are subject to much heavy wear have in the course of ages, by natural selection, acquired long crowns which last longer; such teeth are called **hypsodont** (*e.g.*, the cheek teeth of sheep, horses, elephants). A further development of this kind leads to such teeth as the lower incisors of the kangaroo and the molars of the dugong, in which the crown goes on growing for a long time after the eruption of the tooth, but eventually a closed root is formed. Lastly, as a perfection of hypsodontism, we have **persistent growing teeth**, as in:—

The *dermal spines* of **pristis**,

The *upper incisors* of the **hyrax** and **elephant**,

All the *incisors* of **rodents** and the **aye-aye**,

The *canines* of **suina**, **tragulidæ**, and **cervidæ**,

The *incisors* and *canines* of the **hippopotamus**,


All the teeth of the **edentata**, **wombat**, and many **rodents**.

The habit of male animals of fighting among themselves to obtain the females has led to the development of teeth for the purposes of **sexual warfare**, as in:—

**Raia clavata**,

**Narwal** and **ziphoid cetaceans**, **dugong**,

**Suina**, **tragulidæ**, **camel**, **cervidæ**, **stallion**, **monkeys**.



In some animals the above functions are either not required or are met in other ways. Thus **horny plates** serve in:—

Lamprey, myxine, bdellestoma,  
Tadpole, turtle, tortoise, rhamphorhynchus and pteranodon (?).  
All birds,  
Ornithorhynchus, dugong, manatee, rhytina.

Lack of use leads to degeneration of teeth, as seen by the rudimentary teeth of:—

Bdellestoma, myxine, sword-fish, the larval sturgeon,  
The egg-eating snake *dasypeltis* (*rachiodon*),  
The ornithorhynchus and the mystacoceti,  
The milk teeth of many animals (*see list*),  
The second set of the odontoceti,  
The tusks of the female narwal and dugong,  
The canines of the female suina, tragulidæ, deer and horse,  
The incisors of armadillos, manatee, narwal, rhinoceros,  
The molars of tarsipes, vampire, aard-wolf and carnivorous  
carnivora (*upper*),  
The first premolars in many carnivora and ungulata.

The edentulous jaws of:—

The adult sturgeon, the pipe-fish and hippocampus,  
The toad and lower jaw of the frog,  
The echidna,  
The manis, rhytina, mutica and mystacoceti,  
All modern birds.  
The narwal, sword-fish, and carp have teeth, but not in the buccal cavity.

It was not until the year 1840 that the first  
of these works, "The History of the Jews,"  
appeared. It was written by the Rev. Dr. H. H.  
Thompson, and was published by the  
Rev. Dr. H. H. Thompson, New York.  
The book is a history of the Jews from the  
time of the first migration to the present day.  
It is a very interesting and valuable work,  
and is highly recommended by all who are  
interested in the history of the Jews.  
The book is written in a clear and concise  
style, and is well illustrated with  
many interesting facts and figures.  
It is a very good book for the library,  
and is highly recommended by all who are  
interested in the history of the Jews.

## Tooth succession.

**Fishes** have continuous succession (*Polyphyodont*).

**Reptiles** have continuous succession (*Polyphyodont*).

**Birds** (*extinct*) had continuous succession (*Polyphyodont*).

**Mammalia** have two sets (*Diphyodont*),  
sometimes only one set (*Monophyodont*).

Possibly in **Mammalia** there may also exist traces of a **Pre-milk** set and a **Post-permanent** set.

In all cases (except in **Teleost** fishes) there is a common **tooth band** extending all round the jaw, and giving off one, two, or many sets of teeth from its outer (*labial*) surface.

In **Mammalia** the milk set is usually well developed, but in some it is more or less **suppressed**. Thus the milk teeth may:—

Last all life . . . . .	<b>Whales.</b>
Last till full growth is reached . . . .	<b>Horse.</b>
Last till animal is half-grown . . . . .	<b>Man.</b>
Only a few be formed and functional . .	<b>Hedgehog.</b>
Be erupted, but soon lost . . . . .	<b>Bears.</b>
Be calcified, but not erupted . . . . .	<b>Elephant seal.</b>
Be formed, but not calcified . . . . .	<b>Shrew.</b>
Not be formed at all . . . . .	<b>Sloths.</b>

Sometimes "permanent" teeth are shed in adult age, as in **Dugong**, **Kangaroo**, **Wart-hog**.

In many **ungulata**, **carnivora**, and **insectivora** the first tooth behind the canine is small, cut late, lost early, and has no successor, and it is doubtful if it is a milk or a permanent tooth.

The permanent **molars** are thought by some to be **milk teeth**, by others to be **permanent teeth**, and again by others to be a fusion from both sets.

The **milk dentition** resembles the permanent **dentition**.

Hence milk molars resemble permanent molars and not pre-molars, and carnassial teeth are found in milk dentitions.



But *sexual* teeth are ill-developed in milk dentitions, and in the following animals there are other differences:—

**Orycteropus** has heterodont, rooted milk teeth and homodont persistent growing permanent teeth.

**Chiroptera** have small hook-shaped milk teeth and heterodont permanent teeth.

**Aye-aye** has lemurine milk teeth, and a rodent permanent dentition.

**Wombat** has rooted milk teeth with canines, and a rodent permanent dentition.

The theories to account for mammalia having two sets are:—

1. Descent from **polyphyodont** ancestors and loss of the extra sets.
2. That a **folding** of the tooth band and crowding down of some teeth has resulted from the shortening of the jaw of an originally monophyodont animal.

## SOME DETAILS ABOUT THE MILK TEETH OF MAMMALIA.

### MARSUPIALS.

According to Wilson and Hill the **Functional** set are the **Permanent** set, and the **Milk** teeth are in various states of reduction.

Wombat . . . . .  $\frac{1}{0} \frac{1}{1} \frac{1}{1}$  Milk teeth. Lost early.

#### Other Views.

Kukenthal and Rose . Functional MILK teeth and rudimentary PERMANENT.  
 Woodward (didelphys) Rud. PRE-MILK; Funct. MILK; Rud. PERMANENT.  
 Timms (didelphys) . Rud. MILK; Funct. PERMANENT; Rud. POST-PERM.  
 Leche (myrmecobius). Rud. PRE-MILK; Funct. MILK.

### EDENTATA. (Monophyodont.)

But in

9-Banded Armadillo . Milk teeth till nearly full size.  
 Orycteropus . . . . .  $\frac{7}{4}$  Rudimentary, calcified, heterodont, unerupted milk teeth; plici-dentine, non-persistent growth.

### UNGULATA. (Typical diphyodonts.)

In many  $dm_1$  ( $pm_1$ ?) has no successor.

Timms found a pre-milk tooth in the pig.

Phæochærus sheds  $m_1$ ,  $pm_3$ ,  $m_2$ ,  $pm_1$  of its permanent set.

Proboscidea . . . . . (diphyodont).

Dinotherium  $\frac{0}{1} \frac{0}{0} \frac{3}{3}$  milk teeth, followed by  $\frac{0}{1} \frac{0}{0} \frac{2}{2} \frac{3}{3}$  permanent.

Mastodon, the milk molars often persist and the premolars do not erupt.

Elephants, the milk incisor is followed by a persistent growing tusk. The 3 milk molars and 3 permanent molars erupt one after each other. There are no premolars.

Hyrax has  $\frac{3}{2} \frac{1}{1} \frac{4}{4}$  milk teeth, followed by  $\frac{1}{2} \frac{(1)}{0} \frac{4}{4} \frac{3}{3}$  permanent.

### SIRENIA.

Dugong . . . . . Milk tusk only. (2nd Incisor?)

Manatee . . . . .  $\frac{2}{3}, \frac{0}{1}, \frac{0}{3}$  Milk teeth. Perpetual succession of molars, *à la* Elephant.



**CETACEA.**

(Monophyodont.)

Milk teeth persist all life. Permanent rudiments unerupted.

**CARNIVORA.**

(Typical diphyodonts.)

*In many  $dm_1$  ( $pm_1$ ?) has no successor.*

Felidae . . . . .	$\frac{3 \ 1 \ 3}{3 \ 1 \ 2}$	Milk teeth.	
All others. . . . .	$\frac{3 \ 1 \ 3}{3 \ 1 \ 3}$	Milk teeth.	
Bear . . . . .		Loses milk teeth early.	
Fissipedia . . . . .		Have degenerate milk teeth.	
Otaria . . . . .	$\frac{3 \ 1 \ 3}{3 \ 1 \ 3}$	Milk teeth.	Last a few weeks.
Phoca Greenlandica . . . . .	$\frac{1 \ 1 \ 3}{3 \ 1 \ 3}$	Milk teeth.	Last a week.
Cystophora proboscidea . . . . .	$\frac{2 \ 1 \ 3}{1 \ 1 \ 3}$	Milk teeth.	Lost in utero.
Walrus . . . . .	4	Milk teeth and 2?	Lost at birth.

**RODENTS.**

(Few milk teeth.)

Squirrel . . . . .	$\frac{di_1 \ di_2 \ di_3}{di_1 \ di_2}$	$\frac{dm_1 \ dm_2 \ dm_3}{dm_1 \ dm_2 \ dm_3}$	$\left. \begin{array}{l} di_1 \text{ lost in utero.} \\ di_2 \text{ and } dms \text{ lost in 18 days} \\ \text{(non-persistent growth).} \end{array} \right\}$
Hares . . . . .	$\frac{di_1 \ di_2}{di_1}$	$\frac{dm_1 \ dm_2}{dm_1 \ dm_2}$	
Rabbits . . . . .	$\frac{di_1 \ di_2}{di_1}$	$\frac{dm_1 \ dm_2 \ dm_3}{dm_1 \ dm_2}$	
Mouse . . . . .	$\frac{di_1}{di_1?}$	$\frac{dm_1 \ dm_2}{dm_1 \ dm_2}$	
Beaver . . . . .		$\frac{dm}{dm}$	Last till half grown.
Guinea Pig . . . . .		$\frac{dm}{dm}$	Lost in utero.
Dasyprocta	} . . . .	dm	Monophyodont
Ctenodactylus			
Hystrix			
Rat . . . . .			
Hydromys . . . . .			

**INSECTIVORA.**

(Diphyodont.)

Galeopithecus . . . . .	$\frac{2 \ 0 \ 3}{2 \ 0 \ 3}$	Milk teeth. Cut late. Work with true molars.	
		$di_3$ lost early. Resemble premolars.	
Hedgehog (erinaceus) . . . . .	$\frac{123 \ 1 \ 1234}{123 \ 1 \ 1234}$	Milk teeth. Those in italics functionless.	
Gymnura. . . . .	$\frac{123 \ 1 \ 1234}{123 \ 1 \ 1234}$	Milk teeth. " " "	
Shrew (sorex) . . . . .	$\frac{23 \ 1 \ 34}{4}$	All uncalcified.	
Mole (talpa) . . . . .	$\frac{123 \ 1 \ 1234}{123 \ 1 \ 1234}$	Milk teeth.	Lost early.
		$dm_1$ has no functional successor, and is retained	
		$dm_1$ late; $dm_4$ is two rooted and molariform.	
Centetes	} . . . .	Have good functional milk teeth.	
Hemicentetes			
Macroscelides			
Tupaia			

**CHIROPTERA.**

Milk teeth ill-developed. Functionless. Often unerupted. Some persist with the permanent teeth, and are of very simple form, e.g., Vampire.

**PRIMATES.**

(Diphyodont.)

Aye-aye . . . . .	$\frac{2 \ 1 \ 2}{2 \ 0 \ 2}$	Milk teeth.	Lost early.
-------------------	-------------------------------	-------------	-------------



## GLOSSARY.

Acro-dont . . . .	Teeth as in . . . .	Eel.
Pleuro-dont . . . .	" " . . . .	Iguanodon.
Haplo-dont . . . .	" " . . . .	Dolphin.
Proto-dont . . . .	" " . . . .	Dromotherium.
Tricono-dont . . . .	" " . . . .	Triconodon (Leopard Seal).
Tritubercular . . . .	" " . . . .	Spalacotherium.
Buno-dont . . . .	" " . . . .	Pig, Man.
Seleno-dont . . . .	" " . . . .	Sheep.
Lopho-dont . . . .	" " . . . .	Elephant.
Bilopho-dont . . . .	" " . . . .	Tapir.
Brachyo-dont . . . .	" " . . . .	Pig, Man, Mastodon.
Hypso-dont . . . .	" " . . . .	Horse, Elephant.
Homo-dont . . . .	" " . . . .	Dolphin.
Hetero-dont . . . .	" " . . . .	Pig, Man.
Monophyo-dont . . . .	" " . . . .	Dolphin.
Diphyo-dont . . . .	" " . . . .	Pig, Man.
Polyphyo-dont . . . .	" " . . . .	Shark.
Micro-dont . . . .	" " . . . .	Anglo-Saxon.
Meso-dont . . . .	" " . . . .	Nigger.
Mega-dont . . . .	" " . . . .	Aborigines, Monkeys.
Orthognathous . . . .	" " . . . .	Europeans.
Mesognathous . . . .	" " . . . .	
Prognathous . . . .	" " . . . .	Horse.



The many species of mammals are grouped into **genera**, and they into **families** (sometimes divided into **sub-families**), and they again into **orders** (often divided into **sub-orders**), and they into the two great **sub-classes** of the **class** *mammalia*, according as they have structural characteristics in common.

It is only with the dental characteristics of each class, order, family, and occasionally genus, that we are concerned, and to illustrate these characteristics the dentitions of typical species are selected for description. In addition to this, certain aberrant dentitions of special species are described.

In describing a dentition, attention must be directed to:—

1. The **situation** of the teeth.
2. Their **form** and number.  
(If heterodont, the salient characteristics of each group of teeth.)
3. Their **structure**.
4. Their method of **attachment**.
5. Their **succession**.
6. The shape and movements of the jaws.
7. The **functions** of the dentition.

The classification here adopted is that of F. E. Beddard in his work on "*Mammalia*" (Macmillan & Co.), 1902.

## **Mammalia.**

Hair-clad vertebrates, with cutaneous glands in the female, secreting milk for the nourishment of the young.

1. Teeth on the **premaxillary, maxillary, and mandibular** bones.
2. **Heterodont**,  $\frac{3}{3} \frac{1}{1} \frac{4}{4} \frac{3}{3}$ , highly specialised.

**Incisors** = teeth on premaxillary bones and the corresponding teeth on the mandible.

**Canines** = the tooth immediately behind the maxillary-premaxillary suture, and the mandibular tooth biting in front of it, or

The large prominent tearing teeth placed at the angle of the mouth.

(The two definitions usually indicate the same tooth.)

**Premolars** = cheek teeth having milk predecessors.

**Molars** = cheek teeth behind the premolars, having no milk predecessors.

3. Structure, **enamel, fine-tubed dentine, and cementum**.
4. Attachment by **socket** (*gomphosis*).
5. **Two sets** of teeth (*diphyodont*).
6. The shape and movements of the jaws vary much.
7. **Comminution** of food and **combat** mainly.



**Prototheria** (*πρώτος*, *first*, *earliest*, + *θηρ*, *a wild beast*).

Mammals with no teats, but with a temporary pouch in which the young are hatched or placed after hatching; oviparous.

*Echidna* (*Australian spiny ant-eater*) is edentulous.

*Ornithorhynchus* (*duck-billed platypus*) has horny plates, and rudimentary multituberculated teeth above them when young.

Compare the position of rudimentary teeth in Dugong, Myxine, and *Ornithorhynchus*.

**Eutheria** (*εὖ*, *noble*, + *θηρίον*, *a wild beast*).

Mammals with teats, mammary glands of sebaceous type; viviparous, with a small ovum.

**Marsupialia** (*marsupium*, *a pouch, bag*).

Mammals with furry integuments; angle of lower jaw nearly always inflected; teats lying within a pouch, in which the young are placed; young born in an imperfect condition.

1. Teeth on the maxillary, premaxillary and mandibular bones.

2. **Heterodont**; forms varied, but rather primitive; number  $\frac{3}{3} \frac{1}{1} \frac{3}{3} \frac{4}{4}$ , or sometimes more.

3. **Tubular enamel**, fine-tubed dentine and cementum.

4. **Socketed attachment**.

5. **Diphyodont**, but the milk dentition is reduced to one functional tooth (the last milk molar) and a varying number of rudimentary teeth.

6 and 7. Vary.

(Marsupials are sometimes classed as a separate sub-class, the Metatheria, and not as an order of the eutheria.)

**Diprotodontia** (*δι*, *two*, + *πρώτος*, *fore*, + *ὀδών*, *tooth*).

Herbivorous marsupials, with a pair of strong lower incisors.

1. 3. 4. 5. As in Marsupialia.

2. **Heterodont**.

Incisors,  $\frac{3}{1}$ , the lower being hypsodont, large and procumbent.

Canines, small or absent.

Premolars and molars, with broad, ridged tops.

6. **Narrow jaws**.

7. **Herbivorous**.



**Macropodidæ** (*long-footed*).

Leaping marsupials.

**Macropodinæ.****Macropus** (including **Halmaturus**), Kangaroos and Wallabies.

<b>M. ruficollis</b>	}	The lower incisors are very hypsodont and can be approximated. Pm <sub>4</sub> pushes out dm <sub>4</sub> and pm <sub>3</sub> .
<b>M. benettii</b>		
<b>M. agilis</b>		

**Potoroinæ** (*Hypsiprymninæ*, kangaroo rats).**Bettongia.**


<b>B. leseuri</b>	}	The first upper and the lower incisors are of persistent growth. $\frac{pm_3}{pm_2}$ are large blade-shaped teeth, and push out dm <sub>4</sub> and pm <sub>2</sub> .
<b>B. gaimardi</b>		

Compare the lower incisors of man, lemurs, kangaroos, and rodents as to length.

**Thalacoleo** was thought to have been carnivorous till the herbivorous kangaroo rats were found.**Phalangeridæ.****Phalangerinæ.****Trichosurus.****T. vulpecula** (*Phalangista vulpina*, Brush-tailed opossum).  
Typical diprotodont.**Petaurus** (*Flying phalangers*).**P. breviceps.****Phascolarctinæ** (*φάσκολος*, a leather bag, + *ἄρκτος*, a bear).**P. cinereus** (*Koala*, woolly bear). A rodent-like type of dentition.  
Diet is eucalyptus leaves.**Phascolomyinæ** (*φάσκολος*, a leather bag, + *μῦς*, a mouse).**Wombat**,  $\frac{1}{1} \frac{0}{0} \frac{1}{1} \frac{4}{4}$ ; all the teeth are of persistent growth; there are no tubes in the enamel, the layer of cementum goes all round the teeth; the milk dentition is  $\frac{1}{0} \frac{1}{1} \frac{1}{1}$ ; the condyle is transverse.

Compare the dentitions of rodents, aye-aye, phascolarctos cinereus and wombat.

**Tarsipodinæ.****Tarsipes** has rudimentary molars. Diet, nectar and insects.



**Polyprotodont** (πολύς, *many*, + πρῶτος, *fore*, + ὀδούς, *tooth*).

Carnivorous or insectivorous marsupials, with four or more upper incisors.

1. 3. 4. 5. As in marsupialia.

2. Heterodont.

Incisors,  $\frac{4 \text{ or } 5}{3}$  and small.

Canines, well developed.

Premolars and molars, sectorial or multituberculated, but primitive in form.

6. Moderately stout jaws.

7. Carnivorous or insectivorous.

**Dasyuridæ** (δασύς, *rough*, + οὐρά, *tail*).

**Thylacinus** (*Tasmanian wolf*). (θύλαξ, *a pouch*, + κύων, *a dog*.)

**Thylacine**,  $\frac{4}{3} \frac{1}{1} \frac{3}{3} \frac{4}{4}$ . The dentition is very similar to that of the dog, but the teeth are more numerous and of a more primitive pattern.

Compare the dentitions of the dog and thylacine.

**Sarcophilus** (*diabolus*).

**S. ursinus** (*Tasmanian devil*) is carnivorous.

**Dasyurus**.

**D. viverrinus** is insectivorous.

**D. maculatus** is carnivorous.

**Phascologale** (φάσκωλος, *a leather bag*, + γαλή, *a weasel*).

**P. apicalis** is insectivorous.

**Myrmecobius** (*Banded Australian ant-eater*).

**M. fasciatus**,  $\frac{5}{4} \frac{1}{1} \frac{3}{3} \frac{5}{6}$ . Many sharp cusped teeth. Diet, ants.

**Didelphyidæ** (δι-, *two*, + δελφύς, *a womb*).

**Didelphys** (*Opossums*).

**D. azara**  $\frac{5}{4} \frac{1}{1} \frac{3}{3} \frac{4}{4}$ . Insectivorous and carnivorous.


**Peramelidæ** (*Bandicoots*).

**Perameles**. Insectivorous and herbivorous.

**P. obscura**.

**Notoryctidæ**.

**N. typhlops** (*Australian mole*). Diet, ants and insects.



**Edentata** (*edentatus*, toothless).

**Xenarthra** (*ξένος*, strange, + *ἄρθρον*, a joint (vertebral) ).

**Myrmecophagidæ** (*Mutica* (unarmed); *Ant-eaters*). Edentulous.

*Myrmecophaga jubata* (*Great ant-eater*). Edentulous.

*Tamandua* is edentulous.

*Cycloturus* is edentulous.

Compare the ant-eating tamandua, echidna, orycteropus, and myrmecobius.

**Bradypodidæ** (*βραδύς*, slow, + *πούς*, a foot). (*Sloths*.)

1. Teeth on maxillary and mandibular bones only.
2. Homodont,  $\frac{5}{4}$ , conical, persistent growing.
3. Fine tubed dentine and cementum, no enamel; the pulp cavity is widely filled with vaso-dentine.

Note.—An enamel organ is formed.

4. Gomphosis.
5. Monophyodont.
6. Stout jaws.
7. Herbivorous.

*Bradypus* (*Three-toed sloth*) is typical.

*Cholæpus* (*Two-toed sloth*) has one tooth larger than the rest.

**Dasypodidæ** (*δαρύς*, rough, + *πούς*, a foot). (*Armadillos*.) Similar to last, but there is sometimes an incisor; there are more teeth, and traces of a milk dentition; omnivorous.

**Tatusa.**

*T. peba* (*Nine-banded armadillo*) is diphyodont.

**Dasypus.**

*Peludo* (*Six-banded armadillo*) has rudimentary incisors.

*Priodon* had nearly one hundred teeth.

*Megatherium* (*extinct*) had grooved molars, and vaso-dentine and vaso-cementum as well as hard dentine.

*Glyptodon* (*extinct*) had grooved molars.

Compare the grooved teeth of glyptodon, orycteropus, rodents. Also snakes.

The first of these is the fact that the  
 system is not a simple one, but a  
 complex one, involving many factors  
 which are not easily understood or  
 explained. The second is the fact  
 that the system is not a simple one,  
 but a complex one, involving many  
 factors which are not easily under-  
 stood or explained. The third is  
 the fact that the system is not a  
 simple one, but a complex one, in-  
 volving many factors which are not  
 easily understood or explained. The  
 fourth is the fact that the system  
 is not a simple one, but a complex  
 one, involving many factors which  
 are not easily understood or ex-  
 plained. The fifth is the fact that  
 the system is not a simple one, but  
 a complex one, involving many fac-  
 tors which are not easily under-  
 stood or explained. The sixth is  
 the fact that the system is not a  
 simple one, but a complex one, in-  
 volving many factors which are not  
 easily understood or explained. The  
 seventh is the fact that the system  
 is not a simple one, but a complex  
 one, involving many factors which  
 are not easily understood or ex-  
 plained. The eighth is the fact  
 that the system is not a simple one,  
 but a complex one, involving many  
 factors which are not easily under-  
 stood or explained. The ninth is  
 the fact that the system is not a  
 simple one, but a complex one, in-  
 volving many factors which are not  
 easily understood or explained. The  
 tenth is the fact that the system  
 is not a simple one, but a complex  
 one, involving many factors which  
 are not easily understood or ex-  
 plained.

**Nomarthra** (*νόμος, normal, + ἄρθρον, a joint*).

**Orycteropus** (*Aard vark, earth-pig, Cape ant-eater*) is heterodont, diphyodont, has rudimentary incisors, and the teeth are made of plici-dentine.

**Manis** (*Scaly ant-eater, Pangolin*). Edentulous.

**Ganodonta** (*γάνος, brightness, + ὀδούς, a tooth*).

Extinct ancestors of the edentata; had incisors and canines, and enamel on their teeth, which were triconodont and brachyodont. The teeth of later specimens were fewer in number, had less enamel and were more hypsodont.

**Ungulata** (*ungulatus, having claws or hoofs*).

Terrestrial, vegetarian, hoofed animals.

1. The teeth are situated on the premaxillary (not in the ruminants), maxillary, and mandibular bones.

2. Heterodont;  $\frac{3 \text{ or } 0}{3} \frac{1}{1} \frac{4}{4} \frac{3}{3}$ .

Incisors in the upper jaw are often small or absent; in the lower jaw they are usually procumbent.

Canines are usually small or absent, but they may be large in the males.

Premolars and molars are broad topped, ridged, hypsodont, and well developed.

3. Enamel, dentine and cementum, of which latter there may be a thick layer over the crown.

4. Gomphosis.

5. Diphyodont, milk teeth retained a long time.

6. The jaw is slender and long, and the condyle is globular, to allow of free movements.

7. Herbivorous.

Compare with carnivorous carnivora (felidæ).

The earlier extinct sub-orders of Ungulata had brachyodont and bunodont teeth, small canines and the full mammalian formula, the teeth being in a continuous row. Later sub-orders had large canines, hypsodont and lophodont teeth.

**Proboscidea** (*πρό, before, + βόσκειν, feed, graze*).

Large vegetable-feeding animals, with the nostril and upper lip drawn out into a long proboscis.



## Elephantidæ.

**Mastodon** (*μαστός, breast, + ὀδούς, a tooth*).

There are many species; some have upper and lower tusks, coated with enamel in stripes; the milk molars often persist throughout life; the molars have few ridges and little or no cementum on the crowns.

### Elephas.

**Incisors** only in upper jaw, of persistent growth, composed of an enamel tip, a coating of cementum, and a body of dentine (*ivory*), which has less lime salts (64% instead of 72%) than other dentine, and marked secondary curvature of the fibrils, rendering it strong and elastic.

**Molars**  $\frac{3}{3}$ , erupting one at a time; hypsodont, polylophodont, with the long enamel-covered ridges or cusps bound together with cementum.

There is a milk incisor and  $\frac{3}{3}$  milk molars, which erupt one by one before the permanent molars.

*E. africanus* has fewer ridges on its molars, and these are broadest in the middle, diamond shaped.

*E. indicus* has more ridges (up to twenty-seven), and each is of the same width all across.

Compare the molars of man, pig, wart-hog, elephant, and capybara.

## Dinotheridæ (*δεινός, mighty, + θηρίον, wild beast*).

**Dinotherium** has lower tusks only; milk molars,  $\frac{3}{3}$ , which are displaced by premolars,  $\frac{2}{2}$ ; these latter and the molars  $\frac{3}{3}$  being in place at the same time. They are bi- or tri-lophodont, brachyodont, and have no cementum on the crowns.

## Hyracoidea (*ὕραξ, a mouse*).

A group standing between the ungulates and rodents in character.

**Hyrax** (*Procavia, coney*).

The upper incisor is of persistent growth; behind it is a pad of gum, in which may be found the remains of two unreplaced temporary incisors.

The lower incisor is long and procumbent.

The canine is probably a retained milk tooth.

The premolars and molars are ridged like rhinoceros.

Compare the dentitions of sheep, rodents, and hyrax.



**Perissodactyla** (*odd-toed*).

Premolars and molars are lophodont and similar in pattern.

**Equidæ.**

Incisors have an infolding of the tissues at the tip, called the "mark"; this is worn off the outer incisor by the age of twelve years.

Canines are small in the stallion, rudimentary in the mare.

Premolars and molars are hypsodont.

**Tapiridæ.**

A very primitive group of mammals with bilophodont, brachyodont teeth.

**Rhinocerotidæ** (*ῥίς, nose, + κέρας, a horn*).

The incisors and canines are small or absent.

Compare the pattern on the molars of tapir, rhinoceros, horse, or of orohippus, myohippus, protohippus, equus.

**Artiodactyla** (*even-toed*).

The premolars are simpler in pattern than the molars, which are bunodont or selenodont. The lower canines resemble and range with the incisors.

Group I.—**Suina.—Bunodontia.****Hippopotamidæ.**

$\frac{2}{2} \frac{1}{1} \frac{4}{4} \frac{3}{3}$ ; incisors and canines are of persistent growth, and used for rooting up plants.

**Suidæ.****Sus.**

Incisors are small and procumbent.

Canines are large in the male and of persistent growth; round and striped with enamel in the upper jaw, and triangular, with enamel on the front surfaces only, in the lower jaw.

Molars, bunodont, brachyodont, and the last is larger than the first.

*S. scrofula* is typical of suidæ.

**Phacochoerus** (*φακός, a wart, + χοίρος, a hog*) (*wart-hogs*) shed some of the permanent teeth. Canines large in both sexes; the third molar is very large.

**Babirussa** have long, enamelless canines.

**Potamochoerus** (*Red River hog*) is similar to *phacochoerus*.



**Dicotylidæ** (*Peccaries*).

*D. tajacu* (*Collared peccary*) has smaller canines. Typical *suidæ*.

**Extinct ungulates.**

*Anopletherium* had forty-four teeth, no diastema, and a gradual transition in pattern from the incisors to the molars.

*Oreodon*.—The lower canine is the fifth tooth from the front and bites behind the upper canine.

Group 2.—**Ruminantia**.—**Selenodontia**.

Have no upper incisors; small or no canines; crescentic ridges on the lower molars (*selenodont*). A dense pad of gum occupies the place of the upper incisors.

**A. Tragulina** (*Chevrotains*).**Tragulidæ**.

Small hornless deer, nearly allied to the *Suina*. They have large, persistent growing canines (in the males) and sharp-edged brachyodont premolars.

*T. javanicus*. } Note the differences in male, female and  
African chevrotains. } young animals. Typical *tragulidæ*.

**B. Tylopoda** (*τύλος, knob, padded, + πούς, a foot*).**Camelidæ**.

Incisors  $\frac{3}{3}$ , of which  $\frac{1\frac{1}{2}}{1\frac{1}{2}}$  are lost very early.

Canines  $\frac{1}{1}$ , stout, and stand well apart from the other teeth.

**C. Pecora**.**Cervidæ** (*cervus, a stag, deer*). Solid-horned ruminants.

$\frac{0}{3} \frac{1}{1} \frac{3}{3} \frac{3}{3}$ , small canines, brachyodont molars.

*Elaphodus* (*Michie's deer*) }  
*Cervulus* (*Muntjac*) } have small antlers and long canines.

*Hydropotes inermis* }  
*Moschus moschiferus* } have no horns and large canines.

**Giraffidæ** have no canines and small horns.

**Bovidæ** (*bos, an ox*). Hollow-horned ruminants.

No canines, hypsodont premolars and molars.

**Antelopes, Oxen, Sheep.**

Compare the length of the molars of man, *tragulidæ*, horse, dugong, wombat.



**Sirenia.**

Aquatic mammals nearly related to the Ungulata.

**Dugong** (*Halicore*) has horny plates.

**Incisors** rudimentary in the lower jaw and situated under the horny plates. In the upper jaw the incisor is of persistent growth in the male, rudimentary in the female.

**Canines** absent.

**Premolars and molars**  $\frac{5}{5}$ , conical, growing from open pulps, which eventually close. Some teeth are shed in old age.

There is no enamel on the molars, and only on the front of the male tusk.

The milk dentition is reduced to one incisor.

The diet is sea-weed.

**Manatus** (*Manatees*) have horny plates.

**Incisors**  $\frac{2}{2}$ , rudimentary; canines absent.

**Molars and premolars** bilophodont, brachyodont, and of unknown number. Succession from behind.

Compare the movement of molars in elephant, manatee, wrasse, man.

Straight enamel prisms; remains of vascular canals in the dentine.

**Milk dentition**  $\frac{3}{3} \frac{0}{1} \frac{0}{3}$ .

**Diet**, sea-weed.

**Rhytina.** Edentulous; had horny plates.

**Diet**, sea-weed.

Compare the dentitions and diet of chelonia, rhytina, dugong, ruminants.

**Cetacea** (*κῆτος*, a whale).

Aquatic mammals of fish-like form.

**Mystacoceti** (*μύσταξ*, upper lip (moustache), + *κῆτος*, a whale) (whalebone whales).

Edentulous (many rudimentary teeth of heterodont form); diet is small crustaceans.

**Whalebone** is hardened epithelium covering long papillæ growing from the palate; it is therefore homologous with enamel, and not with complete teeth.

**Balænopteridæ** (rorquals).

**Balænidæ** (right whales).



**Odontoceti** (*ὀδούς, a tooth, + κῆτος, a whale*) (*toothed whales*).

1. Teeth on the maxillæ and mandible.
2. Homodont, conical, often very numerous.
3. Enamel tips, cementum, dentine, the latter often very imperfect in structure.
4. The sockets are often imperfect.
5. The functional teeth are the milk set; rudiments of the permanent set often exist.

Compare odontoceti and seals.

6. Jaws long and narrow.
7. Prehension, piscivorous.

**Physeteridæ** (*φυσσητήρ, a blow-pipe*).**Physterinæ.**

**Physeter** (*Sperm whale, Cachalot*), numerous slightly attached teeth in the lower jaw; rudimentary upper teeth. Diet is cuttle-fish.

**Ziphiinæ.**

**Mesoplodon** has one tooth on each side of lower jaw only, of peculiar structure, and curving over upper jaw.

**Delphinidæ.**

**Narwal** (*Monodon*) has two small rudimentary teeth and two larger ones. One of the latter develops into a long tusk in the male animal. The mouth is edentulous.

Compare tusks of dugong, narwal, suina.

**Orea** (*Killer, or Grampus*) has about forty teeth.

**Phocænæ** (*Porpoises*) have about one hundred teeth.

**Delphinus** (*Dolphins*) have about two hundred teeth.

Tarsiops	}	have rudimentary permanent teeth.
Beluga		
Globicephalus		

**Zeuglodontidæ** (*ζεύγλη, yoke, gown, + ὀδούς, a tooth*).

**Zeuglodon** had double-rooted, heterodont, numerous teeth.



**Carnivora** (*carno, flesh, + vorare, eat*).

Quadrupeds of usually carnivorous habits.

**Fissipedia** (*fissus, cloven, + pes, foot*).

Terrestrial carnivora.

1. 3. 4. 5. As in typical Mammalia.

2. Heterodont,  $\frac{3}{3} \frac{1}{1} \frac{4}{4} \frac{3}{3}$ .

Incisors small and in a straight line.

A diastema occurs in front of the upper canine.

Canines large, pointed, well set, and far apart.

Premolars and molars differ according to diet in each group.

( $\frac{Pm_4}{M_1}$  are the "carnassial" or "sectorial" teeth. In the **Æluroidæ** they are blade-shaped, with scarcely a trace of the inner cusp or "tubercle." In the **Cynoidea** the blade and tubercle are both well marked. In the **Arctoidea** the blade is reduced and the tooth is wide topped.)

6. Jaws short and sharp; the condyles are transverse cylinders and fit closely into their articulation, so affording a strong, pure hinge joint.

7. Mostly carnivorous.

Compare with Ungulata.

**Æluroidæ** (*aíloupas, cat, + eîdos, form*).

Carnivorous, carnivora.

**Felidæ.**

$\frac{3}{3} \frac{1}{1} \frac{3}{2} \frac{1}{1}$ .

Premolars small, except carnassial tooth.

Molars rudimentary in upper jaw.

Carnassials very blade-shaped and large.

Lion, Tiger, Leopard, Lynx, Jaguar, Cat are typical.

**Macroærodonitidæ** (*extinct cats*).

Smilodon, sabre-toothed tiger; very large upper canines.

**Viverridæ** (*viverra, a ferret*).

Small, long-headed carnivora with fuller dentitions.

**Euplerinæ.**

Eupleres, small canines and teeth generally. Diet, worms.

**Viverrinæ.**

Viverra (*civets*), long jaws, rather dog-like.

Arctictis (*binturong*) }  
Paradoxurus } Tuberculated molars. Diet, mainly vegetarian.



**Herpestinæ.****Herpestes** (*mongoose*).*H. albicauda* } { Slender jaws and less specialised teeth.*H. ichneumon* } { Diet, small mammals, birds, snakes, eggs.

Suricate, flat-topped teeth. Diet, vegetarian.

**Hyæniæ.** Carrion feeders.*Hyæna striata* (*striped hyæna*) } { Shorter, stouter teeth, with  
*Crocuta maculata* (*spotted hyæna*) } { large cingula.*Proteles* (*Aard-wolf*) has rudimentary molars.Compare molars of *proteles* and vampire.**Cynoidea** (*κύων, dog, + εἶδος, form*).

Mixed feeders.

**Canidæ.** $\begin{smallmatrix} 3 & 1 & 4 & 2 \\ 3 & 1 & 4 & 3 \end{smallmatrix}$ 

Premolars increasing in size from before backwards.

Molars have tuberculated tops.

*Otocyon* (*long-eared fox*) has forty-eight teeth.*Cyon* (*Canis primævus*) has only m.  $\frac{2}{2}$ .*Canis* is the typical member of the group.In the puppy the "carnassial" teeth are  $\frac{dm_3}{dm_4}$ .Though the milk formula of all the carnivora is  $\frac{3}{3} \frac{1}{1} \frac{3}{3}$  (except in felidæ,  $\frac{3}{3} \frac{1}{1} \frac{3}{2}$ ), it is  $\frac{dm_1}{dm_1}$  that are missing, and so the last milk molars are named  $\frac{dm_4}{dm_4}$ .**Arctoidea** (*ἄρκτος, bear, + εἶδος, form*).

Largely vegetarian.

Premolars and molars broad-topped.

Carnassial teeth very poorly marked.

**Procynoidea** (*Racoons, &c.*).*Nasu* (*coati*).*N. rufa* (*ring-tailed coati*). Diet, iguanas, worms and larvæ.*Ælurus* (*panda*). Diet, eggs, vegetables, insects.*Cercoleptes* (*kinkajou*).



**Mustelidæ** (*mustela*, a weasel).

("Blood-thirsty robbers.") Diet, small mammals.

*Meles* (*badger*).

*Mustela* (*martens and sables*).

*Gulo* (*glutton, wolverine*).

*Putorius* (*weasel, ermine, stoats, ferrets, polecat*).

*Mephites* (*skunks*).

**Lutrinæ.**

*Enhydris* (*Latræx, sea-otter*).

*Latræx lutrix*. Diet, crabs, sea-urchins, fish.

*Lutra* (*otters*).

*L. vulgaris*.

**Ursidea.**

*Ursus*.

*U. maritimus* (*polar bear*). Diet, seals and vegetables.

*Melursus*.

*M. labiatus* (*sloth bear*). Small teeth, few incisors. Diet, fruit and ants.

**Pinnipedia** (*pinna*, a fin, + *pes*, a foot).

Aquatic carnivora.

1. 3. 5. 6. As in Fissipedia.

2. Incisors are reduced in number.

Canines are large.

Premolars and molars are reduced to primitive forms.

Compare with sperm whale and dolphin.

4. The milk dentition is rudimentary and functionless.

7. Prehension, piscivorous diet.

**Otariidæ** (*ὠτάριον*, a little ear).

*Otaria* (*sea lions and bears, fur seals*).

*O. Ursina* (*O. cineria*). Almost haplodont teeth. Erosion is very common.

**Trichechidæ.**

*Trichechus* (*walrus, morse, odobænus*) has large persistent growing canines, composed of dentine covered with cementum, and used for turning over obstacles, clambering over ice, and fighting.

**Phocidæ** (*φώκη*, a seal).

*Phoca* (*common British seal*).

*P. vitulina*. Typical of the Pinnipedia.

*Halichærus*.

*Stenorhynchus* (*ogmorhinus, leopard seal*) has long triconodont teeth.

*Macrorhinus* (*elephant seal*).

*M. leoninus*.



**Rodentia** (*rodere, to gnaw*).

1. 4. As in Mammalia.

2. Heterodont,  $\frac{1}{1} \frac{0}{0} \frac{1}{1} \frac{4}{4}$ .

Incisors, long, curved (upper more than the lower), persistent growing, with sometimes grooved surfaces.

Compare incisors of man, lemurs, horses, kangaroos, rodents.

Canines always absent.

Premolars and molars range from brachyodont, bunodont, to persistent growing, polylophodont teeth. There are often longitudinal grooves at the sides (infoldings of the enamel).

3. Hard dentine, with enamel on the front (or front and sides) only of the incisors, cementum behind. The enamel in the persistent growing teeth shows a pattern (different for each family); it is also sometimes pigmented.

Compare distribution of tissues in *iguanodon mantelli*, *gymnodonts*, *suina*, elephants, rodents.

5. Milk teeth few and rudimentary, or entirely absent.

6. The condyle and glenoid cavity are prolonged forwards and backwards to allow of gnawing.

7. The obtaining of protected food; mastication.

Diet, omnivorous, but mainly vegetable.

**Simplicidentata.** Having one pair of upper incisors.

**Sciuromorpha** (*σκίουρος, squirrel*, + *μορφή, form*).

**Anomaluridæ.**

*A. beecrofti*.

**Sciuridæ** (*σκιά, shadow*, + *οὐρά, tail*) (*squirrels*).

*Sciurus*.

*S. carolinensis* (American grey squirrel) has brachyodont molars.

*Arctomys* (*marmots*).

*A. monax* (*Quebec marmot, woodchuck*) has brachyodont molars.

*Pteromys* (*flying squirrel*).



**Castoridæ.**

*Castor* (*beaver*) has persistent growing grooved molars.  
*C. canadensis*.

**Myomorpha** (*μῦς, a mouse, + μορφή, form*).

**Gliridæ** (*myoxidæ, dormice*).

*M. glis* has brachyodont molars.  
*M. melitensis*.

**Muridæ.****Murinæ.**

*Mus* (*rats and mice*).  
*M. noviganus* (*brown rat*) has brachyodont molars.

**Hydromyinae.****Hydromys.**

*H. chrysogaster* has only m.  $\frac{2}{2}$ , which are brachyodont.

**Microtinæ** (*voles, water rats*).**Microtus** (*arvicole*).

*M. amphibius* (*water rat*) has persistent growing molars.  
*M. glareolus* (*bank vole*) has hypsodont molars.

**Sigmodontinæ.****Cricetus** (*Hamster, pouch-checked rats*).

*C. frumentarius* has brachyodont, bunodont molars.

**Bathyergidæ** (*βαθύς, deep, + ἔργον, work*).

Burrowing animals.

*Bathyergus* (*Cape mole rat, coast rat*) has hypsodont molars.

**Dipodidæ** (*jerboas*) have tubular enamel.



**Hystricomorpha** (*ὑστρίκις*, *porcupine*, + *μορφή*, *form*).

**Caviidæ.**

**Hydrochærus.**

*H. capybara* has large polylophodont, persistent growing third molars, the cusps or denticles partly joined by cementum.

Compare molars of pig, wart-hog, mastodon, elephant, capybara.

**Cavia.**

*C. porcellus* (*guinea-pig*) has tubular enamel.

**Dasyproctidæ.**

**Dasyprocta** (*agoutis*).

*D. agouti* (*golden agouti*) has hypsodont molars and pigmented enamel.

**Hystriacidæ.**

**Hystria** (*ὑς*, *hog*, + *θρίξ*, *bristle*).

*H. cristata* has brachyodont and grooved molars.

**Duplicidentata.** Having two pairs of upper incisors.

**Leporidæ.**

**Lepus.**

<i>L. europeus</i> ( <i>hare</i> )	{	Have <b>two</b> pairs of upper incisors, $\frac{6}{5}$ , persistent growing molars and premolars, <b>no pattern</b> in the enamel, a rather full milk dentition, <b>lateral</b> movement to the jaws.
<i>L. cuniculus</i> ( <i>rabbit</i> )		



## **Insectivora.**

A rather primitive order of mammals.

1. 4. As usual.
2. **Heterodont.**  
**Incisors**, small and procumbent.  
**Canines**, rather small, often two-rooted, and may be placed in the premaxillary bone.  
**Premolars** and **molars**, primitive in pattern, but with elevations of the cingulum on the inner and outer sides, producing numerous cusps.
3. In some the **enamel** is **tubular**, and in many the dentinal fibrils penetrate more or less into the enamel.
5. The **milk** dentition is often much reduced, and many of the milk teeth are functionless.
6. **Jaws** long and slender.
7. **Insectivorous.**

Compare dentitions of hedgehog, mycleridæ, herpestes, myrmecobius.

## **Insectivora vera.**

### **Erinacidæ** (W pattern molars).

**Gymnura** has full mammalian dentition, and canine in premaxilla.

**Erinaceous** (hedgehogs). The canine is small and two-rooted; the first incisors are wide apart.

**E. europeus**. Typical of Insectivora.

### **Tupaiidæ** (W pattern molars).

**Tupaia**.

**T. javanica** is typical of Insectivora.

### **Centetidæ** (V pattern molars).

**Centetes** (*tenrec*) has a fourth molar when old.

**Hemicentetes**.

**Ericulus**.



**Potamogalidæ** (V pattern molars).

Potamogale (aquatic).

**Chrysochloridæ** (V pattern molars).

Chrysochloris (*Cape golden mole*).

**Macroscelidæ** (W pattern molars).

Macroscelide (*elephant mice*).

**Talpidae** (W pattern molars).

Talpa ( <i>mole</i> ).	V V V V V V V V W W W	There is a calcified milk dentition.
	I I I I A A A A M M M	

T. europea. Typical mole.

**Myogale** (*desmans*).

M. moschata is aquatic. Typical Insectivora.

Urotrichus.

**Soricidæ** (W pattern molars).

Have large notched incisors, pigmented and tubular enamel;  
the dentinal fibrils penetrate far into the enamel, and  
they have rudimentary uncalcified milk dentitions.

Soriculus (*Indian shrew*). Typical shrew.

**Crocidura**.

C. cærulescens has white-tipped teeth.

Crassopus fodiens is a water shrew with brown teeth.

**Dermopteria**.**Galeopithecidae** (*flying lemurs*).

Galeopithecus volans has comb-like lower incisors, and a  
functional milk dentition.



**Chiroptera** (*χείρ, hand, + πτερόν, a wing*). (*Bats.*)

1. 3. 4. As usual.
2. **Heterodont.**  
   Incisors small and few.  
   Canines large.  
   Premolars and molars either many cusped or flat-topped.
5. **Milk** dentition rudimentary and often different from the permanent.
6. **Jaws**, long.
7. Either insectivorous or frugivorous.

**Megachiroptera** (frugivorous = hollow-topped molars).

**Pteropidæ.** Some have bituberculate canines.

**Pteropus.**

*P. hypomelanus.*

*P. medius.* Typical frugivorous bat.

**Cephalotes peronii.** The milk dentition does not resemble the permanent. Typical frugivorous bat.

**Cynopterus.**

*C. marginatus* has bituberculated canines.

**Cynonycteris.** (*Harpyia*)

*C. dupræna.* Typical frugivorous bat.

**Microchiroptera** (mainly insectivorous = sharp cusped molars).**Nycteridæ.**

*Megaderma lyra.* Diet, frogs.

**Vespertilionidæ.**

**Plecotus.**

*P. auritus* (*long-eared bat*) shows temporary teeth.

**Phyllostomatidæ.**

*Phyllostoma hastatum.* Typical insectivorous bat.

**Desmodus.**

*D. rufus* (*vampire*) has rudimentary molars. Diet, blood.

Compare the molars of vampire, aard-wolf, seals, tiger, dog, man.



**Primates.**

Hairy mammals with five digits on both limbs, provided with flat nails; teats thoracic.

**Lemuroidea** (*lemur, a ghost*).

1. 3. 4. 5. 6. As usual.

2. Heterodont,  $\frac{2}{2} \frac{1}{1} \frac{3}{3} \frac{3}{3}$

Upper incisors are separated.

Lower incisors and canines are procumbent.

The next tooth in each jaw is large, and functionally is a canine, though not called so in the lower jaw.

Molars are sharp cusped.

7. Omnivorous, but only small animals are eaten.

**Lemuridæ.**

Indrisinæ (vegetable diet).

Indris brevicaudata has only one lower incisor.

Lemurinæ (*true lemurs*).

Lepilemur. Typical lemuridæ.

L. mustelinus.

Lemur.

L. varius (*ruffed lemur*). Typical of Lemuroidea.

Galagininæ (omnivorous).

Lorisinæ.

Nycticebus.

N. tardigradus (*slow lemur, slow loris*). Typical of Lemuroidea.

**Cheromyidæ** (*χείρ, a hand, + μῦς, a mouse*).

Cheromys madagascarensis (*aye-aye*),  $\frac{1}{1} \frac{0}{0} \frac{1}{0} \frac{3}{3}$ , has a rodent-like dentition, but a well-formed milk dentition.

**Tarsiidæ** (insectivorous).

Tarsius spectrum (*tarsiar*).

Adapis magnus (*extinct lemur*) had forty-four teeth and no diastema.



**Anthropoidea** (*man-like*).

**Platyrrhine** (*broad-nosed New World apes*).

**Hapalidæ** (*marmosets*),  $\frac{2}{2} \frac{1}{1} \frac{3}{3} \frac{2}{2}$ , three-cusped molars.

**Hapale**.

**Midas** (*tamarins*). Typical of Hapalidæ.

**M. rosalina**.

**Cebidæ**,  $\frac{2}{2} \frac{1}{1} \frac{3}{3} \frac{3}{3}$ .

**Cebus** (*Capuchin monkeys*). Roots of teeth not well separated.

**Ateles** (*spider monkey*) has oblique ridge on upper molars.

**Mycetes** (*howling monkey*) has oblique ridge on upper molars.

**Pithecia**.

**Catarrhine** (*narrow-nosed Old World monkeys*),  $\frac{2}{2} \frac{1}{1} \frac{2}{2} \frac{3}{3}$ .

**Cercopithecidæ**.

**Cercopithecinae**.

**Cercopithecus** has a rather small third molar.

**Macacus** (*baboons*). The first lower premolar has the crown prolonged on to the anterior root.

**M. rhesus**. Note  $pm_1$ .

**Cynocephalus** (*patrio*).

**P. porcarius** (*chacma baboon*). Typical of baboons.

**Semnopithecinae**.

**Simiidæ** (*anthropoid apes*).

1. 3. 4. 5. As usual.

2. **Heterodont**,  $\frac{2}{2} \frac{1}{1} \frac{2}{2} \frac{3}{3}$ .

**Megadont** (dental index forty-four or over).

The outer incisor is rather caniniform.

There is a **diastema**.

**Canines** are large, sexual, late erupted.

**Premolars** three-rooted in upper and two-rooted in lower jaw.

**Molars** increase in size backwards. Oblique ridge present.

6. **Jaw** is square (molars converging behind) and prognathous (gnathic index above 103). The chin is retreating.

7. **Omnivorous**.

Compare carefully with **man**.



*Hylobates (gibbons)*. Slender canines.

*Gorilla*. The canine and third molar erupt at the same time.

*Chimpanzees (anthropopithecus troglodytes)*. Dentition the most like man, especially in the milk dentition.

*Orang utan (simia satyrus)* has long-rooted teeth.

## Hominidæ.

*Homo*.

*H. sapiens*.

1. 3. 4. 5. As usual.

2. Heterodont,  $\frac{2}{2} \frac{1}{1} \frac{2}{2} \frac{3}{3}$ .

Microdont in higher races.

Incisors similar in pattern and size.

No diastema.

Canines hardly larger than neighbours, not differing in sexes; erupt before second molar.

Premolars single rooted, except upper first premolar.

Molars decrease in size backwards.

6. Jaw is rounded (molars diverge backwards) and orthognathous. The chin is well marked.

7. Omnivorous.

In the lower races of mankind the:—

Teeth are larger and more regular,

Incisors are more oblique sided,

Canines are larger,

Wisdom tooth is better developed and has more room,

Arch is more square in front,

Jaw is usually more prognathous,

Bite is more edge to edge.

Facial angle (*Camper's*).

The angle formed between two lines drawn:—

From the middle of the auditory meatus along the floor of the nose, and

From the forehead between the supra-orbital eminences to the tips of the incisors.

The more prominent the mouth, the smaller the angle will be.



### Gnathic index.

A more modern way of comparing the amount of mouth with the amount of brain.

**Basi-alveolar** = the distance from the anterior margin of the foramen magnum to the margin of the alveolus between the incisor teeth (amount of mouth).

**Basi-nasion** = the distance from the anterior margin of the foramen magnum to the suture between the nasal and frontal bone (amount of brain).

$$\text{Gnathic index} = \frac{B. - A. \times 100.}{B. - N.}$$

**Orthognathus** = gnathic index below 98.

**Mesognathus** = „ „ 98.1 to 103.

**Prognathus** = „ „ above 103.

Compare dog, monkeys, man (young and old).

### Dental index.

A way of comparing the amount of biting surface with the amount of brain.

**Length of teeth (*biting surface*)** = distance from the mesial surface of the first premolar to the distal aspect of the last molar.

**Basi-nasion** = same as before.

$$\text{Dental index} = \frac{L. \text{ of } T. \times 100.}{B. - N.}$$

**Microdont** = dental index 42.

**Mesodont** = „ „ 43.

**Megadont** = „ „ 44 and over.

The shape (crown, neck, root, and pulp cavity) of each human tooth must be learnt minutely and exactly, also the common variations of form.

The arrangement of the teeth in the arch and their articulation must be learnt accurately and in detail.

The “compensating curve of Von Spee” is the upward curve of the occlusal plane of the teeth in the molar region, which enables the



molars and incisors to occlude at the same time. It varies with the shape of the eminentia articularis.

The **movements of the jaws** in mastication, and the anatomy of the muscles, ligaments, and bones which produce them, must also be learnt.

A hinge movement occurs between the condyle and the inter-articular cartilage.

A sliding movement occurs between the interarticular cartilage and the temporal bone.

When opening the mouth, **both** movements take place simultaneously.

The lower incisors do not move in the arc of any circle (or, to put it in another way, the centre of the arc of rotation shifts during the opening and closing of the mouth).

At the moment of coming in contact, the lower teeth are moving vertically upwards.

In lateral movements the jaw rotates round one or other condyle, which condyle usually remains at its most posterior position.

The other condyle moves forward and downward.

Hence the teeth on the biting side move transversely, and on the non-biting side almost antero-posteriorly and downwards.

The movements of the teeth are controlled by:—

1. Shape of the eminentia articularis and glenoid cavity.
2. The shape and size of the lower jaw (*i.e.*, relative position and direction of the plane of occlusion and path of condyle).
3. The ligaments, fasciæ, and neighbouring organs.
4. The muscles. Hence the **habitual movements** are largely voluntary, variable, and adaptable to circumstances.

Compare with movements in tiger, rat, rabbit, ox.

The shape and relations of the **sockets**, and the thickness and consistency of their walls, are to be learnt.



**Preparation of Hard Tissues:**

1. **Saw** into thin slices. (Cut enamel with a diamond disc.)
2. Grind on a **carborundum** wheel as thin as possible.
3. Grind between two bits of ground plate-glass with pumice and water.
4. **Wash.**
5. **Dry** lightly on the hand.
6. Mount in warm hard Canada balsam.

**Preparation of Soft Tissues.**

1. **Fix** in Muller's fluid, corrosive sublimate, or 2% formaline, etc.
2. **Harden** in 80% alcohol.
3. **Dehydrate** in absolute alcohol.
4. **Stain** in borax carmine, etc.
5. **Clear** in oil of cloves.
6. **Imbed** in gum mucilage, paraffin, or celloidin.
7. **Cut.**
8. **Mount** in Canada balsam or glycerine jelly, etc.

If preferred, the sections may be stained, dehydrated, and cleared after being cut, instead of before.

**Preparation of Hard and Soft Tissues together.****Weil's Process.**

1. Saw a fresh tooth into four pieces, under water.
2. **Fix** in 2% formaline.
3. **Wash.**
4. **Harden** in 30% alcohol . . . . . about 12 hours.
5. " in 50% " . . . . . " 12 "
6. " in 70% " . . . . . " 12 "
7. " in 90% " . . . . . " 12 "
8. **Stain** in alcoholic borax carmine . . . . . " 3 weeks.
9. Fix the stain with 70% alcohol and  $\frac{1}{4}$ % HCl . . . . . " 12 hours.
10. **Dehydrate** in 90% " . . . . . " 24 "
11. " in absolute " . . . . . " 24 "
12. **Clear** in oil of cloves . . . . . " 6 "
13. **Wash** in xylol.
14. **Soak** in xylol . . . . . " 1 day.
15. **Imbed** in a weak sol. of Canada balsam . . . . . " 2 days.
16. " in a strong " " " " 2 "
17. " in thick Canada balsam at 70° C. . . . . " 1 day.
18. " in " " " 90° C. . . . . " 2 days.
19. **Grind** when cool and brittle.
20. **Mount** in Canada balsam.



**Hopewell Smith's Process.**

1. Remove the apex from a fresh tooth.
2. **Fix** in 2 % formaline . . . . . about 1 day.
3. **Harden** in 84 % alcohol . . . . . „ 20 days.
4. Wash in normal salt solution (6 %), dry and protect the soft parts with collodion.
5. **Decalcify** in 12 c.c. of 10 % HCl . . . . . „ 15 hours.
6. „ add 1.5 c.c. pure HNO<sub>3</sub> . . . . . „ 33 „
7. „ add 1.5 c.c. pure HNO<sub>3</sub> again . . . . . „ 27 „
8. **Neutralise** in lithium carbonate (6 grs.—1 oz.) „  $\frac{1}{2}$  „
9. Wash in distilled water.
10. **Imbed** small pieces in gum mucilage . . . . . „ 15 „
11. **Freeze**, cut, and float off sections on water, stain.
12. **Dehydrate**, clear, and mount.

**Muller's Fluid.**

Bichromate of Potash . . . . .	2½ parts.
Sulphate of Soda . . . . .	1 part.
Water . . . . .	100 parts.

**Chromic Acid Process.**

1. Place the tooth in half a pint of—
 

Chromic acid . . . . .	$\frac{1}{4}$ volume.
Nitric acid . . . . .	$\frac{1}{2}$ „
Water . . . . .	100 volumes.
2. Change frequently . . . . . 3-4 weeks.  
Wash thoroughly.  
Imbed in paraffin, cut, stain, etc.

**Imbedding.****Gum Mucilage Imbedding.**

1. **Fix**.
2. **Wash** in water.
3. **Imbed** in—Gum mucilage, 5 parts.  
Syrup, 4 „ . . . . . 15 hours.
4. Place on a microtome and cover with mucilage.
5. **Freeze**, cut, and float off sections on water.
6. Stain, dehydrate, clear, and mount.



**Collodion Imbedding** (for large objects).

1. **Dehydrate** in absolute alcohol.
2. Soak in a mixture of equal parts of alcohol and ether.
3. Place in a very thin solution of collodion.
4. Place in a thick " " "
5. Allow the solution to evaporate slowly.
6. Remove the object to 30 % alcohol to harden.
7. **Cut** with a microtome.
8. **Stain and dehydrate.**
9. **Clear** in cedar oil (not oil of cloves).
10. **Mount.**

The time taken will depend on the size and permeability of the object. It is better, when possible, to make cuts in the specimen to hasten penetration.

**Paraffin Imbedding** (for small objects and very thin sections).

1. **Dehydrate.**
2. **Clear** in cedar oil.
3. Place in melted paraffin (45° C.) till saturated (1 hr.).
4. **Cool** rapidly. (To prevent crystallisation.)
5. Mount on a microtome and cut.
6. Warm and wash out paraffin with naphtha.
7. Stain, clear, mount.

In either method the object may be stained in mass before imbedding, if preferred.

**Stains.****Alcoholic Borax Carmine**

Is a general stain for staining large pieces of tissue.

1. Place in the stain till saturated . . . . 2-4 weeks.
2. Place in acid alcohol to fix the stain . . . 12 hours.
3. Dehydrate in 90 % and 100 % neutral alcohol 12 hours each.

**Acid Alcohol:**—70 % alcohol and two drops HCl to a test-tube full.

**Silver Nitrate**

Is used to stain intercellular substances and show up the outline of cells.

1. Wash the fresh tissues in distilled water.
2. Place in 1 % AgNO<sub>3</sub> in the sunlight till of a whitish-grey colour.
3. Wash and mount at once.

THE UNIVERSITY OF CHICAGO  
DIVISION OF THE PHYSICAL SCIENCES  
DEPARTMENT OF CHEMISTRY  
JANUARY 1954  
MEMORANDUM FOR THE RECORD  
SUBJECT: [Illegible]  
[Illegible text follows, consisting of several paragraphs of faint, mirrored text, likely bleed-through from the reverse side of the page.]

**Hæmatoxylene.**

For staining nuclei.

1. Place the section in a dark sol. of hæmat. . . . .  $\frac{1}{4}$  hour.
2. Wash well in water.
3. Dehydrate in absolute alcohol . . . . . 10 mins.
4. Clear in cedar oil and mount.

To counter-stain with **eosin**, add eosin to the absolute alcohol used for dehydrating; this gives a very useful double stain.

**Mummery's Iron and Tannin.**

For staining nerve endings.

1. Wash the sections in water.
2. Place in liquor ferri perchloridi . . . . . 24 hours.
3. Wash quickly and thoroughly.
4. Place in tannic acid (2 grs.—6 c.c. of water) . . . 5-10 mins.
5. Wash in water, dehydrate, clear, and mount.

**Golgi's Method.**

For staining calco-globulin.

1. Place the sections in a mixture of—  
     2 % sol. potassium bichromate, 8 parts.  
     1 % sol. osmic acid, 2 „ . . . . . 24 hours.
2. Remove to 0.5 %  $\text{AgNO}_3$  (in the dark) . . . . . 1 day.
3. Dehydrate, clear, and mount in gum dammar.

**Underwood's Gold Chloride.**

For staining intercellular tissues and canals.

1. Grind section.
2. Wash in 1 %  $\text{Na}_2\text{CO}_3$ .
3. Neutral 1 % sol. of  $\text{AuCl}_3$  (in the dark) . . . . . 1 hour.
4. Wash in water ( „ „ ) . . . . . 10 mins.
5. Warm 1 % sol. of formic acid ( „ „ ) . . . . . 1 hour.
6. Wash in cold water.
7. Dry and mount in glycerine jelly.

**To Stain Bacteria.**

1. Place the sections in a strong alcoholic sol. of gentian violet . . . . . 3 mins.
2. Wash in Gram solution . . . . . 3 „
3. Wash in absolute alcohol till differentiated.
4. Clear and mount.

**Gram Solution :—**

Iodine . . . . .	1 part
Potassium iodide . . . . .	2 parts.
Water . . . . .	300 „



To Show:—

### **Enamel Prisms.**

Grind and mount unstained.

### **Transverse Striæ of Enamel Prisms.**

1. They may be slightly seen in ordinary ground sections.
2. Grind a section, wash it in weak HCl, and stain with carmine.

### **Brown Striæ of Retzius.**

An ordinary ground section.

### **Dentinal Fibrils.**

1. Weil's process.
2. Hopewell Smith's process.

### **Dentinal Tubes.**

1. Unstained ground sections.
2. Underwood's gold chloride.

### **Dentinal Sheaths.** (Sheaths of Neumann.)

1. Golgi's method.
2. Grind a section and wash in HCl and then an alkali (tubes only remain).

### **Interglobular Spaces and Owen's Lines.**

1. Weil's process.
2. Underwood's gold chloride.

### **Vaso-Dentine and Osteo-Dentine.**

1. Weil's process.
2. Chromic acid process.

### **Pulp Cells.** (*Odontoblasts.*)

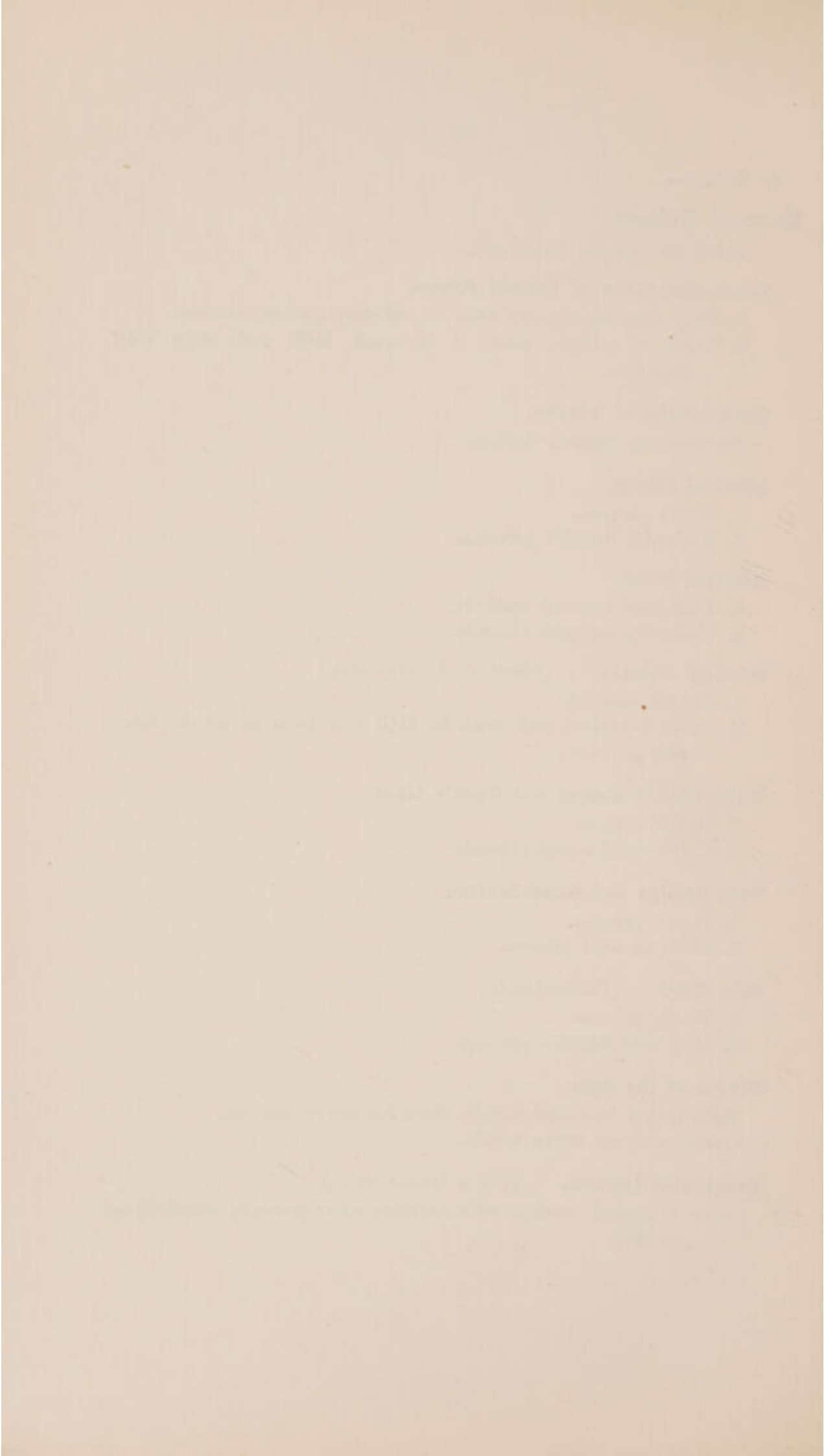
1. Weil's process.
2. Hopewell Smith's process.

### **Nerves of the Pulp.**

Mummery's iron and tannin stain for nerve endings.  
Osmic acid for nerve trunks.

### **Encapsuled Lacunæ.** (*Use a horse's tooth.*)

Stain a ground section with carmine after partially decalcifying in HCl.



**Sharpey's Fibres.**

Same as for encapsuled lacunæ.

**Nasmyth's Membrane.****Cellular structure.**

1. To show nuclei.

Remove from tooth with HCl and phloroglucin, stain in Erlich's acid hæmatoxyline, wash, and mount in Farrant solution.

2. To show outline of cell.

Remove with HCl, and stain with nitrate of silver.

**Position.**

Grind a section, mount on a slide, and wash with HCl; stain with carmine.

**Periosteum and Gum.**

1. Chromic acid method.
2. Hopewell Smith's method.

**Developing Teeth.**

1. Chromic acid method, carmine stain, and paraffin imbedding.
2. Hopewell Smith's method.

**Caries of the Enamel.**

Ordinary ground section.

**Caries of the Dentine.**

Weil's method.

**Germes in the Tubes.**

Break off the enamel from a carious tooth.

Wash in salt sol. and remove soft part with one cut.

Place in gum mucilage.

Freeze and cut.

Stain the sections by Gram's method.

Clear and mount.

**Translucent Zone.**

1. Weil's method.
2. Underwood's gold chloride.



