

The treatment in Germany of gunshot injuries of the face and jaws / tr. and abstracted from recent German publications, by W.H. Dolamore.

Contributors

Dolamore, W. H. (William Henry)

Publication/Creation

London : The British dental association, 1916.

Persistent URL

<https://wellcomecollection.org/works/r7a7byhj>

License and attribution

This work has been identified as being free of known restrictions under copyright law, including all related and neighbouring rights and is being made available under the Creative Commons, Public Domain Mark.

You can copy, modify, distribute and perform the work, even for commercial purposes, without asking permission.



Wellcome Collection
183 Euston Road
London NW1 2BE UK
T +44 (0)20 7611 8722
E library@wellcomecollection.org
<https://wellcomecollection.org>

The Treatment in Germany of Gunshot Injuries of the Face and Jaws

TRANSLATED AND ABSTRACTED FROM RECENT GERMAN PUBLICATIONS

BY

W. H. DOLAMORE, L.R.C.P., M.R.C.S., L.D.S.

*President of the British Dental Association ; Dental Surgeon to St. Mary's Hospital and to
the Royal Dental Hospital ; Member of the Board of Dental Examiners, R.C.S.Eng. ;
Dean School of Dental Surgery, Royal Dental Hospital ; External Examiner
in Dental Surgery to the University, Leeds*

PUBLISHED BY

THE BRITISH DENTAL ASSOCIATION

19, HANOVER SQUARE, LONDON, W.


—
1916

Price 5s. net



22900346222

Med
K29570



The Treatment in Germany of Gunshot Injuries of the Face and Jaws

TRANSLATED AND ABSTRACTED FROM RECENT GERMAN PUBLICATIONS

BY

W. H. DOLAMORE, L.R.C.P., M.R.C.S., L.D.S.

*President of the British Dental Association ; Dental Surgeon to St. Mary's Hospital and to
the Royal Dental Hospital ; Member of the Board of Dental Examiners, R.C.S.Eng. ;
Dean School of Dental Surgery, Royal Dental Hospital ; External Examiner
in Dental Surgery to the University, Leeds*

PUBLISHED BY

THE BRITISH DENTAL ASSOCIATION

19, HANOVER SQUARE, LONDON, W.

—
1916

311491
30274



16779114

WELLCOME INSTITUTE LIBRARY	
Coll.	wellcome
Call	
No.	WG

CONTENTS.

	PAGE
Düsseldorf Hospital	5
First aid	6
Splints	15
Metal cap splint	18
Tin splint	20
Correction of misplacement	23
Shields for plastic operations	29
Nasal splints	29
Mouth opener	35
Oral orifice dilator	35
Plastic operations	36
Local anæsthesia	36
Technique	38
Cases	41
Splints used in Berlin	69
Charlottenburg Hospital	71
Frankfort Hospital	72
Intra-oral splints	72
Extra- and intra-oral splints	73
Surgical treatment	74
Jaw injuries in Japanese-Russian War	75
Jaw cases in Balkan Wars	77
Bone implantation, Axhausen's experiments	79
" " at Düsseldorf and Berlin	15
" " at Frankfurt	75
Appendix	83



The Treatment in Germany of Gunshot Injuries of the Face and Jaws.

TRANSLATED AND ABSTRACTED

By W. H. DOLAMORE.

PROF. DR. WALKHOFF, of Munich, the doyen of German dental surgeons, speaking from his experience of the Franco-German War of 1870 to 1871, recently said that those suffering from injuries of the face and jaws are heroes to-day; but later, if untreated, are objects of dread and loathing to their fellow-men. Proper treatment is therefore of the first importance. Recent German publications disclose methods of treatment seemingly of value and having favourable results. I therefore prepared this abstract as a contribution to the work of the Special Committee appointed by the British Dental Association to collect and publish information on the treatment of gunshot injuries of the jaws. It is presented in the hope that some things therein may be of use in the treatment of our own wounded. The statements and comments, except in a very few obvious instances, are wholly those made by the writers of the papers.

THE HOSPITAL AT DÜSSELDORF.

THE account of the work at the Düsseldorf Hospital is published in three sections¹; others, presumably, will be or have been published. Papers are contributed by Professor Christian Bruhn (Editor of the publication), Dr. August Lindemann, Friedrich Hauptmeyer, Max Kühl and Walter Ahrend. It is not possible, in the space available, to translate these articles *in extenso*, nor to include more than a selection from the many illustrations given. It has seemed best, therefore, to attempt to group the information in the various papers under three headings: first aid in the treatment of wounds of the face and jaws; the use of splints; the treatment of wounds and scars by plastic operations.²

¹ Die gegenwärtigen Behandlungswege der Kieferschussverletzungen Ergebnisse aus dem Düsseldorfer Lazarete für Kieferverletzte.

² In a further pamphlet published by Bruhn, he deals with another aspect of this hospital. From a review of this it seems that as soon as the wounded are able to benefit they take part in work of an educational nature. As far as possible, this follows their previous occupation: carpentering, shoemaking, gardening, typewriting, photography, &c. Some of the convalescent find remunerative work in the town. It is claimed that the patients gain not only mental but physical benefit therefrom, and they are rendering useful service to the State.

The Düsseldorf Hospital contains 225 beds, and was already at work in August, 1914. It may have been arranged before the outbreak of war, for although the number of injuries of the face and jaws has caused surprise, the prevalence of these during the Balkan wars and the Russo-Japanese conflict had not escaped observation.

This is only one of many such hospitals existing in Germany in April, 1915, the date of publication of the first section; hospitals are specified in Berlin, Strasburg and Hanover, but reference is also made to others elsewhere.¹ According to the German method of not "putting round pegs in square holes," the hospitals at Düsseldorf and Berlin (probably the others) were placed in charge of men known to have experience of and to have taken an interest in jaw injuries before the War. Nevertheless, the writers have reason to complain of the means adopted to attempt to treat these cases by surgeons attached to the field armies, the result being that the treatment has been prolonged and complicated when, after the delay of some weeks, the wounded have been removed to the Düsseldorf Hospital.

FIRST AID IN THE TREATMENT OF INJURIES OF THE FACE AND JAWS.

Complaint is made of the type of bandage commonly used (fig. 1). It is admitted that at the dressing station the simplest means must be adopted to cover the wound and arrest bleeding; but the wounded are left often for hours or even days at the field or base hospital without the bandage being renewed. It becomes soaked with saliva, discharges and liquid food, and forms a germ-breeder of the most dangerous type. Unless a splint has been inserted, the bandage gives no support to the broken bones; indeed, if a bandage remains for a period, drawing the chin backwards, the broken fragments are

¹ A Swiss dentist, who made a circular tour of the German hospitals for injuries of the jaw, stated towards the end of 1915 in the *Neue Zeitung* (Zurich) that there was a hospital in Leipzig, under Professor Pfaff and three assistants, with ninety beds. In Möckern, near Leipzig, was a hospital with 200 beds. Berlin had three hospitals with about 600 beds under Williger, Schröder, Klapp, Ganzer, Muschold and Schragenheim. Düsseldorf had three, with about 500 beds, under Bruhn, Hauptmeyer and Kühl; Heidelberg, one under Port, with 120 beds. Other hospitals had been established in Strasburg, Freiburg, Hanover, Bonn, Bremen, &c., with "thousands" of beds.

"It took a certain time," he said, "before the Higher Command realized the ideal results obtained in special hospitals, but then things moved. Without exception to-day the treatment of fractured, often pulverized, jaws is in the hands of dental surgeons."

It must, however, be pointed out that there is ample evidence to show that, if the dental surgeon is in charge he collaborates with a surgeon (*e.g.*, Lindemann at Düsseldorf, and Loos at Frankfort), and this both desire.

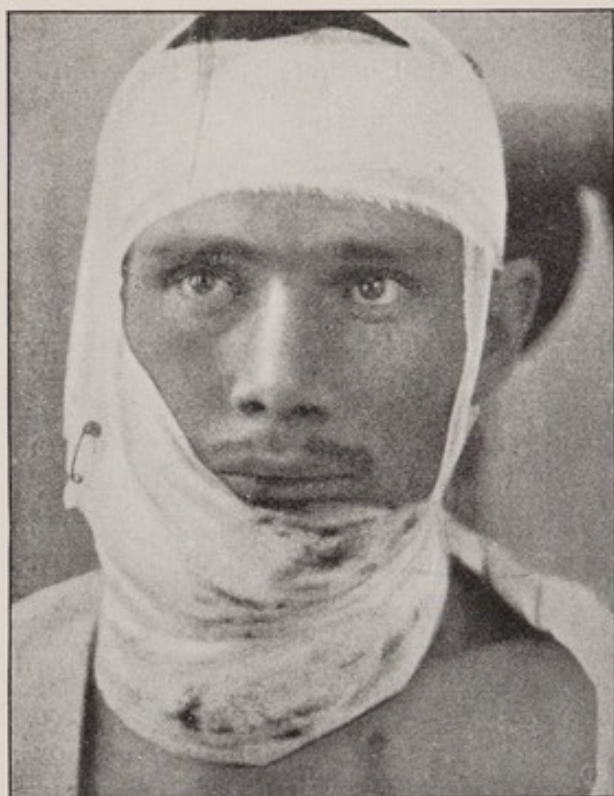


FIG. 1.



FIG. 2.

dislocated dorsally and produce a deformity of the face, giving a bird-like appearance (fig. 2). Further, the soft tissues are deprived of their nourishment, giving rise to suppuration, sloughing and cicatricial contractions, that necessitate extensive plastic operations subsequently. Moreover, adhesions form between the mucous membrane of the lips, tongue and cheeks and the soft tissues over the jaw, which have to be stretched or divided before splints or any prosthetic apparatus can be used. This picture is not rare; though it is said to be almost comical that sometimes, on removal of the voluminous bandage, only a small, slightly discharging wound is found.

All the contributors enter a vigorous protest against attempting to wire the bone in fractures of the lower jaw. In the opinion of the writers, this is not justified in civil practice, unless it can be done aseptically as in simple fractures, which do not occur in the horizontal ramus of the lower jaw. (Bruhn has treated 300 jaw injuries in civil practice at Essen.) In this War the vast majority of fractures are the result of bullet wounds, and there is always some comminution. Cases are mentioned and illustrated where cure was long delayed on account of unwise attempts at wiring, and only commenced after the wire had been removed. Staff-Surgeon Goldammer, writing on "The Surgery of the Balkan Wars, 1912 to 1913," says: "Surgical wiring of the bone is not to be recommended in peace time, still less on the battle-field."

Similarly, the attempt to fix immediately prosthetic appliances, or troughs, to the bone by wiring is condemned. It is pointed out that the conditions of war surgery and of the removal of a bone because of a morbid growth therein are not parallel. Further, it is said that the results attained in Tokio during the Japanese War were by no means satisfactory (see p. 76), though in the case of those who lived to reach the hospital malunions had already occurred, and attempts were made to render life endurable to these pitiable objects, after dividing the malunited bone, by wiring troughs or prosthetic appliances to the separated ends of the bone. Even the immediate stitching up of an extensive, contused wound of the soft tissues of the face is questioned, and in every case is condemned if associated with injury to the jaws, unless and until a splint has been inserted. To illustrate this point some cases are described. Figs. 3 and 4 show the deformity of the face, the contracted mouth, and the puckered scarring, the result of stitching up wounds, with loss of portions of the mandible at the symphysis, fourteen days after the injury, but without the use of a splint. The oral orifice was so small that it would only admit two wooden matches. The cicatrices are obvious in the illustration.

Fig. 5 shows a wound of the upper lip and cheek which had been stitched up immediately, without any notice being taken of the

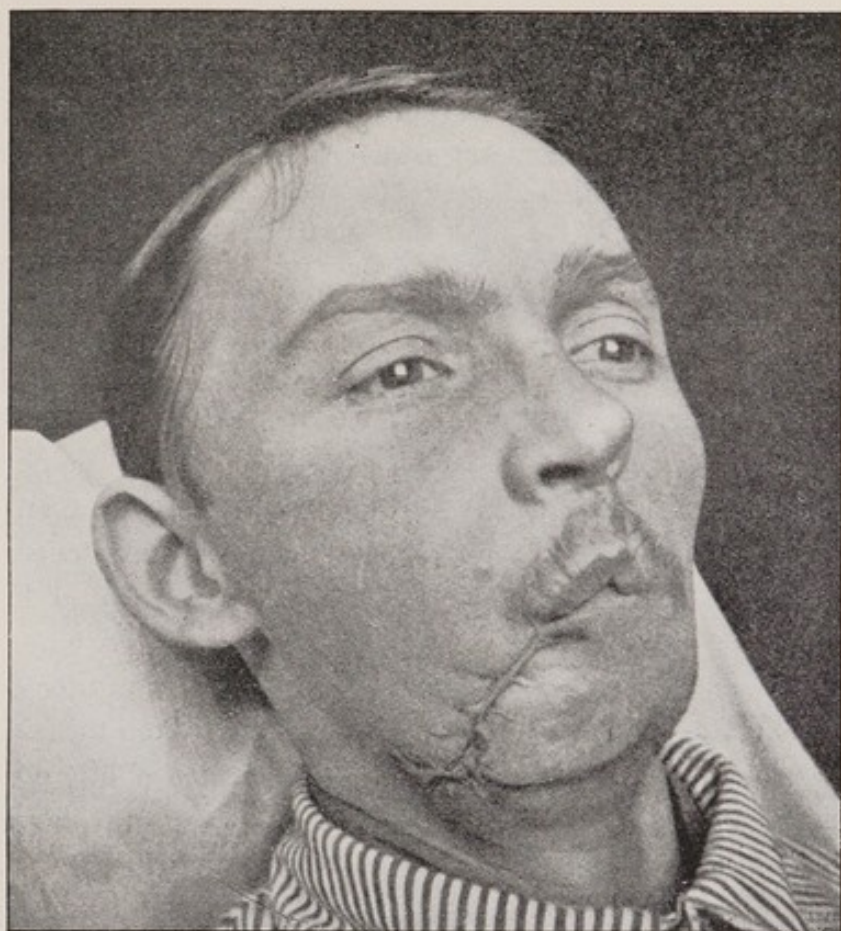


FIG. 3.

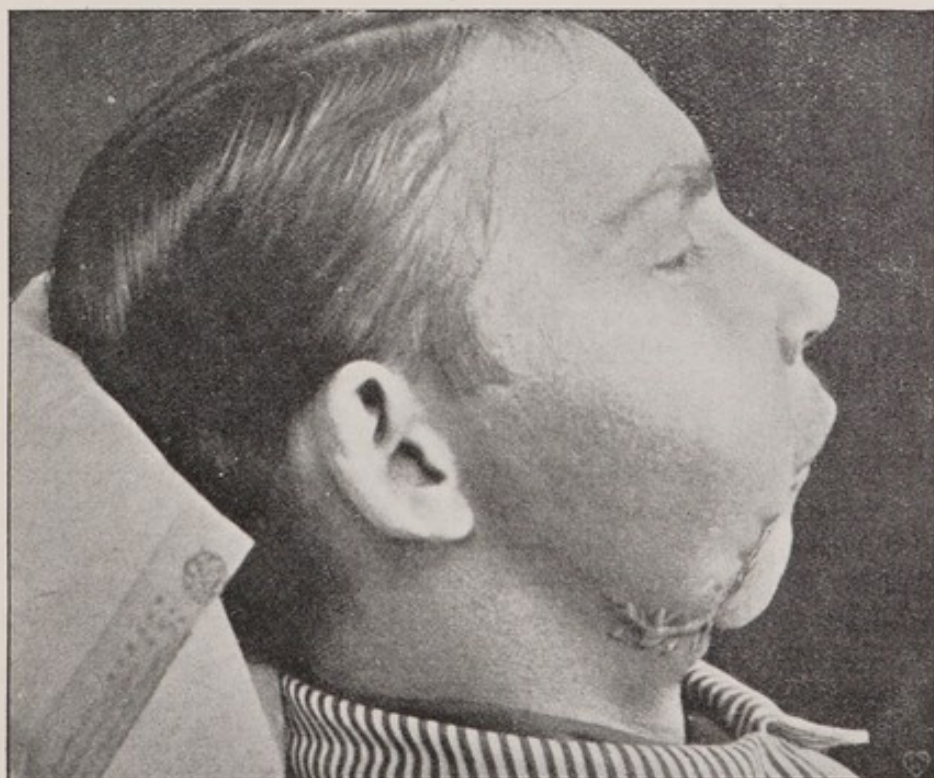

FIG. 4.

injury to the maxilla. Consequently, the suppuration naturally following burst open the wound; sequestra came away and a space was left in the face which a second attempt at suturing failed to close. On admission to hospital the contracted mouth would only admit a thumb.

But when there is little loss of substance and the bone, if fractured, is not displaced, then the early insertion of sutures appears to be demanded, since otherwise the displaced soft tissues tend to shrink




FIG. 5.

and form adhesions with neighbouring tissues. On the other hand, many wounds have not healthy edges and are infected, hence primary union seldom occurs. Often a general anæsthetic cannot be given and the local anæsthetic as used in the field seldom seems efficient, indeed, it apparently increases the inflammation of the tissues. The circumstances are generally adverse to an aseptic, workmanlike operation. The sutures (usually of silk) frequently cut out, damaging the tissues and diminishing the amount available for the subsequent plastic operation. The recollection of the pain endured indisposes the patient to subsequent operative procedures. It is advised that,

if immediate sutures seem advisable, deep wire sutures, ligatured loosely over plates, should be passed through the adjacent sound tissues and the wound drawn together. If materials are not available for this, it is advised that the fracture be attended to and that the wound should be painted with iodine and the adjacent skin covered with oil of mastic (mastic dissolved in benzol); a piece of gauze should be lightly placed in the wound and the wound fixed with strapping or by a four-tailed bandage loosely tied. The mouth should be frequently washed out with peroxide of hydrogen; in default of this, water is better than nothing, and the patient should be rapidly transferred to the special hospital. The distressing dryness of the mouth can be alleviated by use of a lotion consisting of glycerine 400·0, spiritus dil. 50·0, anisi 0·2, ol. menth. pip. 0·2.

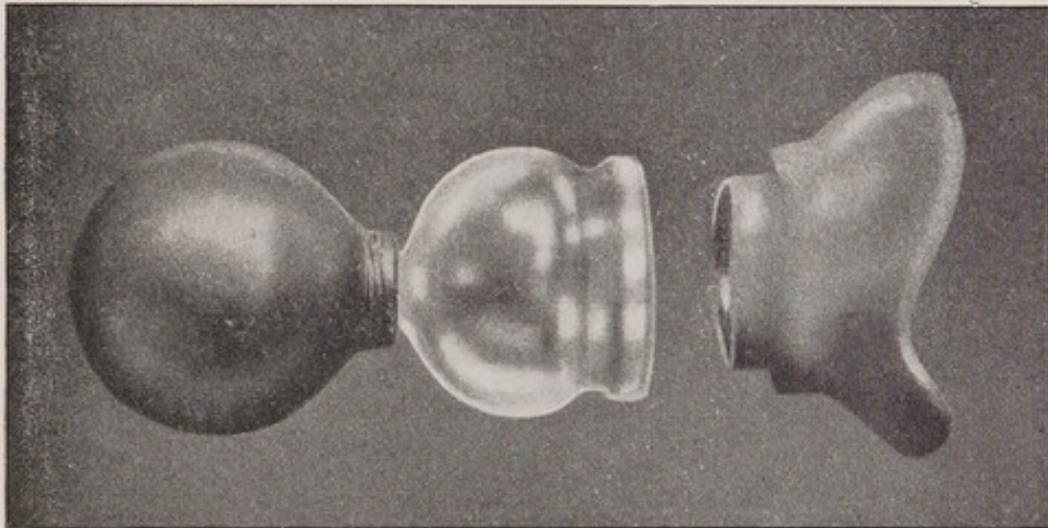


FIG. 6.

At the jaw hospital begins the combined work of the surgeon and the dentist. All dead and separated pieces of bone and any teeth separated from their attachments are removed. Obviously, only that tissue is removed which is shown in the radiogram to be dead, all living tissue is carefully preserved. Then, by fixing the teeth in their correct position by means of splints, the relative relation of the broken fragments of bone, one to the other, will be restored. The root principle is and remains—to remove from the bone all irritation. If the wound is clean, its edges will then be sutured, provided this does not present technical difficulties; on the other hand, if the wound be suppurating and if the damage be great, with or without the opening of adjoining sinuses, then the treatment begun will be continued. Daily, two or three times, especially after meals, the wound and mouth

will be thoroughly syringed out with weak solutions of hydrogen of peroxide or permanganate of potash. The recovery of the wound rapidly follows, but of great assistance is the exciting of a better blood supply by suction, by exposure to sunlight or artificial light, associated with massage of the tissues. These aids to increased nourishment of the tissues are largely used at Düsseldorf, both before and after plastic operations, and it seems that by these means the sloughing of pieces of tissues, portions of flaps, are often prevented. Suction is applied after Bier's method, by means of Klapp's suction glass (fig. 6). When the glass, as bought, does not fit the surface, it can often be made to do so by the interposition of wax. If need be, the wax can be duplicated in tin, which is then joined to the glass by cement or wax.

Concerning splints to be applied in the field, the utility of ready-made bands and wires is mentioned, but some suggestions are made to be adopted in emergencies. One idea is shown in figs. 7 and 8.

This is formed of wire, about a yard of which can be cut off any wire fence to be met with in most places, and can be shaped by hand, no pliers being essential. It is fixed to the military cap. It is applicable to a case where the front portion of the mandible is torn away from the posterior portions. The front fragment drops downwards, with the attached muscles of the tongue, impeding breathing and swallowing. When the splint is fixed, breathing becomes free and swallowing is facilitated. Moreover, the dangerous swelling of the tongue and neighbouring soft parts does not occur. The general design is shown in the illustration. A ligature attached to the teeth is tied to the forepart of the wire. The designer (Hauptmeyer) has used it repeatedly in the field.

In stationary warfare the dentist will have his instruments at hand, but when the Army is moving this will not be so; nevertheless, a handy man can make use of the tools of the master gunner. Similar tools are to be found in the baggage carriage of the hospital train, where there is also gas for soldering. Thus at Cirey (France), Hauptmeyer fashioned a splint for a jaw injury out of a piece of 3-mm. wire, cut from the fence of the railway station, with a piece of tin plate from a preserve tin (to be found everywhere lying about where troops are), the solder being obtained from a telegraph company.

A further instance may be quoted. Figs. 9 and 10 show an injury caused by a bullet. There was a small wound of entry beneath the lobe of the right ear. The nasal septum, the tip of the nose, the hard palate and the alveolar border from 7 to 1 was destroyed. The lip hung down with but a small attachment. The mandible was fractured in front of the right wisdom tooth. The fractured mandible was treated with a tinned wire splint. The wound was washed with peroxide of hydrogen, all destroyed bone and dead soft tissues were




FIG. 8.

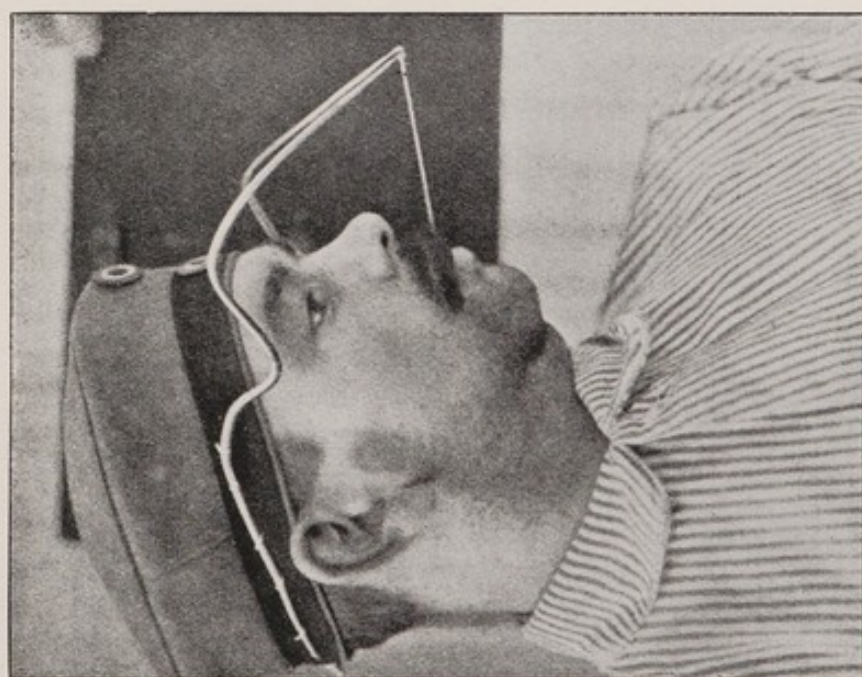

FIG. 7.

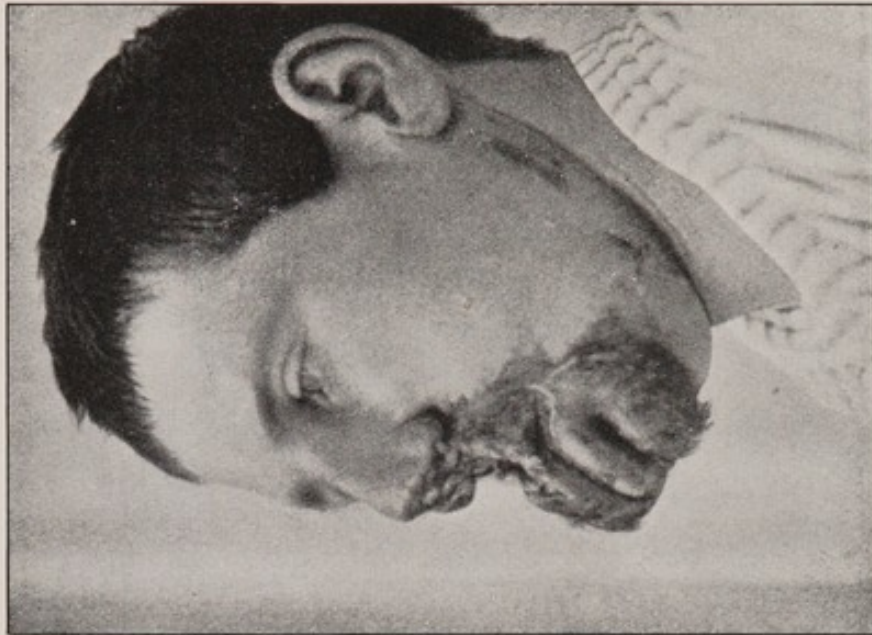


FIG. 10.

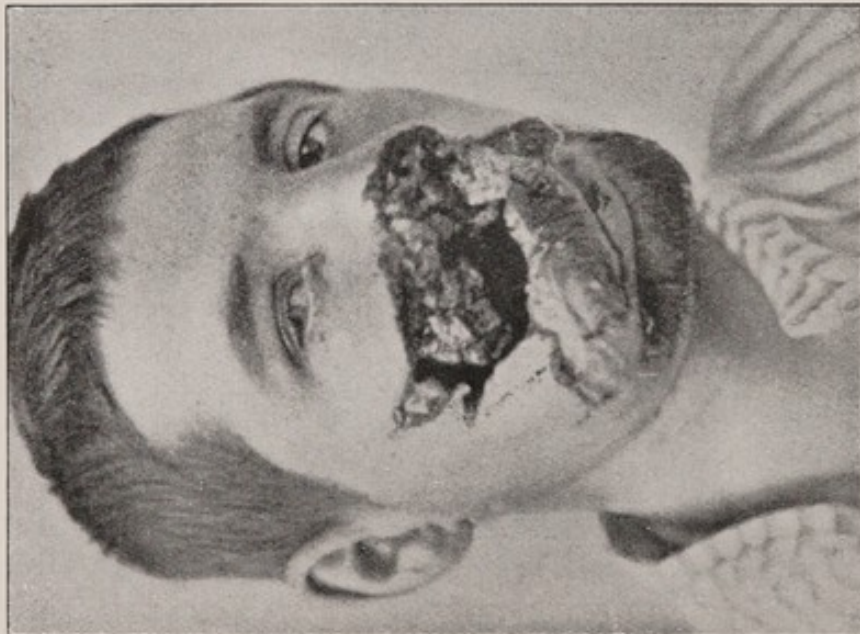

FIG. 9.

removed, and a shield was made and fixed to the teeth to support the cheek, whilst two drainage tubes were inserted in the nostrils to keep these patent. The lip was replaced and kept in position by means of two wire hooks fastened by strapping to the forehead, the pressure on the lips being guarded against by the interposition of gauze (fig. 11.) The wound rapidly healed, and three weeks later the surgeon closed the gap left and removed the scar-tissue (fig. 12). The correction of the injury to the nose followed later.

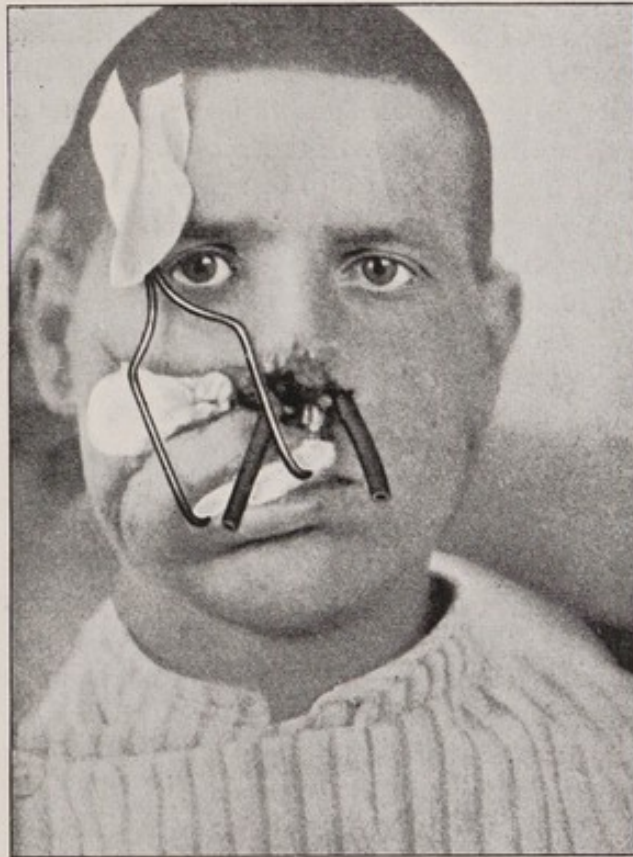


FIG. 11.

Cases in which the front portion of the lip and jaw are broken away and hang down (fig. 13) should be supported by means of a sling of rubber dam fastened by strips of bandages to the military cap or to a bandage made as seen in fig. 14.

SPLINTS.

It is pointed out that the form of splint to be used must vary with the position and character of the fracture, the character of the displacement, the size, number and position of the teeth. It is admitted that each operator will have a preference for a special form

of splint and that he will be able to use this splint with success in many kinds of cases, in some of which another dentist would fail because he had not mastered the special points needed for its application.

Bruhn is of opinion that splints should be made for each case, but he admits the utility of anchor bands and bars for application in emergency, as in field hospitals. At Düsseldorf they are also used in cases where the condition of the patient prevents an impression being obtained, but are regarded as temporary expedients, to be replaced later by other forms of splints. It is pointed out that one difficulty in the use of this form of splint is that the fractured surfaces often separate when the mouth is open. Hence, if the splint is fixed at this moment, then when the mouth is shut the teeth will be found not to be in normal occlusion with those of the maxilla.

The chief splints used appear to be: the metal cap splint and its modifications; the wire splint (Hammond) and modifications; and a splint made of cast tin.

In every case attempt is made to bring the teeth into normal occlusion. When bone is lost, and if, after treatment, a radiogram does not show any new bone formation (although from the description one gathers that this very frequently does occur, even when the ends of the bone are somewhat widely separated), then, subsequently, a bone-graft is inserted.

In the copy to hand no description is given of this operation, but Lindemann states that, in seven months from the beginning of January, 1915, he performed sixty-three cases of bone transplantation (from the context elsewhere it is gathered that they were taken from the tibia). All these were done under a local anæsthetic, and of these fifty-six healed absolutely primarily and seven secondarily. Twice suppuration occurred through accidentally opening small sequestra spaces, twice hæmorrhage occurred, and twice the result was interfered with through sloughing of the scar tissue which crossed the field of operation. Once suppuration followed, which, in the absence of other causes, may be charged to a faulty technique during the injection of the local anæsthetic.

In the absence of a description from Düsseldorf, it may be added, on the authority of Drs. Williger and Schröder, that Lindemann files a point on each end of the implanted bone. They also state that they (at Berlin) cut the ends cone shape; these are then inserted into holes drilled in the ends of the fractured jaw.¹ They insist that the essentials to success are: absolute fixity of the portions of jaw by means of splints; a small operation wound, so that the ends of the bone stumps only are exposed and not separated from the surrounding

¹ See Axhausen's observations (*see p. 79*).

soft tissue; imbedding the transplantate in as much of the surrounding soft tissue as possible before the skin wound is stitched up; the absence of foreign bodies to fix the fragments and awaiting the

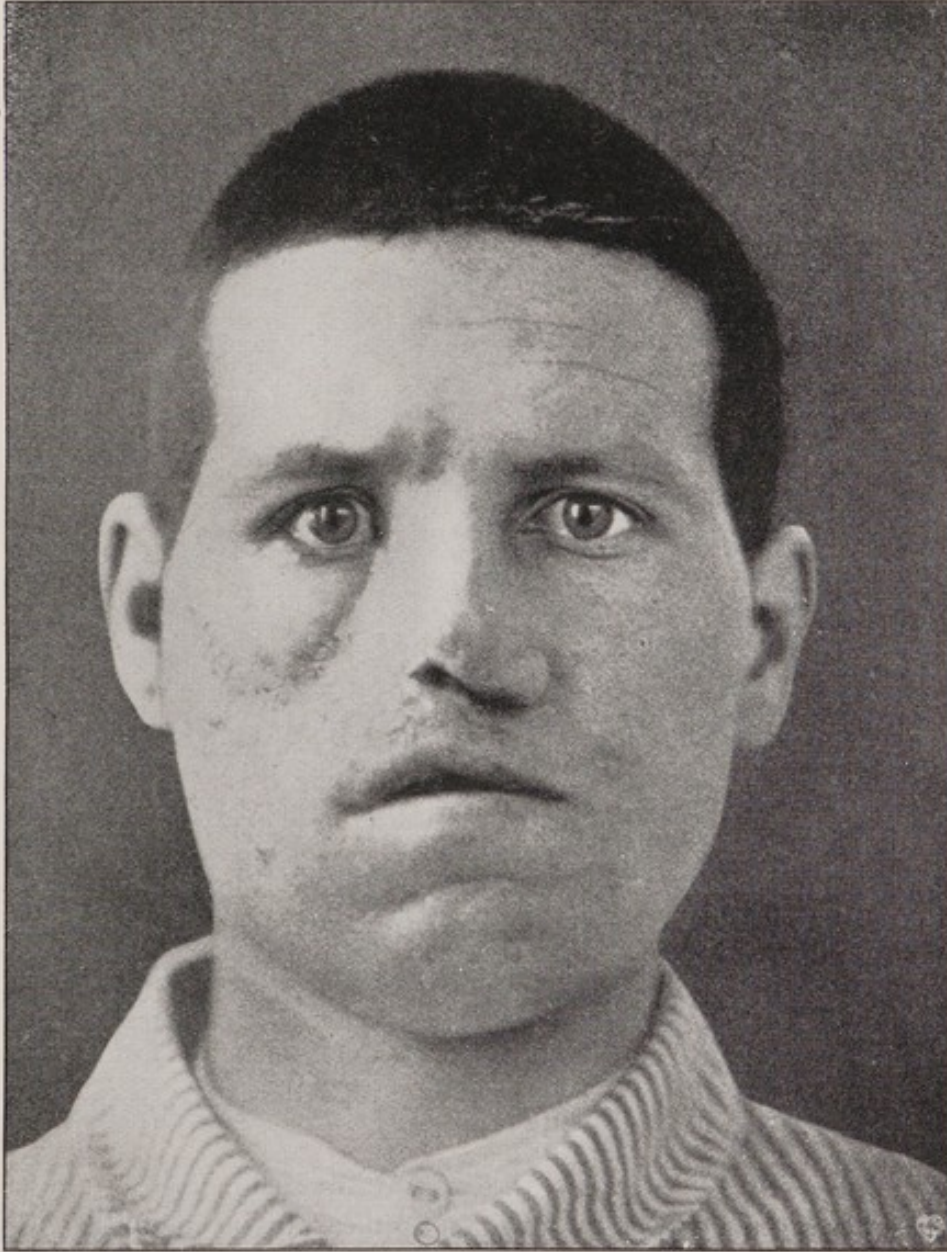


FIG. 12.

complete healing of wounds, &c., before undertaking the operation. Another way of fixing the bone is to cut each end wedge shape, and to slide it into notches cut in the bone stump. They have successfully implanted pieces 5 to 8 cm. long.

The Metal Cap Splint.

The metal cap splint described does not differ from that commonly used, but when the cement does not "stick" it sufficiently securely to the teeth, though it is admitted it usually does, the hold is increased by soldering posts on the inner surface of the caps to pass

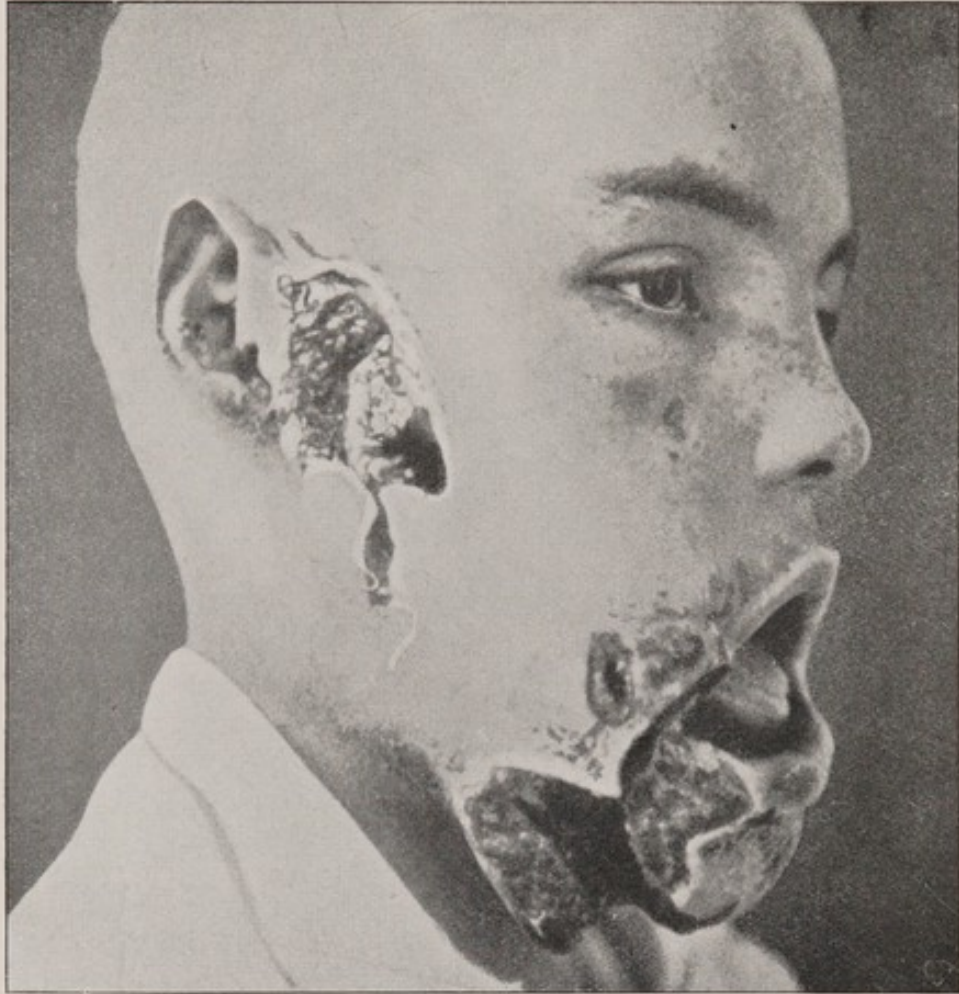

FIG. 13.

into the pulp cavities of teeth. It is said that though the tooth in the neighbourhood of the fracture may appear to be sound, it will be found that, in these gun-shot injuries, the trauma has caused the pulp to die; consequently, there is not the same objection to this method as could be justly urged if it involved killing the pulp purposely.¹

¹ The question of death of the pulps of teeth in the neighbourhood of the fracture was discussed at a meeting of the Verein Österreichischer Zahnärzte. The importance of having radiograms taken to ascertain whether the pulp was dead was insisted on by

A useful suggestion is made for fixing this splint when the two halves of the jaw have fallen together. A jack screw is fixed between the teeth in both portions of the mandible. Then by means



FIG. 14.

of this the portions of the jaw are separated until they are in their correct positions. A notch is cut in both sides of the lingual aspect

Prof. Cieszynski, who believed the early removal of the dead pulps assisted healing. Dr. Pichler regarded dead pulps as damaging the prospect of union. Prof. Weiser stated that the pulps of the teeth some distance from the fracture often die after the bone has united. Dr. Harry Sicker said that, from experiments on animals, he found after division of the inferior dental nerve the pulp remained intact, though without sensory nerves. Even ligature of the inferior dental artery had no effect on account of the collateral circulation. The majority, here and elsewhere, appears to be in favour of saving the teeth after opening up the pulp cavity, &c.

of the splint, so that it will go "home" with the screw in place. The splint is then fixed with cement and the jack screw removed.

When the front portion of the jaw is lost and the two side caps are joined together by a wire, or wires, a small vertical plate of metal soldered to the wire has been found useful to prevent this cutting the lip. A similar plate has been soldered to the wire when its fixation to the teeth is by means of anchor bands. These wires are made use of to hold the tin shields which, as will be shown later, are always used by Lindemann when a plastic operation is performed for restoring lost tissues of the face.

Hooks are soldered to these caps when it is desired to exert traction on displaced portions of bone by means of rubber bands; but, it is said, the hold of the cement has not been found reliable for this purpose, and, therefore, for such cases wire splints are used as described later.

When the maxilla is separated from the cranial bones, a metal cap splint is used with metal arms (Hayward splint). As these arms must be of rigid material, and be in the correct position to avoid irritation of the lips and cheek and to obtain traction in the right direction, it is suggested that first soft iron wires be attached to the caps, and that these be tried in and correctly adjusted. The cap and arms are then sunk in plaster; this is trimmed flush with the arms, and to the model so obtained the rigid wire (nickel wire 3 mm. thick) is bent. Short catches are soldered to the arms to prevent the slipping of the weak elastic bands, by means of which it is attached to the skull-cap. To this also a number of hooks are fixed at a distance of about 1 cm. from each other to allow the bands to be varied in position as seems desirable.

The Tin Splint.¹

The form of the tin splint is shown in the illustrations, figs. 15 and 16. It consists of two or three pieces hinged posteriorly. If there is any tendency of the mandibular fragments to lateral movement, guiding flanges are built up on one side (fig. 18), or on both, inside which the maxillary teeth close. To wire the splint to the teeth, slots are cut in the lower border of the lingual and labial portions to correspond with the spaces between two teeth, say between central and lateral incisors of both sides. A wire ligature is then passed between these teeth, leaving a large loop lingually (fig. 17). The splint is then placed in position, and the wire placed into the slots. This is then pulled tightly; the loop lies in a horizontal groove

¹ This is acknowledged by Hauptmeyer to be modelled on a vulcanite splint designed by Kersting and described in the *Deutsche med. Wochenschrift*, 1904.

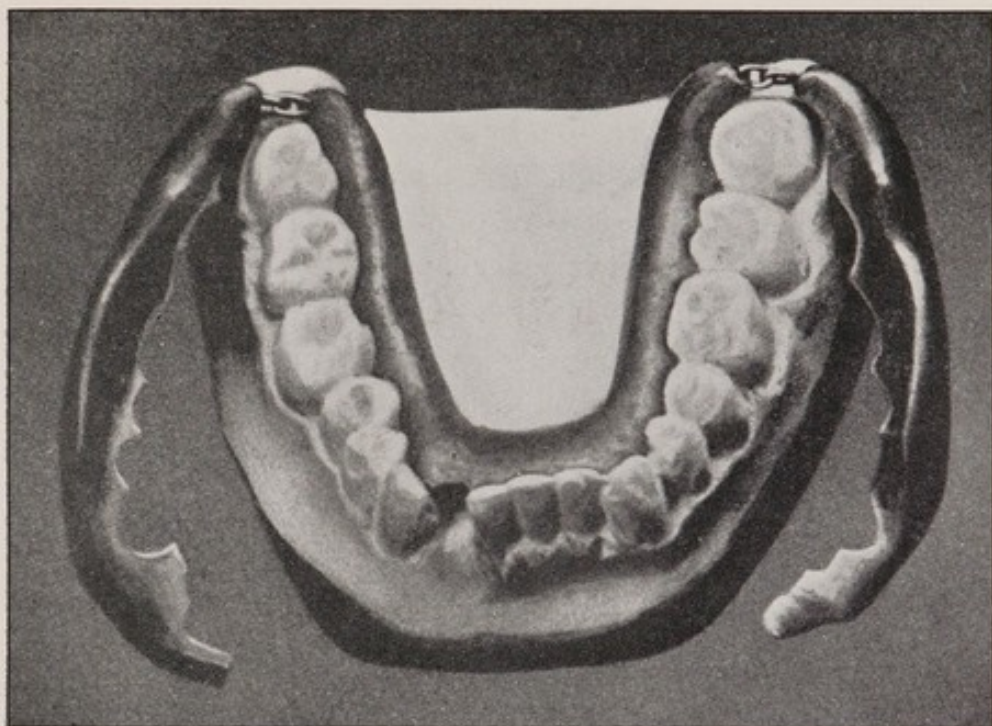


FIG. 15.

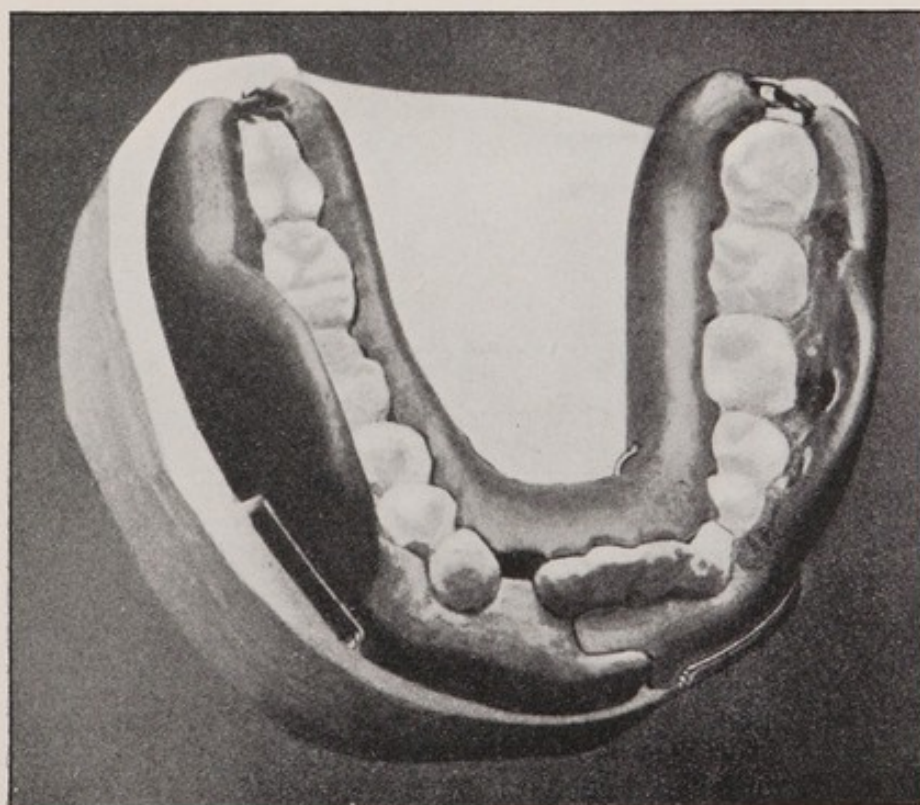


FIG. 16.

cut in the splint. The labial portion, or portions, are then adjusted, the wire being placed in the labial slots, twisted tightly, and the ends turned down (fig. 18). If there be one or more spaces between the

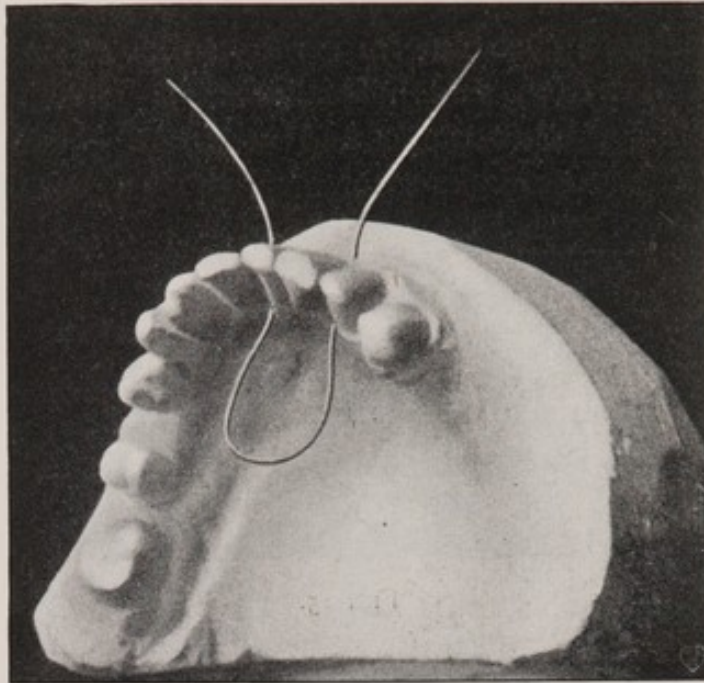


FIG. 17.

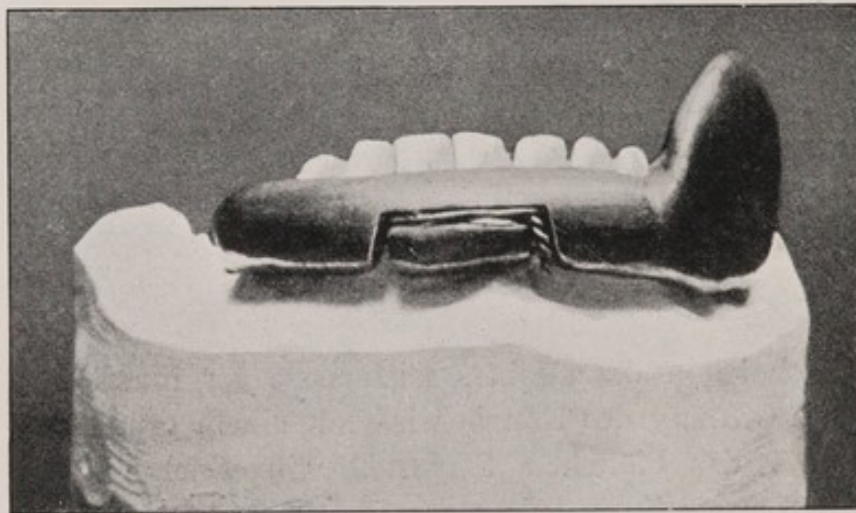


FIG. 18.

teeth, a hole can be drilled through both lingual and labial portions of the splint and the two fixed together with a bolt and nut.¹

¹ Reviewing the first section, Dr. B. Sachse says that with this form of splint the wires often work loose. Screws are better, and more easily removed and replaced.

The indication for the use of this splint is limited and confined to recent fractures with movable fragments, in each of which are several and fairly long teeth. The advantages claimed are the ease of its manufacture and fixation; the facility with which it can be removed for cleansing and reapplied. Bruhn states that, to satisfy the criticisms of visitors to the hospital, he has several times removed a number of splints, taken haphazard, which had been *in situ* for many weeks. In not a single instance was the gum inflamed or red, nor could any effect upon the enamel be detected as would have been the case had the splint been made of vulcanite.

CORRECTION OF DISPLACEMENT.

When the fractured portions are not freely movable they are brought into place:—

- (1) By the intermaxillary traction of rubber rings.
- (2) By the pressure of a screw fastened to a divided metal cap splint.
- (3) By the force of two metal lever arms attached to the teeth by anchor bands and rings and extending out of the mouth, where, after crossing, the ends are joined by rubber bands.

Sometimes the ligamentous union and the cicatricial tissue between and around the fractured ends are divided with a knife before the correction of the misplacement is commenced.

Intermaxillary traction with rubber bands is only of use when the resistance is not great. Its great advantage is the very different directions in which the force can be exerted. When the bone defect is in the mid-line it is possible not only to check the tendency to displacement inwards, but also to pull the fragments forward or backward. As previously stated, the form of splint commonly used is the wire splint, one for the maxilla to form the fixed points and one for each portion of the fractured mandible. It is recommended that these splints should be wired to each tooth to obtain absolute fixation. A series of hooks are soldered to the labial and the lingual wires of all the splints to enable the elastic rings to be fixed in any position required. As in most instances the traction should be in a horizontal direction, a wire loop is soldered to the upper splint, which bends downwards to about the level of the articulating surface of the upper teeth. The elastic band, to obtain horizontal traction, is fastened to the labial hook of the upper splint, passes then over the loop and is attached to the lingual hook of one or other of the mandibular splints. The arrangement is shown in fig. 19. When the portions of the mandible are luxated into position a piece of strong wire, bent to shape across the gap, is securely ligatured to the splints on the mandibular fragments. It serves as a retainer till bony union forms, or a bone-graft be completed.

A useful attachment to the wire splint, designed by Schröder to prevent backward displacement of the mandible, is shown in fig. 20. A vertical rod is soldered to the lower wire, which fits in a hood soldered to the upper. Metal flanges are also used, soldered to the wires, upper and lower, to act as an opposing force when unilateral movement is desired (fig. 21).

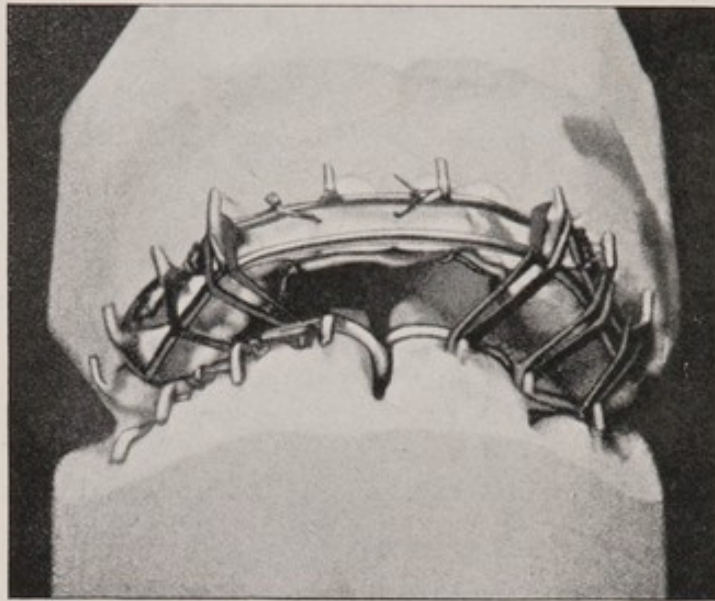


FIG. 19.

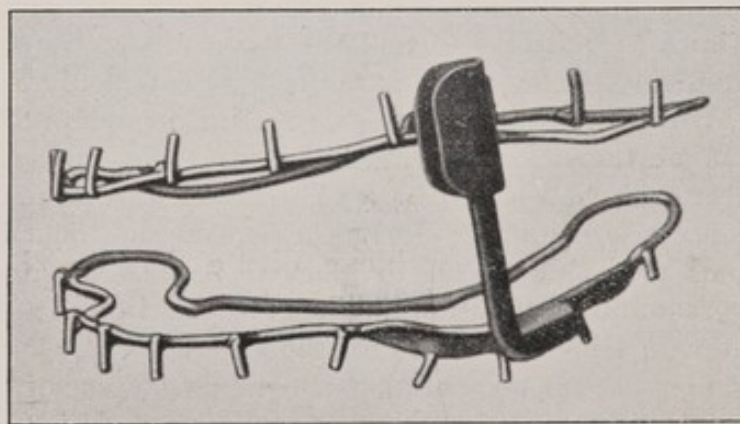


FIG. 20.

When the rubber bands would not exert sufficient force, an expansion screw is used attached to metal caps (fig. 22). The vertical plates shown not only prevent over-expansion of the fragments, since, when the normal position is reached, they lock against the lingual surfaces of the upper teeth, but they secure bilateral symmetry,

because if one side moves more rapidly than the other, its further movement is prevented when it has reached its proper place. This idea may be applicable to orthodontic appliances.

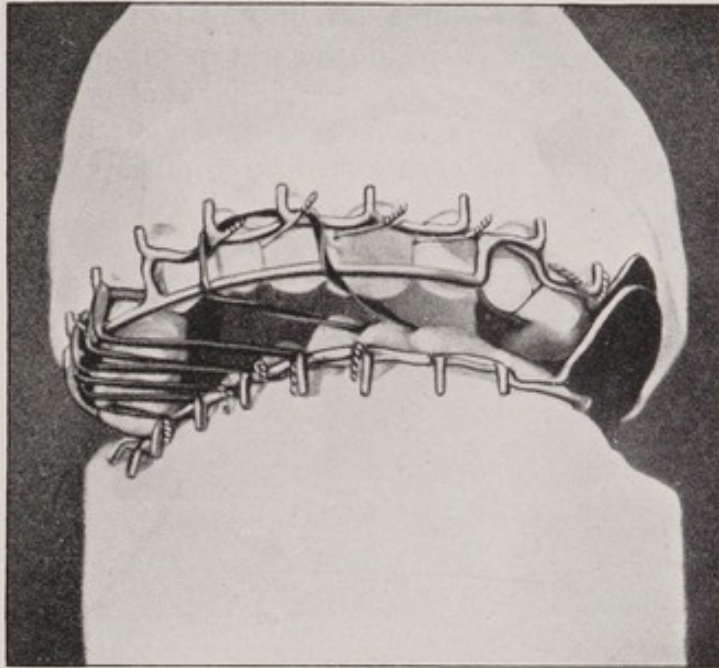


FIG. 21.

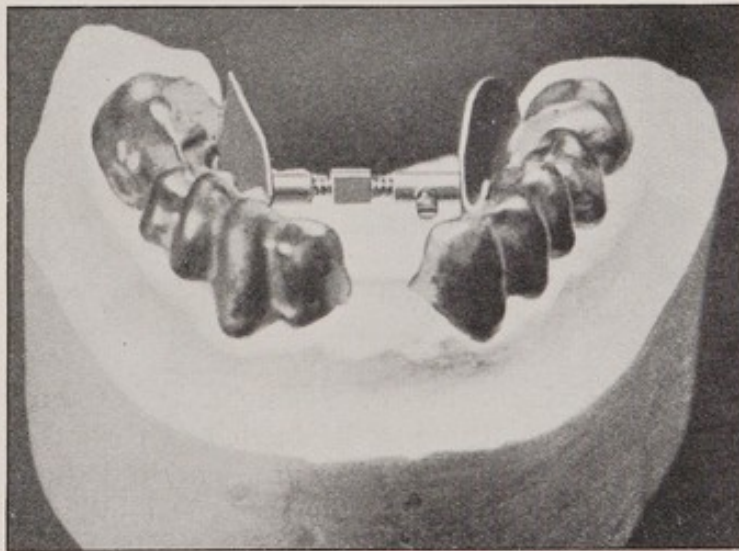


FIG. 22.

The Zielinsky screw used is shown in fig. 23. The central portion has two holes, at right angles, drilled through it for insertion of the lever (*d*), and a right and left screw (*a*) on either side. A sheath (*c*) is continued over the lateral pieces, giving rigidity when these are

separated, and a smooth covering to the whole. The natural sizes are shown in fig. 24.

The splint, with lever arms, as shown in fig. 25, is used in cases of extreme resistance. The bands are screwed and cemented to the teeth. The direction of the force is regulated by the position of the arms. When the bone is in the correct position, the arms are soldered together with soft solder at their point of crossing, and the portions beyond are cut away. After a time the splint is removed and a retention apparatus, caps joined by wire, is cemented to the teeth.

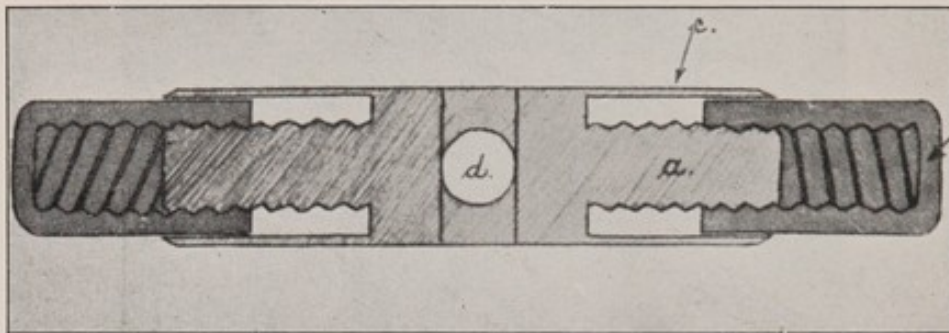


FIG. 23.




FIG. 24.

When teeth are absent in one fragment, both fragments being movable, a cap splint cemented to the teeth and connected by wires to a vulcanite hood, closely fitting over the toothless stump of bone, served in one case to give rigidity till a bone-graft bridged the space left by the lost bone. In another case bone was lost from the symphysis to the middle of the left horizontal ramus. In the right side the molars, premolars and the root of the canine were present; on the left side the teeth were so loose that they had to be removed. Displacement of the right side was prevented by fixing a metal cap splint with a guiding flange locking on the buccal side of the upper teeth. To pull the left side into place, and retain it till the tissues

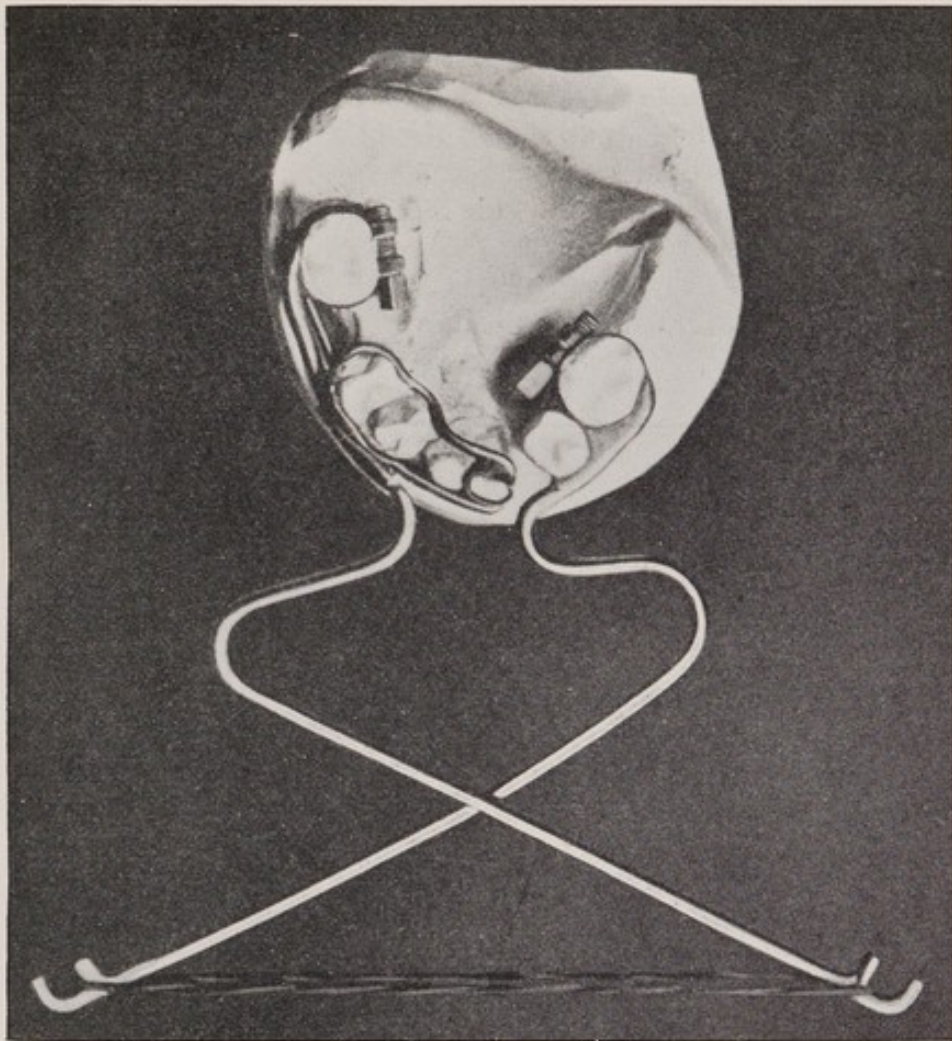


FIG. 25




FIG. 26.

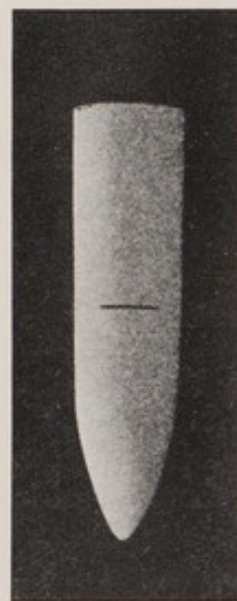


FIG. 27.

had healed sufficiently to enable a bone-graft to be inserted, the following method was adopted: A broad silver needle was driven into the bone, shown natural size in figs. 26 and 27, to the distance shown by the mark. Fig. 28 shows the apparatus used. This kept the right side in position by means of a weak elastic band and drew the left side outwards. As this side had not only fallen inwards, but was tipped over towards the tongue, the rubber bands were so arranged that the fragment was turned on its long axis towards the left and so brought back to its normal position. Though this was worn for

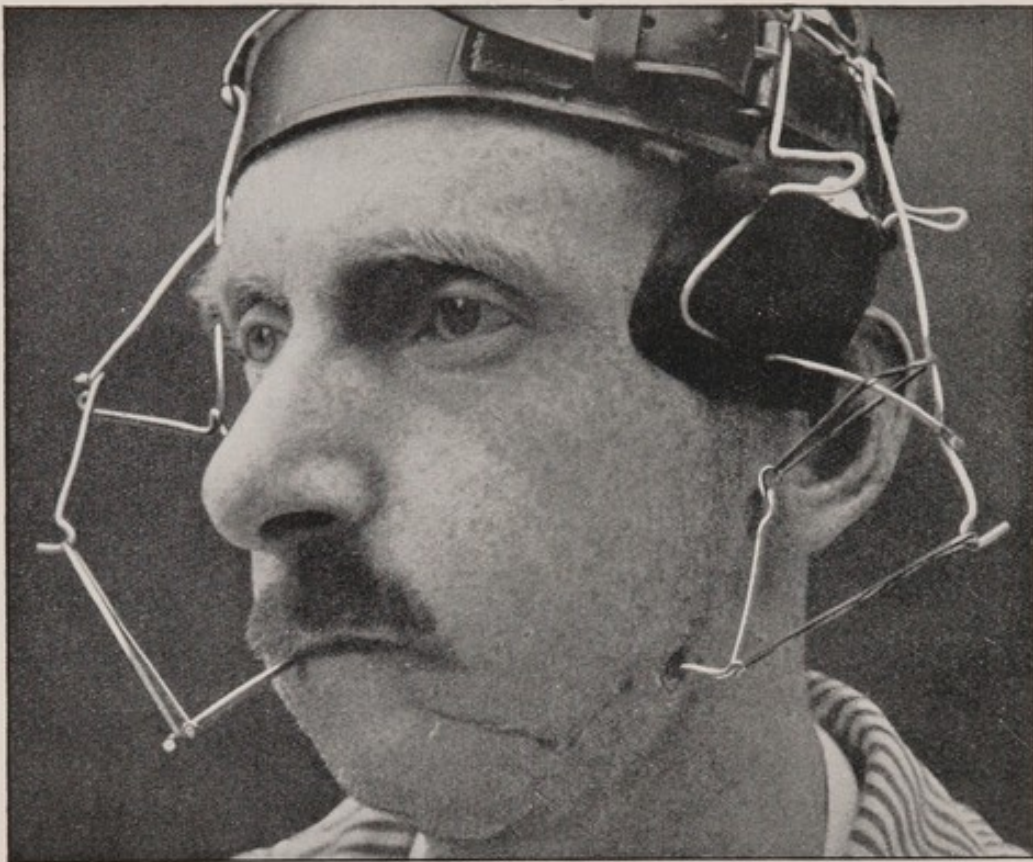


FIG. 28.

several weeks no inflammation was noticed. The needle was left in place till the bone implantation had been performed. After the operation the right side of the mandible showed an inclination to move away from the graft, hence a wire, curled to form a spring, was fixed to a head bandage; several small cross-wires were soldered to the lower end of the wire and these, resting on a pad of wool, pressed against the cheek, so preventing movement. After the implantation, or after the new bone has formed, bridges are used

to support the mandibular fragments and to fill the spaces where teeth have been lost. It is recognized these should be made of gold, and to some extent the difficulty of expense has been met by gifts of gold ornaments, &c., to be used for this purpose.

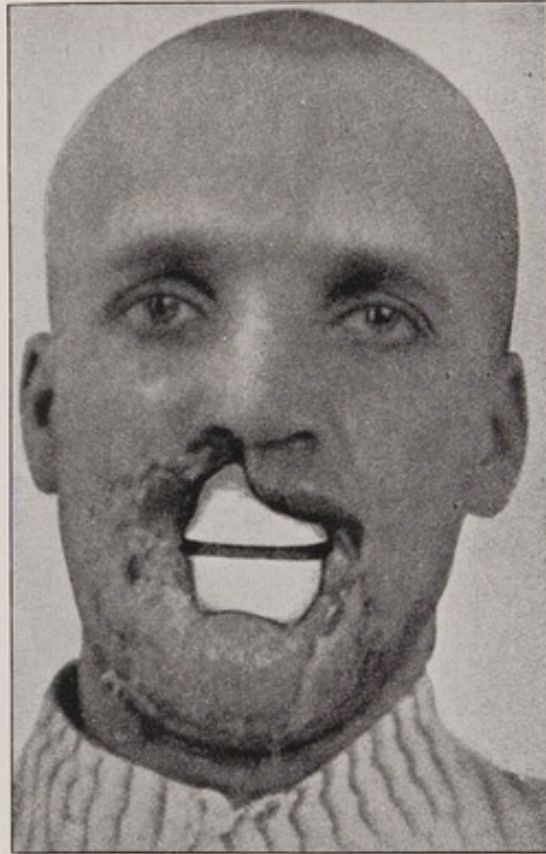


FIG. 29.

SHIELDS FOR PLASTIC OPERATIONS.

Whenever a plastic operation on the face is to be performed, a pure tin shield is previously inserted. It is admitted that when there is a scarcity of tissue this complicates the formation of the flaps and adds to the difficulty of the operation, but these drawbacks are compensated for by the improved results attained. These shields are fixed to the splints or, in the rare case of there being no fracture of the bone, to the teeth (fig. 29). In this case the shields not only support the flaps but are a guide to the depth and fulness of the lips which should be fashioned.

NASAL SPLINTS.

Apparatus to be used in assisting the restoration of the nose after injury is described by Walter Ahrend. A form designed by

Ernst, sold ready-made, is shown in fig. 30. The vertical bars end in two iron plates; these are embedded in a plaster bandage by which they are fixed, without pressure, on to the head. Further support is given by the two lead plates seen to be resting on the malar bones. The general design is apparent from the illustration. Any, or all, of the nasal supports are used as the nature of the injury demands.

But at Düsseldorf the apparatus used has been made at the hospital, quickly and simply. The principle is a double lever with

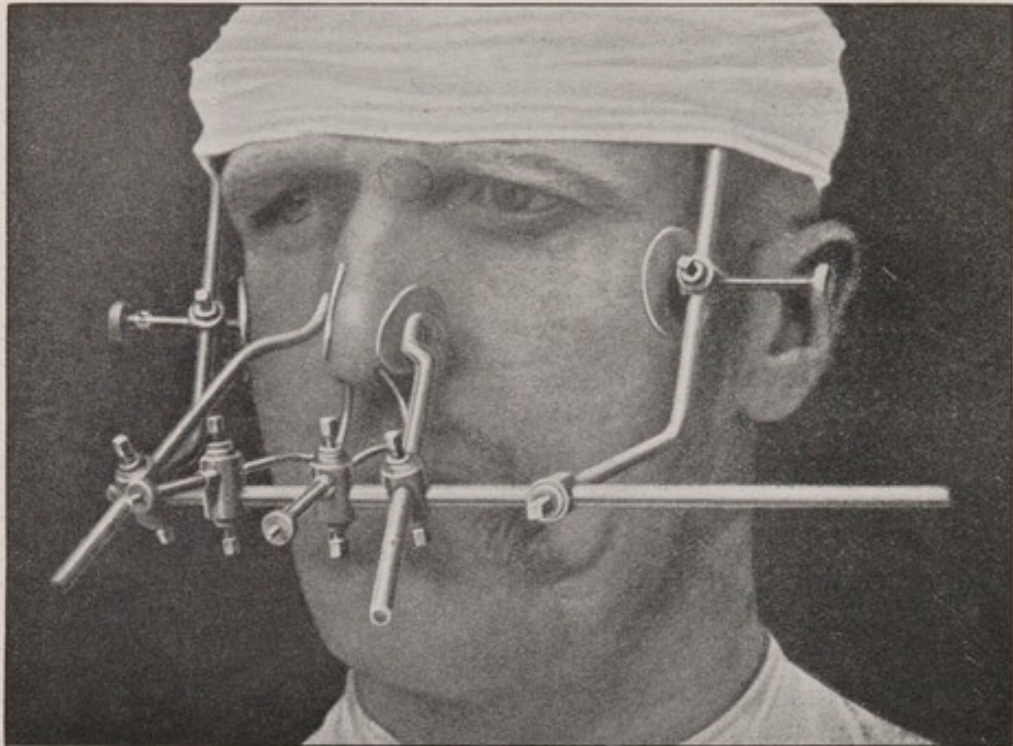


FIG. 30.

a plug inserted in the nares, force being exerted by elastic bands and support being obtained by a wire soldered to a metal cap, cemented to the upper front teeth, or, if no teeth be present, fixed to a head bandage. It is arranged so that, by undoing the elastic bands, the nasal splint can be removed and cleansed by the patient. Silver wire is used. Soft soldering suffices.

The working of the apparatus is apparent from the following cases:—

(1) A bullet wound. Entry below the left malar bone; exit the right cheek. Right maxilla destroyed; right mandible broken. Marked sinking of lower part of nose in consequence of fracture of nasal bones. After division of cicatricial tissue the apparatus

shown in fig. 31 was fixed. Attachment by metal cap splint. The wire *a, b*, is filed thin and fits into, and is movable in, a ring soldered to the horizontal wire. Traction is by the elastic band *b, c*. The wires passing into the nares have attached two olive-shaped bodies, of tin or vulcanite, which press on the inner side of the walls of the fore part of the nasal cavity. These bodies have as large a hole bored through them as is possible to allow the passage of air and are kept covered with vaseline to prevent adhesion.

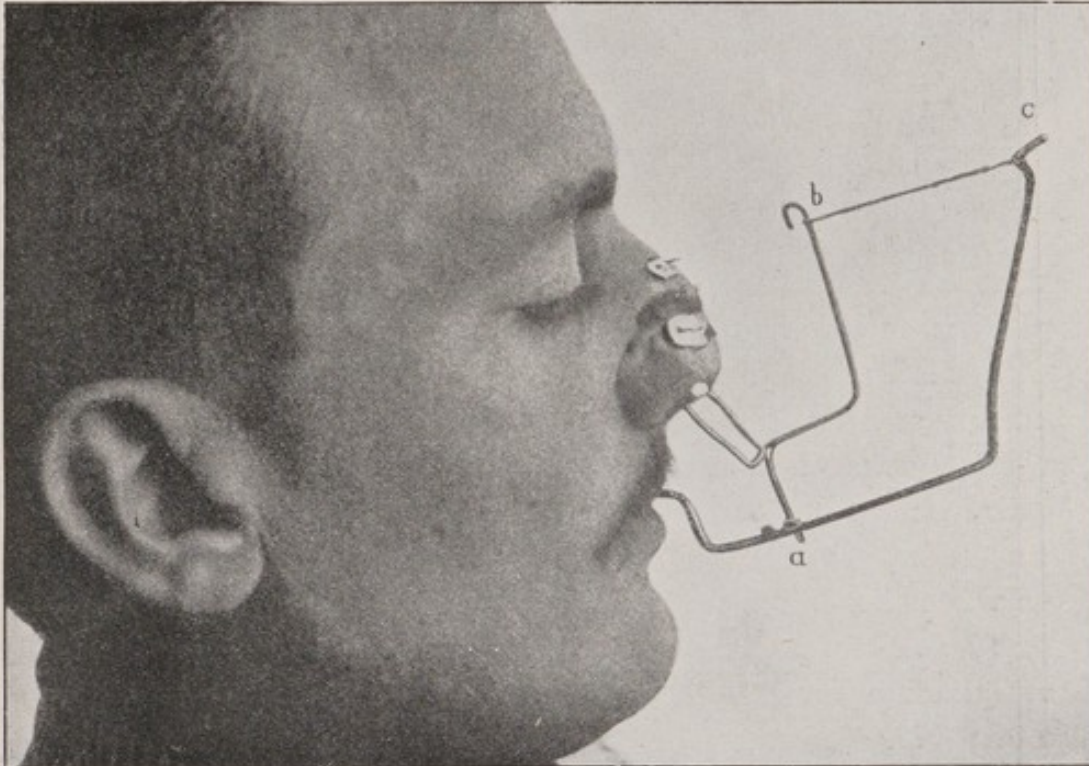


FIG. 31.

(2) Slanting shot. Entry, right cheek. Exit, neighbourhood of right horizontal ramus of mandible. Front portion of body of maxilla and alveolus, with teeth, destroyed. In consequence of partial loss of right ala, the nose by cicatricial contraction was drawn to the right and the right nares was contracted. The apparatus shown in fig. 32 was fixed by means of a metal cap splint. The force was the elastic at *e*. The thin elastic *e, f* was used to steady the lever.

(3) Entry under the left eye. Exit, right corner of mouth. Broad defect in region of hard palate. Loss of upper teeth. In consequence of the loss of the nasal bones, there was a saddle-shaped sinking of the bridge of the nose. Here, because of the loss of the teeth, the

fixed point was a skull-cap to which was fixed a circle of 3 mm. thick silver wire. The lever carries two "olives," and the pointed lower end fits into and is supported by a ring, fig. 33.

(4) Splinter of shell. Destruction of all of the maxillæ, ethmoid and nasal bones and a portion of the malar bones. Nose much depressed. A rubber plate, with vela rubber attached, shut the mouth from the

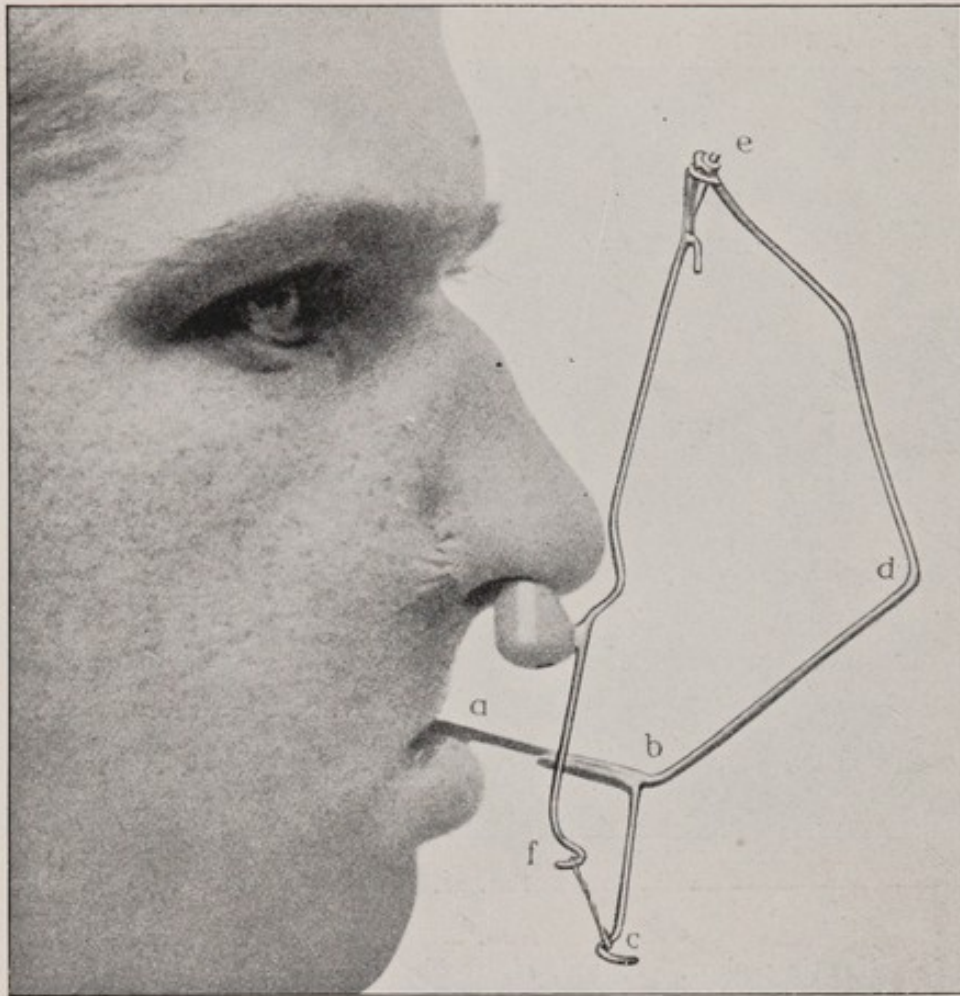


FIG. 32.

damaged parts. Two wire bows pass right and left outwards from this plate and are fixed by attachments to the head cap. The lower end of the nasal lever fits into a ring soldered between these wires. An elastic band passes to the upper end of the lever from a wire fixed to the cap (fig. 34).

The apparatus shown in fig. 35 was designed by Bruhn and Kühl for support of the right nostril during its healing after a plastic operation. Skin flaps were transplanted from the right arm. The

"olive" is moved laterally in the cross splint by means of a screw. Traction is exerted by an elastic band passing from the hook to the notched wire. The apparatus is fixed by means of a metal cap splint.

In the following case, the left cheek was torn and the left maxilla detached from the cranial bones below the malar bone. The nostril was torn and no nasal septum, except a mere rudiment, was left.

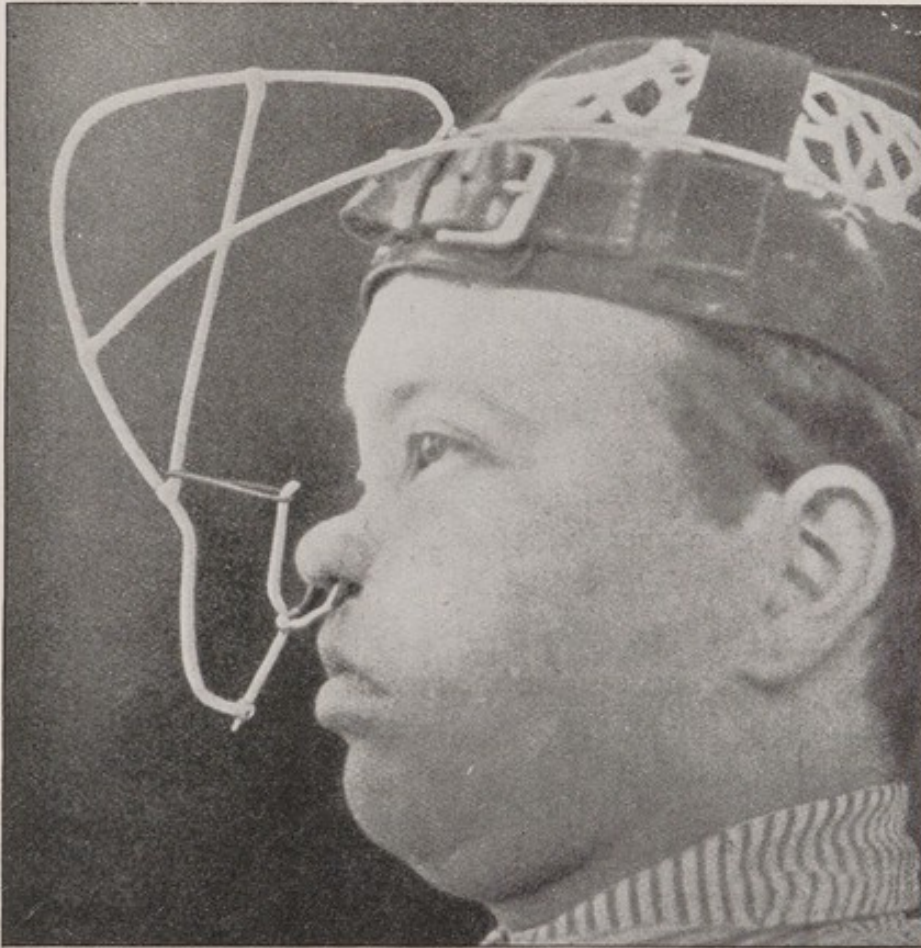

FIG. 33.

A wire splint was attached to the upper teeth with extra-oral wires, which were joined by rubber bands to wires attached to a skull-cap. A square wire, soldered to these extra-oral wires, formed a support to the nasal splint. They were joined as follows: A square tube enclosed the centre of the square wire and was movable on it. This supported a vertical, square cannula into which the post of the nasal splint fitted. This cannula was clamped to the first cannula by means of a movable cross-bar. Hence, the nasal splint was easily removable for cleaning



FIG. 34.




FIG. 35.

(fig. 36). The nasal splint consisted of two tin "olives" which prevented cicatricial contraction.

MOUTH OPENER.

A form of lever to be used when the jaws cannot be separated on account of cicatrices is shown in fig. 37. The rigid wires are fixed to metal cap splints cemented to the teeth, the splint being struck up to a model obtained by forcing open the mouth with a screw wedge. For this purpose an ordinary wooden paper clip is commonly used at Düsseldorf.

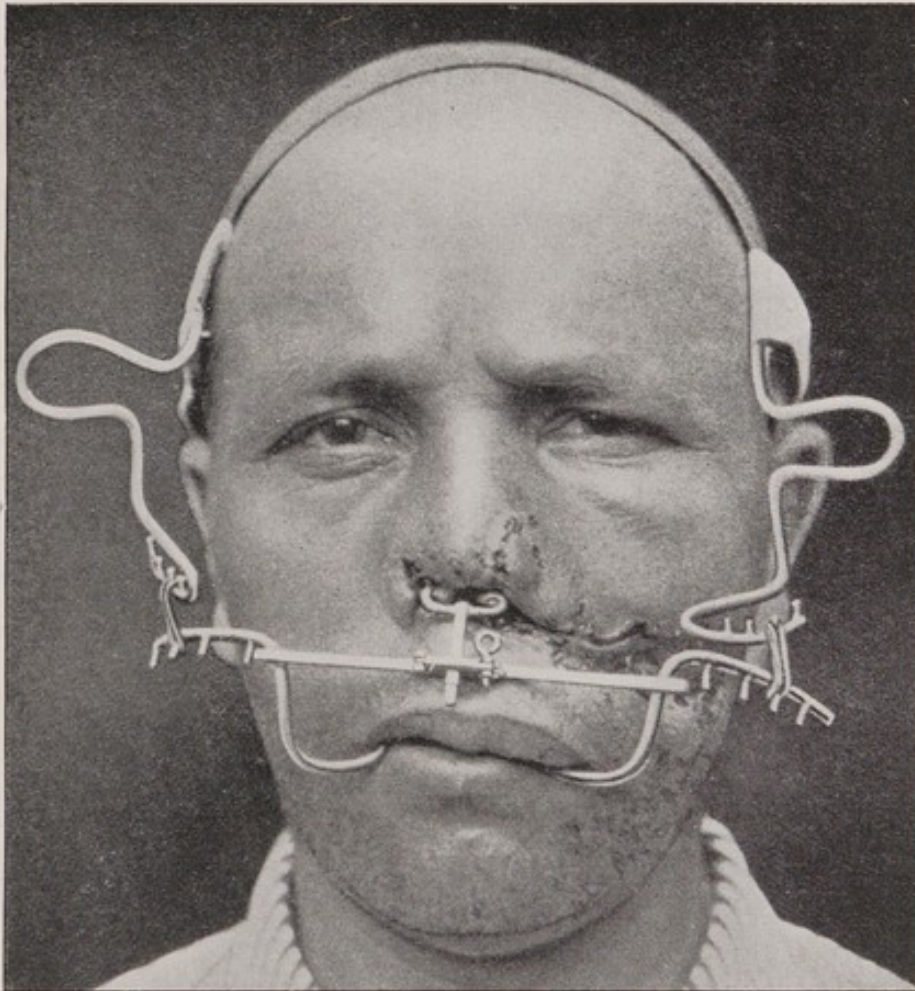


FIG. 36.

ORAL ORIFICE DILATOR.

The forms of this device are shown in fig. 38. The movement in the lower form is caused by the traction of a rubber band attached to the two hooks. It was designed for use when the oral orifice is contracted after plastic operations, especially those undertaken to

form a new lower lip. If only a one-sided action be required, it can be obtained by attaching one side to a band round a tooth; hence this point is fixed, the other moves.

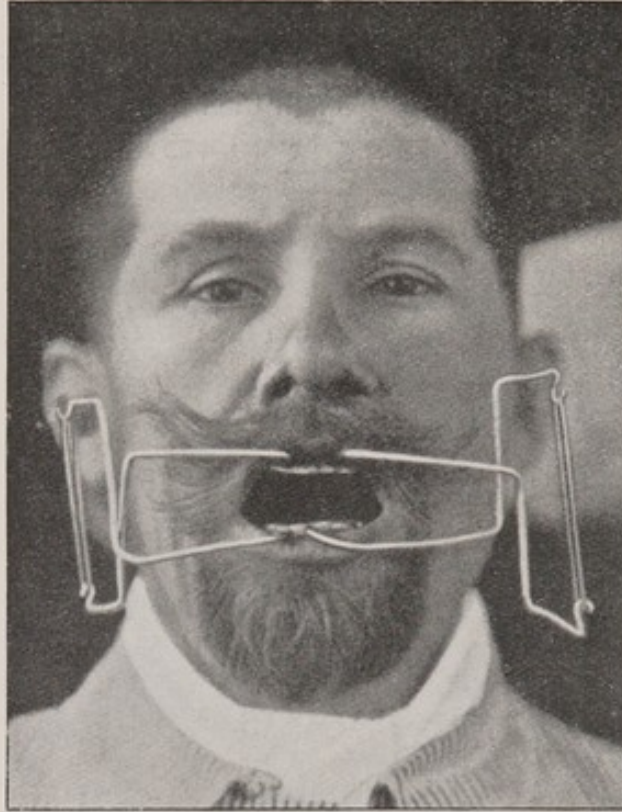

FIG. 37.

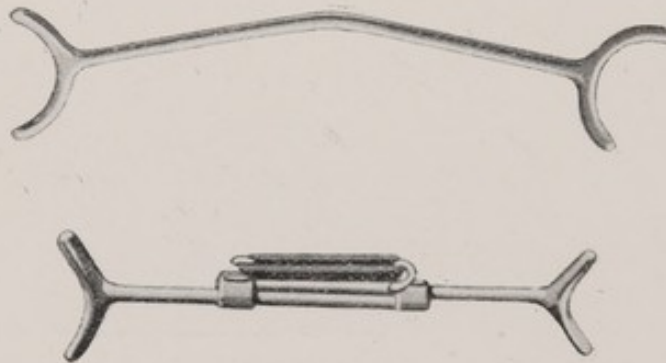


FIG. 38.

PLASTIC OPERATIONS.

LOCAL ANÆSTHESIA IN GUNSHOT INJURIES OF THE FACE.

Lindemann prefers to perform all plastic operations of the soft tissues and all bone-grafts under the influence of local anæsthesia. He regards this as preferable to general anæsthesia, since the latter,

either during the administration of the anæsthetic or during recovery therefrom, is likely to be associated with some disturbing factor, sickness, movement, &c., inimical to the success of the operation.

In every case he uses novocaine with the addition of suprarenin. In severe cases an injection of morphia is given from fifteen to thirty minutes before the operation. Extreme importance is attached to the preparation of the solution and to its being prepared fresh daily. Only powdered novocaine is used, *i.e.*, no "tabloids," &c. The distilled water obtained is redistilled. To the requisite amount of novocaine enough NaCl is added to make a 0.75 per cent. solution. The fluid is filtered through a porcelain filter and then sterilized for twenty-five minutes in a water-bath. The solution is preserved in glass-stoppered bottles with glass over-caps. The suprarenin is added shortly before the solution is to be used and taken from a vessel which enables the transfer to be done in an absolutely sterile manner: usually 1 drop to 1 c.c. of solution. If, as sometimes happens in high percentage solutions from some unknown cause, a coloration of the solution takes place during the boiling in the water-bath, or soon after, it is rejected. If after one injection any solution remains in the syringe this is thrown away and fresh is taken.

For simple cases a purely local injection suffices, but for extensive operations (plastic operations, bone-grafts, &c.) the injection must be into the nerve supplying the region. A 2 per cent. solution of novocaine is used with 1 drop of suprarenin to 1 c.c. From $\frac{1}{2}$ to 2 c.c. of the solution is required. The more accurately the nerve is reached, the less is the solution required. The position at which the nerve is to be injected (primary division or branch) will be determined by the extent of the field of operation. Sometimes two neighbouring divisions must be injected, and in operations in the mid-line of face both right and left divisions. The duration of the anæsthesia is about an hour and a half, but sometimes lasts two hours. If this time does not suffice, as, for instance, in difficult bone-grafts, it is better to finish the operation under a general anæsthetic rather than to complicate matters by making another injection. In the cases under consideration the first division of the fifth does not often require to be injected, but can be reached by the method of Braun [1].

The area of soft tissues supplied by the second division can be anæsthetized by injecting the nerve at its exit from the infra-orbital foramen. But if the operation involves the maxilla, the nerve must be reached before the branches to it have been given off, *i.e.*, in the pterygo-maxillary fossa. Lindemann uses two methods to reach the nerve in this position, either by introducing the needle through the outer part of the lower eyelid (*see* fig. 56), thence through the infra-orbital fissure to the foramen rotundum; or, less frequently, by

introducing the needle below the zygoma, passing the needle downwards into the pterygo-maxillary fossa. The third division of the fifth nerve can be reached at the foramen ovale, also through the pterygo-maxillary fossa, the needle being introduced under the middle of the zygoma. In the case of the field of operation involving the neck, the cervical nerves are injected.

Illustrations are given which partially elucidate the methods, but, as useful literature on this subject, the following references are added :—

- [1] BRAUN. "Hand-und Lehrbuch der Lokalanästhesie."
- [2] BOCKENHEIMER and PAYR. Quoted from Braun.
- [3] OSTWALD and SCHLUSSEK. Quoted from Braun.
- [4] SEIDEL. "Neue Hilfsmittel zur Lokalanästhesie," *Deutsch. Monatschr. f. Zahnheilk.*, 1913, Heft 8.
Idem. Ibid., Hefte 31 and 28.

Lindemann claims that no evil results have followed the injections. But there has occurred passing inflammation of the orbital tissues; temporary disturbance of the function of neighbouring nerves; exceptionally, subconjunctival hæmorrhage and hæmorrhage into the soft tissues below the zygoma, both of which cleared up; once some fluid escaped from the foramen rotundum. In this case there was a fracture of the maxilla, and the nerve being divided, the reaction usual on reaching it was absent. No harm resulted, but it acted as a warning against penetrating beyond the recognized distance. It must be remembered that, in cases of bone fracture, the nerve may be divided, and therefore the reactions expected when the needle reaches the nerve would necessarily be absent, and could not warn the operator that the needle had penetrated deeply enough.

TECHNIQUE OF THE PLASTIC OPERATION.

The field of operation is treated with iodine and mastic oil.

The scheme adopted for shaping the flaps is indicated in the following cases. It appears to be immaterial in which direction their long axes run. Lindemann has not seen any interference with the blood supply, but the base of the flap must not be too small. In turning the flap proceed slowly; if while doing so there appears to be any interference with the blood supply, Lindemann prefers to wait twenty-four hours before completely suturing the flap, but brings it approximately into position by means of the deep wire sutures.

For the wound itself, Lindemann uses a continuous suture of the finest silk, taking up only the surface tissue, there being six to eight stitches to a centimetre. For security a knot is tied here and there.

The chief support is given by deep wire sutures. Nickel wire is

used, and to let the hole made by the needle be as small as possible, and to avoid the thickness formed by wire being doubled back at the eye, Lindemann has adopted Hauptmeyer's suggestion of soldering the wire to the needle (fig. 39). The sutures must not pass through the mucous membrane. They are placed about 1 to 1½ cm. apart and are tied over plates, placed on sound tissue, so tightly that the wound margins are brought together, so taking all strain off the silk




FIG. 39.

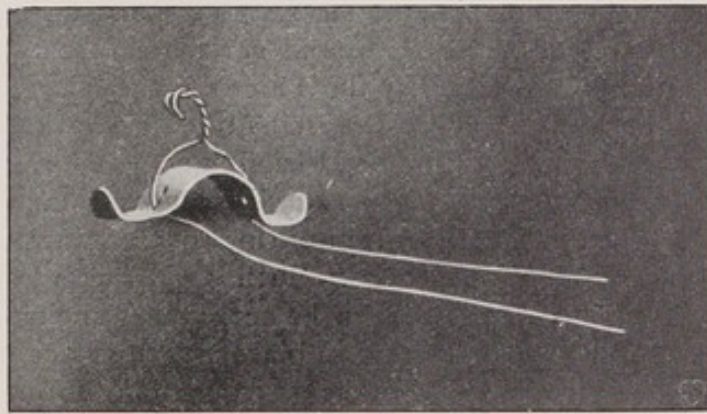


FIG. 40.

sutures. The plates must be so placed as not to interfere with the blood supply, and they must afterwards be watched to see this does not happen. If it should, the pressure must be relieved by loosening the wire. Lindemann uses the form shown in fig. 40 when the flaps are large, which diminishes the skin area pressed upon. They are placed at the base of the flaps. Should primary union fail, the deep sutures keep the flaps in position, and by tightening them the wound margins can be brought in contact. In the case of plastic operations

of the lower lip, support is sometimes obtained by fastening one end of the wire to a head bandage.

A separate flap of mucous membrane must be formed from that of the mouth to form the red margins of the lips and to line these. Where no lining exists, the cheek and deep tissues must be kept separate by mastic plugs till the epithelium has grown over, otherwise adhesions form. The mucous flaps are separately stitched with silk. After the operation, which is lengthy, the wound is again painted with iodine and exposed to the air and to sunlight. The following day the wound is carefully gone over with suction glasses to remove any collections of blood or discharge. No dressing is used but a light bandage is applied at night. On the fourth or fifth day a systematic treatment with suction glasses begins. The suture lines are often painted with iodine and the wound exposed for hours to sunlight, or to concentrated sun rays. The silk sutures are removed about the fourth to the fifth day, by swabbing with spirit, or benzol, after division; the wire sutures from the sixth to the eighth day.

Should the flaps be large and the operative procedure long, a stitch is left loose here and there, and a small drainage tube left in for twenty-four hours. This is usually done in the neck region and nearly always at the side of the nose, where the loose tissue fills the canine fossa. When the flaps cannot be fashioned from the contiguous regions, a flap is taken from the arm or forearm. The flap must have epithelium on both surfaces. This can be attained by cutting a flap and sewing on its wound surface with catgut sutures a layer of epithelium, prepared by the Thiersch method. Such a flap is apt to shrink, especially whilst it remains free during the eight days usually necessary for union of the epithelial layer. To overcome this shrinkage, Lindemann makes a pocket in the subcutaneous tissue by a widely extending cut, and into this pocket introduces two Thiersch layers, separated by gauze. Such a flap cannot shrink and has the further advantage that it can be cut later to the shape shown to be requisite. When the flaps are in place a raw surface 1 to $1\frac{1}{2}$ cm. wide is made to give a bed for the mucous flaps to form the lip margins. When a portion of the mandible has been lost as well as the cutaneous structures, and it is desired, later, to insert a bone-graft, it is necessary to thicken the relatively thin, newly formed chin by means of large fat transplantations; otherwise the mouth will be opened, and naturally the result of much careful work will be spoilt.

Lindemann says that in general the results of these methods are good, but the more familiar one is with the methods of flap operations and transplantations, the more one recognizes that it is best not to attempt at one operation to complete the restoration of soft tissues. Failures teach to moderate efforts to attempt to attain quickly perfect results. The patient, and especially the surgeon, must have patience if perfection is aimed at.

The following cases illustrate the methods of treating wounds followed by Lindemann, and give details of the plastic operation:—

Case 1.—Point of entry, left side of neck behind the ear; exit on the face on the same side. Ascending ramus up to the condyle destroyed. A child's fist could have been passed into the wound of the soft tissues, which opened up the mouth. The piece of tissue

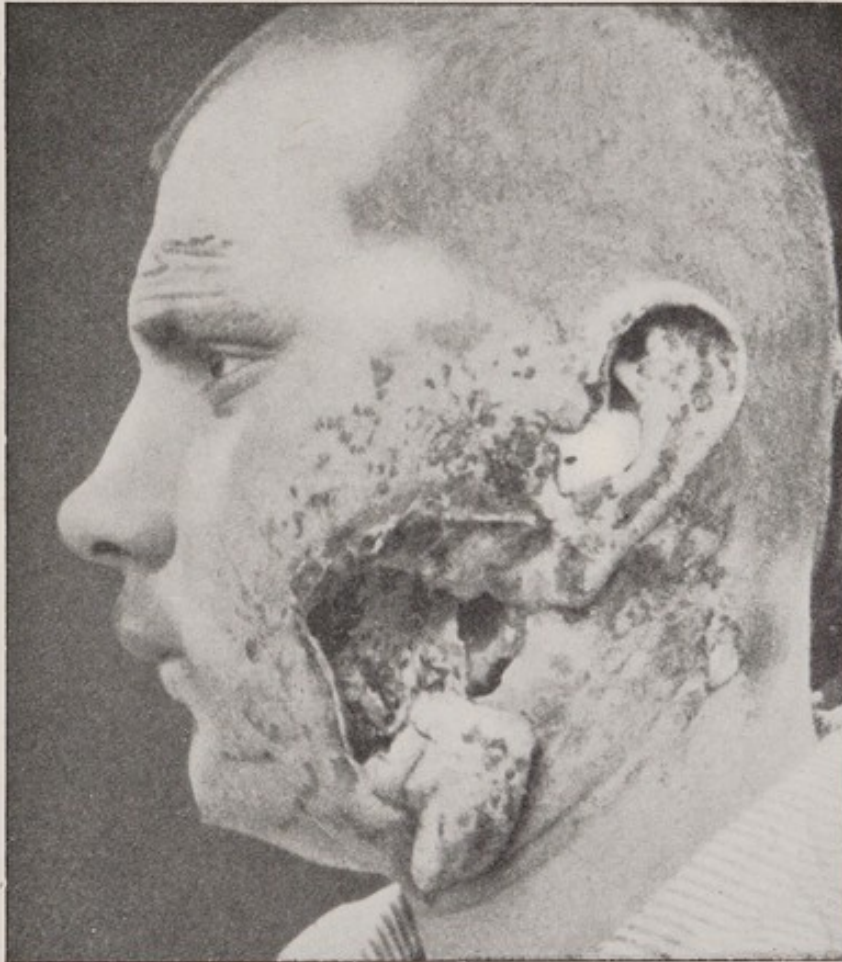


FIG. 41.

hanging down seemed well nourished, but shrunken (fig. 41). The wound was seventeen days old, and suppurating. The bone exposed was stripped of its periosteum, and the tip of it was necrotic. The wound was exposed to the air and to the sun's rays alternately with treatment by suction glasses and by washing. It cleaned rapidly and began to heal, and its edges were drawn together by strips of strapping renewed daily. Later the plastic operation was performed. The good blood supply, due to the thorough exposure to the sun's rays and the suction treatment, caused primary union to follow, except in one small spot behind the ear. The details of the flap

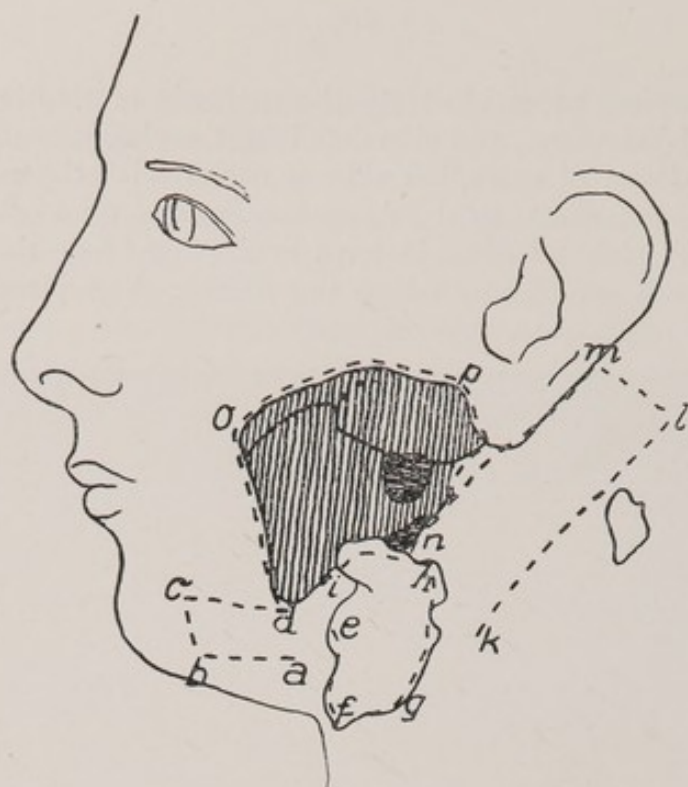


FIG. 42.—*a, b, c, d* = } newly formed flaps with bases at *a d, a i, k n,*
e, f, g, h, i = }
j, k, l, m, n = }
d, o, p, n, extent of pared edges of wound.

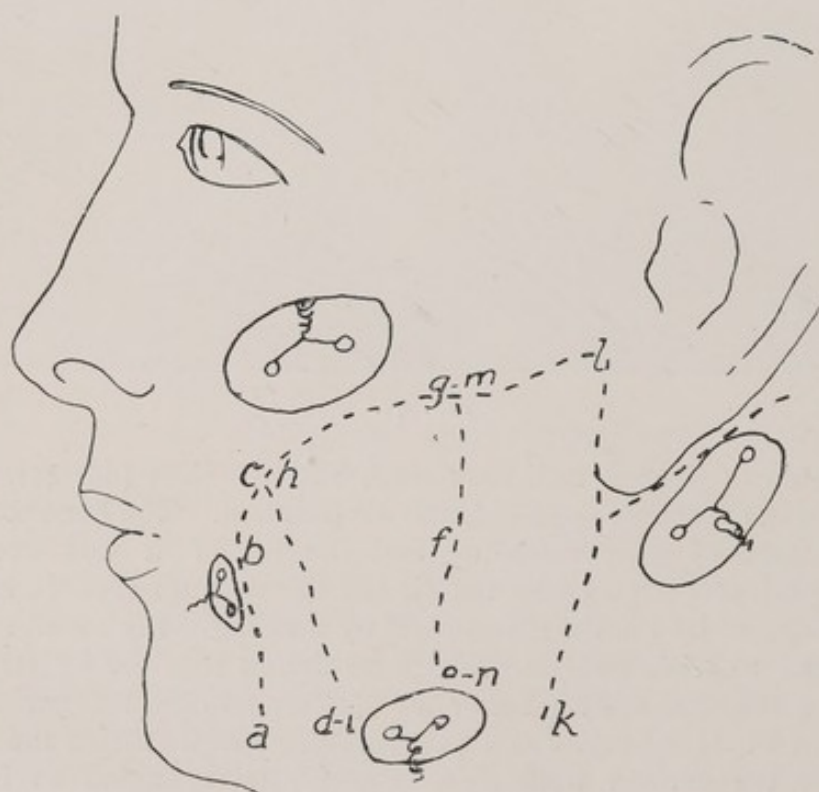


FIG. 43.—After suturing the flaps in position.

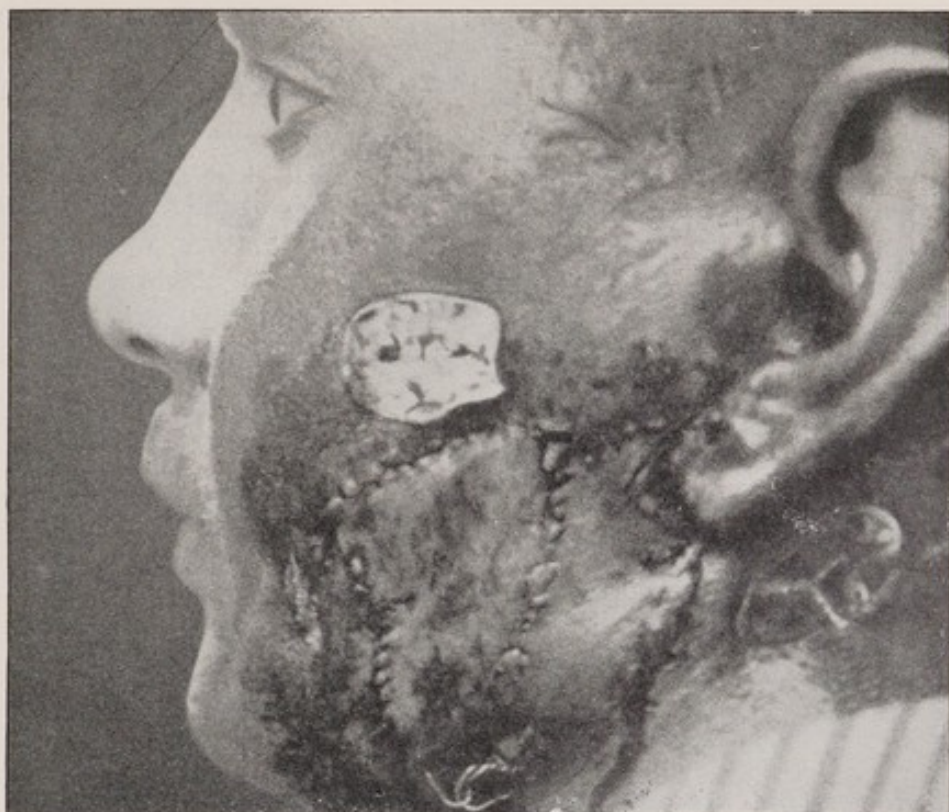

FIG. 44.

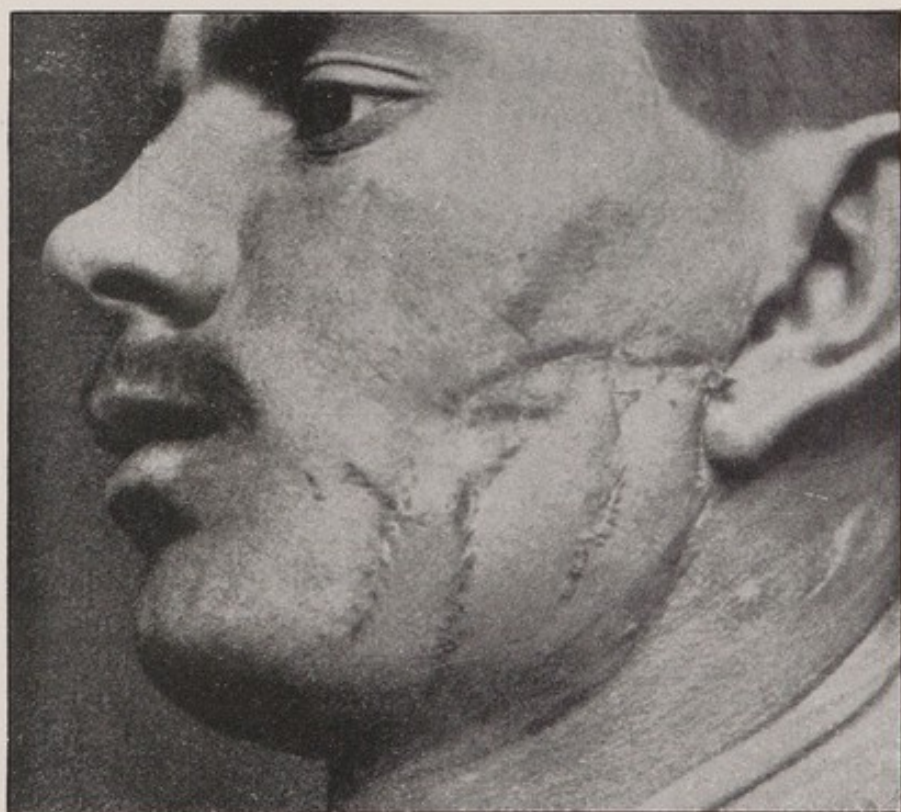

FIG. 45.

operation are shown in figs. 42 and 43. The result immediately after the operation is shown in fig. 44, the ultimate result in fig. 45.

This case illustrates what can be done, even in old-standing cases with coincident help on the dental side. Nevertheless Lindemann states it is a most urgent matter for consideration whether the threatening dangers of hæmorrhage, embolus, &c., were sufficient reason for not transferring the patient immediately to the Düsseldorf, or similar hospital, since by this delay the prospect of the restoration was considerably damaged.

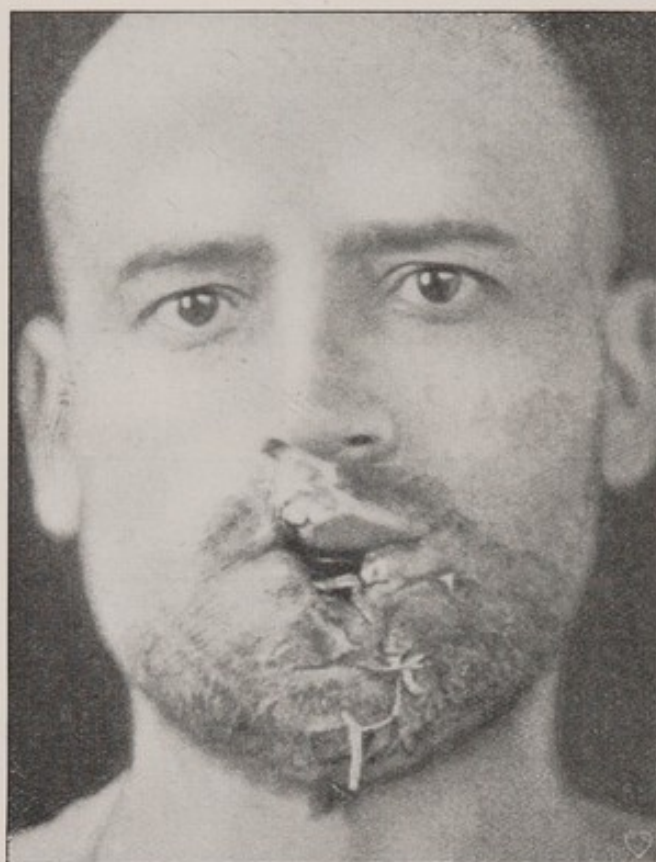

FIG. 46.

Case 2.—This is one of a series of three given by Lindemann to illustrate injuries of the lips treated on the lines usually adopted for operations on hare-lip. The first step was to remove the silk stitches introduced by the army surgeon, as the wound was suppurating, and the ligatures, as can be seen in fig. 46, had cut through the inflamed tissues. The suture placed in the free border of the lip with the intention of closing the wound had so perforated it that a new chasm gaped between the wound margins. The suppuration was undoubtedly partly due to a wire suture passed through the mandible, obviously

with the intention of keeping the broken ends in their correct position, but which, instead, had bared the bone of its periosteum and led to commencing necrosis. After removal of the suture, the suppuration ceased and healing commenced. The operation performed was further complicated by the cicatrices formed by the cutting through

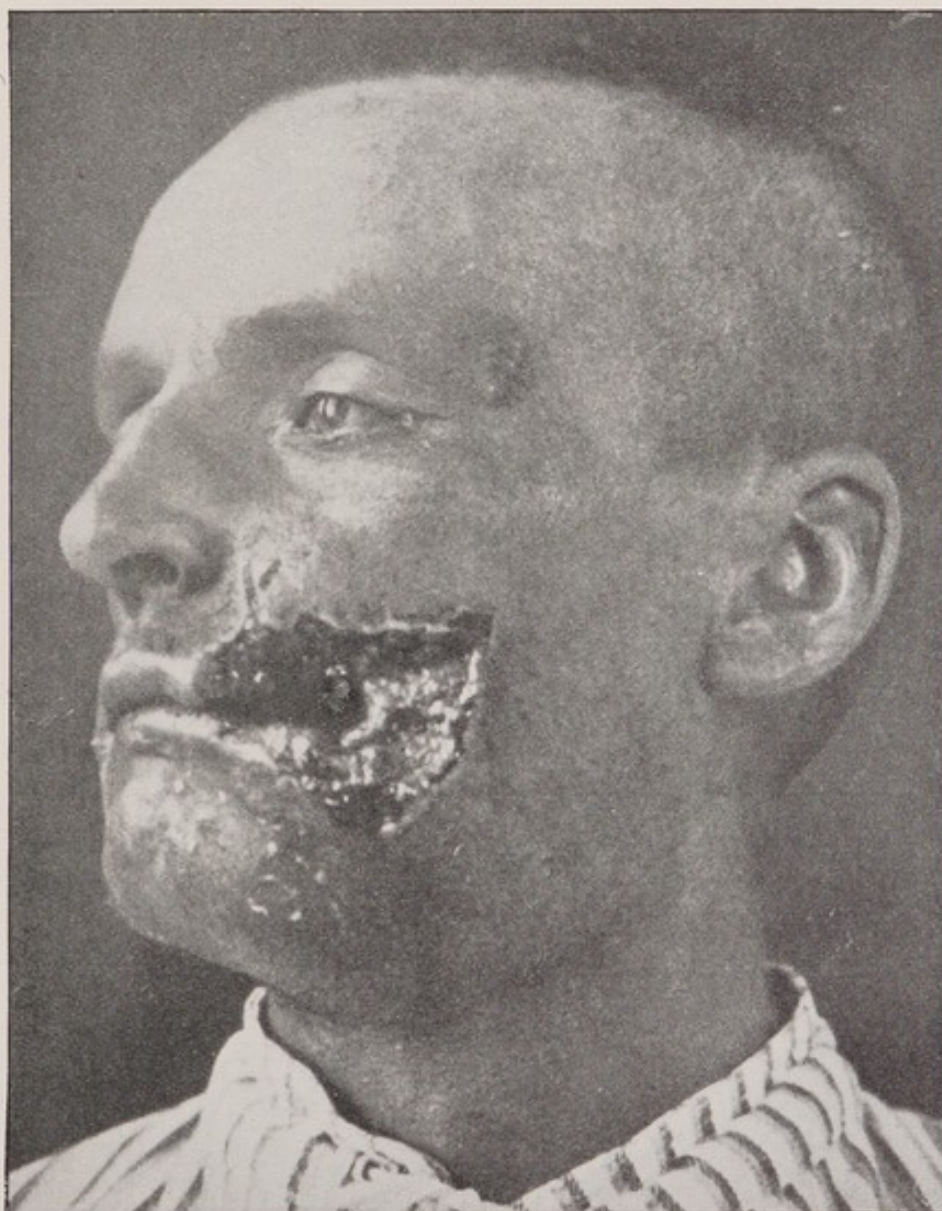


FIG. 47. (See also figs. 48 to 51.)

of the silk sutures, and only after excision of these was an artistic result attained. The contracted oral orifice was stretched to its normal size by use of the oral orifice expander. If a dental splint had been fixed, which could have been inserted in the same time required

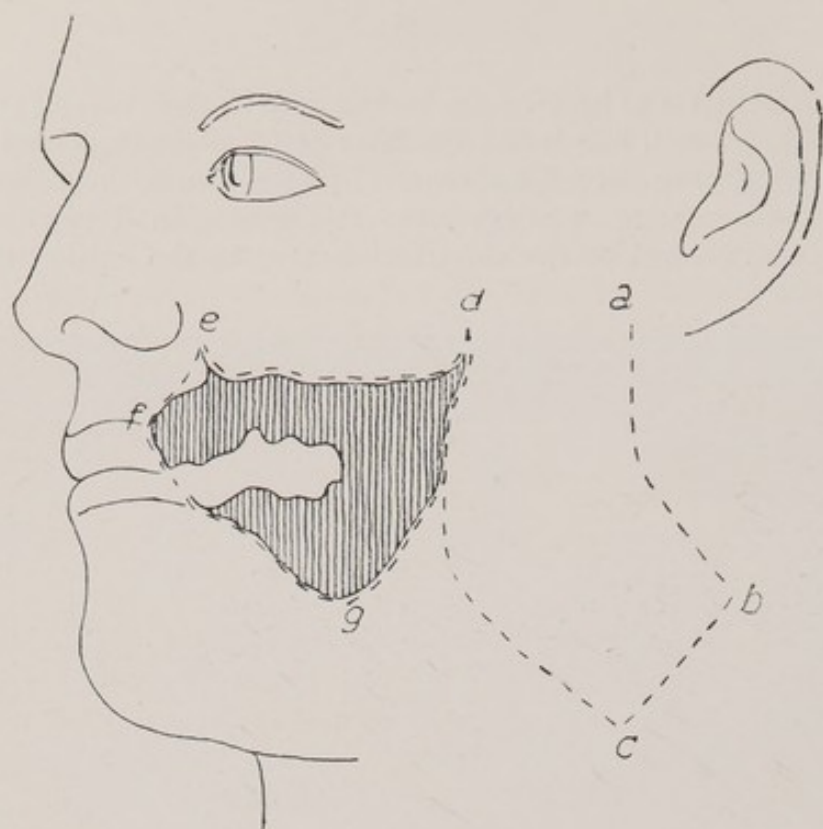


FIG. 48.—*a, b, c, d* = flap with base at *a, d*; *d, e, f, g* = defect with pared edges.

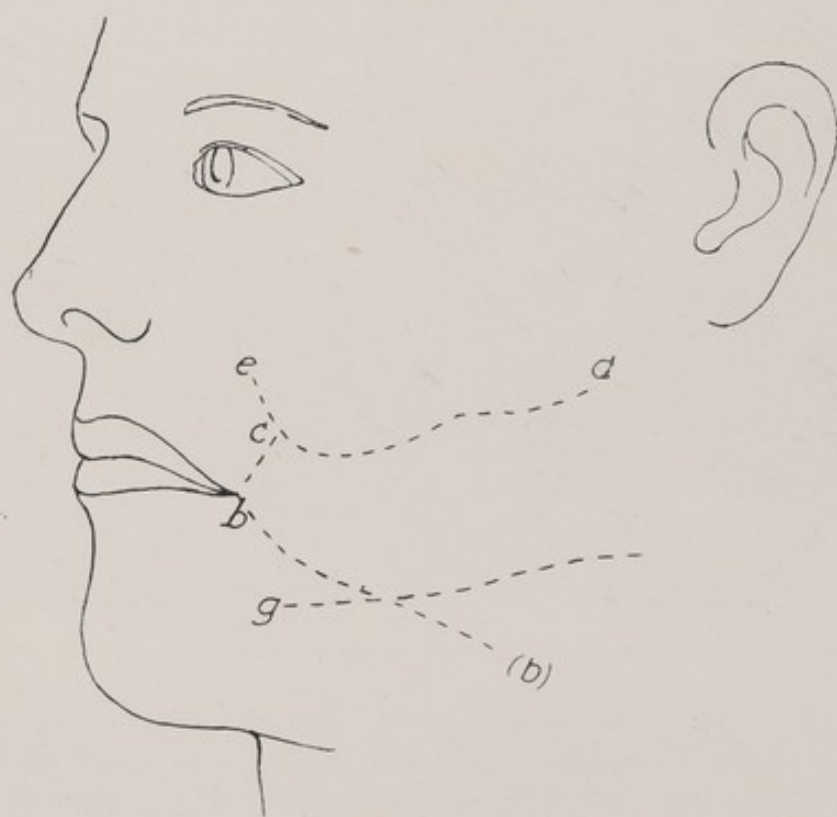


FIG. 49.—After suturing the flaps in position.

for the bone suture, the result would have been quite different. He emphasizes the point that it was incompetent technique to draw the soft parts close together with silk ligatures after inserting the wire suture.

Case 3.—Fig. 47 shows a wound, and figs. 48 and 49 the design of the flaps used to close the same. The turned-up mucous membrane

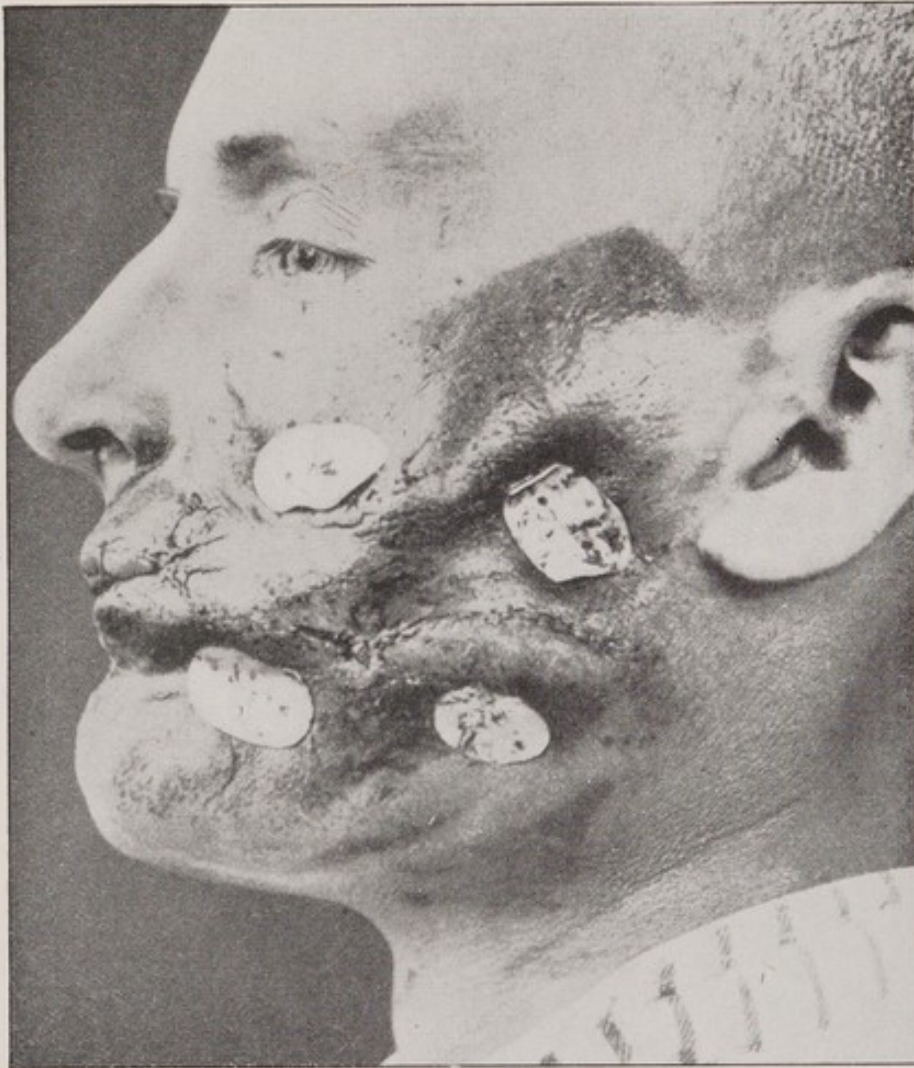


FIG. 50.

could only be gathered up and united with the greatest difficulty. Of importance, in the interest of good union, was the fact that the sutures introduced into the skin and into the mucous membrane did not touch. Fig. 50 shows the patient after operation, and it is worth noticing how the deep sutures, by traction on the plates, have lifted up the wound margins and relaxed the actual wound sutures. Fig. 51 shows the result.

Case 4.—Figs. 52 and 53 show extensive destruction of the cheek and lips. After excising the cicatricial tissue, the wound margins were freshened and three flaps formed and brought together (figs. 54 and 55). During the course of healing, an unsightly cicatrix formed at line *e* on fig. 54, seen also in fig. 56. This was easily removed, and at the same time an unsightly swelling of the lower



FIG. 51.

lip, also the newly formed red margin of the upper lip, was made more prominent. Fig. 57 shows the result. Fig. 56 shows the point and direction at which the needle is introduced for injecting the second division of the fifth nerve at the foramen rotundum.

Case 5.—Fig. 58 shows a patient with both sides of the lip destroyed. The mucous membrane was also destroyed, and it was only with great difficulty that flaps, sufficiently long and broad, could be

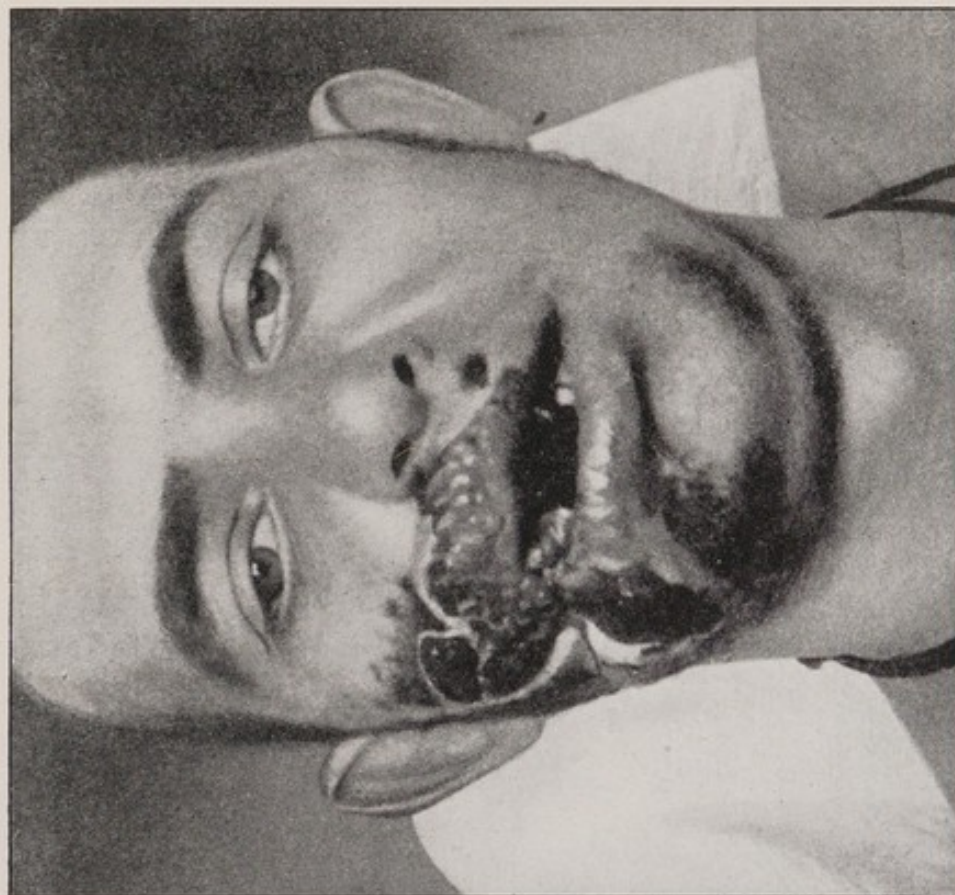


FIG. 53.

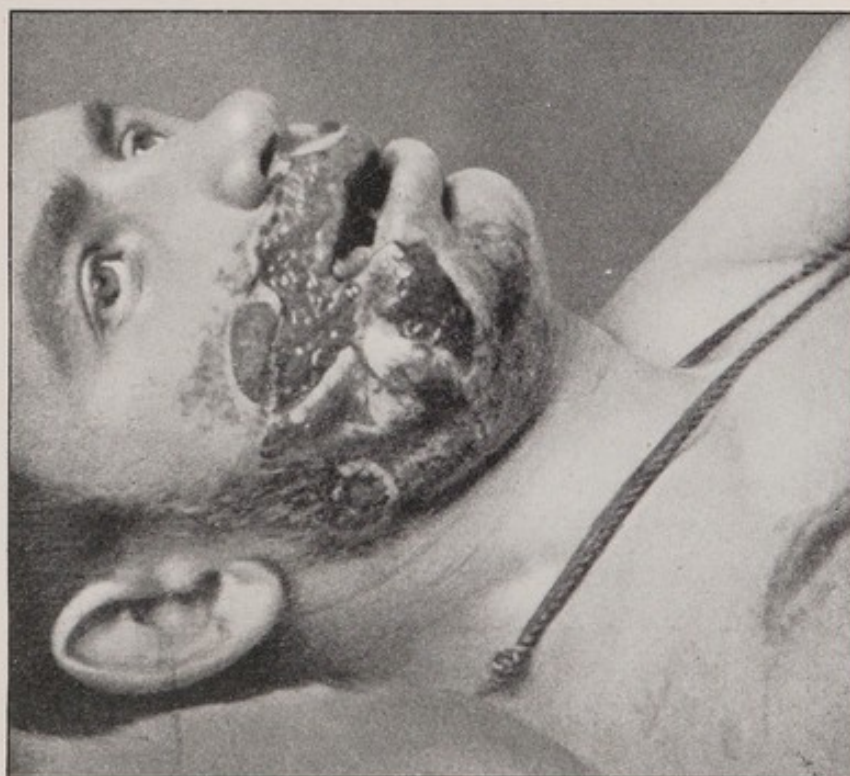


FIG. 52. (See also figs. 53 to 57.)

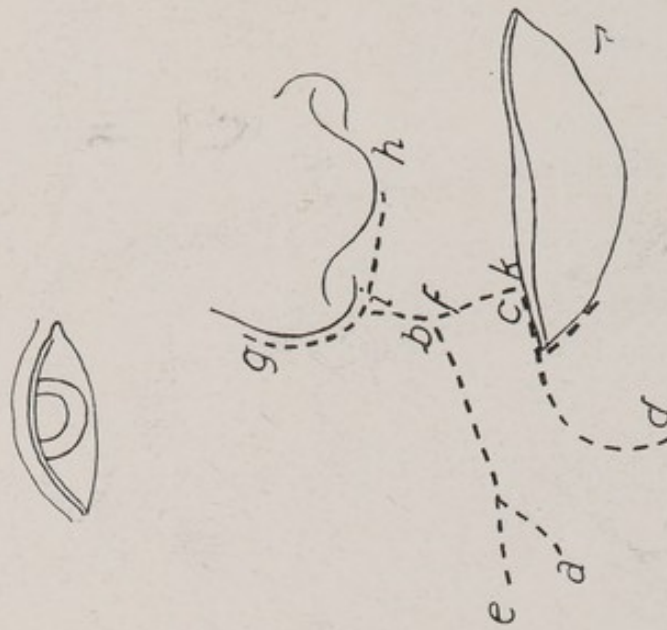


FIG. 54.—a, b, c, d, e, f, g, g₁, h, i, k = extent of paring of edges.

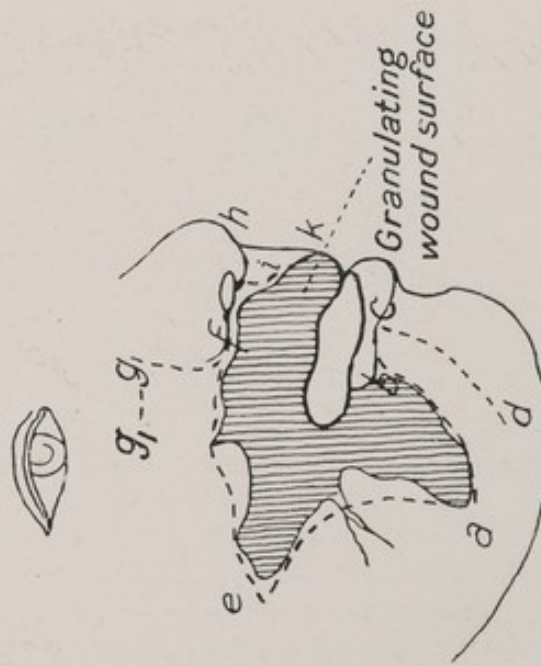


FIG. 55.—After suturing the flaps in position.

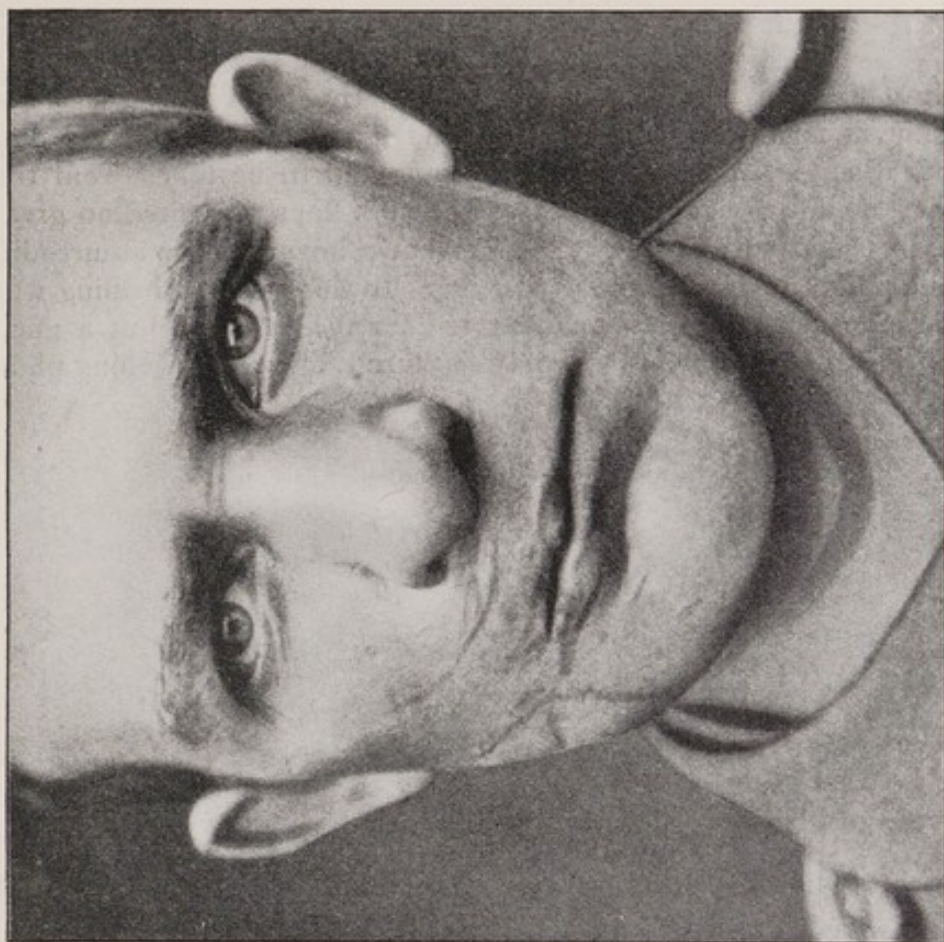


FIG. 57.

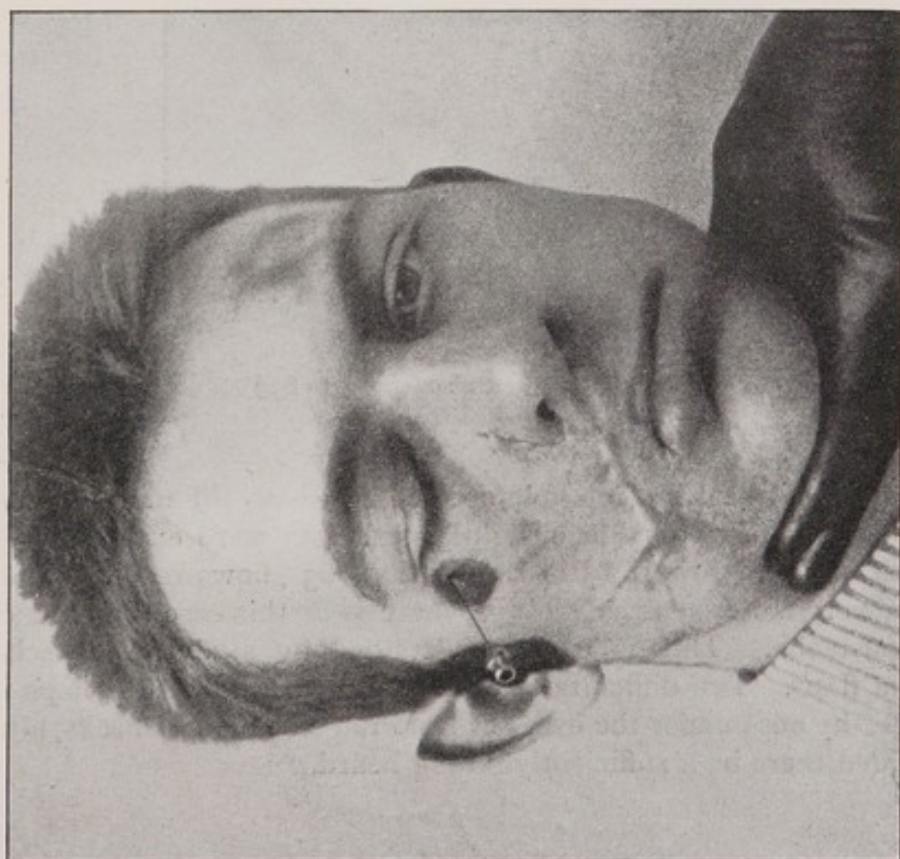


FIG. 56.

obtained to form the red lip margin and to cover the inner surface of the skin flaps forming the lips. As the tissues were also divided at the right angle of the mouth, the flaps had to be taken from the mucous membrane of the cheeks. The skin flaps presented no great difficulty (figs. 59 and 60). Fig. 61 shows how the deep sutures lift up and relax the actual wound margins. In this case the healing was not aseptic and the wound suppurated for a long time, but a good result was obtained, doubtless only because the widely reaching plate

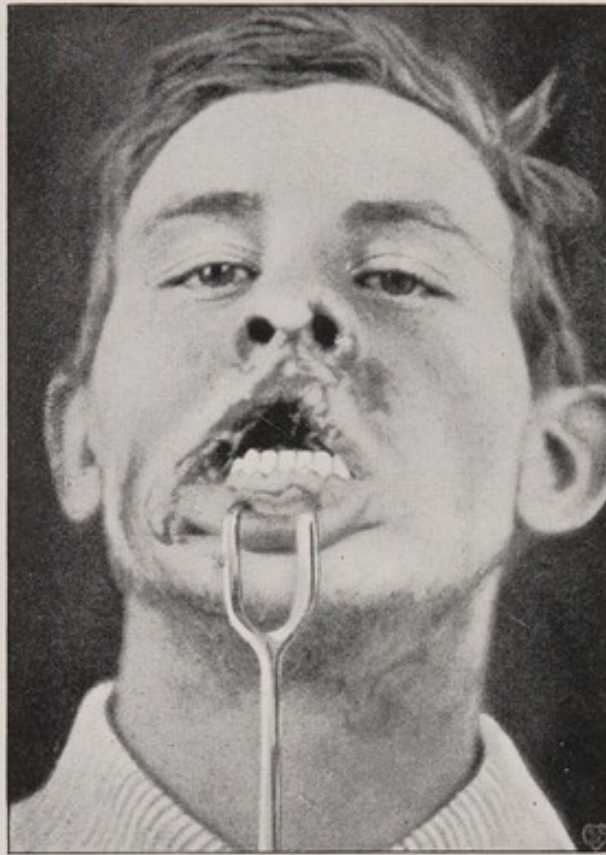


FIG. 58. (See also figs. 59 to 63.)

sutures kept the flaps in their correct positions till union occurred (fig. 62). Afterwards the unsightly cicatrices were excised and the mouth widened towards the right. Fig. 63 shows result. Though not a very material disadvantage, there is in this case the absence of a moustache. This is easily understood by studying the scheme of the flaps. The difficulty can be met by not taking the flaps from beside the nose under the eye, but from the side of the cheeks, always provided there be a sufficiently strong beard.

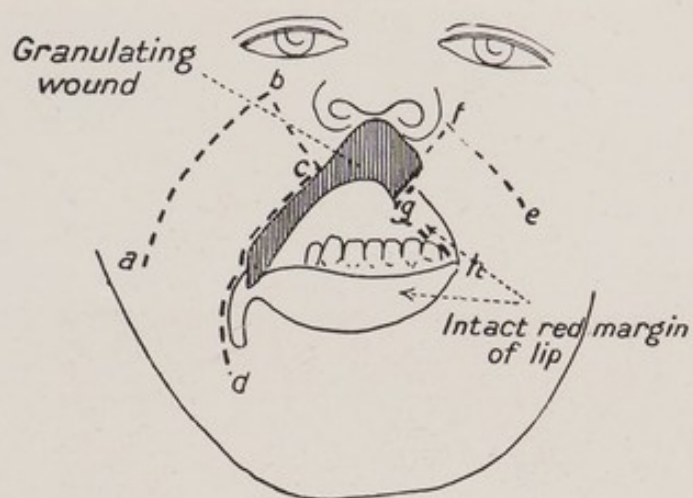


FIG. 59.—*a, b, c, d* = flap taken from right; *e, f, g, h* = flap taken from left.

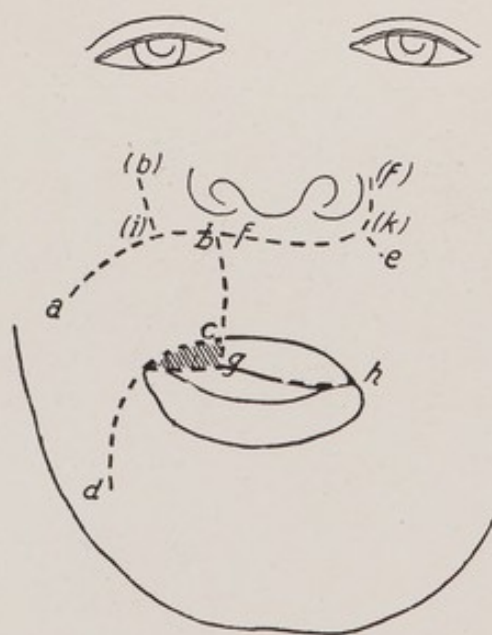


FIG. 60.—After suturing the flaps.



FIG. 62.

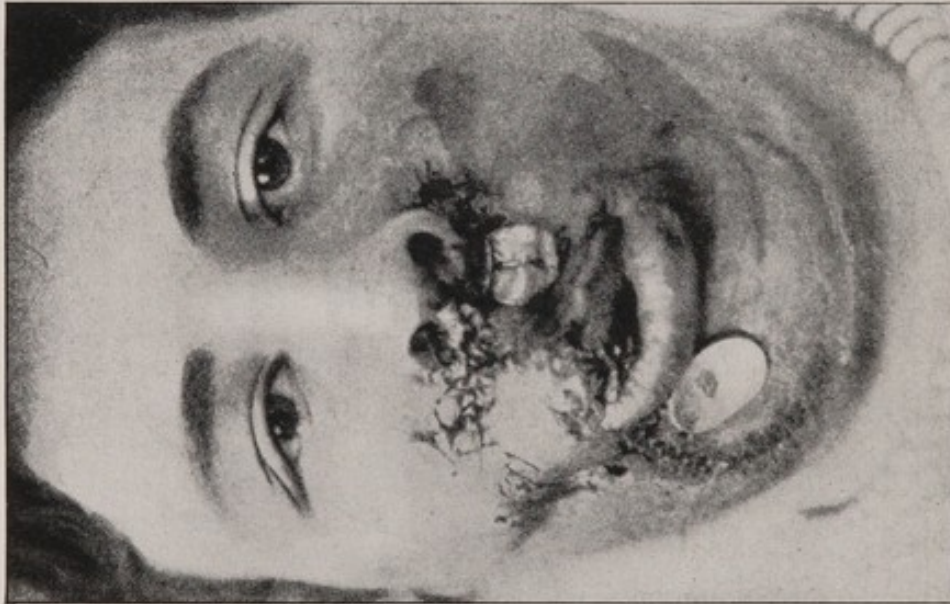

FIG. 61.

Case 6.—Fig. 64 shows condition of patient before operation. Of the upper lip only a small portion remained at the left angle of the mouth. A number of radiating scars made more difficult the designing of the flaps. In the interest of good union it was above every-




FIG. 63.

thing necessary to make provision for a mucous lining and for the red margin of the lips. This was effected by taking a large flap from the mucous membrane of the left cheek and a smaller from the right. The skin flaps are shown in figs. 65 and 66. At the same time the distortion of the nose was corrected. The edges of the torn tissues

were freshened and sutured in the exact position. So long as the nose showed any inclination to deviation, the apparatus shown in fig. 67 was worn, with olives fitting into the nostrils. Fig. 68 shows the patient four weeks after the operation. It was Lindemann's intention subsequently to correct the right angle of the mouth and implant a strip of periosteum in the bridge of the nose.

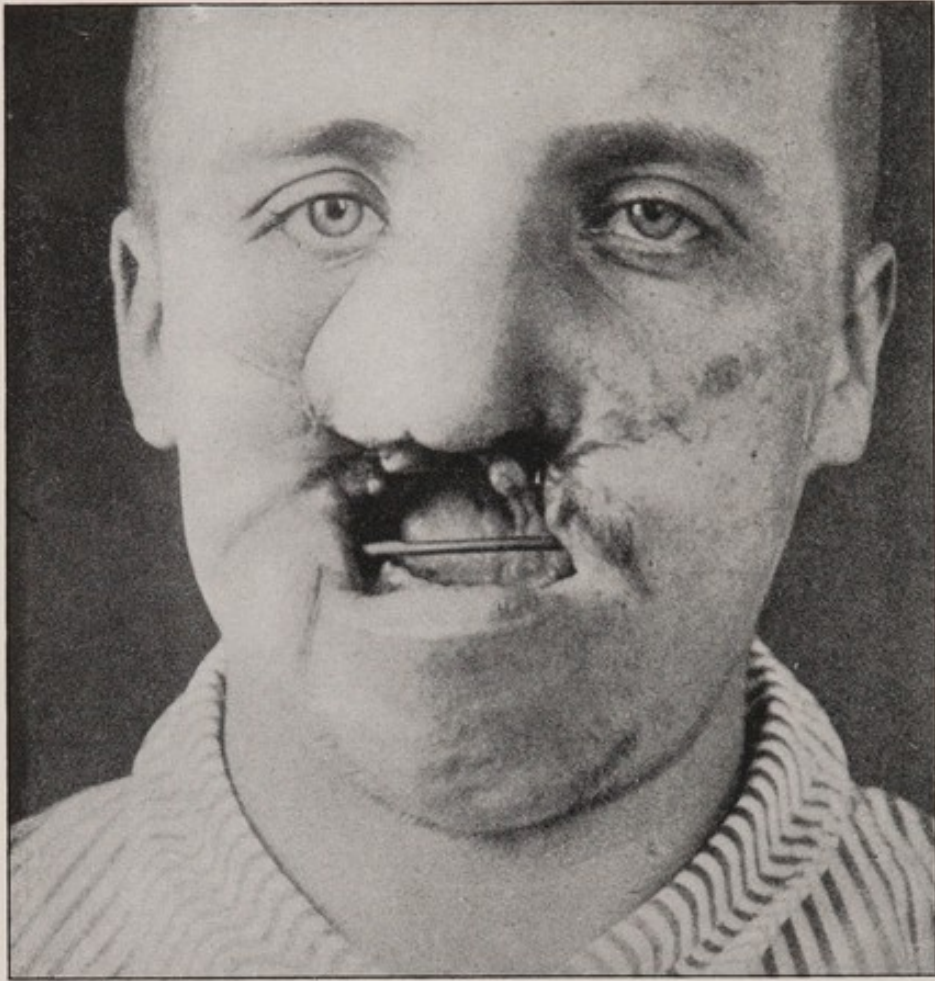


FIG. 64. (See also figs. 65 to 68.)

Case 7.—This case shows the possibility of turning a flap through an angle of 90 degrees. Fig. 69 shows the scars, to remove which the operation was undertaken. Figs. 70 and 71 show the scheme for the flaps; fig. 72 the patient soon after the wound was healed, and fig. 73, taken two months later, shows the growth of a moustache. The puffiness which formed at the base of the flaps consequent on their torsion soon cleared up under the influence of vigorous use of a suction glass.

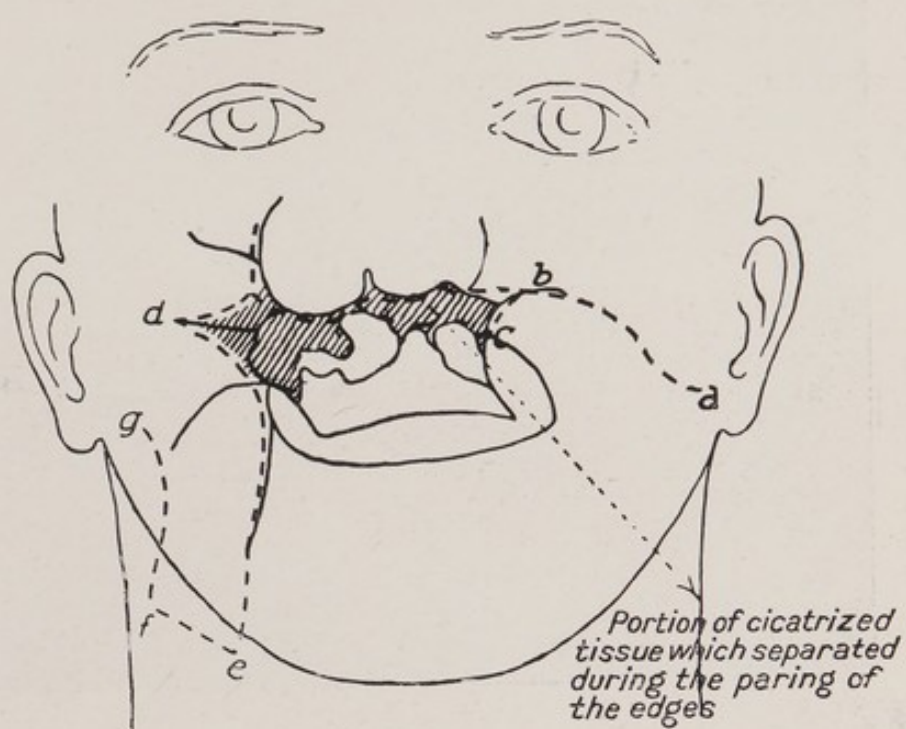


FIG 65.

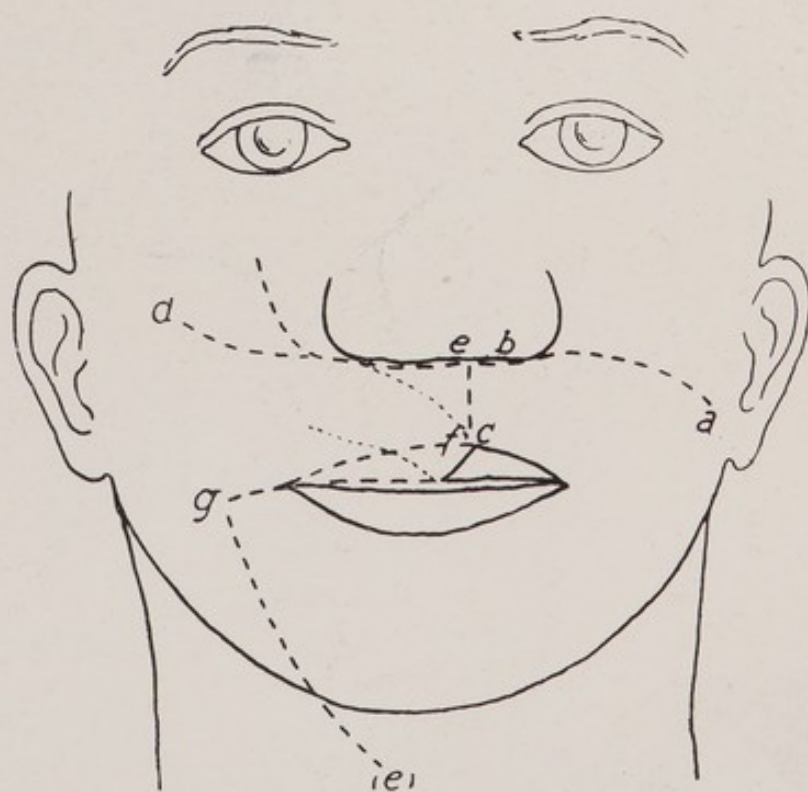


FIG. 66.—After suturing the flaps in position.

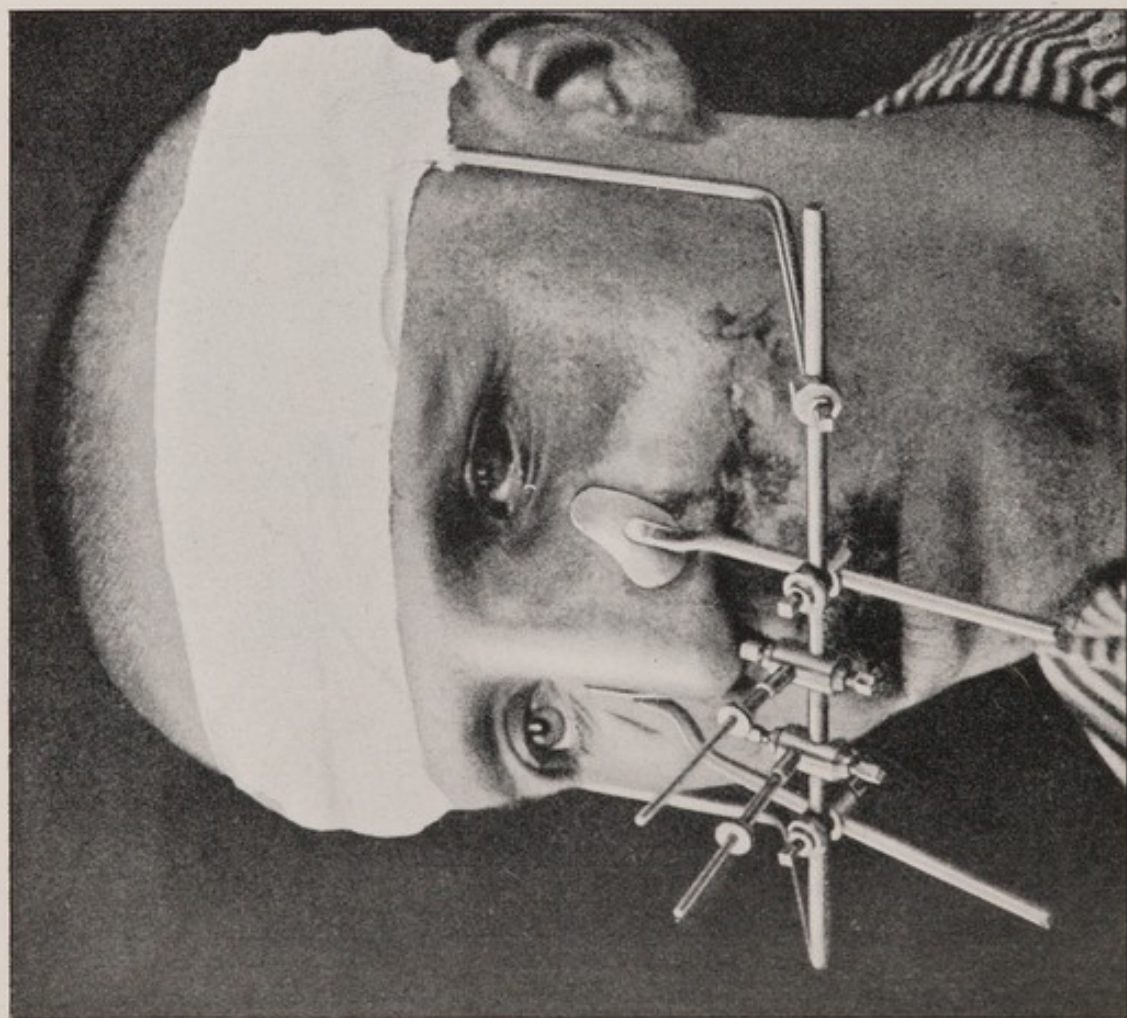


FIG. 67.

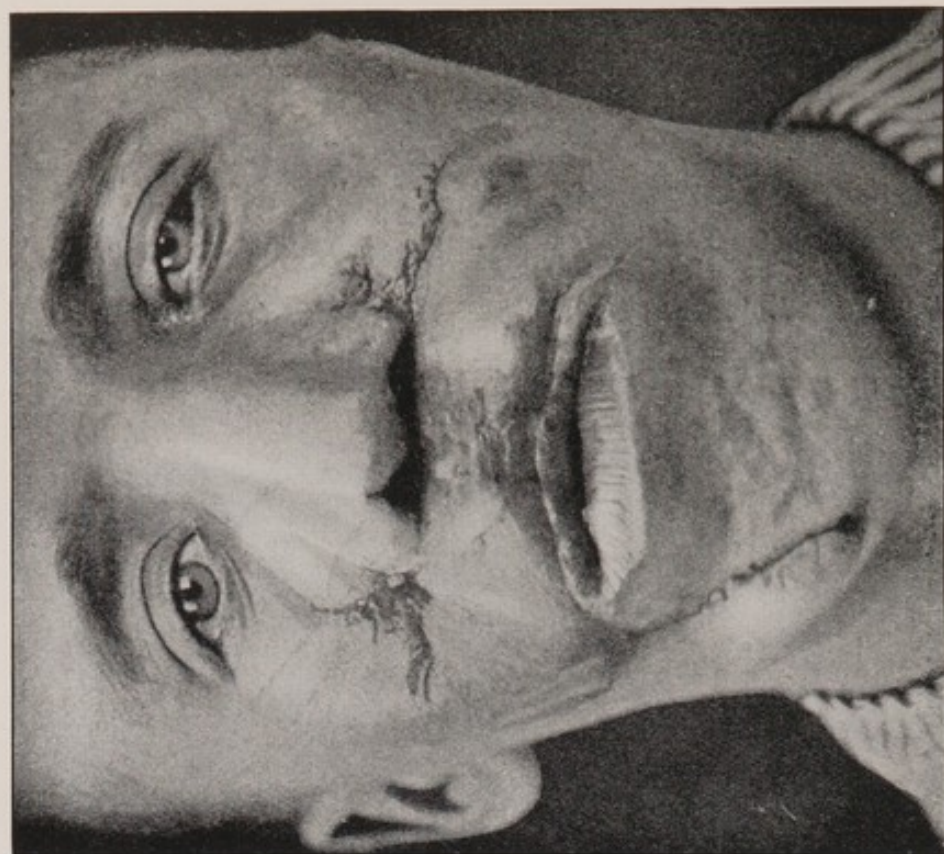


FIG. 68.

Case 8.—A series of cases is given to illustrate the treatment of wounds and scars of the lower lip. The principles are the same as for the upper. Figs 74 to 78 show such a case in which the loss of tissue and scarring are extensive. In this case a small portion of one of the flaps sloughed, and in consequence of adhesions to the underlying bone a considerable depression formed (fig. 77), but vigorous use of suction glasses lifted up the tissues, so that at the time of




FIG. 69. (See also figs. 70 to 73.)

writing only a small depression remained (fig. 78). The use of specially modelled suction glasses is also adopted to cause reformation of the prominence of the chin, assisted by a fat transplantation.

Case 9.—In this case there was a total destruction of the lower lip, chin and fore part of floor of mouth, also of the horizontal ramus of the mandible from the second molar left to the third molar right (fig. 79). During the healing the remaining mucous membrane had

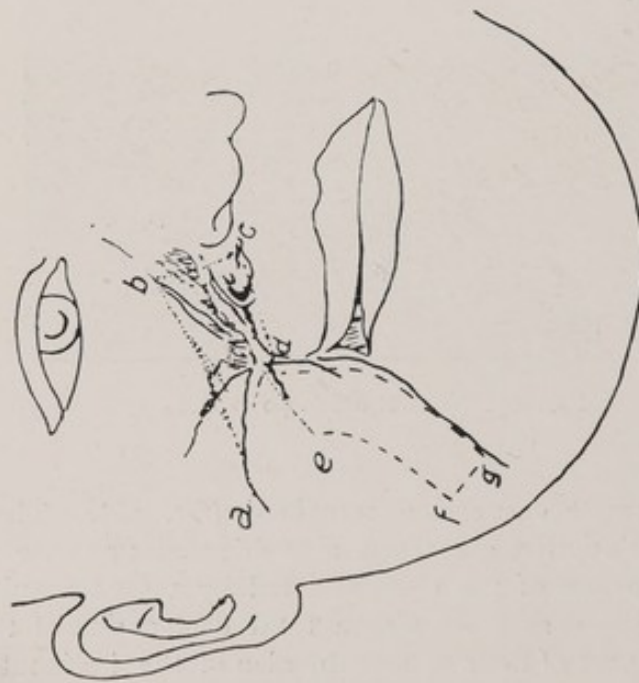


FIG. 70.—*e, f, g, d*, newly cut flaps with base, *e, d*; *a, b, c, d*, excised scar tissue.

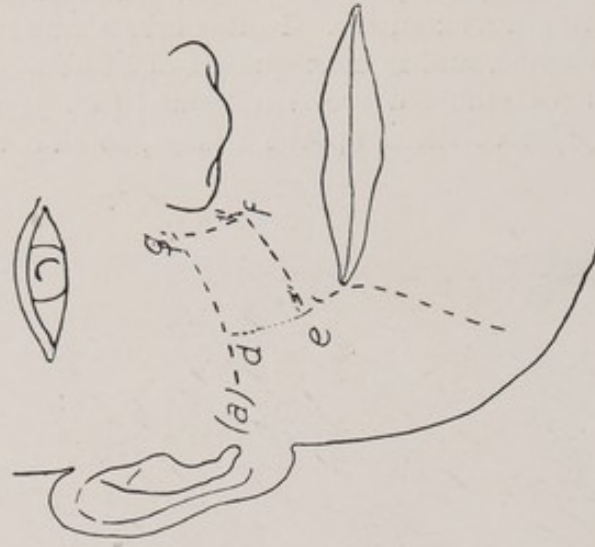


FIG. 71.—After suturing the flaps in position.




FIG. 73.



FIG. 72.

contracted downwards and forwards, whilst at the sides the skin and mucous membrane had united (fig. 80). Gold crowns were fixed to the remaining molars with tubes soldered to the sides. A denture was made and fixed by wires passing into the tubes and also, till the restoration of the lost soft tissue, by means of elastic bands passing from hooks to a wire splint fastened to the upper teeth (figs. 81 and 82). This denture served to restore the mandible as far as was possible, and acted also as a shield over which to mould the skin flaps.

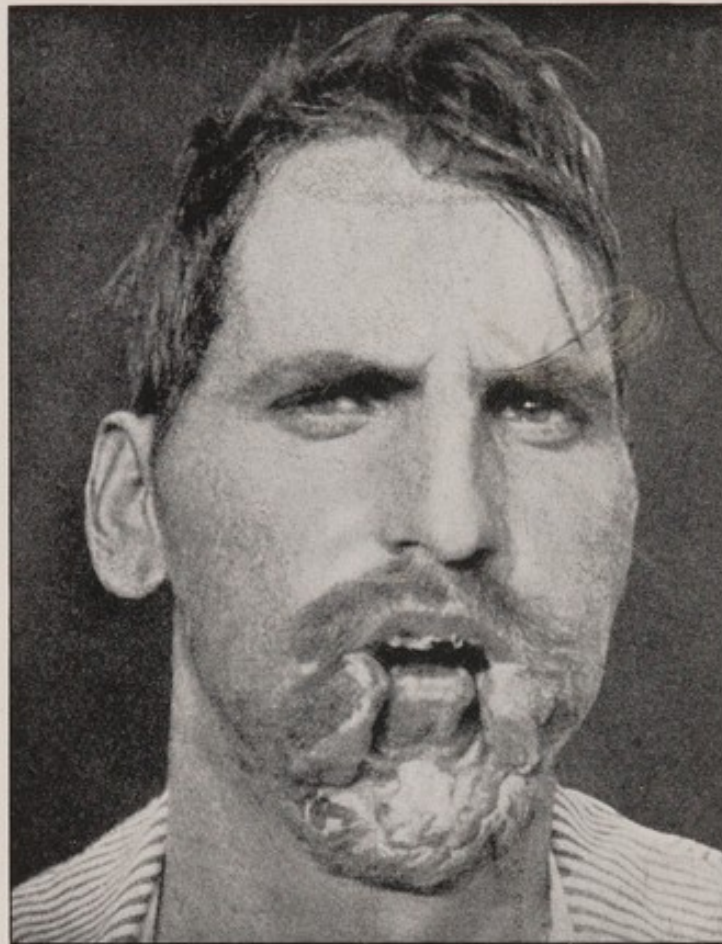


FIG. 74. (See also figs. 75 to 78.)

The plastic operation was undertaken by preparing a flap from the forearm, which was covered by epithelium on both surfaces.

Later this flap was sewn on to the left side of the wound on the face after its margin had been freshened. The suture was of catgut, but wire sutures and plates were used as supports. Fifteen days later the flap was separated from the arm and sewn exactly into the wound. The red margin of the lips was reproduced by two right and left flaps of mucous membrane taken from the lining of the mouth.

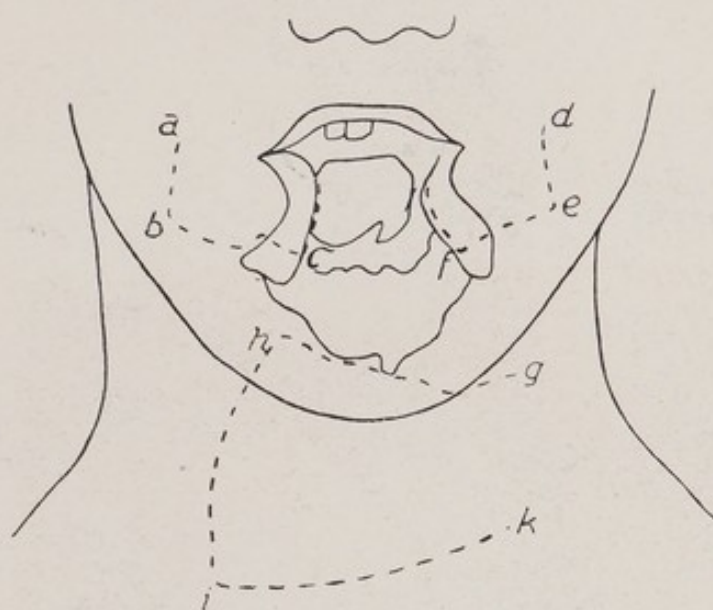


FIG. 75.—*a, b, c* = flap taken from right ; *d, e, f* = flap taken from left ;
g, h, i, k = flap taken from neck.

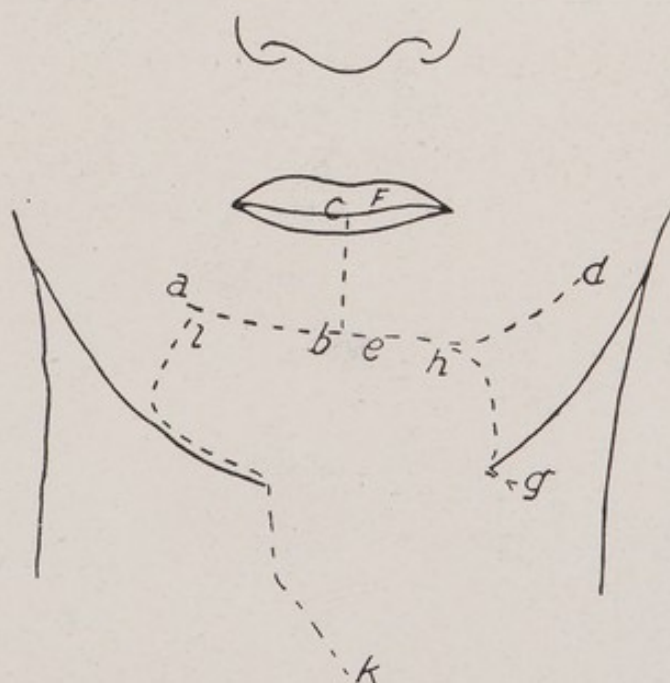


FIG. 76.—After suturing the flaps in position.

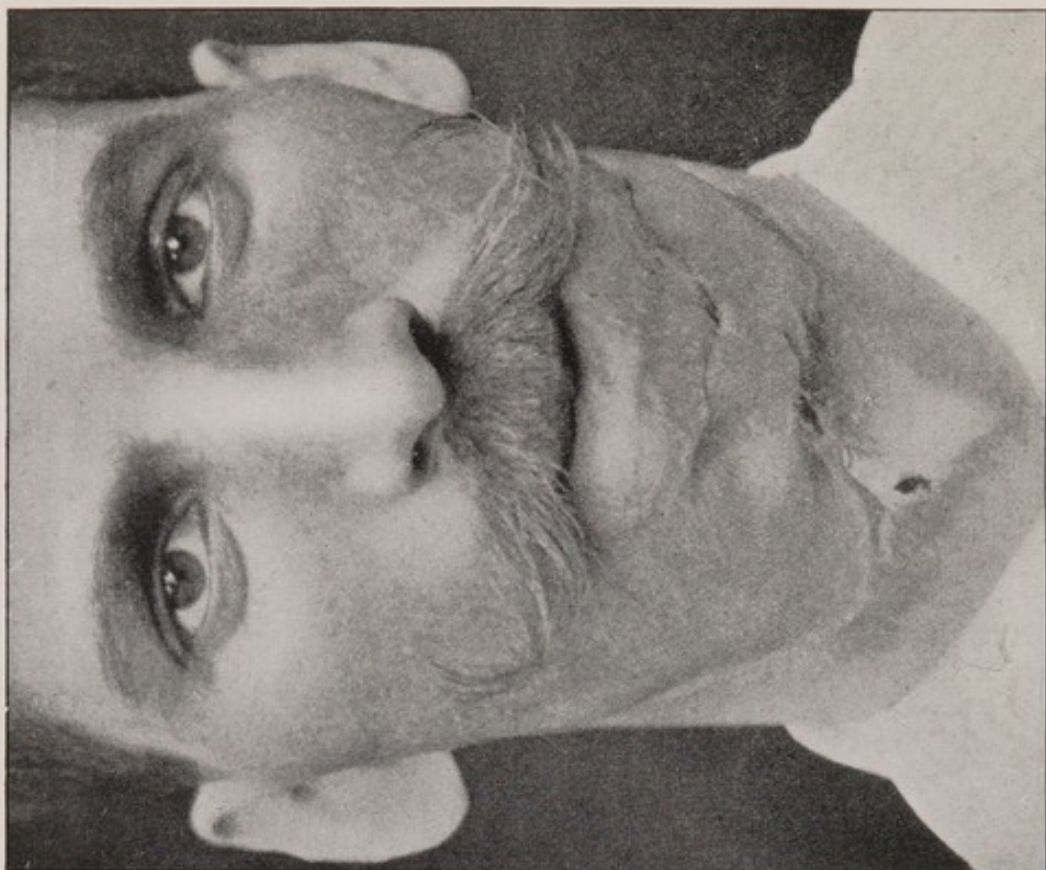


FIG. 78.

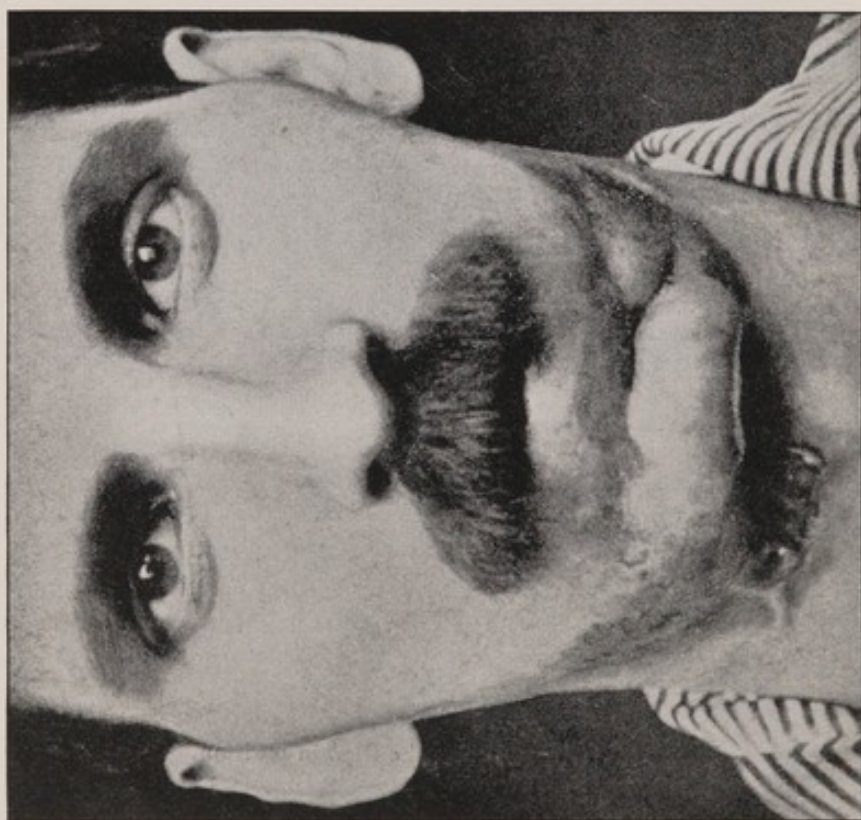


FIG. 77.

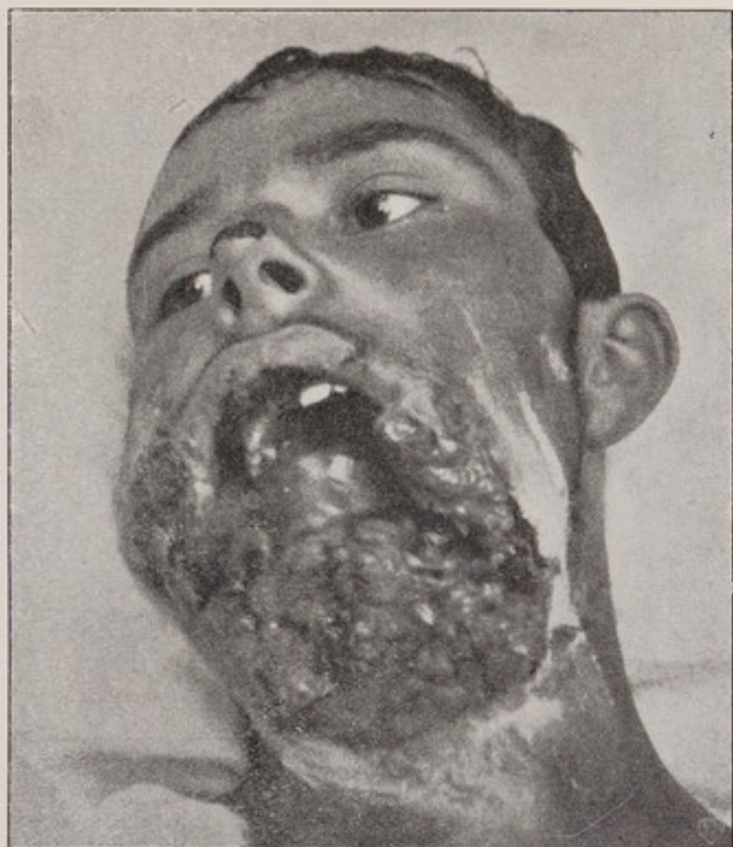

FIG. 79. (See also figs. 80 to 86.)

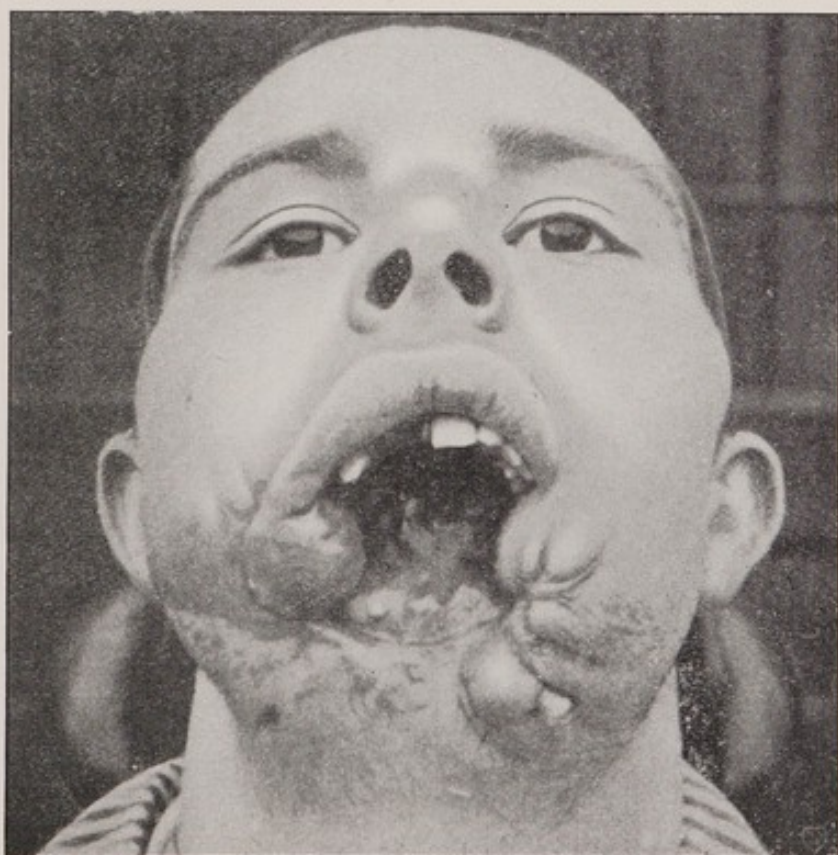


FIG. 80.

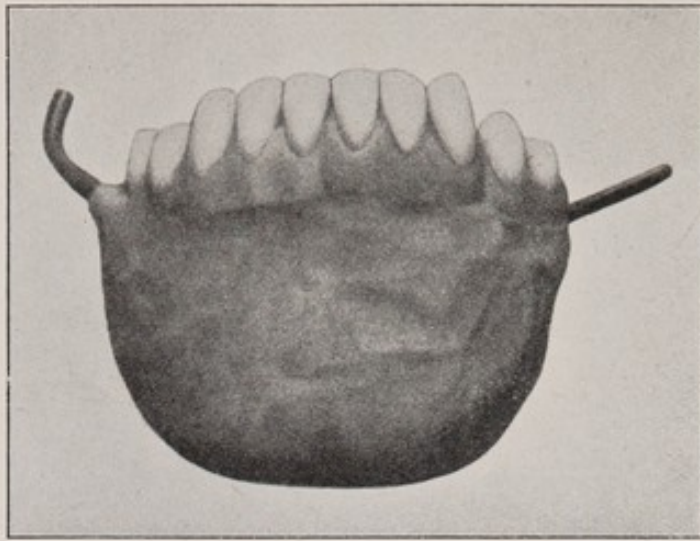


FIG. 81.

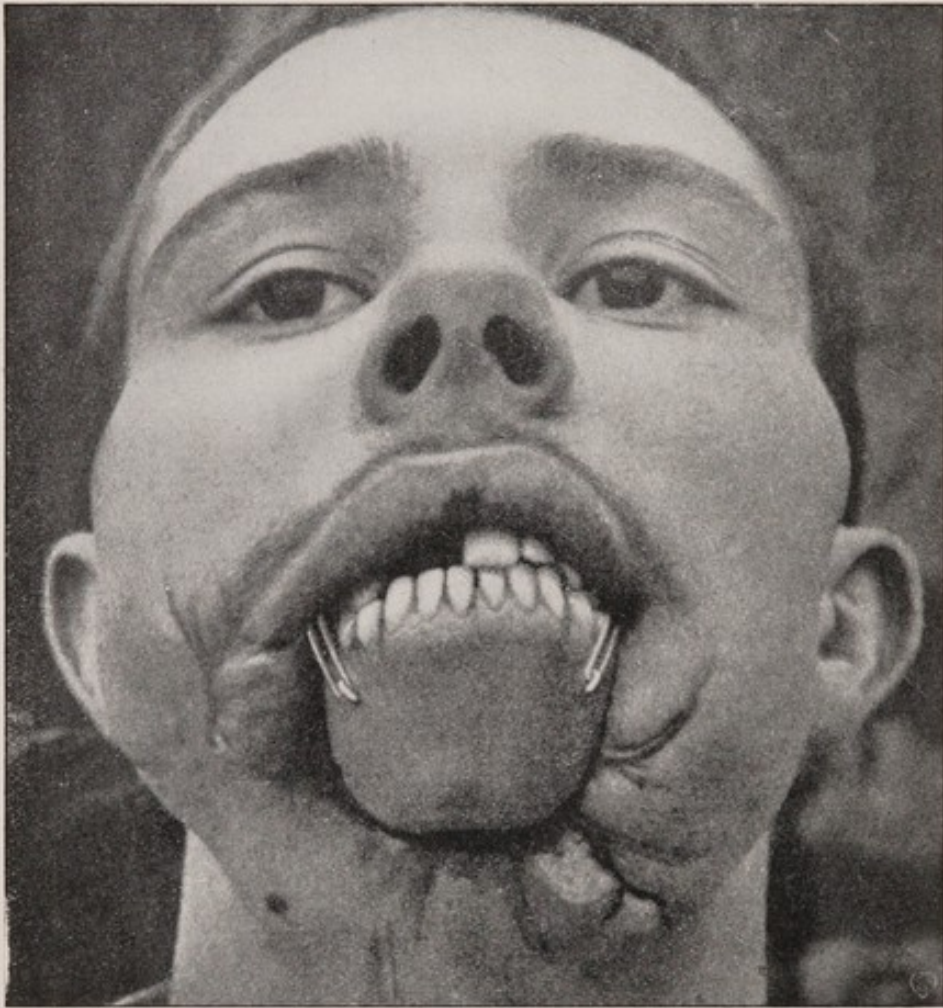


FIG. 82.

Unfortunately a portion of the right side of the flap sloughed. This occurred in the neighbourhood of a deep wire suture, which had doubtless been pulled too tightly, thus interfering with the blood supply. After cutting away the dead tissue two skin flaps were taken from the neck, and the wound covered (fig. 83). As the deep surface of these flaps was not covered by epithelium, where it formed part of the oral cavity, a wire suture, tied over a plate on the cutaneous surface, passed from the oral surface to a wire attached to a head bandage (fig. 84). This supported the flap, whilst a packing soaked in mastic was firmly pressed on the oral surface of the flap to prevent adhesions. After many weeks epithelium grew over the surface.

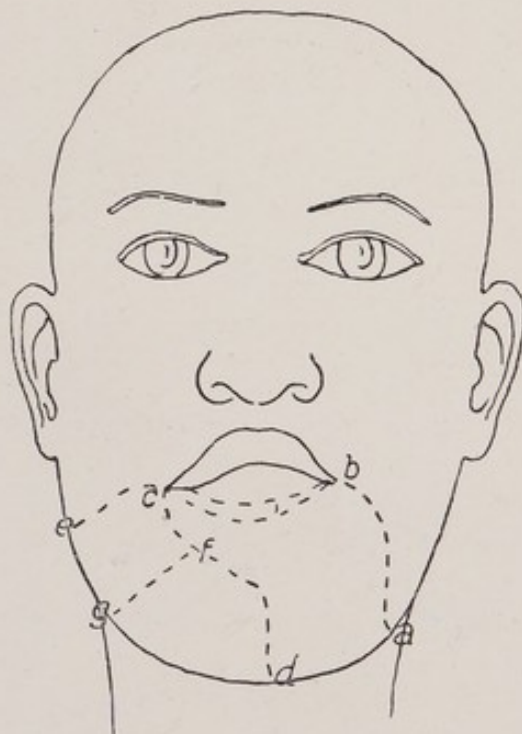


FIG. 83.—*a, b, c, d* = double epithelized flap from right forearm. *d, f, g,* and *g, f, c, e,* = flap taken from neck. The red margin of lip taken from the mucous membrane of mouth.

Fig. 85 shows the patient about two weeks after the last flap operation. A gap below the chin is here packed with gauze. The cicatricial condition of the skin of the neck preventing a flap being taken thence to cover this gap, the wound was allowed to contract, and then the margins were brought together. The defective condition of the lips was corrected by taking a skin flap from the side of the nose, bending it downwards to form a lower lip, the mucous margin and posterior surface of which was formed by a large flap from the mucous membrane of the mouth. Fig. 86 shows the patient five

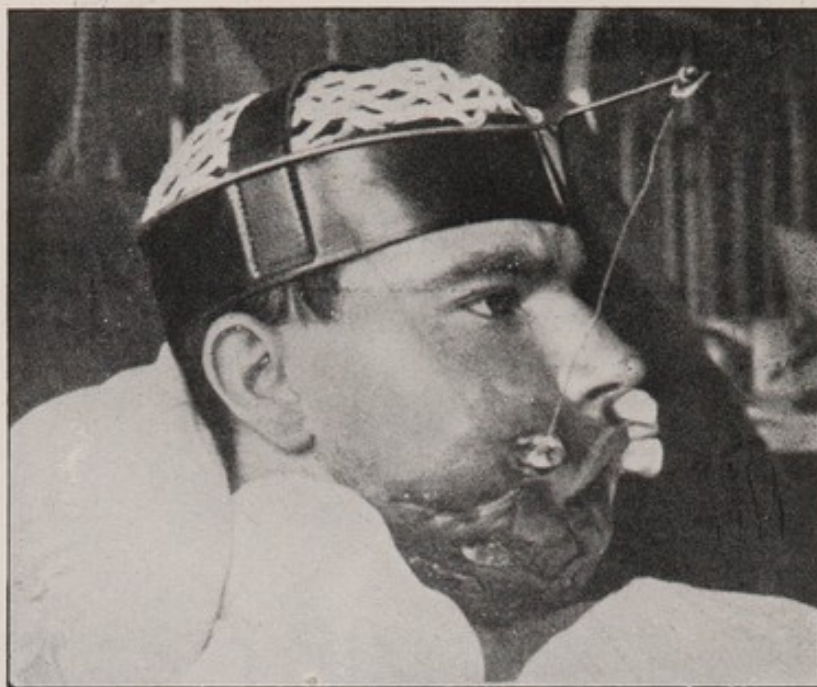

FIG. 84.

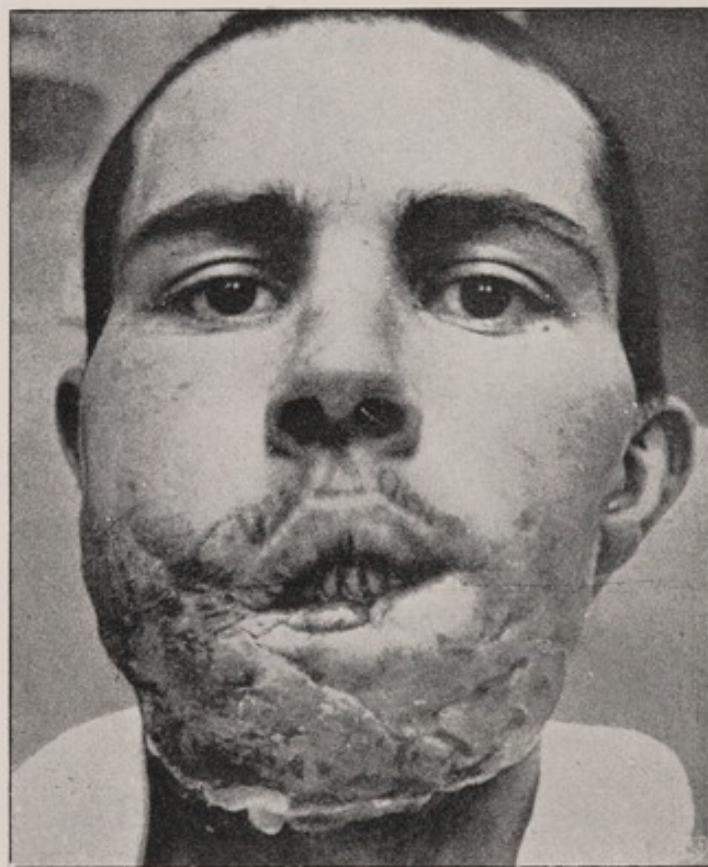


FIG. 85.

days after the last operation. The subsequent problem will be to restore softness to the tissues by massage and the use of suction glasses, and to make good the lost bone by a bone-graft. Previously to this Lindemann proposed to do a fat implantation, with the intention of providing a better resting-place for the bone-graft.

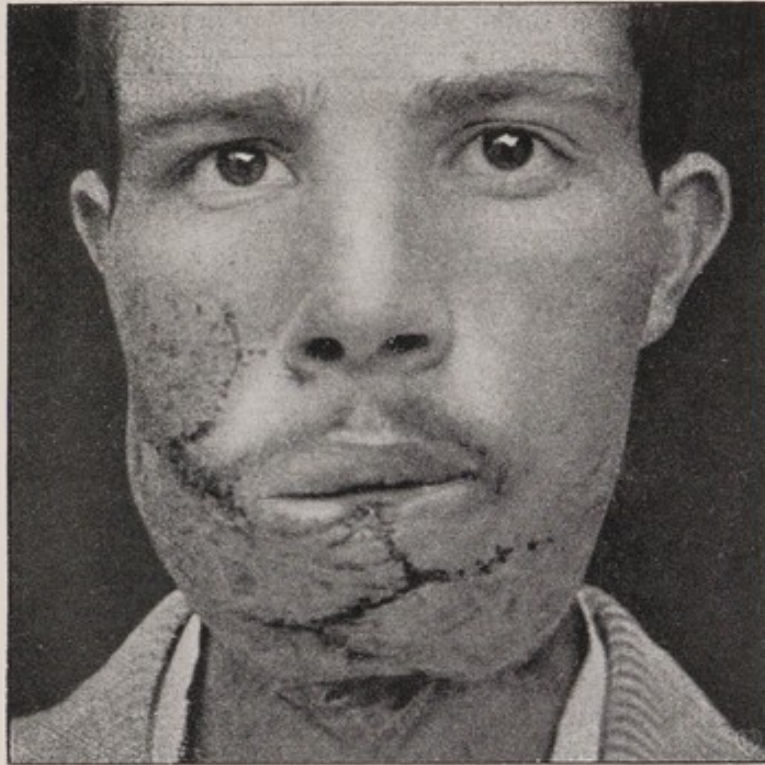


FIG. 86.

SPLINTS USED IN BERLIN.¹

Adverse criticism of Hauptmeyer's tin splint is made by Schröder on the ground that its necessarily complicated manufacture renders it unsuitable for treating large numbers of wounded. In the Berlin Hospital von Sauer's wire band, as modified by Schröder, is used. This is a single wire 2 mm. thick, of iron or, better, of aluminium bronze; to this the teeth are ligatured with fine aluminium bronze wires. If one side of the mandible is tilted inwards the wire is fitted closely and ligatured to the normal side, but is away from the teeth on the displaced side. Traction is exerted on the displaced side by rubber bands passing from the wire to the teeth. At Berlin flanges of differing forms are used (fig. 87), varying in shape from simple rods

¹ From "Die zahnärztliche Hilfe im Felde," by Williger and Schröder.

to small, vertical curved plates. These have a tube soldered to them, which can be slid over the splint wire and readily fixed in any position desired. These flanges lock on the upper teeth and prevent or limit movement. When it is necessary to fix two splints, one to the upper and one to the lower teeth, and to ligature teeth together, a hook on the top of such a vertical flange forms the means of attachment.

When in a fractured mandible no teeth are present in the posterior fragment, movement of this is limited by twisting round the free end of a somewhat longer wire to form a loop. This loop can be embedded in a lump of gutta-percha, which rests on the gum of the edentulous fragment, or is wrapped up in iodoform gauze.




FIG. 87.

For use with the wire, bands to encircle the teeth are kept in eight sizes. These bands are deeper and thicker than Angle's bands, and also differ from the latter in that the clamping screw has a tube drilled through its long axis, into which passes the wire of the splint.

When no teeth are present in the mandible the fracture is treated by means of a broad aluminium splint, which is placed on the lingual side, and to it the bone is wired. These splints are kept ready-made. This idea is taken from the Japanese, and was employed by them in the last war (see p. 76). It is criticized, if applied to fractured mandibles when teeth are present, on the ground that the ligatures may easily lead to necrosis and interfere with healing. Admittedly, what is justifiable in one case may not be so in the other; nevertheless it is unfortunate no facts are given to prove the value of the method as used in Berlin.

Schröder in his book "*Fracturen und Luxationen der Kiefer*," figures and describes a useful suggestion of Brandt's. The use of impression material in, or indeed without, a tray is well known as an emergency splint. Brandt suggests trays of various sizes without

handles but with wire loops soldered to the convex surface of the tray. These serve for the attachment of straps or bandages which can be passed under the chin or over the top of the head. Brandt uses black gutta-percha.

THE CHARLOTTENBURG HOSPITAL.

Lindemann's method of treating facial wounds is criticized by Dr. Ganzer, in charge of the Jaw Hospital at Charlottenburg, who published three short papers on the work at this hospital in the *Deutsche Monatsschrift für Zahnheilkunde*, October, 1915. He agrees with Lindemann in inserting the splint immediately and before attempting to close the surface wound, and also that such cases are better treated at such a hospital than at the field or base hospitals. But, as soon as the splint is inserted, Ganzer closes the wound with wire sutures, using suture plates of glass or of tin, and leaving a drainage tube in the dependent portion of the wound. He claims to have treated fifty such wounds without any failures. Six cases are illustrated. The wounds in these cases appear to be much slighter than those illustrated by Lindemann, and in every case marked scarring is shown at the seat of the wound in the photographs taken from ten to fourteen days after the operation. These scars he proposes to remove later. A further case is illustrated with more extensive damage. Eight days before being seen, the mandible was torn out between the first molars of the right and left side. The second molars remained. There was a wound on the right cheek and the central portion of the lower lip was missing. The tongue fell backwards, so that the patient had difficulty in breathing and in taking food, and could not speak. Bands were made to clasp the molars and were connected by a wire. A flat vulcanite plate, carrying two teeth, was fastened to the wire. Over this denture, acting as a shield, the soft tissues were stitched and the tongue was fastened to the denture by means of a suture. Four days after this the patient could speak and swallow. The photograph taken ten days later shows, apparently, much scarring and contraction of the oral orifice. Although it is stated "that naturally the treatment is not nearly complete," it seems unfortunate the case should have been published before it was, especially as it is for comparison with another's work. Of the remaining forty-three undescribed cases, some must have been finished to justify the criticism. Nevertheless, this criticism of a criticism may be unjust, for photographic reproductions do not always accurately represent facts. It may be noted that the reviewer, in the same journal, of the second and third sections of the Düsseldorf publication, regards Lindemann's results as "wonderful."

THE HOSPITAL AT FRANKFORT-ON-MAIN.

The *Deutsche Monatsschrift für Zahnheilkunde* published in its issue for December, 1915, five papers read at a meeting held at Frankfort on September 25 and 26, 1915. About eighty attended the meeting, including surgeons attached to the hospitals. The President, Alfred Strauss, stated that under the lead of Schaeffer-Stuckert, the local dentists had rendered voluntary help at the beginning of the War, but early in 1915 the organization became official. Five dental centres and three centres for the treatment of jaw injuries were established. Seven dental surgeons were given military rank, and nine others, who were serving in the Army, were ordered to attend. The work done since the official inauguration to the date of the meeting included the making of 1,506 dentures and the treatment of 440 cases of injury to the maxilla or the mandible. The object was to render the men again fit for service at the earliest moment.

The papers read were upon "The Treatment of Fractures of the Jaws on Orthodontic Principles," by Dentist Jacob; "Extra- and Intra-oral Appliances," by Dr. Fritsch; "The Surgical Treatment of Fractures of the Mandible," by Professor Dr. Loos; "Dental Treatment," by Dentist S. Strauss; and "Some Hospital Cases," by Dr. F. Triesch.

INTRA-ORAL SPLINTS.

The splints used in Frankfort were on the lines of orthodontic, fixed apparatus, following the methods advised by Schröder, whose bands, &c., are used. Displacements were corrected by means of expansion arches and screws, rubber bands, intermaxillary traction, and sometimes head and chin caps connected by elastic bands.

Three cases may be mentioned to illustrate the system:—

(1) The right side of horizontal ramus was absent, having been removed, after injury, in a field hospital. The left side was drawn across the mouth, sloping more or less transversely, and pulled backwards. The right ascending ramus was drawn in and up. A wire arch was fixed by ligatures to the teeth of the left side, and this was left long and bent inwards and backwards, so that it ran by the side of the tongue. The end, shaped like a "pelotte," was covered with rubber and rested on, and acted as a spring to push out, the remains of the right ascending ramus. This was not only replaced, but the left side was also pushed back to its normal position.

(2) A double fracture of mandible—one in front of first left molar, the other in front of left canine. The fragment between these teeth was displaced so that the second premolar was inside the first molar. Replacement being impossible, a Schröder band was fixed to the first molar with a socket soldered to the outer side. A wire splint was fixed to the teeth from the first molar right to the left lateral incisor,

and opposite the lateral incisor a four-sided socket was soldered, with its open end backwards. An expansion screw, inserted in these sockets, the free end being in that on the molar band, separated the fragments, and then, room being made, the small fragment was drawn outwards by rubber bands, and when in place fixed by ligatures.

(3) In this case there was an oblique fracture between right canine and lateral incisor; the ends of the bone were separated by about $\frac{1}{2}$ cm. and fixed. Wire splints were made to surround the teeth of each fragment, and were ligatured to them; the canine and lateral incisor were banded. A screw between these bands drew the teeth together, this action being assisted by a rubber band passing between the wires of the two splints. When the bones were approximated, union soon followed.

Stress is laid on the importance of a radiogram in every case, in order to learn the nature of the fracture and of the displacement, and to judge the direction in which force must be applied to correct this.

EXTRA- AND INTRA-ORAL APPLIANCES.

The treatment of fractures by external bandages without internal splints is condemned. Two instances are pictured showing bandages even more elaborate than shown in fig. 1. In both they were absolutely useless and only annoyances to the patients.

Credit is given to Chopart as the first to use the combined extra- and intra-oral method in 1780. A lead rim resting on the teeth was fastened by screws to a padded, wooden splint below the chin. Rüthenick, a Prussian regimental surgeon, used a similar method in 1799. F. Schüttes, in 1900, collected twenty-six variations of this method which had been used; but from the point of view of initiating an advance, the most important was that of Morel-Lavallée (1855). After correcting misplacement, gutta-percha was pressed over the teeth, and after cooling with iced water, was ligatured to the teeth with binding wire. This cap was fastened to a chin-cap, also of gutta-percha, by steel clasps.

The use of the combined method is recognized in fractures of the maxilla, and for those of the mandible when no teeth are present, but, as at Düsseldorf, the method has been extended to other cases. The method is adopted for the correction of displacements. When the fragment is in the corrected position, the extra-oral appliance is removed and the intra-oral splint relied on, or altered, to act as a retentive apparatus.

In all cases the fixed point is a wire, or wires, passing downwards from a head bandage. This is similar to that shown in the illustrations from Düsseldorf, sometimes a plaster bandage and sometimes a bandage with wires encircling the head. The vertical wires are straight, or end in a loop to allow the fixed points to be varied as

required. When there is a loop, a second wire is used to steady it. The traction is by rubber bands.

One case illustrates the use of this method for pulling forward a maxilla, fractured from the skull and driven backwards. Here two vertical wires passed downwards on either side of the nose. From these rubber bands passed horizontally backwards to a wire splint fixed to the maxillary teeth.

In a second case there was loss of bone at the right angle of the mandible; hence, the left portion of the bone was displaced inwards and backwards. This was corrected by a rubber band passing to a vertical wire situated on the left cheek.

In a third case the bone was lost on the right side from behind the second premolar, including a portion of the ascending ramus. On the left side there was an oblique fracture between the second and third molars. The front fragment was displaced backwards to the right and twisted. To a splint fixed to the teeth a wire was soldered. This passed horizontally outwards to the left. To its outer end transverse wires were soldered, "like the wings of a windmill"; hence, the traction would be exerted in the direction proved necessary and the bone twisted and pulled out. Under this treatment the left fracture united correctly. Intra-oral treatment followed.

At Frankfort, sometimes in old-standing cases when fibrous union has formed, with the bone in an incorrect position, this is divided with a knife.

SURGICAL TREATMENT.

Professor Loos insists on the importance of radiograms, not only for ascertaining the condition of the bone, but because in many cases portions of metal have been found embedded in the soft tissues and have interfered with the treatment of wounds of these. He points out the great advantage of having films of the immediate seat of injury in addition to plates.

He strongly argues against wiring the bone in war cases. The suture always acts as a foreign body in these septic wounds. It fails to correct displacement, and, indeed, often only forms an axis around which the bone rotates under the pressure of muscles. He is against the insertion of metal splints between the ends of the bone, at least until the wound is thoroughly aseptic, and time has shown what bone will die and what will live. In exceptional cases union has taken place as long as six months after the injury, even when there has been loss of substance.

Loos cannot bring himself to try to obtain primary union of facial wounds after his experience of primary stitching in the field. When union followed, improvement was always demanded later for cosmetic reasons. He therefore allows these wounds to heal by secondary

intention, but fixes large flaps with a stitch or with strapping, whilst the sinking in of lips and cheek is prevented by rubber or tin shields.

Only passing reference is made in the paper to the methods he adopts in dealing with wounds, scars, &c., since these were to be demonstrated, after the meeting, in the hospital, but in reference to bone transplantation complimentary allusion is made to the work of Lindemann. Loos had at first used non-periosteal-covered grafts, but no details are given. He claims that the results were good. The graft always became loose before finally becoming fixed, and from a study of the radiograms he believes this to have been due to some absorption of the ends of the graft. Some cases were unsuccessful, but not, he believed, owing to this absorption. Once a splinter of shot was found in the bed; twice small sequestra separated from the mother bone; twice, on account of the presence of cicatricial tissues, the covering skin was unfavourable; and once erysipelas occurred, starting from the nose. These accidents have taught him to be yet more careful in his observations and in his method of preparation.

Loos had started a second series of cases, using Lindemann's technique, the grafts being periosteal-covered pieces of tibia. The use of a dental splint is essential, the graft being sprung into place and no sutures used unless the stumps of bone cannot be otherwise fixed. It was too early to compare the results of the two methods.

JAW INJURIES IN THE JAPANESE-RUSSIAN WAR, 1904-1905.

Although fractures of the mandible formed 44 per cent. of the gunshot injuries to the bones of the face in the Japanese-China War, no proper arrangements existed for treatment of these in the war with Russia. As a rule, a bandage was applied by a comrade or by the wounded himself, and the treatment in the field and base hospitals was at least inadequate, possibly wrong. This was the more regrettable as Hashimoto¹ recognizes that "with gunshot injuries of bones in other parts of the body the patient may be content with the healing of the wound and consolidation of the fragments, and not often ask further surgical help. The healing powers of Nature do the rest, and disturbed function is compensated by vicarious movement. But it is different with bone injuries of the mandible; these need quite different technical methods, a portion of which is in the domain of dental surgery. The finer points of treatment are undertaken by the dental surgeon, the army surgeon contenting himself with

¹ From a paper by Viscount T. Hashimoto, General Staff-Surgeon, published in *Archiv für klinische Chirurgie*, 1908.

occasional superficial help. The function of the mandible, the chewing of food, is prevented by relatively slight displacement of the bony fragments; this does not happen with other bones. If, as not infrequently occurs, suppuration follows and necrotic fragments must be removed, the wound may luckily heal but the "bite" will be spoilt, on account of the displacement of the bony fragments, and this renders the mastication of food almost impossible. The consequence is impaired nutrition. On account of the actual damage to the soft parts, pus flows out of fistulous openings into the mouth, and the patient swallows these deleterious products. Shortly, the lasting metabolic disturbances, partly through swallowing toxic compounds, partly due to faulty feeding, together with the consequential alteration of the facial contours, call to mind the cachectic condition coincident with a malignant growth."

Hashimoto was head of the Red Cross Hospital at Tokio, and the cases were seen and treated at that hospital. Mostly the patients suffered from facial deformity, due to muscular displacement of the bony fragments, increased by subsequent cicatricial contraction. The

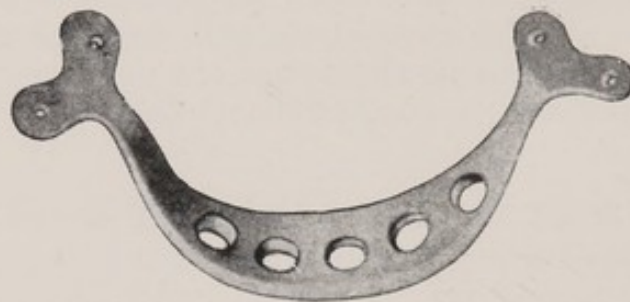

FIG. 88.

cases described differ but little from so many seen at home, and in most instances did not come to Tokio till two or three months after the injury. They suffered from inability to open the mouth, the orifice of which was often contracted so that it would not admit a finger, difficulty in swallowing, impediment of speech, dribbling of the saliva out of the mouth, facial deformity, bodily wasting, &c.

The general remarks on the treatment of these fractures seem open to criticism. Thus they argue against bone-grafts, because the wound is septic, and the fragments of the mandible lack fixity. The former, as has been seen, need not occur, and the latter should be overcome by splints. The centre of interest in the paper is the description of Hashimoto's method of treating cases where there is loss of substance by means of plating.

The form of the plate is shown in fig. 88. It was made in aluminium. The holes in the wings were for the silver wire

sutures which ligature it to the bone, the central holes were for drainage.

With the assistance of Dr. T. Takashima, dental surgeon, there were treated fourteen cases, of which eight were due to bullets and six to shrapnel. In four cases the injury was at the symphysis, ten at the side, three right, and seven left. The splint was fixed to the lingual side of the bone because it would there interfere less with the nourishment of the bone than if fixed under the relatively thin cutaneous covering.

To introduce it Lisfranc's incision was used. The knife was introduced at the angle of the mouth, carried vertically downwards till it reached the periosteum and the tissues were then divided from the bone, right and left. After removing any necrotic tissue, the ends of the bone were freed and the deformity reduced. Holes were drilled in the bone with an electric drill and the splint was fixed in such a position that it could be reached later for removal. The deformity was over-corrected. As a rule, absorption round the holes drilled in the bone made the splint loose after about a month; nevertheless it was left *in situ* for about two to three months. Usually firm scar tissue formed between the ends of the bone, but in one case there was bony union. After removal of this plate a vulcanite retention splint, fastened to the teeth, was inserted and, some months later, a denture. Better results were obtained in fractures at the symphysis than with those at the side. All the cases are described in detail, but from the description it does not appear that the results equal those claimed at Düsseldorf.

JAW CASES IN THE BALKAN WARS.

A series of papers dealing with the surgery of the recent Balkan Wars is published in the *Beiträge für klinischen Chirurgie*, 1914. They include reports from surgeons with the Greeks and with the Bulgarians. The jaw surgery seems to have been of a primitive type; indeed, Goldammer, who was sent by the Prussian War Office and was in charge of a hospital in Salonika, laments that surgeons have not learned to adapt splints. "What we have seen," he says, "of fractures of the lower jaw were entirely disappointing, and I must admit that the results in our own cases were not in the least satisfactory, since all appropriate material was lacking."

Only patients who could not be moved to Athens were retained in Salonika, hence no deductions can be drawn from numbers; but of 232 fractures seen, sixty-four were of the head and face, and of these ten were of the maxilla and ten of the mandible. Goldammer used Sauer's wire splint, as described in a previous section.

Suchanek writes a special article on wounds of the face and neck

Of 3,143 cases of all kinds of injuries seen at Sofia, of which notes were kept (about 50 per cent. of the whole), thirty-eight had bones of the face fractured. Of these fifteen were of the maxilla and eleven of the mandible. Of those of the mandible ten were on the left side and one on the right. This frequency of left-sided injuries is also shown in Goldammer's and Hashimoto's figures. It is explicable because the left side of the face is more exposed than the right when shooting.¹ Whilst simple gunshot wounds of the extremities were aseptic, those of the face had usually been infected from the mouth. Some of the cases were treated with wire splints, but little appears to have been done. Suchanek refers to Hashimoto's methods. He regrets he could not adopt these because the presence of a dentist was necessary, and, apart from this, in the Balkan War the hospital arrangements were bad: even essential things had to be improvised. Goldammer says, in the second war the medical arrangements of the Greeks were much better, and with the Crown Prince's army were good.

That the Turks were not likely to take much interest in such exacting work as jaw surgery can be deduced from the following gruesome story told by Goldammer: The situation of the garrison hospital at Janina was ideal. In the middle of a garden, on a spit of land jutting far out into the sea, it was flooded with light, and air, and sunshine. But within was a hell of dirt, reeking of murder. On approach one landed in a sea of offensive fluid. This, on investigation, was found to flow from a latrine, which, though it must have been blocked for weeks, was still used, not only for its appointed purpose, but as a receptacle for waste food-stuffs and old dressings. The odour permeated the hospital, and yet not a single window was open. Not a doctor was in the building, though many of the patients cried for help and food. The hospital was designed for 150 patients, and fifty attendants were allotted to it. They could be met walking in the town.

Outside the province of this article, but of interest, is the fact, stated by Goldammer as showing the protective value of vaccines against cholera, that the only one who developed cholera in the entourage of the King was Aide-de-Camp C., who died in a few hours. He was the only officer at Headquarters who refused to be vaccinated.

Typhus vaccines were not used by the Greeks, but the Turks at Salonika prepared the vaccine. The result remains obscure, since

¹ This may not be true under the altered conditions of stationary warfare. The only figures given in German literature to hand are by Arkövy. He saw at Budapest twenty-five lower jaw fractures, of which four were in the region of the symphysis, seven on the left side and fourteen on the right. In many cases illustrated the point of entry, however, is in the soft tissues on the left side, below the mandible, the exit being on the right, accompanied by extensive laceration of soft tissues and comminution of bone. Many of the cases are due to hand grenades and shrapnel and to these the argument would obviously not apply.

Goldammer saw undoubted typhus cases in the general wards, but was told by the Turkish medical fraternity that those patients had pneumonia. And of "pneumonia" they died!

Suppuration seems to have been the rule in all these jaw cases, accompanied by hæmorrhage in some. Details of one such case are given: Ligature of the external carotid failing to stop the bleeding, the common carotid was tied. Hemiplegia; exitus lethalis. In another case the remains of one half of the mandible were disarticulated because of hæmorrhage. It may be added that disarticulation of the mandible is performed in Berlin when the bone is the seat of malignant growth, chiefly because it is claimed by some (e.g., Schröder) that a better result is obtained with the prosthesis than if portions of the ascending rami be left. A splint is inserted at the time of operation.

Goldammer claims to have seen beneficial results in the treatment of wounds from the use of "Heliotherapie." The prevalence of sunshine in Greece made the use of this easy. The first application often caused pain and was followed by a rise of temperature. This subsided, and after four or five days it could be applied painlessly. His experiences coincide with those of Lindemann at Düsseldorf.

THE HISTOLOGICAL AND CLINICAL LAWS OF IMPLANTATION, DEDUCED FROM EXPERIMENTS ON ANIMALS.¹

Ollier in his paper, "Traité expérimental et clinique de la régénération des os," published in Paris in 1867, is said to have been the first to give a scientific basis to the operation of bone implantation. He taught that the implantate must be covered by living periosteum, and that it and its periosteum continued alive and became united to the bone of the host. This view was accepted till Barth published his paper, "Histologische Untersuchungen über Knochenimplantation" (*Ziegler's Beiträge*, 1895), founded on much original investigation, which controverted Ollier's statement. Barth contended that the implanted bone only formed a splint; that it and its periosteum died; and, consequently, that it was immaterial whether the periosteum was alive or dead, or whether the bone was calcified or decalcified. He claimed that the new replacing bone was always formed from the periosteal and medullary cells of the mother bone. Barth's views are said to have been accepted generally, though from time to time their validity was denied by surgeons; but the opposition grew, at any rate as regards results obtained from operations on the human subject, and finally at the Congress der deutschen Gesellschaft für Chirurgie, 1908, the opinion of surgeons was unanimous that living

¹ Abstracted from a paper by Dr. Georg Axhausen (*Archiv für klinische Chirurgie*, 1908).

periosteum was essential. Barth himself then admitted that his practical experience in operations had taught him that the methods he adopted were no longer founded on his former histological teaching.

Axhausen's experiments were undertaken to elucidate the matter and to explain the origin of the difference between Ollier's and Barth's opinions. He also desired to find out whether it was possible to implant complete shafts of round bones; whether it was material if the bone was taken from the same species or not; whether the age of the animal from which the graft was taken was of importance, the different behaviour of various bones (tibia, cranial bones, &c.), the conditions favouring union and the possibility of taking the implantate from animals which had recently died.

He performed 146 experiments on rats, rabbits and dogs, and to eliminate the possibility of the new bone growing from the mother bone, he not only implanted live bone, dead bone and boiled bone-grafts between the ends of the divided bones of the subject, but also in the soft tissues of the back. This latter group of experiments was undertaken because in the former group it was difficult to prove whether the callus around the end of the implantate grew from the periosteum or medulla of the implantate, or from that of the mother bone. His experiments are given in detail, but an attempt is made here only to summarize his conclusions. In all experiments histological investigation of the tissues followed. The original paper is illustrated.

The bone tissue dies, even when it is surrounded by living periosteum and medulla.

In the experiments the nuclei of the bone cells disappeared. The disappearance began in the tissue at the periphery of the graft and progressed inwards. The degeneration of the nuclei resembled that due to a fluid stream gradually penetrating inwards. But, exceptionally, in patches at the periphery, small portions of bone remained alive, i.e., the nuclei retained their structure unaltered, though deeper in the bone they degenerated. These patches occurred where the periosteum or medulla had lived and showed signs of development. Very thin pieces of bone might remain alive as an entity, but this was so exceptional as to be of no practical importance. This dead bone was replaced by living bone, where it was adjacent to bone-forming tissue, partly on the surface, but chiefly in the vascular canals, in which new blood-vessels had formed. The absorption of the dead bone was due partly to multinucleated giant cells, especially on the surface, but in the deeper tissue chiefly to small cells with little nuclei, similar to those which Axhausen has described as osteoclasts in connection with osteoplastic and osteoclastic portions of carcinomatous growth in bone. All stages of lacunar absorption could be seen, from slight widening of the Haversian canals to large absorption spaces.

This absorption was followed by redeposition of bone. Sometimes the new bone began to form early, but usually only after there had been considerable absorption. Typical osteoblasts were rare. The experiments did not decide whether the whole bone is replaced or whether islets of dead bone remain permanently embedded, as Marchand has thought possible. Provided the surrounding conditions are favourable, the periosteum and the medullary tissue remain alive, and retain the power to form new bone.

Two conditions are essential:—

(1) The periosteal and medullary cells must be able to live for a while separated from the normal circulation, the *vita propria*.

(2) The embedding tissue must be able, in consequence of a transient inflammation, to pour out a rich lymph stream which shall bring nourishment to these cells, and shall keep them alive till vascular connective tissue develops around them.

The *vita propria* of cells differs. It was shown in the experiments to be less in those of rats than in those of dogs. Obviously the cells must not be subjected to chemical or physical irritants, but the experiments also suggested that keeping the transplantate for a short time in dry sterile gauze damaged the *vita propria*. This is believed to be due to the periosteum becoming dry; hence it is advised that in operations the bed for the implantation should be finished, and then the portions of bone, to be implanted, prepared.

Axhausen believes that the lymph of an organism is specially suited to the nourishment of its own cells, and that in this fact is the explanation that in his experiments the best results were obtained if the periosteal-covered implantate was taken from the same individual; still good, but not equally so, if taken from an individual of the same species; and quite unfavourable, or even useless, if taken from an individual of another species. On the other hand, of first importance is the condition of the embedding tissues. It is not immaterial whether the tissue surrounding the implantate is poorly nourished scar tissue or a soft connective tissue rich in blood-vessels.

It was the quintessence of all experiments that, *ceteris paribus*, the life of the periosteum and medulla and the new formation of bone depended on the ease with which the lymph could reach the cells. Nothing prevented this more than muscle fibres left on the bone, but of importance was the thickness of the fibrous layer of the periosteum. At the cut margins of the periosteum the cells are immediately in contact with the lymph, whilst elsewhere this must first penetrate the fibrous layer before reaching them; also the newly formed vascular tissue early brings to them the nourishment essential to productive activity. Hence at these cut margins there is rapid cell multiplication and early bone development. The periosteum elsewhere, if the fibrous layer be thick, may die, but even then it may be replaced by growth

from the cut edges. The rapid growth of bone at the cut edges of the periosteum was one of the most striking features in all the experiments and led to others in which, by making incisions in the covering periosteum, "cut edges" were multiplied. The same results followed. Therefore, it is advised that long incisions should be made through the covering periosteum of an implantate, and especially when the fibrous layer of the periosteum is thick, as, for instance, on the inner surface of the tibia near the knee.

It is essential that the cells shall be in contact with vascular tissue, but if a complete portion of the shaft of a round bone be implanted, the medulla in the central canal can only be in contact with such tissue at the cut ends. Even at these open ends the medulla may have shrunk back or been knocked out, so that the remainder will be separated by blood-clot from living tissue. This was not so possible in the narrow canals of the femurs of rats—hence, the ends remained alive and bone was formed in it, though the rest of the medulla became necrotic. In rabbits and dogs with larger canals, in no instance did bone form at the ends; the whole medulla died. Complete sections of long bones are not suitable for implantation. If used, the periosteum should be freely incised. Up to the time of this work, only two complete shafts of bone had been successfully implanted in experiments on animals. One of these experiments was performed by Ollier in the pre-aseptic days; the result must have been quite accidental.

Per contra, if a round bone be divided longitudinally and then implanted the medulla may be in contact with vascular tissue and will live except where contact, from one cause or another, is impossible.

The idea that it would be an advantage to take the implantate from a young animal is held by many and seems acceptable, but the experiments did not determine the point.

Living bone *entirely* deprived of its periosteum, all dead bone and boiled bone implanted in the soft tissues became encysted, but did not become in any way united to the tissue. If the bone was covered by periosteum, the newly formed connective tissue grew into it in a few days, uniting it firmly to the surrounding tissue, and in from six to eight days new bone began to form. If implanted between the ends of a bone, the callus forming around the cut ends of the periosteum of the implantate soon fused with that formed from the periosteum of the bone forming its bed.

The experiments showed that the entire removal of all periosteal osteoblasts from a piece of bone was difficult. Hence with bone, apparently stripped of periosteum, union formed in exceptional places.

The experiments showed that when the pieces of bone covered with periosteum were taken from rabbits and dogs several hours after their death, the results were not noticeably different from those

from live animals. Pieces of tibia were taken from dogs fourteen hours after death, and from rabbits thirty hours after. The portion of bone must only be removed from the body at the moment it is required.

In some of the experiments the surface wound opened and the implanted bone was exposed, and in one case an abscess formed; nevertheless, it was determined, microscopically, that this had not destroyed the implanted periosteum and medulla. On the contrary, in the immediate neighbourhood of the suppuration, there was rapid growth and bone had formed. In one case, a portion of bone died, separated from the implantate and was thrown off without preventing union. Hence, Axhausen suggests that should a wound open it is not necessary to remove the graft but to await the natural separation of the sequestrum, if bone should die.

When an implantate has its ends pointed, it is more likely to be infected than if the implantate be fixed by silver wire sutures. This is probably due to the medulla being damaged. Although the surface wound had united, a small abscess was found around such points; the abscess also contained small portions of necrosed bone.

The experiments showed that portions of round bones covered by periosteum are to be preferred to portions of cranial bones covered by periosteum; therefore, in making good defects in the cranial bones it is better to utilize portions of the tibia than to take the material from the neighbourhood of the lesion. Axhausen is of opinion that the lessons learned from these experiments on animals may be applied to operative procedures in human beings.

When indicated as an operative procedure, Axhausen still advocates the implantation of grafts, including the whole circumference of the bone. His experiments on dogs with these were successful, and in the same "Archiv" for 1911 he describes cases illustrating the use of such implantations in man. In this paper the whole question is re-argued.

APPENDIX.

It may be of interest to add an abstract from "Die Zahnärztliche Hilfe im Felde," by Drs. Williger and Schröder, concerning the German arrangements for the sick and wounded in the field, as provided by the Army Order of January 27, 1907. Each Army Corps has a hospital unit, consisting of four chief staff surgeons, six staff surgeons, nine assistant surgeons, two or three dental surgeons, three staff apothecaries, and six field hospital inspectors; to this unit are attached the necessary assistants, whose strength may be added to from the group of hospital volunteers. The dental surgeons are under the control of the chief of the hospital unit (the senior chief staff surgeon). The uniform of the dental surgeon resembles that of the chief staff apothecary. Each Army Corps has twelve field hospitals and three sanitary companies. The sanitary

companies erect dressing stations as near the fighting line as possible and here first aid is rendered. The sanitary wagon contains the necessary instruments for removing diseased teeth. From the dressing stations the wounded are removed as quickly as possible to the field hospitals. These are mobile formations, usually situated in some building where a room can be fitted for dental purposes. But as a dental surgeon is not attached to the field hospital, he must be fetched from the base hospital. The dental surgeon, besides dealing with diseases of the teeth, is called upon to assist in injuries of the jaws. Materials for splints, &c., are provided, but he is cautioned to use these sparingly and to obtain as much as possible by requisition, voluntarily or otherwise, from the dentists or dental mechanics of the place in which he finds himself. The principle in dealing with the wounded being to send those home who can travel, it follows that in the case of a soldier with a simple fracture—say, from the kick of a horse—who can sit in the hospital train, the splint can be fixed soon enough at home. But *per contra*, if, besides the fracture, the soft tissues of the tongue or floor of the mouth be torn, then treatment with splints, &c., is called for either in the field or base hospitals.


The following statements are taken from various papers and annotations published in the *Deutsche Monatsschrift für Zahnheilkunde*.


Early in 1915 the number of dentists was increased to three and an assistant with two mechanics. It is stated at the end of 1915 that the last Army Order increased the number of dentists to five. In addition, many divisions have a "Dental Station." The surgeon attached to each battalion has received a dental outfit to apply dental dressings. Dr. Guido Fischer, of Marburg, has published a Dental Vade Mecum for the use of surgeons under these conditions. The necessity of these changes is apparent from a statement made by Professor Pfaff, of Leipzig. Of fifty jaw injuries, on arriving there only three had splints applied, and of these one was useless; the others had not received any dental help, though the injury was from three to six or more weeks old. All had acute stomatitis and one died of pneumonia consequent thereon.


A further illustration is given by Dr. Warfschmidt, of Konitz. A soldier received extensive injuries of the jaws and face at Lyck, on October 9, 1914, at 4 p.m.; at 8 p.m. he reached the field hospital. On Saturday, October 12, he arrived at Konitz, not having had nourishment in the meantime. The following day (Sunday, October 13), he was seen by Warfschmidt and had till then received no surgical attention. His condition, which is described in detail, was pitiable.

At Frankfort, it was said that many soldiers, especially the elder ones, had to be sent back from the Front on account of their defective teeth.

Another aspect of the earlier conditions is shown in a letter written at the beginning of 1915 by Paul Müller, a dentist, who, in writing from the Front, describes *inter alia* how soldiers had then frequently to travel from 10 km. to 20 km.; to obtain dental treatment at the base hospital, and often to be absent from service for some days. At this hospital they had in three months treated 6,000 to 7,000 patients (including 1,300 to 1,400 officers). The dentists at the hospital took it in turns to go to the Front on days notified to the troops. At three of the four points they visited the French chose the time of their visits to throw grenades. Besides other work, they did about 100 repairs a month to dentures and made about twenty-five new ones. But often mechanical work had to be sent far to the rear, because "for the last fourteen days we have no rubber or artificial teeth; what we have hitherto used we have requisitioned. But how can you commandeer what has ceased to exist?" This discloses the other side of the picture.







54

5

2-14

1 4

4 1

5

4 6

3 10

4 9 10