

Notes on the treatment of irregularities in position of the teeth / by J. F. Colyer.

Contributors

Colyer, Frank, 1866-1954

Publication/Creation

London : Dental Manufacturing Co., 1900.

Persistent URL

<https://wellcomecollection.org/works/fzwuh7f3>

License and attribution

This work has been identified as being free of known restrictions under copyright law, including all related and neighbouring rights and is being made available under the Creative Commons, Public Domain Mark.

You can copy, modify, distribute and perform the work, even for commercial purposes, without asking permission.



Wellcome Collection
183 Euston Road
London NW1 2BE UK
T +44 (0)20 7611 8722
E library@wellcomecollection.org
<https://wellcomecollection.org>

NOTES ON THE

TREATMENT OF IRREGULARITIES

OF THE TEETH

J. F. COLYER

ROYAL DENTAL HOSPITAL.

SCHOOL LIBRARY.

Presented by


J. F. Colyer Esq.



22500408083


Med
K48743







NOTES ON THE
TREATMENT OF IRREGULARITIES IN
POSITION OF THE TEETH.





NOTES
ON THE
TREATMENT OF IRREGULARITIES
IN
POSITION OF THE TEETH

BY
J. F. COLYER, L.R.C.P., M.R.C.S., L.D.S.

*Dental Surgeon to the Dental Hospital of London; Dental Surgeon to
Charing Cross Hospital, and Lecturer on Dental
Surgery in the Medical School*

Publishers
THE DENTAL MANUFACTURING CO., LIMITED
LEXINGTON STREET, LONDON, W.

—
1900



SDb 4

14632 630

WELLCOME INSTITUTE LIBRARY	
Coll.	WelMOMec
Coll.	
No.	WU




PREFACE.

THE subject matter of the following pages formed the basis of a series of lectures given to dental students at Charing Cross Hospital during the early part of last year.

In connection with the new illustrations contained in the book my thanks are due to Mr. L. Danielsson. For the loan of blocks I have to acknowledge my indebtedness to Messrs. Longmans, Green and Co.; to the publishers of the "American Text-book of Operative Dentistry" and the "American Text-book of Prosthetic Dentistry;" and also to the Council of the Odontological Society of Great Britain, Messrs. C. Ash and Sons, and Messrs. S. S. White and Co.

I wish also to express my gratitude to Mr. H. Darby for much kind assistance, and also to Mr. Henry Bale for the care he has bestowed upon the printing of the book.





CONTENTS.

CHAPTER I.

	PAGE
A Brief Review of the Causes producing Irregularities ...	I

CHAPTER II.

The General Principles of Treatment	14
--	----

CHAPTER III.

The Movement of Teeth by Mechanical Appliances	24
---	----

CHAPTER IV.

Irregularities in Position of Individual Teeth not the Result of Crowding	45
---	----

CHAPTER V.

Irregularities in Position of Teeth the Result of Crowding ...	64
--	----

CHAPTER VI.

The Early Treatment of Crowded Mouths	77
--	----

CHAPTER VII.

Cases of Crowding coming under Observation after the Majority of the Teeth have Erupted	91
---	----

CHAPTER VIII.

Cases of Crowding involving the Malposition of several Teeth—	PAGE
General Crowding	115

CHAPTER IX.

Superior Protrusion—Undue Prominence of the Upper Front	
Teeth	146

CHAPTER X.

Protrusion of the Mandible—Underhung Bite—Inferior Pro-	
trusion	199

CHAPTER XI.

Lack of Occlusion—"Open Bite"	216
--------------------------------------	-----

CHAPTER XII.

The Immediate Regulation of Teeth	230
--	-----



NOTES ON THE
*Treatment of Irregularities in Position
of the Teeth.*

CHAPTER I.

A Brief Review of the Causes producing Irregularities¹

THE causes which produce irregularities in position of the teeth may be divided into two groups, viz., *General* and *Local*.

GENERAL CAUSES.

One of the first facts which must strike any investigator into the etiology of irregularities is the comparative freedom of ancient, and even uncivilised modern races, from such defects. This has been well demonstrated by many observers; for instance, Messrs. Cartwright and Coleman failed to find any irregularities in the large collection of skulls in the crypt of Hythe Church,² and Dr.

¹ The word "irregularity" is used throughout as meaning irregularity in position of the teeth.

² The skulls, according to Hasted's "History of Kent," probably belong to the year 456. In the opinion of Mr. Prideaux, the greater portion of the skulls belong to the Celtic type, the remainder being Anglo-Saxon. Two skulls are believed to be Roman and two others Lap and Danish.

Nicols, quoted by Talbot, in an examination of thousands of Chinese and Indians on the Pacific Coast and in the Rocky Mountains, searched in vain for a single instance of irregularity. Dr. Talbot himself, in 1881, examined 300 Chinese and found no irregularities either in the teeth or jaws. On the other hand, Dr. J. M. Whitney¹ has found among the Hawaiians "(a people isolated from all others for at least 1,400 years, with no admixture of races), irregularity of the teeth of both maxillæ almost as common as among the mixed races of to-day." A review of facts as recorded by various writers on the question seems, however, to point to a distinct connection between irregularities and modern civilisation.

Certain irregularities of the teeth and jaws are undoubtedly transmitted from one generation to another, and indeed not infrequently become family peculiarities. A slight overlapping of the centrals, not the result of crowding, may sometimes be traced in the parents and in the children, and in one case which has come under observation the right incisors slightly overlapped the left in the father and in four of the children out of a family of seven. Prominent upper teeth accompanied by a small maxilla, or large mandible, are often transmitted through many generations.

Dr. Talbot is of the opinion that an explanation of some irregularities can be found in "race crossing." Every nation has its own peculiar charac-

¹ *Transactions of the World's Columbian Dental Congress*, vol. i., p. 109.

teristics, which manifest themselves in "the head and skeleton, the general contour and mould of the body, the manners, &c.," and the older the race the more fixed these characteristics become. One race may possess large jaws and equally large teeth, another small jaws and proportionally small teeth, and it is quite conceivable that intermarriage between two such races would lead to irregularities in the jaws and teeth of the offspring. Dr. Talbot, in dealing with this subject, points out that in mixed races such as the Americans, irregularities are prevalent, while in purer races such as the Chinese and African, irregularities are seldom met with. On the other hand, the presence of irregularities in the Hawaiians must not be lost sight of. Mr. J. R. Headridge¹ considers that this view is untenable, and he instances that in dogs, where cross-breeds between parents of very different sizes are frequent, irregularities are very rare.

In practice one certainly meets with cases where one parent has large teeth and jaws, and the other small teeth and small jaws, the offspring inheriting the large teeth of one parent and the small jaws of the other. That intermarriage of races plays a part in the production of some irregularities seems extremely probable. The question, however, demands a more thorough investigation. According to Talbot,² the early Britons possessed

¹ *British Journal of Dental Science*, vol. xxvii., p. 145.

² "The Etiology of Osseous Deformities of the Head, Face, Jaws and Teeth," Third Edition, p. 67.

maxillæ varying in their lateral diameters¹ from 2·12 to 2·62 inches, whilst in modern Englishmen the maxillæ vary from 1·88 to 2·44 inches; the minimum diameter having thus decreased more than the maximum, and a comparison of the maxillæ of Ancient Romans with modern inhabitants of Southern Italy gives a similar result. From these data he seems to infer that a diminution in the size of the jaws has taken place in the inhabitants of England and Italy, but it is not quite clear that these comparisons of the maxillæ of Ancient Britons and ourselves, and of Ancient Romans and modern Italians, are good ones. Modern Englishmen are only to a very small degree, if at all, descendants of the Ancient Britons; and similarly, the present inhabitants of Southern Italy have but little claim to direct descent from the Ancient Romans. Deductions drawn from comparisons of this kind would therefore seem to be of little value.

With the present generation, individuals from the lower social scale have, as a rule, wider maxillæ than those from the higher.

Modern civilisation probably produces these effects in the maxilla partly through the arterial system. The brain and osseous structures of the face derive their main blood supply from the same source, viz., the common carotid arteries. The strain of modern education—indeed the whole

¹ The measurements were taken from the buccal surface of one first permanent molar to the buccal surface of the corresponding tooth on the other side.

environment of the individual—entails a greater call upon the brain than the primitive mode of living, and thus necessitates a larger supply of nutritive material to that structure. This increased supply is probably provided at the expense of the osseous structures, including the teeth, with the result that these structures degenerate.

Modern food and cooking, by calling forth less effort in mastication, may also indirectly deprive the jaws of a certain amount of nutrition.

Selective breeding in some form may have had an influence in the production of the narrow arch of the higher classes of the present day. Mr. Tomes,¹ in referring to this point says, "if the type of face nowadays considered to be beautiful be investigated, it will be found that the oval tapering face with a small mouth, &c., does not afford much room for ample dental arches. On the other hand, the type of face which we consider bestial has a powerful jaw development. Perhaps generation after generation seeking refinement in their wives may have unconsciously selected those whose type of face hardly allows the possibility of a regular arrangement of the full number of teeth. At any rate there is something tangible in the hypothesis and grounds for arguing pro and con."

It therefore seems probable that sexual selection and modern civilisation are factors in the production of irregularities, but one must not forget that the variation produced has been more marked in the

¹ "A System of Dental Surgery," Fourth Edition, p. 112.

jaws than in the teeth. The size and shape of the permanent teeth are to a great extent determined during the first two years of life. At this early stage the teeth are arranged in their crypts in a crowded condition. During the period of eruption a rapid growth of the jaws takes place in a backward direction—thus allowing the teeth to be accommodated in a normal arch—but any severe illness, such as an exanthematous fever at this period, may lead to an arrest of the development of the body, including the maxilla and mandible, and in this way a crowded arrangement of the teeth may be produced.

Irregularities of the teeth are said by Talbot to be more frequent in people congenitally deaf, dumb or blind.

LOCAL CAUSES.

Premature removal of the second deciduous molar is a fruitful cause of crowding. Removal of this tooth at an early age allows the first permanent molar to move forward and so encroach upon the space which would be occupied normally by the second premolar. In the patient, the model of whose mouth is shown in fig. 1, the deciduous molars were retained on the right side for the normal period and no irregularity resulted; on the opposite side the second deciduous molar had to be extracted prematurely, with the result that the first permanent molar moved forward and caused the second premolar to erupt inwards (see figs. 2 and 3).

Premature removal of the deciduous canines may lead to irregularities by allowing the first premolars and lateral incisors to erupt irregularly. Under certain conditions removal of the deciduous

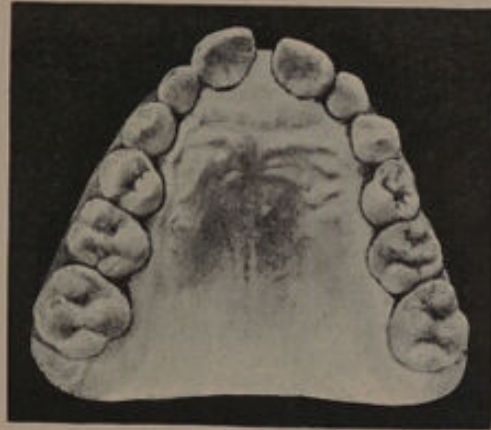


FIG. 1.

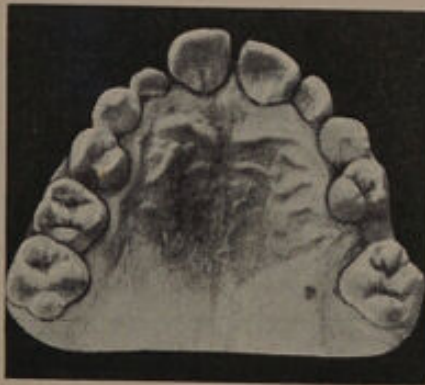


FIG. 2.

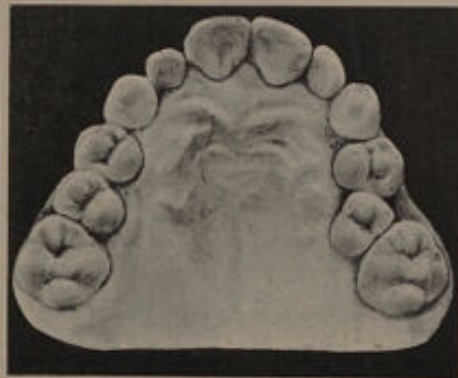

FIG. 3.

canines to relieve a crowded arrangement of the incisors is advisable, but this subject will be more fully discussed when dealing with the treatment of crowded mouths.

Under certain conditions, the early extraction of the first permanent molars may produce irregularity.

In cases where the deciduous molars are very carious, the first permanent molars are practically the sole means by which mastication is carried on, and their early removal under such circumstances would transfer the whole force of the bite to the incisors, with the probable result that the upper ones would be driven forward—an irregularity at times difficult to remedy.

Persistent deciduous teeth.—The loss of the deciduous teeth is, under normal conditions, due to absorption of their roots. Absorption is brought about by the action of the “absorbent organ,” namely, a mass of cells possessing osteoclastic and probably phagocytic properties. The stimulus calling into existence this mass of cells is the erupting permanent tooth. Under normal conditions the whole of the root of the deciduous tooth lies in the line of eruption of the permanent tooth, and absorption gradually proceeds until the entire root is removed. The crown falls away and its place is taken by the permanent tooth. If from some cause, such as crowding, the erupting tooth does not take its normal line, only that portion of the deciduous root which lies in its course is absorbed.

Deciduous teeth which are pulpless or necrosed undergo but little absorption. Such teeth obstruct the movement of the erupting tooth, deflect it from its course, and so cause it to erupt in an irregular position.

Cases of irregular permanent teeth in which the deciduous teeth are still present are therefore due to :—

- (1) The original mal-direction of the erupting tooth ;
- (2) The presence of necrosed or pulpless deciduous teeth.

Mouth breathing is held by many to be an active factor in the production of maxillary deformities, and the frequent association of chronic nasal obstruction with the high vaulted palate would seem to indicate the possibility of a connection

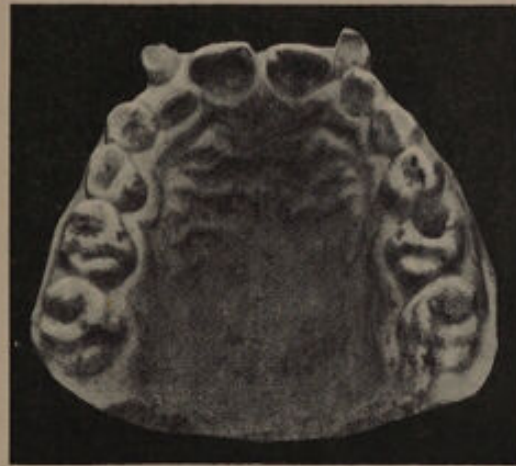

FIG. 4.—A case of irregularity accompanied by persistent deciduous teeth.

existing between the two. In an interesting paper to the *West London Medical Journal* (July, 1896) Mr. Mayo Collier states that if one nostril be blocked up, the rush of air passing under the nasopharynx, and to some extent through the open half of the nasal cavity, lessens the tension in the closed portion of that cavity. This can be shown by the following simple experiment: Take a bent piece of glass with mercury in the bend, and connect one arm with a fairly thick elastic tube and insert this

latter into the blocked nostril. During every inspiration the mercury will fall in one limb and rise in the other, to the extent of an inch or more, and this, according to the author, is equal to a pressure of about half a pound on every square inch. In other words, if each nasal cavity is regarded as a box, it means that in cases of nasal obstruction, during each inspiration there is a force equal to half a pound on every square inch of the bones forming the fossa, and it is possible to conceive that such a force would produce the contracted and high arched palate so often seen. *Old idea*

This view is corroborated by an experiment made by Ziem and quoted by Mr. Mayo Collier. Ziem artificially blocked the nostril of a young animal for a long time, with the result that he noticed "there was a deviation of the intermaxillary bone and the sagittal suture towards the shut up side, also lesser length of the nasal bone, frontal bone, and the horizontal plate of the palate bone, less steep elevation of the alveolar process, smaller distances between the anterior surface of the bony auditory capsule and the alveolar processes, and also between the zygomatic arch and the supra-orbital borders—in other words, the whole side of the face was squeezed in from all points by the unequilibrated atmospheric pressure due to the rarefaction of the air from within the obstructed nasal fossa, with a result that the whole side of the head was prevented from expanding and growing."

Supernumerary teeth often cause irregularities. A divergence of the upper central incisors is at

times due to the presence of a supernumerary tooth, usually peg-shaped. An example of this is shown in fig. 5. Displacement of the incisors internal or external to the arch, or a general crowding of the

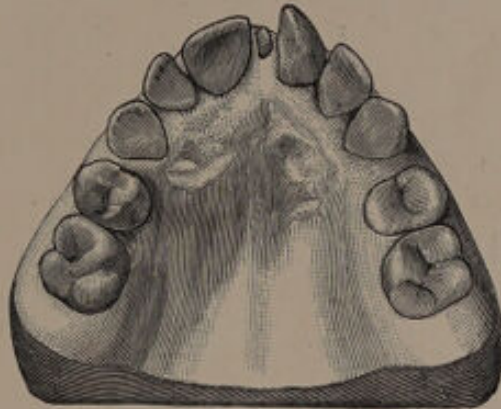


FIG. 5.¹

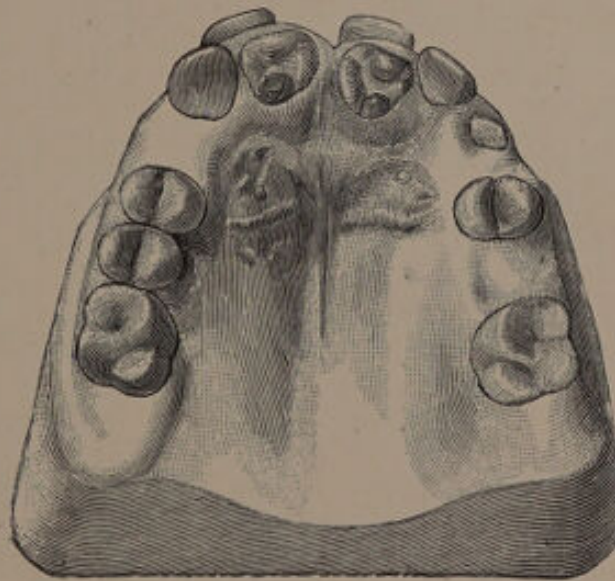


FIG. 6.

teeth may occasionally be traced to the presence of supernumerary teeth. Examples are shown in figs. 6, 7 and 8.

¹ Figs. 5, 6 and 7 are from "Diseases and Injuries of the Teeth."

The habits of sucking the thumb, lip, tongue and toe produce irregularities. A consideration of this group of causes will be found in the chapter dealing with superior protrusion.

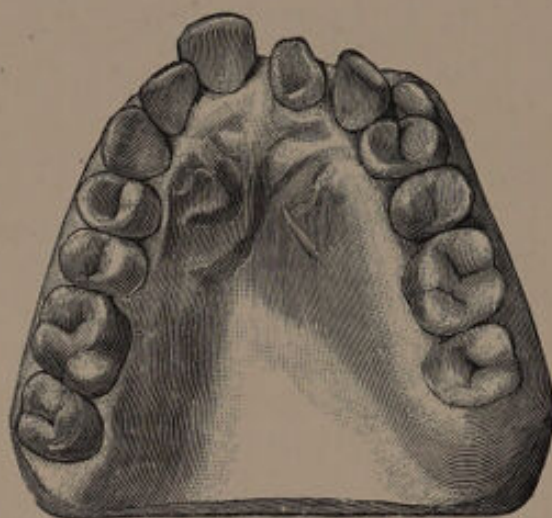

FIG. 7.

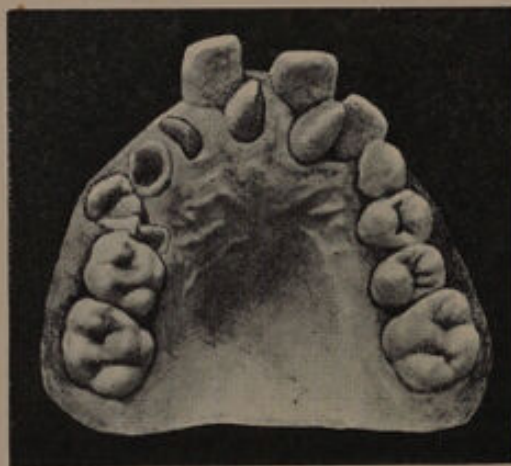

FIG. 8.

The frænum of the lip at times passes between the central incisors and is attached to the muco-periosteum covering the palate. Under such conditions every movement of the lip causes the frænum

to press on the teeth and thus separates them. This cause of divergent centrals was first pointed out by Mr. H. Moon.

Alveolar abscess in connection with the deciduous teeth sometimes leads to irregularity in position of permanent ones, while **cicatrices, hypertrophy of the gums, in addition to injuries, malformation and tumours of the jaws** may be also cited as local causes.

The above remarks on the etiology of irregularities of the teeth are necessarily brief owing to the limited scope of the present volume. Anyone, however, who is interested in the subject will find abundant information in Dr. Talbot's work on the "Etiology of Osseous Deformities of the Head Face, Jaws and Teeth."

CHAPTER II.

The General Principles of Treatment.

Careful supervision of the mouth during the period of the second dentition will do much to prevent or at least to simplify irregularities.

The early treatment of caries in the deciduous molars will often prevent their premature loss, while the timely removal of a deciduous tooth will often prevent a permanent one from assuming an abnormal position. Special attention should be bestowed upon the first permanent molars. Any cavities which appear should immediately be filled. If the distal aspect of the second deciduous molar be carious, attention must be given to prevent food lodging against the first permanent molar, as this would imperil the latter tooth. If caries does appear on the anterior surface of the permanent molar, the advisability of removing the deciduous tooth and making the surface of the permanent molar self-cleansing must be considered. The successful preservation of the first permanent molar far outweighs the slight moving forward of the tooth which would result from the removal of the second deciduous molar. To secure good results children's teeth should be examined at least three

times a year, and the necessity for constant supervision should be impressed on the parents.

In any case where there is a question as to the best method of treatment it is advisable to take **models of the mouth** to be studied in connection with a chart on which the condition of the teeth has been carefully noted. In this way points often become apparent which would be missed by a mere examination of the mouth. In cases coming under observation at an early stage it is advisable to take models periodically, so that the development of the mouth can be watched and perhaps some light gained as to the best method to pursue in the treatment.

The sex of the patient influences the treatment from an æsthetic point of view, as the correction of an irregularity is more important to a woman than to a man.

The age of the patient is also important, as the difficulty of moving and retaining the teeth in a new position increases with the age. As a rule it is not advisable to attempt correction of irregular teeth by mechanical means in adults. The older the patient the more difficult the teeth are to move and retain in a new position. Again, the older the patient the greater the danger of starting pathological changes in the periodontal membrane.

The question of heredity must also be borne in mind. An irregularity which is hereditary is, as a rule, obstinate to correct.

The general health and temperament of the patient will often influence one's decision. In weak, nervous

children mechanical treatment should if possible be avoided, for obvious reasons.

In all cases requiring mechanical treatment the thorough **co-operation of parents and patient** is most essential. Regulating apparatus, unless constantly worn and properly attended to, does much more harm than good. If the practitioner has reason to believe that his instructions will not be faithfully carried out, prolonged mechanical treatment should be avoided.

The facial expression and type of face must be considered in relation to the irregularity. For example :

A narrow arch may be accompanied by a narrow face with a small mouth and correspondingly small features, all of which are in harmony. Expansion or spreading of the arch under such conditions might mar the character of the face.

The removal of the canine usually produces an ugly flatness of the upper lip and allows the angles of the nose to sink.

In cases where, with protrusion of the upper teeth, the lower lip is unduly flat, but the lower teeth are crowded, with perhaps the canines slightly prominent, an attempt to regulate the canines by bringing them into line will tend to increase the flatness of the lower lip and to accentuate the protrusion of the upper teeth.

The teeth must be carefully examined and the following points determined :—

- (a) The general character of the teeth.
- (b) The presence and extent of caries, especially on the approximal surfaces.

(c) The direction of the roots of the teeth. (The value of this point will be referred to in a subsequent chapter.)

(d) The occlusion of the teeth.

(e) The general condition of the gums. In a patient showing a tendency to chronic inflammation, mechanical treatment is not desirable.

The tendency of teeth to shift their positions in the mouth is sometimes termed "**travelling of the teeth.**" In this natural movement the "bite" or occlusion of the teeth is an important factor. If

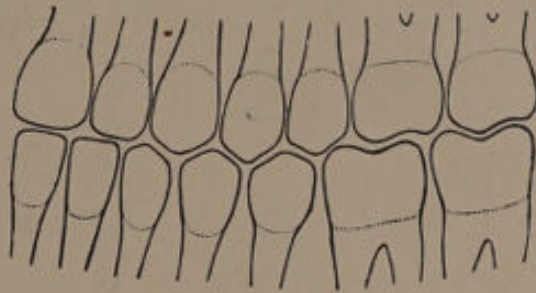


FIG. 9.

a normal articulation (fig. 9) be examined it will be observed that the opposing teeth present inclined planes to one another, and this is particularly noticeable in the premolar region. In each act of mastication pressure is brought to bear upon these surfaces, and as long as the resistance remains equal in all directions the tooth retains its position. Remove this resistance, wholly or in part, and the force exerted by the muscles will in each act of mastication tend to drive the teeth in the direction

of least resistance. Take, as an example, the case diagrammatically illustrated in fig. 10. The first molars have been removed. Each time the posterior plane of the second lower premolar strikes the anterior plane of the second upper premolar the tendency will be to drive this latter tooth in the direction of least resistance, namely, backwards. When once this tooth has travelled backwards the resistance to the movement of the second lower premolar in the posterior direction is removed, so

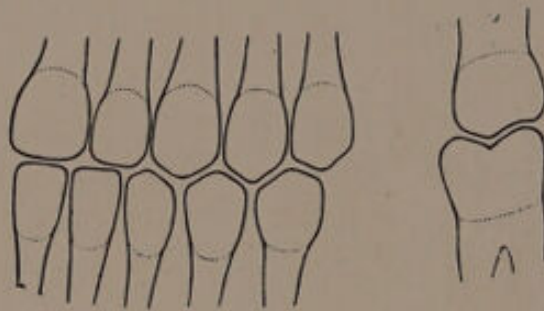


FIG. 10.

that the force of the posterior plane of the first upper premolar striking the anterior plane of the lower second premolar will tend to drive the latter also in a backward direction. In like manner the posterior plane of the first lower premolar will tend to drive back the first upper premolar. In addition to the power derived from the muscles of mastication, the force exerted by the lips, tongue, and the process of eruption are important factors in producing the natural movement of teeth. The lips exert force in a backward direction, the tongue in a forward direction. When employing extraction for the correction of an irregularity an

endeavour should be made to "unlock" the bite. This will be more easily understood by a reference to fig. 11. For the sake of argument we will suppose that the canine has erupted externally to the arch. To provide space the first upper molar only is removed. The bite will remain locked; in other words, the second premolar will require mechanical means to train it in a backward direction, and even then will occlude with the molar—

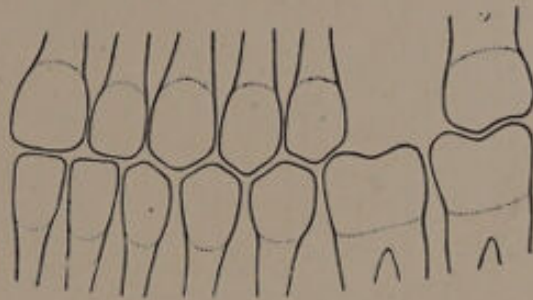


FIG. 11.

an unsatisfactory condition. Mechanical means will also be required to retract the first premolar. If the lower first molar is removed as well as the upper, mechanical methods can be to a very great extent avoided, and the bite will be less disarranged.

When removing teeth in both maxilla and mandible, opposing teeth should if possible be selected. A glance at the diagram (fig. 12), will show the disadvantage of not following this course. In the upper the first molar has been removed, and in the lower the second premolar. There is considerable destruction of the masticating area,

and moreover mechanical methods must be used to retract the teeth. Removal of the upper and lower second premolars, or the upper and lower first molars, would have interfered far less with the masticating area, and would have unlocked the bite and allowed the teeth to travel backwards unaided by mechanical means.

The relation of the teeth to the median line of the face should be remembered in employing extraction,

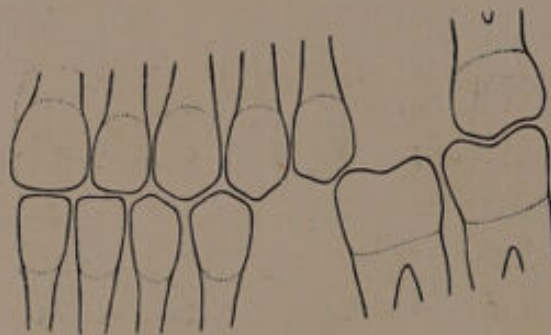


FIG. 12.

although the importance of this point is sometimes a little overrated. In the case of girls, any deviation to one side or the other in the direction of the incisors causes an appreciable disfigurement. The centre of the mouth is likely to shift, when the bite is unlocked, on one side and not on the other. Take, as an example, a case where it has been necessary to remove the first upper premolar on the left side. The posterior resistance to the canine and lateral is removed, with the result that the force of the lip tends to drive all the anterior teeth to that side, and so cause the centre to shift.

An example of this is shown in fig. 13. The patient's appearance has suffered considerably.

Removal of the first right upper premolar as well as the first left upper premolar would have prevented this, because the posterior resistance on both sides being removed, the lips would have forced the anterior teeth back equally on both sides.

Removal of one second upper premolar will not cause the centre to shift, because the bite will be locked by the first upper premolar occluding

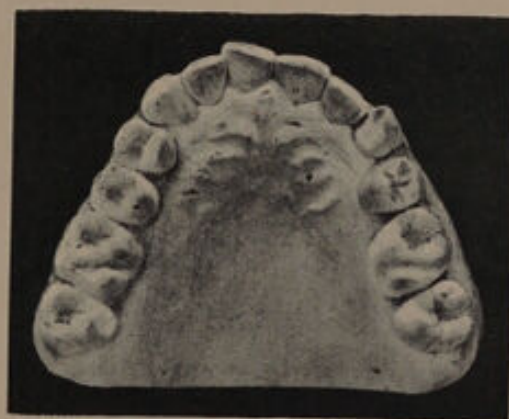

FIG. 13.

with the lower premolars, but removal of the fellow tooth in the lower will remove the posterior resistance, and permit the first premolars—upper and lower—to shift back, and so produce an alteration in the centre of the mouth. Other examples could be quoted. Removal of the first upper and lower right molars and the first upper left molar would cause the centre to shift towards the right side, because the bite is locked on one side and not on the other.

Skiagrams of the teeth will be found most useful in cases where doubt exists as to the direction of the roots of teeth, or the presence or absence of unerupted teeth. The following cases will serve to illustrate the value of the *x*-rays as an aid to diagnosis in irregularities.

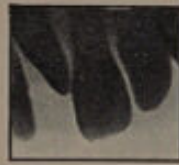

FIG. 14.

In the case shown in fig. 14 the skiagram was taken for the purpose of ascertaining the cause of the separation of the upper central incisors. The skiagram shows the presence of a peg-shaped supernumerary tooth, and also defines its direction.

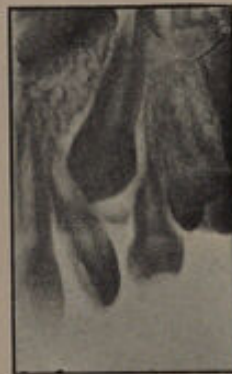

FIG. 15.

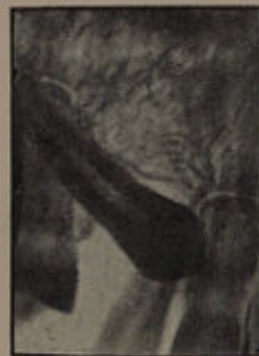

FIG. 16.

The skiagram shown in fig. 15 was taken to determine the relation of the permanent canine to the permanent lateral, the latter tooth having erupted in an irregular position. The position of the per-

manent canine is clearly shown, and indicates that the first premolar should be removed to allow room and so relieve the pressure on the lateral incisor.

Fig. 16 was taken to ascertain the position of an unerupted canine. There was a slight bulging on the palatal aspect of the alveolus, indicating the presence of the canine, but the space between the lateral incisor and first premolar was insufficient. If the canine were in good position removal of the first premolar would be indicated. The skiagram, however, shows that the canine is lying nearly horizontal, and that there is but little chance of its erupting in correct position.





CHAPTER III.

The Movement of Teeth by Mechanical Appliances.

THE movement of teeth by mechanical means is accomplished by the use of certain forces acting from a fixed base known as "the point of delivery." The resistance of the point of delivery or anchorage must be greater than that of the tooth or teeth to be moved. This is essential, and is frequently overlooked.

The point of delivery is usually obtained from the resistance of teeth either by means of a well fitting plate or by embracing two or more teeth with a clamp or band, the force to be used being attached to the plate or band as the case may be. In a few forms of apparatus the occiput is utilised as the point of delivery. Regulating appliances are thus divisible into two main groups: (1) Removable, (2) Fixed.

(1) **Removable appliances.** — Formerly gold or dental alloy was used in the manufacture of the plate, but vulcanite has now almost entirely superseded the metals. With vulcanite a much better fit can be obtained, and the bite can be more easily adjusted.

The successful working of a regulation plate

depends mainly upon the fit, and great care should therefore be taken in obtaining models of the mouth. The back teeth should usually be capped, as the real point of delivery is obtained from the teeth, and by capping them a much firmer hold can be gained.

All plates must be carefully adjusted to the bite of the opposing teeth. The plate should be tried in the mouth and the bite adjusted by the aid of a proper articulator. It is well to allow the lower teeth to bite "well home" into the vulcanite. In this way the plate is kept more firmly in position, and when



FIG. 17.¹

the mouth is closed the lower teeth also act as part of the point of delivery.

Of the forces employed for moving teeth the **screw** is perhaps the most powerful. Its most useful application is in cases where considerable resistance has to be overcome, *e.g.*, when a maxillary canine has erupted internal to the arch. The jack-screw finds most favour, and the mode of using it is shown in fig. 17.

The screw must be adjusted at regular fixed intervals, only a slight degree of force being

¹ From "Diseases and Injuries of the Teeth."

applied at each visit. The force exerted by a screw is not continuous, but this is evidently no disadvantage, as the results obtained from screw force in regulating teeth are entirely satisfactory.

The wedge.—Hickory wood compressed laterally is mostly used. The saliva moistens the wood, causing it to expand and so exert force. In using wooden wedges the grain of the wood should lie parallel to the direction in which it is proposed to move the tooth. The wedge will be found most useful in forcing incisors forward. The method of adjusting the wooden wedge is shown in fig. 18.

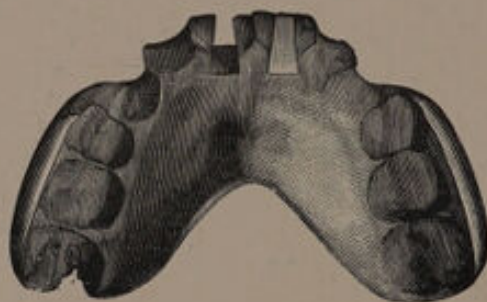


FIG. 18.¹

A double dove-tailed slot is cut in the vulcanite plate, one broad end being away from the tooth, the other being towards the palatal aspect of the plate. Into this slot the hickory wedge is placed. For forcing the premolars backwards wedges of hickory wood are also useful.

Wedges of rubber may also be used. Cone-shaped holes are drilled in the plate, the base of the cone being towards the tooth to be moved.

¹ From "Diseases and Injuries of the Teeth."

A loop of rubber is fixed in each hole, the free ends passing through the apical portion of the cone on the palatal surface. Rubber makes a more powerful wedge than hickory wood, but its action is not so gradual, and it is more likely to cause pain by forcing the teeth forward too quickly.

Wedging may be carried out by the aid of vulcanite pegs. Cone-shaped holes are drilled in the plate and in place of the rubber a vulcanite peg is inserted and is left sufficiently long to prevent the plate being forced at once into place. The peg is also arranged with a sloping surface so that at first it presses on the tooth near the cutting edge, and as the plate is driven up into place by the lower teeth so the tooth is forced forward. It is important that the lower incisors should occlude with the plate and so increase the force transmitted to the teeth to be moved.

The inclined plane is most usefully employed when it is necessary to force forward three or four upper incisors. For this purpose a plate is made capping the lower teeth, and to this an inclined plane is fixed, so that when the mouth is closed the teeth to be moved impinge on the sloping surface and are thus driven forward. The inclined plane must be used with care, as it may force the teeth forward too quickly and set up inflammation.

Elasticity.—The force obtained from the elastic properties both of rubber and metals, especially the latter, is most useful for the mechanical regulation of teeth.

Rubber.—This material is generally used in the

form of small bands. There is always some difficulty in retaining the bands in position on the teeth, the tendency being for them to slip towards the neck and cause inflammation. This can be overcome by cementing to the teeth bands with hooks attached. The bands require frequent renewal and are somewhat uncertain in their action. (Rubber in the form of wedges has already been referred to.)

Pianoforte wire.—This is a most useful material. It is light, strong, inexpensive and capable, in skilful hands, of being utilised to produce any movement, *i.e.*, pulsion, traction, or torsion of a tooth, and moreover it is constant in its action and can be easily controlled. The wire used should be thin (gauges No. 14 to 17). The disadvantage of the wire is the tendency to oxidise in the vulcaniser, but this can be overcome by tinning the wire. The following method is suggested by Mr. Coysh (*Dental Record*, vol. xi., p. 109):—"After cleaning the wire thoroughly it is dipped into chloride of zinc solution, and then for an instant into melted tin, which must not be hot, and the surface of which must be quite clear. Upon removal from this the surplus molten tin is quickly shaken off and the spring cooled in cold water."

Pianoforte wire is used to the best advantage when curved or coiled; in this way greater springiness is obtained. The twist given may be similar to that shown in fig. 19, or to that seen in fig. 20.

For the manipulation of pianoforte wire the pliers designed by Mr. G. Northcroft and shown

in fig. 21 will be found most useful. In twisting up the wire anything approaching an angular bend must be avoided. Care must be taken to arrange that the direction of the force of the spring is




FIG. 19.




FIG. 20.

similar to that in which the tooth is to be moved. A bend should be made in the wire at the free end where it impinges on the tooth. This will permit the wire to be more easily adjusted

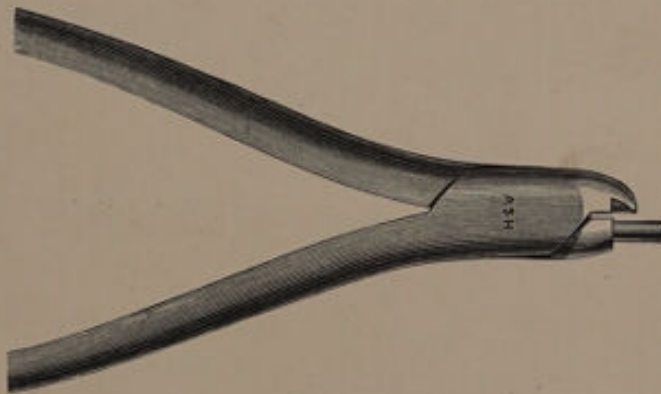


FIG. 21.

in the direction required. It is also important that the coil or turn which gives the spring, and the direction of force required should be in parallel planes. In the figures (22 to 28) some methods of employing pianoforte wire are shown.

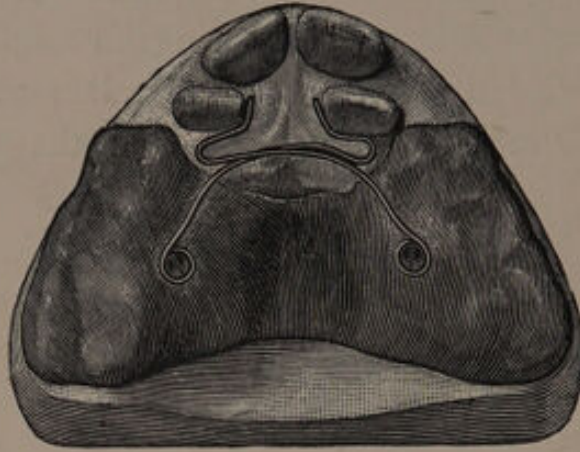


FIG. 22.¹—Plate for pushing outwards and rotating lateral incisors.




FIG. 23.²—Plate for retracting a canine.

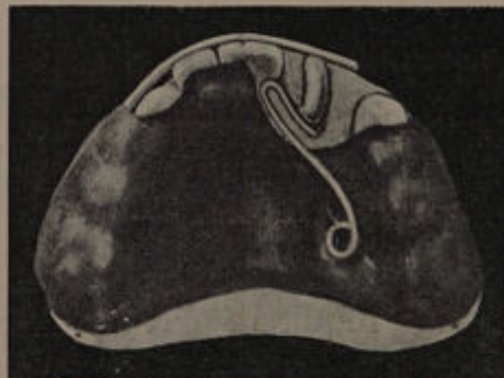

FIG. 24.—Plate for rotating an upper central incisor.

¹ From "Diseases and Injuries of the Teeth."

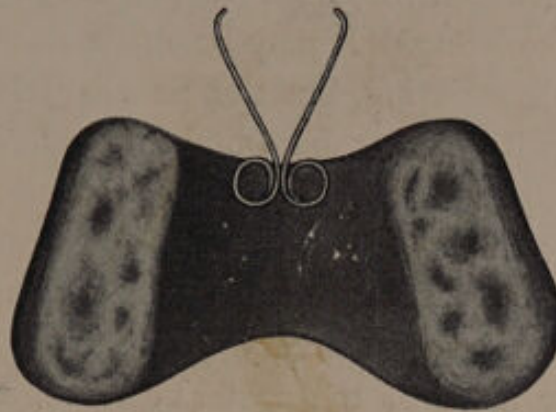

FIG. 25.—Plate for drawing together central incisors.

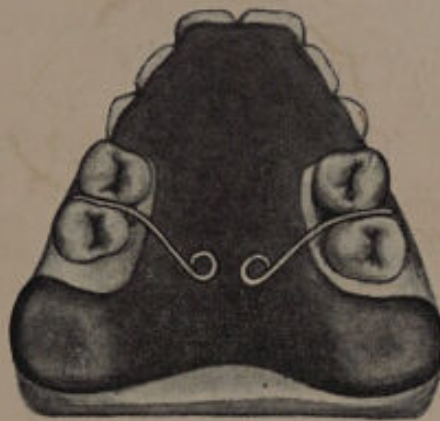

FIG. 26.—Plate for retracting premolars.

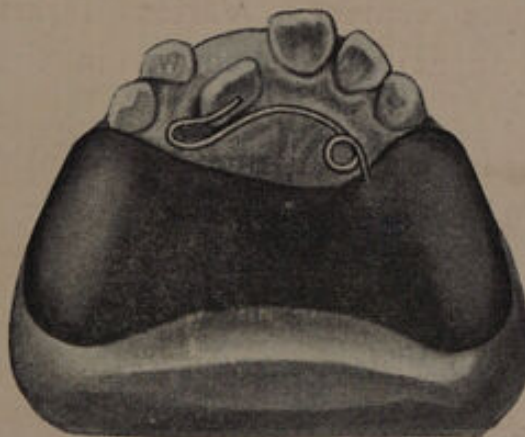

FIG. 27.—Plate for pushing forward an upper incisor.

Gold wire can be used in place of pianoforte wire for regulating. It may be made fairly springy by gentle hammering, but the peculiar elasticity of the steel wire cannot be obtained. Gold wire is neater in appearance, does not stain the teeth and does not oxidise.

(2) **Fixed apparatus.**—With fixed forms of apparatus the “point of delivery” is obtained by banding two or more of the posterior teeth, and fixing

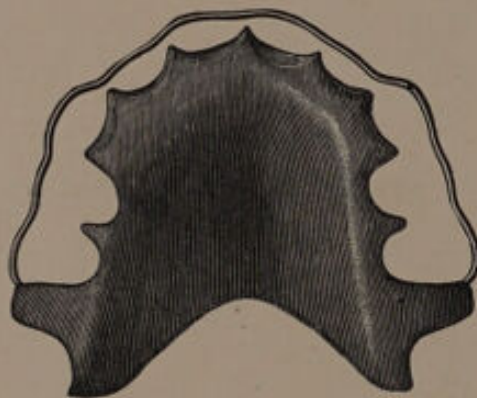


FIG. 28.¹—Plate for retaining the teeth in position after regulation.

to this band the force to be employed. The bands should always be fastened to the teeth with oxy-phosphate cement. Various forms of fixed regulating apparatus are shown in the following illustrations.

In fig. 29 is seen a method (Angle's) for moving a lateral incisor in an outward direction by means of a jack screw. The tooth chosen as anchorage is as nearly as possible in a direct line with the movement desired to be given to the lateral incisor.

A method of employing pianoforte wire is shown

¹ From “Diseases and Injuries of the Teeth.”

in fig. 30. The twist given to the wire is generally known as "Talbot's coil."

Fig. 31 shows a method suggested by Angle for

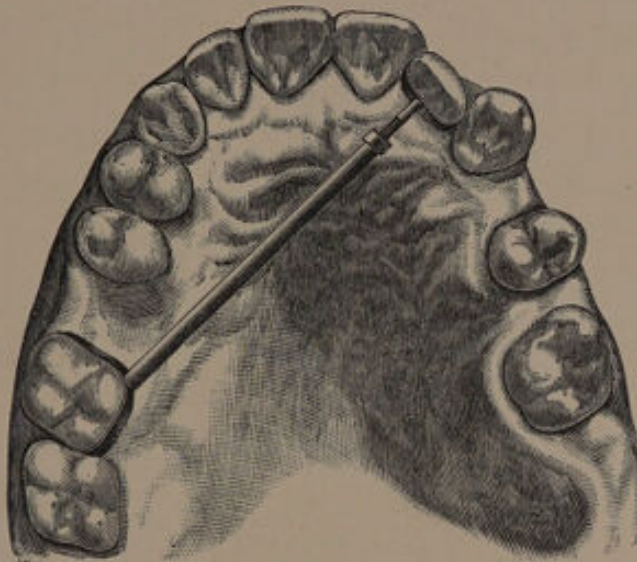

FIG. 29.

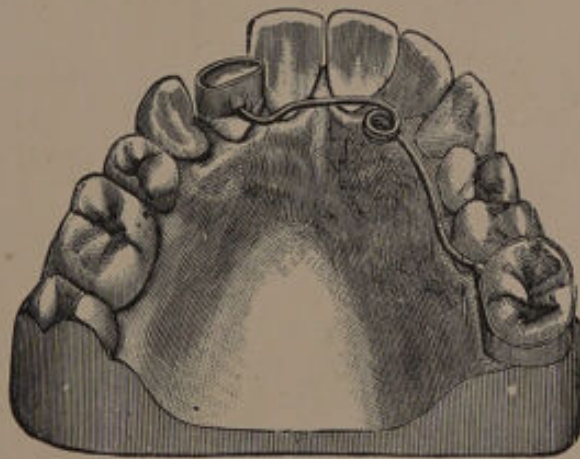


FIG. 30.

retracting a canine. The anchorage tooth and the tooth to be moved are banded. The two bands are connected by a traction screw.

¹ From "Text-Book of Operative Dentistry" (Kirk).

A method of producing rotation, also from Angle, is shown in fig. 32. The tooth to be rotated is banded. Anchorage is obtained from the second premolar, the resistance being increased by the bar shown in the figure. The teeth are then connected by pianoforte wire.

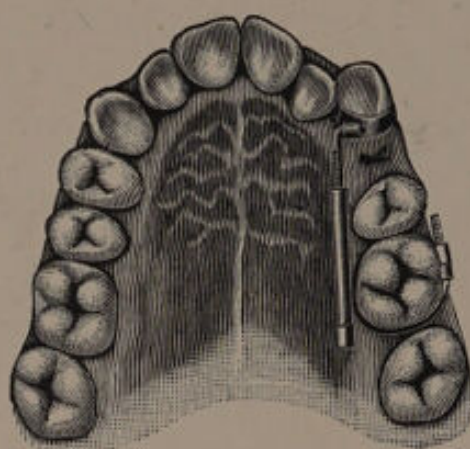


FIG. 31.

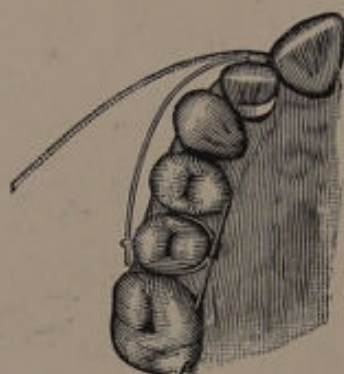


FIG. 32.

A method of moving forward incisor teeth, designed by Goddard, is shown in fig. 33. The first molars are banded, and to the bands tubes are attached into which pianoforte wires are inserted. These are bent to conform to the

arch of the teeth, and their free ends are inserted into tubes on the labial surfaces of bands cemented on the teeth to be moved.

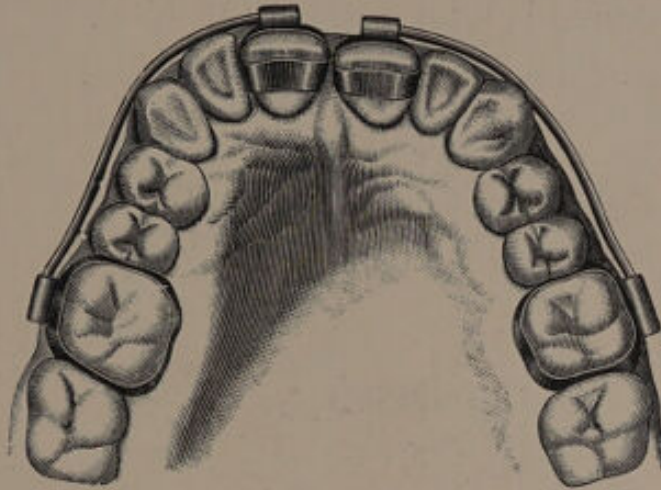


FIG. 33.¹

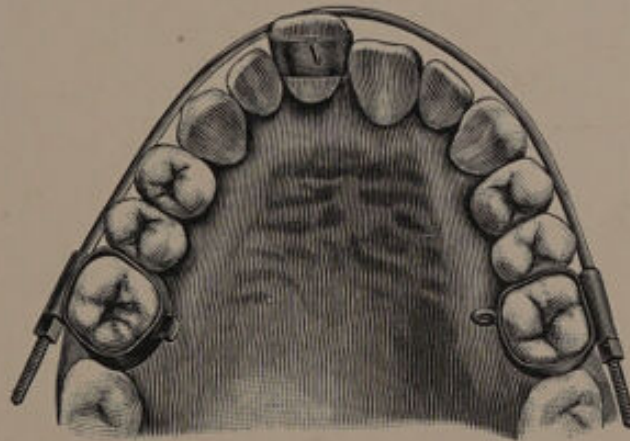


FIG. 34.²

A method of retracting a central incisor is shown in fig. 34.

A method of regulating devised by Angle is

¹ From "Text-Book of Prosthetic Dentistry" (Essig).

² From "Text-Book of Operative Dentistry" (Kirk).

shown in fig. 35. In this case the tooth to be rotated and pushed forward is banded, a tube being soldered to it at the mesio-lingual angle. A piece of wire is inserted into the tube, the other end being secured in a pit made in the deciduous molar.

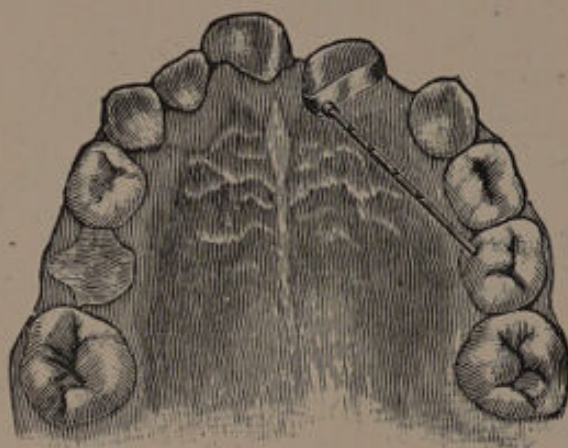


FIG. 35.

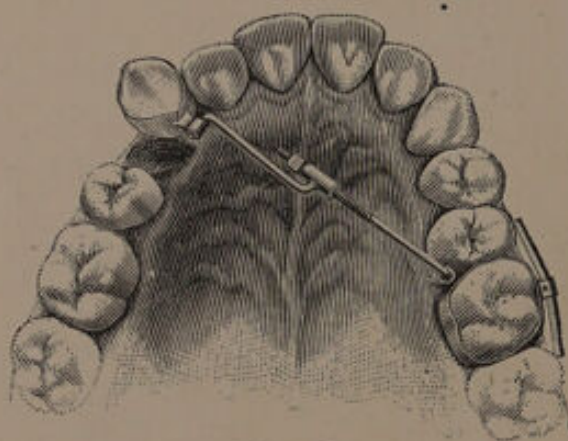


FIG. 36.

The wire is occasionally pinched with pliers and in this way lengthened, and the tooth moved in the required direction. This method is ingenious, but equally good results can be obtained more easily. The apparatus shown in fig. 36 is also from Angle,

and shows a method of retracting a right canine. The left first molar is banded and the anchorage strengthened by attaching to the buccal side of the band a wire which rests on the buccal aspects of the approximal teeth. The right canine is banded and connected with the molar by means of a jack screw. In fig. 37 is shown a method of

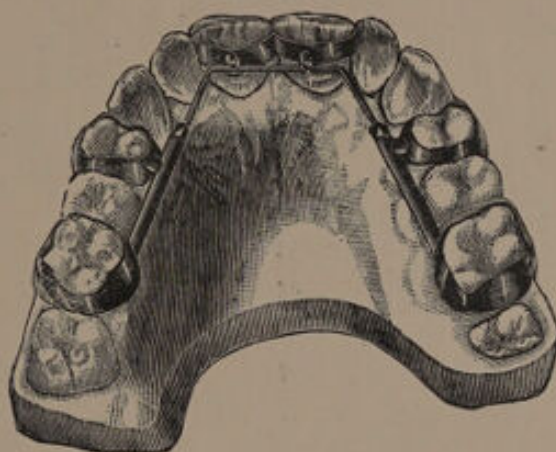


FIG. 37.¹

moving forward incisors—the design of Dr. Matteson. The first premolar and first molar on each side are banded. To the bands a tube is attached. The central incisors are banded, and lugs soldered to the palatal aspects. The lingual bow rests in these, and its free ends pass into the tubes attached to the premolar and molar bands. Force is applied by adjusting the nuts in front of the tubes.

Those interested in fixed appliances should refer to the works of Farrar, Angle, Talbot and Guildford.

¹ From "Text-Book of Prosthetic Dentistry" (Essig).

The position which a tooth assumes when acted upon by mechanical appliances depends largely upon the manner in which force is applied.

With the majority of appliances a movement similar to that shown in fig. 38 takes place. The force P , which is applied to the crown is transmitted

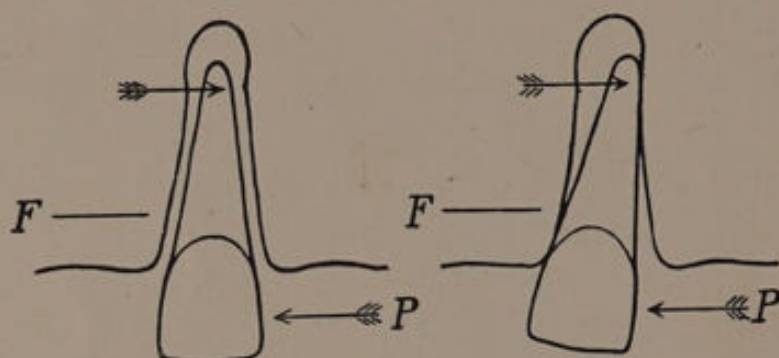


FIG. 38.

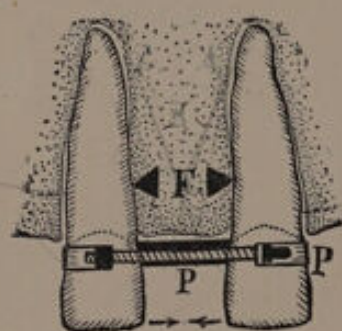


FIG. 39.

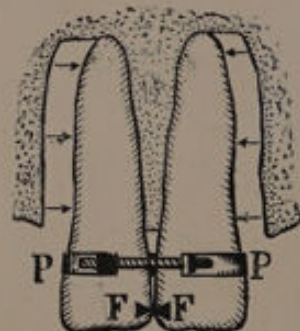


FIG. 40.

to the opposing portion of the alveolus F , and in proportion to the resistance here met with the apex is moved in the opposite direction. The movement of the apex is probably but slight, and for practical purposes the tooth may be said to move in the arc of a circle, the centre of which is represented by the apex of the tooth.

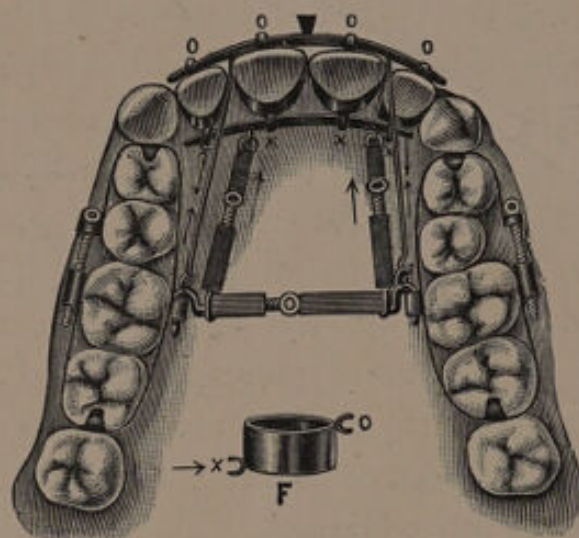
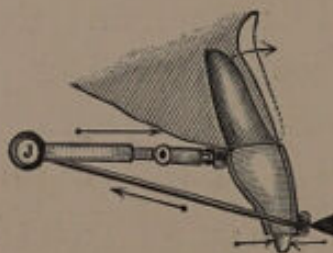
Under certain conditions it is possible to apply

force so as to move both crown and apex in the same direction. The diagrams (fig. 39 and 40) illustrate one method by which this movement may be produced. If a clamp band is attached to two separated central incisors the immediate result of applying force will be to approximate the mesial angles and cause the apical portions of the roots to diverge. When the mesial angles come into contact the fulcrum will be shifted from the alveolus to the point of contact in the crowns, and the continued application of force will cause the teeth to approximate throughout their whole length until they become parallel (see fig. 40).¹ It will be noticed that whilst the alveolar process forms the point of resistance the apices tend to move in directions reverse to the crowns, but directly the fulcrum is transferred to the crowns the apices commence to approximate. This creation of a static fulcrum on some portion of the crown near the occluding surface, and the application of force as high up on the tooth as possible, are the fundamental principles underlying all appliances which claim to move the roots of the teeth bodily.

The appliance shown in fig. 41 is one designed by Dr. Farrar for moving the roots of incisor teeth forward. The premolars and first and second molars on both sides are banded and connected by a jack screw. This latter forms the point of delivery. Each incisor is banded, and to each band lugs are fixed, one on the palatine aspect near the neck, the

¹ This method of moving teeth was first pointed out by Dr. Farrar.

other on the labial aspect near the cutting margin. A transverse bar rests in the palatal lugs, and is connected by two jack screws to the transverse jack screw. This bar receives the force. Into the labial lugs another transverse bar is fitted, and is connected by wire to the ends of the transverse jack screw. This bar forms the fixed point, or

FIG. 41.¹FIG. 42.¹

fulcrum. Fig. 42 is a cross section. For drawing back the roots of the incisors it would be necessary to arrange the fulcrum on the palatal aspects of the teeth near the cutting edges and apply the force on the labial aspects near the necks.

¹ From "Text-Book of Operative Dentistry" (Kirk).

The method introduced by Dr. Case, of Chicago, appears to give good results. The tooth is banded and to the band an upright bar, C, is soldered (see fig. 43). To the lower end of C a traction bar, F, is fixed, this bar being united to the point of delivery. Force is applied by connecting the upper part of the bar C with the point of delivery by means of a bar P. By adjusting the screws connected with the bars P and F the root or the

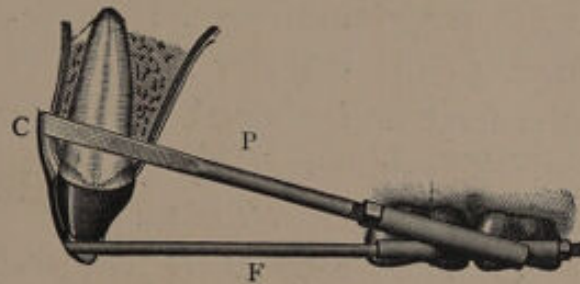


FIG. 43.¹

entire tooth can be moved backwards or forwards as required. Appliances based on this principle for moving teeth are referred to in chapters ix. and x.

When pressure is applied to a tooth the alveolar wall, against which the pressure is indirectly applied, undergoes absorption, and when the tooth has been moved into the position required, and is retained there firmly by suitable means, a fresh deposition of bone takes place and a new socket is formed. The rapidity with which this fresh bone is deposited depends upon (1) the recuperative powers of the patient; (2) the retention or non-

¹ From "Text-Book of Operative Dentistry" (Kirk).

retention of the tooth firmly in its new position by suitable means during the period the tissue is forming; (3) the amount of local disturbance caused by the operation.

COMPLICATIONS AND SEQUELÆ OF MECHANICAL MOVEMENT OF THE TEETH.

The mechanical regulation of teeth may be attended by certain complications or sequelæ.

(*a*) **Periodontitis.**—Inflammation of the periodontal membrane may result from the application of too great a force to the tooth or from direct impingement of the force on the membrane through faulty adjustment. The inflammation of the periodontal membrane may spread to the pulp and so cause its death. Chronic periodontitis frequently attacks teeth which have been regulated. The changes which occur during regulation may tend to lower the vitality of the tissues, and so render them liable to attack.

(*β*) **Caries.**—This is to a great extent an avoidable sequela. The more clean the apparatus and mouth are kept the less will be the liability to caries. The movable types of apparatus have in this respect a strong advantage over the fixed ones. The mouth and all mechanical appliances must be carefully cleaned after every meal. Previous to inserting the plate an alkaline mouth wash¹ should

¹ The following is suggested:—

R	Mag. Carb. Levis	5	iv.
	Aq. Rosæ	3	vi.
	Aquam. ad.	3	xii.
M.	Shake before using.					

After the mouth has been thoroughly cleansed, a teaspoonful is to

be used, and it is also useful to run a little over the surface of the plate which comes in contact with the teeth and gums.

(γ) **Permanent enlargement of the alveoli.**—This condition is due to insufficient re-formation of bone after the tooth has assumed its new position. There may be a lack of recuperative power on the part of the individual from general causes. Growing tissues are more likely to recuperate than fully developed ones, hence the frequency to permanent enlargement of the alveoli in cases of regulation in adults. The enlargement of the alveoli may be the result of inflammatory changes in the tissues due to want of care in regulating. Teeth which have been moved should be retained firmly in their new position, otherwise permanent enlargement of the alveoli may result from undue movement in the socket.

(δ) **Inflammation of the gums.**—In cases where the regulation has been too rapidly carried out inflammation of the gums frequently occurs. It may also arise from want of care in cleansing the plate. The application of a little tincture of iodine, powdered tannic acid or some other suitable astringent will speedily remove the trouble. If, however, the inflammation increases the application of force must be postponed until the gums return to a normal condition.

(ϵ) **Sloughing of the gums.**—This condition is rare,

be taken and floated about in the mouth between the teeth. The magnesia, which is only in suspension, clings about the necks of the teeth and neutralises any acid. Ordinary solutions of alkalies have only a transient effect upon the oral secretions.

and is generally due to allowing the plate to press on the gums and not on the teeth. When it occurs the plate must be immediately abandoned and must not be used again until the tissues have assumed a healthy condition.





CHAPTER IV.

Irregularities in Position of Individual Teeth not the Result of Crowding.

THE abnormal position of individual teeth is in the majority of cases the result of crowding, and those cases will be considered in the chapter dealing with crowded conditions of the teeth. Here it is proposed to deal only with those somewhat uncommon cases which are due to local causes, such as undue persistence of the deciduous teeth.

(a) UPPER INCISORS.

The more common irregularities in position of these teeth are :—

- (1) Displacement external to the arch.
- (2) Displacement internal to the arch.
- (3) Rotation.
- (4) Separation of the central incisors.
- (5) Overlapping.
- (6) Elongation.
- (7) Displacement upwards.
- (8) Total displacement, including transposition.

(1, 2) Displacement external or internal to the arch.

The eruption of an incisor external or internal to the arch may be due to persistence of a deciduous

tooth (see p. 8), or to the presence of a supernumerary tooth. In cases where a superior incisor has erupted so that the lower lip passes behind it the amount of projection will be greatly increased. The habit of sucking the thumb, lip, or even the toe may lead to protrusion of the incisors. Protrusion of an upper incisor may be due to irregularity of the lower teeth.



FIG. 44.

Teeth that erupt internal to the arch may be treated in two ways, either by an upper plate with wires or wedges, or a lower plate with an inclined plane. The above irregularities cannot be treated too early, because the teeth are more easily moved before calcification of the roots is completed.

In those teeth which are making their appearance external to the arch it is generally sufficient to remove the deciduous tooth and leave nature to complete the process of regulation. If, however, the tooth falls outside the lower lip mechanical measures must be resorted to.

After correction it will be necessary to retain the teeth in position for from three to six months.

The following case illustrates this form of irregularity, fig. 44 :—

The projection of the central incisor was due in the first instance, as far as could be ascertained, to persistence of its deciduous predecessor, the irregularity being increased by the action of the lower lip. A vulcanite plate was made, capping

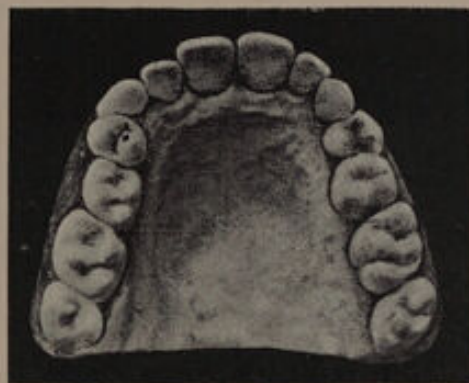

FIG. 45.

the teeth posterior to the deciduous canines, a half round gold wire being inserted on the right buccal side and brought to bear on the labial surface of the projecting incisor. The left central and right lateral incisors were pushed slightly forward by wedges, and room thus gained for the right central when it was brought into line. The model of the tooth in correct position is shown in fig. 45. A retention plate was used for a period of six months.

(3) **Rotation of the incisors** may arise from : (a) Persistence of temporary teeth ; (b) Developmental

mal-direction; (*c*) Presence of supernumerary teeth ; (*d*) The action of the frænum of the lip (see page 12) ; (*e*) The pressure of the erupting canine.

Lateral incisors are more commonly found rotated than central incisors. The amount of rotation may vary from an eighth to half a turn. It is well to bear in mind that rotation of the incisors is frequently a sign that the patient will in the future develop a crowded mouth.

In treatment the first step is to remove, if possible, the cause. The actual rotation of the tooth may be accomplished by either *gradual or immediate torsion*.

Immediate torsion consists in turning the tooth with forceps, gradual in rotating the tooth by mechanical methods. The main points in favour of immediate torsion are the saving of time and the avoidance of a plate. Against the immediate method there are the following disadvantages :—

(1) Liability of the tooth to completely leave the socket during the operation.

(2) The risk of death of the pulp from strangulation of the vessels at the apex.

(3) Fracture of portions of the enamel from pressure of the forceps.

(4) Fracture of the root (in the case of the end being twisted).

As a rule immediate torsion should not be resorted to after the root of the tooth is completed, which usually occurs about the age of ten. Prior to that age the apical foramen is large, and there is less danger of twisting the vessels. Cases are

recorded where torsion has been performed at the age of 12, 14 or even later, and although many of these operations proved successful, some were failures. If the failures amount to only 5 per cent. it is a question whether it would be justifiable to subject patients to even that risk, when by gradual torsion the irregularity can be removed by a safer, if slower, method.

In cases where the root may be considered fully formed, or there is any reason to suspect that it may be twisted, a skiagram should be obtained with the object of ascertaining the shape of the root.

× In cases of immediate torsion a model should be taken prior to the operation, the tooth being cut off the model and refixed in the position it will occupy after rotation. To the corrected model a thin tin splint should be made, to cover the lower third of the tooth to be operated on as well as the approximal teeth. This splint is applied by first drying the teeth and then fixing the splint in position with osteo-plastic cement.

The operation of twisting the tooth should be performed with a pair of forceps which fits the tooth accurately. The blades should be covered with some such substance as thin lead foil, lint, or cotton wool. Mr. Dolamore recommends the use of india rubber, the elasticity of rubber exerting a force in an upward direction. The tooth should be grasped firmly and slowly rotated, steady pressure in an upward direction being maintained during the process of turning, so as to prevent the

tendency of the tooth to leave the socket. It is well to turn the tooth slightly more than is required. Immediately the operation is completed the splint should be applied, and retained in place for about a week. An antiseptic mouth wash should be prescribed.

It is obviously essential to obtain sufficient room previous to performing the operation. At times it is difficult to gauge the precise amount of space that will be necessary, and one should always take into account the direction of the root of the tooth to be turned, as the tooth will not necessarily occupy the whole space.

Should the accident of complete removal of the tooth from its socket occur, the tooth must be cleansed in an antiseptic solution and replaced. In such cases the tooth frequently remains alive, and an interesting example of this was recorded by Mr. A. S. Underwood in the *Transactions of the Odontological Society*, vol. xviii., p. 98.

If the tooth after rotation shows signs of pulpitis the gum should be painted with liq. iodi, but if this fails to produce relief, and the symptoms become aggravated, the pulp cavity should be opened and the pulp removed under an anæsthetic. It is well not to delay the removal of the pulp, as timely interference may prevent discolouration of the tooth substance, or, what is more serious, suppuration, which may eventually lead to loss of the tooth.

Cases of immediate torsion are shown in figs. 46 to 51.

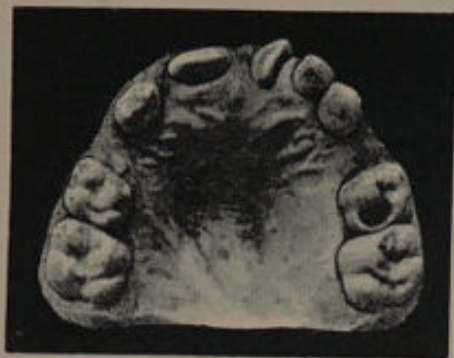

FIG. 46.—Case I. Before treatment.

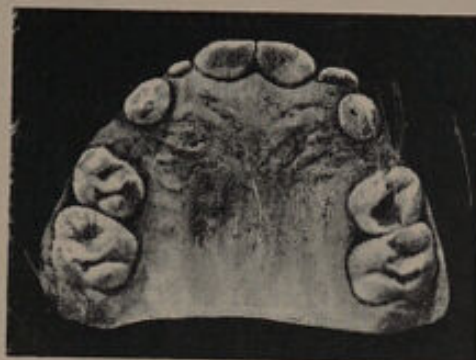

FIG. 47.—Case I. After treatment. The rotated tooth was held in position for three weeks by a tin splint made as suggested in text.



FIG. 48.—Case II. Before treatment.

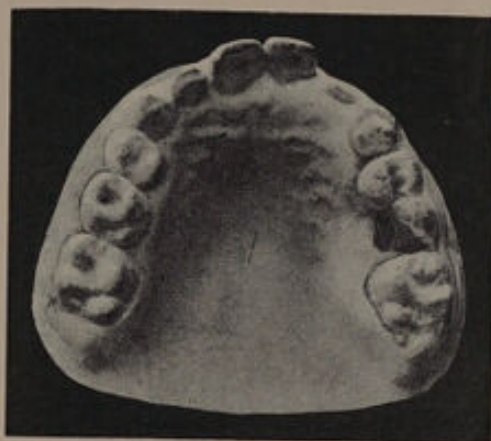

FIG. 49.—Case II. After treatment. The record of the time the splint was used has been lost.



FIG. 50.—Case III. Before treatment.

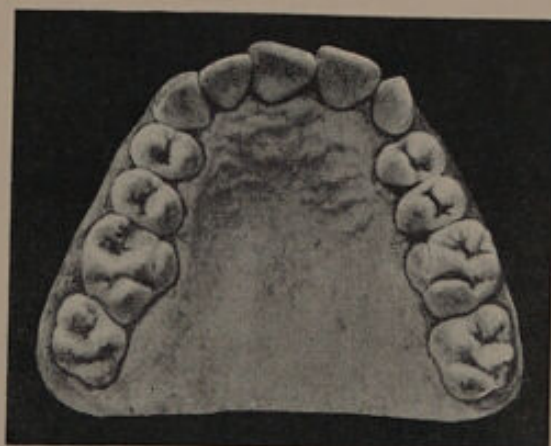

FIG. 51.—Case III. After treatment. This model was taken six years after treatment. The left canine has never erupted.

The gradual or mechanical torsion of a tooth can be carried out in a variety of ways, all of which depend upon the principle of two forces working in opposite directions. In the case shown in fig. 52 the position of the tooth was corrected by applying pressure to the mesial angle of the tooth with a half round gold wire, the distal angle being acted

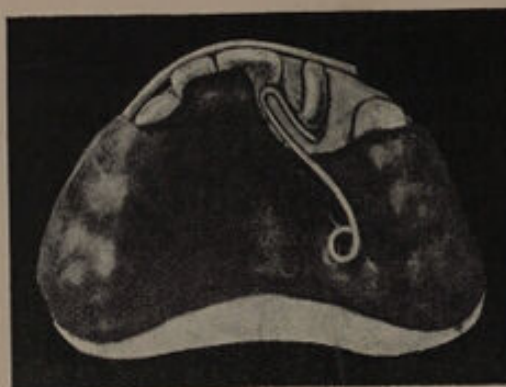

FIG. 52.

upon by means of a spring composed of pianoforte wire. A retention plate was worn for six months. A favourite method is to fix to the tooth a band to which are soldered two hooks at the mesial and distal angles. Elastic bands are stretched from the hooks to attachments in the vulcanite plate. Other methods might be enumerated, but they all depend upon employing two forces acting in opposite directions.

(4) **Separation of the central incisors** may be due to (a) the presence of a supernumerary tooth, (b) the attachment of the frænum of the lip to the gum posterior to the teeth, (c) a combination of

(*a*) and (*b*), or (*d*) the result of too much room due to some undiscoverable cause.

Slight rotation often accompanies separation of the central incisors.

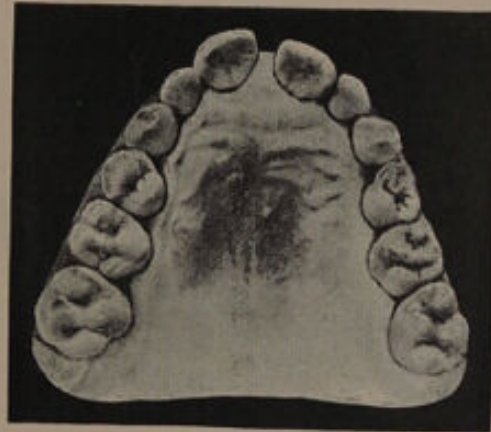


FIG. 53.—Case I. Before treatment.

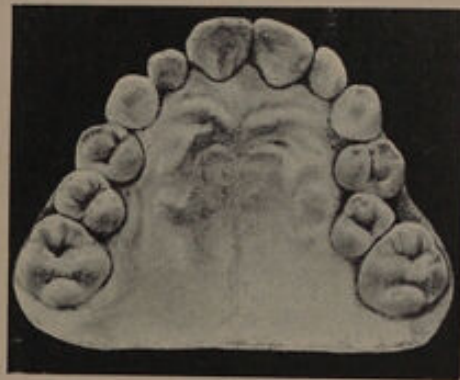

FIG. 54.—Case I. After treatment.

As a general rule it may be said that should the cause be removed before the eruption of the canines, the space between the central incisors will become lessened without mechanical treatment, as the pressure exerted by the canines in erupting will produce the desired effect. Supernumerary teeth

should therefore be removed directly their presence is noticed. The frænum likewise should be cut. That the frænum acts as a cause of divergent centrals is often overlooked, but that such is the

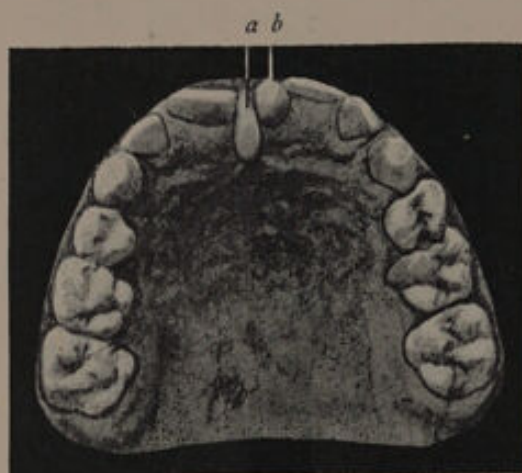


FIG. 55.—Case II. (semi-diagrammatic).—In this patient the separation of the centrals was due to (a) the frænum, and (b) a peg-shaped supernumerary tooth.

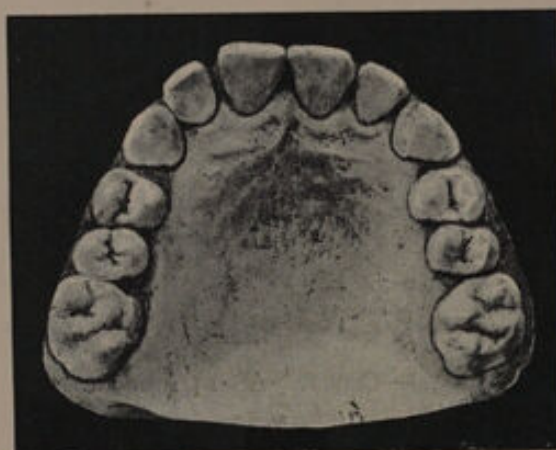

FIG. 56.—Case II. After treatment.

case will be easily seen by an examination of this class of irregularity.

The operation of dividing the frænum is easily performed as follows. The free edge of the frænum

is seized with a pair of artery forceps and drawn forward, a V-shaped piece is then removed from it with a sharp pair of scissors, care being taken to cut the part away where it blends with the gum (a point of great importance). The part running between the teeth should also be removed. A strip of lint moistened with boracic acid lotion

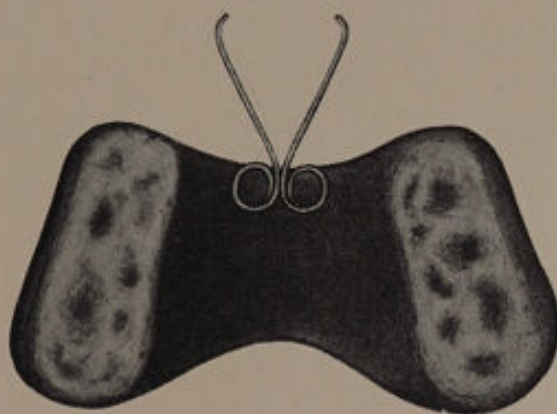


FIG. 57.

should be kept between the cut surfaces until the wound has healed, an antiseptic mouth wash also being given. Cases treated by excision of the frænum are shown in figs. 53 to 56. No mechanical treatment was adopted. Excision of the frænum, if carried out before the eruption of the canines, will be found to lead to excellent results, but in cases treated subsequently to the eruption of these teeth the benefit is not marked, although the space will tend to close slightly. Should the removal of the cause not prove sufficient to correct the deformity, the teeth can easily be approximated by mechanical methods.

A plate of the form shown in fig. 57 will be found useful. After being brought together it will be necessary to retain the teeth in position by suitable means.

(5) **Overlapping of the incisors.**—Slight overlapping of the central or lateral incisors, when not the result of crowding, is often hereditary. The amount of deformity is generally slight and is best left alone.

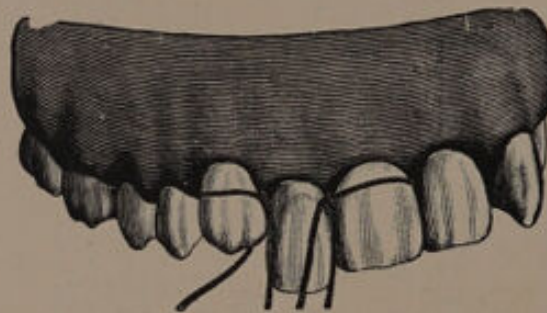


FIG. 58.

(6) **Elongation** of an incisor is usually the result of an accident. In cases where the elongation is but slight, the tooth may be cut down by means of carborundum wheels, care being taken to carefully polish the cut surface. In more severe cases an endeavour may be made (if desirable from an æsthetic point of view) to force the tooth into the socket.

A simple method of reducing an extruded tooth is mentioned by Dr. C. L. Goddard:¹ "Silk ligatures are tied around the necks of adjacent teeth (fig. 58) with the knots between each and the offend-

¹ "Text-book of Operative Dentistry" (Kirk).

ing tooth. Extend one end of each ligature lingually and one labially. Tie the lingual ends together behind the long tooth and in the same knot tie a slender rubber band (figs. 59 and 60). Tie the labial ends together in front of the long tooth. Next stretch the rubber band from the lingual surface of the neck over the cutting edge, and tie it to the

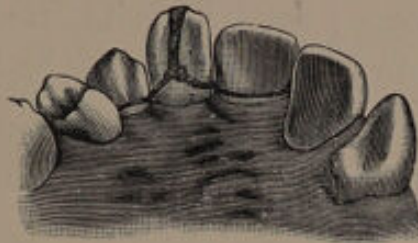

FIG. 59.¹—Palatal view.

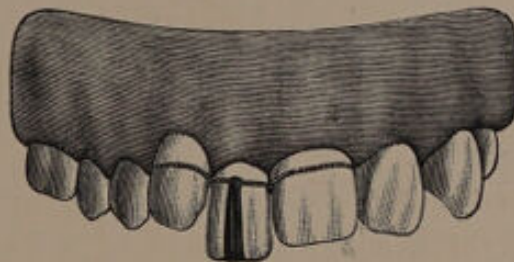

FIG. 60.¹—Labial view.

knot on the labial surface. The tooth is thus hung in a sling which will force it up into place."

Another method is shown in fig. 61.

The teeth approximal to the one to be regulated are banded, and wires are soldered to connect both the labial surfaces and the lingual surfaces together. The wires can be made to rest in tubes soldered to the bands. Upward pressure is exerted by a rubber band or twisted ligature stretched from the

¹ From "Text-book of Operative Dentistry" (Kirk).



labial to the lingual bar over the cutting edge of the tooth.

(7) **Displacement upwards of an incisor** is generally the result of injury, but it may be the result of an error in development. If the correction of such a deformity is considered advisable it may be carried out—(1) by reducing the length of the approximal teeth; (2) by forcibly bringing the tooth into place with forceps; (3) by mechanical appliances.

The first form of treatment may be adopted when the displacement is but slight, and it is better

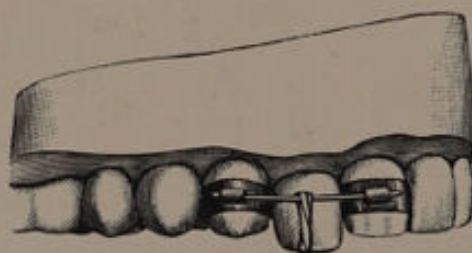


FIG. 61.¹

applied to the treatment of centrals than laterals. With the former, a symmetrical appearance can be obtained by grinding down the cutting edge or rounding off the angles of the fellow tooth. With the lateral incisor reduction of the length of the approximal teeth will naturally give an asymmetrical appearance to the mouth. This may of course be overcome by treating the lateral, central and canine on the other side of the mouth in a similar manner—a plan seldom advisable.

The second method of treatment may be adopted in cases of forcible displacement upwards which are seen at an early date after the accident.

From "Text-book of Operative Dentistry" (Kirk).

Treatment by mechanical appliances may be accomplished by the plan shown in fig. 62, the suggestion of Dr. C. L. Goddard. Caps connected by a wire are attached to the teeth approximal to the one to be regulated. To the latter tooth a band is adjusted, hooks being soldered to the labial and lingual surfaces. Traction force is obtained by an elastic band arranged as shown in the illustration.

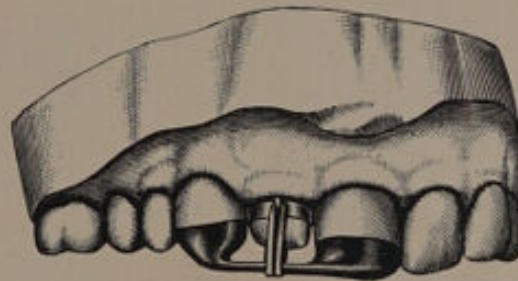


FIG. 62.¹

(8) **Total displacement of the incisors.**—Incisors may be transposed, that is, occupy a position in the arch which should be held by another tooth. For instance, the central and lateral may exchange positions, or the lateral may occupy the position of the canine. Cases of transposition do not call for treatment. The incisors may be completely displaced, as shown in fig. 63. It is needless to say that the only treatment for such abnormalities is extraction. Occasionally the incisors erupt high up in the alveolar arch with their cutting edges directed forward. Such teeth are usually dilacerated, and endeavours to train them

¹ From "Text-Book of Operative Dentistry" (Kirk).

into place would prove futile. Extraction is the only remedy. In cases of cleft palate complicated by hare-lip the incisors adjacent to the fissure are often misplaced. As a rule it is wise not to attempt their regulation, the roots of such teeth being usually curved and twisted. If the condition produces great disfigurement the teeth can be removed and a denture inserted.

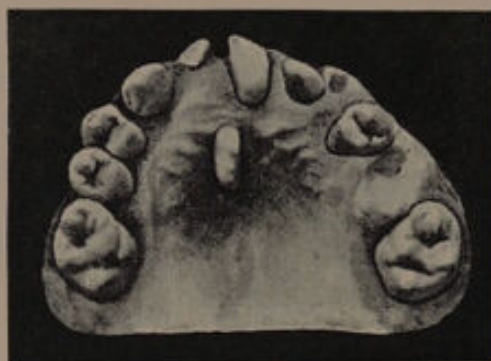

FIG. 63.

LOWER INCISORS.

The lower incisors may erupt internal or external to the arch — conditions usually produced by persistence of deciduous teeth. The obstructing tooth should be removed and the case left alone, the tongue on the one hand and the lips on the other being usually sufficient to bring the tooth into line. In a few cases the lower tooth may be outside the upper incisors; under such conditions the lower tooth must be retracted or the upper pushed out. Total displacement of the lower incisors is very rare.

(b) UPPER CANINES.

Abnormalities in position of upper canines due to causes other than crowding are comparatively rare. The canine may be misplaced external or internal to the arch, may be rotated, or totally displaced. For the methods of correcting the mal-position of canines see pp. 104 to 109.

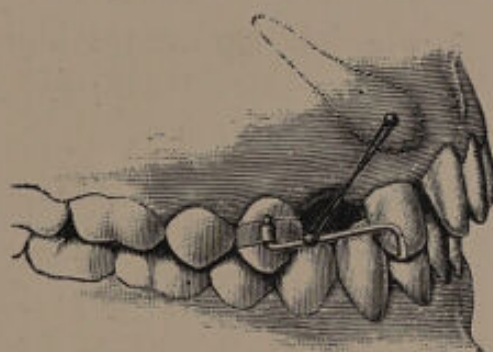


FIG. 64.

Partial eruption of the canine is occasionally met with. An attempt to force the tooth to erupt may be made. An appliance for this purpose is figured in Essig.¹ A band is cemented to the first premolar. To this band a tube is soldered. Into this tube a piece of wire is fixed which extends across the space and under the cutting edge of the lateral incisor. A stud is fixed into the canine tooth and traction applied by means of elastic (fig. 64).

Success is by no means certain, and in one case under treatment the tooth resisted every effort

¹ "Text-book of Prosthetic Dentistry" (Essig).

made to regulate it. In this case the permanent tooth had advanced sufficiently to cause absorption and, consequently, loss of its deciduous predecessor. The patient was anxious to have the space filled in, so the permanent canine was removed and the root found to be twisted. An artificial denture was inserted. A younger sister of this patient presented a similar condition. The right deciduous canine was retained, the permanent canine made its appearance high up in the alveolar arch on the external aspect. A skiagram was obtained and indicated a probably twisted root. The possibility of the permanent tooth ever passing into correct position was slight. Leaving the canine alone meant that in all probability it would erupt to a certain extent and so cause loss of the deciduous tooth as in the sister. The permanent tooth was therefore removed and the root found to be tortuous. As the permanent tooth is not present to induce absorption there is no reason why the deciduous tooth should not be retained for many years and a denture avoided.

The upper canine is completely displaced more frequently than any other tooth. It may erupt into the nose, be placed horizontally in the palate, &c. Extraction is the only remedy.

LOWER CANINES.

Irregularities of the lower canines, from causes other than crowding, are rare. In the case shown in fig. 65 the permanent canine has erupted internal to the arch. The deciduous canine is in position.

The patient was thirty years of age, and the permanent tooth appeared two years previous to her seeking advice. The treatment consisted in removal of the misplaced tooth.

An interesting example of a misplaced lower canine was recorded by Mr. C. Truman in the

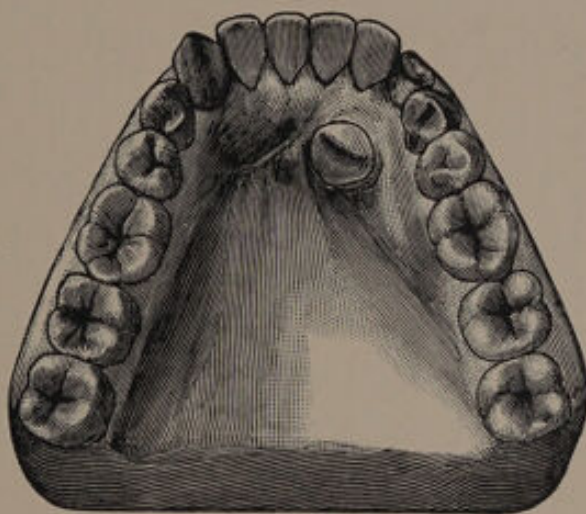


FIG. 65.¹

Transactions of the Odontological Society, vol. xxiii., new series, p. 34. The tooth appeared under the chin, apparently having been directed in its course by the presence of a fistulous opening. Subsequent to its removal a premolar made its appearance in the same position.

(c) PREMOLARS.

Abnormalities in position of the superior and inferior premolars from causes other than crowding are uncommon.

¹ From "Diseases and Injuries of the Teeth."





CHAPTER V.

Irregularities in Position of Teeth the result of Crowding.

IF the skull of a child about six years of age be examined the permanent teeth will be found as follows (fig. 66).

In the maxilla the lateral incisors lie in a plane slightly posterior to the centrals, and are directed more vertically. The premolars are embraced by the roots of the deciduous molars and their crowns are directed inwards, the second more than the first. The first premolar is normally situated close to the lateral incisor. The canine lies above and external to the arch of the incisors and premolars and is directed slightly inwards. The first permanent molar will be in the process of erupting, and the occluding surface will be directed outwards to a slight extent. The second permanent molar is situated high up in the tuberosity of the bone, with its occluding surface directed downwards, outwards and well backwards.

In the mandible the lateral incisors lie in a plane posterior to the centrals, and the canines are placed near the lower border of the bone and lie in a plane anterior to the lateral incisors with a

slight tilt towards the median line. The premolars are embraced by the roots of the deciduous molars and their crowns are directed inwards. The first permanent molars are directed upwards and forwards, the second being under the base of the coronoid process with the occluding surface directed upwards, forwards and slightly inwards.

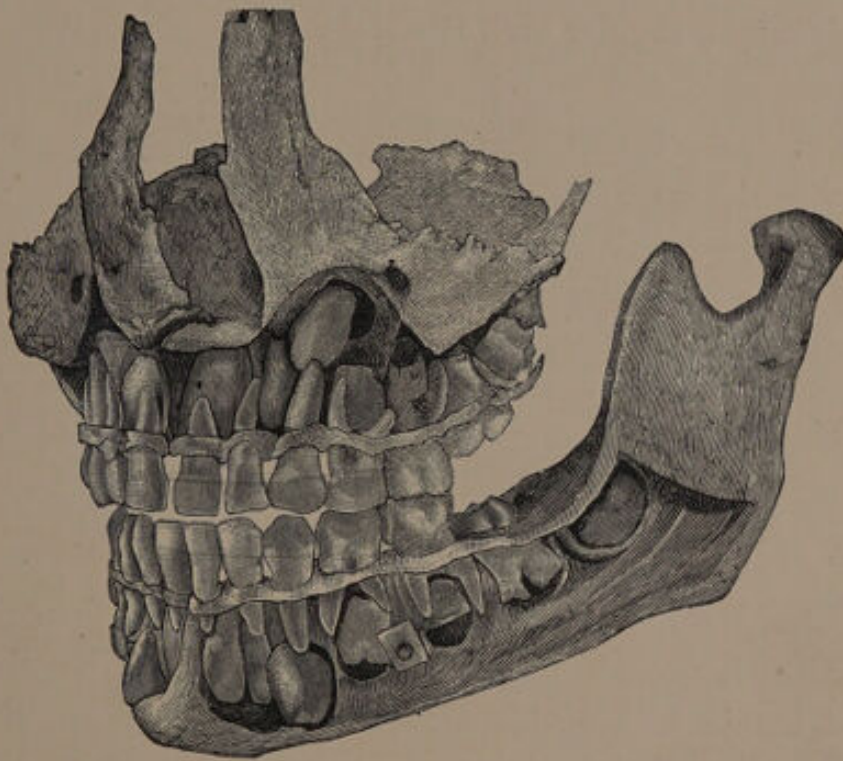


FIG. 66.¹

The permanent incisors, canines, and premolars, when erupted, are confined to the space previously occupied by the deciduous teeth.

The permanent incisors replace the deciduous incisors. Space for the greater breadth of their

¹ From "Diseases and Injuries of the Teeth."

crowns is obtained by their assuming a more sloping direction and thus occupying the arc of a larger circle. The permanent canine is larger than the deciduous canine, but the premolars are smaller than the deciduous molars, the increase in size in the former being counterbalanced by the decrease in the latter. Room for the permanent molars is gained by the backward growth of the jaw. In this way a regular arch is obtained.

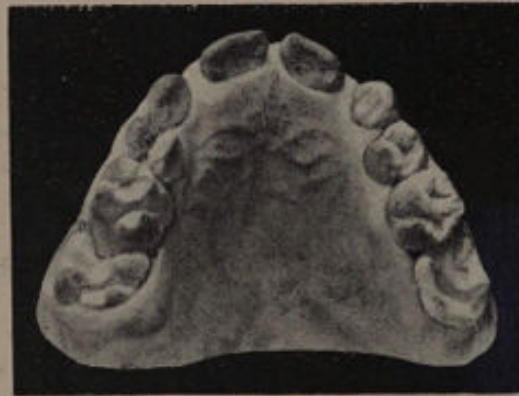

FIG. 67.

In the normal condition a distinct relationship exists between the size of the teeth and the size of the jaws. Within modern times the size of the jaws has diminished to a greater degree than the size of the teeth, with the necessary result that the teeth, when erupted, assume a crowded position in the arch.

Subsequent to birth a certain amount of arrest in the growth of the jaw may result from various causes, but if we accept the present theory of development this would only tend to lessen the space available for the molars. The molars not

having sufficient room would force themselves forward and so encroach upon the space to be occupied by the second premolar. This apparently occurred in the case shown in fig. 67. The molars were abnormally placed, and in their eruption caused so much absorption of the second deciduous molars that the latter were lost at an early period. The encroachment of the first permanent molars on the space previously occupied by the second deciduous molars had the effect of forcing forward the pre-

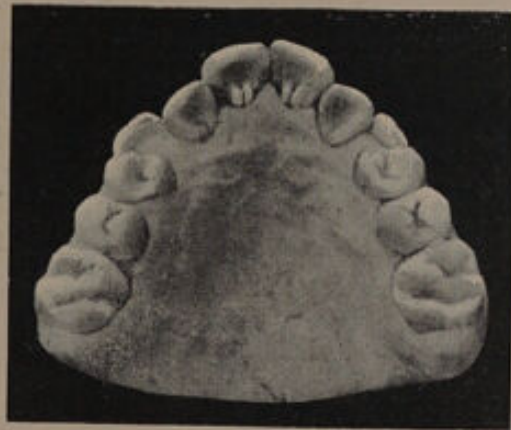

FIG. 68.

molars so that the canine, through lack of space, erupted external to the arch (fig. 68). In a somewhat similar case which has recently come under observation the permanent molars had caused so much absorption of the second deciduous molars that the latter had to be removed (figs. 69 and 70). In both these cases it is difficult to say whether the direction of the permanent molars was the result of crowding due to inherent smallness of the maxilla, or whether it was due to some arrest

in the growth of the bone subsequent to birth. This condition is, however, interesting, and one which is not generally recognised. The early removal of the second deciduous molar as a cause of crowding was alluded to on page 6. A crowded condition of the teeth may also arise from the presence of supernumerary teeth.

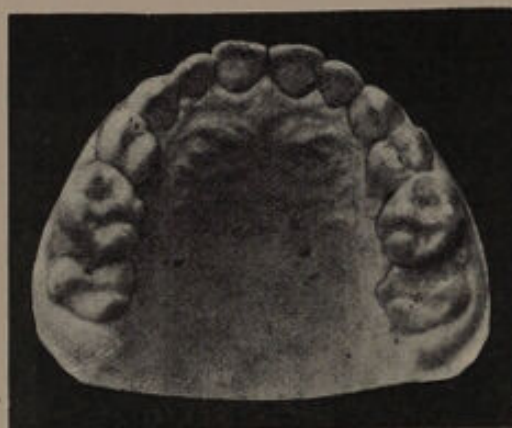

FIG. 69.

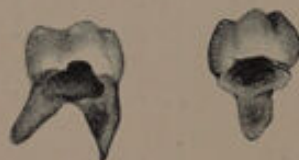

FIG. 70.

The positions which the teeth assume in a crowded mouth depend mainly upon (1) The position of the teeth in their crypts; (2) the order of eruption; (3) the density of the alveolar process; (4) the influence of the tongue and lips; (5) the occlusion of the teeth.

It has already been shown that even under normal conditions the permanent teeth are ar-

ranged in their crypts in an irregular manner, and it necessarily follows that the irregularity of their position will become more marked as the space available for their development diminishes; the lateral incisors will perhaps be placed more inwards and the canines more outwards. The direction which a tooth takes in erupting is probably similar to that of the long axis of the tooth in the crypt. In this way one is able to account in crowded mouths for the frequent eruption of the lateral incisors and the premolars internal, and the canines external, to the arch.

The order of eruption is an important factor in determining the character of an irregularity and well shown in cases of crowding which result from early loss of the second deciduous molar. When the teeth appear in normal order the canine erupts subsequent to the second premolar, hence if there is insufficient room in the arch the canine will be the principal disturbing factor. If there is a moderate interval between the lateral incisor and the first premolar the canine will force its way into the arch causing disturbance in the position of the incisors, but if the interval is slight, the result will be the extrusion of the canine from the arch and, in all probability, external to it. The pressure of the canine will also in many cases force the incisors inward and forward, producing a V-type.

Should the canine erupt previous to the second premolar the disturbance in the position of the anterior teeth will be less noticeable. The incisors, canine and first premolar will erupt in a fairly

regular manner, the premolar being forced towards the first molar. If the space is but slight the second premolar will erupt internal to the arch and cause but little disturbance. On the other hand, if there is a nearly normal interval the second premolar in erupting will, in all probability, cause displacement inwards of the first premolar and so produce a type of saddle-shaped arch. The extent of the disturbance in position of the teeth already in place caused by those erupting depends mainly upon the density of the alveolus. In strong, robust subjects the teeth already in place suffer but little disturbance, and the erupting tooth is, as a rule, the only one irregularly placed, but with patients of feeble constitution, where the bone is soft and yielding, the effect on the teeth already in position is marked.

The tongue, the lips, and the occlusion of the teeth naturally determine to a great extent the position the teeth assume.

GENERAL PRINCIPLES OF TREATMENT.

In deciding upon the method to pursue in the treatment of a crowded mouth, there are at least three points which should be carefully kept in mind.

(1) **The great prevalence of dental caries.**—The ravages of caries are so prevalent and so much on the increase that it is most important that in the treatment of crowded mouths methods should, if possible, be adopted which will help to reduce the

tendency to caries. In this connection it should be mentioned that isolation of the teeth is of the greatest advantage, whilst mechanical appliances should be avoided whenever possible, as they are liable to cause caries either by injury to the enamel or by the lodgment of particles of food against the surfaces of the teeth.

(2) **The increasing liability to lose the teeth by chronic periodontitis.**—Although often lost sight of, the liability for teeth, which have been regulated by mechanical methods, to be attacked by periodontitis, is within the knowledge of all practitioners, and affords another strong argument against the use of mechanical appliances.

(3) **The size of the maxilla and mandible.**—In the majority of cases which come under treatment either the maxilla or the mandible is too small to accommodate the normal number of teeth, and this fact, which is frequently overlooked, should have considerable weight in selecting a line of treatment.

The methods available for the treatment of crowded mouths are :—(1) Expansion of the arch ; (2) extraction ; (3) a combination of expansion with extraction.

Expansion of the arch as a remedy for crowding was first suggested by Dr. Coffin, and consists in moving all the teeth, or a large number of them, in an outward direction. In a previous chapter the question of the movement of teeth, when treated mechanically, was discussed, and it was shown that with the majority of appliances the tooth for all practical purposes may be considered to swing on

its apex. In expansion, then, the crowns are made to occupy a greater arch, but the apical portions remain in practically the same crowded condition. There is, therefore, no true relief to the crowding and hence a relapse frequently takes place. Expansion of the arch sometimes results in a considerable disarrangement of the occlusion of the teeth, while the extreme slope at times given to the anterior teeth is most unsightly. The method has, however, the advantage of bringing the teeth into

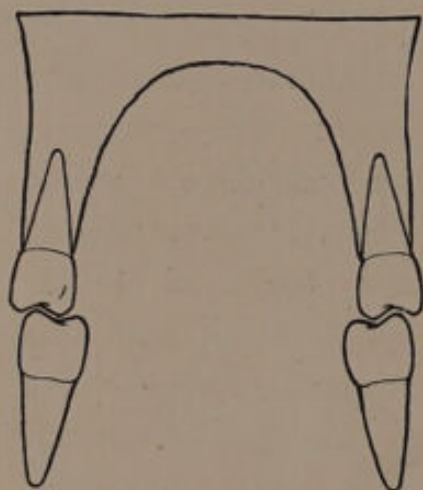


FIG. 71.

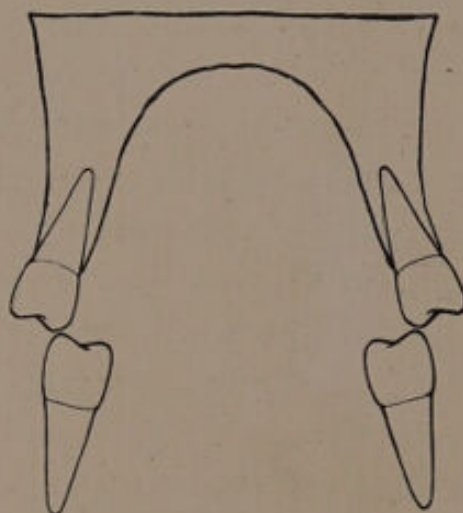


FIG. 72.

a regular arch without the loss of any of their number, and this is a great attraction to many. The normal direction of a tooth is slightly outwards, as shown in the diagram (fig. 71). The effect of expansion under such conditions is to drive the tooth in a still more outward direction and completely disturb the occlusion, as shown in fig. 72. The most suitable cases for expansion are those where the teeth slope inwards (fig. 73). Expansion

then brings the teeth into a normal direction, and occasionally improves the occlusion.

Expansion generally entails a long period of mechanical treatment, and where there is a tendency to approximal decay it is certainly not a desirable operation. It is suitable for cases where the crowding is slight, the teeth of good structure, and where the direction of the teeth will be made normal.

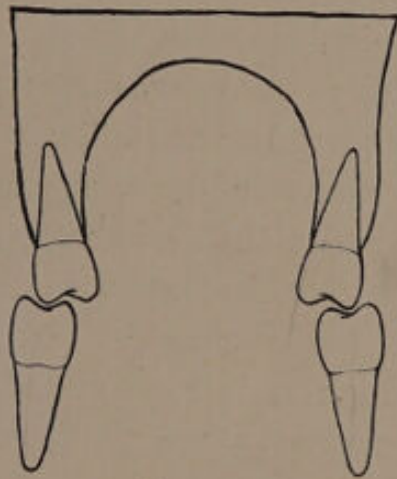


FIG. 73.

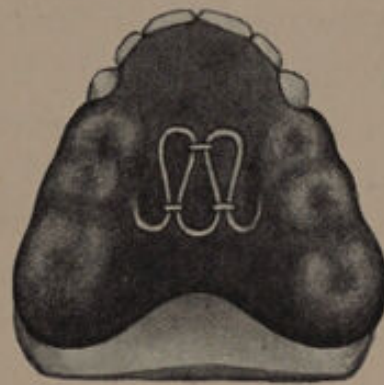


FIG. 74.

The most suitable appliance for expanding the arch is that suggested by Dr. Coffin (fig. 74). It is essential that the plate should articulate accurately with the opposing teeth. The plate should be inserted without being cut down the centre, and should be worn for about forty-eight hours. This will allow it to adjust itself thoroughly to the mouth, and when subsequently cut down the centre it will work more satisfactorily.

Extraction for the relief of crowded mouths possesses many advantages : (1) room is gained

not only for the crowns but also for the roots of the teeth; (2) mechanical treatment is lessened and in many cases dispensed with; (3) isolation of the teeth is often obtained, which is a point of great therapeutic importance in the treatment of caries; (4) the bite is but little disarranged, provided the extraction is judiciously carried out; (5) the teeth invariably assume better directions.

In the large majority of cases extraction is far preferable, and is certainly more rational than expansion of the arch.

Combination of extraction with expansion is occasionally useful in cases where the amount of crowding cannot be wholly overcome by expansion, and yet expansion is to some extent desirable from an æsthetic point of view. A case treated in this way is described on page 138.

When employing extraction it is rarely needful to remove a central incisor. Occasionally the removal of the lateral incisors or canines is necessary, and examples of cases are described on pages 97 to 109. Generally a tooth posterior to the canine can be removed, and a choice has to be made between the first and second premolars and the first permanent molar.

The removal of the first premolar has the advantage of relieving the crowding of the anterior teeth more easily than the removal of either the second premolar or first permanent molar. Its removal causes but little disturbance of the occlusion of the teeth. If, however, the amount of room required is slight there is a risk of creating too

great a space between the canine and the second premolar.

Extraction of the second premolar gives less room than removal of the first premolar and probably more room than removal of the first permanent molar. The occlusion of the teeth is but little disturbed, and any space that may result would be between the first premolar and first permanent molar, and would be less unsightly than a space between the canine and second premolar. Removal of the second premolar has the advantage of freeing the anterior surface of the molar which will lessen the tendency to caries and allow any caries which may exist to be more easily treated. The premolars are less prone to caries than the first permanent molars, but it is doubtful if the difference in liability to caries is as marked as statistics would appear to indicate. Approximal decay is more difficult to cope with in the premolars than in the first molar. Experience teaches that a first permanent molar can be more easily saved than the premolars.

Removal of the first permanent molar gives less room than the removal of the first premolar or, probably, the second premolar. The treatment necessary is also more prolonged and the occlusion of the teeth is frequently much disorganised, the second lower permanent molars tilting and the premolars, both upper and lower, rotating. As an organ of mastication the first permanent molar is most important. It possesses the largest area of crown surface, and is situated in that part of the

arch where the muscles of mastication work to greatest advantage. Unfortunately it is more liable to caries than any other tooth, but if patients are seen at regular intervals the caries can be treated in the early stage and the tooth easily and permanently saved.

Its importance as an organ of mastication is so great, and the disturbance to the articulation caused by its removal so marked, that only when the tooth is unsaveable should it be removed for the relief of crowding. Under all other circumstances the choice should be made between the first and second premolars; if both teeth are free from caries, the first should be removed if the crowding is marked; if but little space is required the choice should fall on the second premolar.



CHAPTER VI.

The Early Treatment of Crowded Mouths.

Is it advisable to commence the treatment of a crowded mouth at an early age? Opinions differ greatly upon this question, many practitioners preferring to delay treatment until the majority of teeth have erupted. I venture, however, to think that if an extended trial were accorded to early treatment it would find many more advocates. At an early age it can frequently be foreseen that a crowded condition of the teeth is inevitable. If the treatment is postponed, the irregular position of the teeth becomes more fixed and more aggravated, and hence more difficult to regulate. Again, if room is made for each tooth as it erupts, when the succession of teeth is complete the case will simply resolve itself into the treatment of a crowded-out canine or premolar, whichever happens to erupt last; whereas, if the treatment is left until the succession of teeth is complete, we shall have to deal with a condition in which probably the whole of the six front teeth are involved, entailing a long and tedious operation.

Granting, then, that early interference with crowded mouths is advisable, the question arises :

on what lines should we proceed with cases that come under notice. For simplicity of description this question will be considered under two headings:—(1) Cases where the first permanent molars are unsaveable: (2) Cases where the first permanent molars are saveable.

**(1) CASES WHERE THE FIRST PERMANENT
MOLARS ARE UNSAVEABLE.**

In these cases I have found good results to accrue from a line of treatment somewhat similar to the following:—The first permanent molars are filled or treated in the manner best calculated to retain them until the second permanent molars have erupted. The crowding of the upper and lower incisors is then relieved by the removal of the four deciduous canines. If the teeth erupt in the normal way, the first and second premolars will come into good position, and we shall then have the following condition: the four incisors and the four premolars will be in a regular arch, with a greater or less space between the lateral incisors and the first premolars, so that the canines erupt just external to the arch; in other words, we shall have to deal with a fairly simple irregularity, namely, the canines high in the arch. To make room for the canines, the first permanent molars should be removed directly the second permanent molars are fairly through the gums. A plate to hold back the second molars should then be inserted. This plate (fig. 75) is made to cover the palate in such a way that it

comes in contact with the palatal surfaces of the incisor teeth, while to the back of it are fixed half-round gold wires which pass around the anterior and buccal surfaces of the second molars, the plate being quite free of the premolars. This form of plate retains the second molars in position, and prevents them from moving forward, while at the

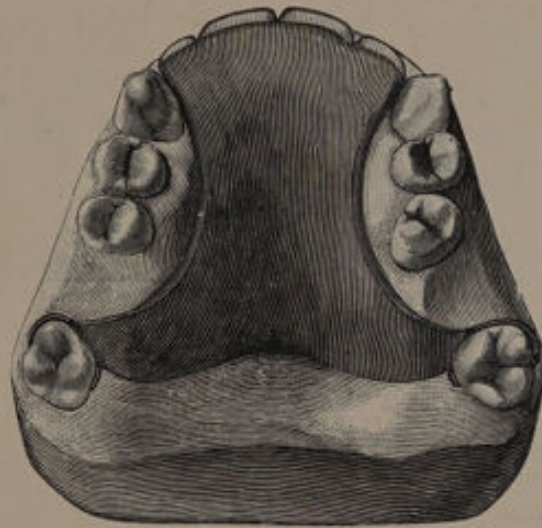


FIG. 75.

same time it allows the premolars to fall back, partly by the action of the bite and partly by the pressure of the canine tooth, so that many cases require no further mechanical treatment—a point of no small importance. Obviously, this line of treatment will not apply in all cases. In some patients the lower front teeth are so crowded at an early age that extraction of at least one of them becomes necessary. A good example of this is seen in fig. 76. Here the first permanent molars are quite unsavable, and the crowding of the lower incisors

is excessive. This condition is due to pressure from the canines, and removal of the first permanent molars will not sufficiently relieve the pressure to allow the laterals to assume anything approaching a normal direction. If left untreated, the lower canines will in all probability erupt in a plane anterior to the laterals. Removal of the

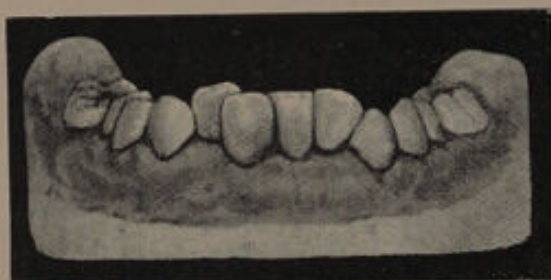

FIG. 76.

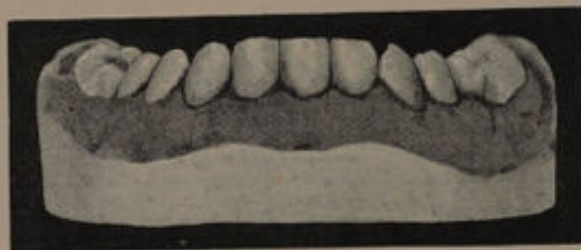

FIG. 77.

right central incisor, however, will relieve the crowding and allow the remaining teeth to assume good directions. The result of treatment is seen in fig. 77.

Another example, which could hardly be carried out on the general principles just indicated, is to be found in cases where, at an early age, it is clear that the maxillary permanent canine will erupt over the position of the lateral. Under such circum-

stances the lateral is forced much internal to the bite, or is twisted and turned in some very abnormal position. The lateral incisors must be extracted, and this should be done before the canines erupt. The first permanent molars should be removed before the eruption of the second permanent molars, in order that the latter may move well forward, and so fill up the gap caused by the extraction of the first permanent molars. This will prevent undue spacing between the anterior teeth, which would be unsightly.

(2) CASES WHERE THE FIRST PERMANENT
MOLARS ARE SAVEABLE.

Attention here should, in the first instance, be directed to the first permanent molars, and these teeth should be filled in as permanent a way as possible. The probable position of the permanent canine should next be determined. If the incisors are in a fairly regular line, or if the lateral has its mesial angle tilted forward, we may assume that the canine will erupt posterior to the lateral. If, on the other hand, the distal edge of the lateral is projected forward and the apex of that tooth is directed towards the median line, we may conclude that the canine will, in all probability, erupt over the situation of the lateral, and the same may be assumed if the lateral is placed much internal to the bite, and the deciduous canine lies close to the central.

In instances where the canine shows signs of

erupting posterior to the lateral, room should be obtained by the removal of the first premolar as soon as possible. In most cases it is advisable to remove this tooth even if unerupted.

The latter operation consists in removing the deciduous first molar, and then the premolar. This was first suggested by Mr. Tomes for the treatment of that irregularity of the lateral incisor where the mesial angle is tilted forward and directed towards the median line, and, as is well known, this irregularity is extremely difficult to correct if left until the permanent canine has erupted.

If a skull exhibiting this condition be examined, it will be noticed that the irregularity of the lateral is produced by the permanent canine pressing on the end of the root of the lateral. To relieve the pressure there is but one method available, namely, to remove the premolar, and so allow the canine to fall back. It may be argued that extraction of the deciduous canine would be sufficient to remedy the condition of the lateral, but if the dried specimen be carefully studied, it will be noticed that the removal of the deciduous canine will not have the desired effect of giving room for the permanent canine.

In performing this operation, an anæsthetic should always be given, as the removal of the premolar is frequently difficult. If we confine our attention to one side of the mouth at a time, nitrous oxide administered in the usual way is quite sufficient; but if it is desirable to remove both premolars at one sitting, then ether must be used or a prolonged

nitrous oxide anæsthesia obtained by one of the methods recently introduced. The most suitable instrument for the removal of the teeth is a pair of Read's upper root forceps with rather long blades. The deciduous molar is first removed, and in attempting the extraction of the premolar the blades should be opened fairly wide; this is worthy of remembrance, because there is a decided tendency not to keep them open sufficiently. The external blade should be kept well outwards. It is well to advise the use of an antiseptic mouth-wash after removal, and if the extraction has been difficult, the wound should be syringed several times a day.

Crowded mouths treated in this manner give excellent results. The canine moves into the space previously occupied by the premolar. Pressure on the front teeth is relieved, a good arch is obtained, and what is most important, the teeth will be in excellent direction. In addition, mechanical treatment is abolished, and the articulation of the molars and premolars remains good. (Figs. 78 to 95 are examples of this form of treatment.)

Out of twenty-one cases of which I have been able to ascertain the results the operation proved satisfactory in all but two. One of the two cases is shown in fig. 95. In this case it will be seen that the lateral incisors projected forward to a considerable extent, and from their positions it was probable that the permanent canines were situated well over the anterior aspect of the roots. In fact, it was a case that would have resolved itself into the removal

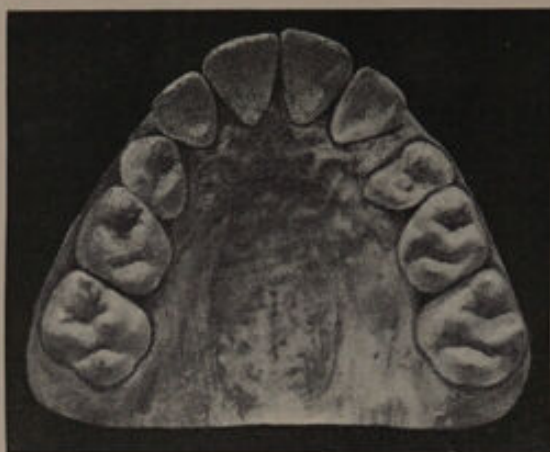

FIG. 78.—Case 1. Upper, before treatment.

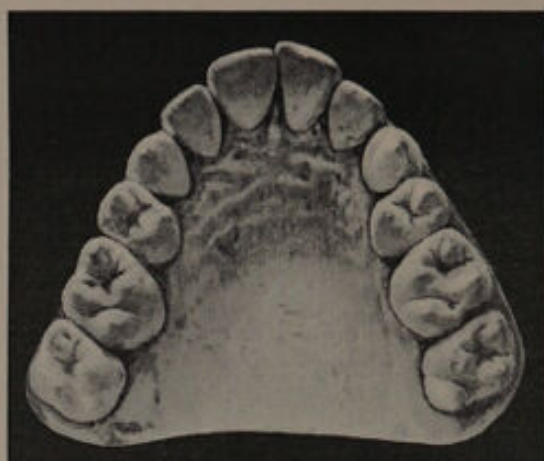

FIG. 80.—Case 1. Upper, after treatment.

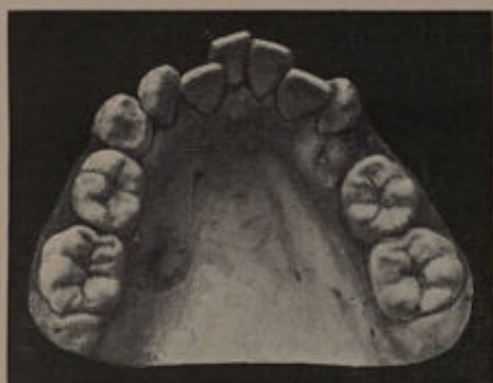

FIG. 79.—Case 1. Lower, before treatment.

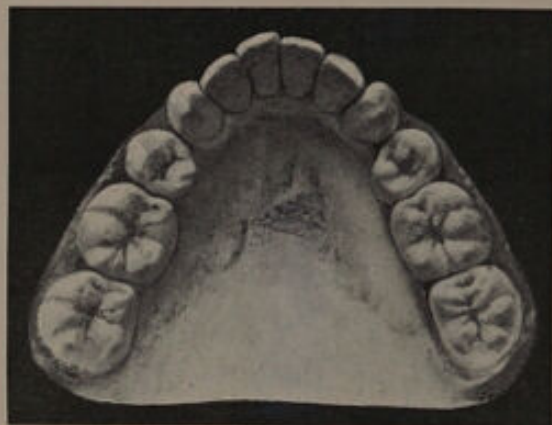

FIG. 81.—Case 1. Lower, after treatment.

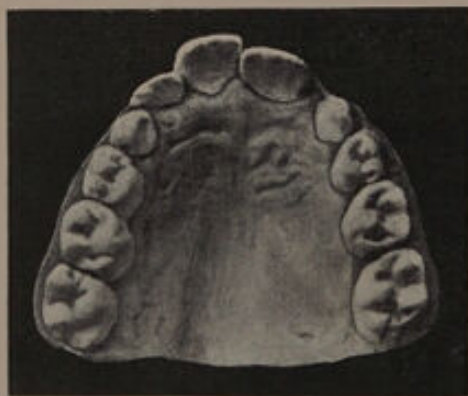

FIG. 82.—Case 2. Before treatment.

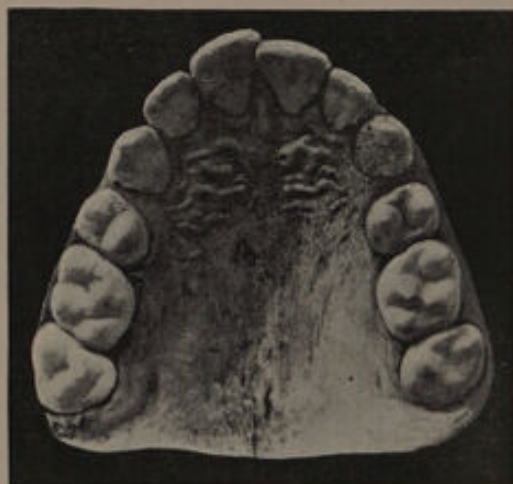

FIG. 83.—Case 2. After treatment.
The mal-position of the right central is due to slight crowding of the lower incisors.

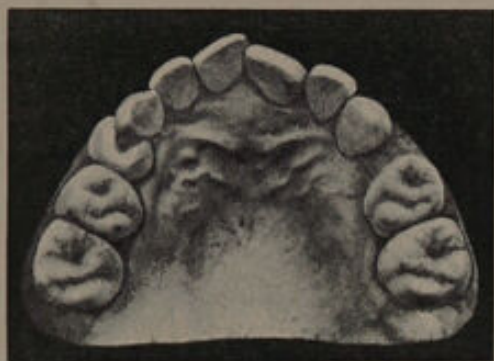

FIG. 84.—Case 3. Before treatment.

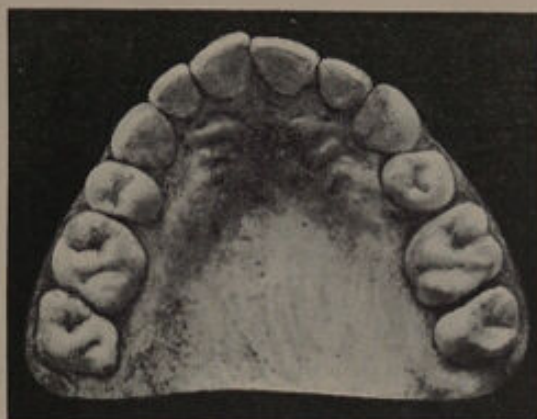

FIG. 85.—Case 3. After treatment.

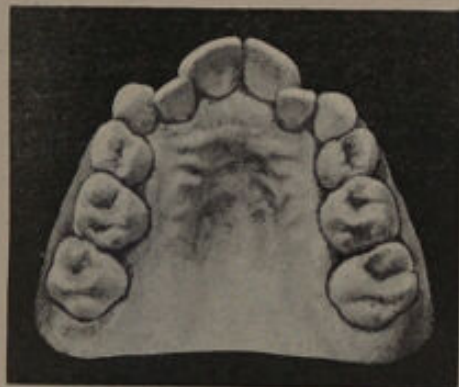

FIG. 86.—Case 4. Before treatment.
In this case the lateral incisors had to be pushed forward over the lower teeth.

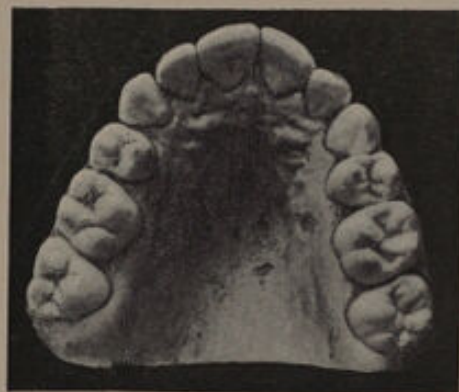

FIG. 87.—Case 4. After treatment.

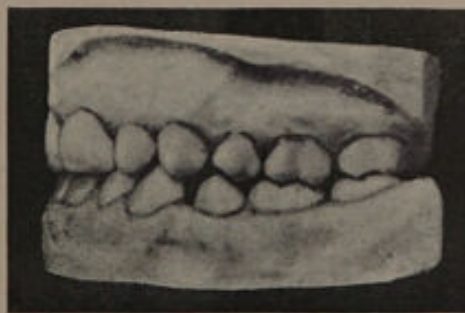


FIG. 88.—Case 4. Side view, showing occlusion of premolars and molars.
After treatment.



FIG. 89.—Case 5 Before treatment.

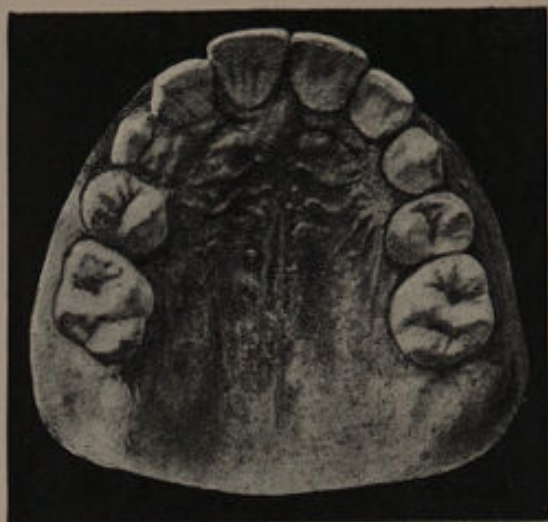

FIG. 90.—Case 5 After treatment.

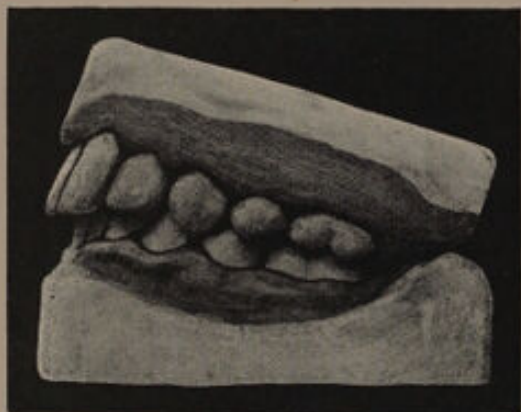

FIG. 91.—Case 5. Side view, showing occlusion of premolars and molars.

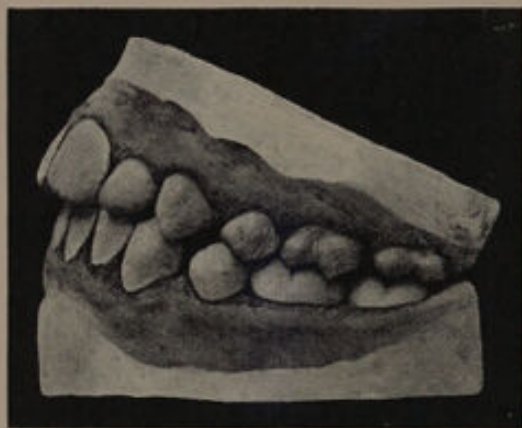

FIG. 92.—Case 6. Showing occlusion of premolars and molars.

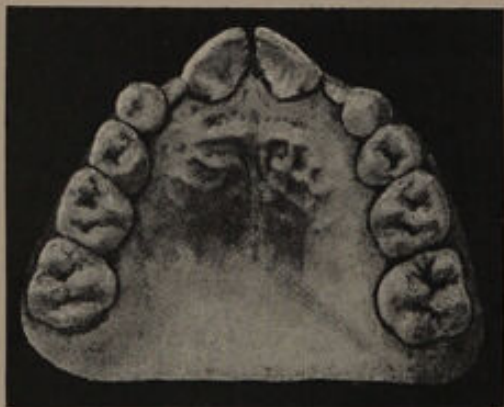


FIG. 93.—Case 6. Before treatment

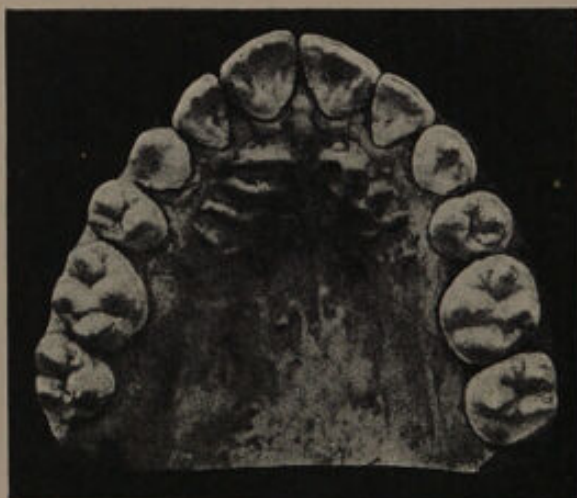

FIG. 94.—Case 6. After treatment.

either of the laterals or the canines. It was hoped that by the early removal of the first premolars the canines would move back and erupt in a good position, but this did not happen, as the direction of the teeth was well towards the median line. The canines came down into the arch (fig. 95 a), but the æsthetic result was bad. It would have been far better to have removed the laterals at an early date, as was done in the cases shown in figs. 96 to 99.

In the other case the operation was carried out to rectify the irregularity of the laterals, the mesial angles of which were tilted forward and towards the median line. The tilting of the laterals has been overcome, but too much space has resulted between the laterals, canines and second premolars. These spaces may of course fill up with the advent of the third molars. Without this early treatment the irregularity of the laterals would undoubtedly have increased, and would have been quite as objectionable æsthetically as the spaces in the region of the laterals, canines and second premolars.

The advantages of extracting the premolars early, where a crowded mouth is in the future inevitable, are :—

(1) Pressure on the front teeth being relieved, any irregular position they may have assumed is rectified easily by natural methods.

(2) The canines and premolars come down in a good direction and form a regular arch.

Against the operation is urged the severity of the treatment. It really is not severe; and

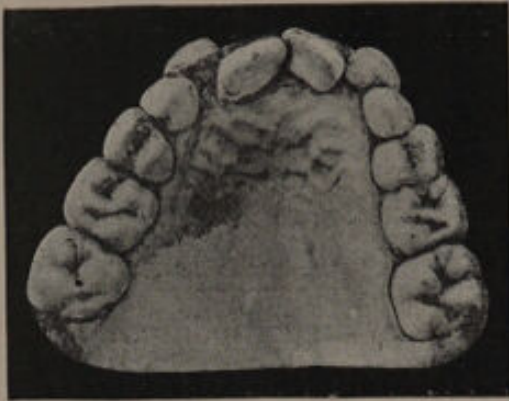

FIG. 95.

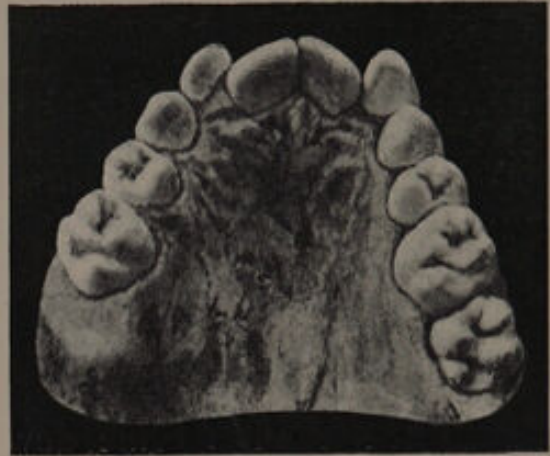

FIG. 95 a.

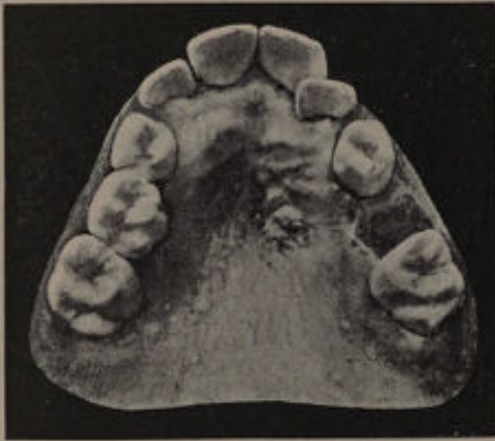

FIG. 96.—Before treatment.

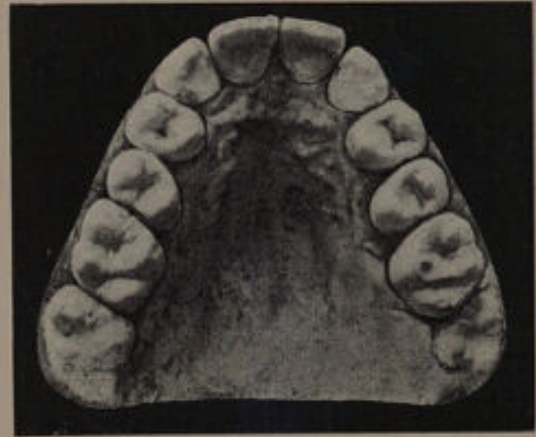

FIG. 97.—Case shown in fig. 96.
After treatment.

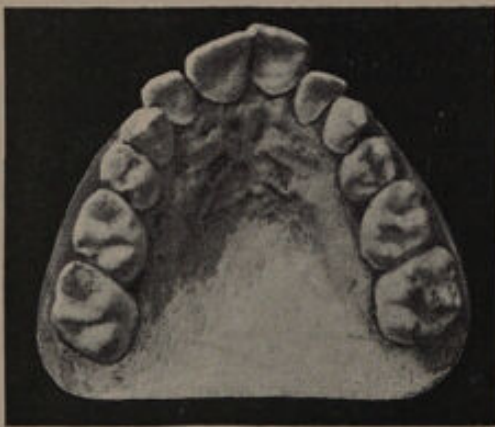

FIG. 98 a.—Before treatment.

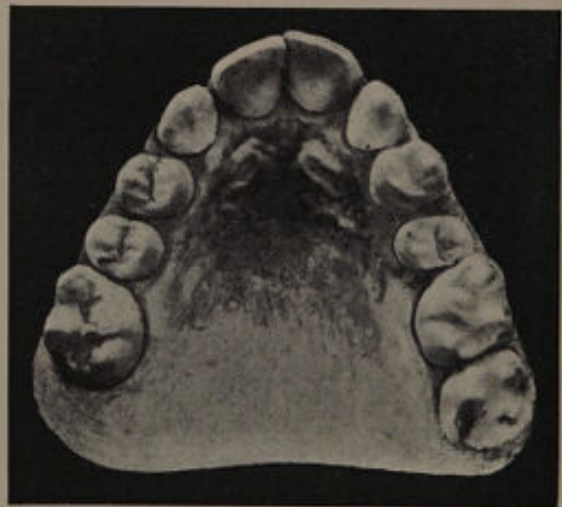


FIG. 98 b.—Case shown in fig. 98 a.
After treatment.

although the wound is perhaps longer healing, it gives rise to but little more trouble than an ordinary extraction.

Another point in connection with this treatment

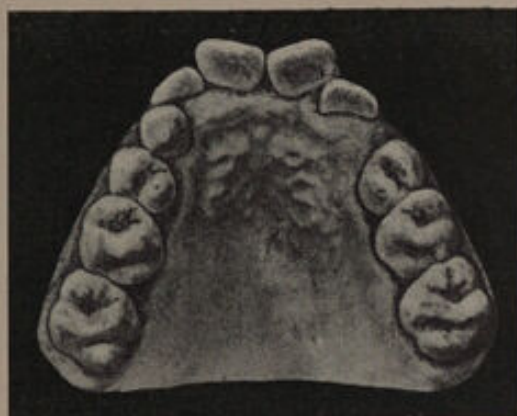

FIG. 99 a.—Before treatment.

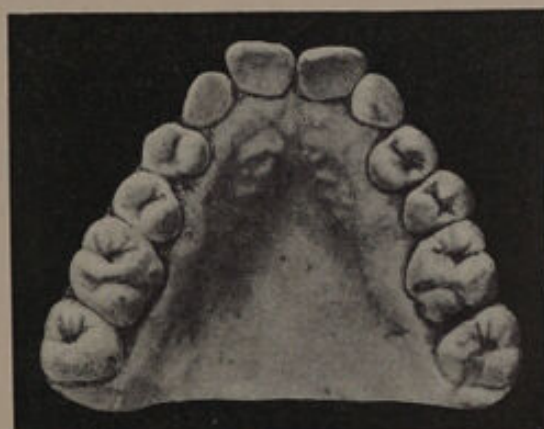

FIG. 99 b.—Case shown in fig. 99 a, after partial eruption of canines. When the canines have fully erupted it is proposed to slightly rotate the central incisors.

is its apparent tendency in some instances to produce a V-shaped arch. This tendency has been clearly demonstrated in several cases which have come under notice, but an examination of the first models have shown premonitions in

this direction. That early removal of the premolars may cause a lessening of width in the canine region is probable, and in the case of two patients, who neglected to pay regular visits, the canines erupted internal to the bite. In both these cases timely extraction of the deciduous teeth would have prevented this condition. The experience of the cases certainly teaches that the actual time for the removal of the premolars must depend largely upon the amount of contraction or irregularity present.

In very crowded mouths, and probably in cases of superior protrusion, the earlier that extraction is resorted to the better, while, with a slight amount of crowding, the removal of the tooth may be delayed. But no hard and fast rule can be laid down, and each case must be decided upon its individual merits.

In cases where the canines show signs of erupting over the situation of the laterals, the removal of the premolars does but little good, and such cases are treated much more satisfactorily by removing the lateral incisors. This should be done before the canines erupt. Cases treated in this way are shown in figs. 96 to 99.





CHAPTER VII.

Cases of Crowding coming under Observation after the Majority of the Teeth have Erupted.

It is unfortunately a fact that, instead of being placed under supervision at an early age when the teeth can be regulated with comparative ease, a large proportion of patients are not brought for treatment until the majority of the teeth have erupted. The consequence is that *the difficulties to be overcome are more pronounced*, and in the end the results obtained are less satisfactory.

In dealing with these cases the following points should be carefully observed at the outset, viz., the character of the teeth, the bite, the direction of the roots, &c. A few typical cases will be given, the reasons for the line of treatment explained, and the results shown.

Cases of crowding complicated by disease of a central incisor.—In considering the treatment of such cases our decision must depend upon—

(a) The prospects of permanently retaining the affected tooth.

(β) The degree of crowding.

(γ) The sex of the patient.

(δ) The age of the patient.

If the pulp of the tooth died subsequent to the completion of the root, and no periodontal mischief supervenes, or if present is only slight, there is a reasonable prospect of permanently saving the root and affixing a crown. Under these conditions the

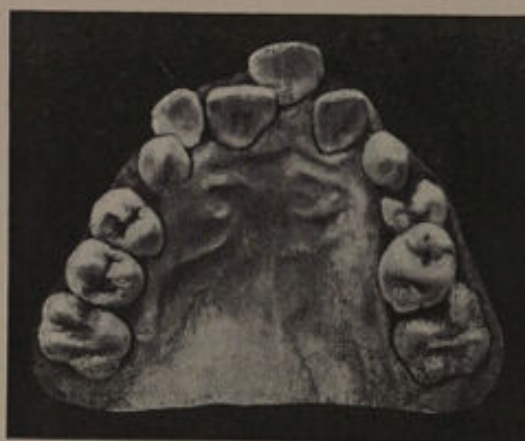

FIG. 100.—Before treatment.

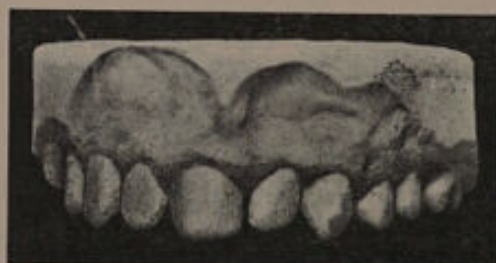

FIG. 101.—After treatment.

central should be saved, and the crowding treated by the removal of a posterior tooth.

If, however, it seems probable that the pulp died prior to the completion of the root, and the chronic periodontal trouble is extensive, the chances of permanently retaining the tooth will be remote, and in most cases it would be advisable to remove it.

The loss of a central incisor in the case of a boy can be usually hidden subsequently by a moustache, but with a girl the disfigurement is serious, and every effort should be made to retain the tooth until it is deemed advisable to insert an artificial denture, the obvious disadvantages of a denture being in

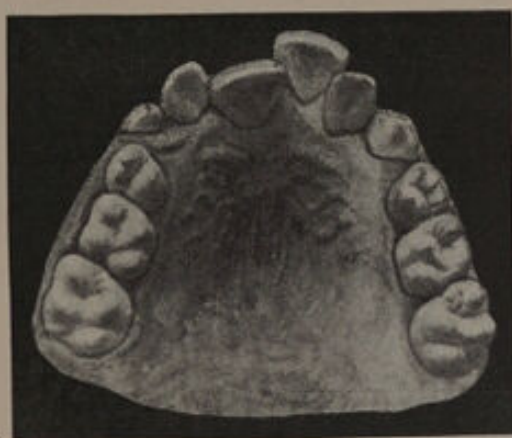

FIG. 102.—Before treatment.

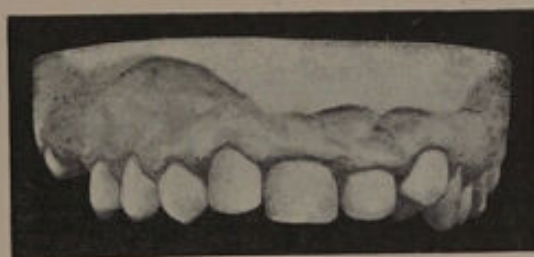

FIG. 103.—After treatment.

this case more than outweighed by the gain in personal appearance. But even with a girl extraction would be the better course if the crowding is excessive and the tooth not permanently saveable.

In the case shown in fig. 100 the left central incisor projected and was attacked by a chronic abscess of long standing, the patient having injured

the tooth by a fall at the age of eight. An unsuccessful attempt having been made to treat the tooth, it was extracted. The first permanent molars,

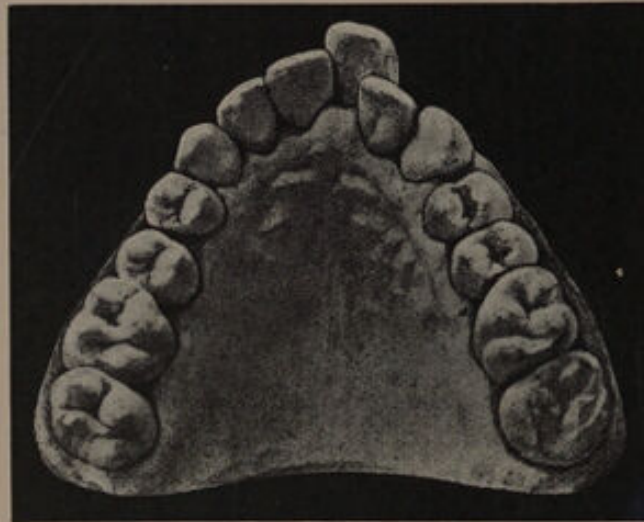


FIG. 104.

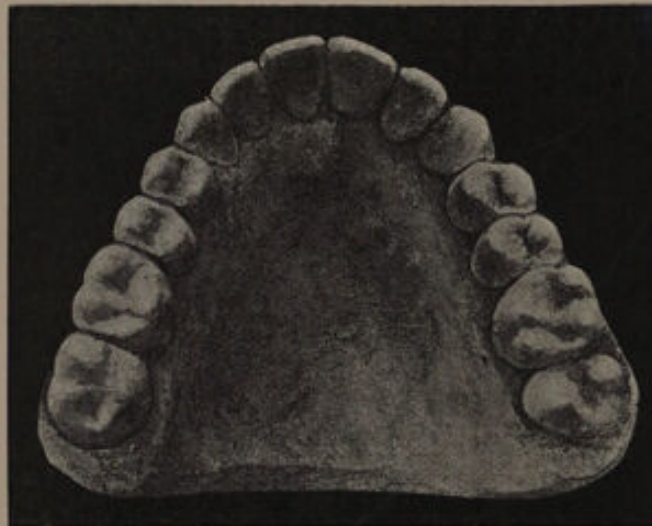


FIG. 105.

which were unsaveable, were also removed. Fig. 101 shows the case after the eruption of the per-

manent canines. A somewhat similar case is shown in figs. 102 and 103.

Crowding resulting in the protrusion of a central incisor.—An example of this irregularity is shown in fig. 104. The patient was 21 years of age. The arch was expanded by means of a plate similar to fig. 234. A half round gold wire was fixed to the outer side and made to impinge upon the projecting incisor, the plate being cut away upon the palatal surface to allow the tooth to move inwards. The result of the treatment is shown in fig. 105.

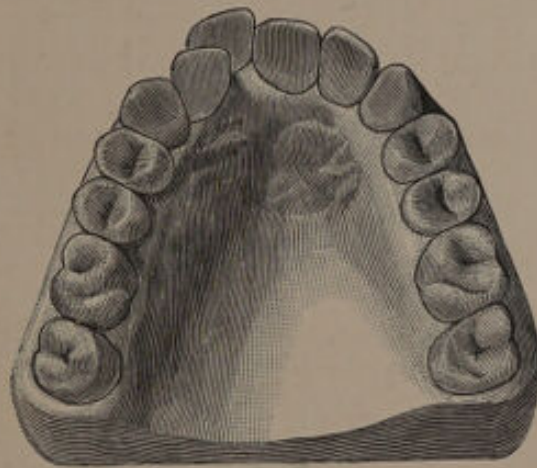


FIG. 106.¹

The model shown in fig. 106 illustrates a similar irregularity. In this case the tooth was removed as the patient, a man aged 24, was shortly going abroad where he would be unable to obtain treatment.

The models shown in figs. 107 and 108 illustrate a case which was under the care of Mr. F. Ewbank. The projection of the right upper central incisor

was due to the forward movement of the upper canine, which had been deflected by a prominent lower canine. The prominence of the lower canine had been caused by a supernumerary lower incisor,

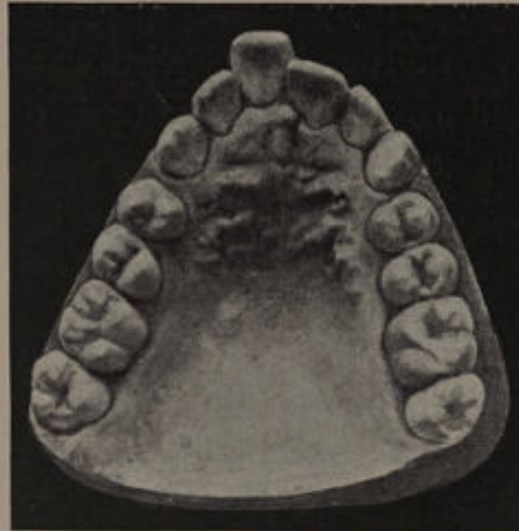


FIG. 107.—Palatal view.

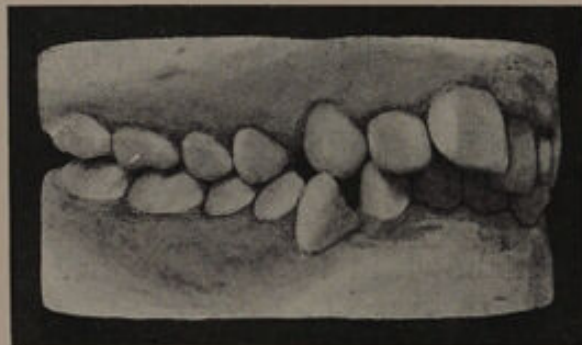


FIG. 108.—Showing occlusion of teeth.

which had been removed. The treatment consisted in first reducing the irregularity of the lower canine by the removal of the first premolar, followed by retraction of the outstanding tooth. A plate was then made capping the upper premolars and molars,

and a gold wire adjusted which exerted pressure on the protruding incisor. The result is shown in fig. 109. This case is extremely interesting from a diagnostic point of view.

Crowding resulting in the exclusion of laterals from the arch.—The advisability of sacrificing a lateral incisor in the treatment of crowding is constantly disputed, some practitioners even going so far as to maintain that under no circumstances is such a course desirable. The principal argument urged

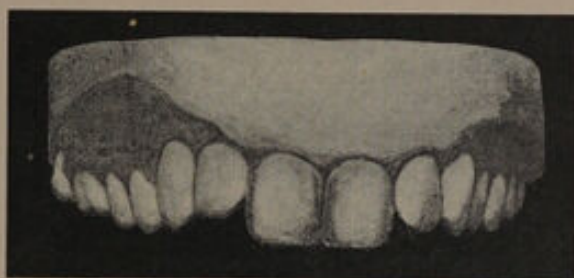

FIG. 109.

against the removal of this tooth is that the canine erupts next to the central and produces an unsightly appearance. It is true that a lateral in correct direction has a better appearance than a canine next to the central, but in cases where the extraction of a lateral is a matter for consideration, the problem to be solved may be put in this way. Is it better to have a canine in correct alignment next to the central and the premolar in apposition to the canine, or a lateral in a mal-direction with, possibly, its cutting edge tilted forward and the canine sloping towards the median line, and in all probability short? Take as an example the case

shown in fig. 110. The laterals are displaced inwards to a considerable extent and are in a vertical direction, the canines being but slightly external to the arch. An examination of the roots of the teeth shows the canines to be sloping towards the median line, while the roots of the first premolars take the same direction. Extraction of the laterals will effect a remedy without mechanical

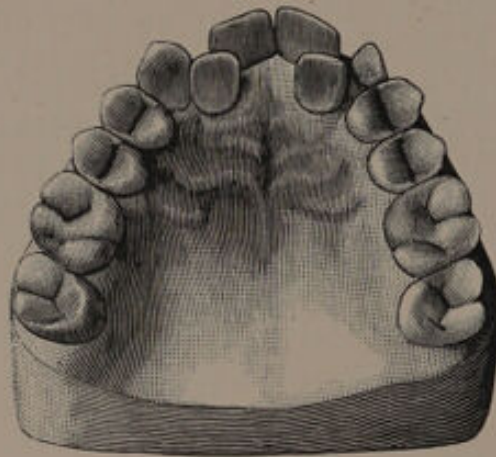


FIG. 110.¹

treatment ; the canines will come down in good direction ; the centrals will fall back and assume a more correct position, while the premolars will move forward also into a vertical position.

If an attempt were made to treat the case by extraction of the first premolar the result obtained would, in all probability, be far from satisfactory. Even with a fairly good result and with the teeth brought approximately into a normal curve, the difference in the slope of the teeth will produce anything but a pleasing appearance. The central will be forced more outwards, the lateral will have

its cutting edge directed forward, that is to say, the neck will be in a plane well posterior to the central, the cutting edge of the canine will be above the level of the lateral and the slope will be considerable.

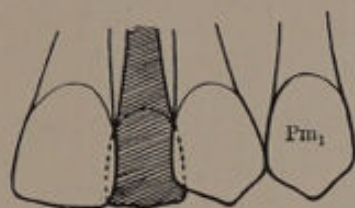


FIG. 111.—Case before treatment, showing positions of incisors and canine.

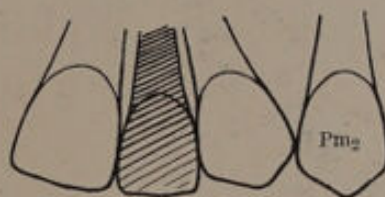


FIG. 112.—Result of treatment after removing the first premolar.

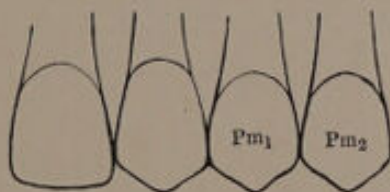


FIG. 113.—Result of treatment after removing the lateral incisor.

Further, this operation will entail prolonged mechanical treatment with all its attendant troubles. Surely a row of teeth in correct alignment with the canine next to the central is more sightly than a row of teeth in bad alignment with the lateral next to the central; and, moreover, it must not be forgotten that the public do not view the teeth with the professional eye of the

practitioner. Diagrams illustrating these points are shown in figs. 111 to 113.

The case shown in fig. 114 is somewhat similar to the last, and calls for the removal of the laterals. The roots of the canines were directed towards the median line and the articulation of the premolars and molars was good.

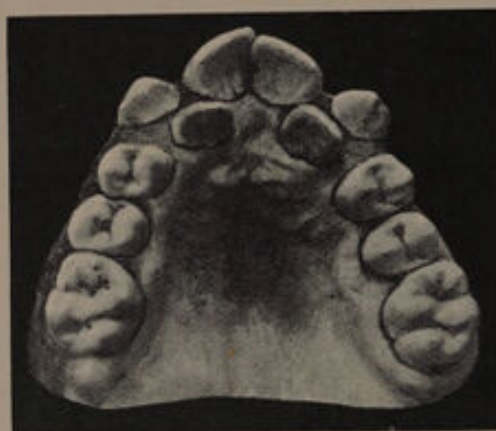

FIG. 114.

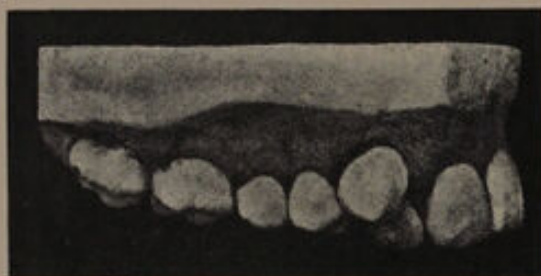

FIG. 115.

Fig. 115 illustrates a case where one lateral had been removed; the opposite lateral was displaced slightly internal to the arch, the canine being external with the root sloping towards the median line. The figure shows the relation of the canine to

the lateral, and also that the centre of the mouth has been driven towards the opposite side. Fig. 116 is a view of the mouth on the side where the canine has been extracted. The teeth are in good direction, and after the removal of the opposite lateral will assume a still better position, as room

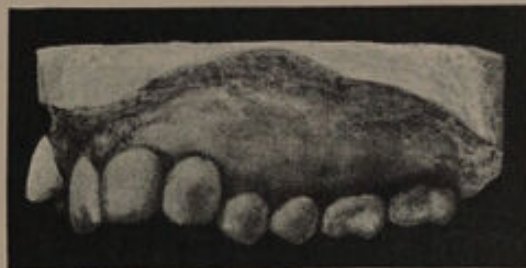

FIG. 116

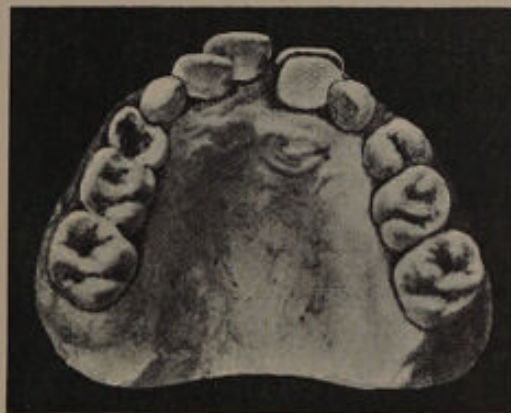

FIG. 117

will be available for the canines to come fully into line. This result was obtained.

Another case calling for the removal of the laterals is shown in fig. 117.

The cases, however, which test the judgment most are those where the root of the canine is directed only slightly towards the median line and

there is a possibility of the tooth coming into good direction if the premolar is removed. Under these conditions the removal of the premolar would be the wiser course, especially if the patient is a girl.

Cases are sometimes met with where the laterals are misplaced to such an extent that their extraction is imperative and the first permanent molars are also quite unsaveable. Under such conditions the molars must be removed, and this should be effected if possible before the second permanent molars erupt. The latter will then come forward and in a great measure prevent a backward movement of the premolars, which would probably leave unsightly spaces between the front teeth.

Cases of crowding in which the canine is displaced external or internal to the arch.—The displacement of a canine external to the arch is the commonest result of a crowded condition of the teeth. A typical example is shown in fig. 118.

In considering this irregularity, it should be remembered that the canine is the most important tooth in the dental arch, forming a kind of key stone, and in a great measure giving character to the face. When extracted, it leaves a depression near the ala of the nose, leading to an expressionless appearance. It is the longest, and probably the strongest and best developed tooth in the whole arch; for these reasons endeavours should be made to retain it. The treatment usually resolves itself into the question of whether the lateral, a premolar, or the molar should be removed, or as a

last resource the canine. In deciding upon treatment in such cases the position of the root of the canine is of importance.

If the root has a direction forward it is useless to remove a posterior tooth as the canine, when it erupts, will slope very much backwards and look extremely ugly ; whereas, if the lateral is extracted, the canine would erupt fairly straight, and give a much better appearance. The accompanying

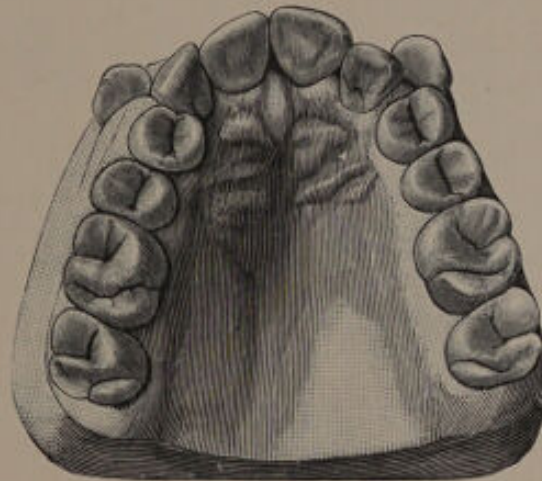


FIG. 118.¹

figures illustrate this point. The question whether a premolar or molar should be removed has been already discussed on pages 74 to 76.

Irregularities of the canine seldom require any mechanical treatment, especially if judgment has been exercised in extracting the teeth with relation to the bite. Nature will frequently overcome the difficulties unaided, and it is therefore a good plan in most cases to wait for a period of from three to

¹ From "Diseases and Injuries of the Teeth."

six months after extraction. If at the end of that period the tooth does not appear to be moving into position, mechanical assistance should be given, and one of the simplest methods in vogue is that shown in fig. 23.

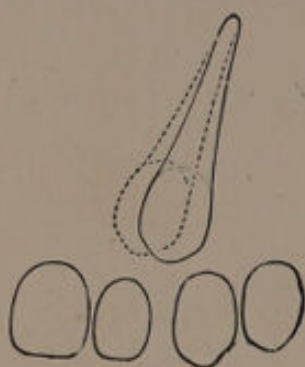


FIG. 119.—Showing the root of the canine lying over the premolar. The dotted lines represent the direction the canine will take if the lateral is extracted.

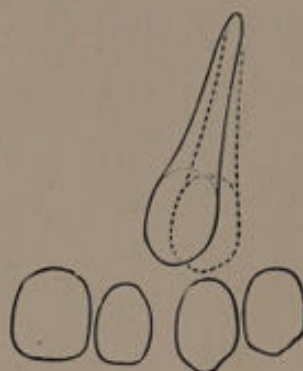


FIG. 120.—Showing the root of the canine lying over the premolar. The dotted lines represent the direction the canine will take if the premolar is extracted.

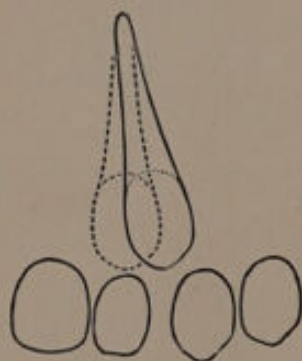


FIG. 121.—Showing the root of the canine lying over the lateral. The dotted lines represent the direction the canine will take if the lateral is extracted.

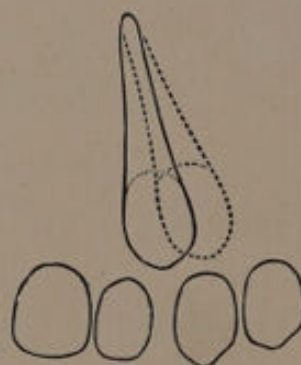
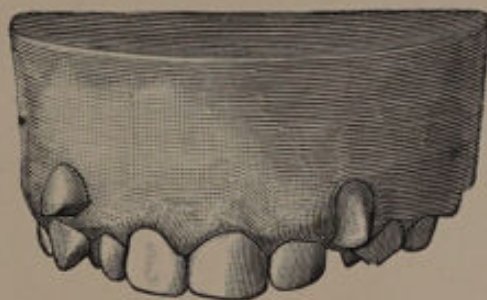



FIG. 122.—Showing the root of the canine lying over the lateral. The dotted lines represent the direction the canine will take if the premolar is extracted.

In removing a premolar for the relief of a crowded canine, attention must be given to the position of the corresponding lower premolar, for the latter may be situated in such a manner as

to prevent the upper canine from coming correctly into line. In certain cases, however, extraction of the canines is quite justifiable, especially those in which, with the arch regular, the laterals are close or fairly close to the premolars, and the canines erupt outwards almost at right angles, as seen in fig. 123. The teeth in such cases usually have twisted roots, which would give rise to difficulty in bringing them into position (fig. 124). Under

FIG. 123.¹FIG. 124.¹—Canine teeth removed from the case illustrated in fig. 123.

such conditions extraction is undoubtedly the best treatment.

The eruption of a tooth within the arch may be due to the persistence of its predecessor, or the tooth may have taken an abnormal direction from some unknown cause. Crowding may also be

¹ From "Diseases and Injuries of the Teeth."

responsible for the irregularity in some instances, and when this is the case there is frequently some rotation of the first premolar. The treatment is to make room either by the removal of the persistent tooth or a permanent one, and then to push the tooth into position by mechanical means.

Fig. 125 illustrates such a case in a patient

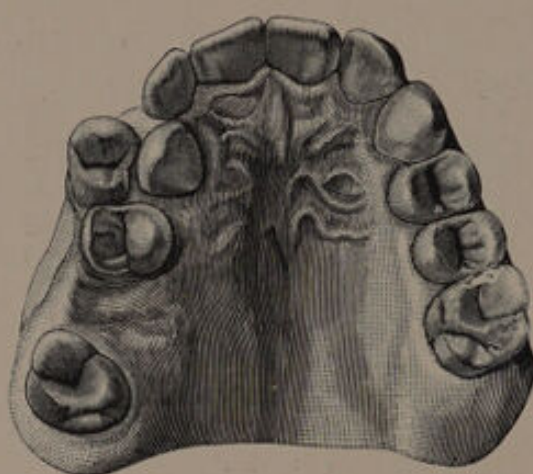

FIG. 125.¹—A case in which the canine has erupted internal to the arch.

aged 18. The crowding was probably the result of early extraction of the deciduous second molar allowing the first permanent molar to encroach upon the premolar space. Treatment consisted in the removal of the first premolar and the roots of the first permanent molar; the canine being brought into line by a strong pianoforte wire spring attached to a vulcanite plate. The result is shown in fig. 126.

In fig. 127 the models of a patient aged 13 are shown. It will be noticed that the canine has

erupted external to the arch: the first upper premolar is situated near to the lateral, and the first molar touches the premolar. The second premolar showed signs of erupting in the palate.

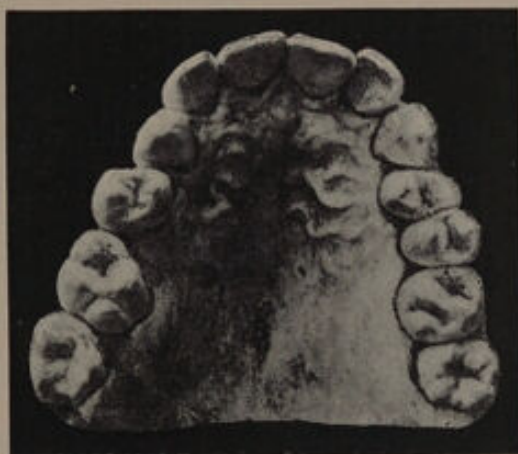

FIG. 126.—This model was taken ten years after the completion of treatment.



FIG. 127.

The second left lower premolar has not erupted and the first molar has been lost.

On the right side of the mouth a somewhat similar condition existed, but the first lower molar

was present. The teeth showed signs of caries. The patient, who was in debilitated health, possessed a peculiarly narrow pinched face with the exception of the upper lip, which projected at the angles of the mouth owing to the prominent canines. In considering this case the following points were taken into account.

(1) The articulation of the teeth was fair, and there was a serviceable masticating surface.

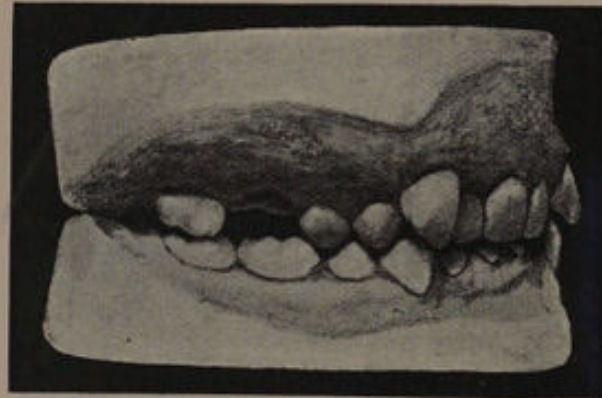

FIG. 128.—Showing occlusion of the teeth on the right side.

(2) Extraction of the first premolar to allow room for the canines would practically rob the patient of the use of the lower premolars, and so considerably lessen the masticating surface.

(3) If extraction of the premolars were carried out, mechanical aid would be necessary to bring the canines into place. This would, however, be highly impolitic in view of the condition of the teeth and the patient's general health.

(4) Extraction of the canines would not be disadvantageous as far as the personal appearance of

the patient was concerned, the face being of a narrow, tapering character.

The canines were removed. When examined three years after the operation the patient presented a very favourable appearance.

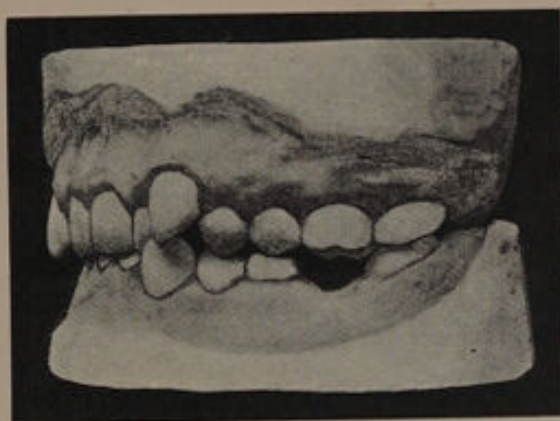

FIG. 129.—Showing occlusion of the teeth on the left side.

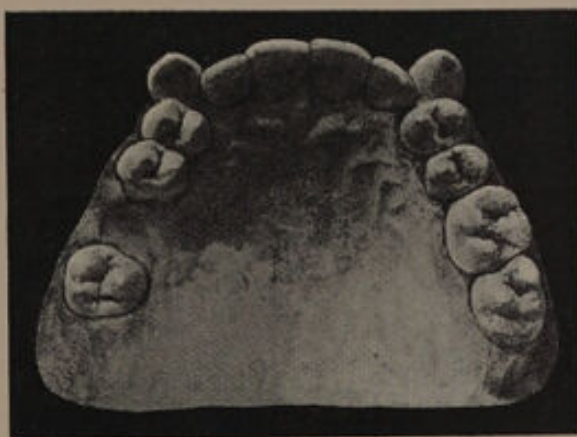

FIG. 130.—Showing palatal view of mouth.

Another case in which extraction of the canines was called for is shown in figs. 128 to 130. The patient was a female, aged 23. The upper and lower canines were both prominent on the left side, and the upper canine on the right side. The canines

caused the lips to project in an unsightly manner. The first premolars were quite close to the lateral incisors. The roots of both the upper canines sloped towards the mesial line. Extraction of the premolars and retraction of the canines would have necessitated a long attendance. The articulation of the teeth, which was good, would have been interfered with and possibly disarranged. The canines, owing to the slope, would never have assumed a good direction. Extraction of the

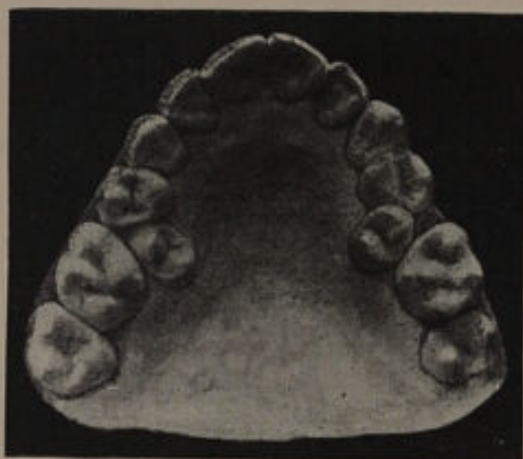

FIG. 131.

canines produced an excellent result, although a slight falling in of the alæ of the nose was produced.

Cases of crowding resulting in displacement of premolars.—Displacement of the second premolar internal to the bite frequently results from crowding. When this occurs the premolar has erupted subsequently to the canine. Fig. 131 is an excellent example of this type of irregularity. The treatment of such a case would be the removal of the abnor-

mally placed premolars. If, however, the molars are unsaveable, it would be necessary to remove them and bring the premolars into the line of the arch.

Another variety of irregularity of the premolar is shown in fig. 132. The crowding is caused by the first permanent molar moving forward. In

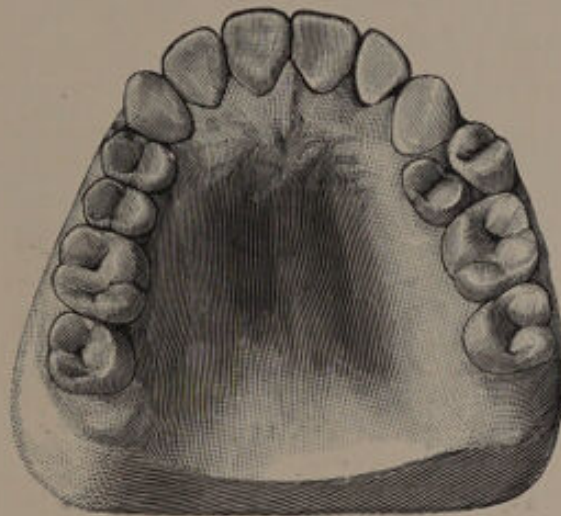


FIG. 132.

treating an irregularity of this nature one of the premolars should be extracted, and in selecting the one to be removed the choice should be determined by their relation to the lower teeth and to the amount of rotation.

Crowding resulting in the displacement of a lower incisor.—An irregular arrangement of the lower incisors caused by crowding is frequently met with, the lower canines being mainly responsible for this condition. The canines are normally developed external to the incisors, the crowns often slightly overlapping the labial surface of the laterals; in

¹ From "Diseases and Injuries of the Teeth."



instances where there is insufficient room for development, the canines encroach on the incisor region and so cause irregularity.

Crowding of the anterior lower teeth is not so important from an æsthetic point of view as crowding of the upper. The most effective method of treating these cases when the crowding is severe is to remove an incisor. In selecting between the

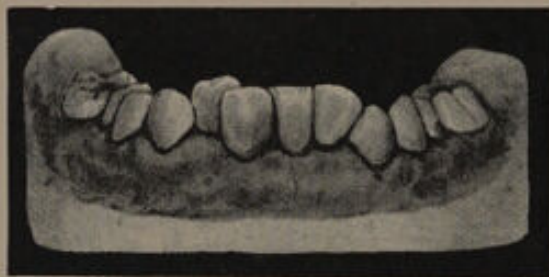

FIG. 133.

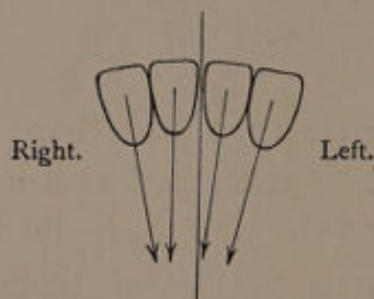


FIG. 134.—Diagram showing direction of the root of the incisors.

four incisors the following points may influence a decision.

(1) A central should, if possible, be extracted in preference to a lateral, for the reason that the symmetry of the mouth will be to a certain extent maintained, the laterals being adjacent to the canines with the single central between them. If a lateral incisor be removed the canine on one side

will be adjacent to a central, and on the other side to a lateral.

(2) An outstanding tooth should be removed in preference to one instanding, as the latter will be

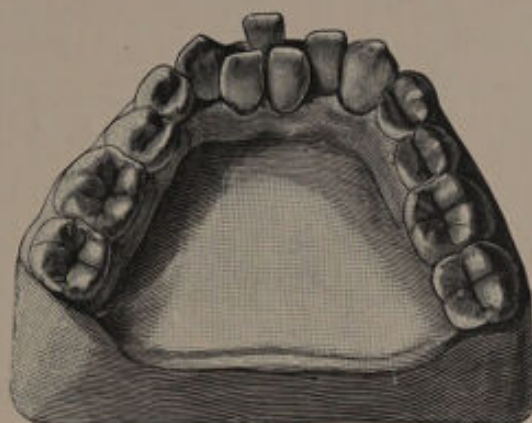


FIG. 135.

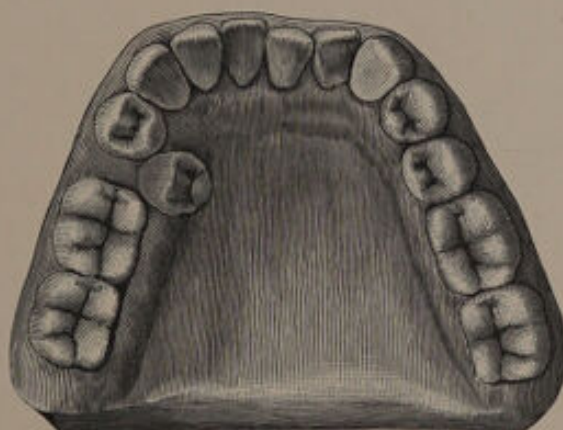


FIG. 136.

more easily brought into correct line, the pressure of the tongue being more powerful than that of the lower lip.

(3) The direction of the roots of the different teeth must be considered. The tooth selected should permit the remaining incisors to assume a

vertical direction. For instance, in the case shown in figs. 133 and 134, removal of the right central incisor would permit the remaining teeth to assume vertical directions, but removal of the left central incisor would result in the right central incisor assuming a distinct slope.

In the case shown in fig. 135 the outstanding central incisor must be removed, and although this in all probability will not provide quite enough room, it will nevertheless permit the remaining teeth to come into a fairly good arch.

Lower premolars placed external or internal to the arch, as shown in fig. 136, require removal.

CHAPTER VIII.

Cases of Crowding Involving the Malposition of Several Teeth—General Crowding.

THE following cases will serve to illustrate some of the methods of treatment which may be adopted when the crowding of the teeth is general.

(a) Cases calling for the Removal of the first Permanent Molars.

Opinions differ as to the correct time to remove the first permanent molars in order to obtain the best results. An examination of mouths in which this operation has been performed would appear to show that the best results are obtained when these teeth are removed prior to the eruption of the second permanent molars, and subsequent to the eruption of the premolars. Under such conditions good spacing between the anterior teeth is obtained, and there is far less tilting of the second lower molars. A strong objection to removing the first permanent molars at this period in crowded mouths is that the second permanent molars (especially the upper) move forward and encroach on the space required for the backward movement of the anterior teeth. In

crowded mouths removal of the teeth should not be carried out until the appearance of the second permanent molars. Many practitioners hold that the operation should be delayed until the latter teeth are fully erupted and in good occlusion, on the ground that a great amount of the tilting of the second lower molars is avoided. A disadvantage of waiting until this period is that the irregularity of the anterior teeth becomes more pronounced and the teeth more firmly implanted, so that the crowding is less easily remedied. It therefore seems advisable to remove the first permanent molars directly the second molars are sufficiently through to allow of their being held back by mechanical means. In this way the crowding can be overcome at an earlier period, and the tilting of the second molars to a great extent prevented.

The following cases illustrate some results obtained from removal of the first permanent molars.

CASE I.—The model shown in fig. 137 illustrates a slight but general crowding of the teeth. The central incisors were carious on their mesial surfaces, and there were signs of incipient caries between the laterals and centrals. The first permanent molars were unsalvageable. The second permanent molars had not erupted. Figs. 138 and 139 show that the occlusion was indifferent, the right second upper premolar falling within the outer cusp of the first lower molar. The condition after the eruption of the second permanent molars is shown in figs. 140 to 142. The crowding of the teeth has been overcome; the occlusion has been slightly im-

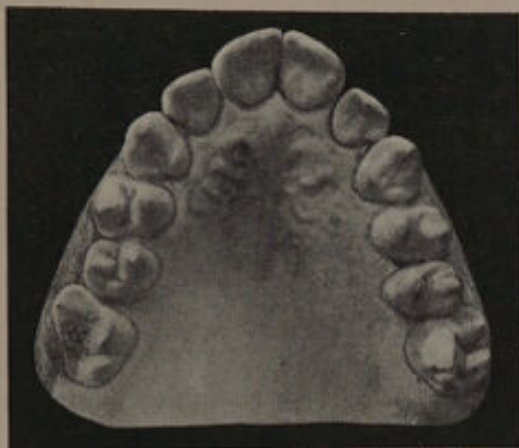

FIG. 137—Before treatment.

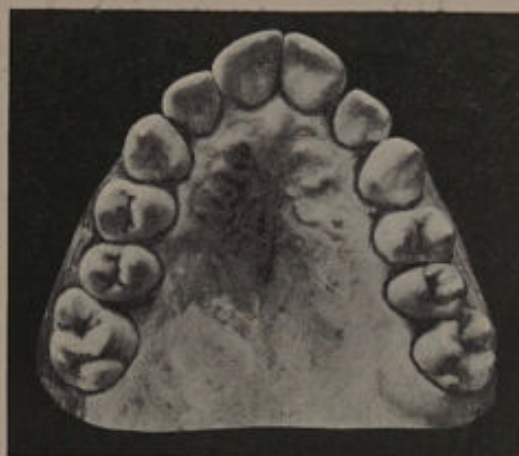

FIG. 140—After treatment.

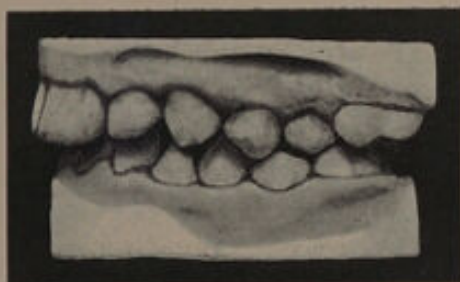

FIG. 138—Before treatment.

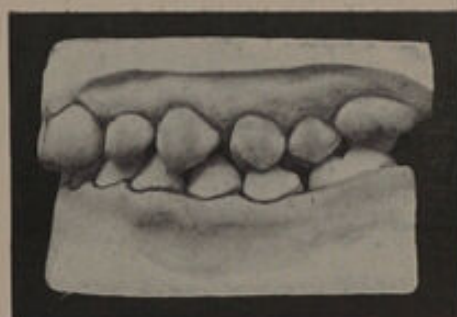


FIG. 141—After treatment.

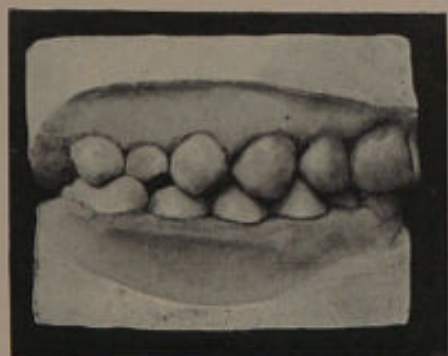


FIG. 139—Before treatment.

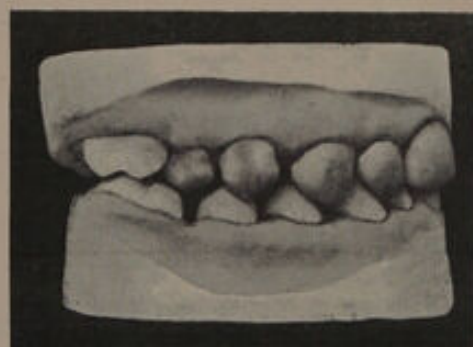


FIG. 142—After treatment.



proved; and what is also important, but little fresh caries has appeared on the approximal surfaces of the incisors. It will be noticed that the second lower molars have tilted slightly. This case shows an average result following the removal of the first permanent molars.

CASE II.—The models shown in figs. 143 and 144 are from a patient under the care of Mr. Clayton Woodhouse, and show a good result obtained by removal of the first permanent molars after the second were well erupted. The crowding is limited mainly to the canines, which are erupting slightly external to the arch. After removal of the teeth a plate was inserted to prevent the second upper molars moving forward and so encroaching upon the space required for the premolars and canines. The result is shown in figs. 145 and 146. The crowding has been overcome, and the occlusion of the premolars and molars is good. No mechanical appliance was used in the lower to prevent the second molars moving forward. There is practically no tilting of these teeth, although it is possible the eruption of the third molars will produce a slight amount. This case illustrates the value of the splint-plate for retaining the second molars in position, and also shows how much can be accomplished by extraction alone.¹

CASE III.—The models shown in figs. 147 and 148 illustrate the unfortunate results which may arise from removing the first permanent molars before the second molars are through sufficiently to be held back. The mouth was left alone after the removal of the teeth, with the result that the second molars moved rapidly forward and the crowding of the canines was not overcome.

¹ The figures 143 to 146 are from the *Transactions of the Odontological Society*.

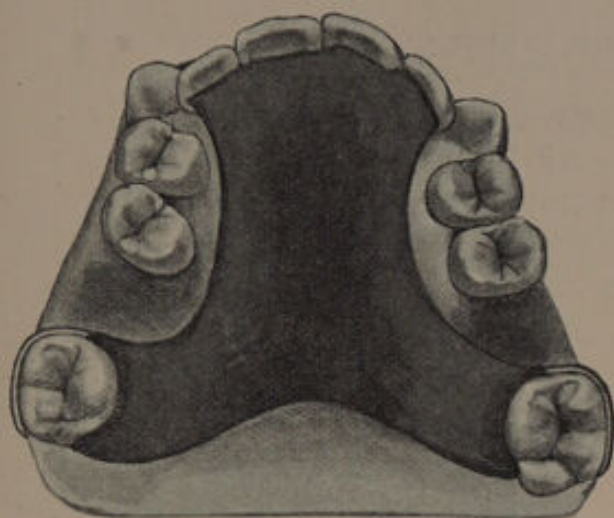


FIG. 143 -- Before treatment.

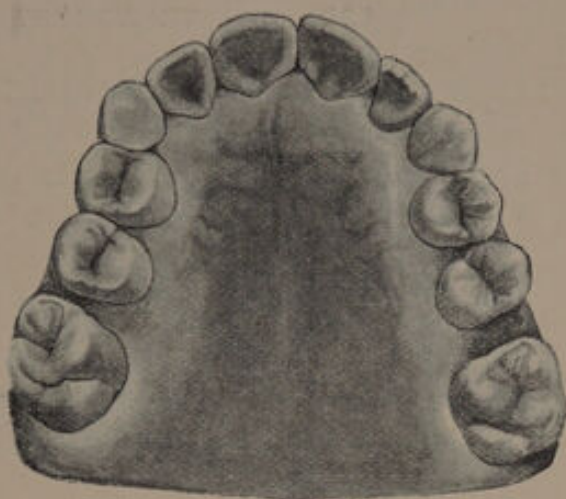


FIG. 145. -- After treatment.

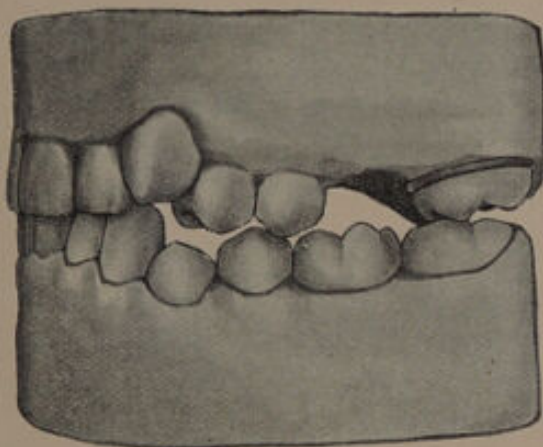


FIG. 144 -- Before treatment.

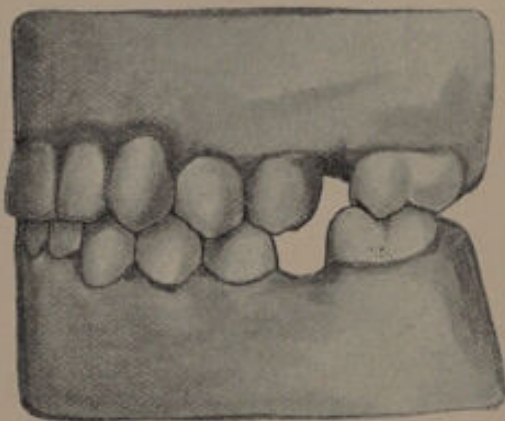


FIG. 146 -- After treatment.

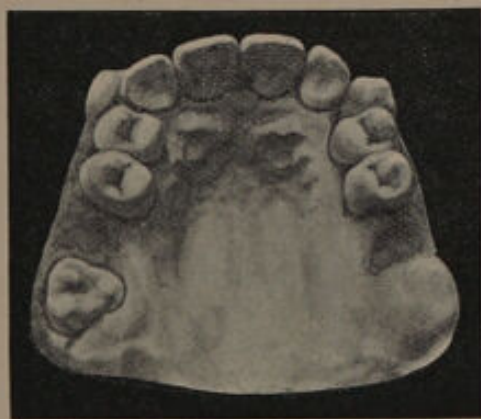

FIG. 147 -- Before treatment.

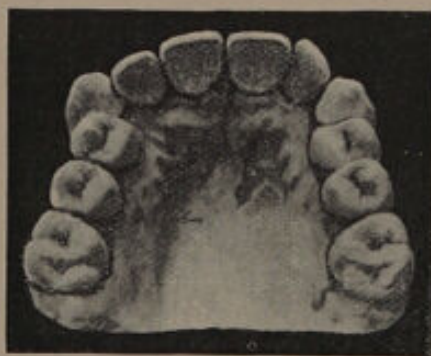

FIG. 148 -- After treatment.

CASE IV.—This case is given to illustrate the excellent results which may be obtained by removing the first permanent molars prior to the eruption of the second molars. The crowding of the anterior teeth was but slight, and the first permanent molars were removed on account of caries. Good isolation of the teeth has been obtained. The lower second molars have tilted but very slightly, and articulate well with the upper teeth. (See figs. 149-153).

**(β) Cases coming under Treatment after the Removal
of one or both of the lower First Molars.**

A certain number of cases come under treatment in which the lower first molars have already been removed and no attention has been directed to the upper teeth. The two following cases are examples.

CASE V.—Owing to the removal of the lower first molars a year previously the second permanent molars have travelled forward and partly articulate with the first upper molars; and the upper left second premolar is displaced inwards, but otherwise there is practically no crowding (see figs. 155 to 157). Some of the upper incisors have been attacked by caries on the approximal surfaces. The left upper first molar has a cavity on the masticating surface, while in the right upper first molar a cavity has been successfully treated on the anterior surface.

The occlusion of the teeth on the right and left sides is diagrammatically shown in figs. 158 and 159.

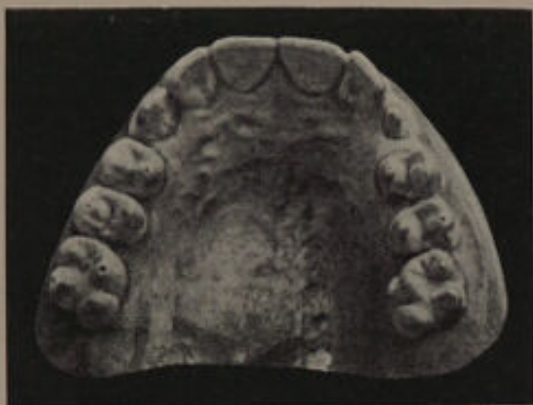

FIG. 149.—Before treatment

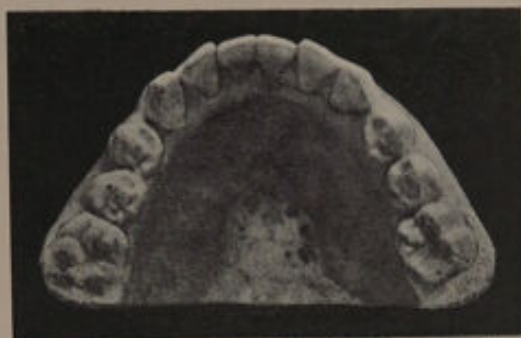

FIG. 150.—Before treatment.

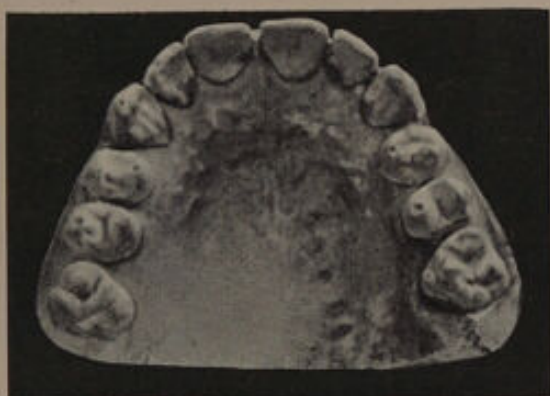

FIG. 151.—After treatment

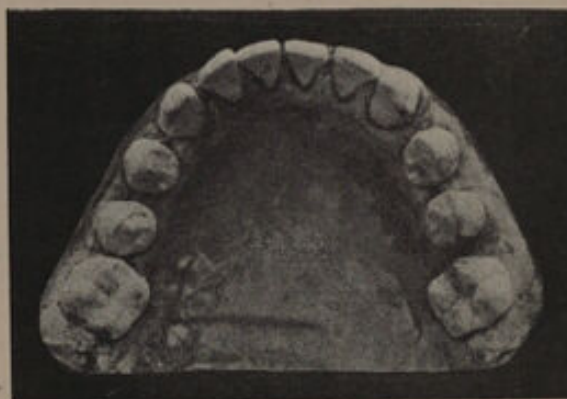

FIG. 152.—After treatment

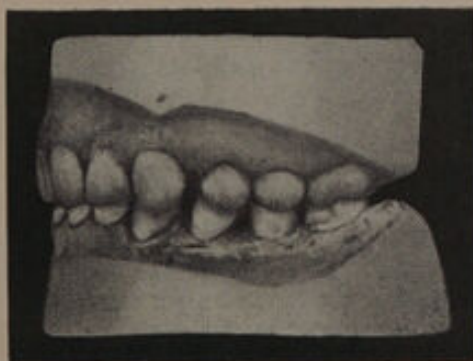


FIG. 153.—Showing occlusion of teeth on left side.
A similar condition existed on the right side.



On the left side it will be noticed that the second upper premolar is internal to the arch. The articulation between the first upper premolar and the lower premolars is indifferent. The upper first molar is prevented from moving forward by the second premolar and is only half opposed, while its posterior cusps prevent the second lower molar from moving forward. The second upper molar is erupting, hence a posterior force is present. Extraction of the second upper premolar will allow the first upper molar and the second lower molar to move forward, and so lead to an improvement in the articulating surface. On the right side it will be seen that the anterior plane of the first upper premolar only partially articulates with the posterior plane of the corresponding lower tooth, and not at all with the anterior plane of the second lower premolar as it should do. Only half the anterior plane of the second upper premolar is used. The first upper molar is only partially in occlusion with the second lower molar and this prevents the latter moving forward. The upper second molar is erupting. Extraction of the second upper premolar would permit the first upper premolar to move backwards and articulate correctly with the lower premolars. The first upper molar and second lower molar would move forward and the articulation would be improved. The upper second premolars were removed, and the result is seen in figs. 160 and 161.

CASE VI.—Another case illustrating a condition necessitating the removal of the first lower molars and the first upper premolars is shown in figs. 162-168. The upper arch is regular, but the laterals are in close contact with the first premolars. The canines are erupting high up and external to the arch. The right lower first molar has been removed at an early date, and the second permanent molar has erupted more forward than is normal, and is tilted. The right second lower premolar is erupting. The left lower first molar is

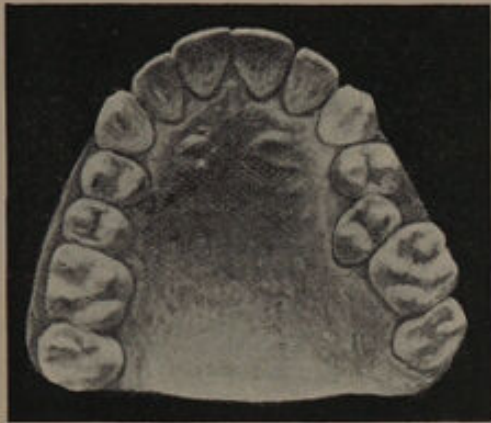


FIG. 155.




FIG. 158-- Right side.

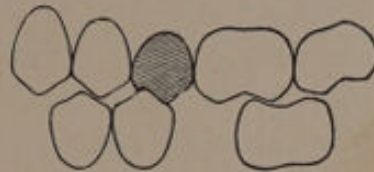


FIG. 159--Left side.

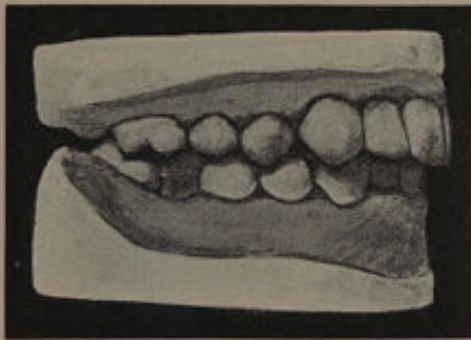

FIG. 156--Before treatment. Right side

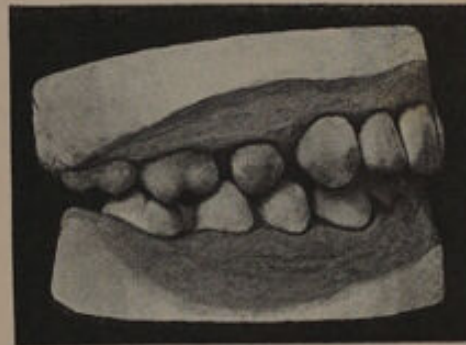

FIG. 160--After treatment. Right side.

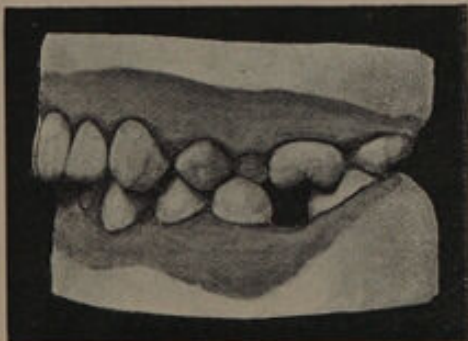

FIG. 157--Before treatment. Left side.

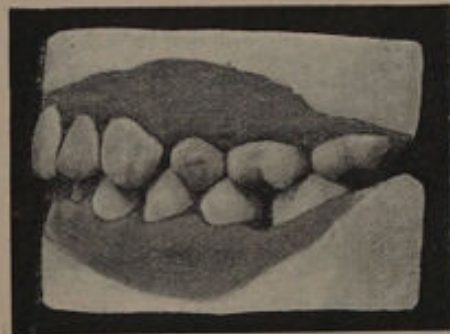


FIG. 161--After treatment. Left side.

unsavable. The articulation of the teeth on the left side (fig. 163) is indifferent. The second lower premolar is erupting and is crowded, while the second lower molar has not yet appeared. Only a portion of the anterior plane of the lower first premolar is in contact with the upper tooth (fig. 164). Removal of the first lower permanent molar will allow the second lower premolar to erupt well back and articulate with the first upper molar, while the first lower premolar will also travel back and articulate with the whole of the anterior plane of the second upper premolar. The lower second molar will move forward so that the anterior portion will articulate with the first upper molar, and the remaining posterior portion will occlude with the second upper molar when erupted. On the right side (fig. 165) the second lower premolar will erupt and occlude with the first upper molar and so form a sufficient masticating area. In considering the treatment of the case it must be remembered that the removal of the left lower first molar is unavoidable. Extraction of the corresponding upper tooth would release the bite, and allow the premolars to move back, but this treatment could not be carried out until the second upper molar had erupted, which would probably mean a year's delay, and by that time the canine, which already shows signs of erupting, would have assumed a position external to the arch. Moreover, considering the space required, it is purely problematical that the premolars could be retracted sufficiently to permit the canine falling into place without exerting some pressure on the incisors. Removal of the right upper first molar would unlock the bite and permit the premolars to move back, but at the same time the second lower molar would move still more forward. This would considerably limit the backward movement of the premolars and prevent sufficient room being made for the upper canine. Still further, removal of the first upper molar would render the anterior portion of the second lower molar useless for masticating purposes. Removal of the first permanent molars would therefore mean prolonged mechanical treatment with perhaps an unsatisfactory result. Removal of the first premolars will result in a good arch

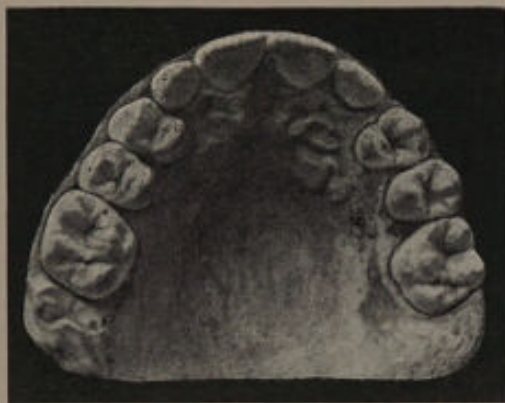

FIG. 162—Before treatment.

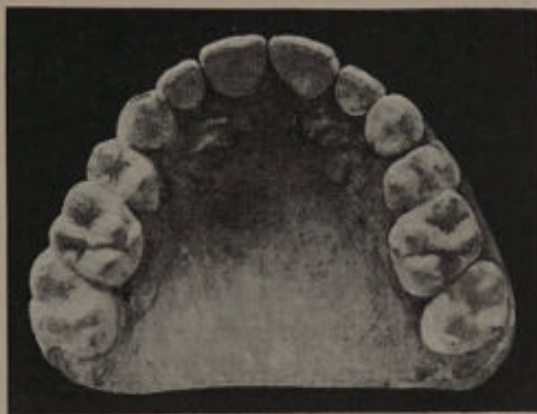

FIG. 166—After treatment.

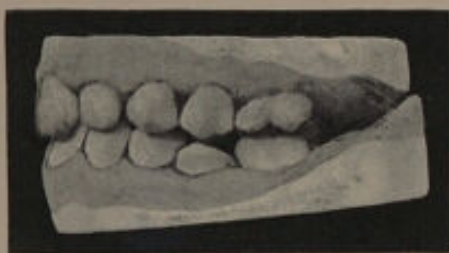

FIG. 163—Left side. Before treatment.

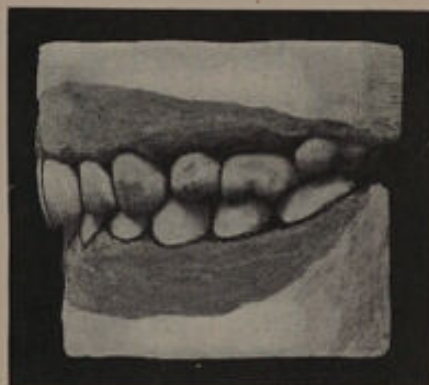

FIG. 167—Left side. After treatment.



FIG. 164.

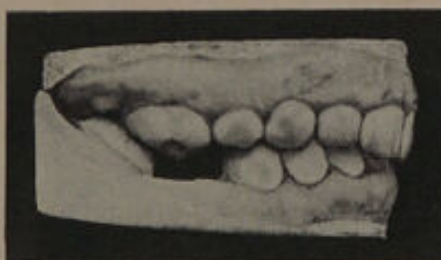

FIG. 165—Right side. Before treatment.

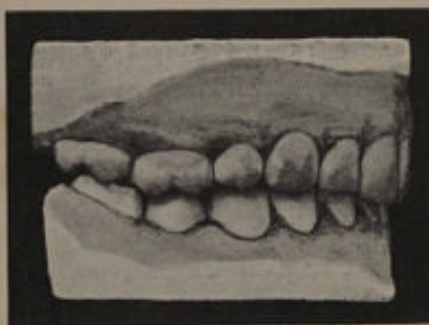

FIG. 168—Right side. After treatment.

without mechanical interference, and less loss and disorganisation of the masticating area.

The treatment consisted in removal of the upper first premolars and left lower first molar. The result is shown in figs. 166 to 168.

(γ) **Cases calling for the Removal of the lower First Permanent Molars and the First Upper Premolars.**

CASE VII.—A somewhat typical example of crowding of the upper and lower incisor teeth is illustrated in figs. 169 and 170. The patient was a girl.

An examination of the upper teeth showed that the roots of the canines were directed backwards. The premolars were free from caries. The first molars were carious, but had been filled for more than three years, and showed no signs of fresh mischief. A comparison of the upper model (fig. 172) with one taken eighteen months previously (fig. 171), shows that the irregularity of the incisors had increased considerably. In the lower the premolars were free from caries, but the first permanent molars were unsalvageable. The crowding of the canines and incisors was marked, the direction of the roots of the latter teeth being shown in figs. 173 and 174. The canines also had their roots directed towards the median line.

In the treatment of this case the following points had to be considered. The longer treatment was deferred in the upper, the more fixed the positions of the irregular teeth were likely to become. If the first premolars could be extracted, the crowding would be more easily remedied, and mechanical treatment could be undertaken immediately.

If the first molars were removed, it would probably be necessary to wait eighteen months or two years, and the treatment would involve the moving of ten instead of six teeth. In the lower the extraction of teeth posterior to the canines would not relieve the crowding of the incisors to any material extent, owing to the direction of the roots of the canines. The first molars, if extracted, would soon allow the second molars to come well forward.

The treatment adopted was extraction of the right central and the first molars in the lower. In the upper the first premolars were extracted, the canines retracted, and the incisors finally brought into line by a plate similar to that shown in

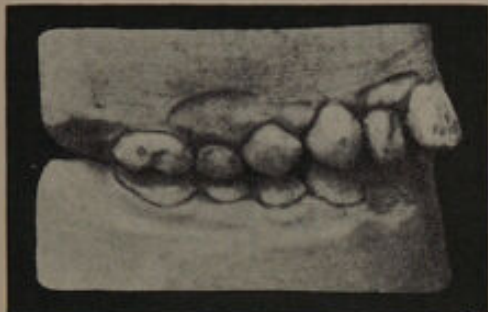

FIG. 169.—Before treatment. Right side.

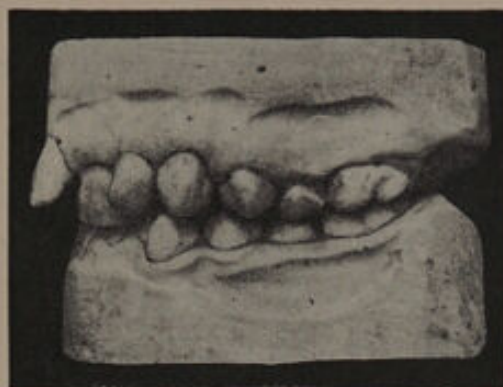

FIG. 170.—Before treatment. Left side.

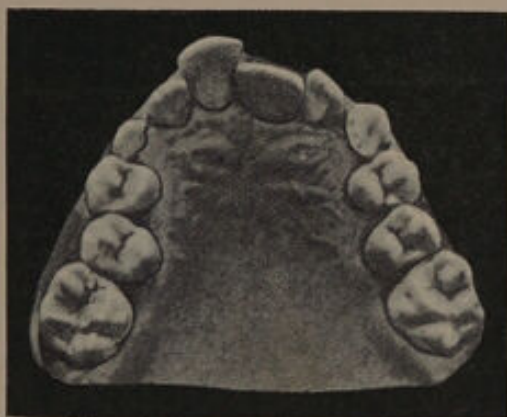

FIG. 171.

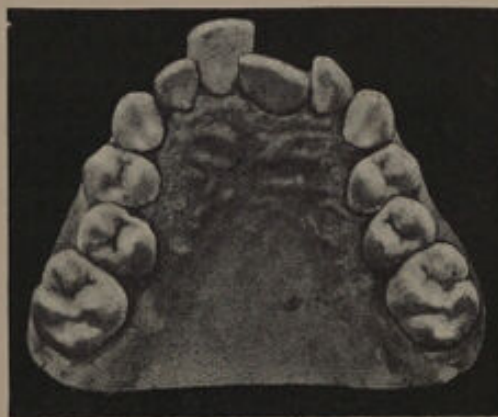

FIG. 172.

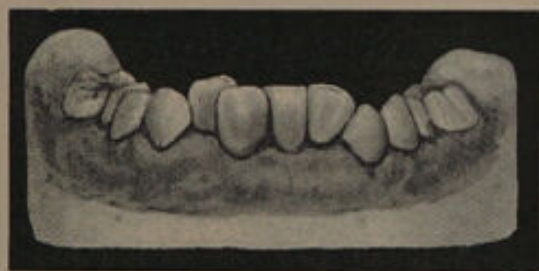

FIG. 173.—View of anterior lower teeth before treatment.

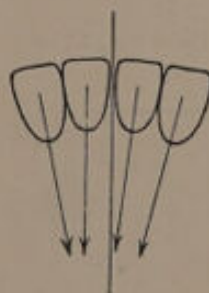

FIG. 174.—Diagram showing the direction of the roots of the lower incisors.

fig. 234. A retention plate was worn for twelve months. The result is seen in figs. 177 to 180.

The model, fig. 176, shows the condition of the teeth after the retraction of the canines, and demonstrates that as soon as the pressure is relieved, the teeth tend to assume normal positions.

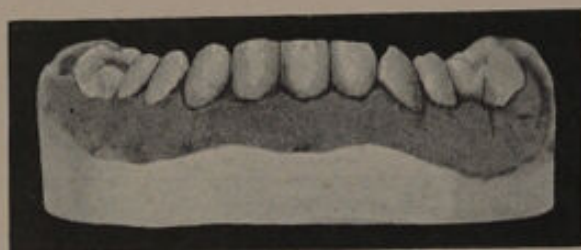


FIG. 175—View of anterior lower teeth after treatment.



FIG. 176.

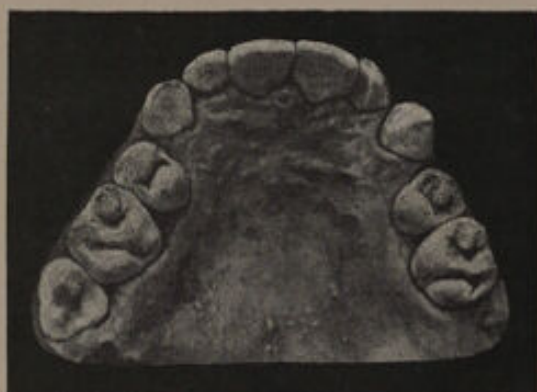

FIG. 177—Palatal aspect after treatment.

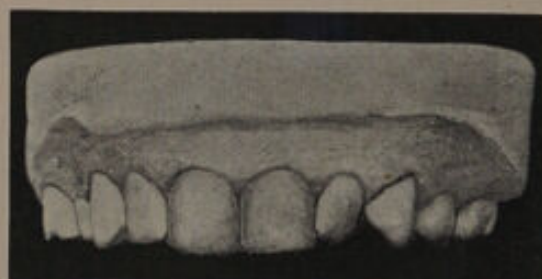

FIG. 178—View of anterior upper teeth after treatment.

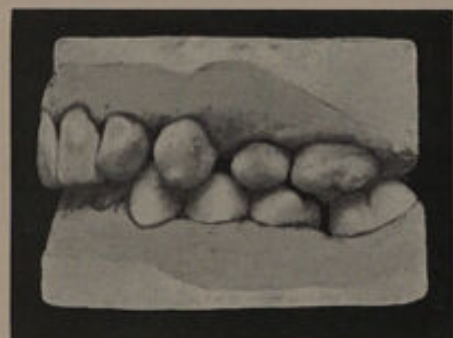

FIG. 179—After treatment. Left side

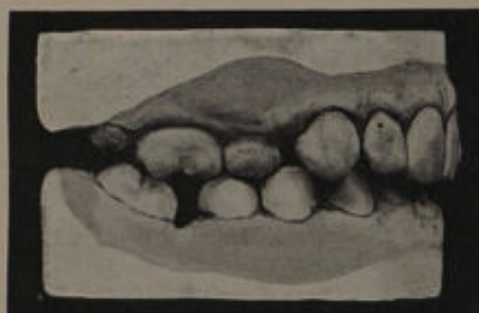

FIG. 180—After treatment. Right side.

(δ) Cases requiring the Removal of the Second Premolars.

CASE VIII.—The patient was a girl, whose anterior upper teeth were crowded, and showed signs of caries on their approximal surfaces (fig. 181). The first molars in the upper were also slightly carious on the anterior as well as the occluding surfaces. Both second upper premolars showed signs of caries on the posterior surfaces. The articulation of the premolars and molars on both sides was good.

In deciding upon a line of treatment, the following points had to be considered. Mechanical treatment was contra-indicated owing to the condition of the teeth. The amount of room required to relieve the crowding was about half the width of a premolar. This could have been obtained by the removal of the first upper and lower premolars. The anterior teeth would then have moved back and the posterior teeth forward; in this way the crowding would have been overcome and a gap prevented. On the other hand, the second premolars showed signs of caries, and their removal would allow the crowding of the anterior teeth to be overcome. The second premolars were extracted, and the result of treatment is shown in fig. 183. No plates were used. The crowding of the anterior upper teeth has been reduced, with the exception of the right lateral incisor. The occlusion of the premolars and molars on the left side before and after treatment are shown in figs. 182 and 184. On the right side a similar condition existed.

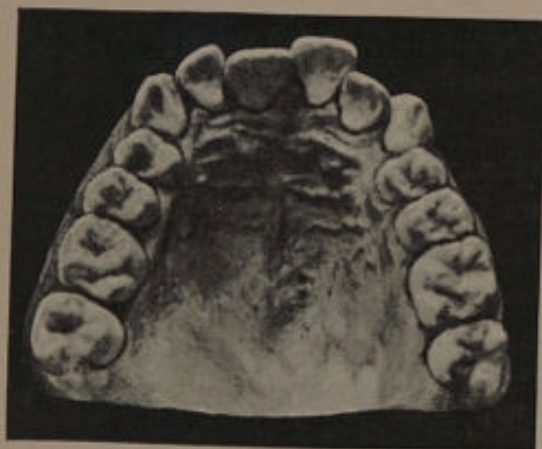

FIG. 181—Before treatment.

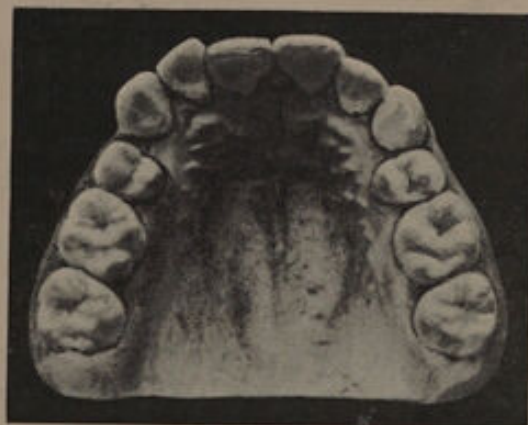

FIG. 183—After treatment.

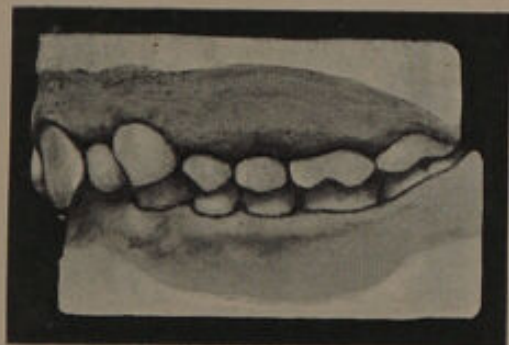

FIG. 182—Before treatment.

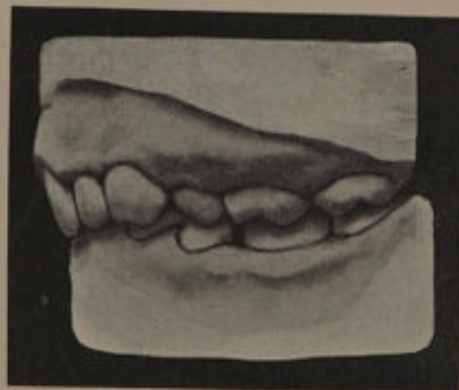

FIG. 184—After treatment.

CASE IX.—In this patient there was a slight general crowding of the upper and lower anterior teeth (figs. 185, 186). The incisors showed a tendency to caries, while the second upper premolars and first molars were carious on their approximal surfaces. The first premolars were free from caries. The first molars were saveable. The second premolars were removed and the result shown in figs. 187 to 190 obtained. The upper anterior teeth have slightly spaced. The crowding of the lower incisors has not been quite overcome, but this is not important. The occlusion of the molars and premolars is good. When last seen, six years subsequent to the operation, the upper anterior teeth were free from caries. This case illustrates the value of the removal of the second premolars when there is slight crowding, and shows clearly that far less disarrangement of the bite occurs than when the first permanent molars are removed.

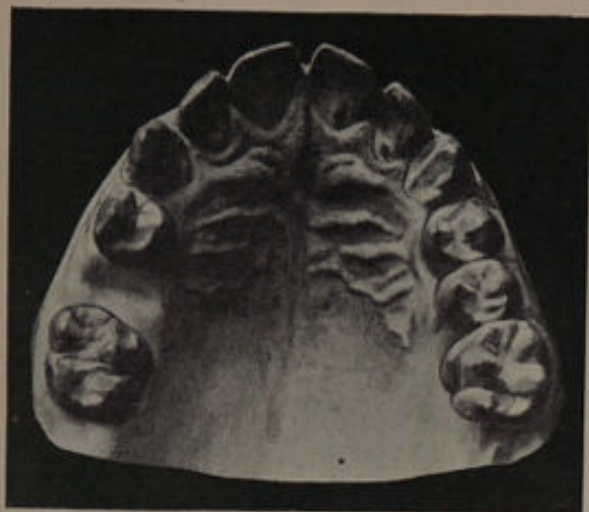

FIG. 185—Before treatment.

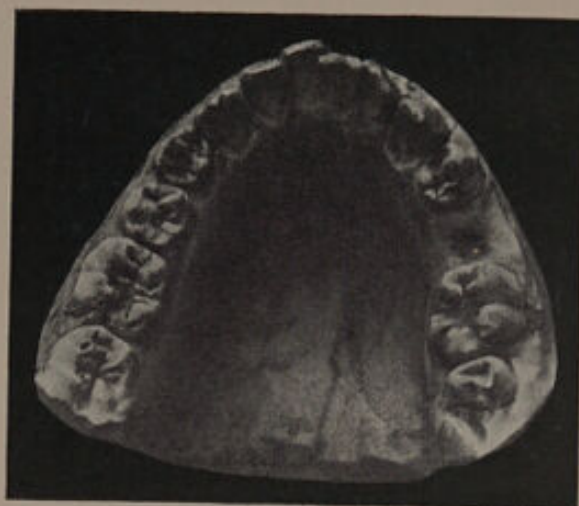

FIG. 186—Before treatment.

These models were taken one month after the removal of the second premolar.

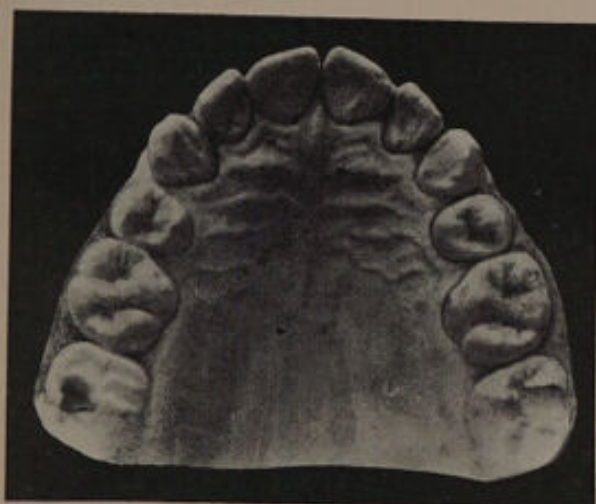

FIG. 187—After treatment.

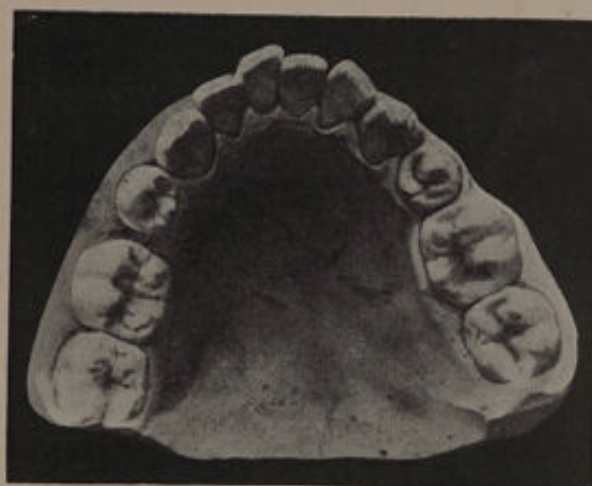

FIG. 188—After treatment.

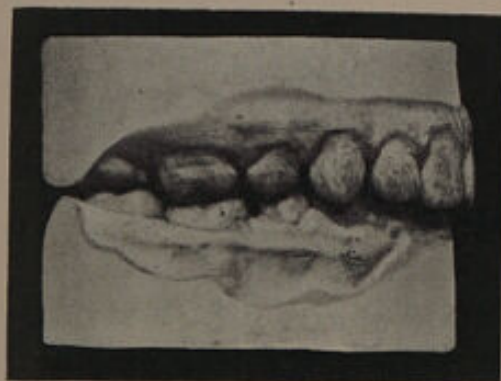

FIG. 189—Showing occlusion of molars and premolars on the right side.

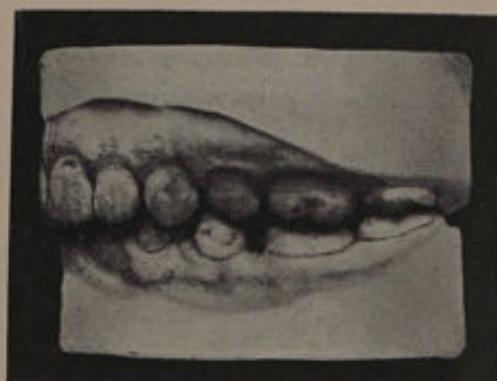

FIG. 190—Showing occlusion of molars and premolars on the left side.

CASE X.—The patient was a girl aged 15 years. The upper front teeth were crowded and irregular (fig. 191). The lower teeth presented a good arch.¹ An examination of the premolar and molar occlusion on the right side showed that only portions of the posterior planes of the first and second premolars were in contact with the lower teeth (fig. 192). This is diagrammatically shown in fig. 194. Removal of the first upper premolar would allow the second premolar to come forward and occlude with both lower premolars, and at the same time allow room for the canine to move backwards, but the second premolar on this side was carious. With removal of the second premolar the first premolar could be brought back and made to articulate satisfactorily with the lower premolars, and the crowding of the front teeth would be overcome. On the left side (fig. 193) the second lower premolar has not erupted, and there are no signs of its presence. The second upper premolar therefore forms but a small portion of the masticating area, and is consequently the tooth to remove.

The treatment consisted in the removal of the second upper premolars. The first premolars were then brought back by mechanical means. A vulcanite plate capping the molars and premolars was then made, half round gold wires being attached to the sides and arranged so as to bring pressure on the mesial angles of the right central and the left lateral. Opposite the palatal aspect of the left central a wedge of compressed wood was inserted and the tooth



FIG. 194.

brought forward. By a similar arrangement the distal angle of the right central was driven forward. A retention plate was used for twelve months. The result is seen in figs. 195-197. A regular arch has been obtained. The occlusion of the teeth on the right side has been improved. On the left side the occlusion has not been impaired, and will be improved when the molars move forward.

¹ This case was under the care of Mr. J. Ackery.

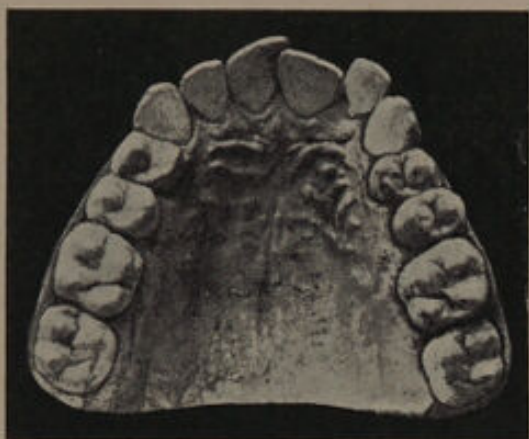

FIG. 191—Before treatment.

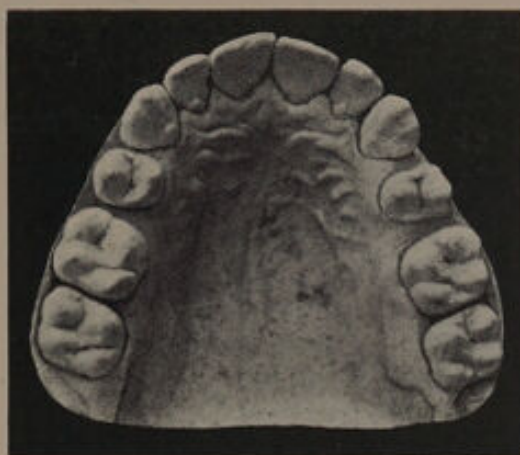

FIG. 195—After treatment.

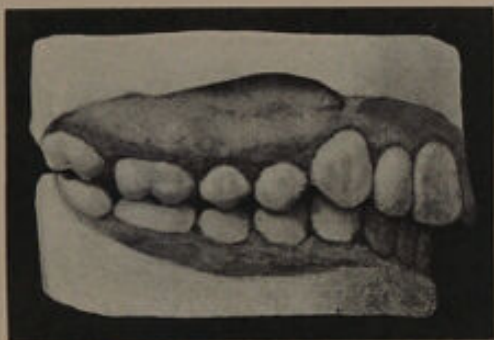


FIG. 192—Before treatment.

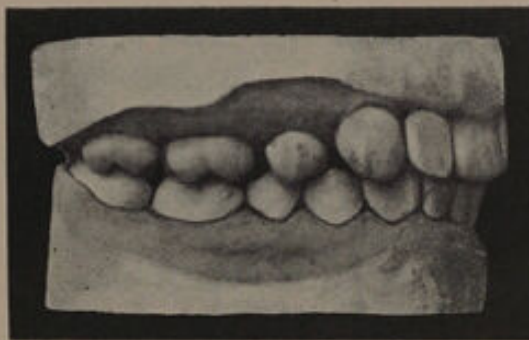


FIG. 196—After treatment.

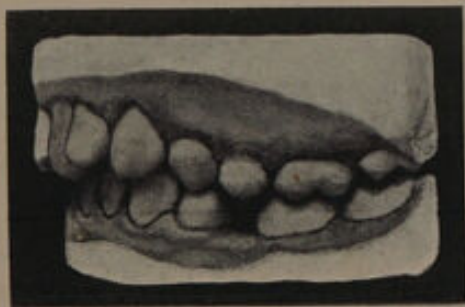

FIG. 193—Before treatment.

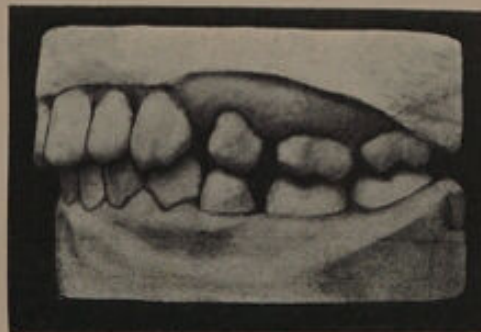

FIG. 197—After treatment.

CASE XI.—In this patient, the second upper premolars were misplaced and internal to the arch. The right upper canine was nearly erupted, but required space, while on the left side the canine was external to the arch, as shown in fig. 198. The teeth were free from caries with the exception of the occluding surfaces of the first permanent molars; the cusps of these latter teeth were imperfectly developed, and their surfaces presented that curious crenated appearance which is occasionally to be seen in cases where the development has been interfered with. The enamel was apparently of good quality, and the lower teeth were regular. An examination of the occlusion of the teeth on the left side (fig. 199) showed that only a portion of the anterior plane of the first upper premolar was in contact with the lower teeth. The articulation of the first molars was good. Removal of the second upper premolar would permit the first premolar to move back so as to articulate well with the lower premolars and leave sufficient room for the extruded canine. The second upper molar, which was erupting, would force the first molar forward, and so assist in closing the gap. The first molar would probably travel forward owing to the ill-developed cusps insufficiently interdigitating with those of the lower tooth. A similar condition was present on the right side. The second premolars were removed and the result obtained as shown in fig. 200.

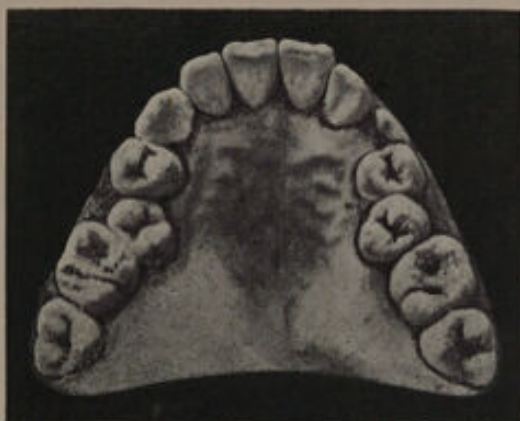

FIG. 198—Before treatment.

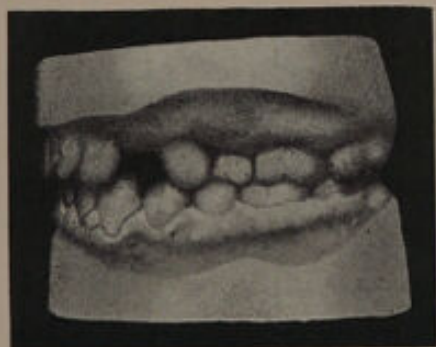

FIG. 199—Left side, before treatment. From models taken just previous to the eruption of the left upper canine.

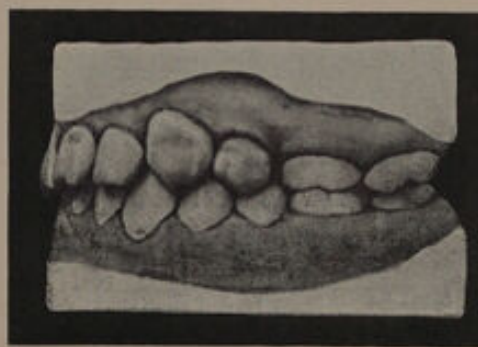


FIG. 200—Left side, after treatment.

(e) **Cases requiring Expansion of the Arch.**

CASE XII.—This patient was a girl. The upper anterior teeth, as shown in fig. 201, were crowded. The relation of the upper to the lower teeth is shown in fig. 202. It will be noticed that the upper central incisors project, and that the upper premolars and molars fall within the bite. The lower premolars and molars have their occluding surfaces directed more inwards than normal. An examination of the direction of the roots of the upper premolars and molars showed that on the right side the teeth were placed vertically, while on the left side they were sloping slightly outwards, a point not in favour of expansion. An examination of the models, however, seemed to show that the bite would be slightly improved by expansion owing to the direction of the lower teeth. The upper central incisors caused the upper lip to project, but towards the angles of the mouth there were slight depressions which indicated that expansion in the regions of the premolars and canines would be beneficial, and that the removal of premolars to correct the irregularity would result in an increase of the depressions. The arch was spread and the central incisors slightly retracted, with the result shown in fig. 203. An examination of the articulation on the left side shows that it has been improved. A similar condition resulted on the right side. A retention plate was worn for twelve months. The patient's appearance was considerably benefited by the operation. In this case there is no reason to suppose that the upper premolars and molars will return to their original positions, as they are naturally retained by the outer cusps of the lower teeth.

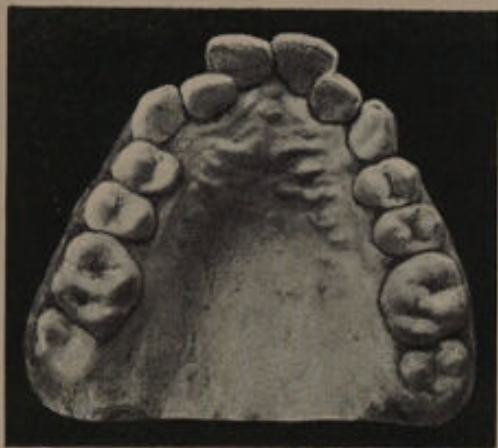

FIG. 201—Before treatment.

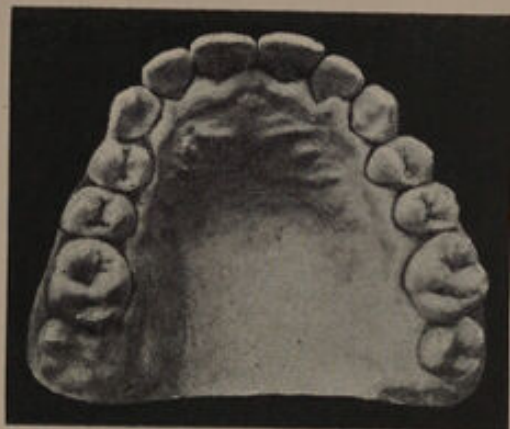

FIG. 203—After treatment.

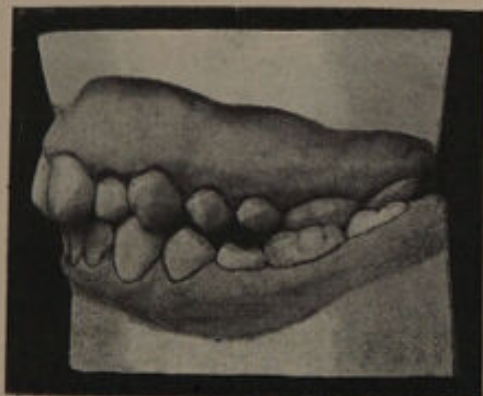

FIG. 202—Before treatment.

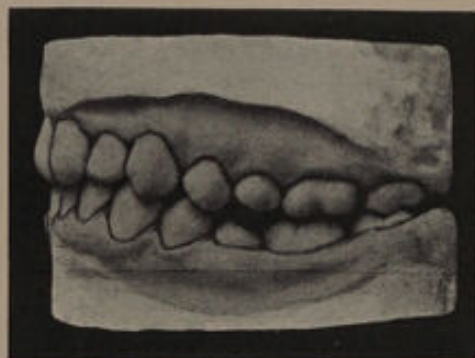


FIG. 204—After treatment.

CASE XIII.—In this patient, a girl, the anterior upper teeth were crowded, the right canine erupting external to the arch. The molars and premolars occluded abnormally with the lower teeth, as shown in figs. 206 and 207. The four first permanent molars were carious on the approximal and occluding surfaces, and were unsaveable. The crowding of the upper teeth was due to an insufficient development of the maxilla, causing those parts of the cheeks and lips which are supported by the upper alveolar process to fall inwards. An examination of the upper teeth shows that they are almost normal as regards their relation to the body of the bone, that is to say, their occluding surfaces are directed downwards and slightly outwards. This is a point against expansion of the arch.

If the first molars are removed the upper front teeth can be brought into a regular arch by retracting the premolars, bringing the canine into place, and pushing the laterals outwards. It is doubtful whether, on the right side, the retraction of the premolars and the pushing forward of the lateral would give sufficient room for the canine; still further, it would not bring the premolars outwards as is desirable from an æsthetic point of view. On the other hand if the first molars were removed and the arch spread, the teeth could be brought into good line, and at the same time the molars and premolars could be pushed outwards.

The first permanent molars were removed and an expansion plate inserted, with the result shown in fig. 208. A good arch was obtained and the appearance considerably benefited. The models shown in figs. 208 to 210 were taken immediately after the conclusion of treatment. The occlusion of the premolars is indifferent, but has since considerably improved. This case shows that with expansion a good arch can be obtained, but that the occlusion of the premolars and molars is likely to suffer by the operation.

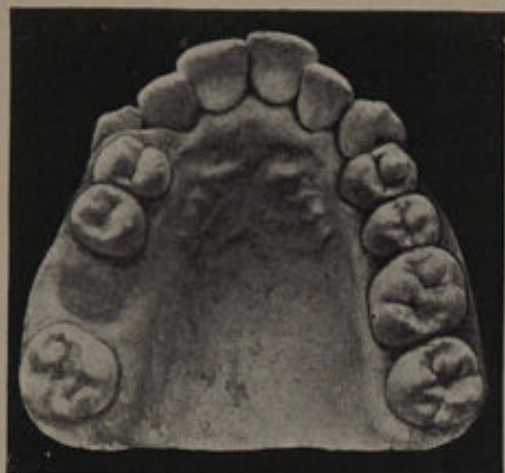

FIG. 205—Showing condition at commencement of treatment.

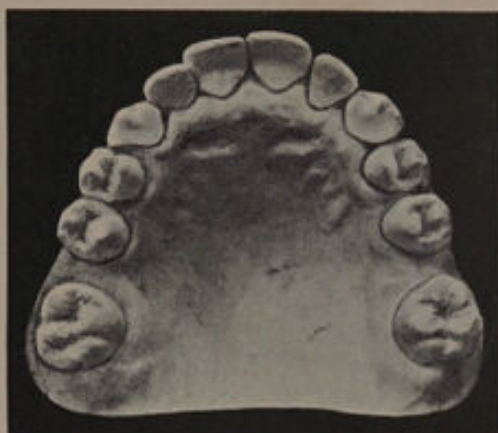

FIG. 208—After treatment.

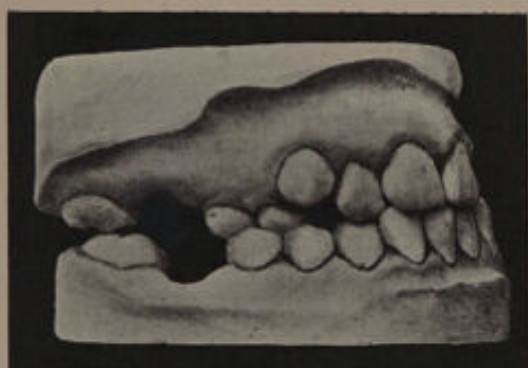

FIG. 206—Right side, at commencement of treatment.

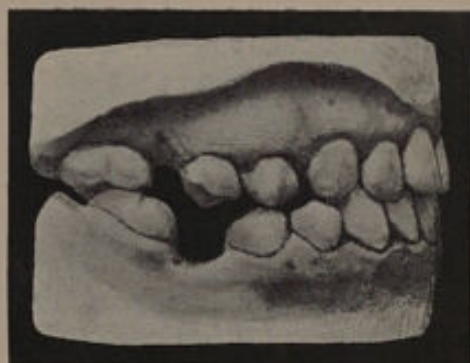

FIG. 209—Right side, after treatment.

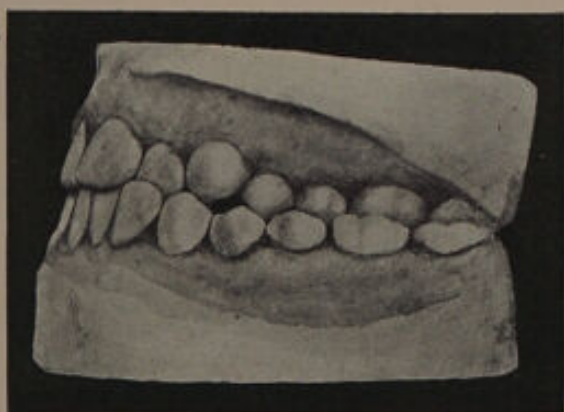

FIG. 207—Left side, at commencement of treatment.

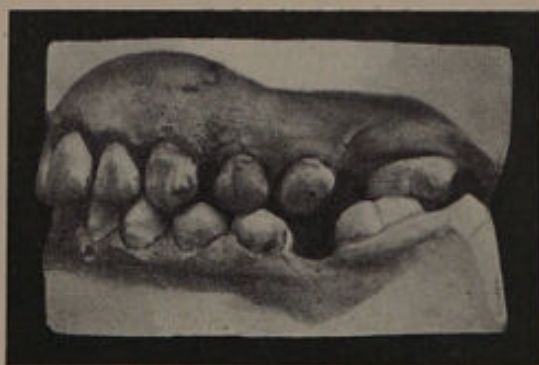

FIG. 210—Left side, after treatment.

(e) **Miscellaneous Cases.**

CASE XIV.—In the case illustrated by fig. 211 there is general crowding of the upper front teeth. In this case the left lower first molar had been removed at an early date on account of extensive caries. The lower second permanent molar has erupted well forward, and is in good contact with the posterior portion of the first upper molar (see fig. 212). It will be noticed that the posterior articulation of the premolars is indifferent, as shown in the diagram (fig. 213),



FIG. 213.

The posterior plane of the second upper premolar is only slightly in contact with the anterior plane of the lower second premolar. The anterior plane of the second upper premolar does not meet the posterior plane of the first lower premolar, and this latter tooth is only partially in contact with the upper premolar. Removal of the upper first premolar will allow the second upper premolar to move forward and articulate in a more satisfactory manner with the lower premolars, the upper first molar and the lower second premolar and second molar would move forward, and so close the gap existing between the lower premolars. The upper canine would move back and leave but a slight space between it and the second premolar.

On the right side the first upper molar is saveable, but the corresponding lower tooth is unsaveable. The second lower premolar is prevented from fully erupting owing to lack of space. The only portions of the upper and lower premolars in contact are a small section of the posterior plane of the first lower premolar with the anterior plane of the first upper premolar. The second lower and upper molars are in place.

Extraction of the upper and lower first molars will remove the posterior resistance to the premolars, and the upper canine, in working its way into the arch, will tend to force the premolars in a backward direction. The second upper and lower molars will move forward and assist in closing the gap.

The treatment consisted in the removal of the first upper premolar on the left side, and the first upper and lower molars on the right side. The result is seen in figs. 215 to 217. The crowding of the anterior upper teeth has been overcome with the exception of the left lateral, which is still slightly overlapped by the central. The occlusion of the premolars and molars on both sides has been improved.

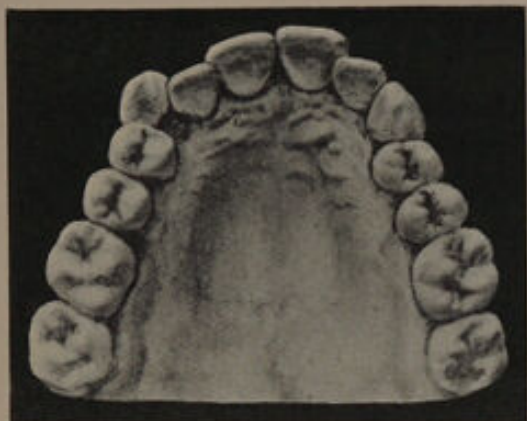

FIG. 211—Before treatment.

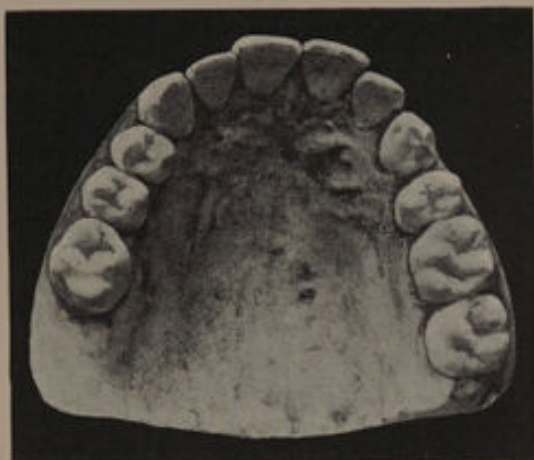

FIG. 215—After treatment.

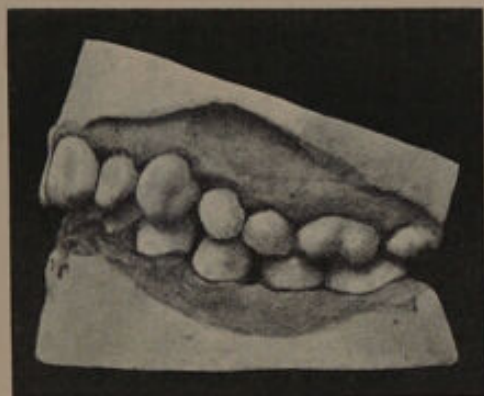


FIG. 212—Left side, before treatment.

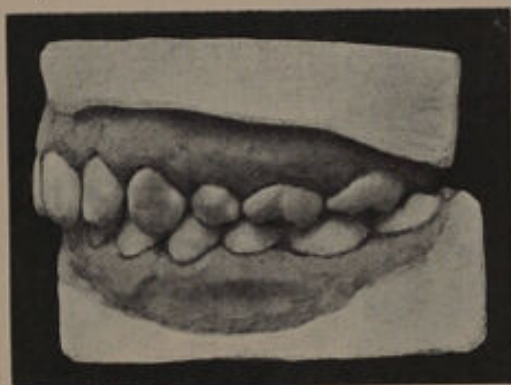

FIG. 216—Left side, after treatment.

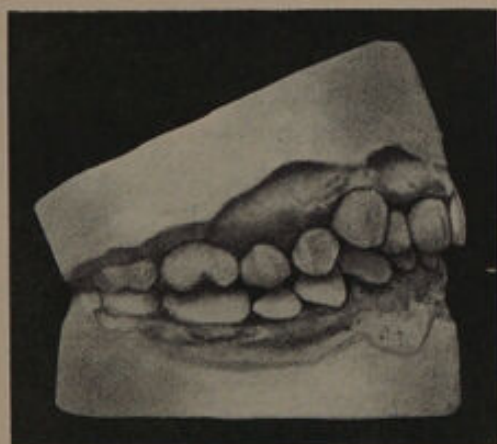

FIG. 214—Right side, before treatment.

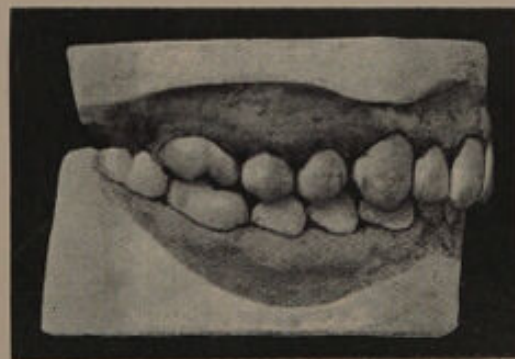


FIG. 217—Right side, after treatment.
The upper third molar has not yet erupted.

CASE XV.—In this patient, a girl, the anterior upper teeth were crowded, the lateral incisor on the left side being internal to the arch (fig. 218). In the lower the arch was regular, but the lower central incisors were absent. The teeth were free from caries. An examination of the roots of the left central and lateral incisors and canine showed that the root of the central sloped in a backward direction, and was placed in a plane anterior to the root of the lateral. The crown also overlapped that of the right central. The direction of the canine root was very slightly backward, and was also in a plane anterior to the lateral. The positions of the three teeth are shown in fig. 220. The occlusion of the premolars and molars was good (fig. 221). On the right side the root of the canine was directed backwards, and the crowding of the central and lateral incisors was slight. The relation of the upper to the lower premolars and molars is shown in fig. 223. In considering the treatment of this case one was met with the difficulty of marked crowding on one side and but slight crowding on the other. On the left side two courses were open: (*a*) the removal of the first premolar or a tooth posterior; (*b*) the removal of the lateral incisor. If removal of the first premolar were carried out the canine would need to be retracted and the lateral incisor pushed out. The result of this operation would probably result in the canine assuming a very sloping direction and being short, the lateral having its cutting edge tilted forward, while the central would be driven still more across the median line. In addition the treatment would require the prolonged use of a plate, and there would be a constant tendency to relapse. On the other hand, removal of the lateral incisor would permit the central to fall back and assume a more vertical direction, the canine would move forward and fill up the gap. There would be true relief of the crowding (both roots and crowns), and no tendency to relapse. On the right hand side but little room is required, and removal of the lateral to correspond with removal of the left lateral is out of the question. The treatment, therefore, resolves itself into the removal of a premolar or molar. The molar is free from caries, so that a

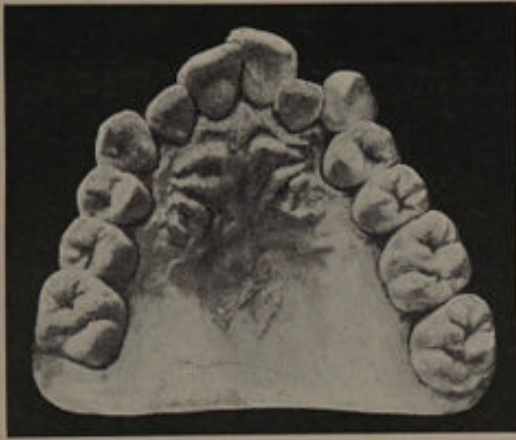

FIG. 218.—Before treatment.

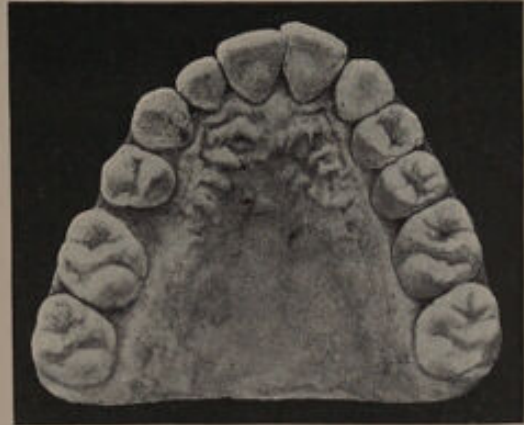

FIG. 219.—After treatment.

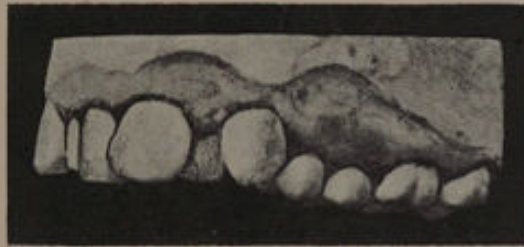

FIG. 220.

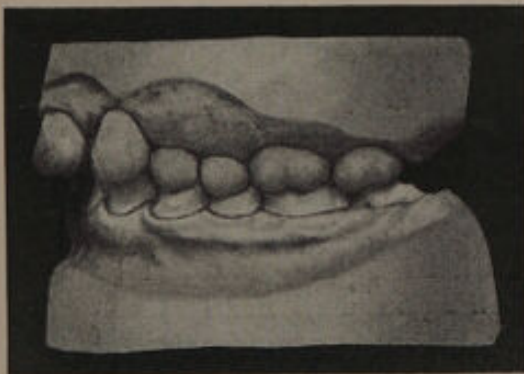


FIG. 221.—Left side, before treatment.

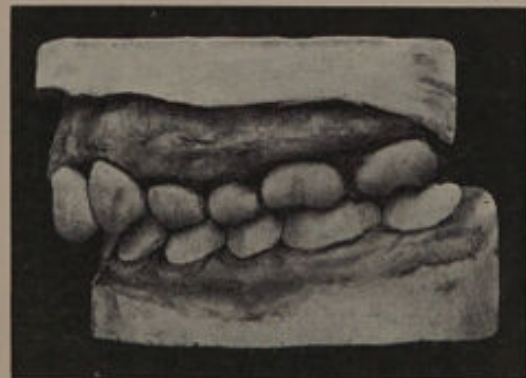

FIG. 222.—Left side, after treatment.

choice must be made between the first and second premolars. Removal of the first premolar would in all probability result in a gap between the canine and the second premolar. Removal of the second upper premolar alone, and retraction of the first premolar would also leave a gap, because the first premolar would eventually occupy the same position as the second premolar. Removal of the lower second premolar as well as the upper second premolar would allow the first premolars, upper and lower, to move back sufficiently to overcome the crowding of the incisors and canine, while the molars would move forward and assist in filling up the gap. In addition, mechanical methods would be avoided. Treatment consisted in the removal of the left upper lateral incisor and the right upper and lower second premolars. The result of treatment is seen in figs. 219, 222 and 224. On the right side a slight gap has resulted between the premolar and canine, but when last seen the molars had moved still more forward and had considerably improved the occlusion of the upper premolar with the lower premolar and first molar. With the advent of the third molars the space will, no doubt, be entirely closed.

CASE XVI.—In this patient there was crowding of the right central and lateral incisors and canine. An examination of the teeth shows that the canine had erupted external to the arch, but the root was directed well backwards. The deciduous canine was present. The central incisor was rotated so that the mesial angle faced forward, the distal angle being under cover of the right central incisor. The left lateral incisor was internal to the arch and slightly rotated, and the root was overlapped by that of the central incisor. It was not therefore possible to rotate the central and bring the lateral into correct alignment. The deciduous canine and left lateral incisor were removed. The canine was then retracted, and the central rotated without much difficulty. The mouth, immediately after the completion of this operation, is shown in fig. 226. A retention plate was made and the patient bidden to wear it for at least one year. She however did not present herself again until nearly six years after the completion of treatment, and the mouth was then in the condition seen in fig. 227. The retention plate had only been worn for four months. The case is instructive as showing the importance of retaining in their places for a considerable time, teeth which have been mechanically corrected.

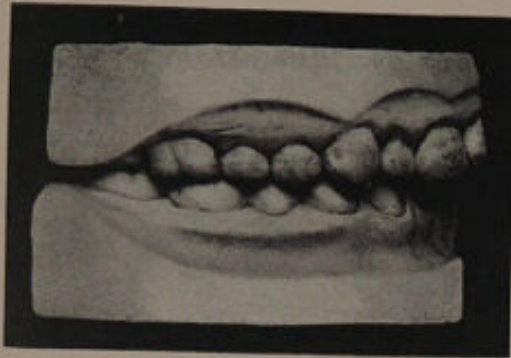

FIG. 223.—Right side, before treatment.

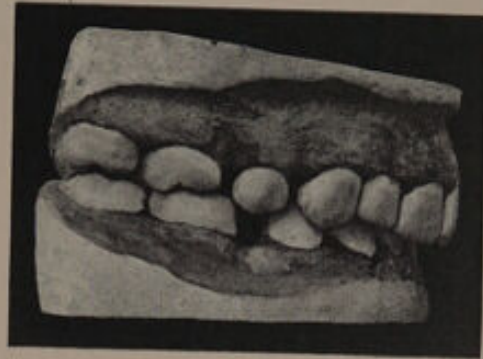

FIG. 224.—Right side, after treatment.

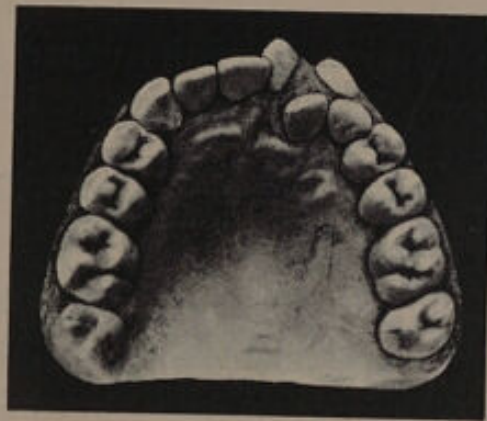

FIG. 225.—Before treatment.

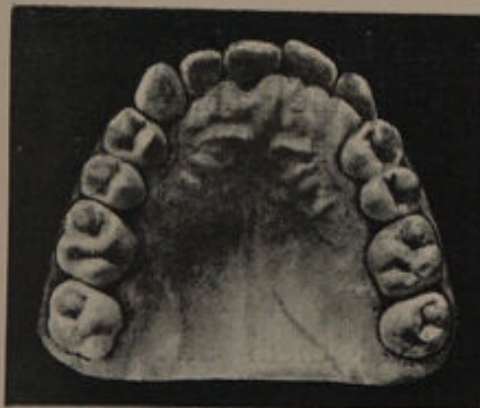

FIG. 226.—Immediately after treatment.

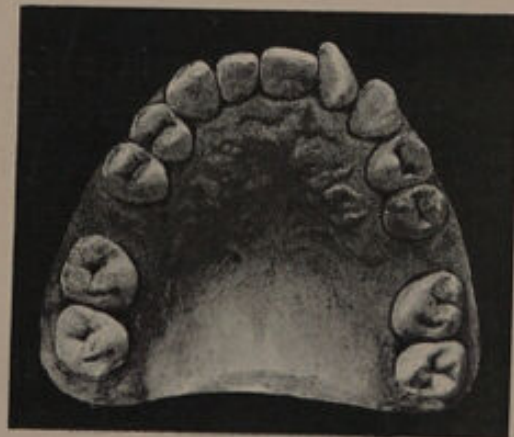


FIG. 227.—Six years after treatment.

CHAPTER IX.

Superior Protrusion—Undue Prominence of the Upper Front Teeth.

AN abnormal projection of the upper front teeth is usually known as superior protrusion. In the majority of cases the lower lip, when the mouth is in repose, passes behind the upper teeth and as the upper lip fails to completely cover them, they remain continually exposed producing what is often a most unsightly appearance. The prominence may be limited to the central incisors, but in the larger proportion of cases the lateral incisors and also the canines are involved.

ETIOLOGY.

The cause in a few instances can be traced to **thumb or finger sucking**. In this habit the palmar surface of the thumb is placed against the palatal surfaces of the central incisors, the lower teeth being closed on the dorsal aspect. The pressure exerted causes the upper central incisors to protrude so that the lower lip passes behind them and aggravates the protrusion when the mouth is at rest. In some cases the thumb or finger is inserted between the teeth so that the teeth impinge on the

lateral surfaces. Under such conditions the upper lateral incisors and also the canines are forced outwards and frequently upwards, producing a type of "open bite."¹ The habit of constantly **sucking the lower lip or tongue** may produce protrusion of the upper teeth, and in the case of a patient under the care of Mr. F. Ewbank the two central incisors had been protruded by the habit of "toe-sucking."

Supernumerary teeth may be cited as a cause of superior protrusion. The extra teeth may erupt posterior to the incisors and so force the latter forward, or the supernumeraries may wedge themselves between the incisors and canines.

The attachment of **the frænum** of the upper lip to the inner aspect of the alveolus has been alluded to on page 12, as a possible factor in starting the protrusion of one or both central incisors.

In some instances the superior protrusion can be directly traced to a **crowded condition of the teeth**, the canines during development and eruption forcing the incisors forward. In other words, the same forces which lead to and produce general crowding of the incisors and canines may under certain conditions cause superior protrusion, the form of irregularity which the crowding takes being undoubtedly largely influenced by the relative positions of the developing teeth in their alveoli.

In a few instances the deformity may be traced to an **excessive development of the anterior portion of the maxilla**, and may be confined to the alveolar

¹ See p. 217.

process, or may involve the whole body of the bone.

An arrest of the development of the mandible will also cause the upper front teeth to be unduly conspicuous, but such a condition can hardly be termed superior protrusion.

Certain abnormal conditions of the teeth and jaws are frequently found in conjunction with superior protrusion, but to what extent the deformity is dependent upon these abnormal conditions is yet to be ascertained.

If a series of models be examined, it will be found that the irregularity is **almost invariably accompanied by a narrowing of the arch.**

G. G. Champion¹ who first drew attention to this fact found that the average width of twelve normal arches was 46.9 mm. while in twenty-six cases of superior protrusion the average was only 41.3 mm. or a difference of 5.6 mm.²

The incisor teeth will also be found to assume a direction more sloping than the normal, the slope being more marked after the eruption of the permanent canines.

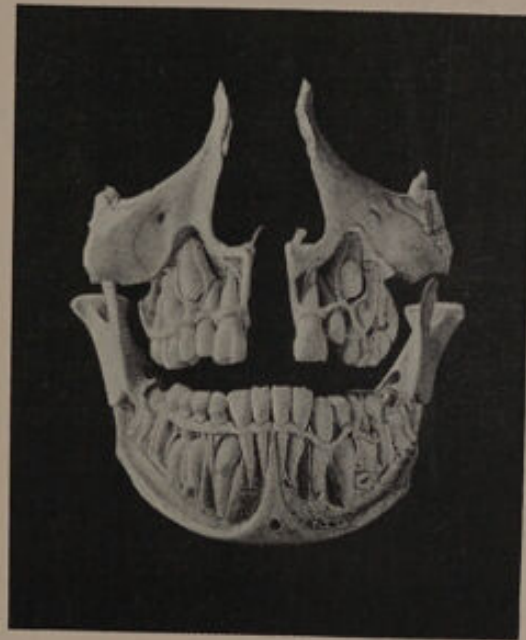The lower incisors are generally higher than usual, and are often arranged in a fan-shaped manner. In many cases they rise high enough to press on the cingula of the upper incisors. This

¹ *Transactions of the Odontological Society of Great Britain* vol. xxvii., p. 127.

² The width of the arch was obtained by measuring from the two most prominent points on the labial surfaces of the first premolars or the first deciduous molars as the case might be.



pressure tends to force these latter teeth outwards and produce, or at any rate aggravate, protrusion. This rising up of the lower incisor teeth is a most important factor in the deformity, and is probably caused by the canine pressing on the roots of the incisor teeth through want of room in the mandible. That the pressure of the canine is a powerful factor

FIG. 228.¹

in the production of this condition is well shown in fig. 228, which is taken from a skull in the Museum of the Odontological Society.

A recognition of this point is important in treatment as it indicates that in order to overcome the uprising the pressure must be relieved.

This question is more fully discussed in dealing with treatment.

¹ From the *Transactions of the Odontological Society*.

Complicating some cases of superior protrusion there is an apparent shortness in the molar region and this, according to Mr. C. S. Tomes, is probably accompanied by a rectangular ascending ramus of diminished length. Mr. Tomes states that if we have the latter with short grinding teeth coincident with well-developed incisors, it is not difficult to see that the upper front teeth will be driven outwards by the lower.

Talbot¹ considers that a **shortness of the ascending ramus of the mandible** causes protrusion of the upper teeth and alveolar process by the lower teeth striking them at an angle instead of perpendicularly, the force of the imperfect occlusion exerting its influence upon the maxilla owing to that bone being weaker in structure than the mandible.

Too early removal of the first permanent molars, with premature loss of the deciduous molars, will at times produce undue prominence of the upper teeth by throwing the whole force of the bite on to the lower incisors and the cingula of the superior teeth.

An abnormal occlusion of the teeth is often found in cases of superior protrusion.

The whole of the upper teeth frequently bite in advance of their normal position. Mr. Champion found in 39 cases of superior protrusion, that in 4 or just over 10 per cent. the molar and premolar occlusion was normal on both sides; in 24 cases or about 61 per cent., the upper

¹ "The Irregularities of the Teeth," by Eugene S. Talbot, p. 65.

teeth were the whole breadth of a premolar in front of their normal position, while in the remaining cases the articulation varied on the right and left sides of the mouth, and in some the molars and premolars met cusp to cusp, or half the breadth of a premolar posterior to the normal bite.

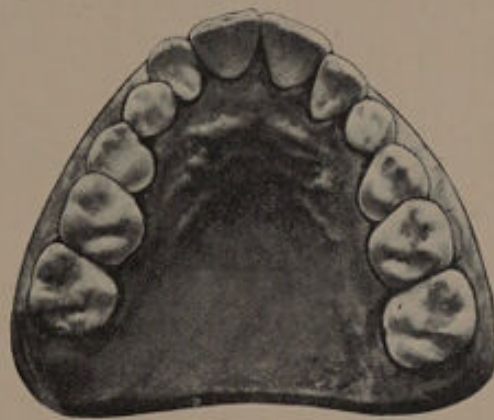

FIG. 229.—Before the eruption of the canines.

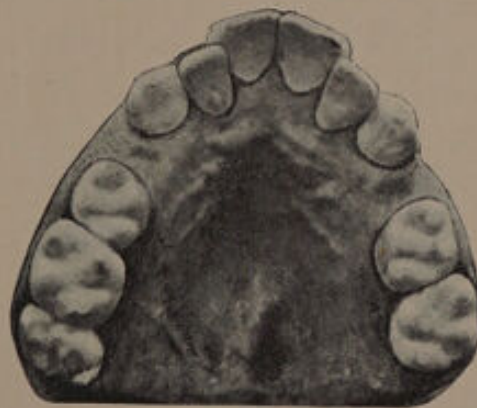

FIG. 230.—After the eruption of the canines.

This abnormal articulation of the teeth is not peculiar to superior protrusion, it is found in other conditions of crowded teeth, and occasionally with the deciduous teeth.

The production of superior protrusion in one instance, and a crowded condition of the incisor teeth in another, may, as pointed out above, be due to the position of the teeth during development.

That a predisposition to superior protrusion may exist, is beyond doubt, as it is a condition which at times can be traced through whole families. Again it is quite possible that the narrowness of the maxilla is influenced in a great measure by the general development of the cranial bones, for frequently the narrow arch is in keeping with the general features.

Some dental surgeons are of opinion that the protrusion does not increase after the complete eruption of the incisors, but an examination of the models of cases before and after the eruption of the canines will, I think, show that this theory is untenable in the majority of cases. In the case shown in figs. 229 and 230, the canines in erupting forced the laterals towards the median line, and the centrals more forward.

Superior protrusion is frequently accompanied by a **short upper lip**, and it is interesting to speculate whether the shortness of the upper lip contributes to the deformity, and if so to what extent.

Under normal conditions the pressure of the upper lip on the labial surfaces of the teeth, counteracts to some extent any force which tends to drive the teeth outwards. If however, the upper lip is short, this counteracting pressure is diminished or altogether absent, and the forces acting on the teeth from within the oral cavity probably cause the teeth to project.

In young adults incipient *pyorrhœa alveolaris* is also to be cited as a cause of protrusion of the upper incisors.

Protrusion of the upper front teeth is at times seen in the first dentition; and with an extended knowledge of young children's teeth it will probably be found that irregularities of this kind are more common than is generally supposed.

THE MECHANICAL METHODS OF RETRACTING TEETH.

Various methods are in vogue for the retraction of teeth and it is difficult to say that any one has a conspicuous advantage over any other. The teeth can be easily and correctly retracted in many ways and the method adopted by individual practitioners is usually the result of custom and fancy.

The premolars can be drawn back with a plate similar to that shown in fig. 26. It is important that the plate should occlude correctly with the lower teeth. In this way the rigidity of the plate will be considerably assisted. It is advisable to retract only one premolar on each side at a time. If both premolars are retracted simultaneously, the second molar is very likely to move forward as the resistance offered by two premolars is frequently greater than that of one molar, especially if the latter is not fully erupted. The premolars should be moved back far enough to allow the anterior planes of the upper teeth to strike the posterior planes of the lower teeth, otherwise the posterior planes of the upper teeth will tend to

drive the lower teeth backwards and so cause the abnormal articulation to persist. See figs. 231 to 233.

The canines can be retracted with an appliance similar to that seen in fig. 23. In adjusting the wires care should be taken to obtain a direct pull back and avoid pressure on the labial surface,

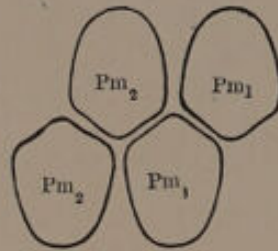


FIG. 231.

Diagram of articulation of superior protrusion cases which often require retraction of the upper premolars.

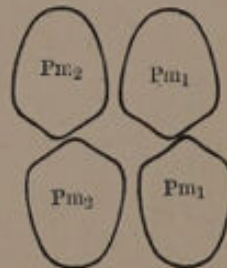


FIG. 232.

Diagram showing the least extent to which upper teeth must be retracted. The posterior plane of the lower teeth will then tend to drive the upper backwards.

otherwise the teeth will be driven towards the palate. As the canine teeth offer a considerable amount of resistance the vulcanite plate should cover the premolars and molar in order to obtain a sufficiently firm hold.

The incisors may be treated by means of a plate similar in character to that shown in fig. 234. The wires should be made of gold (half round),

they should extend to the mesial border of each central, and when adjusting them to the teeth pressure should be exerted on the mesial rather than on the distal half of the tooth. If the pressure falls on the latter the wires will tend to force the

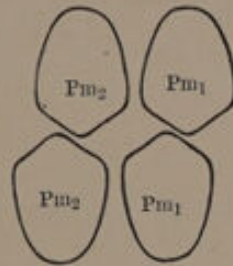


FIG. 233.

Diagram showing an insufficient amount of retraction of upper teeth. The posterior planes of the upper teeth will tend to drive the lower teeth backward and so cause the abnormal articulation of premolars to persist.

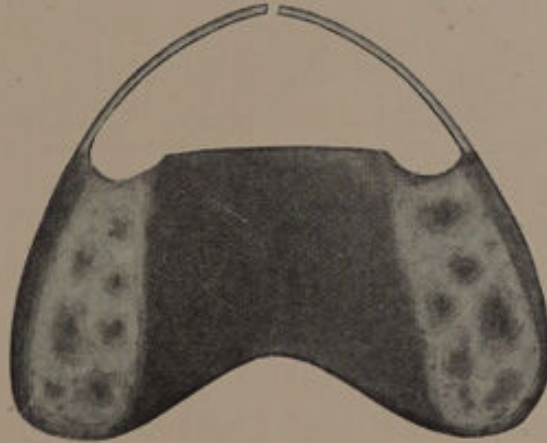


FIG. 234.

teeth towards the median line and cause them to overlap. Gold wire as a means of retracting teeth has the advantage of being easily bent and so brought to bear upon any part of the tooth and in practice is found to answer admirably. This

form of plate is simple, requires no attention on the part of the patient beyond that of cleaning, and is less unsightly than most other appliances.

Another method of retracting teeth which is found in practice to work very well is shown in fig. 235. The plate, however, should be made so as to cap the first permanent molars.

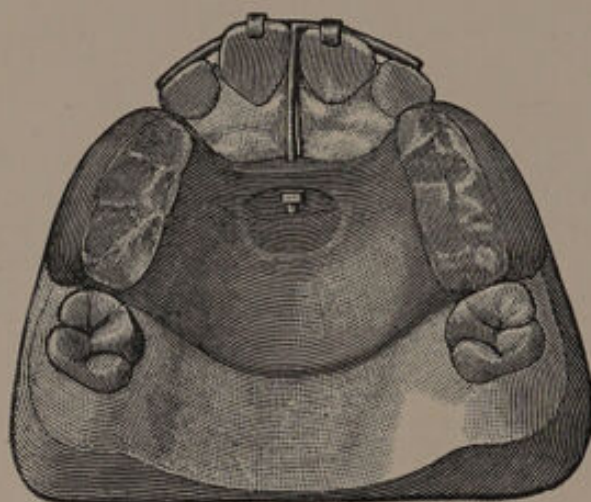


FIG. 235.¹

The apparatus shown in fig. 236 consists of a labial bow of stiff elastic wire, the free ends being run through tubes attached to bands on the first permanent molars. The labial band is prevented from sliding towards the gum by bands on the central incisors. Force is obtained by means of screws on the distal ends of the wire. As fixed points a vulcanite plate may be substituted for molar bands.

¹ From "Diseases and Injuries of the Teeth."

Many practitioners utilise the elastic property of rubber as the retractile force. A vulcanite plate is made covering the posterior teeth and a strip of rubber dam is stretched across the front teeth, the rubber being buttoned on to the sides of the plate. If the rubber is brought below the cutting edges of the teeth, it curls round them, acquires a firm hold and has no tendency to slip

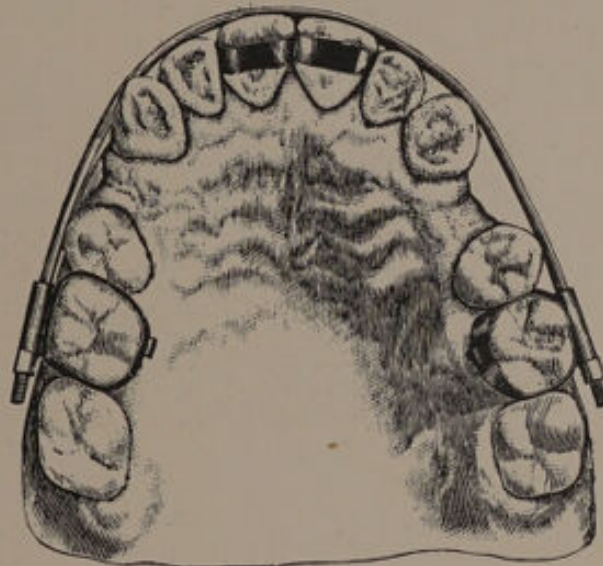


FIG. 236.

upwards. It is claimed for this method that in addition to being brought back, the teeth can also be forced upwards into their sockets provided the buttons are placed high enough in the plate. It must, however, be borne in mind that forcing up the teeth generally means absorption in the neighbourhood of their apices, which is most undesirable.

¹ From "Text book of Operative Dentistry" (Kirk).

In the foregoing methods the fixed point has been obtained directly or indirectly from the posterior teeth. With some practitioners the occiput is employed as the point of resistance. The most useful of these methods is that known as Angle's. The appliance is shown in fig. 237.

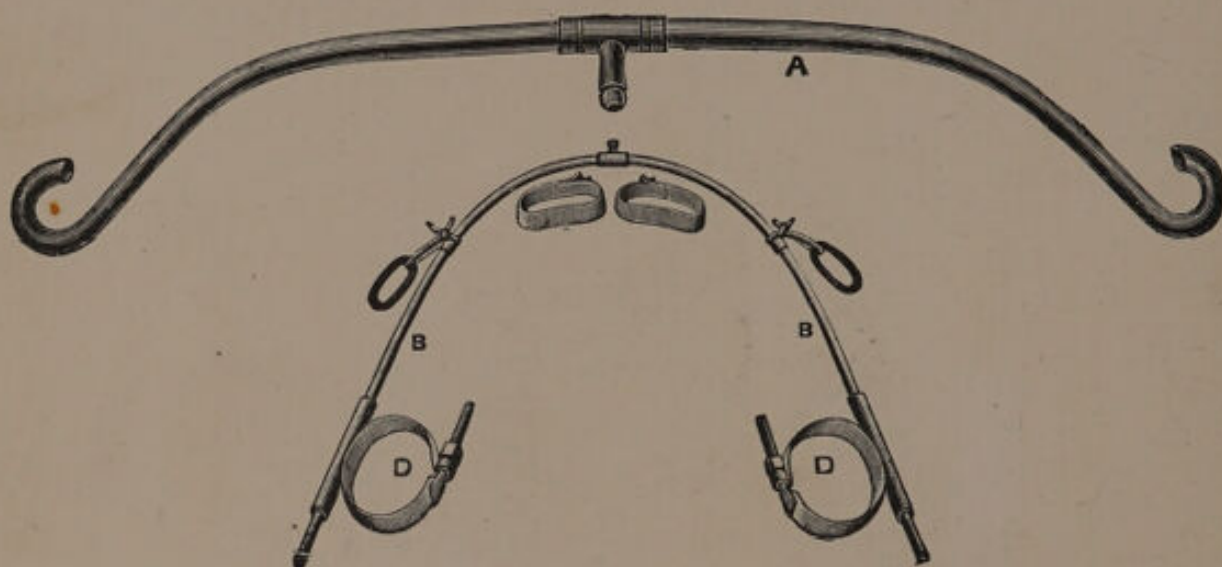


FIG. 237.

The bands *D* are fixed around the first molars, the ends of the labial band passing through tubes soldered to the buccal sides of the molar bands. The anterior part of the labial wire is held in position by bands encircling the central incisors. Notches are formed in the united ends of the bands upon the mesio-labial surfaces, and in these the labial wire rests. The occipital cap is shown in fig. 238, and the force is transmitted to the wire arch in the mouth by elastic bands attached to the traction bar *A* (fig. 237.) When the headgear

is not in use the little elastic bands shown in fig. 237 B are slipped over the ends of the tubes on the molar bands and so keep up a slight tension in a backward direction. It is claimed by Dr. Angle for this method "that not only is the prominence of the teeth reduced, but the malposed teeth are gradually forced to take regular positions and conform to the shape of the ideal arch as it is forced backward through the tubes

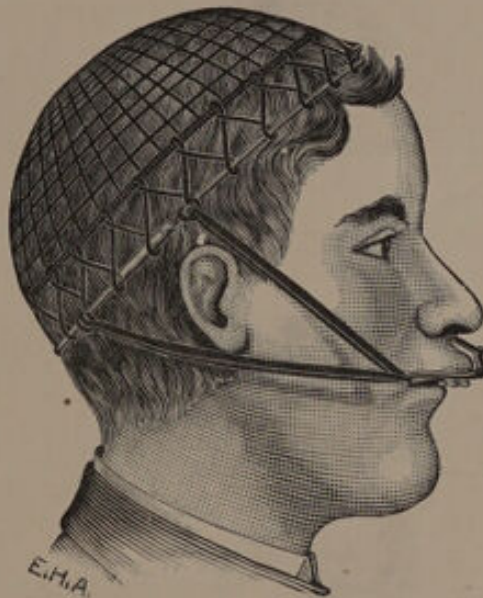


FIG. 238.

on the molars, an action impossible with dividers having fixed caps of vulcanite or gold." A case treated by this method is shown in figs. 239 to 242.¹ The protrusion has been corrected, but the first permanent molars moved forward the distance of about half a premolar.

¹ Recorded in *The Journal of the British Dental Association*, vol. xviii., by L. Jeffreys.

All cases of superior protrusion which have been corrected require the aid of a retention plate for a period varying from six months to a year. A

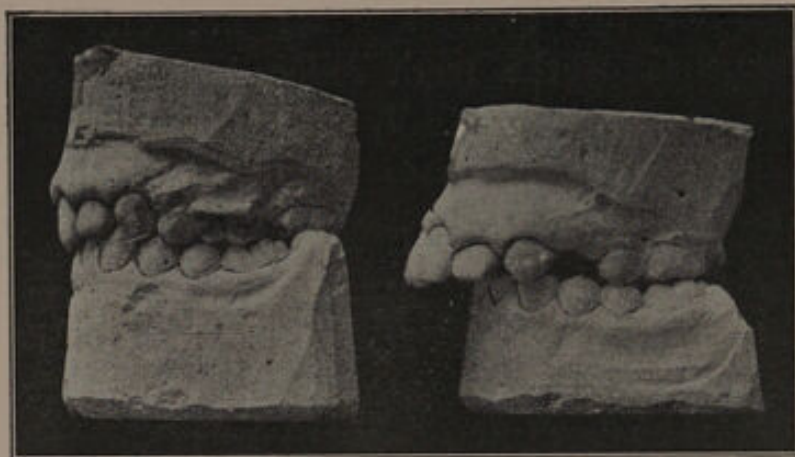


FIG. 239.
After treatment

FIG. 240.
Before treatment

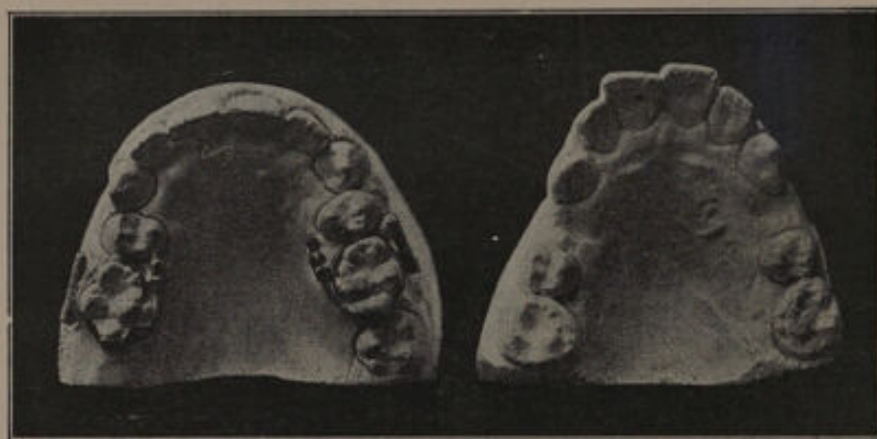


FIG. 241.
After treatment.

FIG. 242.
Before treatment.

useful form of plate is shown in fig. 28. It is important that the arch wire should be rigged. The tendency of the wire to slip towards the gum margin may be overcome by soldering to it a tag

¹ The figs. 239 to 242 are from *The Journal of the British Dental Association*.

which passes over the cutting edge of one of the incisors. If the wire is not kept firmly in its place the teeth in their tendency to relapse will force the wire in an upward direction.

TREATMENT.

To decide on a form of treatment for a case of superior protrusion is at times far from simple. In thinking over the various pros and cons of any special case the following points should be taken into consideration.

(α) Whether the condition is limited to the alveolar portion of bone or involves the body of the maxilla as well. In the former case a good result may be anticipated provided rational measures are adopted. If the body of the maxilla is involved the condition is less amenable to treatment and a satisfactory result from an æsthetic point of view is difficult to obtain. The features in such cases are often moulded in keeping with the prominent teeth and the result of retracting them is to produce an undue flatness of the upper lip and so, to a great extent, mar the facial expression. This was strikingly apparent in a case under my care. On the teeth being retracted the upper lip appeared flattened, and was quite out of keeping with the patient's pointed features. Twelve months later, when the canines had fully erupted, the teeth to a certain extent relapsed, and the result was most beneficial to the expression of the face.

(β) At the age when cases of protrusion come

under observation, the air cells, such as the antrum and frontal sinuses, are only partially developed, but with the advent of puberty a rapid increase in their size takes place with the result that the upper part of the face becomes more prominent and to some extent masks the protrusion of the teeth.

(γ) The condition of the teeth is of great importance because mechanical means must of course be adopted for retraction and retention, and the prolonged use of mechanical appliances with weak teeth is certain to predispose them to caries. Whether the gain to appearance outweighs the harm which is likely to accrue from treatment is therefore a question which must receive careful attention. When caries is already present on the approximal surfaces of the incisors, mechanical treatment should only be adopted if the deformity is very marked.

(δ) The occasional tendency to improve with age. This is seen more especially where the lower incisors impinge on the cingula of the upper teeth. The "bite" of the molars and premolars in such cases sometimes becomes lengthened with the result that the lower lip fails to fall behind the upper teeth, and the pressure of the lower on the upper incisors is also relieved. The opposing forces being thus removed the upper lip is able to bring the teeth back, providing that there is sufficient room in the arch. That improvement in a few cases does take place in this way is unquestionable, but it is only likely to occur where the protrusion is slight.

Providing the action of such causes as the lower lip, the lower incisors and crowding of the upper canines and incisors is overcome, the case will not relapse if a retention plate is worn for a sufficiently long period. The removal of the crowding of the roots as well as the crowns of the teeth is most important, but too frequently overlooked. If the crowns only are relieved the teeth will show a distinct tendency to resume their former positions.

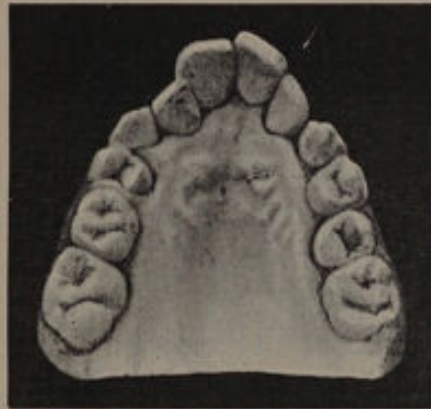

FIG. 243

The cases shown in figs. 243 and 244 illustrate this point. In fig. 243 the crowding of the teeth was marked, the roots of the canines lying over the roots of the laterals; the right lateral was also placed in a plane posterior to the right central incisor. The lateral incisors were removed by Mr. F. Ewbank, with the result that a good arch was obtained, and the crowding of both roots and crowns of the anterior teeth really removed. This case has never shown the slightest tendency to relapse.

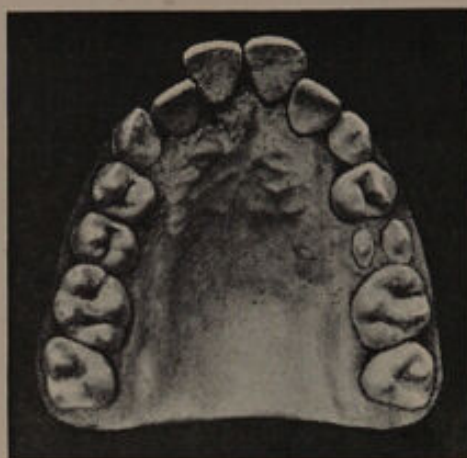

FIG. 244.—This model was damaged, and the cutting edges of the central incisors were restored previous to photographing the model.

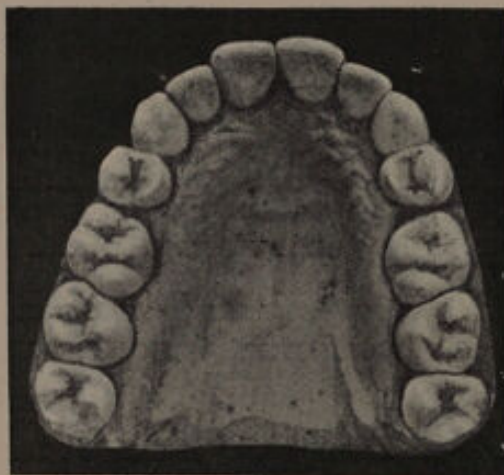

FIG. 245.—Case shown in fig. 244, after treatment.
The model was taken six years after the completion of treatment.

The case seen in fig. 244 was of a somewhat similar type, namely, the laterals were placed in a plane slightly posterior to the canine and central incisors. In this instance the first premolars were, I think, quite rightly removed, and the teeth brought into a good line (fig. 245). The case, even

after a period of eight years, shows a decided tendency to relapse, and the teeth are only kept in their corrected positions by the use of a retention plate at night. In this case the crowding of the roots of the canines and incisor teeth has not been really overcome by the removal of the premolars, although the treatment adopted was undoubtedly correct. In cases, then, where the crowding of incisors and canines cannot be really overcome, a tendency to relapse must be anticipated.

This tendency is also seen in cases where the lower incisors bite behind the cingula of the upper, and is then often due to the fact that the pressure of the canines on the lower incisors has not been relieved, the consequence being that the latter are continually forced upwards.

The details of treatment can be best described by considering some examples of the more common types of superior protrusion met with in practice.

(1) **Cases where the teeth have been protruded from such habits as finger and thumb sucking**, present little difficulty as a rule. There is usually ample space in the arch, and the only treatment needed is to retract the teeth and retain them in position for a period of about six months. The retraction can be accomplished by means of a plate similar to that shown in fig. 234. A retention plate is usually needed for about six months.

(2) **Cases where the whole body of the maxilla is prominent** will require considerable judgment in deciding on the treatment. Generally speaking, they are best left alone for the reasons given on

page 161. In a few instances partial retraction may be beneficial, but the extent to which the teeth may be drawn backwards must depend upon the facial expression. It is often, however, advisable to relieve any pressure that may be present by extraction. In this way the protrusion will be prevented from being increased by the force of eruption of the third molars.

(3) Cases where the alveolar process is alone involved and the lower teeth do not impinge upon

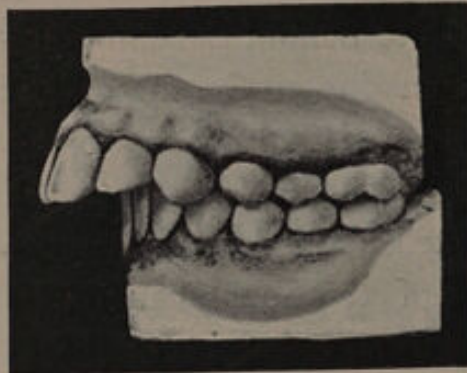


FIG. 246.

the palatal surfaces of the upper. The models shown in fig. 246 illustrate a variety belonging to this class. The upper teeth are in a fairly regular arch, but the premolars and molars are abnormally placed in relation to the lower teeth. The fault is entirely with the upper, the mandible apparently being normally developed.

Provided that the first permanent molars are saveable, the treatment in such a case would be the extraction of the first upper premolars, followed by the retraction of the canines, and subsequently the retraction of the incisors.

In a case similar to that shown in fig. 247 the lower as well as the upper premolars must be removed. The necessity for removing the lower arises from the fact that the lower canines are prominent, owing to a certain amount of crowding, and if the upper premolars only are removed, the lower canines when they are retracted will cause the upper canines to be unduly prominent. The

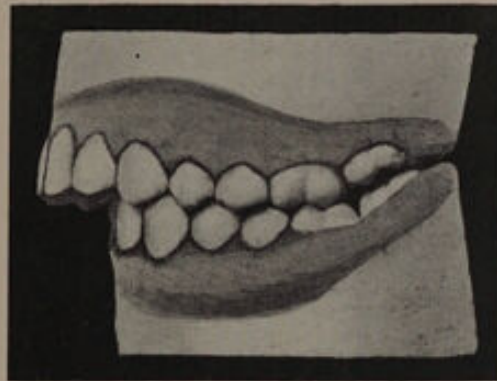


FIG. 247.

removal of the lower premolars will enable the canines in the mandible to move back, and at the same time inwards, and so allow the upper teeth to assume a correct position.

If in a case similar to fig. 246, the first molars are unsaveable, they must be removed. The extraction of the upper teeth may be undertaken as soon as the second permanent molars are sufficiently through to allow of their being retained in position by means of a splint plate, fig. 75. This plate, as before mentioned, will prevent the second molars from moving forward, and will allow them to fully erupt. It will also permit the premolars to travel

back, provided that the bite of the lower incisors in the plate is so arranged that the premolars, upper and lower, are separated from one another during occlusion. No attempt should be made to move back the premolars by mechanical means until the second permanent molars are firmly implanted, as the molars are liable to move forward if mechanical force is used too early.

The lower first molars should be retained until the premolars in the upper occlude with the

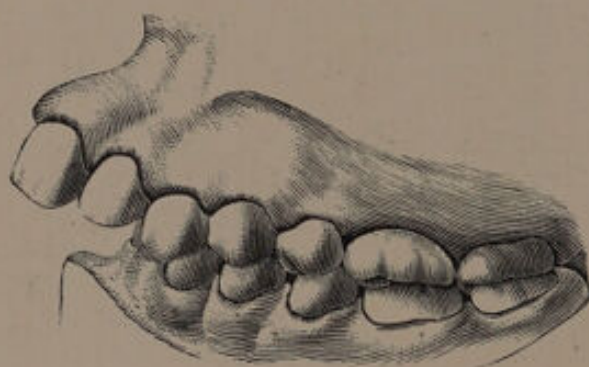

FIG. 248.

posterior planes of the corresponding lower teeth. The lower first molars may be removed then or at the completion of the retraction of the front teeth.

The operation of "jumping the bite" is recommended by some practitioners as a method of dealing with the variety of protrusion under consideration. In the case, fig. 246, the lower premolars and molars are nearly the width of a premolar behind their correct articulation. If by any means the patient can be made to acquire the permanent habit of bringing the mandible forward

so as to make the teeth articulate normally, the bite will have been "jumped." The subject is one which has been largely written upon, and on which there is much diversity of opinion.

An interesting example of "jumping the bite" is recorded by Dr. Bogue (*Dental Cosmos*, May, 1887). The patient was a girl, aged fourteen years.

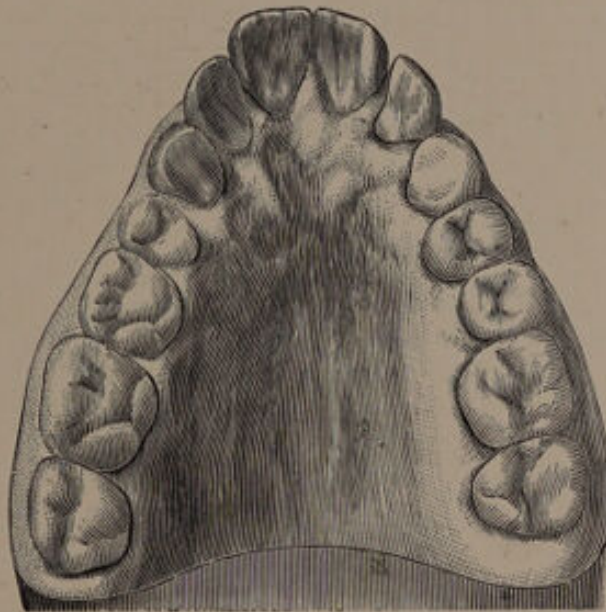


FIG. 249.

Models of the mouth are seen in fig. 248. The curve of the lower alveolar arch was nearly normal, and the positions of the teeth fairly good, but the molars were short. The maxilla, as seen in fig. 249, was somewhat V-shaped. A portion of the treatment carried out was a separation of the canines with the view of increasing the size of the arch. This having been successfully accomplished (fig. 250), it was found that the mandible had moved

forward and articulated in its correct position, as shown in fig. 251. This result was unexpected, and the explanation seems to be that the lower teeth

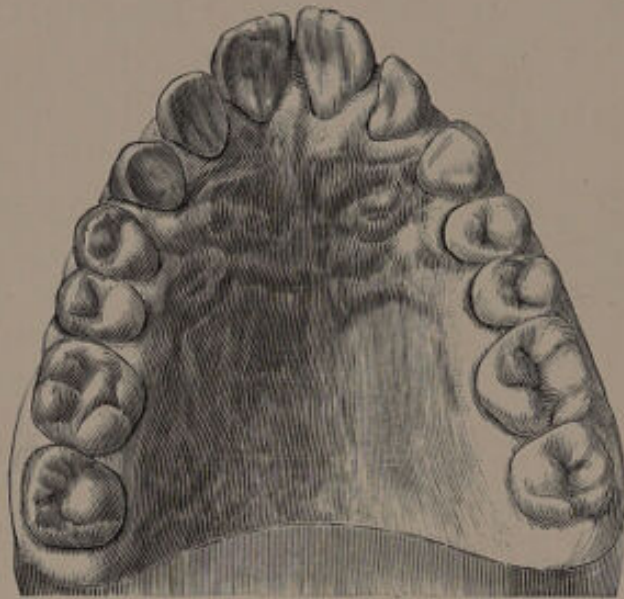


FIG. 250.

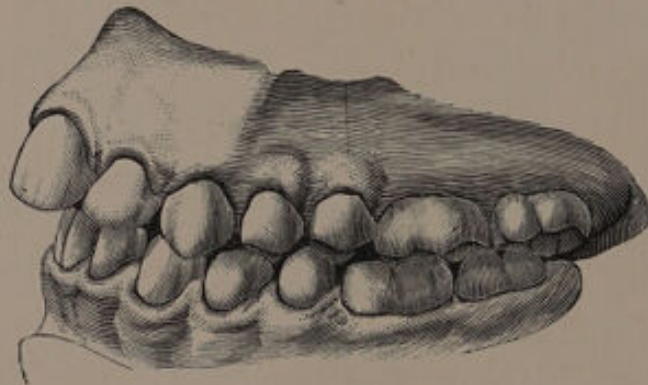

FIG. 251.

were prevented from closing correctly by the upper canines, and that this obstacle having been removed by the separation of the canines, the mandible adjusted itself naturally.

A similar unexpected result is also recorded by Mr. Matheson (*Trans. Odonto. Soc.*, vol. xxiii., p. 25). In a case with a very receding chin, he drew back the upper incisors, and in order to retain them in position he attached a retaining wire to gold caps to fit the second upper premolars. To prevent the premolars themselves coming forward he attached to the caps tiny inclined planes directed downwards and backwards for the lower premolars to bite against. In a week he found that the mandible had come

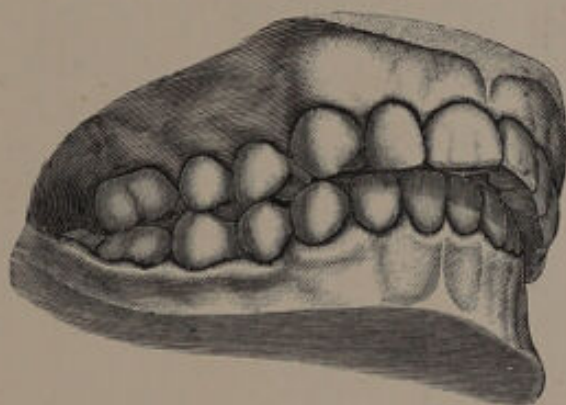


FIG. 252.

forward by the width of a tooth, and the retreating chin had thus disappeared, much to the improvement of the patient's personal appearance.

Fig. 252 illustrates a case recorded by Dr. Cutter,¹ of Cambridge, Mass., in which the lower teeth were brought forward. The upper arch was first slightly expanded, and the arch of the front teeth flattened. The result of this is shown in fig. 253. The next step was to raise the bite and bring the mandible

¹ *International Dental Journal*, vol. xv., p. 355.

forward. "The plate," to quote Dr. Cutter, "was made thick over the bicuspid and first molars, and behind the front teeth deep depressions were made in the plate a little forward of the places where the cusps of the lower teeth would naturally touch the plate. The result was that the patient began to carry the lower jaw forward a little so that the teeth would enter these depressions.

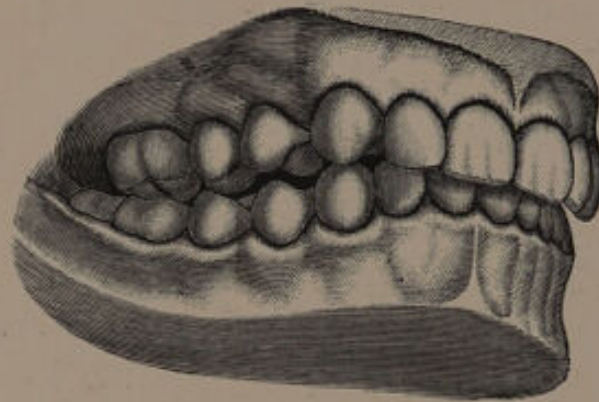


FIG. 253.

"It was found, however, that a plate which covered the bicuspid and first molars prevented these teeth, both in the upper and lower jaws, from elongating and forming a new articulation to correspond with the lengthened bite. Therefore another plate was made for the upper arch. This one was thickened only behind the front teeth, where depressions were made to receive the points of the lower incisors. No other teeth of the lower jaw were allowed to touch any part of the plate. This plate was held firmly in place by wire clasps encircling the sixth-year molars. There was also attached to this plate a wire which passed around the outside of the front

teeth to keep them in the flattened position which they had assumed.

"In making this plate much care was required to have the depressions in just the right places and of exactly the proper depth. A wax and paraffin base-plate was fitted to the plaster model of the upper arch. To the part where the plate was to be thickened soft yellow wax was then added. While the wax was soft the base-plate was inserted in the mouth, and the patient told to throw the

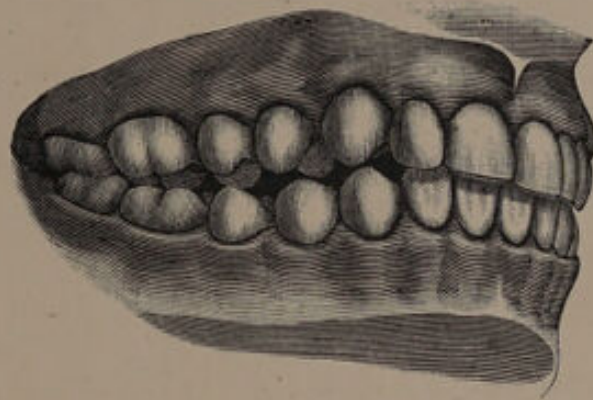

FIG. 254.

lower jaw forward and bite into the wax. It thus determined how much the jaw was then to be carried forward and the bite lengthened. This was an important question, for a slight variation at this point might have produced an unfortunate result. Several plates of this character were made, as the amount to be gained had to be gradually accomplished. Fig. 254 shows the case during this step in treatment."

"When the case was commenced, but one twelfth-

year molar had begun to appear ; when the work was completed, all four of these molars had erupted and interlocked with each other. The result was that the patient could comfortably bring her jaws together only in their newly related positions.

"All that then remained was for the bicuspid and sixth-year molars to complete their articulation, which they did as seen in fig. 255.

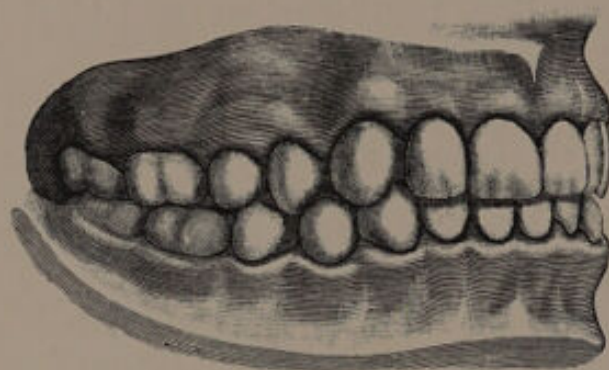


FIG. 255.

"It was necessary to carry the lower jaw forward while the twelfth-year molars were erupting, as the retaining of the jaw in the new position depended entirely on the articulating of these teeth. Unless the operation had been undertaken at just this time, it is doubtful if it could have been accomplished. It would probably not have been possible to secure the retaining of the jaws in the relation they now are had the attempt been made at an earlier or a later time."

Dr. Ottolengui,¹ who claims to have jumped the bite on many occasions, adopts the following plan :

The Dental Practitioner and Advertiser, vol. xxv., p. 194.

—"The frontal prominence of the superior jaw having been reduced as much as is possible, the lower jaw is moved forward to a good occlusion with the anterior part of the jaws, little consideration being given to the posterior teeth. The lower jaw must not be progressed, however, beyond what becomes a part of the best facial contour, especial observation being given to the pose of the lips and the relation of the chin to the rest of the features. As soon as it is decided just where it is most desirable to have the lower jaw, a plate is made which snugly fits the roof of the mouth, and which has, at the anterior part, an inclined plane, which not only prevents the closure of the mouth in the old position, but by catching the tips of the lower teeth, causes them gradually to slide forward in closing, so that the mouth shuts in the desired pose. This plate is worn until the habit becomes fixed. The new bite may become a new habit in two or three months, and a child may adopt it in less time, without the inclined plane and with nothing whatever to produce the change except an indomitable will power and sufficient interest in her own welfare to second the efforts made on her behalf."

It is clear from the above cases, and also from others recorded in the various journals, that patients can be made to acquire, at least temporarily, the habit of protruding the jaw, and so "jumping the bite." Does this habit become permanent, and if so, what structural changes take place in the parts involved? By some¹ it

¹ *Transactions of the World's Columbian Dental Congress*, vol. ii., p. 760.

is maintained that the changes are accomplished in the glenoid cavity (1) by an extension of the condyle on the lower jaw, which practically amounts to a bending backwards of the neck; (2) by the filling up of the cavity posterior to the condyle. These explanations seems incompatible with our knowledge of the anatomy and physiology of the temporo-mandibular articulation. A more probable explanation is that the teeth move forward in the sockets. When the teeth are occluded in the new position, namely, with the bite jumped, there must be a constant tendency on the part of the muscles to retract the mandible to its old position; this backward tendency is arrested by the upper teeth, with the result that the lower teeth are drawn forward in their sockets, absorption and redeposition of bone in the tooth sockets takes place, as when a tooth is moved by mechanical means. It would be interesting to obtain accurate illustrations of cases taken some years after treatment, as the direction of the teeth might assist in elucidating this point.

Mr. Charles Tomes,¹ in referring to this question, states that it is very possible in these cases there is a "return to a normal articulation which had been but recently disturbed by extractions, or by the eruption of teeth in a slightly wrong position."

The models shown in fig. 256 illustrate a type of protrusion which requires for its correction the removal of the lateral incisors. It will be noticed

¹ "A System of Dental Surgery," Fourth Edition, p. 167.

that the canines and incisors are in a crowded condition, the roots of the canines being directed towards the median line, and the roots of the lateral incisors being covered partly by the canines and partly by the centrals. In such a case, if the premolar or molar were removed, the canine would only travel back to a slight degree, and would assume a sloping direction. In all probability the canine would be short, and owing to the root of the central over-

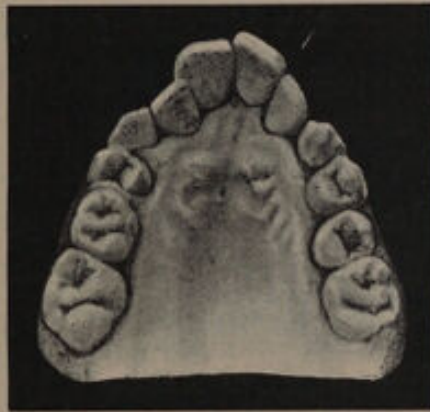

FIG. 256

lying the lateral, it would be extremely difficult, if not impossible, to bring the teeth into anything like a correct or regular arch. Although the irregularity of the crowns might be overcome, the apical end of the roots would still be crowded and predispose the case to relapse. On the other hand, the removal of the lateral incisor would allow the canine to erupt to its correct length and assume a vertical direction. The central incisor could be easily retracted and also brought into correct alignment. Crowding of the apical portions of the

roots would be overcome, and there would be but little tendency to relapse. The result of treatment in this case was entirely satisfactory. A regular arch was obtained, with the teeth in good direction. There has been no tendency to relapse. If the laterals had been retained, in all probability the arch would not have been brought into such a good curve, the teeth would have assumed a sloping direction, and there would have been a constant tendency to relapse.

(4) Cases where the alveolar process is alone involved and the lower incisors impinge on the cingula of the upper incisors, or on the gum posterior to these teeth. These cases are difficult to treat, and the results obtained are frequently unsatisfactory. If the mouth of a patient presenting this form of superior protrusion be examined it will be noticed that the lower incisors are on a higher level than the premolars and molars. This may be due to some abnormal condition of the incisors, the height of the premolars and molars being normal; or the incisors may be normal in their arrangement and the premolars and molars unduly short; or again, both incisors, premolars and molars may be at fault. In order that treatment may be successful it is essential that the lower incisors should not impinge on the cingula of the upper incisors when the latter have been retracted. It is therefore needful that attention should be directed to the treatment of the lower teeth. It has already been pointed out that the abnormal uprising of the lower incisors may be due to

crowding from lateral pressure of the canines, and that the shortness of the range of the molars and premolars probably arises from a defect in the development of the ascending ramus. As a first step in treatment most practitioners endeavour to raise the bite—in other words, induce the molars and premolars to elongate and so prevent the lower incisors from impinging upon the cingula of the upper teeth. Mr. E. Lloyd-Williams¹ suggests that the bite should be raised at an early age, but that no attempt should be made to obtain room for the retraction of the incisors and canines until after the eruption of the second molars. He advises that in opening the bite one pair of teeth should be made to antagonise at a time. "In this way for an ordinary case," he says, "the capping should go as far back as the first molars, and the second molars should be allowed to come down. The surface of the plate for the first molar should then be filed away, the first molar allowed to come down, and subsequently the second bicuspid. In that way, by bringing down one tooth at a time, you ensure a sufficiency of antagonising teeth to make absolutely certain that they are not bitten down again." This deduction is not in accord with my own experience. There are, I think, two strong objections to treatment by raising the bite: (1) the obstinacy, at times, on the part of the molars and premolars to rise; and (2) their

¹ *Transactions of the Odontological Society of Great Britain*, vol. xxxii., p. 94.

liability to relapse by being forced down again into their sockets. It is not surprising that disappointments attend the practice of "bite raising," since the treatment is not in accord with our anatomical knowledge of the condition. Failure to raise the bite seems more likely to occur in cases where the molar and premolar region is well developed. There is a common impression that if teeth are separated from one another they will always elongate. That this is erroneous will readily be seen by a study of that type of irregularity called "open bite." When the ascending ramus is short the premolars and molars are probably prevented from rising to their normal height. If therefore the jaws are separated the teeth will no doubt rise. It is in these cases that the liability to relapse occurs. Raising the bite does not affect in any way the ascending ramus, which is the real cause of trouble. The mouth is in reality propped open artificially, and the muscles which close the mandible are in a state of tension. As soon as the plate is removed the muscles have again free play, and the pressure they exert drives the premolars and molars back to their original positions.

In a few cases, with the eruption of the second molars the bite becomes raised by natural means, probably due to a rapid growth of the ascending ramus about this period. It is possible that cases in which raising the bite by artificial means has been permanent the same natural causes have been at work.

More reliable results can, I think, be obtained by directing treatment to the lower incisors. Where the incisors and canines are not very crowded, their cutting edges should be ground down until they are clear of the upper teeth; at the same time it is most important that all lateral pressure should be relieved by the removal of a premolar or molar. If this is not done, there is a risk that when the third molars erupt they will exert a forward pressure and cause crowding of the front teeth. Where the incisors are very crowded, with the canines lying slightly anterior to the laterals, or where the fan-shaped arrangement is well marked, it is an excellent plan to remove an incisor. The crowding of the remaining teeth is efficiently relieved, the incisors at times fall to their normal level, and are so prevented from impinging upon the upper gums or teeth. Removal of an incisor slightly narrows the lower arch, and this is in my opinion a distinct gain as far as treatment is concerned. Some, however, maintain that the narrowing of the arch may be detrimental to the facial expression because it will allow the lower lip to fall in. This view is incorrect. The prominence of the chin is governed by the mental process, and is in no way dependent upon the alveolar portion of the jaw, which is alone involved in the removal of an incisor. When the upper teeth have been retracted the lower lip should close outside them, and should not be dependent upon the arch of the lower incisors for its position. In the three following cases the lower incisors were in contact with

the upper gums or teeth. In the lower the incisor crowding was relieved by the removal of a central, the upper teeth were retracted after room was made, and no attempt was made to raise the bite. In all three cases the upper incisors are quite free from the lower incisors and fall within the lower lip.

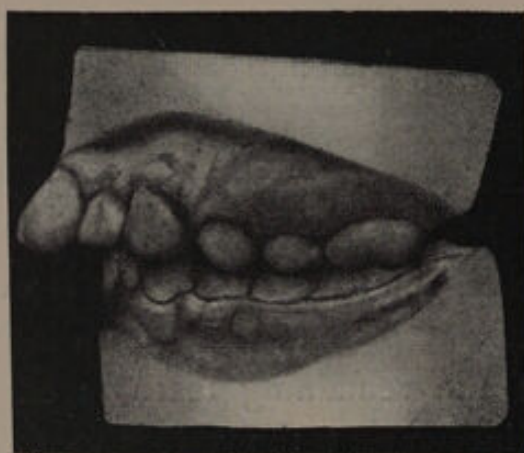

FIG. 257.

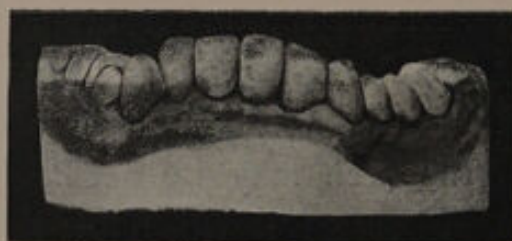

FIG. 258.

CASE I.—The amount of protrusion is shown in fig. 257.

An examination of the models shows that the right upper premolars are erupting normally as regards occlusion with the lower teeth; on the left the upper premolars are not quite half a tooth in advance of their correct positions, the anterior planes of the upper teeth just striking the

posterior planes of the lower teeth. The lower incisors are crowded and show the typical heaped-up appearance already alluded to (fig. 258). The cutting edges of these lower incisors strike the gum just posterior to the upper incisors (fig. 259). The direction of the roots of the lower incisor teeth indicated that the left central should be removed.

This tooth having been extracted, the case was left for a year, as the first permanent molars,

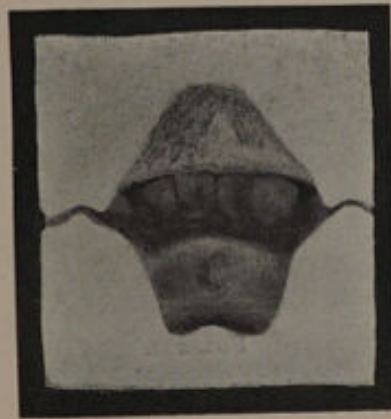

FIG. 259—Showing relation of the lower incisors to the upper teeth at the commencement of treatment.

which were unsaveable, had to be removed, and this could not be done when the patient was first seen as the upper second molars had not then erupted.

When examined one year afterwards the gap caused by the removal of the lower central had closed up, the teeth had apparently dropped down to a lower level (see fig. 260), and were quite

free from the upper gum. By the removal, therefore, of this central tooth one of the great diffi-

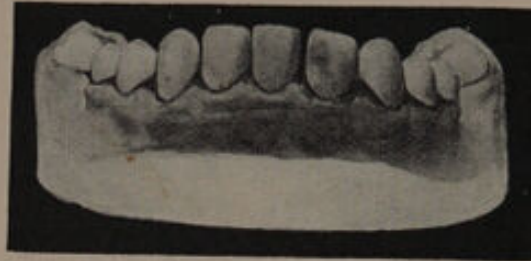

FIG. 260.

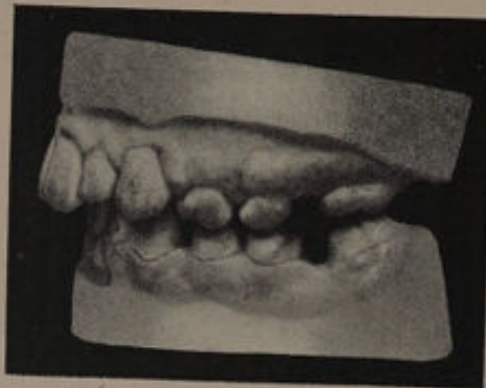

FIG. 261.

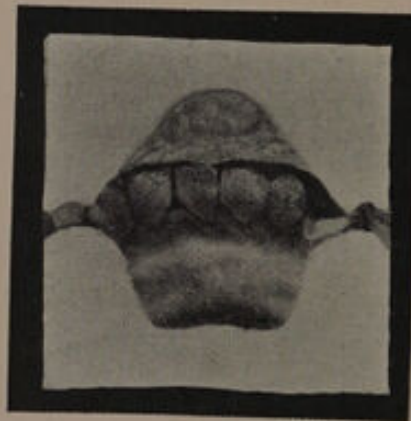


FIG. 252—Showing relation of lower to upper incisors after treatment.

culties in treating this type of case had been overcome. The first permanent molars were now

extracted and a splint plate put in to keep the second permanent molars from moving forward, and at the same time allow the premolars to travel back. The canines were then retracted and the incisors brought in by a plate similar to

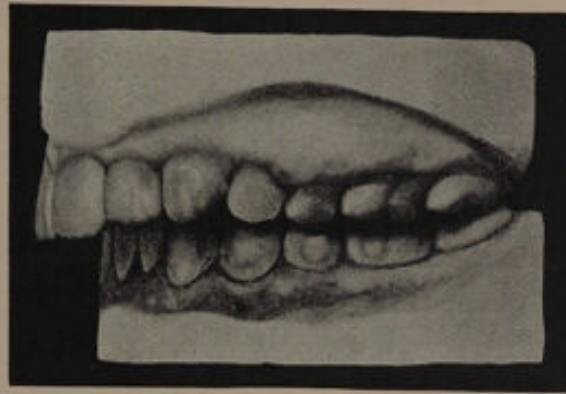


FIG. 263

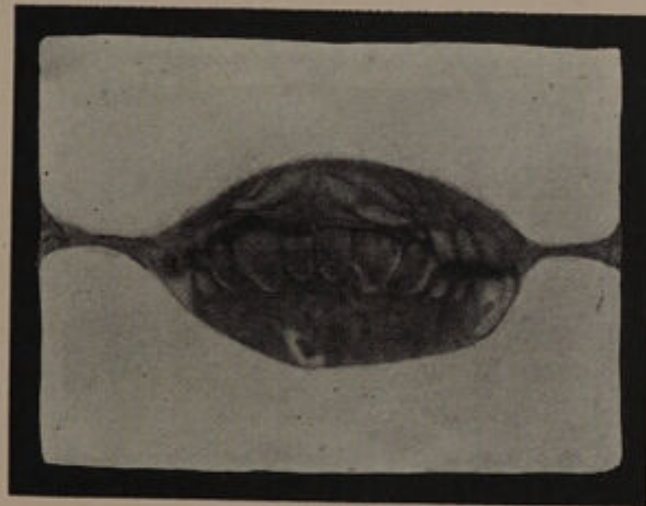


FIG. 264.

that shown in fig. 234. The result is seen in figs. 261 and 262. The lower incisors are quite clear from the upper teeth and the lower lip also passes in front of them. The upper teeth could have been retracted still more, but it was not

considered advisable from an æsthetic point of view.

CASE II.—The models of this patient are shown in figs. 263, 264 and 265. It will be noticed that the premolar and molar region is well developed,

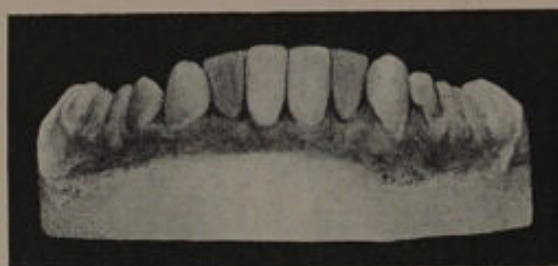

FIG. 265.

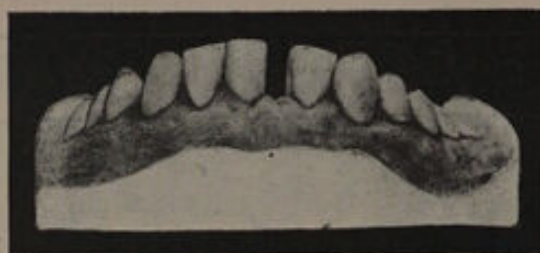

FIG. 266.

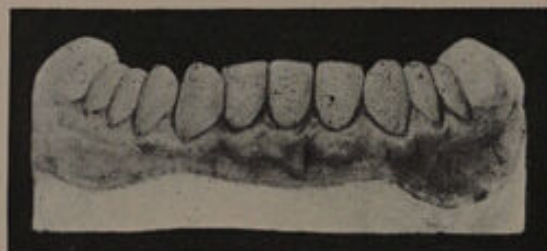

FIG. 267.

that the lower incisors and canines have a fan-shaped arrangement, the cutting edges of the central incisors forming the highest point, and that the central incisors impinge against the cingula of the upper incisors (fig. 264). The left central

incisor was extracted, and the effect on the height of the remaining teeth is seen in figs. 266 and 267. In the upper the first premolars were removed and the canines and incisors retracted, with the result seen in figs. 268 and 269. It will be noticed that

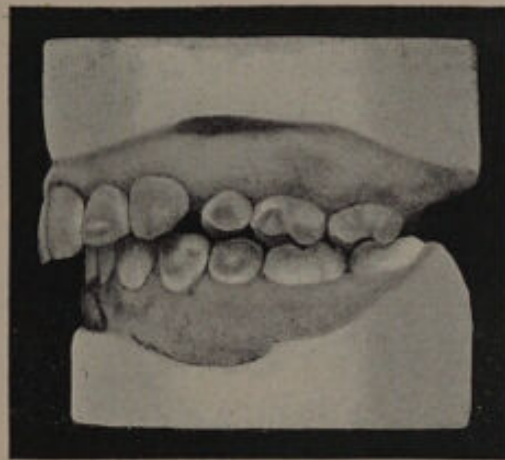


FIG. 268.

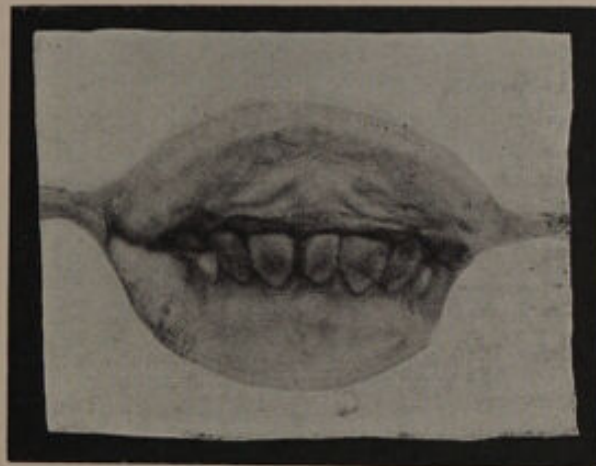


FIG. 269.

the lower incisors are free from the upper teeth (fig. 269), and that the upper premolar and first molar has been brought slightly forward and also driven upwards by the action of the plate.

CASE III.—The models of this patient are shown in figs. 270 and 271. It will be noticed that the molar and premolar region was short.¹ The

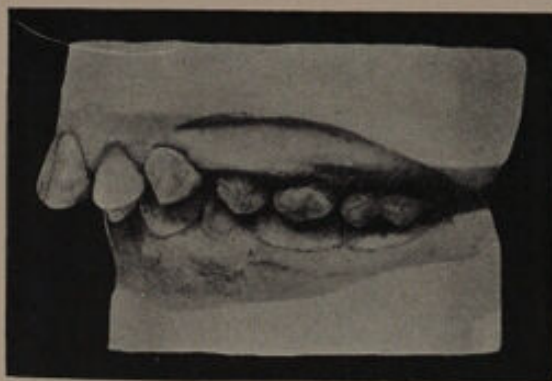


FIG. 270.

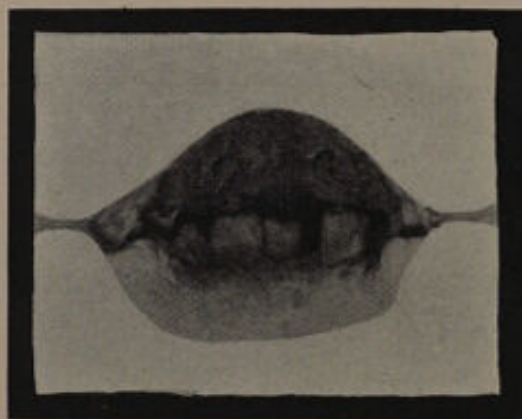

FIG. 271.

lower incisors were very crowded, the canines having their roots directed towards the median

¹ The models of an elder sister are shown on page 129. The presence of a short molar and premolar range in this patient is well marked and interesting.

line. The central incisor was removed, but even this failed to give sufficient room, and in order to relieve all lateral pressure—which is, I consider, most important—the first premolars were subsequently removed. The upper first premolars were

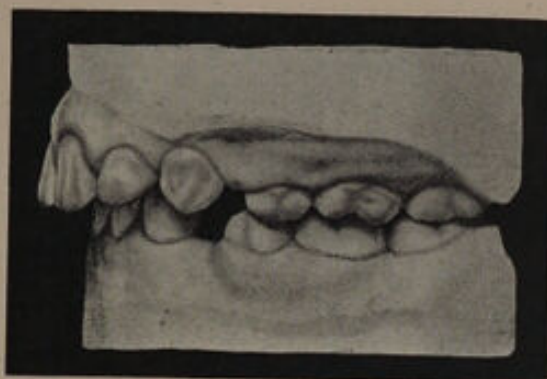


FIG. 272

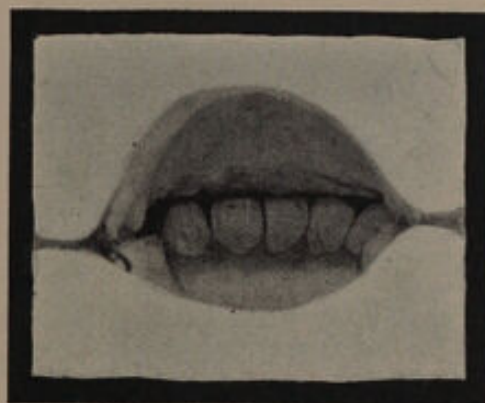


FIG. 273.

extracted, the canines and incisors retracted, and a result obtained as seen in figs. 272 and 273. The lower incisors are free from the upper gum and teeth, the lower lip passes in advance of the upper teeth, and there is no crowding.

THE EARLY TREATMENT OF SUPERIOR PROTRUSION.

I am inclined to think that early treatment of superior protrusion gives the best results, although I am aware that this is in opposition to the view held by the majority of the profession. The advantages gained are :—

(1) The irregularity to be dealt with at an early stage is less in degree, for if treatment is delayed

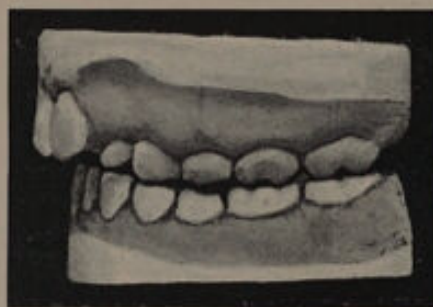

FIG. 275.

until after the eruption of the second molars, the canine, in forcing its way into position in the full arch, will exert a forward pressure on the incisors, and thus considerably augment the irregularity.

(2) The mechanical treatment of the case is considerably reduced.

(3) The articulation of the teeth is less disorganised.

The following cases are examples :

The models shown in fig. 275 are from a patient aged $8\frac{1}{2}$. The protrusion is well marked. The

unerupted first premolars were removed, and the case left until the canines were fully erupted; the lateral incisors had then to be pushed slightly outwards and backwards, with the result seen in fig. 276.

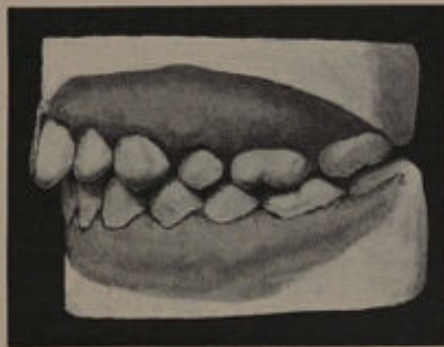


FIG. 276.

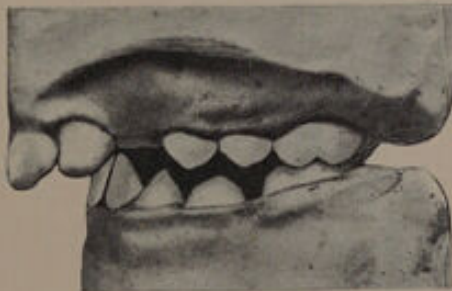


FIG. 277.

The models shown in fig. 277 are from a patient aged 10 years, who had marked protrusion of the incisors. The first premolars were removed directly the canines showed signs of erupting. The case was then left entirely alone until the

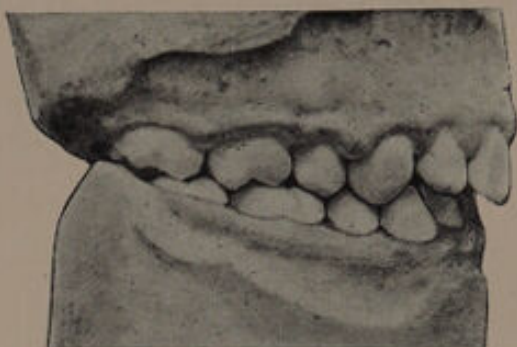

FIG. 278.

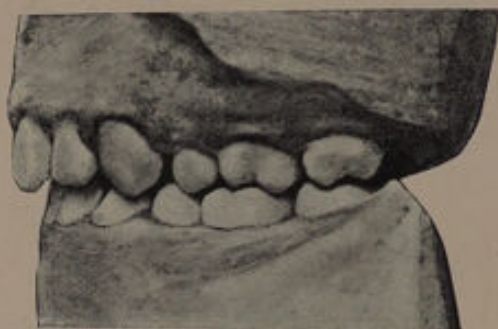

FIG. 279.

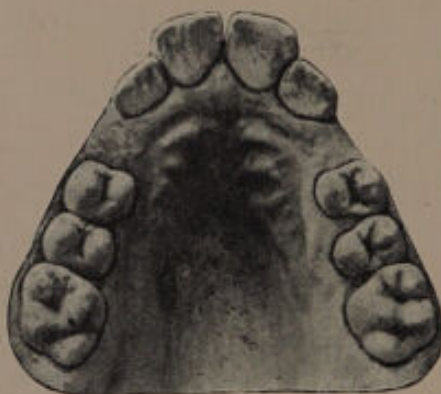

FIG. 280.

canines had fully erupted, when the incisors were brought in, with the result seen in figs. 278 and 279. A glance at the models figured 280 and 281 shows the amount of protrusion which was overcome by extraction alone. A third case treated on some-

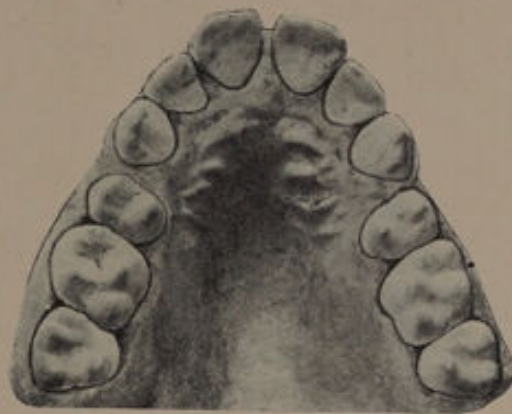


FIG. 281.

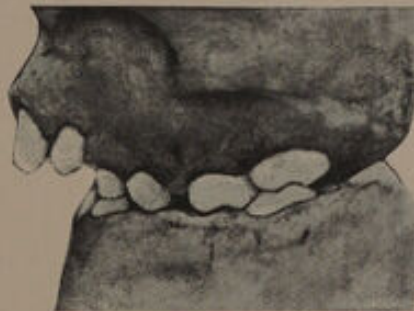

FIG. 282.

what similar lines is shown in fig. 282, only here a plate was inserted to hold back the second deciduous molars, and when it was seen that the tendency for these teeth to advance had been overcome, the plate was cut free from the palatal surface of the

incisors, the bite being opened so as to prevent the lower lip passing behind the upper incisor teeth. Fig. 283 shows the condition of the mouth at the commencement of treatment. The relation of the

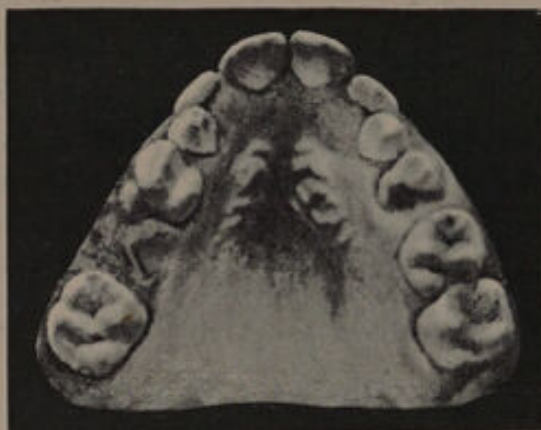

FIG. 283.

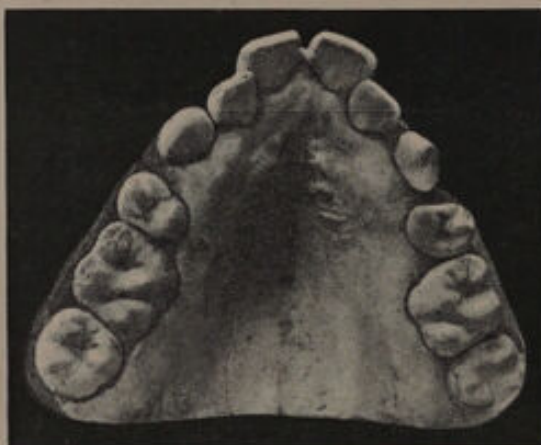

FIG. 284.

teeth after the eruption of the canines is seen in fig. 284. At this stage a plate was inserted to press the laterals slightly outwards. The teeth were then brought in. The result of treatment is seen in figs. 285 and 286.

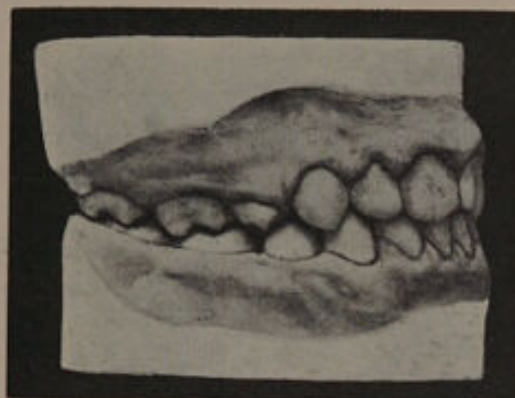

FIG. 285.

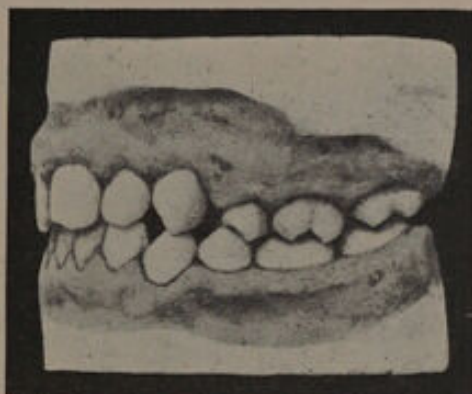

FIG. 286.



FIG. 287.

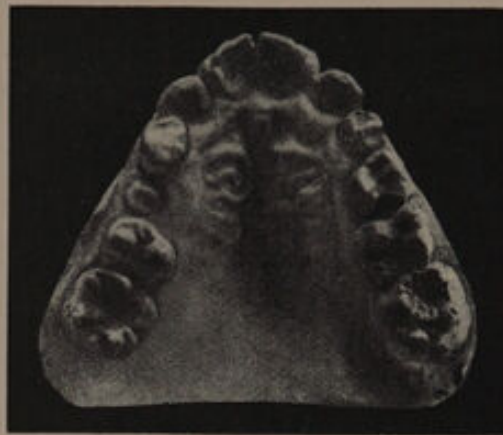


FIG. 288.

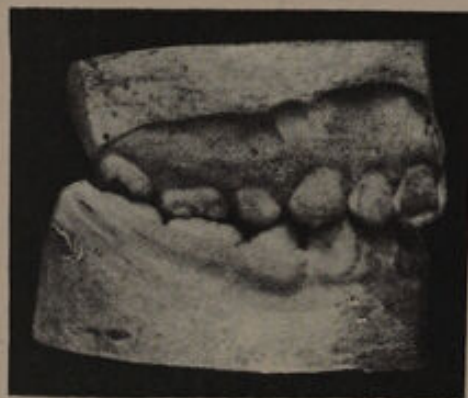

FIG. 289.

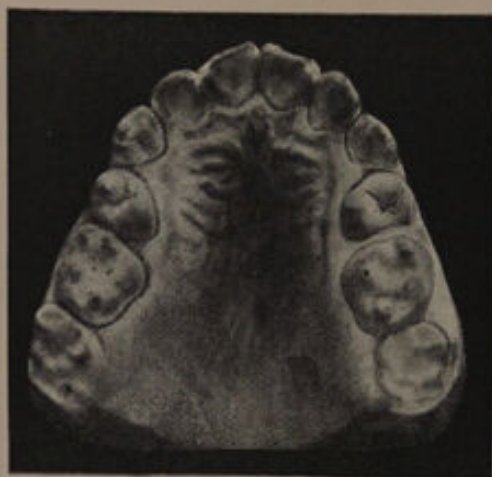

FIG. 290.

In figs. 287 and 288 are shown the models of a patient aged 10. The protrusion is marked. The first permanent molars, which were saveable teeth, were filled and the first premolars removed. A plate was made to retain the right upper second premolar and left upper second deciduous molar in their places. The canines erupted well back. An expansion plate was then inserted to press out-

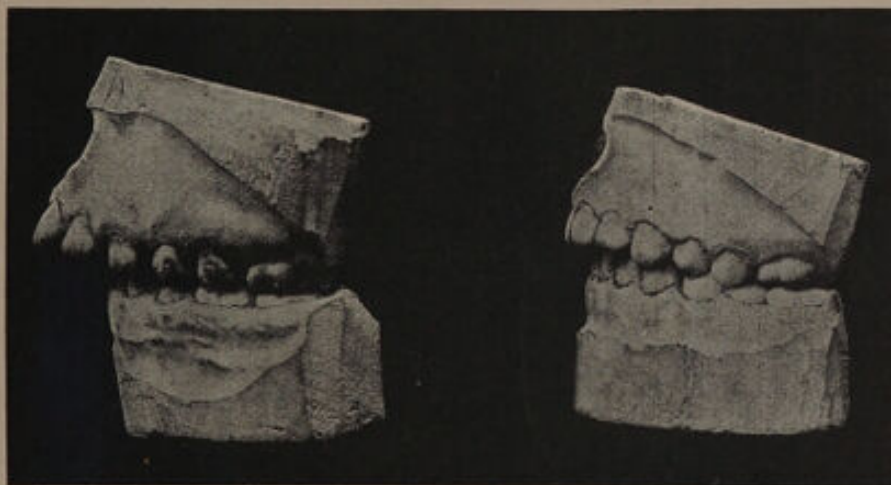

FIG. 291.
Before treatment.

FIG. 292.
After treatment.

wards the canines, second premolars, and first molars. The plate was cut away from the palatal aspects of the incisors, and the bite raised so as to prevent the lower lip passing behind the upper incisors. The pressure exerted by the upper lip resulted in the incisors being brought back almost into place, so that but little mechanical assistance was required. The result is shown in figs. 289 and 290.

In discussing the movements of teeth when

acted upon by mechanical appliances, the method advocated by Dr. Case, of moving both root and crown, was referred to. In the *Transactions of the World's Columbian Congress*, vol. ii., p. 727, a case of superior protrusion treated on his principles is recorded, and Dr. Case claims that the roots as well as the crowns were forced into

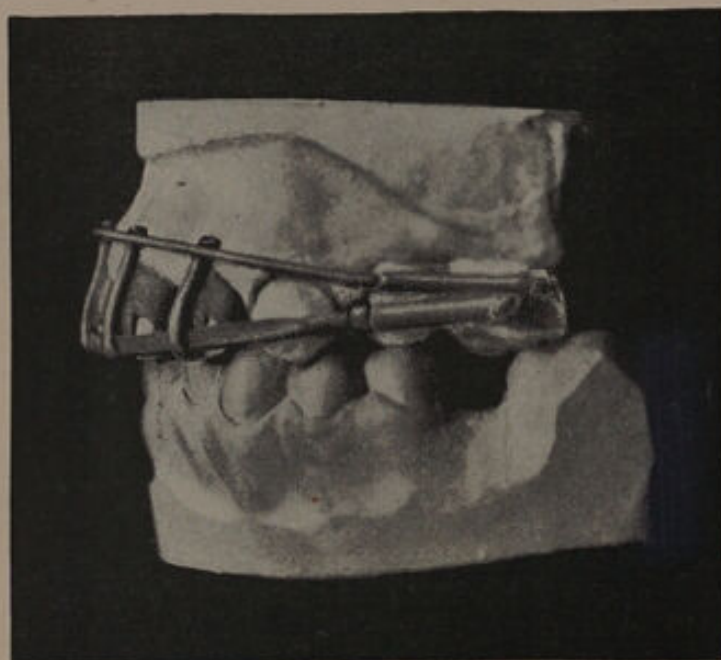

FIG. 293.¹

a more posterior position. The case before and after treatment is shown in figs. 291 and 292, and type of apparatus employed is illustrated in fig. 293. A full description of the method of manufacturing Dr. Case's appliances is given in the "Text-book of Operative Dentistry" edited by Dr. E. C. Kirk.

¹ I am indebted to Dr. Case for the use of blocks 291 to 293.





CHAPTER X.

Protrusion of the Mandible. Underhung Bite. Inferior Protrusion.

IN this condition, when the mouth is closed, the upper front teeth pass within the arch of the lower teeth instead of external to them; the chin is unduly prominent and the upper lip is often short. This abnormal arrangement of the teeth may be limited to the incisors and canines, or it may involve the premolars and molars as well. Protrusion of the mandible is a natural condition in the edentulous.

ETIOLOGY.

Protrusion of the mandible is **frequently hereditary**. It may result from an excessive development of the whole of the mandible, but more often the error in development is limited to the ascending ramus. Under this latter condition the ascending ramus assumes an oblique direction, and causes the horizontal ramus to be pushed forward. This is seen in fig. 294. In the one marked (*a*) the mental process is unduly prominent—a condition not infrequently seen in these cases.

Arrest, or incomplete development of the whole

maxilla, or of the alveolar portion only, may be cited as a cause. In a few instances the deformity can be traced to a constant habit of protruding the mandible.

A protrusion of the anterior lower teeth may result from the habit acquired by some children

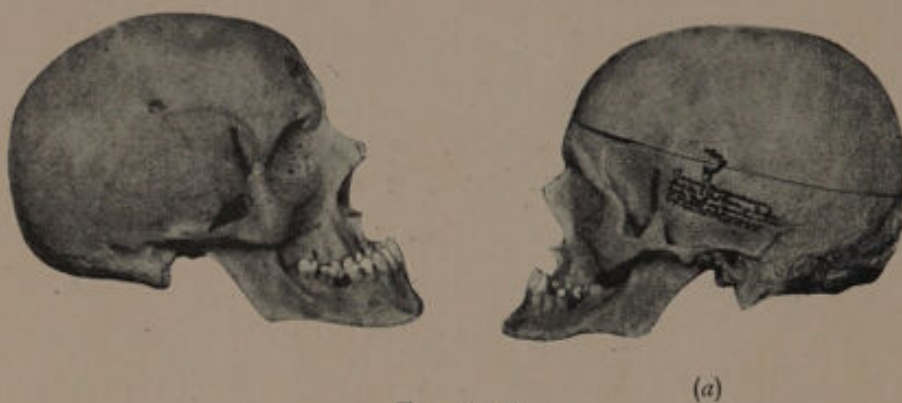

FIG. 294.¹

of hooking the fingers over those teeth, and so exerting pressure in an outward direction. In a few instances the condition may be the direct result of cicatricial contraction. In two instances which have come under my own observation, the protrusion of the mandible commenced with the eruption of the lower third molars. The museum of the Odontological Society also contains models of cases in which the protrusion occurred after puberty.

TREATMENT.

The treatment adopted must depend in a very great measure upon the cause and extent of the deformity, due regard being paid to the

¹ For these illustrations I am indebted to Dr. Grevers, of Amsterdam.

facial expression. When the fault lies in the development of the mandible, treatment is practically out of the question, excepting where the protrusion is slight. If treatment is decided upon, it should be carried out on the lines of (α) expanding the arch of the upper teeth, (β) decreasing the arch of the lower teeth. The former can be accomplished by means of an expansion plate,



FIG. 295.

the latter by retracting the teeth after the removal of an incisor or the first premolars. By this treatment it is often possible to make the arch of the upper teeth pass beyond that of the lower teeth, and a slight improvement in the expression may be gained, but too frequently it results in a complete disorganization of the articulation between the upper and lower teeth. Still further, the superior teeth, even though they may be in a plane

anterior to the inferior, do not overlap, the result being that a retention plate must be worn for a prolonged period to keep them in position.

In cases where the fault lies with the maxilla, a fair result can be obtained by expanding the arch

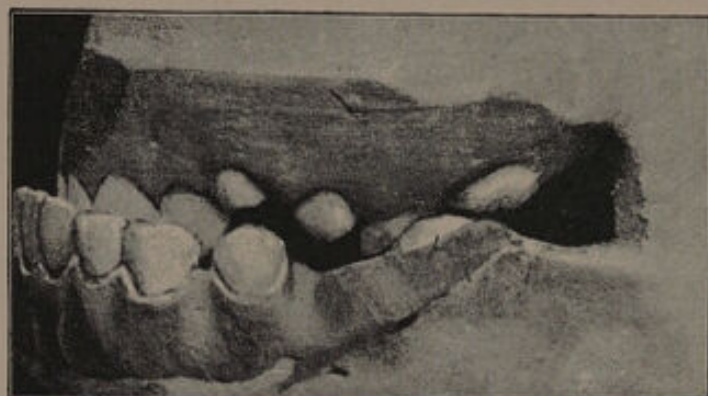

FIG. 296.¹

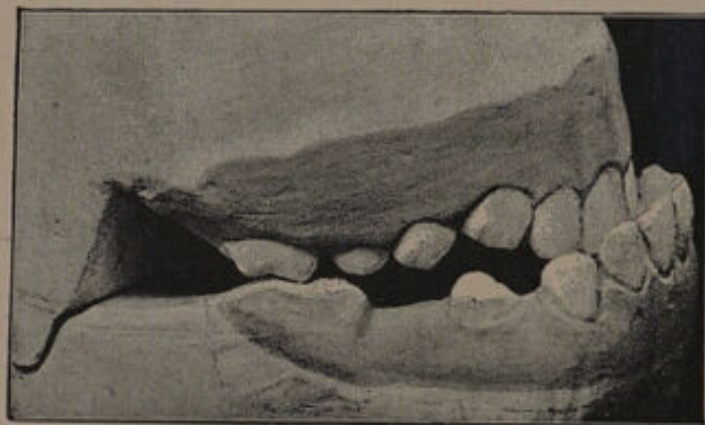

FIG. 297.

of the upper teeth, and at the same time reducing that of the lower. When the condition can be traced to the habit of protruding the jaw, successful treatment may be hoped for, and it is in these

¹ Figs. 296 to 302 are from Ash's Quarterly Circular, June, 1892.

cases that the use of a skull and chin cap produces good results. The pattern suggested by Dr. Angle (fig. 295) will be found useful.

The following cases will illustrate some methods of treatment. The models, figs. 296 and 297, are

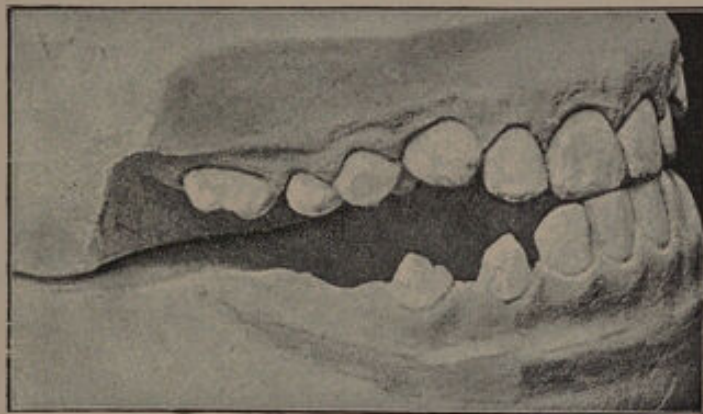


FIG. 298.

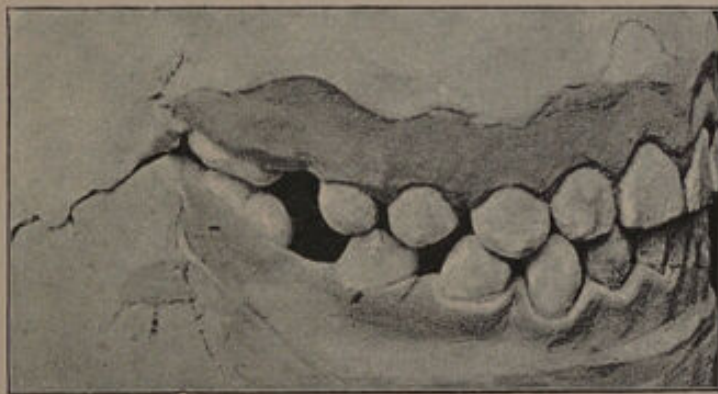

FIG. 299.

from a case recorded by Dr. Heuckeroth and published in Ash's Quarterly Circular, June, 1892. The patient was ten years of age when she first came under observation. The irregularity was attributable to an oblique ascending ramus, by which the

horizontal ramus was pushed forward. The treatment consisted of the use of a skull and chin cap, a plate being made to cover the lower teeth and so open the bite. The treatment was completed in a year but during that period was twice interrupted, first by an attack of measles and afterwards by



FIG. 300.

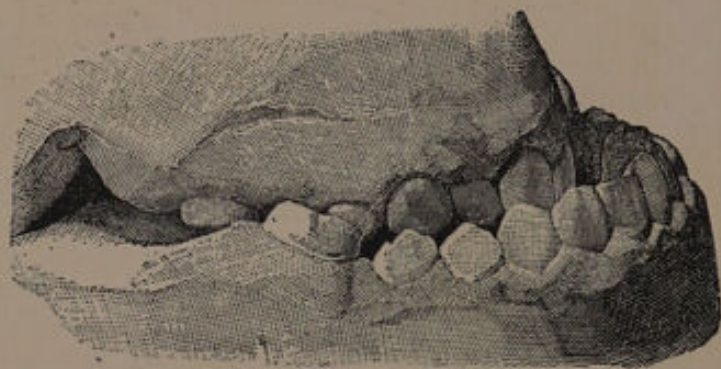


FIG. 301.

scarlet fever. In fig. 299 the final models are shown, the first permanent molars having been removed on account of caries. The treatment resulted in considerable improvement in the facial expression.

In another case recorded by Dr. Heuckeroth

the deformity was still more marked. The patient was eighteen when first seen, and from the models shown in figs. 300 and 301 it will be observed that the upper teeth pass completely within the arch of the lower teeth. At the age of fourteen the first permanent molars in the maxilla were removed to make room for the canines, which had erupted external to the arch. Two weeks after the operation she was attacked by diphtheria, and

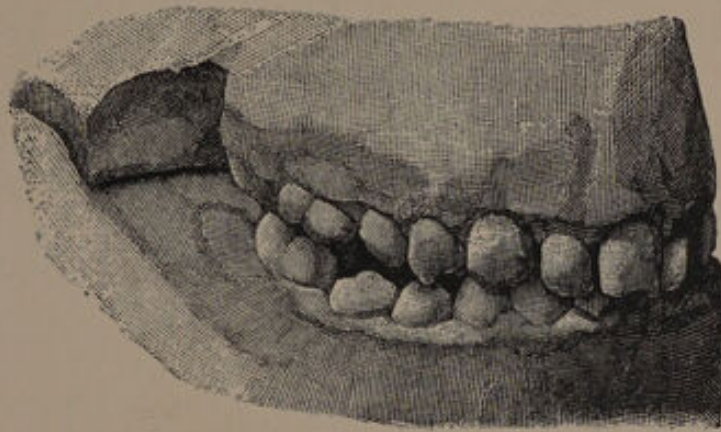


FIG. 302.

on recovery her relations noticed that she frequently kept her mouth open and allowed the mandible to protrude. All attempts to correct this habit proved futile, and the protrusion increased to such an extent that dislocation of the articulation frequently occurred. The patient suffered much pain when eating and drinking, partly owing to the irritation of the tongue by the upper teeth, and no doubt partly to the strain on the muscles and articulation by the protrusion of the mandible.

The patient was of a neurotic temperament, and at the age of sixteen had suffered from hysteria. The treatment adopted consisted of expansion of the upper arch of teeth, and the use of a skull and chin cap.



FIG. 303.¹
Before treatment.

FIG. 305.
After treatment.

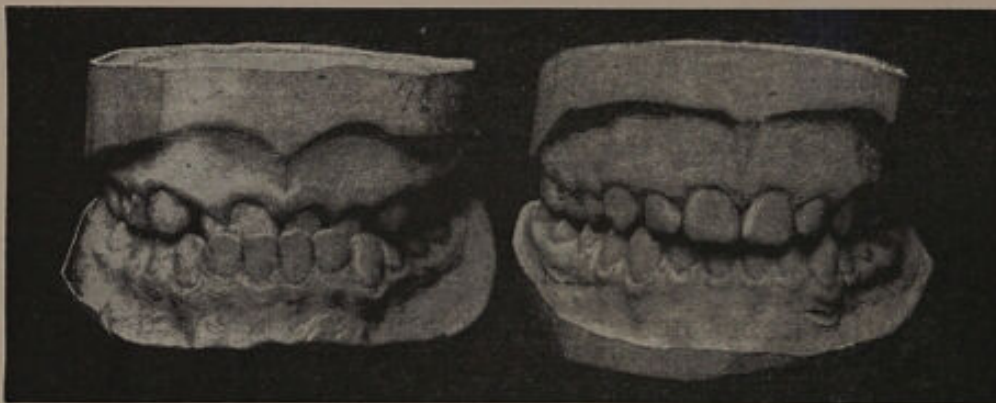


FIG. 304.
Before treatment.

FIG. 306.
After treatment.

The result of treatment, which occupied nine months, is seen in fig. 302. In this case there was undoubtedly some defective development of the

¹ I am indebted to Dr. Case for the use of the blocks, figs. 303 to 307.

maxilla, and the removal of the first permanent molars under the circumstances was hardly judicious. It seems more than probable that the protrusion of the mandible was the result of habit, aggravated perhaps, by the mal-occlusion of the teeth, the skull and chin cap in the treatment only

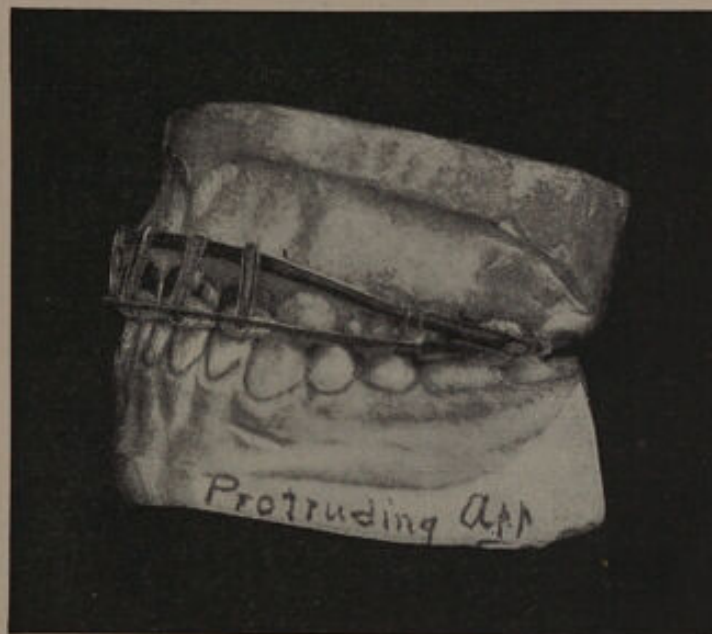


FIG. 307.

forcing the mandible back to its normal position, and not in any way producing structural alterations in the tissues.

In the case shown in figs. 303 and 304, the fault lies with the anterior portion of the maxilla. The patient was under the care of Dr. Case of Chicago, and the treatment consisted of bringing forward the superior incisors by an appliance (fig. 307) based on the principles referred to on p. 41. The result of treatment is seen in figs. 305 to 307.

The models given in fig. 308 show a fair example of a case in which an improvement may be obtained by the treatment being directed to both the upper and lower teeth. The patient was 18 years of age when first seen, and had had the left lower premolar removed in addition to the first permanent molars.

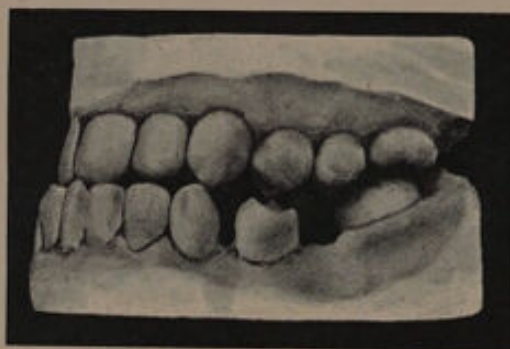

FIG. 308.

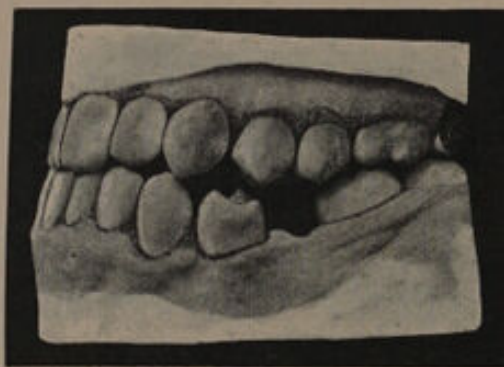


FIG. 309.

The arch of the lower teeth was reduced by the extraction of the left central incisor and that of the upper increased by expansion. The result is shown in fig. 309. There was a distinct improvement in the personal appearance.

The case, the models of which are shown in fig.

310, will help to illustrate one or two points in treatment. The patient was a girl, aged 14. A glance at the figures will show that in complete occlusion there is a good deal of protrusion. In the mandible the first molars have been removed, and in the maxilla the left upper first premolar has been removed to make room for the canine which erupted external to the arch. The superior and inferior premolars fail to occlude, the result being that the whole process of mastication has to be carried out by the molar teeth.

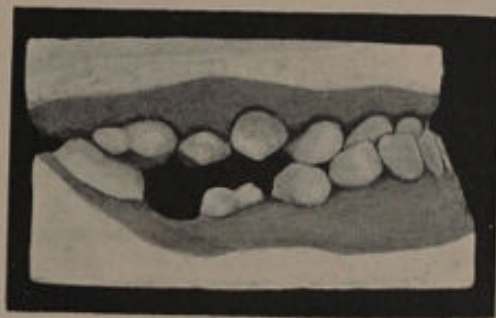


FIG. 310.

On examining the patient it was at once noticed that the mouth was kept slightly open, the lower incisors being brought into contact with the upper. The patient stated that this position was the most comfortable, and that during mastication she constantly suffered from discomfort in the region of the articulation. An examination of the articulation with the teeth in occlusion, as shown in fig. 310, demonstrated that the condyle was brought forward, and was not resting in its normal position in the glenoid cavity. The protrusion was thus to a great

extent artificial, and a fair result could therefore be anticipated with proper treatment.

The lines on which treatment in such a case should be carried out are as follows: The anterior superior teeth should be brought forward so that with the mouth at normal rest they just impinge on the anterior aspects of the lower incisors.

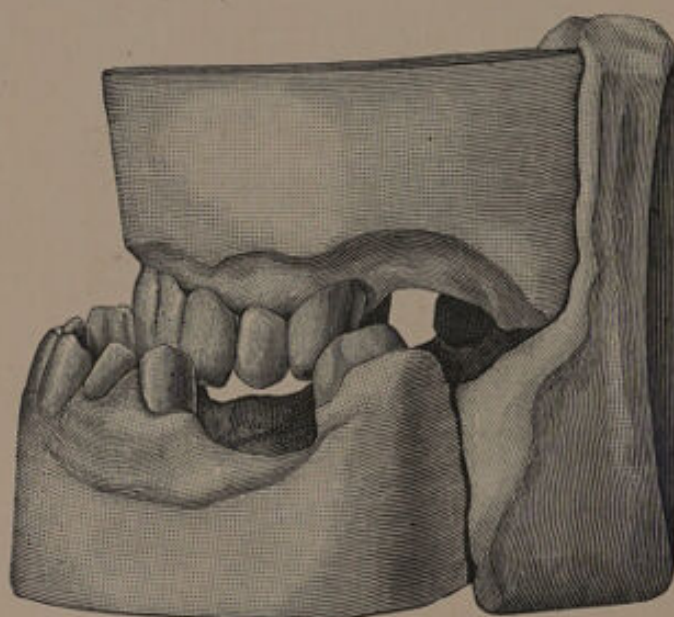


FIG. 311.¹

The next stage should consist in "propping open" the bite by artificial means; unless this is done the upper incisors will be driven forward and made to unduly project. The need for a sufficient masticating surface must not be forgotten. The "propping open" of the bite can be carried out by means of a plate covering the lower premolars and molars, or by means of bridges. A skull and chin

¹ From "Diseases and Injuries of the Teeth."

cap should be worn for some period to counteract any tendency on the part of the patient to return to the old habit of bringing the mandible forward.

In cases such as that shown in fig. 311 the deformity is greatly exaggerated by the loss of the posterior teeth. The insertion of artificial dentures will not only assist in restoring the masticating area, but if the bite is raised will hide the deformity to some extent.

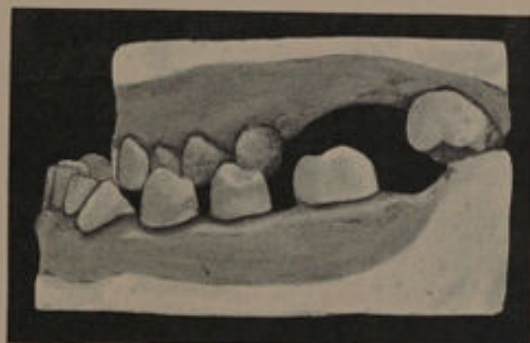

FIG. 312.

When the protrusion of the mandible is so marked that the upper teeth bite completely within the arch of the lower, something should be done to procure a masticating area. Fig. 312 illustrates a case under the care of Mr. H. G. Read. The protrusion is excessive. The upper first premolars are completely within the arch of the lower, and although the second premolars and first and second molars are missing, it can easily be seen that they could have been but little use for masticating purposes.

Mr. Read in this case inserted upper and lower

dentures. The lower denture was well thickened on the lingual side as shown in fig. 313. This inner thickening occluded with the upper teeth and gave a fairly efficient masticating area.

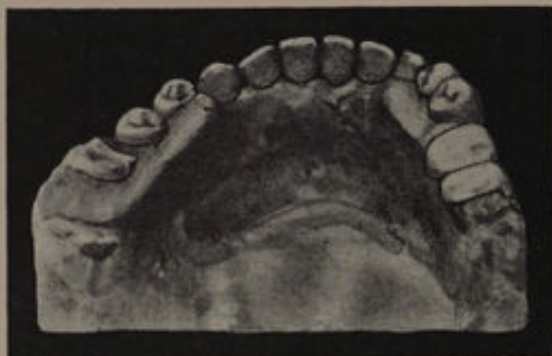

FIG. 313.

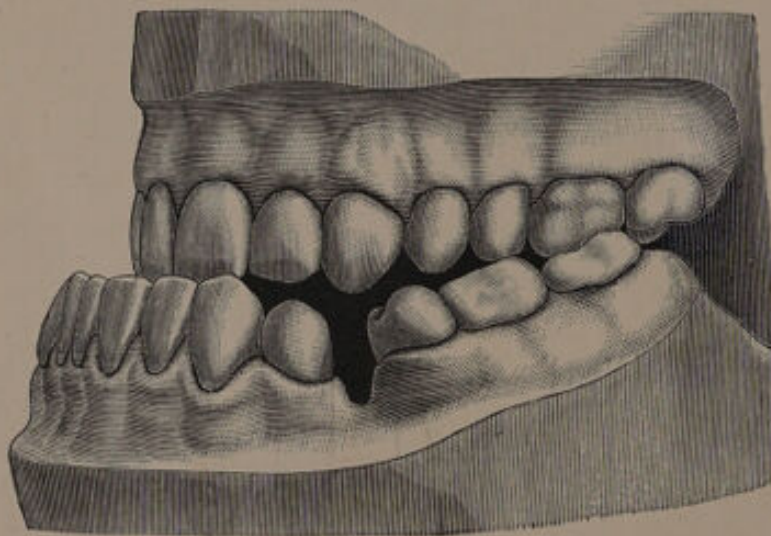


FIG. 314.

In severe types of inferior protrusion similar to those just referred to, it might be possible to improve the condition by surgical means. In the *Dental Cosmos* for July, 1898, Dr. James Whipple reports a case where considerable improvement was obtained

by double resection of the mandible. The patient was a man aged about 23. The amount of irregularity is shown in fig. 314. The operation carried out was as follows:—

Incisions were made and "the muscles and other integuments were detached from the jaw bone. A double saw had been devised, consisting of two saws four inches long, attached to the sides of a single handle, and so adjusted as to make a cut in the jaw, just as wide as the space between the two bicuspidis on the left side. The incision was made through the internal surface of the bone from the superior border to the base. No vessels were ligated, as the hæmorrhage was not profuse after the vessels emptied themselves. The bone was cut almost, but not quite through. No attention was given to the contents of the inferior dental canal. A small hole was now drilled through the bone on each side of the cut near the inferior border for the reception of a wire ligature."

A similar operation to that just described was performed on the right side. After the holes were drilled the remainder of the sawing was done on both sides, and the two small sections of the jaw removed. The cut surfaces of the bone were drawn together by means of soft copper wire ligatures. At the end of three weeks no union had taken place, and on the left side there was suppuration. An alteration was made in the method of fixing the fragments of bone, and at the end of the eighth week union was complete. The condition of the teeth is shown in fig. 315. The mal occlusion

of the teeth was corrected by crowning, the final result being seen in fig. 316. The appearance was greatly improved. It is a debateable point whether operative interference similar to that just described

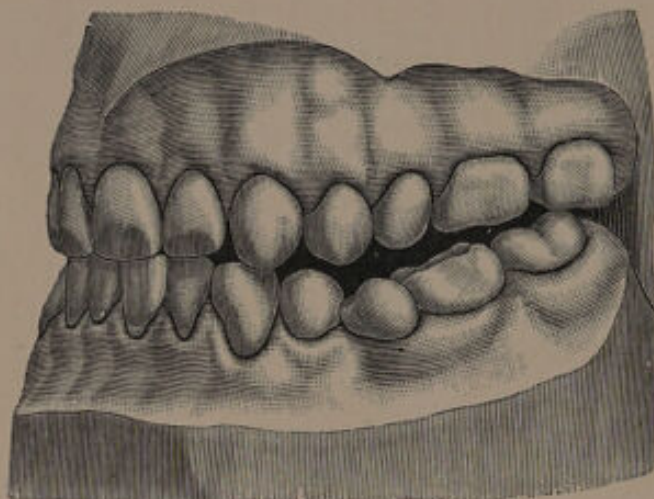


FIG. 315.

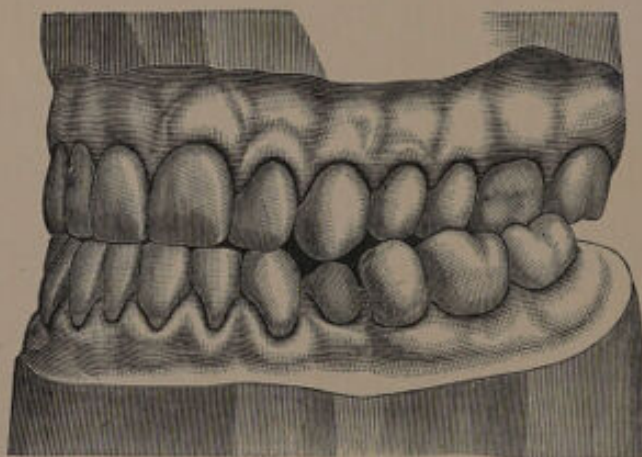


FIG. 316.

is good surgery. The fact must never be lost sight of that such an operation renders the patient liable to all the complications and sequæ attendant upon surgical interference. Even in the case just des-

cribed extensive suppuration seems to have occurred. The surgery of the jaws is still in an unsatisfactory condition, and until one is more certain of obtaining good union without suppuration, surgical interference seems hardly justifiable where more simple measures are at hand to improve at least the masticating area.

215
146
69





CHAPTER XI.

Lack of Occlusion—"Open Bite."

THIS term is applied to that abnormality in which the back teeth alone occlude when the mouth is closed, the remaining teeth being separated by an interval.

From a clinical point of view "open bite" may be considered under three headings:—

(1) Cases where the premolars and the molars occlude, but the cutting edges of the upper and lower anterior teeth are separated from one another by a space more or less oval in shape.

(2) Cases where the majority of the posterior teeth, as well as the anterior teeth, fail to occlude.

(3) Cases of partial lack of occlusion in the premolar and molar regions.

ETIOLOGY.

In cases coming under heading (1) the deformity is invariably the result of **an acquired habit, such as thumb or finger sucking**, the thumb or finger being bent and inserted horizontally between the cutting edges of the upper and lower teeth. The pressure thus exerted forces the superior teeth, as well as the alveolar process, in a direction upwards and slightly outwards. In the lower the teeth are forced down-

wards, but the displacement is not nearly so well marked as in the upper. The artificial teats and similar articles which are given to troublesome children to pacify them are a fruitful cause of this form of "open bite."

In cases coming under heading (2) the etiology is frequently obscure. In a few instances the mischief can be traced to the **use of regulation plates**, the back teeth elongating through being left uncovered.

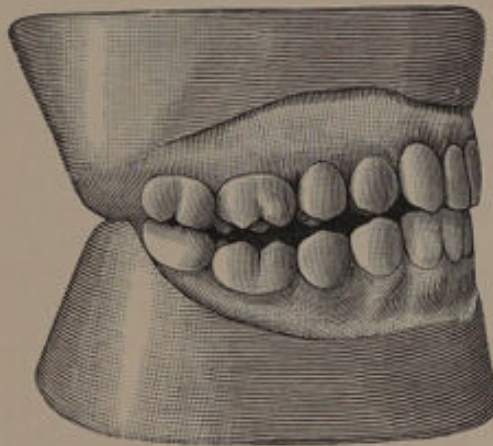


FIG. 317.¹

An example of "open bite," arising in this way is shown in fig. 317. In many cases—more especially the severe ones—the chief cause of trouble lies in some **defective development of the ascending ramus**. Occasionally the deformity can be traced to an obliquity of the ramus, an instance of which is shown in the following figure from Tomes's "Dental Surgery" (fig. 318). This drawing also serves to illustrate another feature in the anatomy of some

¹ From "Diseases and Injuries of the Teeth."

examples of "open bite," namely, the increase in the development of the anterior portion of the mandible. In many cases the defective development of the ascending ramus is probably an actual arrest in growth, known as "shortening," which will necessarily produce an oblique angle.

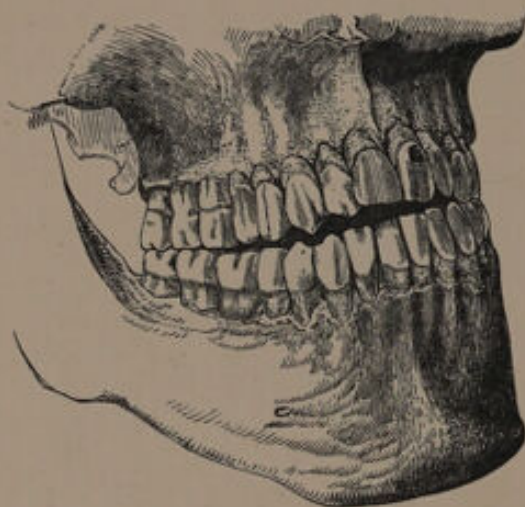


FIG. 318.

Another peculiarity which is noticeable in some patients is the somewhat sharp bend downwards of the horizontal ramus, at the point where the most anterior fibres of the masseter muscle are inserted. "Open bite" can at times be traced to an arrest in development of the anterior portion of the maxilla, and this condition is also frequently associated with the defective development of the ascending ramus already alluded to. An arrest in development of the superior alveolar process, together with a "honeycombed" condition of the teeth, is often met with in cases of "open bite," the palate being unusually high. Such patients

are generally mouth-breathers, and this would lead one to suspect an intimate **relationship between mouth-breathing and "open bite."** On this point Mr. Tomes¹ says: "In most instances, the patients have been unable without effort to breath through the nose, and the mouth has consequently been habitually kept open even during sleep. Possibly the constant traction exercised upon the anterior part of the jaw in keeping the mouth open, may have had some influence in determining the peculiarity of form, and the freedom from the pressure exercised mutually by the antagonistic molar teeth, upon each other, may have led to their rising higher with their sockets than they do when their conformation is normal."

Against this it should be remembered that where mouth-breathing is most marked, only the second molars or rather the most posterior teeth meet, a fair space existing between the first molars. If the posterior teeth rise in the manner suggested by Mr. Tomes, it might reasonably be expected that the same law would apply to the anterior teeth, but such is not the case.

In a paper on "Open Bite," contributed to the *Dental Record*,² Mr. Baldwin recounts the views of Herr Schmidt as follows:—"In most cases of open bite which he has observed, the patient has been of a strumous constitution, and this has caused an enlargement of tonsils, and a generally increased

¹ "A System of Dental Surgery," 4th edition, p. 160.

² Vol. ix., p. 147.

thickening of mucous membrane of both nose and fauces. Thus the difficulty of breathing through the nose is explained, and also there is presented a reason for an additional difficulty of breathing through the mouth. The result of this is that the mouth has been held open, the tongue has been held down to the floor of the mouth, and the tongue's tip has been pressed against the back of the front part of the lower jaw and teeth, in a downward and forward direction. This operating on the yielding bone of a strumous person, has caused the alteration of the angle at which the body of the lower jaw is set to the ascending ramus, so that the deformity of open bite is produced." He also suggests that the impact of the column of inspired air upon the roof of the mouth, is a cause of the abnormal vaulting of the palate in these cases.

This explanation does not account for the bending of the mandible already referred to. The principal force of the muscles at the posterior part of the mandible is upwards, and at the anterior part downwards. The masseter runs as far forward as the point where the facial artery crosses the bone, and it is near this spot that the marked bending occurs. May not this bending be produced by muscular effort? The mouth is kept open of necessity, and the mandible is therefore constantly being acted upon by the depressors of the jaw, while the muscles at the back of the jaw, namely the temporal, masseter and internal pterygoid, are constantly tending to raise it. It is no new

phenomenon to find bones bent in various directions by muscular force, as for example in the case of "rickets," and it seems quite conceivable that the muscles acting under abnormal conditions produce the bending.

With reference to this suggestion, Mr. Tomes¹ thinks that the following is the more probable explanation. "It must be remembered that this bending, and in fact, all the phenomena of open bite arise whilst the jaw is growing rapidly, elongating backwards. May it not be that this backward elongation taking place whilst the child is a mouth-breather, and the symphysis pulled down by its depressor muscle the original growth has taken place in that form, rather than that already formed bone has been bent?"

Partial lack of occlusion in the premolar and molar region is difficult to account for. In some instances, however, it can be traced to a local arrest in the development of the jaw, and in a few others to faulty extraction.

TREATMENT.

It is impossible to lay down any hard and fast rules for the treatment of "open bite," as each case must of necessity be considered on its own merits.

To deal first with *class I.*, namely, **cases where the deformity is limited to the anterior teeth.** In cases seen at an early age, before the eruption of the permanent teeth, much may be done by breaking

¹ "A System of Dental Surgery," 4th edition, p. 164.

the patients of any vicious habits they may have acquired, and with the eruption of the permanent teeth the condition will be to some extent improved. It is well during this period to advise the use of a skull and chin cap. When the habit of thumb sucking, &c., has been continued during the eruption of the second dentition, or when the deformity is severe, treatment is of little avail. But it should be remembered that, although the appearance of the patient is a little unsightly, the premolars and molars articulate, and the teeth can, therefore, perform their function of mastication perfectly well. In these circumstances it is generally best not to interfere, although where the personal appearance is of great importance, the crowning of the upper six anterior teeth might be deemed advisable.

In a very severe case this would hardly be practicable, and it would be better to remove the anterior teeth, and insert a continuous gum denture.

The treatment of cases coming under class II. may be considered under the following headings. (1) Removal of adenoids and enlarged tonsils ; (2) the use of the skull and chin cap ; (3) the removal of teeth ; (4) cutting in the bite ; (5) a combination of all four.

(1) *Removal of Adenoids and enlarged Tonsils.*—As nasal obstruction may be, directly or indirectly, one of the causes producing open bite, it is essential that any adenoids and enlarged tonsils should be at once removed, as all such growths are inimical to health.

(2) *The Skull and Chin Cap.*—The skull and chin cap is strongly recommended by some, and in a few cases may perhaps be efficacious in bringing the teeth into proper occlusion—a result which

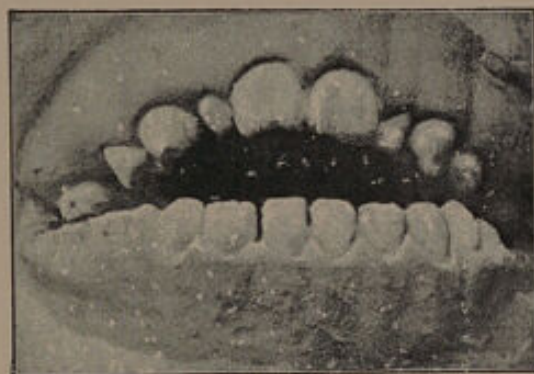


FIG. 319.—The case of Heuckeroth before treatment.

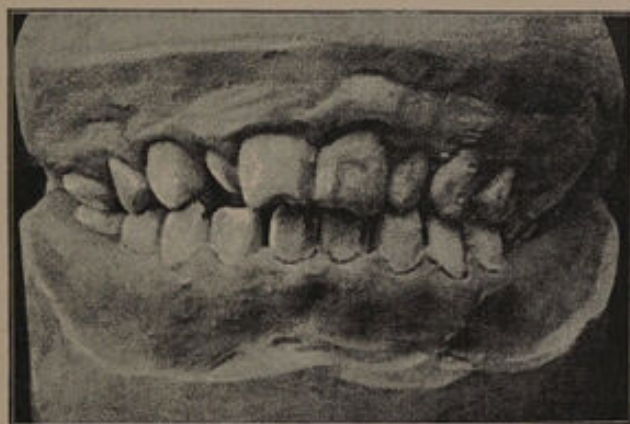


FIG. 320.—The case of Heuckeroth after treatment.

is probably obtained by the posterior teeth being forced into their sockets. Cases treated by this method are recorded by F. Heuckeroth¹ and Tomes.² If this treatment is to succeed the appa-

¹ C. Ash & Sons' Quarterly Circular.

² "A System of Dental Surgery," 4th edition p. 161.

tus must be constantly worn, and, in addition, must be properly adapted, care being taken that the elastic bands stretching between the chin and skull caps exert pressure in an upward and not a backward direction. The most suitable cases for this form of treatment are those which are due to some mal-arrangement of the teeth, and not to defective development of the ascending ramus or angle.

(3) *The Removal of Teeth.*—The extraction of the second molars may be quite sufficient to remedy some examples of open bite, and the case shown in fig. 317 was cured in this way, but, unfortunately, the first molar is generally unsaveable, and under these circumstances the removal of the second molars would not be justified whilst other methods can be resorted to. Under these conditions the treatment most likely to lead to beneficial results is to remove the remains of the first molars, and employ the skull and chin cap, and to follow this up by the operation of "cutting in the bite." In examples of open bite which come under notice before the second molars have erupted, the most satisfactory plan seems to be the removal of the first permanent molars as soon as possible, and the use of a skull and chin cap during the eruption of the second molars. When the deformity is very severe it may be necessary to resort to the extraction of a large number of teeth, as in the case (fig. 321) recorded by Mr. H. Rose in *The Journal of the British Dental Association* for November, 1896, where the whole of the teeth were removed and dentures substituted with beneficial results.

(4) *Cutting in the Bite*.—This method is extremely satisfactory, and may be used alone, or in combination with either extraction, or the skull and chin cap. The treatment consists in grinding down the teeth until the premolars and the molars articulate. This operation, which is by no means a new one, might with advantage be more generally

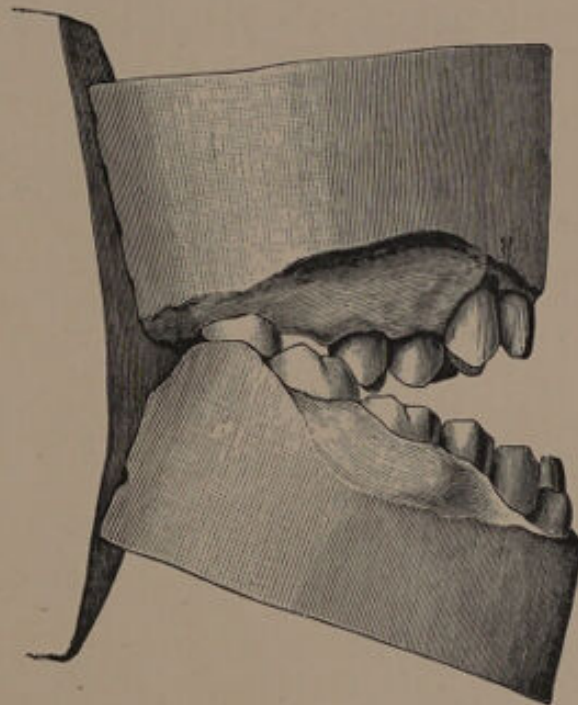


FIG. 321.

adopted. The points in its favour are : (1) it gives the patient a good surface for mastication ; (2) it is permanent—teeth forced down by the skull and chin cap tend to rise again as soon as the apparatus is discarded ; (3) it relieves the patient of a long and tedious course of treatment.

The operation should extend over several sittings, and a fair interval should be allowed to elapse

between each. In the case shown in figs. 322 and 323 the treatment was spread over the period of one year. The objects of leaving an interval between each sitting are (1) any irritability of the pulp caused by the operation has time to subside, and (2) secondary dentine has time to form and so

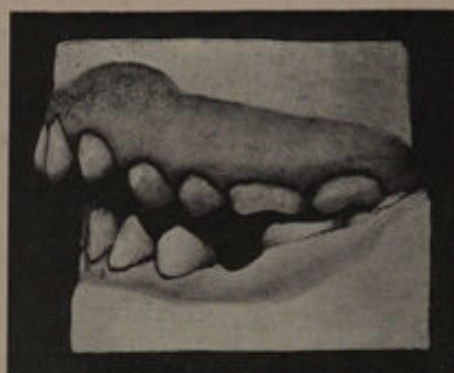

FIG. 322.

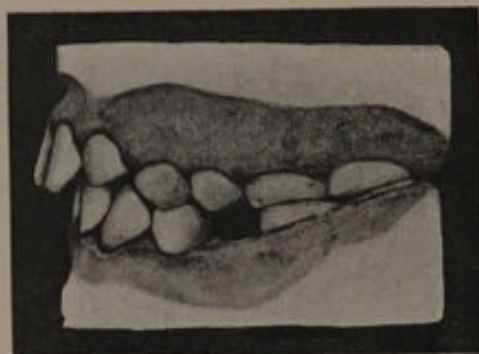

FIG. 323.

allow a greater portion of tooth structure to be removed. The patients should be directed to apply spirits of wine to the cut surfaces twice a day, and the necessity of first drying the surfaces and of keeping them free from saliva for about a minute after the spirit has been applied should be impressed on them. By this means the cut surface of the

dentine is to a certain extent hardened, and any sensitiveness that may exist is allayed. It is also a good plan after each sitting to apply nitrate of silver to the cut surfaces. Another case treated by cutting in the bite is shown in figs. 324 and 325.

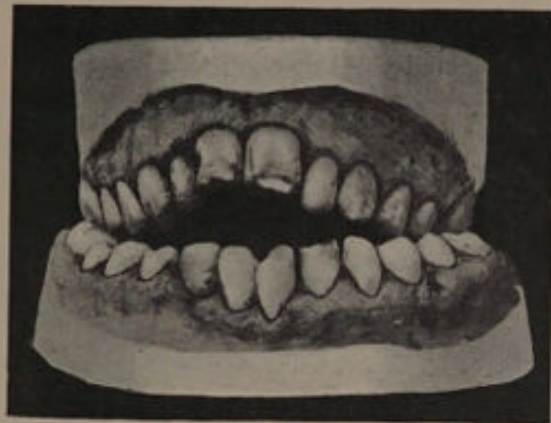

FIG. 324.

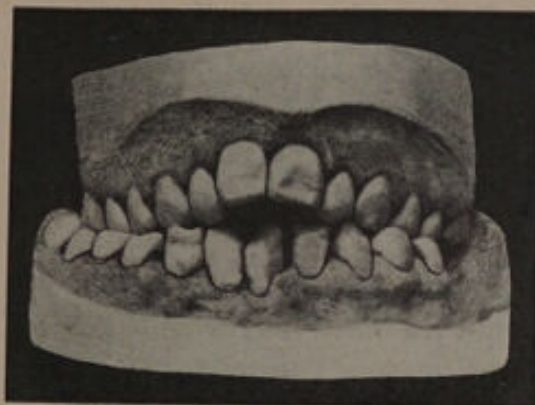


FIG. 325.

(5) *Combination of Methods.*—In very many cases where a single line of treatment is inadequate to produce a good result, a combination of methods may be successful. This is well shown in the case illustrated in figs. 326 and 327. Here improvement to any great extent can hardly be expected by adopt-

ing any one single method, while a combination would be efficacious. In such cases it is useful to pursue the following course:—

(1) To extract the first permanent molars.

(2) To use a skull and chin cap for perhaps six to twelve months, namely, for the period during which the second permanent molars are moving forward in the gap caused by the removal of the first permanent molars, at the same time expanding the arch if needful.

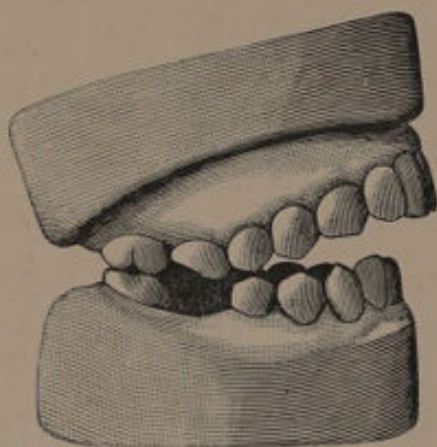


FIG. 326.

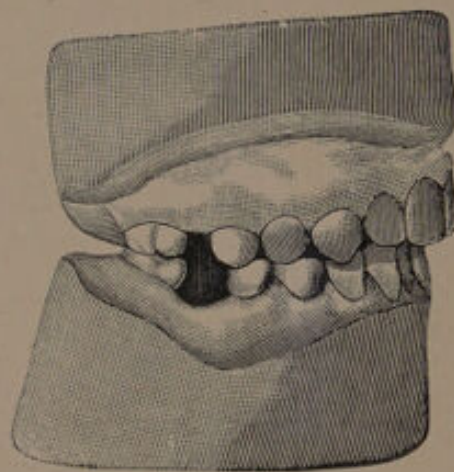


FIG. 327.

(3) To “cut in the bite” if the skull and chin cap is not sufficient to bring the jaws together.

Cases coming under class III., namely, “partial open bite,” can usually be remedied by mechanical means. The models shown in fig. 328 are from the mouth of a patient under the care of Mr. H. G. Read. There is marked lack of occlusion on the right side. In the maxilla the first molar has been extracted, and apparently there has been a considerable absorption of the bone. The second

premolar and second molar have approximated so as to fill the space. In the mandible the second premolar has erupted far back, probably the result of an early removal of the first molar. A carious

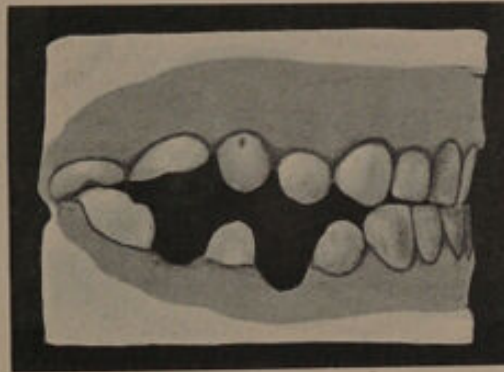


FIG. 328.

cavity on the anterior aspect of the second upper molar was filled, while in the mandible a bridge was arranged. By these means an efficient masticating area was created.





CHAPTER XII.

The Immediate Regulation of Teeth.

IN discussing the treatment of rotated incisors, attention was directed to the operation of actual torsion, an operation which has long been in vogue. Within the last few years the immediate regulation of teeth has been considerably extended, and it is proposed to give a short *résumé* of the methods usually advocated.

In a communication to the Odontological Society,¹ Mr. Sidney Spokes showed some cases of instanding incisors and canines which he had treated by immediate methods. The method pursued is as follows. The temporary teeth are extracted and their permanent successors are then grasped with forceps and forcibly advanced over the edges of the lower teeth. Where there are neighbouring teeth a silver wire interlaced is sufficient to hold the advanced tooth in its new position. In the ten cases shown, four centrals and six laterals had been regulated and were in good positions.

When last seen by Mr. Spokes the pulps in every instance had responded to the thermal test. Of

¹ Vol. xxvii., p. 180.

three cases of canines treated only one was a success. The accidents which may occur are (1) loss of the permanent tooth through injury to its pulp, or by unintentional extraction; (2) fracture of portion of the tooth.

Dr. L. C. Bryan advocates a somewhat different method. The following account of a demonstration given by him, and recorded in the *Transactions of the World's Columbian Dental Congress*,¹ illustrates his *modus operandi*. "The patient, a girl aged 15, had a right superior lateral incisor locking in behind the lower incisors and had space between the central and cuspid for immediate regulation. Cocaine was injected, and with a small circular saw a perpendicular incision was made through the gum and half through the alveolar septum on both sides of the root of the lateral, from the apex of the root to the crown of the tooth. The 3-inch flat steel guard, lined on the gum side with rubber $\frac{1}{8}$ -inch thick, was fitted to the curve of the gum and formed a rest for the long, round front beak of the forceps, and the other beak rested against the distal wall of the lateral up to the gum; with slight pressure the connection of the tooth with the distal alveolar wall was severed, and the tooth came easily forward to its place in the arch in front of the lower teeth, bringing with it the front wall of the alveolus firmly attached to the root and ready to heal quickly and reunite with the neighbouring borders of alveolus. The apex of root was not disturbed

¹ Vol. ii., p. 997.

in its position. As the tooth was somewhat short and did not lock over the inferior incisors and showed a tendency to go back, it was ligated with silk the day after the operation." The forceps recommended by Dr. Bryan are shown in fig. 329.

Dr. Bryan informs me that he has since modified his procedure and has discarded the metal guard for a vulcanite plate, as he found the flat steel guard a somewhat unstable fulcrum. He suggests

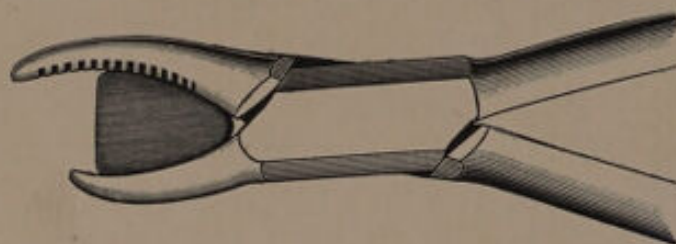


FIG. 329.

that in a case similar to that shown in fig. 330 it would be well to take a model of the case and saw through the plaster cast as one does through the jaw to regulate. This section should be broken out as far up as the root of the tooth goes, and fitted and secured with the crown in the place it will occupy when in line and properly articulated with the lower teeth. This done, a wax plate should be fitted over the whole palate. From the wax a space should be cut out sufficient to accommodate the inner blade of the forceps. The forceps should then be placed in the position they will occupy during the operation, and a depression

forced in the wax with the outer blade of the forceps (*a*). This depression will prevent the outer blade slipping during the operation. The vulcanite at this part should also be strengthened with a strip of metal. A plate of this character, he maintains, forms a thoroughly stable fulcrum.

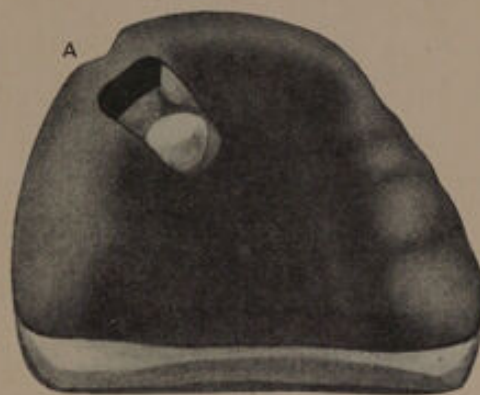


FIG. 330.

Mr. Cunningham, in a paper read before the World's Columbian Dental Congress,¹ has applied the method of regulating somewhat extensively, in one instance five teeth having been moved at one sitting. The paper, which records several cases and is fully illustrated, is well worthy of perusal. The plan suggested by him is as follows:

"(*a*) All the teeth should be thoroughly scaled, cavities filled, and an alcoholic saccharin wash used several times a day before operation.

"(*b*) On day of operation: brushing the teeth and bathing them with saccharin wash—better with

¹ Vol. i., p. 129.

H₂O₂ than H₂O for dilution—same wash after the operation, and frequently next few days.

“(c) It is well except in the simplest cases to have studied a model, making a re-arrangement of the teeth on a duplicate model. If a splint can be prepared from this ready for use immediately after the operation, so much the better.

“(d) All being ready, cut the alveolus with a thin circular saw, $\frac{7}{8}$ -inch to $1\frac{1}{4}$ -inch in diameter, not thicker than thin note paper, into such sections as are necessary. This is quickly done and can be borne quite frequently without any anæsthetic. Forceps, elevator or other instrument is used for pushing, pulling, or rotating the tooth sections into place. Forceps should have the beaks guarded. I use copper sheaths moulded and soldered so as to fit the beaks fairly tightly. Rubber sheaths soft or hard will also do. Dr. Bryan's special forceps with curved support for bringing a tooth inside the arch into line seems well adapted for this purpose. In moving teeth backward or rotating teeth out of line into the arch is much facilitated when a badly carious neighbouring tooth must be extracted. This extraction may be done at the time, but possibly better two days or so previously, as the local post-operative inflammation facilitates the bending and movements of alveolus. In such cases the sectioning of the tooth and its alveolus may be done with a pair of surgical bone cutters, or even with Physick's wisdom teeth forceps.

“The wedge-shaped beaks of the latter are extremely useful when it is necessary to push the

teeth backwards. The movement of the tooth or teeth into the desired position may be very easy, but often requires great strength carefully applied. One to six teeth have been so moved. The chief point in the operation is to move each tooth with its socket entire as far as that may be possible.

"(e) The teeth when in position should be ligated with silk or thin silvered steel wire, preferably the latter, or fixed in a splint. Thin German silver or platinum bands soldered together make a good splint.

"(f) Care must be taken in closing the teeth, as the articulation is almost certain to require adjustment by clicking, &c. Carborundum wheels work quickest.

"(g) When finished, syringe thoroughly with peroxide, saccharin wash, especially any pockets or spaces marking the previous position of the moved teeth. Paint all the bleeding or cut surfaces with Richardson's styptic colloid. To a saturated solution of tannic acid in alcohol and ether (equal parts) pyroxylin (gun cotton) is added as the liquid will dissolve (tannin collodion preparation). The pain has usually subsided by this time, and the patient feels fairly comfortable. The patient should be seen next day in case the teeth have moved, syringing, styptic and cleansing as before. If possible continue this treatment for next few days, the patient always using the wash after meals. In a few cases new ligatures may be unnecessary, ligatures should be removed or dispensed with as required by the indications. A period of three or

four weeks is usually ample time for retention by ligature or splints."

Mr. W. H. Dolamore¹ has had considerable experience with this method of regulating. He attaches great importance to the proper fixation of the tooth after correction, and adopts a metal splint struck over the tooth and fixed with cement. In preference to the circular-bladed saw he uses one somewhat like a Hey's, only thinner.

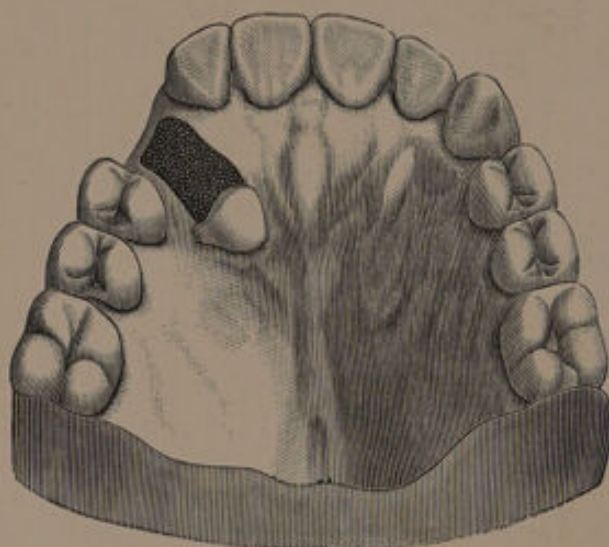


FIG. 331.—Method of treating an instanding maxillary canine.

Dr. Talbot advocates² a combination of surgical with mechanical treatment. His method consists in removing the osseous tissue in "the line of travel of the tooth to be moved, leaving a small amount of process about the root of the tooth,

¹ *Transactions of the Odontological Society of Great Britain*, vol. xxxii., p. 42.

² *Dental Cosmos*, vol. xxxviii., p. 909.

holding intact the peridental membrane" (fig. 331). For this purpose he employs coarse-cut burs. He states that he has practised the method for over

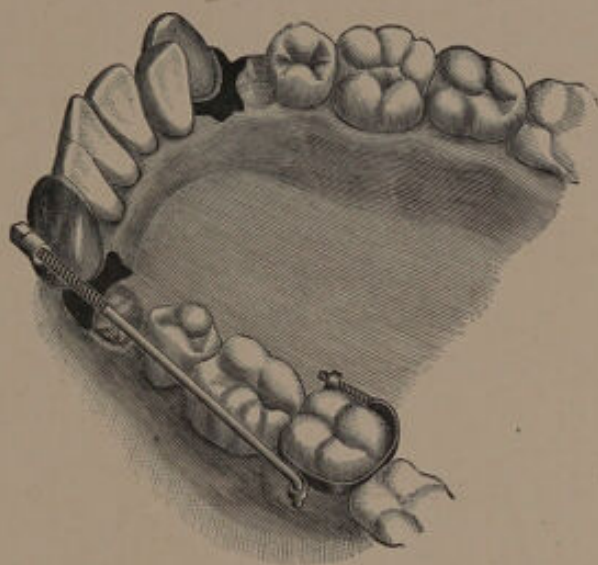


FIG. 332.—Method of retracting a mandibular canine.

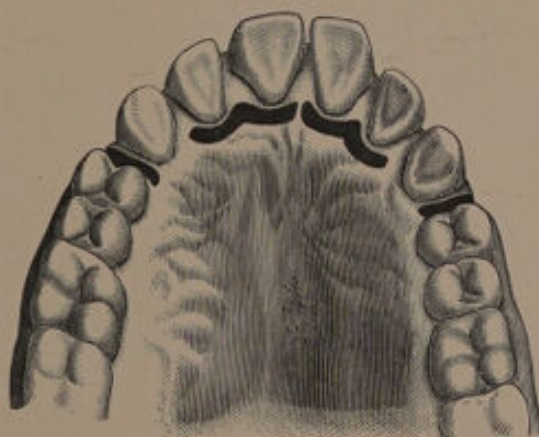


FIG. 333.—Method of treating a case of superior protrusion.

seventeen years, and that although he has had a few cases of infection, such contingencies in his

opinion need not be seriously considered, as with proper precautions no bad results will follow.

There is much to be said for and against immediate regulation, but until its methods have been more fully tested, it will be difficult to express a definite opinion as to its value. The results already obtained certainly justify a more extended trial of the methods advocated.





INDEX.

- Absorbent organ, action of, 8
Adenoids, removal of, 222
Adults, The Regulation of Teeth of, 15
Africans, Teeth of, 3
Alveolar, abscess, as a Cause of Irregularities, 13
Alveoli, Permanent Enlargement of, following Regulation, 23, 43
Americans, Prevalence of Irregularities amongst, 3
Anchorage, point of, 24
Angle's, Dr., appliances, 32-35, 158, 159, 203
Appliances, Fixed, 32
 " regulating (*see* Regulating)
 " Removable, 24
Arch, Expansion of, 71-73, 136
 " narrow, 148

Baby soothers and open bite, 217
Bite, 17, 25, 70, 150-162
 " cutting in, 225
 " disarrangement of, 130
 " Jumping the Bite, 168, 174
 " Open, 147, 180, 216-229
 " propping open, 210
 " raising the, 179, 197, 211
 " Underhung, 199-215
 " unlocking the, 19
Britons, Early, The Teeth and Jaws of, 1, 3
Bryan, Dr. L. C., Method of Regulating, 231
Bryan's Forceps, 232

Canine and lateral, skiagram of, 22
 " Angle's method of retracting, 33, 36
 " erupted externally, 68, 138
 " erupted in the arch, 25, 78
 " moved by a jack screw, 32
 " plate for retracting, 30
 " retraction of, 154
 " separation of, 170
Canines, Abnormalities of, 61-63, 102
 " Deciduous, Premature Removal of, 7
 " Irregularities, 103
 " Partial Eruption, 61
Caries and protrusion, 162
 " Early Treatment of, 14
Case, Dr., Method of Moving Roots and Crowns, 41, 198, 207
Causes, General, 1
 " Local, 6
Centre of the Mouth in Relation to Regulation, 20
Centre, shifting of, 21
Civilisation, a Cause of Irregularities, 4
Children's Teeth, examination of, 14
Chinese, Teeth of, 2, 3
Cicatrices, as a Cause of Irregularities, 13
Cleft palate, 60
Co-operation of Parent and Patient in Regulation, 16
Crowded mouth, Positions of teeth, 68
Crowding, 6, 11, 45, 64, 77, 145, 147

- Cutter, Dr., Method of "Jumping the Bite," 171
- Deciduous teeth, abnormal, 8-9
 " Teeth, Premature Removal of, 6
- Delivery, Point of, 24
- Displacement producing crowding, 110, 111
- Dolamore, Mr., Method of Immediate Regulation, 237
- Elasticity as a Force in Regulating, 27
- Eruption, period of, 6
 " normal condition of, 8
 " of teeth, 64
 " order of, 69
- Extraction, Choice of Tooth when Employing, 73-76
- Extraction deciduous canines, 7
 " disturbing the bite, 176
 " first permanent molars, 7, 150
 " molar, 19, 67, 75, 78-81, 102, 115, 120, 122, 126, 138, 168, 177, 204, 209, 228
 " of canine, 16, 101, 102, 108, 109
 " of deciduous teeth advised, 14, 78
 " of displaced canine, 62
 " of displaced incisors, 59, 112
 " of incisor, 80, 93, 97, 144, 164, 177, 183, 187, 189
 " of opposing teeth, 19
 " of premolar, 19, 20, 74, 75, 82-90, 98, 102, 114, 122, 126, 129, 134, 140, 167, 168, 177, 189, 191, 197, 208
 " of supernumerary teeth, 53
 " of teeth in crowded mouths, chap. v.-viii.
 " premature second deciduous molar, 6
- Extraction, replacement of tooth after 50
 " to relieve pressure, 166
 " to remedy open bite, 224
- Extruded tooth, Goddard's treatment, 56
- Facial Expression in Relation to Regulation, 16
- Family Peculiarities, Influence on Irregularities, 2, 15
- Farrar, Dr., Method of Moving Roots and Crowns, 37, 39
- Fixed Apparatus, 32
- Frænum of the Lip, 12, 147
 " " " Division of, 54
- Glenoid Cavity, changes in during regulation, 176, 209
- Gold Wire, 32
 " and Retraction, 154
- Gums, Hypertrophy of the, a cause of irregularities, 13
 " Inflammation of, following Regulation, 43
 " Sloughing of, following Regulation, 43
- Habit causing protrusion, 200, 205, 207
- Hare-lip, 60
- Hawaiians, Teeth of, 2, 3
- Heredity, Influence on Irregularities, 15
- Heuckeroth, Dr. F., Cases treated by, 203, 223
- Hickory-wood Wedges, 26
- Hypertrophy of the Gums, 13
- Hythe Church, Collection of Skulls in, 1
- Incisors, 148, 181
 Abnormalities of, 45-60
 Displacement, 11, 45, 58, 59, 111
 Elongation, 56
 Overlapping, 56
 Removal, 80
 Rotation, 48
 Separation, 52

- Incisors and Protrusion, 178, 181, 191
- „ attaching a clamp band. Result, 39
 - „ Case's method of moving, 41
 - „ diseased, treatment of, 91
 - „ displacement of, producing crowding, 111
 - „ Farrar's method of moving roots of, 39
 - „ Goddard's method of moving forward, 34
 - „ Matteson's method of moving, 37
 - „ plate for pushing outwards, 30
 - „ Regulated, 47, 230, 231
 - „ Retraction of, 35, 154
- Inclined Plane, Use of, in Regulating, 27
- Indians, Teeth of, 2
- Inferior Protrusion, 199-215
- Inheritance of Irregularities, 2, 6
- Intermarriage, cause of irregularity, 3
- Irregularities, civilisation a cause of, 4
- „ in mixed races, 3
 - „ Inheritance of, 2, 6
 - „ Intermarriage, a cause of, 3
- Irregularity, due to alveolar abscess, 13
- „ due to malformation of jaws, 13
 - „ due to premature removal of second deciduous molar, 6
 - „ due to cicatrices, 13
 - „ due to frænum of lip, 12
 - „ due to hypertrophy of gums, 13
 - „ due to mouth breathing, 9
 - „ due to early removal of deciduous canines, 7
 - „ due to early removal of first permanent molars, 7
- Irregularity, due to sucking thumb, &c., 12, 46, 146, 165, 216
- „ due to supernumerary teeth, 10
 - „ due to tumour of jaws, 13
- Italy, Southern, Teeth of Inhabitants of, 4
- Jaw, growth of, 66
- „ defects of 199, 203, 206, 213, 217, 218, 220
 - „ malformation of, a cause of irregularity, 13
- Jumping the Bite, 168-174
- Laterals, exclusion of, producing crowding, 97
- Lip, short upper, 152
- Local Causes, 6
- Lower teeth brought forward, Cutter's method, 171
- Mandible, Arrest of development, 88
- „ Protrusion of, 199
 - „ resection of, 213
 - „ Shortness of, causes protrusion, 150
- Maxilla and Retraction, 161
- „ excessive development of, 147
 - „ incomplete development of, 199
 - „ prominent treatment, 165
- Mechanical Appliances, 24
- Median Line of Face, Relation of Teeth to, 20
- Molar, First Permanent, 7, 14, 115, 150
- Molar, First Permanent, Unsaveable (Cases), 78-81
- Molar, Second Deciduous, Premature Removal of, 6
- Molars and open bite, 216
- „ encroaching on premolar region, 66
 - „ irregular bite of, 162

- Molars liable to move forward, 168
 „ moved forward, 159
 „ removal of, result, 18
 Molars, First Permanent, saveable, 81-90
 Mouth Breathing as a Cause of Irregularity, 9, 219
 Mouth, Models of, 15, 25
 Mouth, Supervision of, 14
 „ Wash, 42
 Movement of Teeth by Mechanical Means, 24, 42
 Nasal Obstruction as a Cause of Irregularities, 9
 Normal Articulation, 17
 Northcroft's, Mr. G., pliers, 28
 Occlusion of Teeth, 17
 „ Lack of, 216-229
 Open bite (*see* Bite open),
 Opposing teeth, bite of, 25
 „ „ removal of, 19
 Ottolengui, Dr., Method of Jumping the Bite, 174
 Palate, high vaulted in connection with irregularity, 9
 Peg-shaped teeth, 11
 Skiagrams of teeth, 22
 Periodontitis, following Regulation, 42, 71
 Permanent teeth, Irregularity caused by mal-direction, 9
 „ by abnormal deciduous teeth, 9
 Persistent Deciduous, Premature Removal of, 8
 Pianoforte Wire tinning of, 28
 „ „ used in Regulating, 28
 Plates for regulating (*see* chap. iii., p. 24)
 Pliers, Northcroft's, 28, 29
 Point of delivery or anchorage, 24, 32, 158
 Premature Removal of Deciduous Teeth, 6, 7
 Premolars, Abnormalities of, 63
 „ Displacement of, 110
 „ Irregularity of, 111
 Premolar and open bite, 216
 „ displacement of, producing crowding, 110
 „ irregular bite of, 162
 „ plate for retracting, 31
 „ removal of, (*see* Extraction)
 „ Retraction of, 153
 Protrusion, Inferior, 199-215
 „ masked with advent of puberty, 162
 „ of Mandible, 199-215
 „ Superior, 146-198
 Pulpitis after torsion treatment of, 50
 Pyorrhœa Alveolaris as a Cause of Superior Protrusion, 153
 Race Crossing, Effect on Teeth, 2
 Regulating appliances, removable, 24
 „ Immediate, Bryan's method, 231
 „ „ Cunningham's method, 233
 „ „ Dolamore's method, 237
 „ „ Spokes's method, 230
 „ „ Talbot's method, 236
 Removable Appliances, 24
 Retracting Teeth, Methods of, 153-160
 Romans, Ancient, the Teeth and Jaws of, 4
 Rotation, 34, 48
 Rubber bands, use of, 27
 „ for Retraction, 157
 „ wedges, 26
 Screws, 25
 Sequelæ of mechanical movement of teeth, 42
 Sex of patient influences treatment, 15
 Sexual Selection, Influence on Irregularities, 5

- Skiagrams, 22, 49-62
 Skull and Chin Cap, 204, 206, 211, 222, 223
 Springs for regulating, 29
 Sucking, Habits of, 12, 46, 146, 165, 216
 Superior Protrusion, 146-198
 Supernumerary Teeth, Cause of Irregularity, 10, 48, 68, 147
 Supervision of Mouth, Importance of, 14

 Talbot's Coil, 33
 Temporary teeth, persistence of, 47, 60
 Tinning of pianoforte wire, 28
 Tonsils, removal of, when necessary, 222
 Torsion, disadvantages of, 48
 " forceps, 49
 " gradual or immediate, 48

 Transmission of Irregularities, 2
 Travelling of the Teeth, 17
 Treatment, general principles of, 14
 " influenced by sex of patient, 15
 " " by age of patient, 16
 " " by heredity, 16
 " " by health of patient, 16

 Underhung Bite, 199-215
 Unlocking the bite, 19

 Vulcanite pegs, use of, 27

 Wedges, 26, 132
 Whitney, Dr. J. M., on the Teeth of Hawaiians, 2

 X-Rays 22











