

## **Plaster of Paris and how to use it / by Martin W. Ware.**

### **Contributors**

Ware, Martin Wiener, 1869-

### **Publication/Creation**

New York : Surgery Pub. Co., 1911.

### **Persistent URL**

<https://wellcomecollection.org/works/hb296hq7>


### **License and attribution**

This work has been identified as being free of known restrictions under copyright law, including all related and neighbouring rights and is being made available under the Creative Commons, Public Domain Mark.

You can copy, modify, distribute and perform the work, even for commercial purposes, without asking permission.



Wellcome Collection  
183 Euston Road  
London NW1 2BE UK  
T +44 (0)20 7611 8722  
E [library@wellcomecollection.org](mailto:library@wellcomecollection.org)  
<https://wellcomecollection.org>



**PLASTER**  
*of* **PARIS**  
and how  
to use it

*by* MARTIN W. WARE M.D.


157 A




22102159301



Med  
K43649







3/5/11

124



# PLASTER OF PARIS

AND

# HOW TO USE IT

BY

MARTIN W. WARE, M.D.

NEW YORK

Adjunct Attending Surgeon, Mount Sinai Hospital; Surgeon to the  
Good Samaritan Dispensary; Instructor of Surgery,  
The New York Post Graduate Medical School

*SECOND EDITION, REVISED AND ENLARGED.*

Illustrated with 90 original drawings.



SURGERY PUBLISHING COMPANY

92 WILLIAM STREET

NEW YORK

1911

8760575

Copyright, 1911  
By  
SURGERY PUBLISHING COMPANY  
New York.

WELLCOME INSTITUTE LIBRARY	
Coll.	welMOmec
Call	
No.	WO





## PREFACE TO THE SECOND EDITION.

The exhaustion of the first edition and the persistent demand for this book are the incentives for this second edition.

I have availed myself of the suggestions proffered in the kindly criticisms of the reviewers of the original. In appreciation thereof much has been rewritten, revised, rearranged and numerous innovations embodied.

The chapter on Plaster in Dentistry has been omitted as not being germane to the work.

The illustrations have been added to and a great number of new ones substituted.

My acknowledgements and thanks are due to Dr. Erwin Reissman for the execution of the drawings; to Dr. Walter M. Brickner for his valuable advice in editing this book and to Dr. J. MacDonald, Jr., for his encouragement, support and numerous acts of courtesy which have rendered possible this second edition.

MARTIN W. WARE.

*27 East 81st Street, New York.*

## PREFACE TO THE FIRST EDITION.

The material for the subject-matter of this book is based on ten years' dispensary practice in the very large joint disease and fracture service (5,000 cases) of the Good Samaritan Dispensary.

The embodiment in book form of this experience and of what has heretofore been but a fragmentary consideration of the subject is due to the suggestion of Dr. Walter M. Brickner, Chief of the Surgical Out-patient Department, Mt. Sinai Hospital, whose valuable assistance in editing these pages is hereby thankfully acknowledged. Thanks are due to Dr. Maurice Green for his aid in the preparation of the chapter on Plaster of Paris in Dental Surgery. The illustrations are for the most part reproduced by Dr. Erwin Reissman from original photographs and sketches; others from standard text-books of surgery.

MARTIN W. WARE.

1198 *Lexington Avenue.*

Dec., 1906.

# TABLE OF CONTENTS

---

## CHAPTER I

Pages

The Plaster of Paris Bandage..... 1-20

## CHAPTER II

The Application of the Plaster Bandage to Individual Fractures .....21-24

## CHAPTER III

Fractures of the Upper Extremity.....25-32

## CHAPTER IV

Fractures of the Lower Extremity.....33 50

## CHAPTER V

Molded Plaster of Paris Splints.....51-64

## CHAPTER VI

Plaster of Paris in Orthopedic Surgery.....65-99



## LIST OF ILLUSTRATIONS

FIG.	PAGE
1. Preparing plaster bandage by hand.....	2
2. Plaster of Paris cradle.....	4
3. Calot method of preparing plaster bandage.....	5
4. Plaster bandage and manner of handing it to surgeon .....	6
5. Immersion of plaster bandage.....	8
6. Removal of frayed ends of bandages after immer- sion .....	9
7. Illustrating the cuff of cotton at upper, lower, limit .....	14
8. Strip of metal incorporated in bandage.....	15
9. Dividing cast with Gigli saw.....	16
10. Cast removed in lateral halves.....	17
11. Grooves cut with mitre saw.....	18
12. Mitre saw .....	18
13. Stilles shears .....	19
14. Manner of removing cast.....	20
15. Reapplying cast with adhesive straps.....	20
16. Plaster bandage for forearm.....	25
17. Shoulder spica for humerus fracture.....	27
18. Cast for lower arm--elbow.....	28
19. Cast for forearm or wrist.....	30
20. { Thumb spica .....	31
21. {	
22. Posture applying cast for hip fracture.....	34
23. Metal hip rest.....	35
24. Superimposed fists as hip rest.....	36
25. } Extent of cast for hip and femur fracture.....	37
26. }	
27. Application--hip spica in suspension.....	38
28. Cast for fracture of upper half leg.....	39
29. Tricot hose investment in leg fracture.....	39
30. Assistant holding foot for application of plaster bandage .....	40
31. Foot held at right angles by a strip of bandage..	41
32. Ambulatory cast for leg fracture.....	42
33. Splitting of cast to obviate pressure.....	43
34. Fenestrated plaster splint .....	44
35. Veneering strips .....	47
36. " " .....	48
37. " " .....	48

LIST OF ILLUSTRATIONS.

FIG.	PAGE
38. Metal strips to bridge two sections of plaster bandage .....	48
39. Wire worked into bandage to aid suspension....	48
40. Molded splint with wire hooks.....	49
41. Suspended fenestrated cast .....	49
42. Spiral and concentric folding of crinolin.....	51
43. Molded splint applied .....	52
44. Molded splint secured by bandage while hardening .....	52
45. Splint lined with cotton.....	53
46. Molded splint held by adhesive plaster.....	54
47. Molded splints covered with bandage.....	54
48. Molded splint by to and fro passage of plaster roller .....	56
49. Two pieces of flannel for Bavarian splint.....	56
50. Posterior molded splint for humerus fracture....	58
51. Molding splint for humerus fracture with roller bandage .....	59
52. Splint suspended to dry .....	60
53. Braatz spiral molded splint for Colles fracture..	61
54. Cole's sugar tongue splint.....	62
55. Molded dorsal splint for forearm fracture.....	63
56. Plaster of Paris gutter splint for leg fracture....	64
57. Crawling posture while applying hose investment for jacket .....	65
58. Sayre's suspension .....	66
59. Ladders to operate suspension apparatus.....	67
60. Shows correct and incorrect extent of plaster for corset .....	69
61. Method of transporting patient with jacket or spica .....	70
62. Reposing on pillow to permit jacket to dry.....	70
63. Trimming jacket .....	72
64. Finished jacket with lacing correct, incorrect limits .....	73
65. Jury-mast incorporated in jacket.....	74
66. Application—jacket in horizontal position.....	75
67. Jacket applied in hammock.....	76
68. Sling suspension to apply jacket.....	77
69. Bradford frame .....	78
70. Corset applied in frame .....	78
71. Corset and hip spica.....	79
72. Plaster crown a substitute for jury-mast.....	80
73. Lorenz bed .....	80
74. Jacket with figure eight turns of neck for torticollis .....	81
75. Plaster of Paris collar.....	82
76. Plaster coronet with ring to correct torticollis....	84
77. Calot jacket—temporary window.....	86
78. Calot jacket—large window.....	87







## CHAPTER I

### THE PLASTER OF PARIS BANDAGE

Arabian physicians practicing in Spain were amongst the first to utilize plaster of Paris (gypsum) as a dressing, but credit belongs to the Dutch physicians Mathysen and Van der Loo (1852) for having invented the modern plaster of Paris dressing. (More recently it is stated that to Kluge, of Berlin, 1829, belongs the priority of the application of plaster to fractures.)

#### History

The very widespread use of the plaster of Paris bandage in hospital and dispensary practice for purposes of fixation and immobilization of fractured bones and diseased joints is in decided contrast to its limited use in private practice. An inquiry into the reasons therefor finds its best answer in the statement that the plaster of Paris bandage found on the market does not usually come up to the requirements. Therefore a description of what constitutes a properly made plaster of Paris bandage is of the first importance.

The plaster of Paris used in the making of the bandage should be of the superior quality used by dentists, and the quick-setting kind is to be preferred. It is sold packed in tin cans to prevent deterioration (hydration) by absorption of water from the air; and for a like reason it must be stored in places free from moisture when once the original package has been opened. Furthermore the hand or receptacle introduced into the plaster should be absolutely dry. If such hydration has taken place it may be recognized by the gritty particles in the plaster.

#### Materials

Any one of a number of different fabrics may be employed as a substratum in preparing the bandage, such as *gauzes*, *crinolin* (gauze impregnated with starch), *dextrine gauze* and *flannel*.

The use of plain gauze or muslin is undesirable because the mesh is so close that the plaster comes to lie on this fabric and hence the plaster sets very rapidly, and a bandage so prepared becomes too brittle. On the other hand, a gauze too rich in starch or dextrine will wholly prevent the plaster from setting. The mesh of the gauze

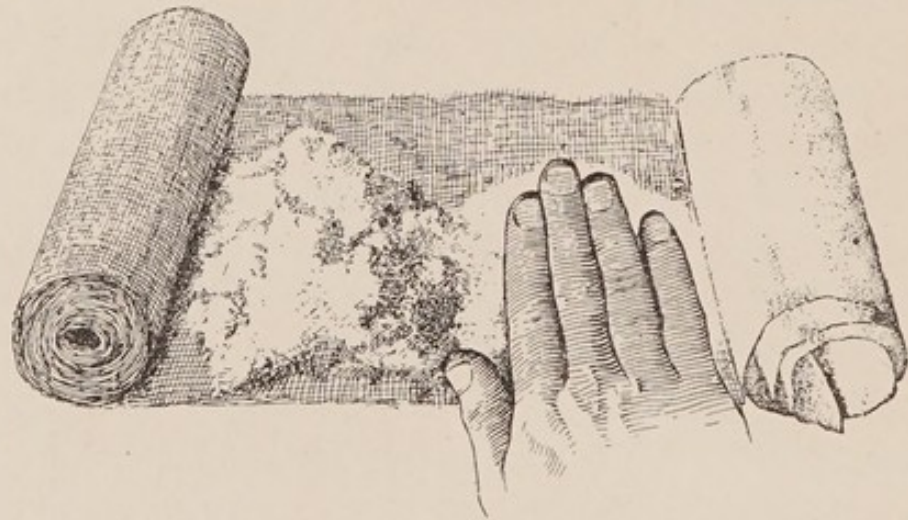


Fig. 1. Preparing plaster bandage by hand.

should be 28x32 threads to the square inch. The best kind of gauze is white crinolin without cross-bars,\* such crinolin as is used by milliners and dressmakers. If the crinolin be found too rich in dextrine the latter may in part be removed by immersion in water for a variable time and then allowed to dry before incorporating the plaster.

The superior plaster of Paris bandage is *made by hand*, for the reason that, made in this way, the right quantity of plaster can be incorporated in the bandage. The crinolin is cut into strips of the

### Manufacture of the Bandage

\*Crinoline can be purchased wholesale at Adams Mfg. Co., 106 Grand Street, New York City.



widths desired, and loosely rolled in ten-yard lengths. One-quarter of a yard at a time being unrolled, a handful of plaster of Paris is rubbed into the gauze with the palmar surface of the fingers, so that all excess of plaster passes to either edge of the bandage. (See Fig. 1.) No more plaster should be rubbed into the dextrine gauze than the meshes will hold, and as each successive yard is incorporated with the necessary quantity of plaster it is *loosely rolled* in such manner that in the center of the bandage there is a hollow cylinder of the thickness of the finger, and *the concentric layers are easily movable on one another*. This arrangement permits the rapid and uniform spread of the water through the bandage, and prevents parts of the bandage from being insufficiently moistened. To guard against unraveling, a pin should be inserted in the last turn which, however, ought to be removed immediately before immersing the bandage in water.

The completed bandages should be placed on end and sealed in individual tins in the bottom of which a small quantity of plaster of Paris is placed, or, likewise arranged on end, they may be packed in bulk in large tin containers. If the plaster cannot be stored in a dry place, it is advisable to wrap each bandage in wax paper or gutta percha tissue, newspaper also answers, and, in any case, it is a wise precaution to seal the can with a strip of adhesive plaster, passed about the overlapping edge of the cover. The individual tins or tin containers protect the bandages from moisture, and, furthermore, permit them to be placed in ovens, as a preliminary to using them, in order to drive off any moisture.

### Storage

**Bandages of  
Commerce**

The disadvantages common to the plaster of Paris bandages of the shops are that the fabric is not of the dextrine order; the mesh is too closely woven—the plaster lies on the bandage instead of in the meshes—and as a consequence, there is an excess of plaster; the bandages are, as a rule, so tightly rolled that the water does not reach the deeper layers. These are the bad features of the machine-made bandage. It is manufactured by dragging the strip of muslin through a compartment (Fig. 2) filled with plaster of Paris, and winding it upon a windlass. *To some extent a bandage of the shops*

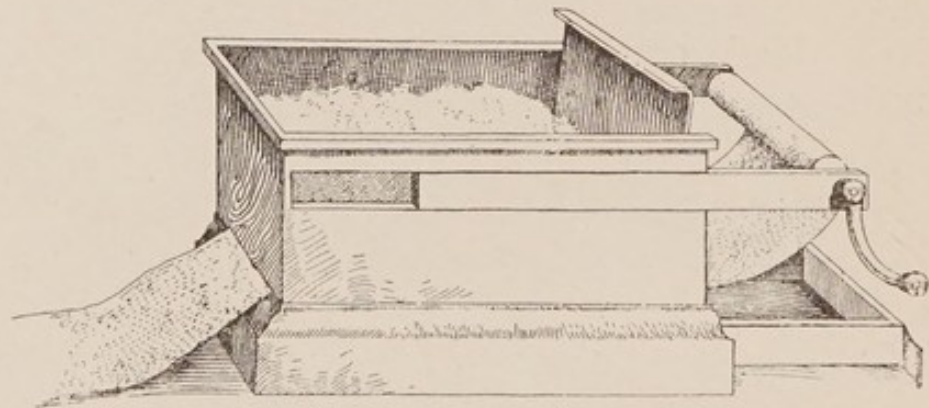


Fig. 2. Plaster of Paris cradle.

*can be rendered fit for use by rerolling it loosely and in this act getting rid of the excess of plaster—before immersion in the water.*

[A very rigid plaster of paris bandage (European manufacture) has recently been put on the market. It is made of exceedingly fine flexible *aluminum bronze wire netting* and is sold in widths of one and one-half, two and one-half, three and one-half and four inches, in four-yard lengths. It is applied in the same manner as the regulation plaster bandage.]



Calot believes that any of the aforesaid methods of incorporating plaster of Paris (dry) with the crinolin fabric before use, causes the plaster bandage to deteriorate. He therefore holds the crinolin bandages, rolled in desired lengths, in readiness for immersion in a plaster cream (3 parts water, 4 parts plaster) in which they are unrolled and rerolled immediately before use. (Fig. 3.)

A form of plaster dressing, well adapted to the making of molded splints, can be obtained by dip-

**Calot  
Plaster  
Bandages**

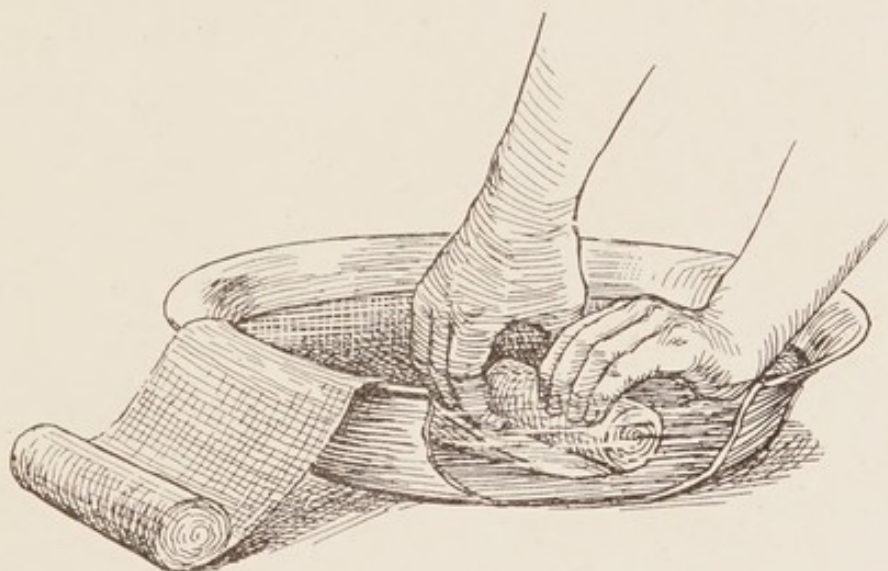

Fig. 3. Calot method of preparing plaster bandage.

ping strands of hemp jute (Beeley), flax or straw, of about the width of the finger, in a cream of plaster of Paris. This is by far the cheapest form of plaster of Paris dressing. Cotton, impregnated with plaster of Paris and placed in seamless sacks of tricot, constitutes another method of making molded splints (Breiger). A modification of the Beeley hemp splints consists in placing into a sheath of tricot or the leg of a stocking, a bundle of thoroughly beaten hemp strands, steeped in plaster cream. This sausage-shaped mass is thor-

oughly kneaded and molded to the parts (Turner). Other fabrics like sail-cloth, which contain sizing material, are also useful for making molded splints; and I have found the fabric known as "Deimel linen mesh" suitable for making molded plaster of Paris splints and by no means to be forgotten and as fundamental in plaster technique is the use of large sheets of crinoline folded on several layers, three generally suffice. Sheets of woven wire made to conform to the parts may subsequently be covered with a few turns of a plaster bandage.

Before starting to apply the bandage, the surgeon and his assistant should be properly gowned.

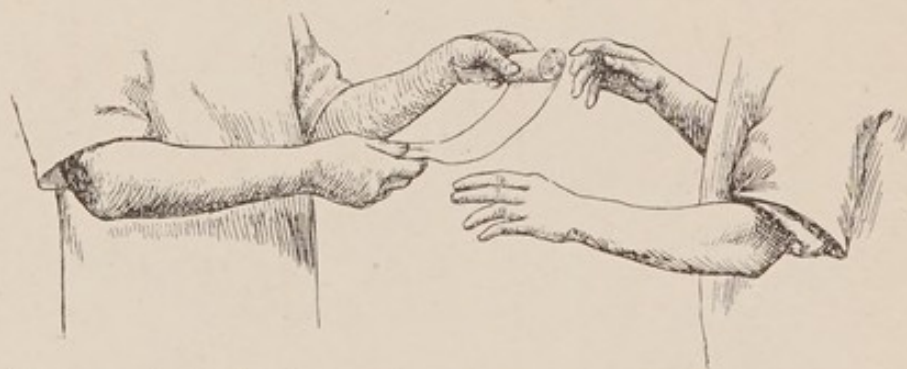

Fig. 4. Plaster bandage and manner of handing it to surgeon.

In every instance the forearms should be bared, so as to permit the greatest freedom of motion in applying the bandage. To protect the clothing from being soiled, a rubber apron or gown should be worn (Fig. 4), or the latter may be improvised from a bed-sheet. Either one should extend to the collar, and it should be sufficiently long to cover the feet, or a pair of rubbers should be slipped over the shoes.

In private practice especially it is also necessary to protect the surroundings from soiling by the plaster of Paris. The floor, the patient's body, and



the couch or table on which the patient is placed should be covered with muslin, gunny sacks, bed-sheets or a rubber sheet. When these are not available, tar paper, newspaper, or ordinary wrapping paper will serve the purpose. It should, however, be borne in mind that if a properly made bandage is used which is squeezed to the extent of ridding it of superfluous water, no drippings will be scattered and the whole procedure of the application of the plaster differs in no way from simple bandaging and no soiling of the surroundings will follow.

The number of bandages intended for use should be removed from the tin container and stood upon end within a foot of the vessel holding the water in which they are to be immersed. The tin container, uncovered, is to be within arm's reach, in case necessity arise to use more bandages. The bandages to be used are to be placed to the right and the container to the left. This arrangement guards against particles of water being spattered upon the bandages still in the container, rendering them unfit for subsequent use.

The vessel in which the bandages are to be immersed should be deep enough to accommodate the widest bandage vertically. But one bandage at a time should be immersed. It is to be placed *end-wise* in the vessel, which contains water as hot as the hand will tolerate. The bandage must be completely submerged, and it should remain so until the bubbles cease to come off. (Fig. 5.) This will take place most readily in the very loosely rolled bandages. The tightly rolled bandages obtained in the shops should therefore be unrolled and rendered loose before they are wet. When the bubbling has

**The Immediate  
Preparation of  
the Bandages  
For Use**



ceased, the bandage is lifted out of the vessel, and squeezed with the hand, merely to free it of the excess of water. In some bandages the edge of the crinoline frays out, and becomes so entangled as to hinder the free unrolling of the bandage. To prevent this, the frayed out ends should be plucked from each side before starting to apply the bandage. (Fig. 6.) After the bandage has become limp from soaking it is often difficult to find the end, wherefor it is advisable to leave a short length of



Fig. 5. Immersion of plaster bandage.

the bandage hang over the edge of the vessel at the moment of immersion.

To obviate a loss of plaster from the wet bandage, Frieberg recently recommended wrapping each bandage in filter paper or the equally pervious Japanese paper napkins and with this wrapper the bandage is placed in water and allowed to remain till bubbling ceases. With the wrapper *in situ* the bandage is removed from the water and squeezed. Water escapes but not so the plaster. Consequently each bandage is richer in plaster and fewer bandages have

to be used. Hence Frieberg regards this method an economical one for institutions using much plaster.

To hasten the setting of the bandage, some manufacturers recommend the addition of salt or alum to the hot water. This is not advantageous inasmuch as the bandage often sets in the hand before it is

**Chemical  
Ajuvants**

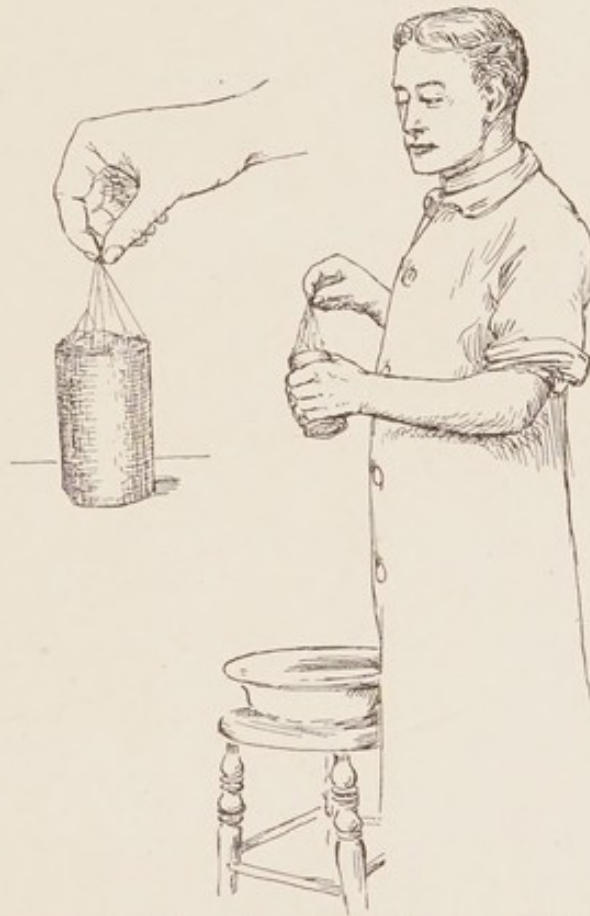

Fig. 6. Removal of frayed ends of bandage after immersion.

unrolled. With the home-made bandage prepared, as previously described, with the best quick-setting plaster, the addition of chemicals to the water is superfluous. Hot water, as opposed to cold, facilitates setting.

The skin has to be protected from the plaster of Paris. This may be accomplished in various ways. The area to be encased in the plaster of Paris band-

**Protection  
of the Skin**



age may be wrapped in cotton wool. The drawback to this is that the cotton becomes "caked" and the bandage subsequently loosens. Better than this is the use of a flannel bandage, or the "ideal bandage," which is to be applied *smoothly, without wrinkles* and without *reverses*, for these are apt to exert pressure on the soft parts beneath when the weight of the plaster is brought to bear. An elegant investment of the skin is afforded by the use of seamless tricot hose, which can be had in various widths at instrument shops and is applicable to the trunk or extremities. For the latter a comfortably fitting sock, stocking, glove, under-shirt sleeve or drawer leg may be used. When the plaster bandage is applied to serve as a cast, the limb need merely be anointed with vaseline.

#### Application and Precautions

No undue traction should be made in applying the successive turns of the bandage. The use of any other than a light hand, when unrolling the bandage on to the member, will be followed by such constriction of the limb and interference with circulation, with the setting of the plaster, that its prompt removal will probably be required. The plaster should be applied spirally, yet free from any reverses; where a reverse might be encountered the bandage should be at once cut and a beginning made anew. The matter of reverses with plaster of Paris bandages holds good only for the plaster bandage in the first layers where such folds would exert pressure. About the outer parts of the bandage they might add strength though none towards the appearance of the bandage.

To give strength to a plaster bandage, to avoid its pressure and to obviate reverses, it has been suggested to alternate the direction of the spirals



by standing first towards the head and then towards the foot in making the successive layers. Thus one set of spirals will pass from right to left, the other from left to right. Such refinement I judge to be impracticable and uncalled for.

In fractures, if the swelling be very marked, it there be evidence that the extravasation has not attained its maximum, the limb should be elevated and subjected to the compression of a rubber bandage, and this should be followed by gentle massage, before the plaster bandage is applied. On the other hand, it should be borne in mind that usually *several hours* elapse after the injury before the surgeon has been called and has made preparations to apply the plaster, and generally, therefore, there need be no dread of an increased swelling beneath the bandage. Indeed, the best means of limiting the swelling after a fracture is the prompt application of a plaster of Paris bandage. If there be any concern that the plaster bandage has set too tight, or will do so, this may be remedied in the following manner: While the plaster is yet soft, cut through the entire length of the bandage with a penknife, and with the bandage shears also divide the bandage, cotton or tricot, underneath. The subsequent contraction of the plaster in the act of hardening will cause a further widening in the furrow made with the penknife, and thus relieve the pressure existing. In fact, where the circumstances are such that the bandage cannot be inspected within the first twenty-four hours after its application, it should always be the practice to divide the plaster as described, in order to forestall any possible unpleasant developments.

To guard against a loosening of the plaster of

Unable to display this page

two edges of the tricot sewn together at the upper limit. Such a finish prevents the plaster anywhere coming in contact with the clothing.

By applying a coat of shellac to the dried plaster bandage it is rendered waterproof, less brittle and obviously more durable.

The plaster of Paris bandage may be applied to a member in continuity or in sections. In the former method, the bandages are wound spirally up and down the length of the limb without reverses until each roll of bandage is exhausted, and a number of bandages is used to cover the same ground until all parts are sufficiently covered. In the latter method, the limb is divided off into segments and each segment is separately invested with one or two bandages, according to requirements; each section of plaster overlapping the adjoining one. The former method provides a stronger dressing.

The finished bandage should be exposed to the air to effect a thorough hardening. When a hot air apparatus is at hand the whole member may be baked for one-half hour.

The upper and lower limits of the plaster bandage must not extend beyond the bandage enveloping the skin. An elegant finish may be given to the edges of a plaster dressing by turning over its ends, in cuff-like fashion, the ends of the flannel bandage. This device must be borne in mind while the plaster is being applied, so that the final turns of plaster at either end may securely hold in place the retroverted fold of flannel bandage. Equally efficient in preventing the ends of plaster from impinging on the skin is a cuff of cotton held in the grasp of the last turns of plaster at either end. (Fig. 7.)



When the flexure of a joint is encroached upon by the plaster, a crescentic section may have to be removed from the latter in order to allow free motion of the joint. This had better be done with a sharp pen-knife or scalpel drawn over the bandage while the dressing is in the plastic state. Again, with the bandage in the plastic state, it can be molded by the pressure of the finger and hands with massage-like motions, to conform it to the contour of the limb. To bring about an adaptation this molding is far superior to, and less dangerous than, the



Fig. 7. Illustrating the cuff of cotton at the upper and lower limits of the plaster of Paris bandage.

employment of traction on the plaster bandage. It is most desirable to exert every precaution to place a plaster bandage correctly in the first instance. For its immediate removal in recent fractures is a painful procedure in contrast to the removal in a chronic joint affection, or some weeks after fracture is in process of healing.

**Toilet After  
Bandage is  
Completed**

Such plaster of Paris as may have been spattered on clothing, carpets or fabrics had best be allowed to dry thoroughly before an attempt is made to remove it. The spots on furniture or wood-work had best be removed while moist, or if dry, they should be moistened. If not much time has been consumed in applying the plaster of Paris bandage, and the plaster on the surgeon's hands

is still moist, it can be readily washed off in warm running water. If it be dry, however, friction of the hands with granulated sugar will speedily dissolve the plaster. Friction with salt will effect a speedy removal by rendering the plaster more brittle, and the same may be said of ablutions with bichloride of mercury.

The discarded portions of plaster bandage and excess of loose plaster should be cast away with household refuse. The water used for immersing the bandages should be decanted from the plaster

**Disposal  
of Refuse**

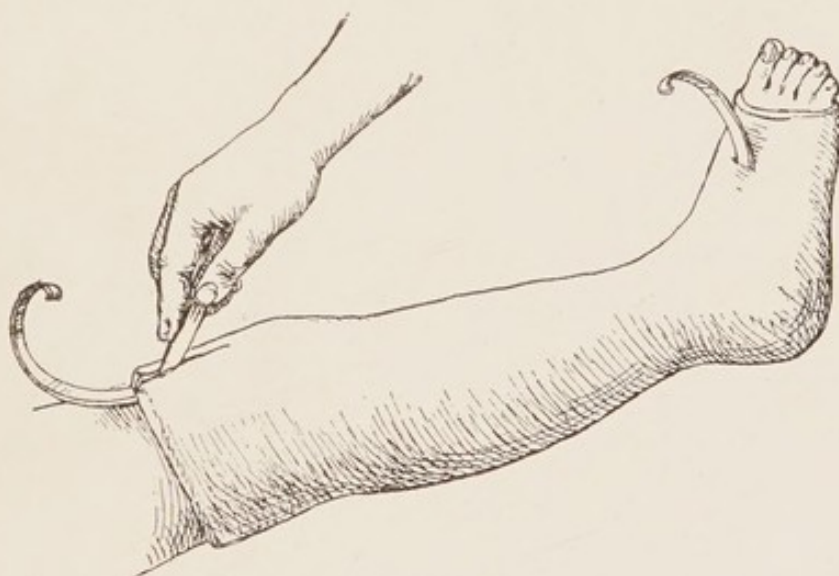

Fig. 8. A strip of metal one-half inch wide incorporated in the bandage.

paste at the bottom of the vessel and emptied into a sink or privy, which is then to be flushed with hot water, preferably from the tap. Under no circumstances should the paste from the vessel be emptied into the waste-pipe, sink or privy, for it is likely to choke it up. The paste, if immediately attended to, may be loosened by shaking the vessel or by imparting a smart blow to it. If this does not suffice, or if the vessel be porcelain, the adherent masses may be lifted or scraped off with a



piece of wood or broken up with a knife. The addition of water, hot preferably, will aid in loosening the plaster. The whole mass is to be thrown away with other household refuse or to be incinerated in a furnace.

**Removal of the  
Plaster  
Bandage**

Some deem it expedient to place a strip of zinc one-half inch wide (Fig. 8), or a wire, on the limb before starting the plaster bandage, and to allow the metal ends to protrude as a guide where to start cutting the bandage. The metal beneath is

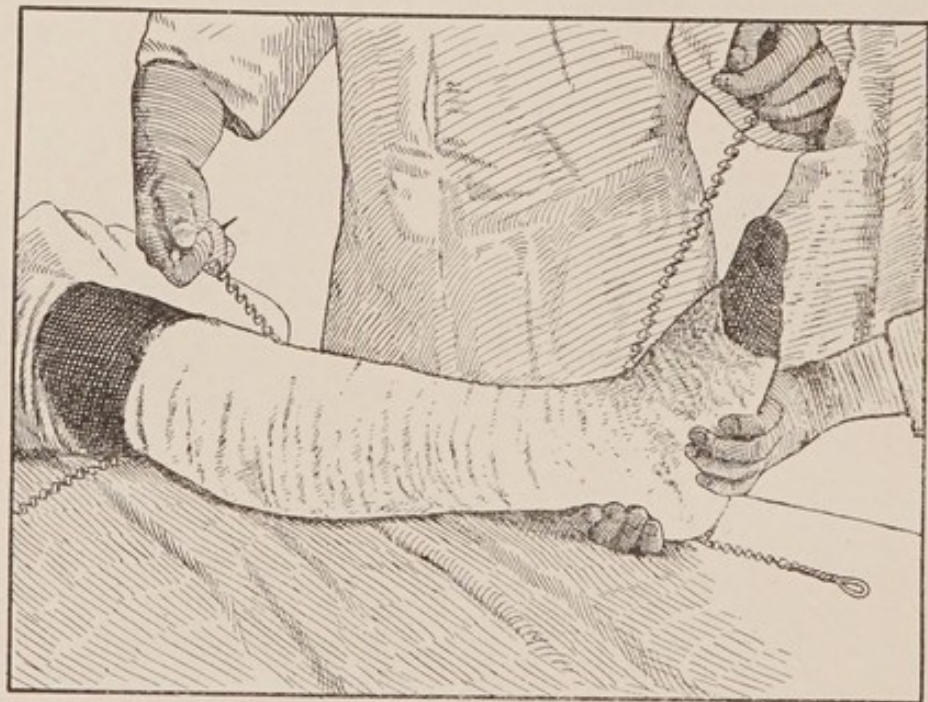


Fig. 9. Illustration of method of dividing plaster cast with Gigli saws placed under the bandages.

to guard the skin against being cut by strokes of the knife. It has also been recommended to place a Gigli saw along the front and back of the limb next to the flannel bandage (Fig. 9) before applying the plaster bandage. To the protruding ends of the saw metal handles are to be attached, and with the aid of these the wire is set in motion and the plaster divided from beneath. Even though



this saw is constructed of aluminum bronze it is liable to corrosion and does not work freely. To offset this disadvantage a well greased silk thread may be substituted for the wire. Eventually the wire saw may be guided along the thread. Such a wire works well along straight lines but not effectively about angles. It is possible with two properly placed wires saws at the front and back

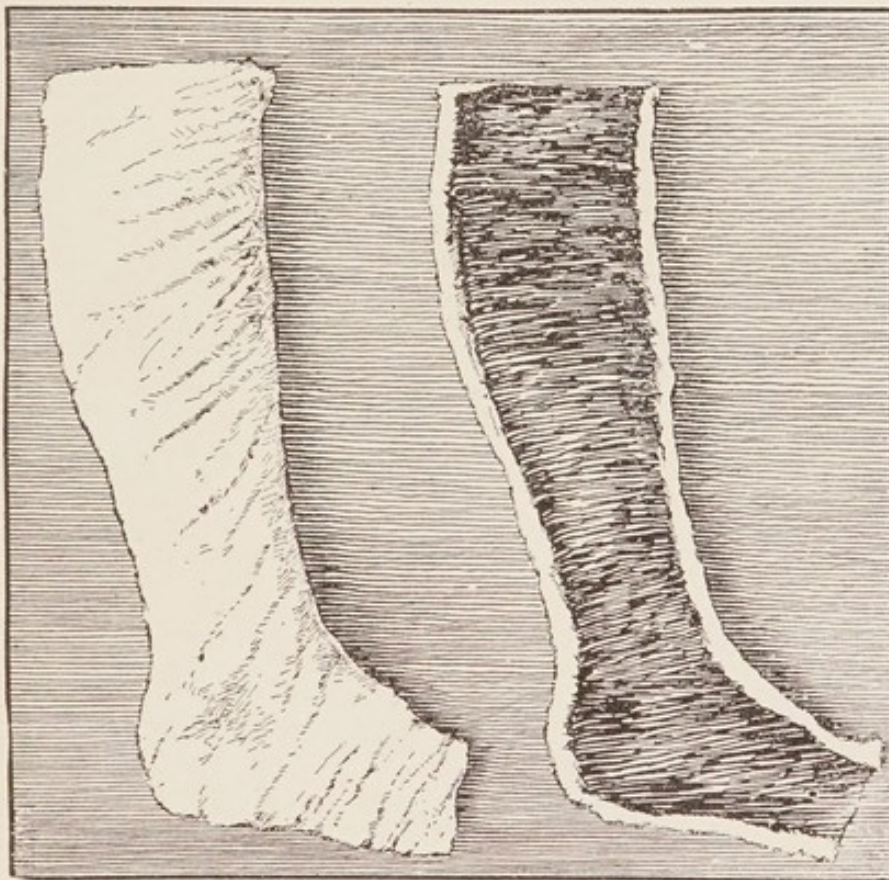

Fig. 10. Plaster of Paris cast removed in lateral halves, having been cut through front and back with Gigli saw.

to divide the cast into lateral halves. (Fig. 10.)

If it is the intention to utilize the plaster of Paris bandage again, care must be taken to preserve its integrity during its removal. This can be best accomplished by cutting a furrow (Fig. 11) into the plaster in its entire length with a penknife, or, more expeditiously performed, with a *mitre*

saw. (Fig. 12.) The investing fabric beneath the plaster constitutes an impediment to the free motion of the saw and therefore gives indication when the plaster is divided, and thus prevents injury to the soft parts beneath. When the penknife is used, the dropping of acetic acid (vinegar) or applying the same with a brush on the plaster, along the path of the knife, will lighten the otherwise irksome task.

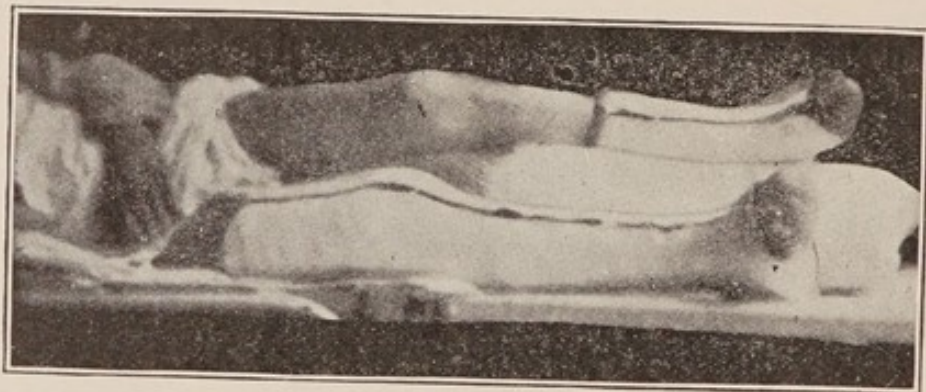


Fig. 11. Showing the grooves cut in the plaster cast with the mitre saw.

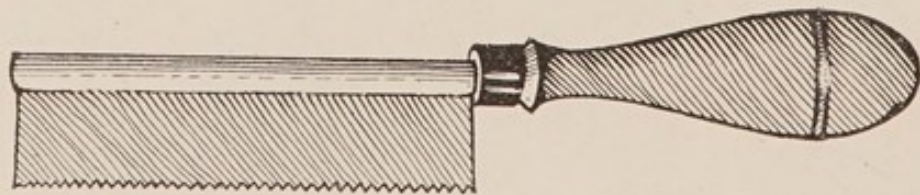

Fig. 12. Mitre saw.

All complicated devices of the circular saw for the removal of the plaster are useless, as the mechanism becomes blocked with particles of plaster. A mitre saw works quickly and with some practice corners and angles can be gotten around very easily by using the heel or toe of the saw. (Fig. 12.)

A very effective instrument for cutting a fur-



row in the plaster bandage are Stilles' shears. (Fig. 13.) The section of bandage removed falls out of the window of the cutting blade. These shears are constructed like some of the bone cutting forceps, but they require some dexterity in passing about an angle like the ankle joint.

After the plaster is divided at every level, the bandage beneath is divided with shears. Now the whole cast may be lifted from the limb, much in the manner that a hoop is sprung from a barrel

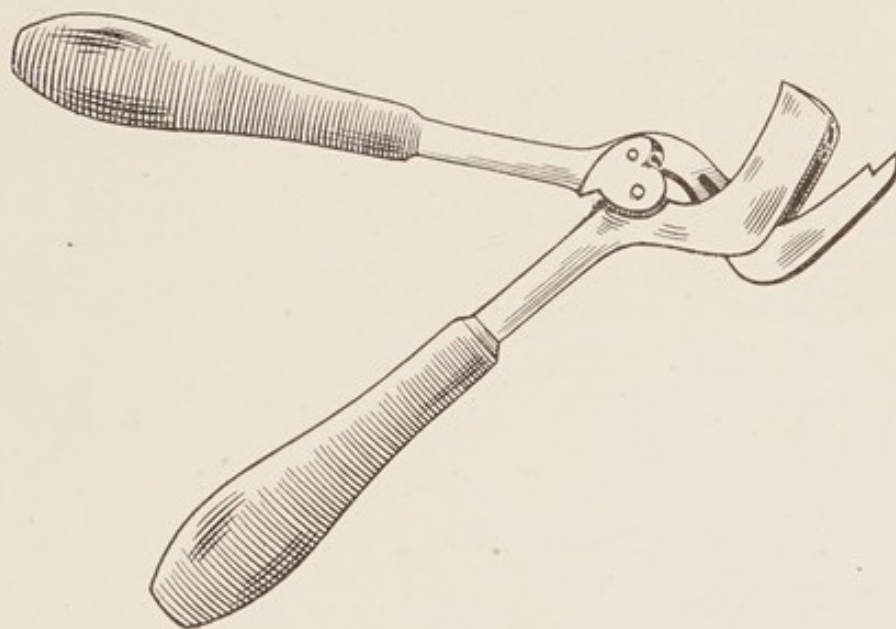


Fig. 13. Stilles shears.

(Fig. 14), or by a motion similar to the opening of calipers. The flannel bandage is adherent to the plaster and comes away with it and may be left thus to serve the purpose of a lining. If, however, it be soiled or wrinkled or loose it should be removed.

Eventually the cast may be lined with absorbent cotton, or the limb invested with another flannel bandage or tricot before replacing the cast. Straps

**Replacement  
of the Cast**



of adhesive plaster are applied circularly over the plaster cast (Fig. 15) at intervals to hold it in place and the whole recovered with a moistened dextrine or starch bandage or ordinary muslin bandage.

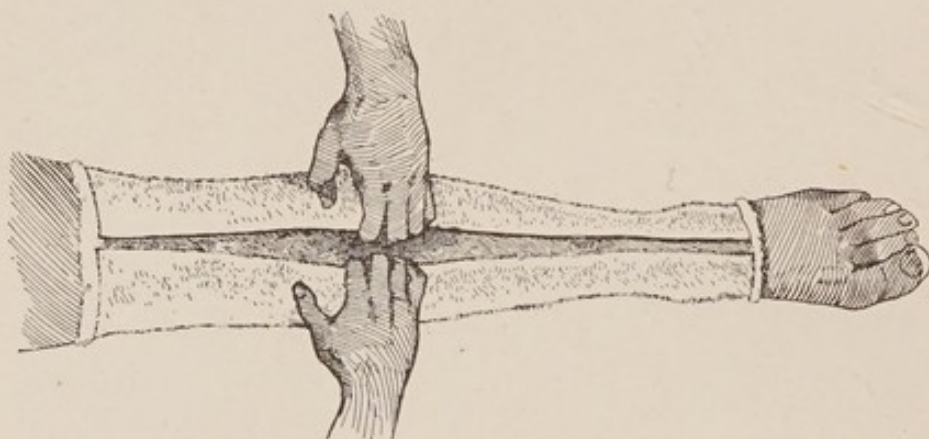

Fig. 14. Manner of removing the cast from the limb.

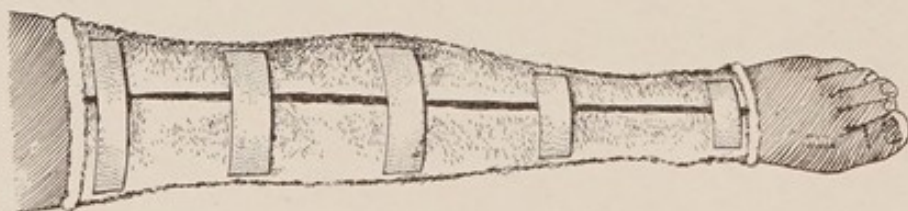


Fig. 15. Illustrating manner of reapplying the cast with adhesive straps.

## CHAPTER II

### THE APPLICATION OF THE PLASTER OF PARIS BAND- AGE TO INDIVIDUAL FRACTURES

There is hardly a fracture of any bone in the body requiring immobilization, for which the use of the plaster bandage has not been advocated. Enthusiasts, indeed, would have us use plaster bandages for all fractures. An enumeration of the fractures for which the plaster bandage is neither desirable nor practical will best show its limitations. These are: fractures of the skull (for obvious reasons); of the clavicle; of the ribs; of the shaft of the femur in infancy, in all cases, and in adolescence, in most cases. Extensive compound fractures afford a contraindication to the use of plaster at the outset. Its use being deferred until the inflammatory signs have subsided. In all other fractures the use of a plaster of Paris cast is in place at some time or other during the treatment. In fractures of the forearm and arm in infants, because of the small dimensions of the parts, plaster of Paris is *rather* to be preferred to splints. The X-rays readily penetrate the plaster, so no objection can be offered to its use on this score. Yet where great detail in radiogram is sought a fenestra may be made at the site of fracture or dislocation. A window in front and at the back of the cast as recommended by Privat. Except when applied to the lower extremities, its weight can be kept down to that of any variety of splint.

The immediate use of plaster of Paris for frac-

**Fractures  
Suitable for  
Plaster**



**General  
Considerations**

tures does not imply its instant application. Usually, several hours elapse before the bandage is applied; by which time the swelling about the fracture will have attained its maximum. If it is desired to reduce this swelling, or keep it at its minimum, elevation of the limb, massage, the use of a flannel or rubber bandage, preliminary to the application of the plaster bandage, will accomplish this. In the use of the plaster of Paris bandage, perhaps more so than with other sorts of splints, an anesthetic is often required, and for the following reason: If the patient be at all restless while the deformity is being corrected and alignment maintained, it is very likely that the plaster bandage will be put on with undue pressure; and violent motions of the patient may crack the quickly-setting plaster. If swelling of the fingers or toes or of the extremities distal to the bandage should supervene, the immediate removal of the bandage is by no means always necessary. Before taking this step we should be guided by the color, warmth of the toes and fingers left exposed for this very purpose, and the amount of pain. If the extremity be *cold, blue, anesthetic, or extremely painful, and a pulse cannot be felt, there should be no hesitancy in the instant loosening of the cast by splitting it.* On the other hand, if, in spite of the swelling, the limb be warm, and not unduly red (inflammation excluded), and the accompanying pain and throbbing be a source of great discomfort, it is desirable to resort to the expedient of elevating the entire member by suspension or by placing it upon cushions, and to secure absolute rest by the administration of an opiate. If, after recourse to these measures for twenty-four hours at the ut-



most, the pain persists or is worse, and especially if the warmth of the extremities gives place to cold, the cast must be split forthwith. Great caution must be exercised when these evidences of circulatory disturbances—*swelling, edema, lividity*—manifest themselves; for neglect to visit the patient frequently may cost him his limb and the surgeon his reputation. It need not necessarily follow that the limb becomes gangrenous—a fate just as bad awaits a limb encased in plaster of Paris, when the patient complains of paresthesia and anesthesia. The undue pressure of the plaster of Paris, responsible for these symptoms, will, if not removed, cause *ischemic paralysis*, terminating in permanent contractures. *A mere splitting of the cast* in its entire length will put an end to all the untoward symptoms just mentioned.

Under the most favorable circumstances, in the course of a week or two, with the subsidence of the swelling the cast may become so loose that it is necessary to remove it, either to pad its interior with non-absorbent cotton, or to make a thicker investment of the limb; after either of which procedures the cast may be replaced. An undue amount of perspiration with severe itching, or the presence of a solid substance which had accidentally made its way beneath the plaster, also demands the cutting of a window for the removal of the foreign body.

When applying a plaster bandage for fracture, whether to the upper or the lower extremity, the body ought to be in a *recumbent position*. The arm, leg or thigh to be bandaged should project beyond the edge of the table and be supported by an assistant. It is impossible to apply a plaster

Posture

bandage to the extremities of an infant struggling in the arms of its mother or nurse; nor is the sitting posture in an adult conducive to that relaxation of the muscles necessary for the proper application of the bandage to the extremities.

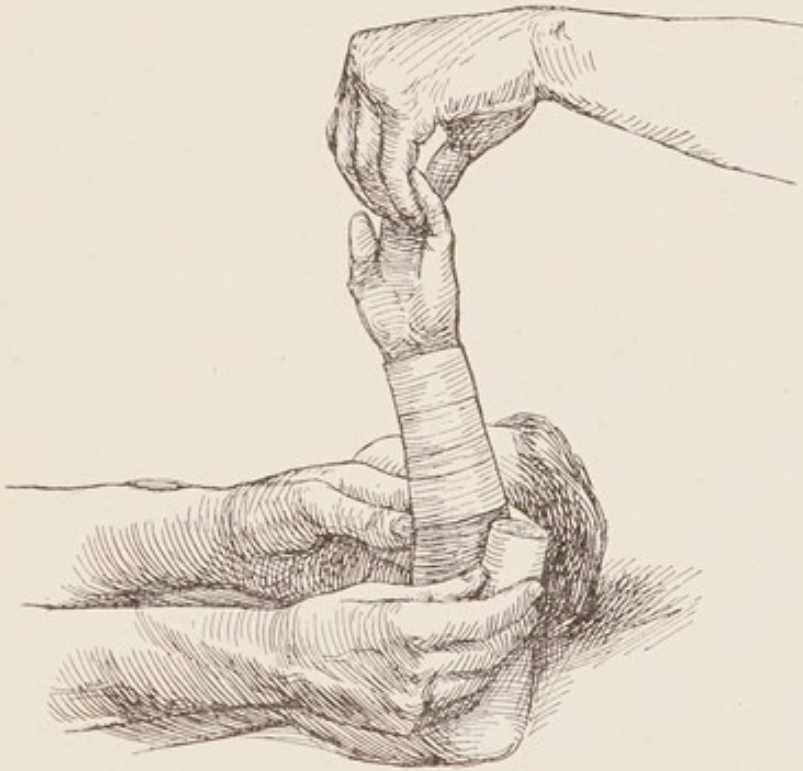
**Extent of  
Bandage**

It may be stated as a general rule that the plaster bandage should in fractures of the shaft of long bones include the adjacent articulations and extend well beyond the joints. Particularly does this obtain with the lower extremity.

## CHAPTER III

### FRACTURES OF THE UPPER EXTREMITY

The patient should be placed on his back, with the body close to the edge of the table, and both forearm and arm extending beyond the edge, supported by an assistant. (Fig. 16.) The deform-



**Fracture of  
One of Both  
Bones of  
Forearm**

Fig. 16. Application of plaster of Paris bandage for fracture of the forearm.

ity is reduced by manipulating the fragments, making hyperextension and flexion in the antero-posterior or lateral direction, associated with supination or rotation. The proper alignment accomplished (an anesthetic to be administered if necessary), the assistant grasps the patient's hand, as in the act of hand shaking, making traction



and executing counter-extension if necessary, or merely supporting the forearm—whichever is necessary to maintain the alignment. The plaster bandage should extend from the wrist to the flexure of the elbow. The flannel bandage immediately investing the forearm, however, should extend to the heads of the metacarpal bones, thus enveloping the hand. The fingers are left free. Thus we prevent edema of the dorsum of the hand, and by the color of the fingers we may judge of the circulation. If the fracture of the radius or ulna, or of both bones, be in the upper third, it may be necessary to flex the forearm on the arm. In that event the plaster of Paris bandage will include the elbow, and must be carried up the arm as far as the fold of the pectoral muscle, to secure the right purchase. If the plaster bandage on the arm extends only a little above the level of the elbow joint or half way up the arm, the weight of the plaster bandage on the forearm, by breaking up the flexion, will cause the upper part of the bandage to press into the soft parts. The flexure of the elbow should be well cleansed, dried and dusted freely with bismuth subgallate (dermatol), before the bandaging, to prevent chafing (dermatitis).

**Fracture of  
Shaft of  
Humerus**

In fracture of the shaft of the humerus in its middle or lower third, when we are not concerned with the abduction of the upper fragment, a plaster of Paris dressing is suitable. The patient occupies a sitting posture. The reduction having been effected, under anesthesia if necessary, the limb is brought into adduction, so that the chest wall forms an internal splint. A thin layer of non-absorbent cotton, well dusted on both sides with dermatol, being interposed between the arm and the chest

wall, the arm is held against the thorax by circular turns of a muslin bandage, which pass obliquely over the shoulder, enveloping it. The forearm is left free, so that by its weight, even though supported by a sling about the wrist, it exerts extension on the lower fragment. (Fig 17.) In the same manner, the plaster of Paris bandage envelops the arm and shoulder, securing them to the chest. A

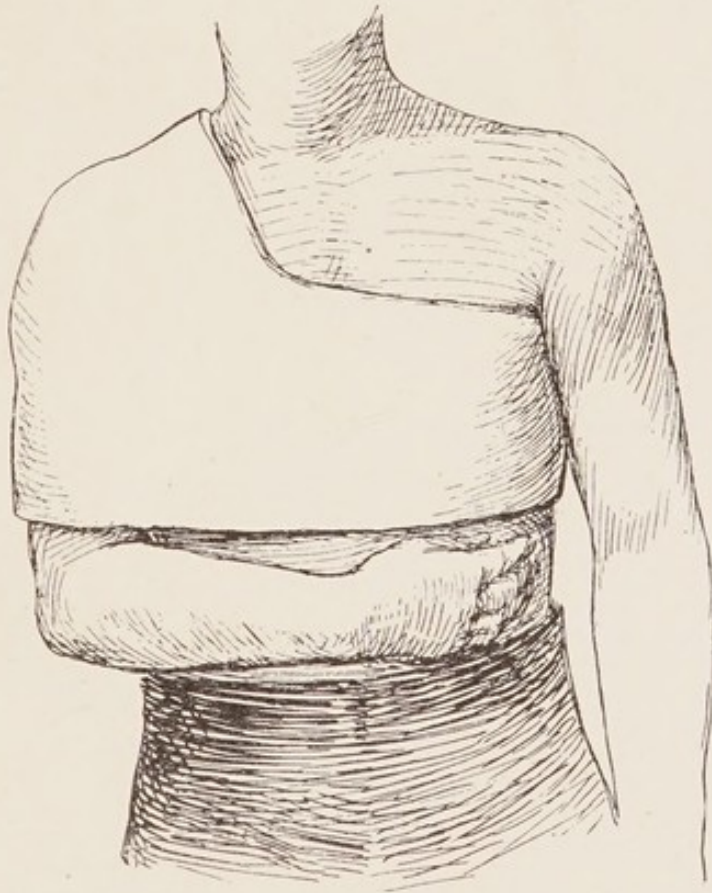


Fig. 17. Plaster shoulder spica for fracture of upper humerus.

layer of cotton wool should be placed over the clavicle and shoulder, to prevent pressure by the plaster bandage. For infants but one bandage, five yards in length, is necessary; for adults, two will suffice. The forearm should be snugly wound with a flannel bandage, to prevent the development of edema. At the expiration of two weeks, when



the plaster bandage is removed if consolidation is firm, a simple tentative dressing may be applied.

**Fracture of  
Joint  
the Elbow**

Experience has taught that the plaster dressing is not well suited to fracture of the elbow joint, other dressings being better adapted. When, however, the plaster bandage is chosen, the following steps in its application should be observed. The patient occupies a recumbent position, and the arm, projecting beyond the edge of the table, is sup-

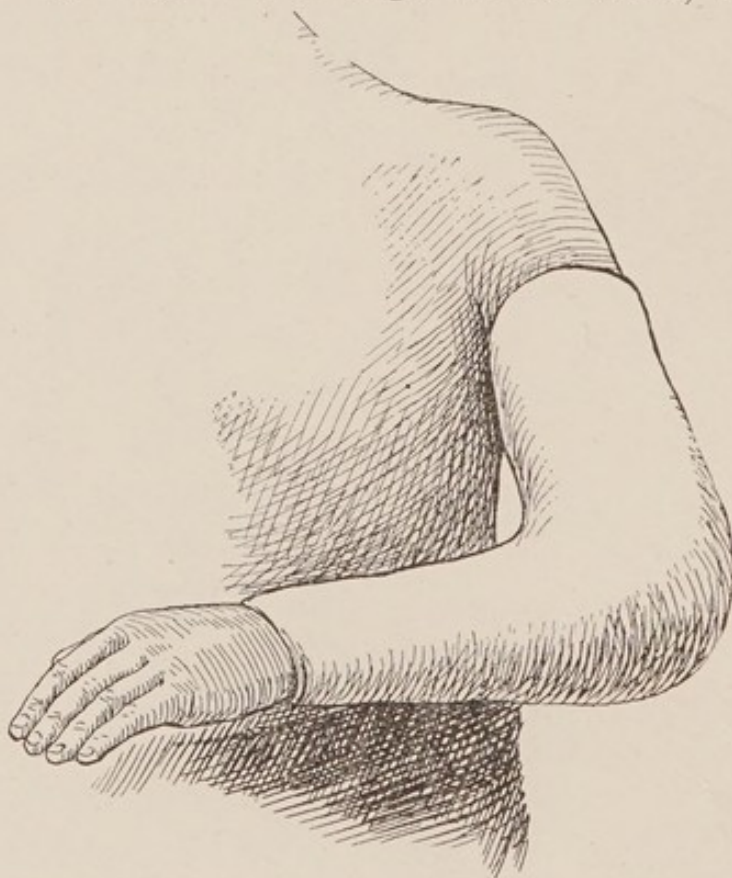


Fig. 18. Plaster cast for lower third of the arm, the elbow, or the upper third of the forearm.

ported by an assistant. (Fig. 16.) The forearm is flexed as acutely as possible. In the flexure of the elbow joint, freely dusted with dermatol, a thin layer of cotton batting is placed, and the bony prominences are also enveloped in non-absorbent cotton. The arm and forearm, from the axillary fold to the wrist, are invested with a flannel bandage, and over

this, in turn, a plaster of Paris bandage is placed. (Fig. 18.) The plaster bandage does not cover the upper and lower limits of the flannel bandage. These are turned back so as to form a cuff at either end, a single turn of the plaster bandage being sufficient to secure them. This cuff prevents the edge of the plaster from pressing into the skin, and guards against unraveling of the flannel bandage.

Allis believes that the essential thing in the treatment of fractures of the elbow is to maintain the normal carrying angle at the elbow. This implies an abduction of the forearm. This degree of abduction is apparent only with the forearm *in extension* and mid supination. Such angle should be restored when it is effaced in elbow fractures and a plaster cast applied with the elbow extended from the upper end of the humerus to the wrist. After two weeks this cast is removed and active and passive motions begun.

In all respects the plaster bandage is to be applied here like the cast described for fracture of one or both bones of the forearm, save that the wrist is included, and the bandage is carried down to the heads of the metacarpal bones. (Fig. 19.) Other varieties of plaster dressings used for Colles' fracture are described further on under the heading Braatz spiral molded splint and a posterior molded splint.

*Caution:* It is this immobilization of the wrist, however, which constitutes a great drawback to the use of plaster of Paris in this fracture, for which many other devices are far better suited.

This is the one finger for which, if it is fractured in any of its parts, a plaster of Paris dressing

**Colles' Fracture**

**Fracture of  
the Thumb**



is suitable. Whether the first or second phalanx or the metacarpal bone, is fractured, the thumb, in the extended and abducted position, is covered with a flannel bandage spica, passing in figure-of-eight turns about the wrist, or a cotton glove, with the other fingers cut off, is slipped over the hand. Either investment is covered with a "spica pollicis" of plaster of Paris, including the wrist and termi-

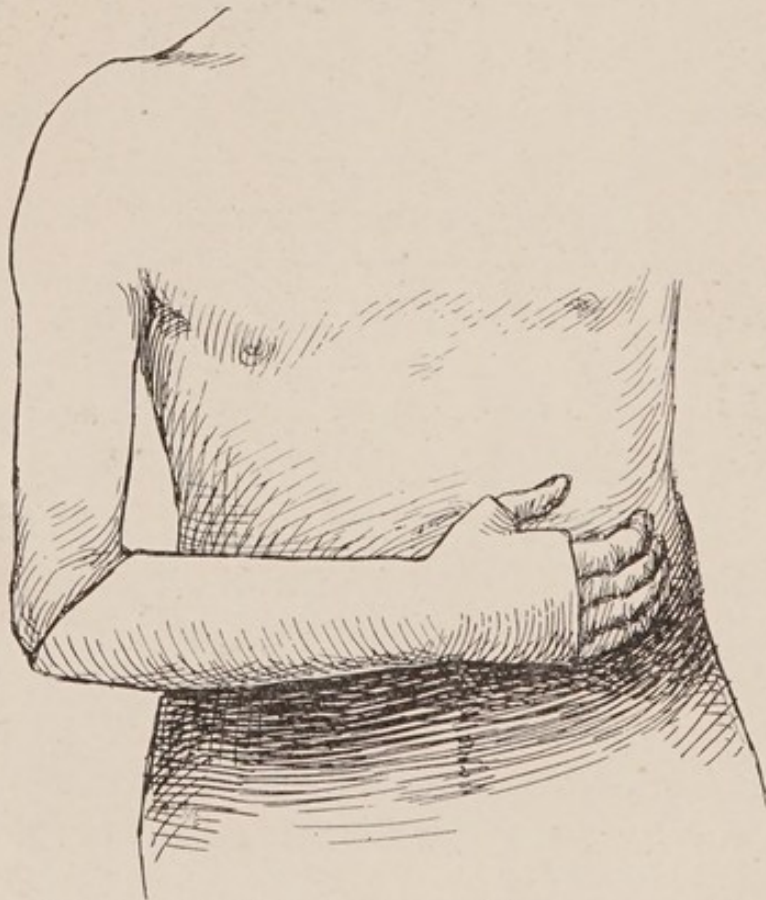


Fig. 19. Cast for fracture of forearm or wrist.

nating an inch above it. (Figs. 20, 21.) The plaster bandage below reaches to the heads of the metacarpal bones. As in all other casts, the edge of the plaster bandage is covered with the last turn of the flannel bandage.

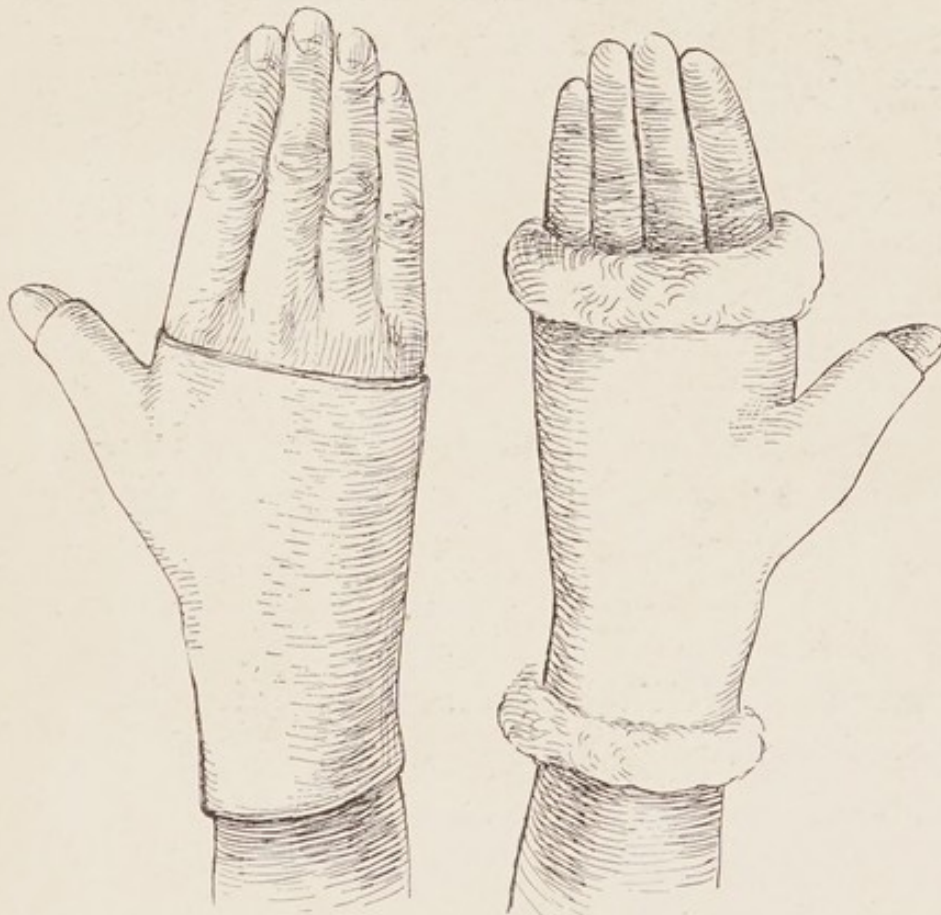
If the fracture be in the shaft, or near the base of the metacarpal bones, or in a carpal bone, the hand, exclusive of the fingers but inclusive of the

**Fracture of  
the Metacarpal  
and Carpal  
Bones**

wrist and two inches of the forearm, is invested with a flannel bandage, and this in turn, is covered with a plaster of Paris bandage two inches in width. (Fig. 17.) For fractures of the heads of the metacarpal bones or phalanges, dressings other than plaster of Paris are commendable.

While no general rule can be formulated as to

**Time Limit for  
Removal of  
Plaster Casts  
in Fractures of  
Upper  
Extremity**



THUMB SPICA

Fig. 20. Dorsal view.

Fig. 21. Palmer view.

when the cast should be wholly set aside in each of the fractures considered, it should be the practice at the end of the second week to remove the cast and inspect the site of fracture. This is done to ascertain, not so much the extent of union as judged by the wanton practice of undue manipulation to elicit mobility, but rather to note whether



there is any marked deformity, *i. e.*, if the alignment is the best possible. For neither a plaster of Paris cast nor any other splint is designed to correct any deformity, but only to hold the correctly placed fragments *in situ*.

When the X-rays are available, and by their use it is clearly seen, perhaps on the fluoroscopic screen, but preferably in radiograms, that the apposition of the fragments is all that could be desired, we may forego the removal of the cast for the purpose of inspection. To obtain a good radiogram it may be desirable to fenestrate the plaster bandage in front and back of the site of fracture, eventually filling in the window with cotton followed by turns of crinolin or plaster bandage.

If, however, on removal of the cast the alignment is apparently straight—to the naked eye as well as the sense of touch, and though the X-ray findings are contradictory to a degree—such malposition will not be incompatible with eventual good function. The cast may be replaced or renewed to await the time of complete union.

## CHAPTER IV

### FRACTURES OF THE LOWER EXTREMITIES

Every cast applied for fracture of the hip, thigh, knee, or leg should include the foot in a right-angled position. Failure to do this will cause drop-foot (*talipes equinus*), which constitutes a hindrance to walking during the time that the cast is in place, and delays walking after its removal. In neglected instances, indeed, this drop-foot requires correction, eventually, and the application of a plaster cast in turn to restore the position to a right angle.

**General Rule**

The use of a plaster cast in fractures of the senile hip is indicated only if it is possible to have the patient walk about on crutches. Other devices are more effective, but at times not applicable, because they necessitate the patient assuming a recumbent position for many weeks, which is apt to cause hypostatic congestion of the lungs. The most effective plaster dressing is that which includes the knee and ankle, enveloping the hip in a spica, the upper limits of which include the ribs below the mammary level. After one week or ten days in a recumbent position such patients may be encouraged to walk on crutches, swinging the broken hip. It rarely comes to pass in the fracture of the hip of the aged, to apply such a plaster dressing. In juvenile cases it is practical.

**Fracture at the Hip Joint**

The patient occupies the recumbent posture, on a kitchen table or a board resting on two horses. The pelvis must be well down to the edge of the table, the sound limb hanging over the edge and resting

**Plaster of Paris  
Hip Spica**



with its foot on some support. The affected limb is held by an assistant, who exerts extension, at the same time abducting the thigh. To prevent the displacement of the body by the traction efforts, the lower end of the table may be slightly raised. (Fig. 22.) In addition, if much traction is called for, a sling made of a twisted bed sheet, is passed beneath the crutch (perineum) and its ends secured to one of the further legs of the table, or held by another assistant stationed at the head, to exert counter extension. The more perfect the reduction the less need for traction extension and the likelihood of dis-

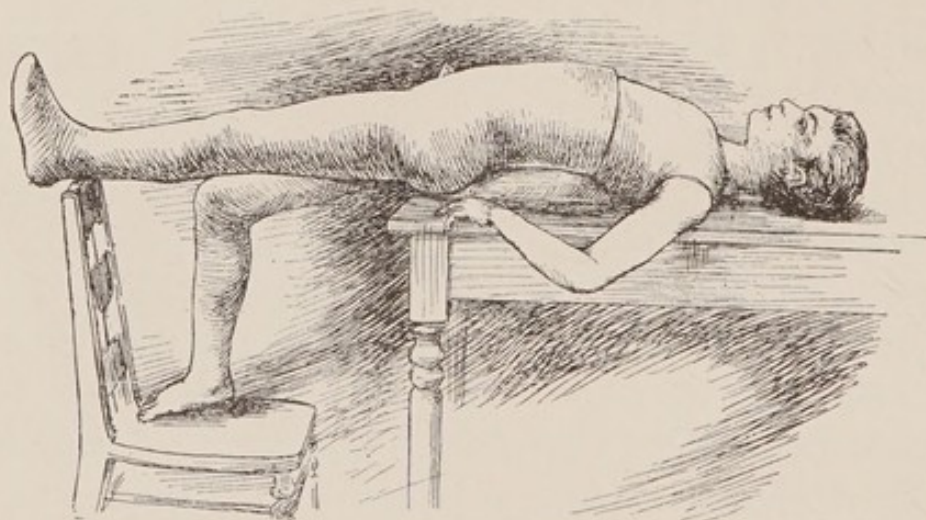


Fig. 22. Posture in applying cast for hip fracture.

placing the patient. For that part of the dressing which invests the lower part of the thigh, the knee, leg and ankle, the pelvis may rest flat on the table, but while the turns of the hip spica are applied, the pelvis must be elevated. This elevation can be accomplished in a variety of ways—by an apparatus such as a hip-rest or by improvised devices. Of the former, the one here illustrated, made of a band of iron or steel bent as shown (Fig. 23), and screwed to a plank, is pushed under the sacrum. Other hip rests as pictured in diagram may be

clamped to table. It is also necessary to have a support under the shoulders so as to bring them on a level with the pelvis. The blade supporting the pelvis is covered in by the turns of the plaster bandages, but it can be easily withdrawn after the plaster has set. Where no hip rest is at hand a sling of stout muslin playing about a pulley secured overhead, may be used to raise the pelvis, the loop of the sling becoming incorporated in the bandage. In other instances the pelvis must be supported on an improvised hip rest—by hands, or on the superimposed fists of an assistant (Fig. 24), or an agate ware basin reversed. These preliminaries effected,

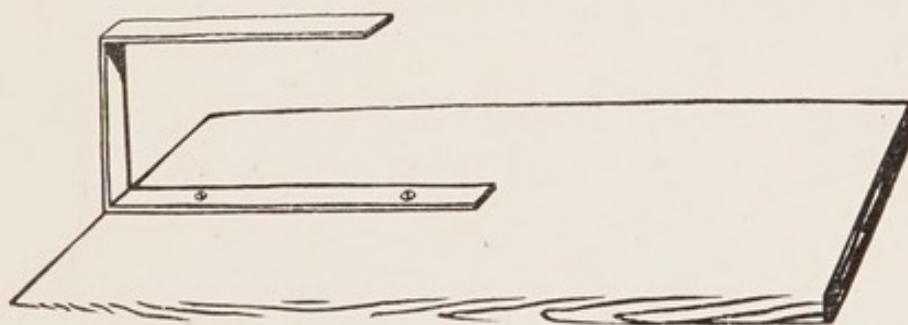


Fig. 23. Metal hip rest, screwed to board.

the bony prominences of the spines and crest of each ilium are covered with cotton batting or pads of piano felt. A flannel bandage now invests the foot, leg, thigh, hip, waist. Over this the plaster of Paris bandage is applied.

A narrow strip of piano felt or a belt made of non-absorbent cotton (batting) is desirable about the waist to fill out the hollow, for in this situation the spica is very likely to crack. This accident may still further be guarded against by increasing the turns of the bandage at that level and reinforcing the bandage at the thigh flexure by superimposing several layers of the bandage made to pass



to and fro. The perineum must be particularly guarded by proper padding, and if the turns of the bandage hug it too closely a crescentic segment must eventually be removed to avoid the production of a pressure sore. This part, also, must be well dusted with dermatol or talcum, and either one of these powders is to be blown in under the upper margin and about the pubis, to prevent irritation of the skin. The bandage should be well molded about the iliac bones and eventually trimmed as shown in

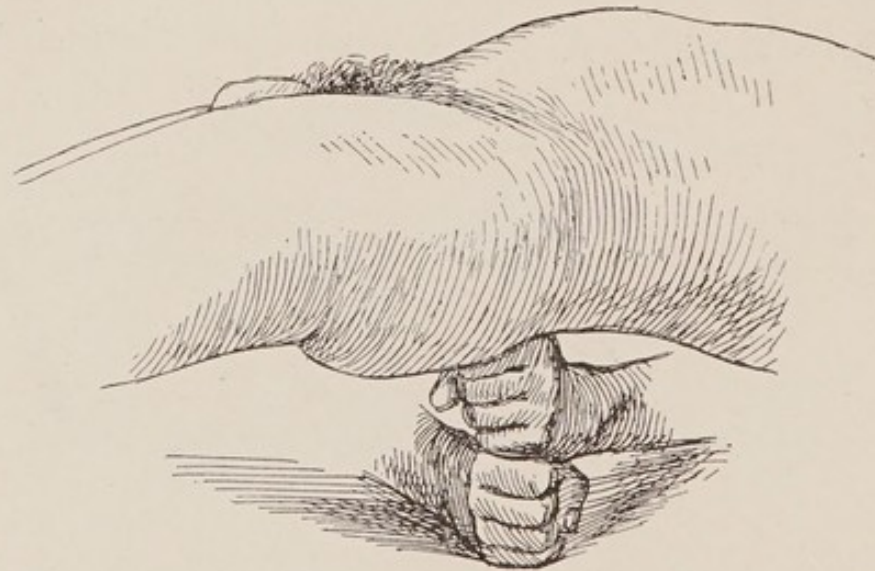


Fig. 24. Superimposed fists for hip rest.

(Figs. 25, 26.) That part of the cast in the vicinity of the genitals may be coated with shellac so that urine or vaginal secretions does not penetrate the cast, rendering it foul and brittle.

**Fracture of  
the Femur  
(Shaft)**

The position occupied by the patient in applying this bandage is the same as described for fractures at the hip. The cast should extend from the waist (umbilicus), and should include the *foot at right angles*.

In children, fracture of the neck of the femur is associated with adduction of the thigh. Where this diagnosis obtains, the extremity should be put up in a position of *marked abduction*. In walking about with the aid of crutches a patten is to be worn on the healthy foot or the sole and heel raised so that the limb encased in plaster clears the floor. (See Fig. 82.)

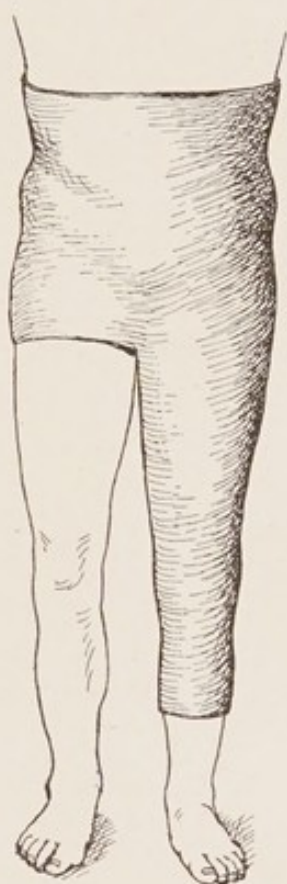


Fig. 25.

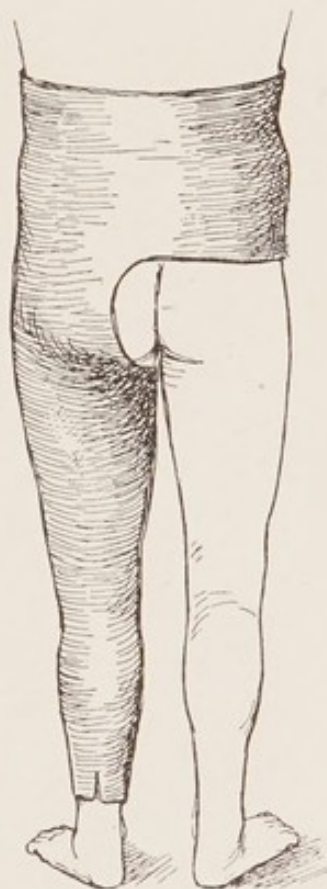


Fig. 26.

Anterior and posterior view—extent of cast for fracture of hip and femur.

In children, a plaster of Paris spica may also be applied by suspending the patient in a Sayre's suspension apparatus. (Fig. 27.)

Fractures involving the KNEE JOINT and FRACTURES IN THE UPPER HALF OF THE LEG require a

Fractures  
Knee Joint  
and Upper  
Half of  
Leg



bandage to be applied extending from Pouparts and investing the foot in a *right angle* position. Attention should be directed to mold the bandage about the knee. (Fig. 28.) To prevent this cast from sliding down a suspender may be carried over the shoulder and secured to holes in the cast or it may be suspended from a belt about the waist.

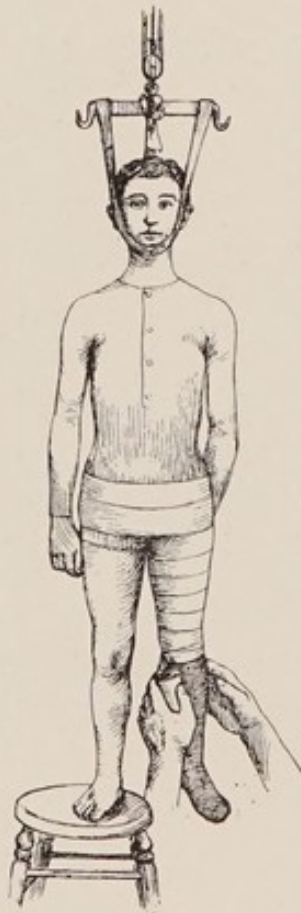

Fig. 27. Application of plaster hip spica in suspension.

Fractures of the  
Lower Half of  
the Tibia and at  
the Ankle  
Joint

These fractures are usually so severe and are accompanied with such deformity that they necessitate a narcosis to make the proper correction. Furthermore, if unattended by a wound they are *the* fractures of the lower extremity best suited for the ambulatory cast.

The patient occupies the supine position. The flannel bandage or tricot hose (Fig. 29) extends from the condyles of the tibia, and the lower margin of the patella, and includes the foot—which is held at right angles by an assistant, as follows: The heel is supported on the left hand in the grasp of



Fig. 28. Plaster cast for fracture of upper half of leg. Note right-angled position of foot, and extent of cast.

the index finger and thumb, whereas with the right hand pressure is exerted upwards on the foot by the right thumb pressing on the ball of the toe, thereby forcing the foot into a right angled position. If now the *knee be flexed* and the limb steadied by

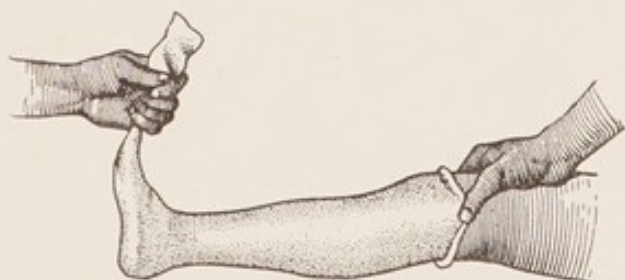

Fig. 29. Illustrating tricot hose investment in fracture of the leg.

another assistant grasping the calf, the muscles of the calf will be relaxed and the right angle of the foot easier maintained. (Fig. 30.) The crest of the tibia is covered with non-absorbent cotton to protect it from pressure. When there is no assistant to hold the foot, a muslin bandage sling is passed



about the great toe (Fig. 31) and either held taut by the patient, if he be conscious, so as to bring the foot at right angles to the leg, or the strings of the bandage are fastened to the upper end of the table. About the condyles the plaster of Paris bandage is to be heavily applied so as to form a cuff.

The cast which is most desirable for *fractures at the ankle joint* differs from the preceding only in the very important particular, the position of the foot.

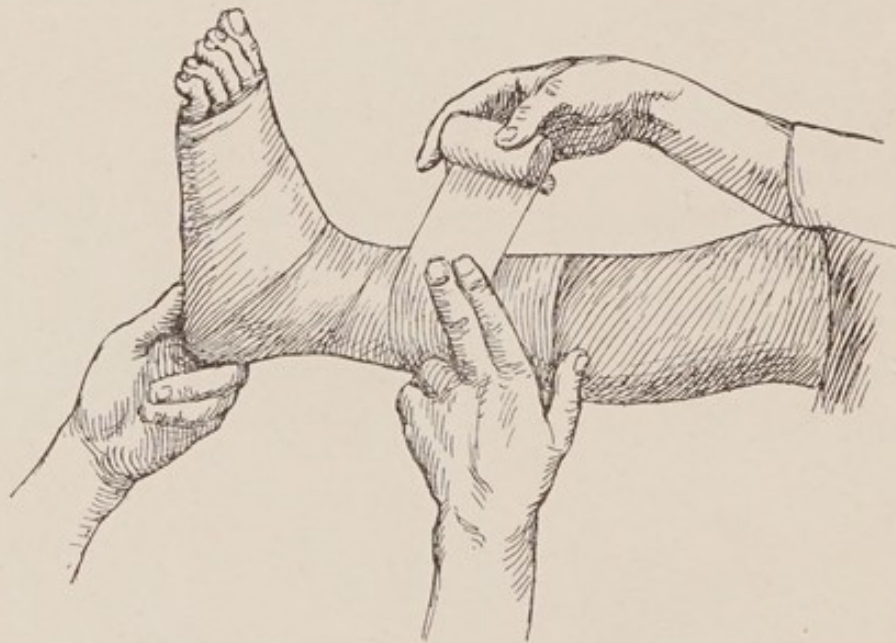


Fig. 30. Manner in which assistant holds foot for application of plaster bandage.

This variety of fracture is most commonly followed by flat-foot. To obviate this it will always be necessary to have the foot *well inverted* (varus) and at a right angle to the shaft of the tibia. The *crux* in a properly applied bandage of the ankle joint is to have the foot at a right angle. (Fig. 32.) Thus the patient is made to walk on the outer side of his foot. When it is intended that the cast should be an ambulatory one, a cuff of plaster should

closely hug the head of the tibia and an extra number of turns of plaster of Paris should be passed about the lower fourth of the leg, some of them embracing the ankle. To protect the tendo-achilles from pressure a pad of non-absorbent cotton should be placed to either side of it.

The upper limit of this plaster cast, while it must closely embrace the condyles, should not encroach upon the popliteal space where it would limit flexion at the knee joint. This is avoidable by cutting out a

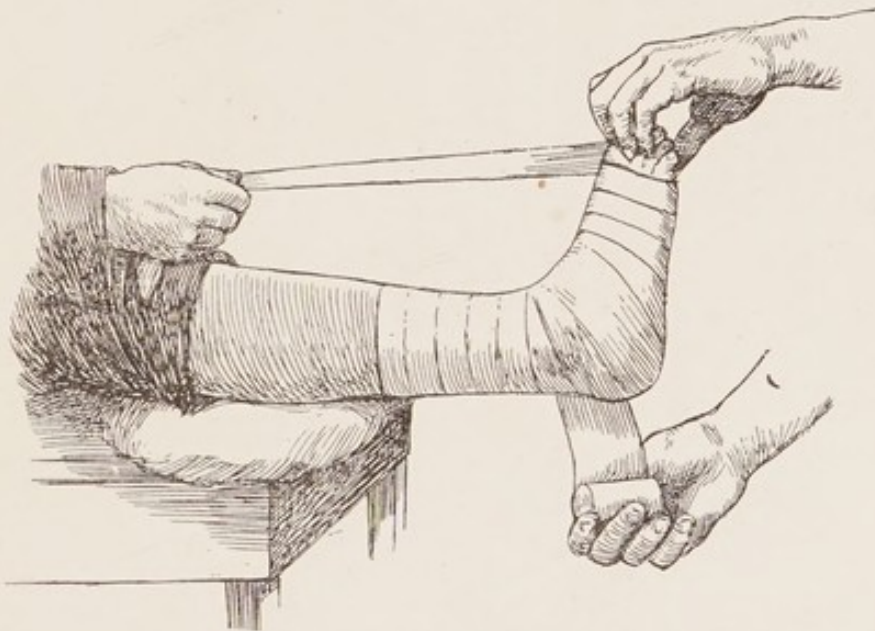


Fig. 31. Foot being drawn up at right angle by a strip of bandage held by patient.

crescentic strip of plaster with the penknife while the bandage is yet in the plastic state. Other points of pressure in this cast are generally encountered on the inner and outer aspects of the foot. These are avoided by not carrying the turns of the plaster bandage so far forward as to impinge on the toes. *If these pressure points do give trouble, greater relief will be afforded by splitting the bandage on either its inner or its outer side, than by*



*cutting off any bandage in the circular direction* (Fig. 33.) Beneath the plaster adhesive straps may be applied to the limb to carry out extension. Those who believe in early massage of fractures divide this cast in two parts (bivalve) so as to permit of its daily removal and reapplication after massage.

A fracture of the bones of the foot may be very

**Fractures of  
the Foot**

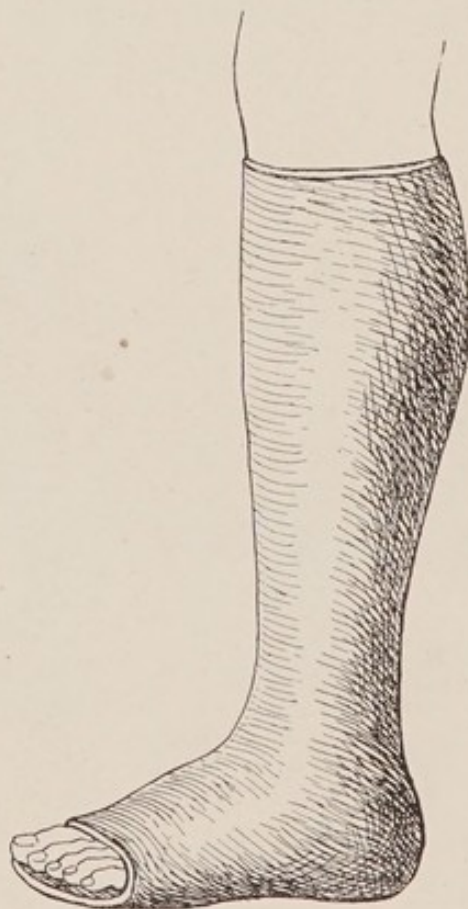


Fig. 32. Ambulatory cast for fracture of leg.

well treated by a plaster of Paris bandage, including the ankle and terminating over the lower third of the leg, below the level of the calf (Fig.).

*Caution:* The dorsum of the foot should be well protected from pressure by a padding of non-absorbent cotton. When the metatarsal bones are fractured, a pad of piano felt should be placed on

the plantar surface as an effort to preserve the transverse arch, and likewise a padding to either side of the tendo achilles to protect it from pressure.

This term applies to an ordinary plaster of Paris bandage in a part of which a window is cut to permit of treating the underlying wound. (Fig. 34.) The opening in the cast should always be larger than the wound.

The window can be made in a variety of ways.

A. The wound, covered with appropriate dressing, may be included in the plaster of Paris dress-

**Fenestrated  
Plaster of  
Paris Dressing  
for Compound  
Fractures**

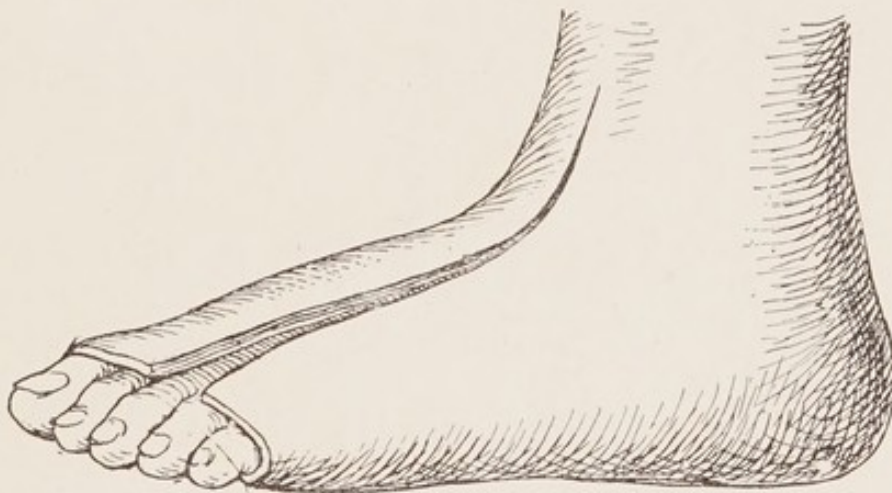


Fig. 33. Demonstrating method of splitting cast to obviate pressure.

ing. Its location having been noted by measurement, a window corresponding to its dimensions is then cut with a penknife from the plaster before it has set. The flannel or tricot investment is not cut away; it is conically split and these flaps are then turned over the rough edges of the plaster. The rough edges of the plaster bandage can be smoothed and still further protected from the discharge of the wound by investing the edges with adhesive plaster, or with gutta percha tissue made to adhere with chloroform, or by an application of shellac.

**Methods of  
Fenestration**



B. The wound, duly protected, is covered with a measuring glass, a graduate or a tumbler of convenient size, the turns of the plaster of Paris bandage passing about the glass.

C. A piece of cardboard, blotting paper or felt corresponding to the size of the wound is penetrated at its center by a pin. This device is placed over the wound and the bandage applied in the usual fashion. The pin appears through the bandage and affords a guide where to make the window. If a duplicate of the blotting paper be slipped over the pin the exactness of the window location will be assured still more. This last is the best method.

**Ambulatory  
Cast**

The treatment of fractures of the leg and particu-

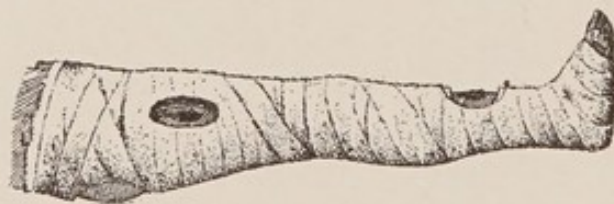

Fig. 34. Showing plaster of Paris splint with two fenestræ.

larly those of the ankle, where there is no axial displacement of the fragments, demanding extension, are best suited for the "ambulatory cast."

It is the practice of some surgeons to have the upper limits of the cast at the condyles of the tibia, others would include the knee joint, extending to the gluteal folds posteriorly and to Pouparts in front.

The indications for the choice of either may be set down as follows: Where the fracture is limited to the ankle joint a cast extending to, and embracing the condyles, is sufficient. All fractures above the middle of the leg call for immobilization of the knee also. Under these circumstances the cast should be

carried up to the gluteal fold posteriorly and Pouparts ligament anteriorly.

Experience has shown that no metal or wood strips need be incorporated in the plaster of Paris dressing. The ambulatory plaster of Paris splint differs from the ordinary plaster dressing applied for a like fracture, in the extent of the immobilization, in the greater number of the plaster of Paris bandages used, and in the increase in thickness of the plaster of Paris bandage by multiplying the turns at certain levels. The one situation favored by increase in thickness to prevent cracking, is just above the ankle joint. The upper limit of the plaster about the condyles of the tibia is also increased in thickness so that the weight of the body transmitted to the cast will not, in being transferred to the knee and thigh, cause the cast to cut into the soft parts, as would be the case with a thin edge of plaster. The ambulatory plaster splint is practicable in a fracture of the ankle or leg without a stirrup, by virtue of the mechanical fact that in a pillar, the stress and strain are distributed on the surface. Hence the column of plaster about the fractured leg carries, in greater part, the superimposed weight of the body. To give some elasticity to the rigid plaster beneath the plantar surface of the foot, some authorities advocate the insertion of a layer of felt. A stirrup may be employed in fractures of the ankle joint. In this event the vertical branches of the stirrup should be invested with rubber tissue to prevent rusting and covered with non-absorbent cotton, it should be placed between the layers of plaster bandage. The Thomas knee splint used in conjunction with such a cast is a very effective way in am-



bulatory treatment of leg fractures. A patten is to be worn on the sound limb.

Exceptionally, fractures of thigh, more frequently those at the hip joint when encased in a plaster of Paris dressing in an abducted position, are treated ambulatory. There, too, some form of hip splint should be used in conjunction as a means of protection.

**The  
Ambulatory  
Plaster of  
Paris Cast**

The use of the ambulatory plaster of Paris splint does not imply that walking with a fractured limb will be possible at once. Only after several days, most commonly at the end of the first week, the patient can make efforts at standing and gradually, as he gains confidence, the limb can be used to walk with. In the course of time the plaster of Paris on the sole of the foot softens. This may be unheeded, for with the free use of the limb the foot is protected with either a felt slipper or an arctic.

**Fracture of  
the Patella**

In very exceptional instances, where there is so scant a separation of the fragments that they can be approximated, as estimated by crepitus or the use of X-rays, the plaster cast surpasses all other forms of treatment, and in such instances, where operation is contraindicated, the use of plaster of Paris is pre-eminently indicated.

The chief point to be considered in its application, is that the turns of the bandage must fit snugly about the upper and lower limits of the patella. This can be accomplished best by molding the bandage down upon the patella while it is in the plastic state. Previous to applying the cast, approximation may be facilitated by passing adhesive straps obliquely about the upper and lower limits of the patella. Subsequent to the application of the plaster of Paris dressing, a radiograph may be taken, to ascertain the relation of the fragments. Inasmuch as it is

to be the purpose to have the patient to walk about, the plaster of Paris cast should *include the foot in a right angled position*, and extend up to Pouparts ligament.

If the plaster cast be effective in maintaining the fragments, it may be removed after the lapse of two weeks, to permit of daily massage, and replaced each time.

This is referred to here for the application of

**Fracture of  
the Olecranon  
Process**

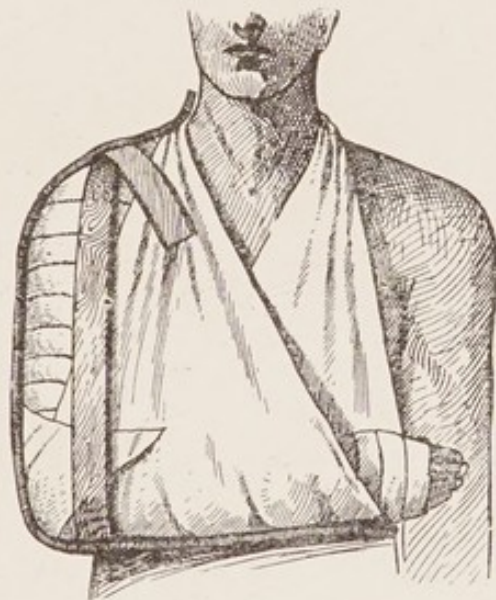

Fig. 35. Veneering strips placed the length of the arm.

plaster of Paris for this fracture corresponds in all essentials with its application for fracture of the patella, just described.

Whenever additional material is incorporated among the layers of a plaster of Paris bandage, it is termed a "compound plaster of Paris bandage." These materials are incorporated to give additional strength to the bandage and incidentally to reduce its weight.

**Compound  
Plaster of Paris  
Splints**

Strips of *veneering* (Figs. 35-37) tin and iron,



wire netting and gutta percha are the materials most commonly employed. The metals are least

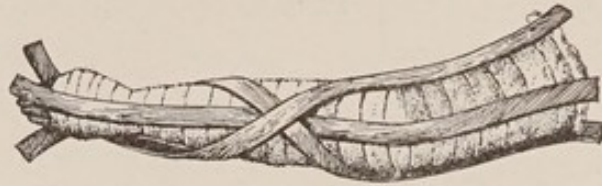

Fig. 36. Use of veneering strips to strengthen the cast.

desirable as they are likely to become rusty, and by this corrosion, break and penetrate the bandage

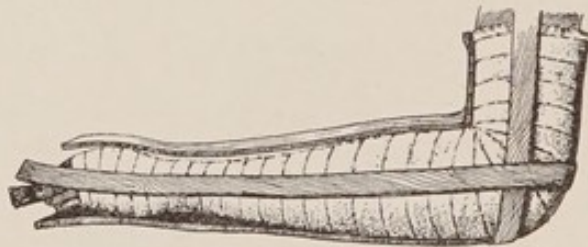


Fig. 37. Veneering strips spirally wound about the cast.

if it be worn a long time, and splints with metal incorporated are difficult to remove.

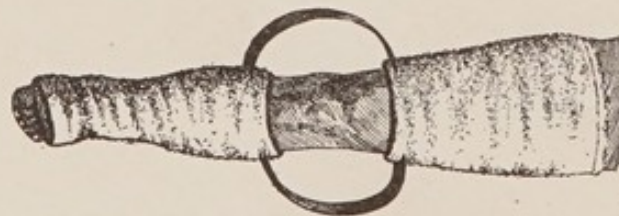


Fig. 38. Bridging strips of metal permitting motion and inspection of the joint.

In dressing after resections of the elbow and knee, these compound plaster of Paris splints find their greatest usefulness.

**Segmented Splints**

When it is desirable to have access to the wounds

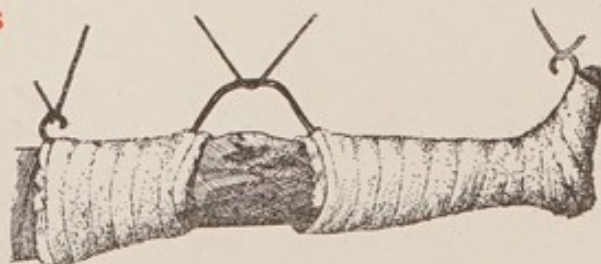
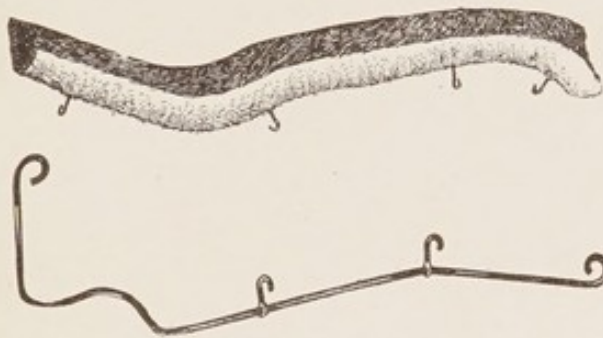


Fig. 39. Wire worked into the two sections of the plaster cast to facilitate suspension of the limb.

of joints (or to wounds extending over a large part of the circumference of an extremity), so that they

may be approached from all sides, the joint (or other surface) is bridged over with bands of metal, or with wire, which are incorporated in the turns of the segments of plaster above and below the joint, as shown in Figs. 38 and 39. A sufficient curvature is given to the strips so as to permit the joint to have some range of motion eventually, and also to permit of any dressings.

A strand of wire with hooks may be incorporated



in any variety of plaster splint. These hooks facilitate the suspension of the limb, as may be necessary in inflammatory conditions. (Fig. 40.)

**Suspended Splints**

Fig. 40. (a) Molded splint with wire hooks for suspension; (b) the wire itself.

A fenestrated splint may also have wire and hooklets incorporated in it to permit of its suspension. (Fig. 41.)

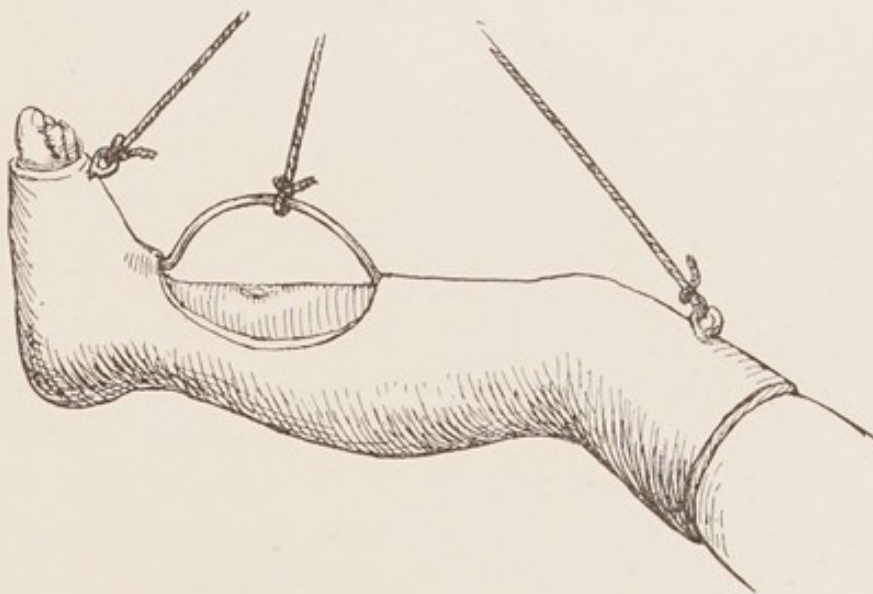


Fig. 41. Suspended fenestrated plaster cast.



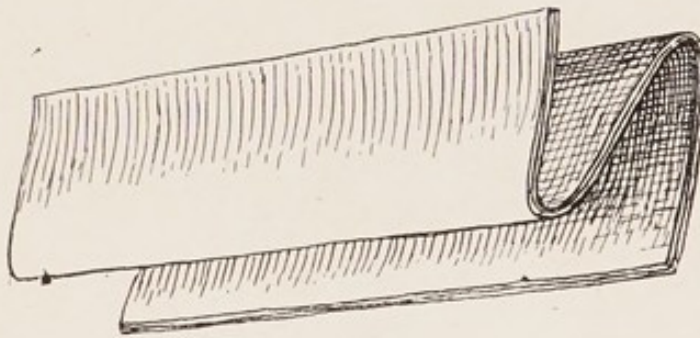
**Heated Splints  
(Perthes)**

In certain inflammatory conditions of the joints, notably in gonorrhoeal arthritis, in addition to the immobilization effected by plaster of Paris, it may be desirable to supply heat to the parts. When this is desired, there may be wound about the cast coils of rubber tubing, or narrow tubing of lead or of flexible tin. Through this tubing very hot water is allowed to pass, and is carried off into a pail.

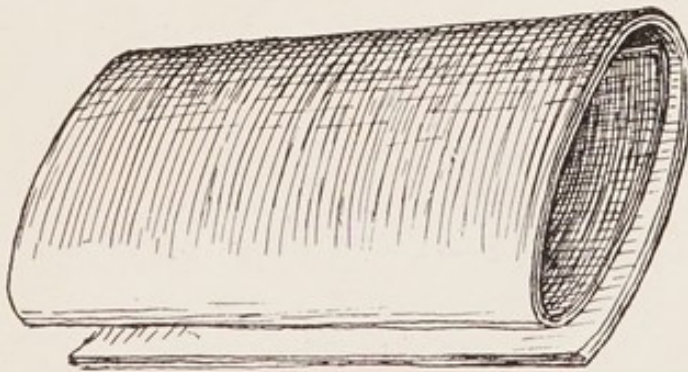
## CHAPTER V

### MOLDED PLASTER OF PARIS SPLINTS

This variety of splint has thus far been but casually referred to in the previous pages. It may be made in a number of ways.



(a) Correct.



(b) Incorrect.

Fig. 42. (a) Spiral folding; (b) concentric folding.

(A) *Pieces of crinolin gauze* of several thicknesses, folded as pictured in Fig. 42, spiral, not concentric, or a single layer of flannel, are first cut to the shape of the parts (antero-posterior or lateral aspects). They are then steeped and kneaded in a plaster of Paris paste contained in a receptacle. The member to be invested is thoroughly anointed with a thin layer of vaselin, and covered on both sides

Molded Splints



with the fabric impregnated with the plaster of Paris. (Fig. 43.) The latter is held in place by several turns of muslin bandage, until it hardens.

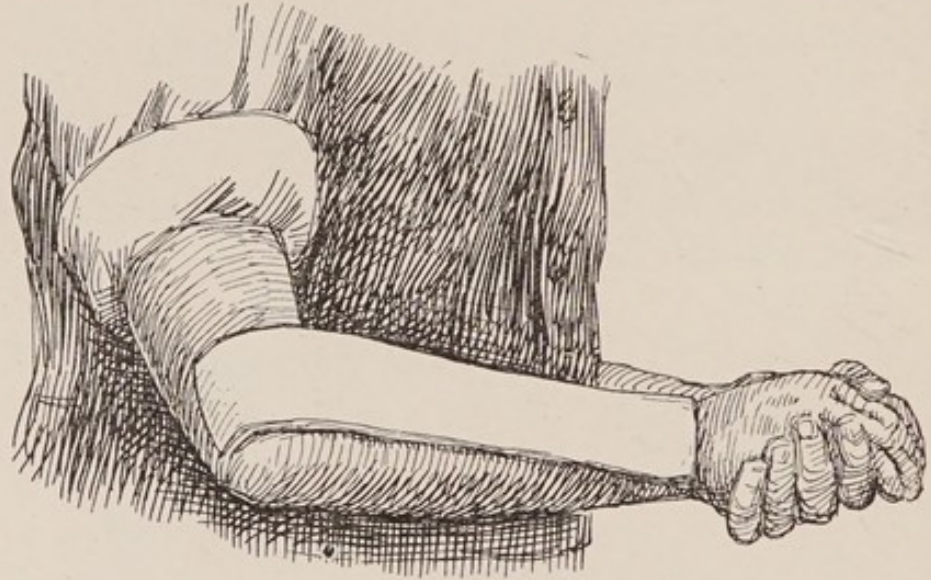

Fig. 43. Molded splint applied.

(Fig. 44.) As soon as the setting is completed, the turns of the muslin bandage are divided, and the

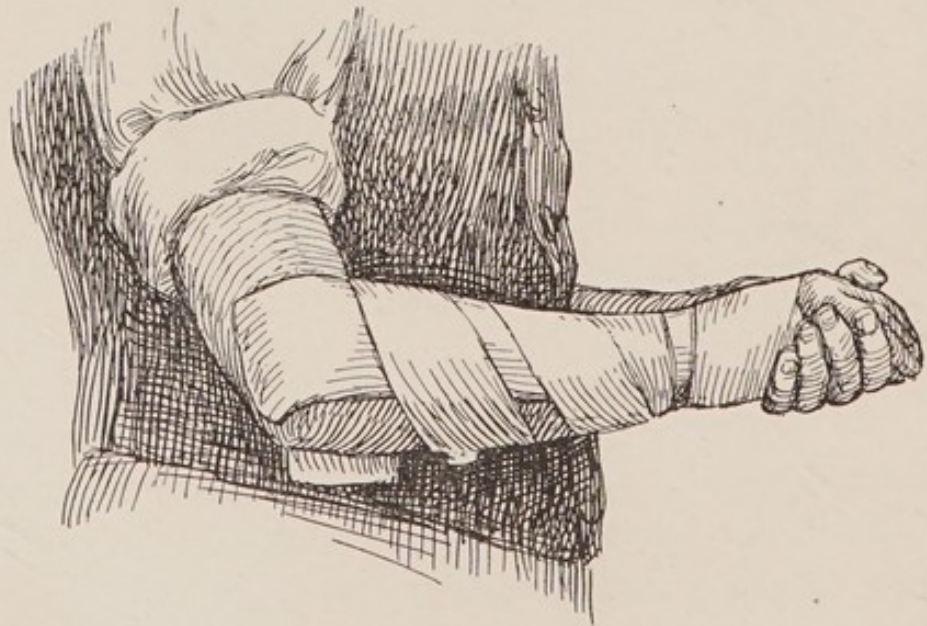


Fig. 44. Secured by bandage while hardening.

splints are set aside, to dry still further, if possible. They are then lined with non-absorbent cotton.

(Fig. 45.) When applied, the splints are to be held securely in place by circular turns of adhesive plaster, one near each extremity of the splint and the other fastened in the center. (Fig. 46) The two splints are then covered with a gauze or muslin bandage (Fig. 47), and this, in turn, is covered with a crinolin bandage, which prevents shifting of the splints.

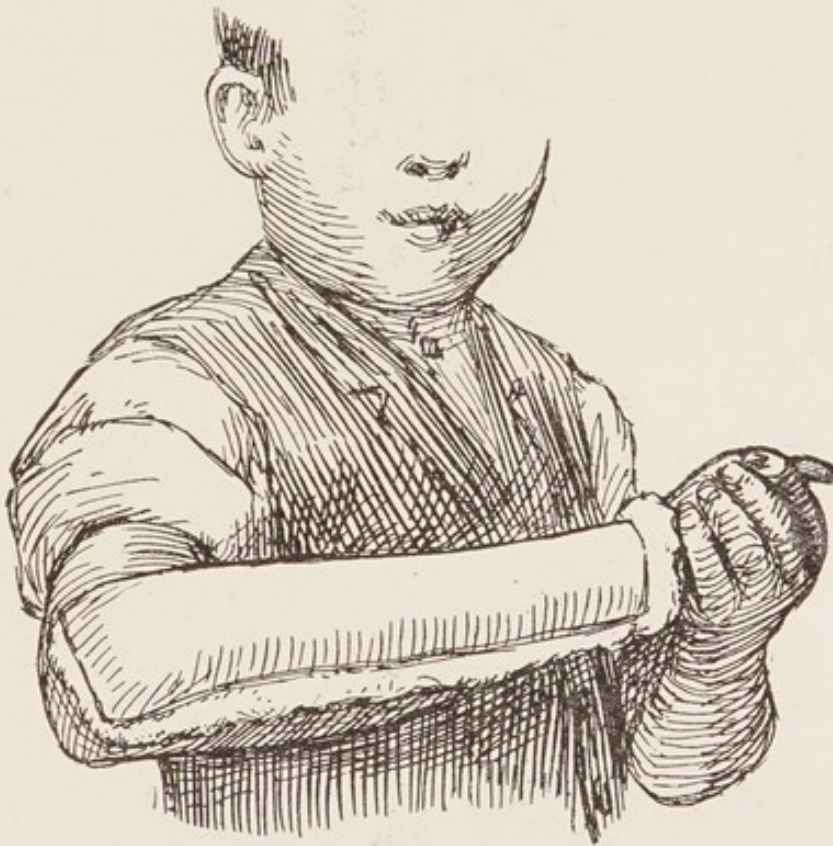

Fig. 45. Splint lined with cotton.

The advantages of this variety of splint over the circular plaster of Paris bandage, consist in its lightness of weight, and the ease with which it can be taken off and put back again, so as to enable inspection and to better the reduction of the fragments, if necessary.

(B) Instead of impregnating the layers of gauze by steeping and kneading them in the cream of plas-





Fig. 46. Two halves of molded splint held together by adhesive plaster.

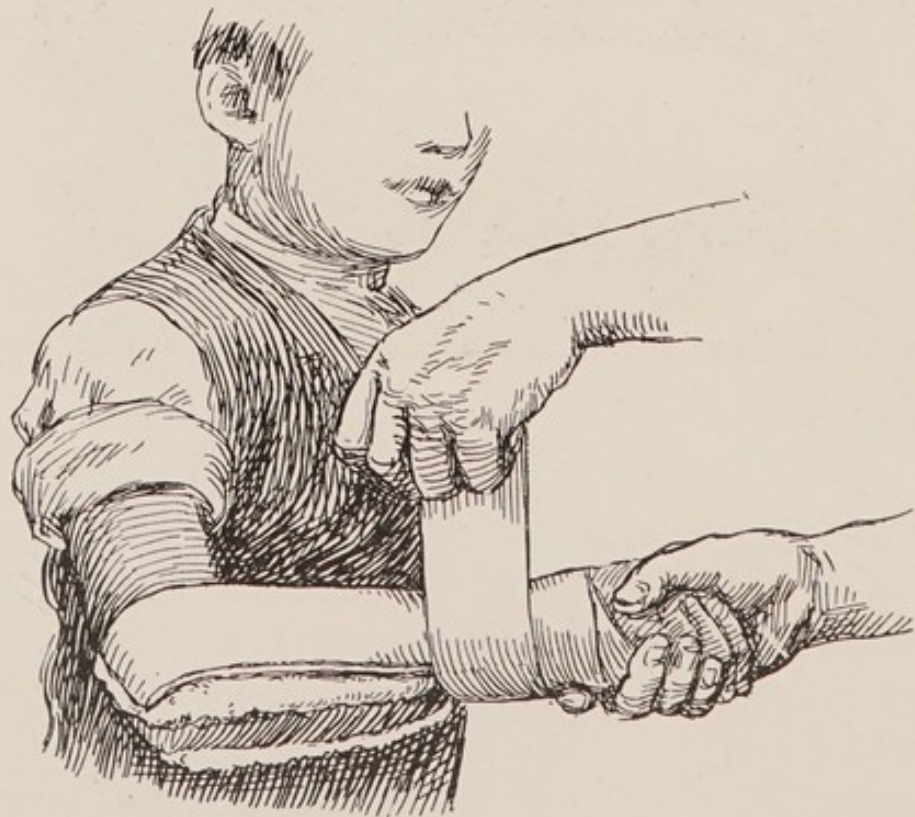


Fig. 47. Splint covered with muslin bandage.

ter, the latter may be poured on the gauze from a pitcher, and rubbed into the meshes with the hand. The impregnated gauze is then applied as in the previous method. This is a rather messy procedure.

(C) A third manner of preparing *molded splints is directly from a plaster of Paris roller bandage*. A bandage of the desired width having been selected, it is cut in the necessary lengths, ascertained by measurement on the limb. To prevent the crinolin from curling up, a weight is placed upon either end. Warm water is then allowed to drip on the several superimposed layers of gauze, to saturate them. They are then applied to the limb and molded in the same manner as described in the first method.

(D) Again, the *plaster of Paris roller bandage*, having first been *made plastic by immersion*, may be cut in lengths to correspond to measurements of the extremity. Several such lengths are superimposed and then molded on the limb as described.

(E) Finally, the *moistened plaster bandage* may be molded *directly* on the limb by playing the bandage to and fro upon it, each end of the bandage being held by an assistant, who grasps the successive turns as they are superimposed (Fig. 48), the surgeon at the same time striking the bandage to make it adhere to the deeper layer. The subsequent steps are identical with those mentioned above.

This variety of molded splints is made as follows: Two pieces of canton flannel, shaped to conform to the circumference of the fractured member, are sewn together lengthwise through their middle (Fig. 49), in single or double line of stitches, the seam always arranged to occupy the posterior aspect of the limb. One-half of the inner layer of flannel is then passed about the limb and secured, by several stitches or by adhesive plaster, to the underlying dressing (band-

Methods of  
Application  
The Bavarian  
Splint



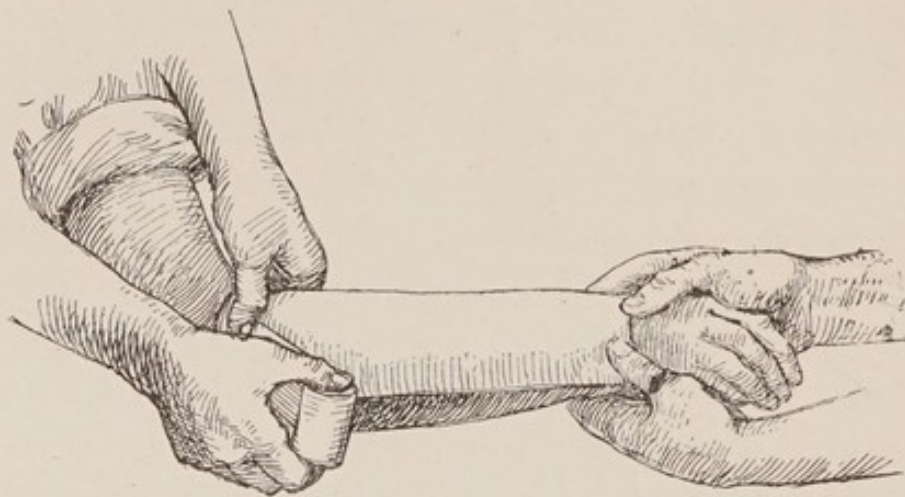


Fig. 48. Molded splint made by to and fro passage of plaster roller bandage.

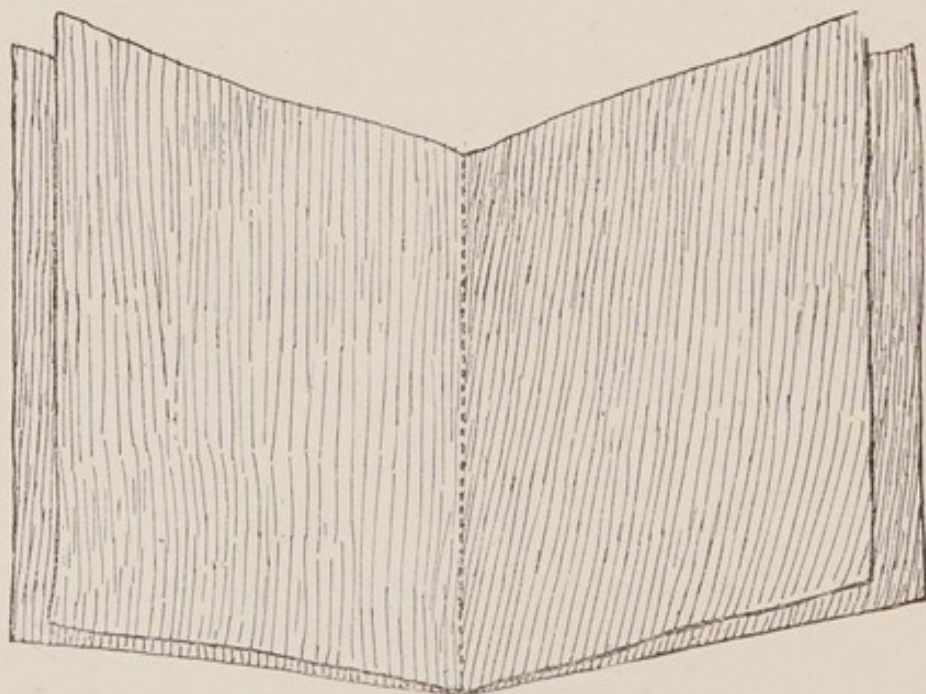


Fig. 49. Two pieces of flannel stitched for Bavorian splint.

age). Plaster of Paris paste is then applied, and thoroughly rubbed into this layer of flannel. Before the plaster has dried the outer layer of flannel on the same side, is superimposed. The two flannel layers on the other side are then similarly manipulated. When both halves have set completely, they may be cut down in front, and turned to either side, the seam posteriorly acting as a hinge, to permit of an inspection of the parts, after which they are turned back again and securely held in place with several strips of adhesive plaster, over which turns of a muslin bandage are passed.

This is another form of molded plaster of Paris splint. A number of strands of hemp are beaten, then dipped into a paste of plaster of Paris and spread out over the limb, previously anointed with vaselin. Additional plaster of Paris paste is rubbed into the strands of hemp, and more of the latter are added, from time to time, to impart the necessary thickness to the splint. First an anterior, and then a posterior, section is molded, and both are held in contact with the limb by turns of a muslin bandage. The latter is divided when the splints have hardened, and these are now lined with non-absorbent cotton and securely held in place by strips of adhesive plaster and a muslin roller.

A length of tricot cylinder is filled with cotton or, preferably, strands of hemp. It is then dipped in the paste of plaster and thoroughly kneaded therein. When completely impregnated, it is applied to the part and shaped to it by turns of a muslin bandage, which holds it in place while it is hardening. Like the other splints, it is subsequently lined with non-absorbent cotton.

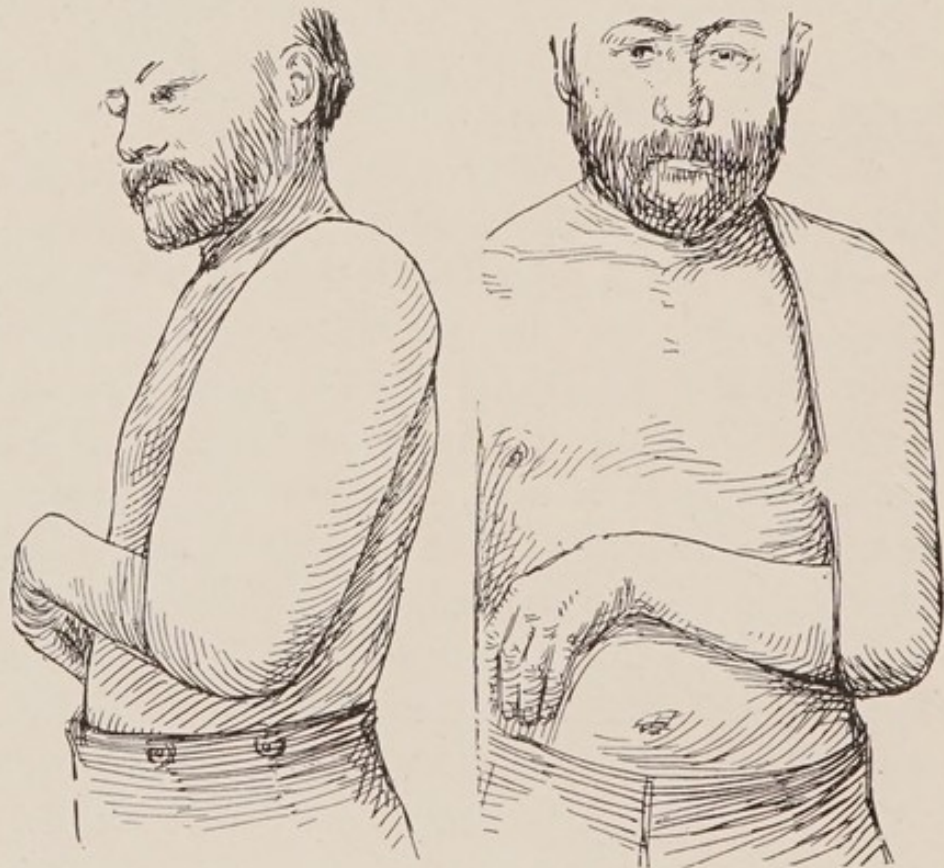
The  
Hemp  
Splint

The Tricot  
Molded Splint



**Molded Splint  
for Fracture  
of the  
Shoulder or  
Arm**

This splint should be made to extend *from the root of the neck to the elbow* and to embrace the arm on all but its mesial side. (Fig. 50.) With the aid of such a molded splint, we can attain complete immobilization when the splint is secured to the thorax with muslin and dextrine bandages. The elbow is left free, so that the forearm acts as a



Lateral view.

Anterior view.

Fig. 50. Plaster molded splint for humerus fracture.

counterextending factor. If the indications warrant immobilization of the elbow joint, the splint may be extended along the outer dorsal aspects of the forearm to the wrist. (Figs. 51, 52.)

**Cole's Splint**

Here we may use a separate anterior and a posterior splint, or, as in the "sugar-tong splint" of



Fig. 51. Molding splint for fracture of humerus with roller bandage.





Fig. 52. Molded splint for fracture of humerus suspended to dry.

Cole, one piece hinged at the elbow. (Fig. 54, page 62.) This latter splint is made by passing a plaster of Paris bandage from the wrist along the flexor aspect of the forearm, the latter being held in a position of pronation, and then, turning about the elbow, the bandage covers the extensor surface of the forearm. The extremities of the bandage are held taut by the surgeon while it is setting. The dressing is held in place by turns of a muslin.

This bandage is suitable for fractures in the lower portion of the forearm or Colles' fracture. A strip of gauze impregnated with plaster of Paris paste, or tricot cylinder filled with plaster paste, is wound spirally about the forearm, beginning at the elbow,

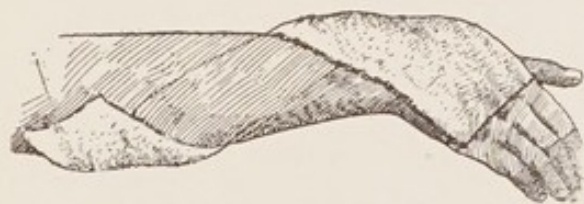

Fig. 53. Braatz's spiral molded splint for Colles' fracture.

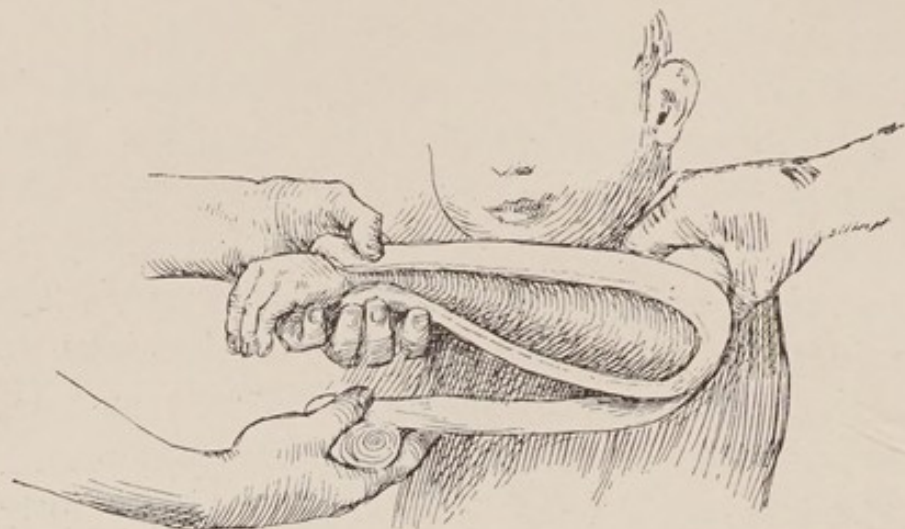
just beneath the internal condyle, then, passing obliquely over the flexor surface of the forearm, it turns about the radial side of the forearm, passing over the lower third of the radius on its dorsal surface, and terminates at the heads of the metacarpal bones. (Fig. 53.) The splint is finally lined with non-absorbent cotton and secured with turns of muslin and starch bandages.

Several layers of crinolin, of appropriate length, are dipped into a paste of plaster of Paris, and are then applied to the dorsum of the forearm, from the elbow to the heads of the metacarpal bones. The forearm is allowed to rest on the thigh (Fig. 55, see p. 63) and if the fracture be in the lower end of the radius or ulna, the hand is sharply flexed at the wrist, grasping the knee. Before applying the splint, the

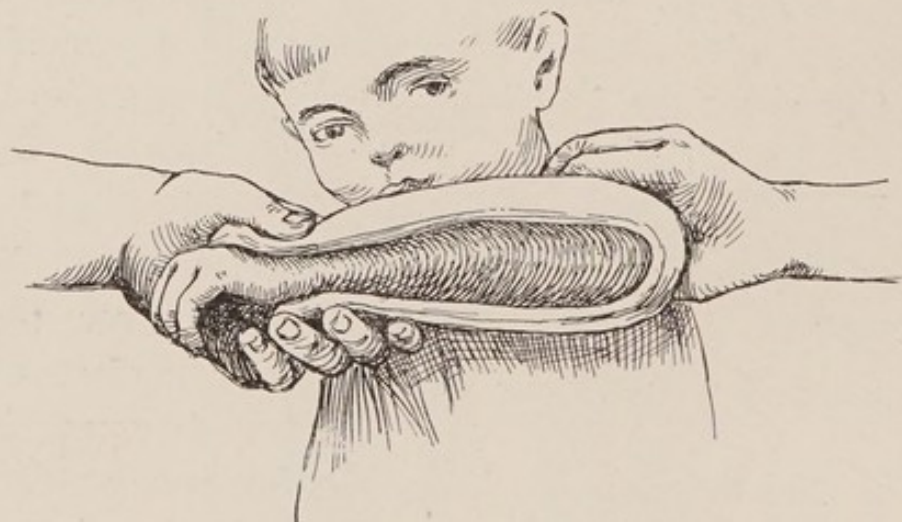
**Braatz's Spiral  
Molded Splint**

**Molded Splint  
for Fracture of  
the Forearm**

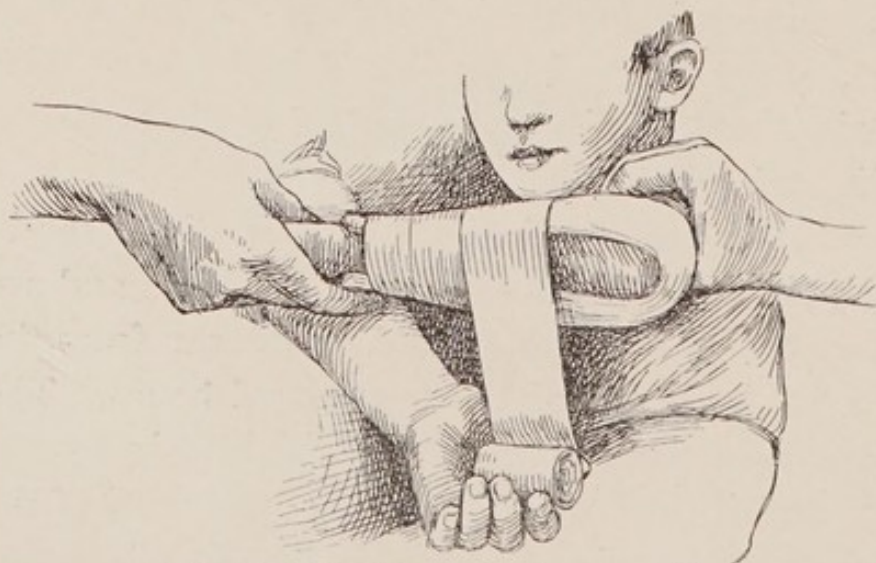




(a) Passing roller bandage to and fro.



(b) Sugar tongue splint molding to forearm.



(c) Securing the sugar tongue splint.

Fig. 54. "Cole" sugar tongue splint for fracture of forearm.

arm is anointed with vaselin, in order that the mold may be easily removed after it has set. The splint is then lined with non-absorbent cotton, dusted with dermatol, and secured to the forearm, first by adhesive straps one inch wide, then by muslin bandages, and lastly by a crinolin bandage. Instead of the layers of crinolin, a roller bandage of plaster of

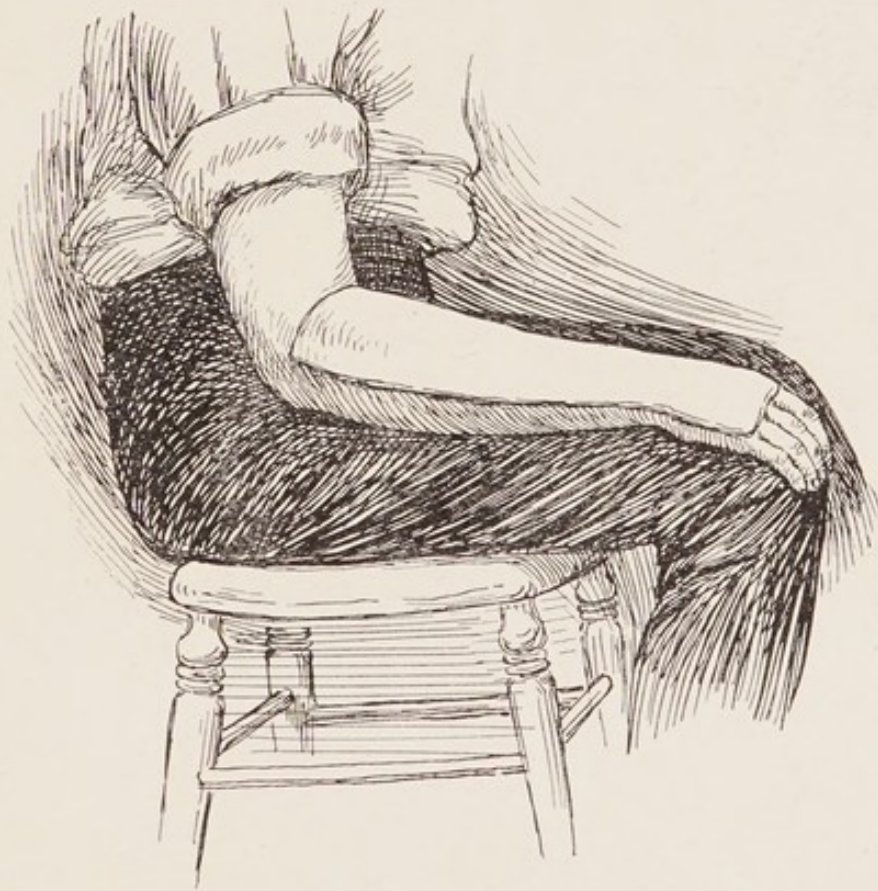

Fig. 55. Molding a dorsal splint for forearm fracture.

Paris, the width of the forearm, may be run up and down, and molded to the shape of the limb. (See Fig. 48, page 56.)

This splint is molded, in the same manner as the one just described, about the foot, which is to be in the right-angled position. It extends up the calf of

**Gutter Splint  
for Fracture of  
Both Bones of  
the Leg.**



the leg to the flexure of the knee joint or above. A splint is also laterally placed. (Fig. 56.) This (Stimson's) splint is suitable for fracture of the leg or injuries of the knee joint, when ambulatory treatment is deemed inadvisable. It is not eligible when there is any deformity that can not be wholly cor-




Fig. 56. Plaster of Paris gutter splint for fracture of one or both bones of the leg.

rected under anesthesia, for the splint embraces but half the inner and outer aspects of the leg. When dry, the splint is lined with non-absorbent cotton dusted with dermatol, and held in position by muslin and crinolin bandages, applied successively.

## CHAPTER VI

### PLASTER OF PARIS IN ORTHOPEDIC SURGERY

It was this device as taught by Sayre that gave the greatest impetus to the use of plaster of Paris dressings. The manner of its application laid down by him survives to this day as the chosen method. A plaster of Paris jacket may be applied with the

Plaster of Paris  
Corset (Jacket)

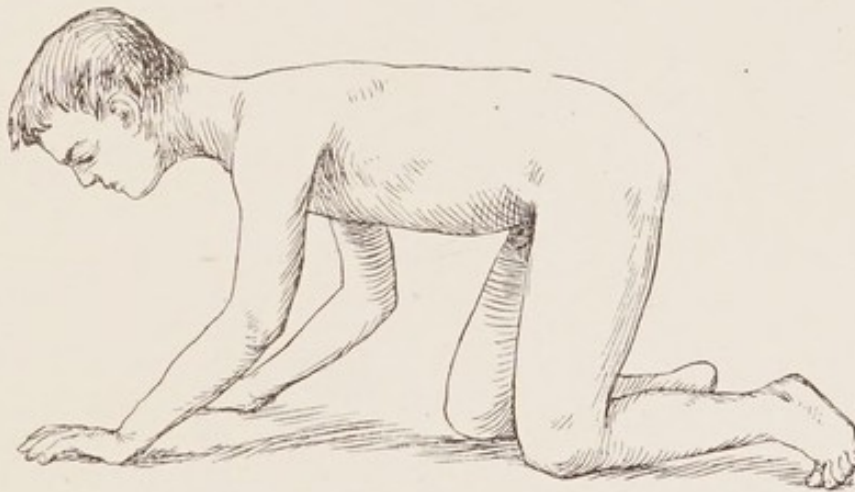


Fig. 57. Crawling posture while applying hose investment for jacket.

patient either in the suspended vertical position (Sayre), or in the swaying horizontal, or recumbent position.

Vertical Suspension.—The patient is stripped of all clothing. The body is cleaned with soap and water, rubbed with alcohol, and freely dusted on all sides with talcum, dermatol, bismuth, or a mixture of these. While in a position as if crawling, *i. e.*, with the body's weight supported on the hands and knees, thus relieving the spine of any pressure, (Fig. 57), a seamless shirt or tricot hose is slipped on. If the latter is used, the upper end is fitted by

Vertical  
Suspension



slitting the hose in the axillary lines to a depth sufficient to bring the ends over the shoulder, where they may be tied, or secured with a few stitches or a safety pin. All folds in the shirt are smoothed away by drawing it down and securing it snugly in the perineum with a safety-pin. The shirt or tricot should be as long again as that part covering the body. The object of this to be described shortly.

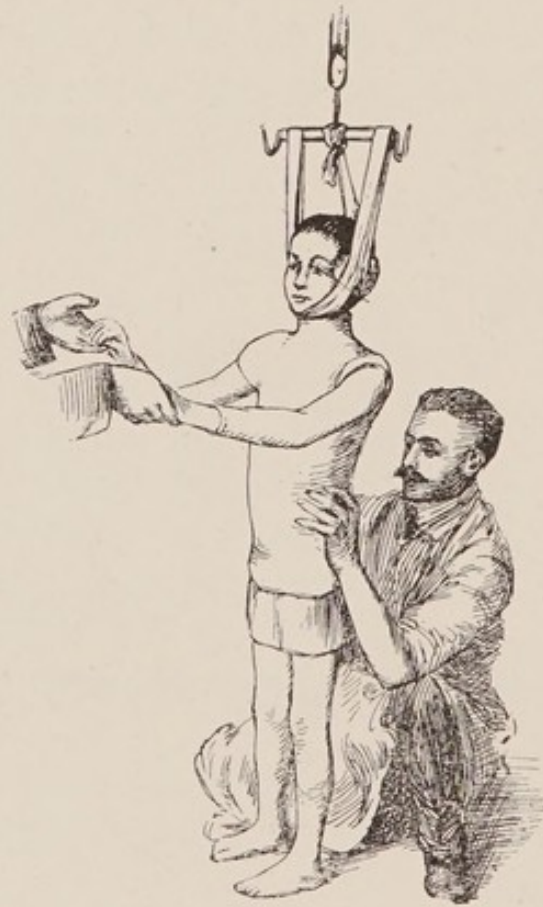

Fig. 58. Sayre's suspension application of plaster jacket.

The patient is lifted, with assistance if heavy, into the suspension apparatus of Sayre. (Fig. 58.) Suspension apparatus consists of a curved iron cross bar with notches, to which is attached an adjustable leather head and chin collar with straps. To a ring in the center of the bar is hooked a pulley, the other end of which is secured either to a pulley in the ceil-

ing, at the top of door frame, or the top of an iron tripod—or two ladders hinged at their upper extremity. By the pull of the rope that plays between the two pulleys the apparatus is raised or lowered. With a diseased spine, the patient should never assume, unsupported, the erect posture. The patient is suspended in the apparatus by the chin, with the arms extended and grasping the cross-bar

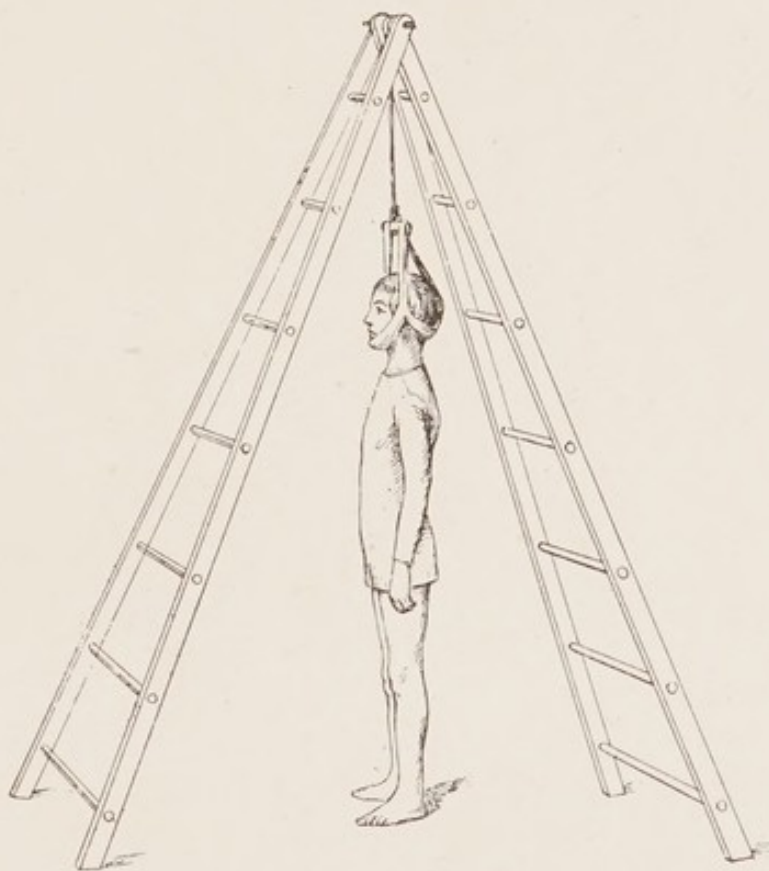


Fig. 59. Use of ladders to operate the suspension apparatus.

to aid in the extension of the spine. (Fig. 59.) The ropes that are fastened to the cross-bar and play about the pulleys above, are drawn upon until the entire body sways, and the tips of the toes touch the floor, or the stool placed beneath so that the patient's trunk is on a level with the arms of the surgeon seated and applying the plaster bandages.



*By no means is it necessary to carry the extension so far that the feet are off the floor.* An assistant grasps the legs to prevent the swaying of the body, as well as its rotation, and to guard against the inadvertent flexion of the thighs. Another assistant controls the rope with one hand, and with the other steadies the extended arms of the patient, so as to prevent rotation of the cross-bar.

All the bony prominences, such as the spines of the ilium, and the gibbus itself, and also any very decided hollow, especially about the waist line—if there be much lateral curvature or lordosis—are covered with a thickness of piano felt. The piece of felt over a prominence may be fenestrated so as to allow the knuckle of bone to engage in the window, and over this window softer material may be placed eventually. This is to protect the prominences from pressure, and to fill in the hollows, also that the symmetry of the jacket may prevent the plaster from cracking. In each axilla felt or several thicknesses of gauze will protect the skin from the friction of the edges of the finished jacket. These pads are successively placed as the turns of the bandage are about to grasp them. It is no longer the practice to place a pad over the gastric area to make allowance for the full or empty stomach.

If the patient rests comfortably in the suspended position, so judged if the head rests easily in the sling, and *extension* and not *suspension* is practiced (the latter intending to raise the feet from the floor wrongly so), the application of the plaster of Paris bandages may follow. The bandages should be four inches wide for the younger children, and for older children, of larger build, six inches. The bandages are passed circularly or spirally around the body. *Below the bandages* should reach the

*great trochanters*, and above they should pass under the axilla and well over the top of the sternum. These limits of the jacket must be well borne in mind; for the commonly committed failure to observe them is chiefly responsible for ill-fitting corsets. If too short below, the jacket presses into the abdomen (Fig. 60), or the latter bulges out beneath

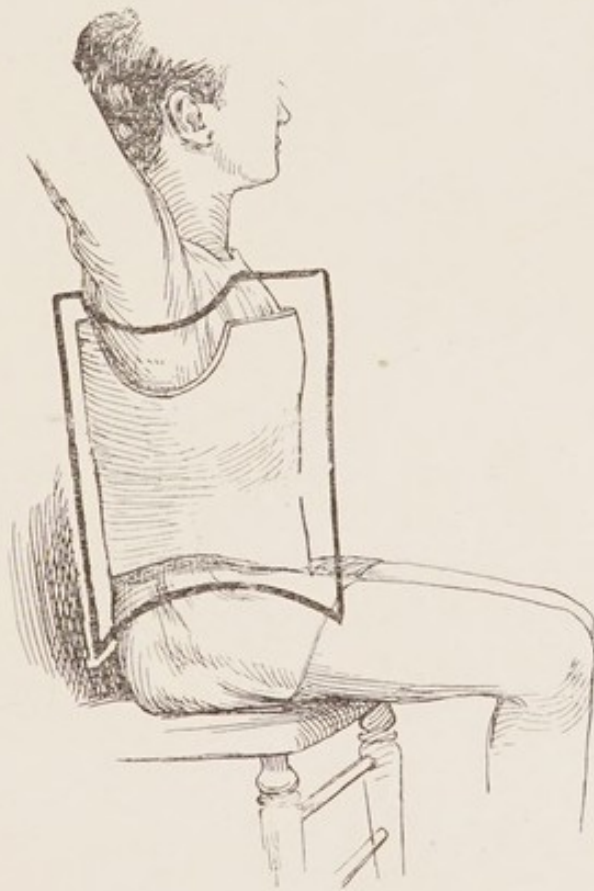

Fig. 60. Heavy line shows correct extent of plaster, the light outline the incorrect.

the edge of the plaster; if not carried high enough, the jacket fails to effect the necessary extension of the spine. After the setting of the plaster is completed, generally at the expiration of a quarter of an hour, the patient is to be lifted out of the swing (Fig. 61.) Being grasped by an assistant from behind, his hands passing beneath the axillæ, the



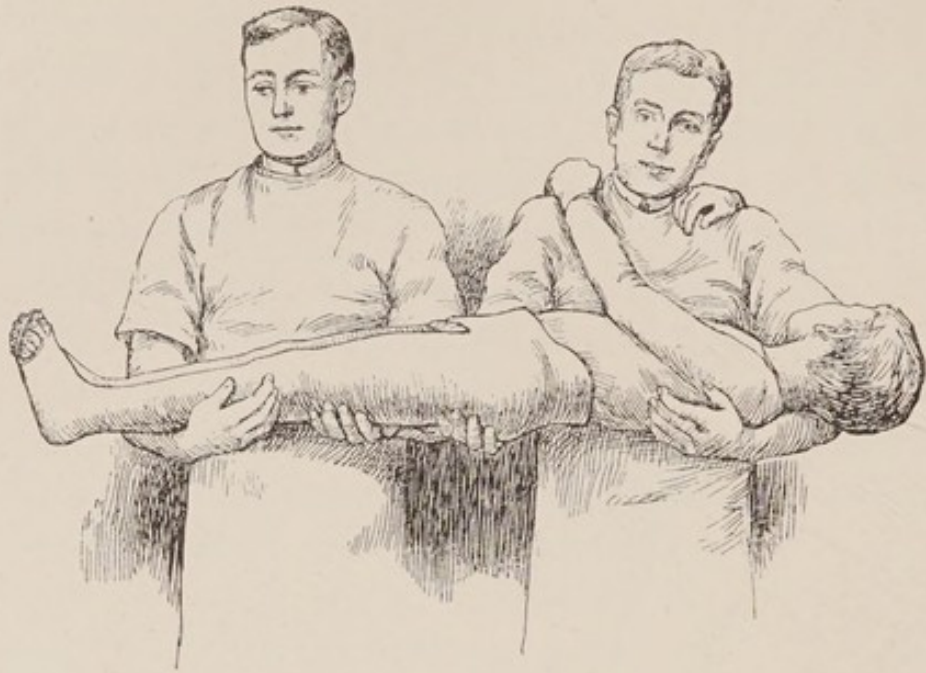


Fig. 61. Method of transporting patient with jacket or spica. patient is borne on the chest of the assistant, and yet another assistant supports the extremities so as to avoid any flexion of thighs, which might indent or crack the plaster, and is placed, temporarily, in the recumbent position, the head resting on a small pillow. (Fig. 62.) Thus placed, any further hardening of the plaster is permitted before proceeding to trim the jacket.

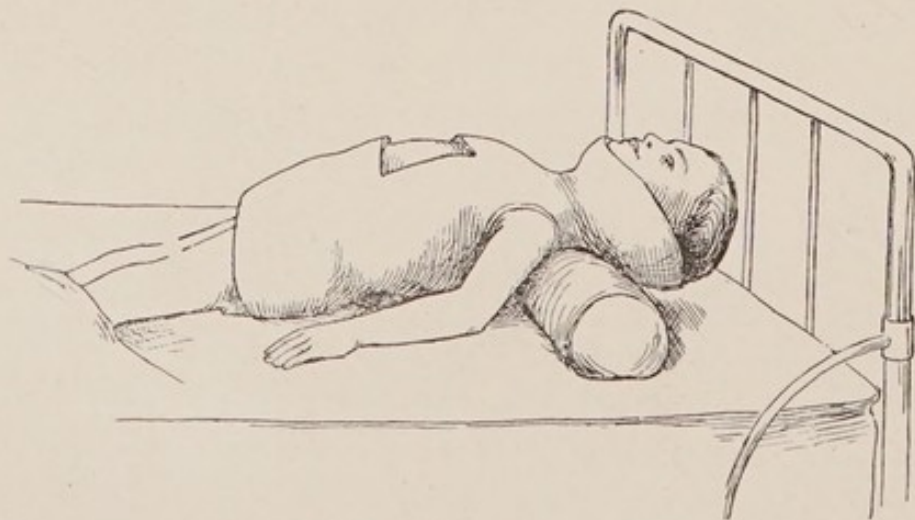


Fig. 62. Patient in bed—reposing on pillow to permit jacket to dry.

Trimming the Jacket.—In order to allow flexion of the thighs on the abdomen a crescent of plaster of sufficient size is removed from each side, at the level of Poupart's ligament. To allow adduction of the arms a crescent-shaped piece is cut from the axillæ. The bandage must not be cut below the sternal notch, and a tongue of plaster must be left about the symphysis pubis. The jacket must be cut on the sides until it conforms to the upper limit of the great trochanter. (Fig. 63.) The patient now assumes the crawling attitude and the jacket is trimmed above, straight across posteriorly from the upper limit of one axillary fold to that of the other. Below, the excess of plaster is cut across posteriorly at such a level that the cast will not touch the chair seat when the patient is sitting. If there be any sinuses leading into cold abscesses, the cast should be fenestrated, to admit of their being dressed. Any small decubitus (pressure sore), or the site at which one is likely to form over the gibbosity may be dressed with balsam of Peru under the jacket *without fenestration*.

Trimming  
the Jacket

The knitted shirt or tricot hose extending beyond the cast is drawn back over it and stitched together. This excess of hose not only imparts a neat finish to the jacket, but also prevents the rough cut edges of the plaster from pressing into the soft parts. When an excess of shirt or tricot is not available, the cast may be covered with several turns of a crinolin bandage, and the cut edges covered with adhesive plaster. If the cast is to be a permanent one, it is now completed. If, however, it is to be a removable one, it is to be cut down the front with a mitre saw or Stilles' bone forceps while the trimming is being done. The opposing front edges thus



formed are bound with adhesive plaster and are fastened together with the same material. For long-continued wear, the edges should be bound with leather or canvas provided with a row of hooklets. These are stitched on and laces thrown about them. (Fig. 64.)

**Jacket with  
Jury-Mast**

Jacket with Jury-Mast.—For the cervical form of Pott's disease, as well as such cases in which the disease is high up in the dorsal vertebræ, it is customary to incorporate a jury-mast in the dorsal part of the jacket. This latter device (as illustrated in

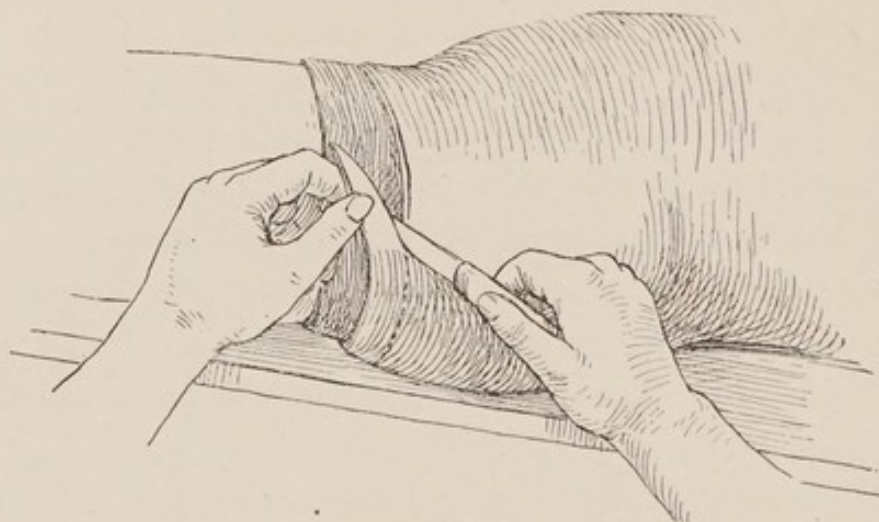


Fig. 63. Method of trimming jacket.

Fig. 65), is a band of steel, whose lower end has pieces of tin attached at right angles to facilitate its fixation in the plaster cast. Its upper end is bent to conform to the spine, and likewise in passing over the occiput to the vertex of the skull. (Fig. 65.) The vertical part of the steel band may be made in two parts, sliding on each other and securable by screws so that the mast may be lengthened at will. To the upper extremity of this band of steel there is attached a short bar which plays on a swivel. From either end of the bar there passes a piece of web-

bing or leather strap around the chin to support the head, and thereby relieve the spine from the pressure of the superimposed weight of the head. The band of steel should be so bent as not to touch the spine or the head. The degree of extension will be the greater the more the steel band is carried away from the head.

Horizontal Suspension.—When a suspension ap-

Horizontal  
Suspension

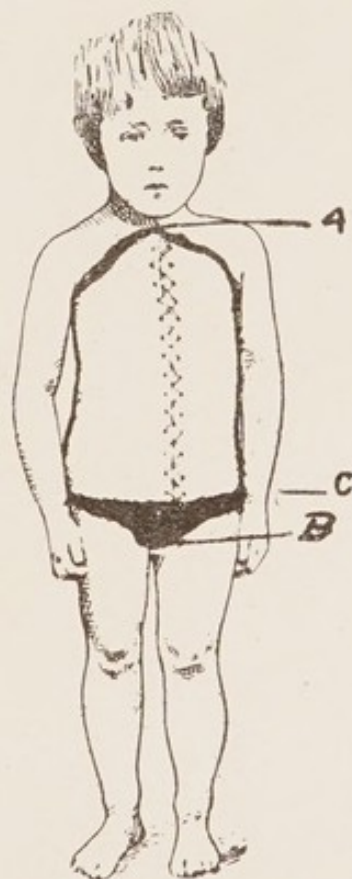


Fig. 64. Plaster of Paris jacket provided with hooks for lacing. Note *a* upper limit; *b* lower limit; *c* incorrect lower limit.

paratus is not at hand, the patient may be placed in the horizontal position, face down, the body being stretched between two tables. (Fig. 66.) The shoulders rest on a pillow on one table, and the thighs on another. One assistant is detailed to apply traction to the thighs, and another, hooking his fingers in the axillæ, exercises traction upward. The



weight of the trunk effects a lordosis, thereby overcoming any existing kyphosis (gibbus). The same precautions are to be observed as in the vertical method, in covering any bony prominences. The plaster bandage is passed in circular or spiral turns around the trunk.

**Goldthwait's  
Method**

Goldthwait's Method.—A jacket may also be ap-

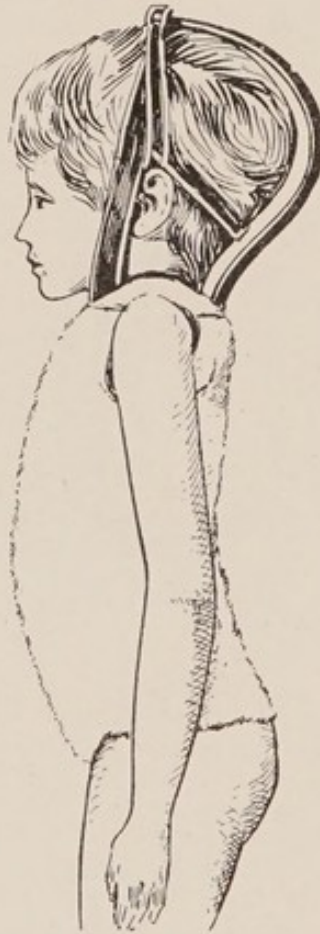

Fig. 65. Plaster of Paris corset, with a jury-mast incorporated.

plied with the patient in a recumbent position, resting upon an appliance consisting of two wire supports, on one of which rests the sacrum, the other being placed beneath the deformity (with pads intervening). With hyperextension, a sufficient leverage is exerted to correct the deformity. The plaster

bandage passes about the supports and includes the pads.

Horizontal Method in Hammock.—In place of the tables, again, a hammock made of extra stout muslin or canvas is suspended between two walls. (Fig. 67.) The patient is placed therein, face downwards, arms and legs extended. The plaster of Paris roller bandage, in its turns about the body, includes the hammock. On the completion of the bandaging, the excess of hammock is cut away. A modification of this consists in placing the patient on his back with a support under the pelvis and a pillow beneath the head. At about the site of the deformity a sling

Horizontal  
Method in  
Hammock

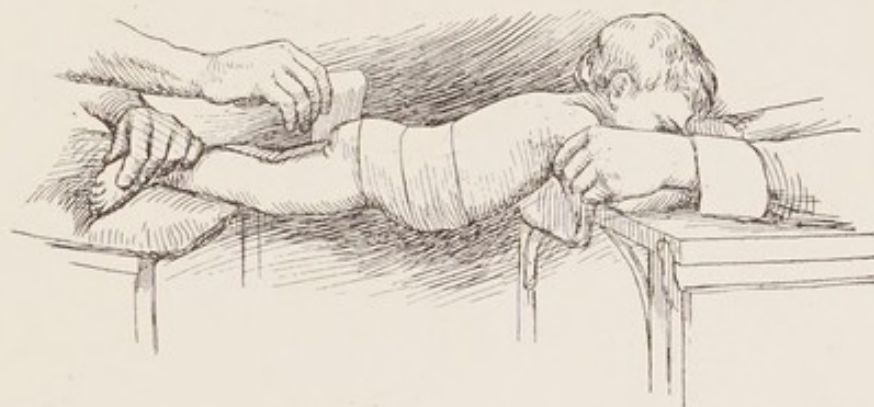


Fig. 66. Application of plaster of Paris corset in horizontal position.

made of stout muslin passes. (Fig. 68.) The greatest prominence of the projection is protected by a layer of saddler's felt. The sling passes to either side of the thorax, to be attached to the horizontal bar of a suspension apparatus. By raising the bar, the counterweight of the body operates towards effacing the deformity. At this particular moment plaster of Paris bandages may be applied, including the sling, which eventually is cut off at the point of emergence from the bandage on either side and the holes are subsequently covered by more turns of plaster bandages.



**The Bradford Frame** The Bradford Frame is similar in application to the hammock. It is a rectangular frame constructed of gas pipe, over which is stretched a piece of canvas. The patient rests on this, face down, arms extended, the hands grasping the frame above, while the feet may be drawn down by an assistant (Fig. 70); or each foot, with the thighs in the abducted position, may be secured, with traction, to the lower part of the frame. A slit is then cut in the canvas (Fig. 69) on each side of, and parallel with, the

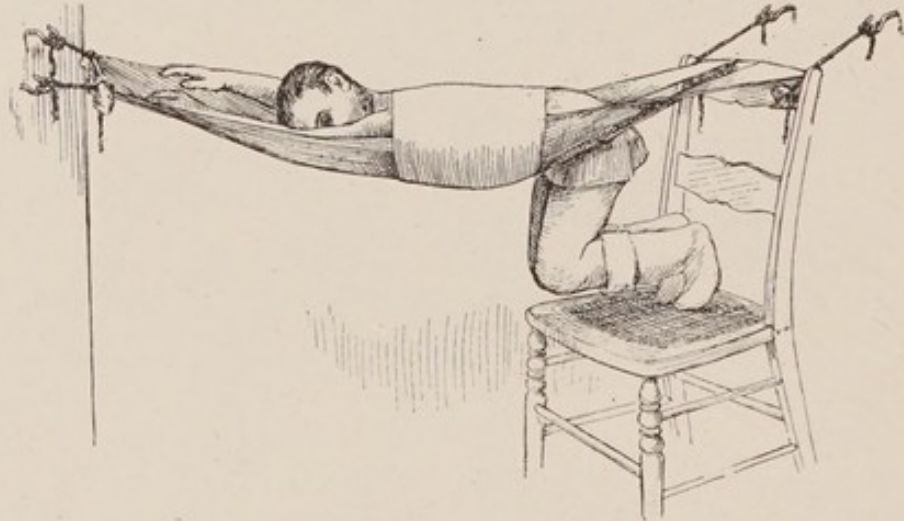


Fig. 67. Application of plaster of Paris corset by horizontal method in hammock.

body. Through these slits the roller bandage passes in its turn about the body, to include the canvas bed. (Fig. 70.) The excess of canvas is cut away after the bandage is completed and a few more turns of plaster made.

*Indications.*—Every form of Pott's disease is suitable for a plaster jacket—save adults in whom the disease is high up in the spine, or where the great dimensions of the plaster jacket, owing to the largeness of the individual, forbid its use.

A paralysis from pressure of deformed spine is often relieved forthwith by its use. Where there are large cold abscesses accessible these had better be treated preceding the application of plaster. Very acute conditions with spasm and pain had better be given treatment in bed in the horizontal position before applying the jacket.

A *laced jacket* is indicated at the start in the less acute cases of spondylitis, and where extensive wounds require surgical dressing. Jackets are also indicated in cases of lateral curvature to supplement

Laced  
Jacket

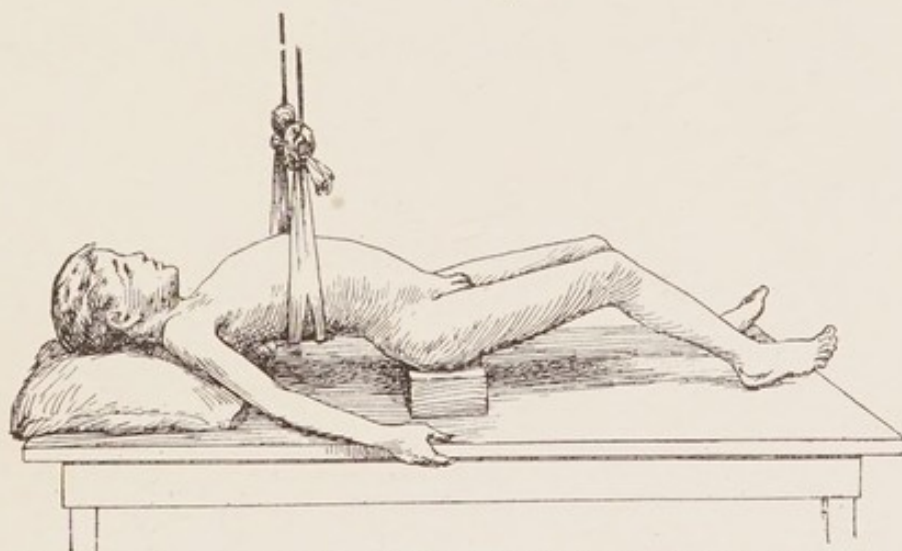


Fig. 68. Suspension in a sling to permit application of corset.

gymnastics, and for cases in which the distorted spine is painful. A plaster of Paris corset is also indicated in fracture of the spine prior to the performance of an operation, or when operation is contraindicated and also after an operation has effectually reduced the fracture, dislocation, or fragments of bone have been removed. In some very exceptional cases of rachitic curvature I have also applied a jacket with benefit, for it prevented the movements of a very tender spine until anti-rachitic treatment became effective.

Rachitic  
Curvature



It may at times be necessary to extend the plaster bandage so as to include the hip in a spica (Fig. 71), as in sacroiliac disease, or in a complicating hip-joint affection; and if the spinal disease be in

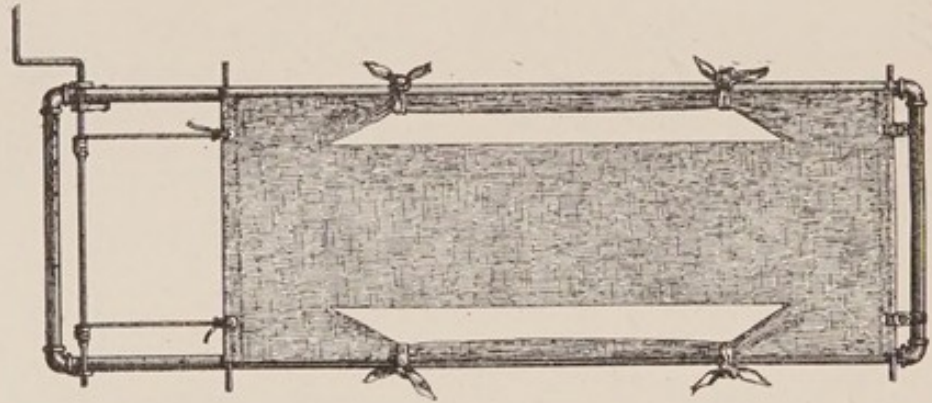


Fig. 69. Bradford frame.

the upper cervical region the turns of the plaster bandage should even pass beneath the axilla and about the shoulders so as to carry them well back.



Fig. 70. Corset applied in Bradford frame.

**Particulars About  
the Jacket**

Particulars About the Jacket.—The jacket should weigh between one and two pounds, and should be of uniform thickness throughout. If there is any decided acuity of the disease, it is far better not to

split the jacket, lest meddling guardians remove it too frequently. A well-fitting and comfortable jacket may remain in place for two months. At the expiration of this time the condition of the skin demands consideration, and the removal of the jacket is necessary for hygienic reasons. Thereafter it may be reutilized, being provided with hooks and

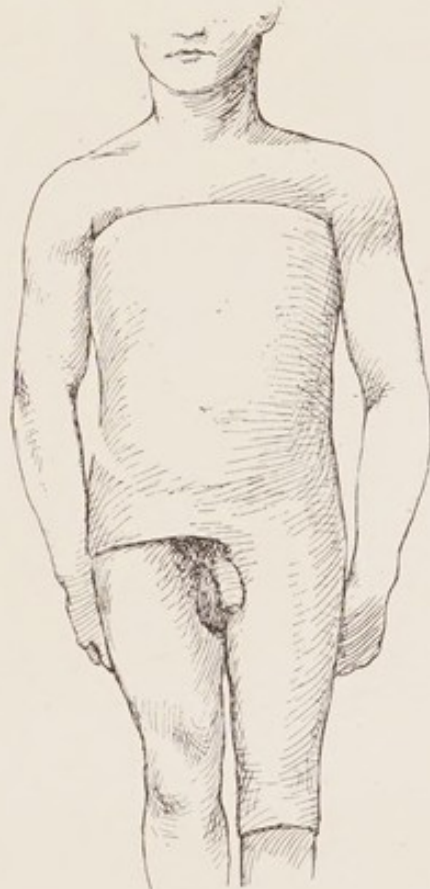


Fig. 71. Combined corset and hip spica.

laced, or brought together with strips of adhesive plaster, and so held in place.

The report of any pain, or the existence of any odor, about the jacket is indicative of an open wound. This, in the case of children, is commonly caused by the presence of a foreign body, playfully



inserted or accidentally finding its way beneath the jacket. The exact location of such a foreign body is betrayed by the staining of the plaster bandage if



Fig. 72. Plaster crown with wires attached—a substitute for jury mast.

secretion is profuse or by site of pain or circumscribed odor. A window cut in the jacket suffices to

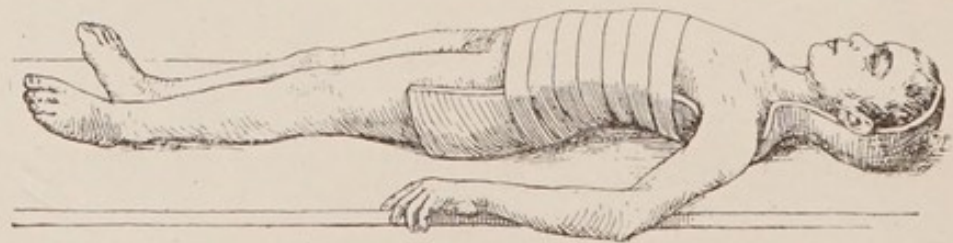

Fig. 73. Lorenz bed.

remove the offending object and permits the application of a dressing.

A plaster jacket may be employed as a mold, from which, by filling the interior with a mixture of plaster of Paris, a cast of the deformity can be made. Over this cast corsets of other material—felt, wood, veneering, aluminum, and celluloid—may, in turn, be molded.

If a jury-mast be not obtainable, a crown of plaster of Paris may be passed about the head and this

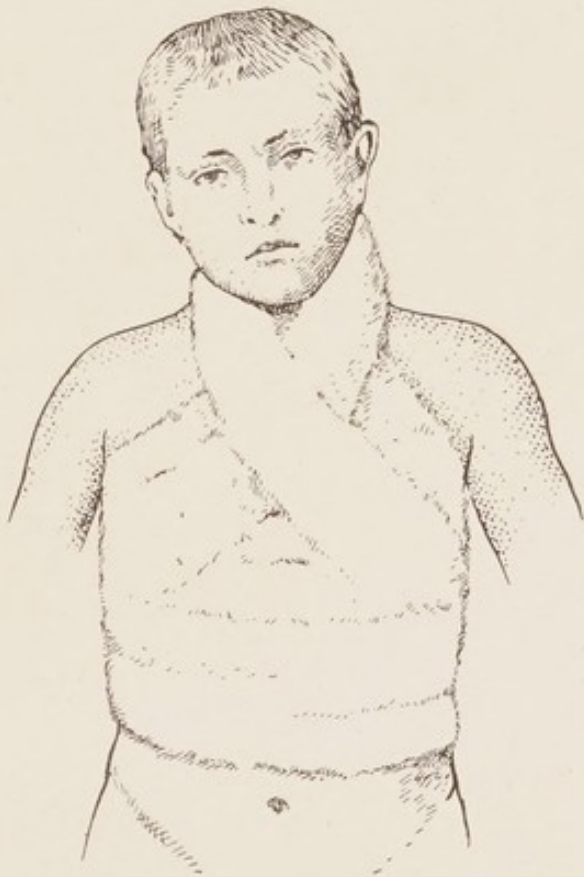

Fig. 74. Plaster of Paris jacket with figure-of-eight turns about the neck for cervical spondylitis or torticollis.

then joined by two steel bands passing to the plaster jacket and incorporated in its turns. (Fig. 72.)

In young infants who are to be carried about, a plaster jacket is impracticable because of its weight, and because it impedes the thoracic movements. As such infants do not assume a sitting or an erect posture, they are best treated in recumbency. For

Lorenz Bed



this purpose the Lorenz bed is admirable. (Fig. 73.) It is a splint molded to the contour of the spine, extending laterally to the posterior axillary line.

**Plaster Collar  
and Jacket**

When the disease is in the upper spine, it may be molded about the neck and head. It is to be padded with non-absorbent cotton, and secured to the trunk by turns of muslin and crinolin bandages.

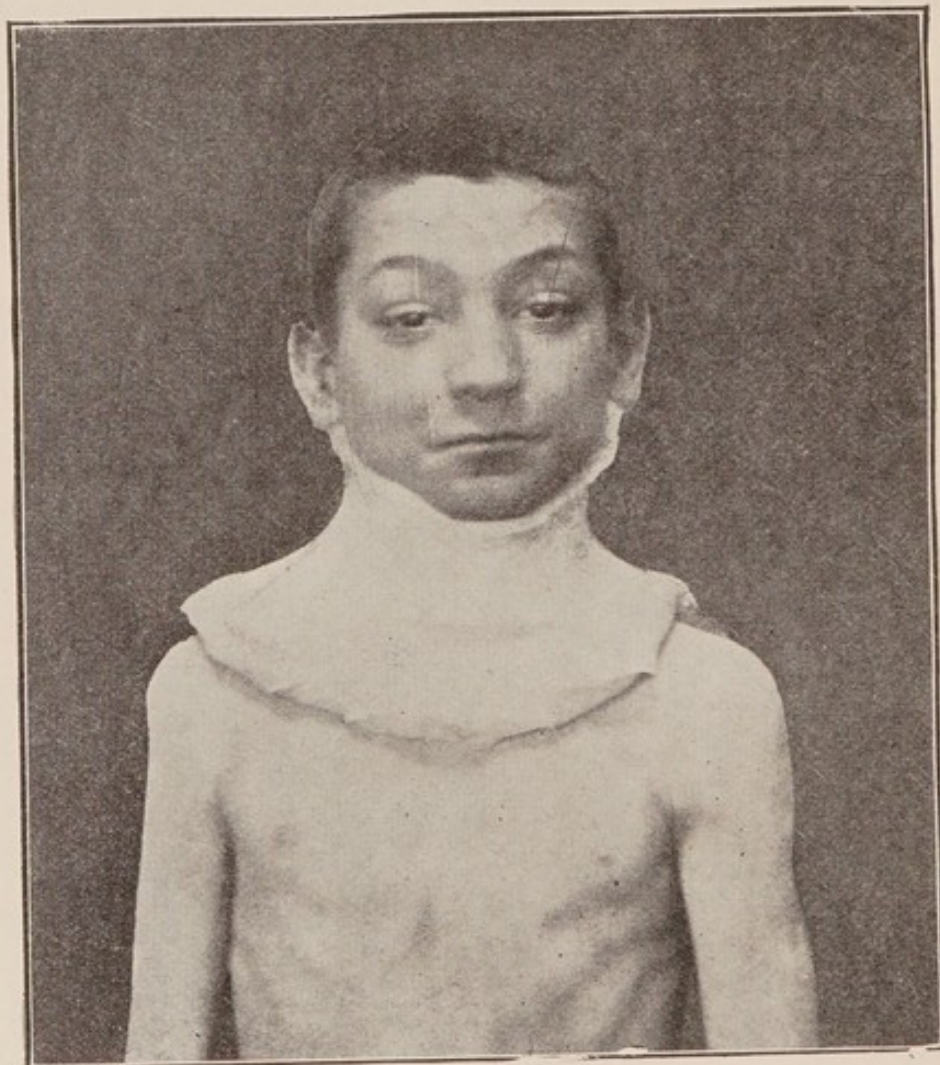


Fig. 75. Plaster of Paris collar.

When the disease of the spine is high up in the dorsal region, or in the lower cervical, the bandages may be extended around the neck (Fig. 74) in figure-of-eight turns; or by like turns the head being included may be fixed; or a separate collar (Fig. 75) may be made, impinging upon the mastoid

processes embracing the lower jaw, extending well on to the shoulders, and resting upon the clavicles. These plastic investments for the neck are indicated in the correction of torticollis, or after resection of the sterno-mastoid for spasmodic torticollis, and for fracture of the cervical spine.

During the period of time, when non-operative measures are resorted to, in the hope of correcting wry-neck, the deviation of the head dependent on *congenital* spastic contraction of the sterno-mastoid muscle, may be overcome by repeated suspension in the Sayre's apparatus. Where this can be accomplished, the position may be maintained by investing the body with a plaster of Paris jacket of light construction and extending it so as to pass about the neck in figure-of-eight turns (Fig. 74, page 81), supporting the chin, anteriorly extending up to the mastoid processes and supporting the occiput posteriorly, or, if the muscle be more unyielding, a tenotomy may be indicated, whereafter the plaster of Paris should also include the head, encircling the occiput and frontal bone.

In the *acquired* form of torticollis, which can be easily righted by manual force, the head can be retained in a corrected position by placing about it a coronet made of plaster of Paris into which a metal ring is incorporated (Fig. 76), by means of a muslin bandage passing through the ring and about the thigh, traction is made in a direction opposite to the existing torticollis. This traction is carried to the extent of producing a torticollis in the opposite side, thereby overcoming the spasm of the affected side.

For the torticollis of *cervical spondylitis* a well-fitting plaster of Paris corset with a jury-mast from

**Torticollis**



which the head is suspended, is the best form of treatment.

*Conclusion:* From the aforesaid it is apparent that a plaster jacket has a wide range of usefulness because of its economic value, being available by a large number of the afflicted indigent poor who can not afford the expense of a brace.

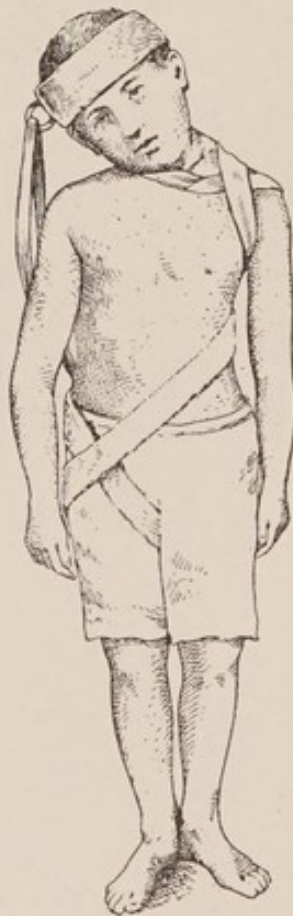


Fig. 76. Plaster of Paris coronet with ring incorporated to aid in correction of torticollis.

Its purpose is solely to immobilize the spine—in no way correcting a deformity, but limiting any aggravation of such deformity. All the while such patients may be about enjoying those hygienic conditions conducive to a cure, which is taken to mean a fixed and deformed spine void of pain in many instances. Under favorable conditions such end-

results follow after wearing a jacket for a couple of years at least.

The Calot jacket is called after Dr. Calot, who de-

Calot Jacket

vised it. The patient is suspended in the Sayre apparatus, but if paralyzed the extension is undertaken with the patient seated on a bicycle seat attached to a tripod, instead of suspension with limbs extended. Calot uses plaster bandages (Fig. 3. See p. 5) freshly prepared by immersing the crinolin roller bandage in a paste of plaster of Paris, unraveling and re-rolling them rapidly. The tricot investment being in place and the bony points protected by pads of felt or cotton, a pad of non-absorbent cotton is placed provisionally over the thorax. The plaster bandages are now wound about the lower part of the trunk as in the ordinary plaster jacket, but passing upward the turns include the shoulder and axilla and invest the neck (Fig. 77); the latter must be protected by a cravatte of non-absorbent cotton placed between two layers of gauze. The turns about the neck are applied in figure-eight fashion. The successful application of the bandage demands an absence of anything like strands, exact adaptation by modeling about the pelvic and shoulder girdle, and no constriction. Calot, after the use of the circular bandages, gives additional strength to the jacket by applying a plastron of plaster of Paris to the thorax anteriorly and posteriorly. Such a plastron consists of several sheets of crinolin previously measured to fit, dipped in the cream of plaster and placed as outlined. Each plastron is split at its upper end for one-third of its length. These split ends pass over the shoulder into the axilla. The split ends from in front and behind are superimposed. The



lower ends of the plastron being longer than the trunk, are turned on themselves and worked in with the bandage. The turns about the neck are applied circularly over the cotton cravatte mentioned above, and in conclusion circular turns are passed over the plastron, whereupon the modeling of the bandage to the pelvic and shoulder girdle begins. Calot recommends that cream of plaster be rubbed in

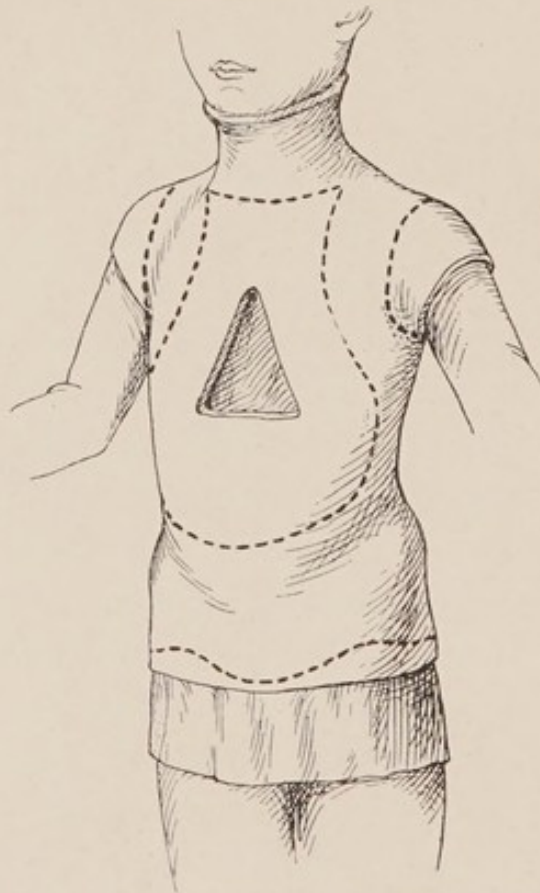


Fig. 77. Temporary window—Calot jacket.

over all the layers at the last moment. At the expiration of fifteen minutes the plaster has set. The body may be taken out of suspension and placed horizontally, the neck resting on a circular cushion. (Fig. 62, p. 70.)

*Trimming.*—After another half hour the bandage is trimmed below to permit of right angled flexion of the thighs and nearly 45 degrees if patient is to remain in bed. In front the bandage must reach over

the pubis. Above the bandage is cut away so as to expose the shoulders and to permit of free range of motion a crescent is removed from the axilla. Anteriorly a small window (Fig. 77) is cut temporarily to remove the cotton pad. The day following the bandage is polished by first covering the jacket with a thin paste of plaster and rubbing it

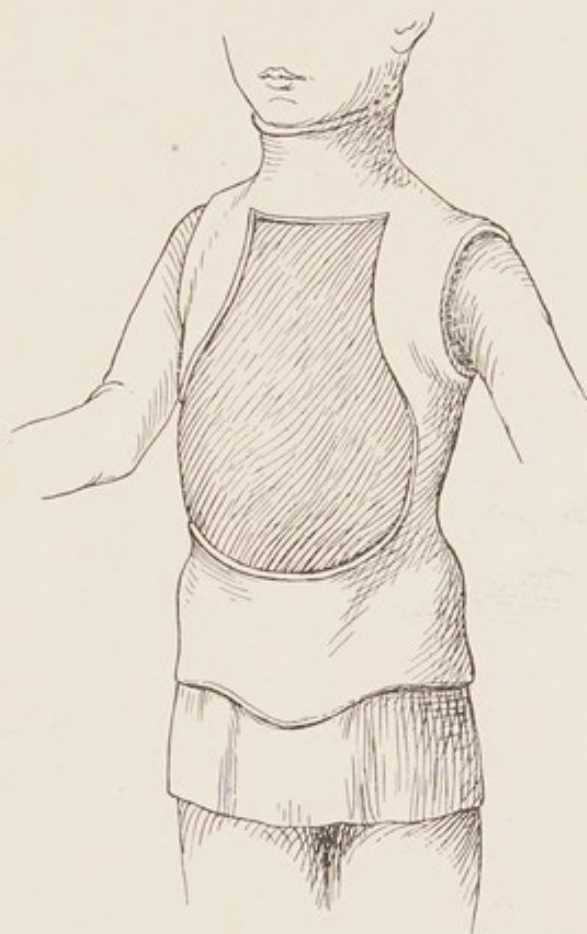

Fig. 78. Calot jacket completed—large window.

down in the act of setting. The large window is cut out as outlined in Fig. 78. Hereafter the fenestra for gibbus is cut posteriorly. The fenestration to be larger by  $\frac{3}{4}$  cm. than the area affected. (Fig. 79.) Beneath the edges of the window small pieces of cotton are wedged. Over the gibbus itself successive layers of cotton are placed until they project



beyond the level of the plaster jacket, and they are held in place and subject to a pressure by circular turns of a crinolin bandage. Each two months additional layers of cotton are placed as the gibbus recedes. The large window in front allows the chest to yield under pressure from behind. At the expiration of each five or six months a new jacket is applied for a period of two or three years, until tenderness and subjective symptoms have disappeared and X-ray pictures show a betterment as compared with the start. Where disease involves the upper vertebræ the plaster must include the

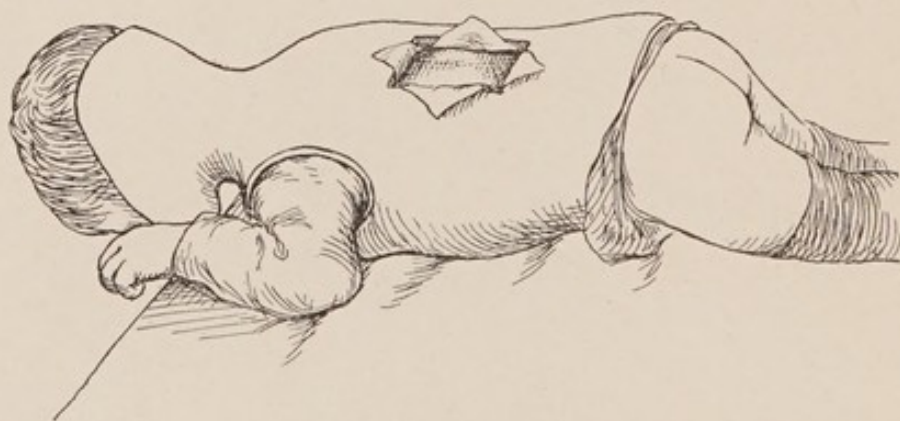

Fig. 79. Fenestra over gibbus in Calot jacket.

head. After due protection of the head and neck by compresses of cotton, the plaster in turns of figure eight pass about the head, suspended not in the leather sling, but a muslin sling, which remains incorporated in the bandage. (Fig. 80.) Subsequently protruding ends of the sling are cut away. Here, too, Calot recommends plastrons in front from the chin, passing round down the neck, under the axilla and posteriorly passing from the vertex over the shoulders beneath the axilla. In other respects the bandage is put on as described. The trimming of the bandage for disease of higher ver-

tebræ implies a cutting away of the plaster about the forehead so that a collar touches the chin and supports the occiput. (Fig. 81.)

A plaster of Paris spica passing about the lower thorax and extending within a few inches of, and at times including, the knee joint, is an effective way of immobilizing the diseased hip joint. (Fig. 83.) The spica is not to be applied, however, until

Hip Joint  
Disease

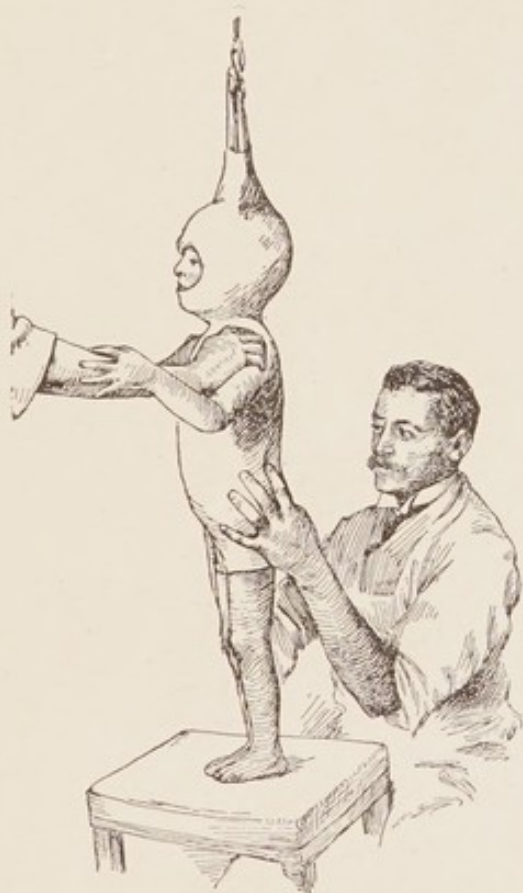

Fig. 80. Calot jacket for disease "upper spine."

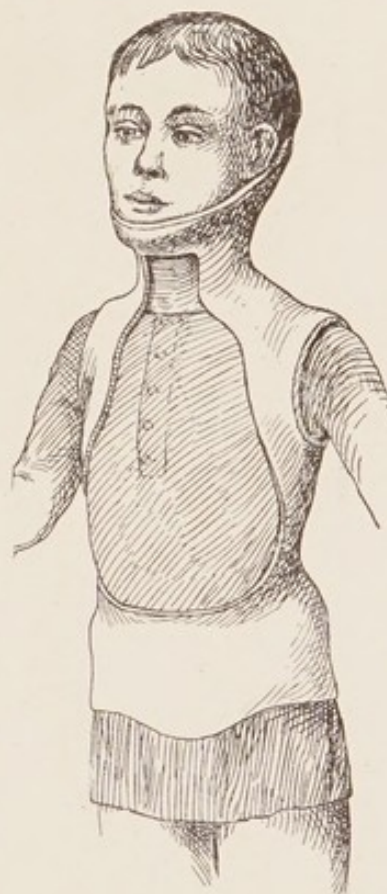

Fig. 81. Calot jacket for disease in upper spine trimmed.

flexion and abduction deformities have been overcome by extension with weights while in bed. The presence of a large, cold abscess, or sinuses leading into the bone or joint do not contraindicate the use of a plaster of Paris spica. Even if it be desirable to apply some form of brace, or traction splint, the plaster spica may be retained, provided the ten-



dency to flexion and abduction are not marked. When sole reliance for fixation is placed upon the spica, the immobilized, diseased side should be kept from the ground by the use of crutches, and a patten is to be worn on the shoe of the healthy limb. (Fig. 82.) On the whole, it must be said, that the plaster spica, however, well applied, is a bulky

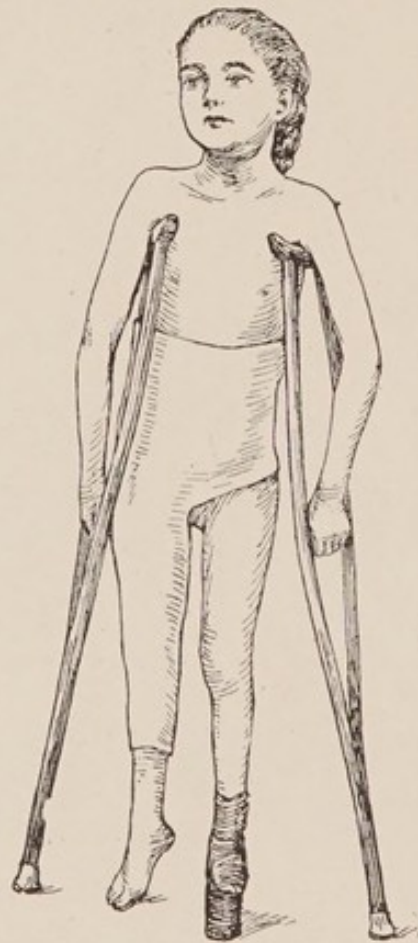

Fig. 82. Method of walking with plaster in hip disease.

and unclean means of treating hip joint disease, as compared with some form of metal splint. *As a word of warning, it should never occur to anyone to apply the plaster spica in order to correct a deformity.*

*Application of the Hip Spica.*—The method of applying a plaster hip spica, described in fractures of the thigh, is equally applicable in hip joint dis-

ease. The great essential in the application of plaster bandages about the pelvis is to have the shoulders resting on a support (pillow), and the pelvis supported on a rest—beneath the sacrum, as described on p. 34, Fig. 22. The lower extremities should be clear of the table.

*Sacro Iliac Joint Disease.*—The spica used for

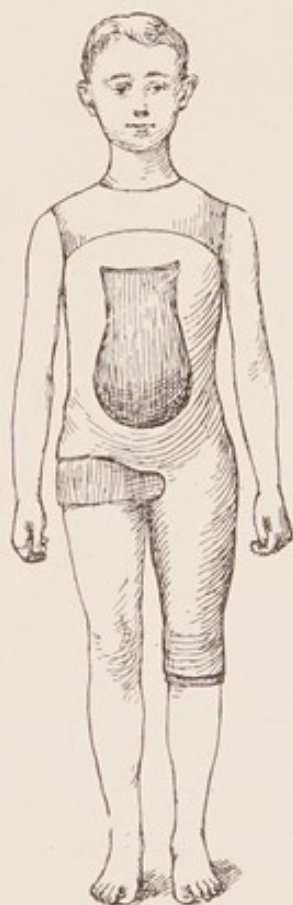

Fig. 83. Calot jacket with extension of cast to include hip in joint disease.

hip disease should be carried up to the axilla. Following Calot's suggestion, a large window may be cut in front. (Fig. 83.)

An effusion of serum or blood in the knee joint, of traumatic or infectious origin (gonorrhoea, tuberculosis), can very often be rapidly dispelled by the absolute immobilization afforded by a plaster

**Knee Joint  
Disease**



cast, investing the thigh, extending as high as the gluteal fold posteriorly, and at times reaching up to pouparts ligament anteriorly, thus not interfering with flexion at the hip joint and preventing a sitting posture, of course, including the knee joint, and extending down the leg below the calf. A cast of the same extent is necessary in tuberculous disease of the knee joint, but not until the flexion deformity has been overcome by gradual extension, with weights and pulleys. Some authorities commend a correction under anesthesia. The knee joint immobilized in the cast (of light construction) must not support the superimposed weight of the body, therefore crutches are to be used or the knee, encased in plaster of Paris, is suspended in the Thomas splint for knee joint disease, and a patten to be worn on the shoe of the health side. With a patten and crutches the Thomas splint may be dispensed with solely relying on the plaster cast.

#### **Ankle Joint Disease**

In all affections of the ankle, there is a great tendency for the foot to assume a position of equinus combined at times with eversion (valgus). To forestall this, the foot must very early be placed in a plaster of Paris cast, in a position at right angles to the leg. (Fig. 86, p. 94.) Where there is much spasm of the tendo Achilles, this may be overcome by the administration of an anesthetic, and if there be still some difficulty, a subcutaneous tenotomy must be resorted to before applying the plaster cast. The cast should not merely invest the ankle, but should be carried up the leg to the condyles of the tibia as practiced in fractures of the ankle joint. If allowed to terminate just below the calf the edge of

cast will work its way into the muscles of the leg.  
(Fig. 84.)

The rigid flat foot, with spasm of the tendo **Flat Foot**  
Achilles and lack of mobility of the smaller articulations, and abduction and eversion in the medio-

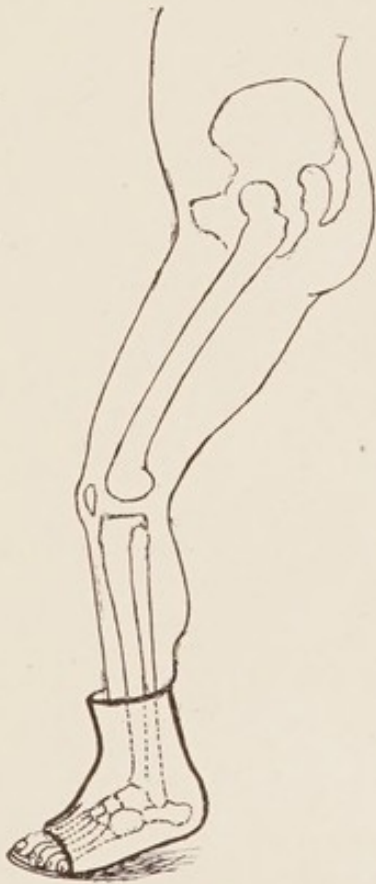


Fig. 84. Wrong plaster cast.  
Demonstrating cast cutting  
into flesh.

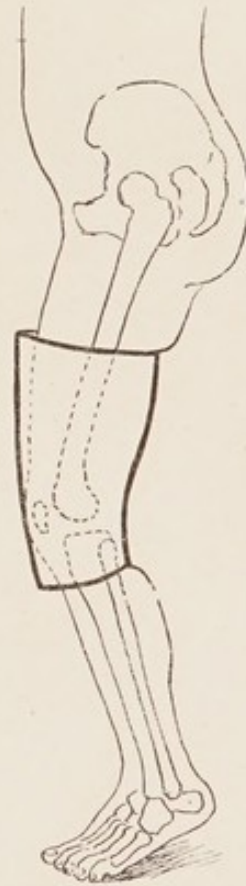

Fig. 85. Wrong knee splint.  
Demonstrating cast cutting  
into flesh.

tarsal articulation, calls for a correction which alone can be maintained by a plaster of Paris dressing. To effect a correction of a rigid flat foot, it is necessary to administer an anesthetic and manually force the foot into an exaggerated adducted (varus) position. It is thus maintained by a plaster of Paris dressing, which extends up the leg be-



yond the calf, preferably embracing the condyles. This plaster cast remains on for four weeks. For the first three weeks the patient occupies the recumbent posture; thereafter he may walk about with crutches. At the expiration of the fourth week the dressing is removed and a plaster mold made, either from the dressing or directly from the foot in its

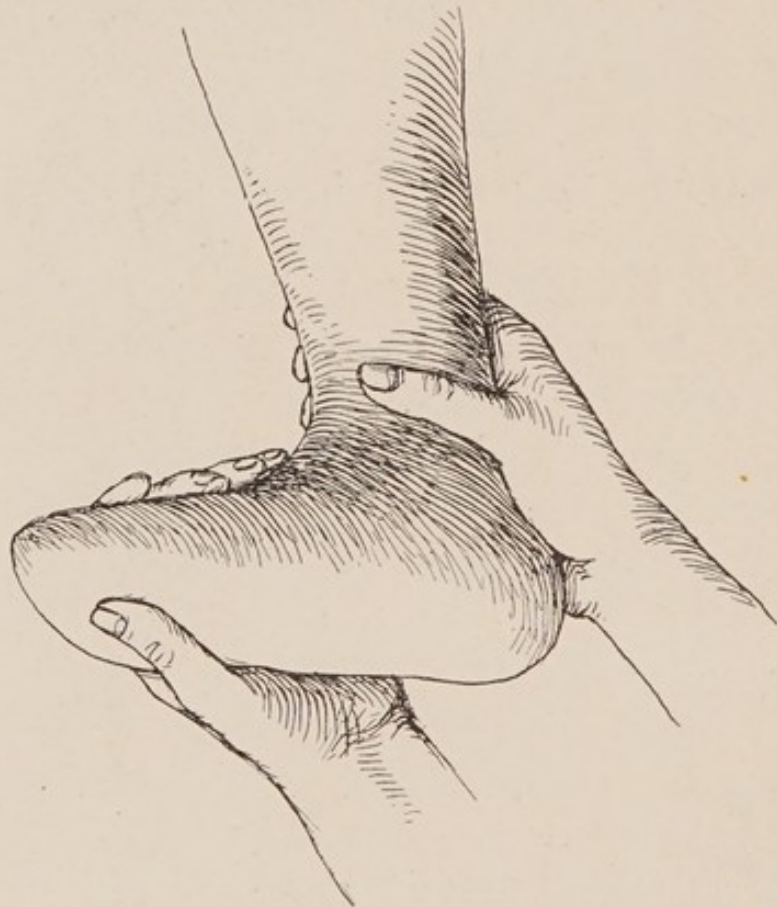


Fig. 86. Holding ankle in right angle position—cast setting.

corrected position. A sheet of steel is then hammered to conform to the plaster mold, on its plantar surface, as far forward as the head of the first metatarsal bone, and to pass obliquely outwards back of the heads of the metatarsal bones, to the cuboid, the posterior limit of this splint corresponding to the middle of the os calcis. On the inner aspect of the cast the splint is hammered out in a

semi-ellipse extending to the internal malleolus. On the outer aspect a tongue of metal is hammered out as a guide to prevent the splint from slipping. This accurately fitted splint, thus hammered out over the plaster mold, is placed in the shoe, and, acting as a lever, it forces the foot into the correct position.

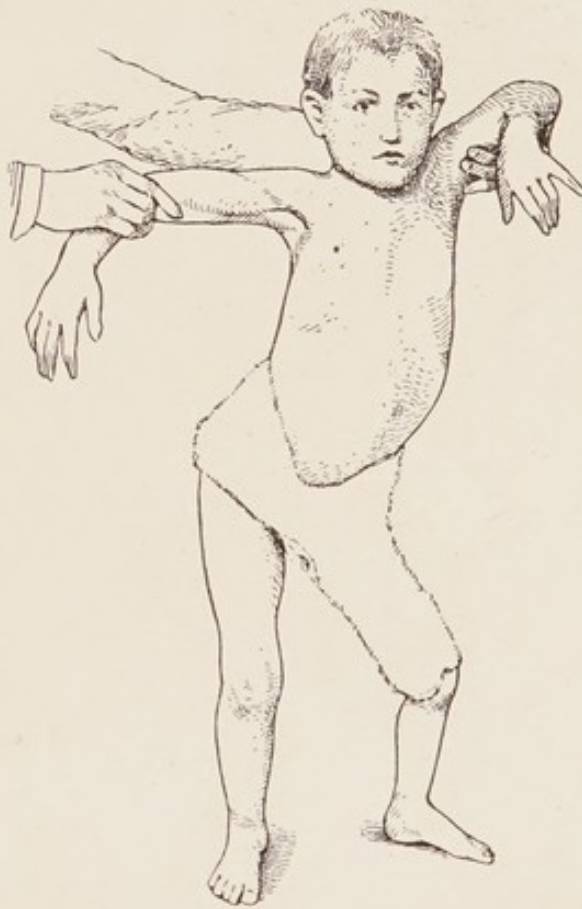

Fig. 87. Lorenz spica for unilateral congenital dislocation of the hip.

Of recent date the teaching has gained ground to apply plaster of Paris dressings to the members rendered flaccid by infantile palsy and forestall the contractures. To be effective such plaster casts should be applied very early in this disease, as soon as the regressive stage has been reached. Such plaster casts constitute a tentative treatment prior to the performance of an athrodesis or facilitating the execution of a tendo-plasty eventually.

**Infantile  
Paralysis**



### Congenital Hip Dislocation

One of the essentials is the successful treatment of a congenital dislocation of the hip is the application of a well-fitting *hip spica in which the patient walks about*. An X-ray picture is first taken as a guide to the location of the head of the femur. Then follows a reduction of the head into the acetabulum under anesthesia, in which it is maintained by *abducting* the limb. In this abducted position the unilateral or bilateral spica is applied, according as the dislocation has been on one or on both sides. (Figs. 87 and 88.) In addition to the abduction, the limb is slightly flexed and rotated in. The spica should preferably pass well up on the thorax, though this is by no means absolutely necessary. Its upper limit may reach the floating ribs. Eventually this may be cut down in front beneath the umbilicus. It should not unnecessarily extend below the knee, in order not to interfere with comfort in walking. (Fig. 89.) The plaster cast remains on at least six weeks. At the expiration of this time it is removed. If a radiograph then made shows the head of the femur in the acetabulum, the degree of abduction is lessened gradually and another cast applied in this corrected position, the adduction being increased with additional inward rotation of the foot. All the time that the cast is on, the patient walks about, thus aiding by this pressure, in forcing the head into the acetabulum and in shaping the latter. After the removal of the last cast, a hip splint is to be worn for some months.

### Club Foot

The deformity known as club foot, if treated immediately after birth, and persistently, can be wholly corrected by the use of plaster of Paris dressings, within a year or two. It is necessary, by a process of manipulations, as in modeling, to bring

the foot from its equinus position into that of a right angle with the leg and to overcome the adduction (varus) and inward rotation. When these have been corrected a plaster of Paris cast is made to invest the foot, extending up the leg to the condyles of the tibia. Great care must be taken in padding the bony prominences with non-absorbent cotton to prevent pressure sores. The best guar-



Fig. 88. Bilateral congenital dislocation corrected with Lorenz spica.

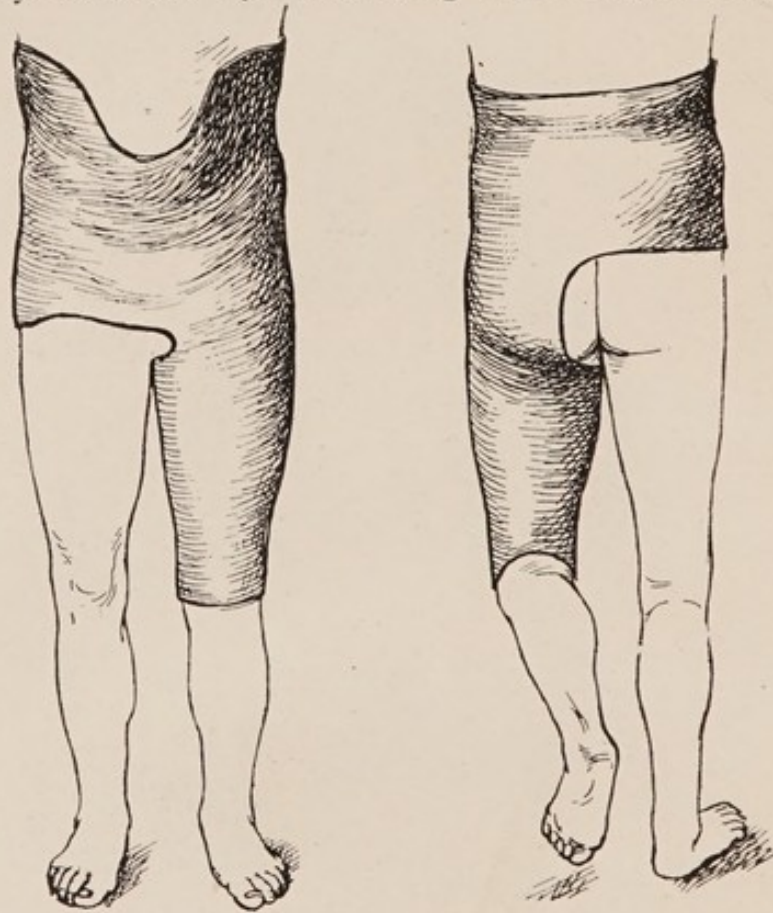
antee against decubitus, is a thorough reduction of all the abnormal positions that occasion the prominences. If the deformity cannot be wholly corrected at the first sitting it is remedied after the removal of the cast at the expiration of two or three weeks. With each renewal of the cast another attempt is made to better the position of the foot. This



correction of the very plastic tissues of the newborn and of the infant calls for anesthetic at times. In adults, however, narcosis is necessary.

**Wolff's  
Method  
Etappen  
Bandage**

Etappen Bandage—Wolff's Method.—The correction is effected under anesthesia, and a plaster cast is applied, as outlined in foregoing paragraph. While this is setting, further correction of the deformity is made by abducting the foot, and brin-



Anterior view.

Posterior view.

Fig. 89. A spica applied for congenital dislocation, showing extent of cast and abduction of leg.

ing it into a right angled position. Over the outer malleolus and over the tuberosity of the head of the first metatarsal bone fenestrae are cut to relieve the pressure. At the end of the first week a wedge is cut from the outer aspect of the cast (Fig. 90), and a transverse linear division made about the ankle joint to the inner aspect of the foot.

The removal of the wedge permits of crowding the foot outwards to effect a better correction. For this, and for succeeding corrections, rendered possible by enlarging the wedge removed, no anesthetic is called for. After each wedge cutting from the plaster, and correction, the gap is filled with new absorbent cotton, another layer of plaster of Paris is applied to hold the foot in its new position. When




Fig. 90. Wolff's method of removing wedge from cast to better the correction of the club foot.

the complete correction of the foot has resulted, the cast is covered with strips of basswood veneering. These are secured in place by crinolin bandages, and coated with glue. A "water-glass" (silicate of soda) bandage is placed over all. The patient is allowed to walk about in this dressing for a month or a year, depending on the degree of severity of the condition.







## INDEX

- A  
Adjuvants, chemical, 9.  
  Alum, 9.  
  Salt, 9.  
Ambulatory cast, 46.  
Ankle  
  Fracture, 40.  
  Joint, 92.  
Application of Plaster, 21.  
B  
Bandages, "Ideal," 10.  
Application of Plaster, 21.  
  Calot, 5.  
  Commercial, 4.  
  Hand-made, 2.  
  Wire, 4, 6.  
Bavarian splint, 55.  
Bradford frame, 76, 78.  
Braatz splint, 61.  
C  
Calot bandage, 5.  
Cast  
  Ambulatory, 46.  
  Removal of, 15, 31.  
  Replacement of, 19.  
  Splitting of, 19.  
Coles splint (sugar tong), 62.  
Collar plaster, 82.  
Colles fracture, 29.  
Containers tin, 3.  
Club foot, 96.  
  Wolff's method, 98.  
Compound splint, 47.  
Congenital hip, 94.  
Corset, 65.  
  Bradford frame, 76, 78.  
  Calot, 85, 89.  
  Goldthwait method, 74.  
  Horizontal method, 75.  
  Sayres, 65, 72.  
  Trimming, 71.  
  Vertical method, 66.  
D  
Dextrine bandage, 2.  
Disease  
  Ankle joint, 92.  
  Hip joint, 94.  
  Knee joint, 91.  
  Sacro-Iliac, 91.  
F  
Fenestrated plaster casts, 43.  
Flat foot, 93.  
Fractures  
  Ankle joint, 40.  
  Carpal, 30.  
  Colles, 29.  
  Compound, 43.  
  Elbow, 28.  
  Femur (shaft), 36.  
  Foot, 42.  
  Forearm, 25, 61.  
  Humerus, 26.  
  Hip joint, 33.  
  Knee joint, 37.  
  Metacarpal, 30.  
  Olecranon, 47.  
  Patella, 46.  
  Thumb, 29.  
  Tibia, 38.  
Fraying of bandage, 9.  
Fricberg's method, 9.  
G  
Gigli saw, 16.  
Goldthwait method, 74.  
Gutter splint, 63.  
H  
Hemp splint, 57.  
Hip rest, 35.  
Hip  
  Fracture, 35.  
  Joint disease, 89.  
  Spica, 33, 34.  
History, 1.  
I  
Infantile paralysis, 93.  
J  
Jacket, 65.  
Jury mast, 72.  
K  
Knee joint  
  Disease, 91.  
  Fracture, 37.  
L  
Lorenz  
  Bed, 80.  
  Spica, 96.  
M  
Massage, 11.  
Materials, 1.  
  Cotton, 2.  
  Crinoline, 2.  
  Deimel, 6.  
  Dextrine, 2.  
  Flax, 2.  
  Flannel, 2.  
  Gauze, 2.  
  Hemp, 2.



## INDEX.

- Jute, 2.  
Muslin, 2.  
Sail cloth, 6, 2.  
Straw, 2.  
Tricot, 2.  
Mitre saw, 18.  
Molded splints, 51.
- O
- Orthopedics, 65.
- P
- Paralysis, Ischemic, 23.  
Paralysis, Infantile, 93.  
Plaster, Bandage  
Continuity, 13,  
Fractures, 21.  
General considerations, 22.  
Precautions, 10.  
Removal of, 15, 31.  
Sections, 13.  
Posture, 73.  
Precautions, 9.  
Protection, skin, 9.  
Protection, soiling, 6.
- R
- Rachitic curvature, 77.  
Refuse, disposal of, 15.  
Removal, bandage, 15, 31.  
Removal, plaster, 14.  
Sugar, 15.  
Salt, 15.  
Replacement, 19.
- S
- Sacro-Iliac disease, 91.  
Sayres suspension, 66.  
Saw  
Gigli, 16.  
Mitre, 18.  
Sections, plaster, 13.
- Shears, Stilles, 19.
- Spica  
Hip, 34, 96.  
Lorenz, 96.  
Shoulder, 27.  
Thumb, 30.
- Splints  
Ambulatory, 46.  
Bavarian, 55.  
Braatz's, 61.  
Coles, 61.  
Compound, 47.  
Fenestrated, 43.  
Gutter, 63.  
Heated, 50.  
Hemp, 57.  
Lorenz, 81.  
Molded, 51.  
Segmented, 48.  
Sugar tong, 47.  
Suspended, 49.  
Tricot, 57.
- T
- Toilet, 14.  
Torticollis, 83, 84.  
Tricot-hose, 39.  
Trimming, corset, 86.
- V
- Vaseline, 10.  
Veneering, 47.
- W
- Wire Bandage, 4.  
Wolff  
Club-foot, 98.
- X
- X-ray  
Calot jacket, 88.  
Congenital hip, 96.  
Fractures, 32.

