

**Nerve injuries and their treatment / by Sir James Purves Stewart and Arthur Evans.**

**Contributors**

Purves-Stewart, J. (James), Sir, 1869-1949.  
Evans, Arthur (Arthur Henry), 1872-

**Publication/Creation**

London : Frowde Hodder & Stoughton, 1919.

**Persistent URL**

<https://wellcomecollection.org/works/qq65uwbg>

**License and attribution**

Conditions of use: it is possible this item is protected by copyright and/or related rights. You are free to use this item in any way that is permitted by the copyright and related rights legislation that applies to your use. For other uses you need to obtain permission from the rights-holder(s).



Wellcome Collection  
183 Euston Road  
London NW1 2BE UK  
T +44 (0)20 7611 8722  
E [library@wellcomecollection.org](mailto:library@wellcomecollection.org)  
<https://wellcomecollection.org>

# NERVE INJURIES AND THEIR TREATMENT

PURVES STEWART & ARTHUR EVANS



OXFORD MEDICAL  
PUBLICATIONS

The Library of the  
Wellcome Institute for  
the History of Medicine

MEDICAL SOCIETY  
OF  
LONDON  
DEPOSIT

Accession Number

Press Mark



22102107028

Med  
K35394



12/6nu  
page

OXFORD MEDICAL PUBLICATIONS



NERVE INJURIES AND THEIR  
TREATMENT

PUBLISHED FOR THE JOINT COMMITTEE OF  
HENRY FROWDE AND HODDER & STOUGHTON  
AT THE OXFORD PRESS WAREHOUSE  
FALCON SQUARE, LONDON, E.C.1

OXFORD MEDICAL PUBLICATIONS

# NERVE INJURIES AND THEIR TREATMENT

BY

SIR JAMES PURVES-STEWART, K.C.M.G., C.B.  
M.D. (EDIN.), F.R.C.P.

SENIOR PHYSICIAN TO THE WESTMINSTER HOSPITAL

HON. COLONEL IN ARMY

LATE CONSULTING PHYSICIAN TO H.M. FORCES IN THE MEDITERRANEAN

MEMBRE CORRESPONDANT ÉTRANGER DE LA SOCIÉTÉ DE NEUROLOGIE DE PARIS

CORRESPONDING MEMBER OF THE PHILADELPHIA NEUROLOGICAL SOCIETY

AND

ARTHUR EVANS, M.S., M.D. (LOND.), F.R.C.S.

SURGEON AND LECTURER ON SURGERY AT THE WESTMINSTER HOSPITAL

SURGEON TO THE ROYAL HOSPITAL FOR DISEASES OF THE CHEST AND TO

THE LONDON TEMPERANCE HOSPITAL

SURGEON TO THE FREEMASONS' WAR HOSPITAL

LATE SURGEON TO THE 4TH LONDON GENERAL HOSPITAL (R.A.M.C., T.)

CONSULTING SURGEON TO BETHLEM ROYAL HOSPITAL

*SECOND EDITION, REVISED AND ENLARGED*

LONDON

HENRY FROWDE

HODDER & STOUGHTON

OXFORD UNIVERSITY PRESS

WARWICK SQUARE, E.C.

1919

714781257



PRINTED IN GREAT BRITAIN  
BY HAZELL, WATSON AND VINEY, LD.,  
LONDON AND AYLESBURY.

WELLCOME INSTITUTE LIBRARY	
Coll.	welMOrnec
Call No.	
	WL

L7

## PREFACE TO THE SECOND EDITION

OWING to the frequency of nerve injuries during the great war, increasing attention has been directed to the subject of their diagnosis and treatment. It is probable, moreover, that, for many years to come, neurologists and orthopædic surgeons will alike be kept busy with the study and treatment of the various disabilities resulting from such nerve injuries.

The present work, based upon our personal experiences, was written and published originally in 1916, at a time when one of us was on foreign service. The inevitable difficulties of communication, due to war conditions, may perhaps be an excuse for some of the deficiencies in the first edition, of which we are only too conscious.

This, the second edition, has been largely re-written in the light of further experience, and, we hope, improved. We trust that it will continue to be helpful, not to the expert neurologist, to whom many of the facts herein stated may appear elementary in their simplicity, but to the wider circle of physicians and surgeons who may have had a less extensive experience of such injuries.

In a combined work by two authors it is difficult to avoid overlapping on the one hand, or gaps on the other, and to secure that continuity of thought which is so desirable. For all the defects of this kind each of us willingly accepts the blame, whilst yielding the praise (if any !) to his collaborator.

J. P. S.  
A. E.



## CONTENTS

### CHAPTER I

	PAGE
A PERIPHERAL NERVE; ITS STRUCTURE AND FUNCTIONS . . . . .	1
A DIVIDED NERVE; ALTERATION IN STRUCTURE AND FUNCTION . . . . .	4
RECOVERY OF A DIVIDED NERVE; ITS STRUCTURE AND ITS FUNCTIONS . . . . .	8

### CHAPTER II

METHODS OF EXAMINATION . . . . .	13
----------------------------------	----

### CHAPTER III

INJURIES OF NERVES, THEIR METHODS OF PRODUCTION AND SYMPTOMS . . . . .	27
--	----

### CHAPTER IV

CONDITIONS SIMULATING A PERIPHERAL NERVE INJURY	43
---	----

### CHAPTER V

PROGNOSIS . . . . .	59
---------------------	----

## CHAPTER VI

PRINCIPLES OF TREATMENT . . . . .	PAGE 70
-----------------------------------	------------

## CHAPTER VII

OPERATIONS ON NERVES . . . . .	83
--------------------------------	----

## CHAPTER VIII

LESIONS OF INDIVIDUAL NERVES AND STATISTICAL TABLES . . . . .	108
CRANIAL NERVES . . . . .	110
CERVICAL SYMPATHETIC . . . . .	123
CERVICAL PLEXUS . . . . .	125

## CHAPTER IX

BRACHIAL PLEXUS . . . . .	129
POSTERIOR THORACIC NERVE . . . . .	155
CIRCUMFLEX NERVE . . . . .	158

## CHAPTER X

ULNAR, MEDIAN, MUSCULO-SPIRAL, POSTERIOR INTER- OSSEOUS, RADIAL, MUSCULO-CUTANEOUS, AND THORACIC NERVES . . . . .	159
---	-----

## CHAPTER XI

CAUDA EQUINA . . . . .	197
LUMBO-SACRAL PLEXUS . . . . .	205
GREAT SCIATIC, EXTERNAL POPLITEAL, ANTERIOR TIBIAL, INTERNAL POPLITEAL, SMALL SCIATIC, ANTERIOR CRURAL, AND OBTURATOR NERVES . . . . .	207
INDEX . . . . .	229

## ILLUSTRATIONS

FIGURE	PAGE
1. A normal nerve-fibre . . . . .	2
2. Diagram of a sensory nerve . . . . .	3
3. A degenerating nerve-fibre . . . . .	4
4. A completely divided sciatic nerve . . . . .	5
5. Muscular atrophy following nerve injury . . . . .	6
6. Delayed desquamation following nerve injury . . . . .	6
7. Trophic ulcers in ulnar nerve paralysis . . . . .	7
8. A primitive end-bulb . . . . .	8
9. Section through a proximal end-bulb . . . . .	9
10. Microscopical section of end-bulb . . . . .	10
11. Motor points of face and neck . . . . .	21
12. Motor points of upper limb . . . . .	22
13. Motor points of upper limb . . . . .	23
14. Motor points of anterior thigh muscles . . . . .	24
15. Motor points of anterior leg muscles . . . . .	24
16. Motor points of back of thigh and leg . . . . .	25
17. Dial of the Lewis Jones condenser-apparatus . . . . .	26
18. Transverse section through a foetal thigh . . . . .	29
19. X-ray of fractured femur, producing paralysis . . . . .	34
20. Ischæmic paralysis . . . . .	37
21. Ischæmic paralysis . . . . .	38
22. Anæsthesia in a case of ischæmic myositis . . . . .	39
23. Peripheral neuritis: one form of 'trench feet' . . . . .	41
24. Hysterical anæsthesia and muscle-spasm . . . . .	44
25. Hysterical anæsthesia of hand and arm . . . . .	45
26. Hysterical anæsthesia of leg . . . . .	46
27. Hysterical anæsthesia of upper limb . . . . .	47
28. Hysterical spasm of right hand . . . . .	49
29. Hysterical paralysis of right thumb . . . . .	50
30. Hysterical anæsthesia of part of hand . . . . .	51
31. Combined hysterical anæsthesia and organic paralysis . . . . .	53
32. Combined organic and reflex paralysis . . . . .	56
33. Combined reflex and hysterical paralysis . . . . .	58
34. Sensory recovery following secondary suture . . . . .	64
35. Sensory recovery following operation for relief of compression . . . . .	68
36. Diagrams showing the progress of sensory recovery . . . . .	69
37. Splint for musculo-spiral paralysis . . . . .	74

FIGURE	PAGE
38. Sir Robert Jones's hyper-extension hand splint . . . . .	75
39. Prosthetic splint for musculo-spiral paralysis . . . . .	75
40. Walking apparatus for use in foot-drop . . . . .	76
41. Shoulder abduction splint . . . . .	77
42. Glove for correcting deformity in ulnar paralysis . . . . .	78
43. Cut surface of a bulbous end, and of a normal nerve-trunk . . . . .	85
44. Complete division of a nerve . . . . .	88
45. Complete division of a nerve, with pseudo-continuity . . . . .	88
46. Complete interruption of a nerve by a central neuroma . . . . .	88
47. Gunshot-wound of the external popliteal nerve . . . . .	89
48. Rifle-bullet wound of the great sciatic nerve . . . . .	92
49. The two ends of a divided ulnar nerve . . . . .	93
50. Transposition of the ulnar nerve . . . . .	94
51. Transplantation of the radial nerve . . . . .	94
52. Anastomosis of the spinal accessory to the fifth cervical nerve . . . . .	95
53. Fifth cervical nerve, showing a lateral neuroma . . . . .	95
54. Median nerve, showing a lateral neuroma and a lateral notch . . . . .	96
55. Two lateral neuromata, separated by a lateral notch . . . . .	97
56. Lateral neuroma on the inner cord of brachial plexus . . . . .	98
57. Operation for the relief of nerve compression . . . . .	99
58. Median nerve, severely compressed . . . . .	100
59. Paralysis produced by displaced fracture . . . . .	101
60. Adhesions about, and fibrosis of the external popliteal nerve . . . . .	102
61. Composite lesion of median, ulnar and internal cutaneous nerves . . . . .	103
62. Gunshot-wound of the brachial plexus . . . . .	103
63. Internal cutaneous nerve, partially divided by a piece of shell . . . . .	104
64. Prosthetic appliance for use in wrist-drop . . . . .	106
65. Gunshot-wound of second and third divisions of trigeminal nerve . . . . .	113
66. Facial paralysis . . . . .	117
67. Paralysis of spinal accessory nerve . . . . .	120
68. Paralysis of spinal accessory nerve . . . . .	121
69. Paralysis of hypoglossal nerve . . . . .	123
70. Cervical sympathetic paralysis . . . . .	124
71. Diagram of cervical plexus . . . . .	126
72. Bullet-wound of great auricular nerve . . . . .	127
73. Motor-supply of the brachial plexus . . . . .	130
74. Cutaneous sensory supply of the upper limb . . . . .	131
75. Rupture of the fifth and part of the sixth cervical root . . . . .	132
76. Traction-injuries of the brachial plexus . . . . .	133
77. Brachial birth-palsy . . . . .	134
78. Total brachial plexus palsy . . . . .	135
79. Anæsthesia in a case of total brachial plexus lesion . . . . .	136
80. Complete lesion of fifth cervical root . . . . .	137
81. Anæsthesia accompanying lesion of fifth cervical root . . . . .	138
82. Combined lesion of fifth cervical root and of recurrent laryngeal nerve . . . . .	139
83. Composite lesion of brachial plexus . . . . .	140
84. Extensive brachial plexus paralysis . . . . .	141

# ILLUSTRATIONS

xi

FIGURE	PAGE
85. Lesion of inner cord of brachial plexus . . . . .	144
86. Lesion of inner cord of brachial plexus . . . . .	145
87. Anæsthesia accompanying lesion of inner cord of brachial plexus . . . . .	146
88. Lesion of posterior and inner cords of brachial plexus . . . . .	148
89. Anæsthesia accompanying injury to brachial plexus . . . . .	149
90. Hysterical paralysis of upper limb . . . . .	151
91. Brachial plexus injury from pressure of cervical rib . . . . .	152
92. Radiogram of cervical rib . . . . .	153
93. Operation to expose brachial plexus . . . . .	154
94. Paralysis of serratus magnus muscle . . . . .	156
95. Muscular wasting following division of fifth cervical root . . . . .	157
96. Anæsthesia in ulnar paralysis . . . . .	161
97. Wound of deep branch of ulnar nerve . . . . .	162
98. Ulnar nerve paralysis . . . . .	163
99. Froment's sign . . . . .	165
100. Ulnar paralysis from bony deformity . . . . .	168
101. Ulnar paralysis. Recovery following operation . . . . .	169
102. Median nerve paralysis . . . . .	172
103. Anæsthesia in median nerve paralysis . . . . .	174
104. Incomplete lesion of median nerve . . . . .	177
105. Combined paralysis of median and ulnar nerves . . . . .	178
106. Paralysis of median, ulnar, and internal cutaneous nerves . . . . .	179
107. Sensory loss in combined lesion of median and ulnar nerves . . . . .	180
108. Sensory loss in combined lesion of median and ulnar nerves . . . . .	180
109. <i>Main de singe</i> . . . . .	181
110. Motor loss in combined lesion of median and ulnar nerves . . . . .	182
111. Motor loss in combined lesion of median and ulnar nerves . . . . .	183
112. Musculo-spiral paralysis . . . . .	188
113. Musculo-spiral paralysis . . . . .	189
114. Sensory loss in musculo-spiral paralysis . . . . .	190
115. Sensory loss in musculo-spiral paralysis . . . . .	191
116. Sensory loss in paralysis of the radial nerve . . . . .	193
117. Paralysis of musculo-cutaneous nerve . . . . .	195
118. Anæsthesia accompanying lesion of an intercostal nerve. . . . .	196
119. Cutaneous distribution of the cauda equina . . . . .	198
120. Cutaneous peripheral sensory supply of lower limb . . . . .	200
121. Upper cauda lesion . . . . .	201
122. Lower cauda lesion . . . . .	203
123. Lesion of lower cauda and of conus medullaris . . . . .	204
124. Diagram of lumbo-sacral plexus . . . . .	206
125. High origin of nerve to semi-tendinosus . . . . .	209
126. Paralysis of the great sciatic nerve . . . . .	210
127. Foot-drop and œdema in paralysis of great sciatic nerve . . . . .	211
128. Sensory loss in paralysis of great sciatic nerve . . . . .	213
129. Paralysis of external popliteal nerve . . . . .	215
130. Anæsthesia in external popliteal paralysis . . . . .	216
131. Paralysis of anterior tibial nerve . . . . .	217

FIGURE	PAGE
132. Incomplete lesion of external popliteal nerve . . . . .	218
133. Anæsthesia in paralysis of posterior tibial nerve . . . . .	222
134. Paralysis of small sciatic nerve . . . . .	223
135. Combined lesion of small sciatic and inferior gluteal nerve . . . . .	224
136. Paralysis of anterior crural nerve . . . . .	226
137. Obturator and ilio-inguinal paralysis . . . . .	227

# NERVE INJURIES AND THEIR TREATMENT

## CHAPTER I

### A PERIPHERAL NERVE

#### STRUCTURE.

A nerve is composed of a number of nerve-fibres ; each nerve-fibre consists of an axis-cylinder, ~~en~~wrapped in a medullary sheath which is enclosed by the neurilemma. The **axis-cylinder**, made up of fine nerve-fibrils, is a prolongation of the nerve-cell body, and it extends uninterruptedly from that cell to its termination at the periphery ; it degenerates as soon as its connexion with that cell is interrupted.

The **medullary sheath** is a structureless substance composed of myelin, a phosphorized fatty material.

The **neurilemma**, or **nucleated sheath of Schwann**, is a thin, toughish membranous layer which encloses the soft substance of the medullary sheath ; on the inner surface of the neurilemma, and partly embedded in the medullary sheath, nuclei occur at regular intervals.

Midway between these nuclei, interruptions occur in the medullary sheath ; these are produced by the neurilemma dipping in towards the axis-cylinder. The medullary sheath on either side of the interruption is somewhat swollen, so that the nerve-fibre presents a nodular appearance, and this region of the nerve-fibre is called '**the node of Ranvier.**'

## 2 NERVE INJURIES AND THEIR TREATMENT

The neurilemma between two nodes of Ranvier is to be regarded as a single cell, or neuroblast, the substance of which has been thinned out and wrapped round the medullated fibre. The nucleus of this cell is that oval nucleus which lies on the inner surface of the neurilemma and is embedded in the medullary sheath.

In a peripheral nerve the nerve-fibres run in small circular bundles known as **funiculi**; each funiculus has an investing sheath of connective-tissue composed of thin lamellæ of white fibrous tissue—the **perineurium**; within the sheath the nerve-fibres are supported by loose connective tissue—the **endoneurium**. Large nerves consist of several funiculi; between these, and surrounding the

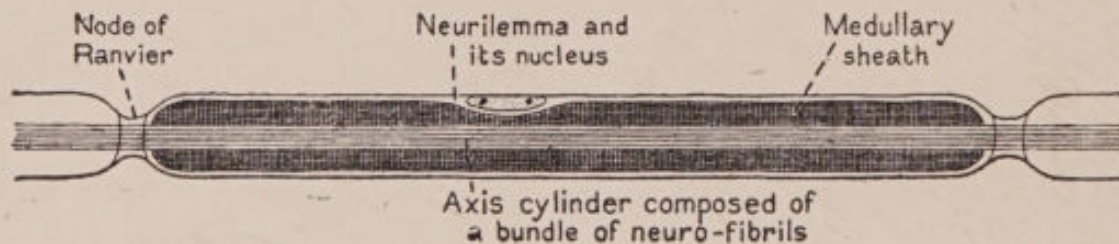


FIG. 1.—A NORMAL NERVE-FIBRE.

whole nerve, is a large amount of loose areolar tissue containing numerous fat cells; in this tissue run the blood-vessels which supply the nerve-structure, sensory nerve-fibres which are distributed to the nerve-trunks (**nervi nervorum**), and lymphatics; to this loose connective tissue the name **epineurium** is given.

A mixed nerve-trunk contains motor and sensory fibres belonging to the cerebro-spinal nervous system; these are 'medullated,' i.e. possess a medullary sheath. It sometimes also contains non-medullated fibres, both afferent and efferent, belonging to the vegetative nervous systems.

The axis-cylinders of the motor nerve-fibres have their origin in the anterior cornual cells, and they pass out from the spinal cord along the anterior nerve roots.

The efferent spino-ganglionic fibres arise from the nucleus sympatheticus in the lateral horn of the spinal

cord, and emerge through the anterior roots. They terminate in a sympathetic ganglion, from whose cells, in turn, the axis-cylinders of the fine efferent vegetative fibres in the peripheral nerve originate.

The axis-cylinders of the sensory nerve-fibres originate in the nerve-cells of intervertebral ganglia on the posterior spinal roots.

### FUNCTIONS.

1. Efferent motor fibres convey motor impulses to the muscles.

2. Efferent vegetative fibres convey vaso-motor impulses to the blood vessels of the corresponding nerve-area, and secretory fibres to the glands of the skin.

3. Sensory fibres convey sensory impressions from the periphery; these impressions are diverse, and may be represented diagrammatically thus:—

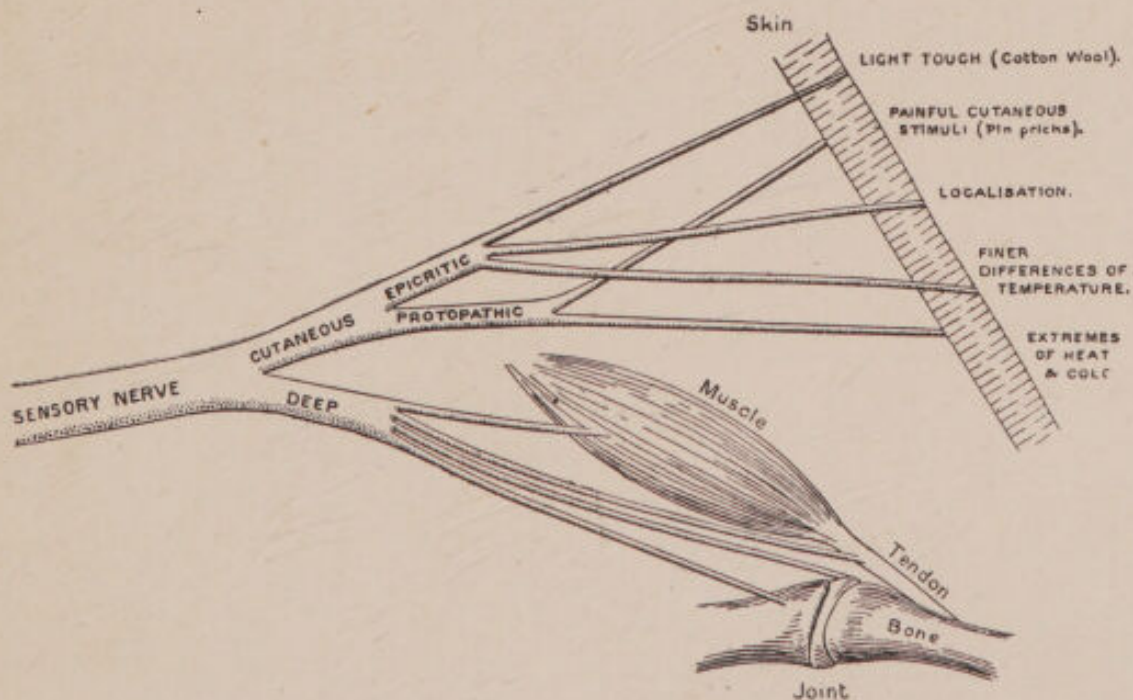


FIG. 2.—DIAGRAM OF A SENSORY NERVE.

There are three main classes of sensibility:

A. **Deep sensibility**, recognizing deep pressure, pressure-pain, joint sensation, active muscle-sensation, and vibration sensation.

## 4 NERVE INJURIES AND THEIR TREATMENT

B. **Protopathic cutaneous sensibility**, recognizing painful cutaneous stimuli: pin-pricks, faradic stimulation, and extremes of heat and cold. (These sensations are probably conducted by the non-medullated nerve-fibres.)

C. **Epicritic cutaneous sensibility**, recognizing light touches (e.g. cotton wool), cutaneous localization, and finer differences of temperature.

4. A nerve exerts a 'trophic' influence on all the structures to which it is distributed, and the nature of this influence on muscles, skin and its appendages, joints, and occasionally even the bones, is demonstrated by the changes which occur when the nerve has been interrupted. (See p. 7.)

### A DIVIDED NERVE

#### ALTERATION IN STRUCTURE.

Soon after a nerve has been divided, its peripheral end degenerates. This process is essentially a cellular regression, occurring in a chain of neuroblasts which have been deprived of their normal physiological function of conducting nerve impulses.

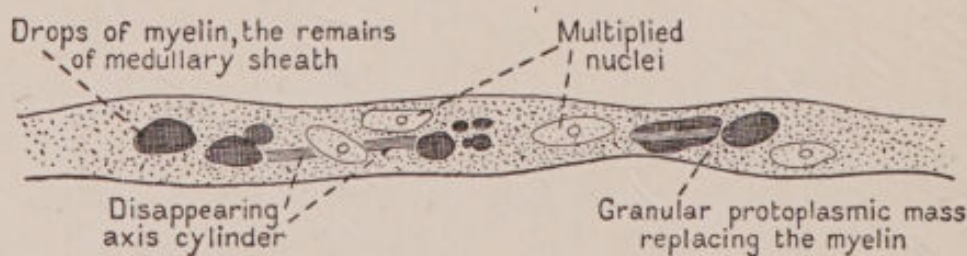


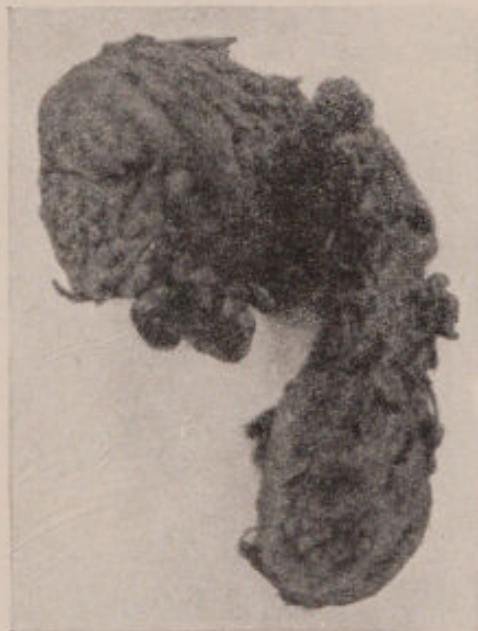FIG. 3.—A DEGENERATING NERVE-FIBRE.

The medullary sheath shows the first sign of degeneration, and becomes broken up into a mass of fatty globules, which are ultimately absorbed; this change in the myelin is accompanied by a similar change in the axis-cylinder, which becomes broken up and ultimately disappears. All that then remains of the nerve-fibre is the neurilemma

sheath, the nuclei of which have multiplied, filled by a protoplasmic mass.

The degeneration takes place simultaneously along the whole length of the nerve distal to the section, and the rapidity and completeness of the process is in no way influenced by the immediate suturing of the cut ends of the nerve.

To the naked eye the proximal end of a cut nerve usually presents a bulbous end which is hard on palpation; the distal end is generally smaller than normal. Usually both ends become involved in scar-tissue uniting one to the other, and both to the surrounding structures.



#### ALTERATION IN FUNCTION.

**1. Motor.** The muscles supplied by the nerve are at once paralysed; by the seventh day they cease to respond to the faradic current, and by about the tenth day a change takes place in their response to the galvanic current. (See Reactions of Degeneration, p. 23.)

**2. Sensory.** The sensory area exclusively supplied by the cut nerve can no longer transmit impressions to the cerebrum; this applies not only to the cutaneous distribution, but to its distribution to muscle, tendon, bone, and joint. (See Fig. 2.)

FIG. 4.—PHOTOGRAPH OF A COMPLETELY DIVIDED SCIATIC NERVE (exact size). The upper end of the photograph is the proximal end of the nerve. The two ends are connected by dense fibrous tissue. Note the slightly bulbous ending of the proximal segment; also the differentiation of the nerve into external and internal popliteal divisions—the upper being the external popliteal nerve. The funiculi stand out clearly in the cross section, this being particularly obvious in the internal popliteal nerve.

## 6 NERVE INJURIES AND THEIR TREATMENT

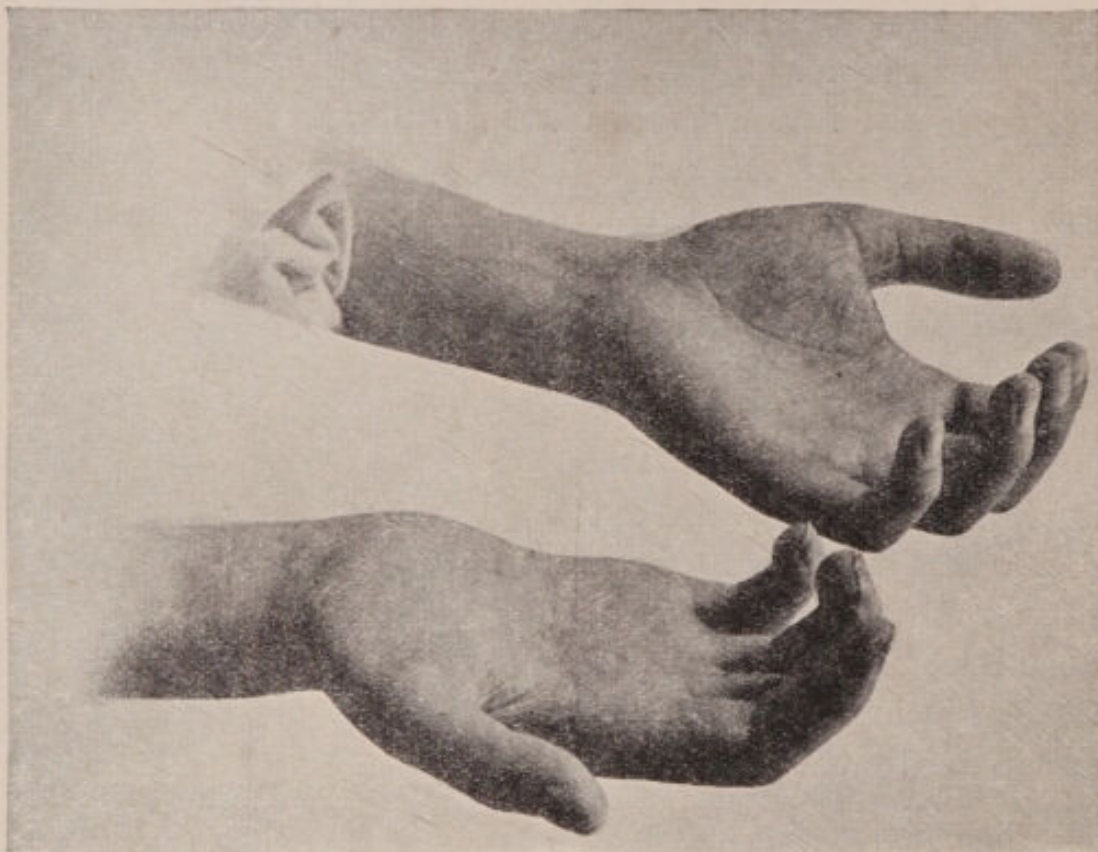

FIG. 5.—THE HANDS OF A SOLDIER WHOSE RIGHT UPPER ARM HAD BEEN WOUNDED, WITH DIVISION OF THE MEDIAN NERVE AND SEVERE COMPRESSION OF THE ULNAR NERVE. The picture shows marked wasting of the right thenar and hypothenar eminences, increased growth and curvation of the nails, and wasting of the finger-pads.

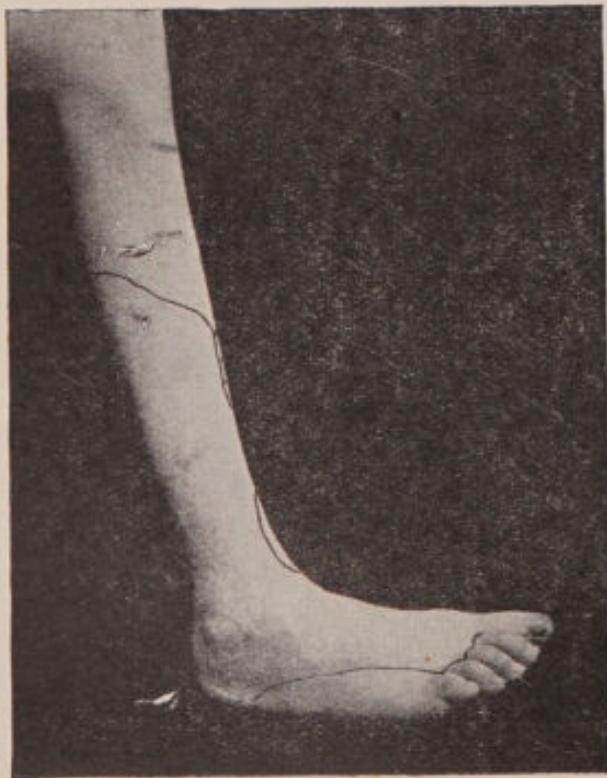

FIG. 6.—FOOT OF A SOLDIER SHOT THROUGH THE RIGHT BUTTOCK WITH INJURY TO THE EXTERNAL POPLITEAL NERVE, showing delayed desquamation over the anæsthetic area—the outer surface of the leg and the dorsum of the foot.

3. **Trophic.** The muscles atrophy (Fig. 5), unless by massage and electrical treatment their nutrition be maintained; the epithelium in the insensitive area does not desquamate at the same rate as that over the normal skin, and scales adhere to the surface (Fig. 6).

In testing for loss of protopathic sensibility it will be

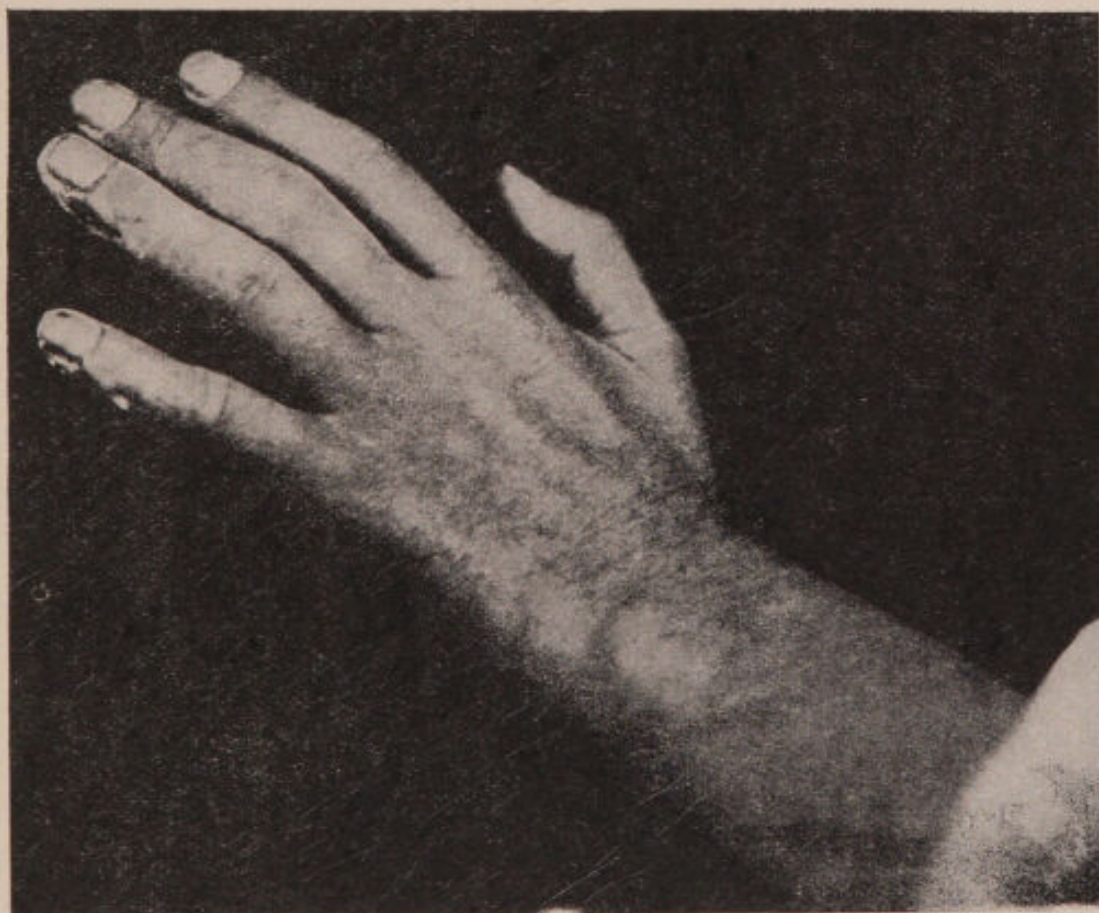


FIG. 7.—PARALYSIS OF THE ULNAR NERVE. Note the 'trophic' ulcers on the ulnar sides of the little and ring fingers. These originated in burns produced by the patient resting his hand upon a radiator, unconscious that it was hot.

noticed that pin-pricks bleed more readily in the anæsthetic area than in the adjoining territory, and leave red spots which may persist for days.

In long-standing cases the skin, especially of the fingers, becomes thin and atrophic, with a smooth, shiny surface—the so-called 'glossy skin'; the nails become longi-

## 8 NERVE INJURIES AND THEIR TREATMENT

tudinally striated and markedly curved from side to side; the finger-pads are wasted, and the finger-tips taper to a point; sometimes there is a horny thickening of the epidermis in the affected area (hyperkeratosis). There may be excess or diminution of sweat in the affected territory of skin.

Areas of skin which have lost protopathic sensibility are particularly liable to injury; it is not uncommon to find ulcers present in these situations, for being insensitive, warnings are unheeded and trauma results (Fig. 7); and indeed, traumata too trivial to be followed by any lesion of healthy skin, under these altered conditions may result in inflammation and destruction of tissue.

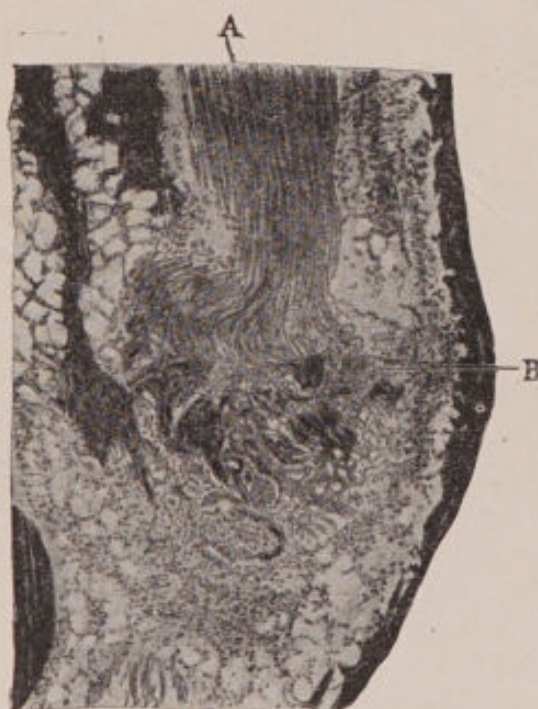


FIG. 8.—A PRIMITIVE END-BULB. Longitudinal section of 'primitive end bulb' in cat's sciatic nerve, twenty-four hours after its division.<sup>1</sup>

- A. Trunk of Nerve.
- B. 'Mushroom.'

### RECOVERY OF A DIVIDED NERVE

#### ITS STRUCTURE.

At the end of three weeks new axis-cylinders are formed within the neurilemma-sheaths by the deposition of a thin thread along one side of a spindle-celled neurilemma-cell; this thread, which is beaded at first, grows in length until it links up with the thread above it; then a lower thread, also secreted by a neurilemma-cell, links up, and so on. Thus the process of regeneration proceeds from the central end outwards.

<sup>1</sup> From Ballance and Purves Stewart's *Healing of Nerves*, 1901.

The new medullary-sheath makes its appearance about the fourth week, when it too is laid down by a process of secretion along one side of a neurilemma-cell.

Fig. 8 is a longitudinal section through a cat's sciatic nerve, twenty-four hours after it had been divided, and left unsutured. It shows the primitive end-bulb or 'mushroom,' already formed in the proximal stump.

The changes in the primitive end-bulb are shown in Figs. 9 and 10. Fig. 9 is a longitudinal section through a proximal end-bulb several months after the nerve had been cut across. In this, new nerve-fibres have been secreted by the neurilemma-cells originally present in the primary 'mushroom,' formed at the time of the injury. Fig. 10 shows how 'new axis-cylinders are intertwined and coiled in all directions,' unable to link on with those in the distal segment.

The same process takes place in the primitive end-bulb and in the distal segment. In the scar tissue intervening between the proximal and distal segments the same process is effected by the action of spider-like neuroblasts, cells which are identical with the proliferated neurilemma-cells.

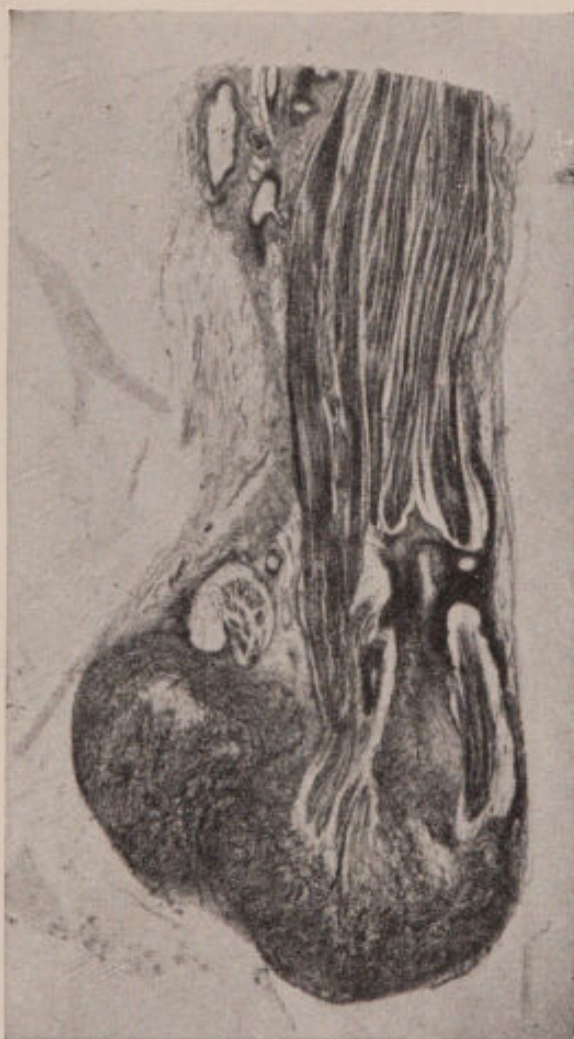

FIG. 9. — LONGITUDINAL SECTION THROUGH THE PROXIMAL END-BULB OF A HUMAN NERVE AFTER DIVISION. ( $\times 4$ .)

## 10 NERVE INJURIES AND THEIR TREATMENT

The same process of regeneration takes place whether the divided ends have been united or allowed to remain separated; in the latter case, however, the axis-cylinders and medullary sheaths are much slower in making their appearance; they never attain to full maturity, but remain permanently in the incomplete beaded stage; if, however, secondary suture be performed subsequently,



FIG. 10.—TRANSVERSE SECTION THROUGH PROXIMAL END-BULB NEAR ITS TIP, showing the intertwisting new axis-cylinders. ( $\times 120$ .)

the new nerve-fibres link up, from above downwards, and gradually grow to normal dimensions.

According to another school of observers, regeneration takes place solely by the out-growth of new fibres from the axis-cylinders of the central cut end; the growing axons finding their way either into old neurilemma-sheaths or into the interstices between them, and in this latter case fresh nucleated sheaths become formed around them. The new fibres are at first pale, but afterwards acquire a medullary sheath, and still later a neurilemma with constrictions of Ranvier.

Unable to display this page

## 12 NERVE INJURIES AND THEIR TREATMENT

If this tingling sign is already present, well below the level of the injury, in a case of apparently complete nerve-paralysis, it indicates that regeneration has already begun and may sometimes save us from unnecessary surgical intervention. In testing for Tinel's sign, we proceed from below upwards, along the course of the injured nerve, watching at which level the tingling is first induced. If we proceed from above downwards, an unintelligent patient may sometimes think he feels a tingling which was due to percussion at a higher level, and thus give inaccurate replies.

It is further observed that when the newly-formed axis-cylinders have become mature, they no longer cause tingling when percussed. It usually takes about one hundred days for maturity to be attained. Thus, when active new axis-cylinders have travelled downwards to about 10 cm. below the limit of the original injury, the site of the actual lesion is already beginning to lose its tingling response to percussion. By the end of another hundred days, the first 10 cm. of nerve below the lesion will not yield tingling on percussion, whereas the next 10 cm. will do so. In other words, in regenerating nerves we find an area, about 10 cm. long, in which Tinel's sign can be elicited. This area travels slowly down the nerve until it reaches the lower end, and gradually disappears. Tinel's sign precedes the return of voluntary movement, muscles-tonus, or normal electrical reactions.

About the time that epicritic sensation begins to reappear, motor power returns, and voluntary power is usually first noted in those muscles nearest the seat of the lesion, followed by its return in those more remote.

The return of voluntary motor power is followed, later still, by that of faradic excitability.

## CHAPTER II

### METHODS OF EXAMINATION

A CAREFUL **history** should first be obtained. We should try to ascertain the date of the injury, the nature of the projectile, if any, the posture of the patient, and the exact position of the limb at the moment of injury. We inquire also as to the immediate sensations, if any, which the patient felt. If he was rendered unconscious at the time, e.g. by cerebral concussion, many of the foregoing questions will be impossible to answer. We then inquire whether the symptoms have since been stationary, or if they have got better or worse since their original onset. It is also important to know whether the wound suppurated or ran an aseptic course, and whether any operation has been performed, e.g., extraction of foreign bodies, ligature of vessels, suture of nerves or tendons, and if so, when?

#### I. SENSORY FUNCTIONS

A few general maxims may here be stated :

It is convenient to investigate sensory functions first, whilst the attention of the patient, and of the physician, is fresh.

We should not weary the patient by too prolonged examination, lest, as he becomes tired or impatient, his answers become inaccurate.

If no sensory changes are present, we recognize the fact in a few seconds ; if changes are present they should be carefully mapped out on the patient's body by a skin-pencil, and subsequently recorded on a graphic chart.

## 14 NERVE INJURIES AND THEIR TREATMENT

In the mapping out of areas of lost or altered sensation, we are largely dependent on the patient's intelligent co-operation. All sorts of ingenious apparatus have been devised for the accurate measurement of minute difference in sensibility, but the simpler our methods of examination, the more accurate are the patient's responses likely to be.

During the examination of sensory functions, the patient's eyes should be closed or covered, so that his attention may not be diverted by watching our manipulations.

Sensation in a peripheral nerve is a complex affair, comprising three main classes of sensibility.

1. **DEEP SENSIBILITY**, which recognizes **deep-pressure** (e.g. by the blunt end of a pencil); this pressure, if excessive, produces a sensation of pain—**pressure-pain**. It also includes **joint-sensation** (or sense of position on passive movement), **active muscle-sensation** (kinæsthetic sense or sense of active muscular contraction), and **vibration-sensation**, produced by placing a sounding tuning-fork over the subcutaneous surface of a bone, or upon a finger-nail.

The sensory fibres, which conduct these varieties of deep sensibility, run, not in the cutaneous fibres, but in the deep afferent fibres from the muscles, tendons, and bones (Fig. 2). So long as these deep fibres are intact, even although the skin be totally anæsthetic, the patient is able to recognize the pressure-touch and pressure-pain of a blunt pencil, the vibration of a tuning-fork, and the position of his joints on passive movement.

2. **PROTOPATHIC CUTANEOUS SENSIBILITY**. This recognizes painful cutaneous stimuli (pin-pricks, faradic stimulation), also extremes of cold and heat. These protopathic fibres are non-medullated; they are the first to regenerate after injury to a cutaneous nerve, so that as a peripheral sensory nerve heals, protopathic sensations are the first to return.

3. **EPICRITIC CUTANEOUS SENSIBILITY**, whose fibres are

the slowest to recover after injury. This group includes the recognition of :

(a) **Light touches**, tested by cotton-wool.

(b) **Cutaneous localization**. This is tested by observing the shortest distance at which the two points of a pair of blunt compasses are recognized by the patient as being separate, the points being applied sometimes singly, sometimes both together—never successively, i.e. one after the other. The patient is instructed to reply 'one' or 'two' according as he recognizes one or two points as being touched.

(c) **Finer differences of temperature**—not merely between hot and cold, but between warm (about  $38^{\circ}$  C.) and cool (about  $24^{\circ}$  C.).

Each variety of sensation should be examined and recorded separately; abnormalities of sensation should be marked on the patient's skin and then copied on to a chart.

When mapping out areas of anæsthesia, it is better, in our opinion, to begin within the anæsthetic area and to work towards the normal skin, not in the reverse direction; for it is easier for the patient to recognize the moment when he first feels a sensation than to tell when he first loses it. On the other hand, when mapping out areas of hyperæsthesia (excessive sensibility) or of paraæsthesia (altered sensibility), we should work from the normal skin towards the abnormal area, watching when the patient first notices a difference in the sensation produced.

### **Clinical Investigation of Sensation.**

The patient's eyes being closed, we begin by testing cutaneous sensation. **Touch** is tested by a tuft of cotton-wool, a soft camel-hair brush, or some similar substance which does not produce pressure. **Pain** is tested by pricking, or better by scratching, with a sharp needle; **cold and heat** by test-tubes containing ice-cold and hot

## 16 NERVE INJURIES AND THEIR TREATMENT

water at 50° C., or still more conveniently by a couple of metal spoons just removed from jugs of cold and hot water respectively. **Pressure-sense** is tested by means of a pencil or other blunt object, or by a series of objects of similar size but different weights, e.g. a shilling and a sovereign. To test **joint-sense**, first see that the limb on the proximal side of the joint is fixed, then passively move the distal end of the limb in a series of varying directions; finally hold it in a particular posture, e.g. flexed or extended, and then ask the patient to tell its position, or better still, to imitate it with the sound limb. During this test we must be careful that the patient's muscles are relaxed, so that he does not move the joint himself, otherwise he may gain information as to its position by means of his kinæsthetic sense. **Vibration-sense** is tested by means of a low-pitched tuning-fork, which is set into vibration and placed on the subcutaneous surface of a bone, or on a finger-nail. In normal individuals a characteristic vibratile thrill is felt.

**Stereognostic perception** is not a simple sensation, but an intellectual judgment as to the shape, consistence, and size of a solid object, without seeing the object, e.g. a key, a coin, a button, or a watch. A combination of different sensations is necessary in order to form a stereognostic judgment, and if one or more of the simple sensations be deficient, we have, as a result, astereognosis, more or less profound.

**Abnormal subjective sensations or dysæsthesiæ** in the territory of the affected nerve are often difficult for the observer to realize, because it requires a particularly intelligent patient to describe his sensations accurately. We usually have to be content with such descriptions as tingling, pins-and-needles, burning, bursting, or stabbing pains. We should inquire whether such dysæsthesiæ occur spontaneously or whether they are provoked by accessory factors, e.g. by direct pressure on some spot, by coughing, etc.

### Types of Anæsthesia in Nerve Injuries.

The area of anæsthesia in lesions of sensory or mixed peripheral nerves corresponds, of course, to the distribution of the affected nerve or nerves. If a purely cutaneous nerve be paralysed (e.g. the radial branch of the musculo-spiral), we have loss of cutaneous sensations, both epicritic and protopathic, whilst deep sensibility in muscles, tendons, and bones is still preserved. If a mixed nerve-trunk be paralysed (e.g. the ulnar nerve above the elbow), muscular paralysis is superadded to anæsthesia, and the sensory loss affects not only cutaneous sensibility, but also deep sensations from the corresponding bones, joints, and tendons.

The area of cotton-wool anæsthesia in a complete peripheral nerve-lesion is always more extensive than the area of analgesia to pin-pricks. But as we ascend the nerve-trunk in a proximal direction, the higher the lesion, the more nearly co-terminous do the tactile and pin-prick areas become, until in a posterior-root lesion, close to the spinal cord, the area of loss to pin-pricks exceeds that of anæsthesia to cotton-wool touches. Thus, the nearer the lesion lies to the central nervous system, the more extensive and definite is the loss to pin-pricks; the nearer to the periphery, the greater is the loss to cotton-wool touches.

In cases where the nerve is not completely severed, but merely compressed by scar-tissue or callus, the area of cutaneous loss to pin-pricks may be more extensive than that of cotton-wool loss.<sup>1</sup>

Another point of importance is, that as a mixed nerve recovers from its paralysis, sensation usually returns before motor power, and protopathic sensation returns before epicritic.

<sup>1</sup> Core, *Lancet*, 1916, p.716; Stopford, *ibid.*, 1916, p. 718.

## II. CLINICAL INVESTIGATIONS OF MOTOR FUNCTIONS

A. We commence by **inspection**, carefully comparing the limb with its sound fellow. The following points should be noted :

1. The **posture** of the limb or affected part when at rest, e.g. drop-wrist in musculo-spiral paralysis, drop-foot in external popliteal paralysis, facial distortion in facial palsy, &c.

2. **Motor paralysis or paresis** on attempted voluntary movement. Such movement accentuates the abnormal posture of the affected part.

3. The presence of **muscular wasting** or of **compensatory hypertrophy**. After an injury it usually takes some weeks before muscular atrophy becomes evident. Compensatory hypertrophy, if it occurs, is still later in appearing.

4. Muscular **tremor** or **spasm**.

5. **Wounds, cicatrices, swellings**, or other **deformities** of the limb or along the course of its nerve-trunks.

By means of simple inspection we are usually able to diagnose the presence of motor paralysis. Further observations, however, are usually necessary to complete our examination.

B. **Palpation.**

1. Palpation in the region of the wound and along the course of the suspected nerve will often reveal the presence of a **nodular swelling** in the nerve-trunk.

The presence of such a swelling is definite evidence of a gross lesion in the nerve, a lesion such as usually necessitates operative intervention.

2. The **bones and joints** of the affected limb should be carefully felt, tracing their outlines and gently observing their range of passive movement, so as to discover whether, after all, the deficiency of voluntary movement may be not really paralytic but perhaps due to mechanical causes, e.g. to fractures or dislocations, to adhesions or ankylosis

of joints, or to inflammatory conditions (e.g. abscesses, &c.), in which any movement of the limb causes pain.

3. **Consistence** of the affected muscles, whether these are **spastic** (stiff and rigid), or **flaccid** (relaxed and soft).

4. **Voluntary movements** of the affected limb. In observing these we must be careful to test the whole limb, from scapula to fingers or from hip to toes, joint by joint, each single movement being separately observed. The limb above the joint under observation must be passively fixed whilst the movement is being attempted. Thus, when testing the power of flexing or extending the wrist, we must fix the forearm ; when testing flexion or extension of the elbow, we must fix the humerus. Meanwhile, both by inspection and palpation, we closely watch for the occurrence of movement in the particular muscle under observation. Sometimes the tendon of insertion of a muscle may be seen or felt to contract, even although the muscle is too feeble to move the joint.

5. Suppose we find that one particular muscle or group of muscles is deficient in power, we proceed to estimate the **degree of motor deficiency**. If the weakness is slight, we recognize it by interposing some resistance, so as to load the muscles. In the case of the hand we make the patient squeeze our hand or compress a spring-dynamometer, comparing the pressure with that of the healthy side. In the case of the leg, we fix the limb with our hand and make the patient execute a movement against resistance.

If the weakness is more marked, loading of the muscles is unnecessary. The weight of the limb itself may already be too heavy a load for the muscles to lift. Thus, in weakness of the extensors of the wrist, we have drop-wrist ; in paralysis of the dorsiflexors of the foot, we have drop-foot. Such postures may occasionally lead us astray unless we are careful to eliminate the weight of the limb, since the weakened muscles may still be capable of a feeble degree of voluntary movement, although insufficient

## 20 NERVE INJURIES AND THEIR TREATMENT

to raise the weight of the limb. To detect minimal movements, we must eliminate the effect of gravity and place the limb in such a posture that its own weight no longer comes into play. Thus, for example, in a case of drop-wrist, we place the forearm in a position midway between pronation and supination, and then see whether the patient can voluntarily contract the extensors of the wrist; or in drop-foot we hold the ankle passively dorsiflexed, and then ask the patient to lift the foot still higher; if the dorsiflexors still retain a little voluntary power, we can see their tendons momentarily stand out under the skin during this effort. Deep-seated tendons, e.g. of the hamstring muscles, may sometimes be felt to contract when they are too feeble to produce movement of a joint.

### III. ELECTRICAL EXAMINATION

#### **Faradic Reaction.**

The terminals of the battery are fastened to two electrodes. The indifferent electrode, which is fastened to one of the terminals, should be a large flat one; this, after being soaked in warm saline solution, is firmly applied to some part of the body remote from that under examination. The testing electrode, connected to the other terminal, is smaller, usually about one inch in diameter, and is fitted with a key so arranged that the current only passes when the key is depressed. The region to be examined is now well sponged with warm saline solution, and the testing electrode, after having first been tried on one's own thenar muscles, is applied to the muscle we wish to test, and is stroked over it until the point of maximal contraction is reached; this is known as '**the motor point,**' and corresponds to the site of entry of the nerve into the muscle. If no contraction is obtained, gradually increase the strength of the current, and when a contraction takes place, compare it with that obtained when the electrode is applied to the corresponding muscle on the opposite side.

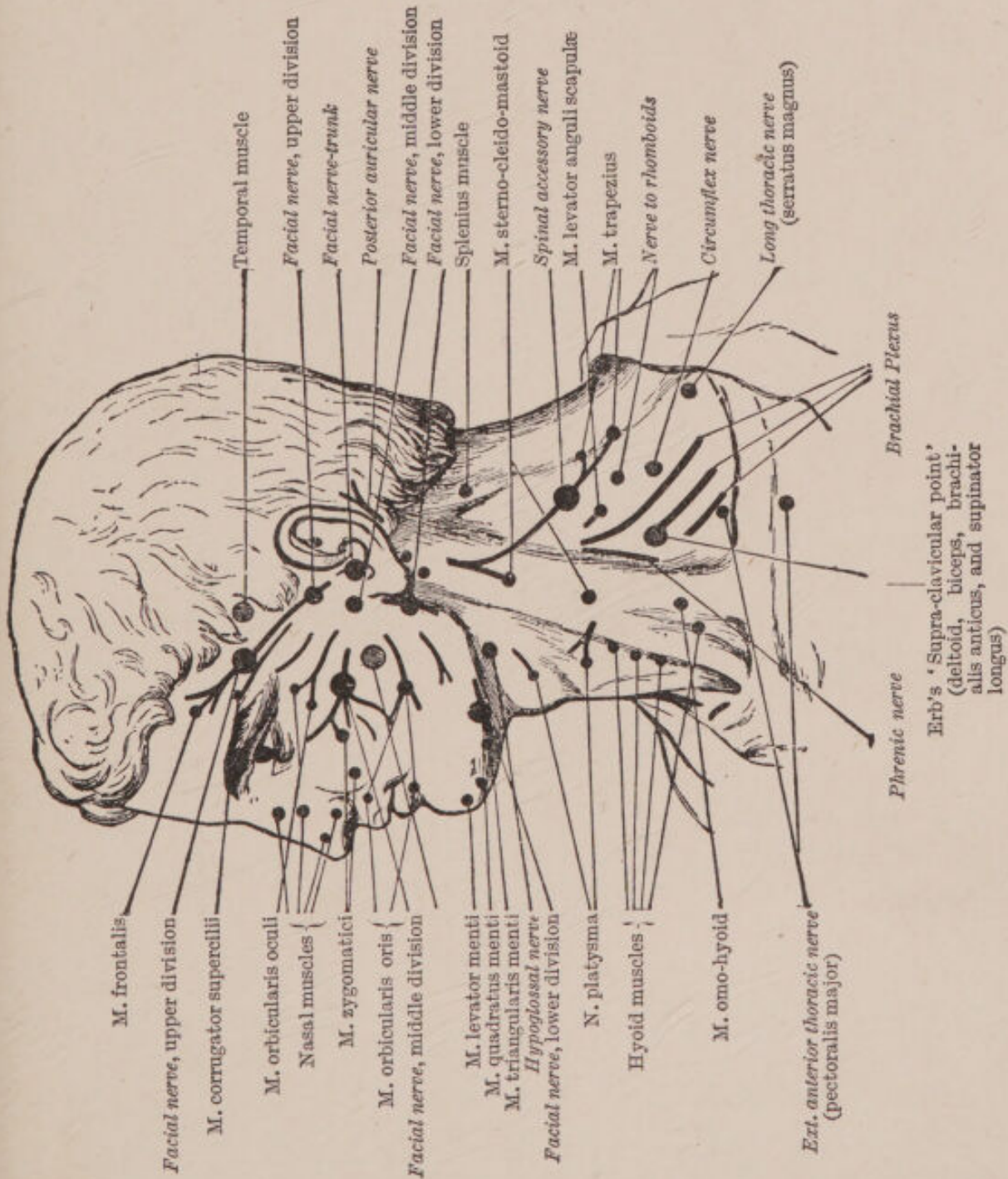


FIG. 11.—MOTOR POINTS OF FACE AND NECK (ERB).

## 22 NERVE INJURIES AND THEIR TREATMENT

If a muscle responds to the faradic current with a brisk contraction, the reaction is said to be normal, and we may safely assume that the lower motor neuron is normal. If no contraction can be obtained with the faradic current, we proceed to examine with the galvanic current.

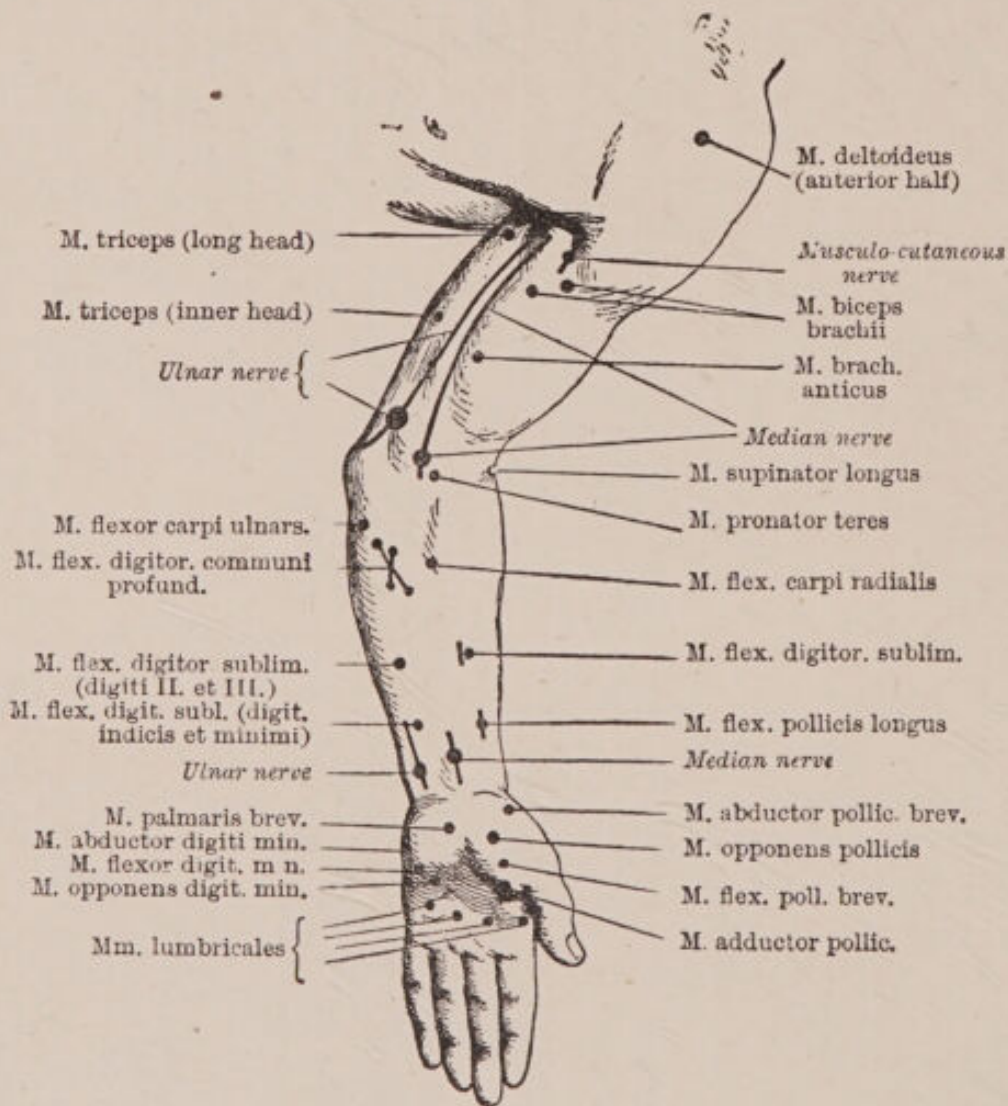


FIG. 12.—MOTOR POINTS OF UPPER LIMB.

### Galvanic Reaction.

Normally, when a galvanic current is passing through a muscle, provided the current be not too strong, no contraction of the muscle takes place, but at the moment of making that current, or of breaking it, the muscle contracts briskly.

The contraction obtained at the making or the closing

of a current, when the testing electrode is the kathode, is normally stronger than when the testing electrode is the anode: this is usually expressed by the formula  $KCC > ACC$ .

### Reactions of Degeneration.

When, as a result of an injury or disease, the lower motor neuron has degenerated, a corresponding change has taken

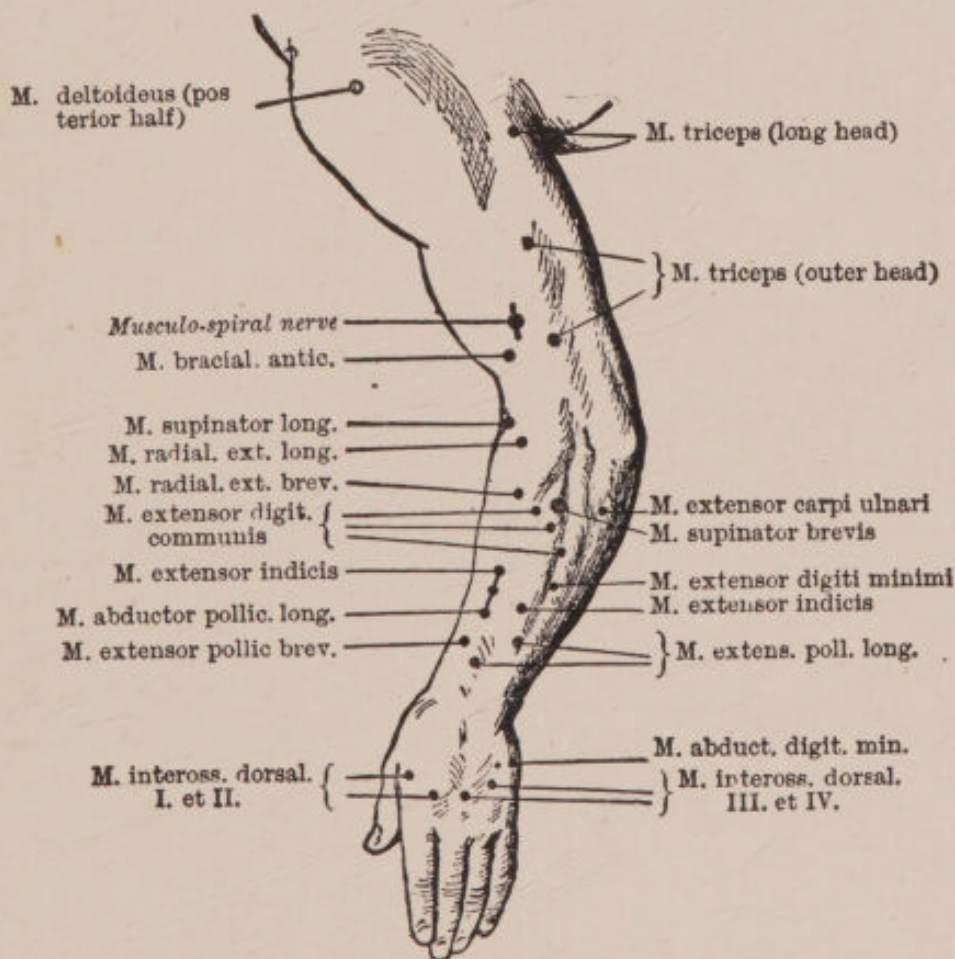


FIG. 13.—MOTOR POINTS OF UPPER LIMB.

place in the muscle-fibre supplied by the nerve; it loses its fibrillar element, the element which contracts with a brisk twitch and which can be stimulated by a faradic shock; it retains its sarcoplasm, a less excitable element which contracts slowly and can still be stimulated by galvanism; but the response of the muscle differs from normal. Whereas in normal muscle the kathodal closing

Unable to display this page

Of these two alterations in the response of a muscle to the galvanic current, far more importance should be attached to the sluggish quality of the muscle contraction than to the presence of polar changes.

To this alteration in response to the galvanic current, with absence of response to the faradic current, the name of '**reaction of degeneration**' is given.

We sometimes meet with cases in which there is a

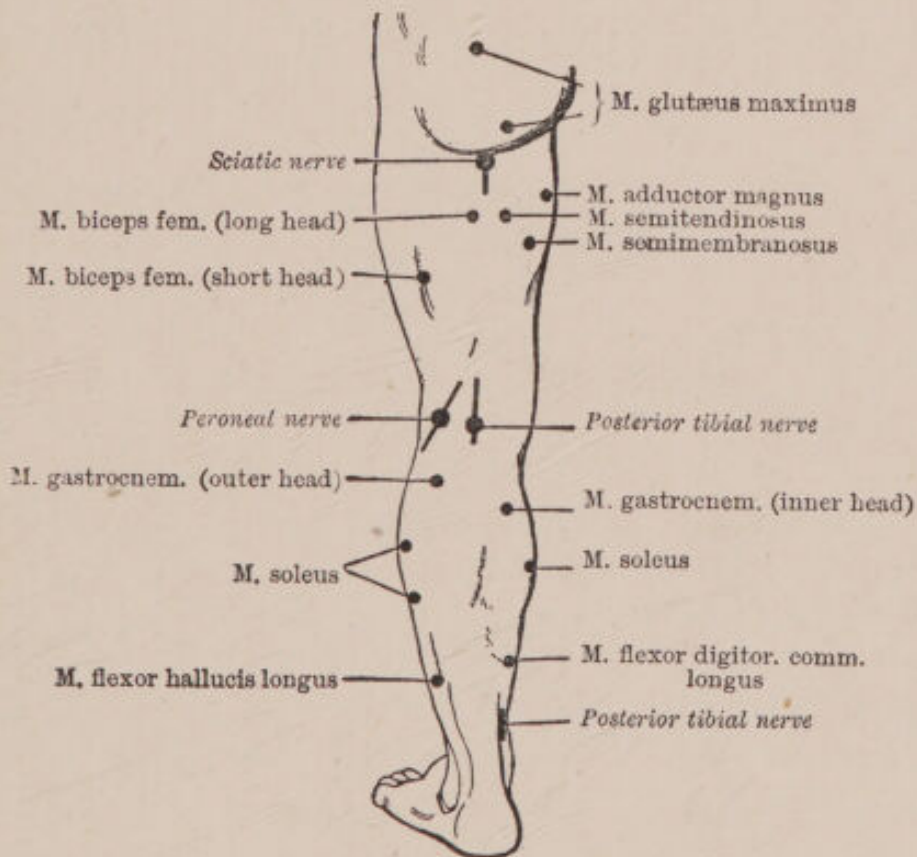


FIG. 16.—MOTOR POINTS OF BACK OF THIGH AND LEG.

sluggish contraction to galvanism, ACC being greater than KCC, and in which the response to faradism is diminished but not lost; this condition indicates a less severe injury to the nerve fibre, and is known as '**partial reaction of degeneration.**'

In addition to these two methods of testing muscle and nerve electrically, we have now at our disposal a third method: this is by means of the condenser apparatus.

**Condenser Apparatus.**

This apparatus was designed by the late Dr. Lewis Jones. The latest pattern consists of ten condensers of different capacities, ranging from 0·025 of a microfarad up to 3·00 microfarads, as shown on the dial (Fig. 17).

Any one of these, by means of a commutator and a metronome, can be charged from the main, preferably at a voltage of about 100 volts, and discharged through the patient's muscle. The essential difference in these various condensers is in their wave-length, i.e. the duration of

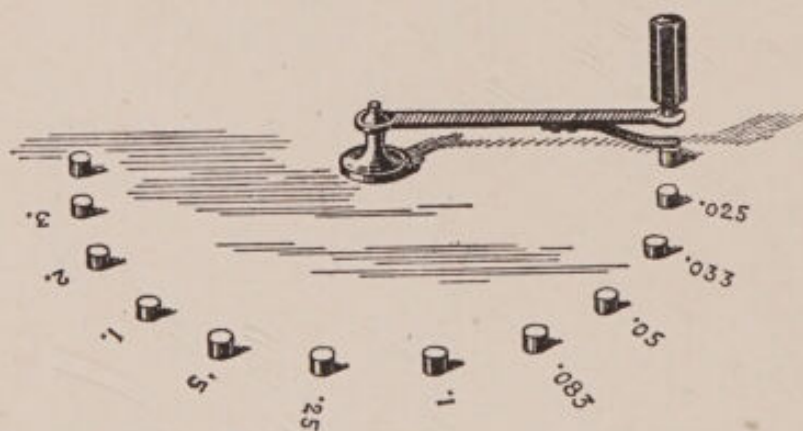


FIG. 17.—DIAL OF THE LEWIS JONES CONDENSER-APPARATUS. The studs are connected with condensers whose capacities range from 0·025 to 3·00 microfarads.

their discharge through the body. The smallest condenser with a capacity of 0·025 of a microfarad takes  $\frac{1}{16000}$  of a second, that with 3·00 microfarads takes  $\frac{1}{130}$  of a second to pass through the body.

Healthy muscles respond to the smallest condenser, 0·025 microfarad; as a muscle degenerates it requires impulses of longer duration to make it contract; thus muscles which show partial R.D. require condensers from 0·10 to 0·5 microfarad, and those showing complete R.D. require from 0·5 to 3 microfarads, or even more.

The advantages which the condenser method claims over the older methods are summed up thus: firstly, it is more rapid; secondly, it is more precise; thirdly, it gives more information; and last, but not least, it is far less painful to the person tested.

## CHAPTER III

### INJURIES OF NERVES, THEIR METHODS OF PRODUCTION AND SYMPTOMS

THE symptoms of nerve injury may occur :

1. Immediately on receipt of trauma.
2. Subsequent to, but resulting from, trauma.
3. Independent of any known trauma.

1. Symptoms occurring immediately on receipt of trauma are due to the fact that the nerve is in one of the following states :

- (a) Divided.
- (b) Torn.
- (c) Contused.
- (d) Compressed.
- (e) Concussed.

2. Symptoms occurring subsequent to trauma, but resulting from it are due to —

- (a) Involvement of the nerve in scar tissue.
- (b) Scar neuroma.
- (c) Involvement of the nerve in callus.
- (d) Pressure by displaced fractured bone.

3. Symptoms occurring independent of any known trauma are due to —

- (a) Compression slowly developed, e.g. by new growths, aneurysms, or cervical ribs.
- (b) Toxic conditions.

## 28 NERVE INJURIES AND THEIR TREATMENT

### 1. SYMPTOMS OCCURRING IMMEDIATELY ON RECEIPT OF TRAUMA

#### (a) A Divided Nerve.

A nerve may be divided subcutaneously, but usually a wound of the overlying structures is present. In civil life the wound is usually occasioned by some sharp-cutting edge, as that of a knife or broken edge of glass; in war, the division of a nerve may be due to bayonet or sword wounds, but is much more commonly produced by rifle or shrapnel bullets, pieces of cartridge-casing, pieces of shell, or by fragments of shattered bone. The nerve may be completely or partially divided.

The distinguishing feature of this group of injuries is that there is definite solution of continuity of the whole or of part of the nerve, occurring at the site of the injury and at the instant of injury.

**If completely divided**, there will be from that instant loss of sensation in the area supplied by the nerve, and loss of movement in the muscles supplied by it.

In about seven or eight days the muscles will no longer respond to the faradic current, and, at that time, or within the next six weeks, on testing by the galvanic current they will exhibit the complete reaction of degeneration.

The muscles at once begin to lose their tone, and this is soon followed by muscular atrophy, which steadily becomes more and more pronounced. The paralysed muscles become insensitive to pressure.

Pressure on the nerve-trunk below the seat of injury does not give rise to pain.

A considerable amount of discussion has taken place with reference to the differential diagnosis between *anatomical* interruption and *physiological* interruption without solution of continuity. From the clinical standpoint such differentiation is frequently impossible, but too much importance need not be attached to this, since an exploratory operation will be necessary in either case.

**Incomplete Division.** The symptoms of incomplete division of a nerve-trunk must vary greatly, dependent upon the exact position of the injury, the extent of the

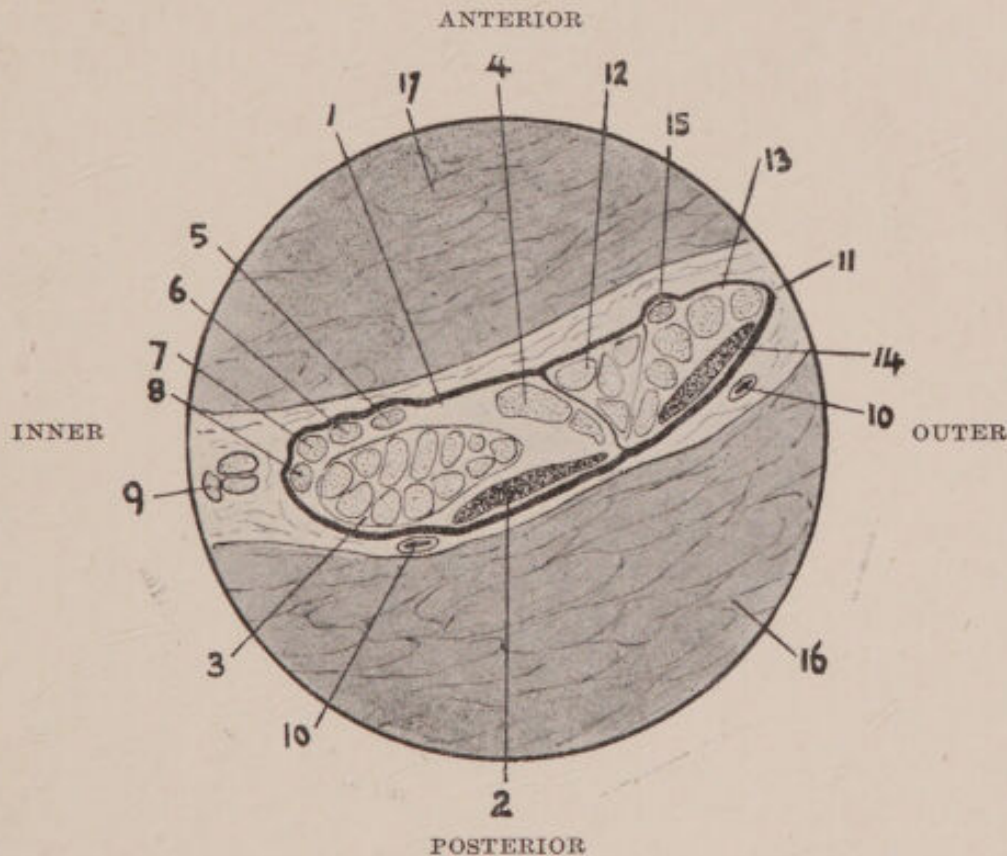


FIG. 18.—TRANSVERSE SECTION THROUGH PROXIMAL PART OF FETAL THIGH, showing the subdivisions of the great sciatic nerve.

1. Tibial trunk. 2. Tibial cutaneous bundle, flattened. 3. Posterior tibial bundle. 4. Popliteus and plantaris bundle. 5. Nerve to adductor magnus. 6. Nerve to semimembranosus. 7. Nerve to semitendinosus. 8. Nerve to biceps (ischial head). These four nerves (5, 6, 7, and 8) here lie within the sheath of the tibial trunk, upon the anterior (deep) surface of the posterior tibial bundle. 9. Small sciatic nerve (posterior cutaneous nerve of the thigh). 10. Branches of sciatic artery. 11. Common peroneal trunk. 12. Anterior tibial bundle. 13. Musculo-cutaneous bundle. 14. Peroneal cutaneous bundle, flattened. 15. Nerve to the femoral head of biceps within the sheath of common peroneal trunk. 16. Adductor magnus. 17. Gluteus maximus.<sup>1</sup>

cross-section involved, and the destination of the nerve-bundles which have been interrupted. We now know

<sup>1</sup> Alwyne T. Compton, "The Intrinsic Anatomy of the Large Nerve Trunks of the Limb," *Journ. of Anat.* 1917, vol. li. p. 103.

that a cross-section of a nerve-trunk reveals a very definite arrangement of nerve-fibres whose destination is determined long before the branches separate from the nerve-trunk to proceed to their respective terminations.

For example, Fig. 18 is a transverse section of a lower limb of a foetus through the proximal part of the thigh. This picture is the result of minute dissections, the various branches of the nerve being followed from the points of their emergence from the parent trunk upwards into the body of the main nerve-trunk. On looking at such a section, it is obvious that a large nerve-trunk is made up of its various branches of distribution, and that these are well-defined and separate structures, though closely bound together for greater or lesser distances before parting company to proceed to their respective distributions—motor or sensory as the case may be. When speaking therefore of an incomplete division of a nerve, it must be understood that we mean rather the complete division of a segment of that nerve, and, so far as the nerves of distribution in that segment are concerned, their lesion could not be more complete were the whole nerve-trunk grossly divided into two obvious pieces. This anatomical arrangement within each nerve can also be demonstrated by the direct electrical stimulation of the distal cut surface of a nerve-trunk, when careful stimulation of the various nerve bundles gives rise to corresponding movements in the particular muscle or group of muscles supplied. From this it is evident that the symptoms of incomplete division of a nerve will depend upon the exact position and extent of the lesion, in other words, upon the particular nerve bundles—motor or sensory—which happen to be involved. Hence we should expect to find paralysis of some of the muscles supplied by the nerve-trunk, others remaining unanected, and complete, partial, or no sensory loss, i.e. **dissociated paralysis**.

All this we should expect from the anatomical arrangement to which we have referred, but in addition we find

other signs, symptoms and sequelæ, the reasons for which are not self-evident.

These, which will be described in more detail when dealing with the individual nerves, are now merely enumerated:

1. Spontaneous pains.
2. Evoked pains.
3. Altered sensations.
4. Trophic changes, contractures, and deformities. (See under Median Nerve, p. 174.)

In some cases of incomplete division of mixed nerves pain is a predominant feature; this pain is in the area of distribution of the injured nerve:—generally the median in the upper limb and the sciatic in the lower. It begins immediately after the injury, or a few weeks later; this area is usually tender on palpation. These symptoms are sometimes found in a very exaggerated form; the pain is described by the patient as ‘like fire running up and down the arm’ or ‘like knives sticking into the flesh.’ Associated with this there is a general wasting of the skin and subcutaneous tissue of the affected digits and of the corresponding part of the palm. The skin is red and moist, especially on its palmar aspect, and sweating is often most profuse; thus in the patient above alluded to, with ‘fire running up and down the arm,’ the sweat literally streamed from the front of his chest and from his axilla. The phenomena are essentially due to hyper-excitability of the sympathetic centres within the spinal cord. To this condition the name of **causalgia** (a burning pain), or **thermalgia** has been given, and in cases which have been operated upon, the nerve has usually been found incompletely divided and embedded in scar tissue.

In certain cases of thermalgia not only do we observe hyperæsthesia of the skin at the site of pain, but even stimulation of the skin at any other part of the body may induce intense pain which is referred to the original thermalgic

## 32 NERVE INJURIES AND THEIR TREATMENT

area. This variety of thermalgia has been called **synæsthesalgia**. Mere contact or pressure does not excite the synæsthesalgic pain ; but if we displace our point of contact, e.g. by gentle friction or tickling, intolerable pain at once appears in the thermalgic area, often accompanied by intense emotional reaction. Moistening of the object which is touched, or wetting the patient's skin before being touched, diminishes the tendency to produce synæsthesalgia.

### (b) A Torn or Lacerated Nerve.

In all other lesions of nerves the force producing the lesion is applied directly over the site of the lesion, but in this variety the force is applied more or less remotely, it is an indirect lesion. The only force which can thus act at a distance is traction, and such lesions have been well named **traction injuries**.

These injuries usually affect the brachial plexus (see p. 133). When a nerve is stretched to the breaking-point the sheath ruptures first, and this is followed, if the stretching continues, by rupture of the nerve-fibres ; the rupture may be partial or complete.

The symptoms are those of a complete or incomplete division of a nerve ; usually those of complete division, for though primarily only some of the nerve-fibres may be torn across, the remainder are so damaged that degeneration ensues ; or if they at first escape, are destroyed later by the organization of the blood effused in the neighbourhood.

### (c) A Contused Nerve.

A nerve is said to be contused when it suffers alteration or loss of its functions due to trauma applied to the nerve or directly over it, when such trauma does not result in anatomical division.

The lesion in contusion varies within wide limits ; it may be very severe, amounting to complete crushing of

the nerve with symptoms of complete division. In less severe cases some only of the fibres are so injured, either by the trauma or later by the organization of enused blood, that they degenerate, whilst others only temporarily lose their conductivity; in these cases some muscles only are paralysed, whilst other cases escape, with 'patchy' loss of sensation. In still slighter cases conductivity is not lost, or there is loss for a brief period, associated with local pain (from injury of the *nervi nervorum*), and numbness and tingling in the area supplied by the nerve; in these mildest cases there is no gross lesion of the nerve.

**(d) A Compressed Nerve.**

In compression, the injuring force is slowly and steadily applied.

Pressure over a nerve gives rise to unpleasant symptoms, tingling and numbness, which symptoms cause the patient to alter the position which occasions the discomfort. If, however, in spite of warnings the patient persists in the action which occasions the discomfort, e.g. the use of an improperly made crutch, or if, owing to sleep or anæsthesia, he is oblivious to the warning, then these preliminary symptoms are followed by those of loss of conductivity of the nerve.

In other cases, where the pressure on the nerve is not from without but from within the limb, as in developing callus, or sclerosing fibrous tissue, or pressure by a fractured bone (see Fig. 19) or other bony deformity, degeneration of the nerve sets in with the full train of its consequences—loss of sensibility, motor paralysis, muscular atrophy, and trophic changes.

It will thus be seen that the symptoms vary in severity with the duration of the compression—from the momentary discomfort experienced by pressure, e.g. on the ulnar nerve as it passes behind the internal condyle, to the complete degeneration of the nerve following involvement in callus. Between these extremes we have other

## 34 NERVE INJURIES AND THEIR TREATMENT

grades of more or less severity, with symptoms more or less pronounced, dependent on the duration of the pressure.

As examples of injuries through compression, arising immediately on receipt of trauma, we have :

**Momentary Pressure**, e.g. on the ulnar behind the internal condyle.

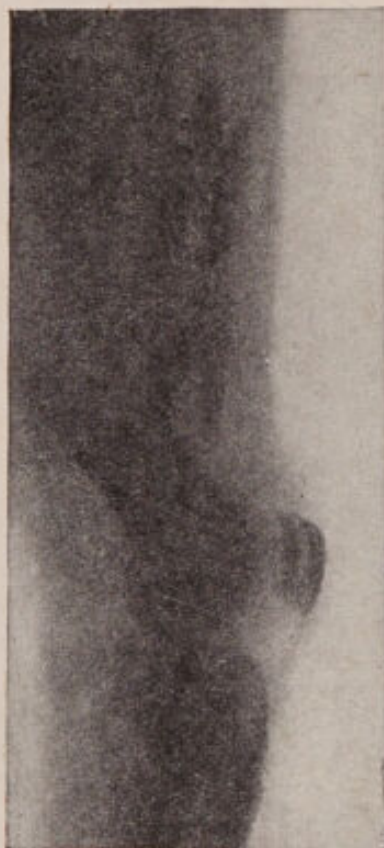

FIG. 19.—X-RAY SHOWING FRACTURE OF FEMUR WITH BACKWARD DISPLACEMENT OF THE LOWER END, CAUSING EXTERNAL POPLITEAL PALSY.

**Sleep Paralysis**, e.g. of the musculo-spiral or ulnar nerve when the arm is hanging over the back of the chair or over the edge of a table, especially if the head be pillowed on the arm.

**Crutch Paralysis**, e.g. when the patient, instead of taking part of the body-weight on his hands by means of conveniently placed handles, lets the whole weight fall on the axillæ; here the musculo-spiral nerve usually suffers, but the circumflex, ulnar, or median nerve may be simultaneously affected.

**Anæsthesia Paralysis**, e.g. of the external popliteal nerve from the pressure of a Clover's crutch, or of the musculo-spiral from pressure of the arm against the edge of the operating table.

It should be noted in fairness to the anæsthetic that it is no more to blame than is the sleep in so-called 'sleep paralysis': in both cases the paralysis is due to pressure improperly applied.

### (e) A Concussed Nerve.

A nerve is said to be 'concussed' when its conductivity has been impaired by trauma in its neighbourhood; the nerve is not directly in the path of the foreign body

inflicting the injury, and on examination no macroscopic change can be detected. It is assumed that a change has taken place in the nerve analogous to that occurring in concussion of the brain, and that the vibrations in the neighbouring tissues, caused by the rapid transit of the injuring body, have thrown the structure of the nerve into a state of 'commotion,' which temporarily places its functions in abeyance.

The symptoms of paralysis follow immediately upon receipt of the injury. On careful examination it will generally be found that the paralytic symptoms are incomplete, that the anæsthesia is transient or even absent, that the muscles are paresed rather than paralysed, and that the muscles have retained their normal electrical reactions. There is little doubt that many cases recorded as 'concussed' nerve are in reality examples of 'functional' paralysis.

## II. SYMPTOMS OCCURRING SUBSEQUENT TO BUT RESULTING FROM TRAUMA

These are all dependent upon compression, and the compressing force is either sclerosing fibrous tissue, or bony callus, or the direct pressure of the fractured end of a bone or of some other bony deformity (see Fig. 19). In these cases there is at the time of the trauma either no symptom suggestive of nerve injury, or slight transient symptoms consequent upon concussion or contusion—a few weeks later symptoms of compression manifest themselves and progress towards complete paralysis (p. 33).

In this group by far the larger number are due to the formation of sclerosing fibrous tissue; this fibrous tissue results from the organization of effused blood and inflammatory exudate. It is most important to recognize this, for if, by massage, movements, and electrical treat-

## 36 NERVE INJURIES AND THEIR TREATMENT

ment, we promote the rapid absorption of the extravasated blood and of the inflammatory exudate, we shall be doing much to prevent the onset of this type of paralysis—and it is an exceedingly common one.

To emphasize the importance of this, see how easy it is to manufacture a compression paralysis! Let a patient with fracture of both bones of the forearm be treated with splints and firmly bandaged; see that not even the fingers are free to move, and take care not to remove the splints for a month or six weeks, and if at the end of that time the hand is not paralysed it is due to good luck rather than to good treatment.

Blood has been effused between and about the ends of the fractured bone, has infiltrated the muscles in that segment of the limb, has invaded the intermuscular planes and loose connective tissues, including the sheaths of the nerves and often the nerve itself. By preventing all movement of the muscles, both active and passive, and by limiting the blood-supply through tight bandaging, we have done the maximum to prevent the absorption of the effused products and have encouraged their conversion into fibrous tissue; and this has occurred throughout all the structures in that segment of the limb—muscles, intermuscular planes, nerve sheaths, &c.

The resulting condition is sometimes known as **ischæmic paralysis**; the muscles may react to faradism or not, there may be sensory loss or not, but there is always motor paralysis; it is all a question of the extent of the fibrosis; there is always sufficient in and about the muscles to cause their contracture and paralysis (partial or complete); there may or may not be sufficient in and about the nerve to cause sensory loss and electrical changes in the muscles.

Fig. 20 is the hand of a boy aged 11, seen in December 1902. Eleven weeks previously he had fractured his radius and ulna. When the splints were removed a month afterwards he found his fingers flexed and was unable to straighten them. The hand was as shown in the photograph—fingers extended

at the metacarpo-phalangeal joints and flexed at the inter-phalangeal joints.

The fingers were blue and cold. The fingers and the palm of the hand were anæsthetic.

On exploration the median and ulnar nerves were found adherent on their deeper surfaces; there was no massive scar formation, but for two inches the nerves were depressed below the level of the rest of their course and needed a scalpel to free them posteriorly. This was over the site of the fracture—as evidenced by the callus formation. The nerves themselves

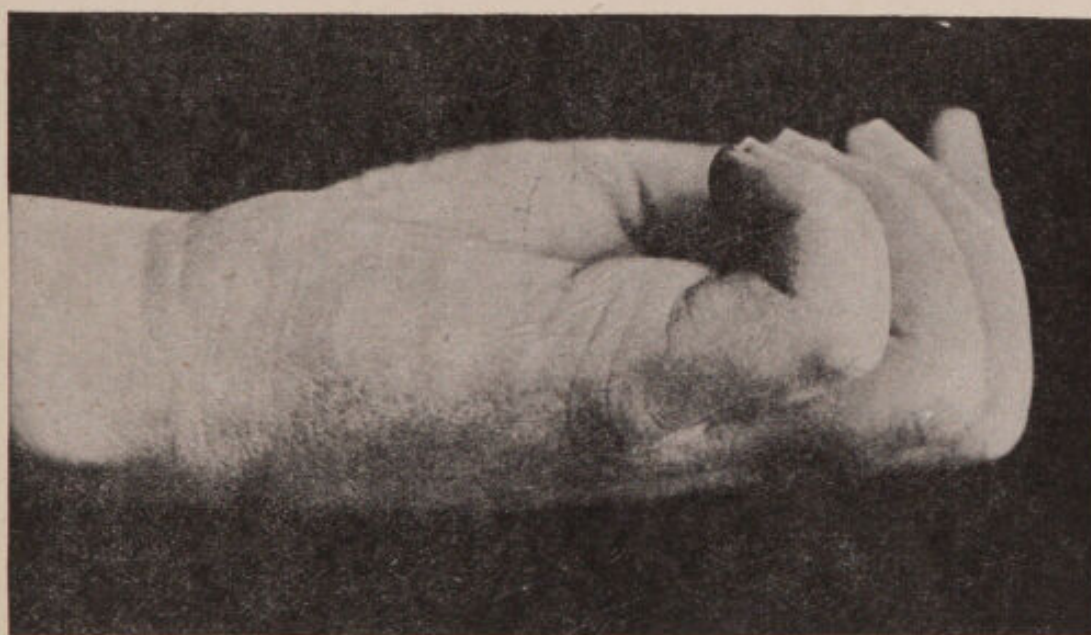

FIG. 20.—ISCHÆMIC PARALYSIS. For the treatment of a fractured radius and ulna the arm was splinted and tightly bandaged for a month. It was then looked at for the first time, when the hand presented the appearance shown in the illustration. The fingers could not be extended and were anæsthetic. There was a diffuse fibrositis at the level of the fracture—in muscles, intermuscular planes, nerve sheaths, and nerves.

in this situation were markedly hardened—due most likely to an overgrowth of fibrous tissue outside of and between the nervous elements. After operation, sensation and motion were speedily regained.

Another example, shown in Fig. 21, is that of a lady of 59 who had sustained a fracture of the right forearm at the age of six, i.e. fifty-three years previously. She said that the limb was for three days in tight splints, and that, until they were taken off, the fingers were blue and swollen. Ever since, the right

## 38 NERVE INJURIES AND THEIR TREATMENT

wrist and fingers had remained permanently fixed in a flexed position.

On examination, there was marked contracture of the right wrist, which was flexed almost to a right angle and could not be extended, even passively. The fingers were similarly contractured, chiefly at their terminal joints, but the thumb was freely movable. The flexor muscles were wasted in the lower two-thirds of the forearm; the surviving upper third of these muscles formed a distinct lump, above the level of the original splint, contrasting with the atrophied parts below. A radiogram of the region of the elbow showed slight thickening

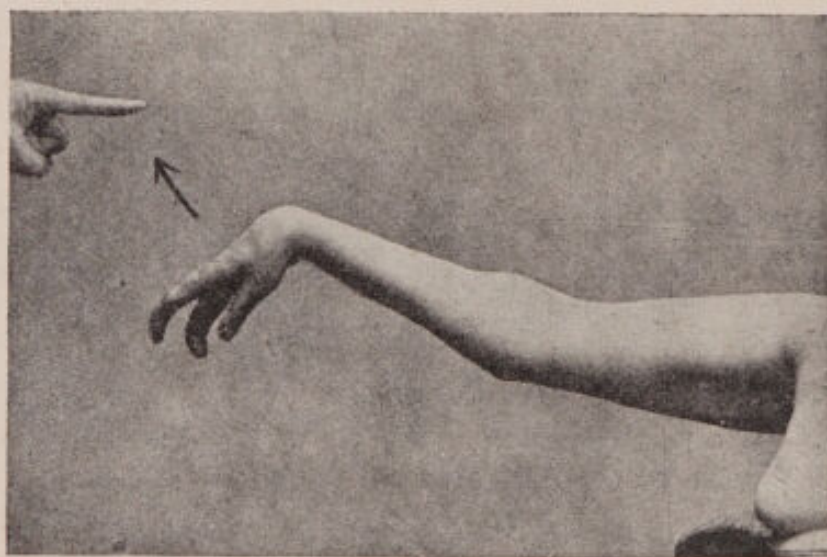


FIG. 21.—ISCHÆMIC PARALYSIS FROM SPLINT PRESSURE.

of the head of the radius, as if from an old fracture of its neck. There was no cutaneous anæsthesia or analgesia.

This type of compression-paralysis seldom calls for operative interference; if the wrist be flexed, the fingers can be straightened. The fingers should be kept extended on splints; a few days later the metacarpo-phalangeal joints are extended and the palm and fingers are bandaged to a flat splint; the wrist is now daily more and more extended, and kept so, on a splint, until hyperextension is obtained. This continuous passive extension, interrupted only for daily massage, soon results in the cure of those cases in which the nerve symptoms are not pronounced. All the other compression paralyses, namely those dependent on

nerve involvement in scar tissue or callus, or pressure on the nerve by a displaced fracture, demand operation with the least possible delay.

Ischæmic paralysis occasionally results from **direct injury to an artery** which supplies a muscle or group of muscles, without the occurrence of any direct pressure whatever. The following is an illustrative example :

A soldier, aged 22, was wounded in the left upper arm, the entry being through the middle of the biceps, the exit at the same level, one inch behind the brachial vessels and nerves.

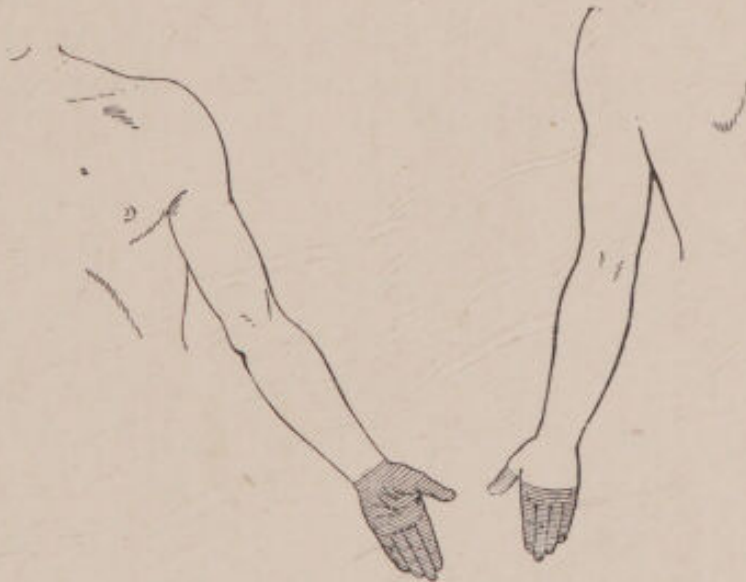


FIG. 22.—ANÆSTHESIA IN A CASE OF ISCHÆMIC MYOSITIS,  
FOLLOWING LIGATURE OF THE BRACHIAL ARTERY.

When admitted to hospital ten days later, the upper arm was swollen and no pulse could be felt at the wrist. Movements of the wrist and fingers were weak. No splint or bandage was applied to the forearm at any period of the treatment.

On the thirteenth day after the injury, secondary hæmorrhage occurred from the exit-wound. The false aneurysm was accordingly laid open, the blood-clot turned out, and the vessels ligatured, above and below the aneurysm. The wound then healed uneventfully. No nerve-trunk was damaged.

On the day after the operation, some return of power was observed in the extensors of the wrist and fingers. Improve-

## 40 NERVE INJURIES AND THEIR TREATMENT

ment steadily continued, but the flexor muscles of the wrist, fingers, and thumb remained permanently paralysed. Gradually the paralysed muscles developed a characteristic hard, doughy consistence. All the other muscles of the arm, forearm, and hand were normal.

Two months after the original injury the motor disability remained unchanged. To pin-pricks there was analgesia of the hand from the wrist downwards. To cotton-wool touches, anteriorly, there was anæsthesia below a level two inches above the wrist, whilst posteriorly sensation was lost only from the knuckles downwards (Fig. 22). Small blisters formed occasionally on the dorsal surfaces of the terminal phalanges.

To faradism or galvanism no reaction could be obtained in the paralysed long flexors of the wrist, fingers, or thumb, whereas all other muscles of the limb reacted normally.

### III. SYMPTOMS OCCURRING INDEPENDENTLY OF ANY KNOWN TRAUMA

These may be divided into two classes :

(a) **Consequent upon compression slowly produced** as by new growths, aneurysms, or a cervical rib. The commonest example of nerve paralysis produced by pressure of an aneurysm or new growth is that of the recurrent laryngeal nerve (see p. 119). For an example of nerve injury consequent on the pressure of a cervical rib see p. 152.

(b) The other group consists of **various forms of peripheral neuritis**. In these the condition is generally symmetrical, either both arms or both legs being affected ; in some cases all four limbs are affected.

The symptoms are both sensory and motor. The sensory symptoms consist in a diminution of epicritic sensibility in the 'stocking' and 'glove' areas ; the patient complains of tingling and of the sensation of 'pins and needles' in the same areas ; the muscles of the limbs are tender on pressure, and this tenderness to pressure is particularly marked in the soles of the feet. The motor

paralysis is most marked in the extensors of the wrists and fingers, and, when the feet are affected, the anterior tibial and peroneal muscles suffer most. This form of neuritis usually occurs as a result of some toxic absorption, e.g. alcohol, lead, arsenic, diabetes, diphtheria, or septicæmia. The neuritis of lead poisoning is not associated with sensory symptoms; there is paralysis of the extensors of the wrist and fingers, but the extensor ossis metacarpi pollicis and the supinator longus usually escape, differing in this respect from musculo-spiral paralysis.

Under this heading must also come one of the forms of **trench feet**. In these cases, as a result of deficient exercise of the leg muscles, combined with long exposure to cold and wet, a condition of peripheral neuritis develops.

Fig. 23 relates to a patient who was in the trenches from Christmas until February.

The floor of the trench was sometimes frozen, but more often wet and muddy. He wore putties and boots. He possessed waterproof boots, but 'they were too much trouble, as they kept on coming off.' Three weeks before admission his heels became swollen and painful. A week later his toes became similarly swollen and tender.



FIG. 23.—PERIPHERAL NEURITIS. One form of 'trench feet.' Notice that the patient walks on his heels; the soles of the feet are markedly hyperæsthetic; he keeps his feet dorsiflexed so as to prevent them from touching the ground.

## 42 NERVE INJURIES AND THEIR TREATMENT

On admission he had pains in the soles and in the toes, dorsal and plantar surfaces, worse at night ; there was marked hyperæsthesia to pressure on the soles and over the dorsum of the toes. The feet sweated excessively. There was no cyanosis or pallor. On standing up the patient could only stand on his heels ; he kept his ankles slightly dorsiflexed because of the hyperæsthesia of his soles. He was treated by the occasional application of an Esmarch's bandage, and the pain and hyperæsthesia diminished. Ten days later he could walk with crutches, resting his weight on the heels. Four days later he could walk alone chiefly, but not entirely, on his heels.

## CHAPTER IV

### CONDITIONS SIMULATING A PERIPHERAL NERVE INJURY

A PATIENT is asked to make a certain definite movement, say to flex his elbow ; he is unable to do so, and the question arises—Is this inability consequent on the injury of a peripheral nerve ?

This inability may be due to :

1. **Some local physical condition** which makes the movement impossible, e.g. fracture, dislocation, synovitis or other inflammatory condition, adhesions, &c. ; to this we have referred in describing the mode of examination of the patient (pp. 18–19).

2. A '**functional**' cause, and not an organic nerve lesion.

3. Even if dependent on a definite organic lesion, the lesion may be in **some part of the nerve track, from cortex to peripheral distribution, other than the peripheral nerve.**

#### FUNCTIONAL OR HYSTERICAL PARALYSIS

The following points will aid in making a diagnosis :

1. In the absence of trauma the paralysis is less likely to be organic ; in the presence of trauma it may be functional or organic.

2. Muscular atrophy may occur in either, but it occurs much earlier and is more marked in organic paralysis.

3. In functional paralysis the muscles always respond to faradic stimulation and to the lowest powers of the condenser, and the reaction of degeneration is never present.

Unable to display this page

Unable to display this page

## 46 NERVE INJURIES AND THEIR TREATMENT

joints flexed, and the inter-phalangeal joints rigidly extended (Fig. 24). There is anæsthesia of the hand and arm to just above the elbow (Fig. 25). When he is told to flex the forearm one can feel the extensors contract, and so with other suggested movements. All the muscles react to faradism. There is no muscular wasting.

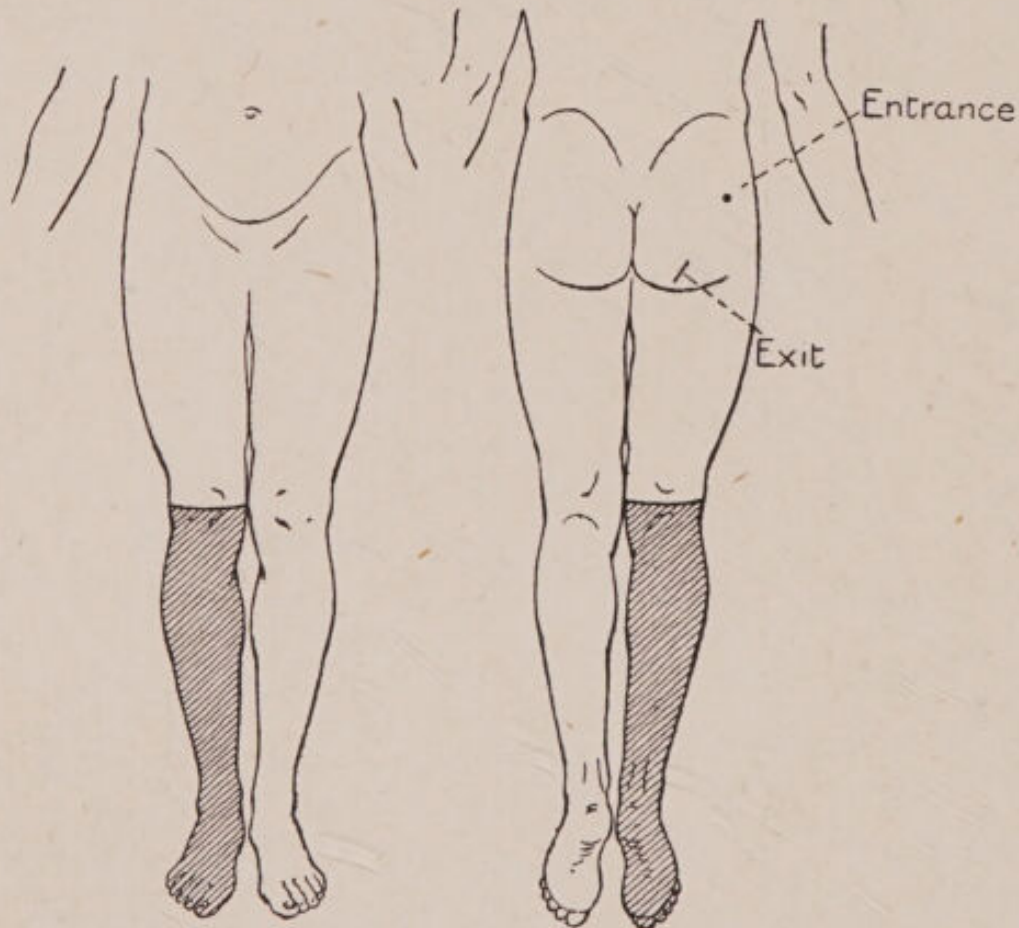


FIG. 26.—HYSTERICAL ANÆSTHESIA FOLLOWING A SHRAPNEL-WOUND OF THE RIGHT BUTTOCK. The entrance and exit are shown on the chart. When seen four months after the injury, patient said his 'leg felt dead.' There was anæsthesia to cotton-wool and pin-prick as high as the knee. A few weeks previously this had extended as high as the groin. There was no muscular wasting; all the movements of the right leg were feeble and tremulous; the knee-jerks and ankle-jerks were normal, and the plantar reflexes were flexor.

A soldier was wounded by shrapnel in September 1914. The entrance was just behind the right great trochanter. Three days later the bullet was removed in Paris, through a small incision in the line of the sciatic nerve, just above the gluteal fold (Fig. 26).

January 21, 1915. He now feels the whole limb dead as far as the toes; there is a feeling of heavy weight in the foot; there is analgesia as high as the groin.

January 31, 1915. There is anæsthesia to pin-pricks and cotton-wool as high as the knee; no muscular wasting; right lower limb tremulous in all its movements, and feebler than

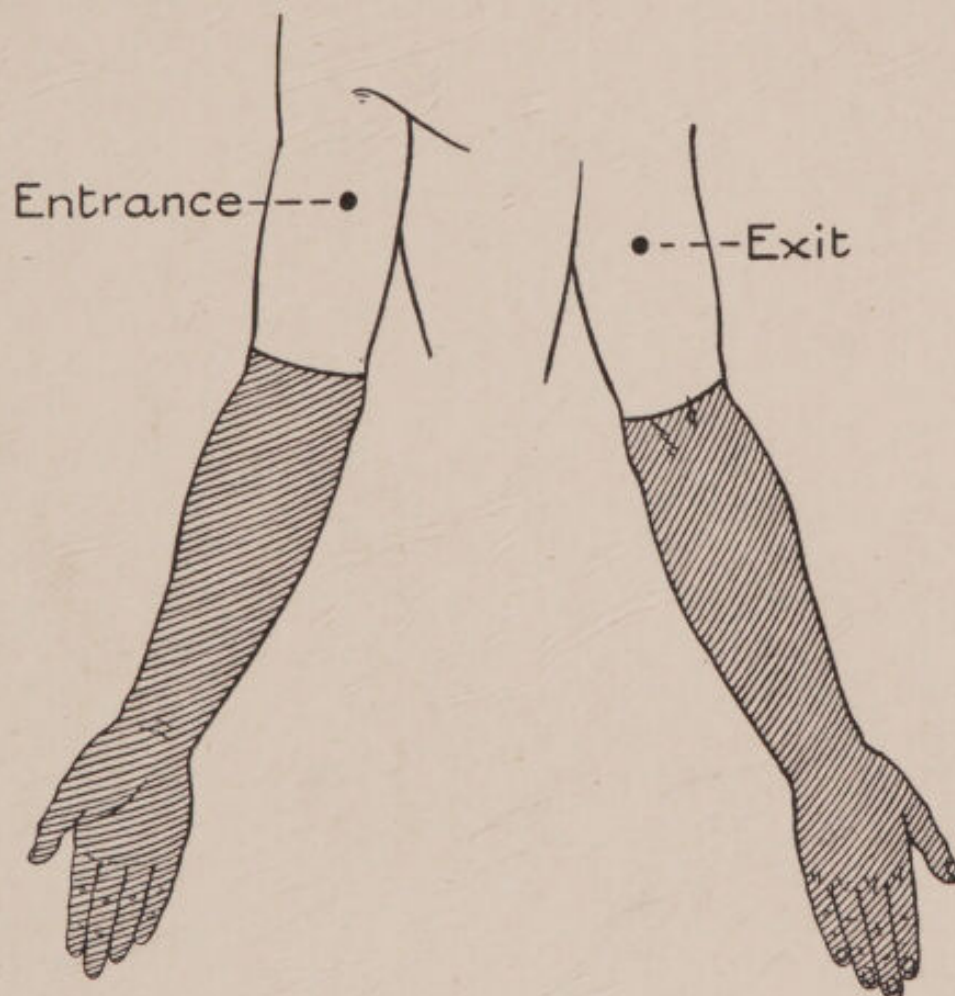


FIG. 27.—HYSTERICAL ANÆSTHESIA FOLLOWING A SHRAPNEL BULLET WOUND THROUGH THE MIDDLE OF THE RIGHT UPPER ARM. There was anæsthesia to pin-prick and cotton-wool below the line of the elbow joint. Joint-sense was lost in fingers, wrist, and elbow; vibration-sense lost below the tip of the olecranon. All movements of the limb were feeble, but none were impossible. There was no muscular wasting.

the left. Gait clumsy with the right limb. Knee-jerks and ankle-jerks normal; plantar reflexes flexor.

Fig. 27. A soldier was shot through the upper arm by a shrapnel bullet at Ypres in November 1914. The entry was in front, in the middle of the right upper arm, internal to the

Unable to display this page

For notes of a case of hysterical paralysis simulating a lesion of the brachial plexus see p. 150.

Another example of hysterical paralysis may here be quoted :

A left-handed Irish soldier, during an encounter with a party of Turks at Gallipoli, bayoneted ten or twelve of them single-handed. For this deed of gallantry he was recommended by his commanding officer for the Victoria Cross. He sustained numerous bayonet-wounds during the combat, fifteen in all.

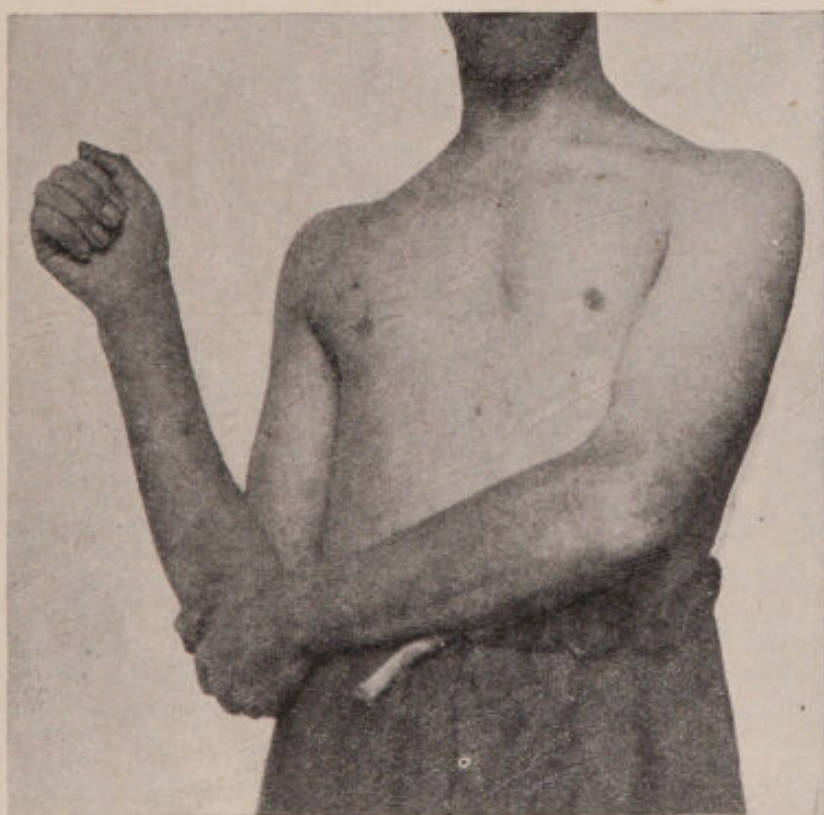


FIG. 28.—HYSTERICAL SPASM OF RIGHT HAND, FOUR WEEKS AFTER BAYONET-WOUND OF THUMB.

With one exception these were all on the right side of the trunk or on the right limbs.

Of the wounds, only two were of any depth, one through the right forearm about its middle, where a small cystic swelling was to be felt four weeks later, when he reached a hospital in Malta ; the other, a perforating wound through the web of the right thumb.

## 50 NERVE INJURIES AND THEIR TREATMENT

When examined, four weeks after the injury, there was tight flexor contracture of the right fingers (see Fig. 28), which could not be passively extended without pain. Nevertheless, no individual muscles were paralysed, though all movements of the fingers were excessively feeble. All the muscle of the hand and forearm reacted briskly to faradism. The reflexes, deep and superficial, were normal and equal on the two sides.

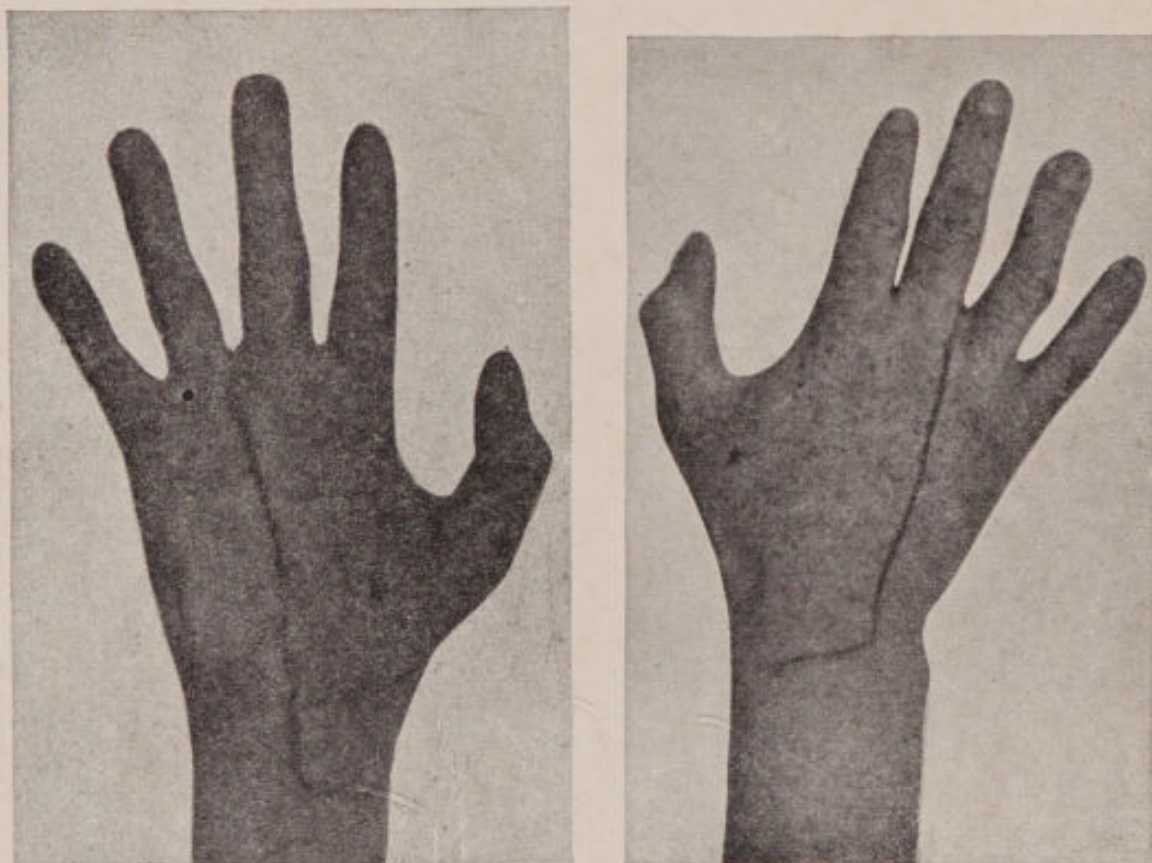


FIG. 29.—HYSTERICAL PARALYSIS OF RIGHT THUMB, FOLLOWING BAYONET-WOUND FOUR WEEKS PREVIOUSLY. Exit- and entry-wounds are indicated, also limits of hysterical anæsthesia.

During the examination this patient showed how readily an hysterical anæsthesia can be produced by suggestion from the physician. At the beginning of the séance he had blunting of sensation to pin-pricks in the right hand only, back and front. Then, as the examination went on, the upper boundary of anæsthesia rapidly extended to the elbow and shoulder, and finally to the right side of the face, trunk, and right lower limb, stopping short at the middle line.

Five days later (January 27), the anæsthesia had receded, to a horizontal line two inches above the right wrist.

By February 2, i.e. five weeks after the injury, the anæsthesia was confined to the radial side of the hand, front and back, stopping short an inch above the wrist, i.e. not corresponding to a lesion of any individual nerve-trunk (see Fig. 29). The contracture of the fingers had disappeared, and all movements of the digits could now be performed freely, except extension of the terminal phalanx of the thumb. The patient said he thought he had had a specially severe blow from the butt of a rifle on that phalanx.

On February 17, nearly seven weeks after the injury, he began to extend the thumb feebly and the anæsthesia had receded to the flexure of the wrist.

On February 24, two months after the wound, he was able to extend the thumb well (see Fig. 30) and all other movements of the limb were normal. There was still a small patch of anæsthesia on the dorsum of the web of the thumb. This in turn disappeared shortly afterwards.

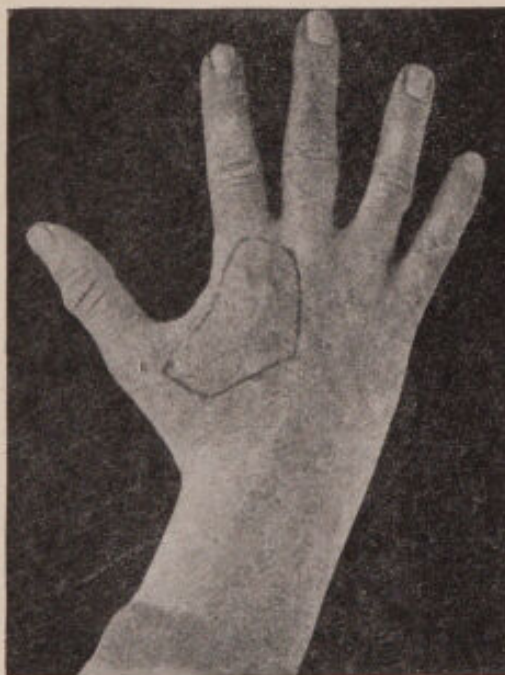

FIG. 30.—HYSTERICAL ANÆSTHESIA OF PART OF HAND, EIGHT WEEKS AFTER BAYONET-WOUND OF THUMB. The motor paralysis has recovered. (Compare previous figure.)

### Combined Organic and Functional Paralysis.

It should be remembered that a patient with an organic lesion may have a functional paralysis superadded to it. In such cases the functional element is usually more extensive in distribution than the underlying organic part, and, as it were, submerges it, so that unless care be exercised in the examination, either the organic factor is overlooked and the whole case is wrongly regarded as

## 52 NERVE INJURIES AND THEIR TREATMENT

functional, or on the other hand the organic paralysis appears to be more serious than it really is. The following is an illustrative example :

A gunner, aged 27, was hit by a shrapnel bullet at Gallipoli. The entry-wound was through the middle of the left triceps, midway between the acromion and olecranon ; the exit-wound was an inch higher up, through the middle of the biceps. The bullet-track thus crossed the line of the musculo-spiral nerve. The patient immediately lost all power in the left upper limb, which felt to him as if it had been blown off. There was no pain at the time of injury, nor afterwards.

When examined, eight days after the injury, there was complete anæsthesia of the left upper limb to all forms of cutaneous stimulation, from the level of the acromion downwards. (See Fig. 31.) Joint-sense was absent at the fingers and wrist, normal at the elbow and shoulder. Vibration-sense was lost in the hand, forearm, and upper arm, normal at the clavicle and scapula.

In the left upper limb the only voluntary movement that could be performed below the shoulder was feeble flexion of the fingers. No movement was possible of the thumb, wrist, or forearm. The biceps and triceps could be felt to contract feebly, but not enough to move the elbow. He could feebly abduct and adduct the shoulder.

To faradism the biceps and triceps reacted briskly, together with all the muscles of the forearm and hand, with the exception of the supinator longus and the extensors of the wrist, fingers, and thumb.

In Fig. 31 the patient is shown during an attempt to flex the elbows and dorsiflex the wrists. On the left side he fails to accomplish this. There is wrist-drop, and the elbow is being passively flexed by the nurse. The entry-wound behind the musculo-spiral nerve is well seen. The upper limit of the anæsthesia is marked on the skin at the level of the shoulder.

Having eliminated ' physical impossibilities ' and functional disease, and being left with the diagnosis of organic nerve disease, we have to decide what part of the nerve system is at fault.

Unable to display this page

## 54 NERVE INJURIES AND THEIR TREATMENT

The main points of difference in the paralysis occurring in these two types is shown in the following table :

### ORGANIC MOTOR PARALYSIS

#### Lesion of **Upper (Cortico-Spinal) Neurone.**

1. Diffuse muscle-groups affected, never individual muscles.

2. Spasticity and hyper-tonicity of paralysed muscles.

3. May have super-added 'associated movements' on attempted voluntary movement.

4. No muscular atrophy except from disuse.

5. Electrical reactions normal.

6. Deep reflexes in paralysed limbs present, and usually increased.

7. If foot affected, plantar reflex is extensor in type.

#### Lesion of **Lower (Spino-muscular) Neurone.**

1. Individual muscles may be affected.

2. Flaccidity and atonicity of paralysed muscles.

3. No 'associated movements.'

4. Early atrophy of paralysed muscles.

5. Reactions of degeneration.

6. Deep reflexes of paralysed muscles diminished, and often absent.

7. Plantar reflex, if present, is of normal flexor type.

Having decided that the paralysis is of the lower motor neurone, we have to determine which part of the track is affected—anterior cornual cell, anterior root, or peripheral nerve.

Anterior cornual cell and anterior root lesions will cause pure motor paralyses unaccompanied by any sensory loss. It is difficult to have a trauma of the spinal cord affecting only the anterior cornual cells, and as lesions of these are usually the result of acute or chronic

anterior poliomyelitis, we need not here discuss them further.

It is, however, necessary to distinguish carefully between injuries of the anterior roots and of peripheral nerves ; so, too, is it necessary to distinguish between injuries of the posterior roots and of peripheral nerves.

We cannot differentiate clinically between a combined lesion of an anterior and posterior root and a lesion of the mixed spinal nerve formed by their fusion ; the symptoms would be the same. But as soon as the nerve divides into branches to form plexuses or individual nerves we have an entirely different combination of motor and sensory phenomena which makes the diagnosis easier. In the former situation the distribution of motor and of sensory paralysis is according to root-areas, in the latter it is according to peripheral nerves. (See brachial plexus, p. 130, and cauda equina, p. 197.)

### **Reflex Paralysis.**

Sometimes after a local trauma to a limb, which need not necessarily implicate a nerve-trunk, but may have been in the bone, joint, or soft parts, the patient develops a curious type of paralysis. This may be either spastic or flaccid in type, and total or partial in degree. The intensity of the paralysis is not necessarily proportional to the severity of the original injury. A trivial trauma may cause severe reflex paralysis.

This condition may easily be mistaken for hysterical palsy, but is readily distinguished by the following characteristics :

1. The skin of the affected hand (or foot) is colder than on the affected side ; i.e. there is local **hypothermia**. It is sometimes cyanosed as well. The difference in temperature between the affected and the normal hand may be as much as 12° or 15° F.

2. The paralysed muscles are often **hyper-excitable to direct percussion**, compared with the healthy side. This is best demonstrated in the intrinsic muscles of the hand (or foot). The electrical reactions, however, are normal, or perhaps slightly increased to faradism.

When the muscular hyper-excitability is poorly marked, it can usually be demonstrated by plunging the limbs of the two sides into cold water, when the muscular hyper-excitability as well as the local hypothermia at once become evident on the affected side.

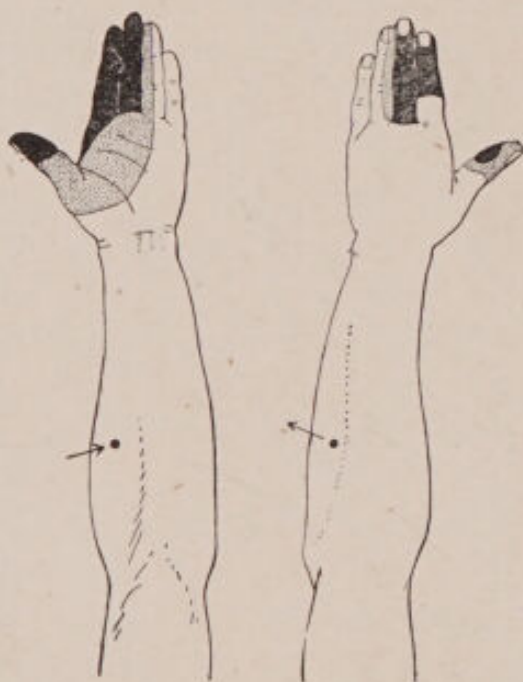


FIG. 32.—PARTIAL LEFT MEDIAN PARALYSIS, COMBINED WITH REFLEX PARALYSIS.

3. The condition is unaffected by psycho-therapy or suggestion, thereby differing from hysteria. It tends ultimately, however, to spontaneous recovery.

This condition (originally described by Babinski and Froment) appears to be due to a functional (but not psychogenic) hyper-excitability of the anterior cornual cells in the corresponding segment of the spinal cord, in cases where the reflex paralysis is of a spastic type; or to a functional (but not psychogenic) inhibition of these same cells in the flaccid variety of case. The hypothermia and cyanosis are doubtless due to disorder of the adjacent nucleus sympatheticus in the antero-lateral cornu of the cord, which controls the blood-vessels of the limb.

Pure cases of reflex palsy are usually easy of recognition. Difficulty, however, sometimes occurs in cases which are combined with an organic nerve lesion on the one hand, or with an hysterical paralysis on the other.

**Case of Reflex Paralysis of Left Hand, combined with partial Median Palsy.**

The patient was wounded by a rifle-bullet in the left forearm. The entry was on the flexor surface of the limb,  $4\frac{3}{4}$  inches above the wrist; the exit was on the extensor aspect, towards the ulnar side, quarter of an inch lower down. The wound was septic and took over three months to heal.

When examined, seven months after the injury, there were signs of a partial lesion of the median nerve, consisting in anæsthesia and analgesia of  $3\frac{1}{2}$  digits (see Fig. 32), together with paralysis, wasting, and loss of faradic excitability of the abductor pollicis alone. All other muscles innervated by the median were normal, also the ulnar group of muscles.

In addition, the fingers of the left hand were cold and blue, especially the index and medius, and the whole left hand was colder than its fellow. There was increased muscular excitability on percussion of the hypothenar muscles, of the interossei, and of the thenar muscles, with the exception of the abductor pollicis.

**Case of Combined Reflex and Hysterical Paralysis of Left Thumb.**

A gunner, aged 30, developed a small whitlow in the terminal phalanx of the left thumb, which was duly incised longitudinally along the palmar aspect of the digit. During his convalescence from this condition it was found that the thumb had become persistently flexed at the metacarpo-phalangeal joint. He himself also noticed deficient sensation in the thumb.

On examination, eight months after the operation, he showed a typical hysterical paralysis of the thumb, which was tonically flexed at the metacarpo-phalangeal joint and extended at the inter-phalangeal joint (Fig. 33). There was total anæsthesia of the thumb phalanges, both on the palmar and dorsal aspects, obviously of hysterical type. There was no voluntary movement of the thumb. If it was passively extended at the metacarpo-phalangeal joint, it slowly returned to its former abnormal posture. The movements of the other digits were all slow and stiff. There was no wasting of the thenar muscles, nor of any of the other intrinsic hand-muscles. So far, the condition was obviously hysterical in nature.

## 58 NERVE INJURIES AND THEIR TREATMENT

The skin of the thumb, however, was bright pink in colour, and much colder than that of the opposite thumb. All the other digits of the affected hand were also abnormally cold,

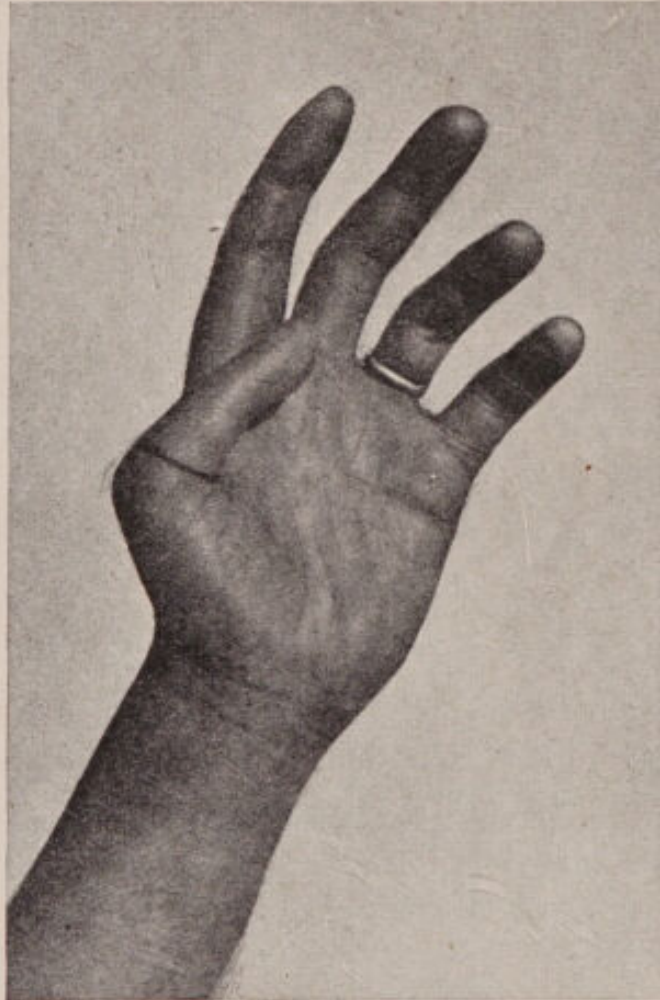


FIG. 33.—COMBINED REFLEX AND HYSTERICAL PARALYSIS  
OF LEFT THUMB.

but less so than the thumb. To faradism all the muscles of the hand reacted briskly and normally. No definite muscular hyper-excitability could be made out in this case.

## CHAPTER V

### PROGNOSIS

THE prognosis after primary and secondary suture will be dealt with later (p. 62). Let us first speak of prognosis in general. A patient, as the result of a wound or other trauma, presents himself with signs of a peripheral nerve paralysis; the prognosis is based on a consideration of the following factors:

1. The electrical reactions.
2. The completeness or incompleteness of the symptoms.
3. The progress of the case under treatment.
4. The condition of the wound complicating the nerve injury.

#### 1. The electrical reactions of the muscles at the end of ten days or a fortnight.

These are of prime importance. No complete diagnosis can be made in their absence, and no accurate prognosis can yet be given.

If the muscles react to faradism and respond to the lowest power of the condenser (0.025 microfarad), the prognosis is good, for we know there is no profound alteration in the nerve, and that the condition of paralysis is either functional or consequent on disuse, and in both cases efficient treatment will speedily result in improvement.

If the muscles do not respond to faradism, and if, too, with galvanism we have sluggish contraction with polar

changes—and still more, if the muscles do not respond to the higher powers of the condenser, namely, to 2 or 3 microfarads, then we know that degeneration of the nerve has taken place, and that under the most favourable circumstances three months must elapse before any return of function can manifest itself.

Between these two groups are others—namely, those in which the muscles, although responding to faradism, require a stronger current than the corresponding muscles of the opposite limb. These all tend towards recovery, some more rapidly than others, and the rapidity of recovery in many cases corresponds to the ease with which they can be made to contract to condenser shocks. A muscle contracting to 0.05 microfarad is likely to regain voluntary power in a few weeks, as compared with one which will only contract to 0.25 microfarad, and which may need months for its recovery.

## 2. Completeness or incompleteness of the symptoms.

If some of the muscles supplied by a nerve still retain the power of voluntary movement, and if, too, the sensory loss be incomplete, whether in distribution or intensity, the prognosis is better than if the symptoms of paralysis are complete; these symptoms are sometimes the result of bruising of the nerve, with hæmorrhage into its substance.

It is in cases with a history such as this, that later, at the operation, we find some thickening in the nerve in more or less of its circumference, with perhaps some limited adhesions.

Some of these cases, under energetic treatment commenced soon after the injury—such treatment being directed not only to the affected muscles but over the site of nerve injury, especially if ionization over this site be employed—show signs of improvement in three weeks or a month, as the blood becomes absorbed.

In that group of cases in which the symptoms are not profound, where we have a condition of muscle which shows paresis rather than paralysis, and in which there is no anæsthesia, or but a transitory one, we may with confidence regard them as due to mild contusion, or in the slightest cases even to 'concussion,' and the prognosis is good, especially if from the sites of entrance and exit we may infer that the nerve has not been directly injured.

### 3. The progress of the case under treatment.

A most important factor in determining prognosis is the response made to treatment.

Many cases under treatment will be found to *improve*, either quickly, as in paralysis from disuse, some cases of functional paralysis, and some concussion injuries, or more slowly, as in those cases of contusion in which the symptoms are dependent upon the pressure of effused blood rather than on actual degeneration of injured axis-cylinders.

Other cases there are in which the *symptoms increase* in spite of treatment, where what at first was no more than paresis becomes definite paralysis, and in which higher and higher powers of the condenser are needed to elicit a contraction of the muscle; here it is evident we are dealing with a progressive paralysing agent. This may be either fibrosing connective-tissue or callus. In these cases, apart from operation, the outlook is hopeless, and the sooner the nerve is exposed and freed from its strangulation the better.

Cases of complete paralysis, which at the end of three months, in spite of massage and electrical treatment, show no improvement, or in which examination at an earlier date reveals a nodular swelling in the course of the nerve, should be submitted to operation, as no good can reasonably be expected from further delay.

The prognosis of nerve injuries which are associated with the intense pain to which the term 'causalgia' is

Unable to display this page

order, and somewhere about these periods after operation :

PRIMARY SUTURE.	<i>Commencement.</i>	<i>Completion.</i>
1. <i>Protopathic sensation</i>	Six weeks	Six months
2. <i>Epicritic sensation</i>	Six months	Twelve months
3. <i>Motor power</i>	Six months	Twelve months

Although epicritic sensation may be recovered in about twelve months, it cannot be spoken of as perfect recovery of sensibility, for it takes another twelve months before the patient acquires the power of accurate localization.

SECONDARY SUTURE.	<i>Commencement.</i>	<i>Completion.</i>
1. <i>Protopathic sensation</i>	Six to twelve weeks (may be as early as three weeks)	Six to twelve months
2. <i>Epicritic sensation</i>	Twelve months	Never
3. <i>Motor power</i>	Nine months	Very rarely perfect

In secondary suture the return of nerve functions is noticed in the same order of appearance as after primary suture. The return of protopathic sensation is sometimes observed at a much earlier date than in the case of primary suture. This is so because by the time the secondary suture is performed partial regeneration of the axis-cylinders in the peripheral may have already taken place ; as a rule, however, it is later rather than earlier. Epicritic sensation takes twice the time to appear and never becomes perfect.

The dates in the above tables are those generally accepted, but recent experiences have shown that secondary suturing is often followed by still speedier return of sensation and motion.

Fig. 34 A is that of a case of external popliteal paralysis in which the external popliteal nerve as the result of a gunshot-

## 64 NERVE INJURIES AND THEIR TREATMENT

wound was converted into what looked and felt like a mass of fibrous tissue; this segment was excised and end-to-end suture performed. Five weeks later there was marked protopathic recovery (Fig. 34 B).

Fig. 107 relates to a soldier who as the result of a gunshot-wound of the upper arm had complete paralysis of the median and ulnar nerves. At the operation the ulnar nerve was found embedded in dense fibrous tissue and the median nerve almost completely torn across and the torn ends involved in massive

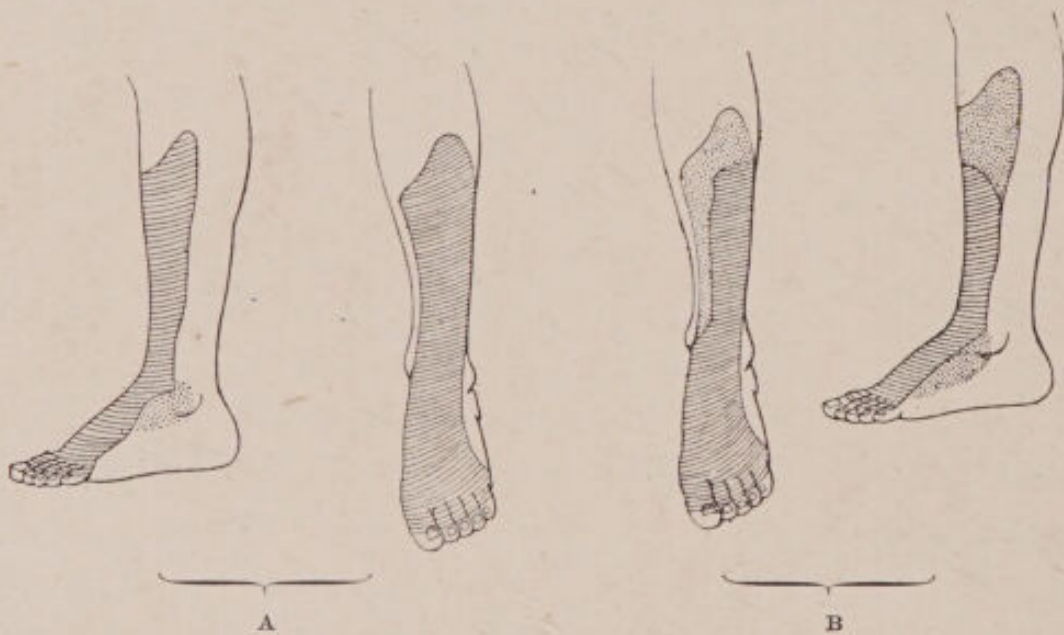


FIG. 34 A shows the loss, both protopathic and epicritic, in a case of complete division of the external popliteal nerve.

FIG. 34 B shows the amount of protopathic recovery, five weeks after secondary suture. Over the dotted area there is only epicritic loss.

scar-tissue. The fibrosed ends of the median nerve were excised, thus completely dividing the nerve, and secondary suture performed. Eleven weeks afterwards the patient could slightly abduct and oppose his thumb; it is worth noting that at this time there was no return of power in the flexor carpi radialis, although, according to the rule, innervation of this muscle should have preceded that of the thumb muscles.

Fig. 52, page 95, relates to a soldier who sustained a gunshot-wound in the neck, followed by paralysis of the spinati, deltoid, biceps, coraco-brachialis, brachialis anticus, and supinator longus muscles. At the operation the 5th cervical nerve was

found completely divided. The proximal portion of the nerve was replaced by scar tissue, and exploration through the fibrosed scalenus anticus muscle failed to discover the central end of the nerve. The spinal accessory nerve was therefore anastomosed to the 5th cervical nerve distal to the lesion. Six months after the operation the patient could voluntarily contract the biceps muscle, and, one month later, the deltoid.

Bowlby states that muscular recovery is not likely to be marked if operation is delayed longer than two years, and that no case of perfect motor recovery has been reported after four years.

Sherren, reviewing twenty-one cases of secondary suture in which the interval between injury and operation was less than three years, notes that some motor recovery took place in all, but that in none was there perfect sensory recovery.

Sometimes, following secondary suture, there is no return of epicritic sensation, nor of motor power, and the only change that follows operation is return of protopathic and of deep sensibility; yet even this limited recovery is of great utility to the patient, since the restoration of protopathic sensibility prevents the formation of ulcers, which sometimes originate as the result of trauma unperceived by the anæsthetic skin (e.g. a match burning to the end of its stem), and at other times as the result of injuries so trivial that they would have had no effect upon normal skin.

## 2. Septic Wounds.

Of all the considerations affecting prognosis in nerve suture, one of the most important is the condition of the nerve with regard to its asepsis or the reverse. Thus, if in a case of primary suture for subcutaneous rupture of a nerve the wound should suppurate—even though the suppuration speedily ceases without the nerve sutures giving way and without any sloughing of the nerve struc-

ture—recovery is much delayed, and this delay may actually double the period necessary for the restoration of the nerve functions. Again, if the original wound has suppurated, and, subsequently to its healing an operation be undertaken for suture of the nerve, even if the most favourable conditions be present, with no wide separation of the ends and no extensive matting of these to surrounding structures, recovery is much delayed. The mere fact that the wound has previously been the seat of suppuration exercises a markedly retarding effect upon regeneration of the nerve.

In still less favourable cases it will be found that there is wide separation of the ends, and these are involved in a mass of dense fibrous tissue which unites them to the surrounding structures.

### 3. The particular nerve under consideration.

The prognosis varies with different nerves. Thus, after uniting a severed musculo-spiral nerve the prognosis, as a rule, is good; muscular return is almost always satisfactory, and its sensory distribution is not of prime importance, so that even if the finer shades of sensory localization fail to reappear, and the return of muscular power to the extensors of the elbow, wrist, and fingers be not perfect, still the patient will have an efficient working hand.

On the other hand, after an operation for secondary suture of the ulnar nerve, the prognosis, so far as ultimate utility is concerned, cannot be so good; for should the recovery of epicritic sensation be imperfect, and complete power of the intrinsic hand-muscles fail to appear—and this is by no means uncommon—the delicacy of touch and finer movements of the hand will be deficient, and its subsequent utility much impaired.

### 4. The site of the lesion.

The site of the lesion, i.e. its distance from the periphery, does not much affect the return of sensation, but

motor return is markedly affected ; thus in wounds of the ulnar nerve at the wrist and at the elbow respectively, return of motor power to the small muscles in the hand takes twice as long in the latter as in the former case.

### 5. Treatment.

It cannot be too often emphasized that the results of an operation depend largely on the non-operative treatment ; this applies to treatment before and after operation in the case of secondary suture, and to post-operative treatment in the case of primary suture. The almost irresistible tendency in surgery is to think, or rather to feel, that a brilliant operation has 'settled everything,' or that if it has not, it ought to have !

This is practically never true in any department of surgery ; it is utterly fallacious and wholly misleading in the surgery of nerves.

If the ends of a divided nerve be separated, or if for any other reason an impermeable block bar the impulses which should pass along it, it is necessary for recovery that, some time or other, an hour or so should be spent in the operating theatre and the freshened ends of the nerve brought carefully together. But in order to obtain the best possible recovery, it is equally essential that every day before that hour arrives and every day afterwards, thought should be given and time spent on keeping muscle, tendon, and joint fit and ready to respond to the impulses which one day the regenerated nerve will convey. (See p. 72.)

### THE PROGNOSIS AFTER RELIEVING COMPRESSION.

This depends upon the exact condition found at the exploration. A nerve may be compressed by a band of fibrous tissue sufficiently tightly to interrupt its conducting power, but with so little alteration in its structure, that the relief obtained on section of the constricting band may be instantaneous.

## 68 NERVE INJURIES AND THEIR TREATMENT

On the other hand, the changes in the nerve may be so profound that even when all outside constricting influences have been removed, there still remains within the nerve an insurmountable barrier to its regeneration. Such cases as these cannot successfully be treated by simple decompression alone.

If the operation of mere liberation from compression

be reserved for those cases in which the nerve at the operation shows no marked departure from normal, and in particular reveals no neuromatous thickening in its interior, the prognosis is, in the large majority of cases, good.

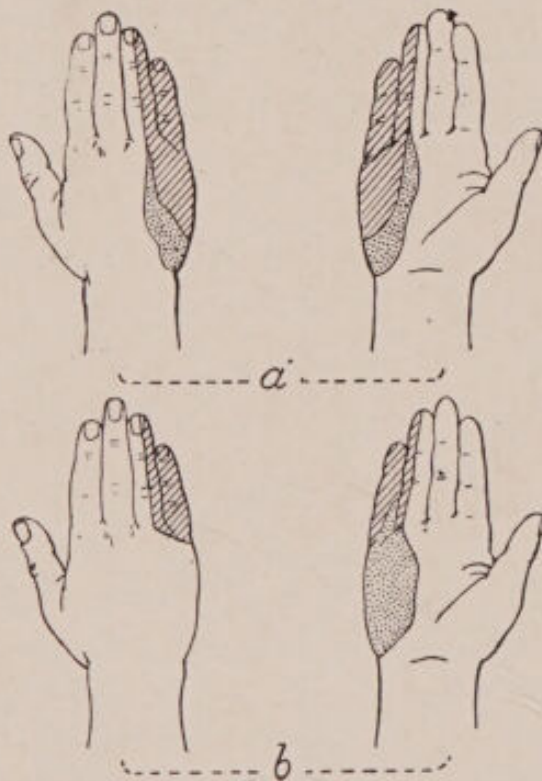


FIG. 35.—ULNAR PARALYSIS. Anæsthesia before, and five weeks after, operation for relief of compression.

Fig. 35 *a* shows the sensory loss in a case of ulnar paralysis in which, as the result of a gunshot-wound in the lower third of the forearm, the ulnar nerve and its dorsal cutaneous branch were compressed in scar tissue.

Fig. 35 *b* shows the improvement in sensibility five weeks after the nerves had been liberated from compression.

Fig. 36 relates to a severe compression injury of the median nerve, consequent on a fracture-dislocation of the right elbow-joint on July 12, 1917. There was also transient paralysis of the musculo-spiral nerve.

The first diagram shows the sensory loss (to pin-prick) on August 8, 1917. Pressure-sense was not tested. The opponens pollicis was the only median muscle which responded to faradism.

An operation was performed on September 22, 1917, the

nerve being dissected out of a dense fibrous mass. (See Fig. 58, p. 100.)

October 16, 1917.—The thenar muscles were now less wasted.

December 28, 1917.—The flexor carpi radialis and the palmaris longus could be seen to contract. The patient could flex all the finger-tips into the palm (including the index finger). The skin had lost its smooth, shiny appearance, and the pulps of the finger-tips were less wasted.

March 2, 1918.—The patient had noted the fact that the nails of the index and middle fingers were much harder to cut than those of the other fingers. The thumb could be fully clenched into the palm. The patient could, with the palms of the hand laid flat on the table, scratch the table with the nail of the index finger without moving the wrist (Pitre's test for complete median nerve recovery).

May 7, 1918.—Pressure over the two terminal phalanges of the index and middle fingers felt like 'pins and needles.'

The thenar eminence was as fully developed as that of the left hand. The patient stated that a month previously a 'chilblain' had formed on the tip of the index finger. This had disappeared.

July 10, 1918.—There was no sensory loss, protopathic or epicritic. Pressure-sense was normal.

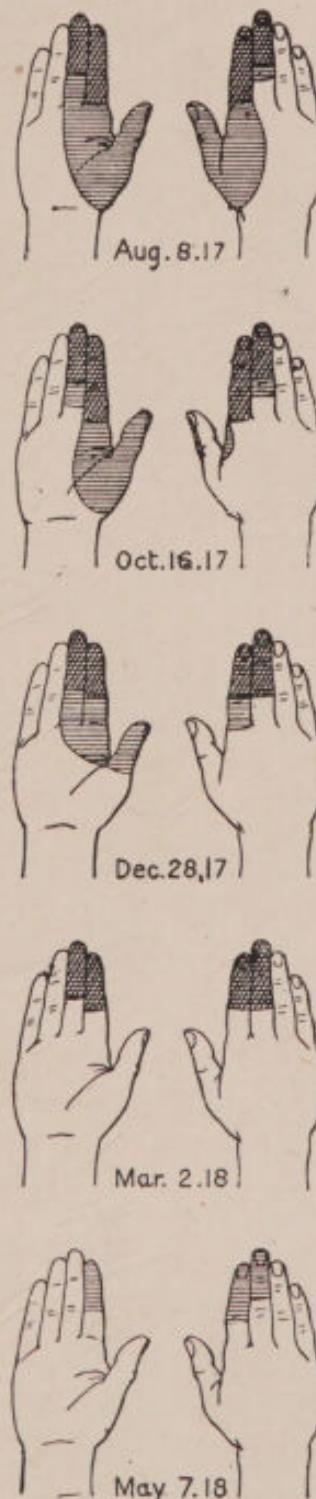

FIG. 36.—MEDIAN NERVE PARALYSIS, RESULTING FROM COMPRESSION, showing the progress of sensory recovery following operation.

Transverse striation indicates loss to pin-pricks. Oblique striation indicates loss of pressure-sense.

## CHAPTER VI

### PRINCIPLES OF TREATMENT

IN considering the treatment of nerve injuries, certain facts should be borne in mind.

1. Nerve injuries are common. Expect them, and test for loss of sensation and motion.

2. The importance of early diagnosis cannot be over-estimated, for treatment should be immediate.

3. A large portion of nerve injuries tend to recover spontaneously.

4. The treatment for a divided nerve is suture, and as the prognosis of primary or immediate suture is better than that of secondary suture, primary suture is the ideal operation.

5. The diagnosis of a severed nerve, immediately after an injury, is only absolute when the severed end of that nerve is actually seen.

6. It therefore follows that the question of immediate suture in projectile wounds will only arise when the wound is so large (either primarily from the original lesion or secondarily from the enlargement of that wound for the arrest of hæmorrhage, or suture of tendon, or treatment of a fracture) that the severed end of the nerve is exposed.

7. The great essential for the success of nerve suture is asepsis.

8. Most projectile wounds are septic.

9. In the large majority of cases many hours must elapse before the surroundings of the patient and of the surgeon are suitable for the performance of such an operation, and by this time the wound is discharging pus ; nerve

suture is now out of the question, and cannot be entertained until the wound is healed.

10. The correct treatment of a patient with a suppurating wound is the efficient treatment of the wound. Don't go fiddling with the nerve : stop the suppuration !

11. In the less extensive wounds with a small entrance and exit, such as those commonly produced by a rifle-bullet, the diagnosis of severed nerve can only be made when the characteristic signs have developed. These are only complete after ten days, and even then the signs may be dependent on conditions which do not necessitate operation ; by the time the diagnosis is established we have passed into the phase of secondary suture.

12. It follows that the operation for the suture of nerves injured by projectiles is almost always secondary.

To sum up : If the diagnosis is undoubted, i.e. if the nerve is seen to be severed, either in the initial wound or that wound enlarged, say for the purpose of checking hæmorrhage, and there is a reasonable chance of the wound being aseptic or of being made so, suture the nerve ; in all other cases wait till the diagnosis is established, and until the wound is healed.

It follows, then, from these considerations that very few nerve injuries will be treated at once by operations directed towards the nerve ; but it cannot be too often emphasized that, apart altogether from the direct treatment of the injured nerve, we must at once, and constantly afterwards, think of the other structures which are liable to serious impairment as a result of the nerve injury.

Whatever the injury to the mixed nerve, it must be remembered that changes begin to take place at once in the muscles supplied by it, in the tendons and tendon-sheaths of the muscles, in the joints which those muscles help to move, and also in the muscles antagonistic to those directly affected. Treatment must be at once directed to the prevention of these changes.

1. MUSCLES. The paralysed muscles become stretched

and elongated, either by the weight of the limb—as when the paralysed deltoid is stretched by the hanging arm—or by the contraction of the unopposed antagonistic muscles, or by both of these factors. Thus in external popliteal paralysis the paralysed anterior tibial and peroneal muscles are stretched both by the weight of the dropped foot and by the contracture of the unopposed calf muscles.

The longer the muscles are allowed to remain in the stretched condition, the greater is the tendency for them to remain in their elongated state. If these muscles be neglected for a sufficiently long time, the elongation becomes permanent, so that even if, by and by, the muscles regain their proper innervation and become able to contract in response to stimuli, whether voluntary or electrical, these contractions may be quite futile and result in no effective movement.

Again, apart from such merely physical effects, actual pathological changes take place in a paralysed muscle. The degenerated muscle-fibres become infiltrated with connective-tissue cells, fibrous tissue and fat, and become converted into a fibro-fatty mass, so that now, instead of contractile muscle-fibres, we have more or less of this inert, non-contractile substance.

It follows from this :

- (a) **The paralysed muscles must not be allowed to stretch.**
- (b) **The muscle-fibres must frequently be made to contract.**

**2. TENDONS AND TENDON-SHEATHS.** A tendon and its sheath can only remain normal when movement of the one within the other regularly takes place.

Let a tendon remain unmoved in its sheath, and it can be taken for granted that soon the one becomes tethered to the other by numerous adhesions. These adhesions, at first fine and easily stretched, steadily become thicker, denser, and less easily stretched, until ultimately the tendon becomes fixed in its sheath.

**Hence it is obvious that tendons must be frequently moved in their sheaths.**

3. **THE JOINTS.** The preceding remarks also apply to a joint kept in one fixed position. Whatever position a joint may be in, somewhere in that joint the synovial membrane is thrown into folds, and what has been said concerning the synovial membrane in tendon-sheaths applies equally here; adjacent folds become adherent, and the adhering folds become more strongly adherent, until by the time the patient has regained power over the muscles which should move the joint, the feebly-moving muscles are unable to overcome the adhesions of the firmly-fixed joint.

At the same time contraction in the lax part of the capsule of the joint is taking place, with additional fixation of the joint.

**It follows that paralysed joints must not be allowed to remain for a lengthy period in any one fixed position.**

If once these changes which take place in paralysed muscles, immobile tendons, and fixed joints be visualized, such changes will never willingly be permitted; paralysed muscles will be prevented from stretching and will be made to contract, whilst tendons and joints will be moved.

### NON-OPERATIVE, EXPECTANT, AND POST-OPERATIVE TREATMENT

A limb whose nerve or nerves have been injured should be carefully wrapped up, and its anæsthetic and paralysed structures protected from cold and from trauma.

The limb should be so fixed that the paralysed muscles are continuously relaxed and prevented from being stretched by their unopposed antagonists.

Thus in wrist-drop the hand should be dorsi-flexed at the wrist joint, so as to secure relaxation of the extensors of the wrist and fingers. Support should be given to the first phalanges—though care should be taken to avoid hyper-extending the metacarpo-phalangeal joints. The two distal phalanges are left unsupported, for extension

## 74 NERVE INJURIES AND THEIR TREATMENT

at these joints is effected by the interossei, which in this case are unparalysed. (See Fig. 37.)

Each common extensor tendon sends a slip to the base of the first phalanx, and the extension action of this muscle is limited to the phalanx. From this point onwards to the terminal phalanges, the tendons cease to belong (from an effective point of view) to the common extensor, and become solely the tendons of insertion of the interossei.

An efficient apparatus is Sir Robert Jones's hyper-extension hand splint (Fig. 38).

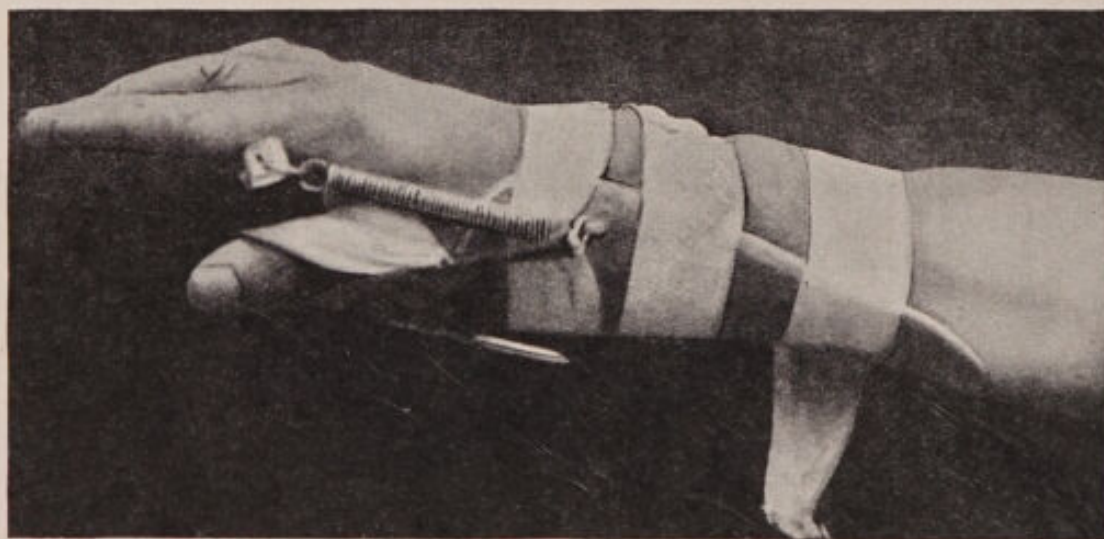


FIG. 37.—SPLINT FOR MUSCULO-SPIRAL PARALYSIS. Note the full voluntary extension of the distal phalanges, although only the metacarpophalangeal joints are extended by the splint.

This splint is still more useful if provided with a thumb-piece to support the thumb in a slightly abducted position, with its terminal phalanx extended.

An excellent splint is one made in papier mâché, which is moulded to the wrist in the dorsi-flexed position. That portion of the splint which supports the proximal phalanges in extension is set on a spring. This spring returns these phalanges to the extended position after they have been flexed by the flexors of the fingers. The thumb is kept abducted and extended by an elastic band, which connects

the radial border of the splint with a leather band encircling the phalanges. This permits flexion of the fingers, and ensures its return to the extended position when voluntary flexion ceases.

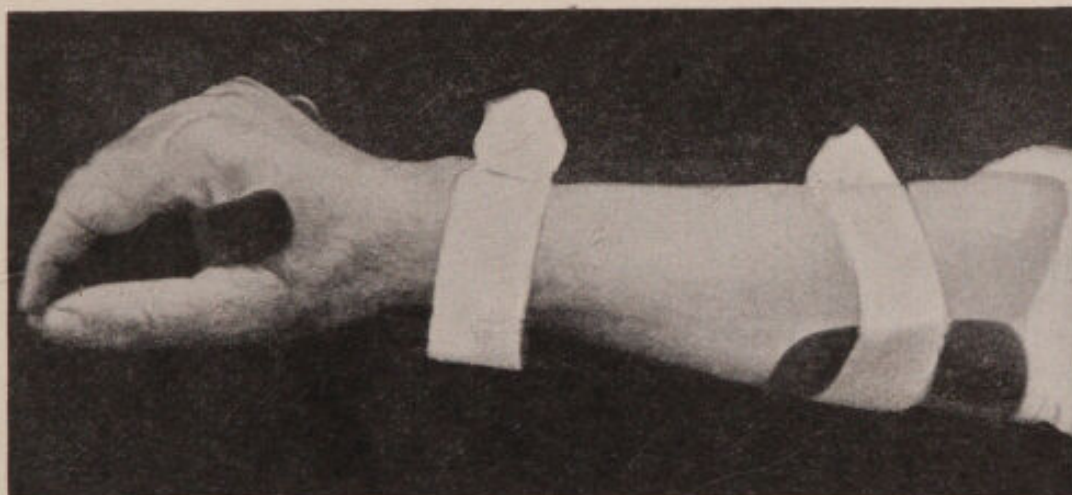


FIG. 38.—SIR ROBERT JONES'S HYPER-EXTENSION HAND SPLINT.

A patient with complete musculo-spiral paralysis, when fitted with such an apparatus, possesses a useful hand (Figs. 37 and 39).

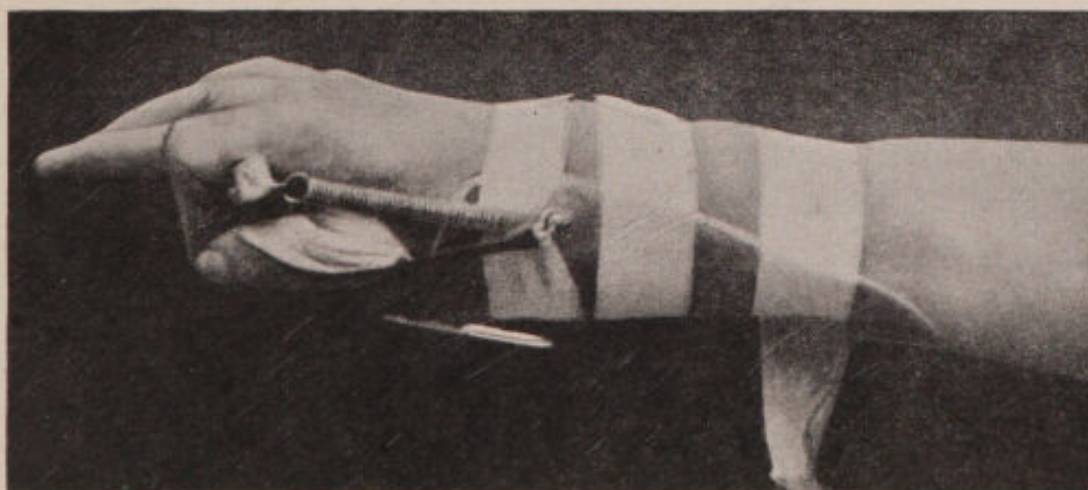


FIG. 39.—PROSTHETIC SPLINT FOR MUSCULO-SPIRAL PARALYSIS.

In cases of injury to the great sciatic or external popliteal nerve resulting in foot-drop, the foot should never be allowed to remain in the extended inverted position (talipes

## 76 NERVE INJURIES AND THEIR TREATMENT

equinovarus). Whilst the patient is confined to bed the foot should be fixed at a right-angle, to prevent stretching of the anterior tibial and peroneal muscles. If the patient is able to be up and about, a substitute for the paralysed muscles is provided by attaching to the boot some toe-raising device (See Fig. 40); at the same time the tendency to varus is overcome by thickening the outer side of the sole and heel of the boot.




FIG. 40.—WALKING APPARATUS FOR USE IN FOOT-DROP.

In paralysis of the deltoid muscle, whether from lesions of the circumflex nerve (exceedingly rare) or from lesions of the fifth and sixth cervical nerves (very common), the paralysed muscle must be taken off the stretch, and this can only be done by abducting the arm so as to approximate the origin and insertion of the muscle.

A very efficient, light, and comfortable splint, and one that does not constrict the chest has been devised by a distinguished barrister. It consists of a small aluminium plate which rests upon the iliac crest. This supports an aeroplane-steel rod which runs up the lateral wall of the thorax. At the apex of the axilla it is bent so as to lie under the abducted arm. Passing under the arm just above the condyles, it is bent again at a right angle and carries a light aluminium splint on which the flexed forearm rests (Fig. 41).

Lesions of the musculo-cutaneous nerve, resulting in paralysis of the biceps, coraco-brachialis, and brachialis anticus, should be treated by continuous flexion of the elbow so as to prevent these muscles being stretched. This can be effected satisfactorily by attaching a leather wrist-strap to a collar worn round the neck.

In ulnar paralysis, if any tendency to deformity be present, the fourth and fifth fingers may be fitted with a small splint of papier mâché moulded so as to maintain slight flexion at the metacarpo-phalangeal articulations, and extension at the inter-phalangeal joints.

Another and better method of correcting this ulnar deformity is by wearing a strong leather glove. To the

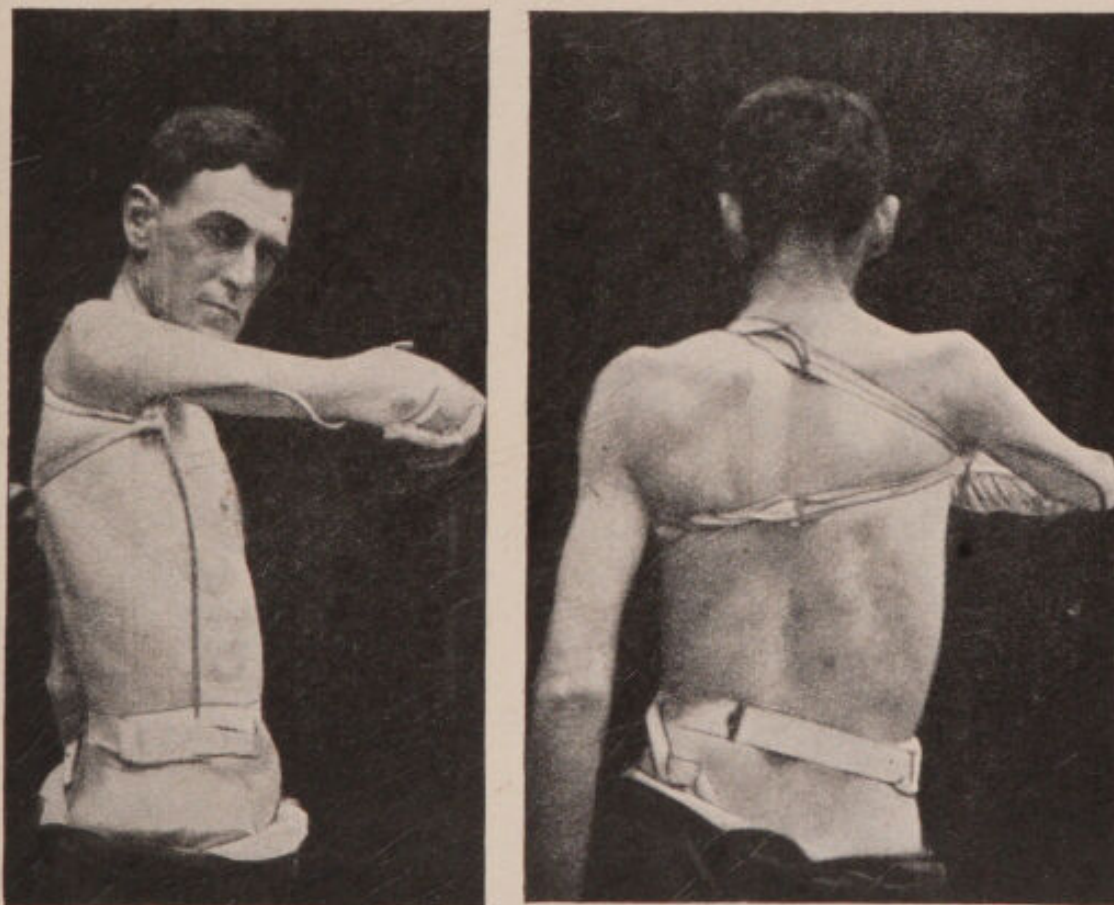


FIG. 41.—SHOULDER ABDUCTION SPLINT.

wrist end of the glove is sewn a stout leather wrist-band. To the dorsal aspect of this are sewn two strips of elastic webbing, and these, having previously been put on the stretch, are sewn along the dorsum of the two ulnar finger-stalls to their extremities. (See Fig. 42.)

The nutrition of the paralysed muscles and their contractility must be maintained, and their conversion into fibro-fatty tissue prevented, by daily massage and electrical stimulation. In the great majority of cases this treat-

## 78 NERVE INJURIES AND THEIR TREATMENT

ment can be carried out as the limb rests on its splint ; if however it should prove necessary to remove the splint, care should be taken to maintain the limb in the same position as it occupied when resting on the splint.

### Electrical Treatment.

In cases where the paralysed muscles will only respond

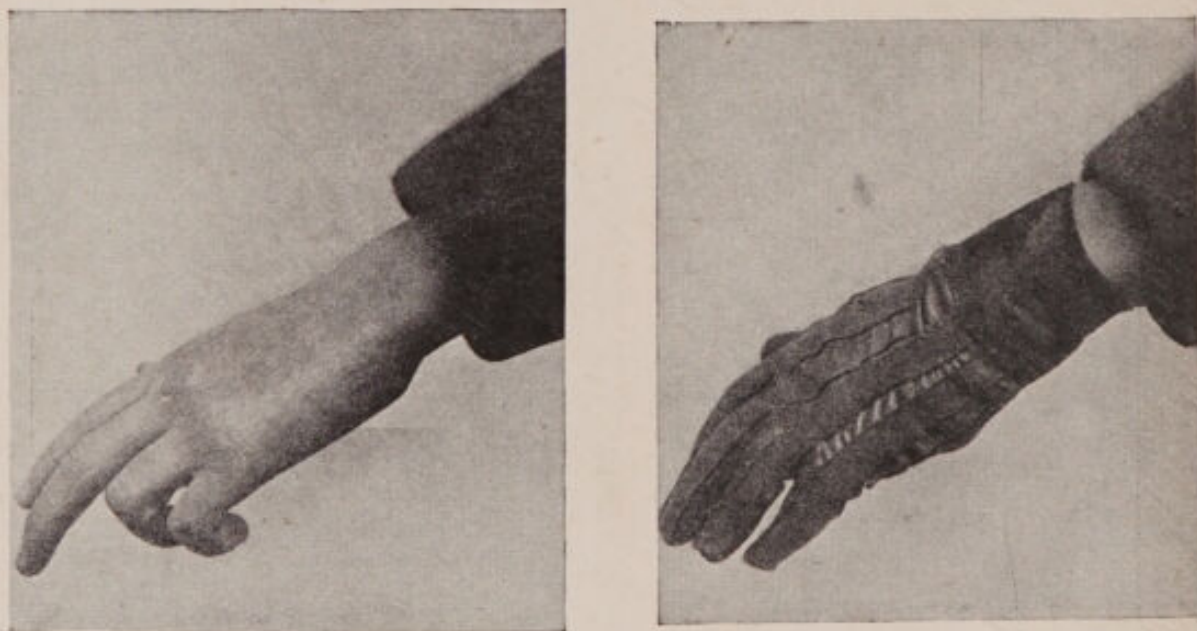


FIG. 42.—LEATHER GLOVE FITTED WITH ELASTIC WEBBING TO OVERCOME THE DEFORMITY OF ULNAR PARALYSIS.

to the galvanic current, this form of electricity should be employed. The lowest intensity of current which will excite contractions should be used, and, as the galvanic current only causes contraction of the muscles at the 'make' and at the 'break' of the current (not during its continuous passage), the current should be rhythmically interrupted. This can most conveniently be effected by introducing a metronome into the circuit, and setting it to beat at a slow rate, say, once a second.

At intervals the muscles should be tested to see whether they respond to faradism, and when they do, this form of electricity should be used in addition to the galvanic current.

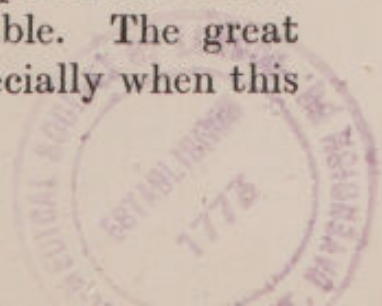
Electrical treatment to the nerves over the site of injury is also a valuable aid to recovery; this is best employed in the form of ionic medication.

### **Massage and Passive Movements.**

Daily the paralysed muscles should be massaged, and the joints passively moved. When the paralysis affects one hand, the patient should himself frequently carry out these exercises with his other hand. Especially is this necessary in those incomplete lesions of the median and ulnar nerves which are associated with fibrous infiltrations in muscle, fascia, skin, and joints, which, unless assiduously stretched, will give rise to persistent deformity.

### **Active Movements.**

Active movements of the affected part and of the whole limb are to be encouraged, for their importance cannot be over-estimated. They help to keep the limb as 'fit' as possible, improve the circulation of the limb, expedite the returning power in the reviving muscles, and materially help to prevent the patient from becoming depressed and discouraged, and ultimately getting to that condition when he no longer looks forward to recovery, and 'acquiesces in his limitations.' If, on the other hand, the returning power of the paralysed muscles is not voluntarily employed, and if too, as often happens, the whole limb is allowed to remain passive during the whole course of treatment, it may easily happen that when the nerve condition which produced the paralysis has recovered, we are still faced with a helpless limb. The man has lost the habit of using it, has come at last to believe in its powerless state, and now we have to deal with a superadded **moral paralysis** which may prove most intractable. The great value of carefully graduated exercise, especially when this



takes the form of actual work done, is being daily proved in those institutions where, in addition to daily massage and electrical treatment, the man is given some definite work to do: basket-making, planing, sawing, wood-carving, painting, metal-work, leather-work, fret-work, &c. These and such as these, carefully chosen to suit the muscular disability of the patient, keep the uninjured muscles normal, educate them to substitute the movements of those temporarily powerless, and, as the paralysed muscle-fibres become innervated, accustom them to respond to voluntary impulses. At the same time they prevent changes in muscle, tendon-sheath, and joint which otherwise may entirely frustrate the best intentions of the recovering nerve.

Under the foregoing treatment, in cases in which the nerve has escaped anatomical division and its fibres have been merely **concussed**, signs of recovery soon manifest themselves, in some cases in a few days, in others in a few weeks; these are the cases in which the paralytic symptoms were incomplete, the anæsthesia transient or even absent, and the muscles paresed rather than paralysed, and in which the muscles had retained their normal electrical reactions.

Somewhat more severe are the cases of **contusion** without loss of anatomical continuity, where blood has been extravasated around and within the nerve-sheath. In these cases a certain degree of muscle wasting may occur, but some electrical reaction to faradism can usually be obtained in one or more of the paralysed muscles, although stronger shocks are required than in the corresponding muscles of the uninjured limb. In such cases improvement often sets in under treatment within three or four weeks, as the blood becomes absorbed, sensation clearing up before motor power begins to return.

In other cases, namely those in which the nerve has been **partially cut across**, the remainder of the fibres either

escaping altogether or being temporarily concussed, or contused with accompanying blood infiltration, part of the paralytic phenomena will clear up under treatment, leaving a residuum of paralysis which may be dealt with surgically.

Other cases will show from the beginning complete paralysis of motion and sensation, with reaction of degeneration in ten days, and no sign of improvement at the end of three months in spite of assiduous treatment. These are usually cases of **complete section** of the nerve, and frequently, examination over the site of injury will reveal an enlargement on the stump of the proximal end.

There is another and larger group of cases resistant to treatment, comprising those nerves which are **compressed** by fibrous tissue, by newly formed callus, or by bony projections. In the case of sclerosing fibrous tissue and callus formation, the symptoms which may not have been very pronounced at first, later become complete.

A final group, not a large one, also frequently resistant to treatment, consists of those cases which from the time of injury or soon afterwards are characterized by the intense pains and trophic changes to which we have alluded under the name of **causalgia** or **thermalgia** (p. 31).

The phenomena of causalgia are essentially of sympathetic origin. They are probably due to irritation of non-medullated nerve-fibres, producing a hyper-excitabile condition of the sympathetic centre in the corresponding segment of the spinal cord, the centre which controls vasomotor, secretory, and trophic influences to the skin.

The four last-mentioned groups demand surgical intervention ; viz. :—

1. Those cases which from the beginning have shown complete paralysis of motion and sensation, and which, in spite of treatment for three months, have shown no sign of recovery.

2. The compression group, as soon as the progressive

Unable to display this page

## CHAPTER VII

### OPERATIONS ON NERVES

#### GENERAL CONSIDERATIONS

IN all operations on nerves, asepsis is imperative.

The nerve should be treated with the greatest possible tenderness.

A nerve should never be held in a dissecting forceps : the sheath gives all the necessary hold one can require.

When a nerve has to be lifted up, pass a strip of gauze under it, and lift it up by means of this—the nerve is less likely to be sharply kinked and injured by the strip of gauze if a small pad of gauze be placed between the two. (Fig. 57.)

Use the sharpest possible knives. Of these, at least three will be necessary : one for making the skin incision (this must be used no further, as it may have become infected in cutting through the skin), a second for the deeper dissection, and a third for the actual nerve sections.

Scissors should never be used for making a nerve section.

For the suture of nerves fine cat-gut is used, and the finest needles which will carry the cat-gut.

In performing end-to-end suture, the ends of the nerve should be brought together without tension, great care being taken to prevent torsion of the ends, and sheath should be sutured to sheath by several interrupted sutures, followed, in all but the smallest nerves, by a continuous suture bringing sheath to sheath around the whole circumference.

It generally happens that in the region of the nerve

injury there is gross alteration in the anatomical relations—the nerve may be involved in a mass of scar tissue, and the muscles and the neighbouring structures so altered that to identify the nerve in the very centre of this confused fibrotic area may be impossible, or if not impossible may necessitate a prolonged and needlessly mutilating operation.

It is wise therefore to make an incision extending well above and below the site of injury, so that the nerve may be readily identified, with the minimum of disturbance, having its normal relationships, and followed, from both sides, to the site of the lesion.

The various conditions which may be encountered, and their individual treatment, will be presently described, but, to save repetition, certain general considerations which apply to all completely divided nerves may here be noted. The proximal end of the divided nerve usually presents a bulbous extremity; the distal end may, or may not be bulbous, but its extremity always feels harder than the rest of the nerve. Both ends are adherent to a fibrous mass which invests them. Some portion of these ends will need excision, but before this is done, they should be utilized for any manipulation which may be necessary. Thus, if it is obvious that their removal will leave a gap between the ends of the nerves, and that these ends can be approximated by stretching the nerves, now is the time to do this. The bulbous ends are grasped, and gentle, steady traction made both proximally and distally. If the stretching is postponed until after the bulbous ends have been removed, the freshened ends of the nerves themselves will have to be grasped, with resulting injury to the nerve-fibres.

To determine how much of the bulbous end should be removed, transverse incisions are made across it, commencing near its free extremity.

At this situation it feels hard; it cuts like fibrous tissue, and on section presents a uniform, smooth, pearly surface,

looking almost like cartilage. (See Fig. 43 A). This markedly differs from the transverse section of a normal nerve. (Fig. 43 B). In this, the whole surface is studded with a number of nerve-bundles, separated by a very small quantity of loose connective tissue. The ends of the bundles protrude slightly beyond the rest of the cut surface, so that the whole area is studded with small, round, whitish, glistening protrusions. Between these two is a series containing less of the one and more of the other. Successive sections are made proximally, until the normal appearance presents itself. Turning to the other end of the nerve, sections are made distally,



FIG. 43.

A = The cut surface of a bulbous end.

B = The cut surface of a normal nerve-trunk.

until the limit of the fibrous area is passed. The same appearance as that shown in Fig. 43 B may be manifested in the distal end, but as a rule the ends of the cut nerve-bundles do not show up so plainly.

As we have seen, one of the commonest factors producing nerve paralysis is fibrous tissue about a nerve—forming adhesions, constrictions, and other pressure effects.

When a nerve has been freed from its adhesions, and the abnormal conditions encountered have been surgically dealt with, it occurs to every operator that steps must now be taken to prevent a recurrence of the condition.

To some of the earliest workers in this branch of surgery it seemed that adhesions could only be prevented if the line of suture were 'protected' by ensheathing this region of the nerve in a portion of excised vein, in a sheath of fascia or of fat, or in a sheet of corgile membrane. The

results in a very large number of cases have been excellent, but it is now evident, comparing numbers of cases in which different methods have been employed, that the use of an enwrapping sheath is not necessary. There is no doubt that sometimes this adventitious covering has become converted into dense fibrous tissue, and has helped to bring about the very condition which its use was intended to prevent. In other instances it has acted as a foreign body, and has kept up irritation in the wound until it has been removed. In every case it has, to a certain extent, interfered with the vascular supply of the portion of nerve so invested.

With regard to this important point of fibrous-tissue formation, with subsequent adhesions, the following facts should be noted :

1. *Fibrosis is mainly dependent on sepsis.* The longer the duration of the sepsis, the more pronounced is the fibrotic condition of the surrounding structures.

To ensure a successful operation, sufficient time must be allowed to intervene between the healing of the wound and the operation on the nerve, to warrant the assumption that the operation will involve only aseptic structures. The interval allowed should not be less than two months from the disappearance of all signs of inflammation in the neighbourhood of the healed wound. And, too, the conduct of the operation on the nerve must be rigidly aseptic.

2. *Clumsy manipulation of a wound* militates against the perfect healing of that wound, and should be scrupulously avoided. All the structures should be delicately handled. It may not be altogether amiss to suggest that the anatomy of the part should be intimately known before the operation, not learned during its performance !

3. *Infiltration of blood* into and between the tissues is always followed by more or less fibrosis. Great care should therefore be paid to hæmostasis, so that the operation wound may be left perfectly dry.

This may occupy a good deal of time, since all the tissues in the damaged area are usually liberally supplied with newly formed vessels, and their section is followed by oozing, which is widespread and persistent.

4. *Two injured surfaces lying in contact tend to adhere.*

To free a nerve from adherent surroundings, whether subsequent suture be performed or not, and to allow it to remain in contact with the bed of injury, is to invite a recurrence of the trouble. We must ensure that the injured portion of the nerve shall be placed in contact with uninjured tissues. This can be effected, either by displacing the nerve, so that it lies over uninjured structures, or by sewing a piece of adjacent fat, fascia, muscle, or muscle-sheath over the bed of injury.

5. *Injured nerve-fibres uncovered by their normal sheath, and so in contact with unusual tissues, run riot—fine axis-cylinders shoot out in all directions, and eventually are found composing the greater part of the bulbous endings (see Fig. 10, p. 10) and assisting in the formation of the surrounding adhesions (82 per cent. of these adhesions contain axis-cylinders<sup>1</sup>).*

It is therefore necessary to close any breach that may exist in the sheath of the nerve, in order not only to protect the nerve-fibres from injury, but also to protect the surrounding tissues from invasion by this 'nerve-callus.'

1. **The nerve may be completely divided.**

(a) **The ends are distinctly separated.**

It will generally be found that the proximal portion of the nerve ends in a bulbous extremity. The distal portion is usually smaller in size than the proximal: its end may be bulbous, although as a rule it is not, but it always feels harder than the normal nerve.

Transverse sections are made across the proximal and distal ends until the cross-sections show the appearances

<sup>1</sup> Capt. Sydney Cone, *British Journal of Surgery*, April 1918.

described on p. 85. These freshened ends are now brought into apposition and sheath is sutured to sheath.



FIG. 44.—COMPLETE DIVISION OF A NERVE. There is obvious solution of continuity in the nerve. Both proximal and distal ends are bulbous.

(b) **There is pseudo-continuity.**

The ends of the cut nerve are united by dense fibrous tissue. On either side of this connecting band the nerve ends in a bulbous enlargement.

It matters not how long or short the connecting band may be, the treatment consists in excising this, together

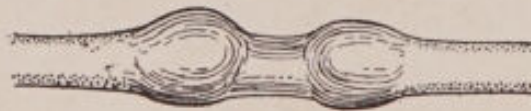

FIG. 45.—COMPLETE DIVISION OF A NERVE. There is pseudo-continuity.

with portions of the proximal and distal ends, until satisfactory cross-sections are obtained. Then suture as usual.

(c) In some cases of complete nerve paralysis there is no

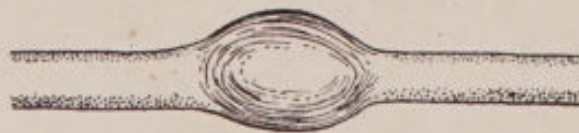

FIG. 46.—COMPLETE INTERRUPTION OF A NERVE BY A CENTRAL NEUROMA.

obvious solution of continuity, but in the apparently uninterrupted nerve we find a condition which closely simulates a terminal bulbous end; to this the name of **central neuroma** has been given.

The swelling involves the whole circumference of the nerve trunk. Such a nerve should be freed from its surroundings, insulated on a glass rod, and, just above the lesion, electrically stimulated at various points around its circumference. If no response is elicited in any muscle supplied by the nerve below the lesion, the neuromatous mass should be excised. The bulb is grasped and traction made proximally and distally, so as to stretch both ends of the nerve. To determine how much of the nerve needs excision, transverse incisions are made, commencing near the middle of the bulbous portion, and proceeding proximally and distally until the nerve presents the appearances already described.

(d) Other cases of complete paralysis reveal a segment of nerve which, though not bulbous, is profoundly altered. It is usually densely incorporated with the surrounding structures, and, when dissected free from these, feels and looks like fibrous tissue.

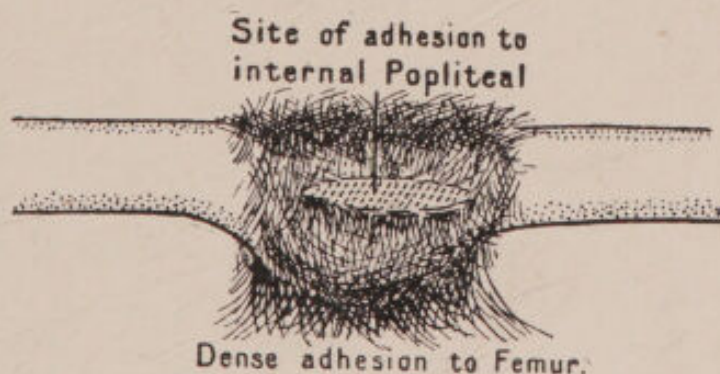


FIG. 47.—A GUNSHOT-WOUND OF THE EXTERNAL POPLITEAL NERVE. The injured segment looks, feels, and cuts like a mass of fibrous tissue.

Around the treatment of this type of lesion much controversy has raged.

The question for solution is this: Should the thickened area be cut out and the apparently normal ends sutured together, or is it better merely to free the segment from its surrounding adhesions and endeavour to prevent fresh adhesions?

In other words, is the thickened area a mass of fibrous

## 90 NERVE INJURIES AND THEIR TREATMENT

tissue which will interfere with the regeneration of the nerve, or are there still nerve-fibres in it which are in process of linking up the two ends, and is the fibrous tissue serving a useful purpose by uniting the ends ?

To determine this, various methods have been employed :

1. Electrical stimulation of the nerve above the fibrous zone, and noting the presence or absence of muscular response.

2. Excision of a small piece of the fibrous zone and immediate microscopic examination for nerve structure, teasing the fragment in a 5 per cent. solution of osmic acid.

3. Injection into the proximal end of the scar area of 1 c.c. of 1% methylene blue, and observing the infiltration of the coloured solution through the suspected mass into the nerve distal to the lesion (scar tissue does not permit the passage of methylene blue ; nerve structures do).

These last two methods have no practical utility, for repeated microscopic examinations have proved that what is commonly referred to as 'fibrosis' in and about an injured nerve consists largely of newly developed axis-cylinders ramifying in all directions, combined with a smaller proportion of fibrous tissue properly so called, constituting a very dense structure, to which the name of 'nerve callus' has been given.

The first method, that of electrical stimulation, is of great utility, for by it we gain information as to whether any part of the injured segment is capable of conducting impulses.

The injured segment and adjoining nerve are freed from their surroundings. A glass rod is passed under the nerve, which is then stimulated by a very weak faradic current. One electrode is attached to some remote part of the body, the other, the testing electrode, is a long metal probe which is applied to the various parts of the circumference of the nerve, proximal to the injured segment.

It renders the examination more satisfactory if a metro-

nome be placed in the circuit, for in this way the primary current is rhythmically made and broken, and the testing electrode can then be placed in contact with the particular site it is desired to investigate and allowed to remain in contact with it. Otherwise it is necessary to repeatedly remove the testing electrode from contact with the nerve.

If no response is obtained by such stimulation above the lesion, the injured segment should be excised.

We are of course assuming that the particular case under consideration has been carefully and repeatedly examined and treated; that it has from early days exhibited all the signs of total paralysis, and that in spite of persistent treatment for three months no sign of recovery has manifested itself.

If it is considered necessary to stretch the nerve, this should now be done; the fibrosed segment being grasped as the traction is made.

To determine how much of the segment needs excision, transverse incisions are made through it, commencing near the middle of the segment and proceeding both proximally and distally, until the cross-sections present the appearances already described.

It is wise not to make these transverse sections completely through the segment, but, until the first sutures have been inserted, to leave an uncut edge. This lessens the possibility of torsion of the proximal and distal ends of the nerve, and thus there is a greater likelihood of the corresponding cut ends of the various nerve-bundles being placed in apposition.

If judicious stretching combined with alteration of the direction of the nerve, or with flexion of the joint over which the nerve passes, does not permit the two ends to be brought into loose contact, a segment, or if necessary a bundle of two or more segments of a sensory nerve, from the patient's own body, should be transplanted between the ends of the nerve.

2. The cut ends of the nerve may be so widely separated that it is not possible to bring them into loose contact.

The following methods may be employed :

(a) *Flexion of the joint over which the nerve passes.* This is particularly useful in operations on the great sciatic, popliteal, ulnar, and median nerves.

It need hardly be said that the amount of flexion must not be such as ultimately to impair seriously the utility of the limb.

Fig. 48 is that of a gunshot-wound through the lower

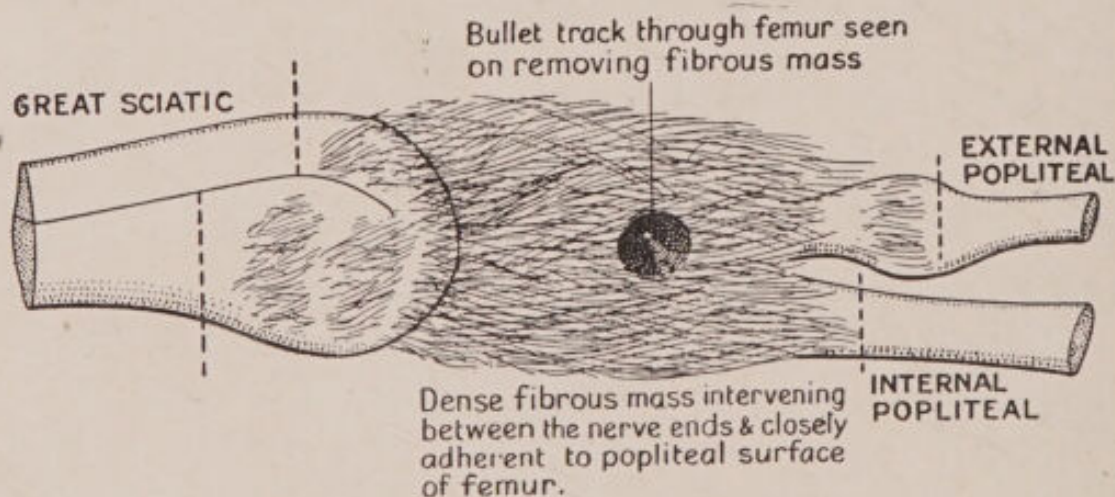


FIG. 48.—RIFLE-BULLET WOUND OF THE GREAT SCIATIC NERVE. The dotted lines show the limits of the portions excised before suturing the ends together.

end of the right femur. The bullet, having perforated the femur, had divided the sciatic nerve; the ends were separated by a gap of  $3\frac{1}{2}$  centimetres. It was seen that the proximal end of the nerve terminated in a large bulb, whilst a smaller bulb was situated in the external popliteal nerve very near to its severed end. There was no bulbous enlargement of the internal popliteal nerve.

The fibrosed ends of the nerves were removed, together with the mass of dense fibrous tissue uniting each to the other and both to the posterior surface of the femur. In spite of the wide separation (7 centimetres after the

ends had been freshened), the ends were easily brought together after stretching the proximal end and slightly flexing the knee.

In such operations as this, great care must be taken to prevent, for at least six weeks, any movement of the joint which may throw strain upon the zone of suture.

Bearing this in mind, the usual general treatment with regard to massage of the limb and movements, both active and passive, of the neighbouring joints is to be commenced three weeks after the operation.

(b) *Altering the position of the nerve so as to shorten its course.*

This is especially applicable to the ulnar nerve.

Fig. 49 represents the two ends of the ulnar nerve following a gunshot-wound at the bend of the elbow.

The proximal portion of the nerve ended in a slight enlargement just above and behind the internal condyle, and for 5 centimetres above this, the nerve was distinctly thickened and was harder than normal, due apparently to hæmorrhage into the nerve and subsequent fibrosis.

Below this, and filling up the ulnar fossa behind the internal condyle, was nothing but fibrous tissue, and the distal end of the nerve was found adherent to the periosteum of the humerus.

The freshened ends of the nerve were sutured together, after bringing them in front of the internal condyle (Fig. 50).

(c) *Transplantation.*

A sufficiently long segment of one of the patient's sensory



FIG. 49.—THE TWO ENDS OF A DIVIDED ULNAR NERVE, following a gunshot-wound at the bend of the elbow.

Unable to display this page

Fig. 52 represents a gunshot-wound of the fifth cervical root. At the site of its emergence from under cover of the *scalenus anticus* muscle, the nerve was replaced by a mass of scar tissue. Careful dissection through the muscle revealed no proximal portion of the nerve to which the distal end could be sutured. The spinal accessory nerve was therefore anastomosed to the fifth cervical nerve, distal to the fibrosed segment.

Six months later the patient could voluntarily contract his biceps muscle.

Another example of nerve anastomosis is the operation for facial paralysis, in which the distal end of the paralysed facial nerve is sutured to the central end of the healthy hypoglossal nerve.

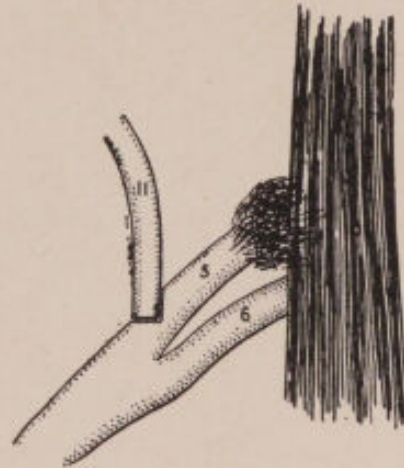

FIG. 52.—ANASTOMOSIS OF THE SPINAL ACCESSORY TO THE FIFTH CERVICAL NERVE.

### 3. Incomplete Division of the Nerve.

A part only of the nerve may be divided. This part may be any proportion of the whole nerve, from a mere surface lesion to one which destroys the greater part of the nerve, leaving but a strand uninjured.

Fig. 53 is that of the fifth cervical nerve which has been



FIG. 53.—Fifth cervical nerve, showing LATERAL NEUROMA.

dissected free from the fibrous *scalenus anticus* to which it was intimately adherent.

The nerve shows a nodular projection at the proximal end of the lesion. This is hard on palpation, and on microscopic examination reveals a medley of nerve-fibres

resembling that found in the bulbous ending of a completely severed nerve. This nodular projection is sometimes called a **lateral neuroma**. Sometimes a similar nodule is found on the distal side of the lesion.

The treatment consists in excising the indurated edge of this traumatic sulcus, paring away sufficient of the fibrosed structure to reveal nerve-bundles on the face of the neuro-matous swelling. The proximal half of this new surface is now sutured to the distal.

Fig. 54 is that of a median nerve in which a narrow strand of apparently unaltered nerve maintains the con-

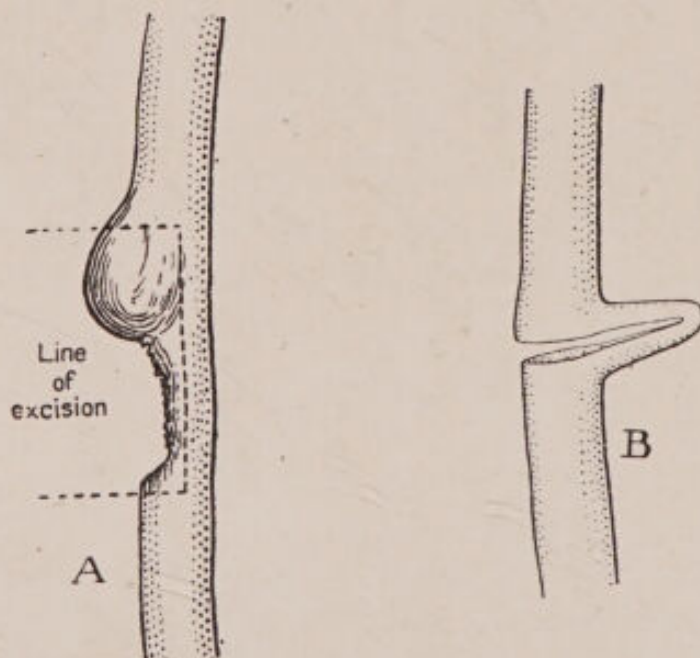


FIG. 54.—A. THE MEDIAN NERVE, SHOWING A LATERAL NOTCH, AT THE UPPER EDGE OF WHICH IS A LATERAL NEUROMA. The dotted line indicates the area which needs excision. B shows the prepared nerve-ends ready for suture.

tinuity. Note in this case, as in the preceding, the lateral neuroma at the upper margin of the lateral notch.

The treatment consists in excising the indurated edge and removing successive transverse slices from the neuro-matous swelling until it presents a surface studded with nerve-bundles. The proximal and distal surfaces are then brought into apposition and sheath sutured to sheath.

Fig. 55 is that of a median nerve incompletely divided. The injury was caused by the patient falling through a window, and receiving a punctured wound in the upper arm on the inner side of the biceps muscle. The nerve was intimately adherent on its outer and posterior surfaces to a fibrous mass, and when dissected out of this, was seen to have **two lateral neuromata** separated by a notch.

Transverse sections revealed fibrosis through the whole of the nerve until sections numbered 3 and 5 were made. These surfaces were then sutured together.

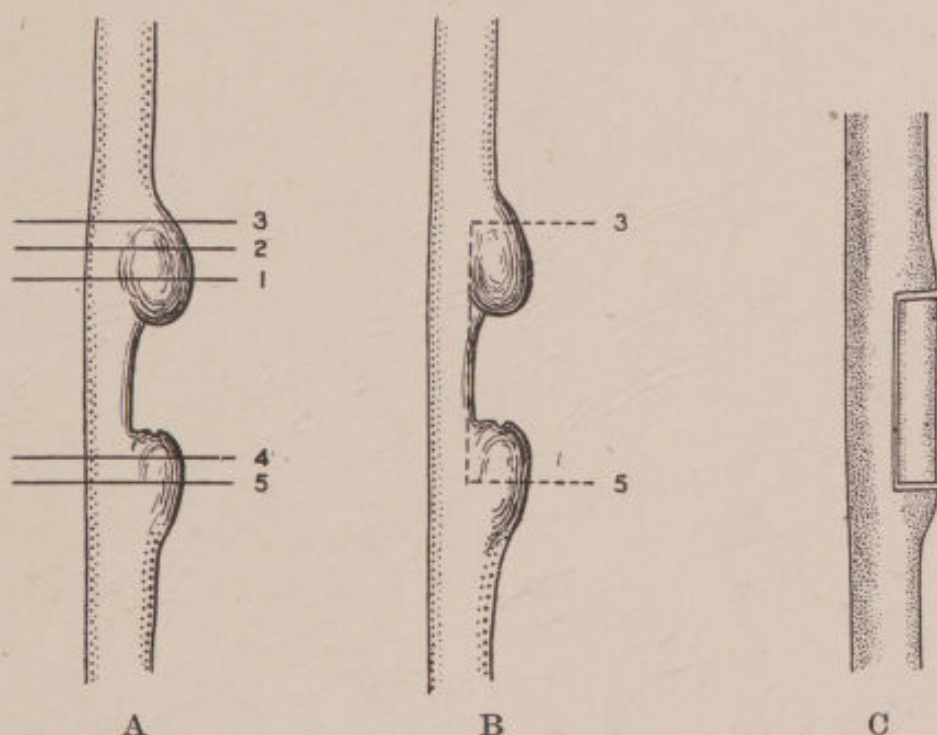


FIG. 55.—AN INCOMPLETE LESION OF THE MEDIAN NERVE. There are TWO LATERAL NEUROMATA, separated by a LATERAL NOTCH. (See letterpress.)

If the nerve remote from the neuromata were normal, then only the portion '3-5' (Fig. 55 B) would need excision, the gap being closed either by direct suture, or by implanting a segment of sensory nerve (Fig. 55 c).

Fig. 56 shows an incomplete lesion of the inner cord of the brachial plexus. At the site of injury the nerve was adherent to a mass of fibrous tissue, in which was the fibrosed and obliterated axillary artery. The nerve

showed a lateral neuroma, but no lateral notch. The neuro-fibromatous mass was excised, and the proximal face of the wound sutured to the distal.

It may happen that when the fibro-neuromatous mass has been excised, the deficiency in the nerve cannot be closed by suture. In this case a nerve graft or grafts should be taken from a convenient sensory nerve, and used to bridge the interval between the proximal and distal surfaces of the divided portion of the nerve. (See Fig. 55 c.)



FIG. 56.—AN INCOMPLETE LESION OF THE INNER CORD OF THE BRACHIAL PLEXUS, showing a lateral neuroma, with no lateral notch.

#### 4. The nerve is compressed.

(a) The compressing agent is usually more or less **dense fibrous tissue**.

The treatment consists in making a clean longitudinal incision through the fibrous tissue down to the nerve, and shelling it out of its bed. This operation of freeing the nerve is termed **Neurolysis**.

This is best done by passing a strip of ribbon gauze under the nerve, proximal or distal to the adherent segment; by this the nerve is lifted up towards the operator, and a sharp knife, carefully used, easily cuts through the fibrous investment without injuring the nerve, and at the same time the nerve is lifted out of its fibrous bed. The nerve is less likely to be sharply kinked and injured by the ribbon gauze if a small pad of gauze be placed between the two (Fig. 57).

If the nerve on liberation appears normal, if in particular there is neither thickening in its structure, nor lateral neuromata, we should be content with its liberation, taking care now to alter its position so that it lies amongst uninjured structures.

If on the other hand we find gross changes in the nerve, they should be treated in the manner already indicated.

Great assistance is afforded in these cases by the results obtained on electrical stimulation. A nerve which conducts impulses through its injured segment needs no further intervention.

In those cases where electrical stimulation above the lesion produces no muscular contraction in the muscles supplied below that level, we must be guided by the appearance of the nerve. One that looks and feels normal

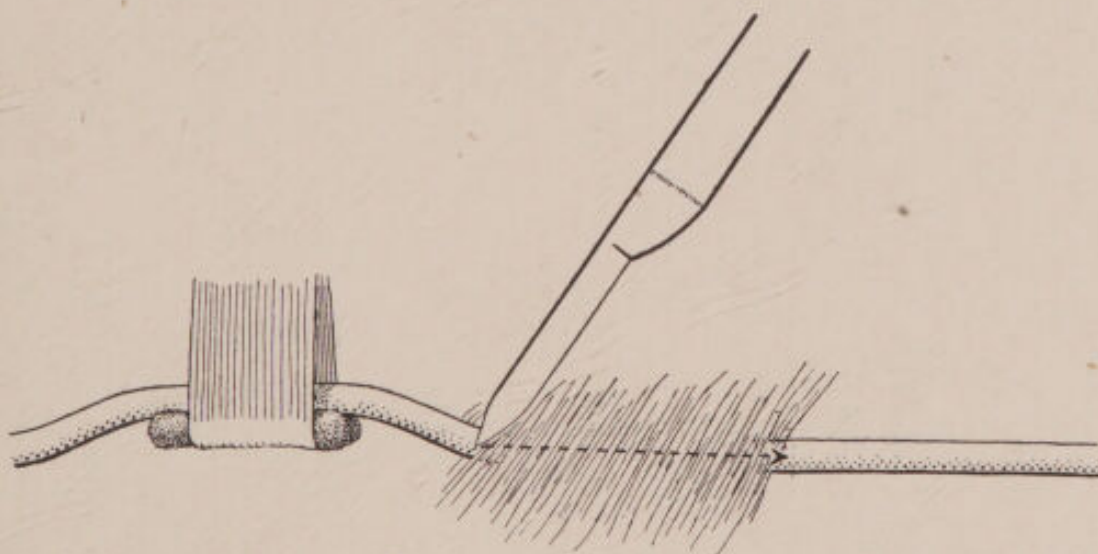


FIG. 57.—The ulnar nerve for a distance of four centimetres embedded in fibrous tissue. A piece of ribbon gauze is passed under the normal nerve; by means of this the nerve is lifted up, and a sharp knife cuts through the fibrous investment.

should be given an opportunity to recover. If on the other hand a neuromatous mass can be felt in the injured segment, this segment should be excised.

Fig. 58 shows the median nerve dissected out of a mass of dense fibrous tissue.

The patient had fallen, sustaining a fracture of the lower end of the humerus with marked dislocation backwards of the lower end. There was great effusion of blood in the region of the elbow joint. Median nerve paralysis developed.

Nine weeks later an operation was performed. The median nerve in the arm was exposed and was followed

downwards into a dense mass of fibrous tissue ; the distal end of the median nerve was exposed on cutting through the superficial head of the pronator radii teres, which was white and fibrous and presented no appearance of normal muscle. Between these two points the nerve bent acutely towards the bone. Careful dissection delivered the nerve out of its fibrotic bed.

There was continuity of the nerve, or rather, the nerve-sheath was continuous, but at the apex of the depressed angle the sheath seemed empty. There was no fibrosis in this segment and no perceptible hardening in the

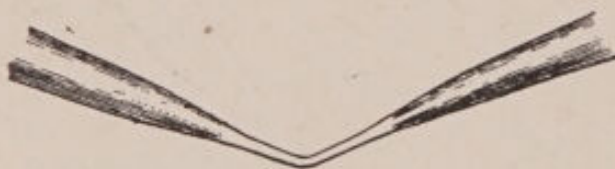

FIG. 58.—THE MEDIAN NERVE, SEVERELY COMPRESSED by dense fibrous tissue, consequent on a fracture-dislocation of the lower end of the humerus.

portions of the nerve above and below—these gradually tapered down to the collapsed angle.

The freed portion of the nerve was then wrapped in a piece of fascia removed from over the biceps.

A month later there was less wasting of the thenar muscles, and three months after the operation the patient could flex all the finger-tips firmly into the palm, including that of the index finger.

(b) In other cases the nerve is **compressed by bone callus**. This condition occurs most commonly in fractures of the shaft of the humerus, when the musculo-spiral nerve is very liable to become involved in the callus, with resulting paralysis.

The nerve should be exposed well above and below the site of injury, and both proximal and distal ends followed into the obstructing mass. The callus which presses upon the nerve is carefully cut away. The nerve is lifted out

of its bony bed, and its position altered so that it may lie on uninjured structures. If this is not possible, a pad of fat should be interposed between the injured segment of the nerve and the exposed bony surface.

(c) The nerve is sometimes **compressed by the displaced end of a fractured bone.**

The treatment consists in the efficient treatment of the fracture. In most cases it will be necessary to cut down on the fracture and plate the ends of the bone. At the same time the condition of the nerve should be investigated. Any loose fragments of bone lying in the immediate neighbourhood of the nerve should be removed.

(d) Symptoms of nerve compression are sometimes produced by the pressure of a slowly increasing bony deformity. See p. 167.

5. The nerve may be found closely adherent to some adjacent structure from which it can be separated intact, but in the region of the adhesion marked thickening can be felt in the nerve.

Fig. 60 is that of the great sciatic nerve in the lower third of the thigh. The external popliteal nerve was closely adherent on its outer and deeper edge to the posterior surface of the femur (Fig. 60 A).

This condition may be treated in one of the following ways :

1. By separating the nerve from its adhesions and then interposing between the injured surfaces a fold of fat or

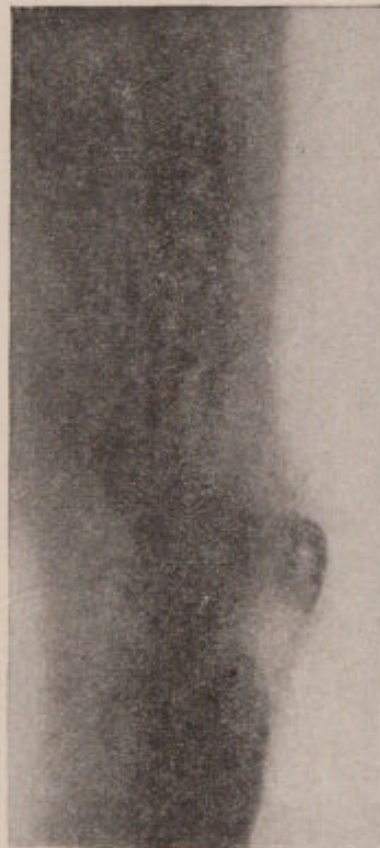

FIG. 59. — BACKWARD DISPLACEMENT OF THE LOWER END OF A FRACTURED FEMUR, producing paralysis of the external popliteal nerve.

## 102 NERVE INJURIES AND THEIR TREATMENT

of fascia, or by altering the position of the nerve, so as to prevent a recurrence of the adhesions.

2. In addition to the above, by making longitudinal

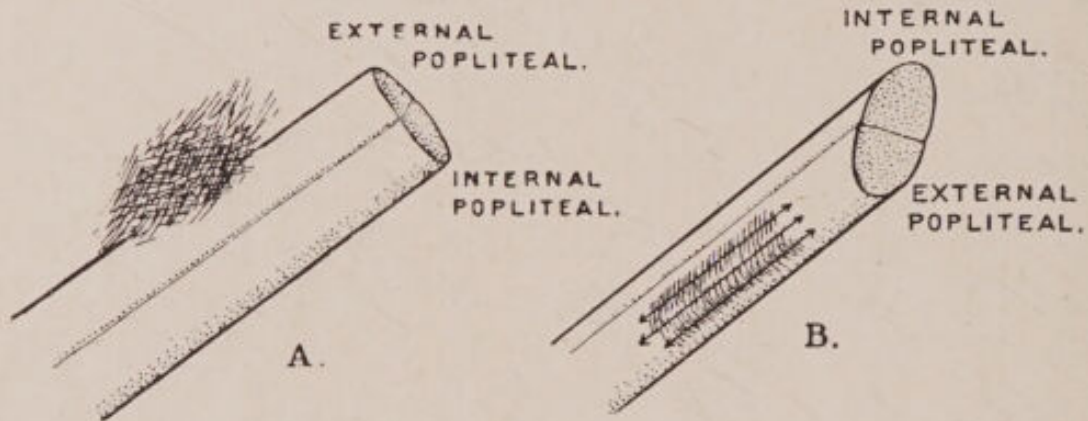


FIG. 60.—SCIATIC NERVE. A, Outer edge and adjoining portion of deep surface adherent to periosteum, with marked thickening in that portion of the external popliteal. B, The nerve freed from adhesions. Three longitudinal incisions are made through the indurated area, extending beyond its limits, and deep enough to go through its substance.

incisions through the indurated area. French writers speak of this operation as '*hersage*,' i.e. harrowing.

3. Excision of the indurated portion and direct suture of the cut edges. If direct suture be impossible, a segment of a cutaneous nerve should be implanted between the cut ends. (See Fig. 55 c.)

6. It is not uncommon to find in one wound diverse lesions of several nerves.

This is particularly common in wounds of the brachial plexus, and of the upper half of the arm. The following are two examples :

Fig. 61 represents a gunshot hole in the humerus filled with fibrous tissue, in which are embedded the ulnar and internal cutaneous nerves, the separated ends of the divided median nerve, and the fibrosed termination of the brachial artery.

The treatment consisted in neurolysis of the ulnar and internal cutaneous, freshening and suturing the ends of the

median nerve, and altering the position of all the nerves, so that they no longer lay in contact with injured structures.

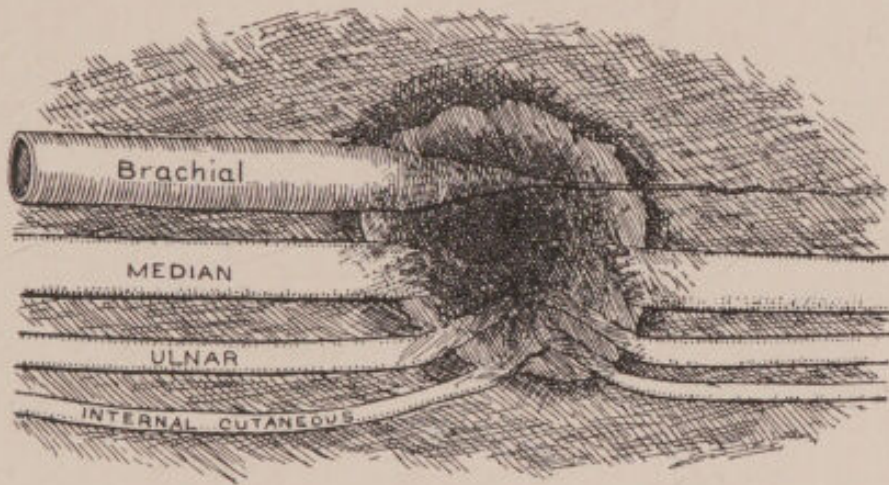


FIG. 61.—A GUNSHOT-WOUND OF THE HUMERUS, with obliteration of the brachial artery, division of the median nerve, and compression of the ulnar and internal cutaneous nerves.

Note the conditions of the brachial artery, rapidly tapering to a fibrous extremity. When first exposed the altered artery and the structures in its neighbourhood, including

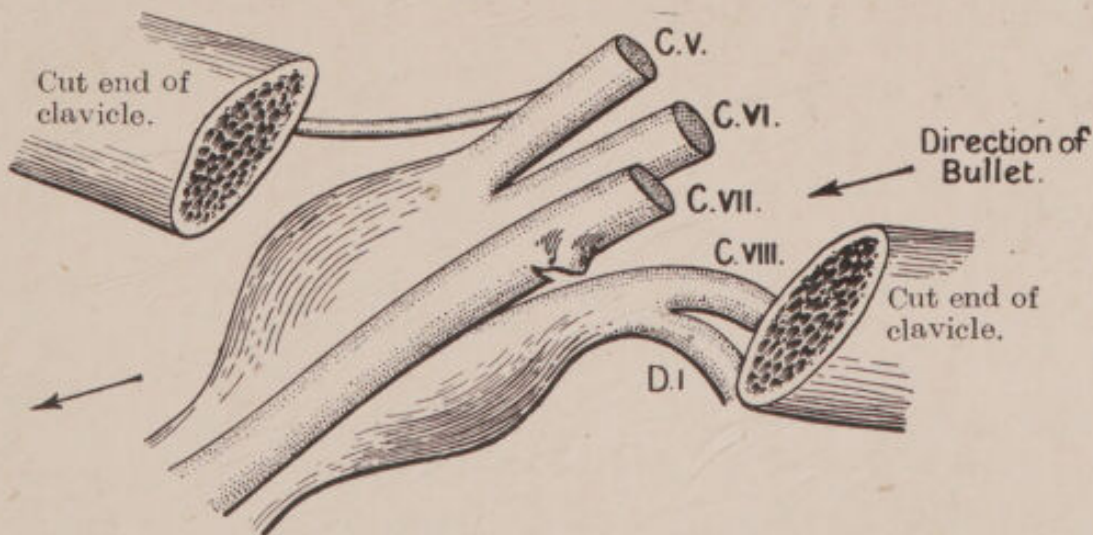


FIG. 62.—A GUNSHOT-WOUND OF THE BRACHIAL PLEXUS.

the nerves, formed one elongated fused mass, from which the various constituents had to be dissected free. It is by no means rare to find this condition of fibrosed obliterated artery; and, when associated with nerve injuries, it is

## 104 NERVE INJURIES AND THEIR TREATMENT

usually the axillary or brachial artery which is thus affected, and for the obvious reason that these vessels are intimately related to main nerve-trunks throughout the whole of their course.

Fig. 62 represents a composite injury of the brachial plexus. The seventh cervical nerve was found to be divided on its inner side; the other nerves were fused into a diffuse neuromatous mass. All these structures were connected by adhesions to the posterior surface of the clavicle.

The treatment in this case resolved itself into the excision and suturing of the incomplete lesion in the seventh nerve, and 'hersage' of the diffuse neuromatous mass in the other nerves.

### 7. A piece of metal or of bone may be lodged in the nerve.

Fig. 63 is that of the internal cutaneous nerve, with a

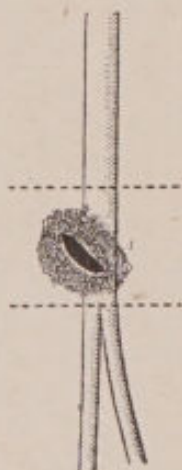

FIG. 63.—INTERNAL CUTANEOUS NERVE, partially divided by a piece of shell, which is embedded in a mass of fibrous tissue—the undivided portion of the nerve is also fibrosed.

small piece of shell partially dividing and lodging in it, embedded in a mass of fibrous tissue; the undivided portion of the nerve is also fibrous.

The treatment in this case was to excise the piece of nerve involved and suture the divided ends.

A similar lesion in a larger nerve, producing symptoms of incomplete division, would be treated by excising only the indurated portion—leaving the uninjured portion of the nerve intact, and treating the resulting deficiency

either by direct suture of the cut edges, or by implanting between them a segment of a cutaneous nerve.

#### HOPELESS NERVE INJURIES.

There still remain those cases where, even after the most carefully conceived and efficiently conducted operations, recovery in the nerve fails to take place.

Also, there are cases which do not lend themselves to operation, e.g. in most cases of complete division of the posterior interosseous nerve.

Other cases are those in which not only is the nerve supply interrupted, but the muscles themselves have been extensively destroyed, either by the original wound or later by long continued suppuration.

In all these cases we are faced with a limb in which certain muscles or muscle-groups are permanently placed *hors de combat*.

As a result the antagonistic muscles are unbalanced. These contract and stretch the paralysed muscles and their tendons, and deformity results. The action of gravity is often an additional factor in producing deformity.

There are thus two factors contributing to the disablement of the limb: the action of gravity, combined with the absence of action in one group of muscles and excess of action in the antagonistic group.

To prevent or mitigate deformity and to increase the efficiency of the limb the following procedures may be adopted.

#### 1. Tendon Transplantation.

This consists in altering the insertion of one or more of the over-acting muscles, so as to convert their distorting action into a corrective and useful action.

As an example, in irreparable damage of the musculospiral nerve, with paralysis of the extensors of the wrist, fingers, and thumb, resulting in a useless hand, with dropped wrist and fingers flexed into the palm—we may

re-distribute the muscular power about the wrist and finger-joints by converting some of the flexor muscles into extensors.

The tendon of the flexor carpi radialis is divided as near its insertion as possible, brought round the outer side of the radius and united to the extensor tendons of the thumb and index fingers. The tendon of the flexor carpi ulnaris is detached from the pisiform bone, and united to the extensor tendons of the three ulnar fingers. Extension of the wrist is made possible by detaching the pronator radii teres from its insertion into the outer side of the shaft of the radius, and uniting it to the tendons of the extensor carpi radialis longus and brevis.

## 2. Tendon fixation.

In this operation the tendons of paralysed muscles are

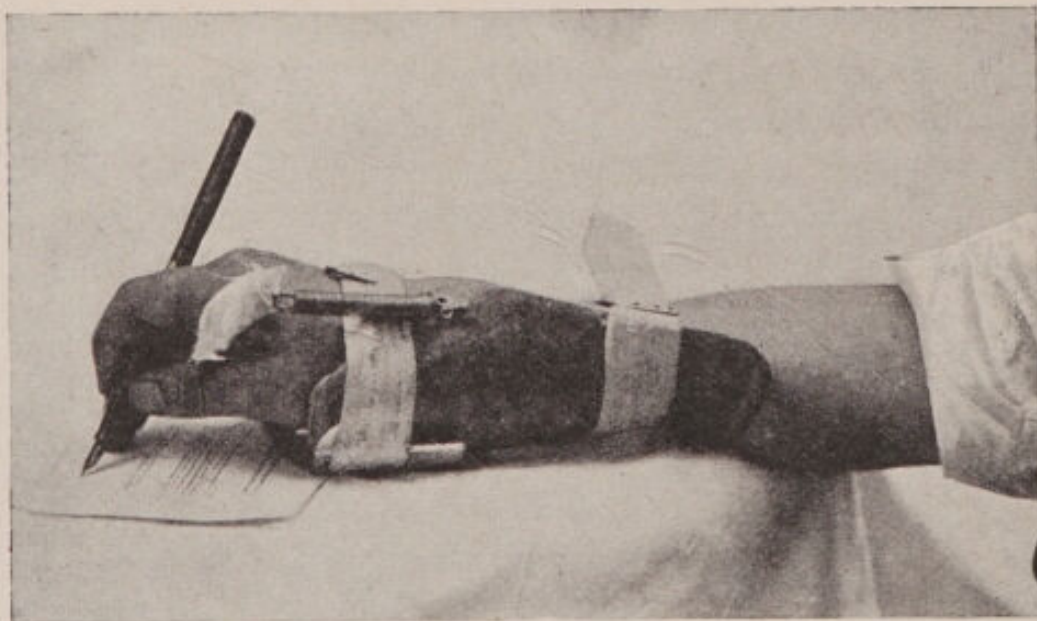


FIG. 64.—PROSTHETIC APPLIANCE FOR THE TREATMENT OF WRIST-DROP.

utilized as ligaments, to prevent deformity of the limb, and to maintain the joint in a useful position.

Thus, in paralysis of the external popliteal nerve, foot-drop and varus may be prevented by implanting the tendons of the tibialis anticus and peroneus longus

into a deep groove cut diagonally across the front of the tibia.

### 3. Mechanical or prosthetic appliances.

By mechanical means we can often not only prevent deformity which would otherwise ensue, but convert a useless into a useful limb. (See Figs. 40 and 64.)

### Stump Neuralgia.

This is sometimes due to the compression of nerve-trunks in the scar of a healing stump. In other cases, however, the pain begins within a few hours of the original amputation, before there can be any question of cicatrization. The pain recurs in paroxysms, often of agonising intensity. It may be felt by the patient either in the stump itself or in the fingers or toes of the 'phantom' limb.

Injection of alcohol into the nerve-trunks of the stump, higher up the limb, relieves some cases. In inveterate cases, as a last resort, it may be necessary to divide the corresponding posterior roots at their point of junction with the spinal cord, thereby producing permanent and widespread anæsthesia of the limb.

## CHAPTER VIII

### LESIONS OF INDIVIDUAL NERVES

THE individual nerves differ greatly as regards the frequency with which they sustain injury, as shown in the following table of nerve injuries personally seen by us during the war.

#### STATISTICS OF 520 CASES OF NERVE INJURIES

##### CRANIAL NERVES :

Optic . . . . .	0	}	53
Ocular (3rd, 4th, and 6th) . . . . .	4		
Trigeminal . . . . .	6		
Facial . . . . .	15		
Auditory . . . . .	0		
Vagus (recurrent laryngeal branch) . . . . .	1		
Spinal accessory . . . . .	6		
Hypoglossal . . . . .	3		
Multiple { 2nd and 5th . . . . .	1		
3rd and 7th . . . . .	1		
5th and 7th . . . . .	3		
5th and ocular nerves . . . . .	4		
5th, 7th, and ocular nerves . . . . .	2		
5th and 12th . . . . .	2		
7th and 8th . . . . .	1		
7th and 10th . . . . .	1		
7th and 12th . . . . .	1		
10th and cervical sympathetic . . . . .	1		
Recurrent laryngeal and 5th cervical root . . . . .	1		

CERVICAL SYMPATHETIC . . . . . 1 1

CERVICAL PLEXUS . . . . . 4 4

Unable to display this page

## CRANIAL-NERVE PARALYSES

Notwithstanding the very great frequency of wounds of the head, cases of paralysis of cranial nerves are relatively uncommon. The reason for this is obvious: wounds which traverse the base of the skull are so often fatal that the patients rarely survive to show cranial-nerve palsies.

Most cranial-nerve paralyses are seen in extra-cranial wounds, where the nerves are implicated after their exit from the cranial base, e.g. in wounds of the orbit, face, mastoid region, and upper part of the neck.

A few cases are due to fractures running down into the cranial floor and damaging the nerves at their foramina of exit; other cases, again, are due to intra-cranial hæmorrhages, e.g. at the front of the pons or medulla.

**First, or Olfactory Nerves.**

*Anatomy.* The olfactory nerve-fibres (which are un-myelinated) arise from a small area of mucosa lining the uppermost part of the nasal septum and outer wall of the nasal cavity. They pierce the cribriform plate of the ethmoid in about twenty small bundles on each side, and terminate in the superjacent olfactory bulb.

These nerves may be injured in fractures of the anterior fossa of the skull.

The sense of smell is tested by holding aromatic substances such as oil of cloves, peppermint, or asafœtida, in front of each nostril in turn, closing the other nostril with the finger. Ammonia or acetic acid must not be used, since these stimulate the sensory fibres of the fifth nerve, and may produce a pungent sensation in the nose even when the sense of smell is lost.

In testing for anosmia we should inquire as to the sense of smell before the injury, and see that the nostrils are clear of blood-clot or other local obstructions, e.g. nasal polypi, or even a swollen mucosa, as in an ordinary cold in the head.

**Ocular nerves :** The third, fourth, and sixth nerves.

*Anatomy.* All these nerves enter the orbit through the sphenoidal fissure, having previously traversed the walls of the cavernous sinus.

The discussion of lesions of the ocular nerves from intra-cranial injuries does not fall within the scope of the present work. It may, however, be mentioned that intra-cranial hæmorrhages of traumatic origin are often associated with ocular palsies, the sixth nerve being the one most frequently affected.

The presence of ocular palsies is recognized by observing impairment of ocular movements, and also, more delicately, by noting the occurrence of diplopia. For the latter, it is essential that the visual acuity has not been materially impaired by any lesion of the eye itself or of the optic nerve.

**The fourth nerve** supplies the superior oblique muscle, whose action upon the eye is to turn the anterior pole downwards and outwards. At the same time it rotates the vertical meridian slightly inwards. The deficiency in movement of the eyeball on paralysis of this muscle is difficult to see, but the patient has diplopia when he gazes downwards or outwards. The patient feels giddy, especially when he looks downwards, as in walking downstairs, and he habitually inclines his head forwards and towards the sound side.

**The sixth nerve** supplies the external rectus. Its paralysis is obvious, since the affected eye cannot be turned outwards, but can be moved in all other directions.

With the exception of the superior oblique and the external rectus, all the ocular muscles are supplied by the **third nerve**.

The third nerve also supplies the voluntary part of the levator palpebræ superioris; it also contains fibres which, through the ciliary ganglion and short ciliary nerves, supply the sphincter pupillæ and the ciliary muscle.

In complete paralysis of the third nerve there is ptosis, or drooping of the upper eyelid, from paralysis of the levator palpebræ, with elevation of the eyebrow on the same side from over-action of the frontalis. In addition to this, there is external strabismus from the unopposed action of the external rectus, and there is inability to move the eye upwards, directly downwards, or directly inwards; the eye can be moved slightly downwards and outwards by the superior oblique.

The pupil is dilated owing to the paralysis of the sphincter iridis, and does not contract to light or on attempted accommodation.

### **The Fifth, or Trigeminal Nerve.**

*Anatomy.* This nerve has two roots, sensory and motor. The sensory root, immediately distal to the gasserian ganglion, divides into three divisions: ophthalmic, superior maxillary, and inferior maxillary; the inferior maxillary is joined by the motor root of the fifth and then becomes a mixed nerve.

The ophthalmic division passes through the sphenoidal fissure into the orbit. It supplies the eyeball and lachrymal gland, the conjunctiva (except that of the lower lid), the skin of the forehead and scalp up to the vertex, the mesial part of the skin of the nose, and the mucous membrane of the upper part of the nasal cavity; it is joined at the gasserian ganglion by pupil-dilating fibres from the cervical sympathetic.

The superior maxillary division passes through the foramen rotundum, across the speno-maxillary fossa, to the infra-orbital canal. It supplies the skin of the upper lip, the side of the nose and adjacent part of the cheek, the lower eyelid, and part of the temple. It also supplies the conjunctiva of the lower lid, the upper teeth, and the mucous membrane of the following regions: the upper lip, the buccal cavity above the level of the angle of the mouth, the upper jaw, including the alveolar margin and the hard palate, the soft palate and uvula, the naso-pharynx and middle ear, and the inferior nasal fossa.

The sensory distribution of the third division is to the posterior part of the temple and adjacent part of pinna, the

anterior and upper wall of the external auditory meatus, as far as and including the anterior part of the tympanic membrane, part of the cheek, the lower lip and chin, the lower teeth, the mucosa of the buccal cavity below the level of the angle of the mouth, the tongue (as far back as the circumvallate papillæ), the floor of the mouth, and the salivary glands.

The motor part of the inferior maxillary division supplies the temporal, masseter, internal, and external pterygoid muscles, the tensor tympani, the mylo-hyoid and the anterior belly of the digastric.

When these motor-fibres are implicated there is paralysis and atrophy of the masseter, temporal, and pterygoid muscles on the affected side. The weakness of the masseter and temporal is readily detected by placing the fingers over the affected muscles and making the patient tightly clench his teeth. The masseter and temporal muscles no longer harden and stand out as they ought to do. Weakness of the external pterygoid is dramatically shown by making the patient depress the chin, when it at once



FIG. 65. — GUNSHOT-WOUND IMPLICATING THE SECOND AND THIRD DIVISIONS OF THE TRIGEMINAL NERVE. Entrance just below right eye, exit in front of right tragus. The line marks out the areas anæsthetic to pin-prick and cotton-wool, due to injury to the second and third divisions of the fifth nerve; the dotted areas are anæsthetic only to cotton-wool touches. There is also anæsthesia of the buccal cavity above the level of the angle of the mouth, of the right upper teeth, of the whole concavity of the right inferior turbinal and the anterior portion of its convexity.

swings over to the paralysed side, owing to the unopposed action of the opposite external pterygoid muscle. The jaw can no longer be voluntarily moved laterally towards the unaffected side.

Complete trigeminal paralysis from trauma is rare, and only occurs when the lesion is at or above the gasserian ganglion.

Partial lesions are relatively frequent. Thus a single division of the nerve may be implicated, or two divisions, especially the second and third, may be involved simultaneously by the one injury (Fig. 65).

Other cranial nerves are often injured along with the trigeminal, notably the ocular nerves, the facial, and the hypoglossal.

#### Seventh, or Facial Nerve.

*Anatomy.* This nerve has a motor and a sensory root, which meet at the geniculate ganglion.

The *motor root* arises within the lower part of the pons; it forms a loop round the nucleus of the sixth nerve. It emerges at the lower border of the pons, immediately to the inner side of the auditory nerve. Between these two nerves is the *nervus intermedius* or *sensory root* of the seventh nerve.

Both roots of the seventh nerve enter the internal auditory meatus and pass along the aqueduct of Fallopius, where they meet in the geniculate ganglion; here they are joined by the great superficial petrosal nerve from Meckel's ganglion, and by the small superficial petrosal from the otic ganglion. As the facial nerve passes along the aqueduct it gives off a branch to the stapedius, and lower down, the chorda tympani leaves it to join the lingual nerve. Here the facial runs in the inner wall of the tympanic cavity, covered by a very thin plate of bone, and here, too, it forms the floor of the aditus ad antrum.

The facial nerve emerges from the skull at the stylo-mastoid foramen and gives off branches to the occipital belly of the occipito-frontalis and to the muscles of the pinna; it then turns forwards, running in the substance of the parotid gland, and

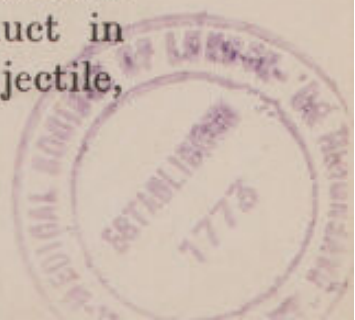
divides into branches which supply the stylo-hyoid and posterior belly of the digastric, and all the muscles of the face, excepting only the levator palpebræ superioris which is supplied by the third nerve.

The sensory root of the facial (*nervus intermedius*) pierces the surface of the pons close to the auditory nerve and lies between it and the motor root of the facial at the floor of the skull, entering the internal auditory meatus along with them. Its fibres arise from the cells of the geniculate ganglion. Centrally from this they run upwards into the medulla, alongside the auditory nerve-fibres, to join a gustatory nucleus closely connected with that of the glosso-pharyngeal. Distally from the geniculate ganglion they run along the great and small superficial petrosal nerves and also along the chorda tympani, conducting taste impulses from the anterior two-thirds of the tongue.

Besides conveying taste-impulses upwards to the brain, (impulses which have reached it *via* the chorda tympani nerve and geniculate ganglion), the *nervus intermedius* innervates the tympanic membrane, the external auditory meatus, and the adjacent skin of the concave surface of the pinna. (This cutaneous innervation, however, is variable, since it may be replaced by fibres from the auricular branch of the vagus.) The *nervus intermedius* also receives, *via* the geniculate ganglion, sensory fibres from the inner ear, and from the middle ear and its prolongations:—the Eustachian tube and the mastoid cells.

The facial nerve may be injured during its passage through the temporal bone by suppuration in the middle ear, or by operations on the mastoid antrum; and, after its emergence from the stylo-mastoid foramen, by cold, by involvement in malignant growths of the parotid gland, and by operations on the parotid gland.

In warfare this nerve is liable to injury both during its course, within the temporal bone, and after its exit from the stylo-mastoid foramen, either alone or in conjunction with neighbouring nerves. The Fallopiian aqueduct in the temporal bone may be injured directly by a projectile,



or it may be implicated in a more widespread lesion of the skull, such as a fracture of the middle or posterior fossa. The facial nerve may also be damaged during its extra-cranial course through the parotid region, or in its terminal distribution in the facial muscles.

### Symptoms.

Facial palsy is easily recognized.

In a complete case the face on the affected side is immobile, and its wrinkles become smoothed out. The lower lid droops, and, owing to the punctum lachrymale not being kept in contact with the conjunctiva, tears trickle over the cheek instead of passing into the lachrymal duct. The eye is more widely open on the affected side, and cannot be closed; on making the attempt the eyeball rolls upwards. The naso-labial fold is flattened, the angle of the mouth droops, and fluid dribbles from the affected side during drinking. During mastication, owing to paralysis of the buccinator, food tends to collect between the teeth and the cheek. The patient cannot purse up his lips, nor whistle. When the patient laughs or attempts to show his teeth, the mouth is drawn over to the non-paralysed side. In short, the face on the paralysed side cannot be moved either voluntarily or emotionally.

If the lesion take place where the nerve is accompanied by the chorda tympani, i.e. in the Fallopian canal below the geniculate ganglion (in which part of its course it is intimately related to the inner wall of the tympanic cavity), we have, in addition, loss of taste in the anterior two-thirds of the tongue on the paralysed side.

Lesions of the facial nerve outside the skull produce no impairment of taste.

Extra-cranial lesions of the facial nerve are often partial, the lower fibres of the nerve being affected without the upper, or *vice versa*.

Figs. 66 and 66 A are those of a soldier who sustained an

extensive shrapnel-wound of the face, extending from the upper part of the pinna to the angle of the mouth.

There is no cutaneous anæsthesia or analgesia.

There is complete paralysis of the right upper face, including the frontalis, orbicularis oculi, and zygomatici muscles. The depressor anguli oris acts well. To faradism the depressor anguli oris alone reacts on the affected side.




FIG. 66.—The face at rest, showing the right eye more widely open than the left, the furrows smoothed out of the right side of the face, and the right angle of the mouth drooping.




FIG. 66 A.—A forcible attempt to close both eyes. The right eye remains open and the eyeball is turned up under the upper lid; the mouth is drawn over to the non-paralysed side.

FIGS. 66 and 66 A.—A LACERATED SHRAPNEL-WOUND OF THE RIGHT FACIAL NERVE.

The prognosis, as in the case of other nerves, is largely based upon the electrical reactions. If the reaction be normal, or slightly diminished to faradism and to galvanism, but with no polar changes, recovery may be expected within a month; if partial reaction of degeneration be present, recovery may be looked for within two months; if reaction of degeneration be present, no recovery

of symptoms can be expected to appear before three months.

**For treatment** see p. 78. If no recovery manifests itself in six months, nerve anastomosis should be performed between the distal end of the facial nerve and the central end of the hypoglossal nerve.

### **The Eighth, or Auditory Nerve.**

*Anatomy.* The auditory nerve comprises two entirely different sets of fibres. Firstly, there are *cochlear fibres* from the auditory labyrinth, subserving the function of hearing. Secondly, there are *vestibular fibres* from the semicircular canals, constituting the most important nerve of equilibration. Affections of the auditory fibres produce auditory phenomena, whereas vestibular lesions often produce giddiness.

Injury to the auditory nerve occasionally takes place in those fractures of the skull which implicate the petrous portion of the temporal bone, and as the nerve is here running with the facial nerve, the resulting deafness is in a large proportion of cases associated with facial paralysis. In testing such cases for deafness, we should first eliminate by visual examination the deafness due to the presence of blood or wax in the meatus. Note that in the deafness due to the affection of the internal ear or of the auditory nerve (so-called 'nerve deafness'), a tuning-fork applied to the skull is not heard on the affected side.

### **The Ninth, or Glosso-pharyngeal Nerve.**

Although it is not infrequently damaged, in conjunction with the vagus and accessorius, by wounds in the region of the foramen lacerum posticum, no case of isolated injury of this nerve has been recorded.

Paralysis of the glossopharyngeal nerve causes anæsthesia of the back of the tongue and pharynx, difficulty in swallowing, and deficient taste in the posterior third of the tongue.

**The Tenth, Vagus, or Pneumogastric Nerve.**

The vagus nerve, in addition to supplying autonomic inhibitory fibres to the heart and autonomic motor fibres to the bronchial muscles, respiratory passages, œsophagus, stomach and intestines, contains voluntary motor fibres for the levator palati, and, through its recurrent laryngeal branch, supplies all the muscles of the larynx, with the exception of the cricothyroid. It is also sensory for the larynx, trachea, and bronchi; also for the œsophagus and stomach.

The vagus nerve may be injured in wounds, and in deep dissections of the neck. In the thorax it may be pressed upon by new growths or by aneurysms. Division of one vagus does not result in death, but its manipulation during operation may cause temporary cessation of pulse and respiration. Paralysis of the **recurrent laryngeal nerve** from pressure occurs in aneurysms of the aorta and in thoracic new growths; division of the nerve is not uncommon and sometimes follows operations for removal of a thyroid lobe, where it is cut or included in a ligature as it runs up behind the thyroid, in the groove between the trachea and œsophagus. The way to avoid injury is to keep the wound dry by clamping vessels before they are cut, and by resisting the temptation to plunge with the artery-forceps if a vessel should bleed when shelling out the lobe from its bed; and best of all, by keeping away from the nerve, by cutting through the posterior part of the gland, and leaving behind that portion which covers in the space between trachea and œsophagus.

If the lesion be of the whole vagus nerve, there is motor paralysis of the soft palate, with motor and sensory paralysis of the larynx.

To recognize unilateral paralysis of the palate, the patient is made to say 'Ah' whilst the uvula and soft palate are watched; normally the base of the uvula and median raphé rise straight up; but if one side be paralysed they deviate to the healthy side.

Paralysis of the recurrent laryngeal nerve is easily diagnosed on making a laryngoscopical examination. The vocal cord on the affected side is found to be fixed in the cadaveric position, i.e. immobile, midway between abduction and adduction.

### The Eleventh, or Spinal Accessory Nerve.

*Anatomy.* This is exclusively a motor nerve. It is distributed to the sterno-mastoid and to the uppermost and lowermost fibres of the trapezius (the middle fibres are supplied by the third and fourth cervical nerves).

The spinal accessory may be injured in front of or behind the sterno-mastoid; if in front, then the sterno-

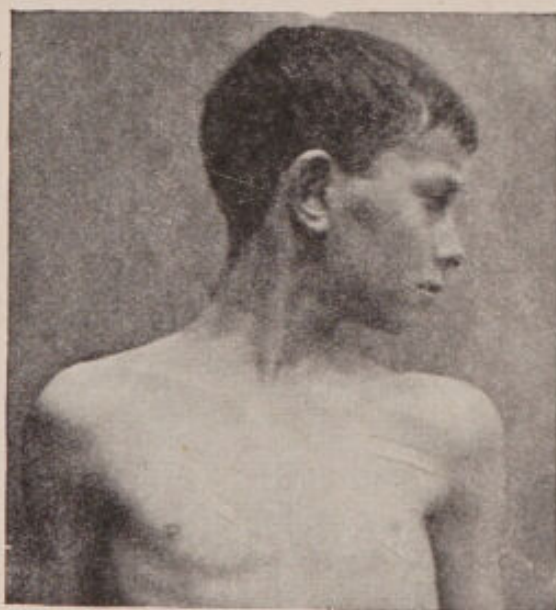


FIG. 67.—Shows the normal appearance of the right sterno-mastoid on rotating head to the left.

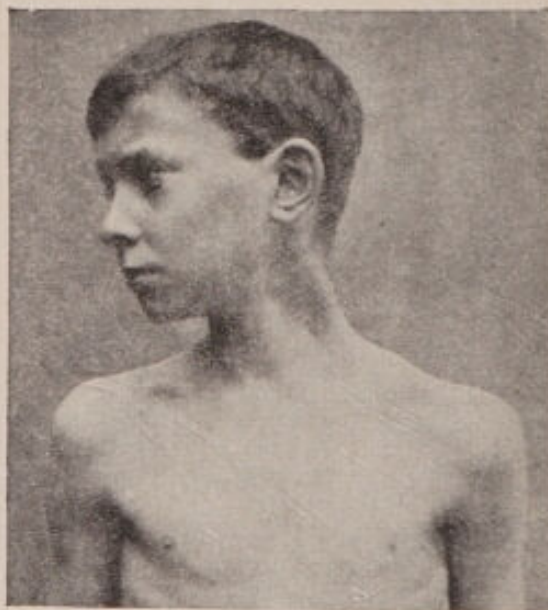


FIG. 67A.—Shows absence of the left sterno-mastoid, but perfect movement of head to the right.

FIGS. 67 and 67A.—PARALYSIS OF LEFT SPINAL ACCESSORY NERVE, FOLLOWING REMOVAL OF TUBERCULOUS GLANDS IMMEDIATELY BELOW THE LEFT MASTOID PROCESS.

mastoid is paralysed, and more or less of the trapezius, according to the amount of the muscle supplied by the cervical nerves; if behind, then the sterno-mastoid escapes. This nerve is most commonly injured when

tuberculous glands are being dissected out of the posterior triangle. Paralysis of the sterno-mastoid is evidenced by no deformity other than the loss of contour on that side of the neck. The head can be moved freely in all directions, but on rotating the head to the opposite side, or on depressing the head against resistance, the sterno-

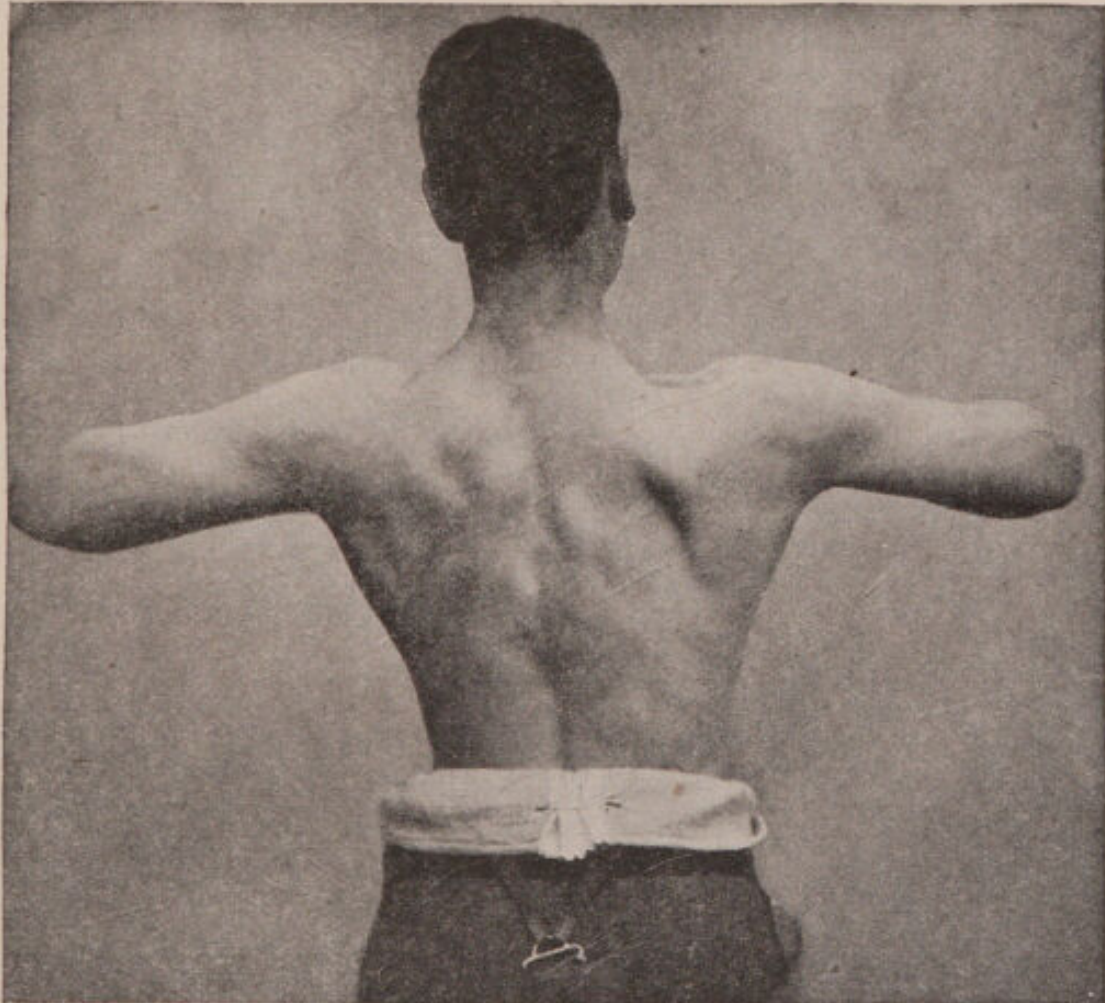


FIG. 68.—PARALYSIS OF THE RIGHT SPINAL ACCESSORY NERVE. Note the altered contour of the right side of the neck from wasting of the trapezius, and the slight 'winging' of the inferior angle of the right scapula.

mastoid does not stand out as on the normal side. (Figs. 67 and 67A.)

Paralysis and atrophy of the trapezius is evidenced by an alteration in the contour of the neck, and by displacement of the scapula (Fig. 68).

The alteration in contour is due to the levator anguli

Unable to display this page

due to concomitant injury of the communicating branch from the cervical sympathetic.

Fig. 69 is that of a soldier shot by a rifle-bullet. The entrance is in front of the right ear—the bullet penetrated the ascending ramus of the mandible; the exit is at the anterior border of the left sternomastoid on a level with the thyroid cartilage.

There is paralysis of the left hypoglossal nerve, and the tongue deviates to the left on protrusion. There is also paralysis of the right lingual and inferior dental nerves, producing anæsthesia of the anterior two-thirds of the right half of the tongue, of the right inferior buccal cavity, and of the right lower teeth.

#### CERVICAL SYMPATHETIC

*Anatomy.*—The cervical sympathetic extends from the root of the neck, behind the subclavian artery, upwards to the base of the skull; it lies behind the common and internal carotid arteries.

Branches from the sympathetic supply—

1. Motor fibres to the pupil dilator.
2. Vaso-motor fibres to the vessels of the head, neck, and arm.
3. The sweat-glands of the head and neck, arm, and upper part of the trunk, extending downwards to the third rib in front, and to the spine of the scapula behind.




FIG. 69.—PARALYSIS OF THE LEFT HYPOGLOSSAL NERVE FOLLOWING A BULLET-WOUND. The drainage tube is in the wound of entrance in front of the right ear, and the arrow points to the scar of exit at the anterior edge of the left sternomastoid.

Unable to display this page

Fig. 70 relates to a soldier who was shot in the right side of the neck. The entry-wound was at the middle of the anterior edge of the sterno-mastoid ; the exit was on the posterior aspect of the thorax, to the left of the second dorsal spine. In addition to paralysis of the brachial plexus (see p. 140), the patient sustained a lesion of the right cervical sympathetic.

There was marked inequality of the pupils—in a dull light the right pupil measured 2·5 mm., the left 4 mm. ; the right pupil dilated very slightly to darkness ; pseudo-ptosis and enophthalmos were well marked. There was no difference in sweating on the two sides of the neck, trunk, and limbs in this case, so that all the fibres of the sympathetic had not been affected.

**Irritation of the cervical sympathetic** gives exactly the opposite signs : dilatation of the pupil, exophthalmos, and widening of the palpebral fissure.

This condition sometimes results from the pressure of an aneurysm or other tumour in the neck ; later, as the pressure increases, the signs of stimulation may be replaced by those of paralysis.

### CERVICAL PLEXUS

*Anatomy.*—The superficial cutaneous branches of the cervical plexus arise from the anterior primary divisions of the second, third, and fourth cervical nerves. From the second and third arise the **small occipital**, **great auricular** and **superficial cervical** nerves, and from the third and fourth arise the **descending** nerves, **sternal**, **clavicular**, and **acromial**. All these are cutaneous sensory nerves. Their situation may be indicated clinically by lines drawn from the mid-point of the posterior margin of the sterno-mastoid : the small occipital upwards along the posterior edge of the sterno-mastoid, the superficial cervical horizontally forwards, and the great auricular midway between these two. The direction of the others is sufficiently indicated by their names.

The deep branches of the cervical plexus, motor in function, are distributed to the sterno-mastoid (C2), the scaleni (C3 and C4), the trapezius (C3 and C4), and the deep muscles of the

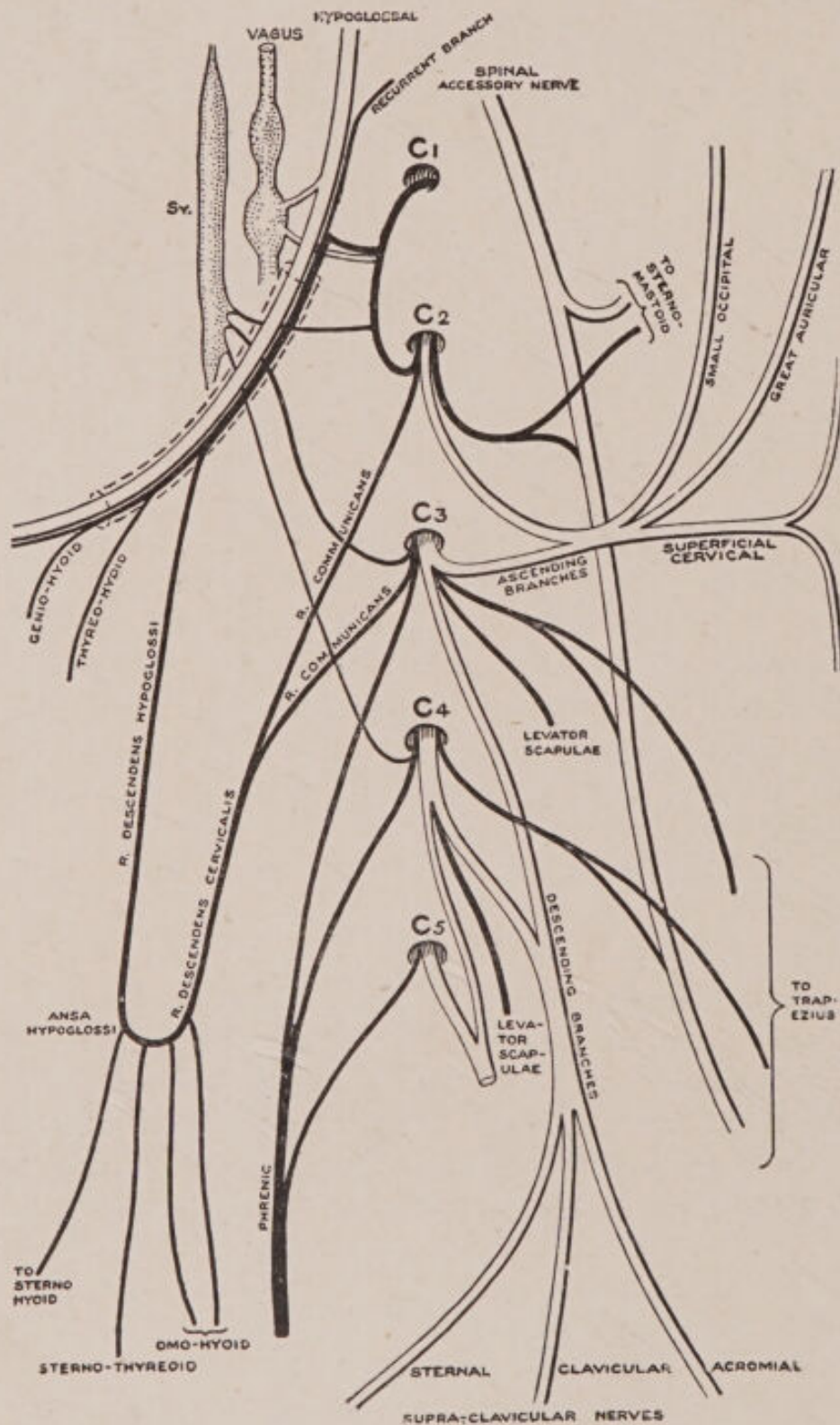


FIG. 71.—DIAGRAM OF CERVICAL PLEXUS (Cunningham's Anatomy).

neck. It will be remembered that the sterno mastoid and trapezius are also partly innervated by the spinal accessory nerve.

The phrenic nerve (C3, C4, and C5), which supplies the diaphragm, arises partly from the cervical and partly from the brachial plexus.

The cutaneous nerves of the cervical plexus are most commonly injured as the result of operations in the posterior triangle of the neck, and particularly in extensive operations for the removal of tuberculous or malignant glands.

Much less commonly the branches of the cervical plexus are injured by bullet-wounds, as in the following example of lesion of the great auricular nerve.

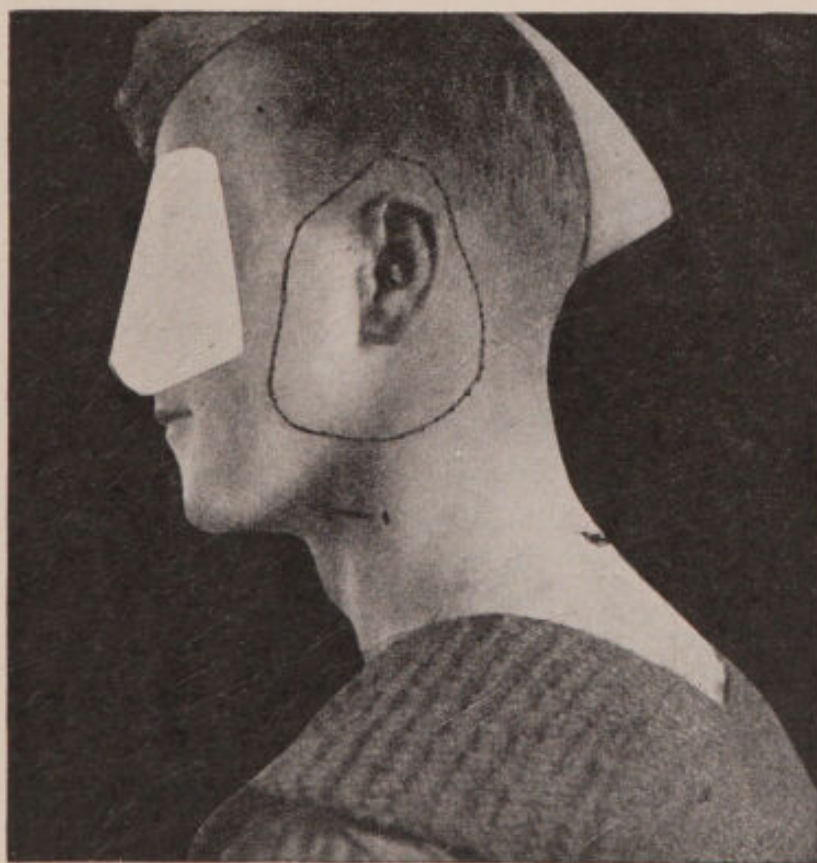

FIG. 72.—BULLET-WOUND OF GREAT AURICULAR NERVE.

A young airman, when flying at a height of 6,000 feet, was hit by a machine-gun bullet from an enemy aeroplane behind him. The entry-wound was immediately to the left of the sixth cervical spine; the exit was through the middle of the left sterno-mastoid muscle, just below the level of the *pomum*

*Adami.* The patient was concussed, and whilst he was still unconscious, his machine fell downwards, nose-diving. He recovered consciousness at 2,000 feet, and succeeded in landing his machine safely within our own lines.

The left upper limb felt helpless for a couple of hours, and then completely recovered motor power. Ever since his wound, however, he had noticed deficiency of sensation in the region of the left ear.

When examined, two and a half weeks after the injury, the wounds of entry and exit were practically healed (see Fig. 72). There was no motor weakness of any muscle of the neck or upper limb. To cotton-wool touches there was anæsthesia of the left pinna, front and back, and of a wide surrounding area on the side of the head and neck. To pin-pricks there was analgesia of a similar area, about half an inch within the area of cotton-wool loss. There was, however, a curious little island on the anterior surface of the pinna, just behind the external auditory meatus, where pin-pricks were still felt acutely. (This area is innervated by the sensory root of the facial—*nervus intermedius*—and partly by the auricular branch of the vagus.)

There was still some tenderness on deep pressure over the roots of the cervical plexus. Active movements of the left scapula and shoulder-joint also caused pain, shooting down the limb to the digits, especially the middle and ring fingers.

Of the muscular branches the most important one is the **phrenic nerve**. This may be injured as it runs downwards on the scalenus anticus to enter the thorax between the subclavian artery and vein. It is particularly liable to be injured when ligaturing the subclavian artery.

Division of one phrenic nerve results in paralysis of the corresponding half of the diaphragm. The inclusion of the nerve in a ligature has been known to occasion persistent coughing, from irritation of its sensory fibres; death with pulmonary symptoms has sometimes followed section of the nerve, but in the majority of cases the prognosis is good. If accidentally divided, its cut ends should be at once united.

## CHAPTER IX

### THE BRACHIAL PLEXUS

*Anatomy.*—The **brachial plexus** is formed by the anterior primary divisions of the 5th, 6th, 7th, and 8th cervical nerves, and the greater part of the 1st dorsal nerve.

These nerves appear in the posterior triangle between the scalenus anticus and scalenus medius muscles, and their upper boundary in the neck is a line drawn from the centre of the sterno-mastoid muscle, at the level of the cricoid cartilage, to just outside the middle of the clavicle.

Immediately after entering the posterior triangle the 5th and 6th cervical nerves unite, the 7th remains alone, and the 8th unites with the 1st dorsal, forming three primary cords; at the same time the four cervical nerves are dividing into anterior and posterior divisions. The secondary cords, usually spoken of as **the cords of the brachial plexus**, are named according to the position they occupy with regard to the axillary artery, and are formed thus (see Fig. 73):—The anterior divisions of the 5th, 6th, and 7th unite to form the outer cord. The anterior divisions of the 8th and the whole of the 1st dorsal unite to form the inner cord. The posterior divisions of the 5th, 6th, 7th, and 8th unite to form the posterior cord. These secondary cords then break up into the various nerves of distribution.

The muscles supplied by, and the cutaneous distribution of these various nerves should be compared with the muscle-supply and cutaneous distribution of the anterior primary divisions from which they originate. The supply, both sensory and motor, of an anterior root is the same as that of the corresponding segment of the spinal cord

from which it arises, and its distribution is according to root-areas. (See Figs. 73 and 74.)

It is a comparison of these two systems of distribution which enables one to diagnose the situation of the lesion.

Fig. 75 is that of a child who, subsequent to a fall which fractured her humerus, developed weakness and wasting of the right upper arm. There is an area of anæsthesia down

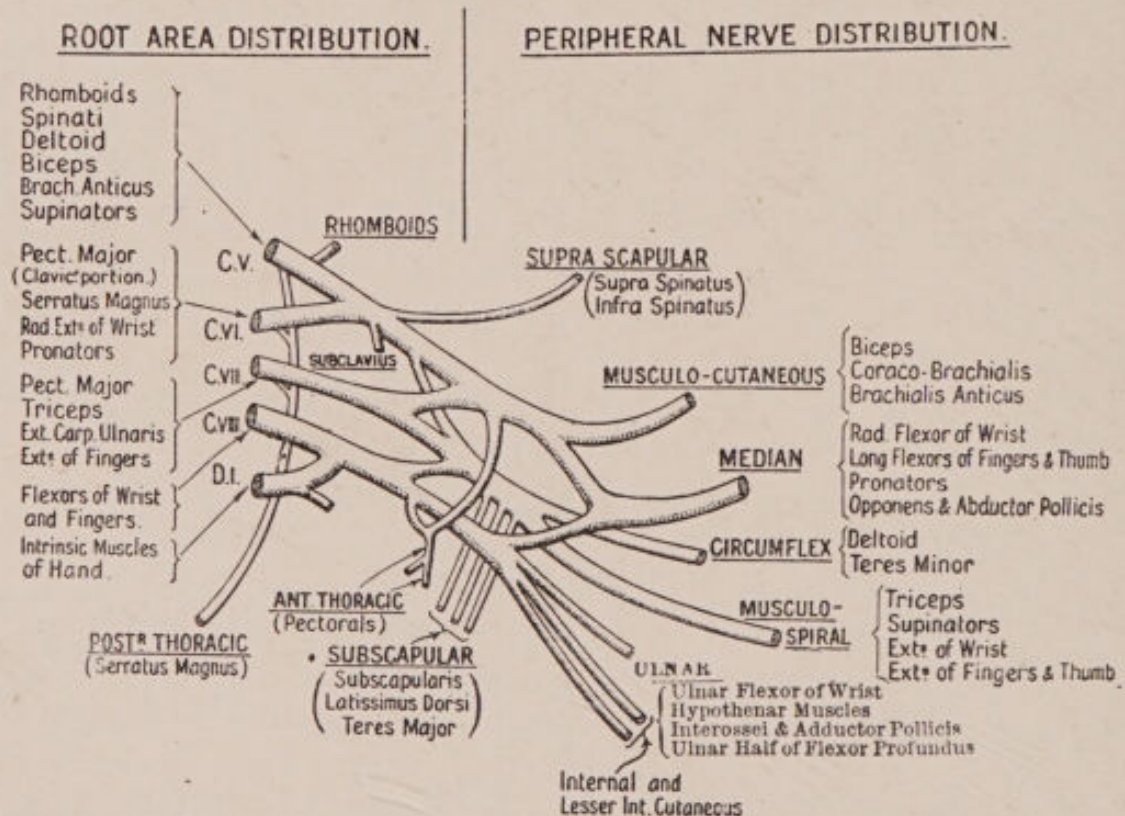


FIG. 73.—THE MOTOR-SUPPLY OF THE BRACHIAL PLEXUS, SHOWING BOTH ITS ROOT-AREA DISTRIBUTION AND ITS PERIPHERAL-NERVE DISTRIBUTION.

the outer side of the upper arm, forearm, and radial side of hand. There is wasting of the deltoid, supra-spinatus, infra-spinatus, biceps, and supinator longus. Abduction of the arm is limited, but the deltoid contracts feebly; flexion of the elbow is impossible, extension is good; supination of the forearm is impossible. The movements of the wrist and fingers are practically normal.

The anæsthetic area corresponds to the peripheral distribution of the 5th and part of the 6th cervical root, and the muscles affected are all supplied by the 5th root.

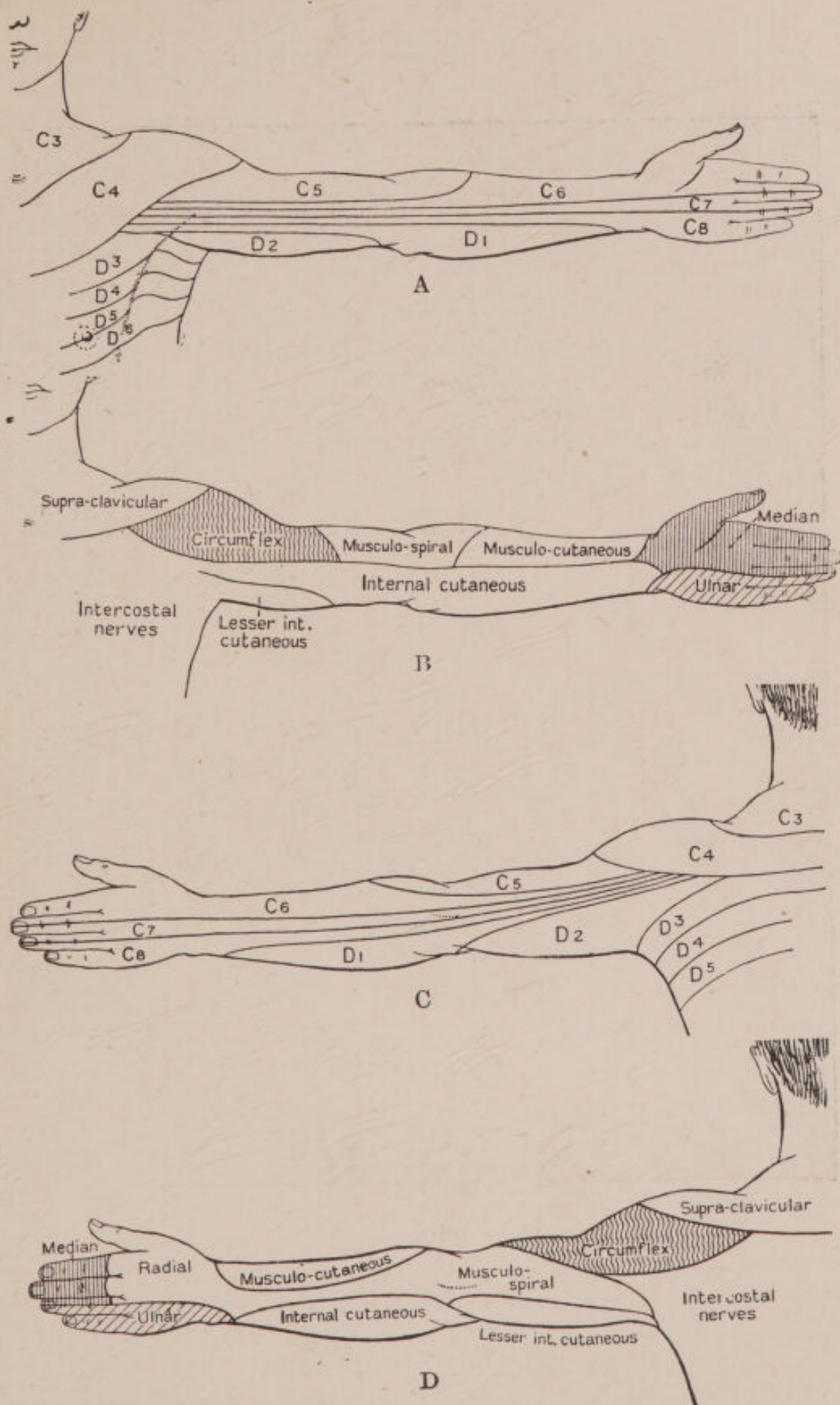


FIG. 74.—THE CUTANEOUS SENSORY SUPPLY OF THE UPPER LIMB. A and C show the areas supplied by the posterior roots; B and D the areas supplied by the peripheral nerves.

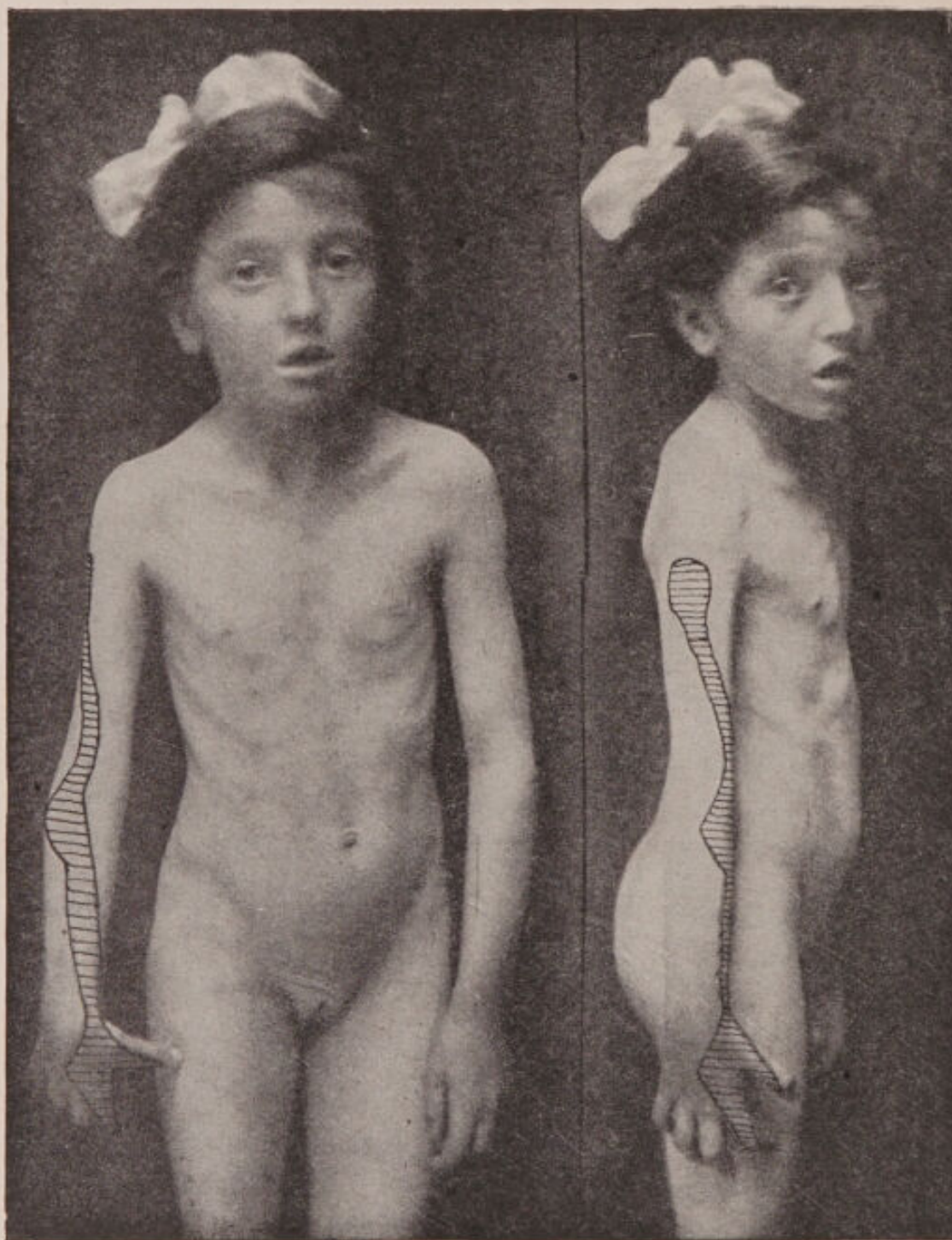


FIG. 75.—RUPTURE OF THE 5TH AND PART OF THE 6TH CERVICAL ROOT. The area of anæsthesia is mapped out. The deltoid, supra-spinatus, infra-spinatus, biceps, and supinator longus are wasted; flexion of the elbow and supination of the forearm are impossible.

Injuries to the brachial plexus are due to violence, direct or indirect.

**Indirect injuries** are always produced by over-stretching,

and are occasioned by violence applied more or less remotely from the plexus. They fall into two classes.

1. Violence applied so as to open out the angle between the head and neck and the shoulder of the same side (Fig. 76) produces a stretching of the brachial plexus in which the strain falls first on the 5th cervical nerve, then on the 6th, and so on, giving rise to **upper-arm paralysis** (Erb-Duchenne type). This lesion is most commonly

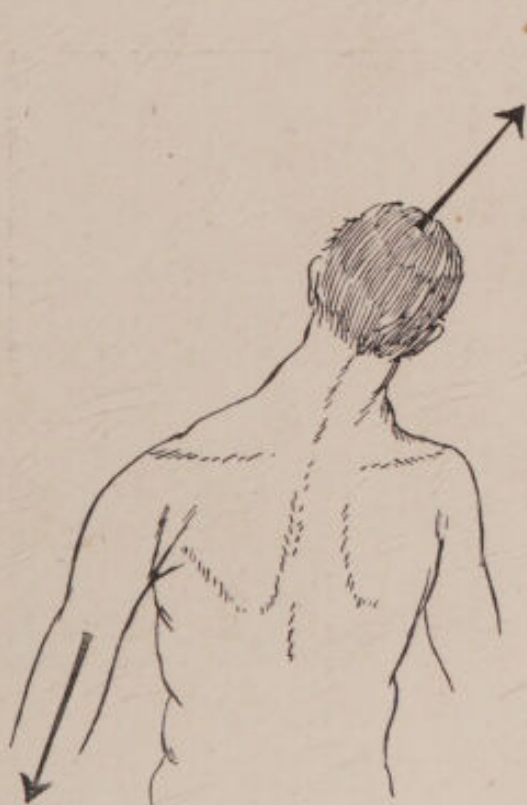


FIG. 76.—DIRECTION OF TRACTION-STRAIN PRODUCING LEFT UPPER-ARM PARALYSIS (Erb-Duchenne type).

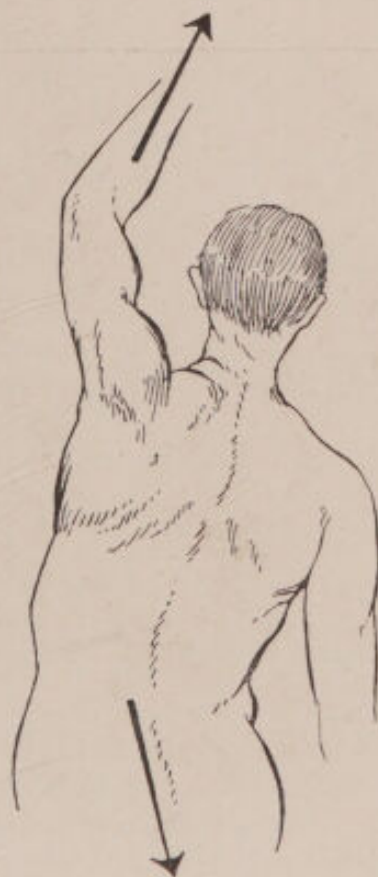

FIG. 76 A.—DIRECTION OF TRACTION-STRAIN PRODUCING LEFT LOWER-ARM PARALYSIS (Klumpke type).

produced by traction on the head in child-birth, or traction on the shoulder in breech presentations.

2. Violence applied so as to open out the angle between the arm and thorax (Fig. 76 A) produces a strain on the plexus which falls first on the 8th cervical and 1st dorsal, then on the 7th cervical, and so on, giving rise

to lower-arm paralysis (Klumpke type). This occurs when a man falling from a height clutches at some means of safety, and the body weight is brought up with a jerk, widening the angle between the arm and thorax wall into a straight line, or, when in breech presentations the arm slips up by the side of the after-coming head, and traction is made on the trunk.

The paralysis resulting from traction on the brachial plexus during child-birth is known as **brachial birth-palsy** ;




FIG. 77.—PARALYSIS OF THE 5TH CERVICAL ROOT FOLLOWING DIFFICULT LABOUR IN A BREECH PRESENTATION. The arm is habitually adducted at the shoulder-joint, extended at the elbow, and hyper-pronated. The left deltoid, biceps, supinators, spinati, and teres minor are paralysed ; the deltoid and supinators do not react to faradism ; the biceps reacts feebly ; the other muscles contract and react normally.

this differs in no respect from other forms of traction injury.

Fig. 77 is that of a child seven days old. The birth was a breech presentation ; it was very prolonged, and great difficulty was experienced in extracting the child.

On examination no abnormality was discovered save in the left upper limb. The arm was habitually adducted at the shoulder, extended at the elbow, and hyper-pronated.

There was total paralysis of the left deltoid, biceps, and supinators, also of the spinati and teres minor; all other muscles contracted normally.

To faradism the biceps reacted feebly, the deltoid and supinators not at all. All the muscles reacted to galvanism, KCC = ACC. We have here a lesion of the 5th cervical root.

Fig. 78 is that of a man who was 'blown up' by an explosion at a munition factory, and deposited forty yards away from

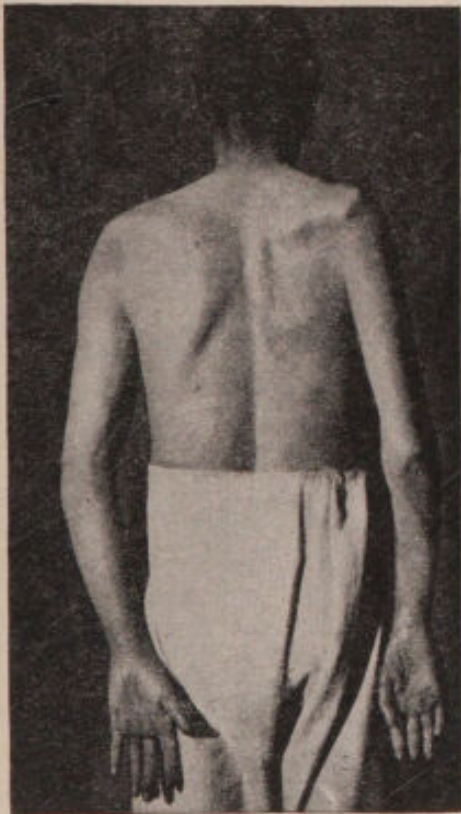


FIG. 78.

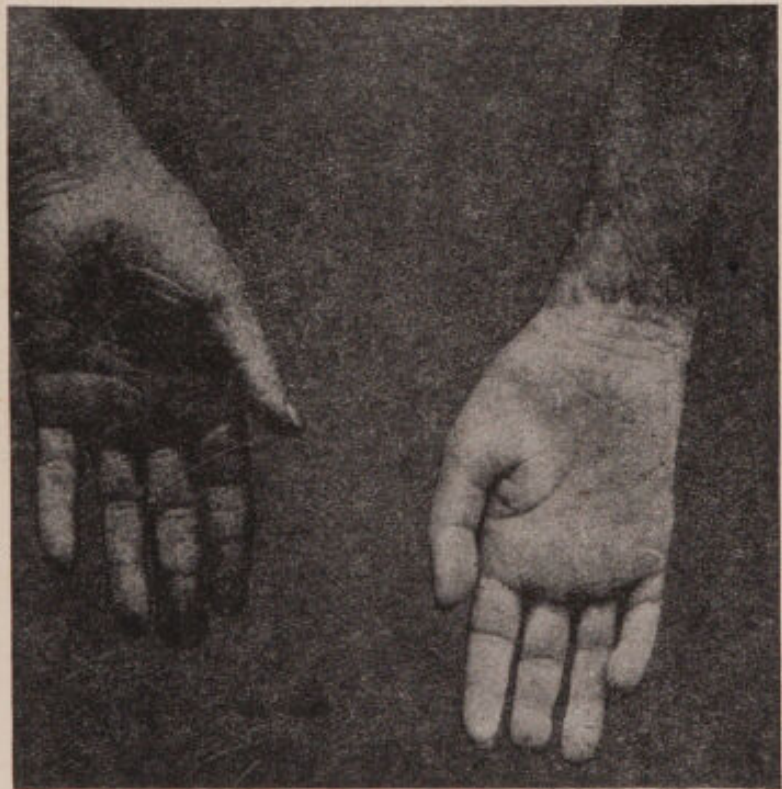

FIG. 78 A.

TOTAL BRACHIAL PLEXUS PALSY, RIGHT-SIDED.

his original position. According to the patient's story he was unconscious for three days. He had not been able to move his right arm since the accident. He stated that no bruising was discovered in the region of his shoulder. When seen, eleven months after the accident, there was marked wasting of the whole right upper extremity, and complete loss of power in that limb. No muscle below the acromion responded to faradism nor to the condenser (3 micro-farads).

The loss of sensation is shown in Fig. 79. Pressure-sense was

lost up to the level of the elbow-joint. The right pulse at the wrist was much smaller than that on the left side. The right pupil was smaller than the left, and there was also slight right enophthalmos. When the right brachial plexus was exposed at an operation a year after the accident, it was found that the scalenus anticus was converted into a dense mass of fibrous tissue. The 5th and 6th cervical nerves were blended into one fibrous mass, and this passed into the altered scalenus muscle. Where these altered nerves entered the scalene muscle an incision was made through its whole substance, but no nerve or muscle structure was discoverable. The other

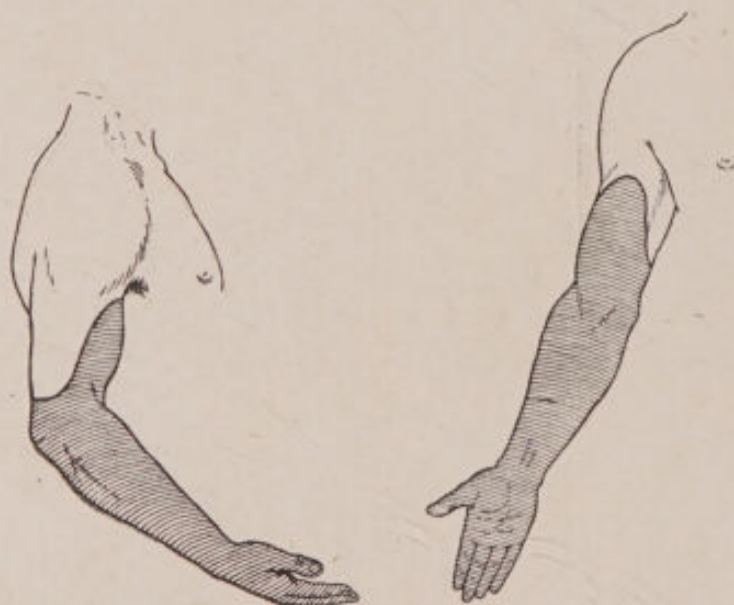

FIG. 79.—ANÆSTHESIA IN A CASE OF TOTAL BRACHIAL PLEXUS LESION.

roots of the brachial plexus were similarly affected as they passed through what was once the scalenus anticus muscle. The condition was hopeless.

#### Direct injuries.

In peace-time the commonest cause of brachial plexus palsy in the adult is dislocation of the shoulder-joint, either from pressure of the displaced head of the humerus (Fig. 88, p. 148), or from pressure of the heel in the axilla when attempting its reduction. It is sometimes produced by violence applied directly to the posterior triangle, or by the pressure of a cervical rib.

Unable to display this page

## 138 NERVE INJURIES AND THEIR TREATMENT

and interossei all responded to the lowest power of the condenser (·025 microfarad).

At the operation it was found that the 5th cervical nerve had been divided near its exit from the scalenus anticus muscle. It was here replaced by a mass of scar tissue. On careful exploration through the substance of the muscle, the proximal end of the nerve was not discoverable.

The spinal accessory nerve was therefore implanted in the 5th nerve as shown in Fig. 52, p. 95.

Six months after the operation the patient could voluntarily contract his biceps muscle, and at the seventh month, the deltoid.

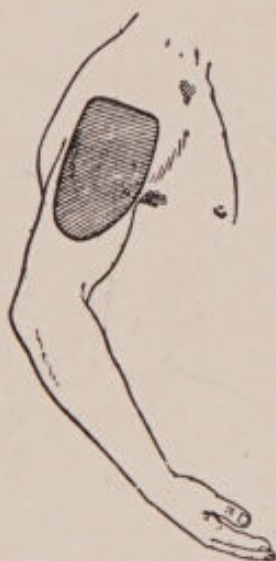


FIG. 81.

ANÆSTHESIA IN  
LESION OF 5TH  
CERVICAL ROOT.

The following is an example of a combined lesion of the 5th cervical root and of the recurrent laryngeal nerve :

A Bulgarian soldier sustained a bayonet-wound which transfixed the root of his neck from behind forwards, the entry being immediately above the middle of the spine of the left scapula, 3 inches internal to the acromion process. There was no exit-wound. His left arm at once fell helplessly to his side. Surgical emphysema of the upper part of the left side of the chest shortly developed, together with some hæmoptysis, and his voice at once became hoarse.

When examined four weeks later, the pupils and cranial nerves were normal, save for the left vocal cord, which was paralysed and fixed in the cadaveric position.

To cotton-wool touches, there was blunting along the outer side of the left upper limb, including the thumb, extending as high as the side of the neck. (See Fig. 82.) To pin-pricks, the upper part of this area was hyperalgesic, whilst from the middle of the deltoid downwards, there was analgesia in the same area as the epicritic loss.

The left trapezius was slightly feebler than the right, especially in its lowest fibres. The left spinati muscles were

wasted and inactive to faradism, and outward rotation of the shoulder was impossible. All other muscles of the left shoulder-girdle were normal, except the deltoid and supinator longus, both of which were totally paralysed, with loss of faradic excitability. The biceps was feeble, but still reacted to faradism. Abduction of the shoulder and flexion of the elbow were impossible, so also was supination of the forearm. All movements of the wrist and fingers were normal. The left

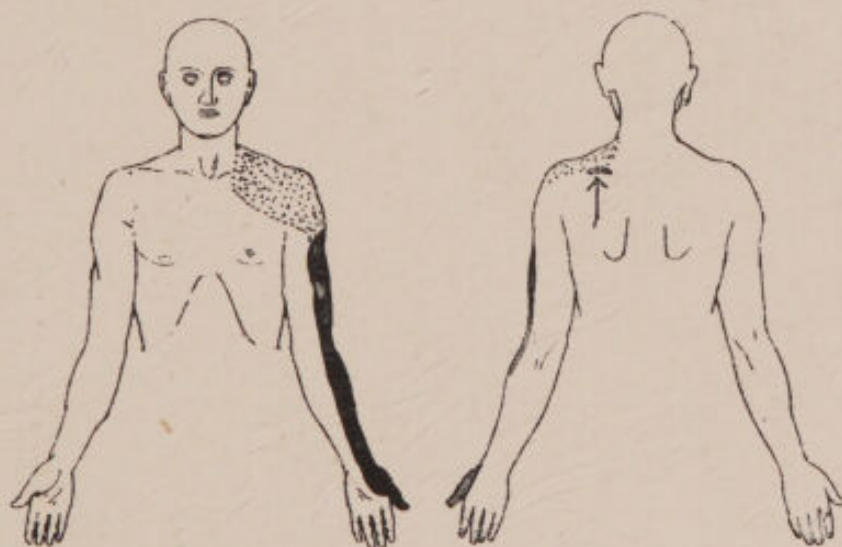


FIG. 82.—COMBINED LESION OF 5TH CERVICAL ROOT AND OF RECURRENT LARYNGEAL NERVE, FROM BAYONET-WOUND.

biceps-jerk and spuniator-jerk were absent, whilst the pronator-jerks and triceps-jerks were brisk and equal on the two sides.

Complicated injuries of the shoulder-girdle are often associated with extensive laceration of muscles, tendons, and ligaments ; in such cases it requires considerable care to recognize what part, if any, of the disability is due to a lesion of the brachial plexus. Complete brachial palsy is rare ; several cords may be simultaneously affected, but the commonest lesion is a partial one of a single cord.

Whilst this is true of the initial lesion, it must be remembered that the initial lesion is not the whole story ; in the neighbourhood of the projectile track blood has

been effused, adjoining portions of nerve structure have been infiltrated with blood, and neighbouring structures have been torn. By the time these cases come up for operation, the blood has become organized, and

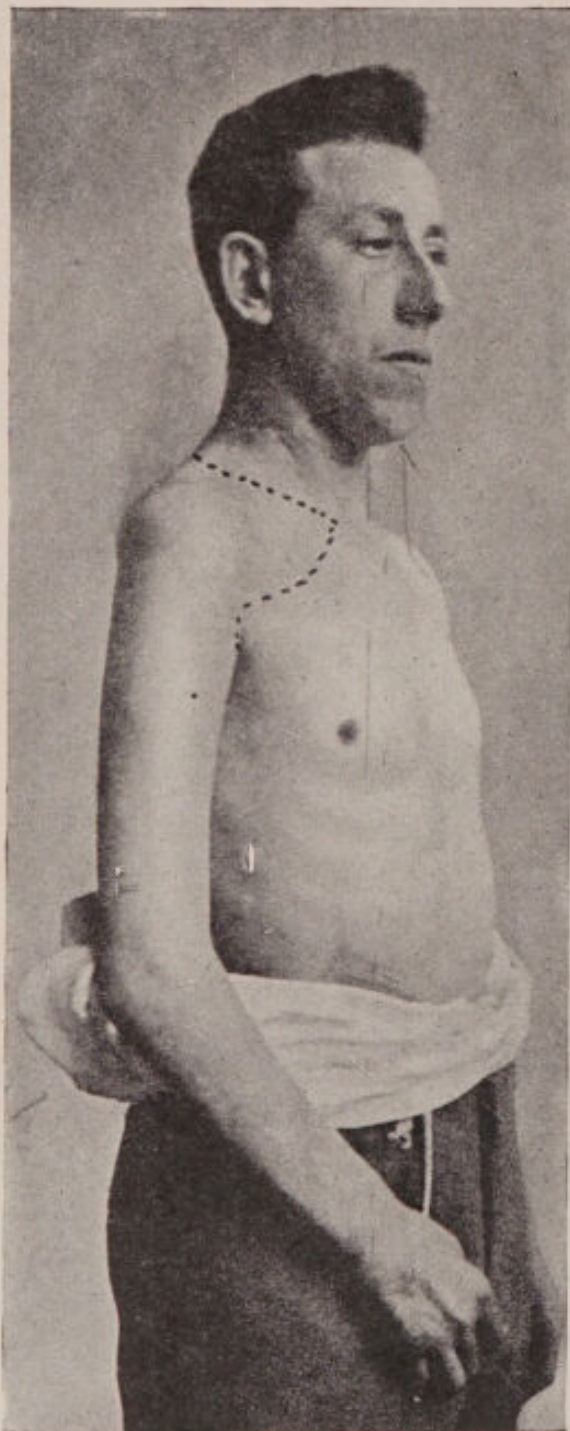

FIG. 83.—COMPLETE DIVISION OF THE RIGHT 5TH CERVICAL ROOT WITH INVOLVEMENT IN SCAR-TISSUE OF THE OTHER ROOTS OF THE BRACHIAL PLEXUS, AND OF THE CERVICAL SYMPATHETIC. The arrow points to the entrance wound at the middle of the anterior edge of the sternomastoid; the exit-wound is behind, at the vertebral border of the left scapula on a level with the 2nd dorsal spine. The whole arm and hand is anæsthetic to pin-prick and cotton-wool; the dotted line shows the upper limit. The pectoralis major, spinati, deltoid, triceps, biceps, extensors of wrist and fingers, flexors of wrist and fingers and the abductor and opponens pollicis are paralysed (slight flexion of little finger is possible), and do not react to faradism; the flexor carpi ulnaris, interossei, and adductor obliquus pollicis react to faradism. There is also right pseudoptosis with enophthalmos, and contraction of the right pupil (see Fig. 70).

the site of the lesion, the neighbouring nerve trunks, and the surrounding structures are wrapped in a mass of fibrous tissue.

Thus Fig. 83 relates to a soldier shot in January 1915. The

entrance-wound is on the right side of the neck at the middle of the anterior edge of the sterno-mastoid; exit to left of the vertebral column on a level with the 2nd dorsal spine. The photo shows the area which is insensitive to pin-pricks and cotton-wool.

The only muscles which reacted to faradism were the flexor carpi ulnaris, the interossei, and the adductor obliquus pollicis; no other muscle reacted to faradism, not even the small muscles of the thumb supplied by the median, so that the 8th cervical

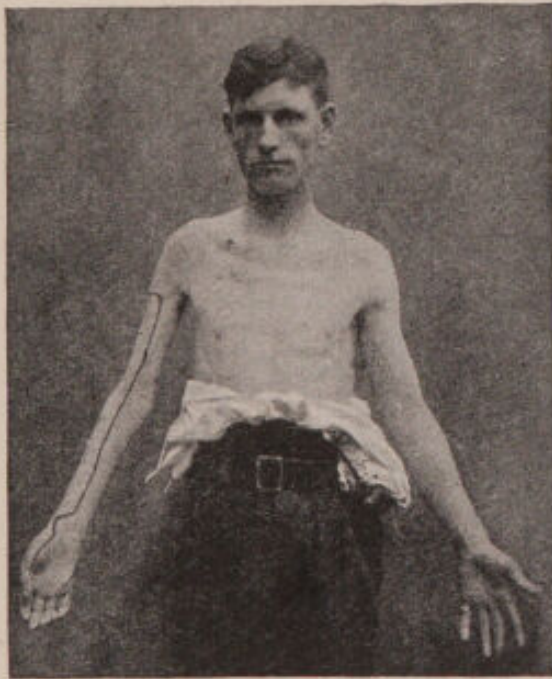

FIG. 84.

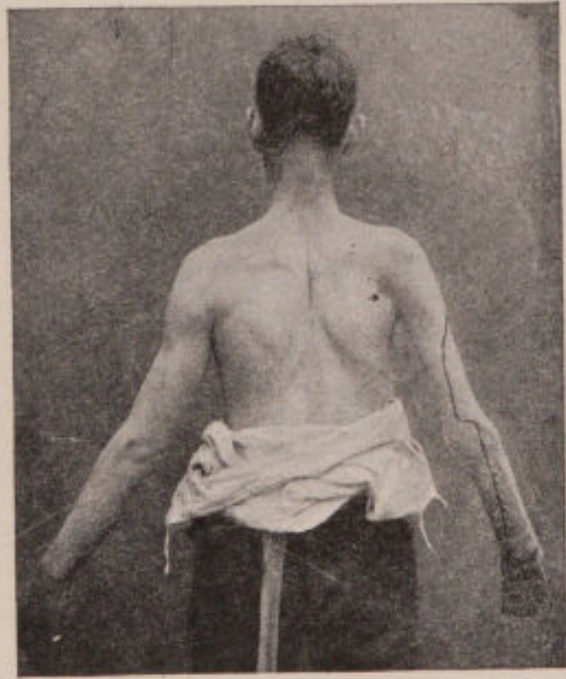

FIG. 84 A.

FIG. 84 and 84 A.—EXTENSIVE PARALYSIS OF THE RIGHT BRACHIAL PLEXUS, FROM A RIFLE-BULLET WOUND.

The entrance is in front, the exit behind (Fig. 84 A); the arrows point to the scars. The line maps out the area anæsthetic to pin-pricks. The following muscles were paralysed and did not react to faradism: biceps, triceps, supinator longus, extensors of wrist, extensors of fingers, and the interossei.

and 1st dorsal did not entirely escape. The 5th, 6th, and 7th cervical were entirely paralysed.

At the operation in June 1915 it was found that the 5th cervical nerve had been cut through, about  $\frac{3}{8}$  inch above its junction with the 6th. The 5th, 6th, and 7th, were matted into one thick mass, and blended with the scalenus anticus muscle, which in this region was nearly all fibrous tissue. In

this case too the cervical sympathetic was paralysed (see Fig. 70 ).

The following case shows how extensive and complicated these lesions of the plexus can be :

Figs. 84 and 84 A are those of a soldier wounded at Ypres by a rifle-bullet in December 1914. The entrance-wound is immediately above and just internal to the mid-point of the right clavicle ; the exit is situated at the axillary border of the right scapula, about midway between the angle of the scapula and the acromio-clavicular articulation.

June 1, 1915. The photographs show the area of anæsthesia to pin-pricks, also the wasted condition of the whole right arm, including the thenar and hypothenar eminences.

The following muscles react to faradism and voluntarily contract : rhomboids, supra- and infra-spinatus, deltoid, flexors of wrist, flexors of fingers, small muscles of thumb. The following are paralysed : biceps, triceps, supinator longus, extensors of wrist, extensors of fingers, and interossei.

The diagnosis here is that of an incomplete paralysis of the whole brachial plexus. The sensory loss is that of the 5th, 6th, and 8th cervical roots ; the distribution of the 7th root to the anterior surface of the limb is preserved, that to the posterior surface is lost.

The motor distribution of the 5th cervical root is mostly preserved, and that of the 8th cervical and 1st dorsal ; there is almost complete loss of the motor distribution of the 7th, and partial loss of that of the 6th cervical root.

June 4, 1915. At the operation it was seen that the 7th root had a lesion on its inner side ; it had been partially divided ; there was some retraction and thickening of the proximal end of the nerve-lesion. Behind this and adherent to it, the 5th and 6th swelled out into a bulbous enlargement, which fused with a similar enlargement of the 8th cervical and 1st dorsal nerves.

This mass was hard to the touch, cut like fibrous tissue, and in places looked like fibrous tissue.

It was evident that the bullet had hit the inner edge of the 7th cervical nerve, incising one half of it, and had then lacerated the contiguous edges of the 5th and 6th cervical, and of the 8th cervical and 1st dorsal nerves; the blood which was effused into and about them had apparently organized and caused them to become densely adherent to each other, and had given rise to a marked fibrosis of the nerves for about one inch of their length; there were also adhesions connecting this mass to the posterior surface of the clavicle. See Fig. 62, p. 103.

### Inner cord of the brachial plexus.

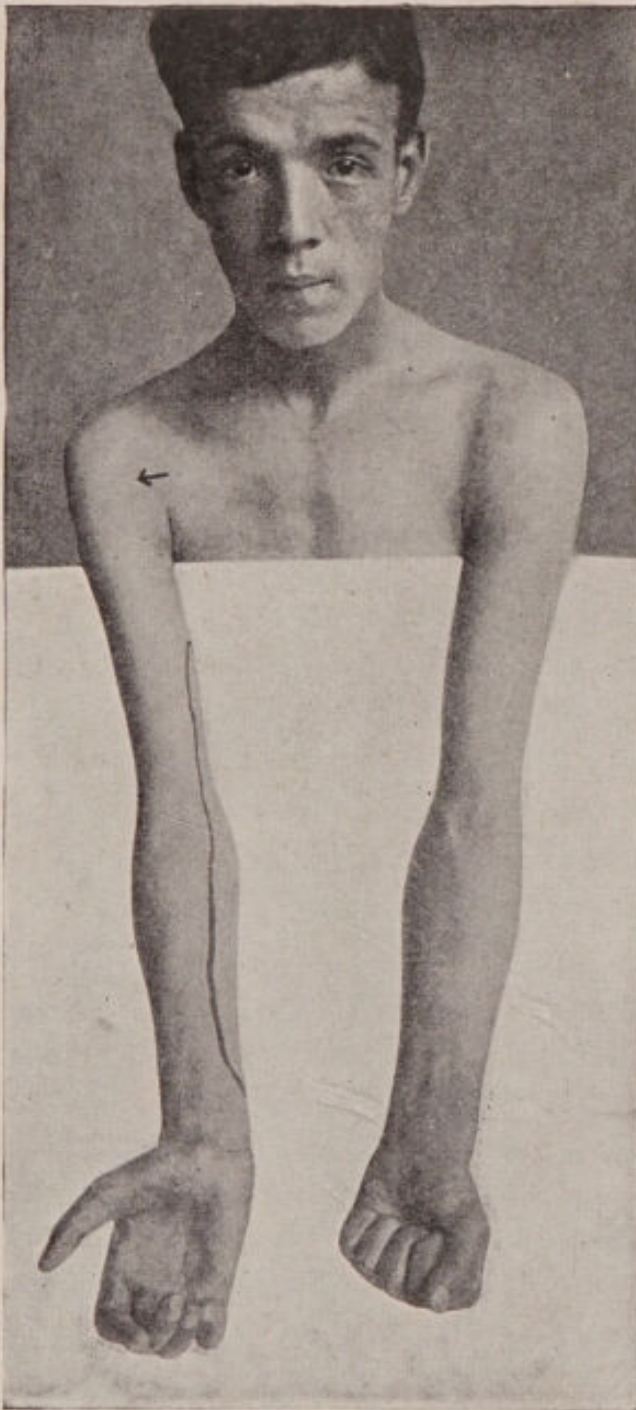
Lesions of the inner cord are evidenced by a loss of sensation along the inner side of the arm, forearm, and hand, and by paralysis of all the intrinsic muscles of the hand, together with paralysis of some or all of the flexors of the wrist and fingers—usually it is only the flexors supplied by the ulnar nerve which are affected (flexor carpi ulnaris and inner half of flexor profundus digitorum.)

Fig. 85 is that of a soldier shot in April 1915, at St. Julien, whilst building a trench parapet. The entrance-wound was behind, about one inch to the left of the 4th dorsal spine. The exit-wound was in front of the right shoulder, just internal to the neck of the humerus. Instantly he lost the use of his right arm and started spitting blood.

For the next month he was unable to use his arm, but later, with massage and electricity, he became able to do anything with his shoulder, arm, and wrist, but could not close his fingers; with the right arm hanging down, the hand became dark blue in colour.

When seen on August 5, 1915, there was an area of anæsthesia on the inner side of arm and forearm. The following muscles contracted voluntarily: deltoid, triceps, biceps, supinators, pronators, and extensors of wrist, fingers, and thumb. The following muscles did not contract and

did not react to faradism: flexors of wrist, thumb and fingers, interossei, and short thumb muscles (abductor, adductor, and opponens). The palm was wasted, and there was some contracture of the flexor tendons. On attempting to close the hand the unopposed extensors of the wrist forcibly dorsiflexed the wrist (Fig. 86).



The sensory loss is that of the 1st dorsal root; the motor loss is that of the 8th cervical and 1st dorsal roots, i.e. the inner cord of the brachial plexus.

At the operation on August 20, 1915, a sheet of dense fibrous tissue was found passing from the coracoid region to the under surface of the pectoralis minor; this was adherent to the sheath of the inner cord of the brachial plexus. The deep surface of the

FIG. 85. — INJURY OF THE INNER CORD OF THE BRACHIAL PLEXUS.

There is anæsthesia of the inner surface of arm and forearm corresponding to the cutaneous supply of the 1st dorsal root; the muscular loss corresponds to the 8th cervical and 1st dorsal roots (i.e. the inner cord), namely, paralysis of all the flexors of the wrist and fingers, and of all the intrinsic muscles of the hand. Note the marked wasting of the palmar muscles, making apparent the long flexor tendons.

cord, which was reddish, thickened, and nodular, was densely adherent to a mass of fibrous tissue, in which was the fibrosed and obliterated axillary artery.

Fig. 87 is that of a soldier wounded by a rifle-bullet. The bullet entered in the left pectoral region, above and external to the nipple; its exit was at the upper end of the left posterior axillary fold.

Two weeks after the injury there was loss of sensation, both protopathic and epicritic, along the inner side of the left forearm and hand, front and back, including two-and-a-half ulnar

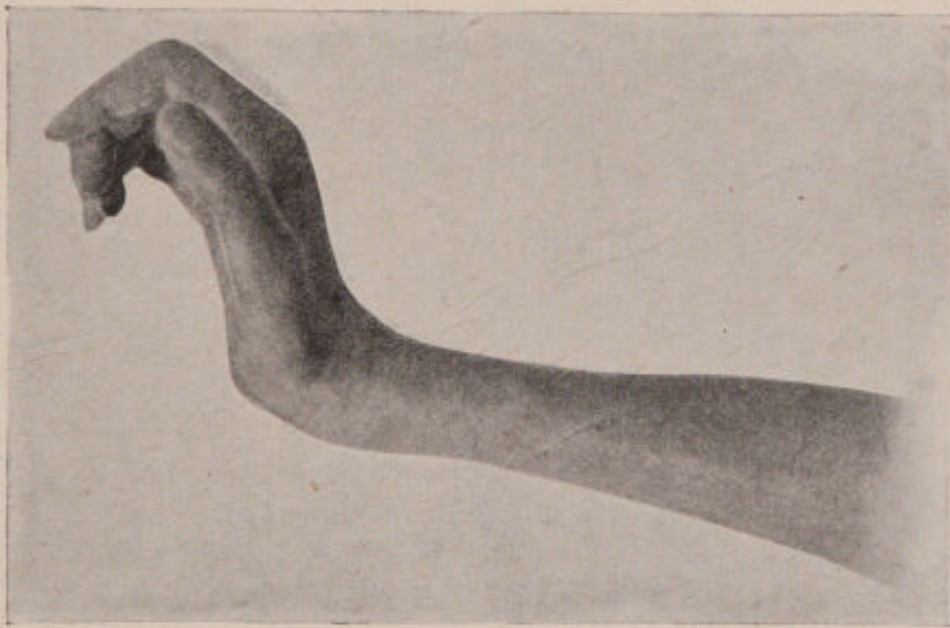

FIG. 86.—INJURY OF THE INNER CORD OF THE BRACHIAL PLEXUS, WITH PARALYSIS OF THE FLEXORS OF WRIST AND FINGERS, AND OF THE INTRINSIC MUSCLES OF THE HAND. There is some contraction and shortening of the long flexors. On making a forceful effort to clench the fist, the unopposed extensors dorsiflex the wrist.

fingers in front and three fingers on the dorsum. Joint-sense and vibration-sense were lost in the two ulnar fingers and in their metacarpals.

The patient could not flex the fingers, oppose the thumb, nor spread out the fingers; to faradism there was no response in the long flexors of the fingers, in the thenar or hypothenar muscles, nor in the interossei; all the other muscles reacted normally. Exploration of the brachial plexus revealed no gross lesion of the inner cord, but there was some scarring in the

tissues on the outer side of the inner cord, along the line of the bullet-track.

### Posterior Cord of the Brachial Plexus.

Lesions of the posterior cord are evidenced by paralysis of the muscles supplied by the circumflex, musculo-spiral, and subscapular nerves, and by anæsthesia of the areas supplied by these nerves.

In a complete lesion the following muscles are paralysed :

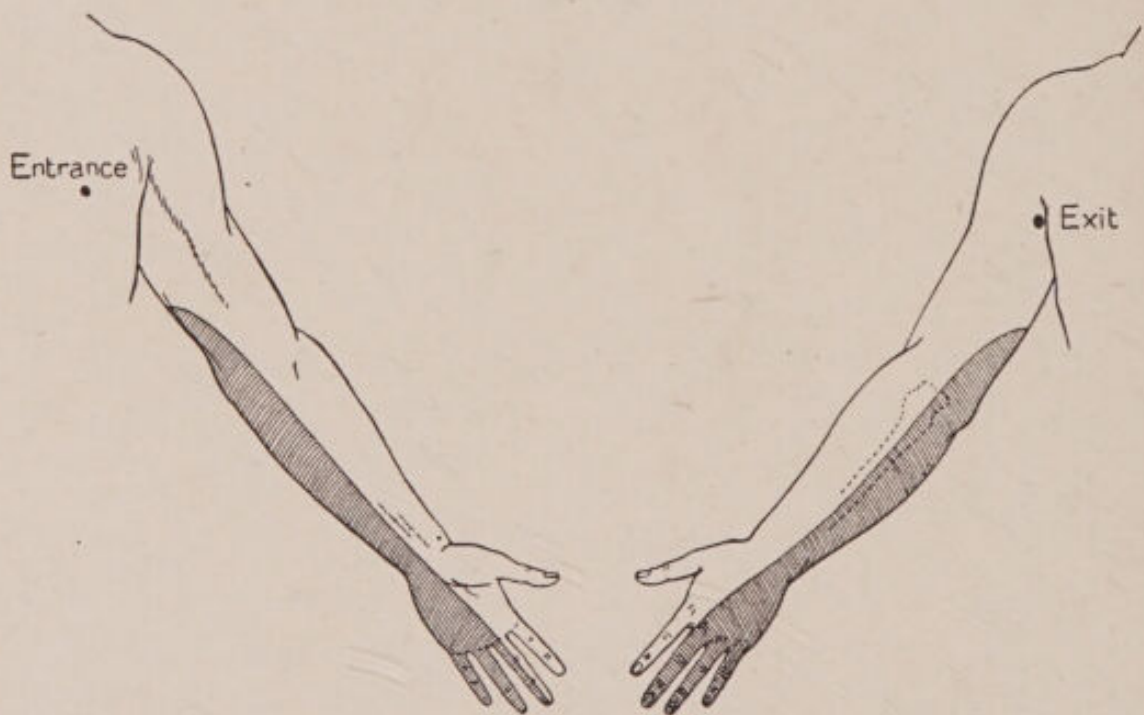


FIG. 87.—INJURY OF THE INNER CORD OF THE BRACHIAL PLEXUS. The shaded area is anæsthetic to pin-pricks and cotton-wool touches. There is paralysis of the flexors of the fingers, of the thenar and hypothenar muscles, and of the interossei. These muscles do not respond to faradic stimulation.

latissimus dorsi, subscapularis, teres major and minor, deltoid, triceps, supinator longus, and the extensors of wrist and fingers.

A soldier had a bullet-wound, entering  $\frac{1}{2}$  inch to the right of the 3rd thoracic spine. The exit-wound was an inch above the middle of the left clavicle, and an inch behind the sternomastoid. The left upper limb at once fell powerless by his

side. He had no hæmoptysis. After the injury he developed intermittent pain along the flexor aspect of the left forearm from the elbow to the fingers, worst at nights.

On examination, a month later, a hard lump was felt above the left clavicle, in the position of the exit-wound, tender on pressure, not movable.

There was no cutaneous anæsthesia or analgesia of the left upper limb. Joint-sense was everywhere normal. The pectoralis major was powerful. The left deltoid was paretic but able to contract, though not enough to produce abduction of the shoulder. The biceps was powerful; the triceps was completely paralysed. There was also paralysis of the supinator longus and of the long extensors of the wrist, fingers, and thumb. The latissimus dorsi was paralysed and did not contract on coughing. All the other muscles of the limb were normal.

To faradism there was loss of reaction in the latissimus dorsi, triceps, supinator longus, and extensors of wrist, fingers, and thumb. All the other muscles reacted normally.

### Combined Lesion of the Posterior and Inner Cords of the Brachial Plexus.

Fig. 88 is that of a man who, when drunk, fell and dislocated his left shoulder. When seen the next day, eighteen hours afterwards, he was found to have a subcoracoid dislocation; this was easily reduced. His left arm and hand were severely paralysed, but he could flex his elbow and, by means of the biceps, supinate his forearm.

One week later the faradic response was lost in the deltoid, triceps, supinator longus, extensors of wrist and fingers, and small muscles of the hand; there was a diminished response in the flexors of the forearm; the biceps response was normal to galvanism,  $KCC > ACC$ , but the contractions were not brisk.

Three weeks after the injury the following was the response to galvanism:  $KCC > ACC$  in deltoid, supinator longus and interossei muscles;  $KCC = ACC$  in the extensors of wrist and thenar muscles;  $ACC > KCC$  in triceps and extensor longus pollicis.

Unable to display this page

4 inches long, with its upper end 1 inch to the right of the 4th thoracic spine. He felt as if he had received a violent blow in the back. The right upper limb at once dropped powerless. The right upper limb at once became numb, especially in the fingers. The patient had no hæmoptysis.

When examined, ten days after the injury, there was loss of sensation to touches and pin-pricks in nearly the whole right upper limb, except along the inner side of the upper arm, and in the median and radial distributions in the hand. (See Fig. 89.) Joint-sense was lost at all the digital joints except

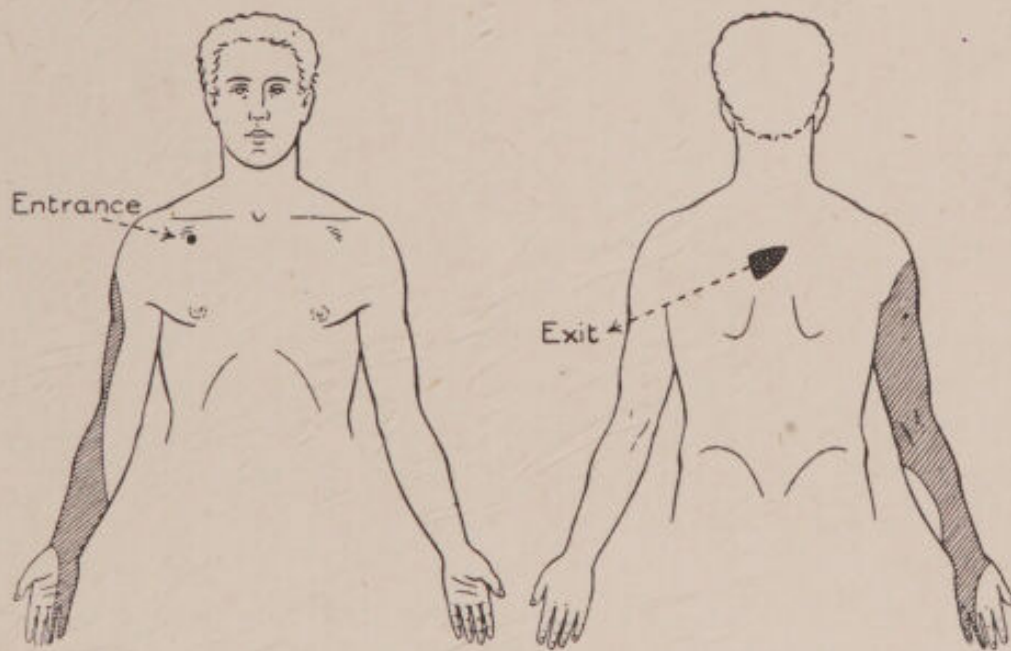


FIG. 89.—LESION OF BRACHIAL PLEXUS, MAINLY OUTER CORD. Anæsthesia of musculo-spiral, musculo-cutaneous, and ulnar areas.

those of the thumb; it was normal at the wrist, elbow, and shoulder. All the muscles of the shoulder-joint were powerful. The biceps was totally paralysed, but the patient was still able to flex the elbow by means of the supinator longus. He could supinate the forearm, but could not pronate it beyond the mid-position. He could not flex the wrist, fingers, nor thumb, but was able to extend them. All the intrinsic muscles of the hand were paralysed (i.e. the lesion also implicated the inner cord). To faradism there was loss of reaction in the long flexors of the wrist, fingers, and thumb, also in the pronators and in all the intrinsic hand muscles. The reaction in the biceps was feeble. There was a brisk response in the extensors of the

wrist, fingers, and thumb, also in the supinator longus, triceps, and deltoid.

### **Hysterical Paralysis simulating a lesion of the Brachial Plexus.**

A lesion of the brachial plexus may have a hysterical paralysis superadded, or a hysterical paralysis may closely simulate a plexus palsy, as in the following case :

An officer, aged 25, was wounded by a bullet in the region of the left shoulder. The entry-wound was in front, just outside the surgical neck of the humerus ; the exit was behind, and one inch below the level of the entrance. No bone was fractured. The whole limb at once dropped powerless and 'dead.' When he came under observation four months later there was total anæsthesia and analgesia of the whole limb from the shoulder downwards, with the exception of a narrow strip running along the radial border of the forearm and hand. Joint-sense was absent at all joints from fingers to shoulder, and vibration-sense lost in the whole limb, including the scapula. The shoulder, elbow, wrist, and most of the fingers were completely paralysed, and the limb dangled like a dead weight, flaccid and helpless. (See Figs. 90 and 90 A.) The only voluntary movements possible were feeble flexion of the thumb, index and middle fingers, and very feeble radial flexion of the wrist. The whole limb was slightly wasted. All its muscles, however, reacted normally, both to faradism and to galvanism. The diagnosis of hysterical paralysis was made.

Under nitrous oxide anæsthesia the patient moved all his fingers energetically, but nothing more. On coming round, before he recovered from the confusion of his anæsthetic, he was induced to move all the forearm muscles, and to flex the elbow repeatedly when aided by the stimulus of faradic shocks under the wrist.

In a few minutes, however, the paralytic symptoms re-appeared as severely as ever, and the patient refused further treatment.

A few weeks later, when driving a motor-car along the street, using his non-paralysed hand only, he had to swerve suddenly to avoid a collision. Involuntarily he placed the paralysed

limb on the steering-wheel, so as to assist his right hand. He then discovered that he was able to move the right limb well at all joints. When re-examined shortly afterwards, the anæsthesia was found to have disappeared, whilst motor power had also returned.

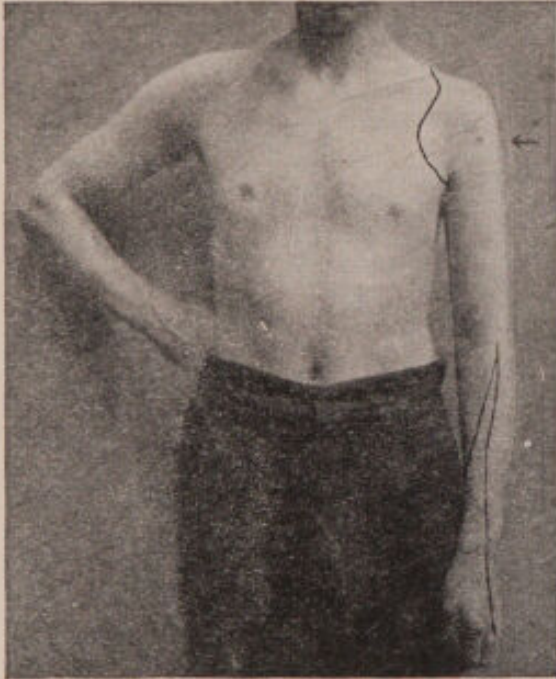

FIG. 90.



FIG. 90 A.

FIG. 90.—HYSTERICAL PARALYSIS OF THE LEFT UPPER LIMB. This immediately followed a gunshot-wound. The arrow points to the entrance scar. The whole limb was anæsthetic save for the radial border of forearm, and radial three fingers. There was total paralysis, save for feeble flexion of thumb, index and middle fingers, and very feeble radial flexion of wrist (i.e. of those muscles subjacent to the non-anæsthetic area).

FIG. 90 A.—The arrow points to the scar of exit. The black line indicates the upper limit of anæsthesia.

### Cervical rib.

Fibres from the 8th cervical and 1st dorsal nerves are occasionally injured by the pressure of a cervical rib. By 'cervical rib' is meant the exaggerated anterior tubercle of the transverse process of the 7th cervical vertebra, the extremity of which is connected by a fibrous band to the 1st rib or to the sternum.

Fig. 91 is the photograph of a woman, aged 28, who for six months had noticed gradual weakness of the right hand, with tingling down the inner side of the forearm and in the two ulnar fingers. The patient presented no abnormality save in the right upper limb, and here there was no anæsthesia to cotton-wool, pin-pricks, nor to temperature; all the muscles were normal except the interossei and hypothenar muscles,



FIG. 91.—RIGHT-SIDED BRACHIAL PLEXUS INJURY FROM PRESSURE OF A CERVICAL RIB. The interossei and hypothenar muscles are wasted; there is hyper-extension of the two ulnar fingers at the metacarpo-phalangeal joints, and the patient complains of weakness in the right hand and tingling down the inner side of forearm and in the two ulnar fingers.

which were wasted. There was slight hyper-extension of the two ulnar fingers at the metacarpo-phalangeal joints. There was slight wasting at the inner side of the thenar eminence, but all movements of the thumb could be freely executed. She could not spread out the fingers of her right hand so well as those of her left.

A radiogram (Fig. 92) showed that the transverse processes of

the 7th cervical vertebra were enlarged, and particularly so on the right side. The right transverse process was therefore removed, and the posterior edge of the scalenus anticus muscle incised.

For the first few days the tingling, of which the patient had previously complained, was felt in the whole of the arm, but this cleared up entirely, including the abnormal sensations in the little and half the ring finger.

This patient later developed similar symptoms in the left hand, from pressure of the left transverse process.

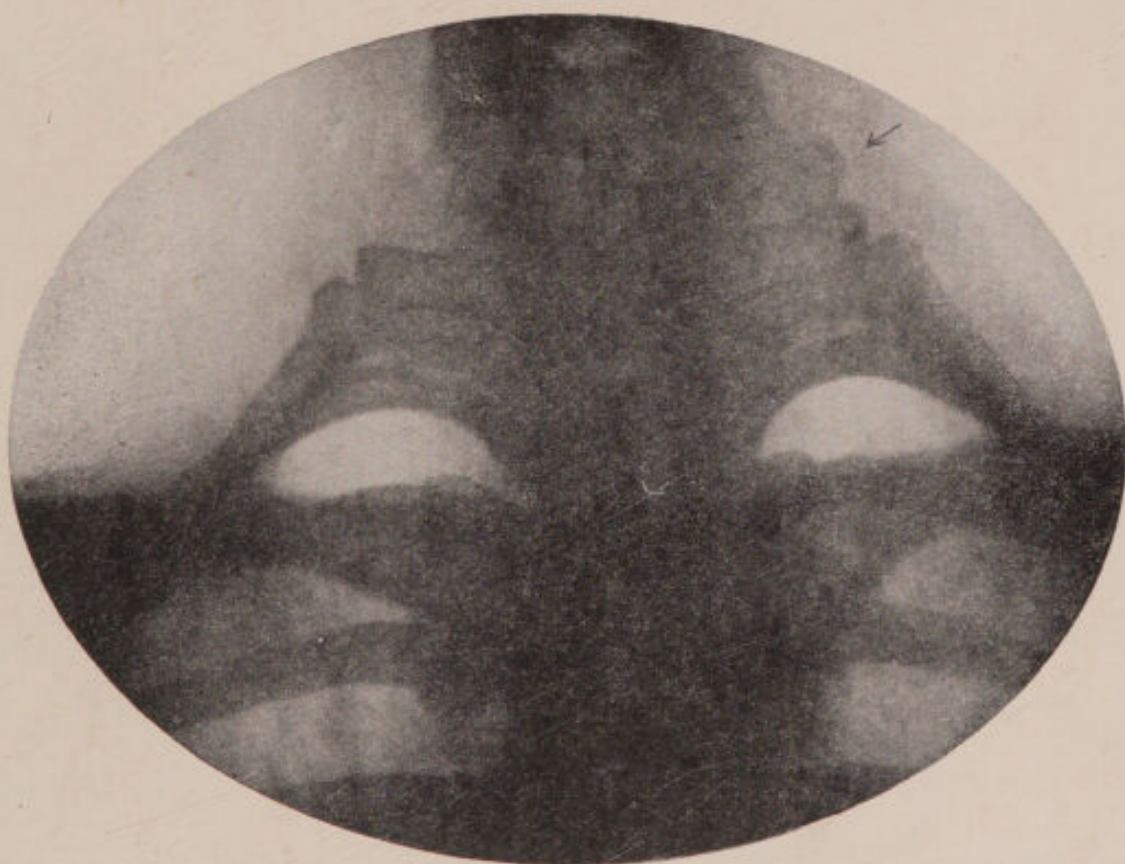


FIG. 92.—RADIOGRAM OF PATIENT SHOWN IN FIG. 91. The picture shows enlargement of the transverse processes of the 7th cervical vertebra, particularly well marked on the right side, to which the arrow points.

### **An operation to expose the brachial plexus.**

An incision is made from the middle of the posterior edge of the sterno-mastoid to the junction of the middle and outer thirds of the clavicle. On opening the deep fascia in the same line the transverse cervical vessels will be seen; divide these between two clamps.

Near the upper end of the wound seek the posterior edge

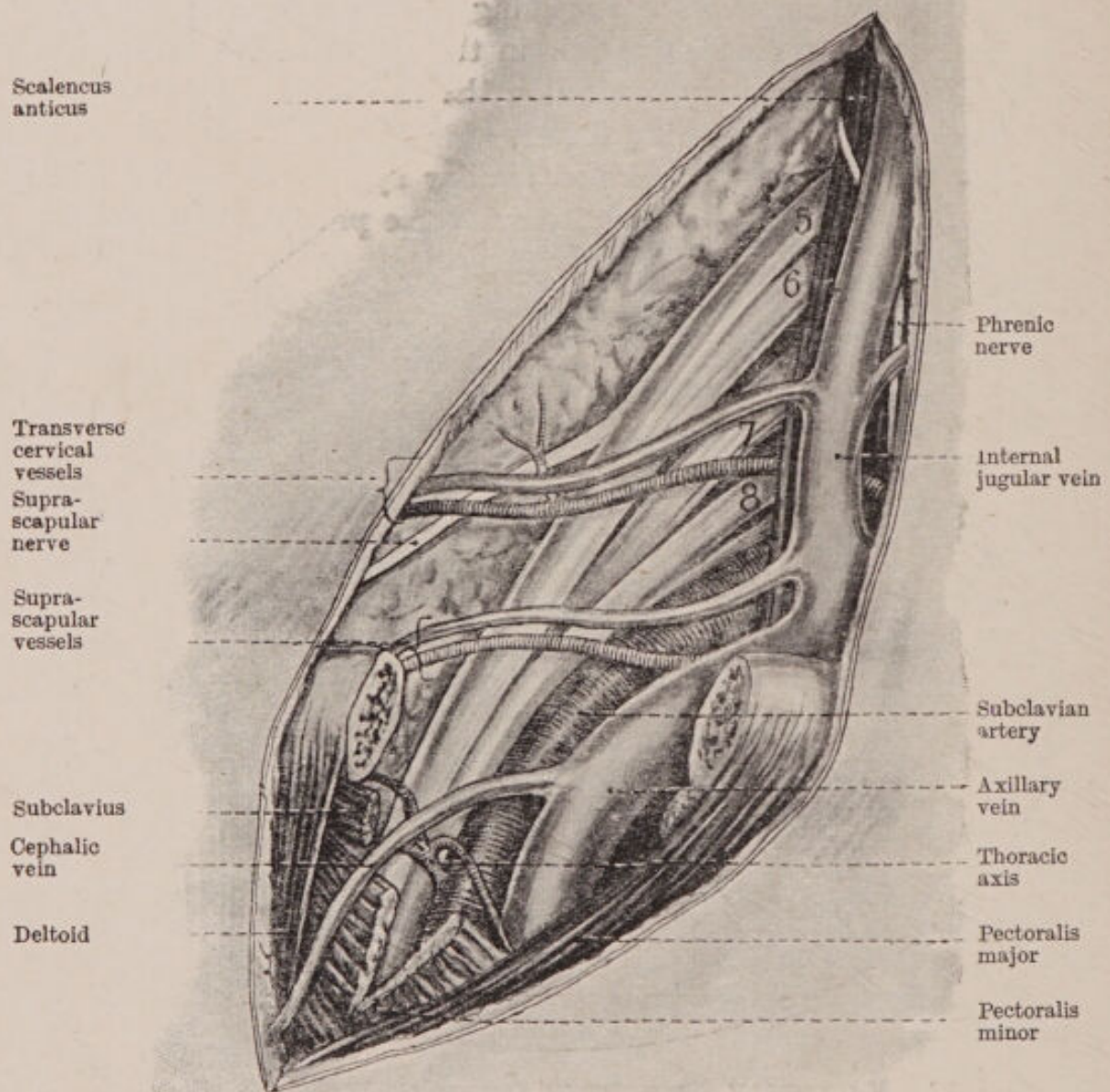


FIG. 93.—AN OPERATION TO EXPOSE THE RIGHT BRACHIAL PLEXUS. The incision commences at the middle of the posterior edge of the sternomastoid, and, having crossed the clavicle at the junction of the outer with the middle third, opens up the interval between the deltoid and pectoralis major muscles.

of the scalenus anticus, and here will be found the junction of the 5th with the 6th cervical nerve. Follow this down, and look out for the suprascapular nerve which comes off from the

outer edge of the conjoined 5th and 6th nerves immediately below their junction. Below and internal to this nerve-trunk the 7th nerve will be found; and below and internal to this, the 8th cervical.

Lower still and deeper, i.e. farther from the surface, the 1st dorsal nerve will be found, posterior to the subclavian artery.

To get a satisfactory exposure of the 1st dorsal nerve, prolong the incision downwards and outwards, in the interval between the deltoid and pectoralis major muscles, and cut through the clavicle. Cut through the periosteum of the clavicle on its superior and anterior surfaces; with an aneurysm-needle separate the periosteum posteriorly. As this is being done, working from below, keep the needle closely hugging the bone; when the eye of the needle appears above, pass a silk ligature through it and withdraw the needle. The silk is now tied to the end of a Gigli saw, and by means of this the saw is passed behind the bone. Saw through the clavicle, and cut through the periosteum, subclavius muscle, and costo-coracoid membrane. If these have not been encountered before, now clamp the supra-scapular vessels in two places, and divide between. If still the lesion be insufficiently exposed, incise the upper margin of the pectoralis minor, or cut right through it.

The exposure thus gained in the various stages is all one can desire (see Fig. 93).

At the end of the operation, suture the pectoralis minor muscle, and wire the cut ends of the clavicle.

## THE POSTERIOR THORACIC NERVE

*Anatomy.*—This nerve arises from the 5th, 6th, and 7th cervical nerves near the intervertebral foramina, and pierces the scalenus medius as two trunks, the lower being the branch from the 7th cervical nerve. It runs down the side of the neck behind the brachial plexus, and enters the axilla between the upper edge of the serratus magnus and the axillary artery. It is a purely motor nerve, and supplies the serratus magnus muscle.

This nerve may be injured from violence applied to the

supraclavicular region, or by wounds in the axilla, as in dissection of the axilla when operating for malignant disease of the breast. When injured in the supraclavicular region it is almost always associated with lesions of other nerves, both of the brachial and cervical plexuses, so that

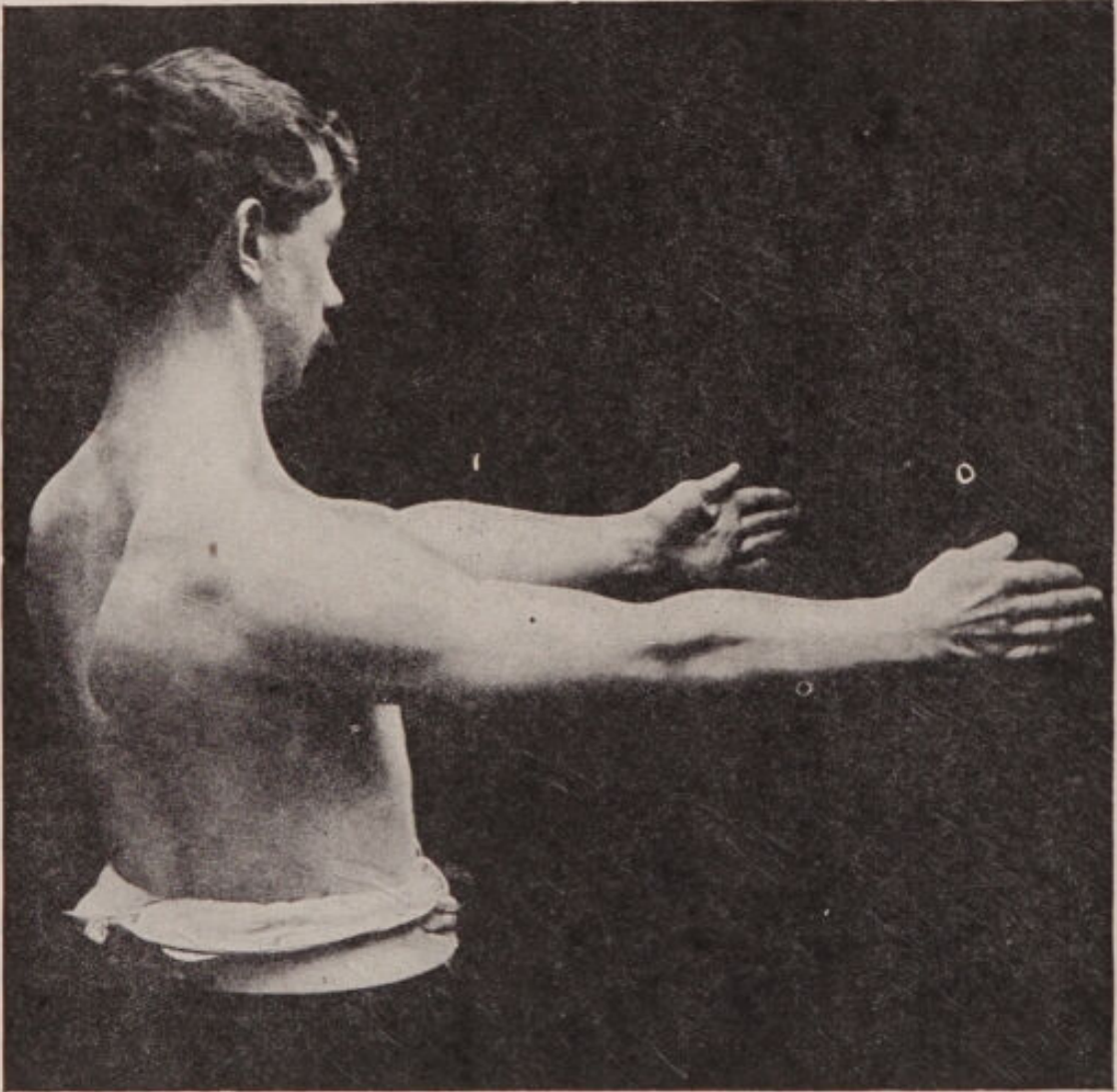


FIG. 94.—PARALYSIS OF THE RIGHT SERRATUS MAGNUS MUSCLE (posterior thoracic nerve), showing the marked projection of the inferior angle of the scapula when the arm is held horizontally in front of the body.

the paralysis of the serratus magnus is generally associated with paralysis of the trapezius, rhomboids, spinati, &c.

When isolated paralysis of the serratus magnus occurs independently of trauma, the affection of the posterior thoracic nerve is generally occasioned by inflammation of

the subscapular bursa, close to which it runs. This may be due to cold, or to effusion from sudden muscular exertion.

The serratus magnus keeps the scapula closely applied to the chest wall, and can advance the scapula towards the front; it also gives the deltoid and other upper-arm muscles a fixed base from which to work. When the serratus is paralysed, the scapula shows no deformity with the arm hanging loosely at rest, since the trapezius and rhomboids keep it in contact with the posterior chest-wall. But on extending the arm horizontally in front of the body the scapula [is detached from the chest wall and becomes 'winged' (see Fig. 94), and this is still more marked if a forward pushing movement is attempted. When paralysis of the serratus magnus is

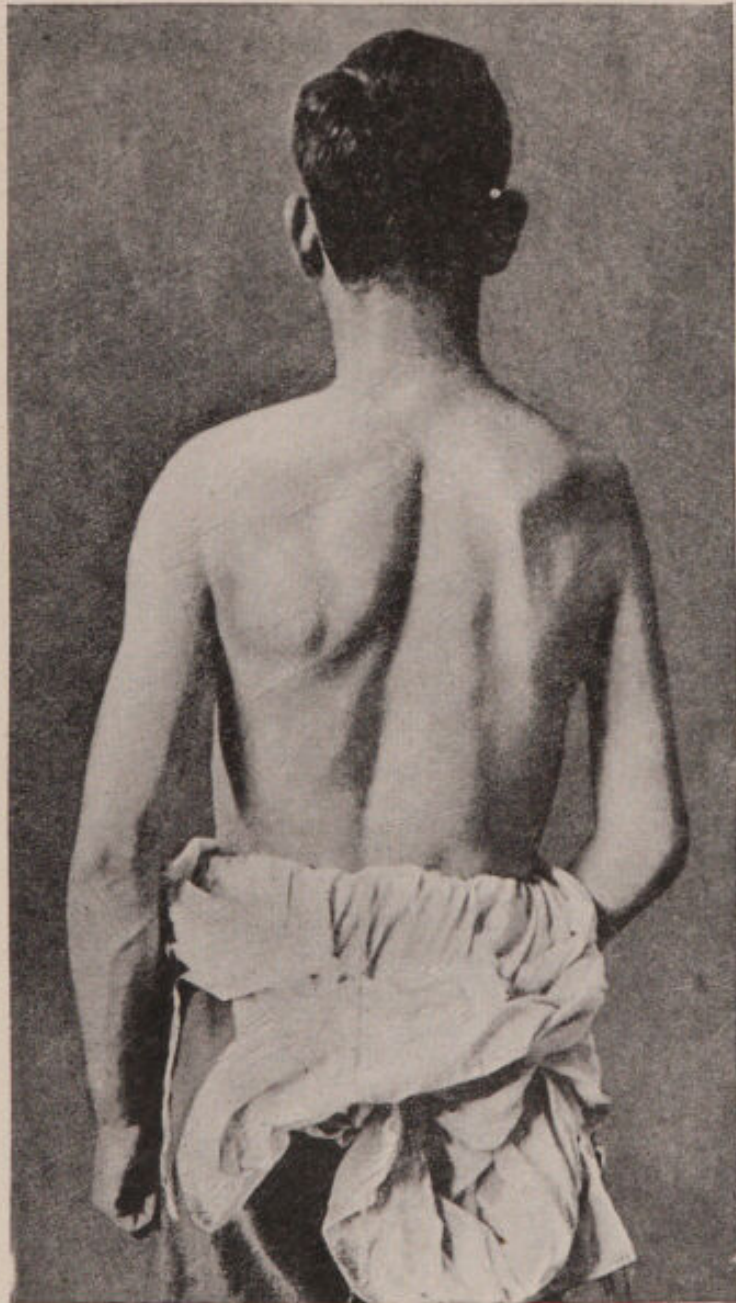


FIG. 95.—PARALYSIS AND WASTING OF THE RIGHT DELTOID AND SPINATI MUSCLES following a gunshot-wound of the right side of the neck, which completely divided the 5th cervical root.

associated with paralysis of the lower fibres of the trapezius, there is deformity of the scapula even at rest, so that its lower angle is displaced towards the middle line, and its axillary border becomes almost horizontal.

### THE CIRCUMFLEX NERVE

The circumflex nerve is seldom injured in projectile wounds; in our own list of over 500 nerve injuries this nerve occurred only once.

The circumflex nerve as it winds round the neck of the humerus may be injured in fractures of the neck of the humerus, in subglenoid dislocations, and from the pressure of a crutch.

**Symptoms.** There is paralysis and wasting of the deltoid and teres minor muscles, with inability to abduct the arm, and weakness of external rotation of the shoulder-joint.

In addition, there is a patch of cutaneous anæsthesia over the central portion of the muscle.

Paralysis of the deltoid is, however, much more commonly dependent on lesions of the 5th cervical root, and it is then associated with paralysis of the spinati and other muscles (Fig. 95).

## CHAPTER X

### THE ULNAR NERVE

*Anatomy.*—The ulnar nerve arises from the inner cord of the brachial plexus, and is derived from the 8th cervical and 1st dorsal nerves.

In the axilla it lies between the axillary artery and the vein, and behind the internal cutaneous nerve; in the upper half of the arm it lies on the inner side of the brachial artery. In the lower half it inclines away from the artery to the inner side of the limb and, passing backwards through the internal inter-muscular septum, reaches the groove between the internal condyle of the humerus and the olecranon process. Entering the forearm between the two heads of the flexor carpi ulnaris, it runs beneath this muscle until it reaches the radial side of the pisiform bone; here it pierces the deep fascia and enters the hand, superficial to the anterior annular ligament.

It gives off no branches in the arm, but immediately after entering the forearm it supplies the flexor carpi ulnaris and the inner half of the flexor profundus digitorum.<sup>1</sup> In the middle third of the forearm the ulnar nerve gives off a dorsal cutaneous branch, which passes downwards and backwards beneath the tendon of the flexor carpi ulnaris, and becomes cutaneous on the inner side of the forearm in its lower fourth;

<sup>1</sup> There is sometimes an anastomotic branch connecting the ulnar nerve with the median in the upper part of the forearm where these two nerve-trunks lie between the superficial and the deep flexor muscles. This anastomotic branch appears to carry motor fibres from the one nerve to the other, thereby reinforcing the double innervation of the flexor profundus. In rare cases nearly all the motor fibres of the ulnar may reach it through this anastomotic branch, and in such a patient a lesion of the ulnar nerve above that level will produce ulnar anæsthesia with little or no motor impairment. (See a case by Halipré, *Revue Neurologique*, 1917, p. 236.)

it supplies the skin over the ulnar side of the dorsum of the wrist, the whole of the dorsal surface of the little finger, and the dorsal surface of the ulnar half of the ring finger over its proximal phalanx. In the lower third of the arm the ulnar nerve gives off a palmar cutaneous branch, which supplies the skin over the hypothenar eminence and the adjacent portion of the palm.

The ulnar nerve is mainly destined for the innervation of the hand, where it supplies the palmaris brevis muscle and then divides into superficial and deep branches. The superficial branch supplies the skin over the palmar surface of the little and half the ring fingers, and the dorsal surface of the two terminal phalanges of the ring finger on its ulnar side. The deep branch supplies all the muscles of the hypothenar eminence (the abductor, flexor brevis, and opponens minimi digiti), all the interossei, the two (sometimes the three) inner lumbricales, the adductor obliquus, adductor transversus, and the deep part of the flexor brevis pollicis.

In the upper arm the fibres for the long flexors of the fingers lie in the postero-external part of the nerve trunk, those for the flexor carpi ulnaris at the inner side, and those for the intrinsic hand muscles, together with the cutaneous sensory fibres, in the antero-internal part; lower down, above the wrist, the cutaneous fibres lie superficially, with the motor fibres for the hypothenar muscles and the inner interossei; the fibres for the outer interossei lie externally.

In civil life the ulnar nerve is most commonly injured in penetrating wounds about the wrist-joint; it is sometimes injured at the elbow as it passes behind the internal condyle, either by a direct blow or accompanying fractures and dislocations.

In warfare, injury of the ulnar nerve by penetrating wounds is common in every part of its course.

### Symptoms of Ulnar Nerve Paralysis.

**Sensory.** In total ulnar palsy there is loss of cutaneous sensation in the little finger and the ulnar half of the ring finger and the corresponding part of the hand, front and

back, not extending above the wrist. The protopathic loss is less than the epicritic, and loss of sensation to deep pressure is limited to the little finger (see Fig. 96). Joint-sense is lost in the little finger, and sometimes also in the ring finger. If the nerve is severed after it has given off its dorsal cutaneous branch, loss of sensibility will be confined to the palmar surface of the hand and fingers

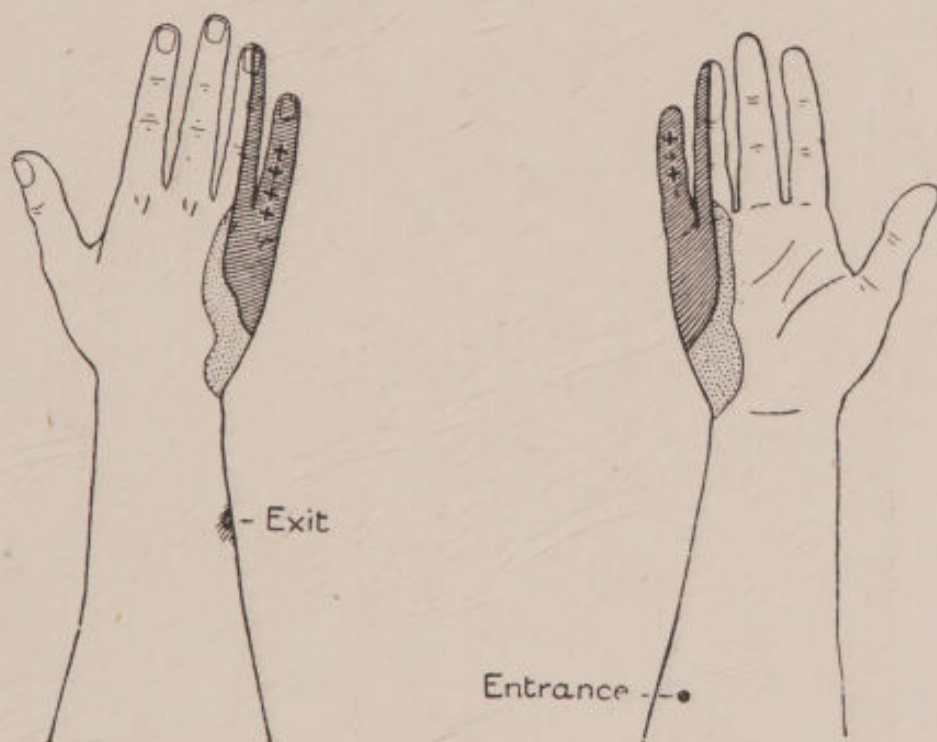


FIG. 96.—WOUND OF THE ULNAR NERVE. The shaded area is that insensitive to pin-pricks (protopathic loss). The dotted area is the additional area insensitive to cotton-wool touches (epicritic loss). The crosses indicate the region where there is loss of sensation to deep pressure. Joint-sense is lost in the little finger and vibration-sense in the two ulnar fingers. The ulnar nerve and its dorsal cutaneous branch were found embedded in dense scar tissue.

and to the dorsal surface of the two terminal phalanges of the ring finger on its ulnar side. If the lesion be lower still, after the nerve has given off its last cutaneous branch, there will be no area of anæsthesia (see Fig. 97). Accidental burns in the anæsthetic area of the hand and fingers are very common (see Fig. 7, p. 7).

Pain at the moment of injury is usually severe, shooting

down the limb to the two ulnar fingers. This pain may persist for a considerable time, but, compared with median palsy, pain is not an outstanding feature, and typical thermalgia (causalgia) does not occur in pure ulnar lesions.

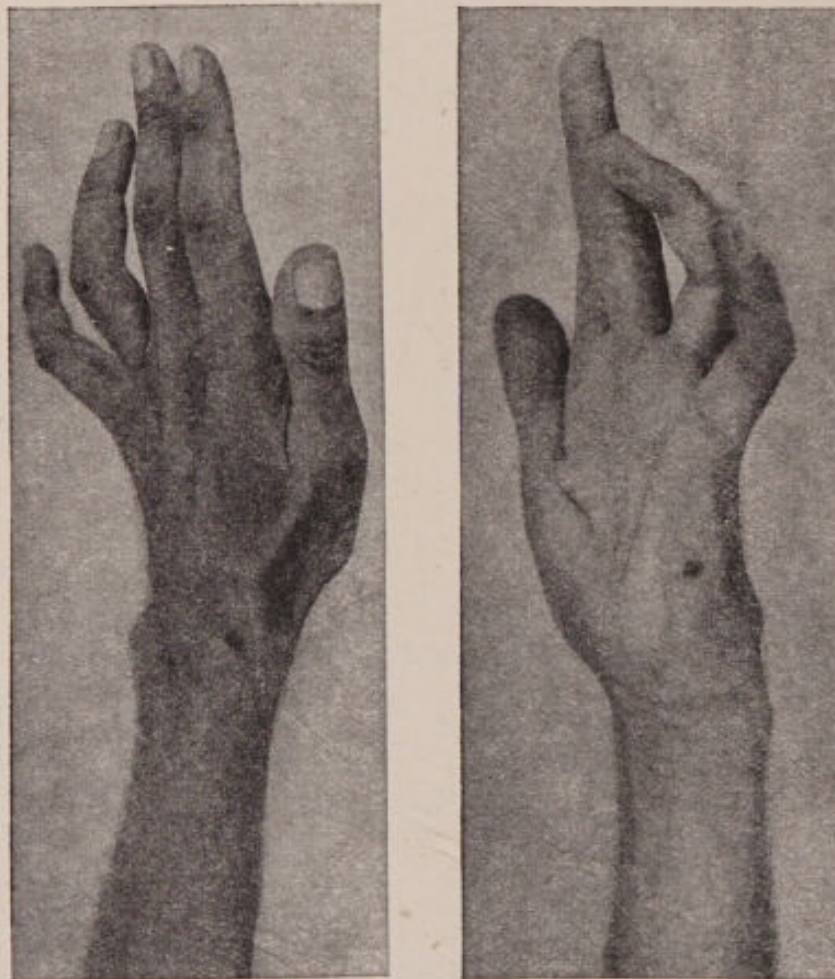


FIG. 97.—BULLET-WOUND OF THE DEEP BRANCH OF THE ULNAR NERVE ACCOMPANIED BY NO SENSORY LOSS, AND WITH JOINT-SENSE NORMAL IN ALL JOINTS. Entrance-wound at ulnar border of hand, two inches below the wrist. Exit-wound on dorsum, the bullet having traversed the carpus. Note the position of the two ulnar fingers: hyper-extension at the metacarpo-phalangeal joints and semi-flexion at the interphalangeal joints.

**Motor.** The muscles between the metacarpal bones, especially those in the first interosseous space, become wasted, and the bones become abnormally prominent.

Owing to paralysis of the interossei (whose action is to extend the two distal phalanges of each finger), the interphalangeal joints become flexed by the unopposed action

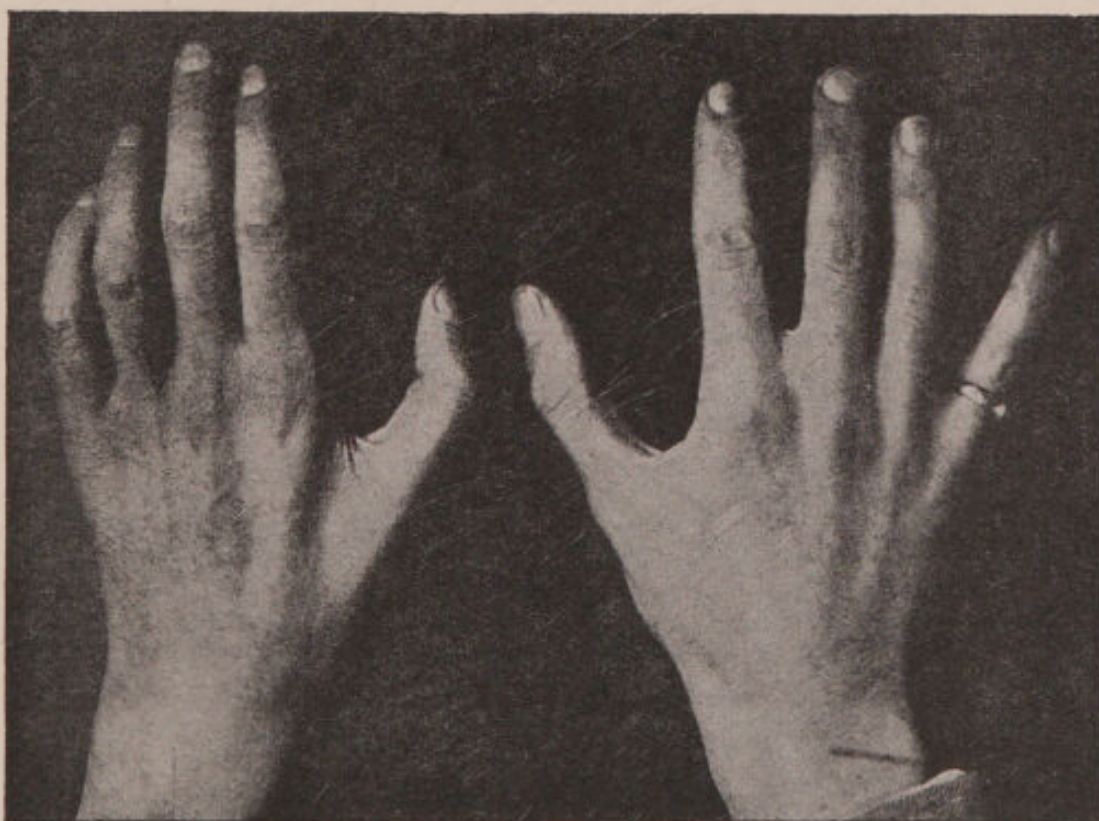
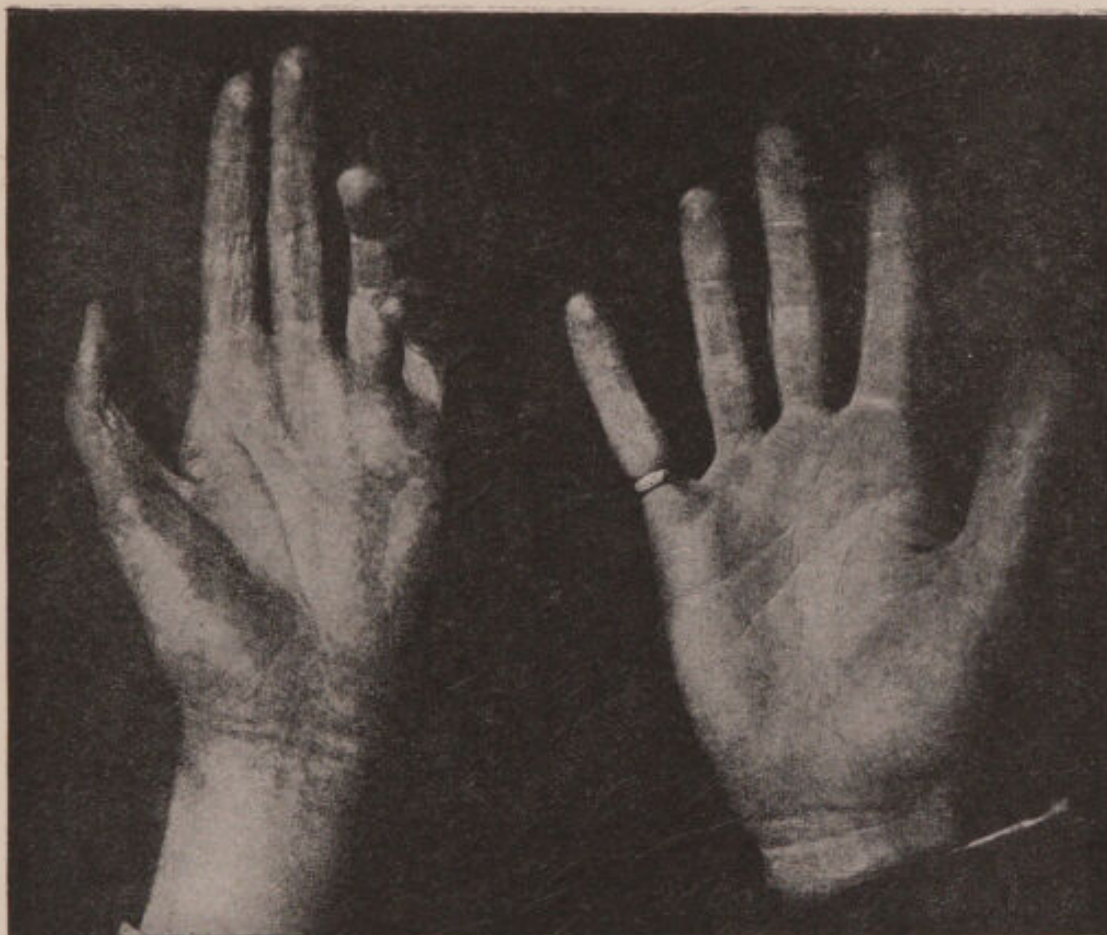

FIG. 98.—A GUNSHOT-WOUND OF THE LEFT ULNAR NERVE ONE INCH ABOVE THE INTERNAL CONDYLE OF THE HUMERUS. Note the characteristic flexion of the fingers, the wasting of the interossei, of the hypothenar muscles, and of the thumb adductors. The patient is trying to abduct all his fingers; compare the two hands.

of the flexors of the fingers; and, owing to paralysis of the two inner lumbricales (whose action is to flex the metacarpo-phalangeal joints), the little and ring fingers become hyper-extended at these joints by the unopposed action of the extensor communis digitorum. This condition is known as claw-hand or *main en griffe*.

An additional sign, due exclusively to paralysis of the interossei, is that the fingers can no longer be spread out in fanlike fashion (Fig. 98), nor can the middle and distal phalanges be fully extended. The little finger is, however, generally kept widely abducted by the unopposed action of the extensor minimi digiti. From paralysis of the adductor obliquus, adductor transversus, and the deep part of the flexor brevis pollicis, the power of adducting the thumb is lost; the hypothenar muscles, the interossei, the thumb adductors, and the ulnar lumbricales waste, and the long flexor tendons become visible as longitudinal ridges in the palm.

One of the most constant signs of ulnar palsy is demonstrated by handing the patient some thin object, such as a sheet of paper, and asking him to catch firm hold of it, first with the normal hand and then with the paralysed hand. Or we may get the patient to hold the paper in both hands and to pull them in opposite directions. On the normal side, the whole length of the thumb is held in contact with the paper, pressing it against the index, the terminal phalanx of the thumb being extended or perhaps slightly flexed. On the paralysed side, however, prehension is weakened, and only the pulp of the thumb-tip touches the paper; the terminal phalanx of the thumb becomes flexed and the paper is held between the tips of the flexed thumb and flexed index finger. Other than at their tips, the thumb and index finger are separated by an open space (Fig. 99). This prehension *à bout des doigts* is carried out by the long flexors of the thumb and index finger, assisted by the opponens pollicis, all of which are innervated by the median nerve. This is the method

normally used when performing movements of delicacy, as when picking up fragile objects which we are anxious not to crush. Energetic prehension, on the other hand, is carried out by the adductors of the thumb and the deep part of the flexor brevis pollicis, innervated by the ulnar nerve.<sup>1</sup>

A lesion at or above the elbow, in addition to the fore-



FIG. 99.—LEFT-SIDED ULNAR PARALYSIS. Froment's sign.

going symptoms, is accompanied by paralysis of the flexor carpi ulnaris and the inner half of the flexor profundus digitorum, so that the patient cannot perform ulnar flexion of the wrist, nor can he flex the terminal phalanx of the little or ring finger. In this latter case the deformity of these two fingers is much less marked.

#### Vasomotor and Trophic Changes.

Horny thickening of the epidermis (hyperkeratosis) over

<sup>1</sup> Froment, *Presse Médicale*, 1915, October 21.

## 166 NERVE INJURIES AND THEIR TREATMENT

the palmar distribution of the ulnar nerve occurs in certain long-standing cases; otherwise trophic changes are uncommon; in particular, we do not meet with the excessive sweating so characteristic of median palsy. More often, the skin is abnormally cold and dry. Sometimes, when the median and ulnar are both injured, the difference as to the sweating of the two cutaneous territories is particularly striking.

**Diagnosis.** The symptoms of paralysis of the ulnar nerve can only be confused with those due to a lesion of the 8th cervical and 1st dorsal roots, or of the inner cord of the plexus, and in these the motor and sensory paralysis have the characteristic distribution of root-areas (see pp. 130-131); i.e. there is anæsthesia along the inner side of the forearm and hand, and all the small muscles of the hand are paralysed (Figs. 85 and 87).

### **Incomplete Lesions of the Ulnar Nerve.**

Incomplete lesions of the ulnar nerve are frequently associated with spontaneous pains in the area of its cutaneous supply. These pains rarely attain the severity of those found in incomplete lesions of the median nerve.

Pain may also be induced by pressure on the nerve at the site of injury, or over the nerve-trunk distal to this. The muscles supplied by the nerve are frequently tender to pressure, and pain can generally be elicited by pinching the hypothenar muscles.

Incomplete lesions are often associated with fibrous changes in the palmar fascia and adhesions in the tendon-sheaths, resulting in irreducible deformity of the two ulnar fingers.

A fibrous 'griffe' which is irreducible is highly suggestive of an incomplete lesion of the nerve.

### **Delayed Ulnar Neuritis.**

Late paralysis of the ulnar nerve, due to chronic interstitial neuritis, is a rare affection which sometimes super-

venes upon an old dislocation of the elbow-joint, or a fracture in its neighbourhood, especially after a fracture of the internal condyle of the humerus which has produced cubitus valgus (see Fig. 100) and alteration in the configuration of the ulnar groove behind the internal condyle. The interval of time which elapses between the original joint-injury and the onset of ulnar symptoms may be many years—as long an interval as 39 years has been recorded. During this latent period, there are no symptoms, beyond the deformity and restricted movement of the elbow-joint. Then, slowly and gradually, progressive symptoms of ulnar palsy develop, running an extremely chronic course, consisting in atrophic paralysis of the intrinsic hand-muscles belonging to the ulnar distribution. There may also be corresponding sensory disturbances, in the form of tingling or anæsthesia, but these are often absent or trivial in degree.

To check the progress of the atrophy, surgical intervention is necessary, in order to free the ulnar nerve from pressure. This may be attained by transposing the nerve-trunk from the back of the internal condyle to the front. If the nerve is severely sclerosed and nodular at its point of injury, it may be necessary to resect the affected zone of induration.

The following are illustrative cases :—

At the age of 6, a little boy fell off a fence, landing on his left elbow and sustaining a fracture of the lower end of the humerus. A radiogram taken 37 years later, when he was a medical officer on active service in Macedonia, showed the old T-shaped fracture, with abnormal thickening and prominence of the internal condyle. At the time of the accident the limb was put up in a rectangular splint; the fracture became united and the movements of the joint slowly recovered, although slight limitation of extension persisted.

Twenty years after the accident he was building a hut in Canada in the winter-time, when the cold was intense. He had to use his left hand a great deal for holding nails. Within

a week or so, he noticed gradual weakness and anæsthesia of the left hand. There was no pain, only pins-and-needles in the anæsthetic area at the ulnar side of the hand. Interosseal atrophy rapidly developed, with claw-hand and inability to extend the two distal joints. For the first two months, this got steadily worse. It then became stationary, and after six months spontaneous improvement set in, so that, at the end of nine months, the anæsthesia had disappeared and there was almost complete motor recovery. Subsequent to this, he used to notice that if he kept his left elbow flexed for five or

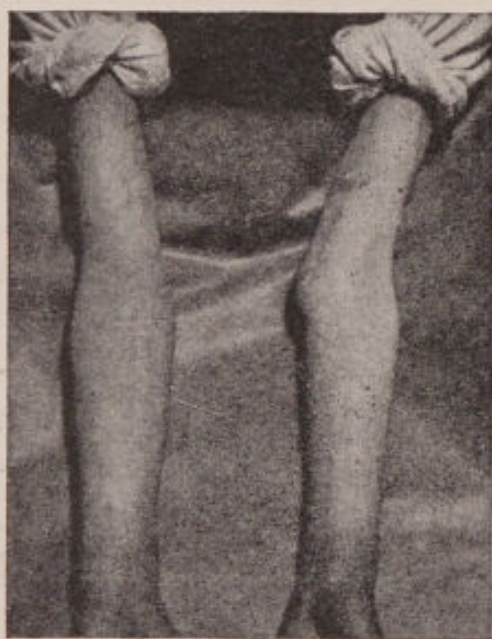

FIG. 100.—ULNAR PARALYSIS, Showing bony deformity of the internal condyle of the left humerus causing the paralysis.

ten minutes, the ulnar area of the hand became anæsthetic, until he relaxed the nerve by extending the elbow, when the anæsthesia cleared up within a minute.

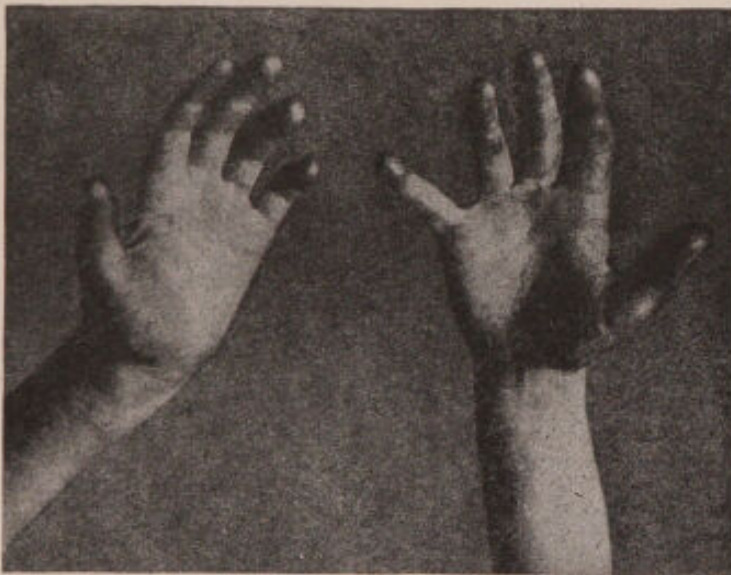A year after the onset of the paralysis, i.e. 21 years after the original fracture, the left ulnar nerve was exposed by operation behind the internal condyle. Fibrous adhesions were found and separated off the nerve-trunk. The wound healed *per primam*. For about a week after this operation, there was severe pain all down the course of the ulnar trunk, requiring morphia. The numbness on flexing the elbow was considerably

relieved after this operation, and it now took prolonged flexion of an hour or more, e.g. during sleep, to produce ulnar anæsthesia.

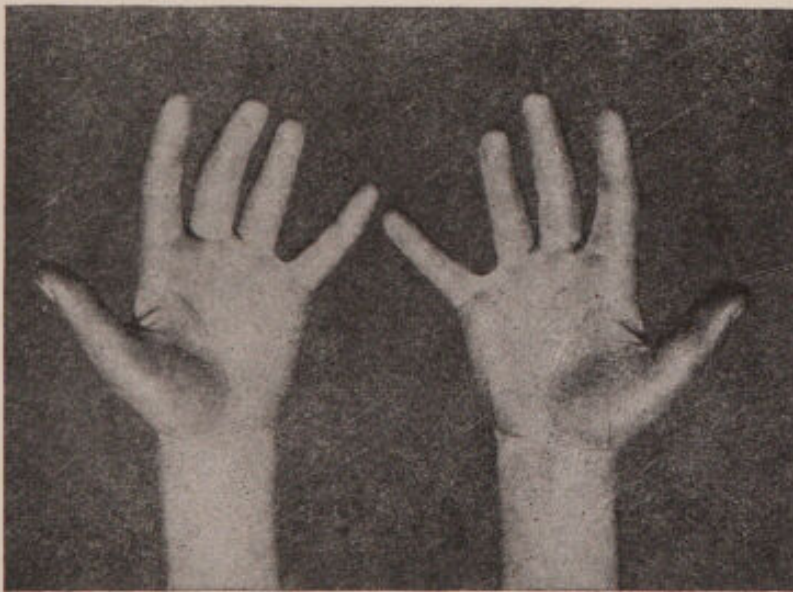
At the age of 41 the pain and anæsthesia increased, in certain flexed postures of the elbow, but there was no increase in the muscular atrophy.

When examined at the age of 43, there was an old-standing deformity of the left elbow, with undue prominence of the internal condyle of the humerus. There was an old operation-scar over the course of the ulnar nerve behind the elbow, and

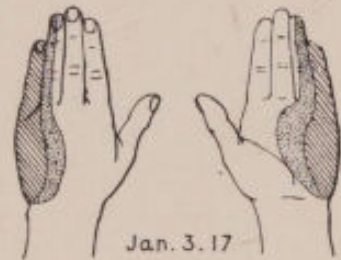the subjacent nerve-trunk felt thickened, compared with the healthy side. There was no absolute anæsthesia to be made out. But in the ulnar area of the hand the compass-test



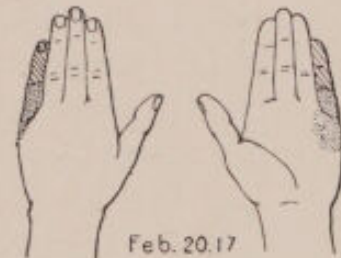A



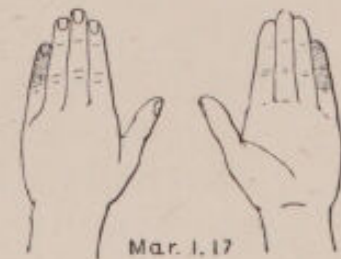B



Jan. 3. 17



Feb. 20. 17



Mar. 1. 17

C

FIG. 101.—LEFT ULNAR PARALYSIS. A shows the wasting of muscles and loss of power in the interossei, as evidenced by the inability to spread out the fingers. B shows the return to normal, following the operation. C shows recovery of sensation at successive dates after operation.

was only recognized at a separation of 2 cm., compared with 1 cm. in the healthy hand. There was well-marked atrophy of the first dorsal interosseous muscle and of all the hypothenar muscles. Abduction of the index was slightly feeble,

## 170 NERVE INJURIES AND THEIR TREATMENT

but all other intrinsic hand-movements were well performed. To faradism there was marked diminution of reaction in all the interossei, especially the first and second.

Figs. 100 and 101 relate to a boy who on August 14, 1916, fell, injuring his left elbow. For ten weeks after the injury his left hand was normal. Later it was noticed that it was becoming weaker than the right hand. When seen on December 18, 1916, he was found to have a bony deformity in the region of the internal condyle. (See Fig. 100.) The sensory loss was as shown in the diagram. Pressure-sense was lost over the three phalanges of the little finger. There was marked wasting of the interossei, and no movement in them. Adduction of the left thumb was weaker than that of the right. There was no response to faradism in the flexor carpi ulnaris, nor in the interossei. To galvanism the contractions were sluggish, with polar changes.

At the operation on February 7, 1917, the ulnar nerve behind the internal condyle was found stretched over a boss of bone. The nerve was therefore transposed to the front of the joint.

February 20, 1917. The patient could now adduct the little finger, and could adduct the thumb more forcibly than before. (For sensory loss, see Fig. 101 c.)

March 1, 1917. There was only epicritic sensory loss over the two terminal phalanges of the little finger (Fig. 101 c). There was no loss of pressure-sense. Adduction of the thumb was normal.

Three weeks later there was no sensory loss of any kind.

### MEDIAN NERVE

*Anatomy.*—The median nerve arises by two heads, one from the outer cord and the other from the inner cord of the brachial plexus. The outer head receives fibres from the 6th and 7th cervical nerves, the inner head from the 8th cervical and 1st dorsal nerve. The two heads of the median embrace the axillary artery. The nerve descends close along the outer edge of the brachial artery, which separates it from the ulnar and internal cutaneous nerves, and crosses it in the lower half of the arm. At the bend of the elbow it lies internal to

the brachial artery, and beneath the bicipital fascia and the median basilic vein. It now leaves the brachial artery and enters the forearm between the two heads of the pronator radii teres. It runs down the forearm between the superficial and deep muscles, inclining towards the radial side. At the wrist it becomes almost subcutaneous, lying directly beneath the tendon of the palmaris longus, and having the flexor carpi radialis on its radial side and the superficial flexor tendons on its ulnar side.

In the upper arm it usually gives off no branch. Immediately after the nerve has entered the forearm it gives off branches which supply all the muscles on the flexor aspect, with the exception of the flexor carpi ulnaris and the inner half of the flexor profundus digitorum. Its anastomotic branch to the ulnar nerve has already been referred to (p. 159, footnote).

The median nerve-trunk passes beneath the anterior annular ligament, lying on the radial side of the flexor tendons, and at its lower border gives off muscular branches to the abductor pollicis, opponens pollicis, and superficial head of the flexor brevis pollicis, to the lumbricales of the index and medius (sometimes of the index alone), and cutaneous branches to the palm and three-and-a-half radial fingers.

This important nerve-trunk is therefore the nerve of pronation, of flexion of the wrist and fingers, and of opposition of the thumb.

### **Sensory Symptoms.**

In complete median palsy, cutaneous anæsthesia is present in the palmar surface of three-and-a-half radial digits and in the corresponding part of the palm, up to the fold of the wrist. The anæsthesia also extends on to the dorsum of the index, middle, and half the ring fingers, except on the proximal half of the proximal phalanges which are supplied by the radial nerve (see Fig. 116, p. 193). Joint-sense is lost in the thumb, index, and middle fingers, and there is generally astereognosis, i.e. inability to recognize by feeling alone the shape of objects placed between the affected digits. Total anæsthesia of the affected territory is rare; more usually we find simple blunting of

sensation to touches and pin-pricks. On the other hand, this blunted cutaneous area is often hyper-sensitive to deep pressure. The extent of anæsthesia varies greatly (see Figs. 103–108).

### Motor Symptoms.

When the nerve is completely divided at or above the elbow, all the muscles supplied by it are paralysed; there

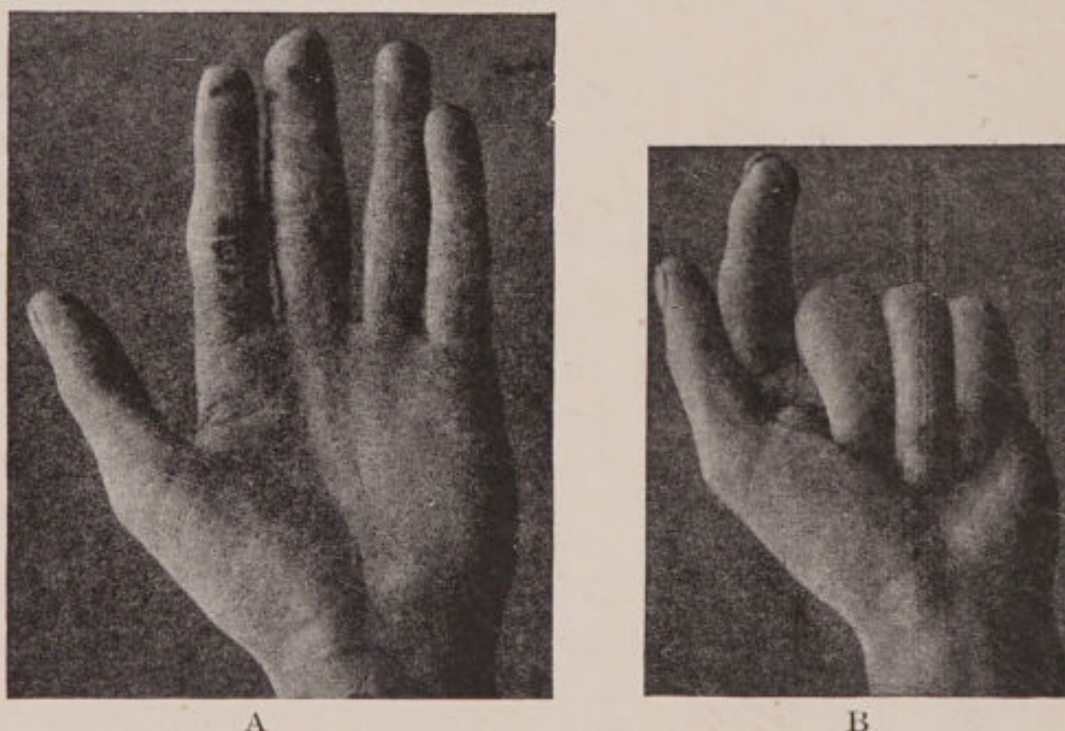


FIG. 102.—PARALYSIS OF THE LEFT MEDIAN NERVE. The nerve was incompletely divided. A shows the hand at rest; note the absence of deformity, also the multiple trophic lesions on the thumb and on the two radial fingers. B shows the maximum flexion of the fingers. Note the position of the index finger, flexed only at its metacarpo-phalangeal joint; note also the inability to flex the terminal phalanx of the thumb.

is paralysis and wasting of the pronators, and the forearm cannot be pronated beyond the mid-position. The patient tries to compensate for this loss of pronation by abducting the flexed elbow, so as to let the hand fall into the pronated position, or, if the elbow be extended, by rotating the whole arm inwards at the shoulder. On flexing the wrist the hand becomes drawn to the ulnar side, consequent on paralysis of the flexor carpi radialis; the long flexors of

the thumb and fingers (except the ulnar portion of the flexor profundus) are paralysed, and in attempting to clench the fist it will be noted that there is no flexion of the terminal phalanx of the thumb, that the index finger can only be flexed at the metacarpo-phalangeal joint, and that the ring and little fingers are usually the only ones whose terminal joints can be fully flexed. Sometimes the ulnar nerve supplies so much of the flexor profundus that in median palsy the middle finger can still be flexed voluntarily (see Fig. 102 B).

Consequent on the paralysis of the thenar muscles, the power to abduct and oppose the thumb is lost (Figs. 110 and 111).

Fig. 102 is that of a man who received a punctured wound of the left upper arm, immediately to the inner side of the biceps,  $3\frac{1}{2}$  inches above the level of the internal condyle. When seen four months later, there was anæsthesia to cotton-wool touches over the palmar surface of the thumb, and of the index, middle, and half the ring fingers, and over the corresponding half of the palm, extending to just below the fold of the wrist (Fig. 103). The anæsthesia to pin-pricks was slightly less extensive and did not include the palmar surface of the radial half of the ring finger. On the dorsum there was anæsthesia to cotton-wool touches and pin-pricks over the terminal phalanx of its thumb, and over the terminal, middle, and half the proximal phalanges of the index, middle, and the radial half of the ring fingers. Deep pressure-sense was lost over the terminal phalanges of the index and middle fingers. Joint-sense was normal in all fingers.

The patient could fully flex his three ulnar fingers, making the finger-tips touch the palm. The index finger could only be flexed at the metacarpo-phalangeal joint by means of its lumbrical. The terminal phalanx of the thumb could not be flexed. The thumb could be opposed and abducted. There were many trophic lesions over the insensitive area.

At the operation the median nerve was found embedded in a mass of fibrous tissue; when dissected free from this, the

nerve was seen to be incompletely divided, the undivided fibres forming the antero-internal segment of the nerve.

When the median nerve is divided below the elbow, i.e. below the point at which the muscles to the forearm are given off, then the only muscles paralysed are the abductor and opponens pollicis and the two outer lumbricales.

It is necessary to emphasize the fact that beyond flattening-out of the thenar eminence, so that the thumb falls back to the plane of the other digits, constituting the monkey hand or *main de singe* (see Fig. 109), the hand

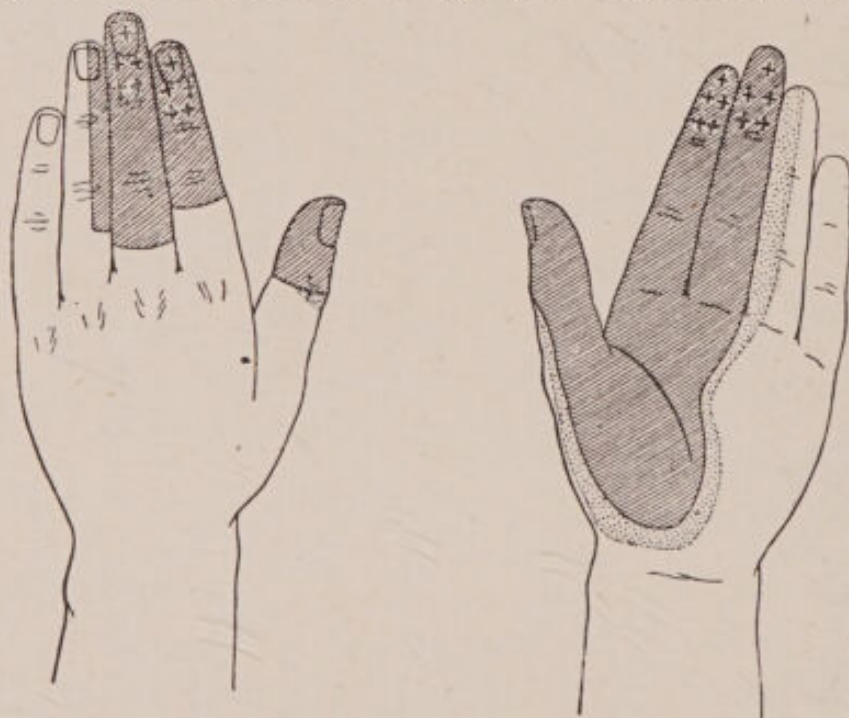


FIG. 103.—PARALYSIS OF THE MEDIAN NERVE. The dotted area is insensitive to cotton-wool touches; the shaded area is insensitive to pin-pricks and cotton-wool touches. The crosses indicate the region insensitive to deep pressure.

when at rest shows comparatively little deformity. Careful routine examination is necessary lest the lesion be overlooked (see Fig. 102 A).

#### Vasomotor, Secretory and Trophic Signs.

These are highly characteristic of median injuries, especially of incomplete lesions of the nerve. The skin and nails of the corresponding area of the hand often show striking changes. The skin of the palm and fingers,

especially of the index, becomes flushed and even cyanosed; sweat secretion may be lost or excessive, and the nails become longitudinally or transversely striated and abnormally curved laterally.

#### INCOMPLETE LESIONS OF THE MEDIAN NERVE

These are commoner than complete lesions.

The symptoms are dependent upon the level of the particular injury, the extent of the cross-section involved, and the destination of the nerve bundles which have been interrupted.

By electrical examination of the exposed nerve-trunk in the upper arm, it is found that contraction of the thenar muscles is effected by stimulation in the posterior region of the nerve; of the pronator muscles by stimulation in the antero-external region, and of the fingers and carpus by stimulation either of the internal or of the external border of the nerve. The nerve-fibres supplying the flexors of the fingers predominate in the postero-external region. When the heads of the median are stimulated above their point of junction to form the median, stimulation of the outer head produces contraction of the pronators, and stimulation of the inner head produces contraction of the flexors of the fingers and carpus.

#### Vasomotor and Trophic Changes.

Incomplete lesions of this nerve are often accompanied by excessive sweating of the median territory of the palm and digits. The most marked trophic change occurs in the nails of the thumb, index, and middle fingers. These grow much faster than the others, are bent claw-like, and become striated both longitudinally and transversely.

#### Painful Symptoms.

Pain is frequently associated with incomplete lesions of the median nerve. The pain may be induced by pressure over the nerve, either at the site of the lesion or

distal to this, or by pressure on the muscles themselves; the pains may be spontaneous.

**Spontaneous pains** are highly characteristic of these injuries. Sometimes the pain is so intense and persistent that this symptom dwarfs all the others, and the patient can think of nothing else.

To this type of case the name of **causalgia** was given by Weir Mitchell. **Thermalgia**, as suggested by Stopford, is a better name.

The pains tend to appear ten days or a fortnight after the injury, gradually increasing in severity week by week, until they reach a maximum. This condition may last for months; the pain then gradually begins to subside spontaneously, and ultimately disappears. These median pains are localized chiefly in the finger-tips, at the fold of the palm with the index and middle fingers, and at the inner side of the thenar eminence. They are stabbing, crushing, and burning in character, constantly present, with waves of exceptional intensity, keeping the patient awake at nights. They are aggravated by heat, and somewhat allayed by cold wet applications; they may be intensified not merely by touching the affected hand, but also by sudden jarring of other parts of the body, by coughing or sneezing, or even by emotion of any sort. These pains are also induced by pressure over the median nerve at any part of its course below the level of the injury.

As a result the patient becomes nervous, suspicious, and morose; he shuns the society of his fellows; he lives centred round his pain; his whole aim is to shield his limb from hurt, to assuage the constant pain, and to prevent the paroxysms.

Fig. 104 relates to an officer who was wounded on August 15, 1917. A piece of shrapnel entered the left upper arm on the inner side, 4 inches above the inner condyle. The exit-wound was on the outer side of the arm,  $3\frac{1}{2}$  inches above the external condyle.

When seen on September 29, 1917, the left elbow was tonically slightly flexed. The left hand was slightly warmer than the right.

The patient states that ever since the morning after the injury he has had pain in the palm of the hand and on the dorsum of the index and middle fingers, and occasionally in the ring finger. He describes this as a 'hot pain, like toothache, but worse.' He also has occasional sudden pains in the interphalangeal joints of the index and middle fingers; these pains shoot up to the shoulder. The hot pain is sometimes relieved by change of posture. The pain is worse when the weather is cold.

To cotton-wool there is hyperæsthesia on the palmar surface of the index and middle fingers. There is no anæsthesia.

To pin-prick there is hyperalgesia of the whole palm, and of the palmar surface of the index and middle fingers.

There is keratosis and excessive desquamation of the palmar aspect of the thumb and radial side of the index finger.

The long flexor of the thumb is paralysed, and so is the flexor of the index finger. All the other muscles of the arm and forearm are normal, including the thenar, hypo-thenar, and interosseous muscles.

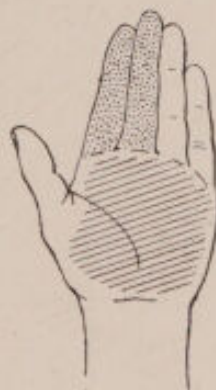

FIG. 104.—INCOMPLETE LESION OF THE MEDIAN NERVE. Dotted area indicates hyperæsthesia to cotton-wool; shaded area, plus dotted area, indicate hyperalgesia to pin-pricks.

### COMBINED PARALYSIS OF MEDIAN AND ULNAR NERVES

Gunshot wounds of the upper arm and forearm often result in injury to both the median and the ulnar nerves (see table, p. 109). The axillary or brachial artery, alongside which these nerves run in the upper part of their course, is often injured at the same time. Symptoms of vascular origin may thus be superadded.

**Sensory Symptoms.**

The anæsthesia is that of the conjoint median and ulnar distribution. This varies greatly. (See Figs. 105–108.)

Fig. 105 is that of a soldier wounded in the middle of the flexor aspect of the right forearm by several fragments of shell. At the operation it was found that the ulnar nerve was completely divided, and the median nerve embedded in fibrous tissue.

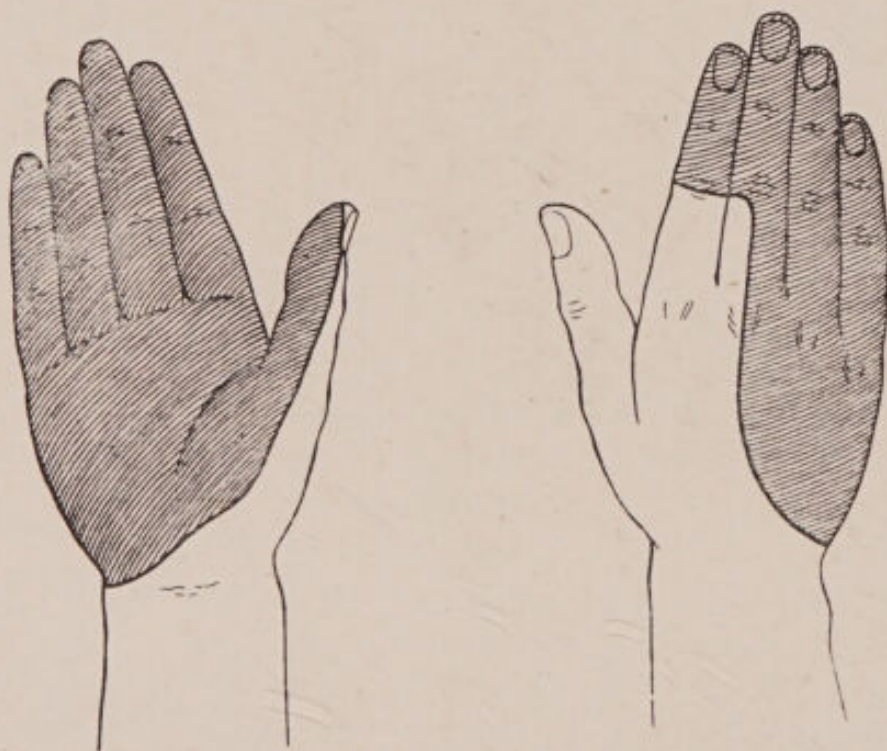


FIG. 105.—COMBINED PARALYSIS OF MEDIAN AND ULNAR NERVES. The shaded area shows the loss to pin-prick and cotton-wool.

Another soldier received a gunshot-wound at Ypres in February 1915; the bullet passed through the right humerus. Entrance-wound, middle of posterior surface of arm  $4\frac{1}{2}$  inches above the olecranon; exit, inner side of arm about its middle.

When seen in July 1915 the exit-wound was still suppurating. The anæsthetic areas are shown in Fig. 106.

The wrist could be extended, but not flexed, supination was powerful, pronation nearly absent. The fingers could be extended, but only partially flexed—the ring and little fingers could be flexed more than the others; the thenar and hypo-

Unable to display this page

**Motor Symptoms.**

The hand is slightly hyper-extended at the wrist and deviated towards the radial side; the thumb has rotated




FIG. 107.—COMBINED PARALYSIS OF THE MEDIAN AND ULNAR NERVES. The median was completely divided; the ulnar severely compressed.

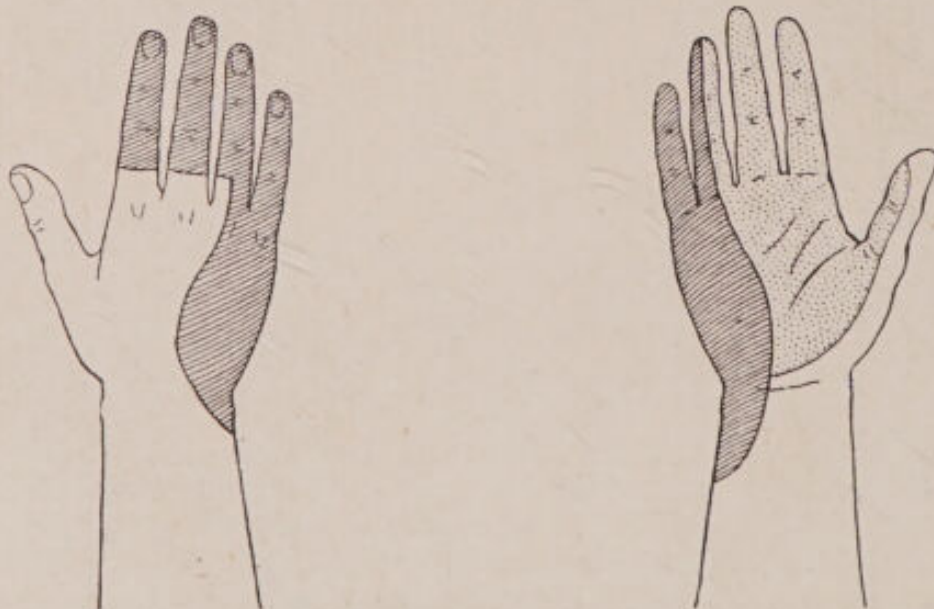


FIG. 108.—COMBINED PARALYSIS OF THE MEDIAN AND ULNAR NERVES. Both nerves were compressed; their deep surfaces were continuous with a mass of scar tissue.

outwards and fallen back into the same plane as the other digits. These latter are kept slightly separated; they are hyper-extended at the metacarpo-phalangeal joints,

Unable to display this page

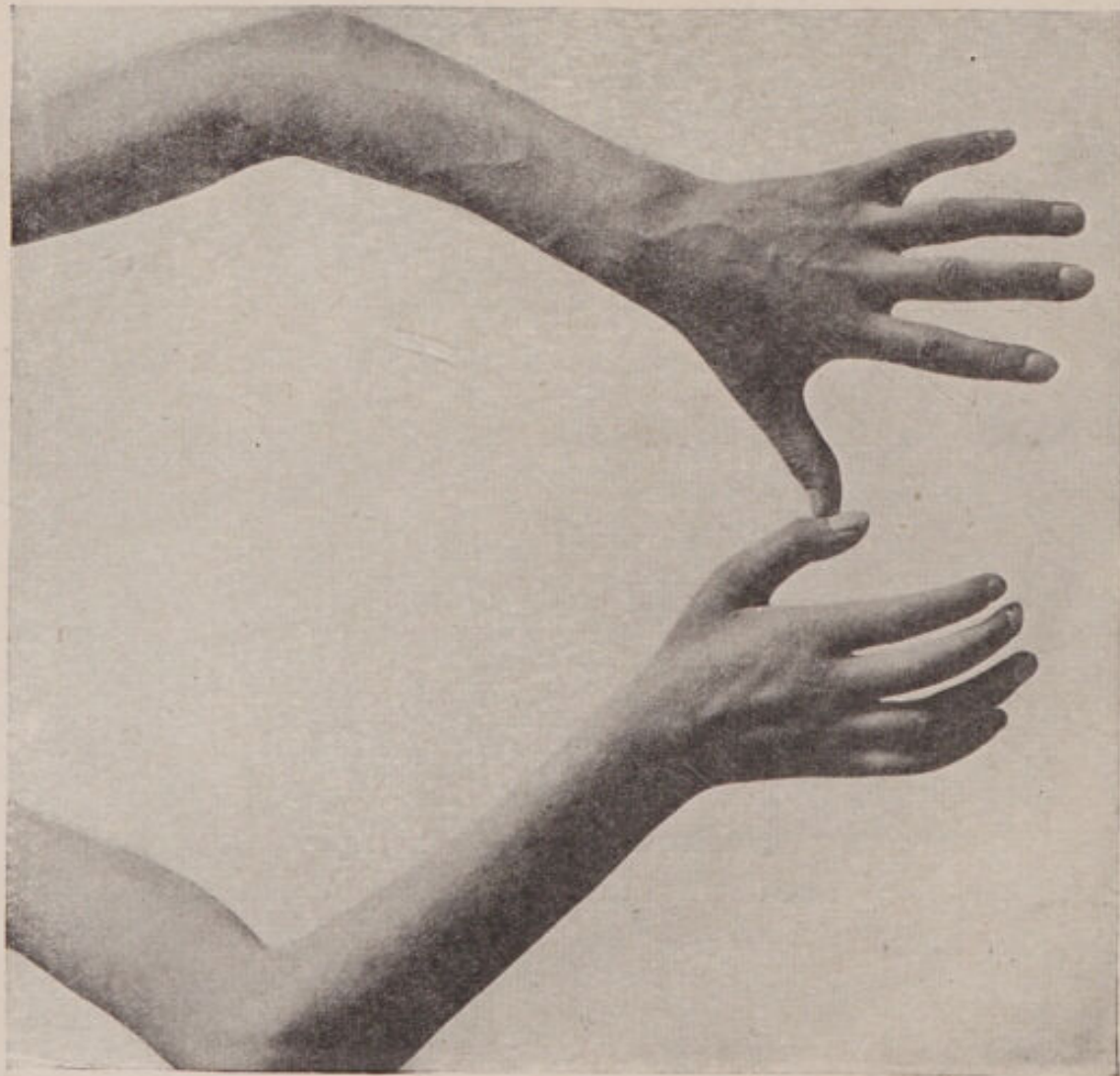


FIG. 110.—COMBINED PARALYSIS OF RIGHT MEDIAN AND ULNAR NERVES, SHOWING PARALYSIS OF INTEROSSEI. The patient is strenuously attempting to abduct all his fingers.

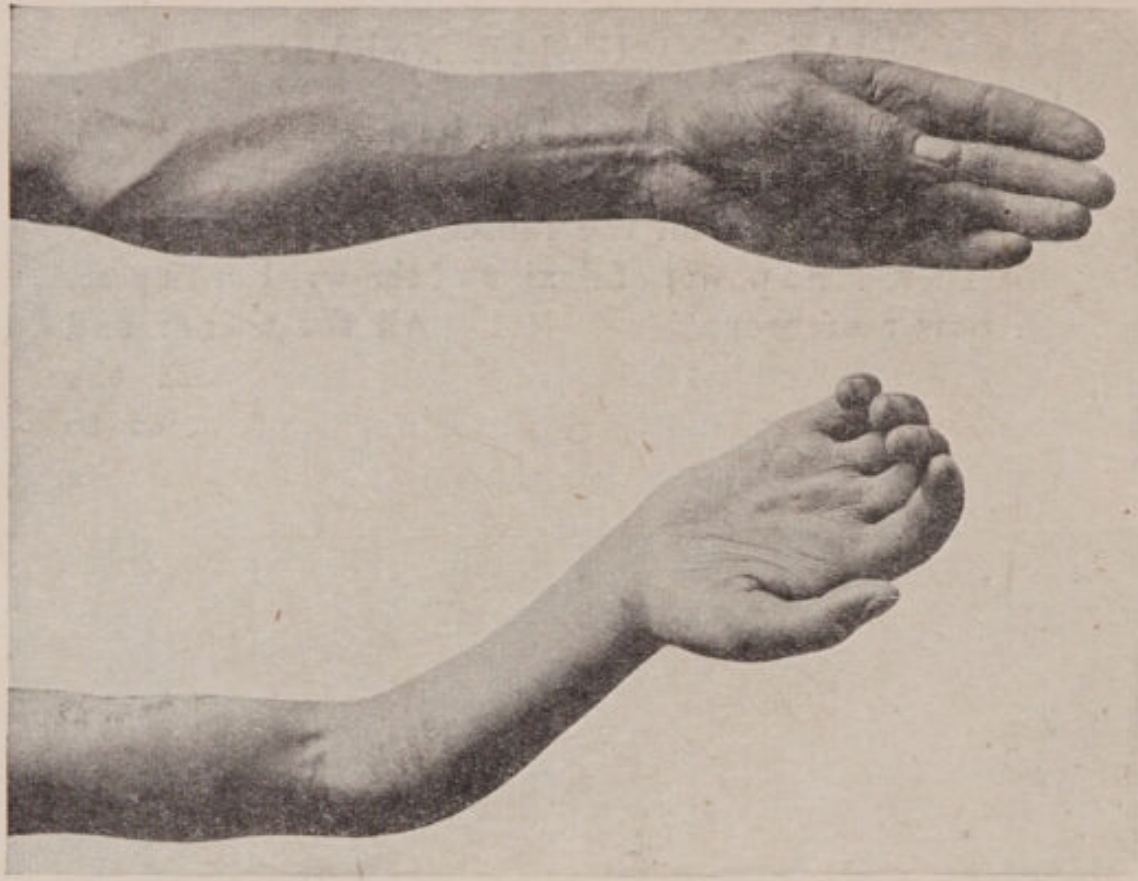

FIG. 110 A.—COMBINED RIGHT MEDIAN AND ULNAR PARALYSIS. The patient is trying to oppose both thumbs. Note the absence of that movement in the right thumb.

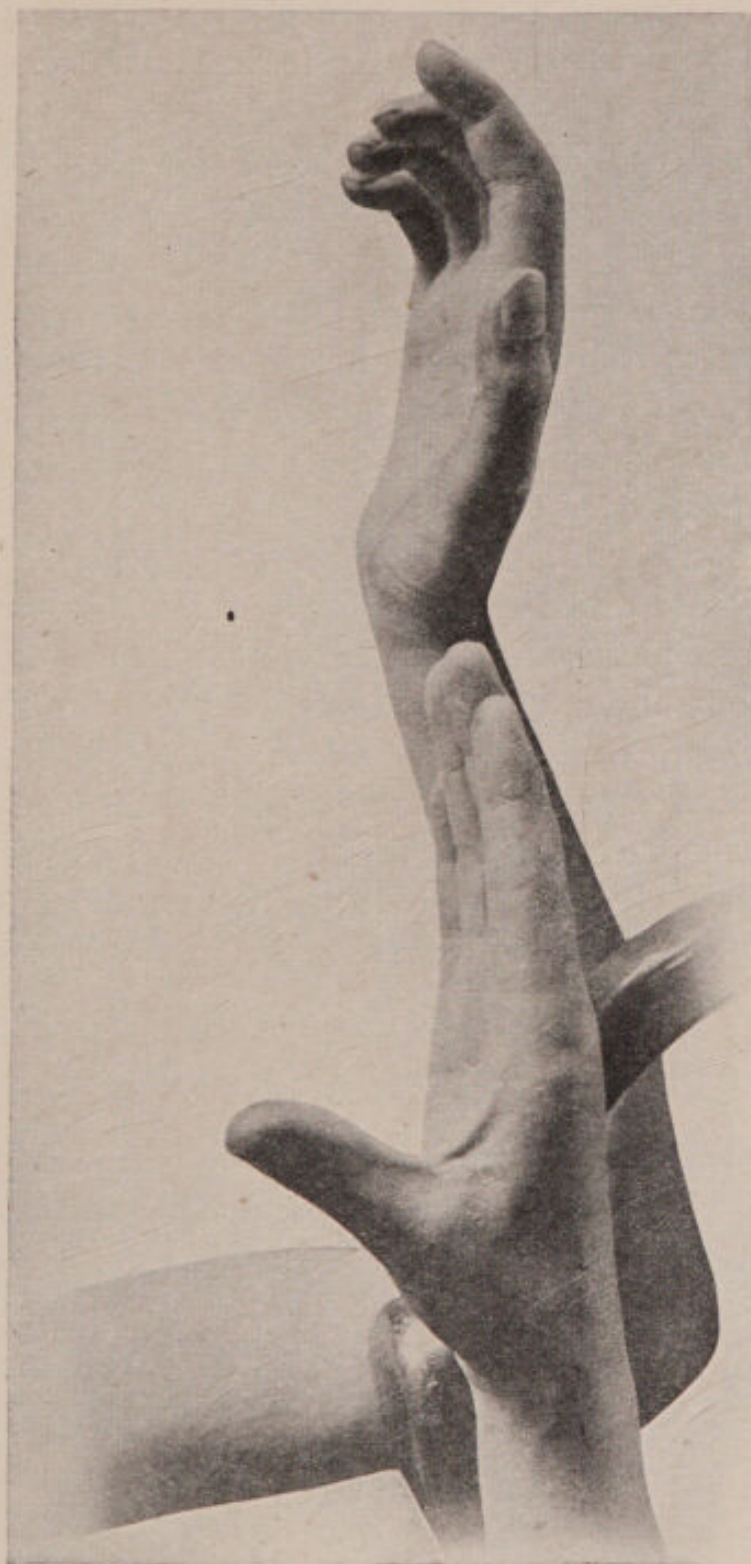

FIG. 111.—COMBINED RIGHT MEDIAN AND ULNAR PARALYSIS.

The patient is vainly attempting to abduct his right thumb. Compare position of thumb with that of a normal abducted thumb below.

The patient can no longer abduct, adduct, or oppose his thumb (Figs. 110 A and 111).

### Incomplete Combined Lesions of Median and Ulnar Nerves.

It is readily understood how a partial or complete lesion of the one nerve may be combined with a partial or complete lesion of the other, thereby producing syndromes of different varieties, according to the particular nerve-bundles damaged in the respective nerve-trunks.

A common variety is where

the flexors of the wrist escape whilst all the other long flexors, together with the intrinsic hand muscles, are paralysed.

In another variety, the intrinsic muscles of the hand are completely paralysed (as is almost always the case) together with the flexor profundus, whilst the flexor sublimis escapes, so that the proximal interphalangeal joints can be voluntarily flexed. Or the long flexor of the thumb may survive by itself. The area of anæsthesia is also subject to variations, according to the extent to which the sensory fibres have been damaged.

Cases of partial combined lesions often develop adhesions in the paralysed joints and tendon-sheaths, rendering the fingers stiff, even on passive movement. Such adhesions should be foreseen and guarded against by suitable massage and passive movements.

Where the brachial or axillary artery has been damaged at the same time as the median and ulnar trunks, the hand becomes swollen and slightly œdematous, with increased liability to trophic ulcers of the fingers.

### THE MUSCULO-SPIRAL NERVE

The musculo-spiral nerve is one of the most commonly injured nerves. Owing to its intimate relationship to the humerus, it is often injured in fractures of that bone.

*Anatomy.*—The musculo-spiral nerve is the main continuation into the upper arm of the posterior cord of the brachial plexus. It derives its fibres from the 6th, 7th, and 8th cervical nerves, and occasionally from the 5th cervical and 1st dorsal nerves.

In the axilla it lies behind the axillary artery, and in the upper third of the arm, behind the brachial artery and the median nerve, resting upon the long head of the triceps.

In the middle third of the arm it winds round the back of the humerus accompanied by the superior profunda artery,

lying in the spiral groove, between the inner and outer heads of the triceps.

In the lower third of the arm the nerve lies on the outer side of the limb. It pierces the external inter-muscular septum at the junction of the upper and middle thirds of a line extending from the insertion of the deltoid to the external condyle, and then passes downwards to the front of the external condyle, lying between the supinator longus and the brachialis anticus.

### Branches of the Musculo-spiral.

In the axilla, before passing to the back of the humerus, it gives off an internal cutaneous nerve, which supplies the upper third of the internal surface of the arm. It also supplies muscular branches to the long and to the inner head of the triceps.

Whilst in the spiral groove, muscular branches are given to the three heads of the triceps; the branch to the inner head of the triceps runs downwards in the substance of the muscle, then passes behind the external condyle of the humerus to supply the anconeus muscle. This branch furnishes articular twigs to the elbow-joint. Before the musculo-spiral nerve pierces the inter-muscular septum, two cutaneous branches are given off; the superior supplies the skin over the postero-external surface of the arm in its lower third, and the inferior supplies a strip on the dorsum of the forearm lying between the areas supplied by the musculo-cutaneous and the internal cutaneous nerves. (See Fig. 74.)

The musculo-spiral nerve, where it lies in the space between the supinator longus and the brachialis anticus, gives off branches to the supinator longus, the extensor carpi radialis longior, and the brachialis anticus.

At the bend of the elbow, under cover of the supinator longus, the nerve divides into its terminal branches—the radial and posterior interosseous nerves.

**The radial nerve** is entirely sensory. It courses down

the forearm under cover of the supinator longus, and in the lower third of the forearm passes backwards under the tendon of the supinator longus, and supplies the skin on the dorsum of the hand and thumb, and on the proximal phalanges of the index and middle fingers, and of the ring finger on its radial side. The sensory distribution is variable. (See Figs. 114 to 116.)

**The posterior interosseous nerve** is entirely muscular and articular in its distribution. It passes backwards on the outer side of the neck of the radius, piercing the supinator brevis muscle. It runs down the back of the forearm between the superficial and the deep muscles. At the middle of the forearm it passes deep to the extensor longus pollicis, reaching the interosseous membrane, on which it runs to the level of the wrist joint.

Before piercing the supinator brevis, the nerve supplies muscular branches to the extensor carpi radialis brevis and the supinator brevis. After emerging from this muscle it gives off a large bundle of nerves which supply the extensor communis digitorum, extensor minimi digiti, and extensor carpi ulnaris near their origin. Lower down the forearm, branches are supplied to the extensor ossis metacarpi pollicis, extensor longus and extensor brevis pollicis, and the extensor indicis.

The antero-internal part of the musculo-spiral trunk in the upper arm contains the motor-fibres for the extensors of the wrist; those for the finger-extensors are collected mainly postero-internally whilst the fibres for the supinator muscles are situated externally.

The commonest site of injury is in the lower third of the arm, as a complication of fracture of the humerus. The nerve may also be injured in the upper part of the arm, from the pressure of a crutch, or by compression of the nerve between the hanging arm and the back of a chair, or by the edge of an operating table. (See compression, p. 34.)

The posterior interosseous nerve is occasionally injured in dislocations of the head of the radius and in fractures of its upper end.

In projectile wounds the musculo-spiral nerve may be injured in any part of its course.

### **Motor Symptoms.**

Injury to the musculo-spiral is evidenced by paralysis of the muscles supplied by it. As a rule, the nerve is injured after its branches have been supplied to the triceps muscle, so that power to extend the arm is preserved, but there is paralysis of the supinator longus and brevis, and of the extensors of the wrist, fingers, and thumb. The supinator longus no longer stands out on forceful flexion of the elbow. The supinator-jerk is abolished. Although the supinator brevis is paralysed, powerful supination can be effected by the biceps when the forearm is bent; when the forearm is extended, pseudo-supination can be performed by the external rotators of the shoulder. The attitude assumed by the limb is characteristic. The forearm is constantly pronated, and if it be passively supinated, it at once returns to the former pronated position, as if pulled by a spring. The hand is in a condition of 'drop-wrist'; the wrist, fingers, and thumb cannot be voluntarily extended, and the fingers are constantly semi-flexed at the interphalangeal joints by the unopposed long flexors (Figs. 112 and 113). No voluntary extension of the fingers at the metacarpo-phalangeal joints can take place. On making a forceful effort to extend the fingers, the wrist becomes flexed by the flexors of the wrist, and extension occurs at the interphalangeal joints with flexion at the metacarpo-phalangeal joints, on account of the unopposed action of the interossei and lumbricales.

If the nerve is severed high up, there may also be paralysis of the triceps with inability to extend the elbow. This is often overlooked, inasmuch as the elbow is passively extended by the weight of the forearm; but if we passively

raise the arm at the shoulder, leaving the elbow bent, the patient cannot voluntarily extend the forearm. The triiceps-jerk becomes lost.

Fig. 112 is that of a soldier who was wounded by a rifle-bullet in the left upper arm, fracturing the humerus. The entry-wound was through the middle of the left biceps, 4 inches above the elbow. The exit-wound, seen in the figure, was slightly to the

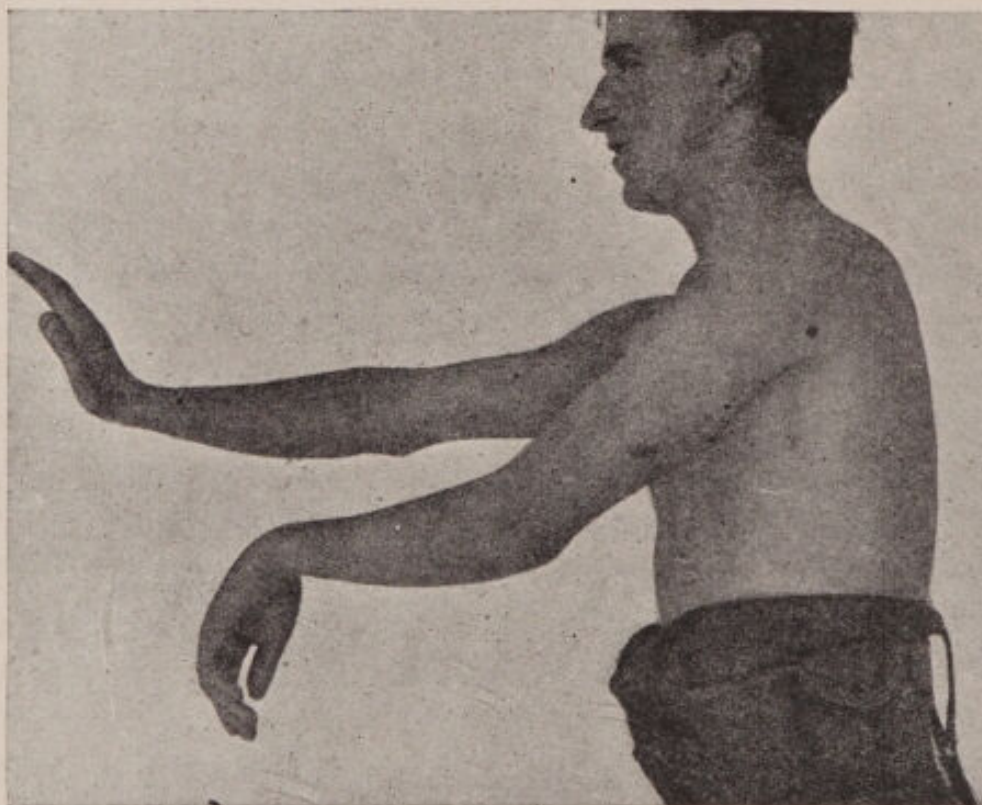


FIG. 112.—PARALYSIS OF LEFT MUSCULO-SPIRAL NERVE FROM GUNSHOT-WOUND THROUGH MIDDLE OF UPPER ARM. The left hand shows wrist-drop.

outer side of the middle of the triceps at the same level. When examined, five weeks later, there was loss of sensation to pin-pricks and diminution to light touches, in the radial distribution of the back of the hand and fingers. To faradism there was loss of reaction in the supinator longus and in the extensors of the wrist, fingers, and thumb, all of which were paralysed. The triceps, innervated above the level of the lesion, was normal.

#### **Musculo-spiral Paralysis from Compression.**

Fig. 113 is that of a soldier who received a bullet-wound

through the triceps muscle at the level of the deltoid insertion.

The extensors of the wrist, fingers, and thumb did not react to faradism, but did to galvanism  $KCC > ACC$ , and to the condenser (3 microfarads).

At the operation the nerve was found flattened out by the fibrosed triceps; there was no solution of continuity of the nerve and no 'hardening' in the nerve itself.

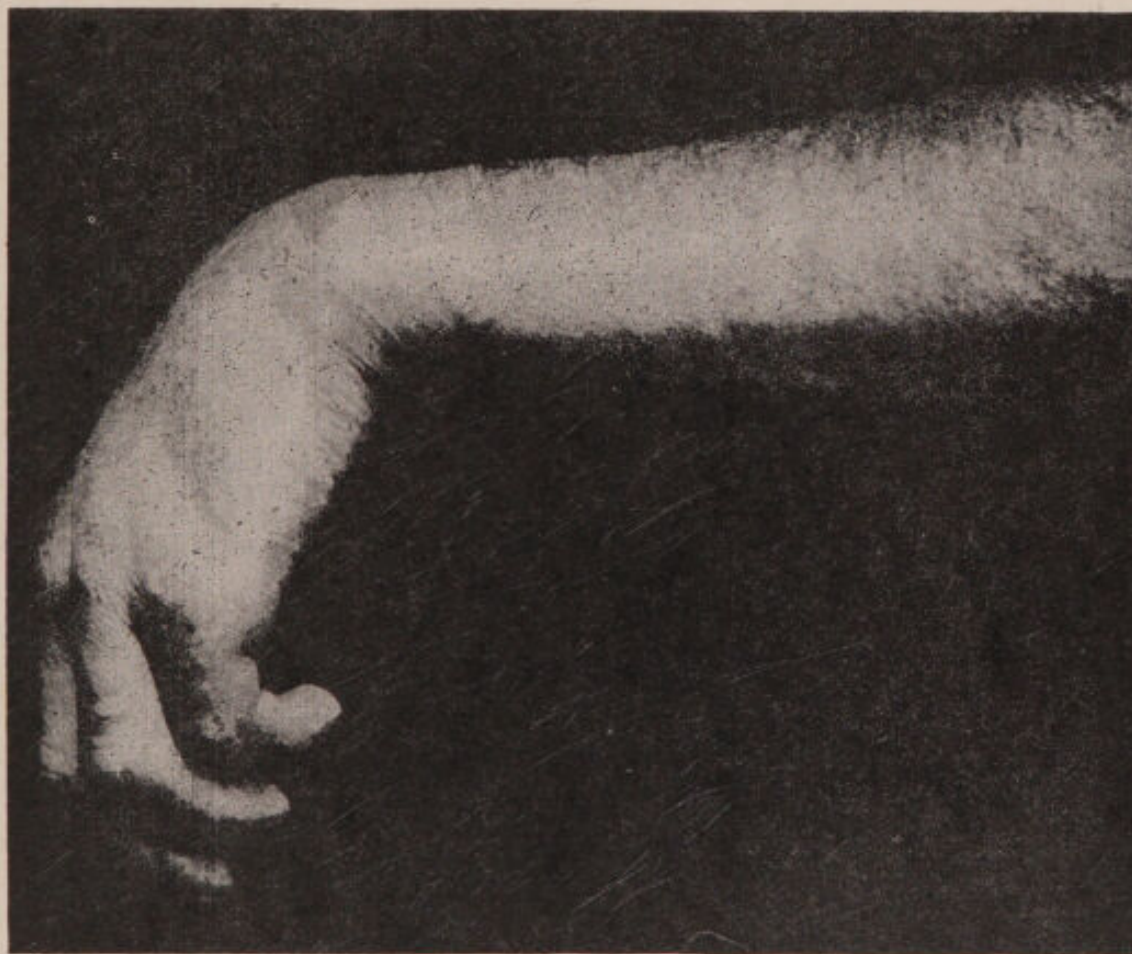


FIG. 113.—PARALYSIS OF THE MUSCULO-SPIRAL NERVE. Note the flexion of the fingers. The nerve was compressed by the fibrosed triceps muscle.

Three weeks after the operation the patient could feebly extend his fingers and thumb.

In a case of musculo-spiral paralysis which recovers, the first muscles to regain voluntary power are the extensors of the wrist, then the extensor communis digitorum and extensor indicis, whilst the long extensors of the thumb, together with the supinator longus, recover distinctly later.

Unable to display this page

The area of loss of sensation to pin-pricks has diminished, the distal part only remaining, corresponding to the dorsum of the fingers. Supinator longus contracts feebly; extensors of wrist fair; extensors of fingers and thumb still paralysed.

April 1915. Pin-pricks as in February. Supinator longus powerful, extensors of wrist good; extensors of fingers and thumb now contract fairly well.

From the rapidity of recovery, as also from the reaction to galvanism, it is likely that here we are dealing with a severe contusion of the musculo-spiral nerve.

In October 1914 a German soldier was wounded by a rifle-bullet. His left elbow was flexed at the moment, supporting his rifle. The bullet entered through the first interosseous space, and passed out in front close to the radial styloid process; it then re-entered the upper arm 2 inches above the elbow to the inner side of the biceps, and made its second exit through the posterior surface of the arm. The left humerus was fractured and badly comminuted.

At an operation for plating the humerus in December 1914 the musculo-spiral nerve was accidentally divided and immediately sutured.

When seen by us in January 1915 there was blunting to cotton-wool and pin-pricks along the outer side of forearm and in the radial distribution of the hand, i.e. thumb and two-and-a-half radial fingers (Fig. 115). There was total paralysis of the supinator longus and of the extensors of the wrist, fingers and thumb.

April 1915. Motor phenomena as before. Anæsthesia recovered, except on the dorsum of the thumb and adjacent part of the hand.




FIG. 115. — MUSCULO-SPIRAL PARALYSIS, with blunting of sensation to pin-pricks and cotton-wool over the shaded area.

## POSTERIOR INTEROSSEOUS NERVE

Isolated injury of this nerve is uncommon.

A soldier, running forward and stooping, was hit by a rifle-bullet at a range of about 500 yards, from the right flank.

The entrance was 2 inches below the external condyle of the right humerus; the exit was in the middle line of the forearm in front, 2 inches below the bend of the elbow. A radiogram showed severe shattering of the head and tuberosity of the radius.

When seen two months later there was no sensory loss, protopathic or epicritic, in the forearm or hand.

Joint-sense was normal; there was doubtful diminution of vibration-sense in the right thumb only. He could flex and extend the elbow; could flex wrist, fingers, and thumb. He could not extend the wrist, fingers, or thumb, and there was no response to faradism in the paralysed muscles.

## THE RADIAL NERVE

A lesion of the radial nerve in the upper part of the forearm is not usually accompanied by anæsthesia; if, however, it be wounded lower down, after it has been joined by branches from the external cutaneous branch of the musculo-spiral, there is anæsthesia on the back of the wrist, the proximal phalanges of the fingers, and the dorsum of the thumb. The anastomosis of these nerves usually takes place in the lower third of the forearm, but it may occur at a higher level (Fig. 116).

Fig. 116 is that of a soldier with a rifle-bullet wound through the upper third of the left forearm. The entrance was on the radial border of the forearm, the exit in the middle line in front. The exit-wound formed a large indurated scar closely adherent to the underlying flexor muscles. There was no motor paralysis.

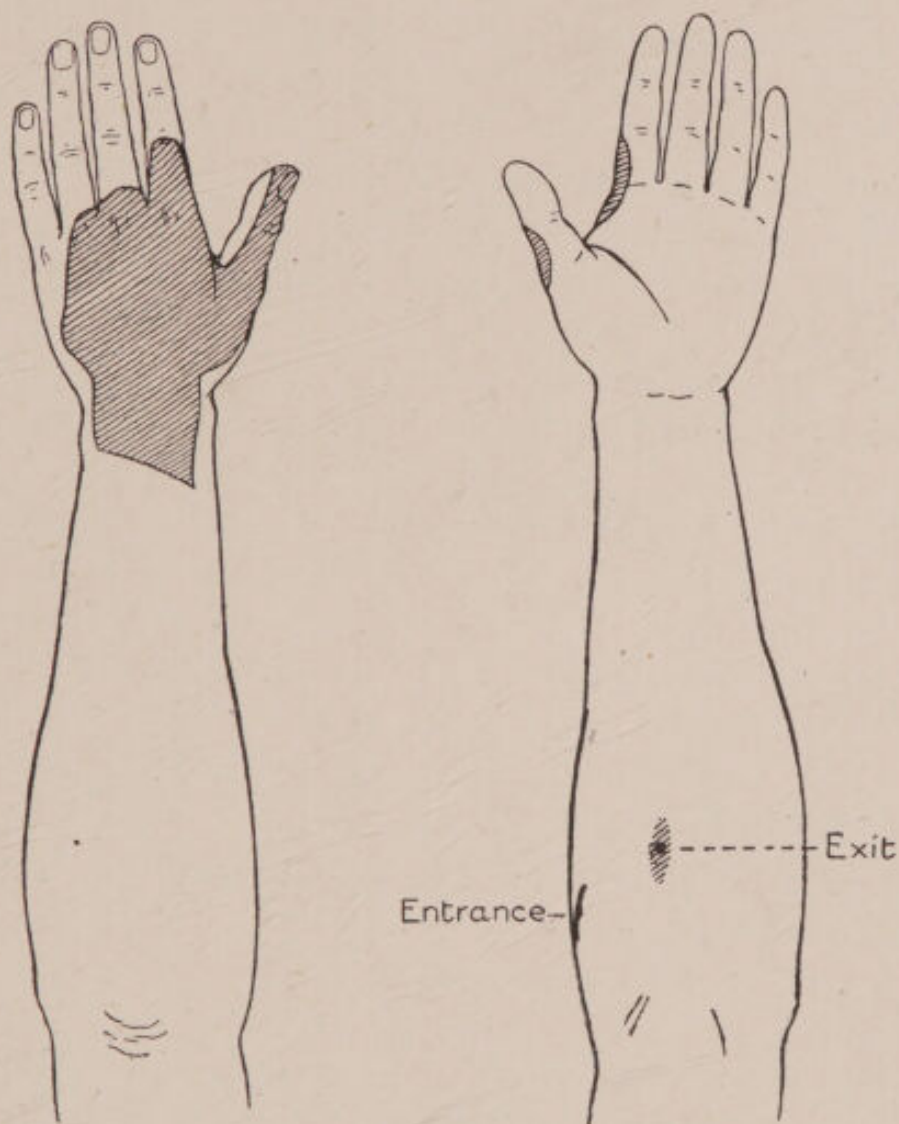


FIG. 116.—PARALYSIS OF THE RADIAL NERVE, due to a bullet-wound of the upper third of the left forearm. The shaded area is anæsthetic to pin-pricks and cotton-wool.

## THE MUSCULO-CUTANEOUS NERVE

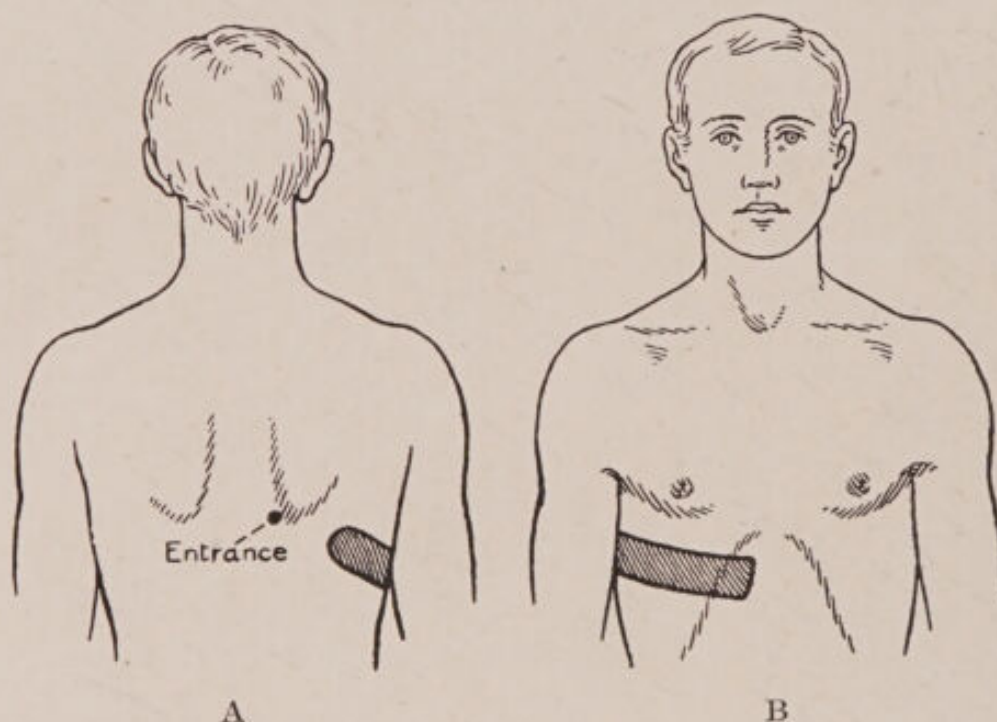
*Anatomy.*—Arising from the outer cord of the brachial plexus, the musculo-cutaneous nerve perforates the coraco-brachialis muscle and then courses down the arm, between the biceps and the brachialis anticus, to the elbow. Here it emerges at the outer side of the biceps tendon, pierces the deep fascia and becomes subcutaneous. It is then distributed as a cutaneous sensory nerve to a large area on the antero-external aspect of the forearm as far as the wrist. In its course through the upper arm it supplies motor fibres to the coraco-brachialis, biceps, and brachialis anticus. There is often an anastomotic branch

Unable to display this page

Unable to display this page

## 196 NERVE INJURIES AND THEIR TREATMENT

Right hæmothorax supervened. In addition there was a zone of analgesia to pin-pricks in the cutaneous area of the 7th dorsal segment on the lateral and anterior wall of the thorax.



FIGS. 118 A and B.—PARALYSIS OF THE SEVENTH RIGHT INTERCOSTAL NERVE AND RIGHT LONG SUBSCAPULAR NERVE. The bullet entered at the inferior angle of the right scapula; the exit was near the apex of the right axilla. The shaded area is that anæsthetic to pin-prick. The right latissimus dorsi was paralysed.

The right latissimus dorsi did not contract voluntarily nor on coughing, showing that in the passage of the bullet through the axilla the **long subscapular nerve** had been damaged.

## CHAPTER XI

### THE CAUDA EQUINA

THE term 'cauda equina' is given to the collection of nerve roots which occupies the spinal canal below the 1st lumbar vertebra, including all the lumbar, sacral, and coccygeal nerve roots. (See Fig. 124, p. 206.)

According to the roots affected, anterior or posterior, we have motor or sensory symptoms, in each case distributed in root fashion. When the whole cauda equina is affected, there is paralysis of all the muscles of the lower limbs, accompanied by total anæsthesia, extending upwards to Poupart's ligament in front, and to the upper part of the buttocks behind; the anæsthesia includes the genitals, and there is loss of control of the bladder and rectum.

As will be seen from the diagrams (Fig. 119), the sensory areas over the anterior, inner, and outer surfaces of the lower limb are supplied by the lumbar roots. The 1st lumbar root supplies the neighbourhood of Poupart's ligament and the iliac crest; the 2nd supplies the upper part of the thigh and the buttock; the 3rd supplies the lower part of the thigh; the 4th supplies the knee and the inner surface of the leg; and the 5th supplies the outer surface of the leg and the dorsum of the foot.

The posterior aspect of the limb is supplied by the sacral roots: the 1st supplies the sole of the foot and the calf; the 2nd supplies the popliteal surface, the back of the thigh, and the lower edge of the buttock; the 3rd, 4th, and 5th sacral

roots supply the perineum; and the coccygeal root supplies the skin over the tip of the coccyx.

### Motor Distribution of the Cauda Equina.

With regard to the motor distribution of the cauda equina, it is fairly accurate to say that the muscles lying in an area of

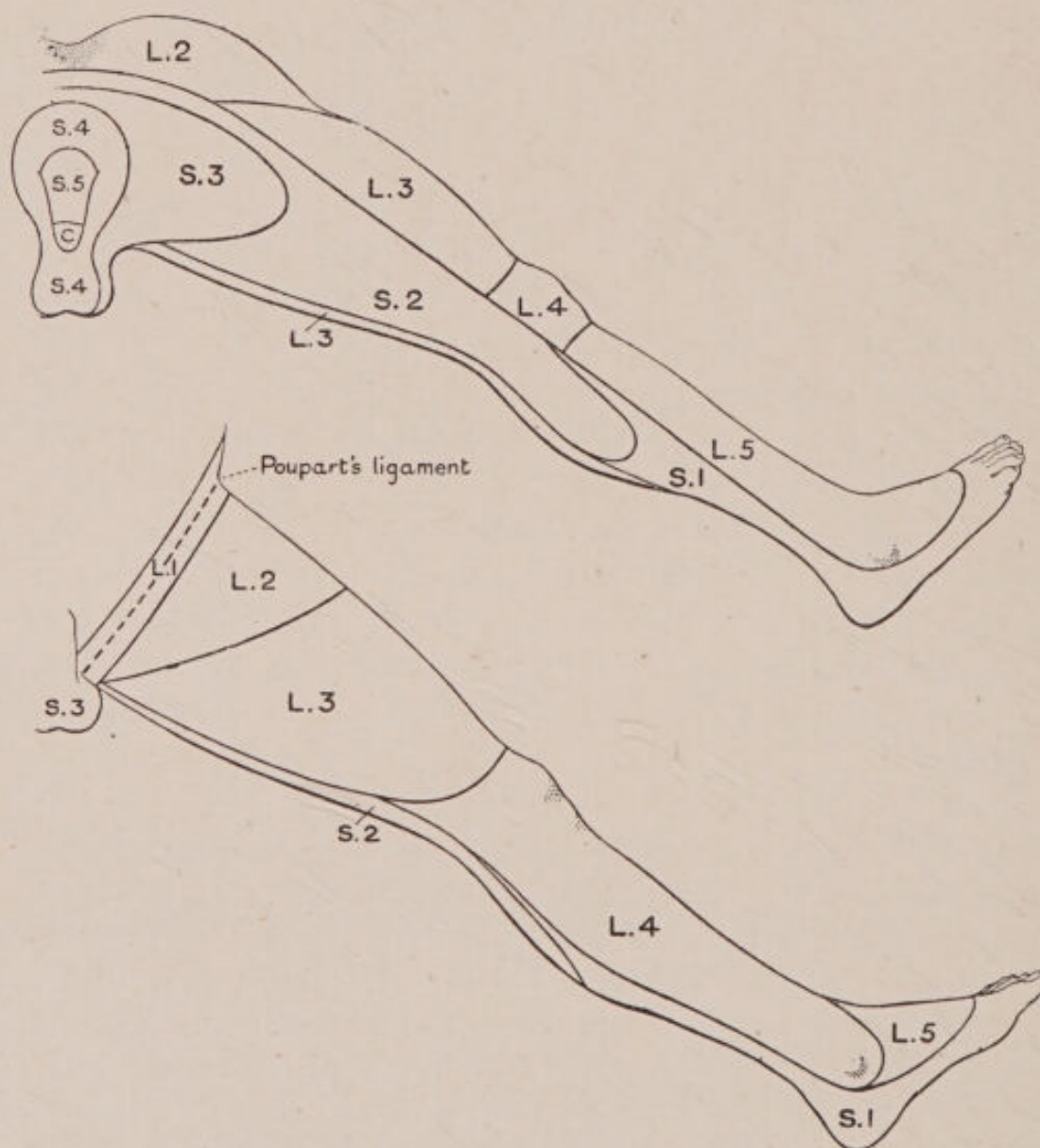


FIG. 119.—THE CUTANEOUS DISTRIBUTION OF THE CAUDA EQUINA.

which the cutaneous supply is a given posterior root, will receive their motor supply from a corresponding anterior root. This is shown in tabular form thus :

## CAUDA EQUINA

	<i>Sensory distribution.</i>	<i>Motor distribution.</i>
1st and 2nd lumbar	Groin, upper part of thigh, and buttock	Psoas, iliacus, and pectineus
3rd and 4th lumbar	Anterior, inner and outer surfaces of thigh, the knee, and inner side of leg	Quadriceps extensor cruris, adductors, and tibialis anticus
5th lumbar	Antero-external surface of leg and dorsum of foot	Extensors of toes and peronei
1st sacral	Sole of foot and calf	Muscles of sole and calf
2nd sacral	Popliteal space, posterior surface of thigh and lower edge of buttock	Hamstrings and glutei
3rd, 4th, 5th sacral } and coccygeal }	Perineum and genitals	Levator ani and perineal muscles

**Symptoms.**

If the lesion includes the *whole cauda equina* there is total paralysis of the lower limbs, with total anæsthesia extending upwards to just above Poupart's ligament in front and to the upper part of the sacrum behind; there is also anæsthesia of the genitals, and loss of control of the bladder and rectum.

If the lesion be *below the 3rd lumbar root* the quadriceps extensor muscles escape, and the knee-jerks are preserved; the hamstrings and all the muscles below the knees are paralysed, and the ankle-jerks are lost.

When the lesion is *below the 2nd sacral root* there is no paralysis of the lower limbs, and all the reflexes of the legs are normal, but the area of anæsthesia is very characteristic, there being a 'saddle-shaped' area of anæsthesia on buttocks, perineum, scrotum, and penis; the anal reflexes are lost, and there is loss of control of the bladder and rectum.

A lesion *below the 3rd sacral root* leaves the sphincter ani unaffected, and the only signs of nerve lesion are paralysis of the levator ani, and anæsthesia of the anus and its immediate neighbourhood.

Lesions of the cauda equina are divided into upper and lower lesions. The following are examples:

Unable to display this page

scapula, and the bullet lodged in the left hip-joint. When shot he felt as if his feet were curling up and then fell slack. At once he noticed loss of power in the right lower limb. When examined eleven days later, the right leg was still powerless; the left leg felt dead, but could be moved; there was no sphincter trouble.

**Sensory loss.** Total anæsthesia and analgesia of the right

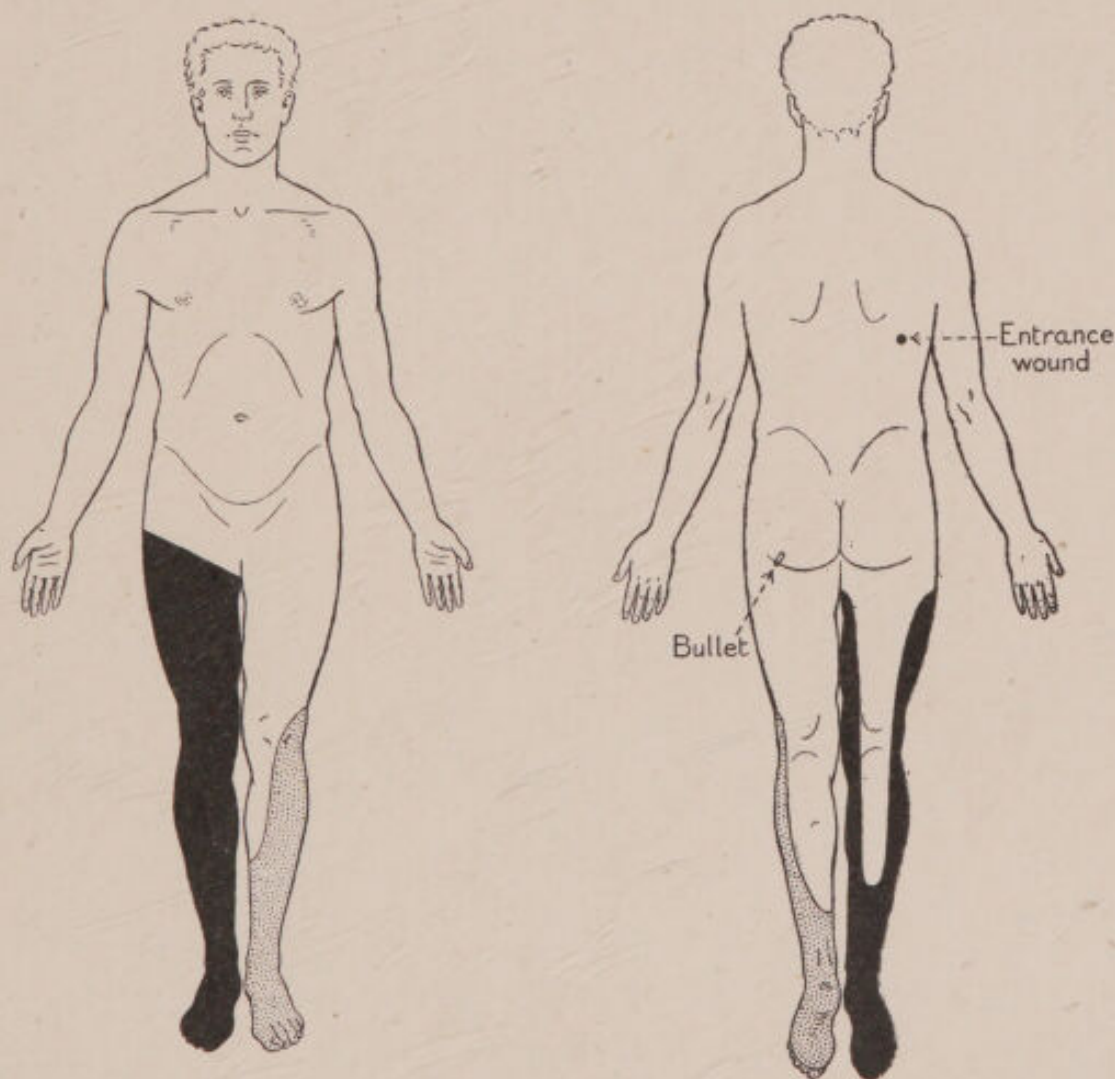


FIG. 121.—UPPER CAUDA LESION. In the right limb all forms of cutaneous sensation were lost, from the 2nd lumbar to the 1st sacral area inclusive. In the left limb there was moderate diminution in the 5th lumbar and 1st sacral areas.

lower limb from the 2nd lumbar to the 1st sacral area inclusive; all forms of cutaneous sensation being lost—touch, pain, and temperature (Fig. 121). In the left lower limb there was moderate diminution of all forms of sensation in the dis-

## 202 NERVE INJURIES AND THEIR TREATMENT

tribution of the 5th lumbar and 1st sacral areas. Joint-sense was lost in all the joints of the right lower limb from the hip downwards; in the left limb joint-sense was lost in the toes; elsewhere it was normal.

**Motor loss.** Total flaccid paralysis of right lower limb at all the joints. Left lower limb feeble at all joints, but no individual movement impossible.

Knee-jerks: left present, right absent.

Ankle-jerks: both absent. Plantar reflexes absent. Sphincters normal.

Electrical reaction: to faradism the right calf muscles reacted normally; no reaction in any other muscles of the thigh or leg. All muscles of the left lower limb reacted normally.

One year later there was some return of power in all the muscles, and the only anæsthesia persisting was a small patch on the front of the right thigh.

### Lower Cauda Lesion.

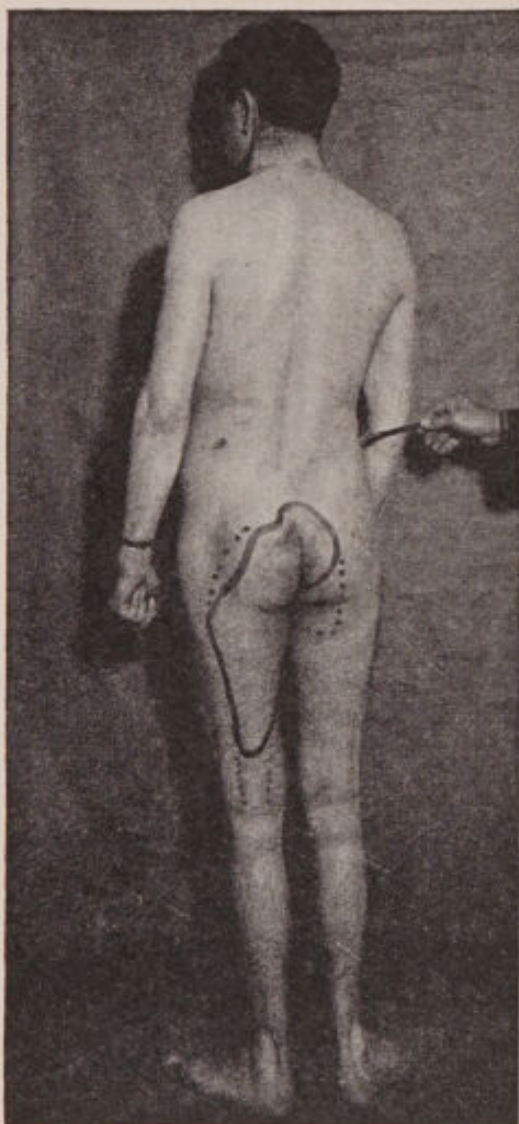Two years previously a labourer when at work was injured by a fall of earth which struck his back in the lumbar region. He was buried up to his waist, and had to be drawn out. He states that his legs were limp and powerless, and that he had loss of feeling up to the waist.

During these two years a catheter was passed twice daily. Now, catheterization is not necessary, and the patient has complete control over micturition. There is still occasional incontinence of fæces. Patient has regained considerable power in his right lower limb and can now stand. The left leg, however, is still weak. A radiogram taken three months ago showed an old fracture of the 5th lumbar vertebra and of the sacrum. There is anæsthesia and analgesia from the 5th lumbar root downwards on both sides (Fig. 122), slightly lower on the right side epicritic loss is more extensive than the protopathic. The genitals are analgesic, but not anæsthetic.

**Motor functions:** the patient can feebly move the toes and ankles of both feet, the left feebler than the right. All other movements of the lower limbs are good. There is a tendency to left-sided drop-foot. Knee-jerks: right brisk, left absent.

Unable to display this page

Sensory functions (Fig. 123): total loss to touch, pain, and temperature on left side of sacrum, back of left thigh, and left side of genitals, i.e. in the distribution of the 2nd sacral root area and all the roots below; on the right side there is partial blunting of all forms of sensation in the distribution of the 3rd sacral root and downwards, including right buttock, right saddle-area, and right side of genitals.



No paralysis of individual movements of lower limbs, although all are slightly feeble; those on the right are stronger than those on the left side.

Knee-jerks present, ankle-jerks absent; bulbo-cavernosus and anal reflexes are absent.

To faradism the sphincter ani does not contract.

November 1914. Has considerably recovered sensation on the right side of genitals. Developed two bed-sores, one on each side of sacrum.

December 1914. Walks feebly with support.

February 1915. Walks fairly well without a stick.

June 1915. Can walk well on tip-toes. Can pass water by straining, without a catheter. There is anæsthesia of the urethra with occasional drib-

FIG. 123. LESION OF LOWER CAUDA AND CONUS MEDULLARIS. The pencil rests on the entrance-wound; the exit-wound is on the opposite side. The anæsthesia on the left side is that of total loss to touch, pain, and temperature, and corresponds to the 2nd sacral root and all the roots below it; on the right side there is partial blunting to all forms of sensation, corresponding to the 3rd sacral root and all the roots below it. Six months previously the anæsthesia had extended to the dotted line.

Unable to display this page

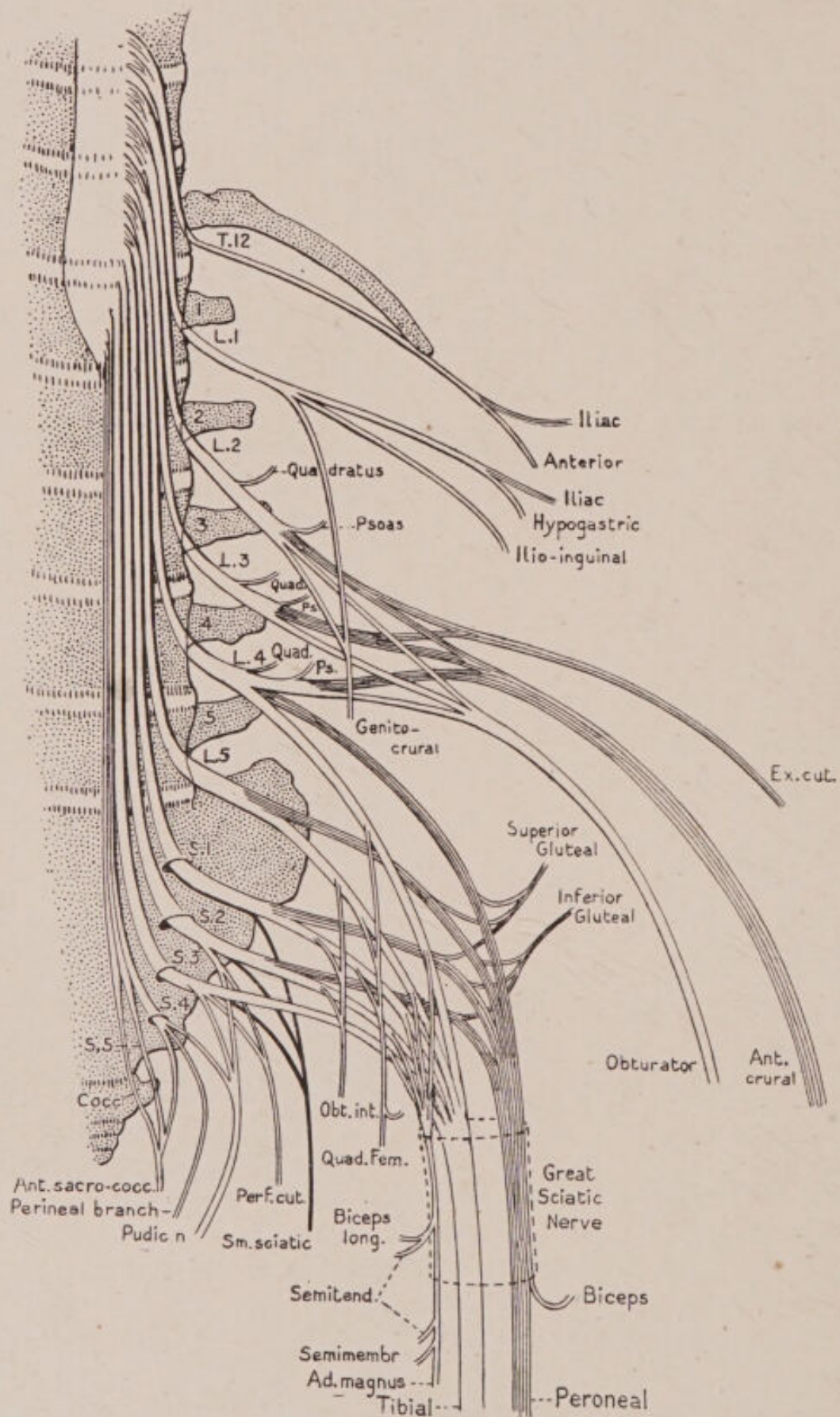


FIG. 124.—THE LUMBO-SACRAL PLEXUS, SHOWING THE CONUS MEDULLARIS AND CAUDA EQUINA. After Cunningham, modified.

The most important nerves of the lumbar plexus are the **obturator** (L 2, L 3, L 4), and the **anterior crural** (L 2, L 3, L 4).

The **sacral plexus** is formed by the anterior primary divisions of the 4th and 5th lumbar nerves, and the 1st and parts of the 2nd and 3rd sacral nerves.

This plexus lies on the pyriformis muscle, and is covered by the parietal pelvic fascia. In front of it are situated the pelvic colon, the internal iliac vessels, and the ureter. The nerves of the plexus converge towards the lower part of the great sacro-sciatic foramen, uniting to form a broad triangular band, the apex of which is the **great sciatic nerve**.

Other important branches of the sacral plexus are, the **superior gluteal nerve** (L 4, L 5, S 1), which supplies the gluteus medius and minimus and the tensor vaginæ femoris, and the **inferior gluteal nerve** (L 5, S 1, S 2), which supplies the gluteus maximus.

The **puddendal plexus** is formed by parts of the anterior primary divisions of the 1st, 2nd, and 3rd sacral nerves, and the whole of the anterior primary divisions of the 4th and 5th sacral nerves, and of the coccygeal nerve. The principal nerves derived from this plexus are the **small sciatic nerve** (S 1, S 2), the cutaneous nerve to the lower part of the buttock, the posterior part of the thigh, and the upper part of the calf, and the **puddic nerve** (S 2, S 3, S 4), supplying the external sphincter, the muscles in the urogenital triangle, and the skin of the scrotum and penis.

Lesions of the lumbo-sacral plexus are less frequent than those of the cauda equina. Partial lesions are the rule. No case of complete lesion of the lumbo-sacral plexus has yet been recorded.

## THE GREAT SCIATIC NERVE

The **Great Sciatic Nerve** passes into the buttock through the great sacro-sciatic foramen, between the pyriformis muscle and the superior gemellus. Its point of entrance into the buttock may be indicated on the surface, at the junction of the upper and middle thirds of a line drawn

from the posterior superior iliac spine to the great trochanter.

The nerve now passes downwards into the thigh under cover of the gluteus maximus, lying midway between the great trochanter and the ischial tuberosity. At the lower border of the gluteus maximus the nerve is comparatively superficial, lying external to the origin of the hamstring muscles. It now passes deep to the hamstrings, and runs downwards upon the adductor magnus muscle till it divides into its tibial and peroneal divisions—usually in the lower third of the thigh.

The great sciatic nerve comprises the two main nerves of the sacral plexus, the **internal popliteal (tibial) nerve**, and the **external popliteal (peroneal) nerve**, bound together in one sheath, along with the nerve to the hamstring muscles lying on the inner side, and the nerve to the short head of the biceps lying on the outer side of the nerve trunk.

The nerve to the hamstring muscles arises with the internal popliteal from the 4th and 5th lumbar, and the 1st, 2nd, and 3rd sacral nerves. It passes into the thigh lying on the inner side of the great sciatic trunk. Just below the level of the ischial tuberosity, branches are given off to the long head of the biceps and the semi-tendinosus; lower down, other branches are given off to the semi-membranosus, semi-tendinosus again, and adductor magnus. This high origin of the upper nerve to the semi-tendinosus accounts for the fact that in lesions of the great sciatic nerve, even when the injury occurs high up the thigh, it frequently happens that the power to flex the leg on the thigh is preserved. (See Fig. 125.)

The nerve to the short head of the biceps arises from the 5th lumbar and 1st and 2nd sacral nerves. It runs down the outer side of the peroneal nerve, from which it parts company about the middle of the thigh.

The tibial and peroneal nerves are loosely held together for a greater or less distance by a common investing sheath;

on opening this the two nerves can be traced up to the plexus, from which they take their origin by distinct and separate roots. Frequently there is no common investing sheath, and the two nerves are distinct right up to their origin; sometimes, indeed, the nerves are separated by fibres of the pyriformis muscle.

It is well, then, to look upon the great sciatic nerve as mainly consisting of two distinctly independent parts—

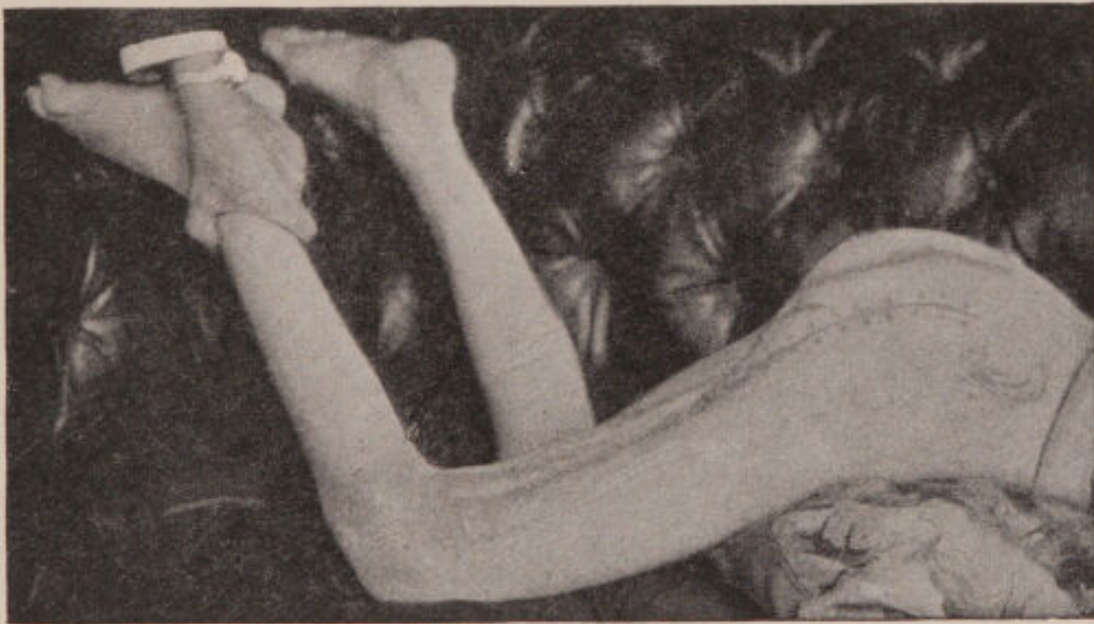

FIG. 125.—PARALYSIS OF THE RIGHT GREAT SCIATIC NERVE. The nerve was completely divided immediately below the sciatic notch. All the muscles supplied by the great sciatic nerve were paralysed, with the exception of the semi-tendinosus. By means of this muscle and the gracilis the patient could strongly flex the knee against powerful opposition. Note the semi-tendinosus standing out clearly on the inner side of the popliteal space, and the absence of the biceps tendon on the outer side.

the tibial and the peroneal. Not only is this true anatomically, but clinically it is very obvious.

When trauma is applied to the great sciatic nerve the resulting lesion may be of the whole nerve or of its peroneal or tibial component; in the latter case it is almost invariably the peroneal nerve that suffers. Thus, in our 71 cases of injury to the sciatic nerve, the whole trunk was affected

in 35, the peroneal nerve in 33, and the tibial nerve in 3 cases only.

### Paralysis of the Great Sciatic Nerve.

In a case of complete sciatic paralysis there is anæsthesia of the outer surface of the leg and of the dorsum and sole of the foot (Fig. 128); in fact, the only part of the leg which is not anæsthetic is the inner surface of the leg and ankle, which region is supplied by the internal saphenous nerve.

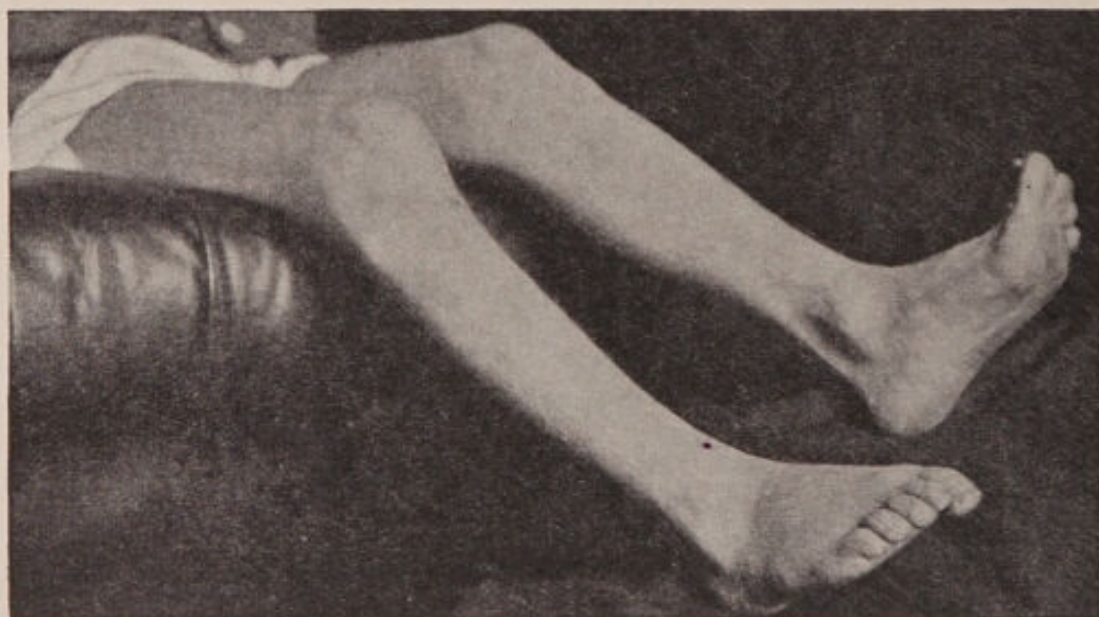


FIG. 126.—PARALYSIS OF THE RIGHT GREAT SCIATIC NERVE WHICH WAS SEVERED IMMEDIATELY BELOW THE SCIATIC NOTCH. All the muscles below the knee are paralysed, and all the muscles on the posterior surface of the thigh, with the exception of the semi-tendinosus. (See Fig. 125.)

At the moment of injury the limb gives way and the patient falls at once, with a sensation of pain in the foot, or sometimes feeling as if the foot were blown off. All the muscles below the knee are paralysed. There is foot-drop, and no voluntary movement of the ankle is possible—whether of flexion, extension, inversion, or eversion, nor is there any voluntary movement in the toes, whether of flexion or extension. When walking, the patient has to raise the knee of the affected side higher than he does on the other side,

in order to clear the ground with his dropped foot. Running is impossible.

The foot and lower part of the leg becomes slightly swollen in the course of a few weeks (see Fig. 127), and other vaso-motor and trophic changes occur, to be presently described (see external popliteal nerve, p. 215).

The ankle-jerk is absent in the affected foot.

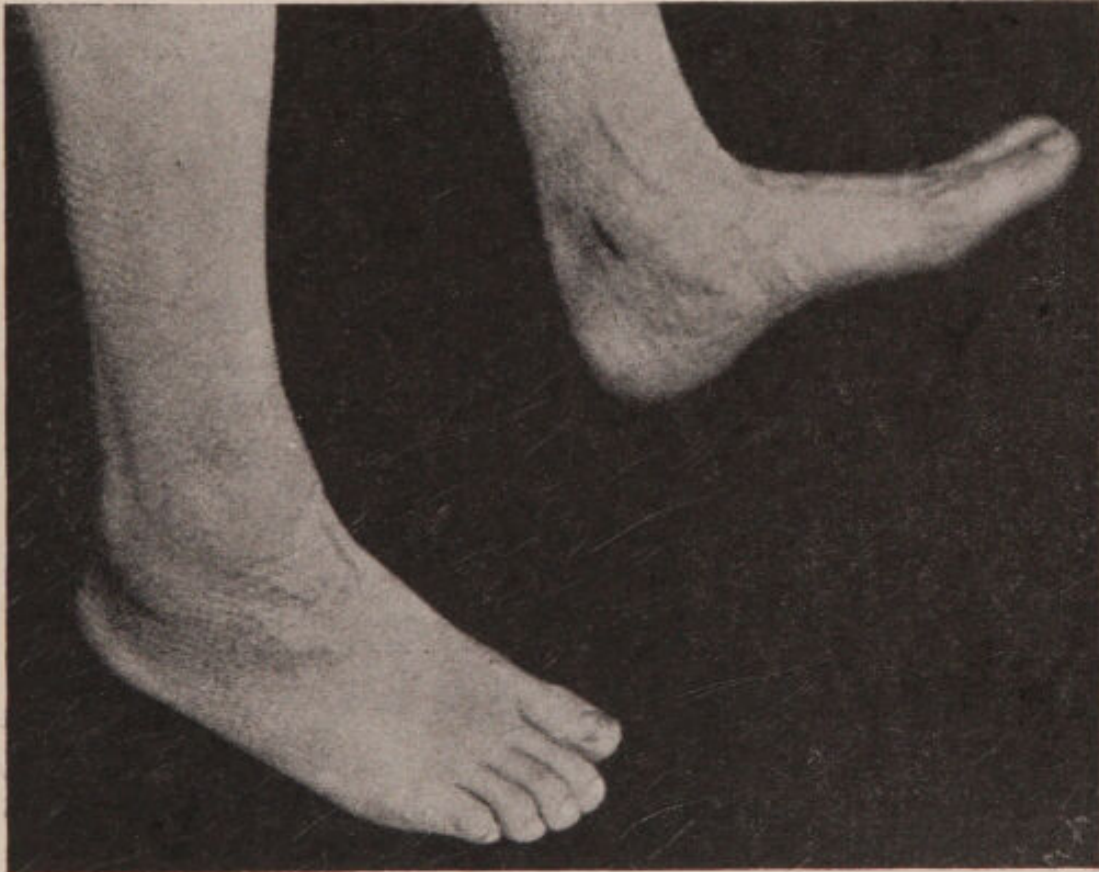


FIG. 127.—PARALYSIS OF RIGHT GREAT SCIATIC, SHOWING DROP-FOOT WITH VARUS. Observe also the oedema of the foot and ankle, on which the marks of the supporting bandage are plainly visible.

In old-standing cases trophic ulcers tend to occur from pressure, at the tip of the heel, at the outer border of the foot, and even on the dorsal surface of the toes. The toenails become thickened and transversely striated. The primary elevation of temperature of the whole foot diminishes, and may recede to normal, whilst the calf of the leg frequently becomes colder than normal.

If the lesion be high up the nerve-trunk, the hamstring muscles may be paralysed, but, even then, some power of flexion of the knee is retained, by means of the intact gracilis, which is supplied by the obturator nerve.

Fig. 125 relates to a soldier who received a perforating wound of the left buttock, followed immediately by paralysis of the great sciatic nerve. All the muscles supplied by the nerve on the posterior surface of the thigh with the exception of the semi-tendinosus, and all the muscles below the knee were paralysed.

At the operation it was found that the whole nerve had been divided immediately outside the sciatic notch, and was here replaced by fibrous tissue. This segment was excised and direct suture performed. Soon after the operation it was found that the patient could still powerfully flex the knee by means of the semi-tendinosus, assisted by the gracilis. The nerve to the semi-tendinosus had thus evidently parted company from the main great sciatic trunk, above the level of the sciatic notch.

### THE EXTERNAL POPLITEAL (PERONEAL) NERVE

*Anatomy.*—The external popliteal nerve arises from the 4th and 5th lumbar, and the 1st and 2nd sacral nerves. (See Fig. 124.) It runs down the back of the thigh in company with the internal popliteal nerve, and the nerves to the hamstrings and to the short head of the biceps, these nerves together constituting the great sciatic trunk. At a very variable point—usually the lower third of the thigh—it parts company from the internal popliteal nerve.

It is only that portion of the nerve which extends from this point to the neck of the fibula which receives the name of the external popliteal or peroneal nerve. It passes outwards through the popliteal space, at first under cover of the biceps muscle. It then becomes more superficial, lying behind and then internal to the tendon of the biceps. Here it lies upon the outer head of the gastrocnemius, immediately subjacent to the deep fascia. Passing subcutaneously behind the head

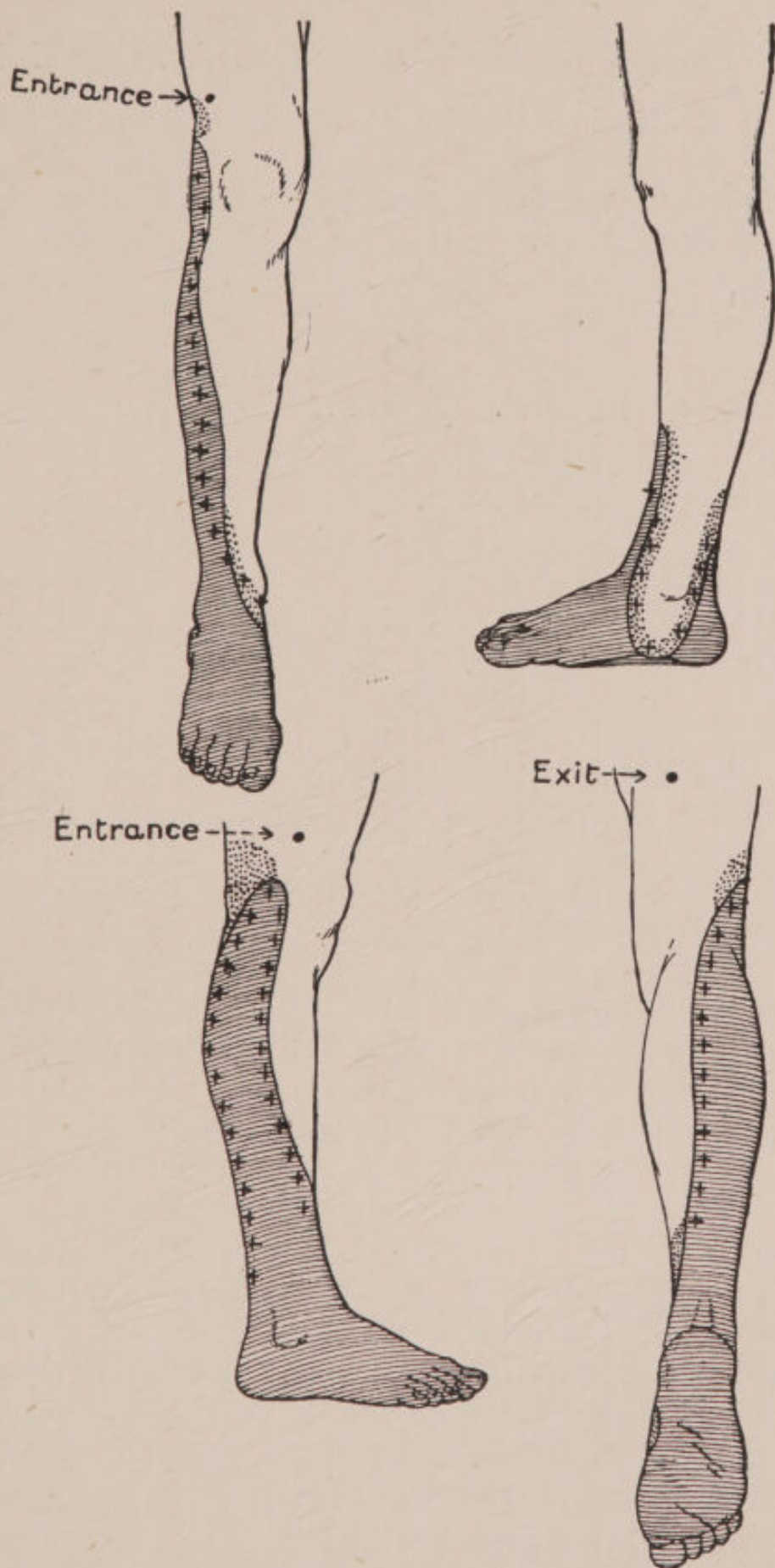


FIG. 128.—SENSORY LOSS IN PARALYSIS OF THE GREAT SCIATIC NERVE. The shaded area is insensitive to pin-pricks, the dotted area is the additional area insensitive to cotton-wool; the crosses mark the loss of sensation to deep pressure.

Unable to display this page

removal of the upper portion of the fibula has resulted in damage to the nerve. (See Fig. 131.)

**Motor Symptoms.** Owing to paralysis of the peronei, tibialis anticus, and extensors of the toes, the foot cannot be dorsiflexed nor everted, the toes cannot be extended, and the foot assumes the position of talipes equino-varus ; it is said to be in a state of 'foot-drop' (Fig. 129).

**Sensory Phenomena.** There is loss of sensation over the areas supplied by the musculo-cutaneous nerve and the lateral cutaneous branch of the external popliteal nerve, i.e. over the outer side of the leg and the dorsum of the foot (Fig. 130). Joint-sense is lost in all the toes, and generally at the ankle as well.

#### **Vasomotor and Secretory Phenomena.**

The foot is slightly swollen and œdematous, especially in the evening if the patient has been walking about during the day. The swollen foot is generally cyanosed, with thinning of the skin on the dorsum and hyperkeratosis on the sole. Sweating is absent

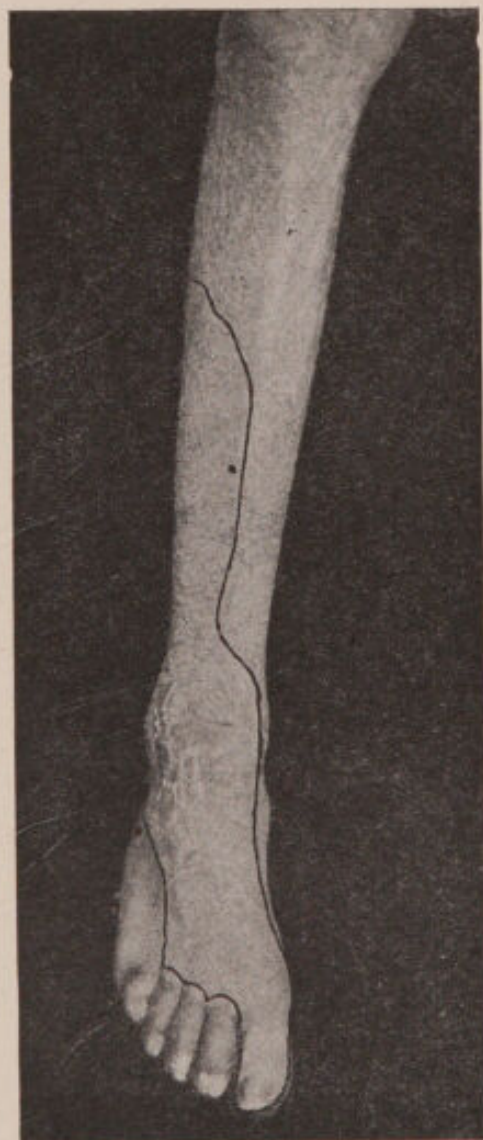

FIG. 129.—RIGHT-SIDED EXTERNAL POPLITEAL PARALYSIS, FOLLOWING A GUNSHOT-WOUND OF THE BUTTOCK WHICH DIVIDED THE PERONEAL HALF OF THE GREAT SCIATIC NERVE.

The outlined area is anæsthetic to pin-pricks and cotton-wool. There is paralysis of the peronei, tibialis anticus, and extensors of the toes. Note the wasted condition of the extensors and peronei, the 'drop-foot,' and the delayed desquamation over the anæsthetic area.

## 216 NERVE INJURIES AND THEIR TREATMENT

in the anæsthetic area of skin, and the foot as a whole is usually warmer than the uninjured one.

Fig. 129 shows the area of anæsthesia in a soldier wounded in May 1915, at Festhubert, by a piece of shell. The entrance-wound was in the right buttock on a level with the top of the great trochanter and  $2\frac{1}{2}$  inches from the mid-vertebral line :

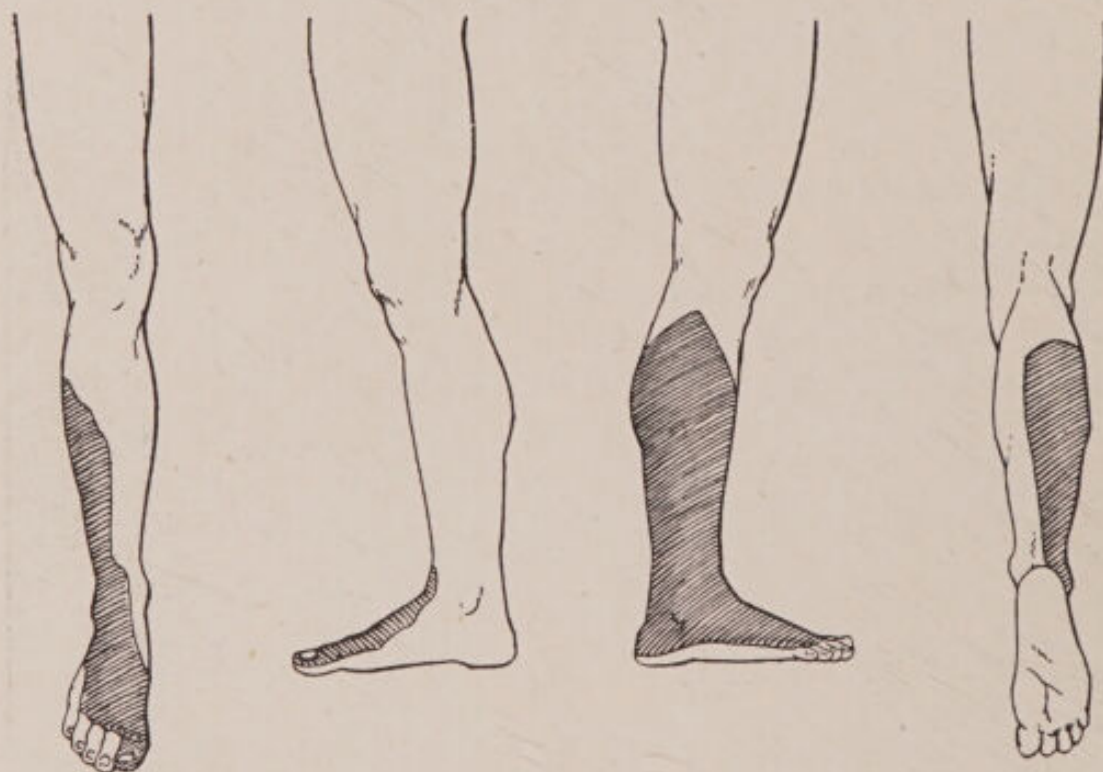

FIG. 130.—EXTERNAL POPLITEAL PARALYSIS. The shaded area shows the extent of anæsthesia to pin-pricks and cotton-wool.

there was no exit-wound, but in the radiogram a piece of shell could be seen lying near the neck of the right femur.

At the operation in July 1915 it was found that the external popliteal nerve had been shot through about one inch below the sciatic notch. In this situation it was replaced by a mass of fibrous tissue which was adherent to the internal popliteal nerve. This area was excised and the ends of the nerve sutured.

### THE ANTERIOR TIBIAL NERVE

*Anatomy.*—The anterior tibial nerve passes inwards and downwards beneath the peroneus longus, the extensor longus digitorum, and the extensor proprius hallucis, to reach the interosseous membrane, on which it descends to the ankle-

joint. Here it passes beneath the anterior annular ligament and the tendon of the extensor proprius hallucis. In this situation it gives off branches which supply the extensor brevis digitorum, the articulations of the tarsus and metatarsus. It terminates in cutaneous branches which supply the cleft between the hallux and the second toe. This space is also supplied by branches of the musculo-cutaneous nerve, so that paralysis of the anterior tibial nerve may be unaccompanied by any sensory loss. (See Fig. 131.) In its course down

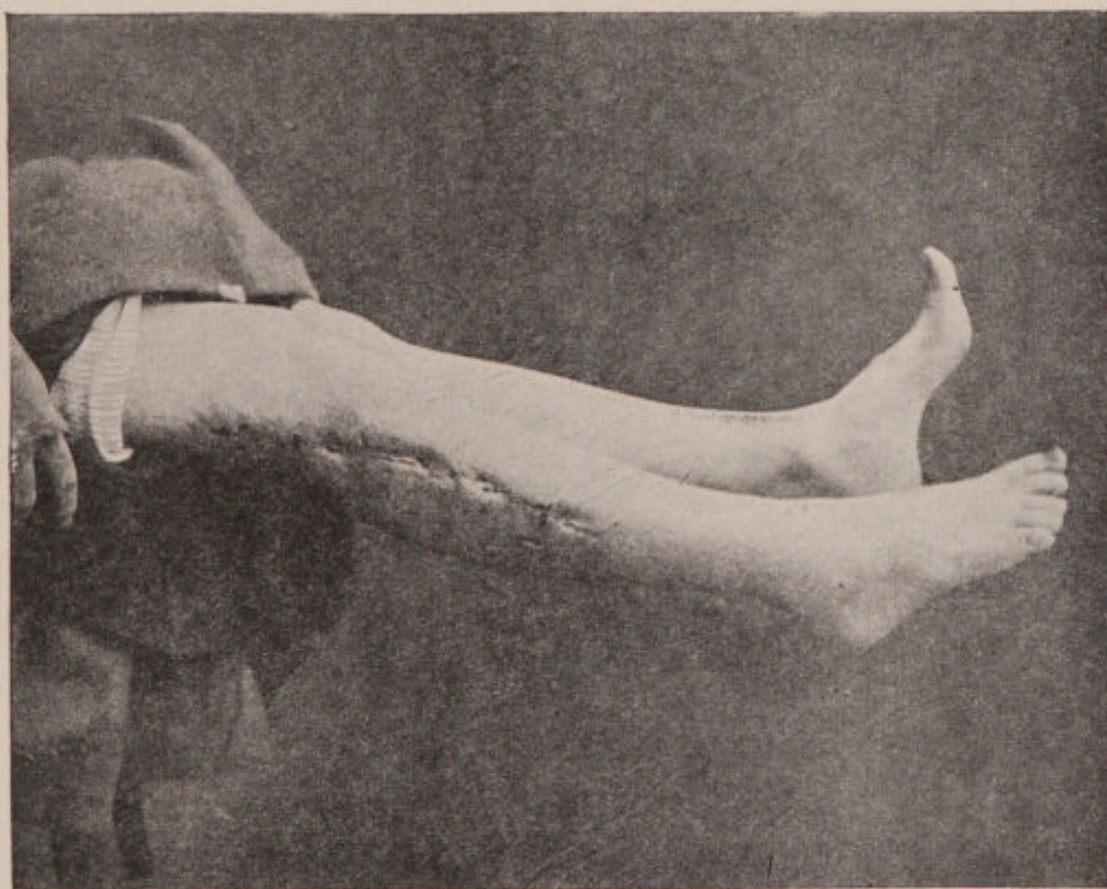


FIG. 131.—PARALYSIS OF THE RIGHT ANTERIOR TIBIAL NERVE. The patient is attempting to dorsiflex both feet. The right foot is in the condition of 'foot-drop.' There is no sensory loss.

the leg, the anterior tibial nerve supplies the tibialis anticus, extensor longus digitorum, extensor proprius hallucis, and the peroneus tertius muscles.

Paralysis of the anterior tibial nerve is very seldom met with in civil practice, but may occur from gunshot wounds of the interosseous space.

The symptoms are paralysis of the tibialis anticus, extensor proprius hallucis, extensor longus digitorum, peroneus tertius, and extensor brevis digitorum; there is usually no sensory loss, but there may be anæsthesia in the first interosseous space.

Fig. 131 is that of a woman, the upper end of whose fibula was removed for a huge myeloid sarcoma. The first stage of the operation consisted in thoroughly exposing the external popliteal, the musculo-cutaneous, and the anterior tibial nerves; these were dissected out and displaced forwards. It was thought that these had been carefully protected from injury during the whole operation, which was a very tedious and prolonged one; but much manipulation of the interosseous space was necessitated by the ramification of the growth and by the free bleeding which followed the removal of the tourniquet, and the anterior tibial nerve must have been injured, for subsequently it was found that the patient had 'foot-drop.'

**Motor Symptoms.** There was no voluntary movement in the tibialis anticus, the extensor longus digitorum, nor in the extensor proprius hallucis. These muscles gave no response to faradic shocks, and there was reaction of degeneration to the galvanic current.

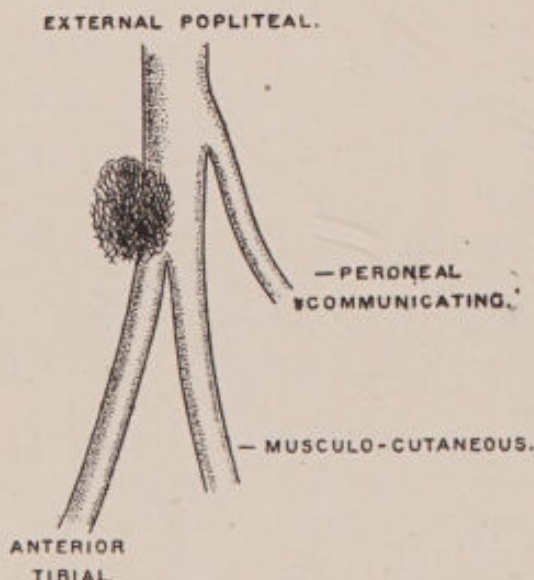


FIG. 132.—GUNSHOT-WOUND OF THE LEFT EXTERNAL POPLITEAL NERVE, INVOLVING ONLY THE FIBRES OF THE ANTERIOR TIBIAL NERVE.

**Sensory phenomena.** There was no sensory loss in foot or leg, *not even in the first dorsal interosseous space.*

Fig. 132 relates to a soldier wounded by a shrapnel-bullet which entered just behind the left bicepstendon at the level of the knee-joint. Four months later, he could firmly plantar-flex the foot and strongly evert foot (peronei acting forcibly), but

Unable to display this page

**communicating nerve** is given off. This passes down the mid-line of the calf covered by the deep fascia. Piercing the fascia in the middle of the leg, it joins the peroneal communicating to form **the external, or short saphenous nerve**. This nerve winds round the back of the external malleolus to gain the outer side of the foot. It supplies cutaneous branches to the outer side and back of the lower third of the leg, the ankle, the heel, and the outer side of the foot and little toe. It also supplies articular branches to the ankle-joint and the joints of the tarsus.

### **Posterior Tibial Nerve.**

This nerve is the continuation of the internal popliteal nerve from the lower border of the popliteus muscle to the internal annular ligament, under which it divides into the two plantar nerves. It runs down the back of the leg between the superficial and the deep muscles, lying on the tibialis posticus muscle, and then on the lower end of the tibia. The nerve at first lies internal to the posterior tibial artery; it crosses the artery at the upper margin of the soleus muscle, and runs down on the tibular side of the vessel to the ankle.

**Muscular branches** are given to the soleus, tibialis posticus, flexor longus digitorum, and flexor longus hallucis.

**A cutaneous branch**, the internal calcanean nerve, is supplied to the heel and the neighbouring part of the sole of the foot.

Beneath the internal annular ligament the posterior tibial nerve divides into its terminal branches, the internal and external plantar nerves.

**The internal plantar nerve** (the homologue of the median nerve in the hand) supplies the abductor hallucis, flexor brevis digitorum, flexor brevis hallucis, and the first lumbrical; it also supplies sensation to the inner part of the sole of the foot and the plantar surface of the three-and-a-half tibial toes.

**The external plantar nerve** (the homologue of the ulnar nerve in the hand) supplies the accessorius, the abductor minimi digiti, the adductor obliquus and adductor transversus hallucis, the three outer lumbricals, and all the interossei; it also supplies sensory branches to the outer side of the sole of the foot, and to the plantar surface of the one-and-a-half fibular toes.

The digital nerves also send cutaneous twigs to the dorsum of the toes, which supply the terminal phalanges.

Complete isolated lesions of the internal popliteal nerve are uncommon.

**Motor Symptoms.** A complete lesion of the nerve results in paralysis of the muscles of the calf and flexors of the foot; consequently, plantar flexion of the foot and of the toes is impossible. Owing to paralysis of the *tibialis posticus*, the foot cannot be forcibly inverted. By means, however, of the intact *tibialis anticus* the foot can still be feebly inverted, but this movement is accompanied by dorsi-flexion of the foot.

**Sensory Symptoms.** There is loss of sensation over the sole of the foot, and over its fibular border; over the plantar surfaces of the toes and the dorsum of the terminal phalanges of the four fibular toes; over the entire heel, plantar and postero-external surfaces, and over the posterior surface of the leg in its lower third. (See Fig. 120.) The portions of this area supplied by the external saphenous nerve are the posterior surface of the leg and the outer border of the foot.

The ankle-jerk and the plantar-reflex are both abolished.

Lesions of the nerve are easily overlooked, since there is no characteristic attitude of the foot.

A soldier in August 1915, at Suvla Bay, was wounded by a rifle-bullet in the right leg. The entrance was in front,  $5\frac{1}{2}$  inches above the inter-malleolar line. The exit was on the inner side,  $3\frac{1}{2}$  inches above the tip of the internal malleolus, and on a line with its posterior edge. The bullet fractured the tibia. There was paralysis of the muscles of the sole of the foot, and loss of sensation, both protopathic and epicritic, over the heel, sole, and plantar surfaces of the toes. There was loss of sensation to deep pressure over most of the heel (Fig. 133).

At the operation it was found that the nerve was completely divided; there was a bulb at each end; the ends were separated for  $2\frac{1}{2}$  centimetres, and were embedded in a mass of dense fibrous tissue which was intimately adherent to the site of the fracture and also to the scar of exit. After freshening the divided ends of the nerve, they were 'bridged' by many strands of catgut, and wrapped in cargile membrane.

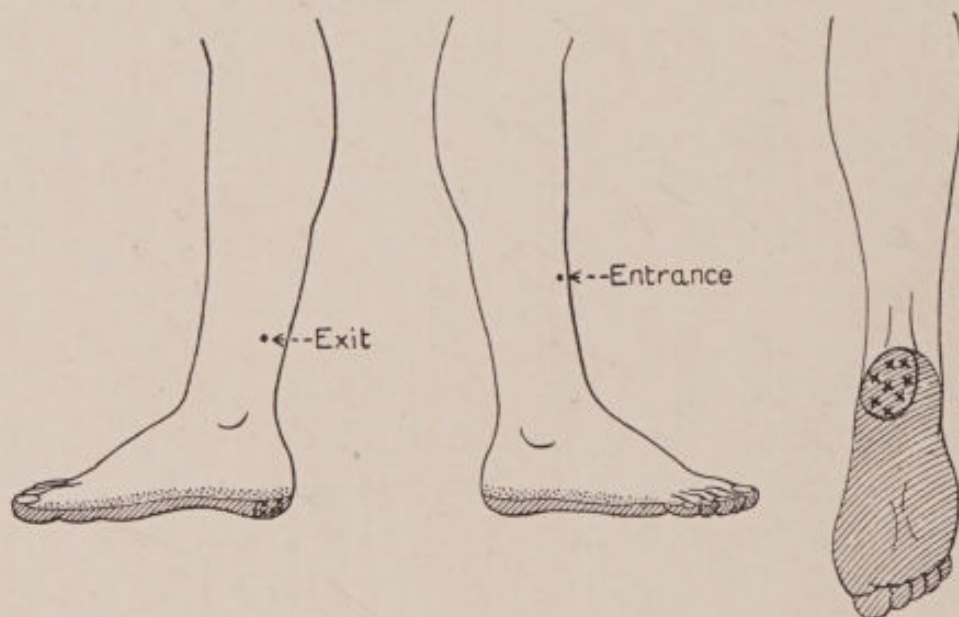


FIG. 133.—PARALYSIS OF THE POSTERIOR TIBIAL NERVE. There was paralysis of the muscles of the sole. The shaded area denotes loss of epicritic and protopathic sensation; the dotted area indicates loss of epicritic sensation alone. The crosses indicate the area over which deep sensation was lost.

#### **Pains associated with Internal Popliteal Nerve Injuries.**

Incomplete lesions of the internal popliteal nerve, whether high up in the sciatic trunk or after its divergence from the external popliteal nerve, are commonly associated with pain. In this respect the internal popliteal resembles the median nerve in the upper limb. (See p. 176.) The spontaneous pain is of a burning character (thermalgia). It is referred to the sole of the foot and the plantar surfaces of the toes; in some cases the pain is also referred to the calf (Fig. 134). The territory of the internal plantar nerve is more painful than that of the external plantar. After attaining their maximum intensity these

pains persist at their worst for several weeks. They then tend to subside—more rapidly than in the case of median-nerve pains.

### THE SMALL SCIATIC NERVE

Lesions of the small sciatic nerve are evidenced by anæsthesia of the lower portion of the buttock and of the posterior surface of the thigh—sometimes, too, of the popliteal area, and the upper half of the calf.

Isolated lesions of the small sciatic nerve are rare.




FIG. 134.—PARALYSIS OF THE SMALL SCIATIC NERVE AND PAINFUL INTERSTITIAL NEURITIS OF THE INTERNAL POPLITEAL NERVE, consequent on a shell-wound of the right buttock. There is anæsthesia of the lower portion of the buttock and posterior surface of the thigh; also marked cutaneous hyperæsthesia in the calf and sole of the foot (the dotted areas), together with wasting of the muscles in these regions.

Generally the injury also implicates some other branch of the lumbo-sacral plexus.

A soldier received a bullet-wound in the buttock at Ypres in April 1915.

There was anæsthesia over the buttock and posterior surface of the thigh, and general wasting of the glutei, hamstrings, and calf muscles; there was tenderness on pressure in the calf and marked hyperæsthesia in the right sole. At the instant he was wounded he thought some one had dropped a box of ammunition on his foot, and felt sure his heel had been crushed.

The pain in his foot was so great that his boot had to be cut away; he could not bear to have it pulled off. The pain increased for two weeks, and remained at its maximum for three weeks. When seen in July the sole of the foot was so exquisitely tender that he could only rest it in bed when lying on its side; he could allow nothing to touch the sole.

At the operation in July 1915 it was found that immediately outside the sciatic notch the great sciatic nerve had been injured on its inner edge; here the sheath was adherent to a mass of scar tissue, in which was compressed the small sciatic nerve.

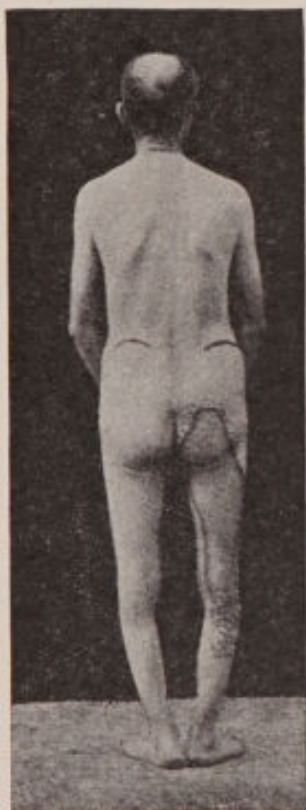

FIG. 135.—COMBINED LESION OF RIGHT SMALL SCIATIC AND INFERIOR GLUTEAL NERVE.

### Combined Lesion of Small Sciatic, Inferior Gluteal, and, partly, of Great Sciatic.

A soldier, aged 36, suffered from malignant tertian malaria, for which he was treated by intra-muscular injections of quinine. One of these injections, unfortunately, was given over the course of the sciatic nerve on the right side, at a level one inch above the gluteal fold. The patient at once developed pain in the course of the sciatic distribution, from hip to heel.

When examined,  $3\frac{1}{2}$  weeks later, he was found to have anæsthesia to cotton-wool touches over the right lower gluteal region, the back of the thigh, and the upper half of the calf. To pin-pricks the area of analgesia was less extensive. (See Fig. 135.) The right gluteal fold was flattened, and the gluteus maximus did not contract on voluntary extension of the right hip. The hamstrings, calf muscles, and dorsiflexors of the right ankle were slightly feebler than on the other side, and the right ankle-jerk was diminished.

## THE ANTERIOR CRURAL NERVE

*Anatomy.*—The anterior crural nerve arises from the 2nd, 3rd, and 4th lumbar nerves, in the substance of the psoas muscle. Gaining the outer side of the psoas muscle, it runs downwards between that muscle and the iliacus, and passes under Poupart's ligament, lying close to the outer side of the femoral artery. Whilst in the abdomen a muscular branch is given to the iliacus muscle. In Scarpa's triangle it splits up into its terminal branches.

**Muscular Branches.**

These are supplied to the quadriceps extensor cruris (vastus internus, vastus externus, rectus femoris and crureus), the pectineus, and sartorius muscles.

**Articular Branches.**

The nerve to the rectus femoris supplies a branch to the hip-joint. The nerves to the vastus internus, vastus externus and crureus, each supply a branch to the knee-joint.

**Cutaneous Branches.**

The middle cutaneous nerves supply the front of the thigh from the apex of Scarpa's triangle to the knee-joint.

The internal cutaneous nerves supply the inner side of the thigh in its lower two-thirds.

The internal, or long saphenous nerve, passing down the thigh in Hunter's canal, becomes cutaneous on the inner side of the knee-joint, and supplies the internal surface and front of the knee-joint, and the internal surface of the leg and of the ankle-joint.

Injury of the anterior crural nerve is rare.

**Motor Symptoms.** The motor loss in paralysis of the anterior crural nerve is evidenced by inability to extend the knee-joint. There is also diminished power of flexion at the hip-joint. The knee-jerk is abolished.

When standing or walking the knee tends to give way, and the patient easily trips over small objects. There is

special difficulty in going up or down stairs—the patient taking two strides on each step, instead of the normal alternate step-forwards of each leg. When going upstairs, he leads off with the sound leg and drags the affected leg up to the same level. When going downstairs, he leads off with the paralysed leg.

**Sensory symptoms.** There is anæsthesia over the front and inner surface of the thigh and knee, and over the inner



FIG. 136.—PARALYSIS OF THE LEFT ANTERIOR CRURAL NERVE. The patient is trying to extend both knees, but fails with the left.

surface of the leg and of the ankle-joint. The anæsthesia extends downwards to about one and a half inches below the inner malleolus.

The **long saphenous nerve** is sometimes injured separately in wounds through Hunter's canal. In addition to anæsthesia over its cutaneous distribution, the patient usually suffers from spontaneous pains in the same area.

## THE OBTURATOR NERVE

*Anatomy.*—The obturator nerve arises from the 2nd, 3rd, and 4th lumbar nerves in the substance of the psoas muscle.

It passes downwards in the psoas muscle and gains its inner border near the brim of the pelvis, behind the common iliac artery. Together with the obturator artery it passes through the opening in the upper part of the obturator foramen, and enters the thigh. Whilst in the opening, it divides into a superficial and a deep part. The superficial part, passing in front of the adductor brevis muscle, but deep to the pectineus and adductor longus, supplies an articular branch to the hip-joint and muscular branches to the adductor longus, adductor brevis, and gracilis. A cutaneous branch supplies a strip of skin on the inner side of the thigh. The deep part passes behind the adductor brevis, and supplies branches to the obturator externus, adductor magnus and adductor brevis, and an articular branch to the back of the knee-joint.

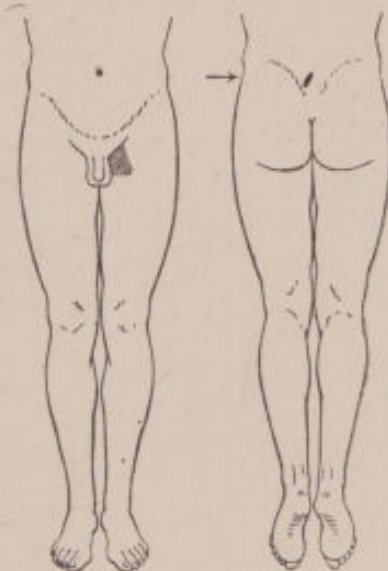


FIG. 137.—LEFT-SIDED OBTURATOR AND ILIO-INGUINAL PARALYSIS.

It is therefore the nerve of adduction of the thigh. The power of adduction, however, is not completely lost in lesions of the obturator nerve, seeing that the adductor magnus received branches from the great sciatic nerve, and that the anterior crural nerve sometimes sends branches to the adductor longus; moreover, the other adductors of the thigh (the pectineus and the lower fibres of the gluteus maximus) are still intact.

Injury of the obturator nerve is rare. The following is an illustrative example :—

An officer was wounded by a rifle-bullet which entered at the outer border of the left iliac crest, 2 inches behind and an

inch above the anterior superior iliac spine. There was no exit-wound, but a radiogram showed the bullet lying obliquely within the pelvis at the level of the 5th lumbar spine.

When hit, he immediately lost power in the left lower limb, fell, and was unable to get up. When examined two weeks later, in a base hospital, he was found to have cutaneous anæsthesia of the uppermost part of the left adductor region, also of the sole and dorsum of the left foot. Together with this, there was paralysis of the adductors, quadriceps, and anterior tibial group of muscles, with drop-foot, evidently from widespread damage to the lumbo-sacral plexus.

When re-examined,  $4\frac{1}{2}$  months after the injury, the condition had cleared up, save for motor signs of left-sided obturator paralysis. There was also a patch of anæsthesia close below the left groin, in the territory of the ilio-inguinal nerve. (See Fig. 137.) Pin-pricks in this area were recognized, but felt 'different' from the healthy side. At the left hip-joint, flexion and extension were good but adduction was feeble. There was wasting, with loss of faradic reaction, in the left adductor muscles. The quadriceps and all other muscles of the limb were now normal, both in motor power and in faradic excitability. The motor weakness of the knee and ankle had also completely cleared up.

## INDEX

- Acromial nerve,  
  site and path of, 125
- Action of gravity, 105
- Adductor obliquus,  
  paralysis of, 164
- Adductor transversus,  
  paralysis of, 164
- Adherence,  
  of injured surfaces lying in contact, 87
- Adhesions,  
  of unmoved tendons, sheaths, and joints, 72  
  prevention of, 85
- Alcohol poisoning,  
  neuritis of, 41
- Anæsthesia,  
  skin areas of, how mapped out, 15  
  types of, in nerve injuries, 17
- Analgesia to pin-pricks,  
  following peripheral nerve lesion, 17
- Anal reflexes,  
  loss of, in cauda equina lesion, 199
- Anastomosis,  
  directions for, 94  
  for facial paralysis, 95
- Aneurysm,  
  nerve paralysis produced by pressure of, 40
- Ankle,  
  loss of movement from paralysis of great sciatic nerve, 210
- Anosmia,  
  testing for, 110
- Anterior cornual cell,  
  lesions of, causes and characteristics, 54, 55
- Anterior crural nerve,  
  *see* Crural nerve
- Anterior root lesions,  
  causes and characteristics, 55
- Anterior thigh and leg muscle,  
  motor points of (*illustration*), 24
- Anterior tibial nerve,  
  *see* Tibial nerve
- Anus,  
  anæsthesia of, from cauda equina lesion, 199
- Arm,  
  functional anæsthesia accompanying musculo-spiral injury, 52  
  (left upper), hysterical paralysis of, 150, 151  
  hysterical paralysis of (*illustrations*), 151  
  (lower), paralysis (Klumpketype), cause, 134  
  motor points of (*illustrations*), 22, 23  
  splinting in injuries of, 74, 75, 77  
  statistics of injuries to various nerves of, 109  
  (upper), paralysis (Erb - Duchenne type), cause, 133  
  wounds, of functional anæsthesia following, 41, 45-8  
  *see also* Brachial plexus
- Arsenic poisoning,  
  neuritis of, 41
- Arteries, fibrosed and obliterated,  
  frequently associated with nerve injuries, 103
- Asepsis,  
  essential for success of nerve suture, 65, 70, 71  
  imperative in all operations, 83
- Astereognosis, 16, 171
- Auditory nerve,  
  injury to, deafness frequently associated with facial paralysis, 118
- Auricular nerve (great),  
  bullet-wound of (*illustration*), 127  
  case illustrating bullet-wound, 127, 128  
  site and path of, 125

Unable to display this page

- Brachial plexus (*continued*),  
 rupture of fifth and sixth cervical root (*illustration*), 132  
 traction injuries, 133, 134  
 wound with diverse lesions of several nerves, treatment, 102, 103, 104
- Brachialis anticus,  
 paralysis of, 76
- Bridging, 94
- Bulbous ends, 87, 88  
 cut surface of (*illustration*), 85  
 removal of, 84, 85, 89
- Burning pain,  
 following injury, characteristics, 31  
*see also* Causalgia
- Buttocks,  
 anæsthesia of, from lesion of small sciatic, 223  
 external popliteal paralysis following gunshot wound, 215  
 "saddle-shaped" area of anæsthesia on, cause, 199  
 sensory area of nerve root supplying, 198, 199  
 shrapnel-wound of, functional anæsthesia following, 46
- Calf,  
 general wasting of muscles from interstitial neuritis of the tibial nerve, 223  
 paralysis of, from internal popliteal injury, 221  
 sensory area of, supplied by first sacral nerve root, 197, 199
- Callus,  
 as a paralyzing agent, 61  
 compression by, 33, 35, 100  
 cases resistant to treatment, 81  
 nerve-callus, 87
- Cargile membrane,  
 use during operation, 85
- Cauda equina,  
 cutaneous distribution of, 197 (*illustration*), 198  
 cutaneous peripheral sensory supply of lower limb (*illustration*), 198  
 definition of the term, 197  
 injuries to, motor and sensory symptoms, 197, 198, 199  
 lower, and conus medullaris, injury to, case illustrating symptoms, 203-4 (*illustration*), 204
- Cauda equina (*continued*),  
 lower injury, case illustrating symptoms (*and illustration*), 202-3  
 motor distribution of, 198, 199  
 non-traumatic injuries, characteristics, 205  
 sensory distribution of, 197, 199  
 upper injuries, cases illustrating sensory and motor symptoms, 200, 201 (*illustration*), 206
- Causalgia or Thermalgia, 222  
 class of case described as, 176  
 injuries associated with, prognosis bad, 61  
 nature of the condition, 31  
 phenomena of, 81  
 resistance to treatment, 81  
 treatment, 81
- Central neuroma, 88
- Cervical nerve (fifth),  
 anæsthesia in lesion of, 138  
 anastomosis to spinal accessory (*illustration*), 95  
 complete lesion of, case illustrating, 137, 138 (*illustration*), 137  
 division, with involvement of others, 140, 141  
 injury to, cases illustrating, 138, 139  
 showing lateral neuroma (*illustration*), 95  
 traction injuries, 133, 134
- Cervical nerves (superficial),  
 site and path of, 125, 127
- Cervical plexus,  
 bullet-wounds of, 127  
 cutaneous branches of, distribution, 125  
 diagram of (*illustration*), 126  
 injuries to, 127  
 muscular branches, 125
- Cervical rib,  
 injuries due to pressure of, 151  
 meaning of the term, 151  
 right-sided brachial plexus, injury from pressure of, case illustrating, 152, 153 (*illustrations*), 152, 153
- Cervical sympathetic nerve,  
 distribution and functions of, 123  
 injury to, 123  
 irritation of, signs and causes, 125  
 paralysis of, signs and characteristics, 124

Unable to display this page

- Cutaneous sensory distribution,  
of the brachial plexus, 129, 130  
(*illustration*), 131
- Deafness,  
from injury to auditory nerve, 118
- Degeneration  
*see* Reaction of degeneration
- Deltoid muscle,  
paralysis of, 123, 146  
through division of fifth cervical root, 140, 141  
paralysis and wasting of,  
following gunshot wound (*illustration*), 157  
in circumflex nerve injuries, 158  
splinting in paralysis of, 76  
(*illustration*), 77  
wasting of (*illustration*), 132
- Dental nerve,  
paralysis of, 123
- Desquamation,  
following injury to external popliteal nerve (*illustration*), 6, 7
- Diabetes,  
neuritis of, 41
- Diagnosis,  
early importance of, 70  
of divided nerve, 71  
of organic nerve disease, 53, 54
- Diaphragm paralysis,  
division of phrenic nerve resulting in, 128
- Diphtheria,  
neuritis of, 41
- Diplopia,  
and ocular palsies, 111  
injury to fourth ocular nerve causing, 111
- Dissociated paralysis, 30
- Divided nerve,  
alteration in structure and function, 4, 5, 7, 8  
anatomical and physiological interruption in relation to, 28  
causes and symptoms, 28-32  
complete, 81  
suture of, technique, 84, 87-8  
with separated ends,  
treatment, 87  
(*illustration*), 88  
complete and incomplete,  
diagnosis and differentiation of, 28, 29, 30  
incomplete,  
definition of, 30  
symptoms of, 29, 30
- Divided nerve (*continued*),  
incomplete (*continued*)  
treatment, 95  
pain following, characteristics, 31  
process of recovery of, 8-11  
reaction of degeneration following, 28  
sciatic (*illustration*), 5  
skin changes, 7, 8  
suture of, technique, 83, 84  
suture the treatment for, 70  
(*illustration*), 8, 9  
*see also* Injuries
- Drop-foot,  
cause of, 19, 214, 215  
and varus, paralysis of great sciatic with (*illustration*), 211  
in anterior tibial paralysis (*illustration*), 217  
in external popliteal paralysis (*illustration*), 215  
method of examination, 20  
position during treatment, 75  
prevention by tendon fixation, 106  
walking apparatus for (*illustration*), 76  
(*illustrations*), 215
- Drop-wrist,  
cause of, 19  
in musculo-spiral paralysis, 187, 190  
(*illustration*), 188  
method of examination, 20  
position during treatment, 73  
prosthetic appliance for, 106  
splint for, 74  
(*illustration*), 188
- Dysæsthesia,  
occurrence of, 16
- Efferent fibres,  
functions, 3
- Electrical examination,  
non-response of muscle to, a sign of nerve degeneration, 59, 60  
of motor functions, 20-6
- Electrical reactions,  
in musculo-spiral paralysis, 189, 190, 191  
of muscles following nerve injury, 59
- Electrical treatment, 90  
non-response to, 91  
observations and instructions, form to be employed, 78
- Electrodes,  
in electrical examination, 20, 90

Unable to display this page

- Fibrosis** (*continued*),  
mainly dependent on sepsis, 86
- Fibrous tissue**,  
formation of, 86  
common factor in production of  
paralysis, 85  
compression by, 67, 81  
cases resistant to treatment, 81  
treatment, 98  
segment of injured nerve re-  
sembling, treatment, 104
- Finger pads**,  
wasting of, following nerve di-  
vision, 8  
(*illustration*), 6
- Fingers**,  
flexion of, in gunshot wound  
of ulnar nerve (*illustration*),  
163  
in median and ulnar paralysis,  
172, 173, 178  
inability to extend, in musculo-  
spiral paralysis, 187, 190, 191  
(*illustrations*), 188, 189  
loss of cutaneous sensation from  
ulnar and median paralysis,  
161, 171, 173  
loss of joint sense in median  
paralysis, 171  
loss of movement in median and  
ulnar paralysis, 181-3  
pains of, in median nerve injury,  
176, 177  
paralysis in median nerve injury,  
173  
paralysis in musculo-spiral in-  
jury, 190, 191  
paralysis of flexors, 143-7  
splinting in musculo-spiral and  
ulnar paralysis, 74, 75, 77  
tapering of, following nerve di-  
vision, 8  
tendon transplantation in in-  
juries of, 105, 106  
tight flexor contracture of, case  
illustrating, 49  
*see also* Ulnar nerve
- Flexion of joint over which the  
nerve passes**, 92
- Foot**,  
anæsthesia of dorsum and sole in  
paralysis of great sciatic  
nerve, 210  
anæsthesia of dorsum in paralysis  
of external popliteal nerve,  
215  
desquamation of dorsum of (*illus-  
tration*), 6
- Foot** (*continued*),  
loss of protopathic and epicritic  
sensation over heel, sole, and  
toes from posterior tibial  
lesion, 221  
paralysis of sole, from internal  
popliteal injury, 221  
paralysis of sole, from posterior  
tibial lesion, 221  
plantar flexion and inversion  
impossible in internal pop-  
liteal injury, 221  
sensory areas of, nerve roots  
supplying, 197, 199
- Foot-drop**,  
*see* Drop-foot
- Forearm**, gunshot wound of,  
functional anæsthesia and muscle  
spasm following (*illustra-  
tions*), 44, 45
- Fractures**, complicating nerve in-  
juries, 62
- Functional anæsthesia**,  
and muscle spasm following gun-  
shot wound of forearm (*il-  
lustrations*), 44, 45  
characteristics, 45  
(*illustrations*), 44, 45, 46, 47
- Functional paralysis**,  
and organic combined, case illus-  
trating characteristics, 51,  
52  
"concussed" nerve frequently  
example of, 35  
points in diagnosis, 43, 44  
reflexes in, 44
- Functional spasm**,  
of left hand (*illustration*), 44, 45
- Functions**,  
recovery of, in primary and  
secondary suture, 63
- Funiculi**,  
description of, 2
- Galvanism**,  
in examination of motor func-  
tions, 22  
in treatment, indications for, 78  
in treatment of facial paralysis,  
117  
non-response of muscles to, a sign  
of nerve degeneration, 59, 60  
reaction of degeneration exhi-  
bited on testing divided  
nerve by, 28  
reactions to, in musculo-spiral  
paralysis, case illustrating,  
189, 190, 191

- Galvanism (*continued*),  
 response to, in injury to cords of  
 brachial plexus, case illus-  
 trating, 147
- Genitals, anæsthesia of,  
 in lesion of cauda equina, 197,  
 199, 204
- Glossopharyngeal nerve,  
 paralysis of, condition due to, 118
- Glove,  
 for use in ulnar paralysis, 77  
 (*illustration*), 78
- Gluteal nerve, 207  
 inferior, and small sciatic, com-  
 bined lesion of, 224  
 (*illustration*), 224
- Glutei,  
 general wasting from lesion of  
 great sciatic, 223
- Hæmorrhage,  
 prevention of, during operations,  
 86, 87  
 into nerve substance, 60
- Hæmostasis, 86
- Hæmothorax,  
 in gunshot wounds of thorax, 196
- Hamstring muscles,  
 general wasting of, from lesion of  
 the great sciatic, 223  
 nerve to, course of, 208  
 paralysis of, from lesion of the  
 great sciatic, 212
- Hand,  
 appearance following lesion of  
 median and ulnar nerves, 181  
 appearance following lesion of  
 median and ulnar nerves  
 (*illustration*), 6  
 condition and appearance in  
 musculo-spiral paralysis,  
 187-9  
 (*illustrations*), 188, 189  
 deformity in median paralysis,  
 172  
 deformity in ulnar paralysis, 163  
 hyperkeratosis of palmar surface  
 in ulnar paralysis, 165  
 hysterical spasm of, following  
 thumb wound (*illustrations*),  
 49, 50, 51  
 ischæmic paralysis of (*illustra-  
 tions*), 37, 38  
 loss of cutaneous sensation from  
 median paralysis, 171, 174  
 loss of cutaneous sensation from  
 ulnar paralysis, 161
- Hand (*continued*),  
 pains in, in median nerve injury,  
 177  
 paralysis of intrinsic muscles of,  
 143, 149, 181, 184  
 (*illustrations*), 144, 145, 149, 181  
 reflex paralysis of, case illustrat-  
 ing, 57  
 return of motor power to muscles  
 of, following ulnar lesion, 67  
 tendon transplantation in in-  
 juries of, 105, 106  
 wasting of palmar muscles in  
 median and ulnar paralysis,  
 181
- Hand splint, 74  
 (*illustration*), 75
- Hersage, 102
- Hopeless nerve injuries, 104, 105
- Humerus,  
 bony deformity of internal con-  
 dyle (*illustration*), 168  
 bullet-wound, median and ulnar  
 paralysis following, 178  
 gunshot hole with lesions of  
 several nerves (*illustration*),  
 103  
 subcoracoid dislocation of, injury  
 to posterior and inner cords  
 of brachial plexus by, case  
 illustrating, 147
- Hyperæsthesia, areas of,  
 how mapped out, 15
- Hyperkeratosis, of palmar surface  
 in ulnar paralysis, 165
- Hypoglossal nerve,  
 function of, 122  
 (left), paralysis of (*illustration*),  
 123  
 paralysis of, atrophy of tongue  
 resulting from, 122
- Hypothenar muscles,  
 wasting in brachial plexus injury  
 from cervical rib pressure,  
 152, 153  
 wasting in gunshot lesion of ulnar  
 nerve, 163, 164  
 (*illustrations*), 6, 181
- Hypothermia, local, 55
- Hysterical paralysis,  
 and reflex, combined, 57, 58  
 differential diagnosis, 55  
 case illustrating, 48, 49, 50-3, 57  
 production by suggestion, 50  
 simulating a lesion of brachial  
 plexus, case illustrating (*and  
 illustration*), 150, 151  
 (*illustrations*), 49, 50, 51, 57

- Ilio-inguinal paralysis, 227
- Iliac crest,  
sensory areas of, 197
- Incomplete division,  
*see* Divided nerve, 29
- Inferior gluteal nerve,  
*see* Gluteal nerve
- Infraspinatus muscle,  
*see* Spinati
- Injuries,  
active movements in, 79  
adherence of surfaces lying in  
contact, 87  
changes in muscles following, 71,  
72  
condition of wound complicating,  
62  
conditions under which they  
occur, 27  
due to concussion, 61  
electrical reactions of muscles  
following, 59  
electrical treatment, 78  
essential points in treatment, 70,  
71  
good prognosis, evidence of,  
61  
ionization over site of, 60  
massage and passive movements  
in, 79  
methods of production and symp-  
toms, 27-42  
mixed-nerve, treatment directed  
to muscle changes, 71  
motor return affected by site of,  
67  
non-response of muscle to electri-  
cal measures a sign of nerve  
degeneration, 59, 60  
of anterior roots and of peripheral  
nerves, distinction between,  
55  
pain following, characteristics, 31  
prognosis after relieving com-  
pression, 67, 68  
recovery of functions after, period  
before complete, 63  
spontaneous recovery of, 70  
statistics of cases, 108, 109  
symptoms, completeness or in-  
completeness of, 60  
symptoms occurring indepen-  
dently of, 40, 41  
symptoms occurring subsequent  
to, but consequent upon, 35-  
40  
tendon transplantation in, 105  
thickening with adhesions, 60
- Injuries (*continued*),  
traction, type of lesions classed  
as, 32  
type resistant to treatment, 81,  
104, 105  
types of anæsthesia in, 17  
ulcers following, protopathic re-  
covery preventing, 65  
various kinds of, and their  
treatment, 84-106  
*see also under names of individual  
nerves ; also* Divided nerve ;  
Operation ; Treatment, etc.
- Inspection,  
in clinical investigation of motor  
functions, 18
- Intercostal nerves,  
injury by rifle-bullet, case illus-  
trating, 195  
(seventh right), paralysis of (*il-  
lustration*), 196
- Internal plantar nerve,  
*see* Plantar nerve
- Internal popliteal nerve,  
*see* Popliteal nerve
- Internal saphenous nerve,  
*see* Saphenous nerve
- Interossei,  
loss of power of, in ulnar para-  
lysis (*illustration*), 169  
paralysis of, 164  
wasting of, in brachial plexus  
injury from cervical rib  
pressure, 152, 153  
wasting of, in ulnar lesion, 163, 164  
(*illustrations*), 163, 182
- Interosseous nerve, posterior,  
course and function of, 186  
injury to, case illustrating symp-  
toms, 192  
isolated injury rare, 192  
occasionally injured in fractures  
of radius, 187
- Interstitial neuritis, painful, 26  
of the internal popliteal nerve, 224
- Intra-cranial hæmorrhages,  
often associated with ocular  
palsies, 111
- Investing sheaths, 85, 87, 208, 209
- Ionization,  
over site of injury, 60, 79
- Ischæmic paralysis, 36, 37, 38  
cause and nature of the condition,  
36  
anæsthesia in (*illustration*), 39  
from arterial injuries, case illus-  
trating, 39  
of the hand (*illustrations*), 37, 38

- Joints,  
 observations on, in relation to treatment, 73  
 palpation of, in clinical investigation of motor functions, 18  
 paralysed, not to remain in fixed position for lengthy period, 73  
 wounds complicating nerve injuries, 62
- Joint sense,  
 how tested, 14, 16
- Jones, Lewis, condenser apparatus (*illustration*), 26
- Jones's hyperextension hand splint, 74  
 (*illustration*), 75
- Kinæsthetic sense,  
 characteristics, 14, 16
- Klumpke type of lower-arm paralysis, 134
- Knee,  
 anæsthesia of, cause, 226  
 failure of extension of, in anterior crural paralysis, 226  
 flexion during suture of divided sciatic nerve, 92  
 sensory areas of, nerve root supplying, 197-9
- Lacerated nerves,  
 symptoms and characteristics, 32
- Laryngeal nerve, recurrent,  
 and fifth cervical root, combined lesion (*illustration*), 139  
 paralysis of, 40, 119
- Lateral neuroma,  
 definition of, 96  
 (*illustrations*), 95, 96, 97, 98
- Latissimus dorsi,  
 paralysed from lesion of the long subscapular nerve, 196  
 paralysis in complete lesion of posterior cord of brachial plexus, 146
- Lead poisoning,  
 symptoms of neuritis of, 41
- Leg,  
 anæsthesia in paralysis of external popliteal nerve, 215  
 anæsthesia of outer surface in paralysis of great sciatic nerve, 210  
 cutaneous peripheral sensory supply of (*illustration*), 200  
 delayed desquamation of outer surface of (*illustration*), 6
- Leg (*continued*),  
 injuries to, statistics, 109  
 motor points of anterior muscle of (*illustration*), 24  
 paralysis from cauda equina lesion, case illustrating, 200-2  
 paralysis of muscles below knee in lesion of the great sciatic, 210  
 sensory areas, nerve roots supplying, 197  
 tonico-clonic spasm, 48
- Levator ani,  
 paralysis of, from cauda equina lesion, 199
- Levator palpebræ,  
 ptosis of eyelid from paralysis of, 112
- Lingual nerve (right),  
 paralysis of, case illustrating, 123
- Long saphenous nerve,  
*see* Saphenous nerve, internal
- Lumbar nerve roots, 197  
 sensory and motor distribution of, 199  
 sensory areas supplied by (*illustration*), 198
- Lumbo-sacral plexus, 205  
 arrangement of (*illustration*), 206  
 characteristics and distribution of, 205  
 lesions of, 207
- Lumbricales, inner,  
 paralysis of, 164
- Main de singe, 174  
 (*illustration*), 181
- Main en griffe, 164, 166
- Manipulation,  
 clumsy, effects of, 86
- Massage,  
 during treatment, 79
- Masseter muscle,  
 injury to, cause and detection of, 113
- Mastication,  
 during facial paralysis, 116
- Mastoid antrum,  
 facial nerve frequently injured by operations on, 115
- Maxillary nerve, inferior,  
 injury, atrophy, and paralysis of masseter, temporal, and pterygoid muscles due to, 112, 113
- Maxillary nerve, superior,  
 source, distribution and function of, 112

- Mechanical or prosthetic appliances, 106
- Median nerve,  
characteristics, distribution, and functions of, 170  
compression by bone callus, 100  
compression by fibrous tissue, 100 (*illustration*), 100  
compression injury of, case illustrating, 68  
division, appearance of the hand (*illustration*), 172  
hand at rest shows little deformity, 172  
incomplete lesions of, 175  
sensory area in (*illustration*), 177  
(left), case illustrating symptoms, 173  
paralysis of (*illustrations*), 172  
loss of cutaneous sensation (*illustration*), 174  
motor symptoms, 172  
painful symptoms, 175  
sensory symptoms, 171  
spontaneous pains, 176  
sweating characteristic of, 166  
vasomotor and trophic changes, 175  
vasomotor, secretory, and trophic signs, 174  
with lateral neuroma (*illustrations*), 96, 97
- Median paralysis,  
pressure sense in (*illustration*), 69  
with reflex paralysis, 57 (*illustration*), 56
- Median and ulnar paralysis, 177, 183  
due to gunshot wound, case illustrating, 64, 178  
loss of sensation (*illustrations*), 178, 179, 180  
paralysis of thumb (*illustrations*), 182, 183  
sensory symptoms, 178 (*illustrations*), 178-81
- Medullary sheath,  
appearance of, during recovery of divided nerve, 9, 10  
substance and function of, 1
- Methylene blue,  
use in treatment of nerve injuries, 90
- Metronome,  
application of, 78, 90
- Micturition,  
loss of control of, in cauda equina lesion, 202
- Mixed nerve trunk,  
paralysis of, type of anæsthesia following, 17
- Moral paralysis, 79
- Motor functions,  
clinical investigation of, methods, 18-20  
condenser apparatus in examination of, 26  
electrical examination of, 20-6  
muscle deficiency, how tested, 19  
recovery of, following secondary suture, 65  
site of injury affecting return of, 66
- Motor nerve fibres,  
alteration in function, 5  
functions of, 3  
of mixed nerve trunk, 2
- Motor paralysis,  
organic, diagnosis, 18, 54  
significance of, in clinical investigation, 18
- Motor points,  
of face and neck (*illustration*), 21  
of the upper limb (*illustrations*), 22, 23  
of thigh and leg (*illustrations*), 24, 25
- Motor power,  
delayed operation lessening chances of recovery, 65  
recovery after nerve division, 12  
recovery in primary and secondary suture, 63
- Motor supply,  
of the brachial plexus (*illustration*), 130
- Motor symptoms,  
of peripheral neuritis, 40, 41
- Mouth,  
condition in facial paralysis, 116
- Movements,  
active and passive, during treatment, 79
- Müller,  
paralysis of non-striated muscle of, 124
- Muscle fibre,  
degeneration of, following injury, 23-5
- Muscle sensation, 14
- Muscle spasm,  
and functional anæsthesia following gunshot wound (*illustrations*), 44, 45  
of right lower limb (*illustration*), 48

- Muscle supply,  
of the brachial plexus, characteristics, 129, 130
- Muscles,  
affections in upper and lower neurone lesions compared, 54  
condition in organic motor paralysis, 54  
deficient, how degree is estimated, 19  
electrical applications to, 78  
electrical examination of, 20, 22, 26  
electrical reactions following nerve injury, 20, 59  
how affected by functional and organic paralysis, 44  
loss of sensation after nerve division, 28  
massage and movements for, 79  
motor fibres conveying impulses to, 3  
non-response to electrical measures a sign of nerve degeneration, 59, 60  
paralysed, cases resistant to treatment, 105  
essential points in treatment of, 72, 73  
following nerve division, 28  
hyperexcitable to direct percussion, 56  
pathognomonic of organic disease, 44  
pathological changes in, 23-5, 72  
response to faradic stimulation in functional paralysis, 43  
spastic and flaccid, consistence of, following injury, 19  
supplied by injured nerve, changes in, 71  
treatment directed to changes in, in mixed nerve injuries, 71, 72  
"trophic" influence of nerves on, 4  
*see also* Nerves
- Muscular recovery,  
delayed operation not favourable to, 65
- Muscular tremor,  
following injury, 18
- Muscular wasting,  
following injury, 18
- Musculo-cutaneous nerve,  
characteristics, 193  
injuries to, 194
- Musculo-cutaneous nerve (*cont.*),  
origin and distribution of, 193, 214  
paralysis of, case illustrating, 194  
condition in, 194  
(*illustration*), 195  
splinting in lesions of, 76
- Musculo-spiral nerve,  
characteristics, 184, 185  
branches of, 185  
common sites and causes of injury, 186  
contusion, case illustrating, 191  
distribution and functions, 184, 185  
injury with functional anæsthesia and paralysis (*illustration*), 53  
portion of radial nerve transplanted between separated ends of (*illustration*), 94  
sensory loss accompanying lesion (*illustration*), 190  
severed, muscular return satisfactory after uniting, 66  
tendon transplantation in injury to, 105  
treatment by transplantation, 94
- Musculo-spiral paralysis,  
electrical reactions, 189, 190, 191  
following toxic absorption, 41  
from compression, 188, 189  
motor symptoms, case illustrating, 188  
of radial branch, type of anæsthesia following, 17  
sensory symptoms, case illustrating, 190-1  
splint for, 74  
(*illustrations*), 74, 75  
(*illustrations*), 188, 189
- Myelin,  
changes in nerve division, 4  
medullary sheath composed of, 1
- Myositis,  
ischæmic, anæsthesia in (*illustration*), 39
- Nails,  
changes in, following nerve division, 8  
increased growth and curvation of, 6
- Neck,  
aneurysm in, irritation of cervical sympathetic by, 125  
motor points of (*illustration*), 21

- Nerve bulbs,  
(*illustrations*), 8, 9, 10
- Nerve callus, 87, 90
- Nerve deafness, 118
- Nerve degeneration,  
non-response of muscles to electrical measures a sign of, 59, 60
- Nerve fibres,  
characteristics, 2, 3, 30  
degenerating (*illustration*), 4  
degeneration following injury,  
method of examination, 23-5  
normal (*illustration*), 2  
structure and composition of, 1  
uncovered by their normal sheath, 87
- Nerve injuries,  
*see* Injuries
- Nerve section, complete,  
obstinate to treatment, 81
- Nerve trunks,  
characteristics, 2  
fibres and structures of, 30  
incomplete division of, 29, 30  
mixed, motor and sensory fibres of, 2, 3  
normal, cut surface of (*illustration*), 85
- Nerves,  
altering position of, to shorten course, 93  
blood vessels supplying structure of, 2  
complete section of, 81  
compressed, *see* Compression  
concussed, characteristics, causes, and symptoms, 34, 80  
contusion of, nature of the condition, 32, 80  
divided, *see* Divided nerve  
ensheathing of, 85  
examination of, electrical methods, 20-6  
fibrosed, treatment, 90  
how to be held and lifted up during operation, 83  
paralysis produced by pressure of aneurysm or new growth, 40  
partially cut, 80  
structure of, 1, 2, 85  
surgery of, observations on, 67  
thickening with adhesions, 60  
torn or lacerated, symptoms and characteristics, 32  
"trophic" influence on structures to which distributed, 4
- Nerves (*continued*),  
*see also under names of individual nerves ; also* Divided nerve ; Muscles ; Injuries, etc.
- Nervi nervorum,  
distribution of nerve fibres to, 2
- Nervus intermedius,  
functions of, 115
- Neurilemma sheaths,  
during nerve regeneration, 8, 9, 10  
substance and function of, 1
- Neuritis, 31  
interstitial (painful) of internal popliteal nerve, 223, 224  
peripheral, characteristics and symptoms, 40  
resulting from toxic absorption, 41
- Neurolysis,  
how performed, 98
- Neuroma,  
central, complete interruption of nerve by (*illustration*), 88  
definition of, 88  
lateral (*illustrations*), 95, 96, 97, 98
- Neurone,  
lower, paralysis of, detection of area affected, 54, 55  
position and function, 53  
paralysis of upper and lower, differential diagnosis, 54  
upper, position and function of, 53
- Node of Ranvier,  
definition of, 1, 2
- Nodular swelling on nerve, 61
- Obturator nerve, 207  
diagnosis and rarity of injury to, 227  
distribution of, 227  
injury to, case illustrating, 227, 228  
paralysis of, 227
- Occipital nerve (small),  
site and path of, 125
- Occupational exercises, 80
- Ocular nerves,  
distribution, areas, and functions of, 111, 112  
(fourth), injury to, patient's characteristics, 111  
(sixth), paralysis of, 111  
(third), complete paralysis of, patient's condition, 112, 113
- Ocular palsies,  
detection of, 111  
intracranial hæmorrhages often associated with, 111

- Olfactory nerves,  
 course and distribution of, 110  
 injured, how sense of smell is tested, 110  
 injuries to, 110
- Operations,  
 asepsis imperative in, 83  
 class of cases demanding, 81  
 essential points in, 70, 71, 83  
 failure of recovery following, 66, 104, 105  
 for liberation from compression, 68  
 general observations on, 67  
 neurolysis, how performed, 98  
 primary *versus* secondary suture, 62  
 results of, depending largely on non-operative treatment, 67  
 suture in, technique, 83, 84  
 to expose the brachial plexus, 153-5  
*see also* Treatment
- Ophthalmic nerve,  
 source, distribution, and function of, 112
- Organic paralysis,  
 and functional combined, characteristics and case illustrating, 48  
 diagnosis of, 43, 53, 54  
 reflexes in, 44
- Osmic acid,  
 use during course of operation, 90
- Pain,  
 areas of, following incomplete nerve division, characteristics, 31  
 in interstitial neuritis of internal popliteal nerve, 223, 224  
 of median nerve lesions, 175, 176  
 of ulnar paralysis, 161, 162, 166  
 sacral root, in cauda equina lesions, 205  
*see also* Causalgia
- Pain pressure, 14
- Pain sensation,  
 how tested, 15
- Palate,  
 paralysis of, resulting from injury to vagus, 119  
 unilateral paralysis of, how recognized, 119
- Palmar muscles,  
 wasting of, 143-7  
 in median and ulnar paralysis (*illustration*), 181
- Palpation,  
 in clinical investigation of motor functions, 18
- Papier mâché wrist splint, 74
- Paralysing agents,  
 fibrosing tissue and callus as, 61
- Paralysis,  
 complete, indications for operative measures, 61  
 dissociated, 30  
 hysterical, and reflex, differential diagnosis, 55  
 cases illustrating, 49-53, 57  
 ischæmic, 36  
 cases illustrating, 36-40  
 moral, 79  
 motor, diagnosis of, 18  
 reflex, 55  
*see also under names of individual nerves*
- Paresis,  
 development into definite paralysis, 61
- Paræsthesia,  
 areas of, how mapped out, 15
- Parotid gland,  
 growths of, and operations on, facial nerve frequently injured by, 115
- Passive movements,  
 during treatment, 79
- Pectoralis major,  
 paralysis of, through division of fifth cervical root, 140, 141
- Penis,  
 anæsthesia of, 199
- Percussion,  
 hyperexcitability of muscles to, 56
- Perineum,  
 "saddle-shaped," area of anæsthesia on, cause, 199  
 sensory area of, nerve roots supplying, 198, 199
- Perineurium,  
 composition and function of, 2
- Peripheral nerve,  
 anæsthesia and analgesia following lesion of, 17  
 and posterior roots, injuries to, differential diagnosis, 55  
 characteristics of the nerve fibres, 2  
 complex nature of sensation in, 14  
 injuries, conditions simulating, 43  
 paralysis, prognosis of, 59  
 structure of, 1, 84, 85

- Peripheral neuritis,  
and trench feet, 41, 42  
characteristics and symptoms, 40
- Peroneal nerve,  
*see* Popliteal nerve, external
- Peronei,  
paralysis of, 214  
(*illustration*), 215
- Pharynx,  
anæsthesia of, glossopharyngeal  
nerve injury causing, 118
- Phrenic nerve,  
division resulting in paralysis of  
diaphragm, 128  
injuries to, causes and results, 128  
path and function of, 127  
persistent coughing resulting  
from inclusion in ligature, 128  
section of, death with pulmonary  
symptoms following, 128
- Pin-pricks,  
analgesia to, in peripheral nerve  
lesion, 17
- Plantar nerve,  
external, distribution of, 220  
internal, distribution of, 220
- Pneumogastric nerve,  
danger of injury to, in thyroid  
operations, 119  
injuries to, causes and varieties,  
119  
its distribution and functions, 119  
manipulation of, during opera-  
tion, 119  
paralysis of palate and larynx  
resulting from injury to, 119
- Polar equality, 24
- Polar inversion, 24
- Poliomyelitis, 55
- Popliteal nerve, external (peroneal),  
condition of injured segment  
(*illustration*), 89  
course of, 208  
differentiation of sciatic nerve  
into (*illustration*), 5  
gunshot wound in which segment  
resembles fibrous tissue,  
treatment (*illustration*), 89  
injuries to, causes and frequency  
of, 214  
injury to (*illustration*), 6  
more vulnerable than the tibial,  
209  
motor symptoms and sensory  
phenomena, 214  
paralysis, case illustrating return  
of protopathic sensation, 63,  
64
- Popliteal nerve, external (*cont.*),  
paralysis following gunshot  
wound of right buttock  
(*illustration*), 215  
percentage of affections in lesions  
of the great sciatic, 210  
structure and characteristics, 208  
vasomotor and secretory pheno-  
mena, 215  
wound involving only fibres of  
anterior tibial (*illustration*),  
218
- Popliteal nerve, internal (tibial),  
areas supplied by, 214, 219  
branches of, 219  
course of, 208  
funiculi of (*illustration*), 5  
motor and sensory symptoms of,  
221  
painful interstitial neuritis of,  
with paralysis of small scia-  
tic, 223, 224  
pains associated with injuries to,  
222  
paralysis of motor symptoms of  
(and *illustrations*), 218  
paralysis of, parts affected, 221,  
222  
percentage of affections in lesions  
of great sciatic, 210  
structure and characteristics, 208  
*see also* Tibial
- Popliteal paralysis, external,  
backward displacement of femur  
producing (*illustration*), 101  
femur fracture causing (*illustra-  
tion*), 34  
tendon fixation in, 106
- Popliteal surface,  
second sacral root supplying,  
197-9
- Posterior thoracic nerve,  
*see* Thoracic nerve
- Posterior interosseous nerve,  
*see* Interosseous nerve
- Posterior tibial nerve,  
*see* Tibial nerve
- Posture,  
in clinical examination of motor  
functions, 18
- Poupart's ligament,  
sensory areas in neighbourhood  
of, 197
- Pressure pain, 14
- Pressure sense,  
how tested, 16  
in ulnar and median paralysis,  
cases illustrating, 68, 69

- Primitive end-bulb,  
(*illustration*), 8
- Prognosis,  
  affected by site of lesion, 66  
  after relieving compression, 67, 68  
  after suture, 62  
  electrical reactions of muscles  
    favouring, 59  
  general observations, 59  
  response to treatment most im-  
    portant factor in, 61  
  septic wounds affecting, 65  
  varies with different nerves, 66
- Projectile wounds,  
  question of immediate suture in,  
    70, 71
- Prosthetic appliances, 106  
  for musculo-spiral paralysis (*il-  
    lustration*), 75
- Protopathic fibres,  
  regeneration of, after injury, 14
- Protopathic sensibility,  
  loss and recovery of, in peroneal  
    paralysis, case illustrating,  
      63, 64  
  nature and characteristics of, 4,  
    11  
  preventing formation of ulcers, 65  
  recovery of, after nerve division,  
    11  
  recovery of, in primary and  
    secondary suture, 63, 64, 65  
  skin areas without, liable to  
    injury, 8  
  testing for, 7, 14
- Pseudo-continuity, 88
- Pterygoid muscles,  
  cause and detection of injury to,  
    113, 114
- Pudendal plexus,  
  characteristics and distribution  
    of, 207
- Pudic nerve, 207
- Pupils,  
  inequality of, in paralysis of  
    cervical sympathetic, 124,  
    125  
  in paralysis of third nerve, 112
- Quadriceps extensor cruris,  
(*illustration*), 226
- Radial nerve,  
  course and function of, 185, 186  
  fractures of, ischaemic paralysis  
    following (*illustration*), 37  
  interosseous nerve occasionally  
    injured in, 187  
  injuries to, characteristics, 192
- Radial nerve (*continued*),  
  paralysis (*illustration*), 193  
  portion transplanted between se-  
    parated ends of musculo-  
    spiral nerve, 94
- Ranvier, node of, 1, 2
- Reaction of degeneration,  
  in facial paralysis, 117  
  meaning of the term, 23  
  not present in functional paraly-  
    sis, 43
- Rectum,  
  loss of control of, in conus  
    medullaris lesion, 205  
  in lesion of cauda equina, 197,  
    199, 203
- Reflex paralysis,  
  cases illustrating, 55-8  
  characteristics, 55, 56, 57  
  median paralysis with (*illustra-  
    tion*), 56  
  of left hand, cases illustrating,  
    57, 58
- Reflexes,  
  deep, in upper and lower limbs, 44  
  in organic and functional para-  
    lysis, 44, 54  
  in upper and lower neurone  
    lesions compared, 54
- Regeneration, 14  
  process of, 8-11  
  test for, 11, 12
- Rhomboids,  
  paralysis of, generally associated  
    with paralysis of serratus  
    magnus, 156
- Root area distribution,  
  of the brachial plexus (*illustra-  
    tion*), 130
- Sacral nerve roots, 197  
  loss of sensory functions in area  
    of, from injury to cauda  
    equina and conus medullaris,  
      204  
  pains in cauda equina lesions, 205  
  sensory and motor distribution  
    of, 197, 198, 199
- Sacral plexus, 208  
  formation and distribution of, 207
- Sacrum,  
  anæsthesia of, from cauda equina  
    lesions, 199
- Saphenous nerve, external,  
  formation and distribution of, 219
- Saphenous nerve, internal,  
  injuries to, 226  
  region supplied by, 225

- Scapula,  
displacement of, in paralysis of  
serratus magnus (*illustration*), 156  
in paralysis of trapezius (*illustration*), 121
- Schwann, nucleated sheath of,  
structure and function of, 1
- Sciatic nerve (great),  
bullet-wound of, case illustrating  
suture, 92  
distribution of, 207, 208  
division of, 92, 210  
(*illustration*), 5  
foetal, distribution and structure  
of, 30  
(*illustration*), 29  
injuries to, characteristics, 209  
percentage of peroneal and  
tibial lesions, 209, 210  
paralysis of, cases illustrating,  
210-2, 223  
sensory loss in (*illustration*), 213  
symptoms and case illustrating,  
210, 223  
(*illustrations*), 209, 210, 211  
structure and characteristics, 207  
with adhesions, treatment, 101,  
102
- Sciatic nerve (small), 207  
and inferior gluteal, combined  
lesion of, 224  
(*illustration*), 224  
paralysis of, case illustrating  
symptoms, 223  
(*illustration*), 223
- Sclerosing fibrous tissue,  
causing compression, 33  
formation of, and compression  
due to, 35, 36  
prevention of, 35, 36
- Scrotum,  
sensory supply of, 198, 199
- Segments,  
excision of, 90, 91
- Sensations,  
abnormal subjective, 16
- Sensibility,  
classes of, in peripheral nerve, 14  
clinical investigation of, method,  
15  
"patchy" loss of, 33  
recovery of, after nerve division,  
11, 12  
in primary and secondary  
suture, period of, 63  
*see also* Protopathic sensibility;  
Epicritic sensibility
- Sensory areas,  
mapping out of, 14
- Sensory distribution,  
of the brachial plexus (*illustration*), 130  
of the cauda equina, 197-9
- Sensory functions,  
examination of, methods and  
maxims, 13  
recovery of, following secondary  
suture, 65
- Sensory nerve,  
diagram illustrating, 3
- Sensory nerve fibres,  
alteration in function following  
division, 5  
of mixed nerve trunk, 2, 3  
sensory impressions conveyed  
by, 3  
varieties of sensibility, 14
- Sensory symptoms,  
of peripheral neuritis, 40
- Sepsis,  
affecting prognosis, 65  
fibrosis mainly dependent on, 86  
injuries complicated by, grave  
prognosis, 62
- Septicæmia,  
neuritis of, 41
- Serratus magnus muscle,  
functions of, 157  
paralysis of, characteristics of the  
deformity, 157  
conditions generally associated  
with, 156  
(*illustration*), 156  
supplied by posterior thoracic  
nerve, 155, 156
- Sexual power,  
loss of, in cauda equina and conus  
medullaris lesions, 205
- Sherren,  
on recovery of functions after  
secondary suture, 65
- Short saphenous nerve,  
*see* Saphenous nerve
- Shoulder,  
bullet-wound of, causing hysteri-  
cal paralysis of arm, 150, 151  
contour of, in paralysis and  
atrophy of the trapezius, 121,  
122
- Shoulder abduction splint,  
(*illustration*), 77
- Shoulder girdle,  
injuries associated with lacer-  
ation of muscles, tendons,  
and ligaments, 139

- Signe de fourmillement*, 11
- Skin,  
   changes following nerve division,  
     7, 8  
   areas of anæsthesia, how mapped  
     out, 15  
   areas without protopathic sensi-  
     bility liable to injury, 8  
   "trophic" influence of nerves  
     on, 4
- Skull,  
   wounds traversing base fre-  
     quently fatal, 110
- Sleep paralysis,  
   due to injury through com-  
     pression, 34
- Smell,  
   sense of, how tested, 110
- Sphincter iridis,  
   paralysis causing dilated pupil,  
     112
- Sphincters,  
   anæsthetic incontinence of, in  
     injury to lower cauda equina  
     and conus medullaris, 203
- Spinal accessory nerve,  
   anastomosis to fifth cervical  
     (*illustration*), 95  
   characteristics, distribution, and  
     functions of, 120  
   injury to, characteristics and  
     results, 120, 121  
   paralysis following removal of  
     tuberculous glands (*illus-*  
     *tration*), 120  
     (*illustration*), 121
- Spinati,  
   paralysis and wasting of, follow-  
     ing gunshot wound (*illus-*  
     *tration*), 157  
   wasting following rupture of fifth  
     and sixth cervical roots  
     (*illustration*), 132  
   wasting in injury to fifth cervical  
     root, 139, 140, 141
- Spino-muscular neurone,  
   *see* Neurone, lower
- Statistics,  
   of cases of nerve injuries, 108,  
     109
- Stereognosis, 16
- Sternal nerve,  
   site and path of, 125
- Sterno-mastoid,  
   in relation to injuries of the  
     spinal accessory, 120, 121  
   (left), appearance on rotating  
     head (*illustration*), 120
- Sterno-mastoid (*continued*),  
   paralysis of, signs and charac-  
     teristics, 120, 121  
   (right), atrophy and paralysis of  
     (*illustration*), 121
- Strabismus, external,  
   accompanies complete paralysis  
     of third ocular nerve, 112
- Stump neuralgia, 107
- Subclavian artery,  
   ligature of, phrenic nerve liable  
     to be injured during, 128
- Subscapular nerve (long),  
   paralysis of, 196
- Subscapularis,  
   paralysis of, 146
- Suggestion,  
   production of hysterical anæ-  
     sthesia by, 50
- Superior gluteal nerve,  
   *see* Gluteal nerve
- Supinator longus,  
   paralysis of, 146, 187
- Suppuration,  
   retarding effect upon regenera-  
     tion of nerve, 66  
   suture impossible during, 70, 71
- Supra-spinatus muscle,  
   *see* Spinati
- Sural branch,  
   of internal popliteal nerve, 214
- Surgical measures,  
   general observations, 67
- Suture,  
   asepsis the great essential for  
     success of, 65, 70  
   direct, cases in which flexion of  
     joint is necessary, 92  
   end to end, directions for, 83,  
     84  
   immediate, question of, in pro-  
     jectile wounds, 70, 71  
   impossible during suppuration,  
     70, 71  
   in various types of injuries, 83-5,  
     88-9, 92, 93, 96, 97, 98  
   post-operative measures, import-  
     ance of, 67  
   primary, suppuration affecting,  
     65  
     the treatment for a divided  
     nerve, 70  
     primary *versus* secondary, 62, 70  
   prognosis after, 62  
   protection of, by investing tube,  
     85  
   recovery of functions in primary  
     and secondary, 63

Unable to display this page

- Tinel's sign,  
  of nerve regeneration, 11, 12
- Tingling test,  
  for nerve regeneration, 11
- Toes,  
  flexion impossible in internal popliteal injury, 221  
  paralysis of extensors of, 214 (*illustration*), 215  
  *see also* Foot
- Tongue,  
  atrophy of, resulting from paralysis of the hypoglossal (*illustration*), 122, 123
- Tonico-clonic spasm,  
  of muscles of the leg, 48
- Touch sensation,  
  how tested, 15
- Traction injuries,  
  symptoms and characteristics, 32
- Transplantation,  
  directions for, 93, 94 (*illustration*), 94  
  of tendons, technique, 105
- Trapezius,  
  paralysis and atrophy of, how recognized, 121, 122  
  right, atrophy and paralysis of, case illustrating, 121
- Trauma,  
  *see* Injury
- Treatment,  
  by anastomosis, directions for, 94  
  by bridging, 94  
  by shortening course of the nerve, 93  
  by suture, technique, 83, 84  
  by tendon transplantation, 105  
  by transplantation, directions for, 93  
  class of case resistant to, 81, 104, 105  
  directed to prevention of muscle changes in mixed nerve injuries, 71  
  electrical, instructions and observations, 78, 90, 91  
  essential points in, 70, 71  
  in complete division, 87  
  massage in, 79  
  non-operative, results of operations depending upon, 67  
  non-operative and expectant, 73  
  of bulbous ends, 84, 89  
  of diverse lesions of several nerves in one wound, 102  
  passive movements in, 79  
  position of injured limb during, 73
- Treatment (*continued*),  
  response to, important factor in prognosis, 61  
  splinting in, 74-8  
  when division is incomplete, 95  
  when ends are distinctly separated, 87, 92  
  when foreign body is lodged in the nerve, 104  
  when injured segment of nerve resembles mass of fibrous tissue, 90, 91  
  when nerve is adherent to some adjacent structure, 101  
  when nerve is completely divided, 87  
    *see also* Divided nerve  
  when nerve is compressed, 98  
  when nerve is embedded in dense fibrous tissue, 98  
  when segments, though not bulbous, are profoundly altered, 89-91  
  when there is pseudo-continuity, 88  
    *see also* Operations
- Trench feet,  
  a condition of peripheral neuritis, case illustrating (*with illustrations*), 41, 42  
  symptoms and characteristics, 41
- Triceps,  
  paralysis of, 147  
    through injury of brachial plexus, 140, 141, 142
- Trigeminal nerve,  
  complete paralysis from trauma rare, 114  
  gunshot injury to, case illustrating, 113  
  injury to, muscles affected by, 112, 113  
  other nerves frequently injured with, 114  
  sensory and motor roots of, their distribution and functions, 112-4
- Trophic changes,  
  in divided nerve, 7
- Trophic influence,  
  of nerves to structures to which distributed, 4
- Trophic ulcers,  
  of fingers in paralysis of ulnar nerve (*illustration*), 7
- Tuning fork,  
  vibration sensation produced by 14, 16

- Ulcers,  
   in areas with lost sensibility, 8  
   recovery of protopathic sensibility preventing formation of, 65
- Ulna,  
   fractured, ischæmic paralysis following improper treatment, 37
- Ulnar and median paralysis,  
   *see* Median and ulnar
- Ulnar nerve,  
   and internal cutaneous, embedded in gunshot wound of humerus, 102  
   bullet-wound, without sensory loss and with joint-sense normal (*illustration*), 162  
   compression in scar tissue, 68  
   cutaneous supply (*illustration*), 161  
   delayed paralysis of, 166, 167  
   distribution and function of, 159  
   divided, ends of (*illustration*), 93  
     position altered to shorten its course (*illustration*), 93  
   embedded in fibrous tissue, treatment (*illustration*), 99  
   gunshot wound, above internal condyle of left humerus (*illustration*), 163  
   incomplete lesions of, 166  
   injuries to, causes, 160  
     prognosis affected by site of, 67  
   motor symptoms, 162  
   pain at moment of injury, nature of, 161, 166  
   secondary suture of, frequent non-recovery of epicritic sensation following, 66  
   sensory symptoms, 160, 161  
   severe compression of, and division of median, appearance of hand (*illustration*), 6  
   sweating less than in median palsy, 166  
   symptoms simulating other lesions, 166  
   transposition of trunk, 167  
   trophic ulcers with (*illustration*), 7  
   vasomotor and trophic changes, 165
- Ulnar neuritis,  
   delayed, characteristics, 166, 167
- Ulnar paralysis,  
   case illustrating, 167-9  
   glove with elastic webbing for, 77  
     (*illustration*), 78  
   pressure sense in, 68  
   relief of compression in, 68  
   sensory loss in (*illustration*), 68  
   splinting in, 77  
   (*illustrations*), 168, 169
- Urethra,  
   anæsthesia of, in cauda equina lesion, 204
- Uvula,  
   movement in paralysis of palate, 119
- Vagus,  
   *see* Pneumogastric nerve
- Vibration sense,  
   tested and produced by tuning fork, 14, 16
- Voluntary movements,  
   following injury, how detected 19, 20
- Walking apparatus,  
   for foot-drop (*illustration*), 76
- Weight,  
   of injured limb, significance of, 19, 20
- Whitlow,  
   of left thumb, reflex and hysterical paralysis following, 57
- Wounds,  
   condition of, complicating the nerve injury, 62  
   suppuration of, retarding effect upon nerve regeneration, 66  
   *see also* Suppuration
- Wrist,  
   condition in musculo-spiral paralysis, 187, 190, 191  
     (*illustration*), 188  
   flexed, treatment, 37, 38  
   flexion and extension of, how tested, 19  
   paralysis from bullet-wound in shoulder, 150  
   paralysis of flexors of, cases illustrating, 143-6, 149  
   tendon transplantation in injuries of, 105, 106
- Wrist-drop,  
   *see* Drop wrist















