

## **Diseases of the nose, and throat / by Charles Huntoon Knight.**

### **Contributors**

Knight, Charles H. (Charles Huntoon), 1849-1913.

### **Publication/Creation**

Philadelphia : P. Blakiston, 1903.

### **Persistent URL**

<https://wellcomecollection.org/works/fw9ng3uc>

### **License and attribution**

This work has been identified as being free of known restrictions under copyright law, including all related and neighbouring rights and is being made available under the Creative Commons, Public Domain Mark.

You can copy, modify, distribute and perform the work, even for commercial purposes, without asking permission.



Wellcome Collection  
183 Euston Road  
London NW1 2BE UK  
T +44 (0)20 7611 8722  
E [library@wellcomecollection.org](mailto:library@wellcomecollection.org)  
<https://wellcomecollection.org>


Unable to display this page





22102303994

**Med**  
**K49688**



DISEASES OF THE NOSE AND THROAT

---

KNIGHT





50084

# DISEASES

OF THE

293 89

# NOSE AND THROAT

BY

CHARLES HUNTOON KNIGHT, A.M., M.D.

PROFESSOR OF LARYNGOLOGY CORNELL UNIVERSITY MEDICAL COLLEGE, SURGEON  
MANHATTAN EYE AND EAR HOSPITAL, THROAT DEPARTMENT; MEMBER OF  
THE AMERICAN LARYNGOLOGICAL ASSOCIATION, OF THE AMERICAN  
MEDICAL ASSOCIATION, OF THE AMERICAN ACADEMY OF  
MEDICINE, OF THE AMERICAN THERAPEUTIC SOCIETY,  
OF THE NEW YORK ACADEMY OF  
MEDICINE, ETC.

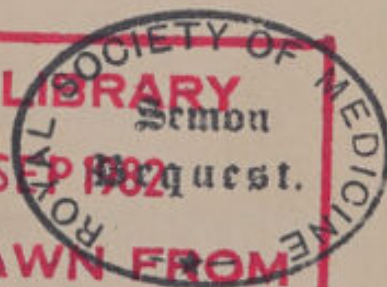
147 ILLUSTRATIONS



R.S.M. LIBRARY

28 SEP 1902

WITHDRAWN FROM  
STOCK



PHILADELPHIA

P. BLAKISTON'S SON & CO.

1012 WALNUT STREET

1903

Copyright 1903  
By P. BLAKISTON'S SON & CO.

WELLCOME INSTITUTE LIBRARY	
Coll.	welMOmec
Call	
No.	WV

PRINTED BY  
THE NEW ERA PRINTING COMPANY  
LANCASTER, PA.

## PREFACE.


The contents of the following pages have formed the basis of a course of lectures at Cornell University Medical College and have been arranged chiefly for the convenience of students.

It has been thought best to include only the essentials of anatomy and limited space has compelled the omission of bibliographical references. The details of anatomy may be found to better advantage in special text books. The intention has been to give credit in every instance to original sources, but the growth of the literature of the subject has been so extensive that a separate volume would be required to contain a complete list of authorities.

The author desires to express his indebtedness to his colleagues for many courtesies and suggestions and the hope that the statement of his opinions has been accomplished with clearness and without excessive dogmatism.

In these days of change and progress it is easy to find many questions to which it is unsafe to give a final and positive answer. Even the accepted views as to the physiology of the larynx and the action of the vocal bands are likely to be amended in the light of recent interesting researches. Theories of nasal pathology, the innervation of the larynx, the whole subject of therapeutics of the upper air track are in a state of unrest which offers a wide field for investigation. It is becoming to approach the study of these matters with an open mind, being prepared at all times to discard the old and test the new. With this spirit this volume is presented in the hope that it may be of some service to seekers after truth.





## CONTENTS.

### CHAPTER I.

ANATOMY AND PHYSIOLOGY OF THE NASAL PASSAGES. METHODS OF EXAMINATION. INSTRUMENTS AND APPARATUS.....	17
---	----

### CHAPTER II.

ACUTE AND CHRONIC RHINITIS.....	36
---------------------------------	----

### CHAPTER III.

ATROPHIC RHINITIS. MEMBRANOUS RHINITIS. CASEOUS RHIN- ITIS. PURULENT RHINITIS.....	61
---	----

### CHAPTER IV.

DISEASES OF THE ACCESSORY SINUSES. ACUTE AND CHRONIC SINU- SITIS. HYDROPS ANTRI, OR SEROUS EFFUSION AND CYST OF THE ANTRUM. FOREIGN BODIES AND NEOPLASMS.....	73
---	----

### CHAPTER V.

DISEASES AND DEFORMITIES OF THE NASAL SEPTUM. DEVIATION. ECCHONDROSIS. EXOSTOSIS. ULCERATION. PERFORATION. HEMATOMA. ABSCESS. CONGENITAL OCCLUSION OF THE NARIS. ADHESIONS. COLLAPSE OF THE NOSTRIL. DISLOCATION OF THE COLUMNAR CARTILAGE. FRACTURE OF THE NOSE.....	114
---	-----

### CHAPTER VI.

NASAL POLYPI.....	150
-------------------	-----

### CHAPTER VII.

BENIGN TUMORS AND MALIGNANT DISEASE OF THE NASAL FOSSÆ. FOREIGN BODIES. RHINOLITHS. EPISTAXIS.....	158
---	-----

### CHAPTER VIII.

SYPHILIS OF THE NASAL FOSSÆ. LUPUS. TUBERCULOSIS. RHIN- OSCLEROMA .....	176
--	-----

## CHAPTER IX.

NASAL NEUROSES. HAY FEVER. NASAL HYDRORRHEA.....	188
--	-----

## CHAPTER X.

ANATOMY AND PHYSIOLOGY OF THE PHARYNX.....	199
--	-----

## CHAPTER XI.

DISEASES OF THE VELUM AND UVULA. BIFID UVULA. NEOPLASMS AND MALIGNANT DISEASE OF THE VELUM. CLEFT PALATE. UVULITIS AND ELONGATED UVULA. ACUTE AND CHRONIC PHARYNGITIS. ATROPHIC PHARYNGITIS. RHEUMATIC PHAR- YNGITIS .....	208
--	-----

## CHAPTER XII.

ADENOIDS IN THE RHINOPHARYNX.....	222
-----------------------------------	-----

## CHAPTER XIII.

HYPERTROPHIED TONSILS .....	240
-----------------------------	-----

## CHAPTER XIV.

DISEASES OF THE LINGUAL TONSIL. ABSCESS OF THE TONGUE. RETROPHARYNGEAL ABSCESS. MYCOSIS OF THE PHARYNX.....	258
--	-----

## CHAPTER XV.

TONSILLITIS. DIPHTHERIA. CIRCUMTONSILLAR ABSCESS OR QUINSY. ULCERO-MEMBRANOUS OR DIPHTHEROID ANGINA .....	268
--	-----

## CHAPTER XVI.

BENIGN NEOPLASMS OF THE TONSIL. TONSILLITHS. MALIGNANT DISEASE OF THE TONSILS. TUBERCULOSIS, LUPUS AND SYPHILIS OF THE PHARYNX. NEUROSES OF THE PHARYNX. FOREIGN BODIES IN THE PHARYNX.....	285
--	-----

## CHAPTER XVII.

ANATOMY AND PHYSIOLOGY OF THE LARYNX. METHODS OF EXAM- INATION .....	302
---	-----



## CHAPTER XVIII.

DISEASES OF THE LARYNX. ANEMIA AND HYPEREMIA. LARYNGEAL HEMORRHAGE. ACUTE AND CHRONIC LARYNGITIS. CHORDITIS TUBEROSA OR VOCAL NODULES. CHRONIC SUBGLOTTIC LARYN- GITIS. ATROPHIC LARYNGITIS.....	320
---	-----

## CHAPTER XIX.

BENIGN NEOPLASMS OF THE LARYNX.....	333
-------------------------------------	-----

## CHAPTER XX.

MALIGNANT DISEASE OF THE LARYNX.....	350
--------------------------------------	-----

## CHAPTER XXI.

TUBERCULOSIS OF THE LARYNX.....	363
---------------------------------	-----

## CHAPTER XXII.


SYPHILIS OF THE LARYNX.....	382
-----------------------------	-----

## CHAPTER XXIII.

NEUROSES OF THE LARYNX. HYPERESTHESIA. ANESTHESIA. PAR- ESTHESIA. NEURALGIA. HYSTERICAL APHONIA. LARYNGEAL VERTIGO. CHOREA. SPASM OF THE LARYNX. LARYNGEAL STRIDOR AND WHISTLING. PARALYSIS OF THE LARYNX.....	391
---	-----

## CHAPTER XXIV.

FOREIGN BODIES IN THE LARYNX. PROLAPSE OF THE VENTRICLE. FRACTURE OF THE LARYNX.....	408
---	-----



## LIST OF ILLUSTRATIONS.

FIGURE.	PAGE.
1. The Nasal Septum.....	18
2. Outer Wall of Nasal Fossa.....	19
3. Mackenzie's Light Condenser .....	28
4. Kuttner's Electric Head Light.....	28
5. Head Mirror with Pomeroy Band.....	29
6. Duplay's Nasal Speculum.....	30
7. Hartmann's Nasal Speculum.....	31
8. Jarvis' Nasal Specula .....	31
9. Jarvis' Rhinometer.....	32
10. Seiler's Septometer .....	32
11. Türck's Tongue Depressor.....	33
12. Bosworth's Tongue Depressor.....	33
13. White's Palate Hook.....	34
14. Kyle's Postnasal Electric Lamp .....	34
15. Universal Powder Blower .....	39
16. Universal Vaporizer .....	40
17. Lobulated Hyperplasia of Turbinates.....	43
18. Cyst of Middle Turbinate Bone.....	44
19. Section of Bony Cyst of Turbinate.....	45
20. Lefferts' Hand Atomizer .....	46
21. Woakes' Nasal Irrigator .....	46
22. Nasal Syringe.....	46
23. Sass' Glass Spray Tubes.....	47
24. Jarvis' Cold Wire Snare .....	50
25. Sajous' Snares .....	51
26. Wright's Snare.....	52
27. Casselberry's Nasal Scissors.....	53
28. Author's Forceps and Scissors.....	54
29. Schech's Cautery Handle.....	55
30. Schech's Handle for Cautery Loop.....	55
31. Berens' Spoke Shave.....	59



32a. Lefferts' Postnasal Syringe .....	65
32b. Holmes' Postnasal Douche.....	65
33. Sound in Sinus Openings .....	75
34. Vertical Section of Nasal Fossæ.....	77
35. Myles' Antrum Trocar, Canula and Washing Tube.....	79
36. Lamps for Transillumination .....	80
37. Myles' Antrum Drainage Tubes.....	84
38. Mikulicz' Antrum Stilet.....	85
39. Hartmann's Canula .....	85
40. Snare Applied to Anterior End of Middle Turbinate.....	86
41. Normal Frontal Sinuses.....	91
42. Asymmetry of Frontal Sinus.....	92
43. Septa of Frontal and Sphenoidal Sinuses.....	93
44. Incisions in Opening Frontal Sinus.....	96
45. Hajek's Curette and Grünwald's Forceps.....	103
46. Probe in Orifice of Sphenoidal Sinus.....	105
47. Adams' Septal Forceps.....	118
48. Nasal Drills, Trephines and Burrs.....	118
49. Steele's Septum Punch.....	119
50. Roe's Septum Forceps.....	120
51. Moure's Osteotome.....	121
52. Incisions in Moure's Operation.....	122
53. Moure's Nasal Tube and Dilating Forceps.....	122
54. Kyle's Operation for Deflected Septum.....	123
55. Fetterolf's Saw File.....	124
56a. Krieg's Operation for Angular Deflection.....	126
56b. Krieg's "Window-resection" Operation.....	127
57. Asch's Instruments for Deviated Septum Operation.....	128
58. Nasal Tubes.....	130
59. Kyle's Septum Knife.....	131
60a. Ecchondrosis of Septum with Furrow on Opposite Side.....	135
60b. Bilateral Ecchondrosis of Septum.....	136
61. Bosworth's Nasal Saws.....	137
62. Dessar's Nasal Bougie .....	138
62a. Nasal Polypi .....	155
63. Nasal Fibroma .....	158
64. Papilloma of Septum.....	160



65. Swollen Turbinates a Source of Epistaxis.....	170
66. Hartmann-Kiesselbach Spot on Nasal Septum.....	171
67. Bellocq's Canula.....	172
68. Cooper Rose's Nasal Hemostat.....	173
69. Simpson's Nasal Plug.....	173
70. Bishop's Nasal Bridge.....	178
71. Hopkin's Nasal Bridge.....	178
72. Martin's Bridge in Position.....	179
73. Harmon Smith's Paraffin Syringe.....	181
74. Lupus of Anterior Nares.....	183
75. Tuberculosis of Turbinates.....	184
76. Muscles of Soft Palate.....	201
77. Constrictors of Pharynx.....	203
78. Bifid Uvula.....	208
79. Chronic Follicular Pharyngitis.....	216
80. Adenoids in Rhinopharynx.....	223
81. Adenoids seen through Anterior Nares.....	228
82. Denhard's Mouth Gag.....	229
83. Schuetz' Adenotome.....	231
84. Meyer's Ring Knife.....	233
85. Loewenberg's Adenoid Forceps.....	233
86. Brandegge's Adenoid Forceps.....	233
87. Schuetz' Antero-posterior Forceps.....	234
88. Motais' Artificial Finger Nail.....	234
89. Gottstein's Adenoid Curettes.....	235
90. Author's Adenoid Forceps.....	236
91. Farlow's Tonsil Snare.....	245
92. Author's Electric Tonsil Snare.....	246
93. Mackenzie's Tonsillotome.....	249
94. Mathieu's Tonsillotome.....	249
95. Farlow's Tonsil Punch.....	250
96. Butts' Tonsillar Hemostat.....	252
97. Mikulicz-Stoerk Tonsil Hemostat.....	253
98. Tonsil Bistoury and Knives.....	256
99. Hypertrophy of Lingual Tonsil.....	259
100. Roe's Lingual Tonsillotome.....	261
101. Syphilitic Ulcer and Perforation of Velum.....	293



102. Same after Complete Healing.....	295
103. Multiple Perforations of Palate.....	296
104. Extensive Perforation of Velum in Late Syphilis .....	297
105. Muscles of Larynx, Lateral View.....	304
106. Muscles of Larynx, Posterior View.....	305
107. Action of Posterior Cricoarytenoid Muscles.....	306
108. Action of Thyroarytenoid Muscles.....	307
109. Action of Arytenoideus Muscle.....	308
110. Nerves and Arteries of Larynx.....	309
111. Superior Aperture of Larynx and Dorsum of Tongue.....	311
112. Laryngeal Mirrors.....	315
113. Escat's Tongue Depressor .....	316
114. Papilloma of Larynx.....	335
115. Fibroma of Larynx .....	336
116. Cyst of Larynx.....	336
117. Cyst of Epiglottis.....	337
118. Subglottic Myxoma .....	338
119. Mackenzie's Laryngeal Forceps .....	340
120. Schroetter-Türck Canula Forceps.....	341
121. Sarcoma of the Larynx.....	350
122. Epithelioma of Vocal Band.....	352
123. Advanced Cancerous Ulceration of Larynx.....	353
124. Laryngeal Curettes.....	354
125. Tuberculosis of Larynx.....	367
126. Tubercular Ulcer of Larynx.....	368
127. Tubercular Ulcer of Ventricular Band .....	368
128. Tubercular Tumor of Larynx.....	369
129. Tubercular Ulcer at Posterior Commissure.....	369
130. Heryng's Laryngeal Curettes and Scarifiers.....	376
131. Schroetter's Laryngeal Dilator.....	384
132. Secondary Syphilis of Vocal Bands.....	385
133. Superficial Syphilitic Lesions of Vocal Bands.....	387
134. Destruction of Vocal Bands by Late Syphilis.....	388
135. Hysterical Paralysis of Adductors.....	392
136. Bilateral Paralysis of Internal Thyroarytenoids.....	400
137. Paralysis of Arytenoideus.....	400
138. Paralysis of Internal Thyroarytenoids and Arytenoideus.....	401

139. Partial Paralysis of Right Recurrent during Respiration.....	402
140. Same during Phonation .....	402
141. Complete Recurrent Paralysis on Phonation.....	403
142. Partial Paralysis of Posterior Cricoarytenoids.....	404
143. Cusco's Laryngeal Forceps .....	412





# THE NOSE.

## CHAPTER I.

ANATOMY AND PHYSIOLOGY OF THE NASAL PASSAGES. METHODS OF EXAMINATION. INSTRUMENTS AND APPARATUS.

### ANATOMY.

The nasal cavities are separated by a median partition, the septum, composed in front of cartilage and above and behind of bone—the perpendicular plate of the ethmoid, or mesethmoid, and the vomer. The shape and dimensions of the cartilaginous septum influence greatly the contour of the nose and the facial expression. This cartilage is quadrangular, its anterior margin forming the outline of the nose, and being joined in front to the lateral cartilages, which together form the alæ and tip of the nose. The nasal bones and the nasal processes of the superior maxillæ complete the framework of the external nose. The septal cartilage articulates above and behind with the anterior margin of the perpendicular plate of the ethmoid, below with the vomer and the bony ridge formed by the junction of the palatine processes of the superior maxillæ. We rarely, if ever, find the cartilaginous partition between the nostrils exactly vertical for two reasons. The prominence of the nose renders it particularly liable to blows and injuries, and the development of the cartilage frequently progresses long after the bones of the face have become consolidated, hence a bending or distortion of the cartilage results. In consequence we meet with a great variety of deformities of the cartilage which will be more fully considered elsewhere.

The posterior portion of the septum, being composed of bone and occupying a more protected situation, is relatively exempt from violence, so that we but seldom observe any displacement or asymmetry of the posterior margin of the vomer, no matter what degree of distortion of the septal cartilage may be present (Fig. 1).



The lateral cartilages are four in number, two on each side. Of these the lower have their anterior margins sharply recurved at their line of junction to complete the formation of the nasal septum, the partition between the anterior nares being called the *columna nasi*. The nasal fossæ extend from the nostrils or anterior nares in front

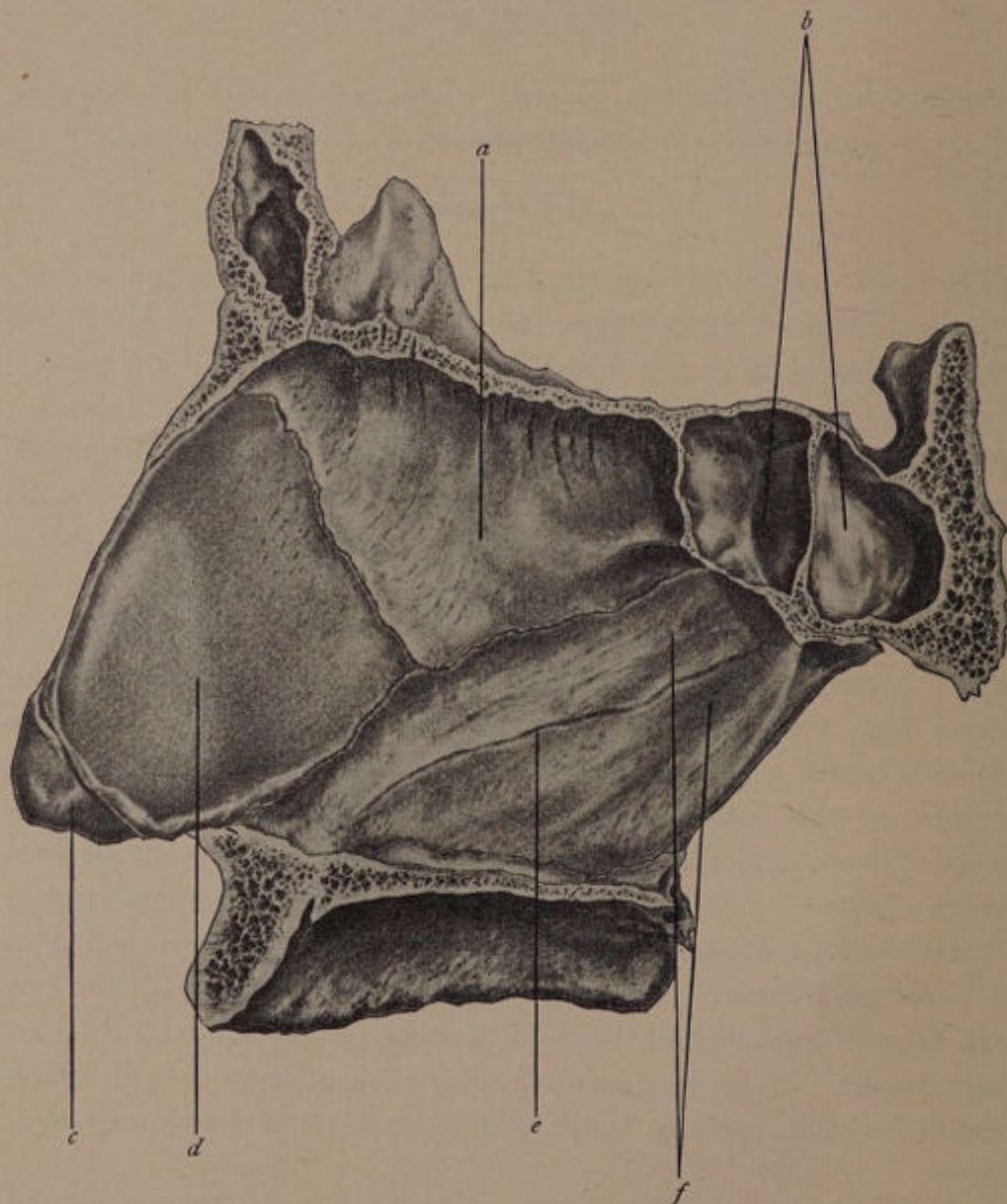


FIG. 1. THE NASAL SEPTUM. (Deaver.)

*a*, Perpendicular plate of ethmoid; *b*, sphenoidal sinus; *c*, inferior lateral cartilage; *d*, septal cartilage; *e*, groove for naso-palatine nerve; *f*, vomer.

to the posterior nares or choanæ behind and from the base of the skull to the hard palate. They are wider below than above and are



almost never symmetrical, owing to deformities of the septum or turbinate bodies.

On the outer wall of each nasal fossa may be found the nasal process and the inner surface of the maxillary bone, the lachrymal, the

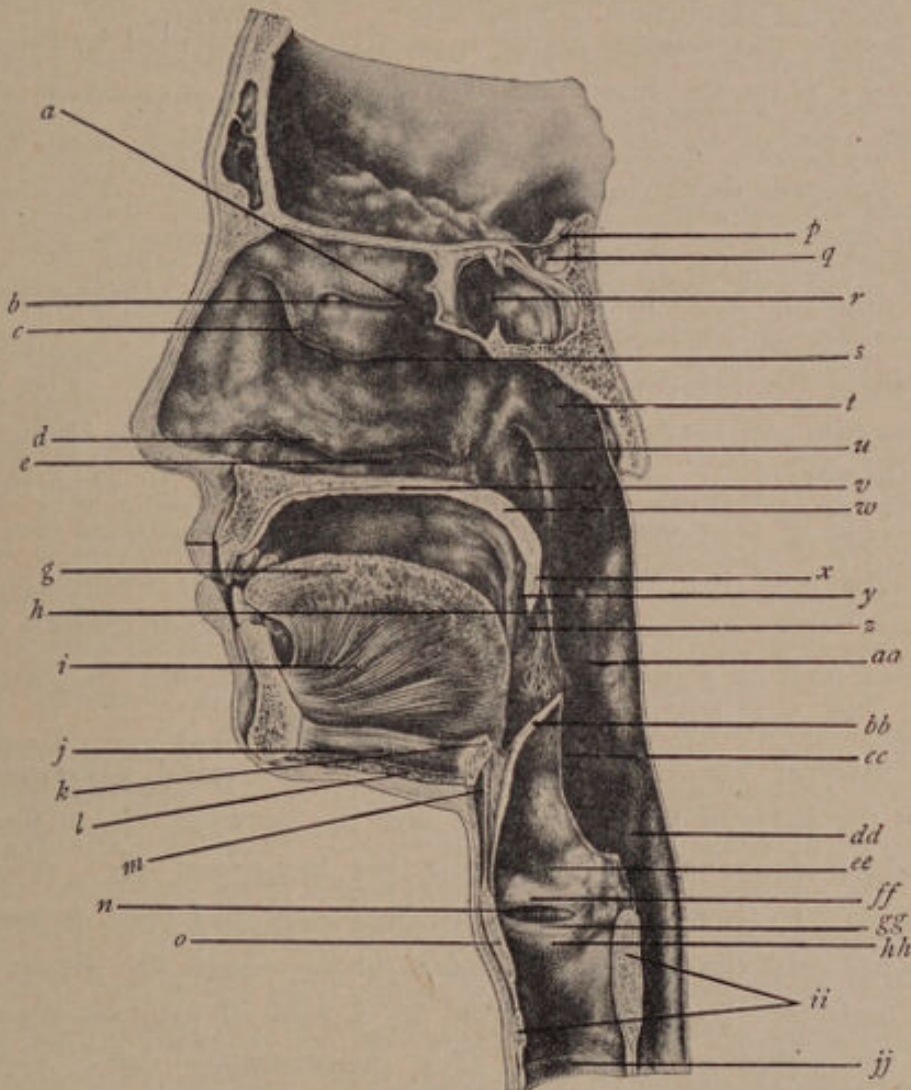


FIG. 2. OUTER WALL OF NASAL FOSSA, WITH MOUTH, PHARYNX AND LARYNX IN VERTICAL SECTION. (Deaver.)

*a*, Superior meatus; *b*, superior turbinate body; *c*, middle turbinate; *d*, inferior turbinate; *e*, inferior meatus; *g*, tongue; *h*, posterior pillar of fauces; *i*, geniohyoglossus muscle; *j*, geniohyoid muscle; *k*, hyoid bone; *l*, mylohyoid muscle; *m*, thyrohyoid membrane; *n*, ventricle of larynx; *o*, thyroid cartilage; *p*, diaphragma sellæ; *q*, cavum sellæ; *r*, sphenoidal sinus; *s*, middle meatus; *t*, rhinopharynx; *u*, eustachian orifice; *v*, hard palate; *w*, soft palate; *x*, uvula; *y*, anterior pillar of fauces; *z*, tonsillar fossa; *aa*, oropharynx; *bb*, epiglottis; *cc*, aryepiglottic fold; *dd*, laryngopharynx; *ee*, suprarimal portion of larynx; *ff*, ventricular band; *gg*, vocal band; *hh*, infrarimal portion of larynx; *ii*, cricoid cartilage; *jj*, tracheal ring.



ethmoid, the palate, the inferior turbinate bones, and the internal pterygoid plate of the sphenoid. The roof of the fossa is bounded by the nasal bone, the nasal spine of the frontal, the cribriform plate of the ethmoid and the body of the sphenoid. The floor of the naris is formed by the horizontal plates of the superior maxillary and palate bones. Each nasal cavity is partially subdivided by horizontal projections from its outer wall, the turbinate bones, which vary in size and number in different individuals, and which with the soft tissues covering them constitute the turbinate bodies. They are frequently described as being "scroll-shaped." In other words, in the normal condition, their septal surface is convex and their under and outer surface is concave (Fig. 2).

Of these, the inferior is the only independent bone. The middle and superior are really processes of the ethmoid, as is likewise the fourth turbinate, or *concha suprema*, which is said to exist in about one in three or four specimens. The superior turbinate is practically a subdivision of the middle, with which it merges anteriorly. The turbinate bodies are of great interest and importance from a pathological as well as a physiological standpoint, not only in themselves but from the relation they bear to adjacent parts.

The inferior meatus is that portion of the nasal passages lying beneath the inferior turbinate body and has opening into it the nasal duct which conveys secretion from the lachrymal sac. The duct itself is half to three quarters of an inch long and runs downwards, backwards and outwards. Its nasal orifice, near the anterior end of the turbinate body, is protected by a fold of mucous membrane called the valve of Hasner. This membranous valve ordinarily prevents distention of the lachrymal sac, as by air in the act of blowing the nose, but recent observations have shown that fluids may pass through it from the nasal cavity. Several other valvular folds of mucous membrane in the course of the duct have been described by recent anatomists.

Above the inferior turbinate and below the middle lies the region known as the middle meatus, into which open the passages from the antrum of Highmore, the frontal sinus, and the anterior ethmoidal cells. The most anterior is that of the frontal sinus, near the superior extremity of a crescentic furrow in the wall of the meatus known as



the *hiatus semilunaris*, and usually just behind it is that of the ethmoidal cells. This part of the meatus including the orifices of the ethmoidal cells and of the frontal sinus is called the *infundibulum*. Sometimes the antrum, or maxillary sinus, has two openings.

The hiatus semilunaris runs obliquely downwards and backwards from near the anterior end of the middle turbinate, and lies below the *bulla ethmoidalis*, an expanded ethmoid cell which projects into the meatus. The unciform process of the ethmoid, a thin plate of bone which articulates with the superior maxilla and with the inferior turbinate, and which enters into the formation of the nasal wall of the antrum, forms the lower boundary of the hiatus semilunaris. The *ostium maxillare*, the larger and more constant orifice of the antrum, is situated at about the middle of the hiatus.

The space above the middle turbinate is called the superior meatus, into which open the posterior ethmoidal cells and the sphenoidal sinus. The orifice of the sphenopalatine foramen, covered by mucous membrane, is just above the posterior end of the middle turbinate body. At the line of articulation of the ethmoid with the nasal process of the superior maxilla near the anterior end of the middle turbinate, appears a prominence on the outer wall of the fossa which has been described as the *agger nasi*. That portion of the fossa included by cartilage is called the vestibule of the naris, and is the only dilatable part of the passage, a point to be remembered in using the nasal speculum. The mobility of the alæ of the nose, which is very highly developed in some of the lower animals, is provided for by the insertion of a number of sesamoid and accessory cartilages between the lateral cartilages and the nasal processes of the superior maxillæ. To these, as well as to the cellular tissue at the margin of the nostril, muscular fibers are attached.

Two other points of interest in the septum should be referred to, the organ of Jacobson, which exists in man in the form of a *cul-de-sac* just within the nostril and above the floor of the nose, and the tubercle of Morgagni, or Zuckerkandl, a spindle-shaped aggregation of glandular tissue over the vomer opposite the anterior end of the middle turbinate body, at the line of junction of the cartilage and the perpendicular plate. It has recently been suggested that the former may bear an important relation to perforations of the septal



cartilage, which are frequently met with quite independently of syphilis, or other constitutional taint, while the latter when present in unusual volume may readily be mistaken for a pathological condition.

The floor of the nasal cavity is not flat, but slopes slightly downwards and backwards and is concave from side to side. The crest of the maxilla forms a considerable eminence just within the nostril, and behind it close to the septum is a shallow *cul-de-sac* indicating the situation of the duct of Stenson, which is marked in the mouth by the incisive papilla. The position of the anterior palatine canal, of which the duct is a subdivision, is important. Here the artery of the septum from the sphenopalatine, the terminal branch of the internal maxillary, anastomoses with the anterior palatine artery from the descending palatine. Erosion or rupture of this arterial twig at the angle formed by the septum and the floor of the nose is a frequent source of epistaxis.

The pituitary membrane lining the nasal cavities, known as the Schneiderian membrane, is continuous with that of the accessory sinuses, with that of the orbits through the nasal ducts, and with that of the tympana through the Eustachian tubes. It is much thicker and more vascular over the lower part of the septum and the turbinate bones, especially the inferior, than elsewhere. The transition from integument to mucous membrane is very gradual. In the vestibule the mucous lining shows numerous vascular papillæ and is covered with squamous epithelium. Just at the nostril are a number of short hairs or *vibrissæ* which are intended to filter the inspired air. The epithelium of what is generally considered the respiratory region of the nose, or that part below the plane of the middle turbinate body, is columnar ciliated. The columnar epithelium lining the olfactory tract is not ciliated. The muciparous glands are tubular and of unusual length, extending through the entire thickness of membrane. In the olfactory region, besides the muciparous glands, we find tubular glands lined with round epithelium containing pigment, called Bowman's glands.

The direction of the inspiratory current is influenced by the shape and position of the nostrils and by the vigor of the act of breathing. Recent experiments indicate that even in quiet inspiration the air



current does not pass directly backwards along the floor of the nose, but describes an upward curve and passes more or less over the middle turbinate body. In expiration it is supposed to be deflected abruptly from the vault of the pharynx and pass out at a lower level.

The nerve of special sense of smell, the olfactory nerve, reaches the upper part of the nasal cavity through perforations in the cribriform plate of the ethmoid. It is distributed to the roof of the nose, to the superior and middle turbinate bodies and to the opposite surface of the septum. The terminal filaments of this nerve, just before reaching the surface of the mucous membrane between the epithelial cells, present fusiform expansions called the olfactory cells of Schultze. The subdivisions of the olfactory nerve, upwards of twenty in number on each side, are invested with a coat from the dura mater and are said to differ from other cranial nerves in containing no white substance of Schwann and in having axis-cylinders with a distinct nucleated sheath which presents few and separated nuclei.

The sensory nerves of the mucous membrane are derived from the fifth pair. Filaments from the external division of the nasal branch of the ophthalmic and from the Vidian supply the roof. The outer wall receives filaments from the superior nasal branches of the sphenopalatine ganglion, from the nasal, from the inner branch of the anterior dental and from the inferior nasal branches of the large palatine nerve. The septal branch of the nasal nerve, nasal branches of the sphenopalatine ganglion, the nasopalatine, and the Vidian are distributed to the septum. The floor is supplied by the nasopalatine and the inferior nasal branches of the large palatine nerve.

The arteries of the nasal cavities are derived from the anterior and posterior ethmoidal branches of the ophthalmic, which supply the roof of the nose, the anterior and posterior ethmoidal cells and the frontal sinuses; from the nasal artery of the internal maxillary, which supplies the septum, the meatuses, and the turbinate bodies; from the posterior dental branch of the internal maxillary, which supplies the antrum (Holden). The veins, which accompany the arteries, communicate with the intracranial veins through the foramina in the cribriform plate, as well as through the ophthalmic vein and the cavernous sinus.



The mucous membrane covering the turbinate bones has a peculiar structure demanding special description. Its spongy character has long been recognized and fifty years ago Cruveilhier defined it as true erectile tissue. Later Kohlrausch, Bigelow and others made careful anatomical studies of this tissue, and still more recently the exhaustive investigation of Zuckerkandl established the existence of so-called "turbinate corpora cavernosa." It seems that the deep layer of the mucous membrane forms the periosteum. Distributed freely through the connective tissue of the membrane are lymph tissue and tubular mucous glands of extraordinary length. Within the lymphoid tissue are numerous venous sinuses surrounded by an abundance of unstriped muscular fiber. The "erectile tissue" thus constituted is subject to rapid and extreme variations in its dimensions under the influence of atmospheric conditions and of mechanical irritation, as well as of mental emotions. In dry air, these bodies retract, in a humid air they swell. When this process of retraction and expansion has been too frequently repeated a condition of vasomotor paresis becomes established, which results in more or less permanent enlargement of the turbinate body, with consequent nasal stenosis. This is the first stage of what will later be described as hypertrophy.

The accessory sinuses, which are supposed to contribute to the resonance of the voice, to diminish the weight of the skull and to afford protection to the nerve centers, are four in number on either side; the maxillary sinus, or antrum of Highmore, the frontal sinus, the ethmoidal sinuses, usually called cells, and the sphenoidal sinus. Of these, the largest is the maxillary sinus, which is a cavity in the superior maxilla bounded above by the floor of the orbit, within by the outer wall of the nasal fossa, and below by the roof of the mouth, its floor therefore being considerably below its normal outlet, which is found in the middle meatus. The frontal sinus lies between the tables of the frontal bone, the roof of the orbit forming its floor. A more or less complete median partition usually separates the frontal sinus into two parts. It also opens into the middle meatus near the orifice of the anterior ethmoidal cells. The sphenoidal sinuses are two excavations in the body of the sphenoid bone sometimes divided by a vertical septum, but frequently communicating so as to



form a single cavity. The ethmoidal cells, as their name denotes, are multiple cavities in the body of the ethmoid, separated by thin bony plates and arranged in two groups, anterior and posterior, the former opening into the middle, the latter into the superior meatus. The nasal orifices of the maxillary and frontal sinuses, and of the anterior ethmoidal cells, are in close proximity, and it has been shown that secretions from the frontal sinus may drain into the antrum and give many of the symptoms of antral disease. The clinical importance of this fact is very great, since opening the maxillary sinus under such circumstances would of course be entirely futile. Not infrequently the posterior ethmoidal cells open into the sphenoidal sinus. The anatomical relations of the accessory cavities and the variations from their normal arrangement are thus seen to be sources of difficulty in positively identifying sinus disease.

### PHYSIOLOGY.

The nose is the organ of the special sense of smell, but its more important duties relate to the act of respiration, it being so constructed as to warm, moisten and filter the inspired air. We may remain in comparative comfort without the ability to detect odors, but complete, or even partial, stenosis of the nostrils is a serious impediment to health. It is merely necessary to cite the familiar example of an individual with "a cold in the head" to indicate the importance of unobstructed nasal passages to the production of a clear and resonant voice. Olfaction, respiration and phonation are therefore all more or less affected by morbid conditions in the nasal chambers.

The sense of smell resides in the upper part of the nasal cavity, the olfactory nerve being distributed as low down as the middle of the middle turbinate body and the opposite surface of the septum. It is essential that odoriferous particles should reach this region, that the mucous membrane should be healthy, and that the nerve supply should be unimpaired. Otherwise the sense of smell may be lost, a condition known as *anosmia*. An interesting perversion of the sense of smell, the subjects of which perceive an odor not present, is called *parosmia*, and is undoubtedly a neurosis. It is some-



times regarded as a precursor of mental alienation. Precisely how odors are appreciated is a matter of pure theory. Mechanical irritation of the nerve filaments in the pituitary membrane, oxidation of odoriferous particles, molecular vibration, the heat-absorbing power of different materials, and finally the pigment-secreting quality of Bowman's glands have all been suggested in explanation of the function. The important degree to which the sense of smell contributes to our pleasure may be realized when we recall the limitations of the sense of taste, all flavors, with the exception of acid, bitter, sweet and salt, being recognized only through the olfactory nerve. The keenness of this sense depends in part upon the extent of the olfactory membrane. For this reason, the turbinate bodies in some of the lower animals are extraordinary in shape and dimensions. It is also said that its acuteness may be developed by practice.

A theory of the sense of smell recently propounded maintains that it is not due to contact of odoriferous particles with the nasal membranes, but to rays analogous to those of light, heat and the Roentgen-ray (Vaschide and v. Melle). The following reasons are given for adopting this hypothesis:

1. Sensations are excited by the surrounding media rather than directly by substances.
2. The origin and, probably, the mode of action of the olfactory nerve are similar to those of the optic.
3. The spectra of chemical odoriferous substances of the same group resemble each other.
4. Odors absorb radiant heat.
5. Some bodies giving off particles have no smell, while others with strong smell give off no particles.
6. Certain bodies neutralize each other's odor.
7. The absorbing power of fabrics varies with their color.
8. The capacity to recognize one odor may be lost while being retained for all others; an olfactory fatigue similar to that affecting the eye for colors.
9. Fluid, as well as air, is a vehicle for odors since the sense of smell is found to be active when the nostrils are flooded with an odoriferous fluid.



The inhalation of air at an unsuitable temperature, of an excessive degree of dryness, or laden with impurities is a source of irritation to the lower air passages and sooner or later of disease. Numerous experiments have been made in order to determine the increase in temperature and saturation which the inspired air undergoes in its transit through the nasal passages. It has been demonstrated that by the time the air reaches the pharynx through a normal nose, whatever the degree of external cold, it has become almost or quite as warm as the blood, and at the same time has become saturated with moisture, however dry the atmosphere may be. The interesting fact has also been established that the nose supplies to the expired air a small proportion of carbonic acid, estimated at about one fiftieth part of that contributed by the lungs. An examination of an individual exposed to a dust-laden atmosphere is sufficient to satisfy one of the extent to which foreign bodies in the inspiratory current are detained in the nasal fossæ. In view of its complex functions it is easy to understand the importance of a normal nose, not necessarily a nose with perfectly symmetrical turbinate bodies, or with a septum absolutely smooth and vertical, but one capable of conveying to the lungs an adequate supply of pure air of proper quality.

The resonance and timbre of the voice are markedly influenced by the shape and size of the nasal cavities, and an agreeable quality is given it by the formation within the nasal chambers of those secondary vibrations to which has been given the name, "over-tones."

An attempt has been made to draw conclusions as to the site of intra-nasal lesions from the varying impressions they produce upon the quality of the voice, but we find it impossible to go farther than to say that stenosis of the anterior nares merely diminishes the resonance of nasal sounds, which is retained in a measure so long as the naso-pharynx remains normal. The so-called "dead voice" of the condition known as adenoids in the vault of the pharynx is an example of absolute loss of resonance.



## EXAMINATION AND INSTRUMENTS.

The first essential to satisfactory examination of the upper air-passages is a good light. Sunlight may be utilized by means of a system of mirrors, but is not always to be had, and for the sake of convenience we resort to artificial sources of illumination. A German student oil lamp, fitted with a Mackenzie condenser (Fig. 3), will answer the purpose, but the Argand gas burner is better. Many attempts have been made to bring the electric light to our service and various head lights (Fig. 4) and lamps for use within the condenser have been devised, but, thus far, they have not been brought to perfection. The best light proposed, up to the present time, is what is




FIG. 3. MACKENZIE'S  
LIGHT CONDENSER.



FIG. 4. KUTTNER'S ELECTRIC HEAD LIGHT.

known as the improved Welsbach light, which consists of a gauze network, chemically prepared, and placed over the Argand flame. This network, or mantle, is rather delicate and must be handled carefully, but when protected by a mica chimney and the bullseye condenser, will burn upwards of 1,000 hours and gives a very beautiful white light. It is so brilliant that many prefer to use it without the bullseye. It is as intense as the electric light, is perfectly steady, and, what is by no means its least advantage, it radiates but little heat as compared with the ordinary gas jet. It is also said to consume a relatively small proportion of gas. The mantle may be renewed at trifling cost, and the original outfit is inexpensive. Having secured a good light we next seek to reflect it upon the parts to be



examined. In the more elaborate apparatus, as Tobold's, the reflector is attached to the lamp. It will be found more convenient, however, to wear the reflector upon the forehead. A concave glass mirror,  $3\frac{1}{2}$  inches in diameter, with a focal distance of about 16 inches and framed in aluminum may be attached to a Pomeroy forehead piece and held to the head by means of a band of leather or silk braid, an inch in width (Fig. 5). It is very light, and may be worn indefinitely with comfort, and is to be preferred for operative work and when one has a large number of patients to examine successively.

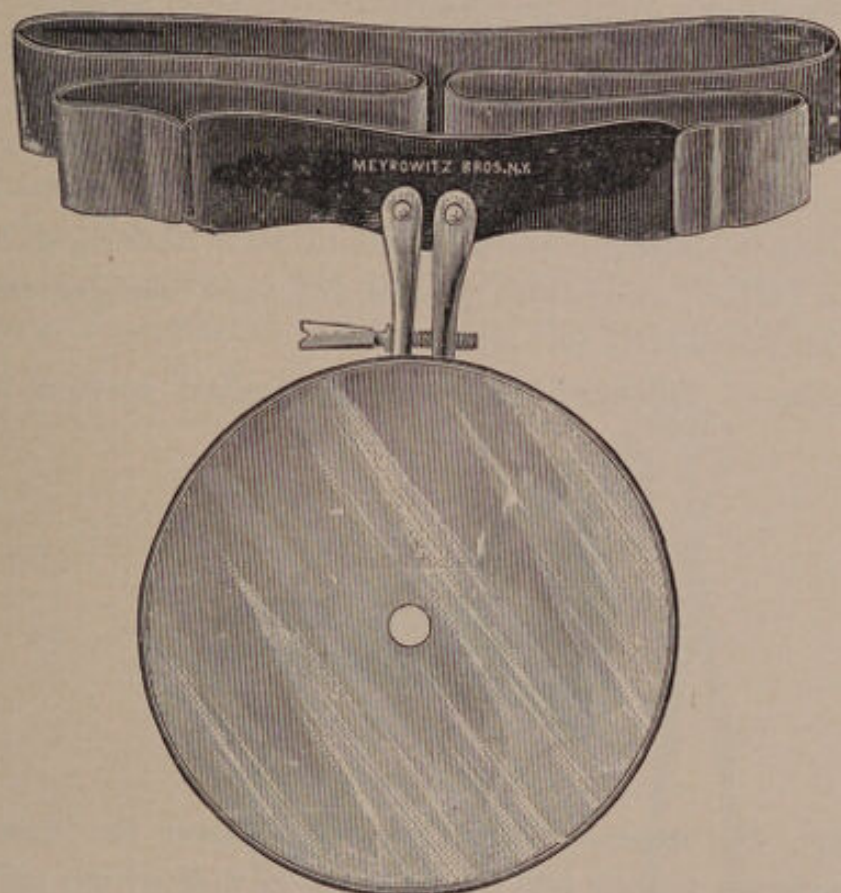


FIG. 5. HEAD MIRROR WITH POMEROY BAND.

In all examinations of the nose and throat let the source of light be on the right of the patient, so that the right hand of the examiner, with which most of the manipulating is usually done, may not interfere. The examiner should sit facing his patient with his knees separated, one on either side of the patient's knees. The position advocated by some, with the knees of the examiner together and on one or the other side of the patient, may be a gain in elegance, but is a sacrifice of steadiness, a point of importance in operating. The



head mirror should be worn over the left eye in such a way that both eyes may be brought into service. After a little experience one knows instantly whether binocular vision is obtained. At first an easy way to settle the question is to close the right eye and if then the open left eye looking through the aperture in the center of the head mirror includes the whole circle of light thrown at the focal distance by the reflector, one may be sure of using both eyes. On very close inspection of points in the depths of the nasal fossæ only one eye at a time can be used. It is well to have all the instruments to be brought in contact with the patient comfortably warmed. In the case of throat mirrors this is indispensable in order to obviate condensation of moisture upon the glass. The mirror should be warmed by holding it face down, over the gas flame for a few seconds, and the degree of heat should be tested on the ball of the examiner's thumb before the mirror is placed in the throat. Nothing so unnerves a timorous patient, aside from general awkward management, as the touch of an excessively hot mirror.

Inspection of the nasal and naso-pharyngeal cavities is called

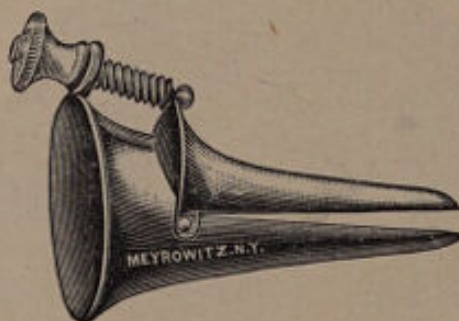

FIG. 6. DUPLAY'S NASAL SPECULUM.

*rhinoscopy*. By *anterior rhinoscopy* we discover the condition of the cartilaginous septum and of the anterior ends of the middle and inferior turbinate bodies. This procedure is very much facilitated by preliminary spraying of the nares with a four per cent. solution of cocaine. The indiscriminate use of cocaine, however, should not be encouraged, and it never should be used until we have first seen the parts in their natural state. We study the posterior nares and the naso-pharynx by means of small mirrors introduced into the oropharynx, or *posterior rhinoscopy*.

A good nasal speculum in *anterior rhinoscopy* is almost as necessary as good illumination. The ideal speculum should be easy of



manipulation, should give the patient no discomfort, and should be capable of admitting a generous flood of light. Such an one we have in the Duplay speculum (Fig. 6). Its solid blades have the double advantage of exerting uniform diffuse pressure and at the same time push aside the vibrissæ, which grow so profusely in




FIG. 7. HARTMANN'S NASAL SPECULUM.

the nostrils of some patients, and which are apt to protrude through the opening of a fenestrated speculum and impede the rays of light. Hartmann's speculum is also a very convenient instrument (Fig. 7). It should be remembered that the walls of the nasal vestibule are but




FIG. 8. JARVIS' NASAL SPECULA.

slightly dilatable, hence the importance of using a speculum the separation of whose blades may be regulated at will. All fenestrated instruments, with uncontrolled springs, are to be condemned. In

operating far back in the nasal cavity the Jarvis speculum (Fig. 8). is found to be more convenient, since it is lighter and more properly self-retaining, and is less apt to get in the way of the operator.

No rhinoscopic examination should be considered complete until inspection of the mucous membrane has been supplemented by palpation with the probe. We thus gain information as to the vascularity, the density and the mobility of the structures normal or




FIG. 9. JARVIS' RHINOMETER.

morbid. It is also frequently important to determine the sensitiveness of the pituitary membrane, or to define areas of suspected hyperesthesia. If still more exactness is desired we may measure the width of the nasal passages at various points by means of Jarvis' rhinometer, or the thickness of the septum with Seiler's septometer (Figs. 9 and 10).

In *posterior rhinoscopy* we frequently have to contend with various obstacles, such as a rebellious tongue which resents the pressure of

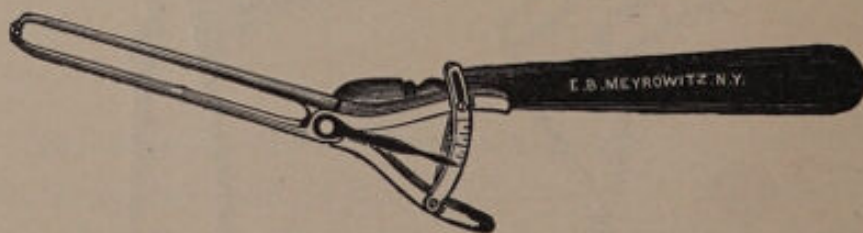

FIG. 10. SEILER'S SEPTOMETER.

the tongue spatula, an irritable pharynx whose muscles contract in the act of gagging almost as soon as the mouth is widely opened, an unusually narrow space between the palate and the pharyngeal wall, or persistent elevation of the velum during our attempt to illuminate the posterior nares. In many cases we succeed in getting a view only by the exercise of the utmost tact and patience, and our subject may have to be put through a course of training for several weeks



before we succeed in getting more than a glimpse of the parts we wish to explore. The tongue should never be roughly handled. A Türk depressor with a smooth tongue piece, held in the examiner's left hand, should be applied to the middle of the dorsum of the tongue not too far back and steady, firm pressure made in a downward direction (Figs. 11 and 12). The rhinoscopic mirror, No. 1, or larger in trained subjects, properly warmed, is then introduced face upwards to the right of and behind the uvula, care being taken to avoid sudden and rough contact with the wall of the pharynx.

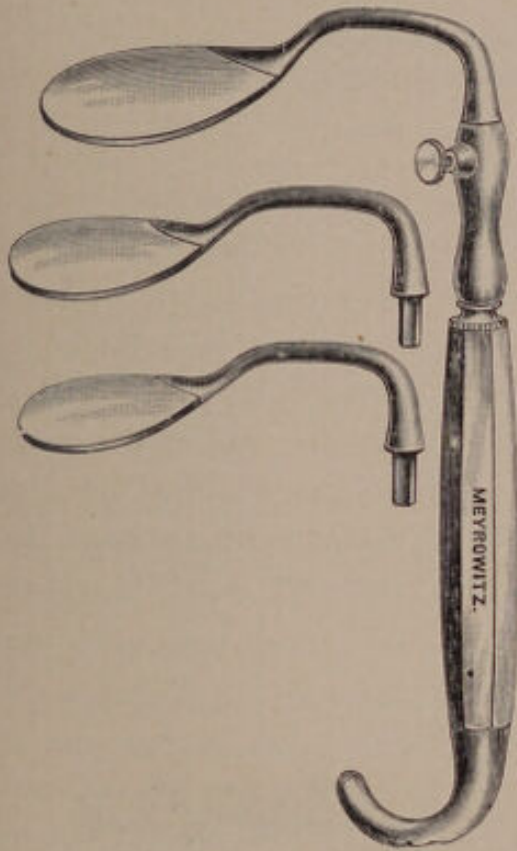


FIG. 11. TÜRK'S TONGUE DEPRESSOR.




FIG. 12. BOSWORTH'S TONGUE DEPRESSOR.

The patient is directed to breathe quietly meanwhile through the nose. By gently raising or lowering the right hand which holds the mirror and by slightly rotating the shaft without shifting the mirror about in the fauces, the examiner will finally get all the details of the rhinoscopic image. It is rarely possible to use a mirror large enough to give a complete picture.

Irritability of the pharynx may usually be overcome by frequent repetitions of examination from day to day. Attempts at the first



sitting should be abandoned in case there is found to be extreme sensitiveness. We may sometimes succeed in establishing tolerance by directing the patient to pass his forefinger far back upon the dorsum of the tongue and over the velum several times a day, thus accustoming the pharynx to the presence of a foreign body. The patient may hold small pieces of ice in the mouth for fifteen minutes before examination, or if the necessity is urgent, we may spray the




FIG. 13. WHITE'S PALATE HOOK.

pharynx with a four per cent. cocaine solution. Cocaine may defeat us by the nausea which it excites in certain individuals. It should be used for purposes of examination only as a last resort, and the patient should always be warned of the discomfort it is likely to cause. In some cases assistance may be gained from the use of a palate hook by which the velum is held forward. One of the most convenient is White's (Fig. 13), which has been modified by dispensing with the joint in the shaft and adjusting a rubber band, so as to make the instrument automatic. For ordinary use it is not to




FIG. 14. KYLE'S POSTNASAL ELECTRIC LAMP.

be recommended, since we find that it is most easily applied in those tolerant throats which permit a satisfactory examination without it. Yet in certain rare cases of doubtful diagnosis, or in which the electric cautery is to be used in the naso-pharynx, it will be found serviceable. After an application of cocaine it is sometimes borne without objection.

A thickened or elongated uvula, or hypertrophied palatal tonsils may add more or less to the difficulties of a posterior rhinoscopy, but they are seldom insurmountable.



A small electric lamp fixed at a right angle and attached to a suitable handle and battery may be passed behind the velum, and gives an excellent illumination of the pharynx as well as of the nasal cavities. After the patient has learned to keep the lamp in place with the closed lips a good view may be obtained by looking through the anterior nares. Such a lamp as that devised by Kyle (Fig. 14), which is protected by a movable aluminum cap, produces little or no discomfort by the evolution of heat.

Digital examination of the naso-pharynx is a procedure too much neglected. It is by no means agreeable to the patient, but it may be done quickly, and it is well for the student to familiarize himself with the landmarks of this region by the sense of touch. In young children, and in those who will not tolerate rhinoscopy, it is the only way by which a knowledge of the extent and disposition of lymphoid hypertrophies may be gained. In practising this method in young subjects the finger may be protected by a jointed metal shield, or this may be dispensed with by adopting the following course. The child is held in the lap of the mother, or of an assistant, who controls its hands. The examiner then standing on the child's left presses his right middle finger firmly upon the patient's right cheek, at the same time bringing its head against his own body. The firm pressure causes the child to open its mouth, when at once the examiner's left forefinger should be passed into the pharynx. The pressure being maintained the cheek is pushed between the teeth of the open mouth, and the examining finger is pretty safe from harm, since the child cannot close its jaws without biting its own cheek. The examining finger may be protected by passing over it a piece of elastic rubber tubing, which interferes but little with the movements of the finger and the delicacy of touch.



## CHAPTER II.

### ACUTE AND CHRONIC RHINITIS.

Inflammation of the mucous membrane lining the nasal passages, or *rhinitis*, may be *acute* or *chronic*. The phenomena of chronic rhinitis are so complex and its complications and consequences so varied as to demand extended description.

The symptoms of acute rhinitis, or coryza, are familiar and need but little attention. The majority of people have a "cold in the head" from time to time, think it of slight consequence and let it run its course. It is certainly worth while, however, to consider the causes of "catching cold" and the measures adapted to its prevention and relief. In addition to individual proclivity based upon a diathetic condition, there may be certain local structural changes and relations within the nasal fossæ which make one particularly liable to catch cold. Moreover, we all recognize the fact that certain occupations which involve exposure to frequent and abrupt changes of temperature or to irritating vapors, increase the liability. The nerve theory of etiology is maintained by some. A neurotic element is no doubt often prominent and the predisposing influence of depressed general health is beyond question. It is undeniable that a general atmospheric state sometimes exists which leads to the development of a pandemic of acute rhinitis. As yet we have no positive proof that rhinitis may be transmitted by contagion. Some of the causes immediate and remote are avoidable, and it is equally true that the course of the disease may be cut short by appropriate treatment. Many of the more serious and distressing chronic affections of the nose have their origin in a neglected cold in the head.

Prophylaxis is a far more important function of the physician than drug giving. The question of ventilation, especially of sleeping rooms, and the matter of quality and kind of underclothing are subjects by no means beneath his notice. They certainly have a most serious bearing upon the susceptibility of a patient to cold from exposure. We all know the danger of sudden chilling of the surface



when overheated. We think less of the ill effects of superheated foul air in our homes and places of amusement. The use of cold water as a means of toughening the cutaneous surface is highly estimated and perhaps justly, but many of its enthusiastic advocates lose sight of the depressing effect it may have upon the general system. By judicious hints as to points of hygiene, dress and diet, it is doubtless possible to prevent many of the catarrhal affections which are so difficult to cure. How far climatic influences are factors in the causation of "catarrh" it is difficult to say. A similar observation is true of the tobacco and alcohol habits. It is not unusual to hear a patient say that he never has trouble except when he comes to New York, while the next visitor may remark that he is never so comfortable elsewhere. One patient will affirm that tobacco and alcohol invariably aggravate his catarrhal symptoms, while the next, an inveterate smoker, will express his belief that tobacco has preserved his health. It seems to be impossible to lay down an arbitrary rule on these points. They are matters of individual experience. In general terms it may be said that the excessive use of these luxuries is harmful. What constitutes excess depends upon the temperament, the occupation and the general habits of life. Moderation in one may be excess in another. The relationship between sexual excitement and turgescence of the nasal erectile tissue is obvious and sexual excess must be included among the factors in the etiology of rhinitis.

As to the propriety of the term "catarrhal diathesis," which is sometimes used to indicate a propensity to inflammation on the part of the mucous surfaces generally, it is reasonable to assume the existence of a constitutional condition which influences the vital resistance and functional activity of the mucous membranes as well as of other tissues and organs of the body.

In the first stage of an acute rhinitis, the mucous membrane is abnormally dry and the patient is conscious of some obstruction to nasal breathing. Sneezing, lachrymation, more or less frontal heaviness, or actual headache, with a feeling of general lassitude and depression, comprise the usual train of symptoms. If the inflammatory process actually extends to one or more of the accessory sinuses, which, fortunately, rarely happens, there is more decided pain, neuralgic in character. There is generally more or less congestion of the



sinuses associated with an acute rhinitis, and especially in the frontal region there may be complaint of sensitiveness and a feeling of tension. The sense of smell may be completely abolished for the time being. One of the most annoying symptoms is the *tinnitus aurium*, frequently accompanied by impairment of hearing and a sense of fulness in the ears, dependent, no doubt, upon extension of the inflammatory process to the naso-pharynx and the orifices of the Eustachian tubes. There may be a mild degree of pyrexia. In the course of a few hours the dryness of the membranes is succeeded by an effusion of watery secretion, more or less profuse, at first mucous and gradually becoming purulent. In the declining stage the discharges become thicker and dryer. If inspected in the prodromic stage the mucous membrane will be seen to be excessively tumefied, dry and glazed, and very red. In the second stage the swelling and redness may persist, but the surfaces are bathed in mucus. In the final stage we find the congestion and swelling less, but the nasal passages are apt to be obstructed by tenacious purulent and inspissated secretion. Usually in a week or ten days the patient is restored to health, but not without perceptible aggravation of a preëxisting abnormality, or certain changes in the tissues which increase the tendency to recurrent attacks.

*Treatment.*—An attack of acute rhinitis may be invariably mitigated and sometimes aborted. At the outset ten grains of quinine with ten grains of Dover's powder should be given to an adult, and proportionate doses to children, unless there is some known contraindication. Measures tending to encourage perspiration are often used with benefit, such as the hot foot bath and hot lemonade internally. Some observers insist upon entire abstention from fluids internally, with the result, it would seem, of adding rather to the patient's discomfort. On the other hand Cohen recommends copious draughts of water. The less local meddling the better, but there seems to be no doubt that an application of cocaine, two per cent. to the inflamed nares, followed by an insufflation of Ferrier's snuff (morph. sulph. gr. i, bismuth. subnitr.  $\bar{\text{ss}}$ , pulv. acacia  $\bar{\text{ss}}$ ) is very soothing and will contribute to the comfort of the patient (Fig. 15). Cocaine should never be entrusted to a patient except in extreme cases and unless we are quite sure of his capacity to resist the fasci-



nations of the habit. The question of the local effect, damaging or otherwise, of repeated and prolonged use of cocaine is still undetermined. The abuse of an agent, so energetic and decided in its action, may do permanent harm. There is no doubt about the comfort it gives by emptying the venous sinuses and thus restoring the caliber of the nostrils. But its effects are transitory, and the temptation to resort to it again and again is almost irresistible. The promiscuous recommendation of cocaine is, therefore, dangerous and should be discountenanced. A solution of cocaine alkaloid, two per cent. in

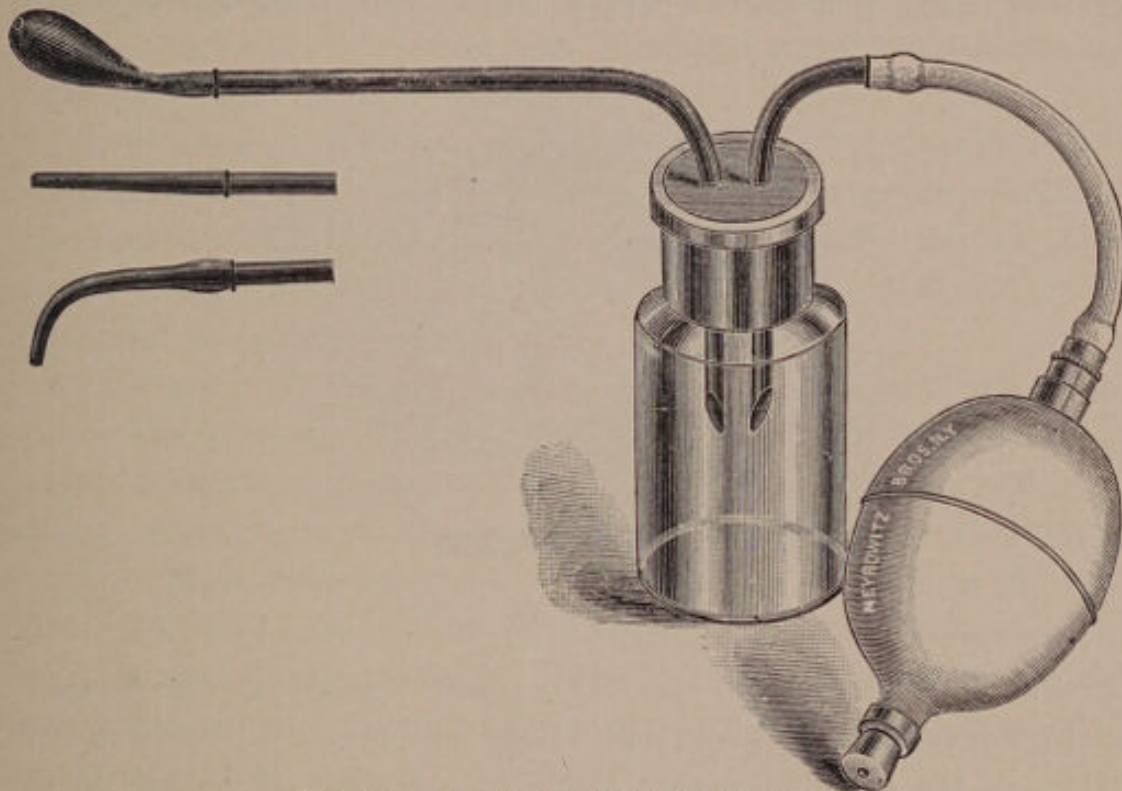


FIG. 15. UNIVERSAL POWDER BLOWER.

equal parts of almond and petroleum oil has been found by Wyatt Wingrave to give more prolonged results though acting somewhat more slowly than a watery solution. A five per cent. watery solution of cocaine hydrochlorate, containing two per cent. sodium sulphate, proved to give as complete effects as much stronger solutions of cocaine alone. Thus the danger of toxic symptoms is much reduced and moreover the combination is more rapid in its action. The inhalation of a vapor of camphor and menthol (5 grs. of each to one ounce of fluid albolene or benzoinated albolene) will usually give temporary relief and may be safely repeated at short intervals. The



patient may be instructed to inhale from a wide-mouthed bottle containing equal parts of powdered camphor and menthol to which a few drops of ammonia have been added. The famous Hager-Brand remedy (acid. carbol.  $\text{5i}$ , alcohol  $\text{5iii}$ , aq. ammon. fort.  $\text{3i}$ , aq. distill.  $\text{5ii}$ ) may be used in a similar way, or may be sprinkled on a handkerchief and inhaled. Many drugs of this class may be satisfactorily inhaled from a nebulizer or vaporizer (Fig. 16).

A combination, the value of which has been somewhat exaggerated, for controlling secretion and reducing the turgescence of the erectile tissue, is a tablet (rhinitis tablet) containing one eighth of




FIG. 16. UNIVERSAL VAPORIZER.

a minim of belladonna fl. ext. and one fourth grain each of camphor and quin. sulph. to be given half hourly until ten or twelve have been taken or the patient becomes aware of a feeling of dryness in the pharynx. In malarial cases quinine is indicated. In rheumatic and gouty subjects the salicylates and antilithics are of service. In this connection it is of interest to note the alkaline treatment of a "cold in the head," as advocated by Bulkley, who gives bicarbonate of soda in full and frequent doses. The necessity of treating a rhinitis complicating the exanthemata in children by means of cleansing and germicidal solutions should be appreciated. The relative importance of general symptoms sometimes leads to neglect of the local conditions with disastrous results. Space does not permit a reference to numerous other remedies, local and general, most of them of indifferent value, with the exception of adrenal extract, to be referred to



in detail in the section on hay fever, and to the use of hourly insufflations of orthoform, either pure or combined with sodium sozoiodolate, as confidently recommended by Spiess. Its use is based on the neuropathic theory of causation, and the applications are said to be more effective if made through the mouth to the vault of the pharynx, the intention being to reduce reflex irritability. In conjunction with the local treatment various drugs classed as antineuralgics or nervines are given internally.

In a small proportion of cases convalescence from a course of acute rhinitis does not ensue and we have established a condition of *chronic rhinitis*, known to the public and to many general practitioners as "catarrh."

For the sake of simplicity, we may divide chronic rhinitis into three varieties, *catarrhal*, *hypertrophic* and *atrophic*, basing this subdivision upon the clinical phenomena characteristic of each. Several other forms, comparatively rare and named from certain prominent symptoms, will be described.

In *chronic catarrhal rhinitis* hypersecretion is the principal symptom. The patient soils many handkerchiefs during the day and is constantly annoyed by the accumulation of secretion in the post-nasal space. Nasal respiration is not perceptibly impeded, or the patient may complain of intermittent stenosis alternating between the nostrils. We have here then an early sequel of an acute process which involves mainly the glandular elements of the mucous membrane, but which will sooner or later develop structural changes of a hyperplastic character.

In the latter case, *hypertrophic rhinitis* supervenes, the main feature of which is persistent continuous obstruction to nasal breathing. The secretions are still apparently in excess. As a matter of fact, their proportion is reduced, but their quality is so perverted and the changed conditions so prevent their normal disposition, that they accumulate in the nasal chambers until removed by violent efforts at expulsion. The attempts at clearing the pharynx, especially in the morning, are often very distressing. These patients are habitual mouth breathers and snorers, and are apt to waken from sleep in the morning with the mouth and tongue dry and parched. Disorders of digestion are not infrequent, attributed perhaps unjustly to putrid



and decomposing secretions finding their way from the pharynx to the stomach. The larynx may be affected and the voice becomes hoarse in consequence of the inspiration of improperly prepared air, the function of the nose being entirely or in part suspended. Among the more annoying, and at times painful symptoms of hypertrophic rhinitis, may be mentioned various reflex disturbances resulting from intranasal pressure. This subject has been actively investigated in recent years and many interesting phenomena have been discovered. It has been clearly demonstrated that very many functional disorders of the eye and notably of the ear may be due to a point of irritation or pressure within the nose. Facial neuralgia, frontal headache, cough and derangements of the voice may be attributable to a similar cause. The relief to ear symptoms following intranasal operations is sometimes very striking. Unfortunately, in many cases the aural difficulty has passed the line of purely functional disturbance before a nasal lesion is sought for or suspected. It is coming to be recognized that chronic turgescence of the turbinate erectile tissue and other nasal lesions, may induce vascular changes in the labyrinth as well as in the middle ear, so that it is safe to predict a considerable extension of the scope of intranasal surgery. On the other hand we must avoid the error of assuming that all human ills have a nasal origin.

It is difficult to fix a line which separates the varieties of chronic rhinitis. The pathological processes merge into each other by such slow gradations that we frequently find several of them represented in the same subject. One nostril may be blocked by hyperplasia while the other is widely expanded in an advanced stage of atrophy.

The diagnosis of an established case of atrophic rhinitis is usually easy, but the difficulty of identifying the two varieties of chronic rhinitis which have been described is greater. We rely upon inspection, touch with the probe and cocaine to differentiate them.

The first (hyperemia) presents a red tumefaction of the turbinate bodies, of uniform smoothness, which is quite sensitive and bleeds freely. It yields to compression with a probe, and in the early stages the pressure being released the tumor instantly reforms, owing to a reëngorgement of the erectile tissue. Later on when vasomotor paresis occurs the furrow caused by the probe is more lasting. The



swelling promptly subsides under cocaine. In the second form (hyperplasia) the tumor is paler in color, irregular in contour, and less sensitive and vascular. Frequently, it is distinctly lobulated, papillated, or even fimbriated (Fig. 17). It is manifestly more dense in structure, may be compressed only by very firm pressure with the probe, and resumes its original shape very sluggishly. It does not completely shrink after an application of cocaine.

In deciding upon a course of treatment it is important that we should distinguish these conditions. In the former case, sedative

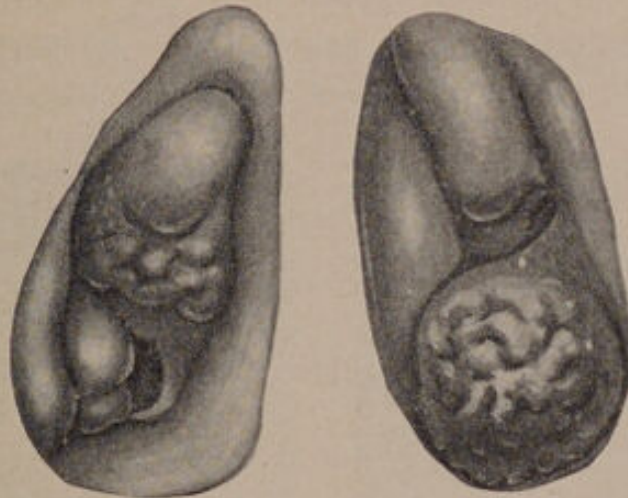


FIG. 17: LOBULATED HYPERPLASIA OF LEFT INFERIOR AND RIGHT MIDDLE TURBinate. (*Grünwald.*)

applications, mild astringents perhaps, and the correction of vicious habits, notably the pernicious practice of violent nose blowing, will suffice. In the latter we have to deal practically with a foreign body which must be removed.

Vaso-motor paresis of the walls of the blood-vessels composing the erectile tissue of the turbinate bodies is a prominent feature of the transition stage of hypertrophy. A physiological process thus gradually becomes pathological and the muscular walls of the venous sinuses undergo degeneration in consequence of which they remain permanently dilated until compressed and obliterated by the surrounding new connective tissue. This constitutes what is sometimes described as a "turbinal varix," seen usually at the posterior end and lower border of the inferior turbinate. Not infrequently, the osseous structures themselves become implicated in the inflammatory process, or undergo enlargement as a result of hypernutrition. A most inter-



esting series of pathological changes ensues involving chiefly the middle turbinate bone, which until recently has received but little attention. The bone may be simply thickened, or it may undergo a process of cystic formation or expansion. The inferior turbinate is but seldom thus affected, whereas in the case of the middle turbinate the discovery of these osseous cysts is a common occurrence. Their development is explained in various ways. In the majority of cases it doubtless results from a rarefying osteitis inducing absorption of the interior of the body of the bone. In other cases the cyst is believed to be due to the prolongation of an ethmoid cell into the body of the middle turbinate and its subsequent expansion. In still other cases, and more rarely, as described by Greville MacDonald, the

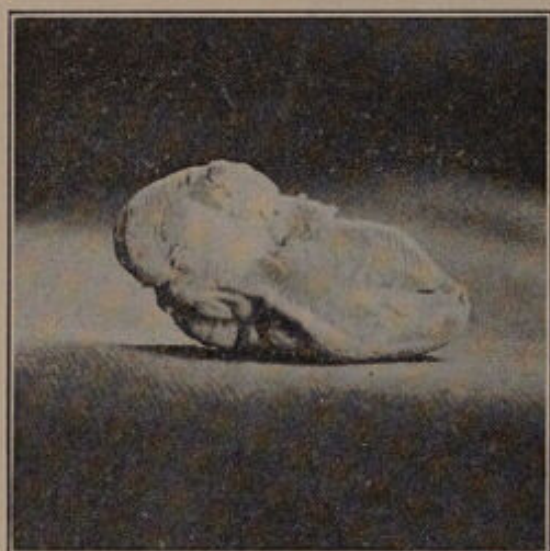
*a**b*

FIG. 18. CYST OF MIDDLE TURBinate BONE. (Author's specimen.) *a*, Nasal surface; *b*, interior of cyst.

mode of formation may be as follows: A hypertrophic rhinitis extending from the soft parts to the periosteum covering the middle turbinate and finally to the bone itself causes its margin to curl outward and upward until it meets the body of the bone at some point where at length adhesions take place. The tube thus formed lined within and without by mucous membrane eventually becomes sealed at its extremities. Distention of this cavity goes on until the glandular elements in its lining membrane undergo absorption from pressure. The last explanation must certainly be considered rather



fanciful. The developmental theory of etiology is accepted by Payson Clark, who professes to have found no evidences of inflammatory action in four cases of *concha bullosa* operated upon by himself, and who has discovered in literature only four cases accompanied by pus formation. On the other hand J. Wright points out the presence of osteoblasts building up bone on the outside of these cysts while osteoclasts are absorbing it within. Thus a preëxisting cavity becomes larger and larger as a result of a low grade of osteitis. These cysts are very common, Zuckerkandl having found them thirty-six

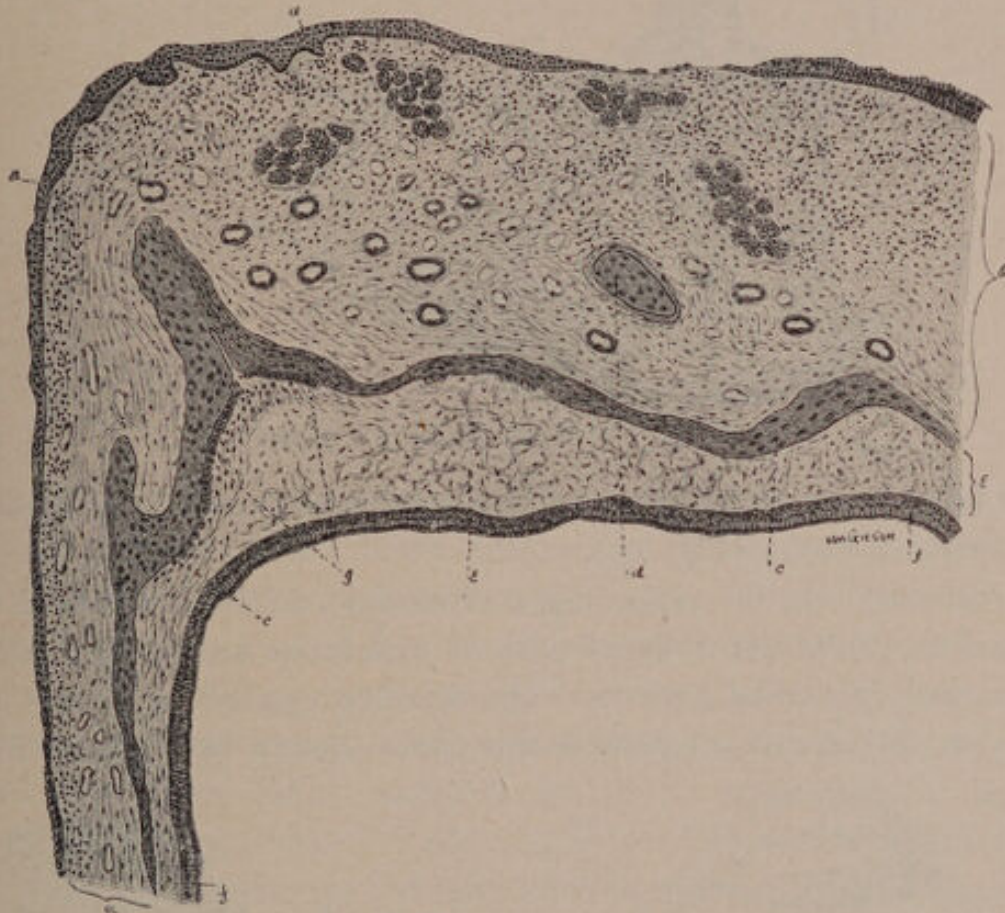


FIG. 19. SECTION OF BONY CYST OF MIDDLE TURBINATE. (Author's specimen.)

*a*, Layer of stratified epithelium; *b*, layer of richly cellular vascular connective tissue, which is rather more dense about the laminæ of bone, *c-c-d*; *e*, layer of very loosely arranged edematous connective tissue resembling myxomatous tissue; *f*, layer of ciliated epithelium; *g*, layer of osteoblasts.

times in 200 post-mortem observations. They are generally met with in adults and are more frequent in women than in men.

The cyst sometimes reaches enormous dimensions, as shown in the accompanying plate (Fig. 18). The mucous membrane covering



it may persist in its hyperplastic condition, may become polypoid, or may atrophy. It is perhaps more usual to find it in the last mentioned state. The tumor might readily be mistaken for a polyp or an ordinary hypertrophy unless carefully examined with a probe, when its hardness and immobility may be detected. Often the bony




FIG. 20. LEFFERTS' HAND ATOMIZER.

shell forming the wall of the cyst is so thin as to be readily punctured with a sharp probe (Fig. 19).

*Treatment.*—In the early stages of chronic rhinitis we should endeavor to soothe the irritated mucous membrane and to reestablish its normal functional activity. The warning against hasty and too free use of destructive agents at this period cannot be repeated often

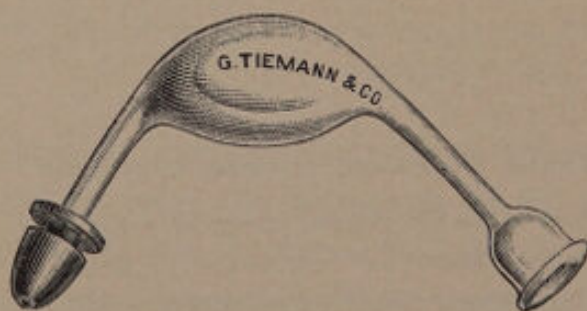


FIG. 21. WOAXES' NASAL IRRIGATOR.




FIG. 22. NASAL SYRINGE.

enough. In our clinics many patients are met with who can distinctly trace their condition of incurable atrophy to excessive zeal in the use of caustics. Some, at least, of these might have been saved by mild measures, and by attention to the general health and mode of life.



It may prove to be necessary to cauterize, but before doing so in any case in which we cannot clearly define areas of hyperplasia, we should see what may be accomplished by diligent use of alkaline and antiseptic sprays or douches. Fluid applications may be made to the nares by means of an atomizer (Fig. 20), or of one of the various nasal douches (Fig. 21), cups or syringes (Fig. 22). The spray tubes as now made of very thick glass, in one piece, and with blunt tips, are entirely satisfactory (Fig. 23). Three styles are needed, up, down and straight. The first two should be five inches in length, the

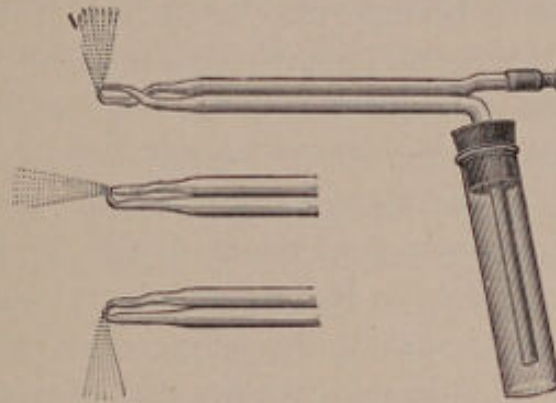


FIG. 23. SASS' GLASS SPRAY TUBES.

last need not be more than three or four inches from the angle to the tip. A hand ball, or one of the compressed air apparatus, according to convenience, may be used to form the spray. The pressure on the latter should not exceed twelve pounds, and often one half that degree of force will be ample, except with the heavier oily sprays.

One of the best known solutions intended for use in this way is Dobell's solution (acid. carbolic gr. iv-x, sodæ boratis, sodæ bicarb. ãã gr. xl, glycerin  $\mathfrak{z}$ iv, aquæ ad  $\mathfrak{z}$ iv). The famous Seiler tablet is quite as familiar to the laity as it is to the profession and in solution of proper strength is agreeable and satisfactory. One of the best solvents for viscid secretion is warm salt water, in other words physiological or normal salt solution (7 parts to 1,000). In the majority of cases the most marked results will be obtained from menthol dissolved in fluid albolene (gr. ii-v to  $\mathfrak{z}$ i). Although oil and water will not mix and we cannot expect the mucous secretions and the albolene solutions to violate this law by showing an affinity for each other, yet we find that oily solutions serve a threefold purpose. They ensure gradual and prolonged action of the medicament



which they may hold in solution or suspension, they prevent the incrustation of secretion which is a more annoying feature of later phases of chronic rhinitis, and they furnish a protective film to the hypersensitive mucosa. It is true that sprays alone will not cure catarrhal conditions; it is true that oily solutions are disagreeable to some patients and act unfavorably upon some mucous membranes; but the fact remains that the spray, properly used, is a valuable and an elegant agent for cleansing and medicating the upper air-passages, the larynx and pharynx, as well as the nasal cavities. It hardly need be said that medicated applications should be preceded by thorough cleansing of the surfaces especially in atrophic rhinitis when the nares are stuffed with hard and dry secretions. One of the best detergent solutions in common use is warm salt water, one teaspoonful of table salt to a pint. It is important to observe this proportion and all lotions to be used in volume from a cup, douche, or syringe are more agreeable and more effective if applied warm. Heating the spray mixture is less important since the temperature of atomized fluids falls almost instantly, but in cold weather the oils and heavy solutions may be sprayed more readily if previously warmed. The use of astringents to control hypersecretion would seem to be indicated, yet we find that drugs of this class are sometimes worse than useless, since the Schneiderian membrane often exhibits more or less intolerance of their action. The discomfort of the patient is sometimes markedly increased by them, their effect in checking secretion is very transient, and the sense of smell is in danger of being impaired by too vigorous and too frequent applications. The use of powders of various kinds has been popular at times, but they offer no advantage over drugs already in solution and are decidedly irritating unless great care is taken in their preparation. The least objectionable is a powder of stearate of zinc with boric acid which combines mild astringent with sedative and antiseptic properties and in certain cases seems to act favorably. Stearate of zinc is an excellent vehicle for other powders, such as aristol, euophen and iodol. It seems irrational, however, to ask the secretion of an inflamed mucous membrane to act as a solvent for these drugs, when the solution may be made more rapidly and accurately before their introduction to the nasal chambers.



The treatment of rhinitis at this period, therefore, consists mainly in the correction of bad habits, the regulation of diet, and the restriction of local measures to the use of remedies which tend to reduce congestion and thus to restore the normal function of the secretory glands.

When the chronic catarrhal process has advanced to the second stage we are confronted by a totally different condition. Here certain structural changes have taken place in the mucosa which lead to permanent narrowing of the nasal passages and which can be relieved only by surgical intervention. The method to be selected will depend largely upon the particular region affected. If nasal respiration is seriously interfered with, if nasal drainage is impeded, if neuralgia or other reflex phenomena can be traced to a point of contact or pressure within the nasal fossæ, or if the sense of smell is impaired by an obstructive overgrowth, the indications for surgical interference are sufficiently clear. We rarely, if ever, meet with a lesion of this kind involving only the sense of smell. We may have reflex disorders or imperfect drainage, due to pressure, without respiratory stenosis. A lesion which prevents breathing through the nose cannot exist without interfering with drainage and generally weakens the sense of smell and provokes more or less reflex disturbance. Other considerations which should influence our choice of a mode of operating are the age of the patient, the duration of his difficulty and the temperament of the individual. In general the older and denser the hyperplasia the more energetic should be our attack upon it, but in children and in nervous subjects we may be forced to reject formidable apparatus and active agents for more tedious and less disturbing methods. Moreover, we must take care to avoid a violence in dealing with the middle turbinate body and the roof of the nasal chamber which may be exercised with impunity in the case of the inferior turbinate and the floor of the nose. If our patient is known to be a bleeder or if there is a reason for wishing to avoid even moderate depletion, of course, one of the bloodless methods of operating is preferable.

Hyperplastic tissue must be looked upon as a foreign body. There is no possibility of wholly restoring a mucous membrane thus affected. Until, therefore, the overgrowth is removed or reduced



by surgical measures or by the slower natural processes, we cannot reasonably expect any substantial relief of symptoms. The majority of these patients have tried the various advertised nostrums for "catarrh," or at least, have been in the habit of snuffing up salt water, before they apply for special treatment, and they may be considered fortunate if they have escaped troublesome complications, especially in the form of inflammation of the middle ear. Patients should be invariably cautioned against violently blowing the nose, especially with compressed nostrils, after the use of a nasal wash or douche. Excessive nose blowing which many with hypertrophic rhinitis practice is damaging to the intranasal tissues as well as to the tympana. In washing out the nostrils the stream of fluid should always be thrown in by the narrower nostril, so that the return current may find unobstructed exit by the other nostril.

There are three satisfactory ways of disposing of hyperplasia of the soft tissues of the nares: (a) By cutting operations with the cold wire snare, scissors, or forceps, (b) the electric cautery, and (c) chemical caustics.

The cold wire snare is best adapted to extreme cases in which the



FIG. 24. JARVIS' COLD WIRE SNARE.

soft tissues protrude into the nasal passage to such a degree as to allow the wire loop to be well embedded (Fig. 24). If the surface of the hypertrophy is smooth and shades off into the adjacent parts it is very difficult to include the desired amount of tissue within the loop. To obviate this objection, Jarvis advises preliminary transfixion of the mass to be snared, the loop being then adjusted over the ends of the transfixion needle. Practically we find that this leads to the cutting out of a furrow of tissue along the track of the needle, if a single needle be used, and if several needles are applied the operation becomes unnecessarily complicated. It is a good rule, therefore, to use the electric cautery for those cases in which the loop can not be employed without the aid of transfixion needles. A very ingenious suggestion by J. E. Boylan, who advocates ablation in preference to cauterization, seems to obviate the objection to transfixion needles.



The point of a fine tenaculum bent at a little more than a right angle is buried in the turbinate body where we desire the wire loop to cut and thus the amount of tissue included may be accurately determined

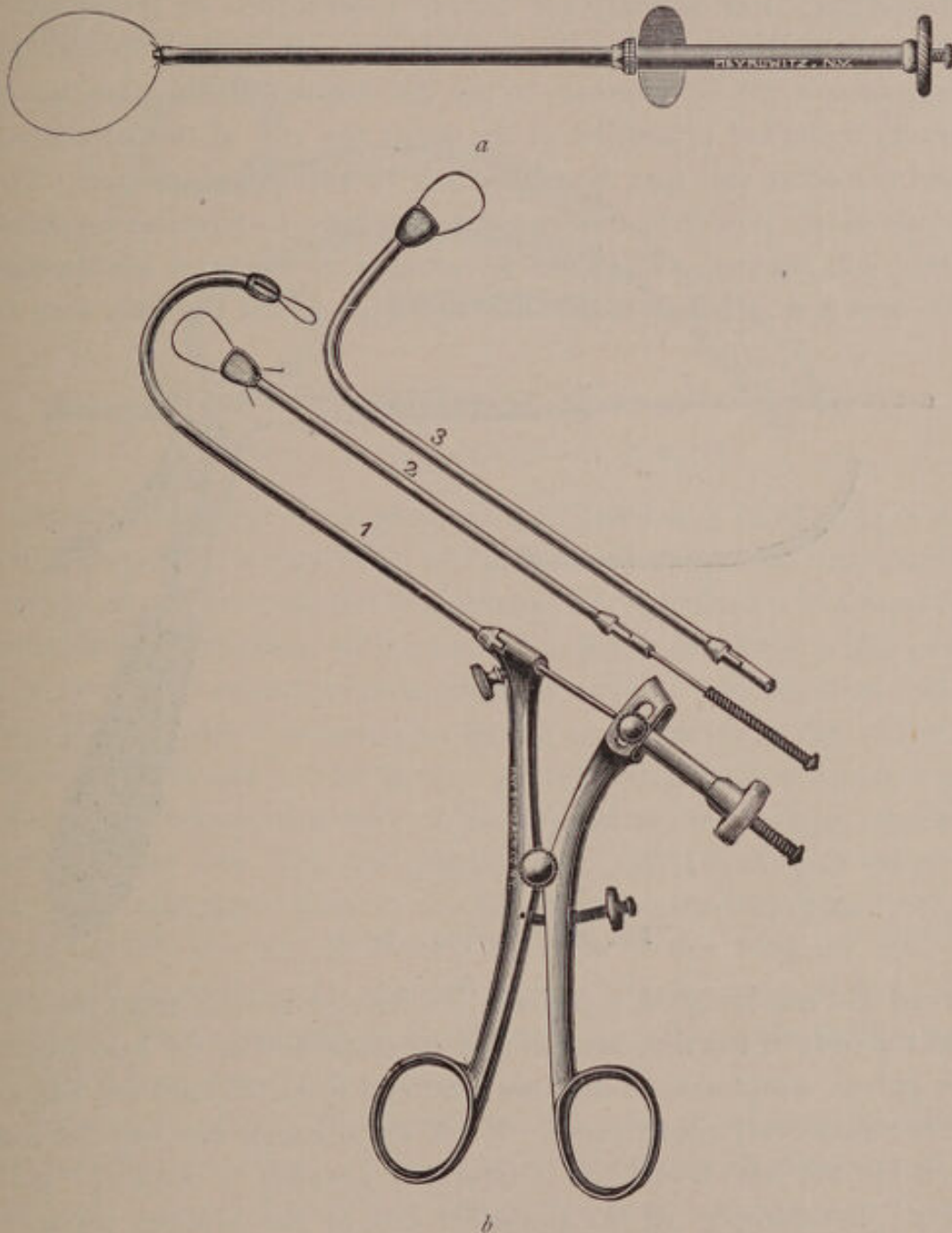


FIG. 25. SAJOUS' SNARES.

*a*, Straight; *b*, angular with three tips.

by passing the loop over the hook. In order to prevent the anterior end from slipping a short incision is made in the base of the turbinate and in it the wire is inserted. The hot wire loop for these minor

operations within the nares is not to be recommended. With it there is danger of damaging adjacent parts which we wish to preserve. It should be reserved for those in whom we have reason to fear hemorrhage. For ordinary use Sajous' modification of Jarvis' snare is a most convenient instrument (Fig. 25). In tumors of unusual dimensions it will be necessary to use the original Jarvis snare, which permits unlimited expansion of the loop; one end of the wire being fixed the other end may be played out to any extent desired. The Sajous snare, however, will carry a loop only so large as its screw thread will exhaust. The great advantages of the latter are the ease with which it is prepared for use and with which the loop may be




FIG. 26. WRIGHT'S SNARE.

turned and manipulated, especially in a narrow nostril, from the fact that the ends of the wire are fixed at the distal end of the instrument. For polyps, neoplasms of medium size, and hypertrophies the Sajous snare meets every requirement. It will cut through not only the soft parts but the bone itself, and is especially adapted to cases of "mulberry" hypertrophy of the posterior end of the inferior turbinate and to enlargement of the middle turbinate in which it is necessary to remove the anterior end of the bone (Fig. 26). In using the cold wire snare it is well to introduce as large a loop as the nostril will accommodate. If the patient is willing to endure the pain the loop may be adjusted before the use of cocaine, the inclusion of more



tissue being thus assured. There is no danger of getting too much tissue, as is true with some of the forceps devised for removing the turbinate bodies. The difficulty is to remove enough to relieve stenosis, and for that reason it may be desirable in some cases, for example, those in which the turbinate bone must be sacrificed, to use

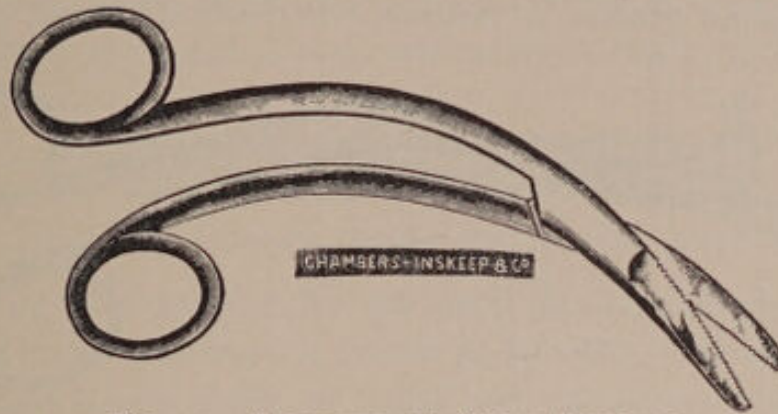


FIG. 27. CASSELBERRY'S NASAL SCISSORS.

serrated scissors like those proposed by Casselberry (Fig. 27), or the author's cutting forceps (Fig. 28). In order to prevent hemorrhage the loop of the snare should be tightened very gradually. In vascular posterior hypertrophies, which are apt to bleed profusely, a half hour or more may be consumed in making the section. On the other hand, some patients prefer to have the snaring done quickly at the cost of a little more pain and loss of blood. By following the latter course we are apt to be informed at once of the amount of the bleeding, whereas otherwise, we may send our patient away with a feeling of security only to be summoned later to check a violent secondary hemorrhage. Since the introduction of cocaine episodes of this kind are said to have been more frequent, probably owing both to reaction from the temporary hemostatic effect of the drug and to the more rapid work which the local anesthesia permits.

The electric cautery judiciously used, is one of the most valuable agents at our command. It has gained a measure of disrepute as a result of misuse. Unsuitable cases have been submitted to it, an improper degree of heat has been employed, imperfect batteries and apparatus have been the source of great annoyance. As a result instances of violent inflammatory reaction, extending even to the meninges, have been reported, violent hemorrhage has followed the withdrawal of an excessively hot electrode, and batteries often failed

to work at critical moments. At the first sitting only a very moderate amount of burning should be done and the utmost care must be taken to exclude possible contraindications. An incipient febrile state or a condition of systemic depression may be sufficient reason for postponing a cauterization, which is by no means always the trifling operation some profess to believe. Perhaps the most convenient

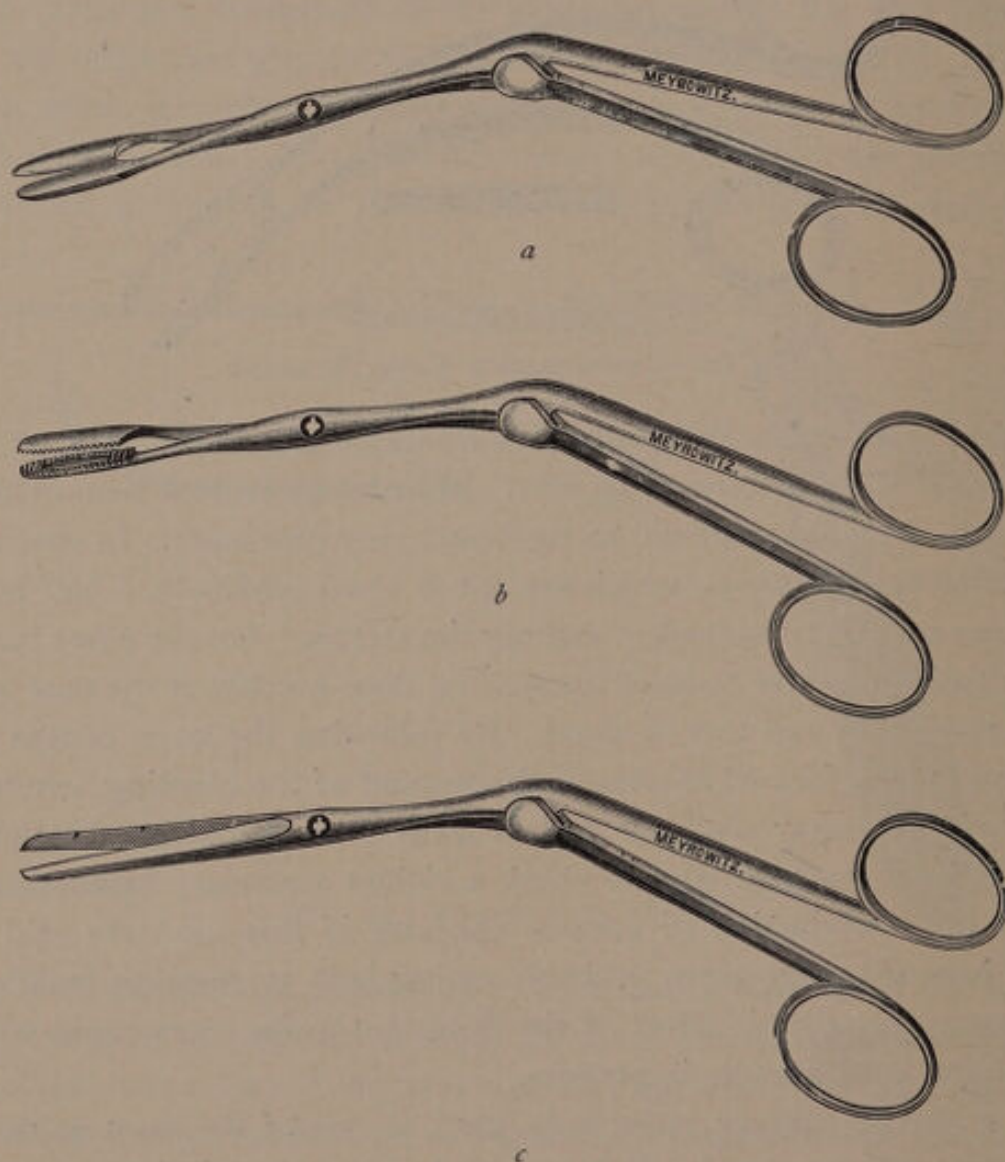


FIG. 28. AUTHOR'S CUTTING FORCEPS, *a*; DRESSING FORCEPS, *b*, and SCISSORS, *c*.

source of the electric current for surgical use at present is the storage battery, of which there are several varieties in the market. Being portable it may be used at the bedside as well as in the consulting room. It has the disadvantage of requiring frequent recharging according to the amount of work demanded of it. The selection of electrodes,



handles and conducting cords is no less important. These articles are generally unnecessarily heavy and clumsy. In using electricity we should always remember that the result is accomplished by the heat and not by the application of force, hence, cumbersome apparatus is superfluous. The electrodes should be delicate, the handles light, and the cords not too thick and stiff. Attention to these details will add greatly to our comfort and satisfaction in using electricity. An




FIG. 29. SCHECH'S HANDLE FOR CAUTERY POINTS.

excellent set of electrodes for the nose, larynx and pharynx with handles of ebony and bone, is known as Schech's (Figs. 29 and 30). The Kuttner handle made of metal and vulcanite is very serviceable, but is heavier. The degree of heat advised by most operators is "a cherry heat." Less heat fails to destroy to a sufficient depth and is more painful while much more than cherry heat is pretty sure to cause bleeding. With cocaine the question of pain does not arise, and if, as is to be preferred, the electrode is applied cold to the surface to be burned the degree of heat must be just on the border line

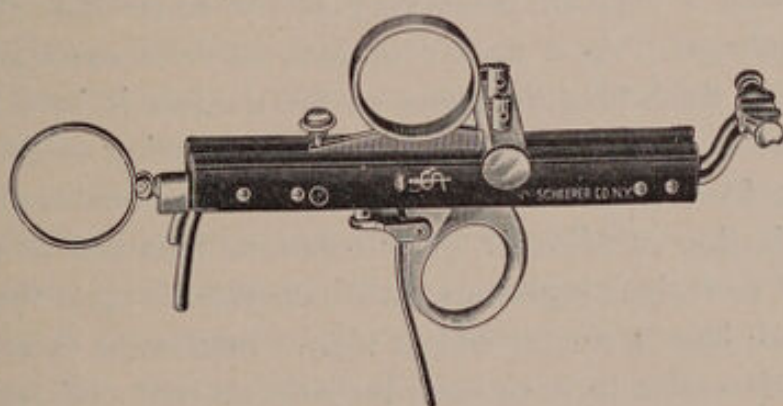


FIG. 30. SCHECH'S HANDLE FOR CAUTERY LOOP.

between cherry and white. Cocaine will be found of great service not only as an anesthetic, but in clearly defining areas of hyperplasia to be destroyed from other regions which are to be avoided by the electrode. The nostril to be operated upon having been thoroughly cleansed with an alkaline wash, cocaine in ten per cent. solution may be applied on pledgets of cotton, the head of the patient in the meantime being bent forward to obviate the passage of the solution back-



ward into the pharynx. In operating far back in the naris the avoidance of this accident is impossible, and the patient should be forewarned of the unpleasant consequences. Unless the nostril is excessively narrow, a septal shield, or a special speculum for protecting the septum is not necessary. The cold platinum point being pressed firmly into the tissues the current is turned on for only a few seconds and no damage is done except at the line of contact. The electrode should be gently withdrawn before it has quite cooled. Otherwise, it adheres and its detachment causes bleeding. A little experience and care are needed to carry out this step of the manipulation successfully. We thus burn through the whole thickness of mucous membrane with two objects in view, first, to destroy redundant tissues and, second, to promote absorption by the resulting cicatricial contraction. Unless this secondary effect is kept in mind more burning than necessary may be done. On the other hand, timid and superficial burning often does more harm than good by aggravating the irritable membrane. The cauterization should be thorough, but over a limited area. At the end of a week or ten days the burning may be repeated if it seems to be required. The use of a sharp-pointed electrode to be plunged into the submucous tissues has been proposed with a view of preserving as far as possible the surface of the membrane. As a matter of fact, in most cases which need to be burned the whole thickness of the mucosa is involved in the morbid process, and there is no object in attempting to save the surface. The foregoing observation applies with equal force to submucous injection of acids or other solutions intended to shrink the tissues and to various ingenious plastic operations upon the turbinate bodies which have a similar end in view. Interest in these conservative methods seems to have been recently revived and we find submucous injections of zinc chlorid in ten per cent. solution advised by Gaudier, who however admits that results are uncertain and that cauterization or resection of the turbinate must be resorted to in many cases. The experience of Hamm, Viollet and many others authorizes the conclusion that a dense hyperplasia cannot be satisfactorily reduced in this way. The interstitial application of chromic acid is facilitated by the use of Goldstein's "turbinal trocar." The trocar and canula, the latter provided with an adjustable ring for



regulating the depth of insertion, are plunged into the hypertrophied tissues and after withdrawal of the trocar a probe armed with chromic acid is passed through the canula and drawn out together with it. Thus a line of caustic is deposited along the track of the instrument. Although these methods may be simple of execution, painless under cocaine, free from violent reaction and from the danger of adhesions we fail to see their advantage or efficacy in genuine hyperplasia, while in simple hypertrophy milder methods will generally suffice. In certain cases of nasal obstruction due to chronic turgescence of the turbinates from vaso-motor derangement Delavan proposes to effect retraction of the swollen tissues by submucous incisions, thus dividing and ultimately obliterating the venous sinuses. A very fine lancepointed knife or needle is used and one or two punctures are made at different points according to the extent of swelling. The results of this method are said to be permanent.

Nearly all the chemical caustics, from strong nitric acid down, have been tried in hyperplastic rhinitis. They share the objection that, unless extreme care be exercised in applying them, they are apt to spread and burn over too wide an area. At the present time chromic and trichloroacetic have supplanted other acids. There seems to be no decided choice between them, except on the ground that toxemia may result from the former in case it is applied too freely, or of individual idiosyncrasy. Chromic acid may be kept in crystalline form and at the moment of using a crystal or two may be fused on the end of a probe. A copper wire, five or six inches long, flattened at its end for half an inch, makes a good applicator. A few crystals are deliquesced by the addition of just enough water and the flat end of the probe is dipped in the thick solution. One side of the probe being wiped dry with a bit of absorbent cotton the other side remains charged with the acid. Thus armed the copper probe can do no harm to the septum, for instance, when we wish to burn only the turbinate body. The action of the acid is very prompt. It soon exhausts itself upon the tissues and there is no need to neutralize it unless an excessive quantity has been accidentally used. Within a week the eschar thus produced separates or comes away in fragments and another application of the acid at the same spot is usually required. There is seldom any complaint of pain or reaction, except



perhaps in neurotic subjects, or in case the application may have been extravagant. Some patients object to the disagreeable odor of chromic acid. In such the trichloroacetic acid may be preferred. Its energy of action is almost, if not quite, equal to that of chromic acid. It is pleasanter to handle and is free from toxic qualities. It may be used with a Gleitsmann applicator, or may be applied by means of a fine nasal probe wound with a thin film of absorbent cotton.

While the active treatment is being carried out local cleanliness and asepsis must be maintained by the use of sprays and irritating conditions of all kinds must be remedied as far as possible. The patient must be seen every two or three days and the formation of adhesions guarded against by the passage of a probe until healing and retraction have well progressed.

A form of nasal obstruction in which the inferior meatus is almost completely obliterated by thickening of all the tissues composing the inferior turbinate body is quite common. The current of air in respiration passes by the middle meatus while the floor of the nose is occupied by the swollen turbinate bathed in detained secretion. The drainage and ventilation of the nasal chamber are manifestly defective, and although the patient may respire through the nose by day he becomes a mouth-breather at night, the posterior nares and pharynx giving evidence of the latter. In order to remedy this condition the bone itself must be removed. This may be done with a pair of strong nasal scissors. The anterior end of the bone is usually most at fault and especially in a narrow nostril it is necessary to apply the blades of the scissors well down at the base of the turbinate. In extreme cases the saw or the cold snare works well, or one of the various conchotomes (Fig. 31) may be preferred. The so-called nasal plane, or spoke shave, has justly lost its popularity. It is apt to carry away too much tissue and many cases of alarming hemorrhage after its use have been reported. The objects in view are to restore the normal patency of the nostril and leave a smooth symmetrical stump. With strong solutions of cocaine (ten to twenty per cent.) and adrenal extract, this operation of turbinectomy, which should never be a complete resection of the bone, may be done painlessly and bloodlessly. Attempts at twisting off a turbinate body or avulsion with forceps are not to be recommended. The entire bone



might be dislocated by immoderate violence. Plugging the nostril except for hemorrhage does not seem to me desirable, although Lake's india-rubber splint, or similar dressings of celluloid are used by many. In the opinion of Pegler the rubber splint, which is aseptic and easily removed and kept clean, saves the necessity of subsequent trimming in consequence of the gentle uniform pressure it exerts upon the roughness inevitably left by the operation. Simp-

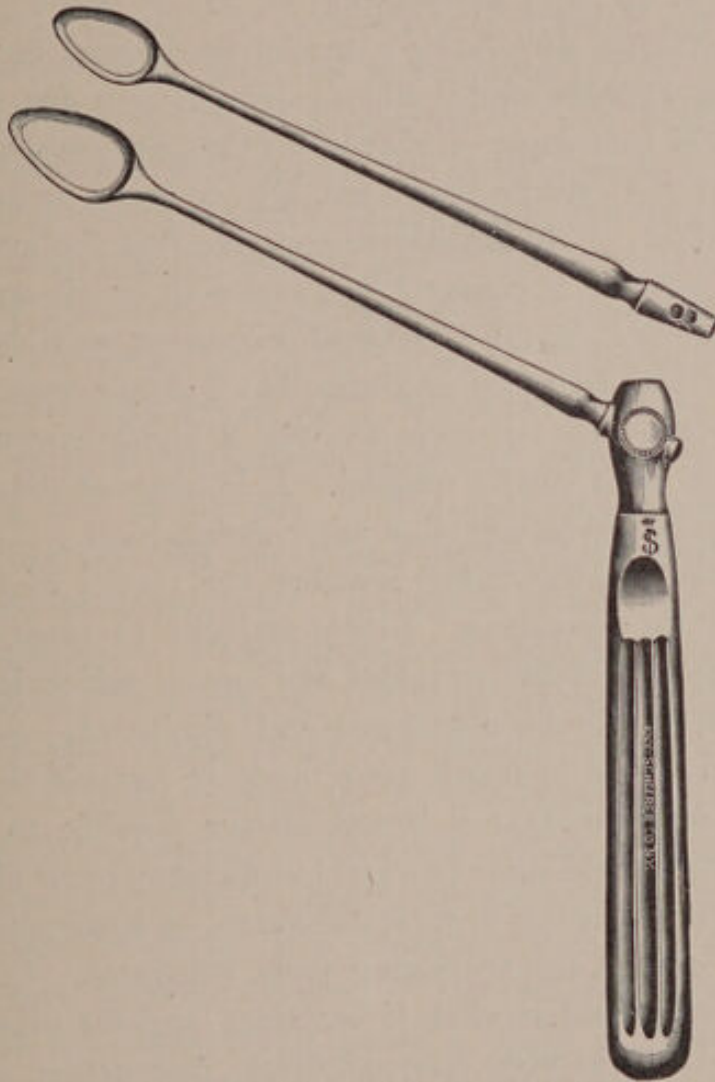


FIG. 31. BERENS' SPOKE SHAVE.

son's tampons of Bernays' compressed cotton, especially when covered with rubber tissue, or by a thin sheet of vulcanite, as suggested by Chappell, are sometimes useful in suppressing excessive granulation, but they must not be left in too long, and care should be taken not to use too thick a tampon lest in expanding it cause intolerable pressure. It is the belief of the author that most of these cases do



better without such a foreign body in the nose even though it may not be very irritating. The case should be carefully watched during convalescence and exuberant granulations should be reduced with the knife or a light touch with the electric cautery.

The use of hot air, first suggested by Vansant for the relief of headache, has been recommended in various morbid conditions of the nasal membranes by Lermoyez and Mahu and more recently by Lichtwitz. The current of air, at a temperature of 70° to 90° C., is propelled against the affected surface by a special mechanical device, consisting of an electromotor pump and an arrangement for warming the air, and is said to exercise a beneficial effect not only in simple engorgement of the erectile tissue but also to some extent in hyperplastic conditions. It is possible to conceive that the nutrition of an affected area may be so changed by continuous or oft-repeated applications of heat as to arrest a diseased process or possibly to promote absorption of inflammatory products, but a dense organized hyperplasia would certainly not seem to offer a highly encouraging field for experiment with such a method. It is believed that more rapid and radical procedures will give more satisfaction.

The question is often asked whether the results of treatment or operation will be permanent. In the majority of cases it is safe to answer in the affirmative provided the causes which instituted the catarrhal process can be discovered and eliminated. So many elements are concerned in many cases, both as regards the individual and his environment, that it is not always possible to ensure this provision. But should signs of nasal insufficiency recur after a longer or shorter interval owing to reestablishment of hyperplasia that fact would be no reason for abstaining from treatment. It is a simple matter to repeat a cauterization if necessary, and the principle should be constantly kept in view that wholesale destruction of intranasal tissue is not the chief end of rhinology. Attempts to restore the function of crippled structures are far more commendable than substitution of cicatrices for erectile tissue even though the latter be impaired. In many cases digestive or systemic derangements are of first importance, and endonasal surgery should be looked upon as a last resort.



### CHAPTER III.

#### ATROPHIC RHINITIS. MEMBRANOUS RHINITIS. CASEOUS RHINITIS. PURULENT RHINITIS.

*Rhinitis atrophica* must be considered a sequel of preëxisting inflammation rather than itself an inflammatory process. Various theories have been proposed to account for it. The majority of cases result from antecedent hyperplasia, the atrophic change in the nasal membrane being due to lessened blood supply from interstitial pressure which obliterates the vessels and at the same time interferes with glandular function. Some authorities believe in a *primary* atrophy and, in a certain proportion of cases, it is impossible to find evidence of preëxisting hypertrophy. A third theory, of which Bosworth is the principal champion, refers the atrophy to a purulent rhinitis as met with in children. Other observers, notably Cholewa and Cordes, maintain that the process begins in the bone, thence invading the mucous membrane. The argument in favor of this view is extremely plausible. Progressive bone absorption, due to causes not yet explained, obliterates the radical arteries and veins lying side by side in the bony canals, whence a portion at least of the blood supply of the soft parts is derived. In consequence the nutrition of the mucous membrane suffers and atrophy ensues. The causes which institute these alleged primary bone changes are not disclosed, but the admission of their existence in a measure explains the inefficacy of treatment in many cases of atrophy. Some authorities regard it as of neurotic origin, a trophoneurosis, and still others as consequent upon disease of the accessory sinuses. The constitutional dyscrasia generally present is considered by some a result, by others a cause, of the nasal lesion. Congenital deformities of the nasal fossæ, especially a short antero-posterior diameter, are looked upon as favoring an atrophic process. The discovery of certain bacteria in the secretions of an atrophic rhinitis has led to the adoption of a bacillary theory. Finally, a recent hypothesis is based on the observation that a metamorphosis of columnar into squamous epithelium, or an "epithelial



metaplasia," may exist from infancy or birth. This condition is thought to be an etiological factor in intranasal atrophy, especially in the presence of marked disproportion between the vertical and lateral diameters of the skull, leading to abnormally wide nasal fossæ.

It is clear that no single theory will explain every case and that in some several of the causes, or conditions, mentioned may be concerned. From a clinical standpoint the evidence that hyperplasia tends to promote atrophy is conclusive, a view sustained by microscopic testimony.

In the early stages of many cases of so-called atrophic rhinitis the pathological changes are limited to the mucous membrane and constitute a true fibrosis. Eventually bone involvement may occur. The latter is thought by some to be especially frequent in tubercular and syphilitic subjects.

Malformations of the nasal fossæ, particularly imperfectly developed turbinate bones, and spurs and deviations of the septum are undoubtedly predisposing causes. Atrophy is apt to follow, also, various exanthematous diseases. It is usually met with rather early in life, a fact which has given prominence to the idea that purulent rhinitis is a predisposing cause. The influence of microorganisms is by no means determined; their presence cannot be denied, but it is probably nothing more than a coincidence. The change in the membrane consists in the usual connective tissue overgrowth following chronic inflammatory processes which results in contraction. This so-called submucous cicatricial contraction involves the blood-vessels as well as the glandular elements, the degree of functional disturbance and the prognosis depending upon its extent.

The *diagnosis* of atrophic rhinitis may sometimes be made from the fetid odor alone. On inspection of a nasal fossa affected by atrophy the passages will be found more or less clogged with masses of inspissated secretion the removal of which exposes the membrane, pale in color and obviously thinned. The shrinkage may be universal or limited to certain areas and, on palpation with a probe, it is a simple matter to demonstrate the extent of the atrophied surface. In extreme cases, it is possible on anterior rhinoscopy to see the posterior pharyngeal wall and the action of the palatal muscles is



plainly visible while the patient pronounces a nasal consonant. It is necessary to distinguish genuine atrophic rhinitis from two other conditions which resemble it in some respects. More or less confusion has prevailed and difference of opinion as to the prognosis and treatment has arisen from a failure to differentiate these various conditions. In the first place we should recognize the occasional existence of a *vascular collapse* of the nasal erectile tissue accompanied by dryness of the mucous membrane. This is much more common in anemic persons and in the female sex. There is no characteristic physiognomy such as we see in advanced atrophy. The mucous membrane is pale and retracted on the subjacent bone. The condition usually involves both nostrils. There may be no impairment of the sense of smell. There is no odor perceptible and the secretions are scanty. The condition may disappear under improvement in the general health and requires no attention locally. Secondly, there is a form of rhinitis with diminished mucous secretion, called *rhinitis sicca* which is observed in adults, usually of the male sex, in those of full habit and a gouty tendency. The mucous membrane, instead of being pale, is congested and tends to become hypertrophied. The turbinate bodies may be turgescient. There may be erosions, especially of the septum, possibly accompanied by perforation. Frequently the condition is unilateral, but it is generally seen on both sides. It is not readily curable by local measures alone, but improves under the use of antilithic remedies.

The *symptoms* of atrophic rhinitis relate chiefly to disturbances caused by altered secretion. The mucus loses its fluid, serous character, tends to become rapidly inspissated, and form characteristic crusts or scabs which attach themselves firmly to the mucous membrane and are very difficult to remove. The retention of these crusts is due not only to their character but to the fact that abnormal widening of the nasal passages prevents the blast of expired air from exerting its usual force. The disappearance of the cilia from the epithelium, a constant phenomenon in atrophy, is no doubt an important factor in derangement of secretion. True ulceration of the mucous membrane is rare, but, when it exists, is a result of the habit of picking the nose to dislodge accumulated secretion. Nosebleed may result from violent attempts to clean the passages by blowing.



The patient has a constant feeling of stuffiness and desire to blow the nose even when the accumulated material is not excessive. One of the most distressing symptoms in bad cases is the fetid odor, or *ozena*, a term which is mistakenly applied by some to the disease itself. It should be reserved for the *symptom* of the disease since *ozena* is met with not only in atrophic rhinitis but in syphilis, malignant disease, and in obstruction from a foreign body or from deformity or disease of the nasal fossæ. It is much more pronounced in some cases than in others. If the patient himself has lost the sense of smell it may not be perceptible to him. Fetor seems to be quite independent of the quality and the quantity of secretion, frequently being very marked when the latter is scanty. No doubt in some cases the fetor may be traced to secretions retained in an accessory sinus, but pronounced *ozena* is not unusual when these adjacent cavities are above suspicion. In certain individuals there seems to be some inherent quality in the tissues or secretions whence emanates a peculiar odor analogous to that sometimes observed from the sweat glands. There is seldom any pain although the patient may complain of a dull, heavy sensation over the bridge of the nose and in the frontal region. On the other hand severe headache especially in the forehead may occur. Many patients show rather sluggish mental operations and are very apt to be depressed in spirits. Not infrequently secondary disturbances of the pharynx and larynx occur and gastric derangements are often met with and, sooner or later, distinct impairment of the general health is noticed. The latter fact, in conjunction with an obstinate cough often present, is likely to excite apprehension of lung disease. In well-marked cases a peculiar facial expression, shown in the widely expanded nostrils, snub-nose, the dull countenance and thick lips, is thought to be characteristic.

The *treatment* of atrophic rhinitis has in view two objects; the correction of the fetid odor and the restoration of glandular function. The former is always feasible, the latter is not when the process of degeneration has advanced to an extreme degree. The fact that the disease, if not caused by a constitutional diathesis is certainly aggravated by a depressed state of the general health suggests the necessity of combining local with general treatment. The use of tonics,



attention to hygiene and the correction of digestive derangements are of the greatest importance.

The internal use of mucin, especially with a view to its influence upon secondary derangements of the digestive tract, has recently been urged. It is given in tablets containing five grains each of mucin and bicarbonate of soda. A watery solution is used as a douche to the nose and pharynx. It is said to counteract the dryness of the membranes and to relieve the gastrointestinal disorders which



FIG. 32, a. LEFFERTS' POST-NASAL SYRINGE.

are a frequent consequence of deficiency of normal mucous secretion due to atrophy.

In approaching the question of local treatment we are amazed at the large number of drugs which have been resorted to at various times. The inference is that in general experience the disease has been found rebellious to treatment. So true is this that many practitioners conclude that cleanliness is all that can be accomplished by any

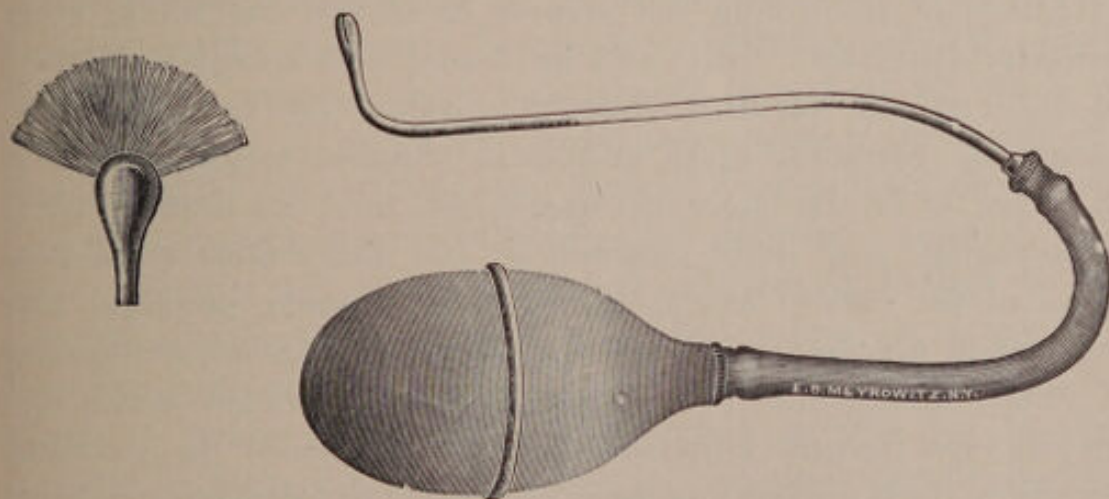


FIG. 32, b. HOLMES' POST-NASAL DOUCHE.

course of treatment whatever. While this may apply to the worst cases of atrophic rhinitis, nevertheless if the process be identified at its inception much may be done. There is no question that thorough cleansing of the surface is important before medication should be



attempted. The removal of the dried secretion is often a very difficult process and cannot be effected by the patient himself, at least, at the outset of treatment. Simple douching of the nose or spraying is only a partial mode of accomplishing the end and must be supplemented by systematic brushing of the surface of the mucous membrane with sterilized cotton wound on the end of a nasal probe. It is a good plan first to soften the secretions thoroughly by means of a coarse spray or douche of normal salt solution as hot as the patient can comfortably bear. In some cases when the crusts invade the nasal pharynx it is necessary to cleanse from behind forward by means of a post-nasal syringe, or Holmes' post-nasal douche (Fig. 32). Having removed all the secretions we are prepared for the application of an agent which will stimulate glandular action provided the glands have not been entirely destroyed. One of the best applications for the purpose in most cases is a solution of menthol in albolene in the proportion of ten grains and upwards to the ounce. Weak solutions are useless. This may be applied twice a day after the use of the salt water. An excellent stimulating application is a solution of formaldehyde, one of the best preparations of which is borolyptol which contains 1 to 500 of formaldehyde. This must be still further diluted since it is very irritating, but it has the double advantage of stimulating the mucous membrane and acting as a powerful deodorant. Citric acid in powder with an equal quantity of sugar of milk has been observed to control the fetor and crust formation. Nitrate of silver, in solution of twenty to sixty grains to the ounce, or even stronger, has been widely used, but seems to offer no advantage over other preparations less disagreeable to handle. Some of the modern compounds of silver, argonin, protargol and argentamin, may be destined to find a permanent place in therapeutics. Hydrogen dioxid finds favor with many practitioners and among the preparations recently introduced may be mentioned the so-called peroxoles, three per cent. solutions of peroxid of hydrogen combined with menthol, camphor, naphthol, and so on, and known respectively as menthoxol, camphoroxol and naphthoxol. They seem to have been used with good results in a great variety of conditions attended by suppuration with the effect of prolonging the well-known bactericidal action of the hydrogen. The characteristic effervescence



and foaming soon subside and the application is said to be entirely free from irritating properties when used of suitable strength. Tampons of gauze soaked in a ten or fifteen per cent. solution packed in the nostril and renewed once or twice in twenty-four hours will lessen crust-formation and ozena. A combination of equal parts of menthoxol, camphoroxol and sterilized water acts very well.

An ideal antiseptic, if all that is claimed for it be true, is offered in gomenol, a vegetable product said to possess extraordinary germicidal power while being free from irritating properties. It is the ethereal oil of *melaleuca viridiflora*, a plant growing near Gomen in New Caledonia. A ten per cent. solution in olive oil, to which a few drops of oil of pine, or oil of wintergreen, have been added, is an agreeable and effective application. One of the best preparations, provided its odor is not objectionable, is ichthyol, which may be used in a five per cent. solution in kerolin or, as preferred by many, in much stronger solution, or even in a pure state over a limited area. Its unpleasant odor is sometimes a bar to its use as regards others if not so far as the patient is concerned. When a deformity or stenosis interferes with nasal drainage or forms a site for the lodgment of secretion it should be removed; otherwise no intra-nasal operation is advisable. Superficial erosions usually undergo repair without special attention as the secretions and the membranes acquire a more healthy character. In some cases a dilated naris, due to deviation of the septum, admits an excessive volume of air which may be reduced by wearing a film of absorbent cotton in the nostril or by replacing the deflected septum. Some of these patients are persistent mouth-breathers, although the nares are sufficiently spacious. They complain that they cannot feel the air in breathing through the nose, a state of things due to anesthesia of the mucosa, or merely to excessive width of the passages. The idea of making an artificial turbinate by means of submucous injections of paraffin has been suggested by Richard Lake. In a case of bone absorption the abnormal width of the nasal canal was counteracted by bolstering up the soft parts with five-minim injections of paraffin made at weekly intervals until a body of proper size was formed. The relief of discomfort was complete. A similar proposal has been made by Brindel, who claims to have observed a disappearance of the tendency to stagna-



tion and drying of secretion and an actual restoration of normal glandular function.

The great interest in serum therapy naturally excited the hope that something might be accomplished in that line in atrophic rhinitis. Experiments have been made by different observers and there is wide divergence of opinion as to the results. Some claim to have cured advanced cases by the repeated injection of ten centimeters of Roux's diphtheria antitoxin. Others pronounce this dose excessive and allege that the treatment is dangerous and inconvenient although it gives positive results in the disappearance of dryness and crust formation with the relief of ozena. This is not likely to supersede safer and equally efficacious modes of treatment.

In addition to the medicinal agents already mentioned for treating atrophic rhinitis we have at command various resources more or less serviceable. Nasal bougies, medicated or otherwise, have been used. Plugs or tampons of cotton have been recommended with the idea of partially obstructing the nasal passages for the purpose of reducing barometric pressure. The result is more or less congestion of the mucous membrane with increased functional activity. The method of Gottstein consists in packing the nasal fossæ with dry non-absorbent wool which is renewed at the end of twenty-four hours. Thus a tendency to crust-formation is corrected, a more healthy action of the glands is established and the mucous secretion becomes more fluid.

Another method of dealing with certain cases in which there are localized areas of diseased tissue consists in the use of the sharp curette. This is adapted only to very limited areas of eroded granular mucous membrane underlying tenacious crusts or scabs of decomposing secretion. It must be used with caution, since, as already said, our efforts should be directed mainly to the preservation and restoration of tissue. Electrical treatment of atrophic rhinitis is applied in the form of the galvano-cautery in cases similar to those in which the curette is admissible; second, by the constant or interrupted current; and, third, by electrolysis. Their effect with the exception of that first named consists in stimulation of glandular function and is effective in cases not too far advanced. These methods are tedious and require frequent repetition and special apparatus. The use of



galvanism gives excellent results in suitable cases, that is, those in which the glands have not been completely obliterated by the atrophic process. A flat sponge electrode connected with the positive pole of a constant current battery is applied to the nape of the neck. The negative pole, a metallic electrode, is placed in direct contact with the mucous membrane of the nose. It is rather more agreeable to the patient to use in the nose a copper wire electrode loosely wound with absorbent cotton. If both nostrils are to be treated the nasal attachment may be double, a section for each nostril, as suggested by Delavan. The strength of the current should not exceed seven milliampères and the duration of each sitting should not be more than twelve minutes. The patient feels a sensation of warmth but no pain, unless the current is too strong. A slight watery secretion is excited by the application and in course of time the quality of the nasal mucus is perceptibly improved.

Cupric electrolysis is warmly commended by some observers. Strong currents are very painful and a general anesthetic may be required. Watson Williams, who claims better results with this than with any other method of treatment, prefers mild currents at intervals of two or three weeks until increased secretion and vascularity and diminished fetor are noted. The parts having been cocaineized "a copper needle attached to the positive pole is inserted into the tissues of the inferior or middle turbinated body, and a steel needle, attached to the negative pole, into the septum, and a current of from five to ten milliampères is passed from ten to fifteen minutes." This process should be repeated until the symptoms yield and on signs of recurrence. The results of vibratory massage are not especially encouraging and the proposal of Flatau to excite tissue proliferation and increased secretion by driving ivory pins into the turbinate bone will hardly appeal to a large number.

Spontaneous recovery sometimes takes place, that is the symptoms cease although normal tissues may not be regenerated. In adolescents approaching puberty and in women at the menopause amelioration follows when these critical periods have been passed. Whatever course of treatment be selected in a case of atrophic rhinitis pronounced results must not be expected in weeks or even months. The secret of success lies in the early adoption of a systematic régime



which includes both local and general medication and which must be continued with persistence.

### MEMBRANOUS RHINITIS.

An inflammation of the nasal mucosa characterized by the formation of a membranous or fibrinous exudate is occasionally seen in which the membrane shows no tendency to invade the pharynx and which is not attended by any indications of constitutional disturbance. The condition differs from diphtheria in being a much milder type of disease as regards local as well as general disturbance. There may be some rise of temperature and a good deal of nasal stenosis but there is no sign of sepsis and the disease is not contagious. It differs from diphtheria, also, in that glandular involvement is rare, the diphtheritic odor is absent and the Klebs-Loeffler bacilli seldom can be found. The membrane is easily removed and generally reforms. Similar conditions are seen after the use of strong caustics in the nose and after the galvanocautery especially in those depressed in health and ill nourished. The importance of the diphtheria bacillus in membranous inflammations is opened to question by the discovery by Meyer of large numbers of virulent bacilli in membrane formed after the use of the galvanocautery as well as in a majority of cases of fibrinous rhinitis. In a great variety of nasal diseases examined by Vansant the mucous secretion showed the presence of the diphtheria bacillus in a large percentage. Pluder believes that fibrinous rhinitis is really a mild form of diphtheria, having found the bacillus in all of five cases examined microscopically. Either the Klebs-Loeffler bacillus is of no consequence, or else there exist "true" and "false" bacilli which even expert microscopists differentiate with difficulty. Unless the possibility of infection be conceded the condition cannot be regarded as very important and active interference is not indicated. In some cases general tonics may be desirable and the comfort of the patient may be increased by gentle removal of the membrane and applications of antiseptics and mild astringents in oily solution.



## CASEOUS RHINITIS.

The name caseous rhinitis is given to a rare and curious form of inflammation in which the nasal passages are occupied by a material resembling cheese or putty. It is said by some to develop in strumous individuals and in connection with nasal polypi. It would seem to be a result of fatty degeneration of secretion which has been long retained either in an accessory sinus or in the upper part of the nasal fossæ. A prominent symptom is a sensation of stuffiness in the nose accompanied by headache. The sense of smell is usually lost and the fetor always present is not apparent to the patient. This state of things may be corrected by careful attention to cleanliness, the cheesy mass being thoroughly removed and the nasal cavities afterwards sprayed with antiseptic solutions. At the same time the morbid condition which gives rise to the perverted secretion must be found and eradicated. In a recent case in my own clinic an intolerably offensive mass of cheesy accumulation was removed from the nose of a fairly intelligent man whose only complaint was of headache and nasal stenosis. Such a condition could result only from the grossest neglect. This disease must not be confounded with a false *rhinitis caseosa*. The latter is always dependent upon a foreign body, a rhinolith, a tumor, or a chronic sinusitis, while in the true no such cause can be found. Its dependence upon a specific microbe, the *Streptothrix alba*, as described by Guarnaccia, and its relation to scrofula, as maintained by Cozzolino and others have recently been stoutly denied by Michele. Its rarity, the rapidity of its cure, the absence of recurrence, a single case having been reported by Massei, added to the fact that the disease is practically unilateral would seem to exclude a scrofulous origin. According to Michele no specific microbe can be found, hence if we accept this observer's views we shall still be in the dark as to the etiology of the disease.

## PURULENT RHINITIS.

Purulent rhinitis is a variety of catarrhal inflammation of the mucous membrane in which pus formation is the prominent symptom. It is not intended to include in the term that form of rhinitis

which occurs as a *specific* infectious disease transmitted to the newborn from the vagina of the mother. It occurs, as a rule, in infants as a result of exposure to irritants, either in the air or in the secretions of the maternal passages. The nasal discharge is very irritating and produces excoriation of the upper lip, and both nostrils are usually affected. There may be but little obstruction to nasal breathing. The secretion is more or less odorous, especially if the nostrils are not faithfully cleansed. A mucous membrane affected in this way is apt to be permanently impaired. By some observers this condition is believed to be an invariable precursor of atrophy.

The treatment consists in careful cleansing of the nasal passages by an alkaline antiseptic solution, followed by an application of mild astringents. In many cases, indications of struma or constitutional impairment demand general as well as local treatment.

A purulent nasal discharge in a child may be symptomatic of adenoids in the rhinopharynx. It may occur in syphilis or as a result of gonorrheal infection; in the former case the usual constitutional treatment is indicated, and in the latter precautions must be taken to prevent contagion, and to protect the eyes.



## CHAPTER IV.

### DISEASES OF THE ACCESSORY SINUSES. ACUTE AND CHRONIC SINUSITIS. HYDROPS ANTRI, OR SEROUS EFFUSION AND CYST OF THE ANTRUM. FOREIGN BODIES AND NEOPLASMS.

The accessory sinuses when inflamed present certain features in common which may be considered before discussing individual cavities.

*Acute* sinusitis may occur in connection with a "cold-in-the-head" either as a result of direct infection or of swelling of the nasal mucous membrane which causes a damming up of secretion. It is met with in the course of the exanthemata, of typhoid, diphtheria and erysipelas, and has been particularly observed as a complication or sequel of influenza. Acute inflammation of the sinuses may, also, follow traumatism and many cases are on record in which a foreign body has been driven into the frontal or maxillary sinus with the result of causing an acute empyema. The sphenoidal sinus and the ethmoid cells are less exposed to injury but similar cases have been reported in connection with these cavities. A blow on the face has been known to cause inflammation of the antrum and a case has been recorded by Rees in which empyema of the antrum in a child two weeks old resulted from compression of the head at birth. A tendency to spontaneous cure of an acute process undoubtedly prevails in the absence of any lesion or anatomical peculiarity which may act as an obstacle to evacuation of the products of inflammation.

A symptom invariably present in acute sinusitis is pain, as a rule referred to the region of the affected cavity and accompanied in the case of the frontal and the maxillary sinus by sensitiveness on external pressure, and by swelling and possibly edema of the overlying soft parts.

A *chronic* sinusitis may follow an acute attack, or may be characterized by the absence of acute symptoms from the outset. The pain associated with chronic sinusitis is seldom intense and its situation is often of but little diagnostic value. For example, supra-orbital



pain may be a symptom of antral rather than frontal sinus disease. In ethmoidal disease the pain is usually referred to the bridge of the nose, while in sphenoidal disease the back of the head is chiefly affected. A unilateral discharge of pus in the adult is always suggestive of sinus disease although bilateral sinusitis is by no means uncommon, having been found by Wertheim in 38.7 per cent. of cases of maxillary empyema. As a rule, the discharge is intermittent and is affected by change of posture; in other words a position that makes the outlet of the sinus more dependent facilitates drainage. A peculiar musty odor is generally present which may be perceptible to the patient himself. This is more marked in antral and ethmoidal disease than in empyema of the frontal sinus. The location of the pus is to some extent a guide as to its origin. Its color also is more or less distinctive, that from the antrum being light yellow or canary colored. It is probable that the variation in the physical characters of the purulent secretion in different cases is to be explained in part by the great variety of microorganisms found in these conditions. The subject has been carefully investigated by Stanculeanu and Baup, whose conclusions are interesting and may be of value with reference to determining the origin of a sinus empyema. Antral suppurations are divided into two groups. In the first there is an antecedent history of dental or alveolar disease and the pus has a decided fetor, due to the presence of *anaërobic* bacteria, or those whose growth is not dependent upon oxygen. The second group comprises those believed to be of nasal origin, the sinusitis followed an acute rhinitis, the teeth are sound and the secretion is mucopurulent and ropy. The pus is not fetid and is found to contain *aërobic* organisms, or those which grow only in the presence of oxygen. Further examination shows that microbes of the former kind inhabit the buccal cavity and are rarely found in the nose. The *aërobic* variety is met with in the nasal cavity and the purulent secretion it excites is more mucoid in character and is quite free from fetor. The pneumococcus either alone, or more frequently together with other microbes, is the organism most often found in the latter. In dental empyemas various bacilli may be discovered—*ramosus*, *perfringens*, *serpens*, *thetoïdes* and *fragilis* and *Staphylococcus parvulus* in order of frequency—all exhibiting marked virulence when injected into animals. Similar re-



sults were obtained in investigating the frontal sinus. In one case both forms of bacteria were found, the frontal sinusitis being consecutive to an antral empyema of dental origin.

In cases of nasal suppuration in which sinus disease is suspected, the nostril having first been thoroughly cleansed of secretion, it is sometimes possible to detect a leakage of pus from the middle meatus under the concavity of the turbinate body, from which fact we infer an affection of either the maxillary sinus, the frontal sinus,

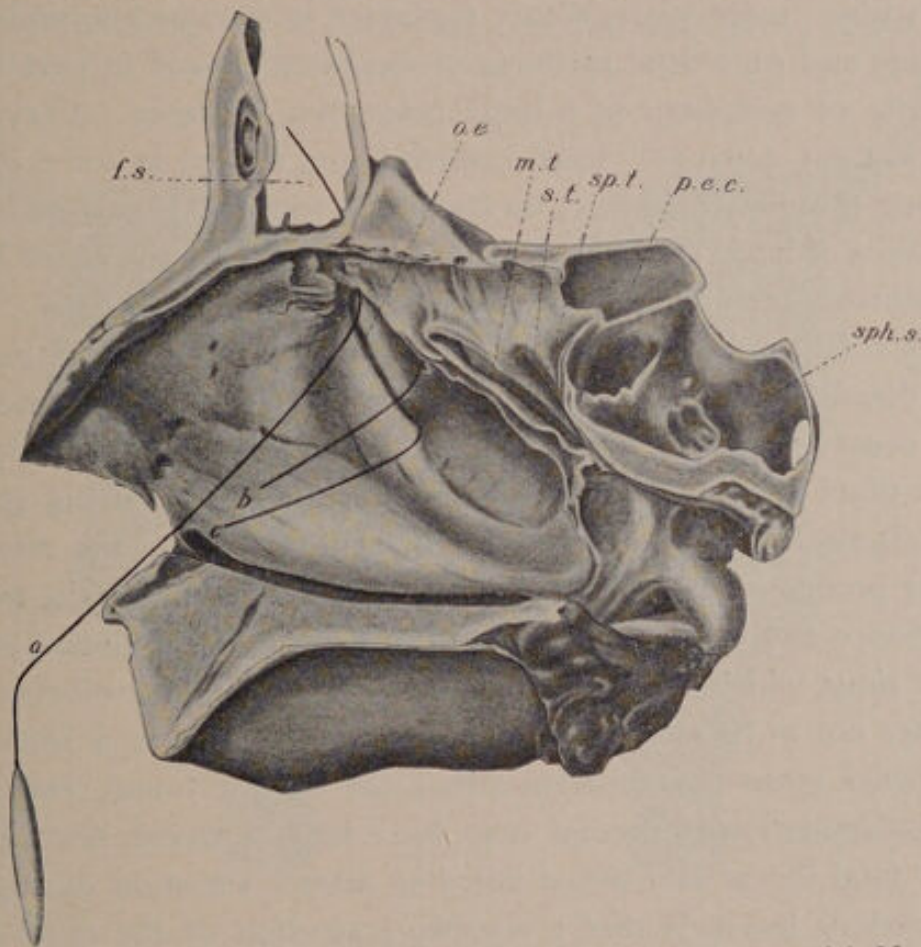


FIG. 33. SOUND IN (a) FRONTAL, (b) ANTERIOR ETHMOIDAL AND (c) MAXILLARY OPENINGS. (Hajek.)

*f.s.*, Frontal sinus; *o.e.*, ostium ethmoidale; *m.t.*, middle turbinate cut off; *s.t.*, superior turbinate; *sp.t.*, supreme turbinate; *p.e.c.*, posterior ethmoidal cells; *sph.s.*, sphenoidal sinus.

or the anterior ethmoidal cells. If pus is seen over the convexity of the middle turbinate, or between it and the septum, it is probably flowing from the posterior ethmoidal cells or the sphenoidal sinus. Escape of pus from the antrum may be encouraged by directing the patient to throw the head well forward and towards the sound side.



When the patient lies down the pus flows backward and causes a bad taste in the mouth with gastric disturbance and morning nausea. The existence of polypi in the region of the middle meatus is apt to complicate an empyema of the antrum, or of the frontal sinus, or of the ethmoidal cells, whether as cause or result is often hard to determine (Fig. 33).

There seems to be no doubt that the accessory sinuses are affected by an inflammatory process much more often than has been supposed until within recent years, a fact explained in part by the prevalence of crude and superficial methods of examination and in part by the obscurity of symptoms in a large proportion of cases. Very many cases are put down as "nasal catarrh," and indeed in some of long standing those affected have no complaint to make except of moderate excess of nasal discharge. This statement is corroborated by the post-mortem researches of E. Fraenkel, Harke and others. From studies conducted at Lichtwitz's clinic, where 243 cases of sinusitis were diagnosed in 12,000 patients, and from results announced by other observers, F. Martin concludes that indications of sinusitis are fifteen times more frequent in the cadaver than in the living subject. This discrepancy is accounted for in acute cases by the relatively greater prominence during life of symptoms referable to the general disturbance and in chronic cases to the latency of symptoms located in the sinus which renders a diagnosis difficult. Post-mortem records are not to be altogether relied upon, since pus in a sinus does not always mean inflammation where the fluid is found, and moreover inflammation if present may have been a recent development in the fatal illness and hence failed to attract attention during life. The obvious lesson is that a cursory inspection of the nasal fossæ should not end the examination of a case of nasal suppuration.

### THE MAXILLARY SINUS.

The antrum of Highmore, being the largest and most accessible of the sinuses, was supposed to be especially prone to suppuration until more exact and thorough methods of exploration taught us that the other adjacent cavities, notably the ethmoid cells, are involved with equal or greater frequency (Fig. 34).



An *acute* inflammation of the antrum tends to resolve under favorable conditions, that is, provided drainage through its normal outlet be adequate. The orifice of this cavity being much higher than its floor, when the patient is erect, and liable to occlusion from swelling of the soft parts in its vicinity, an acute process is apt to degenerate into a chronic empyema. Acute maxillary sinusitis is said to be more frequent in men than in women. It may occur quite early in life. J. H. Bryan quotes Pedley as authority for a case in a child eight years old following caries of a canine tooth, and Shurly refers to a

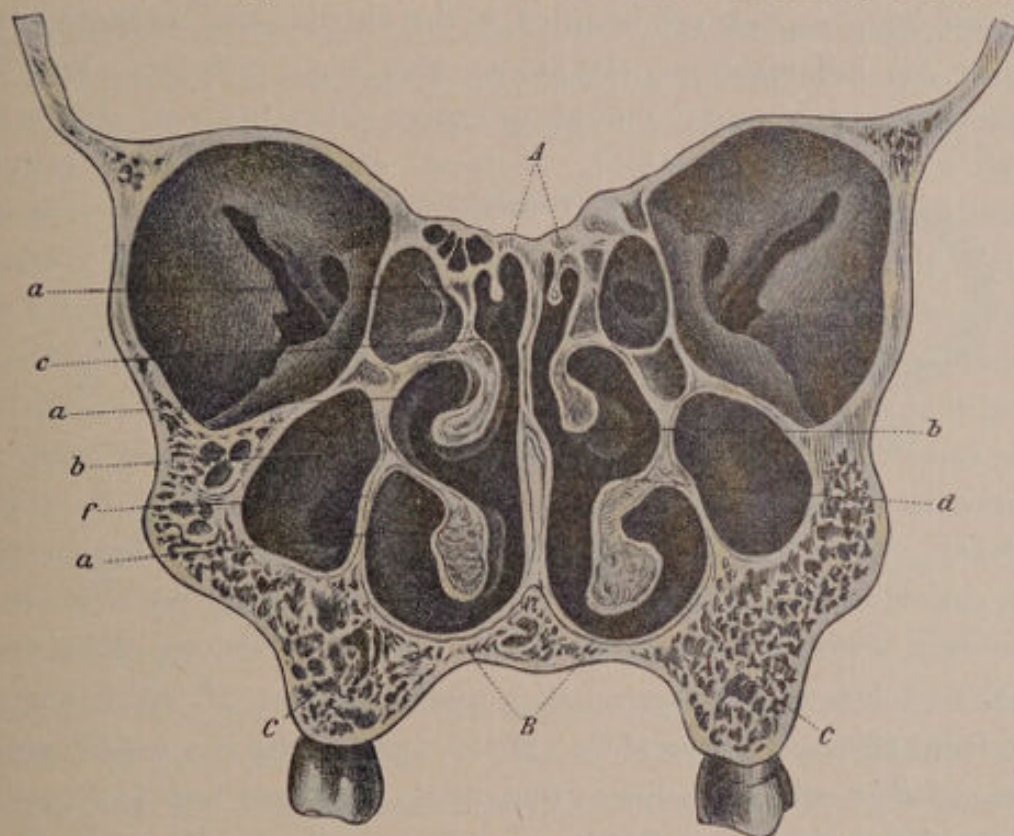


FIG. 34. VERTICAL CROSS SECTION THROUGH POSTERIOR PART OF NASAL FOSSÆ SHOWING THEIR RELATIONS TO ADJACENT PARTS. (Zuckerhandl.)

*A*, Roof; *B*, floor, and *f* outer wall of cavity; *aaa*, superior, middle and inferior meati; *b*, middle turbinate bone; *c*, olfactory fissure, and *d*, respiratory fissure.

case noted by Power in a child eight weeks old due to traumatism by forceps during delivery, while Moure reports two cases in infants three weeks old from premature eruption of a tooth, one of the children being syphilitic. Bryan also describes an extension of nasal diphtheria and of phlegmonous pharyngitis to the antrum. When



the inflammatory products are pent up within the cavity the symptoms are so intense as to leave no doubt about the diagnosis, and explorative puncture is never necessary. In treatment the indications are to subdue local reaction by warm applications externally and to promote drainage by reduction of swelling in the middle meatus. Cocaine, adrenal extract and sprays of menthol usually give relief. In exceptional cases the ostium must be enlarged, the middle turbinate removed, or puncture through the inferior meatus or the canine fossa must be done. In a small proportion of cases the products of an acute inflammation are retained in the antrum and undergo caseation. All inflammatory symptoms may have subsided, but the decomposing pus emits a most offensive odor the real source of which may not be suspected. Removal of the inspissated pus by irrigation through the normal outlet or by an artificial opening dispels the fetor (Avellis). In looking for a cause of *chronic* empyema of the maxillary sinus it is necessary to make a careful examination both of the teeth and of the nasal chambers. It is still supposed that most of these cases may be traced to dental caries, but we have come to believe that a very large proportion owe their origin to a catarrhal inflammation affecting the middle turbinate and its neighborhood. Nevertheless, a tooth apparently sound at its crown may be a source of mischief from a carious process going on at its root. Moreover, septic infection may be conveyed by the lymphatics from a point of decay in the crown of a tooth, the root of which may be free from disease (Grünwald). M. H. Cryer, who has made careful study of this subject, believes that more teeth are lost from antral disease than primarily cause it, an opinion fully confirmed by E. S. Talbot, whose investigations have been exceptionally thorough and extensive. In other words, it is often necessary to seek a cause of antral empyema elsewhere than in the alveolus. It is sometimes possible on anterior rhinoscopy to distinguish well-marked bulging toward the nasal fossa of the outer wall of the nose. There is likely to be some swelling of the face on the affected side together with sensitiveness on pressure or percussion. It has been claimed that dulness on percussion may detect a diseased sinus and succussion has been mentioned as a diagnostic sign, but it must require an exceptionally keen ear to gain any data of value from either. In some



cases, especially those of dental origin, the alveolus on the affected side is swollen, congested and sensitive to pressure. If any doubt remains as to diagnosis we may resort to exploratory puncture with a trocar, either through the inferior meatus, or the canine fossa. In the latter case an ordinary small-sized trocar and in the former the curved antrum trocar designed by Myles will be found convenient. This should be done with the strictest antiseptic precautions, lest a sound antrum be thereby infected (Fig. 35). Hydrogen dioxid injected into the antral cavity through the ostium as proposed by Moreau Brown, is relied upon to give its characteristic effervescence in the presence of pus, but should be used cautiously, since the rapid evolution of gas may produce painful distension. Pus may some-

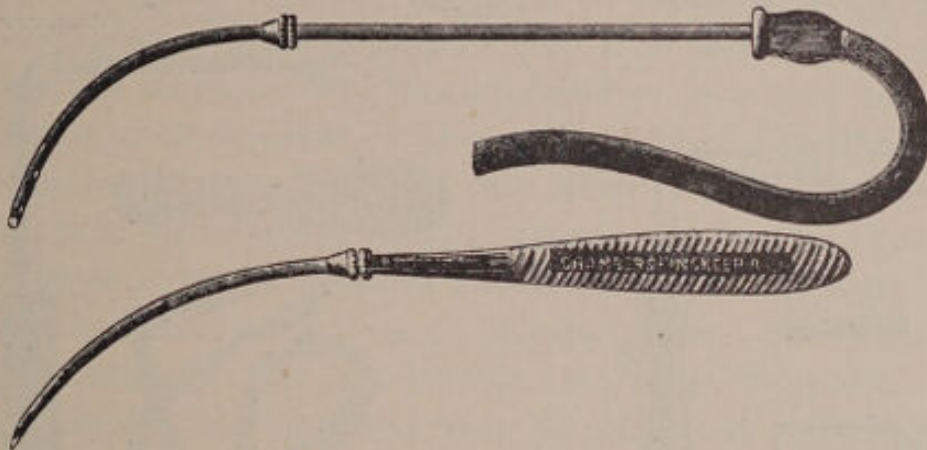


FIG. 35. MYLES' ANTRUM TROCAR, CANULA AND WASHING TUBE.

times be seen oozing from the antrum alongside a probe or canula passed through the ostium. With a Politzer bag attached to the canula, or air douche, one sometimes succeeds in expelling small quantities of pus that cannot be washed out by any process of irrigation. Secretion may sometimes be sucked out of an affected sinus by the process known as "negative politzerization" as recommended by Sestier. The diagnosis may be further confirmed by transillumination of the sinus by means of an electric lamp placed in the mouth (Fig. 36). This test is more satisfactory in a room from which all other light is excluded. Illumination of the face beneath the orbits is thought by Davidsohn to be less conclusive than that of the eyes, which are usually bright in a normal skull with a clear antrum. Exploratory puncture sometimes fails, owing to extreme density of the antral wall, which the trocar cannot penetrate, or to thickness of



the pus whereby it is prevented from flowing through the canula. Transillumination demonstrates the presence of pus reliably, provided we eliminate certain sources of error, but under no circumstances should its exclusive testimony be accepted as final. By examination with the fluorescent screen even more exact information may be gained than with the ordinary electric light in transillumination, but for this special expensive appliances are required. The investigations of Zuckerkandl and others have shown that variations

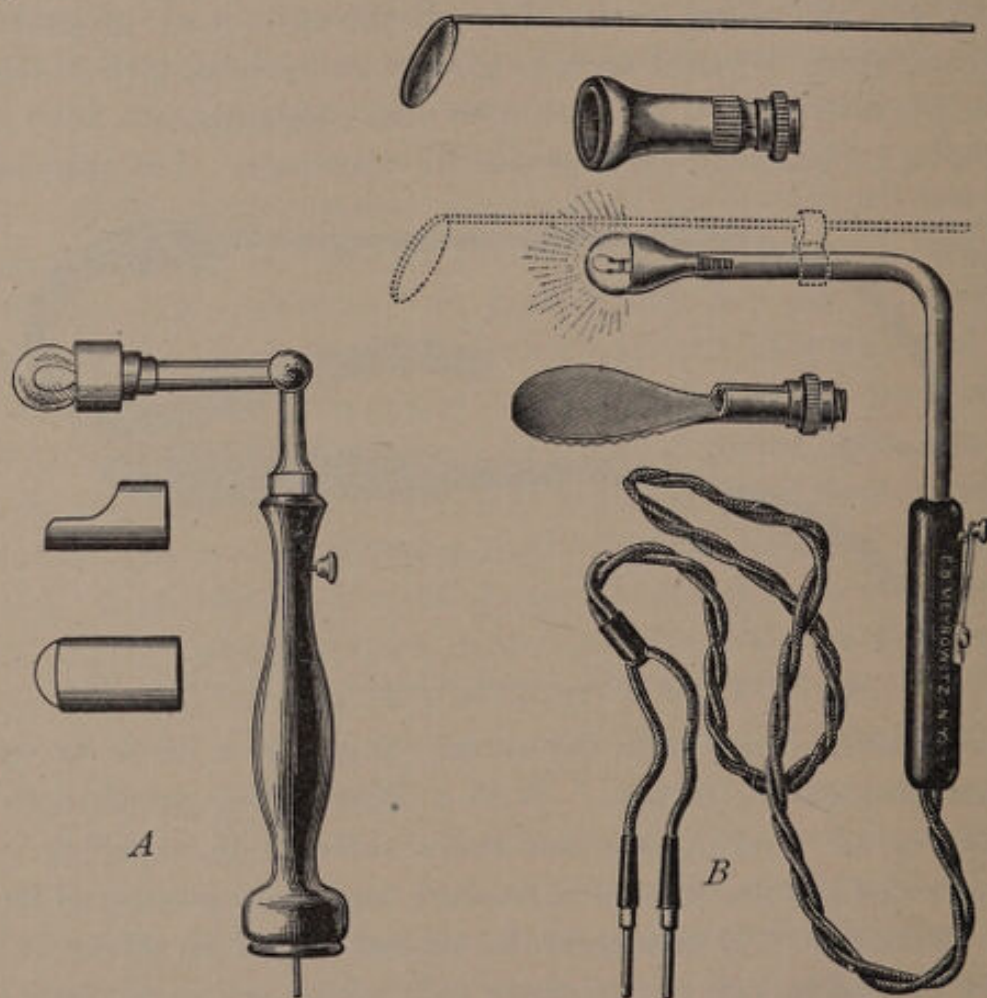


FIG. 36. *A*, HERYNG'S LAMPS FOR TRANSILLUMINATION; *B*, MEYROWITZ' ELECTRIC LAMPS.

from the normal anatomical type are so frequent that we are liable to be led astray by certain abnormalities in the structure of the skull which alter the relations and dimensions of the sinuses. The remarkable diversity in the size of the antrum in different individuals is shown by the observations of Cattlin, quoted by Heath. It is larger in the male than in the female, it contracts in old age, while in very



young subjects it is extremely small or may be entirely absent. He also notes the fact that subdivisions of the cavity by bony ridges and that extensions of the antrum into the malar bone, the alveolus, or posteriorly are far from infrequent. Perfect symmetry is practically unknown. It is easily seen, therefore, how the accuracy of the light test may be impaired. For instance, a relatively small antrum may transmit a deficient amount of light, as compared with the opposite side. A thickened lining membrane and anomalies in the bony wall of the antrum may interfere with this test. The larger the antrum and the thinner its wall the more brilliant will be the light test. Mucocoele and cyst of the antrum are said to exaggerate the intensity of the light. In a case of the latter under my own observation this phenomenon was obvious in consequence of expansion of the antral cavity and attenuation of its anterior wall from pressure. Until the light test was employed this was supposed to be a solid tumor in consequence of its firmness on palpation. Dentary cysts become of special interest to the rhinologist only when they invade the nasal fossa, or, as in the foregoing case, the antrum. Unless the cystic formation begins at the very root of a tooth the swelling is more likely to present itself along the alveolus, obliterating the canine fossa and finally distending the jaw and perhaps the roof of the mouth. The contents, usually thin and clear, may be reddish or coffee-colored, rarely resembling pus (F. C. Cobb). In the latter case, or if there is much inflammatory thickening of surrounding tissues, the light test may show more brilliancy on the sound side. The persistence of translucency in the presence of polypi is illustrated in a case recently reported, in which the antral cavity was filled with ordinary mucous polypi (Lambert Lack). In addition to the extent of the light area in the antral region, normally most intense just beneath the margin of the orbit, we may get more or less reliable information from the appearance of the pupils and from the presence or absence of perception of the flash of light on the part of the patient when his eyes are closed. In a large proportion of cases in which there is no antral anomaly the pupils are brightly illuminated and the patient is conscious of a flash when the current is passed intermittently. Having several times seen the light test frustrated by failure to remove a superior dental plate it seems to me not superfluous to call attention



to the necessity of this precaution. The following instructive case from my clinic at the Manhattan Eye and Ear Hospital exemplifies an error into which we may be led even after the use of every diagnostic resource.

A young man was admitted with a fluctuating tumor about the size of a hickory nut at the root of the left lateral incisor of the upper jaw. It had been in existence two months and was quite painless and insensitive. There was no history of nasal suppuration. Two years ago the jaw was injured by a fall in skating, and a carious tooth was subsequently extracted. Transillumination showed both sides of the face equally bright. With an exploring needle passed through the alveolus creamy pus was withdrawn, and on free incision the abscess appeared to communicate with the antrum. In fact the case was pronounced by several an empyema of the antrum. But on more careful examination it was possible to demonstrate that a cavity existed above this abscess and was separated from it by a firm bony wall, as proved by exploration with the probe and finger. The case was one of suppurating dentary cyst, a diagnosis further confirmed by the absence of symptoms pointing to the antrum as well as of pus discharge from the nasal passages. The abscess cavity slowly filled with granulation tissue and became obliterated, but it is easy to see how the antrum might have become infected as a result of excessive surgical zeal.

The use of the tuning fork in differentiating a diseased from a healthy antrum has recently been proposed by D. A. Kuyk, but its practical value remains to be determined. The sound waves are said to be transmitted feebly if it all through a sinus occupied by fluid, being heard louder and longer through an empty antrum, even though of small size and enclosed by thick walls.

It has been suggested that the source of a nasal suppuration may be determined by plugging the orifices of the sinuses in succession by means of cotton or gauze and then observing when the flow is controlled (Grünwald). In view of the difficulty in locating the anatomical outlets of the various sinuses and of the frequent anomalies in their situation this procedure is not of very practical value.

The fact must not be overlooked that even if pus is present in the antrum it may not have been generated there, since it has been proven



that this cavity may act as a reservoir for pus formed in the frontal sinus or anterior ethmoidal cells. Examination is not complete until we have explored the other accessory cavities for the possible existence of suppuration in them. J. H. Bryan has described an example of direct communication of the frontal with the maxillary sinus, so that pus secreted in the former must inevitably have accumulated in the latter. He also quotes Fillebrown as having observed many cases in which the infundibulum ended below in a pocket so situated in front of the ostium maxillare as to direct a flow of pus from the frontal sinus into the antrum, the discharge not appearing in the nasal passage until the antrum and the abnormal infundibular pocket became filled. Probably some of the cases of "latent empyema" reported by Lichtwitz, Jeanty and others, remarkable for the absence of subjective symptoms, may be explained by the existence of this anomaly. Obviously a diagnosis of suppuration originating in the maxillary antrum should not be hastily assumed.

The diagnostic features upon which we rely when present offer an unmistakable picture. Some or all of them may be so feebly pronounced as to justify the term "latent empyema."

The following may be enumerated as the most trustworthy signs of chronic abscess of the antrum:

1. Nasal suppuration. Pus may be seen flowing from the middle meatus and it is sometimes possible to exclude the ethmoid cells and the frontal sinus as sources of the discharge.

2. Pain, dull aching, or merely a feeling of tension in the antral region with more or less prominence of the face over the antrum and bulging inward of the wall of the nasal fossa.

3. Swelling, redness and sensitiveness on pressure along the alveolus on the affected side. Carious, sensitive teeth may be found.

4. Transillumination shows the suspected side in shadow, the pupil of the corresponding side is dark, and the patient himself sees less clearly or fails to see the flash of light with the eye of that side.

5. Pus may be withdrawn from the cavity of the antrum by means of an aspirating trocar passed through the ostium, the canine fossa, or the inferior nasal meatus.

In many cases of chronic sinusitis the mental depression and gen-



eral disturbance are out of all proportion to the activity of the process going on within the antrum. Patients often complain of neuralgia, ill-defined headaches and lack of mental concentration which are almost incapacitating. It may be possible to explain such conditions by supposing an impression upon the nerve centers from more or less absorption of suppurative products. At any rate it is usual to observe improvement in these particulars after free exit has been given to the discharge and pus formation begins to subside.

The *treatment* of chronic empyema of the antrum must be conducted on general surgical principles; namely, the abscess must be thoroughly evacuated and cleansed of all diseased material. A carious tooth may protrude into the cavity, polypoid degeneration of the lining membrane, or necrosis of the bony wall may each be present and share in perpetuating the suppurative process. Disease involving the ostium maxillare, either deflection of the septum, nasal polypi, or enlargement of the middle turbinate in such a way as to interfere with drainage, must receive attention. A carious molar or



FIG. 37. MYLES' ANTRUM TUBES OF SOFT RUBBER.

bicuspid tooth should be extracted and the antral cavity entered along its socket. At the same time care should be taken to ensure a free opening of the anatomical outlet into the nose so as to give perfect through drainage. Sound teeth should never be sacrificed, but an opening may be made into the antrum through the canine fossa sufficiently large to admit a curette or even the finger for purpose of exploration. When the antrum is entered through the socket of a tooth or through a small alveolar opening it is customary to introduce a tube of soft rubber, vulcanite or silver (Fig. 37), through which the cavity may be drained and irrigated. Its outer aperture is usually provided with a plug for use during eating. The anterior end of the middle turbinate, if enlarged and obstructing the middle meatus, should be removed with a snare or forceps.

Objection is sometimes made to opening the antrum through the



mouth on the ground of danger of reinfection of the sinus from the buccal cavity. To obviate this the antrum may be entered by plunging a curved trocar, or the spear-pointed "stilet" of Mikulicz (Fig. 38), through the outer wall of the nasal fossa in the inferior meatus. Thus an aperture is made quite near the floor of the cavity. Sometimes the bone is so thick and dense as to be pierced with difficulty,



FIG. 38. MIKULICZ' ANTRUM STILET.

and, moreover, unless a considerable portion of the wall of the meatus is removed it is often impossible to keep the opening free. The most serious argument against this method is that it gives us no opportunity to explore the interior of the antrum and after all a more radical operation may be required to effect a cure. While subsequent free exposure of the cavity through the alveolus, or the canine fossa is by no means precluded by previous puncture through the inferior meatus it is believed that cases cured by the latter route alone might have been relieved by way of the ostium maxillare.

In a small proportion of cases of empyema of the antrum the

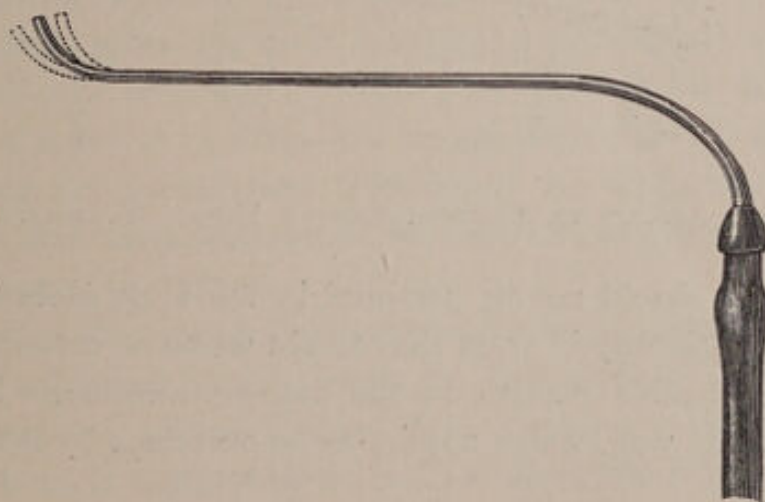


FIG. 39. HARTMANN'S CANULA.

cavity can be entered and washed out through the natural opening. For this purpose a canula shaped somewhat like an Eustachian catheter, fitted with an ordinary piston syringe or rubber bulb, will be found convenient (Fig. 39). In seeking the opening in the antrum the canula should be introduced with the beak directed



towards the concavity of the middle turbinate and passed well back into the middle meatus. It is then turned outward and drawn forward until its tip catches in the uncinate process, when by firm pressure upward and outward we sometimes succeed in entering the antral cavity. It may be necessary to remove the tip of the turbinate, or to correct a septal deformity, in order to introduce the canula (Fig. 40).

The solution used for cleansing the cavity should be bland and unirritating. A warm two per cent. boric acid or normal salt solution answers as well as any. An attempt to cure antral empyema

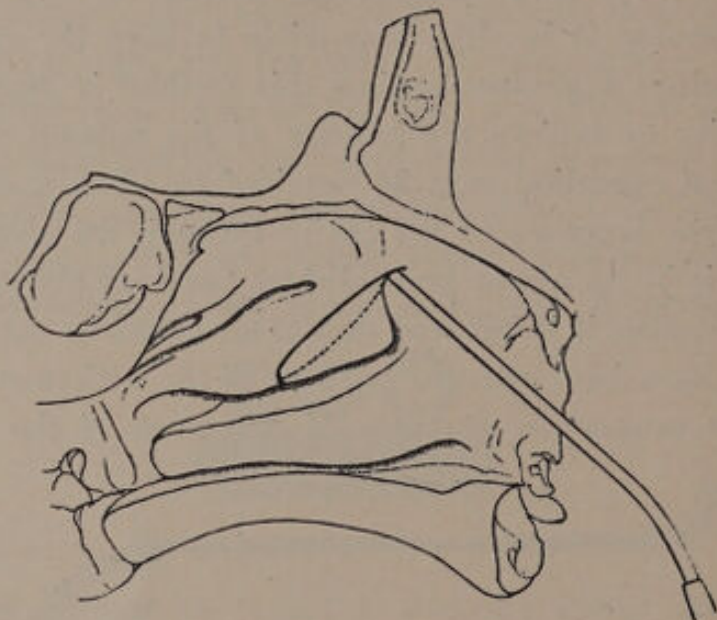


FIG. 40. SNARE APPLIED TO ANTERIOR END OF MIDDLE TURBINATE. (*Hajek.*)

by this means should not be persisted in too long, since failure to give relief in this way in from four to six weeks is certainly indicative of degenerative changes in the mucous membrane lining the antrum or of its wall, which require to be overcome by more radical methods.

The following case illustrates how a sinusitis may be kept up by retention of a foreign body in the cavity of a sinus. The patient was a lady about thirty years of age who had had a molar tooth extracted. Immediately after the operation the fluid used to cleanse the mouth was observed to escape from the right nostril, indicating that the tooth had perforated the floor of the antrum. The aper-



ture in the alveolus closed in a few days and an offensive purulent discharge from the nose appeared. About one year later the antrum was drilled through the canine fossa and irrigation practiced for some weeks. The discharge ceased but recurred and the washings were resumed. The patient then went on very comfortably for a period of five years when she became rather run down in health, had frequent attacks of cold in the head and was, most of the time, conscious of an offensive odor in the nose. She suffered more or less from hemicrania and a dull aching sensation in the region of the antrum. The anterior end of the middle turbinate was removed and the antrum was syringed through the ostium maxillare. The discharge gradually ceased and remained absent for a year when it recurred with all the original symptoms. The antrum was then opened freely by A. B. Duel when a calculous mass, the size of a small bean, was found lying in the cavity. On section this proved to be the fang of a tooth encrusted with salts. The antral opening was kept free for three or four weeks; when all discharge had ceased it was allowed to close. The cure seems to have been permanent.

A similar case recorded by Macintyre is of interest especially from the fact that the foreign body, a lost drainage tube which had slipped into the antral cavity, was demonstrated with the X-rays.

In doubtful cases the latter expedient may be of great value, and it has even been proposed to utilize it for guiding the drill with precision and safety in opening the frontal sinus through the nose. It is said that the position and direction of the drill, which should be not more than three millimeters in diameter, are defined with absolute accuracy (G. Spiess).

In cases of long standing when pus discharge continues to be profuse and offensive by all means the best method of treatment is what is described as the Caldwell-Luc operation. The anterior wall of the antrum is exposed by an incision along the gingivo-labial fold of the upper jaw and the muco-periosteum reflected. The bony wall is then perforated by a drill or trephine and the opening enlarged with bone-cutting forceps, until it is possible to make a thorough inspection of the interior of the cavity. Thus, the existence of trabeculae and of areas of polypoid degeneration, as well as necrosis which would otherwise escape observation, may be detected. Should



conditions of this kind be discovered the cutting forceps and curette must be used with freedom, after which the cavity is washed out with an antiseptic solution and packed with iodoform gauze. The gauze should be removed at the expiration of twenty-four hours, and irrigation repeated daily until suppuration ceases. Gradual contraction of the opening takes place, and, as a rule, no measures are required to close it. After a time the irrigation of the cavity may be entrusted to the patient who readily learns to manipulate the syringe used for washing.

In his operation for the radical cure of maxillary sinusitis Luc advocates the formation of a muco-periosteal alveolar flap, and of a drainage opening in the inferior nasal meatus through which the end of the gauze packing is to be brought, with the intention of closing the buccal wound by means of sutures. Practically, closure of the incision by stitching is found to be unnecessary. It is difficult to keep the wound perfectly aseptic and the stitches are apt to tear out or the wound to become infected. The parts are found to unite readily if disturbance is avoided by care as to diet and movements of the mouth.

Removal of the anterior end of the *inferior* turbinate body is recommended by some as a first procedure with a view to making a drainage opening through the antral wall in the *inferior* meatus. If the turbinate is removed before the antrum is opened it may be necessary to control hemorrhage by packing the nostril with iodoform gauze. Some operators prefer to postpone this step until the close in order to avoid annoyance from bleeding. The incision in the mouth is best made from the first molar tooth forward toward the frenum and should be extensive enough to give ample space for the use of the chisel or trephine. At the moment of incising the lining membrane of the antrum free hemorrhage often occurs. It may be readily controlled by firm pressure for a few moments with iodoform gauze. It is said to be modified very much by the preliminary injection of cocaine or better suprarenal extract solution.

Failures in the radical operation may result from overlooking the existence of areas of polypoid degeneration, or bony septa, which partially, or perhaps completely, subdivide the antral cavity. In a recent case of my own a firm bony partition divided a very large



antrum by projecting from its floor nearly to its roof. Without care and thorough exposure of the parts it might easily have escaped observation. The case referred to is also interesting as illustrating the condition of so-called "latent empyema" in which the symptoms were so obscure that a positive diagnosis of sinus suppuration was very tardily accepted.

The opening in the nasal fossa through the inferior meatus should be made large enough to give good drainage and obviate the danger of premature closure. If made too small it may have to be reopened every few days; if made large it is possible to dispense altogether with drainage tubes and gauze dressings, a very desirable object, since it is believed that many cases of antral suppuration are kept up by too energetic postoperative meddling. A generous opening, moreover, permits us to entrust the care of the case to the patient himself.

In some cases of chronic antral disease the transillumination test will show the absence of accumulated pus immediately after operation. In most of them, however, the changes in the bony wall and mucous lining are so extensive that the light is not transmitted for several weeks, and possibly, not at all. This fact is noted by De Roaldes, every one of a series of cases operated upon by Gordon King and himself showed opacity after a cure of the empyema had been pronounced.

The use of astringent applications to the interior of the cavity during convalescence may be sometimes required. As a rule, simple cleansing by means of antiseptic irrigation is all that is necessary. Sometimes a solution of chlorid of zinc, twenty per cent., or protargol solution, ten grains to the ounce, or one quarter of one per cent. nargol solution, a combination of silver and nucleinic acid, seems to assist in arresting the suppurative process. In others, the formation of pus ceases almost at once and, in from four to six weeks, a cure is established.

It is necessary to refer to the so-called dry treatment of sinus suppuration by insufflation with various powders, which is practically the introduction of a foreign body into a cavity already sufficiently irritated, to condemn it without reservation.

As a precaution against recurrence attention should be given to



the condition of the nasal membrane and to the removal of any obstacle from the region of the antral orifice. It is impossible to emphasize too strongly the importance of this point, as well as the avoidance of meddlesome interference with a reparative process by excessive irrigation with strong solutions, or by plugging the antral cavity with sterilized or medicated gauze for too long a period.

In most cases an artificial opening into the antrum gradually contracts and closes. Occasionally its track has to be stimulated by cauterization. In exceptional cases a permanent fistula remains, and it has been my experience to see several such cases in which the condition caused little or no inconvenience. The continuance of discharge after operation may be explained by complications which have already been adverted to, namely, the persistence of pyogenic membrane in a pocket or adventitious sinus overlooked at the time of operation, or the presence of some neglected nasal anomaly, or finally the fact that the antrum is acting as a receptacle for pus overflowing from the frontal sinus or the ethmoidal cells. Moreover, the influence of the general health upon a suppurative process should be remembered, and if indicated measures tending to improvement in that direction should be adopted.

### FRONTAL SINUS.

Inflammation of the frontal sinus is a frequent complication of an acute coryza and is prone to lapse into a chronic condition in the presence of any occlusion of the *hiatus frontalis*. One of the earliest symptoms in acute cases is pain in the supraorbital region either upon one or both sides according as one or both cavities are involved. In a small proportion of cases there is but one frontal sinus, no median septum being present (Fig. 41). An exceedingly rare condition has been described by Suarez de Mendoza, in which two sinuses on either side, one behind the other, were found. They communicated by small openings with each other and each opened into the nose by a separate passage. It may be that such an anomaly might render its possessor more prone to sinus disease, and it is easily seen that any therapeutic measures, surgical or other, are thereby made more difficult and complicated. Pain may be intense,



neuralgic in character, aggravated by blowing the nose, or a stooping position, or it may consist of simply an aching sensation, or a sense of dullness or weight. There is marked tenderness along the supraorbital ridge and especially on deep pressure under the supraorbital arch. Frequently there are puffiness and swelling of the skin over the affected sinus and of the upper eyelid, and sometimes slight pitting under compression. These symptoms subside with the occurrence of a purulent nasal discharge, or distension of the cavity

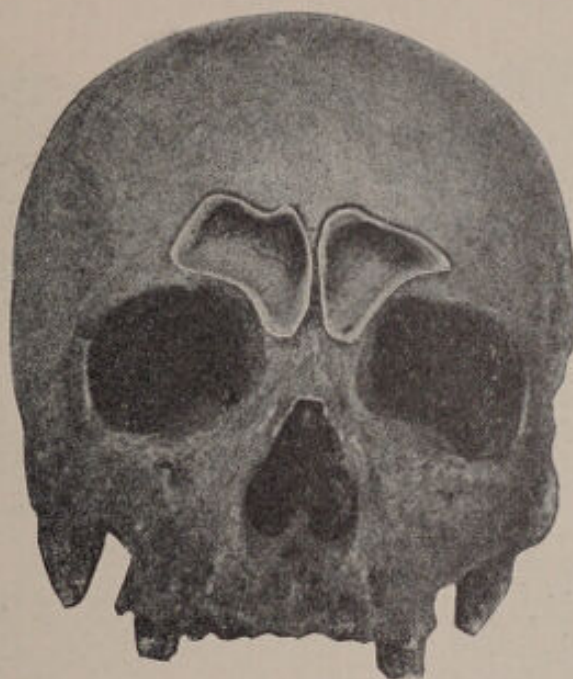


FIG. 41. NORMAL FRONTAL SINUSES OF AVERAGE SIZE. (*Logan Turner.*)

may be followed by exophthalmos and formation of an orbital abscess.

The diagnosis based on the foregoing symptoms is usually free from difficulty. Transillumination offers a less reliable diagnostic sign in case of the frontal sinus than with the antrum owing to the well-known fact that asymmetry of the former is much more frequent (Fig. 42). A small electric lamp, covered except at its end by an opaque shield, pressed well under the supraorbital arch, defines the boundaries of the frontal sinus quite accurately. By using a lamp on either side simultaneously, or a double transluminator like that devised by H. S. Birkett, it is possible to compare the sinuses by illuminating both at the same moment. Thus the rays of light are thrown upward through the floor of the sinus. The single lamp



being placed at various points on the forehead, meanwhile the patient being directed to keep his eyes closed, he himself can map out the sinuses with considerable precision by noticing when the light becomes perceptible as it is shifted about. By what they call "médio-frontal" illumination, Lubet-Barbon and Furet have demonstrated that by placing the lamp in the median line of the forehead a difference in intensity of the light may be observed under the supraorbital arch. Logan Turner, whose researches in this field have been very complete, finds many interesting anomalies and variations in the

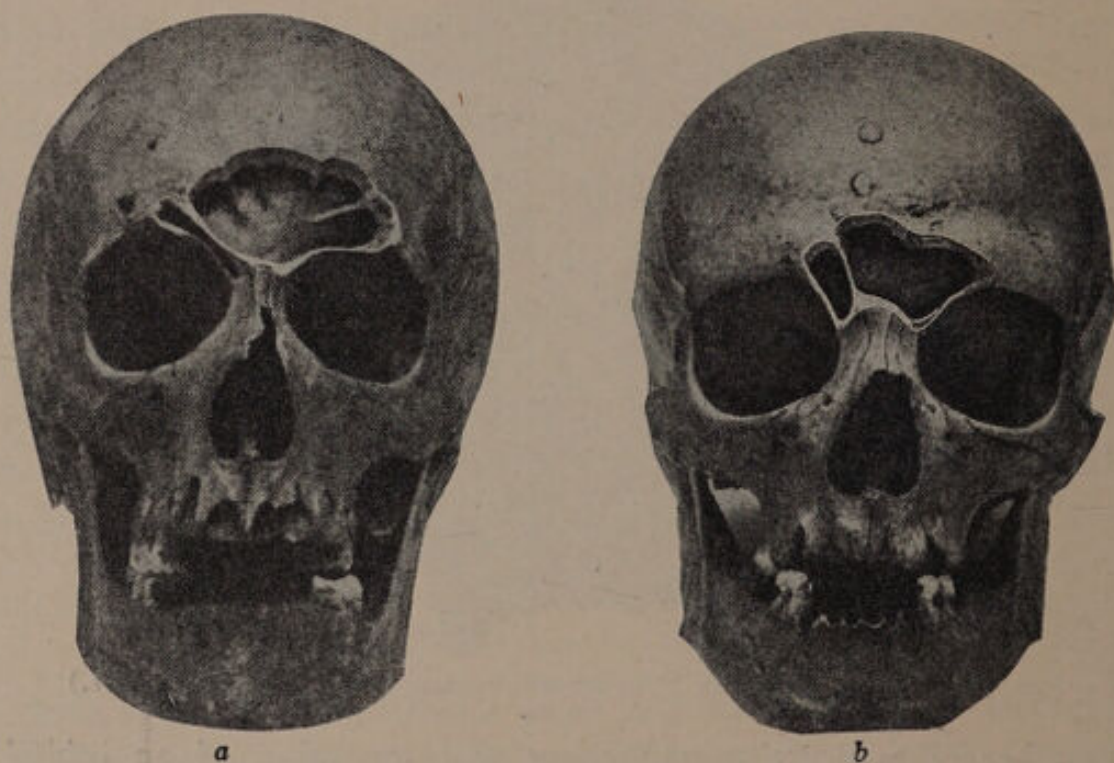


FIG. 42. ASYMMETRY OF FRONTAL SINUS.

*a*, Right sinus almost obliterated and left subdivided by numerous septa; *b*, small right and very large left sinus. (*Logan Turner.*)

frontal sinuses and concludes that the light test is of little or no practical value in chronic suppuration in these cavities, his view being based on the following grounds: "(1) One or both sinuses may be absent, and when this anatomical condition exists, there is opacity on one or both sides of the skull. (2) A certain proportion of healthy sinuses fail to illuminate; this may occur on one or on both sides of the skull. (3) A sinus on one side of the skull may illuminate with less brilliancy than its fellow, although both are perfectly normal. (4) Many sinuses containing pus, and with their



mucous membrane thickened and often polypoid, illuminate with considerable intensity." Darkness may indicate no sinus, a thick-walled sinus, or a diseased sinus, so that in most cases we must arrive at a diagnosis by other means. In chronic cases the absence of subjective symptoms may necessitate reaching an opinion by exclusion. If pus quickly reappears in the middle meatus, the antrum having been emptied of purulent contents by syringing through the ostium and the patient's head being held quite erect, the source of

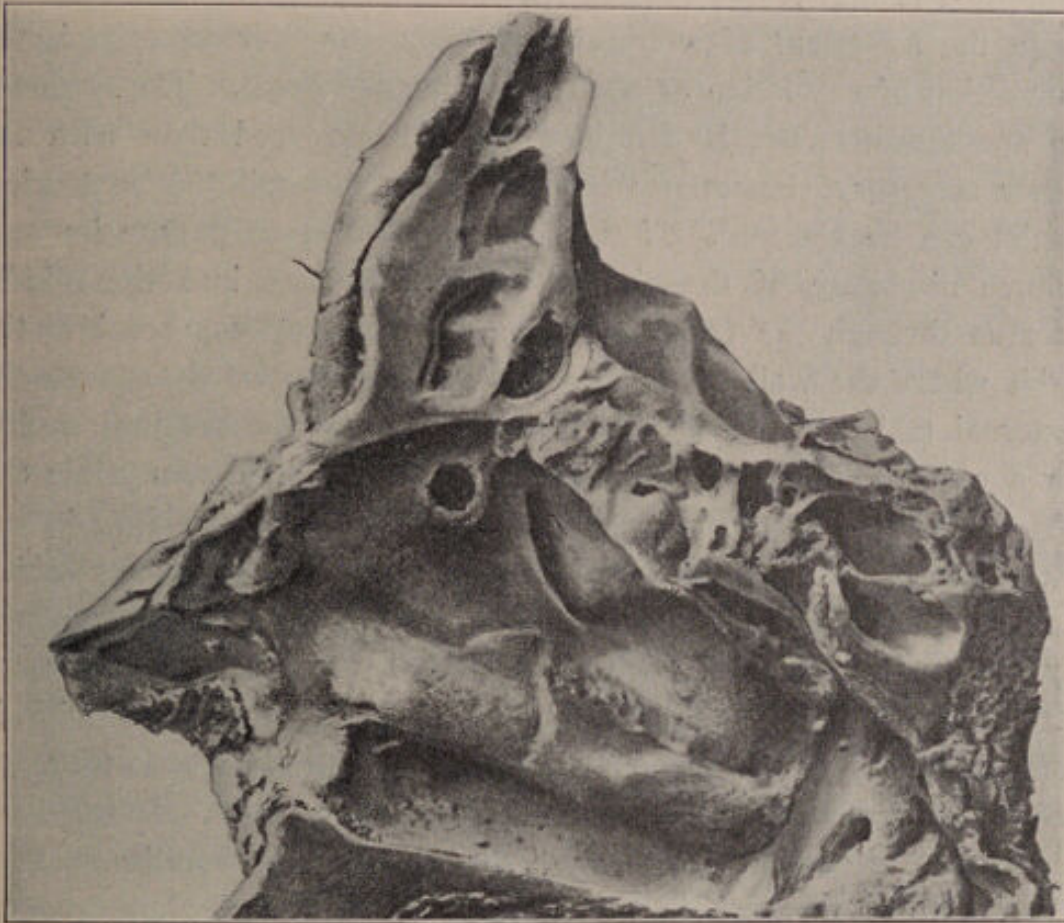


FIG. 43. SEPTA OF FRONTAL AND SPHENOIDAL SINUSES. (*Schadle.*)

pus must be either the frontal sinus or the anterior ethmoidal cells. Even in so-called "latent" cases a certain degree of tenderness on the affected side may be elicited by firm pressure upward against the floor of the sinus. In cases of the latter class also there is apt to be at times more or less swelling somewhere in the region of the sinus. In some cases a positive diagnosis can be made only by catheterizing the sinus through the frontonasal canal with a Hart-



mann or Krause canula, a feat often very difficult of accomplishment. The passage may be tortuous, or it may be necessary to resect the anterior end of the middle turbinate or other obstacle before a probe or canula can be passed. The end of the probe may become engaged in an anterior or fronto-ethmoidal cell, or may be arrested by an irregularity in the canal, but if it seems to have some freedom of movement and has passed a distance of not less than six or seven centimeters from the floor of the nose the presumption is that it has entered the sinus (Fig. 43).

In the *treatment* of a frontal empyema the first essential is the correction of any lesion or obstruction in the nostril. The tendency to spontaneous cure is certainly more pronounced than with the other accessory sinuses provided drainage through the anatomical outlet can be restored. If the case is allowed to pursue its own course discharge of the abscess may take place into the middle meatus through the frontonasal canal, or it may rupture into the orbit where the wall of the sinus is thinnest, outward through the external table, or through the inner table into the cerebral cavity. In a case of long standing which occurred in my own clinic the abscess pointed at the outer limit of the superciliary ridge; in the meantime by pressure upon the eyeball producing symptoms which had led the patient to consult an oculist. The abscess was opened by the usual free incision when the nature of the case was demonstrated. The best method of treating a *chronic* frontal sinusitis is undoubtedly by external operation which naturally leaves more or less of a scar but gives reasonable assurance of cure. In attempting the relief of the case through the nose we are handicapped by being obliged to work in a very narrow passage and, moreover, opportunity is not given to make proper exploration of the sinus cavity. Indeed it is very rarely possible to enter the sinus by passing a probe along the frontonasal duct. One is quite as likely to get into the anterior, or fronto-ethmoidal cells, or even altogether fail to find the orifice of a canal. The latter has been the experience of more than one operator after complete extirpation of the middle turbinate body. The feasibility of guiding the drill or trephine through the nasal fossa to the floor of the sinus by means of the Roentgen ray has been mentioned in speaking of abscess of the antrum. In most



cases the lining membrane has undergone a degenerative process which necessitates thorough curettage. In not a few cases or necrosis of bone may have taken place. Under such circumstances simple drainage is not sufficient to accomplish a cure and the only rational mode of treatment is to make free exposure of the cavity by what is known as the Ogston operation, or one of its modifications. An incision is made from the supraorbital notch toward the middle line, including the skin and periosteum, which are then reflected and the anterior wall of the sinus is opened by means of a trephine, hand drill, or a chisel. If more room is needed a vertical incision may be made in the median line at an angle with the first. Sufficient bone should be removed by means of cutting forceps to enable one to explore the walls of the cavity thoroughly and to pass a drainage tube through the fronto-nasal duct into the nasal fossa. The cavity having been thoroughly cleansed and irrigated with an aseptic solution, the external wound is closed with sutures, a drainage tube being passed through the nasal opening for the purpose of irrigation. So long as signs of suppuration appear with the irrigating fluid used for washing the cavity the tube should be retained. Usually in the course of a week or ten days it may be safely withdrawn.

Various modifications of the original operation for frontal sinus disease as proposed by Ogston have been suggested. Most surgeons prefer to go through the *anterior wall* even at the risk of considerable deformity resulting, which is apt to be the case when nearly all of the wall is removed, as in the operation performed by Kuhnt and others. In an ingenious modification proposed by R. W. Payne, several openings are made into the affected sinus, intermediate bridges of bone being left to serve as a supporting framework to the soft parts. The insertion of a plate of aluminum, platinum, decalcified bone, or ivory to lessen the disfigurement has been suggested by Semon, but so far as I am aware has not been attempted. Paraffin prosthesis is likely to prove useful in this direction.

In order to obviate deformity the following method of operating is described by Lothrop (Fig. 44). A curved incision is made from near the nasofrontal suture upwards parallel with the folds of skin formed by the corrugator supercilii muscle for about fifteen millimeters, gradually curving outwards and following the horizontal



folds. With a drill or trephine an opening is made through the wall just above the supraorbital arch at the inner angle of the orbit and below the inner extremity of the superciliary ridge. According to Lothrop the existence of a diploë in this situation may be relied upon to show the absence of a frontal sinus, and none being found pus, if present, must come from the ethmoid cells. But this cannot be altogether trustworthy, since in several instances to the author's

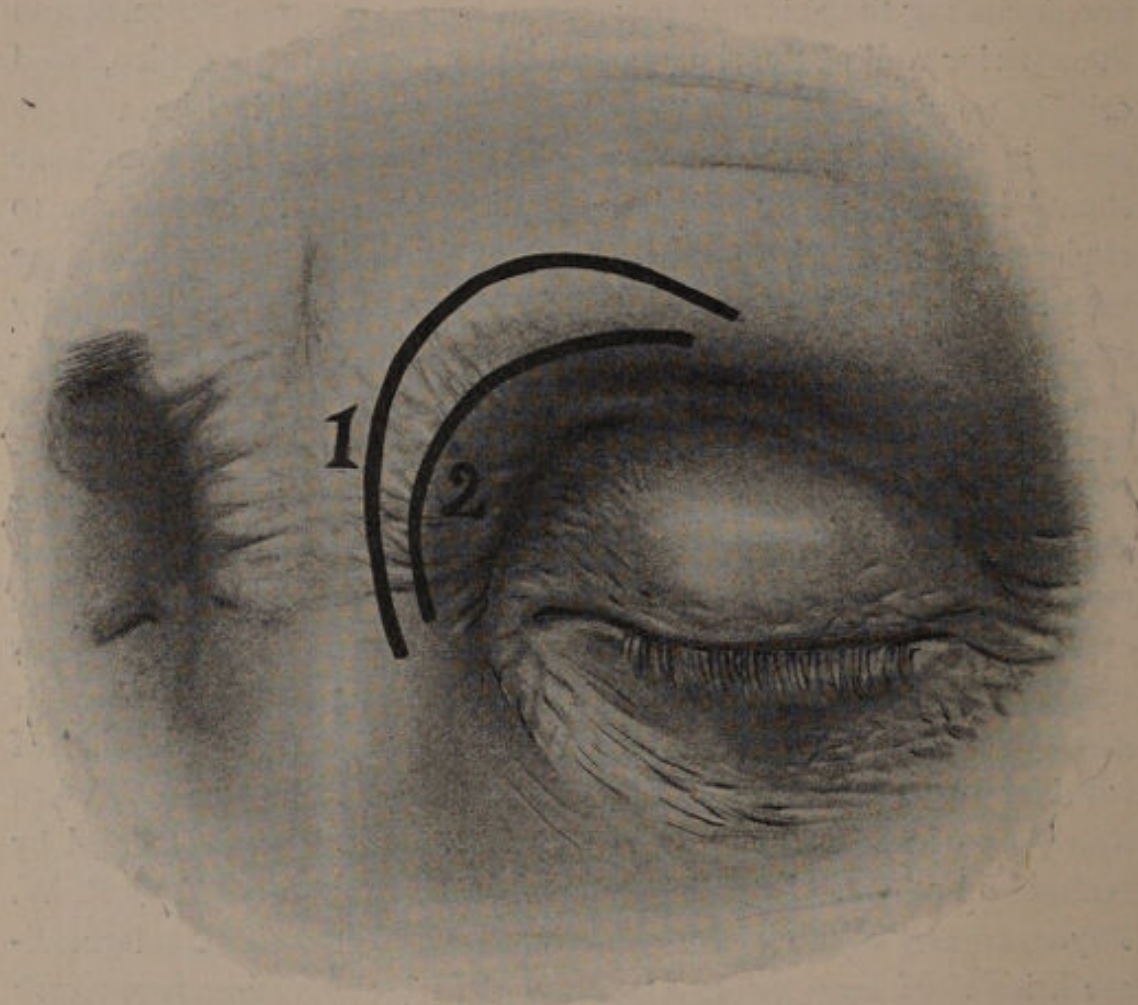


FIG. 44. INCISIONS IN OPENING FRONTAL SINUS. (*Lothrop.*)

1, Anterior wall. Osteoplastic operation, the bone flap thus formed is deflected downwards. 2, Floor, giving access also to ethmoidal cells.

knowledge both cancellated tissue and sinus have been absent. In one hundred crania examined by Max Scheier the frontal sinus was absent five times, and other anomalies were frequent.

Through the opening thus formed the cavity is probed to determine its dimensions and possible changes in its mucous lining. If the sinus is found to be very spacious, the opening must be enlarged



by chiseling a bone flap along the line of incision with the supra-orbital arch serving as a base. This bone flap may readily be pried downwards and fractured along the thin orbital surface of the sinus and is to be replaced at the conclusion of the operation. The advantages claimed for this method are that the sinus may be well opened and that a large opening may be made into the nasal fossa without disturbing the orbit.

The frontal sinus may also be entered through its *inferior surface*, giving a less perfect exposure of the cavity but rendering the ethmoid cells very accessible and being followed by somewhat less deformity. Without the exercise of great care there is, however, more danger of disturbing the orbit or interfering with the lachrymal apparatus. This is sometimes known as Jansen's operation. The objection to it last mentioned is very serious while it is by no means absolutely free from disfiguring effects.

In this operation the incision commences opposite the inner canthus, in front of the margin of the orbit, over the nasal process of the superior maxilla. It curves upwards and outwards along the eyebrow to the supraorbital notch. The periosteum is elevated and the flap turned down so as to expose the internal angular process of the frontal bone. Hemorrhage may occur from the supraorbital and angular arteries and may be controlled by pressure or by ligation. The bony wall of the sinus is opened by means of the chisel just above the internal angular process of the frontal bone where the bone is thinner than on the anterior surface and more easily perforated. If pus escapes through the operative wound at once we have reason to believe that the frontal sinus is affected; if not, the presumption is that nasal suppuration arises from the ethmoid cells which may be easily reached through this wound. The most important step in these operations is the establishment of roomy communication with the nasal fossa by removal of the anterior ethmoid cells. A small probe is passed through the ostium into the nose to be used as a guide. The finger may be introduced into the nostril in order to give the curette the right direction, which should be downward and somewhat backward. Practically, this consists in removal of a greater part of the lateral mass of the ethmoid which fills in the meatus frontalis and, if thorough, no drainage tube will



be required. The external wound is closed completely and protected with a sterile dressing and the nostril is packed with iodoform gauze for twenty-four hours.

In the after-treatment the irrigation of the nasal fossa should be gentle so as to avoid disturbing the wound in the skin and should be limited to a warm two per cent. boric acid solution. The patient should be especially warned not to blow the nose until the wound is thoroughly healed.

Sometimes the external wound fails to unite completely, especially in cases where disease of the sinus has been extensive or the bone has been involved. As a rule, however, union takes place kindly and the relief of symptoms attributable to pressure is almost immediate.

The method of operating practiced by Luc and that recently published by Herbert Tilley differ in some minor details from the procedures just described. The former seals up the external wound and brings a gauze drain from the sinus to the anterior naris, the gauze being removed after two or three days. In Tilley's operation the anterior end of the middle turbinate and all polypoid and granulation tissue and dead bone are first removed through the naris. The posterior nares are then plugged. The external incision runs from just above the internal palpebral ligament below the line of the eyebrow for two thirds of the supraorbital margin. A periosteal flap is raised and a small disk of bone removed. This opening is then enlarged to permit satisfactory exposure of the sinus and access to the ethmoid cells. After all diseased tissue has been removed by curetting and a liberal passage into the nose established the cavity is swabbed with pure carbolic acid or chlorid of zinc, forty grains to one ounce, and packed with antiseptic gauze. No drain is carried into the nose, but the end of the gauze packing is brought out at the lower angle of the forehead wound, which is elsewhere carefully closed with sutures. If no signs of disturbance occur the gauze is left in place for three or four days when part of it is withdrawn and cut off. This is repeated every few days until all is removed and the cavity is lined with granulation tissue, when the wound is allowed to close. Eight out of fourteen cases thus treated were cured, in two pus discharge still continued, and in one



a fatal result ensued from septic osteomyelitis attributed to imperfect nasal drainage and too close stitching of the external wound. This cannot be regarded as a very flattering exhibit, although the cases were probably rather severe in type.

The advantages of being able to dispense with packing and drains due to establishment of free communication between the nasal fossa and the sinus must be obvious. Better union of the external wound is thereby ensured and the risk of sepsis is reduced to a minimum.

The question as to whether a radical external operation should be advised in a given case is not always easy to answer. By no means every case thus handled gets well, if by that we mean absolute cessation of pus discharge. On the other hand the appearance of pus in the middle meatus known to proceed from the frontal sinus is far from being an indication for immediate external operation. Continued difficulty in concentrating the mind, constant headache associated with frontal suppuration and more or less nasal obstruction may be accepted as indications for radical interference, in case intranasal methods have already failed, and provided the patient is willing to submit to probable disfigurement and at the same time take the chance of incomplete relief.

### ETHMOID CELLS.

The mania for classification of disease seems to have reached a climax in the case of the ethmoid cells. Almost every writer on the subject has his own arrangement of the morbid conditions affecting this region based either on a pathological hypothesis or on clinical history. Most of the former are more or less erroneous while the latter are apt to be confusingly elaborate. In view of the frequency of ethmoid disease it is rather surprising that such extreme difference of opinion should prevail as to its origin and nature. Bosworth regards ethmoiditis as the most common form of sinus inflammation, while the post-mortem records of Lapalle show the occurrence of ethmoidal empyema only six times, frontal five, sphenoidal nineteen and maxillary forty-eight times in fifty-five cases of sinus disease. In every instance empyema of other sinuses coexisted—the maxillary five times, the sphenoidal four times and the frontal



twice. An ethmoiditis may be latent, that is, it may be disclosed by no well-defined objective symptoms, or it may be attended by free pus discharge the source of which is obvious. It may be obscured by the concurrence of mucous polypi, not only in the nasal fossæ but even within the cells, and by orbital abscess. The latter complication is certainly very infrequent in this country. The middle turbinate bone may be in a state of bulbous or cystic expansion and all the ethmoid cells may be enormously distended, their bony walls very fragile and more or less carious. Spiculæ of bone may be found in the discharges and the existence of necrosis may be determined by exploration with the probe or the finger. Empyema of the ethmoid cells seems to occur without regard to sex or age, except that most cases of orbital abscess have been reported in young subjects.

The causative relations of ethmoiditis and of sinus disease in general to atrophic rhinitis, or "ozena" as some writers persist in calling it, a theory especially advocated by Grünwald, and to nasal polypi have been fertile topics of debate. Bresgen found empyema of the maxillary sinus or of the ethmoid cells in eleven cases of atrophic rhinitis, Moure in 32 out of 114 cases, while Jacques and George firmly maintain the causative relation of sinus disease to atrophy and assert that implication of the sphenoidal sinus and ethmoid cells most frequently preëxists. The relation of sinus disease to nasal polypi will be discussed at length in the chapter relating to the latter.

A rather rare condition of some interest but fortunately not of very serious import—emphysema of the eyelid—has recently been described by Beaman Douglass. It may occur as a result of disease of the ethmoid cells or of injury to them in operating. As a consequence of violent blowing of the nose after a laceration of the lachrymal duct or of a compound fracture of the nasal bones it does not concern us in this connection. The upper lid rather than the lower is invaded, the air finding its way from the ethmoid cells through the wall of the orbit and forward along the fascia which separates the extrinsic muscles of the eyeball from the intrinsic. The accident is indicated by the occurrence of sharp pain in the orbital region, immediate swelling of the lid and more or less dis-



placement or protrusion of the eyeball. Usually the air is absorbed and the parts resume their normal appearance in a few days with the exception perhaps of some degree of ecchymosis. With a view to avoiding this accident the use of a small blunt-edged forceps instead of a curette in the ethmoid region is recommended as being less likely to perforate the lamina papyracea. The advice is also given, with seemingly less foundation, "never to amputate any part of the middle turbinate" as it constitutes an important guide to the ethmoid cells. In many cases it will be necessary to sacrifice the middle turbinate, or at least its anterior end, in order to gain sufficient operative space, and indeed by so doing we frequently immediately enter the anterior ethmoid cells.

Inflammation of the ethmoid cells may be catarrhal or suppurative. The former often accompanies an acute rhinitis and subsides as the latter disappears, or may degenerate into a purulent process.

Suppuration of the ethmoid cells may be acute or chronic, the former owing to the anatomical construction of the parts tending to develop into the latter. In some cases the only symptom may be a discharge of pus from the nostril. If the anterior group of cells only, or the fronto-ethmoid cells, is affected pus appears in the middle meatus; if the posterior group is diseased pus is apt to spread over the septal surface of the middle turbinate body and to find its way backward to the nasopharynx. The tendency to spontaneous recovery is slight in ethmoid disease and in addition to the pus discharge we may have certain symptoms which are characteristic. Pain is usually deep seated and is frequently referred to the bridge of the nose or the postorbital region. Occasionally mixed with the pus bits of carious bone may be detected. When the bone is affected crepitation may sometimes be elicited by firm pressure at the inner angle of the orbit. Even in the absence of pus there may be a peculiar sickening odor, and when necrosis is in progress there is added the characteristic necrotic odor. There may be ocular disturbance, exophthalmos and contraction of the visual field from pressure upon the orbit, and where there is a great deal of intracellular mischief much distress may result from distention of the ethmoid cells and intranasal pressure. The sense of smell is more or less impaired. Indications of septic infection may be exhibited in febrile reaction



and general systemic depression. In aggravated cases symptoms of meningitis may develop. In fortunate cases the pus is discharged into the nasal chamber; in others, it may open at the inner angle of the orbit. It may reach the antrum or frontal sinus or, in its worst phase, it may penetrate the anterior cerebral fossa and induce a fatal meningitis.

A diagnosis must often be reached by exclusion. In cases in which the foregoing symptoms are pronounced there should be no difficulty in defining the condition; but in others the symptoms may be so obscure as to leave the case a long time in doubt.

A serious prognosis must be given unless free intranasal drainage is established. And even then while pus formation is active the patient is not absolutely out of danger. Kuhnt has recorded seventeen cases of fatal meningitis consecutive to sinus disease.

*Treatment*, in cases of moderate severity, consists in free opening of the ethmoid cells through the nostril by means of cutting forceps, drill or curette and the subsequent thorough cleansing of the parts with an antiseptic solution (Fig. 45). A nasal deformity which interferes with drainage should be corrected. The possibility of other sinuses being involved should not be overlooked. Complication of the case by the existence of nasal polyps is very frequent and they, as well as excessive granulation tissue and necrotic bone, should be removed. These operative procedures upon the ethmoid may be done under local anesthesia with cocaine. Careful examination with the probe for the detection of spiculæ of bone should be practiced and the case should be kept under close watch so long as suppuration continues.

The anterior ethmoidal cells are situated in the upper part of the ethmoid and fill in the floor of the frontal sinus. Most of them are large and many have their walls completed by articulation with neighboring bones. They are very numerous and suppuration involving them is liable to be transmitted to the frontal sinus.

Such being the case the operation which has just been described is applicable only to disease limited in extent and in an unusually wide nasal chamber. In some cases of long standing nearly all the ethmoid cells are involved more or less and a very large portion of them are quite inaccessible through the nasal fossa. In attempting



to curette the field of operation is almost immediately obscured by hemorrhage, so that we run the risk of carrying our instrument in an improper direction or too far, thus either invading the orbital cavity or possibly perforating the cribriform plate and entering the

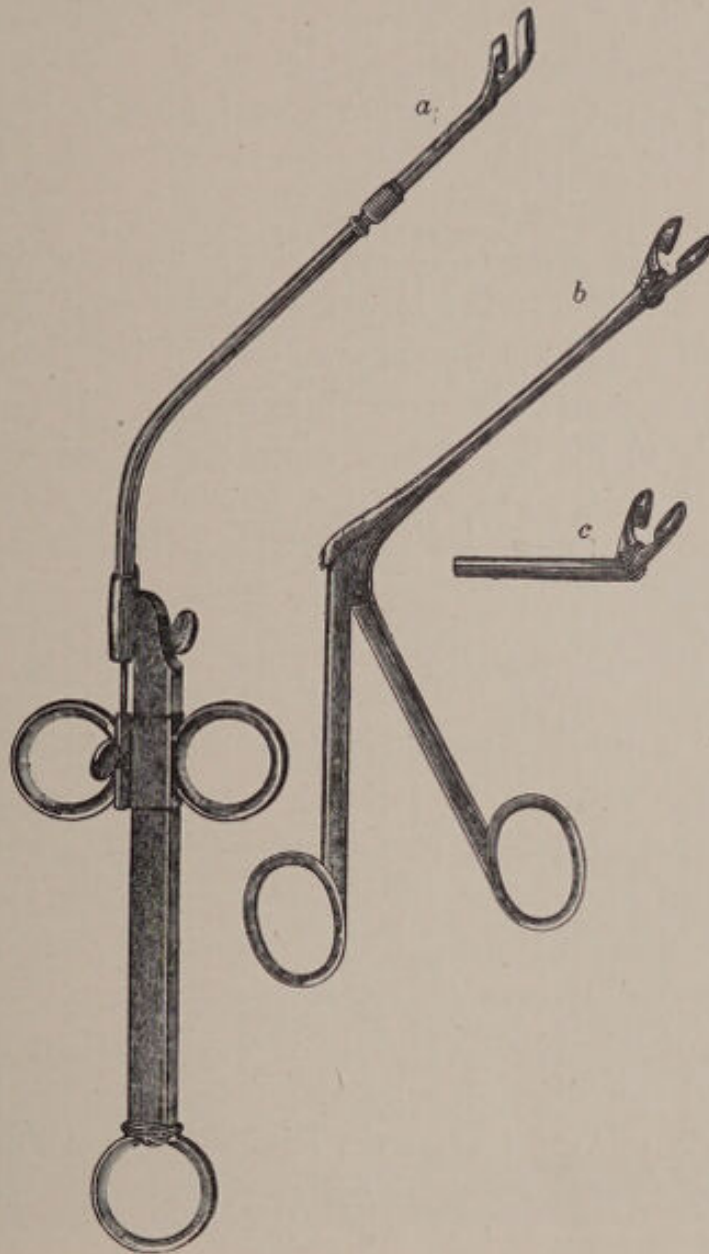


FIG. 45. *a*, Hajek's double curette; *b*, *c*, Grünwald's cutting forceps.

cerebral fossa itself. About all that can be done by the nasal method of treating ethmoiditis is to remove the middle turbinate including the cell which sometimes exists in its body and curette the cells in its immediate neighborhood. When relief is not obtained by this means an external operation is the only safe and radical mode of treatment. An external incision along the inner angle of the orbital



ridge at about the level of that practiced for opening the frontal sinus is recommended. By this incision the frontal sinus is exposed with its floor and the ethmoidal region is brought within easy reach. All the cells can be thoroughly curetted and an opening made into the nasal cavity for drainage, so large that no drainage tube is required. If necessary the posterior group of cells may also be attacked by this route. The external wound, after thorough cleansing and sterilizing of the cavity, is closed as in the operation for frontal sinus disease. Usually the wound heals without much disfigurement, provided it be carefully sutured and nasal drainage be adequate. Care should be taken in irrigating the nasal fossa to use no violence in order that the wound may not be disturbed.

The more formidable operation just described is called for very exceptionally. In the majority of cases the patient will be content with the relief given by opening and draining the cells through the nose, even though the disease cannot be thus completely obliterated.

### SPHENOIDAL SINUS.

Inflammation of the sphenoidal sinus is probably less rare than has been hitherto supposed. It is of rather serious nature since it exhibits but slight tendency to resolve and is disposed to affect the periosteum and bone. The causes acting to produce disease here are similar to those that prevail with reference to the other sinuses, and the pathological changes resemble those occurring elsewhere. The opening of the sphenoidal sinus is so situated as to impede the free escape of secretion. It may sometimes be found by passing a probe obliquely upwards across the middle turbinate body and close to the septum (Fig. 46). The pus secreted in sphenoidal sinusitis usually flows backwards into the pharynx. No doubt many cases of so-called postnasal catarrh are really examples of sphenoidal inflammation. The pain is of an aching character and may be intense and radiating. Ocular symptoms are very apt to develop in sphenoidal disease from involvement of the trigeminus. Impairment or loss of sight and exophthalmos have been observed. In a case under my own care marked ptosis was a prominent symptom which disappeared as the inflammatory signs subsided. It is seldom pos-



sible by rhinoscopy, either anterior or posterior, to determine definitely the origin of the pus; that is, it can not be seen actually flow-

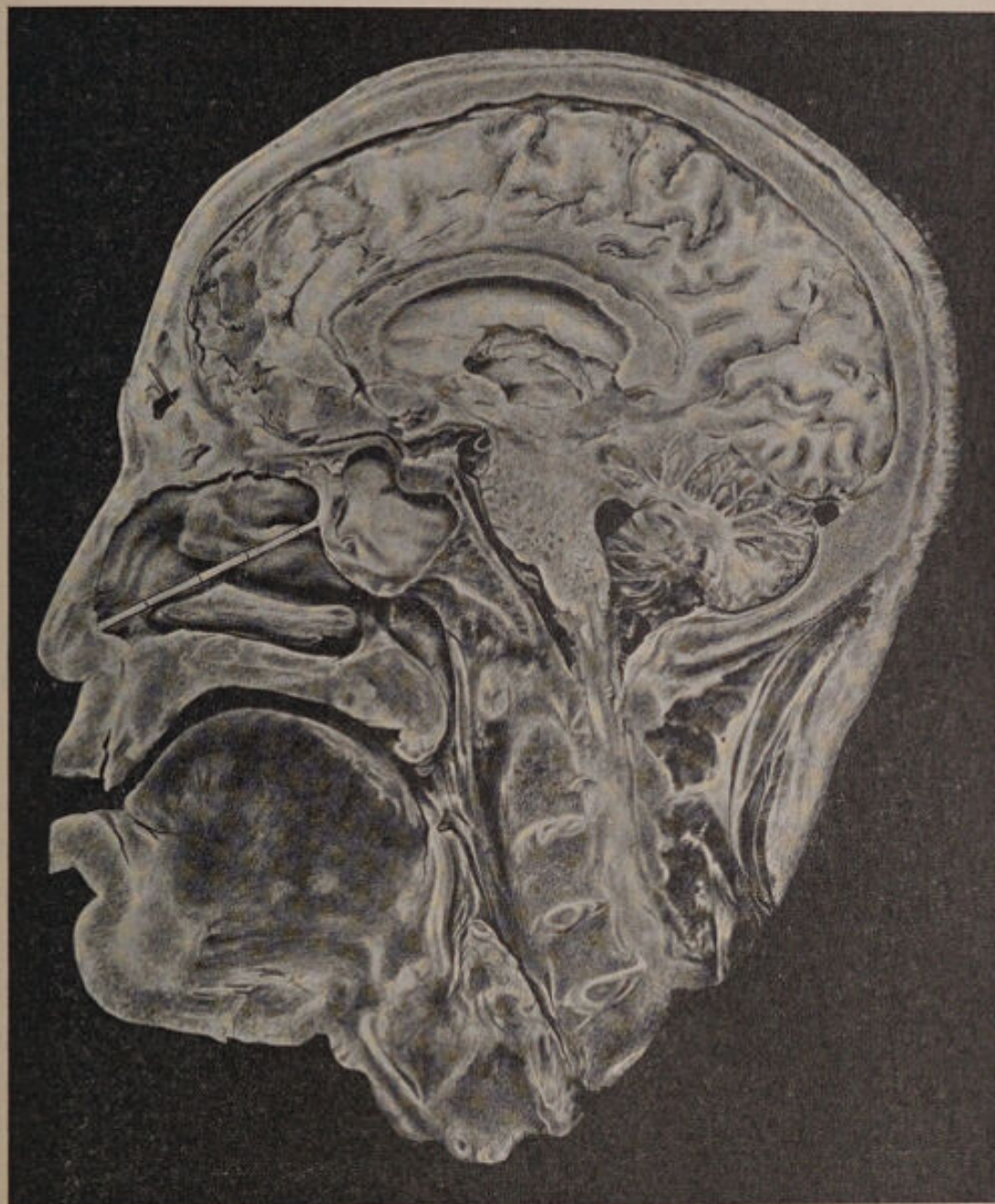


FIG. 46. PROBE IN ORIFICE OF SPHENOIDAL SINUS SHOWING DISTANCE FROM NASAL VESTIBULE, ABOUT  $2\frac{1}{2}$  INCHES. (Bryan.)

Sieur and Jacob profess to be able to catheterize the sphenoidal ostium by passing a curved instrument close to the dorsum of the nose and the under surface of the cribriform plate, instead of going obliquely across the middle turbinate.

ing from the sinus. In general pus from the sphenoidal sinus inclines to spread out over the vault of the pharynx. It may be im-



possible to tell whether the discharge comes from the sphenoidal sinus or the pharyngeal bursa, suppuration of which, under the name of Tornwaldt's disease, is occasionally observed.

The prognosis in sphenoidal sinusitis is less favorable than that of inflammation of other sinuses owing to the difficulty of reaching the cavity. Extension of the disease to the orbit or meninges may occur with fatal results. A case of erosion of the cavernous sinus with fatal hemorrhage has been reported and others of thrombosis involving the circular and cavernous sinuses and the ophthalmic veins have been recorded. An extraordinary case in which the whole body of the sphenoid was extruded, the patient recovering, was reported many years ago by Baratoux.

In the *treatment* of sphenoidal sinusitis the most important indication is early and free opening so as to permit the removal of necrosed bone, if any exists, and thorough drainage of the cavity. The drill or trocar is introduced in the direction indicated for discovering the anatomical outlet of the cavity, namely, obliquely upwards across the middle turbinate body. The distance of the anterior wall from the tip of the nose in the adult varies from three to three and three fourth inches; the average depth of the sinus is about a half inch, but the investigations of Onodi and many others have shown irregularities to be so frequent that these measurements must not be accepted as absolutely reliable. When drainage is once well established and the parts kept aseptic by thorough cleansing, recovery may be expected.

In an elaborate study of the sphenoid by Beaman Douglass attention is directed to the existence in the smaller sphenoidal wings of supplementary cells originally described by Zuckerkandl and Hajek. Their surgical importance is considerable in connection with an inflammation involving either the sphenoidal sinus or the posterior ethmoidal cells. In some cases the main sphenoidal sinus has been found to extend partly or completely into the wing of the bone. In others the sinus in the wing is quite independent and opens by its own passage into a posterior ethmoidal cell or into the *recessus spheno-ethmoidalis*. In still other cases a posterior ethmoid cell is prolonged into the wing of the sphenoid. The relations of these sinuses are described as follows. Above a mere shell of



bone separates them from the optic nerve and chiasm and the brain itself. The nasal fossa and the anterior part of the great sphenoidal sinus form their floor. In front lie the posterior ethmoidal cells, while along the outer wall runs the optic nerve, and if the sinus is of large size the carotid artery and the Vidian nerve may be found in close proximity. The wall of the orbit may be formed in part by that of the sinus. Obviously distention of the sinus by pus or absorption of its contents may create disturbance in contiguous structures, while the risk of damage to the latter in operating is a serious possibility. The existence of this anomaly thus adds not a little to the difficulty of diagnosis and the complications of operative interference. Yet it is claimed that in some cases it may be easier to enter the sphenoidal sinus by cutting away the posterior ethmoidal cells and through the smaller wing than by the route usually followed in the vicinity of its normal opening.

The plan of gaining access to the sphenoidal by way of the maxillary sinus, first suggested by Jansen, has recently been advocated by Furet. He especially advises it in those rare cases of sinusitis with cerebral complication, in which a rapid and thorough operation must be done, also in cases in which an antral empyema coexists, as well as in those in which the maxillary sinus is not involved, but the nasal route cannot be followed owing to atresia or deformity of the nasal fossæ.

The idea of approaching the sphenoidal sinus through the mouth and pharynx, which has been proposed, seems to be a very blind and dangerous procedure. The proportion of cases in which the sphenoid cannot be reached through the nasal passages, if necessary after a preliminary removal of obstructions, must be extremely small.

The particular method of opening the sinus is less important than that the aperture should be ample and as near as possible to the floor of the cavity. Spiess prefers to puncture the anterior wall by means of a trephine propelled by electricity. Hajek tears down the anterior wall with a hook passed through the sphenoidal orifice, while Grünwald, after having enlarged the opening with a sharp spoon, breaks off portions of the bony wall in a downward direction with his punch forceps. If on exposure of the cavity it seems to be necessary to curette its walls the greatest caution should be observed



in the region of its roof, where the thin plate of bone might readily be penetrated with most disastrous results. Free drainage, removal of all diseased tissue, followed by swabbing the cavity with pure carbolic acid and occasional antiseptic irrigations subsequently are said to bring most of these cases to a successful termination in the course of a few weeks. The risk of hemorrhage in opening the sphenoid is much increased by the proximity of the cavernous sinus and of the internal maxillary artery. From the latter a branch passing through the sphenopalatine foramen sends a small twig across the anterior face of the sphenoid to supply the mucous membrane of the nasal septum. In a case reported by Hinkel a very severe hemorrhage occurring on the tenth day is believed to have had its source in the sphenopalatine artery. Several similar cases of bleeding, primary as well as secondary, are on record in which the flow was arrested by the use of a firm tampon. The difficulty of diagnosis and the danger of surgical interference are thus seen to be much greater in the case of the sphenoidal than of the other accessory sinuses.

#### HYDROPS ANTRI. MUCOCELE AND CYST. POLYPI. FOREIGN BODIES AND NEOPLASMS.

The ancient term *hydrops antri* is deemed inconsistent with modern ideas of pathology. It seems to be quite certain that a serous or muco-serous effusion may take place into a sinus cavity in the congestive stage of an inflammatory process which never advances to suppuration. For such a condition the term *mucoccele* is appropriate. In a very remarkable case recorded by H. Luc the frontal and maxillary sinuses of the same side were affected by mucoccele without discoverable cause, the disease being cured by the usual operation performed for empyema of these cavities. He refers to a similar case reported by Laurens in which the duct from the affected sinuses was occluded by an enormous osteoma. It is not improbable that a mucoid collection may occur in a sinus more often than is generally supposed, since a non-inflammatory process of this kind is attended by so few subjective symptoms. It is possible that an escape of fluid into the antrum may occur in the course of a



general dropsy. But these cases are extremely rare. An accumulation of non-purulent fluid in a sinus cavity may be in most cases properly called a *cyst*, the walls of the sinus forming its boundaries, in consequence of disappearance of its original limiting membrane by distention, rupture and absorption. In cases of long standing this is likely to be the course of events, whether the process has its inception in a lymph space or in the acinus or duct of a gland, or begins as a dentary cyst, for the reason that its early symptoms are very ill-defined. Hence an actual cyst wall is seldom seen. It is suspected that some cases of alleged nasal hydrorrhea are of this kind. The antrum of Highmore is the most frequent seat of this phenomenon. When the ostium maxillare becomes blocked from any cause and the secretion causes distention, more or less pain or swelling may call attention to its existence. In time the anterior wall of the sinus becomes so thin that characteristic crepitation on palpation may be detected. In the case referred to in discussing the diagnosis of empyema of the antrum the contrary was true and it was supposed that we had to deal with a solid tumor, until its character was demonstrated by the light test. The quality of the effusion is usually such as to offer no obstacle to transillumination. In a case detailed by Fergusson exploratory puncture showed the nature of a tumor previously supposed to be solid, while Heath refers to a case within his own knowledge in which the upper jaw was removed before the error in diagnosis was discovered. The quantity of fluid varies from a drachm or two to several ounces. It is colorless or faintly straw colored and may be clear or slightly turbid. Cholesterolin is usually found in abundance. Occasionally the fluid is quite dark or even greenish and in a case recorded by Maisonneuve it presented a buttery consistency. The researches of W. Adams, followed by Giraldez, seem to show that cysts beginning in the glandular follicles of the mucous membrane may be single or multiple and may easily escape detection in the ordinary way of tapping the antrum. In general mere evacuation of the fluid effects a cure. If the cysts are very numerous it may be necessary to curette the wall of the antrum and afterward use astringent irrigations. It is wise to open the cavity freely in order that bony septa or foreign bodies may not be overlooked. The inconvenience to the patient result-



ing from such a course is insignificant, while its advantage over simple aspiration must be apparent.

*Polypi* may develop in the lining membrane of a sinus and undergo cystic degeneration precisely as they sometimes do in the nasal chambers. Or their presence may excite a profuse watery secretion which escapes by way of the nasal fossæ and is mistaken for a nasal hydrops. Spencer Watson quotes an interesting case of this kind observed by Paget in which the actual condition was demonstrated by post-mortem inspection. Until symptoms due to pressure or distention appear it may be impossible to offer a diagnosis without a free opening of the sinus. Watson calls attention to certain extraordinary cases of cyst of the antrum associated with optic neuritis and nerve atrophy. It would seem that some of the cases included by him in this category, in which symptoms of cerebral disturbance were exhibited, might to-day be regarded as instances of escape of cerebrospinal fluid, a condition to be referred to in the chapter on nasal neuroses. Intranasal polyps often coexist and it is by no means unreasonable to suppose that a condition favoring the development of the former may extend to the mucous membrane lining the accessory sinuses. This especially applies to the ethmoid cells, which are almost invariably found in a state of polypoid degeneration in inveterate cases of nasal polyp. Nasal suppuration is not proportionate to the degree of sinus disease. It has several times been my experience to open an antrum or a frontal sinus and find extensive degeneration of its mucous lining with scanty pus accumulation. The discharge is sometimes slightly offensive, a fact perceptible to the patient if his sense of smell is preserved. Heath declares that polypi of the antrum are very vascular, a fact undoubtedly true of malignant disease but less admissible regarding simple gelatinous polypi. In fact excessive hemorrhage from a tumor connected with the nasal passages must always be looked upon as a danger signal. Simple mucous polypi are not vascular and spontaneous hemorrhage is very unusual. A polyp attached within the antrum has been known to protrude into the adjacent nasal fossa, but as a rule sinus polypi are small and multiple. The proper treatment for a case of this kind is to thoroughly open the sinus and curette every part of the affected mucous membrane.



*Foreign bodies* are occasionally found in a sinus, especially the maxillary. Missiles from firearms, teeth erupted in the wrong direction or driven into the cavity in attempts at extraction, lost drainage tubes used in treating a sinus empyema are among the most common. In certain countries animal parasites are not infrequently discovered in these cavities, where they often cause extreme disturbance and sometimes extensive destruction of tissue. A diagnosis is difficult unless the larvæ are found in the nasal discharges. A foreign body may be retained a long time without giving any positive indication of its presence. In a case recently reported by Lohnberg a piece of metal was exposed in the ethmoid cells after removal of a large number of nasal polyps. Twenty years before this patient had lost an eye by explosion of a gun and unquestionably the piece of metal had at that time penetrated the orbital wall and become lodged in the ethmoid region. In a second case the patient was hit on the forehead with a wrench, a fragment of felt being torn from his hat and driven into the frontal sinus. It excited a chronic suppuration for which an operation was undertaken and the foreign body was thus discovered. Heath refers to a case in which a knife blade was lodged in the antrum for forty-two years and was finally expelled from the nostril, and describes another remarkable case in which a gun breech found its way into the throat after having remained twenty-one years in the antrum.

*Neoplasms*, either benign or malignant, may be met with in a sinus, having originated there or having invaded it from adjacent parts. The latter is far more frequent, at least as regards malignant disease. In this situation a benign tumor, although less accessible, is operable as elsewhere, but the question of a malignant tendency or perhaps a mixed character, especially at certain periods of life, has always to be answered. Malignant disease involving the antrum and more rarely the other accessory sinuses has generally been regarded as a desperate condition. It may assume the type of sarcoma or epithelioma and is so insidious and rapid in its development that in most cases it is beyond reach by the time its character is made known. The age and condition of these patients generally preclude extensive surgical operations, so that many surgeons prefer to attempt destruction of the growth by the actual cautery and



Unable to display this page



From a study of this subject by Schwenn suppuration, fetor, rapid extension and recurrence would seem to be the main characteristics of malignant disease of a sinus. Pain also is almost invariably present and may be intermittent and neuralgic from compression of a nerve trunk or continuous from distention of the walls of the affected cavity. The tendency of malignant disease of the antrum to perforate at several points on the cheek or into the orbit is observed. Perforation may occur in simple empyema but only at one situation and only in case drainage is absolutely cut off. Ocular symptoms are prominent when the anterior ethmoid cells are involved. It may be difficult to determine whether displacement of the eyeball, disturbance of the lachrymal apparatus, or other eye symptoms are due to trouble originating within the orbit or in the ethmoid cells, especially when there is no nasal obstruction and no visible tumor in the nasal fossa. In most cases there is more or less obstruction of one nostril and in nearly every case the septum is attacked. Nasal breathing may not be much impeded. On the contrary when the disease springs from the posterior ethmoid cells the growth projects into the nasopharynx and obstructs the passages. In the latter case also the orbit is almost always invaded with involvement first of the sixth and then of the optic nerve and corresponding ocular disturbance. Tumors of the sphenoidal sinus cause a great variety of symptoms, impairment of hearing, of vision, of smell, of taste, trigeminal neuralgia, ill-defined headaches and finally cerebral symptoms. Their growth is usually very rapid, and the success of radical interference is extremely remote.



## CHAPTER V.

DISEASES AND DEFORMITIES OF THE NASAL SEPTUM. DEVIATION.  
ECCHONDROSIS. EXOSTOSIS. ULCERATION. PERFORATION.  
HEMATOMA. ABSCESS. CONGENITAL OCCLUSION OF THE  
NARIS. ADHESIONS. COLLAPSE OF THE NOSTRIL.  
DISLOCATION OF THE COLUMNAR CARTILAGE.  
FRACTURE OF THE NOSE.

### DEVIATIONS OF THE SEPTUM.

The etiology of deviated septum has been the subject of much controversy. It is met with very early in life and has been pronounced congenital in certain cases. It is doubtful whether syphilis is a factor in its causation, but many cases exhibit more or less evidence of scrofulous taint. In a certain proportion of cases we succeed in getting a history of traumatism and, when we consider how exposed the nose is to external injury and how much of the time is spent upon this organ in babyhood, we realize that the condition may be induced by frequent repetitions of mild degrees of violence, as well as by a single severe injury.

The attempt has been made to classify deviations of the septum in accordance with the forms they assume, but the variations are so unlimited that a strict classification is not feasible and is clinically valueless.

In general we may speak of horizontal, vertical and sigmoid deviations. In the first the long axis of the deformity is antero-posterior, in the second it is at or near a right angle to the floor of the nose, and in the last the septum is seen to bulge into one nostril above and to the opposite side at its lower part, thus assuming a sigmoid or S form. In some cases the bowing of the cartilage is gradual and symmetrical, in others there is a narrow deep furrow on one side and a corresponding sharp prominence on the other, as if the septum in its plastic state had been compressed in its vertical plane, or, as Lennox Browne puts it, "a crumpled partition" exists.



The first is by far the most frequent form and the second the rarest. Sigmoid deviations are quite common and are perhaps the most difficult to deal with. One of the most intractable deformities of the septum is that in which an anterior deflection of the cartilage is associated with a displacement of the bony septum into the opposite naris, constituting what may be called a *horizontal sigmoid* deviation. Opinions differ as to whether excessive height of the palatal arch almost always seen in connection with a deviated septum bears a relation of cause or effect. The concurrence of adenoids with septal deflection and a high narrow hard palate, especially in young subjects who are mouth-breathers, is a matter of common observation. It is probable that the same diathetic state is concerned in the etiology of each of these conditions. The fact that deviations of the septum are seldom seen in early life, with a history of injury, would enforce the theory that most of these cases are due to arrest of palatal development, or overgrowth of septal tissue, or both combined. In early fetal life the hard palate is above the level of the Eustachian tubes and gradually descends in process of normal development. The Gothic arched palate must be looked upon as a frequent result of the maldevelopment often associated with adenoids in the rhinopharynx and consequently as one of the causes of septal deformity. Mayo Collier contends that deflections occur at the thinnest and weakest part of the septum, in consequence of relatively increased atmospheric pressure due to rarefaction of air on inspiration, which latter results from some form of obstruction in the nostril. This certainly cannot be regarded as a satisfactory explanation of all varieties of deviation.

In the majority of cases the cartilaginous septum is chiefly affected; no matter how great a bending may exist in the anterior part we find the posterior margin of the vomer maintaining a vertical position. Hence there is always a sacrifice of breathing space, the wider nostril admitting no more air than its narrowest portion allows to pass. The simplest form of deviation is that consisting of a bowing of the cartilage, one side being concave, the other convex, without marked thickening. Associated with the deflection more or less enlargement of the inferior turbinate body opposite the concavity of the septum is likely to exist as a result of nature's effort to prevent



the admission of an undue volume of air. The hypertrophy, therefore, is a result, not a cause, of the deviation, though the latter may appear to be the case at first glance.

The frequency of deviation is remarkable; an absolutely straight septum is almost unknown. Inspection of a very large number of skulls in various museums has shown that distortion of the bony septum is present in much more than half of the cases examined. It is reasonable to infer that deformities of the cartilage are far more frequent. Associated with the deviation, in a large proportion of cases, there is more or less thickening of the septum, especially at the apex of the bend in the form of ecchondrosis, or hyperchondrosis, and over the vomer, exostosis. A thickening is also particularly observable along the junction of the quadrilateral cartilage with the vomer and the perpendicular plate of the ethmoid. Its preponderance along sutural lines gives credibility to the traumatic theory of causation, an arthritis being excited by a blow or fall which results in piling up of tissue along the lines of articulation. In other cases, however, where there is an absence of thickening, which would seem to be of inflammatory origin, the impression is given that the bending is a result of overgrowth, or hypernutrition, the development of the septum continuing after the bones of the face have undergone consolidation, so that there is insufficient room in the vertical line for its accommodation.

The symptoms induced by a deviated septum are those referable chiefly to nasal stenosis. In cases of extreme displacement, there may be some deformity of the external nose, the tip being tilted or twisted from the median line. Not infrequently the symmetry of the nostrils is impaired, or the columna nasi may be displaced. The effects of nasal stenosis are displayed, to a considerable degree, in the region immediately behind an obstruction and in the lower air tract as well. In no small proportion of cases laryngeal symptoms may be distinctly traceable to a deviated septum, and a condition of congestion in the postnasal space may involve the Eustachian tubes and lead to a train of annoying ear symptoms. Behind the stenosed area, the air being rarefied with each inspiration, a condition of chronic congestion is induced in the mucous membrane which eventually leads to hypernutrition and hyperplasia. In case of complete



stenosis, the functions of the nostril are entirely abolished. The impediment to inspiration is still further aggravated by collapse of the nostril on the affected side in consequence of the increased rapidity of the entering current of air, or weakness of the alar muscles. The effect upon the voice of stenosis due to septal deviation is often very marked; the quality and tone are impaired both from the abolition of the resonating chamber and from the associated catarrhal condition; in consequence, increased phonatory effort is likely to result in voice strain. In addition, we may have developed a train of reflex nerve symptoms to be elsewhere considered when the deviation is so exaggerated as to cause pressure upon a turbinate body.

The diagnosis of deviation is not difficult if one takes pains to compare the nostrils and to explore the nasal fossæ by means of a probe, with the finger tip, or, if need be, with a septometer. (See Fig. 10.)

The prognosis under the present method of managing these cases is good so far as the lesion itself is concerned. As regards complicating disorders the outlook will depend in great measure upon the duration of the condition. In nearly every case we shall succeed in giving a certain amount of amelioration, if not complete cure, which will be permanent provided corrective measures are not undertaken too early in life.

The only *treatment* for the condition is surgical. The earliest attempts to correct the deformity consisted in pressure upon the displaced cartilage by means of the finger repeated by the patient himself at short intervals. Various plastic operations have been recommended in which the mucous membrane is dissected up and redundant portions of the deflected cartilage excised, the soft parts being subsequently replaced or brought together by means of sutures. More elaborate operations consist in raising the tip of the nose by external incision or by the incision of Rouge, so as to allow free admission to the nasal cavities. Among the early operative resources, for a long time popular, was that known as the method of Blandin, which consisted in the removal of one or more segments of cartilage by means of a punch, no effort being made to save the mucous membrane. Of course, this resulted in permanent perfora-



tion of the septum. For many years what is known as Adams' operation was practiced, in which the septum was seized with forceps and was fractured in such a way as to permit its replacement in the middle line (Fig. 47). The broken septum was retained in proper position by inserting ivory plugs which were worn until firm union. The results of this operation have been more or less disappointing

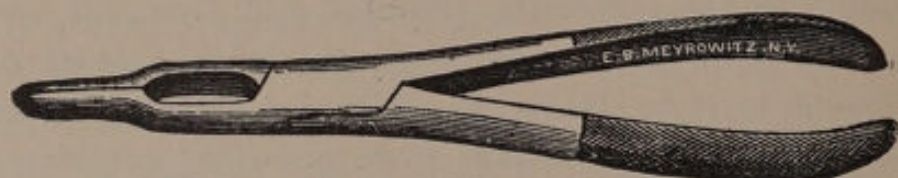


FIG. 47. ADAMS' SEPTAL FORCEPS.

for the reason, in the first place, that the shape of the deformity varies so much in different cases that no one method is applicable to all. In addition, great thickening at the apex or convexity of the deformity may be often more important than the deflection itself. In not a few instances simple removal of the overgrowth of tissue on the convex side will restore the air current sufficiently so that any attack upon the septum beyond this is found to be unnecessary. In

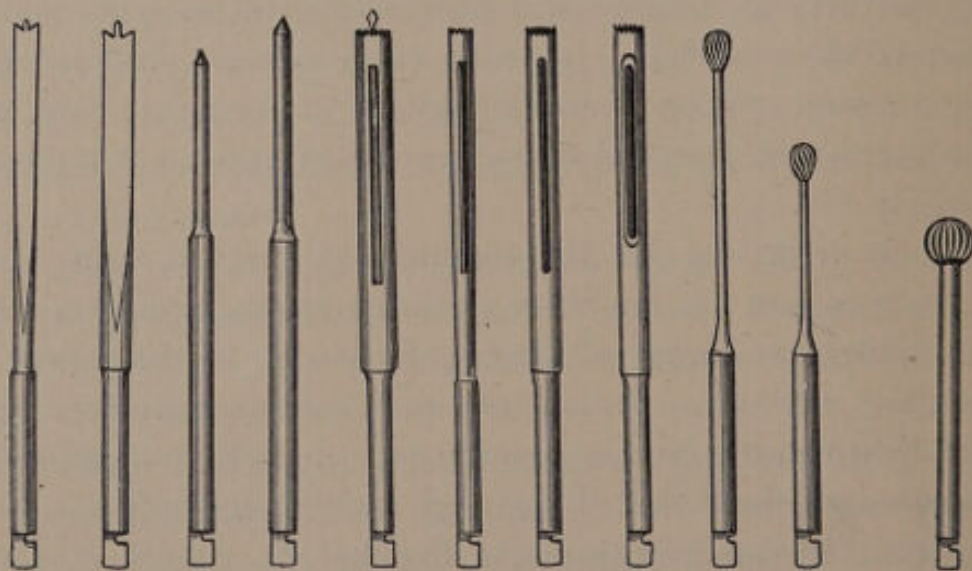


FIG. 48. NASAL DRILLS, TREPHINES AND BURRS.

many cases removal of the thickened portion with a saw will answer every purpose. In others where the thickening does not constitute an abrupt spur or ridge, the drill, or nasal trephine of Holbrook Curtis (Fig. 48) will be found to give better satisfaction. The trephine may be passed at several levels or the projecting shoulders left above and below its track may be smoothed off with rongeur



forceps. The drill and trephine are most conveniently operated by the electro-motor, and the saw also may be used with electric power, but the handsaw is rather more manageable and safer. It may be necessary to reduce a swollen turbinate before attempting to replace a bent septum. All these minor, or preliminary operations may be done under cocaine anesthesia. But few would be able to endure the pain involved in fracturing and readjusting the septum itself without a general anesthetic. For cases of simple deflection without thickening the pin operation of Roberts occasionally gives good results. In this operation an incision is made along the prominence of the deflection with a bistoury, the parts are then pushed over into position, where they are held by means of a long steel pin passed through the columna from the concave side across the line of incision and into the septal tissues above and behind. The head of the pin

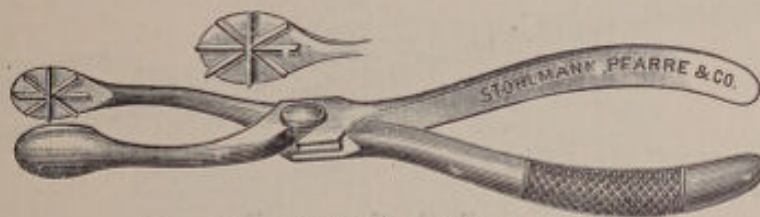


FIG. 49. STEELE'S SEPTUM PUNCH.

protrudes from the nostril, or may be concealed in the vestibule, and does not interfere with breathing; it should remain in place a week or longer until the replaced septal fragments have become consolidated. More than one pin may be required to give proper support. It is important that the cartilage should be thoroughly loosened in order to obviate undue pressure from the shaft of the pin; otherwise there is danger of its cutting its way through the tissues. The obvious advantage of this method, where applicable, is that nasal breathing is not interfered with. An attempt to remedy the deformity by multiple incisions, or by stellate incisions with a forceps like that devised by Steele (Fig. 49) and modified by Sajous and others, has been only moderately successful. Roe prefers to break the septum without lacerating the soft parts, and for this purpose uses a special forceps, one blade of which is larger than the other and fenestrated (Fig. 50). The blades are made of different sizes and may be adjustable to a common handle. In operating the solid or male blade is inserted in the convex side and the ring blade in the



opposite nostril. The solid blade fits the ring loosely, and when the instrument is closed other portions of the septum than that immediately compressed are not disturbed. The importance of fracturing the bony septum in most cases is insisted upon, and it is claimed that it may be done with this instrument without any of the risks incident to the twisting and rocking motions necessary with other septal forceps. In many cases the comminution of the septum accomplished by Roe's forceps does not wholly overcome the redundancy of tissue which must be provided for by preliminary incisions of the cartilage. These incisions should be made oblique, or beveled, so as to permit the fragments to override each other. Thus the thick ridges formed when the septum has been straightened after cuts at a right angle to its vertical plane are in large part avoided. If the




FIG. 50. ROE'S SEPTUM FORCEPS.

cartilage is not excessively redundant these incisions may be made from the concave side only to the perichondrium of the convex side, the finger in the latter nostril readily guiding the knife. Usually two incisions, a horizontal and a vertical one, crossing at the point of greatest deformity are required, and a special cartilage knife with a shield which may be used to limit the depth of the cut is recommended. Turbinate hypertrophies, adhesions and so far as possible ridges and spurs of the septum should be removed before attempts at straightening are undertaken. A ridge projecting from the intermaxillary bone in the floor of the nose often present in these cases may sometimes be broken with the forceps, but not infrequently a saw or chisel may be needed if the bone is very dense. For holding the septum in right position a metal plate wound with cotton or gauze to the proper size is preferred to any other mechanical appliance as well as to the tubes in common use. It is left in place for three or four days, then removed, the parts cleansed with a warm borated bichlorid solution, 1 to 5,000, and a fresh plug inserted for two days,



by which time the septum is usually firm in its corrected position. Any tendency to recurrence of deformity may be arrested by the introduction of a non-perforated hard rubber or aluminum tube for a few days. The preliminary work is done with cocaine and suprarenal extract; the actual fracturing under primary chloroform anesthesia.

A mode of operating recently suggested by E. J. Moure presents several interesting features and is claimed by its promotor to have certain advantages over the Asch operation presently to be described. He evidently misconceives some of the details of the latter operation as practiced at present, especially as regards the management of the

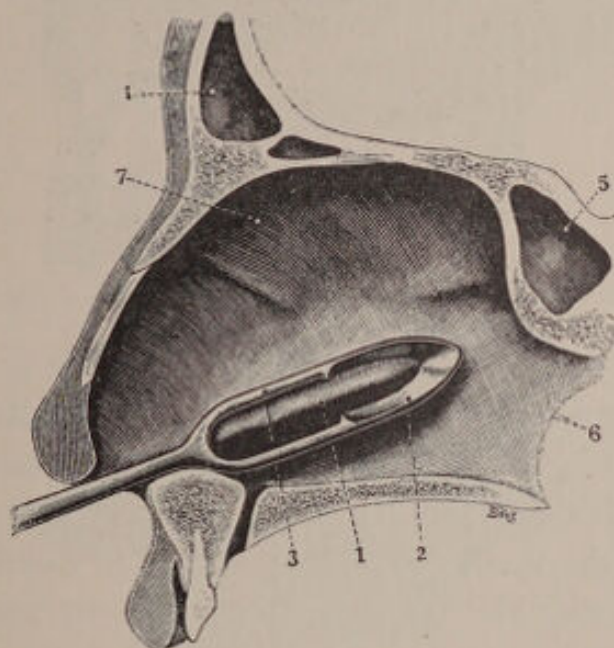


FIG. 51. MOURE'S OSTEOTOME.

tube. Three stages of Moure's operation are outlined as applicable to the majority of cases, but of course not all, since the three conditions to be met are not always found. In the first place a ridge of cartilage, or ecchondrosis, at the apex of the deviation is removed with an elliptical ring osteotome (Fig. 51). In the second place the antero-inferior border of the cartilage, which is often luxated into the nostril opposite the convexity of the deviation, is shaved off with a bistoury, after having been button-holed by an incision along its most prominent part. Finally after these wounds have healed, that is, in the course of a month, the deviation itself is attacked. The direction of the incisions and the intranasal splint used for supporting



the septal fragments differ from those in other operations. The cuts are made with scissors, almost identical with those of Asch, the first one nearly parallel with the floor of the nose and as close as possible to the inferior attachment of the cartilage (Fig. 52). A second cut

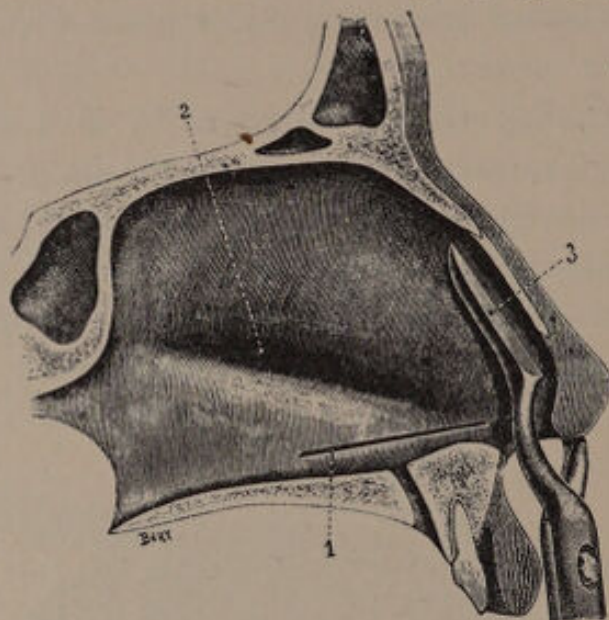


FIG. 52. INCISIONS IN MOIRE'S OPERATION.

is made obliquely upward and as close as possible to the dorsum of the nose, leaving a somewhat narrow bridge of cartilage between the anterior ends and a very wide one between the posterior ends of the incisions. This triangular movable fragment of cartilage is held in front at the tip of the nose by a band of cartilage and behind by the perpendicular plate of the ethmoid and the vomer. A special

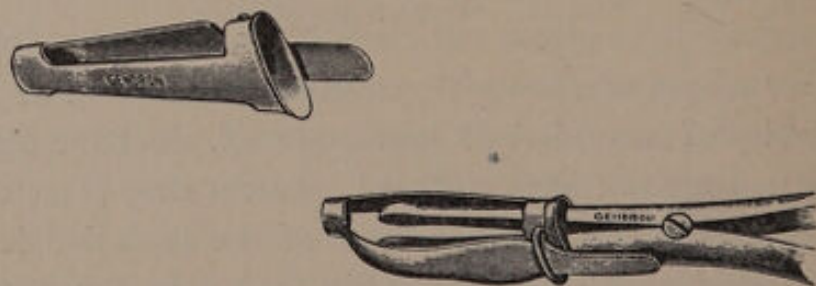


FIG. 53. MOIRE'S NASAL TUBE AND DILATING FORCEPS.

tube, composed of two parallel blades, the outer one rigid to rest upon the turbinate, the inner one malleable, is then introduced. The malleable blade is then moulded against the deviated cartilage, thus correcting the deflection to the desired degree, by means of dilating forceps passed into the tube (Fig. 53). The tubes, which are made



in pairs, one for either nostril, are left in situ for at least eight days, a single tube being used only on the convex side in a given case. This method of operating is said to be rapid and not attended by much hemorrhage. Local anesthesia with cocaine is all sufficient, pain, if any, being due to the tube rather than the operation itself. No local treatment is advised, unless there is a good deal of purulent

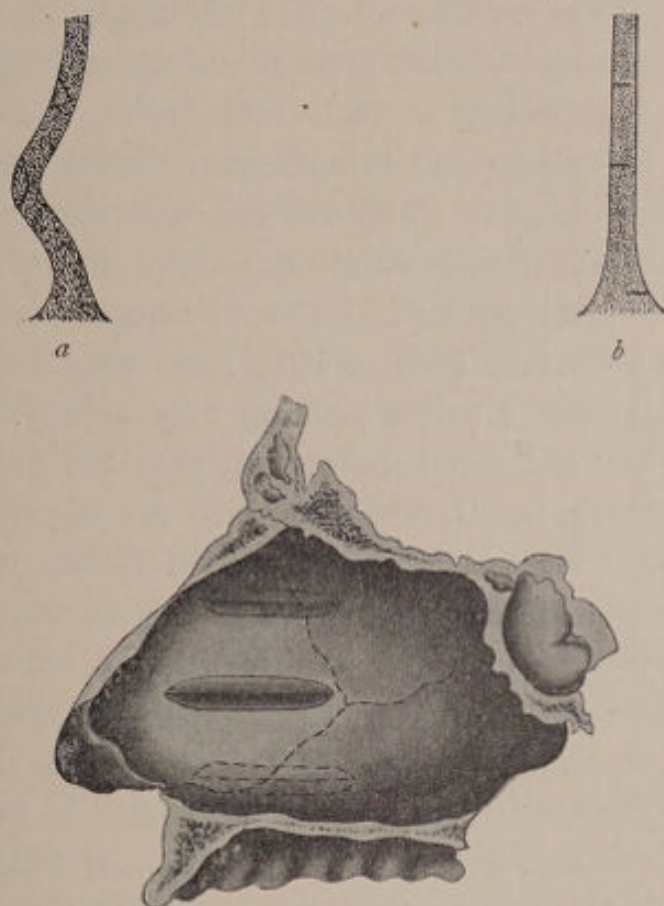


FIG. 54. KYLE'S OPERATION FOR DEFLECTED SEPTUM BY REMOVAL OF V-SHAPED SEGMENTS.

*a* and *b* show the location of incisions and the position assumed by the septum after the removal of the wedge-shaped pieces.

secretion, in which case the nasal fossæ may be douched twice a day with warm boracic acid solution, and the same may be applied externally for the relief of pain. Uniformly good results are claimed for this method of operating at least in adults. It is considered unwise to touch the septum until development is complete, that is, not before the sixteenth year.

In the operation described by Braden Kyle a V-shaped wedge of muco-chondrial tissue is resected antero-posteriorly, the base of the



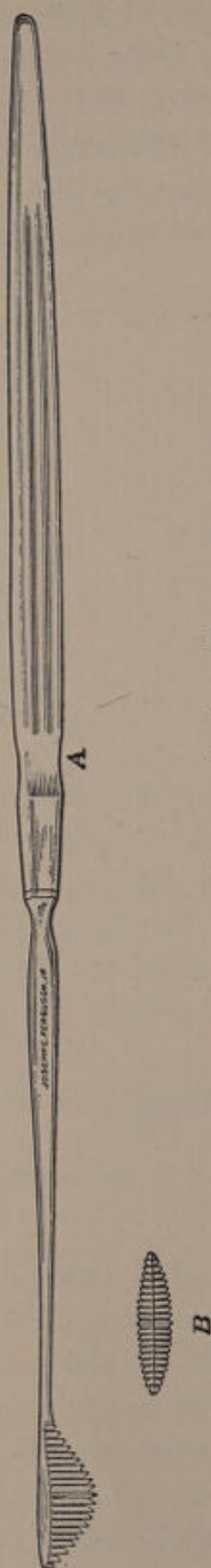

FIG. 55. FETTEROLF'S SAW FILE.

wedge looking toward the convexity and its apex toward the concavity of the deviation. It may be necessary to remove several of these V-shaped pieces in order to overcome redundancy, especially one on the concave side near the floor of the nose, and even the bony septum may be included (Fig. 54). The so-called "V-shaped sawfile" devised by Fetterolf is preferred for making the excisions (Fig. 55). If the incisions are made at the proper places and in sufficient number there will be no need of great violence in breaking up resiliency. Malleable metal tubes are preferred for supporting the replaced septum, and may be left in situ many weeks without risk, since they may be perfectly fitted to the position they occupy. There is no danger of perforation provided the blood supply is not interfered with by making the incisions too close together in parallel lines. It is important also to preserve intact the mucous membrane of the septum on the side opposite the cuts.

A rare variety of septal deformity consists of a displacement of the whole mass of the partition so that its lower border rests on the floor of one or the other nostril. There is little or no curvature or redundancy. Invariably there is more or less bending of the anterior nasal spine toward the narrow nostril combined with hyperostosis, so that the vestibular floor is converted into a mere fissure. Such a deformity is supposed to be an immediate result of violent traumatism, the associated hyperplasia of bone and cartilage being a natural consequence of the subsequent reparative process. For the condition described the *supralabial operation* of Harrison Allen seems to be admirably adapted. Strange to say, it is very little known, but its merits have recently been

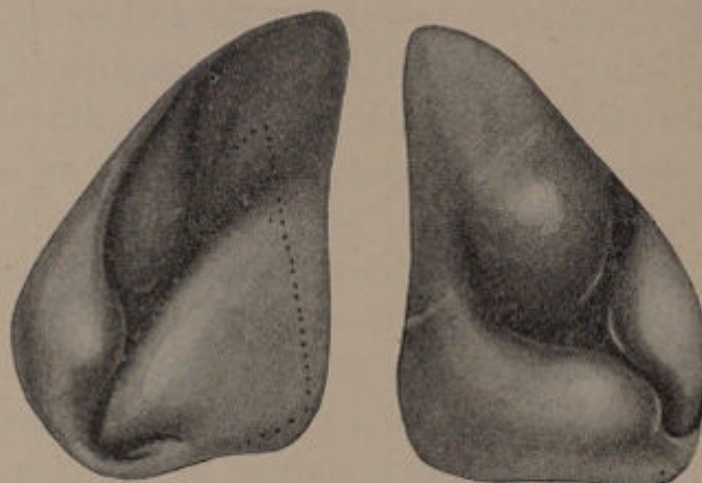


forcibly urged by A. A. Bliss, from whose description the following is condensed. The frenum of the upper lip is first divided with a small sharp-pointed bistoury. A chisel with a cutting edge one fourth to three eighths of an inch in width is passed into the wound upward to the base of the maxillary crest and then driven with a few blows of the mallet directly backward through the nasal spine as far as the nasopalatine foramen. At once it will be found possible to push the septum over with the finger as far as may be desired, provided the section has been complete. Unless the premaxilla is unusually high, so that the floor of the vestibule is on a higher plane than the floor of the naris in general, the mucous membrane will not be perforated by the chisel. In any case the accident is not of much consequence. The septum is held in its corrected position by means of a rubber tube splint, cold water dressings are applied externally, and the nares are sprayed every two hours with an alkaline antiseptic solution. The operation is done under light etherization, and roughnesses may be smoothed down at once or later under cocaine. The simplicity of this procedure, its effectiveness and the absence of marked reaction commend it in this peculiar form of septal deviation. The patient is kept in bed a day or two and the tube is dispensed with after the second week, making the duration of treatment about the same as in other operations.

The fact has been mentioned that one of the earliest methods resorted to for relieving the subjective symptoms caused by a deviated septum was the formation of a perforation by punching out more or less of the deformed cartilage. Later attempts were made to save the mucous membrane by dissecting it from the cartilage and resecting as much of the latter as might seem desirable. Among the first to do this operation was Ingals, who removes a triangular segment of cartilage from the anterior face of a convex deviation, then detaches the posterior remnant of cartilage from the floor of the nose, forces it into the median line and holds it in position by a tampon of lint charged with iodoform and boric acid. The cartilaginous triangle removed has its apex above and its base below, and its dimensions vary of course with the degree of deformity. The bony ridge jutting from the floor of the nose which supports the septum must be removed with saw, chisel, or trephine. In cutting the car-



tilage Sajous' knife is used and care is taken not to damage the mucous membrane covering the concavity. If the depression is abrupt or angular it is difficult to avoid perforating, but the flaps of mucous membrane formed on the convexity will cover such a lesion. The direction and extent of the primary incision through the mucous membrane must vary with the shape of the deformity, and the soft parts are separated from the cartilage with a specially designed spud so as to give a wide exposure of the latter. Escat is quoted by Shurly as practicing a submucous injection of water in order to lift off the membrane covering the concavity and thus protect it from injury while the cartilage is being incised. Anteriorly the soft tis-



a

FIG. 56. KRIEG'S OPERATION FOR ANGULAR DEFLECTION OF SEPTUM.

sues are quite adherent and must be dissected up, while posteriorly it is easy to raise them with a suitable elevator.

The "window resection" operation of Krieg aims to remove all of the deflected cartilage from between the layers of mucous membrane, while Boenninghaus also removes the bony septum so far as it may be involved (Fig. 56). Relying upon the assumption that the nasal septum is merely a partition and in no sense a support to the external nose Otto Freer, without knowledge of having been anticipated, has recently advocated an operation practically identical with that of Krieg and Boenninghaus, differing only in one particular. Instead of removing the bony septum he fractures it with Roe's forceps after having fissured the bone with chisel or trephine. No intranasal splints are needed, but it is his custom to pack the



nostril with a strip of lint loaded with powdered subnitrate of bismuth. This dressing is said to remain aseptic for at least ten days. The objects of the tampon are to prevent secondary hemorrhage and to hold the flaps in place. The operation is done under local anesthesia with cocaine crystals, which are claimed to give most complete insensibility to pain with a minimum of toxic effects. In some cases chloroform must be used when the forceps is applied to the bony septum. In addition adrenalin provides a bloodless operative field. It is said that in some cases new cartilage and bone are regenerated from the preserved perichondrium and periosteum. Experience with the method up to the present time seems to show that this is not

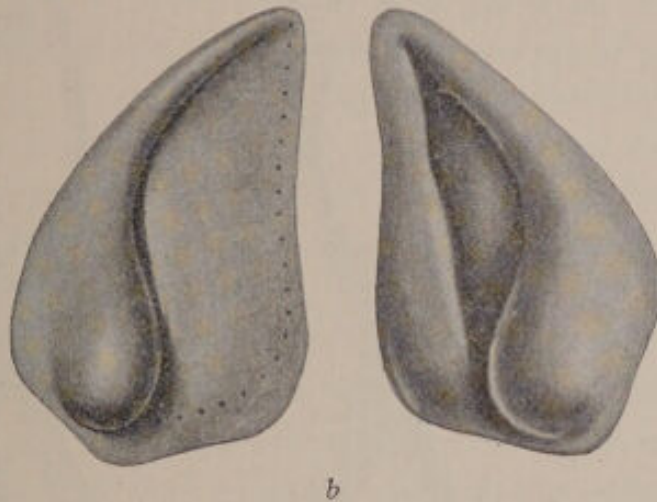


FIG. 56. "WINDOW-RESECTION" OPERATION FOR CURVED DEFLECTION TO RIGHT WITH LOWER BORDER OF SEPTAL CARTILAGE PROJECTING IN LEFT NARIS.  
(Krieg.)

essential, and the mucous membrane in the course of time resumes its function and becomes moist and free from incrustation. Such an operation demands great patience on the part of the operator and extraordinary fortitude in the patient, since its completion requires an hour or more. Yet the ultimate results are declared to be so satisfactory that it seems worth while to resort to it in certain intractable deflections, including the bony septum.

In hardly any other field is the fact so conspicuous that the perfection of an operative procedure is due not to a single individual but to contributions from many sources. Although these operations on the nasal septum carry personal titles, which for convenience they are likely to retain, yet in no instance can it be said that they are



the exclusive creation of those whose names they bear. Thus the Asch operation, which is just now popular in this country, is really an adaptation of various new and useful technical details to a principle which has long been recognized.

This operation must be done under general anesthesia and with

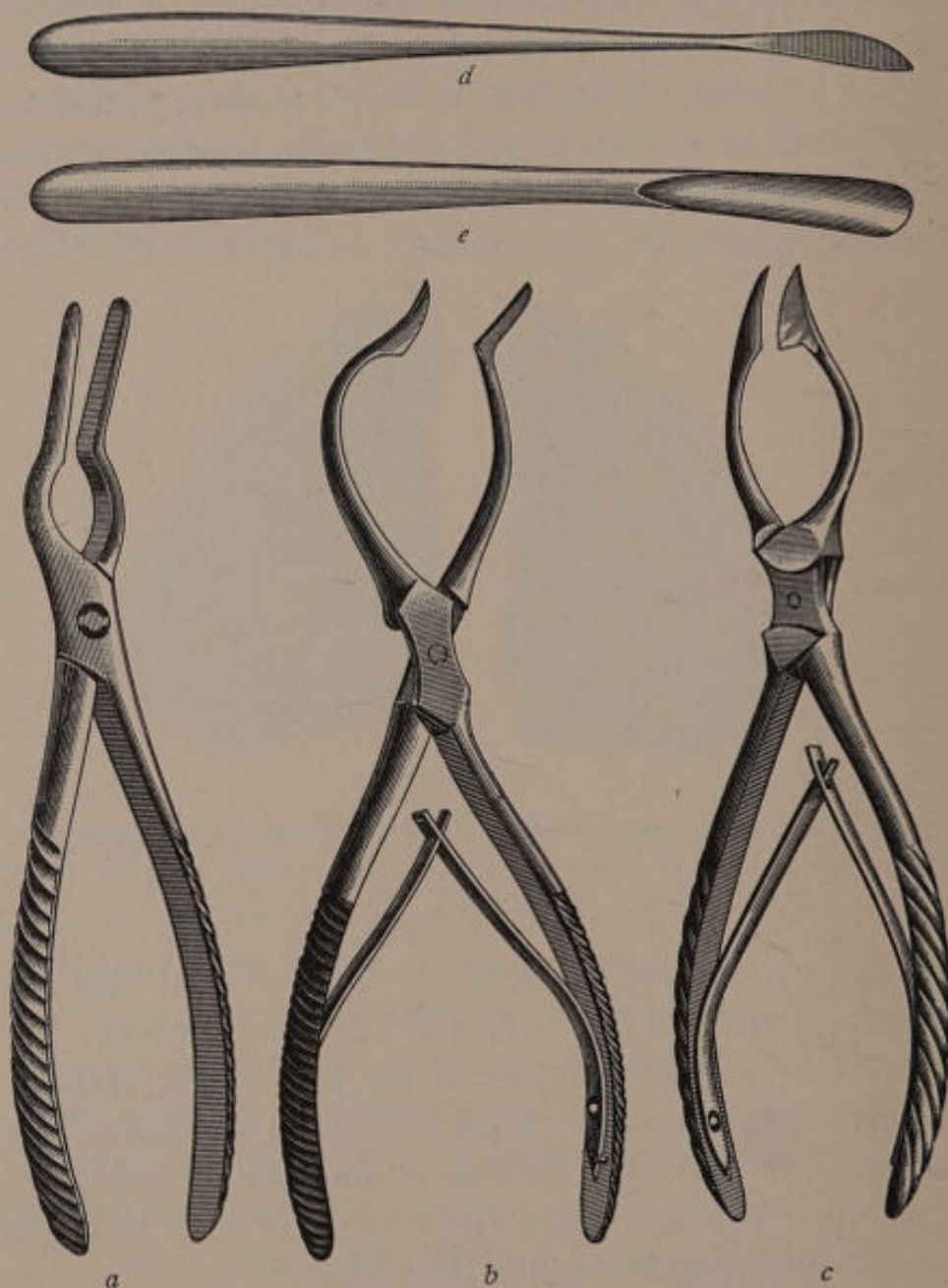


FIG. 57. ASCH'S INSTRUMENTS FOR DEVIATED SEPTUM OPERATION.

*a*, Compressing forceps; *b*, angular scissors; *c*, straight scissors; *d*, sharp separator; *e*, blunt separator.

the head of the patient dependent, in what is known as Trendelenberg's or Rose's position. Thus the risk of blood or coagula being



drawn into the larynx is abolished (Fig. 57). The special instruments required are first a pair of scissors, somewhat after the pattern of a "button-hole" scissors, that portion of the shank between the cutting edge and the joint being curved outward to avoid compressing the columna when the instrument is closed. Second, a curved gouge for breaking up adhesions. Third, a septal forceps, of the Adams' or similar design. Fourth, an intranasal splint to hold the parts in position until repair is complete. Various shapes and materials have been experimented with, tin, cork, Bernays' sponge, soft rubber and hard rubber. A hollow tube, made of the last mentioned material, flattened laterally and with its anterior end larger and shaped to fit the vestibule of the naris gives the best satisfaction. Some of these vulcanite nasal tubes have numerous perforations into which the mucous membrane is supposed to protrude and thus prevent the tube from slipping. By many a smooth tube is preferred, and if one of correct size has been selected and the spring of the cartilage has been destroyed it will stay in place. It permits nasal breathing and drainage and can be easily kept clean with the least possible disturbance of the wound. Before the operation the nostrils should be thoroughly irrigated with an antiseptic solution. The next step is to introduce a finger into the stenosed naris in order to learn the precise shape of the deformity and whether adhesions are present. The latter may be broken down with the finger or with the gouge. One blade of the scissors, which is blunt and dull, is passed into the contracted nostril, the other, which is sharp, into the wide nostril, and the cartilage is divided through its whole thickness at its point of greatest deviation on a line nearly parallel with the floor of the nose. A second cut is then made across the middle of the former and as nearly as possible at a right angle to it. Thus the cartilage is divided into four triangular segments nearly uniform in size. These segments are then broken at their bases by twisting them vigorously with the septal forceps. This step of the operation demands the exercise of force, since success depends upon its thoroughness, and it is surprising what amount of traumatism these structures will tolerate without resentment. A supporting tube should be selected as large as the nostril will admit and retain without excessive pressure, a matter which it is well to determine beforehand,



by inserting the larger end of the tube into the nostril. It is best to proceed deliberately and control the bleeding if possible between the stages of the operation. In rare cases the tube and even a tampon must be inserted before the hemorrhage can be checked. The patient should be kept quiet for a day or two and the parts gently irrigated with a warm boric acid solution every twelve hours without moving

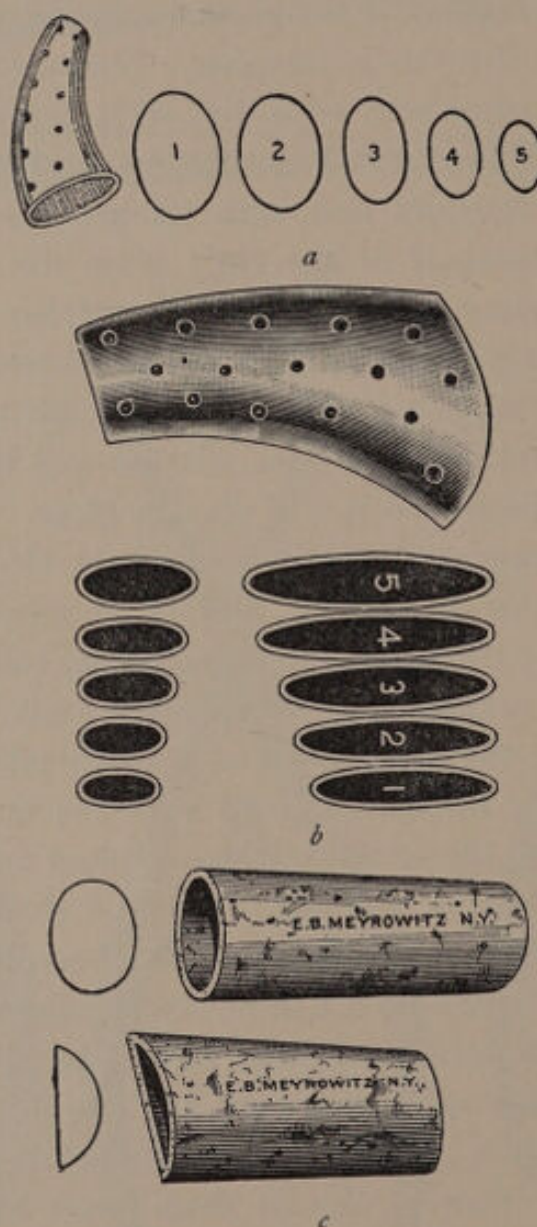


FIG. 58. NASAL TUBES. *a*, Asch's hard rubber; *b*, Kyle's malleable; *c*, cork.

the tube. The occurrence of much pain, marked swelling of the external parts, or decided elevation of temperature are indications for withdrawal of the tube and possible substitution of a smaller size. The secret of success in this, as in all operations for deviation,



lies in destroying the resiliency of the cartilage. The intranasal tube should be worn for at least two weeks and, in extreme cases, even longer and should be large enough to fill the nostril without producing painful pressure (Fig. 58). It should be left undisturbed for three or four days, cleansing of the nostril being conducted through it by means of douches or coarse spray of alkaline solution. The tube may be easily removed after thoroughly washing the nostril with an alkaline solution and spraying with albolene, and its replacement may be made painless by cocainization. Unless some special indication arises it is desirable to avoid handling the parts more than is absolutely necessary to keep them clean.

The amount of bleeding occurring during these operations for deviation of the septum is frequently considerable but is usually arrested by the pressure of the tube with the addition of a plug on the opposite side if necessary. As a rule, a tube is placed only in the convex side. An accident which sometimes happens is annoying but not a source of any great discomfort, namely, the occurrence of



FIG. 59. KYLE'S SEPTUM KNIFE.

necrosis along the line of incision. My personal preference for making the division of the cartilage is a sharp-pointed curved bistoury which can be more precisely controlled than the scissors, the incisions being made along the lines of greatest deviation and exactly to the desired extent. A septum knife, devised especially for this purpose, is thought by some to be more convenient (Fig. 59). One of the best methods of checking bleeding when not very excessive is the introduction of pledgets of absorbent cotton soaked in hot water, or adrenal extract.

As a preliminary to operation it is customary to cleanse the nasal fossæ thoroughly with a mild formalin solution or a saturated boric acid solution. Immediately after the operation for deviated septum the parts frequently look unpromising in consequence of thickening of the cartilage from overlapping fragments. Not infrequently we find projecting from the floor of the nose a spur or ridge from the intermaxillary bone which may finally require removal by means of



a saw, chisel, or trephine. Nevertheless, it is well not to be in too much of a hurry to attack these thickenings and irregularities since it is remarkable to what extent their absorption is accomplished.

It is very obvious that repair is retarded and the patient is subjected to needless discomfort by too much meddling with the parts after operation. It is impossible to keep these wounds absolutely aseptic and the effort to do so by assiduous cleansing with powerful antiseptics is to say the least unwise. While evidence of the bactericidal power of nasal mucus is not conclusive this fluid does not appear to be a good medium for germ growth, and it is certainly a clinical fact that wounds of the intranasal structures do uniformly well, provided they are not subjected to extraordinary irritation or the original violence was not excessive. As a rule, gentle cleansing once in twenty-four hours with a simple detergent solution, Seiler's or Dobell's, will be enough to prevent accumulation and decomposition of secretion and will give nature a fair chance.

An excellent method of treating certain forms of simple deviation of the cartilaginous septum without thickening was suggested at about the same time by Watson and Gleason, of Philadelphia, their methods differing only in certain unimportant details. The operation of the latter consists of forming a U-shaped flap of the whole thickness of the cartilage by inserting a saw at the lower limit of the deflection and sawing first obliquely and then directly upwards as far as necessary to include all of the deformity, the arms of the U being extended, if need be, by means of a blunt bistoury; in the case of the anterior arm the bistoury is passed on the convex side, and of the posterior arm on the concave side, of the septum. In this way the lines of incision may be prolonged to any desired extent. The flap should be made large enough to completely include the deformity, and is forcibly pushed over to the concave side so as to destroy the spring at its attachment above as completely as possible. Thus the pendulous U is retained by the margins of the incision. The chief advantage of this mode of overcoming the deformity is that there is seldom necessity of intranasal support. The disadvantage is that a considerable amount of irregularity is necessarily left and it occasionally happens that slight perforations may exist at some part of the wound. With this, as with other modes of oper-



ating, it is well to postpone measures for correcting irregularities for a considerable time in order to allow the parts to mould themselves.

In Watson's method a similar incision is made upwards at the crest of the deviation without going through the mucous membrane on the concave side. The muco-cartilaginous flap thus formed is forced over to the wider nostril, where it is held by its beveled edges. This provides for a horizontal deviation. If a vertical deflection coexists a wedge-shaped piece of the cartilage, large enough to dispose of the redundancy, is excised.

These operations may be done under cocaine. Most patients prefer general anesthesia. The latter is indispensable when the forceps is to be used in fracturing the osseous septum. Great care should be exercised in handling the bony septum, especially its upper portion. The magnitude of septal operations must not be underestimated, and the general condition of the patient should be considered. In certain physical states the loss of blood and the shock to the nerve centers from the intranasal traumatism are elements of grave danger. Interference should by all means be postponed until the conditions, local and systemic, are restored to a desirable standard. There is reason to believe that the disasters which have been chronicled as sequels of these operations, but by no means peculiar to them, such as hemorrhage, suppurative sinusitis and even sepsis, are referable to neglect of careful scrutiny of the patient's condition. It is often a difficult matter to decide what is the best operation in a given case. In a large majority the Asch operation will give a satisfactory result, at least when the bony septum is exempt from deformity. Owing to the warnings given by Emil Mayer and by Asch himself, attempts to fracture the bone with the forceps are regarded as dangerous. In a case reported by Robert Levy fatal sepsis occurred and Freer refers to a case in which suppuration of the sphenoidal sinus followed the operation. Such accidents as these, and fracture of the turbinates, as in the experience of Stucky, would seem to be fairly explained by some error in technique or some obscure morbid state in the individual operated upon. The violence required even to fracture the bony septum is in no degree comparable with that inflicted in many traumatisms with no untoward results beyond merely local damage.



Hemorrhage in the Asch operation with the head dependent is naturally more free than when the patient is erect, but has been somewhat reduced since it became the custom to use a thorough preliminary application of adrenalin. The objection offered to the Asch tube that it is too much curved is overcome in part by Mayer's modification and completely by that suggested by McKernon, in which the lower border of the tube is straight, and in addition the last has its upper anterior border rounded so as to fit into the hollow of the nasal vestibule without producing irritation. Moreover, it has the advantage of not being perforated. Most of the tubes in common use are too small at their distal end to give enough support to a deflection extending far back in the naris. All tubes made of hard rubber or other inflexible material are unsatisfactory for the reason that they cannot be molded to the nostril. The latter objection is obviated in the malleable tubes used by Kyle and others. The cork splint of Berens and the compressed cotton tampon (Bernay's sponge) of Simpson, either of which may be readily shaped to suit the case, deserve further trial. The former is cut as desired at the time of operation and is made aseptic by being coated with iodoform collodion. A thin plate of vulcanite has been added by Chappell to the septal surface of the latter, which makes the splint firmer and prevents adhesion of the cotton fibers. If the cotton swells excessively it is a simple matter with a broad-bladed forceps to extract a layer or two from the middle of the splint. Wholesale resection of the osseo-cartilaginous partition between the nares is not to be unreservedly advised until it can be conclusively proved that it is free from risk to the contour of the external nose and that it gives results superior to those obtained by other methods less tedious. Success will surely attend any method of operating which destroys the elastic spring of the septum and disposes of excess of tissue by resection or properly planned incisions.

One of the most annoying complications of a deflected septum is a disfigurement of the external nose caused by an abrupt bend at the junction of the cartilage with the nasal bones. It is most common in traumatic cases and frequently one or the other nasal bone is depressed. It is impossible to correct the deformity until the bone has been restored to its normal place. This may sometimes be done with



a Sinexon's nasal dilator, or with a powerful forceps, like that devised by Walsham, one blade of which is to be applied within and the other outside the nostril. In some cases there is a good deal of thickening at the prominence of the angle, a result of the original injury, which may be shaved down by a guarded electric burr introduced through the nostril, the skin having first been dissected from the hard parts. Or it may be more comfortably removed by external incision, provided the patient is willing to wear the trifling scar that may follow such a wound. In most cases cosmetic effects are considered less important than restoration of breathing space, yet by the exercise of a little care and ingenuity much may be done to remedy these unsightly distortions.

#### ECCHONDROSIS AND EXOSTOSIS OF THE SEPTUM.

Ridges or spurs of the nasal septum may consist of cartilage or of bone. In the former case they are called *ecchondroses*, in the latter *exostoses*. They may exist quite independently of deflection of the septum. Exostoses are met with generally far back in the region

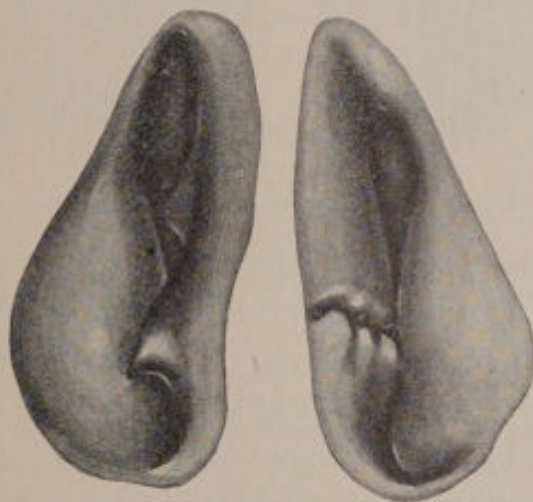


FIG. 60, a. ECCHONDROSIS OF SEPTUM EMBEDDED IN RIGHT INFERIOR TURBINATE, WITH DEEP GROOVE ON OPPOSITE SIDE. (Krieg.)

of the vomer, although it is not unusual to see indications of ossification in anterior ecchondroses of long standing, especially those near the floor of the nose, or a septal ridge may consist of cartilage in front and behind of bone. The possible admixture of osseous tissue has an important bearing on the selection of a mode of correcting



Unable to display this page



injury, would exclude a traumatic theory of etiology. In fact, it seems impossible to explain the origin of these singular deformities.

By far the best instruments for removing these overgrowths is the nasal saw. The ring-knife or "spoke-shave" is much inferior especially in dealing with dense bone. A long thin-bladed saw with teeth set and cutting from behind forward has given me the most satisfaction. It makes very little difference whether the handle be straight or angular, as one may readily become accustomed to either (Fig. 61). It is well to make a preliminary cut through the mucous

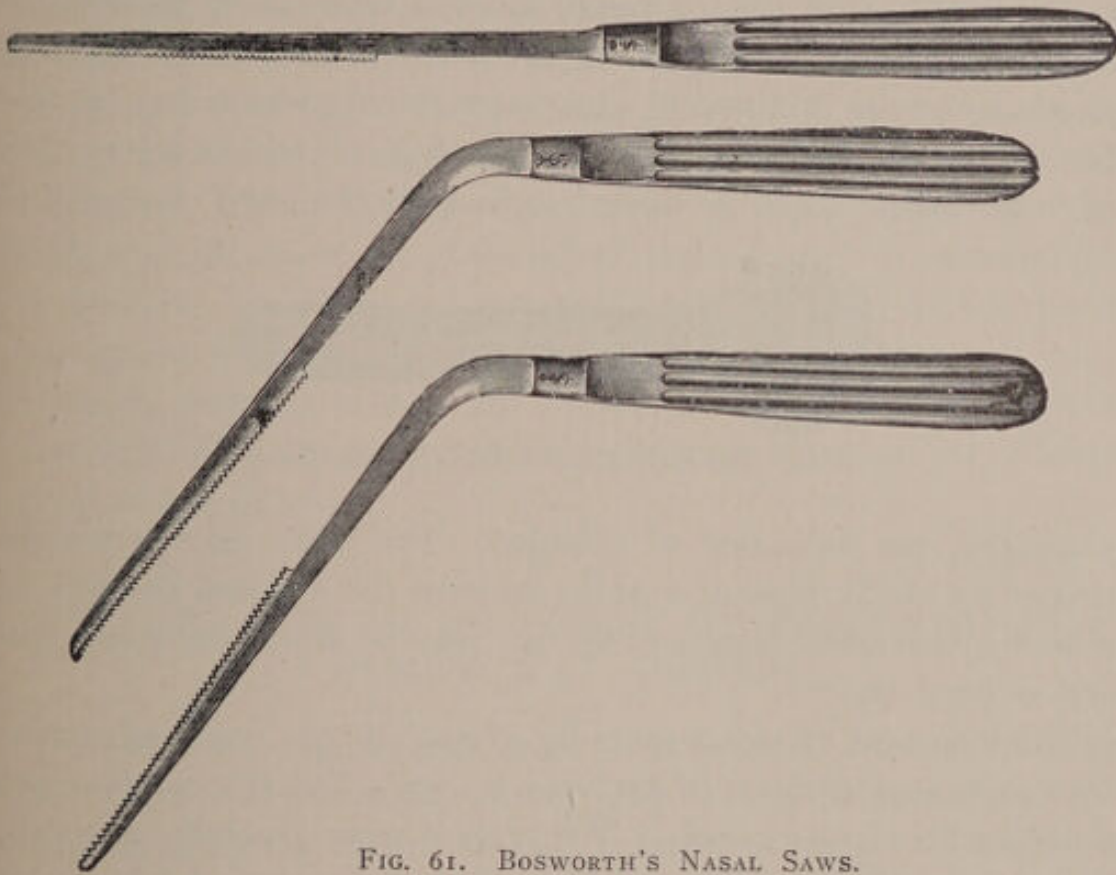


FIG. 61. BOSWORTH'S NASAL SAWS.

membrane from below upwards in order to obviate the danger of stripping up the soft parts. The excision of the mass itself is most conveniently made from above downwards. The saw should be applied at an angle until the soft parts are cut through, when it may be brought to a vertical position and the section completed, the object being to prevent slipping of the instrument and consequent incomplete removal of the redundant tissue. Under cocaine and the adrenal extract the operation is painless and almost bloodless. In excep-



tional cases each of these agents may fail to produce its legitimate effect, owing usually to individual idiosyncrasy. In the opinion of many secondary hemorrhages have been much more frequent and serious since their introduction, and firm plugging of the nostril is therefore advised by some in all these cases. My own feeling is strongly averse to the routine use of the intranasal plug, and my experience has been to be called upon to apply it quite as frequently before the cocaine-suprarenal era as since the use of these drugs became general. Fifteen or twenty minutes after the conclusion of the operation, when all oozing has ceased, both nostrils should be sprayed freely with the suprarenal solution followed by mentholized albolene. The patient should be cautioned to keep quiet, avoiding physical exercise and mental excitement for the succeeding twenty-four hours, and the necessity of a nasal plug will seldom arise. The after-treatment should be limited to keeping the parts clean and to



FIG. 62. DESSAR'S HARD RUBBER NASAL BOUGIE.

preventing the formation of adhesion. The latter may be accomplished by gently passing a probe between the opposed surfaces or a hard-rubber nasal bougie (Fig. 62) may be introduced every second or third day.

The treatment of septal spurs by electrolysis has many advocates. There are two methods of applying it, one called the unipolar and the other the bipolar system. The latter is more generally practiced. The source of electricity may be a thirty-cell galvanic battery, or preferably the Edison current, of 100 volts, modified by a suitable controller. A strength of from fifteen to forty milliamperes is required. The needles may be of steel, or gold-plated, in an adjustable handle. The former material is recommended by Moure and others, but a steel needle at the positive pole oxidizes and must be renewed at each sitting. Iridoplatinum needles are free from this objection and being indestructible may be fixed in a permanent handle (W. E. Casselberry). The pain of the operation is very



slight under cocaine, and there seems to be no doubt that cartilaginous spurs may be dissipated by this method. Bone is not affected by it and one objection to its use on the anterior part of the septum is the possibility of bony foci in an old ecchondrosis. The energy and duration of the current should not be excessive for fear of perforation of the septum, an accident which may be avoided by suspending the application the moment a mottling of the mucous membrane of the opposite side appears. The action of electrolysis is sorbefacient, that of the electric cautery is mainly destructive. Yet in reading the histories of reported cases of so-called electrolysis one cannot escape the suspicion that many of them belong in the latter category. We read of a slough separating at the end of a week followed by a granulating surface with pronounced loss of substance. Surely this is not electrolysis! Many authorities vigorously denounce the use of the galvano-cautery on the septum. My own experience convinces me of its safety and efficiency in ecchondroses of moderate dimensions. I am persuaded that much of the prejudice against it is founded upon its improper use in unsuitable cases. Electrical methods at best are inferior to cutting and are permissible only in timorous patients or in those to whom a loss of blood might be detrimental.

#### ULCERATION OF THE SEPTUM. PERFORATION. HEMATOMA. ABSCESS.

*Ulcers* of the septum may occur as a result of mechanical irritation due to special occupations or may develop in certain symptomatic conditions attended by local vascular changes. The apex or the concavity of a deflection is apt to be the site of ulceration owing to the lodgment of secretion which the patient is in the habit of removing with his finger. This is noticed particularly in young people, an abrasion of the septum following a wound due to the habit of picking the nose. Ulcerative processes may also follow acute fevers, typhoid, or specific disease. In the last the process is very apt to begin in the perichondrium or the periosteum and involve the mucous membrane secondarily. In syphilis the bone as well as the cartilage is apt to be affected. This is true of almost



no other ulceration occurring in the nose. The situation of the ulcer depends entirely upon its cause, but most ulcers are seen about the middle of the cartilaginous septum.

Over-treatment may be resorted to in consequence of the desire of the patient to obtain relief. In most cases simple cleanliness followed by the application of mild astringents will be all that is necessary. Exuberant granulations may need to be removed by cauterization or curetting. The formation of scabs should be prevented by the application of an ointment of vaselin containing ten grains to the ounce of boric acid, or a mixture of white precipitate ointment and oxide of zinc ointment in the proportion of one of the former and three of the latter. The last mentioned is particularly useful in specific ulcerations and, of course, in the latter condition we are called upon to adopt at the same time a vigorous constitutional course of treatment. A probable result of ulceration, especially when it is extensive and deep is a *perforation* of the cartilage, an accident which may not be of serious import, but, on the other hand, may be followed by some inconvenience as well as disfigurement. A perforation situated well forward and having thick edges is affirmed by Myles to cause the greatest annoyance. A theory of etiology held by C. W. Richardson and others is that the destructive process results from lowered vitality and resisting power of the cartilage due to defective innervation. Tubercular disease is discovered in a considerable proportion of cases of perforation. Its occurrence in workers in mercury, arsenic and other chemicals has long been known, and Toeplitz reports having discovered it in a large number of those employed in an establishment for the manufacture of Paris green. When the perforation involves only the cartilage it is usually of simple origin, although the ravages of syphilis may be, in rare cases, limited to the cartilaginous septum. Often the perforation may be traced to an injury which results in the formation of a *hematoma*. In the majority of cases a hematoma undergoes resolution without destruction of tissue; in others suppuration takes place and the tissues break down unless an early outlet is given to the pus. An *abscess* of the septum, if allowed to pursue its own course, almost invariably results in perforation with more or less sinking in of the dorsum of the nose. It is a curious fact that a perforation of considerable size may exist



without the knowledge of the patient. It has been many times my experience to see almost complete loss of the cartilaginous septum after typhoid fever without external deformity or any inconvenience resulting. The rapidity of the process and the resulting deformity vary greatly in different cases. At a meeting of the Laryngological Society of London, W. G. Spencer related the case of a boy in whom a hematoma just within the nares followed a fall on the face. There was no suppuration or immediate deformity, but two years later the bridge of the nose began to sink and the nasal septum became much thickened and twisted, probably in consequence of chondritis and softening resulting from the injury. There was no history of syphilis. On the other hand, Haviland Hall referred to the case of a woman of sixty in whom a septal abscess destroyed the cartilage and caused marked deformity within three or four weeks. It seems to be the general belief that in young people during the period of development these occurrences produce more deformity than in adults. Perforations are very apt to give more trouble when their long diameter is vertical than when it is horizontal. Frequently a whistling noise is noticed in respiration in the former case which is a source of some annoyance, and the tendency to incrustation of secretion along the margins of the opening is much more pronounced than when the perforation is antero-posterior. It occasionally happens that a perforation results from necrosis along the line of incision after the operation for deviated septum.

The treatment of perforation of the septum is limited to a correction of the tendency to erosion of the margins; no operative closure of the opening being feasible unless it be very small or the septal tissues be so redundant as to permit of a plastic method of closure, and, indeed, the disturbance which the condition causes is generally so trifling that interference is not warranted.

It is important that we should recognize the existence of abscess promptly in order to evacuate the pus very early by a free incision. If the collection of pus is extensive it may be necessary to incise upon both sides, but usually a single incision is sufficient. The important point is to make the cut near the floor of the nose and wide enough to give good drainage. It is well to keep the edges of the cut apart by a bit of iodoform gauze until the suppurative process begins to



abate. At first the pus cavity should be thoroughly washed out with peroxid of hydrogen or boric acid solution and the nostrils should be cleansed with an alkaline spray or douche. There is seldom any difficulty in diagnosing an abscess. The tumor which it forms is generally bilateral and symmetrical and is distinctly fluctuating to the finger or the probe.

### CONGENITAL OCCLUSION OF THE NARES.

Closely allied to the subjects just considered is that of stenosis of the nares by bony occlusion of congenital nature. Many cases of partial or complete obstruction due to a web of soft tissue or adventitious membrane are on record, but those in which the obstacle is bony are very rare. Of the latter, in nearly every case the condition has been observed in the posterior nasal region. The impediment may consist of an exostosis from almost any part of the bony framework of the nasal fossa, or of a plate of bone growing from the floor or outer wall of the cavity. Unless both choanæ are involved the subjective symptoms may be insignificant. Under the latter circumstances a nursing infant might suffer from the effects of malnutrition. On the other hand, a single patulous nostril may carry enough air to conceal the condition until the child reaches an age to observe that but one nostril is doing its duty. In a case of my own, a girl of eighteen, no discomfort was caused by the anomaly, except slight impairment of hearing on the corresponding side. In this case the obstruction was complete and consisted of an outgrowth from the hard palate. The septum was deflected towards the stenosed side and the turbinate structures in that fossa were almost rudimentary. The sense of smell was less acute than normal. With the electro-trephine a button of bone one quarter of an inch thick at its lower and one eighth at its upper margin was removed, evidently from a plate springing from the floor of the nose. The immediate result was restoration of the nasal air track and after a few weeks manifest improvement in the sense of smell. No impression was made on the hearing and the patient was annoyed as she had not been previously by accumulation of secretion in the affected nostril. In a case of this kind, therefore, the wisdom of interference is doubtful. The state of



things is very different, however, in acquired stenosis from a developing exostosis or in a condition of double atresia. Here the subjective disturbance may be very distressing, or intervention may be imperative for preservation of life. In order to determine the character of an obstruction, whether bony or membranous, it will be necessary to explore with the finger in the posterior naris and with a sharp probe from the front. A soft obstruction may be penetrated and destroyed with the galvano-cautery, one of bone must be attacked with the drill or trephine. The tendency to closure by granulation tissue and adhesions is very marked, and in many cases it has been found necessary to use nasal tubes and dilators for a long period in order to preserve the patency of the nostril.

Membranous occlusion may exist at almost any part of the nasal passage as a congenital malformation, or as a result of struma or syphilis. It may be relieved by multiple incisions, or, if very thick, by excision of redundant tissue and the subsequent use of a nasal tube so long as a tendency to contraction persists.

### INTRANASAL ADHESIONS.

An accident likely to occur after cauterization of the turbinate body or after an operation upon the septum, especially in a narrow nostril, is an adhesion or synechia between the walls of the nasal fossa. Price Brown justly lays great stress upon the fact that in many cases this results from neglect of after-treatment, the absence of pain and discomfort leading the patient to underestimate the importance of attention. A similar condition may result from erosions or ulcerations occurring spontaneously and is frequently seen in the strumous. The adhesion may consist of bone, of cartilage or of fibrous tissue. It most frequently exists between the middle turbinate and the septum, or the turbinates themselves may unite. An ulcerative process may be instituted by a foreign body or by pressure resulting from a hyperplastic rhinitis. Adhesions obstruct breathing more or less according to their situation and are frequent causes of a variety of reflex disturbances. In many cases a chronic catarrhal naso-pharyngitis or a persistent tinnitus aurium may be the only prominent symptom. When the adhesion is composed of fibrous tissue it may be divided with



scissors or with the galvano-cautery knife; when composed of bone or cartilage the redundant tissue must be removed with a saw or drill. In the after-treatment the case should be watched with great care in order to prevent recurrence; and, with this object in view, it is important that a considerable bridge of tissue should be removed. If care in this respect be observed the use of plugs and tampons will be quite unnecessary. On the contrary some consider it safer to insert a tampon of rubber tissue or even absorbent cotton soaked in albolene, which it is claimed may be left in many days without discomfort or danger, in the meantime the passage being cleansed daily with antiseptic sprays. In the course of convalescence it may be necessary to touch exuberant granulations with some astringent solution, chromic acid, zinc, or nitrate of silver. Until complete repair is accomplished the patient is not absolutely secure against reformation of the synechia.

### COLLAPSE OF THE NOSTRIL.

In consequence of weakness of the muscular apparatus controlling the nostrils or a maladjustment of the lateral cartilages some individuals suffer more or less inconvenience from collapse of the *ala nasi* especially during forced respiration and in sleep. The condition is frequently aggravated by thickening or by distortion of the *columna nasi* or by an *ecchondrosis* of the septum. In the latter case the trouble is restricted to one nostril and chiefly impedes inspiration. The difficulty may be overcome by directing the patient to wear a tube which supports the nostril and reaches just within the vestibule or the so-called nasal dilator, consisting of a pair of pads connected by a U-spring, one pad intended for either nostril. The pad or dilator may be worn only at night or for a limited period during the day. At the same time it is claimed that good results may be obtained from massage and from electrization of the alar muscles. A septal deformity must be corrected. W. J. Walsham succeeded in supporting a collapsed nostril by the following ingenious operation. A flap of mucous membrane with its base uppermost was dissected from the inner wall of the nasal vestibule. The surface of the depression where the lower lateral cartilage bends was then made raw. The



epithelium covering the flap, the width of which was about three sixteenths of an inch, was then scraped off, the flap rolled upon itself like a bandage and secured in the depression at the border of the cartilage by a stitch of fine fishing-gut passed through the septum into the opposite nostril and back again. The little ball of tissue prevented the ala from caving in during inspiration and the cure of the condition is said to have been permanent. Harke, who has given a good deal of attention to this subject, notes the frequent failure of removal of a posterior obstruction to restore nasal breathing owing to paresis or possible atrophy of the muscles which should dilate the nostril. He favors mechanical support for the weakened structures, and it would seem entirely reasonable to expect results from measures intended to improve muscular tone in other situations.

#### DISLOCATION OF THE COLUMNAR CARTILAGE.

There is no separate *columnar* cartilage, the name being applied to the reflected portions of the lower lateral cartilages which assist in forming the partition between the nostrils. Obstruction of one or the other nasal vestibule may be caused by distortion of this cartilage or by displacement of the lower border of the cartilage of the septum. The entrance of the naris, or *limen vestibuli*, may be converted into a narrow longitudinal slit, the outer limit of which is a prominent fold on the inner surface of the ala especially described by Roughton. When collapse of the nostril is added to these anomalies of the cartilage the affected side becomes almost useless especially on inspiration. Attempts have been made to remedy the difficulty by divulsion and by section of Roughton's band without success. The wearing of rubber tubing in the nostril, or the use of nasal expanders, or any form of dilatation is merely palliative. These measures give a certain amount of comfort to those who are averse to operative interference. If the columnar cartilage is at fault a V-shaped incision through the mucous membrane permits the cartilage to be exposed and the excess shaved off with a blunt bistoury or scissors. The triangular cartilage is not so readily reached for a plastic operation and the projecting portion may as well be cut



off *en masse* without regard to saving the mucous membrane. If the area of the latter thus sacrificed is not too extensive the soft tissues are regenerated and the membrane recovers its function. Otherwise more or less scar surface results over which incrustations of secretion may give some annoyance. The best remedy for this is the application of unguents containing ichthyol or carbolic acid. Cocaine should be applied freely and may be injected into the membrane in case it is necessary to cut near the muco-cutaneous junction. No dressing is needed except a pledget of sterilized cotton or gauze to hold the flaps in place after a plastic operation.

### FRACTURE OF THE NOSE.

What is called a broken nose is usually a luxation of the septal cartilage. The degree of violence required actually to fracture the nasal bones or the intranasal framework is generally so extreme as to induce grave symptoms of cerebral damage. The precise location and extent of the local lesion may be obscured by swelling, unless the case is seen very soon after receipt of the injury, and the diagnosis and treatment may call for the exercise of the utmost skill and patience. If the nasal bones are simply depressed it is an easy matter to replace them by means of an elevator passed into the nostril and retain them in place with pledgets of iodoform or nosophen gauze. If they are impacted it is often very difficult to raise them, and if the case is complicated by comminution and displacement of the septum and perhaps by fracture of the maxilla the problem confronting us is much more serious. In the latter case some form of extranasal apparatus will be required as well as an intranasal support. Restitution of displaced parts having first been effected, the nostrils may be plugged with iodoform gauze, or a rubber hood, or finger-stall, may be inserted and stuffed with the desired quantity of sterilized cotton. Either of these will check hemorrhage and give adequate support, but the latter is more readily removed. Both of these are objectionable because they compel mouth breathing, and to avoid the discomfort of that condition a hollow tube of rubber, vulcanite, or malleable material, like that used after an operation for deviated septum, may be introduced and around it cotton or gauze



may be packed as needed. For an external splint successive layers of gauze impregnated with plaster of Paris, which are moistened and then molded properly and allowed to set, will be found satisfactory. A splint made of sheet zinc and lined with felt extending from the tip of the nose to the forehead is recommended by W. H. Daly. This is molded to the nose and held in place by five tails, two at its lower edge which pass around the head under the ears, two from its upper edge across the forehead and above the ears, and a fifth which passes backward over the vertex from its upper margin. The five ends are fastened together at the back of the head. F. C. Cobb advises a firm head-band of steel, to which are attached pads capable of being adjusted to any part of the nose and the pressure of which may be regulated according to necessity. It is prevented from slipping by bands going across the head and under the chin. A rather ingenious splint has been devised by Jesse Hawes for a bad case of fracture in which he was annoyed by an upward tilting of the tip of the nose. It consists of a piece of No. 15 spring brass wire bent in the form of a rectangular letter U, long enough to extend from the middle of the upper lip over the top of the head. The arms of the U are intended to rest on either side of the nose, its lower portion being slightly bent outward so as to avoid pressure on the upper lip. Each arm is bent sharply forward at an angle opposite the supraorbital ridge and a second time in such a way as to carry it backward over the top of the head. The angles of the wire well padded are pressed firmly under the supraorbital ridge where they are held by a broad band of adhesive plaster, completely encircling the head above the eyes. The tip of the nose is then drawn down by means of silk ligatures passed through the septum and the mucous membrane and cartilage of the alæ and fastened to the transverse part of the splint. Depressed portions of the nose may be supported by means of intranasal springs of wire covered with rubber tubing and attached to the horizontal arm of the splint. The elastic property of rubber may be utilized in an external support of tubing, especially when lateral displacements exist. Many surgeons discard splints of all kinds, relying wholly upon the natural support given by the arch of the nasal bones. Perfect results are secured provided readjustment of the parts to a normal posi-



tion has been accurate. In exceptional cases following extraordinary violence, or when a tendency to recurrence of deformity is displayed some form of splint may be required. Under ordinary circumstances with an Adams' or Asch's septum forceps and by manipulation of the external nose with the fingers a fracture may be reduced with cocaine anesthesia. In children and in complicated cases general anesthesia is a decided advantage. J. Wright reminds us of many curious and some valuable expedients familiar to the ancients, who were evidently acquainted with the objection, which most of us share in modern times, to the prolonged retention of absorbable material in the nasal fossæ. Plugs of cotton or gauze are far inferior to vulcanite or metal tubes. When a broken nose has been neglected and fragments have become consolidated in a false position it is not easy to restore the normal contour of the nose. It may be necessary to refracture the nasal bones, and for this purpose Walsham has designed a powerful forceps, one blade to be applied externally and the other internally. This involves more or less contusion of the skin, to obviate which J. O. Roe advises intranasal dissection of the skin from the surface of the bone and applying both blades through the nostril. E. J. Senn advocates exposure of the nasal bones by an incision along the dorsum of the nose and dissection of the soft parts. The bones are then broken with a small chisel, mobilized and shaped by means of a padded elevator introduced through the nostril, and held in place by passing a needle armed with silver wire transversely under the fragments, the ends of the wire then being attached to disks of lead, or preferably cork or other pliable substance. The disks should be well padded with gauze. Intranasal splints of rubber tubing are inserted, the external wound is carefully stitched with fine sutures, and over all a plaster of Paris mask is held with adhesive strips. The wire is withdrawn in five or six days, the tubes and the plaster mask in fifteen to eighteen days.

In many of these cases the nasal bones are not involved, but the septum is distorted and thickened, the redundant tissues permitting a resort to a series of subcutaneous plastic operations like those described by Roe. A transverse depression of the dorsum below the nasal bones, or a marked divergence from the middle line of the tip of the nose may be thus corrected. In other cases, when the



traumatism has been considerable, the train of events comprises the formation of a hematoma of the septum, followed by suppuration, perforation and more or less loss of tissue. Under such circumstances it often happens that some kind of prosthetic device or an external plastic operation may be required. In some cases of old fracture followed by saddle-back deformity the plan of making an incision along the dorsum or transversely above the alæ and inserting a plate of metal gutta-percha, or celluloid has been successful, while in others the foreign body provoked irritation and had to be removed. The subcutaneous injection of paraffin, to be referred to more at length in the chapter on Syphilis, is well adapted to these cases. The experience of Moszkowicz, in Gersuny's clinic, shows that a mixture of solid and liquid paraffins in such proportion as to give a melting point of from  $96.8^{\circ}$  to  $104^{\circ}$  F. works most satisfactorily. It is said never to be absorbed, but becomes encapsulated and eventually is penetrated by a network of new connective tissue.



## CHAPTER VI.

### NASAL POLYPI.

The term nasal polyp properly refers to a gelatinous swelling or tumor of the mucous membrane of inflammatory origin. Some authorities use it indiscriminately to include various forms of benign neoplasm. As a matter of fact, a true polyp is in no sense a neoplasm, although for a long time it was wrongly called "myxoma." Attention has been drawn to the erroneous use of the latter term by Hopmann and Chiari, and in this country by Jonathan Wright. In some cases of long standing the proportion of connective tissue is in excess and gives to the mass a considerable density. Recent polyps have a pulpy character and consist in large part of fluid. This feature is so marked that the qualifying adjective "edematous" is used. In some respects a polyp develops like granulation tissue, cellular elements predominating. It grows more vascular, increases in size by its own weight and finally becomes distinctly pedunculated. The formation of cells and fibrous tissue goes on indefinitely, the serous infiltration progresses at the same time, until a mass resembling a new growth is presented. The process described presupposes the existence of a condition of inflammation, yet it is rather unusual to see a well-defined polyp develop in the course of an acute attack of rhinitis. As a rule nasal polypi are multiple and are observed in both nostrils, more frequently in men than in women, possibly in consequence of the relatively greater exposure of the former to the causes which produce inflammation of the nasal mucous membrane. Although there is, perhaps, no special diathesis predisposing to polypoid formation it is not uncommon to find examples of the disease in several members of the same family. The well-known theory that polypi are symptomatic of disease of bone is not generally accepted, although in advanced cases it must be admitted that a tendency to the involvement of bone is shown. Nasal polypi are seldom seen in children; they are essentially a disease of adult life.



The bone changes taking place in many old cases of nasal polypi are often more important than the polyps themselves. Attention restricted to the latter will not prevent recurrence. A very radical operation, including the bony structure, is essential, and oftentimes it is necessary to remove nearly the whole of the ethmoid bone. To be sure of keeping within the bounds of safety we should advance with great caution, removing the tissue piecemeal with curette or small cutting forceps. Chronic multiple polypi attended by pus formation and bone disease will seldom yield until we resort to radical procedures of this character, if necessary under a general anesthetic. Doubtless many cases of nasal polyp can be cured, without touching the bone, by repeated operations, but in old cases when disease of the bone is well established nothing short of its removal will suffice.

The theory of Woakes that nasal polypi are a direct consequence of a "necrosing ethmoiditis" has met with much opposition and would seem to be conclusively refuted by those cases of polyp seen to spring from the surface of the nasal septum, or from the wall of a sinus, in which there is no suspicion of bone disease. Soon after its announcement Martin, whose histological studies furnished a basis for the theory, declined to accept it, and later Lennox Browne and Spencer Watson asserted that none of the clinical features of necrosis can be discovered in polyp cases. Baumgarten believes that necrosis is a frequent but not invariable accompaniment of ethmoidal suppuration, while Grünwald declares that polyps may be associated with empyema of *any* of the accessory sinuses and not exclusively of the ethmoid cells. Hajek combats the theory of Woakes and maintains that ethmoid disease is merely a late stage of inflammation extending from the surface, the process being favored by the relative thinness of the mucous membrane in the region where polyps are usually found. The osseous fragility mistaken for necrosis may occur as resorption of previously compact bony tissue or as new formation of bone, and necrosis is always a result and not a cause of deep-seated inflammation.

Inflammatory processes in the ethmoid region simply vary in degree and may be superficial, may affect the medullary substance of the middle turbinate, or may involve the framework of the ethmoid labyrinth. The ease with which the deeper structures are invaded



is explained by the direct continuity found to exist between the mucous membrane and the medulla of the bone. The changes in the bone consist of new formation and resorption, thickening and rarefying osteitis, the two processes going on at the same time, one or the other usually being in excess, but neither occurring alone. Cordes is of the opinion that polyps may or may not be indicative of sinus disease, that affections of the bone may be either primary or secondary, and that a tendency to recurrence must be accepted as a sign of bone involvement. The evidence that sinus disease is an etiological factor in nasal polypi is far from convincing, although these conditions no doubt often coexist. In this connection the announcement by Lichtwitz and other observers of the discovery in the post-mortem room of many cases of pus in the antrum which gave no sign during life is of interest, and yet it is quite incorrect to assume that every such accumulation of fluid should be regarded as a sinus empyema. In the bone changes referred to the periosteum is thickened and crowded with large nucleated cells. The surface of the bone is marked by depressions filled with large cells, many of which are multinucleated. The bone cells are abnormally large and numerous. At points where the process has reached an advanced stage are found groups of osteoclasts surrounding areas of disintegrating bone undergoing absorption.

The theory referred to has a recent advocate in Lambert Lack, who defines a nasal polyp as a localized patch of edematous mucous membrane dependent upon subjacent bone disease. Glandular elements are often very pronounced and not infrequently dilatation and cystic formation result from obstruction of a gland duct. In every case of polyp, whether moderate or extensive, examined by this observer bone lesions of the nature of rarefying osteitis and not a true necrosis were found. Evidences of bone disease may be detected by careful examination with the finger under general anesthesia. Spicules and loose pieces of bone embedded in soft gelatinous mucous membrane may be plainly felt. A blunt probe may be used but is likely to pierce the friable tissue and come in contact with the bone, thus possibly giving a false impression of necrosis. In some cases of long standing it may be discovered that the turbinate body has undergone absorption, having been entirely



replaced by a mass of pulpy soft tissue. In others more recent the interior of the middle turbinate bone gradually disintegrates and the cell in its anterior end expands and forms a bony cyst sometimes reaching extreme dimensions. This process, which has been described in another section, often occurs quite independently of polypoid degeneration in the mucous membrane and indeed the latter may be in a condition of advanced atrophy.

From the standpoint of treatment Lack divides polyp cases into four classes. (1) Those in which the polyps are few and the process in the bone has subsided. Removal with the snare effects a permanent cure. (2) Cases of incipient bone disease with enlargement of the turbinate and edema of the mucous membrane. Here the anterior end of the bone, or as much as may be necessary, is to be removed. (3) Cases more advanced than the preceding in which a few polyps and a limited area of bone disease are present. In addition to the snare, the loop of which should be adjusted as high as possible around the base of the growth, cutting forceps and the ring knife for curetting are useful, the latter being employed under nitrous oxide anesthesia and good illumination. (4) Cases of extensive bone disease and multiple polyps. A radical operation under a general anesthetic is indicated in this condition. A spoke-shave, or forceps, is used for removing the principal masses, a large ring knife, or Meyer's adenoid curette, is recommended for completing the operation. The scraping should be done cautiously, especially in the region of the cribriform plate, the morbid tissues being identified from time to time by digital examination. Healthy tissue is smooth, firm and resistant to the knife as well as the finger. If the posterior part of the ethmoid is to be attacked the nasopharynx is first tamponned, and in all cases the operation is done with the patient turned well over on the side. On the completion of the operation the nostril is packed with gauze soaked in glycerin-iodoform emulsion, the dressing being changed and the nose irrigated every two or three days. Uniformly good results are claimed for this mode of operating, which presents decided advantages over the tedious nibbling operation in common practice. Some ecchymosis about the eye is a not unusual sequence. A suppurative otitis is not more common after this than other procedures and cerebral compli-



cations have never been noted. Febrile reaction, especially frequent in sinus cases, subsides on withdrawal of the packing and a resort to nasal irrigation.

In elderly people and in individuals with organic disease or a weak constitution, intranasal surgery of even moderate severity is often followed by alarming reaction. An operation of the magnitude of that just described involves an intolerable degree of shock and milder methods in repeated sittings must be preferred. In fact, the proportion of cases in which such extensive sacrifice of tissue is demanded is extremely small, although there are doubtless inveterate and recurring cases which can be cured in no other way.

The *symptoms* of nasal polypi, at the outset, are those of acute or chronic rhinitis and usually begin with what the patient himself calls "cold in the head." Instead of a disappearance of the obstruction as usually experienced after recovery from a cold the nasal stenosis is persistent. If one side is affected the patient may not suffer extreme inconvenience; but if both nostrils are involved mouth breathing results with its usual discomfort. Asthenopia or other ocular disturbances, reflex neuralgias, cough and asthma are among the disorders which nasal polypi are known to excite. In well developed cases the patient may be conscious of a movement of a pedunculated polyp during nasal respiration. If its pedicle be unusually long the polyp may present itself at the anterior naris and if its attachment becomes excessively attenuated it may be actually blown out in the use of the handkerchief. There is usually a profuse discharge of watery secretion and speech acquires the so-called nasal quality. The sense of smell is impaired or completely lost either from mechanical obstruction to the admission of odoriferous particles or from degeneration of the mucous membrane of the olfactory tract with the contained nerve filaments. Accessory sinus disease may result from obstruction to the outlet of a sinus especially in cases complicated by bone involvement, or may itself institute a condition of the mucous membrane predisposing to edema and polypoid development.

On inspection a mucous polyp appears as a bluish, opalescent, semi-transparent tumor frequently crossed by small blood-vessels and bathed in watery fluid with occasional flakes of purulent secretion.



On puncture the fluid contents escape and the tumor shrivels up more or less. Its *apparent* capacity for absorbing moisture, often noticed by the laity, is remarkable and the symptoms it produces are much aggravated in damp weather. On examining with a probe the fact that it is pedunculated may be readily demonstrated. It is a clinical fact that a polyp situated at the posterior naris is more firm than one in the interior of the nasal fossa owing to the normal predominance of fibrous tissue in the former region, a feature which is to some extent true of anterior polyps as a result of irritation to which the latter are subjected. In a very large proportion of cases the favorite site of polypi is the margin or free surface of the middle turbinate body. When a sinusitis coexists they are often seen springing from the lips of the ostium maxillare. They rarely arise from the septum although adhesions may take place between a polyp

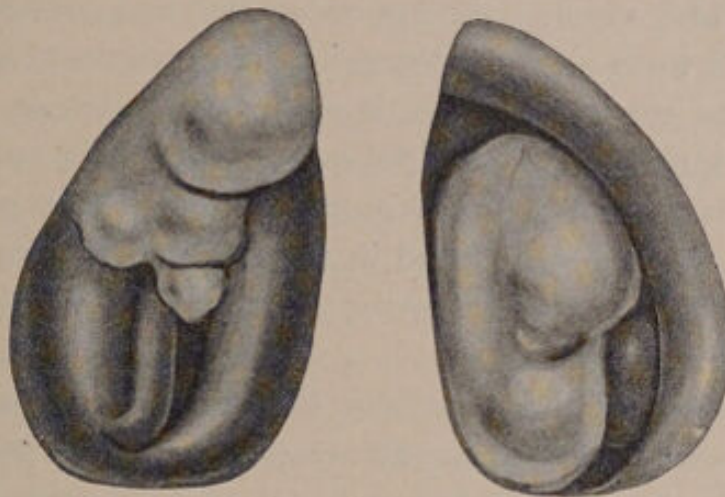


FIG. 62a. NASAL POLYPI. (Grünwald.)

and the septal surface. They may develop to such a degree as to displace the septum or expand the nasal fossa so as to produce considerable facial disfigurement. They are rarely single and, in some cases, an immense number have been removed; in all probability under the latter circumstances the polyps were really compound, several being attached by a common pedicle. They are almost always associated with hyperplastic and later with atrophic changes in the mucous membrane of the turbinate bodies as well as of the septum. They may remain without decided change for a long period, but seldom disappear spontaneously (Fig. 62a).

The prognosis is good, provided the patient will submit to treat-



ment of a character and for the time necessary to accomplish a cure. When polyps are symptomatic of sinus disease the prognosis is naturally less favorable, and a cure is dependent upon correction of the sinus trouble. The tendency to recurrence is marked unless the underlying inflammatory condition, or bone lesion, is capable of relief.

The *treatment* consists in removal with instruments or destruction of the mass by cauterization. In former times it was a common practice to inject astringents into the substance of the tumor such as preparations of iron, zinc, or tannic acid and more recently a solution of ethylate of sodium has been recommended by B. W. Richardson as being more effective than the other agents mentioned. A crude method of removing these growths in old times consisted in introducing a polypus forceps, seizing whatever happened to fall between its blades and by a process of twisting and pulling, dragging from the nasal fossa as much tissue as the instrument might grasp. It was a fortunate circumstance if the whole turbinate bone were not removed together with the polypoid mass. It is impossible by this method to operate with precision or safety and in consequence the forceps have been abandoned in favor of the snare except possibly in cases of very small circumscribed growths whose attachment can be clearly defined.

The bleeding excited by avulsion of a nasal polyp usually prohibits any further operative interference for the time being, whereas, with the cold wire snare it is possible to proceed with such deliberation as to make the operation completely bloodless. The number of snares in the market is somewhat appalling. My own preference for ordinary routine work is Sajous' modification of the Jarvis instrument (Fig. 25). In the Sajous snare the loop is held at the distal end of the stylet which permits more exact manipulation than with canulated snares in which the wires are fastened in the handle of the instrument and are sure to twist on attempting to turn the loop. The capacity of the Sajous snare is limited by its screw thread; in other words the loop cannot be larger than the thread of the screw will exhaust. In using the snare for very large polyps the Jarvis instrument which permits an unlimited expansion of the loop is preferable. This is especially true of polyps which project



into the nasal pharynx and where the loop is to be manipulated with the assistance of the finger passed through the mouth behind the velum. In ordinary cases for routine work the Sajous snare is found thoroughly satisfactory. The loop is introduced in a vertical position between the polyp and the septum, then turned horizontally and crowded over the base of the growth. Care should be taken to hold the instrument firmly after it has once been placed and the thumb screw when the loop has become engaged may be turned slowly or rapidly at will or as the patient permits. Some prefer the hot wire *écraseur*, but it seems better to cauterize if need be after removal of the polyp. In most cases cauterization is quite unnecessary and the danger of damaging healthy mucous membrane with the heat should not be lightly considered. It is well to cocaine the parts as thoroughly as possible before adjusting the loop, although it is difficult in these cases to get satisfactory anesthesia, and inconvenience from hemorrhage is greatly reduced by the use of suprarenal extract.

Many operators prefer an angular snare in order to preserve an unobstructed operative field. In those cases of nasal polyp in which the turbinate body itself, including the bone, must be in part sacrificed division of the structures should be very slow and any superfluous weight in the instrument is objectionable. It is an advantage to have as little metal in the snare as may be consistent with strength. My own favorite Sajous snare, which has "uncapped" a multitude of turbinates, weighs only about half an ounce.

The after-treatment of polyp cases is very simple and should be limited to the use of cleansing and antiseptic sprays. Hemorrhage is rarely so free as to require special attention, but occasionally a firm tampon is necessary. The patient should be kept under observation for some time in order to meet the first indications of recurrence and to correct the catarrhal condition invariably present.



## CHAPTER VII.

### BENIGN TUMORS AND MALIGNANT DISEASE OF THE NASAL FOSSÆ. FOREIGN BODIES. RHINOLITHS. EPISTAXIS.

*Fibroma* of the nasal fossa is one of the most unusual of neoplasms. In the naso-pharynx it is more frequent owing to the fact that fibrous tissue is more plentiful at the upper and posterior parts of the nasal cavity and in the vault of the pharynx than elsewhere in the upper air track. The admixture of fibrous tissue in sarcomatous and other tumors is not infrequent; but a pure fibroma is rare (Fig. 63).

The degree of nasal obstruction caused by a fibroma depends upon its location and dimensions. The tumor is usually smooth, round,

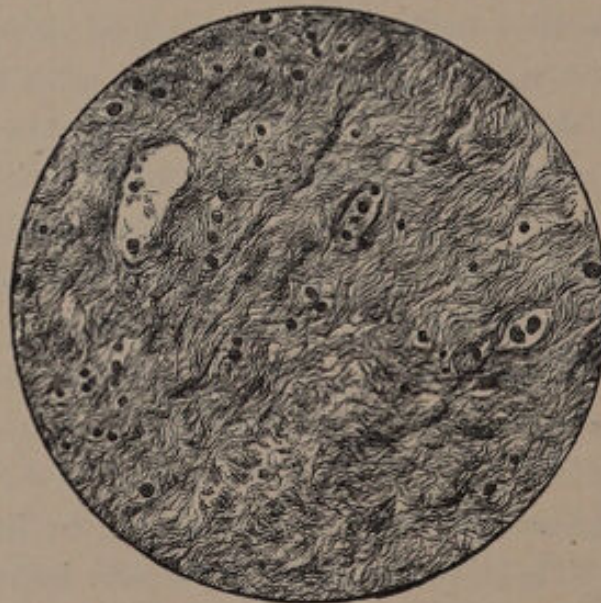

FIG. 63. SECTION OF NASAL FIBROMA. (Author's specimen.)

symmetrical and of a darker color than an ordinary polyp, and evidently is much denser in structure. It is usually distinctly pedunculated and can hardly be mistaken for a tumor of any other character except possibly an old nasal polyp.

A case of pure fibroma of the nasal fossa came under my observation several years ago. It occurred in a young man of twenty-one



who complained of catarrhal symptoms and obstruction of the left nostril. There never had been any hemorrhage, the sense of smell had not been impaired and the general health was excellent. The patient had some cough with moderate expectoration, but there was no suspicion of pulmonary disease. On anterior rhinoscopy a movable tumor could be detected in the left posterior naris attached to the end of the middle turbinate. On posterior rhinoscopy the tumor seemed nearly to fill the left choana. It was smooth, round, symmetrical and darker in color than a gelatinous polyp, but was supposed to be a tumor of that kind containing an unusual proportion of fibrous tissue. It was removed with a cold wire snare without difficulty and with relief of the catarrhal symptoms. Under the microscope there was no trace of myxomatous tissue. The tumor was dense, non-vascular, and near its surface were collections of small round cells suggesting sarcoma, but doubtless of inflammatory origin. The fibrous structure was very marked, especially at the center of the tumor.

There is no difficulty in removing a nasal fibroma by the methods used in the treatment of nasal polyps, namely, with the cold wire snare, or if the pedicle is very thick and vascularity is suspected, the cautery loop.

A fibroma of the naso-pharynx seems to be a very different type of neoplasm. Many of the cases on record were undoubtedly mixed in structure and had a semi-malignant character. They are decidedly recurrent and many of the naso-pharyngeal fibromata reported were subjected to repeated operations before their final disappearance. The last mentioned neoplasms are, also, more vascular and they are not amenable to ordinary modes of treatment. Several of those on record were notably reduced in size by the use of electrolysis and the operation for their removal, when of large size, by the usual surgical procedures is so appalling that electricity offers a desirable substitute for the knife. In many cases the growths are so large as to necessitate division of the soft palate or even excision of the upper jaw in order to give satisfactory access.

Among the rarer neoplasms met with in the nose may be mentioned osteoma, enchondroma, angioma and cystoma.

True *papillomata*, or warty growths, are of somewhat more fre-



quent occurrence (Fig. 64). There seems to be no doubt that some observers have mistaken simple hyperplasia of the mucous membrane for papilloma. Usually they appear anteriorly in the nasal cavity and they seldom attain very great size. They are more or less pedunculated and irregular in contour. They may resemble mucus polypi in color but are less smooth and regular. It may be difficult to establish a diagnosis without the aid of the microscope. Usually removal with the snare or scissors, followed by cauterization of the base, is successful in disposing of them.

A bony tumor, or *osteoma*, in the nasal fossa is extremely rare and is usually unmistakable in character from the resistance it offers to the probe or exploring needle. Generally it is found to invade the nasal cavity from one of the accessory sinuses. It is a most

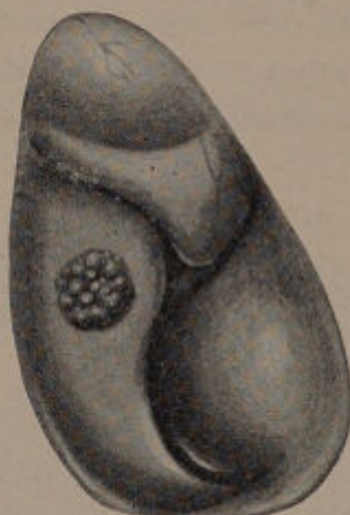


FIG. 64. PAPILLOMA OF SEPTUM, LEFT SIDE. (Grünwald.)

serious lesion and can be reached, as a rule, only by an extensive external operation.

Cartilaginous tumors are still more rare. They present symptoms very similar to those of osteomata and are handled in a similar way. An ecchondrosis, or inflammatory thickening of cartilage, is extremely common and should not be confused with a chondroma, or tumor composed of cartilage. The former involves the septum and seldom is seen in the young. A *chondroma* usually occurs early in life, is single, and is not necessarily connected with the septum.

*Nasal cysts* have been observed in a very small number of cases, not more than three or four such having been recorded. Cystic changes in old nasal polypi are not uncommon. A simple retention



cyst may be met with at almost any part of the upper air track, while dermoid cysts are rarely seen elsewhere than in the nasal cavities. A genuine cystoma, or cystic dilatation of the normal lymph-channels, is usually found in adults and may develop at almost any situation. One case of the kind in my experience, in which the tumor occupied the floor of the nose in the left vestibule, was cured by free incision and packing the cavity with sterilized gauze.

In spite of the fact that the Schneiderian membrane is highly vascular, *angiomata* very seldom occur in this locality. Doubtless many cases reported as such have been confused with other neoplasms richly supplied with blood-vessels. No cause for their development can be discovered, although it probably exists in some condition of malnutrition affecting the walls of the blood-vessels.

The symptoms are such as would result from interference with nasal breathing and drainage added to epistaxis which may be severe or so frequent as to affect the general health.

Pathologically these neoplasms consist primarily in a dilatation of the blood-vessels whose walls, supported by a network of connective tissue, become very much thinned and easily rupture. *Angiomata* may spring from a turbinate body or from the septum; usually they have been seen in the latter situation near the anterior nares, constituting the so-called "bleeding polyp of the septum."

Their appearance is characteristic. An irregular, elastic tumor of reddish or purplish color, from which hemorrhage may be readily excited by rough handling, is seen attached to the mucous membrane by a broad base or a much constricted pedicle. It is of slow growth and there is no danger attending it aside from hemorrhage which may be prevented by the selection of a suitable mode of treatment and the avoidance of violence.

Either the cold-wire or the galvano-cautery snare may be used in its removal. The loop should be adjusted well down upon the base of the tumor and should be tightened very slowly, especially if the cold-wire *écraseur* be employed. Recurrences after thorough extirpation are not usual.

It is obvious that a great deal of confusion exists in the nomenclature of intranasal neoplasms. For example the term "papilloma" has been erroneously applied by Hopmann and others to



papillary hypertrophies. A genuine papilloma has definite histological characteristics which differentiate it positively from hypertrophy, or hyperplasia. Again simple varicosities, or vascular dilatations of the blood-vessels of the mucosa, have often been wrongly called "angiomata." In reading the descriptions of many cases of so-called "nasal fibroma" one cannot avoid the conviction that the tumors possessed a mixed character or were actually malignant. Moreover, some of these neoplasms originated in an accessory sinus or in adjacent structures and not in the nares, and hence cannot be properly classified as "nasal" fibromata. Those formidable cases in which occurs "frog-face" deformity from expansion of the nasal bones, and violent hemorrhages take place, both spontaneously and when attempts at removal of the neoplasm are undertaken, are probably in this category and belong within the scope of general surgery.

According to Lennox Browne the question of transformation of benign into malignant growth is settled in the affirmative. The testimony offered by one of his alleged cases, in which the patient himself "attributed his trouble to the frequent and long-continued introduction of a Eustachian catheter" is certainly far from acceptable. This distinguished authority asserts that "sarcomatous degeneration is most commonly witnessed" while epitheliomatous transformation is more rare. He cites several cases supposed to be confirmatory. An interesting and curious case reported by Bayer in 1887 is more to the point. A villiform carcinoma was found implanted upon a base of innocent mucous polypoid tissue. Even in this case there remains a doubt as to which tissue was primary. A case of carcinoma developing from a simple papilloma, under the observation of M. R. Ward, was proved by microscopic examination to be a genuine example of transformation.

In a most interesting case of adenocarcinoma reported by F. E. Hopkins, there is reason to suspect that malignant transformation was provoked by violent manipulation, although the evidence is somewhat presumptive. It appears that on three occasions, at intervals of a year each, attempts had been made to remove supposed "myxomatous" tissue by forcibly dragging it out with polypus forceps. Symptoms of an intranasal growth had existed for many



years and its benign character was inferred from the form, color and consistence of the neoplasm removed as well as from the fact that but slight hemorrhage followed the operation. No microscopic examination was made at this time. In commenting on this case Jonathan Wright remarks upon the rarity of lesions of the kind and upon the rapidity of their evolution, adenocarcinoma being somewhat slower than pure carcinoma. He has collected twenty authentic cases, discarding those not supported by microscopic testimony, a lack of which applies to more than half of those in Bosworth's list, but including several, like that of Beaman Douglas, of possible extra-nasal origin.

Whether we accept these unusual instances as authentic, or, with Billroth, look upon the whole matter as a "traditional myth," the occurrence is not so frequent as to deter us from interference in suitable cases.

### MALIGNANT DISEASE OF THE NOSE.

Malignant disease may have its origin in the nasal fossa, but frequently begins in adjacent structures and gradually crowds into the cavity of the nose. Carcinoma, presenting in the form of epithelioma, is rather more frequent than sarcoma according to Bosworth's figures, but in the opinion of J. S. Gibb, who adds 70 cases of sarcoma and 48 of carcinoma, "primary carcinoma of the nasal chambers is undoubtedly rare," while sarcoma is believed to be more common than statistics would seem to indicate, many cases remaining unrecognized and more not being reported. The latter is usually of the round-celled variety and may occur at any age. The former is seen seldom before middle life. Men are more prone to the disease than women. The starting point of the disease may be in the antrum, and as the growth progresses tumefaction of the face appears, accompanied by occlusion of the nostril from pressure upon the nasal wall of the antrum, or protrusion of the mass through the ostium maxillare. Pain may not be pronounced until the disease is far advanced, but there is apt to be at an early period a bloody discharge from the affected nostril. Free and even fatal hemorrhage may occur. In a case of fibrosarcoma reported by the



author several years ago the tumor grew in all directions, finally invading the cerebral fossa and causing total blindness. In the meantime the growth had extended to the pharynx and impeded respiration. Previously on several occasions severe hemorrhage had taken place, spontaneously, and when attempts were made to clear the air track by snaring off portions of the tumor. At length, during a fit of wild delirium consequent upon cerebral irritation, the patient thrust his fingers in his mouth and dragged out a large piece of the growth hanging over the margin of the velum. Immediately there was a fierce gush of blood from the nose and mouth and in a few hours the patient succumbed. It was impossible to determine where the disease began, as it was first seen at a late stage and no autopsy was permitted. However, at a radical operation with removal of the upper jaw, undertaken by Weir several months before at the New York Hospital, it was found that the ethmoidal cells and the sphenoidal sinus were filled with neoplasm, the limits of which beyond could not be safely traced. In view of the uncertainty regarding the implantation of malignant tumors of the nose it is an open question whether all cases of this kind should not be referred to the general surgeon for radical operation. Piecemeal removal with forceps and snare is a superficial method which permits the base of the neoplasm to pursue its destructive invasion of adjacent parts. By many it is positively discountenanced (A. F. Plicque), while others are of the opinion that although no operation whatever is feasible in carcinoma, sarcoma is best treated by removal through the nose with the cold-wire snare (Bosworth). Of course the latter applies only when the disease is known to be strictly confined to the nasal chamber. In a case of this kind operated upon by Melville Black it was my privilege to watch the course of events several years subsequently. The growth involved the right middle turbinate and was removed with snare and forceps. Its sarcomatous nature was established by repeated microscopic examinations. About five years have elapsed without sign of recurrence.

Implicit faith in the microscope as a guide in diagnosis is not advisable, at least as applied to sarcoma. A young woman once came to my clinic with stenosis of her right nostril. An extremely vascular tumor extending far back in the nostril was removed and



quickly recurred. Microscopic examination pronounced it a sarcoma and all preparations were made to expose and remove the neoplasm by an excision of the upper jaw, when she called attention to a tumor over the crest of her tibia. Under rapidly increasing doses of potassium iodide the periosteal node and the nasal sarcoma (?) disappeared simultaneously. Such experiences should not discredit the microscope nor the examiner. Different sections of the same new growth may present totally different appearances, and it is often impossible to differentiate a small round-celled sarcoma from a syphiloma. They should rather teach us to be cautious in accepting testimony derived from a single source in cases of this kind. When there exists the least doubt as to the nature of a neoplasm a tentative antisyphilitic course of treatment is always indicated.

The difficulty in diagnosis is often vastly augmented, especially in elderly patients, by the concurrence of malignant disease and simple mucous polypi. The presence of the latter may obscure the case until in the process of clearing out the polyps with the snare we may be startled by an alarming hemorrhage from an exceedingly sensitive growth, which proves to be malignant. Fetid discharge, hemorrhage and distortion of the face from intranasal pressure are seldom or never observed in gelatinous polypi and are invariably present earlier or later in malignant disease.

In some cases neighboring bony tissues become affected. If the disease is located in the antrum the orbital plate is pushed up, forcing the eye from its socket, the skin of the face becomes adherent to the anterior wall of the antrum, which finally breaks down, permitting the protrusion of a fungous mass of vascular sensitive tissue. Cases which survive to this stage are most distressing from the disfigurement, the pain and the insupportable fetor attending the profuse ichorous discharge. The glands are seldom implicated. The development of epithelioma is much more insidious and rapid than that of sarcoma and may proceed without much pain or tumefaction until a late stage. Malignant disease may cause death by invasion of the cranial cavity, by exhaustion, hemorrhage, or metastasis, the last-mentioned being more frequent in sarcoma. The record of results of operative interference is not encouraging, at least when the disease is so extensive as to require an excision of the upper jaw.



According to H. T. Butlin, whose researches on this subject have been most thorough, the chief operative dangers are from exhaustion, blood-poisoning and pulmonary complications. He believes that measures to secure a better showing are feasible, but, if not, that the operation should be condemned. Recurrence is almost inevitable, and in any case malignant disease of the nose must be regarded as one of the most formidable and intractable with which we have to deal. This discouraging view is in a measure refuted by the brilliant results secured by Abbe in several cases of malignant disease which would ordinarily be regarded as inoperable. In one case in particular the right upper jaw and roof of mouth and part of the roof on the left side were removed, after a tracheotomy and ligation of both external carotids. This patient, a man 63 years old, was exempt from recurrence five and a half years after operation, the effects of which, in part owing to a well-fitting plate, were scarcely perceptible. For details of the major operations the reader is referred to works on general surgery. In most cases we shall be called upon to rely solely on the free and constant use of anodynes.

#### FOREIGN BODIES IN THE NASAL CHAMBERS.

The introduction of a foreign body into the nose, either intentionally, accidentally, or in the act of vomiting, frequently occurs and may result in considerable disturbance. A one-sided purulent nasal discharge in a child is always suggestive of a foreign body. The objects children select are shoe-buttons, pebbles, or in fact any article small enough to be admitted to the anterior nares.

As a rule, if no attempts have been made to extract the foreign body it will be found lodged well forward in the nasal fossa. In many cases it is retained for years and in the meantime the patient is supposed to be suffering from nasal catarrh. Usually a purulent discharge is the only symptom and frequently its character is so acrid as to produce more or less excoriation of the nostril and lip. The pressure of a foreign body may cause erosion of the mucous membrane with which it is in contact and occasionally perforation of the cartilaginous septum may result. In the event of laceration of the membrane the discharges show more or less admixture of



blood. Syphilis may produce a one-sided nasal discharge but is attended by other symptoms which are confirmatory. Sinus disease generally causes discharge from one nostril but it is rarely observed in children and is seldom accompanied by obstruction to nasal breathing which is usually a prominent symptom of a foreign body.

A definite diagnosis can be made only by inspection and sometimes by the use of the probe. It may be necessary to cleanse the parts thoroughly of secretion and to apply cocaine, and, in young children and in nervous subjects, a general anesthetic may be required. As a rule, foreign bodies are within reach and can be extracted readily by means of a nasal forceps. Sometimes a blunt hook, like a strabismus hook, may be passed behind the object and thus its removal effected. The loop of a cold-snare is sometimes found to be useful. If the foreign body has slipped or been displaced into the postnasal space it may be necessary to push it forward by means of the finger passed through the mouth behind the palate or it may be removed through the mouth. Sternutatories, the use of douches and the Politzer air-bag have been recommended for the removal of foreign bodies. The two latter methods are attended by more or less risk to the ears and, moreover, are less reliable than the nasal forceps. In rare cases in which the foreign body is of such a character as to imbibe moisture and increase in size after its introduction, or in cases in which it has become impacted, it may be necessary to do an external operation in order to secure more space for manipulation, or the object may have to be crushed and removed piecemeal.

Many cases in which teeth have been found misplaced in a nasal fossa have been recorded. An interesting example noted by Krieg is that of a girl nineteen years old in whom the right external incisor "had lost its way upwards" and was seen impinging upon the border of the inferior turbinate. Extraction would of course be indicated provided any subjective disturbance results from the anomaly.

### RHINOLITHS.

A nasal calculus usually has a foreign body of some kind as a nucleus. A plug of inspissated mucus, or a coagulum, may furnish a base for the incrustation of salts, in which case the rhinolith, in



its complete formation, would appear to be without a nucleus. The shape of these calculi corresponds closely to the conformation of the nasal fossa. Some of those on record reached a most enormous size.

The causes which induce them are not clear. It would seem probable that some malformation of the nasal passages must be in part responsible for them, possibly in combination with some obscure change in the character of the nasal secretion. They are found to contain the ordinary ingredients of nasal mucus with a large proportion of organic material and, in some cases, a small quantity of iron.

As a rule, the symptoms are those which naturally would be excited by a foreign body. In some of the more remarkable cases on record the disturbances were very profound. Distortion of the nose and hard palate and even perforation of the palate at its junction with the velum, facial paralysis, and ocular disturbances may be enumerated. The discharge from the nose is almost always offensive, profuse and unilateral.

The diagnosis is usually free from difficulty and may be established by inspection and the use of the probe.

The treatment is similar to that of a foreign body, although a calculus may be too large to be removed entire and must be crushed beforehand. The density of the mass is sometimes so great as to make this by no means easy. A small lithotrite has been found useful for this purpose.

### EPISTAXIS.

Nose-bleed may be traumatic, spontaneous or vicarious. Traumatic nose-bleed may result from blows upon the external nose or from injuries to the mucous membrane from the introduction of foreign bodies, from violent blowing or sneezing, or from picking the nose. When the injury is of a serious character fracture of the nasal skeleton may involve the base of the skull and bleeding may arise from the ear as well as the nose, that from the latter being comparatively unimportant. In some cases the blood finds its way forward, but in young subjects or unconscious patients a considerable quantity may flow backward and into the stomach, the persis-



tence of the bleeding being finally betrayed by the occurrence of hematemesis. In post-operative hemorrhages one knows where to look for the source of the bleeding; otherwise, it may be a matter of considerable difficulty to determine precisely its origin.

Spontaneous nose-bleed may be symptomatic of an intranasal neoplasm or it may occur in various constitutional conditions affecting the general circulation. It may be indicative of disease of the blood-vessels or of certain changes in the character of the blood itself which prevent coagulation. It is not uncommon in hemophilia and several members of a family may habitually have nose-bleed.

A sudden spontaneous nose-bleed in persons fifty years of age and upwards should always excite suspicion of cardiac or other organic disease. This form of epistaxis has been carefully studied by George Coates, who finds the occurrence preceded by long-continued high arterial pressure and immediately by cardiac failure, either valvular or in the wall of the heart, accompanied by engorgement of the whole venous system. In these cases the indication is to relieve the turgid veins and the arterial pressure. After the capillaries and arterioles have been dilated by agents like nitroglycerine, so-called heart tonics, strychnia and strophanthus, are useful. Plugging the nostril is seldom necessary and is generally futile, because the real difficulty is not in the nose, but yet it may have to be done as a last resort.

A very rare variety of epistaxis associated with multiple telangiectases of the skin and mucous membranes has been reported by William Osler. The angiomas were in various regions, but especially on the face which they much disfigured. In one fatal case they were found in the mucous membrane of the stomach, as well as in the nose, and the nasal septum was marked by numerous dilated veins. A relationship between telangiectases and hepatic affections is suggested, and obviously local measures, so far as the hemorrhage from the nose is concerned, can have only a palliative and temporary effect.

Vicarious epistaxis has been observed in women whose menses are suppressed and in functional uterine disease. Epistaxis is a common symptom in many exanthemata and fevers and is especially



noted as an early symptom in typhoid. It is also a very frequent occurrence in diphtheria and is included among the symptoms of adenoids in the rhinopharynx.

Fatal nose-bleed is an extremely rare accident and is hardly likely to occur except in hemophilia or in an individual already in a condition of extreme systemic depression. When confronted by a case of nose-bleed it is of the first importance to determine the source of the bleeding. It is not at all an unusual experience to meet with cases in which attempts to arrest the bleeding have been made by plugging the nostrils, whereas had the precaution been taken to determine the origin of the bleeding this disagreeable and somewhat dangerous process of plugging might have been avoided. In a very

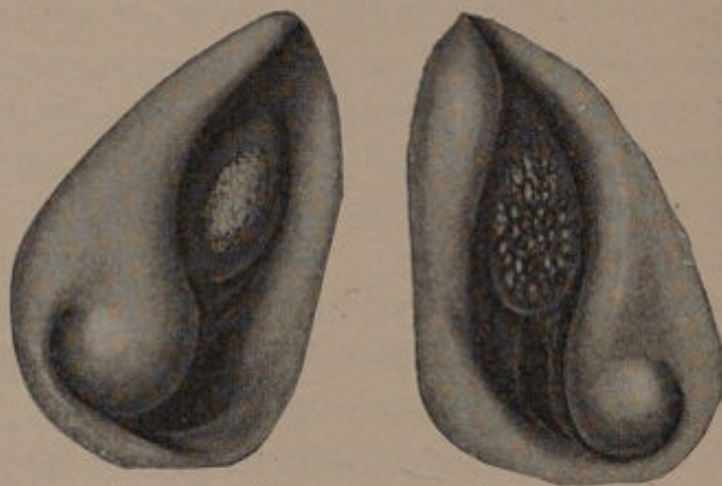


FIG. 65. SWOLLEN, GRANULAR TURBINATES A FREQUENT SOURCE OF EPISTAXIS.  
(Krieg.)

large proportion of cases a careful examination will discover that the blood comes from a turgid granular turbinate body, or much more frequently from (Fig. 65) an eroded point on the septal cartilage within a very short distance of the anterior naris and above the floor of the nose. This is referred to by some writers as "Kiesselbach's spot," so named from an observer who has drawn especial attention to the small artery in this situation as a source of nasal hemorrhage (Fig. 66). Pressure exerted at that point fortified by the application of some styptic hardly ever fails promptly to control the bleeding. When the flow is very profuse, or is taking place in a patient nervous and frightened or young and obstreperous, it is no easy matter to keep the field clear long enough to discover the bleeding point; but, with a little patience, it is possible to see the blood ooze drop by drop



or, perhaps, in a distinct jet from the region referred to. In persons of advanced years with atheromatous arteries nose-bleed may be a conservative process and is not to be hastily checked. The loss of blood may be considerable without doing a very great amount of damage but, nevertheless, the alarm of the patient compels us to resort to a variety of measures for the purpose of checking the bleeding. Even if nothing were done in most cases a course of events similar to that observed in hemorrhage from other sources would doubtless ensue; the bleeding would persist until the depletion began to produce a sensation of faintness when the diminished blood pressure would permit the formation of a coagulum to act as a natural

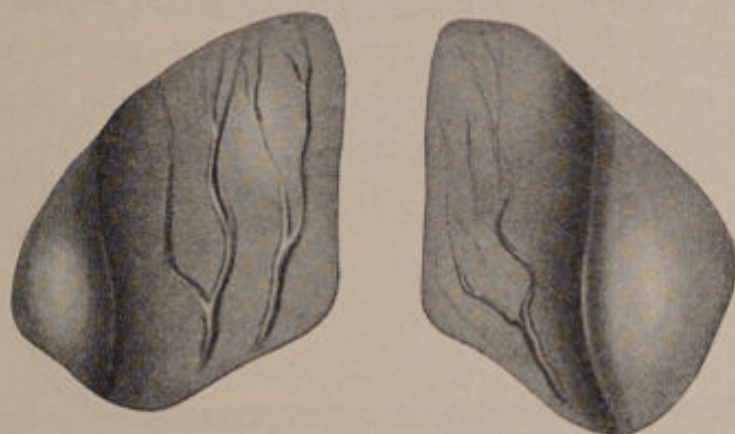


FIG. 66. DILATED VESSELS ON SEPTUM IN REGION KNOWN AS "HARTMANN-KIESSELBACH" SPOT. (*Krieg.*)

tampon. Among the milder measures used may be mentioned, raising the hands above the head, the application of ice, held in the mouth or placed in the nostril, or applied to the root of the nose either in the form of an ice-bag or gauze wrung out in iced water. In some cases hot water, at not less than 158° F., applied to the nostril seems to be effective, and this is certainly found to be an excellent way of stopping the hemorrhage which follows operative work, especially the operation for deviated septum. Hot water applied to the nape of the neck is said to have a decided effect. Various other domestic remedies have been used from time to time, but if these simpler methods do not avail and provided we cannot discover the isolated point of bleeding on the septum which has been described, plugging of the nostrils may be necessary. In the first place an attempt should be made to control the bleeding by plugging the ante-



rior naris and this is best done by means of narrow strips of sterilized gauze introduced far back in the nostril, successive layers being pushed in with a probe or nasal forceps. In order that packing from the front may be effective the gauze must not be more than half or three quarters of an inch wide, it must be carried as far back as possible and succeeding folds must be so small as to ensure a firm solid plug. The mistake is often made of attempting to put in too much at a time. This process is much simplified by the use of the Darmack packer, a metal canula through which the gauze is pushed by means of a rod or piston. The gauze may be dusted with tannogallic acid powder, or soaked in a saturated solution. After having packed in this way, if bleeding still persists and the blood finds its way back to the posterior naris, we shall be obliged to pack posteriorly as well as in front. The introduction of the posterior nasal plug may be accomplished with Bellocq's canula (Fig. 67), or bet-




FIG. 67. BELLOCQ'S CANULA.

ter a flexible catheter may be passed along the floor of the nose until its end appears in the oro-pharynx whence it may be drawn out through the mouth and a pledget of lint attached to it by a strong ligature. By pulling the catheter back again, the plug is drawn into the posterior naris, its passage being assisted by pressure from behind with the forefinger. It is important that the size of this plug should be correct; if too small, it will be drawn into the nasal fossa; if too large, it will become wedged between the velum and the pharynx and prove ineffective. Traction now being made on the ligature attached to the post-nasal plug, an anterior plug should be put in so as to completely fill the nasal fossa. The plug thus introduced should be removed not later than forty-eight hours; if left in beyond that time it is apt to become a source of danger from decomposition. Before attempting to remove the plugs it is wise to soften them thoroughly by soaking with oil or fluid vaseline. The nasal



hemostat of A. Cooper Rose consists of a hard-rubber tube covered with a soft-rubber bag which after its introduction is injected with air or water. It adapts itself to the irregularities of the walls of the nasal fossa in such a way as to exercise uniform pressure (Fig. 68). The withdrawal of the tube may be effected by turning a stop-cock at its end and allowing the air or water with which the bag is inflated to escape. A similar apparatus may be constructed out of a flexible

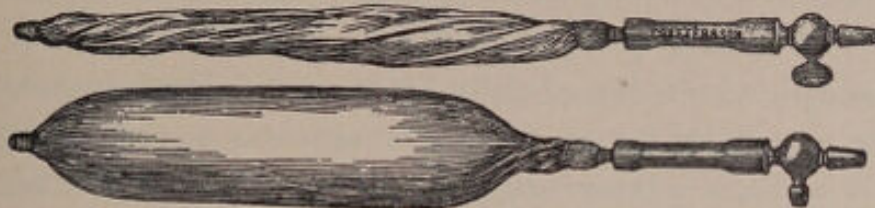


FIG. 68. COOPER ROSE'S NASAL HEMOSTAT.

catheter covered by a rubber hood. In treating cases of epistaxis too much emphasis cannot be laid upon the desirability of avoiding the so-called styptics, especially the iron preparations. In severe cases they are not only ineffective but they produce a very disagreeable mess in the nasal fossa and, in all probability, the hemorrhage which they are able to control would cease spontaneously. Hemorrhages of moderate severity may be checked by directing the patient to stand erect with both arms elevated above the head, in order to divert the blood pressure from the head to the upper extremities.




FIG. 69. SIMPSON'S PLUG OF BERNAYS' COMPRESSED COTTON.

If the bleeding comes from the septum pretty well forward simple pressure upon the ala of the nose with the head thrown slightly forward will control it. In mild cases a spray of peroxide of hydrogen into the affected nostril will sometimes form a sufficiently firm coagulum to stop the bleeding. A very excellent way of controlling bleeding when situated well forward and near the floor of the nose is by the introduction of the nasal plug of Bernays' sponge (W. K. Simpson), a flat disk of compressed cotton which absorbs moisture



and expands to about three times its original thickness (Fig. 69). The hemostatic power of suprarenal extract is very striking, whether used locally or internally. Even in cases of hemophilia it is said to have controlled a nose-bleed where other remedies had failed. It is important that fresh or aseptic solutions be used. Very unpleasant symptoms have followed the application of an infected solution. The following method of preparing a reliable solution is suggested by W. H. Bates. One part of powdered suprarenal is mixed with ten parts of boiling saturated solution of boracic acid. It is then filtered and should be boiled daily before use. Thus prepared it will retain its properties for months, although it is somewhat less effective than a plain watery solution. Under the name "adrenalin" the blood pressure raising principle of the suprarenal gland is said to have been isolated in pure and stable form (Takamine). All the extraordinary effects observed from the use of the extract are produced by this agent in vastly magnified degree. A permanent sterilized solution of adrenalin chloride, 1 to 1,000, is now being used diluted with distilled water or physiological salt solution, and if experience substantiates all that is claimed for it we shall be in possession of the most valuable of recent additions to our pharmacopeia.

Attention has recently been called to a rare source of hemorrhage in epistaxis by Brown Kelly, who describes several illustrative cases, after a careful study of the etiology of this form of nose-bleed. The anterior ethmoidal veins, from which the blood comes in these cases, anastomose with the veins of the dura mater and with the superior longitudinal sinus. Their close connection with the intracranial veins, and the absence of valves in their walls may account for their tendency to bleed. The practical value of a recognition of this source of hemorrhage lies in the fact that the flow may be checked by firm plugging of the roof of the nose, leaving the lower part of the passage free for breathing.

Whenever a localized hemorrhage can be defined, either from the septum, from the ethmoidal veins, or from an eroded turbinate body, it is better not to waste time by trying the various measures which have been described, but rather at once make direct pressure upon the spot from which the blood comes. An application of solid silver



nitrate, or better the electric cautery, is generally efficacious and is certainly most satisfactory as regards the comfort of the patient. It is necessary to dry the bleeding point as thoroughly as possible with sterilized cotton and be prepared to make the application instantly on withdrawal of the cotton. Thus it is certain that many patients may be saved the discomfort and danger of plugging, a discomfort often amounting to pain both at the time and subsequently, and a danger implicating especially the accessory sinuses and the ears.

Without underestimating the significance of a nose-bleed it may be said that its importance is usually exaggerated and that most patients are unduly alarmed by its occurrence.



## CHAPTER VIII.

### SYPHILIS OF THE NASAL FOSSÆ. LUPUS. TUBERCULOSIS. RHINOSCLEROMA.

The primary lesion of acquired syphilis has been met with in several instances on record in the form of a small elevated papule soon undergoing ulceration which presents no special features by which it may be identified. A chronic indurated ulcer of the ala, of the turbinate body, or of the septum, accompanied by swelling of the submaxillary and sublingual glands, and a characteristic cutaneous eruption, is always open to suspicion. In the second stage of syphilis we meet with mucous patches and with ulcerative processes either superficial or deep; in the latter case, the bone is apt to be affected and more or less extensive necrosis is followed by proportionate deformity. These deep ulcerations involving the framework of the nose are usually classed in the tertiary period and begin in the form of gummatous infiltration of the mucous membrane or as an inflammation of the bone or cartilage. In the former case the necrotic process in the hard parts is secondary to ulceration involving the mucosa and the periosteum or perichondrium. In the latter case death and destruction of bone or cartilage take place primarily and are followed by ulceration of the overlying mucous membrane. In some cases the affected bone instead of becoming necrosed and exfoliating undergoes a process of rarefying osteitis, or becomes so thickened as to obstruct the nasal passage, or, on the contrary, it may be absorbed. A syphilitic process sometimes invades a sinus, involves a nerve passing through one of the various foramina, or even extends to the meninges.

Chancre and the early secondary lesions seldom require any special local treatment beyond cleanliness. They are usually painless and do not lead to extensive damage. The early recognition of gummatous infiltration in the nasal structures is of the utmost importance, not only because of the danger of delay to the integrity of the framework of the nose but also because the earlier constitu-



tional treatment is begun the more prompt is the response. Usually the symptoms are those of ordinary coryza, and comprize sneezing, lachrymation, headache, impeded breathing and loss of smell. The secretions are free and watery and on inspection the mucous membrane is seen to be red, swollen and may be edematous. In the majority of cases the septum is chiefly involved and may be thickened so as to cause more or less stenosis. On palpation with a probe the swelling is found to be less resistant and less hard than that of an ecchondrosis, or exostosis, but is sensitive and somewhat vascular. If the condition is not appreciated at this stage breaking down of tissue and the destruction of bone and cartilage will take place with surprising rapidity. In later stages we have presented the unmistakable odor of necrosis with profuse, bloody discharges which tend to inspissate and adhere to the ulcerated surface in the form of dark greenish-yellow scabs. Small "worm-eaten" sequestra may be extruded and if a probe be used the sensation of necrosed bone may be obtained. Generally when the vomer has been lost by this process the nose becomes flattened and widened and very characteristic facial disfigurement results, the so-called "saddle" nose. In some cases the external nose may be involved by the ulcerative process or perforation into the cerebral cavity may take place.

The question as to the management of a nasal sequestrum resulting from syphilis is often presented and, in many cases, interference for removal of bone already dead and loose is permissible. As a rule, under active constitutional treatment a line of demarcation gradually forms and the bone affected becomes detached and may be removed without danger of damaging tissues that should be preserved. In some cases, the sequestra are so voluminous that they cannot be extracted through the nasal passages and we are compelled to resort to the operation suggested by Rouge, which consists in separating the upper lip by incision along the gingivo-labial furrow and throwing up the alæ of the nose in such a way as to expose the nasal fossæ. If necessary, the margins of the vestibule may be chipped with bone-forceps in order to give additional space. Although this operation appears formidable in reality it is found to be comparatively simple. The bleeding which occurs may generally be controlled by pressure and after removal of sequestra the parts are



simply replaced without the necessity of sutures or any special dressing. Various suggestions have been made looking to the correction of deformity resulting from syphilitic necrosis, among them the nasal support of vulcanized rubber, suggested by Bishop (Fig. 70), and the artificial bridge of platinum or aluminum in the form proposed by Martin and modified by Hopkins (Fig. 71). My own experience with these devices leads me to believe that nothing of the sort should be undertaken until the patient has been subjected to a long course of specific medication and we are assured that his tissues are in such a condition that they will repair themselves kindly



FIG. 70. BISHOP'S ARTIFICIAL NASAL BRIDGE.

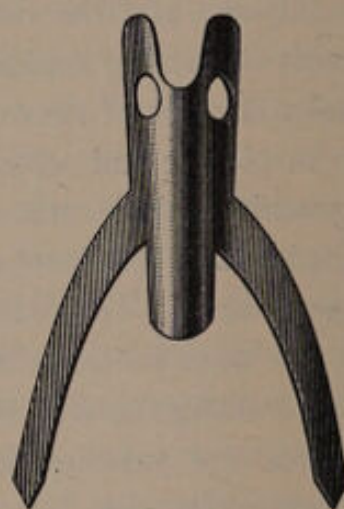


FIG. 71. MARTIN'S BRIDGE MODIFIED BY HOPKINS.

after operative interference; otherwise there is danger that the attempt to restore the contour of the nose may itself excite irritation and ulceration. The latter has happened in several instances in my own experience and a bridge has had to be removed, although, at first, the correction of the deformity was very gratifying and the apparatus gave no discomfort whatever. In its introduction the incision of Rouge is employed, the arms of the bridge, the shape and dimensions of which must be adapted to each individual case, being imbedded on either side in the superior maxilla. In certain cases, where the deformity is not extreme, it is found to be feasible to introduce a plate of platinum or celluloid underneath the skin, either by incision along the dorsum of the nose externally or by dissection of the skin from the dorsum by means of a sharp pointed bistoury introduced through the nostril (Fig. 72), the plate being



pushed up into the pocket thus formed. In several cases in which it was necessary to remove a metallic plate the newly-formed connective tissue excited by its presence proved to give adequate support to a previously collapsed dorsum.

For the correction of these deformities the subcutaneous injection of melted sterilized paraffin, which may be moulded to any desired form and in two or three months hardens to an almost cartilaginous consistency, has been practiced on the suggestion of Gersuny. Sunken parts may be thus supported to the proper extent and the tissues are expected to tolerate the presence of suitably prepared

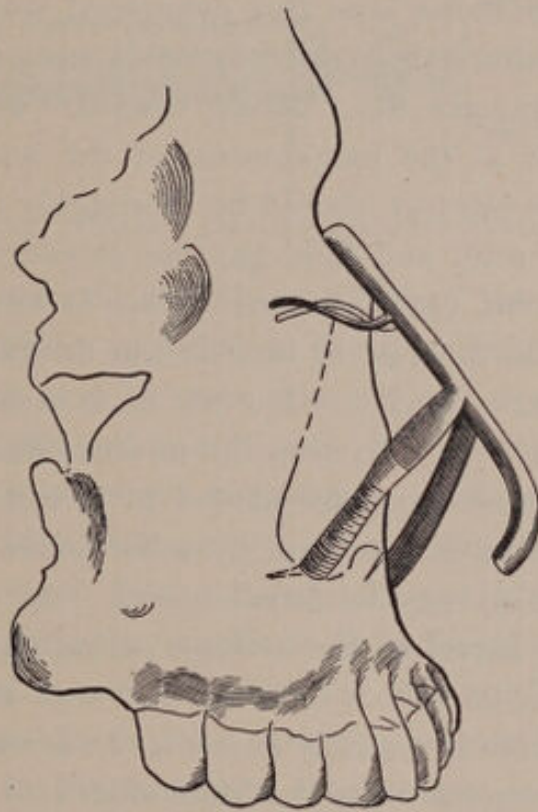


FIG. 72. MARTIN'S BRIDGE IN POSITION.

paraffin much more kindly than they do a plate of metal. The experience of A. Stein in one case of saddle nose and one of caries of the septum was most gratifying. He used paraffin melting at  $48^{\circ}$  to  $49^{\circ}$  C. carefully sterilized. The so-called paraffin used by J. F. Lynch in a similar case was not the hard substance used in making candles but was a "white vaselin," which is quite soft at ordinary temperatures but is said to become firm after a time. The experience of Delangre with suppuration in three out of seventeen cases in which paraffin had been injected for cosmetic or other effect in



various regions enforces the importance of strict observance of antiseptic details. Similar precaution is insisted upon by A. C. Heath, in whose case considerable local reaction followed the injection of a drachm and a half of paraffin, although the final result seems to have been fairly successful. It appears that the first to use solidifying oils under the skin was J. Leonard Corning, of New York, who injected a mixture of paraffin and cocoa butter not for cosmetic effect but for the purpose of immobilizing a muscle to prevent spasmodic contractions. Almost instant consolidation of the oil and prevention of embolism was ensured by spraying the injected area with ether. A mixture of the kind just mentioned would seem likely to provide more substantial support in nasal cases than a substance of semisolid consistence like "white vaselin," which must remain more or less fluid at the temperature of the body. It is equally important that the mixture should be thoroughly sterilized and that a combination of solid and fluid paraffin should be made giving a proper melting point ( $96.8^{\circ}$  to  $104^{\circ}$  F.). If too high, it must be injected so hot and fluid as to involve the danger of causing local reaction and thrombosis: if too low the mass does not become solid enough to give support. To keep the mixture fluid during the process of injecting a syringe surrounded by a soft rubber sheath or hood as suggested by Eckstein, or by a hot water chamber like that proposed by Quinlan may be found useful. An electric coil might be applied to the barrel of the syringe perhaps more conveniently. A rather large needle should be used and care should be taken to introduce the paraffin in a steady current. In several cases treated in this way by Harmon Smith at the Manhattan Eye and Ear Hospital a melting point of  $110^{\circ}$  was used and five minims of a four per cent. solution of cocaine were injected before the paraffin. There seem to have been no complications, and the results, while not perfect, were sufficiently good to encourage further experiment. His experience shows that it is better not to have the mixture too fluid, and by the use of a syringe of his own device, the piston of which is worked by a screw movement, it is possible to inject it in almost solid consistence (Fig. 73). It is asserted by A. B. Comstock and apparently proved by a series of interesting experiments that the mass becomes organized and actually traversed to some extent by fibrils of con-



nective tissue. This method is certainly quite promising and is much easier of application than the insertion of metallic supports.

In many cases, however, loss of tissue and cicatricial contractions compel a resort to plastic surgery by the formation of flaps from the forehead, the cheeks, or other parts of the body. Nasal deformities due to syphilis are divided by Roberts into: (1) Those in which some part of the external nose has been ulcerated away; (2) those in which destruction of the septal cartilage has caused a transverse depression of the dorsum; (3) those in which in addition to the

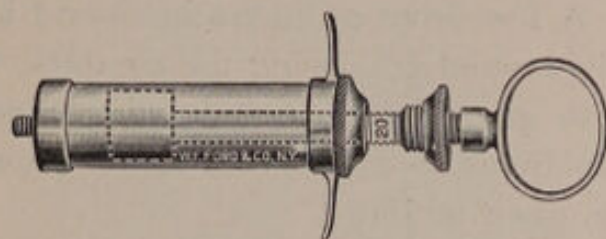


FIG. 73. HARMON SMITH'S PARAFFIN SYRINGE.

sinking of the dorsum cicatricial retraction of the alæ or tip of the nose is present. Those included in the first group are most easily remedied, but much may be done even after extensive loss of tissue by judicious, well-planned operations. Very often a great deal of patience and a long time are required to accomplish much, but in view of the repulsive deformity and the depressed mental state observed in these cases they certainly deserve careful study. The incisions in all rhinoplastic operations should be free enough to give a generous flap and to avoid tension, the resulting scars being much less disfiguring than the original unsightly deformity.

In a few cases in which loss of tissue from specific disease has not been excessive the subcutaneous, or intranasal, operations described and very successfully practiced by J. O. Roe are applicable, but in the majority the destruction has been so extensive that not enough material can be found within the nose with which to build up a supporting framework.

The constitutional treatment of syphilis of the nose is that of the disease in general. Progressive doses of a saturated solution of iodid of potash are given in milk or vichy, half an hour after meals, beginning with ten drops, a drop or more being added to each dose until we get evident signs of iodism or indications of an impression



upon the process going on in the nasal chambers. In the secondary and late lesions, especially if early treatment has been neglected, a combination of mercury with iodine is indicated, either in the form of the protoiodid, one sixth of a grain three times a day, by inunction, or by calomel fumigations.

The use of alcohol should be prohibited, and the patient should be put upon full diet, instructed to get all the fresh air possible and to use locally a douche or spray of Dobell's solution or some similar detergent. In nursing infants the nasal obstruction may be a very serious matter. A few drops of adrenalin chlorid instilled into the nares will usually succeed in opening the air track, but it is clearly most important to get the patient under the influence of specific medication as rapidly as possible. In addition a tonic and supportive treatment is often indicated.

### LUPUS AND TUBERCULOSIS.

By many authorities lupus and tuberculosis are considered identical, the former being looked upon as a modified or superficial variety of the latter. The appearance, clinical history and general tendency of these diseases differ sufficiently to justify a distinction, although it must be admitted that the nature of many cases is very doubtful. Many of their features are perplexingly similar, some resemble syphilis in certain points, while indications of mixed infection are presented in a small proportion of cases.

Lupus occurs in the form of small nodules which coalesce and ulcerate, or absorption may take place, a feeble tendency to repair appearing at the margins of the lesions (Fig. 74). The nodules are very hard and distinct, hyperemic at first and becoming paler until finally they break down and ulcerate. The lesion spreads in a peculiar serpiginous way supposed to be characteristic. It usually begins on the anterior part of the septum, thence extending to the alæ and the skin of the face, the formation of new nodules and of a typical bluish cicatrix going on at the same time. Sometimes the process is reversed, the disease beginning in the integument. The bony structures are never involved but the cartilages occasionally are attacked. One or both nostrils may be affected and there is more or



less stenosis. The discharges at first watery become thick and fetid as ulceration progresses, with tendency to crust-formation. Pain is usually complained of, and the nodules and ulcers are quite sensitive to the touch. Sometimes itching is a prominent symptom. The deformity resulting from absorption of nodules and consequent atrophy or from cicatricial contraction is often extreme. The dis-

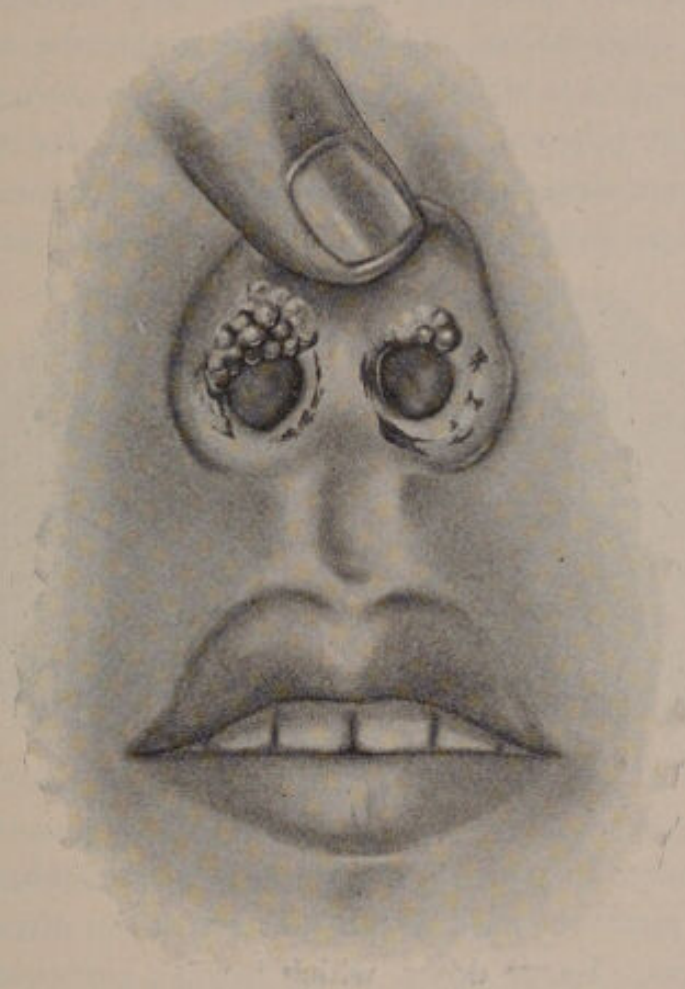


FIG. 74. LUPUS OF ANTERIOR NARES (*Gerber*), showing lesions involving mucocutaneous junction and attempts at repair.

ease is very resistant to treatment, although cases of spontaneous recovery have been met with.

Nasal tuberculosis is very rare. It may be primary but is usually secondary to manifestations elsewhere. It occurs in the form of nodules or tumors of variable size which ultimately undergo ulceration (Fig. 75). The secretions are free, thick and offensive and may be tinged with blood. Unlike those of lupus the nodules of tuberculosis are insensitive and pale in color, and the ulcerative process



of the latter does not spread in a serpiginous way and shows no tendency to repair. The crucial test in diagnosis is the presence of the tubercle bacillus, the bacillus of Koch. It is hard to find in the scrapings but is pretty sure to be discovered in a section of a tubercular tumor, or nodule. General symptoms depend upon the activity and extent of coincident lesions in the lung or elsewhere. Anti-syphilitic treatment generally aggravates the local condition both in lupus and tuberculosis. If thought desirable the tuberculin test may be resorted to, a definite reaction generally being exhibited in cases of genuine tuberculosis, as well as in lupus. Its value in detecting latent or incipient cases or confirming suspicion in those giving no positive sign is unquestionable. Its use should be restricted to

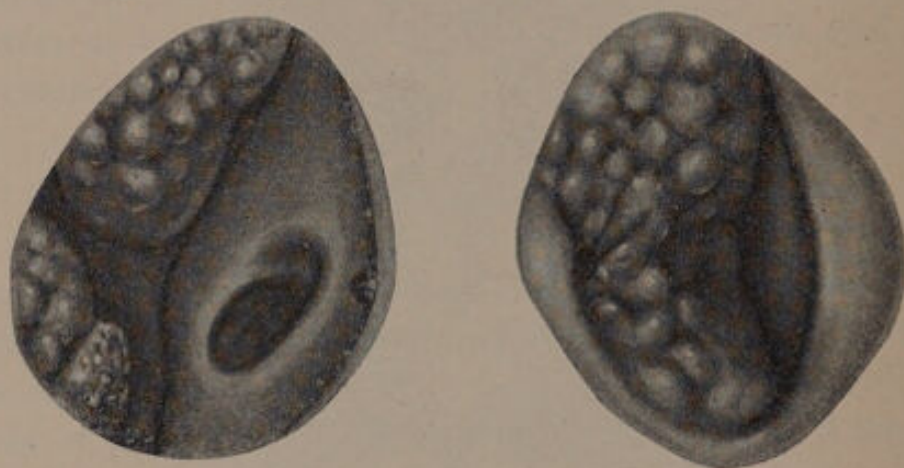


FIG. 75. TUBERCULOSIS OF TURBINATES ON RIGHT SIDE AND OF LEFT SIDE OF SEPTUM WITH PERFORATIONS. (*Gerber.*)

cases of this class in which a diagnosis is of the utmost importance in order that measures may be taken to arrest the disease with some hope of success. Large doses, which involve corresponding violent local reaction, are not required for this purpose. Proofs are abundant that the large doses once used encouraged dissemination of the bacilli by producing softening of the tubercular foci. But experience with smaller quantities, two to five milligrammes, seems to have demonstrated its innocuousness, and its reliability for diagnostic purposes.

The tubercular tumor which shows no inclination to ulcerate is apt to select as its site a turbinate body; the tubercular ulcer, formed by the coalescence and breaking down of two or more miliary nodules generally begins at the anterior part of the septum whence



it may extend to the external parts. Perforation of the septal cartilage may take place. It would seem to be difficult to make a diagnosis from the appearance of the ulcer which varies greatly in different cases. It may be round or ovoid, its edges may be flat or elevated, its surface may be smooth, covered with grumous secretion, dotted here and there with caseating tubercles, or obscured by masses of exuberant granulation.

The *treatment* of lupus and of tuberculosis should be conducted on similar lines. After careful cleansing of the parts all morbid deposit should be thoroughly removed by means of the curette and the exposed area is then rubbed with pure lactic acid. The parts must be kept scrupulously clean with Dobell's solution or a carbolyzed alkaline wash, and if reaction and pain are excessive the surfaces may be coated with an emollient ointment. One of the best is a mixture of orthoform with albolene or lanolin, a drachm to the ounce. General medication must be resorted to according to indications. In tuberculosis, as a rule, we are dealing, not with a local disease, but with a general diathesis, and the importance of good hygiene, pure air and sunshine, nutritious diet and supportive treatment is beyond question.

It seems to be clearly proven that tubercle bacilli may be found in the nasal fossæ of the perfectly healthy but especially of those attendant upon tubercular subjects, hence the necessity of care to avoid producing abrasion of the nasal mucosa through which the germ might find entrance to the system.

### RHINOSCLEROMA.

The opportunity of studying rhinoscleroma in this country is extremely rare. In 1893 Jackson could discover only three reported cases. Since then a few have been added to the list, with one exception having been imported from abroad. This disease was first described by Hebra, whose account in some particulars is still accepted as correct. It is a chronic inflammatory process involving the mucous membrane of the upper air track, usually beginning in the nose at the anterior part of the septum, and sometimes extending thence to the pharynx, larynx and even to the trachea. It is char-



acterized by extreme thickening and ivory-like hardness of the affected parts, which are sensitive to the touch but are free from spontaneous pain. It develops very slowly without edema or acute symptoms. It eventually causes great external deformity as well as internal distortion from cicatricial retraction and gradual filling of the passages with indurated masses. The tip of the nose becomes enormously broadened, hard and lobulated. When the pharynx is invaded the palate is thickened, leathery and covered with fine scales. The smooth nodular appearance of the external nose is compared by Kaposi to that of keloid. In some cases the course of the disease is reversed and it appears on the palate, in the larynx, or even in the trachea before any signs are present in the nares. The evidence seems to be almost convincing that a rare lesion described as *chorditis hypertrophica chronica inferior* and what is known as Stoerk's blenorrea are identical with rhinoscleroma. This view is held by Freudenthal, who has given a very careful and complete report of a case under his observation. The typical bacterium of rhinoscleroma is said to be the capsule bacillus of Frisch, resembling the pneumococcus of Friedlander, but not easily demonstrable. In a case reported by Roe, which is said to be the first instance of the disease originating in this country, it was difficult to find the bacilli in the cells, although certain bacilli were cultivated not unlike the pneumococcus.

The *treatment* of the condition appears to be very unsatisfactory. The morbid tissue may be removed by the knife, or by curetting, or may be destroyed with the galvanocautery. Various chemical caustics, especially lactic acid, have been tried, with only temporary amelioration. Internal medication makes no impression on the lesion. In some cases the nodules soften and break down, as in one reported by C. W. Allen, in which almost the entire mass sloughed away, exposing the bones of the upper jaw and the nasal septum. Generally the disease is extremely chronic, although the duration of Roe's case was only three and a half years. Its resemblance to malignant disease and the fact that the nose is often not its primary site have suggested the propriety of substituting the name "granulation sarcoma," or a similar title, for rhinoscleroma, which latter is manifestly inappropriate. In this connection Freudenthal suggests that good



results may be possible with injections of Coley's fluid as in sarcoma, and he refers to the favorable reports of Pawlowsky with injections of *rhinosclerene*. In one case, that of Lubliner, the lesion absolutely disappeared after an attack of typhoid fever.



## CHAPTER IX.

### NASAL NEUROSES. HAY FEVER. NASAL HYDRORRHEA.

Neurotic disturbances met with in the nose may affect the special sense of smell, or the secreting function of the mucous glands, or may excite certain reflex phenomena.

*Parosmia* is a perversion of the sense of smell in which the subject perceives odors which do not exist. When the odor is offensive the term *kakosmia* is applied. It may be due to a pathological change in the nerve terminations or to some central nerve lesion. This phenomenon has been met with as a precursor of insanity and in the course of syphilis, hysteria and epilepsy.

An exaggerated sense of smell, or *hyperosmia*, is met with in conditions of neurasthenia and in hysteria as well as in certain sexual derangements in women.

*Anosmia*, or loss of smell, may be partial or complete and may result from injury or disease affecting the olfactory nerve or the nerve centers in the brain. It may be the result of some peripheral irritation, such as pungent gases or strong local applications to the nasal mucous membrane might produce. The sense of smell is also lost or impaired in simple acute and chronic inflammatory conditions, as a sequel of grip, and sometimes in connection with adenoids and polypi, or other lesions causing nasal obstruction. Finally loss of the sense of smell may be referred to functional or reflex disturbances. Thus anosmia may be divided into three classes (Onodi). (1) Essential or true anosmia, central or peripheral, depending on the part of the olfactory nerve affected; (2) mechanical or respiratory anosmia resulting from atresia of the nares, congenital or acquired. Under this head are included conditions which prevent access of air to the nasal chambers, such as deformities, new growths and inflammatory swellings; (3) functional anosmia, as in hysteria, and as a reflex from ovarian or uterine disturbance, from psoriasis buccalis, and from cauterization of the inferior turbinates.



The prognosis of anosmia depends in great degree upon its cause. Many cases even of long standing are benefited by treatment, especially when the condition is a sequel of influenza or neurasthenia. In advanced atrophy of the nasal mucous membrane the loss of smell is usually complete and permanent.

Local treatment should be conducted with caution. In the first variety the mode of treatment is governed by the cause and its location. The relief of mechanical anosmia is generally feasible by removing the nasal impediment. In functional anosmia stimulation of the olfactory tract with galvanism and the internal use of general tonics are sometimes effective.

### HAY FEVER.

Since the subject of reflex neuroses was first brought up an immense number of affections have been traced to disease of the nasal chambers. It must be admitted that many of these relationships have their origin in the imagination of the observer. In other words, a genuine nasal reflex is relatively rare. The typical, most familiar example of a nasal neurosis is hay fever, at times accompanied by reflex asthma. It is otherwise known as hyperesthetic rhinitis, or periodical vaso-motor rhinitis, as well as by other titles. Three conditions seem to be essential to its development, the neurotic temperament, nasal hyperesthesia associated or not with a deformity or neoplasm of the intra-nasal structures and, finally, an exciting cause in the shape of some irritant, either pollen, or emanations of some kind, animal or vegetable, or certain peculiar atmospheric states. It is allied in many of its features to other neurotic disturbances, paroxysmal sneezing and similar phenomena known as autumnal catarrh and rose cold. These occur independently of any special period of the year and are sometimes known as pseudo-hay fever. Rose cold is so called from its occurrence in June, the month of roses, although the attacks are not limited to that period. It is a well known fact that sneezing, cough, and lachrymation may be caused by irritation of certain areas in the nasal mucous membrane. It is possible to demonstrate with a probe sensitive regions but the idea that they are always to be found in similar situations in all indi-



viduals is erroneous. The influence of heredity as a predisposing cause is unquestioned; in at least half the cases of hay fever we succeed in getting a history of some neurotic manifestation in other members of the family. It is a curious fact that the disease seems to be limited to the Anglo-Saxon race and it is said to be more prevalent in males than in females. It is not always easy to discover the irritant which excites an attack. Dust of any kind, tobacco smoke, pollen of various plants, as rag-weed, or golden-rod, and emanations from certain animals are capable of producing it. The name rose cold is derived from the fact that symptoms of this kind are induced by roses, but the famous case of J. N. Mackenzie in which characteristic attacks were caused by an artificial rose proves that the phenomena may be of purely psychical origin. Many interesting cases are on record in which attacks closely resembling hay fever have developed in connection with renal irritation. Paroxysmal coryza of nephritic origin subsides with the relief of urinary symptoms and is not periodic, but recurs if for any cause the renal derangement becomes aggravated.

Haig, Bishop and others who have made extensive study of this subject, attribute hay fever to an excess of uric acid in the fluids of the body. Daly, Bosworth and others profess to find invariably some intranasal abnormality which acts as an exciting cause. Price-Brown traces the outbreaks to an antecedent hypertrophic rhinitis. Excessive alkalinity of the nasal secretions is thought to explain the condition in some cases. The argument in support of the uric acid as well as of the nasal stenosis theory of causation is measurably weakened by the fact that these states are very prevalent in those without a suspicion of hay fever. That they often coexist admits of no question; that they are occasional excitants is very probable. An attack is sometimes provoked by indiscretion in diet and consequent digestive derangement. Extraordinary mental emotion or nervous excitement will aggravate or may even induce an attack. Certain localities seem to be relatively free from the disease and yet some suffer where others are exempt, and again the latter may succumb in a region where they have previously escaped. Hay fever usually occurs in adolescence or early middle life, but has been observed in children and even in infants. It is essentially a disease of the well-



to-do, or at least of those whose affairs involve more or less nerve tension and excitement. Yet not a few cases have come to my notice in those whose lives were placid and free from care, but such persons have usually given a highly neurotic individual or family history.

The symptoms of hay fever vary somewhat in different individuals and in the time when they appear. Usually the attack begins early in August and ceases with the advent of frost or cold weather. In some seasons the outbreak may be delayed and occasionally its duration is abbreviated, whence the inference that atmospheric states may have some influence. One of the earliest symptoms is a sensation of itching and burning of the eyelids, particularly at the inner canthus. Sometimes there is decided itching in the pharynx or roof of the mouth. This may persist for hours or days and is accompanied by sneezing and suffusion of the eyes. The attack may come on with great abruptness or by degrees. Stenosis of the nostrils results from turbinate turgescence and presently a serous discharge begins which soon becomes remarkably free. Mental as well as physical depression, especially in very neurotic subjects, may be pronounced. The eyelids frequently become very much swollen and there may be marked photophobia. In some cases asthma supervenes, resembling, in all respects, the ordinary attacks of this affection. Examination of the nose may show nothing more than would be expected in the early stage of acute catarrhal rhinitis, but the membranes are much less injected or are actually pale and soggy in appearance, and the serous effusion is much more abundant. In the interval of health nothing abnormal may be found in the nose, or some deformity may be discovered which may be reasonably looked upon as an aggravation if not the cause of symptoms.

The prognosis as to the attacks is favorable; so far as the cure of the disease or the tendency to it is concerned, we cannot speak so hopefully except possibly in those cases in which we are able to discover a positive nasal lesion. The prognosis when little or no structural change can be detected and in individuals of highly neurotic temperament is decidedly less favorable.

In any case we are justified in promising some degree of amelioration of symptoms as a result of treatment. Many patients will prefer to secure exemption from the trouble by resorting to localities



where experience has taught that they may be reasonably free from disturbance. A sea voyage will sometimes afford escape. A residence at a moderately high altitude appears to give immunity to some. The use of nerve tonics and sedatives is considered of value, and stimulants give temporary relief, but their use is not to be advised except in extreme cases.

The importance of internal medication is urged by adherents of the uric acid theory as well as by many of those who find the first cause of hay fever in the nasal fossæ. Without doubt cures have followed correction of nasal anomalies, yet the attention given to hygiene, diet, exercise and clothing, not to mention the use of tonics, by most practitioners shows that the sole reliance is not placed upon local treatment. Bishop, who is a stout advocate of the uric acid idea, gives the acid phosphates (Horsford) in one or two teaspoonful doses night and morning, and never fails to stop an attack by a combination of atropia and morphia in suitable cases, one part of the former to fifty of the latter, one sixteenth to one eighth of a grain of this mixture being given to an adult. Atropine has always been well thought of in asthma and seems to be especially adapted to that associated with hay fever. In extreme cases the addition of morphine may be desirable, but the use of such drugs should never be left to the discretion of the patient. Iodide of potassium, or sodium, or syrup of hydriodic acid finds favor with some, while others recommend strychnia in full doses, or the three valerianates of zinc, iron and quinine, one grain each. It is apparent that we have no specific for hay fever and in many cases the administration of drugs does more harm than good. In the presence of symptoms of anemia or of asthmatic attacks we may expect the best results from internal medication.

In these days when the accessory sinuses are attracting so much attention perhaps it is not surprising that they should be accused of joining the hay fever conspiracy. Accordingly we find E. Fink protesting that the sinuses, and especially the antrum, provide the secretion which is one of the prominent features of the disease. Insufflations of aristol made through the ostium are said to cure the most obstinate case. A degree of suspicion is thrown on the genuineness of this contention by the earnestness with which treatment of the coincident neurasthenia is urged.



Of local remedies nothing gives an equal degree of immediate comfort as cocaine applied to the mucous membrane of the nose on a pledget of lint or in the form of a spray. It should never be entrusted to a patient, and when a strength greater than four per cent. is required for the desired effect a detrimental impression upon the nervous system is almost inevitable so that its advantages seem to be more than overbalanced. Moreover, its action is so transient that we are forced to conclude that its indiscriminate recommendation is not justifiable. The evils of the cocaine habit, a risk not to be ignored, are unhappily familiar. Great hopes have been entertained as to the value of a recent addition to the pharmacopeia in the suprarenal extract. So far as observations have gone it seems to modify the symptoms, and hitherto no bad effects have been observed. Yet it is still on trial and no final conclusion as to its permanent value is permissible.

The aqueous extract of the suprarenal gland possesses astringent and hemostatic qualities, and is, at the same time, a tonic to muscle fiber. A great advantage of the drug is that it is non-toxic and may be used liberally without detrimental effects. Not only is it free from toxic properties itself, but it seems to possess the power of limiting the toxic effects of cocaine with which it may be used in combination or alternately. It apparently contracts the blood-vessels and thus retains the cocaine in the tissues, prolonging its anesthetic effect. The difficulty hitherto has been to secure a stable solution especially in warm weather; decomposition takes place rapidly and a solution, although retaining its peculiar blanching properties, becomes irritating and unfit for use. It is found that glycerine in ten to twenty-five per cent. solution will prevent putrefaction for several days. The limit of solubility in water is about fifteen grains to the drachm.

A formula for a permanent solution which may be kept for several months is thus given (L. S. Sommers):

R

Adrenal .....	20 grains.
Phenic acid.....	2 grains.
Beta-eucain .....	5 grains.
Distilled water.....	2 drachms.

M. Macerate for ten minutes and filter.



The effect of the solution upon the mucous membrane is apparent almost at once and reaches its maximum in from three to five minutes. The formula just given may be used without the eucaine. It causes slight smarting which soon subsides. Retraction of the swollen turbinates is almost immediate and lasts several hours. In moderate cases it is not unusual to see a single application give permanent relief. More immediate and pronounced results are claimed by some if the adrenal be given internally as well as used locally. One grain of the powder, representing eight grains of the fresh suprarenal gland, may be given in tablet or capsule every two hours, until dizziness, or cardiac palpitation, develops, or the nasal mucosa shows the characteristic effects of the drug. For local use the following solution, said to be permanent, may be applied in spray or on cotton (E. F. Ingals):

℞	
Suprarenal capsule.....	15 grains.
Boric acid.....	4 grains.
Cinnamon water.....	1 drachm.
Camphor water, hot.....	2 drachms.
Boiling water q.s. ad.....	4 drachms.
S. Macerate four hours and filter.	

A one per cent. aqueous solution of resorcin is said by Oppenheimer to be an almost perfect preservative.

A solution of suprarenal extract with chloretone, recently introduced, is fairly permanent and as active as a freshly prepared solution of the dried gland. Each minim represents one grain of fresh gland and the mixture contains 0.8 per cent. of chloretone. The combination of hemostatic, anesthetic and antiseptic properties thus formed promises to be valuable. Adrenalin chloride mentioned in the chapter on Epistaxis has similar efficacy and is a more stable preparation. During the paroxysms of hay fever more or less comfort is derived from inhalations of camphor and menthol, equal parts in an inhaler, or in albolene solution so mild as to be quite free from irritating effects.

In a small proportion of cases a weak solution of chromic acid,  $\frac{1}{8}$  of a grain or less to the ounce of water, has been found efficacious in hay fever (Macdonald). A combination of muriate of quinine, 1 drachm, glycerite of carbolic acid, B. P., 1 ounce, and perchloride



of mercury, 1/1000 part (Andrew Clark), is useful in cases exhibiting no structural change, but the application is more or less painful and excites disturbance resembling a violent attack of hay fever which lasts a day or two. It is customary to cleanse the nostrils thoroughly, spray with cocaine in 10 per cent. solution, and then paint the mucous membrane of the nasal fossæ with Clark's solution. Considerable burning is caused in spite of the cocaine, and for the next twenty-four or forty-eight hours a violent attack of coryza occurs.

In cases accompanied by structural anomalies or new growths it is possible to accomplish much more definite results than in others, in which only the remedies just described are applicable. Ecchondroses and exostoses of the septum impinging upon a turbinate are found to act as exciting causes. Hyperplasia of the turbinate tissue in contact with the septum is productive of similar results. Nasal polypi are well known to be sources of irritation, and the removal of these various abnormalities is almost always followed by some improvement if not an absolute cure. Sensitive spots, identified by exploration with the probe, either upon the septum or the turbinate bodies, may be destroyed by the galvano-cautery or chemical caustics.

The observation that the internal use of ipecac prevents the local effects of this drug produced in certain individuals has led to experiments with plants known to cause similar disturbances, especially the rag-weed (Holbrook Curtis). Some very curious results are recorded with tinctures and fluid extracts of golden-rod, lily of the valley and other plants. A solution representing in each drachm five minims of the fluid extract of *Ambrosia artemisia* is recommended to be given between meals and at bed-time two weeks before the hay fever is expected, the dose to be increased to the point of tolerance during the attack. My own experience with it thus far has not been such as to justify any confidence. In a few cases in which a favorable report was made it seemed to be necessary to eliminate the credulity and the faulty observation of the patient.

The tendency to attacks of hay fever and their severity seem to diminish with advancing years, and if immunity for several successive seasons can be obtained, if the nasal membranes can be re-



stored to a condition of health and if, at the same time, the neurotic disposition can be modified we may hope for a disappearance or a mitigation of the disease. The prominence of the neurotic element varies greatly in different cases and in the same case in different seasons, but is never absent. It is rather more pronounced in cases of paroxysmal sneezing than in other neuroses. In some individuals attacks of sneezing occur on rising in the morning, on sudden exposure to bright sunshine, or after the ingestion of a hearty meal. A cure of these cases has been accomplished by hypnotic suggestion. Not every one is amenable to hypnosis, yet, contrary to the general belief that hypnotism is applicable only to "fools and weaklings," the experience of Lloyd Tuckey shows that "strong, muscular and intelligent men and women" are the best subjects. In many cases, however, a nasal lesion must be removed in order to obtain a permanent cure.

In spite of all that can be done the melancholy spectacle is all too frequent of an individual who has exhausted the resources of the general practitioner, who has experimented with every known quack nostrum, who has had most of his original intranasal structures removed by the ardent rhinologist and who still remains the unhappy victim of hay fever.

### NASAL HYDRORRHEA.

A flow of watery secretion from the anterior nares under the name of nasal hydrorrhea is looked upon by some authorities as a modified form of hay fever. It occurs independently of season and is, undoubtedly, a vaso-motor affection. In some cases on record it seems to have been of malarial origin, occurring periodically, and accompanied by chills and fever, a cure resulting from the administration of quinine. The few cases reported show great variation in clinical history, nasal discharge being the only fixed symptom. The quantity of secretion is more or less abundant, even a pint or more of fluid escaping in twenty-four hours, sometimes from one and again from both nostrils. It seems to have been observed in one instance as a symptom of general edema, in other cases associated with cerebral disease, and it has been seen in hysterical patients. Under



these circumstances it is, of course, merely a symptom; in other cases the hydrorrhea is so pronounced as practically to constitute in itself a disease. A serous secretion from the nostril in nasal polypi and in polypi of the accessory sinuses is very common, but under these circumstances must be placed in another category. In connection with trifacial neuralgia and certain genito-urinary disturbances in either sex it must be regarded as purely a reflex disorder. The subjects of this affection are very sensitive to atmospheric conditions and the discharge is usually preceded by sensations of tickling in the nostrils and attacks of sneezing.

It is usually met with in adults, the case reported by Cathcart in a girl nine years old being quite exceptional.

Examination of the nose shows turgescence of the mucous membrane, which may be redder than normal and is bathed in watery secretion. In cases of long standing the membranes become somewhat pale. There may be considerable nasal stenosis and paroxysms of reflex asthma may occur.

Looking upon the affection as a symptom of a general diathesis it is obvious that local treatment alone cannot be efficacious. In view of the evidence of a malarial element the use of quinine is always indicated. Mustard foot baths with atropine and morphine internally have been known to check an attack. Violent local measures should be avoided, but relief may be obtained from applications of menthol in albolene or, if distress is extreme, by the use of cocaine. A more prolonged effect from adrenalin has been claimed in some cases, while in others it has utterly failed. Decortication of the nasal mucous membrane recommended by Moure and daily massage of the nasal fossæ with cotton tampons soaked in borated vaseline and containing a little cocaine advised by Jankelevitch may be resorted to in the failure of other measures. The internal use of strychnin, hydrotherapy and the external application of the continuous electric current have each been found beneficial. Applications of hot air, as described in the chapter on Rhinitis, have been effective in the hands of G. Mahu, who seems to have observed an extraordinary number of these cases.

This condition must not be mistaken for the very rare phenomenon which has been the subject of recent study, namely,



the spontaneous discharge of cerebro-spinal fluid from the nose. Undoubtedly some of the latter have been reported as cases of nasal hydrorrhea, but it is very clear that they have no similarity and that the affection about to be considered has no relationship with hay fever. One of the earliest cases described was in a girl of fifteen who had hydrocephalus from birth (Leber). She had severe headaches, dizziness, and impaired vision and, finally, an epileptic fit which was followed by the continuous escape of fluid from the left nostril.

In another case intermittent discharges from the nose were preceded by severe headache, chiefly over the left eye, top and back of the head. When the flow was established the patient was relieved and appeared to be in perfect health in other respects (St. Clair Thomson).

In one case the discharge of watery fluid was preceded by very grave cerebral disturbance indicative of pressure as shown by the existence of optic neuritis and the occurrence of symptoms of tumor of the brain (Freudenthal). The flow was continuous night and day, in this respect differing from that of nasal hydrorrhea which usually stops at night. In the chemical analysis of the fluid, however, we have a pretty definite means of differentiating these conditions. The chief points which serve to identify cerebro-spinal fluid are first, its clear watery character; second, its low specific gravity; third, the small amount of proteid in it and the absence of albumin, and fourth, the presence of a substance "possibly related to pyrocatechin which reduces Fehling's solution but is not dextrose." The history of these cases shows the importance of avoiding measures intended to check the flow, since cerebral symptoms recur almost as soon as any obstacle is offered to the escape of the fluid. It is remarkable that the leakage may continue indefinitely without any marked impairment of the general health.



# THE PHARYNX.

## CHAPTER X.

### ANATOMY AND PHYSIOLOGY OF THE PHARYNX.

The pharynx extends from the posterior nares to the cricoid cartilage and is divided into three portions, the upper, or *rhinopharynx*, ending at the level of the palate, the middle, or *oropharynx*, extending to the vestibule of the larynx, and the lower, or *laryngopharynx*, opening into the esophagus at the lower border of the cricoid cartilage.

The superior division has opening into it the orifices of the posterior nares, or choanæ, those of the Eustachian tube on either side and below it is continuous with the buccal pharynx. Lesions in this division of the pharynx are of special interest from their relation to the Eustachian tubes, the sphenoidal sinus and the posterior nares. The orifice of the tube on either side is on a line with the inferior turbinate body and between them is sometimes found a mass of lymphoid tissue called the Eustachian or tubal tonsil. It is generally continuous with other adenoid vegetations on the wall of the rhinopharynx and hardly deserves an independent name. The posterior lip or margin of the Eustachian tube is much more prominent than the anterior and forms a decided eminence called the Eustachian cushion. Behind it is a depression of considerable depth, the fossa of Rosenmüller, where large quantities of adenoids often accumulate and their removal with a large sharp-edged instrument is attended by some risk to the cushion.

The middle division of the pharynx, or oropharynx, contains aggregations of lymphoid tissue between the pillars of the fauces known as the palatal or faucial tonsils, and similar masses at the base of the tongue called the lingual tonsil. The former present pathological conditions of great importance in both an acute and a chronic form. Acute disturbances of the lingual tonsil are less common, but the



latter lymphoid mass often undergoes considerable enlargement and becomes a source of functional derangement affecting the pharynx and the larynx. The lingual tonsil also at times is involved in phlegmonous inflammation. Cases reported as abscess of the tongue are doubtless often a suppurative inflammation involving this structure. Across the base of the tongue we also see, especially in adults, a varicose condition of the blood-vessels quite independent of any special or marked change in the lymphoid tissue. An interesting and curious phenomenon at the posterior wall of the pharynx, visible through the mouth in the form of a pulsating vessel, has lately attracted a good deal of attention. It seems to have no special significance and is unimportant except when we may be called upon to use the knife in this region.

The laryngo-pharynx, the third division, is of special interest to the laryngologist in connection with foreign bodies, which are apt to lodge at the point where the pharynx merges into the esophagus, and in connection with neoplastic formations invading it from the larynx. Many cases of dysphagia, or odynphagia, have their origin not in the swallowing track, but in the laryngeal cavity where compression by the inferior constrictor causes a feeling of obstruction or a sensation of pain.

The pharynx measures from above downward about four and a half inches. Its narrowest portion is at its junction with the esophagus. Its lateral diameter is greater than its anteroposterior, being widest on a level with the cornua of the hyoid bone. Its wall is composed of a fibrous coat, the pharyngeal aponeurosis, which is lined by mucous membrane and surrounded by muscles, the pharyngeal constrictors.

The pharyngeal aponeurosis is best marked at its upper portion where it is attached to the posterior part of the body of the sphenoid bone in front of the pharyngeal tubercle. Thence it runs outwards to the apex of the petrous portion of the temporal bone to the cartilage between it and the occipital bone to the Eustachian tube and the internal pterygoid plate.

The mucous membrane is closely adherent to the base of the skull; in parts it is thick and spongy; in the neighborhood of the openings of the nares and Eustachian tubes it is thinner, while below it is pale



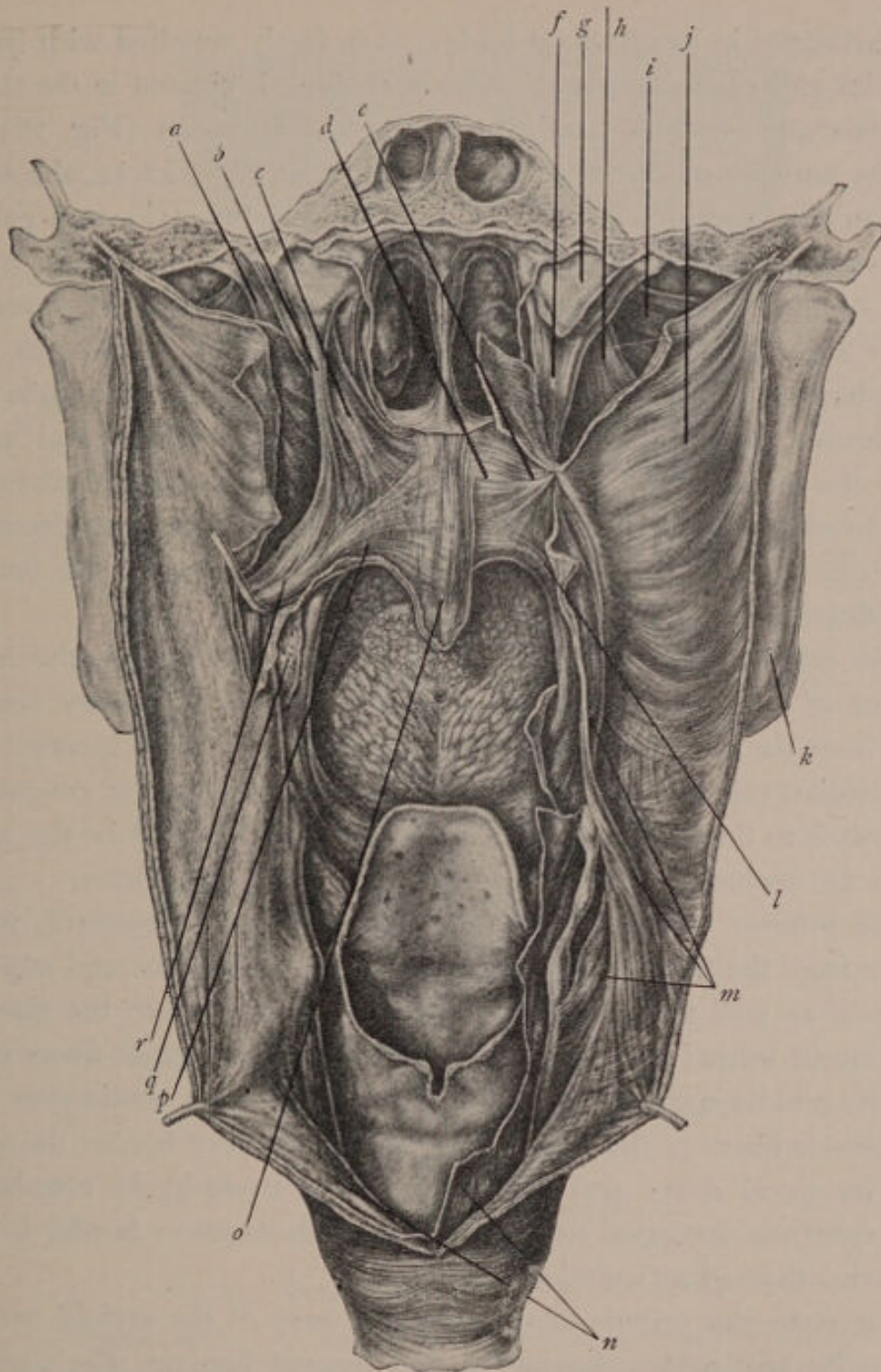


FIG. 76. MUSCLES OF SOFT PALATE SEEN FROM BEHIND. (Deaver.)

*a*, Tensor palati muscle; *b*, salpingopharyngeus muscle; *c*, levator palati muscle; *d*, aponeurosis of soft palate; *e*, tensor palati tendon; *f*, tensor palati muscle; *g*, Eustachian tube; *h*, internal pterygoid muscle; *i*, external pterygoid muscle; *j*, pharyngeal aponeurosis lining constrictors; *k*, lower jaw; *l*, palatoglossus muscle; *m*, palatopharyngeus muscle; *n*, mucous membrane; *o*, azygos uvulae muscle; *p*, posterior fasciculus of palatopharyngeus muscle; *q*, tonsil; *r*, palatopharyngeus muscle.



and arranged in longitudinal folds. It is freely supplied with lymph follicles and racemose glands. Its epithelium is ciliated in the rhinopharynx and becomes stratiform in the lower portion (Fig. 76).

The muscles of the pharynx are the three constrictors, the superior, middle and inferior, fortified by fibers of the stylo- and palatopharyngei muscles. The superior constrictor surrounds the upper part of the pharynx with the exception of a semi-lunar space on either side named the "sinus of Morgagni" which is filled in with the pharyngeal aponeurosis and contains the Eustachian tube and the levator palati muscle. It is quadrilateral in shape and arises from the lower third of the edge of the internal pterygoid plate and its hamular process, from the pterygo-maxillary ligament, from the posterior fifth of the mylohyoid ridge and the side of the tongue. The fibers pass backwards to meet in the median raphe.

The middle constrictor is fan-shaped and arises from the lesser cornua of the hyoid, from the whole length of the greater cornua, and from the stylo-hyoid ligament. Its fibers are also inserted into the median raphe. The upper ones overlap the superior constrictor and reach to the basilar process of the occipital bone, while the lower fibers are included within those of the inferior constrictor.

The inferior constrictor is a thick muscle, very powerful, which arises from the thyroid cartilage behind the oblique line and superior tubercle as well as from the inferior cornua and from the sides of the cricoid behind the crico-thyroid muscle. The upper fibers overlap the middle constrictor while the lower ones are continuous with the muscle fibers of the esophagus. Near its upper border the superior laryngeal nerve and artery pierce the thyro-hyoid membrane. The recurrent laryngeal nerve enters beneath its lower border behind the crico-thyroid articulation.

The stylo-pharyngeus arises from the base of the styloid process internally and passes downward and inward between the superior and middle constrictors. Its fibers diverge, some joining the palatopharyngeus to be inserted into the posterior border of the thyroid cartilage, and the rest mingling with the constrictors.

The palato-pharyngeus forms the posterior pillar of the fauces. It arises from the aponeurosis of the soft palate by two heads separated by the insertion of the levator palati. The upper head blends



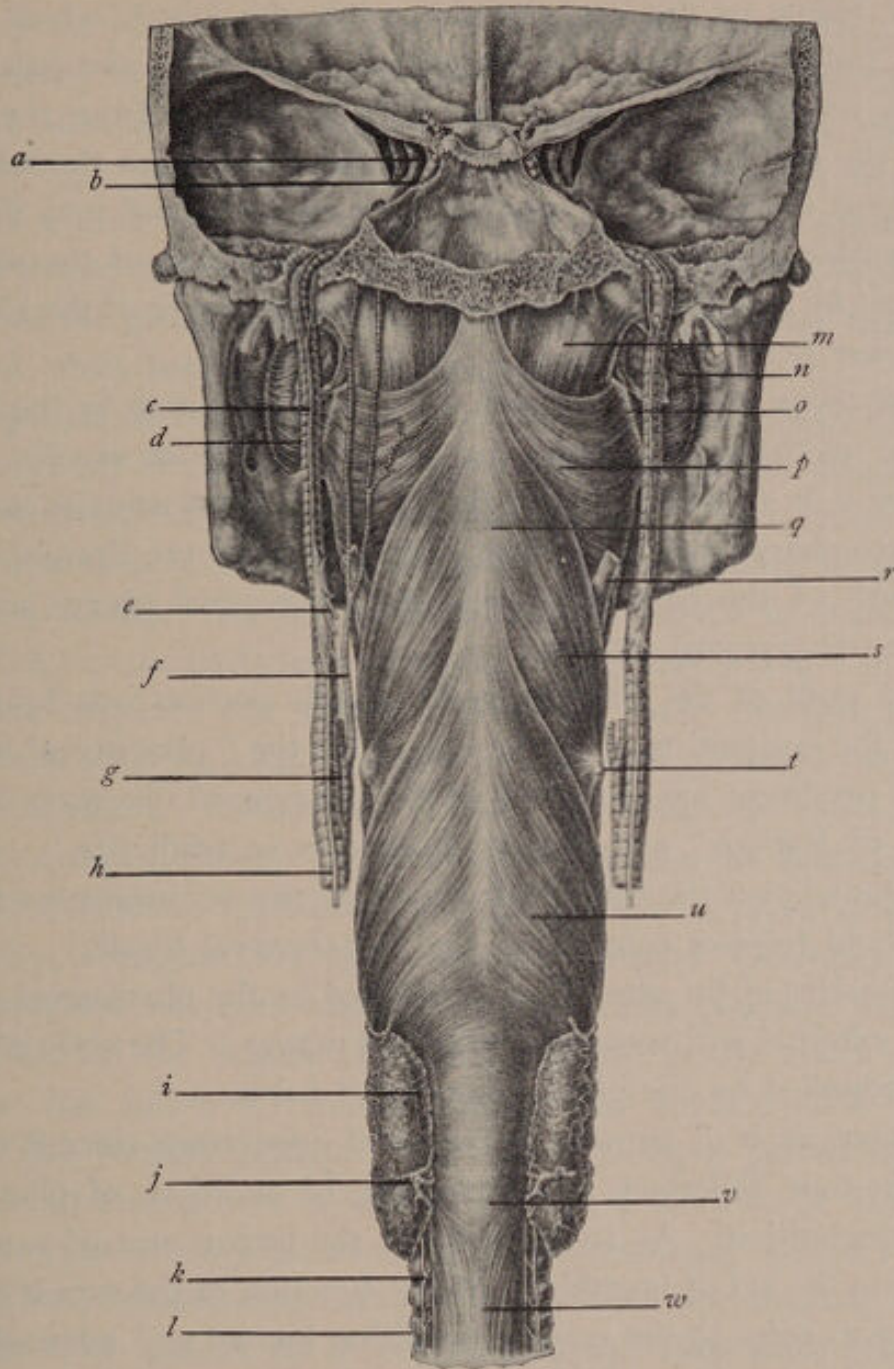


FIG. 77. CONSTRUCTORS OF PHARYNX. (Deaver.)

*a*, Ophthalmic artery; *b*, internal carotid artery; *c*, sympathetic nerve; *d*, internal carotid artery; *e*, superior cervical ganglion of sympathetic; *f*, ascending pharyngeal artery; *g*, external carotid artery; *h*, common carotid artery; *i*, lateral lobe of thyroid body; *j*, inferior thyroid artery; *k*, recurrent laryngeal nerve; *l*, trachea; *m*, pharyngeal aponeurosis and sinus of Morgagni; *n*, buccinator muscle; *o*, pterygomaxillary ligament; *p*, superior constrictor muscle; *q*, raphe; *r*, stylopharyngeus muscle; *s*, middle constrictor; *t*, greater cornu of hyoid bone; *u*, inferior constrictor; *v*, circular muscular fibers of esophagus; *w*, longitudinal muscular fibers of esophagus.



with its fellow of the opposite side while the lower, which is the thicker, follows the curve of the posterior border of the palate. It also has its origin by one or two narrow bundles from the lower part of the cartilage of the Eustachian tube known as the salpingo-pharyngeus muscle. It is inserted by a narrow band into the posterior border of the thyroid cartilage near the base of the superior cornu and by a broad expansion into the fibrous layer of the pharynx at its lower part (Fig. 77).

The pharynx is separated from the vertebral column by the longus colli and rectus capitis antici muscles and by loose areolar tissue. Laterally it is in relation with the styloid process and its muscles, the glosso-pharyngeal nerve, the lateral lobes of the thyroid gland, the sheath of the carotid vessels, the pharyngeal plexus and the ascending pharyngeal artery.

In the vault of the pharynx at its middle portion just below the body of the occipital bone is a pouch called the "pharyngeal bursa." It is the persistent lower portion of the pharyngeal diverticulum, the "pouch of Rathke," and usually disappears in adult life.

Distributed over the wall of the rhinopharynx are numerous groups of lymphoid follicles comprising the "pharyngeal tonsil."

The muscles of the pharynx are supplied by the pharyngeal plexus and the external and recurrent laryngeal nerves. The stylo-pharyngeus is supplied by the glosso-pharyngeal nerve.

The pharynx is of unusual interest and importance since it is concerned in four functions, of respiration, of audition, of phonation, and of deglutition. As an example of the importance of a normal pharynx to the act of breathing and the function of the ears it is only necessary to refer to the morbid condition known as "adenoids" in the rhinopharynx, in which "mouth-breathing" and various aural disturbances are conspicuous.

Neoplastic growths, cicatricial contractions and malformations are met with in this region which may affect one or all of these functions. Aside from gross lesions it is necessary that the glandular apparatus of the pharyngeal mucosa should do its duty properly in order to furnish adequate lubrication for the lower pharynx in the act of swallowing. A resonant voice of pleasing quality can be produced only in the absence of deformity or anomalies in the pharyngeal wall.



The uvula with the velum assists the epiglottis in shutting off the buccal cavity in normal nasal respiration, and helps to close the nasopharynx during deglutition. It also directs the nasal secretions towards the glosso-epiglottic fossæ. When enlarged it frequently becomes a source of local or reflex irritation, while a considerable part of it may be sacrificed without detriment. On the other hand paresis of the palatal muscles, or a cleft of the soft palate has a pronounced effect both on speech and swallowing.

The palatal or faucial tonsils are made up of a collection of crypts or lacunæ, ten to twenty in number, lying between the palatal folds and resembling in structure Peyer's patches. Their function has been the subject of much speculation. They were once supposed to furnish a lubricant for the bolus of food and again to absorb from the saliva certain particles as a pabulum for leucocytes. In a normal state they are not visible. Whatever their function may be they would seem no longer capable of exercising it when hyperplastic and diseased. It has been shown that leucocytes may migrate from the lymphoid tissue into the lacunæ between the epithelial cells. Recent experiments have demonstrated that grains of carmin placed in the crypts appear later in the lymphoid tissue (Goodale). Similar absorption has been observed with various powders placed on the surface of the tonsils (Hendelsohn) and in the lower animals infection has followed rubbing the tonsillar surface with streptococci. The foreign particles were found to have passed not only between but through the epithelial cells, the conclusion of Stöhr that leucocytes pursue only the former course thus being opened to question. These experiments have a most important bearing on the conveyance of disease by infection, although they were conducted upon hypertrophied and therefore abnormal tonsils, and possibly throw no light on the function of normal lymphoid tissue. The latest investigations of this subject, with special reference to tuberculosis, show that the tonsils "as portals of infection" are no more susceptible than other portions of the mucous surface. In one hundred cases of pharyngeal tonsil examined by Rethi, six of tuberculosis were found. On the other hand, in more than two hundred specimens of lymphoid tissue examined microscopically and bacteriologically by Goruc not one showed a giant cell, a tubercular



nodule, or a tubercle bacillus. A similar result was obtained by Jonathan Wright in a series of 121 cases examined with that observer's well-known care and skill. Undoubtedly, however, tubercular infection may take place by this route without involving the lymphoid tissue itself, and several interesting experiences suggest that a latent tuberculosis may be excited to activity by operative interference with hypertrophied lymphoid tissue in persons previously unsuspected (Lermoyez and Chappell). Yet the occurrence of the latter is so rare as not to constitute a valid objection to operation in these cases, and the study of the subject up to the present time does not indicate whether normal is more or less prone than morbid lymphoid tissue to absorb pathogenic germs. On the other hand the recent investigations of Pirera, while substantiating the view that the palatal tonsils are ready routes of entry for microorganisms, chiefly by their lacunæ, seem to show that a condition of hyperplasia and especially of fibrosis may impede their absorption. In a case recently observed by the author suppuration of the cervical glands complicating a follicular amygdalitis was followed by suppression of urine and other signs of renal irritation, attributable, it is believed, to streptococcic infection. Such occurrences are not very uncommon and lend additional importance to simple inflammatory derangements of the pharyngeal structures.

### METHODS OF EXAMINATION.

The method of examining the rhinopharynx has already been described. Most of the oropharynx is within reach of the eye, yet even here a pharyngoscopic mirror is often useful. The probe is essential especially in examining pockets in the tonsillar region, and the index finger gives us valuable information as to the consistency of certain morbid growths and the mobility of neoplasms. Sharp-pointed foreign bodies often become engaged in the follicles at the base of the tongue or in the tonsillar crypts, where they may be detected by the finger when invisible to the eye. When the pharynx is very irritable, or the tongue arches and cannot be depressed by moderate force, a fair exposure of the parts may generally be obtained by directing the patient to take a deep inspiration and then



sing a long "ah." Under ordinary conditions the walls of the laryngopharynx are in contact and are open to inspection only under the use of a dilating pharyngoscope. It has been proposed to examine the upper pharynx with the patient lying flat upon the back with the head well extended, the examiner standing at the head of the patient and introducing a large laryngeal mirror, the shank of which of course rests in the right angle of the patient's mouth instead of the left as usual. The awkwardness of the position and the satisfactory view generally obtained with the ordinary way of making an examination of the upper pharynx will tend to prevent this method from becoming popular.



## CHAPTER XI.

DISEASES OF THE VELUM AND UVULA. BIFID UVULA. NEOPLASMS AND MALIGNANT DISEASE OF THE VELUM. CLEFT PALATE. UVULITIS AND ELONGATED UVULA. ACUTE AND CHRONIC PHARYNGITIS. ATROPHIC PHARYNGITIS. RHEUMATIC PHARYNGITIS.

### BIFID UVULA.

Bifurcation of the uvula is a very common congenital mal-development. It is an elementary palatal cleft. The two divisions of the uvula are often quite symmetrical and placed side by side (Fig. 78). In a unique case reported by T. A. DeBlois one uvula was situated in front of and almost concealed the other. The furrow rarely involves the muscular tissue. It seldom has any importance except, as sometimes happens, when one of the segments is so displaced as to cause cough by tickling the pharyngeal wall. In such cases, unless

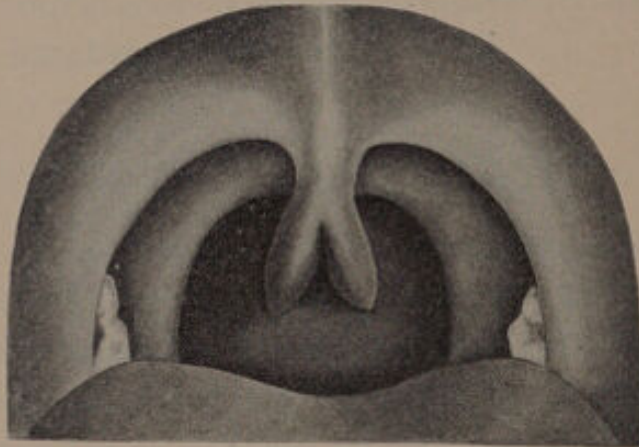


FIG. 78. BIFID UVULA.

the tissues are extremely redundant, the two halves of the uvula may be united by denuding their opposed surfaces and bringing them together by means of one or two sutures, or if the tissues are in excess one or the other of the subdivisions may be excised.

Other malformations of the soft palate are sometimes seen, such as absence of the uvula or velum, asymmetry of the palatal arches,



and perforation of one of the faucial pillars. In a case of the author's perforations large enough to admit an ordinary lead pencil and unknown to the patient were discovered in each posterior pillar in identical situations. The result of syphilitic ulceration in producing distortion and adhesions will be elsewhere considered. Inequality of the sides of the palate may be congenital, independently of a paretic condition, while the latter is not infrequently observed as a sequel of diphtheria, or as a symptom of cerebral disease. Paralysis of the velum in non-diphtheritic nasopharyngitis of high intensity has been noted in several cases, among them one of my own, in which the loss of power persisted more than a month. Spasm of the velum, rhythmic or intermittent, may occur in connection with a general chorea, producing a distinctly audible sound, and more rarely in chronic rhinopharyngitis, causing what is described as "clicking tinnitus." Neoplasms of the palate, with the exception of the small warty growths often seen at the margin of the velum, are rather rare, although this structure may suffer by invasion from other parts.

No satisfactory cause can be assigned for the development of new growths in this region. In several instances a neoplasm supposed to be a papilloma has proved malignant. A few cases of fibroma, of lipoma, and of angioma of the velum have been reported. A case of cyst of the right posterior pillar has been recorded by Jonathan Wright. Adenoma is much more frequent and is often combined with other morbid tissue. It usually occurs in adults and has been seen more often in women than in men. Nearly all these growths may be safely and readily removed with knife, scissors, or snare, although some deeply embedded tumors require considerable dissection. With angiomata a cutting operation should be avoided. In a case of the latter once under my care the electric cautery worked admirably. The simpler forms of these benign neoplasms grow very slowly if at all, produce no inconvenience and may properly be left alone.

Malignant disease appears in the form of sarcoma, or of carcinoma, the former, as in other situations, at almost any age, the latter usually in adult life. Owing to the scanty lymphatic circulation in this region glandular involvement is rather tardy. This fact



combined with the relatively non-virulent tendency of sarcoma gives reason to hope for good results from early surgical intervention in this disease. All kinds of sarcomata are met with. Their growth is slow and painless until ulceration develops. The chief symptoms relate to the function of the palate. Finally deglutition becomes impeded, an ichorous discharge occurs from an ulcerated surface, and hemorrhage, even fatal, may take place. It is often difficult to differentiate this lesion from epithelioma and it is always necessary to exclude syphilis by progressive doses of iodide of potash.

Epithelioma is more common late in life and in the male sex. Its evolution is rapid and highly malignant. Pain is an early and prominent symptom. Ulceration with fetid discharge, hemorrhage and glandular infiltration follow in order. Cachexia is usually pronounced. Surgical interference offers little hope and the Coley method of injection with the toxins of the bacillus prodigiosus and of erysipelas, sometimes effective in sarcoma, is not available. Local anesthesia with cocaine, nirvanin, or orthoform, detergent washes and general anodynes comprise all the resources at our command.

*Cleft palate* and its appropriate treatment have been fertile topics for discussion many years. Space does not permit an exhaustive review of the subject, and in fact the condition is more apt to fall into the hands of the general surgeon than to the specialist. Suffice it to say that all shades of divergent opinion prevail with regard to its management, from one holding that mechanical correction of the defect is better than surgical intervention to the view that attempts at surgical closure should be undertaken in the earliest months of life. The technical details of uranoplasty seem to vary with the fancy of the operator. No less than twenty operations with slight variations bear the name of their respective promoters. Excessive tension on the flaps, disturbance of the wound especially by pressure from the tongue, and possibly septic infection have been recognized as interfering with the reparative process. The first is obviated by the formation of mucoperiosteal flaps by curved incisions in the hard palate along the alveolus on either side and by incisions carried well backward in the soft palate internal to the hamular process. An attempt to meet the last two difficulties is made in a method of operating recently proposed in which a tracheotomy is done and



after the cleft has been closed by sutures the oral cavity and the wound generally are firmly packed with sterilized gauze (J. F. McKernon). The trachea tube is retained for ten or twelve days, and the dressings are renewed each day, in the meantime feeding being carried on by the rectum. An objection to this plan from an aseptic standpoint appears in the fact that the salivary secretion is so stimulated that daily change of the dressings, with more or less disturbance of the wound, is necessary. The added risk of opening the trachea is not small and the irritation attendant upon a firm packing of the buccal and pharyngeal cavities is hardly compensated for by any improvement in results as compared with simpler modes of operating. The prognosis as regards defective speech is better the younger the patient. In older persons of sensitive organization the moral effect of being relieved of a deformity of this kind is very considerable, irrespective of other benefits. Defective speech after closure of a palatal cleft is due in part to muscular atrophy and in part to tension of the velum which the muscles are too weak to overcome. With a view to improving these conditions Makuen proposes first division of adhesions between the pillars and the remnant of tonsils, second forcible stretching of the velum with the finger after division of tense fibers of the palatal muscles, and finally training and development of the palatal muscles by various direct and indirect voluntary exercises. Marked improvement has been observed in cases in which these procedures have been carried out, but it does not appear that perfectly normal speech is to be expected unless operative interference has been undertaken quite early in the formative speech period.

#### UVULITIS. ELONGATED UVULA.

Elongation of the uvula may result from frequent attacks of inflammation involving the velum as well as the pharyngeal structures. It causes sensations of tickling or of a foreign body in the pharynx, which may lead to a dry persistent cough aggravated while the patient is in a recumbent position. Asthmatic attacks and even alarming glottic spasm may be induced by a long uvula. In a voice user the condition may be most important and require immediate



correction. In moderate cases astringents, such as nitrate of silver, or chromic acid, ten or twenty grains to the ounce, will give relief. In some cases the general relaxed condition, due to anemia, should receive attention by the internal use of ferruginous preparations. In post-diphtheritic paralysis associated with a catarrhal condition, nerve tonics and electric applications are indicated, but no radical local treatment is required. Cases that resist these methods need surgical intervention and removal of the tip of the uvula, or uvulotomy must be done. Many instruments have been proposed, so-called uvulatomes, for this purpose, but it will be found quite as convenient to seize the tip of the uvula with the nasal forceps and remove as much as desired by means of the nasal scissors; the angle which these instruments possess carries the hands of the operator out of the line of vision. Anesthesia may be obtained by the previous application of a ten per cent. solution of cocaine. The tip of the uvula, being drawn somewhat forward, the line of incision is more or less oblique and the cut surface is thus made to look backwards so that contact with food in swallowing is to some extent avoided. Bleeding is usually very slight and, in most cases, the pain of the operation and subsequent discomfort are not of much consequence. Now and then, however, bleeding is considerable and if not checked by astringent applications, requires to be controlled by a ligature, or the actual cautery, or as suggested by Carroll Morgan, by means of a clip like that attached to a garter.

With the electro-cautery loop the tip of the uvula may be removed bloodlessly, but less quickly than with the uvulatome. The stump is perhaps a little more sensitive after a burning than a cutting operation. Occasionally after a uvulotomy in neurotic subjects, severe neuralgic pain is experienced, but usually with care as to diet all reaction subsides in forty-eight hours. It is well not to include the muscular tissue of the uvula in the section. Yet almost complete extirpation of this appendage is now and then witnessed without apparent detriment to the function of the velum.

Acute uvulitis is generally an accompaniment of inflammation of adjacent structures or a pharyngitis. The uvula sometimes reaches the most extraordinary dimensions from edema, and in aggravated cases pain and obstruction to swallowing, or breathing, may be ex-



treme. Multiple punctures of the swollen mass with a sharp pointed bistoury will permit the serum to drain off and encourage retraction. In moderate cases the effect of adrenal extract is said to be marvellous. Reference is made elsewhere to S. Solis-Cohen's extraordinary experience with an alarming edema of the velum following an application to the fauces of a suprarenal-chloretone solution. Such a phenomenon may be explained by a drug-idiosyncrasy on the part of the individual or perhaps by some peculiarity in the constitution of the medicinal preparation. It may be necessary to excise portions of the relaxed and edematous tissue in order to give relief. Recovery is expedited by spraying the fauces with a solution of tannin, or alumnol, ten to twenty grains to the ounce of water. Astringent gargles, or lozenges, are sometimes useful.

Edema of the uvula, often without very acute inflammatory symptoms, may occur in the gouty or rheumatic and in those having some renal derangement. In all such cases the condition of the kidneys should be especially investigated.

## ACUTE AND CHRONIC PHARYNGITIS.

The mucous membrane of the pharynx is subject to inflammatory changes similar to those occurring in the nasal cavities. The upper division of the pharynx, known as the rhinopharynx, is part of the air track and here we find important pathological processes involving the lymphoid tissue as well as neoplastic formations of interest. In the middle portion of the pharynx diseased conditions are of two-fold importance for the reason that the oropharynx is part of the food track as well as of the air track; hence, lesions in this situation may affect swallowing as well as breathing. The third division of the pharynx, or laryngopharynx, begins at the level of the arytenoids and extends to the lower border of the cricoid, is a portion of the food track only and rarely falls under the eye of the laryngologist except as disease reaches it from the laryngeal cavity. Foreign bodies may be detained or neoplasms may develop in this region and thence invade the laryngeal cavity, thus involving the functions of deglutition, phonation and respiration.

Inflammation of the pharyngeal mucosa may be acute or chronic.



In the large majority of cases of so-called "cold-in-the-head" the prominent subjective symptom is a sensation of dryness referred to the region above the level of the soft palate. To the eye the surface appears dry, glazed and more or less swollen. This stage of inflammation resembles that occurring in other mucous membranes and the course of events is similar to that observed in the nasal cavities, but we find the membrane of the pharynx less sensitive and more tolerant of strong applications. The soft palate and pillars of the fauces may be somewhat swollen and edematous. In the course of a few hours serous exudation begins and if the process is very intense rupture of capillaries may occur and the secretion is stained with blood. Finally it becomes thicker and more viscid, and if fibrinous elements predominate, as is apt to be the case in severe types of the disease, an exudate, or superficial false membrane forms resembling that of diphtheria but not infectious. This condition is sometimes called "*membranous*" pharyngitis. If the inflammation extends beyond the limits of the rhinopharynx pain in swallowing may be extreme, otherwise in cases of moderate severity there may be nothing more than a feeling of fulness or uneasiness in the throat. There is constant desire to clear the throat and to swallow. The degree to which the voice and the senses of smell and hearing are affected depends wholly upon the intensity and extent of the pharyngeal inflammation. There is usually some fever and general disturbance and the patient may really feel quite ill. The prognosis, in the absence of complications in the form of some organic or constitutional disease, is good, the parts resuming their previous condition in the course of a week or ten days. In many cases, however, a chronic catarrhal condition results.

The patient seldom attaches enough importance to his trouble to seek advice, so that we rarely see these cases early enough to do any good with ice applications externally. About all that can be done is to soothe the irritated parts by bland alkaline sprays followed by a protective coating of mentholized albolene, two to five grains of menthol to the ounce. Benzoinated steam inhalations are sometimes grateful. Attention should be given to a gouty or rheumatic diathesis, as well as to possible derangements of the gastrointestinal track, and a brisk purgative is often indicated. If the sufferings of



the patient are considerable codeine or some of the coal-tar products, as phenacetin with salol, may be used cautiously. Belladonna, in the familiar *rhinitis tablet*, is sometimes useful. The local use of astringents is not to be recommended as they merely aggravate the discomfort.

A very large proportion of *chronic* inflammatory conditions met with in this region are secondary to some lesion or deformity of the nasal chambers which will require correction before anything can be accomplished in the way of relieving the pharyngeal conditions. A simple catarrhal pharyngitis will sometimes yield to mild sedative or astringent applications which have been referred to in speaking of the therapeutics of rhinitis; in cases which prove more rebellious it will be necessary to look for some etiological factor within the nose or in the accessory sinuses. In not a few cases too of chronic pharyngitis the cause must be sought in the digestive track. Dyspeptics almost invariably present more or less of an index of their condition in the mucous membrane of the pharynx. Occasionally we meet with an inflammatory condition involving chiefly the follicular elements of the pharyngeal mucous membrane constituting what is known as granular or follicular pharyngitis, or clergyman's sore throat, in which enlarged papillæ, or lymphoid nodules hyperplastic in character, are distributed at intervals over the surface of the membrane. The temptation to remove these protuberances by means of the curette or destructive caustics should be resisted since, in many cases, the condition is symptomatic and radical measures directed to the local lesion will be in danger of encouraging a tendency to atrophy of the mucous membrane and may leave the patient more uncomfortable than he was originally. In some aggravated cases it may be justifiable to touch the follicles with a chemical caustic, preferably trichloroacetic acid, or the point of an electric cautery, care being taken to avoid making the application too extensive. On inspection of the fauces of certain individuals suffering from chronic pharyngitis there may be seen in the middle of the pharyngeal wall an area of dry, glazed mucous membrane, dotted here and there with enlarged follicles and perhaps coated with a layer of tenacious secretion, and bounded on either side by a vertical band of red, thickened mucous membrane (Fig. 79). These lateral



bands extend to the posterior pillars, which are themselves often much thickened, and they have been considered important enough to receive the independent title "pharyngitis hypertrophica lateralis." As a matter of fact they should always be looked upon as indicative of disease in the vault of the pharynx or in the nasal chambers. According to the histological researches of Cordes the bands consist of collections of lymphoid follicles embedded in a fibrous

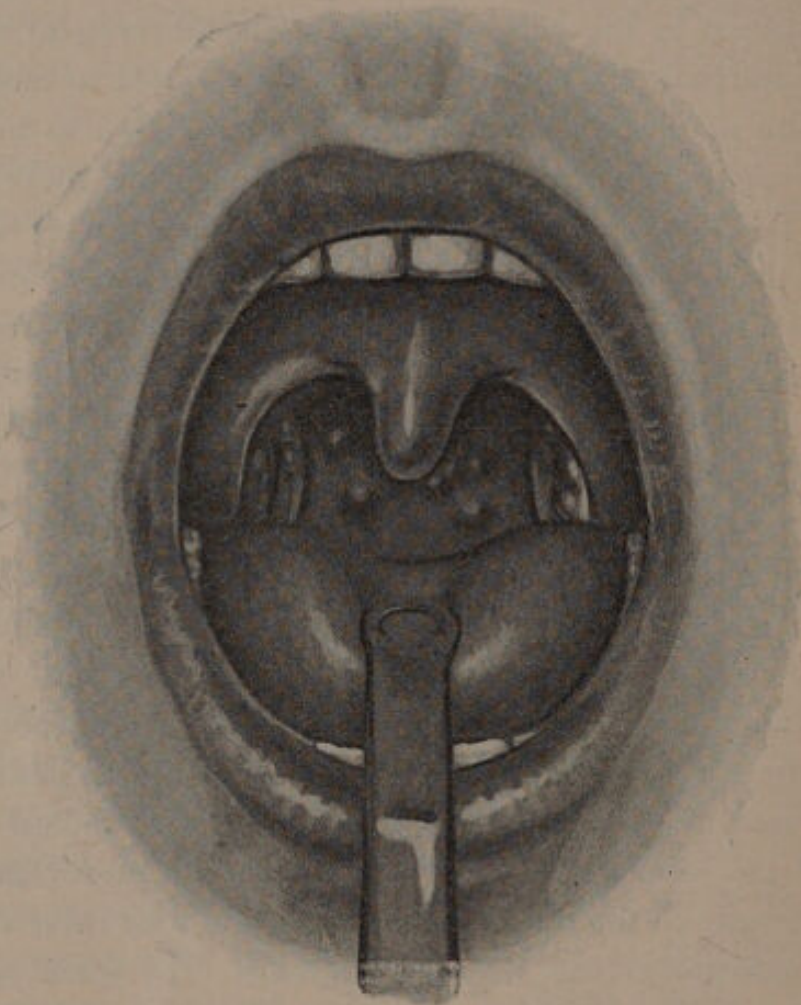


FIG. 79. CHRONIC FOLLICULAR PHARYNGITIS AND HYPERTROPHY OF LATERAL BANDS. (*Grünwald.*)

reticulum and are analogous in structure to the palatal tonsils and to adenoids in the pharyngeal vault. It is clear that the remedy for them is to be found in giving first attention to the morbid condition higher up in the air track which acts as the exciting cause. The accumulation of secretion in the nasopharynx in chronic pharyngitis is sometimes a source of annoyance which may be relieved by irri-



gation of the parts by means of the postnasal syringe with warm alkaline solutions. Equal results may be obtained in some cases of irritable pharynx with more comfort to the patient by means of a spray forced through one anterior naris and allowed to escape by the opposite nostril. In the early stages, if the secretion is profuse, a mentholized albolene spray through the anterior nares will be found to give relief. Not infrequently annoying aural complications result from blocking up of the Eustachian tube. When the aural symptoms are purely congestive, they may be relieved to some degree by mentholated spray or applications of suprarenal extract to the vault of the pharynx.

Inflammatory conditions in the nasopharynx are not infrequent complications or sequelæ of the exanthemata and in the latter case may be benefited by general tonic treatment in combination with local applications.

A chronic nasopharyngitis is perhaps the most annoying and frequent of the morbid conditions with which we meet. The victims of it are generally burdens to themselves and sources of disgust to their neighbors from the constant hawking and clearing efforts demanded by the tenacious secretions accumulated in the vault. There is no doubt that many patients get into the habit of rasping their throats in this way quite unnecessarily. They should therefore be urged to resist the desire as far as possible. In the treatment of this condition our main reliance is on the selection of a suitable astringent so applied after careful cleansing as to reach the whole surface. In some cases, a postnasal application must be supplemented by one made through the anterior nares. Sulphocarbolate of zinc, ten grains to the ounce, alumnol, ten to twenty grains to the ounce, have, in my experience, proven the most agreeable and effective astringents. Nitrate of silver, twenty to thirty grains to the ounce, glycerol of tannin, or tincture of iodine, in cases of long standing in which the tissues are hyperplastic, may be more serviceable. These agents are best applied with a probe, the tip of which is bent at a right angle and wound with cotton. Once or twice a week is often enough for the stronger applications, the daily use of the milder solutions being continued in the intervals. The treatment should always be preceded by thorough cleansing of the parts



with alkaline irrigations by means of the anterior douche or the postnasal syringe. For the more aggravated cases even more powerful applications may be indicated. Bosworth recommends undiluted monochloroacetic acid and suggests lactic acid thirty to sixty grains to the ounce, or a guarded *porte-caustique* of his own device intended for fused chromic acid or nitrate of silver may be used. These energetic measures are neither agreeable to the patient nor very efficacious, the authority just quoted admitting that results are unsatisfactory even from prolonged treatment. Internal medication may have no specific effect but is often important in conditions of anemia, of gastrointestinal derangement, or in the gouty or rheumatic diathesis. Beverly Robinson speaks highly of cubebs internally with a view to rendering the mucous secretion more fluid and hence more easily disposed of. Alcohol except in very moderate quantities should be interdicted, and the use of tobacco, especially when the habit of inhaling the smoke is practiced, should be restricted. The mode of life in general as to bathing, dress, exercise and diet must be supervised, but above all it is essential to remove an intranasal abnormality or obstruction which may interfere with normal ventilation and drainage of the nasal track. While excessive vigor in intranasal surgery is to be deprecated, it is surprising to what extent distressing subjective symptoms may be relieved by removal of an apparently unimportant nasal lesion. Such anomalies develop so gradually that the patient becomes accustomed to them and fails to appreciate their magnitude, whereas an equal degree of obstruction suddenly imposed would be intolerable. After all has been done a certain proportion, unfortunately a large one, of these cases continue to be annoyed by their "dropping" in the throat and by their morning clearing out process, and after going from one specialist to another and one climate to another with possible temporary improvement settle down to the conviction that they are incurable. Ultimately nature takes charge of the case and with advancing years more or less mitigation of symptoms is experienced.



## ATROPHIC PHARYNGITIS.

Pharyngitis sicca, or atrophic pharyngitis, is the result of an inflammatory process induced by some local irritation, or probably consecutive to a similar state in the nasal chambers. It may be associated with a constitutional condition characterized by malnutrition. The glandular secretion is perverted in quality and tends to adhere to the surface of the pharynx in dry scales or crusts, or as a thin film of inspissated mucus. On the other hand sometimes the surface looks dry, thin and glazed, and has the appearance of having been varnished. The perverted secretion is itself a source of irritation and leads to connective tissue cell proliferation and eventually a contracting process takes place which obliterates the blood supply and destroys the secreting glands. A great variety of bacteria are found in the secretions but there is no evidence to prove that they are, in any degree, an etiological factor. A subjective sensation of dryness, accompanied by burning or itching and a desire to swallow, are the most prominent symptoms. There may be some difficulty in swallowing owing to deficient lubrication or to rigidity of the muscles. In most cases the dry secretions are very tough and adherent. The patient is annoyed by a constant desire to relieve himself by hawking and even thus does not succeed in dislodging the mucus. When the secretions have been cleared off the membrane is obviously thinner than normal and is very apt to be somewhat mottled, in certain regions being congested, in others, pale. An unpleasant odor is imparted to the breath by the decomposing secretions.

The prognosis, as in atrophic rhinitis, depends upon the stage of advancement of the process.

No treatment will restore glands that have been destroyed. But, if the disease is attributable to certain local irritants which can be removed and if the atrophy has not progressed too far, the results of treatment are more encouraging. Any associated nasal deformity or disease must be removed. The first essential, as in cases of nasal disorders, is perfect cleanliness, which must be secured at the outset by careful and thorough spraying or swabbing of the region with an alkaline wash followed by a mild degree of local stimulation; the



latter may be attained by the application of strong solutions of ichthyol or formalin. These stimulating applications should be used with caution and their strength must be determined for each individual case. At the conclusion of treatment the parts should be protected by spraying with a solution of menthol in albolene, about five grains to the ounce. By patient perseverance in this course much may be accomplished even in apparently bad cases, at least as regards the relief of distressing symptoms. Electricity in the form of faradism has been found of benefit, the positive pole being in contact with the pharyngeal wall while the negative is held in the hand of the patient (Seiss). The current may be applied for two or three minutes with advantage. Galvanism, used as in the case of nasal atrophy, is beneficial. Massage, by means of a mechanical vibrator, or by hand with a probe wound with cotton, is of service. If desired the cotton may be moistened with thymol, iodine, or carbolic acid in oily solution. Sometimes one agent and again another seems to act more satisfactorily.

Internally we might expect good results from drugs known to influence glandular secretion, such as jaborandi, pilocarpin, or the iodid salts. Occasionally they appear to give temporary relief by supplying moisture to the dry surfaces, but they cannot be long continued without danger of disturbing the stomach. Careful attention should be paid to the digestive function and if necessary constipation should be corrected by the use of saline or other laxatives. Good hygiene and the general régime and treatment referred to in speaking of rhinitis are equally important in inflammation of the pharynx.

### RHEUMATIC PHARYNGITIS.

The effects of the rheumatic diathesis upon the fibrous tissues of the pharyngeal wall are generally admitted but no definite local symptoms can be considered characteristic. Cases vary in their subjective phenomena and we have to rely on the general symptoms and on the rheumatic history in making a diagnosis. The general rheumatic disturbance, such as inflammation of muscles and joints, may not appear until after the pharyngeal symptoms have become established, or the latter may be secondary and insignificant. In most



cases the local appearances are less intense than in ordinary acute pharyngitis and are abrupt in onset and disappearance. The pain in swallowing is out of proportion to the inflammatory appearances and is not influenced by the usual local remedies employed in simple tonsillitis or pharyngitis. It is usually met with at or after middle life and not infrequently follows exposure. Fatigue and depressed general health predispose to an attack. Relapses are frequent and it is noticed that outbreaks of the affection are common in the spring and fall of the year or after a decided fall of temperature.

Local treatment is of little avail, although the application of heat is sometimes grateful. Cases usually respond as soon as the system is under the influence of anti-rheumatic medication. The salicylates, especially the salicylate of sodium in ten-grain doses every four hours, give the most satisfaction. Some cases seem to act better under the alkaline treatment, small doses of bicarbonate of soda, of sodium phosphate, or of Rochelle or Carlsbad salts being administered at short intervals.

While it seems to be established that a very large proportion, according to St. Clair Thomson from thirty to thirty-eight per cent., of cases of acute rheumatism begin with an angina, yet the local pharyngeal indications are indefinite. Apparently the parenchymatous or follicular form of amygdalitis, rather than the phlegmonous, or quinsy, is the rheumatic type. At any rate antirheumatic remedies are often effective in the former and are much less so in the latter. Possibly the rheumatic virus may enter the system by way of the pharynx, as is the case with other poisons, and leave no local indications.



## CHAPTER XII.

### ADENOIDS IN THE RHINOPHARYNX.

The name tonsil has been applied to various collections of lymphoid tissue beside those between the palatal folds; at the base of the tongue is the *lingual* tonsil; in the vault of the pharynx the *pharyngeal* tonsil; in addition, small masses in or near the ventricles of the larynx are called the *laryngeal* tonsils; and of still less importance the aggregations within the nostrils are known as the *nasal* tonsils.

The collection in the vault of the pharynx, the pharyngeal tonsil, or *adenoids*, is perhaps the most important. It is a conglomerate gland, covered by thin mucous membrane and columnar epithelium, sometimes ciliated. It is a vascular body and, like the faucial tonsil, is a *normal* organ which is disposed to undergo atrophy at about maturity. The idea that tonsils are normal bodies is vigorously combated by Bosworth, who contends that a visible tonsil is an abnormality and should be removed like any other tumor. No one at the present day is likely to affirm that an organ is "normal" which is itself diseased or may be the cause of morbid conditions elsewhere, yet it is often equally difficult to define the boundary between a normal and an abnormal tonsil and to decide whether in a given case a mass of lymphoid tissue needs to be removed. Many diseased tonsils are carried through life without detriment and the latter question hinges mainly on the degree of subjective disturbance they excite rather than on their dimensions or degree of abnormality. Nodules of lymphoid tissue are undoubtedly normal in certain regions. Perhaps we may admit the correctness of the view that "the tonsils are pathological entities when they can be demonstrated clinically," but that is very different from saying that all tonsils should be removed. The points to be determined are, first, whether the enlarged lymph nodes have ceased to perform their function, presumably that of defending the system against infectious germs, and,



sécond, whether they are a cause of local or general derangement.

The pharyngeal tonsil has been particularly described by the German anatomist Luschka and is sometimes called "Luschka's bursa or tonsil," this name being restricted to the main aggregation of lymphoid tissue in the middle of the pharyngeal vault. A large crypt or lacuna in the midst of this bursa often ends in a dilated extremity which sometimes becomes distended by accumulation of secretion owing to obstruction of its outlet, thus forming a cyst of

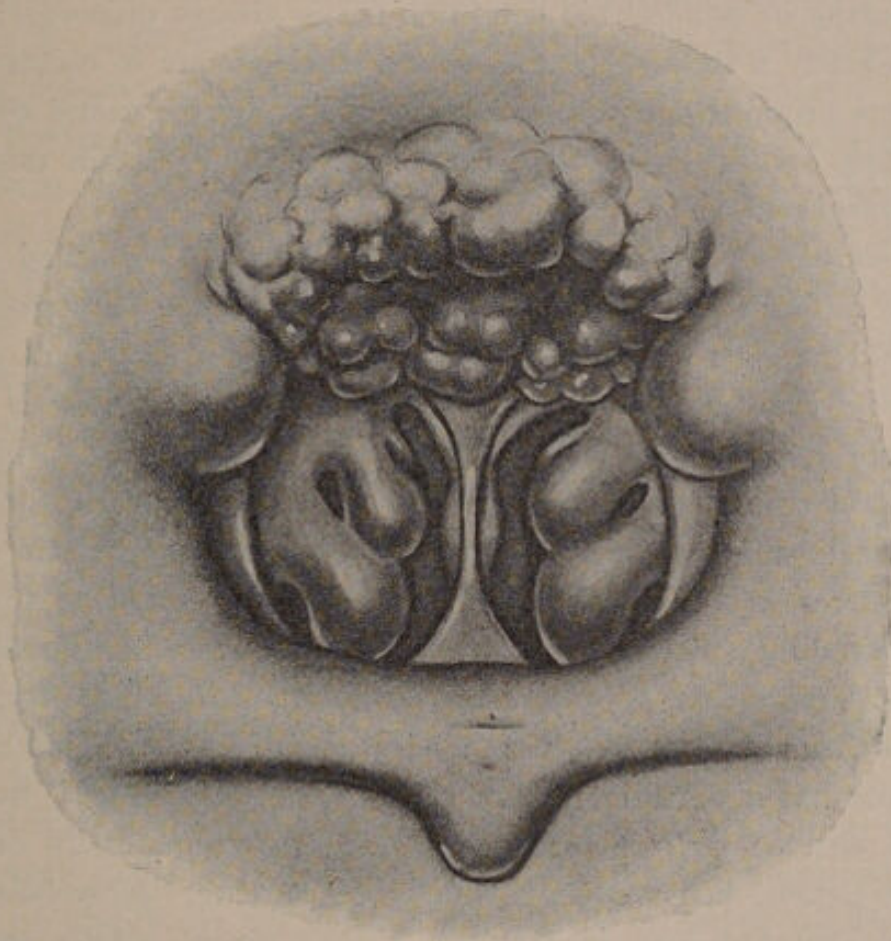


FIG. 80. ADENOIDS IN RHINOPHARYNX. (*Grünwald.*)

considerable dimensions which occasionally undergoes suppuration. It has been particularly studied by Tornwaldt and from him is known as Tornwaldt's disease, or cyst of the pharyngeal bursa. The pharyngeal tonsil, or adenoid vegetations, becomes of interest and importance in its enlarged condition from the obstruction it offers to nasal respiration, from disturbance it may excite in the ear by pressure in the region of the Eustachian tube or orifice, and from



the causative relation it bears to various other disorders, reflex derangements as well as infectious diseases (Fig. 80).

Adenoids may be met with very early in life, if they are not actually congenital. They are always an impediment to health and in a nursing infant may be a serious obstacle to nutrition. They are seldom seen in adults, although several marked examples in very old subjects have been recorded. Remnants of lymphoid tissue and the evidences of the damage it has done are frequently recognized in elderly people.

The cause of this morbid condition is not always discoverable, but it is evidently a frequent sequel of the exanthemata in children and, in a large proportion of cases, is associated with a general dyscrasia resembling struma which has been described by Potain under the name *lymphatism*.

The subject of the condition, when it exists in a marked degree, presents a facial expression which is in a measure pathognomonic. If a child he goes about with open mouth and a very dull countenance, the eyes are heavy and stupid, the external nose is rather small and undeveloped and the upper lip is thick and prominent. Effacement of the naso-labial furrow and distention of the transverse nasal vein are often noticeable. The palatal arch is usually high, narrow and V-shaped, and the upper jaw tends to protrude. Nasal breathing, through the day, may be natural or impeded, but at night respiration is noisy and labored. The child frequently awakens from sleep suddenly as though startled by troubled dreams. The voice has a peculiar quality called the "dead voice" in which there is decided lack of resonance. Hearing is generally impaired and the patient has frequent attacks of earache. Nose-bleed is a common symptom and, in children, should always excite suspicion of the existence of adenoids. A purulent discharge from the nostrils, often producing excoriation and eczema of the upper lip, is a very common occurrence, especially in the lower classes as a result of uncleanliness. Frequently the patient is disturbed by hacking cough, paroxysmal in character, or actual attacks of laryngismus may be induced by this pathological condition. Asthma, chorea, enuresis and prolapse of the rectum are some of the ills attributed with more or less reason to adenoids. Deformity of the chest wall, "pigeon



breast," is referred by some to labored respiration caused by the clogging up of the postnasal space. Probably the thoracic deformity is due quite as much to the depraved systemic condition as to the mechanical obstruction to breathing. We find many cases occurring in the same family, whether attributable to heredity or to the fact that the patients are all in a similar environment is not determined. It would seem as though climatic and atmospheric conditions play an important part in the development of the lesion. Dampness, bad air and unsanitary surroundings certainly predispose to it. Enlargement is not always due to hyperplasia or increased connective tissue but may be a simple temporary turgescence; consequently it is not unusual to see extreme changes in the dimensions of the adenoid mass. When it has been subjected to repeated attacks of acute or subacute inflammation more or less permanent thickening results. Lennox Browne suggests a relationship between adenoid vegetations and laryngeal neoplasms in children from the fact that the former are "responsible for much infantile laryngitis," a condition doubtless predisposing to neoplastic formation. He refers to cases of dyspnea after removal of a tracheal canula in diphtheria relieved by ablation of adenoids (Martha) in confirmation of his opinion that excision of tonsils and adenoids is advisable even in an acute stage of diphtheria as a means of averting the necessity of a tracheotomy. The propriety of eliminating morbid conditions in the upper air track in new growths of the larynx cannot be questioned, yet the proportion of the latter to hypertrophied tonsils and adenoids is so small that an etiological connection is very doubtful. In the light of the present improved therapeutics of diphtheria the radical disposal of enlarged tonsils in the course of that disease as proposed will hardly meet with general favor.

From a pathological standpoint four varieties of adenoid growths have been described (Kyle). First, a soft, diffuse, friable mass, composed mostly of lymphoid tissue and covered with a thin layer of epithelium. Second, an edematous, or cyanotic, form in which the gland tissue is but slightly increased, the enlargement resulting rather from venous stasis and edema. It is apt to occur in children affected by some intestinal irritation or circulatory disturbance.



Third, a hard variety in which there is decided increase of connective tissue as well as of lymphatic elements. Fourth, also a hard form caused by repeated attacks of acute or subacute inflammation followed by organization of connective tissue and moderate contraction. It is usually secondary to intranasal disease.

For practical purposes a division into soft and hard meets all requirements. It is quite probable that many adenoid cases are needlessly subjected to operative interference, owing to lack of appreciation of the fact that in some children these lymphoid structures are very sensitive to external impressions and systemic derangements. They are prone to temporary turgescence or inflammation, when many of the subjective symptoms caused by established lymphoid hyperplasia or by an acute inflammatory process may be exhibited. Preparations may be made to operate on a case of this kind and when the time comes little or nothing may be found to be attacked.

The symptoms of adenoids vary with the degree of their development and the relative dimensions of the nasopharynx. A moderate mass in a contracted pharynx may create grave disturbance, while a large volume may be carried in a capacious pharynx without much complaint. The temperament of the patient also has a bearing on the subjective symptoms. In a nervous impressionable child the general perturbation is more marked than in one of phlegmatic disposition. As already suggested the symptoms refer primarily to the functions of respiration and audition. A very large proportion of cases of impaired hearing in adults may be traced to neglected adenoids in childhood. A very curious condition of mental lethargy denominated *aprosexia* (Guye), marked chiefly by inability to concentrate the attention, is clearly referable to this condition. Children previously stupid and backward frequently gain average intelligence after having been relieved of their impediments. The dullness in these children is explained in part by impairment of hearing and in part by the obstruction to the cerebral lymphatic circulation. An interesting example of this condition reported by Jonathan Wright occurred in a boy of fifteen who complained that "he could not remember or fix his mind on his tasks." Two or three minutes after a digital examination, which revealed a considerable collection



of adenoids, he fell in a slight convulsion lasting less than a minute. On recovery he appeared dazed and stupid for some moments and was impressed by the belief that he had been given an electric shock. This and a similar case are looked upon as instances of nasopharyngeal reflex as well as of aprosexia, the former assumption being less well founded than the latter. Care should be taken not to confound the shock and faintness attendant upon an examination like that made in these cases, and especially apt to occur in children of the adenoid class displaying the neurotic disposition, with a true reflex. There is an unmistakable impression upon the general health as a result of the restlessness at night caused by mouth breathing. The obstacle to respiration is aggravated by the increase of blood in the parts in a recumbent position and by the muscular relaxation occurring in sleep. In most cases the faucial tonsils are also hypertrophied and drag the tongue back over the larynx in such a way as to still further constrict the air channel. A peculiar change in the quality of the voice is almost invariable, but frequently in addition there is a faulty enunciation of some of the consonants, or actual stuttering results. Frequently the glands at the angle of the jaw or in the lower cervical triangle are enlarged. The sense of taste may be impaired or lost from dry mouth. The act of swallowing may be interfered with, and not infrequently food is regurgitated into the nasopharynx from relaxation of the soft palate.

The diagnosis is seldom difficult; usually the facial expression is characteristic and the condition may be surmised at a glance. Attention has recently been directed by Champeaux to the fact that the so-called "adenoid facies" may be simulated in certain conditions of nasal obstruction and may be quite pronounced when no adenoids whatever are present, and on the contrary some cases of extreme lymphoid hyperplasia do not exhibit the typical physiognomy. The following are enumerated by Chappell among the conditions causing respiratory stenosis resembling that due to adenoids. Most of them are peculiar to early life and several are so rare as to be unworthy of consideration. (1) Lymphatism and lithemia, (2) syphilitic and gonorrheal rhinitis, (3) congenital occlusion of the nares, (4) digestive disturbances, (5) congenitally high arched palate, (6) small or occluded nostril, (7) unusually small postnasal



space, (8) anterior projection of the bodies of the cervical vertebræ, (9) some malformations of the soft palate, (10) hypertrophy of the tongue. Natier also insists that in certain neurotic children a state of "false adenoidism" sometimes exists which may be corrected by attention to the general health and by the use of methodical breathing exercises, and in which operative treatment should be avoided. It would appear, therefore, that a positive opinion cannot be safely based upon suspicious appearances. The rhinoscope, or the finger, must be used in every case. In young children pharyngoscopic examination may not be feasible, yet with a little patience a satisfactory view may be obtained even in unpromising subjects. Digital examination gives us infallible testimony. It is not very agreeable to the patient but may be done with celerity and safety in

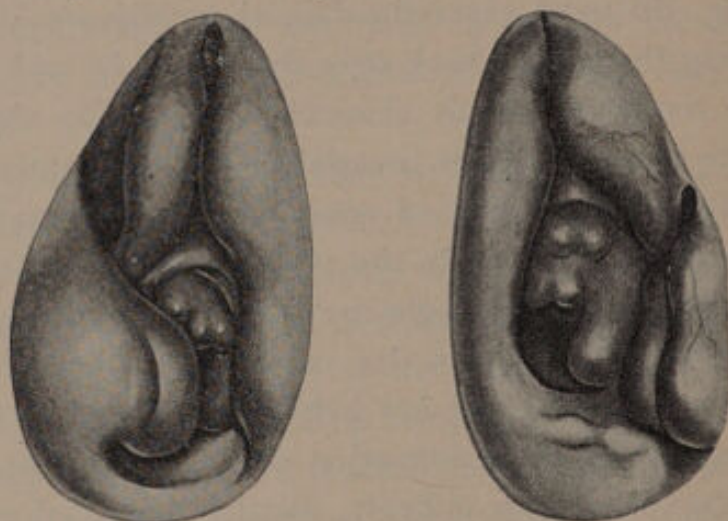


FIG. 81. ADENOIDS IN VAULT OF PHARYNX SEEN THROUGH DILATED ANTERIOR NARES. (*Grünwald.*)

a way elsewhere described (p. 35). The sensation conveyed to the finger by a mass of adenoids is unmistakable. It has been likened to that of a bunch of "earth worms." The soft form of adenoids is elastic, compressible, lobulated and vascular, so that the examining finger on its withdrawal is stained with blood even though but little force has been used. The hard variety is more resistant and smoother as well as less vascular. If a rhinoscopic view is possible the arches of the choanæ are seen to be obscured by pendulous masses hanging from the vault and often invading the posterior nares. The view obtained in the mirror is very deceptive and should not be relied upon in estimating the quantity of adenoid vegetations



in a given case. An opinion as to treatment must be based upon the history of the case and the information gained by exploring with the finger (Fig. 81).

The prognosis is good provided the condition be recognized early and the adenoids thoroughly removed. If allowed to remain with the hope of the occurrence of atrophy, associated derangements, as for example in the ears, may progress to an irremediable degree. In the hard variety of adenoids there is no use in wasting time over local applications or in an endeavor to improve the general condition of the patient. The depraved general state is so clearly aggravated by, if not the direct result of, the local condition that the latter demands first attention. Engorgement of the adenoid mass due to inflammatory or intestinal disturbance may be relieved by appropriate treatment and does not require the radical interference de-

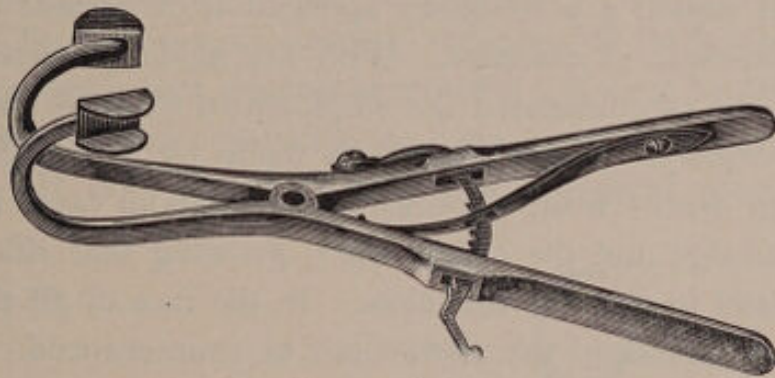


FIG. 82. DENHARD'S MOUTH-GAG.

manded in established disease. In the soft variety and in very young children when the symptoms have not long existed removal of the mass by simply scraping with the index finger will frequently suffice. In infants of two years and under this may be readily done without an anesthetic, attention being paid as far as possible to asepticism by preliminary cleansing of the hands of the operator and of the nasopharynx with a saturated boric acid solution. In these cases and when an anesthetic is used the jaws must be held apart with a mouth gag (Fig. 82).

In older children in whom obstructive symptoms are persistent it is a better plan to remove the growths thoroughly under ether or other anesthetic. Thus the shock of the operation is less and opportunity is given for deliberate and careful exploration and, consequently, more thorough removal.



Contrary to the generally received opinion that chloroform is a safe anesthetic in children T. H. Halsted maintains with much reason that the lymphatic diathesis especially favors the depressing effect of chloroform upon the heart. This observer prefers ether, and to mitigate its suffocative effects and the after nausea he recommends the instillation into the nares of two or three drops of a five or ten per cent. solution of cocaine. Nevertheless many operators rely upon chloroform at all ages, in spite of the fact that it is less safe than ether. The indiscriminate use of cocaine is unwise, yet it seems to be clearly established that reflex respiratory inhibition may be prevented by an application of a two per cent. solution of cocaine. According to George Crile a much weaker solution, even a 0.5 per cent., is effectual. It is well known that atropine prevents cardiac inhibition. This observer goes so far as to advise in operations in this region a preliminary application of cocaine or eucaïne and a hypodermic of atropine. With the mode of anesthetization presently to be recommended the employment of these drugs is entirely unnecessary. The statement is made by James Ewing that about fifteen deaths from chloroform in lymphoid cases have come to his knowledge and the conviction is growing that chloroform is especially fatal in cases of this class. In the face of all the adverse testimony its continued use should not be countenanced.

The number of casualties under general anesthesia has reached so large a total, very many cases never having been reported, that we are called upon to exercise the utmost care and intelligence in the administration of whatever anesthetic may be selected. So far as possible all contraindications should be eliminated and the actual responsibility of giving it should be entrusted only to an expert. The observation and experience of F. W. Hinkel fully corroborate the views just expressed and justify the conviction that chloroform should never be used in these cases. Its advantages by no means outweigh its perils and should not be considered in the presence of other anesthetics relatively safe and equally effective.

Ethyl bromide and ethyl chloride are used more or less, but their dangers have been repeatedly pointed out, especially as suggested by Zematsky in atheroma and alcoholism, conditions which seldom prevail in adenoid cases. Great care should be employed in the



manufacture of ethyl bromide. It is possible that some of the accidents attending its administration and consequent prejudice against it may be due to the use of an impure product. Eman and De Roaldes, whose experience with it has been extensive and favorable, lay stress on this particular. It should be given to a patient only in the recumbent position, and unconsciousness may be induced rapidly by giving five to ten grammes of ethyl bromide before chloroform or ether. Schmidt mentions the occurrence of death in five cases under ethyl bromide presumably due to cardiac weakness. On the other hand Gleitsmann, who formerly preferred the well-known A.C.E. mixture, has used ethyl bromide in many hundred cases without an accident. Emil Mayer has had excellent satisfaction with the Schleich mixture, of which about four drachms is sufficient to produce complete narcosis in four to six minutes, and recovery is equally rapid, but his confidence in this combination is not generally shared because of the notoriously unequal volatility of its ingredients.

It is improbable that general agreement will ever be reached as to the kind of anesthetic desirable, or even as to the necessity of any anesthetic. It is the custom with many general practitioners to




FIG. 83. SCHUETZ'S ADENOTOME.

scrape the vault of the pharynx of very young children with the finger nail, but the nail is far from being an aseptic or an effective instrument in most cases. This method without anesthesia may answer in clinics, but will not do in private practice, if we wish to retain the trust and good will of our little patients. A vigorous opponent of anesthesia appears in H. Gradle, who thinks to have solved the problem by a special adenotome, modified from one proposed by Schuetz (Fig. 83). The size and curve of the instrument are such as to fit any pharynx above the fourth year, and in rather



a large experience he has found it invariably capable of removing all the growth with much less hemorrhage than after any other mode of operating. Its quick action is relatively painless, and there is less shock and less risk than with any instrument under general anesthesia. The latter this observer condemns, *except* in unmanageable children, or when the faucial tonsils are to be removed at the same time.

The method of giving ether elaborated by Fillebrown and Rogers is sometimes recommended, but is more especially useful in long operations in which it is important that the manipulations of the surgeon should not be interfered with. In their apparatus ether vapor is forced through a tube to the patient's face by means of a bellows worked by the foot.

My own preference is strongly in favor of the use of nitrous oxide gas, followed by ether, as being decidedly the safest and most expeditious mode of procedure. The danger of anesthesia is thus reduced to the lowest possible degree and the operation itself is much expedited by preliminary use of nitrous oxide.

All danger of asphyxiation from inspiration of foreign matter is obviated by placing the patient in Rose's position with the head dependent over the end of the operating table so that blood clots and débris accumulate in the pharynx rather than gravitate towards the larynx. The upright position in operating was preferred by the late F. H. Hooper, who was among the first in this country to realize the serious importance of adenoid hypertrophy. His contributions to the literature of the subject and his suggestions as to operative technique possess a permanent value. His views as to position in this as well as in other operations in the upper air track have some advocates at the present day, among them T. R. French, who has devised a chair to which the patient is strapped after partial anesthesia in a horizontal position. In order to avoid disturbance of circulation and cerebral anemia the patient must be very slowly raised to a sitting posture. The advantages claimed are first, marked reduction in amount of blood lost, second, lessened chance of ear complications owing to thorough drainage of blood from the rhinopharynx, third, retention of the usual relationship between operator and patient, whereby the operation is much facilitated. In



Unable to display this page



ceps have been devised for the purpose. Those first used were intended for avulsion (Fig. 85) but in attempting to tear the growth from its site there is danger of stripping up the mucous membrane so that cutting instruments are now preferred (Fig. 86). The blades of the forceps in use to-day are much larger than those originally employed with the object of enabling us to do the operation

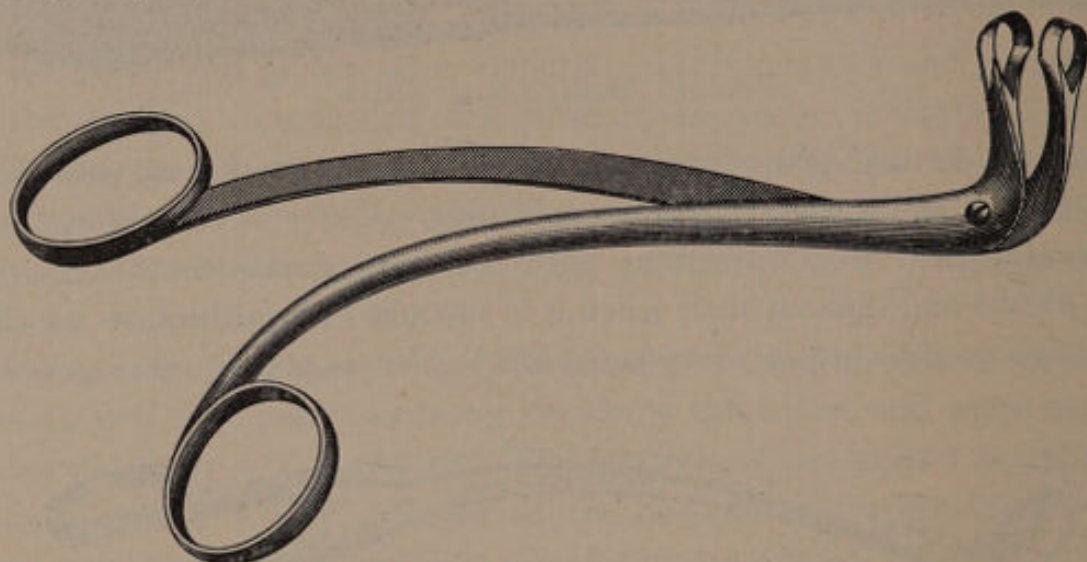


FIG. 87. SCHUETZ' ANTERO-POSTERIOR FORCEPS.

more rapidly. It is a good plan to have a variety of forceps and curettes, some to cut antero-posteriorly and some laterally (Fig. 87). The forefinger or steel finger nail as recommended by Dalby or Motaïs (Fig. 88), with the Gottstein curette (Fig. 89) and the large-bladed forceps of the author (Fig. 90) comprise the instruments capable of meeting all possible contingencies. Many operators




FIG. 88. MOTAÏS' ARTIFICIAL FINGER NAIL.

express strong preference for the cold wire snare to be introduced through the nostril or by means of a curved canula behind the velum. In rare cases in which the patient refuses to submit to the knife or in which we may apprehend hemorrhage the galvano-cautery may be resorted to, applied under the guidance of the mirror behind the velum with the aid of the palate hook, the parts having been thor-



oughly cocainized. We should endeavor in every case to remove or destroy the tissue as thoroughly as possible, and after the forceps and curette have been employed the parts should be explored for

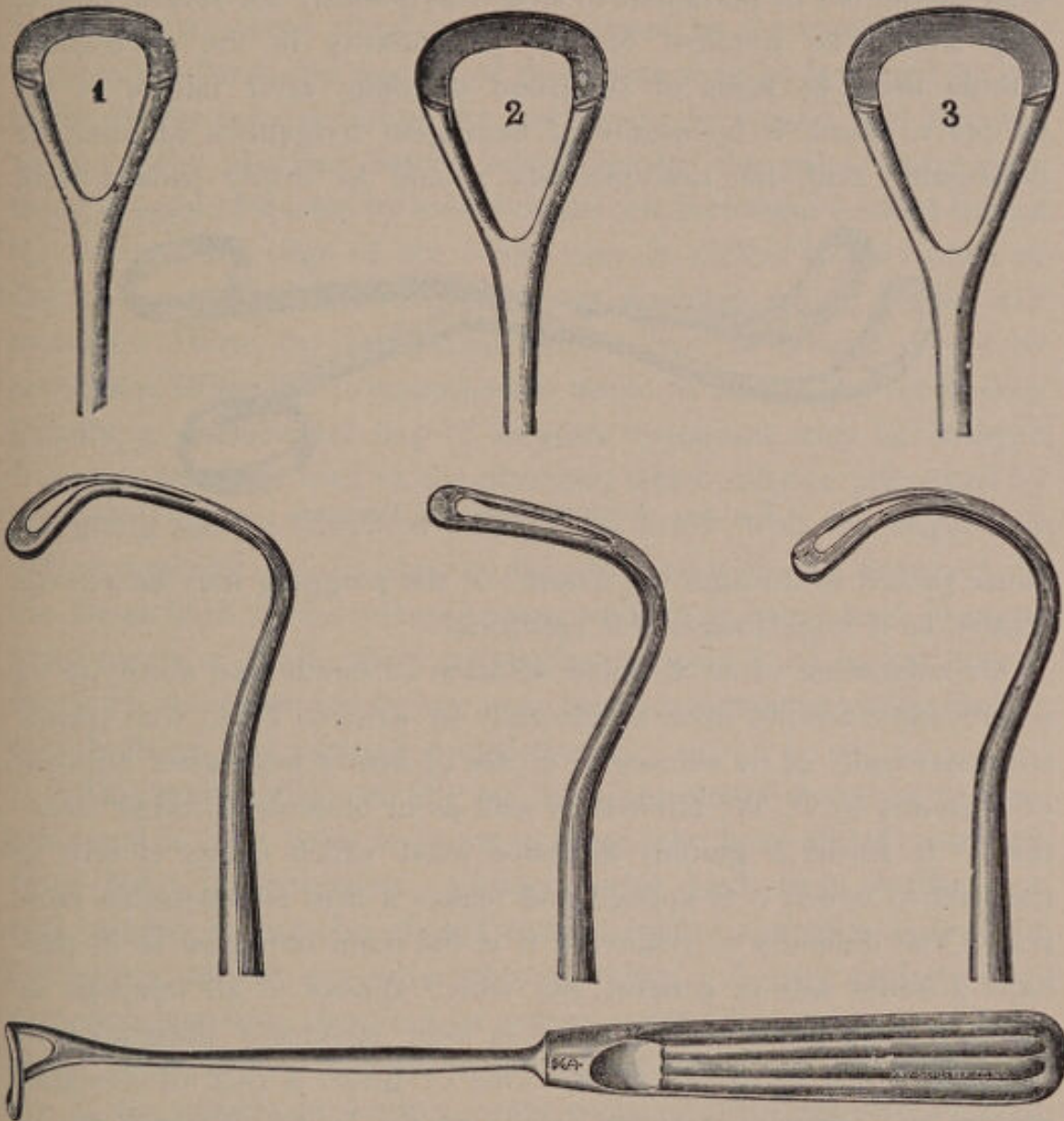


FIG. 89. GOTTSTEIN'S ADENOID CURETTES; SHOWING SIZE AND SHAPE OF BLADES.

possible remnants or tabs of adenoid tissue still requiring attention.

The after-treatment consists simply in keeping the patient at rest. It is unwise and unnecessary to disturb him by any application or douching; the drainage in this region is so perfect that indications of septic infection are almost unheard of. A number of cases of hemorrhage and several of fatal bleeding after removal of adenoids



have been reported by J. E. Newcomb and others, and serve to impress upon us the importance of securing the history of all cases before operation as well as of careful attention afterwards. Children should not be permitted to sleep continuously for several hours; they should be watched for any irregularity in the circulation. Should there be signs of persistent bleeding, after failure of attempts to check it by means of astringent irrigations of alum or tannogallic acid, the naso-pharynx should be firmly packed with

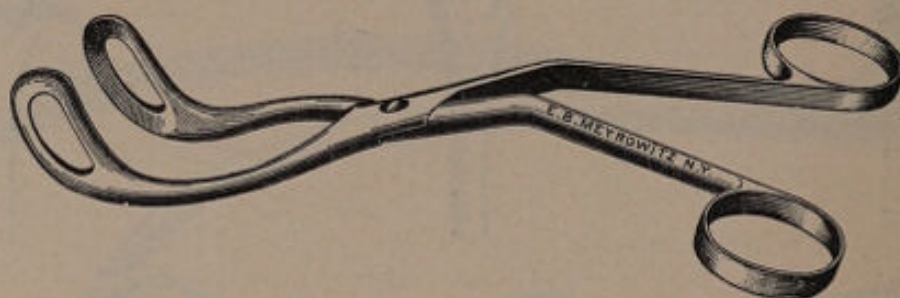

FIG. 90. AUTHOR'S ADENOID FORCEPS.

gauze passed in through the mouth; or the plugging may be accomplished as it is performed for epistaxis.

A combination of an alcoholic solution of tannin and antipyrin as a hemostatic was hit upon accidentally by Roswell Park, who speaks enthusiastically of its efficacy in a case of hemorrhage after removal of adenoids by F. W. Hinkel, as well as in bleeding in other situations. It forms a gummy adhesive mass which clings closely to the part to which it is applied and makes a firm impenetrable tampon. The difficulty in removing it is the main objection to it, perhaps a minor one in general, but which applies to all tampons in cases of hemophilia. This point is very strikingly illustrated in cases described by A. A. Bliss. One of these, a case of deviated septum and adenoids, resulted fatally on the fourth day, recurrence of bleeding taking place on the slightest attempt to disturb the tampon. The obvious lesson is that all operative cases should be carefully investigated beforehand for the possible existence of hemorrhagic diathesis. It is a strange fact that some of the victims of hemophilia underestimate, or exhibit a moral perversity which leads them to conceal, their weakness, and our first intimation of its existence may be the occurrence of bleeding after operation. It is probable that in the product of the suprarenal gland we have an antidote



to this condition more reliable than any hitherto possessed, but the fact remains that cutting operations in bleeders are better avoided.

In the use of cutting instruments in the post-nasal space certain accidents may occur which may be obviated by the exercise of ordinary care. First, the margin of the velum may be lacerated by the blade of the forceps unless the instrument be passed well into the vault of the pharynx before being opened, the palate meanwhile being dragged forward by means of the left forefinger hooked behind it. Second, the edge of the vomer may be nicked if the handle of the forceps be too much depressed, not a serious matter but as well omitted. Third, the Eustachian cushion may be bruised or cut by carelessly tilting the instrument too much to one or the other side. Finally, a considerable flap of mucous membrane may be stripped from the posterior wall of the pharynx, which may be prevented by ploughing up the lymphoid tissue from below with the finger nail before applying the forceps, or by pressure with the finger tip at the lower limit of the adenoid mass while it is being torn from its attachments. While these incidents are usually of minor importance, on the other hand they may become somewhat embarrassing complications and prolong convalescence.

Inflammation of the middle ear is an occasional sequel of adenectomy and is most liable to occur in those who have already suffered from aural complications. Children who have had otorrhea, or been subject to earache, should receive special attention as regards precaution against exposure after operation. A very curious phenomenon has been observed in several cases after removal of lymphoid hyperplasia and may be referable to excessive energy in the use of the curette or forceps, or to some peculiar neurotic state of the patient, namely torticollis, a complication developing two or three days after operation and subsiding in the course of a week as the wound gradually heals.

The question is often asked as to the probability of relief of symptoms and of recurrence after removal of adenoids. In a large proportion of cases the relief is immediate and marked. Patients who have previously disturbed the household by noisy breathing at night will sleep so tranquilly as to excite the alarm of anxious parents. In certain individuals, however, in whom the habit of



mouth breathing is firmly established and in whom, also, the parts are ill developed from prolonged disuse, nasal respiration is not immediately free. Under these circumstances we are sometimes obliged to resort to measures for closing the mouth during sleep and aiding the patient to learn the use of the nose for breathing. A shield worn within the lips or simply binding up the chin will generally answer the purpose. Recurrence of adenoids may take place, even after thorough removal, especially when the operation has been performed early in life, in children of pronounced lymphatic tendencies. In many, however, it must be admitted that relapse is due to incompleteness of the operation, or to a coexistent obstruction within the nasal cavities. The last mentioned factor is of the utmost importance and in all cases of adenoids at any period of life nasal stenosis which is always productive of a state of hyperemia and favors the reformation of lymphoid tissue should be remedied.

In older children and adults general anesthesia is not requisite. With cocaine and a large curette the operation may be done at one sitting, which is by most considered preferable to frequent repetitions of a performance always uncomfortable and often painful. In manageable subjects the forceps may be used with the aid of a palate hook and under the guidance of the mirror. This is really the most satisfactory and precise mode of operating, but is seldom found to be applicable, and we are compelled to rely upon the tactile sense in determining the character and distribution of the vegetations. The fossæ of Rosenmüller as regards the ears, and the choanæ, as regards breathing, are critical situations and are most effectively and safely reached with the forefinger, or, in case the operative field can be seen, with a small curette. Neglect of the latter region is a prominent cause of failure in the operation. Masses of lymphoid tissue may be crowded into the nares by the forceps or curette, or may be actually attached at some point anterior to the choanæ. Hence the suggestion of Ingals to clear out the posterior nares by means of nasal cutting forceps passed from the front is valuable. Or possibly a small ring knife may be of service in this situation. In any case to give the best results the operation must be thorough, every vestige of morbid tissue being sought for and removed. No doubt it is possible for any one to pass a curette



into the nasopharynx and scrape away more or less tissue, but this is not adenectomy as it should be done and tends rather to bring the operation into disrepute owing to incomplete relief and recurrence of symptoms. Properly done there is no procedure in the domain of rhinology more prompt and satisfactory in its effects.



## CHAPTER XIII.

### HYPERTROPHIED TONSILS.

Hypertrophied tonsils appear in two forms: the hard or fibrous tonsil which results from repeated attacks of acute, or subacute, amygdalitis, and the soft, or adenoid, which is the more frequent variety and occurs earlier in life. The former is apt to be accompanied by more or less chronic pharyngitis, and to persist after puberty, marked examples having been observed in advanced life. The second variety of hypertrophied tonsil is almost always associated with lymphoid hyperplasia in the nasopharynx, as well as at the base of the tongue. In other words, the hypertrophy includes what has been called "the lymphoid ring," or "ring of Waldeyer." The mucous membrane of the follicles, rather than the parenchyma of the tonsil, is affected. The tonsils may be excessively enlarged only when acutely inflamed. They atrophy earlier and more completely than the hard variety, but frequently the former merge by slow gradations into the latter in consequence of repeated attacks of inflammation resulting in the formation of new connective tissue. The hard tonsil is hyperplastic, the stroma of the gland being developed by the growth and proliferation of connective tissue. The second form of enlarged tonsil is a genuine hypertrophy, the glandular tissue being mainly involved.

From a clinical standpoint with special reference to treatment we may divide enlarged tonsils into three varieties: first, those whose size interferes with deglutition or respiration; second, flat tonsils not especially enlarged but prone to recurrent attacks of inflammation and frequently the foci of suppurative inflammation, the formation of pus taking place not necessarily in the body of the tonsil, but in the adjacent tissue; third, a class of tonsils in which there may be little or no apparent hypertrophy or encroachment upon the pharyngeal space because of adhesions of the pillars to the surface of the organ as a result of repeated attacks of inflammation. Thus the tonsil, in the process of hypertrophy, carries with it the palato-



glossal fold which may be spread out over its surface as a thin veil; or, the anterior pillar may be considerably thickened. In either case adhesions should be released if possible before attempts at reduction or removal of the gland are undertaken. Considerable shrinkage of the tonsil is often observed to take place after this procedure and excision may not be necessary. As to the best way of removing the first variety there is but little room for discussion. The guillotine usually succeeds in excising nearly all of the gland, or quite enough to answer the purpose. In the third form also this instrument is available, at least after an adherent pillar has been set free. In the second form, in order to gain the best results and protect the patient against further trouble, it may be necessary to resect masses of lymphoid tissue containing diseased follicles lying deep in the sulcus between the palatal folds, especially at their junction above—the supratonsillar fossa.

The degree of enlargement varies greatly in different cases. There may be hardly perceptible swelling, although the crypts may be in a state of chronic disease, or the tumefaction may be so extreme as to bring the surface of the tonsils almost in contact.

The disturbance excited differs to a surprising extent; in neurotics moderate enlargement produces an excessive amount of discomfort; whereas, in phlegmatic subjects, an enormous hypertrophy seems to excite but trifling annoyance. Usually the hypertrophy is, more or less, symmetrical. In rare instances we find one tonsil large, the other being nearly normal. Should the latter condition exist we may have reason to suspect the existence of syphilis, or the development of a neoplasm. When the formation of connective tissue is a marked feature the surface of the tonsil is apt to be smooth, the crypts being, to a greater or less degree, obliterated. The tonsil looks dense, hard, and fibrous. The true hypertrophied tonsil, in which the lacunæ are chiefly involved, is apt to be irregular in contour and even lobulated.

The symptoms caused by hypertrophied tonsils are variable. There is no pain except when they are inflamed but there may be discomfort and a sensation like that caused by a foreign body, with desire to swallow and, at times, some dysphagia with tendency to regurgitation of fluids through the nose. Usually the development



is very gradual and the surrounding parts seem to become accustomed to their presence. Reflex vomiting has been reported in some cases, and gastric disturbance is mentioned by many observers, either as a reflex neurosis, or from irritation of the alimentary canal by perverted secretions. Earache, impaired hearing and *tinnitus aurium* may be referable to the condition, but are much more likely to depend upon an associated lymphoid hypertrophy in the vault of the pharynx. The latter condition, also, is usually responsible for mouth-breathing and the heavy, stupid facial expression seen in children the victims of this anomaly. Reflex asthma and paroxysmal cough are said to have been cured by ablation of these bodies. Enlargement of the tonsil is probably never congenital, although it has been met with at a very early period of life, and it is not unusual to find examples of it in several members of the same family. Those affected may be inclined to a strumous diathesis, or have a feeble constitution. But, on the other hand, we not infrequently meet with this condition in those who present no evidence of scrofulous taint or malnutrition. It rarely makes its appearance after maturity and, in many cases, we secure a history of previous attacks of acute inflammation. It is a curious fact that, in some cases in which repeated attacks of tonsillitis occur, there is no decided increase in the size of the tonsils; while, on the other hand, we now and then see extreme hypertrophy without any history of, or special tendency to, acute inflammation. The damage caused by enlarged tonsils includes not only the immediate neighborhood of the pharynx but the general health. In addition they play an important part in the matter of infection and are a serious complication in the event of contagion. They are a source of constitutional disease by the mechanical impediment they offer to respiration and by vitiation of the inspired air resulting from decomposing secretions incarcerated in their diseased lacunæ. In addition we observe that various reflex disturbances may be referred to them. Yet, in spite of the mass of evidence against them, we still hear the advice given to allow the patient to outgrow the condition. There is no valid excuse for such advice. While a child is outgrowing the enlargement he is exposed to all the dangers that have been recounted, whereas, under modern methods of operating, the risks of surgical interference have been reduced to a mini-



mum. The danger attending their removal is far less than that involved in the retention of diseased or hypertrophied tonsils in the pharyngeal cavity. The improvement in general health and in the local conditions, which almost invariably follows removal of the offending bodies, is sufficient argument in favor of the operation.

*Treatment.*—The constitutional treatment of enlarged tonsils by itself is seldom satisfactory. The best of hygiene, and diet, and the use of the most powerful tonics are not capable of eradicating the fibrous tonsil. Nevertheless, anything which tends to improve the general health should be employed as an adjunct to local treatment. In some instances, a soft tonsil may be reduced to some extent by the use of astringent applications, or interstitial injections of iodine or corrosive acids. Massage of the tonsil has been recommended by many and seems to have been used with success in some cases. The process of absorption may be assisted by compression of the tonsil between the fingers, and electrolysis has been resorted to for a similar purpose. But these methods are all tedious and seem to be justifiable only in case of contraindication of more radical surgical measures. As to the latter it becomes necessary to determine what method of operating may be best adapted to a given case, as well as what may be the best time for operating. The suggestion is sometimes made that it is better to postpone interference until some improvement in the general condition may be secured. I have never seen reason to consider interference premature even in children who appeared to be in extremely poor general condition. It is not wise to operate upon a tonsil when it is acutely inflamed, although it has often been done and is still advised by some. The pain, the subsequent reaction, and the hemorrhage are apt to be unusual under these circumstances; nevertheless, we should not hesitate to interfere in case of threatened asphyxia from extraordinary swelling. It is injudicious to operate during the prevalence of an epidemic of scarlet fever or diphtheria, and indeed some go so far as to interdict the operation in a general hospital. In view of the startling frequency with which the Klebs-Loeffler bacillus, not to mention other septic organisms, has been found by Lichtwitz and others on the surface of a tonsillotomy wound such advice may not seem misplaced. The mode of operating depends upon the shape, the size and the



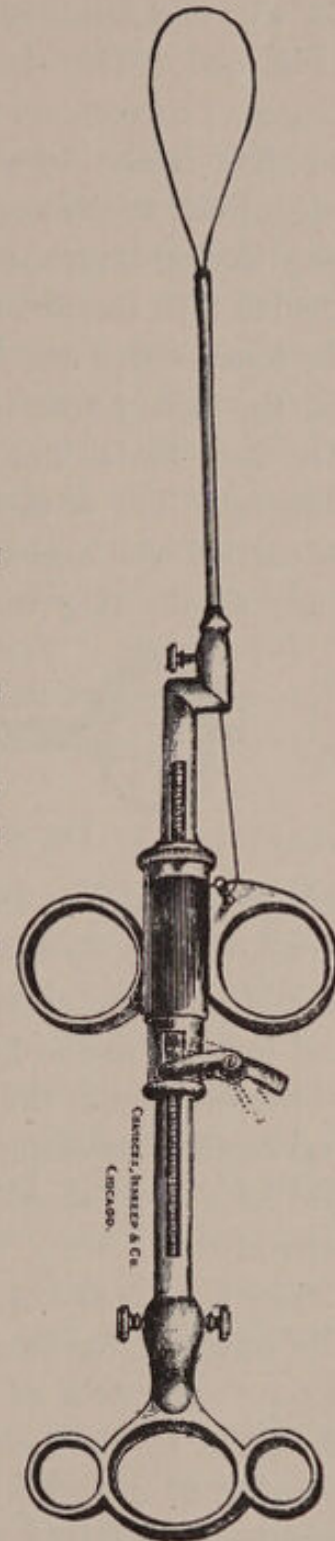
relations of the tonsil. The best method of removing the tonsil as a rule is with the amygdalotome; but, in certain cases, owing to the peculiar shape of the organ we shall be obliged to resort to other methods; for the latter reason, or in consequence of a fear of hemorrhage, which is justified in some cases, we may be compelled to select a bloodless substitute for the knife. Various chemical caustics have been tried with more or less success. Nitrate of silver, fused on a probe and passed into the crypts, chromic acid applied in a similar way or inserted into the body of the tonsil through small incisions and London paste applied to the surface of the tonsil with a spatula, have given some degree of satisfaction. These agents have to be reapplied at short intervals according to the amount of execution they do and the degree of reaction that follows them. Ignipuncture with Paquelin cautery and the galvano-cautery are much more energetic and precise agents, and in proportion to their greater effectiveness they are more painful and are followed by more intense reaction. In a trained, tolerant patient, after application and interstitial injections of cocaine, the whole tonsil may be destroyed with the electric cautery at a single sitting (Cullen); but, with a view to the patient's subsequent comfort, it is well to be satisfied with partial destruction of the gland at one time, accomplishing its complete removal in numerous sittings. Galvano-cautery puncture is well adapted to flat embedded tonsils, the removal of which with the knife or guillotine is difficult or impossible. It is a good plan to select three or four adjacent crypts and cauterize them in succession, the cold electrode being passed to the bottom of the crypt and brought out hot to the surface of the tonsil. In this way large segments of tonsillar tissue may be destroyed and there is little or no danger of retention of sloughing tissue which may become a focus of suppuration. It should be noticed that the electro-cautery method of dealing with enlarged tonsils is objected to on the ground that it leaves a large uneven surface and a sensitive cicatrix. It is believed that these objections are not well founded. If the electro-cautery is used with discrimination there is no reason why a perfectly smooth, insensitive stump should not be left by it as well as after the cutting operation. As a matter of historic interest it may be mentioned that, at one time, enucleation of the hypertrophied tonsil



by means of the finger was the recognized method of operating. At the present day it must be considered obsolete, although it has been quite recently recommended by Lambert Lack. He holds that it is especially adapted to small flat tonsils and that the gland can be enucleated completely and comparatively without loss of blood through an incision of the mucous membrane not penetrating the capsule and just behind the anterior pillar. The cold-wire snare is still a popular instrument in the hands of some operators. It is necessary to have a powerful instrument and considerable time should be consumed in cutting through the base of the tonsil in order to obviate the danger of hemorrhage (Fig. 91). The usual precautions as to diet, exercise, etc., should be observed as a prevention of secondary hemorrhage. There is sometimes difficulty in adjusting the loop of the cold-wire snare around the base of the tonsil which may be overcome by dragging the organ from its bed by means of a tenaculum or vulsellum forceps. In adults with prominent tonsils somewhat constricted at their base, and in children under general anesthesia this is a most excellent way of operating.

The hot-wire snare offers advantages over the cold-wire in completing the section much more easily and rapidly and in providing greater security against hemorrhage. We meet here, also, with difficulty in engaging the tonsil in the wire loop which the author has endeavored to overcome by constructing a loop-adjustor or electric tonsil-snare. It is an adaptation of an idea proposed by Toison for the cold-wire ecraseur and consists of a double canula carrying

FIG. 91. FARLOW'S TONSIL SNARE.





the wire and attached to a solid steel shaft from which it is insulated (Fig. 92). The shaft ends in a ring whose vertical diameter is longer to correspond with that of most tonsils. The ring may be of different sizes. In using the instrument the wire loop is shaped to adapt itself to the ring to which it is fastened by a fine thread. The ring having been carried over the tonsil with the loop towards the median line, traction is made so as to bring the wire in contact with the tonsil above and below; at this instant, the current being turned on, the wire burns through the thread which holds it to the ring. The loop buries itself in the tonsil and is no longer in danger of slipping. The advantages of this instrument are that the loop can be carried well over the base of the tonsil and the soft parts are held away by the ring and protected from the heat of the current. In




FIG. 92. AUTHOR'S ELECTRIC TONSIL-SNARE.

using electricity it is to be always remembered that the heat must be allowed to do the work and should not be excessive. Traction should be made upon the wire only when it is cool. Thus traction and burning are to be made in alternation. In spite of the absence of hemorrhage at the time of operation there are now on record several cases of secondary hemorrhage, hence excessive use of the voice and hard food should be prohibited until the eschar has completely separated.

The total result of the operation is not limited to the tissues actually removed, the parts left behind being cauterized to a considerable depth. The pain of the operation itself may be almost completely abolished by parenchymatous injections of cocaine, or nirvanin, a chloride of orthoform which has a very great advantage in being practically nontoxic. The latter is much less poisonous than cocaine, and moreover its analgesia is more prompt and prolonged. It has decided antibacterial properties, hence its solution may be kept sterile, or may be made so by boiling without damage, and there is no possibility of septic infection from its use hypodermically. It does not act through the unbroken skin or mucous membrane, and for this



reason cannot be substituted for cocaine in superficial use. A one half or at most a two per cent. solution is found to be strong enough.

Obviously the electro-cautery loop method of treating enlarged tonsils is adapted only to adults, or to children under general anesthesia, and to protuberant tonsils. It cannot be used with flat deep-seated tonsils. The reaction is always considerable but may be controlled in a measure on general principles. It is a good plan to remove at one sitting but one tonsil, the second being attacked at the expiration of a week or ten days. Yet at the solicitation of the patient I have several times removed both tonsils in succession and have never had reason to regret having done so. In a recent case in which two enormous tonsils were excised with the cautery loop after interstitial injection of nirvanin the patient, a sturdy girl of thirteen, declared that the operation was painless and she had surprisingly little subsequent suffering in spite of the great extent of burned surface.

There are four conditions which justify the use of the electric cautery as a substitute for a cutting operation: (1) Hemophilia; (2) vascular anomalies; (3) peculiarity in the shape of the tonsil, and (4) refusal on the part of the patient to submit to the knife.

A patient known to be a bleeder should never be cut.

Among the vascular anomalies, a misplaced ascending pharyngeal artery or a large vessel in the margin of the anterior pillar, may be wounded by the knife. Injury to the plexus of veins at the lower border of the tonsil may give rise to hemorrhage; and an abnormally large tonsillar artery frequently bleeds freely. It is sometimes impossible to tell from the appearance of the tonsil whether hemorrhage may be expected; a very vascular looking tonsil often bleeds but little. In my experience this accident has occurred usually in adults with the hard fibrous tonsil in which the section has been made near the middle of the gland where the blood-vessels do not readily retract in consequence of a preponderance of new connective tissue. In the opinion of A. A. Bliss the tonsillar artery itself is seldom cut, unless the excision be very complete, which he concludes is rarely if ever necessary. This view is also held by Damianos, who in reporting a fatal case in a hemophile states that about 150



cases of severe bleeding after tonsillotomy are on record, seven of which were fatal. His objection to complete removal seems to be based on the idea that the tonsillar artery is so embedded in the inelastic fibrous capsule of the gland that its severed end is prevented from contracting.

Anatomical peculiarities comprise the flat or embedded tonsil, the so-called "submerged" tonsil, which cannot be included in the ring of the guillotine and with which the use of the knife or scissors is tedious and possibly dangerous. Adhesion of the anterior pillar, in this situation described by Harrison Allen as the "opercular fold," and the advisability of its detachment have been already referred to. Several cases of violent bleeding have followed section of this fold. Yet if the pillar is very thin, evidently consisting only of mucous membrane, and encloses no blood-vessel of importance, its existence may be disregarded and the blade of a tonsillotome be carried directly through it, provided the tonsil protrudes sufficiently to allow the ring of the guillotine to surround it. In tonsils of this class electro-cautery puncture is generally the most satisfactory method.

Although we call this a bloodless method of operating, a more extensive experience has demonstrated that it is not absolutely free from the risk of bleeding. A number of cases are on record in which an alarming hemorrhage has taken place on the fourth or fifth day from violent detachment of the eschar, as a result of excitement in laughing, or crying, or of laceration by a morsel of hard food. Ordinary caution in these particulars should ensure protection against the accident. The operation itself may be rendered comparatively painless by local anesthesia, yet there is doubtless more reaction after burning than cutting. The fauces should be first thoroughly cleansed with an antiseptic spray and the surface of the tonsil swabbed with a ten per cent. cocaine solution. Then with an ordinary hypodermic syringe six or eight minims of a two per cent. solution of nirvanin are injected into the upper and an equal quantity into the lower part of the tonsil. In about three minutes anesthesia will be quite complete.

In a large majority of cases the operation of choice is one of the various cutting methods. Most tonsils can be removed with the knife more quickly and thoroughly than in any other way, and the



resulting wound is less irritable and heals more kindly than one left by a caustic. The accepted instrument for use in cutting operations is a modification of Physick's tonsillotome, proposed several years ago by Morell Mackenzie (Fig. 93). Many so-called improvements have been suggested which complicate the instrument and add to the



FIG. 93. MACKENZIE'S TONSILLOTOME.

difficulty of the operation. Mackenzie's amygdalotome recommends itself for its strength, its simplicity, its safety and its efficiency. Rightly used it is capable of ablating almost the entire tonsil and that without endangering the large blood-vessels in the cervical region. In certain cases a forked guillotine, like that of Mathieu (Fig. 94), may be serviceable. Spear or fork attachments have




FIG. 94. MATHIEU'S TONSILLOTOME.

been known to catch in the ring and in several instances a guillotine has thus been broken, either as a result of faulty construction or awkward manipulation. Some operators still prefer a stout bistoury



or scissors, but their use is far from easy in a field obscured by blood and constantly shifting with muscular contractions. It is sometimes difficult to remove the morbid tissue thoroughly and tonsil punches in a variety of shapes have been devised for the purpose of reaching the bottom of the tonsillar fossa. In order to protect the patient against recurrence of circumtonsillar phlegmon it is quite important to remove these deep-seated masses. Morcellement, or ablation of the tonsil by crushing with powerful flat-bladed forceps followed by excision of the crushed portion, called by Ruault "amygdalothrip-

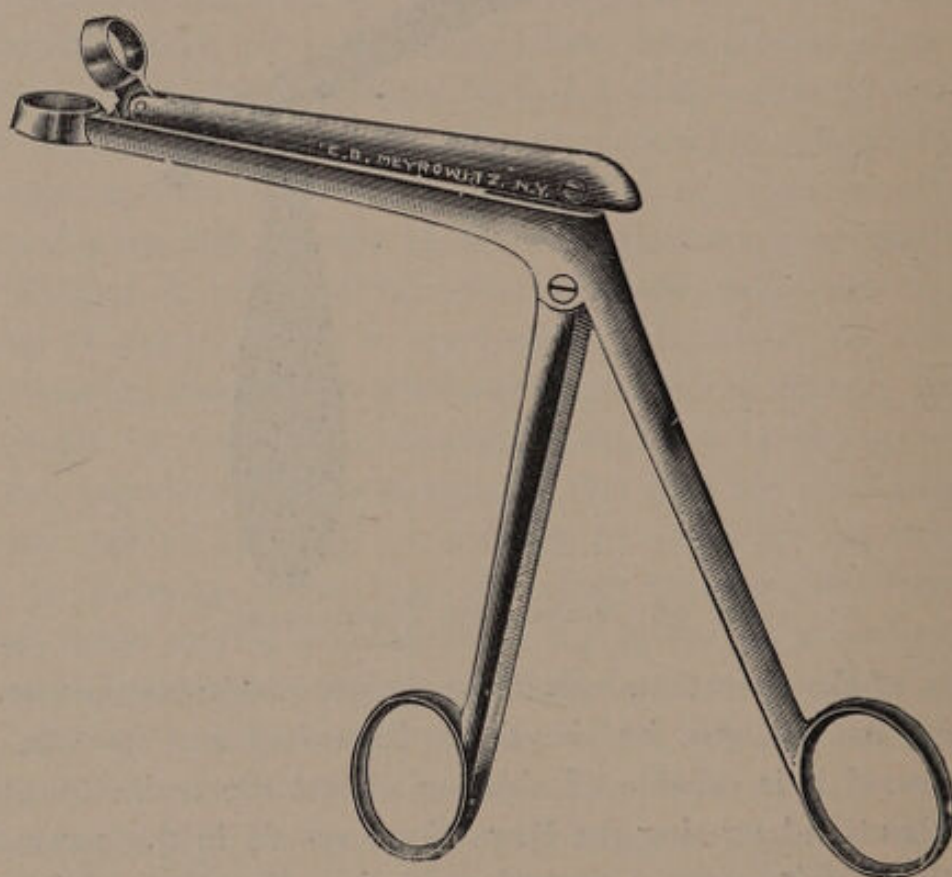


FIG. 95. FARLOW'S TONSIL PUNCH.

sis," is said to be a satisfactory way of disposing of these hypertrophies. The tonsil punch is adapted to cases in which the knife is impracticable (Fig. 95). In this connection a very curious and happily rare anomaly may be mentioned as offering an obstacle to removal of a tonsil, namely an elongated styloid process. It has been met with by G. L. Richards, who was obliged to divide the bone with cutting forceps before the section of the tonsil could be completed. In several instances a lacunar concretion, or tonsillith,



has been found to impede the passage of the knife blade. Such conditions are more likely to occur in adults than in children and are extremely infrequent at any age.

It has been said that excision of the tonsils is the only operation in the upper air track requiring the exercise of brute force, and it is certainly true that failures in the management of the Mackenzie instrument result from the use of too light a hand. Firm outward pressure with the forefinger on the shaft of the guillotine must be kept up while the blade is being closed. Otherwise the ring tends to slip off and with a mere shaving of mucous membrane. The expression "brute force" needs to be modified by the adjective "reasonable." I have seen a muscular young athlete tear a large rent in the posterior pillar by the exercise of too much energy. In this connection it might be mentioned that a mouth-gag is not needed in adults and without an anesthetic, and that a tongue depressor is always superfluous, the guillotine itself acting in that capacity. The remarkable feat of amputating a uvula and excising a tonsil at the same time has been accomplished by introducing a guillotine upside down, the handle pointing upwards, a most unnatural and awkward position not to be recommended.

It is my custom to excise both tonsils at one sitting, the left one first and then the right. Double guillotines intended to cut both at once are awkward and unreliable. If the operation can be done without an anesthetic the patient sits facing a window, his head resting against the body of an assistant whose hands should steady the head and especially *support* the tonsil about to be excised. It is unnecessary and perhaps dangerous to try to force the tonsil inward by external pressure with a single finger. Reliance should rather be placed upon the act of gagging and firm outward pressure with the instrument to force the gland within its grasp. In removing the left tonsil the handle of the instrument should be held in the operator's right hand. The shaft, the blade being open, is passed over the dorsum of the tongue, turned quickly so as to bring the fenestra over the tonsil, and pressed firmly outward with the forefinger of the left hand. This pressure upon the shaft of the instrument and the act of gagging provoked by the presence of the guillotine in the fauces, drive the tonsil well into the ring, advantage of which should



be taken to push the blade home with the thumb of the hand holding the instrument. Usually the excised portion of tonsil is held by shreds of mucous membrane in the groove of the ring. The instrument is quickly withdrawn, opened, and the manipulation repeated upon the right tonsil, the guillotine being held in the operator's left hand. Used in this way the Mackenzie instrument will be found to make almost a complete enucleation of the tonsil in most cases. It is customary to have pretty sharp bleeding for a few moments at the completion of the operation. In several cases an alarming secondary hemorrhage has taken place a considerable time after operation. For example, in one reported by Moure a week had elapsed. In one of the author's cases the bleeding occurred on the second and in another on the fifth day. Several times in my experience it has seemed wise to abandon a contemplated adenectomy on account of excessive loss

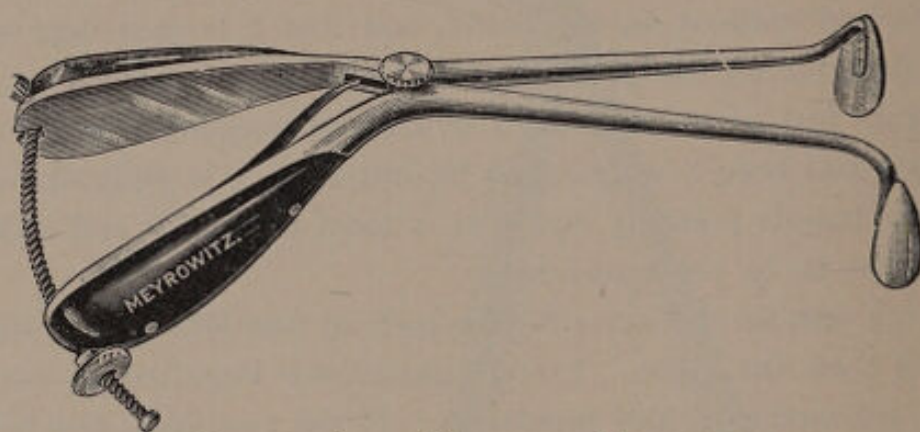


FIG. 96. BUTTS' TONSILLAR HEMOSTAT.

of blood from an excised tonsil. If the hemorrhage does not subside after the loss of a few ounces of blood it is time to consider measures for its arrest. In most cases the application of cold externally and holding bits of ice in the mouth will suffice. If these fail, a mixture of tanno-gallic acid—one part of gallic and three parts of tannic, in the proportion of about twenty grains to the ounce of water—may be used as a gargle; and small quantities of the solution may be swallowed; the act of swallowing driving the styptic into the stump of the tonsil. Parenchymatous hemorrhage will almost invariably be checked by this procedure. Hemorrhage from a large tonsillar artery cannot be thus controlled and we then shall be obliged to resort to some other method. Direct pressure by the finger, or by means of one of the various tonsillar hemostats (Fig. 96), should



be tried without wasting time over styptics (Fig. 97). Ligation of the tonsil after transfixing the stump with a tenaculum is sometimes feasible; but it is not easy to ligate a tonsillar artery from which brisk hemorrhage is taking place in a nervous frightened child, or even in an adult. The electric cautery, or Paquelin cautery will check persistent oozing but will rarely control an arterial jet. An ingenious proposition by Levis succeeded in an obstinate case under his care; the stump of the tonsil was transfixed by a tenaculum; it was then twisted to bring the flat handle between the teeth and the jaws were bandaged together; on withdrawing the instrument next day there was no return of hemorrhage. When hemorrhage is to be apprehended from any source Seifert advises the use of the gal-

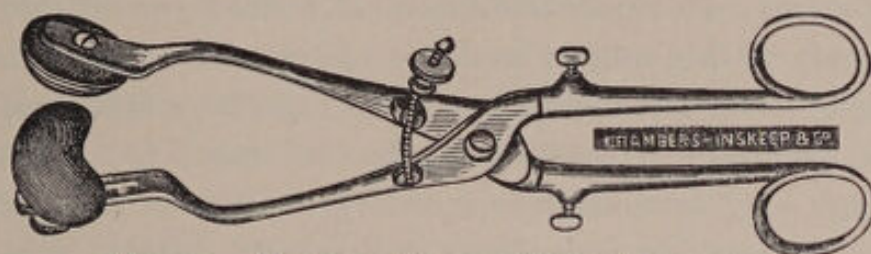


FIG. 97. MIKULICZ-STOERK TONSIL HEMOSTAT.

vanocautery snare in operating and suggests that one be content to remove not more than three fourths of the tonsil, the latter precaution, however, appearing somewhat superfluous in addition to the former.

Ligation of the carotid artery for tonsillar hemorrhage has several times been done, but in at least one such case it seems clear that the bleeding was on the point of ceasing spontaneously. On anatomical grounds the external carotid, between its superior laryngeal and ascending pharyngeal branches, would be the vessel indicated for ligation, but in view of the fact that the importance of this accident has been vastly overdrawn a less formidable procedure would seem to be preferable. If a stump of tonsil has been left the loop of a cold-wire snare may be passed over its base and gradually tightened, or if the excision has been complete the tissues may be transfixed with a needle in a long handle and the wire slipped over its ends. A very ingenious device by Dawbarn consists in surrounding the bleeding area with a submucous ligature, or "purse string" ligature, passed in four directions. A double-curved needle in a holder



and loaded with a stout ligature of silk or catgut is passed from before backward beneath the bleeding point, then vertically upward behind it, then directly forward and finally downward to the spot where the needle first entered. The pillars need not be included by the ligature which is practically buried at all points and may be allowed to slough out or may be removed after two or three days. In most cases a tonsillar hemorrhage, if allowed to take care of itself, will cease spontaneously on the supervention of faintness with decreased blood pressure, and the last remedy used gets the credit of having checked the bleeding. This may not be an agreeable mode of controlling a hemorrhage, but the episode is robbed of most of its terrors when the patient can be assured that nature's way of stopping a leak in a blood-vessel is usually effective. The results of careful study of this subject made by Lefferts have been amply confirmed by others. His conclusions were (1) that a fatal hemorrhage after the operation of tonsillotomy is very rare; (2) a dangerous hemorrhage may occasionally occur; (3) a serious one, serious as regards both possible immediate and remote results, is not very unusual; and (4) a moderate one, requiring direct pressure or strong astringents to check it, is commonly met with. My own experience with alarming hemorrhage is limited to four cases, two in adults and two in children under ten years of age. In all the guillotine was used. In the case of the children the bleeding ceased spontaneously after the failure of several domestic measures and when exsanguination had become extreme. A similar course was followed with the adults, although in one of the latter direct pressure seemed to be of some service, while in the other efforts to stop the flow by torsion and electric cautery were unsuccessful.

The use of general anesthesia in removing tonsils has been the subject of much discussion. The pain of cutting or burning may be mitigated in some degree by the application of cocaine, or the parenchymatous injection of cocaine or nirvanin. It has been suggested that cocaine increases the liability to secondary hemorrhage, but there is no good foundation for such an assumption. General anesthesia seems to me, by all means, more humane, especially in young children, in spite of the opinion of many authorities that it is wholly uncalled for. The argument offered against it generally



is that it deprives us of the assistance of the patient in preventing the admission of blood to the air passages, which is not strictly true if the anesthesia be not profound. Cases of fatal asphyxia are on record from the entrance of blood into the larynx during tonsillectomy under chloroform. Some maintain that anesthetization excites as much resistance as attempts to excise the tonsil without it. My own position is that if given in a proper way, in suitable quantities, ether will be found on the whole the most satisfactory and certainly the safest anesthetic. If the administration of ether is preceded by inhalations of nitrous oxide gas, a very moderate quantity of the former is required, the unpleasant suffocative effects of ether are obviated, the reflexes are not abolished, and the after effects are much reduced in unpleasantness. By giving a general anesthetic in this way we do not involve any greater risk, we save the patient much nervous shock, we permit ourselves much better opportunity to examine the case carefully and especially to explore the naso-pharynx, which is always a most important thing to do, and if any morbid condition is found there it may be relieved at the same time. It is best to remove the faucial tonsils first in succession, the mouth being held open by a mouth-gag; the patient is then turned upon the side or a little upon the face to permit the blood to drain from the mouth, and, after the hemorrhage has subsided, he should be replaced upon the back and a rapid exploration made of the vault of the pharynx with the forefinger. It may be necessary to give a little more ether when this additional step is taken.

It seems to be a fact that the danger of hemorrhage after the removal of a tonsil has been much exaggerated. The number of cases of excessive bleeding on record in proportion to the number of tonsils removed is extremely small. Nevertheless, especially in adults, the possibility of its occurrence should be borne in mind, and before the operation is undertaken the patient should be thoroughly informed and, if an adult, should be, in a measure, allowed to select the mode of operation.

The question of the advisability of removing enlarged tonsils seems to be no longer open. Their injurious effects are so obvious, the benefit following their removal is so apparent, and the risks of



the operation are so slight, that there should be no hesitancy in advising it when the necessity arises. We should endeavor to remove as much of the morbid tissue as possible, in other words to do a "tonsillectomy," and in order to accomplish this it may be necessary in exceptional cases to dissect out the deep-seated masses with blunt scissors or tonsil knife (Fig. 98), rather than undertake to use the amygdalotome. It is not sufficient to make a superficial section for the reason that a remnant of tonsillar tissue containing diseased follicles is very prone to become the subject of an acute inflammatory process under circumstances which excited its occurrence before operation. It rarely happens that the faucial tonsil reproduces itself after radical excision. In very young subjects with a tendency to lymphoid hypertrophy there may be possibly a

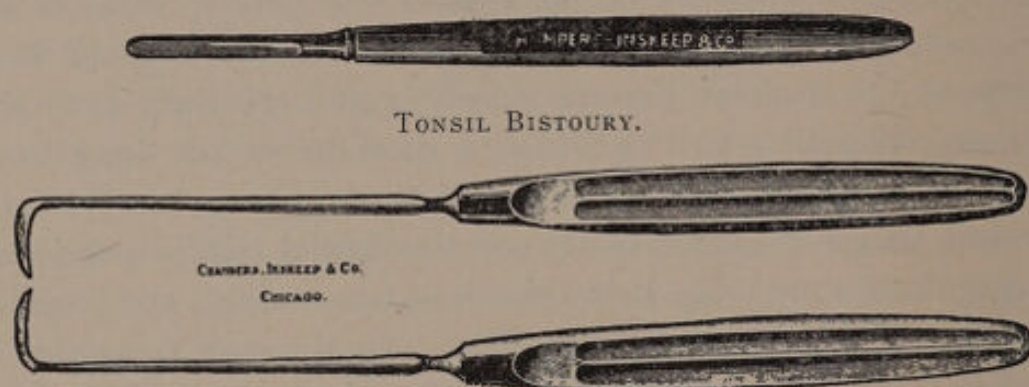


FIG. 98. TONSIL KNIVES.

slight inclination to recurrence. But, as a rule, we find that the improved general condition following a nearly complete extirpation results in progressive shrinkage of what small stump may be left. On the other hand in certain cases a moderate growth of lymphoid remnants may take place precisely as in the case of adenoids in the pharyngeal vault. Yet the experience of Coakley, who states that he did amygdalotomy four consecutive times within as many years on the same patient, is most extraordinary.

Three questions are almost invariably asked whenever a tonsillectomy is proposed; whether there is any risk from hemorrhage or other sources, second, if the tonsils are likely to grow again, and finally what effect if any their removal may have upon the voice or other bodily function. The first two have perhaps been sufficiently discussed. A fear of sexual impairment sometimes suggested is



based upon a process of reasoning similar to that which discovers in suicidal mania a direct result of excision of the tonsils because two or three individuals are reputed to have taken their own lives shortly after having been cut. The question of damage to the voice deserves to be treated more seriously and is more important especially in those whose livelihood or enjoyment of life may be involved. At intervals this objection finds expression in medical literature. Personally I have never experienced a case which gave it a shadow of foundation. At first there is almost always a startling change in the quality of the voice which may disturb the patient and distress his friends, but this passes away in a few weeks at most, and is succeeded by marked improvement in fulness and resonance as he learns to modulate his voice and adapt his palatal muscles to their new relations.

A curious post-operative phenomenon, at times possibly leading to confusion and even alarm, merits passing notice, namely "tonsillotomy rash." It is extremely rare, having been mentioned only by Lennox Browne and one or two other writers, but has recently been described anew by Wyatt Wingrave and E. A. Forsythe. It may occur as a papular, roseolar or erythematous eruption, usually beginning on the neck, chest and abdomen and thence extending sometimes to the extremities. It may be attended by considerable itching, but disappears in two or three days without desquamation and with little or no constitutional disturbance. Its occasional occurrence should be kept in mind with a view to escaping a possible disquieting error in diagnosis.

In conclusion no good reason can be offered for allowing the tonsils to remain when they are clearly proved to be causes of local as well as systemic derangement, and no method of removal other than surgical is worth considering, except in those very rare conditions which have been enumerated.



## CHAPTER XIV.

DISEASES OF THE LINGUAL TONSIL. ABSCESS OF THE TONGUE.  
RETROPHARYNGEAL ABSCESS. MYCOSIS OF THE PHARYNX.

### HYPERTROPHY OF THE LINGUAL TONSIL.

The lingual tonsil is composed of tissue analogous in all respects to the lymphoid tissue situated between the palatal folds and in the vault of the pharynx. This tissue exhibits similar pathological changes wherever found and in its enlarged state at the base of the tongue causes peculiar symptoms which are very apt to be misinterpreted. When we consider that hypertrophy of the lingual tonsil must impede the action of the epiglottis and the movements of the tongue it is easy to understand how functional disturbances may result. It is a notorious fact that changes in the lymphoid tissue in this situation are often met with late in life and in the female sex.

The symptoms which it causes vary greatly in different persons. They are dependent not so much upon the degree of the hypertrophy as upon the temperament of the individual. A moderate amount of hyperplasia, in some cases, will excite an extraordinary degree of disturbance. A sense of fulness and tickling in the throat and a constant desire to clear the passages by the act of hacking or coughing are most often complained of. The condition is a serious one in those who use the voice, either in singing or public speaking. The effort to overcome the mechanical obstacle offered by a mass of lymphoid tissue at the base of the tongue may demand the exercise of muscles which should not be employed in voice formation; and, in consequence, the patient soon becomes hoarse and tired, and may actually lose his voice for a time. Finally structural changes may be engendered in some part of the vocal apparatus productive of partial or complete aphonia. Reference has already been made to the morbid conditions of the vocal bands met with under these circumstances. A number of reflex symptoms have been detailed in the line of neuralgic pains, asthmatic attacks, spasm of the glot-



tis, etc., which are comparatively rare occurrences. R. Levy divides these cases into six classes. First, those attended merely by discomfort, or paresthesia. Symptoms may have been excited and the mind of the patient fixed upon this locality by swallowing a foreign body or a rough particle of food, and the patient seeks to be relieved of something which he imagines is still sticking in his throat. Some of these people consult a physician because they apprehend cancer or tuberculosis. In a second class cough is a very persistent and distressing symptom, which is only temporarily controlled by sedatives, but yields promptly after the use of the galvanocautery in adults and in children to swabbing with tincture of iodine and glycerine. Third, dysphonia, vocal fatigue, throatache and impure tone production may be especially noted in singers, to whom these conditions are of the utmost moment. Fourth, dyspnea, resembling that caused by spasm of the larynx and occurring chiefly at night, may

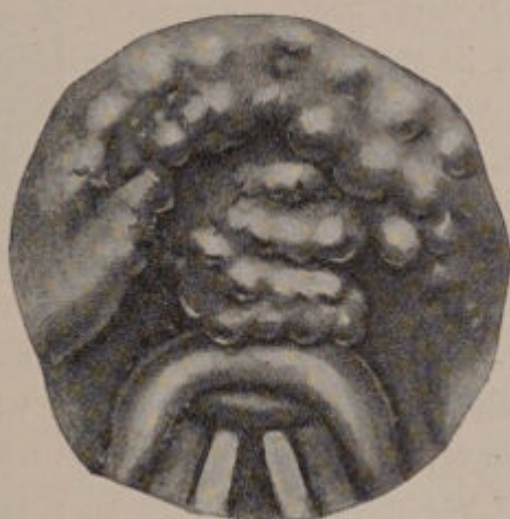


FIG. 99. HYPERTROPHY OF LINGUAL TONSIL. (*Grünwald.*)

be so extreme that the patient dreads going to bed, and eventually the general health may suffer from loss of sleep and mental distress. Fifth, dysphagia may exist to a degree sufficient to impair nutrition, and sixth, hemorrhage may occur from an associated lingual varix. The last is certainly rare. Nevertheless in view of the extreme disquietude caused by the appearance of blood in the sputa it may be a satisfaction to be able to assure a patient that it comes from the base of the tongue and not from the lungs.

The diagnosis is usually made without difficulty by simple inspection with the laryngeal mirror (Fig. 99). Irregular masses of



lymphoid hyperplasia, frequently covered with enlarged veins, may be seen which sometimes incarcerate the tip of the epiglottis. The masses are in some cases so large as to be distinctly pedunculated and may be visible without the mirror through the open mouth. Protrusion of the tongue fails to separate its base from the epiglottis. A most conspicuous feature in the picture is often the remarkable size and number of varicose vessels. Lingual varix may exist without much hypertrophy of lymphoid tissue. The presence of multiple turgid vessels should of course restrain us from the use of cutting instruments in this region. In elderly people lingual varix is very commonly observed and rarely possesses any significance. It may be associated with varicose vessels in other situations.

The symptoms may sometimes be relieved temporarily by painting the region with cocaine. In many cases the condition is aggravated by impaired general health, neurasthenia, or deranged digestion. Improvement in these particulars under general medication, possibly combined with the local application of astringents, will often effect a cure. In other cases, the persistent cough and the phonatory disturbance demand more energetic treatment and we are compelled to resort to destruction of the masses by the use of caustics, or the electro-cautery, or to removal by means of the snare or the knife. The process of cauterization with electricity is painful and disagreeable while effective if persevered with. The knife in this region is a dangerous instrument for the reason that the parts are apt to be rather vascular and, moreover, it is not an easy place in which to control bleeding by pressure. The cold-wire snare is, perhaps, equally effective and certainly safer, but we need for this purpose an instrument of unusual power. Various lingual tonsil-lotomes have been proposed shaped very much like the guillotine used in excising the faucial tonsil, but somewhat curved to fit the dorsum of the tongue (Fig. 100). The reaction from the operation of removing these masses is sometimes considerable, especially when the electro-cautery has been used, and is best relieved by holding pieces of cracked ice in the mouth, or by the application of cocaine.

The lingual tonsil is no doubt subject to inflammatory attacks precisely as are the other lymphoid masses in the "adenoid triangle,"



or "lymphoid ring." In the opinion of H. L. Swain, who has seen a number of cases, the condition is often overlooked. A series of sixteen cases has been reported by Seifert and almost an equal number by other observers. They may be less frequent, or perhaps less clearly recognized, than similar affections of the palatal tonsils, or possibly the intensity of the process in the latter overshadows a concomitant trouble at the base of the tongue. Phlegmonous inflammation, or "lingual quinsy" may be a very serious disease. It rarely extends beyond the anatomical limits of the tonsil, but when it does invade the floor of the mouth it resembles a true "angina




FIG. 100. ROE'S LINGUAL TONSILLOTOME.

Ludovici." The constitutional disturbance is extreme, as indicated by the high temperature and rapid pulse. Pain is severe and constant and is intensified by attempts to speak or swallow and by the slightest movement of the tongue. The swelling may be enormous so that the tongue protrudes from the mouth and there is a continuous dribbling of saliva. The breath becomes horribly fetid and the tongue is covered with a thick leathery fur. Dyspnea may result from swelling or from edema of the epiglottis and the vestibule of the larynx. The danger from this source, or from asphyxiation following a rupture of the abscess, is considerable, especially in the aged and in those weakened by long illness.

It is difficult and may be impossible to introduce the finger for palpation, and even if we succeed a sense of fluctuation is very



obscure and indecisive. We may be forced to make a diagnosis without even a glimpse of the parts involved.

From this brief description it must be clear that this is a much more serious and alarming process than similar affections of the other tonsillar masses. Fortunately it is much more infrequent. Doubtless some of the cases of so-called "abscess of the tongue," and very likely the fatal cases of alleged "quinsy" should be classified under this designation.

The causes acting to excite inflammation of other lymphoid tissue operate equally in the case of the lingual tonsil. A depressed state of the general health, a rheumatic diathesis, or a foreign body may be concerned as factors in the causation of inflammation of the glands at the base of the tongue. An interesting example of the last-mentioned cause was observed by the author many years ago, in which a wisp of straw taken into the mouth with a draught of water became engaged in one of the lingual follicles. After several days of extreme distress the patient was relieved by spontaneous rupture of the abscess.

The general treatment should be conducted on the lines laid down in speaking of the faucial tonsils. Early and free incision for the release of pus, and even if the presence of pus cannot be demonstrated, is clearly indicated. The best instrument for this purpose is a sharp-pointed curved bistoury with a rather short thin blade. Hemorrhage is apt to be very free. If an abscess is opened and pus evacuated the relief of symptoms is immediate, and in any case scarification does no harm. Hot alkaline and antiseptic mouth-washes and hot fomentations externally are usually soothing and grateful. The necessity for stimulating and supportive treatment may be urgent.

*Neoplastic formations* and tumors in the region of the lingual tonsil are rather uncommon. Among the most interesting of the latter may be mentioned accessory thyroid tumors, instances of which have been reported by H. T. Butlin, J. E. Schadle and others. A remarkable phenomenon in a case recorded by Schadle was presented in the form of vascular turgescence of the tumor during a period of suppressed menstruation. This growth was removed by McBurney by an external incision, its real nature not having been previously fully



determined. In a case reported by Theisen an accessory thyroid as large as a hen's egg was observed deeply embedded in the base of the tongue. It appeared to be quite vascular, which fact together with the patient's age (67) was thought to preclude operation. The tumor diminished somewhat in size under internal use of thyroid extract. An interesting point in the history is that the woman had a goiter in early life, all trace of which had disappeared.

### RETRO-PHARYNGEAL ABSCESS.

Retro-pharyngeal abscess is a phlegmonous inflammation involving the cellular, or the lymphoid, tissues of the pharyngeal wall. In the majority of cases no cause for the suppuration can be discovered; in a few, it succeeds abscess formation in the cervical region; in others, it is secondary to caries of the vertebræ; in a small proportion of cases it is a sequel of an exanthem; and, finally, it may be produced by a foreign body. In a large number of cases, in children, the lymphoid tissues are evidently the seat of the disease and the course of the lesion is usually extremely slow. In adults, on the other hand, the abscess is more apt to simulate suppuration in cellular tissues elsewhere and is attended by more disturbance and local reaction. In children it is usually considered a sign of struma. Its development is very slow, the general health of the child becomes gradually impaired, food is refused as the difficulty in swallowing increases and, finally, a peculiar throaty quality of the voice becomes pronounced and there is more or less impediment to breathing. The dyspnea ultimately becomes very alarming and, in fact, may be the first symptom to draw attention to the throat.

On examination the pharynx is seen to be occupied by a bulging tumor, usually upon one side of the middle line over which the mucous membrane is glazed and tense. Usually the tumor occupies the oropharynx but, in rare instances, it is much lower and may not be visible by direct inspection. In adults the local symptoms may be much more acute at the onset and there is more or less constitutional disturbance. Pain referred to the faucial region aggravated by swallowing directs attention at once to the throat. The obstruction to swallowing may be so considerable as to interfere with nutri-



tion. The breathing is seldom seriously impeded. The appearances presented resemble those of an abscess in other situations and the diagnosis of pus formation may be confirmed by palpation with the finger; a peculiar elastic sensation indicative of fluid and analogous to fluctuation may be readily recognized.

If left to itself an abscess in this situation will usually discharge in a week or two; but, in children, it sometimes runs a very chronic course, extending over many weeks. In the latter case, while the local disturbance may not be very serious, there is danger that the patient may succumb in consequence of impaired nutrition. In children and in individuals very much reduced in strength, or advanced in years, spontaneous rupture of the abscess, or opening by incision may be attended by some risk from entrance of pus into the larynx. In milder cases, simple incision with a guarded bistoury and evacuation of the pus will result in cure. Erosion of an artery with fatal hemorrhage has occurred in several cases on record. Edema of the glottis is a complication of especial seriousness in weak children. In some instances of extensive suppuration external opening of the abscess may be required by an incision along the anterior border of the sterno-cleido-mastoid muscle. This more formidable operation is demanded only in cases of extraordinary extent, or where the abscess is seated low down in the pharynx. Ordinarily simple puncture or incision through the mouth under local anesthesia will suffice. In unmanageable children a small quantity of chloroform may be required. Local applications are useless since the formation of pus is generally inevitable and rapid and its evacuation is necessary. There is seldom necessity for special dressing of the abscess cavity. During convalescence a semi-fluid diet and the use of antiseptic sprays and gargles, especially after taking food, are plainly indicated. Attention should be given to the general health and the correction of a strumous diathesis.

### PHARYNGO-MYCOSIS.

Mycosis of the pharynx, first described by B. Fraenkel, is a term applied to a fungous development which sometimes appears upon the surface of the tonsil, upon the lymphoid tissue at the base of the



tongue, or within the follicles distributed over the mucous membrane of the pharynx. The vault of the pharynx also is often invaded. It consists of a deposit of spores of the *leptothrix buccalis*, a fungus which is almost invariably present in the oral cavity and yet its transference to the fauces is comparatively rare.

Impaired general health is usually regarded as a predisposing cause and, in a large proportion of those subject to it, digestive derangements are pronounced. In some cases the saliva is said to have an acid reaction. In a small number of cases it has been observed to follow tonsillitis and diphtheria, but there is no proof of any special relationship. In a large majority of cases the patients seem to be in perfect health, and absolutely no constitutional disturbance is observed.

The symptoms which it induces are not of very pronounced character. It is not at all uncommon to discover deposits of mycosis in those who are unaware of any trouble whatever. Occasionally slight hacking cough and a feeling of irritation in the pharynx are present, but there is never acute local inflammation, except as a coincidence. The appearances it presents are almost unmistakable; yet it is not a rare experience to see cases that have been diagnosed and treated as follicular tonsillitis. Such an error may occur when the fungous growth is unusually exuberant, or is attended by inflammatory conditions. The uniform absence of the latter and the colorless appearance of the exudate differentiate it positively from diphtheria. It occurs in the form of filamentous tufts projecting from the surface of the membrane, usually from a follicle, milky white in color. If one of these projecting masses be seized with the forceps it frequently may be drawn from the lacuna with ease. Sometimes its removal is followed by the escape of a little blood. The condition is perfectly innocuous and spreads slowly. Having been removed by mechanical means or by destructive agents it frequently shows a marked tendency to recur.

The treatment of the disease is very troublesome since success depends upon the complete and thorough destruction of all the spores; should any be overlooked they will be sure to reproduce themselves. A variety of agents have been employed, including absolute alcohol, perchloride of iron, pure carbolic acid, iodine prep-



arations and all the stronger astringents, but the galvano-cautery gives the best results. Large masses of lymphoid hyperplasia, which offer a favorable site for the development of the mycotic product, should be removed. The milder cases which give but very few symptoms may, very properly, be let alone, or be treated by simple antiseptic gargles and the correction of possible digestive disturbances. The galvano-cautery and pyoctanin are relied upon by R. P. Lincoln in the treatment of this disease. The latter is used in powder rubbed briskly into the affected region daily until all signs of the growth disappear. Enlarged follicles, or hyperplastic masses of lymphoid tissue containing the tufts may be burned away with the electric cautery or excised.

A membranous disease presenting the gross appearances of a genuine mycosis, according to Kyle and others, is a *keratosis* beginning in the submucosa. It is pronounced not bacterial, although the lepto-thrix has been found in certain cases, probably as an accidental occurrence. This is the view elaborated by Siebenmann, who maintains that the bacteria are purely saprophytic and that they are in no respect etiological. Similar conclusions are reached by Geo. B. Wood, who thinks that the peculiar formation of keratosis is the result of a low grade of inflammation sufficient to stimulate the growth of normal epithelium and not intense enough to lead to the pus formation of an acute process or the accumulation of the cheesy masses characteristic of a chronic lacunar amygdalitis. Brown Kelly expresses the opinion, based on an exhaustive study of the subject, that there are two distinct diseases, mycosis and keratosis, which present the following differences:

1. Keratosis is found in adults, mycosis at any age.
2. The cause of keratosis is unknown, mycosis is due to some derangement of buccal secretion or of the digestive tract, or possibly to a rheumatic or other diathesis.
3. The symptoms of keratosis are slight or absent, those of mycosis are pronounced.
4. In keratosis the mucous membrane is normal, in mycosis inflamed.
5. The exudate of keratosis is tough, firmly adherent, and assumes characteristic shapes, that of mycosis is soft and easily detached.



6. Keratosis affects only the tissues of Waldeyer's ring, mycosis may occur at any part of the mucous membrane.

7. Keratosis, except for the presence of leptothrix, bears no resemblance, while mycosis is similar to thrush, sarcina and other mycoses.

8. Keratosis is not influenced while mycosis may be cured by local applications.

These views are in a sense a compromise between Heryng's theory as to keratosis and that of Miller, who describes several different forms of bacilli as causative factors. According to the latter none of these organisms can be cultivated in any known media, while Jacobson claims to have cultivated the leptothrix on potato. The pathogenic nature of the leptothrix is thought to be proved by the fact that this organism was found by Pearce in two cases extending deeply into healthy tissues. Jonathan Wright believes that the thickening of the epithelial lining of the affected crypts is a result of a chronic inflammatory process caused by the irritative action of the mycelium. Similar phenomena are often observed in other parts of the air track. By staining sections of tissue containing the mycelium with gentian violet and Gram's iodine he was able to demonstrate the *bacillus maximus buccalis* as well as the leptothrix. He has been unable to confirm the observation that the mycelial threads sometimes penetrate the epithelial layer and even the subjacent tissues. On the contrary he has always found them only in the lacunæ surrounded by innumerable spores.

Thus there appears to be hopeless confusion as to the importance of the rôle played by the various organisms, and after all the lesion is of interest chiefly as a microscopic picture and not by reason of any marked clinical signs.



## CHAPTER XV.

TONSILLITIS. DIPHThERIA. CIRCUMTONSILLAR ABSCESS, OR QUINSY.  
ULCERO-MEMBRANOUS OR DIPHThEROID ANGINA.

### TONSILLITIS.

Inflammation of the tonsil may involve the mucous membrane covering the gland, that lining the crypts, or the substance of the organ itself; the first is called superficial, the second, lacunar or follicular, and the last, parenchymatous amygdalitis. These are practically stages of the same disease; the last is frequently complicated by the formation of a phlegmon, in that case constituting a circumtonsillar abscess, or quinsy. The attempt has been made to classify inflammation of the tonsils on a bacteriological basis, but clinically we find so many varieties of microörganisms in healthy as well as in inflamed throats, some of them pathogenic and others non-pathogenic, that such a classification seems to be of little or no practical value. There is an accumulation of evidence to show that the tonsils may be the avenues by which morbid germs enter the system and cases in which disease has affected the lungs, the pleura, the meninges and the joints through the tonsillar crypts seem to be fully established.

Considerable discussion has taken place as to the infectiousness of simple inflammation of the tonsils, and while there seems to be some ground for accepting the theory of contagion it must be admitted that in nearly all cases a predisposition to the disease exists and that where epidemics occur the victims are exposed in general to similar atmospheric conditions. Moreover, it is a matter of common observation that instead of being protected against succeeding attacks, as is true of contagious diseases, one who has suffered from tonsillitis is very liable to recurrence.

A predisposing cause of tonsillitis is found in certain local morbid conditions such as affect lymphoid structures generally. Exposure to cold is recognized as an exciting cause, especially in indi-



viduals who have been overheated or are in a condition of depressed general health. There seems to be reason to believe that, in a large proportion of cases, the rheumatic diathesis prevails either in the individual or in the family and, from this standpoint, the theory of heredity gains some credence. In a certain number of cases errors in diet and functional irregularities in the female seem to induce an attack. In many no cause can be discovered. In acute cases it is usual to observe that the involvement of one tonsil is followed after a few days by that of the other. In some both tonsils may be affected at the same time and in all there is more or less simultaneous congestion of the fauces and pharynx.

We recognize *acute* and *chronic* forms of tonsillitis, and from a clinical and therapeutic standpoint it seems to be unnecessary to make any further discrimination. There is usually no difficulty in identifying an acute amygdalitis and in fact a diagnosis is generally made by the patient himself. The most conspicuous local symptoms are more or less intense pain on swallowing accompanied by a sense of fulness and obstruction in the fauces. There is some sensitiveness on external pressure in the tonsillar region and indeed all the muscles of the neck may be quite stiff and painful. Pain may be felt in the ear of the affected side and almost constant *tinnitus aurium* may be present. Constitutional disturbance is usually decided. Headache, muscular pains, anorexia, chills and high temperature comprise a train of symptoms apparently out of proportion to a local disturbance of such simple character. On inspection of the affected parts the tonsils are seen to be red and turgid, and the palatal folds, the velum itself and the uvula may be swollen and edematous. If the crypts are involved their orifices are indicated by accumulations of yellowish-white secretion which may coalesce into a membranous formation resembling the exudate of diphtheria. If the cervical glands are swollen, which is not apt to be the case, except at a late period or in very intense forms of amygdalitis, the diagnosis may be quite dubious. The voice is thick and muffled, or may be husky from laryngeal congestion, and the relaxed condition of the vocal bands may require attention after the subsidence of the pharyngeal inflammation. The nasopharynx, the Eustachian tubes and the middle ear may become involved in an inflammatory proc-



ess, especially in those who have had previous ear trouble or who are run down in health.

In the chronic form of tonsillitis there may be little or no enlargement of the gland but the lacunæ which compose it are clogged with epithelial débris, decomposing secretions and bacteria which are a source of local irritation and may doubtless be a cause of a modified form of general septic infection. Such tonsils are prone to acute exacerbations when their volume may be temporarily very much increased. We are familiar with several varieties of reflex disturbance from these chronic inflammatory conditions referable to the acts of breathing and swallowing and, in some cases, the quality of the voice as well as its power may be distinctly impaired. The odor of the breath may be markedly offensive in cases of long standing in which the secretions have been retained in the lacunæ, and frequently little masses or balls of yellowish inspissated secretion may be extruded which emit a very foul odor on being crushed.

In the *treatment* of acute tonsillitis the first thing to be done is to administer an active purge; a saline laxative is the most satisfactory. If febrile reaction is prominent the internal use of drop doses of aconite every hour is efficacious. Quinine is very commonly prescribed in this disease, especially when febrile reaction is marked, but probably without good reason, and, moreover, the detrimental effect of this drug upon the ears, which in many of these cases are already to some extent impaired, should be remembered. Chlorate of potash in tablets containing five grains each, one to be dissolved in the mouth every two or three hours, seems to be soothing in cases of mild type. A combination of chlorate of potash with tincture of the chloride of iron is believed by many to have a specific effect upon these septic processes, but there seems to be no valid foundation for this view, and certainly in my experience cases do equally well under doses less nauseous and less disturbing to the digestive track.

Guaiac, in the form of lozenges, or as an ammoniated tincture, may be given every two or three hours until the bowels are acted upon. The salicylates, and more recently salol, have been used with satisfaction especially in cases in which the rheumatic diathesis is conspicuous. Some of the coaltar products, especially acetane-



lide and phenacetin, are popular, but should be used cautiously. During convalescence it is found necessary to resort to general tonics, since there often results a remarkable degree of systemic depression.

Locally the use of sprays, inhalations and pigments is decidedly preferable to that of gargles. The act of gargling in acute inflammation is a source of irritation and any good accomplished must be thus more or less counterbalanced. The bicarbonate of soda in powder applied with a spatula sometimes gives marked relief. Externally water compresses or poultices of flaxseed may be a source of comfort. In the early stages of an acute inflammation of the tonsils the application of cold by means of Leiter's coil, or icebags, is serviceable. As a rule these cases are seen too late to be amenable to cold applications and heat is found to be more grateful and effective. Friction of the neck with some stimulating embrocation is thought to do good by diverting the blood from the inflamed region to the surface. Swabbing the inflamed tonsil with pure tincture of iodine is said by Floersheim to give prompt relief even when suppuration seems imminent, but his experience has not been fully corroborated. In fact in some cases a decided aggravation of the subjective symptoms has been noted. It is claimed that an attack may be aborted by painting the fauces with a strong silver nitrate solution (1 dr. to 1 oz.). To most people this is an extremely disagreeable application and its value is doubtful. A mild solution is certainly irritating and useless, and the strong solution should be employed only in the early stages. Its mode of action is undetermined, whether as an antiseptic or by substituting a simple for an infective inflammation. In the experience of some attacks of follicular tonsillitis have been frequently aborted "by cleansing the tonsils with a saline solution, swabbing with peroxide of hydrogen, and then spraying with suprarenal, and repeating this treatment in twelve hours" (O. T. Osborne). A certain amount of suspicion always attaches to alleged "abortive" methods of treatment but that last mentioned has at least the negative advantage of being harmless. When several agents are used at the same time or successively it is rather difficult to decide which should receive credit for the effects observed. Pigments of menthol, twenty grains to the



ounce of fluid albolene, applied at short intervals often give great relief. In the interval of the attacks any chronic morbid condition should be relieved or corrected as a prevention of recurrence.

Chronically inflamed tonsils assume a great variety of shapes. Frequently portions of them may be so enlarged as to permit of partial excision. Many of them are flat and so hidden behind the pillars as to be quite inaccessible. Others are riddled by distended crypts more or less filled with caseous material, a variety known as the "honey-combed" tonsil. When the tonsils are not enlarged the treatment consists in emptying the lacunæ by scooping out the caseous contents and then obliterating the diseased crypts by the use of some chemical caustic or the galvano-cautery. If the tonsil is enlarged the best treatment is removal with the guillotine or the wire snare, hot or cold, according to indications. In case radical interference be declined something may be done by applications of strong tincture of iodine, or by inserting into the crypts a probe charged with trichloroacetic acid. Substantial results are obtained only by prolonged use of this method and with tonsils in which hyperplasia is not a prominent feature. In some of these cases habitual daily gargling with antiseptic solutions seems to be of benefit. It is claimed that the muscular exercise required by the act serves to empty the follicles clogged with detritus and is a healthy stimulant to the function of all the faucial region quite independently of any medicinal quality possessed by the fluid in use. By the ordinary mode of gargling only the anterior surfaces of the velum and tonsils and the dorsum of the tongue are reached. It is possible however for some individuals with a little practice to throw the fluid into the nasopharynx, or even the larynx, but the advantage of such a feat in pharyngeal gymnastics is doubtful. Laryngeal gargling is far from easy, but may be effected by the method of Guinier, described as follows. A small quantity of fluid is taken into the mouth, which is held open. The head must not be thrown back for fear of increasing the desire to swallow. While the lower jaw is protruded so as to draw forward the epiglottis the patient attempts to phonate any vowel sound, when the fluid at once finds its way into the larynx and bathes all the region above the vocal bands, provided the tendency to swallow, or to take an inspiration, can be resisted.



The method of von Troeltsch, modified by Hagen, for gargling the pharynx is somewhat easier. The mouth being about half full of fluid is held open while a partial act of swallowing is attempted. This carries the fluid well into the pharynx where the expired air is made to gurgle through it in the usual way, as long as possible. When the process of exhalation is completed the tongue is placed firmly against the upper incisor teeth and by a quick forward jerk of the head the fluid is ejected, much of it passing into the nasopharynx and out by the nostrils (H. L. Swain). Frequent repetition of the attempts at swallowing while the mouth is open dilates the pharynx, relaxes the velum and thus favors the escape of the fluid by the nose, provided there is no nasal obstruction. The solutions used in this way should be saline, alkaline, or mildly astringent, and should be looked upon merely as adjuvants to other therapeutic measures and modes of local medication.

A follicular tonsillitis in the acute stage is not to be regarded as a trivial matter. Cases in which septic absorption, followed by glandular suppuration, suppression of urine and other complications, has developed are well authenticated. Even in the absence of these disasters the affection is one calling for the most careful supervision, both on account of the immediate discomfort entailed and because of the subsequent systemic depression.

## DIPHTHERIA.

It is not proposed to make an exhaustive review of the subject of diphtheria but it is important to be able to differentiate its local phenomena from those of other diseases which it resembles.

The early diagnosis of diphtheria is often extremely difficult and there are forms of similar membranous inflammation that are confusing. A bacterial examination may settle the question but frequently there is neither time nor opportunity for this and we are obliged to rely upon clinical signs. The discovery of the Klebs-Loeffler bacillus in connection with a false membrane, may be considered definitive, but its existence in the pharynx does not necessarily prove the presence of diphtheria. Many times the bacillus has been found in individuals in perfect health. There must be, there-



fore, a special susceptibility of the individual, or virulence of the poison, or possibly a still undiscovered toxin, to determine the actual development of the disease. In children the discovery of the bacillus, even in the absence of local symptoms other than slight sore throat, should put us on our guard. Such a case should be isolated until all doubt as to the character of the condition has been dissipated. It is necessary if possible, to make a complete examination of the suspected region; small deposits of false membrane may exist at the root of the tongue, or behind one of the palatal folds, where they may be overlooked.

A membrane so firmly attached that its removal causes bleeding is probably diphtheritic. Rapid extension of the deposit and invasion of the nasal chambers add to the gravity of the prognosis. Involvement of the larynx, especially in children, is a very serious phenomenon. Sudden fall of temperature is indicative of collapse while a rapid rise means septic absorption. A rapid pulse is not necessarily a bad sign but irregularity and weakness are unfavorable. Albuminuria occurs in a large proportion of cases but becomes serious only when complicated by suppression of urine and other signs of severe kidney lesion. In diphtheria the systemic depression is out of proportion to the local phenomena. In other words we have to deal with a constitutional disease of which the symptoms presented on the mucous membrane are a local expression. In an average case the membranous exudate seems not merely upon the surface but to be incorporated in the substance of the mucosa. The attendant hyperemia differs from that of an acute inflammation in being more livid in hue, and the subjective symptoms are distinctly less intense. A non-diphtheritic pseudomembrane may be readily removed and its careful detachment is not apt to leave a bleeding surface. The color of a diphtheritic membrane is usually yellowish white at first, but it soon becomes blackened by admixture with blood and necrotic tissue. At the same time a decided fetor of the breath may be detected and the cervical glands may be swollen and sensitive. A croupous membrane is thin, glazed and white, does not become discolored and is easily detached. In follicular tonsillitis the exudate is discrete and indicates the mouths of lacunæ, or if it becomes confluent does not extend beyond the surface of the tonsil.



There is reason to believe that not every membranous deposit in the upper air track is due to the Klebs-Loeffler bacillus, while on the other hand certain non-membranous inflammations owe their origin to this organism. True diphtheria is caused by a specific bacillus or its toxins, but there are many microscopic organisms similar in character which are strictly non-pathogenic. The morphological features of the diphtheria bacillus are not reliably distinctive. The chemical test sometimes employed is not absolute, owing to varying degree of acid-producing power in different bacilli. Animal inoculation may furnish satisfactory evidence, provided we can exclude the possibility that certain non-diphtheritic bacteria are fatal to lower animals. Moreover, pathogenic bacilli may lose their virulence in artificial cultures and hence fail to produce an effect. Immunization of a control animal with diphtheria antitoxin might be conclusive, but this takes time, a point of vital importance in diphtheria. Nearly every practitioner has had fatal cases, in which the bacteriological testimony was negative,\* and on the other hand has been compelled to keep a suspected patient in quarantine for weeks solely on microscopic evidence. Hence we are forced to reach a diagnosis mainly from the clinical history and local appearances, looking to bacteriology only for the somewhat uncertain confirmation it is authorized to give.

The following points in tabular form may be serviceable.

*Tonsillitis.*

Begins abruptly, with chill, rapid rise of temperature—104 degrees or more—headache, muscular pains and general malaise.

Tonsils swollen and covered by an exudate in the form of a non-adherent pseudomembrane, or more often the mouth of each separate follicle is clogged with yellowish white secretion.

*Diphtheria.*

Comes on gradually, usually without chill.

Moderate rise of temperature, vomiting and albuminous urine.

Tonsils not especially large unless previously hypertrophied, but more or less covered by thick adherent membrane.

Cervical glands apt to be swollen and sensitive.



*Tonsillitis.*

Spots or patches of membrane easily brushed off without causing bleeding and seldom reform.

Exudate is limited to the follicles or surface of the tonsil and the mucous membrane is uniformly red.

The bacilli of a simple inflammatory process are present.

*Diphtheria.*

Membrane removed with difficulty and exposed surface bleeds. Returns in a few hours.

Membrane may be found almost anywhere on the mucous surface which is not intensely red, but is usually dark red or livid around the membranous deposit.

Pathognomonic Klebs - Loeffler bacilli usually found.

## CIRCUMTONSILLAR ABSCESS; OR QUINSY.

Circumtonsillar abscess, or quinsy, is an acute inflammation of the tissues contiguous to the faucial tonsil as well as of the gland itself resulting in the formation of pus. In a large proportion of cases the focus of suppuration is located immediately at the upper border of the tonsil and involves the soft palate. In rare instances it occurs behind the tonsil simulating retro-pharyngeal abscess; and, still less frequently, the pus may be incarcerated underneath the tonsil which may be pushed into the faucial space without being itself especially affected. Abscess of the tonsil proper is a rare occurrence, but when pus is formed in the situation last referred to it is not unusual for it to escape through one of the tonsillar crypts.

The valuable researches of J. L. Goodale show some interesting facts regarding tonsillar, or intrafollicular abscesses. In most cases the intratonsillar process was found alone, in a few it was accompanied by circumtonsillar inflammation. There seem to be no clinical signs which define an abscess in a follicle, except that a severe grade of infection is indicated by a more profound constitutional disturbance than is met with in a simple proliferative amygdalitis. Suppurative foci are often found to be numerous, and in such case the streptococcus pyogenes was observed to be more abundant than forms of staphylococcus, the crypts contained a large amount of



fibrinous exudate, and in several instances pus had burrowed into an adjoining crypt. In cases accompanied by circumtonsillar inflammation the interfollicular lymph channels and the connective tissue lymph spaces near the base of the tonsil were crowded with polynuclear neutrophiles, in one case seen to extend directly from an abscess within toward the base of the tonsil. It is surmised, although the evidence may not yet be thought complete, that an intrafollicular abscess is a sequel of primary infection of a crypt by the streptococcus pyogenes and is not of embolic origin, and that circumtonsillar inflammation may be due to discharge of a tonsillar abscess into the efferent lymph channels.

Quinsy is a rare disease in childhood and the tendency to it disappears with advancing years. In exceptional cases a first attack occurs in late adult life. In children the natural objection to an examination makes it far from easy to reach a diagnosis. Fixation of the lower jaw, always symptomatic, adds to the difficulty. If the finger can be inserted into the mouth a unilateral sometimes fluctuating tumor may be detected. The necessity of protecting the examining finger, or using a mouth-gag, is especially important. Pain and often torticollis together with marked constitutional disturbance are present. The danger from edema, or spontaneous rupture of the abscess in a child is far greater than in an adult.

The causes of quinsy are not always evident. Exposure to cold is a recognized exciting cause and seasonal influences are very marked, cases being much more frequent during the spring and fall months than at other periods of the year. It seems to be an hereditary disease, or at least many cases occur in the same family. It is sometimes possible to get a distinct history of rheumatism in the individual or in the family; although it is perhaps less frequently the case in this than in other forms of amygdalitis. Previous enlargement of the tonsil would seem to provide a tendency to inflammation, although cases are often observed in which the tonsillar tissue itself seems to be but little, if at all, hypertrophied.

Many cases begin as a simple acute lacunar amygdalitis. An attack of quinsy is usually announced by a chill or at least by chilly sensations. There are more or less pyrexia and systemic disturbance, muscular pains, headache and general malaise. A feeling of discom-



fort in the fauces soon develops into actual pain aggravated by swallowing, and the pain may shoot up toward the ear of the affected side and assume a lancinating character. As a rule, in twenty-four to forty-eight hours distinct tumefaction appears in the classical situation at the upper border of the tonsil between the palatal folds. There may be more or less edema of the velum and uvula and the function of the velum may be so impaired as to cause regurgitation of fluids into the nose on attempts at swallowing. The voice is characteristically altered and muffled, the patient is annoyed by accumulation of thick, tenacious mucus in the fauces, the attempts to clear the passages by hawking being exceedingly painful. The salivary secretion is markedly increased and inability to dispose of it adds to the patient's discomfort. Fortunately the affection is usually limited to one side although there may be consecutive inflammation involving the second tonsil. If allowed to pursue its course spontaneous rupture of the abscess may take place either through the anterior pillar or between the pillars at the upper border of the tonsil.

From the symptoms that have been detailed there should be no question in making the diagnosis of quinsy. In some instances digital examination gives a positive sense of fluctuation but it is not always to be relied upon since the pus may be so deeply seated as to fail to give the characteristic sensation on palpation.

Cases are on record in which quinsy has been mistaken for other lesions; among them, aneurism, malignant disease, diphtheria and syphilis; but, after a careful study, such mistakes seem hardly possible. In a case of aneurism, supposed to be quinsy, a bistoury was plunged into the tumor with the result of producing hemorrhage which was controlled only by ligation of the carotid artery. In this case palpation had previously detected pulsation which should have been accepted as a warning. In malignant disease there is usually more or less of an ulcerative process which does not occur in quinsy; while the rapid development of peritonsillar inflammation would tend to exclude malignancy. With diphtheria there is probably more danger of confusion, at least in the early stages; but enlarged cervical glands, albuminuria and the presence of bacilli in the exudate, together with the absence of very marked or intense local symptoms



would establish a diagnosis of diphtheria. A syphilitic gumma of the tonsil or in its neighborhood might, when inflamed, resemble quinsy, but it is rare to have acute symptoms in connection with a gummatous process and, in the majority of cases, we discover other manifestations of syphilitic infection.

As a rule, the pus formed in the course of quinsy, succeeds in finding an outlet, the patient obtains relief from painful symptoms by rupture or puncture of the abscess and recovery ensues. The prognosis, under most circumstances, is good. In some cases, the process of suppuration may be slow, the tissues enclosing the pus may be so brawny and tough as to yield slowly to the pointing of the abscess. The condition may be practically converted into one of *chronic* abscess of the tonsil. In other cases, when the patient is very reduced in strength or advanced in years, there may be danger from the escape of pus into the air-passages and the occurrence of asphyxia, or the pus may find its way into the mediastinum by way of the pharyngomaxillary fossa. A fatal result may follow from absorption of pus and the formation of metastatic abscesses, thrombi, etc. Such occurrences are extremely rare. The pus may bore its way through the wall of a neighboring blood-vessel and lead to the occurrence of hemorrhage. Happily, the large blood-vessels in the vicinity are protected by a considerable amount of connective tissue and they are not easily reached, although a number of cases in which the internal carotid artery has been invaded are on record, all terminating fatally.

An interesting contribution to the subject of hemorrhage from a circumtonsillar abscess has recently been made by W. F. Chappell. In a case which he reports an abscess was opened by a small incision in the usual situation, and four days later a hemorrhage of about six ounces occurred and was repeated in still larger amount in four hours. It was controlled by astringent applications, but five days afterward a third bleeding to about eight ounces was followed by persistent oozing. The abscess cavity distended with clots was then freely opened and packed with iodoform gauze after having been irrigated with hydrogen peroxide. Under daily renewal of this dressing the cavity healed and no more bleeding took place. After the second hemorrhage an examination of the urine showed albu-



minuria with epithelial and pus cells and granular casts. During convalescence a severe attack of rheumatism involving the muscles of the calves and to some extent certain joints occurred, and the opinion is expressed that this as well as the nephritis must be attributed to the tonsillar abscess. In a search of the literature of the subject this observer finds several interesting similar cases and a surprising mortality. In most of them the internal carotid appears to have been opened by ulceration, in one the lingual artery (Thomas Watson), and in one the blood seemed to come from "rupture of a small abscess on the posterior surface of the velum" (Brewer). In Chappell's case the ascending pharyngeal artery, seen at the posterior wall of the cavity, was suspected. In some of the cases referred to the abscess was incised, but in most of them spontaneous rupture took place, a fact which suggests the importance of early opening of a circumtonsillar abscess. In the event of hemorrhage there can be no doubt that exposure and firm packing of the abscess cavity should be practised before resort is had to ligation of the carotid, the latter expedient having been used successfully in two of the cases noted.

The *treatment* of quinsy consists, in the early stage, in an attempt to abort the disease and prevent the formation of pus. Unless seen early it is impossible to accomplish this. Revulsives in the shape of hot foot baths, diaphoretics and an active purge will sometimes succeed, in conjunction with the internal use of a very old fashioned but excellent remedy, guaiac. On the rheumatic theory in recent years salicylates have supplanted the older drug but are little, if at all, more effective and are probably less safe. The alkaline treatment with bicarbonate of soda recommended many years ago has also given good results. It is used internally, as well as locally. The tincture of aconite, recommended by Ringer, is also of use. When the symptoms are very acute gargles are a source of so much pain that they are not only ineffectual but the muscular effort required seems to aggravate the local disturbance and so counteract, in a measure, any good effect they may have. The objection does not apply to the use of sprays or pigments, some of which are found to be efficacious. One of the best applications in any form of inflammation of the tonsils is a combination of the three sodas, the bicar-



bonate, biborate and salicylate, of each equal parts, a teaspoonful of the mixture being dissolved in about four ounces of hot water and sprayed into the throat or, if preferred and the parts be not too sensitive, the solution may be used as a gargle. At the same time the salicylate of soda may be given internally in doses of ten grains every two hours until its physiological effects are obtained. Ammoniated tincture of guaiac may be used as a gargle by adding a tablespoonful to a glass of hot milk, a mouthful of the mixture being swallowed every hour until the bowels are acted upon. In the early stages external applications of dry cold in the form of ice-bags are sometimes of service.

When the foregoing measures appear to have failed and signs of suppuration are distinguished, the only resort is to surgical measures. If the pus points at the upper border of the tonsil an incision should be made through the anterior pillar with a sharp-pointed bistoury, the blade of the knife being held parallel to the fibers of the palato-glossus muscle and directed obliquely upwards and inwards. A small cataract knife will be found a very convenient instrument since its triangular blade makes a large vent for the escape of pus and the thinness of the blade facilitates its introduction. When the knife is passed in the situation described there is no risk of striking any important blood-vessels except, of course, in the existence of some abnormality. Usually pus begins to escape before the knife can be withdrawn and the relief to the patient is immediate. The preliminary application of cocaine does very little good in the way of deadening the pain of the cut which is, of course, considerable but momentary. The pus may be so deep seated as not to be reached by an incision which may be considered safe; in such case the insertion of a blunt probe into the cut may succeed in opening the abscess wall and, even if pus does not escape, the incision relieves tension and encourages its progress towards the surface. Sometimes the wall of a deep-seated abscess may be ruptured by plunging an ordinary polypus forceps into the wound and forcibly separating its blades.

In some cases of tonsillar abscess in which an accumulation of pus exists at the bottom of a crypt or in which the focus of suppuration is just outside the tonsillar capsule, a method of treatment recently



revived by G. A. Leland will be found efficacious although somewhat heroic. A vertical incision of considerable extent is made in the tonsil itself with an angular tonsil bistoury and then the finger is introduced into the wound and the tissues broken down by a gradual tearing process. Local anesthesia is usually sufficient. Sometimes a dense-walled cavity is opened in which is found a quantity of pus. Reaction is seldom excessive and the relief of symptoms is generally immediate. In these cases it is supposed that the trouble begins in a tonsillar crypt, thence extending to the circumtonsillar tissue. Breaking down the tissues, as suggested by Hoffmann, and called by him "discission," may be effected by means of a large stiff probe, but the forefinger answers better.

When pus is not disclosed by scarification the process of suppuration should be promoted by hot applications externally and by means of hot inhalations and gargles. The external application most grateful and effective is a hot flaxseed poultice which should be large enough to cover the whole side of the neck and should be overlaid by a piece of oiled silk. When pus evacuates itself, or is released by incision, the inflammatory process promptly subsides and practically the attack is over. But the tendency to the disease may still remain and if predisposing causes such as enlarged tonsils can be recognized they should be removed. It is not safe, however, to guarantee a patient against recurrence of quinsy after partial excision of the tonsils, since it not infrequently happens that an attack will take place within a few months after a tonsillotomy. Hence the necessity of a "tonsillectomy" rather than a tonsillotomy. The importance of extirpating the upper part of the tonsil as a preventive of peritonsillar phlegmon has recently been insisted upon by Ricardo Botey. The gland is often deeply seated in the angle between the pillars to which it may be firmly adherent. The ordinary methods of excision do not reach it and it must be enucleated by a careful dissection. Attention to the mode of life and the habits in general, and the correction of a rheumatic tendency will do more to banish a predisposition than local treatment alone. An attack of quinsy is almost always brought on by overexertion and is favored by a state of low vitality. Recovery is apt to be tedious and needs to be assisted by tonics and generous diet.



## ULCERO-MEMBRANOUS OR DIPHTHEROID ANGINA.

It must have fallen to the lot of every practitioner of wide experience to be puzzled by a form of sore throat resembling diphtheria but free from violent constitutional disturbance. In these cases a true ulcerative process goes on involving a very limited area or the entire surface of the tonsil, extending through the whole thickness of the gland or affecting only its superficial portion. The mildness of the associated systemic disturbance differentiates it from a confluent follicular amygdalitis. Usually but one tonsil is involved and adjacent parts are not extensively invaded. The submaxillary glands of the corresponding side are generally enlarged and remain hard some time after the throat symptoms disappear. The gross appearance of the membrane suggests diphtheria, but no Klebs-Loeffler bacilli and indeed few microorganisms of any kind are to be found, except the *fusiform bacillus* of Vincent, which is uniformly present in large numbers and is thought to be the special microbe of the disease. Both a bacillus and a spirillum are present, the former being fusiform in shape and straight or curved and staining promptly with aniline fluids. The fusiform bacillus is found normally in the mouth and has been discovered in pus from the antrum and in that of a perilaryngeal abscess; it has not been cultivated in artificial media and has not been proved to be pathogenic to animals. Although this seems to be a comparatively mild disease, Watson Williams asserts that it is very fatal in children. Usually the membrane clears off in a week or two and the parts resume their former appearance except so far as tissue may have been destroyed by ulceration, and even then the resulting deformity is far from commensurate with the loss of tissue. In a recent case in my clinic an ulcer occupied the left tonsil and the mucous membrane near the last molar teeth. It was irregular in contour, quite deep and sloughy in appearance, and was extremely sensitive. The cervical glands were implicated and were very hard and tender. Although there was no history of syphilis, the young man was put on mixed treatment and in the meantime a smear from the surface of the ulcer was examined under the microscope. The specimen was found to be crowded with fusiform bacilli and spirilla. Internal treatment



Unable to display this page



## CHAPTER XVI.

BENIGN NEOPLASMS OF THE TONSIL. TONSILLITHS. MALIGNANT DISEASE OF THE TONSILS. TUBERCULOSIS, LUPUS AND SYPHILIS OF THE PHARYNX. NEUROSES OF THE PHARYNX. FOREIGN BODIES IN THE PHARYNX.

Benign neoplasms of the tonsil comprise lymphoma, fibroma, papilloma, angioma and lipoma. The first is rarely seen except in combination with other neoplasms, especially sarcoma. In its simple form it is a lymphoid hyperplasia and may be a local manifestation of a diathesis.

Fibromata are met with in the tonsil either as sessile tumors, or infiltrations, so to speak, or more commonly, as small pedunculated tumors springing from the mucous lining of a crypt.

Papillomata are very commonly seen on the velum and uvula and less frequently on the surface of the tonsil, invariably pedunculated and resembling the adjacent mucous membrane in color.

Angiomata are rare except in combination with, or secondary to, other neoplasms. One or two examples of lipoma are on record.

*Tonsilliths*, or tonsillar concretions, are now and then met with in a distended tonsillar crypt where they may give rise to very little reaction, or are productive of symptoms which might be expected from a foreign body. Not infrequently they are discovered in an attempt to excise an apparently enlarged tonsil. These concretions are composed mainly of calcareous material, phosphate and carbonate of lime and epithelial débris, frequently with a parasitic nucleus, the *leptothrix buccalis*.

The treatment of a tonsillar calculus consists in its removal followed by thorough curetting of its bed, with excision of redundant portions of tonsillar tissue. Small concretions in the lacunæ are not very uncommon. The largest tonsillith on record weighed 26.8 grammes (Robertson). It was somewhat egg-shaped, and the most remarkable thing about it was that, in spite of its enormous size, its existence was not suspected until its expulsion during a violent



Unable to display this page



lesions of the tonsil are usually either superficial in the form of mucous patches, or occur later as deep destructive ulcerations, somewhat resembling cancer. A gummatous infiltration of the tonsil before the stage of softening looks more like sarcoma. In cancer there is always a neoplasm which ultimately breaks down. In syphilis there may be a moderate amount of lymphadenitis which on examination is found to be general. In cancer only the neighboring lymphatic glands are indurated and they are painful, or sensitive. Hemorrhage in syphilis is rare while in cancer it may be frequent and free. The absence of cachexia in the former and its presence in malignant disease at an early stage may usually be determined. A microscopic examination will usually settle any question as regards epithelioma, but in sarcoma is somewhat less conclusive. In many cases the early symptoms simulate so closely those of simple hypertrophy of the tonsil that amygdalotomy may be proposed and in several instances it has actually been done under this misapprehension. Such an error may be excusable, but is not likely to occur if a digital examination discloses an unusual degree of induration. Moreover, unilateral enlargement of the tonsil should always suggest the possibility of syphilis, or a neoplasm. A tentative course of iodide of potash may assist in removing doubt as to syphilis. A most interesting case of tonsillar tumor first reported by Bryson Delavan as a tertiary ulceration simulating sarcoma illustrates how the microscope at times fails to clear up a doubtful clinical diagnosis. After two months of soreness and swelling of the tonsil a deep ulcer with sloughy base and everted edges formed, the body of the gland being indurated. There was some pain on swallowing and the cervical glands were slightly enlarged. The mass was removed with the cold-wire snare and sections were examined by several pathologists, some of whom pronounced it sarcoma while others were in doubt. The slow development of the tumor and the presence in the microscopic sections of an extraordinary number of endothelial cells led to the adoption of a diagnosis of syphilis. Iodide of potash was given continuously. One year later the tumor was as large as ever, was quite hard, and was adherent to the pillars of the fauces without infiltrating adjacent tissue. It was somewhat nodular but was not ulcerated. A few of the cervical glands were indurated. The neo-



plasm was dissected out under ether by R. P. Lincoln, who placed sections in the hands of several experts. They agreed in excluding malignant disease, but were divided between syphilis and simple inflammatory hyperplasia. Eighteen months later there had been no recurrence.

In several cases noted by Newman and others malignant degeneration of an old syphilitic gumma has been observed.

The prognosis in malignant disease is, of course, extremely unfavorable.

In the early stages the disease may be retarded by removal of the primary lesion together with the affected glands, but surgery affords little hope as regards complete eradication of the disease. Early external operation has been resorted to in many cases but final results have been as a rule far from encouraging. It is hardly ever possible to reach the disease through the mouth. Extensive incisions in the neck with division of the upper jaw for exposure and extirpation of infiltrated glands, as well as of the primary lesion, are required. A preliminary tracheotomy is not essential. A radical operation of this kind may be justifiable with a view to prolonging life and in the hope that recurrence which is inevitable may take place in a region where less suffering may be imposed upon the patient. The round-celled sarcoma, or lymphosarcoma is especially virulent and according to David Newman "it is a malady in which, even from the onset, little hope can be entertained of saving the patient." Early operation in epithelioma gives a somewhat better chance, but the chief difficulty, as pointed out by Butlin, lies in the intimate relation between the pharyngeal structures and the cervical lymphatics, so that dissemination of the disease takes place promptly. Yet in several cases of the spindle-celled variety of sarcoma the tumor was found to be enclosed by a capsule from which it was actually shelled out. Electrolysis or cataphoresis, or the injection of toxins after the method recommended by W. B. Coley may be tried and they seem to offer some hope of success, at least in sarcoma. In the majority of cases we are dependent wholly upon palliatives for the relief of pain. The application of cocaine to the diseased or ulcerated surface, insufflation of orthoform, and the hypodermic injection of morphine give temporary amelioration.



## TUBERCULOSIS OF THE PHARYNX.

In spite of the fact that the bacillus is supposed to be capable of entering the system through intact epithelium and that it is frequently found in the air tract of perfectly healthy people, authentic cases of tuberculosis affecting the structures of the pharynx are very few. As a rule, in this situation it is secondary to pulmonary disease or coincident with it; or, it may occur as a sequel to tubercular disease of the cervical vertebræ. Primary cases have been reported but there is always a suspicion that a deep-seated or limited lesion in the lung may have escaped detection. In a case of my own a deep ulcer involving the right side of the base of the tongue was diagnosed as carcinoma and the whole tongue was excised. There were no signs of pulmonary disease at the time and none appeared subsequently.

The diagnosis is often difficult either because of the absence of significant appearances in the lesion itself or because of the existence of a mixed infection, the condition being masked by certain phenomena due to syphilis. In a typical case of disseminated miliary tuberculosis the character of the lesion may be sufficiently clear; the nibbled, worm-eaten appearance permits of little chance of confusion with the deep ulceration of syphilis. Moreover, a bacterial examination will generally discover the bacillus. The tubercular deposit may involve the tonsil, the velum, or any part of the pharyngeal wall. Associated with the local lesion we usually find more or less pronounced cervical lymphadenitis.

The early symptoms are those of subacute inflammation and their real character may not be suspected in the absence of physical signs in the lung. At the outset considerable swelling is observed, followed by the formation of yellowish spots of miliary tubercle which, after a time, may soften and form small ulcers, usually round and superficial, covered by a grayish secretion and surrounded by pale mucous membrane. Thus several independent foci of ulceration may develop giving the tissues a so-called worm-eaten appearance. Indications of an attempt at spontaneous repair may be observed at some points but the cicatrices are prone to break down.

Pain is generally pronounced and aggravated by swallowing until



deglutition may become impossible, or the patient may complain merely of sensations of dryness and heat. The voice is affected either by more or less involvement of the larynx or by accumulation of secretion the expulsion of which the patient dreads to attempt. The breath is fetid. There may be a dry cough or expectoration may be free if the lungs are involved. The usual general symptoms of tuberculosis sooner or later present themselves. In addition, the presence of bacilli in the scrapings from the ulcer may establish the diagnosis.

The prognosis is necessarily bad both because a lesion in this situation must be considered indicative of a severe type of disease and because of the interference with nutrition owing to dysphagia.

The treatment is that of general tuberculosis and, in addition, certain local applications may give good results in primary cases and in those not complicated by extensive pulmonary or laryngeal disease. In any case we are called upon to adopt measures for the relief of pain. An ulcerative process favorably located may be treated by curetting and lactic acid, followed by insufflation of iodoform and orthoform which together seem to produce anesthesia and promote cicatrization. The use of pineapple juice as a spray or a gargle is recommended by some as a detergent and mild astringent as well as for the relief of pain. Spraying with a solution of suprarenal capsule seems to be somewhat effective in the mitigation of irritability, and in extreme cases the local use of cocaine and of morphine internally may be required. Suitable climatic conditions and the usual constitutional remedies are indicated.

Odynphagia in this disease as well as in some cases of tuberculosis of the larynx often demands first attention. The pain in swallowing may be so extreme that the patient finally gives up attempting to eat. The natural result is a rapid decline in strength and vitality. In the majority of these cases nothing has been found to equal orthoform as a local sedative. Cocaine enables the patient to swallow with comparative comfort but is often objectionable on account of the paresthesia it excites. A most excellent mode of administration is in the form of a lozenge containing one quarter of a grain of orthoform, one or two to be dissolved in the mouth ten or fifteen minutes before food is taken. Thus we are enabled to



employ one of our most valuable resources, namely hypernutrition, in combating the inroads of tuberculosis.

### LUPUS OF THE PHARYNX.

Lupus of the pharynx in some respects resembles tuberculosis, but exhibits several important points of distinction. The pain and constitutional disturbance met with in the latter are quite absent. The evidence that lupus is a modified form of tuberculosis and that most patients affected with the former die of tuberculosis does not seem to be wholly sufficient. Moreover, the presence of tubercle bacilli in a lupoid lesion has not yet been clearly demonstrated. It is very slowly progressive and is not attended by severe subjective symptoms. The function of the pharyngeal structures may be interfered with if the velum or the epiglottis are involved owing to thickening from infiltration, destructive ulceration, or cicatricial bands. The affected region presents a granular appearance in the shape of small nodules, soft, insensitive, non-vascular, and in color differing but slightly from the surrounding mucous membrane. There may be considerable destruction of tissue and the resulting deformity from cicatrization, if repair takes place, may be very marked.

In many cases the process is mistaken for syphilis but the history of the case, the superficial character of the ulceration and its rapid cicatrization independent of special treatment, should establish the diagnosis. Glandular involvement is rather rare in lupus, whereas a general lymphadenitis is almost invariable in syphilis. Tentative treatment may be misleading for the reason that strumous conditions, under which lupus is sometimes classed, are often benefited by alterative medication, while some cases of syphilis offer obstinate resistance to specific remedies.

The majority of cases terminate fatally, but some cures are recorded as a result of thorough ablation of diseased tissue and cauterization. Tonics and careful nutrition are no less important.

In a case under my observation many years ago in the service of Dr. Asch at the New York Eye and Ear Infirmary, the disease involved the entire velum and thence extended to the larynx. It gradually yielded with moderate deformity under persistent applications



of saturated solution of silver nitrate and Fowler's solution internally, and later perchloride of iron locally, two drachms to the ounce, combined with the internal use of iron and cod-liver oil. In this case the duration of the disease, from the beginning of treatment to the time when a cure was pronounced, was upwards of two years.

### SYPHILIS OF THE PHARYNX.

Manifestations of syphilis are met with in the pharynx at any stage of the disease, either independently or coincident with cutaneous eruption.

The primary sore, or *hard chancre*, has been observed many times upon the tonsil and sometimes presents appearances which permit of its easy recognition. The first symptom is a sore throat, aggravated by pain in swallowing, which does not yield to ordinary treatment. The affected tonsil may be considerably enlarged and very early the nearest lymphatic glands become indurated. The ulcer itself is somewhat granular, grayish in color and implanted upon more or less induration. Its surface is usually level with the surrounding parts. In the course of two to six weeks a confirmatory secondary syphiloderma may be expected. According to Rhodes we must usually wait for this episode before venturing on a certain diagnosis. A superficial ulcer seated upon an indurated tonsil, rebellious to local treatment and accompanied by enlarged cervical glands is merely suspicious until an eruption appears. *Erythema* of the fauces in syphilis is apt to develop in connection with a roseola of the skin and differs from a simple acute erythema in being less intensely red, comparatively free from swelling and sensitiveness, and limited by a distinct line of demarcation at the junction of the soft with the hard palate. The erythema may invade the tonsils and the pharyngeal membrane generally.

The most common and obstinate and most dangerous, because highly contagious, lesion of syphilis met with in the air passages is the *mucous patch*. Although classified as a secondary lesion it may be met with early or late in the course of the disease. It is most apt to occur in conjunction with a papillary syphiloderma, but is more persistent than the cutaneous lesion. Mucous patches seldom give



rise to decided subjective symptoms, although they may be slightly sensitive to condiments, acids and hot or cold drinks. When the patches coalesce and cover a large area they may become decidedly painful. In its early stages a mucous patch looks like a small opalescent erosion of the mucous membrane, resembling a surface that

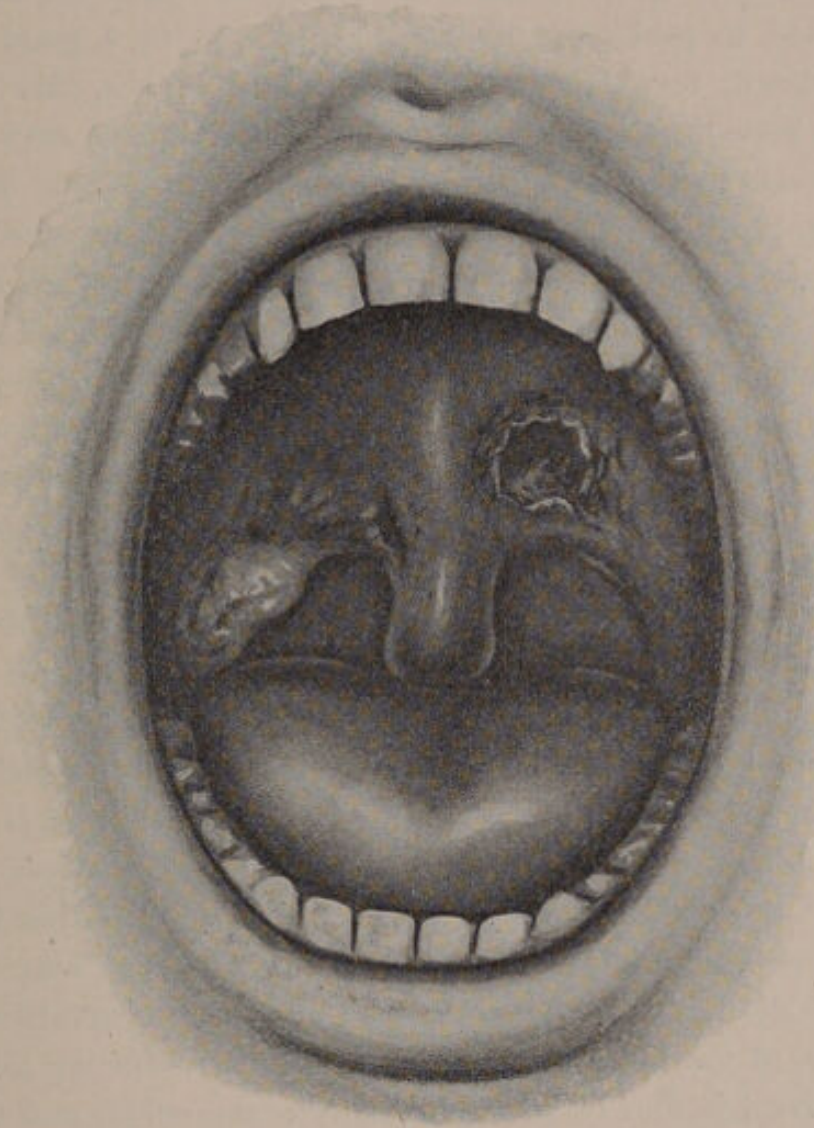


FIG. 101. SYPHILITIC ULCER OF RIGHT PILLAR WITH PERFORATION OF VELUM ON LEFT SIDE. (*De Blois.*)

has been touched with nitrate of silver. There is seldom any induration except in patches of long standing; in the latter case, several may coalesce and form a considerable ulcerated surface which may project more or less above the surrounding membrane. In the



folds of mucous membrane it is not uncommon to see them presenting a distinctly fungating appearance resembling condylomata.

While these patches are very rebellious to treatment in some cases and show a persistent tendency to recurrence, in others they disappear promptly under superficial cauterization. Ordinarily there is no extensive or deep destruction of tissue, but when the patch has been exposed to prolonged irritation there may be a good deal of breaking down, resulting in true ulceration. When this state of things has been developed, the suffering of the patient may be considerable even to the degree of interfering with proper nutrition. This is especially the case when the soft palate is involved or the parts employed in the act of deglutition are affected (Fig. 101).

Most of the ulcerating processes met with in syphilis are due to a breaking down of gummatous infiltration and are presented in two forms, the superficial and the deep. This division is purely an arbitrary one and the course pursued in each case is the same; namely, in the first place, a distinct induration which presently undergoes softening with rupture of the overlying mucosa and the formation of a ragged excavated ulcer of greater or less depth in proportion to the degree of infiltration. This manifestation of syphilis may be met with at almost any part of the pharyngeal wall and is productive of those deforming and disabling cicatrices which are so familiar. A gummatous process in the mucous membrane is exceedingly insidious and extensive damage may be done before the importance of the condition is appreciated; especially is this the case when the soft palate is involved. Irreparable damage may be done by the ulceration and by the subsequent cicatricial contraction (Fig. 102). One of the most intractable conditions which we are called upon to correct is that of adhesion between the velum and the posterior pharyngeal wall resulting from this process.

Recognition of an ulcer due to disintegration of gummy infiltration is usually free from difficulty. The edges are sharply cut, surrounded by a well defined areola and the surface of the ulcer is more or less excavated and covered with purulent secretion and shreds of slough. In the early stages, however, before necrosis has taken place identification of the condition is less easy and many cases are recorded in which a softening gummy tumor has been mistaken for



simple abscess and has been uselessly subjected to the knife (Fig. 103).

No lesions in the upper air tract respond more promptly to suitable treatment than syphilitic manifestations, except those occurring in so-called malignant syphilis or in individuals in depressed general

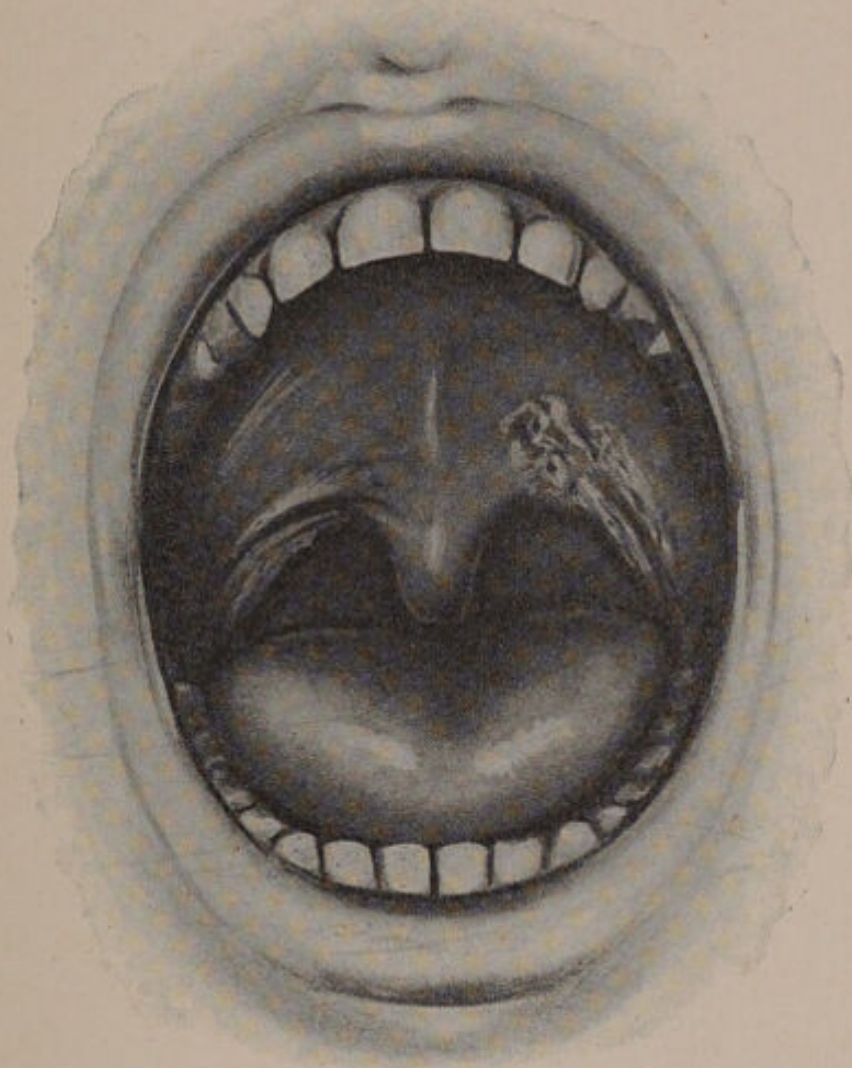


FIG. 102. SAME AS FIG. 101, AFTER HEALING WITH MODERATE DEFORMITY.  
(*De Blois.*)

health, and in those who persistently neglect treatment or violate hygienic laws. The treatment of these various lesions should be in line with that of syphilis in general, supplemented by certain local applications in some cases. The chancre usually requires no attention beyond the use of an antiseptic gargle or, if it is very sensitive,



the occasional application of a local anesthetic like cocaine. A similar statement applies to erythema of the pharynx (Fig. 104).

The mucous patch, on the other hand, requires more careful attention on account of its contagiousness and for the additional reason that if it be allowed to persist it is apt to extend over more surface

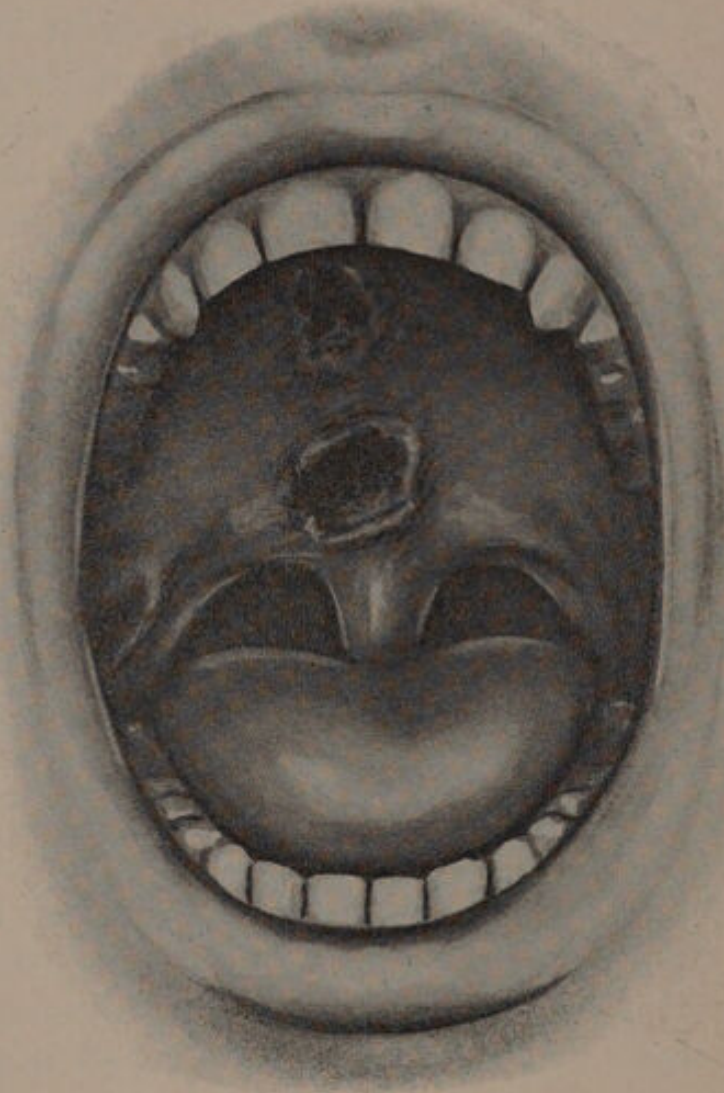


FIG. 103. MULTIPLE PERFORATIONS OF PALATE FROM SOFTENING GUMMATA.  
(*De Blois.*)

and to greater depth. All irritants, in the first place, such as alcohol, tobacco and highly seasoned food, should be abandoned. Gargling with an alkaline solution, especially after eating, will be found soothing and is usually effective. Repair of the patch in refractory cases may be expedited by careful application to its surface every second



or third day of the solid stick of nitrate of silver. The gummy tumor, before softening has ensued, may usually be speedily dissipated by rapidly increasing doses of iodide of potassium. When ulceration has taken place the necrotic tissue must be removed as far as possible, the surface of the ulcer kept clean, and occasionally cau-

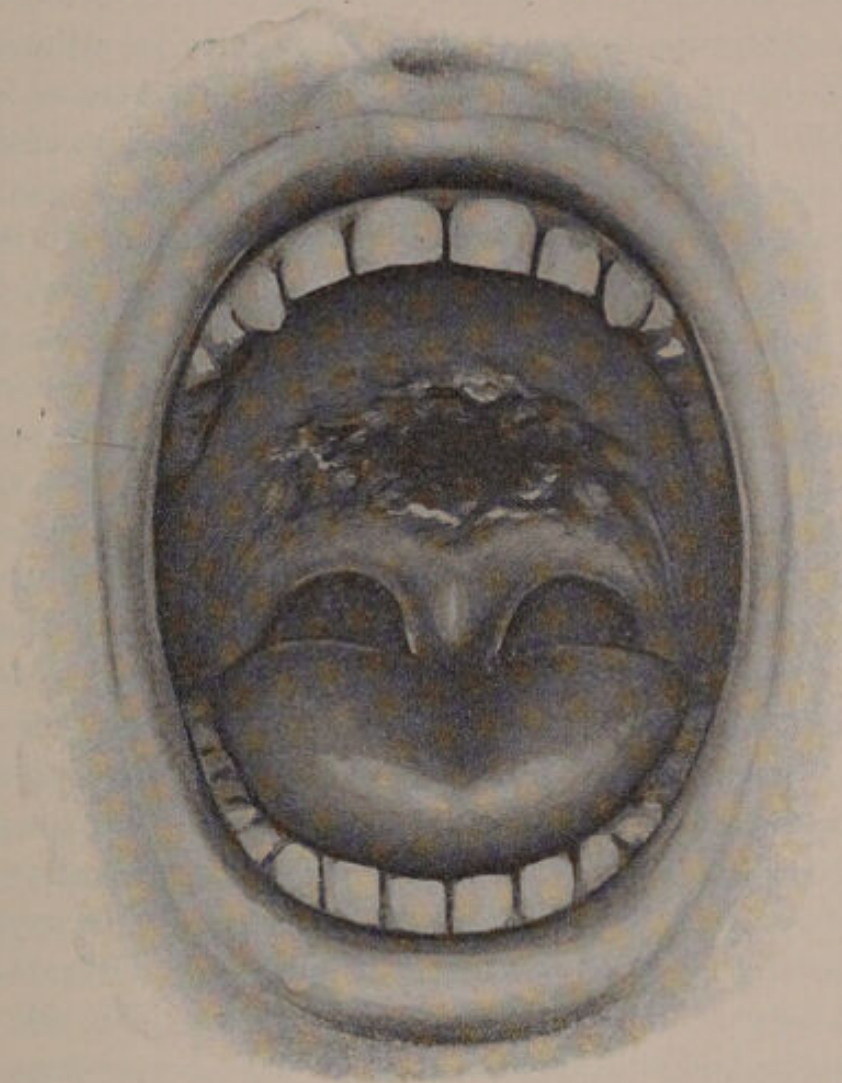


FIG. 104. EXTENSIVE PERFORATION OF VELUM IN SYPHILIS. (*De Blois.*)

terized with nitrate of silver; at the same time the internal treatment being vigorously pushed. In many cases the action of the iodide should be aided by mercurials, either in the form of inunctions or internally and, in many cases, recovery may be assisted by the use of tonics.

The contractions which result from syphilitic ulceration are fre-



quently incurable. The cicatrices are usually perfectly characteristic. When adhesion of the velum to the pharyngeal wall is complete the patient is able to get his supply of air only through the mouth and, in consequence, the act of eating may be seriously impeded. It is very important, therefore, that we should if possible restore the normal nasal air tract. In some cases this is to a certain degree feasible; in others the naso-pharyngeal cavity may be obliterated by adventitious bands to such an extent that its restoration is quite impracticable. The tendency to reformation of adhesions after their division is always very marked. To obviate this many devices have been proposed such as the passage of a strip of lint through the nose which is allowed to fall between the velum and the wall of the pharynx. A plate of lead suspended in the pharynx by threads passed through the nose, or a gutta-percha plate, has been successful in accomplishing the object. In several cases under my own care the patient was provided with a set of dilators of various sizes by which the opening was kept free; but readhesion or contraction took place when systematic dilatation was suspended. When the adhesions are very thin and involve simply the margin of the velum a proposal made by Andrew H. Smith to cauterize the raw surfaces, after division, by means of monochloroacetic acid has been found successful, the slough caused by the acid being retained long enough to allow the formation of protecting granulations. Various ingenious plastic operations have been designed for removing these adhesions, some of which have been partially successful. Several cases operated upon by the late J. E. Nichols resulted very favorably. By his method a perforation of the velum is made on either side as far from the middle line as possible. Through these perforations setons are passed and worn for many weeks or until cicatrization around them is complete. The perforations are then joined by incisions carried from side to side between them, thus releasing the velum. A plate of gutta-percha or vulcanite is worn suspended from the nostrils to keep the fresh surfaces apart until repair is complete. Although by these various methods we succeed in fairly restoring the air tract it is clear that the damage to the structure of the velum often must be irreparable. It is surprising how difficulty in swallowing and defects of speech may be overcome in course of time



and by the exercise of care, provided there has been no great loss of tissue. In cases of excessive destruction of palatal tissue the only resource is the adjustment of an obturator, or artificial palate.

## NEUROSES OF THE PHARYNX.

*Anesthesia* is occasionally met with in the pharynx as a result of specific disease and of diphtheria. It has been observed in hysteria, in epilepsy and in general paralysis of the insane. As a result of progressive bulbar paralysis it is a much more serious condition than in the other diseases mentioned. It may be induced temporarily by morphine or the bromides.

Treatment is seldom if ever necessary and in the presence of a grave central nerve lesion would be unavailing.

*Hyperesthesia* of the pharynx occurs in acute inflammations and in those addicted to the excessive use of stimulants and tobacco, or it may be a manifestation of hysteria. It is frequently a serious obstacle to successful examination of the upper air passages, and may sometimes be overcome by the administration of bromides, by the local use of cocaine, or by sucking of ice.

*Paresthesia*, in which abnormal sensations, as burning, pricking, or itching, may be complained of, is peculiar to hysterical females and neurotic subjects. An exciting cause may be frequently discovered in certain enlarged follicles of the pharynx or the base of the tongue, the destruction of which will result in cure. When the perverted sensation amounts to pain we recognize a distinct neuralgia of the pharynx, the treatment of which will depend upon its cause but which usually yields to local sedative applications. In hay fever a very persistent and annoying itching in the pharynx and in the roof of the mouth is often present.

*Spasm* of the pharyngeal muscles occurs in various conditions such as hysteria, epilepsy, and in certain cerebral diseases. Clonic spasm, especially of the levator palati muscle, may be seen in connection with facial spasm or with a general chorea. Spasm of the pharyngeal constrictors has been traced in several cases to cerebral tumor. Faucial spasm may be symptomatic of an acute inflammatory condition, or it may occur in the course of hydrophobia.



*Paralysis* of the pharynx is very frequently observed as a sequel of diphtheria or from disease of a central area in the medulla. It is one of the earliest symptoms of progressive bulbar paralysis. Involvement of the soft palate is attended by forcing of food into the nasopharynx during attempts at swallowing and when paralysis of the glottis coexists fluids and food may invade the larynx and trachea. In bulbar paralysis other symptoms characteristic of the disease are more prominent and the prognosis is generally fatal. When occurring as a sequel of diphtheria or in connection with facial paralysis the prognosis is much more favorable and recovery takes place without the adoption of any special line of treatment, but it may be expedited by the use of tonics internally, strychnia and the local application of galvanism. In so-called myopathic paralysis a muscle, or group of muscles, is supposed to be impeded in action by infiltration with inflammatory products, the nerve supply not being primarily affected. Such conditions are rare but may follow simple inflammatory conditions as in cases reported by the author and others.

*Foreign bodies* in the pharynx are usually sharp-pointed articles, such as fish-bones, pins, or sharp spiculæ of bone. Objects with smooth surfaces pass on, as a rule, into the esophagus or into the larynx. Symptoms are often very misleading, as the erosion of the surface which it causes generally induces a sensation as though the foreign body were still present. A sharp body, such as a needle, will frequently pierce the tissues and thence migrate to another part. It is often a very difficult matter to locate a foreign body in a nervous patient or when it has been long *in situ* and has excited irritability and inflammation.

By the use of the laryngeal mirror, the parts having been anesthetized with cocaine if necessary, the object may be discovered perhaps imbedded in the follicle of a tonsil or of one of the glands at the base of the tongue or lying in the hyoid fossa. Inspection of the parts may be, with advantage, supplemented by digital examination and sometimes extraction may be effected by means of cotton wound on a probe, or upon the finger. In most cases the use of the forceps will be necessary. If left alone a small object may become encysted and do no further damage. On the other hand hemor-



rhage may follow penetration of a blood-vessel, or sepsis may ensue from the development of phlegmonous inflammation. When a large irregular body becomes impacted in the lower pharynx its removal by external pharyngotomy may be required.



# THE LARYNX.

## CHAPTER XVII.

### ANATOMY AND PHYSIOLOGY OF THE LARYNX. METHODS OF EXAMINATION.

#### ANATOMY AND PHYSIOLOGY.

The larynx, or voice box, is composed of two large cartilages, the thyroid, or shield cartilage, the cricoid, or ring cartilage and a third somewhat smaller, the epiglottis, a leaf-like lid or valve which aids in diverting ingesta from the chink of the glottis. In addition to these single cartilages there are six smaller ones arranged in pairs, the arytenoid, the cornicula laryngis (Santorini), and the cuneiform (Wrisberg). All are closely bound together by ligaments, membranes and muscles.

The cricoid, the foundation cartilage of the larynx, is attached below to the first ring of the trachea and articulates above with the thyroid. It is thicker and heavier posteriorly, where it supports the arytenoid cartilages, the latter being surmounted by the cartilages of Santorini, or cornicula laryngis, and the cartilages of Wrisberg, or cuneiform cartilages. The last three are called the cartilages of motion, because they are especially concerned in the movements of the vocal bands.

The thyroid cartilage consists of two alæ, united in front at an angle of 80 to 90 degrees to form the *pomum Adami*. Each ala is nearly square and has extending upwards and downwards from its posterior border the superior and inferior cornua, the former being attached to the hyoid bone by the thyrohyoid ligament, the latter articulating with a facet on the side of the cricoid cartilage.

The arytenoid cartilages articulate with facets on the upper border of the cricoid, are triangular in shape on cross section and give attachment to all the intrinsic muscles of the larynx except the crico-



thyroid. The anterior angle of each arytenoid is prolonged at its junction with the vocal band and is called the vocal process. It is plainly visible in the laryngeal mirror. The cornicula laryngis surmount the apices of the arytenoids, projecting backward and inward. The cuneiform cartilages are buried in the aryepiglottic folds in front of the cornicula.

The thyroid and cricoid, which consist wholly of hyaline cartilage, and the arytenoids, which are hyaline except at their summits, are prone to calcify in advanced life. The others, yellow elastic cartilages, show no such tendency. In addition to those mentioned several insignificant sesamoid cartilages are sometimes met with in the larynx. They are very inconstant and when present are of no importance.

The cricoid and thyroid cartilages are united in front and at the sides by the cricothyroid membrane, and the thyroid is joined above to the hyoid bone by means of the thyrohyoid membrane and ligaments.

The larynx is bound to the first ring of the trachea by the crico-tracheal membrane. The posterior wall of the larynx is held in position by various muscles and is in relation with the anterior wall of the laryngopharynx.

The epiglottis, a leaflike plate of yellow elastic cartilage, is attached to the angle of the thyroid below its median notch. It varies much in size and shape, is somewhat depressed and folded laterally upon itself during deglutition, and is joined to the base of the tongue by three bands known as the median and lateral glosso-epiglottidean folds. It is fixed to the hyoid bone by a membrane called the hyo-epiglottic ligament; and from its base pass two bands of membrane which form the lateral boundaries of the superior aperture of the glottis known as the aryteno-epiglottidean folds.

The thyrohyoid membrane is composed of elastic fibers uniting the hyoid bone with the upper margin of the thyroid cartilage and is bounded laterally by the thyrohyoid ligaments which pass from the superior cornua of the thyroid to the greater cornua of the hyoid. This membrane is pierced by the superior laryngeal nerve and arteries.

The cricothyroid membrane is subcutaneous at its middle portion



and laterally is overlapped by the cricothyroid muscle. It is crossed by a small communicating branch between the two superior laryngeal arteries, known as the inferior laryngeal or cricothyroid. Two or three small vessels penetrate the membrane and supply the mucous membrane of the larynx.

The lateral portions of the cricothyroid membrane pass upward

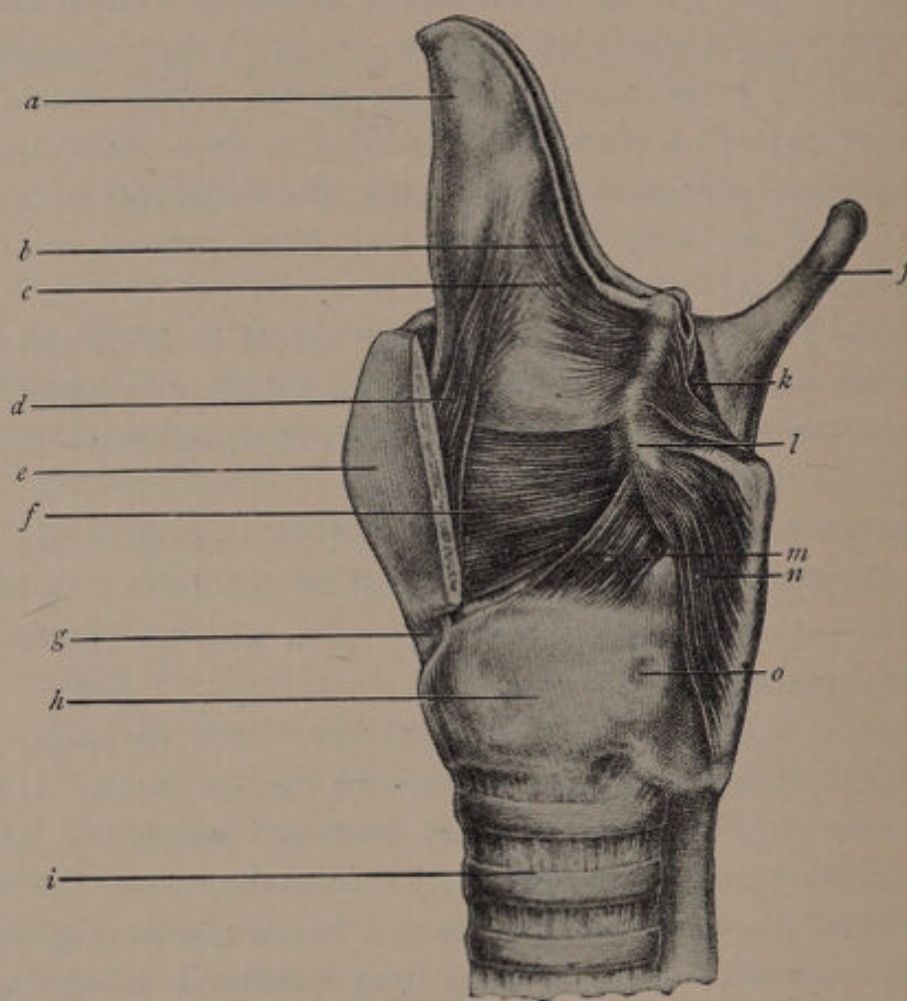


FIG. 105. MUSCLES OF LARYNX, LATERAL VIEW. (Deaver.)

*a*, epiglottis; *b*, aryepiglottic fold; *c*, aryepiglottic muscle; *d*, thyroepiglottic muscle; *e*, thyroid cartilage; *f*, thyroarytenoid muscle; *g*, cricothyroid membrane; *h*, cricoid cartilage; *i*, trachea; *j*, superior cornu of thyroid cartilage; *k*, arytenoideus muscle; *l*, muscular process of arytenoid cartilage; *m*, lateral cricoarytenoid muscle; *n*, posterior cricoarytenoid muscle; *o*, facet for articulation with thyroid cartilage.

from the inner border of the cricoid and form the inferior thyroarytenoid ligaments, or the true vocal bands, extending from the vocal process of the arytenoid cartilages to the angle of the thyroid



cartilage near its center. These bands are covered by the thyroarytenoid and lateral cricoarytenoid muscles.

The superior thyroarytenoid ligaments, ventricular bands, or false vocal bands, consist of fibrous tissue extending antero-posteriorly just above the true vocal bands. Muscular fibers within their folds

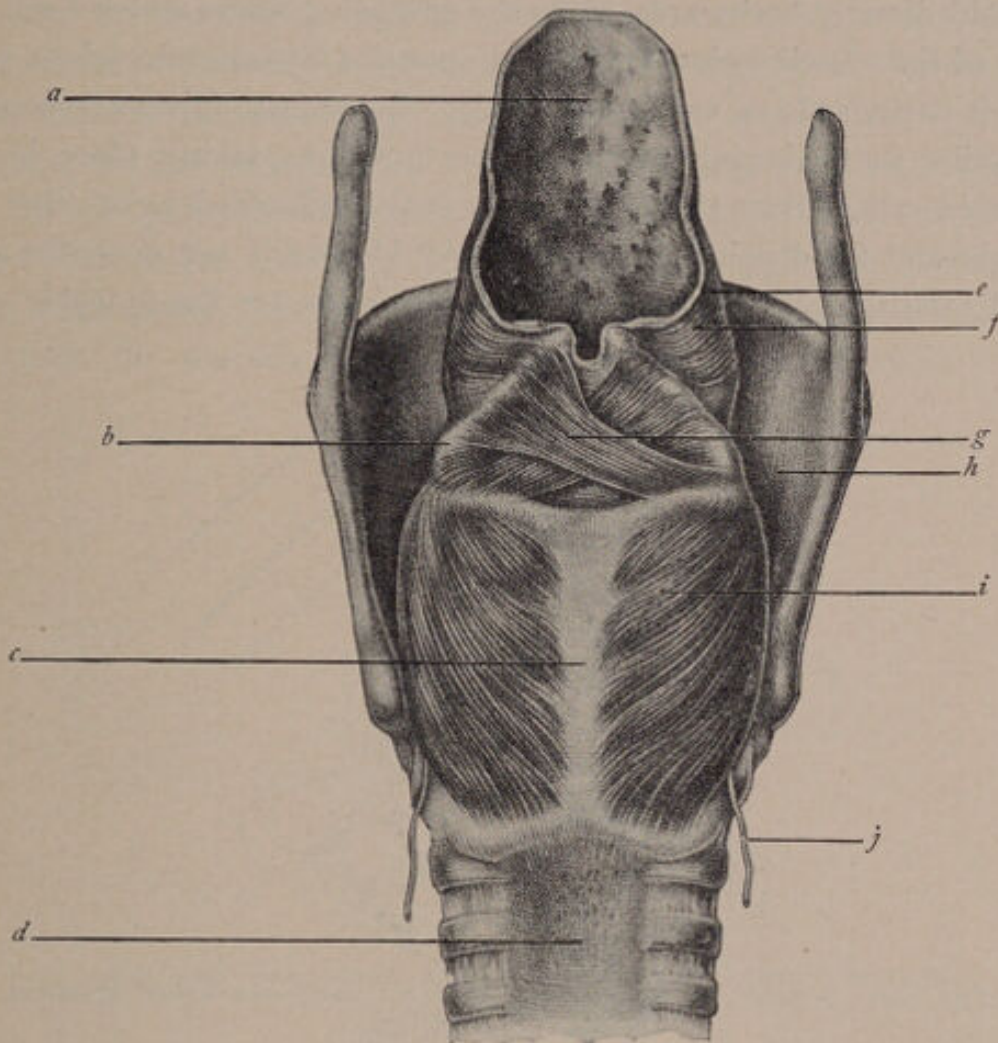


FIG. 106. MUSCLES OF LARYNX, POSTERIOR VIEW. (*Deaver.*)

*a*, laryngeal surface of epiglottis; *b*, muscular process of arytenoid cartilage; *c*, cricoid cartilage; *d*, trachea; *e*, aryepiglottic fold; *f*, aryepiglottic muscle; *g*, arytenoideus muscle; *h*, thyroid cartilage; *i*, posterior crico-arytenoid muscle; *j*, recurrent laryngeal nerve.

are described by some anatomists as the superior or external thyroarytenoid muscles. They assist the inferior thyroarytenoids (Fig. 105).

The muscles controlling the movements of the laryngeal cartilages are divided into two groups, extrinsic and intrinsic. The extrinsic are



the sternothyroid, the thyrohyoid, the stylo- and palato-pharyngeus and the inferior constrictor of the pharynx. Of the intrinsic muscles the cricothyroid is attached to the front and side of the cricoid and to the lower border of the thyroid cartilage. The lower fibers pass to the border of the inferior cornua and act by pulling the cricoid directly backwards while the spreading fibers which form the rest of the muscle swing the cricoid upon the cricothyroid joints, pulling it backwards as well as upwards. Some anatomists erroneously describe the swinging or tilting movement as taking place in the thyroid rather than the cricoid, but most authorities agree that the origin and fixed point of the cricothyroid muscle are upon the thyroid cartilage and that therefore the posterior are the movable ends

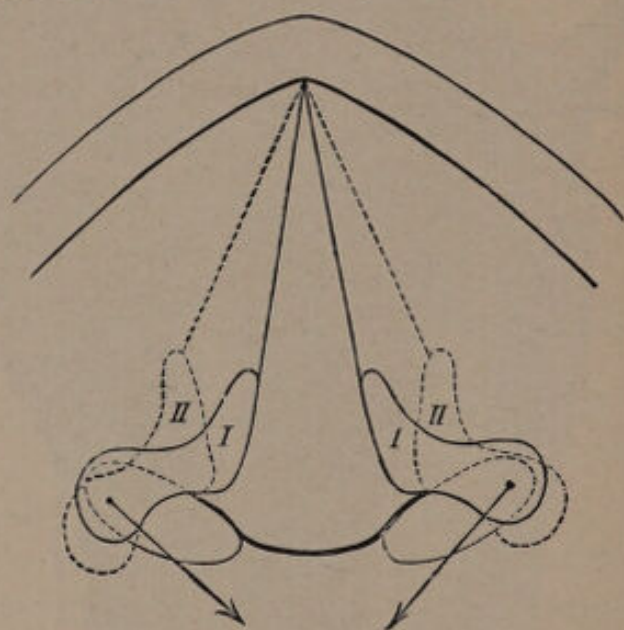


FIG. 107. SCHEME OF ACTION OF POSTERIOR CRICO-ARYTENOID MUSCLES.  
(Landois and Stirling.)

of the vocal bands. For this reason Jurasz advocates calling the muscle "thyrocricoid" instead of cricothyroid. The practical effect, stretching of the vocal bands, is the same in either case. This muscle is a tensor of the vocal bands (Fig. 106).

The posterior cricoarytenoid muscle arises from the cricoid cartilage and is inserted into the outer angle or muscular process of the arytenoid cartilage. Its upper fibers rotate the arytenoid whilst the lower fibers pull the whole mass of the arytenoid outwards. It is, therefore, a dilator of the glottis, or abductor of the vocal bands (Fig. 107).



The lateral cricoarytenoid muscle springs from the upper border of the cricoid between the origin of the cricothyroid and the cricoarytenoid articulation, and is inserted into the forepart of the muscular process of the arytenoid. It rotates the cartilage inwards and draws it forwards, relaxing and approximating the cords.

The thyroarytenoid muscle arises from the lower two thirds of the inner surface of the thyroid close to its angle and slightly from the cricothyroid membrane. It passes outwards and backwards and is inserted into the anterior surface of the arytenoid cartilage and to its base close to the attachment of the lateral cricoarytenoid muscle. The lower and inner portion is parallel with and blends with the vocal band. The upper and outer portion is placed immediately beneath the mucous membrane and overlies the ventricle. These

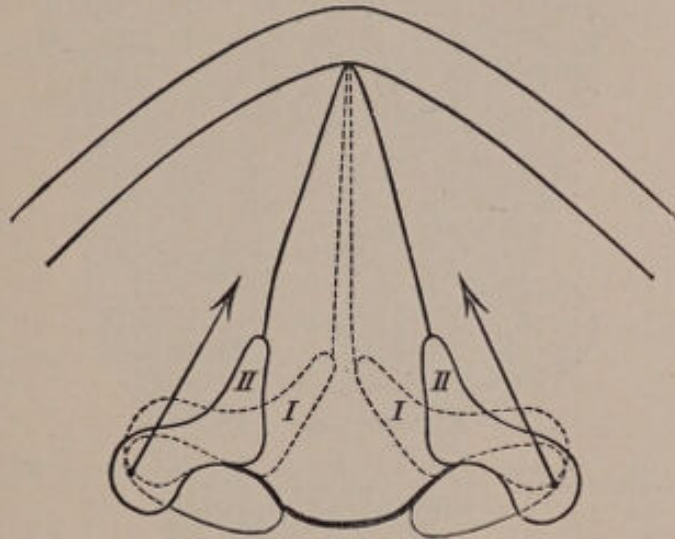


FIG. 108. SCHEME OF ACTION OF THYRO-ARYTENOID MUSCLES.  
(Landois and Stirling.)

two divisions of the muscle are sometimes known respectively as the inferior, or internal, and the superior, or external thyroarytenoids (Fig. 108).

These muscles rotate the arytenoids and draw the vocal bands downward and inward and thus approximate them. At the same time they relax the vocal bands as a whole. Some fibers attached to the free border of the vocal band are said to be capable of making tense a portion only of the band, leaving the rest relaxed, thus resembling somewhat the stop action of the finger on a violin string. They also make the band thinner and wider.



The arytenoideus muscle consists of transverse fibers passing across from one arytenoid cartilage to the other, and attached to their posterior surface. Superficially, oblique fibers pass from the base of one cartilage to the summit of the opposite cartilage. A few of the latter pass under the arytenoepiglottidean fold and side of the epiglottis, constituting the epiglottarytenoideus muscle. This muscle approximates and depresses the arytenoid cartilages (Fig. 109).

The thyroepiglottideus muscle, a part of the thyroarytenoideus, is composed of fibers which extend from the thyroid cartilage to the

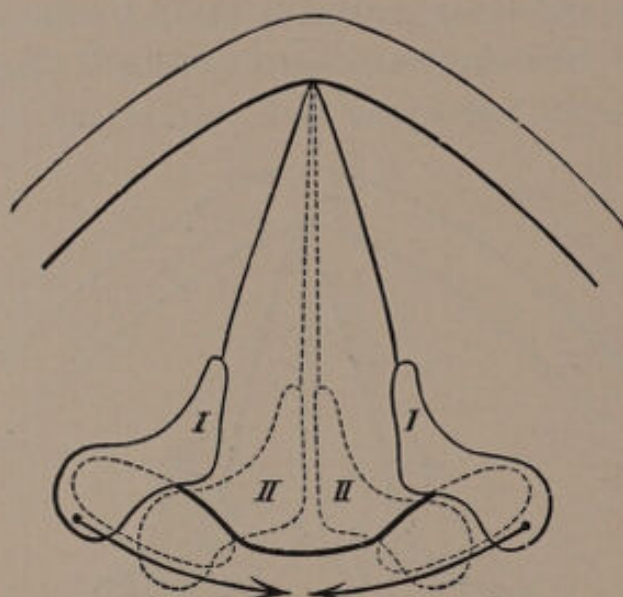


FIG. 109. SCHEME OF ACTION OF ARYTENOIDEUS MUSCLE.  
(Landois and Stirling.)

arytenoepiglottidean fold and the outer wall of the pharyngeal pouch and epiglottis.

The nerve supply of the larynx is derived from the laryngeal nerves, superior and inferior. The superior has two branches. The external is distributed to the cricothyroid muscle and sends a few filaments to the mucous membrane of the larynx; it is chiefly a motor nerve. The internal branch is larger and is purely sensory. It pierces the thyrohyoid membrane and distributes branches to the epiglottis and to the mucous membrane of the larynx as far down as the true vocal bands.

The inferior, or recurrent, laryngeal nerve is the motor nerve of the larynx. It ascends between the trachea and the esophagus,



enters the larynx immediately behind the cricothyroid joint and divides into two branches, an anterior to the thyroarytenoideus, the cricoarytenoideus lateralis, and muscles of the epiglottis, and pos-

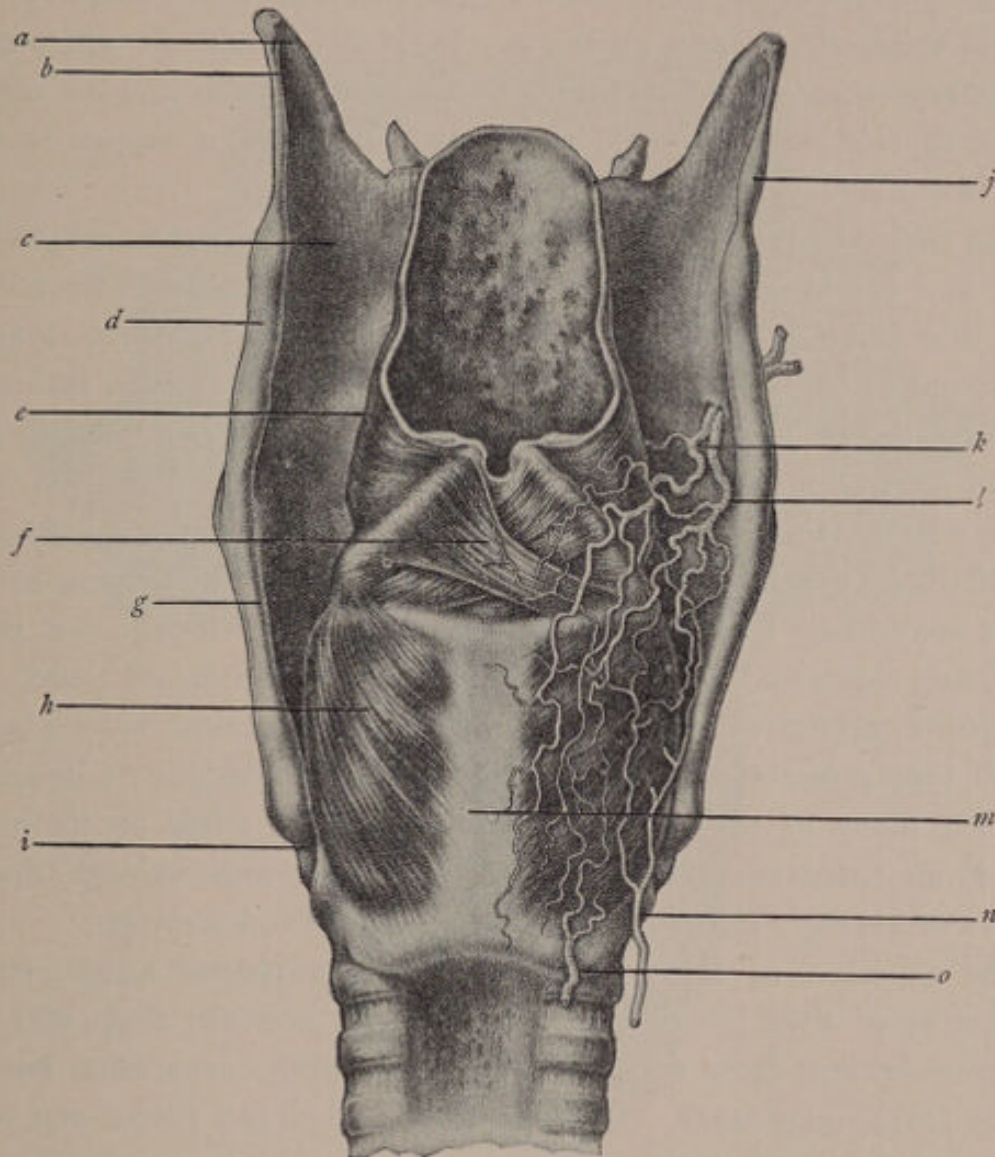


FIG. 110. NERVES AND ARTERIES OF LARYNX. (*Deaver.*)

*a*, greater cornu of hyoid bone; *b*, thyrohyoid ligament; *c*, thyrohyoid membrane; *d*, superior cornu of thyroid cartilage; *e*, aryepiglottic muscle; *f*, arytenoideus muscle, *g*, posterior border of thyroid cartilage; *h*, posterior cricoarytenoid muscle; *i*, cricothyroid articulation; *j*, cartilago tritacea; *k*, internal laryngeal nerve; *l*, superior laryngeal artery; *m*, cricoid cartilage; *n*, recurrent laryngeal nerve; *o*, inferior laryngeal artery.

terior branches to the posterior cricoarytenoideus and arytenoideus, and communicates with the superior laryngeal by slender filaments near the posterior border of the thyroid cartilage (Fig. 110).



The arterial supply is derived from the superior and inferior thyroid, the epiglottis receiving some branches from the dorsalis linguæ from the lingual.

The aperture of the glottis is triangular in shape, bounded in front by the epiglottis, behind by the arytenoid notch and on either side by the arytenoepiglottidean fold. Between these folds and the wings of the thyroid on either side are shallow depressions known as the "pyriform sinuses."

The cavity of the larynx is lined by mucous membrane, somewhat thick and red in color except over the true vocal bands where it is pale, thin and adherent. Numerous elastic fibers and mucous glands are found in the submucous tissue. The cavity is divided into two portions, the supra- and infra-rimal, the true vocal bands being the line of separation. Immediately above each vocal band lies the ventricle of the larynx, bounded above by the ventricular band, and externally by the thyroarytenoid muscle. It is lined by mucous membrane continuous with that of the larynx and from its anterior part, extending upwards about one half inch, is the laryngeal pouch, or "sacculus laryngis." Its mucous membrane contains many glands which supply secretion for lubricating the vocal cords. At its outer side are fibers of the thyroarytenoideus muscle, while on its inner side is an extension of muscular fibers of the arytenoepiglottideus known as Hilton's muscle or the *compressor sacculi laryngis*.

The superior, or false vocal cords, or ventricular bands, stand further apart than the true vocal bands and between them and the arytenoepiglottic folds on either side is a shallow depression known as the *fossa innominata*. Their contour is full and round and they are covered by red, moist mucous membrane, while the true vocal bands are pearly white or opaline in appearance and present flattened surfaces as seen from above. On cross-section the latter are more triangular, and strictly speaking are neither bands nor cords. Their average length in the adult is seven lines (14 mm.).

The rima glottidis, or triangular space between the vocal bands, is limited behind by the interarytenoid commissure, and in front by the thyroid cartilage. Its dimensions vary in respiration and phonation. The infrarimal portion becomes almost circular below the vocal bands and is continuous with the trachea (Fig. 111).



The larynx is spoken of as the organ of voice, and we are apt to lose sight of the important part played by other structures in voice formation until our attention is drawn to them by some defect in

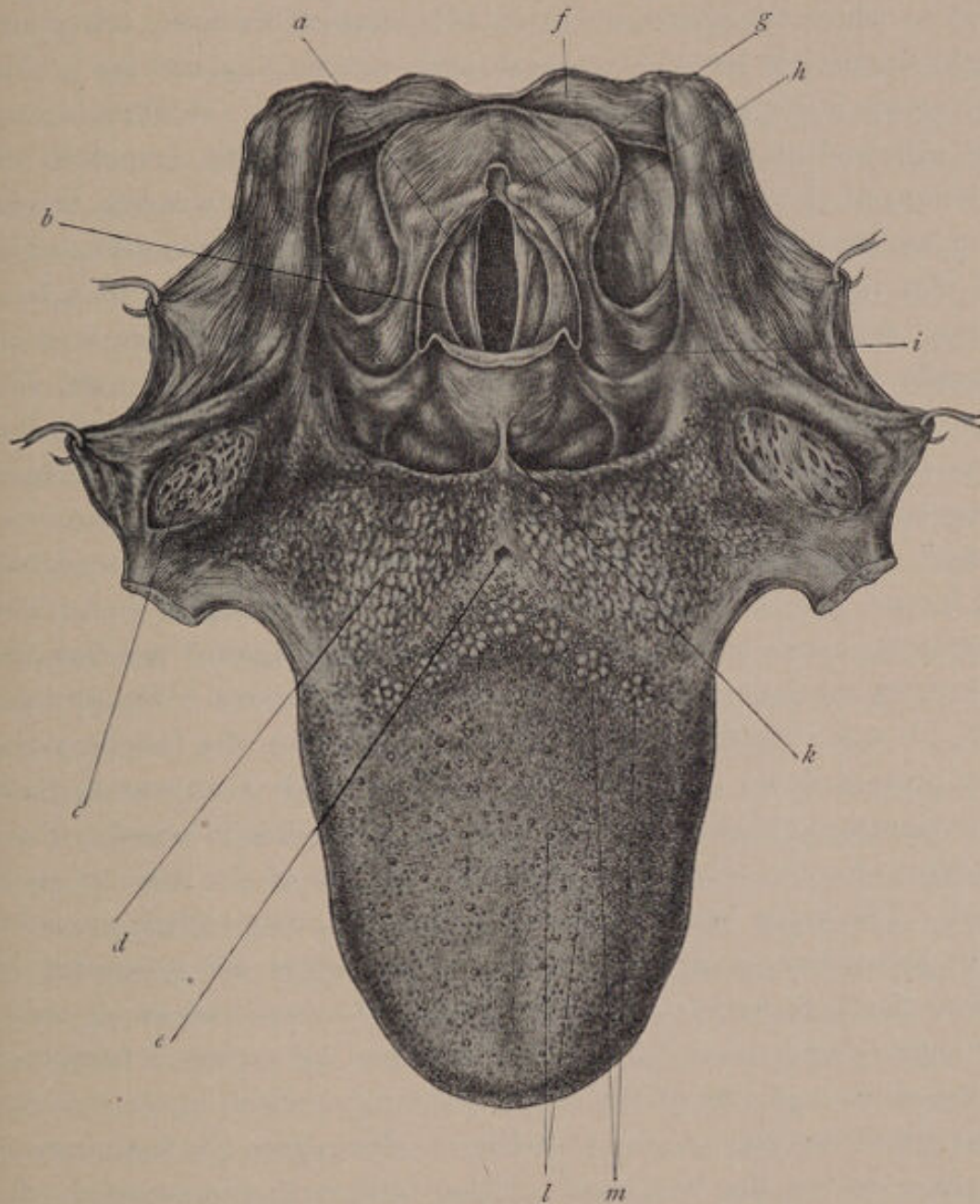


FIG. 111. SUPERIOR APERTURE OF LARYNX AND DORSUM OF TONGUE. (Deaver.)

*a*, vocal band; *b*, ventricular band; *c*, tonsil; *d*, adenoid tissue at base of tongue; *e*, foramen cecum; *f*, posterior wall of pharynx; *g*, corniculum laryngis; *h*, cuneiform cartilage; *i*, epiglottis; *k*, median glosso-epiglottic fold; *l*, fungiform papillæ; *m*, circumvallate papillæ.

structure or function. The nasal chambers and the accessory sinuses, the lips, the teeth, the tongue, the velum and pillars of the fauces, the trachea and lungs, as well as the shape and size of the



larynx itself, all share in influencing the timbre and the pitch of the voice. The larynx is not even essential to audible and articulate speech, as has been shown in a famous case of complete laryngectomy in which the pharynx was entirely shut off from the lower air-track, the patient learning to speak and even sing by sucking in and storing air in his pharyngeal pouch (Solis-Cohen). Similar facility was acquired by a patient wearing a trachea tube for complete obstruction of the larynx (Czermak) and by one also wearing a tube after an attempt at suicide by cutting his throat (Bourguet). The old idea that the epiglottis closes the larynx, like the lid of a box, during deglutition, has been supplanted by the view that it curls laterally in such a way as to direct the food into the pyriform sinuses (Carmalt Jones). In a few cases, in which the epiglottis has been absent, destroyed by disease, or removed, its duty has been assumed by the ventricular bands, and no impression has been observed, either upon swallowing or speech. It is not very movable, the larynx rather rising to meet it in the act of deglutition. The ventricular bands assist in protecting the larynx against the invasion of foreign substances, but are not concerned in normal voice production. It was once thought that in the formation of the falsetto voice they pressed down upon the vocal bands in such a way as to limit their vibration (Mandl), but this view is not capable of proof. They substitute for the true cords when the function of the latter is abolished. The vocal bands are not flat, but on cross section are seen to be triangular or prismatic. Their free edges are composed of yellow elastic fibers by which their contour is preserved under varying degrees of tension. They are lubricated by secretion furnished by the mucous glands of the sacculus laryngis, which opens into the ventricle of the larynx, the ventricle of Morgagni. A few mucous glands exist on the true cords. They are very numerous on the ventricular bands, and on the latter are also found irregular collections of lymphoid tissue, the "laryngeal tonsil." The color of the vocal bands is pearly white or opaline. They are about one quarter of an inch shorter in the female than in the male, being about three fourths of an inch long in the latter. Vocal sound is caused by impact of the expired air upon their free margins. The interesting mode of action of the thyroarytenoid muscles, of which the vocal



bands are considered by some to be the tendinous portion, has already been described. The bands move slightly with respiration, approaching each other on expiration and separating a little on inspiration, unless the latter be forced, when the reverse is true.

The aid of the extrinsic muscles, especially the sternothyroid, in securing efficient action of the intrinsic is essential, in order to fix the thyroid cartilage. The cricothyroid and thyroarytenoid muscles cannot come into full play without this preliminary fixation. Yet the abnormal use of the extrinsic muscles, as well as conscious or voluntary contraction of any of the laryngeal muscles, seems to be fatal to purity of tone and results in that disagreeable quality which is familiar to us as the "throaty" voice. The range of the speaking voice is very limited in most people and is modulated by infinite gradations. The tax upon the larynx in singing is much greater, because a wide range is covered, sometimes more than two octaves, and moreover the utmost precision in striking the intervals, never less than a semitone, must be assured. When we consider the complicated and delicate mechanism of the larynx we may appreciate the importance of favorable conditions, atmospheric and other, to the preservation and full development of the singing voice. Large demands are made upon the organism in general in vocal efforts of extraordinary character, hence the importance of maintaining the general health at a high standard if the best results are to be attained.

The hygienic value of exercises in voice culture, regardless of any special musical talent, cannot be too highly estimated. The majority of people, unaccustomed to athletics or outdoor sports, seldom if ever use their lungs to full capacity. The respiratory gymnastics, involved in well-directed vocal training, undoubtedly have a tendency to overcome a predisposition to pulmonary weakness and contribute to an improved vitality which enables one more successfully to resist disease in general. The local effect of such exercises, under intelligent guidance, is often marked in a disappearance of small collections of hyperplasia in the mucous membrane of the air track, or even on the vocal bands themselves, and in a correction of a tendency to inflammatory outbreaks. The relation of nasal and pharyngeal anomalies to functional and ultimately structural derangements of the larynx has been already discussed.



Aphonia, or loss of voice, and dysphonia, or hoarseness, are symptoms of various diseases to be considered. Anything which interferes with the mobility, or elasticity, of the vocal bands may act as a cause. Similar results may follow inflammatory, or obstructive, lesions elsewhere in the air track, the bands themselves remaining unimpaired. The causes affecting the vocal bands may be divided into inflammatory, muscular, or arthritic, and neurotic. As an example of the first the voice of a laryngitis may be mentioned. In acute laryngitis it may be entirely lost; in chronic laryngitis it is whispering, or raucous. In rheumatic laryngitis the muscles are crippled, or there may be ankylosis of the cricoarytenoid joint. In either case approximation of the vocal cords is difficult or impossible. Illustrations of neurotic aphonia are met with in hysteria, which is purely functional, and in disturbed innervation from pressure of an aortic aneurism on the recurrent nerve.

The vocal bands resemble the reed of a wind instrument only in the fact that their margins vibrate under the influence of the passing column of air. The character of the voice is infinitely diversified by elongation and shortening, widening and narrowing of the bands constantly taking place in the production of different tones. This extraordinary combination of actions distinguishes the natural larynx absolutely from every possible artificial mechanism. When we consider how manifold are the elements concerned we shall begin to realize what a complicated process vocalization is and how futile must be any attempt to formulate a theory of voice culture universally applicable.

The shape and dimensions of the resonating cavities, a normal construction and healthy action of all parts of the vocal apparatus, even the texture of the tissues themselves, and more than all the musical intelligence and temperament of the individual participate in the formation of a voice of satisfactory power and pleasing quality.

## METHODS OF EXAMINATION.

In laryngoscopy, or examination of the larynx, the position of the patient, and the source of light are similar to those in examining the nose and pharynx. The only additional instrument needed is a large-



sized mirror to be introduced into the fauces with its reflecting surface downwards. It is a good plan always to begin examinations of the larynx with the tongue at rest in the floor of the mouth; then, to depress it by means of a tongue-spatula; and finally, to support the protruded tongue between the thumb and finger. The laryngeal mirror should be as large as the fauces will conveniently accommodate in order to obtain a complete image (Fig. 112). The patient should be directed to breathe quietly, to open the mouth without extraordinary effort, and care should be taken to avoid violent traction upon the tongue as well as dragging it downward upon the lower incisor teeth. It is rather more satisfactory for the examiner

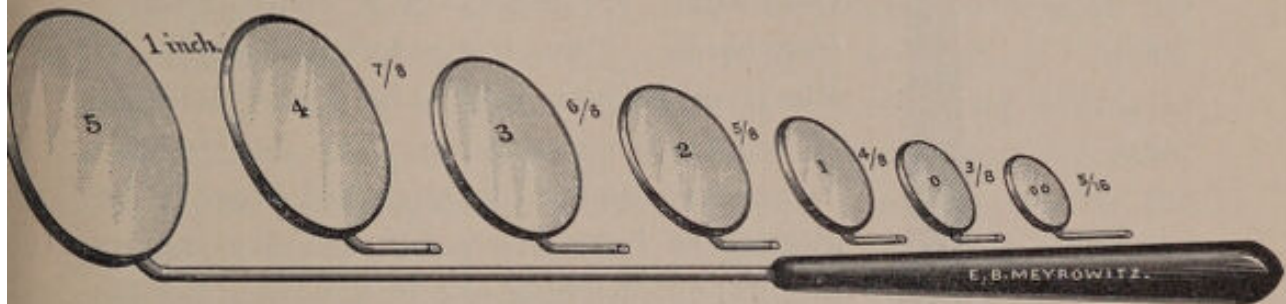


FIG. 112. LARYNGEAL MIRRORS.

himself to hold the patient's tongue except in the exercise of certain manipulations in which both hands are required, the movements of the head being thus under better control.

The introduction of the mirror in some individuals excites gagging and it is frequently impossible to obtain a satisfactory view without the aid of cocaine, or some form of local anesthesia, or careful preliminary training of the patient. Sometimes it is a good plan to direct him to close his eyes during the examination. If gagging occurs, panting respirations will sometimes overcome the intolerance; or a four per cent. solution of cocaine may be sprayed into the fauces. It is well to avoid the pharyngeal wall, if possible, but the mirror should be introduced boldly, its back against the velum, which should be lifted firmly upwards. Timidity in this procedure frequently will be more disastrous than firmness. In introducing the mirror it is sometimes annoying to meet with considerable obstruction from upward curvation of the dorsum of the tongue which may be overcome by directing the patient to phonate a long "ah." After the mirror has been placed in position, the interior of the



larynx may be brought into view by causing the patient to sing a falsetto "e" or to make the attempt, which is sufficient. In this way the movements of the cords and the arytenoids may be studied. In some instances the peculiar shape of the epiglottis is a source of difficulty. Occasionally it will be observed to drop over the *rima glottidis* and cut off the view of the cords. In other cases a lateral compression is noticed giving the conformation known as the

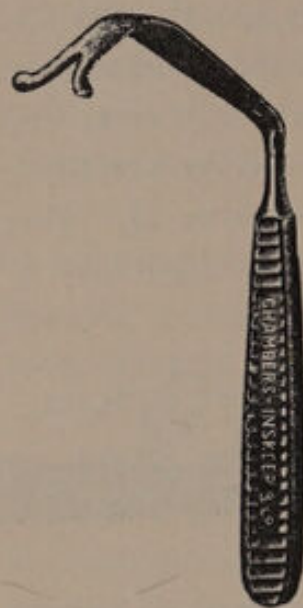


FIG. 113. ESCAT'S  
TONGUE DEPRESSOR.

"omega" shaped epiglottis. The impediment thus offered may be sometimes overcome, if an examination is imperative, by dragging the epiglottis upwards and forwards, after cocainizing, by means of a sharp hook or tenaculum. The long tongue spatula of Bleyer or Escat is said to be particularly useful in examining children. The former has a curved end intended to be passed over the epiglottis, the latter has a bifurcated extremity, the prongs of which rest in the sinus pyriformis on either side (Fig. 113). The left index finger makes a very good tongue depressor and to children is less terrifying than an instrument. Traction may be made by hooking

it around the hyoid bone. The first laryngeal object seen in the mirror will be the tip of the epiglottis. We shall then identify the ventricular bands and the prominences of the arytenoids and finally the white vocal bands. It should always be remembered that the laryngeal image is transposed antero-posteriorly, that is, the parts seen in the upper part of the mirror while apparently most remote are really at the anterior wall of the larynx; those at the lower border are most distant and at the posterior commissure. The first view, especially in an untrained patient and without cocaine, will give us the most reliable picture of the laryngeal cavity, since prolonged examination excites muscular contraction and causes more or less congestion which may be misleading. It is sometimes possible by tilting the mirror to get a view of the entire laryngeal wall and even a glimpse into the ventricles, as well as a considerable distance down the trachea, and in rare cases the bifurcation



is visible. As a rule the anterior wall of the larynx is best seen in the ordinary method of making the examination. In order to get the posterior wall of the larynx and trachea more fully exposed we sometimes adopt what is known as the position of Killian, in which the patient is made to stand erect while the examiner is seated, the head of the subject being bent forward so that the eye of the observer looks upward at an angle. This is found to be very useful in case of certain lesions which are met with at the posterior wall of the larynx. A similar object is attained in the suggestion of Mermod in which a second mirror attached at a right angle to the laryngoscopic mirror is introduced into the cavity of the larynx. Obviously it has a limited application. The misnamed instrument, the "autoscope" of Kirstein, is intended to give a direct, or "orthoscopic," view of the larynx. Its essential part is a long spatula or concave piece designed to grasp the base of the tongue on either side of the median glossoepiglottic ligament. In the meantime the patient's head is extended forcibly in such a way as to bring the anteroposterior axis of the mouth in line with the vertical axis of the trachea. At the same time firm pressure upon the tongue drags the epiglottis forward and upward, and provided the patient is capable of submitting to this irksome position, in some cases a very good direct view of the larynx may be obtained. It is necessary for the patient to be seated and the examiner to stand in front of him and a brilliant source of light should be provided. The original Kirstein's instrument had attached a small electric lamp, but the usual methods of reflection will serve the purpose. This mode of examination is claimed to be especially applicable to children and for the removal of foreign bodies—but, with a little tact and patience, the ordinary methods will usually succeed.

It is possible to gain additional information in some cases by other methods than inspection. External palpation, for instance, will show us whether the thyroid is, or is not, symmetrical, whether abnormal sensitiveness is present, and it is claimed to be of especial value in detecting laryngeal paralysis, which might not otherwise be recognized, in consequence of the absence of normal vibration on the affected side. A certain amount of corroborative evidence may be obtained by auscultation of the larynx; and it is a good plan for the



examiner to educate his ear to the character of the voice, since in certain conditions peculiar qualities are more or less characteristic; for example, the rough, harsh voice of syphilitic laryngitis, the weak whispering voice of tuberculosis, and the metallic voice and especially the cough of some forms of paralysis are in some degree distinctive. In addition we may get some valuable points, especially in cases of laryngeal neoplasm, by the use of the probe. We may learn, for instance, some facts as regards the mobility and the density of a tumor of the larynx. Above all one should never permit one's interest in the examination to prolong the process beyond the endurance of the patient, and if local hyperesthesia is so great as to prove insurmountable, it will certainly be better to postpone attempts to get a view until the patient has been rendered manageable by the various methods of training elsewhere described.

### GENERAL THERAPEUTICS.

The fact should never be forgotten that the larynx is only one part of the human machine, and that many laryngeal affections are aggravated and perpetuated as well as caused, by some systemic disturbance. One of the first indications in nearly every laryngeal lesion is to secure, as far as possible, absolute rest, not only as regards actual talking but by the avoidance of functional excitement as in the act of laughing, and in violent exercise. The use of tobacco and alcohol should be prohibited in acute and in many chronic conditions. The digestion must be looked into and a tendency to constipation corrected. Cough resulting from disease in the lungs or bronchi, or of a reflex character, must be investigated and its cause removed if possible. The habit of clearing the upper air passages by the act of hawking is a source of irritation, and is usually excited by some trouble in the nasal chambers. It is, therefore, important that in all cases of laryngeal disease the nose and pharynx should be carefully examined and be relieved of anomalies and deformities, although the immediate subjective symptoms the latter induce seem to be insignificant.

As to local therapeutics we may medicate the larynx by means of powders, inhalations, vapors or sprays. Fumigations are seldom



resorted to in laryngeal difficulties and the use of lozenges and gargles in any form is, of course, futile. Gargling the larynx by the method of Guinier has been described and practised occasionally, but it is by no means easy of accomplishment and cannot be considered very practical. Insufflations in laryngeal disease are limited with advantage to ulcerative processes. In some forms, as tuberculosis and carcinoma, certain powders seem to be beneficial in relieving the pain and promoting asepsis. Medicated steam and vapors are most grateful in the simpler forms of acute inflammation.

For routine treatment the use of the spray is generally practicable and much more satisfaction will be obtained by employing the straight tube, the patient being taught to practice deep inhalations at the moment of application. Used in this way little or no resistance or spasm of the larynx is likely to be excited; whereas, a blast of air directly upon the vocal bands, even if the solution it conveys be not very irritating, will frequently produce distressing or alarming spasm. A similar objection applies to the introduction of applicators carrying medicaments into the larynx. The latter are reserved for inveterate cases of laryngitis in which the sensitiveness of the larynx is so obtunded that little or no contraction is excited by the presence of a foreign body. The sponge probang and brush of the early days of laryngology have been pretty generally discarded. The special form of medication to be applied, whether antiseptic, astringent, sedative or stimulant, will depend upon the particular lesion to be treated. These matters, as well as the question of instrumentation, will receive consideration under appropriate sections. We sometimes secure good results from some form of external application, either in the line of depletion, as with leeches, counter-irritation with iodine or the blister and, in certain acute and subacute conditions, Leiter's coil, or a form of water poultice, will serve as revulsives.



## CHAPTER XVIII.

DISEASES OF THE LARYNX. ANEMIA AND HYPEREMIA. LARYNGEAL HEMORRHAGE. ACUTE AND CHRONIC LARYNGITIS. CHORDITIS TUBEROSA, OR VOCAL NODULES. CHRONIC SUBGLOTTIC LARYNGITIS. ATROPHIC LARYNGITIS.

### ANEMIA OF THE LARYNX.

Anemia of the larynx may be observed in connection with general anemia, or as a pretubercular condition. In the chronic form of tuberculosis we find the laryngeal mucosa distinctly pale, even independently of structural changes. In chlorosis, in neurasthenic conditions, and especially in young girls about the age of puberty it is often seen. It merits especial attention as a forerunner of tuberculosis.

### HYPEREMIA OF THE LARYNX.

Hyperemia of the larynx may result from overuse of the voice, from the abuse of alcohol and tobacco, and is, also, observed in certain occupations in which one is exposed to irritating atmosphere, smoke, dust, or chemical fumes. It is most marked where the tissues are lax, as on the aryepiglottic folds and ventricular bands; on the epiglottis and vocal bands it is less pronounced. It is also met with in the course of various exanthemata, either antecedent to or associated with skin lesions characteristic of these diseases. It may be a chronic, so to speak, normal condition in habitual voice-users, especially baritones and basses.

### HEMORRHAGE OF THE LARYNX.

Hemorrhage of the larynx is a rare occurrence and seldom has any significance. It is extremely unusual to see a laryngeal hemorrhage in tuberculosis, although the sputa may be stained with blood, especially after violent attacks of coughing; whereas, in the ulcerative stage of carcinoma it is not infrequent. It may result from trauma-



tism, or from a foreign body, and has been met with in the course of syphilis as a consequence of destructive ulceration extending from the larynx to the base of the tongue and involving the lingual artery. It is seldom of sufficient moment to demand attention. A simple spray of astringent character will usually control it. Some writers recognize a so-called "hemorrhagic laryngitis," the main feature of which is the formation of scabs composed of coagulated blood adhering especially to the vocal bands, rather than a free bleeding. Gottstein regards it as a form of laryngitis "sicca," to be referred to later.

### ACUTE LARYNGITIS.

Inflammation of the larynx may occur at any age or in either sex. It is more often met with in those exposed to severe weather or sudden changes of temperature and is rather more common in males in consequence of their particular occupations.

The causes of laryngitis are those affecting mucous membranes in general. Sudden changes in atmospheric conditions from hot to cold, mouth breathing due to nasal stenosis, damp clothing, especially in voice-users, functional activity of the larynx in bad air, or by a bad method, or to excess, are among the most frequent.

Predisposing causes are a depressed state of the system and gastrointestinal disturbances. Previous attacks of inflammation are thought to establish a proclivity and it is not unreasonable to suppose that the mucosa is rendered more vulnerable by preceding disease.

In the various exanthemata inflammation of the larynx is observed which differs in no respect from simple catarrhal laryngitis except that, in some varieties, the laryngeal condition is characterized by the development of lesions similar to those occurring upon the skin. In chicken-pox, for example, vesicles are observed upon the epiglottis which break and resemble aphthæ. In measles, diffuse patches or maculæ frequently occur. In scarlatina the laryngitis is occasionally complicated by the formation of a pseudo-membrane and an unusual degree of edema is apt to develop especially when renal complications arise. In the laryngitis of typhoid fever a decubitus ulcer may develop or ulceration involving the lymphoid tissue resembling that of Peyer's patches is not infrequently noticed. The laryngitis of



erysipelas is rare and exceptionally dangerous when the phlegmonous type is assumed.

The pathology of acute laryngitis resembles that of inflammation of other parts of the air track except that the catarrhal product is deficient in mucus owing to the relative scarcity of glandular tissue. In the first stage, as elsewhere, there is active hyperemia with dryness, followed by tumefaction of the membrane and serous exudation which finally becomes tenacious and turbid from the admixture of epithelial cells and leucocytes. In the majority of cases resolution takes place and the parts resume their normal appearance without change. In other cases the condition lapses into one of chronic inflammation. In some instances erosions of the mucosa take place but no true ulcerative process is observed.

The first symptoms noticed are usually slight hoarseness, a tendency to cough, and subjective sensations of dryness and tickling, sometimes with a feeling of constriction. The use of the voice is uncomfortable and even painful in aggravated cases. Sometimes the voice is completely lost early in the attack. In children the swelling of the mucous membrane produces more impediment to respiration in consequence of the relatively smaller dimensions of the larynx in the young but it seldom becomes serious unless complicated by edema. There may be slight pyrexia especially in children or nervous individuals; and in sleep the breathing may be somewhat noisy or strident. In the mirror the mucous membrane is seen to be uniformly congested, or injected vessels may be identified at various regions. Occasionally when the coughing is very violent rupture of small vessels may take place and the sputum is tinged with blood. The vocal bands lose their pearly hue or may be concealed by swelling of the ventricular bands.

The *treatment* should be more active in the case of children than in adults, although in the latter a laryngitis should never be neglected, owing to its weakening effect upon the membranes and the possibility of a chronic condition supervening. It should begin with a calomel purge, fractional doses, one tenth of a grain, being given every half hour until characteristic effects are produced. The patient should be kept in a warm even temperature, may be given hot drinks to promote the action of the skin and should be



prohibited the use of the voice. If cough is a prominent symptom it should be controlled by the use of an opiate, preferably codeine or heroin, and by means of steam inhalations. The compound tincture of benzoin in water at the boiling point, one drachm to the pint, makes a soothing medicated vapor useful in these cases. It is said that dilute nitric acid in doses of from ten to fifteen drops every half hour for four or five doses, and then at longer intervals for a few hours will enable a singer or a public speaker to use his voice provided the remedy be resorted to at an early stage. The relief from this measure is only temporary and it is, by no means, to be recommended except in cases of emergency. Menthol inhalations, or vapors of menthol, applied by means of the atomizer or nebulizer, will often give relief, the strength of menthol being about five grains to the ounce of fluid albolene. It is well in using the spray in these acute conditions to employ the straight rather than the down tube, the patient being instructed to inhale at the moment the spray is formed. It is unwise to use too much energy in local treatment. All applications should be emollient and protective.

We may secure relief by the external application of a water poultice, a piece of flannel wrung out in hot water, applied next the skin and covered with a larger piece of oiled silk, known in Germany as the Priessnitz compress, this being renewed at intervals and worn until improvement is well established. If the case is seen in the early stage it is sometimes possible to abort it by external counter-irritation, depletion by means of leeches, or the application of Leiter's ice-water coil. By far the most important indication of all, in cases of acute laryngitis, is to enforce absolute rest. The patient should be isolated so far as possible, kept in an equable temperature and not allowed to use his voice in any way. In the event of the development of edema to a threatening degree it will be necessary to resort to scarification or puncture of the swollen tissues with Tobold's concealed lancet. If relief is not obtained in this way the question of intubation or tracheotomy is before us. The former, in several cases recorded, has given most excellent results, but if the edema is situated high in the larynx it may be ineffectual on account of the occlusion of the upper orifice of the tube by the overhanging tumefaction. Or the serous infiltration may extend beyond the lower end of the



tube. In still other cases it may constitute what has been termed a "solid edema," upon which scarification makes no impression. In such case relief must be obtained by passage of a catheter through the stenosed air track, as proposed by McEwen, or by a tracheotomy. Usually edema affects the vestibule of the larynx where it is within reach, but cases have been reported by Semon and by Risch in which the process was limited to the vocal bands. An extraordinary obstacle was met with by Casselberry in attempting an intubation for edema of the glottis. The jaws were so firmly fixed by spasm of the masseter muscles as to render opening of the mouth impossible. It is advisable to select a tube rather under the size indicated by the age of the patient and in adults it may be passed under the guidance of a laryngeal mirror. A combination of scarification with intubation may be efficacious when the tube is found too short to compress all of the swollen area. In a case recorded by W. F. Brook efforts to introduce the tube lacerated the tissues and released the effused serum. All the evidence seems to show that a trial should be made of these measures before resort is had to the more formidable external operation. Fortunately, owing to the fact that simple catarrhal inflammation does not invade the submucous areolar tissue to any extent, edema as a complication of an acute laryngitis is very exceptional. By propagation from the pharynx, as pointed out by Sestier, it is much more common, and it is sometimes consecutive to disease involving the perichondrium or the cartilages of the larynx. Secondary to syphilitic or tubercular infiltration it is more apt to be a chronic than an acute edema and seldom demands attention. Fauvel refers to it as being possibly the first symptom of renal disease, yet Mackenzie affirms that he once examined 200 cases of Bright's disease without discovering a single instance of edema of the larynx. Local depletion by means of leeches applied over the larynx externally and spraying the fauces and larynx at intervals with a solution of suprarenal extract may relieve the turgid structures. In this connection the experience of S. Solis-Cohen in a case of asthma in which acute edema of the palate, pharynx and epiglottis followed a free application of the suprarenal-chloretone solution is of interest. A disease of which the laryngeal edema may be symptomatic must of course receive appropriate treatment. Primary "edematous



laryngitis " is an exceedingly rare phenomenon. Edema of the glottis as a symptom or sequel of disease is not infrequently observed and occasionally reaches proportions to excite alarm or involve danger. In the convalescent stage of acute laryngitis it may be necessary to brace up the relaxed membranes by means of mild astringent applications; the one preferred at the present time is a ten or twenty-grain watery solution of alumnol. Preparations of iron, chloride of zinc and nitrate of silver are more distasteful and offer no superiority. Within recent years many new silver combinations have been offered. Among the most promising is silver vitelline, or argyrol (Barnes and Hille), a proteid containing thirty per cent. of silver. It is very soluble, is absolutely free from irritating or caustic properties, and possesses great penetrating power owing to the fact that it does not precipitate albumen or sodium chloride. Hence we may expect the most brilliant results in derangements supposed to be dependent upon invasion of the submucous structures by bacterial organisms.

### CHRONIC LARYNGITIS.

Chronic laryngitis is, as a rule, a sequel of the acute form, or may reach the larynx by extension from the pharyngeal cavity. By far the larger number of cases of chronic laryngitis owe their origin primarily to a nasal stenosis or disease in the nasal chambers which causes mouth-breathing or some change in the condition of the air supplied to the lungs as regards purity, temperature, or moisture. The abuse of alcohol and tobacco, exposure to irritating vapors in certain occupations, excessive use of the voice as met with in open-air speakers and street hawkers, are frequent causes. In addition certain derangements of the fauces, such as hypertrophied tonsils or an elongated uvula, are predisposing causes. The influence of certain diatheses, as gout and rheumatism, should not be overlooked. Sooner or later in the condition of chronic laryngitis, a proliferation of connective tissue cells takes place resulting in thickening of the tissues, this thickening not only involving the epithelial layer but the submucosa as well. Structural changes may invade the muscular tissues. Involvement of the framework of the larynx is met with only in the existence of constitutional trouble, such as syphilis,



tuberculosis, or malignant disease. Frequently, the pathological changes are circumscribed and affect a very limited area of the mucous membrane, constituting what is known as "singers' nodes" or *chorditis tuberosa* of Türck. These developments are most frequent at the junction of the anterior with the middle third of the vocal bands. Sometimes the node is on the margin and again on the upper surface of the band and apparently incorporated with it. In the former case if the lesion is unilateral a depression may be seen at a corresponding point on the opposite cord. In many cases the lesion is bilateral and symmetrical. The cord as a whole is slightly if at all altered in appearance, or there may be a moderate amount of hyperemia, especially in the immediate neighborhood of the node. A similar circumscribed increase in connective tissue elements is sometimes noticed at the posterior commissure, or near the vocal processes, where the condition has been termed by Virchow *pachydermia laryngis*.

The symptoms of chronic laryngitis are unmistakable. The voice may be partially or completely lost. It is apt to break unexpectedly and, in all cases, a condition of dysphonia exists and the patient is himself conscious of being compelled to make an extra effort to produce a tone. After a night's rest there is always an accumulation of viscid tenacious secretion, the expulsion of which is accomplished by more or less violent cough and, at all times, the patient is disposed to cough especially in attempting to speak or after the use of the voice. Sometimes the voice, even when exceptionally hoarse, well clear up slightly after a few minutes' use. Patients frequently complain of a sensation of constriction or foreign body in the region of the larynx. Upon inspection with the mirror we find a congested mucous membrane with blood-vessels well defined upon the epiglottis or in the larynx itself. The tissues at the base of the cords are frequently more hyperemic than the margins of the cords themselves; or the margins of the vocal bands may be irregularly eroded. As a rule, the most marked changes are seen at the posterior wall of the larynx. Thickening of tissue occurring at that situation may interfere with approximation of the arytenoid cartilages and the aphonia may be due in part to the obstacle thus offered. Interference with the action of the intrinsic muscles of the larynx is mechanical and not a true paresis.



Unable to display this page



paid to the effect of suitable vocal exercise upon hyperplastic changes of the mucous membrane in chronic laryngitis and especially in the thickening known as "singers' nodes." A careful study of these cases will sometimes teach us whether this mode of handling them is likely to be effective. In cases of long standing, when the nodes are very dense and extensive, we can hope to accomplish but little. In more recent cases it is possible that suitable exercise of the voice may be of advantage, the theory being that dispersion of the infiltration or hyperplasia is effected by a so-called vocal massage of the laryngeal structures. The term used in this sense is certainly a misnomer. The spontaneous disappearance of the nodes under absolute rest is sometimes observed and the question arises whether the moderate use of the voice in such vocal exercises as are recommended is not practically a modified rest.

The recent observations of Garel and Bernand fail to confirm the opinion of Fränkel that the changes resulting in the formation of these nodes begin in the glandular structures. In some cases they proved to be small fibromyxomata; in others the changes were in the mucous membrane and chiefly vascular. In their experience the nodes sometimes disappear spontaneously, the galvanocautery has often been employed with success, but ablation with cutting forceps is much to be preferred. From examinations of the tissues composing the nodes made by Rice, Kanthack, Chiari and other investigators it seems to be proven that they are not of glandular origin but consist mainly of connective tissue and epithelial elements. Attention has been drawn by F. I. Knight to the confusion existing between this condition and a diffuse granular inflammation involving the whole cord, or *trachoma* of the vocal cord. As a matter of fact there may be few or none of the usual local signs of inflammation. The term *chorditis* is therefore open to criticism; moreover, it might be more appropriate to refer to these nodes as "vocal" rather than "singers'" nodules, since they occur not infrequently in those who do not sing. There seems to be no evidence to sustain the suspicion of a relationship between vocal nodules and a tuberculous diathesis. In reviewing the anatomy of the larynx reference was made to the curious distribution of the thyroarytenoid muscle to the margin of the vocal band. The interesting question suggests itself whether



persistent and oft-repeated tugging or strain upon certain fibers may not induce a hyperemia or even a minute hemorrhage to develop later a vocal nodule.

It seems to be desirable to distinguish between "trachoma" of the vocal cord, a condition of diffuse inflammation resembling a granular or follicular pharyngitis and involving the whole extent of the band; "pachydermia laryngis," which is a hyperplastic overgrowth at the posterior commissure and in the neighborhood of the vocal processes; and, finally, "chorditis tuberosa," or vocal nodules, isolated nodular masses usually seated at the junction of the anterior and middle thirds of a vocal band, commonly bilateral, often only on one side. However closely allied these conditions may be pathologically, their respective clinical pictures are sufficiently in contrast to award them separate titles. They equally impede phonation and are equally resistant to treatment, which should be invariably preceded by careful elimination of morbid conditions in the superior air track.

The surgical treatment of these thickened tissues, sometimes advocated, as a rule should be avoided since there is great danger that the intralaryngeal manipulations, essential to the removal of a broad-based sessile overgrowth, will do more damage than the hyperplasia itself. Occasionally if the growth is pedunculated, or on the margin of the cord and in a well-trained subject it is possible to excise the little tumor with a small cutting forceps, or to destroy it with a fine electric cautery point. Capart divides the treatment of "singers' nodes" into hygienic, medical and operative. Although several instances of spontaneous disappearance have been recorded, he believes that even prolonged rest of the larynx has no beneficial effect except upon an associated laryngitis. He condemns local treatment by sprays and insufflations of astringents and antiseptics, and especially cauterization with nitrate of silver and chromic acid as being either ineffective or positively dangerous, in consequence of a tendency for these agents to spread and cause violent reaction. In operative treatment are included ablation and destruction with the galvanocautery. For the former a light and very delicate forceps is advised. The galvanocautery is reserved for nodes too small to be grasped with forceps.



At best the management of these cases is very discouraging. In most cases the forceps is not available, the use of the cautery demands the utmost skill and delicacy and is to be thought of only in trained and tolerant subjects, and finally the enforcement of absolute rest, while most essential, is almost impossible.

### CHRONIC SUBGLOTTIC LARYNGITIS.

An inflammatory process sometimes seems to expend itself on the under surface of the vocal bands and the adjacent wall of the larynx. It often leads to considerable thickening and in the laryngeal mirror gives the image referred to by Mackenzie as that of "a second vocal cord." The affected region is usually redder than normal and looks dense and firm. At first it is uniformly smooth, but in old cases may become somewhat irregular and even eroded. It has been described by Gerhardt as a *chorditis vocalis inferior*, but the process is by no means limited to the vocal bands, a considerable area beyond them being involved. It is not common in this country. Some observers trace it to some constitutional diathesis, scrofula, syphilis, or tuberculosis, while others regard it as related to rhinoscleroma. The symmetry, color and density of the swellings, obvious to the eye as well as on examination with a probe, differentiate this disease from edema and from that rare variety of myxomatous degeneration to be described elsewhere. It has been mistaken for eversion of the ventricles, a lesion the occurrence of which is denied by many authorities. Its chief title to importance rests on the fact that it may embarrass respiration to a degree necessitating an intubation or a tracheotomy. Systematic dilatation may be required or the hypertrophied tissues may be reduced by excision or by applications of the galvanocautery. In some cases the movements of the vocal bands are decidedly interfered with by thickening or by infiltration of the muscles by inflammatory products and the voice suffers proportionately. In others the vocal bands move with normal freedom and may quite conceal the hypoglottic swelling during phonation. The probable relationship of this affection to a constitutional diathesis enforces the importance of internal medication. Iron preparations, especially the iodide of iron, are said to be useful. Bosworth warns



against the administration of iodide of potash, lest an edema add to the volume of the obstructing hyperplasia. Yet the cautious use of the latter drug seems to be indicated when there exists a suspicion of syphilitic taint. Local applications, other than those directed toward reducing hyperemia or actual removal of the infiltration are worse than useless.

### ATROPHIC LARYNGITIS.

Pathological changes similar to those occurring in the nose and pharynx and resulting in atrophy may take place in the larynx, when there is presented the condition known as atrophic laryngitis, or *laryngitis sicca*. Some confusion has arisen from the use of different terms to indicate what are probably identical diseases, the blennorrhea of Stoerk, the *ozena laryngis* of Baginski, and so on, according to the prominence of a given symptom. As a matter of fact the disease is extremely rare and is a sequel of an analogous condition in the air track above, which latter is actually the more important. The chief characteristic of atrophic laryngitis is a perversion of secretion, whereby the mucus having lost a proportion of its watery elements tends to form crusts or scales which adhere firmly to the membrane. At times these scabs cling so closely that a little bleeding takes place when they are forcibly dislodged. They may consist largely of blood and have a very fetid odor, which they impart to the breath. The mucous membrane may be eroded and if the vocal bands are affected their margins are notched and irregular. The crusts may be seen at almost any part of the larynx or extending down into the trachea. In a case described by B. Tauber the larynx and upper part of the trachea were lined completely by a blackish cast of incrustated secretion which had to be removed daily with forceps. The voice may be completely absent until the desiccated secretion is expelled, and the crusts may be so thick as to cause dyspnea. Their presence is provocative of violent and often painful paroxysms of coughing. In some cases there is more or less concomitant acute or subacute catarrhal inflammation, when the membranes are swollen and red, while Gottstein describes a chronic form in which the mucosa is dirty gray in color. This affection seems to be peculiar to adults and is said to be more common in



women. It is not infrequently seen in those who use alcohol to excess and in syphilitics. Massei and others maintain that atrophy in the larynx is a direct extension of a similar state in the pharynx, while Bosworth lays great stress on the theory that catarrhal processes are limited by anatomical boundaries and do not extend by continuity of tissue. In any case it is a clinical fact that the morbid process in the larynx is secondary to some abnormality, atrophic or other, in the nose or pharynx which compels mouth breathing or interferes with suitable purification of inspired air. The presence of certain bacteria in the secretions, especially the *bacillus fetidus*, is looked upon by some as an etiological factor, but by most observers as a coincidence or consequence.

The prognosis and treatment resemble those applying to atrophy in other situations. If the process is not too far advanced the normal function of the affected region may be restored by preliminary cleansing of the surface followed by soothing or slightly stimulating applications in an oily vehicle. The crusts may be softened with an alkaline spray, or may require detachment mechanically. Inhalation of benzoinated steam is grateful and helps to loosen the secretions. Kyle highly recommends embrocations of petroleum externally. Internal medication is needed if the general health is poor or in the existence of a constitutional dyscrasia. It has sometimes seemed to me that the prolonged use of large doses of iodide of potash rather predisposed to atrophy, yet it is an almost indispensable drug in syphilis. At best response to treatment is slow, and the nose and pharynx must first be free from disease.



## CHAPTER XIX.

### BENIGN NEOPLASMS OF THE LARYNX.

A benign tumor of the larynx may be defined as one which shows no tendency to general dissemination and does not recur after thorough removal. The latter part of the definition would seem to exempt one variety of benign growths, namely, papillomata, which do show a disposition to return after apparently complete extirpation. However, the presumption is that even with these recurrence is due to failure of complete removal, although many cases are on record in which apparently thorough resection followed by cauterization through a thyrotomy wound has proved ineffectual.

In the etiology of benign tumors in general it may be said that any condition or circumstance which promotes hyperemia or catarrhal inflammation is a predisposing cause. Voice strain, local irritants, and a general tendency on the part of certain individuals to neoplastic formations, a "verrucous diathesis," are included among these causes. How far overuse or misuse of the voice should be considered a factor is more or less of an open question in view of Moreil Mackenzie's famous case of papilloma occurring in a deaf mute. The majority of cases of laryngeal neoplasm have been met with in the adult and in the male sex. There are on record several congenital cases.

The symptoms include alteration of voice varying with the situation of the tumor, cough, more or less interference with breathing, especially in children, spasm of the larynx, moderate concomitant inflammation in some instances, hyperesthesia amounting in exceptional cases to actual pain, and in some varieties hemorrhage. Among rare phenomena associated with certain benign neoplasms noted by Fauvel may be mentioned salivation and perversion of the sense of taste. Impairment of voice varies from slight hoarseness to complete aphonia, and is more pronounced when the vocal bands are involved, or when the growth is sessile and small than when



pedunculated even though voluminous (Czermak). The respiratory disturbance is influenced more by the size of the tumor, although paroxysmal dyspnea may occur under excitement, on exertion, or when the glottic aperture is still further narrowed by sudden swelling from catarrhal inflammation. A change in position of a pedunculated growth may have a similar effect. When inspiration is more impeded than expiration, the growth is probably *above* the vocal bands (Lewin). An extraordinary subjective symptom, or more properly premonition of laryngeal neoplasm, was recently detailed to me by a young man with papilloma. He is an amateur short distance runner, and after a very keen competition he once noticed a feeling of intense *heat* in the region of the larynx followed by partial loss of voice, the former lasting for upwards of an hour and the latter continuing through the following day. This was repeated after several subsequent contests until the partial aphonia became permanent and he was led to seek relief.

The tendency to malignant degeneration of benign growths in the larynx has been the subject of much controversy. The testimony is for the most part in refutation, Felix Semon finding ground from extensive statistics he has collected to maintain that it is less marked when operation has been done than when the tumors have been let alone. It must be admitted that new growths may become modified from their original type. For instance, a fibroma may grow more vascular and finally appear as a genuine angioma, or may undergo fatty degeneration. A case of transformation into a myxoma has been recently reported by Masucci.

The verdict on this question must be that malignant degeneration of an innocent neoplasm as a result simply of irritation or traumatism is not proven. When a cancer germ shall have been identified it will be easier to believe in the possibility of such change. In the meantime the practice of endolaryngeal surgery may be continued in skilful hands without fear of instituting a malignant character in benign tumors of the larynx.

The prognosis is good, unless the growth is excessive, or, as in the case of some papillomata, shows a propensity to recur, when the voice may be permanently more or less impaired. Several cases of spontaneous detachment and expulsion are on record, as in one of



four congenital cases reported by H. A. Johnson, in which a papilloma was expelled during a paroxysm of whooping cough. As a rule the development of the growth is so gradual that ample time is given for a tracheotomy before indications of dangerous stenosis are presented.

In order of frequency benign tumors of the larynx may be enumerated as follows: papilloma, fibroma, cystoma, myxoma, angioma, enchondroma, lipoma, and adenoma. The most frequent by far is the first mentioned, *papilloma*. Papillomata commence in the papillæ of the mucosa, involve the epithelial cells and form wartlike growths, called by Virchow *pachydermia verrucosa*. They are usually situated on the vocal bands and at the anterior part of the larynx (Fig. 114). They rarely occur elsewhere and almost never at the



FIG. 114. PAPILLOMA OF LARYNX. (Schnitzler.)

posterior commissure. A form of excrescence resembling papilloma occurring in tubercular laryngitis in the interarytenoid space is not entitled to be thus classified. They are frequently more or less pedunculated, some authorities to the contrary notwithstanding, and they usually develop rapidly, especially in children and, in most cases, occupy the supraglottic region. I have never seen a papilloma of the larynx which was not somewhat constricted at its attachment, in other words pedunculated, and in many cases fungous or cauliflower expansion of the mass of the tumor was very apparent.

*Fibroma* is a neoplasm of adult life. It is usually sessile and single, situated on one or the other vocal band, varying in size from that of a millet seed to a hazelnut or, in rare cases, even almost filling the laryngeal cavity (Fig. 115). Usually it is round, symmetrical and redder than the band to which it may be attached. A single



case of fibroma of the larynx has come under my observation, in which I removed a growth the size of a small pea from a vocal band with Mackenzie's forceps. Growths in this class are spoken of as soft fibromata or fibrocellular, when their structure is made up in large part of cellular elements.

*Cystomata* have been met with in adult life as late as the sixty-



FIG. 115. FIBROMA OF LARYNX ON PHONATION (a) AND DURING RESPIRATION (b).

fourth year as well as in young children. They occur in the form of retention cysts of the muciparous glands at almost any situation, the vocal cords included (Fig. 116). The epiglottis seems to be the favorite site (Fig. 117). In a case of cyst of the epiglottis under my care several years ago a tumor the size of a hickory nut was attached by a long pedicle to the left margin of the epiglottis. That organ was dragged downwards by the tumor so as to conceal the interior of the larynx. The tumor itself was not to be seen until

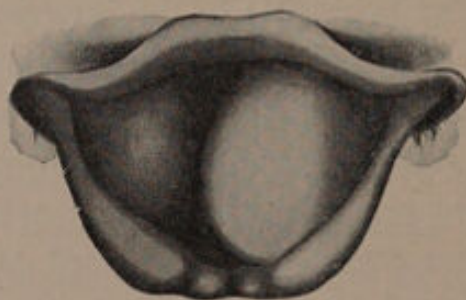


FIG. 116. CYST OF LARYNX. (Ingals.)

forced into view by the act of retching. It was easily removed with the cold-wire snare. In some cases in which the tumor was small and sessile simple incision has been sufficient to effect a cure, as in a case described by Payson Clark, in which the tumor, attached to a vocal band, could not be seized with forceps. It was therefore in-



cised with a concealed lancet. A little milky fluid escaped, and the cyst walls collapsed and shrank away.

These neoplasms are neither sensitive nor vascular. It is well enough to cocaine the parts before removal is attempted, but any special precautions against hemorrhage are superfluous. The diagnosis is usually clear. They are pedunculated and elastic and are more or less translucent, provided their contents are fluid and serous, but not if they contain gelatinous, colloid, or bloody material as in certain rare cases (Lefferts). The size of these growths varies. They may become so large as to necessitate a tracheotomy or even as in one case a pharyngotomy. They may occur at any age. One about the size of a hempseed has been found post mortem in a child

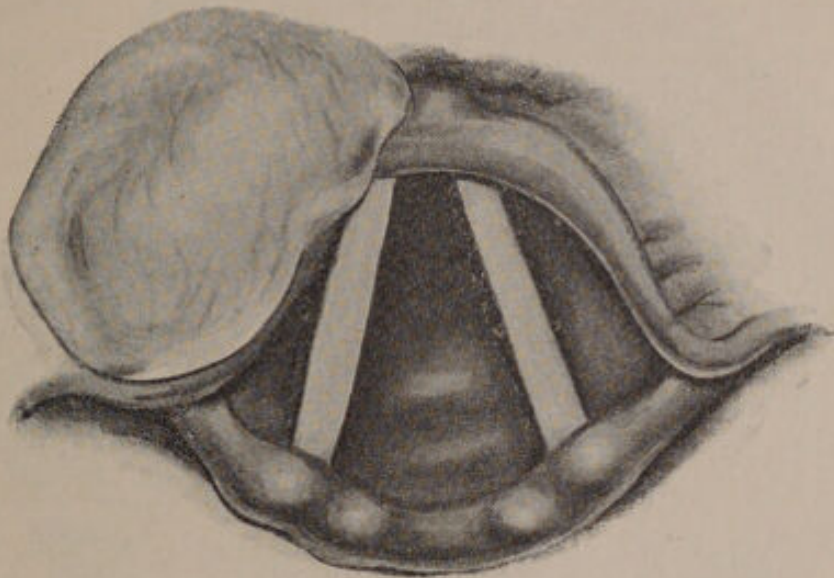


FIG. 117. CYST OF EPIGLOTTIS.

fourteen days old (Abercrombie), and one the size of a hazelnut is reported to have caused the death of an infant thirty-seven hours after birth (Edis).

*Myxoma* may occur in two forms, either as a pedunculated tumor generally situated upon a vocal band, or in the form of a sessile diffuse mass, a sort of myxomatous degeneration.

A case of diffuse subglottic myxoma came under my observation several years since in the person of a woman forty-eight years of age, who had been hoarse and annoyed by wheezing respiration for a year or more (Fig. 118). She had some cough and was supposed to have asthma. No pulmonary lesion could be detected, but with the



laryngoscope a mass of finely lobulated tissue could be seen extending from the under surface of the vocal bands down into the trachea and encroaching upon the air-tube. Portions of this mass were removed with Mackenzie's cutting forceps until it became evident that the lower limit of the growth could not be reached through the mouth. So much relief was given by partial removal that treatment was intermitted for more than a year when the patient began to have a good deal of dyspnea and stridulous breathing. An external operation was then done under cocaine anesthesia, the cricoid and three upper rings of the trachea being divided and a large quantity of soft

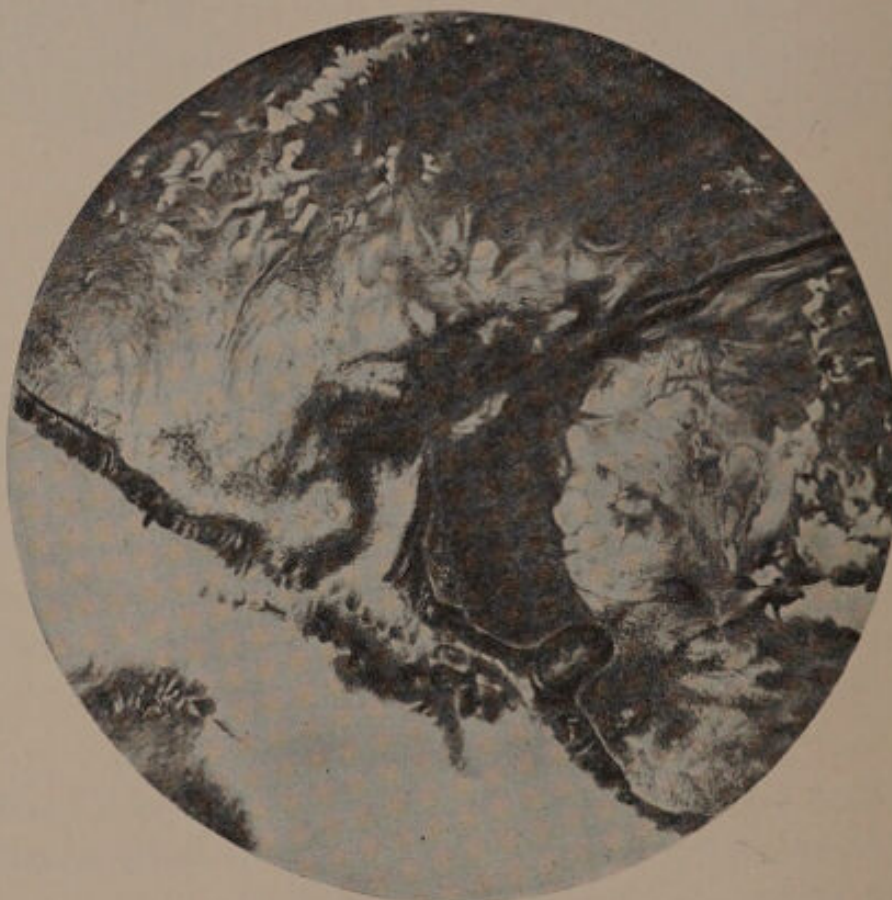


FIG. 118. SUBGLOTTIC MYXOMA.  
(Author's specimen.)

pulpy material was removed with the curette and cutting forceps. The tracheal tube was worn for three days and at the end of the third week the tracheal opening had healed and the patient was discharged from the hospital.

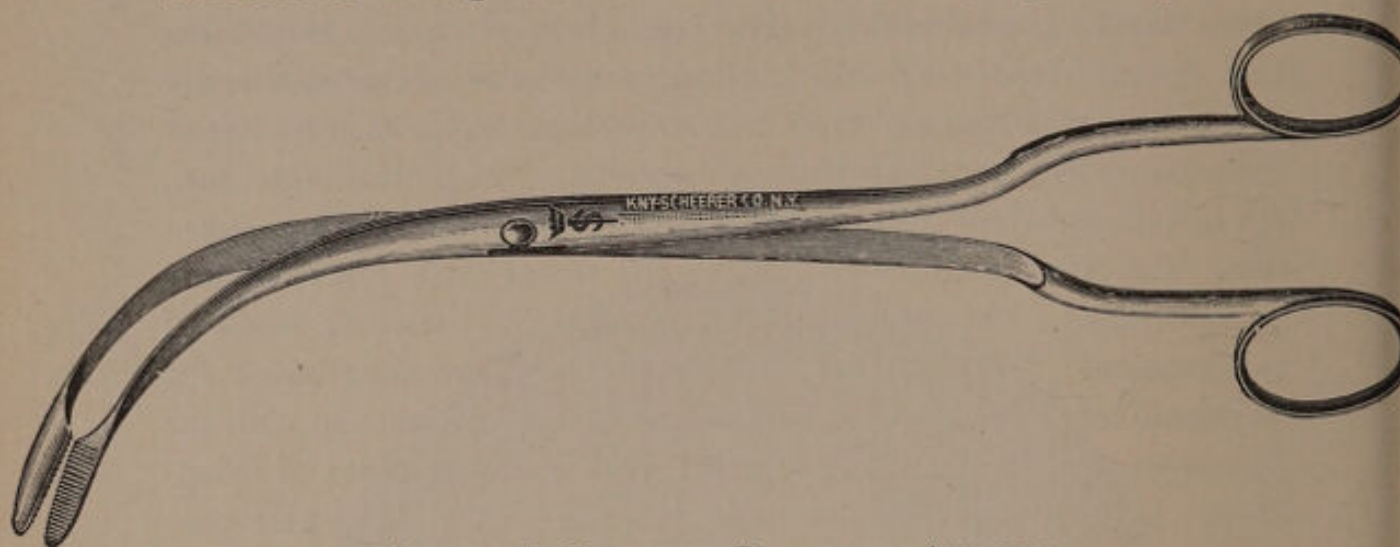
Under the microscope the growth was seen to be made up chiefly of myxomatous tissue.



Unable to display this page



reported by Holt in a man of eighty years. It was pedunculated, upon the rim of the glottis, and had given rise to symptoms for twelve years. It was drawn into the larynx and caused fatal asphyxia. In a second case, reported by Jones, the lipoma, two inches in diameter, was removed through the mouth. In a third case, reported by Mac-



MACKENZIE'S LARYNGEAL FORCEPS FOR AVULSION.

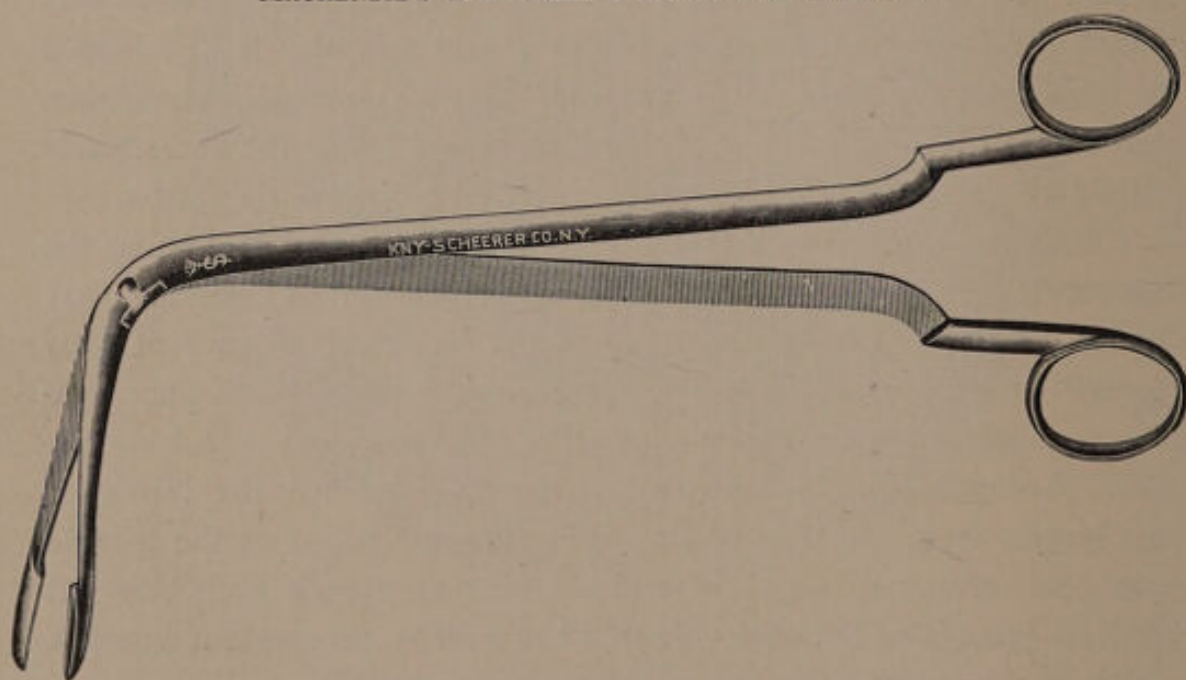


FIG. 119. MACKENZIE'S LARYNGEAL CUTTING FORCEPS.

leod, a pharyngotomy for a tumor as large as an orange was followed by fatal hemorrhage. Bruns records the case of a woman, twenty-five years old, who had a congenital lipoma removed piecemeal with the galvanocautery in fifteen sittings.

The existence of *adenoma*, which is included in the list, is denied



by many authorities. F. Massei has reported two cases, but his, as well as several described by other observers, is far from being well

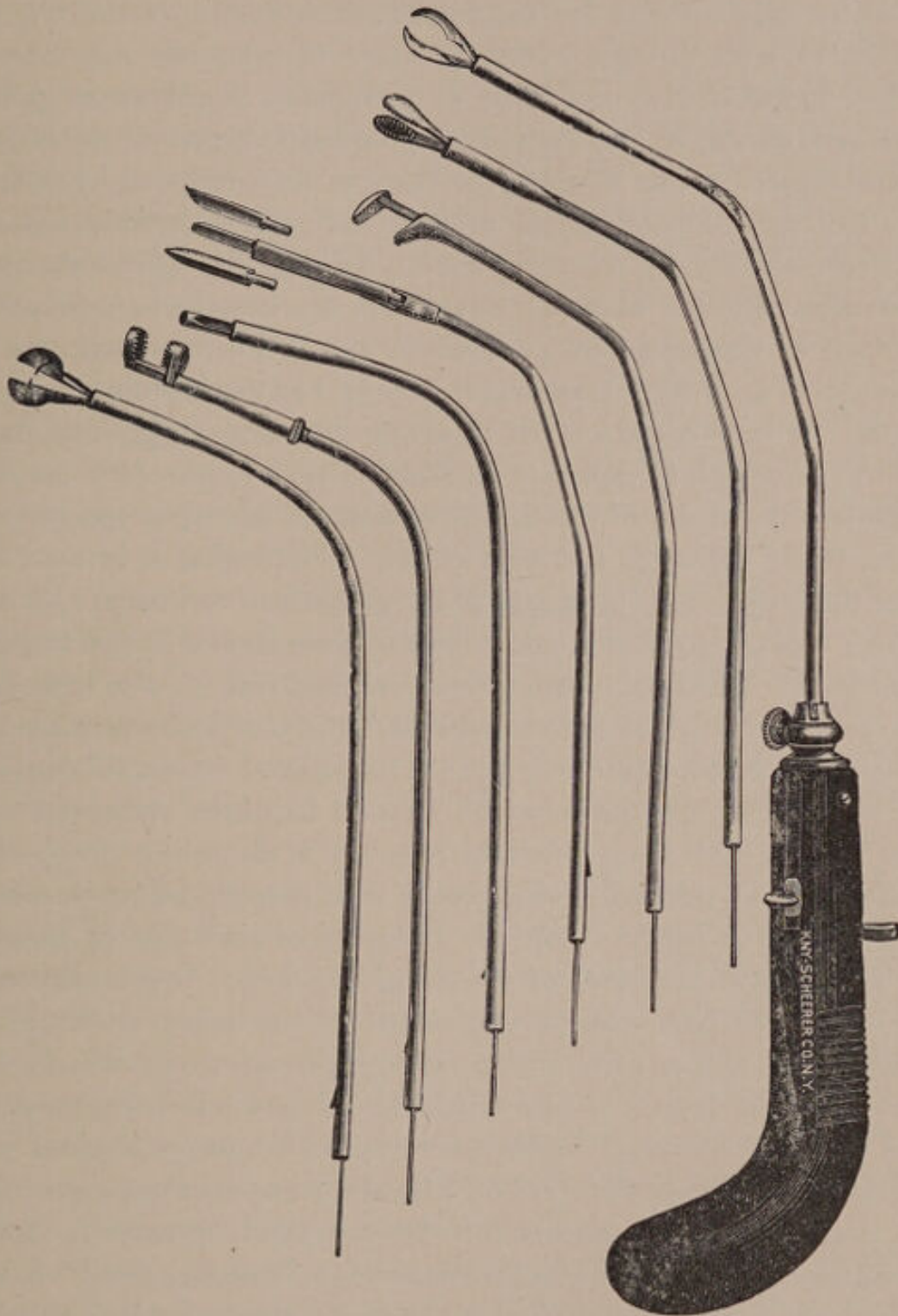


FIG. 120. SCHROETTER-TÜRCK CANULA FORCEPS.

authenticated. To the foregoing may be added *lymphomata* and *accessory thyroid tumors*, each of them so rare as to be considered clinical curiosities.



The *treatment* of these cases of benign tumor must be guided by the character of the growth and its situation. Unless very extensive or excessively vascular the best results are obtained by endolaryngeal operation with forceps, except in cases of relapsing papillomata. Many operators give preference to instruments like the snap guillotine of Mathieu, or Dundas Grant's guarded forceps, but the instrument adapted to the majority of cases is that designed by Morell Mackenzie, a double curette forceps, one pattern intended to cut anteroposteriorly, the other transversely (Fig. 119). One of the most convenient forceps, where for any reason Mackenzie's is found to be difficult of manipulation, is known as the Schroetter-Türck canula forceps (Fig. 120). Some cases can be handled by the cold-wire snare. A very crude way of removing neoplasms, suggested years ago by Voltolini, in case it is found impossible to introduce the forceps into the cavity of the larynx, consists in passing a sponge-probe below the cords and then quickly withdrawing it in the hope that the growth may be caught in its meshes and torn away. It has a very limited application and cannot be considered a highly surgical procedure. Chemical caustics have been used from time to time with the design of destroying these growths, but the difficulty here as elsewhere is to restrict their action to the neoplasm. In at least one case of multiple papillomata in which removal had been attempted with the forceps and the growth had shown a disposition to prompt recurrence, an intubation tube coated with chromic acid was passed and allowed to remain *in situ* for a number of hours; on its removal it brought with it masses of sloughing neoplasm. Incidentally may be mentioned an ingenious application of intubation attributed to Lichtwitz. A tube made with a fenestra permits the growth to protrude into its lumen, where it may be snipped off without risk to the wall of the larynx. Bosworth advocates the use of chromic acid fused on a probe, or conveyed on a hooded porte-caustique, especially to destroy small fragments left by the main operation. Morell Mackenzie, who at one time recommended "London paste," finally abandoned it because it excited spasm of the glottis and inflammation of adjacent mucous membrane. It must be admitted that the use of agents of this kind in effective strength is attended by danger.

The galvanocautery is more precise and manageable and is decid-



edly more satisfactory in its results. The use of the galvanocautery below the epiglottis is objected to by Lennox Browne and other observers, but cases in my own experience lead me to believe that it is a most valuable agent here as elsewhere under proper precautions. No manipulation of the larynx of any kind should be undertaken without preliminary training of the patient. Unless the larynx is under good control there is great danger that the constrictors may bring in contact with the hot electrode or into the grasp of the forceps portions of the laryngeal structure which should not be damaged. Since the introduction of cocaine endolaryngeal surgery has been greatly facilitated. We may succeed in getting a sufficient degree of tolerance with a ten per cent. solution of cocaine in the larynx itself, and it is a good plan to paint over the pharynx and velum as well a solution of similar strength. In using the laryngeal forceps of Mackenzie the following method of technique may be adopted: The parts are first well sprayed with cocaine, a large laryngeal mirror held in the left hand of the operator is introduced and the forceps, having been warmed and anointed with vaseline, is passed over the epiglottis into the larynx with blades closed. If resistance is excited the patient is directed to take gasping respirations, or to phonate the falsetto "e" and thus the larynx is brought to a higher level and at the same time the spasm relaxes and the neoplasm becomes visible. Advantage of this momentary glimpse should be taken to open the blades and seize the growth. It sometimes happens, in cases of multiple papilloma for example, that it is only necessary to open and close the blades without actually seeing the growth at the moment, when more or less of the neoplastic tissue will be included in their grasp. In the use of Mackenzie's forceps there is but little danger of seizing sound tissues provided the instrument be kept in the middle line. It is not well to repeat manipulations more than two or three times at a sitting, yet the larynx will stand a surprising amount of rough handling without special objection.

In selecting the method of operating, as said before, we should be guided by the character and situation of the neoplasm. In most cases Mackenzie's forceps are the best adapted for papilloma. To prevent recurrence we may advantageously fortify the mechanical treatment by certain applications to the larynx, such as some of the more power-



ful astringents, or absolute alcohol, as successfully practiced by Delavan and others. With the last mentioned agent the author has had more or less experience and under proper conditions is disposed to regard it with favor. In the case of a middle-aged lady who showed the larynx almost filled with papillomata so that on several occasions tracheotomy for relief of dyspnea seemed necessary, the tumors yielded to a combination of absolute alcohol with the use of the Mackenzie forceps, when under the forceps alone the growth would recur almost as fast as it could be removed. The extirpation of the tumors in this case was completed by T. H. Halsted, who reports favorably on the effect of alcohol instillations. The treatment with absolute alcohol is accomplished by means of a laryngeal syringe; not more than six or eight drops are applied at a time, the application being made every second day and after the use of cocaine. In one case, that of a child eight years of age, the alcohol seemed to excite an excessive degree of irritation and had to be abandoned. It was resumed after the lapse of a few weeks for the reason that no endolaryngeal manipulation was feasible without a general anesthetic. The first reapplication of the alcohol was followed within twenty-four hours by extreme stenosis from swelling which demanded a rapid tracheotomy.

Although the use of the galvanocautery in the larynx has been condemned several cases in my own experience have given most brilliant results both as regards extirpation of the tumor and restoration of vocal function. I can recall several cases of growths tucked under the vocal band quite beyond the reach of forceps in which extirpation was effected with a slightly curved electric point with most satisfactory results. I would, therefore, emphatically repeat that with reasonable precautions and dexterity in the manipulations it is here, as elsewhere, a most valuable agent.

The use of the snare in the larynx is attended with some difficulty in adjusting the loop. My only experience with it was in the case of cyst of the epiglottis already quoted which occupied the laryngeal face of this appendage and here the loop of the snare was readily engaged. Mackenzie's guarded-wheel ecraseur, or a similar instrument devised by Stoerk, is more serviceable than the unguarded snare in the cavity of the larynx.



The question of splitting the thyroid, or opening the trachea rarely arises except in children, in growths of unusual extent or dimensions, or in those which show a tendency to recur. My own experience with opening the trachea for removal of benign neoplasm is limited to the single case of subglottic myxoma in which I did a high tracheotomy. The operation was uneventful and its results were satisfactory.

In many instances spontaneous disappearance of laryngeal growths has been observed to follow the functional rest imposed upon the larynx by a tracheotomy. Lennox Browns calls attention to the danger in very young subjects of damage to the lungs attendant upon the sudden inrush through a tracheal opening of a large volume of air as compared with that habitually admitted through a larynx partially obstructed by neoplasm. If resorption of laryngeal growths may be reasonably expected after a tracheotomy, it would seem to be more judicious to adopt this alternative rather than expose the patient to the risks of endolaryngeal manipulation with its uncertain results in the early periods of life.

In the adult with multiple or very large neoplasms it is sometimes a wise precaution to open the trachea before removal of the growth through the mouth is attempted. In some cases portions at least of a tumor may be reached from below. The ingenious suggestion that tumors may be excised from the vocal bands by means of a fine-bladed knife passed through the cricothyroid membrane or through the thyroid cartilage at the level of the bands, as done by Rossbach in two cases, and guided in the proper direction by the aid of the laryngeal mirror held in the usual position will hardly be regarded as generally feasible.

A brilliant illumination of the laryngeal cavity, a tolerant subject, and a firm steady hand on the part of the operator are indispensable to success in endolaryngeal surgery. The rarity of this combination and the comparative harmlessness of most benign neoplasms of the larynx may at times raise a question of the admissibility of direct interference, especially in a young and intractable patient. Under such circumstances Kirstein's method, by which the larynx is brought under direct inspection through forced depression of the tongue and extension of the head, may be available. Here, too, a general anes-



thetic may be advantageous, although in most cases cocaine gives us every facility that can be desired. At a recent meeting of the Laryngological Society of London, Herbert Tilley referred to a large papilloma in a child four years old which he removed with perfect ease under deep chloroform anesthesia, the patient being in a sitting position. As a rule general anesthesia, at least to a profound degree, is not to be recommended, or if the operator feels compelled to resort to it he should be prepared to open the windpipe at a moment's notice.

Under the most favorable conditions the removal of a laryngeal neoplasm through the mouth is a procedure demanding considerable dexterity. A growth at the anterior commissure and especially below the vocal bands is not easily reached; its structure may be so dense or its attachment so firm as to resist the action of a cutting forceps. At a first experience with forceps even in soft papillomata one is apt to be astonished at the toughness of the new growth and to relax the hold of the instrument in the fear that normal tissues may have been seized. In the event of failure from inaccessibility of the tumor, as for instance when it is concealed beneath a vocal band or in a ventricle of the larynx, or from any cause, the propriety of an external operation is suggested. Laryngofissure is not to be lightly advised both on account of the added risk involved in the operation itself, and especially because of the danger of permanent damage to the vocal function. Morell Mackenzie's dictum that "an extralaryngeal method ought never to be adopted unless there be danger to life from suffocation or dysphagia," is probably as true to-day as it was when uttered, but does not include a tracheotomy done in the hope of promoting resorption of the neoplasm. The conclusion of Bruns that the chief objection to an external operation lies in the danger of impairment of vocal function loses a measure of its force when we take into account the fact that the neoplasm itself is probably responsible for a large part of the structural damage in the larynx. Moreover in case it becomes necessary to split the thyroid in order to gain access to the growth a sufficiently accurate readjustment of the parts may be secured provided a section of the cartilage is not made completely through its upper border. A point of far more importance and strongly favoring endolaryngeal methods is the fact that recur-



rences have been much more frequent after thyrotomy than after the former.

Internal medication cannot be recommended with special confidence. Improvement has been claimed by some from the use of full doses of arsenic, and following the suggestion of Kaposi as applied to cutaneous warts others have had good results with *Thuja occidentalis*. Small doses of protiodide or biniodide of mercury are advised by Watson Williams in the postoperative treatment and he also speaks well of the local use of a two to five per cent. solution of salicylic acid in absolute alcohol, as proposed by Dundas Grant.

In comparing the relative merits of intubation, endolaryngeal operation, thyrotomy and tracheotomy enough experience has accumulated to authorize pretty positive conclusions. Prolonged intubation, as pointed out by Wachenheim, is well known to be dangerous. The irritation caused by the tube provokes the formation of webs and adventitious bands and consequent stenosis. Two recent postdiphtheritic cases in my clinic signalize this danger. In each of these cases the larynx was split by Duel and after division of cicatricial bands beneath the vocal cords an intubation tube with a retaining arm or pin, like that suggested by John Rogers, was inserted. The final results were satisfactory, but the sojourn of the tube in these diphtheritic cases was even shorter than would be necessary in an average case of papilloma, a fact which would discredit the feasibility of intubation in the latter condition. On the other hand Robert Levy reports the case of a child four years old who wore a tube one hundred and eleven days almost continuously with the result of dispersing a collection of laryngeal papillomata.

In adults, and to a much less extent in children, endolaryngeal operations have been found satisfactory, except in certain cases of relapsing papillomata. Ablation may have to be done over and over again and the growths are reproduced with amazing rapidity. It is said that Bond once operated on a girl of eighteen, who in ten years had been relieved of papillomata about every two months. Hovell operated under chloroform fourteen times on a boy three and a half years old. Stoker records a case of a man of thirty years with the unparalleled record of having submitted to 220 operations since seven years of age. Fortunately these histories are seldom repeated, and



in these days with tractable patients and the aid of cocaine very different results may be expected.

As to thyrotomy in benign neoplasms of the larynx when we read of Walker Downie's case of six operations in one year, of Permevan's two thyrotomies, cauterization and death from asphyxia, of Abbe's case of four thyrotomies, cauterization and tracheotomy, and finally of Lendon's seventeen thyrotomies in two years followed by stenosis and a permanent trachea tube we are quite prepared to pronounce sentence of banishment upon this procedure. It is high time to discard an operation that is not only more or less hazardous, but gives no assurance of curing the disease for which it is performed.

Turning to tracheotomy we find a far more encouraging showing. The reports of Hunter Mackenzie, Massei, Garel and many others establish the fact that the physiological rest given to the larynx by making a tracheal fistula determines a disappearance of laryngeal papillomata in from six weeks to five years. This occurrence has been observed so often that tracheotomy must be considered the classical mode of treating papilloma of the larynx in very young children, while in older subjects the tracheal opening permits a resort to endolaryngeal manipulations with deliberation and without danger.

In all cases of development of a benign neoplasm in the larynx it is essential to pay attention to the condition of the upper air-track and in every instance make sure that the nasal cavities and the nasopharynx are free from obstruction. In the opinion of many lymphoid hypertrophy in the latter situation is a very frequent cause of neoplastic formation in the larynx. Lennox Browne holds this view, while Shurly declares that he has never met with a laryngeal papilloma in one having at the same time adenoids in the pharyngeal vault. It cannot be supposed that nasal, or pharyngeal, diseases are the sole cause of laryngeal neoplasms, but on the ground that the former increase the susceptibility of the passages below their elimination is certainly indicated.

The after treatment in these cases of operation for laryngeal neoplasm consists in the adoption of bland and soothing sprays for the correction of a catarrhal condition, and the enforcement of absolute rest. To prevent recurrence Fauvel advises insufflation of equal



parts of savine and alum. Astringent sprays may be useful and in several cases sprays of alumnol have seemed to me particularly effective. In case of violent postoperative reaction it may be necessary to resort to the more vigorous methods used in controlling simple inflammation of the larynx as already described. As a matter of fact acute inflammatory stenosis following an operation within the larynx is extremely unusual, and the less interference during convalescence the better.



## CHAPTER XX.

### MALIGNANT DISEASE OF THE LARYNX.

#### SARCOMA OF THE LARYNX.

Sarcoma of the larynx is an embryonic *connective* tissue growth, and may be met with at almost any period of life. Bosworth has collected 47 cases of sarcoma of the larynx, the youngest being nineteen, the oldest seventy-five years of age. It is therefore not a frequent lesion and there is no evidence of heredity. So far as can be determined there is no reason to believe that local inflammation exercises any predisposing influence. It may remain limited to the larynx for a considerable time, and, only after a long period may extend beyond the cartilaginous walls to involve the external structures and the lymphatic glands. In a case at present under my own observation a trachea tube has been worn for upwards of two years without marked progress of the disease. It usually occurs as a uni-

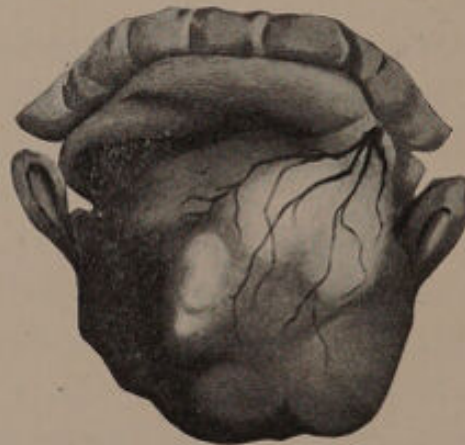


FIG. 121. SARCOMA OF LARYNX. (Chappell.)

formly round tumor which seldom ulcerates though its surface may become eroded. Occasionally it is nodular and shows a tendency to extend downwards into the trachea. In many cases a microscopic examination is necessary to determine its character, but it is often difficult to get satisfactory sections for the purpose. In more than half the cases the vocal bands themselves were involved; next in



order of frequency the ventricular bands and, in two cases, the epiglottis (Fig. 121). Both round- and spindle-celled forms of sarcoma have been met with in the larynx, as well as lymphosarcoma, fibrosarcoma and myxosarcoma, primarily, or by extension from adjacent parts.

The symptoms depend upon the size and location of the tumor. Usually hoarseness, cough and dyspnea are present, but there may be no pain. There is seldom any hemorrhage of severe character but the sputum may be tinged with blood. The tendency to generalization is very tardy. The cervical glands are seldom involved owing to obliteration of the lymphatics by cell proliferation. Cachexia is not marked and may not develop until the laryngeal disease has existed for a long period.

The prognosis of sarcoma of the larynx is bad. In the majority of cases we are compelled to choose between a tracheotomy for the relief of laryngeal stenosis and *complete extirpation*. The latter must be regarded in most cases as merely postponing an inevitably fatal result. In a few cases of partial extirpation for very limited disease the operation has been successful. The mode of operating depends upon the size and situation of the tumor. Out of twenty-one cases of operation through the natural passages by the forceps, snare or knife collected by Bosworth, six were cured, eight were improved, two recurred, four were fatal, and in one there is no record of ultimate result. Whatever external operation is undertaken it is desirable to do a preliminary tracheotomy. One is often disappointed to find on splitting the larynx that the disease is much more extensive than it appeared in the mirror, so that what promised to be a partial extirpation must be converted into a complete laryngectomy.

### CARCINOMA OF THE LARYNX.

For many years the terms sarcoma and carcinoma were used interchangeably to indicate malignant disease. Confusion on this point has been largely dispelled by limitation of the term carcinoma to *epithelial* tissue growth.

Cancer of the larynx may be extrinsic, intrinsic, or both combined. Krishaber includes in the first those lesions involving the epiglottis,



the arytenoids, the aryepiglottic folds and the pyriform sinuses, and in the second those springing from the vocal bands, the ventricular bands, the ventricles and the region of the larynx below the vocal bands.

Among carcinomatous lesions epithelioma largely predominates, although cases of medullary cancer and scirrhous have been recorded (Fig. 122). Its rarity is evidenced by the fact that in 11,131 cases

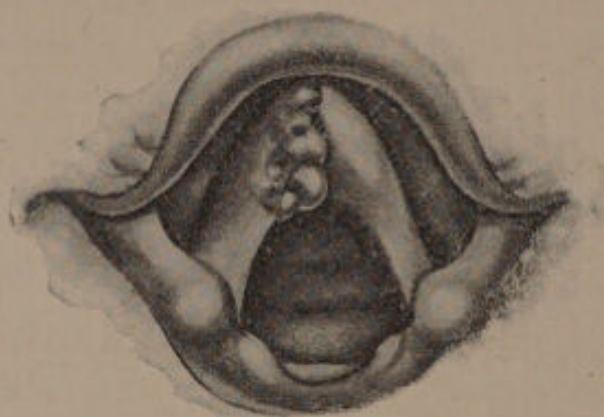

FIG. 122. EPITHELIOMA OF RIGHT VOCAL BAND AT ANTERIOR COMMISSURE.  
(Schnitzler.)

of cancer collected by Gurlt only 63 of the larynx were found. Hereditary influence was thought to have been discovered in about twenty-five per cent. of the cases, and the disease is frequently traced to overuse of the voice. There is usually a history of chronic laryngitis preceding the development of the neoplasm. It is essentially a disease of middle life and of old age, but one case on record occurring in a child. It generally involves a vocal band, and until a very advanced period of development remains intrinsic. Glandular infiltration in intrinsic disease is rather a late phenomenon, the lymphatics in the interior of the larynx not anastomosing directly with those of the exterior (Fig. 123).

The earliest symptom in the majority of cases is impairment of voice. It is generally progressive until complete aphonia may become established. Dyspnea is seldom marked at an early stage. The characteristic cachexia is usually observable, sometimes developing rather early. The patient presents a grayish-yellow complexion, his features become shrunken, and he has the appearance of premature old age. The glands in the neck sooner or later begin to show signs



of infiltration, those near the cornua of the hyoid bone being first affected. The breath may become fetid, especially in the event of ulceration, more or less expectoration occurs, frequently stained with blood, or profuse hemorrhage may take place. Sharp pain, lancinating in character and radiating towards the ear of the affected side is regarded as somewhat pathognomonic, but is not unknown in other conditions, and is often not a prominent symptom in cancer.

An ulcer of the vocal band in the neighborhood of or rather in front of the vocal process surrounded by a livid red areola, and associated with more or less thickening and with decided impairment of mobility of the corresponding side of the larynx, occurring in a person of middle age or older, must always be looked upon with sus-

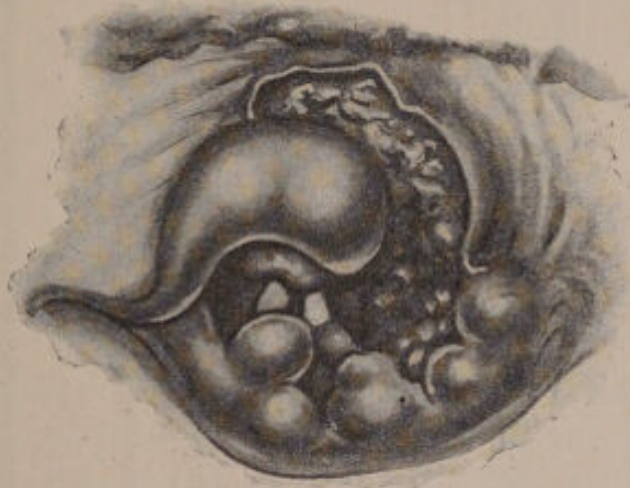


FIG. 123. ADVANCED CANCEROUS ULCERATION LEFT SIDE OF LARYNX.  
(Schnitzler.)

picion. It is not always possible or justifiable to remove a sufficient piece of the ulcer or neoplasm for microscopical examination; a superficial section of the growth will often give misleading or negative testimony, and the manipulations necessary in order to secure a specimen are apt to stimulate development.

It has been a frequent experience to rely upon the microscopical diagnosis in doubtful cases and to make all preparations for a radical operation, when unexpected amelioration in the local condition took place and finally the lesion disappeared altogether. Several years ago a middle-aged man came into my service at the Manhattan Eye and Ear Hospital with a clinical history of epithelioma of the larynx. He had been under treatment at another hospital, where it was re-



ported that the microscope had pronounced the lesion to be epithelioma. A preliminary tracheotomy was done from which the patient made a good recovery, with the expectation of undergoing laryngectomy a week later. In the meantime he changed his mind and refused to submit to radical interference. He left the hospital and was not seen again until a year afterwards when he returned with voice almost completely restored and with hardly a trace of infiltration in the larynx at the site of the supposed epithelioma. The case

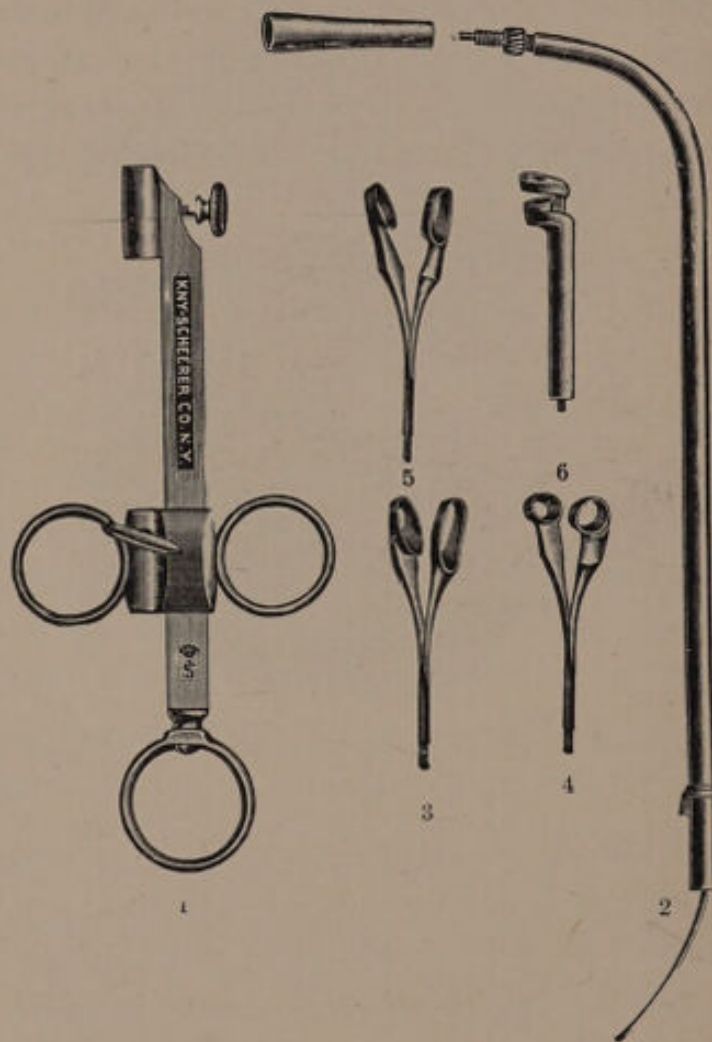


FIG. 124. KRAUSE'S LARYNGEAL SET, 1, 2 and 3; HERYNG'S CURETTES, 4 and 5; LANDGRAF'S CURETTE, 6.

recited is, by no means, an unusual one, and illustrates the difficulty in making a positive diagnosis from the microscopic examination of a small fragment removed *per vias naturales*. One may more readily appreciate this fact when recalling the various appearances presented by different parts of a complete section of a morbid growth.



In a recent case of thyrotomy for epithelioma of the larynx all the diseased tissue removed was divided into two portions and one sent to each of two competent microscopists. Their reports were absolutely contradictory. Such an experience is no discredit to the microscope, but its negative testimony should be accepted with hesitation in the face of positive or even suspicious clinical signs. Many authorities rely confidently upon the microscope and attribute its failure to give definite evidence to the use of an inefficient instrument in cutting out a piece. Moritz Schmidt, for example, insists that a double curette like that of Landgraf (Fig. 124) which cuts out a large thick segment of tissue must be used. This observer also calls attention to several rare forms of cancer especially difficult of recognition. While it usually appears as a well-defined tumor, it may have its origin in the deep tissues and give rise to a proliferating or vegetating condition on the surface of the mucosa closely resembling papilloma. Again the picture of malignant disease seated in the ventricle of Morgagni may simulate that of a perichondritis, or a cancerous mass at the posterior wall or below the cricoid may involve the recurrent nerve and thus its first symptoms may be those of laryngeal paralysis. He relies upon iodide of potash to exclude syphilis in doubtful cases and lays great stress upon the *yellowish white color* considered pathognomonic of a cancerous lesion as well as upon the fact that the latter seldom develops primarily at the posterior part of the vocal bands. Felix Semon describes a snow-white, sharply pointed lesion, resembling a papilloma, but less bulbous and rounded, as "extremely suggestive of malignant disease." The same authority gives interesting details of a case seen by himself and several other eminent surgeons in which the clinical history of cancer was almost unequivocal. A tracheotomy preparatory to a complete extirpation disclosed a number of apparently infected glands and the major operation was abandoned. A year later the patient reappeared still wearing his trachea tube but with no trace of glandular infiltration and no laryngeal stenosis. It seemed that in the meantime he had been taking Clay's mixture of Chian turpentine, a preparation that once had quite a reputation as a specific in cancer. Semon attaches no importance to the use of this article, but holds the view that the case was really one of syphilitic perichondritis and that the glandular swelling



was purely inflammatory. Iodide of potassium was given without result when the case was first seen and unfortunately the glands removed at the operation were not examined microscopically, so that the nature of the lesion remains in more or less doubt.

The diagnosis of carcinoma of the larynx in its early stage is extremely important, since it is only at this period that we may hope to do anything in a surgical way. The tumor may be seated at a point where a radical operation would certainly include it all. Hence if the parts can be exposed in the early period of development we shall succeed in prolonging life if not in ridding the patient permanently of his disease. The propriety of attempting to exclude certain other diseases by tentative treatment always suggests itself. The tuberculin test may be of service as regards tuberculosis. In using iodide of potash in order to eliminate syphilis attention should be drawn to the fact that very large doses must be given and that amelioration in many ulcerative conditions occurs at the first administration of the drug, whereas no impression whatever is made by it upon that rare form of fibroid degeneration sometimes occurring in old syphilis. Moreover complications may arise from the coexistence of syphilis or tuberculosis with cancer. Under such circumstances a syphilitic history or the discovery of tubercle bacilli may divert us from the more serious lesion. Transillumination and the Roentgen ray have been used to demonstrate an area of infiltration. The results they give are more curious than valuable, since by the time an infiltration has become extensive and dense enough to give decided reaction other evidences are sufficiently pronounced.

The prognosis in cancer of the larynx is gloomy, and the results of operation are worse the longer the delay.

*Treatment* may be palliative or radical. In case radical interference is not feasible or be declined, we are compelled to meet the various symptoms as they arise. So far as the patient is concerned the most distressing symptom in the final stages if not at the outset is pain. As a last resort we have morphine in some form, either hypodermically or by the mouth, but it is well to try first the effect of various local anesthetics. Much temporary relief may be obtained from applications of morphine, 4 grains, tannin and carbolic acid, each 30 grains, in half an ounce each of glycerin and water (Ingals).



A solution of carbolic acid,  $1\frac{1}{2}$  dr., tinct. iodine 4 dr., and glycerin 2 dr., has been found very serviceable in mitigating the pain of an ulcerative lesion in malignant disease as well as in syphilis. A considerable degree of comfort may be given in the early stages by spraying with cocaine in ten per cent. solution, or stronger, or with a ten per cent. solution of nirvanin, a recent succedaneum of cocaine, which is found to be quite equal in anesthetic power and is much less toxic. The latter does not act unless there is a lesion of the mucous membrane or it is injected into the tissues. It has the advantage over cocaine that its solution may be sterilized without impairment by boiling. The pain of epithelioma may be mitigated by insufflating the ulcer, after cleansing with an alkaline wash, with orthoform—new. Several hours' respite from pain may be secured by thorough application of the powder. If applied after cocainization a certain quantity is likely to be retained in contact with the ulcerated surface.

Liégeois reports good results from the internal administration of *Thuja occidentalis*, as well as from local application of the same drug. In a case of recurrent epithelioma of the larynx, after an operation by Kraus, the patient was given Fowler's solution of arsenic. During this course three pieces of the tumor were coughed up and death finally occurred from intercurrent pneumonia five and a half years after the tracheotomy, the neoplasm having apparently disappeared. The favorable reports of such treatment might be thought to throw suspicion upon the diagnosis.

The surgical treatment of cancer of the larynx may be conducted through the mouth or by external operation.

The development of laryngology has naturally aroused great hopes for the endolaryngeal method, which are likely to be revived by a recent report by B. Fraenkel of nine cases, five of which were successful. In one case in which a neoplasm was extirpated with the galvanocautery loop five recurrences took place. In one the cervical glands had to be removed by repeated external operations. The importance of constant watchfulness is insisted upon, so that the time for an external operation, should it prove to be imperative and practicable, may not be permitted to pass. Allowance must be made for the unusual diagnostic acumen and manual dexterity of this operator.



Similar cases have been reported by Mermod and Kraus, the latter observer very properly limiting the endolaryngeal operation to polypoid or circumscribed cancers. One of the firmest advocates of endolaryngeal extirpation is Jurasz, who limits the method to the first stage when functional disturbance is slight and the disease is local and circumscribed. He thinks well of the electric cautery, but prefers excision by means of a punch forceps of his own design. From a recent thorough review of this subject Gouguenheim and Lombard conclude that the endolaryngeal route is not available for cancers even of limited extent. The following arguments in its favor, first that many intrinsic cancers tend to remain circumscribed indefinitely, second, that in old people no external operation of magnitude is to be considered, and, finally that some pedunculated epitheliomata threatening asphyxia demand rapid interference are not admitted to be convincing. They recognize that a tracheotomy often seems to retard the growth of a neoplasm and express decided preference for partial laryngectomy in operable cases. It would be unfortunate if the results first quoted should unduly stimulate the zeal of surgeons in this direction, lest improper cases be selected for endolaryngeal operation and thus valuable time be lost. Amelioration of the local condition has frequently been observed to follow rest of the larynx secured by tracheotomy. The majority of cases apply for advice so late that relief of symptoms by the use of local applications and, if necessary, the introduction of the trachea tube, comprise all that we are justified in doing. In a small proportion in which an early diagnosis may be positive and in which the disease is known to be distinctly circumscribed fissure of the larynx with thorough removal of the soft parts involved and beyond, will offer some hope. The objects we should have in view are in the first instance to eradicate the disease, if possible; and if that is not feasible to add to the comfort and prolong the life of the patient. The latter course may seem less humane than a well-directed euthanasia, yet public sentiment does not permit us to treat the human subject with the consideration we apply to the lower animals under similar circumstances. It may be laid down as a general law that cases in which the disease is progressive and has invaded the larynx so far as to necessitate *complete* removal of that organ with its cartilages and the adjacent glands, should



not be subjected to radical interference. The probability is very strong that the disease has by this time crept along some lymphatic channel beyond the reach of the eye where it will escape the knife, and become a focus for recurrence within a very short time. Statistics show, up to the present time, that nearly ninety per cent. of operative cases are fatal, either immediately or from recurrence—by no means a reassuring outlook. With increased accuracy in diagnosis and improvement in operative technique the results may become more favorable. The best individual statistics hitherto published are those furnished by Gluck, of Berlin, fourteen successful partial laryngectomies and only three deaths in a series of thirty-five complete excisions. He attributes his success to prevention of aspiration pneumonia by a preliminary resection of the trachea, the air-track being thus absolutely isolated from the site of operation. In view of the fact that the laryngeal tissues are enclosed in cartilaginous walls, through which no lymphatics pass, the chances of recurrence after removal of cancer of the larynx strictly intrinsic are less than in other situations. There is a marked difference between intrinsic and extrinsic cancers in the greater tendency of the latter to involve the cartilage as well as the lymphatics, a point which has a very important bearing on the prognosis and the mode of operating. For the reason suggested above Watson Cheyne and other authorities regard the glandular trouble as not the most serious operative complication. The septic element is by far the most important factor as regards mortality from the operation. A careful observance of all precautions and a judicious selection of time and method of operating will surely reduce the danger from this source. Desirable conditions as to the patient are enumerated by Delavan as follows: He should not be too old, he should be possessed of good vitality, he should suffer from no physical defect that may retard recovery, and his temperament, intelligence and surroundings should be favorable to a comfortable existence after operation. The personal equation is perhaps too little considered. It is a notorious fact that certain individuals go through the most formidable surgical procedures with equanimity while others collapse under a comparatively trifling ordeal. To some the loss of an important organ with deprivation of vocal function is intolerable. Confirmed melancholia and suicidal tendency have been



known many times to develop after complete laryngectomy. The various artificial devices for supplanting the human larynx, while most ingenious and interesting, are very poor imitations of the original mechanism, and to many would seem impossible. The kind of voice cultivated by several subjects whose larynx had been removed for cancer in such a way that communication between the lungs and the pharynx was entirely closed cannot be considered very satisfactory. In discussing operative interference in a given case the patient should be taken into our confidence and the ultimate decision left in part at least to him after a fair presentation of the question.

The opinion is held by some authorities that the rule applicable to malignant disease in general should be rigidly enforced as regards cancer of the larynx, that is, the extirpation should include a wide area of adjacent healthy tissue and every suspicious lymph gland and channel. Unfortunately, perhaps, the average American will hardly bring himself to submit to the mutilation involved in the application of this principle, especially since even thus absolute certainty of immunity cannot be ensured. He will prefer rather to accept the comfort afforded by anodynes and a tracheotomy, when compelled to face that necessity, and in the meantime get what pleasure he may out of life. In a recent eloquent and forceful plea for early naked eye diagnosis of cancer of the larynx and complete laryngectomy a distinguished authority, J. N. Mackenzie, has made the admission that there is no single unequivocal laryngoscopic sign of cancer. A conclusion must be reached from a study of the congeries of symptoms, local and general, subjective and objective. Excision of a piece of suspected tissue for microscopic purposes, except as a very final resort, is objectionable because (1) it opens the way to autoinfection and metastasis, (2) it stimulates the growth of the cancer, and finally (3) it is often inconclusive, misleading, and is sometimes practically impossible. It is not an uncommon experience for a laryngeal neoplasm previously benign in appearance and clinical history to suddenly undergo absolute change of behavior after attempts at removal for curative or diagnostic purposes. As a general rule growths of the larynx of doubtful nature, especially in middle-aged or older persons, should not be tampered with unless we are prepared to meet this contingency. It is not my purpose to discuss the various methods of



performing excision of the larynx. Our patients are entitled to all the art and skill bestowed by constant familiarity with the details of surgical technique. Hence it becomes our duty to secure the counsel and assistance of the general surgeon in these cases. It remains the business of the specialist to cultivate the utmost proficiency in identifying the early symptoms of laryngeal cancer before the disease has become inoperable. The proposition made several years ago by H. T. Butlin to do an *explorative* laryngofissure in every case of tumor of the larynx suspected of malignancy has not met with universal favor. Should it be accepted as a justifiable diagnostic resource it would seem wise never to undertake it without a distinct understanding that the operator be authorized to proceed to any extent indicated by the character of the neoplasm thus exposed. In a series of thirteen thyrotomies recently reported there were three deaths directly attributable to the operation. The opinion is expressed by Semon that while it is not free from risk the dangers of splitting the thyroid are almost always avoidable. The fact has often been noted that the disease is invariably found to be more extensive than it appeared to be in the laryngeal mirror. Therefore the wisest policy seems to be to place our reliance on other means of diagnosis and resort to a thyrotomy only when we are prepared to go to the full length of surgical interference.

In comparing thyrotomy as an *operative* procedure with other methods hitherto practiced it must be admitted that much may be said in its favor. The technique of the operation as perfected by Butlin, Semon and others gives a much more favorable showing as regards operative mortality. Yet even in the most skillful hands fatalities occur, and even the preliminary tracheotomy, considered essential, is neither so easy, especially when the trachea is entered below the isthmus, nor so safe as is often represented.

In a recent review of the statistics of thyrotomy by Ernest Waggett, based upon the experience of the surgeons just mentioned, the superiority of laryngofissure over total extirpation in the three particulars of (1) preservation of function, (2) death rate from the operation, and (3) exemption from recurrence seems to be clearly established. He comments adversely on Mackenzie's demand for extensive operation in malignant disease of the larynx both on ac-



count of the deplorable state in which the patient is left and chiefly because it offers no security against recurrence. Sendziak, who has investigated this subject most carefully, has tabulated 640 cases operated upon by the endolaryngeal method, by thyrotomy, by partial and by complete excision. He regards operative interference with favor and believes thyrotomy to be safest and most promising as to cure, that term implying no recurrence three years after operation. All the testimony bearing on the question tends to enforce the importance of early identification of malignant disease and seems to justify the conclusion already expressed that conditions so extreme as to require a *complete* laryngectomy render a given case inoperable.

Many malignant tumors of the larynx develop slowly, as declared by Ruault, seven or eight years passing without very pronounced change. With this fact in mind and viewing the disappointing results of radical intervention, it may be worth while to consider measures for controlling the nutrition of the affected region, either by such a procedure as ligation of the arteries supplying the larynx after the method of Dawbarn, or by the frequent application of agents like adrenal extract whose ischemic power is well established.

It remains to be seen whether phototherapy, which has been tried with a promise of success in tuberculosis as well as in superficial forms of external cancer, is capable of exerting an influence upon the less accessible and possibly more resistant type of malignant disease as developed in the larynx. Some of the cases reported up to the present time showed more or less improvement and one definite cure has been recorded (Scheppegegrell). Unfortunately that last mentioned was not confirmed by the microscope, yet the accuracy of the diagnosis based on the clinical history is confidently affirmed. Delavan asserts that not a single authentic case of cure can be found, but he believes in the extraordinary possibilities of the method and that in every case of reputed cure sufficient time should be allowed to elapse to prove its permanency. It seems fair to conclude that all cases manifestly inoperable should be allowed the chance it offers.



## CHAPTER XXI.

### TUBERCULOSIS OF THE LARYNX.

Tuberculosis may attack the larynx primarily or secondarily; in the former case, the process is usually acute; in the latter, chronic.

Primary tuberculosis of the larynx is believed by some authorities to be not very uncommon and is thought to have certain distinguishing characteristics. According to Bernheim, in the beginning milary granulations may be seen in the arytenoid region accompanied by a general laryngitis of mild grade. Finally ulcers form which take on a vegetating or papillomatous character. Tubercle bacilli may be found in the sputum or in scrapings of the ulcers, sometimes only after careful and prolonged search. Twenty-nine cases of primary tuberculosis of the larynx have been reported by Aronsohn, three of which are authentic, in seven the coincident pulmonary lesion was limited and believed to be secondary, while in nineteen the diagnosis of primary laryngeal disease was based solely on clinical signs, which of course cannot be accepted as conclusive. Opportunities to verify a diagnosis are rare because death seldom occurs until the presence of the disease in other situations is manifest. Early identification is obviously important, in order by suitable local treatment, diet and hygiene to prevent the disease from becoming generalized. Some authorities, also, recognize a pretubercular or prebacillary state in which no positive signs of tuberculosis can be discovered either in the lungs or larynx, which demands attention and in which much may be done to ward off the more serious lesions of the actual disease. At this time the larynx is free from ulceration and infiltration, but, as pointed out by Ringk, may be anemic or hyperemic. The former is usually characteristic of a chronic, the latter of an acute process. In the former case irritating applications should be avoided, lest edema or erosions be induced. In the latter astringents are of value and measures should be taken to correct a general catarrhal condition. Weakness of the voice amounting at times to partial aphonia, subnormal morning temperature with more or less



rise the latter part of the day, associated with anemia of the larynx or possibly a circumscribed hyperemia of one vocal band, should always excite apprehension, even though cough may be moderate, sputa scanty, and tubercle bacilli not found. The depth and limitation of an incipient pulmonary lesion may prevent its detection by physical signs, and admitting their absence we may not be justified in pronouncing such a case one of tuberculosis. We are urged, however, to take steps to bring about an improvement in the local conditions which will tend to diminish a susceptibility to tubercular infection of the larynx. This especially refers to use of the voice and to intimate association with others known to be infected. The family history and the question of heredity are concerned so far as these factors may be capable of impairing constitutional vigor and power of resistance. In accordance with modern views we are not authorized in condemning an individual because his ancestors had tuberculosis. An inherited tendency, if such a thing exists, may almost surely be corrected in a climate which permits continual life in the open air. Unfortunately this is not always practicable and oftentimes the prescribed treatment and regime must be carried out under most unfavorable circumstances.

As to etiology, any condition, local or general, which favors the growth of the tubercle bacillus, may invite the disease to the larynx. A condition of low vitality combined with the existence of a catarrhal state of the mucous membrane affords predisposition. We find laryngeal tuberculosis more frequently in the male sex than in the female for the reason that the occupations of men expose them more generally to the exciting causes. It is most likely to develop between the ages of twenty and thirty years.

Subjects of tubercular laryngitis are liable to intercurrent attacks of simple inflammation, and are prone to exhibit temporary improvement in summer, in mild weather and under change of climate. The frequency of the disease is very startling. Heinze, of Leipsic, reports 4,486 autopsies, in 1,226 of which tuberculosis was found; of the latter 51.3 per cent. showed laryngeal lesions, more than one half being ulcerative, a proportion confirmed by the statistics of the Brompton Consumption Hospital but nearly twice as large as that admitted by many investigators. The mode of invasion of the larynx



is either by direct infection through the inspired air or by the expectorated sputum, or indirectly by conveyance of bacilli from tubercular foci in the lungs through the blood current or the lymph channels. The latter is doubtless more frequent. If the contrary were true tubercular laryngitis would be much less rare than it is. Various theories have been propounded to explain the comparative immunity of the larynx. It is said that the bacillus of Koch, which is supposed to be the essential element in infection, requires not only suitable soil but a quiet resting place for its development, and that abrasions of the mucous membrane of the larynx, which might permit the entrance of the bacillus, are promptly protected against it by the formation of exudate or granulations. E. L. Shurly, who expresses skepticism as to the importance of the part played by bacilli in infection, combats the foregoing views and calls attention to the fact that while some parts of the larynx are almost never at rest the ventricles are certainly sufficiently quiescent and secluded as regions for the lodgment and cultivation of germs. There is no reason to believe that the laryngeal mucosa differs from similar tissue elsewhere in its defensive power. As to the bacillus, while it has been proved to retain its vitality in a bronchial gland in a state of latency for twenty years, it has also been demonstrated that some tubercular lesions contain no bacilli. This of course must be taken for what it is worth as negative testimony, and is in consonance with Cohen's suggestion that certain elements capable of conversion into tubercle bacilli exist normally in the tissues. The majority of observers will probably agree with Delafield and Prudden that the effect of the bacilli is governed by their number and virulence, by the nature of the tissue in or upon which they rest, and by the vulnerability of the individual. Although some authorities deny that mouth breathing is a factor in tubercular infection it is believed that the importance of nasal stenosis as favoring derangements of any kind in the lower air-track should not be underestimated. Yet it must be considered injudicious to undertake operative measures for the correction of nasal atresia in a tubercular subject unless it is quite certain that his vitality is capable of withstanding the additional drain.

The pathological changes characteristic of laryngeal tuberculosis consist of cellular infiltration and edematous phenomena, together



with tubercle bacilli, especially in the miliary form associated with ulceration or caseation. In the early stage the capillaries are engorged, the tissues are crowded with leucocytes and small round cells, the glands are distended with serum and cells and finally become obliterated. Nodules of granulation tissue appear and feeble attempts at organization are seen, but finally necrosis, softening and ulceration take place. The breaking down process begins in the deeper layers, thence extending to the surface of the mucous membrane, or to the perichondrium, in the latter case sometimes involving the cartilage itself. Tubercular foci are identical with those found in other situations, consisting of scattered masses of large epithelioid cells, usually enclosing one or more giant cells, embedded in a zone of granulation tissue and surrounded by loose irregular small cells of infiltration tissue. In localized disease a compact wall of cells and fibrous connective tissue surrounds the morbid deposit. The tubercle is not vascular and bacilli may be found both within and without the cells. The secretion of a tubercular ulcer is found to contain disintegrated epithelial cells, mucus, a small amount of pus, and generally tubercle bacilli. Free pus formation is not a usual feature.

The earliest symptoms of laryngeal tuberculosis relate chiefly to the voice. There is more or less huskiness, the voice becomes low pitched, and attempts at loud phonation may result in diphonia, or double voice. The impediment to breathing is not, at the onset, at all marked although respiration may be labored and more or less stridulous. The amount of sputa is not excessive until the lungs become involved to a considerable extent. There is little or no trouble in swallowing until the late stages of the disease when deglutition may become not only difficult but painful. The impediment to swallowing may be due either to simple inflammatory swelling especially of the posterior laryngeal wall, to involvement of the perichondrium or cartilages themselves, or to more or less extensive ulceration. In the early stages there is little or no pain, although the patient may complain of a sensation as of a foreign body, or simply a feeling of uneasiness or dryness. There may be more or less external tenderness on pressure over the thyroid cartilage. One of the most distressing and persistent symptoms even at the beginning is cough. The cough of laryngeal tuberculosis is most marked in the



morning and when the patient first assumes the recumbent position at night.

The diagnosis of laryngeal tuberculosis in typical cases is free from difficulty. There is hardly any laryngeal disease, however, which presents so many variations from what we are accustomed to call the typical form. In the early stages of the disease, a feature by no means invariable, which strikes us with most force in the laryngeal mirror is the pallor of the mucous membrane. This is especially marked in the chronic form and is not proportionate to the degree of general anemia. Infiltration and tumefaction are observed particularly in the interarytenoid space and of the ary-epiglottic folds. The normal prominences of the arytenoids are effaced by a pyriform swelling involving both sides of the larynx and usually quite symmetrical. They assume the so-called "club-shaped" contour (Fig. 125). The

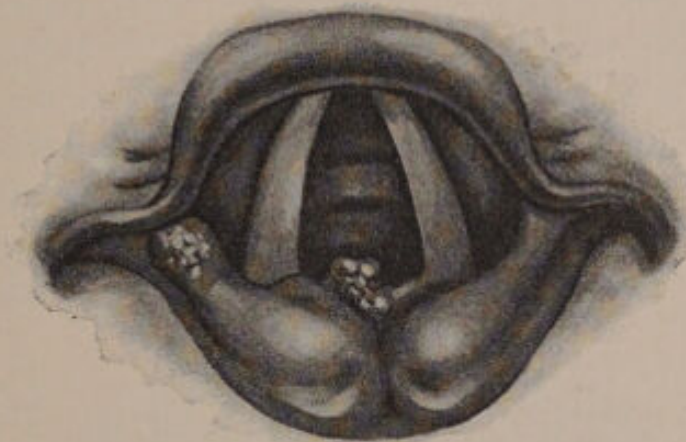


FIG. 125. TUBERCULOSIS OF LARYNX. CLUBBING OF ARYTENOIDS AND PAPILLARY EXCRESCENCES AT POSTERIOR COMMISSURE. (*Schnitzler.*)

epiglottis may be infiltrated and swollen, or "turban-shaped." In exceptional cases the infiltration of the larynx is unilateral, and the uncertainty of diagnosis is much increased (Fig. 126). The mucous membrane has an edematous, soggy look. The movements of the arytenoids are interfered with by infiltration of the muscles or possibly by an inflamed cricoarytenoid joint. The importance of the latter has been especially insisted upon by W. Fowler, who in upwards of fifty autopsies found implication and more or less disorganization of the joint in every instance. Aphonia may be due to this cause, or simply to a general weakness of the intrinsic muscles of the larynx,



or to an intercurrent laryngitis. When there is apparent unilateral paresis it is generally observed upon the right side and is due to involvement of the right recurrent nerve by pleuritic adhesions, consolidation of the right apex, or pressure from bronchial glands. Ulceration is met with in late stages and is due to a breaking down of

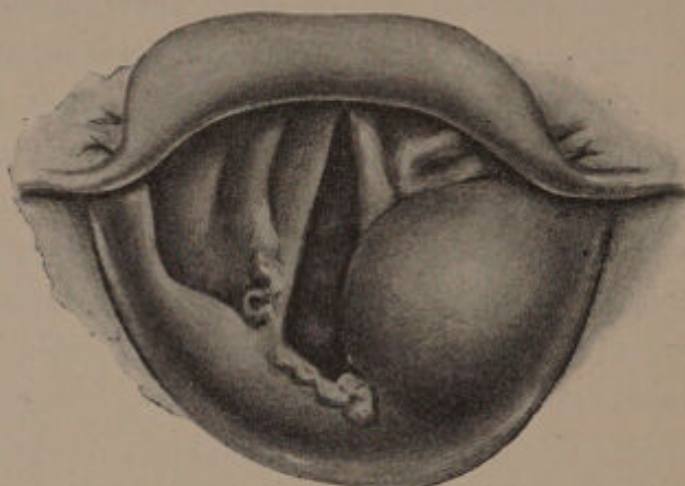


FIG. 126. TUBERCULAR ULCER WITH EXTREME SWELLING OF LEFT ARYTENOID.  
(Lennox Browne.)

small tuberculous foci which coalesce, giving the ulcer a characteristic *worm-eaten* or nibbled margin (Fig. 127). Superficial erosions resembling aphthæ may occur. Necrosis and caries are not uncommon and may involve almost any of the cartilages. Among the un-

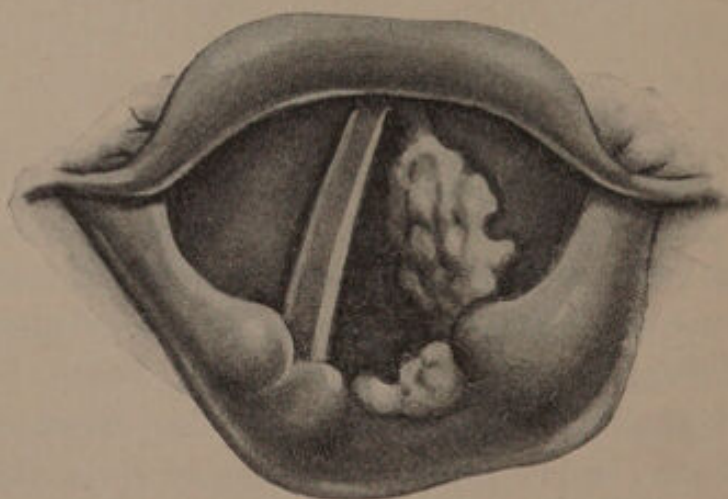


FIG. 127. TUBERCULOSIS OF LARYNX IN ULCERATIVE STAGE.  
(Lennox Browne.)

usual forms of tubercular development within the larynx are what have been designated granulomata, papillary excrescences at the posterior commissure, and distinct tumors or nodules, usually rounded



and smooth and covered by mucous membrane not differing from that of other parts of the larynx (Fig. 128). These tumors seldom soften and ulcerate, and are most frequently seen on the lateral walls of the larynx, or in the trachea just below the vocal bands. Wart-like growths between the arytenoids are occasionally seen in syphilis and in chronic laryngitis, but point to incipient tuberculosis when

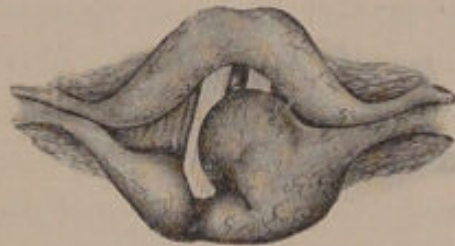

FIG. 128. TUBERCULAR TUMOR OF LARYNX. (*Rice.*)

associated with pallor of the mucous membrane or suspicious pulmonary signs. Granular hyperplasiae at times reach a considerable volume, especially when springing from the margins or base of an extensive ulceration. They usually shrink before offering any serious impediment to breathing. The contrary was true in a case once reported by the author, that of a boy twelve years old, in whom laryngeal stenosis from tubercular granulomata demanded an intu-



FIG. 129. TUBERCULAR ULCERATION AT POSTERIOR COMMISSURE AND VOCAL PROCESSES. (*Schnitzler.*)

bation and finally a tracheotomy, death occurring a few weeks later from general tuberculosis. The youth of this patient and the presumption that it is an instance of primary laryngeal tuberculosis give the case especial interest (Fig. 129).

The symptoms of general tuberculosis, anorexia, emaciation, hectic, rapid pulse, night sweats, cough with expectoration, and possibly



hemoptysis are marked in proportion to the degree and activity of pulmonary involvement. Nutrition may be interfered with by a very extensive laryngeal lesion before signs of pulmonary disease are in evidence.

A differential diagnosis must be made from cancer and syphilis. Confusion is not likely to arise from other sources. In the former there is sooner or later marked cachexia, more or less constant pain, frequently shooting toward the ear of the affected side, aggravated by swallowing and more intense when fluids are taken. The lesion itself begins as a neoplasm, later becoming a deep, ragged ulcer coated with grumous, fetid secretion and surrounded by a livid or purplish areola. The mobility of that side of the larynx affected is impaired early by the infiltration. The voice is lost and stenosis may be extreme. In syphilis the voice is hoarse and low-pitched, but complete aphonia is rare until late destructive ulceration or cicatricial contraction occurs. The latter condition may also cause excessive dyspnea. The ulcer itself is comparatively free from pain, and the constitutional symptoms are as a rule unmistakable. The lesion is usually clean cut with raised indurated edges and covered with necrotic detritus. Characteristic scars in the pharynx or elsewhere, or traces of the disease at some other part of the body, even in the absence of a history, or of active symptoms, will usually solve the problem. The greatest perplexity arises in connection with latent syphilis, or "syphilis ignoré," and in cases of mixed infection. An example of the latter in my own experience was betrayed by typical ulceration of the fauces which healed under mixed treatment leaving characteristic scars. The patient had already been sent to a mild climate for tuberculosis, the latter diagnosis having been based on pulmonary and general symptoms confirmed by tubercle bacilli in the sputum. Lupus, glanders and leprosy, all very rare diseases, may simulate the local appearances of tuberculosis, but the history of these is usually conclusive. In exceptional anomalous cases the diagnosis must be held in abeyance almost indefinitely. This applies particularly to primary tuberculosis of the larynx. Pulmonary disease may be so deep-seated, or limited, as to give no signs, and, moreover, infection may take place in the larynx and may remain localized in that organ for a considerable time. In very rare cases of chronic



laryngitis the hypertrophy of the mucous membrane may be so extreme as to resemble a tubercular infiltration, but such conditions usually occur in those whose occupation and habits account for the extraordinary thickening.

In the laryngeal mirror the characteristic appearances of a tubercular larynx are the semi-solid, edematous infiltrations or the "worm-eaten" ulceration involving the epiglottis, the arytenoids, or the aryepiglottic folds. Usually the lesions are symmetrical or bilateral. The ulcer of tuberculosis is covered with pale granulations, its floor is not deeply excavated, and its edges are irregular and nibbled, owing to the confluence of small marginal ulcerations and breaking down of minute tubercular foci. There is seldom an areola as in cancer and syphilis; on the contrary, the surrounding parts are pale.

The prognosis in tubercular laryngitis is admittedly bad, but by no means hopeless. Life may be threatened by suffocation, by inanition, or death may occur from hemorrhage, yet the laryngeal lesion itself is seldom fatal except as it may interfere with the patient's nutrition through inability to swallow. Serious hemorrhage, unless of pulmonary origin, in laryngeal tuberculosis is extremely rare, and sudden stenosis from edema or swelling equally so.

*Treatment.*—The fact must be recognized that in most cases the laryngeal lesion is simply one phenomenon in a constitutional disease. We are called upon to treat, however, not only the general condition but certain local lesions which interfere with the patient's comfort and tend to shorten his life. A prominent subjective symptom is the persistent cough. The neurotic element is, in some cases, very marked and may be overcome in a measure by the use of sedatives, such as the bromide of potassium or sodium which may be given in full doses, or small doses frequently repeated. It is important to protect the patient from irritating atmospheres as far as possible, to keep him in a uniform temperature, and to insist upon rest of the larynx and, when dysphagia is present, to provide nutriment easily swallowed and highly concentrated. It is found that large mouthfuls of food or drink may be swallowed with greater ease or less discomfort than small quantities. When odynphagia is very marked what is known as Wolfenden's method of feeding may be resorted to with success. The patient is directed to lie prone upon the face with



his head over the end of a lounge and is made to take nourishment in fluid form through a tube. It is a curious fact that some patients who can swallow absolutely nothing without pain in the ordinary position are able to do so with ease when in this attitude. Hovell recommends a simple and but little known method of relieving pain in swallowing by means of firm pressure with the hands of one standing behind the patient. The pressure should be applied parallel with the posterior border of the ramus of the lower jaw, the fingers being directed upwards, and gives greater relief the more firmly it is exerted.

There seems to be a difference of opinion about the effect of altitude in laryngeal tuberculosis. It is very certain that some patients do well, while others do not thrive, at high altitudes. As a rule, if heart complications or weakness exist, and in acute tuberculosis, it is best to keep the patient near the sea level. It has been observed that tubercular cases giving a history of long-standing antecedent catarrh which has advanced to atrophy do badly at high altitudes.

The usual general medication of supportive character is to be adopted. Cod-liver oil, or jecorol, hypophosphites alone or combined with oil, and in some cases the glycerophosphates of lime or soda will be found useful. Shurly warmly advocates iodine internally. He claims the best results when it is combined with some proteid, and is accustomed to give it in bouillon or milk. Arsenic, creosote, guaiacol and many other drugs are employed with possible benefit. Tuberculin, except as a diagnostic test, has been practically abandoned. It is impossible in a limited space to review all the internal remedies recommended at various times, and were all to be enumerated we should still be forced to the conclusion that at present a cure for tuberculosis does not exist. Our chief reliance in restricting and suppressing the disease must be upon a more faithful observance of hygienic laws in general and more stringent precautions as to those already infected.

Fatty foods if assimilated seem to be of service. An excellent and somewhat palatable preparation of "mixed fats" (Russell emulsion) is generally well borne. Careful nutrition is important. Tuberculous patients should be encouraged to eat rather more than they seem to desire. The appetite may be stimulated with bitter tonics or alco-



hol, unless the latter proves too irritating. In many cases alcohol seems to take the place of food and large quantities are consumed with apparent benefit. A life in the open air and sunshine should be urged. Avoidance of bodily fatigue and mental worry must be ensured as far as possible.

The local treatment of tubercular laryngitis is most important and in some degree encouraging. Soothing inhalations, such as compound tincture of benzoin, oil of pine, eucalyptus and menthol, agents whose object is two-fold, are indicated. In the first place they reduce hyperemia and irritation; and, in the second place, they correct the tendency to the formation of viscid secretions in the cavity of the larynx, the expulsion of which is accomplished with great difficulty. The most gratifying results in these respects will be found in connection with the use of menthol. Whatever view may be held in regard to its antiseptic properties there seems to be no question that it reduces congestion of the mucosa and renders the secretions more fluid and less tenacious. It may be applied directly to the diseased surface drop by drop with a laryngeal syringe in fifteen to twenty per cent. solution, or in much less strength with a nebulizer or fine spray. At first it is quite pungent and even painful without cocaine, but in a few moments a cool soothing sensation supervenes which is rather agreeable to most people. Menthol is soluble in olive oil or fluid albolene and may be used in the larynx either hot or at ordinary temperature, whichever seems more grateful to the patient. Weak solutions may be used at short intervals so as to keep up a continuous effect and give as good results as those of greater strength.

The use of iodoform, either by insufflation or in ethereal solution, or in an oily emulsion has been much in vogue and still is highly recommended. It is believed that equally effective and less disagreeable medicaments may be selected. It is more or less valuable in the ulcerative stage combined with morphine and an astringent, as follows: morphine, 10 gr., tannic acid, 2 dr., iodoform, 6 dr. (Bosworth). This may be insufflated daily with an ordinary powder blower, care being taken not to use an excessive amount of the powder. Formalin as a pigment in one to ten per cent. solution is highly recommended by Lake, either alone, or preferably combined with lactic acid according to the following formula. Formalin, 7 per



cent.; lactic acid, 50 per cent.; glycerine, 20 per cent.; and water to 100 per cent. It is important to use a fresh preparation as the solution loses its strength in a week or two. Formalin may also be used in powder as presented under the name *paraform*. In efficient strength the applications are quite painful although the pain is not very lasting. Decidedly better results, as regards relief from pain and coughing, follow the use of orthoform or anesthesin. It may be mixed with an equal quantity of powdered gum acacia or subnitrate of bismuth and is free from objection on any ground. It acts best on an ulcerated or abraded surface. The parts having been gently cleansed with a detergent are sprayed with a two per cent. solution of cocaine, eucaine, or nirvanin. Thus the surfaces are benumbed and the powder, which should be applied liberally, is not rejected by the act of coughing. In this way a respite of several hours or more may be given. The remarkable effects of insufflations of resorcin in promoting the repair of ulceration have been affirmed by McCall and others. It is best applied every other day mixed with orthoform in the proportion of one or two parts in three. These measures are almost certain to allay pain, and if resorted to shortly before food is to be given the nutrition of the patient may be sustained much more effectively than would otherwise be practicable. If they fail to arrest the cough we shall be compelled to have recourse to opium or one of its alkaloids, heroin, codein, or morphine. The first mentioned is perhaps the best as regards certainty of action and freedom from unpleasant after-effects, although its precise status in therapeutics is not yet fully established, several cases in which rather alarming symptoms followed its administration having been reported. In irritable pharynges and especially in the hyperemic form of tuberculosis excellent results have been observed from spraying the larynx with a suprarenal extract solution containing one grain of phenic acid to each drachm. In these cases it is important to use only a straight spray, the patient being taught to inhale at the moment. With a down spray there is danger of provoking spasm of the larynx and a violent paroxysm of coughing. Long curved tubes intended for insertion into the cavity of the larynx itself are quite unnecessary.

The modern method of treating tubercular laryngitis, by no means universally accepted, is based upon surgical principles as applied to



tubercular deposits in other regions. An attempt is made to remove the diseased tissues by curetting, or excision, and to convert the tubercular lesion into a healthy granulating ulcer by destruction of the morbid structures with a corrosive acid, preferably lactic acid. Many years ago the practice of puncturing the edematous and infiltrated tissues was proposed by Marcet. The painful tension often present in these tumefactions is thus relieved. According to Moritz Schmidt the swelling subsides and in addition beginning ulcerations heal. The fear once entertained of infection and ulceration of the wounds thus made is not supported by clinical experience. On the contrary repair takes place and relief of odynphagia may be quite complete. In this connection it should be noticed that spontaneous repair of tubercular ulcers in the larynx has several times been observed. Tubercular subjects moreover, almost invariably improve temporarily under any new system of treatment and it is difficult at first to determine how much potency should be ascribed to a new drug or application. Much-vaunted specifics prove after extended trial to be inert. One after another they have to be abandoned and the search for an antidote must be renewed. Hence one turns with hope to surgery, believing that although the disease itself may not be cured, prolonged suffering and a distressing death from an ulcerative tubercular laryngitis may be thereby averted.

The details of treatment of a tubercular larynx by curetting are described as follows. In the first place the patient may have to be put through a course of training in order to overcome the intolerance of the passages. It is impossible to perform any manipulations in the larynx satisfactorily unless the parts are under control. Usually, even if they are very irritable, sufficient tolerance may be established by a preliminary spraying of the larynx and fauces with a ten per cent. solution of cocaine. In curetting the larynx the field of operation is often embarrassingly obscured by the effusion of blood. This source of difficulty may be in a measure obviated by the use of a solution of suprarenal extract in alternation with cocaine. The ideal case for surgical treatment is one in which the tubercular infiltration is situated at the posterior wall of the larynx, either in the region of the arytenoids or at the posterior commissure. Tubercular deposits in other situations are less accessible but still if not too extensive they



may be amenable to this mode of treatment. The parts having been prepared a laryngeal curette, of the model of Krause or Heryng (Fig. 130), is passed into the larynx under the guidance of the mirror and the affected surfaces are thoroughly and boldly scraped until we are reasonably sure that the tubercular deposit has been completely removed, or has been sufficiently exposed. And here is the main difficulty. It is impossible to tell positively when the limits of the disease have been reached. We are compelled to rely upon a judgment authorized by careful study of the parts beforehand.

After the bleeding that has been excited has subsided we are ready for the application of the acid. The laryngeal applicator, wound

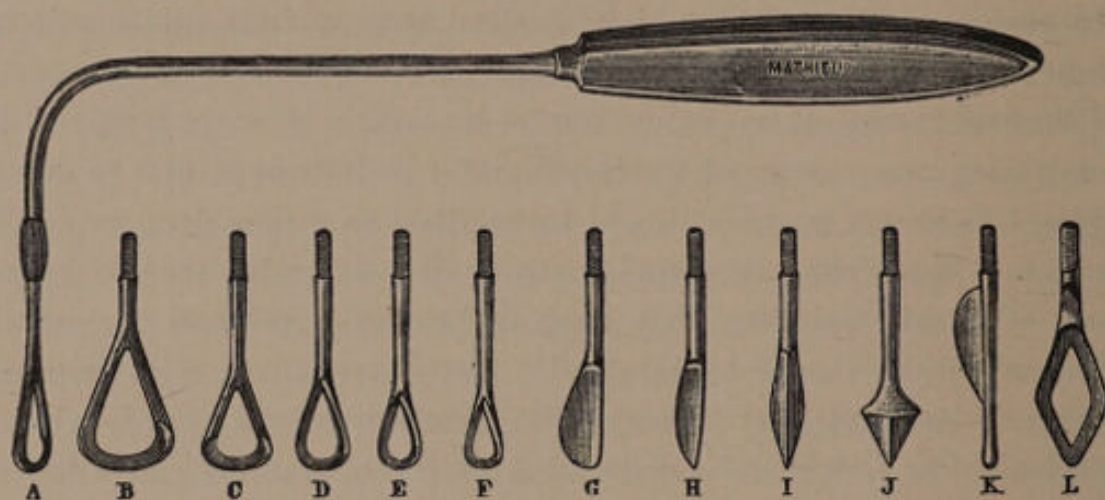


FIG. 130. HERYNG'S LARYNGEAL CURETTES AND SCARIFIERS.

at the end firmly with a small pledget of cotton, is dipped into the solution of the acid, and passed into the larynx, the mirror showing the way as with the curette. It is not enough simply to touch the abraded surface; the acid must be thoroughly rubbed in. The help of the patient is needed, and he should be taught to hold the tongue firmly between the folds of a napkin with the thumb and forefinger of the right hand. Lactic acid is said to have an affinity for morbid tissue and does not act upon healthy mucous membrane. While this statement may be true we should never begin treatment with the full strength of the acid, and care should be taken to avoid using an excessive quantity. It is best at first to use not stronger than a twenty per cent. solution, until we know what degree of reaction may be excited and how well the pain of the application may be endured, gradually increasing to full strength, if the patient is courageous and the parts not too sensitive.



When the effect of the cocaine has worn off there is always more or less discomfort, and usually actual pain, which may last several hours. After the lapse of a week the process of rubbing in the acid may be repeated with increased strength. The number of applications will depend upon the situation and extent of the lesion and upon the effects. Usually we see, after the second or third application, an effort at repair of the ulcerated surface. It is well to suspend interference for a week or two, or until signs of arrest of the reparative process, or of the development of new tubercular foci are evident. Cicatrization goes on with more or less rapidity until, in the course of two or three months, complete repair may be attained. It is unfortunate, however, that the cicatrices show a tendency to break down, either because of the failure of complete extirpation of the disease, or of inherent weakness in the tissues.

The use of lactic acid following curettage has many opponents, both because of the excessive pain often incident to the treatment and for the more important reason that results are far from satisfactory. Better results with practically no discomfort to the patient are claimed by Freudenthal for an elaboration of the menthol treatment proposed years ago by Rosenberg. The details of this treatment are as follows. The larynx is first thoroughly cleansed with some detergent solution, after which the parts are insufflated with three to six grains of powdered saccharated suprarenal gland. Cocaine has been discarded because of the paresthesia it causes in many patients, for the reason that it often affects the heart unfavorably, and finally on account of the fact that its solution is prone to decompose. These objections do not apply to powdered adrenal. After a few minutes an emulsion of menthol-orthoform made by the following formula is *slowly* instilled with a laryngeal syringe:

R.

Menthol .....	1-15
Ol. amygdal. dulc.....	30
Vitelli ovorum .....	25
Orthoformi .....	12.5
Aquæ destell. q. s. ad.....	100

Ft. emulsio.

The relief from pain lasts several hours or even days, so that a patient is able to take nourishment with ease. Under this method



it is claimed that infiltrations disappear and ulcerations heal, and it apparently has no objectionable features.

In the absence of ulceration excision of tubercular masses may be effected with a double curette or punch forceps. Applications or injections of cocaine, or nirvanin, permit this to be done without extreme pain. It is only suited to cases of very circumscribed disease. Indeed radical interference of any kind should be reserved for limited ulcerations and infiltrations within easy reach, for primary laryngeal disease and for cases in which pulmonary disease is circumscribed, incipient, and quiescent. It may be justifiable for the relief of excessive pain, or dysphagia, which yields to no milder measures. When the epiglottis alone is involved removal of this appendage through the mouth is feasible and seems to entail no special inconvenience. Such cases have been reported by Solis-Cohen and Hajek, and R. Lake mentions having three times removed the larger part of the epiglottis with the galvanocautery snare without pain and with good effect. Ulceration in this situation is often very distressing, yet a patient under my observation at the present time has lost nearly one third of his epiglottis and has never had a particle of pain. In laryngeal operations of this kind it is absolutely necessary that we should have the full consent and coöperation of our patient, not to mention the need of more than average dexterity on the part of the operator. Attention has been called by Lake to the occurrence of postoperative pyrexia as a positive indication for discontinuing operative interference.

In line with this mode of attacking tuberculosis of the larynx it may be mentioned that thyrotomy has several times been resorted to and that laryngectomy has been done fifteen times for actual or supposed tuberculosis, eight total and seven partial operations (Gleitsmann). It is hard to conceive that any circumstances would justify these procedures. On the theory that rest of the larynx is essential to secure repair of laryngeal ulcerations tracheotomy was practiced for several years. My experience with it leads me to believe that it merely adds one more source of discomfort without commensurate advantage. When the condition has become so serious that feeding by enemata or with an esophageal tube must be considered the time for active treatment of any kind is past and palliation is our last resource.



The influence of the chemical rays of light upon morbid processes has long been appreciated, and the subject has been recently taken up with renewed interest. In ancient times sun and air were considered essentials to health and life, and all the customs of the people were based on this idea. Electric light produces effects upon the system similar to those of sunlight, and modern phototherapy is the direct outcome of the old theory of light as a therapeutic agent. The power of sunlight at least to retard the growth of tubercle bacilli in culture tubes seems to have been demonstrated. The stimulus of light to the function of ciliated epithelium expedites chemical changes, or in other words oxidation, which result in activity. Thus the rays of light do double duty in destroying germs and in exciting movements of cilia which serve to clear out secretions and irritating particles from the upper air-track. Especial attention has been given to this matter by Freudenthal, who has experimented with the arc light and the incandescent light in tuberculosis of the lungs as well as of the larynx. A special lamp not yet perfected is designed to be placed over the thyroid and held in position for from thirty to sixty minutes. In cases of tubercular ulceration and infiltration of the larynx the subjective symptoms were relieved and a definite cure of the laryngeal lesion was observed. This method, which is certainly free from disagreeable features, is deserving of further trial. In this connection the observations of Wolfenden and Ross as to the therapeutic effect of the X-rays are of interest, their conclusion being that the rays stimulate rather than check the growth of bacilli.

Submucous and intratracheal injections of various substances, as advocated by Watson Williams, Chappell, Donellan and others, especially creosote, guaiacol, 20 per cent., lactic acid, and biniodide of mercury, 1 to 1,000, have not been widely adopted, but they seem to be efficacious in some cases. The galvanocautery is used by a limited number, but is generally regarded as more or less dangerous. Williams in particular advises the galvanocautery point in the subglottic region for flat diffuse infiltrations which cannot be easily reached with forceps. In the experience of some it has never caused an acute edema of the glottis or violent reaction of any kind, and it is especially recommended by Gouguenheim and Tissier for fungous vegetations, or "pseudo-polypoid" formations.



Electric cataphoresis, whereby the tissues are saturated with a medicament antagonistic to the morbid germ and stimulant to healthy repair, deserves more attention than it appears to have received. Guaiacol and oxychloride of copper have given the most satisfaction. Spherical electrodes of pure copper are preferred to needles for use in the larynx, since the former make no lesion of the mucous membrane. A weak galvanic current with the positive pole connected with the laryngeal electrode and the negative applied to the nape of the neck, may be used every other day, the interval and the duration of the sittings being regulated by the strength of the patient and the results. Some throats are so irritable that this method is not feasible even with cocaine anesthesia. The following advantages are claimed for cupric electrolysis (Schepppegrell). (1) There is no destruction of tissue, or lesion of the surface through which pathogenic germs may reinfect the system. (2) There is no reaction nor hemorrhage. (3) It requires no extraordinary skill, and is especially easy when direct laryngoscopy (Kirstein) can be used. (4) It is applicable to all cases of laryngeal tuberculosis.

Percutaneous galvanism and faradization have been used in tuberculosis of the larynx to a limited extent with apparently definite and favorable results, but no final conclusion regarding them has been reached.

It is somewhat the custom to pronounce the doom of an individual discovered to have tuberculosis and to content ourselves with efforts to ease his steps to the grave. Experience teaches that this desperate view should not be entertained. A few cases get well, some are cured, many have their lives prolonged, a large proportion are inevitably fatal. Yet we should not sit inactive and permit the ravages of the disease to go on unresisted. It is rather our duty, without relaxing the search for a remedial agent, to teach that hygienic living, pure air, and good food furnish the most effective weapons against the approach of the subtle enemy. As indispensable adjuvants we should insist upon voice rest, the avoidance of local irritants of every kind, the adoption of a diverting occupation, and abstention from over-exertion and physical fatigue. All of these conditions, which render home treatment possible and most desirable, are at the command of only the well-to-do. Segregation of those less fortunate in hospitals



and sanatoria should be under the strictest surveillance. Although tubercular subjects are as a rule sanguine and cheerful, yet upon certain temperaments the depressing effect of intimate association with other invalids is quite detrimental.

The principles governing the question of radical interference as laid down by Heryng are believed to be logical. In brief he regards cases of advanced pulmonary disease attended by hectic and emaciation, diffuse miliary tuberculosis and extreme inflammatory stenosis of the larynx as decidedly inappropriate for operation. In addition it is contraindicated in neurotic and timorous patients in bad general condition. Suitable cases for such treatment are few; cures in the proper sense of the word are fewer still; but even from the most conservative standpoint, except in extreme cases, we have within reach the means which enable us to assure amelioration of symptoms and prolongation of life. Obviously when called upon to treat a case of laryngeal tuberculosis we are brought face to face with a complex problem to be viewed from many sides. We may at least refrain from inflicting additional torture upon the sufferer by useless and possibly harmful local meddling.



## CHAPTER XXII.

### SYPHILIS OF THE LARYNX.

The lesions of *hereditary* syphilis in the larynx are somewhat rare. It may be admitted that a syphilitic dyscrasia is responsible for many derangements of the air-track in the new-born, but that pathological phenomena characteristic of syphilis are as frequent in hereditary as in the acquired disease is by no means established. On the other hand J. N. Mackenzie believes that laryngeal lesions in congenital syphilis are not infrequent, and are simply not found because not sought. Two cases have been reported by Monti of syphilitic development in the larynx in intra-uterine life. A division into secondary and tertiary is not found to be practicable, the first manifestations of hereditary syphilis often being deep destructive ulcerations. Usually the laryngeal lesions are associated with or follow characteristic affections of the eye, malformations of the teeth, or other phenomena distinctive of syphilis. Two thirds of the cases occur in the first year of life. Alteration of the voice and of the cry of the child, the occurrence of cough, dyspnea and attacks of laryngismus are commonly observed. Laryngoscopy is difficult but by no means impossible in the early years of life. Kirstein's mode of examining the larynx may be found feasible when the ordinary methods fail.

The best treatment of hereditary syphilis of the larynx consists of inunctions with mercurial ointment or the internal administration of gray powder. Some cases do better when mercury is combined with the iodides or hydriodic acid, or with general tonics.

Locally, mentholized or borated albolene in vapor or spray has a beneficial effect. The question often arises whether in the existence of evidences of active hereditary disease, enlarged tonsils and adenoids should be removed. The coexistence of a syphilitic taint should certainly not be regarded as a contraindication, if it is evident that these hypertrophies are making an impression upon the general health. Intralaryngeal infiltration or distortion from cicatricial con-



traction may so impair the lumen of the child's larynx as to suggest the necessity of tracheotomy or intubation. The latter mode of relieving the stenosis is preferable unless an excessive amount of cicatricial tissue be present. If the obstruction of the larynx has come on rather *gradually* it is probably due to cicatrices and, whether in children or adults, we are confronted by a most serious complication which is capable of relief only after a very tedious and rather unsatisfactory course of treatment. Internal medication cannot be expected to make any impression on adventitious bands of scar tissue, and we are forced to choose between the introduction of a trachea tube, an intubation, and division with dilatation of the stricture. A tracheotomy may be required as a preliminary to attempts to overcome the stenosis by the use of bougies. Months and even years may be spent in the process of stretching a syphilitic stricture of the larynx and after all the result may not be permanent. In any case the phonatory function of the larynx will have been impaired or lost. Experience with the O'Dwyer tube of vulcanite or metal is quite encouraging. The metal tube has a proportionately larger lumen and its weight tends to keep it in place. In one of O'Dwyer's cases the tube was worn upwards of a year. In the exhaustive reports on this subject by Lefferts and by W. K. Simpson abundant evidence appears of the value of intubation in these cases and of the ease with which the tube is tolerated for a very long period. In view of the tardy and often disappointing results from this method partial resection of the larynx has been advocated by certain authorities. Schroetter, a most enthusiastic partisan of systematic dilatation after tracheotomy, has had several successful cases with the use of tubes of gradually increasing diameter, and similar success has been achieved by others (Fig. 131). Dilatation from below through a trachea tube has been recommended by Stoerk and may be preferable in some cases. Rapid stretching of a syphilitic stricture is almost invariably followed by excessive inflammatory reaction and should never be employed. The "dilating laryngotome" of Whistler, an almond-shaped dilator in which is concealed a knife blade to be protruded by a lever in the handle of the instrument, seems to have given excellent satisfaction in many cases. It has been modified by Lennox Browne by making the shaft of the instrument hollow and



thus the operator is enabled to make the incisions with more deliberation and certainty without fear of completely obstructing the air-track. The results of treatment are much more gratifying and permanent in the larynx, as elsewhere, provided the bands of scar tissue are thin and not very numerous. In many cases, especially if the stenosis involves the trachea as well as the larynx, the only resource is a trachea tube to be inserted as low as possible and permanently retained. Stenosis of the larynx developing somewhat *rapidly* is generally caused by edema or by gummatous infiltration. The marvellous and prompt relief given in these cases by internal medication, even when a tracheotomy seems unavoidable, has been insisted upon

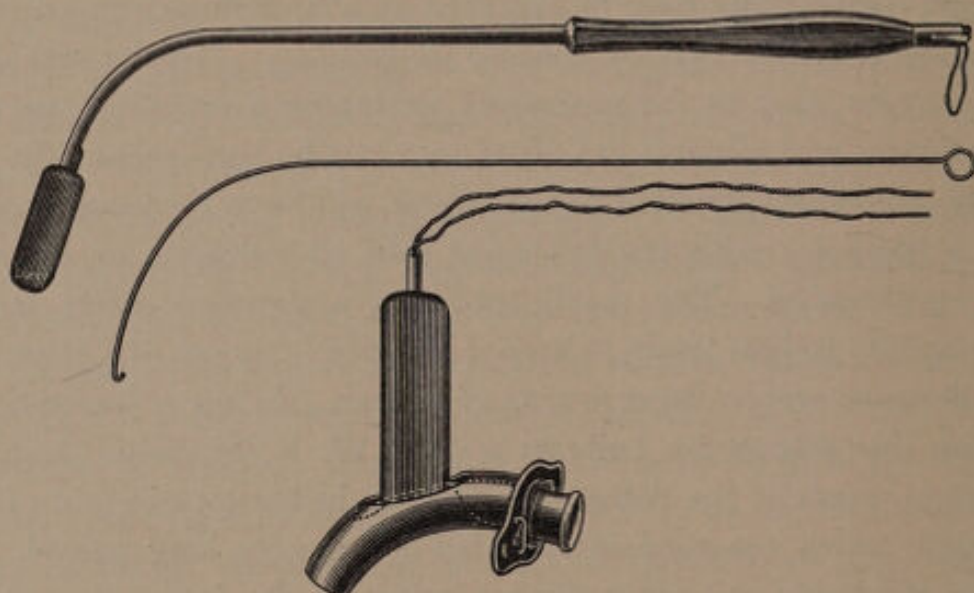


FIG. 131. SCHROETTER'S LARYNGEAL DILATOR.

The metal plug is attached to the introducer by a twine which is drawn through the hollow handle by means of the slender flexible hook. The plug fits into the fenestra of the trachea tube and is held in place by the inner tube the upper part of which is prolonged as a solid rod.

by Krishaber and others. A boy, ten years of age, was once brought into my clinic cyanotic and gasping for breath. There seemed to be no time to ask questions, so I at once opened the trachea. The history of the case afterwards obtained proved clearly that the boy was a victim of hereditary syphilis. The usual treatment was followed in a few days by subsidence of the laryngeal stenosis so that it was possible to remove the trachea tube. The laryngoscope showed extreme deformity of the larynx from old ulceration and cicatricial bands, but the breathing space was ample and very likely might have



been rendered so by internal medication alone without the aid of a tracheotomy.

The lesions of *acquired* syphilis of the larynx are limited to those of the so-called secondary and tertiary periods. Wide discrepancies exist among authorities as to the frequency of its occurrence, one observer having met with it in only 2.9 per cent. (Lewin) of all laryngeal cases observed; another found it in 34 per cent. (Sommerbrodt).

Predisposing causes of syphilis of the larynx in the acquired disease are preëxisting catarrhal conditions, neglect of treatment in the early stages, and bad hygiene such as often prevails among the poorer classes. Primary syphilis has not been met with in the laryngeal cavity. A case of chancre of the epiglottis reported by Moure is unique.

Secondary lesions generally coexist with a cutaneous eruption, or closely follow it. An erythema of the larynx is very apt to accom-

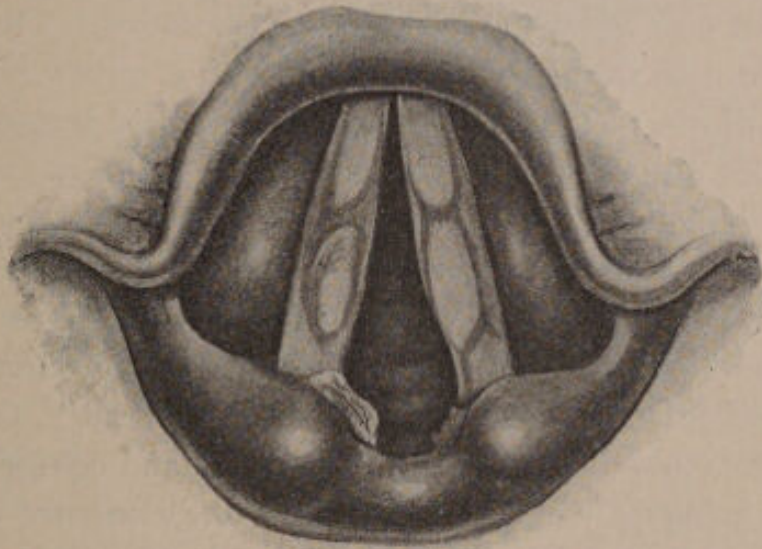


FIG. 132. EARLY SECONDARY LESIONS OF VOCAL BANDS. (Schnitzler.)

pany a similar condition in the fauces, and differs but little from a simple erythema except that the redness of the former is less intense and less diffuse, the membrane having a mottled appearance. It causes no symptoms of importance except more or less hoarseness, and requires no very energetic local treatment (Fig. 132).

The possibility of the occurrence of mucous patches in the larynx has been denied by many excellent observers, but numerous authentic



cases are now on record. When present on the epiglottis they often appear as condylomata or warty excrescences. These lesions are seldom symmetrical. They disappear under treatment or spontaneously but are prone to recur. They are often found associated with general erythema which involves the pharynx as well. They may be single or multiple and in the mirror present the appearances characteristic of mucous patches in other regions, namely, elevated erosions with a surface of a peculiar grayish hue and surrounded by a more or less pronounced areola of redness. It is quite probable that the existence of mucous patches in the larynx often fails to attract attention on account of the slight functional disturbance they excite, and of the greater importance of coincident symptoms.

The form of superficial ulceration named by Whistler "relapsing ulcerative laryngitis" possibly begins as a mucous patch. The voice is generally husky and raucous. The singing voice is likely to be absolutely abolished and the probability of its recovery is very doubtful. Respiration may be wheezy. There is more or less irritating cough without an excessive amount of expectoration. There is seldom any pain. In examining the larynx with a mirror we find instead of a uniform redness of the mucosa a mottled hyperemia, and erosive patches may be seen on the ventricular bands, upon the free edge of the epiglottis, on the arytenoids, or at the posterior commissure. Gottstein describes them as "round or elongated grayish-white spots of thickened epithelium, slightly raised above the congested tissue which surrounds them, and either sharply circumscribed or shading off into the congested mucous membrane." Ordinarily, there is no very obvious change in the texture and conformation of the mucous lining of the larynx except in the existence of diffuse condylomata. Occasionally the edges of the vocal bands may be eroded or notched and adhering to them may be seen masses of viscid secretion. Usually confirmatory symptoms elsewhere in the body are present. A cutaneous eruption, posterior cervical or epitrochlear lymphadenitis, or some of the other well-known symptoms of secondary syphilis, may establish the diagnosis. The impairment of general health may be no more than might be reasonably expected from the systemic disturbance unless the laryngeal lesions are so aggravated as to interfere with rest at night, or with comfort by day (Fig. 133).



The so-called *tertiary* lesions of acquired syphilis are of much more serious importance. They may begin in the deeper tissues or may reach them by extension from the surface of the mucous membrane. They occur as gummatous tumors or infiltration and as ulcerations superficial or deep, resulting from disintegration of gummatous infiltration. The latter present the form of circular or crescentic ulcers, with sharp elevated edges, sometimes undermined, surrounded by an inflamed areola. The color of the mucous membrane is somewhat

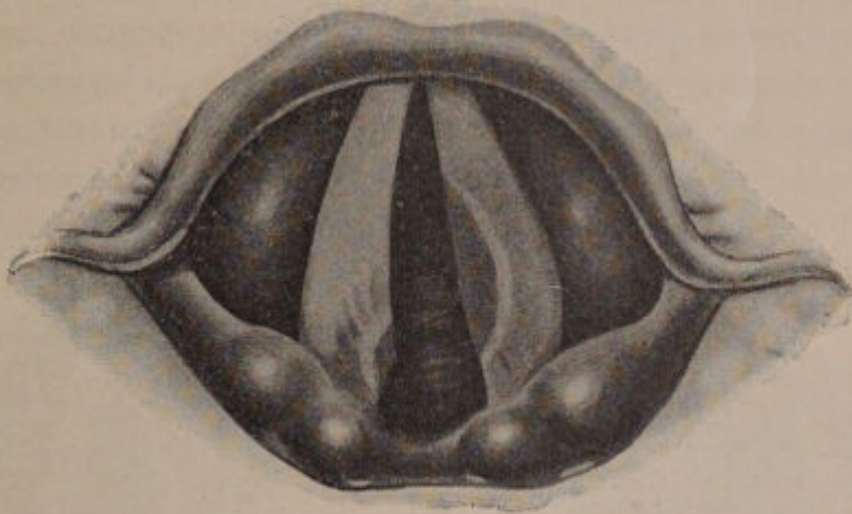


FIG. 133. SUPERFICIAL LESIONS OF VOCAL BANDS IN EARLY SYPHILIS.  
(Schnitzler.)

less red than in simple inflammations. The resultant deformity varies with the degree of infiltration, the loss of tissue, or the disposition and extent of cicatricial formations. The effect upon the voice depends entirely upon the site of the lesion, whether upon the vocal bands themselves or at some point where the action of the intrinsic muscles of the larynx is only slightly interfered with. Dyspnea may be due to infiltration, cicatricial contraction, edema, or ankylosis of the cricoarytenoid joint. More or less cough is usually present, and the expectoration is sometimes streaked with blood when an active ulcerative process is present. Deglutition may be impaired and painful if an ulcer involves the margin of the glottis. There may be no cachexia or impression upon the general health unless swallowing is interfered with (Fig. 134).

In all therapeutics there is no more satisfactory and definite result of treatment than in the disappearance of a gummy tumor under the



influence of iodide of potash, provided the stage of softening has not been reached. It is a remarkable fact that one of these tumors may remain quiescent for months or even years and then from some inexplicable cause begin to break down and ulcerate. A gummatous infiltration may be diffuse or in the form of circumscribed tumors, single or multiple. Dyspnea is proportionate to the degree of encroachment on the respiratory track and interference with phonation varies with the relation of the lesion to the vocal bands. There is always danger of an access of inflammation or edema which may cause a dangerous stenosis. There is seldom much pain unless the rim of the glottis is involved in ulceration, or the perichondrium and the cartilages become affected. Necrosis or caries of the cartilage may take place. A fragment of dead cartilage may be extruded in the act of coughing, or may become embedded in a dense mass of

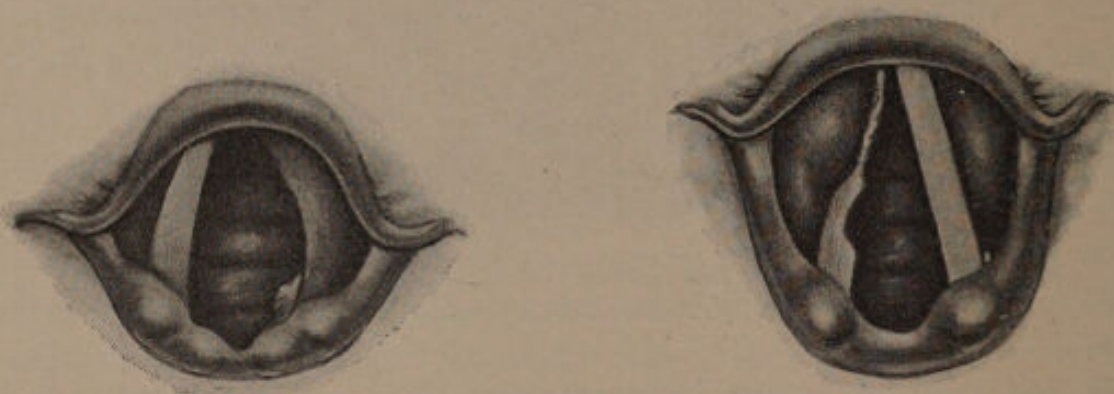

FIG. 134. DESTRUCTION OF VOCAL BANDS BY LATE SYPHILITIC ULCERATION.  
(Schnitzler.)

cicatricial tissue. Usually a gummy tumor develops rather rapidly and presents as a symmetrical painless tumefaction covered by normal mucous membrane. It may be impossible, especially in the absence of a positive specific history, to differentiate the condition from a malignant neoplasm without resort to a test with antisyphilitic treatment. The importance of recognizing a gummy tumor before the process of disintegration has begun must be obvious. When ulceration is established we have to look forward to the deformity from distorting scars which always follows repair of a syphilitic ulcer.

The prognosis in tertiary syphilis should be guarded. The patient may be in danger from edema implanted upon a more or less extensive infiltration, or from hemorrhage due to invasion of a blood-vessel by an ulcerative process.



The *treatment* should be active and in accordance with the method of treating syphilis in general. In secondary laryngeal lesions mercurials are indicated and, locally, the condition should be handled by soothing or stimulating inhalations as in simple chronic laryngitis. Nitrate of silver, unless ulcerations are present, is best avoided from its tendency to promote hyperplasia. In the deeper tertiary lesions the iodides in rapidly increasing doses, combined with cod-liver oil and general tonics, and alternating with mercurial inunctions, or used together with them, will give the best results. In the tertiary ulcers, nitrate of silver in strong solutions, or fused on a probe, and even the galvanocautery, may be required to stimulate healthy reparative action. Stenosis due to infiltration will usually yield to saturation of the system with the iodides. The management of that resulting from cicatricial contraction has been described.



## CHAPTER XXIII.

NEUROSES OF THE LARYNX. HYPERESTHESIA. ANESTHESIA. PARESTHESIA. NEURALGIA. HYSTERICAL APHONIA. LARYNGEAL VERTIGO. CHOREA. SPASM OF THE LARYNX. LARYNGEAL STRIDOR AND WHISTLING. PARALYSIS OF THE LARYNX.

### SENSORY NEUROSES. HYPERESTHESIA OF THE LARYNX.

Hyperesthesia, or excessive sensitiveness of the larynx, is usually symptomatic of some inflammatory condition, and is especially noted in phthisis and in carcinoma. The degree of normal sensitiveness differs greatly in different individuals and is apt to be more marked in those of nervous temperament. It is exaggerated in alcoholics, while, in syphilis, it is usually diminished. In conjunction with abnormal pallor of the mucous membrane it must be regarded as of rather serious import in relation to the probable development of tuberculosis.

### ANESTHESIA OF THE LARYNX.

Anesthesia of the larynx may result from some lesion involving the trunk of the superior laryngeal nerve. It is frequently marked in central nervous troubles, in hysteria, and as a sequel of diphtheria. In some cases of chronic laryngitis there is diminution in the sensitiveness of the laryngeal mucosa. In anesthesia of central or bulbar origin nothing can be effected by treatment. In other cases the use of nerve tonics is indicated, and faradism is of service, the internal electrode being placed in the sinus pyriformis in order to bring it as near as possible to the superior laryngeal nerve (Ziemssen). If the lesion is bilateral there is danger from the entrance of food or foreign bodies into the air passages.



## PARESTHESIA OF THE LARYNX.

Paresthesia, or perverted sensation, of the larynx, includes burning, tickling, a sensation of a foreign body, a constant desire to swallow, and a simple feeling of irritation. It may be associated with some organic structural lesion, or the consequence of lymphoid hypertrophy at the base of the tongue. It may occur as a reflex phenomenon from disease in some remote region, or it may be merely a symptom of neurasthenia or hysteria. The tickling sensation is very annoying, and occurring in the course of certain tubercular lesions of the larynx or in the pretubercular stage, is provocative of distressing cough.

## NEURALGIA OF THE LARYNX.

Neuralgia of the larynx is said to occur in the course of rheumatism and gout and in malaria. Pain is a prominent symptom in cancer and phthisis and in connection with some acute inflammatory troubles, but genuine functional neuralgia of the larynx is believed to be a rare occurrence. Associated with spontaneous pain there may be tenderness on pressure over the larynx externally, especially in the vicinity of the greater cornu of the hyoid. There is no abnormal appearance to be seen in the laryngeal mirror. Reported cases, like that of Schnitzler, in which the pain was so intense that the patient was on the verge of suicide, and which was cured by brushing the larynx with a solution of chloroform and morphine, and like that of Bosworth, in which tracheotomy was contemplated for the relief of a sense of suffocation and in which a cure was effected by aconitia pushed to its physiological effect, would suggest that the condition must be regarded as, in large part, hysterical. In all probability, any pronounced impression would have induced a cure. Such cases are amenable to hypnotic suggestion. Most of these sensory neuroses occur in neurotic subjects and in those in impaired general health. The indications then are clearly for the use of general tonics and good hygiene, combined with mental diversion. The galvanic current, the positive pole in the larynx, has been found beneficial.



## MOTOR NEUROSES. HYSTERICAL APHONIA.

An interesting functional neurosis not infrequently met with in females, hysterical aphonia, is characterized by complete loss of voice without any gross lesion of the larynx. Phonatory movements of the larynx are symmetrical but incomplete; the cords fail to approximate in attempts at phonation, or at once retreat after momentary adduction, and the patient merely succeeds in producing a whisper. The loss of voice may be as complete as in inflammatory conditions, but while the laryngeal picture in the latter is abnormal, in hysterical aphonia there is no deviation from health. The ability to cough is retained, this condition thus differing from a genuine paralysis, and under general anesthesia phonatory power is usually restored. There is rarely any interference with breathing, a single case having been

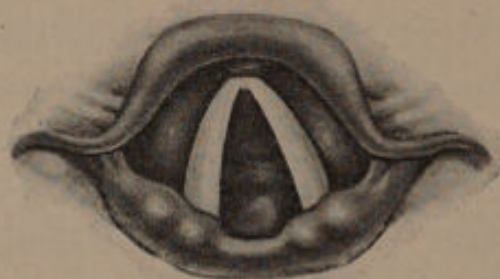


FIG. 135. HYSTERICAL PARALYSIS OF ADDUCTORS. (*Schnitzler.*)

reported by Meschede in which the affection simulated bilateral abductor paralysis, and the necessity of opening the trachea was being considered, when the voice was suddenly recovered and the dyspnea ceased. The loss of voice and its recovery are generally equally abrupt. The occurrence of sudden shock or extreme excitement will act as a stimulant to phonation or, if any doubt remains as to the character of the trouble, the administration of an anesthetic will clear it up. Not infrequently hysterical aphonia is of reflex character dependent upon uterine disease, or upon some lesion in the nasal chambers or the naso-pharynx (Fig. 135).

## LARYNGEAL VERTIGO.

Laryngeal vertigo, also called laryngeal apoplexy, laryngeal syncope and complete glottic spasm, is a rare condition usually preceded



by a sensation of tickling or discomfort in the larynx and paroxysmal cough. The patient grows dizzy, generally falls, becomes momentarily unconscious, and presently recovers without any subsequent ill effects. There are sometimes some congestion of the face and slight convulsive movements which are not to be confounded with those of true epilepsy. The condition resembles somewhat the epileptiform seizures which occur in tabes. There is no laryngeal lesion discoverable. Charcot likens it to Menière's disease and believes it is reflex in character, resembling the vertigo occurring in aural and gastric disturbances. Nearly all the cases observed occurred in males past middle life. The attacks may vary from a single one to as many as fifteen a day as reported by Charcot. McBride believes the attacks are due to forced expiratory efforts against a partially closed glottis which causes congestion as in prolonged paroxysmal cough and whooping-cough. F. I. Knight, who has made a careful study of this subject, corroborates the views of McBride in large part, but notes the fact that the presence of spasm of the glottis in most cases has not been proved, and he surmises that even in its absence the head symptoms and loss of consciousness occurring in these cases may be readily explained by the disturbance of the cerebral circulation consequent upon rapid respiration.

The prognosis is good. There is seldom any serious complication and the correction of any local disease or general disturbance should be followed by a disappearance of the laryngeal symptoms. In all cases careful examination should be made of the pharynx, base of the tongue and upper air-track; not infrequently hyperemia or varix at the base of the tongue will be discovered which may be relieved by the use of the galvanocautery. Astringent applications to the pharynx and counter-irritation over the larynx have been recommended.

In some cases the bromides or other nerve sedatives, iron, ergot and salines will be found beneficial and careful attention should be paid to the diet and the condition of the digestive track. Stimulants should be avoided.



## CHOREA OF THE LARYNX.

Chorea of the larynx usually occurs in connection with some other neurotic symptom or with general chorea. Almost invariably a local lesion like an elongated uvula, hypertrophy of the glands at the base of the tongue, or enlarged tonsils will be found to coexist as an exciting cause. The most conspicuous symptom is a dry explosive cough at short intervals through the day only. The voice is not affected, although phonation may be somewhat jerky. It is usually met with in girls approaching maturity, although one case has been observed at the age of forty-two (F. I. Knight). Gottstein believes that many of these cases are examples of so-called "nervous cough" rather than a genuine chorea, but so many cases have been reported by such careful observers as Lefferts, Roe and others that there can be no doubt as to the occasional occurrence of true choreic spasm of the glottis. The best results in treatment have followed the adoption of good hygiene, the use of electricity, bromide of potassium internally, or Fowler's solution in physiological doses. In all cases nasal stenosis should be corrected, and the abnormalities above referred to must be removed.

## SPASTIC APHONIA.

Spastic aphonia, or dysphonia, is the name given to a condition of violent adductor spasm occurring only on attempts at phonation and ceasing when the effort to speak is discontinued. It has been observed only in adults and generally in females. It is apt to follow overuse of the voice and has been compared by Schnitzler to "writer's cramp." In some cases the cartilaginous portion of the glottis remains open, in others the adduction is so forcible that the vocal bands actually overlap and stenosis is complete. In some the spasmodic movements are irregular, or clonic, producing what has been called by James "stammering of the vocal cords." In some cases the attacks increase in frequency and severity and are finally excited by other causes than the attempt to speak. Distinct pain or a feeling of cramp in the region of the larynx is sometimes present.



## SPASM OF THE LARYNX IN CHILDREN. LARYNGISMUS STRIDULUS.

Spasm of the larynx, or paroxysmal closure of the glottis, may be caused by some irritation of the recurrent laryngeal nerve, or of the trunk of the vagus, or may be of purely reflex origin, as from adenoids, difficult dentition or intestinal parasites. In children it is most common in the first two years of life and may be produced by very slight causes. It is more frequent in male children and in the winter months. Ill-nourished rachitic children are especially prone to laryngismus. In these cases also glandular enlargements, particularly affections of the bronchial glands, and diseases of the nervous system, notably hydrocephalus, are named as etiological factors. In children of highly nervous temperament a catarrhal inflammation of the larynx, or of the air-track generally, gastric or intestinal irritation, or any profound emotion may induce an attack. Usually there are no premonitory symptoms. The child goes to sleep at night in usual health, is suddenly awakened and after giving two or more short crowing inspirations ceases to breathe. After a few seconds and several long noisy inspirations normal respiration is resumed. Such attacks may be repeated at short intervals and interfere but little with health or comfort except at the time. In more severe cases the muscles of the extremities may be involved and general tonic convulsions may occur, with momentary loss of consciousness and irregular heart action. Attacks of this type are very terrifying as well as dangerous. In the milder cases it is noticed that the paroxysms are more apt to come on at night and that the intervals between them are shorter.

The prognosis is generally good, the liability disappearing with improvement in nutrition and decrease of nervous irritability. Death occasionally occurs in weak children from asphyxia or general convulsions. A fatal result may also follow sooner or later from pressure due to effusion in the ventricles of the brain. When the attacks are severe and frequent so that the general health begins to suffer the outlook is less favorable.

In the *treatment* of this condition it is important that attention be directed to the general health with a view of warding off the attacks.



At the same time the paroxysm itself must be relieved if possible, although it is clear that many of the measures resorted to under these circumstances are utterly useless. Yet in the presence of relatives frantic with fear and of a child cyanotic and apparently dying from apnea we are obliged to do something. In severe cases swallowing is impossible and respiration is suspended so that we are debarred from the use of internal remedies and inhalations until the spasm subsides. Tight clothing should be loosened and a supply of fresh air furnished by opening the windows. Friction of the extremities and purgative enemata are indicated. Immersion in a hot bath with cold affusions to the head may be useful. When the spasm does not yield catheterization of the larynx, intubation, or tracheotomy may be called for. The first mentioned is recommended by Gottstein. As a rule the case terminates by relaxation of the spasm or asphyxia before these resources can be made available. Artificial respiration and possibly stimulation of breathing by electricity may be of service. In the intervals the diet must be carefully regulated as regards both quantity and quality of food. Gastrointestinal derangements must be corrected and excessive nervous irritability must be controlled by sedatives, especially bromide of potash. Antipyrine has been used successfully, and various antispasmodics are now and then resorted to. Rickets, struma, lymphadenitis, anemia and other constitutional disorders require appropriate treatment. The use of morphine would probably be considered inadvisable by most practitioners, yet Bosworth regards a sixteenth of a grain of morphine combined with one five-hundredth of atropine hypodermically as effective and quite safe in a child of eighteen months. Scarification of the gums should be done in impeded dentition, and feeding with a spoon instead of allowing the child to take the breast, when as occasionally happens the act of nursing seems to excite an attack, should be tried. In high-strung nervous children the avoidance of undue excitement is very important.

#### SPASM OF THE LARYNX IN ADULTS.

The occurrence of spasm of the larynx in adults is very rare. Among the most frequent causes may be mentioned hysteria and pressure upon the pneumogastric or inferior laryngeal nerve by a



new growth or an aneurismal tumor, the compression being sufficient merely to irritate the nerve trunk without completely impeding its function. In epilepsy, hydrophobia, tetanus, chorea and locomotor ataxia spasm of the glottis is not uncommon. It frequently follows a local application to the larynx, especially if much force be used or the character of the application be irritating. Foreign bodies are very apt to provoke a spasm; neoplasms are less likely to do so because in their process of slow development the parts become accustomed to their presence. Bosworth refers to cases cured by correction of a deviated septum, reduction of nasal hypertrophies and removal of nasal polypi, and mentions having seen "some very interesting cases of laryngeal spasm in the chronic pharyngitis of alcoholism." A unique and perhaps dubious case is that of Hack in which the spasm is supposed to have been induced by a hyperemic condition of the mucous membrane of the pyriform sinus in which situation the superior laryngeal nerve is quite superficial. Except when occurring as a phenomenon of locomotor ataxia the seizures are generally nocturnal. They are very transient and seldom involve any danger to life except in tabes, although Heryng reports several cases of reflex spasm from intranasal disease in which tracheotomy was required. The treatment of the case otherwise depends upon the cause. Local lesions of the upper air-track must be corrected and so-called nerve tonics and sedatives may be indicated. Nearly all patients of this class are below par in general health and in a state of nervous erethism which predisposes them to all sorts of functional disturbances. Any modification of regime or habits which may contribute to improvement in these particulars must be enforced.

#### LARYNGEAL STRIDOR AND LARYNGEAL WHISTLING.

Two curious conditions are met with in young patients which may be mistaken for more serious lesions. The first, *laryngeal stridor*, appears in infants at or soon after birth, and is sometimes accompanied by a moderate amount of cyanosis and dyspnea. There is no aphonia. A difference of opinion exists as to its cause. It resembles ordinary laryngismus stridulus and has been considered by some a reflex spasm due to adenoids. Others believe that it is caused by



a paralysis of the posterior crico-arytenoid muscle. It seems probable, however, that it is due simply to that flaccidity of the laryngeal structures which exists in early life (Sutherland and Lack). The epiglottis folds on itself and the resilient walls of the larynx tend to collapse, thus impeding respiration. The condition is rarely dangerous and ordinarily requires no special treatment. Examination of the larynx is not easy and it might be difficult to differentiate this condition from that resulting from papillomatous growths or membranous obstruction.

After a very thorough study of the subject, A. Logan Turner and John Thomson reach the following conclusions: that the stridor is due to disturbance of respiratory coördination probably resulting from faulty or retarded development of the cortical center; that the altered conformation of the larynx is not congenital but is merely an exaggeration of the infantile type resulting from the constant sucking in of the aperture of the soft larynx in the peculiar breathing; that the sound is not pharyngeal nor tracheal, but is made in the larynx; that this neurosis is not due to adenoids or other reflex irritation. They believe that enlargement of the thymus or lymphatic glands is not concerned, because these lesions were not found in several cases examined post mortem, and because in two cases of pressure from enlarged glands the stridor was chiefly expiratory, the larynx did not move up and down in respiration, and respiratory distress was much more marked than it commonly is in cases of intralaryngeal obstruction. It is supposed that the stridor in the class of cases under discussion is produced partly in the larynx and partly by abnormal approximation of the aryepiglottic folds.

A very rare and curious phenomenon has been described under the name of "laryngeal whistling." A recent case was that of a boy of thirteen who produced a strange shrill whistle with the mouth wide open. It was possible to examine the boy with a mirror, but it was found in the production of the sound that the epiglottis was forcibly drawn downwards so as to prevent a view of the interior of the larynx; hence, it was impossible to determine precisely the origin of the sound, whether produced in the chink formed by forcible retraction of the epiglottis, or by the aryepiglottic folds, or by an extraordinary degree of tension of the cricothyroid muscles over which the



patient might, perhaps, have an unusual amount of control. It has been suggested also that this lad might have caused the sound with a membranous formation similar to the syrinx of birds. In a similar case reported several years ago by John O. Roe it was possible to study the parts during production of the sound, the patient being an adult and very manageable. This observer concludes that the whistle was produced by vibration of the vocal bands only in their middle third, the limitation of their action being assisted by contraction and depression of the ventricular bands. In high tones the arytenoids were seen to be forcibly drawn up under the epiglottis. A similar mechanism was found in the case of a professional ventriloquist in producing the primary ventriloquial tones, although he could not make a laryngeal whistle. The explanation here offered was confirmed by Elsberg in two cases of his own, and several other examples of this curious phenomenon are quoted. A different explanation is given by G. Hudson Makuen, and it may be that the feat of laryngeal whistling is capable of performance in various ways. He had an excellent opportunity to study the condition in the case of a young man who could whistle a tune with his mouth open. He found and was able to demonstrate to others that the aryepiglottic folds were pursed up precisely as the mouth is in whistling and that no other part of the larynx was used, the vocal bands having no more share in the laryngeal whistle than in the ordinary lip whistle. In still another case reported by C. E. Munger the ventricular bands seemed to be chiefly concerned, space for the air blast being left at the posterior fourth of the vocal bands which were elsewhere in firm contact.

### PARALYSIS OF THE LARYNX.

Interference with the action of the laryngeal muscles may be of myopathic origin or referable to some lesion of the nervous system, either central or of one of the laryngeal nerves in continuity. A typical example of the former may be seen in the aphonia occurring in tubercular laryngitis, due, in part, to mechanical interference with muscular movements by infiltration at the posterior commissure, and, in part, to a general muscular atony.

A very common form of myopathic paralysis is seen in the loss of



power of the thyroarytenoid muscles resulting from overuse of the larynx when inflamed. Vocal fatigue from muscular strain, whether in speaking or singing, often results in this condition. The thyroarytenoid muscles are the most important and interesting of the intrinsic muscles of the larynx as regards purity and sweetness of tone. Some of their fibers are distributed to the margin of the cord and are capable of limiting vibration to one portion of the vocal band. It is easy then to appreciate how inflammation of the bands may interfere with their delicate mechanism. Impairment of the action of these muscles produces very marked alteration in timbre and range of the voice, which is weakened and may be altogether lost. The laryngoscopic picture is perfectly characteristic and unmistakable. Instead of a close approximation of the cords an elliptic opening from

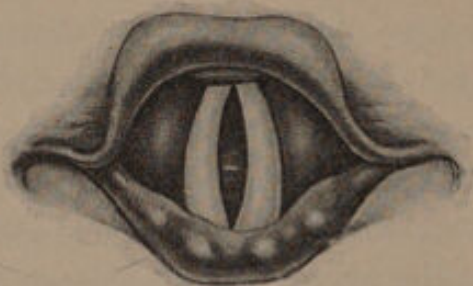


FIG. 136. BILATERAL PARALYSIS OF  
INTERNAL THYROARYTENOIDS.

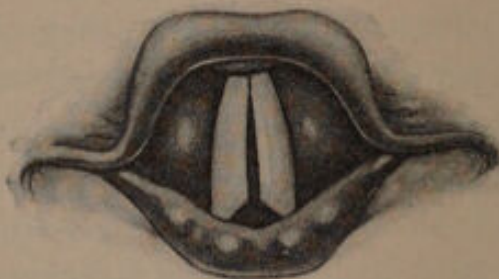


FIG. 137. PARALYSIS OF ARYTENOIDEUS.

the vocal process to the anterior commissure remains on attempts at phonation. A similar picture is presented, only to a more marked degree, when the cricothyroid muscle is paralyzed (Fig. 136).

The arytenoideus muscle may be affected in case of lesions of the superior laryngeal nerve which, at the same time, involve the cricothyroid muscle, when in addition to the elliptical opening between the bands anteriorly, a triangular opening exists at the posterior part of the *rima glottidis*, the only portions of the vocal bands in contact being the vocal processes (Fig. 137).

This muscle may also suffer in connection with a chronic catarrhal laryngitis, in incipient tubercular disease, in diphtheria and in hysteria. The voice may be hoarse, feeble, or entirely lost, attempts at phonation being very tiresome owing to waste of air in the expiratory blast (Fig. 138).



Bilateral paralysis of the lateral cricoarytenoids is a very rare condition. The laryngeal image is almost identical with that of bilateral paralysis of the recurrent laryngeal nerve. It may result from lead-poisoning, diphtheria, or from one of the exanthemata.

Unilateral paralysis is also very infrequent and is due to causes similar to those just mentioned. It is characterized by impaired rather than complete loss of voice, the unaffected cord attempting to compensate for the paralysis of the opposite cord by crossing the

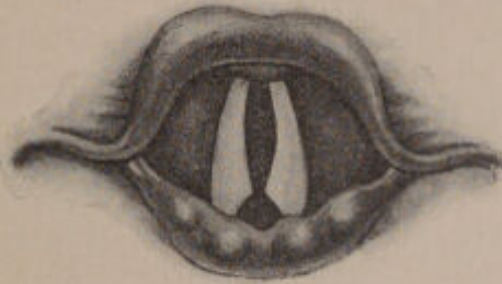

FIG. 138. PARALYSIS OF INTERNAL THYROARYTENOIDS AND OF ARYENOIDEUS.

middle line, the arytenoid cartilage on the sound side passing in front of the opposite arytenoid.

The prognosis, in all these forms of paralysis, is, as a rule, favorable provided we can place the patient under proper conditions.

The first indication in all is to secure rest for the larynx; in the second place, to remove the cause of the affection if it can be discovered. Electricity, by means of faradism or galvanism, may be used every day for ten or fifteen minutes, one electrode being placed within the larynx, the other externally. The general health should receive attention and the use of tonics, exercise, full diet and strychnia to its physiological effect, will assist recovery.

The most common form of paralysis of the vocal bands due to nerve lesion is *recurrent laryngeal paralysis*, which may be traced, in a large proportion of cases, to pressure upon the recurrent laryngeal nerve at the root of the neck, generally by aneurism of the arch of the aorta, or by enlarged lymphatic glands, mediastinal tumors, or esophageal growths, or by pleuritic adhesions at the apex of the lungs in tuberculosis. The last mentioned cause is met with more frequently upon the right side than upon the left. A central lesion from cerebral apoplexy, embolism, or occurring in the course of locomotor



ataxia, may lead to similar phenomena. The neuritis following diphtheria or typhoid fever may also result in paralysis of the inferior laryngeal nerve. In this condition the cord affected assumes the cadaveric position midway between abduction and adduction, the apex of the arytenoid being tilted forward. The unaffected cord crosses the middle line in phonation to meet the opposite cord, the sound arytenoid passing in front of the paralyzed arytenoid, giving a very distorted laryngeal picture. The loss of voice is usually not very

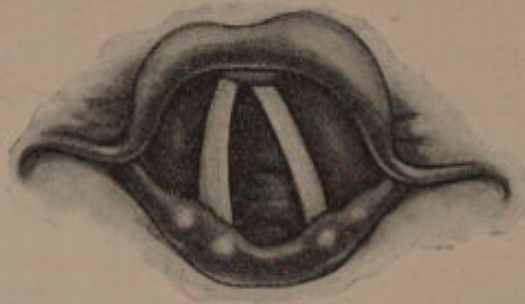


FIG. 139. PARTIAL PARALYSIS OF RIGHT RECURRENT DURING RESPIRATION.

marked, complete aphonia being the rule only when both recurrent nerves are affected. Paralysis of one nerve usually develops slowly and, as it progresses, the opposite cord has time to compensate for the loss of action on the part of the paretic vocal band (Fig. 139).

The prognosis of recurrent laryngeal paralysis depends upon the location of the disease and upon its duration. When it has existed

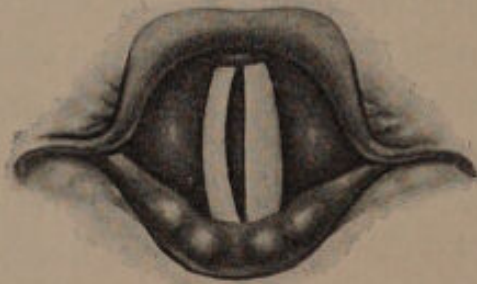


FIG. 140. PARTIAL PARALYSIS OF RIGHT RECURRENT DURING PHONATION.

for many months degenerative changes may have occurred in the muscles which cannot be overcome (Fig. 140).

The treatment should be governed by the nature of the cause of the affection. Post-diphtheritic cases recover under tonic doses of strychnia and the use of electricity. These methods, of course, should not be used in cases of paralysis due to aneurism or to pres-



sure upon the trunk of the nerve, although there is no objection to exercising the intrinsic muscles of the larynx by means of the faradic current if there is any hope that the function of the nerve may be eventually restored (Fig. 141).

A lesion of the *superior laryngeal nerve* results in complete anesthesia of the laryngeal mucosa as well as in paralysis of the cricothyroid and occasionally in paresis of the arytenoideus, in some cases the superior laryngeal nerve sending a few motor fibers to the latter muscle. The loss of sensation is sometimes an important feature necessitating artificial feeding, since anesthesia of the larynx may lead to inspiration of particles of food which would not be promptly rejected.

The laryngeal picture has been referred to in speaking of paralysis of the arytenoideus muscle, the only parts of the vocal bands in con-

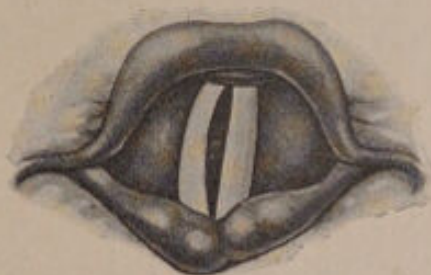


FIG. 141. COMPLETE RIGHT RECURRENT PARALYSIS ON PHONATION.

tact being the vocal processes, an elliptical opening remaining anteriorly and a triangular opening posteriorly during phonation. A large proportion of these cases result from diphtheria.

Recovery may be spontaneous in the course of a few months or may be deferred a year or more, but it may be expedited by judicious treatment, counter-irritation, stimulation with electricity, massage and tonics. In this, as in most other forms of paralysis, care should be taken to avoid overuse of the voice and all intercurrent inflammatory conditions should receive attention.

Paralysis of the abductors, or posterior cricoarytenoid muscles, may be bilateral or unilateral. The most frequent cause of bilateral abductor paralysis is a syphilitic lesion involving the special nerve center. It may occur in locomotor ataxia. Again, it may be due to lesions in the course of the nerve, such as neoplasm, aneurism, or



goitre. It may occur in lead-poisoning and is said to follow toxemia from various other chemical poisons (Fig. 142).

The dyspnea resulting from this condition comes on by degrees and is inspiratory. It is distinctly progressive, is aggravated by exertion or excitement and may become at any moment of serious import. Expiration is usually unaffected and the voice is unchanged except, perhaps, being slightly weaker than normal.

In the mirror, the image on phonation is unaltered; but, during respiration, the cords are seen lying near together in the middle line instead of being abducted.

The treatment will depend upon the cause discovered. If of syphilitic origin the disorder may frequently be remedied by the adminis-

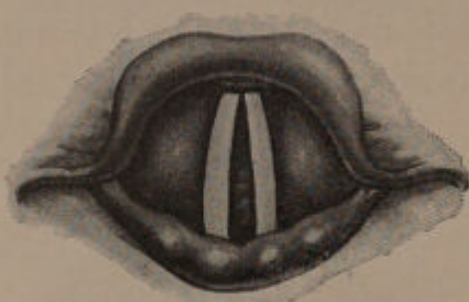


FIG. 142. PARTIAL PARALYSIS OF POSTERIOR CRICOARYTENOIDS DURING RESPIRATION.

tration of iodide of potassium, pushed to its fullest extent, at the same time, the muscular tone being preserved by means of electricity. The possibility of sudden laryngeal stenosis should be kept in mind and the probable necessity of intubation or tracheotomy. The latter seems to be preferred. In a case of my own in which the paralysis followed extirpation of a goitre, an intubation tube was worn for a short time but became so irksome to the patient that she insisted upon the trachea tube being introduced. The obvious advantage of the latter is that with the trachea tube *in situ* the patient is still able to phonate, which is not the case with an intubation tube. It has been proposed in inveterate cases of bilateral abductor paralysis to split the larynx and excise the paralyzed cords, a radical mode of treatment which has not received universal acceptance. Section of the recurrent laryngeal nerves which would result in placing the cords in the cadaveric position and, at the same time, abolish the voice, has been suggested by Krause. Section of the nerve of *one side only* might give adequate breathing space without destroying the voice.



Unilateral paralysis of the abductors may be due to causes similar to those acting in the case of bilateral paralysis, except that it has never been known to follow a central lesion, but the former is by no means a condition of equal seriousness. The voice is preserved and nothing anomalous is to be seen in the mirror during phonation, but on inspiration the affected cord occupies the middle line, while the sound cord is abducted in a normal way. Active treatment is seldom called for, except in syphilis, since the symptoms are usually unimportant.

The preponderance of abductor over adductor paralysis has led to the enunciation by Felix Semon of a law ascribing to the posterior cricoarytenoid muscles, the only abductors of the vocal bands, an especial vulnerability, in consequence of which adduction of the cords is the phenomenon first noticed in general laryngeal paralysis. The question has been hotly discussed. Recent investigations by Grossman seem to show that after division of the recurrent nerve the vocal bands assume a median position for a few hours or days, as the case may be, gradually becoming cadaveric. The primary position in adduction he explains by temporary action of the cricothyroid and the external muscles which, of course, are not affected by abolition of the function of the inferior laryngeal nerve. This view, however, drawn from experiments on the cat, is opposed by the best authorities, who find that in human beings the bands at once become cadaveric on section of the recurrent. A possible explanation of a posticus vulnerability may be found, as suggested by Grabower, in a peculiar difference in the way in which the nerve terminates in the abductors and in the adductors, in the latter its endings being broader and firmer. Hence we might expect the innervation of the adductors to be more vigorous and resistant than that of the abductors. Whatever explanation of the fact may be offered the majority of observers seem to agree that under electrical stimulation the laryngeal adductors exhibit more vitality than the abductors. In studying the innervation of the larynx confusion is apt to arise from the fact that the nerves of either side may cross to supply the muscles of the opposite side. Moreover many observations have established the fact that motor fibers from the superior laryngeal nerve sometimes pass to the adductor muscles. The whole question is so intricate and opportuni-



ties for observing paralysis of the larynx are so rare that a final solution of the problem has not been reached.

In relation to the question of laryngeal paralysis it may be of service to keep in mind the following propositions.

1. All the intrinsic muscles of the larynx are attached to the arytenoid cartilages, except the cricothyroid.

2. The cricothyroid arises from the thyroid cartilage and is inserted into the cricoid, hence in contracting it pulls up the anterior border of the latter, tilts the arytenoids backwards and makes tense the vocal bands, in the meantime the thyroid cartilage being immovably fixed by the action of the external muscles, the sternothyroid and the thyrohyoid.

3. The superior laryngeal nerve is the sensory nerve of the larynx, but sends motor fibers to the cricothyroid muscle and sometimes to the arytenoideus.

4. The inferior, or recurrent, laryngeal nerve gives motor fibers to all the intrinsic muscles, except the cricothyroid.

5. Nerve fibers in the vagus supplying antagonistic muscles run in separate bundles throughout the length of the recurrent nerve.

6. Adjacent cortical centers at the lower end of the ascending frontal convolution exist for both the adductors and the abductors and are bilateral in action. Hence bilateral *spasm* of the larynx follows irritation of the cortical center of either side, that of the adductors predominating because of the greater strength of these muscles.

Owing also to the bilateral action of the cortical centers laryngeal *paralysis* never results from a unilateral lesion.

7. In progressive disease affecting the innervation of the larynx the abductors are the first to succumb to paralysis and atrophy. If recovery takes place the reverse course is pursued and the adductors are first to regain tone.

8. In *complete* recurrent paralysis the vocal bands at once assume a cadaveric position, midway between adduction and abduction.

It is desirable but often quite impossible to differentiate between paralysis of the vocal bands and *ankylosis* of the cricoarytenoid articulation. Disturbance in the joint may follow exposure to cold, infection, rheumatism, tuberculosis, or traumatism. A feeling of discomfort or of slight pain on swallowing or when lying down may be



complained of. It is difficult for the patient to locate the sensation but it may be defined by palpation over the cricoid in the neighborhood of the joint. The pain is to be distinguished from that present in an aggravated degree of hyperesthesia of the superior laryngeal nerve by the fact, affirmed by Grünwald, that in the latter pressure must be applied at "the upper lateral border of the thyroid at its center." In some cases crepitation may be detected. In the laryngeal mirror nothing abnormal may be seen until periarthritic swelling supervenes, or the movement of the vocal band on the affected side, instead of being smooth and gliding, is uneven and jerky. The excursion of the band on attempts at phonation may be incomplete or entirely absent. If the band is fixed in a position simulating that of one of the forms of paralysis it may be possible to make a diagnosis only by excluding the probable causes of disturbed innervation. In most cases of ankylosis there is more or less permanent thickening about the joint, which of course is not a feature of paralysis. A position of a vocal band unlike that of a neurosis, that is, neither in adduction, abduction, nor cadaveric, a jerky movement of the band on phonatory efforts, and finally variable motility, or in other words more freedom of motion at one time than at another, are presumptive evidence of cricoarytenoid arthritis. The case is strengthened by a distinct history of rheumatism, of syphilis, or of tuberculosis. The greatest difficulty arises in connection with cases of complete fixation of the crico-arytenoid joint without thickening. A most important point, especially noted by Watson Williams, is the relation to each other of the arytenoids. Their relative positions in paralysis have been described: in ankylosis the sound arytenoid on phonation does not cross the crippled one, pushing it aside, but merely crowds up against it without displacing it. In certain old cases of paralysis the joint may become ankylosed from disuse, so that the point last mentioned is not invariably reliable.



## CHAPTER XXIV.

FOREIGN BODIES IN THE LARYNX. PROLAPSE OF THE VENTRICLE.  
FRACTURE OF THE LARYNX.

### FOREIGN BODIES IN THE LARYNX.

The subject of foreign bodies in the larynx carries the laryngologist somewhat beyond the limits of his territory, since in many cases a body supposed to have entered the larynx is found not in that cavity, but in the pharynx, the trachea, or a bronchus. It will be convenient, therefore, not to confine this consideration strictly to the larynx.

The importance of a foreign body in the larynx depends upon the shape and size of the object and upon its point of lodgment. Fatal asphyxia may follow the inspiration of a very large body, whereas a small sharp-pointed object, like a fish-bone, pin, or piece of glass, may not interfere seriously with the air current. An object with rough, irregular surfaces is much more apt to be caught in the laryngeal cavity than one with a smooth surface. A glass bead, for example, is likely to slip through the glottis, lodge in a bronchus and become the source of very serious mischief. A case which attracted great attention several years ago was that of a well-known clergyman who inhaled a cork he was holding between his teeth (Rushmore). The body passed directly through the larynx and lodged in a bronchus. Efforts to remove it through an opening in the trachea were unsuccessful and death from pneumonia finally ensued. The feasibility of reaching the foreign body in cases of this kind by a bronchotomy done from behind has been suggested. Almost any object that the mouth can hold is liable to be drawn into or towards the glottis so as to impede respiration. Children particularly have a fashion of putting everything in the mouth; whence, in deep inspirations preceding laughing or coughing there is danger of the foreign body being sucked into the lower air-track.

Usually the signs of invasion of the larynx by a foreign body are unmistakable; but, it is remarkable that one, even of large dimen-



sions, under some circumstances, may be retained for a considerable time without producing much disturbance. Several years ago I reported a case of tooth-plate, which fell into the larynx during a puerperal convulsion and was not discovered until one week later when the patient complained of sore throat. Lennox Browne, a few years ago, recorded a case in which a plate of artificial teeth was impacted in the larynx twenty-two months before it was recognized. S. W. Langmaid once removed a pin from the larynx two years after it had been inhaled, in the meantime hoarseness being the only symptom. Johnston's famous case of a toy locomotive, impacted in the larynx and removed several months after a tracheotomy for relief of the immediate symptoms, is probably unique.

In a large proportion of cases collected by Durham spontaneous expulsion took place in from one to seventeen years, and Gross records a case in which a piece of bone was retained in the air passages for more than sixty years. Cameron's case of a penny in the larynx for six years, and Cohen's two remarkable cases in which a foreign body, one of them a pebble stone, remained in the air-track for ten years without doing much damage, are noteworthy.

In striking contrast to the tolerance displayed in cases like those just mentioned is the violent and prolonged spasm often excited by a drop of water or a crumb of bread which may barely get into the larynx in that unpleasant phenomenon known as "swallowing the wrong way." Occlusion of the trachea has been known to follow the escape of caseous material from an ulcerating bronchial gland, and vomited matter not infrequently finds its way into the larynx, especially in the newborn, in weaklings, in alcoholics and during anæsthesia. Numerous instances of lumbricoids in the larynx, many of them fatal, have been recorded, and the introduction of leeches in drinking water seems to be a not uncommon accident in certain countries. A single instance in which the tip of the epiglottis curled back and became engaged in the rima glottidis so as to induce dangerous symptoms has been recorded by Ruehle. Cases in which an elongated uvula has not only irritated the larynx but caused serious embarrassment to breathing have come under my observation. In one in particular the patient was supposed to have edema of the glottis. Several cases in which the fragment of a broken dental or surgical



instrument has fallen into the larynx have been reported, and no less than twenty examples of broken or corroded trachea tubes dropping into the windpipe are to be found in literature.

The first symptom excited by a foreign body in the larynx is a paroxysm of coughing which, in some cases, is successful in expelling the intruder. Spasmodic contraction of the muscles in violent efforts at coughing may, on the other hand, drive a sharp-pointed body into the wall of the larynx where it will remain until removed by artificial means. Hemorrhage may be excited by a body of this character. Bosworth narrates an unusual case in which repeated attacks of hemoptysis were apparently caused by a calcareous mass resembling a tooth lodged in a bronchus without giving any physical signs. The bleedings ceased after the foreign body had been expelled by coughing. In all cases in which the accident is suspected attempts at laryngeal examination should be made but, owing to the perturbation of the patient, it is often impossible to get any view. Under these circumstances it often happens that a mistaken diagnosis is the result. The symptoms have been attributed, in some cases, to croup or whooping-cough. In a very extraordinary case referred to by DeForest Willard a tracheotomy was done and prolonged search made for an article afterwards found in the child's pocket, certain lung symptoms which were present being due to a pneumonia developing from ordinary causes.

In a case of my own in which the voice was lost and no other symptom was present after the first disturbance the electric current was applied to the larynx for more than a week with the hope of restoring the lost vocal function; at the end of that time a laryngeal examination discovered, lodged in the ventricle of the larynx near the anterior commissure, a *shoe-hook*. Six weeks later the boy was brought to my clinic where, after several ineffectual efforts at extraction through the mouth, I performed partial laryngo-fissure and removed the hook. Recovery was complete and, in the course of six weeks, perfect use of the voice was regained. It is claimed that Kirstein's method of examining the larynx in children under these circumstances, is particularly successful. My own experience in the case just detailed was not satisfactory. Quite recently an almost identical case has been reported by E. Fletcher Ingals, but



in the latter the foreign body was pushed upwards by means of a Trousseau tracheal forceps and then extracted with the finger passed into the mouth.

In every case, unless the symptoms be urgent, in which the presence of a foreign body in the air-track is suspected a careful laryngoscopic examination should be made before attempts at removal are undertaken. In many cases a tracheotomy for relief of dyspnea must be done at once, and an examination made later. The precise location of a foreign body may be defined by means of the Roentgen rays when it cannot be discovered by inspection. Little or no reliance should be placed on the statement of a patient as to its situation, since subjective sensations are altogether misleading. It is a very common experience for a patient to point with confidence to the exact spot, where nothing can be detected except slight redness, or perhaps an abrasion or scratch made in transit by a foreign body which has been swallowed. These *imaginary* foreign bodies comprise a very large proportion of those which the surgeon is called upon to remove. On the contrary, a pin or a small fish-bone may become embedded in a lymph follicle at the base of the tongue, or in a tonsillar crypt, where it may readily elude a superficial search. Here the use of a probe to push aside folds of mucous membrane is often of service. Rough palpation with the finger is unwise, because a sharp object may be pushed still further into the tissues, or a movable one may be dislodged and fall into the larynx.

The management of foreign bodies in the larynx demands the exercise of great ingenuity and dexterity. As examples of clever devices employed for their removal may be mentioned the electro-magnet in the case of metallic articles (Voltolini, Garel and Goul-lioud), a sponge after Voltolini's method (Max Thorner) and cotton wool wound on the end of the finger (Crawley) in the case of a cockle-burr in the larynx, and finally a brush dipped in mucilage to extract a thread (Brandeis). When the stenosis is due to spasm rather than to the volume of the object the inhalation of chloroform or the local use of cocaine may be of advantage. An impacted body which interferes but slightly with breathing may be dealt with somewhat deliberately. A smooth movable body is more dangerous because of its liability to shift its position and fall into a bronchus.



A sharp-pointed or angular body, if roughly handled, may damage the wall of the larynx excessively, may even cause emphysema of the cellular tissue, or induce hemorrhage by penetrating a blood-vessel. It is sometimes necessary to break up and remove piecemeal an irregular object. A pin, lying in the larynx with point upwards, must, if possible, be seized and pushed downwards before any attempt should be made to withdraw it. In adults, as a rule, the manipulations may be conducted under local anesthesia with cocaine. In children, general anesthesia will, not infrequently, be demanded. In young subjects, the interior of the larynx may often be reached by the tip of the finger. If the body is seated high up it may be removed by hooking the finger beneath it. In other cases we have to choose one of the various laryngeal forceps. Mackenzie's or Cusco's (Fig. 143),




FIG. 143. CUSCO'S LARYNGEAL FORCEPS.

or if preferred tube-forceps, or the cold-wire snare may be selected according to circumstances. If it become apparent that an unwarrantable amount of force may be needed to dislodge an impacted body the alternative of external operation is presented. In the latter case we should hold before us the importance of preserving the function of the larynx by accurate replacement of the vocal bands, an object not easy of accomplishment if section of the thyroid cartilage has been complete. To secure perfect apposition of the halves of the larynx it is well, therefore, to leave the upper margin of the cartilage undivided. This mode of procedure, especially in young subjects in whom the parts are pliable, does not interfere with a satisfactory exposure of the interior of the larynx. In order to prevent reflex inhibition of heart action applications of cocaine to the mucous mem-



brane both before and during a fissure of the larynx are recommended, and great care should be taken to keep the incisions in the middle line.

The use of emetics and experiments with inversion in children should not be resorted to unless we are prepared to open the trachea, since the foreign body may be propelled from below to a position in which it may completely block up the lumen of the larynx. This especially applies to a body known to be jagged or irregular in contour, and if it has passed beyond the larynx Weist advises never to try inversion without a preliminary tracheotomy. If the trachea must be opened it is well to enter at as low a point as possible, to make a long incision and possibly to resect a part of two or more tracheal rings in order to provide for easy exit of the foreign body in case it should be dislodged by coughing. The method of inversion proposed by Padley seems to be applicable to adults and comparatively free from danger. The patient is made to lie on his back with his knees flexed over the end of a bench which is considerably higher than the opposite end. He should inspire deeply and not attempt to speak. Forcible concussion of the chest sometimes helps to dislodge the foreign body. The supine position favors its escape and should it impinge upon the chink of the glottis the patient is readily able to resume the upright posture. In Roe's collection of seven hundred and sixty-three cases of foreign bodies in the air-passages we find only three relieved by inversion and six by emesis when the larynx was involved, while nine recovered after inversion and two after the use of emetics when the substance was in the trachea. From an analysis of the combined statistics of Weist (one thousand cases), Durham (seven hundred and six cases), Gross (one hundred and eighty-three cases), and his own, Roe concludes that a foreign body should not be allowed to remain in the air-passages for any length of time without operation in case attempts at extraction by other means have failed. When the larynx is occluded by a large foreign body, or by the spasm its presence excites, the trachea should be opened without delay, though the patient appears to be moribund or even dead. The discouraging opinion attributed to Louis that in cases of this kind we are helpless because *no interval* exists between perfect health and death seems to be unfounded, in view of the success



attending artificial respiration and similar restorative measures in analogous conditions. A rapid tracheotomy followed by judicious and prolonged artificial respiration will sometimes save a case apparently desperate. Coins and flat objects that are apt to take a transverse position in the larynx are conveniently reached with Watson William's forceps. A coin in the esophagus has several times been successfully extracted with Smith's coin-catcher. Opposite the cricoid, the narrowest part of the gullet, a foreign body is most likely to be arrested. Coolidge once removed a foreign body from the right bronchus by passing an alligator forceps along a urethroscope which had been introduced through a tracheotomy wound. The gradual solution of fish bones by means of vinegar and of meat bones by a dilute solution (one to five per cent.) of hydrochloric acid has been suggested. A fish hook with its barbed point embedded in the tissues would seem to be almost impossible of removal by any internal method, but Christison's scheme of threading the wire attached to the hook through a hole drilled in the ball of a probang was highly successful in one case. Fortunately the wire had not been swallowed and it served as a guide to the bulb of the probang which latter so dilated the walls of the esophagus as to loosen the points of the hook and allow it to be withdrawn without catching. In the larynx a similar plan would not be feasible and an external operation would be the only alternative, either a subhyoid pharyngotomy or a laryngotomy. In a recent case in my clinic at Cornell Medical College a metallic heel plate was removed by Mack from the laryngopharynx of a shoemaker who was in the habit of holding these objects in his mouth while at work. Three sharp prongs projecting from the surface of the plate had to be disengaged by pressure with the finger, in the meantime traction being made on the plate which had been seized with canula forceps. Very little reaction followed, although the plate had been in the pharynx eight or ten hours, and had excited almost constant and irresistible desire to swallow.

It is seen, therefore, that almost every case of foreign body in the larynx, or in neighboring regions, presents features peculiar to itself which must be met according to circumstances.



## PROLAPSE OF THE VENTRICLE OF THE LARYNX.

Prolapse of the ventricle of Morgagni is a rare condition, very apt to be confounded with a new growth or with a simple inflammatory hyperplasia. It consists of protrusion of the sacculus laryngis as a result of sudden voice-strain or violent coughing, possibly in conjunction with atomy or paresis of the muscle known as the compressor sacculi laryngis, or Hilton's muscle. In one case in my experience a protruding mass simulating prolapse of the ventricle was excised, when it proved to be a tubercular infiltration. Serious doubt as to the possibility of eversion of the ventricle was suggested long ago by Fraenkel and by Chiari. Moure believes that the condition of apparent prolapse is really one of chronic inflammation, and this view has received recent confirmation by Noack, who found that the tissues of a supposed everted ventricle were composed of vascular and edematous hypertrophies. It is maintained by Schroetter that an apparently prolapsed ventricle is in reality an example of chronic subglottic laryngitis, the thickened and projecting tissues giving the misleading impression of a tumor which seems to spring from the site of the ventricle.

The treatment consists simply in replacement of the ventricle by means of a laryngeal probe and of faradization of the muscles of the larynx together with prohibition of the use of the voice for a considerable period. It may be found impossible to restore the prolapsed sacculus, in which case ablation would be the proper procedure, provided the subjective symptoms are very pronounced.

## FRACTURE OF THE LARYNX.

Fracture of the larynx is a rare accident and may result from direct violence, as from a blow or by choking, from bullet wounds, or from muscular action during a violent paroxysm of coughing (Sajous). A large proportion of cases have been observed in early life, so that ossification of the cartilages incident to old age cannot be regarded as a predisposing factor.

In most cases the thyroid alone is fractured, but in many the cricoid also is involved and in a few the hyoid bone is broken.



External deformity is at once quite marked either as a depression or an unusual prominence of the thyroid, accompanied by more or less swelling of the external soft parts. If the mucous lining of the air-track is lacerated hemorrhage may occur, and aphonia and cough with blood-streaked sputa are prominent symptoms. Dyspnea may be present early or not for several days after the accident. Emphysema may be limited to the neighborhood of the injury or may be diffused over the whole body, as in the case of a child six years old reported by Hume. The foregoing symptoms, together with crepitation on palpation, should establish the diagnosis. In severe cases when the cartilage is comminuted or the fracture is compound, but little doubt can exist. In simple cracks or linear fractures there may be more difficulty. The prognosis in cases of the latter class is favorable. A penetrating wound over the thyroid cartilage may be demonstrated by blood-stained sputum and impairment of voice, the latter remaining permanent.

In treatment the first indications are to replace distorted fragments and control inflammatory reaction by cold affusions. Swelling and edema may necessitate a tracheotomy or intubation. The latter is preferable, both with a view to supporting depressed fragments of cartilage and to preventing contraction of the air-tube during the process of repair. An O'Dwyer intubation tube as large as the larynx will accommodate should be selected and its introduction may be facilitated by preliminary spraying with cocaine and suprarenal extract. In a case reported by W. K. Simpson a very large, somewhat conical, tube was used which served as a dilator as well as an air-tube. In cases of extensive damage an intubation tube does not reach far enough and the only alternative is an opening in the trachea at the lowest possible point.



# INDEX.

## A

- Abscess of nasal septum, 140
  - retropharyngeal, 263
  - of tongue, 262
  - of tonsil, 276
- Absolute alcohol in laryngeal neoplasms, 344
- Accessory sinuses, 24
  - disease of, 73
  - in hay fever, 192
  - thyroid tumors, 262
- Adenectomy, accidents in, 237
  - anesthesia in, 230
- Adenoids, 222
  - facies of, 227
  - and laryngeal neoplasms, 225
  - recurrence of, 238
- Adhesions, intranasal, 143
- Adrenalin, 174
- Allen, C. W., on rhinoscleroma, 186
- Amygdalotomy, 248
- Amygdalothripsis, 250
- Anchylosis of cricoarytenoid joint, 406
- Angina of Vincent, 283
- Anosmia, 25, 188.
- Antrum, anomalies of, 81
  - asymmetry of, 81
  - Caldwell-Luc operation for empyema of, 87
  - cyst of, 81, 109
  - foreign bodies in, 87, 111
  - neoplasms of, 111
  - polypi of, 110
  - transillumination of, 80
- Aphonia, hysterical, 393
- Aprosexia, 226
- Aronsohn on primary laryngeal tuberculosis, 363
- Arytenoids, clubbing of, in tuberculosis, 367
- Arteries of the nasal mucous membrane, 23
- Asch's operation for deviated septum, 128
- Atrophic rhinitis, 61
- Autoscopy, 317

## B

- Bands, ventricular, 310
  - vocal, 312

- Bates, W. H., on suprarenal extract solution, 174
- Bernays' cotton sponge, 59, 173
- Bifid uvula, 208
- Bishop, S. S., on hay fever, 192
- Birkett's double transluminator, 91
- Bliss, A. A., on Allen's operation for deviated septum, 125
  - on hemorrhage after adenectomy, 236
- Bodies, foreign in air track, 409
- Bone changes in nasal polypi, 151
- Bosworth on laryngeal spasm, 398
  - on neuralgia of the larynx, 392
- Boylan, J. E., on a method of ablating nasal hypertrophies, 50
- Brady, A. J., on a case of angioma of the larynx, 339
- Brindel on paraffin in nasal atrophy, 67
- Browne, Lennox, on malignant transformation of benign growths, 162
- Bryan, J. H., on acute sinusitis, 77
  - on the antrum as a reservoir for pus, 83
  - on probing the sphenoidal sinus, 105
- Bulla ethmoidalis, 21
- Butlin, H. T., on cancer of nose, 166
  - on explorative laryngofissure, 361

## C

- Cancer of larynx, 351
  - of nose, 165
- Capart on the treatment of singers' nodes, 329
- Casselberry on a case of edema of the glottis, 324
- Catarrhal diathesis, 37
- Cerebrospinal rhinorrhea, 198
- Champeaux on adenoid facies, 227
- Chappell, W. F., on conditions resembling adenoids, 227
  - on hemorrhage from circumtonsillar abscess, 279
- Charcot on laryngeal vertigo, 304
- Cheyne, Watson, on laryngectomy, 359
- Chorditis tuberosa of Türck, 326
- Chorditis vocalis inferior of Gerhardt, 330
- Chorea laryngis, 395



- Circumtonsillar abscess, 276  
     hemorrhage from, 279  
 Clark's solution for hay fever, 194  
 Clark, Payson, on a case of cyst of the larynx, 336  
 Cleft palate, 210  
 Coakley, C. G., on recurrence of excised tonsils, 256  
 Coates, George, on epistaxis in the aged, 169  
 Cobb, F. C., splint for fractured nose, 147  
 Coley's toxin treatment of sarcoma, 112  
 Collapse of nostril, 144  
 Columnar cartilage, dislocation of, 145  
 Comstock, A. B., on subcutaneous use of paraffin, 180  
 Concha bullosa, 45  
     suprema, 20  
 Congenital occlusion of nares, 142  
 Corning, J. L., on subcutaneous injection of solidifying oils, 180  
 Coryza, 36  
 Crile, Geo., on cocaine in adenectomy, 230  
 Cupric electrolysis in atrophy, 69  
 Curtis, Holbrook, on hay fever, 195  
 Cyst of larynx, 116  
     of nose, 160  
     of pillar of fauces, 206  
     of turbinate, 44
- D
- Daly, W. H., on a splint for fractured nose, 147  
 Darmack packer, 172  
 Dawbarn's purse string ligature for tonsillar hemorrhage, 253  
 Delavan, D. B., on galvanism in atrophy, 69  
     on laryngectomy, 359  
     on X-ray therapy for cancer, 362  
 Dentary cysts, 81  
 Deviated septum, Asch's operation, 128  
     Harrison Allen's operation, 124  
     Gleason's operation, 132  
     Ingals' operation, 125  
     Krieg's window resection operation, 126  
     Kyle's operation, 123  
     Moure's operation, 121  
     Roberts' operation, 119  
     Roe's operation, 119  
     Watson's operation, 133  
 Diphtheria, 273  
 Diphtheroid angina, 283  
 Dissection of tonsillar abscess, 282  
 Dislocation of columnar cartilage, 145  
 Dobell's solution, 47  
 Douglas, Beaman, on emphysema of eyelid with ethmoid disease, 100  
     on supplementary cells in sphenoidal wings, 106  
 Duct of Stenson, 22
- E
- Edema glottidis, 323  
 Electric cautery in nasal hypertrophy, 53  
 Electrolysis in septal spurs, 138  
 Emphysema of eyelid in ethmoid disease, 100  
 Empyema of antrum, 76  
 Epiglottis, function of, 312  
 Epistaxis, 168  
 Ethmoid cells, disease of, 99  
 Ethmoiditis and ozena, 100  
 Examination, digital, of nasopharynx, 35
- F
- Ferrier's snuff, 38  
 Fibroma of larynx, 335  
     of nasopharynx, 159  
     of nose, 158  
 Fink, E., on hay fever, 192  
 Foreign bodies in larynx, 409  
     in nose, 166  
     in pharynx, 300  
 Fossa innominata, 310  
 Fowler, W., on cricoarytenoid arthritis in tuberculosis, 367  
 Fracture of larynx, 416  
     of nose, 146  
 Fraenkel, B., endolaryngeal treatment of carcinoma, 357  
 Freer, Otto, on operation for deviated septum, 126  
 French, T. R., position of patient in adenectomy, 232  
 Freudenthal, W., on rhinoscleroma, 186  
 Freudenthal's emulsion, 377  
 Frisch, bacillus, of, 186  
 Frontal sinus, on catheterizing the, 94  
     inflammation of, 90  
     Jansen's operation for empyema of, 97  
     Kuhnt's operation for empyema of, 95  
     Lothrop on method of opening, 95  
     Luc's operation for empyema of, 98  
     Ogston's operation for empyema of, 95  
     Herbert Tilley's operation for empyema of, 98  
 Fusiform bacillus of Vincent, 283



## G

- Galvanism in nasal atrophy, 69  
 Galvanocautery for laryngeal neoplasms, 342  
 Garel and Bernand on vocal nodules, 328  
 Gargling, 272  
 Gersuny on paraffin prosthesis, 179  
 Gibb, J. S., on carcinoma of nose, 165  
     on malignant disease of the sinuses, 112  
 Gleitsmann, J. W., on ethyl bromide in adenectomy, 231  
 Gluck on laryngectomy, 359  
 Goldstein's turbinal trocar, 56  
 Goodale, J. L., on tonsillar abscess, 276  
 Gottstein on atrophic laryngitis, 331  
     definition of a mucous patch, 386  
 Gouguenheim and Lombard on endolaryngeal treatment of cancer, 358  
 Grabower on posticus vulnerability, 406  
 Grossman on position of cords after section of recurrent, 406  
 Grünwald on location of pain in cricoarytenoid arthritis, 408

## H

- Hack on laryngeal spasm, 398  
 Hager-Brand remedy for coryza, 40  
 Hartmann-Kiesselbach spot on nasal septum, 171  
 Halsted, T. H., on chloroform in adenectomy, 230  
 Hawes, Jesse, splint for fractured nose, 147  
 Hay fever, 189  
 Hemophilia, 236  
 Hemorrhage after adenectomy, 236  
     from circumtonsillar abscess, 279  
     after tonsillotomy, 252  
 Heryng on laryngeal spasm, 398  
     on indications for radical interference in tuberculosis of larynx, 381  
 Hiatus semilunaris, 20  
 Hilton's muscle, 310  
 Hinkel, F. W., on chloroform in adenectomy, 230  
     on hemorrhage after adenectomy, 236  
 Hopkins, F. E., on malignant transformation of a nasal "myxoma," 162  
 Hot air in nasal disorders, 60  
 Hovell's mode of relieving odynphagia, 372  
 Hume on emphysema in fracture of larynx, 417  
 Hydrogen peroxide in nasal atrophy, 66

- Hydrops antri, 108  
 Hydrorrhea, nasal, 196  
 Hygienic value of voice culture, 313  
 Hyperosmia, 188  
 Hypertrophied tonsils, 240  
     indications for use of cautery in removing, 247  
     recurrence of, 256  
 Hypnosis in hay fever, 196  
 Hysterical aphonia, 393

## I

- Incision of circumtonsillar abscess, 281  
 Infundibulum, 21  
 Ingals' solution of suprarenal capsule, 194  
 Intubation for laryngeal neoplasms, 342

## J

- James on spastic aphonia, 395  
 Jurasz on endolaryngeal treatment of carcinoma, 358

## K

- Kakosmia, 188  
 Keratosis, 266  
 Kelly, Brown, on keratosis and mycosis, 267  
     on an unusual source of epistaxis, 174  
 Killian's method of examining the larynx, 317  
 Kirstein's autoscopy, 317  
 Knight, F. I., on laryngeal vertigo, 394  
     on trachoma of the larynx, 328  
 Krause on section of recurrent nerve for abductor paralysis, 405  
 Kuhnt on meningitis and sinus disease, 102  
 Kyle, D. B., on varieties of adenoids, 225

## L

- Lack, Lambert, on Woakes' theory, 152  
 Lake, R., removal of epiglottis in tuberculosis, 378  
     on artificial turbinate of paraffin, 67  
     on the treatment of tubercular laryngitis, 373  
 Laryngeal growths, absolute alcohol in, 344  
     and adenoids, 348  
     galvanocautery in, 342  
     internal medication, 347  
     intubation, 342, 347  
     spontaneous disappearance of, 345  
     thyrotomy, 348  
     tracheotomy, 348



- Laryngeal stridor and whistling, 398  
 vertigo, 393
- Laryngitis, acute, 321  
 atrophic, 331  
 chronic, 325  
 chronic subglottic, 330  
 hemorrhagic, 321  
 sicca, 331
- Laryngofissure, 347
- Laryngoscopy, 314
- Larynx, adenoma of, 340  
 anatomy of, 302  
 anemia of, 320  
 anesthesia of, 391  
 angioma of, 339  
 arteries of, 310  
 benign neoplasms of, 333  
 carcinoma of, 351  
 chorea of, 395  
 cystoma of, 336  
 ecchondrosis of, 339  
 edema of, 323  
 foreign bodies in, 409  
 fibroma of, 335  
 fracture of, 416  
 hemorrhage of, 320  
 hyperemia of, 320  
 hyperesthesia of, 391  
 lipoma of, 339  
 muscles of, 305  
 myxoma of, 337  
 nerves of, 308  
 neuralgia of, 392  
 papilloma of, 335  
 paralysis of, 400  
 paresthesia of, 392  
 sarcoma of, 350  
 spasm of, in adults, 397  
 spasm of, in children, 396  
 stenosis of, in syphilis, 383  
 syphilis of, 382  
 tuberculosis of, 363
- Latent empyema, 83
- Lefferts, G. M., on tonsillar hemorrhage, 254  
 on intubation in syphilitic stenosis of larynx, 383
- Leland, G. A., on the treatment of circumtonsillar abscess, 282
- Leptothrix buccalis, 265
- Levy, R., on hypertrophy of lingual tonsil, 259
- Lichtwitz on latent empyema, 83
- Lingual quinsy, 261  
 tonsil, hypertrophy of, 258  
 varix, 260
- Luc, H., on mucocele, 108
- Luschka's bursa, 223
- Lymphatism, 224
- Lymphoid ring, 240
- M
- Mackenzie, J. N., on hay fever, 190  
 on laryngectomy, 360
- Mackenzie's laryngeal forceps, method of using, 343
- Malignant disease of sinuses, 112
- Makuen on laryngeal whistling, 400
- Maxillary sinus (see Antrum), 76
- Mayer, Emil, on Schleich's mixture in adenectomy, 231
- McBride, P., on laryngeal vertigo, 394
- Medio-frontal illumination, 92
- Meschede on hysterical aphonia, 393
- Morgagni, tubercle of, 21  
 ventricle of, 310
- Moure on prolapse of laryngeal ventricle, 417
- Mucin in atrophy, 65
- Mucocele, 108
- Mulberry hypertrophy, 52
- Mycosis pharyngis, 264
- N
- Nares, congenital occlusion of, 142
- Nasal fossa, angioma of, 161  
 benign tumors of, 158  
 chondroma of, 160  
 cyst of, 160  
 fibroma of, 158  
 foreign bodies in, 166  
 osteoma of, 160  
 papilloma of, 159  
 syphilis of, 176
- Nasal hydrorrhea, 196  
 hypertrophy, chemical caustics in, 57  
 submucous injection in, 56
- Nasal neuroses, 188  
 polypi, 150  
 tampons, 59
- Nasopharyngitis, chronic, 217
- Nasopharynx, digital examination of, 35  
 fibroma of, 159
- Natier on false adenoidism, 228
- Necrosing ethmoiditis, 151
- Nerves of nasal mucous membrane, 23
- Newcomb, J. E., on fatal hemorrhage after adenectomy, 236
- Nichols, J. H., on the treatment of syphilitic adhesion of velum, 298
- Nose, anatomy of, 17  
 examination of, 28  
 fracture of, 146  
 lupus of, 182  
 malignant disease of, 165  
 physiology of, 25



Nose, tuberculosis of, 183

O

Odynphagia in tuberculosis, 371  
 Olfaction, theory of, 26  
 Onodi on anosmia, 188  
 Organ of Jacobson, 21  
 Osler, W., on epistaxis in telangiectasis, 169  
 Ostium maxillare, 21  
 Ozena, 62, 64  
     and ethmoiditis, 100  
     laryngis of Baginski, 331

P

Pachydermia laryngis of Virchow, 326  
 Padley's method in foreign bodies in air passages, 414  
 Paraffin in deformed noses, 79, 140  
     in nasal atrophy, 67  
 Parosmia, 25, 188  
 Paroxysmal sneezing, 189  
 Pharyngeal bursa, 204  
 Pharyngitis, acute, 214  
     atrophic, 219  
     chronic, 215  
     follicular, 216  
     membranous, 214  
     rheumatic, 220  
 Pharyngo-mycosis, 264  
 Pharynx, anatomy of, 199  
     anesthesia of, 299  
     foreign bodies, 300  
     hyperesthesia of, 299  
     hypertrophy of lateral bands, 216  
     lupus of, 291  
     methods of examining, 206  
     paralysis of, 300  
     paresthesia of, 299  
     spasm of, 299  
     syphilis of, 292  
     tuberculosis of, 289  
 Polypi of antrum, 110  
 Pomum Adami, 302  
 Priessnitz compress, 323  
 Purse string ligature, 253

Q

Quinsy, 276

R

Recurrent laryngeal paralysis, 402  
 Rhinitis, acute, 36  
     atrophic, 61  
     caseous, 71  
     chronic catarrhal, 41  
     hypertrophic, 41  
     membranous, 70

Rhinitis, purulent, 71  
     sicca, 63  
 Rhinoliths, 167  
 Rhinopharynx, adenoids in the, 222  
 Rhinoscleroma, 185  
 Rhinoscopy, anterior, 30  
     posterior, 32  
 Rhodes, J. E., on chancre of tonsil, 292  
 Rice, C. C., on vocal nodules, 328  
 Richards, G. L., on elongated styloid process as an obstacle in tonsillectomy, 250  
 Rima glottidis, 310  
 Roe, J. O., on foreign bodies in the air track, 414  
     on laryngeal whistling, 400  
 Rose cold, 189  
 Rouge's operation for deviated septum, 117  
     for nasal sequestrum, 177  
 Roughton's band, 145

S

Sacculus laryngis, 310  
 Schmidt, Moritz, on cancer of larynx, 355  
     on tubercular laryngitis, 375  
 Schnitzler on neuralgia of the larynx, 392  
 Schroetter on dilatation of syphilitic stricture of larynx, 383  
 Schwenn on malignant disease of the sinuses, 113  
 Seiler's tablets, 47  
 Semon, Felix, on cancer of larynx, 355  
     on malignant degeneration of benign growths of the larynx, 334  
 Semon's law, 406  
 Sendziak, on thyrotomy, 362  
 Senn, E. J., on treatment of broken nose, 148  
 Septum, abscess of, 140  
     deviations of, 114  
     ecchondrosis of, 135  
     exostosis of, 136  
     hematoma of, 140  
     perforation of, 140  
     ulceration of, 139  
 Sheppegrell, W., cupric electrolysis in tuberculosis of larynx, 380  
     a case of laryngeal cancer cured with X-ray, 362  
 Shurly, E. L., on bacilli in tubercular infection, 365  
 Sieur and Jacob on probing the sphenoidal sinus, 105  
 Simpson, W. K., on intubation in fracture of larynx, 417



- Simpson, W. K., on intubation in syphilitic stenosis of larynx, 383
- Singers' nodes, 32
- Sinusitis, acute, 73  
bacteria in, 74  
chronic, 73  
frequency of, 76  
location of pus in, 75  
relation of teeth to, 78  
traumatism as a cause of, 77
- Smith, A. H., on monochloroacetic acid in adhesions of velum, 298
- Smith, Harmon, on paraffin prosthesis, 180
- Sobel and Herrman on Vincent's angina, 284
- Sommer's formula for adrenal solution, 193
- Spastic aphonia, 395
- Sphenoidal sinus, inflammation of, 104  
sinusitis, Hinkel on hemorrhage after operation for, 108  
Jansen's operation for, 106
- Stanculeanu and Baup on microorganisms in sinusitis, 74
- Supralabial operation for deviated septum, 124
- Suprarenal extract, 174  
edema of uvula following, 213  
in hay fever, 193
- Sutherland and Lack on laryngeal stridor, 399
- Swain, H. L., on gargling, 273  
on lingual quinsy, 261
- T
- Tauber, B., on a case of atrophic laryngitis, 331
- Thomson, St. Clair, on rheumatic pharyngitis, 221
- Tilley, Herbert, on papilloma of larynx removed under chloroform, 346
- Tongue, tumors of, 262
- Tonsillectomy, 282
- Tonsil, abscess of, 276  
benign neoplasms of, 285  
calculus of, 285  
chronic abscess of, 279  
epithelioma of, 286  
sarcoma of, 286
- Tonsils, faucial, 205  
laryngeal, 312  
lingual, 222, 258  
pharyngeal, 222  
hypertrophied, 240  
as portals of infection, 205
- Tonsilliths, 285
- Tonsillitis, acute, 268  
chronic, 272
- Tonsillitis, infectiousness of, 268
- Tonsillotomy, anesthesia in, 254  
hemorrhage after, 247  
method of performing, 251  
results of, 256  
rash, 257
- Tornwaldt's disease, 223
- Trachoma, 328
- Transillumination of the antrum, 79
- Tubercle of Morgagni, or Zuckerkandl, 21
- Tuberculosis of larynx, cupric electrolysis, 380  
galvanocautery in, 379  
local treatment, 373  
phototherapy in, 379  
submucous and intratracheal injections, 379  
surgical treatment of, 375
- Tuckey, Lloyd, on hypnosis in hay fever, 196
- Turbinal varix, 43
- Turbinate bodies, 24
- Turbinates, hyperemia of, 42  
hyperplasia of, 43
- Turner, Logan, anomalies of the frontal sinus, 92  
and Thomson on laryngeal stridor, 399
- U
- Ultero-membranous angina, 283
- Uvula, disease of, 208  
edema of, 212  
elongated, 211
- Uvulitis, 211
- Uvulotomy, 212
- V
- Vansant on hot air in nasal disorders, 60
- Vascular collapse of turbinate, 63
- Valve of Hasner, 20
- Varix, lingual, 260
- Vegetations, adenoid, 222
- Velum, diseases of, 208
- Ventricle of the larynx, prolapse of, 416
- Ventricular bands, function of, 312
- Vertigo, laryngeal, 393
- Vocal bands, 312  
nodules, 328
- Voltolini's sponge probang for laryngeal neoplasms, 342
- W
- Waggett, Ernest, on laryngofissure compared with total extirpation, 361
- Waldeyer, ring of, 240



- Walsham, W. J., on operation for collapse of nostril, 144  
Whistler on relapsing ulcerative laryngitis, 386  
Whistler's dilating laryngotome, 383  
Williams, Watson, arytenoids in anchylosis and in paralysis, 408  
    on cupric electrolysis in atrophy, 69  
Window resection operation for deviated septum, 126  
Woakes' theory of nasal polypi, 151  
Wolfenden's method of feeding in tuberculosis of the larynx, 371  
Wright, J., on mycosis pharyngis, 267  
    on nasal polypi, 150  
    on tubercle bacilli in lymphoid tissue, 206
- X
- X-rays in entering the frontal sinus, 87  
    in tuberculosis, 379
- Z
- Zuckerkindl, on anomalies of the sinuses, 80  
    tubercle of, 21





