

Mesenteric embolism and thrombosis : a study of two hundred and fourteen cases / James Marsh Jackson, Charles Allen Porter and William Carter Quimby.

Contributors

Jackson, James Marsh.
Porter, Charles Allen.
Quimby, William Carter.

Publication/Creation

Chicago : American Medical Assn., 1904.

Persistent URL

<https://wellcomecollection.org/works/aa6jg4rz>

License and attribution

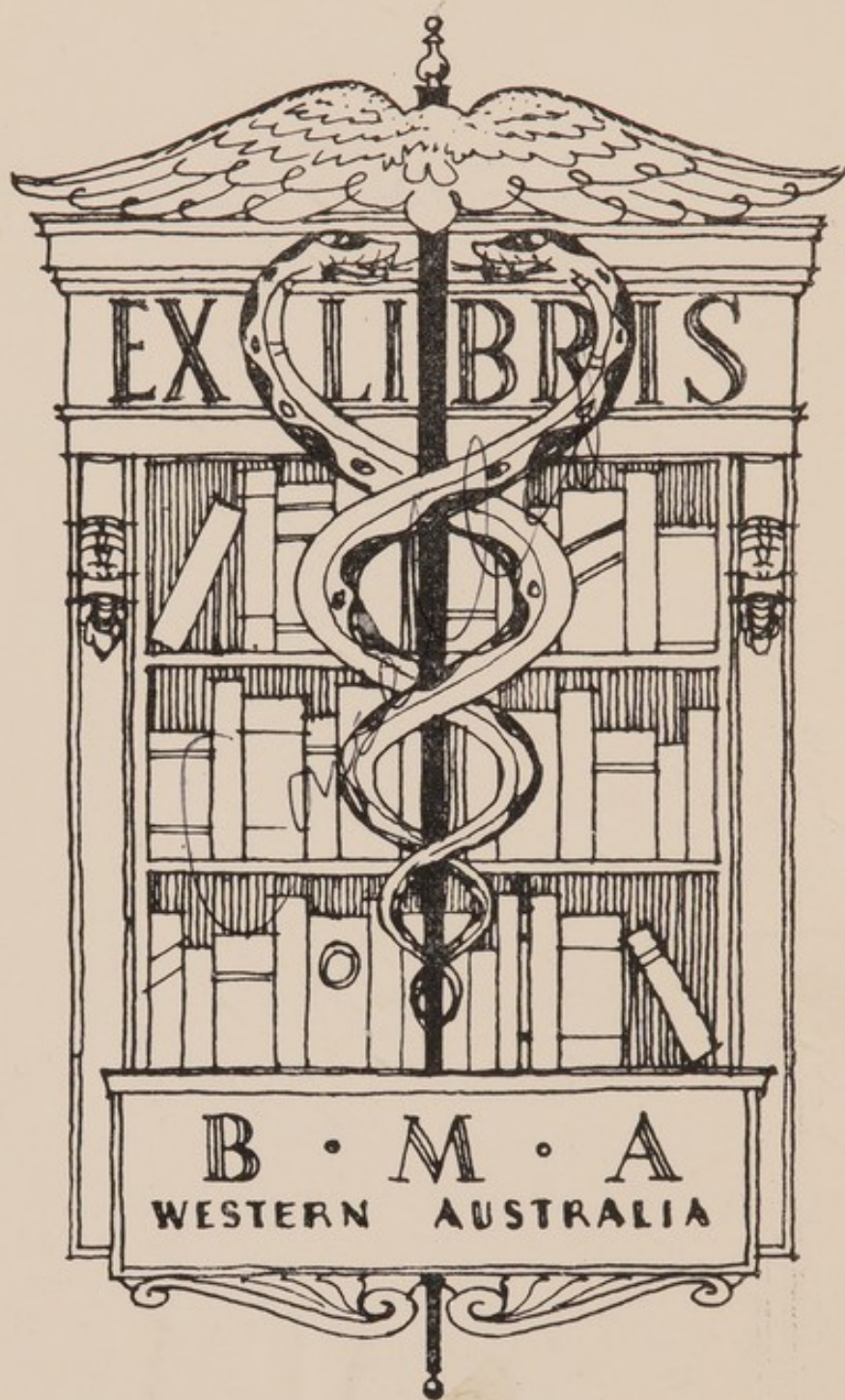
This work has been identified as being free of known restrictions under copyright law, including all related and neighbouring rights and is being made available under the Creative Commons, Public Domain Mark.

You can copy, modify, distribute and perform the work, even for commercial purposes, without asking permission.

MESENTERIC EMBOLISM
AND THROMBOSIS

JACKSON — PORTER — QUINBY

UNIVERSITY OF WESTERN AUSTRALIA
LIBRARY




22101734593

Med
K32190



STORE
616
—
34

UNIVERSITY OF
WESTERN AUSTRALIA
LIBRARY



Alfred

**MESENTERIC EMBOLISM
AND THROMBOSIS.**

**A STUDY OF TWO HUNDRED AND
FOURTEEN CASES.**

§§§

JAMES MARSH JACKSON, M.D.,
Out-Patient Physician to the Massachusetts General Hospital;

CHARLES ALLEN PORTER, M.D.,
Assistant Surgeon to the Massachusetts General Hospital,

AND

WILLIAM CARTER QUINBY, M.D.,
Boston.

§§§

CHICAGO :
PRESS OF AMERICAN MEDICAL ASSOCIATION
ONE HUNDRED AND THREE DEARBORN AVENUE
1904.

33188

16805838

WELLCOME INSTITUTE LIBRARY	
Coll.	welMOmec
Call	
No.	WI

MESENTERIC EMBOLISM AND THROMBOSIS.

A STUDY OF TWO HUNDRED AND FOURTEEN CASES.

JAMES MARSH JACKSON, M.D.

Out-Patient Physician to the Massachusetts General Hospital.

CHARLES ALLEN PORTER, M.D.

Assistant Surgeon to the Massachusetts General Hospital.

WILLIAM CARTER QUINBY, M.D.

BOSTON.

Though, comparatively speaking, embolism or thrombosis of the mesenteric vessels is rare, it is, nevertheless, one of the most serious of abdominal diseases. This, together with the facts that, until recently, the attention of the profession has not been called to the condition by any comprehensive article, and that those existing are not in the English language; that it forms a disease picture of very difficult clinical diagnosis, and that in any case, operation offers practically the sole chance of recovery, seems to us to justify this investigation.

In the list of cases, 214 in number, on which this article is based, an attempt has been made to collect those cases occurring in our Boston hospitals, and further to collect all those which were accessible from friends in the profession and from the literature. In every case, where possible, the original report has been consulted.

Pathologically, occlusion of mesenteric vessels was described as early as 1847 by Virchow.¹ The clinical picture received but little attention, however, till the article by Litten² in 1875.

There followed experiments by several men, notably Cohnheim, Litten, Cohn and others, which showed con-

1. Ges. Abhandlungen, pp. 338, 420, 451.

2. Virchow's Archiv, vol. lxxiii, p. 289.

clusively that the results of stoppage of blood supply to the intestine are divided into four stages: First, necrosis; second, gangrene; third, hemorrhagic infarction; and fourth, abscess formation.

The general results of stoppage of blood supply are well given by Ribbert in his *Allgemeinen Pathologie* (Leipzig, 1901). He says (p. 162):

What happens to a vascular area in which the circulation is incompetent? It must necessarily at last be destroyed, but the conditions of this destruction are not always the same.

In the cases in which an end artery is involved the area, under certain conditions, receives so little blood from capillaries or veins, that it becomes essentially paler than the surrounding areas; when beside this, the small amount of blood which is present loses its color, the area becomes clear, yellow white.

More frequently, however, a marked filling of the area with blood occurs, which, by its presence, stops further accession of blood to the part. Then in the first few hours the area is a red color, but becomes rapidly pale by decolorization of the contained blood, which occurs by separation of the blood coloring matter, this leaving by diffusion or disintegration. Then the area is pale and forms an anemic infarct.

In other cases, either of end artery or of insufficient arterial anastomosis, the afflux of small quantities of blood continues, either from the narrow, arterial anastomoses or from the capillaries or veins. The area then remains red. Microscopically the vessels are turgid, but with no motion of their contents worth mentioning; or often complete stasis occurs. But we soon see something more. We see in the experiment that the blood corpuscles leave the vessels by diapedesis, reaching the surrounding tissues, the spaces of which they fill. Then the area takes on a dark, black-red color, and a firm consistency. A hemorrhagic infarct has occurred, which does not grow pale, but preserves its red color.

He then (p. 166) contrasts intestine to kidney, brain, spleen, etc., in which we usually get an anemic infarct, saying:

It is different in the case of the intestines. Occlusion of the superior mesenteric artery always causes hemorrhagic infarction. To be sure, there are present anastomoses with other vessels, but these do not suffice for nutrition. But they carry so much blood to the part that the excluded area is made turgid and diapedesis takes place. Then the gut wall and mesentery become black red, and thickened by the mass of blood. Similar hemorrhagic infarction occurs also from venous stasis.

Experiments done by Welch and Mall³ on this point show, first, that the blood which produces the hemorrhagic infarction enters by the anastomosing arteries, and not by reflux from the veins; second, that the hemorrhage can not be explained by any demonstrable change in the vascular wall, but is the result of retardation and stasis of the circulation, and clumping of red corpuscles in the veins and capillaries, attributable in large part in cases of arterial obstruction to reduction or loss of lateral pulsation of the blood current; third, that the ischemia is increased by the tonic contraction of the intestinal muscles which follows for two or three hours closure of the superior mesenteric artery; and that, fourth, the sudden and complete shutting off of the direct arterial supply to a loop of intestine 5 to 10 cm. in length, is followed by necrosis and hemorrhage of the loop, even when the vessels at each end of the loop are open.

From this it is evident that closure of mesenteric vessels does not, as a rule, call forth the formation of a competent collateral circulation, in spite of their rich anatomic anastomoses, such as is usually established in other areas of the body. The reason for this condition has been the object of much experimental research. (For a critical review of the various theories concerning the absence of collateral circulation, the reader is referred to the recent and very able articles on the subject by Deckart⁴ and by Neutra,⁵ only the more important of which we abstract here.)

THEORIES CONCERNING ABSENCE OF COLLATERAL CIRCULATION.

Cohnheim⁶ explains the intestinal infarction which occurs, in spite of the manifold arcades anastomosing with the vessels of the muscularis, submucosa, and even mucous membrane, by saying that coincident with the closure of a main trunk of an artery, the anastomoses are plugged also, thus forming an artificial end-artery. This, however, by no means explains the process in general, and in only one case (Ponfick⁷) is it expressly stated that a part of an embolus of the main trunk of

3. Ref. in Allbutt's Series, vol. vi, p. 228.

4. Mitt. a. d. Grenzgeb. d. Med. u. Chir., vol. v, p. 511.

5. Centralblatt f. d. Grenzgeb. d. Med. u. Chir., vol. v, No. 18, p. 705.

6. Vorlesungen u. allg. Path., vol. i, p. 150, et seq.

7. Virchow's Archiv, vol. i, p. 623.

the superior mesenteric artery became loose and was carried to smaller branches.

Litten's experiments lead him to the conclusion that the superior mesenteric artery is a "functional end-artery."⁸ His experiments showed that the formation of a mesenteric collateral circulation needed a higher blood pressure than the blood of the body can reach.

Faber⁹ says that the infarction is due to back pressure of blood in the portal system, which overcomes and is greater than the pressure in the anastomosing vessels. The reason why the inferior mesenteric artery does not take up the work of the closed superior artery, he explains by saying that it is a smaller vessel and can not suddenly assume the functions of a larger one. Further, after closure of the superior mesenteric artery, the pressure in the superior mesenteric vein necessarily sinks to *nil* immediately. The pressure in the portal system is thus lowered, making the flow from the inferior mesenteric vein easier. It is thus easier for blood in the inferior mesenteric artery to flow by its natural channel.

Though this view does not cover all the points, it has been accepted by most writers as the best one existing. Rosenbach¹⁰ says:

An increase of the blood pressure is not necessary for the establishment of a collateral circulation, for normal blood pressure is sufficient, when the resistance in the capillaries forming the collateral circulation is lowered, that is, when there is compensatory dilatation of them. But this can not occur in an intestine which is contracting violently, as is that part which is infarcted. The intestine is thus in the most unfavorable condition. It is contracted ad maximum, thus narrowing the vessels which serve for the formation of anastomoses. It needs by its contractions more blood than usual for its nourishment. Thus a vicious circle is present, and infarct and stasis of marked degree with intestinal hemorrhages occur.

As exceptions to the general rule, a few cases are found in which the postmortem examination showed that a collateral circulation had been formed.

A case of Karcher¹¹ showed a plugged superior mesenteric artery, but no dilated, collateral anastomoses. The process was at least two months old. Karcher says that

8. Deutsch. med. Woch., 1889, No. 8.

9. Deutsch. Archiv f. klin. Med., vol. xvi, p. 527.

10. Berl. klin. Woch., 1889, p. 269.

11. Schweizer Correspondenzblt., 1897, No. 18.

the circulation must have been through the colica sinistra. In the case of Chiene¹² we also have evidence of healing. Here both mesenteric arteries were occluded. The circulation was carried out by the superior hemorrhoidal artery, and the colica dextra and sinistra. The retroperitoneal plexus of arteries was much dilated, and served as union between the internal iliac artery and those of the mesentery. In one of Cohn's cases,¹³ a previous infarct of a portion of the transverse colon was found, which was healed by collateral circulation. An embolus had lodged in the ramus colica. Collateral circulation was established by the dilated branches of the pancreatico duodenalis and inferior mesenteric arteries, in a case reported by Virchow.¹ Again, the cases of Kaufmann¹⁴ show what is to be regarded as partially formed collateral circulation. In one case the ileocolic artery was occluded, but that portion of the colon supplied by it was unaffected. In the other case, with the superior mesenteric artery closed, an anastomosis with the pancreatico-duodenalis was found. On this point Neutra⁵ says:

That in just these cases (which out of all the cases are exceptions) collateral circulation could form is explained—besides by the sufficient duration of the process—by an especial condition of the involved vessel system. One can assume that in these individuals the anastomosis between the superior mesenteric artery and the neighboring streams was congenitally richer than the normal. Besides this, one can also assume that in the superior mesenteric artery, before the entrance of sudden occlusion, there was already an impediment of the circulation by some cause (stasis by weak heart, atheroma, emphysema) so that opportunity was offered for a collateral circulation to form, and that then the final embolus did not have its usual severe results.

Of interest here is the case of Robson¹⁵ and that of Roughton.¹⁶ In the first the abdomen was opened for internal hemorrhage, following a wound by a file. The superior mesenteric vein was found bleeding and was tied. In the second, also from trauma, one of the vasa intestini tenuis arteries was ruptured close to its origin from the superior mesenteric artery. It was ligated. In both cases complete recovery resulted.

12. Jour. Anat. and Physiol., London, 1869, vol. III, p. 65.

13. Klinik d. Embol. Gefässkrankheiten, p. 548.

14. Virchow's Archiv, vol. cxvi, p. 353.

15. British Med. Jour., 1897.

16. Lancet, 1899.

It is well known that occlusion of mesenteric arteries causes clinical pictures very nearly identical with those following closure of veins, in spite of the differences found from a point of view of pathologic anatomy. It has, therefore, been deemed best by the writers to discuss the cases as a whole, leaving attempts at clinical differentiation for later consideration.

The following twenty-seven cases are new to the literature, and are therefore given in some detail:

CASE 1. (Dr. James Marsh Jackson.)—Man, 65 years. Was always very strong. Served in the Civil War on the coast survey. For twenty years has been resident engineer of a large mine. For several years has had a weak heart, and has been unable to walk upstairs without great discomfort. For a long time has taken laxatives (Carlsbad), more often of late, and in increasing amounts. Now rarely walks more than a block, and even then is obliged to stop for breath. Some years ago had several attacks of angina pectoris. In 1897 had "blood poisoning" of foot from a corn, and was sick for a long time. This was followed by gangrene of the toe and amputation. His family physician has known for several years that patient had diabetes, and what he considered a mitral regurgitation. In January, 1900, the urine contained 7 per cent. of sugar; later only smaller amounts. For past three years has had neuralgia of jaw, for which he has used from 1/20 to 1/10 grain of nitrate of strychnia. Is now taking 1/5 of a grain daily with relief.

Present Illness.—Jan. 4, 1901, patient ate hearty lunch of corned beef, which caused some gastric distress. On the next day the morning movement was constipated. Felt well, however, until January 6, when he ate a breakfast of fish balls and coffee, and had a very small movement following Carlsbad. He had considerable general pain in the abdomen, and lay on the sofa most of the day. Towards night the pain became quite severe, for which he took a large dose of castor oil. The oil operated in about four hours; first movement constipated, next two very loose. After this the pain was slightly relieved, but soon began again and kept him awake most of the night. January 7 the pain still bothered him a great deal, and the abdomen became somewhat distended during the day. January 8, at 1 a. m., the pain became so severe that he could stand it no longer and sent for me.

Physical Examination.—Abdomen distended, especially over the left side; everywhere tympanitic. Very slight general tenderness. Pain constant, dull, with exacerbations all over abdomen, but especially in region of umbilicus. Lungs negative. Systolic murmur at mitral area of heart; aortic second sound not accentuated. Heart otherwise negative. No

pyrexia; pulse slightly intermittent. A high enema repeated in an hour had no result. Morphia was then given and he slept through the rest of the night.

January 8, 8 a. m. The enema was repeated without any result. Castor oil was then given, but did not operate. In the evening Dr. F. C. Shattuck saw him in consultation and concurred in the diagnosis of intestinal obstruction of unknown cause; operation not advised. Repeated doses of Seidlitz powders were then given. No movement followed; no gas. At night $\frac{1}{4}$ gr. morphia was again given. At this time there was moderate distension of the abdomen; general tympanites; no tenderness on pressure. Pain was general over the abdomen, especially marked at the umbilicus. Patient restless, preferring to sit up most of the time. Desires to pass gas but can not.

January 9. Bowels have not moved during the past night. The abdomen is more distended; the pulse is rather poor, and the patient looks rather seedy. Showed considerable improvement after $\frac{1}{5}$ gr. of strychnia. In consultation with Dr. J. Collins Warren the condition above described was found. Rectal examination showed a mass the size of a small orange, high up toward the middle line, which felt like an impacted omega loop. No fecal matter in the rectum. A high enema of oil was then given, followed by one of magnesium sulphate, glycerin and water. Three hours later a movement took place, consisting of about two quarts of fecal matter; no blood or mucus. More comfortable after this. Pulse regular and of good volume, but still intermits occasionally. White count: 13,400. Temperature 100, pulse 108, respiration 25. Some thirst.

January 10. Fairly good night. Abdomen still distended. Some belching of gas, no vomiting. Oil and magnesium enemata repeated with two good results. Has taken nourishment every two hours in small amounts. Rather restless all day, complaining of general discomfort in abdomen. At night abdomen seemed harder in right iliac region, and very tympanitic over left iliac and epigastric regions. Color good; respiration rather rapid, but not labored. Slight nausea, but no vomiting. Very thirsty. Has passed no gas and has not much pain. Bowels have moved four times during the day.

January 11. Slept only a short time last night, when he became very restless and complained of considerable pain in epigastrium. Drank freely of water and liquid nourishment. At 3:30 a. m. had a severe pain in epigastrium. Morphia had but little effect. Pulse fairly good. At 7:30 a. m. considerable pain, bad pulse, slightly cyanotic, respiration gasping. He responded well to $\frac{1}{5}$ gr. of nitroglycerin, and at 9:30 a. m. was quite comfortable. Operation was considered, but given up on account of condition of the patient. At noon he

Symptoms
resembling
cholera case

again collapsed and large doses of stimulants were necessary to obtain any reaction. From this time on he gradually failed and died at 3 p. m. Before death he had an involuntary movement and passed gas. After death about two quarts of dark brown fluid, smelling of stomach contents, flowed from mouth and nose. The stomach had evidently not passed anything along for hours.

Analysis of Urine.—Dr. J. Bergen Ogden, Harvard Medical School. Jan. 11, 1901. Urine in 24 hours small, specific gravity 1033½, color high, amount of sediment considerable, reaction strongly acid, chlorids much diminished, urophæin increased, E. phosphates much diminished, indoxyl much increased, alk. phosphates diminished, urea 1.84 per cent., uric acid increased, albumin very slight trace. Sugar present, 3.57 per cent. No acetone or diacetic acid. Bile pigments absent. Sediment, numerous granular and brown granular casts, some with renal cells, abnormal blood and little fat adherent. Numerous free renal cells, and a few blood globules. A few small caudate cells as from renal pelvis. We find this urine to contain sugar. The normal solids are all diminished excepting the uric acid. The indoxyl is very high, which is confirmatory of the diagnosis of intestinal obstruction. The chlorids, phosphates and urea are diminished, probably on account of a low diet. The very low chlorids might also be consistent with a serous effusion. There is considerable disturbance of the kidneys, apparently of the nature of an active hyperemia, rather severe and probably due to a toxemia. There is also evidence of an irritation of the pelvis of the kidney, probably from the same cause. As to the meaning of the sugar, there may have been a diabetes mellitus antedating the present trouble. On the other hand, the sugar may be secondary to the marked abdominal trouble. In the absence of previous history pointing to diabetes, the glycosuria should be considered secondary.

AUTOPSY. DR. W. F. WHITNEY, HARVARD MEDICAL SCHOOL.

Jan. 12, 1901, 18 hours postmortem. The body of a large man with abundant fatty tissue. Rigor mortis present. The body was slightly warm with marked lividity of the dependent portions.

Head.—Not opened.

Pericardium.—Contained a normal amount of fluid.

Heart.—Large. Weighed 400 grams. The valves were normal in appearance. The mitral valve measured 11 cm., and the tricuspid 13 cm. The aorta showed numerous opaque, yellow and calcified patches on its inner surface. The openings of the coronaries were slightly obstructed, and there was a similar condition to that found in the aorta, but less extensive throughout these arteries. The heart substance was pale.

Microscopic Examination.—A slight increase of the fibrous tissue was found between the bundles of muscular fibers, which were somewhat atrophied, otherwise there was nothing remarkable.

Lungs.—Somewhat adherent to the chest cavity and rather engorged in blood in the dependent portions, but otherwise not remarkable.

Abdominal Cavity.—Contained a moderate amount of bloody, serous fluid. The coils of the intestines were very much distended with gas and of a dark, bluish-red color. The stomach itself was normal. The ileum, for the greater part of its course, was discolored, bluish-red in color, the membrane injected with a little bloody mucus in the interior, and about midway in this part the walls were thickened through infiltration of blood. On section the veins leading to this point were found filled with a dark red, loosely adherent antemortem thrombus. The lower two feet of the ileum and the head of the colon were normal. The greater part of the ascending and transverse colon presented a similar aspect to that of the ileum but less in extent. The veins leading to this were also found to be thrombosed in a like manner.

Pancreas.—It was imbedded in fatty tissue, but appeared normal to the eye.

Liver.—Was of normal size. On section it was rather opaque and yellow with indistinct lobular markings. Microscopic examination showed atrophy of the liver columns, slight increase of the fibrous tissue and fatty infiltration of the cells.

Spleen.—Small and soft.

Kidneys.—One of them weighed 200 grams. On section the surface was somewhat pale, slightly opaque with marked injection at the base of the pyramids.

Microscopic Examination.—The vessels of the malpighian bodies were found to be dilated and the connective tissue between the tubules was increased, with a marked atrophy and granular degeneration of the epithelium. The arteries of the kidney were considerably thickened, but this was in general diffuse. In the straight tubules were a few hyaline casts. The thrombosed vessels in the mesentery showed very little change in the wall of the vein that would be regarded as a cause for the thrombosis. In one of the pieces examined, in addition to the vein, a small artery was also found to be thrombosed, the wall of which showed a marked thickening and irregularity of the intima, and to which a thrombosis was very intimately adherent, and seemed as if it might have been the starting point of the process.

Diagnosis.—Arteriosclerosis with hypertrophy of the heart; slight, chronic interstitial myocarditis; hepatitis and nephritis; thrombosis of the mesenteric vein and artery; infarction of the intestine; commencing gangrene.

It is to be regretted that the pancreas was not examined microscopically in this case, and that a thorough dissection of the mesenteric vessels could not have been made. It is, however, fair to assume that the thrombosis could not have extended further than the secondary branches, otherwise the entire intestinal tract would have been infarcted, which is shown above was not the case. It is probable that the thrombosis was due to mechanical pressure of the overloaded colon on vessels in which the circulation was deficient from conditions of the walls of the vessels and the heart.

CASE 2 (Dr. Gannett).—A. R., woman, 65 years, entered Massachusetts General Hospital May 18, 1902.

Family History.—One sister has myxedema, one brother and sister died of tuberculosis.

Past History.—Scarlet fever and measles as child. For eight to ten years has been treated for heart trouble.

Present Illness.—Has been failing gradually for four to five years, and is troubled with dyspnea and palpitation. Has had several severe attacks of orthopnea in last few years. Her present attack has lasted six to eight months, but she did not stay in bed all the time. At times has attacks of severe precordial pain, bearing no relation to exertion. For one or two months legs have been swollen, the swelling gradually increasing and extending upward. No swelling of face and hands. Appetite fair. Vomits occasionally, but only after coughing. Bowels regular. Temperature 98.6, pulse 80, respiration 40.

Physical Examination.—Well developed and nourished. Complains of precordial distress. Cheyne-Stokes respiration. Lungs, râles at both bases, otherwise negative. Heart, apex, fifth space six and one-half inches from middle line. Enlarged, sounds distant and feeble. Systolic murmur at apex. At third left interspace a long, loud diastolic murmur. Pulmonary second sound increased. Pulse regular, small volume, rather high tension, arterial walls thickened. Abdomen large, lax, much subcutaneous fat, with marked dullness on percussion, extending well up into flank, dullness shifting with change of position. No tenderness, nothing abnormal felt. Very marked edema of thighs, legs and feet. Reflexes normal. Blood, hemoglobin 90 per cent., whites 13,000. Urine, high color, acid 1.023. Albumin, slightest possible trace; sugar absent, chlorids diminished, urea 2.77 per cent.; sediment shows very rare hyaline cast and abnormal blood globule; considerable blood, and some squamous cells; many bacteria.

Clinical Diagnosis.—Hypertrophy and dilatation of heart, arteriosclerosis, failure of compensation.

May 21. Considerable improvement in pulse since entrance, but has much distress at times with breathing. Is very noisy.

May 23. Pulse and general condition remain about the

same. Still considerable dyspnea, but not so marked as at entrance. Incontinence of urine and feces. Edema of legs and abdomen is increasing.

May 25. Considerable hematemesis is present.

May 26. General condition not so good. Râles more numerous. During afternoon became unconscious, and failed rapidly. Died 6:15 p. m. Temperature never went above normal, pulse gradually increased to 110.

AUTOPSY. DR. J. H. WRIGHT.

Arteriosclerosis with slight dilatation of aorta. Hypertrophy and dilatation of heart. Thrombus in right auricular appendix of heart. Embolic thrombus of branches of pulmonary artery in each lung, with hemorrhagic infarcts of lungs. Stenosis of celiac axis, and superior mesenteric artery at their origin. Obturating thrombus of the superior mesenteric artery. Chronic, passive congestion of lungs, spleen, liver and intestines. Double hydrothorax. Anasarca. Senile degeneration of kidneys and uterus. Chronic perisalpingitis and peri-ophoritis. Adenoma of left adrenal. Chronic perisplenitis. Obsolete tuberculosis of pleura. Right otitis media, umbilical hernia. Cholelithiasis. A very few cc. of fluid in pelvic cavity. A small piece of omentum adherent to the abdominal wall, in the region of the umbilicus. Anterior margin of right lobe of liver, two fingers' breadth below costal margin in mammillary line. The mucosa of small intestine shows injection of small vessels, and in places the valvulae conniventes are of a dark red, hemorrhagic appearance. No ulcers. Abdominal cavity and intestines otherwise negative.

CASE 3 (Dr. J. J. Minot).—E. H., widow, 68 years, entered Long Island Hospital, Nov. 10, 1903.

Previous History.—General weakness, with nausea and vomiting.

Physical Examination.—Well developed, slightly emaciated. Somewhat weak, answers slowly but rationally. Anemic. Left pupil slightly larger than right, reaction normal. Tongue is protruded, straight, somewhat dry and coated. Pulse irregular, slightly rapid, of fair volume and tension. Arteries excessively calcified. Chest expansion fair. Heart sounds weak, no murmurs heard. Lungs, good resonance throughout, moist râles in both lower backs. Abdomen, lax and tympanitic, no tenderness or tumors. Liver and spleen normal, not palpated. Extremities, knee-jerks and plantars present. Patient is able to move left leg and arm but slightly, and with less strength than on right.

Clinical Diagnosis.—Myocarditis, arteriosclerosis, interstitial nephritis, rheumatoid arthritis.

Nov. 11, 1903. Patient slept well during the night, and this morning was comfortable. About five minutes after she had been talking with the nurse in her usual manner, she sud-

denly became pulseless and white, and vomited a large amount of thin, dark fluid, filled with dark, membranous material, varying from small fragments to 2 cm. in diameter. Artificial respiration was of no avail, and patient died.

Examination of urine, specific gravity, 1.023 acid, very slight trace of albumin, sugar absent, bile absent. Several squamous cells, occasional hyaline and granular casts.

Examination of vomitus. Dark brown liquid. Lactic acid and blood present.

AUTOPSY. DR. G. B. MAGRATH.

Anatomic Diagnosis.—Chronic adhesive pleuritis, chronic adhesive pericarditis, hypertrophy and dilatation of heart, emphysema of lungs, fatty metamorphosis of liver, chronic nephritis, multiple infarcts of ileum, senile endometritis, mural thrombus of aorta, general arteriosclerosis, edema of brain, acute fibrinous pericarditis, double hallux valgus. Several coils of the lower part of the ileum are united to one another by fresh, fibrinous adhesions. The coils at the site of the adhesions injected, dark red, and marked by opaque, white patches. The mesentery at the site of these areas is thickened, on section, edematous, the cut surface yielding on pressure, in addition, puriform fluid. These coils lie in the pelvis. Vermiform appendix, and mesenteric lymph nodes normal. On section, the above coils show considerable loss of substance, involving the mucous membrane, the area extending completely around the intestine. Color, opaque, yellowish brown. In places, partly detached sloughs are present, about 2 cm. in width; 30 cm. of gut are involved in lower one-third of ileum.

Aorta on section shows some general dilatation; circumference at the left subclavian, 7.5 cm.; the inner surface is marked by numerous indentations, alternating with elevations, the former calcareous and shell-like, the latter white, or yellowish white; 7 cm. above the celiac axis the front wall shows two regions, approximately 1 cm. in diameter, overlaid with adherent, gray-red clots. One of these clots is somewhat sessile; the lower part of the abdominal aorta and the common iliac are almost wholly calcified.

Microscopic examination shows arteries of involved gut occluded by arteriosclerotic thickening, with few thrombi in finest branches.

CASE 4 (Dr. R. H. Fitz).—B. J., 54 years, widow, cigar maker. Entered Massachusetts General Hospital, Jan. 24, 1903.

Previous History.—Pleurisy three years ago, no other illness. Has had 11 children, youngest 15 years ago; one miscarriage before last child was born. Menopause 4 years ago. Tea, two cups per day. Seldom takes alcoholic liquor.

Present Illness.—Two weeks ago, while in bed in the morning, patient was awakened by pain in the right hypochondrium,

of considerable severity, dull and heavy in character, not radiating. A few minutes later she vomited, and continued to vomit all the forenoon, with gradually diminishing frequency. Vomitus was slight in amount, green and bitter. There was no chill or feverishness. Pain could not be traced to anything unusual in diet. Bowels had been regular. After this attack, patient felt well until six days later, when a second attack of pain and vomiting occurred. This time the pain did not disappear, but has continued with greater or less severity up to the present time (kept her awake all last night, but is better to-day.) Has vomited almost every day this week (to-day at least 10 times). Has been able to retain but very little nourishment. She has felt cold most of the time, but has noticed no feverishness. Has noticed no jaundice. Bowels have only moved twice in last week, nothing abnormal noticed in character of stools. Urine is red and "thick" and burns as she passes it. Sleep has been poor on account of pain. No appetite.

Physical Examination.—Well developed, somewhat obese. Skin and mucous membrane of good color. Pupils equal and react. Teeth, upper false, many lower ones wanting. Tongue moist, with slight white coat. Throat negative, lungs negative. Heart, apex palpable, fifth space, $4\frac{1}{4}$ inches from median line. Right border dullness $1\frac{3}{4}$ inches to right of median line. Sounds very irregular in force and rhythm. Pulmonic second sound slightly increased. No murmurs. Pulse very irregular, rather small volume, and low tension. Abdomen, large, flabby, tympanitic. In the right lower quadrant there is marked tenderness and resistance to palpation, most marked midway between umbilicus and anterior superior spine of right ilium. In the lower abdomen is felt a mass, tender on palpation, and elongated in transverse diameter. No tenderness or spasm in region of gall bladder. Liver dullness from sixth rib to one inch above costal margin, edge not felt. Spleen negative. Reflexes normal. Slight edema of ankles. Temperature 102, pulse 90, respiration 25.

Diagnosis.—Acute endocarditis.

January 24. Blood, hemoglobin 90 per cent., whites 20,200.

January 25. Urine high color, acid 1,030; albumin, large trace; no sugar, no bile, no diazo. Chlorids diminished, urea 3.03 per cent. Sediment, few hyaline casts, with renal cells, and oil globules adherent, many fine and coarse granular casts, some with renal cells adherent. Rare compound granule cell. Numerous squamous epithelial cells. Few leucocytes and small round cells. No blood seen.

January 26. Whites 28,400. Marked iodophilia.

January 27. Patient has grown steadily worse since entrance. Temperature increased and rising, and pulse steadily rising. Complained of abdominal pain, but for the last twenty-four hours has been semi-conscious. Abdomen, though soft,

is generally tender. Cheyne-Stokes respiration. Heart action very irregular in force and rhythm. Died, 6:35 on January 27.

AUTOPSY. DR. J. H. WRIGHT.

Anatomic Diagnosis.—Fibrous endocarditis of mitral valve (mitral stenosis). Fibrous endocarditis of aortic and tricuspid valves. Hypertrophy and dilatation of the heart. Thrombi in the left auricular appendix. Embolism and thrombosis of branches of the superior mesenteric artery, with hemorrhagic infarction of the cecum and portions of the ileum and ascending colon. Infarcts in the spleen and kidneys. Thrombosis of a large branch of the superior mesenteric vein. Meckel's diverticulum. Cholelithiasis. General peritonitis.

Icterus, especially of anterior portions of trunk. Head not examined. Small amount of opaque fluid in peritoneal cavity, with grayish yellow flocculi. The coils of the intestine generally show marked injection of the serosa, and at their margins of contact present grayish yellow streaks of fibrinous exudate. Cover-glass specimen from this exudate shows many leucocytes, and innumerable bacteria, among which are bacilli and micrococci. The walls of the cecum and one-half the adjoining ascending colon, and over a distance of 100 cm. of ileum, show marked changes in color. In the situation of the portion of the ascending colon mentioned, the cecum and lower part of the ileum are black to black-red in color and gangrenous in appearance. Higher up the color fades out gradually from the blacker, gangrenous appearing condition of the lower portion, to the normal appearing intestine, about 100 cm. from the ileocecal valve. The change in color varies from the black-red of the lower portion to gray-red, and beyond the distance mentioned to the normal color. The parietal and visceral peritoneum present more or less of a grayish fibrinous exudate in places. Lungs, no adhesions, negative. Pericardium negative. Heart, old endocarditis of mitral aortic and tricuspid valves. Aorta, negative.

Superior mesenteric artery: At point where ileocolic branch is given off, is an occluding, gray-red, fleshy mass, which is slightly adherent at one point to the intima. This mass is continued into the ileocolic branch, and its branches as gray-red to blackish-red masses, and on following out two or three of the larger branches of the ileocolic it is seen to be continuous in them, till they disappear in the gangrenous portions of the ileum and cecum. In a large radicle of the superior mesenteric vein of the portal system, which arises from the region of the cecum and the ileum, there is, in its lumen, over a distance of several centimeters, a gray-red thrombus-like mass occluding it. This material is invested by a grayish-red, membranous-like covering, and on section shows rather blackish-red, slightly soft central portions, with somewhat denser, gray-red peripheral portion. Liver, negative. Gall bladder, spleen, kidney,

etc., as above. No ulcerations in intestines on section, and except for gangrenous portions already described, they are not remarkable. Appendix negative.

There is given off in the ileum, at a point about 90 cm. from the ileocecal valve, a diverticulum 5 cm. long by 2 to 3 cm. wide, the lumen and mucosa of which are continuous with those of the intestines.

CASE 5 (Dr. Fitz).—J. K., man, 25 years, entered the Massachusetts General Hospital Dec. 16, 1898.

Clinical Diagnosis.—Gastric ulcer. Secondary anemia. Hematemesis and melena. Picture that of cirrhosis with ascites. Gradual loss of strength, and death with subnormal temperature.

AUTOPSY.

Thrombosis of portal, superior mesenteric, and splenic veins, and of some of the radicles. General anemia. Superficial ulceration in mucosa of stomach. Perisplenitis. Hyperplasia of spleen. Old pleural adhesions. Fatty degeneration of heart. Edema piæ. Peritoneal cavity, slight amount clear fluid. Intestines smooth, shiny and pale. Heart not remarkable. Liver small. In portal vein, pink, firm, fleshy mass, adherent to wall, which extends up to where the vein breaks into liver branches. The thrombus divides and extends slightly into the liver. At origin of portal vein the thrombus divides and extends along the splenic and superior mesenteric vein. In this latter the thrombus can be easily traced down into some of the finer radicles in the mesenteric insertion of the intestine. The character of the thrombi change in the smaller vessels to a gray-red, firm, fibrinous material, adherent to the wall, with intervals of a darker red, soft blood clot material. The splenic vein presents a similar condition to the superior mesenteric, near the end of the superior mesenteric vein, a calcareous plate, size of finger nail. Intestines show some reddening of mucosa. Stomach on section, horse-shoe shaped, superficial loss of substance near pylorus.

The following four cases are from the Johns Hopkins Hospital, Baltimore, and are published by the courtesy of Dr. J. C. Bloodgood:

CASE 6 (reported by Dr. Bloodgood). C. C., male, age 52, engineer.

Past History.—Had been a soldier.

Present Illness.—Three weeks ago sudden abdominal pain, not very severe in character, associated with vomiting. Since then intervals of moderately severe pain, chiefly in umbilical region, and vomiting. A few days before admission, acute abdominal pain in region of umbilicus, with vomiting. This attack was aggravated by the administration of cathartics on the next day. No passage of fecal matter, blood or flatus, from

this time, three days before admission. Nothing retained by stomach. Abdomen slightly tender above and to right of umbilicus and moderately distended. On admission to the surgical wards at Johns Hopkins Hospital, Sept. 15, 1896, examination showed patient to be excessively fat. Temperature 100 degrees, pulse 72, respiration 24. Facies typical of a severe, intraperitoneal lesion. Abdomen moderately distended, slight muscle spasm, but no tenderness. Palpation difficult, on account of thick abdominal walls. No mass detected on palpation. Rectal examination negative, no fecal matter in rectum. Prepared for operation at once.

OPERATION.

Laparotomy September 15, by Dr. Bloodgood. Under ether anesthesia, a large moveable mass was felt slightly to right and above umbilicus. Bloody fluid in peritoneal cavity, no fecal odor. The moveable mass proved to be omentum adherent to coils of small intestine beneath it. The mass was excised. About 8 cm. of a loop of ileum was gangrenous; the neighboring intestine was congested and covered with fibrin. No perforation. No fecal extravasation. The mesentery seemed normal. The omentum and mesentery very large from fatty deposit; intestine not greatly distended. The gangrenous loop of intestine was drawn out of the wound, and the intestine drained by tubes, inserted above and below. The operation lasted one hour, transfusion of salt solution (1 liter) at end.

After operation patient vomited a great deal of bile-stained fluid. This vomiting continued intermittently during the next three days.

September 17. Gangrenous intestinal loop came away from wound, without bleeding. Temperature 100.5. Pulse, 120. Pulse became very weak during night and rose to 160.

September 18. Temperature 103. Death 10:30 a. m.

AUTOPSY SEPTEMBER 18. DR. FLEXNER.

Anatomic Diagnosis.—Thrombosis of mesenteric veins, necrosis and gangrene of small intestine, general fibrino-purulent peritonitis. Abscess in omentum. Operation wound. Extension of venous thrombosis in portal vein. Congestion of liver and spleen. Chronic, diffuse peritonitis. Chronic interstitial orchitis. Hydrocele. The jejunal loops within the abdominal cavity were much dilated, dark in color, and contained much fluid. The ileal loops were much less distended, the large intestine moderately distended. The gangrenous loops involve the lower end of the jejunum, and the beginning of the ileum. The jejunum adjoining the gangrenous portion very dark in color. The superior mesenteric artery was free. The superior mesenteric vein and its branches to the gangrenous loop and to the intestine on either side were occluded by firm, partially adherent thrombi. The main trunk of the por-

tal vein was also filled by firm thrombi extending from that in the mesenteric vein.

CASE 7 (reported by Dr. Mitchell).—G. W., male, age 41, saloonkeeper. Patient was admitted to the Johns Hopkins Hospital as an emergency case July 18, 1900. Had been suffering severely for four days with agonizing pain just to the left of the umbilicus. Considerable nausea and vomiting for last 36 hours. No movement of bowels for two days before admission.

On admission, condition very alarming. Temperature 102 degrees, pulse 140, fair volume. Respiration 31 to minute, thoracic. Skin bathed in perspiration. Lips and mucous membranes pale. Abdomen uniformly distended, tender on pressure, especially on right side. Liver dullness obliterated in upper line. Left side of abdomen tympanitic on percussion, dullness over right lower abdomen, extending nearly to median line. Palpation not possible because of tenderness. Below umbilicus there was a prominence visible in the median line. No visible peristalsis. The general aspect of the man strongly suggested a severe internal hemorrhage. Dr. Mitchell made the diagnosis of mesenteric thrombosis and immediate operation was advised.

OPERATION.

Laparotomy 12:40 p. m., July 18, by Dr. Mitchell, under cocain and chloroform anesthesia. The peritoneal cavity was found to contain a large quantity of thin, dark brown, bloody fluid. A large distended blue-black coil of small intestine was found, running transversely above the umbilicus, down right side of abdomen and across below umbilicus. Above this was distended, and below it, collapsed intestine. The loop was brought out of the incision, and on incising the mesentery the veins bled very dark, black blood; the arteries did not bleed. The exact location of loop was not made out. The mesenteric glands were much enlarged. The adjacent mesentery very black in color and much thickened. The mesentery was tied off with heavy silk and divided. The abdomen was partly closed with silver sutures. The intestine was then divided well back of gangrenous portion and the distal and proximal ends brought through wound and packed off with iodoform gauze. No attempt was made to wash out the general peritoneal cavity.

Cultures from the peritoneal cavity were sterile; *Bacillus coli communis* was obtained from resected intestine. Patient did not stand operation well and did not rally from it. Condition gradually grew worse and death occurred at 9 p. m., seven hours after operation. Two large involuntary stools were passed before death.

No autopsy was permitted.

In looking through the Autopsy Reports of the Johns Hop-

kins Hospital, in all our 1,600 cases we have found 4 cases in which hemorrhagic infarction of the intestine have occurred without being suspected in life. One of these cases has already been reported by Dr. Welch and Dr. Flexner. A second was in a case of splenomegaly, with a gas-bacillus infection. This was an outside autopsy, and as there was no clinical history it was not reported in detail. There was thrombosis of the portal, splenic and mesenteric veins. Through the courtesy of Dr. Osler, in whose service the remaining two cases were while in the hospital, we are able to give the details of their clinical histories, which, with the pathologic findings, are of interest in the study of mesenteric thrombosis as a terminal process.

CASE 8.—K. M., widow, age 60, admitted to the medical wards of the Johns Hopkins Hospital Jan. 14, 1898. Complained of pain in the stomach.

Family History.—Unreported.

Past History.—Had malaria many years ago. Rheumatism in right leg and arm two years ago. General health fair. Has done very hard work. Habits excellent. Bowels regular. Subject to slight dyspeptic attacks, with vomiting, off and on for seven years. Frequency of micturition.

Present Illness.—Has not felt well for some months. About four weeks ago shortness of breath, from which she has suffered for years, grew worse, being very extreme on least exertion. Palpitation of heart, with dyspnea. Some swelling of feet. Pain and soreness in upper abdomen. Vomiting immediately after eating. On admission patient seemed in great distress. Slightly cyanotic. Lungs clear. Heart dullness not increased. Systolic murmur at apex. Pulse 92 to the minute, regular; vessel sclerotic. Abdomen full. Liver large and tender.

January 22. Temperature rose during the night from 98.2 to 103.7 degrees and patient became comatose. Pulse 148. Heart's action violent, pulsation over whole precordia. Respiration not increased, but deep and full. Face covered with sweat. Pupils contracted.

January 23. Temperature rose to 108 degrees, pulse 120, otherwise condition remained the same. There were a few râles heard at the base of the lungs. Leucocytosis 12,000. Death at 11:15 p. m.

AUTOPSY, DR. LIVINGOOD, JANUARY 24.

Anatomic Diagnosis.—Arteriosclerosis, small kidneys; chronic diffuse nephritis. Hypertrophy of left ventricle. Thrombosis of coronary arteries of stomach. Hemorrhage into serosa of stomach. Thrombosis (firm, white thrombi) of several branches of superior mesenteric vein. Hemorrhagic infarct in lung. Portal vein normal. No note on condition of mesenteric arteries.

CASE 9.—D. B., male, age 52, admitted to the medical wards, service of Dr. Osler, Oct. 13, 1898. Complaint, shortness of breath and swelling of abdomen.

Family History.—Unimportant.

Personal History.—Always healthy. Indefinite history of inflammatory rheumatism ten years ago. Gonorrhoea twice. Syphilis. Heavy drinker. Had been to Johns Hopkins Hospital four times since 1896 with roughening of aorta, mitral insufficiency and stenosis, and arteriosclerosis.

Present Illness.—Two weeks before admission return of cardiac weakness. Bowels very constipated. On admission, marked dyspnea and cough. Abdomen very much swollen; small properitoneal hernia; ascites. Marked tenderness in right hypochondrium. Temperature 96.5, pulse 68 to the minute, collapsing. For three or four days previous to October 28 patient complained of pain, usually in right hypochondrium, at times more general. October 28 at 3 a. m., sudden, severe, sharp pain in abdomen. The pain persisted almost continuously from this time on.

October 29. Abdomen somewhat distended and exquisitely tender. Great nervousness and excitability. Temperature 98 degrees, pulse 88, small and weak.

October 30. General condition same. Temperature 100, pulse 112 in morning. Death at 6 p. m.

On October 28 patient had five stools; on October 29, two stools. No blood passed. No mention made of vomiting.

AUTOPSY, OCTOBER 30, 1898, DR. FLEXNER.

Anatomic Diagnosis.—Arteriosclerosis; hypertrophy of the heart. Sclerosis of the aortic valves. Free globular thrombus in the left ventricle. Marantic thrombosis in right auricle. Thrombosis in superior mesenteric artery (or embolus). Hemorrhagic infarction of intestine. Acute peritonitis. Chronic passive congestion. Stomach polyp. Peritoneal cavity contained much bloody fluid.

The infarcted intestine consisted of all the jejunum, ileum, cecum, ascending colon and part of the transverse colon. The intestine was much distended, deep red in color, and covered with fibrinous deposits.

CASE 10 (Dr. C. A. Porter).—Miss C. D., 76 years, April 21, 1902. About a week ago she was suddenly seized with severe pain in the epigastrium and back. On April 20 she was again taken with sharp pain, running transversely across the epigastrium. This came on after going upstairs after tea. She vomited at once, and several times later, without much pain. The pain continued for some hours, but she had a normal movement that evening. Dr. Cushman of Dudley Street, Boston, was called and gave morphia gr. $\frac{1}{4}$, with strychnia. The pain and nausea continued, despite treatment, until morning, though she slept some hours. In the morning she was distinctly

worse. The patient was seen by Dr. C. A. Porter at 11 that morning.

Physical Examination.—Face drawn, pulse 105 and weak. Heart was somewhat enlarged. The belly was moderately distended, but not tender. The pain was referred to just above the navel, crosswise over this area of the abdomen. No urine had been passed since the night before. The rectum was collapsed and some dullness was made out in the left flank. Ten ounces of urine was drawn by catheter. This showed albumin and casts (fatty, etc.). She grew worse in general condition and vomited dark material. Laparotomy was done at 5:30 p. m. of the same day by Dr. C. A. Porter. A foul odor was emitted by the intestines. The cecum was dark green in color and surrounded by adherent omentum. All the small intestines were contracted and dusky in color. The veins of the intestines were full but not distended. The arteries did not pulsate. She died on the table.

AUTOPSY. DR. WRIGHT.

Autopsy showed the heart to be normal. The mitral valve was thickened and calcareous. A thrombus 1 cm. long was attached weakly to this curtain. The aortic valves were normal. The superior mesenteric artery for 6 inches below its origin was occluded by a gray-red thrombus mass, with a granular surface, adherent to the arterial walls. The small intestines were dark red, with purple fluid in the intestinal cavity. The walls of a large part of the cecum and of the adjacent ascending colon were green and foul. The appendix was normal. The spleen showed two infarcts, the kidneys a glomerulo-nephritis.

CASE 11 (Dr. C. A. Porter).—M. H., woman, 38 years. Jan. 25, 1899.

Past History.—More or less chronic diarrhœa for last three or four years. Has had three children, the last five weeks ago. In bed ten days; normal convalescence. Previous pregnancy was in 1897, after which she was in the Massachusetts General Hospital for "milk leg."

Present Illness.—Well till four days ago, when she had some pain in right hypochondrium, not severe, but enough to prevent her working. Pain soon moved to umbilicus, where it remained constant, something like a colic, coming and going. Vomited evening before entrance. Bowels moved every day till day of entrance; nothing peculiar about stools. Pain has gradually increased in severity. Entered hospital about 7 p. m. Had severe pain in abdomen and poor pulse at 8 p. m. Enema brought away a few small fecal masses of normal color and consistency.

Physical Examination.—At 9 p. m. Temperature 98.6, pulse 80, of poor quality; respiration 23. Leucocytosis 50,200. Woman pale, rather poorly nourished. Hollow eyes with dark veins about them. Eye clear, expression rather "pinched," though perfectly bright and intelligent. It was evident that she was

laboring under peritoneal shock. She talked freely, though evidently in extremely poor condition. The tongue was moist, the center covered with a superficial, brown "fur." Heart and lungs negative. Respiration thoracic.

Abdomen.—Liver dullness normal above, in right mamillary line; two finger breadths below upper limit of dullness tympany is found. Area of splenic dullness also diminished. Abdomen in general somewhat distended, left side more than right. Both recti rigid, left more than right. Pain most marked directly within umbilical cicatrix. Tenderness greatest over area size of palm of hand, to the left of umbilicus, where the muscles resist the slightest pressure. Dullness in left lower quadrant. No peristalsis heard on auscultation.

Vaginal examination showed a rather large uterus, not tender. Some induration without tenderness in left side of pelvis; no bulging. Rectal examination negative.

Urine.—Red color, acid, albumin $\frac{1}{4}$ per cent., sugar absent. Sediment contained some pus, considerable normal blood, a few granular casts and squamous epithelium from bladder or vagina.

OPERATION. DR. C. A. PORTER. ETHER.

Incision in left rectus six inches long. About 500 c.c. of slightly red-tinted turbid serum escaped, containing a few flocculi of lymph. Culture from this was sterile. Examination of gall bladder, appendages and appendix was negative. On retracting left rectus outwards, from directly under tender area there emerged a coil of dull, dark, plum-colored intestine. Five coils were glued together by recently exuded lymph. There was no circulation in this bowel; no kink or band. At the lower end there was an abrupt line of demarcation, below which the intestine was of normal consistency. Above the blackened bowel the color faded gradually into what seemed like normal intestine, though the walls of the gut were somewhat thicker and firmer than normal, with here and there engorged vessels. The mesentery was thickened to twice the normal, felt rather firm, with indurated lines running toward the bowels; evidently thrombosed veins, as the arteries could be felt to pulsate. The bowels could not be kept within the cavity, so the ascending colon, which was much distended, was punctured and collapsed, the incision then sutured. This gave more room. There were no signs of injection in the large intestine. The blackened gut was rapidly removed by a wedge-shaped incision in the mesentery, one inch below the abrupt lower line of demarcation, and six inches above the upper, ill-defined border. On dividing the mesentery the arteries spurted freely. In all of the veins, on the other hand, moderately firm, dark thrombi were found. The patient's condition did not allow time for a suture of the resection, so, after toilet of the peritoneum with salt solution, the two ends of the gut were brought out of the abdomen, sur-

rounded by gauze, and the wound rapidly closed. Patient put to bed in very poor condition. Time of operation, 35 minutes.

January 26. Early in the morning the pulse became poor, 120 to the minute. Temperature 102.5. No nausea or vomiting. No reaction to stimulants, and death followed at 7 p. m.

AUTOPSY. DR. J. H. WRIGHT.

Heart and lungs not saved. The portal vein and practically all its branches are distended, firm to the touch, bluish in color and filled with clotted blood. No extensive dissection of interior of veins was made in order not to destroy the specimen. A part of the portal vein at its entrance into the liver was opened and found to be occluded by a gray, red, firm, fleshy mass, adherent to the intima of the vessel and extending a short distance into one or two of the branches going into the liver. No thrombus in splenic vein. The mesentery of the small intestine shows a defect which has been closed with sutures. Opposite this point a portion of the small intestine is absent. The remaining jejunum for about two feet above resected end is a dark red to blackish color, infiltrated with dark bloody fluid, and its serosa showing fibrinous exudate. The mesentery supplying this is not infiltrated with blood, but fairly normal in appearance. Liver and spleen not remarkable. Kidneys show a pale opaque appearance on section. No atrophy; markings normal. Uterus and appendages not remarkable.

Anatomic Diagnosis.—Resection of intestine; extensive thrombosis of portal vein and its large branches; hemorrhagic infarction of a portion of jejunum; acute degenerative nephritis.

CASE 12 (Dr. C. A. Porter.)—Man, 47 years, electrotyper. Entered Massachusetts General Hospital Jan. 8, 1904. Transferred from Dr. Shattuck's service.

Family History.—Negative.

Past History.—Children's diseases. Chorea 28 years ago.

Present Illness.—Cough, dyspnea and palpitation for four months. Precardial pain, radiating from arms, occasionally for last three months. Attack lasts 15 minutes. Some distress after eating. Pain often comes on after exertion. Some amaurosis at this time. Ever since youth has had occasional trouble with piles, pain and itching, and sometimes palpable masses coming down; considerable pain and tenderness.

Physical Examination.—Well developed and nourished. Lungs, a few moist râles at each base. Breathing rapid and somewhat labored. Lips faintly cyanotic. Patient breathes easiest in upright position. Heart, apex fifth space one-half inch outside nipple line, rhythm regular. Systolic murmur loudest at apex and transmitted outward. Diastolic murmur at base, transmitted downward. Pulse, good volume, fair tension, quick and of Corrigan character. Capillary pulse not ob-

served. Visible pulsation of brachial carotids and femorals. Radial arteries sclerotic. Pistol shot murmur in groins. Abdomen full, soft, tympanitic. External tabs of old hemorrhoids, internal hemorrhoids palpable and visible on straining, purplish and sloughing. No edema.

Urine.—Normal color, turbid, acid, 1,025, trace of albumin, sugar absent. Sediment, some granular and hyaline casts. Few blood corpuscles and cells, with crystals.

OPERATION, JANUARY 8. DR. C. A. PORTER. ETHER.

Under anesthesia, which was given by the drop method, with plenty of air, it was noticed that the patient, who had an aortic and mitral lesion, was somewhat cyanotic in his ears, although his pulse remained good. His hemorrhoids and veins of the lower extremities appeared dark blue. After he was thoroughly under ether, which he took without struggling, the circulation improved. With a ligature 3 piles were tied off, and a good deal of hypertrophied skin removed by a circular incision. An iodoform gauze plug was inserted into the rectum, with a morphia suppository. During the afternoon, after recovery from ether, he complained of some pain in his lower abdomen, distension and increasing dyspnea. His temperature was normal, pulse about 100, rather weak tension, sounds rather indistinct. During the night he had a movement, and after morphia was more comfortable, though the distension steadily increased, with some pain in the lower abdomen, and especially marked tenderness on deep pressure in the left iliac fossa and just to the left of the umbilicus.

Examination January 9 at 9 a. m., showed no edema of the legs, respiration 35 to the minute, slight cyanosis, pulse weak and irregular. Abdomen was markedly distended, tension extreme. Rectal tube brought away some gas, but no fecal matter. He vomited about one pint of brownish material, without fecal odor. At 12 o'clock the abdomen, in spite of turpentine stupes, and washing a quart of brownish, foul-smelling material from the stomach, was still more distended, though the washing of the stomach had given him slight temporary relief. Examination of the dependent portions of the abdomen revealed the presence of some fluid. Tenderness in the left iliac fossa was more marked. The white count was 15,000, the temperature 97.5, heart sounds heard all over abdomen. The urine had not been passed until early morning, and then was about one pint in amount.

In view of the age of the man, with aortic lesions, and arteriosclerosis to some degree, and of the relative suddenness of the onset of this pain, with marked distension and tenderness in the abdomen and the inability, in spite of enemata, to move the bowels, it appeared as if the diagnosis was probably a mesenteric embolism or thrombosis, and though his condition ap-

peared most discouraging, it seemed best to make a small incision under primary ether, and at least open up the intestine, as the increasing distension was undoubtedly causing heart failure, in spite of strychnin and digitalin in repeated doses.

Dr. Musgrave, on examination of the patient before operation, thought that he found evidence of a small embolus at the base of the right lung, but owing to the shallowness of the respiration this could not be absolutely determined.

OPERATION. DR. C. A. PORTER. COCAIN AND ETHER.

On making a rapid median incision below the umbilicus, the intestines throughout were found to be violet in color, with poor circulation. They were distended and obviously paralyzed. On removing some coils it was seen that they were filled with air and fluid, which at once gravitated to the dependent portions, as in an autopsy subject. The abdomen contained about one quart of turbid fluid, with flakes of fibrin here and there on the gut walls. The bowels were opened with a small nick and about three quarts of slightly brownish fluid escaped. This was thin and watery. The patient's pulse suddenly failed and he died on the table, in spite of stimulation, oxygen and artificial respiration. The mesentery was spread out, and on various areas of it and on the intestine were found petechial extravasations of blood varying in size up to one-half inch in diameter. There was no edema of the mesentery. Throughout the distribution of the mesenteric artery it could be felt everywhere as a firm cord, rolling under the finger. A portion of the mesentery, with the vessels, was excised for examination. The veins bled. There was no hemorrhage from the rectum. Examination of excised piece showed all the arterial walls much thickened and one of them occluded. Veins free. Autopsy was refused.

In this case, the operation for hemorrhoids seemed to have no direct connection with the cause of death, because the symptoms set in too soon to have been caused by a propagated thrombus from the rectal vessels. It is possible, however, that the depression during the recovery from ether, the vomiting and postoperative distension, may have been factors in causing thrombosis of the artery, or more probably, that an embolus became detached from an aortic valve.

CASE 13 (Dr. C. B. Porter).—D. M., man, 31 years, fireman, entered Massachusetts General Hospital Dec. 27, 1901.

Family History.—Father died at 55 of cancer of tongue. Habits, tobacco in moderation, no alcohol.

Past History.—Children's diseases. Gonorrhoea twice, no chancre. Otherwise well.

Present Illness.—Three weeks ago began to have pain all through abdomen, very severe, lasting four days, at first general, but finally localized in right groin. Vomited often on first day, retaining nothing. Could not urinate for three days,

when great relief after passing urine, which was bloody. Has been somewhat bloody ever since. Never any jaundice. Severe chills daily about 6 p. m., followed by sweating.

Physical Examination.—Well developed and nourished. Lungs negative. Heart slightly enlarged to right. Abdomen full, slightly resistant in right side, with tenderness, not sharply localized. Tympanitic throughout. Liver dullness from fourth rib in nipple line to costal margin, not palpated.

December 27. White count 43,000. No plasmodia. While in ward, chills have continued, without discovery of plasmodia. Has had morphin for pain. Urine has shown a little pus and blood. Rare, brown granular casts at first, later fatty, granular casts, and few fatty, epithelial cells, first, later fatty, granular casts, and few fatty, epithelial cells.

January 5. Whites, 19,000.

OPERATION. DR. C. B. PORTER. GAS AND ETHER.

An incision six inches long was made an inch below the right costal border and parallel to it. The liver was large, tense and injected, with a few adhesions on its upper surface. The surface of the liver under these adhesions seemed slightly softer than the rest and pitted a little on pressure. A trocar inserted at this point did not discover any pus. The gall bladder was normal. The whole liver was palpated as far as the hand could reach. Nothing abnormal found beyond enlargement and congestion. The right kidney was palpated and found normal. A gauze wick covered with rubber dam was placed over the soft areas in the liver above mentioned and the wound closed.

January 6. Temperature this a. m. 98, p. m. 105, and had a chill. Pulse 140 and very weak.

January 7. Another chill, with partial collapse. Is delirious and very restless at times.

January 8. Is weaker and looks more emaciated. Whites 23,000. Lungs negative. No plasmodia.

January 9. Whites 27,000. Bowels move well with enemata. Takes food well. Has a great deal of pain in right side.

January 12. Has been growing steadily weaker since last note, with occasional chill, sweating and collapse. Delirious. Dressing has been changed and wick removed; no discharge. The liver was tapped with a trocar to-day, but no pus found. There is dullness and diminished breathing at base of right lung. Aspiration failed to withdraw any fluid.

January 14. Collapsed this afternoon and died.

AUTOPSY. DR. J. H. WRIGHT.

Gangrenous appendicitis, with abscess formation in the adhesions and gangrene and perforation of the wall of cecum near appendix. Suppurative phlebitis of the ileocolic and superior mesenteric veins, and suppurative thrombophlebitis

of the portal vein, with multiple abscesses of the liver. Abscess in right kidney. Laparotomy wound. Localized peritonitis in region of right lobe of the liver. Acute hyperplasia of spleen. Bronchitis. Streptococcus septicemia.

Bacteriologic Report.—January 13. Culture from liver puncture shows numerous colonies of the *Staphylococcus pyogenes aureus*.

CASE 14 (Dr. C. B. Porter).—J. D., male, 64, married. Hardware worker. Entered Massachusetts General Hospital, Oct. 30, 1901, 7 p. m.

Present Illness.—Three days before had sudden, severe pain in the belly. It was situated somewhat to the right of the navel. On that day he had diarrhea, but no vomiting. Since the first day he has been in constant pain about the umbilicus, with increasing distension. No tenderness accompanied the pain, but there has been persistent nausea and vomiting, increasing meteorism, and no motions for two days.

Physical Examination.—Fairly well-developed and nourished. Heart not enlarged. Good impulse, no murmurs. The pulse was 80, of fair compressibility, but irregular. Lungs show nothing abnormal. Temperature 100, respiration 23. The abdomen was distended, especially about the navel, where there was some tenderness. Costal and iliac grooves are not obliterated. Immediately to the left of the navel was a dull area, about the size of a dollar. This area felt like a rigid rectus, although that muscle was soft above and below the mass. The belly was elsewhere tympanitic, except in the flanks, where shifting dullness was observed. Rectal examination showed no ballooning. White count, 24,000. Iodophilia, marked reaction.

OPERATION. DR. C. B. PORTER.

At the laparotomy a large quantity of free, clear fluid escaped. (Culture sterile.) Immediately presenting in the field, as the recti were drawn back, was seen a coil of bowel, which appeared to be doubled into a loop and held there by a second encircling coil. Including the mass was a sheath of adherent, indurated omentum. The loop of obstructed bowel was dark red in color. Here and there were bright, yellowish green mottlings, three-quarters of an inch in diameter, covered with thick fibrin. Over the reddened areas the vessels could be made out as darker streaks, running about the circumference of the gut. The mesentery, immediately attached to this part of the bowel, was of fair color, thickened, but bled scarcely at all when cut, except for slow, dark ooze. The omentum was here hard and very friable, and twice its normal thickness. The entangled coils were separated by blunt dissection, with the greatest care, until the whole six inches of discolored bowel was free. There were no changes evident in the coil that was tied around the loop just described, while at either

end of the gangrenous bowel was a sharp line of demarcation. The gangrenous bowel was resected, and an end-to-end anastomosis made. The cut edges of the mesentery were infiltrated, friable, and bled only as a dark ooze. No other obstruction, or discolored bowel was seen, and no fibrin flakes came to light, except those adherent to the dead loop.

The microscopic examination, by Dr. W. F. Whitney, of the bowel removed, "shows mesenteric artery and vein filled with a more or less adherent thrombosis, especially so in the artery, the inner coat of which was proliferated. In places, the thrombosis seems pure red, and in others more or less stratified or mixed. Diagnosis, thrombosis of mesenteric vessels with gangrene of the bowel." The operation appeared at first to relieve the condition, but soon there was a recurrence of all the previous symptoms. The abdomen was tender and distended. Nothing passed the rectum to his death, three days later.

AUTOPSY.

Autopsy showed three feet of small bowel matted together, under an adherent omentum. The bowel affected was proximal to the scar of the resection. It was exactly similar to, though not so far diseased, as the bowel taken out at the operation. There were darkened and light green areas, the latter and fibers attached. There was free fluid, but no flakes. Culture taken of fluid showed a growth of some sort, but the tube was accidentally destroyed before a microscopic examination was made. On separating the omentum from the bowel a rent was made at the joint of the resection at the mesenteric attachment. All about the suture, at this point, the bowel was green and gangrenous, and whether it had yet leaked could not be told from its appearance.

CASE 15 (Dr. M. H. Richardson).—B. W., woman, 61 years, entered Massachusetts General Hospital March 25, 1897.

Family History.—Negative.

Past History.—Malaria and typhoid.

Present Illness.—Perfectly well until five weeks ago, when ankles and arms became swollen. This went in a short time, and she began to have pain in abdomen, not localized, and increased on motion. Attacks have increased in frequency until past week, when they have been almost constant. Vomited during attacks of pain. Vomitus greenish until last few days, when it has been dark and very foul. Bowels regular until five weeks ago, since then extreme constipation. Has passed no gas. Pain not related to eating. No blood by mouth or stool. Has been losing weight slowly for some time.

Physical Examination.—Well developed and fairly well nourished. Heart negative. Abdomen much distended and tympanic. Intestinal coils visible. Nothing could be felt be-

cause of the distension. Patient drowsy, lips dry, breath foul and tongue coated. Temperature 100, pulse weak, 110-120.

Clinical Diagnosis.—Carcinoma of descending colon.

OPERATION. DR. M. H. RICHARDSON. ETHER.

March 26. A three-inch incision in median line, at level of umbilicus. Hard mass felt by examining hand, at lower end of descending colon. Wound then closed with silkworm gut sutures. Patient then turned on right side, and incision made down and forward from costal border to crest of ileum, following outer edge of quadratus lumborum. Descending colon grasped, purse-string suture placed in it, and gut united to skin with sutures. Opening then made in intestines, and a Mixer tube inserted. Rest of wound then closed.

Patient's condition did not warrant doing a resection. The mass was a hard, firm tumor, apparently filling the whole of the lumen, about the size of a hen's egg. An enlarged mesenteric gland also felt. About sixteen ounces of liquid feces and gas escaped from the tube.

March 27. Very comfortable night. Vomited once, fecal in character. Tube draining freely, and distention gone entirely.

March 28. Comfortable. Taking liquids well. No distention.

March 29. Temperature 100. Condition improving. Some leakage about tube.

March 31. Pulse weak and intermittent. Has failed much during last two days.

April 2. Pulse better, and general condition improved.

April 8. Temperature 101.2. This morning some nausea.

April 11. Condition much better. Sensorium clear.

April 24. As well as usual last night. At 5 a. m. sudden labored breathing. Cold extremities. Imperceptible pulse. In spite of forced stimulation, died in less than an hour.

AUTOPSY. DR. J. H. WRIGHT.

April 24, 1897. Adenocarcinoma, stricture of descending colon, with suppuration of neighboring retroperitoneal tissue. Lumbar colotomy. Laparotomy wound. Arteriosclerosis with thrombi of aorta and superior mesenteric artery, with beginning infarction of small intestine. Anemic and hemorrhagic infarcts of kidneys. Arteriosclerotic atrophy of kidneys. Ovarian cystoma. In abdominal aorta, a mass about the size of the little finger, not adherent, comprised of friable, grayish material, intermixed with black blood clot, in variable proportions. In superior mesenteric artery, at origin, a grayish-red, friable, firm, adherent mass, filling the vessel. The aorta shows rather numerous yellow patches, but no calcareous plates. The thoracic portion shows a gray-red clot adherent to intima, in the neighborhood of a small yellowish patch. The small intestines, for the most part, lie in the pelvic cavity. They are rather dark colored, not black, their serous

veins injected. The mucosa and wall veins infiltrated with fluid, mucosa red colored.

CASE 16 (Dr. M. H. Richardson).—J. F., man, 26 years, shoemaker. Recommended to Massachusetts General Hospital March 15, 1901, for appendicitis.

Past History.—Always well and strong, with exception of occasional attacks of pain in lower abdomen, for last three years, which have not been severe enough to keep him in bed, and have been relieved by movement of bowels after taking Epsom salts.

Present Illness.—Began night before last, with a very severe pain in lower abdomen, which traveled from side to side, and was not relieved by movement of bowels. Yesterday morning vomited. The pain continued and was so severe that he was awake all last night. Copious movements of bowels this morning after salts. Pain remains in lower half of abdomen, not localized in any one spot.

Physical Examination.—Large, well-nourished man, 210 pounds. Heart and lungs negative. Abdomen fat, slightly tympanitic, and not very tender in region of pain. Very slight tenderness over appendix. Doubtful mass to be felt in appendix region. Sent to ward. Temperature 100.7, pulse 104, respiration 24, whites 9,800. March 16. Whites 7,600.

OPERATION. DR. M. H. RICHARDSON.

A four-inch incision along outer border of right rectus. Appendix found slightly enlarged and reddened, bound down by a few adhesions, and twisted upon itself. Base tied off with silk, and appendix cut through with Pacquelin cautery. Mesentery clamped and tied off with silk. Wound closed by fine silk suture of peritoneum and fascial layers. Good condition at end of operation.

March 17. At 8 a. m. began to complain of abdominal pain and distress, and vomited a large amount of normal stomach contents. Pulse and temperature rising. Abdomen distended. Vomiting continued, becoming fecal in character. No result from enema repeated three times in as many hours. Turpentine stupes on abdomen. At 11 a. m. pulse poor, 140. Considerable distension. Temperature rising, and vomits every 15 to 20 minutes.

OPERATION. DR. J. G. MUMFORD.

Wound opened. Distended bowel protruded through it, and small amount of turbid serum evacuated. Bowel shows no sign of peritoneal inflammation, but a coil of small intestine about four to five feet long, near ileocecal valve, has a dark, mottled appearance, and its mesentery shows thrombosis of the vessels leading to it. Peritoneal cavity washed out with salt solution and Mixer tube placed in cecum. Considerable gas escaped through the tube. Patient at this period collapsed. Strych.

1/20 and oxygen. Wound closed with drainage and patient sent to ward. Feces discharged freely through tube, but without relief to general condition. Died 6 p. m. in spite of repeated stimulation. No autopsy permitted.

CASE 17 (Dr. F. B. Harrington).—J. M., man, 42 years. Twelve days ago attack of pain, most marked in epigastrium. Had never had similar attacks. Up and about in a few days. Eight days later had a chill with pain and collapse. Seen on the twelfth day. Temperature 103, pulse 106. Tenderness in right iliac region.

OPERATION.

Abscess about the appendix, which hung over the brim of the pelvis. The appendix was removed; showed perforation. Patient did well for two or three days, then began to vomit and have return of pain. Seen on fourth day after operation. Abdomen distended and painful. Vomiting; bowels had moved. Death on sixth day after operation.

AUTOPSY.

Only a local examination was allowed and this had to be done under very adverse circumstances. About two feet of the beginning of the jejunum was of a blackish brown color, and covered with flakes of fibrin. No general peritonitis. Mesentery of affected gut thickened. Intestinal contents bloody. Both arteries and veins of affected mesentery firmly thrombosed. Cavity of appendix abscess perfectly walled off, and all the intestines in this neighborhood found normal.

CASE 18 (Dr. F. B. Harrington).—H. L., man, 40 years, tailor, entered Massachusetts General Hospital Sept. 20, 1902. Yesterday morning while at work was seized with sudden, violent abdominal pain, which prostrated him completely. Was nauseated and vomited. Doctor prescribed morphia, without much relief to pain, which continued and grew worse during day. Vomiting increased and continued during day. Condition has been growing gradually worse.

Physical Examination.—Well-developed man. Pulseless, sighing respiration, no heart murmurs, lungs full of râles, abdomen distended and painful all over on pressure, no rigidity, extremities cold. No rectal examination made. Whites 21,000.

OPERATION. DR. F. B. HARRINGTON. $\frac{1}{8}$ PER CENT. COCAIN.

Six-inch incision along right rectus. Peritoneum dark and free fluid present. Coils of small intestine found flaccid, black and foul smelling. Gangrene found to involve cecum and ascending colon to hepatic flexure, besides all of the ileum. Continuing from gangrenous areas, the intestine changed gradually to almost normal color. At this stage patient became restless and primary ether was given, also for very poor condition, strychnia, 1/20 gr., with no effect. Small perforation found in small intestine, through which much dark venous blood

was oozing. Perforation tied with silk. Purse-string stitch of silk put in small intestine and Mixter tube inserted. Small amount of gas escaped, but no intestinal contents. Patient collapsed and died.

AUTOPSY. DR. J. H. WRIGHT.

Sept. 20, 1902. Obturating thrombus of superior mesenteric artery, due to endarteritis. Hemorrhagic infarct of small intestine, and of portion of large intestine. Arteriosclerosis of aorta. Chronic disseminated tuberculosis (possibly syphilis) of the lungs. Chronic interstitial orchitis. Leiomyomata of kidney. Heart, not remarkable. Lungs, disseminated nodules of tuberculosis. Aorta, arch and thoracic portions normal, abdominal portion, intima contains several gray, firm plaques and a few scar-like depressions. Abdominal aorta and common iliacs of small caliber. At beginning of superior mesenteric artery is a 2 cm. red, fleshy thrombus, firmly adherent to intima. The mass is propagated as a rather black, soft, red clot, a short distance into artery and branches. Infarct of intestines from beginning of ileum to hepatic flexure; mucosa, black red.

CASE 19 (Dr. R. B. Greenough).—D. F., man, 56 years, carpenter. Entered Massachusetts General Hospital December 8, 1903.

Family History.—Wife left husband because he was such a heavy drinker, but says that he has not drunk to excess for past five years. Has a son and daughter in good health.

Past History.—Always has been rugged and strong. Denies venereal trouble. Wife says he had a paralytic stroke two months ago. He says he has been told by physicians that he had heart and kidney disease.

Present Illness.—Says he has lost 21 pounds since January, 1903, when his weight was 156 pounds; loss has been steady. Also that two months ago began to be constipated, with abdominal pain, not localized, but fairly constant. That two days ago he began to vomit and have acute pain in belly; that vomiting has been constant since then, without any bowel movement at all. Has had no tapelike movements at any time and no signs of gall-bladder trouble. Has never had bloody stools. During last two days has felt badly all over. Son says father was well as usual until yesterday forenoon, when the symptoms above mentioned set in. Patient describes vomitus as being "watery."

Physical Examination.—Fairly well developed, spare old man, in poor mental condition. Rather pale. Tongue very red, suggesting prolonged vomiting of late. Heart negative, except for soft systolic murmur in second left interspace, suggesting roughening of the aortic arch. Lungs not examined posteriorly. Over whole chest anteriorly are heard numerous musical râles, with slight hyperresonance and prolonged expiration.

Breathing is labored, but not shallow. Liver and spleen not remarkable by percussion. Abdomen full, tense, tympanitic, except in flanks, where it is dull. Tenderness is general. Rectal examination negative. Pulse 100, temperature 96.4 by rectum, whites 6,000, December 18, 4 p. m.

OPERATION. DR. R. B. GREENOUGH. ETHER.

December 18. Eight-inch median incision. Peritoneum opened, allowing escape of a little bloody serum, and exposing a large amount of gangrenous small gut. Rapid examination failed to show any strangulation, due to hernia or bands, and a diagnosis of mesenteric thrombosis was made. As the gut seemed absolutely dead, it was thought best to resect. Small intestine tied off by plain catgut just above cecum, this being a little below line of demarcation. Gut quickly cut from mesenteric attachment, up to line of demarcation, a distance of 12½ feet and tied and cut as below. Almost no bleeding from mesenteric stump. Mixer tube inserted in upper portion. Cavity loosely packed with gauze. Dry dressing and swathe. Stomach washed, removing considerable foul matter. Infused intravenously with 1½ pints of salt solution. Crile breeches put on. Patient sent to ward in fair condition, with pulse of excellent quality. Patient's pulse remained good, but respiration feeble. Once he recovered consciousness enough to recognize his wife, but soon relapsed, and respiration becoming weaker, he died at 2.50 a. m. No autopsy.

Pathologic Report.—A piece of small intestine, dark blue in color. The veins of the mesentery were filled with recent thrombi. Hemorrhagic infarction. W. F. Whitney.

CASE 20 (Dr. R. B. Greenough).—A. M. S., woman, 37 years, entered the Massachusetts General Hospital Oct. 11, 1902, with the diagnosis of gallstone colic.

Past History.—Six years ago had an attack of acute abdominal pain lasting three or four days and relieved finally by morphia. Vomiting and chill, but no jaundice. No clay-colored stools; no dark urine.

Present Illness.—Three days before entrance, sudden chill and vomiting. The latter has persisted. Pain was present, referred to the epigastrium and back. It was dull, but occasionally spasmodic. Urine smoky. Stools loose, otherwise normal. No jaundice. Vomiting dependent on character of the food taken; contained no blood.

Physical Examination.—Temperature 100.6, pulse 132, respiration 40, leucocytosis 21,000. Some rigidity and dullness in right hypochondrium. No mass nor any tenderness. Heart sounds normal. Vaginal examination negative. Urine dark, acid, specific gravity 1.026, trace of albumin, sugar present, sediment, numerous granular and epithelial casts. Small round cells. Rarely a blood globule, much fat, free and on casts and cells. Was put to bed, but in middle of night woman showed

a marked change for the worse. Pulse 140 to 150, respiration 40. Marked distension of the abdomen, with shifting dullness on right. About a quart of blood was passed as the result of an enema.

OPERATION. DR. R. B. GREENOUGH.

Bloody fluid, free in cavity. Small intestine very dark throughout. Several reddish-blue spots on cecum and ascending colon. Nothing else was discovered. The patient died immediately after the operation.

AUTOPSY. DR. J. H. WRIGHT.

Polypous endocarditis of mitral valve. Embolism and thrombosis of superior mesenteric artery, with partial infarction and gangrene of cecum and ascending colon. Incipient infarct of small intestine. Multiple infarcts of spleen and kidney. Early pregnancy. Streptococcus septicemia. In the peritoneal cavity about 100 c.c. of thin dark red fluid. On the serous surface of the cecum is an irregular dirty yellowish necrotic-looking patch apparently representing gangrene of the wall of the gut. This patch is 2 or 3 cm. in diameter. On the serous surface of the ascending colon another larger similar patch of gangrene. The small intestine, throughout a large portion of its length, is generally of a dull reddish-gray color, as from the presence of a reddish fluid within. At one or two points fibrinous shreds are present in the peritoneal cavity. There is no generalized exudate on the surface of the intestines. The aorta was opened from behind and in the superior mesenteric artery a reddish-gray mass 3 or 4 cm. long is found occluding this vessel. Prolongations of this occluding mass extend a short distance into the large branches. There is no hemorrhage into the mesentery of the small intestine. Dissection of the intestines shows considerable amounts of a foul dark-brown opaque fluid contained in them. The mucous membrane of the cecum and the ascending colon, over a large proportion of their extent, is dirty brownish in color, softened, more or less disintegrated and necrotic. The mucous membrane of the greater part of the small intestine, from the ileocecal valve upward, is more or less reddish-brown in color and in places is emphysematous in appearance. Multiple infarcts are found in the spleen and kidney. Thrombus in renal artery. Polypous endocarditis of the mitral valve.

Bacteriologic Report.—Cultures on blood serum from heart, liver and spleen show streptococci.

CASE 21 (Dr. E. A. Codman).—C. S., man, 68 years, jail officer, entered Massachusetts General Hospital June 26, 1901, 11 a. m.

Past History.—Last winter had a loss of power in the limbs and wasting of muscles. Doctor called it poliomyelitis of unknown origin. He recovered from this, except for right thumb.

Present Illness.—Three weeks ago he began to have abdominal pain and an occasional attack of vomiting. Pain was referred to the stomach. Last Saturday the pain became more severe, and he called in his physician who found tenderness about the navel, and pain referred to right inguinal region and hypogastrium. Temperature normal. Very little distension, but some tympanites. No constipation. Vomiting for past ten days has been more frequent. This morning sent to Massachusetts General Hospital for very severe abdominal pain.

Physical Examination.—Rather poorly developed and nourished man. Lungs and heart negative. Arteries thickened. Pulse rapid and of small volume. Abdomen somewhat distended and tender, the greatest tenderness being just to right of umbilicus, along rectus. Some dullness in flanks. Patient looks sick. Urine shows no blood. Temperature 101.5, pulse 110, respiration 40.

OPERATION. DR. E. A. CODMAN.

Median incision, umbilicus to pubes. On reaching the peritoneum, it was seen to be dark, and on opening it a quantity of blood-stained fluid gushed out. Just to the right of the incision a long piece of dark-red, much thickened intestine was seen. This was grasped and drawn out. About five feet of it was discolored, and the mesentery was thickened and hard throughout, showing what was probably obstruction in the superior mesenteric artery. Small intestine pulled out, until healthy gut was met with on each end. Tied off and clamped. On section of mesentery many vessels were found filled with clots. Ends of intestine fastened in lower part of wound. Upper part closed with sutures. In ward, under stimulation, condition improved somewhat.

June 27. Condition grew poorer steadily through the night in spite of stimulation. Did not vomit, but had a great deal of pain. Somewhat relieved by morphia. Died at 11:20 a. m. No autopsy.

Bacteriologic Report.—A few unknown bacilli.

Pathologic Report.—Specimen, about 5½ feet small intestine, center foot of it dark. Hemorrhages scattered through the rest of it. Mesentery very much thickened at gangrenous part. Veins filled with loose clot. Arteries empty.

CASE 21 (Dr. J. G. Mumford).—C. C., 19 years, plumber's boy, entered Massachusetts General Hospital May 16, 1902.

Family History.—All healthy.

Past History.—Pneumonia at 4, otherwise well. Habits, considerable tobacco, no alcohol.

Present Illness.—Eight days ago complained of cold in head and stopping up of nose, also had a little sore throat. Six days ago face began to swell, and region of left malar bone became discolored and tender. The swelling rapidly increased, so that his eye became closed. A few days ago, on blowing

nose, had quite a discharge of material, looking something like dark, clotted blood. Discharge continued during yesterday and to-day. It is mucopurulent. Sleeps most of the time. Frontal headache to-day and yesterday. No chills or sweats. This morning complained of cramps in the belly, which are now quite severe. No diarrhea.

Physical Examination.—Temperature 101.2, pulse 10, respiration 30. Well developed and nourished, face slightly flushed and apathetic. Inspissated mucus on lips and teeth. Pupils equal and react. Teeth good. Tongue red and dry, also throat. Right tonsil negative, left mucous membrane is reddened. Inferior turbinate swollen. No swelling of face. Slight tenderness over upper portion of superior maxilla. Very slight tenderness over left mastoid. Lungs negative. Heart, apex, fifth space, three inches from middle line dullness not enlarged. Sounds regular and of good quality. Pulmonic second sound accentuated. Systolic murmur loudest at apex, somewhat transmitted to axilla. Pulse regular, small volume, fair tension. Abdomen full, firm, somewhat more resistant on right than on left, no tenderness; dullness in right flank extending almost as far up as the umbilicus, over an area about four inches wide and six inches long. Slight dullness in extreme left flank, which changes with change of position. Liver dullness from sixth rib in nipple line to costal margin. Spleen negative. No edema of extremities. Blood, hemoglobin 90 per cent., whites 31,000, iodophilia positive; no Widal reaction. Urine, high, acid, 1,034, albumin a trace, sugar absent, chlorids diminished, sediment, few normal blood globules, some leucocytes and squamous cells, no diazo reaction.

May 17. Pulse of better quality and patient does not look so poorly. Some relief of pain in bowels by stupes. Enema with fair result. Seen by Dr Goodale, who finds a septic condition of mucous membrane of pharynx and left nostril. Abdomen somewhat tender on palpation on left side, in iliac region, much less marked, tenderness on right. Blood, whites 36,000.

May 18. Patient was slightly delirious during the night and did not sleep well on account of abdominal pain. Abdomen this morning is distended and rigid, with diffuse tenderness more marked in the lower portion, but not well defined in any one spot. Bowels moved once during the night, with a little relief. Patient stupid and restless. Murmur at apex less marked. Pulse much better than at entrance, and patient not so typhoidal. Marked restlessness. Vomited early yesterday and again during the afternoon, the vomitus consisting of curdled milk. No vomiting since yesterday afternoon. Whites 44,000. Transferred to surgical service with diagnosis of antrum abscess. Septicemia.

Seen by Dr. J. G. Mumford. Abdomen much distended,

tympanitic, very tender to pressure. Temperature rising, general condition growing worse, with increase of abdominal symptoms.

OPERATION. DR. J. G. MUMFORD. ETHER.

Incision in median line. Much free fluid in cavity. Intestines show marked infection and blue color, as if of beginning gangrene. Mesentery light yellow approaching colorless with no vessels seen in area supplying eight feet of intestines which are in the above condition. Areas of fine hemorrhagic spots about the size of one-half dollar on intestines and adjoining mesentery. Small areas in mesentery, suggestive of fat necrosis. Cadaveric odor. Appendix not found, but its region appeared normal. Cheesy gland removed from mesentery. Abdominal cavity washed out with salt solution. Incisions (one in flank for counter opening) wicked. Sent to ward in poor condition.

May 18, 11:30 p. m. Restless, pulse 130, temperature 104, respiration 35. Died at 8:40 a. m. No autopsy.

The following cases are from the Boston City Hospital:

CASE 23 (Dr. Withington).—D. L., man, 47 years, entered May 30, 1898; died June 17, 1898. Chronic diffuse nephritis, with ascites and dilated heart. No symptoms referable to abdomen.

AUTOPSY.

General arteriosclerosis. Hypertrophy and dilatation of heart. Chronic diffuse nephritis. Chronic passive congestion of liver and spleen. Edema and atelectasis of lungs. Thrombosis of branches of superior mesenteric artery.

CASE 24 (Dr. Henry Jackson).—P. C., man aged 39 years, entered September 28, died October 8. Old myocarditis and endocarditis. Now has broken cardiac compensation. Temperature never over 100. Leucocytosis 20,400. October 8 had sudden, severe pain in epigastrium and slight bloody vomitus. Collapsed and died.

AUTOPSY.

Acute peritonitis. Hydrothorax. Pericarditis. Hypertrophy and dilatation of heart with infarction of heart. Mural thrombus in left ventricle. Thrombus in descending branch of left coronary artery. Emboli in mesenteric, left renal and middle meningeal arteries. Bronchopneumonia. Congestion and edema of lungs. Acute bronchitis. Old infarcts of spleen. Infarct of intestine. Chronic passive congestion of liver. Cholelithiasis. Cyst and softening of cerebellum.

CASE 25 (Dr. Ames).—C. A., man, 44 years, entered Boston City Hospital Aug. 6, 1901, died August 14. Story of weakness in legs. Occasional cardiac pain. Sudden dyspnea, then

pain in foot, frontal headache. Whites 19,600. Hemoglobin 100 per cent. Subcutaneous hemorrhages of left leg, pinhead to one-fourth inch in size.

August 10. Noisy. Right hemianopsia. No heart murmur.

August 14. Died delirious, with no signs from belly, no tenderness.

AUTOPSY.

Thrombosis of pulmonary artery. Thrombosis of right auricle, with extension into left auricle, through patent foramen ovale. Embolus of left renal artery, both iliaes, superior mesenteric, hepatic, splenic, innominate and left carotid. Infarct of spleen and kidneys. Acute softening of left occipital lobe of cerebrum. Scar of old cyst in right corpus striatum. Cholelithiasis. Infarct of intestine from duodenum to splenic flexure.

CASE 26 (Drs. J. C. Munro and E. H. Nichols).—Boy, 17 years, entered Boston City Hospital July 22, 1901.

Family History.—Negative.

Past History.—Whooping-cough and measles. A year ago had severe crampy pains in abdomen, with vomiting, constipation and tenderness; no fever. Attack lasted five days.

Present Illness.—July 18, drank several glasses of ice water and the next morning had sharp abdominal pain, mostly on the right side. He vomited after breakfast, had a few watery movements and attributed symptoms to diarrhea. Food distressed him.

July 20. Chill in evening. Vomited, had much tenderness on right side. That night several watery movements due to salts.

July 21. Had to go to bed; two chills; vomited again, with severe abdominal pain and increased tenderness in right lower quadrant. To-day another chill, with fever, which has been present since July 18.

Physical Examination.—Icterus of scleræ. Heart negative. Lungs, râles at right apex. Some tenderness on deep pressure in hepatic area. Tender under outer edge of right rectus, where small mass could be felt.

OPERATION. DR. NICHOLS.

Appendectomy with drainage.

July 23. Temperature still up. Delirious. Slight tenderness in hepatic area.

July 26. Whites 10,200. Small, offensive, purulent discharge from wound. Daily chill.

July 29. Chill, vomited twice.

OPERATION. DR. MUNRO.

August 5. Drained pus, retroperitoneal, from broken-down gland. Exploratory punctures of liver negative. Died August 15.

AUTOPSY.

Operation wounds. Localized adhesive peritonitis. Pus pockets and softened lymph nodes about cecum. Thrombosis of superior mesenteric vein and branches. Suppurative pyelophlebitis, with multiple abscesses of liver. Infarct of spleen. Acute bronchopneumonia. Acute splenic tumor. Hyperplasia of mesenteric lymph nodes. Fatty degeneration of heart. Ulcers of colon. Chronic tuberculosis of retrocecal lymph node. Appendectomy stump.

CASE 27 (Dr. Paul Thorndike).—Negro, 21 years, entered Boston City Hospital Sept. 2, 1902.

Family History.—Negative.

Past History.—Healthy. Has had four or five attacks of gonorrhœa. Last one about one year ago. Denies lues. Rarely drinks. Smokes to excess. Had acute epigastric pain lasting about twenty-four hours last summer.

Present Illness.—Malaise all last week. Five days ago began to have colicky pains, accompanied with chills and fever. Abdominal pain general, constant, with colicky exacerbations. Chills quite severe. Next day vomited medicine. Pain has continued to grow worse till to-day, when patient was given "tablets" by outside physician. He felt hot and feverish all the time. Bowels only moved with medicine. Stools natural color, soft consistency. Passed some gas. Micturition not frequent, and without pain. No cough. Feels weak.

Physical Examination.—Well developed and nourished. Anxious expression. Tongue thick, brownish, dry coat. Pulse regular, slightly rapid, fair volume and tension. Heart and lungs negative. Area of liver dullness normal. Spleen not made out. Abdomen, protrusion of umbilicus, with opening, which admits the little finger tip. No hernia. Muscles of abdomen held moderately rigid. Tympanitic, except for an area on the left, beginning on level with umbilicus, extending down to Poupart's ligament, limited internally by the middle line. Percussion note over this area is almost flat. Flatness extends deep into flank, except for a small area, where there is high-pitched tympany. Over flat area muscular spasm is marked, with considerable tenderness, not definitely localized in one spot. On deep palpation, tenderness is also elicited in right lower quadrant, but not so marked as on the left. No mass made out. No herniæ. Rectal examination, slight tenderness high up on left. Extremities negative.

September 3. Enema returned only slightly tinged. No vomiting.

September 4. Increasing severity of abdominal symptoms and white count.

OPERATION. DR. THORNDIKE.

Incision below umbilicus in middle line. Very slight amount of blood-stained serum escaped. Small intestines collapsed.

Colon distended. A hard, firm mass could be felt lying beneath the intestines. Luster of small intestine preserved, slightly darker color than normal. Venous network in wall plainly seen as fine, dark lines. Toward the mesentery the larger veins appeared thrombotic. No area of necrosis or sloughing. Mesentery of small intestine enormously thickened in a wedge shape. The thickened portion two to three inches on section. It was reddish brown in color, with occasional hemorrhagic areas. Incision into mesentery revealed dark venous blood. Mesenteric glands enlarged and indurated. Almost whole mesentery was involved, so cavity was closed with drainage.

September 8. After operation, collapse. Better next day. Occasionally vomited dark green fluid. Hiccough and restless. Abdomen distended. Obstipation.

September 10. Moribund for two days. Abdomen distended and tender. Diet.

AUTOPSY. DR. SOUTHARD.

Mesentery size of tangerine orange. Enlarged glands give vaguely knotted character to mass. Stomach greatly dilated with gas. Bowels of a dark color throughout. Superior mesenteric artery and branches free. Bowel contains tarry, dark, mashy material.

Anatomic Diagnosis.—Infarction of intestine, with (a) enlargement of mesenteric lymph nodes; (b) suppurative pylephlebitis of superior mesenteric system; (c) abscess of mesentery; (d) acute general peritonitis. Infarction of liver. Sub-endothelial hemorrhage of hepatic vein. Cloudy swelling of kidney. Celiotomy. Chronic adhesive perityphlitis. Slight chronic fibrous pleuritis.

ETIOLOGY.

All those disease which lead to the formation of thrombi whence emboli can arise, are of direct etiologic significance for mesenteric occlusion. Endocarditis, atheroma of the aorta and arteriosclerosis, especially of the mesenteric arteries, are of first rank. Sclerosis of the mesenteric arteries has been found, even in cases in which the peripheral vessels or the aorta showed no atheroma, and this process can involve even the finest branches. The results of this are evident, and are well stated by Neutra.⁵ He says:

By the calcification, the arterial wall loses its elasticity and becomes narrowed, a condition which hinders the formation of a collateral circulation through the anastomoses. This can be observed clearly in a case of Deckart, where only a small twig was plugged, causing the formation of a ring-shaped ulcer, because the lumen of the neighboring vessels was nar-

rowed by numerous deposits on the intima, so that in common with the loss of elasticity of the arterial wall an adequate collateral circulation was prevented. The calcification may be of such a degree that the plaques, without any thrombus, nearly fill the whole vessel lumen, as is seen in a case of Adénot. A similar if not identical process is described by Litten, which he calls "lattice-work endarteritis," which gives rise to thrombosis of the involved artery. According to the statements of this author, it is characteristic of this disease, that in spots it surrounds, in a ring-like form, the whole circumference of an otherwise healthy vessel.

Lorenz¹⁷ has published a case of closure of the superior mesenteric artery, which followed multiple neuritis, as a terminal process. The process was characterized by a growth of the intima of the finer branches, combined with nodular dilations.

In the case of venous thrombosis, all conditions causing stasis in the portal system play a causative rôle. Here it is a question whether the thrombus is primary in the mesenteric veins, and, therefore, an ascending one, or itself secondary to a process beginning higher up. As a matter of fact, both sorts of cases seem to occur. Of etiologic importance for the primary thrombosis are all intestinal changes which allow penetration of bacteria into the vessels. Such are the severe enteritides, surgical infections, puerperium, milk leg and phlebitis of the lower extremities; cachexias, such as that of cancer or malaria, sepsis and typhoid fever. Here also should be mentioned the cases which have followed a suppuration in the region of the appendix, as illustrated by our cases (Nos. 16, 17, 26), and also the case of Welch and Flexner,¹⁸ in which the *Bacillus aerogenes capsulatus* was found. Local disease of the vein wall, such as syphilis, etc., has been found (Borrman,¹⁹ Gull²⁰).

Secondary venous thrombosis follows cirrhosis and syphilis of the liver; pylephlebitis and processes at the liver hilum which by pressure or the formation of adhesions cause portal stasis. Koester²¹ maintains that slowing of the circulation is, in itself, unable to cause venous thromboses, and gives this only as a predisposing cause. Neutra opposes this view, however, and certainly the weight of evidence of reported cases seems to be in

17. Zeitschr. f. klin. Med., 1891, vol. xviii, p. 497.

18. Jour. Exper. Med., 1896, vol. i, p. 35.

19. Deutsch. Archiv f. klin. Med., 1897, vol. lxx, p. 281.

20. Guy's Hospital Reports, London, 1883-84, p. 15.

21. Deutsch. med. Woch., 1898, p. 325.

his favor. In several cases also thrombosis of the veins has followed arterial emboli, apparently by the stasis thus brought about.

COURSE OF DISEASE.

The cases can be divided into two groups—acute and chronic. The first group is by far the larger, and is composed of cases of sudden onset of colicky abdominal pain, often at a time when the patient was in apparently full health. This is then followed by nausea and vomiting, often bloody, and diarrhea, also often bloody; or the picture is one of obstinate intestinal obstruction of the paralytic type. Often not even flatus is passed. In many cases the temperature falls below normal. The abdomen rapidly becomes distended with gas, peristalsis is absent, and death occurs often in a few hours or days.

The second and smaller group is formed by cases of insidious onset and chronic, sometimes remitting symptoms; by cases having no symptoms referable to the abdomen during life; and by cases where spontaneous cure resulted.

The tendency is to consider the cases of arterial embolism as forming the acute group, and those of venous thrombosis as making up the bulk of the chronic cases. On analyzing our list of 214 cases we find the following: In only 197 cases is an accurate statement obtainable which can form a basis of separation into arterial and venous varieties. Of these, 120 cases, or 61 per cent., were of arterial closure, while 77 cases, or 39 per cent., were venous. In 71 of the arterial, and in 50 of the venous group, accurate data as to duration are given. They are tabulated as follows:

VEIN.		ARTERY.	
Duration.	Per cent.	Duration.	Per cent.
24 hours.....	20	24 hours.....	20
2 days.....	18	2 days.....	22
3 days.....	8	3 days.....	10
5 days.....	12	4 days.....	6
1 week.....	16	5 days.....	3
10 days.....	2	1 week.....	17
2 weeks.....	8	10 days.....	6
3 weeks.....	10	2 weeks.....	10
1 month.....	4	3 weeks.....	4
6 weeks.....	2	1 month.....	1
		5 weeks.....	1
	100		100

It thus becomes evident that the course is surprisingly similar in each variety of cases, and that no differentiation can be made on this point.

In each group there were 7 cases of markedly chronic course, that is, over two months. Of these, those due to venous closure were more apt to show gradual and continuous progression, while the arterial often ran a course of various attacks, interrupted by longer or shorter intervals of comparative health. On these latter Neutra lays special stress, and calls them chronic, relapsing cases (c.f. cases of Alexander,²² Kaufmann,¹⁴ Spiegelberg,²³ Goodheart,²⁴ Rolleston²⁵ and others).

These cases are apparently due to a thrombosis which makes more marked progress from time to time, with the establishment of a competent circulation, through collaterals in the meantime.

That partial healing takes place has been inferred from what has already been said in discussing the formation of collateral circulation (c.f. also case of Packard²⁶). In a few cases also, 14 in number, recovery has taken place. In 4 of these, the diagnosis was established at operation. In several of the others, however, the diagnosis seems perfectly justified (Aufrecht,²⁷ Finlayson,²⁸ Moos,²⁹ Schlesinger,³⁰ etc.).

PATHOLOGY.

The pictures found at postmortem examination are most varied, dependent, firstly, on the situation of occlusion, and secondly, on the duration of the process. So the infarcted area may show only simple hyperemia, or there may be gangrene, perforation and peritonitis, either localized or general. In the large majority of cases there is free fluid in the general cavity, often blood-stained, and usually in amount sufficient to be demonstrable during life. In about three-fifths of the cases the infarcted area showed a well-marked line of demarcation. In some cases, however, the boundary between healthy and diseased gut is absent. This occurs, according to Neutra, in two ways. Firstly, in some favorable conditions collateral circulation develops, but not one which is sufficient to care for the whole infarcted area, and so protects

22. Berliner klin. Woch., 1866, p. 35.

23. Virchow's Archiv, vol. cxlii, 1895.

24. Pathological Transactions, 1890.

25. Trans. Pathological Soc., London, 1892, vol. xlili, p. 49.

26. Proc. Path. Soc., Phila., 1898, n. s. i. p. 288.

27. Deutsch. Archiv f. klin. Med., 1902, vol. lxxii, Nos. 5-6.

28. Glasgow Med. Jour., 1888, p. 414.

29. Virchow's Archiv, vol. xli. p. 58.

30. Cited by Neutra.

only the margins; secondly, it is conceivable (especially in thrombosis) that the occlusion in the terminal branches is irregular, and so the end line becomes hazy. In a considerable number of cases the process involved the whole small intestine, ascending, and part of the transverse colon. Closure of the inferior artery causes changes, most marked in the large intestine. Smaller areas of involvement are most numerous in the ileum. The contents of the intestine are bloody in about two-thirds of the cases in which accurate data as to this point are given.

Ulcerations of the intestinal mucosa, often ring-shaped and surrounding the whole circumference, also are not rare. The mesentery is often thickened and edematous, and in several instances there was found an extravasation of blood between its layers, forming a tumor of varying size, sometimes palpable. The intestine is often found distended by gases of decomposition, and in a few cases its wall has been the seat of air vesicles, shown in the case of Welch and Flexner,¹⁸ to be due to the *aerogenes capsulatus*. Subserous hemorrhages from finest petechiæ up to 3 or 4 cm. are also found. The mesenteric glands and lymphatic tissue are often swollen. In cases of venous closure, in contradistinction to embolus of the mesenteric arteries, the large intestine is only seldom affected. The probable reason for this is to be found in the more abundant anastomoses, between the inferior mesenteric vein and the inferior cava, with the hemorrhoidal vein.

Here we may also mention the views of Sprengel³¹ who, basing his theories on the experimental work of Kader,³² finds cases which he classes as hemorrhagic infarction on the one hand, and anemic gangrene on the other. The first is the result of plugging of an arterial or venous supply, while the second only occurs when on closure of an arterial supply the return stream is impossible. Corresponding with this, he makes two clinical groups—the one with intestinal hemorrhages or bloody vomiting, the other with simple ileus. This division is worked out very prettily, but is disbelieved by Talke,³³ and we agree with him. He very pertinently quotes cases of simultaneous closure of artery and vein where, instead of the

31. Verhandl. d. Deutsch. Gesellsch. f. Chir., Berlin, 1902, vol. xxxi, p. 55.

32. Deutsch. Zeitsch. f. Chir., vol. xxxiii, p. 57.

33. Bruns' Beiträge z. klin. Chir., vol. xxxviii, p. 743.

anemic gangrene to be expected from the statements of Sprengel, there was found hemorrhagic infarction (cases of Taylor,³⁴ Grosskurth³⁵). On the other hand, a case of Grawitz³⁶ was anemic with only arterial closure.

It is also interesting from a comparative pathologic point of view to find that this same process is common in the horse, due to the parasite *Strongylus armatus*, which often is situated in the mesenteric arteries, causing chronic endarteritis and thrombosis, with the formation of a so-called aneurisma verminosum. The sequelæ as regards emboli and infarction are wholly parallel to those found in man.

AGE AND SEX.

Sixty-four per cent. of the cases occurred in men, and 36 per cent. in women. One case occurred at 1 month, another at 5 years, and another at 8 years. The rest are seen as follows:

	Per cent.		Per cent.
10 to 19 years.....	4	60 to 69 years.....	15
20 to 29 years.....	12	70 to 79 years.....	8
30 to 39 years.....	16	80 to 89 years.....	3
40 to 49 years.....	22	90 to 99 years.....	2
50 to 59 years.....	18		

It is thus seen that over one-half of the cases occur between 30 and 60 years of life.

DISCUSSION OF SYMPTOMS AND PHYSICAL SIGNS.

Pain.—Five cases were found in which no symptoms referable to the abdomen were present. In 157 cases accurate data as to the pain were given.

	Per cent.
General abdominal pain.....	51
Pain in epigastrium.....	8
Pain about umbilicus.....	7
Pain in lower abdomen.....	4
Pain in right hypochondrium.....	4
Pain in upper abdomen.....	4
Pain in hypogastrium.....	3
Pain in right iliac fossa.....	3
Pain in right side of abdomen.....	2
Pain in left hypochondrium.....	1
Pain in left side.....	1
Pain absent.....	8
Pain radiating.....	4

In two cases pain radiated from right to left hypochondrium, while one case of each of the following was met: From navel to bladder; from vulva to navel; from right iliac fossa all over abdomen; from bladder to cecum and umbilicus; and from the epigastrium to the

34. Path. Transactions, 1881, vol. xxxii, p. 61.

35. Inaug. Diss., Giessen, 1895.

36. Virchow's Archiv, vol. cx, p. 434.

right side of umbilicus. In most cases the pain is sudden in onset, and usually constant and dull, with colicky exacerbations of extreme severity. The intermittent character comes out strongly in some instances, while in others it is less evident. The causation of the pain is generally admitted to be due to the intestinal contraction. Borszéký³⁷ so considers it, and refers to the experimental work of Kader.³² Schnitzler,³⁸ however, maintains that in cases of the intermittent recurring character, such as have just been mentioned, the pain is identical with that described by Charcot in the so-called intermittent claudication. We have here an artery which has become much reduced in caliber by the endarterial process, but which under good heart action is wholly competent. Lessening of blood pressure by heart weakness, however, causes a local anemia in the area supplied by the diseased vessel, which in turn gives rise to the pain called by Schnitzler "intermittent anemic dysperistalsis." A case of Schnitzler and one of Lepine³⁹ well illustrate this type.

Nausea and Vomiting.—This is usually present following the pain. When the onset of the disease is more gradual, this may or may not be present. According to the severity and duration of the process, the vomitus is either normal stomach contents, bile-stained, fecal or finally clear blood.

Diarrhea or Constipation.—According to Kussmaul and Gerhardt, bloody stools are essential for the diagnosis. Several other authors, among them Deckart and Neutra, oppose this view, and our present analysis bears them out. Of 153 cases, in which accurate data on this point are given, we find:

	Per cent.
Obstipation	22
Bloody stools.....	19
Diarrhea without blood.....	13
Normal stools.....	12
Diarrhea, later becoming bloody.....	10
Obstipation followed by bloody diarrhea.....	6
Normal stools, succeeded by obstipation.....	5
Normal stools followed by bloody diarrhea, diarrhea followed by obstipation, bloody diarrhea followed by obstipation, obstipation followed by diarrhea, each.....	3
Obstipation followed by normal stools, bloody diarrhea followed by normal stools, normal stools followed by diarrhea, each.....	0.3

37. Bruns' Beiträge z. klin. Chir., vol. xxxi, p. 704.

38. Wiener med. Woch., 1901, Nos. 11-12.

39. Quoted by Schnitzler.

Adding these together, we find that blood occurs in the stools at one time or another in 41 per cent. of the cases. The statement that obstinate constipation was present from the beginning Neutra thinks improbable. He considers this due to lack of observation or explains by saying that the spasmodic contractions of the intestines, which cause the colicky pains, pass so quickly into the paralytic stage that there was no movement of the bowels as a result. The first statement can naturally neither be proved nor disproved, but the latter is warranted by the large number of cases where bloody intestinal contents were found at autopsy, although this had not appeared during life. It is certain, however, that though the above percentages may not be absolutely accurate, blood is found in the stools with sufficient frequency to make it of considerably more diagnostic value than Borszéký's statements imply.

Abdominal Tenderness.—This was noted in 115 cases. In 30 per cent. of these it was absent; in 70 per cent., present. Its localization, when present, is shown by the following:

	Per cent.
General abdominal tenderness.....	67
Localized about navel.....	8
Localized about cecum.....	7
Localized in epigastrium.....	7
Localized in hypogastrium.....	4
Localized on left side of navel.....	2
Localized in right hypochondrium.....	2
Localized at McBurney's point.....	1
Localized at right costal border.....	1
Localized at several points in hypogastrium....	1

Distension.—This is usually a rather late sign, and one of increasing severity. It was mentioned in 125 of the cases. In 22 per cent. of these it was absent, in 78 per cent. present. When present it was:

	Per cent.
General	96
Localized below navel.....	2
Localized in right hypogastrium.....	1
Localized in upper abdomen.....	1

The experiments of Kader, already mentioned, showed the following events on ligation of the superior mesenteric artery: Contraction of the coils of intestine and anemia of them; then hyperemia followed by complete intestinal paralysis, when stasis had occurred; then lastly came distension from gases of decomposition.

Intestinal Obstruction.—This is one of the most important appearances and occurs rapidly in many cases. Deckart (and Rosenbach already quoted) explains this by nutritional disturbances. In some instances the en-

suing peritonitis is undoubtedly the cause of the ileus, but that this is not always the case is shown by cases where it follows immediately the closure of the vessel, at a time when there can be no question of either peritonitis or necrosis of the gut wall.

A symptom of minor importance is hiccough, which is found in a few cases. In our cases there has been found also a marked increase in the leucocyte count, and a positive iodine reaction (iodophilia). In a certain number of cases sugar has been found in the urine (see Case 1), but it has not been possible to determine from the reports whether this was present before his intestinal symptoms began. In Case 1 it was already present. Its previous absence would make its finding of some worth, however, since from the experiments of Tangl and Harley⁴⁰ and Kolisch,⁴¹ one of the results of closure of the mesenteric vessels is glycosuria. Also an increased elimination of indoxyl is often seen in these cases. There is often evidence of nephritis of varying grades of severity.

The temperature usually falls below normal, though not infrequently an increase is observed, which perhaps is due to accompanying processes, such as peritonitis, endocarditis or toxic absorption from the intestinal contents.

Of interest are those cases referred to by Talke,⁴² in which purpuric spots are seen. He makes the occurrence of purpura of considerable diagnostic value. Such cases also demonstrate the embolic nature of purpura in certain instances. Here must also be noted the articles by Osler, the last of which appeared in the *American Journal of Medical Sciences* for January, 1904. Several cases are here given of disease of the so-called erythema type, in which, together with purpuric spots and various other cutaneous symptoms, there occurred also abdominal symptoms, such as pain and bloody intestinal movements. The case described by Talke showed undoubted embolism of the mesenteric vessels. In none of Osler's cases was this present. From a clinical point of view it would seem, however, that an early differential diagnosis were impossible.

Diagnosis.—This is admitted by all to be exceedingly

40. Pflüger's Archiv, vol. ix.

41. Centralblt. f. klin. Med., 1892, p. 737.

42. Bruns' Beiträge z. klin. Chir., 1903, vol. xxxviii, p. 743.

difficult, and the more so because the symptoms have the same causation, as in several other acute abdominal lesions. Gerhardt⁴³ makes the following diagnostic postulates:

1. There must be present a source of the embolus.
2. There are present copious intestinal hemorrhages, unexplainable by disease of the gut wall or by hindrance to the portal circulation.
3. There is quick and marked fall of body temperature.
4. Colicky abdominal pains, which may be very severe.
5. Later distension of the abdomen and free fluid occur.
6. Emboli of other parts may have been present before or may occur simultaneously with closure of the mesenteric vessels.
7. There occurs sometimes a large, palpable blood tumor between the layers of the mesentery.

Clinically it is very rare to find all these points present, and so the diagnostic value of the above schema is considerably impaired. It can not be wholly discarded, however, but, as Neutra says, only in the presence of the greatest number of points of this schema can the diagnosis be made with any degree of certainty.

Schrötter⁴⁴ says that if the characteristic disease picture develops in the case of a younger individual, with a heart lesion, one immediately thinks of embolus. In an older individual, with arteriosclerosis, a sudden occurrence of the symptom-complex makes embolism most probable. With slow development, at any age, thrombotic processes of either artery or vein are more probable. According to Köster,⁴⁵ it is impossible to differentiate between closure of arteries and that of veins.

The conditions which are most often confounded with these cases of intestinal paralysis are those where the obstruction is due to a mechanical hindrance. These are intussusception, volvulus, strangulation by bands or obstruction from gallstones or cancer. Also those diseases which may cause blood in the stools or vomitus must be ruled out. Such are gastric or duodenal ulcer, heart and liver disease.

43. Würzburger med. Zeitschrift, 1863, vol. iv, p. 141.

44. Nothnagel's Spezielle Pathol. u. Therapie, vol. xv.

45. Deutsch. med. Woch., 1898, p. 325.

Naunyn⁴⁶ considers dysenteric, foul-smelling hemorrhagic stools characteristic of intussusception, but these also are found in closure of mesenteric vessels. Nothnagel⁴⁷ thinks the variations in size and shape of the sausage-shaped tumor in intussusception, caused by the contractions, to be of value. We must remember, however, that there are cases of mesenteric occlusion which have tumors of the mesentery caused either by hemorrhage or edema.

In volvulus, which is usually of the lower bowel, it is impossible to inject any great quantity of water.

Obstruction due to cancer, gallstones, etc., is usually more gradual in onset, and in the previous history there will most often be found data for differentiation.

The differentiation from portal thrombosis is usually impossible, since this is, in many instances, only an earlier stage in the same disease process. In this connection, Stefan⁴⁸ thinks that the presence of a large amount of fluid in the abdomen, in a case where intestinal obstruction of the paralytic type has occurred suddenly, speaks for mesenteric as against portal thrombosis. Tuberculosis and malignant disease must first have been ruled out. Occasionally in portal thrombosis we are able to note the gradual increase in the size of the spleen. Schrötter⁴⁴ also mentions in differential diagnosis the rare cases of aneurism of the hepatic artery. This rarely causes symptoms until it ruptures, when severe abdominal pain occurs. The sac has usually become adherent to the intestine or bile passages, and so there occurs hematemesis or melena. In this condition, however, it is to be noted that the attacks are usually recurring, and last through weeks, that often jaundice is present, and that signs or symptoms of peritonitis are absent.

So, too, the various clinical tests showing the presence of sugar, or much increased indoxyl in the urine, or the increase of white cells and marked iodophilia in the blood, since they are all consistent with intestinal obstruction from various causes, show nothing specific for those cases due to occlusion of mesenteric vessels.

46. Mitt. a. d. Grenzgeb. d. Med. u. Chir., 1896.

47. Spezielle Path. u. Therapie.

48. Nederl. Tijdschr. voor Geneesk., 1900, from Centralblatt f. klin. Med., 1901, p. 178.

49. Diseases of the Intestine. 1902, vol. II.

We must agree with Hemmeter,⁴⁹ therefore, when he says that in the large majority of cases the nearest to a recognition of the correct state of affairs that will be made is the diagnosis of intestinal obstruction.

Prognosis.—As has been seen in speaking of the course of the disease, the condition is a very fatal one. Even granting the diagnosis to be correct in all the reported cases, we have a mortality of about 94 per cent. The condition is admirably summed up by Neutra, whom we quote: "In cases of acute onset, the prognosis is indeed very grave, but by no means absolutely bad, since behind these severe symptoms there may be hidden a chronic process which favors the formation of a collateral circulation, and on this the prognosis depends. If, on the other hand, the course is a chronic one, and only a few exacerbations are present, between which there is complete absence of symptoms, the prognosis, nevertheless, is moderately bad, since in these cases it must be assumed that because of some hindrance a competent collateral circulation can not be formed. Accordingly, thrombosis of mesenteric arteries is of relatively better prognosis than embolus."

Treatment.—Basing his treatment on what has gone before, Neutra advises, in the early stages, drugs to increase the blood pressure, or a light abdominal massage to displace the clot, if possible, and spread it into smaller branches. Both of these means seem to the writers to be illusionary. It does not seem to us that any treatment is rational except that of exploratory laparotomy, in every case where the patient's general condition will warrant it, and as soon as even a tentative diagnosis has been made.

Operation.—Operation has been done for the condition in 47 of the reported cases, with a mortality of 92 per cent., only 4 cases having recovered so far as reported. It seemed, therefore, to be of interest to review the pathologic findings in the non-operated cases, to see whether in these, had the diagnosis been made, operation could have been of any avail. The case showing the largest extent of resected gut is that of Elliot, in which 48 inches were removed, with complete recovery. Making this the upper limit, the autopsies show 24 non-

operative cases, having the following extent of involvement:

One case showing 1 inch.
 One case showing 2 inches.
 Two cases showing 4 inches.
 One case showing 8 inches.
 One case showing 10 inches.
 One case showing 1 foot.
 One case showing 16 inches.
 Two cases showing 20 feet.
 Two cases showing 2 feet.
 One case showing 31 inches.
 One case showing 38 inches.
 Four cases showing 39 inches.
 One case showing "several inches."
 Four cases showing "one coil."
 One case showing 2 coils.

That some of these cases would not have been benefited by excision of the gangrenous area is undoubtedly true. The extremely low general condition of the patient or the high situation of vessel closure prevents us supposing any other course than a lethal one. In 15 of these cases, however, there is nothing brought out in either the history or autopsy protocol to contraindicate a resection. These cases have to do with a small area and the vessels in its immediate supply, and these conditions have been found most frequently in cases of venous closure.

We feel also that faulty technic has been a factor in some of the operative failures. In many cases it is impossible, even with good demarcation lines, to be sure that the gangrene has reached its limit. For this reason those operations in which the resection has been followed by immediate anastomosis seem unwise. They also expose the patient to an operation which is too long and involves too much trauma.

The method of procedure which we advise, therefore, is to bring the involved gut well out of the wound, with liberal, sound margins left at either end, and after resection to fix the open ends in the wound, well walled off with gauze tampons. If peritonitis is present, a speedy flushing out of the cavity with hot saline solution, through the Tait tube, is advisable, and adds but little to the trauma of the operation. With both ends of the intestine thus open, the distension can be relieved, and the intestine watched for signs of further gangrenous involvement. Such an operation as we describe ought not to necessitate over fifteen or twenty minutes anesthesia.

We do not claim that many cases can be successfully treated by this or by any other method, but it does seem as if an occasional case might be saved, and certainly

this method puts the patient in the best position to recover, if such be possible.

LATER CASES.

While the preceding article was in press, the following cases occurred, which we add to the above list. The first is a good illustration of the venous type of thrombosis, occurring as a terminal event, after operation for umbilical hernia, in an excessively obese old woman, with poor heart action.

CASE 28.—(Dr. C. A. Porter.) Woman, 64 years, entered Massachusetts General Hospital Feb. 17, 1904.

Previous History.—Has always been healthy. Has had five children, the youngest 33 years old. At last childbirth had double milk-leg, and has had enlarged veins of legs ever since. Sixteen years ago varicose ulcers appeared on each leg, and have persisted. Thirty years ago she first noticed a bunch, the size of a walnut, just to the left of the umbilicus. Since that time this bunch has been enlarging slowly to its present size. One year ago first noticed a bulging of abdominal wall, size of one's palm, just above the umbilicus. Soon after this she had stoppage of the bowels, and vomited for two or three days; was relieved by big dose of physic. For past six or seven years has been able to get about only when wearing an abdominal swathe. For many years has had some pain in the rupture.

Present Illness.—February 13 and 14 she had very small movement from bowels, with some cramps. Took physic without result. February 15 began to have severe pain in abdomen, about umbilicus, associated with much vomiting. This has continued. Bowels have not moved since February 14.

Physical Examination.—Markedly obese. Heart and lungs negative. Abdomen tympanitic and considerably distended. In region of umbilicus is a tumor, evidently an umbilical hernia, the size of a small football. Abdomen is tender just above this tumor. Ulcer on each leg.

Operation.—(Dr. C. A. Porter.) February 17. Radical cure of an incarcerated umbilical hernia, which contained about six inches of the transverse colon and a large amount of omentum. The patient made a fair recovery from ether, considering her condition at entrance. Convalescence was complicated by slight fever, due to a mild wound infection, which showed itself first March 6, when a pocket of pus was evacuated and drained.

March 11. Slight syncopal attack, cyanotic, dyspnea, hands cold. This was relieved by a bed rest, digitalis and strychnia. During the next week she was kept on digitalis and strychnia; had to have a bed-rest to relieve the dyspnea. During this time hands were for the most part cold and blue, but now and then became warm.

Death.—March 22. In the morning she became distinctly worse and very cyanotic; complained of colicky pains in the abdomen. Physical examination showed the abdomen markedly distended, with some dullness in both loins. At 5 p. m. she vomited a large amount of brown material, without fecal odor, which proved on examination to be chiefly blood. She rapidly failed, and died early in the evening.

AUTOPSY.

Anatomic Diagnosis.—(Dr. Oscar Richardson.) March 23, 1904. Thrombosis of the portal vein, with hemorrhagic infarction of the small intestine, and with hemorrhage into the stomach and intestine. Congestion of the spleen and pancreas, with small hemorrhagic areas in their tissues. Ascites, cholelithiasis; arteriosclerosis of the aorta; fatty infiltration of the myocardium of the right ventricle, with hypertrophy and dilatation of the heart. Chronic pleuritis. Hemorrhagic edema of the lungs. Thrombosis of the right common and external iliac and femoral veins. Edema of the lower extremities. Small abscess in the mass of adhesions at the base of the old operation wound.

Peritoneal cavity contains a large amount of reddish fluid. At a point 270 cm. above the ileocecal valve, the small intestine, over a distance of 120 cm. above this point, presents walls of a marked blackish-crimson color. At each end of this strip of intestine this marked change in the color of the wall ceases suddenly. The mesentery supporting this strip of intestine shows no distinct change in its color, but is slightly thicker than normal. In places, toward the root of the mesentery, engorged veins are plainly visible. The serosa of this involved portion of gut presents fine, fibrinous-like material on its surface. The descending colon, sigmoid and rectum, on section, show nothing remarkable. The small intestine, on section, contains a large amount of blackish, bloody semi-fluid material. The bloody character of this material is most marked in that portion of the small gut which shows the marked discoloration of its walls. These walls, on section, are of a blackish-crimson color, opaque, and there drips from them a thick fluid, blood-like material. The mucosa of the small intestine below this infarcted strip is more or less reddened. No ulcers are found in either the small or the large intestine. On section of the portal vein it is found to be distended and occluded by a large, grayish-yellow to blackish-red, fibrinous mass, about 10 cm. in length, which is in places adherent to the intima. The circumference of the vein is 4.5 cm. The adhering mass is continued a short distance into the great branches of the portal vein in the liver, and is propagated from there on into the small branches as blackish-red, more or less firm blood clot. From the lower portion of the portal vein this occluding thrombus mass is propagated into the gastric, splenic and su-

perior mesenteric veins and their radicles, as black more or less firmly-clotted blood. As far as can be determined, the inferior mesenteric vein appears to be much more free from the clotted blood than any of the other branches of the portal vein. The intima of the splenic vein, near its junction with the portal, shows a place where the clotted blood is adherent to it. A large branch of the superior mesenteric vein, apparently the colica dextra, is distended with blackish-red clotted blood, and is plainly traceable to the mass of fibrous tissue, colon and omentum at the base of the healed wound in the abdominal wall.

The mesenteric arteries are free, and the intima smooth. The right common and external iliac veins and the first portion of the femoral vein, on section, present a grayish-red to blackish-red fibrous mass of material, which is rather firmly adherent to the intima in places.

Culture from clot in portal vein showed a colon-like bacillus; those from the liver show this same bacillus, and also a few streptococci. All other cultures were negative.

In this case it appeared as if the primary thrombosis formed in the portal vein, from which the other mesenteric vessels were filled by backward extension. It is impossible to explain the origin of this thrombosis. It may have been due to infection of the wound, though this appears to us unlikely, as the peritoneum was not involved in the infection, or secondly and most probably, the thrombosis developed as a result of her poor cardiac action for a period of ten days.

The following case has been kindly sent by Dr. Elmer H. Copeland of Northampton, Mass., under whose care the patient was:

CASE 29.—Man, aged 61 years. Typhoid 36 years ago; well and active since.

Present Illness.—Feb. 6, 1904. Attack of pain in left inguinal region, with some tenderness. Bowels had not moved for two days. Temperature, 96.5 F. After active catharsis, bowels moved several times, with relief of the pain. No blood in movements. The pain returned soon, however, and could not be relieved.

Operation.—(Dr. G. W. W. Brewster, Boston.) Feb. 9, 1904. Entire small intestine of dark red color, like "bologna sausage," with several spots of a darker red. Abdomen washed out and closed. Operation gave no relief of pain, which continued to be spasmodic in character. Temperature rose to 103, with vomiting (not bloody) and abdominal distension, and patient died February 11, fifty-three hours after operation.

AUTOPSY.

These several spots of gangrene above mentioned were present at autopsy, and also an area of gangrene six inches in length, about six feet below the pylorus, which extended around the entire circumference of the gut. Below this the intestine was empty; above, it contained semi-fluid, slightly bloody fecal matter. The blood vessels were not examined.

The following very interesting case is at present in the wards of the Massachusetts General Hospital under the care of Dr. J. W. Elliot:

CASE 30.—Man, 22 years, electrician, entered the medical wards of the hospital April 7, 1904, with the diagnosis of a duodenal or peptic ulcer.

Previous History.—Until three years ago had been very robust. One year ago had pneumonia.

Present Illness.—Perfectly well until three weeks ago, when he began to have pain in epigastrium, and inability to keep food on his stomach. Has good appetite, but vomits all he eats. At first vomitus consisted of food eaten, but lately has been of "coffee grounds" character. For past week has vomited three or four times a day, never any fresh blood.

Physical Examination.—Well developed and fairly well nourished. Pupils equal and react. Glands in both sides of neck, right axilla and groin, varying in size from a pea to a large bean. Left epitrochlear gland hard and shot-like. Heart and lungs negative. Abdomen full, muscles held rather rigidly, tympanitic throughout, no masses. Considerable tenderness beneath left rectus, and some spasm in epigastrium. Small scar on dorsum of penis.

April 14. Vomited some blood last night, and does not feel very well. Has some pain in epigastrium, with tenderness. Abdomen slightly distended. Vague sense of mass in right hypochondrium, with distinct resistance of right rectus. Liver dullness slightly diminished.

Urine: acid, specific gravity 1030; albumin absent; sugar absent. Leucocytes, 7,300.

Operation.—(Dr. Elliot.) April 14. Median incision in epigastrium. No free fluid. Sponge passed to pelvis brought up a little fluid, not cloudy or foul. Thorough palpation of stomach gave no evidence of disease. It was not dilated. Pylorus not abnormal. Small intestine looked rather dark, as if the contents were bloody. Upper part of jejunum distended. This was brought forward to anterior wall of stomach and gastrojejunostomy made. Mucous membrane of jejunum very thin and friable.

April 15. Vomited some dark material this morning, and color is rather cyanotic. Urine: acid, specific gravity 1033; albumin absent; sugar absent.

April 16. Some fever to-day and abdomen tender and distended; relieved by enema. Leucocytes, 9,300.

April 18. Patient more comfortable. Vomited this afternoon after potassium iodid. Abdomen soft. Retaining nutrient enemata well, which, however, have to be given small. Taking considerable amount of liquid by mouth.

April 22. Patient looks brighter and in better condition. Is now taking soft solids. Wound united by first intention.

April 25. Gaining. No complaints.

April 28. Excellent appetite. Retains and digests all food. Is having soft solids, chicken, etc.

May 1. Daily gain.

May 2. Complained of slight pain in abdomen to-day, which soon passed away.

May 3. This morning patient was seized with abdominal pain, not localized, cramp-like, accompanied by some nausea and vomiting. Abdomen soft, slight tenderness in left lower quadrant. During day patient had steady pain, with rare remissions. At night slightly more easy, when a vague resistance and sense of mass was felt in left lower quadrant. Two enemata have had no result. Leucocytes, 21,400.

May 4. Pain persists. Rigidity of left rectus with tumor felt beneath it. Slight spasm of right rectus. No dullness, no nausea. Leucocytes, 24,600.

Operation.—(Dr. Elliot.) May 4. Small amount of cloudy fluid found in peritoneal cavity. A coil of much distended and almost black small intestine lay beneath the incision, with neighboring coils slightly adhering to each other, and a little fibrin on them. Mesentery black almost to its root. Coil pulled out and 14 inches found gangrenous, but peritoneum still intact. Affected gut resected and ends brought out of wound. No strangulation present.

May 11. Since this second operation the patient's condition has been fairly satisfactory. He occasionally has considerable pain in the wound. Nourishment by mouth is retained, though there is at times some nausea. There is no pyrexia or other evidence of peritonitis or further gut involvement. The seat of the diseased gut could not be determined at operation because of the poor condition of the patient. If his condition permits, a secondary anastomosis of the resected intestinal ends will be done in the near future.

It seems evident that whatever the process that existed before the time of the first operation, the definite intestinal involvement began May 2, at the time when the pain and vomiting occurred. Though no gastric lesion was found at the first operation, the marked improvement in the patient's condition for over two weeks would seem to exclude the existence of a mesenteric

thrombosis or embolism before this date. At present we can only speculate as to the nature of the original trouble.

The pathologic report of the above case by Dr. J. H. Wright is as follows:

Pathology.—"Specimen consists of a loop of intestine 25 or 30 cm. long, with a small amount of mesentery about 1.5 cm. in its widest part, attached. With the exception of lengths of 14 and 16 cm. at either extremity of the loop the intestine presents the following appearance: It is of a black-red color, and at least twice as wide in diameter as normal, the peritoneal surface showing some fibrous thickening. On section the entire wall of the intestine is densely infiltrated with blackish, opaque, thick fluid. The same fluid is found in abundance in the lumen of the intestine. The mucous membrane in general is of a blackish, moist appearance, with no definite ulcerations. The portion of the mesentery adherent to the intestine is markedly infiltrated with black thick fluid. The condition of the intestine ceases rather abruptly at a point about 4 to 6 cm. from each extremity of the specimen, where there is a fairly well-marked constriction. The serous surfaces of these extremities of the specimen also show some fibrous thickening.

"Microscopic examination of pieces of the mesentery attached to the intestine shows thrombosis of good-sized veins, but none of the arteries. The thrombus material in the veins is composed chiefly of red blood corpuscles, together with a small amount of fibrin and a few polynuclear leucocytes. Some of the veins show infiltration of their walls with polynuclear leucocytes. There is no thickening of the vein walls. The tissue shows extensive hemorrhage. The appearances in the sections do not admit of a definite conclusion as to whether the thrombosis of the veins was the cause of the conditions in the specimen or not; the thrombosis might be secondary."

About one month after the operation of May 4 the exposed ends of intestine were brought together by an end-to-end suture. This was not immediately successful, but the resulting fecal fistula had wholly closed in about four weeks more. The patient was discharged well on July 14, 1904.

We have here, therefore, the fifth reported case of recovery through operation.

OTHER CASES.

The following cases are quoted briefly from the literature:

ADÉNOT.—Woman, 48 years. Operated for myoma of uterus. A coil of intestine adherent to the tumor, as is also the transverse colon in its upper portion. Resection of a piece of the mesentery of colon near its upper border. Death the next day.

Autopsy.—In lower part of descending colon a ring-shaped

area of gangrene with large perforation. Thrombosis of vessels leading to it.

ADÉNOT.—Woman, 73 years. Two weeks previously operation for strangulated hernia, with immediate relief. The wound did not heal and was coated gray. On the fourteenth day persistent diarrhea, not bloody. Died five days later.

Autopsy.—Gangrene of wound. Foul, dark fluid in pelvis. Lower two-thirds of descending colon gangrenous, with large perforations. Heart normal. All vessels show marked atheroma, especially the descending aorta and mesenteric arteries. Clot in the inferior mesenteric artery.

ALEXANDER.—Man, 36 years. Sudden vomiting of large amount of dark blood. Blood in stool. Loss of appetite and headache. No tenderness or resistance in abdomen, but marked distension. Watery stools followed. Heart and lungs negative. Peritonitis and death. This same condition has occurred three times during the last few years.

Autopsy.—Turbid red fluid in cavity. Small intestine distended. Several coils, dark blue. Roots of mesenteric veins are very wide and filled with firm non-adherent clots, which are continued into trunk of inferior mesenteric vein, and are here adherent. Trunk of superior mesenteric vein is also full of clots down to gut wall. Main trunk of inferior mesenteric vein is as large as a child's arm. Splenic and portal veins thrombosed. Cause was chronic pylephlebitis.

ALKAN.—Man, 64, alcoholic. Well till five weeks ago. Feeling of fullness in region of stomach, frequent belching of gas and anorexia. Copious vomiting of late. Abdomen negative. Liver palpable two finger breadths below costal margin. Bowels regular and normal; diarrhea later, not bloody. Lungs negative except for slight emphysema. Aortic second sound slightly accentuated. Temperature 36.5 C. Stomach contents show stasis. HCl diminished, lactic acid absent. Urine contains neither albumin nor sugar. On seventeenth day sudden pain in lower abdomen. Distended below navel. Liver not palpable, its area of percussion dullness gone. Pulse 80 to 100. Reddish-yellow diarrheal stools. Distension increased. Collapsed and died the following day.

Autopsy.—Intestines have lost their gloss. Fresh fibro-purulent adhesions between coils. Bloody ascites. Whole lower ileum, ascending colon and 20 cm. of transverse colon discolored and gangrenous. Extensive myocarditis, causing an aneurism cordis, which contains a thrombus. Colica media and dextra arteries thrombosed at their origin.

ALLEN.—Woman (age not given). Compensated mitral stenosis. Collapsed after delivery. No signs of hemorrhage or of rupture of uterus. Death without any abdominal symptoms.

Autopsy.—Showed embolus of superior mesenteric artery.

ALTMANN.—Woman, 73 years. Thrush and deglutition pneumonia. No abdominal symptoms.

Autopsy.—Distension of abdomen, especially in right hypogastrium. Atheromatous patches of superior mesenteric artery, with secondary embolus of several end branches. One and a half meters of lower ileum infarcted and almost necrotic. Gas and bloody slime in small intestine. General severe arteriosclerosis. Small dissecting aneurism of right iliac artery.

ANDERSON.—Man, 17 years. Always delicate. Five years ago, rheumatism. For six months since this, constant dyspnea on exertion and occasional epistaxis, always from left nostril. One year ago, attack of pain in abdomen, with nausea; no vomiting. Feet and legs red and swollen. Dyspnea and blood in stools. Now, for two weeks, has had severe pain across abdomen; nausea, but no vomiting. Melena. Heart dilated, double aortic murmur. Urine negative. These symptoms continued for about three weeks, no further details, no autopsy. Author considers the case embolus of superior mesenteric artery. This diagnosis is doubted by Litten.

ARONSOHN.—Man, 45 years. Sudden severe pain in epigastrium, which disappeared by degrees. Eight days later pain recurred, more severe, and lasted till death, five days later. Pain was accompanied by dyspnea and cyanosis. No vomiting or diarrhea. Moderate distension of abdomen. No tenderness on pressure. Temperature 36, respiration 45, pulse 100. Rales in lungs. Death twelve days after first attack of pain. Last day comatose.

Autopsy.—Trunk and branches of superior mesenteric artery thrombosed. Embolus in a cerebral artery. Mucosa of whole small intestine swollen and suffused with blood. Bloody fluid in pelvis. Pulmonary edema. Hypertrophy and dilation of right heart.

AUFRECHT.—Girl, 8 years. Double pleurisy at 2 years of age; at 4 years diphtheria. For three days severe pain in right side of abdomen; vomited six times, clear blood, amounting to about one-quarter liter. General spasm and retraction of abdomen, which is tender on the slightest pressure, especially at the right costal border. Here there is felt a resistance over area the size of a dollar. Pulse 132, small; temperature 38 C. Cardiac dullness enlarged, systolic murmur at base; pulmonic second sound accentuated. Lungs negative. Urine not albuminous. Next day, epistaxis. Pain worse. On second day dark, bloody, thin stools. Abdomen distended. On fifth day no more blood in stools; abdomen soft, still slightly tender. One week later general condition good, no more pain, stools regular. Three days later pain of short duration below liver. Stool contains two bloody and many slimy mucous particles. One month later, discharged relieved. Cardiac condition the same. Feels well and weight is increased.

BARTH.—Man, 47 years, alcoholic. Scarlet fever as child.

Intermittent fever while in Algiers. At 33, phlebitis of leg; well in three months. Onset of present illness, with pain in abdomen, nausea and vomiting.

Clinical Diagnosis.—Hepatic colic, without jaundice. Pain most marked in epigastrium, radiating to right of umbilicus. Frequent attacks, but little influenced by morphia. Slight distension. Seventeen days later, sudden distension and hiccoughs. No ascites, cutaneous veins not enlarged. Liver small, retracted under costal margin. Abdomen very tender. Following distension, no movement of bowels or gas. Before this they had been regular. Vomitus green. Rectal temperature 37.2, pulse 140, thready. No bile or albumin in urine. Collapsed and died before operation could be done.

Autopsy.—Abdomen contains about one liter of sterile, reddish-brown serum. Intestines distended, and their peritoneal surface injected. Area in middle of jejunum violet color, with fibrin on surface. No line of demarcation. Thickened and lardaceous mesentery very striking. Mucous membrane of involved intestine grayish red. No ulcerations. Thin, reddish, fluid contents. No stenosis. All mesenteric veins thrombosed, as well as those of diseased portions. Splenic vein closed. Arteries free. Firm, gray-red clot at hilum of liver, in portal vein. Liver small, but not sclerotic. Gall ducts free. Spleen not enlarged.

BAYER.—Man, 58 years. After movement of bowels, tried to push back with force an ordinary prolapsed hemorrhoid. Sudden unconsciousness. Next day pain in chest and bloody sputum. Râles in lungs. Epsom salts caused diarrhea. For a few days severe pain in lower abdomen; no stools or gas. Vomited. Painful resistance in ileocecal region. After two days dark, bloody stools. Fetid breath; collapse. Hemorrhoids inflamed and very tender. Streaks of blood in sputum for several days. Gradual diminution of symptoms and recovery. The hemorrhoids were apparently thrombosed, and part of the thrombus was separated by the pressure. Then followed pulmonary embolus, and later embolus of branch of superior mesenteric artery, causing intestinal paralysis and paralytic ileus.

BECKMANN.—Woman, 80 years. No clinical data.

Autopsy.—Mitral and aortic valves thickened and stiff. Chronic endarteritis of whole arterial system. A cyst between layers of mesentery at lower border of liver. Mucosa of duodenum and jejunum swollen and hyperemic. Contents, fluid blood. Ileum dark bluish-red. Obturating thrombus of superior mesenteric artery, at origin of ileocolic. Origin of embolus not evident.

BEWLEY.—Man (age not given). Vomiting, pain and distension of abdomen. Obstipation.

Operation.—One foot of small intestine gangrenous, no obstruction found. Soon died.

Autopsy.—Thrombosis of mesenteric and portal veins.

BONNE.—Man, 28 years. Headache, and enlarged spleen. After a short time, diarrhea and pain in stomach. Fever. Blood examination showed red corpuscles pale and disintegrated. Symptoms of peritonitis from perforation. Death.

Autopsy.—Fluid blood in cavity. Mesentery thickened. Spleen enlarged, surrounded by adhesions. Organized thrombus in splenic vein. Soft, non-adherent thrombus in portal vein, reaching into mesenteric vein; 80 cm. of intestine supplied by this latter, infarcted and necrotic in spots. Author explains this by primary splenic tumor, following infection, causing inflammation of wall of vein, and subsequent thrombosis.

BORNHAUPT.—Man, 22 years. Formerly always well. Following debauch, severe pain in abdomen, vomiting and obstipation. No flatus. Abdomen soft, tympanitic, not distended, tender or resistant. Frequent stercoraceous vomiting, cyanosis, quickened respirations, collapse and death.

Autopsy.—Diffuse injection of both layers of peritoneum, slight amount of sero-hemorrhagic fluid in cavity. Area 10 cm. long, bluish-red and necrotic in small intestines 50 cm. above cecum. Inferior line of demarcation good; superior one obscured. Rest of small intestine hyperemic. Effusion of blood into mesentery for 2 cm. Contents of stomach blood colored. Mesenteric vessels not examined, but author suggests autochthonous thrombus. Large blood clot in left pleural cavity.

BORRMANN.—Man, 63 years. Sudden attack of pain in abdomen. For three months stools were painless but diarrheal. Lassitude, vomiting. A year and a half later, similar attack, more severe. Abdomen sensitive to pressure. Continued vomiting of bloody masses. Collapse and death on sixth day.

Autopsy.—Turbid, bloody serum in cavity. Coils distended. Serosa infiltrated with blood. Several coils show hemorrhagic infarction, with thickened walls. Blackish fluid in duodenum. Mucous membrane of stomach and duodenum scattered over with vesicles of decomposition. Obstruction of portal vein by adherent thrombus, which is propagated into mesenteric vein, and is grayish-red in color. Mesenteric arteries free. Syphilis of liver. Author considers syphilitic disease of vessel wall the primary factor.

BORSZËKY.—Man 54 years. In full health. Sudden, severe pain in abdomen, soon followed by bloody defecation. No vomiting. Abdomen slightly distended, and very tender everywhere, especially in ileocecal region. No movement nor gas, even after enema. Abdomen became more and more distended, and this was followed by constant vomiting. Four days from onset sent to hospital. General spasm and distension of abdomen; no visible peristalsis. Abdomen tympanitic, except in ileocecal region, where there is dullness, which does not shift with change of position. Mass the size of a hen's egg under

this dullness. It feels elastic and does not change in consistency. Whole abdomen very tender. Vomiting has become fecal. Heart and lungs negative. Rectal examination negative. Pulse very arrhythmic; cold, clammy extremities; lips cyanotic. Marked dyspnea; temperature 37.3. Operation under cocain. Intestines all dark and adherent; very friable, and were torn in several places while loosening adhesions. No obstruction found.

Autopsy.—Celiotomy. Turbid red fluid in peritoneal cavity; 210 cm. of small intestine, beginning 225 cm. from the beginning of the jejunum, show hemorrhagic infarction, gut wall thickened and firm. Obliterating thrombus in superior mesenteric artery 8 cm. from aorta. Mitral stenosis and insufficiency, with cardiac hypertrophy.

BRADFORD.—Man, 20 years. Never very well. Seven years ago, bronchitis. One year ago, abscess on foot. Now has pain in abdomen, slight diarrhea. For six days headache. Has vomited once. Pain localized at navel and is constant. Abdomen tympanitic; slightly tender in right hypochondrium; liver not enlarged, no mass felt. Bowels moved by enema; motion contains no blood. Urine negative. Lungs negative. Systolic apical murmur. For next five days temperature about 101 F., respirations 38, pulse 96. Pain constant, occasional severe vomiting, abdomen not distended. Then sudden vomiting, dark green in character, pain increased. On the next day vomiting became stercoraceous and an indefinite mass was found in left iliac fossa, which could be moved up to left lumbar region. Operation next day. One foot of small intestine dark blue, no volvulus or constricting band. Slight amount of reddish fluid in cavity. Death.

Autopsy.—Hemorrhagic infarcts, 18 inches long, in upper jejunum; mesentery thickened, its veins thrombosed. Trunk of superior mesentery vein thick, and filled by decolorized clots. One mesenteric gland contains pus and connects with vein; no sharp line of demarcation, no ulcerations in intestine. Liver, spleen and heart normal.

BREUER.—Woman, 56 years. For several years slight heart trouble. Several severe attacks of angina, with following polyuria. For two years frequent cramps in abdomen. Relieved by various means, such as laxatives, etc. Stools formed, never bloody. Several days before death frequent attacks of pain, lasting several hours. Obstipation, then meteorism, vomiting and fever. A short time before death, discharge of blood-black soft masses. No autopsy.

BURGESS.—Woman, 23 years. Three weeks ago felt sudden pain while lifting a heavy box. This has been constant ever since. Has vomited all taken. Bowels moved. Nothing abnormal noticed. Abdomen full in lower region. No visible

coils. Very tender. Urine negative. Pulse 150, temperature 97.5; collapsed. Death in a few hours.

Autopsy.—Peritonitis in lower abdomen. Several inches of small intestine black red. Venous phlebitis from calcareous mass in mesentery. Clot extends into portal vein. Fluid blood contents of small intestine.

BUTLIN.—Man, 31 years. Dry gangrene of two fingers of left hand from frostbite. A few days after had pain in abdomen with vomiting of blood. Death from collapse.

Autopsy.—Clot in brachial artery extending into radial and ulnar. Acute general peritonitis from perforation of jejunum, which was wholly gangrenous. Clots in superior mesenteric and hepatic arteries. Clot on interventricular septum in left ventricle.

CATTANI.—Man, 69 years. For four days loss of appetite and obstinate constipation. Pain in abdomen, fecal vomiting and collapse. Clinical diagnosis: Ileus.

Autopsy.—Embolus in trunk of superior mesenteric artery. The involved intestine very much reddened and friable. Large amount of blood in stomach and intestine. Scattered hemorrhages in the mucosa. Slight amount of turbid fluid in the abdominal cavity. Atheroma of aorta, with mural thrombus in thoracic portion. Renal infarcts.

CHIENE.—Body in dissecting-room. Blood vessels injected from femoral. Celiac axis and mesenteric arteries closed by old emboli. Aneurism of abdominal aorta, from which the mesenteric takes origin. Trunk of celiac axis changed to a hard cord, both mesenteric arteries obliterated. The collateral circulation takes place by way of the superior hemorrhoidal, middle and left colica arteries. The retroperitoneal plexus of arteries is enormously dilated, furnishing connection between the internal iliacs and mesenterics.

CHUQUET.—Man, 62 years. Cirrhosis of liver, edema of legs and ascites. Free fluid in abdomen. Heart and lungs negative. Pulse 110 to 120. Urine contains bile, but no albumin. Incontinence of urine and feces. Sudden death in coma.

Autopsy.—One coil of small intestine is brownish-red as if gangrenous. Mesentery much thickened at its intestinal insertion. Mucosa sodden. No blood in lumen. All veins full of thrombi, which are continued into trunk of superior mesenteric vein.

COHN.—Woman, 45 years. Mitral insufficiency, pneumonia, pleurisy. Along the transverse colon, hard lumps, which disappeared after diarrhea. Anemia and death later from the pneumonia.

Autopsy.—Old clot at the apex of the left ventricle. Gray, ochre yellow remains of a previous hemorrhage in the transverse colon. Veins much dilated. Corresponding artery (i. e., ramus colicus), completely filled by fibrous clot.

COHN.—Woman, 71 years. For three months swelling of body, later of feet. Mitral insufficiency. Sudden fainting, with convulsion and vomiting. Not conscious till next day. General tenderness in belly, especially on left. Free fluid demonstrated in cavity. Small liver. Pulse 180, small and weak. No albumin in urine.

Autopsy.—Superior mesenteric artery plugged 2½ inches from origin. Mucosa of small intestine hyperemic; no ulcers. Large blood tumor between the layers of the mesentery. Mesenteric glands enlarged. Cardiac hypertrophy with thickening of mitral valve.

COHN.—Woman, 28 years. Syphilis and Bright's disease. Marked ascites and diarrhea. Died in five weeks. (No other data).

Autopsy.—One foot of small intestine, just above cecum, infarcted. Thrombus in corresponding branch of superior mesenteric artery. Splenic infarct. Liver enlarged, heart normal. Atheroma of aorta, with fibrin on one spot.

CONCATO.—(Age and sex not given). Three days before death colicky pain in epigastrium, increased on pressure. Tympanitic distension; no vomiting. Subnormal temperature.

Autopsy.—Turbid, foul serum in abdominal cavity. Sclerosis of aorta with mural thrombi. In several larger and smaller branches of superior mesenteric artery are obliterating clots. Infarction and necrosis of intestine, beginning 1 meter below the duodenum. Mucosa discolored in places, partly ulcerated. Ascending colon normal; transverse hyperemic. Intestinal contents bloody.

CONTI.—Man, 65 years. Previous cerebrospinal meningitis. Two years later in hospital for atheromatosis. No special pain or trouble. Sudden illness like acute peritonitis and died.

Autopsy.—Whole superior mesenteric artery full of easily separable clots. Rent in transverse colon 1 cm. Small intestine and ascending colon edematous. In the right half of the transverse colon two large subserous hemorrhages. Hypertrophy of left heart wall. Thrombus of aorta.

COUNCILMAN.—Man, 61 years. Senile gangrene of feet. Increasing general abdominal pain for two days before death.

Autopsy.—In aorta several parietal thrombi. In superior mesenteric artery an obliterating embolus attached to a calcareous patch. Infarct of whole small intestine with necrotic areas in its mucosa. Intestine much distended, with flakes of fibrin on its surface. General peritonitis; no intestinal perforation. Gut wall thickened. Embolus of thigh artery with subsequent gangrene. Renal infarcts.

COUNCILMAN.—Man, 62 years. Eight months ago had symptoms referable to heart. For past month has had orthopnea and anasarca. Sudden pain in abdomen and tenderness, increasing till death, eight days later. Eight days before death,

diarrhea, not bloody. No vomiting, but hemoptysis present. Temperature slightly raised.

Autopsy.—Total occlusion of superior mesentery artery from atheromatous aorta. Infarct of small intestine; thin, hemorrhagic fluid contents. Gut wall much thickened with hemorrhage; its wall covered with slight fibrinous exudate. Cardiac hypertrophy and aortic insufficiency. Roughened aorta. Source of thrombus not definitely made out.

COUNCILMAN.—Woman, 85 years. Has had bronchitis at intervals. First symptom, pain in abdomen, vaguely referred to right iliac fossa, and growing worse after a few hours. This lasted through whole illness. Died in twelve days. After second day abdomen was distended. Constipation, with no result from enemata, and no gas. Vomiting began on the fourth day, becoming fecal at the end. Temperature until the eighth day was subnormal, then rose to 101.5. Pulse 70.

Autopsy.—Marked atheroma of aorta, with parietal thrombi. One of these extends into the superior mesenteric artery, not wholly closing the lumen. Intestine distended, only moderately reddened, however. No intestinal infarction. Marked distension of the gut. Heart muscle very friable. The slight amount of blood which reached the intestines was insufficient, thus causing obstruction.

DECKART.—Woman, 53 years. For past five years complained of short breath, easily tired, palpitation, dizziness, etc. For fourteen days broken compensation. Diagnosis: Mitral insufficiency, arteriosclerosis, myocarditis, emphysema. Improved under treatment. Was allowed to sit up. Collapsed. Complained of pain in abdomen. Mass in hypogastrium very tender on pressure. Visible peristalsis in upper part of abdomen. Frequent vomiting, at first bile stained, later becoming fecal. Constipated; few scybalae after enema, never any blood. Rectal and vaginal examination negative. Indoxyl in urine markedly increased. Pulse 120 to 150. Temperature 37 C.

Operation.—Sero-hemorrhagic fluid in abdominal cavity. Intestines dark. Artificial anus made. Collapse with pulse of 50. Death.

Autopsy.—Lower jejunum and upper ileum infarcted. Clot in one of main branches of superior mesenteric artery.

DECKART.—Woman, 47 years. For seven years following a fever has had frequent vomiting, headache, dizziness and swollen feet. Later perspiration and diminished vision. One attack of uremia relieved by venesection. Symptoms of uremia and anemia. Several days before death had severe colicky pains in abdomen. The stools were bloody. Cardiac dullness increased to left. Abdomen "boat-shaped." Albumin and casts in urine, no blood. Retinal hemorrhages. Once during illness had many petechiæ on thighs and abdomen.

Autopsy.—One hundred c.c. fluid in Douglass fossa. Throm-

basis of some of the branches of the superior mesenteric artery. In lowest part of ileum a ring-shaped bluish-red area corresponding to defect of mucous membrane on inside. Ileocolic artery partly closed by tenacious yellow white mass. Deposits on intima in several branches of superior mesenteric artery.

DECKART.—Man, 40 years. Lues at 20. For many years had had difficulty with heart occasionally, called by physician neurasthenic. Nine years ago was operated for obstruction to feces. Has been well since. Attack began with sudden vomiting. Marked colicky pain, greatest on the right below navel. Marked pain on pressure all over the abdomen, especially in ileocecal region. Marked abdominal distension. No visible peristalsis. No murmurs heard over abdomen. Ileocecal region bulges a little. Percussion over this region dull to dull-tympanitic. No free fluid made out. Bowels moved several times first night; after this no more movements, not even gas. No result from enema. Vomiting constant. Liver dullness demonstrable. Mass felt in left hypogastrium. Lungs, heart and rectal examination negative. Urine acid, yellow color, slight amount of albumin, indol increased.

Operation.—Intestines above bladder adherent about pus pocket. This was opened and drained. Death. Temperature 37.9, pulse 140, respiration 28.

Autopsy.—Peritonitis. Infarct of lower jejunum and upper ileum from embolus in superior mesenteric artery. Lower mesenteric veins also thrombosed.

DELATOUR.—Man, 31 years. Frequent hematemesis, chronic splenic tumor, spleen removed by operation, the vessels being ligatured at the hilum. Two days after, double pneumonia, constipation. On the twenty-third day after operation sudden abdominal pain, violent vomiting, increased temperature, abdomen distended; collapsed and died in twenty-four hours.

Autopsy.—Bloody fluid in abdominal cavity. Whole middle third of small intestine blackish red. No peritonitis. Clot in splenic vein extending downward and blocking both inferior and superior mesenteric veins.

DINKLER.—Old man. Sick two days. Diagnosis, intestinal catarrh. Fourteen hours after entrance died, with signs of intestinal obstruction or paralysis.

Autopsy.—Dilatation and hypertrophy of heart. Marked atheroma. Dissecting aneurism of ascending aorta. Intercostal and celiac axis torn and thrombosed. Intestinal symptoms were caused by closure of superior mesenteric.

DREYFOUS.—Man, 52 years. Alcoholic. Ascites, with frequent aspiration. Cirrhosis of liver. Eight days after the last aspiration had general pain in abdomen. Bilious vomiting and dyspnea. No blood in vomitus or stools. Dullness and mass in right iliac fossa painful on pressure, and separated from liver by area of tympanites. Death that night.

Autopsy.—Slight amount of fluid in cavity; 60 cm. of small intestine in right iliac fossa, dark red, dilated, with thickened wall, its mesentery 3 cm. thick. Intestinal contents, semi-fluid blood. No ulcerations. All venous radicles thrombosed. Old, adherent clot in one of the branches of the superior mesenteric vein, and above this a recent clot, extending into portal vein. Superior mesenteric vein shows histologic changes corresponding to a thrombophlebitis.

DREYFOUS.—Man, 40 years. For past year gradual loss of appetite; difficult digestion; marked constipation; great loss of weight. Later on, diarrhea. No ascites. Abdomen negative. Nausea but no vomiting. Rectal examination discovers a tumor surrounding whole circumference of gut; not ulcerated; hard. Lymph glands enlarged. Urine negative. Abdomen began to increase in size, slightly tender to pressure, and contained a slight amount of free fluid. Subcutaneous veins slightly enlarged. No jaundice, hematemesis or melena. Sudden death on seventh day.

Autopsy.—Slight amount of free fluid in cavity; no peritonitis; 60 cm. of lower end of small intestine red colored; its wall and mesentery thickened and edematous. Marked injection at insertion of mesentery. Veins in this region thrombosed; mucous membrane dark red; contents bloody. No sharp line of demarcation. Thrombosis of portal vein. Epithelioma of rectum. Author considers thrombus marantic.

DREYFOUS.—Woman, 49 years. Syphilitic cirrhosis of liver. Ascites; small liver; enlarged spleen; marked dyspnea; dilatation of abdominal veins. Some edema of lower extremities. Urine negative. Following abdominal aspiration, abundant hematemesis; diarrhea, with tenesmus. Marked general abdominal pain. Diarrhea followed by obstipation. Prostration; death in two days.

Autopsy.—Slight amount of ascitic fluid. Beginning 25 cm. below duodenum, 1 meter of small intestine is dark-red colored and contains fluid blood. There is no sharp line of demarcation. Intestinal wall infiltrated with blood. Stomach dilated, its mucosa showing hemorrhages. Esophageal veins varicosed. All mesenteric veins completely closed up to the portal vein, which also is completely occluded. Splenic vein thrombosed.

DROZDA.—Man, 59 years. Under treatment for aneurism of ascending aorta and aortic regurgitation. Dizziness and short breath. Sudden occurrence of bloody stools. Abdomen distended and tender on pressure. No spontaneous pain in abdomen. Frequent bloody stools, later consisting of clear blood. Pulse, rapid, irregular, thready. Slight edema of lower extremities. Collapse and death.

Autopsy.—Mesenteric arteries everywhere free and thick-walled. Veins only slightly filled with blood. Serosa of up-

per half of jejunum rough in spots, with punctiform hemorrhages. Hemorrhagic infarction and swelling of mucosa, with transverse necroses between its folds. Mucosa of rest of intestine pale. There existed, therefore, no embolus of the superior mesenteric artery, but only a circumscribed infarction of the intestinal mucosa.

DROZDA.—Man, 22 years. Inflammation of joints; mitral endocarditis; nephritis; later hemiplegia. Collapse and diarrhea. Stools foul. Two days later, bloody. Speech disturbance became worse, and death on second day.

Autopsy.—Bloody fluid in cavity. Peritoneum everywhere smooth and shiny. Splenic and renal infarcts. In ileum and large intestine, blood-stained fluid. Diffuse hemorrhagic infarction and swelling of mucosa of ascending colon. Same in transverse and descending colon. Punctiform necroses. Mesenteric glands enlarged. In trunk of superior mesenteric artery, at origin of fourth jejunal branch, is an obdurating, adherent clot. Its periphery is laminated and reddish-brown; its center softened.

DROZDA.—Man, 61 years. Occasionally diarrhea. Sudden stupor, with restlessness. Few days later, almost complete unconsciousness. Pulse 96; head strongly turned to the right; bulbi turned to the right; left facial paralysis. Abdomen distended; not tender. Bloody stools.

Autopsy.—Heart negative. Sclerosis of aorta in spots. Two atheromatous ulcers in abdominal aorta, with slight thrombus masses on them. Small sclerotic area in superior mesenteric artery, on which is a gray-red, slightly adherent, soft thrombus, which completely fills the lumen. Intestines distended. Slight amount of blood-stained serum in cavity. Hemorrhage into mesentery. Whole small intestine filled with fluid blood, with sero-hemorrhagic infiltration of its wall. Several necrotic areas in mucosa of ileum. Yellow, softened area in optic thalamus. Chronic hydrocephalus.

DUN.—Man, 39 years. Under treatment for bronchitis, emphysema, passive congestion of liver and dropsy. Presystolic murmur at heart apex. Sudden pain across abdomen just below ribs, colicky in nature. A few days later vomited large amount of bloody material. Diarrhea, not bloody. Firm pressure on abdomen relieved pain during paroxysm.

Autopsy.—Emboli of superior mesenteric artery, colica dextra, ileocolic and vessels of small intestine. Hemorrhagic infarction of small and large intestine over area supplied by above vessels. Mucosa suffused with blood, necrotic. Much blood inside bowel. Old renal infarcts. Changes in mitral valves.

DUNLOP.—Man, 51 years. Entered in extreme collapse, with story of privation. Two days before had severe, cramp-like pain in hypogastrium, accompanied by vomiting. Abdomen

soft, not distended, not tender. Stercoraceous vomiting. Subnormal temperature. Clear, fluid bloody dejection, with diminution of pain. Died moribund.

Autopsy.—Two coils of mid-ileum congested and almost black, sharp line of demarcation running into mesentery; no peritonitis. Wall thickened and edematous, mucosa intact. Intestinal contents, fluid blood. Veins of congested mesentery plugged by dark-red masses. Arteries patent. No other thrombus found in venous system. Author considers thrombosis primary.

EISENLOHR.—Man, 36 years. Under treatment for ten months for aneurism of thoracic aorta. Symptoms were severe pain in right intercostal nerves, later in left. Increasing dyspnea; small pulse; edema of lower extremities; cardiac dullness increased; loud systolic and diastolic murmurs. Urine small in quantity, contains much albumin and few casts. For a month diarrhea, then sudden attack of colicky pain in abdomen, which is distended and very tender on pressure. Frequent vomiting of dark brown masses. Only a small quantity of blood in stools. Death. Clinical diagnosis, embolus of superior mesenteric artery.

Autopsy.—No free fluid in cavity. Atheroma of aorta. Thoracic aneurism size of a hen's egg. Intestines distended, bluish-red, covered with slight fibrinous exudation. Beginning at junction of descending colon and sigmoid flexure, the intestine is gangrenous. Superior and inferior mesenteric arteries free. In veins of involved portion dark, slightly adherent thrombi. There were also thrombi in several branches of the superior mesenteric vein. The mucosa of several parts of jejunum, ileum and colon infarcted. Mucosa of sigmoid, dark green and disintegrated. Trunks of all veins free.

ELLIOT.—Man, 25 years. Ten months before had incarcerated inguinal hernia. This was reduced, but had caused some pain, especially in the last two weeks. While playing ball had severe pain in abdomen; vomited. Whole abdomen tender on pressure. No distension. In ileocecal region a sausage-shaped tumor.

Operation.—Large quantity of bloody fluid in abdominal cavity. Intestinal coil blue; mesenteric glands swollen; 48 inches of intestine resected; open ends left in wound. Two weeks later end-to-end suture. Recovery. Veins of resected portion thrombosed.

ELLIOT.—Man, 70 years. Clinical diagnosis, intestinal obstruction from probable cancer of descending colon. Three days before entrance, dull pain in epigastrium, increasing in severity, paroxysmal in character. Distension of abdomen. Transverse colon visible through abdominal wall. Nausea, but no vomiting. No movement of bowels. Three or four bloody stools later. Atheromatous arteries. Operation on the

sixth day. Gas and fecal fluid in abdominal cavity; transverse colon dark and distended. Artificial anus. Increasing weakness, and death in a few days.

Autopsy.—Gangrene of a portion of the descending colon, three or four feet long. Perforation, general peritonitis. Chronic endarteritis and thrombosis of inferior mesenteric artery.

FABER.—Man, 39 years. Amputation of right leg following trauma. This was followed by suppuration in knee joint and bedsores. Gradual weakness and death. No other clinical data.

Autopsy.—Heart normal. Branch of superior mesenteric artery plugged. Source of embolus not given. The surface of whole small intestine, especially in the lower third, dark red. Clear, bloody, fluid contents. Large intestine distended with gas and brown masses. Thrombosis of right and left femoral veins. Slight amount of serous fluid in abdominal cavity. Occasional vomiting during last three days. Temperature last day, 35.1 C.

FABER.—Man, 61 years. In youth had a severe attack of articular rheumatism. Several attacks. Now has chronic effusion in legs, and very short breath. No palpation. Appetite good, bowels regular. Distension of abdomen and vomiting. Liver three finger breadths below costal margin. Systolic murmur at apex. Lungs dull behind. No blood by rectum. Temperature 37 C., at death 36.4 C.; pulse 80. Urine clear, albumin present, specific gravity 1010, acid. Picture that of general anasarca.

Autopsy.—Globular thrombus in left ventricle. Recent splenic and renal infarcts. Embolus in superior mesenteric artery 11 cm. long, 3.5 cm. from origin. Whole small intestine dark blue. Contents bloody.

FABER.—Woman, 82 years. No clinical data.

Autopsy.—Mitral insufficiency, with endocarditis. The inferior coils of the small intestine markedly injected and covered with fibrous deposits. Mesentery, near intestine, strewn with air vesicles. Below the involved portion the small intestine contains thin fluid, grayish-red masses. The disease involves the upper jejunum, the mucosa of which is discolored and contains large air vesicles. Further down, the mucosa is only red and infiltrated. In the corresponding part of the superior mesenteric artery is a gray, adherent, obdurating thrombus. Above the thrombosed spot is a circumscribed thickening of the intima.

FABER.—Woman, 73 years. Under treatment for leg ulcers. No clinical data. Gradual increasing weakness and death. Clinical diagnosis, senile gangrene of both feet, with ulcers of leg; marasmus.

Autopsy.—Sclerosis of arch and descending aorta, with mural thrombi. Infarcts of spleen and kidneys. Small intes-

tine for a large extent filled with bloody masses. Large intestine dilated. Mucosa of lower ileum and cecum injected and ecchymosed. Mesenteric glands not enlarged. In trunk of superior mesenteric artery, at origin of colica media, a firm, adherent, obdurating thrombus. Heart normal.

FALKENBURG.—Man, 30 years. Clinical diagnosis, peritonitis from perforation following perityphlitis. Attack nine days ago. On the sixth day, two days ago, sudden pain in abdomen; no movement of bowels or gas. Abdomen swollen. During last twenty-four hours has had repeated vomiting, not blood stained, and hiccoughs. Abdomen much distended, tympanitic; dull in dependent portions. General tenderness; no spasm. Vomiting ceased on entrance. Heart and lungs negative. Rectal examination negative. Collapsed. Temperature 36.6 C. Abdominal facies. Pulse 120, small and irregular. Hiccough persists. Death on day of entrance.

Autopsy.—Old thrombosis of the trunk, with extensive recent thrombi of the branches of both mesenteric veins. Hemorrhagic infarction of the intestine, hemorrhagic peritonitis. Healed ulcers in the appendix.

FALKENBURG.—A woman, 56 years. Previous history negative. For one-half year has complained of palpitation, dyspnea and oppressive feeling in breast. Copious movement of bowels followed by severe, cutting, not localized, abdominal pain; distension and tympanites on following day. Bilious vomiting, abdomen soft, very tender; liver much enlarged; no fever. Slight cyanosis. Slight edema of lower extremities. Heart enlarged; sounds clear; pulse scarcely palpable, 140. Urine contains albumin. For twenty-four hours following admission no movement of bowels nor gas. Just before death, one involuntary tarry movement. Under diuresis the general condition became better, the liver smaller. Had been out of bed for two days when attack of pain, above mentioned, occurred.

Autopsy.—Chronic, adhesive endocarditis, atheromatosis. Marked stenosis of mitral valve. Embolus of superior mesenteric artery; hemorrhagic infarction of several coils of ileum; atrophy of liver; cholelithiasis.

FINLAYSON.—Woman, 45 years. Aortic insufficiency. A year ago attack of hemiplegia. Sudden, severe pain in left arm and epigastrium. Several hours after this, copious, painful, bloody diarrhea. Later distension and tympany of abdomen. Arm powerless from pain, not from paralysis. No pulse below bend of elbow. Other pulse good. Abdominal symptoms disappeared under morphia and heat. Recovery.

FIRKET AND MALVOZ.—Woman, 60 years. No history. Brought to hospital moribund.

Autopsy.—Atheroma of cerebral arteries, with several areas of softening. Adhesive peritonitis. Four brown infarcts of

small intestine, from 4 to 20 cm. long. In the branches of the superior mesenteric artery at two spots are adherent thrombi, resting on an atheromatous base. Marked atheroma of superior mesenteric artery and aorta. Splenic and renal infarcts.

FITZ.—Elderly man. Globular thrombus in left ventricle. From this emboli to splenic artery. At first these were not sufficient to obstruct the main artery, but in course of time its closure became complete. In consequence of the incomplete primary obstruction, the spleen became greatly enlarged, and with the final cutting off of the supply of arterial blood, thrombi formed in the splenic vein, and from this point extended into the superior mesenteric vein. As a consequence of the obstruction of the latter, hemorrhagic infarction of the small intestine occurred.

FRANKENHAÜSER.—Woman, 23 years. Habitual constipation; pain in abdomen for two weeks. For past four days, obstipation and severe pain in upper abdomen. Abdomen distended, especially in upper part. Marked tenderness, especially near navel. Increased resistance on the left, with slight dullness. Severe fecal vomiting, cold extremities, increased pulse. Death in two days, with increasing weakness.

Autopsy.—Thrombosis of portal vein, following phlebitis and periphlebitis. Thrombus extends into superior mesenteric vein. Over 1 meter of small intestine infarcted. Large amount of serous fluid in abdominal cavity.

FRASER.—Man, 30 years. Three years ago rheumatic fever with endocarditis. For past two years, dyspepsia. For several weeks a severe abdominal pain and vomiting. Pain referred to lumbar region. No other abdominal symptoms. On night of admission sudden diarrhea, becoming bloody and followed by copious hemorrhage and death.

Autopsy.—Hypertrophy of left ventricle with chronic mitral endocarditis. Five feet of ileum, beginning three and one-half feet above ileocecal valve, congested, edematous and almost gangrenous. Sharp line of demarcation. Corresponding mesentery thickened. Superior mesenteric vein thrombosed. Liver fatty. Old splenic infarct.

GARMSSEN.—Woman (age not given). Manual extraction of placenta following miscarriage. Foul lochia, sudden abdominal pain, five watery movements. Pain increased next day. Marked distension of abdomen, with dullness in right hypogastrium, its limits increasing. Chills increasing. Became jaundiced, and had swelling of right leg. Increased vomiting.

Autopsy.—Purulent catarrh of uterine mucosa; portion of necrotic placenta remains. Purulent general peritonitis. Middle of small intestine shows hemorrhagic infarction, with thickened wall. Veins leaving area full of adherent clots, which can be traced into portal. Recent and old thrombi of splenic and right crural vein; recent thrombus of hypogastric

vein; splenic infarct. Process one of septic infection from uterus, with weakness of heart.,

GARRÉ.—Woman, 75 years. For five days had gastric trouble and diarrhea. For past two days has vomited. Has passed no gas, and but small stools. Abdomen distended and generally tender. No resistance or mass felt, no peristalsis seen. Temperature normal, pulse 120; general arteriosclerosis; no cardiac lesion. Rectal examination negative.

Operation.—Bloody serous ascites. About one meter of small intestine grayish-black, without sharp line of demarcation. No obstruction found. No resection was done. Death on the following night. Autopsy not allowed.

GARRÉ.—Man, 61 years. Three years ago spontaneous thrombus of right thigh veins; well during past year. Stools normal. Moderately alcoholic. Sudden pain over whole abdomen, with no previous disturbance of digestion, accompanied by vomiting, not fecal. No stools or flatus in spite of enemata. After sixteen hours vomiting stopped, but pain continued, and he began to hiccough. Next day again vomited, abdomen was distended and pain was worse. Patient became dyspneic. Rigidity of abdominal muscles. No intestinal peristalsis seen. No murmurs on auscultation. Abdomen tympanic, with slight dullness on the sides; generally tender. A mass was felt in epigastrium, with a round edge above, becoming vague toward umbilicus. Liver and spleen not enlarged. Pulse small, soft, 140. Respiration quickened. Cardiac dullness increased to the right; tones clear. Diagnosis, ileus.

Operation three-quarters of an hour after entrance. Much foul-smelling, reddish fluid evacuated. Black, gangrenous coil of small intestine found in region of umbilicus. It was much distended and adherent to omentum; deposits of fibrin on coils. No sharp line of demarcation. Discolored area 1½ meters long was excised, and ends united by Murphy button. General cavity washed out with salt solution. Collapsed. Temperature 36.4. Died seven hours after operation. Examination of excised tissue shows veins dilated and thrombosed. Arteries empty. No autopsy.

GERHARDT.—Man, 43 years. Acute articular rheumatism, syphilis, endocarditis; hemorrhages from stomach; systolic aortic murmur; sudden severe pain in abdomen; bloody diarrhea and vomiting. No tenderness in abdomen even on deep pressure. Poor pulse. Death in fifty-six hours.

Autopsy.—Recent verrucose endocarditis; clot in left heart. Punctiform extravasations in duodenum. Two and one-half feet of small intestine above cecum and whole large intestine to anus of a bluish red color. Wall infiltrated with blood. Contents bloody; in rectum a fresh blood clot. Su-

perior mesenteric artery free; inferior contains an embolus at its aortic origin.

GIMARD.—Man, 20 years. For three and one-half months signs of aortic insufficiency and hypertrophy of heart. Obstipation, epistaxis, purpura, fever, albuminuria.

Autopsy.—Aortic valve intact. Clot, with polypoid excrescences in ascending aorta. Multiple ecchymoses of pleurae, peritoneum and intestinal mucosa. Closure of several arteries in intestinal wall. The skin eruption, as well as the ecchymoses of gut, due to emboli of capillaries.

GINSBURG.—Woman, 66 years. Apoplectic seizure with left hemiplegia; heart disease. Death in a week, with no characteristic abdominal symptoms.

Autopsy.—Thrombosis of aorta following an embolus of the superior mesenteric artery. Arteriosclerosis of aorta, dilated right heart, fibrous myocarditis. Emboli of Sylvian, superior mesenteric and superior thyroid arteries. Hemorrhagic infarction of ascending colon.

GINSBURG.—Woman, 49 years. Signs of failure of cardiac compensation. A week later severe abdominal pain, meteorism. Marked tenderness on pressure of abdomen. Stools normal; vomiting. Pulse 88. Death in twenty-four hours.

Autopsy.—Endocarditis of mitral and aortic valves. Thrombus in left auricle. Embolus of superior mesenteric artery. Upper ileum and lower jejunum dark brown, red. Reddish fluid contents of ileum; 250 c.c. of bloody fluid in cavity.

GINSBURG.—Woman, 65 years. Sudden signs of failure of cardiac compensation. One month later embolus of left pleural artery, quickened pulse. Hematemesis. Marked bloody diarrhea two weeks later. No great pain in abdomen; distension, but no tenderness. Heart arrhythmic. Collapsed.

Autopsy.—Dilatation of right heart; mural thrombus in left heart. Embolus in superior mesenteric artery. Hemorrhagic infarction of whole small intestine. Fibrino-purulent peritonitis.

GINTRAC.—Man, 45 years. For two years palpitation and dyspnea. Ascites and edema. Death.

Autopsy.—Thrombus above union of splenic and superior mesenteric veins. Bonelike deposits between intima and media. Clear serous fluid in cavity.

GOODHEART.—Woman, 49 years. Several years before had a sickness in lower abdomen, with severe pain and diarrhea. Later frequent recurrence of this condition, but never in connection with any dietary indiscretion. For a half year much discomfort and tenderness in belly after eating. Sudden vomiting of dark masses; dark stools. Free fluid in abdomen, which is distended. Frequent vomiting of blood. Urine albuminous; no blood. Abdomen tapped and 5 liters withdrawn. This was followed by severe bloody vomit, bloody stools and

collapse. Death ten days later. During last few days there was a blowing murmur in splenic region.

Autopsy.—Atheroma of aorta; no heart lesion. Stomach veins thrombosed; no ulceration of mucosa. In ascending colon, intense congestion, sharply marked off from the rest of the intestine. The corresponding branch of the superior mesenteric artery thrombosed. An arteriovenous aneurism between splenic artery and vein.

GULL.—Man, 23 years. Has been well, except for transient edema of hand and part of right forearm several days before, which could not be explained. Primary lues five months ago. Sudden pain in abdomen, followed by very profuse intestinal hemorrhages. No fever. Distension of abdomen. Slight amount of vomiting, not containing blood. Urine pale, 1015, slight trace of albumin. Collapsed on third day. On sixth day no more blood in stools. During second week stools contained pieces of tissue, microscopically similar to valvulæ conniventes. Casts in urine. Gradual, complete recovery. Author excludes invagination, because the tissues passed by stool consisted only of mucosa, and not all layers of the intestinal wall. He suggests syphilitic changes of vessels.

GERSTER.—Thrombosis of mesenteric vessels. Gangrene of intestine. Operation. Death.

LEAH S., 47, May 17, 1901.

Family History.—Negative.

Past History.—Two attacks of cerebral embolism during last eight years.

Present Illness.—Three weeks ago, after lifting heavy weight, patient began to have very severe pain in abdomen, particularly in region of umbilicus and back. The pain did not radiate. There were no other symptoms at first. For the past two weeks her bowels have not moved except with enema, and then scantily. Obstipation for past three days. No gas. All ingesta vomited immediately for last three days, and on day of admission, according to patient, vomitus was fecal. No urine passed for thirty-six hours before admission.

Status Presens.—Heart slightly enlarged. Aortic second sound accentuated. Abdomen distended and tympanitic, except in dependent portions, where was dullness. No distinct mass felt. In right iliac region and across median line, indefinite resistance, with considerable tenderness. Albumin present in abundance. Temperature 98.6, pulse 120, respiration 36.

Operation done immediately. Subcutaneous injection of 8 ounces salt solution. Incision four inches long in median line, at level of umbilicus. On opening peritoneal cavity some bloody serum escaped. Incision made eight inches, presenting intestines normal in appearance. In left iliac fossa a loop of tense, black, gangrenous gut seen. Trendelenburg position, and loop pulled into wound. Margins sharply defined; no constriction found.

Mesenteric vessels at this portion thrombosed. About fourteen inches gangrene. Mesentery ligated and resection done. Murphy button, drain and closure. Patient in collapse. Thirty ounces salt during operation. Died a few minutes after reaching bed.

Autopsy.—Thrombosis of mesenteric veins; thrombi dark red in color; arteries clear; mesentery as a whole edematous. Intestine congested, with small ulceration in mucosa. Mesenteric glands enlarged. Branches of portal vein contain recent thrombi. The splenic vein is thrombosed, and spleen is large and congested. Cultures and spreads from portal thrombi show presence of streptococci.

GORDON.—Woman, 45 years. Lues 10 years ago. Now has tertiary ulcer of hard and soft palate. Ten months previously operated for strangulated femoral hernia, with complete recovery. Seized while at meal with severe griping pain in abdomen. Vomited early next morning. No distension of abdomen. Tumor in right iliac region, apparently a distended coil. No bowel movements after onset of pain.

Operation.—Bloody fluid in cavity. Coil of intestine dark-colored; its serosa still preserves its gloss. Sharp demarcation line above, gradual one below. Intestinal wall and mesentery thickened. Resection and end-to-end suture over a bobbin; two feet removed; contained foul blood; no ulceration of mucosa. Vessels bled freely. Three days after operation complained of severe pain in abdomen. Morphia gave but slight relief. Temperature subnormal; pulse 128. General condition satisfactory for next two days, when intestinal leakage was found on the dressing. Wound opened and packed, and in two days a slough came away, representing the entire suture line. Resulting fecal fistula closed in two weeks. Recovery. Author suggests syphilitic endarteritis.

GRAWITZ.—Boy, 17 years. Severe intestinal catarrh and hemorrhage. Just before death, severe pain in abdomen. Diagnosis: Typhoid, with ulcers and peritonitis from perforation.

Autopsy.—Chronic enlargement of spleen. Thrombosis of pancreatic, superior mesenteric and portal veins. Fresh hemorrhagic peritonitis. Chronic enteritis of jejunum and ileum, with recent hemorrhage and hemorrhagic infiltration of them. Malaria cachexia.

GRAWITZ.—Man, 48 years. Frequent attacks of lead poisoning. No appetite for a long time. Sudden attack of apoplexy lasting several days, with a short intermission. Unconscious on admission to hospital. Urine contained much albumin. Heart arrhythmic. Profuse vomiting two days before death. No other symptoms.

Autopsy.—Cerebral arteries sclerosed. Hemorrhages of cerebrum. Hypertrophy and dilatation of heart. Dissecting aneurism of aorta. Endarteritis. Trunk of superior mesen-

teric artery free, branches plugged. Lower jejunum and ileum infarcted over area 25 cm. in length. Mesentery thickened, with hemorrhages. Several coils adherent by localized fibropurulent peritonitis. No exudate in abdominal cavity. Splenic infarct.

GROSSKURTH.—Man, 41 years. Eight months ago apoplectic stroke. Unconscious 20 hours. Left hemiplegia. Leg soon recovered; arm better in four months. No facial paralysis; slight disturbance of speech. Since this has never been quite well. Pains in chest and back and loss of appetite. Now has pain in abdomen and distension. Five or six chocolate brown dejecta. Pain in back prevented sleep. No vomiting or loss of weight. Distension more marked on right than on left. Abdomen tympanitic, elastic resistance, slight tenderness in hypogastrium and epigastrium; no tumor. Inferior epigastric veins dilated. Lungs negative. Aortic second sound slightly accentuated. Pulse 88; urine slight in amount; indoxyl normal. Rectal examination negative. Distension and pain grew worse. Laparotomy. Coils of small intestine distended and dark bluish black. Large intestine normal. No obstruction. Wound closed. Death that night.

Autopsy.—Almost whole small intestine shows hemorrhagic infarction, most marked in lower jejunum. Fibrin on coil. Thrombosis of superior mesenteric artery at junction of colica media and pancreatico-duodenalis. Superior mesenteric veins also thrombosed. No sharp line of demarcation. Abdomen contains 1 liter of bloody fluid. At orifice of sixth intercostal artery grayish-red mural thrombus. Splenic infarct. Contents of small intestine bloody.

HAHN.—Man of 56. Well till one year ago, since when difficulty in breathing, dropsy and catarrh. Cardiac and renal disease. Abdomen soft, retracted; no tenderness except in region of stomach. Râles in lungs. Pulse regular, thready, 78; temperature, 34.3 C. Urine, 1,016; $\frac{1}{2}$ per cent. of albumin, hyaline casts, with pus and small round cells. Sudden vomiting, followed by pain in epigastrium. That night became cyanotic, with increased respirations and board-like rigidity of abdomen. Wild delirium, in which he died.

Autopsy.—Hypertrophy and dilatation of both ventricles. All the small intestine and 20 cm. of the ascending colon contained blood. Mucosa swollen and injected. Embolus of superior mesenteric artery at its origin. Intima of artery at this place is destroyed by atheroma.

HALIPRÈ.—Man, old. Entered in collapse and died before examination was made.

Autopsy.—Small intestine distended and turgid, as if strangulated. Mucosa eroded. Wall of gut crepitated between the fingers. Aorta atheromatous; superior mesenteric artery completely obliterated.

HANDFORD.—Forty-one years (sex not given). For twelve weeks marked jaundice, then sudden, severe pain in abdomen. Hematemesis and melena. Rapid loss of strength and death in twenty-four hours.

Autopsy.—Jaundice caused by cancer of head of pancreas. Portal vein inside the liver filled with purulent material, that outside the liver by decolorized blood clot. Mesenteric veins contain recent clots. Interstitial hemorrhage of gut wall involving all layers. Thrombus several days old in vena cava near liver.

HAMILTON.—Man, 68 years. Eighteen years before had an attack of jaundice. For four days, indefinite abdominal pain, more marked on left, and followed by diffuse pain over whole abdomen, increasing in severity. Marked peristalsis and distension. General tenderness, especially in cecal region. Slight flatus and a little blood per anum. Frequent foul-smelling vomiting. Pulse small; temperature slightly increased. No operation, because of poor condition.

Autopsy.—Slight amount of bloody fluid in cavity. All small intestine dark green, shiny and dilated. Colon only slightly congested. In upper part of superior mesenteric vein, pale, obliterated thrombus, reaching into portal vein, which it incompletely fills. Splenic vein free. Inferior mesenteric vein filled by dark, recent thrombi. Arteries free. Atheroma of abdominal aorta. Dilatation of heart, with thrombus in auricle.

HEGAR.—Woman, 51 years. Considerable time before, myoma of uterus removed. Sudden severe, colicky pain in abdomen, accompanied with diarrhea, which later on was bloody. This ceased in a few days. Pulmonary embolus and death on the tenth day.

Autopsy.—A mural obdurating thrombus at origin of inferior mesenteric artery. Mucosa of descending colon, sigmoid flexure and rectum reddened and containing discrete, large hemorrhagic effusions. Intestinal contents not bloody.

HILTON-FAGGE.—Woman, 35 years. As a child had abscess in lumbar region. After delivery thrombosis of left and later of right crural veins. Three weeks later diarrhea; one week after this, sudden violent abdominal pain and vomiting. Pain paroxysmal in character, never wholly remitting. Abdomen flaccid, soft, with no tenderness or mass to be felt. Vomitus viscid and blood-stained. Collapse and death soon after onset of pain.

Autopsy.—Four inches from end of duodenum to about middle of intestine the color is deep purplish-black. Edges sharply marked off. Injection extends a little way into mesentery. No peritonitis. Gut wall edematous and contains thin, red fluid contents. No distension of affected bowel. Clot

in mesenteric veins extending up to division of portal. Thrombi in femorals. Heart normal.

HIRTZ AND JOSUÉ.—Woman, 33 years. Three weeks ago noticed belly growing bigger, quickly at first, then more slowly. Eight days later began to have attacks of pain in dorsal and lumbar regions. Several attacks of epistaxis and weakness. Has edema of legs and ascitic fluid in abdomen, with collateral dilatation of subcutaneous abdominal veins. Liver dullness normal. Spleen enlarged. Pulmonic second sound accentuated. Medium-sized goiter. Pulse 102; temperature 37.5 C. Urinary and vaginal examinations negative. No blood in stools or vomitus. Three days after entrance, several attacks of bilious vomiting, with very violent pain in abdomen. Death two days later in coma.

Autopsy.—Large amount of serous fluid in cavity. Middle of small intestine, for 50 cm., red-wine colored, rigid and thickened. Contains sero-hemorrhagic fluid. Several pale areas in wall of involved portion, which is over 1 cm. thick. Portal trunk changed to a rigid tube and thrombosed. Mesenteric veins obliterated down to intestinal insertion. Spleen enlarged and infarcted. Heart negative.

HOWSE.—Woman, 48 years. Two attacks of pain in abdomen several months ago. Has been dissipated. Diarrhea, with coffee-ground stools at times. Sudden severe pains in right hypochondrium, lasting but a short time. Attack soon followed by profuse vomiting, not bloody. This lasted till death, three weeks (?) later. During this time had gangrene of left foot, for which leg was amputated above the knee. Abdomen was distended. Temperature 99 to 102 F.

Autopsy.—Main trunk of superior mesenteric artery stopped by firm thrombus extending back into aorta. Aorta healthy above. Extended ulcerative process of the mucosa of the last part of small intestine and first part of ascending colon. No enlargement of Peyer's patches. Fistulous openings between several coils of small intestine. Several branches of superior mesenteric artery closed at their ends by thrombi.

JASTROWITZ.—Man, 31 years. Lues, splenic tumor, enlarged liver. No ascites. Sudden bloody vomitus and stools, jaundice and fever; hematuria; collapse and death.

Autopsy.—Large extravasation of blood into mesentery and intestine. Portal vein filled by a dark, brown-red thrombus, which is continued into its branches. Gumma of liver, compressing the portal vein.

JOHST.—Woman, 33 years. Always well. Two years before had pain in region of left rib margin on exertion and on eating. No vomiting. At same time belly was distended and sensitive to pressure. Stools regular except during the severe pain. One-half year later, sensitiveness increased in left hypogastrium, with slight swelling there. This grew larger during

next few months, but has not done so of late. One year later had pain as before, and was delivered of a well-developed child, dead, at term. Since this has had severe general abdominal pain. Anorexia and thirst. Frequent vomiting. Stools till entrance regular; has seen no blood. Since delivery there has been fever, and urine has been small in amount. Abdomen distended. Visible peristalsis below navel. General abdominal tenderness. Tympany above, dull tympany below. Spleen enlarged. Liver dullness not percussible below. Lungs negative. Urine by catheter, contains slight amount of indican, slight trace of albumin. Clear, blood-stained fluid withdrawn from abdomen by aspiration. Looks very sick. Temperature 37.2 C.; pulse 60, regular, hard; hemoglobin 90 per cent.; leucocytes, 1 to 136. Death on second day following entrance.

Autopsy.—On opening abdomen, dark blue coils lie below navel region. Lower two feet of ileum and upper part of jejunum normal. Sharp demarcation at either end. Walled-off pus pocket between spleen and diaphragm. Wall of infarcted intestine thickened; it contains small amount of dark bloody fluid. Dark red and brown clots in branches of mesenteric vein. Following this up, the portal vein is found completely thrombosed at origin of splenic vein.

JÜRGENS.—Man, 27 years. Symptoms of heart failure. Eighteen days before death, sudden paralysis of both legs. This was somewhat better, when he had sudden pain in abdomen, incontinence of urine and feces, distension and tenderness of abdomen, constipation. Just before death vomited bloody material. Irregular pulse. Urine contains uric acid crystals and a slight amount of albumin. Collapse and death on same day as advent of abdominal pain.

Autopsy.—Mitral stenosis and insufficiency. Thrombus in left heart. Slight amount of turbid, bloody fluid in cavity. Intestinal coils, smooth, shiny, violet-colored, with ecchymoses. Same changes in large intestine. Splenic and renal infarcts. Embolus of abdominal aorta and inferior mesenteric artery. Origin of superior mesenteric artery free, its branches not being investigated. Clot in aorta also probably closed superior mesenteric artery.

KARCHER.—Woman, 41 years. Severe heart failure, with mitral stenosis. Embolus of popliteal artery. Dyspnea and palpitation on exertion. Pain in right inguinal region. Slight constipation. Copious intestinal hemorrhage, with severe, sudden, colicky pain in abdomen, localized on the left below the umbilicus. Collapse. Distended abdomen, tender on pressure. Liver dullness normal. Trace of albumin in urine. Accompanying abdominal pain, had severe pain in left leg. Next day abdominal pain gone. Two weeks later another attack of colic and vomiting. No blood in stools. Amputation of leg for gangrene of foot. Death two months after first attack.

Autopsy.—Mitral stenosis and insufficiency. Aortic and tricuspid stenosis. Pulmonary, renal and splenic infarct. Embolus of left profunda femoris artery. Dilatation of heart. Thrombi in right and left auricles. Slight amount of free fluid in abdominal cavity. Superior mesenteric artery closed at its origin by grayish-red adherent obturating thrombus. Left half of pancreas bulging and contains 10 c.c. of pus. An opening in the superior mesenteric artery communicates with this abscess cavity. Hematochromatoses of jejunum. Mucous membrane of lower ileum reddened. Karcher says that the colica sinistra artery did all the work, since he was unable to find any abnormal anastomoses, though the disease process was two months old.

KAUFMANN.—Woman, 80 years. Brain tumor or abscess. Attack lasted few hours, with colicky pain in abdomen.

Autopsy.—Thrombus in left ventricle. Laminated embolus in superior mesenteric artery. With exception of duodenum whole small intestine, ascending and transverse colon purple-colored. No peritonitis. Contents of small intestine thin, slightly reddish. Canalized thrombus of aorta. Encephalomalacia. Thrombus of vertebral arteries.

KAUFMANN.—Woman, 62 years. For a long time attacks of pain in abdomen, with intervals of good health. Then attack of vomiting and diarrhea. Stools were bloody, vomiting became foul smelling, then fecal. Obstipation after first few days. General pains in abdomen, especially on motion. Abdomen painful on pressure. Urine contained blood and albumin. Pulse too poor to warrant operation. Temperature not changed. Soon died.

Autopsy.—Abdomen distended. Serosa of several coils dull, brown, red. Adhesions between coils. A small perforation in ileum. General peritonitis. Necrosis of all small intestine except upper part of jejunum. Necrosis sharply marked off from normal gut. Intestinal wall in places very thin. Veins full. Contents of intestine yellowish-green, turbid fluid. Necrosis of mesenteric fat. Glands swollen. Hemorrhages between the layers of the mesentery. Embolus in superior mesenteric artery at origin of colica media. Intima not altered. Small globular thrombus in left auricle. Atheroma of aorta and its larger branches. Renal infarcts.

KENDAL-FRANKS.—Man, 48 years. In hospital for large leg ulcer, with varicose veins. Frequently constipated. Two months later abdominal pain at umbilicus, radiating from it. Persistent vomiting on the next day. No bowel movements nor gas after onset of pain.

Operation on Fifth Day.—Volvulus of one coil of small intestine in left hypochondrium. Mesentery of this portion thickened, its veins thrombosed. Gangrenous gut resected; end-to-end suture. Death on second day.

Autopsy.—Intestine below suture is becoming gangrenous. Old, firm blood clot in portal vein, propagated to smaller veins of mesentery. Only a minute channel left beside portal vein clot. Author considers volvulus secondary to the gangrene.

KILIANI.—Man (age not given). For twelve days pain in right hypochondrium and diarrhea on first day. Later constipation. Pain continuous with colicky exacerbations. Abdomen tense, very tender and hard. No blood observed in stools. Heart action irregular. Diazo and Widal negative.

Operation on Third Day.—Diagnosis of peritonitis. Large part of ileum gangrenous, with one small perforation. Mesentery much thickened and inflamed. No pulse felt in large branches of mesenteric artery. Abdomen closed. Death a few hours after operation.

Autopsy.—Ten feet 6 inches of intestine gangrenous. Interstitial myocarditis. Thrombus in left ventricle. Branches of superior mesenteric contain red clots; inferior mesenteric closed at aortic origin.

KÖSTER.—Woman, 53 years. Five years before had apoplectic stroke, followed by right hemiplegia and aphasia. Eight days ago had severe headache, pain in left abdomen and obstipation, without vomiting. Abdomen very tender. Pulse irregular, vessel sclerotic. Remission of symptoms for a month when had sudden vomiting, severe pain in abdomen and died.

Autopsy.—Moderate amount of bloody fluid in cavity. Small intestine for 1.6 meters above cecum reddened with fibrin on serosa. No sharp line of demarcation. Veins easily seen. An organized pale gray clot in branch of superior mesenteric artery. Mitral stenosis.

KÖSTER.—Man, 31 years. Several years before, obstinate diarrhea, not bloody. Well since. Onset of sudden pain in region of bladder, radiating to cecal and umbilical regions, but soon becoming general. Vomiting and hiccough, increasing in severity. Obstipation; slight amount of bloody fluid followed enema; no gas. Abdomen distended with dullness in flanks and tenderness. Heart and lungs negative. Pulse 112, soft, regular. Trace of albumin in urine. Operation next day, followed by death.

Autopsy.—Dark, foul fluid in cavity. Intestines distended. Almost all of descending colon bluish-black. Sharp lines of demarcation. Rectum normal. Aorta and mesenteric arteries normal. Whole superior mesenteric vein thrombosed.

KÖSTER.—Man, 57 years. Entered April 1, 1897; died April 23, 1897. Always well till end of 1896, then poor appetite and belching after eating. No vomiting or pain; stools normal; gradual loss of weight and strength; pale; abdomen distended, not tender; marked ascites. Temperature 37 C. On second day sudden cyanosis and dyspnea. Collapse. Six liters of clear fluid withdrawn by aspiration. Death one hour later.

Autopsy.—Hemorrhagic infarction of 5 cm. of lower jejunum, without sharp line of demarcation. Mesenteric veins leaving this area contain dark red, easily separable thrombi. Superior mesenteric vein trunk free. Aorta and mesenteric arteries normal. Liver enlarged and cirrhotic; contains nodules of primary carcinoma. Heart pale and flabby. Author considers thrombus due to poor and impeded circulation, the hepatic cancer a side issue.

KÖSTER.—Woman, 40 years. Entered May 2, 1896; discharged May 18, 1896; re-entered Aug. 6, 1896; died Aug. 6, 1896. Well till typhoid, five months ago. Discharged well in two months. One month later, sudden abdominal pain and distension. Fecal vomiting. Abdomen very tender, especially to right of navel. Pulse 100. Repeated enemata, came back unchanged.

Operation.—Intestines much distended and injected, with considerable fluid in cavity. The lower part of ileum was sharply bent and closed by adhesions to omentum and to other coils. Bands cut and adhesions broken up. On pressure over a swelling on posterior abdominal wall there appeared some turbid fluid, apparently the contents of a broken down lymph gland. This was covered by an omental flap and cavity closed. Next day has spontaneous stool; vomited once. Discharged without symptoms in two weeks. Immediately after this she began to complain of burning and pain in epigastrium after eating. This steadily increased in severity. Much belching of gas and hiccough, but no vomiting. Had to take laxatives. On day before entrance to medical clinic had sudden severe pain in region of navel as if a band were stretched from navel to back. She passed stools and much gas. That evening began to vomit. Pulse strong; temperature normal. Urine contains no albumin; indican much increased. Abdomen distended; slightly tender in right iliac fossa and to right of navel. No dullness or resistance. Heart and lungs negative. Following movement of bowels by enema, pain and vomiting stopped. Twelve days later slight edema of both legs. This soon disappeared and patient was discharged. Well for next three weeks. Then sudden attack of vomiting and pain in belly, without any warning. Collapsed that afternoon; cold sweat; cyanosis; imperceptible pulse. Died one hour later.

Autopsy.—Small intestine lay as dark horizontal coils, surrounded by pale, large intestine on three sides. Slight amount of free fluid; peritoneum slightly injected. Infarcted intestine extends from just below end of duodenum to cecum. Wall thickened and doughy; contents bloody. Mesentery much thickened and infiltrated with blood; the veins filled with dark, loose thrombi. Portal vein normal. Author finds only possible origin of thrombosis in infection from broken down gland, and doubts this.

KÖLBING.—Man, 31 years. Sudden pain in right arm, which soon became red, swollen and dry. Two and one-half months later arm amputated. For several months has had disturbance of speech, which was sudden in onset. Now for several days had had bloody sputum. Abdomen negative. Normal temperature and pulse. Stuttering speech. Cardiac dullness increased on both sides. Systolic murmur over apex and pulmonary area. Posteriorly and inferiorly, right lung is dull, with bronchial breathing and snapping râles. Urine albuminous. On sixth day, yellowish diarrhea. Pain in abdomen. On ninth day diarrhea persists; very restless; general condition worse. On twelfth day much blood in stools. Compensation of heart broken for past twenty-five hours. Death.

Autopsy.—Multiple infarcts of lungs and spleen. Thrombosis of left internal carotid. Myocarditis and hypertrophy of heart. Thrombus in left ventricle. Beginning arteriosclerosis. Embolus of superior mesenteric artery, but coils supplied show only slight redness and swollen follicles.

KÖLBING.—Woman, 31 years. Three years ago, typhoid; otherwise always well. Parturition one month ago; discharged on ninth day. Four days ago after several days of diarrhea, had sudden pain in abdomen, increasing in severity. Vomiting; stool thin, no flatus, no blood. Belly gradually distended. Temperature normal till entrance, when it was 38.8 C. at night. Abdomen tympanitic over a visible coil; slightly tender. Mass of dilated intestine below liver, running across to left costal border. Vomitus has fecal smell. Heart and lungs negative. Pulse 125, regular, small.

Diagnosis.—Ileus from strangulation.

Operation.—One liter of clear ascitic fluid evacuated. Presenting coils much injected, not very distended. Cecum and descending colon collapsed; 50 cm. of upper part of jejunum dark bluish-red and gangrenous. Mesentery infiltrated and vessels thrombosed. Resection. Veins plugged; arteries spurt lively. Lower end of duodenum sewed up (because it was too short for anastomosis), and upper end of jejunum joined to stomach by anterior gastroenterostomy. On second day abdomen much distended, especially in region of stomach. Vomiting of bilious fluid. Gastric lavage gave relief. One week later abdomen again distended about stomach; much flatus passed. Right parotitis with fever. Two weeks later edema of dependent parts of whole body and labia minora. No albumin in urine. Intestinal tract negative. Good appetite. Edema gradually disappeared. Discharged well two months after operation.

KUSSMAUL.—Man, 26 years. Peri- and endocarditis; empyema. On fourteenth day sudden profuse bloody diarrhea. Tympany and subnormal temperature. Death in thirty-six hours.

Autopsy.—Trunk of superior mesenteric artery free. Embolus at origin of last jejunal artery, sending processes into finest arcades. Lowest jejunum and ileum dark, bloody red. Extravasation of blood between the layers of the mesentery. Capillary hemorrhages in intestinal wall. Bloody fluid in abdominal cavity. Necrotic areas in mucosa of intestine. Infarcts of kidneys and spleen.

LABBÉ.—Man, 65 years. Chronic cough for two years, night sweats and all the signs of phthisis. Six months later severe diarrhea and cold feet, followed by gangrene of toes. Right popliteal obliterated. Now has pain in abdomen, which is soft but tender. Constipated. Four days later violent abdominal pain, belly slightly retracted. Pulse 120. Sudden, abundant watery diarrhea. Feeble and exhausted. Died.

Autopsy.—Whole course of right femoral thrombosed. Clot also in vein. Subacute general peritonitis. Occluding thrombus in superior mesenteric artery just below its origin. Atheroma, in plaques, of mesenteric artery and its branches. Old thrombus in hepatic artery. Lungs show advanced tuberculosis; cavity at right apex. Heart slightly enlarged, otherwise not remarkable. General atheroma of arteries.

LANGERHANS.—Aortic insufficiency and stenosis.

Autopsy.—Old and recent infarcts of spleen and kidneys. Recent hemorrhagic infarct of cecum, and stenosis of jejunum from scar following embolic infarct. Emboli are in smallest arterial twigs.

LAVERAN.—Man, 41 years. Severe abdominal pain for a week, with obstinate vomiting. Abdomen slightly distended and very tender, especially in epigastrium. Bloody vomiting. Bowels moved only by enema. Motions contained blood. No fever. Rapid, small pulse. Death on second day.

Autopsy.—Old, firm gray clot in superior mesenteric artery. Fifty cm. of middle of small intestine shows hemorrhagic infarction. Infarction spleen and kidneys. Clot in left ventricle, extending into aorta, giving rise to emboli.

LEECH.—Man, 50 years. Dyspepsia for five or six months, accompanied by abdominal pain and constipation. Sudden severe pain, with obstipation, lasting five days, and relieved by purgatives. Five months later, still constipated, abdomen slightly distended; tympanitic except in left flank. Visible peristalsis in right iliac region. Rectal examination negative. Three days later, tongue foul; slight result from enema, with some gas. On the next day, after calomel, a copious movement, with blood and great abdominal pain. Frequent pulse; normal temperature. Death next day.

Autopsy.—Dark purple gut from eighteen inches below duodenum to within one foot of cecum, containing a small amount of dark fluid blood. Whole mesentery thickened, with veins

thrombosed. Some cirrhosis. No constricting band; no fecal matter in intestines. Slight chronic peritonitis.

LÉPINE.—Man, 40 years. Admitted for intense abdominal neuralgia. For past five years has had intensely painful abdominal crises, with watery vomiting, coming on at long intervals. These have become more and more frequent and violent, till they now occur nearly every day. Anorexia. Slight edema of feet. No motor or sensory trouble with legs. Pain in hypogastrium. Marked tenderness. Abdomen tympanitic. No diarrhea. Increasing respiration. Pulse 120. Was found beside his bed, collapsed. Died rapidly.

Autopsy.—Abundant hemorrhage in pelvis. Intestine contains more than 1 liter of thin blood. Sixty cm. below duodenum to cecal valve, mucous membrane shows hemorrhagic infiltration in spots; no ulcer. Many calcified glands in mesentery. One of these glands presses on a branch of the superior mesenteric artery, which is here blocked by an old clot. Main trunk of the artery free. Other organs normal. Author considers clot and pains due to compression by this gland. There was no gangrene of intestine.

LEREBOULLET.—Man, 53 years. A long time ago, dysentery; later, endocarditis. Of late has had palpitation and dyspnea, which sent him to hospital. Here had abundant gastrointestinal hemorrhage, causing syncope. Diagnosis at that time was mitral insufficiency and stenosis, with intestinal hemorrhages and hematemesis. Better in three months. Eight months later same sort of an attack. Bloody vomitus and stools. Debility and syncope. Moderate distension of abdomen. No spasm or tenderness. Lungs, stomach, liver and intestines all negative. Double heart murmur. Pulses equal. No atheroma of radials. Bloody stools and vomiting gradually stopped. Markedly better on the eighth day. Discharged well.

LILIENTHAL.—Man, 50 years. Often has diarrhea. Slight dyspnea. Complains now of dyspnea, diarrhea and abdominal pain, which has been present four weeks. Pain in right iliac fossa, now radiates over whole abdomen. Loss of appetite, thirst and nausea. Liver not enlarged. Resistance all over epigastrium. No blood in diarrhea. Heart not enlarged; pulmonic second sound accentuated. Pulse regular, weak, small. Some atheroma of artery. Collapsed on evening of entrance. Area of dullness in hypogastrium at this time. One bloody dejection. Moribund.

Operation.—Gut deeply blood stained and its vessels seemed to be filled with clots. Blood in lumen.

Autopsy.—Old tuberculosis at apex of lungs. Hypostatic pneumonia; myocarditis; duodenum normal. Rest of small intestine down to cecum, dark colored. Sharp line of demarcation, both above and below. In superior mesenteric

vein, just above its bifurcation, is a thrombus which extends into minute subdivisions of vein.

LOBERT.—Boy, 17 years. Severe intestinal catarrh. Pain in abdomen. Later intestinal hemorrhages. Death.

Autopsy.—Heart normal; aorta narrow with thin wall. Brownish red turbid fluid in cavity. Coils, dark red. Jejunum and ileum show hemorrhagic infiltration of their wall, with fibrin deposits. Sharp lines of demarcation. Bloody fluid contents. Mucosa dark red, edematous and in spots diphtheritic. Mesenteric glands enlarged; arteries free; roots of mesenteric veins closed by firm, dark red thrombi. These extend into portal vein. Spleen much enlarged. Malaria cachexia.

LOCHTE.—Man, 51 years. Under treatment for a long time for arteriosclerosis, bronchitis and emphysema. Sudden severe pain in the abdomen on the right, below. Collapse. An inguinal hernia was present, so a diagnosis of internal strangulation was made. Died in sixteen hours.

Autopsy.—Beginning necrosis of small intestine and gangrene. Complete closure of superior mesenteric artery by an embolus 5 cm. long coming from a mural thrombus in the left heart.

LORENZ.—Man, 35 years. Two and a half months' story of gradually increasing multiple neuritis following exposure to cold. Gradually increasing paralysis, complicated with diarrhea. Urine contains much acetone; no albumin; increased indoxyl. A month later, vomiting, diarrhea, pain in abdomen and death.

Autopsy.—Thickening of walls of coronaries; 100 c.c. green, thick pus in abdomen. Small intestine slightly distended, with greenish fluid contents. Areas of losses of substance in jejunum corresponding to arterial branches in mesentery, with thickened walls in spots of milky color, which almost occlude the lumen.

LOTHROP.—Man, 35 years. Sudden severe pain in abdomen. Marked tenderness. Bloody diarrhea and vomiting. Temperature slightly raised. Collapse and death. Duration, three days.

Autopsy.—Slight amount of clear fluid in cavity. Coils of small intestine chocolate-brown colored, lusterless. Jejunum and ileum infarcted without sharp line of demarcation. Several branches of superior mesenteric artery thrombosed. Embolus near origin of colica media. Contents of intestine dark brown, semi-solid. Two old splenic infarcts. Cardiac hypertrophy and dilatation with chronic endocarditis of mitral and aortic valves.

LOTHROP.—(Age and sex not given). Moribund at entrance. History unknown.

Autopsy.—Infarction of ten feet of ileum. No peritonitis.

Embolus in superior mesenteric artery near the ileocolic artery. Chronic endocarditis.

LOTHROP.—Man, 40 years. Sudden onset three days before entrance with vomiting and pain. Bloody diarrhea after two days. Traces of blood in vomitus. General condition bad. Diagnosis not established.

Operation.—Slight amount of serous fluid in cavity. All visible intestinal coils of a chocolate-brown color. No obstructing cause found. Death in twelve hours after operation.

Autopsy.—Lesion of mitral valve. Embolus in superior mesenteric artery near ileocolic. Infarction of part of the ileum. Beginning peritonitis.

LYCETT.—Male child, 1 month; breast fed. Maternal syphilis. Mother said child was well till 10 a. m., when he became restless, drawing up knees and straining. Was collapsed on admission, with peritoneal facies. Abdomen distended; dull in dependent portions. Two dejecta without blood. Vomiting, later becoming fecal. Died in a few hours.

Autopsy.—Cavity contained eight ounces of dark, bloody fluid. General peritonitis absent, although there were four inches of small intestine gangrenous and perforated. Author says there was obstruction to arterial supply by syphilitic arteritis. (Did not demonstrate it.)

MADER.—Woman, 35 years. For two months headache and repeated chills. Cough, pain in side, edema of feet, frequent vomiting, increasing pallor. Temperature except at chill, normal or subnormal. Lungs negative. Systolic cardiac murmur, regular action, pulmonic second sound not accentuated. Urine moderately albuminous, with a few casts. Blood cultures negative. On tenth day, during chill, severe pain in abdomen; hic-cough. Vomited; four bloody dejecta. Death five days later, with increasing weakness, slight jaundice; abdomen always very tender.

Autopsy.—Mitral endocarditis; vegetation on aortic arch. Liver enlarged. Spleen enlarged, with large infarcts. All small intestine grayish red with fibrin deposits. Superior mesenteric artery thrombosed.

MAYLARD.—Woman, 26 years. Gastrojejunostomy for symptoms of pyloric obstruction. After operation, extreme restlessness and pain in abdomen. No movements of bowels. No vomiting. Distension of abdomen shortly before death on fourth day.

Autopsy (incomplete).—Last three feet of ileum involved. Thrombosis of mesenteric veins.

MAYLARD.—Woman, 28 years. Thyroidectomy of left half of gland. After operation, pain in abdomen without distension or tenderness. One bloody stool. No vomiting. Later distension and death on third day.

Autopsy (incomplete).—Whole ileum black, containing blood. Mesenteric veins thrombosed.

MCCARTY.—Man, 77 years. Attack of influenza. Six days later out of doors. On reaching home, had severe pain in right hypogastrium. Admitted on sixth day of illness, with diagnosis of ileus. Abdomen not tense or tender. Outline of distended coils could be seen. Dullness in both flanks. No bowel movements or gas after onset of pain. Vomitus bile-stained. Pale and collapsed. Bilateral inguinal herniæ.

Operation.—Necrosis of lower part of ileum. Peritonitis from perforation. Artificial anus made. Death in ten hours after operation.

Autopsy.—Marked atheroma of aorta, with loss of substance in several places. Thrombosis and embolus of several branches of the superior mesenteric artery.

MCWEENY.—Girl. Erysipelas following opening of cervical abscess. Few days later, violent pain in stomach, and death in a few hours.

Autopsy.—Thrombosis of superior mesenteric vein, with dilatation of tributaries and intense congestion of the portion of intestine from which the veins spring. Bowel contained about one quart of blood.

MENGIN.—Man, 54 years. Ten years ago acute articular rheumatism, complicated by endocarditis. There remains from this a murmur at base of heart replacing first sound. Five days before entrance, bloody diarrhea and syncope. Urine red. No increase of temperature. Collapsed on entrance. Stools like liquid tar. Abdomen distended. Lungs, peripheral and hemorrhoidal veins all negative. Improvement during subsequent days, and discharged well on the fourteenth day.

MERKEL.—Man, 83 years. In hospital for incontinence of urine. After two weeks complained of thirst and pain in belly. Fever. No tenderness in abdomen except in region of bladder. Obstipation. Pulse small and frequent. Coma, delirium, and death three weeks after entrance.

Autopsy.—General arteriosclerosis. Globular thrombus and pedunculated vegetation in left ventricle. Thin purulent fluid in pelvis. About two feet above cecum one inch of ileum has thickened wall, infiltrated with blood. Mucosa dark, bluish-red. Small intestine contains a large amount of fluid blood. Adherent thrombus in last iliac artery, propagated into the finest branches.

MEYER.—Woman, 65 years. General arteriosclerosis. Complains of headache, pain in chest, palpitation and irregular movements of bowels. For two years has been under treatment for anemia. No tenderness of abdomen. Lungs show bronchitis, with slight emphysema. Unexplained pyrexia. Death from increasing weakness and high temperature in seven months.

Autopsy.—Peritonitis. General necrosis of intestinal wall. Multiple emboli of intestinal vessels. Fatty degeneration of heart. Atheroma of aorta. Softened infarct in spleen and kidney. Nephritis.

MICHAELIS.—Man, 50 years. Recurrent mitral endocarditis, myocarditis, nephritis, gastritis. Small punctiform hemorrhages in small intestine. Mesenteric vessels free; 300 c.c. yellowish red fluid in cavity. Emboli are in subserous layers of intestine, and only here.

MONRO AND WORKMAN.—Man, 18 years. Two weeks previously, sudden giddiness, pain in head and abdomen. Fever, cough, pain in side, constipation, night sweats, anorexia. Temperature 104, pulse 96, respiration 28. Pneumococci in sputum. No Widal. Urine negative. Abdomen very slightly tender. Heart negative. Had several bloody stools, one containing a slough, apparently from gut. One-half hour after this had crampy pains in abdomen; felt faint; subnormal temperature. Two days later, severe abdominal pain all over abdomen; not affected by pressure. Moderate distension. Vomiting. One bloody stool. Death six and one-half weeks after onset.

Autopsy.—Twenty inches of ileum, cecum and ascending colon show intense venous engorgement, almost gangrenous. Arteries empty; veins thrombosed. Peyer's patches sloughed. Many ulcers in cecum. No perforation. Spleen and mesenteric glands enlarged.

Moos.—Man, 19 years. Acute articular rheumatism for past eighteen days, accompanied by pericarditis and endocarditis. Spots of ecchymoses over skin of chest. Embolus of arteria centralis retinae and left popliteal. Several days later colicky, general abdominal pain, accompanied by tympanites. No tenderness. Twelve hours after pain, severe diarrhea, first tarry, then clear blood. Greenish vomiting. Subnormal temperature. Recovery. Intestinal hemorrhages continued, with decreasing frequency, for eight weeks.

MOYES.—Man, 39 years. In bed eighteen weeks with cough; occasional hemoptysis, short breath, dropsy of lower limbs and weakness. Presystolic murmur at apex. Rales in lungs. Urine scanty, high specific gravity, no albumin. Sudden pain in abdomen, about costal margin, especially on left. Tenderness on pressure over epigastrium. Pain continuous with colicky exacerbations. Diarrhea on the fourth day; worse on fifth and sixth. Contained no blood. Slight vomiting on fifth day of thin, fluid blood. Temperature normal. Collapse and death on the sixth day.

Autopsy.—Thrombus in superior mesenteric artery at origin of colica dextra. Acute peritonitis. Infarct of lower jejunum, ileum and ascending colon sharply marked off from normal transverse colon. Intestinal contents bloody. Mucosa of af-

fectured area infiltrated with blood and friable. Mesentery dark red. Heart enlarged with stenosis and roughening of mitral valve.

MUNRO.—Man, 51 years. Three weeks before entrance, while lifting a heavy bar, felt a tearing sensation in lower abdomen followed by pain. That night, and again on following morning, passed blood by bowel. Then obstipation and colicky pain. Vomitus fecal in character. Marked distension of abdomen, with pain in region of transverse colon. Cecum evident as a tumor. Mass in left iliac fossa size of an orange. Subnormal temperature and pallor.

Operation on Second Day.—Mass in left side proved to be a decolorized infarct of sigmoid. Two other infarcts in mesentery of small intestine. Ascending, transverse and descending colon dark and much distended, with thinned walls. Small intestine red and injected. Death in twenty-four hours.

NORDENFELT.—Man, 57 years. Anorexia for four months. Belching. Loss of weight and increasing languor. Distension of abdomen; tenderness; no pain. Later icterus. Marked ascites. Veins of abdominal wall much dilated. Sudden cyanosis and pulmonary edema. Collapse and death.

Autopsy.—One coil of intestine livid and much dilated. Intestinal mucosa gray-black; no ulcerations. No sharp line of demarcation. Contents blackish-brown. Involved area is 60 cm. below duodenum. Corresponding veins are full of recent, easily separable, almost black thrombi. Cirrhosis of liver. Atheroma of aorta; no lesions of heart.

OPPOLZER.—Man, 50 years. Mitral insufficiency. Short breath, palpitation, slight ascites. Off and on, diarrhea. While leaving hospital was seized with sudden severe pain in whole abdomen; marked distension; pain colicky; vomiting. Very copious painful bloody movements. Abdomen tympanitic above, dull below. Just before death the region which was dull became tympanitic. Heart enlarged; systolic murmur at apex. Pulmonic second sound accentuated. Bronchitis on left. Pulse 90 to 95, respiration 44. Urine contained a trace of albumin; no casts. Collapsed after pain. Died in three days.

Autopsy.—Stenosis of mitral valve. Coagulum in left ventricle. Embolus two inches long in trunk of superior mesenteric artery. From end of duodenum to middle of transverse colon intestine of a brownish-red color. Mucosa soft and swollen. Hemorrhagic erosions in stomach. Soft clots in mesenteric veins. Clot in left ventricle gave rise to embolus.

OSLER.—Woman, 75 years. Sudden severe pain in abdomen, not definitely localized. Distension and frequent vomiting. Abdomen tender on pressure. Marked diarrhea at first, soon giving way to obstipation. Death.

Autopsy.—Warty heart vegetations. Brownish-yellow em-

bolus in superior mesenteric artery. Infarct of small intestine, with exception of first foot of jejunum and last six inches of ileum.

OSLER.—Man, 40 years. Sudden severe pain in abdomen. Became faint, fell to ground and vomited. Pain general. Severe diarrhea, at times blood-tinged. Later tympanites. Vomiting persisted for a week, at end of which time he died.

Autopsy.—Superior mesenteric artery closed by clot coming from aortic aneurism at diaphragm, from the wall of which the mesenteric artery takes origin.

OSLER.—Woman, 55 years. Nausea and vomiting for a week. Pain in abdomen and tympanites. Incessant vomiting, becoming fecal at end.

Autopsy.—Great congestion of jejunum and ileum, with swelling and infiltration of wall. Superior mesenteric artery blocked at orifice by firm thrombus.

OTT.—Man, 50 years. Alcoholic. Weakness of left leg and arm. Denies lues. Five days later, severe pain in hypogastrium. No diarrhea. Enema brought away a large amount of clear, dark blood. This was followed in a half-hour by more blood. Pulse scarcely palpable. No source of hemorrhage found in rectum. General arteriosclerosis. Heart normal. Urine negative. Five days later, no more blood in stools. Motion of left leg has returned. Arm a little better. Discharged relieved.

OTT.—Man, 42 years. Thirteen years ago, typhoid. Eight years ago, pleurisy. For years difficulty in breathing. Mitral insufficiency, chronic bronchitis, chronic nephritis and emphysema. Swelling of feet and distension of abdomen. Free fluid in abdomen. Sudden chill with bilious vomiting and pain in abdomen. Radial pulse disappeared. Heart beat 156, rectal temperature 40 C. That night diarrheal stool containing $\frac{1}{4}$ liter of blood and slime. Signs of hemorrhage infarct of lung. Later, no more blood. Discharged relieved, seven weeks after entrance.

PACKARD.—Man, 75 years. For three weeks pain in abdomen. Suddenly fell to floor with agonizing pain in epigastrium. Vomited; collapsed. Liver and spleen negative. Resistance and tenderness in epigastrium. Lungs negative; systolic murmur over apex and aortic area. Urine contained albumin and casts. Temperature 95 F., pulse imperceptible. Heart beat 66 per minute. Radials calcified. Respiration dyspneic. Died in twelve hours.

Autopsy.—Ruptured aortic aneurism. Lower ileum shows injection but no gangrene. Here the mesentery near its intestinal attachment is puckered in two large areas. Above this the large arterial trunks running down in the mesentery were united by large, apparently compensatorily dilated trunks, forming abnormally wide anastomoses. In the areas of cica-

tricial tissue, and between them and the intestine, no vessels were visible. Intestinal condition evidently many weeks old.

PARENSKI.—Woman, 60 years. In youth typhoid and intermittent acute articular rheumatism. Five months before death attack of left hemiplegia. Day before death distension of abdomen and obstipation.

Autopsy.—Atheroma of aorta. Recent infarcts of spleen and kidneys. Mucosa of small intestine hyperemic, swollen, with numerous ecchymoses. Wall thickened. Numerous ulcers. Contents thin, bloody.

PARENSKI.—Man, 67 years. No clinical data relating to abdomen. Had frozen ears and fingers. Became unconscious and died.

Autopsy.—Aortic aneurism. Areas of softening in brain. Three hemorrhagic infarcts of the intestine, one in the jejunum and two in the ileum. Circumscribed peritonitis around the involved areas. Infarcts averaged two feet each. Ring-shaped ulcers in mucosa of involved intestine. Boundaries of infarction sharply marked off.

PARENSKI.—Woman, 90 years. No data as regards previous illnesses. In hospital for abscess on inside of right thigh, size of fist. Skin about abscess became gangrenous. Sudden unconsciousness. Small, rapid pulse. Distension of abdomen. Constipation. Death on second day.

Autopsy.—Atheroma of aorta, renal infarcts, mucosa of several coils of jejunum and cecum swollen and hyperemic. Several small ecchymoses and necrotic areas. Arteries supplying these parts filled with fibrinous clots.

PARENSKI.—Man, 67 years. For several years frequently in hospital for leg ulcers; then right leg swollen, tender and red, with lymphangitis extending up thigh. Illness began with a chill, followed by fever, weakness, loss of appetite and thirst. Diagnosis, erysipelas. Well in seven days, when had some colicky, abdominal pain, diarrhea, distension of abdomen. Pain increased by pressure. On ninth day pain grew worse and patient died of pulmonary edema.

Autopsy.—Clot in a branch of the superior mesenteric artery one inch long. Eight inches of small intestine dark red, almost wholly necrotic. Peritonitis. Atheroma of descending aorta. Fresh renal infarcts, with chronic interstitial nephritis. Pneumonia of upper left lobe.

PÉRON AND BEAUSSENAT.—Man, 48 years. Family history negative; previous history, never sick. Markedly alcoholic. Has tertiary syphilis. Ten days following a debauch, began to vomit. Had severe pain in abdomen and kidney region. Pain most marked in right iliac fossa. Abdomen retracted, tender, with spastic muscles. Bowels regular. No appetite. Vomits whatever he has taken. Pulse 70 to 80, temperature 38.4 C. External hemorrhoids. No albumin or sugar in urine.

Ten days later had tearing sensations in abdomen, accompanied by vomiting. Poor pulse, slight distension, peritoneal facies. On next day operation. One and one-half liters of ascitic fluid evacuated; a coil of jejunum blue colored. Death.

Autopsy.—Slight agglutination of intestinal coils; 100 cm. of jejunum, beginning 90 cm. below duodenum, shows ulcerated mucous membrane. Mesentery thickened. Both superior and inferior mesenteric veins plugged by recent thrombi. Portal and splenic veins thrombosed. Spleen enlarged.

PICQUÉ AND GRÉGOIRE.—Man, 47 years. Mentally degenerate. Had vomited for several weeks; then sudden increase of vomiting, distension of abdomen, with mass on left, which is dull and tender. No blood by rectum. Pulse 120; temperature 38 C. Urine slightly albuminous. Rectal examination negative. Laparotomy. Gangrene of intestine, but no stricture. Thrombo-phlebitic process of superior mesenteric vein, extending into portal.

PICQUÉ AND GRÉGOIRE.—Man, 49 years. Four days' story of obstipation which followed a diarrhea. Pain in epigastrium and vomiting. Abdomen not distended, but resistant. Liver dullness not increased. Temperature 38.8 C.; pulse 118. Heart and lungs negative. Urine albuminous, small in amount. Laparotomy. Jejunum black with thickened mesentery. Celiotomy. Death in twelve hours. Nothing definite found.

PIEPER.—Man, 38 years. For seventeen days acute articular rheumatism. On the eleventh day endocarditis. Twenty-four hours before death, profuse vomiting and bloody, foul-smelling stools, followed by colicky pains in abdomen. Pain not localized. Subnormal temperature. Death.

Autopsy.—Peritonitis. Hemorrhagic infarct of spleen. In the superior mesenteric artery an adherent, fibrous clot, filling the main trunk and a branch of the ascending duodenal artery. Small intestine and ascending colon infarcted. Mucosa swollen, dark red, with numerous capillary extravasations. Venous hyperemia. Hemorrhages in mesentery. Glands infiltrated. Fluid blood within intestine.

PILLIET.—Woman, 70 years. Sudden death. Abdomen distended.

Autopsy.—About 60 cm. of small intestine is dark bluish-red. Mucosa of altered portion gangrenous and of an opaque, brown color. Corresponding veins filled with red, partly disintegrated thrombi. Small arteries not dilated.

PILLIET.—Man, 72 years. Varicose veins in the legs. One day ago, while chopping wood, was seized with severe pain in the lower abdomen, accompanied by nausea and vomiting. Abdomen began to increase in size; very tender on pressure. No movement of bowels. Vomiting of coffee ground material. Death on the same day.

Autopsy.—Forty cm. of small intestine dark red, distended.

Mucosa friable, gangrenous. The corresponding mesentery hard, thickened. Contents of intestine, red fluid. Mesenteric veins thrombosed.

PINNER.—Man, 50 years. Sudden diarrhea, ceasing in a short time. Three days after this tenesmus, with passage of slight amount of fluid blood. Persistent vomiting, coincident with diarrhea. On the third day collapse with subnormal temperature. Died on the fifth day.

Autopsy.—Thrombosis of the inferior mesenteric artery at origin. The hepatic and splenic flexures, and especially the cecum, infarcted and necrotic. Rectum and sigmoid free.

PLÈS.—Man, 44 years. Chronic phthisis, hypertrophy of heart, mural aortic thrombus, embolic infarcts of spleen and kidneys, embolus of superior mesenteric arteries, hemorrhagic infarction of intestine with blood contents.

PONFICK.—Woman, 42 years. Resection of left elbow joint. Eleven days after operation, sudden pain over whole abdomen. On next day diarrhea; no blood. Temperature increased. Death two days after pain.

Autopsy.—Chronic recurring endocarditis. Emboli of trunk of superior mesenteric and celiac arteries. Small emboli at intestinal insertion of mesentery. Between these and embolus of main trunk the arteries are free. Wall of duodenum and jejunum slightly swollen. Hemorrhagic infarct of lower ileum with partial necrosis of the wall. Intestinal coils distended. Purulent peritonitis. Intestinal contents, fluid reddish-yellow.

PONFICK.—Man, 41 years. Diagnosis, typhoid (?). High fever and delirium. Two days before death, distension of the abdomen and general tenderness, especially in the right ileocecal region.

Autopsy.—Slight amount of free fluid in abdominal cavity. Mucosa of duodenum and jejunum edematous; contents not bloody. On one spot in the ileum round bullæ; contents of this portion of intestine is bloody. Fibrinous pericarditis. Endocarditis of aortic valve.

PUTNAM.—Woman, 35 years. Sudden copious diarrhea, followed by severe paroxymal pain, going from right hypochondrium across epigastrium, to left. Stools tarry. A few days later, severe, colicky, abdominal pain, not localized, followed by bile-stained vomiting. Distension of abdomen on second day. No visible peristalsis. Tenderness on pressure in right hypochondrium. Liver not enlarged. Death on the third day.

Autopsy.—Gangrene of last two feet of ileum, with mesentery thickened by extravasation of blood. Several hard lumps in mesentery, near its intestinal attachment. Blood vessels not investigated.

REITZENSTEIN.—Man, 39 years. For years has had cramps in legs. Once hematuria, from varicose veins in the bladder. Has had indefinite belly pains in past years. Varicose veins

of legs. Has been feeling poorly for several days. Sudden pain in abdomen; fever; diarrhea, later becoming bloody, stercoraceous and bloody vomiting. Heart slightly enlarged to the right. Temperature 38.7 C. Varicose veins of both legs. Abdomen slightly distended, with resistance in right side, about the ascending colon. Slight tenderness about umbilicus on following day. On third day collapse without pain. Bloody vomiting and diarrhea increased. Next day very anemic, pulse hardly palpable, 150. Vomiting and diarrhea stopped completely. Patient collapsed and died. Diagnosis, paralytic ileus from thrombosis of mesenteric veins.

Autopsy.—Confirms diagnosis. Four or five coils of small intestine gangrenous in jejunum and upper ileum. Veins dilated and full of clots. Transverse colon distended to the size of a man's arm. Obturating thrombus at junction of mesenteric and portal veins.

RIESMAN.—Fat old woman. History of pain in the abdomen, in its upper part, preceded by loss of appetite and cold in head. Pain was never very severe. Tenderness in epigastrium. Diarrhea. Vomiting, later becoming fecal. Pulse rapid and feeble. Temperature normal to subnormal. Signs of collapse. Sudden profuse intestinal hemorrhage. Became unconscious and died about a week after onset of severe symptoms.

Autopsy.—Hemorrhagic infarction of 33 cm. of small intestine and its mesentery from thrombosis of superior mesenteric vein. Localized, acute, fibrinous peritonitis. Atrophic cirrhosis of liver. Small spleen, with infarct. Mesenteric arteries free.

RIIS.—Man, 57 years. Strangulated hernia on the right side. Complained of enormous pain in lower belly. Seven hours after entrance the hernia was spontaneously reduced. Then distension, tympanites, several copious bloody dejecta, collapse and death.

Autopsy.—Dark, bloody fluid in cavity. Ascending colon and ileum show hemorrhagic ecchymosis. Chronic endocarditis of left ventricle, atheroma of aorta. Recent embolus in right renal artery. None found in superior mesentery.

RIIS.—Woman, 47 years. Aortic and tricuspid regurgitation, mitral stenosis. Ascites and edema of legs. Pain in lower abdomen, running from vulva to navel. Distension and tympanites. Frequent vomiting. Soon died.

Autopsy.—Endocarditis. Scleroses in aorta, bloody serum in cavity, bloody discoloration of all the layers of the intestine. Between the layers of the mesentery a hematoma. No closure of branches of superior mesenteric arteries could be found.

ROBSON.—Man, 20 years. Wound of abdomen by a dull file. Signs of internal hemorrhage. Vomiting of blood. Dullness in flanks. Liver dullness not obliterated. Pulse feeble, 190; temperature subnormal. Collapsed.

Operation.—Dark blood in abdomen and pelvis. Hemorrhagic effusion underneath peritoneum of small intestine. Bleeding comes from wound of trunk of superior mesenteric vein. The vein was ligatured. The abdominal cavity was washed out. Patient recovered.

ROLLESTON.—Man, age not given. Enlarged spleen, anemia, profuse hematemesis, ascites, thrombosis of left femoral vein. Fluid after tapping did not recur, but died in three months, with exhausting diarrhea.

Autopsy.—Clot in mesenteric vein, extending into portal and splenic veins.

ROUGHTON.—Man, 21 years. Caught between bumpers of cars. Compression of abdomen. Marked tenderness and rigidity. No wound of abdominal wall. Collapsed.

Operation.—Abdomen full of blood. Rupture of vasa intestini tenuis, close to origin from superior mesenteric artery. Proximal end thrombosed. Distal bleeding freely. Artery tied. Recovery.

SACHS.—Man, 32 years. Alcoholic. For a long time has had pains in abdomen. Sudden tearing pain in abdomen, with passage of blood. Vomiting fecal in character. Marked abdominal distension and spasm. Dullness in abdomen. After initial diarrhea, no movement of bowels.

Operation.—Much foul-smelling fluid in abdominal cavity, presenting coils, dark blue. Died soon after operation.

Autopsy.—Hemorrhagic gangrene of almost the whole small intestine. Glands enlarged. Thrombosis of the portal vein, which is continued into the superior mesenteric vein. Author considers thrombosis idiopathic.

SAXER.—Man, 50 years. Four months previously, amputation of left thigh for embolic gangrene of leg. Severe pain in abdomen and profuse diarrhea. Death in forty hours.

Autopsy.—Chronic fibrous endocarditis of mitral and aortic valves. Thrombus of left auricle. Dilatation and hypertrophy of heart. Embolus of superior mesenteric artery with beginning gangrene of nearly the whole small intestine. Thrombi in roots and trunk of superior mesenteric vein. Fibro purulent peritonitis. Thrombus of left femoral artery and vein. Right renal infarct. Author considers venous thrombi secondary to arterial embolism.

SCHLESINGER.—Man, 23 years. Rheumatism four years before. Now has endocarditis with murmur. Five days later spleen enlarged. No chill or distension of abdomen. High temperature and frequent stools. Was constipated before this. Tenesmus. One stool clear blood. Severe abdominal pain. Nausea. No blood or albumin in urine. Abdomen tender on left, half-way between umbilicus and anterior superior iliac spine. Got better.

Diagnosis.—Embolus of small branch of superior mesenteric artery. Splenic infarct.

SCHNITZLER.—Woman, 55 years. Pleurisy many years ago. Twenty years ago tumor excised from right breast. Constipated for five years. Right iritis with blindness. Glaucoma three years ago. For four years has had attacks of pain in abdomen. Pain confined to stomach and umbilical regions and followed meals. It was accompanied by vomiting not of a coffee-ground character. During last half-year has not vomited but pain has become spontaneous, colicky and more severe, and is situated in lower abdomen. Bowels have not moved during this time without enema or castor oil. Retention of urine during pain. Has taken Carlsbad cures without relief. Has acquired morphia habit. Slight icterus. Liver palpable below costal margin. No visible peristalsis. Abdomen soft above, several points of tenderness on pressure below. Stools normal, very foul. Urine negative. Indoxyl diminished. Heart and lungs negative. Temperature 37 C.; pulse 96. No atheroma of artery.

Diagnosis.—Gallstones, with adhesions giving obstruction.

Operation.—Twelve stones removed. Cystic and common ducts free. Slight adhesions about gall bladder. No hypertrophy or stenosis of gut. Operation had not the slightest effect on pain. Six weeks later, slight distension and one spontaneous, black stool. Death.

Autopsy.—Five hundred c.c. of bloody fluid in cavity. Intestine distended. Adhesions between coils. From end of duodenum to beginning of transverse colon intestine is discolored and suffused with blood. Copious hemorrhages, necroses and ulcers of intestinal mucosa. Superior and inferior mesenteric arteries completely closed at their origins. Atheromatous spots in ascending and descending aorta.

SIEVERS.—Woman, 56 years. Well till six years ago, when had vague pain in back and extremities, and difficult digestion. One-half year ago, cough and dyspnea. Swelling of lower extremities. Now all symptoms are worse. One short remission, then ascites, slight cyanosis, urine albuminous. Normal temperature, weak pulse. Sudden severe pain in belly while at stool. Vomiting. Abdomen distended with slight general tenderness. No fever; tenesmus; obstipation. Death in twenty-nine hours.

Autopsy.—Slight amount of serous fluid in left pleural cavity. Hypertrophy of left ventricle. Calcified plaques in arch and ascending aorta. Aneurism, size of fist in thoracic aorta, containing laminated thrombus. No trace of peritonitis or free liquid in cavity. A portion of jejunum, the whole ileum, cecum, ascending and transverse colon, dark red. Red fluid contents. Sharp demarcation below; not so above. Mucosa ecchymosed; no ulcers. Mesentery normal. Dark red, non-

adherent embolus in middle third of superior mesenteric artery. No infarction, however. Normally colored, firm feces in descending colon.

SMITH.—Man, 30 years. Cramps in stomach. Lightness in head, and shivering fits. Anemia. Swollen legs. Some months later, entered for severe abdominal pain, which had been present two weeks. Abdomen tensely distended, is very tender and contains free fluid. Diarrhea. Dry retching. Moderate pyrexia. Systolic murmur at base and apex. No albumin in urine. No leucocytosis. No enlargement of cutaneous veins. Collapsed and died a week after entrance.

Autopsy.—Cirrhosis of liver, thrombosis of portal vein, sudden extension of thrombus to gastric and mesenteric veins, peritonitis.

SPAETH.—Woman, 52 years. Several attacks of articular rheumatism and cardiac complication. Six years previous, apoplexy. Just after taking unpleasant, sharp-tasting soup, vomited, and had severe pain in stomach and abdomen. Violent diarrhea at onset, becoming watery, later consisting of clear blood. Death in two days. Poisoning suggested.

Autopsy.—Mitral insufficiency and stenosis. Cardiac hypertrophy. Small amount of bloody fluid in cavity. From ileocecal valve upward for a distance of $2\frac{1}{2}$ meters, dark red color. Contents of this and of the large intestine, bloody slime. No embolus could be found in superior mesenteric artery. Atrophic liver and shrunken kidneys. Area of softening in striate nucleus. No poison found.

SPIEGELBERG.—Man, 82 years. Three years previously epistaxis, followed by black stools for several days. Two months later, hematemesis for a week and blood in stools. Then edema and ascites. Tapped several times. Quick collapse after fourteenth tapping, and death.

Autopsy.—No lesion of heart. Intestines not remarkable. Portal vein much calcified. Process extends into splenic and mesenteric veins. An adherent, gray-red thrombus in superior mesenteric vein, continued into portal. Large arteries somewhat thickened. Aortic intima, friable.

SPRENGEL.—Man, 22 years. In hospital for gonorrhoea. In bed two weeks. Left leg swollen. Pain, first in stomach region, then deeper in abdomen, to right of bladder. For four days no stools or gas. Vomitus. Abdomen slightly distended. Dullness in dependent portions (ascites). No blood by rectum. Vomitus, reddish-brown, shows blood. Pulse small, 120 to 140.

Laparotomy.—Whole small intestine distended and dark blue. Mesenteric veins much distended and hard, as though thrombosed. Mesenteric glands enlarged. Died two hours after operation.

Autopsy.—Venous vessels of affected part thrombosed. Thrombi are closely adherent, of various colors and softened in

spots. Thrombus extends to the portal vein. Mesenteric arteries intact. Thrombi in pelvic and vesicle plexus of veins. Gonorrhoeal abscess of prostate.

SPRENGEL.—Man, 38 years. Twenty years ago, inflammation of bowels, lasting five weeks. Otherwise well. Seized while at work with severe abdominal pain. Vomited. These symptoms lasted three days, when they ceased. Bowels had not moved. On entrance not very sick. Pulse 80 to 84, regular. Respiration not increased. Temperature not given. Periodic, violent hiccough. Heart normal. Rectal examination negative. Abdomen symmetrically distended, with fullness in epigastrium. Intestinal murmurs present. Dullness in left lumbar region, nearly up to external border of rectus. Liver dullness only slightly diminished.

Diagnosis.—Intestinal obstruction in lower part of ileum. No general peritonitis.

Operation.—Free, reddish-brown fluid in cavity. Ten cm. of small intestine gangrenous. Good line of demarcation. This was excised and ends left in wound. Cavity drained. Veins found plugged. Good convalescence, only complicated at first by rather persistent hiccough. Five weeks later secondary operation for closure of fecal fistula. End-to-end suture without Murphy button. Good result. Recovery.

SPRENGEL.—Woman, 25 years. Over three years before, sudden spontaneous swelling of left arm. Thrombosis of subclavian vein. No inflammatory process in axillary glands. A few months later two attacks of profuse hematemesis. No melena.

Two and one-half years later, in hospital for swelling in right inguinal region of ten weeks' duration. Swelling slightly painful and hampers walking. On examination the mass is seen to occupy the right labia. It comes down on coughing and does not go wholly back, but is connected with a swelling above Poupart's ligament, which fluctuates.

Diagnosis.—Lymphangiectatic sac.

Operation.—Sac excised and communication with peritoneal cavity sewed up. Healing per primam. Up in three weeks. Then had sudden severe pain in region of stomach. Nothing found locally. No distension. Slight dullness of dependent parts of abdomen. Vomited once; no blood. Lungs negative. Pulse quickened, regular. Pulmonic second sound not accentuated. First sound at apex slightly roughened. Next day pain slightly less; no distension. Liver dullness normal. Kidneys not palpable. Temperature 38.8 C. On third day after onset of pain the temperature was normal. Abdomen dull except above or to the left, which was tympanitic. Resistance in umbilical region. Several reddish-brown fluid movements. Poor general condition.

Diagnosis.—Intestinal obstruction. Tubercular (?).

Operation.—Free, bloody fluid evacuated. Mass on left of

navel consisting of matted omentum and coils of intestine. About middle of small intestine, gangrenous area 38 to 50 cm. long. No invagination or peritonitis. Resection of more than 100 cm. of intestine. Murphy button. Death twenty hours after operation.

Autopsy.—Slightly patent foramen ovale. At junction of left subclavian and jugular veins an organized, obliterating thrombus. Spleen enlarged; vessels free. Peritoneum shows peculiar small pouches, which communicate with the general cavity by small openings. This condition is most marked in Douglas fossa. Trunk of mesenteric artery and vein free. An enlarged vein runs to hilus of liver furnishing collateral circulation for portal vein, which is thrombosed. Finer branches of mesenteric vein contain old thrombi.

STEFAN.—Case of acute ileus. Sero-sanguinolent fluid found in cavity at operation. A piece of intestine found gangrenous was resected. Soon died.

Autopsy showed thrombosis of portal and mesenteric veins.

STUBBS.—Man, 20 years. Sudden severe pain in abdomen, rapidly increasing in severity, and most marked about the navel. No tympanites. No tumor or pain on palpation. Nausea. Temperature and pulse normal. Obstipation in spite of cathartics. Another attack in twenty-four hours. Abdomen very tender this time. Death.

Autopsy.—Marked general cyanosis of body. Large amount of bloody serum in cavity. Hemorrhagic infarction and partial gangrene of small intestine. Mesenteric glands enlarged. Small dark tumor in mesentery proved to be embolus in large branch of superior mesenteric artery. Slight fibrinous peritonitis.

TALKE.—Man, 33 years. For four weeks has had pain in abdomen which originally followed an indiscretion in diet, but which now bears no relation to meals. Gastric lavage relieved pain. Stomach contents normal. Sudden severe pain in upper half of abdomen, which continued without remission for four days. No vomiting at first. Stools regular. Pain became colicky and spread over whole abdomen. On third day vomiting, first of stomach contents, later stercoraceous. On following day (fourth) fecal vomiting. Flatus, but no stools. Severe colicky pain over whole belly. Temperature normal. Abdomen not distended; soft and compressible. No tumor. Urine negative. Pulse small, regular. Next day abdomen slightly tender. Three dark red stools of foul odor. Hematemesis. Pain better and left clinic on fifth day showing only weakness. Re-entry two days later. Patient says that he had similar attack to present one three and one-half weeks before, at which time he had a hemorrhagic rash on legs. No pains in joints at this time. Rash lasted only a few days. Now his pulse is small and thready. The abdomen is not distended and

nowhere very sensitive to pressure. On the fingers, elbows, knees and feet are numberless cutaneous petechiæ, varying from size of pinhead to that of a grain of rice. The interphalangeal joints of hands and feet are slightly swollen and sensitive to pressure. Temperature 37.5 C. Subcutaneous injection of gelatin. Blood in stools. Condition remained about the same for three days, when he had sudden pain of piercing character in region of stomach. Collapse and death on following day.

Autopsy.—Numerous petechiæ in skin of extremities. Peculiar bluish-red coloring of anterior surface of thigh below iliac crest. Also large purple spots on anterior surface of left leg. Abdomen slightly retracted. Slight edema of legs. Parietal peritoneum slightly injected. Several coils of small intestine dark in spots by subserous infiltration. Serosa glistening. Liver not enlarged. Whole upper jejunum bluish-black. Mesenteric glands not enlarged. No thrombi in mesenteric veins, which are full. At line of closure of posterior and left aortic valves are two small red spots. Under endocardium of left ventricle a few hemorrhagic spots. Bluish-red spots over middle lobe of right lung, under serosa. A few drops of red serum in pelvis. In two large branches of superior mesenteric artery are gray, red, friable thrombi, almost filling vessels. In celiac axis and inferior mesenteric artery no thrombi. Pedunculated thrombus in thoracic aorta. A smaller one in aortic arch. Contents of lower ileum brown, bloody; of large intestine, grayish black. Mucosa of jejunum ulcerated, the ulcers running longitudinally for the most part. Mucosa of cecum anemic. Infarct of right kidney.

Anatomic Diagnosis.—Flat loss of substance of aortic intima with thrombi. Emboli in larger branches of superior mesenteric artery. Small gastric ulcers. Pseudomelanosis of gut wall. Diphtheritic enteritis with ulcerations. Right renal infarct.

TAYLOR.—Child, 5 years (girl). Sudden attack of pain in abdomen and vomiting. Death in eighteen hours.

Autopsy.—Abdomen distended. Dark fluid blood in cavity. Beginning eight or nine inches down jejunum, to within three inches of cecum, gut is deep red color, with fluid bloody contents. Mesenteric glands enlarged. Mesenteric artery and vein obliterated by thrombus mass.

THOMAS.—Old woman. Pain in abdomen, about umbilicus, for three days, following ptomain poisoning. Abdomen fairly rigid and tender on deep pressure a little to the right of the umbilicus. Occasional vomiting. Rapid, small pulse, subnormal temperature, abdominal facies. Sudden copious bloody dejection. Death in thirty-six hours.

Autopsy.—Thrombosis superior mesenteric vein.

TRÜBEL.—Woman, 74 years. Six weeks before, hemiplegia.

Sudden unconsciousness three days after. Abdomen not tender. Stools normal. Two weeks later, pain in left lower extremity, obstipation, death.

Autopsy.—Ascending and transverse colon dilated. Serosa of lower ileum and cecum shows fibro-purulent deposits. Slight hemorrhagic infarction of part of jejunum and whole ileum. Punctiform necroses in cecum. Mucosa of transverse colon edematous and ecchymosed. Loose clot near origin of superior mesenteric artery. Arterial wall thickened, especially above the thrombus. Intima grayish-yellow. Thrombus appears to have occurred gradually, without any symptoms or subjective trouble. Myocarditis and recent endocarditis of aortic valve.

TRÜBEL.—Woman, 55 years. Articular rheumatism. Palpitation, shortness of breath, pain in side and fever. Several days later sudden pain over whole abdomen. Obstipation. Tenderness on pressure. Next day collapse. Hiccough. Eructations and vomiting, containing no blood. Death. Diagnosis was correctly made.

Autopsy.—Slight amount of fluid in cavity. Peritoneum rough in spots and covered with fibrin. Wall of lower ileum swollen, its mucosa showing hemorrhagic infarction, and transverse yellow necrotic areas in spots. In upper part of large intestine black-red masses; in ileum, thin, fluid, bloody contents. Obturating, adherent clot in superior mesenteric artery just below second ileo-jejunal branch. Hemorrhagic infarct of lung. Chronic degeneration of heart muscle. Mitral stenosis. Recent endocarditis.

TRÜBEL.—Man, 71 years. Shortness of breath, dizziness, edema of lower extremities. Bilateral hydrothorax. Thrombosis of right femoral. After several months, sudden vomiting of slimy masses. Pain in epigastrium, obstipation, normal temperature. Later, vomiting of thin, reddish fluid. Death.

Autopsy.—Slight amount of bloody fluid in cavity. Intestinal coils dark red. In stomach, bloody contents, with swollen mucosa, showing several hemorrhages. Hemorrhagic infarction of mucosa of whole small intestine, ascending colon and right half of transverse colon. Adherent gray-red thrombus in trunk of superior mesenteric artery. Recent endocarditis. Chronic myocarditis.

TRÜBEL.—Woman, 37 years. Always sickly. For ten years palpitation and shortness of breath. Now has marked dyspnea and edema. Patient is subicteric. Sudden stabbing pain in region of navel. Later, clear red, bloody dejecta. Vomiting. Collapse. Next day, fever, constipation, frequent vomiting. On second day, eructations; meteorism and again bloody, fluid stools. Death. Diagnosis was correctly made.

Autopsy.—Bloody fluid in cavity. Whole small and large intestine contained bloody fluid. Mucosa of small intestine and of ascending and transverse colon shows bloody imbibition.

Duodenum normal. Dark, adherent thrombous masses in trunk of superior mesenteric artery. Insufficiency and stenosis of mitral and tricuspid valves.

TYSON AND LIVINGTON.—Woman, 66 years. Slight pain over liver, sickness, constipation with slight epigastric tenderness for two or three days. Temperature normal. March 7, better. Bowels moved two or three times, less flatulence; still sick, with vomit of green, watery color. March 8, worse vomiting, with abdomen distended; constipation. General condition much worse. Admitted Saturday, March 9. Constant vomiting of coffee-ground nature. Abdomen distended, and constipated for one week, except on the 7th, when bowels moved three times. Chest normal. Temperature 99.5 F.

Laparotomy done on eve of admission. Turbid sanious fluid in abdomen. Small bowel congested and on tracing it down, as indicated by the greater depth of color, it was found slightly fixed on the right iliac fossa. This was freed, and about a foot of fan-shaped, gangrenous bowel appeared, greatly thickened, black, lusterless, and in parts sloughy. The attached mesentery was in a similar condition. Recognizing the condition as one of thrombosis, the affected part was excised, well clear of the gangrene, and Murphy button, with sutures, was used. Considerable difficulty was had with the mesentery, owing to its thickened and rotten state, which extended back to its spinal attachment. Dead part removed to the extent of 22 inches, and the adjacent edges brought together on the flat, so as to give greater purchase to the sutures, than in the end-to-end suture. The abdomen was flushed out with hot sterile water and sewn up. Patient collapsed after operation, although she improved somewhat later and was able to retain some fluid nourishment (one-half ounce peptonized milk). She again became worse, in spite of repeated stimulation and saline injections, and died March 11, thirty-six hours after operation.

Autopsy.—Atheromatous erosion of descending aorta and blocking of a branch of superior mesenteric vessel. The button was in a good position and the bowel water tight. The mesentery was also well secured. The part of the gut excised was the ileum, one foot from junction with cecum. The greater part of it was gangrenous, the wall of which was so greatly thickened as to lessen the lumen, until almost complete obstruction ensued. The operation lasted just over an hour, lengthened by the difficulty of dealing with such rotten and swollen mesentery. It was only with great care that sutures could be tied tight enough to stop bleeding without cutting through.

VAN HOOK.—Man, 52 years. Vague, general pains in body, followed by sudden, severe abdominal pain, chiefly in right iliac fossa, and but little influenced by morphia. General tym-

panites. Extreme tenderness on pressure. Temperature 104; pulse 130.

Diagnosis.—Peritonitis following appendicitis.

Operation.—Abdomen contains thin, straw-colored fluid, with flakes of fibrin. Intestines injected. Arteries did not bleed. Death in forty-eight hours. No autopsy.

VIRCHOW.—Man, 40 years. History of previous constipation.

Autopsy.—Parietal thrombus of left heart. Endocarditis. Purpuric spots in mesentery. Mesenteric glands swollen. Veins full. Dark red adherent thrombus in superior mesenteric artery $2\frac{1}{2}$ inches from origin. Hyperemia and ecchymoses of involved intestine. Intestinal contents bloody. Much brownish-red fluid in cavity.

VIRCHOW.—Endocarditis of mitral and aortic valves. Superior mesenteric artery changed to a hard, firm cord, by a dry, obturating clot, extending into aorta. No changes in jejunum or ileum. Inflammatory hemoptysis from infarct of lung. Purulent clot of pulmonary vein and superior mesenteric artery. Small inflammatory area in heart muscle. Clots in left heart. Adherent thrombus in superior mesenteric artery below origin of branches of second order. The process extends into all the branches, ending in the fine twigs just before reaching the intestine. Intestine shows no noteworthy changes. Connective tissue of mesentery contains small abscesses. Mesenteric glands swollen and dark red. In this case the embolus came from a pulmonary vein.

WATSON.—Man, 61 years. Twelve days before had senile gangrene of foot, then sudden, severe, not localized, abdominal pain. Subnormal temperature. No other symptoms. Pain continued till death.

Autopsy.—Embolus of superior mesenteric artery. Infarct of whole small intestine, most marked in upper jejunum. Clot 4 cm. from aorta reaching almost to gut. General peritonitis. Thrombi in aorta. Embolus of femoral artery. Old and recent renal infarcts.

WATSON.—Man, 78 years. Chronic heart and kidney disease. Died without any symptoms pointing to abdomen. Observed for three days. Unconscious on entrance; regained it after a few hours. Normal temperature.

Autopsy.—Complete thrombosis of main trunk of superior mesenteric artery. Hemorrhagic infarction of intestine. Fifty cm. of ileum above cecum dark red and covered with fibrin in patches. Wall of intestine much thickened. Mucosa hemorrhagic, showing areas of superficial necrosis. Hemorrhagic infarct of right kidney; hydronephrosis of left. Chronic interstitial nephritis. Chronic leptomeningitis. Endarteritis of cerebral vessels. Acute endocarditis. Chronic pulmonary emphysema.

WELCH AND FLEXNER.—Man (age not given). Ill for two

years with diabetes and cirrhosis of liver. Had several profuse hemorrhages from stomach during six months preceding death. Thrombosis of right femoral vein. Abdomen became distended and tender one week before death, with severe pain in right hypochondrium. General tympanites, with obliteration of liver dullness. Died comatose.

Diagnosis.—Peritonitis from perforated gastric or duodenal ulcer.

Autopsy.—Free gas in cavity. Intestines moderately distended. Turbid bloody serum in cavity. No actual pus. Three areas of hemorrhagic infarction of jejunum. No perforation. Extensive thrombosis of mesenteric, splenic and portal veins. Over area of jejunum not infarcted, a collection of gas vesicles. Cultures showed *Bacillus aerogenes capsulatus*.

WESTHOFF.—Woman, 41 years. Acute articular rheumatism ten years ago, followed by mitral stenosis and insufficiency. For some time had ascites and edema of legs. Attack of sudden, colicky pain in abdomen, from which 10 liters of sero-hemorrhagic fluid were withdrawn by aspiration. Death in two days.

Autopsy.—Stenosis and insufficiency of mitral, insufficiency of tricuspid valves. Slight atheroma of aortic arch. Large amount of bloody fluid in cavity. Renal infarcts. Both superior and inferior mesenteric arteries thrombosed. General distension of small intestine. Serosa dull, dark red. Coils adherent, with fibrin. Mucosa red and dysenteric looking. Wall friable. Same condition in large intestine down to sigmoid.

WHIPPLE.—Man, 48 years. Bright's disease one year before entrance, albuminuria and retinitis. For three days nausea and pain in abdomen. For one day, retention of urine. Abdomen moderately distended, dull in dependent portions. Tender in hypogastrium. Constant vomiting of yellowish-green fluid. Obstipation. Distension increased and patient grew weaker.

Diagnosis.—Ileus.

Operation.—Chocolate-colored fluid in cavity. The presenting small intestine dark and distended, matted together toward the pelvis. Puncture of intestine. Collapse and death.

Autopsy.—Thirty-eight inches of ileum deep red in color, with thickened wall, in spots gangrenous. Branches of superior mesenteric artery thrombosed.

WITTMANN.—Girl, 14 years. Chorea, followed by polyarthriti rheumatica. This was complicated by endocarditis of mitral and aortic valves. There then occurred manifold dark reddish-blue spots in the skin, which were painful. Localized especially about the joints. Died.

Autopsy.—Embolie closure of both Sylvian arteries, with extensive softening of brain. Emboli of main branch of su-

perior mesenteric, left subclavian, crural and right popliteal arteries. Old metastatic infarcts of spleen and both kidneys.

BIBLIOGRAPHY.

1. Adénot: Thrombose de l'artère mésentérique inférieure et gangrène du colon. *Revue de médecine*, 1890, p. 252.
2. Albrecht: Ueber arterio-mesenterialen Darmverschluss an der Duodenojejunal-grenze, und seine ursachliche Beziehung zur Magenerweiterung. *Virchow's Archiv.*, 1899, clvi, 285-328.
3. Alexander: Thrombose der Pfortader und ihrer Aeste. *Berliner klin. Woch.*, 1866, p. 35.
4. Alkan: Ueber ein Fall von Embolie der Art. mes. sup. *Deutsche med. Woch.*, 1903, xxix, p. 106.
5. Allen: Embolism of Mesenteric Artery. *Lancet*, 1900, I, p. 1074.
6. Altmann: Ein Fall von ausgedehnter hæmorrhagischer Infarcierung des Darmes durch thrombo-embolische Prozesse in der Art. mes. sup. *Virchow's Archiv.*, vol. cxvii.
7. Anderson: Case of supposed embolism of the superior mesenteric artery. *Glasgow Med. Jour.*, 1890, p. 63.
8. Aronsohn: Embolie de l'artère mésent. sup. et de l'artère sylvienne gauche. *Gaz. des Hôpitaux*, Sept., 1868.
9. Aufrecht: Ein Fall von Embolie der Art. mes. sup. mit Ausgang in Helligung. *Deutsch. Archiv f. klin. Med.*, 1902, vol. lxxii, Nos. 5-6.
10. Barth: Thrombose spontanée de la veine porte. *Semaine Médicale*, 1897, p. 395; also *Soc. méd. des hôp.*, 1897.
11. Bayer: Hæmorrhoiden und Ileus. *Die aerztliche Praxis*, 1902, No. 1. (Neutra.)
12. Beckmann: Embolie der Art. mes. sup. *Virchow's Archiv.*, xiii, p. 501.
13. Bertin: *Etude critique de l'embolie*, Paris, 1869.
14. Bertrand: *Contribution à l'étude des oblitérations mésentériques*. Thèse de Paris, 1878.
15. Bewley: Portal thrombosis. *Dublin Jour. of Med. Sci.*, 1894, xcvi, p. 275.
16. Bier: Die Entstehung des Collateralkreislaufs. *Virchow's Archiv*, cxlvii.
17. Bollinger: *Atlas und Grundriss der pathol. Anatomie*. Jahresbericht *Virchow-Hirsch*, 1896-97 (Deckart).
18. Bonne: From Köster.
19. Bornhaupt: Ein Fall von Darmnekrose mit einer fraglichen aetiologischen Basis. *Deutsche med. Woch.*, 1901, June 13, p. 383.
20. Borrmann: Beiträge zur Thrombose des Pfortaderstammes *Deutsch. Archiv f. klin. Med.*, 1897, vol. lix, p. 281.
21. Borszéky: Ileus durch Embolie der Art. mes. sup. *Beiträge zur klin. Chirurgie*, 1901, vol. xxxi, p. 704.
22. Boucly: Thèse de Paris, 1894.
23. Bradford: A case of thrombosis of the sup. mes. vein causing intestinal obstruction. *Clin. Soc. Trans.*, 1898, p. 203; also *British Med. Jour.*, 1898.
24. Bruni: *Sopra un caso di embolie dell' arteria splenica e meseraica sup.* *Gazz. med. Ital. prov. venete*, Padova, 1877, p. 379.
25. Breuer: Zur Therapie und Pathogenese der Stenocardie und verwandte Zustände. *Münch. med. Woch.*, 1902, Nos. 39, 40, 41.
26. Bränniche: Purpura. Endocarditis. *Hospitalstidende*, 1891, vol. ix (Talke).

27. Bruckmüller: Propfbildung in der Arterien der Pferde. Oesterr. Bl., vol. xl, 1873 (Neutra).
28. Bühner: Münch. med. Woch., 1900 (Talke).
29. Burgess: A case of hemorrhagic enteritis from septic phlebitis of the superior mesenteric vein. Sheffield Med. Jour., 1892-3, i, p. 317.
30. Butlin: Growth in left ventricle with embolus in brachial and other arteries. Brit. Med. Jour., 1879, p. 657.
31. Carnabel: Infarctus intestinal avec gangrène totale d'une portion intestinale, consécutive à une embolie d'une branche importante de l'artère més. sup. Bull. and mém. Soc. de Chir. de Bucharest, 1901-2, iv, pp. 143-150.
32. Cattani: Embolia della art. mes. sup. Gaz. degli Hosp., Feb., 1883, Milano.
33. Chambers: Primary resection of the intestine for gangrene, Maryland Med. Jour., Baltimore, 1894, xxxi, 139-141.
34. Chavannaz: Sphacèle d'une portion de l'intestine grêle. Bull. soc. anat. et physiol. de Bordeaux, 1892, xlii, 85.
35. Cheyrou-Lagrèze: Etude sur les ulcerations gastro-intestinales consécutives aux oblitérations artérielles. Thèse de Paris, 1881.
36. Chiene: Complete obliteration of the celiac and mesenteric arteries, the viscera receiving their blood supply through the extra-peritoneal system of vessels. Jour. Anat. and Physiol., London, 1869, iii, p. 65.
37. Chuquet: Thrombose d'une des branches de la grand veine mésentérique coïncidant avec une cirrhose atrophique chez un alcoolique. Bull. soc. anat., 1878, p. 124.
38. Claisse: Archiv de méd. expér., No. 3, 1891.
39. Coats: An example of embolism of the superior mesenteric artery. Glasgow Med. Jour., 1880, p. 495.
40. Cohn: De embolia, eiusque sequ. Diss. Vratisl. 1856.
41. Cohn: Klinik der embol. Gefässkrankheiten, p. 548.
42. Cohnheim: Vorlesungen ueber allgemeinen Pathologie, vol. 1, pp. 150-492.
43. Cohnheim: Untersuchungen über die Embolischen Prozesse. Berlin, 1872.
44. Concato: Revista Clinica, 1866.
45. Conti: Sopra un caso di embolia della art. mes. sup. Centblt. f. klin. Med., No. 4; also Gazz. med. Ital. prov. venete, Padova, 1883.
46. Councilman: Three cases of occlusion of the sup. mes. art. Boston Med. and Surg. Jour., 1894.
47. Czerny: Demonstration von Magenresectionspräparaten. von Langenbeck's Archiv, vol. xxxi, p. 429.
48. Czerny: Beiträge zu den Operationen am Magen. Wiener klin. Woch., 1884.
49. Deckart: Ueber Thrombose und Embolie der Mesenterialgefässe. Mitt. a. d. Grenzgeb. der Med. und Chir., 1899, vol. v, p. 511.
50. Delatour: Thrombosis of the mesenteric veins as a cause of death after splenectomy. Annals of Surgery, 1895, xxi, p. 24.
51. Denarié: Hemorrhagie intestinale mortelle par thrombose des artères mésentériques. Mém. et compt. rend. Soc. d. sc. méd. de Lyon (1882), 1883, xxii, part 2, pp. 28-32. (Lepine's case.)
52. Dinkler: Deutsche med. Woch., 1901, p. 20 V. (Talke).

53. Dreyfous: Quatre observations de thrombose de la veine mès. sup. Bull. de la soc. anat., 1885, p. 274.
54. Drozda: Jahrbuch der Wiener Krankenanst., 1896 (Neutra).
55. Dun: Case read for Dr. McCail Anderson (see No. 7). From Glasgow Med. Jour., 1888.
56. Dunlop: A case of thrombosis of the sup. mes. veins. Lancet, 1900, I, p. 1800.
57. Durand-Fardel: Pylephlébite adhésive; athorome du tronc porte Impaludism; Lesions anciennes de la rate. Bull. de la soc. anat., Paris, 1883, p. 380.
58. Edler: Ein Fall einer eigentümlichen Hauterkrankung neben Endocarditis. Inaug. Diss., Berlin, 1872 (Talke).
59. Eisenlohr: Zur Thrombose der Mesenterialvenen. Jahrb. der Hamburg. Staatskrankenanstalten, vol. II, 1890, p. 76.
60. Elliot: Annals of Surgery, 1895.
61. Eppinger: Ueber eine der wichtigsten Erkrankungen der Arterien. Wien., 1852.
62. Erichsen: Ueber das Vorkommen von Embolien und Thrombosen in der Art. mes. St. Petersburg med. Zeit., 1875-76.
63. Faber: Die Embolie der Arteria mesenterica superior. Deutsch. Archiv f. klin. Med., 1875, vol. xvi, p. 527.
64. Falkenburg: Zur Casuistik der Thrombose und Embolie der Mesenterialgefäße. Archiv f. klin. Chir., vol. lxx, p. 992.
65. Federici: Di un solo aneurisma sviluppato dalle arterie celiaca e mesent. Rivista clinica, Bologna, 1881.
66. Finlayson: Report of a case of embolism of the mesenteric artery which recovered. Glasgow Med. Jour., 1888, p. 414.
67. Firket and Malvoz: Thromboses des branches de l'artère mès. sup. Archiv. de méd. expér., vol. lli, 1891.
68. Fitz. Trans. Assn. Amer. Phys., 1887, II, p. 140.
69. Flament: De la thrombose et d'embolie des artères mèsent. Inaug. Diss., Paris, 1876.
70. Fletcher: Ueber die sogenannte Periarteritis nodosa. Beiträge z. path. anat. Ziegler, vol. xi, 1892, p. 323.
71. Frankenhäuser: Ein Beitrag zur Casuistik des Ileus paralyticus. St. Petersburg med. Woch., 1890.
72. Fraser: A specimen of omentum and bowel from a case of fatal hemorrhage from the bowels. Thrombosis of sup. mes. veins. Glasgow Med. Jour., lli, 1899, p. 437.
73. Frerichs: Klinik der Leberkrankheiten (Welch).
74. Gabriel: Zur Diagnose des Aneurysma der Art. mes. Wiener klin. Woch., 1901, p. 1051.
75. Gallavardin: Embolies et thrombosis des vaisseaux mèsentériques. Gaz. des Hôpitaux, 1901, pp. 929 and 957.
76. Galliard: Méd. moderne, 1894, p. 861 (Welch).
77. Garmsen: Ein Fall von haemorrhagischer Infarction des Dunndarms, etc. Inaug. Diss., Kiel, 1895.
78. Garré: From Talke.
79. Gerster: Thrombosis of mesenteric vessels; gangrene of intestine; operation; death. Mt. Sinai Hospital Reports, New York, 1901-2, viii, p. 111.
80. Gerhardt: Wurtzburger med. Zeit., 1863, iv, 3, p. 141.
81. Gimard: Arch. gén. de méd., Oct., 1883 (Talke).
82. Ginsburg: Ueber Embolien bei Herzkrankheiten. Arch. f. klin. Med., vol. lxix.
83. Gintrac: Bull. Acad. de Paris, 1842-43, vol. viii.

84. Goodheart: Arterio-venous aneurism of splenic vessels with thromboses of mes. veins. *Path. Trans.*, 1890.
85. Gordon: A case of hemorrhagic infarction of the small intestine; successful resection. *Brit. Med. Jour.*, i, 1898, p. 1447.
86. Grawitz: Fall von Embolie der Art. mes. sup. *Virchow's Archiv*, 1887, vol. cx, p. 434.
87. Grawitz: From Neutra.
88. Grosskurth: Ueber die Embolie der Art. mes. sup. *Inaug. Diss.*, Glessen, 1895.
89. Gull: Case of probable thrombus of sup. mes. vein and renal veins. *Guy's Hospital Reports*, London, 1883-84, p. 15.
90. Gutsch: Zwei Fälle von Magenresektion. *Von Langenbeck's Archiv*, vol. xxix, p. 650.
91. Hahn: Ein Fall von Thrombose der Art. mes. sup. *Inaug. Diss.*, München, 1889.
92. Hallpré: Note sur un cas de sphacèle de l'intestine grêle consécutif à une oblitération de l'artère més. sup. *Bull. Soc. anat.*, Paris, 1892, lxxvii, p. 719.
93. Hamburger: Stauungshydrops und Resorption. *Virchow's Archiv*, 1895, cxli, p. 398.
94. Hamilton: *Lancet*, 1899, ii (Talke).
95. Handford: *Lancet*, 1892, ii (Talke).
96. Hegar: Enucleation eines grossen intraparietalen Myoms. Embolie der Lungenarterie und der Art. mes. inf. Thrombose der linken crural Venen. *Virchow's Archiv*, vol. xlviii, p. 332, 1869.
97. Hilton-Fagge: A case of acute thrombosis of the sup. mes. and portal veins, attended with rapidly lethal collapse. *Trans. Path. Soc.*, London, 1876.
98. Hirtz and Josué: Gangrene of the intestine from portal thrombosis. *Lancet*, Oct. 6, 1900, p. 1025; also *Soc. méd. des hôp.*, 1900, p. 872.
99. Howse: Thrombosis of the sup. mes. art. *Trans. Path. Soc.*, London, 1878, vol. xxix, p. 101.
100. Jastrowitz: Ein Fall von Thrombose der Pfortader ausluetischer Ursache. *Deutsche med. Woch.*, 1883.
101. Johnson: Case of tubercular peritonitis in which symptoms of intestinal obstruction resulted, probably from thrombosis of certain tributaries of sup. mes. vein. *Clin. Soc. Trans.*, 1898, p. 212.
102. Johst: Ueber die Thrombose der mes. Venen. *Inaug. Diss.*, Königsberg, 1894.
103. Jürgens: Ein Fall von Embolie der Aorta abdominalis. *Münch. med. Woch.*, 1894, No. 43, p. 843.
104. Kabarktschieff: Thrombose mésentérique. *Thèse*, Montpellier, 1899.
105. Kader: Experimentelle Beitrag zur Frage des lokale Meteorismus bei Darmocclusion. *Deutsch. Zeit. f. Chr.*, vol. xxxiii, p. 57.
106. Karcher: Fall von Embolie der Art. mes. sup. *Schweizer Corres. Blt.*, 1897, No. 18.
107. Kaufmann: Ueber den Verschluss der Art. mes. sup. durch Embolie. *Virchow's Archiv*, vol. cxvi, p. 353.
108. Kendal-Franks: *Trans. Roy. Acad. of Med. in Irleand*, 1893.
109. Killiani: Thrombosis of superior and inferior mesenteric artery. *Annals of Surgery*, xxxviii, p. 110.
110. Köster: Zur Kasuistik der Thrombose und Embolie der grossen Bauchgefässe. *Deutsch. med. Woch.*, 1898, p. 325.

111. Kölbinger: Beiträge zur Magendarmchirurgie. Die Thrombose der Mesenterialgefäße. Beiträge zur klin. Chir., vol. xxxiii, 1902.
112. Kolisch: Experimenteller Beitrag zur Lehre von der alimentärem Glykosurie. Centralblt. f. klin. Med., 1892, p. 737.
113. Kraft: Darmgangrän hervorgerufen durch Embolie und Thrombose der Mesenterialgefäße. Hospitalstidende, vol. v, 1897.
114. Krönlein: Klinischer und topographischer Anat. Beiträge zur Chir. des Pankreas. Braun's Beiträge z. klin. Chir., vol. xiv, p. 663.
115. Küster: Ueber Magenresection. Centralblt. f. Chir., 1884, No. 45, p. 754.
116. Kussmaul: Zur Diagnose der Embolie der Art. mes. Würzburger med. Zeit., vol. iii, p. 210.
117. Labbé: Phthisie pulmonaire. Grangrène sénile. Perforation intestinale par suite de thrombose de la més. sup. Bull. soc. anat., 1867, p. 329.
118. Langerhans: Pathologisch-anatomische Präparate. Verhandl. des XV Kongresses f. innere Med., Wiesbaden, 1897, p. 537.
119. Laveran: Un cas d'embolie de l'artere més. sup. Arch. de méd. et pharm. militaire, Paris, 1887.
120. Lauenstein: Die Gangrän des Colon transversum als Komplikation des Pylorusresektion. Centralblt. f. Chir., 1885, No. 8.
121. Lazarus-Barlow: A Manual of General Pathology. London, 1898; also Phil. Trans. Roy. Soc., clxxxv, 1894, p. 779.
122. Leduc: Thrombophlebitis mésaraïca. Cirrhose hépatique d'origine syphilitique. Thrombose de la veine porte, mésenterique, et splénique, etc. Progrès Méd., 1884.
123. Leech: Thrombosis of mesenteric veins. Sheffield Quart. Med. Jour., 1897-98, p. 370.
124. Lépine. From Adénot.
125. Lereboullet: Etude clinique des haemorrhagies intestinales dues aux embolies de l'artere més. Rec. de mém. de méd., Paris, 1875.
126. Letulle and Maygrier: Phlébite puerpérale d'une branche de la veine mésaraïque. Soc. anat., 1897, p. 540.
127. Lillenthal: Thrombosis of the sup. mes. vein; report of a case where abdominal section was performed. Mathews' Quart. Jour. Rectal Diseases, 1898, p. 158.
128. Litten: Ueber die Folgen des Verschlusses der Arteria mesaraïca superior. Virchow's Archiv, vol. lxxiii, p. 289, 1875.
129. Litten: Ueber circumscribte gitterförmige Endarteritis. Deutsch. med. Woch., 1889, No. 8.
130. Lobert: Ein Fall von Thrombose der Pfortader. Inaug. Diss., Griefswald, 1887.
131. Lochte: Münchener med. Woch., 1896, p. 410; Sitzung des aertzlichen Vereins in Hamburg, April 7, 1896.
132. Lorenz: Beitrag zur Kenntniss der multiplen degenerativen Neuritis. Zeit. f. klin. Med., 1891, xviii, p. 493.
133. Lothrop: A report of three cases of embolus of the mesenteric artery. Boston Med. and Surg. Jour., 1894.
134. Lund: Et Tilfaelde af Tarmgangraen som en Folge af Thrombophlebitis mesaraïca. Hospitalstidende, March 23, 1898, p. 325.
135. Luzzatto: Embolla semplice dalle arterie mes. Gazz. med. Ital. prov. ven., Padova, 1877, p. 147.
136. Lycett: British Med. Jour., 1898, ii, p. 84.
137. Mader: Embolie der Art. mes. sup. mit. consecutiver Gan-

grän der Jejunum. Jahrbuch d. Wien. k. k. Krankenanstalten, 1895, ix, part 2, p. 249; also Wien. med. Bl., 1897, xx, p. 349.

138. Mall: Johns Hopkins Hospital Reports, vol. i, p. 37.

139. Maragliano: Ein besondere Form von geschwuriger Darmentzündung mit Durchbohrung des Ileum. Berl. klin. Woch., 1894, p. 303.

140. Maylard: Two cases of post-operative thrombosis of the mesenteric vessels followed by death. British Med. Jour., 1901, Nov. 16, p. 1454.

141. McCarthy: Acute intestinal obstruction, probably due to embolism of several terminal branches of the sup. mes. art. Lancet, 1890, March 22, p. 646.

142. McWeeny: Thrombosis of the superior mesenteric vein. Lancet, 1893, Dec. 23, ii, p. 1576.

143. Mengin: Thèse de Montpellier, 1871 (Lereboullet).

144. Merkel: Pericystitis globulose; Vegetationen im linken Ventrikel und Embolie eines Zweiges der Art. mes. sup. Wien. med. Presse, viii, 30, 31, 1867, p. 740.

145. Meyer: Ueber multiple Embolie der Darmgefäße. Inaug. Diss., Würzburg, 1896.

146. Michaelis: Zur Casuistik der Embolie der Darmarterien. Virchow's Archiv, vol. clvi, p. 181, 1899.

147. Minkowski: Mitt. aus der med. Klin. zur Königsberg, 1888, p. 59.

148. Mollière: De l'embolie des art. més. Etude critique et bibliographique. Lyon méd., No. 8, 1871, pp. 691 and 779.

149. Monro and Workman: Thrombosis of the mesenteric veins in enteric fever. Trans. of Glasgow Med. Chir. Soc., April 6, 1900, in Glasgow Med. Jour., 1900.

150. Moos: Beitrag zur Kasuistik der embolischen Gefäßkrankheiten. Virchow's Archiv, xli, p. 58, 1867.

151. Moyes: Embolism of the superior mesenteric artery. Glasgow Med. Jour., 1880, xiv, p. 485.

152. Munro: Embolism of the mesenteric vessels with symptoms of obstruction; abdominal section. Lancet, i, 1894, p. 147.

153. Naunyn: Ueber Ileus. Mitt. a. d. Grenzgeb. d. Med. und Chir., 1896.

154. Neutra: Ueber die Erkrankungen der Mesenterialgefäße und ihre Bedeutung für die Chirurgie. Centralbt. f. d. Grenzgeb. d. Med. u. Chir., vol. v, No. 18, 1902, p. 705.

155. Nordenfelt: Ett fall af trombos i vena mes. sup. (Neutra). Hygiea, Stockholm, 1897, lix, part 2, p. 228.

156. Nothnagel: Die Erkrankungen des Darmes und der Peritoneums. Nothnagel's Series, Wien, 1898, p. 460.

157. Oppolzer: Ein seltener Fall von Enterorrhagie und Gangrän des Darmes infolge von Embolie der Art. mes. sup. Allg. Wiener med. Zeitung, 1862, No. 9, p. 77.

158. Osler: Practice of Medicine, 1893, p. 404.

159. Osler: Thrombosis and embolism of the sup. mes. art. Medical News, Philadelphia, 1883.

160. Ott: Zur Embolie der Mesenterialarterien. Münch. med. Woch., 1900.

161. Packard: Case of rupture of aorta (without aneurism or atheroma), with evidences of former mesenteric infarction. Proc. Path. Soc., Phila., 1898, n. s., i, p. 288.

162. Parénski: Wiener med. Jahrbucher, 1875; also 1876, p. 275.

163. Péron and Beaussenat: Thrombo-pyléphlebite. Lésions intestinales consécutives. Bull. de la soc. anat., 1894, p. 589.
164. Picqué and Grégoire: Thrombo-phlébite de la veine més. sup. avec gangrène de l'intestin grêle. Semaine Méd., No. 3. (Soc. de Chir. Séance du 8 Janvier, 1902.)
165. Pieper: Embolie der Art. mes. sup. Med. Centralzeitung, Berlin, July 17, 1865.
166. Pilliet: Thrombose de la veine mésaraique. Progrès Médicale, 1890, No. 25, p. 497.
167. Pinner: Naturforscherversammlung, Heidelberg, 1889.
168. Ples: Embolie der Art. mes. sup. Inaug. Diss., München, 1893 (Meyer).
169. Ponfick: Zur Kasuistik der Embolie der Art. mes. sup. Virchow's Archiv, I, p. 623.
170. Putnam: Intestinal obstruction due to thrombosis of the sup. mes. art. New York Med. Record, vol. vii, p. 208.
171. Reichel: Zur Pathologie des Ileus und Pseudoileus. Deutsch. Zeit. f. Chir., vol. xxxv, 1892, p. 495.
172. Reitzenstein: Ileus infolge von Thrombose der Vena mesenterica. Münchener med. Woch., 1903, No. 6, p. 257.
173. Rhein: De l'embolie de l'artère més. sup., Thèse, Paris, 1875.
174. Ribbert: Lehrbuch der Allgemeinen Pathologie, Leipsic, 1901.
175. Riesman: Hemorrhagic infarct of mesentery and intestine. Proc. Path. Soc. Phila., 1898-99, n. s., li, pp. 53-59.
176. Riis: Zur Embolie der Art. mes. sup. Inaug. Diss., Würzburg, 1884 (Meyer).
177. Robson: A case of perforating wound of the abdomen. British Med. Jour., 1897.
178. Rolleston: Infarcts of the spleen associated with thrombosis of the splenic vein. Trans. Path. Soc., London, 1892, xliii, p. 49.
179. Rosenbach: Zur Symptomatologie und Therapie der Darminsufficienz. Berl. klin. Woch., 1889, p. 269.
180. Roughton: A case of ruptured mesenteric artery. Lancet, 1899.
181. Sachs: Zur Kasuistik der Gefässerkrankung. Deutsch. med. Woch., 1892, p. 443.
182. Saxer: Beiträge zur Pathologie der Pfortaderkreislaufe. Centralblt. f. allgem. Path. und path. Anat., 1902, vol. xiii, p. 577.
183. Schloffer: Ueber traumatische Darmveränderungen. Mitt. a. d. Grenzgeb. f. Med. und Chir., vol. vii, 1901.
184. Schlesinger: From Neutra.
185. Schnitzler: Zur Symptomatologie des Darmarterienverschlusses. Wiener med. Woch., 1901, Nos. 11-12.
186. Schrötter: Erkrankungen der Gefässe. Nothnagel's spezielle Path. und Therapie, vol. xv.
187. Sheild: Ruptured mesenteric arteries. Practitioner, Nov., 1898, p. 473.
188. Sievers: Zur Kenntniss der Embolie der Art. mes. sup. Berl. klin. Woch., 1902, p. 183.
189. Smith: A case of thrombosis of the portal system. Dublin Jour. of Med. Sci., 1894, xcvi, p. 274.
190. Spaeth: Ein Fall von Embolie der Art. mes. sup. Würtemb. Corresp. Bl., 1882.
191. Sperling: Ueber Embolien bei Endocarditis. Inaug. Diss., Berlin, 1872.
192. Spiegelberg: Drei seltene Sectionsbefunde. Verkalkung der

Wandungen der thrombotischen Pfortader. *Virchow's Archiv*, vol. cxlii, 1895.

193. Sprengel: Zur Pathologie der Circulationsstörungen im Gebiet der Mesenterialgefäße. *Verhandl. der Deutsche Gesellschaft für Chirurgie*, Berlin, 1902, vol. xxxi, p. 55.

194. Stefan: Bijdrage tot de casuïstiek der gevallen van acute portaderthrombose. *Neder. Tijdsch. voor Geneesk.*, 1900, from *Centrablt. f. klin. Med.*, 1901.

195. Stubbs: Embolism of sup. mes. art. *Phila. Reporter*, 1890.

196. Talke: Ueber Embolie und Thrombose der Mesenterialgefäße. *Beiträge zur klin. Chirurgie*, 1903, vol. xxxviii, No. 3, p. 743.

197. Tangel and Harley: Notiz über einige anatomische Veränderungen nach Unterbindungen der drei Darmarterien. *Centrablt. f. d. med. Wissensch.*, 1895, p. 673.

198. Tangel and Harley: Beitrag zur Physiologie des Blutzuckers. *Pfuger's Archiv*, vol. ix.

199. Taylor: Obstruction of the mesenteric artery and vein, followed by intestinal and peritoneal hemorrhage, with rapidly fatal termination. *Path. Trans.*, xxxii, 1881, p. 61.

200. Thomas: The causes of acute abdominal pain in the healthy, exclusive of traumatism. *British Med. Jour.*, 1903, pp. 186-188.

201. Tietze: Klinische und experimentelle Beiträge zur Lehre von der Darmincarceration. *Langenbeck's Archiv*, 1894.

202. Treves: Intestinal obstructions. *New York*, 1899, p. 447. (Wm. Wood & Co.)

203. Trübel: Vier Fälle von Verschluss der Art. mes. sup. *Jahrb. d. Wiener Krankenanstalten*, 1894 (Neutra),

204. Tyson and Livingston: Case of acute intestinal obstruction due to embolus of a branch of sup. mes. art. *Trans. Clin. Soc. London*, xxxv, 1901-2, pp. 114-116.

205. Van Hook: Embolism of a branch of the sup. mes. art. *Am. Gyn. and Obst. Jour.*, New York, 1897, p. 602.

206. Virchow: *Ges. Abhandlungen*, pp. 420, 338, 451.

207. Wagner: *Arch. d. Heilkunde*, 1868 (Talke).

208. Watson: The diagnosis and surgical treatment of cases of embolism of the mesenteric blood vessels, with reports of cases. *Boston Med. and Surg. Jour.*, 1894, vol. cxxxI, p. 552.

209. Welch: Thrombosis. Embolism. In Allbutt's "System of Medicine," vol. vi, pp. 155, 228, New York and London, 1899.

210. Welch and Flexner: Observations concerning the Bacillus *Aerogenes Capsulatus*. *Jour. of Experimental Medicine*, 1896, i, p. 35.

211. Westhoff: Zwei Fälle von haemorrhagischer Infarcierung des Darmes nach Embolie der Art. mes. sup. resp. Thrombose der Pfortader. *Inaug. Diss.*, Kiel, 1895.

212. Whipple: A case of intestinal obstruction due to thrombosis of some of the mesenteric vessels; laparotomy; death; necropsy. *Lancet*, 1900, i, p. 705.

213. Wikner: Ein Fall von Morbus Werlhofii (Talke). From *Virchow-Hirsch*, 1894.


214. Wittmann: *Jahrb. f. Kinderheilkunde*, vol. ix (Talke).


215. Zesas: Ueber das Verhalten des von seinem Mesenterium abgelösten Darmes. *Archiv f. klin. Chirurgie*, 1886, vol. xxxiii, p. 303.

216. Zimmermann: *Arch. d. Heilkunde*, vol. xv (Talke).

217. Zoega-Manteuffel: Ueber die differentielle Diagnose des Ileus. *St. Petersburg med. Woch.*, 1890, p. 397.







616.34

(5876)

