

## **Tumors of the cerebellum / by Charles K. Mills [and others].**

### **Contributors**

Mills, Charles K. (Charles Karsner), 1845-1931.

### **Publication/Creation**

New York : A. R. Elliott, 1905.

### **Persistent URL**

<https://wellcomecollection.org/works/zmg8vv9q>

### **License and attribution**

Conditions of use: it is possible this item is protected by copyright and/or related rights. You are free to use this item in any way that is permitted by the copyright and related rights legislation that applies to your use. For other uses you need to obtain permission from the rights-holder(s).



Wellcome Collection  
183 Euston Road  
London NW1 2BE UK  
T +44 (0)20 7611 8722  
E [library@wellcomecollection.org](mailto:library@wellcomecollection.org)  
<https://wellcomecollection.org>

# TUMORS OF THE CEREBELLUM

CHARLES K. MILLS

CHARLES H. FRAZIER

GEORGE E. DE SCHWEINITZ

T. H. WEISENBURG

EDWARD LODHOLZ

155 H




22200196558


Med  
K34920














# TUMORS OF THE CEREBELLUM

BY

CHARLES K. MILLS, M. D.

CHARLES H. FRAZIER, M. D.

GEORGE E. DE SCHWEINITZ, M. D.

T. H. WEISENBURG, M. D.

EDWARD LODHOLZ, M. D.

---

Reprinted from the  
NEW YORK MEDICAL JOURNAL AND PHILADELPHIA MEDICAL JOURNAL  
for February 11 and 18, 1905

---

NEW YORK:  
A. R. ELLIOTT PUBLISHING COMPANY  
66 West Broadway  
1905



COPYRIGHT, 1905, BY A. R. ELLIOTT PUBLISHING CO.

5095421

WELLCOME INSTITUTE LIBRARY	
Coll.	weIMOmec
Call	
No.	WL



## TABLE OF CONTENTS

1. The Diagnosis of Tumors of the Cerebellum, Especially with Reference to Their Surgical Removal. By CHARLES K. MILLS . . . . .	I
2. Remarks Upon the Surgical Aspects of Tumors of the Cerebellum. By CHARLES H. FRAZIER . . . . .	39
3. Cases Illustrating the Papers of DR. MILLS and DR. FRAZIER . . . . .	86
4. The Ocular Symptoms of Cerebellar Tumors. By GEORGE E. DE SCHWEINITZ . . . . .	119
5. The Pathology of Cerebellar Tumors. By T. H. WEISENBURG . . . . .	135
6. The Functions of the Cerebellum. By EDWARD LODHOLZ . . . . .	171

## ILLUSTRATIONS

Fig. 1. Vertical section of head, showing the comparatively small cavity in which the cerebellum is contained and its inaccessibility . . . . .	38
" 2. A head rest that may be used to advantage in operations upon the head . . . . .	47
" 3. Photograph of a horizontal section of the head cut on a level with the external auditory meatus . . . . .	61
" 4. Operation for the combined exposure of one cerebellar hemisphere and the occipital lobe of the cerebrum . . . . .	66
" 5. Operation for the simultaneous exposure of both cerebellar hemispheres, necessitating ligation of the occipital sinus . . . . .	67
Fig. 1. Sarcoma in left cerebellopontile angle . . . . .	144
" 2. Fibroma compressing the lateral lobe of the cerebellum and the lower surface of the temporal lobe . . . . .	152
" 3. Fibroma compressing the lower surface of the cerebellum and the left side of the pons . . . . .	155

Unable to display this page



THE DIAGNOSIS OF TUMORS OF THE  
CEREBELLUM AND THE CEREBEL-  
LOPONTILE ANGLE, ESPE-  
CIALLY WITH REFERENCE  
TO THEIR SURGICAL  
REMOVAL.

By CHARLES K. MILLS, M. D.,

PHILADELPHIA,

PROFESSOR OF NEUROLOGY, UNIVERSITY OF PENNSYLVANIA;  
NEUROLOGIST TO THE PHILADELPHIA GENERAL HOSPITAL.

In time it is probable that as regards tumors of the cerebrum, especially those located on its lateral aspect anywhere from the cephalic tip to the occipital pole, success both in diagnosis and in operative treatment will reach from twenty-five to fifty per cent. By success is meant the exact localization and removal of tumors, the operation from the surgical point of view being entirely successful, and partially so from the point of view of the removal of the disease. Supposing that fifty per cent. of such cases are reached, ten to fifteen per cent. will not recur, or at least not in periods varying from three to ten years. In the remainder the painful and distressing general symptoms of brain tumor will be removed for a



time, the neoplasms recurring in some cases after an interval, while in others the cases may terminate fatally. Life in most instances will not only be prolonged, but will be made much more comfortable. Tumors of the mesal aspect and of the base of the brain will always be uncertain in result, although an occasional growth situated on the orbital or temporal surface may be successfully reached. We must, therefore, after growths located on the lateral aspect of the cerebrum, look to tumors of the cerebellum and cerebellopontile angle for our next highest percentage of successes in spite of the hitherto unsatisfactory, and in some instances even disheartening, results of surgical procedure.

The surgical aspects of the subject, including the methods and results of operation and statistical details, will be fully considered by Dr. Frazier; but as I have had much experience in observing operations on the cerebellum, I may be permitted, in introducing a discussion of the symptomatology and diagnosis of cerebellar tumors, to say a few words about the accessible sites for operation.

Although an operation is difficult and often unsuccessful, tumors in certain cerebellar locations may be regarded as "operable." These are: 1. Tumors situated wholly or in large part in one

lateral lobe. 2. Tumors situated upon or in part invading the vermis or middle lobe. 3. Tumors of the cerebellooblongatopontile angle. Only in the case of a tumor located in large part in one lateral lobe of the cerebellum does an operation afford a really good chance for success, but in rare cases both tumors of the vermis and of the cerebellobulbar angle can be reached and removed.

With regard to tumors of the vermis or middle lobe, the writer has had no personal experience with operative procedure. I believe, however, that in some instances tumors resting upon or even invading the vermis may be reached and removed. The operation in this case should include an opening on each side of the median line, and possibly the ligation of the sinus and the removal of the bone intervening between the two openings. Such an operation is feasible, although, perhaps, difficult.

The diagnosis of the existence of a tumor in the cerebellum is as a rule comparatively easy, but to exactly locate and infer the size and extensions of such a growth is a more difficult task; and yet when operation for removal of the tumor is under discussion, the focal diagnosis becomes of paramount importance.

In the first place, brief consideration will be given to general symptomatology and diagnosis.



In a large majority of cases of cerebellar neoplasm the well known general symptoms of brain tumor, namely, headache, nausea, and vomiting, optic neuritis, and vertigo, are present and are of pronounced character.

While the headache in many cases is intense, and in some even agonizing, in others it is of moderate severity and in rare instances, of which a few have come under my observation, it may be entirely absent or it may not appear until late in the course of the disease. In about half the cases the headache is referred to the back of the head or to this region, and at the same time to other parts, as to the nape of the neck and various portions of the cranial vault. Frontal headache of a severe type is occasionally observed in cases of cerebellar tumor, just as in some instances of frontal neoplasm the pain is most intense or is present alone in the occipital region. Too much stress therefore must not be placed on the site of the pain.

Nausea and vomiting are symptoms of frequent occurrence, although they occasionally disappear for long periods in the progress of a case. The mechanism of these symptoms is much the same as that of the vertigo due to dural irritation, which will presently be considered.

With regard to optic neuritis and its conse-

quences, it is only necessary to say that our experience is similar to that of others who have found this sign of intracranial tumor more constant in cerebellar tumors than in those located in almost any other region of the brain. The development of the choked disc or optic neuritis is often rapid, or at least goes on at a much accelerated pace after it has reached a certain moderate height. The choking of the disc is extreme, and hæmorrhages are numerous. Unless operative interference checks the progress of the inflammation, blindness speedily occurs, and this is one of the reasons for early surgical procedure, even when the case has not a hopeful outlook as regards removal of the growth.

Dr. de Schweinitz, in his paper on the ocular phenomena of tumors of the cerebellum, to which the reader is referred, fully considers the ophthalmoscopic appearances and conditions in this affection. Nearly all the cases included in the series from which the inferences contained in this paper are drawn were seen by him.

The vertigo which is so frequently a general symptom of brain tumor, wherever situated, is usually due to irritation of branches of the trigeminal nerve, which are distributed near the inner surface of the dura, the irritation of the fifth nerve being reflected to the bulbar nuclei of



this nerve and thence to the pneumogastric nucleus. This is usually one of the causes of the vertigo in tumors of the cerebellum when the growth is connected with the dura, which is not the rule. In other cases it should be regarded as a focal rather than as a general symptom of cerebellar tumor, as it is caused by the disturbing influence exerted by the tumor upon the cerebellovestibular apparatus.

A distinction must always be made between cerebellar vertigo and cerebellar ataxia, although the two are often so interblended that this is not easily done. Subjective vertigo is common, the patient usually describing it as a feeling of dizziness. Both subjective and objective vertigo may be extreme and exhibit striking characteristics which indicate their focal origin. In a case recorded by Osborne,<sup>1</sup> for example, in which a large glioma was situated in the right cerebellar lobe, the patient was unable to sit up, and could not turn her head without having an attack of vertigo. The dizziness was relieved by complete rest in bed, but came on again with less frequency, although with much severity. The patient would always lie with her head to the right, saying that she became dizzy if it were turned

---

<sup>1</sup> Osborne, O. T., *Journal of Nervous and Mental Diseases*. N. Y., Vol. xxix, October, 1902.

to the left. Later epileptoid seizures took the place of the vertigo.

I shall discuss next the strictly focal symptoms of tumor of the cerebellum.

Nystagmus is one of the most frequent symptoms of cerebellar tumor. It is present in growths variously situated in the cerebellum or jointly in the cerebellum and adjacent parts, as for instance in the middle lobe, in one lateral lobe when the neoplasm is close to its junction with the middle lobe, in the prepuncle or jointly in this and the oblongata. A tumor or other lesion confined to the flocculus is said to give rise to nystagmus. The nystagmus of cerebellar or cerebello-pontile disease may be of various types, as regards the manner of its occurrence, its direction, and the rapidity or slowness of the oscillations. It may be present when the eyes are quiet and looking straight forward, or under these circumstances it may be absent, but capable of being elicited by having the eyes turned either to the right or to the left, or upward or downward. It may be horizontal or vertical or both in the same case. The movements are sometimes rapid and fine or slow and comparatively coarse. In the case of Bruce referred to later in this paper, the nystagmoid movements, which were present in all positions, were increased on lateral move-



ments; on looking to the right the oscillations were slower and larger. They were of intermediate rapidity and extent in looking upward or downward. It has been suggested that the nystagmus can be brought out when it is not present, or that it is greater if present, when the eyes are turned toward the side of the lesion, a view which was supported by one case of cerebellar abscess recorded by Spiller,<sup>2</sup> but was not confirmed by a case of cerebellar tumor reported by this writer in the same paper. We have not been able as yet to make any inferences of localizing value from a study of cerebellar nystagmus, although it would seem probable that in a case of destructive lesion affecting the cerebellovestibular tract, the nystagmus would be greater when the eyes were directed toward the side of the tumor. I shall refer presently to the views of Bruce on this subject.

The question of the existence of a true paresis or paralysis as the result of a cerebellar lesion is one that has been discussed both by physiologists and clinicians. That a general paralysis has been observed as both the result of experimental lesions of the cerebellum and of cerebellar hæmorrhage, tumor, or abscess in man cannot be

---

<sup>2</sup> Spiller, W. G., *Amer. Jour. of the Med. Sciences*, February, 1904.

doubted, but in many cases at least this symptom is due to the effect of the lesion on neighboring parts, as for instance on the pyramidal tract or tracts. Asthenia or muscular weakness is, however, a real cerebellar symptom. Sometimes it is overlooked, the symptoms which are dependent upon this weakness being attributed to incoordination or other cause.

In a valuable paper by Grainger Stewart and Gibson<sup>3</sup> these writers report at length their observations with regard to the state of voluntary movements in the five patients which form the basis of their paper. In all of these cases the patients exhibited weakness of the legs, as tested not only in standing and walking, but also by movements in bed. Weakness of the spinal muscles was present in three cases. Niemeyer, Hughlings Jackson, and Risien Russell, who are cited by Stewart and Gibson, have shown that paresis or weakness of the spinal or trunkal muscles results from cerebellar lesion. Jackson believes that destructive lesion of the vermis causes paralysis or paresis, most marked in the muscles of the trunk, next in the lower extremities, and least in the upper limbs. Discussing the weakness of the spinal muscles, Stewart and Gibson

---

<sup>3</sup> Stewart, T. Grainger, and Gibson, G. A., *Edinburgh Hospital Reports*, Vol. v, Edinburgh and London, 1898.



referred to the relief which is sometimes afforded by the use of crutches. In several cases of tumor of the cerebellum I have observed distinct evidences of weakness of the muscles supporting the vertebral column. It is probable that some of the difficulty experienced by the patients in maintaining their equilibrium, and some of the tendency to fall or pitch to one side or the other, are dependent in part at least upon asthenia or paresis rather than entirely upon incoordination. In Case V of the series appended to this article and that of Dr. Frazier the general musculature was flaccid, and the head showed a tendency to fall backwards or a little to one side, apparently because of weakness of the supporting muscles of the neck.

Batten<sup>4</sup> has called attention to what he believes to be the diagnostic value of the position of the head in cases of cerebellar disease. He refers to the fact that Risien Russell has observed in animals after ablation of a cerebellar hemisphere, that the head sinks on the shoulder on the side on which the operation is performed, the eyes being deviated to the same side and upward, and the chin to the opposite side. The spinal column is concave on the side of the ablation. Batten observed a case of tubercle of the right lateral

---

<sup>4</sup> Batten, T. E., *Brain*, Part 101, Spring, 1903.

lobe of the cerebellum in which the patient's head sank towards the left shoulder, the face looked upwards toward the right and the chin rotated to the right. The spinal column, as in animals experimented upon, was concave towards the same side. The same symptoms have been observed by Batten in hydrocephalus.

At a meeting of the St. Louis Medical Society on September 17, 1904, at which some remarks were made by the writer on the diagnosis of cerebellar tumors, Dr. J. J. Putnam, of Boston, spoke in the discussion of a case in which this symptom or some modification of it was present.

The symptom known as hemiasynergia, first described by Babinski,<sup>5</sup> who believes it to be present on the side on which a cerebellar tumor or other lesion exists, has been sought for in all cases of cerebellar tumor recently observed, but so far it has not been found a reliable sign of cerebellar disease. This symptom is brought out in the lower extremity by having the patient, with his eyes shut, flex the leg fully on the thigh and the thigh on the abdomen, and then require him to extend the limb to its full length. If the extension is done normally, the leg and thigh movements are performed synchronously or rather synergically, but the leg is first straight-

---

<sup>5</sup> Babinski, *Revue neurologique*, May 30, 1902, p. 470.



ened out and then the entire limb is brought to a horizontal position by a second movement. I have noted the presence of this symptom in several cases, but in some instances when shown at one examination it would fail to be elicited at another in the same extremity. It was present on the side of the lesion on several occasions when one of the cases recorded in connection with this paper was examined. On other occasions the limb was extended synergically. Shortly after eliciting the sign at an examination made in the ward of the hospital, this patient was taken before the class in the amphitheatre and hemiasynergia could not be demonstrated. In the case of Spiller, several times referred to in this paper, it was present on the side of the tumor and was observed by the writer.

As is said elsewhere, a tumor circumscribed to the outer part of one lateral lobe may not give rise to any symptoms, or at least, to any of diagnostic value. Excepting cases of this kind, all tumors of the cerebellum cause, or at least may cause, incoordination. Some grade of ataxia has been present in all cases of cerebellar tumor studied by me. The degree and character of this ataxia have varied greatly in different cases. It is always present in tumors of the vermis, unless it may be in cases to which Bruce has referred,

in which a symmetrical distribution and slow development of the tumor prevent the appearance of the ataxia. The Romberg symptom is practically always present, but it may differ greatly in degree. It differs from the static ataxia of a case of advanced tabes in that it is much less markedly increased by closing the eyes. The sway is, however, usually somewhat increased with the eyes shut; but unless the cerebellar disease is much advanced, the patient will often be able to keep relatively steady on his feet for a considerable time.

The cerebellar gait is, as it has often been described, a staggering or titubating gait. The steps are more irregular in their lateral and vertical amplitude than those of a tabetic, unless the disease in the latter case is advanced to a point where the patient can barely maintain himself in the erect position while walking. The pose and the gait of a case of cerebellar tumor, or of other lesions of the cerebellum, are due not alone to incoordination. Vertigo and muscular weakness, specially weakness of the muscles attached to the spinal column, as well as incoordination, act in their production.

The direction in which the patient sways on standing or tends to pitch or fall in walking may be a matter of much diagnostic importance.



Often it plays a considerable part in the discussion of the site of operation. According to Starr<sup>6</sup> the staggering in four fifths of the cases of cerebellar tumor is away from the side of the lesion. This is not my own experience. In those cases coming under my observation in which either necropsy or operation has revealed the tumor, the swaying or staggering has been oftener toward the side of the lesion than toward the opposite. In two cases reported by Schede,<sup>7</sup> because the patient tended to fall toward the left, the tumor was located on the right, and in both cases an operation showed that it was situated on the left. In one of these cases the tumor could have been successfully removed. In several cases of which the writer has personal knowledge the focal diagnosis was wrong as to the side on which the operation was performed, although we should certainly have the data to enable us to avoid this mistake—one which is not made by skillful diagnosticians with regard to any other region of the brain, unless it is occasionally the prefrontal.

In discussing this question of the side of the cerebellum on which a lesion is situated, as determined by a study of the symptomatology of

<sup>6</sup> Starr, M. A., *Organic Nervous Diseases*, 1903, p. 612.

<sup>7</sup> Schede, *Deutsche med. Wochenschr.*, July, 1900, No. 30.

the case, it should first be borne in mind that one half of the cerebellum exerts its influence on the same side of the body as itself, its action on the spinal cord being direct and not crossed. Bruce has so well presented the facts which should guide us in determining the side on which a tumor is situated that I shall take the liberty of presenting his views, founded as they are upon both close pathological and clinical investigation.

The limits of a paper intended to be chiefly clinical will not permit me to present at length the facts and arguments of this article, one of the most valuable contributions to cerebellar localization of recent years. I shall, however, summarize a few of its most salient points.

The cortex of the vermis contains the termini of at least six different tracts from the spinal cord. Bruce<sup>8</sup> holds that the direct cerebellar tract and the anterolateral tract of Gowers, which go to the cortex of the middle lobe, are afferent to the cerebellum. One tract from the nucleus of Deiters passes downwards into the anterolateral column of the spinal cord; another tract sends fibres to both the sixth and the third nuclei. The first of these tracts, which has been given the name of the vestibulospinal tract, has been traced to

---

<sup>8</sup> Bruce, Alexander, *Trans. of the Edinb. Medico-Chirurgical Soc.*, January, 1899.



the lowest part of the thoracic cord, and gives off fibres to the anterior cornua, these distributions being to the same side of the spinal cord as the nucleus. The third connection of Deiters's nucleus is with the roof nucleus of the middle lobe of the cerebellum. This tract is efferent. The cortex of the middle lobe of the cerebellum is connected by sagittal fibres with the roof nuclei.

The dentate nucleus is the chief seat of origin of the prepeduncle, fibres passing by way of the prepeduncle to the red nucleus and the thalamus. This nucleus being partly in the middle and partly in the lateral lobes, a tumor situated deeply enough to invade it or fibres passing from it to the prepeduncle will cause disturbance of equilibration of a peculiar kind.

"We may expect," says Bruce, "disturbances of equilibrium to be produced by symmetrical lesions situated within an area bounded by the intracerebellar path of the two inferior peduncles, of the two superior peduncles, and the dentate nuclei, in which the latter arise. This area contains the middle lobe (superior and inferior vermis, the roof nuclei, and the sagittal fibres connecting the latter with the cortex), and the cerebellovestibular tracts from the roof nuclei to the nucleus of Deiters. Lesions within this area may produce no such disturbances, provided they are

symmetrically situated with reference to the mesial plane, and especially if their growth is so slow that compensation is established *pari passu* with the disturbances they may tend to cause. On the other hand, lesions situated in the lateral lobes may produce no disturbance of equilibrium, provided they are situated entirely external to the intracerebellar paths of the upper and lower peduncles and of the nucleus dentatus (area of possible latency). If, however, these structures are interfered with, either by pressure or by direct involvement, then the characteristic symptoms of cerebellar disease will be produced, and will depend in their character and amount on the nature and extent of this interference. If the cerebellovestibular tract, or Deiters's nucleus, be injured, then the usual stimuli will not pass either to the anterior cornua of the cord or to the sixth (fourth) or third nuclei. Hence may result the weakness of the same side, the tendency to fall to that side, the impairment of the conjugate deviation to that side, the tendency of both eyes to be directed to the opposite side, and the lateral nystagmus which occurs, especially when the eyes are directed towards the same."

In what is here said the tumor is regarded as acting destructively, but if it acts as an irritative lesion it may cause rigidity or spasm of the same



side, with a tendency to fall toward the opposite side, the eyes being turned to the same side by irritation of the sixth nucleus of that side.

It may be asked, How is one to determine whether the tumor is acting as an irritative or a destructive lesion? The answer to this should be found in a study of the spastic or non-spastic condition of the limbs of one side, and a careful consideration of the side to which the eyes are turned.

In the case of Dr. Spiller, which was operated on by Dr. Frazier, the patient tended to always pitch or fall toward the right, and the tumor was found at necropsy on this side. The same was true of several cases observed by me.

Bruce,<sup>9</sup> in a second paper, has recorded a case of cerebellar tumor in which the principles of localization as taught in his first paper, were successfully put into practice. In this case the ataxic, asthenic, and ocular symptoms pointed to the left side, the patient pitching towards the left. The tumor was found on this side.

The diagnosis of a tumor confined to the middle lobe is relatively easy, and has already been indicated in the references just made to the two articles by Bruce.

---

<sup>9</sup> Bruce, Alexander, *Scottish Medical and Surgical Journal*, September, 1899.

In one of three cases recorded by Preston<sup>10</sup> a tumor of the vermis, probably "operable," was revealed by necropsy. This case exhibited abolition of the muscular sense (?) in both arms and legs, with inability to stand or walk and a tendency to always fall backward, never to either side. Necropsy showed a bilobar tumor compressing the vermis like a saddle in its inferior part. It also exerted some compression upon the quadrigeminum; it apparently had attachments to the callosum, falx, and tentorium.

While all the facts necessary for final decision regarding the effects on the brain of the direction of movement of lesions situated in different parts of the vermis are not yet at our command, it is probable, as usually taught, that destruction of the cephalic portion of the vermis will cause a tendency to fall forwards and irritation a tendency to fall in the opposite direction; while destruction of the caudal portion will cause a tendency to fall backwards, and irritation will bring about the muscular adjustment necessary to counteract this tendency. It has already been shown that destructive lesion involving the lateral lobe and vermis or that part of the lateral lobe containing portions of the cerebellovestibular and cerebellospinal mechanisms causes a tendency to

---

<sup>10</sup> Preston, *Allenist and Neurologist*, St. Louis, April, 1892.

Unable to display this page



ported results of lesions of the cerebellum experimentally produced and the effects of tumors resides in the fact that the former immediately and for a long time are irritative phenomena, while the latter, owing to their usually slow growth, produce their effect by inhibition, pressure, and destruction.

The asthenia, atonia, and astasia which Luciani so strongly emphasizes as the chief effects of destructive lesions of the cerebellum experimentally produced are well illustrated by clinical facts. The case of cerebellar tumor is asthenic, although not paralyzed, is atonic or flaccid rather than spastic, and is astatic or incoordinate. The extent and position of his asthenia, atonia, and astasia depend upon the extent and location of the lesion.

While clonic spasm is an infrequent local symptom of cerebellar tumor, it is occasionally observed. In a case recorded by Spiller, which was seen by the writer in consultation, the patient had at times fine twitching movements of the right extremities, although at times the movements were on both sides of the body.

Tremor, especially of the head and upper extremities, has been recorded as one of the results of physiological experiment on the cerebellum. It occurs in a large percentage of the cases of

Unable to display this page

speaking now of cases of tumor of the cerebello-pontile angle, in which the fifth nerve or its roots may be directly implicated. The cerebellum is above all a motor organ; its most distinctive focal symptoms, vertigo, ataxia, asthenia, and nystagmus being affections of motility.

A few words might be said in this connection about the diagnosis of cerebellar neoplasms from tumors of one or two other regions of the brain.

Tumors situated in one lateral lobe, but invading deeply so as to involve the cerebellovestibular apparatus and perhaps the vermis, may need to be differentiated from tumors of the superior parietal region. The chief diagnostic points in favor of the tumor being cerebellar are the absence of astereognosis and that of symptoms showing the loss or disturbance of muscular or cutaneous sensibility. Nystagmus as a rule is not present in parietal tumors, although this is a rule not without exception, especially if the tumor should extend far enough backward to involve the visual motor region of the cerebral cortex. Vertigo may be present in a parietal tumor, but the peculiar and extreme form of vertigo which has been described as due to disturbance of the cerebellovestibular tracts and centres is not observed in parietal cases. These cases are generally more distinctly unilateral in their symp-



toms, although unilaterality is occasionally quite marked in cerebellar tumors. The invasion symptoms of parietal tumor will help in diagnosis.

Tumors of the cerebellum need occasionally to be differentiated from prefrontal growths. This diagnosis is difficult only when the tumor is confined to the external portion of one lateral lobe, so that the symptoms given, such as ataxia and nystagmus, are not marked or are not present at all. I have seen but little of the frontal ataxia of Bruns; so little indeed as to make me doubtful of its existence as a true ataxia. The symptom when present is probably a pseudoataxia due to the impaired mentality of the patient in consequence of which his powers of attention and inhibition are so affected that he does not govern his movements quite normally. When a prefrontal growth is situated on the left, mental symptoms of a distinctive character are present, these being absent in cerebellar growths. The cerebellar patient is often feeble in pursuing his mental processes, which, however, are in themselves quite clear. If the prefrontal tumor invades backward, aphasia, agraphia, and unilateral motor paralysis may ensue.

As indicated when discussing the subject of nystagmus, disorders of ocular movements, and especially of associated movements, are among

the most frequent symptoms of cerebellar disease. Various cranial nerve symptoms are often observed in tumor of the cerebellum, but these are not necessarily present. They are the result either of pressure in the case of tumors of large size and marked density or of the invasion of the oblongata and pons and the nerve roots by tumors situated toward the inferior surface of the cerebellum. I am not speaking here of the special forms of tumor of the cerebellopontile angle, as, for instance, those which arise from the eighth nerve, but of growths which originate in the cerebellum proper. Neural symptoms when present are of much importance in questions of focal diagnosis and of prognosis; in the former in deciding the side on which the lesion is situated, in the latter by pointing to a less favorable outcome than when the neoplasm is confined to the substance of the cerebellum.

The nerve symptoms may be referable to any of the cranial nerves or their connections from the third to the twelfth. Among the most frequent are those indicating paralysis or paresis of associated ocular movements, paresis of the musculature supplied by the sixth or the seventh nerve, impairment of hearing from implication of the cochlear portion of the eighth nerve, disorders of taste due to involvement of the glosso-



pharyngeal or chorda tympani, and loss or perversion of sensation because of trigeminal disturbance. The nerves, their roots, or the tracts with which they are connected in the oblongatopons may be involved separately or conjointly. When the neural symptoms are due to pressure they are probably usually to be referred to direct nerve or nerve root involvement. While unilateral symptoms may point to true nerve implication, this distinction is by no means a sufficient one, as tumors of the cerebellum not infrequently involve jointly one lobe, one peduncle, and one side of the oblongata or pons.

Among the pontooblongatal pressure symptoms which may result from a cerebellar tumor are hemiparesis and vasomotor, cardiac, and respiratory disturbances. Convulsions, unilateral or general, but more commonly the latter, with unconsciousness, have occurred in a considerable percentage of the cases which have come under my observation.

With our present knowledge and views regarding the anatomy and physiology of the cerebral olfactory apparatus, it is at times difficult to determine how loss of smell, which is common in cerebellar tumors, is produced. In some cases it may originate in much the same way as optic neuritis and blindness occur, that is, from neural inflammation or from nerve choking.

With regard to the deep reflexes, little that is of value in focal cerebellar diagnosis is as yet at our command. We have observed the knee jerks lost, exaggerated, crossed, and differing on the two sides either as regards loss, impairment, or increase. Unilateral differences are sometimes of corroborative value when the question of the side on which a tumor is situated is under consideration. In one of the cases appended, for instance, the knee jerk was exaggerated on the side opposite to that on which the tumor was presumably situated, probably because the neoplasm exerted pressure downward on the pyramidal tract before its decussation. The Babinski response is usually absent, although it was present on the side opposite the lesion in one case. The superficial reflexes are usually unchanged.

Incontinence of urine and feces is present in a few cases apparently as symptoms referable to the presence of the tumor. Such incontinence is of course present in cases of tumor of the brain, no matter what its situation, when the disease has advanced to such a point, or the suffering of the patient has become so great that his mind is obtunded.

Other symptoms which have been occasionally



recorded in cases of tumor of the cerebellum are polyuria, glycosuria, and muscular wasting.

In the discussion of the papers of Bruce reference is made to the fact that tumors of one lateral lobe of the cerebellum may in some instances not give rise to symptoms, and, as indicated by Bruce, this is in those cases of lateral lobe disease in which the lesion does not extend inward far enough to invade the cerebellovestibular or cerebellospinal apparatus. This is not, however, the only explanation of cerebellar lesions without cerebellar symptoms. In other cases of very slowly developing tumors the cerebellum gradually accommodates itself to the lesion. It is well known that cases both of cerebral and cerebellar tumors are recorded in which the growths have undoubtedly been present for many years, and the fact was not discovered until they were unexpectedly revealed by necropsy.

Bruce, as already indicated, has also called attention to the fact that a tumor symmetrically disposed as regards the vermis, that is so developing as to uniformly implicate both halves of the vermis and equally the adjacent portions of the lateral lobe may not cause marked disturbance of equilibrium. Those cases of tumors of parts adjacent to the cerebellum, like the quadrigeminum, for example, in

Unable to display this page



bosis, multiple sclerosis, chlorosis, nephritis, intoxications, and infections, also syphiloma and tubercle. He also believed that they were not cases of hydrocephalus, although he was somewhat doubtful on this point.

In two cases of tumor not situated in the cerebellum, but so located as to obstruct the ventricular outlets, hydrocephalus was produced and the symptoms of cerebellar tumor were present. In three other cases in which no signs of internal hydrocephalus were present, cerebellar symptoms were exhibited. The necropsy in these cases showed absolutely nothing.

Cases such as these must be borne in mind when considering the diagnosis of a tumor of the cerebellum.

#### TUMORS OF THE CEREBELLOPONTILE ANGLE.

With regard to the connections of the growths with the nervous system, at least two forms of tumors are found in the cerebellopontile angle or recess, and this fact should be recognized when surgical procedure is contemplated. In the first place, the tumor mass may involve the substance of the cerebellum or one of its peduncles, and the oblongatopons, and, secondly, the tumor may originate in one or two of the cranial nerves and be largely confined to them, the acoustic being

especially the seat of such growths. With regard to tumors in both the substance of the cerebellum and of the bulb, many have been put on record and several have been seen by the writer. In a case of multiple sarcomatosis for several weeks under my care, and later passing into the hands of Dr. Spiller,<sup>12</sup> who records the case in full in a paper on multiple sarcomatosis, tumors, probably sarcomatous, involved the nervous substance in both cerebellar recesses, numerous other tumors being present in other regions both of the brain and spinal cord. When a tumor involves somewhat deeply the substance of the cerebellum and pons, it can only be partially removed, and even to accomplish this it will be necessary to assume considerable risk, as the operation is both difficult and dangerous. The cerebellopontile tumors most amenable to operation are the fibromata of the eighth nerve, which will next be briefly considered.

Besides reviewing the literature of the subject, Fraenkel and Hunt have recorded five cases of tumors of this kind with necropsies. With regard to the particular nerves on which these tumors occur, they say that "the eighth shows a marked predisposition and is most frequently in-

---

<sup>12</sup> Spiller and Hendrickson, *Am. Jour. of the Med. Sci.*, July, 1903.



volved, rather rarely on both sides. The trigem-  
inus is next in order. The facial is believed by  
some to be occasionally the seat of these tumors;  
its proximity to the acoustic nerve renders path-  
ological decision difficult." One point of great  
importance with regard to these tumors of the  
acoustic nerve is their peculiar formation, the  
manner in which they are encapsulated and the  
ease with which they can be removed with opera-  
tion if they are or become accessible through the  
work of the surgeon. They are usually oval or  
rounded and vary in size, some being as large as  
a hen's egg. They are attached to the nerve  
trunk, which has undergone atrophy because of  
their presence.

The pathology of fibromata of the acoustic and  
other cranial nerves is fully considered by Weis-  
enburg.

Although an acoustic neurofibroma is so close-  
ly related to the brain stem as to be within a few  
millimetres of it, nevertheless the symptoms of  
bulbar involvement may be entirely absent. This  
has been pointed out by von Monakow, in whose  
case vomiting, difficulty in deglutition, and bul-  
bar disorders of circulation and respiration were  
entirely absent. Von Monakow<sup>13</sup> indicates as  
the best diagnostic points for a neurofibroma

<sup>13</sup> *Berl. klin. Wochenschr.*, August 13, 1900, No. 33, p. 721.



of the acoustic, the absence of such symptoms as vomiting, dysphagia, etc., on the one hand, and on the other hand, the presence of general symptoms of cerebral tumor, such as headache, vertigo, and choked discs in association with cerebellar ataxia, rapidly developing deafness, paresis of the seventh and fifth nerves on the same side as the deafness, with associated ocular palsy, also on the same side, dysarthria and Gerhardt's symptom being absent. In such cases in addition, peripheral ear disease should be excluded. If ataxia is present, the tendency will usually be to deviate or fall toward the side of the lesion.

In the five cases of cerebellopontile nerve tumors reported by Fraenkel and Hunt, operation was attempted in only one; it would probably have been successful in one or two others if the procedure had been undertaken at the right time. In the case on which operation was performed the growth was nodular, was in the left ponto-oblongatal cerebellar space, and was of about the size of a hen's egg. It was broken up by the index finger and the fragments removed. The patient died of symptoms pointing to central cardiac and respiratory disorders.

Two cases of fibromata of the acoustic, of which photographic illustrations are given in the paper of Dr. Weisenburg, have recently fallen

under my observation. In one case an operation was performed over the cortical facial region and a lesion was found in this position. The main lesion, however, was undoubtedly the tumor of the cerebellopontile recess. The chief focal symptoms were one sided deafness, tinnitus, facial monospasm, hypæsthesia on one side of the face, nystagmoid movements, slight paresis of right abducens, vasomotor and cardiac disturbances; severe headache, nausea, vomiting, and optic neuritis were also present.

The fuller history of this case is given in the paper of Dr. Weisenburg. The notes of the other case are appended.

In this case a fibromatous tumor of the acoustic was unexpectedly found at necropsy in the cerebellooblongatopontile space. The record of this case is given to show how such a growth can be entirely overlooked. The necropsy revealed not only the presence of this tumor, but also marked hydrocephalus, which may have accounted for most of the symptoms presented by the patient, such as spasticity, mental hebetude, headache, and optic neuritis, but it was insufficient to account for them all. The patient's hearing on each side was never positively determined. Examinations for any of the special senses were unusually difficult after she came



to the hospital, and grew more and more so as days advanced. It is probable that she had loss of hearing on the side of the growth.

The patient was a woman forty-eight years old. The facts which could be obtained regarding her history before admission to the University Hospital were meagre. It was learned, however, that three or four years before she had an attack which was supposed to be one of grippe, and following this, inflammation of the middle ear on both sides accompanied by pus, which required the membrane of the tympanum on the right to be opened. This history clouded the diagnosis as regarded involvement of the acoustic nerve by intracranial neoplasm; in addition, as already stated, it was difficult to make a careful examination, owing to her mental state.

It was also learned from one of her physicians that two or three years before coming into the hospital she had complained of a feeling of cushions under her feet, and that at this time she had some anæsthesia of the right side of the face and of the right hand and leg. About a year before admission her legs began to grow stiff and she had sharp shooting pains in them. This stiffness increased and she had some difficulty of gait. At times she had been troubled with double vision. She had always been a sufferer from headache, but it was stated that this had not increased. For a year she had had difficulty in controlling her bowels and bladder.

Examination showed the patient to be dull and



apathetic. Her memory was greatly impaired, she was easily confused, and it was at times almost impossible to fix her attention. Her legs were markedly spastic, being flexed at nearly a right angle. The Babinski reflex was not present. The knee jerks were exaggerated. The left pupil was considerably larger than the right. Sensation was apparently everywhere preserved, although it was difficult to test for fine differences in sensation. Facial and masseter paralysis were not present, and except as above noted, the examinations, which were thoroughly made, were negative. An eye examination by Dr. de Schweinitz showed double choked discs and many hæmorrhages; there was no apparent muscle palsy.

An operation was performed by Dr. Frazier in this case for the relief of her general symptoms, the prefrontal region being selected. The ventricle was reached a short distance from the surface after the trephine opening had been made.

Probably a diagnosis could have been made in this case if the patient had been studied early and continuously. Late in the case the general symptoms were those of brain tumor, but the only focal symptoms which could be clearly determined by a study of the case and its history were the anæsthesia of one side of the face, and the probable impairment of hearing. Some of the symptoms, like the double spasticity, paræsthesia of the feet, and sharp shooting pains, seemed to point to spinal disease.





Unable to display this page

## REMARKS UPON THE SURGICAL ASPECTS OF TUMORS OF THE CEREBELLUM.

By CHARLES H. FRAZIER, M. D.,

PHILADELPHIA,

PROFESSOR OF CLINICAL SURGERY, UNIVERSITY OF PENNSYLVANIA;  
SURGEON TO THE UNIVERSITY HOSPITAL.

### ANATOMICAL CONSIDERATIONS.

The difficulties that attend any attempt on the part of the surgeon to expose, much less remove tumors from the cerebellum, differ very materially from those encountered in tumors of the cerebrum. Speaking upon this subject on another occasion I said that it seemed as though, in encompassing the cerebellum with such large cranial sinuses, nature has intimated that this organ was never to be subjected to exposure at the hands of the surgeon. When one takes into consideration the position of the lateral and the occipital sinuses with relation to the only means of access to the cerebellum, and the plane of the tentorium cerebelli, one realizes at once that there are especial technical difficulties in surgical attacks upon the cerebellum. (See Fig. 1.) Furthermore, it must be remembered that there are very distinct dangers attending manipulations upon the cerebellum and more particularly, if, in an attempt to get sufficient exposure to excise a tumor, one should



make too much traction upon the medulla oblongata. Even when one has removed a considerable portion of the skull below the superior curved line, there will be exposed to view but a small portion of the gross surface area of the cerebellum. Neither the upper surface, that is in relation with the tentorium cerebelli nor the anterior surface which is in relation with the petrous surface of the temporal bone, nor the mesial surface will be exposed to view by this procedure; whereas in the cerebrum the entire cortex and a considerable portion of the base can be laid bare by a very simple osteoplastic operation. Furthermore the cavity of the cerebellum is very much smaller than that of the cerebrum, so that there is very much less space in which to conduct the manipulations necessary either for exposure or removal of the tumor. In the adult skull one hemisphere of the cerebellum is contained in a cavity whose greatest dimension is only 10.5 cm. In addition to the difficulties that are associated with operations in a space so small and difficult of approach one is hampered further by the fact that even under normal conditions the cerebellar hemispheres are compressed in a relatively smaller space than the hemispheres of the cerebrum, and are under such tension that when tension is relieved by the reflection of a dural flap the cerebellar tissue almost invariably protrudes through the opening.

The tissues cannot be displaced or retracted neither to the same degree nor with as much ease as can the cerebral lobes. Thus the operator will be embarrassed in attempting to expose a lesion deeply situated, as for example at the cerebellopontile angle, a favorite seat for tumors.

In addition to the larger sinuses, the lateral and occipital, certain tributaries of sufficient size to cause, when injured, profuse and sometimes alarming hæmorrhage, penetrate that portion of the occipital bone which must be removed. The most constant of these is a branch of the lateral sinus which passes obliquely through the skull and appears in the surface between one and two centimetres to the inner side of the mastoid process; occasionally one or more will be found just below the superior curved line in the neighborhood of the occipital protuberance.

The occipital bone overlying the cerebellum is very variable in thickness. In the region of the mastoid process and of the occipital protuberance the bone is exceedingly thick, but from these two processes the thickness of the bone gradually decreases until at a point about midway between the two it will be found comparatively thin.

#### INDICATIONS FOR OPERATION.

In general terms it may be said that the indications for operation in cases of suspected tumors



of the cerebellum do not differ materially from those which have been endorsed in the treatment of tumors of the cerebrum. In both classes of cases once the diagnosis has been made, operation if it is to be performed at all, should not be postponed for any length of time. Physicians are too prone to put off the time indefinitely almost and to spend months in the often fruitless administration of antisyphilitics, or to spend an unwarrantable amount of time in efforts to establish a diagnosis beyond a peradventure of doubt, or to localize the tumor with mathematical accuracy. Kocher says there should be less delay in bringing to the surgeon a lesion of the encephalon, whether it be a neoplasm, tubercle, gumma or abscess. "There is no more excuse to-day for delaying operation in cases of tumors because the tumor could not be exactly localized, than there would be for declining to operate upon a case of intracranial hæmorrhage because one was unable to determine positively the seat of the clot. Failing in one place to find the tumor, other trephine openings may be made or a very extensive area may be exposed by an osteoplastic resection. How often, Kocher says, has one trephined over the anterior branch of the middle meningeal artery when the autopsy revealed the clot in the region of the posterior branch." The surgeon might come in for his share of criticism because of his lack of



precise knowledge concerning the neurological aspects of the disease. In order that the very best results be obtained the internist and the surgeon must work hand in hand in this as well as other fields. In cases of suspected tumors of the viscera an exploratory operation is now regarded as perfectly justifiable, and why? Because physicians have come to realize that if operation is postponed until the presence of the tumor can be demonstrated by palpation or other means, the lesion is by this time so extensive that the time for a radical operation has passed. As the exploratory operation is recognized as the surest, safest, and most reliable diagnostic measure in tumors of the stomach, it should be considered of equal value and importance in tumors of the brain. Postponement of operation should be discountenanced if for no other reason than because in cases of long duration patients with tumors of the brain make very poor subjects for operative intervention; the operation is of itself one of considerable gravity and the condition of the patient should be so good as to enable him to withstand its depressing effect.

Unfortunately tumors of the cerebellum are in the majority of instances more difficult of localization than tumors of the cerebrum and in many cases localization is well nigh impossible. Instead of regarding this, as has been the case so often, as

Unable to display this page

results of palliative operation in one of our patients (Case 4). The patient before the operation suffered from intense headache, was almost blind, and vertigo was so pronounced that he could not stand without support. The tumor could not be found but a large portion, perhaps one third to one half of one cerebellar hemisphere, was removed. His headache was relieved at once, within a week he was able to see as he lay in bed small specks on the ceiling, and on getting up was able to go about with but very little instability. Nothing could be more gratifying to the physicians in attendance than the relief which was afforded the patient by this comparatively simple procedure. In one of Krause's cases, after a palliative operation, the patient was relieved of many of the subjective disturbances and lived for a period of three years in comparative comfort.

*Operative Technique.*—Regarding the position of the patient, it is advisable to operate with his head and shoulders considerably elevated. This will diminish the hæmorrhage to a certain extent. The effect of the elevated position upon the blood pressure may be counteracted by applying a firm bandage to the lower extremities. In order to afford greater freedom for the necessary steps of the operation, I use an extension—a very simple appliance—which is easily attached to the operating table and



upon which the head rests (see Fig. 2). While using it in all operations upon the brain I find it most serviceable in operations upon the cerebellum where the quarters are especially cramped. In two operations upon the cerebellum Schede placed his patients in the sitting posture, leaning far forward. This posture, according to Schede, diminishes to a considerable degree the hæmorrhage, but the position is a very awkward and difficult one in which to retain the fully anæsthetized and relaxed patient. The patient may be placed upon his side but it is difficult to retain the patient in this position and there is always the tendency of the patient to roll over on his side, in which position the respiratory act will be embarrassed, and, inasmuch as many of the sudden deaths are due to respiratory failure, it is advisable to take such precautionary measures as will avoid any disturbance of the respiration.

*Incision.*—The incision should begin at the tip of the mastoid process on the affected side and follow a line parallel with, but one centimetre above the superior curved line, to the median line. From this juncture a vertical incision may be made downwards to enable one to reflect the flap sufficiently to expose the field of operation. Hæmorrhage from the scalp in this region is so profuse that some precautions should be taken to reduce to a minimum the amount of blood lost. A very excellent plan is





FIG. 2.—"A head rest" that may be used to advantage in operations upon the head. The device is a very simple one and does not require a screw or bolt to secure it in place.





to incise but an inch or an inch and a half at a time, proceeding at once to arrest the hæmorrhage in one section before incising the next. Considerable bleeding may be prevented if one reflects the pericranium simultaneously with the overlying muscles and their attachments. If this precaution is taken the muscles will not be mutilated to the same extent as would be necessary if an attempt was made to reflect them independently of the overlying periosteum. What may be not only a troublesome, but an alarming feature is the hæmorrhage from the various sinuses that traverse the occipital bone; these have already been referred to in the section on the anatomy. Suffice it to say that one should always be prepared with suitable means for controlling the bleeding from this source, since if uncontrolled, the patient may lose in a very short time a pint of blood or more. In one of our cases (Case 5) two anomalous sinuses almost as large in diameter as a quill were found near the occipital protuberance. Before the hæmorrhage could be checked the patient lost so large a quantity of blood that it was deemed advisable to suspend further interference until the patient had recovered fully from the effects of this complication. Following the administration of appropriate remedies, the patient reacted within a reasonable time, but about twelve hours after the operation, suddenly and



without any warning, the cardiac and respiratory functions failed and within ten minutes the patient was dead. Whether the loss of so much blood had anything to do with the termination of the case, is a matter purely of speculation. This instance is cited solely as an illustration of what may be a very serious complication, namely, hæmorrhage from the venous channels traversing the occipital bone. One should try to control the bleeding first with Horsley's wax and if, as in the case above referred to, this fails, the outlet of the sinuses should be closed with plugs of wood, which can be whittled to the proper thickness and length from ordinary swab sticks.

There need be no anxiety about the cranial sinuses as a possible source of hæmorrhage. The lateral sinus is fully exposed to view when the bone has been removed, and injury to this structure could result from carelessness only. The occipital sinus does not come within the field of operation unless one intends to remove the intervening bone, in which case the sinus will be exposed to view, and if necessary may be ligated (see Fig. 5).

*Removal of Bone.*—With Krause, Schede, and others I believe that it is unnecessary to preserve the overlying bone, therefore, the osteoplastic flap, which has done so much to revolutionize the surgery of tumors of the cerebrum, is not to be employed

in the exploration of the cerebellum. As both V. Bergmann and Kocher have said, the muscles and aponeurosis are thick enough at this point to offer adequate protection to the underlying structures and to make bony closure of the opening unnecessary.

An opening in the skull is made preferably with a chisel at a point about midway between the occipital protuberance and mastoid process. Here the bone is comparatively thin and as Foirier says this is the point of greatest safety. The opening so made is enlarged with rongeur forceps in all directions; outwards as far as one can go without opening the mastoid cells, upwards until the lateral sinus is entirely exposed to view, inwards to within a centimetre of the median line, and downwards to a point at least one centimetre distant from the foramen magnum. The removal of bone will be facilitated by using rongeur forceps, the blades of which are at an angle of about 65 degrees with the handles. As one approaches the region of the lateral and occipital sinus, the forceps should be laid aside for a moment and a dural separator introduced to separate the dura and the sinuses from the skull.

I prefer the chisel to the trephine for making the initial opening for two reasons: first because the opening can be made more rapidly with a chisel,



and secondly because the operation of a trephine in this region is a somewhat awkward procedure.

*Exploration.*—After a dural flap, with its base downwards, has been reflected, one proceeds to search for the tumor, unless it has been decided to resort to the *two stage operation*. The principles which we have applied in deciding this question are precisely those which have been adopted in our operations for tumors of the cerebrum (see *American Journal of the Medical Sciences*, February, 1904). If, when the preliminary stages of the operation have been completed, the condition of the patient, as revealed by the blood pressure and pulse record, is one of depression or shock, the final stage of the operation should be postponed until the patient has reacted. Having decided to continue the operation the surgeon proceeds to inspect and palpate the surface exposed to view. If the cerebellar tissues protrude considerably through the opening once the dura is incised, the presence of a tumor or an internal hydrocephalus should be suspected. It should be borne in mind, however, that under normal conditions the cerebellum is under greater tension than the cerebrum, and when the dura is incised the normal cerebellum will protrude in many cases through the opening to a slight degree.

If the clinical symptoms, to which are added the presence of an anomalous condition revealed by

the sense of sight or touch, lead one to believe the tumor is situated in the lateral hemisphere, the subsequent steps of the operation should consist in an exploratory incision into the cerebellar tissue, and, if the tumor is found, in its complete extirpation. The impunity with which we can freely incise the cerebellar hemisphere without the risk of such disturbance of function as would follow a similar procedure in the motor area of the cerebral cortex should be borne in mind. A failure to find or expose a tumor of the cerebellar hemisphere because of an insufficient exploratory incision should be regarded as inexcusable unless the tumor was of very small dimensions. If on the other hand there is reason to believe the growth is situated at the cerebellopontile angle, a favorite site for cerebellar tumors, the subsequent steps of the operation will be attended with some difficulty. It may be possible in exceptional cases with the aid of a retractor to displace the cerebellar tissue sufficiently to expose the tumor, but in the great majority of cases one must resort to one of two methods to bring the tumor into view; either a portion of the cerebellar hemisphere must be removed or the ventricles must be punctured.

#### PUNCTURE OF THE VENTRICLES.

This procedure has been resorted to for two purposes, first as a purely palliative measure to relieve



Unable to display this page

to the escape of cerebrospinal fluid than to the removal of a large section of the skull. Therefore in those cases in which the pressure symptoms are very marked but the tumor cannot be localized he recommends the removal of the cerebrospinal fluid by Quincke's lumbar puncture. This procedure he says is much to be preferred to any others, but failing in this recourse should be had to direct puncture of the lateral ventricles. According to Oppenheim lumbar puncture is indicated in a very limited number of cases, chief among which are those in which the tumor is associated with an internal hydrocephalus and especially when the tumor encroaches upon the posterior fossa and threatens the life of the patient. In a series of 50 cases collected by Piollet (*Archives provinciales de chirurgie*, Vol. x, p. 728) lumbar puncture was employed in eight cases; in four patients there was transitory amelioration, and four died within a few days. The sudden disturbance of pressure is no doubt responsible for a large majority of the fatalities. In a few cases the fatal issue has been attributed to the pressure of the structure of the posterior fossa against the foramen magnum, an accident which could easily happen when the communication between the cerebral and spinal cavities was partly or altogether shut off and the vacuum created by aspiration drew the pons and medulla forcibly into



the foramen magnum. If lumbar puncture is resorted to, such an apparatus should be used as Koenig suggested, in which the pressure is recorded while the fluid is being withdrawn. With this precautionary measure the danger of lumbar puncture would be reduced to a minimum. Fürbinger who is very much opposed to this practice attributes the deaths to pressure exerted upon the bulb by the arrest of cerebrospinal fluid from the ventricles at the foramen of Magendie.

#### CONTINUOUS OR INTERMEDIATE DISCHARGE OF CEREBROSPINAL FLUID.

The advisability of affording means for the escape of cerebrospinal fluid as a palliative measure might well be considered in connection with puncture of the lateral ventricle or lumbar puncture. There are cases on record in which, subsequent to operation, the flap has been punctured repeatedly for the purpose of relieving tension. After an exploratory operation, in which the tumor was not found, Terrier punctured the flap repeatedly and withdrew a considerable quantity of fluid, but the patient died in the third week after this form of treatment was adopted. Jaboulay noticed the beneficial effect attending the escape of cerebrospinal fluid through a fistula in the cicatrix and recommends the establishment of such a fistula in cases

in which the improvement after operation was only transitory or in which there was no improvement. Theoretically at least such a treatment should afford some relief from the effects of intracranial pressure and might be justifiable in inoperable cases, but one must bear in mind the constant danger of infection that must needs attend the presence of a communicative tract between the surface and the underlying structures.

#### EXPOSURE OF THE CEREBELLOPONTILE ANGLE.

To return to the question of exploration from which we digressed to consider the propriety of puncture of the lateral ventricles: To enable one to expose a tumor situated in the cerebellopontile angle two methods were proposed, tapping of the lateral ventricles, and removal of a large portion of the cerebellar hemisphere. The former method we disapprove of on the grounds that it is so fatal in its tendencies. The alternative on the other hand is attended with very different results. The impunity with which large sections of cerebellar tissue may be cut away not only without endangering life but without disturbance of function is an observation which was made by physiologists long ago. That the deduction naturally to be drawn from this bit of laboratory information has not been made use of by surgeons more generally is a matter of some



surprise. The danger of exerting undue pressure or traction upon the pons or medulla in attempting to expose or remove the tumor is more to be dreaded than any other stage of the operation. It was only recently that Woolsey (*Annals of Surgery*, September, 1904) reported a case of neurofibroma of the acoustic nerve; the tumor was removed but the patient died three hours after the operation, and death was believed to be due to hæmorrhage within the pons. Woolsey was convinced that this was due to the traumatism indispensable to the frequent introduction and withdrawal of the fingers engaged in the removal of the tumor. Here is a case in which had a considerable portion of the hemisphere been removed prior to the attempts to extract the tumor it is more than likely that the unfortunate accident would not have occurred. My experience with this procedure has been limited to two cases which will be referred to again. In one of these (Case 2) a considerable portion—from one third to one half—of the hemisphere was removed deliberately in searching for the tumor, without any appreciable effect upon the patient's general condition. In another case (Case 4) the same practice was adopted with equally negative results in so far as the patient's respiratory or circulatory functions were concerned. In neither of these cases was the tumor found at the first operation, but the amelioration

that followed was striking. At a second operation upon one of these (Case 2) the tumor presented itself upon the surface of the remainder of the cerebellar tissue and was removed without any difficulty. This experience at once suggested to my mind what would seem to be additional argument in favor of the deliberate removal of a large portion of the hemisphere; on the one hand serving as a means of affording adequate exposure with the minimum degree of traumatism to pons and medulla, on the other serving as a means of relieving intracranial tension temporarily, and at the same time, by removing a certain amount of resistance, of facilitating the growth of the tumor toward the surface of a point where it can be more easily seen and removed. Last year Hudson (*American Journal of the Medical Sciences*, September, 1903) reported two operations for cerebellar tumors, in one of which at least a large portion of the hemisphere was removed in searching for the tumor. The patient reacted promptly and although the tumor was not found, began at once to improve. On a subsequent occasion the wound was reopened and a large cyst found and evacuated. I feel convinced that this procedure, if more universally adopted, will do much toward increasing the percentage not only of tumors found, but of tumors removed, and will at the same time reduce the mortality.



#### SHORTEST ROUTE TO THE CEREBELLOPONTILE ANGLE.

Before concluding our remarks upon the means of exposing tumors in the cerebellopontile angle a word should be said concerning the best method of approach. One has but to turn to a cross section of the cerebellum to see that the shortest distance from the surface of the skull to this snug corner is along a line parallel with the petrous portion of the temporal bone (see Fig. 3). Krause, in describing an operation for the division of the eighth nerve (*Beiträge zur klinische chirurgie*, Bd. XXXVII, Heft. 3), and others have made this anatomical observation. The distance along this line being the shortest it goes without saying that the cerebellopontile angle should be approached from the lateral rather than superior or inferior aspects of the cerebellum. The bony opening should extend as near to the mastoid process as possible. This is not only the shortest but the safest route in that the manipulations are carried on at a point farthest distant from such vital structures as the pons and medulla.

#### OPERATIONS UPON THE FIFTH AND EIGHTH NERVES IN THE CEREBELLAR FOSSA.

In an exploration of the anterior aspects of the cerebellum in the cerebellopontile angle for tumors, one exposes the posterior plane of the petrous portion of the temporal bone, and with it the fifth,

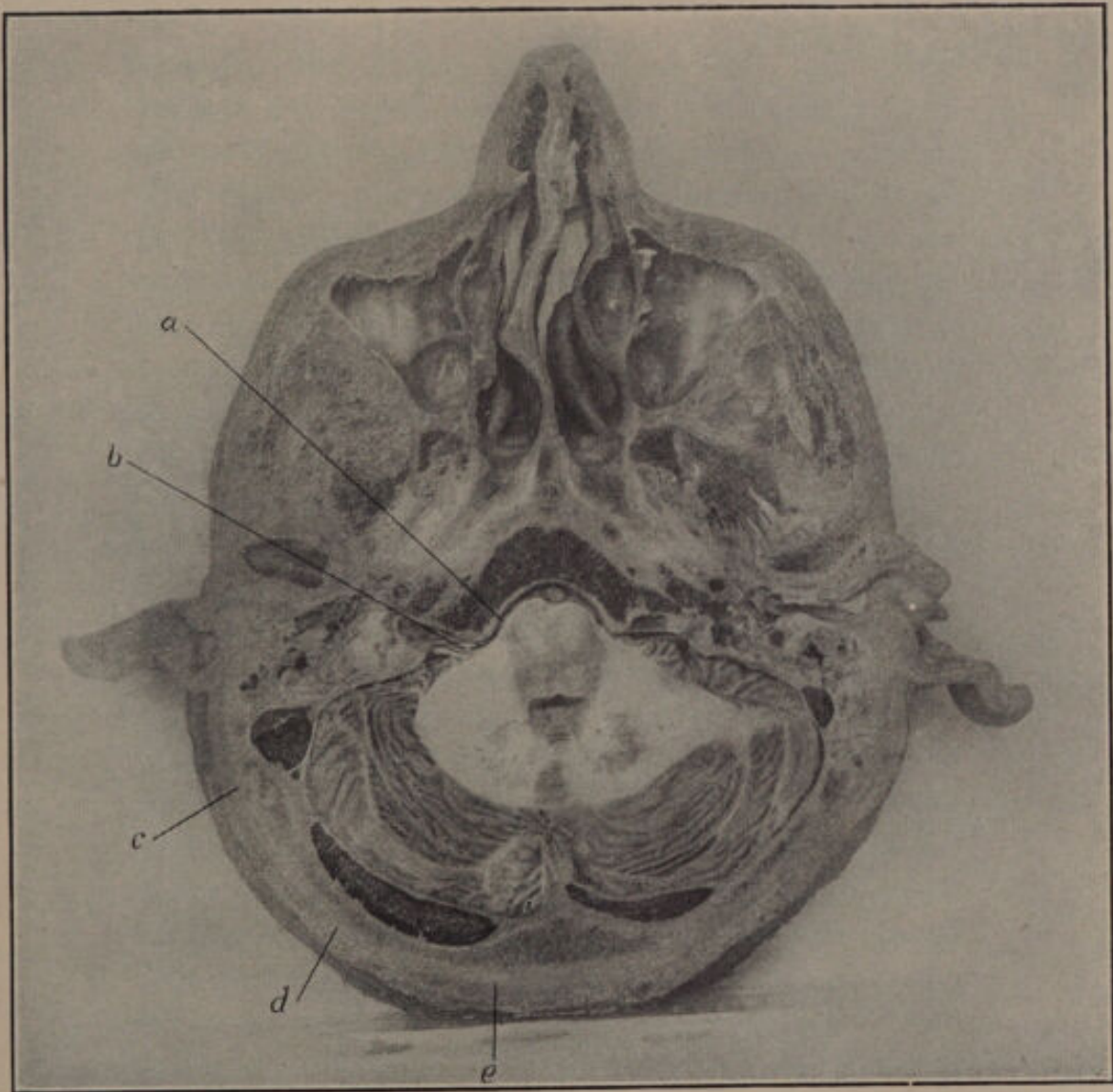



FIG. 3.—Photograph of a horizontal section of the head cut on a level with the external auditory meatus; *a*, representing a point at the cerebellopontile angle; *b*, the auditory nerve entering the internal auditory meatus; *c*, *d*, *e*, three points on the skull. Note the distance between point *a*, and the points *c*, *d*, and *e* as illustrating the shortest route to the cerebellopontile angle respectively. The shortest distance from the skull to the angle is measured along a line drawn between *a* and *c*. The farther away from *c* or the nearer to *e* the greater will be this distance.





seventh, and eighth nerves (see Fig. 4). The seventh and eighth nerves will be seen passing from the cerebellum to enter the internal auditory meatus. The eighth nerve is the larger of the two and overlies the seventh nerve in such a way that it almost entirely conceals it from view. Farther along, at the apex of the petrous portion of the temporal bone, will be seen the sensory root of the trigeminus as it passes into the groove in which it traverses the petrous bone to enter the Gasserian ganglion. These three nerves, together with the ninth, tenth, and eleventh, may be said to be accessible, so that it is quite possible, if the indications arise, to divide any of them. It is not likely that, in operations for the relief of trifacial neuralgia, one would be called upon to divide the sensory root in the cerebellar fossa because the root and ganglion are more easily approached by the temporal route. In one of the cases of our series we seriously discussed the possibility of dividing the root in the cerebellar fossa and fully intended to do so under certain conditions. The case was one in which there were certain symptoms of cerebellar tumor and in addition intense trifacial neuralgia. If the tumor could not be found it was thought best to afford the patient relief at least from the neuralgia by dividing the sensory root. However, a cyst was found and evacuated and no further intervention seemed advisable. The



patient was relieved entirely and has remained free from pain now more than a year since operation. There is no conceivable indication for any operative attack upon the seventh nerve within the fossa, but in the case of the eighth nerve Krause has recommended and practised its division for the relief of persistent tinnitus aurium. As recommended for tumors of the cerebellopontile angle, so here the nerve should be approached from the lateral rather than posterior aspect as from this point is measured the shortest distance from the skull to the nerve. The only difficulty, if there is any in the operation, will be met with in separating the eighth from the seventh nerve. The latter as has been said lies directly behind as one views the field from the side and the precaution must be taken to separate one from the other before attempting a nerve section. This is readily done with the aid of a small blunt hook (see Fig. 4).

SIMULTANEOUS EXPOSURE OF BOTH HEMISPHERES;  
BILATERAL CRANIECTOMY.

The difficulty in localizing cerebellar tumors is known to all clinicians. In an analysis of the 116 cases which we have collected we find that in 55 per cent. the operation was a failure because the tumor was not found. The diagnosis of cerebellar tumor is in many cases not so difficult, but in many of these





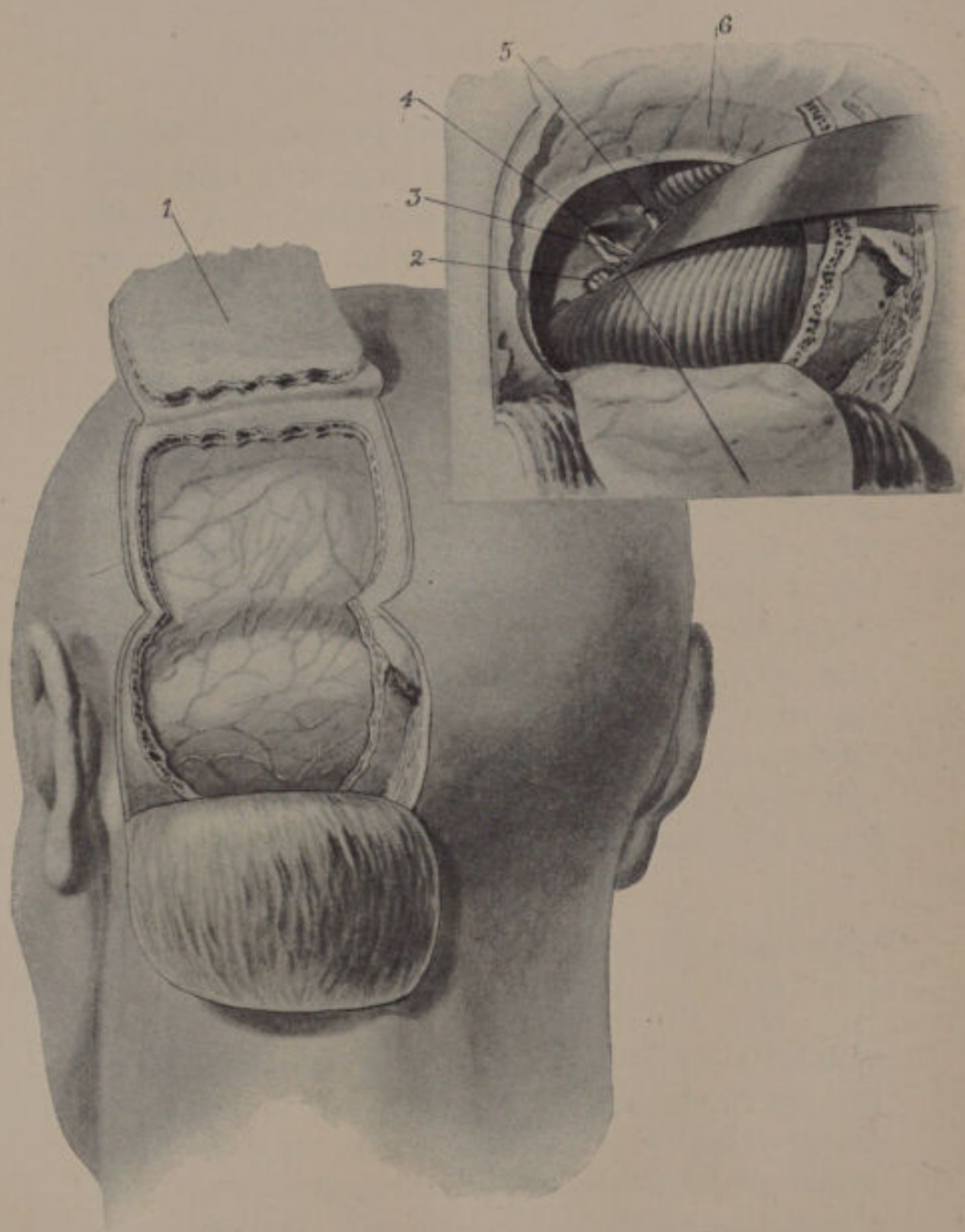


FIG. 4.

FIG. 4.—The larger figure to the left illustrates the operation for the combined exposure of one cerebellar hemisphere and the occipital lobe of the cerebrum. The smaller figure,

above and to the right, illustrates the structures in relation to the anterior aspect of the cerebellum and the petrous portion of the temporal bone. Attention is called especially to the position of the 5th, 7th, and 8th cranial nerves. This drawing was made by viewing the structures from the lateral aspect, such an exposure as would be made in exploring for tumors of the cerebellopontile angle. 1. Osteoplastic flap reflected in an operation for the combined exposure of occipital lobe and cerebellum. 2. Ninth, tenth, and eleventh cranial nerves. 3. Auditory nerve drawn to one side by refractor in order to expose. 4. The facial nerve which lies directly beneath it. 5. The root of the trigeminus as it enters the groove at the apex of the petrous portion of the temporal bone.

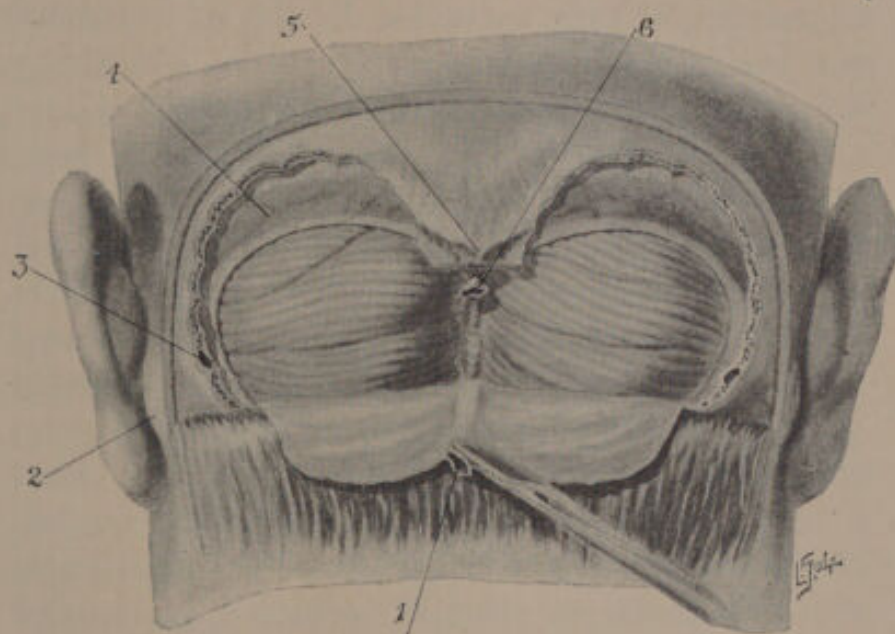



FIG. 5.—Operation for the simultaneous exposure of both cerebellar hemispheres, necessitating ligation of the occipital sinus. 1. The occipital sinus, which has been ligated previously and reflected with the dura. 2. Mastoid process. 3. A large tributary of the lateral sinus, invariably opened in cerebellar craniectomies and of varying dimensions; said to be sometimes as large as the lateral sinus. 4. Lateral sinus. 5. Occipital protuberance. 6. Occipital sinus.





it will be almost impossible to determine beforehand whether the tumor is in the right or left lobe. Therefore in the course of an exploratory operation, when one has failed after a thorough search to find the tumor on the side which was opened first one must decide whether to proceed at once to explore the opposite side. In most instances further exploration should be postponed until the patient has reacted from the effects of the injury already inflicted. In one of our cases already referred to (Case 4) a section of the cerebellar hemisphere was removed to relieve tension temporarily and with most gratifying results. But whether this procedure is justifiable in the light of the probable existence of a tumor on the other side, might with propriety be questioned. In order to enable one to examine both hemispheres at one sitting the authors discussed the feasibility of performing a craniectomy on both sides and removing the intervening bone. This operation was performed upon the cadaver from which the illustration in Fig. 5 was drawn. The operation may be carried out as follows: An opening is made on either side in a manner similar to that when the operator is confined to one side. The dura and with it the superior longitudinal sinus are separated so that they may escape injury when the overlying bone is divided; a pair of forceps or preferably a Gigli saw may be



used to section the intervening bridge of bone. The Gigli saw is to be preferred because it is less likely to comminute the bone, which must be divided very near the foramen magnum. The falx cerebelli is punctured in either side of the occipital sinus and the sinus divided between two ligatures (see Fig. 5). This will enable one to reflect a flap of the dura covering both hemispheres and afterwards to displace the cerebellum with greater freedom than would be possible if an unyielding bridge of bone remained between the two openings. In the preparation of this paper we found upon perusal of the literature that this procedure has been recommended by Kocher, Nothnagel (*Path. u. Ther.*, Vol. IX), and Krause (*Beiträge zur klin. Chir.*, Bd. XXXVII). The latter performed this operation in a case in which there was much uncertainty as to the position of the tumor; in order to relieve tension still further, he punctured one lateral ventricle. The results were reported to be satisfactory in so far as the freedom with which the various aspects of the cerebellum could be exposed. The patient died one week later and the autopsy revealed an internal hydrocephalus, but no tumor. We are not prepared to endorse this operation as a routine procedure but believe it should be restricted to those cases in which the tumor is believed to occupy a position near the mesial surface. Under any circumstances

it should be practiced at two sittings; the additional trauma and hæmorrhage which must accompany such an extensive incision and the removal of such an extensive section of bone would we believe add materially to the gravity of what under any circumstances is an extraordinarily serious operation.

#### LIGATURE OF THE LATERAL SINUS.

A discussion of the operative procedures in the region of the cerebellum would be incomplete did we not include some reference to ligation of the lateral sinus. In an attempt to expose tumors particularly of the anterior surface of the cerebellum the operator is hampered by the tentorium cerebelli, and the suggestion has been made by Kocher, Krause, and others that the tentorium cerebelli be divided down to the petrous portion of the temporal bone after the lateral sinus has been ligated. It is stated by Krause that one of the sinuses can be ligated without much risk, and on at least one occasion the idea was put into effect. The advantage to be gained by this modification of the technique I do not believe compensates for the additional risk that must be entailed. If the mortality following operations upon the cerebellum is to be reduced, the technique must be as simple as possible, the least



Unable to display this page

TABLE I.—CASES UNDER AUTHOR'S OBSERVATION DURING PAST TWELVE MONTHS.

Case 1..	Craniectomy.	Tumor found and removed.	Recovery.
Case 2..	Craniectomy.	Tumor found and removed.	Recovery.*
Case 3..	Unilateral craniectomy.	Tumor not found.	Recovery from operation, without improvement. Patient would not consent to further exploration.
Case 4..	Craniectomy..	Tumor not found; one-third of hemisphere removed	Striking improvement. Restoration of vision, relieved of headache, vomiting, and vertigo.
Case 5..	Craniectomy; 2 stage operation planned.	Dura not opened.	Death, sudden and unaccountable, twelve hours after first stage.
Case 6..	Craniectomy.	Cyst found and evacuated.	Recovery from operation; great relief of headache and other symptoms.

\* Since this writing there has been a recurrence of the growth.

Still further condensed the results were as follows: Of 6 cases: 1 died after first stage of operation; 2 recovered after removal of tumor; 1 relieved after evacuation of cyst, no recurrence more than a year after operation; 1 considerably improved after palliative operation; 1 no improvement; tumor not found.

My personal experience with this series of cases leads me to believe that the dangers attending cerebellar operations have been somewhat exaggerated.



The present generation of surgeons has inherited the traditional fear of operations within the cranial cavity. It was not very long ago that operations upon the Gasserian ganglion were regarded as desperate undertakings, when it was a case of kill or cure, whereas at the present time the operation is undertaken with no especial concern except upon individuals, who on account of their advanced years might be unfavorable subjects for any major operation. And so it is with tumors of the brain generally and especially with regard to tumors of the cerebellum. Physicians put off the question of operation until the patient's condition becomes critical and the surgeon undertakes the operation with fear and reluctance. It was not so long ago that Oppenheim classed all tumors of the cerebellum as inoperable, but in the last editions of his book (1902) he frankly confesses that his opinion on this point is in need of revision.

The dangers and risk peculiar to this operation lie in the proximity of the medulla and pons to the field of operation and the traumatism to which they may be subjected in the course of the operation. It is on this account that stress has been laid upon the advisability of approaching the cerebellopontile angle from the lateral aspect in order not to injure these structures. In a case of Woolsey's previously referred to, the autopsy revealed a hæmorrhage in

the pons which the operator attributed to the traumatism to which it was subjected while he was removing piecemeal a tumor of the auditory nerve. If in the fatal cases a careful examination of pons and medulla had been made we believe that in a majority some evidence of traumatism would have been found. *It is only in the avoidance of every possible source or degree of traumatism to these vital structures* that surgeons can hope to obtain better results. In this connection we refer again to the impunity with which a considerable portion of one cerebellar hemisphere can be removed, since by so doing the operator not only can explore and expose the tumor, but also remove it without the necessity of exerting undue traction or pressure directly or indirectly upon the pons. This of course applies especially to tumors that were not within the hemisphere.

We have been struck especially with the comparatively slight depression attending operations upon the cerebellum and with the rapidity with which reaction ensues. In one of our cases the patient lost a large quantity of blood in a very short time, but recovered promptly from the effects, after the administration of appropriate remedies. This patient died twelve hours after the operation suddenly and unexpectedly, but ten minutes before he died his general condition was reported as excellent.



Our experiences, however, we believe to be exceptional, as there are recorded in literature many cases in which the patients died on the table or a few hours after the operation.

We have noted, however, that the gravity of the operation does not seem to have been affected by the act of removing the tumor; whether the operation was solely exploratory or palliative, or whether a tumor was removed, the effect upon the patient was the same.

In all these operations careful records of the blood pressure were made, with a view of ascertaining whether the actual removal of the tumor was attended with or followed by lowering of the blood pressure. The results, however, were negative.

STATISTICAL STUDY OF 116 CASES OF OPERATION  
UPON THE CEREBELLUM, COLLECTED BY FRAZIER.

The following statistics were compiled from the 116 cases of cerebellar tumors found in the appended table, pp. 334 to 337:

	Per cent.
Tumors found.....	45
Tumors not found.....	55
Removal with recovery.....	15
Removal with improvement.....	13.9
Removal without improvement.....	0.9
Improvement without removal.....	13.9
No improvement without removal.....	13.9
Death when tumor was removed.....	12.9
Death when tumor was not found and not removed.....	28.7

A COMPARISON OF THE STATISTICS OF SUCCESSIVE DATES, SHOWING AN INCREASE IN THE PERCENTAGE OF RECOVERIES AND IMPROVEMENTS, AND A REDUCTION IN THE MORTALITY.

Results.	Frazier's table.—1904. Per cent.	Duret's table.—1903. Per cent.	Oppenheim's table.—1902. Per cent.
Recovery .....	15	14	7.5
Improved .....	28	25	7.5
Unimproved .....	15	..	13
Mortality .....	42	60	71

A COMPARISON OF THE STATISTICS OF TOTAL NUMBER OF CASES IN FRAZIER'S COLLECTION WITH THE STATISTICS OF THE LAST FIVE YEARS, SHOWING A MANIFEST IMPROVEMENT IN THE RESULTS.

Results.	Total number of cases. Per cent.	Cases reported during past five years, 1899—1904. Per cent.
Recovery .....	15	24
Improved .....	28	28.5
Unimproved .....	15	11
Mortality .....	42	35.8

From a review of these tables one is struck at once with the progress that has been made in this field of surgery from every point of view. The percentage of tumors found is yearly growing larger, the percentage of partial or complete recoveries is larger and the mortality has fallen from 70 per cent. to 38 per cent. We believe that the results of surgical intervention upon the cerebellar hemisphere will continue to improve, if not generally, at least in the hands of those who are giving this subject especial thought and attention.



FRAZIER'S TABLE OF 116 CASES OF CEREBELLAR TUMORS IN WHICH OPERATIVE TREATMENT WAS RESORTED TO.

No.	Authors.	Age, Sex.	Nature and Position of Tumor.	Tumor Found or Not Found.	Results.
1	Albert. <i>Wien. med. Woch.</i> , 1895, No. 1.....	39 years. M....	(Autopsy) Endothelioma of tentorium, penetrating left lobe .....	Not found.....	Improvement. Death December 6th.
2	Annandale. <i>Edinburgh Hosp. Rep.</i> , 1895, p. 127 .....	.....	Sarcoma of right lobe.....	Removed .....	Improvement after two months.
3	Azais. Montpellier thesis, 1900-1901, No. 31.....	37 years. M....	Sarcoma in substance on superior aspect.....	Not found.....	No relief, pain worse; death in two weeks.
4	Beck. Thèse de Paris, 1896, p. 221.....	42 years. F....	(Operated on at the age of 27 for tumor of breast.) Carcinoma of pons.....	Not found.....	Death, third day after operation.
5	Bennett. <i>Lancet</i> , May, 1887, p. 768.....	7 years. M....	Tubercle of right lobe.....	Removed .....	Death from shock several hours after.
6	Von Bergmann. <i>Berl. klin. Woch.</i> , 38, p. 219.....	.....	Cyst .....	Removed.....	Recovery.
7	v. Bergmann. <i>Deutsche Med.-Zett.</i> , 1901.....	12 years. F....	Cyst under tentorium, arising from gliomatous tumor.....	Removed.....	Recovery.
8	Bevor-Ballance and Lunn. <i>Brain</i> , 1897.....	.....	Fibrosarcoma, anterior right cerebellum .....	Removed.....	Recovery.
9	Birdsall. <i>Med. News</i> , 1837.....	.....	Spindle cell sarcoma, left side; medulla compressed .....	Not found.....	Death after two months; metastasis into neck.
10	Borellus. <i>Neurol. Central-bl.</i> , 1897, p. 1063.....	23 years. M....	Fibroma, size of goose egg in right fossa.....	Not found; no distinct local symptoms .....	Death shortly after operation.
11	Bradford and Knapp. <i>Jour. of Ment. and Nerv. Dis.</i> , 1892, p. 97.....	28 years. M....	Glioma of left lobe.....	Not found.....	Improvement as to headache; death several weeks later.
12	Brewer. <i>Med. News</i> , 1899.....	26 years. M....	Tumor, situated near median line .....	Removed .....	Improvement; recurrence; death in two months after second operation.
13	Bruce, Edinburgh. <i>Lancet</i> , 1899, p. 159.....	34 years. M....	Central tumor, including pons and vermiform process.....	Not found.....	Sudden death three days later.
14	Bullard and Bradford. <i>Boston Med. and Surg. Journal</i> , 1891, I, 231....	.....	Tubercle of cerebellum.....	Not found.....	Death during operation; hemorrhage from wound of superior longitudinal sinus.



15 Carracciolo, R. <i>Pollicinico</i> Vol. IX, Fasc. 12.....	.....	Tumor of R. cerebellar lobe with compression and dis- placement of bulb.....	.....	.....	.....
16 Chipault and Raymond, <i>Cliniques</i> , 1898, VIII Lesson .....	25 years. F....	Tumor (perhaps tubercle), prob- ably situated inside and be- low left lobe.....	Found, but not removed .....	Improvement; cerebral hernia; reappearance of symptoms af- ter two months.	.....
17 Chipault and Raymond, <i>Cliniques</i> , 1898, VIII Lesson .....	28 years. F....	Tumor of anteroinferior portion of both lobes, including pe- duncles .....	Not found.....	No improvement; death several weeks later.	.....
18 Churton, <i>Brit. Med. Jour.</i> , 1899, I, 1098.....	30 years. M....	Doubtful tumor (ataxia, head- ache, etc.).....	Not found.....	Rapid recovery.	.....
19 Collins and Brewer, <i>Med.</i> <i>Rec.</i> , 1897, May 15.....	28 years. M....	Tubercle of right lobe (autopsy)	Removed .....	Sudden death during second op- eration, after recurrence.	.....
20 Cuneo, <i>Congr. de chir.</i> <i>It.</i> , 1899.....	32 years. M....	Sarcoma of left lobe.....	Removed .....	Death on twentieth day, menin- goencephalitis.	.....
21 D'Alloco et Sajanlt. <i>Re-</i> <i>form. med.</i> , 1896.....	19 years. M....	Cystic gliosarcoma of entire cerebellum .....	Puncture of cyst; tumor not re- moved .....	Death on eighth day.	.....
22 Deansley, <i>Lancet</i> , 1901..	14 years. M....	None discovered.....	Not found.....	Improvement.	.....
23 <i>Ibid.</i> .....	30 years. M....	Not found.....	Not found.....	Slow and slight improvement.	.....
24 <i>Ibid.</i> .....	18 years. M....	Not found.....	Not found.....	Almost complete relief.	.....
25 Descos, <i>Lyon méd.</i> , XCIL	.....	.....	Not found.....	Death.	.....
26 Deaver and Mills, <i>Boston</i> <i>Med. and Surg. Jour.</i> , 1892, II, 221.....	11 years. M....	Pulsating tumor of occipital region. Autopsy; diffuse gli- oma of 4th ventricle and of both lobes .....	Not found.....	Death after several months.	.....
27 Dercum and Heath, <i>Phila.</i> <i>Hosp. Rep.</i> , 1890, I, 270.	.....	Tumor; hydrops of ventricle...	Not found.....	Death on fifth day.	.....
28 Diller, Pittsburgh, <i>Med.</i> <i>Review</i> , 1892, 292.....	39 years. M....	Autopsy; gumma about as large as a pigeon's egg in right lobe, including the vermiform.	Not found.....	Death forty-eight hours after, without return of conscious- ness.	.....



No.	Authors.	Age, Sex.	Nature and Position of Tumor.	Tumor Found or Not Found.	Results.
29	Durante. <i>Chir. nerv.</i> , Chl-pault, Vol. 1, 1902....	11 years. F....	Glioma of median lobe.....	Not found.....	Death twenty minutes later. Enormous dilatation of ventricles and aqueduct of Sylvius.
30	Durante. <i>Ibid.</i> .....	37 years. F....	Tumor of right lobe.....	Removed .....	Death one hour afterward from shock.
31	Duret. <i>Congrès fr. de chir.</i> , 1903.....	45 years. M....	Sarcoma of left lobe.....	Not found.....	Operative recovery; death sixteen days afterward.
32	Ferrier and Burghard. <i>Brain</i> , 1901.....	12 years. M....	Fibroendothelioma of right lobe.	Removed .....	Recovery.
33	Fischer. <i>Journal of Nerv. and Ment. Dis.</i> , 1895, 544.	30 years. F....	Glioma of right lobe (autopsy).	Not found.....	Death in the third week (infection).
34	Fison and Luckham. <i>Lancet</i> , 1900, II, 329.....	16 years. M....	Tubercle of left lobe.....	Not found.....	Death four hours after operation.
35	Frazier and McCarthy, N. Y. <i>Med. Jour. and Phil. Med. Jour.</i> , Jan. 22, '04.	10 years. M....	Glioma of right hemisphere....	Removed .....	Symptoms relieved. Improvement continuing two months after operation.
36	Frazier and Mills. <i>Ibid.</i> ..	23 years. F....	Sarcoma of left hemisphere, about size of hazel nut.....	Removed .....	Recovery.
37	Frazier and Mills. <i>Ibid.</i> ..	41 years. M....	Tumor not found.....	Not found.....	Recovery from operation, no improvement; patient declined further operative intervention.
38	Frazier and Mills. <i>Ibid.</i> ..	F. ....	Cyst .....	Cyst evacuated..	Recovery.
39	Frazier and Mills. <i>Ibid.</i> ..	Adult, M.....	Tumor not found.....	Not found.....	Recovery from operation, immediate relief from headache, vomiting, vertigo, and dimness of vision.
40	Gerster. <i>Am. Jour. of the Med. Sc.</i> , May, 1896....	.....	Tumor .....	Not found.....	.....
41	Gherardo, Ferreri. <i>Ann. di medicina navale</i> , Feb., 1900. <i>Gaz. hebdom.</i> , 1900, p. 357....	18 years. F....	Myxosarcoma .....	Removed .....	Death in coma some days after operation.
42	Gibson Hildebrandt. <i>Jahresbericht</i> , 1895.....	25 years. F....	Cystic fibrosarcoma of right lobe .....	Removed .....	Recovery.
43	Grainger Stewart. <i>Edinb. Med. J.</i> , 1894.....	Adult, M.....	Tumor .....	Not found.....	Death.



44	Guldenarm, <i>Hermanides. R. S. Weekblad.</i> , 1895, p. 302.....	31 years. M....	Tumor of vermiform, encroaching on right lobe.....	Not found.....	Improvement for three months.
45	Guldenarm, <i>Edin. Med. Journal</i> , 1894.....	53 years. F....	Sarcoma of left lobe.....	Removed .....	Death, the day after operation.
46	Guldenarm and Winkler, <i>Chir. nerv.</i> , Chipault, Vol. 1, 1902.....	.....	Endothelioma attached by a pedicle to right tentorium...	Not found.....	Temporary improvement; death three months later.
47	<i>Ibid.</i> .....	29 years. M....	Endothelioma of left lobe.....	Removed .....	Patient greatly relieved; sudden and unaccountable death.
48	Guldenarm and Ziegenweldt, <i>Ibid.</i> .....	41 years. M....	Fibrosarcoma between hemisphere and tentorium.....	Not found.....	Death, nine days after operation.
49	Guthrie and Stansfield Collier, <i>Brit. M. J.</i> , 1899, II, 1289.....	9 years. M....	Gliomatous cyst of median lobe..	Evacuated .....	Results perfect after eighteen months, except for persistence of headache.
50	Hedra, <i>Texas M. News</i> , 1902, 380.....	32 years. M....	Tumor, combined with abscess; character of tumor not determined .....	Abscess evacuated; tumor not found .....	Died about eight weeks after first operation.
51	Heidenhain, <i>Arch. f. klin. Chir.</i> , 64, p. 848.....	12 years. M....	Sarcoma, non-encapsulated, median line between superior and inferior vermiform processes.	Not found.....	Died suddenly in collapse night after operation.
52	Herw. <i>Brit. M. J.</i> , 1893. ....	.....	Large tumor.....	Not found.....	.....
53	Horsley, <i>Brit. Med. J.</i> , 1887, 818.....	.....	Tumor affecting median lobe...	Two operations; not found.....	Temporary improvement; death eighteen months later.
54	Hudson, <i>Amer. Jour. of the Med. Sc.</i> , Sept., 1903. ....	9 years. F....	Cyst of right hemisphere.....	Cyst found and evacuated .....	Considerable improvement, moderate cerebellar hernia; no recurrence.
55	<i>Ibid.</i> .....	M. ....	Tumor, size of pullet's egg, one inch below surface in hemisphere .....	Removed .....	Patient developed serious diarrhoea, and died from exhaustion on eleventh day.
56	Iterson in <i>Hermanides. R. S. Weekblad.</i> , 1895, p. 302 .....	13 years. M....	Cyst of left lobe in centre.....	Removed .....	Recovery, with hernia of cerebellum.



No.	Authors.	Age, Sex.	Nature and Position of Tumor.	Tumor Found or Not Found.	Results.
57	Jaboulay (Soc. of med. sc. of Lyons, 1899), <i>Providence méd.</i> , 1899, p. 321.	30 years. M....	Tumor as large as nut in right lobe .....	Not found.....	Death one hour after second operation.
58	<i>Ibid.</i> , 1901.....	26 years. M....	Chronic tuberculous mastoiditis. Tubercle of right lobe (histological examination)...	Not found.....	Death in coma, nine days later.
59	<i>Ibid.</i> and <i>Lyon méd.</i> , August 11, 1901.....	34 years. M....	Glioma of left lobe.....	Removed .....	Recovery with persistent deafness in left ear and amblyopia (four and a half months after operation).
60	Jaboulay and Destot. <i>Ibid.</i>	30 years. M....	Fibrocaceous tubercle in right lobe .....	Not found.....	Sudden death after second operation.
61	Jaboulay. <i>Lyon méd.</i> , 1902.	40 years. M....	Glioma, principally in left lobe.	Removed .....	Disappearance of headache and vertigo; improvement of vision.
62	Jaffe. <i>Deutsche. med. Woch.</i> , 1897, No. 5....	52 years. F....	Fibrosarcoma of right lobe.....	Not found.....	Collapse on table; death twelve hours afterward.
63	Janz. <i>Schmidt's Jahr.</i> , 1897 .....	4 years. M....	Tumor .....	Not found.....	Death immediately after operation.
64	Janz. <i>Schmidt's Jahr.</i> , 1897 .....	21 years. M....	Tumor .....	Not found.....	Death immediately after operation.
65	Keen. <i>Am. Jour. of the Med. Sci.</i> , 1894, 38....	14 years. M....	Cystic neuroglioma on floor of third ventricle.....	Not found.....	Death after nine hours.
66	Keen. <i>Am. J. of the Med. Sc.</i> , 1894.....	31 years. M....	Tumor, left hemisphere.....	Removed.....	Immediately after operation considerable aggravation; after 4½ months some improvement.
67	Korteweg and Winkler. <i>Ibid. Trans. Med. and Clin. Soc., Edinburgh.</i> Vol. XV.....	.....	Cyst of left lobe.....	Evacuated .....	Recovery.
68	Krause. <i>Deutsche med. Woch.</i> , 1902.....	11 years. M....	No tumor, internal hydrocephalus .....	None present...	Very much improved; lived three years.
69	Krause. <i>Deutsche med. Woch.</i> , 1902, No. 51, p. 367 .....	18 years. F....	No tumor, internal hydrocephalus .....	None present...	Died suddenly, one week after operation.
70	Lamplasi in Lobella ( <i>La Psichiatria</i> , 1891, VIII, 261) .....	2 years.....	Solitary tubercle of left lobe; dilatation of the ventricles...	Not found.....	Death after four days.



71	Lamplasi-Hildebrandt, <i>Jahresbericht</i> , 1895....	45 years. M....	Small tumor .....	.....	Death thirteen hours after operation.
72	Lloyd, Suckling. <i>Lancet</i> , 1887, II, 863.....	12 years. F....	Glioma affecting whole left lobe and part of vermiciform.....	Partially removed .....	Collapse after twelve hours; death after forty-eight hours.
73	Macewen. <i>Brit. Med. J.</i> , 1893, II, 1367.....	.....	Tubercles .....	Two tubercles removed .....	Improvement; reappearance of symptoms seven months later; death nine months (small tubercle in wall of fourth ventricle).
74	<i>Ibid.</i> .....	.....	Tumor .....	Not found.....	Improvement, except for amaurosis.
75	<i>Ibid.</i> .....	.....	Tumor .....	Not found.....	Improvement; death in fourth month (pulmonary tuberculosis).
76	Maudsley and Fitzgerald, <i>London Med. Record</i> , 1890 .....	28 years. M....	Tumor of left lobe.....	Removed .....	Recovered from operation, but remained blind and deaf.
77	Maudsley, Internat. Med. Congress of Australia, 1899 .....	30 years. M....	Glioma .....	Removed .....	No return of pains or attacks of vomiting.
78	Maunseil, <i>New Zealand Med. J.</i> , 1889.....	18 years. M....	Hydatid cyst of meninges under tentorium, involving left lobe .....	Removed .....	Recovery, with persistence of blindness.
79	Moran and Kerr. <i>Virg. Med. Semi-Monthly</i> ....	.....	Cyst .....	Removed .....	Improved.
80	Munn. <i>Internat. J. of Surg.</i> , 1895, 40.....	.....	Diffuse glioma of right lobe....	Removed .....	Improvement immediately following operation; death thirty-six hours later.
81	Murri (of Bologna). <i>Lancet</i> , 1897, I, 291.....	17 years. M....	Fibrosarcoma of left lobe.....	Partially removed .....	Improvement after one month.
82	Newton, R. E. <i>Australas. Med. Gaz.</i> , 1903, XXII, 219 .....	42 years. M....	Hydatid cyst, containing about 6 drachms, in left hemisphere.	Evacuated .....	Vomiting and headache relieved at once; nearly all other symptoms subsided.
83	Nota. Chlpault. <i>Chir. nerv.</i> , Vol. 1, 1902.....	7 years. M....	Tubercle. ....	Not found.....	Death.
84	O'Kynzle, Tuffler. <i>Soc. d'anat.</i> , 1902.....	18 years. M....	Large tubercle of right lobe...	Not found.....	Death on day following second operation.



No.	Authors.	Age, Sex.	Nature and Position of Tumor.	Tumor Found or Not Found.	Results.
85	Parkln. <i>Lancet</i> , Dec., 1896	3 years. M....	Diffuse glioma of veriform and surrounding parts of median lobe	Removed	Recovery; no recurrence after 2½ years; persistence of optic neuritis.
86	Parry. <i>Glasgow Med. J.</i> , 1893, II, 36.	15 years. M....	Tubercle of posterior part of left lobe.	Removed	Death.
87	Pershing. <i>Med. News</i> , 1898		Glioma	Removed	Death.
88	Portempski. <i>Arch. della Soc. Ital. di chir.</i> , 1892, 21	22 years. M....	Tumor	Not found.	Partial relief.
89	Rotgans and Winkler. <i>Ibid.</i>	21 years. M....	Cyst	Evacuated	Recovery.
90	Saenger. <i>Munch. med. Woch.</i> , 1899, 845.	47 years. F....	Gliosarcoma of base, affecting left auditory and trigeminal nerves	Not found.	Improvement (oozing of cerebro-spinal fluid for several weeks); death nine months later.
91	Saenger. <i>Neurolog. Centralbl.</i> , 1899, p. 1117.		Tumor between pons, medulla, and cerebellum.	Tumor found; not removed.	Slight improvement.
92	<i>Ibid.</i>			Tumor found; not removed.	Partial recovery.
93	M. Schede. <i>Deutsche med. Woch.</i> , 1900, 477.	Adult. M....	Encapsulated glioma of right lobe	Removed	Recovery.
94	M. Schede. <i>Deutsche med. Woch.</i> , 1900, 477.	17 years. M....	Cystic glioma of right lobe.	Evacuated	Temporary improvement; sudden death several days later.
95	Schönborn (Hirsch). <i>Inaug. Dissert.</i> Wurzburg, 1891	24 years. F....	Cystic myxosarcoma of right hemisphere and cuneus.	Tumor found(?)	Temporary improvement; death on eighth day.
96	Springthorpe. <i>Austral. M. J.</i> , 1890, 509.	13 years. M....	Glioma	Not found.	
97	Allen Starr. <i>Brain Surgery</i> , 1893, case XXII.	30 years. M....	Gliosarcoma of left lobe, including pons	Not found.	Death on twelfth day (coma).
98	Starr. <i>Brain</i> , 1893.	10 years. M....	Cystic glioma of right hemisphere	Partially removed	Temporary improvement; death on eleventh day.
99	Starr and McBurney.	7 years. F....	Cystic gliosarcoma of veriform process, extending to both hemispheres.	Not found.	Death on sixth day.



100	Starr. <i>Brit. M. J.</i> , 10-16, 1897				Glioma, right hemisphere	Not found	Improvement; death on eighth day.
101	Starr. <i>Ibid.</i>				Tumor	Not found	Unimproved.
102	Allen Starr. <i>Brain Surgery</i> , 1893	(?) F.			Gliosarcoma, subcortical of vermiform, with central cyst	Not found	Death on sixth day (convulsions).
103	<i>Ibid.</i>	10 years. M.			Gliosarcoma of right lobe	Removed	Temporary improvement; death on fourteenth day.
104	Stef. Personali. ( <i>Rif. med.</i> , 1900). <i>Revue de neurologie</i> , 1901, 408	(?) M.			Tumor of lateral lobe	Removed	Extreme emaciation; meningitis; death.
105	Stieglitz. <i>Journal of Nervous and Mental Disease</i> , 1895, 729				Gliosarcoma (size of large nut) of right lobe (autopsy)	Not found	Death (infection, purulent meningitis).
106	Suckling. <i>Am. Jr. Med. Sci.</i> , 1895	12 years. F.			Glioma, left lobe	Removed	Death in collapse.
107	Syme. <i>Internat. Colonial Med. J.</i> , 1899	47 years. M.			Tumor of left lobe	Not found	Sudden death from respiratory failure following operation.
108	Tanton. <i>Bull. et. mém. de la Soc. anat.</i> , Paris, 1903, III, 584				Colloid tumor	Not found	Death about two months after-ward.
109	Terrier in Aubray. <i>Th. de Paris</i> , 1896	Adult. M.			Tumor of left lobe	Not found	Temporary improvement; death two months later.
110	Thomas and Lund. <i>Boston M. and S. Jo.</i> , 1905	5 years. M.			Tumor of vermiform	Not found	Patient died following morning.
111	<i>Ibid.</i>	8 years. M.			Glioma of vermiform with large hydrocephalus	Not found	Death on fourteenth day.
112	Tricomi. <i>Riforma med.</i> , 1899	9½ years. F.			Glioma of peduncle and quadrigeminal lobe	Tumor not found	Death on the following day.
113	Von Voss. <i>Deutsche Zeitschrift f. Nervenheilkde.</i> , 1902, XXI, 48	35 years. F.			Gliosarcoma, left hemisphere	Not found	Died in convulsions three days after operation.
114	Weir. <i>Annals of Surg.</i> , 1887, I, 506	26 years. F.			Tumor	Not found	Death two months later.
115	Wyman. <i>Med. News</i> , 1890, I, 134	Adult. M.			Small tumor in left lobe	Not found	Death during operation.
116	Ziegenwilde. <i>Psych. en neurol.</i> , 1899				Suspected in cerebellum. on autopsy found between right cerebellum, tentorium, and pons	Not found	Death.



Unable to display this page

two weeks in July. About the middle of August, 1903, and in October, 1903, her gait became staggering. During the latter part of November up to the time of admission to the hospital she had been unable to walk more than a few steps without support. Since August, 1903, the headaches had been more or less constant. On admission to the hospital she complained especially of nausea and of severe frontal headache, of pain in the back of her head and neck, and in her back. This patient was admitted to the University Hospital under the care of Dr. J. D. Steele, and was later transferred to the service of Dr. Mills. Careful examinations were made by Dr. Steele, but with negative results, except as regards her nervous system, and the existence of patches of brown pigmentation over the entire body. Examinations of both urine and blood were negative.

Later repeated examinations were made by Dr. Mills and also by Dr. Spiller in consultation. The results of these examinations can be summarized, as but little change took place until the time of operation, except for the worse as regards particular symptoms, like optic neuritis, headache, nausea, and ataxia. The patient exhibited marked ataxia of station. The incoordination in standing was usually not increased by closing the eyes. Numerous examinations showed a tendency of the patient to deviate, pitch, or fall to the left in standing and walking; exceptionally the tendency was in the other direction. Testing the extremities separately, fairly marked ataxia was present on the left, and to a slighter extent on



the right. On several examinations the patient showed distinct asynergia in the left lower extremity. The symptom was not, however, uniformly present, and on at least one occasion some asynergia seemed to be present in the right. The Babinski response was present on the right; both knee jerks were absent and the tendon and muscle jerks in the upper and lower extremities were generally depressed. Apparently the movements of both external straight muscles were at times impaired, although the report of Dr. de Schweinitz showed abducens weakness only on the left. On the negative side nystagmus was absent, as were also involvement of the fifth, seventh, or other cranial nerves, and of disturbances of sensation. The patient continued to suffer greatly from headache, vertigo, nausea, and vomiting, the optic neuritis increasing and becoming of the highest grade.

Eye examinations were made by Dr. G. E. de Schweinitz, who reported as follows: December 8, 1903, the vision of each eye equals hand movements. The pupils react sluggishly to light and convergence. There is a history of diplopia and there probably is paresis of the left external rectus, but the double images cannot be elicited, and this is inferred only from the failure of rotation in the line of the direction of the action of the left externus. The ophthalmoscope reveals the following conditions: in the right eye there is a high grade of papillitis (choked disc), the apex of the swelling being 7 D. It is intensely injected, and the sloping margins of the elevation

are thickly infiltrated with hæmorrhages. In the left eye there is an exactly similar condition, and in addition a typical macular figure resembling that seen in albuminuric retinitis. Careful testing of the visual field indicates that while it is contracted there is no hemianopic defect.

December 17, 1903, Dr. Frazier operated. An incision was made, following and a little above the superior curved line from the mastoid process to the occipital protuberance, and thence downwards in the median line for a distance of 4 cm. The opening in the skull was made with the chisel and enlarged with the rongeur forceps. The dura was normal in appearance and seemed thinner than usual, and seemed unusually tense. A dural flap was reflected and the surface of the hemisphere inspected. Failing to determine the presence of a tumor by the sense of sight or touch, an incision was made in the left cerebellar hemisphere, which revealed a small encapsulated tumor of about the size of a hazelnut; the tumor was easily shelled out. The protrusion of the cerebellar tissue was so great that it was necessary to remove, in addition, about one fourth of the cerebellar hemisphere in order to be able to close the dural wound. The patient reacted promptly from the operation, and convalescence was uninterrupted.

The following reports were made by Dr. de Schweinitz after the operation:

December 20, 1903.—The changes evident to the ophthalmoscope are almost exactly those which have been recorded, with the exception of



some fresh hæmorrhages which have appeared on the nasal halves of the swollen nerve heads.

January 4, 1904.—The ophthalmoscopic appearances noted by Dr. Shumway are double optic neuritis, plus 6 D. The vision of the right eye is doubtful light perception. The left eye is absolutely blind. A repetition of his examination on the following day by Dr. de Schweinitz confirmed the observations. No changes were noted at the next examination, on the 7th of January.

Examination, January 17, 1904.—There is marked subsidence of the swelling of the discs, the apices of which are not more than 3 D., and the edges of the disc margins are beginning to appear. The macular figure noted before is very marked, and is now evident in both eyes. The retinal vessels are beginning to shrink and atrophy is rapidly supervening. There is no light perception. This examination was repeated on January 25th, with practically the same results, possibly still further diminution of the swelling of the discs. Some weeks later, after the patient was dismissed from the hospital, the ordinary signs of postneuritic atrophy were present. The eyes were divergent, the pupils large and not responding to light.

This patient who presented the typical symptoms of a tumor involving in large part one lateral lobe of the cerebellum, and therefore one of the most desirable cases for operation, was greatly benefited so far as the focal symptoms of a cerebellar tumor and the general symptoms of an intracranial growth were concerned. Her head-

ache, nausea, vomiting, and vertigo disappeared in spite of her almost total blindness; her ataxia was also almost entirely relieved. The optic neuritis had advanced to such a degree, even before she was admitted to the hospital, that operation did not save her from blindness, although surgical procedure was adopted about ten days from the time of her admission.

CASE II.—Tumor of left lateral lobe of the cerebellum; operation; recovery; relapse.

F. M., ten years old, was referred to the University Hospital by Dr. D. J. McCarthy, with a diagnosis of tumor of the cerebellum, and was admitted to the wards of Dr. Frazier, March 7, 1904. After admission to the hospital he was seen in consultation by Dr. William G. Spiller and also by Dr. Mills.

One point of interest in the family history was the fact that one brother of the patient had some pulmonary disease, chronic in character. The patient, up to the time of his present illness, had been a healthy child, had gone to school at the age of six years, and had been able to keep up with his classmates.

Toward the end of December, 1903, the mother noticed that the boy was not as lively as before, and that he stayed in the house in preference to going out of doors. She took him to the Episcopal Hospital, where he was treated for a cough. At this time he had lost some weight and was generally run down in health. After treatment he improved, gaining weight, but he was unsteady in walking.



About the middle of January, 1904, the boy began to suffer from severe headaches, apparently causeless, these being accompanied by vertigo. At this time the patient held his head up straight and avoided stooping, fearing increased dizziness. During two or three weeks vomiting had been added to his other symptoms, this occurring two or three times a week. Evacuation of the contents of the stomach did not bring relief.

At about the time of his admission it was noted that he had not had any convulsions, that his hearing was unaffected, that he had not complained of interference with vision, that a gradual increasing ataxia was present, and also that his headache, vertigo, and vomiting were augmenting.

The analysis of his urine showed no albumin, casts, or sugar, and a specific gravity of 1.018, the examination being practically negative.

Examination showed that his mental state was distinctly that of lassitude; he was drowsy, took little notice of his surroundings, and manifested when examined, a degree of impatience which was almost irritation. General physical examination of heart, stomach, and other viscera showed nothing of special importance, except of the lungs as given below.

The respiratory excursions were of fair amplitude, apparently equal on both sides. The percussion note showed an impairment over the left apex down to the third rib. Over this area faint crepitant râles were heard on inspiration. Expiration was prolonged, somewhat blowing.

Fremitus, both local and tactile, were slightly increased. Various examinations showed ataxia, this present to some extent in the upper extremities as well as markedly present in the lower. No Romberg sign was noted. The examination by Dr. Spiller given below covers, however, the important points in his neurological symptomatology. His pupils were dilated and there was a suggestion of photophobia.

The patient complained of severe headache, locating the pain in the frontoparietal region. Tapping with the finger elicited pain all over the head, this being especially marked over the temporoparietal portion on the left. No scars or other evidences of injury were discovered.

Shortly after admission while suffering from severe headache, the patient's pulse became exceedingly irregular, both as to volume and rhythm, and its rate was greatly decreased and weakened.

Eye examination of the patient was made by Dr. G. E. de Schweinitz and Dr. John T. Carpenter. The examination made March 8th showed the following: V. of O. D.  $\frac{6}{9}$ , of O. S.  $\frac{6}{7.5}$ . The amplitude of accommodation of each eye is 12 D. The pupils are round and the irides react promptly to light and accommodation and convergence. With the exception of a slight esophoria, there is no defect of muscle balance and no diplopia. The ophthalmoscope reveals the following conditions: Right eye papillitis (choked disc), the apex of the swelling being 4 D., the vessels on the surface of the disc  $1\frac{1}{2}$  D. higher. The nerve edges



are entirely obscured. The surrounding retina is not involved. In the left eye there is an exactly similar swelling of the disc, with the exception that its nasal edge is more involved. There is a moderate concentric contraction of each visual field, more marked upon the left than upon the right side.

Examination by Dr. Spiller on March 9th showed the following: The tenderness of the scalp to percussion formerly noted had disappeared. He held his head retracted, because he said it caused him pain to hold it straight. There was no distinct rigidity of his neck; movements of the head were free in all directions; passive movements caused headache. The movements of the eyeball were free in all directions; some nystagmoid movements were present when looking to the extreme right or left. The fifth and seventh nerves were not involved on either side. The tongue showed a slight tendency to deviate to the right when protruded; no distinct fibrillary tremors of the tongue were noted.

The grasp of each hand was fair and equal on both sides. The finger to nose test did not reveal distinct ataxia. The upper limbs were slightly but not distinctly atrophied. The biceps, triceps, and wrist reflexes were not distinct on either side. The voluntary movements of the upper limbs were normal. There was no loss of sensation to touch or pain. The muscles of the trunk were fairly well developed.

The voluntary movements of the lower limbs showed normal muscular power and no wasting.

The patellar reflex was lost on both sides; even when sitting on the edge of the bed with reinforcement there was no response. The Achilles jerk was not present on either side; the Babinski reflex could not be obtained on either side; there was no ankle clonus. The heel to knee test did not reveal ataxia. Sensation for touch and pain was normal. At the time of this examination the gait was not ataxic with eyes open; it was slightly so when the eyes were closed. There was no sway when standing erect, either with the eyes open or closed. No hemiasynergia was present on either side; Koenig's sign was also absent on both sides. The operation was performed by Dr. Frazier on March 13, 1904. The bone overlying the left lobe of the cerebellum was very thin and the dura was unusually tense. Immediately after the dura was opened the hemisphere protruded to a much greater degree than usual. No adhesions were found either between the skull and dura or between the dura and cerebellum. The latter did not pulsate. A thorough exploration of the left hemisphere failed to reveal the presence of a tumor. As a palliative procedure one third of the cerebellar hemisphere was removed. The patient's condition immediately after the operation caused some anxiety, but after intravenous injection and mild stimulation the patient improved rapidly and spent a comfortable night. The wound healed by first intention. On March 27th the patient's condition was noted as being greatly improved. His whole disposition had changed;



he was bright and cheerful and complained neither of headache nor vomiting.

In November, 1904, the patient returned to the hospital, because of recurrence of some of the symptoms. On the following day an incision was made, following the line of the old cicatrix, and an infiltrating tumor of about the size of a walnut was found in the hemisphere, apparently taking its origin from some point near the cerebellopontile angle. The patient reacted promptly after the operation, the wound healed by first intention throughout, and convalescence was uninterrupted. The tumor was a glioma. After the notes of the case were sent to the press the patient relapsed, showing that the growth was probably infiltrating and had not been fully removed.

Eye examination made after the operation by Dr. G. E. de Schweinitz and Dr. J. T. Carpenter, March 14th. The condition of the right disc is unchanged. On the left side there has been a subsidence of the swelling, which is now 3 D. in place of 4 or  $4\frac{1}{2}$  D.

CASE III.—Tumor of the cerebellum, probably of the vermis and left lateral lobe; operation; tumor not found; recovery from operation, with relief of symptoms.

J. H., forty-one years old, was admitted to the University Hospital March 6, 1902, under the care of Dr. Mills and Dr. Frazier. No history of nervous or tuberculous disease or of tumor could be ascertained, but an aunt had suffered from can-

cer of the face, probably dying from this affection. The patient denied syphilis.

About two years before admission to the hospital he began to have headache, most marked behind the eyes and in the temporal regions. His sight also began to fail at this time, and his gait became unsteady, he tending to totter or fall to the right side. His headache improved under treatment, but his sight and gait remained the same.

In May, 1901, he had a crisis of vomiting, which lasted for about a week; he vomited almost daily, immediately after eating, there being little retching or straining accompanying the vomiting. The left leg at this time seemed weaker than the right. His bowels were constipated, and were moved by laxatives daily for two years before he came to the hospital. He had no pain in the anus or in the legs. He was not paralyzed and had no vesical symptoms. There was no history of vertigo; his hearing was not disturbed and his memory was good. On rising in the morning he had on a few occasions attacks of faintness or weakness, but he had never lost consciousness.

Examination of the urine two days after admission to the hospital was negative.

Several examinations of this patient, made by Dr. Mills and Dr. Spiller shortly after admission, gave the following results: Vertical nystagmus was present when the eyes were at rest or when they looked upward or downward, the nystagmus becoming lateral when the eyes were turned to the right or left. The patient in walking took



short, unequal steps, showing a lack of confidence; at times he exhibited a tendency to go to the right. In standing the feet were kept wide apart, as he swayed greatly and would have fallen if not supported when the feet were together. The sway was not distinctly increased by closure of the eyes. Ataxia was present in the left upper extremity, and doubtfully in the right. Speech and mental response were both slow. The tongue was protruded straight and without fibrillary tremor. The knee jerks were prompt, the left distinctly exaggerated. The Achilles jerk was present on each side. Ankle clonus was not present on the right, but was slightly indicated on the left. The Babinski reflex was not present on either side, the movement of the toes being that of slight flexion on both sides.

An eye examination was made by Dr. Howard Mellor, March 7th, the date of his admission. Visual acuity and the amplitude of accommodation were not recorded. He reported the following: The pupils are equal in size and the irides react promptly to light and in convergence. The ophthalmoscope reveals the following conditions: A low grade neuritis with involvement of the surrounding retina (neuroretinitis), which is most marked in the left eye. There is very distinct vertical nystagmus when the patient looks directly forward, and extremely marked lateral nystagmus on looking to either side. When the gaze is directed upwards or downwards, the vertical nystagmus increases. The rotations of the eyeballs are normal in all directions.

The patient left the hospital and was readmitted on October 9, 1902. His difficulty in walking had gradually increased until he was able to walk only a few steps with a cane, and at times he fell. When assisted he walked by raising the leg and foot high, and bringing it down heavily. His feet were always wide apart. Ataxia was marked. He had not vomited since leaving the hospital. The nystagmus was the same as on the first admission. A twitch of the orbicular muscle in the left eye was noticeable at times. He could hear a watch at three feet, on the right side, on the left he could hear it at a distance of two inches. He had no tinnitus or other abnormal sounds. He complained of no trouble with the bladder or rectum. He had no astereognosis.

Examination by Dr. de Schweinitz, October 9, 1902.—V. of O. D.  $\frac{6}{22}$ , of O. S.  $\frac{6}{22}$ . The patient reads J. 2 at 33 cm. with each eye. The pupils are equal and respond promptly to light and convergence. The nystagmus recorded in the previous examination continues unchanged. The ophthalmoscope reveals the following conditions: The right optic nerve is beginning to be atrophic, the vessels being reduced in calibre, and there is an area of atrophy of the chorioid surrounding the nerve head. In the left eye a moderate neuritis with indications of beginning atrophy is evident.

No atrophy, rigidity, contractures, or spasticity was present in the lower extremities on either side. Late in the case the muscles of mastication were normal on the right, and distinctly weak, although not paralyzed fully, on the left.



When the mouth was opened the jaw tended to go slightly toward the left. Sensation was unimpaired everywhere. No hemiasynergia was present on either side.

The prominent symptoms in this case just before the operation were secondary optic atrophy, headache and vomiting, nystagmus, cerebellar gait, exaggerated reflexes, deafness on the left side, weakness of the left motor fifth, and probably some weakness of the soft palate on the left side.

October 25, 1902, the patient was operated upon by Dr. Frazier. Upon the left side of the head a horseshoe-shaped flap was reflected, the incision beginning at the tip of the mastoid process following the superior curved line, and terminating in the median line of the neck, opposite the spinous process of the second cervical vertebra. The skull was opened as usual with a chisel and mallet, and the opening enlarged with a rongeur forceps. There was an escape of a moderate amount of cerebrospinal fluid. Inspection and palpation of the cerebellar hemisphere revealed no abnormality. There was no thickening of the meninges, no alteration in color or consistence of the cerebellar tissue. It was deemed inadvisable to make any further inspection and the wound was closed. The patient recovered from the effects of the operation, and declined any other intervention, although Dr. Mills and Dr. Frazier advised an exploratory operation upon the opposite side.

Unable to display this page



this patient is one of unusual interest, because of the remarkably rapid improvement which followed. Within one week of the operation the patient's headache had entirely disappeared, his vision was restored so that he could see minute objects on the ceiling as he lay in bed, and his vertigo and ataxia had almost entirely disappeared. At no time during the convalescing period was the patient's condition such as to give any concern. He was kept under observation in the hospital for a period of two months, and inasmuch as there was not the slightest return of symptoms he was allowed to go home with the understanding that he would return to the hospital if any of his cerebellar symptoms recurred.

CASE V.—Tumor probably of the cerebellum involving the vermis and right lateral lobe; operation in two stages planned; death from hæmorrhage from bony sinuses twelve hours after first operation.

J. C., fifteen years old, was referred by Dr. Samuel Freeman and Dr. Frank V. Cantwell, of Trenton, N. J., to Dr. Mills for opinion and treatment. He had a history that fifteen months before coming under observation he had begun to suffer with headache, this having been preceded by dizziness; he also began to suffer from vomiting six months before, and exhibited a staggering gait one month later. The attacks of headache, dizziness and nausea and vomiting increased in frequency and in severity, and the uncertainty of gait became steadily more and more marked.

When the patient was first examined it was

found that he was suffering intensely from headache, which was almost continuous, while his dizziness, nausea, and vomiting were of frequent occurrence.

The eye examination made by Dr. G. E. de Schweinitz, July 5, 1904, resulted as follows: V. of O. D.  $\frac{4}{9}$ , of O. S.  $\frac{4}{6}$ . Amplitude of accommodation markedly defective, the patient being able to read only D. = 1 at 18 cm. The pupils are large, but their reactions are normal. There is paresis of the left external rectus muscle, and lateral nystagmus develops when the eyes are directed to the left, that is to say, in *lævoversion*. The ophthalmoscope reveals the following conditions: In the right eye papillitis, the apex of the swelling being 3 D. It is vascular in the extreme, but the centre of the disc is not markedly filled in. The veins are full and carry very dark-colored blood. There is no macular figure. In the left eye the papillitis is greater than on the opposite side, the apex of the swelling being 5 D. with decided engorgement, and the appearance to which the name choked disc is ordinarily given. The veins are even fuller and darker than upon the other side. The peripheral visual field for form of each eye is normal. There are no scotomas.

Comment.—The double optic neuritis (choked disc), together with paresis of the left external rectus muscle and lateral nystagmus, especially when the eyes are directed towards the left, are ocular signs frequently seen in cerebellar diseases.



At one examination it was noted that in standing or walking the patient was markedly ataxic and asthenic, always tending to the right, and that ataxia, less marked, was present also in the upper extremities as determined by having him touch his nose with the finger and in other ways. This ataxia was doubtfully more marked on the right. Hemiasynergia was not present.

His mental condition was good, except in so far as he was irritated, depressed and worried by the pain.

His muscles were flaccid and atonic. There was no distinct paralysis of the extremities, but his head showed some tendency to drop backwards, especially when he would look upward. This was probably due to weakness of the supporting muscles of the neck.

At a second examination a few days later it was noticed that he swayed markedly to the right, standing with eyes shut and considerably with eyes open. He invariably staggered or tended to the right in walking, his gait being somewhat titubating. There was some ataxia in both arms, possibly a little more on the right. No hemiasynergia was present. Tremor was marked in both upper extremities, a little more so on the left; it was coarse, jerky and increased by action. The muscular sense was preserved, as was also stereognostic perception. The right side of the face was apparently hypæsthetic, as were also the arm and leg of the same side. This symptom, however, seemed variable or doubtful, as the patient did not always answer in the same

way as regards the impression made. The head was not carried towards either shoulder, but, as stated above, sometimes it had a tendency to droop or fall backwards. Both knee jerks were plus. The Babinski response was absent on each side. Incontinence of urine or fæces was not present.

Paresis of the left external rectus, with nystagmoid movements when the eyes are turned far to the left, was present; no such movements were shown when the head was turned to the right upwards or downwards. When the patient followed the finger with his eyeballs von Graefe's sign was very distinct. About  $\frac{1}{8}$  inch and possibly even more of the white of the eyeball was seen between the iris and the upper lid on each side.

The knee jerks were slightly plus; the ankle jerks about normal; the muscle jerks a little below normal. The tongue was protruded straight and was not atrophied. It exhibited no fibrillary tremor.

Speech was a little peculiar, but the patient said that it had always been the same as it was at this time.

According to Dr. B. A. Randall's report, the patient had nearly normal ears in appearance and function with possibly a trace of tympanitic reduction of hearing; the auditory nerves seemed to be in perfect condition.

There was no thyreoid or other glandular enlargement of the neck. The thorax was small, narrow, and poorly shaped and developed; the



supraclavicular and infraclavicular spaces were prominent; the expansion was poor. In front and back of the lungs the breath sounds were clear but faint. The action of the heart was regular; there were no murmurs. The abdomen was flat.

The patient came under observation July 6, 1904, and was admitted the same day to the University Hospital, where he was seen by Dr. Spiller in consultation with Dr. Mills. The diagnosis of tumor of the cerebellum probably involving the right lateral lobe, was made.

The operation was performed by Dr. Frazier July 9, 1904, with the object of exposing the right lateral lobe of the cerebellum. The usual incision was made and the skull opened in the customary way. Upon reflection of the musculo-cutaneous flap, two large anomalous sinuses were exposed, making their exit at a point about 2 cm. from the occipital protuberance and a little below the superior curved line. The blood poured out from these sinuses in great quantities, and every attempt which was made to control the hæmorrhage by pressure, Horsley's wax, etc., failed, until some small plugs of wood, made from swab sticks, were driven into the bone. By this time the patient had lost a considerable amount of blood, and was evidently suffering from its effect. Stimulation was resorted to; a hypodermic of strychnine was given and a pint of 1 to 50,000 adrenalin salt solution was administered intravenously. By this time the blood pressure had fallen to 55, and for the next fifteen minutes re-

mained at 50. It then fell to a point too low to estimate, and another pint of 1 to 50,000 adrenalin salt solution was given intravenously. In twenty-five minutes the blood pressure rose to 100, and the adrenalin was discontinued. The blood pressure began to fall again and resort was had again to intravenous injections of adrenalin. Owing to the excessive hæmorrhage it was decided to postpone the actual exploration for the tumor until the patient had fully reacted. The operation was performed at 2 p. m., and from that on to 1 a. m. on the following morning the patient's condition gradually improved. At 1 a. m. his pulse was only 96 and of fair volume. His color good and his respirations were 15. At 1.15 a. m. his pulse was 98, and his respirations were 14. At 1.30 a. m. his condition was reported as unchanged, with the exception that his respirations had dropped to 11. At 1.40 a. m., without any warning, the pulse suddenly shot up to 120, respirations dropped to four. The patient became cyanotic and died at 1.45 a. m. No autopsy was permitted.

It is difficult to account for the death of this patient. One can hardly attribute it to the excessive hæmorrhage at the time of the operation, although this may have been a contributory cause. The condition of the pulse and blood pressure showed that the patient had almost fully reacted soon after the operation. The slow respiratory rate suggests the possibility of an injury to the respiratory centre, although this would hardly have been inflicted by any step in the oper-



ation, inasmuch as no attempt was made to explore the cerebellar fossa.

CASE VI.—Cerebellopontile operation for tumor of pons; probable second lesion in parietal lobe; cyst evacuated; permanent disappearance of severe headache and facial neuralgia.

This patient, a woman, about forty-five years old, first came under the care of Dr. Mills in November, 1902. One year before coming under observation she had an attack of vertigo without unconsciousness and after this partial paralysis of the left third nerve was observed, ptosis, dilated pupil and paresis of the internal rectus being present, according to the physician then in attendance. She also appeared from the history to have had temporary paralysis of the left side of the face. She had subsequent similar attacks, some of these shortly before coming under observation. In one of the recent seizures she was found in the cellar, pacing up and down with her hands above her head, eyes dilated and apparently struggling against suffocation. She was taken upstairs and put to bed; she tried to speak, moving her jaws without uttering any sound; her face was pale, her eyes were open. At the time of the first examinations she had paresis of the left side of the face, partial ptosis, pupils equal and responsive, the superior rectus not being as active on the left side as on the right.

In the fall of 1902 the patient was under the care of Dr. Mills in a private hospital. During this period her chief symptoms were occasional headache, general nervousness, and at times slight

mental confusion. The partial palsies of the third and seventh nerves as above noted were present.

In the summer of 1903 she went to a mountain resort, and while there she had an attack of convulsions, after which she had partial paralysis in the right half of the body. The physician called in to see the patient because of the attack of spasm, wrote to me as follows regarding his observations:

"When I saw the patient she was in a semi-comatose state, and from superficial observation and the history given I thought that I had a hysterical condition. A dose of potassium bromide aroused her from the stupor following the convulsions, which, with the stupor, had lasted eight or ten hours. The spasms had not been especially pronounced, and had subsided some three hours previous, with the exception of some twitching around the mouth. From the account given, the contractions were alike on each side, and at the time of my visit no paralysis was present, although it was stated that at some previous time she had had left-sided paralysis, but not in this attack. Mentally she was unbalanced. She seemed to grasp the purport of a question, but generally gave meaningless answers. She was hunting for some imaginary thing which she had lost, and every moment or two earnestly asked the time of day. On attempting to arise in the morning, she fell from the bed, prone, evidently the commencement of her convulsive attack. Inquiry elicited the fact



that there had been some previous brain lesion, which I could not definitely locate, but the knowledge of which, with the other symptoms, excluded the idea of hysteria."

When seen shortly after this, in addition to the symptoms already noted, she also showed some amnesia for names, and some mental change or weakening hard to describe and complained much of headache. Ophthalmoscopic examination made about this time by Dr. S. D. Risley showed no optic neuritis, but bad eye grounds, probably due to eye strain.

An eye examination was made by Dr. G. E. de Schweinitz on September 10, 1903, who reported as follows: V. of O. D.  $\frac{6}{5}$ , of O. S.  $\frac{6}{5}$ . Amplitude of accommodation, 4 D. The pupils are round and react normally to light, accommodation and convergence. There is slight ptosis of the left eye and paralysis of the left inferior rectus muscle. The ophthalmoscope reveals the following conditions: Both optic nerves are round, their nasal and upper edges being veiled. The central lymph sheaths are fuller than normal and the veins somewhat overdistended. This is particularly true of the lower temporal vein of the left side. The veiling of the disc edges is evident, as well by indirect as by direct method of ophthalmoscopy, and taken into consideration with the overcapillarity of the disc surface, may be regarded as indicating a congestion of the nerve heads. Actual neuritis is not present, as there is no swelling of the papillæ. The visual fields are normal.

The patient was examined by Dr. Mills, Dr. Dercum, and Dr. Spiller in consultation on September 11, 1903. Resistance to passive movements in the lower limbs was about equal. Knee jerks were much exaggerated on both sides; ankle clonus was easily obtained and persistent on the right; it was faint and not persistent on the left. Her station was erect and normal with eyes open. She swayed distinctly with eyes closed, the sway being greater towards the right. Her gait was a little uncertain, much more so with the eyes closed. She showed a slight tendency to drag the right foot as if it stuck to the floor. In walking backward with her eyes closed she put the left foot backward and drew the right foot to it. The Babinski reflex was doubtfully present on the right side, but was not obtained at all on the left, the toes responding by plantar flexion. When a pencil was laid lengthwise or crosswise on either foot she was unable to give the correct position; the position seemed to her usually as being across the toes. Touch was felt everywhere, but distinctly better in the upper and lower limbs on the left side and on the left side of the face than in the corresponding parts of the right side. Pain stimulus was felt everywhere, but like tactile sensation was more distinct in the left upper and lower limbs and left side of the face. Sensation for cold and heat was everywhere normal.

The grasp of the right hand was distinctly weaker than that of the left. The fingers of the right hand were kept partially flexed at the junc-



tion of the second and third phalanx, the thumb extended. She could fully extend the fingers, with the exception of the middle one. Apposing the thumb to the little finger on the right hand was very difficult. Triceps tendon jerks and wrist reflexes were exaggerated on each side, distinctly more so on the right than on the left. The palm of the right hand was a little puffy, but not distinctly œdematous. She could raise the right upper limb to the full extent above the head; resistance to passive movements was much impaired in the right upper limb. She experienced difficulty in placing the first finger of the right hand on the nose, usually carrying it to one side of the nose. She was uncertain as to the position of her little finger when it was raised, usually saying it was the ring finger; she knew the other fingers on the right hand when they were raised. Stereognostic perception was greatly impaired on the right hand and not on the left. She could not, for instance, recognize a knife, pencil, or other object in the right hand, but recognized them promptly in the left. The sense of position of the toes of both the right and the left foot seemed to be preserved. She exhibited a slight weakness in drawing up the right corner of her mouth, but drew the left side up better. She closed her eyelids firmly on each side, and wrinkled her forehead well and equally on the two sides. The tongue was protruded straight and showed fibrillary tremor. She said that her tongue had felt numb and stiff for two days before the examination. The masseters and temporals contracted

firmly on each side. She heard a low ticking watch only when it approached to within about two inches of either ear, the hearing seeming to be the same in each ear. Sugar and salt were tasted promptly on each side of the tongue.

Dr. J. W. McConnell examined the patient on September 12, 1903, and reported that subsequent to the above examination she had an attack of twitching of the right arm and the right leg with unconsciousness. There were no changes from the examination of the previous day. She complained of intense pain in the left parietal region, and also said that she had some numbness in the left arm and leg.

After this she was seen from time to time by Dr. Mills, and on several occasions for him by Dr. T. H. Weisenburg, who made a few notes as follows: September 14, 1903. Paresis of the left internal rectus was present. Astereognosis was not present in the right hand, and the sense of position of the right hand was normal.

September 16, 1903.—She had a left-sided peripheral facial palsy, also a paresis of the left external rectus and of the internal rectus. No sensory changes were present on the left side.

The patient was again examined by Dr. Mills and Dr. Spiller on September 22, 1903. The left side of the face was paralyzed in the entire distribution of the seventh nerve. She complained of much pain, confined to the left side of the face and in the distribution of the fifth nerve. The masseter and temporal muscles contracted well in chewing on each side. No distinct objective



disturbance of sensation on the left side of the face was made out. The left external rectus seemed to be the only external ocular muscle distinctly paretic. Astereognosis in the right hand was almost complete.

She complained of much pain on both sides of the forehead, extending down the left side of the face to the lower border of the lower jaw. The pain did not extend below the median line of the lower jaw; it extended to the mastoid process, but not beyond this on the left side; it did not extend into the neck. She had constant pain in both temples, but it was greater in the left than in the right. All points of exit of the fifth nerve were painful to pressure; as much so on the right side as on the left. Sensation for touch and for pain on the two sides of the face seemed to be normal; she felt a touch or pin prick as well on the left side of the face as on the right. In such instances as when chewing a hard crust of bread, the left masseter contracted, but not so well as the right; in opening the mouth the lower jaw did not deviate distinctly. She complained of a sense of numbness in the left side of the face; this involved the entire distribution of the fifth nerve and extended up on the left to the temple, but not far beyond the border of the hair. There was considerable improvement in the paralysis of the orbicularis palpebrarum. There was complete paralysis in the lower distribution of the left facial nerve. The right side of the face was normal.

She did not have any nausea and seldom had

spells of vertigo, although formerly the latter occurred frequently. She showed a tendency at times to fall backwards or towards the left, but did not stagger as much as formerly; closing the eyelids did not affect the gait very distinctly. Hemiasynergia was not present on either side.

As the patient was slowly getting worse and was suffering extremely with pain in her head and face, it was finally decided to remove her to the University Hospital for the purpose of having an operation, which might at least be palliative. Her pain increased until it became torturing, and for days before the operation it was necessary to keep her continuously under the effects of morphine or codeine. No change of any moment occurred in her focal symptoms after the above recorded notes.

The operation was performed by Dr. Frazier on October 14, 1903, under ether anæsthesia. A musculocutaneous flap together with the periosteum was reflected and an opening was made in the skull with the chisel and enlarged with Rongeur forceps. Nothing abnormal as regards pulsation nor consistency of the left lateral lobe of the cerebellum was noted. The dural flap was reflected; at one point this flap was adherent to the underlying brain. Cerebellar tissue bulged only moderately through the wound. On exploring with the index finger in the region of the cerebellopontile angle some adhesions were separated on the lateral aspect of the cerebellum. This was followed by a gush of fluid which had evidently been walled off by adhesions. After



Unable to display this page

on this date (October 15th) resulted as follows: No cutaneous anæsthesia was present on either side; not even any hypæsthesia on the left. There was great impairment of the motor division of the fifth nerve, the masseter and pterygoid muscles being tested. Complete paralysis in the muscles supplied by both the upper and lower branches of the seventh nerve was present. She was completely deaf in the left ear. Slight paralysis in the right upper extremity was noticed. Astereognosis or pseudoastereognosis was present in the right hand. Anæsthesia for both touch and pain and hyperæsthesia were absent. She had had no pain in the face or head since the operation, and had required no anodynes.

On October 19th the wound was again dressed and the stitches were removed; the wound was all healed, with the exception of one angle; a small piece of gauze was inserted for drainage. The patient's general condition had been very good. Her pupils were now normal.

On October 24th the surgical condition was entirely satisfactory; the wound was all healed, with the exception of one spot, which was rapidly granulating. The patient's general condition had rapidly improved since last noted. She was regaining strength, had been sitting up and was quite comfortable.

On October 29th the patient was discharged, the surgical condition left nothing to be desired; the wound was completely healed; there was no bulging of the flap, no signs of inflammation or œdema of the scalp. The patient had not had



Unable to display this page

## THE OCULAR SYMPTOMS OF CEREBELLAR TUMOR.

By G. E. DE SCHWEINITZ, M. D.,

PHILADELPHIA,

PROFESSOR OF OPHTHALMOLOGY, UNIVERSITY OF PENNSYLVANIA.

The ocular signs of cerebellar growth are chiefly concerned with changes in the fundus oculi, particularly the nerve head, and with anomalies of the external ocular muscles and the movements of the eyeballs.

### I. PAPILLITIS, OR CHOKED DISC.

(a) *Frequency*.—In order to ascertain the percentage of choked disc or papillitis in cases of suspected intracranial tumor, Dr. John Weeks<sup>1</sup> has collected the reports of 677 brain tumors, and finds that those which involve the corpora quadrigemina give the highest percentage, namely, 100; next come tumors of the parietooccipital region, with a percentage of 87.8, while new growths of the cerebellum furnish a percentage of 87.2. In his list are the records of 164 cases of cerebellar tumor, and only 21 times was optic neuritis absent. In an analysis of intracranial tumors with respect to the existence of optic neuritis published by Edmunds and Lawford,<sup>2</sup> 23 cases of neoplasm of the cerebel-

---

<sup>1</sup> *Transactions of the Section on Ophthalmology of the American Medical Association*, 1899.

<sup>2</sup> *Transactions of the Ophthalmological Society of the United Kingdom*, IV, 1884, p. 82.



lum are reported, and in 20 of them optic neuritis was present, being absent only three times. It is not necessary to elaborate these statistics, because the fact would not materially be altered that with the exception of growths of the corpora quadrigemina, and possibly those of the parietooccipital region, cerebellar tumors yield the highest percentage of papillitis, or so called choked disc.

(b) *Character of the Neuritis and Nerve Head Changes.*—It is a matter of common observation that optic neuritis develops with rapidity in cerebellar tumors, indeed, with greater rapidity than when they are elsewhere situated. In the words of Mr. Gunn, intense double optic neuritis, with great engorgement of the papillæ and with surrounding retinal change coming on quickly, suggests a cerebellar growth. In addition to a papillitis of an intense type, that is, one having the characteristics to which the term choked disc is applied, a cerebellar growth may also originate a more moderate swelling of the nerve head, somewhat condensed in appearance and comparatively free from undue capillarity.

It is not possible to state exactly how much time must be consumed before the optic neuritis of cerebellar neoplasms is evident. As already stated, the development is usually a rapid one, and the neuritis may appear within a few weeks, or even a

few days, after other signs of involvement of this region are evident, for example, intense headache, vomiting, and vertigo. Sometimes longer periods of time are required before optic neuritis is discovered. In one of my cases with other well marked signs of cerebellar growth there was no neuritis; six months later there was well marked neuritis in one eye and intense papillitis in the other.

It not infrequently happens that patients come to ophthalmoscopic examination after the papillitis has already subsided and a postneuritic atrophy is present, or at a period when the swelling of the disc is rapidly disappearing and atrophy beginning. Optic nerve atrophy, without signs of preexisting neuritis, and blindness, unassociated with ophthalmoscopic lesions, have been reported.

It is well known that the papillitis of intracranial tumor is sometimes unilateral and that when there is a one sided optic neuritis, or a marked difference between the two sides, it is suggestive of the fact that the cerebrum is the seat of the growth, and, on the whole, in favor of the tumor being on the same side as the excess of neuritis. Less frequently unilateral neuritis occurs in cerebellar tumor. It was noted four times in 164 cases of the Weeks collection. Referring to this point Mr. Gunn<sup>3</sup> writes as follows: "Taking the important analysis

---

<sup>3</sup> *Brain*, XXI, 1898, p. 335.



of 601 cases of tumor made by Dr. J. M. Martin, and paying attention to the relation between position, occurrence of optic neuritis, and difference of neuritis on the two sides, I find that there was unilateral neuritis (or excess) in 10 cases of frontal tumor, and in 8 of these it occurred on the same side as the tumor. In four cases of neuritis difference, in cases of temperosphenoidal growths, the one sided excess was always on the same side. Putting these together, we have the unilateral excess of neuritis on the same side as the tumor in 12 out of 14. The unilateral character of the neuritis was noted in 10 cases of tumor of the parietooccipital lobes and in the cerebellum. In 5 of these it was on the same side as the tumor and in 5 on the opposite side."

He further points out that a one sided difference of neuritis is more common in tumors of the cerebral lobes than in tumors of the cerebellum. In the collection before referred to it occurred in 20 per cent. of all of the cases of neuritis with tumors of the cerebrum, and in only about 3 per cent. of those associated with tumor of the cerebellum. I have not seen unilateral neuritis in cerebellar growth, although, as in the present collection, I have noted an excess of neuritis on one side as compared with the other.

(c) *Retinal Changes*.—It has been known since

the observations of von Graefe, Schmidt, and Wegner, more than thirty years ago, that appearances exactly simulating those seen in retinitis albuminurica, particularly the so called macular figure, may be found in brain tumor. This stellate macular figure, in addition to the swelling of the nerve head, has been noticed with particular frequency in cerebellar tumors and has been the subject of comment especially by Dr. James Taylor and Mr. Marcus Gunn.\* While it is more common to find this stellate figure in cerebellar growths than in others elsewhere situated, it is not peculiar to them, and Mr. Gunn himself remarks that he has seen it in frontal tumors. One of the best marked examples in my own observation occurred in a growth which was certainly in the cerebrum, although its location was not proved by autopsy, and another excellent example appeared in a subcortical growth of the midregion of the brain which had pressed upon the optic tracts and produced hemianopsia, and which was removed by Dr. Hearn and Dr. Da Costa in the Philadelphia Hospital. I have also seen it in perfect degree in several cerebellar tumors, one particularly in the Orthopædic Hospital and another under the care of Dr. Mills and Dr. Frazier in the University Hospital, a full eye

---

\* *Transactions of the Eighth International Medical Congress, Edinburgh, 1894.*



examination of which is recorded in the present paper.

Other retinal changes not significant of cerebellar tumor may also appear, for example, postneuritic atrophy, perivascularitis, areas of atrophy marking the position of former hæmorrhages, exudations and sclerotic alterations in the retinal vessels, if the patient has also been the subject of general arteriosclerosis.

(d) *Visual Acuity*.—It is well known that optic neuritis caused by intracranial growth is perfectly compatible with good visual acuity, but if the growth is situated in the cerebellum there is apt to be early great disturbance of vision, rapidly proceeding to blindness. Edmunds and Lawford referring to the frequency of blindness under these circumstances, compare it with the optic neuritis which occurs in tumors of the basal ganglia, which in their table yield next to cerebellar growths the highest percentage of optic neuritis, but in only five of the twenty cases was blindness present, as against nine which progressed to blindness in twenty-three cases of cerebellar tumor. Moreover, of the twenty cases with optic neuritis, seven were blind on admission to the hospital and two others became blind before death. They suggest that as cerebellar tumors are not so rapidly fatal as basal tumors, time

is allowed for the neuritis to pass on to atrophy and to blindness.

Dercum<sup>5</sup> in 1893 tentatively advanced the following explanation of early blindness in cerebellar growths: "The proximity of the quadrigeminal bodies naturally suggests itself as in some way explaining this blindness. A consideration of anatomy will show that if a growth be situated in the vermiform process, especially anteriorly, and that if this growth continues to enlarge, it will sooner or later press upon the superior cerebellar peduncles, and very probably upon the quadrigeminal bodies themselves. Now if we recall the relation which the fibres of the optic tracts bear to the primary optic centres one can readily understand how, if pressure or irritation occurs at this point, a neuritis would be the consequence. Further, the irritation being direct, one can, perhaps, understand why the neuritis should be of a high grade; and finally, also, why this neuritis should be associated, sooner or later, with total blindness." Recognizing, however, that this hypothesis, especially in so far as it refers to the development of the neuritis, is unsatisfactory, Dercum has abandoned it.

Oppenheim<sup>6</sup> thinks that upon the hydrocephalus which almost always accompanies in considerable

<sup>5</sup> *Journal of Nervous and Mental Disease*, 18, 1893, p. 683.

<sup>6</sup> *Die Geschwülste des Gehirns*, by Prof. Dr. H. Oppenheim, Wien, 1896, p. 144.



degree tumors of the cerebellum, depends the decided choked disc and its prompt arrival, as well as the early amblyopia, to be followed later by amaurosis. According to him, the rapid, sometimes sudden, appearance of amaurosis is due to a compression which injures the chiasm and which is caused by a bulging forward of the floor of the third ventricle. A similar explanation is applicable to those cases of amblyopia and blindness without eyeground changes which have been observed by Curschmann, Gerhardt, and others. The optic nerve atrophy, which is sometimes noted in cerebellar disease without evidence of much preexisting neuritis, Oppenheim also attributes to pressure upon the chiasm.

It would seem, therefore, that the blindness may be explained in part by direct pressure from hydrocephalus, and in part by the compression of the optic nerve fibres and their subsequent atrophy owing to the high grade of engorgement œdema, or to an actual neuritis. The relation which the destruction of the ganglion cells of the retina bears to this blindness requires further study, and it may be that their disintegration will account for some of the cases of early and even sudden blindness in cerebellar tumor associated with papillitis of marked degree.

(e) *Effect of Operation on Papillitis.*—In so far

as the pathological examinations of cerebellar optic neuritis are concerned, they do not differ from those which have been made in the optic neuritis of other intracranial growths, and it is not germane to the present topic to discuss this subject concerning which there is still much difference of opinion. In general terms, microscopical examination would seem to indicate that in a certain number of cases of papillitis, be they of cerebral or cerebellar origin, there is a true *engorgement œdema*, and that the evidence of inflammation, in any decided degree at least, is lacking, while in other cases the inflammatory signs are marked. When the engorgement œdema is the marked feature, the ophthalmoscope reveals the typical picture of choked disc. When, on the other hand, the inflammatory condition predominates, the elevation of the disc may be less marked and the process may extend to the surrounding retina. In other words, there is an *inflammatory optic neuritis*. Now, if one sees the case during the period of engorgement œdema, before inflammatory exudates are present, naturally it is desirable to reduce the swelling of the nerve head. Horsley, Bruns, Erb, James Taylor, and many others have called attention to the fact that there may be a subsidence of the optic neuritis after operation undertaken with a view to the removal of an intracranial tumor, even when the tumor was



not removed, and Taylor has recorded a number of examples of this character. Certainly, as Horsley points out, removal of pressure is one of the factors in the reduction of optic neuritis in intracranial tumors, and as Hill Griffith has said, should there be recovery after blindness with optic neuritis by trephining, the indications are that the optic nerve condition was produced by pressure.

Saenger<sup>7</sup> reports prompt subsidence of double sided choked disc after palliative trephining for cerebellar growth and advises this operative procedure in tumors which cannot be removed in order to relieve pressure symptoms and especially to avoid impending blindness. In seven cases of double choked disc he has noted a disappearance of this condition after such trephining. In two of the patients described by Dr. Mills in the present paper and trephined by Dr. Frazier, with removal of the growth, there was decided and comparatively prompt subsidence of the choked disc. In one of these blindness occurred, but the patient was practically blind when she was trephined. In the other the visual acuity before the operation, which was good, that is, two thirds of normal, has been maintained until the present time and the neuritis has partly subsided.<sup>8</sup>

---

<sup>7</sup> *Münch. med. Wochenschr.*, XLVIII, 1901, p. 2.

<sup>8</sup> Since this sentence was written the patient has been seen, and the vision has begun to fail and a partial ophthalmoplegia has developed; evidently there has been recurrence.

If it be true, as Merz declares, that increased intracranial tension alone is sufficient to produce choked disc, provided this tension shall be maintained uninterruptedly for a certain time, and if further it is true, as would seem from reported cases, that there is reduction of such tension by trephining, even where the tumor is not removed, then certainly Saenger's advice that such palliative trephining should be performed early, especially in the choked disc of cerebellar tumor, which is almost sure to produce blindness, is sound and should be followed.

## II.—ANOMALIES OF THE OCULAR MUSCLES AND OF THE MOVEMENTS OF THE EYEBALLS.

Owing to the anatomical relations of the cerebellum, tumor formation in this region may bring about involvement of certain of the cranial nerves, particularly the facial and the auditory. In so far as the eye muscle nerves are concerned, the abducens is by far the most frequently affected, and convergent paralytic strabismus with involvement of one or both abducens nerves is not an unusual symptom in cerebellar growth. In a case reported by Saenger with gliosarcoma of the left cerebellar hemisphere, there was double abducens paralysis with marked thinning of the nerves, and in a similar growth recorded by Sander the abducens paralysis was ex-



plained by finding a lesion in its nucleus. Wernicke states that sixth nerve paralysis is most apt to be present as a distant symptom when the tumor is situated in the cerebellum. In this respect the sixth differs from the third nerve, which, as Swanzy has well shown, is more likely to give distant symptoms with a lesion of the cerebral hemisphere.

In one case recorded by Dr. Mills in the present paper where the cerebellum and the pons oblongata were exposed and a cyst was discharged, there was paralysis of the branch supplying the left levator palpebræ and the left inferior rectus. According to Oppenheim ptosis and reflex immobility of the pupil without loss of sight and paresis of accommodation have been observed, and he quotes Mackenzie, Bruns, and other authors as having observed a more or less complete ophthalmoplegia.\* A rare ocular muscle palsy is one that affects the superior oblique, that is to say, the trochlearis is involved. Referring to the ætiology of these conditions, Oppenheim remarks that the paralyzes must depend upon a lesion of the nerve trunks themselves, or upon pressure exerted on the region of their nuclei. When ophthalmoplegia is evident, it may be explained by an involvement of the corpora quadrigemina.

---

\* In one case at present under my observation there is paralysis of all external ocular muscles except the inferior recti, which are beginning to be involved, and the superior obliques.

Bruns,<sup>10</sup> referring to the difficulty of telling on which side of the cerebellum a tumor has its situation, speaks of the help obtained in this respect when certain nerves are paralyzed, for example, the trifacial, the facial, and the auditory, and refers as a frequent symptom to the presence of associated paralyses of ocular movements which then appear toward the side of the tumor. So frequent are these paralyses that in large tumors of the cerebellum Bruns considers them to be constant.

Oppenheim, discussing the same subject, remarks that this symptom, that is, a paralysis of associated parallel movements of the eyes toward the side of the tumor with deviation of the eyes toward the opposite side, depends upon a one sided compression of the pons. It is, therefore, the rule that the eyes of these patients cannot be moved toward the side of the tumor. He warns, however, that the symptom cannot be absolutely trusted, inasmuch as in two cases under his own observation there was paralysis of associated parallel movements toward one side when the vermiform process was the part involved in the tumor formation.

According to Gowers, an unsymmetrical position of the eyes, one directed upward and inward and the other one downward and outward, has been ob-

---

<sup>10</sup> *Neurologisches Centralbl.*, 18, 1899, p. 519.



served as a rare symptom of tumor of the middle peduncle of the cerebellum.

Nystagmus is almost always present in cerebellar tumors. It may be rotary or vertical, but is most frequently lateral. Sometimes it is not observable when the gaze is directed forward but develops at once in right or left l evoversion.

It would seem also that in a certain number of cases the nystagmus is evident only when the eyes are turned toward the side on which the tumor is situated, and, indeed, that such nystagmus may be the sole ocular sign of the cerebellar growth. For example, Pineles<sup>11</sup> observed in a patient with normal eyegrounds nystagmus only when the eyes were directed to the left. Post mortem examination revealed a walnut sized tubercle in the left cerebellar hemisphere, the middle of the lobus quadrangularis being also involved. This development of nystagmus when the eyes are rotated toward the side of the tumor has been commented upon by a number of observers. It has been noticed by Mills, Spiller, and by myself in several cases which we have examined together. In place of a true nystagmus, a nystagmoid movement is often observable when the eyes are turned from side to side, particularly if there is an associated paralysis of the external rectus. There is no doubt that nystagmus may be

---

<sup>11</sup> *Arbeiten aus Obersteiner's Laboratorium*, Heft 4, 1899.

regarded as a direct cerebellar symptom. It has also been referred, according to Arnheim who quotes Russell in this respect, to a paralysis of the ocular muscles.

That double optic neuritis, internal strabismus, and nystagmoid movements on looking both to the right and to the left, must not, however, be regarded as characteristic or pathognomonic of cerebellar tumor, is evident from a case recorded by Bramwell,<sup>12</sup> in which these symptoms were present and the lesion consisted of a dilatation of the ventricles, especially of the fourth ventricle, the result of a previous meningitis and an obliteration of the foramen of Magendie. The oscillation of the globes in blindness from cerebellar tumor must not be confused with true nystagmus.

There is nothing characteristic in the *pupil reactions* in disease of this region. If there is blindness and loss of light perception, there is naturally loss of the light reflex, while, if light perception remains, this reflex is preserved.

So, also, the field of vision furnishes no characteristic changes. It may be perfectly intact or concentrically or irregularly contracted, according to the degree of atrophy existing in the optic nerves. In some cases there seems to have been hemianopsia, but probably only a contraction of the

---

<sup>12</sup> *Brain*, XXII, 1899, p. 68.



visual field resembling this phenomenon due to atrophy in the optic nerve, or alteration in the ganglion cells of the retina. It is of course conceivable that hemianopsia could occur as an associated symptom if with the cerebellar growth there were other lesions which pressed upon some portion of the optic pathway.

# THE PATHOLOGY OF CEREBELLAR TUMORS.\*

By T. H. WEISENBURG, M. D.,

PHILADELPHIA,

INSTRUCTOR IN NEUROLOGY AND NEUROPATHOLOGY, UNIVERSITY OF PENNSYLVANIA; ASSISTANT NEUROLOGIST TO  
THE PHILADELPHIA GENERAL HOSPITAL.

It is not the purpose of this paper to consider minutely the histology of cerebellar growths, as this information can be obtained in any textbook on neurology. The pathological aspects of the various conditions which give the symptoms of cerebellar tumor will be considered, especially in a surgical sense.

It is difficult to make a satisfactory classification of such a subject, but the following plan will be adopted:

1. The ordinary tumors in their order of frequency, as glioma, tuberculoma, cysts, and so forth, of the cerebellum itself.
2. Growths of the surrounding regions giving cerebellar symptoms, as of the fourth ventricle, medulla oblongata, pons, and corpora quadrigemina.
3. Growths in parts besides those mentioned, giving cerebellar symptoms.
4. Abscess of the cerebellum.

---

\* From the Neuropathological Laboratory of the University of Pennsylvania.



5. Internal hydrocephalus, with symptoms of cerebellar tumor.

6. Cerebellar symptoms without any lesions.

7. Lesions of the cerebellum without any symptoms.

Excellent statistical studies of the frequency of the cerebellar and other cranial growths have been made, and without the desire to add to the already voluminous literature on the subject, it has been thought advisable to give a brief report of the brain tumors now in the neuropathological laboratory of the University of Pennsylvania, which is under the direction of Professor William G. Spiller. This collection has largely been accumulated in the last three or four years, and is from the services of Dr. Mills and Dr. Spiller, although in a number of instances specimens have been obtained from other sources.

Tumors of the cerebral cortex and subcortex.....	27
Cerebellar tumors.....	9
Tumors of the brain stem.....	9
Tumors implicating both brain and cord.....	4
Tumors of the cerebral cortex and subcortex:	
Sarcoma .....	13
Fibrosarcoma .....	2
Endothelioma .....	4
Glioma .....	3
Gumma .....	2
Carcinoma .....	1
Adenoma .....	1
Tuberculoma .....	1
Cerebellar tumors:	
Glioma .....	5
Sarcoma .....	1
Fibroma (in the cerebellopontile angle).....	3

Tumors of the brain stem :	
Pons: Tuberculoma .....	2
Glioma .....	1
On the pons and medulla oblongata: Sarcoma.....	1
On the medulla oblongata: Chondrosarcoma.....	1
Within the fourth ventricle: Sarcoma.....	2
On the corpora quadrigemina: Fibroma.....	1
Within the corpora quadrigemina: Glioma.....	1
Tumors of the brain and cord: General sarcomatosis, with large tumors, especially in the cerebellopontile angle.....	4

Sections of at least seven other brain tumors were not considered, because definite knowledge of the location of the growths was lacking.

According to statistics tumors of the cerebellum are less frequent than of the cerebrum. Schuster, in a statistical table of some thousand cases of brain tumor, found 21.6 per cent. to be cerebellar. When the relative size of the cerebellum and the cerebrum is considered, it is probable that new growths are more frequent in the former.

Tuberculous growths are more common in persons below the age of twenty years, while glioma, sarcoma, and cysts of various kinds are more frequent in the adult. The frequency of fibroma, especially of the acoustic nerve, is becoming better recognized. Syphilitic tumors of the cerebellum are rare. Of the other forms of new growths, as carcinoma, lipoma, angioma, psammoma, and dermoid cysts, there are very few instances in the literature.



The lateral lobes of the cerebellum possibly because of their greater size, seem to be more frequently the seat of tumors than the middle lobe, although writers differ upon this point. Tumors within the middle cerebellar peduncle are rarely found, although a tumor within this peduncle is present in one of the specimens in the laboratory. Growths in the anterior and posterior cerebellar peduncles are also uncommon. The angle formed by the cerebellum, medulla oblongata, and pons is a favorite seat for new growths, these tumors growing either from within or upon the acoustic, facial, or trigeminus nerves, and frequently are fibromata.

*Tuberculoma.*—In 152 tuberculous brain tumors collected by Allen Starr, occurring in childhood, 47 were in the cerebellum. In the adult they are found with equal frequency in this region and in the pons and the cerebral cortex. They are nearly always multiple, and secondary to a tuberculous process elsewhere in the body. A tendency to symmetrical arrangement is also observed (Oppenheim). Their size varies from a small nodule to a large fist. Macroscopically, it is hard to distinguish a tuberculoma from a syphiloma. Both have poor blood supply and a tendency to caseate, the tuberculous growth to pus formation. Again, both have a tendency to grow

from the meninges, although the tuberculous growths are found in the substance of the brain, and may have granulation areas and miliary tubercles about their border. It must be recalled, however, that syphilitic tumors of the cerebellum are rare.

The growth of a tubercle may be either rapid or slow. Tuberculous tumors may give no clinical symptoms. This has been explained by the slowness of the growth, the cerebellum gradually accommodating itself to increased pressure. Very recently, however, Raubitschek was able to demonstrate the persistence of the axis cylinders in tuberculous growths by Bielchowsky's method. This, as in multiple sclerosis, explains the persistence of function. Surgically, it is not advisable to operate upon these growths, as they are multiple and cannot be removed.

*Glioma.*—The cerebellum is a favorite seat for glioma. Five of our cerebellar growths were of such nature. Gliomata are almost always primary and single, although metastasis has been noted. The tumor may be as small as a cherry or as large as a hen's egg; it always grows from the brain substance itself, and is of slow growth. It is not sharply defined, but infiltrates into the brain substance, and it is difficult to tell it from normal brain tissue, although sometimes there



is an increased consistence to pressure and there may be a slight swelling. The border zone of the tumor may present an increased number of blood vessels and there may be islets of new tissue.

Gliomata may be hard or soft, depending upon the excess of cells or fibrils, and have a yellowish white or reddish appearance. Cystic formation is very common, some authors believing that the whole tumor mass may disappear, leaving nothing but a cyst wall, and that it is necessary to examine microscopically the capsule to determine the gliomatous origin. Cysts form in the neighborhood of these tumors, and the surgeon may tap one of these cystic formations, believing it to be the only lesion present. It is wise, as Oppenheim has pointed out, to remove always a part of the cyst wall for microscopic examination. The fluid inside of these cysts may be whitish or bloody in character. Fatty, hæmorrhagic, and myxomatous changes occur in gliomatous tumors.

Microscopically, it is difficult to distinguish a glioma from a sarcoma unless a differential stain has been employed. There is some doubt as to the simultaneous occurrence of glioma and sarcoma, the so called gliosarcoma, some authors believing this to be impossible, as the former is of

ectodermal and the latter of mesodermal origin. Others believe that by metaplastic processes a sarcomatous structure may develop from neuroglial tissue. According to certain pathologists, a gliosarcoma should only be diagnosticated where a sarcomatous, perivascular cellular mass is found within a glioma.

It can readily be understood from the slow growth and from its infiltrating character why clinical symptoms of brain tumor do not always appear, or not until late in the disease. Surgically, it is difficult or even impossible to remove completely such a tumor. Sections made from the specimens removed at the operation in Cases I and II of Dr. Mills and Dr. Frazier showed a glioma in each instance.

*Sarcoma.*—This form of brain tumor is about as common as the glioma, although in our experience sarcomata have been more frequently found. The growth may be small, flat, or nodular, or may be of large size. It is primary and usually solitary. Sarcoma always grows from the meninges, periosteum, or cranial bones, or from the pial covering of the blood vessels. It never grows from the brain substance, and therefore, unlike the glioma, it often compresses the brain tissue and may be distinct from it, although not infrequently it infiltrates the latter. Even



when growing within the brain a distinct margin sometimes may be found, due to the softened area surrounding it. It is usually harder in consistency than a glioma, and is slow in its growth.


The tumor may soften or caseate. Myxomatous, hæmorrhagic, and cystic changes are not uncommon. Cystic changes are especially common in the cerebellum, not only in sarcomata, but also in gliomata. In one of Dr. Spiller's cases small sarcomatous masses were found in the walls of a cyst. If the fibrous tissue is very marked we have a fibrosarcoma.

Sarcoma may manifest itself as a diffuse multiple sarcomatosis. In an excellent article Spiller recorded two such cases and called attention to the rarity of this disease. He quotes Schlesinger, who subdivided the tumors under the head of multiple sarcomatosis into

(a) Diseases of the nervous substance and meninges,

(b) Multiple sarcomatosis of the membranes without sarcoma of the brain or cord, when it is (1) in the form of multiple small tumors, or (2) a diffuse sarcomatous infiltration of the membranes.

Of twenty cases recorded by Schlesinger, fourteen implicated the brain and cord or their membranes. "In nine of these fourteen cases cere-





Unable to display this page

bellar tumor was found, and in three the medulla oblongata was affected. It appears, therefore, that when the brain or its membranes are implicated in sarcomatosis, usually the structures of the posterior cranial fossa are affected, and that in about two thirds of the cases a tumor of the cerebellum is found."

In Spiller's first case a large sarcoma was found in the left cerebellar lobe, and in his second case a tumor was found in each cerebello-pontile angle, the larger one being on the left side, as shown in Fig. 1. Tumors were also found in this case in the Gasserian ganglia, pituitary body, floor of the fourth ventricle, right internal auditory meatus, and right jugular foramen, and numerous small tumors were found in the pia of the spinal cord.

It may be impossible, as in Spiller's second case, to make a correct diagnosis in sarcomatosis of the brain and of the pial covering. Extensive alteration may cause few clinical symptoms, because the soft tumor masses grow in the pia and about the cranial nerves and spinal roots, and may produce little or no compression or destruction of the nervous tissue. Spiller insists upon the importance of remembering this fact, for when evidences of sarcomatosis are found, the case is an inoperative one.



Occasionally the process may invade the brain substance, while the nerve roots may escape. It is, according to Spiller, because of this escape of the nervous tissue in many cases that a correct diagnosis of the extent of the process may be impossible.

The infiltration of the pia may resemble that caused by syphilis or tuberculosis. Again, as in Nonne's case, the macroscopical examination may be normal.

Sarcomatous tumors, according to Westphal, occur more often in the young. When tumors occur in the posterior cranial fossa they have a predilection for the cerebellopontile angle and the internal auditory meatus.

Isolated sarcomata whether of the cerebellum or of any other region of the brain are, next to fibromata, among the most favorable forms of tumor for surgical removal. Of course the question of multiple sarcomatosis must always be carefully considered when deciding upon operation. With regard to surgical procedure the hard non-infiltrating sarcomata are the most favorable. Experience shows, however, that a sarcoma which appears to be infiltrating when the brain and tumor mass are first exposed, is often separable from the brain substance.

*Syphilitic Growths.*—Gummata are rarely found

post mortem, although they are possibly the most common cranial growths. They are especially rare in the cerebellum. The resemblance between this growth and tuberculoma has already been discussed. In a recent article Mills recorded two cases in which the diagnosis of a tumor in the cerebellopontile angle was made. At the necropsy no tumors were apparent, but microscopically in the first case a diffuse syphilitic basal meningitis was found and in his second case besides a meningitis at the base, there were numerous areas of softening throughout the brain, extending from the gray into the white matter. These areas of softening were yellowish red in color, soft in consistence, and were well defined from the surrounding brain substance. Microscopically, there was an intense round cell infiltration about the blood vessels and within the tissues.

These cases illustrate well the nature of syphilitic new growths. It is well known that a syphilitic basal meningitis, or meningoencephalitis, may attack any cranial nerve or combination of cranial nerves, but according to Mills they show a predilection in favor of the nerves from the second to the seventh inclusive, of these the fifth perhaps most frequently escaping.

Syphilitic growths are rapid in development,



but it must be remembered that the various pathological conditions which lead on to these growths have been long present.

*Fibromata.*—These tumors are rare, but they are relatively more frequent in the cerebellum than in the cerebrum, and especially in the cerebellopontile angle. This has been better recognized within the last few years, because of the relatively successful surgical removal of tumors growing in this area.

A fibroma invading the cerebellopontile angle may be only a part of a general neurofibromatosis; this, however, is rare, or, what is more common, it may be the only expression of this process, a central neurofibromatosis. The growth is slow, and generally is unilateral, although in rare instances it may be present on both sides. Henneberg and Koch pointed out that these tumors are more often found on the left side in the ratio of three to two. In the cases reported by Dr. Mills, the pathological reports of which are here given, the neoplasms were on the left side. In an examination of the tumors situated in the pons, medulla oblongata and the cerebellum, we found that the majority were on the left side. It seems, therefore, that tumors of these areas are more prone to grow on the left side.

The fibroma may be as small as a cherry or

the size of a large egg. The growth is firm, hard, nodular, and has a distinct capsule surrounding it. It is loosely attached to the brain by an atrophic nerve trunk, a few blood vessels or a meningeal process, and these attachments may be easily ruptured. These tumors are in organic relation, especially with the acoustic nerve, and more rarely with the trigeminus and facial nerves. They nearly always grow from the endoneurium and rarely from the peri- or epineurium. Consequently we may find medullated nerve fibres either in the periphery of the tumor or in its centre. As a rule, if the process involves the other cranial nerves, we have a general neurofibromatosis.


The fibroma may undergo a cystic, fatty, or myxomatous degeneration. Very often in its advanced stages it may assume a sarcomatous tendency. Histologically we find a connective tissue structure with entire absence of nerve elements, except sometimes a few medullated nerve fibres either in the periphery or its central part. These are remnants of the nerve on which the fibroma grows and should not be mistaken for a part of the new growth. Most writers persist in calling these tumors neurofibromata. The best example of a true neurofibroma is the amputation neuroma, therefore, a fibroma would be a better term for these growths.



In a number of cases of fibroma of the acoustic there were associated cortical changes. Henneberg and Koch reported hyperplasia and hypertrophy of the glia cells of the cortex, especially of the deeper layer, and in another case endothelioma and psammomata of the dura mater. Fraenkel and Hunt made a similar observation. In another case reported by these authors there were protrusions and minute herniæ attached to and sometimes perforating the dura. Histologically, these consisted of large cells of the spindle type and of glia cells.

At times the fibromatous process may involve the whole of the intracranial portion of the acoustic. In a case of Alexander and v. Frankl-Hochwart, an anatomical examination of the labyrinth showed a degenerative atrophy of the cochlear nerve, the spiral ganglion, the organ of Corti, and the striæ vasculares.

These tumors compress greatly the lateral lobes of the cerebellum, the pons, and the medulla oblongata. In one of Dr. Mills's cases the temporal lobe was compressed. Because of the slow growth and the nature of the tumor, clinical symptoms may not appear at all, or only late in the disease. In one of Dr. Mills's cases there were no symptoms of such a growth, the tumor being found at necropsy.





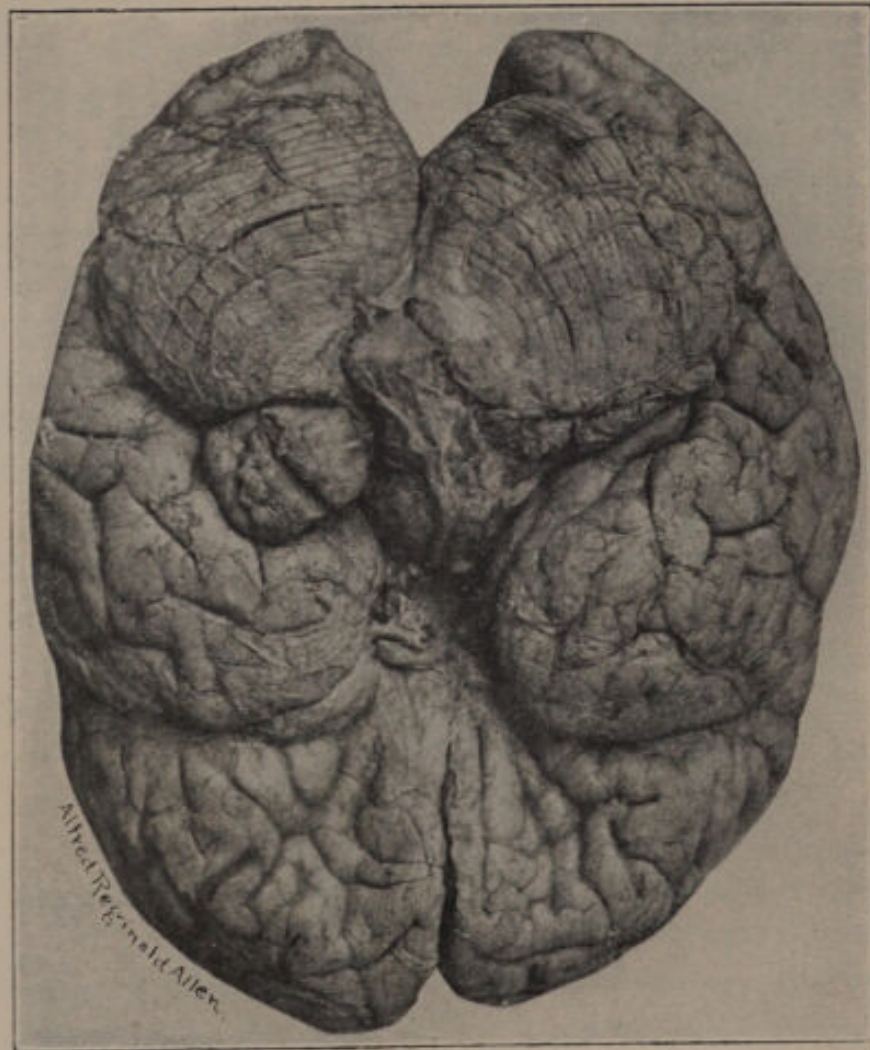


FIG. 2.—Fibroma growing from the left acoustic nerve compressing slightly the left lateral lobe of the cerebellum and the lower surface of the left temporal lobe.

The following pathological report of two cases of fibroma in the left cerebellopontile angle are from the service of Dr. Mills. They are referred to by him in the discussion of tumors of the cerebellopontile angle, the first extensively, the second briefly. The clinical report of the second case is appended:

CASE I.—A tumor (Fig. 2) 3 cm. wide and  $2\frac{1}{2}$  cm. in length anteroposteriorly was found in the left cerebellopontile angle, compressing slightly the forward part of the left lateral lobe of the cerebellum and the under surface of the temporal lobe. The pons and medulla oblongata were not compressed. There was marked internal hydrocephalus. Microscopical examination showed it to be a fibroma.

CASE II.—A tumor (Fig. 3) 5 cm. wide and 3 to 4 cm. in length anteroposteriorly was found in the left cerebellopontile angle. The tumor was very firm and nodular, and compressed considerably the under surface of the left lateral lobe of the cerebellum and the left side of the pons. At no place did the tumor infiltrate the brain tissue, and it could be entirely enucleated. Microscopical examination showed it to be a fibroma.

*Cysts.*—Cystic degeneration of gliomata and sarcomata are very common, especially if they are situated in the cerebellum. This has been



discussed when speaking of sarcoma. Other tumors, as fibroma and carcinoma, are prone to undergo cystic change, but more rarely. Some authors believe that the whole tumor may disappear and only a cyst remain. In other cases only a microscopical examination will detect a small tumor mass in the walls of the cyst. Spiller has pointed out that the wall of a congenital cyst may be the starting point for a neoplasm, and this possibility should not be ignored.

The most common cystic changes found in the brain are due to parasitic growth, the *cysticercus cellulosæ* and the *ecchinococcus*. These, however, are so rare in this country that they will not be here discussed.


Cysts due to traumatism are recorded, but their genesis is by no means clear. Congenital cysts are rare. They are probably offshoots of the primary cerebral vesicles. Dermoid cysts have been recorded as occurring in the cerebellum in several instances.

*Carcinoma.*—Carcinoma of the cerebellum is rare. This form of neoplasm is always secondary and grows from the dura or in the substance of the brain. Saenger recorded infiltration of the cerebral pia with cancer cells. The possibility of toxic changes must be considered, as it is not improbable that through intoxication caused by

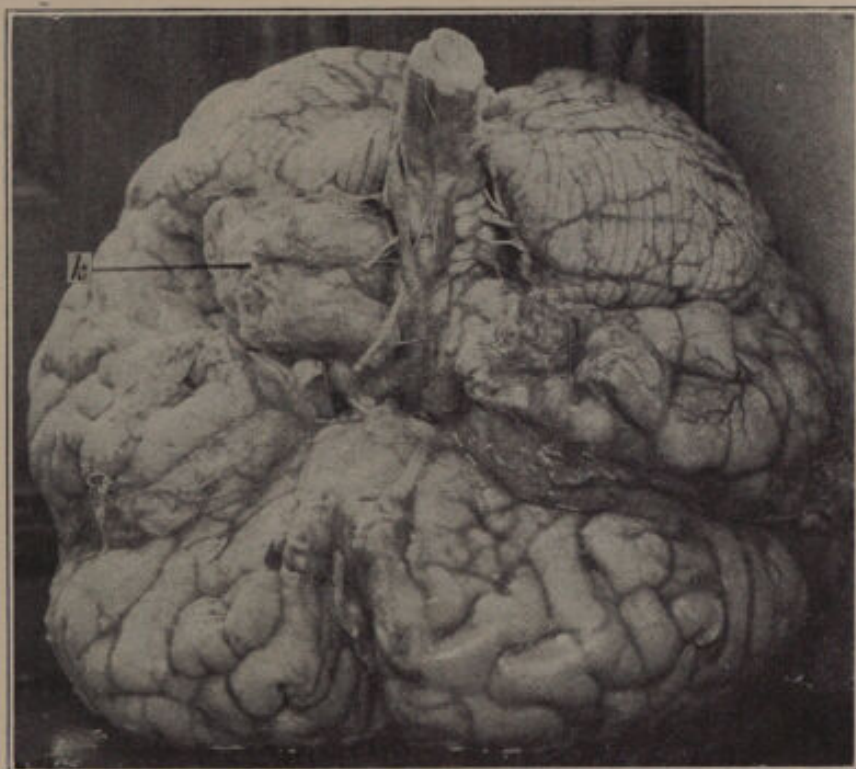

FIG. 3.—Fibroma growing in the left cerebellopontile angle compressing the lower surface of the cerebellum and the left side of the pons.





a carcinoma elsewhere in the body, symptoms of brain tumor may be present.

*Osteoma.*—In several instances an osteoma has been described as occurring in the cerebellum. It is probable that these growths are not primarily of bone formation, but are the result of calcification of such tumors as tuberculoma, fibroma, sarcoma, and even lipoma. Other neoplasms, as adenoma, lipoma, angioma, psammoma, and cholesteatoma are hardly ever found in the cerebellum, so they will not be discussed. It must also be remembered that aneurysm of the vertebral or basilar artery may give symptoms of cerebellar growth.

*The Influence of Cerebellar Growths.*—At the operation when the dura is removed there is nearly always increased tension and the parts may bulge. The surface of the cerebellum is flat and the fissures may be abolished. The pia covering the neoplasm is generally poor in its blood supply. The tissues near the growth may be softened. If the tumor is in the lateral lobe of the cerebellum it may compress the fifth, seventh, and eighth cranial nerves. The occipital lobes may even be compressed through the tentorium. If the cerebellar tumor is large it may compress the corpora quadrigemina, pons, and the medulla oblongata, and these structures may be flattened



or deformed. Pressure may also be exerted upon the cranial nerves at the base of the brain. The influence of cerebellopontile growths upon surrounding structures has already been discussed.

The cerebrospinal fluid is almost always increased in cases of cerebellar tumor, because pressure is exerted upon the communication between the lateral ventricles and the fourth ventricle, or upon the veins of Galen, which convey the blood from the choroid plexus to the sinus rectus. Because of this internal hydrocephalus undue pressure is brought to bear upon the different cranial nerves, as the optic and olfactory. The optic chiasm may be directly compressed through pressure from the third ventricle.

Alterations in the posterior roots and the posterior columns of the spinal cord have been recorded as occurring in conjunction with tumors of the brain. Such changes have been also found by Dr. Spiller. According to Batten and Collier they are especially present in cerebellar growths, and are due to the increased pressure. Dinkler and Becker believe that toxic or nutritional changes are at fault.

*Tumors of the Fourth Ventricle, Medulla Oblongata, Pons, and Choroid Plexus.*—It is not in the province of this paper to consider *in extenso* neoplasms of these areas, but inasmuch as these

growths sometimes give symptoms of cerebellar involvement, they will be briefly considered.

Tumors of the fourth ventricle and of the medulla oblongata may give no appreciable clinical symptoms. They may either be cystic or hard, and may grow in the substance of the medulla oblongata. This is especially true of parasitic and congenital cysts. Hunt recorded two congenital cysts of the fourth ventricle in which the cerebellum was greatly compressed and yet there were no cerebellar symptoms.

Neoplasms growing within or upon the corpora quadrigemina nearly always compress the middle or the lateral lobes of the cerebellum. They also cause internal hydrocephalus. Two such specimens are in our collection.

Tumors of the pons may cause pressure symptoms upon the cerebellum, or the growths may involve the middle cerebellar peduncles. Growths of the chorioid plexus, as in a case of Arnold's, where a psammoma of the size of an apple was found, may compress the pons, medulla oblongata, and the cerebellum.

*Tumors in the Cerebrum Giving Symptoms of Cerebellar Growth.*—Ascherson recorded an instance in which a sarcoma was found in the centrum ovale of the left side in the upper motor area. This neoplasm measured  $1\frac{1}{2}$  by  $2\frac{3}{8}$  inches, and



could easily be enucleated. It caused a compression of the lateral ventricle in the same side. This author cites Raymond as having recorded an almost similar case. Ascherson is of the opinion that the cerebellar symptoms were due to pressure exerted through the lateral ventricle, and he emphasizes the importance of early symptoms before those of pressure are apparent. In this connection the fact that tumors of the post-parietal cortex or subcortex, may give unilateral ataxia should be borne in mind. The diagnosis between post parietal and cerebellar tumors is given in the paper of Dr. Mills.

*Abscess.*—Chronic otitis media is the most frequent cause of abscess in the cerebellum. It may be due to such other causes as traumatism or may be a part of a general pyæmic process, but these instances are uncommon. The abscess occurs mostly in the anterior outer part of the cerebellum, and is generally single. It may involve also the adjoining temporal lobe. The abscess may be encapsulated or it may keep on forming pus. Surrounding it, œdema and softening of the brain substance are found. Pus may travel along the facialis and acousticus, and cause extradural abscesses. Hydrocephalus, sinus thrombosis, and thrombophlebitis are frequent complications.

*Internal Hydrocephalus.*—This condition is most often caused by a brain tumor, but it may be congenital or acquired. Spiller recorded an instance in which the symptoms were those of cerebellar tumor, and at the necropsy the cerebral ventricles were much distended, but the fourth ventricle was of normal size. The aqueduct of Sylvius was almost entirely occluded when examined, and the occlusion must have been congenital or have occurred early. Byrom Bramwell recorded a similar case, but here a localized meningitis caused a closure of the foramen of Magendie. The possibility of internal hydrocephalus should always be kept in mind when a cerebellar growth is considered.

*Symptoms of Cerebellar Tumor Without Lesions.*—In a very important paper, Nonne called attention to those cases in which the majority of the symptoms of brain tumor were present, and in which either spontaneously or under mercurial treatment the symptoms disappeared, leaving, perhaps, a partial optic nerve atrophy. There was no reason in any of the eight clinical cases he reported to suspect syphilis.

He also records three similar cases with necropsy, in two of which symptoms of a tumor in the posterior cranial fossa was diagnosticated. At the necropsy in the first case, internal hydro-



Unable to display this page

lower limbs and sensation was also somewhat impaired. The patellar jerks were absent. There was no albumin in the urine.

Dr. Roberts operated at the point of great tenderness in the left posterior parietal region. There was nothing abnormal found and the brain appeared to be in a healthy condition.

The patient's symptoms steadily disappeared, the pain in the head became better and in a short time she seemed almost well.

Another case was studied by me repeatedly.

This woman was in the nervous wards of the Philadelphia General Hospital in the service of Dr. Spiller. She was 52 years of age, denied venereal history, and her past history was unimportant. Five years ago she began to have violent vertical headache, which has persisted more or less since. One year ago she began to have objective vertigo, and convulsions, Jacksonian in type, which always involved the left side of the face, and the left arm and leg. Sight also became poor at that time, and her memory was not as good as formerly. In my examination she showed a paresis of the left arm and leg, these being spastic, and the reflexes were exaggerated. The Babinski sign was present on this side. There was also a paresis of the lower distribution of the left seventh nerve, and a paralysis of the left abducens and the left fifth nerve, both in its motor and sensory distribution. Optic neuritis was present in both eyes.



On protruding her tongue she had a clonic to and fro movement which became apparent on talking or moving the tongue. She became steadily worse and finally was comatose. The urine examination was negative. She rallied, however, her symptoms steadily disappeared and she was discharged from the hospital four months afterwards, the only remaining symptom being a dimness of vision.

These two cases are similar to those recorded by Nonne. No adequate explanation for them can be given.

*Lesions of the Cerebellum Without Symptoms.*—These lesions may be either congenital, acquired early in life, or may be tumors. It is not surprising that injuries to the cerebellum early in life or that tumors of slow development which occur in the same period give no appreciable symptoms, because the functions of the cerebellum in such cases have probably been assumed by other parts of the brain. Lesions of the lateral lobes of the cerebellum are less liable to cause symptoms than when they implicate the entire cerebellum. Spiller recorded three cases of lesion of the cerebellum in which there were no symptoms, and he also reviewed the literature upon this subject. In his first case one cerebellar lobe was smaller than the other, and it was sclerotic. In the second case there was a tumor

upon the corpora quadrigemina in which the lateral lobe of the cerebellum was compressed. The third was one of tumor within the vermis.

Cases are recorded in which tubercles involved an entire lateral lobe and gliomata and cysts occupied the middle lobe, and yet there were no symptoms. Oppenheim refers to a case of Putnam's, where the only symptom for years was an optic nerve atrophy, in which at necropsy a cyst of the cerebellum was found. He also refers to Bramwell's case, where in a thoroughly studied case no symptoms were apparent, while at necropsy four tumors were found.

It can readily be understood why symptoms may not be apparent in a gliomatous tumor, because of its infiltrating character, and in tubercles, in which the axis cylinders are retained; but it is difficult to explain the absence of symptoms in the other instances.

The notes of the case of cerebellopontile tumor, as shown in the illustration, Fig. 3, and Case II of this paper, were furnished by Dr. Mills. The patient was seen by Dr. Mills in consultation with Dr. W. W. Keen; she was also examined in consultation by Dr. W. G. Spiller. The tumor sprang from the eighth nerve, and the chief focal symptoms were one sided deafness, tinnitus, facial monospasm, hypæsthesia of one side of the face, nystagmoid



movements, slight paresis of right abducens, and vasomotor and cardiac disturbances. Severe headache, nausea, vomiting, and optic neuritis were also present.

This patient was a married woman, 30 years of age, five of whose maternal relatives had died of cancer. Four years before coming under observation the ossicles of her left ear were removed, on account of an annoying tinnitus, but without the desired result. About one year later she began to suffer from severe headache. The next year slight optic neuritis was observed in both eyes, the neuritis going on to atrophy and blindness, which was complete in less than two years. Headache, nausea, vomiting, and depression were recurring symptoms, and taste and smell were impaired. During two or three years she was treated for various complaints as anæmia and neurasthenia, and both Graves's disease and interstitial nephritis were suspected. About six months before coming under observation she had a convulsion with loss of consciousness, this being followed by several others of a similar kind.

The patient was having at somewhat frequent intervals attacks beginning with pain in the head, which was referred to the forehead and eyes. In these she became nauseated and then vomited, becoming pale or even cyanosed, with loss of consciousness. The vomiting was preceded or accompanied by marked facial monospasm, in

which the mouth was drawn forcibly to the left and the eyelids were drawn together. Only the left side of the face was involved in the seizure. Examination showed that she had no ataxia of station or gait. Hearing on the right side was good, on the left side it was abolished. The mouth deviated slightly to the left when opened widely. Hypæsthesia to pain was present on the left side of the face and head, and sometimes appeared to be present in the left hand. The patient was not mentally impaired, but was easily exhausted mentally, and was at times irritable and depressed as the result of her sufferings. During the time she was under observation she had frequently recurring headaches, usually severe, sometimes accompanied with nausea or even vomiting, and sometimes with the facial spasm already described. Irregular nystagmoid movements occurred when the patient turned the eyeballs to the extreme right or left. She had complete loss of smell, and loss of taste on the left side of the tongue. On one occasion it was thought that the facial spasm was accompanied by some spasmodic movements of the left hand, but this was doubtful, and even the observer thought it may have been a voluntary movement.

The question of the existence of exophthalmic goitre was one which arose for diagnostic discussion several times during the history of this case. The diagnosis of this affection was first made a year or two before coming under our observation. It was also considered and favorably regarded by some of those who saw her in con-



sultation late in the case. Her eyes had somewhat the staring expression of the blind; they were rather large, but her relatives stated that she had always had prominent eyes, and the exophthalmos was apparent rather than real. The enlargement of the thyreoid was so doubtful as to cause some disagreement among those who examined her as to its existence. A slight enlargement of the gland on one side seemed sometimes to be present. Her pulse frequently, perhaps usually, was between 100 and 110, and sometimes rose above the latter point. It was a pulse such as is not infrequently seen in the late stages of an exhaustive intracranial disease. Graves's disease was finally excluded. In the light of the post mortem findings, it is not improbable that some of the symptoms simulating this affection were due to the tumor, from its position, causing vasomotor and cardiac disturbances.

Ocular and ophthalmoscopic examinations were made by Dr. W. C. Posey, who reported as follows: Ocular movements good in all directions, except externally to the right, where there is a slight limitation of movement, the right eye not being brought as far as normal into the external canthus. On fixation in the median line and below, the eyeballs are quiet. Marked lateral nystagmic movements appear, however, as soon as the eyes leave these primary positions, the nystagmus being most marked on extreme outward rotation to the right and to the left. The pupil in the right eye is round, and is 5 mm. in size; that in the left eye is oval, 3 by 4 mm.,

with its long axis at  $50^{\circ}$ . The irides do not respond to light or accommodation stimuli. The ophthalmoscopic examination reveals clear media in each eye, with the signs of regressive optic neuritis. The swelling of the nerves, however, is still very marked, both papillæ projecting into the fundi to the extent of 2 or 3 mm. The nerves are gray and succulent looking, and the retinal arteries and veins are tortuous and cord like. One nerve is not more swollen than the other. There are no extravasations or hæmorrhages, or traces of either of these in the fundi. The patient is totally blind.

Other examinations were made by Dr. Posey, but they did not demonstrate anything different from what is above recorded.

Eventually an operation was performed in this case by Dr. W. W. Keen, by whom the patient was seen in consultation with Dr. Mills. Although a tumor at the base was considered, it was thought for several reasons that the lesion was probably in or beneath the facial centre. In the first place sufficient consideration was not given to the tinnitus and deafness. Owing to the fact that a peripheral operation had been performed early for the relief of the latter, it was supposed that the impairment and disturbance of hearing were due to causes which were at least in part peripheral. The facial monospasm was much like that which is observed in the case of subcortical or cortical growth. It is interesting to note that some disease of the cortex was present at the position of the trephining, as demonstrated at



the necropsy, but no tumor was found here. The patient died a few hours after the operation.

*Bibliography.*

Schuster. *Psychische Störungen bei Hirntumoren*, Stuttgart, 1902.

Raubitschek. *Wiener klin. Wochenschrift*, September 29, 1904.

Oppenheim. *Die Geschwülste des Gehirns*, Wien, 1902, page 6.

Spiller. *American Jour. of the Med. Sci.*, February, 1904, page 16.

Spiller. *American Jour. of the Med. Sci.*, July, 1903.

Mills. *University of Pennsylvania Med. Bulletin*, May, 1904.

Henneberg and Koch. *Archiv. f. Psychiatrie*, Vol. XXXVI, No 1, page 51.

Fraenkel and Hunt. *Medical Record*, December 26, 1903.

Alexander and v. Frankl-Hochwart. *Obersteiner's Arbeiten*, Vol. XI, 1904, page 385.

Spiller. *University of Pennsylvania Med. Bulletin*, June, 1901, page 13.

Saenger. *Neurolog. Centralblatt*, 1901, page 188.

Batten and Collier. *Brain*, 1899.

Dinkler. *Zeitschrift für Nervenheilk.*, Vol. VI.

Hunt. *American Jour. of the Med. Sci.*, March, 1904.

Ascherson. *Lancet*, September 10, 1904, page 759.

Spiller. *American Jour. of the Med. Sci.*, July, 1902.

Bramwell. *Brain*, Spring, 1899, Vol. XXII, page 66.

Nonne. *Deutsche Zeitschrift für Nervenheilk.*, Vol. XXVII, Nos. 3 and 4.

Spiller. *University of Pennsylvania Med. Bulletin*, June, 1904.

Oppenheim. *Loc. cit.*, page 156.

## THE FUNCTIONS OF THE CEREBELLUM.

By EDWARD LODHOLZ, M. D.,

PHILADELPHIA,

DEMONSTRATOR OF PHYSIOLOGY, UNIVERSITY OF PENNSYLVANIA.

Probably there is no part of the nervous system that differs more in size and functional importance, in closely allied species, than the cerebellum. Its development depends to a great extent upon the means of orientation of the animal. Reptiles possess a cerebellum functionally less active than swimmers, and in these it is less developed than in birds. Indeed in this animal which is capable of going through the most complicated movements of all animals the cerebellum is relatively enormous. However, the size is not always proportionate to the variety of movements. In the frog, which is capable of complex coordination, the cerebellum is relatively small. It is an unexplained anatomical fact that in birds the lateral lobes are absent, whereas in apes and man they are quite large.

Possibly no one has given so much impetus to the study of this part of the nervous system as Flourens (1). Practically all his experiments were performed upon pigeons, animals which show marked effects following the removal of parts of the cerebellum. Many of the phenomena here ob-



served can be of but comparative interest to the student of human physiology. For this reason the work of Luciani has done much to further our knowledge of the function of the human cerebellum. He experimented upon dogs and monkeys, animals in which the cerebellum is more closely allied to the human cerebellum than that of pigeons.

So early as 1809 Rolando (2) removed portions of the dog's cerebellum, and several other physiologists studied the mammalia previous to Luciani's time, but none was able to surmount the tremendous technical difficulties necessary, for instance, to remove the whole cerebellum and keep the animal alive for a considerable period after the operation.

Luciani (3) showed the immediate symptoms differed very much from those which subsequently developed. If the narcosis is not too deep, and the loss of blood inconsiderable, the more important symptoms which immediately follow removal of the cerebellar cortex, are extreme restlessness; pleurothotonos, the concavity being toward the operated side; tonic stretching of the fore extremity on the homonymous side; clonic contractions of the other three extremities; and spiral twisting of the neck with the head turned toward the well side. Nystagmus and strabismus are present, the eye of the side operated upon being drawn down and inward,

that of the well side up and out. If the animal attempts to stand, he falls to the side of the lesion and rolls in the same direction.

When the whole cerebellum is removed there is marked restlessness and irritability of the animal; the head is drawn back, and the animal tends constantly to move or fall backwards. There is convergence of the eyeballs. If the wound remains aseptic these symptoms last from eight to ten days when they generally ameliorate, the tonic spasms become clonic or oscillatory, the animal is able to walk with less difficulty, and the tendency to roll from side to side or fall backward is less marked. Long before the animal learns to walk he is able to swim. This fact, first described by Luciani, has great physiological importance. The last symptom to disappear is opisthotonos.

The symptoms which occur with constancy after removal of the cerebellum give us but little information as to the exact rôle this part of the nervous system plays in the intact cerebrospinal axis. Wundt states that "the functions of the cerebellum belong to the darkest part of the central nervous system." The truth of this statement becomes more apparent when the multitudinous connections of the cerebellum with other portions of the brain and spinal cord are considered.

The old idea that the cerebellum has distinct



functions independent of its connection with the rest of the cerebrospinal axis is rapidly disappearing.

The centre for coordination has been located in the cerebellum by Flourens, and the symptoms which follow ablation of a part, or the whole of the cerebellum seem to substantiate this assertion. However, cases have been recorded in which a large portion was congenitally absent associated with normal ability to execute coordinate movements.

Total ablation in animals is always followed by an amelioration of the symptoms after varying intervals of time, and eventually incoordination entirely disappears.

When the cerebellum is inactive it appears that cells in other parts of the nervous system are capable of performing the functions normally assigned to the cerebellar cells. The experiments of Ewald (4) and Luciani confirm this statement. They demonstrated that if compensation was completely established after partial cerebellar destruction, a return of symptoms would appear if certain cerebral motor areas were destroyed. The symptoms never reappear after the second operation.

A close functional relation has been found to exist between the semicircular canals and the cerebellum. Total destruction of the canals is followed by symptoms identical with cerebellar ablation. Stefani (5)

found degeneration of Perkinje's cerebellar cells after removal of the semicircular canals. From this the inference may be drawn that the canals are the peripheral organs and the cerebellum is the centre. Lange, a student of Ewald, found when the semicircular canals were removed from a decerebellarized animal, in which full compensation had been established, that the characteristic symptoms appeared such as are observed in a normal animal following destruction of the canals. Stefani concludes that the semicircular canals functionate not only through the cerebellum, but also through other parts of the nervous system. Luciani thinks these, and other experiments, disprove the belief of Magendie (6) that the cerebellum is the centre of static and dynamic equilibrium. He believes it does play an important rôle in the maintenance of equilibrium, and agrees with Galio (7) that we move in space by the aid of impulses coming from the special senses.

The results obtained from excitation of the cerebellar surfaces have added to some extent to our knowledge of the influence of the cerebellum upon nervous activity. It is a mooted question whether ablation produces symptoms the result of stimulation consequent to the trauma of the operation, or paralysis due to destruction of the cells. Ferrier (8) showed that unilateral burning of the cerebellum



produced symptoms on the opposite side of the body to those following ablation. But this method is unscientific, for it is impossible to determine whether symptoms are due to stimulation or depression.

Electrical stimulation properly applied eliminates depression as a factor. A recent work by Lewandowsky (9) has shown that the electrical current produces results differing from those following ablation. When weak currents were applied to the cerebellum the following symptoms were noted: Restlessness; evidences of vertigo; lateral movements of the head; or the animal assumed a recumbent position and placed the head between the front paws. Strong currents caused curvature of the spinal column, when the left side was stimulated the concavity was toward the right side, the dog always fell toward the right. Occasionally nystagmus was observed. When the current was broken the movements occurred on the other side, but were decidedly weaker. It will be noticed, as Lewandowsky states, that the symptoms following stimulation are on the opposition side of the body to that produced by ablation.

Sherrington (10) reports a very interesting phenomenon following stimulation of the cerebellum. He discovered in decerebrate rigidity, a condition of long maintained muscular contraction following

removal of the cerebral hemispheres, that inhibition can be produced by excitation of the anterior (cerebral) surface of the cerebellum. He demonstrated that faradaization caused a relaxation of the muscles of the neck, head, and lower limbs, especially on the same side. He concludes that stimulation of the cerebellum "cannot only excite contraction of the muscles, but can inhibit contraction." However, the exhaustive studies in cerebellar ablation and stimulation have not given us very satisfactory knowledge of how this organ normally functionates, although many errors have been corrected and new facts added.

The teaching of the Gall school that the cerebellum has a sexual function has been disproved by Bouillaud, Luciani, and others. These investigators demonstrated that impregnation and birth of offspring would occur in an animal from which the whole cerebellum was removed.

Flourens was the first to locate in the cerebellum the centre for coordinated movements.

Luciani demonstrated that coordinated movements returned in animals from which the cerebellum had been removed.

The teaching of Rolando that the cerebellum was essentially motor has been modified by Dalton (11), Luys (12), Mitchell (13), and Luciani. These authors consider it an organ in which motor impulses



are strengthened. Removal of the organ causes muscular weakness, which was described by Luciani as due to three factors: Asthenia (weakening of muscular energy), atonia (lessening of muscular tone), and astasia (uncertain and unsteady movements).

That asthenia is present is shown by the fact that animals with unilateral ablation swim toward the crossed side, but walk toward the same side. Astasia is represented by the intention tremor which develops at varying lengths of time after removal of either part or whole of the cerebellum. Atonia can be readily detected by the feebleness of the muscles which becomes manifest after the disappearance of the primary spasm.

Many physiologists have defended the theory of Lussana (14) that the centre for muscle sense is located in the cerebellum. The vertigo frequently present suggests a sensory function. But human beings with atrophy of the cerebellum still possessed a normal amount of muscle sense. Luciani's careful work has gone far to disprove the existence of such a centre in the cerebellum. The theories advanced to explain the normal functions seem too inadequate to account for all the phenomena. It appears conclusive that the cerebellar cells are continually exerting an influence upon other nerve centres, but with reference to the

true nature of this action nothing is known with certainty.

*References.*


1. Flourens, *Recherches expérimentales sur les propriétés et les fonctions du système nerveux*, Paris, 1824 and 1842.
  2. Rolando, *Saggio sopra la vera struttura del cervello*, Turin, 1823.
  3. Luciani, *Ergebnisse der Physiologie* (Asher and Spiro), 1904, 2 Abth, s. 260.
  4. Ewald, *Untersuchungen über den Endorgan des N. octavus*, Wiesbaden, 1892.
  5. Stefani, *Arch. ital. di biol.*, XXX, 2, page 235.
  6. Magendie, *Précis élémentaire de physiologie*, Paris, 1823.
  7. Galio, *Arch. ital. di biol.*, XXXVIII, 3, page 383.
  8. Ferrier, see Luciani, *Biol. Zentralbl.*, XV, 9 and 10.
  9. Lewandowsky, *Arch. f. Anat. und Phys.*, phys. Abth., 1903, page 132.
  10. Sherrington, *Jour. of Phys.*, Vol. XXII, page 319.
  11. Dalton, *Amer. Jour. of the Med. Sci.*, 1861, page 83.
  12. Luys, *Arch. génér. de méd.*, 1864, page 385.
  13. Weir Mitchell, *Amer. Jour. of the Med. Sci.*, 1869, page 320.
  14. Lussana, *Jour. de la physiologie*, 1862, page 418.
- A complete bibliography of this subject is given by Luciani, *Ergebnisse der Phys.* (Asher and Spiro), 1904, s. 210.





The first of these is the fact that the  
the second is the fact that the  
the third is the fact that the  
the fourth is the fact that the  
the fifth is the fact that the  
the sixth is the fact that the  
the seventh is the fact that the  
the eighth is the fact that the  
the ninth is the fact that the  
the tenth is the fact that the  
the eleventh is the fact that the  
the twelfth is the fact that the  
the thirteenth is the fact that the  
the fourteenth is the fact that the  
the fifteenth is the fact that the  
the sixteenth is the fact that the  
the seventeenth is the fact that the  
the eighteenth is the fact that the  
the nineteenth is the fact that the  
the twentieth is the fact that the  
the twenty-first is the fact that the  
the twenty-second is the fact that the  
the twenty-third is the fact that the  
the twenty-fourth is the fact that the  
the twenty-fifth is the fact that the  
the twenty-sixth is the fact that the  
the twenty-seventh is the fact that the  
the twenty-eighth is the fact that the  
the twenty-ninth is the fact that the  
the thirtieth is the fact that the  
the thirty-first is the fact that the  
the thirty-second is the fact that the  
the thirty-third is the fact that the  
the thirty-fourth is the fact that the  
the thirty-fifth is the fact that the  
the thirty-sixth is the fact that the  
the thirty-seventh is the fact that the  
the thirty-eighth is the fact that the  
the thirty-ninth is the fact that the  
the fortieth is the fact that the  
the forty-first is the fact that the  
the forty-second is the fact that the  
the forty-third is the fact that the  
the forty-fourth is the fact that the  
the forty-fifth is the fact that the  
the forty-sixth is the fact that the  
the forty-seventh is the fact that the  
the forty-eighth is the fact that the  
the forty-ninth is the fact that the  
the fiftieth is the fact that the  
the fifty-first is the fact that the  
the fifty-second is the fact that the  
the fifty-third is the fact that the  
the fifty-fourth is the fact that the  
the fifty-fifth is the fact that the  
the fifty-sixth is the fact that the  
the fifty-seventh is the fact that the  
the fifty-eighth is the fact that the  
the fifty-ninth is the fact that the  
the sixtieth is the fact that the  
the sixty-first is the fact that the  
the sixty-second is the fact that the  
the sixty-third is the fact that the  
the sixty-fourth is the fact that the  
the sixty-fifth is the fact that the  
the sixty-sixth is the fact that the  
the sixty-seventh is the fact that the  
the sixty-eighth is the fact that the  
the sixty-ninth is the fact that the  
the seventieth is the fact that the  
the seventy-first is the fact that the  
the seventy-second is the fact that the  
the seventy-third is the fact that the  
the seventy-fourth is the fact that the  
the seventy-fifth is the fact that the  
the seventy-sixth is the fact that the  
the seventy-seventh is the fact that the  
the seventy-eighth is the fact that the  
the seventy-ninth is the fact that the  
the eightieth is the fact that the  
the eighty-first is the fact that the  
the eighty-second is the fact that the  
the eighty-third is the fact that the  
the eighty-fourth is the fact that the  
the eighty-fifth is the fact that the  
the eighty-sixth is the fact that the  
the eighty-seventh is the fact that the  
the eighty-eighth is the fact that the  
the eighty-ninth is the fact that the  
the ninetieth is the fact that the  
the ninety-first is the fact that the  
the ninety-second is the fact that the  
the ninety-third is the fact that the  
the ninety-fourth is the fact that the  
the ninety-fifth is the fact that the  
the ninety-sixth is the fact that the  
the ninety-seventh is the fact that the  
the ninety-eighth is the fact that the  
the ninety-ninth is the fact that the  
the hundredth is the fact that the







Unable to display this page

