

**A practical treatise on fractures and dislocations of the jaws : for students and practitioners / by Chalmers J. Lyons.**

**Contributors**

Lyons, Chalmers J.

**Publication/Creation**

Toledo : Ransom & Randolph, 1919.

**Persistent URL**

<https://wellcomecollection.org/works/evz78zvt>

**License and attribution**

This work has been identified as being free of known restrictions under copyright law, including all related and neighbouring rights and is being made available under the Creative Commons, Public Domain Mark.

You can copy, modify, distribute and perform the work, even for commercial purposes, without asking permission.



Wellcome Collection  
183 Euston Road  
London NW1 2BE UK  
T +44 (0)20 7611 8722  
E [library@wellcomecollection.org](mailto:library@wellcomecollection.org)  
<https://wellcomecollection.org>

FRACTURES AND  
DISLOCATIONS  
OF THE JAWS

— LYONS —

13130

107-





22200189708


Med

K49103









A Practical Treatise on

**FRACTURES  
AND DISLOCATIONS OF  
THE JAWS**

*For Students and Practitioners*

*by*

**CHALMERS J. LYONS, D. D. Sc.**

Professor of Dental Surgery, University of Michigan  
Associate Surgical Staff University Hospital, Member  
of Staff St. Joseph's Hospital  
Ann Arbor, Michigan

1919

Published by  
**THE RANSOM & RANDOLPH CO.**  
TOLEDO, OHIO



95400

13130

6832159

WELLCOME INSTITUTE LIBRARY	
Coll.	welMOmec
Call	
No.	WU


TO MY FRIEND AND COUNSELOR,  
DR. CYRENUS G. DARLING,  
WHOSE HIGH IDEALS EVER HAVE  
BEEN AN INSPIRATION TO ME, THIS  
LITTLE VOLUME IS AFFECTION-  
ATELY DEDICATED.

Copyrighted 1919 by  
CHALMERS J. LYONS

## Contents

	PAGE
DEDICATION.....	5
PREFACE.....	9
INTRODUCTION.....	11-17
The Literature of Ancient Times: Hippocrates, Cornelius Celsus, Galen, Ambroise Paré, Bunon.	
CHAPTER I—Dislocation of the Jaws.....	18
Definition, Classification, Etiology, Symptoms, Treatment. Unre- duced and Congenital Dislocations.	
CHAPTER II—Fractures of the Jaws.....	23
Definitions; Etiology; Influence of Age, Sex and Environment; Pre- disposing Causes; Determining or Exciting Causes.	
CHAPTER III—Varieties of Fractures.....	34
Classes and Types.	
CHAPTER IV—Signs and Symptoms of Fracture.....	36
Objective Signs: Deformity, Abnormal Mobility, Malocclusion, Crepitus, Edema. Subjective Symptoms: Pain, Loss of Function, History.	
CHAPTER V—Diagnosis.....	42
The X-ray in Diagnosis and Treatment.	
CHAPTER VI—The Process of Repair.....	48
Re-establishing Normal Conditions; Conflicting Opinions; Functions of Compact and Cancellous Bone.	
CHAPTER VII—Complications in the Process of Repair.....	54
Infections, Ruptures, Lacerations, Embedded Fragments, Trismus; General Complications.	
CHAPTER VIII—Prognosis.....	59
Influences that Affect Recovery: Age, Alcoholism, Disease, Infec- tion, Location.	
CHAPTER IX—Treatment.....	61
Reduction, Retention, Prevention, Control. Muscle Strain. Ban- daging. Interdental Ligation. Methods of Military Surgeons. Splints. Headgear. Correction of Lateral Displacement.	
CHAPTER X—Gunshot Fractures.....	80
Formulary of Dr. George B. Hayes. The Lodge Cast Tin Jacket. War Surgery at Neuilly, France. Method of Dr. George L. Villian. Growth of Bone.	
CHAPTER XI—Treatment by Bone Grafts.....	94
History. Fundamental Principles. Albee's Method. Gallie and Robertson. Technic.	
CHAPTER XII—Anesthesia in the Reduction of Fractures.....	98
Local Preferable. Conductive or Nerve Blocking. Intra- and Extra-Oral. Instrumentarium and Technic. Cautions.	





## P R E F A C E

This little work has been written in the endeavor to meet the demand of medical and dental students and of the physician and the dentist for something concise, simple, practical and modern on Fractures and Dislocations of the Jaws. It was in the hope of presenting a practical treatise on this subject that the work was undertaken. It is the result of experience gained in twenty years of practice and twelve years as a teacher of oral surgery.


It has been the aim throughout the book to present nothing that does not have practical value. Nearly all of the methods of treatment that are presented, or modifications of them, have been used by the author from time to time in his practice or in the University Hospital Clinics.

An attempt has been made to give proper credit to those who previously have recorded their ideas. If it appears that proper credit has not been given, it is because the author has incorporated ideas which he has acquired and approved from sources that are so varied that they can not at this time be traced. It has been the aim to bring together in one place the many valuable suggestions on, and methods of treatment of, Fractures and Dislocations of the Jaws.

The author is deeply indebted to Dr. George B. Hayes, Neuilly, (Paris), France, for his permission to review and incorporate in this little work some of his most brilliant achievements in War Dental Surgery, without which this work would be incomplete; to Dr. James G. Van Zwaluwenburg, of Ann Arbor, Michigan, for his contribution on the "Use of the X-ray in Diagnosis;" to Drs. Gallie and Robertson, of Toronto, Ontario, for the privilege of incorporating their ideas on bone grafts; to Dr. Don M. Graham, of Detroit, Michigan, for valuable illustrations on interdental ligation; to Major Joseph D. Eby, of Atlanta, Georgia, for his contribution on war fractures; to Captain E. Ballard Lodge, of Cleveland, Ohio, for his method of casting splints in block tin, and to the publishers for their many courtesies shown in the preparation of this little work.

CHALMERS J. LYONS

Ann Arbor, Michigan, May, 1919.





## INTRODUCTION

In looking over the literature relating to the practice of medicine and surgery, we find that the oldest documents which are in existence at the present time are the various treatises contained in the collection which bears the name of Hippocrates.

Hippocrates (460-367 B.C.), the celebrated Greek physician, discusses at some length fractures and dislocations of the jaws. Many of his arguments in the treatment of these classes of human ills are of such excellence that it always has been a question which has excited curiosity, by what steps the treatment had attained to such perfection at so early a period.

Indeed, the principles laid down by Hippocrates in this work over two thousand years ago are so sane that many of them can be followed successfully today. His extensive practice and, no doubt, his great familiarity with the accidents occurring at the public games of his country, furnished him with ample opportunities for becoming acquainted with fractures and dislocations as his treatises on this subject abundantly testify. In fact, until within comparatively recent years, the plan of treatment of such cases was not at all to be compared with his skillful mode of adjusting fractured bones and of securing them by means of waxed bandages. Not only was Hippocrates skillful in the treatment of these conditions, but his methods were based on a knowledge of anatomy that seems almost incredible when we consider the state of knowledge of the people twenty-four centuries ago.

The writer believes that it will be of some interest in the history of fractures and dislocations to insert here abstracts of some of the early teachings of the great Greek physician.

He says in part: "The jaw bone, in few cases, is completely dislocated, for the zygomatic process formed from the upper jaw bone (*malar?*) and the bone behind the ear (*temporal?*) shuts up the heads of the under jaw, being above this one (*condyloid process?*). Of these extremities of the lower jaw, the one from its length, is not much exposed to accidents, while the other (*the coronoid?*) is more prominent than the zygoma, and from both these heads nervous tendons (*ligaments?*) arise, with which the muscles called temporal and masseter are connected; they have these names from their action and connections, for in eating, speaking and the other functional uses of the mouth, the upper jaw is at rest, as being connected with the head by synarthrosis, and not by diarthrosis; but the lower jaw has motion, for it is connected with the upper jaw and the head by enarthrosis. Wherefore, in convulsions and tetanus the first symptom manifested is rigidity of the lower jaw. These are the reasons why complete dislocation



does not readily take place; and this is another reason, because there is seldom a necessity for swallowing so large pieces of food as would make a man gape more than he easily can open his mouth, and dislocation cannot take place in any other positions than in great gaping, by which the jaw is displaced to either side.

“This circumstance, however, contributes to dislocation, then, of nerves (here Hippocrates probably means ligaments), and muscles around joints or connected with joints, such as frequently are moved in using the member, are the most yielding to extension, in the same manner as well-dressed hides yield the most. With regard, then, to the matter in hand, the jaw bone rarely is dislocated, but frequently is slackened (partially displaced) in gaping, in the same manner as many other derangements of muscles and tendons arise.”<sup>1</sup>

While the language Hippocrates uses in his descriptions is not as concise and coherent as it might be, yet when we consider the time and conditions under which it was written we must refrain from making any criticisms. His description of the symptoms of dislocation of the jaw is worthy of more modern ages:

“Dislocation is particularly recognized by these symptoms: the lower jaw protrudes forward, there is displacement to the opposite side, the coronoid process appears more prominent than natural on the upper jaw, and the patient cannot shut his lower jaw but with difficulty. The mode of reduction which will apply in such cases is obvious: one person must secure the patient’s head and another taking hold of the lower jaw with his fingers within and without at the chin, while the patient gapes as much as he can, first moves the lower jaw about for a time, pushing it to this side and that with the hand, and directing the patient himself to relax the jaw, to move it about, and yield as much as possible; then all of a sudden the operator must open the mouth while he attends at the same time to three positions: *First*, the lower jaw is to be moved from the place to which it is dislocated to its natural position; *second*, it is to be pushed backwards, and *third*, along with these the jaws are to be brought together and kept shut. This is the method of reduction, and it cannot be performed in any other way.”

This last statement is dogmatic, but stated in Hippocrates’ time, it can be overlooked, for he was the only person at that time who could speak upon any subject in medicine with any degree of authority.

Further he says: “A short treatment suffices; a waxed compress is to be laid on and bound with a loose bandage. It is safer to operate with the patient laid on his back and his head supported on a leather cushion well filled, so that it may yield as little as possible; but some person must hold the patient’s head.

<sup>1</sup>Galen, in his Commentary on the passage, explains it as applying to displacement of the muscles. It would seem to be the species of incomplete displacement described by Sir Astley Cooper.



“When the jaw is dislocated on both sides, the treatment is the same. The patient is less able to shut the mouth than in the former variety, and the jaw protrudes farther in this case, but is not distorted; the absence of distortion may be recognized by comparing the corresponding rows of the teeth in the upper and lower jaws. In such cases reduction must be performed as quickly as possible. The method of reduction has been described above.

“If not reduced, the patient’s life will be in danger from continual fevers, coma attended with stupor (for these muscles when distorted and stretched preternaturally induce coma), and there usually is diarrhœa attended with bilious, unmixed and scanty dejections; and the vomitings, if any, consist of pure bile, and the patients commonly die on the tenth day.”

So thorough was Hippocrates’ descriptions of dislocation of the lower jaw that it was copied by all the subsequent authorities in ancient times.

His discussions on “Fractures of the Jaws” are equally interesting. Many of these he describes as occurring among the ancient athletes and gladiators. From his description it can be seen that he had large experience in the treatment of fractures of all kinds, and his observations and findings are worthy of reproduction here:

“In fracture of the lower jaw, when the bone is not fairly broken across and is still partially retained but displaced, it should be adjusted by introducing the finger at the side of the tongue and making suitable counterpressure on the outside; and if the teeth at the wound be distorted and loosened, when the bone is adjusted, they should be connected together, not only two but more of them, with a gold thread if possible, but otherwise with a linen thread, until the bone is consolidated; and then the part is to be dressed with cerate, a few compresses and a few bandages, which should not be very tight, but rather loose. For it should be well known that in fracture of the jaw, dressing with bandages if properly performed is of little advantage, but occasions great mischief if improperly done. Frequent examinations should be made about the tongue and prolonged pressure should be applied with the fingers in order to rectify the displaced bone.<sup>2</sup>

“But if the bone is fairly broken across it is to be set in the manner now described. When adjusted the teeth are to be fastened together as formerly described, for this will contribute much towards keeping the parts at rest, especially if properly fastened, and the ends of the threads secured with knots. But it is not easy to describe exactly in writing the whole manipulation of the case; but the reader must figure the thing to himself from the description given. Then one must take a piece of Carthaginian leather; if the patient be a younger person it

<sup>2</sup>Galen, in his Commentary, explains that our author means all this is to be done by the patient and not by the physician.



will be sufficient to use the outer skin, but if an adult, the whole thickness of the hide will be required. It is to be cut to the breadth of about three inches, or as much as will be required, and having smeared the jaw with a little gum (for thus it sticks more pleasantly), the end of the skin is to be fastened with glue near the fractured part of the jaw at a distance of an inch or a little more from the wound. This piece is to be applied below the jaw; but the thong should have a cut in it, in the direction of the chin, so that it may go over the sharp point of the chin. Another piece of thong like this or somewhat broader is to be glued to the upper part of the jaw at about the same distance from the wound as the other thong; this thong should be so cut as to encircle the ear. The thongs should be sharp-pointed at the part where they unite, and in gluing them the flesh of the thong should be turned to the patient's skin, for in this way it will be more tenacious. Then we must stretch this thong, but still more so the one at the chin, in order to prevent the fragments of the jaw from riding over each other, and the thongs are to be fastened at the vertex and then a bandage is to be bound round the

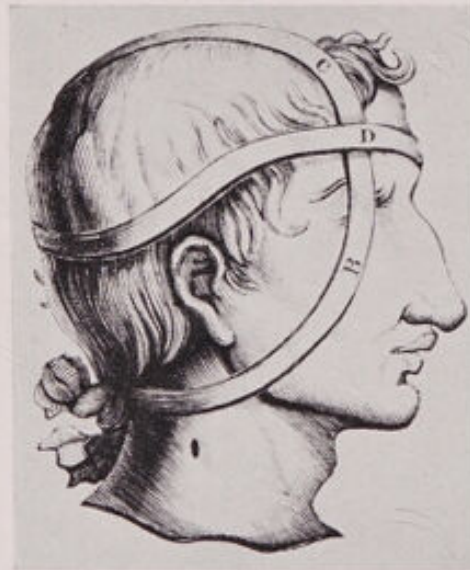

Fig. 1

forehead (*Fig. 1*) and a proper apparatus is to be put over all to prevent the bandages from being displaced. The patient should lie upon the sound side of the jaw, not resting upon the jaw but upon the head. He is to be kept on a spare diet for ten days and then nourished without delay. If there be no inflammation during the first days, the jaw is consolidated in twenty days, for callus quickly forms in this as in all the other porous bones, providing there be no sphacelus (exfoliations). Those physicians who have not judgment combined with dexterity, expose themselves in fractures of the jaws as in other cases, for they apply a variety of bandages to a jaw bone, sometimes properly and sometimes improperly. For all such bandaging of a fractured jaw bone



has a tendency rather to derange the bones connected with the fracture than to bring them into their natural positions.

“But if the lower jaw be disjointed at its symphysis, it is the work which anyone can perform to rectify it; for the part which protrudes is to be pushed inwards by pressure with the fingers and the part which inclines inwards is to be forced outwards by pushing with the fingers from within. It is after having applied extension to separate the fragments that this is to be done, for thus they will be more easily restored to their natural position than if one should bring them together by using force. This is proper to be known as applying to all such cases. When you have set the parts, you must fasten the teeth on both sides to one another as formerly directed. The treatment is to be accomplished with cerate, a few compresses and bandages. This part in particular requires a short but complex bandaging, for it is nearly cylindrical, though not exactly so. (*Figs. 2 and 3.*)

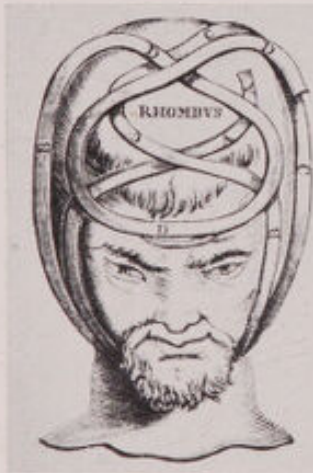

Fig. 2



Fig. 3

“If matters be properly adjusted and the patient kept quiet there will be speedy recovery and the teeth will be uninjured; but if not the recovery will be more protracted; the teeth will be distorted, will give trouble and become useless.”

From Hippocrates' writings we can see that he had an extensive knowledge of the subject of fractures. His thoughts on bandaging alone are invaluable, and today if the same careful attention were given to bandaging the jaws in case of fracture, the indifferent results in many cases would not exist, but normal conditions would be more nearly established.

Hippocrates was followed by a great number of others, some of whom were much interested in fractures of the jaws.

Aurelius Cornelius Celsus, a celebrated Roman physician and writer who lived about 25 A.D., in his writings, “*De Medicina*,” states: “In the fractures of the other bones we frequently find one fragment



detached from the other; in the mandible the fragments, although thrown out of place, always adhere one to another. Consequently, in this fracture we must first of all replace the fragments to their normal position, passing from the inside of the mouth and from the outside with the forefinger and thumb of both hands. Then in case of a transverse fracture (in which case an unevenness in the level of the teeth is produced), it is necessary, after having set the fragments in place, to tie together the two teeth nearest to the fracture with a silk thread (corresponding to our wiring today), or else, if these are loose, the next ones. After this one should apply externally to the part corresponding to the lesion a thick compress, dipped in wine and oil and sprinkled with flour and powdered olibanium. The compress is to be fixed in place by means of a bandage or a strip of soft leather with a longitudinal slit in the middle to embrace the chin, the two ends being tied together above the head."

Galen's Commentary is the next of the ancient works on fractures, and in fractures and dislocations of the jaws he reiterates and comments on much of Hippocrates' writings.

Avenzoar, a renowned Arabian physician, about the beginning of the twelfth century, in his writings, a compendium of practice "Al-Teisir," describes bandages for the fixation of the mandible. Apparently he depended entirely upon bandages to retain the fragments in position.

About this time a text-book of surgery was compiled and it is interesting to note some of the methods of treating fractures of the jaws. In this compilation we find the following on the treatment of fractures: "Take olibanium, mastic, colophen, glue, dragon blood; all this must be mixed with liquified resin and become ointment, which is placed over until complete consolidation, and everything must be fixed with the little lances in order that the portions be prevented from moving out of place. In the fracture of the mandible if the lower teeth are not in contact with the upper ones, the patient cannot masticate. Then the patient must be taken by the lower maxillæ and the parts moved here and there until the lower teeth will touch the upper ones."

In 1275 A.D., Wilhelm from Saliceto wrote the "Proxeos Totius Medicinæ," in which he speaks of the fractures of the jaws. In this he suggests a modification of the primitive methods of ligating the teeth. He suggests not only ligating and binding the teeth proximal to the fracture not only between themselves but also to the corresponding teeth of the maxillæ.

Ambroise Paré, "The Father of French Surgery," 1517-1590, wrote considerable on fractures and dislocations of the jaw. He says: "Then will be applied a leather ferrule such as from which the soles of a boot are made, which has been divided in the middle at the level of the chin, long and wide as the mandible. And then will be made a ligature two fingers wide and as long as necessary, cut at the ends, having only one



finger wide, and at the level of the chin it will be parallelly cut, for the purpose of embracing and pressing better over the chin; and at the four extremities the shorter will be sewed at the top of the head to a night cap or calotte, and the other two longer ends will be kept transversely and sewed behind the same cap, everything done as skillfully as possible in order to hold well the fracture."

Bunon (1743), in his treatise on the diseases of the teeth, mentions two cases of fractures of the jaws which he succeeded in curing in a short time by the method of binding the teeth, the preceding attempts of experienced surgeons having failed entirely. One of these cases is particularly interesting. The seat of fracture corresponded with the bicuspid which, however, had become dislodged from the effect of the wound; the neighboring teeth also were loosened. Bunon filled the empty space left by the bicuspids with a piece of ivory provided with two holes; then by an ingenious crossing of threads passing from the second molar on one side to the second bicuspid on the other, very tightly tied, he formed one single block and succeeded in bringing about consolidation of the loosened teeth and the complete cure of the fracture, which was effected in less than a month. (Guerini from Brophy.)

The foregoing is given merely as a preface to the following chapters on fractures and dislocations of the jaws to show that long before the Christian Era considerable thought was given to this subject. The development of the treatment of fractures of the jaw has hardly kept pace with the treatment of fractures of other parts of the body, probably on account of comparative scarcity of the number of cases, but modern machinery and modern methods of travel are adding yearly to the increasing number of cases of fracture and dislocation of the jaws.

The greatest factor of all times in producing fractures of the jaws was the great European War. It is reported that in one hospital alone in Germany more than five hundred cases of fracture of the jaws were being treated at one time. New methods and new appliances were introduced in the treatment of these war cases that have placed the treatment of fractures and dislocations on an entirely new basis.



## Chapter I

### Dislocation of the Jaws\*

**A** DISLOCATION is defined as an abnormal displacement of the articular portions of the bones entering into the formation of a joint. While dislocations of the lower jaw are not rare, yet these dislocations are not as common as are dislocations in other parts of the body.

<sup>1</sup>Stimpson states that "compared with other surgical injuries, dislocations (in general) are infrequent; the proportion to fractures is about one to ten." In a compilation of fifteen hundred and twenty-seven dislocations, he found sixty-one dislocations of the lower jaw.

Two principal classifications may be made of dislocations of the lower jaw viz., bilateral and unilateral. Of these the bilateral is the more common, the proportion being about five to two, according to Malgaigne.

These again may be classified as:

1. *Simple*, one in which the joint is not penetrated by a wound.
2. *Compound*, one in which the contiguous tissue is torn to the outer surface and the wound is in communication with the outside air.
3. *Complete*, one in which the articular surfaces are completely separated.
4. *Complicated*, one which is associated with other injuries, such as fracture.
5. *Habitual*, one which frequently occurs after reduction.
6. *Recent*, one in which there is no complicating inflammation.
7. *Pathologic* or spontaneous, one which results from disease.
8. *Traumatic*, one due to an injury or to violence.

#### ETIOLOGY

In order to understand the etiology of dislocations of the lower jaw, a knowledge of the comprehensive mechanism of the temporomandibular articulation and the normal movement of the mandible should be acquired.

†In the temporomandibular articulation, the socket is formed partly by the mandibular fossa and partly by the articular eminence, and over the latter an approximately congruent surface for the head of the condyle is formed by the articular disk. The two temporomandibular articulations act simultaneously. When the mouth is opened, the head

---

\*As the subject of dislocations of the jaws is one that must necessarily be brief when compared with that of fractures of the jaws, it is deemed best by the author to reverse the usual order in which these subjects are generally presented, and will discuss dislocations first before taking up the more important subject of fractures.

<sup>1</sup>Stimpson's "Fractures and Dislocations."

†Sabotta and McMunich Human Anatomy.



of the condyle, with the inter-articular disk, glides forward on the articular eminence, and when the mouth is closed it slips back into the mandibular fossa. The opening and closing of the mouth are consequently attended by a sliding of the mandible (a sliding joint).

In addition to this modified form of hinge movement, the articulation possesses a second kind of motion, viz., the lateral displacement of the mandible in reference to the skull. In this movement, one condyloid head remains in the mandibular fossa and rotates on pivots on the center, (the rotation being accomplished by the action of the *pterygoideus internus* muscle), while the other advances on the articular eminence, a movement which is impossible when the mouth is opened

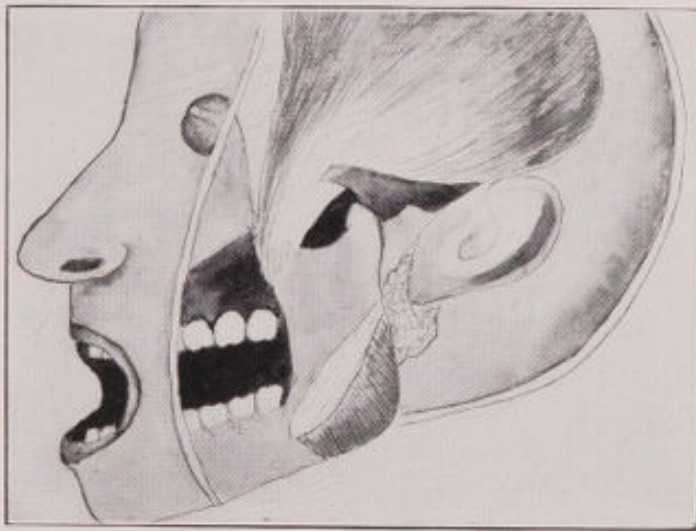


Fig. 4

to its greatest extent. Both the hinge and the lateral movements are combined in the act of mastication.

The movements of the jaw are limited by the capsular ligament. The anterior portion of the capsular ligament is not strong and usually is ruptured in dislocations of the jaw.

Dislocations of the lower jaw usually occur when the mouth is open and when the heads of the condyles are forward on the articular eminence. The head of the condyle then may pass over the articular eminence on one or both sides. (Fig. 4.) If on one side a unilateral dislocation is constituted, and if both condyles pass over the articular eminence a bilateral dislocation results. The contraction of the *masseter* and *temporal* muscles draws the condyles up against the inferior surface of the zygoma, where it becomes locked. Backward dislocation cannot occur without fracture of the tympanic portion of the temporal bone.

Backward dislocations are caused by great violence received upon the chin from before backward. One or both heads of the condyle may be driven through the tympanic plate into the external auditory canal. This may occur quite easily if the mouth is held partly open when the



blow occurs, or in an edentulous jaw when there is no support given it by opposing teeth.

The symptoms are pain and hemorrhage from the ear, immobility of the lower jaw, and displacement backward.

The author, in 1914, had a case of this type where the backward displacement was the distance of 1 cm. The patient was working in a railway machine shop and was struck on the chin by a flying piece of iron. The lower jaw also was fractured at the symphysis.

A few cases of upward and outward dislocations have been reported by LeFevre, Roberts, Neis and others, but this type of dislocation is very rare.

By far the most common type of dislocation is forward. Any pathologic changes in the glenoid fossa which would result in a condition that would reduce the depth of articulation would predispose to dislocation of the jaw.

The direct causes arise in active muscular contraction during forced opening of the mouth, such as yawning, laughing, vomiting, epileptic attacks, inserting mouth gags for operations in or around the mouth, extraction of teeth, etc.

The indirect causes follow from some form of violence directed to the anterior portion of the lower jaw when the mouth is open, which forces the angles of the jaws backward and the condyles forward, the axis of motion being in the region of the bicuspid teeth. This may be a kick from a horse, a blow from a fist, a fall, or any other form of violence at the point named.

A blow on the side and posterior portion of the mandible may be sufficient to cause unilateral dislocation.

#### SYMPTOMS

In bilateral dislocations (*Fig. 5*) the mouth is held open—the patient can open the mouth wider but is unable to close it. Palpation will indicate that the condyles are out of their normal position. The patient will be in considerable pain, such as is felt in cramps, this being due to the contraction of the masseter and temporal muscles. Excitation of the parotid gland due to the spasmodic contraction of the muscles will cause a profuse flowing of saliva. Deglutition and talking will be difficult.

In unilateral dislocation (*Fig. 6*) of the lower jaw, the jaw will be drawn to one side and the mouth partly open. Palpation will indicate the head of the condyle on one side in front of the articular eminence. A prominence may be seen on the side of the face at this point. There will be considerable pain in an attempt to move the jaw. As in bilateral dislocation, there will be profuse flowing of saliva and deglutition will be attempted with difficulty. The X-ray may be used to determine the character of the dislocation and amount of injury to the contiguous osseous structures.



## TREATMENT

The immediate reduction of a dislocation is very desirable to successful treatment. This usually can be accomplished by pressing downward and backward on the posterior portion of the mandible with the thumb, which should be padded with gauze for protection against the teeth, and at the same time elevating the anterior portion with the fingers. This usually will force the heads of the condyles back over the eminentia articularis into the glenoid fossa.

Another method is to place a small block of wood, such as a pencil, between the molar teeth as a fulcrum and force the chin upward and backward with the fingers.

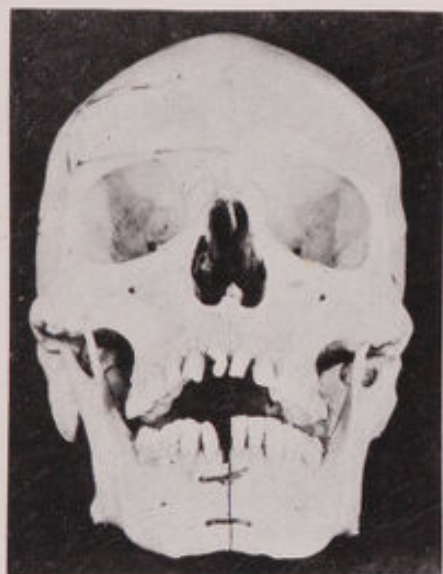

Fig. 5

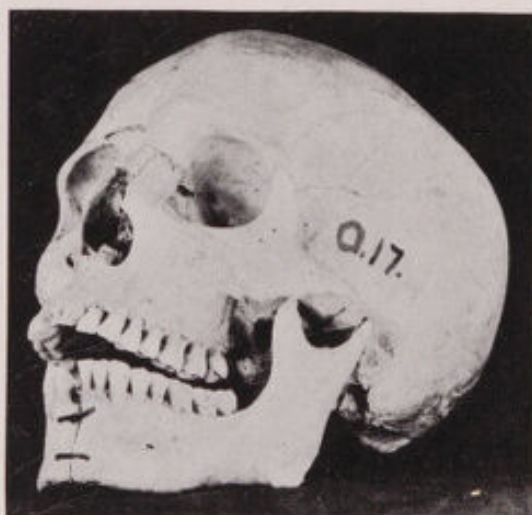

Fig. 6

In some obstinate cases an anesthetic may be resorted to in order to relax muscular tension. A few cases have been reported where the coronoid processes of the mandible have become engaged under the malar process and prevented reduction. These cases are extremely rare and hardly can be taken into account in the treatment of dislocations. Usually the head of the coronoid process rests against the inferior surface of the malar process and prevents closure of the mouth.

In unilateral dislocations the treatment described above is applied to the affected side with the additional effort used to free the chin at the mid-line.

After the dislocation has been reduced, the parts should be put at rest for a few days by a figure-of-eight bandage. This will enable the tissues to take on their normal tone. After the removal of the bandage the patient should be cautioned about opening the mouth too wide so as to prevent a repetition of the accident.

Certain obstacles to the reduction of dislocations of the jaw may arise which will greatly interfere with the success of the operation.



In early childhood the pain or fear of pain may make a general anesthetic desirable to complete the reduction successfully. Swelling of the soft parts when reduction is not made immediately may greatly interfere with the reduction. Contraction of the *temporal* and *masseter* muscles, excited by the traumatism or fear of pain, also may complicate the procedure of establishing normal conditions. Here again resort to a general anesthetic may be necessary.

In habitual dislocations of the mandible, the patient soon has no difficulty in making the reduction himself. Habitual dislocations are brought about either by a change in the depth of the articulation caused by pathologic changes, or by a loss of tone in the fibres of the capsular ligament. Genzmer uses pure tinct. iodin .5 to .75 cc. in these cases, by repeated injections into the joint. This he believes will give tenacity to the capsular ligament. Dubrenil has used a 10 per cent. solution of chlorid of zinc in 2 minim doses, with apparent good results. These injections are attended with considerable pain, prolonged anesthesia of the parts and some danger. The author prefers to put the parts at rest by a chin-piece and straps similar to that used for holding the lower jaw firmly against the upper, (*Fig. 56*), when in a short time the tissues will regain their normal tone.

#### UNREDUCED DISLOCATIONS

In old dislocations in other parts of the body which have been unreduced, the prognosis is not bad, as the parts become accustomed to their new positions. In dislocations of the mandible which have not been reduced, the movements of the mandible are exceedingly limited; and osseous ankylosis of the jaws is the usual result, this condition coming on gradually and without pain or serious disturbance to the patient. The irritation and inflammatory condition produced by the new arrangement seems to set up a metaplasia and the cartilages are gradually transformed into fibro-osseous tissue.

#### CONGENITAL DISLOCATIONS

<sup>2</sup>Smith reports a case of an idiot who lived to the age of thirty-eight with congenital dislocation. This was an unilateral dislocation and was a result of defective development of the joint.

<sup>2</sup>Smith's "Fractures and Dislocations."



## Chapter II

### Fractures of the Jaws

In the discussion of the subject of fracture of the jaws, in this and the succeeding chapters, we must begin with the fundamental principles involved, without which a clear and definite understanding of the subject will not be possible. We must first, then, obtain a satisfactory definition.

#### DEFINITIONS AND ETIOLOGY OF FRACTURE

The word *fracture* (*fractura*, from *frangere*, to break), or in other words, breaking, conveys to the mind so clear an idea that a definition perhaps might tend to obscure it. However, many definitions have been given. Grove defined fracture as a division of the bony fibers occasioned by external violence or muscular contraction. Richard Wiseman, in the seventeenth century, defined fracture as "a solution of continuity in bone suddenly made either by contusion or flexure." This definition so completely expresses the conditions of fracture that the author finds it difficult to improve upon it.

In considering the relative frequency of various kinds of fractures, Stimson says: "The liability to fracture of the different bones of the body varies greatly in consequence of their difference in size, shape and degree of exposure to external violence or extreme muscular action."

Consequently, on account of the more exposed position, shape and lack of support, the mandible is more susceptible to fracture than that of the maxillæ. In a classification of 2,358 fractures of the different bones of the body, 27 fractures of the mandible were observed and only three of the maxillæ, making the ratio of nine to one. The author's own records coincide with this ratio.

In order to omit none of the questions involved in fractures of the jaws, the discussion of the subject will be arranged under eight heads, viz.: (1) the etiology; (2) the varieties; (3) the signs and symptoms; (4) the diagnosis; (5) the process of repair; (6) the complications; (7) the prognosis, and lastly (8) the treatment.

#### ETIOLOGY

We shall study under this head the predisposing and the exciting causes of fracture of the jaws.

The predisposing causes may for convenience and clearness be divided into two parts: first, certain general predispositions unconnected with any morbid state; second, the effects of certain diseases in facilitating the occurrence of fracture.

The general predisposing causes of fracture of the jaws are connected with the influence of age, sex and occupation. Seasons could be



added to the general predisposing causes in the discussion of fractures in general, but can scarcely be said to have any influence on the occurrence of fractures of the jaws.

*Influence of Age*—The bones of the jaw are more flexible in early life and more brittle in old age. Consequently an accident which might produce a fracture in old age might not yield the same result early in life on account of the difference in the degree of fragility of the bones. That fractures of the jaws have been observed at all times of life from early childhood to extreme old age, but by no means with the same degree of frequency, is shown by the following evidence:

Guret, in 1862, tabulated 1388 cases (hospital and dispensary) of fractures in general, with reference to the ages of the patients, and found in the first decade 265; in the second, 193; in the third, 274; in the fourth, 224; in the fifth, 154; in the sixth, 155; in the seventh, 72; in the eighth, 38, and in the ninth, 8. Combining them with statistics showing the relative number of people living at the different ages, he found the highest relative proportion of fractures in the period above the age of sixty years.

Malgaigne, in 1847, tabulated 2377 fractures in all parts of the body, classed according to age, and he found that fractures occur most frequently in subjects of from 25 to 60 years, becoming more rare above and below these ages as we depart from them respectively; so that as regards the rarity of fractures the extremes of life approach one another.

The writer knows of no authentic statistics that have been compiled relating to fractures of the jaws according to age. Such fractures result largely from the pursuit of certain occupations, and making easy their occurrence from living in certain environments. As these occupations are pursued during the so-called earning period of a man's life, it follows, then, that the highest relative proportion of fractures of the jaws occurs between the ages of 21 and 50 years. Our statistics at the University Hospital, Ann Arbor, Michigan, bear us out in this statement. As a matter of fact fractures of the jaws in early childhood and above the age of 60 years are rare. In the early years children are not exposed to those conditions or environments which are so favorable for accidents of this kind; neither are those at the other extreme of life likely to be so subjected.

*Influence of Sex*—Fractures of the jaws are more numerous in men than in women because of the greater exposure of men to accidents which cause them. In the early years the difference is slight. In middle life the fractures of the jaws are many, many times greater in men than in women. Then, again, above 50 years the difference is slight.

*Influence of Occupation and Environment*—Occupation and environment are the greatest factors in the predisposing causes of fractures of the jaws. The rapidity of twentieth-century travel not only by train



but automobile is responsible for many of these accidents. The building of sky-scrapers and other buildings in the cities is adding greatly to the increasing number of jaw fractures. Then the large manufacturing establishments with powerful machinery (some of it unprotected), with its beltings and cables, coupled with a tendency to carelessness on the part of the employes, take their toll, also, in accidents of this description.

#### PREDISPOSING CAUSES OF FRACTURE OF THE JAWS

Fractures from diseases are known as spontaneous or pathologic fractures. These affections may behave in two ways: *first*, they may render the osseous tissue more fragile or brittle; and *second*, they may increase inordinately the power of the muscles acting on the bones, the latter being brought about by an inflammatory process going on in the osseous tissue which stimulates muscular activity. A discussion of these affections follows.

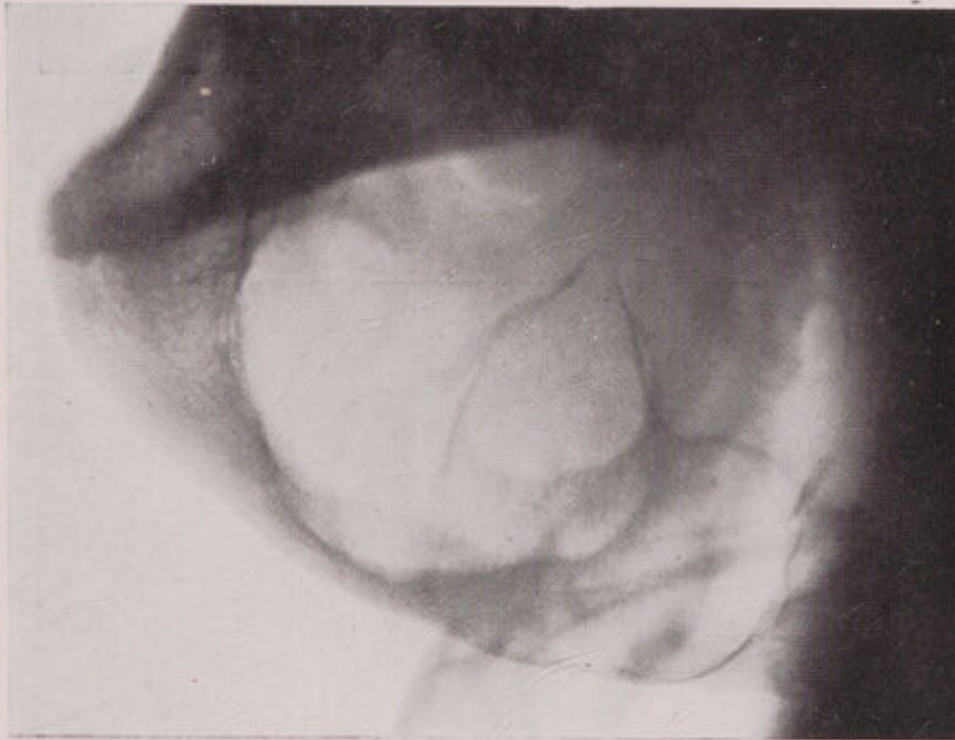


Fig. 7—Sarcoma of the jaw.

*Rachitis*—Inability due to rachitis is found only in children. This disease is one which involves the bone only during the period of growth, and its strength and firmness is diminished. This disease affects only the long bones; consequently as the mandible is developed similar to long bones, this would be weakened by this disease and spontaneous fracture would be encouraged. This condition, however, is rare.

*Carcinoma and Sarcoma of the Jaws*—A malignant tumor may lead to fracture of the lower jaw by the tumor occupying the bone itself primarily or secondarily, and destroying it to such an extent that the slightest muscular force will be sufficient to fracture it. (*Fig. 7.*)

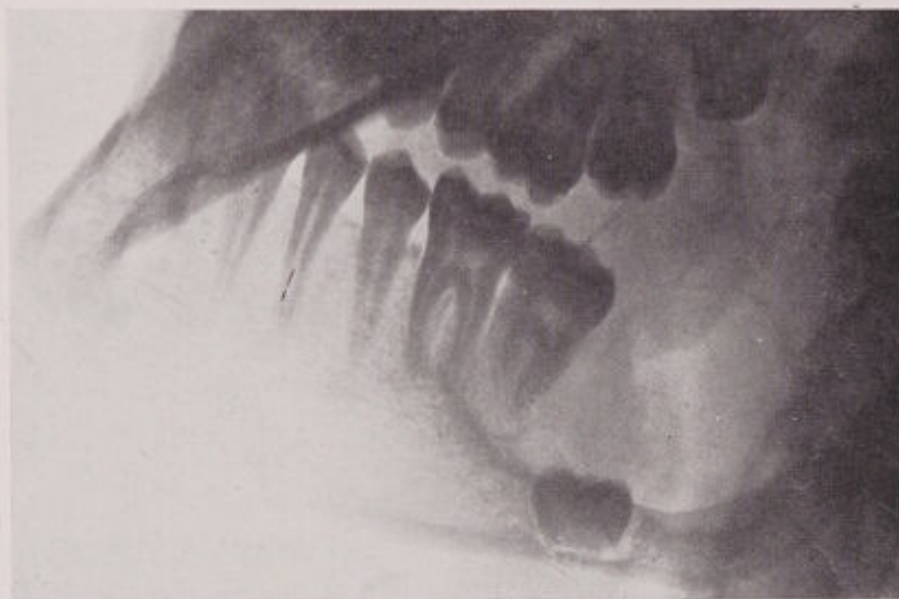

Fig. 8

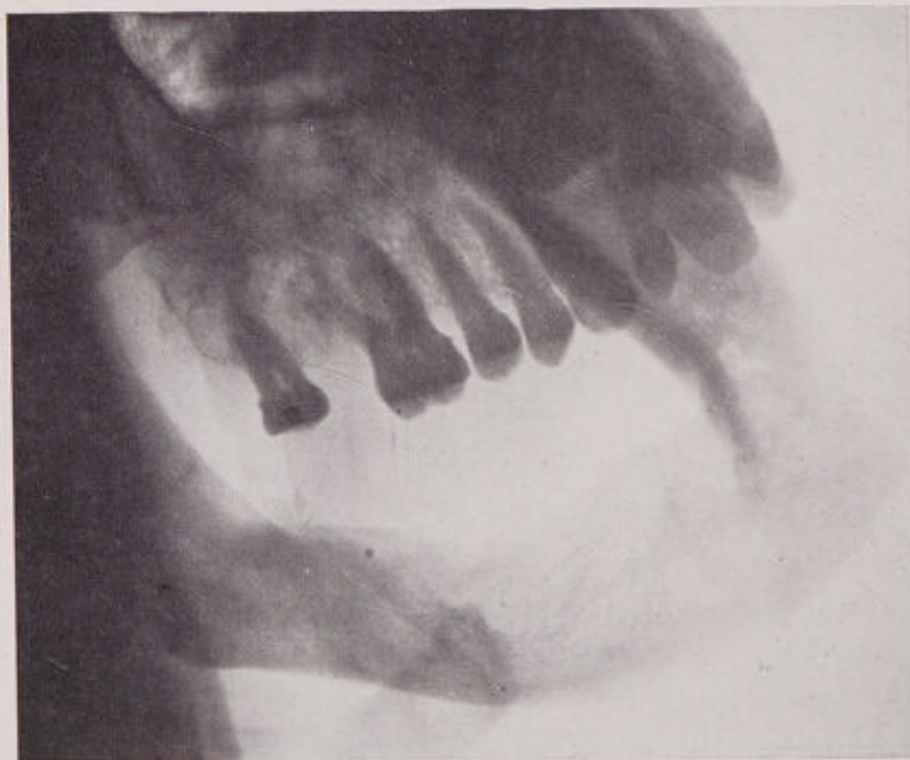

Fig. 9—Spontaneous fracture of the mandible in a man age 35, due to osteomyelitis.



*Dentigerous Cysts*—Such cysts may remain and develop in the jaw until a very large portion of the osseous structure is destroyed. Here too the slightest muscular contraction may be sufficient to cause a fracture. A case recently came under the author's attention (*Fig. 8*), of a young man 17 years of age, where the cyst had been developing for a period of less than six months. The cyst involved all of the coronoid process and a large area in the posterior region of the horizontal portion of the mandible. Just distal to the first molar tooth less than two millimeters of the bone substance was intact. Fortunately this case was operated on before spontaneous fracture occurred.

These cysts produce cystic degeneration of the cancellated bone, and cause direct absorption by pressure of the cystic contents on the cortical layer. Their action is purely local in character.

*Osteomyelitis*—Acute osteomyelitis of the mandible occurs most frequently in children between the ages of five and sixteen.

Infection of the cancellous portion of the bone may occur from the extraction of an abscessed deciduous tooth and involve a varying portion of the bone. This may continue until the entire mandible is involved and a spontaneous fracture may result as a consequence of muscular contractions. A case of this kind has come under the writer's attention. The patient, a little girl of six years, had a deciduous molar tooth extracted, followed by a deep infection which finally involved all of one side of the mandible. A fracture ensued and before the infection was brought under control, the entire ramus had to be removed.

#### THE DETERMINING OR EXCITING CAUSES OF FRACTURE

The exciting causes of fracture of the jaws are classified under two heads, viz., direct and indirect. When the bone yields at the point where the force is applied we say that the fracture is direct, or by direct violence; when it occurs at a point at some distance from the point where the force is applied it is then known as fracture by indirect violence. In case of fracture by direct violence the soft tissues are usually simultaneously injured. These may be simply contused or they may be badly lacerated, or they may be badly torn and missing (as in gun-shot wound), and the bone protruding. There are exceptions, however, to these conditions of the soft tissues, and occasionally it may be difficult to ascertain whether the fracture is caused by so-called direct or indirect violence.

Fracture by indirect violence is due to the overbending of the bone or by force being exerted through the bone that overtaxes the normal elasticity of the bone. In the jaws, fracture by indirect violence usually is observed in the mandible and rarely in the superior maxilla. *Fig. 10*, fracture of the condyloid process, is an illustration of this kind. The point of violence was the chin resulting from an automobile accident. The seat of fracture was at the neck of the condyle.

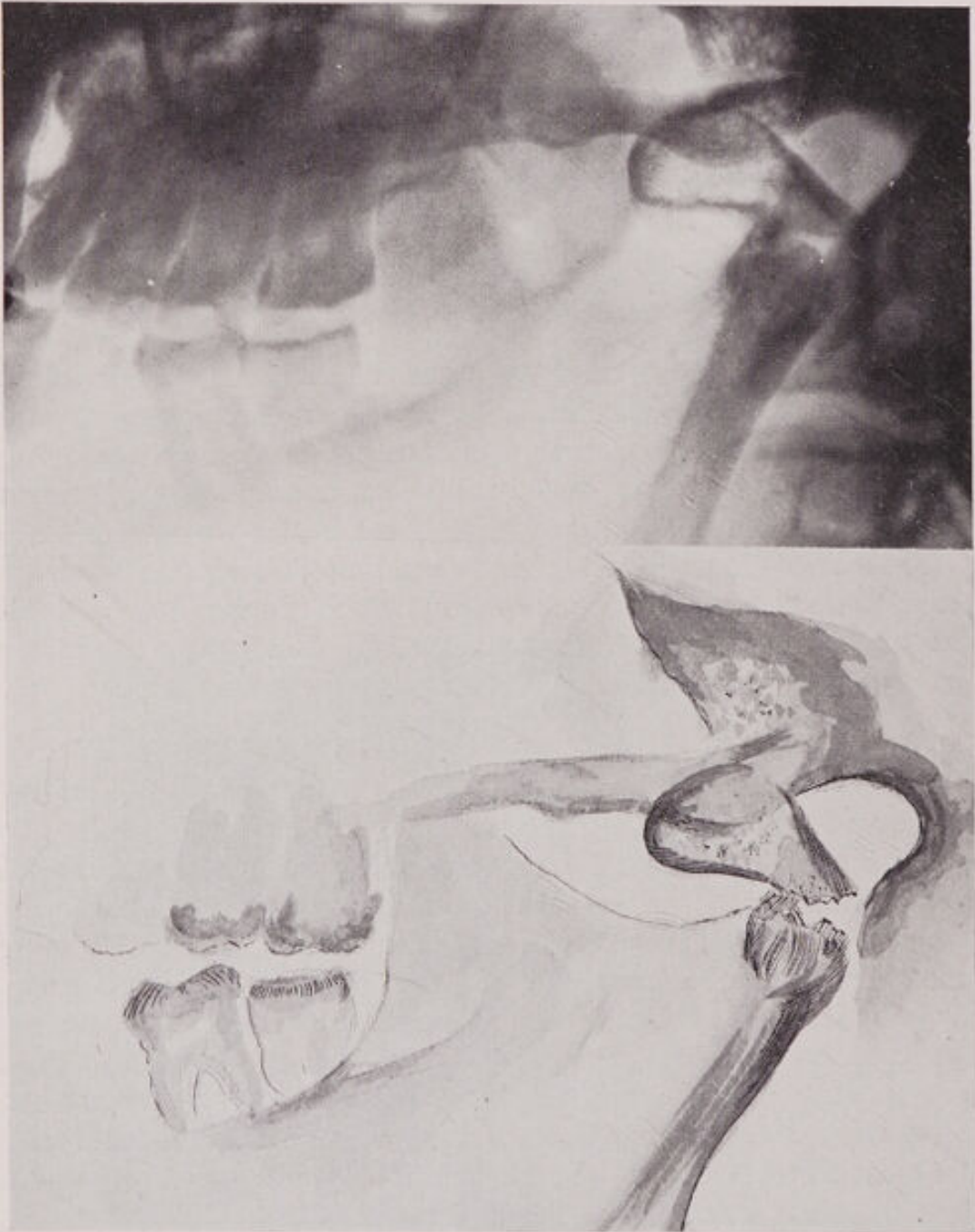


Fig. 10



The bones involved in fractures by indirect violence may be torn, twisted or pulled apart. In the case illustrated by *Fig. 10* the head of the condyle was torn from its articulation and dislocated in front of the eminentia articularis.

*Falls and Blows*—Probably two of the greatest factors in the determining and exciting causes of fractures of the jaws are falls and blows. Falls may occur from various heights, upon a surface hard or soft, smooth or rugged, or there may be something like a succession of falls, as for example, a workman falling from a building, striking a beam or scaffolding, which breaks the fall, then later tumbling to the ground. Nothing is more variable in the results of fracture of the jaws than a fall. A fall of a few feet sometimes will result in a more serious fracture than a fall from much greater heights.

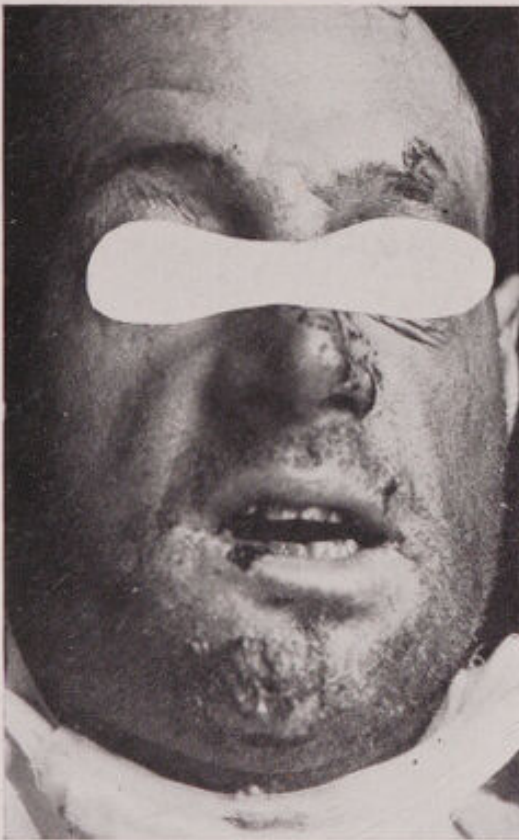

Fig. 11

Fig. 11—Result of fall from scaffolding.

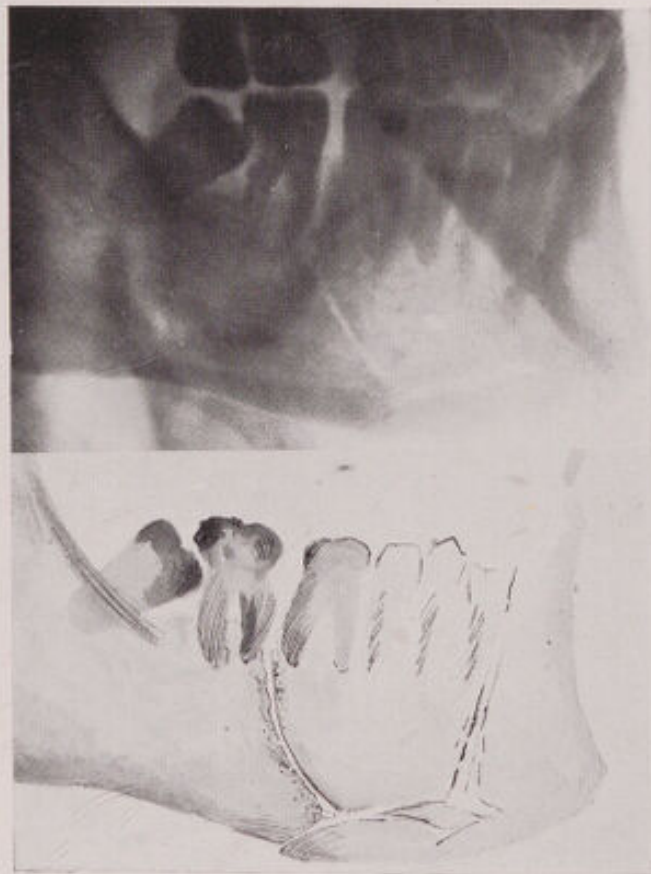

Fig. 12

Fig. 12—Shows multiple fracture of jaws in same patient.

Blows of all kinds on the face, from contact with a horse's hoofs, a human fist, a baseball, stone, or club, or a piece of machinery, all are responsible for many fractures of the jaws. These usually are fractures by direct violence but occasionally the fracture occurs at a point distant from the site of the injury, and fracture by indirect violence results.

*Pressure or Crushing Force*—Hamilton reports two cases of fracture where the etiological factor was pressure or crushing force. The first

was a fracture of the mandible in front of the right cuspid tooth in a lad eight years old, produced by his being pressed between two wagons, the pressure coming upon the two angles of the jaw. The second was a case in which a double fracture was produced in a young woman by the grasp of her husband's hand. Both of these fractures were those produced by indirect violence.

*Fracture of the Mandible as a Result of the Extraction of Third Molar Teeth*—Fractures of this kind are not numerous, yet they cannot be

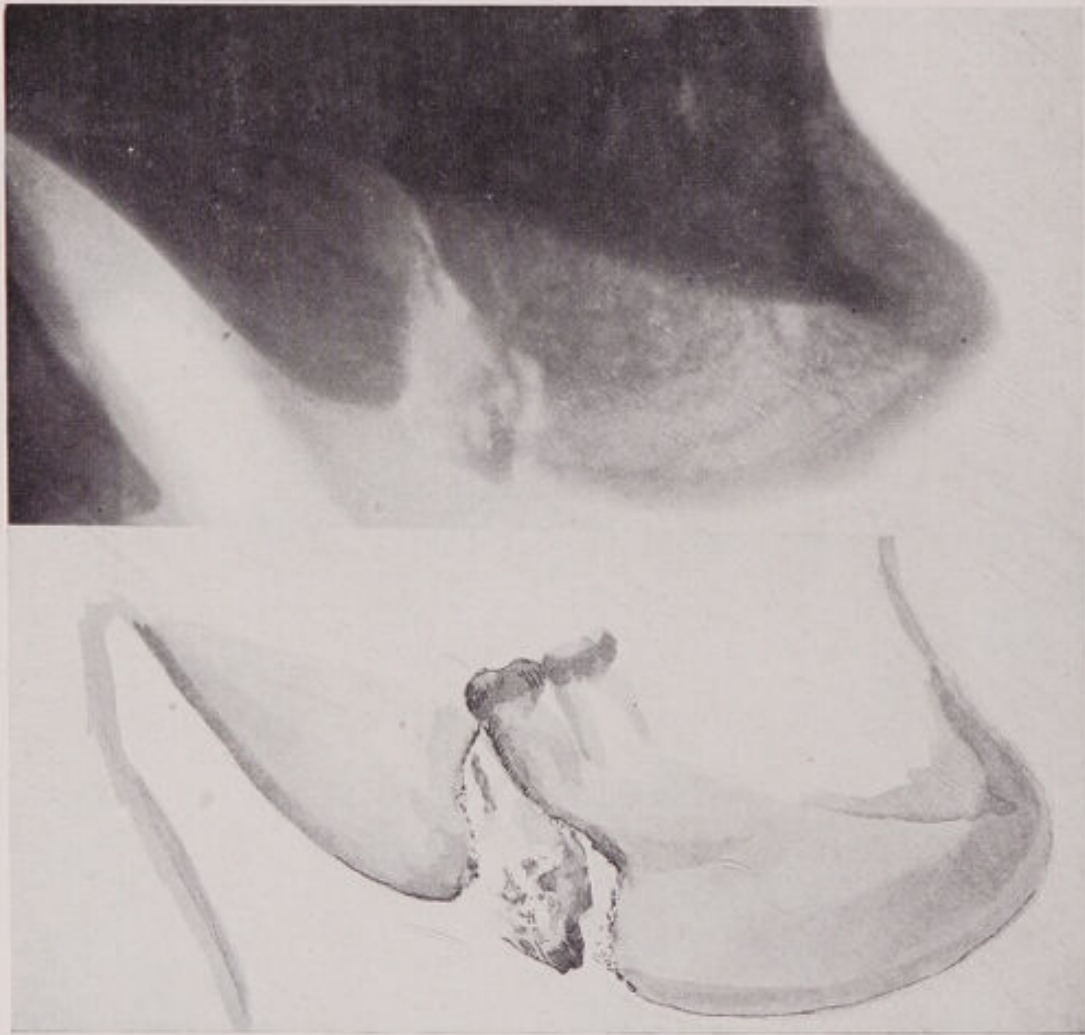

Fig. 13

considered rare. Such fractures are brought about by too much stress being exerted upon the jaws in the attempt to remove the tooth, or by the cutting away of the osseous tissue to such an extent that the mandible becomes unduly weakened at this point and slight stress in the attempt to remove the tooth results in fracture. *Fig. 13* is a case of this kind; *Fig. 14* is a result of sequestra in the same case.

An interesting classification of the etiology of fractures of the maxillæ we have been discussing is given by Piperno, as follows:



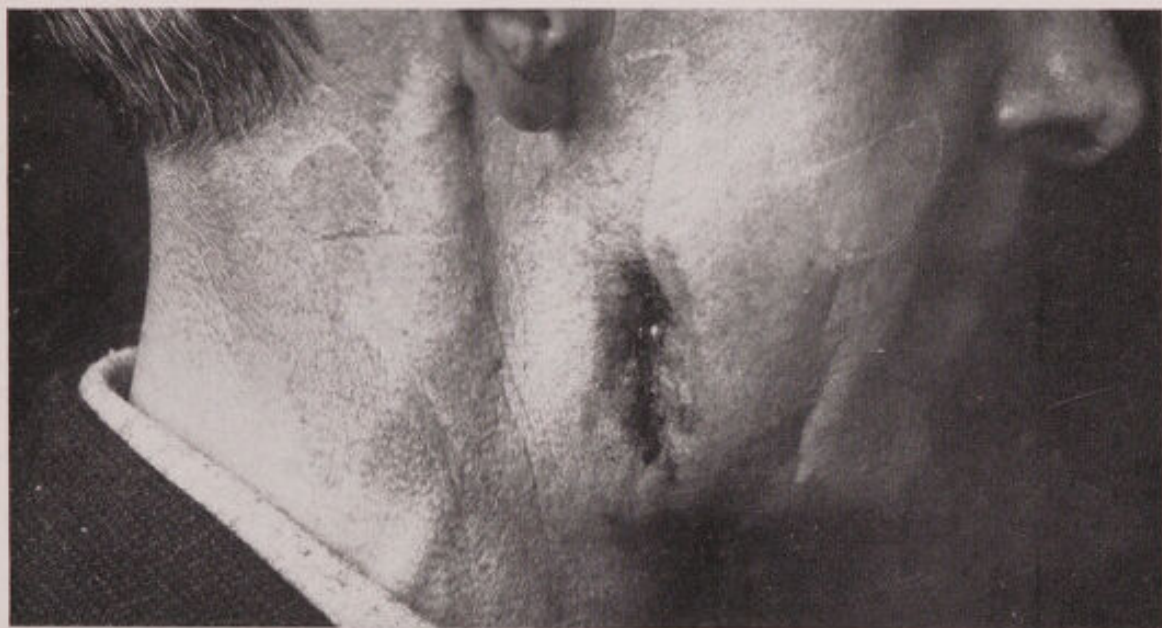

Fig. 14

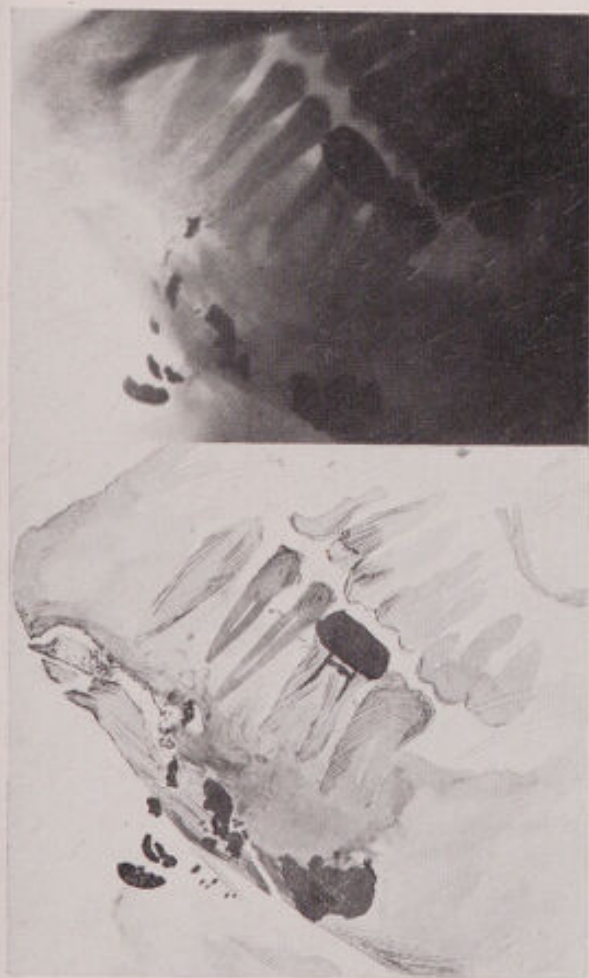


Fig. 15

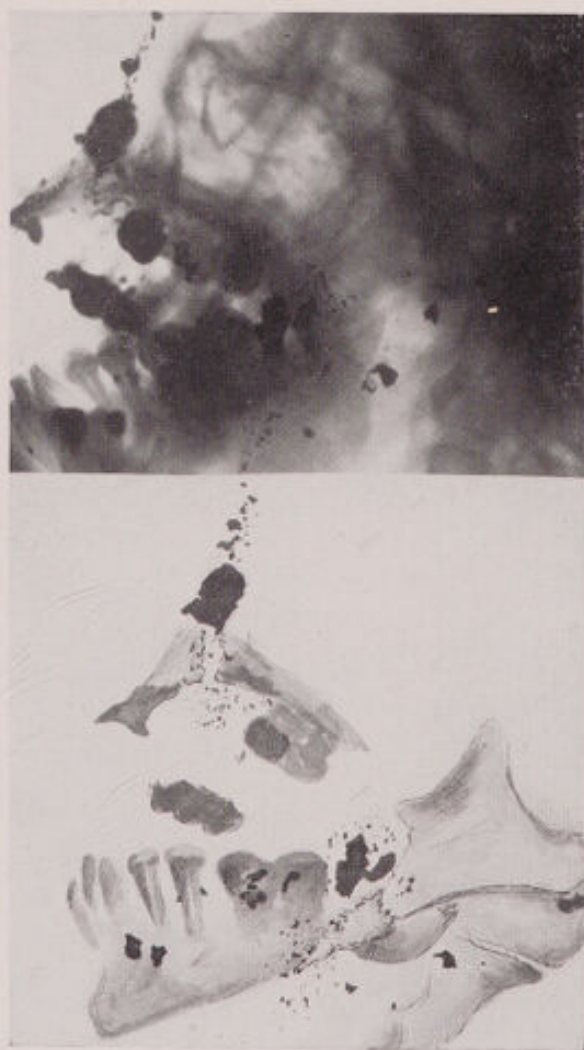


Fig. 16

## 1. A Direct Blow:

- (a) At the level of the upper lip.
  - (b) On the lower part of the bone.
  - (c) On the superior alveolar border from below upward.
  - (d) On the median part of the face from before backward.
  - (e) On the base of the nose from above downward.
  - (f) On the mandible from below upward.
  - (g) On the malar bone:
    - (1) A lateral blow when the head is relaxed.
    - (2) A central blow when the head is moving toward a central body.
    - (3) An anterior blow when the head is resting on the occiput.
    - (4) Any external blow when the head is resting on the opposite malar bone.
  - (h) Simultaneously on the face and cranium.
  - (i) Direct blows on the various portions of the face and in different directions.
2. Gunshot injuries.
3. Crushing injuries, from car wheels, etc.

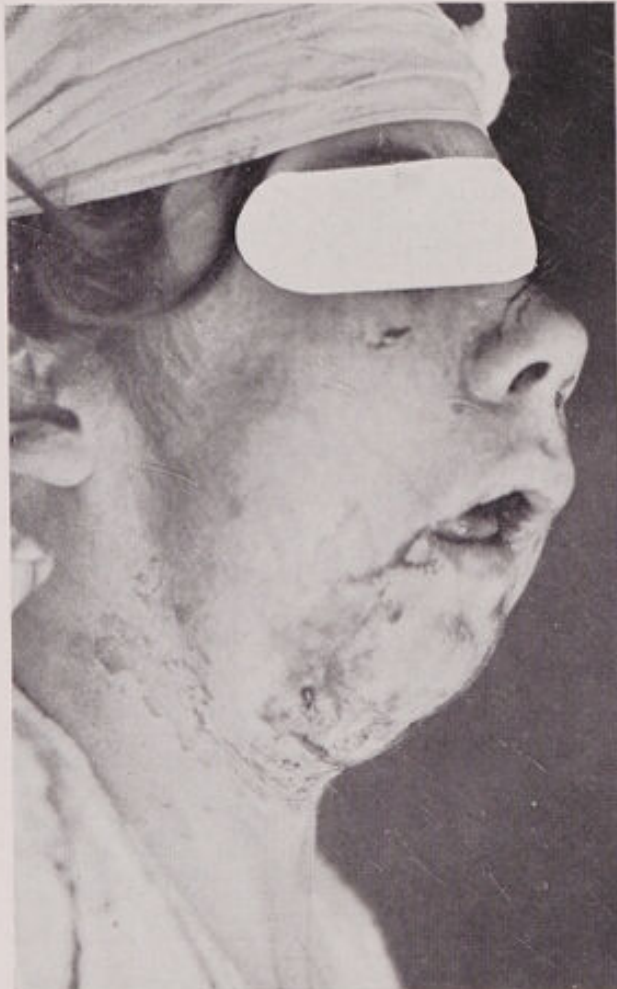

Fig. 17—Same patient as Fig. 16



This classification of the etiology of fractures of the maxillæ is complete and practically covers all of the possibilities in accidents of this kind.

A similar arrangement can be made of the fractures of the lower jaw, as follows:

1. A Direct Blow:

- (a) At line of lower lip from above downward.
- (b) On the lower border of the mandible either in front or on either side.
- (c) At the angle of the jaw from the side.
- (d) At the angle of the jaw from behind forward.
- (e) On the inferior alveolar border from above downward.

2. Gunshot wounds.

3. Crushing injuries around the jaws from any violent accident.

Gunshot wounds—special features:

- 1. Extensive laceration of the soft part.
- 2. Extensive splintering and fissuring of the bone and the bruising of the tissues along the track of the bullet which usually prevents prompt repair of the wound. (*Figs. 15 and 16.*)

3. Infection of the wound, in practically every case on account of infected material being carried into the wound with the bullet.

### Chapter III

## Classification—Varieties of Fractures

In a general sense fractures may be divided into the two great classes of simple and compound. Sometimes these are spoken of as closed and open.

A simple or closed fracture is one in which there is no communication between the air and the bone—in other words, the tissue between the bone and the air is intact, only the bone being involved.

A compound or open fracture is one in which there is an external wound leading to the break in the bone, or where the intervening tissue is involved as well as the bone—in other words, two or more different tissues are involved in the fracture.

All fractures come under one of these two heads.

Brophy says that these types of fracture may be divided again into two classes: incomplete and complete. According to the character and direction of the fracture, these two classes may be separated into the following types:

Incomplete: (a) greenstick, (b) fissured, (c) depression. Complete: (a) transverse, (b) oblique, (c) spiral, (d) longitudinal, (e) comminuted, (f) impacted, (g) complicated.

*Definitions:* *Incomplete Fracture* is a fracture in which the bone is not completely separated.

*Greenstick Fracture* is one in which the bone is bent and the fracture takes place on the convex side of the bend. This type of fracture only occurs in very young people when the lime salts are not completely deposited. This type of fracture of the jaws is very rare. It is seen chiefly in fracture of the long bones in early childhood.

*Fissured Fracture* is one in which there is a crack or fissure in the bone.

It is occasionally found in bones forming the vault of the skull, and is difficult to diagnose. The normal sutures of the bones of the skull may be mistaken for fissured fractures and vice versa in cases of fractured bones of the head. This type of fracture is usually the result of indirect violence or when the fracture occurs at some distance from the point of violence.

*Depression Fracture* is one in which a fragment is depressed below the surface. This is seen in fracture of the skull, as a result of contusion.

Under the incomplete fractures we may find a fracture commonly known as splintered fracture in which a small portion of the bone is splintered off into sharp fragments, the fragments being attached to the bone. This is seen in fracture of the lower jaw where there is a multiple fracture or where the jaw is fractured in several places. (*Figs. 12 and 15.*)



*Definition of Complete Fracture*—A Complete Fracture is one in which the bone is broken entirely across.

In the class of complete fractures, (*a*), (*b*), (*c*), (*d*), viz., transverse, oblique, spiral and longitudinal, are so named from the relative direction of the fracture, the direction of the fracture, therefore, implying the kind.

*Comminuted Fracture* is one in which the bone is crushed and a portion of the bone is splintered into small fragments. This is frequently seen in gun-shot wounds and in crushing injuries around the jaws from a violent accident. (*Figs. 15 and 16.*) In the mandible the cancellated portion usually is flattened or crushed and the cortical portion splintered.

*Impacted Fracture* is one in which one fragment is driven firmly into the other. It is seen in complete fracture of the superior maxillæ when the bones are driven back inward and toward the base of the cranium.

*Complicated Fracture* is one in which in addition to the bones involved, some important structure such as nerve, vessel or joint is injured, as in *Fig. 10.*

## Chapter IV

### Signs and Symptoms of Fractures

The signs and symptoms of fracture can be divided into two groups: *first*, Objective signs, or those which can be observed directly by the surgeon. They are deformity, abnormal mobility, malocclusion of the teeth, crepitus and swelling; *second*, Subjective symptoms, or those symptoms for his knowledge of which the operator has to depend upon statements from the patient. They are pain, tenderness, loss of function, and history of the patient.

#### OBJECTIVE SIGNS

*Deformity*—The deformity which may be present will vary in extent. It will depend upon the force and direction of violence, the changes produced in the relation of the fragments to each other, the extravasation of blood into the wounded tissues, and the inflammatory processes which have taken place. The amount of force and the direction from which it is received will play an important part in separating the fragments. This may be sufficient to drive one end of the fragment through the adjacent soft tissues.

The changes produced in the relation of the fragments to each other usually are recognized by observing the occlusion of the teeth. However, this is not so simple in those cases in which the natural occlusion of the teeth of the particular individual is abnormal. Neither is it a simple problem to recognize in an edentulous jaw. In fracture of the arms or legs the relation of one fragment to the other can be ascertained sometimes by mensuration, but in the jaws this method is not practicable on account of the normal asymmetry, the difference not being due to traumatism. In these cases the surgeon must depend largely upon palpation in ascertaining the amount of displacement. Difficulties and uncertainties will exist in palpating on account of swelling and blebs. The inflammatory processes which have taken place will vary with the character of the injury, the idiosyncrasy of the individual and the time which has elapsed between the injury and the presentation for treatment.

Extravasation of blood into the tissues, or ecchymosis, rarely is absent in the deformity which is produced. The appearance of ecchymosis may be delayed, however, for several days. It is more marked and more extensive in older patients. The blood which escapes from the fractured parts makes its way along the muscular tissues and first may make its appearance at some distance from the fracture. Its appearance is an objective sign of fracture.



*Abnormal Mobility*—Mobility appearing in a bone where it did not previously exist, or permitting a portion of it to move while the remainder remains at rest, is pathognomonic of fracture. This condition usually is present in fracture of the horizontal portion of the mandible. In attempting to elicit this sign of fracture the parts of the jaw at some distance from the supposed site of fracture should be grasped between the thumb and fingers of each hand and gently manipulated. The manipulation should be deliberate and gentle and conducted in such a manner as to cause little or no damage to the wound. In many cases it will not be necessary to look for this sign, for the displacement of the fragments and malocclusion of the teeth will be sufficient evidence of fracture.

*Malocclusion of the Teeth*—This is a symptom that may or may not be present in fracture of the jaws. The presence of malocclusion of the teeth will depend upon the extent and locality of the fracture and largely upon muscular tension upon the fragments. A single fracture posterior to the last molar teeth rarely will cause displacement of the anterior fragment and in such cases the teeth usually are in natural occlusion. The natural occlusion of the patient may not be normal occlusion and the surgeon may be deluded by the abnormal appearance; so this is a sign that also has its uncertainties and sometimes may be misleading.

*Crepitus*—This is always a positive sign of fracture. Crepitus is a sensation communicated through the hands of the operator by one fragment of bone grating upon the other. It sometimes is audible. Crepitus may be demonstrated by the operator grasping one fragment with one hand and gently manipulating the other fragment with the other hand in the endeavor to rasp one fragment against the other. Crepitus cannot always be obtained in fracture and only can be brought out in complete fracture. It is not present in greenstick, fissured or depression fractures; neither can it be elicited in impacted fractures. It is more commonly present in fractures of the mandible. On account of a possible injury to nerves and vessels in the endeavor to obtain crepitus, only very gentle manipulation should be attempted. The fragments may be splintered and in violent rasping of one fragment against the other, the splinters may cut or pierce the soft tissues connected with the fracture.

*Edema*—This is a condition that nearly always is present in fracture of the jaws. The character and extent of the swelling will vary with the location of the point of violence, the amount of traumatism and the quality of the tissues involved. (*Fig. 18.*) <sup>1</sup>The irritation produced by the violence may produce changes in the vaso-motor nerves, such as paralysis, which also may lead to an increase of the vascular

<sup>1</sup> Ziegler.







secretion. It is not definitely known just what changes the vessels suffer under these conditions, but it is thought that some changes in the endothelial cells and cement substances of the vascular walls take place, rendering them more permeable. As a consequence of the increase of vascular secretion into the tissue spaces, the lymph flow is unable to carry it off as rapidly as it accumulates and œdema results.

It may be due to arterial congestion in the periosteum or muscular tissue as the result of the trauma, or it may be due to stagnation of the blood. When, through trauma, there is a marked hindrance to the outflow of blood from the capillaries, the pressure in the capillaries rises and the fluid portion of the blood seeks a lateral outlet so that an increased amount of fluid escapes from the vessels. The amount of escaped fluid is the larger, the greater the degree of discrepancy between the inflow and outflow; it is therefore increased through a coincident increase of the blood inflow. The immediate result of an increased transudation from the blood vessels is an increase in the lymph flow and this may be sufficient to carry off all the fluid. If it does not so suffice the fluid collects in the tissue spaces and then results the condition of edema.

#### SUBJECTIVE SYMPTOMS

*Pain and Tenderness*—Spontaneous pain when the parts are at rest, particularly when there is little or no displacement of the parts, is slight, and not distinctly limited to the parts involved. It may be a referred or a reflected pain. In fracture of the jaws it usually is felt in any area supplied by any one of the three divisions of the fifth nerve. (*Fig. 19.*) The patient complains more of pains over the upper anterior part of the head than at the seat of fracture. The phenomena of reflected pain is thought to be due to certain nerve cells in the Gasserian ganglion having portions of their nerve fibers running in one or more divisions of the fifth nerve; thus the source of irritation may be in one division of the nerve and the seat of pain may be in one of the other divisions, the brain being unable to interpret correctly the source of irritation.

Localized pain upon palpation or in movements of the jaw is a valuable symptom. The localized pain is best elicited by gentle palpation with the tips of the fingers along the line of the supposed fracture, and when the point of fracture is reached greater pain usually is noticed by the patient.

Spontaneous pain usually will subside shortly after the accident, and pain as a diagnostic symptom can be determined only by the methods stated above. Indeed, if there is little or no displacement of the fragments, the knowledge of a fracture will not be present to the patient, and several weeks may intervene before the patient will observe a tenderness, and it may be mistaken for the tenderness due to the contusion of the parts.



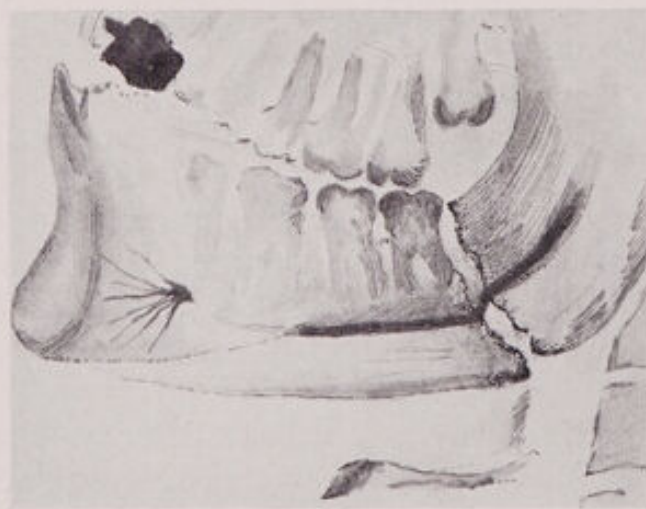
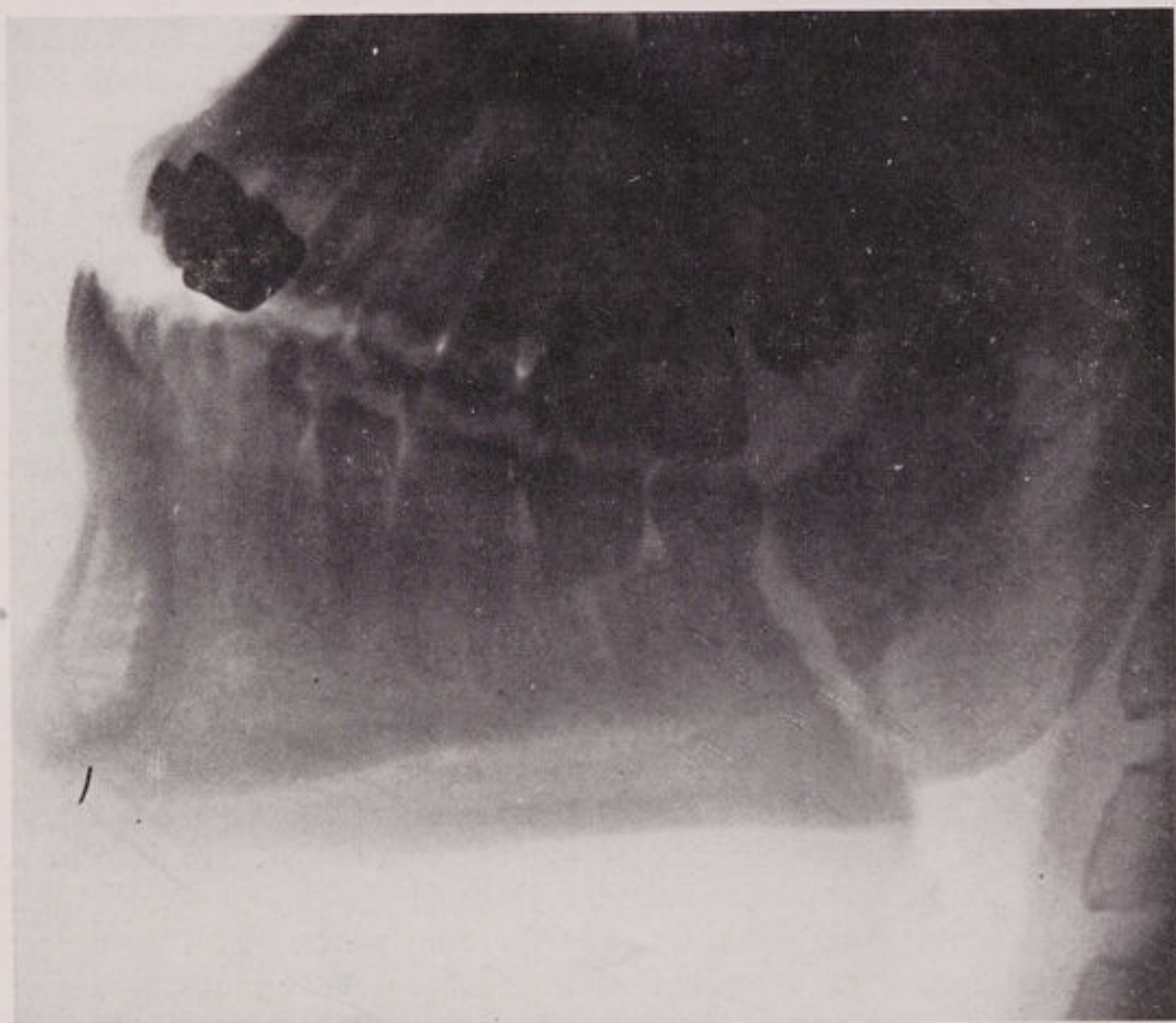
Fig. 20



Pain as a diagnostic symptom in pathologic or spontaneous fracture often may be misleading. When there is a marked displacement of the parts pain usually is very severe, on account of the abnormal position of the sensory nerves supplying the parts. (*Fig. 20.*) Pain and tenderness under these conditions is a constant accompaniment of fracture.

*Loss of Function*—This is a common result of fracture of the jaws, especially when the fracture occurs in such a locality that muscular tension causes displacement. However, the surgeon should not forget that certain traumatic injuries in and about the jaws will produce a disturbance in the normal functioning of the jaws. As an example, fracture produced in the removal of an impacted tooth may cause little or no displacement and trismus may result, causing the operator to confuse the loss of function with the trauma instead of with the fracture.

*History*—This is a very important part of the procedure in determining the extent and character of the injury. The nature of the accident and the manner in which the force was applied, the interference of function, immediately or later, and occasionally the patient's knowledge of a snap heard or felt at the time the bone was broken—this is indispensable knowledge for the surgeon to have in determining correct diagnosis. These are not all present in every case, and the history should form only a link in the chain of evidence which makes up the diagnosis. In some cases the character of the injury is so apparent that it can be recognized at a glance; in others it may be so obscure that the most experienced observer may be in doubt, and resort must be had to all of the means of making a correct diagnosis.



## Chapter V

### Diagnosis

This is a subject of great interest and importance in determining our methods of treatment. *First*, from a scientific point of view it is essential that all knowledge should be accurate. This is sometimes difficult to obtain in fracture of the jaws and the operator should not be too hasty in formulating his conclusions; *second*, accuracy of diagnosis enables the operator to frame a scientific classification of the fracture and to determine the best methods of prosecuting the treatment of the case; *third*, it is by an accurate determination of the nature of the fracture, coupled with the physical condition and habits of the patient, that enables us to determine the prognosis of the case.

In formulating the diagnosis, a complete history of the patient should be obtained, which should include age, occupation, habits, presence or absence of venereal diseases, and the history of the presence of any other diseases which would have a tendency to lower the vitality of the patient. In all cases of suspected fracture of the jaw, the dental arches should be carefully inspected. The outline of the facial bones should be palpated gently for a possible fracture. (If there is considerable swelling this may not be wholly satisfactory). If there is a fracture, tenderness will be manifest usually at the line of fracture upon palpation.

The subject of diagnosis has been treated to a considerable extent under the head of signs and symptoms, so that there will be little to add here concerning the consideration of these factors in making a diagnosis. The examination of the patient should be conducted systematically with the view to learning not merely the existence of the fracture, but also such details and complications as may be present and may affect the treatment and prognosis. It should include an examination of the condition of such vessels, nerves, etc., as may have been injured at the time of the examination in order that such injuries, if their later consequences should become manifest, may not be attributed to the methods of treatment. The deformity which is present, or the abnormal occlusion of the teeth, may make it self-evident that a fracture exists; yet this alone is not sufficient evidence upon which to make a judicial and final diagnosis. (A multiple fracture may easily be overlooked, which will defeat the whole process of treatment if not reduced at the time of beginning the treatment.)

The investigations which lead up to a judicial diagnosis call for the exercise of the highest mental faculties, and should be conducted without prejudice or haste. We should never be ready to accept as clear



that which is obscure. Simply because a fracture is self-evident, we should not be satisfied until we know the character and extent of it and know that one or more other fractures do not exist.

It is our plain duty in each and every case to ascertain the real nature and character of the fracture before beginning the treatment. It must ever be kept in mind that the application of the right methods of treatment depends entirely upon an accurate diagnosis. If there is an extensive injury with a great amount of swelling and trismus, a general anesthetic may be resorted to in order to ascertain the exact conditions that are present.

One of the greatest adjuncts to the operator in diagnosing the extent and character of fracture of the jaws is the use of the X-ray.

#### THE X-RAY IN DIAGNOSIS AND TREATMENT OF FRACTURE OF THE JAWS

Thus far nothing has been said relative to the use of the X-ray in diagnostic work in connection with fracture of the jaws. We deem the subject of sufficient importance to elaborate upon it in this work to quite an extent. Dr. James G. Van Zwaluwenburg, professor of Roentgenology in the medical school in the University of Michigan, who has collaborated with me in the diagnosis and treatment of fracture of the jaws in the University Hospital, at my suggestion kindly consented to summarize this part of the subject:

"While the diagnosis of fracture of the lower jaw usually can be made without difficulty on the clinical evidence alone, the satisfactory treatment requires a knowledge of the exact relationship of the fragments, the presence of extra fragments, their relationship to the teeth and the tooth sockets, and the viability of the teeth, which only can be obtained by satisfactory X-ray examination.

"This is best done by means of stereographic plates or films. Elsewhere in the body it usually is possible to radiograph a fracture along axes at right angles, and thus determine with a fair degree of accuracy the direction and the magnitude of the displacement of the fragments. In the case of the jaw, however, anatomic conditions make this almost impossible. But the sense of the third dimension, of depth, is satisfactorily provided by making a plate for each eye and then by means of mirrors or prisms, observing the two images simultaneously. With proper attention to details it is possible to view the parts radiographically in exactly the same position and in the same scale as they lay when the exposure was made. The advantages of this method are obvious.

"Fractures of the jaw may be examined either by plates (extraoral), or by films (intraoral). A greater area can be shown and the conditions for stereoscopy can be controlled better with plates than with films, and therefore, a better idea of the exact relationships is obtained; on



the other hand, the danger of obscuring the pathology by the superposition of the shadows of the opposite jaw and its teeth requires more careful attention to the position. Films, intraorally, also may be made in stereo, but pain and swelling usually prohibit the use of films in fractures; and, at best, it is impossible to demonstrate the entire width of the jaw without grossly distorting the projected shadows. For these reasons the plate method will be found the more generally useful.

"Stereographic plates may be made in any plane, and the requirements are absurdly simple. It requires, in principle: (a) that the two plates occupy exactly the same position with respect to the subject; (b) that the position of the tube is shifted the interpupillary distance of the observer; (c) the direction of movement of the plate must be parallel to one edge of the plate, and (d), the subject must be immobilized.

"In practice, the injured part is placed on a shallow wooden box with open edge containing the plate, the head is fixed by a weighted strip of cotton, the tube is placed in the selected position, and the plate and its holder rotated until one edge is parallel to the selected direction of tube-shift. After the first exposure the plate can be exchanged and the tube shifted without in any way disturbing the patient. As a general rule the direction of tube displacement is so chosen as to lie at right angles to the principal lines of the image.

"Any obliquity of projection may be reproduced by a corresponding obliquity in the position of the plates when in the stereoscope, and an undistorted picture may be studied. If the space relations existing at the time of exposure are faithfully reproduced, the image will be seen undistorted and in the actual size and depth of the original.

"A small diaphragm and a medium hard tube are required. The immobilization of the patient is the most important factor in the production of sharp definition. The slight tremor and the nutation with every pulse beat, while imperceptible to the eye, invariably result in a degradation of the definition of the radiogram unless prevented by suitable straps or bands. The patient's comfort also is of prime importance, since a microscopic tremor cannot be avoided in a strained and uncomfortable posture.

"By making two tube-shifts, first parallel to one edge of the plate and then at right angles or parallel to the other edge of the plate, we may expose three plates providing two stereograms, the second plate being common to both stereo sets. Although usually unnecessary, this procedure may give valuable information.

"The lower jaw may be studied in two projections, the postero-anterior (transcervical), and the lateral. The transcervical is useful only in fractures in the region of the incisors, and the image usually is badly confused by the superimposed shadows of the cervical vertebræ.



The lateral position is much to be preferred. Projection should be from a point below and slightly posterior to the angle of the sound jaw and the head well extended. In this way the entire body and ramus of the injured jaw usually may be thrown in the clear of all confusing shadows. The temporomandibular articulation requires good marksmanship for satisfactory demonstration.

"The interpretation of the plates usually is obvious. The fracture plane in the jaw usually is transverse and in the line of projection. Displacements of the fragments, the presence of multiple fragments, foreign bodies and the teeth involved, are noted without difficulty. Secondary changes due to infection, normal healing processes, or necrosis are seen only after the lapse of sufficient time to allow of demonstrable changes in the lime content of the bone.

"The reparative processes are essentially of two kinds, osteoclastic and osteoplastic. In point of time the former precedes the latter and in the absence of infection is not very marked. Under the influence of pyogenic organism, osteoclasia becomes excessive in degree and irregular in distribution, and the osteoplastic changes are similarly increased, frequently at a considerable distance, and especially along the periosteum. When a fragment is completely separated from its blood supply, osteoclasia fails from death of the osteoclastic cells; and such a sequestrum retains its normal density in a field of reduced density, giving the impression of an increased density by contrast. In course of time it suffers some loss of lime salts by attack from the periphery by the cells of the tissue exudate, but at a considerably slower rate than the vital tissues about it. These effects are more marked and more prompt in the presence of an infection.

"Some care is necessary to differentiate between a sequestrum and the increased density caused by the over-riding of an oblique fracture, a problem that usually is obviated by stereographic plates, since the exact relationships are obvious in all cases.

"Opaque foreign bodies are most easily localized by stereographic study, introducing some opaque marker to serve as a point of reference. Fine cross wires applied to the outside of the cheek with adhesive, serve very well for this purpose.

"Pathologic fracture of the lower jaw from a primary destructive process is uncommon. It is a legitimate subject for X-ray study. Not only may the fracture be demonstrated but the nature of the primary disease may be demonstrated with a high degree of certainty. Osteomyelitis, tuberculosis, malignant growths, dentigerous cysts and phosphorus necrosis all are well demonstrated and usually quite easily recognized.

"The adequate demonstration of fractures of the upper jaw is a matter of some difficulty. Whereas the lower jaw is one of the densest



of the bones of the body, the upper jaw, made up of thin bony plates, casts a comparatively feeble shadow, and in addition is so placed that it is difficult to escape the confusing shadows of the neighboring structure. It depends for its strength on its cellular structure. As a result its thin walls form a series of surfaces no two of which are in the same plane, and no position can be selected that will insure a projection in the plane of a possible fracture. Fortunately, the upper jaw is much less liable to injury and the diagnosis of fracture is fairly easily made on the clinical evidence.

“Three distinct principles may be followed in the study of this portion of the face: (a) by intraoral radiography; (b) by tangential projection, and (c), by direct transradiation.

“The intraoral method by the use of dental films usually is feasible in fractures of the upper jaw, but it is open to the objection that only a small field can be studied on each film and the correlation of many films is often a matter of some difficulty. In addition, the projection is necessarily rather oblique and the superposition of shadows may be disconcerting.

“The tangential projection aims to demonstrate the depression of a fragment below the level of its surroundings, and its greater distance from the surface of the face than one would expect. This is done easily. Unfortunately, it rarely tells the student anything more, anything of the size or number of the fragments or of the possible complications, for fracture of the upper jaw almost invariably is associated with injuries of and hemorrhage into the antrum of Highmore, and more or less extensive damage to the palate. Neither of these can be demonstrated satisfactorily by the preceding methods.

“In a direct transverse projection, two positions are available, the lateral and the postero-anterior, and study is much simplified by the use of the stereogram. All the arguments advanced in a preceding paragraph in favor of this method of study apply here with even greater force. In fact, the interpretation of the single plate (giving a flat image), is exceedingly difficult except in the hands of an expert, but the employment of the binocular image serves to reduce the confusion to a minimum. Even so the difficulty of recognizing a fracture in the absence of marked displacement is no mean one. For this reason it is the practice in this hospital to make stereograms in both positions at one sitting, rather than to run the risk of having to ask the patient to return for further study.

“The lateral stereogram especially is valuable to demonstrate the displacement of fragments in the region of the molars, the presence of foreign bodies and the involvement of other structures on the lateral



aspect of the face. The postero-anterior, on the other hand, tells us more of the extent of the damage to the incisor regions and the upper portions of the face, besides giving us a complete view of the accessory sinuses, the palate and the nose.

“Except for the hemorrhage into the antrum and the danger of its infection, complications are rare. Small fragments, although entirely separated from the rest of the bone, rarely necrose but retain their vitality by virtue of their connections to the rich blood supply of the submucosal layers of the antrum (periosteal). Callus formation never is seen, and the presumption is that, in common with all other bones of membranous origin, healing is by fibrous union.”

## Chapter VI

### The Process of Repair

In the preceding chapters we have discussed the etiology of fracture of the jaws, the different varieties, the signs and symptoms and the different methods of making a judicial diagnosis. We will now discuss the part that the tissue-cells play in reestablishing normal conditions.

What is the function of the periosteum in bone regeneration?

Just what takes place in the behavior of the tissues in the process of repair of bone is a question concerning which there is diversity of opinion. There seems to be, indeed, a conflicting state of opinion about the theory of bone growth. Havers, whose name has been identified with the vascular canals in bone (Haversian canals), in 1692 gave the first accurate account of osseous structure, and described the periosteum as simply a connective tissue, limiting and vascularizing membrane. Antoine de Heyde, in 1684, published the first experimental observations made on frogs and came to the conclusion that callus was formed by calcification of blood clot extravasated around the broken bone ends. It was, however, in the middle of the eighteenth century (1739-1743), that the first systematic work on this subject was carried out by Durhamel, who was the originator of the modern, generally-accepted theory of the function of the periosteum. In his view the periosteum became thickened and succulent around a fracture, and by pushing the new tissue in amongst the fragments it formed the callus. It was he who founded the term "cambrium layer" of the periosteum (a layer of cells between the bark and the wood), which now is quite extensively used.

There seems to be a wide variance in the opinions of various investigators as to the function of the periosteum in bone regeneration. MacEwen ("Growth of Bone," 1911), is emphatic in the statements that the function of the periosteum is simply a limiting membrane, and that it does not have the property of osteogenesis; and in reporting his experiments apparently has some ground for this contention. He submits several experiments made upon young dogs where a resection of a part of the whole thickness of the radius was removed, leaving the periosteum. No bone was formed by the periosteum in ten weeks. He finds failure of periosteal flaps to produce new bone. In support of his contention that the periosteum is simply a limiting membrane, he finds that when regeneration of bone has taken place from the epiphyseal cartilage pushing the cut fragments toward the gap and the proliferation of bone cells from the cut ends of the bone (the periosteum not being intact), a marked hypertrophy of the bone occurs.

Cohn and Mann, in *Surgery, Gynecology and Obstetrics*, 1915, reported experiments which seem to support the argument of MacEwen.



Their experiments included transplanting of bone denuded of periosteum into muscle, into the medullary canal and into newly-made bone defects, covered and not covered with periosteum; the transplanting of periosteum denuded of bone around the carotid artery and the observation of periosteum left *in situ*. It was found that the isolated bone-grafts did not act as foreign bodies, were not absorbed after sixty days, and even showed a tendency to outgrowth. It was found also that grafts placed in the medullary canal or in bone defects showed proliferation and healing power; and that the periosteum left *in situ* did not show bone proliferation nor was its presence at all essential to the healing of a fracture or of a defect.

Other investigators are of the opinion that the experiments of MacEwen, Cohn, Mann, and others who contend that the periosteum has not the property of osteogenesis, were carried out with the outer layer of the periosteum, while the inner layer which Hey Groves terms the "epiosteal" layer, or the osteogenetic layer of the periosteum, was not considered. Hey Groves summarized as follows: "The periosteum is chiefly a limiting membrane of the bone. The dense bone can live, grow, undergo repair, and produce fresh periosteum after the latter has been removed.

"In young bones it is possible to remove the periosteum in such a way as to produce an osteogenetic membrane, this being probably due to the lifting of the epiosteum with the periosteum. In adult bones this is impossible except after trauma or inflammation. Nevertheless, the retention of the periosteum though not necessary, is highly desirable in bone-repair, because its removal takes away much of the epiosteum and because it affords a ready means of vascularization."

#### FUNCTION OF COMPACT AND CANCELLOUS BONE IN THE PROCESS OF REPAIR

About compact and cancellous bone there never has been the same difference of opinion as about the periosteum. Ollier proved that quite apart from both the periosteum and the marrow, compact bone could live and produce new bone and undergo the callus repair of fracture. The deep surfaces of the bone, like the superficial, are capable of osteogenesis under suitable stimulus.

Quite apart from the epiosteal and endosteal layers of cells which may be regarded as originating from compact bone, Axhausen has shown that the wide Haversian canals contain active osteoblasts and favorable conditions for new bone formation. It has been observed in gunshot fractures in France that when the ends of the fragments have been exposed and bare, that by stimulating the ends by a drill, buttons of granulation tissue would be pushed out in a short time and soon would cover the entire ends of the bones. These ends could then be put in apposition and union of the fragments would result. Summarizing,



then, we can state that compact bone, if it has the proper blood supply, is quite independent of either endosteum or periosteum for both growth and repair.

We will consider now just what takes place in the repair of bone. The process of repair fundamentally is that which takes place in the union of the soft parts. There may be primary union or it may be secondary, i.e., by granulation-tissue, this being genuine osseous tissue. When a bone is fractured, considerable blood will be effused from the ruptured medullary and Haversian vessels as well as those of the periosteum. Also, more or less blood is poured out from all of the lacerated tissues which are immediately adjacent to the seat of fracture. In rare cases the periosteum may not be torn, but from the very nature of the injury it must necessarily be more or less stripped from the broken extremities. However, in the large majority of cases, it is torn and lacerated. Ollier called attention to the desirability of preservation of its continuity at some part of the periphery of the bone, and to the fact that when a lateral or longitudinal displacement has occurred the membrane is stripped partly off one fragment, but without having its continuity broken, and thus forms what he calls a "periosteal bridge," uniting the two fragments.

The portions of the periosteum where the continuity has not been preserved are so structurally attached to the adjacent tissues that when reduction of the fracture is accomplished they undoubtedly take their relative normal position to the bone, thus forming a tubular sheath which connects the ends of the fragments. At the same time that the blood is poured out into the gap between the fragments, it also is effused from the vessels of the soft parts into the interstices among the muscles, an ecchymosis results.

The injured tissues infiltrated with blood soon become invaded by leucocytes and effused blood plasma. Fibrinous coagulation takes place and the ends of the fragments are embedded in a dense, ill-defined mass of firm cellular exudate. The periosteum becomes much thicker, softer and more vascular; a thin layer of gelatinous or viscid liquid is found between it and the bone for a short distance from the edge of the fracture. In about fourteen days the effused blood is completely absorbed, leaving a firm, dense, cellular, vascularized, partly-organized mass of granulation tissue. The bone undergoes rarefying osteitis and the fracture becomes fixed. This mass of tissue has the consistency of jelly and is of pearly-white appearance. It is most abundant in and beneath the periosteum and extends between the ends of the fragments and envelops them. This is known as the "provisional callus."

At first the "provisional callus" is composed of embryonal elements which soon become cartilaginous in those portions formed by the periosteum. Lime salts then are deposited at different points within it, and about the fourth or fifth week ossification occurs, which forms a



spindle-shaped ferrule around the extremities of the fragments, providing there is little or no displacement, in which case the reparative tissue is more irregularly disposed. (*Fig. 21.*)

Simultaneous with the development and formation of the "provisional callus" similar changes are taking place in the cancellous bone. The blood-clot has become infiltrated with leucocytes. The blood is next absorbed, the connective tissue and endothelial cells proliferate, and granulation tissue, osseous in character, forms from both bone fragments. This is known as the "definitive internal callus," which soon fuses and develops into porous bone.

"Owing to the physical obstacle presented by the dense osseous tissue, the proliferation of the connective and vascular tissues occupying

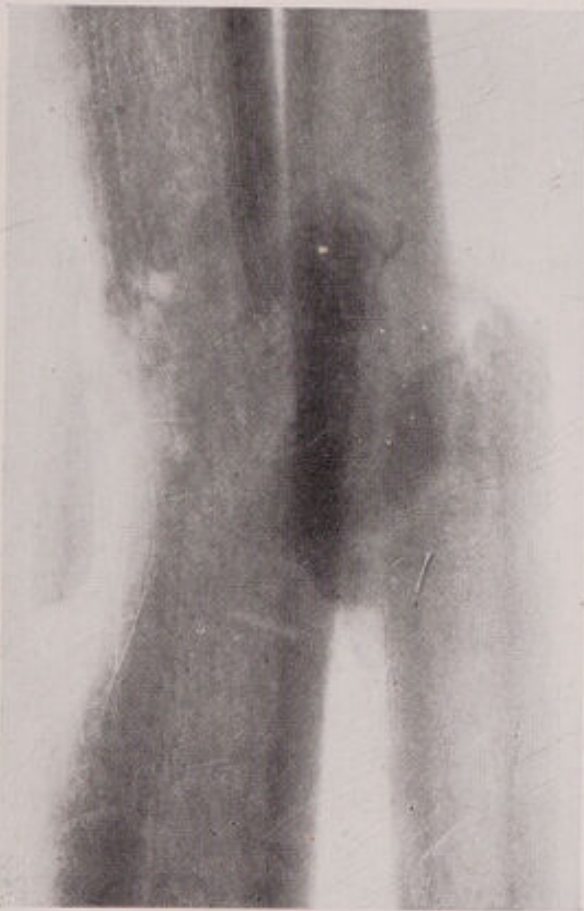

Fig. 21

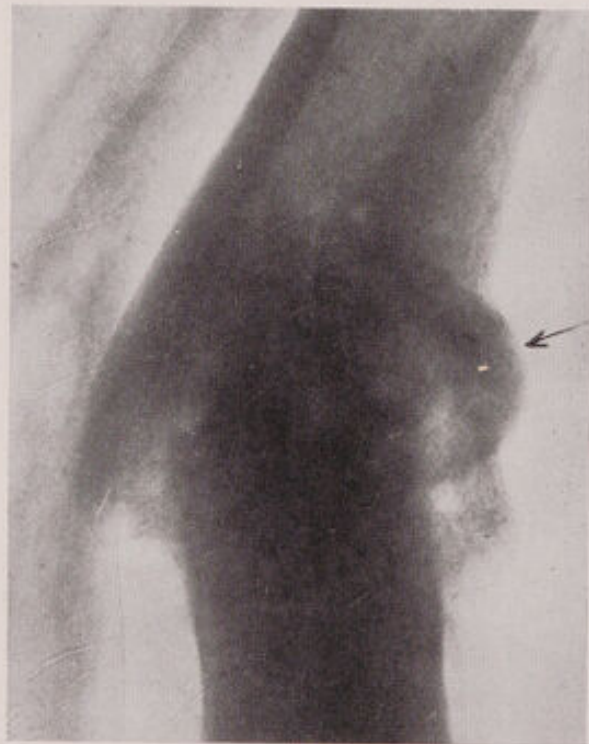


Fig. 22

the Haversian canals in the compact tissues contiguous to the fracture progresses but slowly, the lime salts gradually disappearing so that it is comparatively late before the granulation tissue thus produced ossifies, definitely uniting the fragments. When union finally has been completed, the excess of external (*Fig. 22*) and internal callus is absorbed and in time the site of fracture may be hard to detect if the reduction has been perfect." (DeNancreed.)

The removal of excess of callus results from the phagocytic action of certain cells called "osteoclasts." While the callus is forming and



rarefying, the process of repair is going on in the contiguous soft parts and they regain their normal condition and function. Occasionally injury to adjacent muscular or nerve tissue may cause more or less permanent disability of these structures.

Fragments of the cortical layer of bone broken off at the time of the injury may remain attached to the epiosteal layer of the periosteum, preserve their vitality, share in the same processes and form a part of the callus. (*Fig. 23.*)

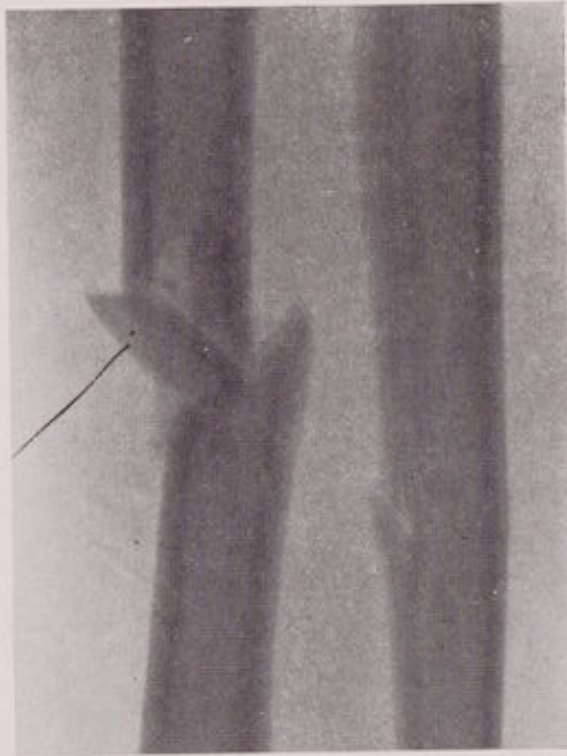


Fig. 23—Interposed Fragments

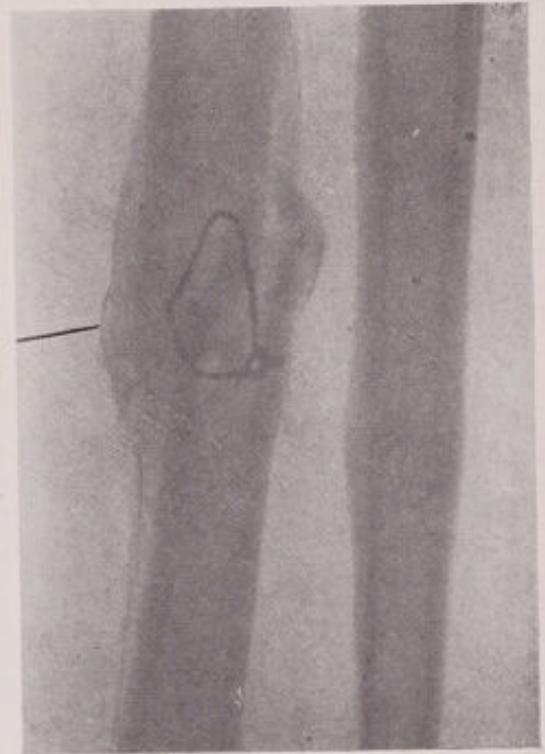

Fig. 23—Result

Occasionally there may be an excess of rarefying osteitis and a lack of production of osteoblasts, so that the callus may not ossify; in such cases the bone is absorbed for a considerable distance between the ends of the fragments. (*Fig. 24.*)

In cases of an open or compound fracture, when it becomes infected and suppuration ensues, the process of repair is slower, because the suppuration of the wound delays or prevents the formation of the provisional callus and it has to depend upon the formation of the "definitive callus," which is not so favorable for rapid repair. The callus thus formed is larger and more irregular than after simple fracture. It remains sensitive and tender for a long time and is covered by an adherent scar at the seat of the wound.

Fragments not attached to the periosteum may become engaged in the callus, and there act as a foreign body and will greatly interfere with the evolution of the callus. The detached fragments produce a constant irritation, with a resultant inflammatory and suppurative wound



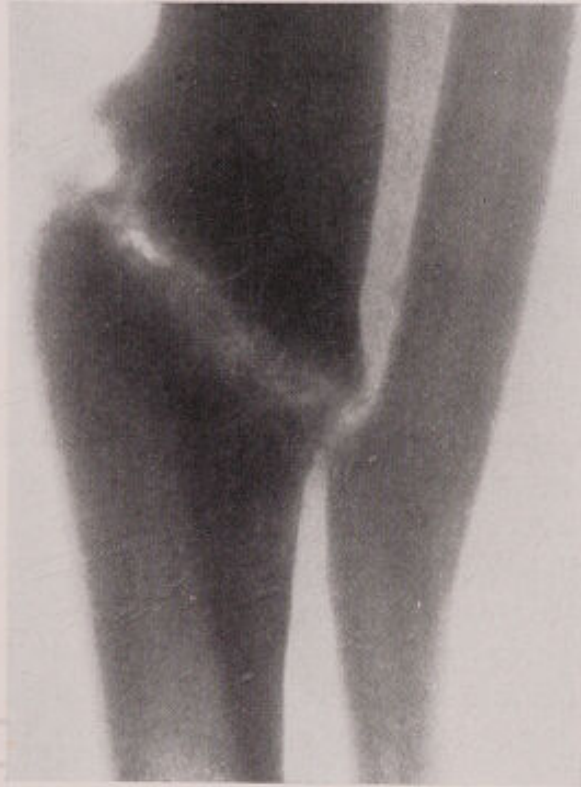

Fig. 24

in the exterior. The fragment becomes a sequestrum and exfoliation must take place before the process of repair is complete. (*Fig. 13.*) Fragments that are attached to the periosteum usually will maintain their vitality and will be an aid in the process of repair.

## Chapter VII

### Complications in the Process of Repair

The complications in the process of repair may be local or general. The *local complications* may be the result of the violence that produces the injury. In fracture of the jaws infection often is present. The extent of the infection will vary with the character and extent of the injury. The infection rarely is present in simple fracture of the jaws, but is common in compound fractures, and will result in suppurative necrosis of the sequestra and subsequent exfoliation. When there is extensive laceration of the wound the suppuration usually will remain as a local complication, the pus escaping freely to the mouth-cavity between the fractured parts. The violence produced may cause the loss of vitality of one or several teeth. This may be followed by the occurrence of a dento-alveolar abscess which, if in the vicinity of the site of the fracture, will markedly defer the process of repair. Or, if the abscess has formed some distance from the site of fracture, the pus which is developing at the ends of the roots may find its way along the line of fracture and become an obstacle to the process of repair.

In fracture of the maxillæ the antrum frequently is involved, and may become infected as well as the maxillæ itself. This presents another serious problem in the successful treatment of the case. Again, in extensive fractures of the maxillæ the brain-case may be involved by an associated fracture and coma or even death may result immediately.

The rupture of blood vessels is a serious, although infrequent, complication. In the maxillæ the rupture of the internal maxillary artery may not be amenable to early successful treatment and would be followed by fatal results. In fracture of the mandible, rupture of the vessels usually will cause little untoward sequella other than ecchymosis.

Secondary hemorrhage is one of the complicating problems in fractures of the jaws. This is quite a common factor in gunshot fractures. It comes on after suppuration has been established and is the result of infective inflammation causing disintegration of the hemostatic thrombus, ulceration or sloughing of the walls of the vessels. This may occur any time between the beginning of the process of repair and the complete sealing of the fractured vessel.

The laceration or severing of the sensitive nerve trunks will lead to anesthesia of all of the parts peripheral to the fracture. Later on extreme neuralgia may occur on account of the nerve fibers becoming engaged in the cicatrix. The latter condition sometimes can be relieved only by neurectomy.

Another local complication may occur by the short ends of the fragments becoming engaged in the overlying muscles and fasciæ so that its reduction will be difficult. Particularly is this true in compound



fracture of the mandible. This is more frequently the condition that presents in those cases when reduction of the fracture has been delayed.

In these cases, after reduction of the fracture has been accomplished, the continued impingement upon the soft tissues will delay the process of repair.

Trismus is an early local complication that nearly always is present. This is brought on by the violence that is produced upon the soft tissues and the temporomandibular articulation. In extreme cases a general anesthetic may have to be resorted to in order to obtain sufficient relaxation to make a diagnosis and subsequent reduction.

#### GENERAL COMPLICATIONS OF FRACTURE OF THE JAWS

The first of the general complications that will be considered is fat embolism. It is a clinical fact that free fat may be found in the urine during the first few days following a fracture. It is not clear just what takes place under these conditions. Some writers are of the opinion that the free fat is dislodged from the marrow spaces in the bones at the time of fracture, is carried into the circulation, and collects especially in the capillaries of the lungs. It also may pass through the lungs into the capillaries of the greater circulation, and then is found in the intertubular and glomerular capillaries of the kidneys.

If sufficient quantities collect in the lung capillaries there will be a marked disturbance in the circulation, which may lead to the production of pulmonary œdema followed by pneumonia. This condition has been observed more frequently in alcoholics and in the aged.

The symptoms of fat embolism are rapid respiration, little or no temperature, face having a tendency to cyanosis, followed by unconsciousness with fatal termination. Pneumonia is a rather frequent complication. Interdental ligation in fractures of the jaws favors its occurrence by limiting the patient's ability to properly take care of the excessive supply of the secretions of the mouth at this time. Some of these bacteria-laden secretions may be inspired and pneumonia set up, or it may occur as the direct result of fat embolism.

Of the late complications in fracture of the jaw, delayed union or failure of union is not uncommon. Delayed union is observed most frequently in fracture of the inferior maxillæ, and rarely in fracture of the upper jaw. Failure of union is rare. (*Fig. 25.*) In a record of 1313 cases of fractures in various parts of the body, only one failure of union was observed.

\*“The anatomical conditions differ greatly in detail in delayed union, and may be classified under two groups: one containing most of the cases in which the fragments are united end to end or laterally, and more or less closely, by fibrous tissues, and another, very rare, in which a distinct joint is formed between them (pseudo arthrosis). The varieties

\*Stimson.



of the first form are numerous, the variations depending upon the relative position of the fragments, the extent of the preliminary rarefaction, the amount of fibrous tissue and the presence or absence of a productive osteitis or partial ossification of the bone. The process of repair in any of the different forms imposed upon it by the character of the fracture and the amount of displacement, may be arrested at any period. The fragments may be in close apposition and united by a short, firm bond of fibrous tissue, with only slight motion between them, or they may overlap in such a way that the surfaces of the fragments are not apposed, and the union is only by the thickened interposed connective tissue.

In the second form, the creation of a joint between the fragments shows in more or less complete distorted forms; the joints have a fibrous

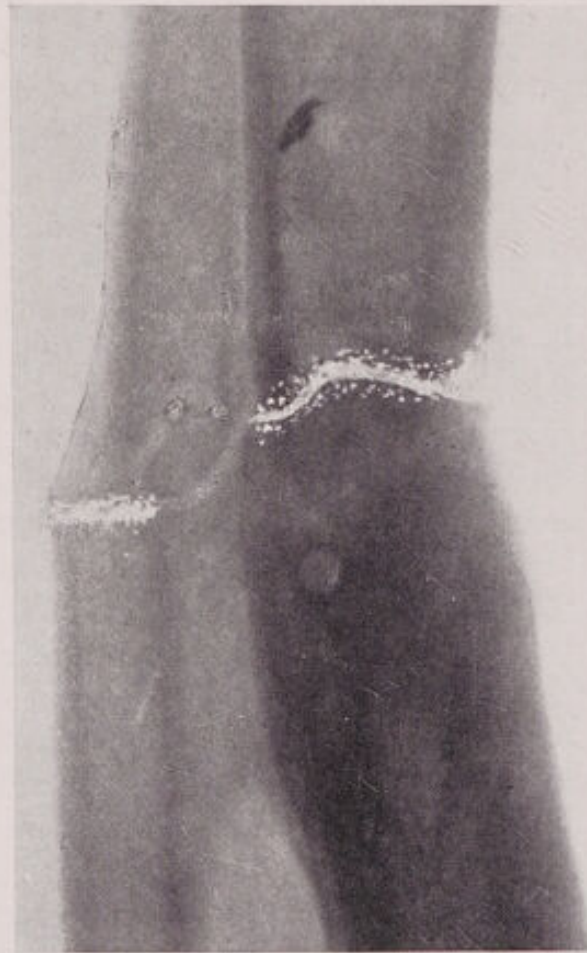

Fig. 25

capsule embedding cartilaginous or bony nodules, a cavity which contains a synovia-like liquid, and the ends of the fragments are rounded, eburnated, usually enlarged, sometimes smooth and polished, and covered with a fibrous lining.

In the March (1914) *Journal of the American Medical Association*, the author described pseudo-arthritis in connection with the operation on the mandible for ankylosis of the jaws.



What are the causes of faulty union in fractures? There seems to be certain predisposing factors which, when present, will induce these complications, such as syphilis, alcoholism, tuberculosis; and such chronic diseases as cause a marked lowering of the vitality of the patient. Another condition which interferes with the normal process of repair of fracture of the jaws is faulty relation of the fragments to each other, with soft tissue interposed between them. Infection of the mouth is still another factor that must be considered in the process of repair of fracture of the jaws. It is very essential that after the fracture is reduced the mouth be kept free from infection if normal repair is not to be delayed. A loose fragment detached from the periosteum may become interposed between the fragments where it will become necrosed, and greatly delay the union. These sequestra usually will exfoliate in time, when repair usually will take place.

The treatment of delayed union consists in opening the tissues at the site of fracture, and with a small bone drill, boring several small holes over the surfaces of the fragments, thus stimulating granulation. It seems that after the lapse of time, usually sufficient to produce normal repair, the property of osteogenesis becomes greatly diminished and a stimulation of the parts is necessary to re-establish the process of repair.

#### STIFFNESS OF THE TEMPOROMANDIBULAR JOINT

Stiffness of the temporomandibular joint is seen soon after the fracture. When the joint itself is not involved in the injury, the stiffness is caused by injury to the muscles and soft parts which sets up œdema and a condition of trismus follows. In case the injury extends into the joint, the stiffness usually is brought about by the proliferation of fibrous tissue into or around the region of injury.

True ankylosis may result from fractures of the inferior maxillæ when the injury extends into the joint. (*Fig. 26.*) †In these cases if the articular cartilages be preserved in whole or in part, they sometimes undergo direct metaplasia into fibrous tissue or fibro-cartilage, or into mucinous tissue which gradually become fibrous. In many of these cases the amount of fibrous tissue is not great and the ankylosis is produced mainly by cartilage and bone. Immediately following a fracture, when the joint is involved, there is more or less abundant hemorrhage into the joint. Later inflammation sets in. The capsule and surrounding parts become swollen and edematous, infiltrated with inflammatory products. There is an effusion into the synovial cavity. Portions of the coagulum may persist and become organized, forming osseous tissue in the joint. Thus the cartilages gradually are transformed into a vascular fibrous or fibro-osseous tissue. The joint cavity is traversed into a number of small spaces bounded by dense fibrous tissue and containing synovial fluid. In the advance stages the whole of the articular cartilages may

†Lyons, *Journal A. M. A.*, 1914.



disappear and be replaced by fibrous tissue. Secondary changes take place in the newly-formed fibrous tissue, which in time is converted into a mass of spongy bone and complete osseous ankylosis results.

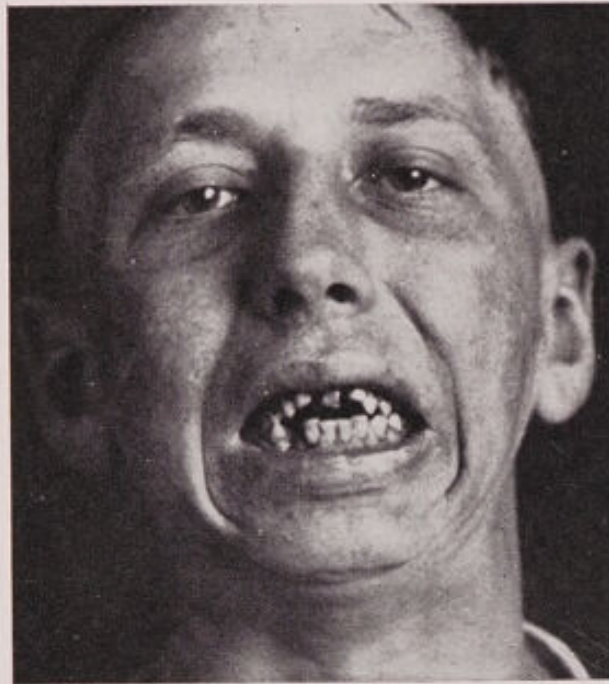


Fig. 26—Result of fracture of the condyloid process in early childhood.

In the treatment of fracture of the jaws by interdental ligation, there usually will be considerable stiffness of the joint following repair, on account of the inactivity of the parts during the time the reparation processes were taking place. This is more marked at the time of removing the ligatures. The stiffness will disappear gradually under use of the jaws, unless the joint itself has been injured and the changes referred to above have taken place. If the muscular tissues have been violently injured, there may be cicatricial adhesions or a shortening of the muscular tissues which may permanently prevent the normal opening of the jaws, after repair has taken place.



## Chapter VIII

### Prognosis

The prognosis in fracture of the jaws must vary greatly according to the location of the fracture, the character of it, and the complications which are present or which follow. The age and the resistance of the patient always will be predominating factors which will influence a favorable or unfavorable prognosis. The time which elapses between the injury and the reduction of the fracture also will influence the prognosis. The prognosis should have reference to several points, viz., the effect of the injury in respect to the favorable or unfavorable termination of the case, its simple or complicated course, the influence of each complication, the time required for recovery, and lastly, the result as to normal occlusion of the teeth and normal function of the jaws.

Age has a considerable influence in affecting the prognosis. The younger the patient the better the prognosis, because in the young, fractures unite more easily and promptly than in the adult. As an example, thirty days are required for repair of simple fracture of the mandible in an adult; in a child fifteen or twenty days will suffice.

The lowering of the vitality through chronic alcoholism or disease likewise will have its influence in delaying repair of fracture. Such chronic diseases as syphilis and tuberculosis lead to a state of constitutional dyscrasia which always delays union and may prevent it entirely.

In a patient afflicted with any acute disease, the process of repair may be expected to be considerably retarded. If the fracture has existed two or three weeks previous to the reduction, and there is considerable movement of the fragments, consolidation will not take place as rapidly after the parts have been brought into normal relation as it will if reduction is made at the time of the injury.

The presence or absence of infection in fractures of the jaws plays an important role in the duration of the treatment. The development of dento-alveolar abscesses, as a result of devitalization of teeth through the injury, may prolong the process of repair by pus burrowing along the path of least resistance and discharging in the interstice between the fragments.

#### INDIVIDUAL TYPES OF FRACTURE

In the preceding chapters we have considered some of the points in general in prognosis, especially those relating to the causes of delayed union and non-union, and now we will consider the prognosis of individual types of fracture.

In a simple fracture of the mandible where the fragments remain or are replaced in perfect contact, repair will take place in from twenty



to thirty days without untoward symptoms, without deformity or malocclusion, and without any detriment to the function of the jaws.

If in a simple fracture the fragments remain nearly in apposition, although not perfectly so, the prognosis will be almost as favorable, although it will take a somewhat longer time for repair to take place, and there may be slight deformity manifest, principally in malocclusion of the teeth.

All compound, comminuted and complicated fractures, which in their very nature present additional obstacles in the way of complete reduction, may not present as favorable prognosis. It may be stated that while the efficiency of proper retaining splints should not be sacrificed for simplicity, yet the more simple the splints are in construction the more favorable will be the prognosis.

In fractures of the superior maxillæ, the fragments will not be subjected to muscle-strain as in those of the lower jaw, and the retention of them in normal position will not be so complicated.

Fracture of the condyle with displacement offers less in the way of favorable prognosis than any other fracture of the lower jaw. This is due to the fact that the injury responsible for the fracture usually will produce a traumatism in the temporomandibular joint which may result later in ankylosis. Ankylosis may be temporary or permanent.

Gunshot fractures of the jaws which are necessarily in most cases compound and comminuted, are in a much less degree amenable to treatment than most other fractures. The splints for supporting the fragments must necessarily be more complicated, and infection always is present. A certain proportion of gunshot fractures demand, for the purpose of obtaining the best results, a definite course of treatment, having in view the control of the infection as the primary consideration, and the relief of the deformity by means of splints as the secondary consideration. In most cases, however, both are to be regarded as necessary indications of treatment.

Pain and tenderness and partial loss of function of the jaws is a common sequelæ in fractures of the jaws. This may last for several weeks and possibly a few months. It is not to be regarded as a serious complication, for in time the jaws will resume their normal condition and function, if successful reduction of the fracture has been accomplished.

In summarizing, then, we may say that to form a judicious prognosis in fracture of the jaws, the operator must take into consideration the age of the patient, the state of strength or debility, of health or sickness, the presence or absence of infection, the location of the fracture, its nature, its recent or ancient date, its complications, and the plan of treatment pursued.



## Chapter IX

### Treatment of Fractures

The treatment of fractures of the jaws consists, generally speaking, in the fulfillment of three principal indications:

*First*, to reduce the broken fragments.

*Second*, to retain them in normal position until consolidation has taken place.

*Third*, to prevent or control inflammatory processes.

To reduce a fracture of the jaws the fragments should be grasped between the thumb and fingers of either hand and by gentle manipulation be carried into normal position. In cases where teeth are present, the normal position is ascertained by observing the natural occlusion of the teeth. When the fracture occurs in an edentulous jaw, the operator must be guided by the general contour of the parts and by palpation upon the surfaces

If the reduction is not made until some time after the injury, it may require considerable time and patience to bring the fragments into normal relation. In these cases the reduction is complicated by the cicatrix of the soft tissues. When the reduction is made soon after the injury, the parts should be carried gently into normal position so as not to injure the soft parts, such as nerves and vessels. Again, the handling of the parts roughly may carry infection into the deeper structures.

After successful reduction of the fracture is made, the next question which confronts the operator is that of the retention of the fragments in their normal position. This is a question which should not be passed upon without a thorough consideration of all of the factors involved, such as muscle-strain, amount and character of displacement, direction of line of fracture, and the time which has elapsed between the injury and the time of operation.

A thorough knowledge of the function of a bone and of the muscles which affect it is indispensable when judging of its injuries. There are no fractures in the human body where muscle-strain plays a more important part in displacement of the fragments than in fractures of the inferior maxillæ. We will now consider the influence of muscle-strain in displacement of the fragments in a fracture of the mandible.

#### MUSCLE-STRAIN

The movements of the inferior maxillæ are controlled by the following muscles: *temporalis*, *masseter*, *pterygoideus externus*, and *pterygoideus internus*, which are situated in the posterior portion of the inferior maxillæ and are the elevators of the jaw. Then there are the *digastricus*, *mylohyoideus*, *geniohyoideus*, which are situated in the



anterior portion of the inferior maxillæ and are the depressors of the lower jaw. In order to understand the influence of the action of these muscles in displacement of the fragments and its consequent importance in the selection of the treatment to be pursued in fractures of the mandible, it will be necessary to review briefly the origin, insertion and function of these muscles.

The *temporalis* is a broad, strong muscle, rather flat, which covers the planum temporale and the temporal fossa, and is inserted into the inner surface, apex and anterior border of the coronoid process of the inferior maxillæ. Its action is to aid in closing the mouth by pulling the points of its insertion upward and backward. While a fracture of the coronoid process is rare, yet in such a fracture the fragments would be pulled apart by the action of this muscle. (*Fig. 27.*)

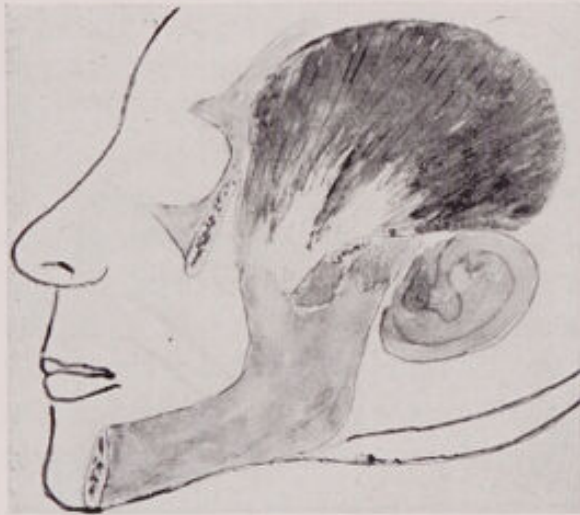

Fig. 27

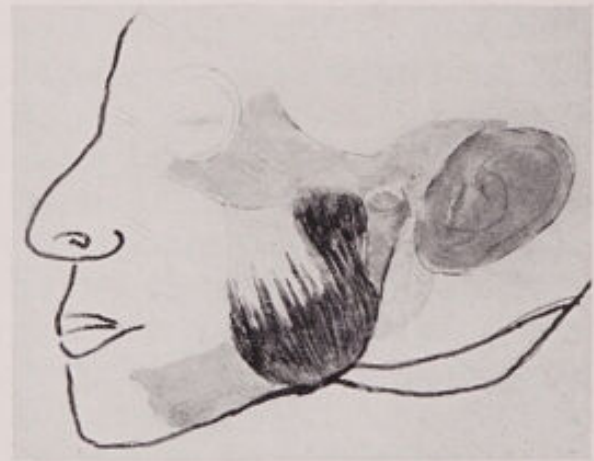


Fig. 28

The *masseter* is a thick, strong muscle, which has its origin from the inner and lower border of the anterior and middle third of the zygoma. It is inserted into the angle of the jaw and adjacent portions of the body and of the ramus. This muscle being very large and strong is able to close the lower jaw with great force. (*Fig. 28.*)

The *pterygoideus internus* acts in conjunction with the masseter in elevating the lower jaw against the upper. It has its origin in the pterygoid fossa of the sphenoid bone, and is inserted on the inner surface of the angle of the jaw just opposite the insertion of the masseter. This muscle, in conjunction with the *temporalis*, pulls the posterior fragment upward and inward in fracture of the inferior maxillæ in the region of the molar teeth. (*Fig. 29.*)

The *pterygoideus externus* (*Fig. 29*) is a fairly strong muscle situated in the infra-temporal fossa between the *temporalis* and the *pterygoideus internus*. Its origin is by two or more separate heads: the larger from the outer plate of the pterygoid process of the palate bone and from the tuberosity of the superior maxillæ; the smaller one from



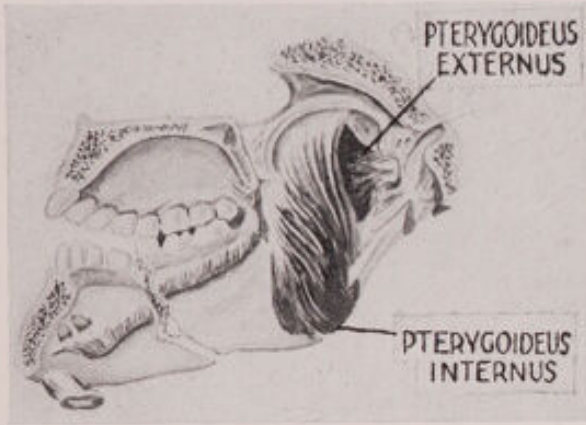


Fig. 29

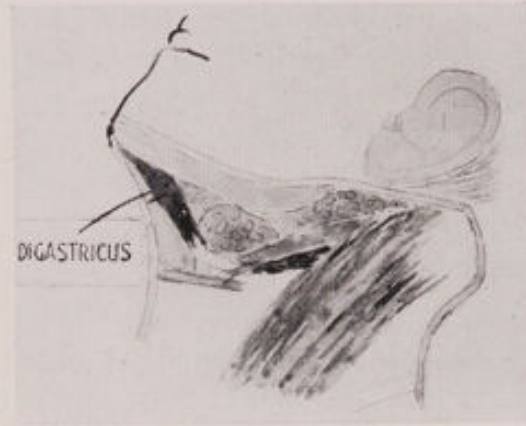


Fig. 30

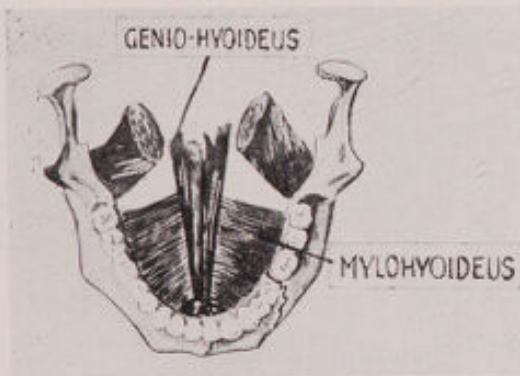


Fig. 31

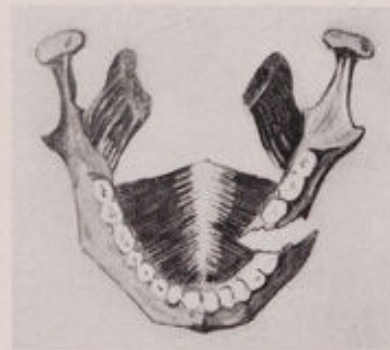


Fig. 32

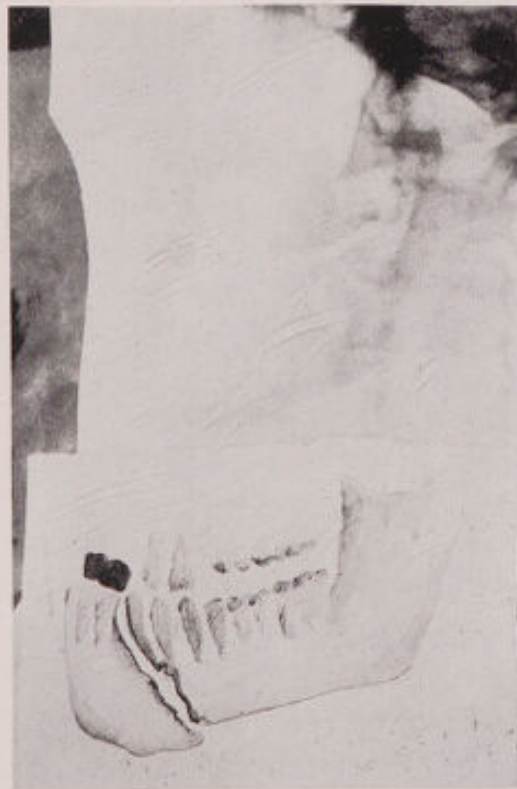


Fig 33

the infra-orbital crest of the greater wing of the sphenoid bone. These two heads become united, and the muscle becomes smaller and is inserted by a short tendon into the pterygoid fossa of the head of the mandible.\* "This muscle draws the condyle of the mandible and the articular disk forward upon the articular eminence; when the muscle of one side acts alone it draws forward the mandibular condyle to which it is attached, the other one pivoting in the mandibular fossa and the result being an apparently lateral movement of the mandible." It is this muscle that controls the upper end of the ramus of the jaw while the *masseter* and *pterygoideus internus* control the lower portion.

In dislocation of the jaws it is this muscle in conjunction with the *temporalis* which holds the jaw in front of the articular eminence and prevents it slipping back into normal position.

In fracture of the jaw it is the *pterygoideus externus* of the opposite side which pulls the mandible forward, giving it a twisted appearance, thus separating and holding the fragments apart.

We now have considered the influence of the muscles of the posterior portion of the inferior maxillæ or the elevators of the lower jaw. Next we will study the depressors of the jaw, or those muscles in the anterior portion.

The *digastricus* is a two-bellied muscle. The function of the posterior belly is to aid the *stylohyoid* and *infra-hyoid* muscles in fixing the hyoid bone and secondarily influences the movements of the mandible in opening the jaws. The anterior belly of the *digastricus* is a thick, heavy muscle which passes from the intermediate tendon which is attached to the hyoid bone to the digastric fossa of the mandible. Its action is to depress the lower jaw. (*Fig. 30.*)

The *mylohyoideus* is a broad and flat muscle which is situated in the sub-mental and sub-maxillary regions, and is partly covered by the anterior belly of the *digastricus*. The two muscles of opposite sides unite in the median line and form a muscular layer which extends across the mandibular arch and constitutes the floor of the mouth. Each muscle has its origin in the mylo-hyoid line of the mandible, and runs obliquely to the median raphæ, and some of the fibres are inserted into the upper border of the hyoid bone. Its action is to aid in deglutition and assist the *digastricus* in depressing the lower jaw. (*Fig. 31.*)

The *geniohyoideus* is a strong, flattened muscle, which has its origin from the mental spine of the mandible, and is inserted in the anterior border and upper surface of the hyoid bone. (*Fig. 31.*) Its action is to depress the lower jaw when the hyoid bone is fixed. In cases of fracture of the anterior portion of the mandible with loss of substance, the action of the *mylohyoideus* muscles tend to draw the two sides of the mandible together. In case of multiple fracture of the mandible from

\*Sabotta-McMurrich.



above downward and backward, the depressors will draw the fragments to which they are attached downward and forward, and the elevators will draw the remaining fragments upward and backward, causing a marked displacement. (*Figs. 32 and 33.*)

In a simple unilateral fracture the same condition will be present, only the displacement will not be so marked on account of the support of the structures of the opposite side of the jaw to the long fragment.

When the line of fracture is oblique and from above downward and forward (*Fig. 31*), the displacement will not be so great, for the action of elevators and depressors opposing each other will have a tendency to pull the fragments together rather than apart. In fact, in a unilateral fracture of this kind, the line of fracture may be hard to detect on account of little or no displacement.

In fractures of the inferior maxillæ the displacement may be not only from above downward, but also the line of fracture may run from the buccal to lingual and backward, or buccal to lingual and forward. When the line of fracture is from buccal to lingual and forward, there will be considerable displacement of the parts. The action of the *mylohyoideus* will depress the end of the short fragment, while the *pterygoideus internus* will tend to rotate the short fragment outward, and the *pterygoideus externus* of the opposite side will move the long fragment forward. (*Fig. 32.*) When the line of fracture is from without inward and backward, the displacement will not be so great as when the actions of the muscles oppose each other, and the only displacement will be in the long fragment being moved forward by the action of the *pterygoideus externus*.

In oblique fractures at the symphysis, if the superior genial tubercle is left on one fragment and the inferior genial tubercle on the other fragment, there will be little or no displacement, as the action of the anterior belly of the *digastricus* and the *geniohyoideus* muscles would equalize the force of muscle-strain in such a manner as to maintain normal conditions. If, however, the line of fracture is such as to leave both the genial tubercles on one fragment, there will be marked displacement, since the action of the depressors will pull the fragment to which they are attached downward, while the other fragment will be forced upward by the action of the elevators at the angle of the jaw.

In summarizing, it may be said that normally the three extremities of the jaw, viz., the condyle, the angle and the chin, all have diverging or converging muscular support; this arrangement of the muscles in connection with the ligaments holds the jaw firm in all of its complicated movements. When the jaw is fractured, normal control is vitally interfered with, and the traction of the muscles attached to the fragments will force and retain them out of normal position, which always is manifest in displacement of the fragments and abnormal occlusion of the teeth.



A thorough knowledge of the physiological action of the muscles which control and influence the lower jaw is necessary in order to make a successful diagnosis and to determine the character of the treatment which should be pursued.

The conditions surrounding fractures in the superior maxillæ are very different from those of the mandible. The superior maxillæ is an immovable bone. There are no muscles attached to the upper jaw which will influence displacement of the fragments to any marked extent. However, in cases of compound fracture the force of gravity may play an important role in the displacement of the fragments, and it must be taken into consideration in the selection of the treatment for the case. This force may be quite pronounced in case of complex horizontal fracture of the superior maxillæ, and it may be with some difficulty that the parts are retained in normal apposition on account of it. There usually will be little or no displacement of the fragments in fractures of the upper jaw from other influences.

In the selection of the treatment of fracture of the jaws, all of the forces which favor displacement of the fragments must be taken into consideration. The splints and ligatures should then be so constructed as to overcome these forces so that the fragments may be maintained at rest until consolidation takes place.

Having considered the influence of the strain of the muscles of mastication upon the retention of the fragments, we will now discuss some of the means of overcoming this force.

#### RETENTION OF THE FRAGMENTS

We will take up first the use and abuse of bandages as a means of retention of the fragments in fractures of the jaws.

Hippocrates, more than a score of centuries ago, recognized the absolute inefficiency of bandages alone in the retention of the fragments in fracture of the jaws; yet with all of the teaching that has succeeded that of the famous Greek physician, this method is still practiced by some men with its consequent deplorable results.

A bandage *per se* should be considered only as a means of first aid, and should be used only until proper splints can be constructed, or used in conjunction with a splint as a means of further support.

The most simple bandage and the one that can be applied with the greatest ease, is the so-called four-tailed bandage. (*Fig. 34.*) This is made from a strip of bandaging material (heavy muslin or linen) three inches wide and long enough to encircle the head. It is then split from each end, leaving about four inches in the middle of the bandage intact. The central portion is then placed over the chin, the upper tails tied behind the occiput and the lower tails tied over the top of the head. These can be supported further by tying the upper tails to the lower at the back of the head. This makes a firm temporary bandage and can be quickly applied.



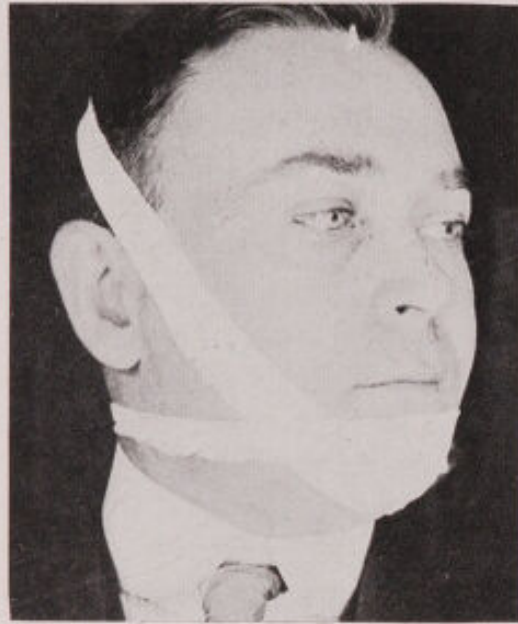

Fig 34

A modified Barton or figure-of-eight bandage (*Fig. 35*), is more satisfactory than the four-tailed bandage if it is to be left on for some time. This is adjusted by winding a two-inch roll of bandaging material very tight and firm around the chin and over the top of the head several times. The bandage is now turned on itself and wound behind the occiput and around the forehead for several turns, and then brought below the ears and around the chin for several more turns and pinned. Such a bandage sets the lower jaw firmly against the upper teeth and also prevents the external pterygoid muscles from forcing the fragments



Fig. 35

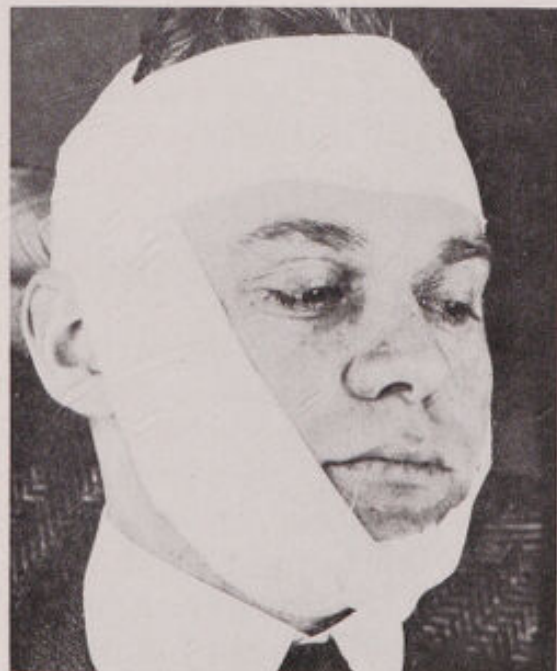

Fig. 36



forward. A crossed or oblique bandage (*Fig. 36*) is also a satisfactory bandage when there is little displacement of the fragments and it is advisable to retain normal occlusion until adequate splints can be constructed. The bandaging material is wound around the anterior-posterior of the mandible and the top of the head; it is then turned on itself and wound around the forehead and behind the occiput.

The strength and efficiency of bandages can be greatly enhanced by supplementing a bandage in which has been incorporated plaster of Paris. This should be applied over the first bandage and allowed to set, thus forming a plaster of Paris cast. After the bandage has set, and before dismissing the patient, the bandage should be sawed in two in the temporal region so as to provide for ready release of the jaws in case of emesis. The parts of the plaster of Paris bandage that have been cut may be readily united with zinc oxid adhesive tape. This double bandage, in the opinion of the writer, is the only one that should be considered effective in retaining the teeth in natural occlusion. Such a bandage cannot be used successfully when there is considerable swelling and contusion of the soft tissues.

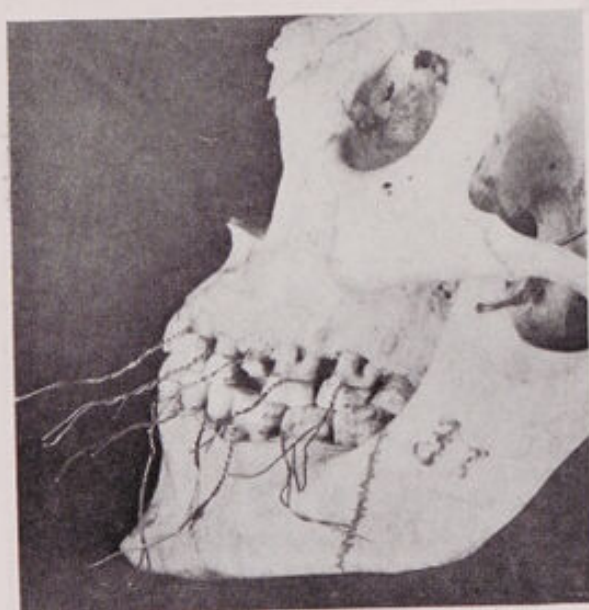


Fig. 37

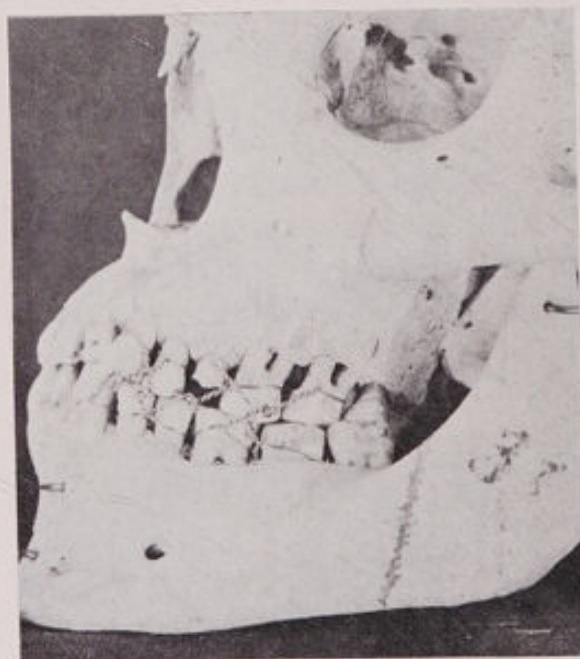

Fig. 38

#### INTERDENTAL LIGATION

The methods of interdental ligation for the fixation of fragments in fractures of the jaws is one of the oldest methods in use. Hippocrates used this method twenty-five hundred years ago. This method consists of fixing the lower jaw to the upper by means of wire or silk ligatures. The author has found that copper bronze wire, gauge 24, is most suitable for this purpose. One of the simplest methods of interdental ligation is by passing the wire ligature around several individual teeth in the upper jaw and around the same number in the lower jaw.



These ligatures are twisted on themselves (*Fig. 37*), and afterwards the twisted wires from the upper teeth are criss-crossed to those on the lower teeth and twisted together. (*Fig. 38.*) As an illustration, the wires from the upper first molar are passed forward and down to the lower first bicuspid; the wires from the upper second molar to the lower second bicuspid; the wires from the lower first molar to the upper first bicuspid; the wires from the lower second molar to the upper second bicuspid, etc. This wiring should be done on both sides of the jaws. The greater the number of wires the stronger will be the fixation. The criss-crossing of the wires prevents any anterior-posterior movement of the fragments. A sufficient number of wires must be placed on each side so that if one wire breaks during the process of repair, there will be others left to retain the parts, as new wires cannot be placed after the jaws are wired in occlusion.

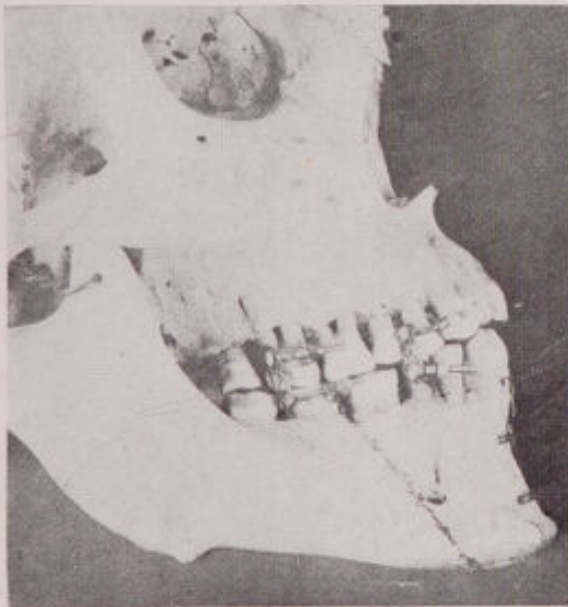


Fig. 39

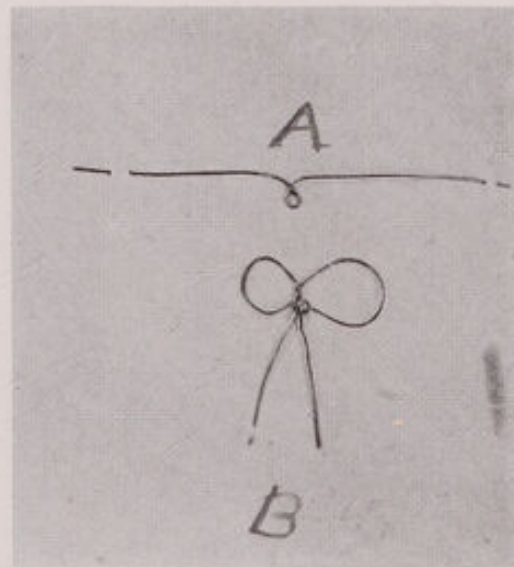


Fig. 40

Another method of interdental ligation is by the use of the Angle fracture bands. These bands are made similar to the Angle orthodontic bands, with the addition of a lug on the buccal surface of the band for the purpose of attaching interdental wires. Several of these bands can be placed on the opposing teeth of the upper and lower jaws and the ligation made from these lugs. (*Fig. 39.*) The ligatures can be criss-crossed, since this operation will make the fixation firmer. Copper-bronze orthodontic wire is used in conjunction with these bands.

Colonel Robert T. Oliver, of the United States Army, has suggested a very clever method for interdental ligation. This method was published and illustrated in a paper on "Fractures of the Jaws," by Dr. Don S. Graham, *Items of Interest*, March, 1912; and to Dr. Graham full credit is extended for the excerpt therefrom inserted here. The

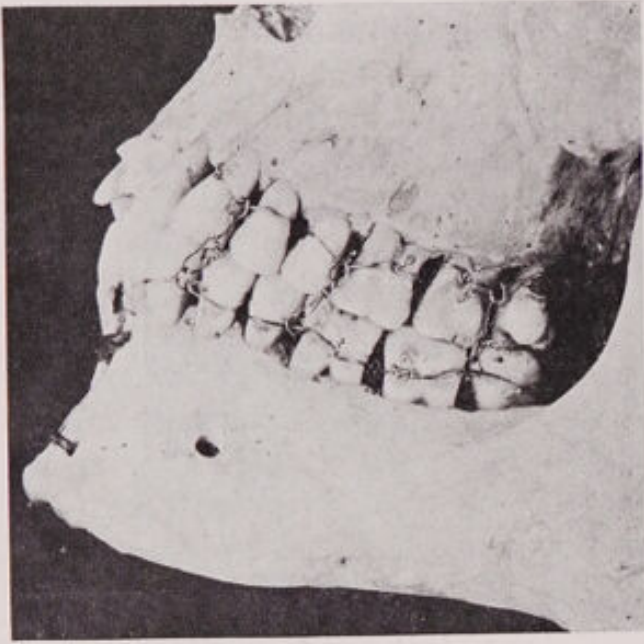


Fig. 41

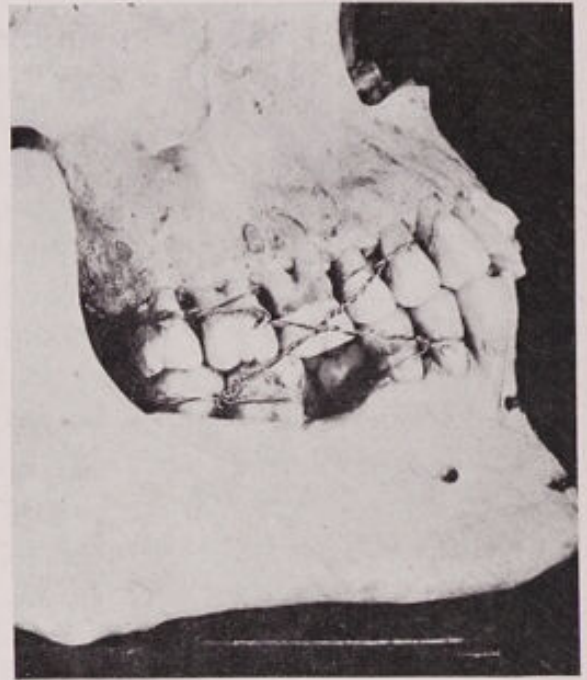

Fig. 42

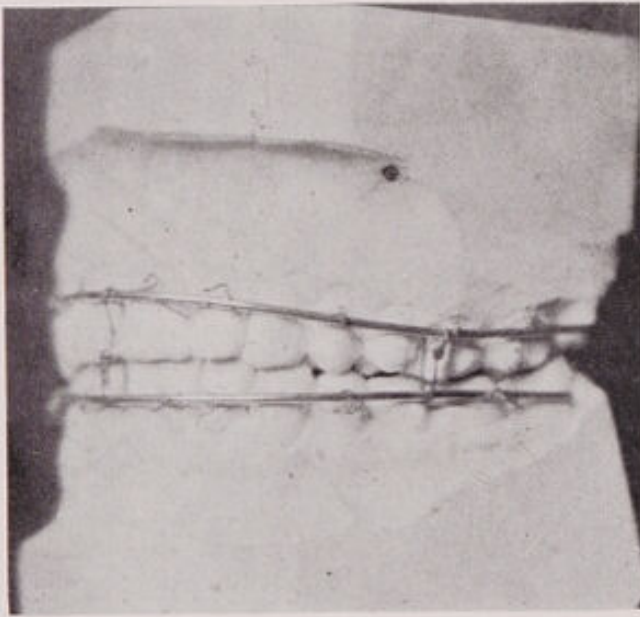


Fig. 43

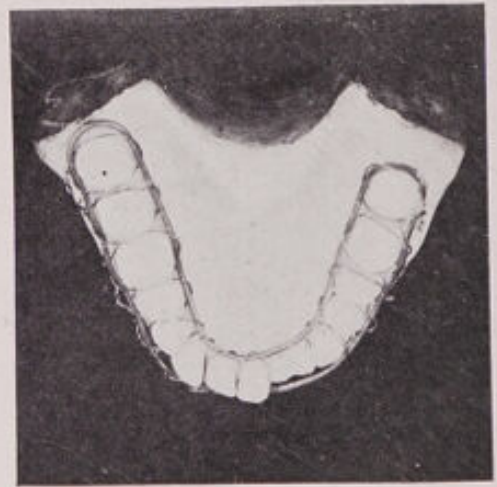


Fig. 44

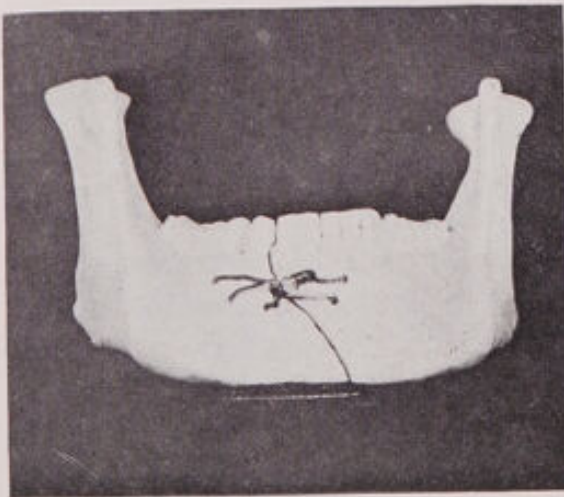


Fig. 45

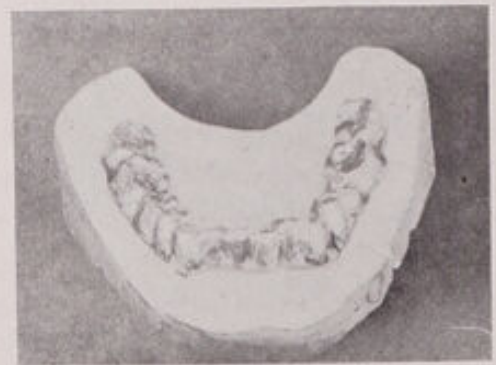


Fig. 46



method consists in forming a loop (*Fig. 40A*), with each individual ligature, and passing the ligature around the teeth in groups of two, both above and below, leaving the loop on the buccal surface in the inter-proximal space. (*Fig. 41.*) Secondary wires are then passed from the loop above to the loop below and the fixation made in this manner. This procedure has the advantage of enabling the operator to cut the secondary wires if emergency should arise demanding that the jaw be opened before the process of repair is complete, and again to replace the jaws in the fixed position and to rewire them.

A modification of this method has been called to the writer's attention by Major Joseph D. Eby and Dr. S. L. Silverman, of Atlanta, in which the ends of the wires are passed through the loop before being twisted together. (*Fig. 40B.*) This forms a perfect slip-knot on the teeth and makes a firm fixation. (*Fig. 42.*)

Dr. T. L. Gilmer, of Chicago, has devised another method of interdental ligation which has proven very satisfactory. (*Fig. 43.*) This method consists of ligating a wire arch, gauge 16, to the upper and lower teeth. Secondary wires are then attached to these arches for the fixing of the lower to the upper jaw. Four or five secondary wires, gauge 24, are attached between the jaws to the wire arches. This method has also the advantage of enabling the operator to get into the mouth in case of emergency and again replacing the secondary wires without any disturbance to the case.

*Fig. 44* is a satisfactory method of wiring the jaws where there is a single fracture of the mandible. This consists of a wire arch, gauge 16, on both the labial and lingual surfaces of the teeth. This arch is then wired to each individual tooth around the jaw. If, for any reason, interdental ligation is indicated, secondary wires may be attached from the arch to the upper teeth.

*Fig. 45* shows a method of wiring the jaws together for fracture at the symphysis. Pure silver wire, gauge 18 or 20, is placed through the mandible on either side of the line of fracture. The silver wire is placed in position by first drilling holes through the mandible with a bone drill. The ordinary dental bur is contraindicated for this work as the head of the bur soon becomes clogged up with bone dust and will break off. These holes should be drilled through the mandible about one centimeter on either side of the line of fracture, two holes on either side about five millimeters apart. Care should be taken not to disturb the roots of the teeth. Silver wire is then passed through the upper hole from the labial surface to the lingual and back through the lower hole on the opposite side of line of fracture from lingual to labial. The other wire should be passed through the two remaining holes. This forms a criss-cross of the wires and prevents movement of the fragments. This wire is left in position for from thirty to forty days. In simple fracture of the symphysis, no other treatment need be resorted to.



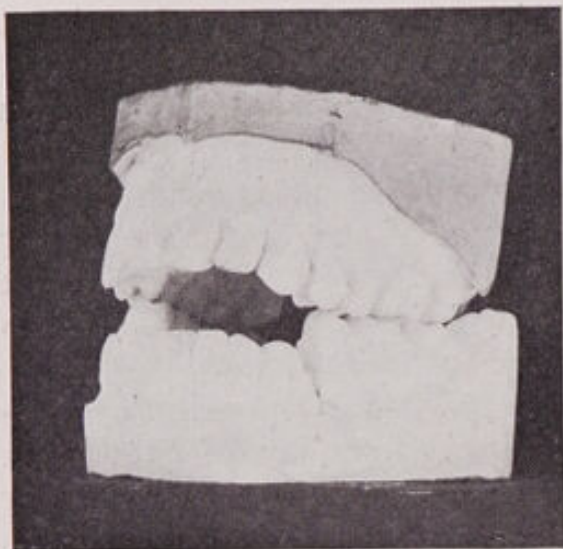


Fig. 47




Fig. 48

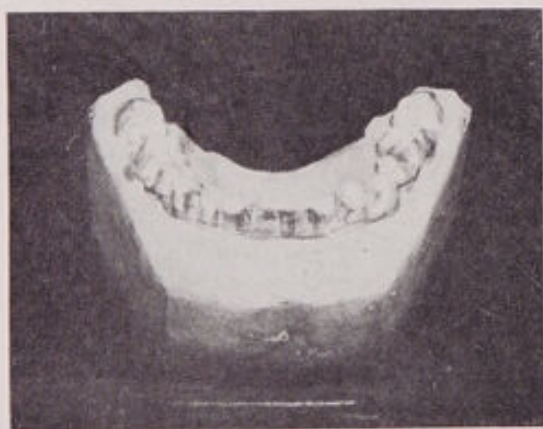


Fig. 49

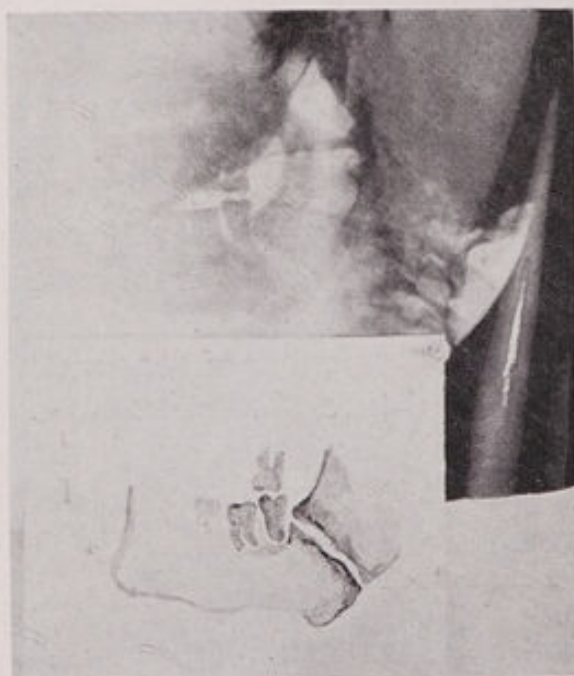

Fig. 50

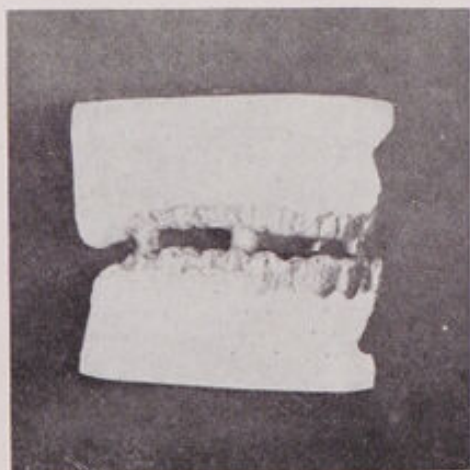

Fig. 51

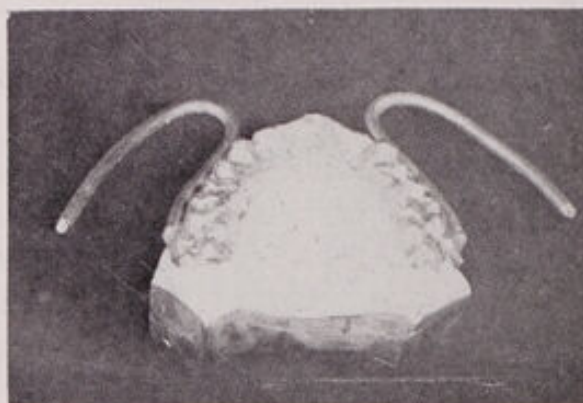


Fig. 52



*Fig. 46* shows a splint for retaining the fragments in multiple fractures of the mandible anterior to the angle of the jaw. An impression is taken of both upper and lower jaw in soft modeling compound. Models are then made from the impressions. (*Fig. 47.*) The model of the lower jaw is divided at the line of fracture and re-assembled and articulated with the model of the upper jaw. (*Fig. 48.*) Correct articulation of the teeth presupposes that the fragments are in correct apposition. A splint can either be cast in silver or swaged out of German silver. If the splint is cast, tinfoil should first be pressed over the model before using the casting wax, so that when the splint is cast it will fit the teeth loosely. In the swaged splint, German silver, gauge 32, is used. It is permissible to swage this splint roughly, as it is better that it fit over the teeth loosely. This splint is reinforced by soldering a German silver wire, gauge 18, around the lower margin of the splint. Small holes should be cut in the occlusal surface for the purpose of letting out the surplus cement when setting the splint to place. The teeth should then be dried with alcohol and the splint filled with thinly-mixed cement. The parts are then forced into position and the teeth into the splint. The splint should be held until the cement is thoroughly hardened. The writer has found that this adjustment can be strengthened further by having orthodontic wires already in the inter-proximal spaces before setting the splint. These wires can be thrown around the teeth and over the top of the splint and twisted together for the purpose of binding the splint to the teeth. The swaging can be done either by a shot or a paraffin swager or by making a die and counter-die of the model.

A vulcanite splint can be made instead of a metal splint, if desired. The vulcanite splint should fit the teeth loosely; and this can be accomplished by covering the model with heavy tinfoil before vulcanizing. The vulcanite splint should be as thin as it is possible to produce it. It can be strengthened by running a German silver wire in the wax model before vulcanizing. A metal splint is more desirable than vulcanite in practically every case on account of cleanliness.

In case we want to use interdental ligation in conjunction with the splint, the occluding surfaces of the splint should be cut out so that the lower teeth come in direct contact with the upper teeth when the mouth is closed. (*Fig. 49.*) This splint, plus the interdental ligation, is indicated in multiple fracture of the lower jaw when one fracture is distal to the last molar tooth. (*Fig. 50.*) With these splints the bandage as an additional support is permissible and frequently indicated.

In multiple fracture of both upper and lower jaw, the same method of making the splint can be used for both jaws. The models should be so cut and articulated that they show the normal relation of the teeth. These splints are then made over the articulated models and may be soldered together so that when set to place the teeth will be in normal



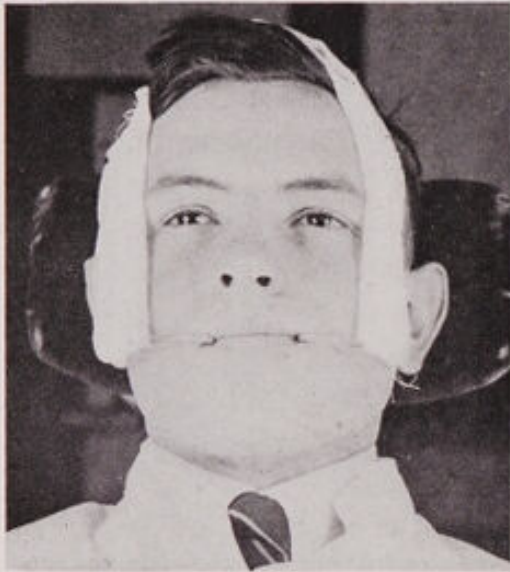

Fig. 53

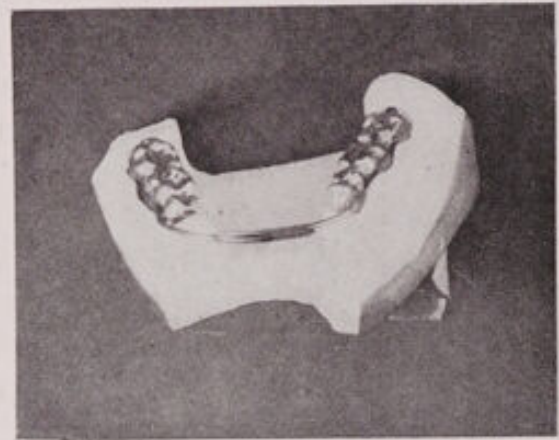


Fig. 54

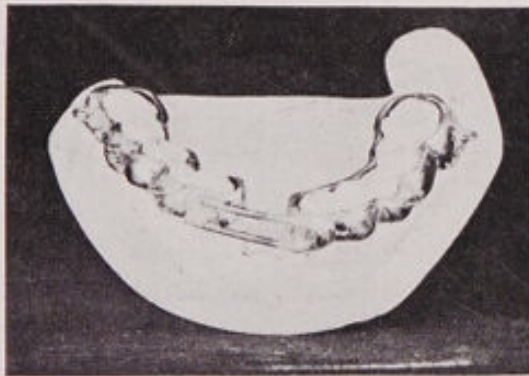

Fig. 55

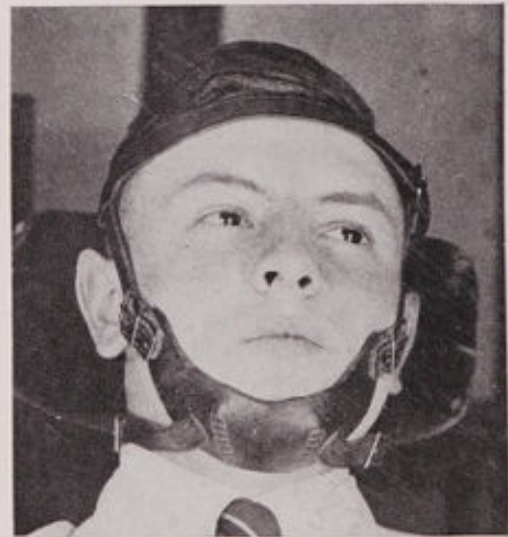

Fig. 56




Fig. 57



occlusion. Metal splints of this kind are preferable to the vulcanite splint for the same reason as given before—that they are more sanitary.

The Gunning splint (*Fig. 51*) is made in about the same way with the exception of lugs being soldered between the upper and lower splints for the purpose of feeding the patient and irrigating the mouth. It also may be made of vulcanite. This splint should not be used in multiple fractures where one of the lines of fracture is distal to the last molar tooth, for the reason that the jaws are held partly open. A V-shaped space would be made in the line of fracture, and if faulty union did not occur, faulty occlusion of the teeth would be the result after the process of repair was completed.

*Fig. 52*, Kingsley splint, may be used for fractures of either the upper or lower jaws. The splint is made the same as that shown in *Fig. 49*, with the addition of heavy extension wires soldered to the buccal surfaces of the splint. These wires should be gauge 8 or 10 and should be so bent that the ends of them extend to the outside of the mouth, along the contour of the face. This splint is placed in position and held firmly by a bandage running from one of the wire extensions around over the head to the one on the opposite side. Such a splint is indicated where there is a complete fracture of the upper jaw and the parts are suspended only by the soft tissues. This method is applicable to the lower jaw and the bandage should go around under the chin, firmly holding the splint against the teeth. *Fig. 53* shows the splint applied to the upper jaw.

*Fig. 54* shows a splint for caring for fractures where the symphysis has been lost or shot away. The two lateral halves in such a fracture should be lying very loosely, only supported by the temporomaxillary articulation. An impression is taken of each half of the lower jaw, models are made, and a metal splint swaged or cast to the model. To each side of the splint is soldered a wire extension conforming to the shape of the lower jaw. The splints should then be fitted over each lateral half, the wires paralleled, and the two halves of the splint cemented to the teeth. The fracture should then be reduced and normal occlusion obtained. The two parallel wires from either side should then be soldered with soft solder in the mouth. In case it is not possible to solder these wires together, they can be wrapped with copper-bronze wire, gauge 28, and the splint completed in that manner. This method maintains the normal space of the mandible which has been lost, so that a bone graft may be resorted to later on. Such a splint should be worn until consolidation takes place, which may not be for three or four months.

*Fig. 55* represents a splint similar to the one just described which may be used in conjunction with interdental ligation in cases where a portion of the substance of the bone is lost, and where there also is a fracture at the angle of the jaw. After the splint is set, wires, gauge 18,





Fig. 58

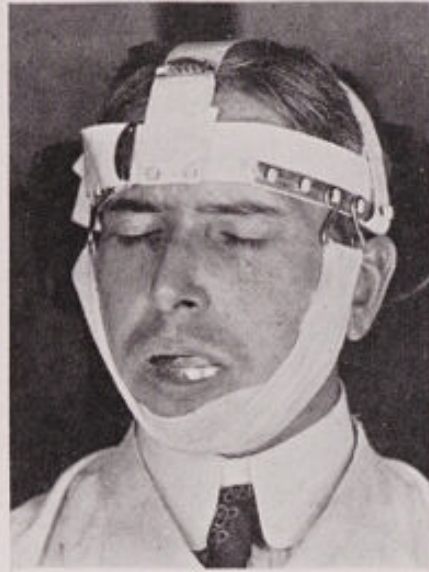

Fig. 59

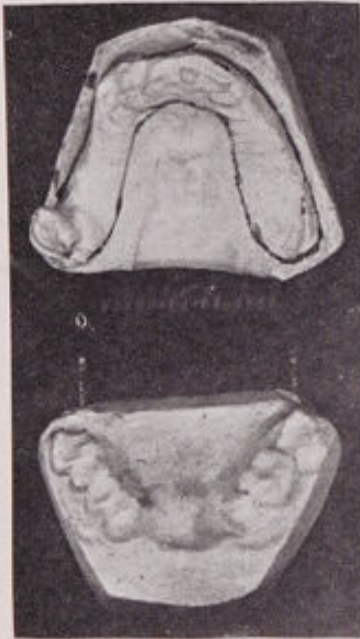


Fig. 60

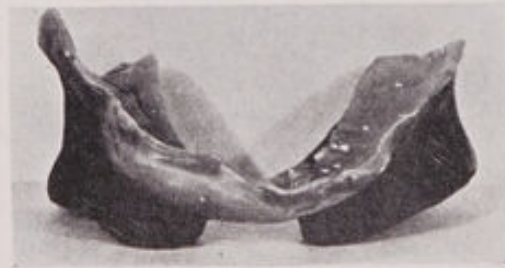

Fig. 61



Fig. 62

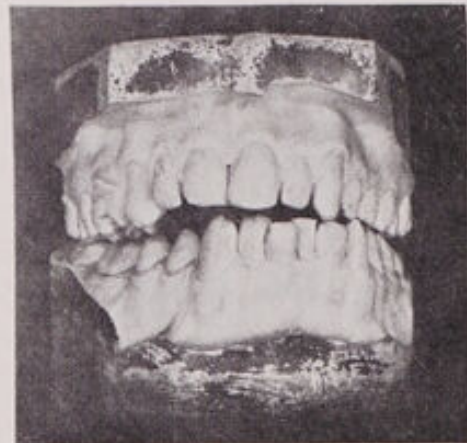


Fig. 63



may be soldered to each half by soft solder for the purpose of maintaining the space. Small rings may be soldered to the buccal surfaces of the splint for the purpose of performing interdental ligation.

*Fig. 56* is a leather harness, which the author has used with considerable success in holding the lower jaw firmly against the upper. This consists of a chin-piece to which is attached straps with buckles which go over the top of the head and also a set which surround the neck. Smooth absorbent cotton should be placed in the chin-piece to make it more comfortable for the patient.

The harness is indicated in complete fracture of the superior maxillæ when it is desirable to use the lower jaw as a splint for holding the superior maxillæ in position. Interdental ligation should be used in conjunction with the leather harness.

#### ADVANTAGES OF A HEADGEAR IN THE TREATMENT OF FRACTURES OF THE JAWS

In many types of fractures of the jaw it is very desirable to have a fixed support for the retention of the fragments. A most satisfactory type of headgear is one designed by Dr. Jas. A. Aiguier<sup>1</sup>. (*Fig. 57.*) This is buckled around the forehead and occiput and has two firm bands crossing over the top of the head. It is sometimes desirable to reduce the fracture immediately after the accident, and hold the fragments in normal relation as a temporary procedure until permanent splints may be made and adjusted. This may be accomplished by taking two lower impression trays and cutting the handles off. (*Fig. 58.*) The backs of the trays are placed together and soft-soldered. This makes a most excellent bite plate to be used as first aid. The bite trays are then filled with modeling compound and the patient's jaws are forced into the impression material, producing what is generally termed a "mush bite." The headgear is then placed in position, using a linen bandage around the lower portion of the chin connected to the rings on the headgear. (*Fig. 59.*) Aiguier suggests the use of wide strips of rubber dam instead of linen bandage. The rubber dam will permit of constant pressure being applied at all times and will force the lower jaw up against the splint. This immobilizes the jaws temporarily. Such an appliance can be used for either the upper or lower jaw, or both. In case the fracture is not too extensive, the modelling compound impression may be trimmed up and the appliance may be used in this manner as a permanent splint.

*Fig. 60* shows plaster models of jaws of a patient of the author who had a compound multiple fracture of the mandible. The line of fracture occurred at the angle on both sides of the lower jaw. There was a transverse fracture on the right side and a comminuted fracture on the

<sup>1</sup>*Dental Cosmos*, July, 1918.



left side. As there was only one molar tooth in the upper jaw, a vulcanite rim was made, as outlined, on the model of the upper jaw. The fracture of the mandible was then reduced and the teeth of the lower jaw were forced into impression wax which previously had been added to the vulcanite rim, thus producing a "bite." The "bite" was then reproduced in vulcanite and vulcanized to the rim. (*Fig. 61.*) The splint was inserted in the mouth and the teeth of the lower jaw forced into the vulcanite "bite" and held in position by means of a headgear. Complete repair took place in five weeks.

In fractures of the superior maxillæ, the headgear can be used very satisfactorily in connection with the Kingsley splint, as in *Fig. 53*, instead of linen bandages.

*Fig. 62* shows a type of headgear used by the French dentists in war dental surgery. The illustration shows it being used in connection with a Kingsley splint.

The headgear may be used satisfactorily as a means of a fixed base for attaching appliances for the support of the soft tissues when extensive laceration has occurred.

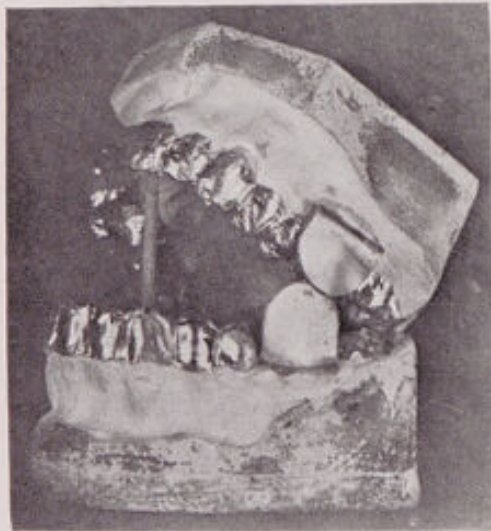

Fig. 64

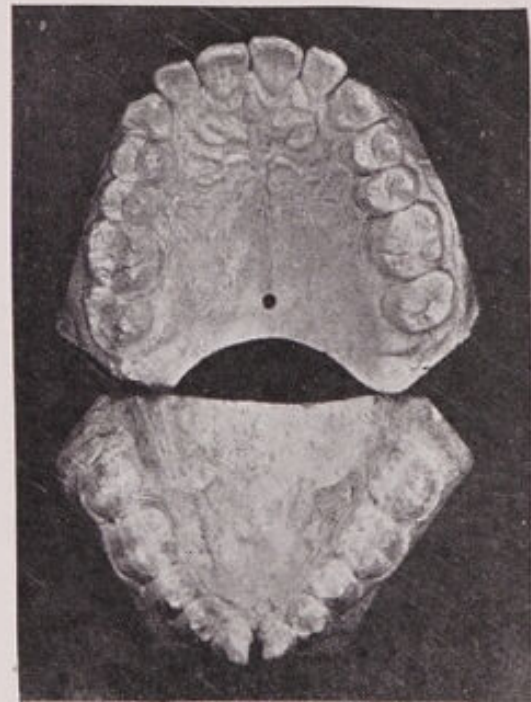


Fig. 65

#### CORRECTION OF LATERAL DISPLACEMENT

*Fig. 63* shows lateral displacement as result of fracture of mandible.

*Fig. 64* shows a method for compensating for lateral displacements. Wings may be attached to plates of the upper and lower jaws or may be attached to the teeth by means of bands. One of these plates sliding just outside of the other, acting as inclined planes, gradually will bring the lower jaw into normal alignment. These wings may be used as a



part of a splint, and the lateral displacement may be corrected at the same time repair of the fracture is taking place.

#### LOSS OF SUBSTANCE

Cases of fracture of symphysis of lower jaw with loss of substance, may be taken care of in two different ways. One manner of treating these cases is in retaining the fragments by a permanent splint in normal position, this splint being put on as soon as possible after the injury, then later resorting to transplantation of bone. The other method is letting the two fragments collapse as in *Fig. 65*. After the bone-salts begin depositing, that is, in from ten days to two weeks following the fracture and the collapse of the fragments, a splint is cast to cover the teeth on both sides of the mandible. This splint is cast out of tin and silver; 80 parts of silver and 20 parts of tin. A jackscrew, 14-gauge, is attached to the anterior portion of the splint and the fragments gradually are forced apart until normal occlusion is obtained. This method of spreading the fragments causes an irritation to the parts which is sufficient to stimulate bone-growth so that a section of new bone may be deposited from cuspid to cuspid. The strength of the retention splint may be further enhanced by small screws inserted in the inter-proximal spaces. The splint at these points is reinforced sufficiently to permit of a screw, 20-gauge in diameter, being inserted. The same results may be obtained by using the splint illustrated in *Fig. 93*.



## Chapter X

### Gunshot Fractures of the Jaw

The methods of treatment of gunshot fracture of the jaws do not differ greatly from those used in civil practice. The principles of treatment are the same. The only difference is that there are greater complications entering into gunshot fracture than into those met with in civil practice.

There will be greater laceration of the soft tissues of the mouth and face, which will greatly complicate the making of a correct diagnosis and the prosecution of the necessary treatment. The bone itself will be lacerated universally and splintered into many fragments; and repair under these conditions will be delayed. Every case will present an infected wound, which will greatly interfere with the process of repair. Other factors will enter into the treatment of gunshot fractures in war time, such as delay in instigating the treatment, which cause new problems to arise. Conditions make it impossible to treat many of these cases until some time after the injury.

In these cases frequently partial consolidation of the soft tissues has taken place, and large masses of cicatricial tissues have formed which greatly interfere with the reduction of the fracture, and make it difficult to retain the fragments in normal relation. Not only does this condition hinder the reduction and treatment, but it makes a clear and definite diagnosis difficult.

That pioneer in war dental surgery, Dr. George B. Hayes, of the American Ambulance, at Neuilly, France, has formulated the following questions relative to the treatment of gunshot fractures:

*\*First*, the choice of disinfectants and the method of application.

*Second*, the various forms of bandages and contraindications for their use.

*Third*, the making of interdental splints.

*Fourth*, the conditions demanding immobilization of the mandible.

*Fifth*, the extraction of certain teeth or their immediate fixation.

*Sixth*, the means of overcoming trismus and treatment.

*Seventh*, the indications for bone grafting and choice of tissue to be grafted.

*Eighth*, the relative advantages of different kinds of forces and means of application in the reduction of fracture.

These are some of the questions that are pertinent in the management of gunshot fractures of the jaws that must be taken into consideration before instigating the treatment.

In the treatment of these cases many different problems will be presented and the ingenuity of the operator in designing and constructing

\*Dental Cosmos, 1917.



splints which will meet these problems will be a large factor in the success or failure of the treatment.

Major Joseph D. Eby, D. C., has designed a very clever method of treatment of gunshot fracture of the jaws which is simple, and designed to be used when the advantages of a well-equipped dental laboratory are not available. Full credit should be given Major Eby for the following description and illustration of this valuable method:




Fig. 66.—Instruments and materials for inside portion of splint, except modeling compound.

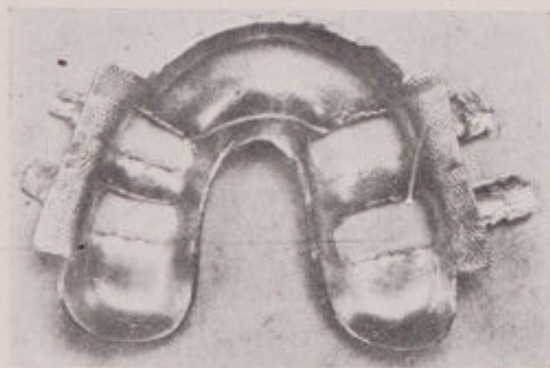


Fig. 67

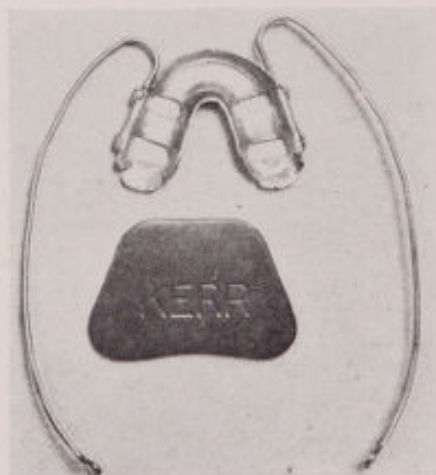

Fig. 68

Fig. 67.—Angle tray (preferably) with handle cut off, palatal portion cut out, labial border lowered and cuts made for buccal attachments.

Fig. 68.—Showing relations between tray and wires with buccal flanges and flaps conformed into tubes. Wires should not be bent until after the inner portion is all adjusted.





Fig. 69



Fig. 70



Fig. 71

Fig. 69.—Inner portion adjusted, wires in place, plaster bandage head-cap half completed, showing placement of strips for connections.

Fig. 70.—Anterior view same as Fig. 69.

Fig. 71.—Posterior view same as Fig. 69.



Fig. 72



Fig. 73



Fig. 74



Fig. 75

Fig. 72.—Head-cap completed, side view.

Fig. 73.—Completed front view.

Fig. 74.—Completed rear view.

Fig. 75.—Illustrates the disassociation of all surrounding parts.



Fig. 76

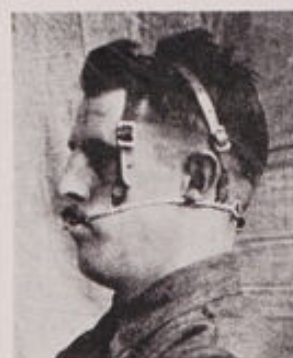

Fig. 77

Figs. 76 and 77.—Showing the use of leather straps; these should be padded.



Captain E. Ballard Lodge, D. C., has designed a cast tin jacket splint, which has a practical application in the management of many of these cases of gunshot fractures of the jaws. Captain Lodge has kindly consented to summarize his technic and it is inserted herewith, including illustrations supplied by him:

"Models of the teeth having been made and articulated upon an anatomical articulator, place warmed pink base-plate wax in such manner as to cover the crowns of the teeth to within a millimeter of the gingival margins, on both the lingual and bucco-labial sides. The wax is to fit approximately only, not too accurately, since if it should so fit, it would be too difficult to apply the completed splint to the teeth. The gingival margin, bucco-labial, may be reinforced by an extra thickness of wax if thought desirable for additional rigidity of the splint. Imprints of the teeth from the occluding model should be made in the wax.

"The pattern is now removed and a funnel of wax is fused to one of the heels of the pattern and a small cylinder or strip of wax is similarly fastened to the other end (*Fig. 78*), care being exercised to avoid distortion of the wax pattern.



Fig. 78



Fig. 79

"It is now invested in an investment of plaster of Paris and finely chopped asbestos, equal parts, (sold under the name of 'Tenax'). The funnel and the cylinder are, of course, to be left exposed at the top, as seen in *Fig. 79*.

"As soon as the investment has hardened, it is placed in a pan of water and the wax boiled out. It then may be heated by brush flame of blowpipe or otherwise to dry out. The resulting mold is now ready to receive the molten tin. Block tin is melted in a large spoon. This can be done over a large alcohol lamp if gas burner is not at hand.

"The metal is poured into the mold and will appear, when full, at the opposite side. A bench vise, if at hand, may be used to hold the mold while pouring the metal. Obviously, the funnel side of the mold should be on a level, or at least not below the side where the metal is

expected to appear. In a minute or two the tin will have crystallized and may be placed in cold water. The investment being removed, the funnel and cylinder are cut off and any rough edges smoothed up with a file. (*Fig. 80.*)

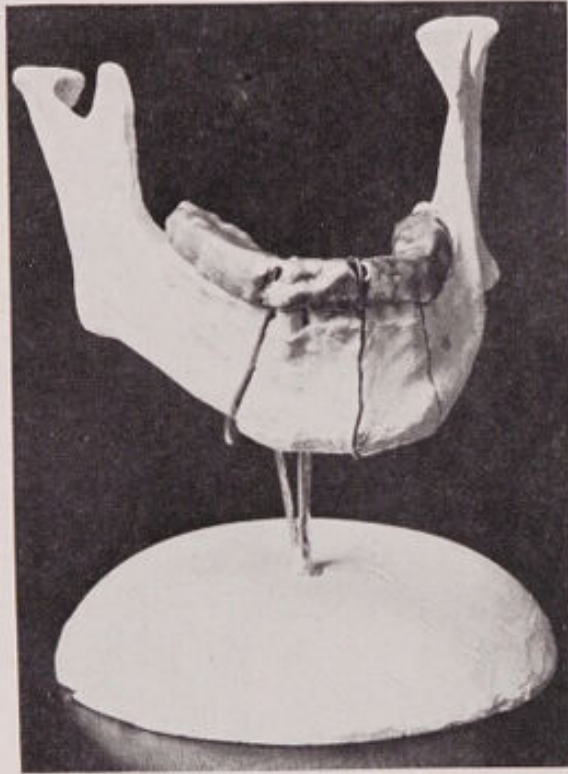

Fig. 80

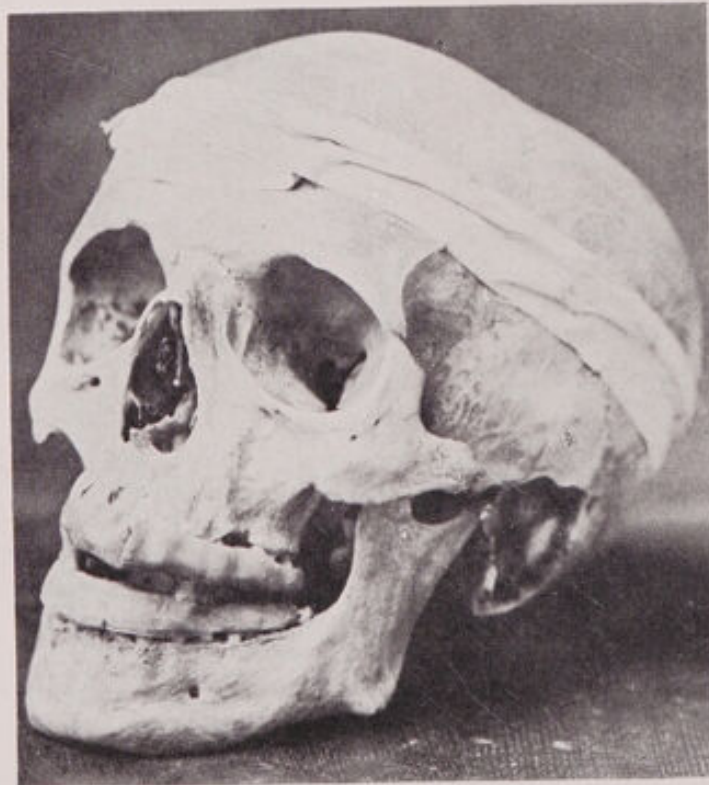

Fig. 81



“A block tin splint in the form of a Gunning splint may be used. This consists, merely, in two jacket splints, one for the upper and one for the lower teeth, properly related upon the anatomical articulator and united at the heels and at the cuspids, a space being left at the anterior portion for feeding. (Fig. 81.) To insure success, it is wise to have a good head of metal at the funnel end.

“Oxyphosphate of copper is to be preferred for cementing the jacket splint in place. This cement, unlike oxyphosphate of zinc, does not become foul. The oxyphosphate of copper being antiseptic, is better tolerated by the gums in event there should be some contact with the latter.

“The writer does not claim originality in the use of block tin as a material for the construction of jacket splints, but the fact of constructing these splints with but one investment may be new. Perhaps the greatest value of this method lies in the fact that an efficient splint can be made out in the woods and with few appliances in a very brief period of time.

“The writer has constructed a usable cast tin jacket splint for a lower jaw, inclusive of upper and lower impressions, making of plaster models, and mounting on the anatomical articulator, in fifty-three minutes.”

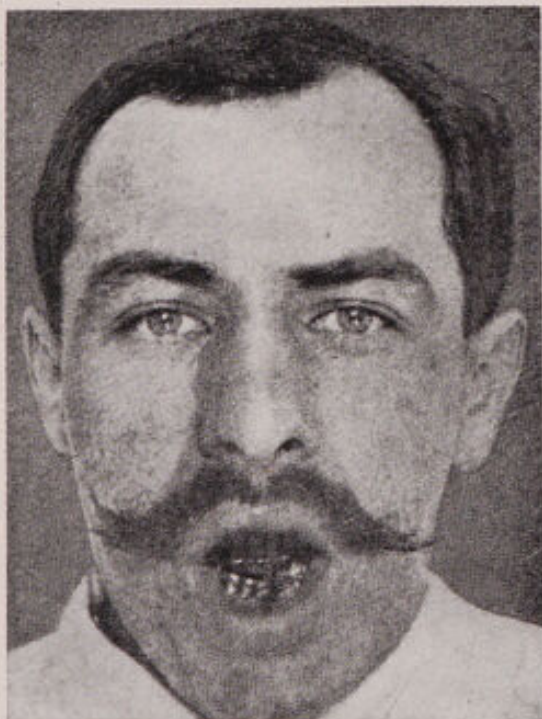


Fig. 82

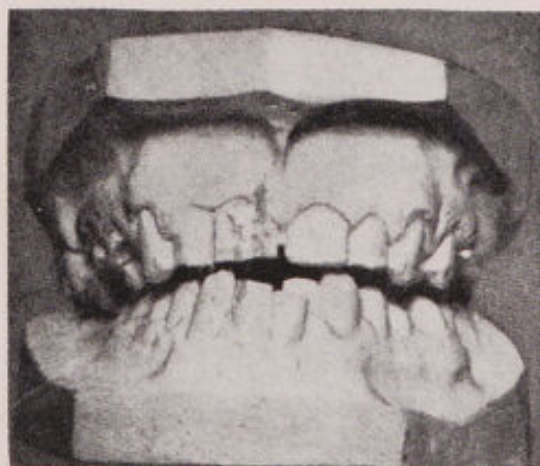


Fig. 83

This work on fractures and dislocations of the jaws would not be complete without having incorporated in it something of the brilliant achievements of our brave confreres in France.

The following is a brief review of some of the cases treated by Dr. George B. Hayes and his associates, in the Dental Section of the



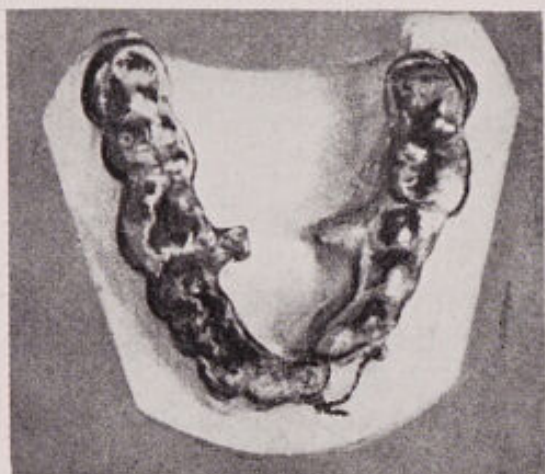


Fig. 84

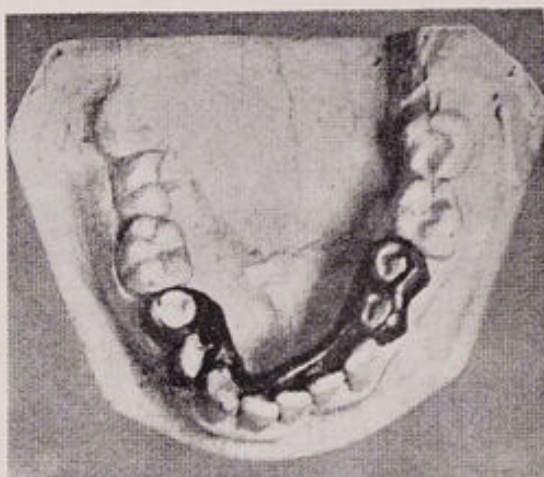


Fig. 85

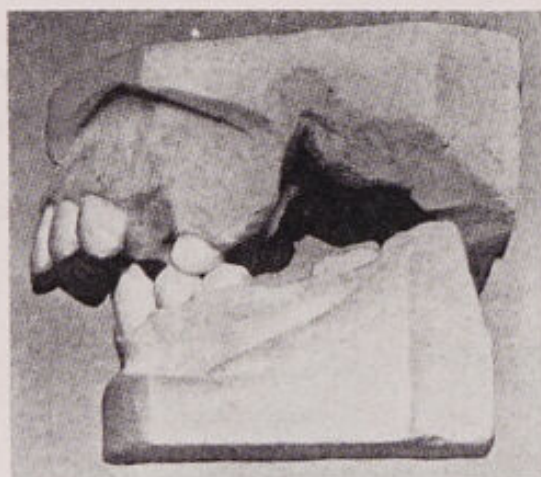

Fig. 86

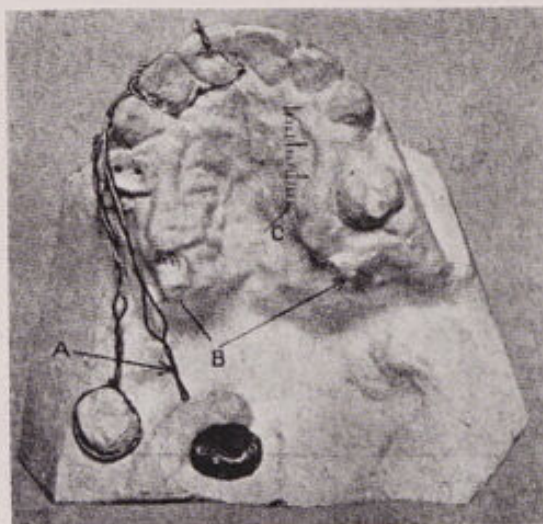

Fig. 87



Fig. 88



American Ambulance, at Neuilly, France. These were published in full in the *Dental Cosmos*, 1916.

*Fig. 82* shows a case of fracture at the symphysis with loss of substance and the right central incisor, the bullet striking the chin at the right of the median line, passing along the outer plate, with exit through the cheek near the mental foramen on the right side. This case did not receive dental treatment for six months after the injury, at which time consolidation had taken place with overlapping of the front teeth (*Fig. 83*), and with persistent suppuration in the line of the fracture internally.

To treat this case the jaws had to be spread apart. This was done by swaged German silver splints adjusted on the lower right and left sides of the arch. A jackscrew was used for the purpose of spreading the lateral halves. (*Fig. 84.*) Later a bridge splint was cemented to place. (*Fig. 85.*) Complete consolidation took place in about six months.

*Fig. 86* shows a very interesting case of gunshot wound across the superior maxilla where the anterior portion was cut off from the posterior portion, the anterior portion being thrown forward a distance of 2 c. The ball entered the cheek just above the opening of the Steno's duct, passing directly across the mouth with exit on the opposite side, fracturing the maxilla and forcing the nasal bones into the antrum. The tuberosity with all the molar teeth on the left side was gone, the anterior portion loosened and movable. The treatment consisted of suturing the mucous membrane to place. Irrigation with simple antiseptic mouth washes many times a day was instituted. The displaced parts were drawn into closer proximity by the use of twisted wires. (*Fig. 87.*) One of these wires posteriorly was fastened to the upper molar tooth. Another wire posteriorly was fastened to the soft tissue, using a Brophy lead plate for this purpose. *Fig. 88* shows parts approximated. A simple obturator was used to close the opening in the hard palate. Consolidation took place in four months.

*Fig. 89* illustrates a compound fracture of the jaw with lateral displacement. *Fig. 90* shows plaster casts of the mouth. The patient was wounded by a bullet striking the right cheek just back of the commissure of the lips, striking the ramus and fracturing the jaw at the angle. No dental treatment was instituted for seven months, at which time the wound was found to have healed externally, the body of the jaw being carried out of line to the right by the width of three incisor teeth. Movements of the mandible were limited, rendering mastication impossible. Lower right first and second molars were loose and involved in the fractured portion.

The treatment consisted in the removal of these two loose teeth and a splint made of swaged German silver which was cemented to the lower teeth, extending from the left second bicuspid to the right second bicuspid (*Fig. 91*), with hooks for intermaxillary elastics. On the upper



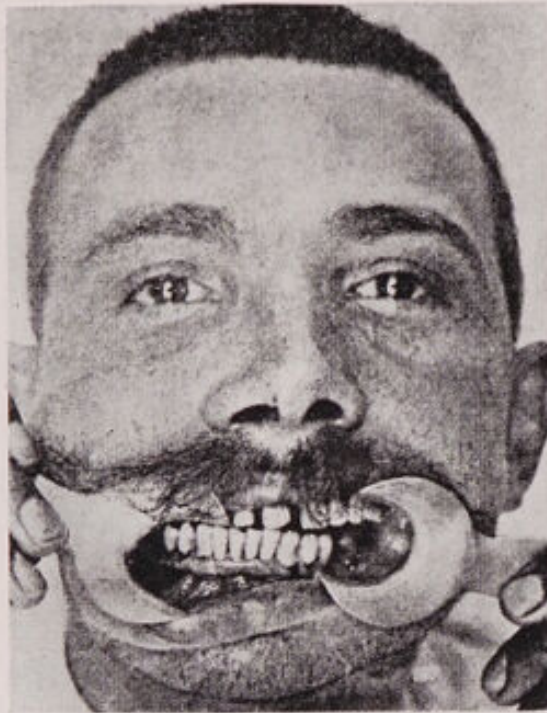


Fig. 89

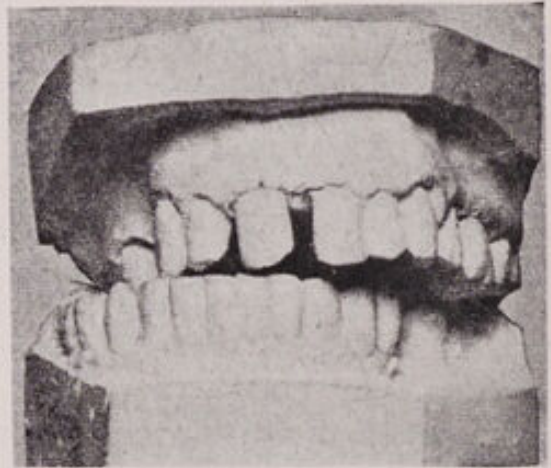


Fig. 90

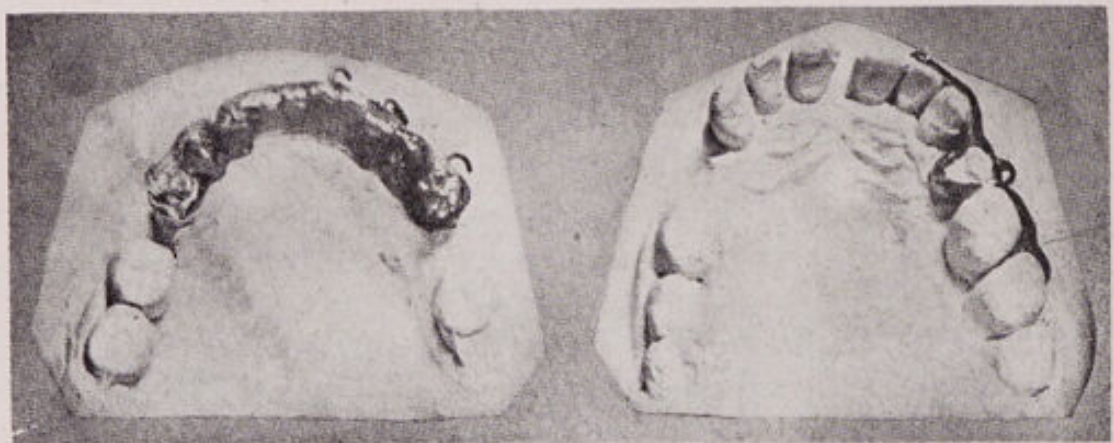


Fig. 91

left first bicuspid a metal band was adjusted with wings extending to the lateral and the second molar on the buccal surface, to increase the base of resistance and a ring to serve as a point of forced application. Intermaxillary elastics were applied and worn continually. Normal occlusion was established in thirty days. (*Fig. 92.*)

*Fig. 93* shows a method of obtaining normal occlusion and also a retention splint. This patient presented a double compound fracture of the mandible with loss of substance; was without dental treatment for five weeks and was wounded by a ball which, after passing through the shoulder, entered the left cheek, fracturing the lower jaw in the region of the mental foramen, and also at the symphysis, with loss of bone and four teeth. At the time of the beginning of dental treatment the sides of the jaw were drawn together in a V shape, bringing the two cuspids in contact. A partial fibrinous union had taken place. The



mouth was in a badly-infected condition. The treatment consisted of adjusting vulcanite plates connected by a jack screw for spreading the lateral halves. These were made from two impressions taken separately. Sufficient spreading to establish normal occlusion was obtained in fifteen days. These vulcanite plates were then removed and replaced by a metallic splint. This splint was made as follows: On the right side a piece was swaged to cover the crowns of all the teeth with the cusps uncovered for close articulation; on the left side a band on the molar united by two strong bars reinforced; on the right side a metallic wing was added buccally to overcome the tendency of the jaw to return to its original position. This also aided in relieving the strain on the molar.

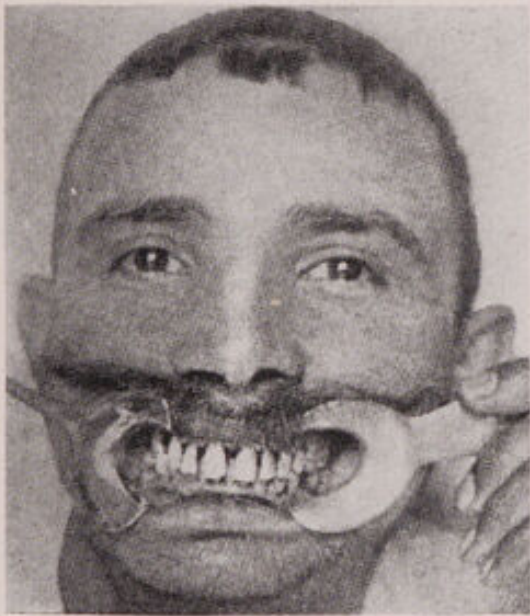


Fig. 92

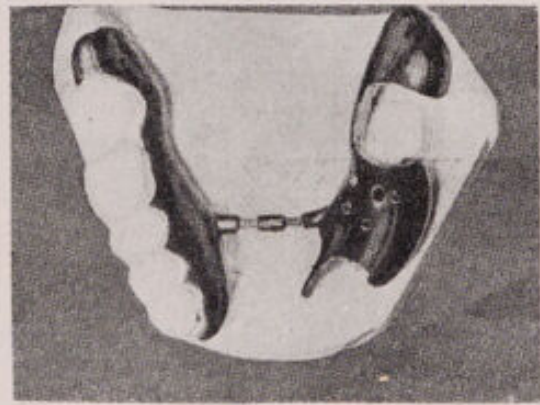

Fig. 93

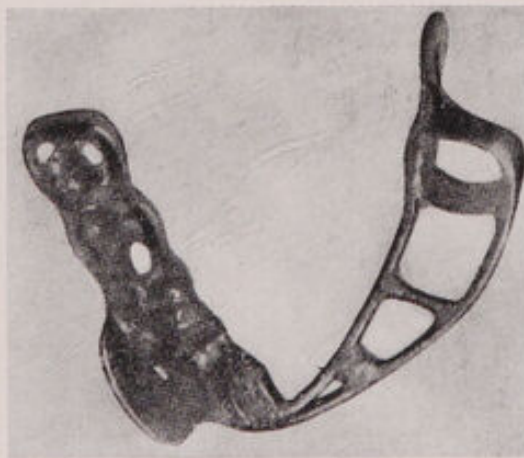


Fig. 94

The band on the right molar also carried a wing extending backward over the inner plate of the jaw for additional support. (*Fig. 94.*) After four months, incomplete consolidation only had taken place.



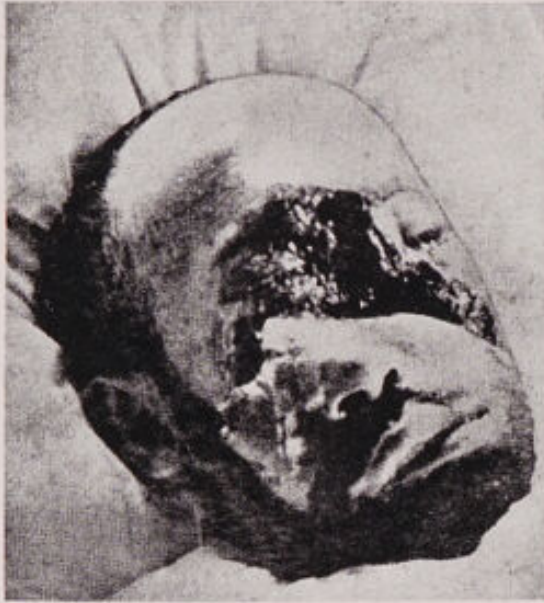

Fig. 95




Fig. 96

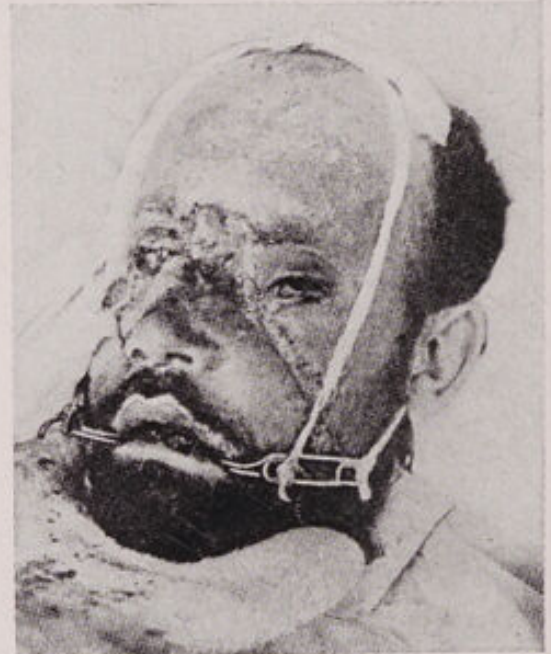

Fig. 97

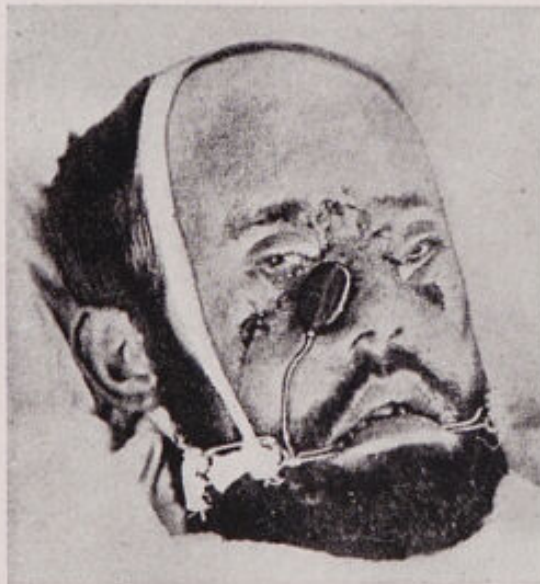

Fig. 98

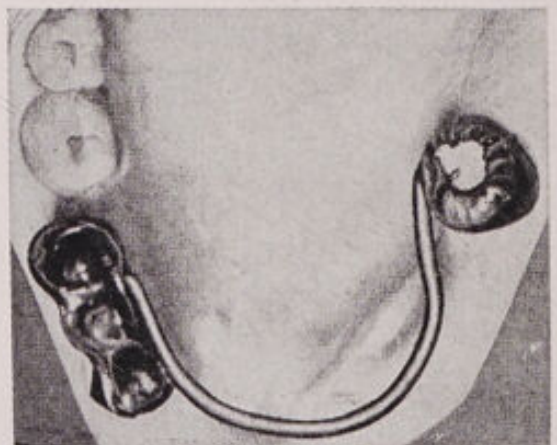


Fig. 99

*Fig. 95* shows an interesting case of gunshot fracture and ingenious method of treatment. This patient had been wounded by a piece of shell striking the face from left to right, making a clean incision with little loss of substance, symmetrical in line from the root of the nose obliquely downward, backward almost to a level between the corner of



the mouth and the tragus of the ear, sectioning off all the bones of the nose, maxilla and palate, and fracturing the molar and bicuspid teeth above on both sides. The entire section had fallen forward, leaving a large, gaping wound of wedge shape, disclosing the pharynx from above. No dental treatment was instigated for seven days after the wound.

The treatment consisted of adjusting a dental impression tray (*Fig. 96*), with wire attachments to the maxilla, passing out of the corners of the mouth, extending backward onto the cheeks. This permitted the whole sectioned-off portion to be lifted up to place. The splint was maintained by linen bands over the head. (*Fig. 97*.) The mouth and wound were washed every two hours, and once a day the splint was removed and cleaned and readjusted to hold the face in proper position. Later on a buffer to support the nose was added to the wire splint. (*Fig. 98*.) The patient was out of bed in thirty days, with partial consolidation of the parts.

*Fig. 99* represents an orthodontic splint which was used successfully in the treatment of one of these gunshot fractures. The patient was wounded by a ball entering the open mouth while talking, fracturing the mandible as indicated by *Figs. 100-101*. Many of the teeth and a portion of the bone were shot away. The exit of the ball was through the submaxillary triangle on the left side. There was extensive suppuration both externally and internally. Twenty-seven sequestra were removed. Perfect bone union took place by the use of the simple, removable, regulating splint which also served as a retainer. No intermaxillary ligation was resorted to. In two months and a half perfect consolidation had taken place.

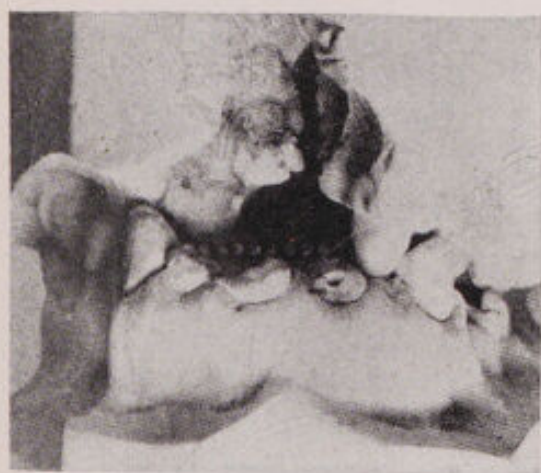

Fig. 100

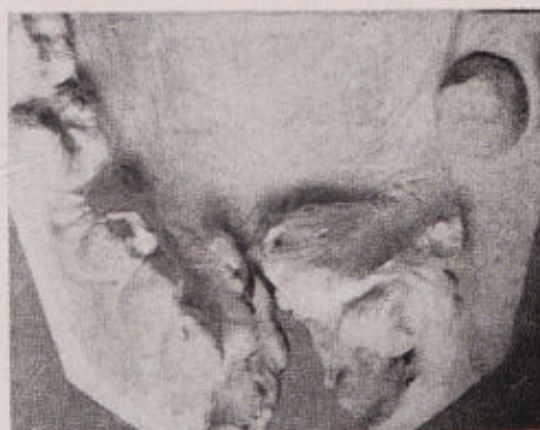

Fig. 101

#### FRACTURE POSTERIOR TO MUSCULAR ATTACHMENT

Dr. George L. Villian<sup>2</sup>, of Paris, has designed a very ingenious method for re-establishing and maintaining normal mandibular move-

<sup>2</sup>La Restauration Maxillo-Faciale, October, 1917, *British Dental Record*, 1917.



ments in cases where the fracture occurs posterior to the muscular attachments on the mandible; as an illustration—a fracture involving the head of the condyle or a fracture through the upper third of the ramus. These fractures always have been very difficult to treat. Many of these fractures have occurred on the battle fields of France through gunshot wounds. This ingenious splint is designed not only for the purpose of maintaining normal mandibular movement, but also for the purpose of opposing the force which has a tendency to raise up the extremity of the long fragment. This splint also can be used when there is loss of substance of one side of the jaw. The appliance, (*Fig. 102*), consists of a shaft which acts in connection with hinged rods and stop pegs. The shaft in this case acts as a gliding guide directing the fragment of the mandible in sagittal direction, while the hinged rods cause the fragment to describe its normal path in the downward motion. The appliance can produce the normal downward motion while modifying the center of rotation at the time indicated for the individual case. It supplants entirely the action of the pterygoideus muscles in the downward motion and in the same movement it counteracts or opposes itself to the action of the temporal muscle.

In this case the base or point of support of the shaft is similar to that of the condyle (the head of the rod should be placed on the superior




Fig. 102

maxilla, as far distally as possible on the line connecting the condyle with the point of fixation of the lower end of the shaft on the mandible). The mandible describes the path of a radius very much the same as the path described in the first stage of downward motion in opening the jaws, whereupon the stop peg (*A*) is reached and action (articulation) comes into play at the point of the hinging of the rods at (*B*), causing the mandible to describe a path, the analysis of which is similar to that of the natural downward motion. The upward movement is inversely also normal. The patient can execute the various movements by means of a rod sliding in a tube which permits of lengthening or shortening of the



shaft, (C). The backward movement is limited by the length of the course of the shaft (the rod striking the end of the tube.) The lateral motion finally is taken care of by means of the play in the hinge joints. A lower stop peg serves the purpose of limiting vertical deviation when necessary, and weakens the pressure exercised by the elevator muscles on the posterior molars in cases where there is loss of tissue in the region of the temporomaxillary articulation.

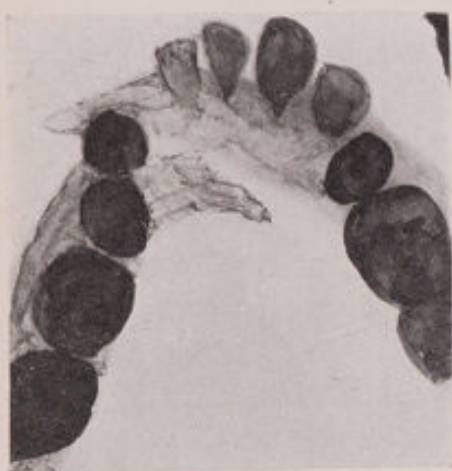

Fig. 103

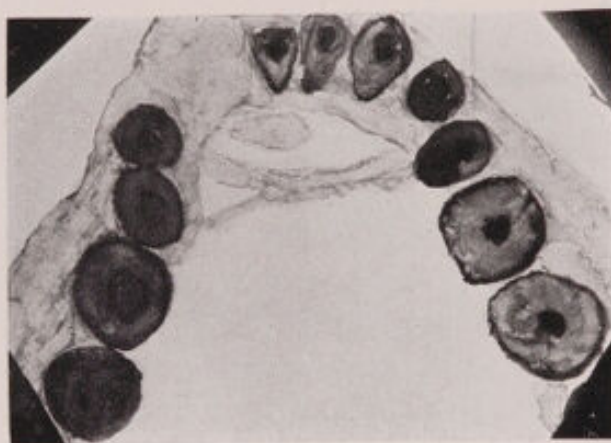


Fig. 104

*Figs. 103-104* show extensive growth of bone in some of the gunshot fractures of the jaws. This is a rather common condition which results from gunshot fractures and may be accounted for in one of two ways: *First*, that the periosteum with the epiosteum is stripped up from the adjacent fragments and new bone develops therefrom; *second*, that with the loss of substance the force of the depressor muscles acting upon the fragments may be sufficient to set up an irritation which causes a metaplastic change in the connective tissues resulting in the development of bone. These bony spurs vary in size and shape. In some cases the whole floor of the mouth may be filled. At this time, and with our present knowledge of the conditions, we cannot say that this is a permanent growth. In time the osteoclasts may cause a resorption of these spurs in the same manner as they do in the over-production of bone from the external callus in the normal process of repair.

The above cases vividly illustrate that in gunshot fractures of the jaws, individual ingenuity in the diagnosis and the selection of the treatment to be pursued will play a very important part in the restoration of them. No two cases will present the same difficulties nor require the same treatment. Each case when presented should be studied from every angle before instigating the treatment, with the view in mind of restoring normal conditions as nearly as possible.



## Chapter X

### Treatment By Bone Grafts of Fracture of the Jaws

The first authentic report of successful bone-grafting was done by Merrem in 1809, when he experimented on bone-grafting in skulls of animals after trephining.

In 1858, Ollier, after extensive investigation on animals and on human subjects, concluded that bone grafts covered with periosteum remain viable.

It has been clearly demonstrated by Albee, Gallie, Robertson, Phemister and others, that autogenous grafts, or those derived from the individual into which they are to be engrafted, are the most successful.

Albee states that "The fluids, albumins and tissues of every individual vary in degree from those of every other, and while the incompatibility may be slight, it is sufficient cause for using, wherever feasible, the individual's own tissue for the repair of his defects."

Fracture of the jaws from gunshot wounds causes almost an universal loss of substance, and where this loss of bone is sufficient to cause a marked deformity with loss of function of the jaws, the bone-graft should be resorted to, provided the resistance of the patient and tissues favor the repair.

In bone grafting about the jaws there are two fundamental principles which must govern the operative procedure. *First*, the whole operation must be done extraorally so that no part of the wound comes in contact with the bacteria-laden fluids of the mouth; *second*, the upper and lower jaws must be absolutely fixed by means of interdental ligation so that there may not be the slightest movement of the parts.

The graft should be placed into the lower portion of the mandible and should be shaped so as to conform to the contour of the lower jaw.

\*Albee's method is to cut a section of bone from the tibia, the size and shape that is desired, by means of twin motor saws. He then cuts a gutter on the lower and outer portion of the mandible of exactly the same size. Then holes are drilled through the lower portion of the mandible on either side of the prepared gutter. The inlay bone-graft is then adjusted to place and retained by means of kangaroo tendon sutures, which are passed through the holes and tied around the graft. (*Fig. 105, after Albee.*)

†Drs. W. E. Gallie and D. E. Robertson, of Toronto, have done most satisfactory work in bone-grafting on the jaws of soldiers who have lost sections of their jaws through gunshot fractures.

\*Albee, Bone Graft Surgery.

†Journal A. M. A., April, 1918.



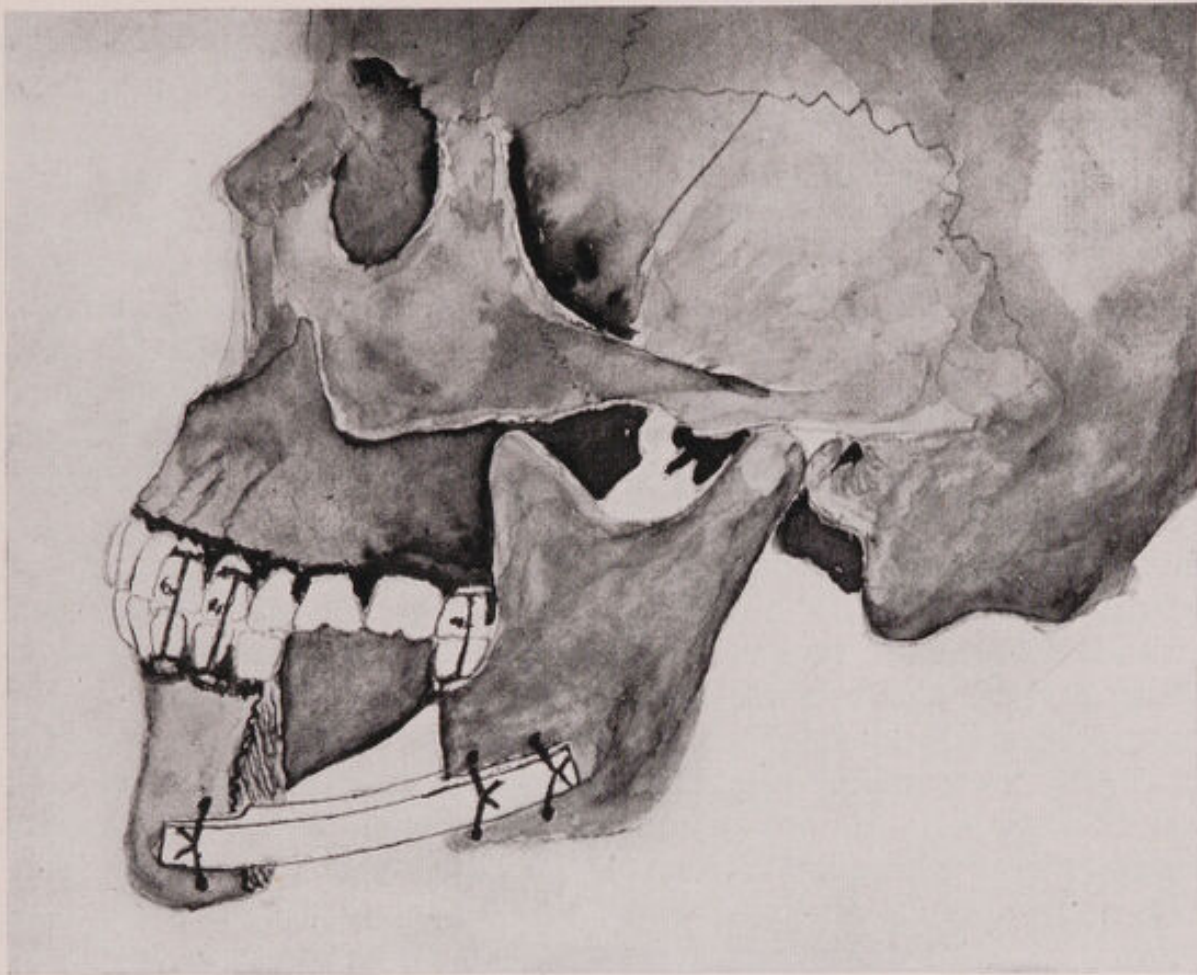


Fig. 105—(After Albee)

Through the courtesy of these gentlemen the author is able to give a brief review of their work with illustrations.

Just what takes place in the behavior of the tissues in the process of bone-grafting is summarized by them as follows: "When a piece of living bone has been separated from its circulation and implanted elsewhere in the body of the same patient, the immediate result, as indicated in specimens recovered within a few days of the operation, is the coagulation of all cells and vessels to which the surrounding lymph is unable to percolate. This means the death of all the cells in the lacunæ and most of those in the Haversian canals. Such a condition is indicated by the immediate change in the staining property of the protoplasm and nucleus, and is later proved by the complete absorption of these structures after the lapse of from three to four weeks. On the surface of the graft and in the open mouths of the Haversian canals, however, are many osteoblasts which are in a position to absorb nutriment from the bathing lymph, and these cells are capable of living and proliferating and of producing those changes that make the autogenous graft so valuable in reparative surgery.

"At the end of the first ten days after the implantation of the graft, the proliferation of these osteoclasts proceeds to attack the dead



bone of the grafts, and rapidly produce excavations about the edges which are at first filled with proliferating cells, and later by new bone laid down by these cells on the walls of the excavation.

“While these changes are occurring on the surface, a re-establishment of the circulation has been taking place, as the result of the ingrowth of new blood vessels into the mouths of the Haversian canals. This proceeds with extraordinary rapidity, and in small transplants is complete in approximately two weeks. Along with these blood vessels, the osteoblasts spread inward from the surface, and at the end of three weeks the same changes that have been described on the surface are occurring within the substance of the bone. At first cavities are excavated along the course of the Haversian canals not far below the surface of the bone. Later this cavity formation, which appears to be a solution of the bone by a secretion from the proliferating osteoblasts, spreads deeply into the transplant, until ultimately the whole graft is permeated by blood vessels and osteoclasts that are occupied in the absorption of the dead bone. A few days after the formation of a cavity by these proliferating osteoclasts, the older cells return to their adult function of bone production, and soon the older part of the cavity becomes lined with a layer of new bone. This layer increases in thickness and trabeculae develop from wall to wall, until the whole cavity is filled with living cancellous tissue, except in those areas in which the proliferating cells are continuing the work of excavating.”

The technic used by Drs. Gallie and Robertson of inserting bone-grafts in the jaw, is as follows:

The fragments are exposed by a long incision along the lower border of the jaw. The motor saw is then applied to the fragments, and a saw-cut made along the inferior border extending an inch, to an inch and a half back from the end of the fragment, about half an inch deep. (*Fig. 106.*) Great care must be taken to avoid opening into the cavity of the mouth or into the sockets of the teeth. An osteotome is then driven into the saw-cut and a greenstick fracture produced, widening the wedge-shaped gap for the reception of the graft. An interdental splint which previously has been cemented to the teeth of both jaws is now locked with the teeth in normal occlusion. The graft is made by resection, three inches of a rib. This piece of rib is then split on the flat in order that the endosteal surface may be bathed in lymph. Half of the graft is then driven into the slots in the fragments, the smooth side of the rib facing toward the mouth cavity. This leaves the rough, cancellous surface of the graft facing outward and sunk somewhat below the outer surface of the jaw. (*Fig. 107.*) This depressed area is then filled out by laying a piece of the other half of the rib in the gap with the smooth side out. The fragments and grafts are now fastened solidly in place with kangaroo tendon passed through



drill holes. (*Fig. 108.*) This adds additional security although it is really unnecessary, as the principal graft is self-retaining, being wedged solidly into the saw-cuts in the fragments.

Homoplastic bone grafts, or those from another individual, may be employed in operations about the jaws, but not with the same certainty

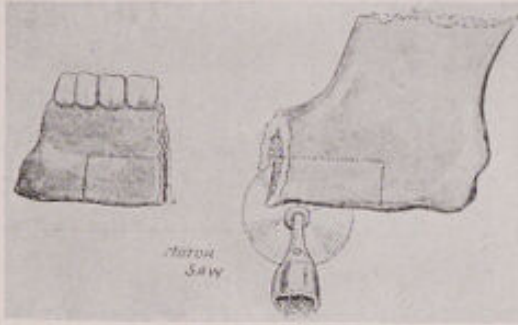


Fig. 106—(Gallie-Robertson)

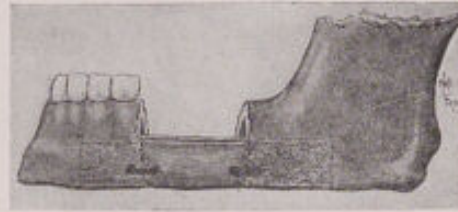


Fig. 107—(Gallie-Robertson)

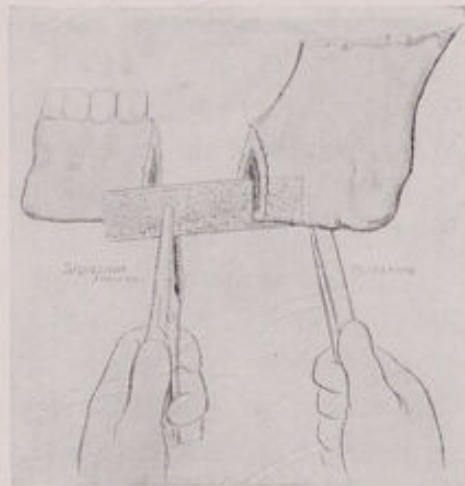


Fig. 108—(Gallie-Robertson)

as the autogenous, for the reasons already stated. In the use of homoplastic grafts there always is danger of transmitting disease from the donor to the host.

In the operation of bone-grafting, strict asepsis must be established and maintained. The inlay bone-graft, and also the groove in the body of the fragments into which it is to be inserted, should be subjected to the minimum amount of traumatism. Bruising or comminution of these tissues is not permissible if success is to be assured.

Bone-grafting following gunshot fractures of the jaws should not be resorted to until after the soft parts have resumed their normal position and function, and when the patient has resumed his normal resistance. This operation is contraindicated in patients with low resistance, or in patients suffering from certain acute or chronic diseases which will exert an influence in retarding the process of repair of bone.



## Chapter XII

### Anesthesia in the Reduction of Fractures

It has been the experience of the author that local anesthesia is preferable to general anesthesia in accomplishing reduction of fractures of the jaws. Local anesthesia eliminates the dangers of general anesthesia; it eliminates the probability of the patient's vomiting following the operation, which is of great importance, especially if interdental ligation has been resorted to. It also assures at least a partial co-operation on the part of the patient which is very desirable when one is endeavoring to establish natural occlusion.

The so-called conductive anesthesia or nerve-blocking is the method of choice in producing local anesthesia. This can be accomplished in one of two ways, viz., the intraoral method or the extraoral method.

In many cases of fracture of the jaws there will be so much traumatism that the intraoral method of conductive anesthesia will not be practicable; and again, on account of septic conditions of the oral cavity, a perfectly aseptic technic cannot be carried out by this method. These objectionable features are all obviated in following the extraoral method in producing conductive anesthesia.

The technic for the intraoral method of conductive anesthesia has been so thoroughly exploited and the method is so well recognized that little need be stated here relative to it. In extraoral conductive anesthesia a most thorough knowledge of the anatomy of the parts involved is absolutely necessary to insure successful results.

The instruments used are either an all-glass or glass and metal syringe; one that can be thoroughly sterilized. Preferably an iridio-platinum needle, five cm. in length, is indicated. The anesthetic medium is a 2 per cent. novocain-suprarenin isotonic solution.

The extraoral injections must be made under the conditions of surgical cleanliness, otherwise either superficial or deep infection, or both, may follow. The skin of the parts where the needle is to be inserted should be cleansed with green soap followed by alcohol. The parts then should be painted with a 7 per cent. solution tincture of iodine.

The technic for local anesthetization of the lower jaw may be described as follows: The point of deposition of the anesthetic solution is the same as that in intraoral conductive anesthesia, namely, the pterygo-mandibular space. By palpating with thumb and fingers, the position of the lower border of the internal surface of the body of the mandible is ascertained. The needle is inserted two cm. anterior to the angle of the ramus and pointed toward the tragus of the ear. (*Fig. 109.*) A small amount of solution should be injected to anesthetize the superficial structures. The needle is then advanced toward and backward



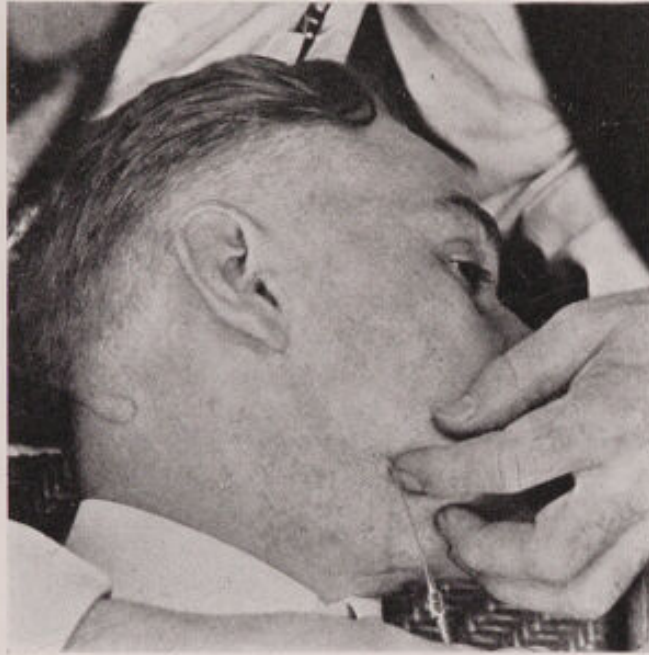

Fig 109

along the internal surface of the mandible, keeping as close to the bone as possible along the line of the mylohyoid groove for a distance of four cm. to the pterygomandibular space. Two cc. of the anesthetic solution is here deposited. If this technic is carried out successfully, no obstruction will be encountered by the needle in its path toward the pterygomandibular space. (*Fig. 110.*) It is an easy matter for the needle to strike the mylohyoid ridge and this should indicate that the needle is being passed in a false direction. It should be withdrawn and the direction of the needle changed. The path of the needle follows

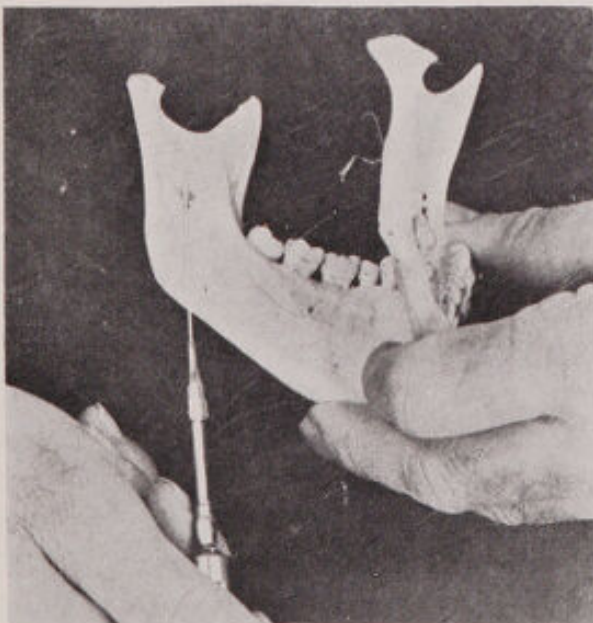

Fig. 110

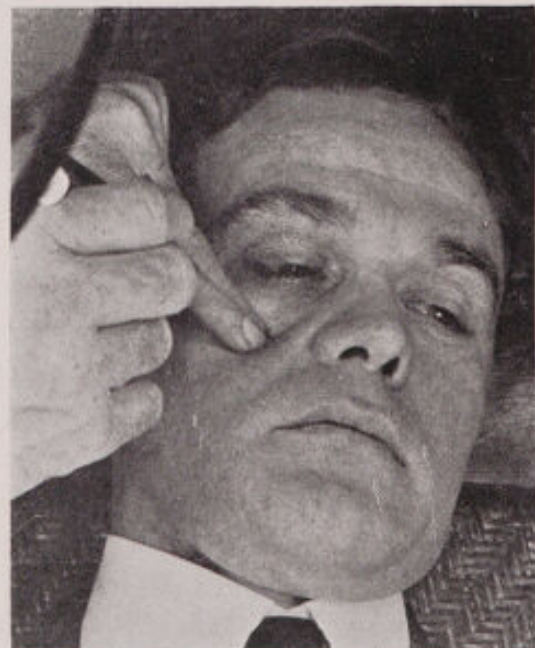


Fig. 111



along the line of the inferior alveolar nerve, and when it is advisable to anesthetize the lingual nerve the needle should be advanced one cm. further, which brings the point of the needle near to the place where the lingual nerve separates from the inferior alveolar nerve. One cc. of the anesthetic solution should be deposited here.

The anastomosis at the symphysis may be taken care of by blocking off the inferior alveolar nerve at the mental foramen of the opposite side. This may be accomplished either intraorally or extraorally. The technic of the extraoral method is as follows: The needle should be inserted one cm. below and three mm. anterior to the apex of the second bicuspid tooth. It should be advanced directly to the mental foramen, where one cc. of the anesthetic solution is deposited. The area anesthetized will be all of the lower jaw from the pterygomandibular space to the mental foramen. When it is desirable to anesthetize the anterior portion of the upper jaw, it can be done by blocking off the infraorbital

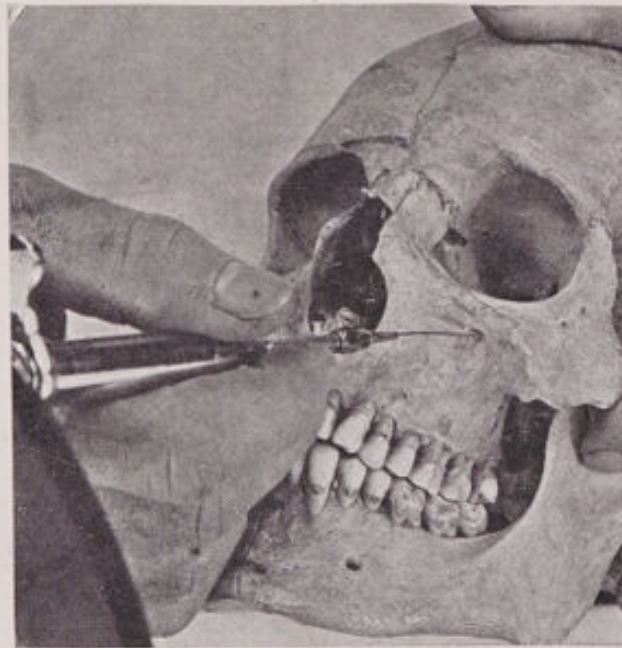

Fig. 112

nerve on one or both sides. The technic of this operation is as follows: By palpating about one cm. below the infraorbital margin on the anterior or facial surface of the superior maxilla, the infraorbital foramen may be felt. (*Fig. 111.*) After injecting five min. of the anesthetic solution around the foramen with a fine needle, we insert the point of the needle into the foramen and advanced it to the distance of one and one-half cm. (*Fig. 112.*) The needle should be directed slightly toward the median line. One cc. of the anesthetic solution is deposited in the infraorbital canal. Complete anesthesia may be obtained of the anterior portion of the maxilla by blocking off the nasopalatine nerve at the incisal foramen, one cm. posterior to the central incisor teeth.



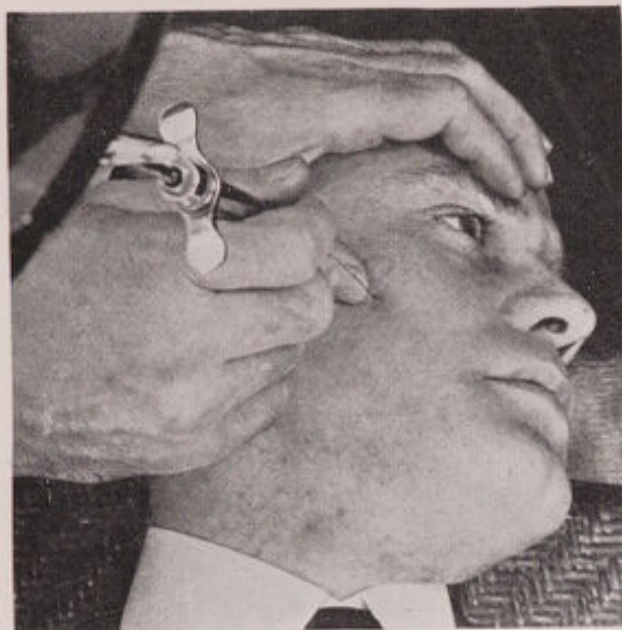


Fig. 113

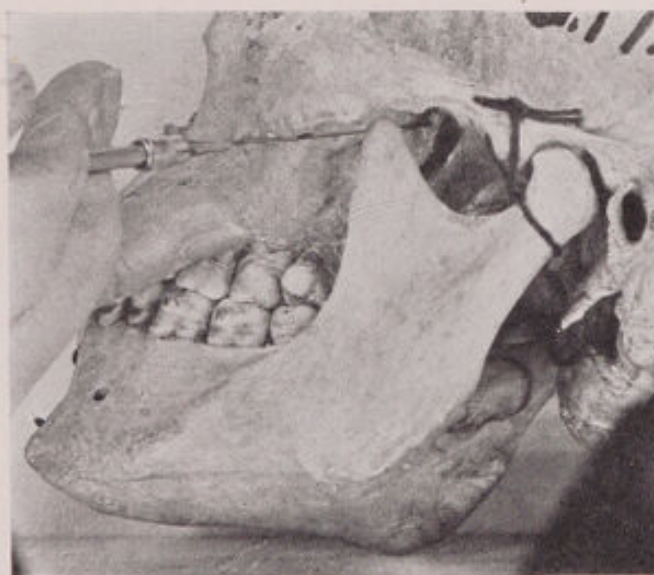


Fig. 114

On account of the difficulties of completely blocking off the whole maxillary division of the fifth nerve by the intraoral method, which is still further complicated in fractures of the maxilla, the extraoral method is most satisfactory in producing complete anesthesia of the parts supplied by this nerve.

The technic of this injection is as follows: The jaws should be closed. Beginning one cm. below the tragus of the ear, a horizontal line four cm. in length is drawn forward. The end of this line marks the place for the insertion of the needle. This point is immediately behind the lower angle of the malar bone. From this point the needle is inserted into the tissues (*Fig. 113*), and five min. of the anesthetic



solution deposited. The needle is advanced then through the masseter muscle until it comes in contact with the tuberosity of the maxillary bone, when it is advanced carefully along the surface of this bone. The needle should be inserted to a depth of four cm. when it passes into the sphenomaxillary fossa (*Fig. 114*), where two cc. of the anesthetic solution is deposited. The area anesthetized is the whole half of the maxilla. It usually is necessary to anesthetize both sides in the reduction of fractures of the maxilla.

The duration of the anesthesia is sufficient with any of these injections to complete any ordinary operation, the period being from forty-five minutes to two and one-half hours.

The period of waiting after completing the injection of the anesthetic solution should be from ten to twenty-five minutes.





















