

Elementary and dental radiography / by Howard Riley Raper ; with 354 illustrations.

Contributors

Raper, Howard Riley, 1886-1978.

Publication/Creation

New York : Consolidated Dental Mfg. Co.; [etc., etc.], 1913.

Persistent URL

<https://wellcomecollection.org/works/a4v5yxdp>

License and attribution

This work has been identified as being free of known restrictions under copyright law, including all related and neighbouring rights and is being made available under the Creative Commons, Public Domain Mark.

You can copy, modify, distribute and perform the work, even for commercial purposes, without asking permission.

**wellcome
collection**

Wellcome Collection
183 Euston Road
London NW1 2BE UK
T +44 (0)20 7611 8722
E library@wellcomecollection.org
<https://wellcomecollection.org>

616.314-073.75

ELEMENTARY
AND
DENTAL RADIOGRAPHY

HOWARD·RILEY·RAPER, D.D.S.

19.d



22102172055

61

Med

K42436

21 pages
p. 15.

24,541 CANCELLED

ELEMENTARY AND DENTAL RADIOGRAPHY

BY

HOWARD RILEY RAPER, D.D.S.

Professor of Roentgenology, Operative Technic, Materia Medica and Therapeutics at the Indiana Dental College, Indianapolis. Past Dental Surgeon to the Indiana School for the Feeble-Minded Youth. Member Institute of Dental Pedagogics, local, state and national dental societies. Associate member A. M. A., Section of Stomatology.

WITH 354 ILLUSTRATIONS

FIRST EDITION

Adopted as a Text-Book by the National Association of Dental Faculties


NEW YORK:

CONSOLIDATED DENTAL MFG. CO.

LONDON:

CLAUDIUS ASH, SONS & CO., LTD.

1913



odontologys
71428423

Copyright, 1913
By HOWARD R. RAPER

Copyright, 1913, in the United Kingdom
By CLAUDIUS ASH, SONS & CO., LTD., LONDON

WELLCOME INSTITUTE LIBRARY	
Coll.	weIMOmec
Call	
No.	WN

One of "his boys," the writer,
grasps this opportunity to show
his love and respect for
GEORGE EDWIN HUNT,
M.D., D.D.S.
by dedicating this book to him.



PREFACE.

The object of this book is to teach, first, the elementary principles of radiography; second, special dental radiography.

The first part of the book is written on the presumption that the reader knows nothing about electricity, photography, or the X-rays, and might therefore be used by anyone who wishes to take up radiographic work, whether a dentist or a physician. In dealing with the preliminary subjects mentioned, an earnest effort has been made to avoid useless, impractical and confusing elaboration.

The second part of the book is devoted to dental radiography, and is consequently of interest mainly to dentists and specialists in radiography who do work referred to them by dentists. It gives in detail the special technic involved in the practice of dental radiography, also a chapter with one hundred and eighty-three halftone illustrations, demonstrating sixty-four different uses to which the radiograph may be put in the practice of dentistry.

The use of the radiograph in the practice of modern dentistry is not a mere fad; it is a necessity, if one wishes to render the best dental service. Nothing but great good can come from its more frequent use. To the end of bringing about a more extensive use of the radiograph by dentists this work is published. At present it is the only work of its kind on the book market.

So many people have helped me in the compilation of this volume that I refrain from naming and thanking any particular individual. A publication of this kind, of necessity, represents the work of many.


June 5, 1913.

H. R. R.



CONTENTS

CHAPTER	PAGE
Elementary Radiography	
I. Electricity	1
II. X-Ray Machines	14
III. X-Ray Tubes and the X-Rays	41
IV. Making Radiographs	65
Dental Radiography	
V. Making Dental Radiographs	85
VI. Reading Radiographs	136
VII. The Uses of the Radiograph in Dentistry	146
VIII. The Dangers of the X-Ray	273
IX. Purchasing a Radiograph Outfit	292
X. Stereoscopic Radiography	297





Elementary and Dental Radiography.

CHAPTER I.

Electricity.

Dental radiography is the science and art of making pictures of the teeth and contiguous parts with the X-rays. Its place and value in the practice of modern dentistry will be dealt with later.

Before we can produce X-rays we must have at our disposal that something called electricity.

Electricity.

Electricity is a form of energy closely related to motion, light and heat. We know it is closely related to motion, light and heat because these forms of energy can be made to produce electricity, and electricity conversely can be made to produce them. Electricity is discernible to but one of the special senses, namely, feeling. It cannot be seen, heard, smelled or tasted. Victims of severe shocks have noted a peculiar taste, which they call the taste of the electricity, but it is my opinion, neither proved nor disproved as yet, that this taste is due to the presence of new chemical bodies formed in the saliva by electrolysis. In other words, the passage of the current of electricity through the saliva causes chemical changes to occur, resulting in the formation of new chemical bodies, and it is these new bodies, not the electricity, that produce a taste.

Conductors.

When electricity passes from one place to another the substance through which it passes is said to be a conductor. A substance through which electricity passes with great difficulty, when at all, is said to be a non-conductor. Metals are the best conductors of electricity. Silver is the best, then copper. Copper wire is the most used of any conductor of electricity. German silver carries electricity very reluctantly, and bismuth is the poorest conductor of the metals. It was formerly thought that electricity traveled on the surface of a conductor, but if this were true a round wire could be made to carry more current by simply flattening it and so making the surface greater; while, as a matter of fact,

the flattened wire would carry less, because of the condensation of the metal incident to flattening. The human body is a conductor. Wood, glass and vulcanite are examples of non-conductors.

When electricity passes from one place to another through a conductor, what is known as the electric current is established.

There are four kinds of electric currents: (1)

Currents. The continuous, constant, or direct current, commonly designated D.C.; (2) the pulsating; (3) the interrupted; (4) the alternating or oscillating, designated A.C.

The direct current is one in which the electricity is presumed to flow through the conductor in one direction at a uniform rate of pressure.

The pulsating current is one in which the electricity flows through the conductor in one direction, but at variable pressure.

The interrupted current is one in which the electricity flows through the conductor in one direction while in motion, but which is completely arrested in its flow at frequently recurrent intervals.

The alternating current is one in which the electricity flows through the conductor first in one direction, then in the other. When the current, flowing in a given direction, reverses, flows in the opposite direction, and then resumes its original direction of flow, it is said to have completed a cycle. The number of cycles occurring in a second determines the frequency of the current. We thus have, for example, a 60-cycle frequency current, making sixty complete alternations per second.

Electricity travels from one place to another be-

Potential. cause of a difference in potential. The term potential means latent, inactive, or stored-up energy.

Take lightning as an example of traveling electricity. Why does it occur? One cloud has a potential, figuratively speaking, of say 30, another of 20. These clouds approach close enough to one another so that electricity can jump the atmospheric gap between them, which it does, passing from the one with a potential of 30 to the one with a potential of 20 and equalizing the potential of each to 25. The light of lightning is caused by the resistance of the atmosphere to the passage of electricity. If such a thing were possible and an electric conductor stretched from the one cloud to the other, the potentials would be equalized as just described, but without the occurrence of the phenomenon called lightning, because the electricity would unostentatiously flow through the conductor instead of through the highly resistive atmosphere.

All electricity-producing machines then, simply create a comparatively high potential, so that when a path is afforded—*i. e.*, when conductors are attached to the machine—the electricity leaves, in its effort to equalize potential.

Velocity. Electricity travels at an inconceivably rapid rate of speed, instantaneous results being obtained hundreds of miles distant on pressure of a button. It is stated that the velocity of electricity is about the same as light, which latter travels about 186,000 miles per second. To comprehend this great speed compare it to the velocity of sound, which travels only 1,090 feet per second.

In dentistry and medicine the terms used can often be translated literally into their meaning. For example, "odontalgia" is a combination of two Greek words meaning tooth and pain; "tonsilectomy" is a combination of a Latin and a Greek word meaning tonsil and excision. Electrical terms are, however, derived principally from proper names. For example, volt, the unit of measurement of electric pressure, has no literal meaning at all, but is so called in honor of Alexander Volta, a great electrician. And so with the terms ohm, watt and ampere.

Volt. When electricity leaves the electricity-producing, or, if you choose, potential-creating, machine, it passes into the conductors at a given pressure.

This pressure is measured in volts, just as pressure in a water-pipe is measured in pounds. The volt, then, is the unit of measurement of pressure of electricity. Just what is a "unit of measurement"? Take, for example, the unit of linear measurement; it is called the "meter," and is one-ten-millionth of the distance from the equator to one of the earth's poles. The unit of linear measurement, then, the meter, is a definite name applied to a definite distance. So the volt is a definite name applied to a definite degree of electric pressure, or, which means the same as electric pressure, electromotive force, designated E.M.F. This force is sufficient to maintain a current of electricity of one ampere (the unit of measurement of volume of electricity) through a resistance of one ohm (the unit of measurement of resistance to the flow of current offered by an electric conductor). Let us then fix this firmly in our minds. The volt is the unit of measurement of electromotive force, or pressure. Though it is not commonly used, the writer much prefers the word "pressure" to "force," believing it to more clearly express the meaning.

Ohm. No conductor carries electricity without offering a certain amount of resistance to its flow. This resistance, which might be compared to the friction offered by the sides of a pipe to the flow of water, is measured in ohms. The ohm, then, is the unit of measurement of resistance offered to the flow of electricity by a conductor, and is equivalent of the resistance afforded by a column of mercury having a cross-section of one square millimeter and a length of 106.28 centimeters, at a temperature of 0° C.

We have considered pressure and resistance. **Ampere.** Now we come to the energy itself, which may be compared to the water in a water-pipe, and is measured in amperes. The ampere capacity of an electric conductor corresponds to the cross-section of a water-pipe, which latter is measured in square inches. Thus the larger the pipe, which means, of course, more square inches in its cross-section, the more water it will carry; and so the larger the electric conductor of a given material the greater its ampere capacity, and the more electricity it will carry.




FIG. 1

The analogy between the water in the water-pipe and the electricity in the conductor is not perfect, however. A given-sized pipe will carry a column of water of a given cross-section and no more, because water is practically non-compressible. When the flow of the water is opposed to gravity, as when drawing water from a faucet, this complete cross-section must be obtained, too—that is, the pipe must be full—before any pressure will establish a current through the pipe. Not so with electricity in a conductor. A wire which has a normal capacity of say 30 amperes will carry a current of 10, and it can be made to carry 40 or 50 by increasing the pressure, because electricity is compressible.

Amperage, or the volume of electricity carried in a conductor, depends on two things—the pressure of the current and the resistance of the conductor. Hence Ohm's law, which is that the volume of the current can be obtained by dividing the pressure by the resistance. In other words, the amperage can be obtained by dividing the volts by the ohms.

Problem: An electromotive pressure of 100 volts is acting against a resistance of 50 ohms. What is the ampere strength of the current?

Solution: 100 volts divided by 50 ohms equals 2 amperes.

To give the exact amount of electricity represented by the ampere, it is that amount which, when passed through a standard solution of silver nitrate in distilled water, will cause a deposition of metallic silver at the rate of 1.118 milligrams per second.

Watt.

Electromotive power (not electromotive pressure or force; note the word "power"), or the ability of a current to do work, depends on two things—the pressure measured in volts and the volume measured in amperes. This is also true in hydraulics. The amount of work a stream of water will do depends on pressure and volume. The watt is the unit of meas-

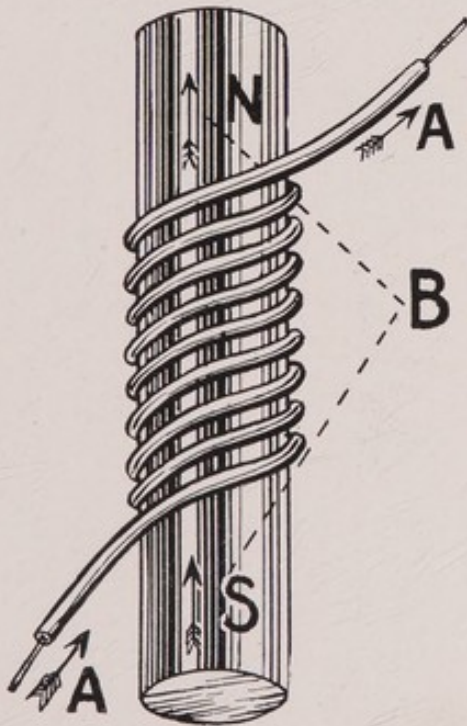


Fig. 2.

Fig. 2. Arrows A represent the direction of flow of electric current. Arrows B represent the direction of flow of magnetic flux in the magnet.

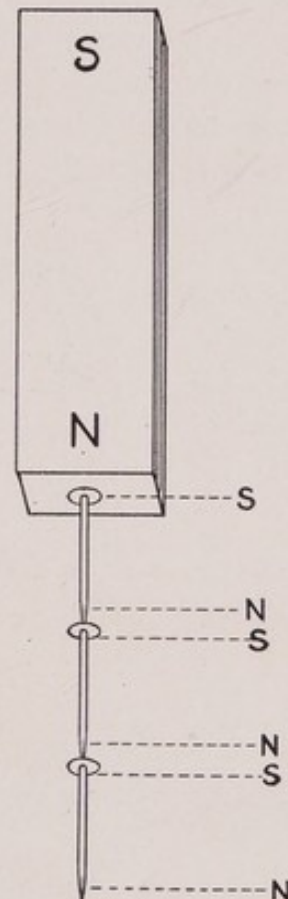


Fig. 3.

Fig. 3. Bar magnet with polarity indicated.

urement of electromotive power, and the wattage of a current is obtained by multiplying the volts by the amperes. Thus, if we had a current of one ampere under a pressure of one volt, one watt would be operative.

When 1,000 watts are active for an hour—that is, when a current 1,000 watts strong has been in motion, the current turned on, for one hour—the electrometer will register one kilowatt-hour. So bills for electricity are made out for so many kilowatt-hours.

Magnetism.

Magnetism is a form of kinetic energy very closely related in its nature to electricity. Magnetism produces electricity, and vice versa.

The substance in which this energy, or property, magnetism, resides is called a magnet.

If a bar of magnetized steel be dropped into iron filings, and then raised, the filings will adhere to the ends of the bar, but not to the center. (Fig. 1.)

The ends of the bar represent, respectively, the north, or positive, and the south, or negative, poles of the magnet. If, now, this bar be broken at its exact center, instead of having a half magnet all north pole and another half magnet all south pole, we have two magnets with two poles each. If one of these magnets be broken at its center the same thing occurs, namely, two magnets, each one-half as large as the first,

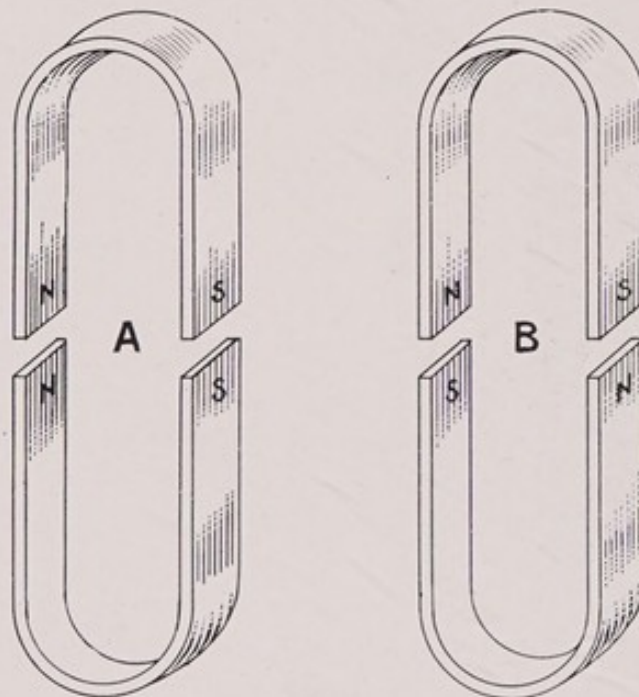


Fig. 4. When poles are arranged as in A repulsion exists between the magnets. When poles are arranged as in B the magnets are attracted to one another with the magnetic flux of each north pole flowing into the south pole of the other magnet.

are made. This redivision can be repeated down to the molecule, which would have a north and a south pole.

Magnets are of two kinds—the natural magnet, or “loadstone,” and the artificial magnet.

The earth may be considered a large magnet, the poles of this magnet being near the north and south poles of the earth. The natural magnet is iron ore, found in nature with all the properties of the magnet, and representing a portion of the great magnet, the earth.

Artificial magnets are of four kinds—the electro-magnet, the permanent magnet and the induced magnet.

If a bar of soft iron be wrapped with insulated wire (wire covered with a nonconductor) and a current of electricity be sent through the wire, the iron bar becomes magnetized while the current passes through the conductor, but loses its magnetism when the current ceases to flow. Such a magnet is called an electro-magnet. (Fig. 2.) If the current be sent through the conductor in the opposite direction to that shown in the diagram, polarity of the magnet will be changed: the north pole will become the south pole and the south pole the north pole.

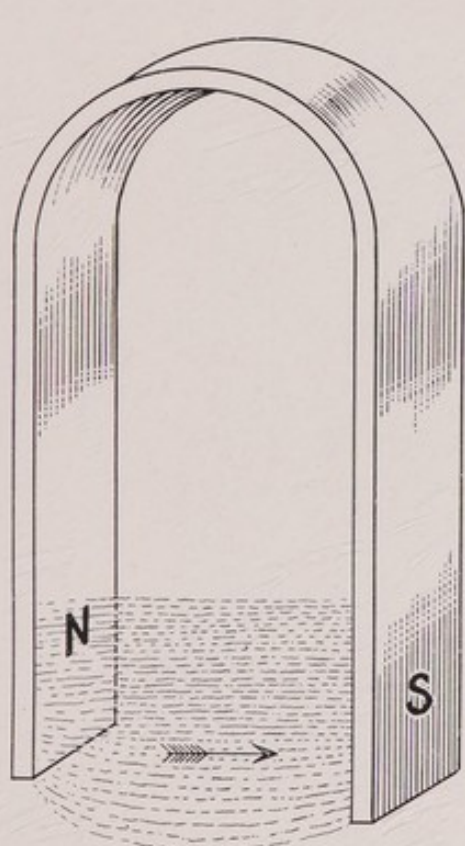


Fig. 5.




Fig. 6.

If hard steel, instead of soft iron, be used as the core and wrapped with insulated wire and a current of electricity be sent through the wire for a great length of time, then the current shut off and the wire removed, it will be found that the steel retains its magnetism and will continue to retain it over a number of years. Such a magnet is called a permanent magnet (Figs. 1 and 4, for example), though it is not actually permanent and will lose its magnetism in time. The permanent magnet in greatest general use is the "horseshoe" magnet (Figs 4 and 5), which is simply the bar magnet (Figs. 1 and 3) bent into horseshoe or staple shape.

Instead of using the electric current, a permanent magnet can be made by rubbing hard steel with another magnet.

Fig. 3 shows a magnet holding three nails. As long as the magnet

remains in contact with the first nail it will hold the second nail, and the second will hold the third. But remove the magnet and no attraction exists between the nails. While the magnet touches the first nail each nail is an induced magnet, with a north and south pole, as shown in the figure.

While either the north or south pole of a magnet will attract a piece of unmagnetized iron or steel, only unlike poles of two magnets will be attracted to one another. Thus, if two north or two south poles of magnets be brought in close proximity repulsion instead of attraction exists between them. (Fig. 4.)

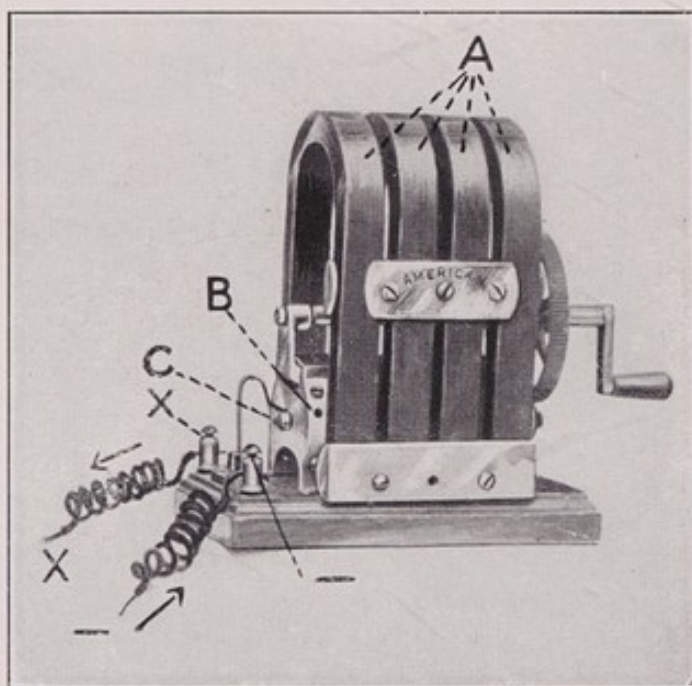


Fig. 7. Magneto-Dynamo. A, the magnets or field. B, casting surrounding revolving conductor or armature. C, appliance for outlet of electricity from armature. An alternating current is generated by this machine.

In 1831 Faraday discovered that when an electric conductor is set in motion so as to cut the lines of force of the magnet at right angles, an electric current is induced in the conductor.

Fig. 5 shows the lines of force of a horseshoe magnet passing from the north to the south pole. Imagine now a spool wrapped with copper wire, not as thread is wound around a spool, but lengthwise of the spool, the wire passing over its ends. Place this spool between the poles of the magnet, revolve it on its axis, and the copper wire—that is, the electric conductor—is made to cut the force of the magnet at right angles and an alternating current of electricity will be produced in the wire (Fig. 6), the current flowing in opposite directions as the different poles are passed.

Add to this arrangement a means for carrying the current away from the apparatus and we have the magneto-dynamo, now very extensively used in automobiles. (Fig. 7.)

Dynamos.

Dynamos may be divided into two classes: the magneto-dynamo, just described, and the electro-dynamo.




Fig. 8. A Direct Current Generator or Electro-Dynamo.

All dynamos consist of three cardinal parts, to wit: the field, or magnets; the armature, or revolving conductor, and the rings, or appliance for carrying off the electricity. If the current sent out is direct instead of alternating, a commutator instead of rings must be used. A commutator is an appliance which changes the alternating current induced in the armature into a direct current as it leaves the dynamo.

The electro-dynamo, an example of which is shown in Fig. 8, differs in principle from the magneto-dynamo only in the kind of magnets used. Permanent magnets are used in the magneto-dynamo, whereas electro-magnets are used in the electro-dynamo.

Immense electro-dynamos, or generators, as they are called, make

our commercial currents, steam power being used to revolve their armatures. By commercial current is meant the electric current supplied to us by the electric light and power companies.

Let us trace a current of electricity through what is known as the electric circuit. When the armature is revolved the potential at C, of




Fig. 9. Six Pole Direct Current Generator, parts disassembled. E, electro-magnets with poles of different denominations directly opposite one another—the field. Large alternating current generators have as many as 40 poles in the field which revolves, the armature remaining stationary. A, armature. C, commutator.

Fig. 7, rises. The potential of the positive wire attached to binding post + (which post is connected to C) is instantly raised to that of C, and the current ceases to flow, potential being equalized between the armature and the positive wire. If now the positive wire of the high potential be brought in contact with the negative wire, which is of low potential, the current flows into the latter. The negative wire is attached to the negative binding post, which is connected to the magnets themselves. Thus the current passes through the negative wire into the magnets, which have a low potential. The current will continue to flow, making a circuit from C, out through the positive wire, back through the negative wire, into the magnets until their (the magnets') potential is raised

to that of C. If an incandescent light bulb be connected to the positive and negative wires the current will pass from the positive wire, through the bulb, and into the negative wire. As the electricity passes through the bulb it heats the filament of carbon to incandescence, producing light and some heat. Most of the electricity is used up in the production of the light and heat—this is true if the circuit is what is called “well balanced”—but what is not, travels in the negative wire toward the magnet, equalizing potential until it dissipates itself in the effort.

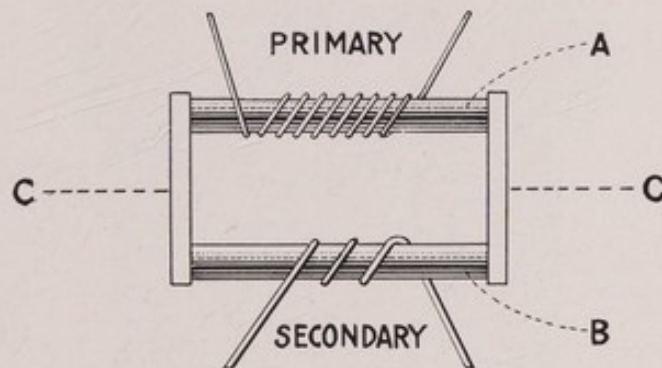


Fig. 10. Diagram of a step-down transformer.

Commercial circuits supply either a D.C. (direct current) or an A.C. (alternating current). The wiring from the D.C. dynamo to the consumer is an intricate problem, difficult to understand. It is enough for us to know that the D.C. is supplied, as a rule, only to downtown districts of cities, by a circuit giving 110 volts pressure, or a special three-wire circuit, which supplies either 110 or 220 volts, according to the manner of the connections made to the mains. The amperage depends on the size of the wires; the more amperage desired the larger the wires connecting to the mains must be.

The A.C. leaves the generator at a voltage of from 1,000 to 3,000 and flows in the mains at this pressure. Such great pressure is both dangerous and uselessly high for ordinary uses, such as lighting, running motors, operating X-ray machines and the like. So, by means of a transformer, the voltage is reduced to any desired strength, usually from 100 to 125 volts. The commercial A.C. is either 60 or 133-cycle, usually 60.

Since the principle involved in the transformer is quite similar to the one met with in X-ray machines a description of it would not be out of place in this work. Fig. 10 shows the plan of construction of a transformer. A represents an iron core, around which is wrapped insulated wire. This is the primary winding through which passes the primary current at the high voltage of from 1,000 to 3,000. As always, the amperage depends on the size of the wire. B represents another iron

core, around which is also wrapped insulated wire. This is the secondary winding, through which the secondary current passes. C shows soft iron connections between the two cores.

When the electric current is established in the primary winding a current is set up or induced in the secondary winding. Bear in mind there is no electric connection between primary and secondary windings.




Fig. 11. A Transformer.

The primary current enters, and leaves unaltered except for a slight loss in amperage, but in its passage it induces a current in the secondary.

If the wire used in the secondary winding be of the same length and size as that used in the primary winding, the induced secondary current will be of practically the same voltage and amperage as the primary current. But if the wire in the secondary be shorter and larger, the induced current will be lower in voltage and higher in amperage. Or if the wire of the secondary winding be longer and smaller than the wire in the primary winding, the induced secondary current will be higher in voltage and lower in amperage than the primary current. The wattages of the primary and secondary currents remain practically the same. For example, suppose the voltage of the primary current is 1,000, the amperage 5, the wattage would be 5,000. Suppose now, by means of the

transformer, the voltage is lowered to 100; there would be a raise in amperage to 50. Notice the wattage remains the same, 5,000. The figures do not represent what actually happens, since they do not take into account the loss of current due to the internal or intrinsic resistance of the transformer, but they do represent roughly the general principle of the action of the transformer.

A transformer which lowers voltage—the kind used on A.C. circuits between mains and consumer—is known as step-down transformer; one which raises voltage is a step-up transformer.

The transformer does not alter the nature of the current. That is, the secondary is an alternating current, the same as the primary, the change being only in voltage and amperage. Transformers cannot be used on a direct current.

The foregoing is calculated to give the reader a speaking acquaintance with electricity, the wonderful force which produces X-rays. Further treatises of the subject will be made as necessity demands. It will be noted that but one source of electricity has been considered, namely, dynamo electricity—that furnished by light and power companies. Be it known, however, that electricity can be produced by means other than the dynamo—by friction and chemical change, for examples. We have considered only the source of electricity which is used to operate the X-ray coils.

CHAPTER II.

X-Ray Machines.

It was stated in Chapter I that an electric current is necessary to produce X-rays, but nothing was said concerning the strength of the current required. It takes a current very high in voltage, varying from 30,000 to 300,000 or more volts, and low in amperage, the amperage being measured in milliamperes.

The ordinary commercial circuit for lighting purposes is almost invariably either D.C., 110 volts, or A.C., 60-cycle, 100 to 125 volts. The amperage varies according to the amount of electromotive power needed, ranging from 4 to 5 to over 100 amperes. The commercial current, *as supplied*, is therefore useless. However, it will operate a machine which will give the desired current.

X-Ray Machines.

X-ray machines are of two classes: Those that generate their own electricity without any external electric supply, and those that depend on a commercial current or storage batteries to excite them.

There is but one of the first class, namely, the static machine (Fig. 12), and of the second class there are three—the Ruhmkorff coil (Fig. 13), the high frequency or Tesla coil (Fig. 14), and the "interrupterless" coil (Fig. 15). All of the latter class are literally induction coils, just as the transformer, described in Chapter I, is an induction coil, but when the term induction coil is used we may assume that it is the Ruhmkorff coil that is referred to. We shall follow the precedent and call the Ruhmkorff coil the induction coil, though it is no more an induction coil than the high-frequency or "interrupterless" coils.

The static machine is so much inferior to the induction coil for picture work, and so large and difficult to operate, compared with any coil, that the only reason for using it would be the lack of a commercial current with which to operate a coil. Even in such an event—the lack of a commercial current—I would advise the use of an induction coil operated by storage batteries (Fig. 16) in preference to the static machine.

**Induction
Coil.**

The induction coil is the most popular apparatus for giving the electric current necessary for X-ray picture work. It is a step-up transformer to this extent, namely, its primary current is of comparatively low voltage and high amperage, while the secondary is very high in voltage and low in amperage. It differs from the transformer in mechanical construction, and also in that the primary current must be an interrupted current, and the secondary, induced current is



Fig. 12. A static machine.

practically a uni-directional one. It will be recalled that the primary and secondary currents of the transformer are both alternating.

Installation.

Let us trace a current of electricity from the mains through an induction coil and auxiliary appliance leading to it. (Fig. 17.)

Wiring from the mains to the coil should always be done by a competent electrician. A wire of a given size will carry only a certain amperage without heating. If this amperage be exceeded greatly the wire

may become hot enough to set fire to surrounding building material of a combustible nature. There are, therefore, laws governing the size of wires to be used to carry different amperages. Coils are rated by their manufacturers to consume a certain number of amperes, and wiring




Fig. 13. Induction or Ruhmkorff coil.

should be done according to this rating. The amount of amperage necessary to operate a coil varies directly according to the size of the coil—the larger the coil the more amperes it takes. Assuming the coil to be of a medium large size, the lead wires used to connect it to the mains should be capable of carrying at least 30 amperes without heating. By “lead wires” I mean the wires leading to the machine—not lead (the metal) wires. The wires are copper.

Fuses.

Somewhere near where the wires enter the building, and also at the coil itself, will be found fuses. (Fig. 18.) A fuse is a wire, an alloy of lead, of a given size, and fusing point capable of carrying only a limited amperage without melting. Thus, if more than 30 amperes be sent through a 30-ampere fuse, the wire is heated to its fusing point, it melts, the circuit is broken, and the flow of electricity is stopped. A fuse is a




Fig. 14. High-frequency coil.

sort of safety valve. About 30 ampere fuses should be used for a medium large induction coil. This information, however, will always be given by the manufacturers of the coil.

Switches.

Somewhere near where the wires enter the building, and also at the coil, are placed switches. An electric switch (Fig. 19) is an appliance for throwing the electric current into, and out, of an extended or auxiliary circuit.

Assuming that the current at our disposal is D.C., it must first be passed through an interrupter.

Interrupters.

An interrupter is an electric apparatus by means of which a constant current is converted into an interrupted one. Interrupters are of three kinds: (1) The electrolytic, Fig. 20; (2) the mercury turbine, Fig. 21, and (3) the mechanical or vibrator, Fig. 22.

For picture work, in connection with the induction coil, the electrolytic, or, as it is sometimes called in honor of the inventor, the Wehnelt interrupter, is quite the best. With it the constant current may be

interrupted at the rate of from 60 to 30 000 interruptions per minute. The mercury turbine gives from 200 to 3,600 interruptions per minute, and the vibrator from 250 to 1,000 interruptions a minute.




Fig. 15. Interrupterless coil.

The electrolytic interrupter consists of a glass jar containing a solution of sulphuric acid in water, the electrolyte, in which is immersed a platinum point electrode, A (Fig. 20), and a lead electrode, B. The platinum is covered with a porcelain sheath, C, except for its point, which projects into the electrolyte. Little or much of the point may be exposed in the acid by the regulating arm, D.

We have two wires now leading from the mains to our apparatus.

Of these one is the positive wire which brings the electric current, and the other is the negative or return wire. The positive wire must be attached to the binding post of the platinum electrode, marked +. (Fig




Fig. 16. Induction coil for use with storage cells.

20.) But how can we tell which is the positive wire? Cut some of the insulation off the ends of the wires, immerse them in a glass of water, and bubbles will be given off from the negative wire. When making this test, care should be taken not to touch one wire to the other, so making a short circuit. The term (short circuit) almost explains itself. The desired circuit in this instance is from the positive wire, through the water, which is highly resistive to the flow of electricity, into the negative wire and back to the mains. Suppose that the wires come in contact

(that portion of the wires from which the insulation has been removed), the current no longer passes through the water, but takes the shorter path of less resistance, passing directly from positive to negative wire. All the amperage formerly used and choked back by the resistive water flows through the wires, heating them rapidly.

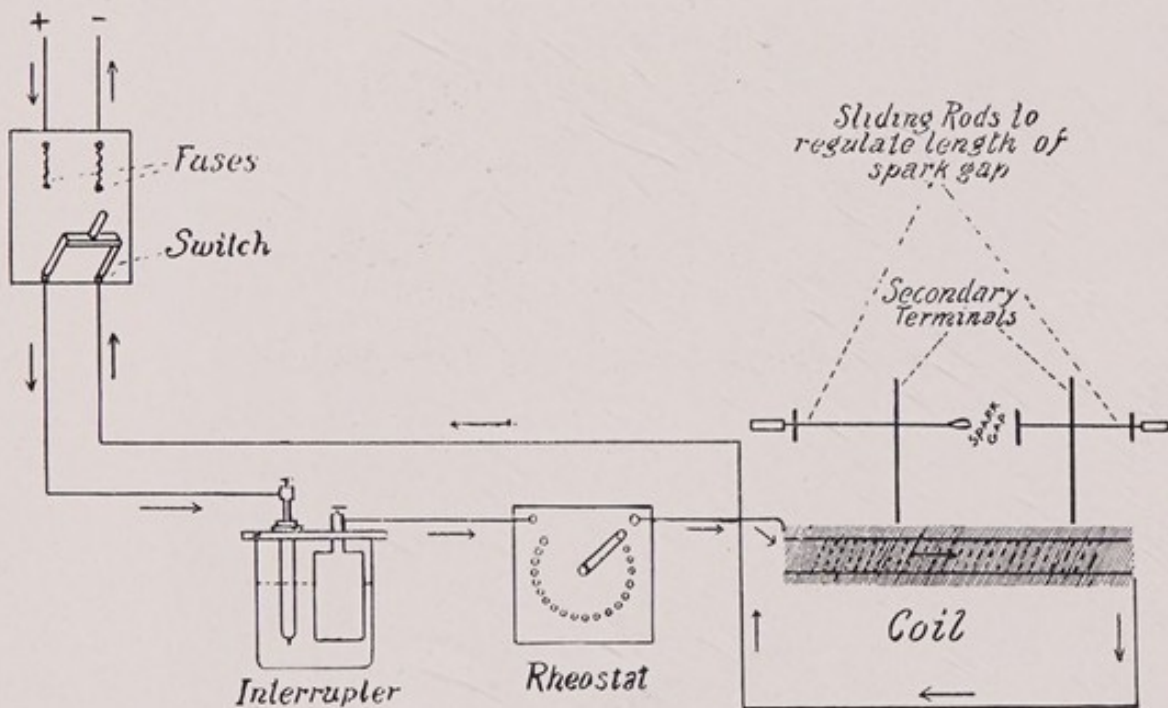


Fig. 17.

The course of the electric current, through the electrolytic interrupter, is from platinum through the acid electrolyte, and on through the lead electrode. As the current flows through the acid solution, a chemical change occurs and a gas is formed. This gas accumulates in the form of a bubble around the exposed platinum point, and momentarily stops the flow of the current. Then the bubble bursts and the current is re-established only to be stopped again in the manner just described, and so on. The more platinum exposed in the solution the slower the interruptions and the more amperage will pass through the interrupter. In order that the amperage may be increased without producing a corresponding decrease in the number of interruptions per minute, interrupters are made with several platinum points. (Fig. 23.) Thus with a multi-point interrupter, when more amperage is desired, more points are thrown into the circuit by means of small switches for the purpose. A two-point

interrupter will draw enough amperage, and give sufficiently rapid interruptions, for dental radiographic work.

The current is sometimes stopped altogether by the interrupter. This may be due to the accumulation of a large bubble of gas, on the platinum point, which will not burst. By moving the point—or points if the inter-




Fig. 18. Patent fuses or cutouts.

rupter is multipointed—up and down several times by means of lever D, Fig. 20, the bubble will be broken and the current re-established.

On a D.C., 110-volt circuit the electrolyte should be 15 to 20 per cent. acid; on a D.C., 220-volt circuit, from 5 to 8 per cent. is strong enough. The jar should be one-half or three-quarters full. As the solution stands, some of the water evaporates, so raising the per cent. of acid in the electrolyte. As this occurs, more water should be added. The strength of the solution can be easily and accurately determined by means of a special hydrometer. (Fig. 24.) As the water evaporates, and the solution gets stronger, its specific gravity raises. The hydrometer is sensitive to this change of specific gravity, and shows by a special marking the exact per cent. of the solution.

As the current passes through the interrupter, heat is produced. Hence the glass jar is placed in a metal-lined box, and the box filled with water. (Fig. 23.) Even with this means for cooling, when used continuously for fifteen minutes or longer, the electrolyte becomes so heated that the interrupter no longer works properly. In dental picture work, though, the time of operation is a matter of seconds. It, therefore, will be understood that no trouble ever occurs due to heating of the electrolyte.

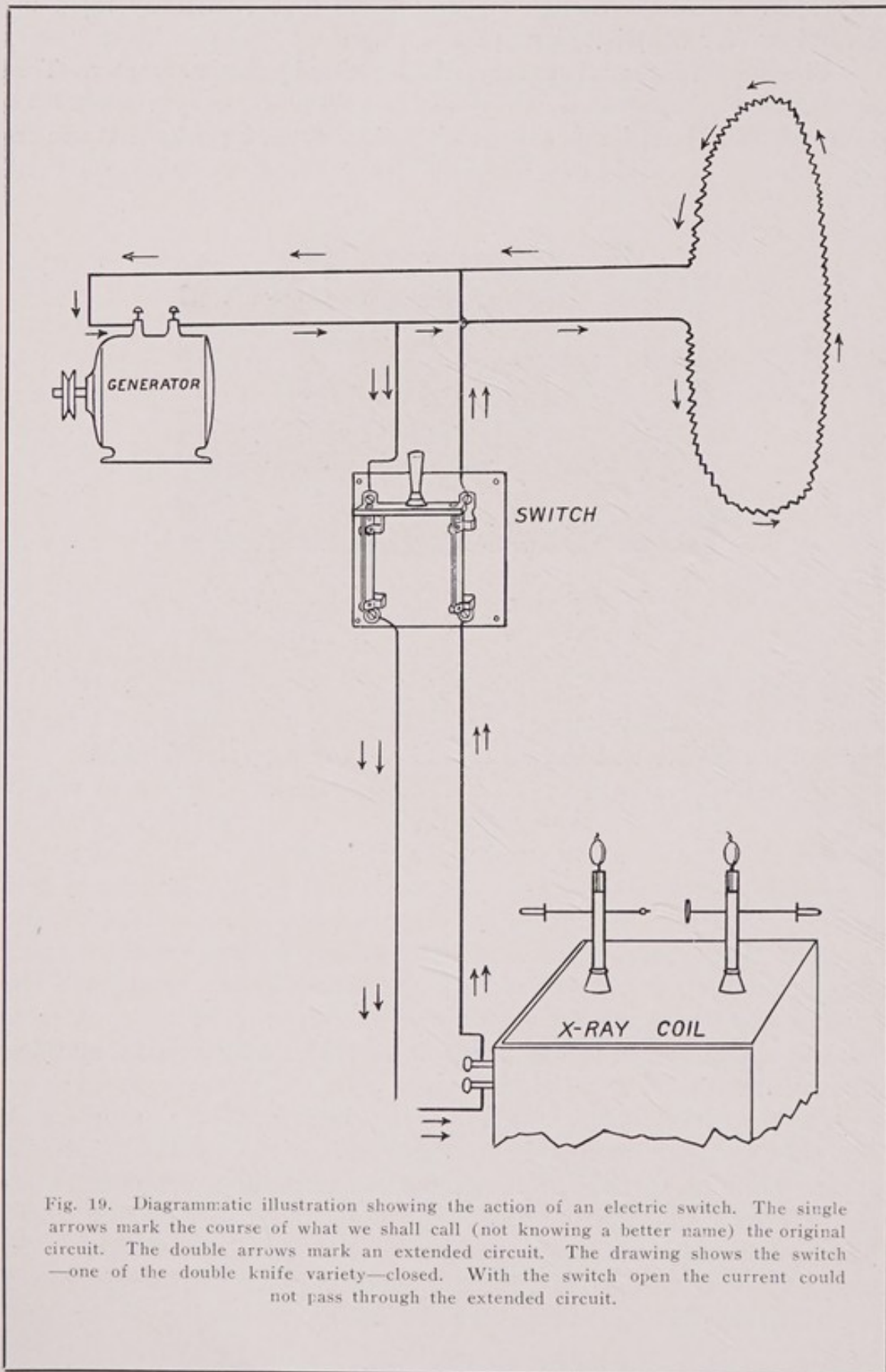


Fig. 19. Diagrammatic illustration showing the action of an electric switch. The single arrows mark the course of what we shall call (not knowing a better name) the original circuit. The double arrows mark an extended circuit. The drawing shows the switch—one of the double knife variety—closed. With the switch open the current could not pass through the extended circuit.

When the X-rays are used for their therapeutic value, long exposures are made; so long that undue heating of the electrolytic interrupter would be sure to occur. Hence, for this work the mercury turbine interrupter (Fig. 21) is best. In principle the mercury turbine is a mechanical interrupter, depending on no chemical change for its action, being operated by means of an electric motor. We shall not consider it




Fig. 20. Non-water cooled one-point electrolytic interrupter.

further, for it should not be used for picture work, except in the absence of an electrolytic interrupter.

The mechanical interrupter, or vibrator (Fig. 22), is used only on the smallest coils. The principle on which it operates is the one involved in the construction of electric bells; Fig. 25 illustrates the principle. A is a movable arm with fulcrum at B. When the current travels, the path marked with arrows, the electro-magnet, C, draws the movable arm, A, over to it, breaking the circuit at D. When the circuit is broken the electro-magnet loses its magnetism and the spring, E, draws the movable arm back, re-establishing the circuit. The rapidity of interruptions may be regulated by altering the strength of the spring. A popular form of vibrator is the ribbon vibrator illustrated in Fig. 26.

Rectifier.

In tracing the current directly from the supply wire into the interrupter, we have assumed, as stated, that we are receiving our supply from a D.C. circuit. Suppose, however, that the only current at our disposal is A.C., as is often the case. It is necessary to send the alternating current through a rectifier (Fig. 27) before allowing it to enter the interrupter.

A rectifier is an electrical apparatus by means of which an alternating current is converted into a uni-directional, pulsating current, and




Fig. 21. Mercury turbine interrupter.

consists of a glass jar containing an electrolyte, a solution of ammonium phosphate usually, in which is immersed a steel electrode and an aluminum electrode. The jar, the electrolyte, and the two electrodes constitute one cell. Fig. 27 shows a one-cell rectifier.

With the direct current, we are able to test and determine which of the two lead wires is positive. This is impossible with the alternating current, because polarity changes at each alternation. Either of the lead wires may therefore be attached to the steel electrode, and a wire connected from the aluminum electrode to the platinum of the interrupter. As long as the aluminum remains the negative electrode of the rectifier, the current flows from steel to aluminum and on, but when the current reverses and starts to flow from aluminum to steel, a chemical change occurs in the aluminum, making it a non-conductor and choking off the flow. Thus a current of 60-cycle frequency, after passing through a one-cell rectifier, becomes practically (there is a slight inverse current) a

uni-directional current with 30 interruptions per second. If, after passing through the rectifier, as just described, the current is an interrupted one, the questions arise: Why send it through an interrupter? Why not directly on to the coil? Because the interruptions are not sharp and complete enough. The current is pulsating rather than interrupted.

By connecting three or four rectifier cells in a certain way (Fig. 28), we are able to obtain practically a uni-directional, constant current.

If the supply current is 60-cycle, as is usually the case, the electrolyte in the interrupter remains the same as for a D.C., 110-volt circuit, namely,




Fig. 22. Vibrator or mechanical interrupter.

about 20 per cent., but if the A.C. supply is 133-cycle, the solution should be stronger—about 30 per cent.

From the interrupter the current passes into the rheostat, as per Fig. 17.

Rheostat.

A rheostat (Fig. 29) is an apparatus by the use of which we are enabled to regulate the quantity of electricity entering an electric machine. The rheostat does not have much effect on voltage.

Fig. 30 illustrates the rheostat. A represents coils of wire, often German silver, offering great resistance to the flow of electricity. When the arm, B, is on button 1, the current must pass through all the resistive wire on its way to the electric machine, induction coil, motor, or what not. This resistive wire chokes back amperage. On button, 2, there is less resistance; on button, 3 still less, until on the last button the current passes directly into the machine. The rheostat illustrated acts

also as a switch, completely breaking the current when the arm, B, is on button, o.

From the rheostat the current passes into the coil proper, follows the wire of the primary winding, and passes back through the negative lead wire to the mains.




Fig. 23. Seven-point electrolytic interrupter, water-cooled.

A different method of wiring to that shown in Fig. 17 is illustrated in Fig. 31. At first glance it seems that the primary current is not interrupted, the interrupter being on the negative wire with the current passing through it after passing through the coil. But since the current cannot enter the coil any faster than it leaves, the manner of its exit will govern its entrance, and hence the current of the primary is interrupted just the same, whether the interrupter be placed on the positive or negative lead wire.

Coil.

The coil consists of a soft iron, cylindrical core, around which is wrapped insulated copper wire, the primary winding. (Fig. 32.) (The necessity for good insulation will be appreciated if we stop to consider what would

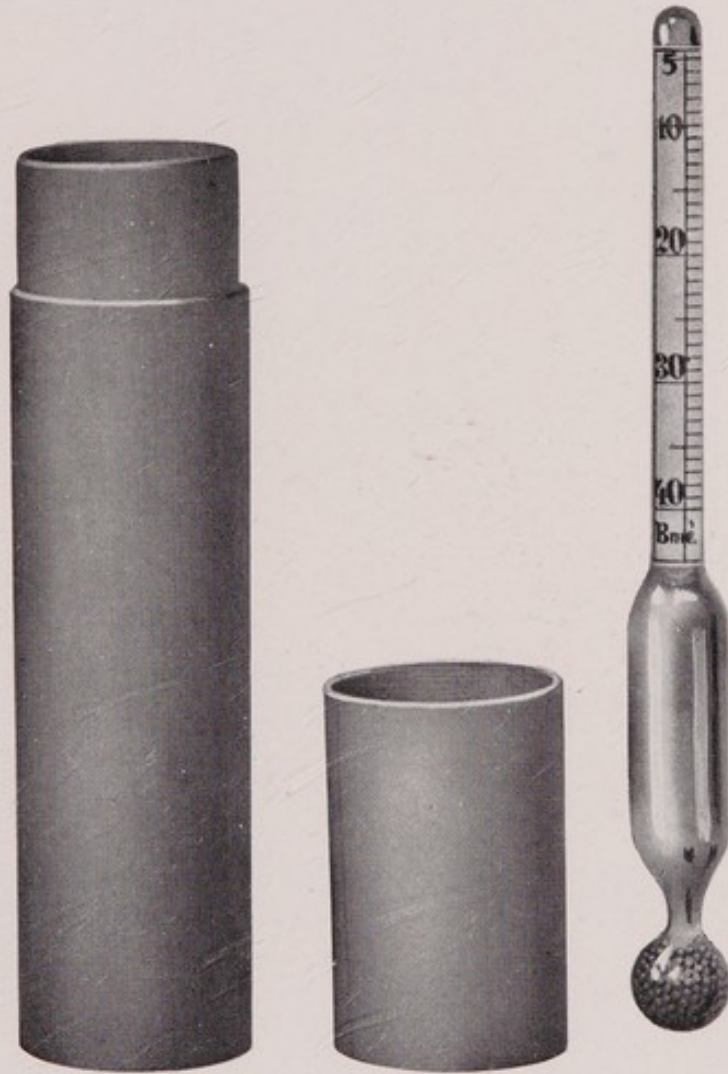


Fig. 24. Acid hydrometer.

happen if the core were wound with uninsulated wire. If this were done the current would not follow the windings of the wire at all, but would choose the shorter path of less resistance, passing along the iron core, making a short circuit.) Over the primary winding is placed a heavy insulation of mica or vulcanite, and around this is wound more insulated wire, the secondary winding. (Figs. 32 and 33.)

There is positively no electric connection between the primary and secondary windings. The primary current passes through the primary

winding and into the negative lead wire. But in its passage it has induced or created a secondary current in the secondary winding.

Coils are rated and designated according to the maximum number of inches of atmosphere the secondary current can be made to jump. As the current jumps from one terminal to the other of the secondary winding, a spark occurs, due to the resistance of the atmosphere to the

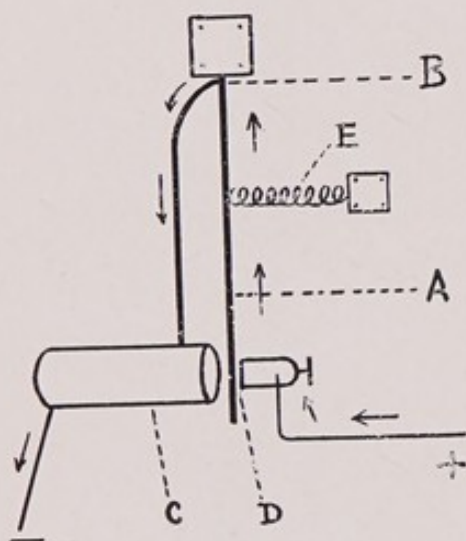


Fig. 25.

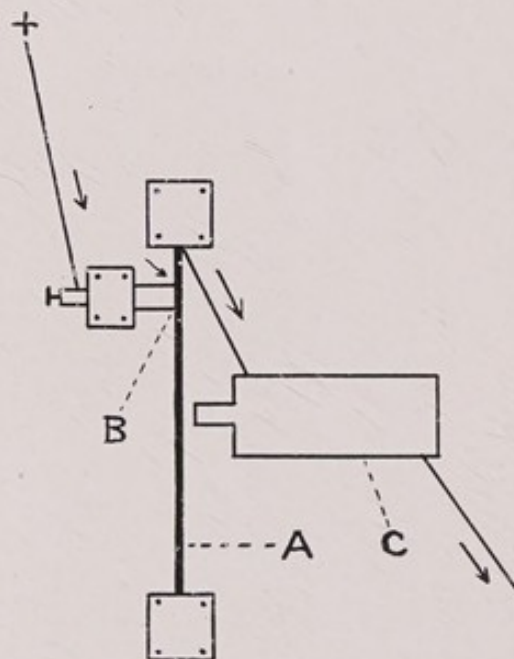


Fig. 26.

Fig. 25. A, movable arm with fulcrum at B. C, electro-magnet. D, break. E, spring.
Fig. 26. A, piece of ribbon steel. B, point where circuit is broken. C, electro-magnet.

flow of the current. When we speak of a coil as, say a 12-inch coil, we mean that the spark gap of that coil is twelve inches long; that its secondary current can be made to jump twelve inches of atmosphere. The larger the coil the longer the spark gap. From 6-inch to as high as 40-inch coils are manufactured. From 8-inch to about 18-inch coils are the sizes generally used.

The wire of the primary winding is from 12- to 8-gauge; of the secondary from 34- to 29-gauge. The length of the windings varies according to the size of the coil, of course. The wire in the primary of a 12-inch coil is about 100 feet long, in the secondary about 28 miles long. The wire in the primary of an 18-inch coil is about 140 feet, and in the secondary 38 miles long.




Fig. 27. One-cell rectifier.




Fig. 28. Three-cell rectifier.

At each "make" and "break" of the circuit of the primary current, a current is induced in the secondary. The secondary current induced at the break of the primary flows in the same direction as the current in the primary, while the current induced at the make flows in the opposite direction. Thus the secondary is an alternating current; but the current of the make is so much weaker than the current of the break that, for practical purpose, the secondary may be considered a uni-directional, pul-

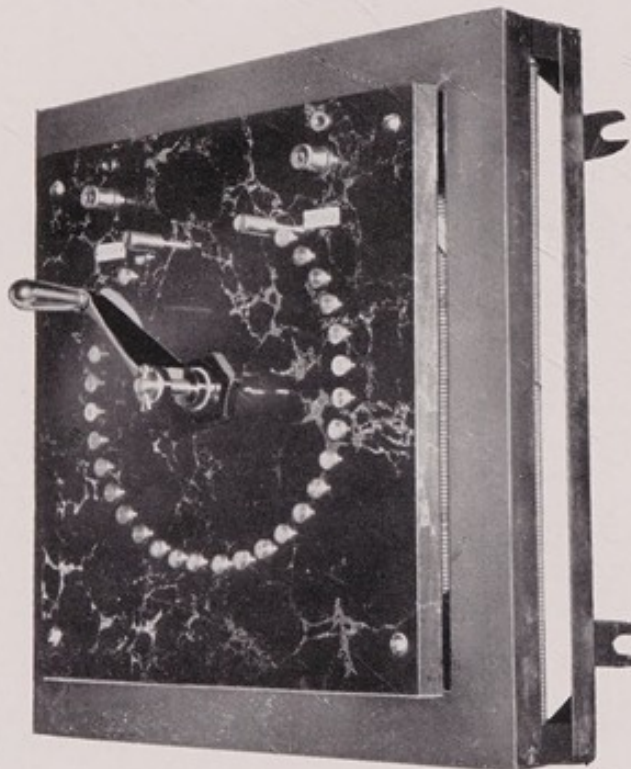


Fig. 29. Twenty-nine button rheostat.

sating current. The current of the make is what is known as the inverse current, and it is the effort of all coil manufacturers to make a coil giving as little inverse current as possible.

The voltage of the secondary current cannot be determined accurately. Authorities differ very greatly in their estimate of the number of volts required to jump one inch of atmosphere, giving the figure as low as 10,000, and as high as 60,000. What voltage is required to jump each succeeding inch after the first, is also a question shrouded in very great uncertainty.

Estimating each inch of atmosphere at 10,000 volts, which perhaps is getting as near the truth as possible at the present time, the voltage

furnished by any size coil can easily be determined. Figuring on this basis, an 8-inch coil in full operation supplies a current with a potential of 80,000 volts; a 20-inch coil, 200,000 volts.

The amperage, or, to be more exact, the milliamperage of the secondary current of an induction coil varies according to the resistance

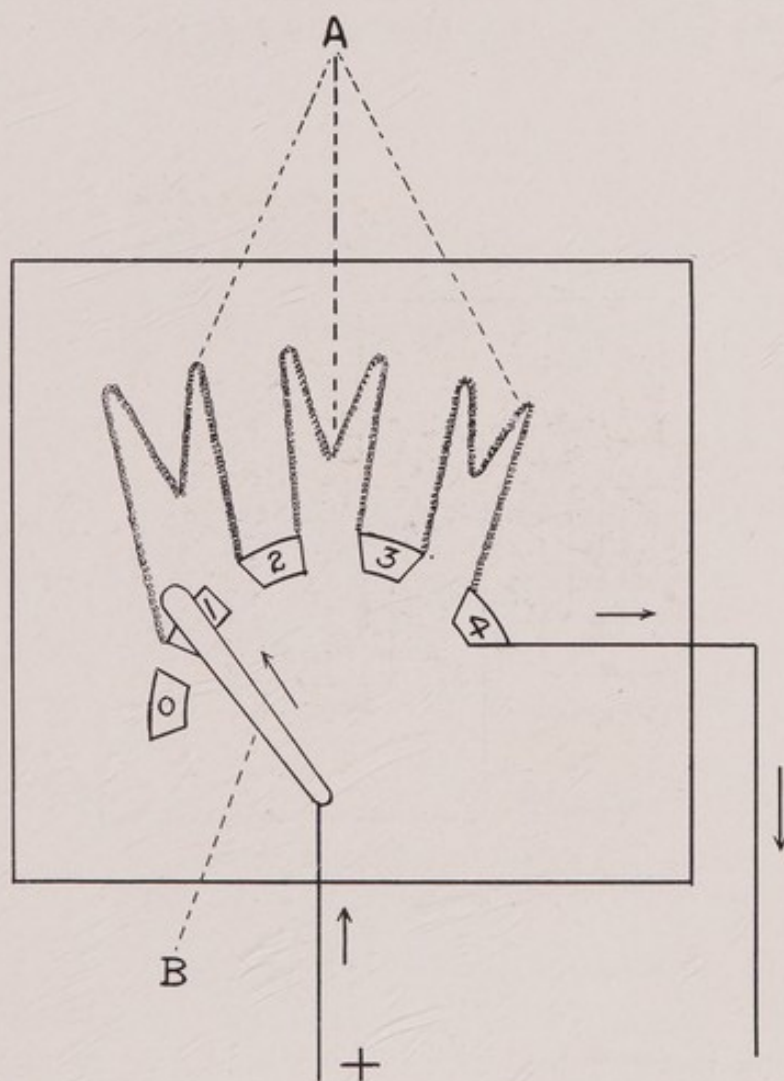


Fig. 30. Diagram of rheostat.

through which the current is forced. Thus, allowing the rheostat to remain on the same button, the milliamperage is increased or decreased accordingly as the spark gap (Fig. 17) is shortened or lengthened. With the spark gap at its maximum length, the milliamperage is least. As the sliding rods are pushed closer to one another, so lessening the length of the spark gap, milliamperage increases. Different coils are capable of forcing different milliamperages through their maximum length of spark gap. Thus one 10-inch coil may be able to force twenty milliamperes

through ten inches of atmosphere, while another could send only two milliamperes through such a resistance. All coils give a high milliamperage on a short spark gap, the amount running into hundreds of milliamperes. Instead of the sliding rods, some coils have an arrangement, as per Fig. 34, for regulating the length of spark gap.

The milliamperage strength can be estimated roughly by the appearance of the spark. A thin, blue spark indicates low amperage. A

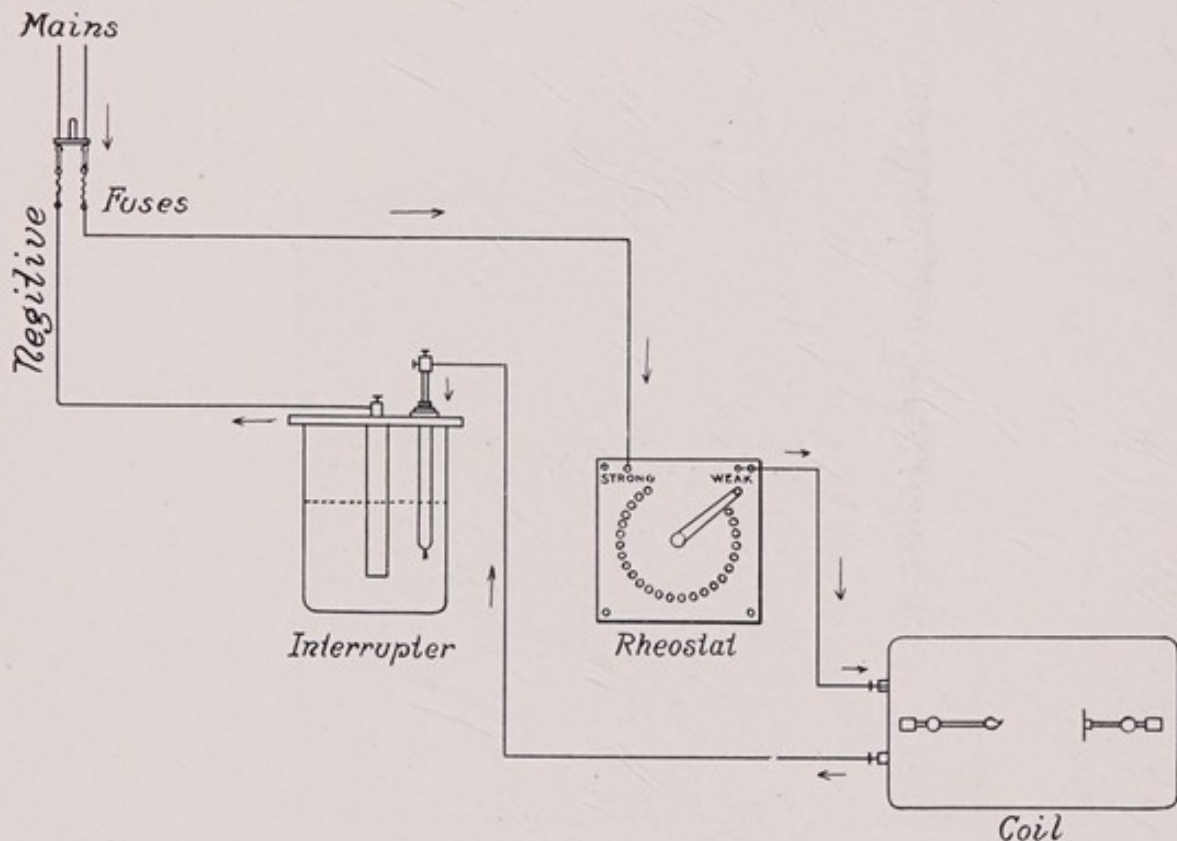


Fig. 31.

fat, fuzzy spark, the caterpillar spark, indicates high milliamperage. To do rapid dental radiographic work a coil should give at least six inches of the fat, fuzzy spark.

Amperemeters and milliamperemeters are used on the primary and secondary currents, respectively, to measure their volume. (Fig. 13.) While these meters may be considered luxuries rather than necessities, they are certainly very useful luxuries.

Coils Dangerous.

How dangerous are the currents of an induction coil? is a question often asked. Both primary and secondary currents of an induction coil are dangerous. The larger the coil the greater the danger. If one should come in contact with a terminal of the coil, he would receive a severe, painful shock. It would be much more severe and painful if

the victim happened to be standing on a conductor, for then the current would pass entirely through the body into the conductor. If one should come in contact with both terminals of a large coil, so that the entire current would pass through the body, the accident might result fatally.

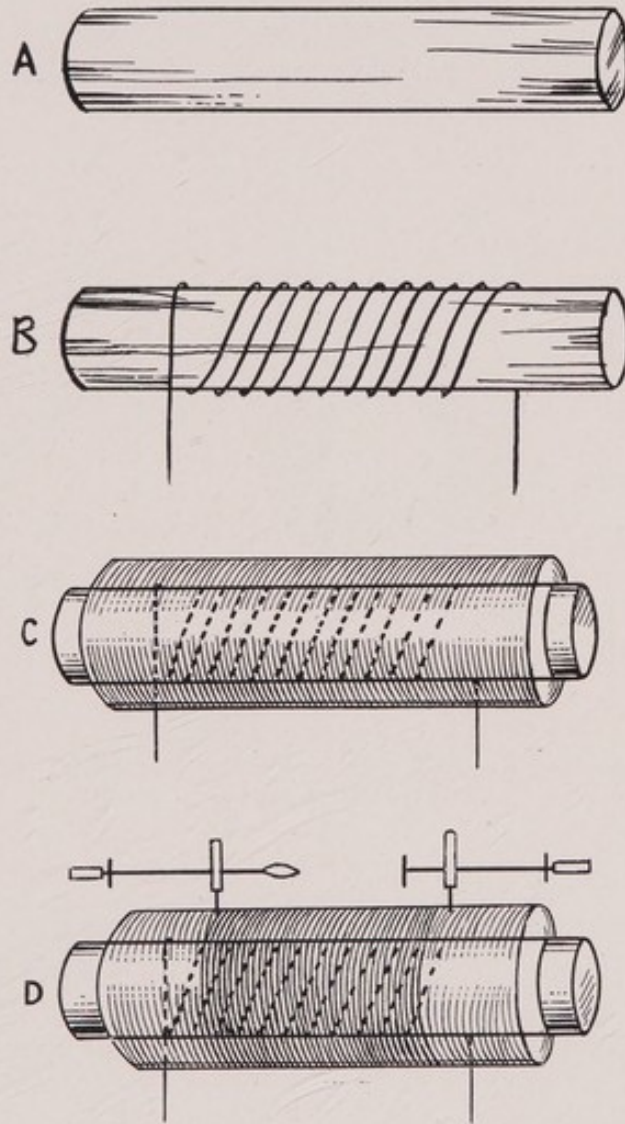


Fig. 22.

A, iron core. B, iron core with primary winding. C, iron core, primary winding and insulation. D, iron core, primary winding, insulation and secondary winding.

High-Frequency Coil.

Now let us consider the high-frequency coil. (Figs. 14 and 35.) In mechanical construction the high-frequency coil may be considered a kind of double coil with the secondary of the first coil acting as the primary of the second coil. The primary current of the first coil should be A.C.

From the supply wire the current passes through the primary winding of a step-up transformer (first coil) at the usual commercial 100 to 125 volts, 60-cycle. (Fig. 35.) An alternating current of the same frequency as the primary, but higher in voltage and lower in amperage, is generated in the secondary of the transformer, and passes into the condenser, which acts as a reservoir. As the current leaves the condenser and jumps the regulating spark gap, it is oscillating at a frequency of

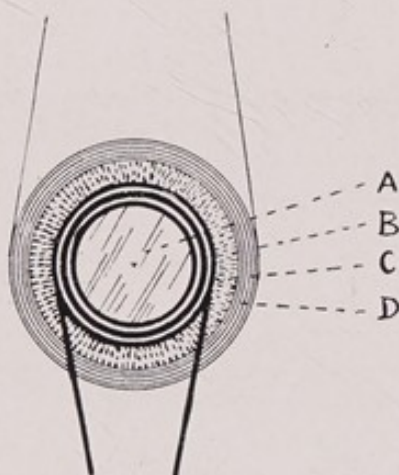


Fig. 33

Cross-section diagram of induction coil. A, iron core. B, primary winding. C, insulation. D, secondary winding.

from 10,000 to more than a million. It passes through the primary winding of the Tesla coil, inducing a secondary current of the same high frequency. This Tesla coil is the same as an induction coil (Figs. 32 and 33), except that some inert substance, instead of soft iron, is used for the core.

The secondary current of the second coil is the one supplied by the machine, the one to be used to generate X-rays. Like the current of the Ruhmkorff, or induction coil, this current is high in voltage and low in amperage. The current of the induction coil is, however, practically a uni-directional one, while the current supplied by the high-frequency coil is alternating at the inconceivably high frequency of tens of thousands or millions. Hence the term "high frequency," which is applied to the current and the coil producing it.

The frequency is governed by the size of the condenser; the smaller the condenser the higher the frequency. Thus most "high-frequency and X-ray machines" are equipped with a switch, by means of which all, or

a part, of the condenser may be used. When using the coil for X-ray work, this switch should be turned to "low frequency," so that all of the condenser is used. When using the coil for "high-frequency" treatments—using the current as a therapeutic agent—the switch should be on "high frequency," so that only a part of the condenser is used.

By means of the regulating spark gap, we can control to an extent the secondary current of the second coil—the current supplied by the

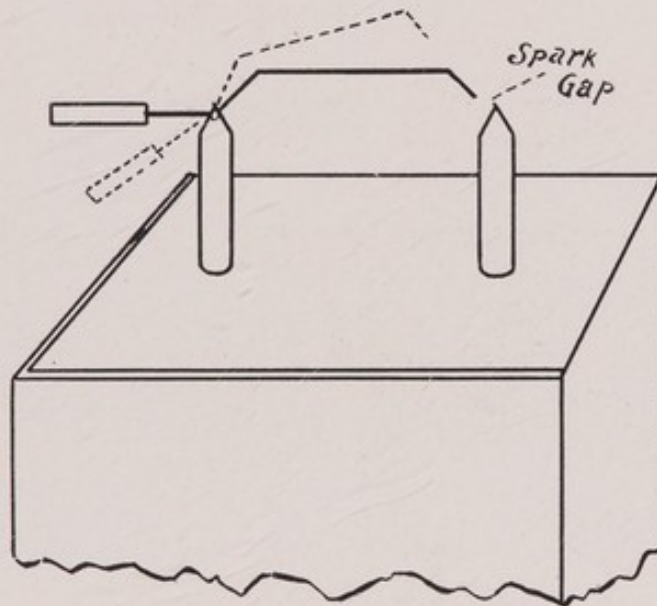


Fig. 34.

machine for use. Widening the gap increases voltage at the expense of the amperage; narrowing the gap increases amperage at the expense of the voltage. The wattage remains the same. For X-ray work the gap should be as short as possible, without reducing the voltage to a point where the current will not pass through the X-ray tube.

The ideal current for exciting an X-ray tube (in other words, producing X-rays) is a uni-directional one. Compared with that of the high-frequency coil the current of the induction coil more nearly approaches this ideal. Because of this, the writer advises the use of the induction coil in preference to the high-frequency coil, unless a very small machine is desired. We thus eliminate large high-frequency coils from further consideration.

The small, portable, suitcase, high-frequency coils called "X-ray and high-frequency coils," may be used where the lack of space makes the installment of a larger machine impossible or undesirable, when a transportable coil is wanted, and when the purchaser wishes to make the minimum cash investment.

As stated, the primary, or supply, current of a coil, built on the high-frequency plan illustrated, should be A.C. When attaching the portable coil (Fig. 14) on an A.C. circuit, therefore, all that needs to be done is to screw the attachment into a lamp socket.

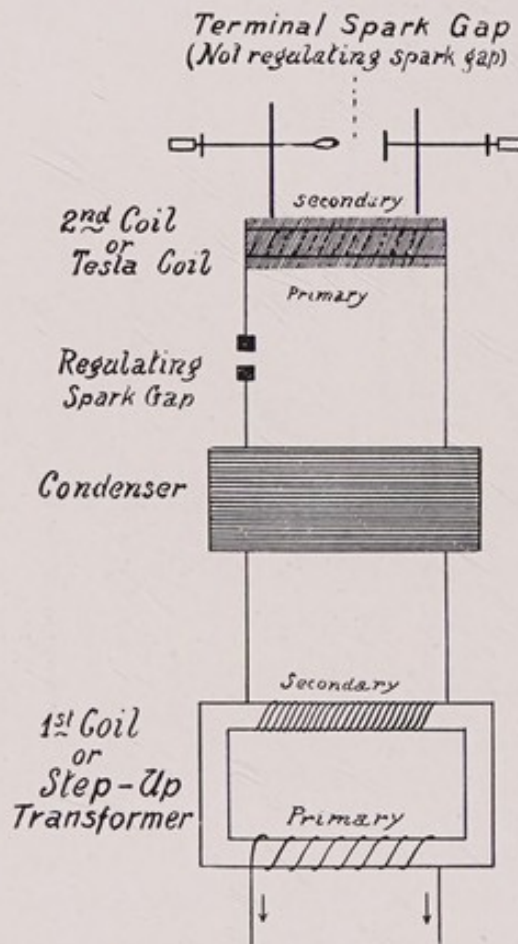


Fig. 35.

Rotary Converter.

When the supply current is D.C., a rotary converter should be used. A rotary converter (Fig. 36) consists of an electric motor set in motion by the supply current, which motor in turn revolves the armature of an A.C. dynamo, which generates the electricity that is sent into the coil. Instead of having the D.C. motor and the A.C. generator as separate machines connected by a common shaft, so that movement of the armature of one machine revolves the armature of the other, the rotary converter can be made so as to be enclosed in one casing. (Fig. 15.)

Tracing the current, as per Fig. 37, coming through the fuse and switch, the current passes through the positive wire to the starting box

or rheostat. It leaves the starting box through two wires, passing through one to the field of the motor marked S.F., through the other to the armature of the motor, marked ARM, and out of the motor through the negative lead wire. A new circuit is formed from the generator side of the converter marked A.C., passing through the coil.

It may be well to state just here that an electric motor is, in construction, practically the same as a dynamo or generator. In fact, taking




Fig. 36. Rotary converter, or motor-dynamo.

a given machine, it may be used as either a dynamo or a motor. If its armature is revolved by some power, it will generate electricity, and it is then a dynamo; if a current of electricity is sent into its field and armature, the armature revolves; and it is then an electric motor. Motors are made to be operated by both D.C. and A.C. circuits; that is, we have D.C. motors which can be run only by a direct current, and A.C. motors which can be excited only by an alternating current.

Instead of a rotary converter, some machines are equipped with a mechanical vibrator (Fig. 22), which interrupts the current as it enters the coil. This is not so efficacious as the converter. Machines with the mechanical interrupter are advertised to operate on either A.C. or D.C. circuits.

The length of the spark gaps of portable machines varies from four to ten inches. They are seldom able to give a fat, fuzzy spark longer than half the length of the spark gap. The full-length spark is almost always thin and blue.

**Danger of
Currents.**

As a general proposition the alternating is the most dangerous of electric currents. Mysterious and surprising as it is, however, high-frequency currents, such as high-frequency coils produce, are much less dangerous than the current of an induction coil. If one should touch a

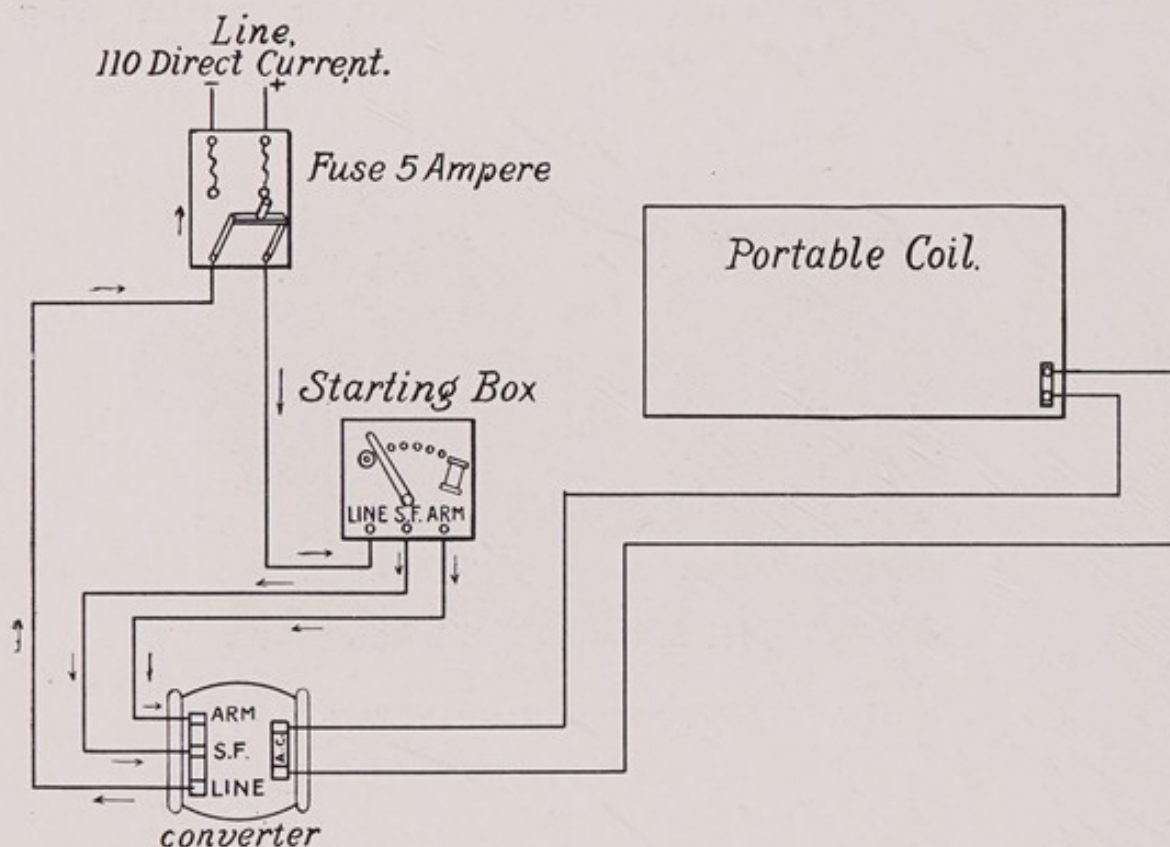


Fig. 37.

terminal of a high-frequency coil a spark would jump to the hand just as it came within sparking distance of the terminal. This spark might make a blister, but if the experimenter had been standing on a non-conductor, no further discomfort would be felt. Indeed, one may take a small steel bar and, standing on a non-conductor, touch a terminal of the coil and so take into the body enough current to cause great injury, if it were of the nature of the induction coil, without receiving any sensation at all. If he should stand on a conductor, however, the shock would be painful. If he should grasp both terminals, so that the entire current passed through the body, the result would be severe pain and probably injury. The larger the coil the more dangerous the current.

The primary current of the portable high-frequency coils is not as dangerous as the primary current of the stationary induction coils, be-

cause they draw only from three to ten amperes, while the induction coils seldom draw less than twenty and as high as sixty amperes.

**Interrupterless
Coil.**

The "interrupterless" coil, or transformer, as it is often called (Fig. 15), is the newest and perhaps the most powerful X-ray machine made. On the market these coils are known by such trade names as "The Snook Roentgen Apparatus," "The Peerless Roentgen Apparatus," "The Solace Interrupterless."




Fig. 38. Interrupterless coil, showing switch and rheostat, rotary converter, transformer and rectifying switch.

The interrupterless coil consists of a rotary converter, a step-up transformer, and a rectifier switch. (Fig. 38.) The step-up transformer may be of the closed magnetic circuit core type (Fig. 10), or the open core type (Fig. 32). These machines are of two kinds: Those built to be operated on a D.C. circuit, and those designed for the A.C. circuit.

Let us consider the former first: The converter is set in motion by the commercial direct current. It generates an alternating current, which is sent through the primary of the transformer. The induced current in the secondary is of the proper voltage and amperage for X-ray work, but it is alternating. It should be direct. It is made so by means of the rectifying switch, and is then an ideal current for X-ray work. The rectifying switch is a revolving mechanical device similar to a commutator in principle.

The A.C. machine is similar to the D.C. machine, the principal difference being the addition of an A.C. motor. An alternating current motor transmits mechanical power to the "rotary converter," which, in this case, becomes simply an A.C. generator, not, strictly speaking, a rotary converter, though it is usually so called.

Since the supply current is alternating, and it is an alternating current that must be sent into the primary of the coil, one may logically ask, Why not send the commercial current directly into the primary, instead of operating an A.C. motor, which, in turn, revolves the armature of an A.C. generator, which produces the current which is sent into the coil? The answer is that the rectifier switch must work in synchronism with the generator, which supplies the current to the coil. In other words, the rectifier switch must be on the same shaft, and revolve in unison with the generator in order to rectify the alternating current induced in the secondary winding of the coil.

The interrupterless coils are rated according to the amount of "energy" they create, not according to their spark gap length. The spark gap is usually ten or twelve inches long. The machines are rated to have a capacity of so many kilowatts. Take a "4 kilowatt" machine, for example. Its primary current, we will say, is 100 volts, 40 amperes (4,000 watts), the secondary current something like 100,000 volts, 40 milliamperes (4,000 watts). This system of rating is being adopted by manufacturers of induction coils also.

CHAPTER III.

X-Ray Tubes and the X-Rays.

Thus far we have considered only the electric phase of the subject. We shall now describe the apparatus through which the electricity is passed, and which generates the X-rays, namely the X-ray tube.

An X-ray tube is a bulbular glass tube, from which the atmosphere has been exhausted to quite a high degree of vacuum—about 1/1,000,000 part of an atmosphere. It should be remembered that there is a something which occupies all space, even vacua, and that something is known as ether. There is, of course, ether in the X-ray tube. X-ray tubes are often called Crooke's tubes, but they resemble the tube made by Professor Crooke only in having a high degree of vacuum. In mechanical construction they are quite different.

Tubes may be divided into two classes: those designed to be used on an induction coil or interrupterless coil, and those made to be used on a high-frequency coil. We shall describe the former first.

Sealed in the X-ray tube are the anode, Fig. 39, A (also called anti-cathode and target), and the cathode, B. The anode is usually flat, placed at an angle of 45 degrees to the long axis of the tube, and made of some high-fusing metal, such as platinum, iridio-platinum or tantalum. The cathode is concave, saucer shape, and usually made of aluminum.

Since, in connecting the tube to the coil, it is necessary to attach the connecting terminal tape or wire from the positive side of the coil to the target end of the tube, we must be able to determine which is the positive terminal of the coil. This may be done on an induction coil, as follows: Cut out the resistance of the rheostat, adjust the sliding rods to about one-half the distance of the maximum spark gap, and throw on the switch. The spark will jump the gap so quickly that it is impossible to learn by simple observation in which direction it is traveling. By watch-

ing the large disc terminal, however, this can be determined. If on throwing the switch on and off the spark is noticed to cling to the edge of the disc *always*, then the current is passing from the disc. If, however, the spark occurs from the surface of the disc just as the current is turned on (it may then seek the edges), the current is traveling from the small bulb to the disc. (Fig. 40.)

With the tube properly connected to the coil as per Fig. 41, the current is shunted (Fig. 42) through the tube, instead of jumping the

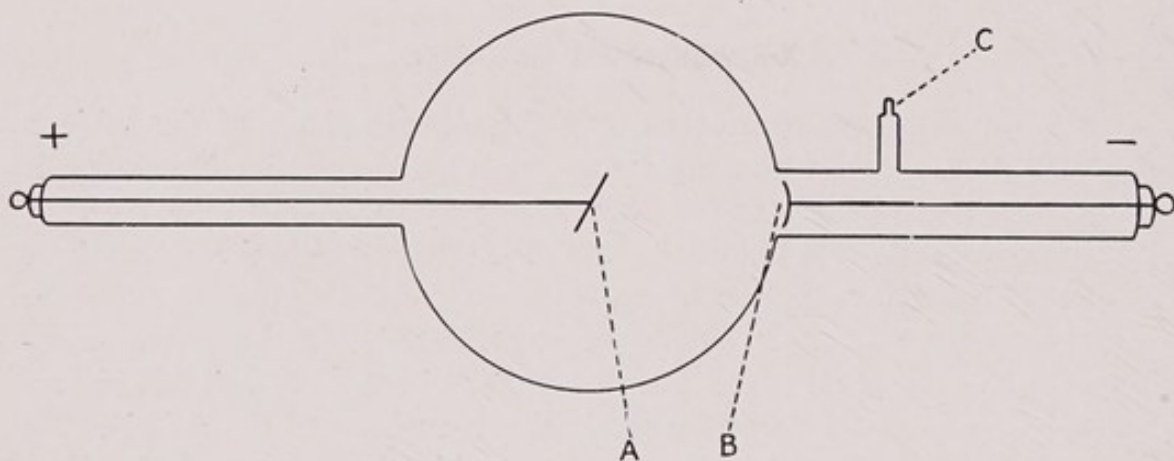


Fig. 39. A, anode. B, cathode. C, point at which the atmosphere was pumped from the tube.

spark gap, passing from anode to cathode. Whether the current will choose the path through the tube or jump the spark gap depends on which offers the less resistance. A current of electricity always travels the path of least resistance.

Tubes are designated according to the degree of their vacuum. Thus we have the high or hard tube, in which the vacuum is well-nigh complete; the medium tube in which the vacuum is less complete, and the soft or low tube, in which the vacuum is least complete. High tubes offer the greatest resistance to the passage of the electric current through them, then comes the medium, while the low vacuum tube offers the least resistance. For dental picture work a tube should be high or medium, preferably high.

The operator may determine whether a tube is hard, medium or soft, as follows: Connect the tube to the coil. (Fig. 41.) Separate the sliding rods to give a spark gap of two or three inches and turn on the current. Unless the tube is very low indeed, the current will jump the spark gap instead of passing through the tube. Let us suppose the cur-

rent does jump the spark gap. Now widen the gap a little; turn on the current, and it passes through the tube. The tube will, therefore, be rated as one of low vacuum, offering a resistance slightly greater than two or three inches of atmosphere. When the current jumps the spark gap instead of passing through the tube, the tube is said to have "backed up" so many inches—the number of inches of the gap—of "parallel spark." Thus a low tube will back up two or three inches of parallel

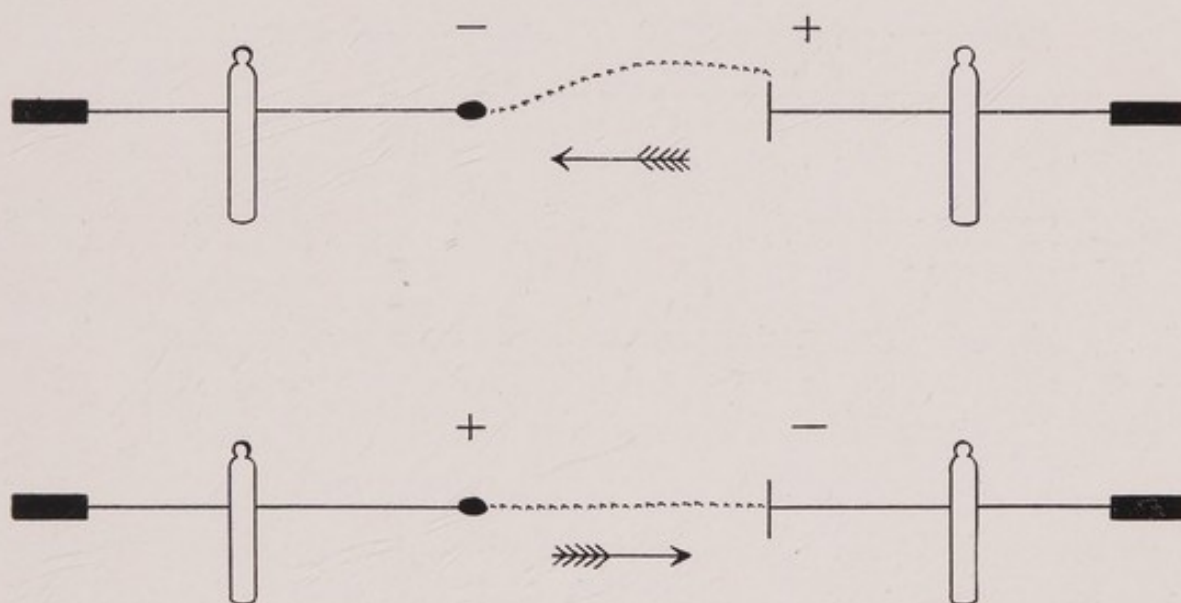


Fig. 40.

spark; a medium tube will back up four or five inches of spark; a high tube will back up six or seven inches of spark, and a very high tube will back up eight or nine inches of spark. Very high tubes offer so much resistance that only the largest coils are able to force sufficient milliamperage through them to generate a sufficient number of X-rays for picture work. A tube that will back up more than nine inches of spark is too high to be useful; it is impossible to force enough milliamperage through it.

From the foregoing it will be seen that any coil smaller than one with an eight-inch spark gap could not well excite a high tube, and that at least a ten-inch coil is necessary to light a very high tube. It seems, too, that any coil with a spark gap wider than eight or ten inches is needlessly large. The coils with the long spark gaps are, however, seldom able to throw a fat, fuzzy spark farther than eight or ten inches. The throwing of a thin, blue spark a greater distance is simply incidental and

without practical usefulness. Thus an eight or ten-inch coil may be as powerful as one with an eighteen or thirty-inch spark gap; that is, capable of forcing as high a milliamperage through a high tube. If, however, a coil can force any kind of a spark at all through from eighteen to thirty inches of atmosphere, we may be sure it will send a high milliamperage through a good radiographic tube, or, what is the tube's equivalent

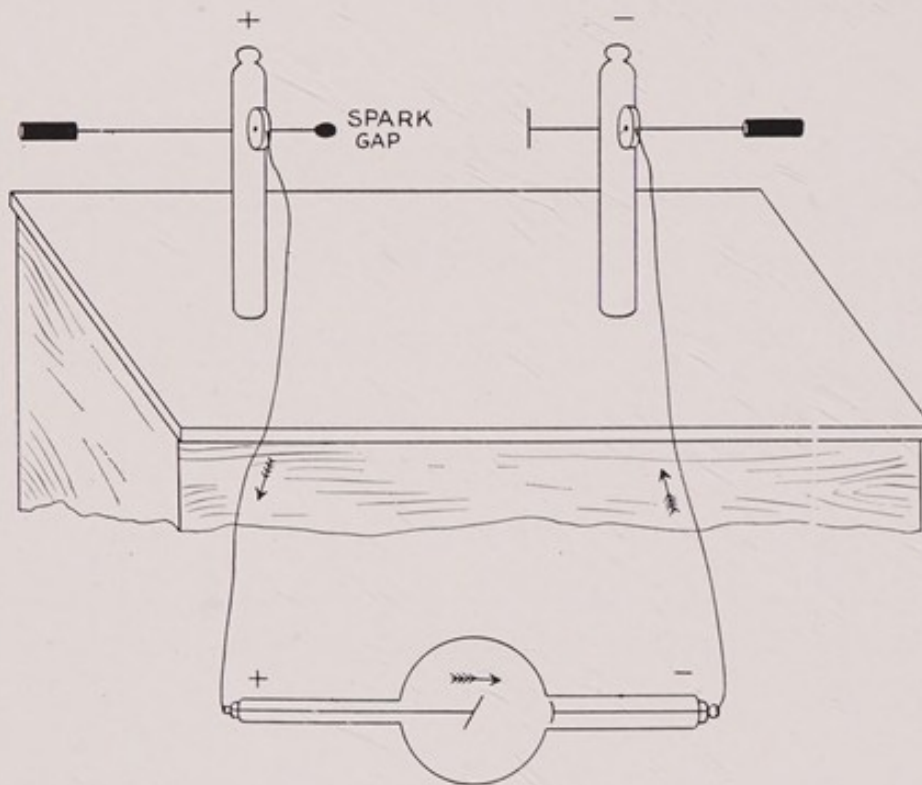


Fig. 41. The X-ray tube connected with the induction coil.

in resistance, six or eight inches of atmosphere. It is so well understood to-day that the coil with the very wide spark gap is not necessarily more powerful, that manufacturers are making practically all of their coils with from an eight to a twelve-inch spark gap, then rating them according to the milliamperage they can force through this resistance.

To light a tube well a coil should be capable of giving a fat, fuzzy spark, the distance of the parallel spark which the tube backs up.

The tube thus far described is the simplest form of X-ray tube. Next in simplicity is the bi-anodal tube. (Fig. 43.)

Bi-anodal Tubes.

When the two anodes are connected, as in Fig. 43, the positive terminal may be attached to either anode or assistant anode, preferably the anode. The advantage of the assistant anode is a matter on which authorities have widely different opinions. One manufacturer, a man

who is making one of the very best tubes on the market, tells me that he puts the assistant anode in his tubes because some of his customers demand it, and he is able to do so without impairing their efficiency; that his tubes would be just as good with but one anode. Remember the vacuum of an X-ray tube is not perfect; there are some gases in the tube. The function of the assistant anode is to draw these gases back of it away from between anode and cathode. Thus, if the removable wire

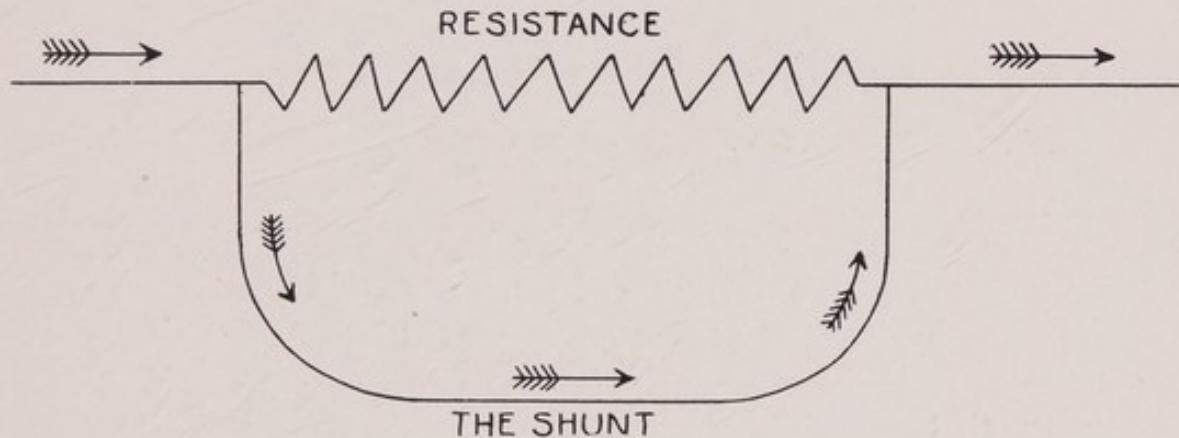


Fig. 42. The arrows show the current flowing through the shunt.

connecting the anode and assistant anode (Fig. 43) be removed and the tube hitched to the coil, the positive terminal being attached to the anode, the tube will work with a slightly lower vacuum, because the assistant anode does not draw gases back of it. Tubes with assistant anodes are supposed to be capable of transmitting a greater milliamperage.

We have divided X-ray tubes into two grand classes: those designed to operate on an induction coil or interrupterless coil, and those designed to operate on a high-frequency coil. Each of these classes may be subdivided into tubes with a means for regulating their vacuum (Fig. 44), and tubes without a means for regulating their vacuum (Figs. 39 and 43).

Tubes without regulators are no longer in general use, because, with use, they soon become too hard and must be sent back to the manufacturers to be opened and repumped. This is expensive and annoying. A tube too high for use will sometimes drop in vacuum and regain its former usefulness if allowed to rest—remain unused—for a month or so.

There are different methods of regulating the vacuum of X-ray tubes. The most popular and efficient is the one we shall now consider.

The vacuum is governed by means of a movable arm, which increases or decreases the distance be-

Methods of Regulating Vacuum.

tween A and B, Fig. 44. This distance we shall call the tube-regulating spark gap. The shorter the gap the lower the vacuum can be made; that is, the shorter the gap the less perfect the vacuum can be made.

The current enters the tube and, let us imagine, tries to pass from anode to cathode. The vacuum in the center of the tube is more perfect

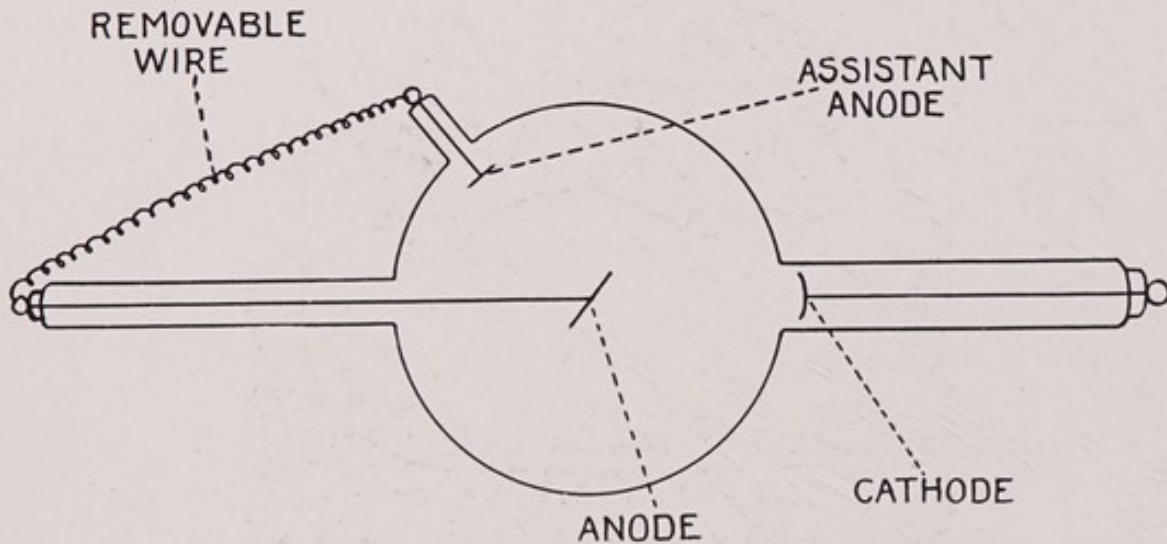


Fig. 43. A Bi-Anodal X-ray tube.

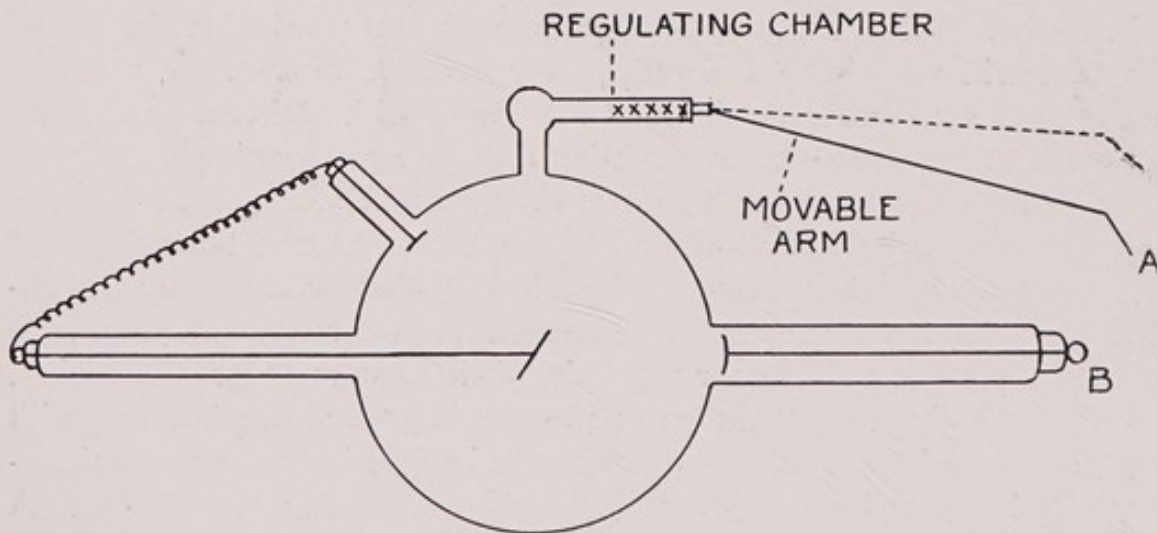


Fig. 44. X-ray tube with vacuum regulator.

than around the walls. Hence the path of least resistance is through the regulating chamber, through the movable arm, through the tube-regulating spark gap, into the negative terminal tape; unless, of course, the tube-regulating spark gap is very wide.

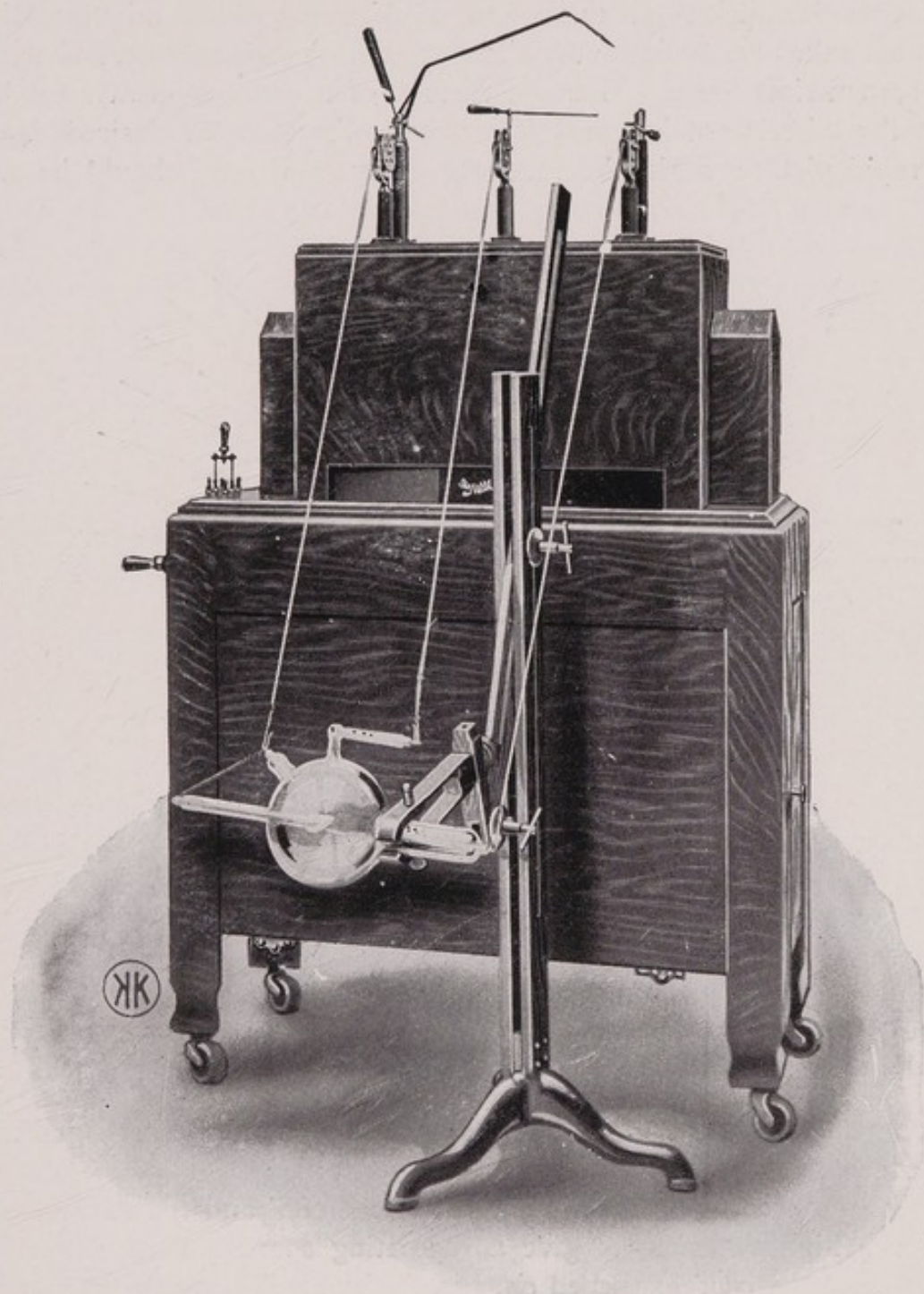


Fig. 45. Showing the manner of connecting the third terminal on the coil with the regulating chamber.

The regulating chamber contains asbestos impregnated with some chemical, sodium or potassium hydrate, for examples. When the current passes through the regulating chamber, heat is created, which causes the chemical to give off gases. These gases lower the vacuum of the tube, so that the current may pass directly from anode to cathode. When the

tube cools thoroughly—in the course of fifteen to thirty minutes—these gases are taken up again by the chemicals in the regulating chamber, and the vacuum rises again. Thus the vacuum of the tube is always too high when the tube is not in use, but can be lowered to the desired degree. For rapid picture work, the tube-regulating spark gap should be three

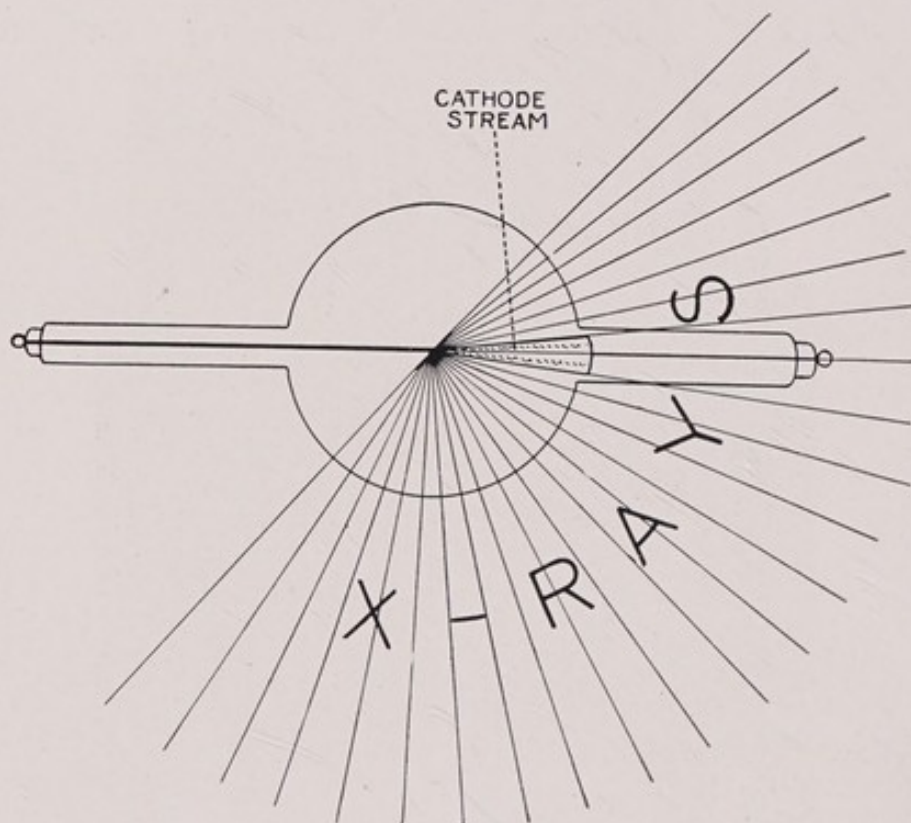


Fig. 46. Showing the direct X-ray and the cathode stream.

to five inches. As the tube gets old the tube-regulating spark gap must be made shorter to obtain the same condition of tube.

When the tube is properly hitched to the coil, and the movable arm set for a high vacuum—to give a regulating spark gap of about four inches—and the current turned on, practically all the current will at first pass through the regulating chamber and jump the tube-regulating spark gap. As explained, this lowers the vacuum, and in a few seconds the current is passing from anode to cathode. All of the current may pass directly through the tube now for a few seconds, but the passage of the current from anode to cathode raises the vacuum and presently some current will be seen to jump the gap for a while. And so on, just as the vacuum raises a little, it is immediately lowered by some of the current passing through the regulating chamber.

Instead of the movable arm, a terminal tape and a third terminal on the coil may be used. (Fig. 45.) Thus the tube-regulating spark is transferred from the tube to the coil. The hitching of a tube to a coil with a third terminal is very simple. Hitch the positive terminal to the anode, or assistant anode if desired, and the negative terminal to the cathode, as usual; and the third terminal to the regulating chamber. The advantages of the third terminal over the movable arm are that the sparking is taken away from the tube and so away from the patient (in radiographic work the tube is always near the patient), and, on some coils, Fig. 13 for example, the gap may be regulated from the end of the coil where the rheostat and switches are located, so making it unnecessary for the operator to move from his position to change the tube-regulating spark gap.

When the current passes from anode to cathode, the cathode stream (Fig. 46) is given off from the cathode. The cathode stream is a form of vibratory motion of the ether. Leaving the concave surface of the cathode, the cathode stream is focused to strike the anode or target at a point. X-rays are given off from this point (Fig. 46). The cathode stream can be seen in a tube of very low vacuum, appearing blue.

Great heat is generated at the point on the target where the cathode stream strikes it. Hence the necessity of making the target of some very high fusing metal. A small hole may be burned superficially into the target without spoiling the tube. The tube in Fig. 47 has a long sheath of metal connected with the target to take up the heat. Tubes are made with a means for cooling with water. These are intended for treatment rather than picture work, though they may be used for the latter.

X-rays were discovered by William Conrad Roentgen, professor of physics at the Royal University of Wurzburg, Germany, in the summer of 1895. Roentgen applied the name X-rays because he did not know just what he had discovered; X, the algebraic symbol for the unknown, being adopted to signify this ignorance. They were not called X-rays because the rays cross, forming an X, as is popularly supposed.

The Roentgen Congress, in Berlin, 1905, adopted a uniform set of technical terms in which the word Roentgen always occurred. Thus we have the phrase Roentgen ray for X-ray and such words as Roentgenology, Roentgenologists, Roentgenogram, etc., etc. While approving of a move for a uniform nomenclature, many of the new words are long and unwieldy and the writer shall, in this work, use many of the old and better-known terms.

X-rays are invisible, vibratory waves of or in the ether. The most

popular theory is that they are light waves with an inconceivably rapid rate of vibration. Red light rays vibrate at the rate of four hundred billion per second; violet rays vibrate at the rate of seven hundred and

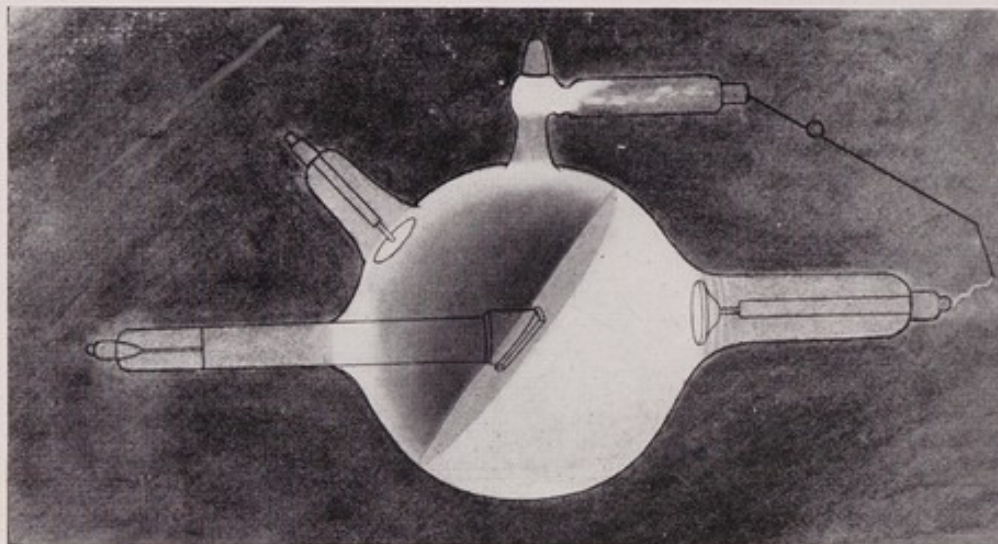


Fig. 47. X-ray tube properly lit up.

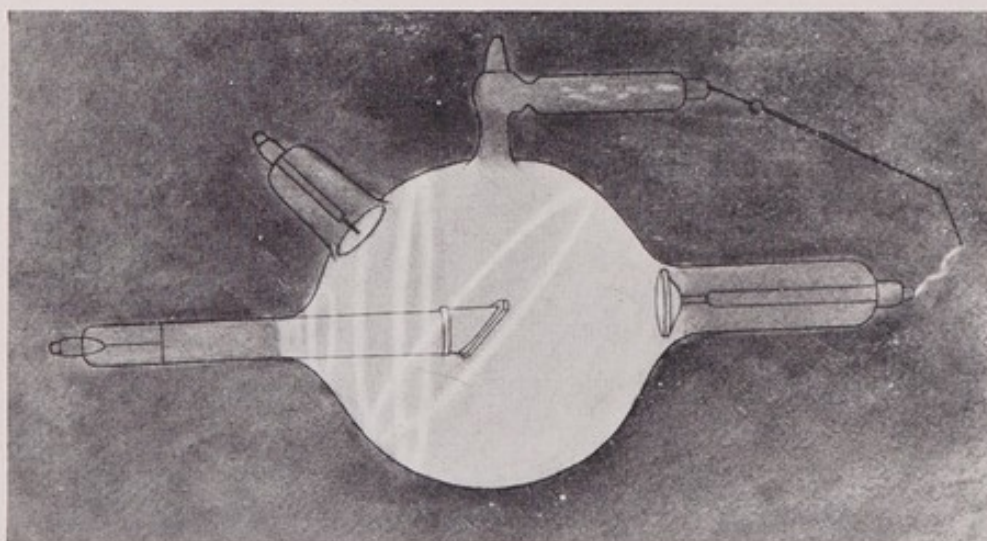


Fig. 48. X-ray tube with the current passing through it in the wrong direction.

fifty billion per second. The intermediate colors—blue, green, yellow and orange—vibrate at intermediate degrees of rapidity.

Though human vision is limited to about three hundred and fifty billion variance, the difference between four hundred billion and seven hundred and fifty billion, may we not fairly assume that there are light

rays of a higher and lower vibration invisible to us? Ultra-violet rays have a more rapid vibration than violet rays, and have no action on the retina, and are therefore invisible. X-rays vibrate more rapidly than ultra-violet rays. The rapidity of their vibration is estimated at 288,224,000,000,000* (two hundred and eighty-eight quadrillions, two hundred and twenty-four trillions—French notation) per second.




Fig. 49. The inverse spark gap on the left is open, on the right is closed.

When light strikes an object and can be seen as light, it is because the light is reflected from the object to the eye. X-rays are invisible because they cannot be reflected. When they strike an object they are either absorbed or pass through it. X-rays are not discernible to any of the special senses. They pass from the focal point on the target in regular, diverging lines. (Fig. 46.) They cannot be reflected, refracted, or condensed, and penetrate objects directly according to the density of the object.

The passing of the X-rays through the glass of the tube gives rise to a green fluorescence (green light) in the active hemisphere—the hemisphere in front of the target—of the tube. Whether a tube is working well or not can be determined by this fluorescence. There should be a definite line of demarcation between the active and inactive hemispheres of the tube. A tube working properly should light up as per Fig. 47. The light is never quite steady; it wavers a little. High, medium and low tubes give slightly different fluorescences when in operation. The fluorescence from a high tube is a very light yellowish green; from a low

*Custer's "Dental Electricity."

tube a bluish green and from a medium tube an intermediate shade of green.

Just here let it be said that an exact colored picture of an X-ray tube in operation has never been made. I obtained the services of an artist and spent a great many hours on the work, but was unable to make a picture worthy of reproduction. The light from an X-ray tube in




Fig. 50. Series spark gap.

operation is of a peculiar brilliancy that cannot be reproduced in crayons, water-colors, or ink.

When the vacuum of a tube is so low as to render it useless for radiographic purposes, a definite blue color can be seen here and there in the tube, the cathode stream can sometimes be seen appearing blue, and the line of demarcation between the active and inactive hemispheres of the tube is not well defined.

When a tube is punctured the vacuum gets very low, of course, and its appearance in operation may be as just described, or, as sometimes occurs, it gives rise to a fluorescence as variegated as a rainbow, or it may not light at all. A punctured tube can sometimes be repaired by the manufacturer.

When the vacuum of a tube is too high, the tube lights up reluctantly a very yellowish green, and the line of demarcation is not at all distinct.

Fig. 48 illustrates fairly well the appearance of a tube with the current passing through it in the wrong direction. When this condition is seen the current must be turned off quickly, or the tube will be ruined. Sometimes, when the tube is properly hitched to the coil light rings back of the target, similar to those shown in Fig. 48, may be seen. This

signifies that the coil is generating considerable inverse current. Recall that, while the current generated by the induction coil is practically a unidirectional one, there is an inverse current which is sometimes strong enough to manifest itself as just mentioned, especially when the vacuum of the tube is low.

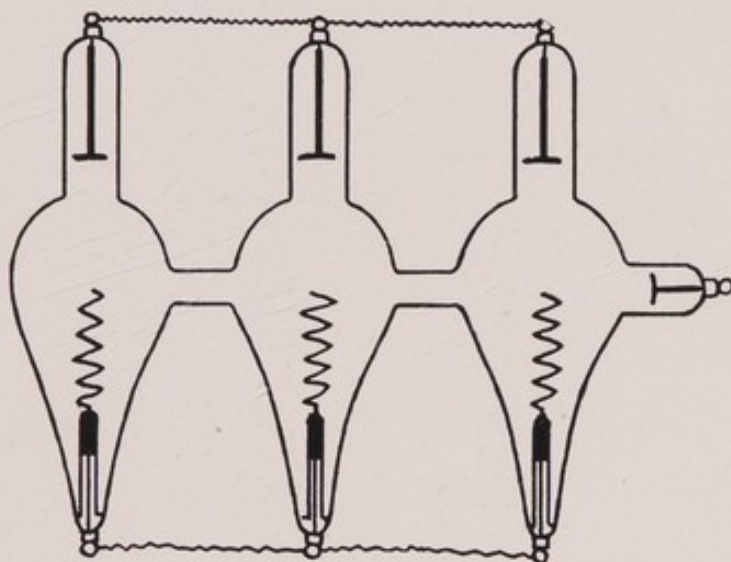


Fig. 51. A triple valve tube.

**Cutting Out
Inverse
Current.**

There are several ways to keep this inverse current from passing through the tube. The simplest way is to make a spark gap between the coil and terminal tape, which gap, for want of a better name, I shall call the inverse spark gap, since it is used to cut out the inverse current. (Fig. 49.) This gap may be made at either the positive or negative terminal, or both, as is found necessary. It cuts out the inverse current because this current is comparatively weak, not strong enough to jump the gap and pass through the tube. The main current jumps the gap easily. Unless inverse current is observed in the tube there should be no inverse spark gap—the little sliding rods should touch the binding posts of the terminal tapes. (Fig. 49.)

Series spark gaps (Fig. 50) may be used between the coil and terminal tape to cut out the "inverse." The current passes easily from point to disc, but reluctantly from disc to point. Thus the series spark gap may be used to cut out inverse current from a tube, with the points toward the positive terminal tape and the points away from the negative terminal tape. Fig. 50 shows the points toward the positive terminal tape. They should be turned in the opposite direction at the negative terminal—away from the tape.

The third, last, and the most efficient means of cutting the inverse current out of an X-ray tube is by means of a valve tube. (Fig. 51.) The valve, or Villard tube, is a tube of low, or, as it is often called, Geissler vacuum— $1/1,000$ to $3/1,000$ of an atmosphere—with a disc electrode and a spiral electrode, both made of aluminum. The exact reason for its action is not known, but the electric current cannot travel

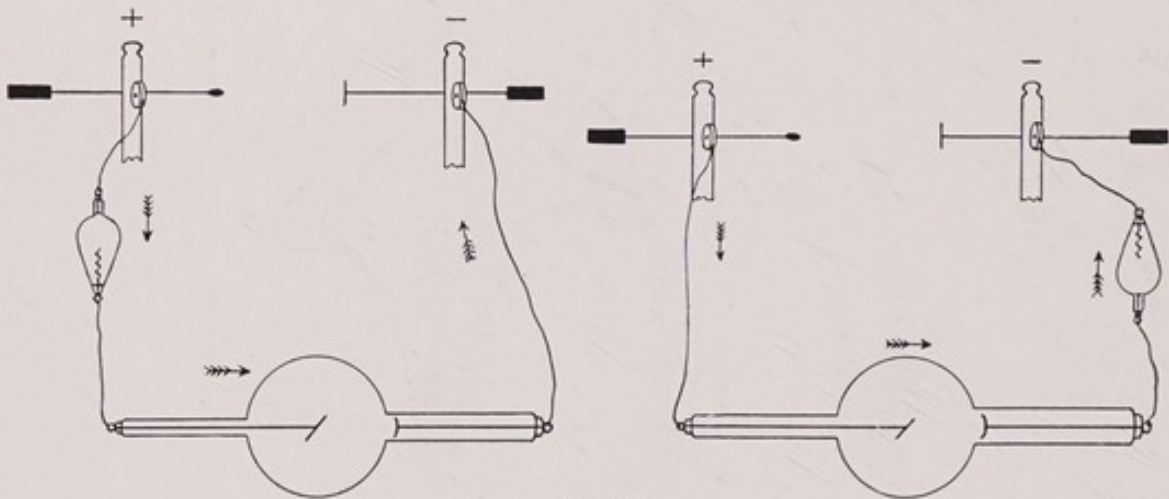


Fig. 52.




Fig. 53. An oscillimeter.

through it well except in one direction—from disc to spiral. Thus, to cut out inverse current the disc end of the valve may be attached to the positive terminal tape of the coil, and, by means of a piece of conducting tape, or wire, the spiral end connected with the target side of the tube. Or the disc end of the valve may be attached, with a piece of conducting tape, to the cathode side of the tube and the spiral end of the valve to the negative terminal tape of the coil. (Fig. 52.)

It is claimed by some that the valve tube acts only as an additional resistance to the flow of the inverse current, cutting it out of the X-ray tube in the same manner that the inverse and multiple spark gaps do.

The oscillimeter, or oscilloscope (Fig. 53) is a Geissler vacuum tube with two straight aluminum electrodes. When a unidirectional current passes through it a violet light occurs at the negative electrode. When an

Oscillimeter.

alternating current passes through it the light occurs at both electrodes. When the current sent through it is stronger in one direction than in the other the electrodes light unevenly, the brighter electrode representing the negative of the stronger current.

The oscillimeter is made to be used between the coil and the tube,

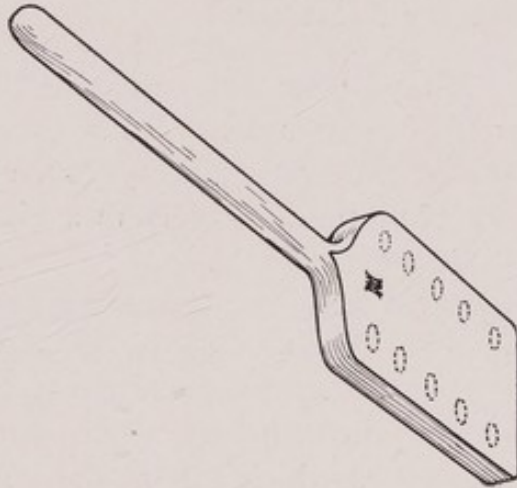


Fig. 54. The Meyer penetrometer.



Fig. 55. A fluoroscope.

when the latter is covered, to detect inverse current. I have never felt the need of it, though I use an opaque shield over my tube.

Demonstration of X-Rays.

As has been stated, the X-rays are not discernible to any of the special senses. Their existence, however, can be demonstrated as follows:

Place an X-ray tube in a wooden box so that when the current is sent through it no fluorescence can be seen. Excite

the tube in a dark room and approach it with some object coated with calcium tungstate or platino-barium cyanide, and the object will be seen to fluoresce or glow something like phosphorus. This fluorescence is due to the action of the X-rays (which penetrate the wood of the box easily) on the calcium tungstate or platino-barium cyanide. Hence the closer the object to the tube the more and stronger the X-rays which strike it, and the brighter the fluorescence.

**Power of
Penetration
of X-Rays.**

X-rays from different tubes differ in length and power of penetration. A low tube gives the shortest and least penetrating X-rays; then comes the medium tube, while the X-rays from a high tube are longest and most penetrating.

The degree of penetration may be determined by means of a penetrometer. (Fig. 54.) This particular kind of a penetrometer consists of two small flat pieces of wood fastened together, with a sheet of lead between them. Holes are made through both wood and lead. Into these holes are placed thin metal discs which just fit the holes. The different holes receive different numbers of discs.

To use this style of penetrometer we must have a fluoroscope. A fluoroscope (Fig. 55) consists of a light proof box, tapered and made to fit over the eyes at one end, and covered at the other end with pasteboard coated with calcium tungstate or platino-barium cyanide. If one should look into the fluoroscope holding it toward ordinary light nothing could be seen—one would look into perfect darkness. But if the fluoroscope should be held so that the X-ray struck its screen—i. e., the pastboard covered with calcium tungstate or platino-barium cyanide—it would be seen to fluoresce, or glow, or light up.

If now the penetrometer is held between the fluoroscope and the source of the X-rays a shadow will be seen on the screen, because the lead in the penetrometer is opaque to X-rays. Whether the X-rays will penetrate the metal in the holes depends on how much metal there is to penetrate and how penetrating the X-rays are. Thus the more penetrating the rays the more holes can be seen.

There are a great many different kinds of penetrometers. I shall not describe them here, but will give the scale of the two most popular, the Benoist and the Walter, together with that of the Meyer (Fig. 54).

	Benoist.	Walter.	Meyer
Soft, or low tube	1—2	1	1—2
Medium	3—5	2—3	3—4
Hard or high	6—12	4—6	5—10

While the penetrometer is a very valuable appliance, it is far from being a necessity in the practice of dental radiography.

Secondary Rays.

As X-rays pass through the glass of the tube more X-rays are generated. These are known as "secondary rays." They are short and feeble and do not travel parallel with the direct X-rays, but pass

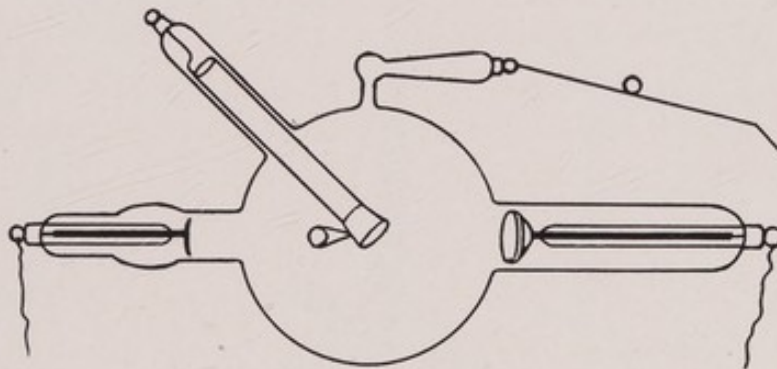


Fig. 56. High-frequency X-ray tube.

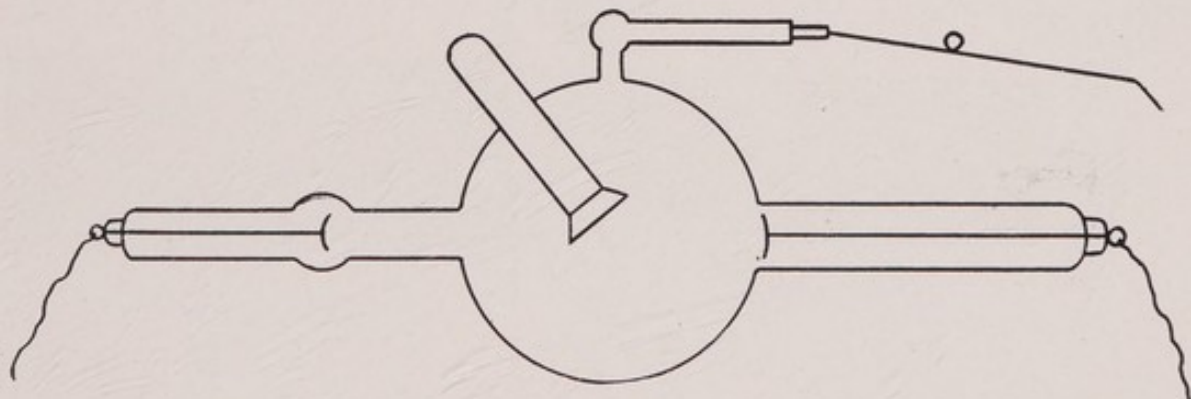


Fig. 57. High-frequency X-ray tube.

out from the tube in every direction intersecting the direct rays. Secondary rays are also given off from any object which X-rays strike. Thus, direct rays will strike a wall; secondary rays are given off from the wall and strike the other walls, the floor, and the ceiling, whereupon a new set of X-rays, tertiary rays, are produced. When the tertiary rays strike an object still another set of X-rays are generated, and so on, each new set of rays being much shorter and weaker than the former. So a room in which an X-ray tube is excited is filled with X-rays—not with the direct rays, but with the comparatively feeble and inconsequential secondary, tertiary and other subordinate rays.

X-Ray Tubes.

X-ray tubes are of different sizes. The bulb varies in diameter from five to eight inches. Thus we have the five-inch tube, six-inch tube, and so on. The six-inch tube is about right for dental work.

With use the glass of the active hemisphere of the tube discolors to a purplish color. This does not materially affect the tube.

The fatal injury to most tubes is a puncture. One means of guarding against punctures is to keep the tube clean. "A fruitful cause of




Fig. 58. Tube rack for tubes when not in use.

puncture is the discharging of the current from the tube into the rack on which the tube is kept when not in use. The tube may have been discharged by the operator touching the terminals before putting the tube away, but if the tubes are stored in the same room where high-frequency and other coil discharges are taking place, they will recharge themselves from the atmosphere and discharge onto the rack, no matter of what material the rack may be made. A safe way of putting away tubes is to connect the anode and cathode terminals together by a wire during the time the tube is at rest."

The general principle of construction of the high-frequency X-ray tube (Figs. 56 and 57) are those already given in the description of the tubes built to be operated by a unidirectional current. The chief differ-

ence between the high-frequency tubes and those already described lies in the different means resorted to in the former to dispose of one direction or wave of the alternating current, or, to speak more definitely, one cathode stream.




Fig. 59.




Fig. 60.

Fig. 59. Plain X-ray tube stand.

Fig. 60. Tube stand, with a lead glass protection shield and a compression diaphragm.

Either end of a high-frequency X-ray tube may be connected with either terminal tape of a high-frequency coil. While this is theoretically true, it will sometimes be found in practice that the tube works better hitched up one way than the other.

When the tube is hitched up the current oscillates through it and two cathode streams are generated. One of the streams is focussed against the target and X-rays are given off from the focal point, while

the other is focused into a funnel in the back of the target. (Fig. 56.) X-rays cannot be given off from this funnel; hence the tube lights up in the active hemisphere as illustrated in Fig. 47. This funnel scheme is




Fig. 61. A pedestal, with a lead glass protection shield, compression diaphragm and plate holder.

one way of taking care of one cathode stream while the other is being used for X-ray production. Another scheme is to move one cathode back so far that the cathode stream focuses before reaching the back of the target. (Fig. 57.)

The high-frequency tube may be used to advantage on an induction coil which is generating a great deal of inverse current.

One may wonder why a valve (Fig. 51) or a rectifier (Fig. 27) could not be used to cut out the flow of current in one direction, and a tube like the one in Fig. 44, for example, used on a high-frequency coil. Neither the valve nor the rectifier is capable of cutting out one

direction of flow of a current of such high potential (voltage). The valve is able to cut out the inverse current of an induction coil because it (the inverse current) is comparatively weak; and the rectifier can cut out one wave of the commercial A.C., because the voltage is only a little over a hundred. The voltage of the high-frequency coil is perhaps a hundred thousand.

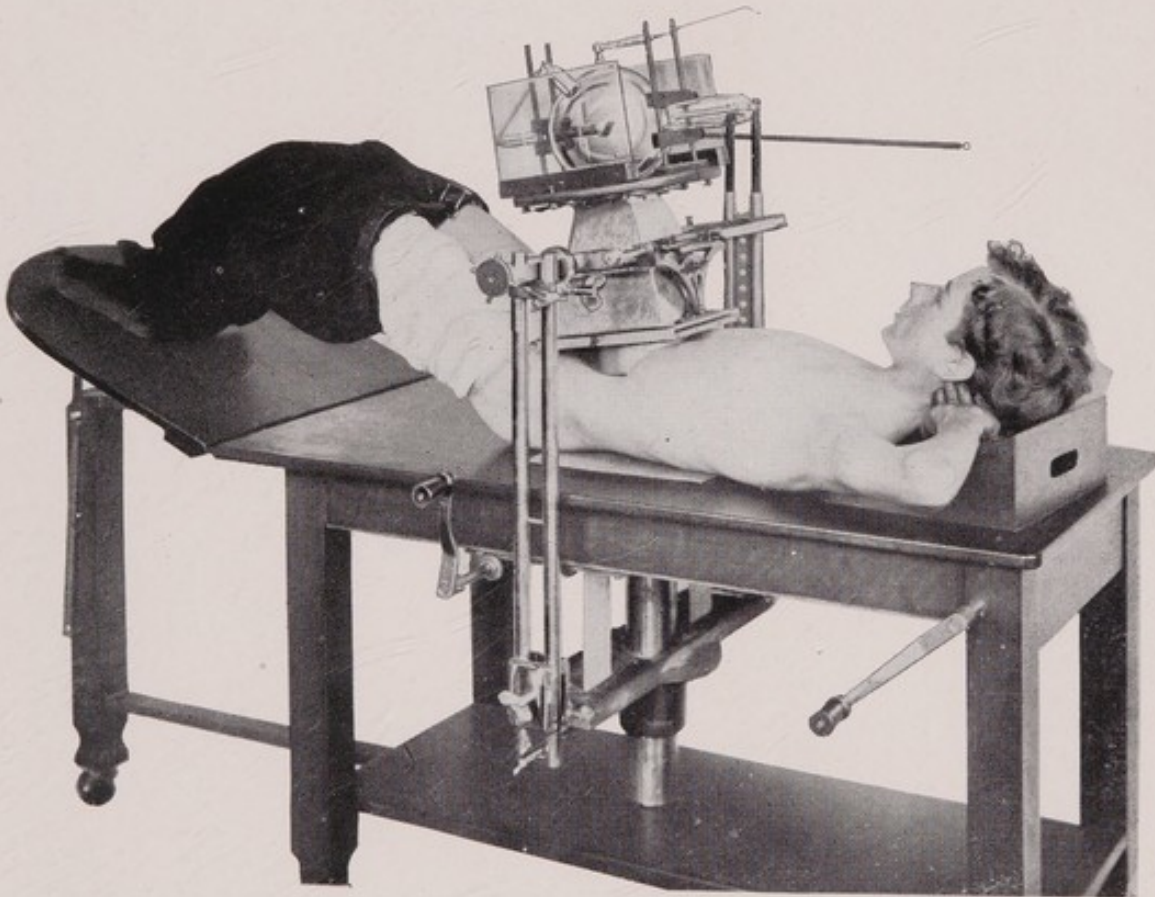


Fig. 62. Table, with a lead glass protection shield and compression diaphragm.

To avoid "straining" a tube, it should not be again used, after having been used till hot, until it has cooled thoroughly. Overheating the tube will destroy the gases in it, and so raise the vacuum to such a degree as to make it impossible to force a sufficient milliamperage through it to produce a sufficient number of X-rays. Sending a very strong current through a tube of low vacuum will also destroy the gases of the tube and spoil—strain—it.

Fig. 58 is a tube rack for holding the tube when not in use.

It is obvious that there must be some kind of a device for holding the tube when in use. This may be either a plain tube stand (Fig. 59), or a tube stand with a lead glass, protection shield and a compression




Fig. 63. Doctor Blum's wall bracket tube holder with lead glass protection shield and compression diaphragm.

diaphragm (Fig. 60), or a pedestal with a lead glass protection shield, compression diaphragm, and plate holder (Fig. 61), or a table with a lead glass, protection shield and compression diaphragm. (Fig. 62.)

Dr. Blum, of New York, uses a wall bracket fixture to support a lead glass, protection shield and compression diaphragm. The tube, one of the water-cooled type, is seen fitting into the lead glass shield.




Fig. 64. A Protection Shield.

(Fig. 63.) This would be, I imagine, a very adaptable and satisfactory apparatus.

A tube stand should be heavy enough to be firm and not allow any vibration of the tube while in use. The parts coming in contact with the tube must be made of an electric non-conducting material; otherwise the current would pass from the tube into them, so puncturing the tube.

The uses of the compression diaphragm are: To hold the patient immovable; to compress the soft parts as when making a picture of the kidney, for example; to aid the operator in directing the rays through a part at the proper angle and to cut out the secondary rays given off from the tube.

A protection shield, often called a Friedlander's shield (Fig. 64), which is opaque to X-rays except for the window or opening in it, and which is used to cover X-ray tubes, also cuts out some, but not all, secondary rays given off from the glass of the tube. Thus if the X-rays from an

X-ray tube are directed on a part through a diaphragm, only the direct rays strike the part, as in the diagram study shown in Fig. 65. While, with the Friedlander shield, *some* of the secondary rays might strike the part also. (Fig. 66.)

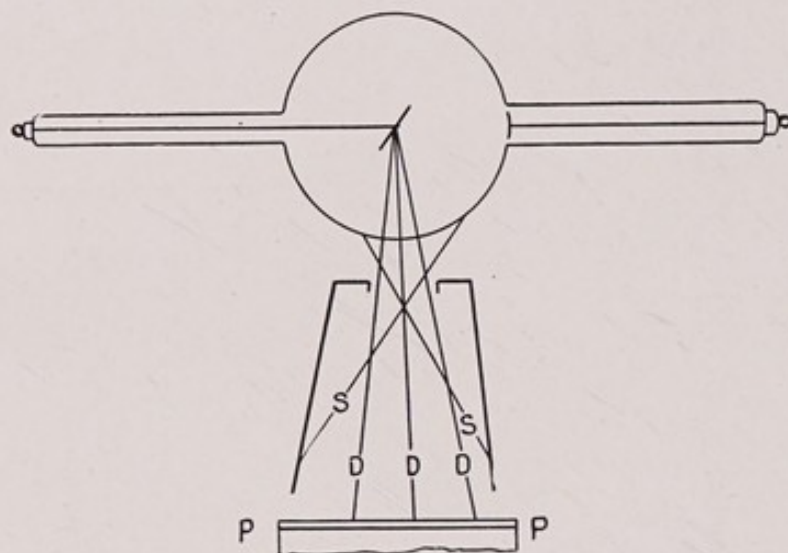


Fig. 65. D D D, direct ray. S S, secondary ray. P P, part.

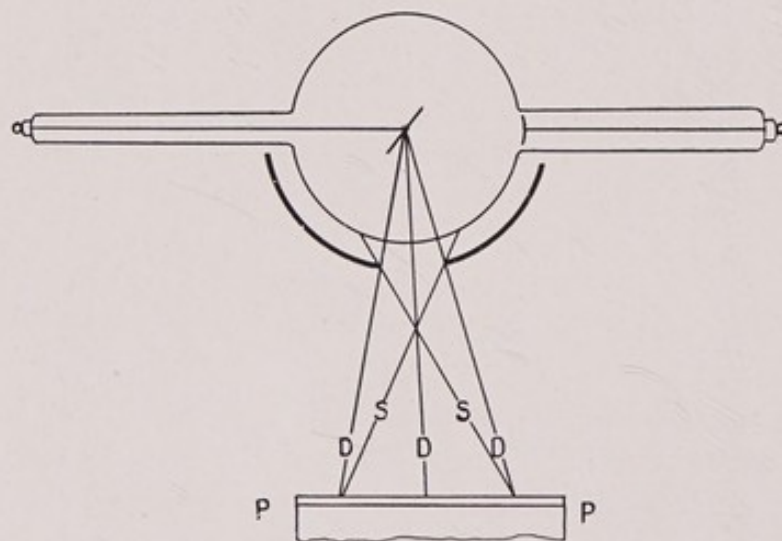


Fig. 66. D D D, direct rays. S S, secondary rays. P P, part.

When there is inverse current passing through a tube supplemental X-rays are produced thereby. It is desirable that these rays should not strike the plate when making a picture. Either a compression diaphragm, or a protection shield will cut out these rays—or at least most of them.

CHAPTER IV.

Making Radiographs.

The X-ray picture is variously called radiograph, skiagraph, Roentgenograph, radiogram, skiagram and Roentgenogram. The word radiograph is a combination of a Latin and Greek word meaning *ray* and *write* or *record*. The word skiagraph (spelled also sciagraph) is a combination of two Greek words meaning *shade* or *shadow* and *write* or *record*. The word Roentgenograph is a combination of a proper name, Roentgen, and the Greek word meaning *write* or *record*. The terminal gram occurring in the words radiogram, skiagram and Roentgenogram—as well as the more common words such as telegram, program, epigram, and others—is of Greek origin and denotes that which is written or marked.

The use of the X-rays for radiographic work depends on two properties of the rays. First, they penetrate substances in direct proportion to the density of the substance, and second, they affect the photographic plate or film the same as white light does.

Photographic Plates.

A photographic plate is a piece of transparent plate glass about an eighth of an inch thick, one side of which is coated with an emulsion of a silver salt, usually silver bromide, and gelatine, albumen, or collodion. The use of the gelatine, albumen or collodion is simply to stick the salt to the glass. When a thin coating of this emulsion has dried on the glass we have what is called the photographic "dry plate." In appearance it is similar to translucent greenish-white glass, but on close inspection one is able to detect that one side is a little less glossy than the other. The less glossy is the coated side, also called the sensitive, the film, or the emulsion side of the plate. The term "dry plate" is to-day an almost superfluous one, practically all the plates used being dry plates. There is, however, a photographic plate known as the "wet plate," but, since it is never used in radiography, I shall not describe it.

The dry plate is made in the absence of white light, put up in light-proof packages, and so supplied to consumers. These packages must not be opened except in a dark room, for the slightest exposure to a white light will spoil them.

The difference between the photographic dry plate and the photographic film is only that the plate is a piece of glass coated with a silver salt, while the film is a thin sheet of transparent celluloid coated with a silver salt. As with the plate, the sensitive side of the film is a little less glossy than the uncoated side. The film curls slightly toward the coated side, unless it is of the "non-curling" variety, when it is straight, or may even curl slightly away from the coated side.

Special X-ray Plates and Films.

X-ray pictures may be taken on ordinary photographic plates or films made to be used in cameras. While this may be done, the results obtained are not nearly so good as when special X-ray plates and films are used. The special X-ray plates and films differ from the ordinary plates and films in that a thicker coating of the emulsion is put on them. This is sometimes accomplished by coating the celluloid or glass two or three times, one coat on another. When this is done the film or plate is said to be multi-coated. X-ray films and plates should not only be thickly coated, but, which is more important, should also be extremely sensitive—that is, easily acted upon by light—for, though the X-rays have a wonderful power of penetration, their action on the silver emulsion is feeble compared to the white light of day.

The following manufacturers make X-ray plates of any desired size: The Eastman Kodak Company, Rochester, N. Y.; Cramer Dry Plate Company, New York City; Hammer Dry Plate Company, St. Louis, Mo.; The Lumiere N. A. Company, Burlington, Vt.; and the Ilford Mfg. Co., Ilford, London, England (American agents for Ilford goods, E. B. Meyrowitz, 104 East 23d Street, New York City). But two manufacturers, the Ilford Mfg. Co., London, Eng., and the Eastman Kodak Co., Rochester, N. Y., make special X-ray films.

I wish here to advise against buying large quantities of either plates or films at a time. They deteriorate in a few months.

Technic of Making Radiographs.

The making of a radiograph of the hand is one of the simplest operations in radiography, and for that reason it will be described to teach elementary principles. The following technic of making a radiograph will, of necessity, be much broken into by descriptions of materials and appliances used.

A 5 x 7-inch plate is about the right size to make a radiograph of

the hand. Plates are supplied by the manufacturer packed in light-proof boxes, holding usually one dozen plates, with the warning on the box. "Open only in a dark room." The "dark room" is simply what the name states—a room from which light is excluded. A closet without a window makes a good dark room, except that there is seldom running water in it. It is not absolutely necessary to have running water in the dark room, but it is very convenient. If a closet cannot be utilized a room, light-

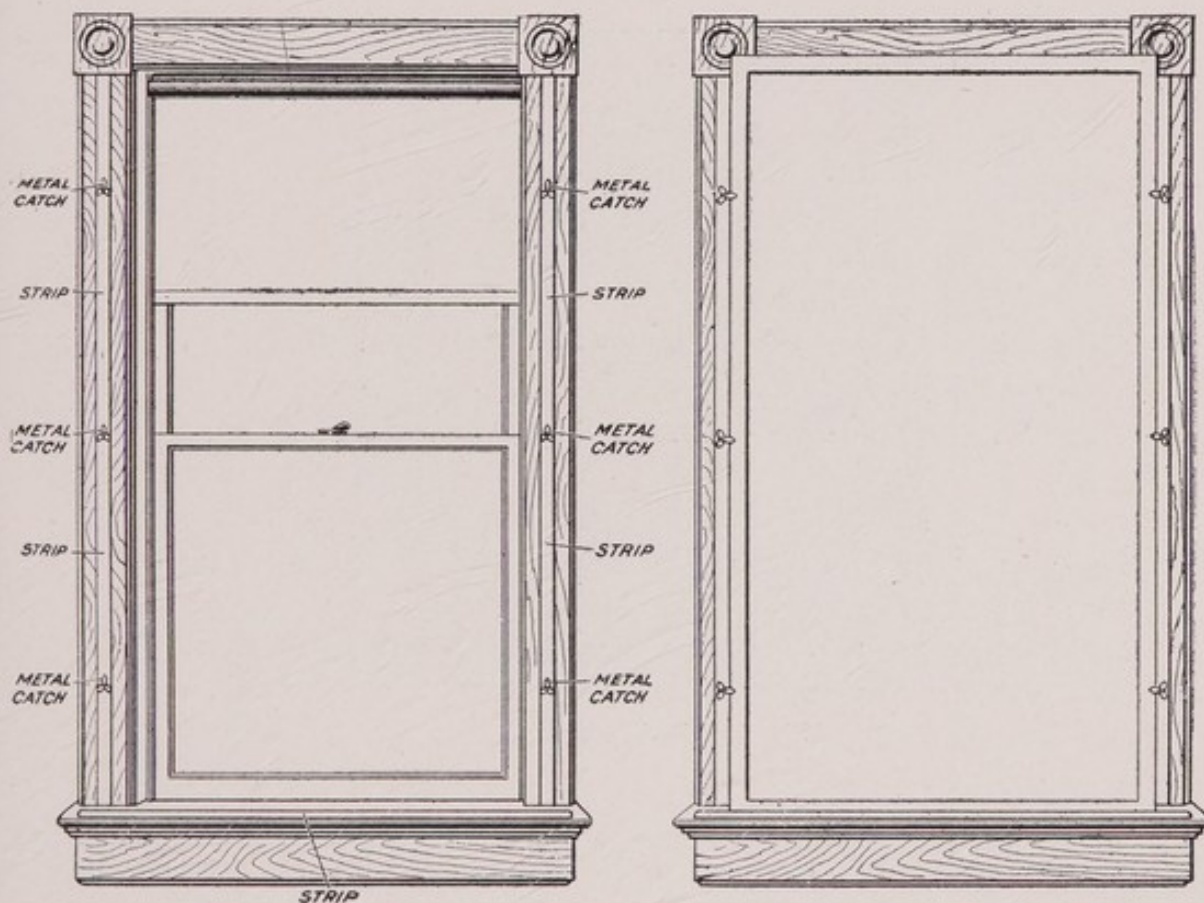


Fig. 67. To left, window ready for frame. When frame is in position the metal catches are turned to hold it. The frame fits inside of the strip on the sill. Figure to right shows frame in position.

proof except for one window, may be made dark by covering the window with a frame on which is tacked some material such as the leather or rubber used for side and storm curtains in buggies. If this material does not completely turn the light, it should be painted with thick black paint. The frame should be made to fit over, not into, the window casing. (Fig. 67.) With the frame so placed, if a little light comes in around it, it does not come directly into the room, but is reflected to the side. The more perfect the darkness of the room the better, but the *very little* light

which can enter through a window with the blind drawn down, and with a well-made frame over it will not cause any trouble. If the door to the room permits light to leak in around it, such light should also be shut out.

It would be impossible, of course, to work to any advantage in a perfectly dark room, for we could not see what we were doing. Hence the necessity of having a dark room lantern (Fig. 68), which will give sufficient light to guide us in our work, without being of such nature as to have any action on plates or films. The term "developing light"—the




Fig. 68. Dark room lantern.

light given by the dark room lantern—may mislead one to believe that the light in some way aids in developing a plate by its action on it. But such is not the case. The light is of value only because it enables the worker to see. The light may be a candle, a coal oil lamp, or an incandescent electric light shining through red glass. While such a lantern can easily be made, the writer warns against it, for, though the light of a home-made lantern may appear the same to the eye as the light of the lanterns manufactured by photographic supply manufacturers, its action on a plate or film may be disastrously different. The lantern shown in Fig. 68 consists of a 16-candle power incandescent light with a frosted glass bulb, in a light-proof tin box, the front of which is of removable glass. The light shines first through the frosted glass of the bulb, then an orange-colored glass, then a ruby glass.

In the dark room, with only the light of the dark room lantern we

open our box of plates,* take out one, carefully close the box, and place the plate in an envelope of black, light-proof paper just large enough to receive it. Now place plate, black envelope, *et al.*, in another envelope of black and orange-colored paper, putting the open end of the first envelope in first. We may now expose this package to ordinary daylight and artificial light with impunity, and the plate is ready for use in the making of a radiograph. These envelopes are obtained from the plate manufacturers.




Fig. 69. Showing how to handle a plate by its edges.

While in the dark room, before putting the plate in the envelope, we must note which is the sensitive side, and bear this in mind until the outside envelope is marked properly to designate it. As formerly stated, the sensitive side is a little less glossy. Another way to determine which is the coated side is to look through the plate just *at the edge*. When the glass side is up, one is able to look through the glass and see the film beneath. The sensitive side of the plate should present toward the smooth side of the envelope—away from the seam side.

The plate should be handled by the edges. (Fig. 69.) This applies to the handling of the plate at all times, and to the handling of the film as well. Unless the fingers are wet or greasy, touching the sensitive side

*Experienced photographers prefer to handle sensitive plates in absolute darkness, and soon learn to detect the film side of the plate by feeling lightly with the fingers, thus obviating the need of the dark room light when "loading" plates.—Ed.

of the plate is not likely to result in spotting the picture, but it is always well to eliminate as many chances of failure as possible.

We are now ready to arrange tube, hand, and plate in their proper relative positions to take the picture. In all radiographic work it must

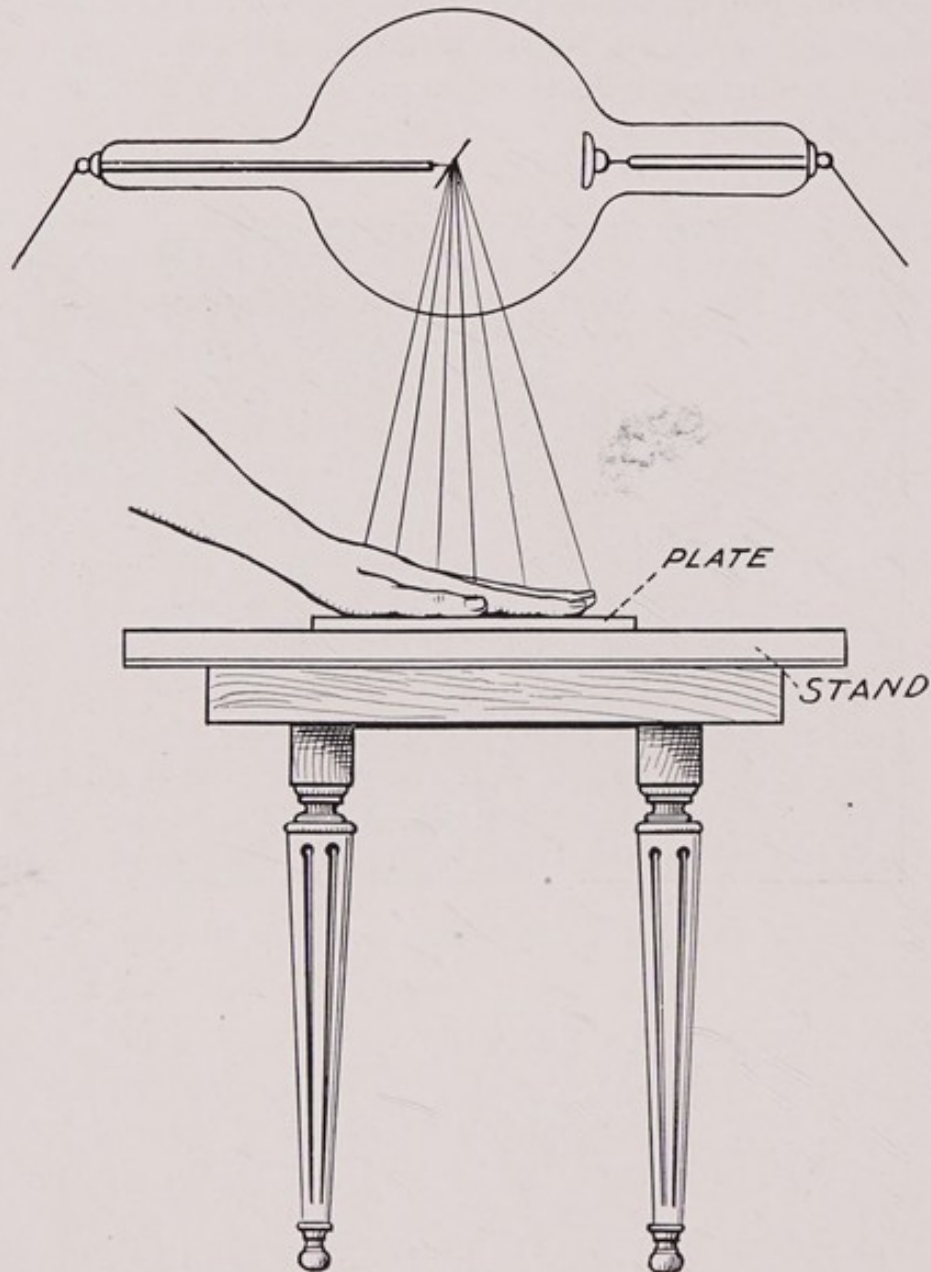


Fig. 70. Showing relative positions of tube, hand, and plate for making a radiograph of the hand.

constantly be borne in mind that we are making a shadow picture; that we are simply throwing a shadow on the plate, using X-rays as the source of light.

Lay the plate on a stand, sensitive side up. Place the hand on the plate. Adjust the tube at a variable distance directly above the hand. (Fig. 70.)

The distance from the tube to the hand may vary from about 10 to 20 inches, measurements being taken from the target, not from the glass of the tube. It is not necessary to have the target and the plate parallel to one another (in the same plane) as some writers direct. On the contrary, the position as in Fig. 70 is a better arrangement.

Assuming now that the tube is properly hitched to the coil and working properly, we are ready to make the exposure—to take the picture.

In giving demonstrations, I find that at this point someone invariably volunteers to “turn out the light.” This is not necessary. The only reason for having the rooms even slightly darkened is to enable the operator to observe how his tube is working. The picture could be taken in bright daylight; the envelopes will protect the plate against all light except the X-rays.

When the switch is turned on and the X-rays produced, they, the rays, shine down on the plate penetrating the paper of the envelopes as though the plate were not covered at all. The rays penetrate the hand also and act upon the plate beneath. They penetrate the bones of the hand less readily than the flesh, and hence there is less action on the plate directly beneath the bones. In other words, there is a shadow of the hand thrown on the plate, the shadow of the bones being denser than the shadow of the flesh. The shadow of the flesh, in fact, may be so light that it is scarcely discernible, or even entirely blotted out. This is the case when a very high tube is used and a long exposure made.

Duration of Exposure.

The length of time of the exposure of the plate to the action of the X-rays when making a radiograph depends on several things. (1) The milliamperage sent through the tube. Other factors remaining the same, the more milliamperage sent through the tube the shorter the exposure necessary, because the higher the milliamperage sent through the tube the greater the number of X-rays produced. A coil equipped with a milliamperemeter enables the operator to observe the exact number of milliamperes passing through the tube. (2) The nature of the X-rays. Other factors remaining the same, the more penetrating the X-rays the shorter the exposure necessary. The higher the vacuum of the tube up to a given point, the more penetrating the rays from it. A low tube is useless for radiographic work. (3) The distance of the plate from the tube. Other factors remaining the same, the shorter the distance between the plate and the tube the shorter the exposure necessary. (4) The thickness of the part to be radiographed. Other factors remaining the same, the thicker the part the longer the exposure necessary. (5) The density of the part

to be radiographed. Other factors remaining the same, the denser the part the longer the exposure necessary. (6) The sensitiveness of the plate. Other factors remaining the same, the more sensitive the plate the shorter the exposure necessary. The product of some manufacturers is more sensitive than others. As a plate or film grows old it becomes less sensitive, finally becoming entirely useless.

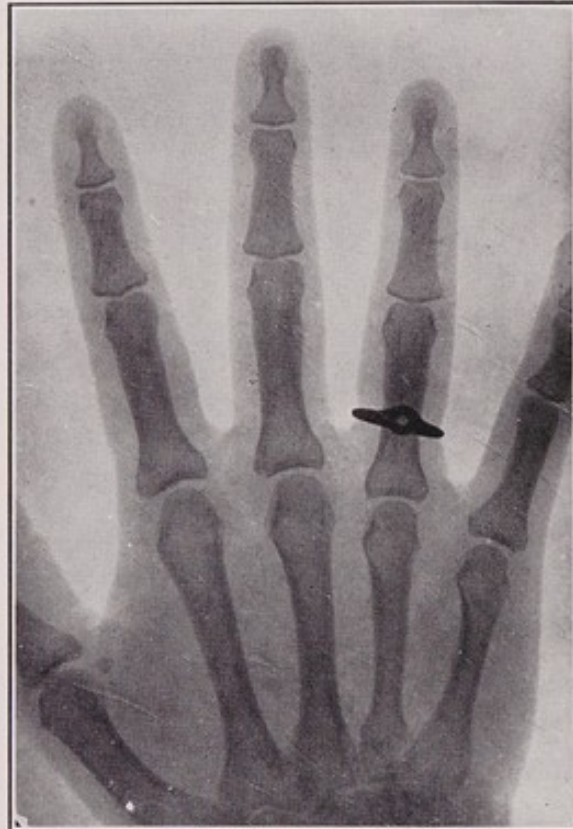

Fig. 71. Radiograph of the hand, made from a pose similar to Fig. 70. (Reduced one-half.)

It will be seen from the foregoing that so many things enter in for consideration that the exact time of exposure cannot be stated with any degree of clearness. Elaborate systems of calculation have been worked out so that if the distance of the tube from the plate, the penetration of the X-rays measured with a penetrometer, the milliamperage sent through the tube, and the thickness of the part be known, reference can be made to a printed table and the exact time of exposure necessary learned. While commending such work as efforts along the right line, I consider them failures so far as practical application in dental work is concerned. Notice that in the calculation the density of the part and sensitiveness of the plate are not taken into account at all.

Each man must learn to properly time his exposure by personal experimentation. This statement is likely to be contradicted by those who construe it to mean that no idea at all of the time of the exposure can be learned except by experiment. That is not what I am saying, however. The idea I wish to convey is that these tables of calculation, on the time of exposure, give only the approximate length of time of exposure necessary, and that a very little experience and the use of judgment render them useless. They are always useless except when a penetrometer is used and the coil is equipped with a milliamperemeter.




Fig. 72. Trays for developing and fixing solutions.

To make the negative (the picture on the glass of the plate) of the radiograph shown in Fig. 71, the factors were as follows:

1. Machines used—an 18-inch induction coil, with a two-point electrolytic interrupter, operating on 110-volt, D. C. circuit. All resistance of rheostat cut out.

2. Strength of current. Machine not equipped with amperemeter or milliamperemeter. Approximate amperage of the primary current, 26. Secondary current sufficiently powerful to obtain a fat, fuzzy spark 10 inches long.

3. Penetration of X-rays. Tube backs up 7 inches of parallel spark. Distances of tube regulating spark gap 4 inches. Therefore, the tube is high and the rays from it quite penetrating when it is properly lighted.

4. Distance of target from plate. Seventeen (17) inches.

5. Thickness of part. That of the hand, about $1\frac{1}{2}$ inches at thickest part.

6. Density of part. That of hand.

7. Plate used. Lumiere special X-ray plate. (An ordinary plate might have been used to take such a picture.)

8. Time of exposure of plate to action of rays. Five seconds.

9. Time plate remained in developer. Two and one-half minutes.

It should always be the effort of the operator to make the exposure

as short as possible (though it was not done in this instance), so that the patient may not be unnecessarily exposed to the X-rays. So far as overexposure of the plate itself is concerned, however, we, in dental work, need not fear it much. If we expose the plate unnecessarily long we may correct our mistake by leaving it in the developing solution a shorter length of time.

During exposure, the patient, tube and plate must be perfectly immobile. After the exposure we are ready to "develop the negative."

Method of Development.

Remove the plate from the envelope in the dark room, exposing it only to the ruby light. It has not changed in appearance at all. It still looks like a piece of translucent, white glass. But the picture is there. It needs only to be developed.

This is done by immersing the plate, sensitive side up, in an aqueous solution of chemicals, the developer. This developer oxidizes the silver which *has* been acted upon by the X-rays, but *does not* oxidize the silver which *has not* been acted upon by the X-rays.

Place the plate in the tray (Fig. 72) containing the developer with the film side up, quickly covering the plate with the solution. It is better to begin development in absolute darkness, not turning on the lantern till needed for first examination of the plate, and even then using as little light as possible. A dark room lantern may be comparatively safe, but when handling very sensitive plates no light at all is safer still. Many properly exposed plates have been "fogged" in the "dark" room. Trays can be purchased from any photographic supply house. Always use a tray sufficiently large to easily receive the plate. The action of the developer will be hastened and made more uniformly perfect by slightly raising then lowering one end of the tray, and so moving the developer over the surface of the plate.

The length of time it takes the image to "come up" or show varies according to the length of exposure. The shorter the exposure the longer the plate must remain in the developer. For example, when the negative of Fig. 71 was made three others were made, all the factors remaining the same—same machine, same strength current, and so on—except the time of exposure and the time the plate was left in the developer. One plate was exposed $2\frac{1}{2}$ seconds, and was left in the developer five minutes; another was exposed 10 seconds and left in the developer two minutes, and another was exposed 30 seconds and left in the developer $1\frac{1}{2}$ minutes. The four finished negatives are so nearly alike that they can scarcely be distinguished one from the other.

Developing is not completed as soon as the image shows. Sometimes

the image can be seen better by removing the plate from the developer and holding it up to the ruby light. If the exposure has been well timed the "high lights" will commence to appear (*i.e.*, the plate will begin to turn dark in places) in about 15 seconds, and the image can be seen tolerably well in 30 seconds. If this is the case the plate should be left in the developer about 5 minutes. From the foregoing we may make the following rule: Leave the plate in the developer about 20 times as long as it takes for the high lights to appear, or 10 times as long as it takes for the image to appear. This is not an inflexible rule. Indeed, no inflexible general rule can be made, because of the difference in the action of different developers. Another rule is to leave the plate in the developer until the image is about lost—and the plate seems almost black.

The actual time of developing will vary; 2 or 3 minutes for over-exposed plates; about 5 minutes for plates which have been well exposed; 15 to 40 minutes for under-exposed plates.

There are a very great many different developing formulas, any one of which may be used. In making up developers, chemicals should invariably be dissolved in the order as named. The following are some of the most popular developer formulas:

M—Q DEVELOPER *

	Avoirdupois	Metric System
Water	10 ounces =	300 c.c.
Metol	7 grains =	1½ grammes
Hydrochinon	30 grains =	2 grammes
Sulphite of Soda (desiccated).....	110 grains =	7 grammes
Carbonate of Soda (desiccated).....	200 grains =	13 grammes
10 per cent. solution Bromide Potassium.....	40 drops =	40 drops

HYDROCHINON DEVELOPER

No. 1

	Avoirdupois	Metric System
Hydrochinon	300 grains.....	20 grammes
Sulphite of Soda.....	6 ounces.....	180 grammes
Water	48 ounces.....	1,440 c.c.

No. 2

Carbonate of Potassium.....	4 ounces.....	120 grammes
Water	32 ounces.....	960 c.c.

To DEVELOP, take

No. 1, 6 ounces (180 c.c.); No. 2, 4 ounces (120 c.c.); 10 per cent. solution Bromide of Potassium, 3 to 10 drops. Mix the developers in the order given, and use cold.

*M—Q stands for "metal—quinol." In photography the word "quinol" is used as an abbreviation for "hydroquinol." This is unfortunate, because quinol and hydroquinol are different substances. There are several words and different spellings of the same word used to designate the substance—hydroquinol. They are: hydroquinon (spelled also hydroquinone); hydrochinol (spelled also hydrokinol); hydrochinon (spelled also hydrochinone, hydrokinon, and hydrokinone).

PYRO DEVELOPING FORMULA

Pyrogallic Acid Solution

	"A"	Avoirdupois	Metric System
Pyrogallic Acid	1 ounce	30 grammes
Sulphuric Acid	20 minims	1 c.c.
Water	28 ounces	840 c.c.

SODA SOLUTION

	"B"	Avoirdupois	Metric System
*Carbonate of Soda (Anhydrous).....	2 ounces	60 grammes
*Sulphite of Soda (Anhydrous).....	3 ounces	90 grammes
Water	28 ounces	840 c.c.

To DEVELOP, take

"A," 1 ounce (30 c.c.); "B," 1 ounce (30 c.c.); Water, 8 ounces (240 c.c.). This developer will then contain 1.56 grains Pyro per ounce.

The developer may be made and kept in stock solutions as above, if desired. A better plan is to buy the prepared developing powders. They may be purchased at any photographic supply store. The chemicals come in glass tubes or packages mixed in the proper proportions, and all that is necessary to make the solution is to dissolve them in the quantity of water (distilled or tap water either) suggested on the package. The package or tube usually contains a sufficient quantity to make 4 to 8 ounces of developing solution. The advantages of this over mixing the chemicals yourself are: First, the convenience and saving of time, and second, only small quantities being made at one time, the developer is used immediately, and is therefore always fresh when used.

A developing bath does not keep well in stock solution unless the bottles are full and well corked. Even then discoloration and disintegration occur in the course of a month or so. It is always advisable to use as fresh a solution as possible. Packed in the box with the plates will always be found a formula for a developer recommended by the manufacturer of the plates. It is not at all necessary to use the particular developer recommended.

During the hot summer months it is necessary to use ice in the developer, ice water to make the solution, or place the tray containing the developer in another larger tray with ice water in it. If the developer is too warm it will soften the emulsion, cause frilling at the edges, blistering and fogging of the negative. The developer should be between 60 and 75 degrees F. If too cold, development takes place slowly, and the negative, when finished, is pale and thin. I use tap water in the winter and have no trouble due to improper temperature. In the summer, though, even using ice water and ice, the work is often discouraging. If possible during the hottest weather defer development until the cool of the evening.

*If crystals are used, double the quantity.

Fixing.

When development is complete, remove the plate, dip it in clear water, then immerse it in the fixing bath. The fixing bath is a solution of chemicals which dissolves out the unaffected silver. Leave the plate in the fixer for two or three minutes after the milky appearance of the glass side of the plate has disappeared. A plate must be removed promptly from the developer as soon as development is complete, or the negative will be overdeveloped, spoiled, but it may be left in the fixing bath for hours longer than necessary without danger of spoiling the negative.

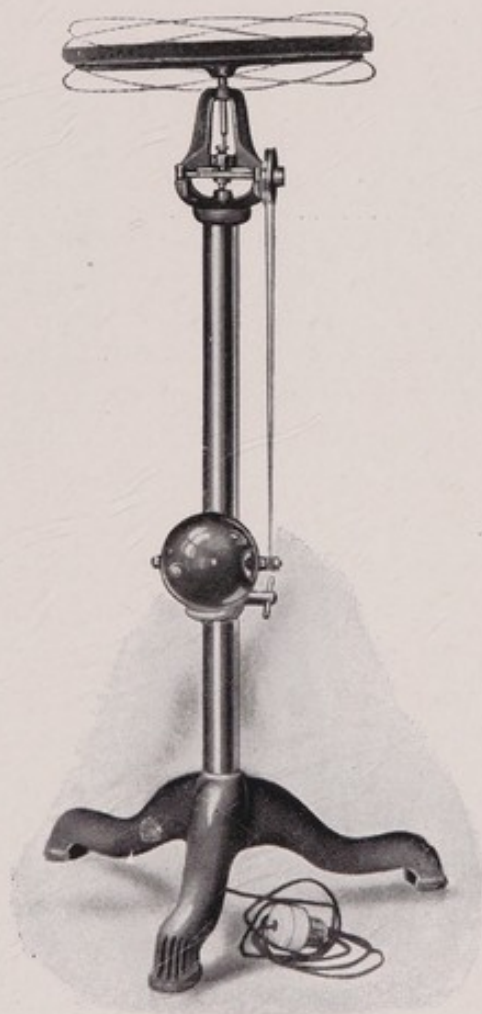


Fig. 73. Titubator.

It will not injure the plate to remove and replace it in the baths at any time during developing or fixing.

The actual time required for fixing varies from 5 to 20 or 30 minutes. The thicker the emulsion the longer time it requires for fixing. Movement of the fixing solution over the surface of the plate will hasten

fixing. A titubator (Fig. 73) is a machine on which the fixing bath tray may be set, and the bath kept in constant movement over the plate.

When several negatives are being made at the same time, it is well to use a fixing box (Fig. 74) instead of a tray. If the plates were piled one on another in the tray, they would probably stick to one another and, when pulled apart, the emulsion would be scarred. The plates stand on end in the fixing box, fitting into grooves.

Hyposulphite of soda is the standard fixer. There are not a great number of fixers, as there are of developers, to choose from. Hypo-sulphite of soda and water alone will fix plates, but is not so efficacious as when other chemicals are added to harden the emulsion.

ACID-FIXING BATH

	Avoirdupois	Metric System
Water	64 ounces	2 liters
Hyposulphite of Soda.....	16 ounces	450 grammes
Sulphite of Soda (Anhydrous).....	$\frac{3}{4}$ ounce	20 grammes
When fully dissolved, add the following hardener:		
Powdered Alum	$\frac{1}{2}$ ounce	15 grammes
Citric Acid	$\frac{1}{2}$ ounce	15 grammes

A stock solution may be made as given in the foregoing formula, or the prepared fixing powder purchased, and the fixing bath made by simply dissolving the powder in a stated quantity of water. There is nothing secret about the formulas of the prepared fixing powders. They are all practically the same as the formula given. The advantage in using them lies in the saving of time and energy that would otherwise be spent weighing chemicals. If prepared developing and fixing powders are used, it will not be necessary to have a pair of scales for this work. A graduated glass for measuring liquids will be all that is needed. During the hot months, it is expedient—not necessary—to use a freshly mixed fixer. If this is done the negative is less likely to frill or blister. Unlike the developing bath, however, the fixing bath will keep without disintegration for months. If scum or sediment appears after standing for some time, this may be removed by filtering the solution through filter paper or cotton.

The temperature of the fixer should be at least as low as that of the developer, and better lower, say about 50 degrees F.

When fixed, if the plate is held up to the light (any light, for the plate is no longer sensitive to light), the shadow of the bones of the hand will appear as transparencies; the flesh shows a little less transparent than the bone, and the balance of the plate will be opaque and black. Thus the shadows show light, and where no shadow was thrown the plate is dark. Hence the name negative which is applied to this picture on the plate. The making of the positive picture on paper, the print, as it

is usually called, from the negative will be described presently. The plate is no longer sensitive to white light, and may therefore be exposed to it any time after having been in the fixer a minute or so.

Great care must be exercised not to get any of the fixing bath into the developer. A very little "hypo" will spoil the developer. It is well to label the trays so that the tray used to hold the fixer one time will not be used for the developer another. Or, instead of labeling the trays, a black one may be used for the developer and a white tray for the fixer.




Fig. 74. Fixing box.

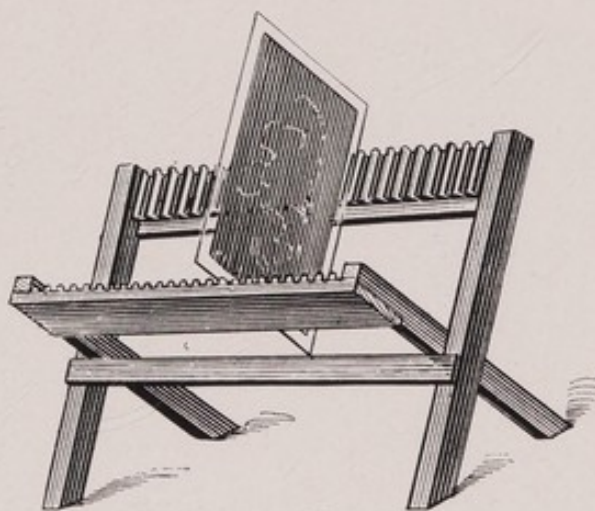


Fig. 75. Plate, or negative, rack.

Washing.

When fixing is completed the negative must be washed in clear water to remove all "hypo" from it. If the negative be placed in a tray, the tray in a basin or sink and the tap turned up, or, in other words, if the negative be washed in running water it requires 15 to 30 minutes to thoroughly wash it. Where running water cannot be had,* and sometimes during hot weather when tap water is too warm, the negative may be placed in a larger vessel of water and left for about an hour, changing water several times. A tray of water used on a titubator is efficient. The water must be changed often, and the time required is about three-quarters of an hour or longer. When several negatives are being made, it is advisable to use a washing box similar to the fixing box. (Fig. 74.)

*"Running water" is much to be preferred, as the friction or movement of the water is a great factor in cleansing the plate. After a few months, if plates show cloudiness, or a metallic luster is observed, this means that the plates were not thoroughly washed. It is even advisable, after washing, to rub the surface of the film side with clean, wet cotton, holding the plate under a faucet during the act.

Drying.

The next, and the last step in the making of the negative, is to dry it. The plate should be set on edge. Drying should take place in a clean atmosphere, so that no dust or soot will fall on and stick to the coated surface of the negative. Plate racks (Fig. 75) may be used, but are not a necessity. The plate may be set on edge at an angle of about 95 degrees by simply leaning it up against some perpendicular wall. (Fig. 76.) Dry-




Fig. 76. Negatives leaning against perpendicular wall, drying.

ing requires several hours. It may be hastened by placing the negative in a breeze. By immersing the negative in a mixture of formalin and alcohol, then placing it in the breeze of an electric fan, drying will be very materially hastened. The use of the formalin and alcohol sometimes causes spotting and blurring of the negative. If all the salts of the fixer are not well washed out of the emulsion, it will not dry promptly, but will become rough and sticky, and, when finally dry, it will be full of little holes.

Summarizing the making of the negative, it consists of exposing, developing (washing—mere dipping in water), fixing, washing, and drying.

If the negative when finished is very dark, so dark that parts of the image are lost, the plate was either overexposed, or overdeveloped, or

both. I prefer usually to say that it was overdeveloped, for even if it had been exposed unnecessarily long, this mistake might have been corrected by leaving it in the developer a shorter length of time. If the negative is almost entirely transparent and the image can hardly be seen, it is due to underexposure, or underdevelopment, or both.

The mistake of overexposure or overdevelopment can be corrected to an extent by the use of a "reducer."

The following solution is a reducer:

- *A. Water 16 ounces (480 c.c.)
 - Hyposulphite of Soda..... 1 ounce (30 grammes)
 - B. Water 16 ounces (480 c.c.)
 - Potassium Ferricyanide 1 ounce (30 grammes)
- Mix 8 parts of solution "A" and one part of solution "B," and use in subdued light.

The negative can be placed in this solution directly after fixing, without washing. Or it may be washed—it makes little or no difference. If a dry negative is to be reduced, it must be soaked in water for at least half an hour before placing it in the reducer. When sufficiently reduced, wash thoroughly for about three-quarters of an hour, then dry. The work of reducing may be done in any light.

When not in use keep solution "B" protected from the action of light. Remember that this solution is one of the most powerful poisons known. Handle it with extreme caution.

The mistake of underexposure cannot be corrected to an appreciable extent by any means.

The mistake of an underdevelopment can be corrected to an extent by the use of an "intensifier."

After having fixed the negative, wash it well in running water for about thirty minutes or longer, then place in the following solution:

- Mercuric Bichloride 200 grains (13.3 grammes)
- Potassium Bromide 120 grains (8.0 grammes)
- Water 6½ ounces (195 c.c.)

Keep the plate in this solution a short time, when it will be observed to be bleached uniformly white (the longer the negative is bleached the denser it will ultimately become). Remove from the bleaching solution, wash in running water for a few minutes, then blacken in the following solution:

- Sodium Sulphite 1 ounce (30 grammes)
- Water 4 ounces (120 grammes)

Or

- Ammonia 20 minims (1 c.c.)
- Water 1 ounce

* "Electro-Therapeutics and Roentgen Rays," Kassaban.

It is now being blackened, the negative is again washed, then dried. Intensifying should be done in a subdued light—not in bright daylight.

An old negative, one which has been made for some time, may be intensified by first soaking in water, then following the technic given.

Prepared reducers and intensifiers, with directions for their use, may be purchased at any photographic supply house.




Fig. 77. Showing how the printing frame is held up to the light to expose the photographic paper. Also showing the back of the printing frame, the frame half open, and the photographic paper in position.

While reducers and intensifiers have their place in dental radiography, they are used only to correct mistakes, and they do not entirely correct the mistakes. It is usually expedient to make a new negative rather than to attempt to reduce or intensify a faulty one.

Round transparent spots on the negative are caused by air bubbles, or air "bells," as they are called, attaching themselves to the emulsion side of the plate while in the developer.

Spots of irregular size and character appearing on a negative are due often to the use of an old developer. In radiographic work, where the appearance of a spot may determine a diagnosis, it is to be hoped that fresh developer will always be used. By fresh developer I mean developer not, at most, over a month or so old, having been kept while in stock in a filled, tightly stoppered bottle, and free from all scum and sediment. A developer containing pyrogallic acid disintegrates so rapidly that it must be used immediately after mixing—it will not keep at all. "Pyro" developers stain the hands badly.

Positive Prints.

When the negative is dry we are ready to make the positive pictures. The pictures are made on sensitized paper, a very fine grade of white paper, one side of which is coated with a silver salt somewhat as plates and films are coated. These papers sell under such various names as Velox, Cyko, Artura, and Azo, and may be purchased in any size, put up in light-proof packages. Papers are not as sensitive as plates and films, and an orange instead of a ruby light may be used in the dark room.

Place the negative, emulsion side up, in the printing frame (Fig. 77). Place a sheet of paper, sensitive side down, over the negative, and close printing frame. The sensitive side of the paper may be determined by observing that the paper curls slightly toward it; or by biting a corner of the paper, when the sensitive side will stick slightly to the teeth.

To make the exposure now, either artificial or daylight may be utilized. Before making the exposure be sure that the balance of the paper in the package is well protected against the light. Hold the printing frame so the light will shine through the negative and strike the paper. (Fig. 77.) It is not necessary to hold the printing frame immovable during exposure. The time of exposure varies greatly according to the density of the negative; the denser the negative the longer the exposure must be. Some idea of the time of exposure necessary may be learned from the directions enclosed with the paper. To make the print for Fig. 71, a 16 c.p. electric light was used, holding the printing frame about 8 inches from the light and exposing the paper—Azo—3 minutes.

Development of Prints.

With the 16 c.p. light turned off, in the orange light, the paper is now removed from the frame. As with the plate there is not the slightest change in the appearance of the paper after exposure, but the image is there, it is latent, it needs only to be developed.

The developing formulæ for papers are, broadly speaking, the same as for plates. It is very important that the developer for paper be freshly mixed, for the slightest discoloration of the bath will soil the paper. It is not desirable to save the developer used to make the negative and use it again for the paper. It is too liable to cause discoloration of the print. "Pyro" is a very poor developer for paper.

Immerse the paper quickly, sensitive side up, gently passing the tips of the fingers over the surface, to hasten development by agitating the developer, and to keep the paper submerged. As soon as the image appears as desired, transfer it to clean water, then quickly into the fixer. (It is kept in the water but a moment or so.) If, when placed in the developer, the image comes up so quickly that it gets too dark before it

can be transferred to water and fixer, it has probably been overexposed. Shorten the time of exposure, and if the image still comes up too quickly, dilute the developer. If the whites of the prints come up gray, add a few drops of a 10 per cent. solution of bromide of potassium to the developer.

Any number of prints—pictures—may be made from a negative.

The fixing bath for prints is the same as for plates, but the bath used to make the negative should not be saved and used again for prints. It might discolor them.

Allow prints to remain in the fixer 15 to 20 minutes. This dissolves out the unaffected silver.

Next wash print in running water for an hour. No visible change occurs in the print from the time it leaves the developer. Fixing and washing are done to make it permanent. The temperature of the developer, fixer, and water should be the same as for plates, to obtain the best results.

When thoroughly washed remove the prints from the wash water and place on a piece of clean glass face down one on the other, and press out the water. Then lay them out separately on a frame, covered with cheese cloth. The cheese cloth being very thin, allows the prints to dry on the side next the cloth as well as the upper side.

When dry the prints may be mounted on cardboard.

Dental Radiography.

CHAPTER V.

Making Dental Radiographs.

In the foregoing chapter we dealt with the general elementary principles of radiography. We shall now take up a more concrete consideration of dental radiography.

The first radiograph of the teeth was exhibited by Prof. Koenig to the Society of Physics at Frankfort-on-Main, Germany, in February, 1896—only a few months after the discovery of the X-ray. Five months later an article appeared in *Dental Cosmos* by Morton, entitled "X-Rays in Dentistry." Since then there have been scores of articles written on the subject and published in various dental, medical, and Roentgenographic journals.

Most dental radiographs are made on films held in the mouth during their exposure to the X-rays, the patient being seated in the dental chair. Ordinary films, as stated in Chapter IV, are not efficacious.

Special X-Ray Films.

As stated previously, but two manufacturers, the Ilford Co. and the Eastman Co., supply special X-ray films.

The Ilford film, being a foreign product, cannot be delivered with desired promptness. It is, however, the best X-ray film on the market, and may be obtained from the American agent for Ilford goods, E. B. Meyrowitz, 104 West 23d St., New York City. Ilford films of practically any size—4x5 in., 5x7 in., 8x10 in., etc.—can be purchased in packages, one dozen films to the package.

Ilford films are also supplied just ready for dental use in sizes of about $1\frac{3}{8} \times 1\frac{5}{8}$ in., one film to the packet, wrapped in black paper and covered with a rubber-like, moisture-proof material, such as tailors use to mend clothes.

For the past several years the Eastman Kodak Mfg. Co., of Rochester, N. Y., have supplied films for radiographic work. These films are covered with the same emulsion that is used to make cinematograph (moving picture) films. There are two kinds of cinematograph films, the positive and the negative. The positive films yield very satisfactory radiographic results, but the negative films are little or no better than

ordinary films for cameras. This explains why some of the films heretofore supplied by the Eastman Company have proved satisfactory, while others have not, for both the negative and positive films have been sold under the label "X-ray films." I have been in communication with the Eastman Kodak Mfg. Co., and have informed them of the failure of their negative cinematograph films to meet the requirements of a good X-ray film, but to guard against a possible mistake it would be well when ordering to state that the *positive* film is wanted. The negative film is a little faster than the positive, but sufficiently contrasty results cannot be obtained with it.

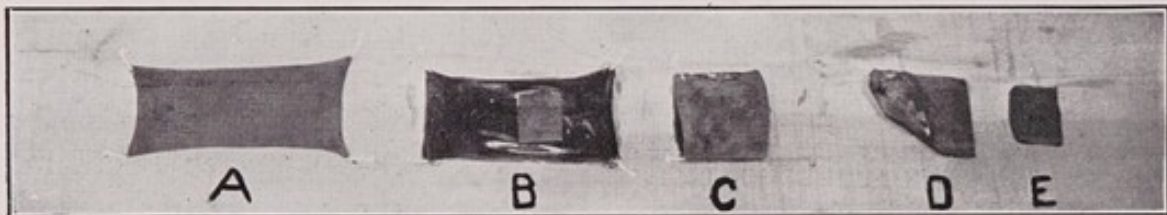


Fig. 78. A, rubber-dam stretched out and fastened to a board with pins. B, the rubber covered with cement and the film packet on it. C, pins removed from one end and the rubber lapped over packet. D, all pins removed. E, excess rubber trimmed off.

The Eastman Company will supply films in any size to order; or in little black paper packets, ready for dental use, two films about $1\frac{1}{4} \times 1\frac{3}{4}$ in., to the packet, the sensitive side of the films presenting toward the black side of the packet.

The special 4x5 in. X-ray film, formerly manufactured by the Seed Dry Plate Mfg. Co., of St. Louis, is now made by the Eastman Kodak Co., of Rochester, successors of the Seed Dry Plate Co. The old Seed film was not a non-curling film. The "Seed Positive Film," now manufactured by the Eastman Co., however, has a coating of gelatin on the back of the film to keep it from curling. With the film thus coated on both sides it is impossible to tell by observation which is the sensitive side. The way to determine this is by the manner in which the films are packed in the envelopes. Of the twelve films in the package, eleven have the sensitive surface presenting away from the seam of the enclosing envelope. The twelfth film—the one farthest from the seam—has the sensitive surface presenting toward the seam.

Because it is efficacious and is furnished promptly and at a reasonable cost, the most popular dental X-ray film is the Eastman film supplied in small packets. The black paper of the packet is thick enough to protect the film against moisture when taking pictures of the upper teeth, but additional protection is needed when making radiographs of the lower

teeth. This protection may be given by covering the packet with rubber dam. The rubber dam is staked out with pins to prevent curling, and covered with ordinary rubber cement, such as is used to repair the inner tubes of bicycles and automobile tires. Allow the cement to dry a minute or so. Place the packet on one end of the rubber, remove the pins at said end, and fold the rubber; so covering the packet. Trim off the excess rubber. (Fig. 78.)




Fig. 79. Illustrating method of covering a more or less circular film with black paper.

This method of protecting the film against moisture is so much better—easier, quicker, more efficient, and less expensive—than the usual method of covering the film with unvulcanized plate rubber that a description of the latter will not be given.

Lately I have adopted a method of covering film packets to protect them against moisture, that is just as efficacious and much more convenient and less expensive than the one just described. Take a piece of mending tissue, such as is used by tailors to mend clothing, of such size that when folded over the film packet (Fig. 78, C and D) it will extend beyond the packet on the three open sides, about one-half inch. Warm the edges of the tissue slightly by passing over the flame of an alcohol lamp or Bunsen burner, and pinch them together. Then warm them (the edges) to stickiness again and turn them back and stick them to the tissue covering the back—*i. e.*, the nonsensitive side of the film packet.

If the large Ilford or Eastman films are used the operator may cut the original large film into any size or shape, and cover with two thicknesses of black, lightproof paper. This must, of course, be done in a dark room. A pair of scissors, with long, sharp cutting blades, will be found especially suitable for this work. Cover the film so the sensitive

will be the smooth side of the packet. Fig. 79 illustrates a method of wrapping up more or less circular or oval films. By unwrapping an Eastman film packet one can learn how best to cover a square or rectangular film. If the films are to be used to radiograph the lower jaw or teeth the packet should be covered with rubber dam as described. Two films may be put in a packet if desired. The advantages of this are as follows: If one negative is spoiled, or spotted during development, possibly the other will not be. If the patient be referred from another dentist or physician, one negative may be given to the man referring the case and the other retained and filed away.

Instead of wrapping the film in black paper, as suggested above, one may have little black paper envelopes of the desired size made and use them. Instead of using rubber dam, one may have small oiled paper envelopes made and protect the films against moisture by enclosing the packet in them.

With the films ready for use we may now proceed as follows:

**Technic for
Dental
Radiographs.**

Be it understood that some of the steps in the technic* given hereinafter are for the beginner, and may be eliminated after the operator is acquainted with his coil, tubes, films, etc.

First test the coil and see that it gives a fat, fuzzy spark, at least 6 or 7 inches long. This almost invariably necessitates cutting out all the resistance of the rheostat. I cut out all the resistance of the rheostat on my 18-in. induction coil and obtain a fat, fuzzy spark 10 inches long.

Some of the most modern induction coils are made with "multiple inductance." With this equipment, by changing a plug or switch, the induced current is made stronger or weaker in milliamperage. The higher the milliamperage sent through a tube the greater the number of X-rays produced. Thus the more rapid the work to be done the higher the inductance should be. Some of the very largest induction coils on their highest inductance, and the interrupterless coils, can force 30 or 40 milliamperes through a high vacuum X-ray tube. With such a current dental radiographs can be made instantaneously. A tube will not stand such a current without injury for longer than about fifteen seconds at most.

Some induction coils, not yet on the market, but under construction,

*There are some special steps in technic when using a high-frequency coil instead of an induction coil or transformer. These steps are not mentioned here, but will be found immediately following the summary of the conditions under which the negative for Fig. 115 was made.

will be, if we are to believe the men who are making them, able to force from 80 to 200 milliamperes through a hard tube. A tube could not stand such a current longer than a second or so, if so long.

After testing the coil, throw off the switch and hitch up the tube. Have the terminal tapes tight, so they will not come unhooked from the tube while it is in operation. When a terminal becomes disconnected from the tube while the current is passing through it a puncture of the tube sometimes results.

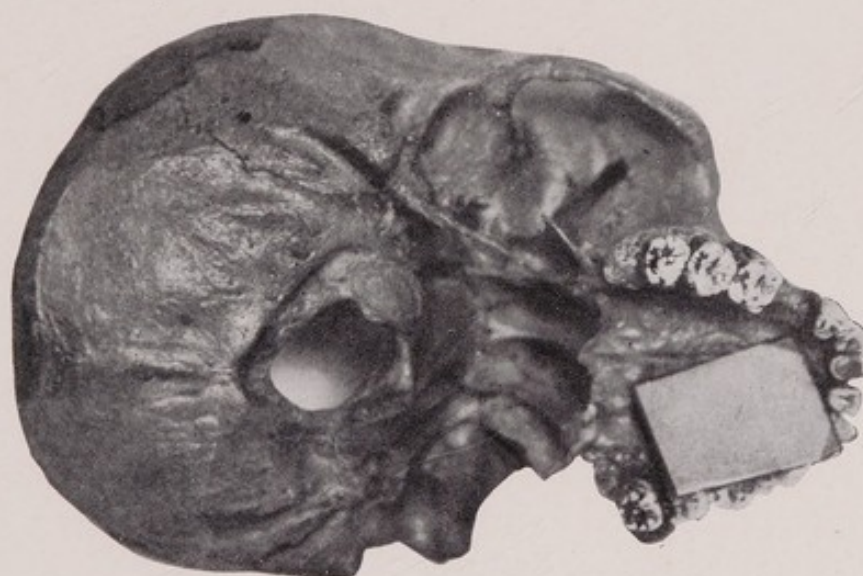

Fig. 80. Position of the film in the mouth for making radiographs of the upper bicuspid and first molar region.

Set the tube-regulating arm to give a tube-regulating spark gap of 4 inches. This is not an invariable rule. Perhaps the gap should be 5 inches when a tube is new and reduced to 3 or 2 inches when the tube is old. And so with many statements following—they are subject to variation; they are calculated only to give a beginner something tangible to start with.

When the tube is hitched to the coil, separate the sliding rods the entire distance of the maximum spark gap. See to it that the terminal tapes or the tube are not near any conductor, or the current may jump to it—the conductor. If this occurred from the tube it might be punctured.

Turn on the switch just for a moment, then off, then on, then off, and so on, slightly lengthening the time the current is left on until it is observed to pass through the tube without a spark at the tube-regu-

lating spark gap. This warms the tube gradually. In cold weather it is well to warm it slightly over a register before sending the current through it. Sometimes no spark will occur at the tube-regulating spark gap at all. This simply means that the vacuum of the tube is such that it does not need lowering.*

Turn the current on now for a few moments and see that the tube lights up properly. In order to observe the fluorescence the room should be either dark or semi-dark. Turn off the current, shorten the spark gap, turn on the current again, and observe whether it passes through the tube or jumps the spark gap. Repeat this until the current jumps the gap. This tells us the condition of the tube by showing how many inches of parallel spark it will back up. The tube should back up about 6 inches of spark. After the operator is well acquainted with his tube and coil this test of the vacuum of the tube will not be necessary. The operator will be able to judge the vacuum fairly well by the fluorescence of the tube and the length of the tube-regulating spark gap.

We are now ready to pose the patient. As we do this we must constantly bear in mind that we are simply throwing a shadow on the film, and that, like all shadows, this one is liable to be distorted unless the tube, the part to be radiographed, and the film are in their proper relative positions.

The ideal position would be so that the X-rays would strike the part to be radiographed and the film at right angles, as in Fig. 70. But this is quite impossible when radiographing the upper teeth.

**Position of Film
and Direction
of Rays.**

With the film in the mouth, as per Fig. 80, the common mistake will be to have the tube too low (Fig. 81). The result of this is shown in the radiograph in Fig. 81, and the reason for it in the diagram (Fig. 82) in which the angle of the rays, the object, and the film are in about the same relative positions as in Fig. 81.

The proper position and the radiograph made from this pose are shown in Fig. 83. Fig. 84 diagrammatically illustrates the pose in Fig. 83.

*Instead of setting the tube regulating spark gap at a certain distance and leaving it there while the exposure is being made, as I have suggested and will continue to suggest, it is the common practice for radiographers to make the tube-regulating spark gap short—*i. e.*, about two or three inches—turn on the current for a second or a fraction thereof, until the tube lights up properly, then widen the gap to its maximum length, then turn on the current again for a moment to see that the tube lights up properly with the gap so widened, and, if so, make the exposure with the gap its maximum width, a distance too great for sparking to occur. If, after lowering the vacuum, inverse current is seen in the tube it means that the vacuum has been lowered too much. Allow the tube to cool.



Fig. 81. The tube too low, and the resulting radiograph.




Fig. 82. Diagrammatic illustration of the X-rays striking the tooth and film at such an angle as to cause a lengthening of the shadow cast on the film. (For this idea of diagrammatic illustration the writer is indebted to Dr. Price.)



Fig. 83. The proper pose for making radiographs of the upper bicuspid and molar region, and the radiograph which was made from this pose.

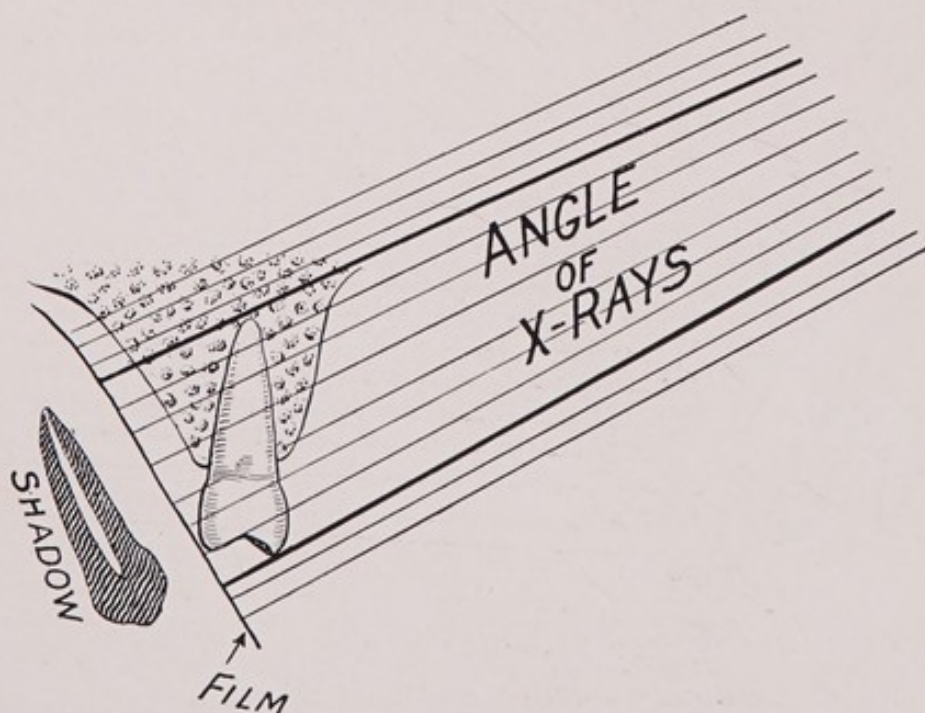


Fig. 84. Diagrammatic illustration of the rays striking the tooth and film at such an angle as to avoid either lengthening or shortening the shadow cast on the film.



Fig. 85. The tube too high, and the resulting radiograph.

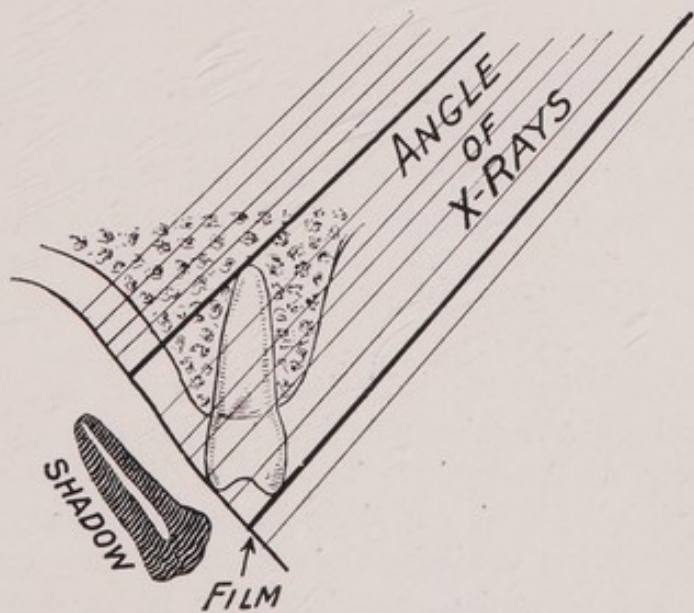


Fig. 86. Diagrammatic illustration of the rays striking the tooth and film at such an angle as to cause a shortening of the shadow cast on the film.

If the tube be placed too high the teeth on the radiograph will be shorter than the teeth themselves, somewhat distorted and blurred (Fig. 85). Fig. 86 diagrammatically illustrates the pose in Fig. 85.

A study of Figs. 82, 84 and 86 will show that in order to make a radiograph which will not picture the teeth too long nor too short the X-rays should strike the film almost, but not quite, at right angles to its surface. The angle of the film in Figs. 82, 84 and 86 is what it would

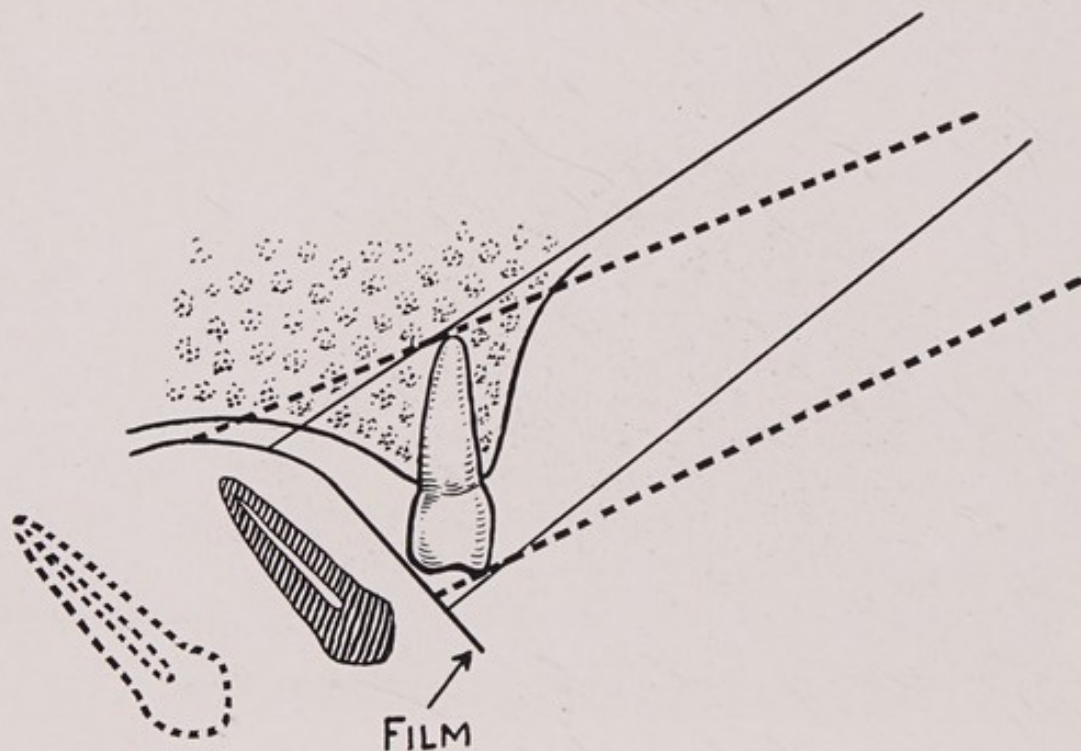


Fig. 87.

be in the average mouth. Suppose, however, the vault is very flat. In such an event the angle of the X-rays as illustrated in Fig. 84 to be correct would cause a marked lengthening of the shadow, as illustrated by the dotted lines and drawing in Fig. 87. The angle of the X-rays should be as in Fig. 86 to avoid, as nearly as possible, any distortion. (Notice in Fig. 87 that the bending of the film would cause a lengthening of the shadow.)

Just in proportion as the vault becomes more flat the film departs from the vertical and the tube must be at a different and higher angle. And so, inversely, as the vault is higher the film may be placed more nearly parallel with the teeth and the tube may be lowered.

From the foregoing it will be understood why we can never be *sure* that our radiograph gives the *exact* length of upper teeth.

Owing to the fact that it causes distortion, bending of the film should be avoided as much as possible.

Fig. 83 shows the proper pose for making a radiograph of the bicuspid region. The slight changes of this pose necessary to make radiographs of the anterior and extreme posterior teeth are apparent. When making radiographs of the posterior upper teeth the mistake at first will probably be that the X-rays will not be directed at a point far enough back on the face and pictures of the bicuspids will be made when the operator desired to picture the molars.

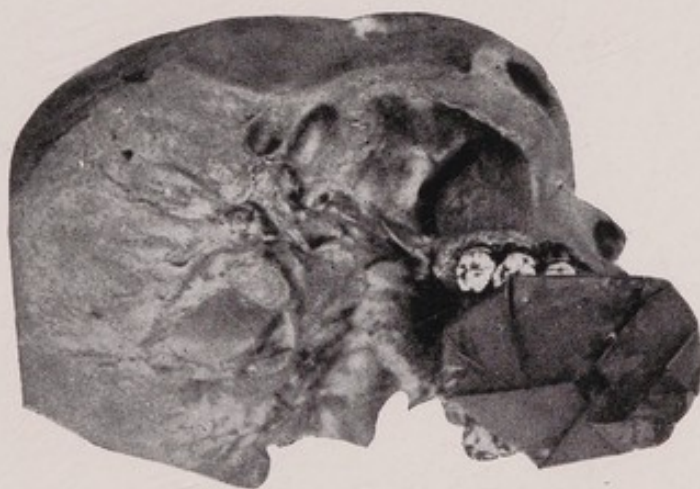

Fig. 88. As a film is placed in the mouth for the pose and radiograph shown in Fig. 89.

Instead of placing the film in the mouth, as in Fig. 80, a larger film may be used and placed as in Fig. 88, the sensitive side toward the upper teeth. With the film in this position the patient is instructed to close the mouth, so holding the film firmly in position. With the film in such a position either the tube must be placed higher and the rays directed more nearly straight down; or the head must be tipped downward toward the tube, which accomplishes the same result, viz., causes the rays to strike the film more nearly at right angles. (Fig. 89.) The radiograph made on a film held in this position is very likely to be distorted. (Fig. 89.)

The usual position of the film for taking pictures of the lower teeth is illustrated in Fig. 90. With the film in this position it should be covered with rubber or oil paper to protect it against moisture.

Fig. 91 shows the proper pose for taking pictures of the lower bicuspid and molar region. If the radiograph does not show the apices of




Fig. 89. The pose with the film in the mouth, as in Fig. 88, and the radiograph made from this pose.

the roots it is because the film was not pressed down far enough, or the tube was not low enough. The slight differences in the poses to make radiographs of the anterior teeth and the third molars from the pose shown in Fig. 91 are apparent.

With the film placed in the mouth as in Fig. 89, except with the sensitive side of the film presenting toward the lower instead of the upper teeth, and a pose as per Fig. 92, radiographs of the lower teeth may be made.

**Distance Between
Tube and Patient.**

The distance the tube is placed from the film is about 12 to 20 inches, measurements taken from the target of the tube. A good rule to follow is to place the tube so that there is a distance of about 8 inches between the glass of the tube and the patient's face. If, as is almost invariably the case, a 6-inch tube is used, this makes the distance between the target and film about 12 to 13 inches.* I never have the glass of the

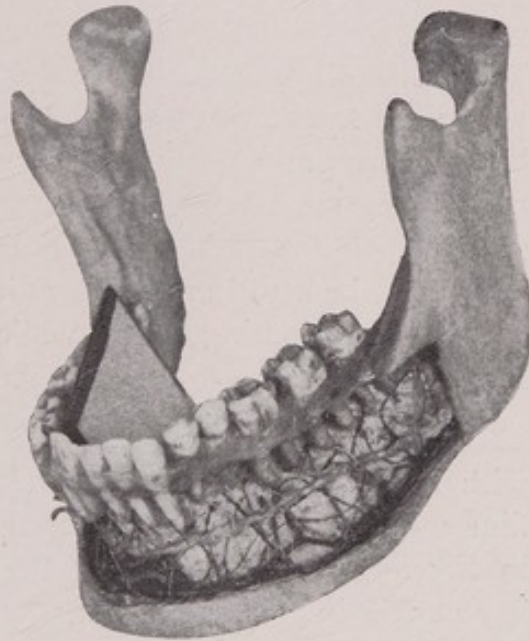

Fig. 90. Position of the film in the mouth for making radiographs of the lower molar and bicuspid region.

tube closer than 6 inches from the face. A tube of medium vacuum must be brought a little nearer to the film than one of high vacuum if the same length of exposure is to be made, because the X-rays from it are not so penetrating. The advantage in having the tube as far away as possible lies in the fact that both the patient and film are then more nearly out of range of the soft, secondary rays. These rays may burn the patient (set up a dermatitis) and fog the film.

In most works on radiography the writers advise 18 inches as the proper distance between target and film. I believe this to be needlessly

*Eight inches between the glass of the tube and the patient's face, plus three inches the distance from the glass of the tube to the target, plus one to two inches the thickness of the maxilla and overlying parts, equals twelve to thirteen inches the distance between the target and the film.

long. As I have just stated, I bring my tube much closer, and I have never had any trouble from dermatitis or fogging of the radiograph. By bringing the tube as close as I do I am able to get a clearer, better picture in about one-half the time of exposure that would be required if the distance between the target and the film were 18 inches.

Before placing the film in the mouth, after the tube and the patient are in their proper positions it is well to turn on the current for a moment, that the patient may become accustomed to the sound and light. Otherwise the patient would probably be startled, move involuntarily and spoil the picture.

Protection of Films.

If the films have been in the same room while we have been testing the tube, or even if they have been in a room immediately adjoining the operating room, they must have been kept in an X-ray proof, lead-lined box, the lead of which should be about $\frac{1}{8}$ inch thick (Fig. 93). All films, plates or papers must be kept in such a box if they are to remain in the same room, or even an adjoining room, while the tube is lit, to keep them from becoming fogged.

Methods of Holding Films in the Mouth.

If the position of the film is as per Fig. 88, with the mouth closed, the problem of holding the film while making the exposure is solved. If, as in Figs. 80 or 90, however, the film must be held immovable by either patient, assistant, or operator. The patient can hold the film, and it is best that he should. If the operator or assistant holds it he or she should wear X-ray proof gloves to protect the hands. Otherwise the repeated exposure of the hands to the rays might prove disastrous. See chapter on "Dangers of the X-Rays."

Dr. Tousey, of New York, and Dr. Ketcham, of Denver, have designed little devices, film holders, for holding the film in the mouth during its exposure.

It has been recommended that a modeling composition impression of the mouth may be made, a place cut out for the film, which is placed therein and the impression reinserted in the mouth. This method of holding films I consider extremely impracticable, because of the time consumed in unnecessary work and the considerable bending of the film.

When using square or rectangular film packets bend the sharp corners to keep them from digging into the tissues of the mouth.

When making radiographs of the lower teeth with the film in the mouth, as per Fig. 90, the patient should be warned not to swallow during the exposure. Movement of the tongue in swallowing would move the film.



Fig. 91. Proper pose for making radiographs of the lower molar and bicuspid region, and the radiograph made from this pose.

**Time of
Exposure.**

As stated in Chapter IV, the length of time of exposure depends on several things. With the coil capable of giving a fat, fuzzy spark 10 inches long, the tube backing up 7 inches of parallel spark and the distance of the target from the film about 12 inches, the time of exposure for an Eastman film will be between 5 and 10 seconds.

I have seen tables giving the exact time of exposure for the different teeth—upper molar teeth so many seconds, upper anterior teeth so many seconds, lower molar teeth so many seconds, and so on—but such tables are utterly useless. No fixed rules for the length of time of exposure can be made and adhered to. For example, I had been making 10-second exposures. I purchased a new tube—the same make tube I



Fig. 92. Pose for making radiographs of the lower anterior teeth, and the radiograph made from this pose. The lack of detail in this radiograph is due to the fact that a negative cinematograph film was used. When a terminal of the tube is brought as close to the patient as is shown in this picture it is necessary to place a piece of wood or glass, or some other non-conductor, between the terminal and the patient—in this case over the patient's breast—to prevent the current "sparking" into the patient.

had been using—and found that with it pictures could be made in half the time, 5 seconds. Then after using the tube a few weeks it became necessary to again increase my time of exposure to 10 seconds.

As to a longer exposure being required for some teeth than for others, very little need be said. The time of exposure for radiographing third molars is slightly longer than for any other teeth of the same mouth.

Age increases the density of bone, and so the time of exposure neces-

sary to make radiographs will be somewhat proportionate to the age of the patient.

**Use of
Intensifying Screen.**

The time of exposure can be shortened from one-half to four-fifths by using an intensifying screen. An intensifying screen is a piece of paper, or cardboard covered with calcium tungstate, or platino-barium cyanide.

The coated side of an intensifying screen is placed against the coated



Fig. 93. Lead-lined, X-ray-proof box.

side of the film or plate, and both screen and film are placed in the light-proof packet as usual. Thus we get a double action on the film when it is exposed, the action of the X-rays themselves and the action due to the fluorescence of the intensifying screen.

When using an intensifying screen the uncoated side of the film should present toward the object being radiographed. This is contrary to the rule that to obtain the best results the coated side of the plate or film should present toward the object to be radiographed.

The advantages of the intensifying screen are: (1) Just in proportion as it reduces the time of exposure it protects both patient and operator against any ill-effects of the X-rays. (2) By shortening the time of exposure the life of the tube is lengthened. From a financial standpoint

this is of importance. (3) By using an intensifying screen one is able to do tolerably rapid work even with a very small coil.

The disadvantages of the intensifying screen are: (1) It causes a granular appearance of the negative, blotting out detail. (2) It is liable to spot the negative, due to unequal fluorescence of its surface. (3) It fluoresces for a minute or so after exposure, and if the plate and screen do not maintain their exact relation to one another blurring of the negative results. (4) Unless one owns several screens, so that a number of packets may be made at a time, their use necessitates the making of a film packet before each exposure, which is discommoding.

Such grosser lesions as an impacted tooth, for example, can be radiographed satisfactorily with the intensifying screen, but when we wish to obtain detail, such as is necessary to observe pulp stones or a necrotic condition, for example, the use of the intensifying screen is contraindicated. An intensifying screen disintegrates with use.

Because, as I have said, the intensifying screen fluoresces for some time after the exposure has been made it has been the practice of radiographers to lay the plate and screen aside for some time before disturbing their relation to one another. Dr. Sidney Lange, however, believing that the continued fluorescence will cause blurring of the negative even though the relation of the screen to the plate be not disturbed, removes the plate from the screen immediately after exposure. His results from this practice are excellent.

Development of Negative.

After the film has been exposed we are ready to develop it—to make the negative.

The trays for the developer and fixer should be about 4x5 inches, or smaller. The author uses little white enamel soap dishes, about 3x4 inches.

If, owing to the particular developer or film used, development requires a considerable length of time, say, perhaps 20 minutes, and one does not wish to remain all this time in the dark room, the tray containing the developer and developing negative may be covered with a heavy board on the down side of which is tacked or glued thick felt or plush, and the operator may then leave and return to the dark room at will, the film being protected against the light from the opening of the dark room door.

Choice of Developer.

What developer shall we use? I obtained the formulas for the developers used by twelve different radiographers, and they were all different! From this we may conclude that any clean, properly mixed developer will do the work.

The writer uses a prepared developer which may be purchased at

almost any photographic supply store, the Eastman M. Q. developer, the formula for which is given in Chapter IV. This developer is sold for developing photographic paper, but it develops films and plates perfectly. The label on the tube containing the chemicals directs that they be mixed with 4 ozs. of water for one kind of photographic paper, "Regular Velox," and 8 ozs. for two others, "Azo" and "Special Velox." I use 6 ozs. of water. After the powder is dissolved in the water in my graduate I put 3 ozs. of the solution in the tray for immediate use and 3 ozs. in a 3-oz. amber glass bottle. In this bottle, tightly corked, the developer will keep as long as a month. Even if it does discolor slightly it can




Fig. 94. Films hung up to dry

still be used for negatives, though it might stain paper. When the negatives are developed—one or many may be developed—the developer in the tray is thrown away. I never try to save developer that has been used, with the idea of using it again in the future.

Since writing the foregoing I have been using another prepared developer, rodinal. My limited experience with it teaches me to believe that it is as good as the M. Q. developer. My chief reason for using it, however, is because it is so extremely convenient to handle. It is a liquid. When I wish to develop a film I take $2\frac{1}{2}$ ozs. of tap water to 2 drams of rodinal. This makes a 1-10 solution. The water and the rodinal are simply placed in the tray together, and the developer is ready for use; one does not need to wait for powders to dissolve.

When conditions and length of exposure are as given above, the time the film remains in the developer is usually about 5 minutes; the high lights come up in about 15 seconds and the image can be seen tolerably well in 30 seconds.

Fixing and Washing.

The time in the fixer varies according to the film used. The Eastman film requires about 5 minutes; the Ilford film, because it is so much thicker, 15 or 20 minutes.

The writer uses a prepared acid fixing powder, mixing about a pint at a time. The solution will keep indefinitely. As with the developer, no attempt is ever made to save for future use any of the solution once used.

The negative should be washed in running water for 15 to 30 minutes, then hung up to dry. (Fig. 94.)

Instead of washing the negative in water for 15 to 30 minutes it may be soaked in Thioxydant, a "hypo eliminator," for about five minutes. This dissolves out all the "hypo," and so accomplishes the object of washing. Thioxydant is a proprietary preparation made by the Lumiere Dry Plate Mfg. Co. The advantage in using it lies chiefly in the saving of time. It may also be used in the summer to advantage, when tap water is so warm that it softens the emulsion and washing is fraught with the liability of spoiling the negative. It may be used for photographic paper as well as for plates and films.

Drying requires several hours, unless the negatives are placed in the breeze of an electric fan as suggested in Chapter IV. It requires a longer time for the Ilford negative to dry than for the Eastman product, because the emulsion on it is thicker.

Making Prints.

When the negative is dry we may then make as many prints therefrom as desired, immediately or years after. The technic for making prints was given in the preceding chapter.

The negative is laid on the glass in the printing frame, film side up, and the paper placed over it sensitive side down, and so on as given. The best prints can be made on glossy, contrasted paper. Using glossy, contrasty Azo paper, the time of exposure to a 16-candle power electric light at a distance of about a foot is from 1 to 10 minutes. When the negative is badly overexposed or overdeveloped, and it is therefore very dark, the time of exposure to a 16-candle power electric light may be as long as 20 to 30 minutes. If the exposure be made to sunlight instead of the electric light this time may be reduced to a couple of seconds. I use M. Q. developer to make my prints.

Lately I have used, with a moderate degree of satisfaction, a sunlight photographic paper made by the Eastman Kodak Company and sold under the trade names of "Solio" and "Kresko." Unlike the photographic papers thus far described, this paper is not affected, except after pro-

longed exposure, by ordinary daylight. So the room in which it is used need be neither dark nor semi-dark.

The exposure must be made to sunlight, and, for the average celluloid, dental negative, is about one hour long. At the end of this time the picture is printed. It can be seen, and needs no developing to bring it out as other photographic papers do. At this stage the picture looks like and in fact is a "proof," the like of which photographers submit to their patrons. It will "fade" or, to speak more accurately, become dark and so blot out the picture, as all proofs do, unless the unacted-upon silver salt is dissolved out. This may be accomplished and the print made per-



Fig. 95. A roller.

manent by placing it in an ordinary fixing solution for about eight minutes. Then it is transferred to running water and washed for about an hour.

Instead of using the ordinary fixing bath much better results may be obtained by placing the print in "Solio Toning Solution," a preparation made by the Eastman Kodak Company. This solution not only fixes the print by dissolving the unacted-upon silver salt, but, because it contains gold chloride, changes the color from a reddish-brown to a rich chocolate, and so makes a better-looking print.

A printing frame the back of which is in two pieces joined with a hinge (Fig. 77) is necessary for this work. By releasing only part of the back and raising it on its hinges, we may look at the print from time to time in the course of its development, without altering the relative positions of the negative and paper.

The greatest disadvantage in using this paper lies in the fact that we must have sunlight for our exposures. In this climate (Indiana) many days pass without any sunshine and, during such a period, sunlight paper cannot be used successfully.

The directions given for the use of "Solio Toning Solution" advise

placing the print in a solution of sodium chloride, for five minutes, after its removal from the toning solution, before placing it in the wash water. This step is not imperative.

Prints may be made more glossy and altogether more beautiful by placing them on a ferrotype, or squeegee board. The ferrotype is a sheet of metal on one side of which is baked black enamel. After the prints are washed they are laid face down on the enamel side of the ferrotype, rolled with a roller (Fig. 95), covered with a lintless blotter and rolled

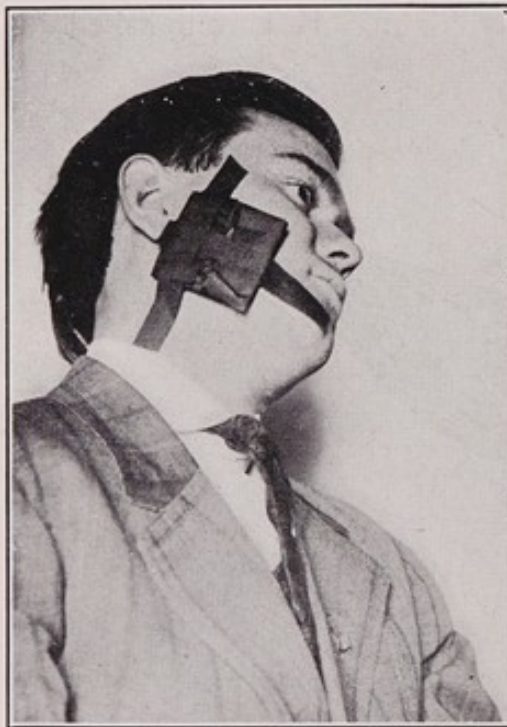

Fig. 96. Film packet held against the cheek with adhesive tape.

again with a roller. The ferrotype is now set on end, and as the prints dry they fall off. Before placing the prints on the ferrotype the enamel surface should be polished with ferrotype polish. Ferrotype polish is a solution of paraffin in benzine. It is put on the ferrotype, allowed to dry for a few minutes, then the enamel surface polished with chamois skin. If the prints do not come off the ferrotype as they should, but stick tightly, more paraffin should be added to the polishing solution. The most common cause for prints sticking to the squeegee board, however, is the failure to allow them to dry thoroughly.

Placing Films Outside the Mouth.

In all the poses thus far described the film has been placed inside the mouth. Though it is not often expedient to do so, because of the longer exposure necessary, it is nevertheless sometimes advisable to place the film outside the mouth. (Fig. 96.) The

film packet may be held, sensitive side toward the cheek, with adhesive tape. With the film placed as in Fig. 96, the pose should be as in Fig. 97. The time of exposure for this pose is about six times as long

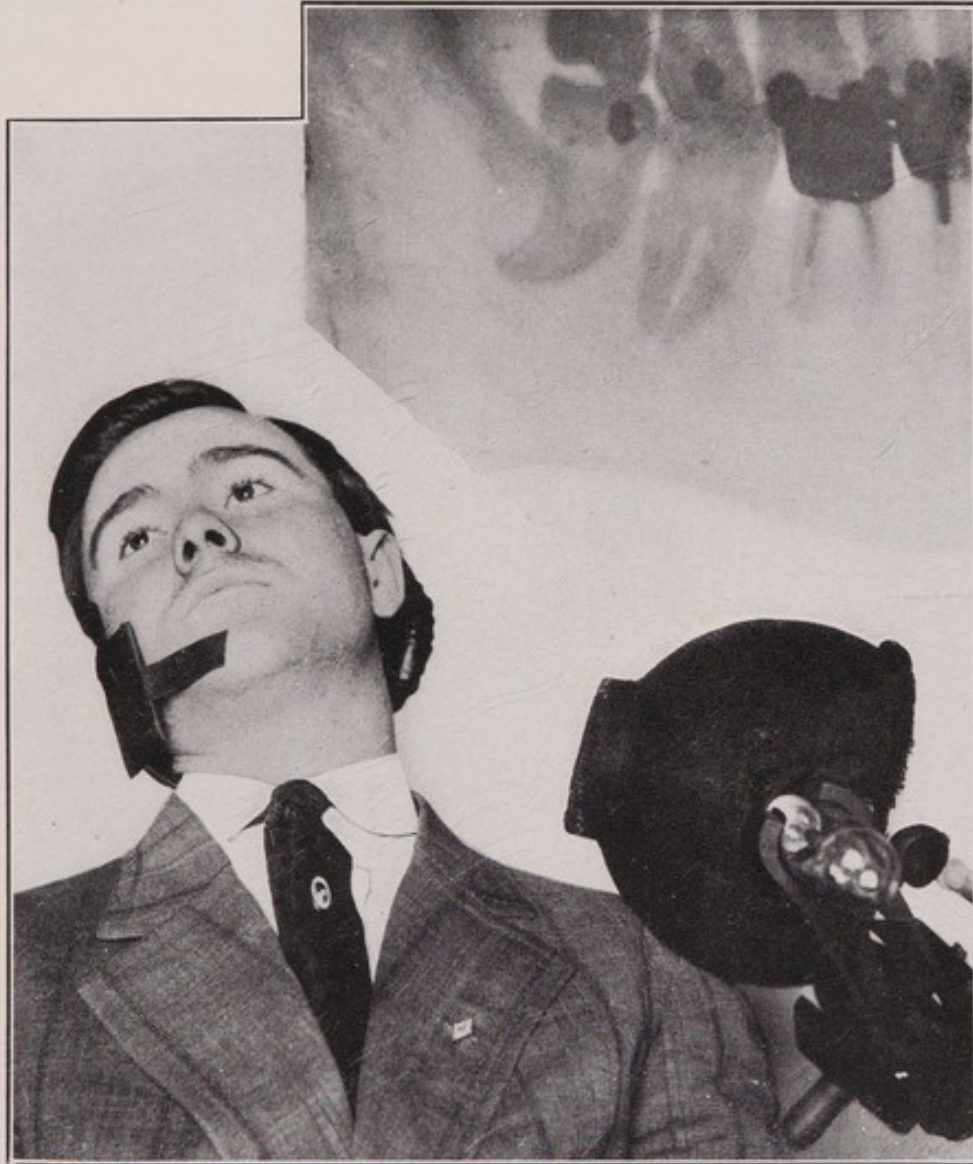


Fig. 97. Pose for making a radiograph of the lower molar region with the film outside of the mouth, as in Fig. 96, and the radiograph made from this pose.

as it would be if the film were placed inside of the mouth and the same field radiographed. The increase in time exposure necessary is due to three things: First, the increased distance between the target and the film. Second, the great thickness of tissue to be penetrated. Third, the increased distance between the teeth and the film; the closer the object to be radiographed is to the film or plate the better and more quickly it can be radiographed.

Owing to the curvature of the dental arch it is often extremely difficult to obtain a good picture of the lower incisors with the film placed to the lingual and parallel to the long axis of the teeth. This is because

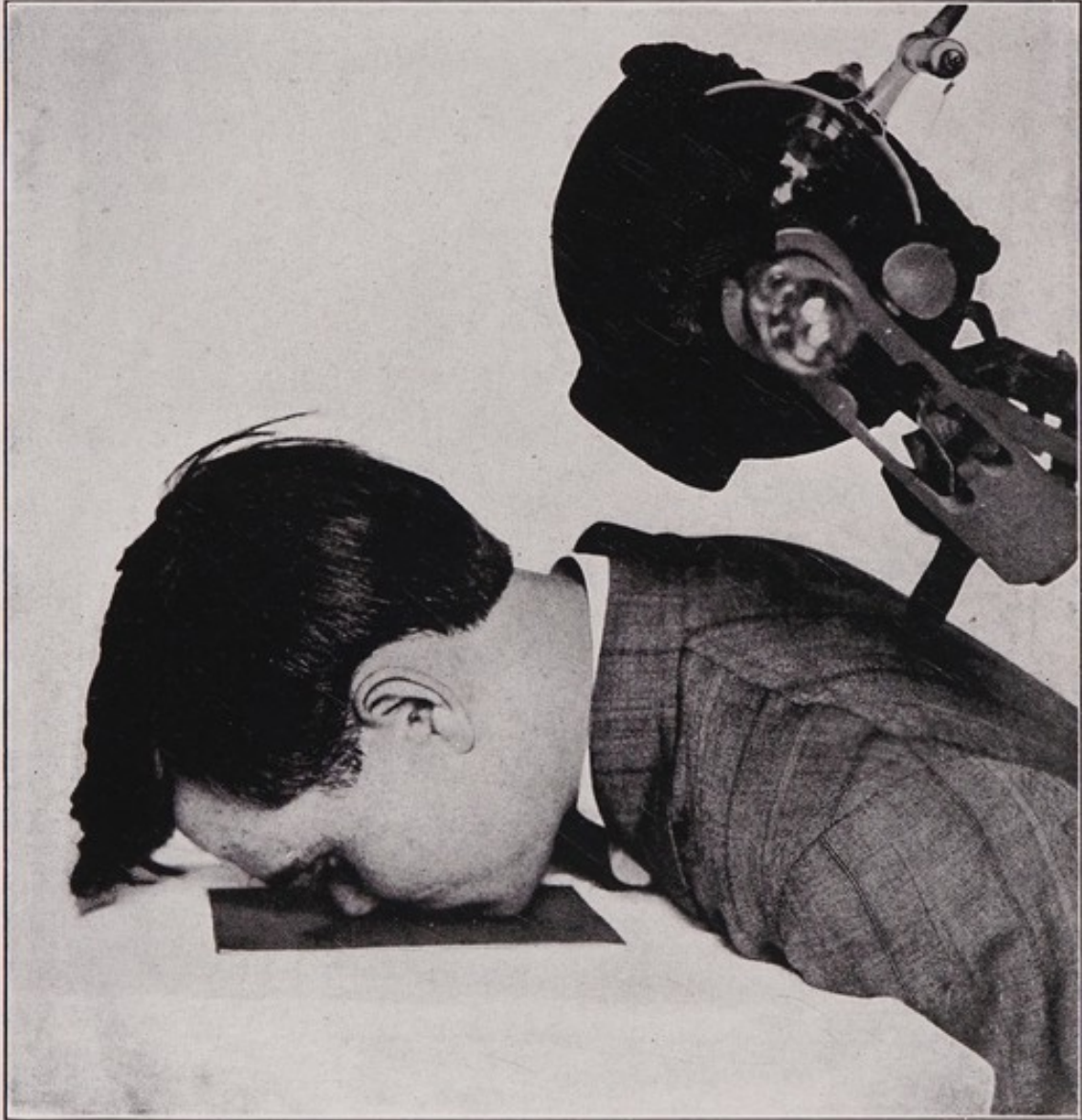

Fig. 98. Pose for making a radiograph of the lower incisors, and the antra.

the film cannot be placed in this position without bending it considerably, and the bending results in distortion and blurring of the radiograph. A film may be placed in the mouth as in Fig. 92, or a plate or large film, 4x5 inches or larger, may be placed on a stand, sensitive side up, and the patient posed as in Fig. 98. It is usually necessary to have the patient remove the collar for this pose. Fig. 98, because of its lack of perspective, is perhaps a little misleading. The rays are not directed straight through the neck, as the picture seems to show. The tube is a

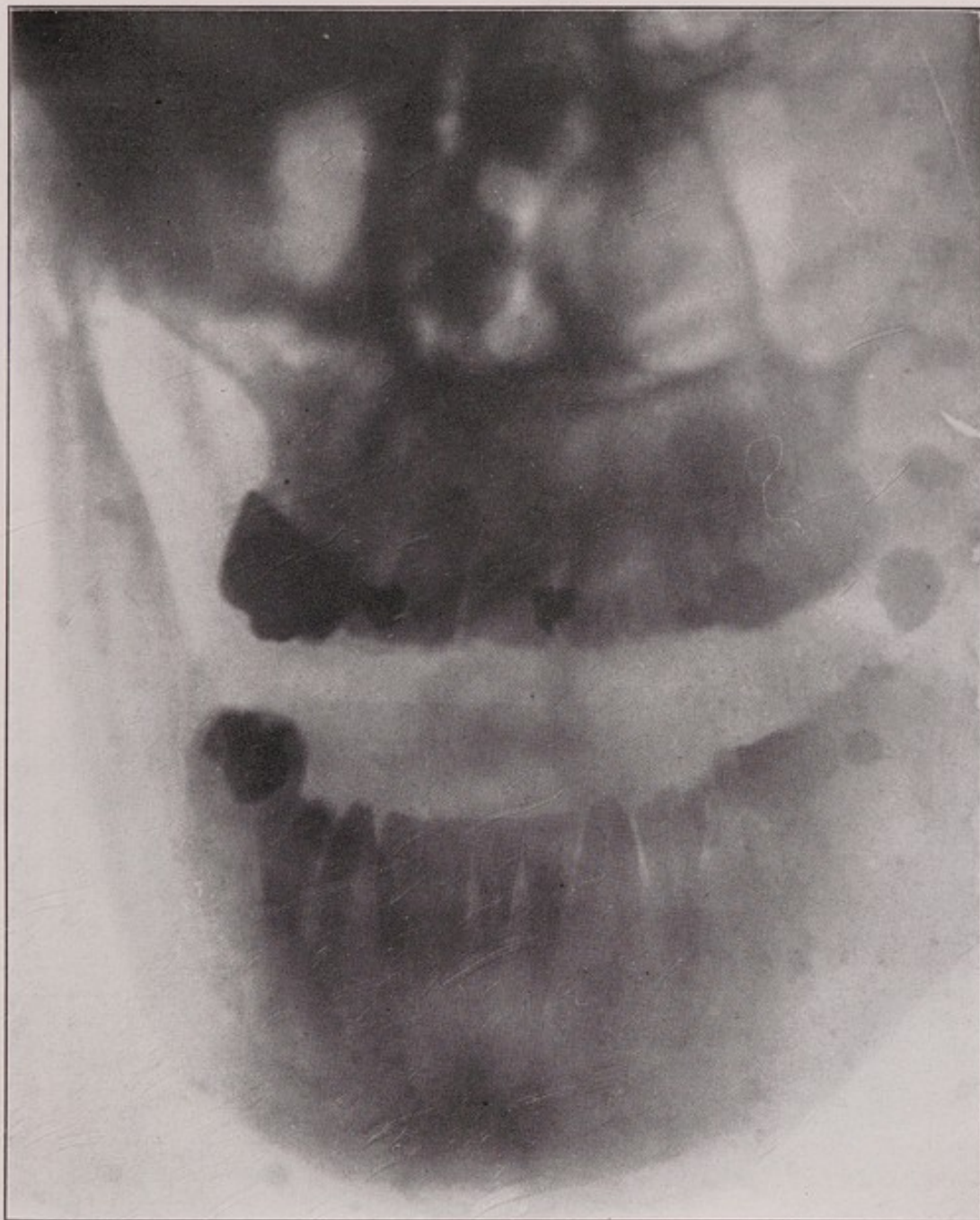

Fig. 99. Radiograph made from the pose shown in Fig. 98. Notice how clearly the antra show

little to one side. Fig. 99 is the radiograph made from the pose Fig. 98. Notice how clearly the antra of Highmore show in this picture. I believe that in posing my patient as just described to make radiographs of the lower incisors I have by accident stumbled on to the best pose for making pictures of the antra.

Except Fig. 98, all of the poses so far described have been with the patient in the dental chair, and films have been used.

**Poses for
Large Plate
Radiographs.**

To make the radiograph shown in Fig. 100 the pose was as in Fig. 101 and the radiograph was made on a 5x7 plate.

Fig. 101 illustrates the principle of posing for large plate radiographs. Modifications of this pose

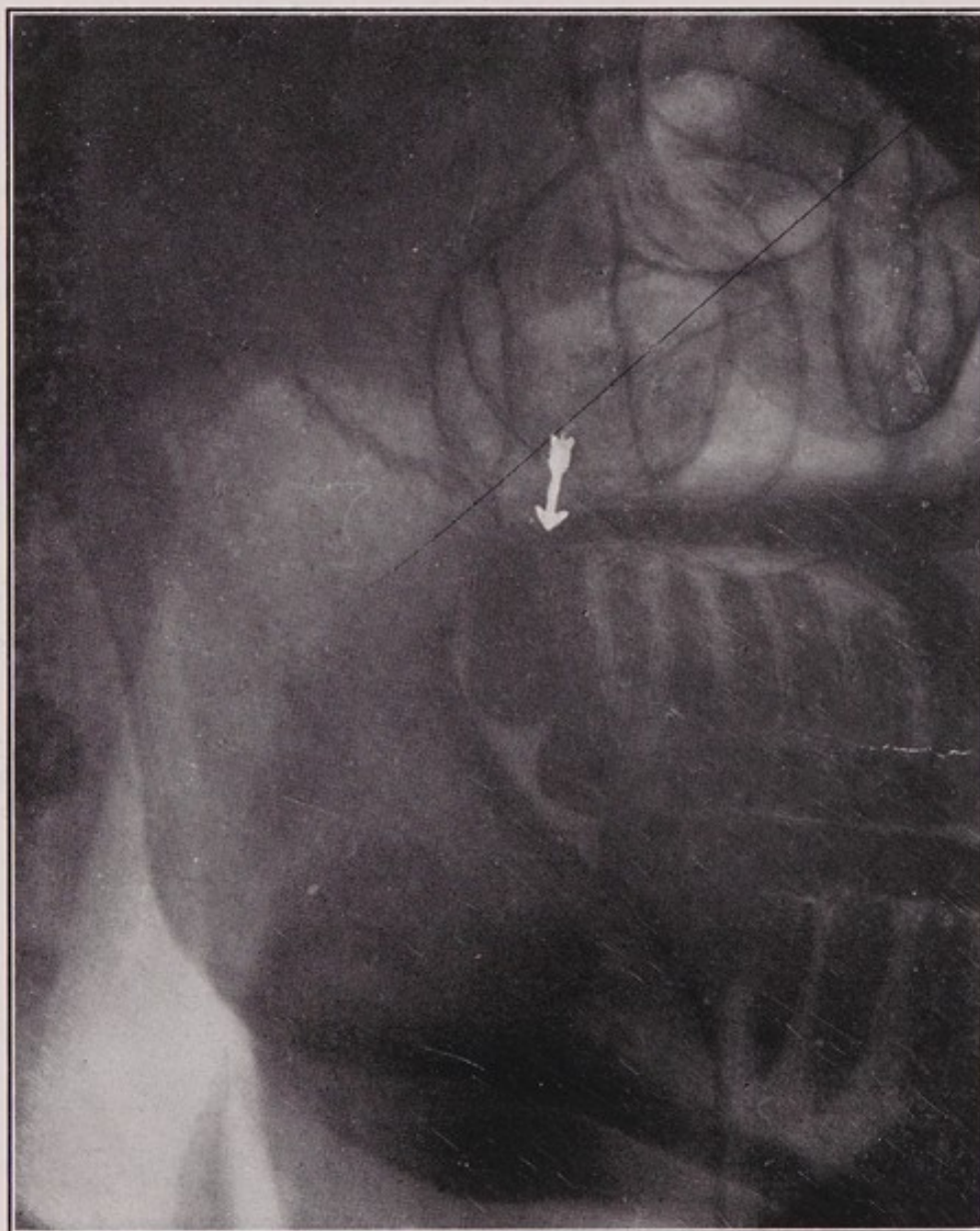

Fig. 100. Radiograph made from the pose similar to Fig. 101. The arrow points to an impacted upper third molar. The lack of detail in this, and all radiographs made from a similar pose, is due to a superimposition of shadows—the shadow of one side of the jaw is mingled with the shadow of the other. (Radiograph by A. M. Cole and Raper.)

are of course necessary, according to what particular region is to be pictured.

The objection to this pose as illustrated is that the part being radio-

graphed is not close enough to the plate. With the apparatus used the patient could not be posed lying on the side, because the shoulder would have been in such a position that the tube could not have been brought close enough to the part. The pose would have been better had the patient been lying on the stomach with the head turned to one side and the cheek resting firmly against a plate placed on a book about three or four inches thick (Fig. 330).

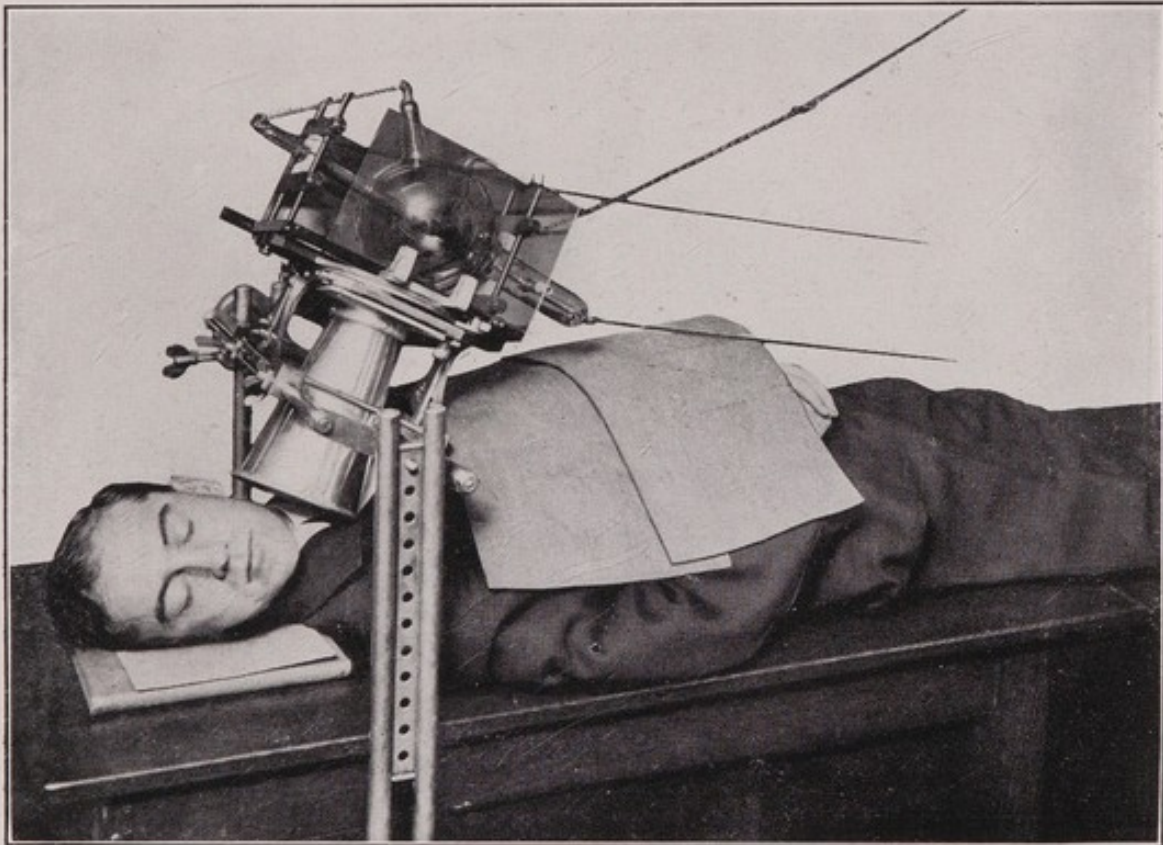


Fig. 101. Pose for the radiograph shown in Fig. 100.

Note that the patient is covered with rubber matting such as is used in halls and on stairways. This serves as an insulator to keep the current from jumping to the patient's body. In case the current did jump to the body of the patient a blister would probably be made at the point of entrance and the shock would be more or less painful, but not dangerous.

The tube is of course insulated from the metal of the compression diaphragm. An additional precaution to guard the patient against shock is to hook a chain—any conductor, in fact—to the metal of the compression diaphragm and adjusting apparatus and fasten the other end to a chandelier, gas pipe or water pipe. With this arrangement, if any current passes into the compression diaphragm or metal adjusting apparatus it will follow the chain into the gas or water pipe, and on to where the

pipe may lead, until it dissipates itself, eventually reaching the earth, *possibly*. This is called "grounding the current."

While it is always best to have the patient in a recumbent position to make a radiograph such as Fig. 100, it is not necessary to use a special

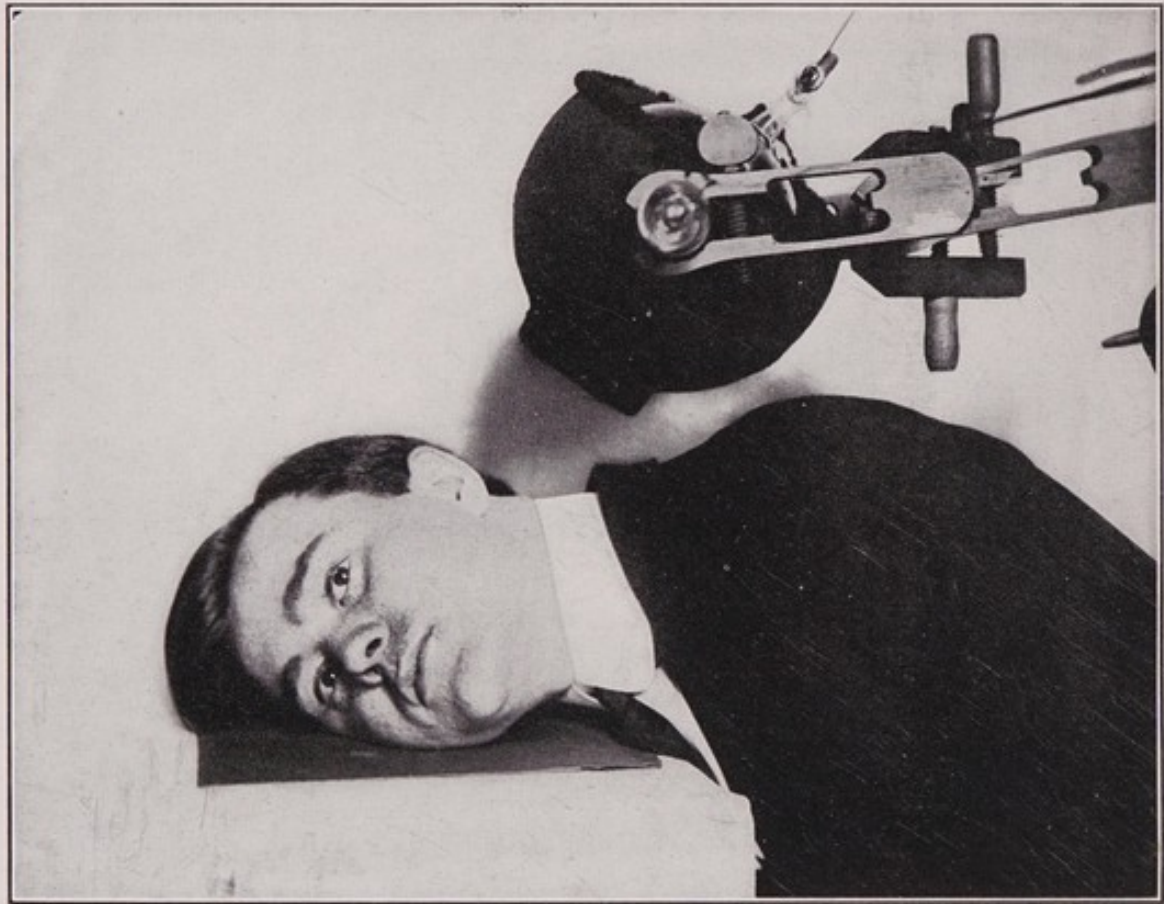


Fig. 102. Pose for the radiograph shown in Fig. 103.

cause they are less expensive and just as well adapted for the work. Plates could not be used satisfactorily inside the mouth, because they will not permit the slightest bending. Large plate radiographs are sadly lacking in detail compared to those made on films held in the mouth. radiographic table and compression diagram as is shown in Fig. 101. The patient may recline on the ordinary couch, and a plain tube stand used to hold the tube. Though it is hardly practical, because the position is so awkward, it is nevertheless possible to take radiographs similar to Fig. 100 without having the patient assume the recumbent position. Seat the patient on a stool or chair and have him lay the head on the plate, which is placed on a stand (Fig. 102). Fig. 103 is a radiograph made from a pose similar to Fig. 102.

Fig. 100 was made on a 5x7-inch plate, Fig. 103 on an 8x10-inch

plate. Plates are used instead of films for these large radiographs because. This loss of detail is due, not to the fact that a plate instead of a film is used, but to the greater distance between the teeth and the photographic emulsion, and a superimposition of shadows.

The most popular pose for taking a radiograph of the antra of Highmore is shown in Fig. 104, and the radiograph made from this pose

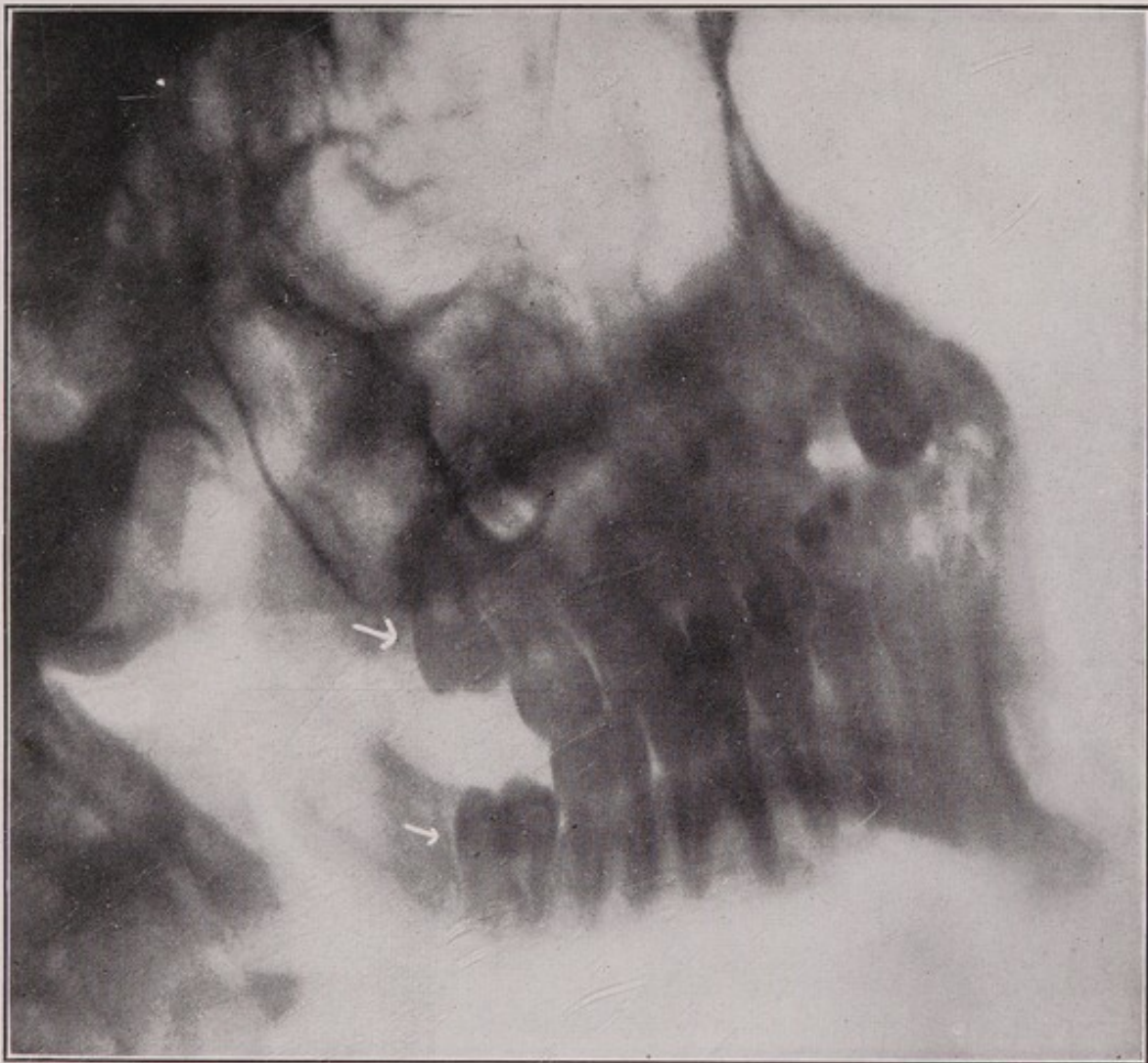

Fig. 103. Radiograph made from the pose shown in Fig. 102. The arrows point to unerupted upper and lower third molars.

in Figs. 105 and 106. This radiograph shows also the frontal sinuses and the ethmoidal cells. To obtain the best results when making such a picture a diaphragm should be used. To avoid unnecessary straining of the tube it is well to use an intensifying screen. Instead of using the radiographic table and having the patient posed as in Fig. 104, the patient may assume a pose similar to Fig. 98.

A picture of one of the antra, or a part of it, may be made on a film

held in the mouth, the pose being quite similar to Fig. 85. A picture of one antrum can also be made on a plate by a modification of the pose, shown in Figs. 101 and 102. (Fig. 107.)

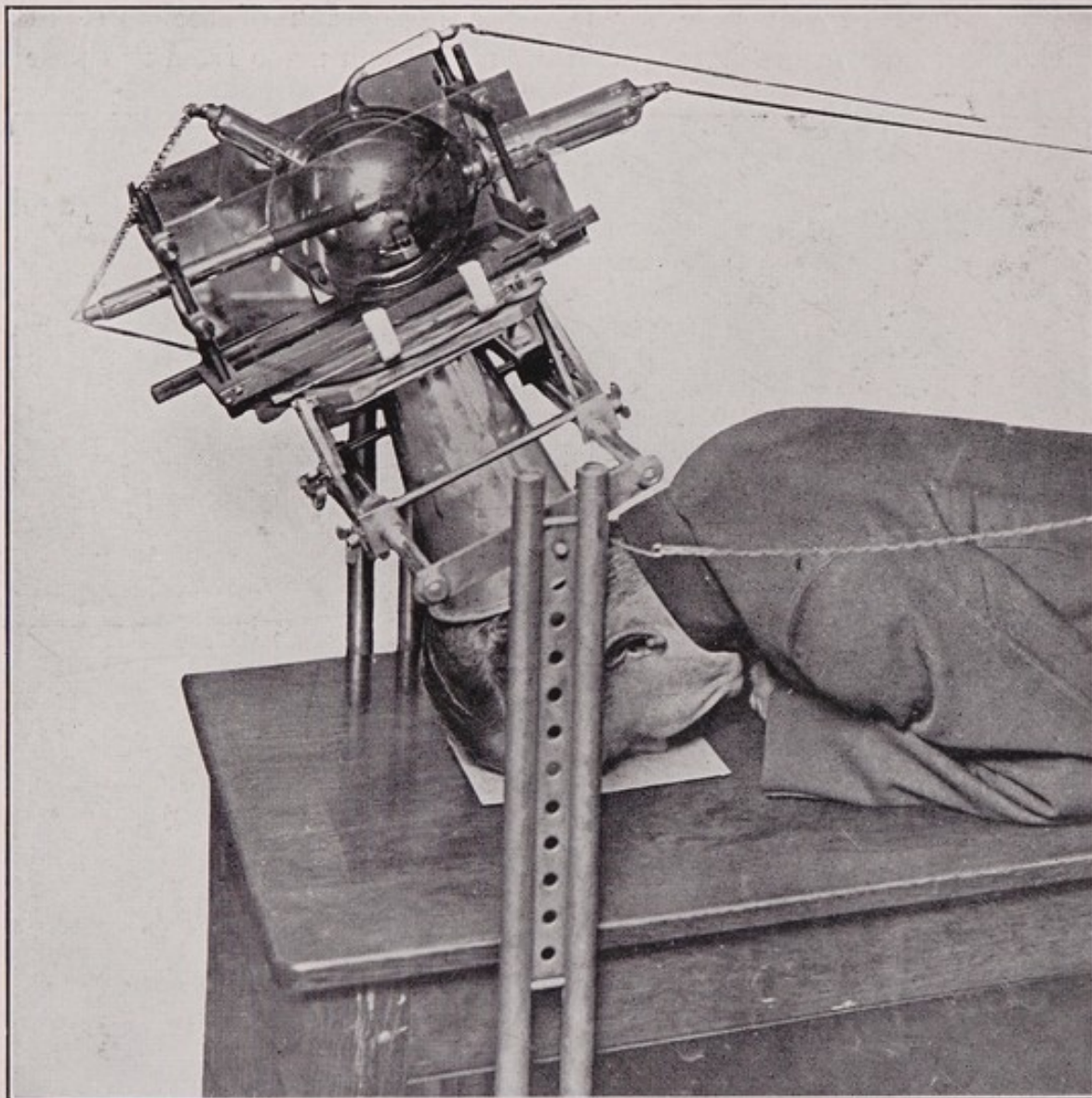


Fig. 104. Pose for making radiograph of the antra of Highmore.

**Advantages
of Film
Radiographs.**

The advantages of the small dental radiographs made on films held in the mouth over the large plate radiographs are: (1) There is no superimposition of shadows, and therefore a clearer, better radiograph can be made on the small film. (2) The patient may be seated in the dental chair while the exposure is made when small films are used. (3) The time of exposure is shorter for the small films. (4) Small machines with which it is necessary to make an

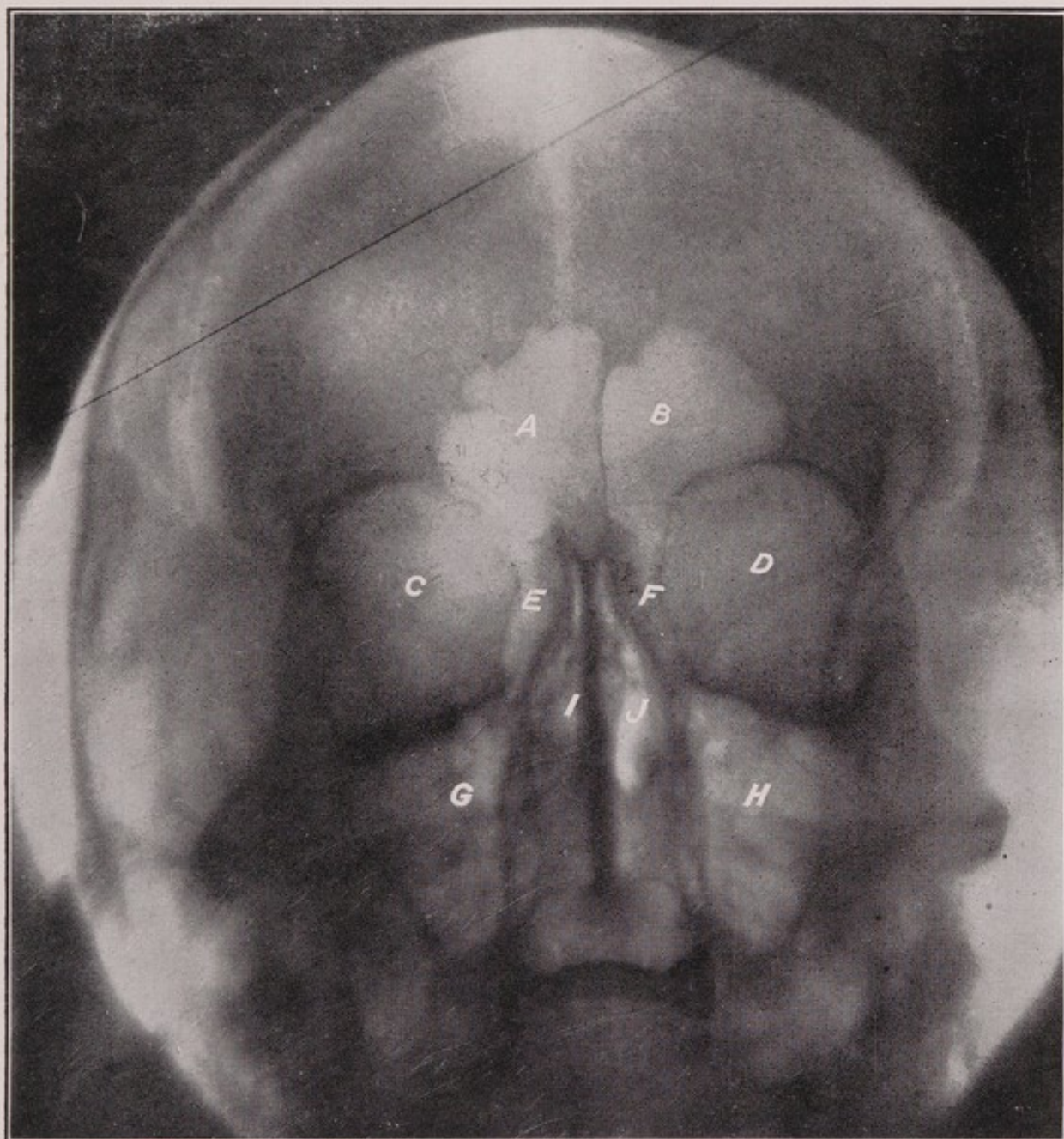

Fig. 105. Radiograph made from the pose shown in Fig. 104. A, B, frontal sinuses. C, D, orbits. E, F, ethmoidal cells. F does not show as well as E because the cells of this side are full of pus. G, H, antra of Highmore. I, J, nasal cavity. As an aid in reading this radiograph observe Fig. 106. (Radiograph by A. M. Cole, of Indianapolis.)

exposure of one minute or longer for large plate radiograph will make a good dental radiograph on a film held in the mouth in 10 to 30 seconds.

(5) A compression diaphragm, though always a valuable appliance, is not so essential when small films are used as it is when large plates are used. (6) The negative on celluloid cannot be broken.

The great advantage of the large plates over the small films is that a larger field can be pictured.

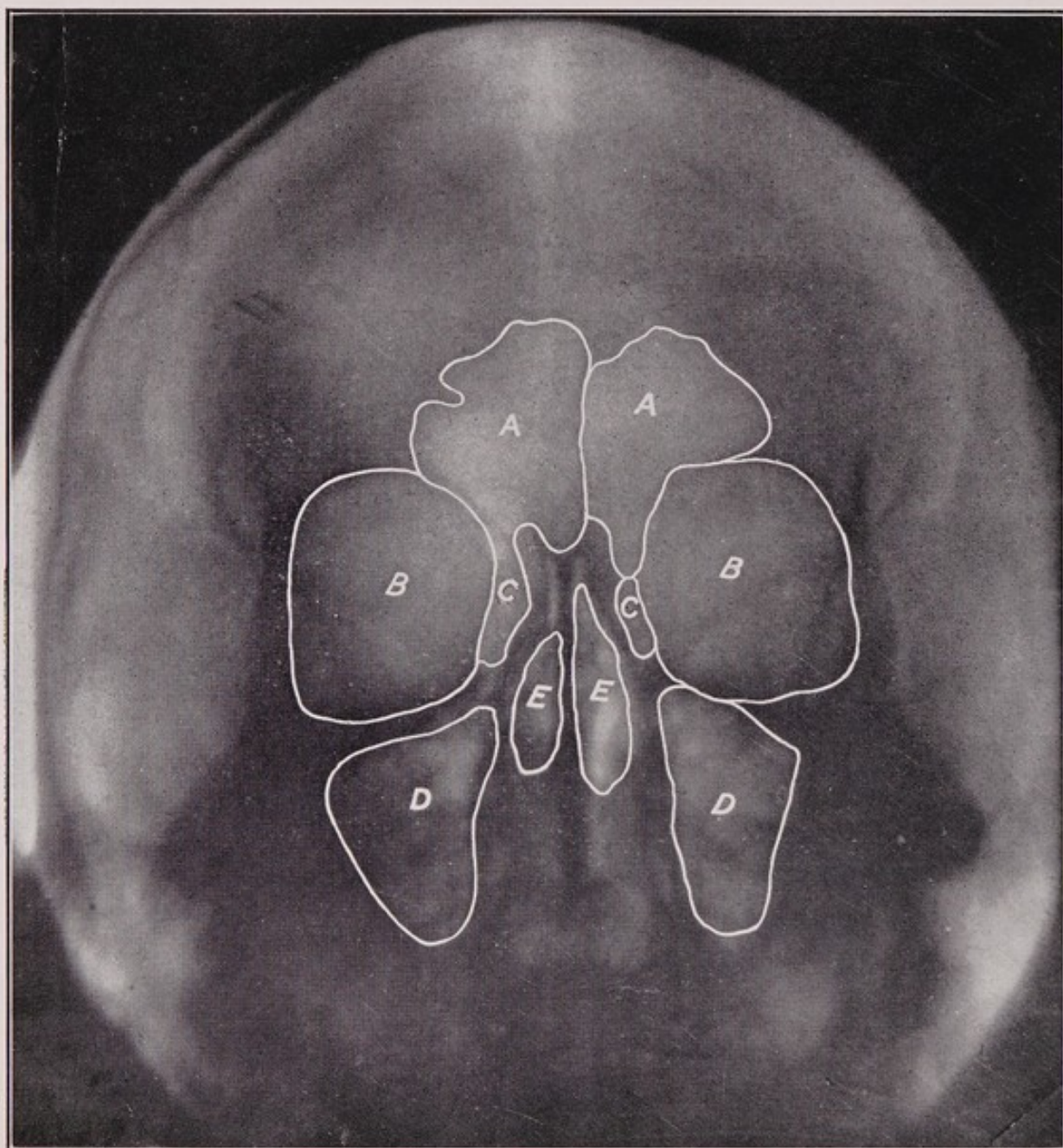


Fig. 106. Same as Fig. 105. A, frontal sinuses. B, orbits. C, ethmoidal cells. D, antra. E, nasal cavities.

**Radiographs
Made on Paper.**

Instead of using a photographic plate or film a radiograph may be made directly on photographic paper. This paper should be the most sensitive made, so that the exposure will be as short as possible. Glossy "bromide" paper is the best. Fig. 108 illustrates a radiograph of the hand made directly on bromide paper. (Reduced one-half.) When cutting the films as desired and covering them with black paper—in other words, when making the film packet—a piece of bromide

paper may be cut the same size and shape and wrapped up with the film. The paper will then, of course, be exposed at the same time the film is, and may be developed also at the same time. (Figs. 109 and 110.)

After making a radiograph as shown in Fig. 89, it may be trimmed

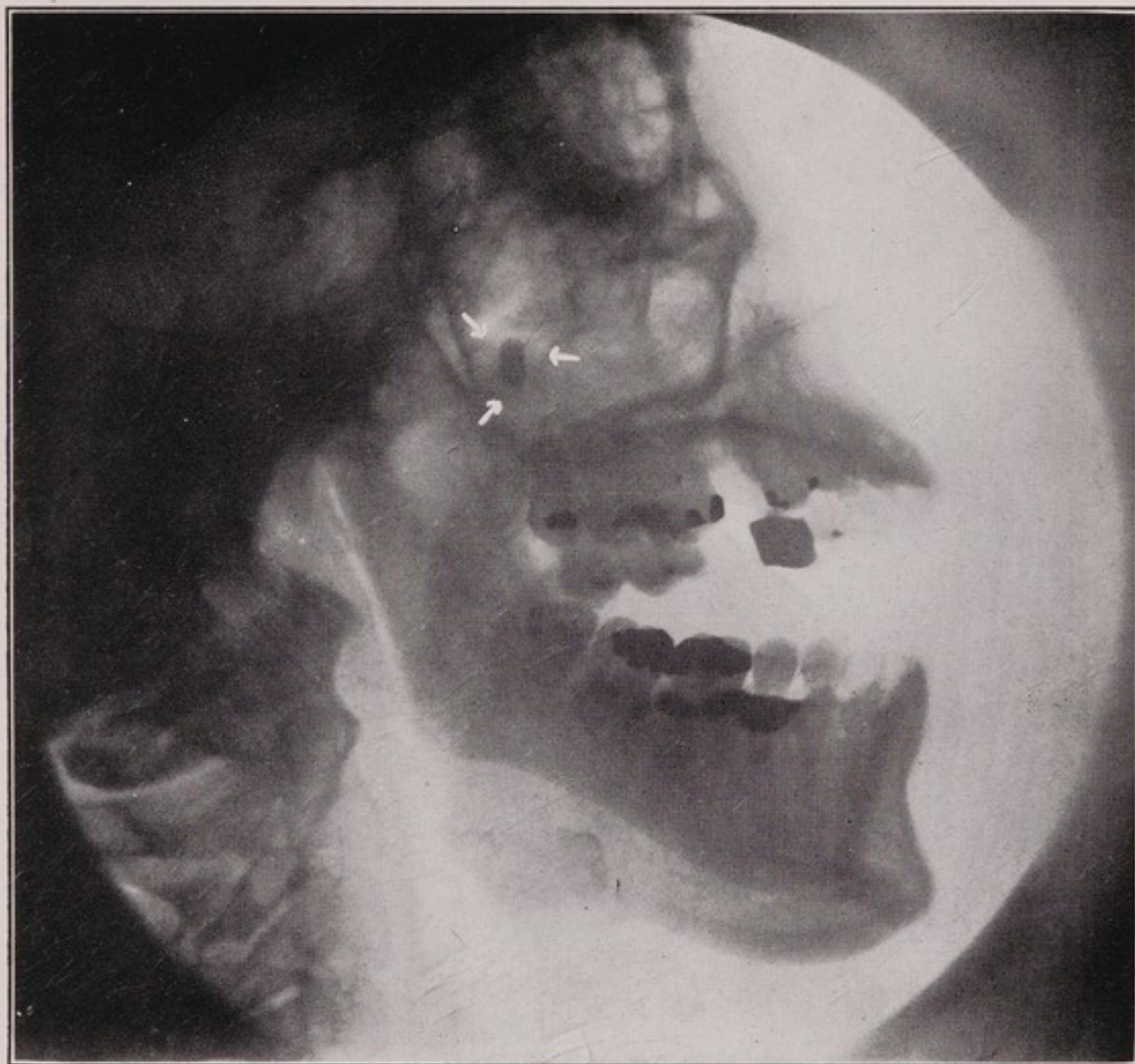


Fig. 107. The more or less oval shadow at which the arrows point is a piece of tooth root in the antrum. (Radiograph by Carman, of St. Louis, Mo.)

to a more symmetrical form. In other words, the film or bromide paper, as wrapped up in the film packet, may be left an indefinite unsymmetrical form and trimmed to a more pleasing outline after the picture is made. The length of exposures when making a radiograph directly on bromide paper is slightly longer than when using a film or plate. Unlike the other sensitized papers—Azo, Velox, or Cyko—the bromide paper must not be exposed to the orange light. The light must be the same as for films and

plates, a ruby light. The radiograph made directly on paper lacks good detail.

Prints from negatives may be made on bromide paper. The advantage in using it is that less time is taken up in making exposures, and the disadvantage is that, since the work must be done in the comparatively weak ruby light instead of the orange light, it is difficult to tell just when development is complete.

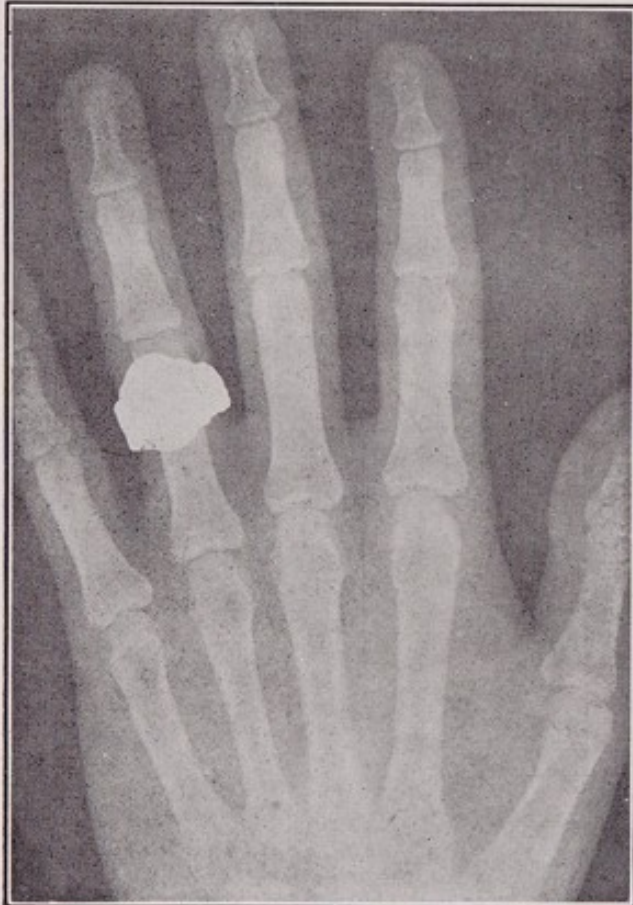

Fig. 108. Radiograph made on bromide paper. The conditions for making this radiograph were exactly the same as those given in Chapter IV for the negative of Fig. 71, except the time in the developer, which was about 100 seconds.

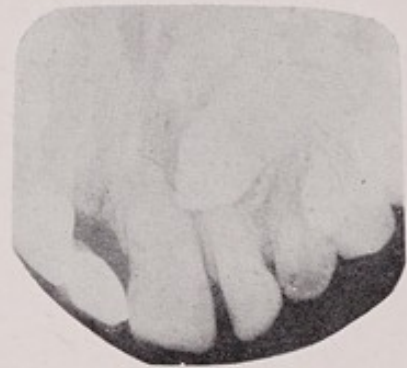

Fig. 109. Dental radiograph made directly on bromide paper.

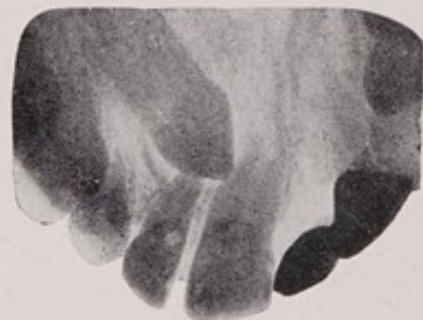

Fig. 110. The negative for this radiograph was made at the same time with Fig. 109, the film being enclosed in the same packet with the bromide paper.

Lantern Slides.

Lantern slides may easily be made from a good negative. A lantern slide plate is a photographic plate $3\frac{1}{4} \times 4$ inches, manufactured especially for the purpose. Like all other photographic plates, it should be "worked" in the ruby, never the orange, light. The negative is placed in the printing frame, sensitive side up, and the slide laid over it, sensitive

NOTE.—Fig. 110 appears to be reversed. This is due to the fact that it is a print from the film. In the film itself the teeth would appear in same positions as in Fig. 109.—ED.

side down. The average celluloid, dental, radiographic negative is of such density that the time of exposure of the plate to a 16-C. P. electric light, at a distance of two feet, is between one and two seconds. Allow the slides to remain in the developer a few seconds after the radiograph shows best, until it shows a little too dark. Wash in water quickly and transfer to the fixing bath, where it should remain until the picture shows clearly as desired. The writer uses Seed's lantern slide plates and Seed's prepared metol-hydrochinone developer. After fixing, the slide is washed and dried the same as any photographic plate. When dry a piece of transparent glass, the same size as the slide, is laid on the film side of the slide and the two stuck together at their edges with binding tape, such as is used for *passe-partout* work. The piece of clear glass is used to protect the emulsion of the slide against scratching.

If the negative from which the slide is to be made is larger than the slide, as is always the case when the negative is on glass, the work had better be turned over to a professional slide-maker.

Dr. Kells makes lantern slides of, instead of from, his celluloid dental negatives. This is accomplished as follows:

On a clear glass $3\frac{1}{4} \times 4$ inches place a piece of black paper the same size, with a hole in the centre large enough to show all of the negative that the operator wishes to exhibit. Place the negative directly over this hole in the paper. Place another piece of glass $3\frac{1}{4} \times 4$ inches over the whole and bind the two pieces of glass together at their edges with binding strips. The advantage of this method over making photographic slides are: The ease and dispatch with which they may be made—a dark room and equipment is not necessary—and, since we are using the negative itself, there is no loss of detail such as might occur when the other method is employed and a new picture is made on the photographic slide. The disadvantage is that the negatives with good detail are usually so dark that the light from the lantern is not strong enough to penetrate them.

That the student of dental radiography may learn the different conditions under which radiographs of the teeth and jaws are made, I give the following summaries in which are recorded the important factors.

The summaries, in the order in which they follow, to and including Fig. 115, represent some experimental work done by the writer. These reports, like most reports, make very dry reading, but they contain some information of importance. A study of the summaries for Figs. 81, 111, 97, 99 and 103, will give a tolerably good idea of what can be done with an induction coil. A study of the summaries for Figs. 112, 113, 114 and 115 will give an idea of what can be accomplished with a small, suitcase, high-frequency coil.

A careful reading of the "comment" at the close of some of the summaries is especially advised, because therein will be found some valuable pointers.

To make the negative of the radiograph shown

Fig. 81.

in Fig. 81 the conditions were as follows:

1. Machine used: A Scheidel, 18-inch, induction coil with 2-point, electrolytic interrupter, operating on a 110-volt D. C. circuit. All the resistance of the rheostat cut out.

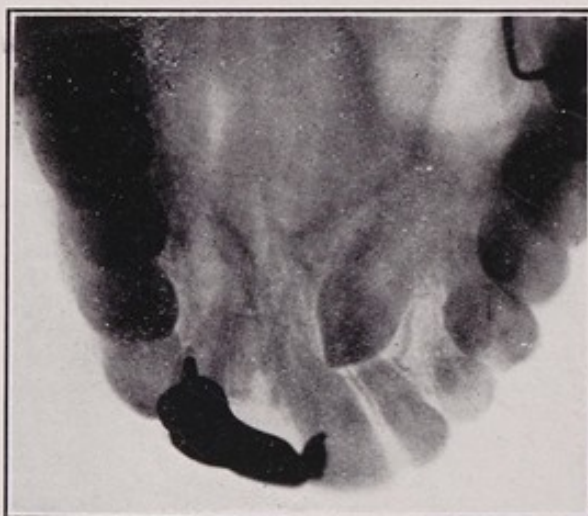

Fig. 111. The two circular shadows in the corners are due to small paper clips used to hold the intensifying screen and film together.

2. Strength of current: No meters on machine. A rough guess would be 26 amperes in the primary, about 13 milliamperes sent through the tube. Ten (10) inches of fat, fuzzy, yellow spark obtainable.

3. Make and condition of tube used: Green and Bauer, "Clover-leaf," 6-inch tube. Length of tube-regulating spark gap, $3\frac{1}{2}$ inches. Tube backs up 7 inches parallel spark. The tube vacuum is therefore high, and the X-rays produced penetrating. No penetration guide used.

4. Distance of target from film: Between 12 and 13 inches. Distance of glass of tube from face, about 8 inches.

5. Thickness of part: That of superior maxillary bone and overlying tissues, *about* $1\frac{1}{2}$ inches.

6. Density of part: That of superior maxillary bone and overlying tissues. (Density varies slightly with age, growing denser.)

7. Film used: Eastman (positive cinematographic) X-ray film.

8. Time of exposure: Eight (8) seconds.

9. Time in the developer, and developer used: Five (5) minutes in Eastman's "M. Q." prepared developer.

Comment: When using an Ilford film the exposure can be reduced one-half, *i. e.*, to 4 seconds, and the time in the developer remains 5 minutes. The negative of Fig. 83 was made on an Ilford film, exposure 4 seconds.

It will not be amiss here to give my readers some idea of how I "guessed" at the amperage and milliamperage, respectively, of my primary and secondary currents. The fuses just in front of my coil are 30 ampere fuses. I know, therefore, that I am drawing something less than 30 amperes. I know also that I must be drawing almost 30 amperes with all the resistance of the rheostat out, and I make a rough guess of 26, leaving a margin of 4 amperes between the current I am using and one which would "blow" (burn) the fuses. Having guessed at the amperage, I calculate that the average induction coil is capable of forcing one-half as many milliamperes through a high vacuum tube as it draws amperes in its primary. Thus, if the coil draws 26 amperes the milliamperage output through a high vacuum tube is 13.

A high frequency coil is capable of forcing two-thirds as many milliamperes through a high tube as it draws amperes in its primary, and the interrupterless coil can force about four-fifths as many milliamperes through a high tube as it draws amperes into its primary. This is only an estimate, not a mathematical fact.

To make the negatives of the radiograph shown in Fig. III the conditions were as follows:

- Fig. III.**
1. Machine used: Same as for Fig. 81.
 2. Strength of current: Same as for Fig. 81.
 3. Make and condition of tube: Same as for Fig. 81.
 4. Distance of target from film: About 13 inches. Distance from glass of tube to patient's face, about 8 inches. Pose as in Fig. 89.
 5. Thickness of part: Same as in Fig. 81.
 6. Density of part: Same as in Fig. 81.
 7. Film used: Ilford film, with a Kny-Scheerer intensifying screen. (I wish to thank the Kny-Scheerer Mfg. Co. for their kindness in making a dental intensifying screen after my instructions, and furnishing me with samples for experimental purposes.)
 8. Time of exposure: One (1) second.
 9. Time in the developer, and developer used: Four (4) minutes in the Eastman "M. Q." developer.

Comment: Had the intensifying screen not been used, the time of exposure would have been about four (4) seconds. Thus the use of the screen shortened the time of exposure necessary three-fourths ($\frac{3}{4}$).

To make the negatives of Fig. 97 the conditions were as follows:

- Fig. 97.**
1. Machine used: Same as for Fig. 81.

2. Strength of current: Same as for Fig. 81.
3. Make and condition of tube: Same as for Fig. 81.
4. Distance of target from film: About 14 inches. Distance of glass of tube from face, about 8 inches. Pose as in Fig. 97.
5. Thickness of part: Tissues of neck, mandible and overlying parts—about 3 inches.
6. Density of part: That of tissues of neck, mandible and overlying parts.
7. Film used: Ilford film.
8. Time of exposure: Thirty-five (35) seconds.
9. Time in the developer, and developer used: Five (5) minutes in Eastman "M. Q." developer.

To make the negative of the radiograph shown in Fig. 99 the conditions were as follows:

- Fig. 99.**
1. Machine used: Same as for Fig. 81.
 2. Strength of current: Same as for Fig. 81.
 3. Make and condition of tube: Same as for Fig. 81.
 4. Distance of target from film: About 16 inches. Distance of glass of tube from patient's neck, about 8 inches. Pose as in Fig. 98.
 5. Thickness of part: That of the tissues of the neck, the mandible and overlying parts—about 5 inches.
 6. Density of part: That of the tissues of the neck, mandible and overlying tissues.
 7. Film used: Lumiere, "Sigma," double-coated, 5x7-inch X-ray plate.
 8. Time of exposure: Thirty-five (35) seconds.
 9. Time in developer, and developer used: Fifteen (15) minutes in Eastman "M. Q." developer.

To make the negative of the radiograph shown in Fig. 103 the conditions were as follows:

- Fig. 103.**
1. Machine used: Same as for Fig. 81.
 2. Strength of current: Same as for Fig. 81.
 3. Make and condition of tube: Same as for Fig. 81.
 4. Distance of target from plate: Between 12 and 13 inches. Distance of glass of tube from patient's face and neck, about 6 inches. (This is bringing the tube about as close to the patient as it can be placed with safety.) Pose similar to Fig. 102.
 5. Thickness of part: That of the tissues of the neck, the mandible and overlying tissues for the lower jaw, and the cheek, the superior maxillary bone and overlying tissues for the upper jaw—3 to 4 inches.
 6. Density of part: As above, under "thickness of part."

7. Plate used: Lumiere, "Sigma," double-coated, 8x10-inch X-ray plate.

8. Time of exposure: Forty-five (45) seconds.

9. Time in the developer, and developer used: Ten (10) minutes in the Eastman "M. Q." developer.

Comment: After such an exposure the tube would be very warm, and should be allowed to cool thoroughly before using again.

The rule to allow the film or plate to remain in the developer twenty times as long as it takes the high lights to show up well is often inapplicable when developing these large pictures on plates. It is sometimes necessary to leave the plate in the developer thirty or forty times as long as it takes the high lights to appear. Allow the plate to remain in the developer until almost all black—not jet black, but darkened well. It is difficult to the point of being impossible, usually, to see the image while the plate is in the developer; only an obscure suggestion of the radiograph can be seen.

Had the negative for Fig. 103 been left in the developer but 5 or 6 minutes instead of 10, or had the exposure been made slightly shorter, say 40 seconds, then the outline of the mandible would not be lost, as it is.

Fig. 100. To make the negative of the radiograph shown in Fig. 100 the conditions were as follows:

1. Machine used: Kelly-Koett, "Grosse-Flamme," induction coil on third inductance, with 7-point electrolytic interrupter, operating on a 110-volt D. C. circuit.

2. Strength of current: Primary about 40 amperes. Milliamperage sent through tube, about 20. Fat, fuzzy spark obtainable full length of spark gap, 12 inches.

3. Make and condition of tube: Green and Bauer, "Cloverleaf" 6-inch tube. Length of tube regulating spark gap, about 4½ inches. Tube backs up 7 or 8 inches of parallel spark.

4. Distance of target from plate: About 16 inches.

5. Thickness of part: See Fig. 101.

6. Density of part: That of tissues of the neck, mandible and overlying parts for the lower jaw, and superior maxillary bone and overlying parts of the upper jaw.

7. Plate used: Lumiere, X-ray plate, 5x7 inches.

8. Time of exposure: Ten (10) seconds.

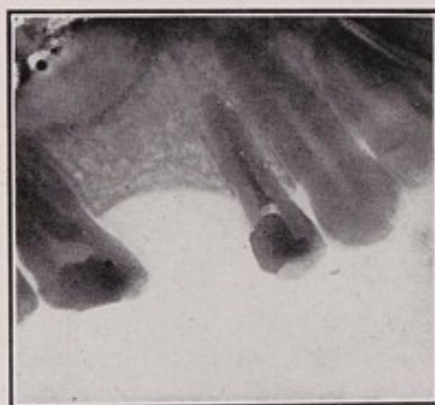9. Time in developer, and developer used: Five (5) minutes in "M. Q." prepared developer.

Comment: The Kelly-Koett, Gross-Flamme, coil is one of the most powerful induction coils made.

Fig. 105.

To make the negative of the radiograph shown in Fig. 105 the conditions were as follows:

1. Machine used: Kelly-Koett, "Gross-Flamme" induction coil on inductance four, with 7-point electrolyte interrupter, operating on 110-volt D. C. circuit.
2. Strength of current: Primary, 50 amperes. Milliamperes sent through tube, about 25.
3. Make and condition of tube: Green and Bauer, "Cloverleaf" 6-inch tube. Length of tube regulating spark gap, 5 inches. Tube backs up 8 inches of parallel spark.

**Fig. 112.**

4. Distance of target from plate: About 19 inches.
 5. Thickness of part: That of the cranium coverings and contents, about 8 inches. (Fig. 104.)
 6. Density of parts: That of the cranium, coverings and contents.
 7. Plate used: Cramer X-ray plate, 8x10 inches, with intensifying screen.
 8. Time of exposure: Three (3) seconds.
 9. Time in developer, and developer used: Seven (7) minutes in water, 32 oz.; soda sulphite, 12 dr.; hydrochinone, 2 dr.; edinol, 75 gr.; potassium bromide, 90 gr.; potassium carbonate, 2 oz.
- Comment: Had an intensifying screen not been used, the time of exposure would have been about ten (10) seconds.

Fig. 112.

To make the negative of the radiograph shown in Fig. 112 the conditions were as follows:

1. Machine used: Scheidel-Western, portable high-frequency, 6-inch coil, operating on 104-volt A. C. circuit. (I wish to acknowledge my indebtedness and express my sincere thanks to the Scheidel-Western X-ray Coil Mfg. Co., who furnished me with their coil for experimental work.)

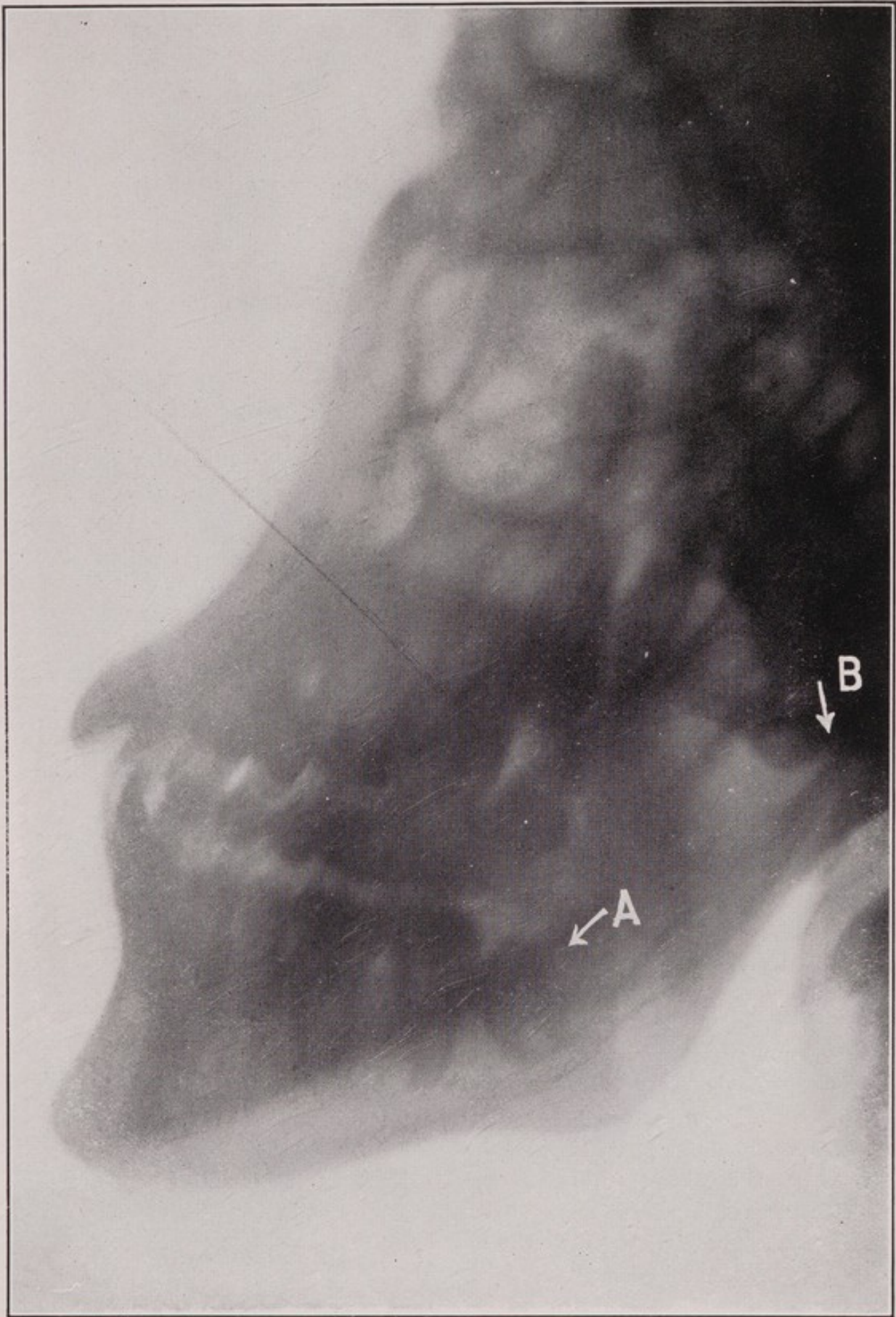


Fig. 113. Arrow A points to an impacted lower third molar. Arrow B points to the temporomandibular articulation, which shows very clearly in this picture.

2. Strength of current: No meters. A rough guess, 12 amperes in primary. Milliamperage sent through tube, about 8. Fat, fuzzy spark 6 inches long obtainable.

3. Make and condition of tube: Green and Bauer, 6-inch, high-frequency tube. Tube-regulating spark gap, 5 inches. (In my limited experience I have found that the tube-regulating spark gap must be longer for high-frequency tubes to obtain the same condition of vacuum.) Tube backs up 6 inches of parallel spark.

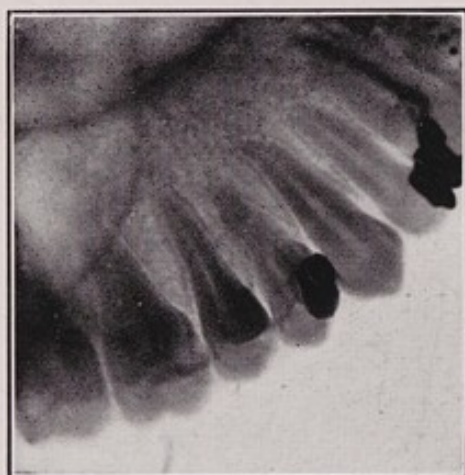

Fig. 114.

4. Distance of target from film: Between 11 and 12 inches. Distance between glass of tube and patient's face, about 7 inches.

5. Thickness of part: That of superior maxillary bone and overlying tissues.

6. Density of part: That of superior maxillary bone and overlying tissues.

7. Film used: Ilford X-ray film.

8. Time of exposure: Ten (10) seconds.

9. Time in developer: Five (5) minutes in "M. Q." developer.

Comment: How can a tube backing up 6 inches of parallel spark be operated by a coil the terminals of which are only 6 inches apart? is a natural and fair question. This is accomplished by placing an upright piece of plate-glass between the terminals of the coil, which prevents sparking between them.

With conditions as above, an exposure of about 20 seconds is necessary when Eastman films are used.

Be it understood that 10 seconds for Ilford films and 20 seconds for Eastman films do not represent the minimum exposures for the making of dental radiographs under the conditions as above. For example, I

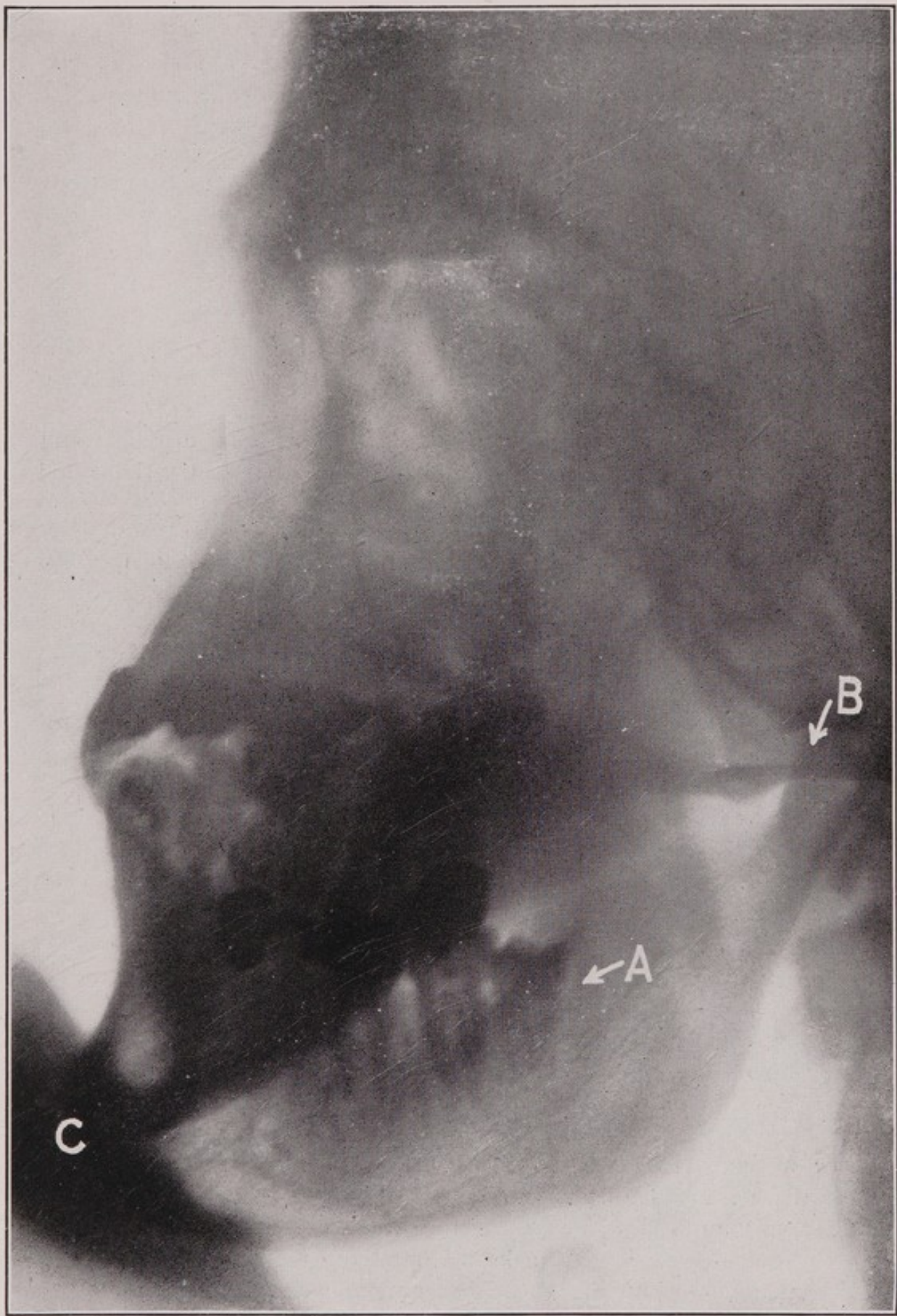


Fig. 115. Arrow A points to an unerupted lower third molar. Arrow B points to the temporo-mandibular articulation, which shows very clearly in this radiograph. The triangular spot marked C is the result of not completely covering the plate immediately when it was placed in the developer.

was able to obtain a tolerably good radiograph after a 10-second exposure on an Eastman film by leaving it in the developer 14 minutes. To obtain the best pictures, however, the exposure should be 10 seconds for Ilford films and 20 seconds for Eastman films.

To make the negative of the radiograph shown in Fig. 113 the conditions were as follows:

- Fig. 113.**
1. Machine used: Same as for Fig. 112.
 2. Strength of current: Same as for Fig. 112.
 3. Make and condition of tube: Same as for Fig. 112.
 4. Distance of target from plate: Between 12 and 13 inches. Distance of glass of tube from patient's face and neck, 6 inches. Pose similar to Fig. 102.
 5. Thickness of part: That of tissues of the neck, mandible and overlying parts for the lower jaw, and the superior maxillary bone and overlying parts for the upper jaw—3 to 4 inches.
 6. Density of part: As above under "thickness of part."
 7. Plate used: Lumiere, "Sigma," double-coated, 8x10-inch X-ray plate.
 8. Time of exposure: Sixty (60) seconds.
 9. Time in the developer and developer used: Seven (7) minutes in Eastman "M. Q." developer.

Comment: The tube-regulating spark gap was set at a distance of 5 inches, or perhaps a little longer, and at no time did the current jump the gap. Theoretically, as the current passes through the tube the vacuum becomes higher. I was considerably surprised, therefore, to observe after the current had been passing through the tube for about 50 seconds that the blue cathode stream could be seen, indicating a very low vacuum. My friend, Mr. Darling, a designer of coils, informs me that this lowering of the vacuum is due to heating of the tube. The milli-ampereage sent through it heats the entire tube, which means, of course, that the regulating chamber and its contents are heated, gases from the regulating chamber are liberated, and so the vacuum is lowered, without at any time a spark occurring at the tube-regulating spark gap.

It is well to mention here, perhaps, that there is very often a blue color back of the target in high-frequency tubes, which does not signify a low vacuum. However, when a blue cathode stream can be seen, or when there are areas of blue in any part of the active hemisphere, it signifies a vacuum too low for good picture work.

To make the negative of the radiograph shown in Fig. 114 the conditions were as follows:

- Fig. 114.**
1. Machine used: Scheidel-Western, portable high-frequency, 6-inch coil, operating on a 70-volt A. C. circuit generated

by a rotary converter. The rotary converter being set in motion by the commercial 110-volt D. C.

2. Strength of current: The primary current furnished by the converter, about 5 amperes. Milliamperage sent through tube, 3 or a little over. A tolerably fat, fuzzy spark four (4) inches long obtainable. The spark, instead of being white or yellow as when the milliamperage is high, is of a blue or purplish color.

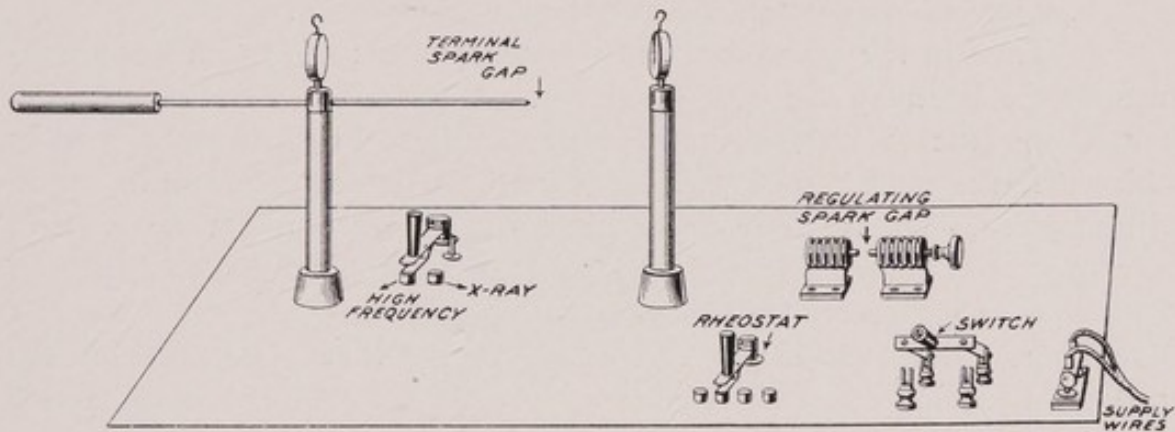


Fig. 116. Diagram of portable, high-frequency coil.

3. Make and condition of tube: Same as for Fig. 112.
4. Distance of target from plate: Same as for Fig. 112.
5. Thickness of part: Same as for Fig. 112.
6. Density of part: Same as for Fig. 112.
7. Film used: Ilford X-ray film.
8. Time of exposure: Fifteen (15) seconds.
9. Time in the developer and developer used: Six (6) minutes in the Eastman "M. Q." developer.

Comment: Because of the considerable difference in the milliamperage sent through the tube it might be expected that there would be an increase in the time of exposure necessary when operating the high-frequency coil from a rotary converter. Using the same coil, the time of exposure when the coil is excited by the rotary converter should be, to obtain the same results, about one-half longer than when the coil is operating from the commercial 104-volt A. C.

To make the negatives of the radiograph shown in Fig. 115 the conditions were as follows:

- Fig. 115.**
1. Machine used: Same as for Fig. 112.
 2. Strength of current: Same as for Fig. 112.
 3. Make and condition of tube: Same as for Fig. 112.
 4. Distance of target from plate: Between 12 and 13 inches. Dis-

tance of glass of tube from patient's face, about 6 inches. Pose similar to Fig. 102.

5. Thickness of part: That of the tissues of the neck, the mandible and overlying parts for the lower jaw, and the superior maxillary bones and overlying parts for the upper jaw.

6. Density of part: As given under "thickness of part."

7. Plate used: Lumiere, "Sigma," double-coated, 8x10-inch X-ray plate.

8. Time of exposure: Seventy-two (72) seconds.

9. Time in the developer, and developer used: Fourteen (14) minutes in the Eastman "M. Q." developer.

Comment: When the time of exposure is so long, 72 seconds, as in this case, the matter of a couple of seconds or so makes little or no difference. That is to say, the time of exposure might have been, say, 70 or 75 seconds, and the same results obtained as with an exposure of 72 seconds; and this without altering the time in the developer. When developing an especially sensitive plate, such as the one used in this case, the Lumiere "Sigma" plate, for a considerable length of time it is not expedient to keep it constantly exposed to the ruby light. Fogging might result.

It will be noticed that to make this negative the time of exposure was only one-fifth longer than to make the negative for Fig. 113. According to my remarks under the heading "Comment" in the summary of the conditions under which Fig. 114 was made, the exposure should have been "about one-half longer to obtain the same results." But notice, please, that it was necessary to leave the plate for Fig. 115 in the developer twice as long as for Fig. 113. Therefore, I did not get the same results when I increased my exposure only one-fifth.

Technic for Use of High- Frequency Coil.

There are two or three special and important points concerning the operation of a high-frequency coil that I shall mention here:

First, move the lever at the back of the coil onto the button marked "low frequency" (sometimes "X-rays")—off of the button marked "high frequency." (Fig. 116.) By doing this all of the condenser of the coil is used, and so the rate of frequency lessened. For high-frequency treatment work only a part of the condenser is used, with the lever arm on the button marked "high frequency."

Second, cut out all the resistance of the rheostat, separate the sliding rod or rods to the maximum spark gap—usually about 6 inches—and turn on the current.

Third, widen and narrow the "regulating spark gap" until the cur-

rent is as high in milliamperage as it can be and still jump the terminal spark gap. It will be remembered that widening the regulating spark gap (up to a certain point) increases the voltage of the output current at the expense of the milliamperage, and that narrowing it increases the milliamperage at the expense of the voltage. Alter the regulating spark gap to get as heavy a spark as possible. It should require but a few seconds to accomplish this regulation. Sometimes it is impossible to obtain as fuzzy a spark as you know the machine is capable of giving. This is due to the fact that the little approximating metal studs at the regulating

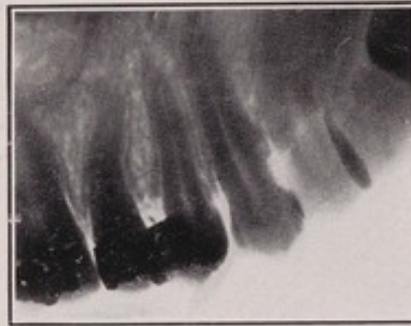


Fig. 117. Radiograph by Peabody, of South Orange, N. J.

spark gap are dirty. Place a piece of emery cloth between the studs, screw them together until they hold the cloth loosely, then draw the cloth back and forth over the face of the stud. Clean both studs in this way.

Fourth, place a piece of plate glass between the terminals in order that a high vacuum tube, one with a resistance equivalent to 6 or more inches of parallel spark, may be used.

Fifth, connect the tube to the coil, set the tube-regulating spark for about 5 inches, turn on the current and see that the tube lights up O. K.

I recall and shall here set forth an experience I had while making a radiograph on a large plate with a small, high-frequency coil. I had followed the technic given above, posed my patient, and turned on the current for a one-minute exposure. For the first thirty-five seconds the tube maintained a good light. Then suddenly the current ceased to pass through it. At first I thought I had burned out a fuse. (I was using 15-ampere fuses on the supply wires to protect the coil.) But by turning the switch on and off I learned that in this surmise I was wrong, for when the switch was on there was a humming sound in the coil, and as I turned it off a spark occurred as the circuit was broken. I shortened the tube-regulating spark gap, thinking perhaps the

**An Instructive
Experience.**

vacuum in the tube had suddenly and mysteriously become so high that the current could not pass through it, but when the current was turned on, the only evidence of the fact was a slight humming inside the coil. I disconnected the tube, removed the plate glass from between the terminals and turned on the current, but no spark jumped the gap. Not until then did I realize that the trouble was at the regulating spark gap. I changed the adjustment of the gap slightly and immediately a spark jumped the terminal spark gap. The metal at the regulating spark gap had gotten warm and expanded, thus altering the width of the gap and shutting off the current.

With two exceptions, all the summaries of conditions under which radiographs are made have been records of my own work. (These two exceptions are Fig. 100, made by Dr. A. M. Cole and myself, and Fig. 105, made by Dr. Cole.) That my readers may have some idea of the governing circumstances under which other men make radiographs, I print the following summaries. For the report and radiographs we are indebted to the men whose names appear beneath the radiographs.

**Using an
Interrupterless
Coil.**

To make the negative of the radiograph shown in Fig. 117 the conditions were as follows:

1. Machine used: Kny-Scheerer interrupterless coil. Four and one-half kilowatts. Eleven-inch spark gap. Operating on 104-volt A. C. circuit.
2. Strength of current: Primary, 50 amperes. Milliamperage sent through tube, 40. Fat, fuzzy spark obtainable full length of spark gap, 11 inches.
3. Make and condition of tube: Machlett tube, Excelsion brand. Tube backs up about 6 or 7 inches of parallel spark. Penetration of X-rays, 8 Wehnelt, which is the same as 6 Walter. Very penetrating.
4. Distance of target from film: About 12 inches.
5. Thickness of part: That of superior maxillary and overlying tissues.
6. Density of part: That of superior maxillary and overlying tissues.
7. Make of film: Eastern X-ray film.
8. Time of exposure: One (1) second.
9. Time in developer and developer used: Five (5) minutes. Formula not given.

Comment: "Four and one-half kilowatts" expresses the rating of the machine. Chapter II.

Had an Ilford film been used instead of an Eastman, the time of exposure would have been one-quarter second. It will be noticed that

Dr. Peabody considers the Ilford film four times as fast as the Eastman, while my own experience leads me to believe that it is only about twice as sensitive.

When making exposures that necessitate the splitting of seconds, an automatic switch timer may be used to advantage.

To make the negative of the radiograph shown in Fig. 118 the conditions were as follows:

Fig. 118

1. Machine used: A Ritchie, 10-inch induction coil, with 1-point electrolytic interrupter, operating on a 110-volt D. C. circuit.

2. Strength of current: Fat, fuzzy spark 10 inches long obtainable.

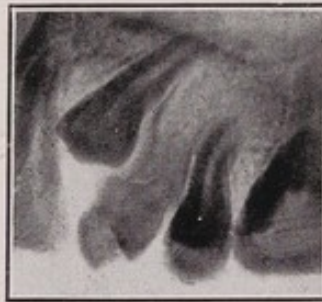

Fig. 118. By Lodge, of Cleveland, O.

3. Make and condition of tube: Hartford, 7-inch tube. Length of tube-regulating spark gap, $3\frac{3}{4}$ inches. The tube backs up four (4) inches of parallel spark.

4. Distance of target from film: Ten (10) inches.

5. Thickness of part: That of superior maxillary and overlying tissues.

6. Density of part: That of superior maxillary and overlying tissues. Patient 12 years old.

7. Film used: Eastman dental film.

8. Time of exposure. Six (6) seconds.

9. Time in the developer and developer used: Ten minutes in: Solution A, Water, 64 oz.; metol, 120 grs.; hydrochinon, 120 grs.; Seed's sulphite of soda, 2 oz. Solution B, water, 16 oz.; Seed's carbonate of soda, 2 oz. For use take of A, 4 oz.; of B, 1 oz., and of water, 4 oz.

To make the negative of the radiograph shown in Fig. 119 the conditions were as follows:

Fig. 119.

1. Machine used: Scheidel-Western, 12-inch induction coil, with electrolytic interrupter, operating on a 110-volt D. C. circuit.

2. Strength of current: Eighteen (18) or twenty (20) milliamperes sent through tube.
3. Make and condition of tube: Green and Bauer "Cloverleaf." Length of tube-regulating spark gap: $2\frac{1}{2}$ inches.
4. Distance from target to film: About 18 inches.
5. Thickness of part: That of the body of the mandible and overlying tissues.
6. Density of part: That of the body of the mandible and overlying tissues.
7. Film used: Seed's special X-ray film.
8. Time of exposure: About 6 seconds.

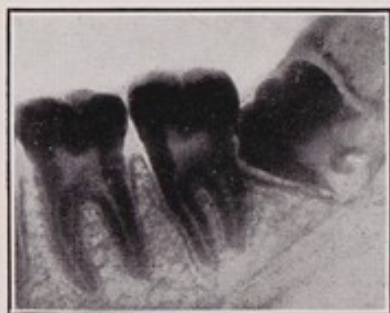

Fig. 119. By Ketcham, of Denver, Colo.

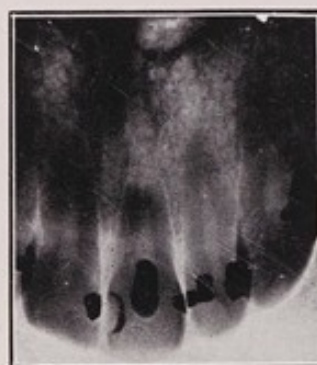

Fig. 120. By Blum, of New York.

9. Time in developer and developer used: About 20 minutes in: Sodium sulphite, 3 oz.; potassium carbonate, 2 oz.; eikogen, 2 oz.; water, 2 quarts. Dissolve in boiling water and filter when cool. Take one part of the developer to three parts of water for use.

Fig. 120.

To make the negative of the radiograph shown in Fig. 120 the conditions were as follows:

1. Machine used: A Wrappler 12-inch induction coil, with 2-point, electrolytic interrupter, operating on a 110-volt D. C. current.
2. Strength of current: Twenty-five (25) amperes in the primary. About 9 inches of fat, fuzzy spark obtainable.
3. Make and condition of tube: Muller, water-cooled. Penetration about 7 Benoist. Length of tube-regulating spark gap, $3\frac{1}{2}$ inches. Tube backs 6 to 7 inches of parallel spark.
4. Distance of target from film: About 14 inches.
5. Thickness of part: That of superior maxillary bone and overlying tissues.
6. Density of part: That of superior maxillary bone and overlying tissues.

7. Film used: Eastman positive cinematograph film, sold for dental radiographic purposes.

8. Time of exposure: About 10 seconds.

9. Time in developer and developer used: About 8 minutes in: Water, 10 oz.; sulphite of soda (crystals), 4 oz.; carbonate of potash, 3 oz.; adurol, $\frac{1}{2}$ oz. From the concentrated solution take 2 oz. to 6 oz. of distilled water, and to this mixture add 15 drops of 10% solution of potassium-bromide.

To make the negative of the radiograph shown in Fig. 121 the conditions were as follows:

Fig. 121.

1. Machine used: A Scheidel 12-inch induction coil, with 1-point, electrolytic interrupter, operating on a 110-volt D. C. circuit. All of the resistance of rheostat cut out.

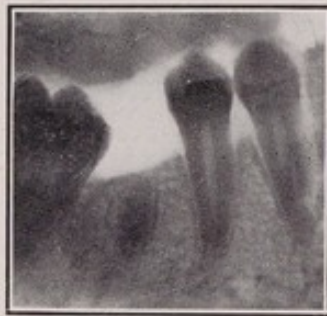

Fig. 121. By C. Edmund Kells, Jr., of New Orleans, La.

2. Strength of current: Thirty (30) amperes in primary. Twelve (12) inches of fat, fuzzy spark obtainable.

3. Make and condition of tube: "Cloverleaf" 6-inch tube. Length of tube-regulating spark gap, 4 inches. Tube backs up $10\frac{1}{2}$ inches of parallel spark.

4. Distance of target from film: Eight (8) inches.

5. Thickness of part: That of lower jaw and overlying parts.

6. Density of part: That of lower jaw and overlying parts.

7. Film used: Eastman's positive cinematograph emulsion.

8. Time of exposure: One (1) second.

9. Time in the developer and developer used: (Time not given.) Developing started in metol-hydroquinone and finished in hydroquinone.

Comment: Notice that the distance between the target and the film is 8 inches. Therefore, the distance between the glass of the tube and the patient's face is only about 4 inches. With the tube this close a "filter" (Chap. VIII) should be used to protect the patient. An aluminum filter was used in this case.

CHAPTER VI.

Reading Radiographs.

Seeing things is truly a mental effort. Though an object or shadow be reflected on the retina of the eye, it is not "seen" unless it has an effect upon the brain. When we say, "train the eye" to see such and such a thing, we mean really, train the mind—the brain.

To correctly read a radiograph, to see all there is in it to be seen, and to understand it to mean what it stands for, requires experience and an intimate knowledge of the anatomy and pathology of the parts under observation. Experience is an important factor. Upon looking over old negatives, I see many things of interest in them now which I did not observe a year ago.

Illuminating Boxes.

It is always advisable to study the negative in preference to the print. Some of the finest details are lost in the print. The negative may be held up to a window or an artificial light, or it may be placed in an illuminating box (Fig. 122) for observation.

While the illuminating boxes on the market are suitable for studying large plate or film negatives, they are needlessly large and poorly adapted for studying the small, dental, film negatives. A small illuminating box can easily be made. A light-proof box, with a window of frosted glass and a light inside, may constitute the illuminating box. It is well to paint the inside of the box white, so increasing the power and uniformity of illumination. With the negative held against the frosted glass of the window on the outside and the light lit inside, one is able to study the negative to great advantage. Little spring steel clips, similar to the ones used to hold a slide or a microscope, may be used to hold the negative against the frosted glass window.

The use of a reading glass in connection with an illuminating box will enable one to observe the negative to the best possible advantage.

The Relative Values of Dense Areas in Negatives.

The denser the part, the deeper will be the shadow thrown on the film, and, consequently, the more transparent the negative in that region. Thus in the negative, metal fillings, posts and metal crowns appear as transparent areas; gutta-percha, cement,

enamel and porcelain a little less transparent; then in the order of their respective densities, dentin, bone, gum tissue, and, last, the cheek appears—when it is shown in the negative at all—as the least transparent part, except that part of the negative on which the X-Rays have fallen directly without anything intervening except the black paper of the packet. The contrast between tooth and bone tissue is very marked. Unfilled canals and pulp chambers appear as dark streaks and areas in the teeth. Filled canals and pulp chambers appear light. Pulp stones appear as lighter




Fig. 122. An Illuminating Box.

spots in the dark of the pulp canal or chamber. Abscess cavities appear as dark areas. It is easy to distinguish enamel from dentin, and the periodontal membrane can clearly be seen as a dark streak following the outline of roots. A bit of calculus in the periodontal membrane will appear as a light spot. This calculus must be on either the mesial or distal side of a root to be seen. It could not be radiographed if it occurred on the buccal, or labial, or lingual.

**Negatives, Prints
and Half-tone
Reproductions.**

All the foregoing may be seen in good negatives, but all this cannot be seen in prints and half-tones. I recall distinctly having read an article on Dental Radiography in which the writer printed a half-tone and told his readers to “observe the enamel, the dentin and the periodontal membrane.” The writer of this article wrote his

paper with either a negative or a good print before him, and assumed that all he saw there would be reproduced in the half-tone. It was not. The half-tone was so dark that all detail of the picture was lost, and the best that could be done was to distinguish between bone and tooth structure. Let us stop to consider the steps in the making of a half-tone picture and the chance for the loss of detail is apparent. From the negative a new picture is made on photograph paper, the print. From this another picture is made on a half-tone plate, and from this the half-tone picture is printed on paper with ink.

The finest details of a negative cannot be shown in a half-tone, and, though I have seen many prints that seemed to have fully as much detail as the negative, there is usually at least a slight loss of minute detail even in well made prints.

I have stated, that in order to make a half-tone picture it is necessary first to make a photographic print or picture from the negative, then, from this, to make the half-tone picture. Thanks to the efforts of Dr. Ottolengui and his co-workers, I am able to print half-tones made directly from negatives. The difference in the appearance of a half-tone made from a negative and one made from a photographic print is shown in Fig. 123 (made directly from the negative) and Fig. 124 (made from the photographic print, but reversed in the process for easier comparison).

**Relative Values
of Shadows in
Prints.**

Densities—deep shadows—we have seen appear as transparencies in the negative. The print, or positive, is the opposite of the negative. Hence, in prints, and half-tones made from them, we see the deep shadows of metal fillings, crowns and posts appearing very dark, gutta-percha, cement, enamel and porcelain a little less dark, and so on. On the print, filled canals appear dark, unfilled ones light, abscesses appear as light areas, and so on, always the opposite of the negative.

In order to avoid confusion of the right and left sides when studying a negative, bear the following in mind: When looking at the negative from its film side it is as though you observed the part radiographed from the position occupied by the tube during the exposure. When looking at the negative with the film side presenting towards the light, away from the eye, it is as though you observed the part from the position of the film during exposure. This is the case, granting that the sensitive side of the film presented toward the object radiographed at the time of exposure, a condition that should always obtain except when an intensifying screen is used.

If the technic previously given is followed, and the sensitive side of the film or plate be placed so as to present toward the part to be radio-

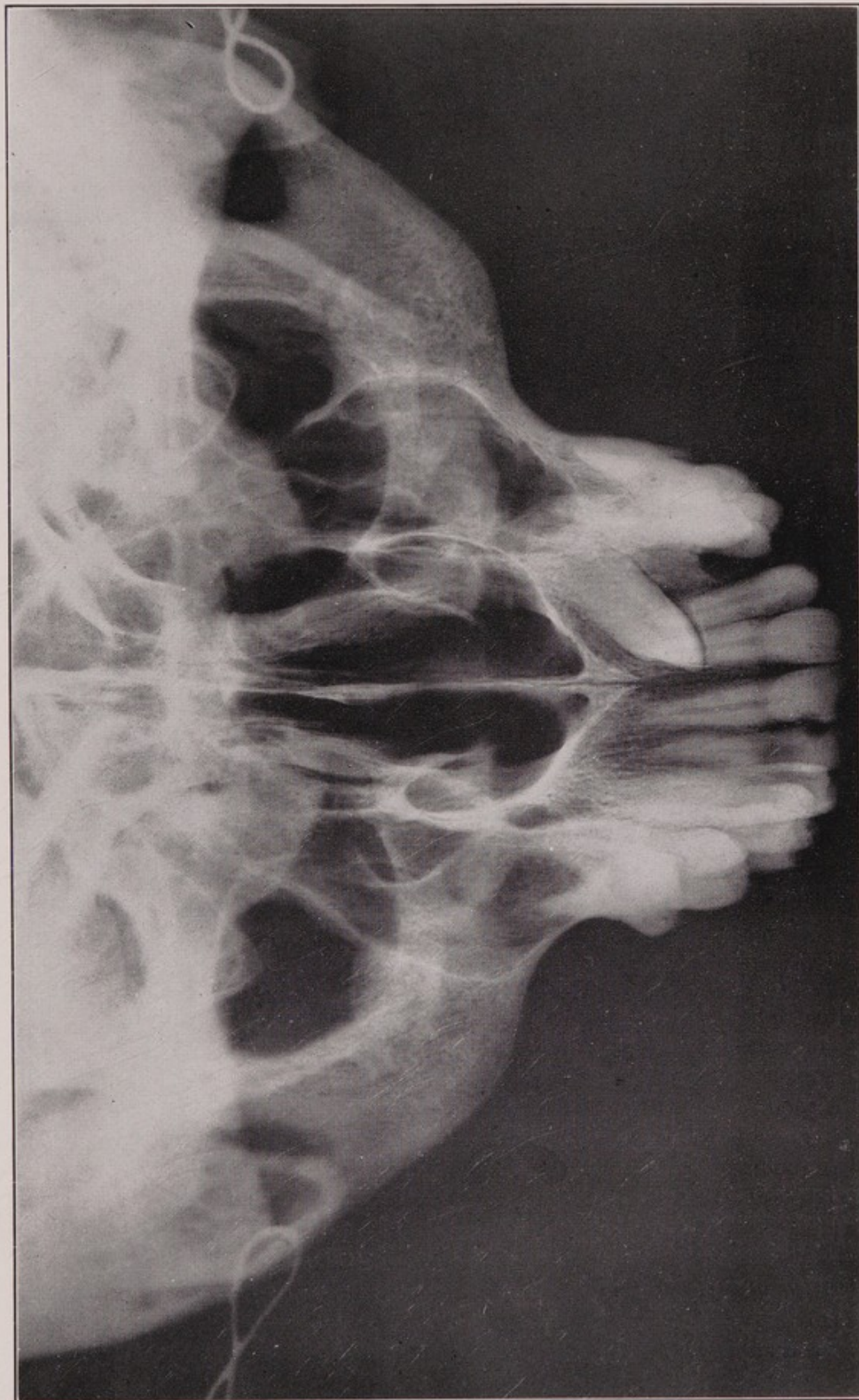

Fig. 123. The same as Fig. 124, except that the half-tone was made directly from the glass negative instead of from a photographic print. This radiograph is of a dry skull. (Radiograph by Cryer.)

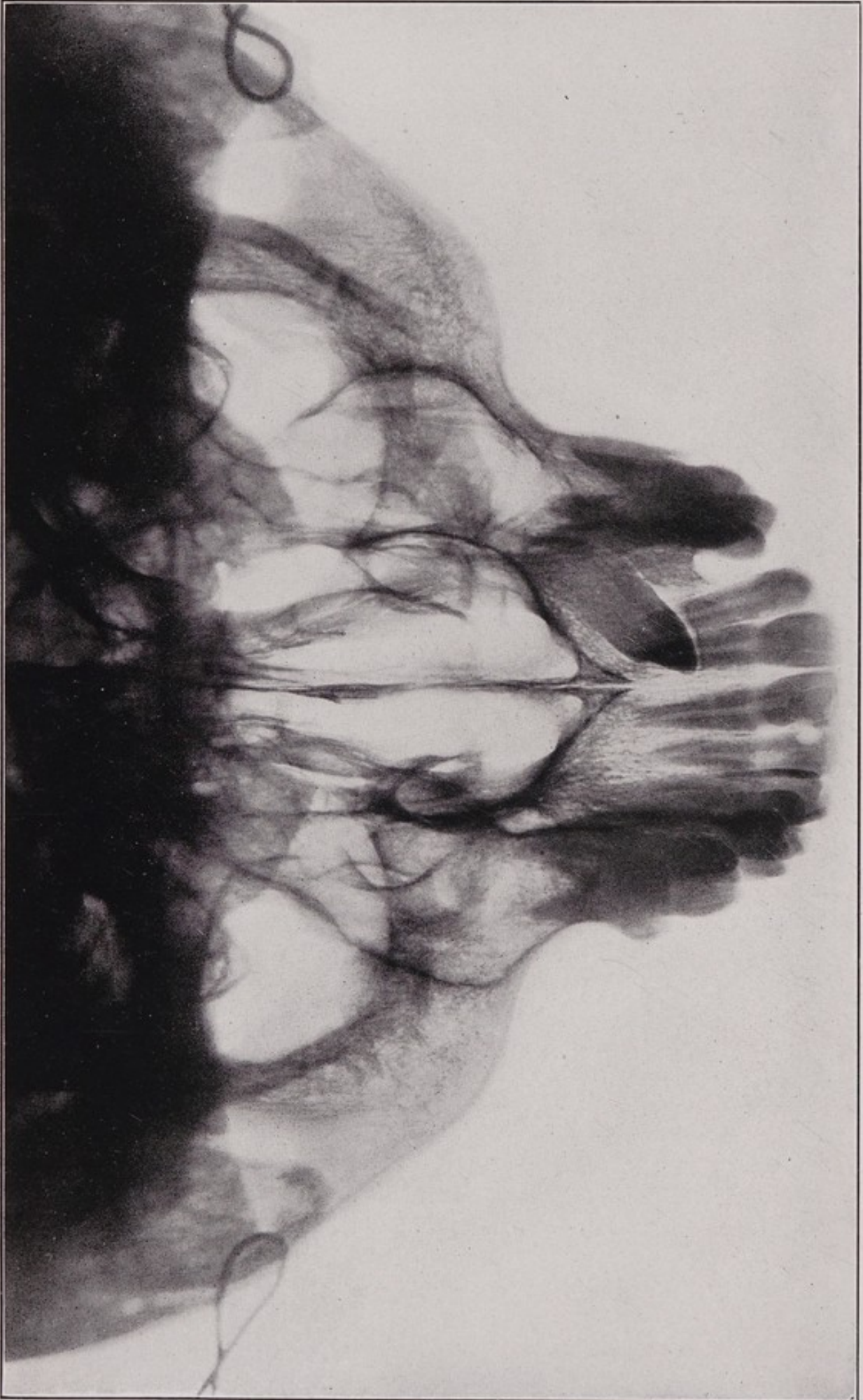

Fig. 124. The same as Fig. 123, except that the half-tone plate was made from a photographic print, but reversed for easier comparison. (Radiograph by Cryer.)

graphed, and then the negative placed in the printing frame with the sensitive side up (this must be done, or there will be a loss of detail) when observing prints, it is as though one looked at the part from the position of the film or plate during exposure.

When observing half-tones made from photographic prints it is the same as when observing the prints themselves, unless special steps have been taken in the process of making the half-tones to reverse the sides, as was done in Fig. 124. When observing half-tones made from negatives it is the same as observing negatives from the film side.

When looking at radiographs made directly on paper, it is as though you observed the part from the position of the tube during exposure.

How to mark negatives is a subject that has caused the use of a great deal of perfectly good paper and ink. After trying several methods, I no longer attempt to mark my negatives, but place them in envelopes and mark the envelopes as desired. The Lumiere Dry Plate Co. print the following outline on the backs of their envelopes:

**Marking
Negatives.**

- No.
- Name.....
- Address
- Date
- Case
- Tube used
- Exposure
- Distance of Tube from Plate.....
- Developer
- Referred by Doctor.....
- Remarks

I have lately heard of an "X-Ray ink" for marking negatives, but have been unable to procure any. The desired markings are placed on the envelopes or black paper covering the plate or film, the marking being done on the side of the envelope or black paper presenting toward the sensitive side of the plate or film, so that when the exposure is made the ink markings are between the source of the rays and the sensitive side of the plate or film. This ink must, I think, contain some salt of lead or bismuth, for the X-Rays penetrate it very poorly, and consequently there is a shadow cast on the negative.

My objections to marking small dental films in this manner is that occasionally the shadow of the markings will occur in such a place in the radiograph as to spoil the picture. The older methods of placing wires bent to form the figures or letters for marking, or a stencil of sheet metal, between the source of rays and the plate, is highly unsatisfactory, so far as their application to the marking of small dental radiographs is con-

cerned. After the negative is made, markings may be scratched in the film. But, as I said before, no system of marking the negative itself is as satisfactory as marking the envelope in which it is kept.

Perspective.

One of the most unfortunate limitations of the radiograph is that it lacks perspective. For example, though we are able to observe the exact mesio-distal

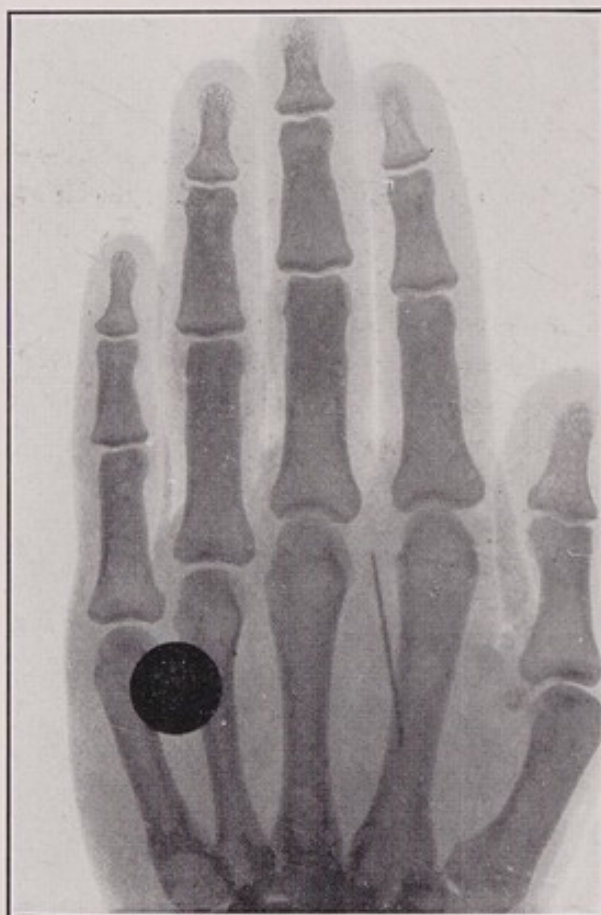

Fig. 125. (Reduced one-half.)

position of an impacted tooth, we are unable to determine its bucco- or labio-lingual position, with any degree of accuracy.

The closer the object, which is being radiographed, is to the film during exposure, the clearer the resulting shadow will be. Thus, for example, if an impacted cuspid lay lingually to the other teeth, and the film were held inside the mouth as usual, the detail in the picture of the cuspid would be a little greater than the detail in the other teeth. If the cuspid lay to the labial,—farther away from the film,—detail in it would be less than in the other teeth. But, on the whole, this method of determining bucco- or labio-lingual location is unreliable.

While I agree with Dr. C. H. Abbot, of Berlin, who has done some writing and experimental work to prove that radiographs are not totally lacking in perspective, yet I do declare, from the standpoint of their practical application to dentistry, that they are simply shadow pictures. And let me here warn you that like all shadows, X-Ray pictures are often extremely misleading; one might say, for the word seems to fit so well, treacherous. To eliminate the chance of misreading, because of distortion of the radiograph, it is often expedient to make several pictures of the same part or field, changing the pose. Even this, however, does not

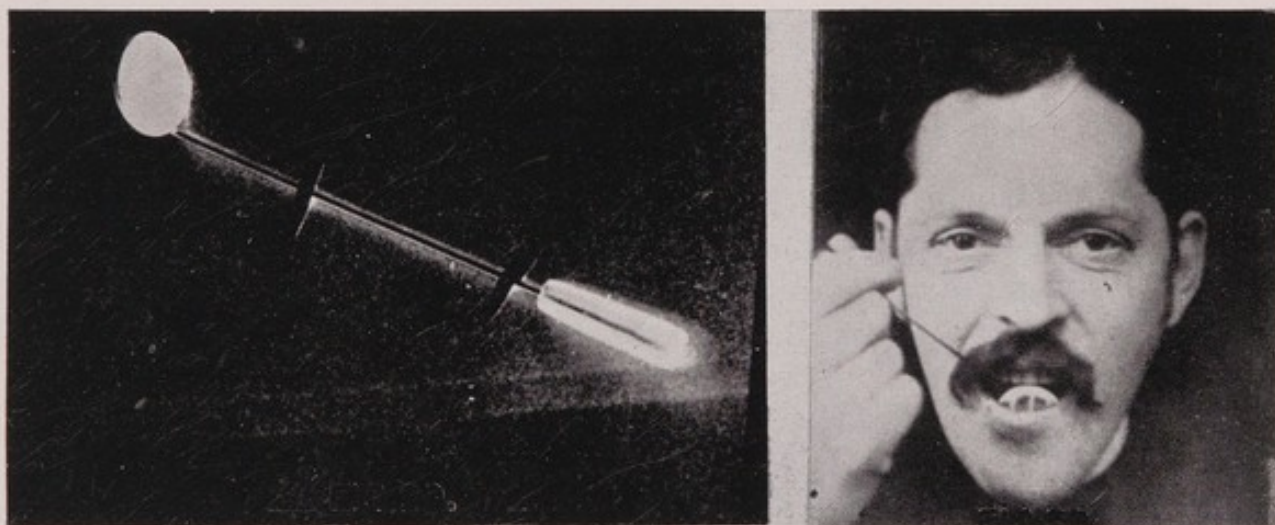


Fig. 126. A dental fluoroscope. Fig. 127. Shadows of teeth cast on the fluoroscope.

preclude the possibility of misinterpretation. To correctly read radiographs, a man must be, not only a student of radiography, anatomy, histology and pathology, but he must have and use that gift of the gods—common sense. He must not jump at conclusions, and he should ever regard the radiograph as a shadow picture, liable to all the apparent misrepresentations of shadows.

A study of Fig. 125 will convince anyone of the lack of perspective in at least some radiographs. One is unable to determine, from observing this radiograph, whether the coin pictured is in the flesh of the hand, on the back of the hand, or in the palm of the hand. Likewise, from simple observation, it is impossible to tell whether the needle is in, on, or under the hand. By deduction, we may come to this conclusion: The coin was nearer the plate, during its exposure, than the needle, because the outline of the coin is much clearer than that of the needle, and other things remaining equal, the closer the object being radiographed is to the plate, the clearer its shadow will be. Still we cannot determine

the exact location of either needle or coin. We know only that the coin was somewhat closer to the plate, during its exposure, than the needle. That is all.

The coin lay under the hand on the envelope holding the plate, the needle on the back of the hand, when the exposure for Fig. 125 was made.

Stereoscopic Radiography.

To overcome the fault of the lack of perspective and, to some extent, the distortion in radiographs, one must resort to stereoscopic radiography.

Stereoscope radiography is the science and art of making radiographs, which, when observed through a stereoscope, have perspective. The technic of making stereoscopic radiographs, together with a discussion of their value and efficiency, will be dealt with at some length in a subsequent chapter.

Dental Fluoroscope.

A work of this kind would be incomplete without some mention of the dental fluoroscope. The simplest and most efficient dental fluoroscope has been designed by Dr. Tousey (Fig. 126). Like all fluoroscopes, this one depends on calcium tungstate, or platino-barium cyanide, for its action. A disc of cardboard, coated on both sides with either of the above named chemicals, is placed between two discs of transparent glass, and the glasses and cardboard (or fluorescent screen, for the cardboard becomes a fluorescent screen when it is coated with calcium tungstate or platino-barium cyanide) held together by means of a circular band of metal. A handle now, and we have a dental fluoroscope, the screen protected against moisture, and either side of it may be used.

To use the fluoroscope, the operating room should be dark. It is best that the operator remain in this darkened room for some time until his eyes become accustomed to the darkness before making the exposure. Hold the fluoroscope inside of the mouth, and have the tube placed so that the X-rays will pass through the part to be observed, and strike the fluoroscope. Fig. 127 shows the fluoroscope and a shadow of the teeth thrown on it.

The disadvantages of the fluoroscope are:

1. The operator must expose himself to the actions of the X-rays.
2. Either the time for observation must be made very short, or both operator and patient must be exposed to the rays unnecessarily and dangerously long.
3. The picture on the fluoroscope lacks detail.
4. No record of the case, other than a mental picture, can be kept;

while a negative may be referred to as often as expediency or necessity demands.

5. From an educational standpoint, the fact that prints, lantern slides and half-tones can be made from negatives is a great advantage.

To learn to eat olives, one must eat them, so I am told. To learn to read radiographs, one must read them, and so we pass to the next chapter, wherein we shall study, in a practical way, the reading of radiographs.

CHAPTER VII.

The Uses of the Radiograph in Dentistry.

The use of the radiograph in the practice of modern dentistry is almost limitless. Some of the cases hereinafter mentioned are such as the general practitioner of dentistry might not be called upon to diagnose or treat oftener than once or twice in a lifetime, if at all. But by far the greater number of them are such as are met repeatedly in the practice of dentistry.

The radiograph may be used in the following cases: (1) In cases of delayed eruption, to determine the presence or absence of the unerupted teeth. (2) In cases where deciduous teeth are retained long after the time when they should have been shed, to learn if the succedaneous teeth be present. (3) To learn if the roots of children's teeth be fully formed. (4) To determine whether a tooth be one of the primary or secondary set. (5) To determine when to extract temporary teeth. (6) To show the orthodontist when he may move the coming permanent teeth by moving the deciduous teeth. (7) To observe moving teeth. (8) In cases of supernumerary teeth. (9) In cases of impacted teeth as an aid in extraction. (10) To determine the number of canals in some teeth. (11) As an aid in filling the canals of teeth with large apical foramina. (12) To learn if canals are open and enlarged to the apex before filling and to observe the canal filling after the operation. (13) To determine whether an opening leading from a pulp chamber be a canal or a perforation. (14) In cases of pulp stones (nodules). (15) In cases of secondary dentine being deposited and pinching the pulp. (16) To learn if the filling in the crown encroaches on the pulp. (17) In cases of teeth with large metal fillings or shell crowns which do not respond to the cold test, to learn if the canals are filled. (18) To learn if apical sensitiveness is due to a large apical foramen or an unremoved, undevitalized remnant of pulp. (19) In cases of chronic pericementitis ("lame tooth"). (20) In cases of alveolar abscess to determine which tooth is responsible for the abscess. (21) In cases of alveolar abscess to determine the extent of the destruction of tissue—bony and tooth. (22) In cases of alveolar abscess to learn how many teeth are involved. (23) In cases of abscess of multi-rooted teeth to learn at the apex of which root the abscess exists. (24) In cases of

abscesses of crowned teeth to learn whether the canals are properly filled. (25) As an aid in differential diagnosis between chronic alveolar abscess and pyorrhea alveolaris. (26) To observe destruction of tissue due to pyorrhea alveolaris. (27) In cases of pericemental abscess. (28) In cases of persistent suppuration which does not yield to the usual treatment. (In fact in all cases that do not yield promptly to the usual course of treatment.) (29) To observe the course of a fistulous tract. (30) To observe the field of operation before and after apicoectomy. (31) To locate foreign bodies, such as a broach in the pulp canal or tissues at the apex of a tooth; a piece of wooden toothpick in the peridental membrane, etc. (32) To determine the presence or absence of a bit of root imbedded in the gum tissue. (33) To diagnose fracture of a root. (34) To observe the size and shape of the roots of teeth to be used in crown and bridgework. (35) As an aid and safeguard when enlarging canals for posts. (36) To examine bridges about which there is an inflammation. (37) To observe the field before constructing a bridge. (38) To observe planted teeth. (39) In cases of cementoma. (40) In cases of bone "whorls." (41) To locate stones (calculi) in the salivary ducts or glands. (42) In cases of bone cysts. (43) In cases of dentigerous cysts. (44) In cases of tumor, benign or malignant. (45) To observe anomalous conditions, such as the fusion of the roots of two teeth for example. (46) To observe the location and extent of a necrotic or carious condition of bone. (47) To diagnose antral empyema. (48) To observe size, shape and location of the antrum as an aid in opening into it. (49) To locate foreign bodies, such as tooth roots or broaches, in the antrum. (50) To observe cases of luxation. (51) In cases of fracture of the jaw before and after reduction. (52) In cases of ankylosis of the temporo-mandibular articulation or the joint formed by the tooth in the jaw. (53) To observe the field of operation before and after resection of the mandible. (54) In all cases of facial neuralgia with an obscure etiology. (55) To observe the inferior dental canal. (56) In cases of Ludwig's angina. (57) In cases of insomnia, neurasthenia, insanity* and kindred nervous disorders. (58) In cases of periodic headaches. (59) In cases of facial gesticulatory tic (spasmodic twitching of a set of the facial muscles). (60) To allay the fears of a hypochondriac. (61) In cases where the patient cannot open the mouth wide enough for an ocular examination. (62) In research work to study osteology, the development of teeth, action of bismuth paste, bone production and destruction, changes occurring in the temporo-mandibular articulation when jumping the bite, blood supply to parts, resorption of

*Dr. Upson—Cleveland.

teeth and the causes for it, etc. (63) As a record of work done. (64) In cases of hidden dental caries.

It is with a mingled feeling of enthusiasm and misgiving that I now attempt to illustrate the above named uses of the radiograph. It is not reasonable to hope that half-tones will show all that can be seen in negatives. As a result, things may be mentioned in the text that cannot be observed in the half-tones; but, be assured, all clinical factors mentioned in the text were observable in the original radiographs.

Thanks to the help rendered by the many radiographers, whose names appear beneath the half-tones, and the practitioners, whose names are mentioned in the text, I will be able to illustrate almost all of the above enumerated uses. I have tried to make this collection of radiographs representative—that is, to have it represent the work of Americans in the field of dental radiography.

In describing cases which have not come under direct personal observation there is, of course, considerable liability to mistakes. I ask my readers to bear this in mind.

It shall be my policy to print as few radiographs as possible to fully demonstrate the different uses. For example, I could print hundreds of different radiographs illustrating the use “in cases of delayed eruption to determine the presence or absence of the unerupted teeth.” But only a few will be used, because that is all that is necessary to demonstrate the value of the radiograph in such cases, and to use more would be superfluous in a work of this kind.

1. In Cases of Delayed Eruption to Determine the Presence or Absence of the Unerupted Teeth.

Upper, permanent laterals missing in the mouth of a girl, eighteen years of age. Spaces between the centrals, and the centrals and cuspids. In this case the deformity seemed particularly distressing because, save for the spaces between her teeth, the young lady was positively beautiful.

A radiograph (Fig. 128) was made and shows that the laterals are not impacted in the upper maxilla. It therefore became necessary to move the centrals together and construct a bridge. Had the laterals been present in the maxilla, and space made for them by moving the centrals together, they would probably have erupted into their places. Had they not erupted after space had been made for them the tissues covering them could have been dissected away, holes drilled into the teeth, little hooks cemented into these holes and the teeth elevated orthodontically.

When there seems to be a congenital absence of a tooth from the jaw it is expedient—which is expressing it mildly—to use the radiograph before constructing and setting a bridge. Failure to do this might result in what

Fig. 129.

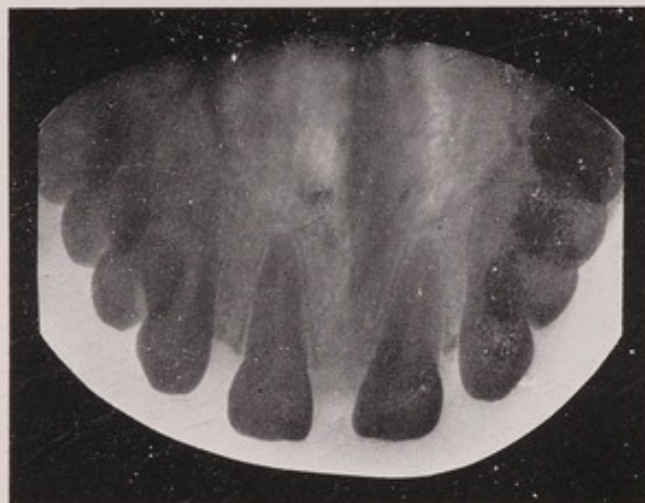

Fig. 128. Congenital absence of the upper lateral incisors. Age of patient, eighteen years.

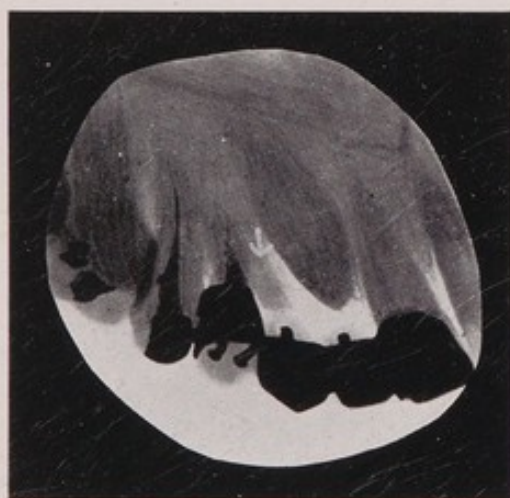

Fig. 129.

Fig. 129. Bridge from central to first bicuspid. Unerupted cuspid. The arrow points to a bit of tooth root. (Radiograph by Ream of Chicago.)

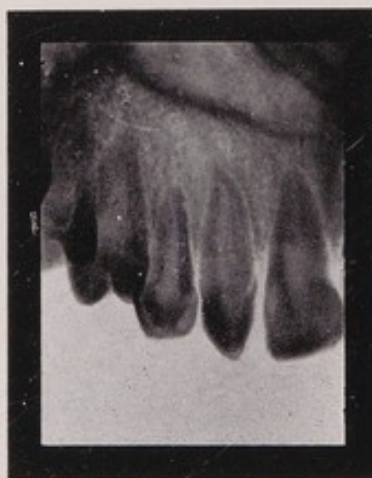

Fig. 130.

Fig. 130. An upper cuspid in the place of the lateral. A temporary cuspid in the place which should be occupied by permanent cuspid. The lateral missing from the jaw.

is shown in Fig. 129—an unerupted cuspid covered with a bridge. Such a condition as this may or may not cause local inflammation, neuralgia, or any of a series of inflammatory and nerve disorders. In this case the bridge covers not only an unerupted cuspid, but also a bit of tooth root.

Fig. 130.

In a case presented to me an upper permanent cuspid was seen occupying the place of the lateral incisor, and a temporary cuspid was in the space

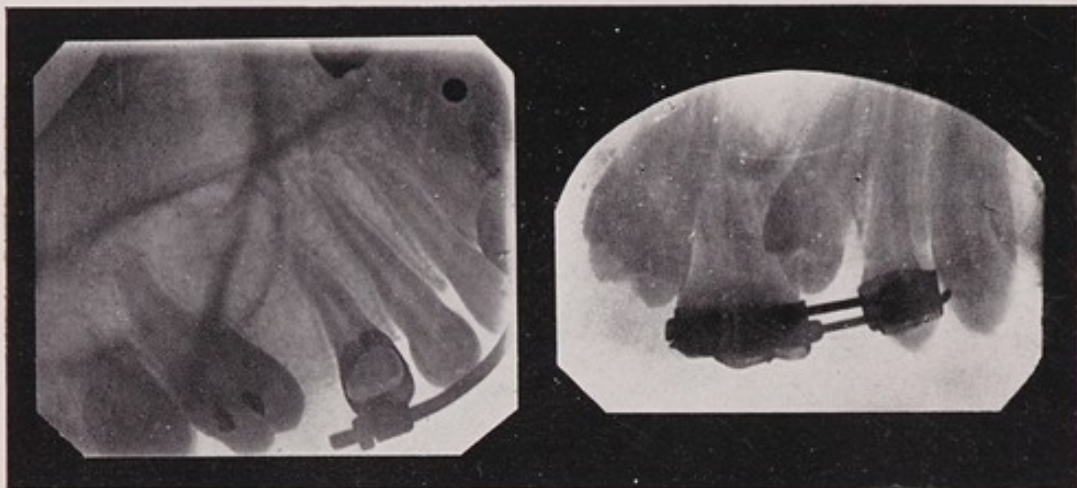

Fig. 131.

Fig. 132.

Fig. 131. Congenital absence of the upper second bicuspid. Observe the orthodontia appliance in position. (Radiograph by Lewis of Chicago.)

Fig. 132. Delayed eruption of an upper second bicuspid. The orthodontia appliance in position is being used to make space in the arch for the delayed tooth. (Radiograph by Lewis of Chicago.)

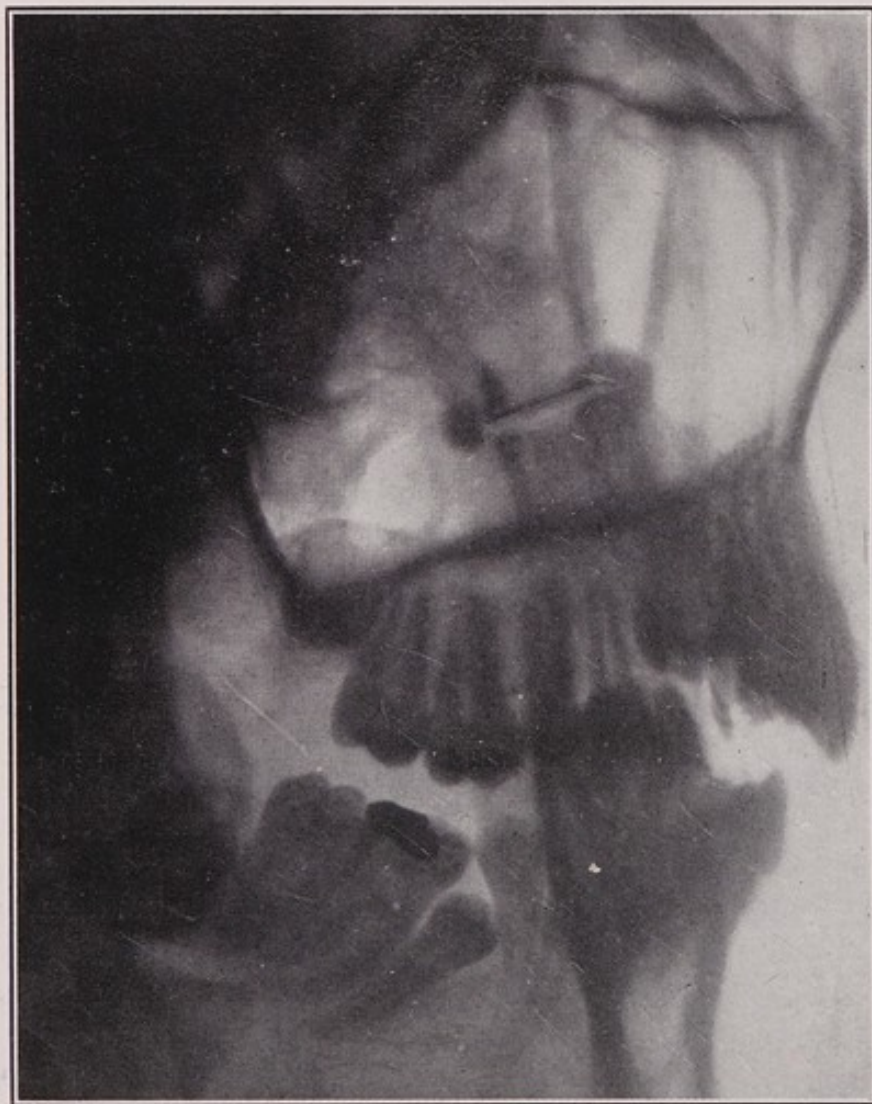

Fig. 133. A badly impacted lower second bicuspid, with no space at all for it in the dental arch. (Radiograph by Pancoast of Philadelphia.)

which should have been occupied by the permanent cuspid. A radiograph was made (Fig. 130) to locate the missing lateral. It was not present in the jaw. Though I am not absolutely sure of this, I nevertheless feel quite certain that the permanent lateral was mistaken for a

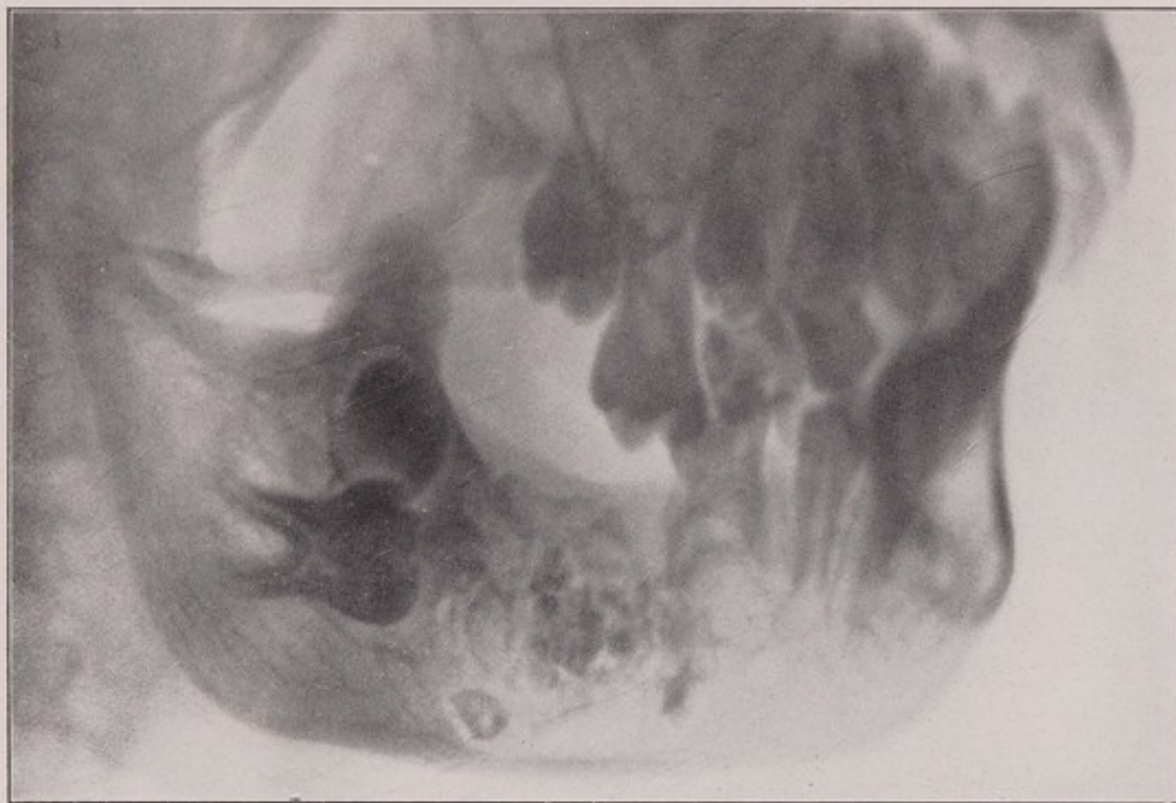


Fig. A.

Odontoma in patient eight years old. (Radiograph by Schamberg, of New York.)

temporary tooth and extracted when the patient was about seven or eight years old—a mistake which could not have happened had the dentist used radiographs.

Figs. 131 and 132. Fig. 131 proves the absence of a second bicuspid and shows that bridgework must be resorted to, to fill the space. Fig. 132 discloses the presence of a second bicuspid and shows that it will not be necessary to make a bridge. As they appeared before radiographs were taken the cases, from which Figs. 131 and 132 were made, were similar.

Fig. 133. Fig. 133, a case of Dr. Cryer's, shows a badly impacted lower second bicuspid with no space at all for it in the dental arch.

With the exception of the third molars no teeth are so liable to be delayed in their eruption as the upper cuspids. For this reason, when making a radiograph to determine the presence or absence of an unerupted cuspid

Fig. 134.

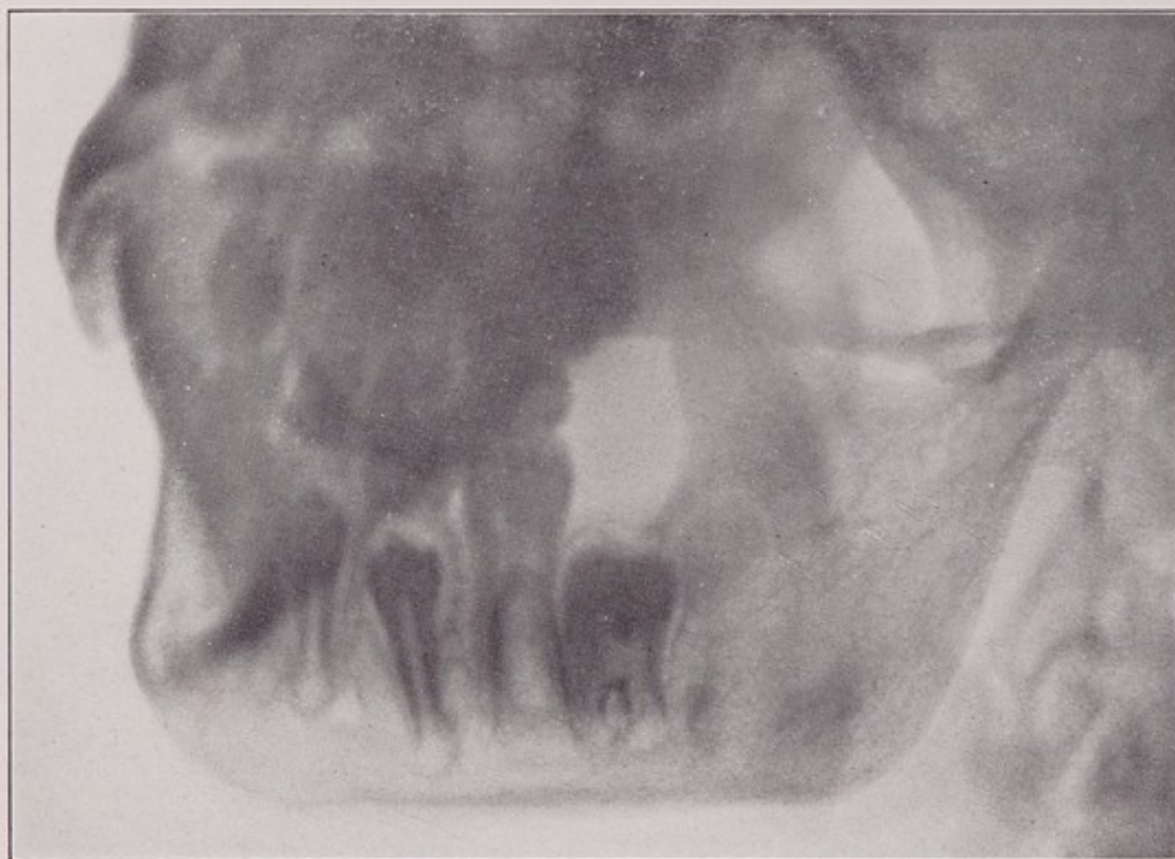

Fig. B.

Same patient, opposite side of jaw. (Radiograph by Schamberg, of New York.)

or a third molar, I feel tolerably sure, before I make the picture, that the tooth will be found somewhere in the jaw. When the missing tooth is a central, lateral, bicuspid, or lower cuspid, I am in doubt as to what to expect. My experience teaches me that when these teeth are missing they are just as likely to be entirely absent from the jaw as present in it, and simply unerupted. So far, I have never seen either long delayed eruption or congenital absence of the first or second molars.

Since the first publication of the above, Dr. Ottolengui has reported two interesting cases (*ITEMS OF INTEREST*, February 19, 1913), from which record I quote in part, as follows:

**Missing
First Molar.**

“Very shortly after Dr. Raper had published the quoted statement, that up to that time he had not seen a case wherein first or second molars were congenitally absent, a little girl patient of mine came in for her periodical examination, and I noted that since her previous visit

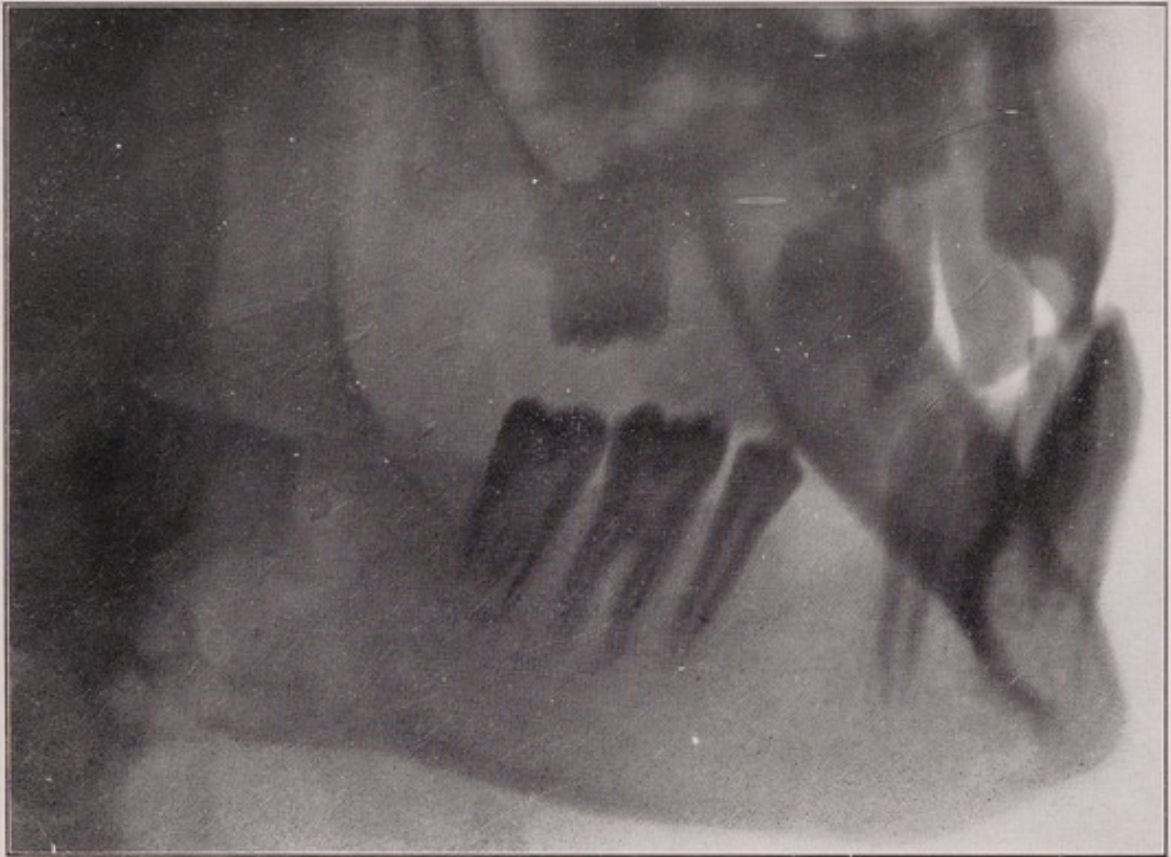


Fig. C.

Patient aged 13. Right side. Two upper and one lower molar absent. (Radiograph by Geo. M. McKee, of New York.)

she had erupted three first permanent molars, but the fourth had not appeared. I immediately began to wonder whether or not I was about to discover an authentic case of congenital absence of a first molar. I say authentic, because in records of this kind it is not always that one may be sure that the history is authentic. But in this particular case there can be no doubt. The child was the sister of another girl in my care and had been under my observation since she was four years of age. I have casts of her mouth at the age of five, which show the primary denture complete. I may add also that there never had nor has been any caries, and consequently there was no possibility that a molar had been extracted, a suspicion always warranted when we find a first molar absent from the

mouth of an adult. An ordinary small mouth radiograph was made, and while it did not disclose the shadow of a molar, neither did it satisfactorily show what really existed. I therefore determined to have a large radiograph made, so that we might have a picture of the entire bone.

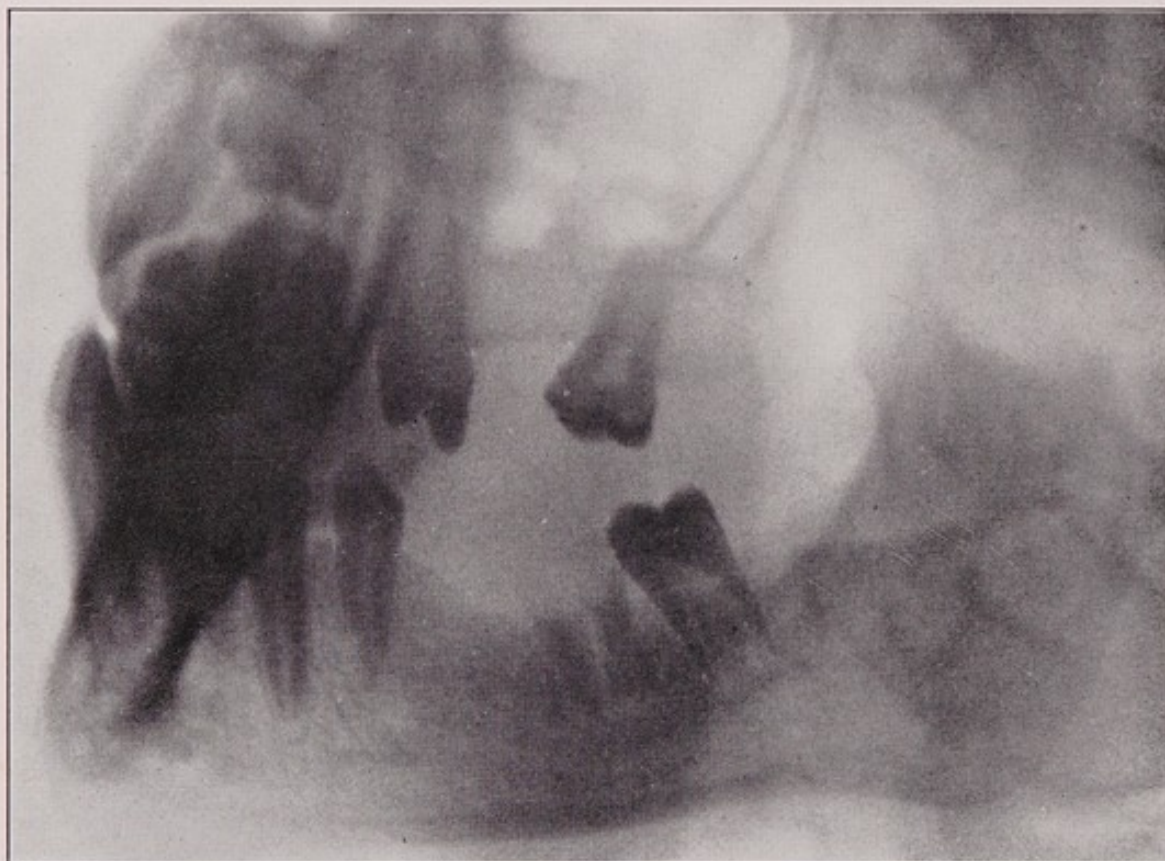

Fig. D.

Same patient. Left side. Same molars absent. (Radiograph by McKee, of New York.)

“The patient was sent to Dr. M. I. Schamberg, who made radiographs of both sides of the mandible, that we might compare them. The radiographs are reproduced in Figs. A and B. My surprise may be imagined when I found that in the region which should have been occupied by the second bicuspid and the first molar, there was a well-defined composite odontoma. And perhaps even more astonishing is the position of the molar lying distally of the tumor. Whether this tooth, which is seen lying horizontally in the bone, is the first molar or the second molar, is a question that has been raised by an orthodontist of national reputation, a man of keen judgment and well informed as to tooth forms. While I am willing to admit that this looks more like a first than a second molar, especially when we compare with the normal side (Fig. B), still

I very much doubt that it is the first molar. The odontoma is more apt to be a composite of the bicuspid and first molar. But in any event, interesting as this case is, it cannot be entered in the literature as a record of congenital absence of a first permanent molar, because that tooth is either in the bone or else is included in the odontoma, whereas by "congenital absence" I understand to be meant complete non-existence.

**Missing
Second Molars.**

"The second case which I am permitted to report is from the practice of Dr. Thaddeus P. Hyat, and is in the hands also of Dr. George B. Palmer for orthodontic treatment. The patient is a boy of fourteen, and we are assured that no permanent teeth have been extracted, yet no less than thirteen permanent teeth are missing. In the upper jaw the absent teeth are: both lateral incisors, three bicuspids, both second molars and both third molars, a total of nine teeth (note that both upper laterals are absent, while both upper cuspids are present). In the lower jaw the following teeth are absent: the first bicuspid and the third molar on the right side and the second bicuspid and the third molar on the left side.

"Figs. C and D are radiographs of the two sides of the head. In the upper the first molars are easily distinguished, but there are no evidences of the second and third molars. In the mandible the third molars are absent, but the other four molars are present, though in one case the crown has been lost by caries. Considering the boy's age, this seems to be an authentic record of congenital absence of two second upper molars, and of all four third molars, as the extraction of any of these teeth could not have been forgotten.

**Missing First,
Second and
Third Molars.**

"Dr. Hyat has kindly asked another patient of his to call at my office that I might examine a very similar case. In this instance the patient is a woman about thirty-five years of age. She is a highly cultured person engaged in the editorial department of one of our leading magazines. She is quite positive that the only tooth she ever had extracted was one lower first molar. If this be true she has fourteen teeth congenitally absent as follows: In the upper jaw the missing teeth are the two lateral incisors, the first, second and third molars on the left side, and the second and third molars on the right side. In the lower jaw the missing teeth are the second bicuspid and all three molars on the right side, and both bicuspids and the third molar on the left side. Again we have the upper laterals missing, and the upper cuspids present.

"In this mouth we have the strange anomaly of three molars missing from the upper jaw on the right side, and three molars missing from the lower jaw on the left side. Enumerated in full the absent molars were all four of the third molars, three of the second molars and two of the first molars."

Fig. 134 is representative of a class of delayed eruption that is most common. I could print as many as forty or more radiographs of such cases. Fig. 123 was a beautiful example. The age of the patient



Fig. 134. Age of patient, fourteen. An unerupted malposed cuspid. No room for it in the dental arch. Observe the tipping of the lateral, which is probably due to the pressure of the cuspid against the apex of its root.

in this particular case (Fig. 134) was some months over fourteen. The radiograph was made for an orthodontist who was just beginning treatment of the case. There was no evidence of the presence of the cuspid and no room for it to erupt. When the arch was broadened and space made for it the cuspid erupted. It required some mechanical guidance to make it come into its exactly proper position.

The mere making of space for them in the arch will usually result in the eruption of unerupted teeth, unless they are badly malposed. If, after space is made, the tooth does not move, the gum and process over it should be slit surgically. If this does not suffice to induce eruption, the soft parts and process must be cut away, and sometimes it may be necessary to resort to the use of orthodontia appliances to assist eruption, as formerly suggested.

2. In Cases Where Deciduous Teeth are Retained Long After the Time When They Should Have Been Shed, to Learn if the Succedaneous Teeth be Present.

Case—Girl, age seventeen, large cavity in upper, second, deciduous molar. Whether to fill this tooth or extract it depended on whether there was a second bicuspid to take its place in case of extraction. It was not at all loosened and there was no visible evidence of the presence of the suc-

Fig. 135.

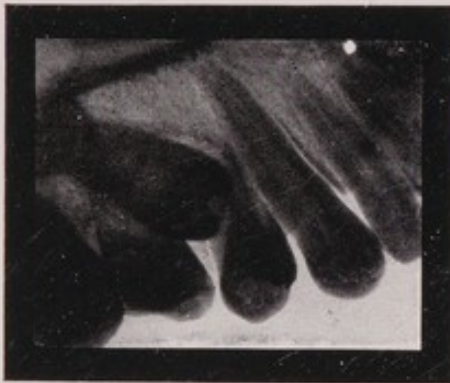

Fig. 135.

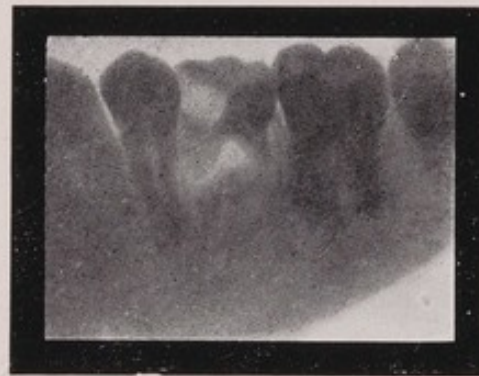

Fig. 136.

Fig. 135. Age of patient, seventeen. Retained upper, second, temporary molar. The radiograph shows that the second bicuspid is present in the jaw.

Fig. 136. Age of patient, twenty-one. Retained lower, second, temporary molar with a large cavity in the crown of the tooth and the roots almost entirely resorbed, despite the fact that there is no oncoming second bicuspid.

ceeding bicuspid. Fig. 135, however, shows the bicuspid to be present. The half-tone may not do so, but the negative now before me has perspective enough for me to see that the bicuspid is being deflected toward the lingual. The deciduous tooth was extracted and the bicuspid erupted promptly.

Case—young man, age twenty-one, lower, second, deciduous molar with pulp exposed. Question: Should the tooth be treated, filled and retained in the mouth, or extracted to make room for the second bicuspid? Fig. 136 demonstrates the futility of attempting to treat the tooth—its roots are almost entirely resorbed despite the fact that there is no succedaneous tooth in the jaw—and shows also that there is no bicuspid to take its place. Extraction and bridgework are indicated.

Fig. 136.

Fig. 137.

Fig. 137 shows two retained temporary upper cuspids with the permanent cuspids impacted and malposed.

Fig. 138.

Fig. 138 shows two retained, primary, lower central incisors with no sign of the permanent centrals. Age of patient, seventeen.

Figs. 139 and 140.

Case—a young man, age twenty-two; with a retained, temporary, lower, second molar. The temporary tooth was too short to reach its antagonists in occlusion. For this reason the patient, a dental student, wished to have it crowned. Before making the crown, a radiograph was taken (Fig.

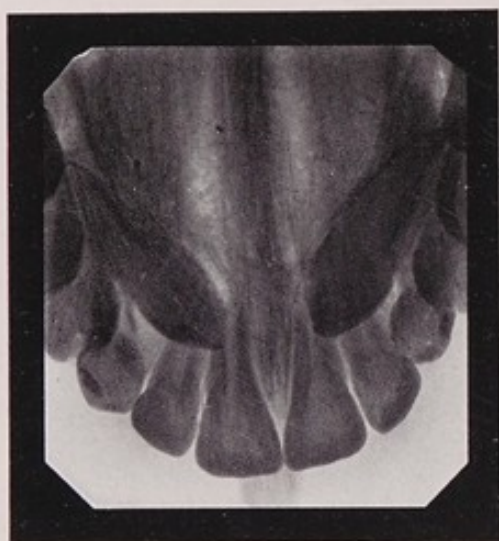**Fig. 137.**

Fig. 137. Two retained temporary cuspids, with the permanent cuspids impacted and malposed. (Radiograph by Lewis, of Chicago.)

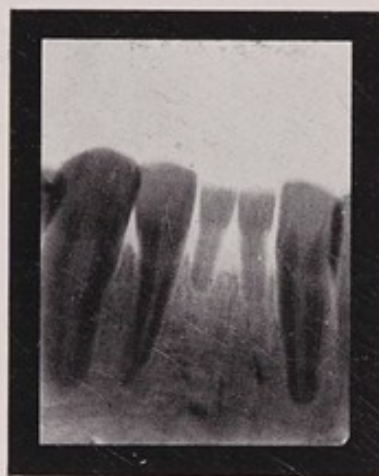**Fig. 138.**

Fig. 138. Two retained temporary, lower, central incisors. No permanent centrals present. Age of patient, seventeen. (Radiograph by Blum, of New York City.)

139) after the development of which it was seen that the making of a crown was not indicated. From the appearance of the radiograph one might suppose that the temporary tooth was loose—its roots being almost entirely resorbed. But such was not the case.

Fig. 140 is a radiograph of the same case one month after the extraction of the temporary molar. Notice how rapidly the bicuspid is erupting into its place. The force of eruption, which had been held in abeyance for about eleven years, became promptly active upon removal of the abating object.

Case—young man, age twenty-one. A retained, temporary, upper cuspid with no observable sign of the succedaneous cuspid. A radiograph was made (Fig. 141), but, being a poor one, it failed to show the looked-for tooth. Yet from the reading of this radiograph I was able to state with a moderate degree of certainty that the cuspid was present in the jaw. If the

Figs. 141 and 142.

tooth itself cannot be seen, what is there in the picture to lead one to believe that the permanent cuspid is present? The arrow points to the upper end of a dark line. The dark line represents dense bone and such a line almost always is to be noted in radiographs of impacted teeth.

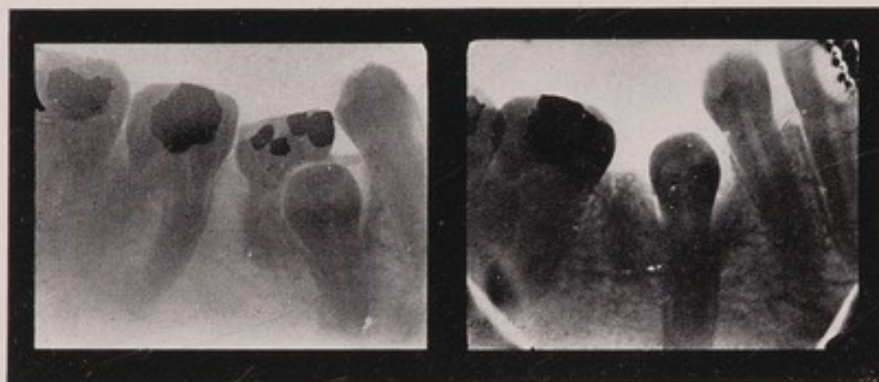

Fig. 139.

Fig. 140.

Fig. 139. Retained temporary, lower, second molar, with the succedaneous tooth beneath it. Age of patient, twenty-two. The dark spots in the temporary tooth and two permanent molars are metal fillings. All of the mesial root and some of the distal root of the temporary tooth resorbed.

Fig. 140. The same as Fig. 139 one month after extraction of the temporary tooth. Observe how rapidly the bicuspid is erupting. When this picture was made it could be seen in the mouth.

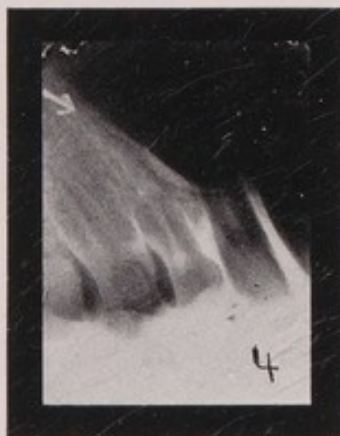

Fig. 141.

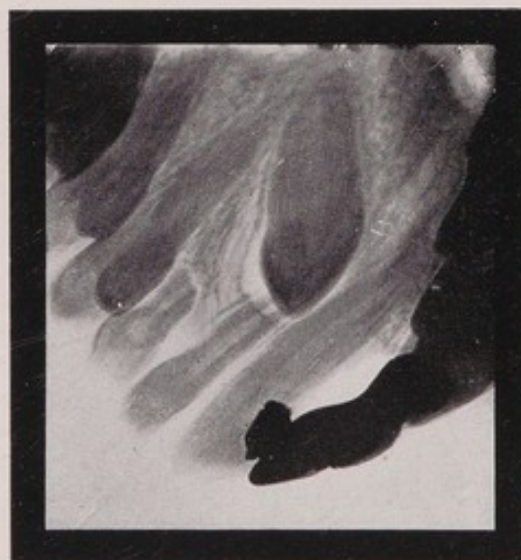

Fig. 142.

Fig. 141. Age of patient, twenty-one. A retained temporary upper cuspid. The arrow points to a dark line following along the side of the impacted cuspid. The impacted tooth itself cannot be seen.

Fig. 142. The same as Fig. 141, but taken at a different angle and showing the permanent cuspid.

To verify or disprove my deductions another radiograph was made (Fig. 142), which shows the impacted cuspid clearly.

The question arises naturally, What operative procedure should be

resorted to in such cases as the one just described? Had the patient been younger, or had the root of the temporary cuspid been much resorbed, or had the pressure of the impacted tooth been causing resorption of the permanent lateral root, or central root, or had the patient been suffering from neuralgia, periodic headaches, or any nervous disorder—had any of these conditions existed the temporary tooth should have been extracted immediately, space made in the arch for the permanent tooth and such orthodontic assistance given as might prove necessary to cause it (the permanent cuspid) to erupt into its proper place. As none of

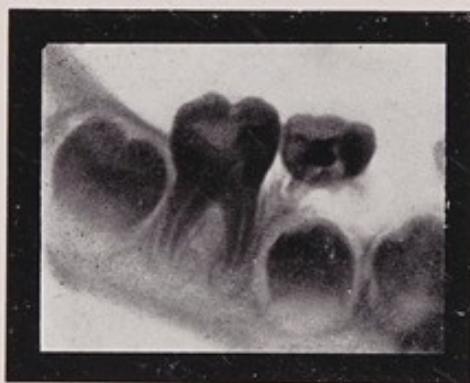


Fig. 143. The roots of a lower, first, permanent molar not quite fully formed. Age of patient, eight years and four months. Only the crowns of the second bicuspid and second molar are formed.

these conditions did exist, and as the patient expressed a definite disinclination to have anything done unless absolutely and imperatively necessary, the case was dismissed with the understanding that the condition should be kept under rigid observation. The man may go through life without trouble, or inside of a year he may be suffering almost any nervous disorder from simple neuralgia to insanity*; or he may lose the temporary cuspid as a result of the resorption of its roots, or he may even lose the lateral or central as a result of absorption of their roots, or suppuration may occur.

3. To Learn if the Roots of Children's Teeth are Fully Formed.

Case—patient, eight years and four months old.

Fig. 143.

A large cavity in a lower first, permanent molar.

To remove absolutely all of the decalcified dentin meant extensive exposure of the pulp, and, therefore, pulp devitalization, extirpation and canal filling. But should we practice pulp devitalization in such a case? If the roots of the tooth are fully formed, yes;

*Dr. Upson.

if the roots are not fully formed, no. A radiograph (Fig. 143) was made and shows that the roots of the tooth are not quite fully formed. Accordingly exposure of the pulp was avoided, the unremoved, decalcified dentin painted with silver nitrate, a paste of zinc oxide and oil of cloves placed in the bottom of the cavity and the tooth filled with cement, the object of this treatment being to conserve the pulp in the tooth at least until the roots are fully formed.

Often a child meets with some accident which breaks off the angle of a central or lateral incisor. To restore the angle sometimes necessi-

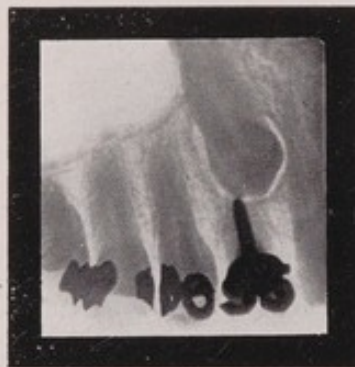

Fig 144. Post-collar crown on a temporary cuspid root. The permanent cuspid erupted down to the post of the crown. The dark shadows in the region of the temporary cuspid crown are numbers used to mark the negative. (Radiograph by Kells, of New Orleans.)

tates the removal of the pulp and the placing of a post in the canal. The question should always be raised, "is the tooth's root fully formed?" If it is, we may proceed with the devitalization, but if not, some temporary restoration should be made and the pulp conserved until it has fulfilled its function of root development. Whether the root is fully formed or not can be determined only by the use of the X-rays.

In a child's mouth we occasionally find an anterior tooth so badly decayed that crowning is indicated. Again we are confronted with the question, "is the root fully formed?" And whether we should devitalize and crown the tooth or keep it patched with cement for a year or so depends entirely upon the answer which the radiograph may make to this question.

4. To Determine Whether a Tooth be One of the Primary or Secondary Set.

What treatment we give a tooth depends very largely on whether it be of the permanent or deciduous set. If a man knows his dental anatomy as well as he should it is usually easy for him to determine whether a tooth be a primary or secondary one. Occasionally, however, we find a tooth (usually an upper lateral incisor) that looks as

much like a member of one set as the other and the radiograph must be used to arrive at a definite conclusion. To mistake a permanent tooth for a deciduous one and extract it (Fig. 130) is an inexcusable and disastrous blunder.

Sometimes a tooth is so badly decayed (the crown may be entirely destroyed) that it is impossible to determine by simple ocular observation whether it be a temporary or a permanent one. The radiograph can be used to great advantage in such cases. If the carious tooth be one of the temporary set, with the succedaneous tooth ready to take its place, it should be extracted. If the carious tooth be a permanent one, the radiograph shows the size and condition of its roots.

Case—a post-collar cuspid crown became loose. A radiograph (Fig. 144) was made and shows that the crown is placed on a temporary cuspid root. Part of the root of the temporary tooth is resorbed and the permanent cuspid has erupted down to the end of the post of the crown. The very dark shadows in the region of the temporary cuspid crown are caused by lead numbers placed against the film packet to mark the negative.

5. To Determine When to Extract Temporary Teeth.

The best rule ever formulated for the extraction of deciduous teeth reads, "Extract a deciduous tooth only when its successor is ready to take its place." There are many cases where the operator is able to detect the presence of the succedaneous teeth by ocular and digital examination. In about as many cases, however, the only way to determine the presence of such teeth is by the use of the radiograph. Thus the rule just quoted is one which, when followed, necessitates the use of the radiograph. Fig. 145 is of a case where extraction of the temporary first molar is indicated, and extraction of the temporary second molar is contraindicated. The temporary second molar should not be removed for a year or so—not until the second bicuspid is just ready to take its place.

Often in practice we are confronted with abscessed temporary teeth. The age of the patient is such that we cannot decide whether the teeth are loose as a result of the abscessed condition, or because of resorption of the roots and the presence of the succedaneous teeth. A radiograph of the case will enable us to decide, and our treatment will be governed accordingly. Not only will the radiograph show the operator when deciduous teeth should be removed, but will aid him in their removal—especially in cases where the temporary teeth are badly decayed—by showing the exact size and location of the temporary teeth's roots and the position of the succedaneous teeth.

6. To Show the Orthodontist When He May Move the Coming Permanent Teeth by Moving the Deciduous Teeth.

It impressed me very much when I first heard of radiographically observing, and then regulating, teeth before their eruption. I heard of this in a lecture by Dr. Ottolengui. I quote Dr. Ottolengui:

"One of the difficult operations which confronts the orthodontist at times is the bodily movement of the bicuspid buccally. Very often in the past at-

Fig. 146.

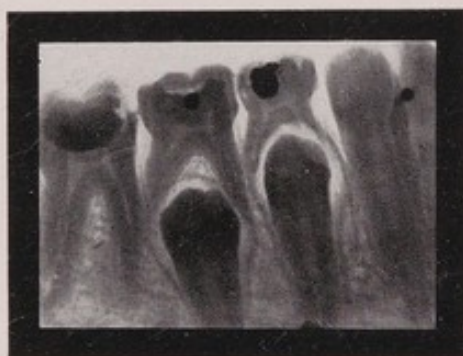


Fig. 145. This picture shows that the temporary first molar should be extracted. The temporary second molar should not be extracted for a year or so, when the second bicuspid will be just ready to take its place. (Radiograph by Lewis, of Chicago.)

tempts to widen the arch, after the eruption of the bicuspid, has resulted in tipping the crowns buccally, the apices of roots remaining in the original apical arch. Hence, one of the chief advantages of early orthodontic interference lies in the fact that the temporary molars may be moved buccally, carrying with them the underlying bicuspid, and this advantage is made more clear if it be recalled that at this period the bicuspid roots are but partly formed. Even when the roots of the temporary molars are already considerably absorbed, still enough may be left to serve to deflect the oncoming bicuspid in the direction desired.

"This slide (Fig. 146), from the collection of Dr. Matthew Cryer (radiograph by Pancoast, of Philadelphia), shows nicely the usual relation of the erupting bicuspid to their predecessors, the temporary molars. It will be noted that the apices of the bicuspid are still unformed, and it is clear that if these teeth can be led into proper positions during eruption, the formation of the apices afterward affords the most permanent 'retention.' A casual glance at the upper temporary molars might create a doubt as to the probability of moving the unerupted bicuspid, but there is an easily overlooked factor, viz., the palatal roots of these molars do

not show in radiographs of this region at this period, because they lie behind the crowns of the bicuspid; that is to say 'behind,' in relation to the source of light, the X-ray tube."

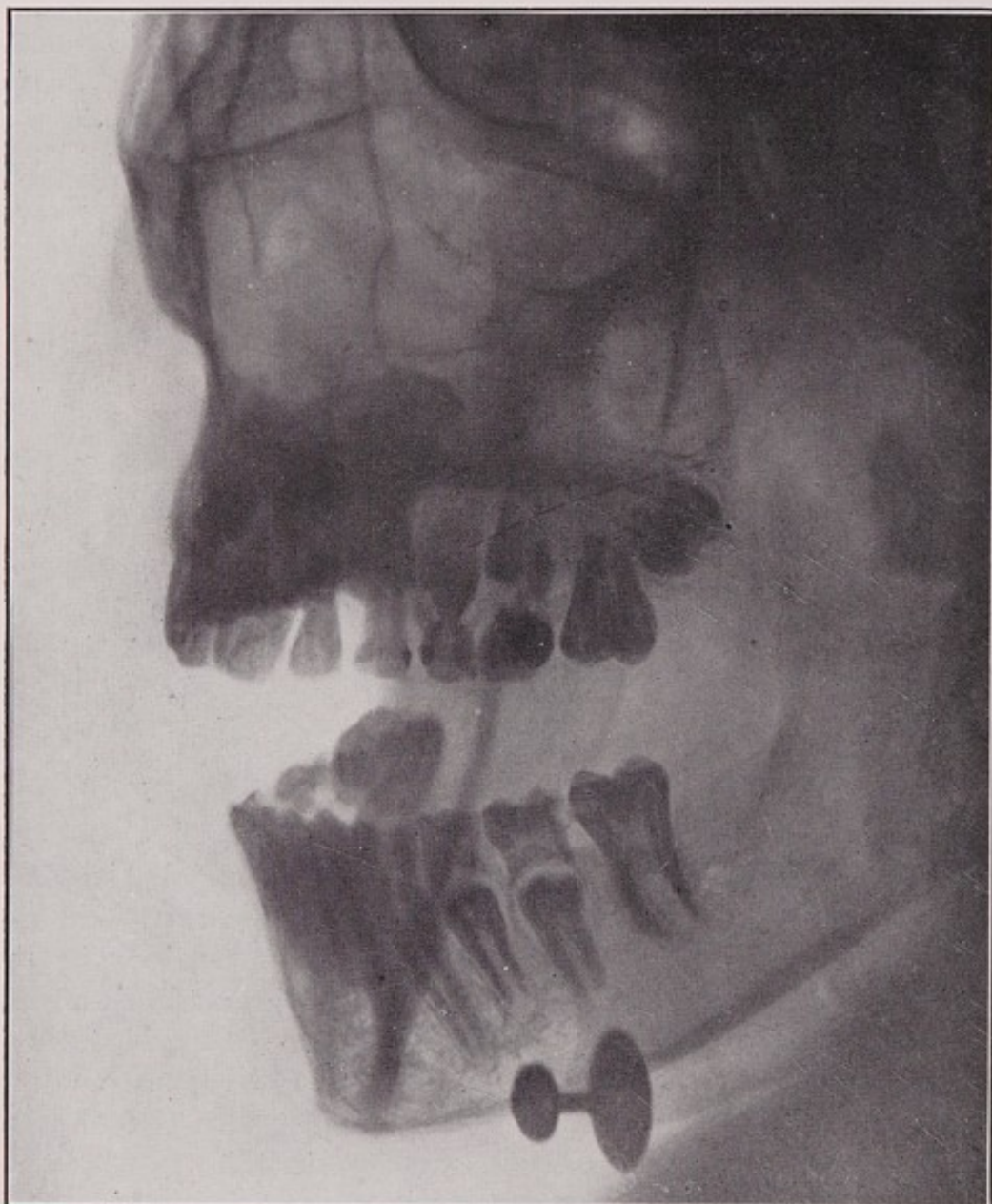


Fig. 146. Radiograph made to show relation of temporary molar roots to advancing bicuspids. (Collection of Dr. Cryer. Radiograph by Pancoast, of Philadelphia.)

7. To Observe Moving Teeth.

Fig. 147 demonstrates the congenital absence of the upper lateral incisors. The orthodontic appliance, seen in the radiograph, is being used to draw the centrals together. It was highly important in this case that the teeth be

moved through the alveolar process *en masse*, and not tipped. The movement desired was one which would make the roots parallel when the crowns of the teeth came together, so that posts could be set in the canals of the central incisors, and a bridge made to restore the lost laterals. Fig. 148 was taken about a month after Fig. 147. It shows that the teeth had been moved together, but there was too much tipping of the

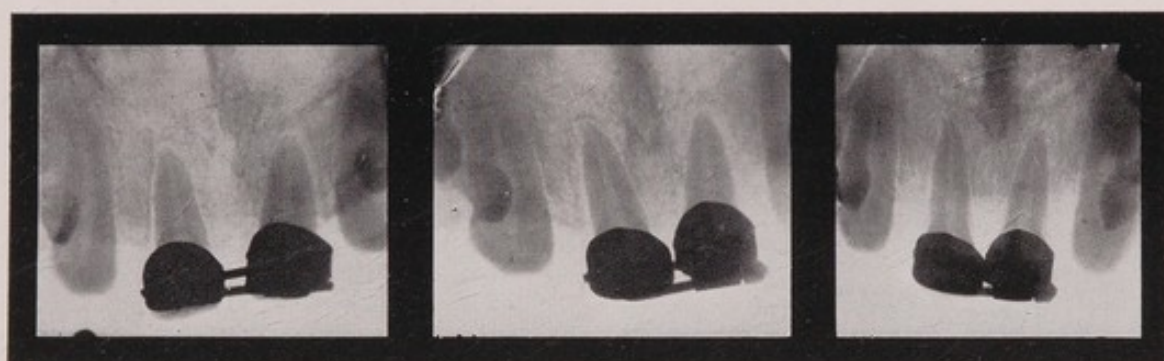

Fig. 147.

Fig. 148.

Fig. 149.

Fig. 147. Congenital absence of upper lateral incisors. The orthodontic appliance seen is being used to draw the central incisors together.

Fig. 148. This radiograph was made one month after Fig. 147. It will be seen that there has been considerable movement of the teeth. The left central is tipped considerably.

Fig. 149. Made one month after Fig. 148. The central incisors are together and their roots almost parallel.

left incisor—not enough movement of the tooth at the apex of the root, compared to the movement of the crown. It, therefore, became necessary to modify the force which was being used. This was done, and Fig. 149 shows the teeth together and the roots almost parallel.

A case in the practice of Dr. C. Edmund Kells, **Figs. 150, 151 and 152.** Jr., and reported by him in the May number of *ITEMS OF INTEREST*, 1911. Fig. 150 shows a malposed permanent cuspid above the temporary cuspid, the root of which is somewhat resorbed. Age of patient, eleven years. Fig. 151 was made one year and seven months after Fig. 150. "Compare this picture with Fig. 150, and it will be seen that the permanent cuspid has migrated in a line with its long axis," causing resorption of the permanent lateral root. The temporary cuspid was extracted, but the permanent tooth did not erupt into its position in the arch. It was, therefore, concluded that the tooth "would have to be brought down by some mechanical means." Accordingly, the gum tissue and overlying process were "slit down to the cuspid and then gently spread apart, and the

cuspid was exposed to view." A piece of iridio-platinum wire was then shaped, as shown in Fig. 152, and the hook was worked supposedly under the mesial prominence of the cuspid, and a rubber ring attached to the loop on the other end, and secured to a lug on the molar band, all as shown in Fig. 152, which is a skiagraph of the case with the appliance

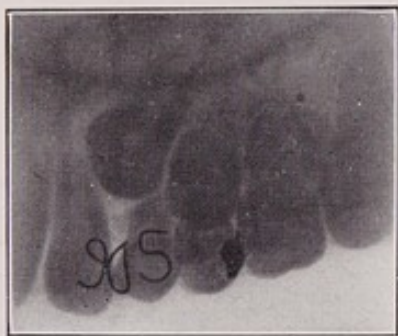

Fig. 150.

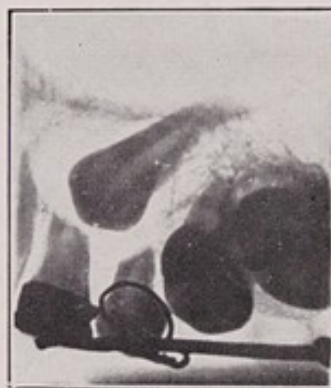

Fig. 151.

Fig. 150. Malposed, permanent cuspid above the temporary cuspid, the root of the latter somewhat resorbed.

Fig. 151. Same as Fig. 150 one year and seven months later. Observe that the cuspid has migrated in the line of its long axis. The permanent lateral root is badly resorbed.

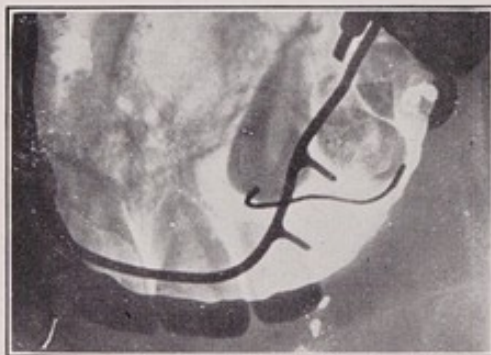


Fig. 152. Same as Figs. 150 and 151 after removal of the temporary cuspid. The wire hooked over the cusp of the tooth was thought to be placed over the mesial prominence until the radiograph was made.

in position. Imagine my surprise to find by this picture that the hook was not anywhere near where I had thought I put it. Instead of being well up under the mesial prominence, it was merely caught under the point of the tooth, and, of course, it slipped off shortly after the patient left the office. Upon her return a hook $\frac{3}{8}$ of an inch longer was fitted in place, and this time, with a radiograph as a guide, there was no mistake about its placement. The appliance was worn for several weeks, at

the end of which time the point of the cuspid having been brought to the surface of the gum, it was removed and the tooth allowed to erupt by its own volition. Despite the great destruction of its root the lateral remains firm and apparently healthy.

s. In Cases of Supernumerary Teeth.

A case in the practice of Dr. B. S. Partridge, Chicago. Patient's age, twelve years. The teeth were being regulated, and the radiograph, Fig. 151,

Fig. 153.



Fig. 153.

Fig. 153. A and B, supernumerary tooth bodies. C, the crown of the temporary cuspid. D, the permanent cuspid. (Radiograph by Lewis, of Chicago.)

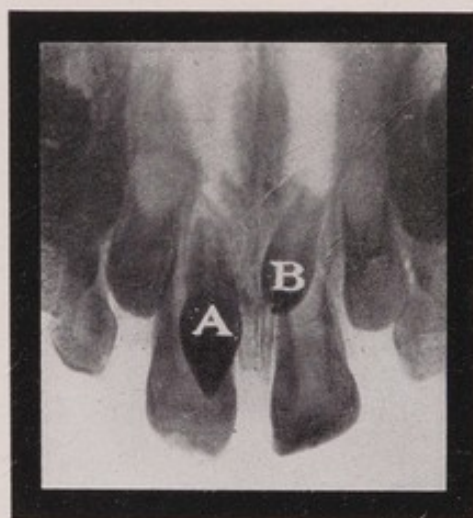

Fig. 154.

Fig. 154. A and B are supernumerary teeth. (Radiograph by Lewis, of Chicago.)

was taken to determine the presence or absence of the permanent lower cuspid. A little supernumerary tooth (A) could be seen in the mouth occupying a part of the space which should have been occupied by the permanent cuspid. The two shadows marked "B" are two more supernumerary tooth bodies. The larger shadow marked "C" is the crown of the temporary cuspid, which had never erupted. The large shadow to the left, marked "D," is the permanent cuspid pressing against the side of the lateral at the apex of its root. The three supernumerary bodies and the crown of the temporary cuspid (the root was resorbed) were removed, allowing the permanent cuspid to erupt.

Fig. 154.

Just lingually to each central incisor is a supernumerary tooth. One (A) could be seen in the mouth, but there was no evidence of the other. Neither central nor lateral incisor roots are as yet fully formed, and the

laterals have not yet erupted. Indeed, before the picture was made, it seemed that a peg-shaped lateral was erupting just lingually to the central. The radiograph shows this tooth to be supernumerary.

Dr. T. W. Brophy, of Chicago, reports a case of insistent suppuration due to an impacted supernumerary tooth, which was found by the use of the radiograph. Dr. Brophy calls attention to the fact that a correct and definite diagnosis could not have been made by any means at our command except the X-rays. The case recovered promptly upon removal of the supernumerary tooth. I regret that I have been unable to obtain radiographs of this case.

Fig. 155. An impacted upper fourth molar.

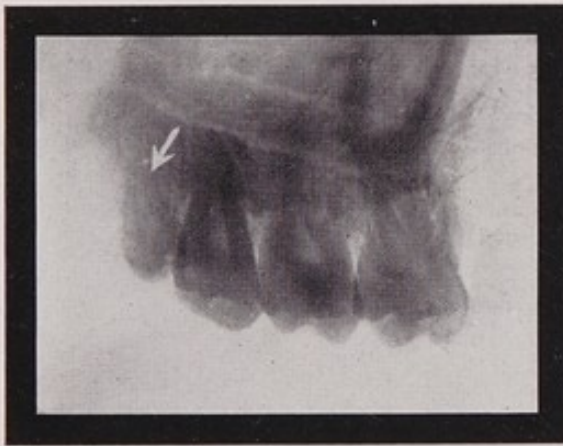


Fig. 155.

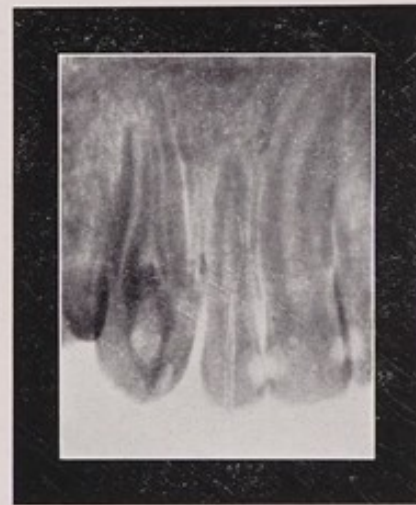


Fig. 156.

Fig. 156. A supernumerary tooth in the canal of a cuspid tooth. (Radiograph by Clarence Van Woert, of New York City.)

To me this is a most remarkable case—a supernumerary tooth in the canal of a cuspid tooth—a tooth inside of a tooth. The supernumerary tooth has a root canal, and the crown is covered with enamel. There is no doubt of the fact stated, because Dr. Van Woert, after radiographing the case, drilled into the permanent cuspid and found the enamel-covered supernumerary within. The radiograph is not as good as I wish it were. The upper two-thirds of the roots of the teeth shows fairly well but there is a confusion of shadows in the lower third and in the crown.

Fig. 156.

9. In Cases of Impacted Teeth as an Aid in Extraction.

Impacted, lower, third molar tipped to the mesial. The picture shows that in this case a knife-edge stone in the dental engine could be used to advantage, cutting away the mesio-occlusal portion of the third molar, and

Fig. 157.

so greatly facilitating the removal of the tooth. Observe the absorption of the distal surface of the second molar (the light area), due to pressure against it; and the large abscessed cavity (light area) between the second and third molars, extending down to the apex of the second molar. This radiograph is of particular interest, because it shows so clearly an abscess caused by impaction.

Figs. 158 and 159.

That the pressure of an impacted tooth may cause absorption of the tooth against which the pressure is brought to bear, is further illustrated in Figs. 158 and 159.

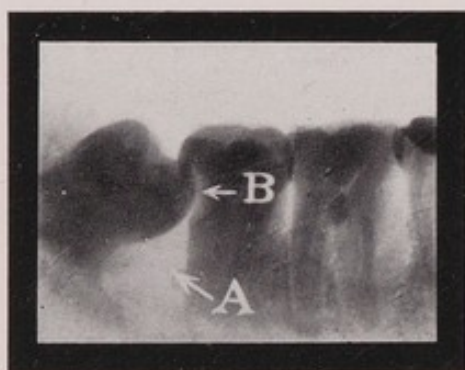

Fig. 157.

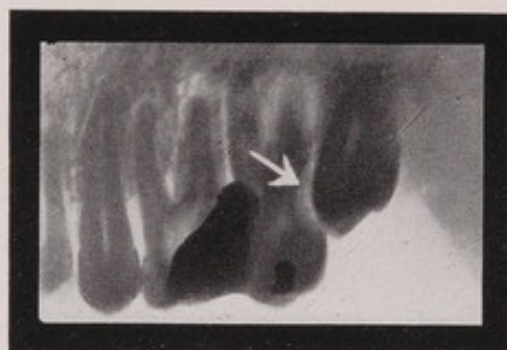


Fig. 158.

Fig. 157. An impacted lower third molar. The light area between the second and third molars represents a destruction of bony tissue, arrow A. Arrow B points to a light area, which represents the absorption of the second molar. (Radiograph by Blum, of New York City.)

Fig. 158. An impacted upper third molar. The arrow points to a light area representing absorption of the upper second molar. Notice the very poor filling encroaching on the pulp of the first molar and filling the interproximal space between the first and second molar. (Radiograph by Ream, of Chicago.)

In Fig. 158 the arrow points to a light area representing absorption of the upper second molar, due to the pressure of the third molar against it. A study of this radiograph gives the dental surgeon a good idea of how he should apply his force in extraction.

Fig. 159 is a case of Dr. Cryer's. I quote Dr. Cryer: Fig. 159 "shows an impacted, lower, third molar resting against the posterior root of the second molar. It will be seen that the root of the second molar is much absorbed, which caused considerable trouble. Removal of the second molar gave relief to the patient. . . . The upper third molar is in an awkward position."

Figs. 160 and 161.

Figs. 160 and 161 show impacted upper third molars. The value of these radiographs to the operator, about to extract, is apparent.

Fig. 162.

This radiograph (Fig. 162) shows the surgeon just how much bone must be dissected away before the malposed tooth can be removed. Patients seldom

know that the removal of a tooth is not always a simple operation. They are therefore inclined to blame the operator if the tooth is not quickly removed, instead of crediting him with working dexterously on a difficult operation. They are likewise unwilling to pay a fee in proportion to the

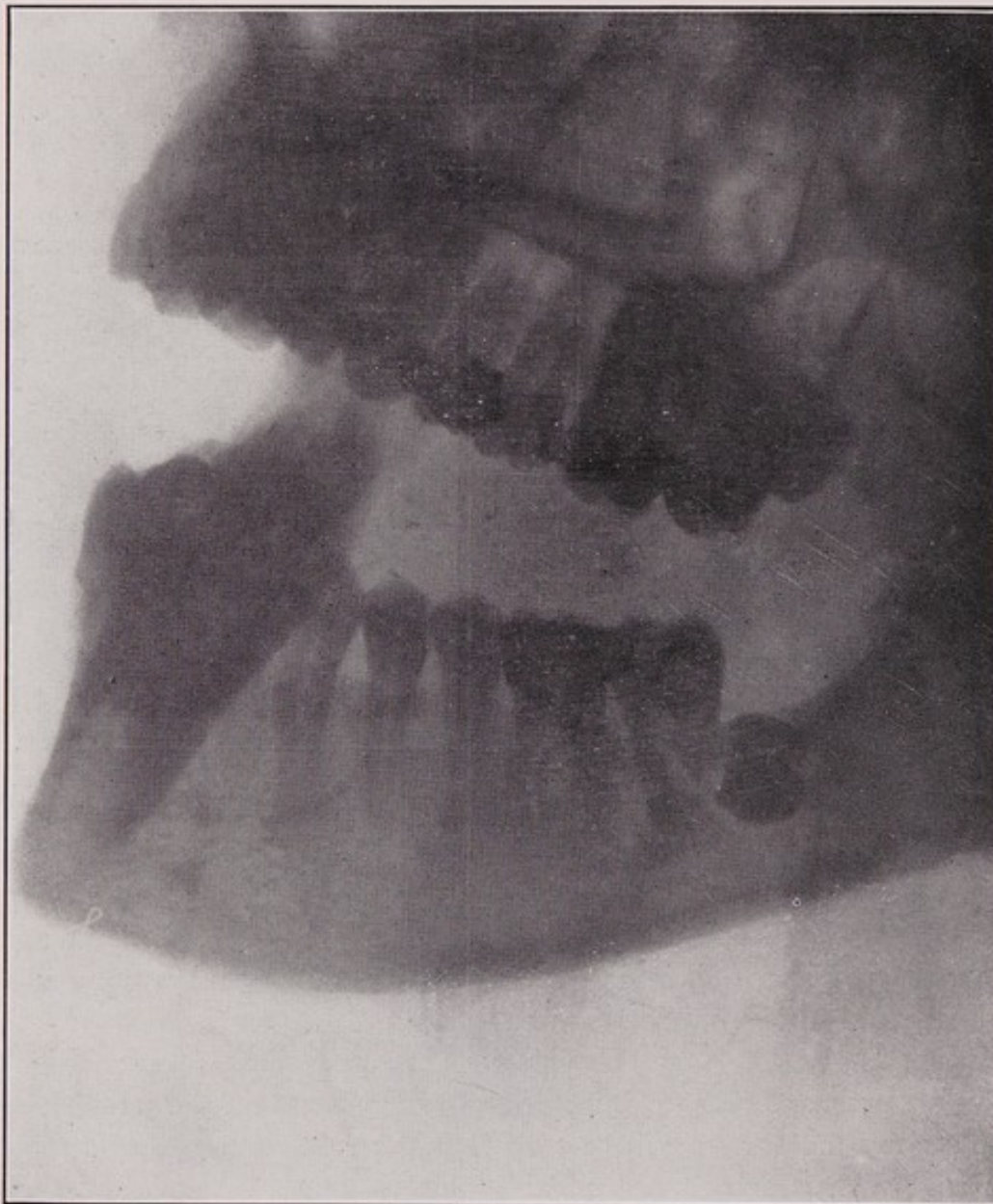

Fig. 159. Impacted upper and lower third molar. Absorption of the distal root of the lower second molar. (Radiograph by Pancoast, of Philadelphia.)

difficulty of the operation, as compared to other operations. The removal of the third molar, shown in Fig. 162, is a more difficult operation than the removal of a vermiform appendix. By showing patients radiographs of such cases the dentist will gain their earnest, intelligent co-operation. They will know just what is done for them, and for the first time in their

lives they will understand that the extraction of a tooth may be a serious, difficult and expensive operation.

The following report of this case is by Dr. F. K. Ream, of Chicago. "Patient's age, seventy-two years. Symptoms: Swelling near symphysis thought to be the result of wearing an artificial denture. Considerable pain. Diagnosed

Fig. 163.

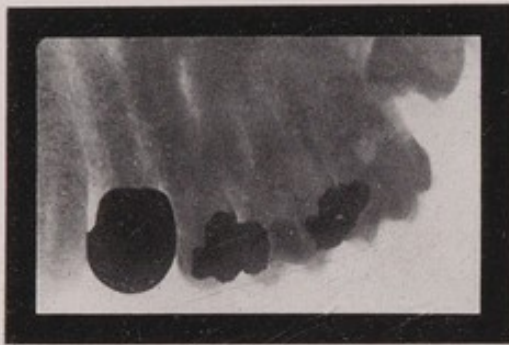

Fig. 160.

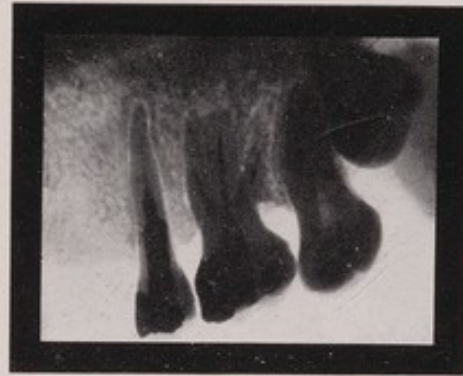

Fig. 161.

Fig. 160. Impacted upper third molar. (Radiograph by Lewis, of Chicago.)

Fig. 161. Impacted upper third molar. Notice the difference in the position of the impacted tooth shown in this case and in Fig. 160. (Radiograph by Blum, of New York City.)

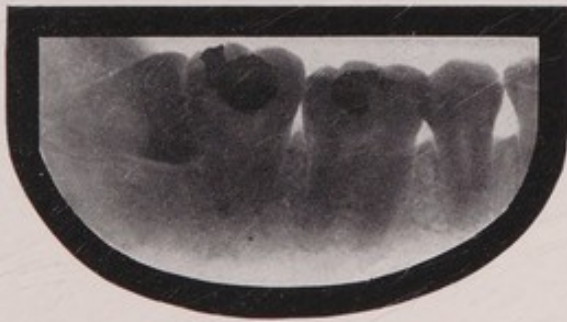

Fig. 162.

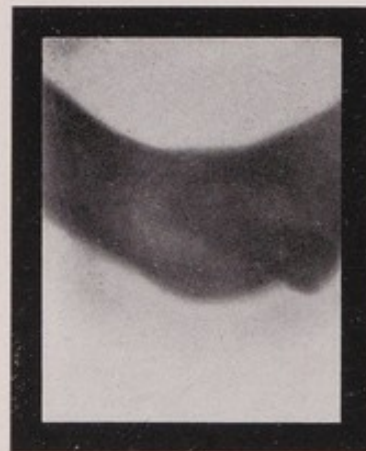

Fig. 163.

Fig. 162. Impacted lower third molar with its occlusal surface presenting mesially. The radiograph shows the dental surgeon how much bone must be burred away before the tooth can be removed. (Radiograph by Ream, of Chicago.)

Fig. 163. Impacted bicuspid in an otherwise edentulous mouth. Age of patient, 72 years. (Radiograph by Ream, of Chicago.)

cancerous by surgeons, and patient advised to go to the hospital for operation. The radiograph (Fig. 163) shows an impacted bicuspid in the otherwise edentulous jaw. Operation: Alveolar process burred away and tooth removed. Result: Immediate and complete recovery."

Fig. 164.

Fig. 164 is a case of Dr. Cryer's. I quote Dr. Cryer: Fig. 164 "shows a lower third molar passing under the second molar and becoming lodged between the first and second molar, the crown of the third molar pushing against the root of the first molar. The first molar was extracted, which cleared up the neuralgia, and the third molar pushed up into the place of the first molar."

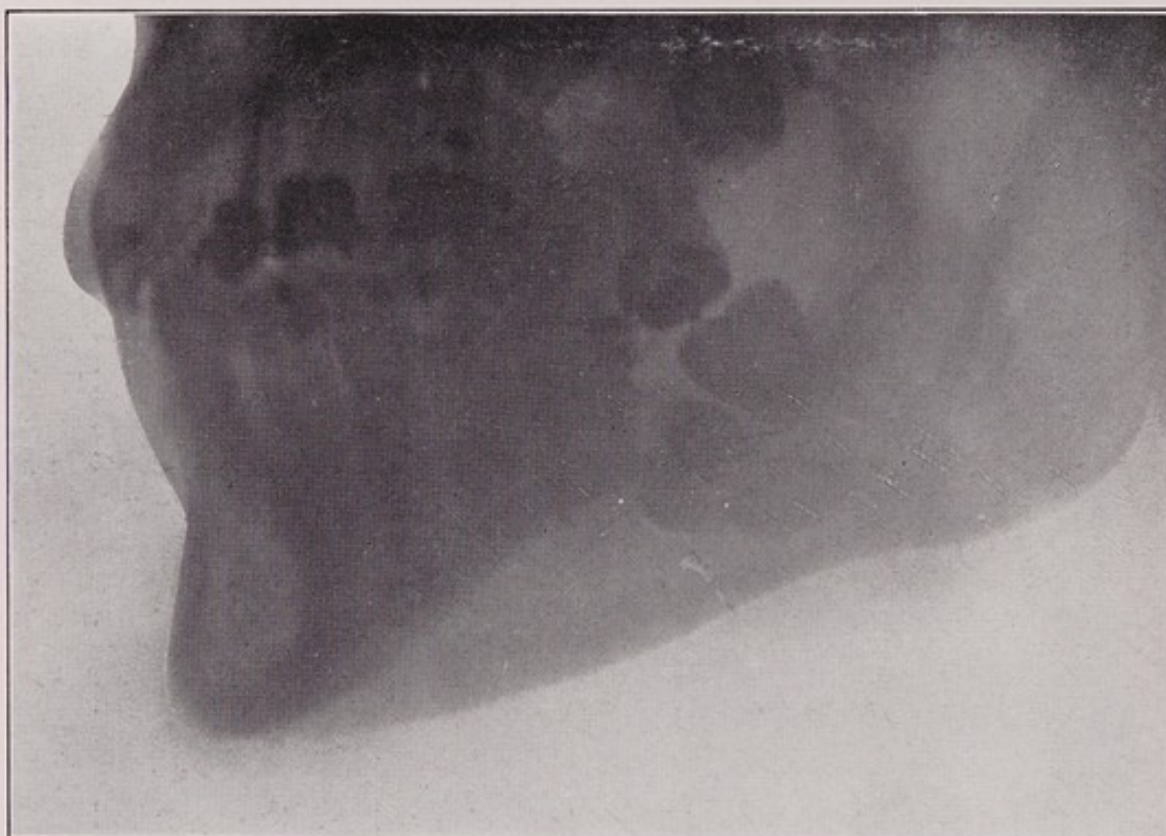

Fig. 164. Lower third molar lodged between the first and second molars. (Radiograph by Pancoast, of Philadelphia.)

Fig. 165.

Fig. 165 is also a case of Dr. Cryer's. The radiograph shows an impacted upper third molar, with the occlusal surface presenting upwards. Dr. Cryer's remarks concerning this case are interesting. I quote Dr. Cryer: Fig. 165 "shows the occluding surface of the upper third molar pointing upward towards the posterior portion of the orbit. The patient had been suffering from disturbance of the eye for a long time. Considerable improvement took place in the eye soon after extraction of the inverted tooth."

10. To Determine the Number of Canals in Some Teeth.

It will be noticed that I say "to determine the number of canals in *some* teeth." Of course, it is not necessary to use the radiograph each

time we open into a tooth to learn how many canals that tooth may have. But occasionally I do find it necessary or expedient to use the radiograph to verify or disprove the existence of some unusual condition suspected.

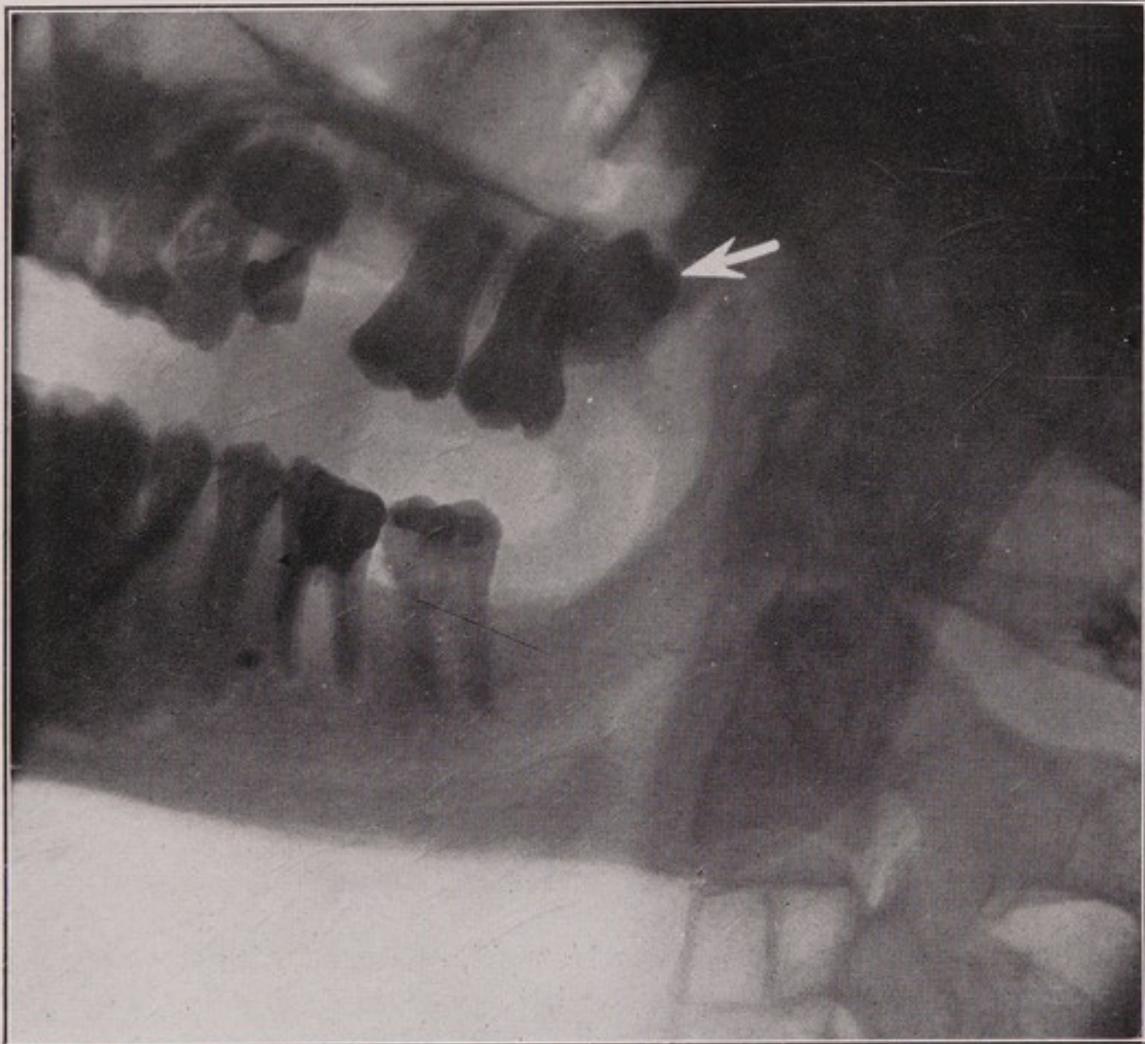


Fig. 165. Impacted upper third molar with the occlusal surface pointing upward. (Radiograph by Pancoast, of Philadelphia.)

Fig. 166. Case: An upper first molar in which but one small canal could be found. After searching for the other two canals for a few minutes, the one canal was filled with gutta-percha, and a radiograph made (Fig. 166); this shows that the tooth had but one canal. In this case the radiograph saved considerable work and worry on the part of the operator. I have known second and third molars to have only one canal, but this is the only case I have ever encountered in which a first molar had but one canal.

Fig. 167. This case was in the hands of one of the most expert operators in Indianapolis. The lower first bicuspid had been devitalized, and the pulp removed,

but the tooth remained sore. Radiography was resorted to to learn, if possible, the cause of the persistent pericementitis. A piece of ligature wire, such as is used by orthodontists, was placed in the canal and radiograph Fig. 167 made. The wire follows the enlarged canal. But this particular tooth happens to have two canals. The unopened canal is seen to the distal of the wire. If a man, having the skill of the operator who handled this case, misses a canal, as this man did, then I firmly believe that the mistake is one that any man, however skillful, is liable to make.

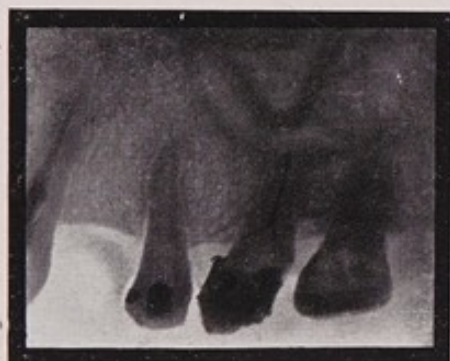

Fig. 166.

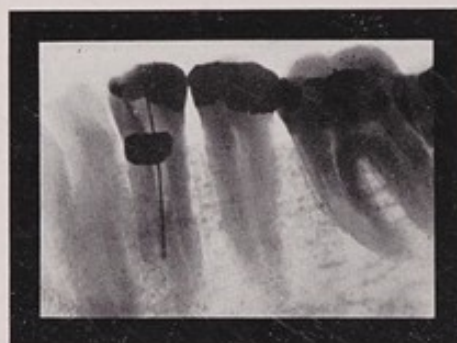

Fig. 167.

Fig. 166. Upper first molar with but one canal which is filled.

Fig. 167. The dark streak in the first bicuspid is a wire passing into the canal. This tooth has another canal, which can be seen as a light streak distally to the wire. The more or less oval dark spot at the neck of the first bicuspid is a buccal cervical filling. The cavity in the crown of the tooth is stopped up with gutta-percha.

Let me say here that a lower bicuspid, or cuspid with two canals, is not such an unusual occurrence, as it is generally believed to be. Men have shown me such teeth, and spoken of them as though they were rare anomalies. As a teacher of operative technic, I devote a part of my time to the dissection of teeth. In this work I handle thousands of disassociated human teeth. In my work of last year, for example, I estimate that I observed six to eight thousand teeth. And among these I noticed not less than seven lower cuspids and five lower bicuspid with two canals each.

Without printing the radiograph, which is not a very good one, I quote the legend which appears beneath it in the last edition of Buckley's "Modern Dental Materia Medica, Pharmacology and Therapeutics." "In this case the author desires to insert a bridge. On opening into the third molar and second bicuspid, which teeth were to be used for the abutments, we were unable to find any canals in the bicuspid, and only a small canal in the molar. The skiagraph confirms the clinical findings."

II. As an Aid in Filling the Canals of Teeth with Large Apical Foramina.

To demonstrate this use of the radiograph a central incisor with a large apical foramen was chosen, and an orthodontic ligature wire passed into the canal until the patient received sensation. The worthlessness of the "sensation test," as a guide in filling to the apex of canals is demonstrated by Fig. 168, which shows the wire penetrating the tissues four or five millimeters beyond the apex of the tooth. After the radiograph (Fig. 168) was made, the wire was removed, and that part of it penetrating the apex cut off, or as nearly as could be judged from the appearance of the radiograph.

Fig. 168.

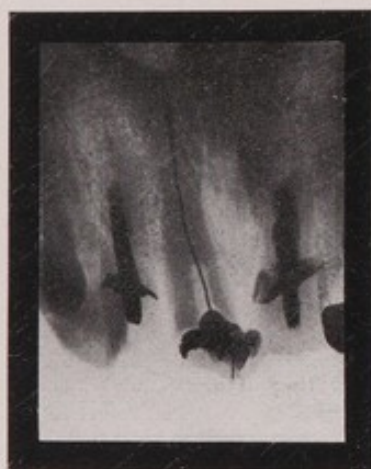

Fig. 168.

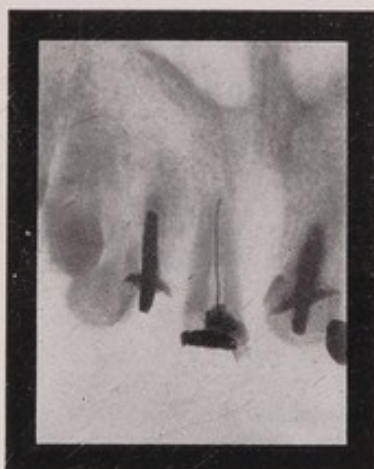

Fig. 169.

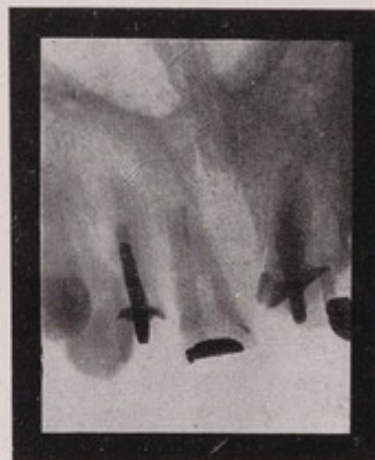

Fig. 170.

Fig. 168. A wire passing through a large apical foramen in an upper, central incisor, extending several millimeters into the tissues above the apex of the root.

Fig. 169. The same case as Fig. 168, after the wire has been removed, a part of it cut off and reinserted into the canal. The wire reaches just to the apical foramen.

Fig. 170. The same case as Figs. 168 and 169, showing a canal filling of gutta-percha closing the apical foramen, not penetrating through it, and not leaving a little of the canal unfilled at the apex of the root. The entire canal is not filled, because there is to be a post set in it.

Next the shortened wire was reinserted and another radiograph (Fig. 169) made. This shows that my judgment in cutting off the wire in this particular case was unusually good. The wire reaches just to the apex. It may be necessary to make two or three trials before the wire is placed just to the apex.

Fig. 169.

With the length of the wire as a guide to the length of the root, the proper distance was measured on a canal plugger, and the distance marked on the plugger by passing it through a little piece of base-plate gutta-percha, stopping the gutta-percha on the plugger at a distance from its end equivalent to the length of the wire. The end of the canal plugger was then

Fig. 170.

warmed slightly, and brought in contact with a small piece of gutta-percha canal point. With the piece of gutta-percha so fastened on the canal plugger, it was carried into the canal a sufficient distance to reach, but not pass, beyond the apex. (Fig. 170.) A slight twist of the plugger will disengage it from the gutta-percha, when the latter may be tamped firmly, but not too forcibly, to place. No further filling of the canal was done in this case, the canal being left open to receive a post. The method just described is positively the only one which enables the operator to fill canals with large apical foramina perfectly.

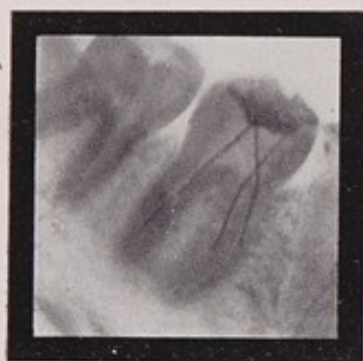

Fig. 171

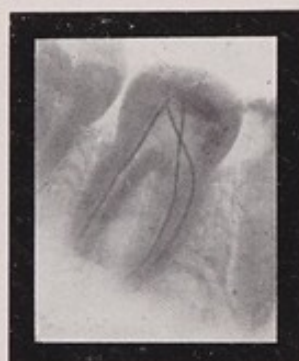

Fig. 172

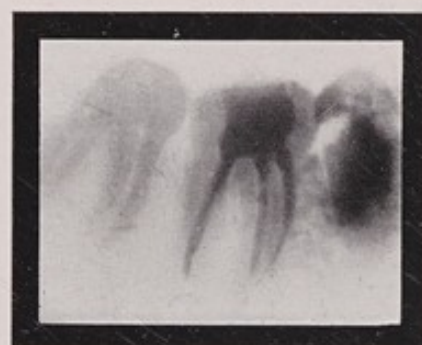


Fig. 173

Fig. 171. At the end of the first sitting after removal of the pulp from the lower first molar. The dark streaks are wires passing into the canals as far as they (the canals) are enlarged—almost to the apex in the distal and about one-half the distance to the apex in the two mesial. The dark shadow in the crown of the tooth is gutta-percha, used to stop up the cavity and hold the wires.

Fig. 172. The same case as Fig. 171 after several sittings. The wires now pass well to the apex in all canals.

Fig. 173. The same case as Figs. 171 and 172. This radiograph shows the tooth after filling.

What will happen if the canal filling either fails to reach the apex or passes a little beyond it? An abscess may result. If the canal filling fails to reach the apical foramen, in such cases as the one just described, an abscess is sure to occur. If perfectly aseptic gutta-percha is used as a canal filling, and the tissues above the apex are not infected, then the passage of a little gutta-percha into the apical tissues will probably not result in suppuration or even inflammation, so well do tissues tolerate gutta-percha. But the fact remains: *The ideal canal filling is one which fills the canals, neither falling short of the end of the root nor passing beyond it.*

12. To Learn if Canals Are Open and Enlarged to the Apex Before Filling, and to Observe the Canal Filling After the Operation.

Fig. 171.

Shows a lower first molar at the end of the first sitting, after the extirpation of the pulp. The wire (the dark streak) in the distal canal reaches almost

to the apex of the root. The two wires in the mesial canals penetrate only about one-half the distance to the apex. These wires pass into the canals as far as they (the canals) are enlarged. Wires are placed in the canals to learn to what depth the latter are enlarged, because the wire shows so much better in the radiograph than the open canal. In fact, the wire can be seen very clearly as a dark streak when the canal itself as a light streak cannot be radiographed at all.

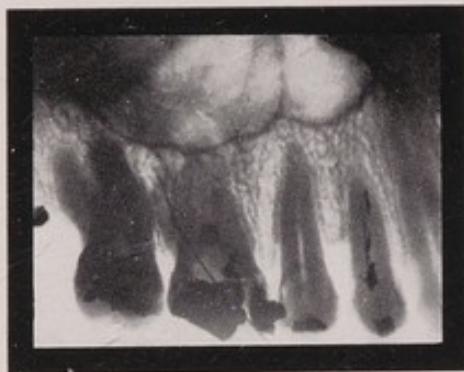

Fig. 174. Wire passing to the distal through a perforation in the upper first molar. (Radiograph by Blum of New York City.)

Sufficient enlargement of the canals required several sittings. The technic for enlarging the canals consisted of pumping sulphuric acid into them, neutralizing it, then reaming them out with thumb, spiral broaches. Sulphuric acid was sealed in the mesial canals at the end of the first and second sittings. Fig. 172 shows the wires well to the apex in all three canals.

Fig. 172.

This radiograph shows the tooth after filling. Even after the canals are enlarged we sometimes fail to reach the apex with the gutta-percha filling. For this reason it has become my custom lately to fill only a part of the canal, then make a radiograph to see that the filling reaches the apex before finishing the operation. Dr. M. L. Rhein, of New York City, was, as far as I am able to learn, the first man to make a practice of using the radiograph as a regular routine in canal work.

Fig. 173.

The advantages in using the radiograph in this connection are as follows: All guesswork is eliminated—we know exactly what we are doing. If the canal is tortuous, and we start through the side of the root, the radiograph shows us the mistake, keeps us from making a perforation, and, in many cases, enables us to follow the canal to the true apex. If the root is unusually short the radiograph keeps us from going through

the apex, and if it is unusually long it keeps us from making the error of not penetrating the canal far enough. The radiograph shows patients just what is being done for them.

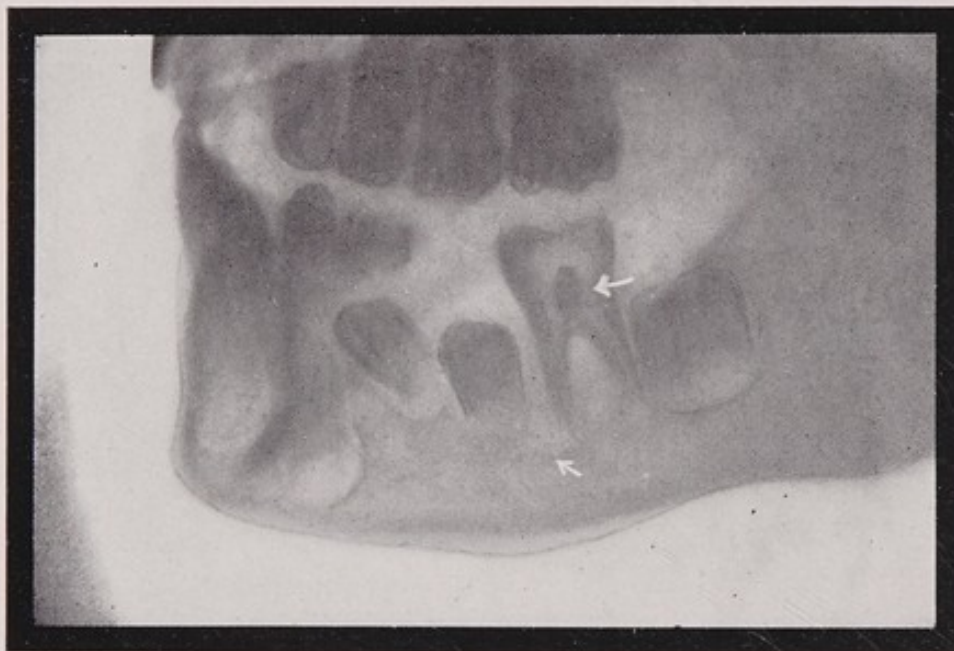

Fig. 175. The upper arrow points to a pulp nodule in the lower first molar. (Radiograph by Pfahler of Philadelphia.)

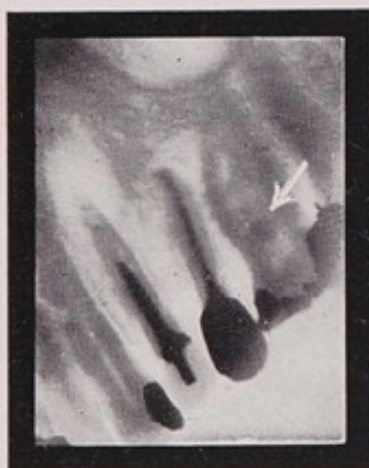

Fig. 176

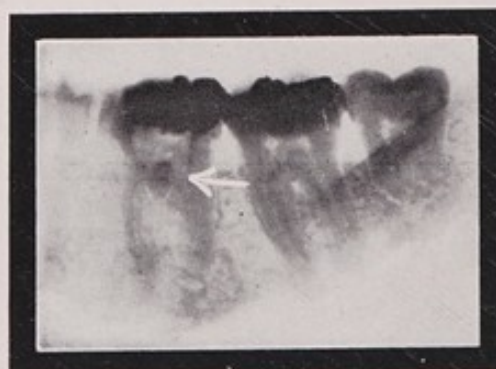


Fig. 177

Fig. 176. The arrow points to a pulp nodule. (Radiograph by Cummings of Boston.)

Fig. 177. Pulp nodule in the lower first molar. (Radiograph by Lewis of Chicago.)

When a canal filling fails to reach the apex of a root by about a millimeter, this does not always mean that the canal has not been properly enlarged and filled. For, remember, the pulp does not enter the root through one large foramen, but usually through several minute openings.

So, often, the extreme apex of the root is almost solid dentin and cementum.

Having observed quite a large number of radiographs in the last few years, allow me to state that many, altogether too many in our profession, fail to enlarge and fill to their apices all canals which really could, and should, be so treated. There are, perhaps, some cases where the buccal canals of upper molars and the mesial canals of lower molars simply cannot be enlarged to their apices. But this fact is no excuse for enlarging and filling only the upper third of such canals. (Fig. 165, lower first molar.) The stock excuse for poor canal work is "our patients will not pay a fee sufficiently large to enable us to give the necessary time to the work." But do those who thus excuse themselves really give their patients any choice in the matter? If one should show a patient a radiograph demonstrating the fact that he had only penetrated the canals about one-third their length, then explain why he should go farther, and why it would take time to do so, would the patient say, "Oh! let 'er go," or would he or she say, "I want done whatever is best?"

It is extremely difficult to radiograph the buccal roots of upper molars.

13. To Determine Whether an Opening Leading from a Pulp Chamber Be a Canal or a Perforation.

When one opens the tooth himself, and does not use a small, round bur on the floor of the pulp chamber, he may feel certain that any opening found must be a canal. But in cases where the pulp chamber has been opened by another operator, it is often impossible to decide whether an opening leading from the pulp chamber be the mouth of a canal or a perforation through the tooth. Likewise in cases where decay has attacked the walls and floors of the pulp chamber, almost destroying them, it is sometimes difficult to differentiate between a canal and a perforation. Pass a wire through the opening and make a radiograph.

Fig. 174.

A wire passing to the distal through a perforation in the upper first molar.

14. In Cases of Pulp Stones (Nodules).

There has been a great deal of dispute as to whether or not pulp nodules can be shown radiographically. The right answer is in the affirmative.

Fig. 175.

The upper arrow points to a large pulp nodule in the lower first molar. Age of patient, eight.

Fig. 176.

A case in the practice of Dr. Chas. E. Patten. The patient, female, age forty, suffered from intermittent attacks of severe pain in the region of the

upper bicuspid and first molar. A radiograph was made (Fig. 176) and shows a shadow in the pulp chamber of the first molar. The molar was devitalized and a pulp nodule, located at the mouth of the lingual canal, removed. The canals were then enlarged and filled. Result: Complete cessation of recurrent pain.

A case in the practice of Dr. H. H. Schuhmann, of Chicago. I quote Dr. Schuhmann: "Mr. K. suffered from severe pains under left side and at angle of jaw. Pains intermittent and intense at night. No reaction to per-

Fig. 177.

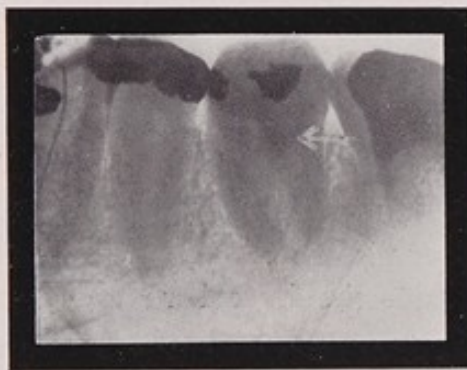

Fig. 178



Fig. 179

Fig. 178. The arrow points to what might be mistaken for a pulp nodule. The shadow is, however, an amalgam filling on the buccal at the cervical.

Fig. 179. Simple occlusal filling in the molar, encroaching on the pulp.

cussion or application of heat or cold. Radiograph showed what I took to be a pulp stone, and, upon opening the tooth and applying arsenic three times the stone was removed. Patient now has no neuralgic pains whatever."

In this radiograph the arrow points to a shadow which might be mistaken for a pulp nodule. The shadow is, however, not a pulp stone, it is a small amalgam filling on the buccal surface at the cervical margin.

Fig. 178.

The radiographs which I have printed demonstrate that the pulp nodules can be radiographed. I may add that personally I have radiographed a number of cases successfully. But, let me confess, I have not as yet produced as clear a picture as the ones shown in Figs. 175, 176 and 177.

15. In Cases of Secondary Dentin Being Deposited and Pinching the Pulp.

This use was recently suggested in a dental magazine by Dr. Cryer. Such a condition as the one referred to might exist and be responsible for neuralgia or other nerve disorders. Likewise it could probably be ob-

served radiographically. At the present time, however, I am unable to show a radiograph of such a case.

16. To Learn if the Filling in the Crown of a Tooth Encroaches on the Pulp.

Case: Neuralgic pains in the lower left side of face. Thought to be due to a necrotic condition of the bone in the region of the lower first molar, which had recently been extracted. A radiograph (Fig. 179) shows the bone healthy. The simple occlusal filling in the second molar penetrates into the pulp chamber. This filling was removed, and the semi-vital pulp devitalized, removed, and the canals filled. The result was an immediate and complete recovery.

Fig. 179.

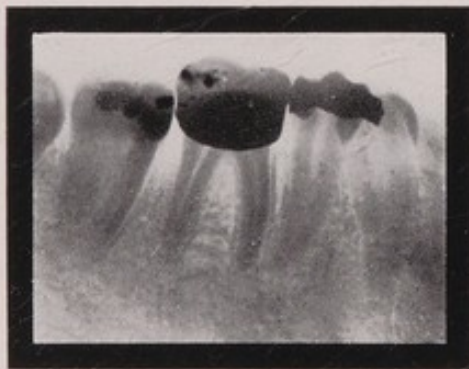


Fig. 180

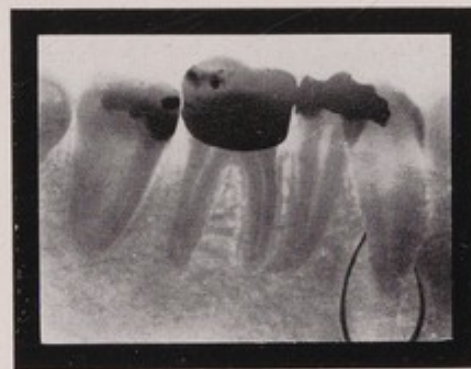


Fig. 181

Fig. 180. The first bicuspid seems to hold a disto-occlusal filling. This appearance is due to a slight irregularity—a slight lapping of the teeth. The filling which appears to be in the distal of the first bicuspid is in the mesial of the second bicuspid. The simple occlusal filling in the first bicuspid encroaches into the pulp chamber slightly.

Fig. 181. The same as Fig. 180 with the diseased area at the apex of the first bicuspid outlined, to enable the reader to see it better in Fig. 180.

17. In Cases of Teeth with Large Metal Fillings or Shell Crowns Which Do Not Respond to the Cold Test, to Learn if the Canals Are Filled.

Case: Slight swelling and pain in the lower bicuspid and first molar region. The patient stated that this condition had occurred and recurred many times in the past five years. At no time had the swelling been great, and the pain was never severe. The slight swelling and an annoying pain would last for a few days, then disappear for a month or so. There was no discharging sinus. The first molar bore a gold shell crown, the second bicuspid held a large mesio-occluso-distal amalgam filling, and the first bicuspid had a small filling of amalgam in the occlusal surface. The three teeth—the first molar and the two bicuspid—were isolated one at a

Figs. 180 and 181.

time and tested with cold water. The patient was uncertain as to whether he received any sensation when the cold was applied to the shell-crowned molar, but thought that he did. The second bicuspid responded well, and the first bicuspid did not respond at all. This seemed to indicate a vital pulp in the molar and second bicuspid, and a devitalized one in the first bicuspid. But, when looking for a dead pulp, one would naturally suspect either the molar with the shell crown, or the second bicuspid with the large filling, instead of the first bicuspid with the small occlusal filling.

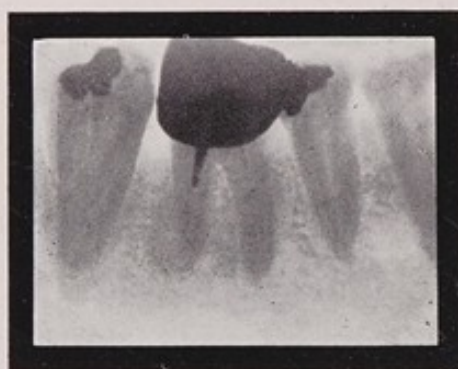


Fig. 182. The roots of the shell crowned first molar are not properly filled. Only the upper third of the distal canal is filled and the mesial canals are not filled at all. The tooth was sore and caused annoying neuralgic pains.

The temperature test is a valuable one, but it cannot be depended upon absolutely. A radiograph (Fig. 180) was made. It shows the canals of the molar and second bicuspid unfilled. The tissues at the apices of the roots of these teeth are healthy, which, together with the positive reaction to the cold tests indicates that their pulps are vital and healthy. The simple occlusal filling in the first bicuspid enters the pulp chamber slightly, the canals of the tooth are unfilled, and the light area at the apex of the root indicates disease (inflammation) of the bone in that region. These things, together with the fact that the tooth did not react to the cold test, indicate a putrescent pulp in the first bicuspid. The tooth was opened, and the diagnosis confirmed.

In practice, case after case presents, the patient complaining of a slight soreness or annoying pain in the region of a shell-crowned tooth, or a tooth with a large metal filling in it. The tooth fails to respond to the cold test, and we suspect that the canals are poorly filled, or perhaps not filled at all. Are we justified in removing the crown or filling to examine the canals? Before the radiograph came into use we were, but not to-day. It is not fair to your patient nor yourself to remove a canal filling unless you can improve on the operation. Fig. 182 is a radiograph of a case of the

Fig. 182.

class just alluded to. After the radiograph was made I had no hesitancy in telling the patient that the crown should be removed and the canals refilled. There were only about four millimeters of canal filling near the mouth of the distal canal, and none at all in the mesial canals. Before the radiograph was made I was unable to decide whether the soreness and neuralgia were caused by food packing down between the first and second molar (the contact point is bad) or improper or no canal filling.

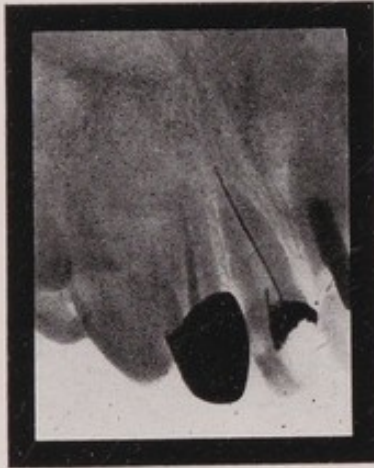

Fig. 183

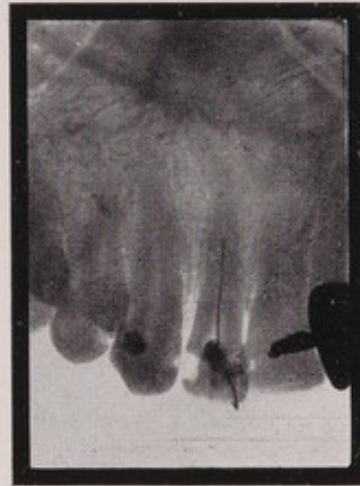

Fig. 184

Fig. 183. Wire just penetrating the apical foramen. Showing that the apical sensitiveness is not due to an unremoved, undeitalized remnant of pulpal tissue.

Fig. 184. The wire in the canal of the lateral fails to reach the apex, proving that the apical sensitiveness is due to an unremoved, undeitalized remnant of pulpal tissue.

18. To Learn if Apical Sensitiveness Is Due to a Large Apical Foramen or an Unremoved, Undeitalized Remnant of Pulp.

In the treatment of teeth we often pass the broach into the canal until we reach what we know must be the neighborhood of the apex, when pain is produced. It is often difficult to decide whether this pain is due to some remaining vital pulp tissue in the canal, or the penetration of the broach through the apex. Fig. 183 is from such a case. The wire passing to the point of sensitiveness goes through the apical foramen, and so proves that the sensitiveness is not due to unremoved, undeitalized pulp tissue. In Fig. 184 the wire reaching the point of sensitiveness fails to reach the apex, proving that the sensitiveness is caused by an unremoved, undeitalized remnant of pulp.

Let us stop to consider how this question of whether or not we are penetrating the apex is decided when radiographs are not used. We pump phenol or some other obtundent into the canal, working our broach farther

and farther until we strike the end of the canal ending in a blind alley, or go so far into the apical tissues we know that no tooth root could be as long as the distance we are penetrating. The use of the radiograph saves all this guesswork, obviates the necessity of causing considerable pain and is a time-saver.

19. In Cases of Chronic Pericementitis (Lame Tooth).

A putrescent pulp is the most common cause for pericementitis, either chronic or acute. Therefore, when the affected tooth is crowned or filled, as it almost always is in chronic pericementitis, radiographs should be



Fig. 185



Fig. 186

Fig. 185. Gutta-percha canal filling in the upper lateral passing through the side of the root to the distal. The canal filling also penetrates the apical foramen. The light area to the mesial along the apical third of the root indicates an abscess. The mesial surface of the root is roughened in the region of the abscess. (Radiograph by Lewis of Chicago.)

Fig. 186. Canal filling penetrating the tissues between the roots of the lower first molar. (Radiograph by Kells, Jr. of New Orleans.)

made to learn whether the canals are properly filled, and treatment may be rendered accordingly. Fillings and crowns without contact points, or fillings with bad gingival margins, or crowns which do not fit well at the cervix or penetrate beneath the gum margin into the peridental membrane, are sometimes the causative factors in chronic pericementitis. These things may be detected usually without the aid of the radiograph. Often, however, a radiograph will demonstrate the fault in a very convincing manner. Look at Fig. 182, for example. Observe between the first and second molar the absence of a contact point, the bulging of the crown band into the interproximal space, and the slight caries of the alveolar process.*

*The illustration does not show the carious process, which, however, is readily diagnosed in the original film.

Figs. 185 and 186. Figs. 185 and 186 demonstrate lesions that might be responsible for chronic pericementitis, which could not be detected by any means other than the use of the radiograph.

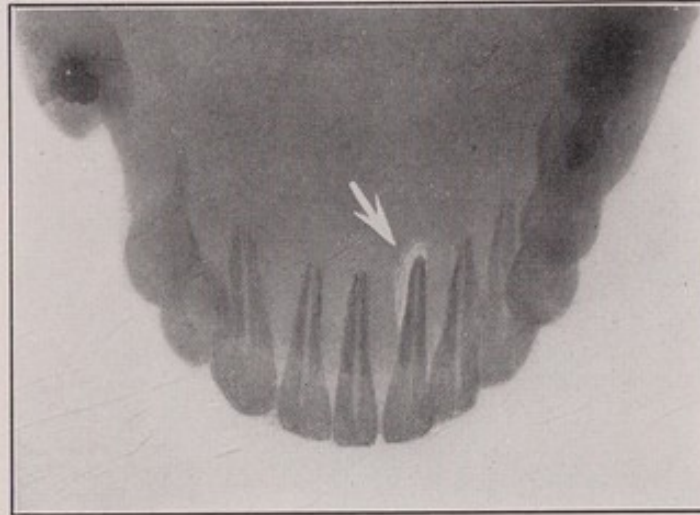


Fig. 187. The arrow points to a small abscess cavity (the light area) at the apex of a lower central incisor. None of the lower anterior teeth had cavities in them.

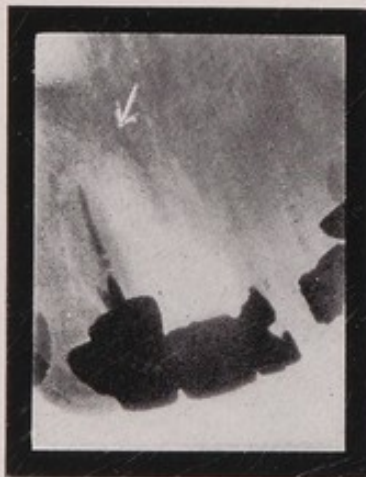

Fig. 188



Fig. 189

Fig. 188. An abscess at the apex of an upper lateral incisor. This abscess pointed directly over the dummy central incisor, which is swung in on a post collar crown on the lateral and an inlay in the central incisor. The central does not show clearly,—but clearly enough to show that there is no abscess cavity at its apex.

Fig. 189. The same as Fig. 188 two weeks after curettage of the pus sinus. There is some deposition of new bone.

20. In Cases of Alveolar Abscess to Determine Which Tooth is Responsible for the Abscess.

Fig. 187.

Case: A pus sinus opening on the labial between the lower central incisors near their apices. All of the lower anterior teeth sound and apparently

healthy. Fig. 187 shows which tooth is responsible for the abscess. This tooth was treated and the abscess cured. The light area to which the arrow points, about the apex of the central, represents the abscess cavity. Acute abscesses cannot always be shown in radiographs, because there may not be sufficient destruction of bony tissue. Chronic abscesses, which have become acute, can, of course, be shown radiographically.

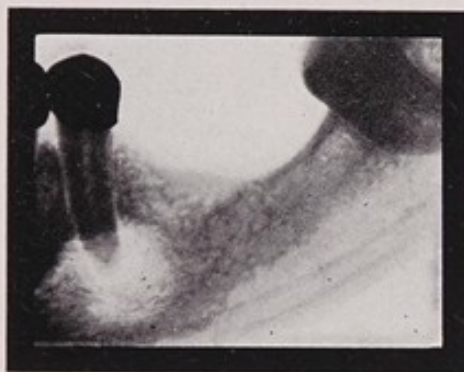


Fig. 190. Abscess at apex of lower second bicuspid. The tooth carries a gold shell crown. Canal is not filled. The inferior dental canal can be seen plainly in this radiograph—light streak between two dark lines along the lower border of the mandible.

Figs. 188 and 189. Case: A bridge from an upper lateral incisor, with a post collar crown to a central with an inlay abutment, restoring a lost central incisor: a sinus pointing directly above the dummy central. The lateral had been treated for an abscess two years previously. The abscess had yielded to the treatment, the canals were filled, and the bridge set. At the time when the inlay was placed in the central it was vital. A radiograph (Fig. 188) was made to determine whether the existing sinus was due to a recurrence of the abscess of the lateral or death of the pulp and abscess of the central. The radiograph shows that the lateral is responsible. As the canal is fairly well filled (it falls short of the apex by only a fraction of a millimeter), it was deemed unnecessary to remove the crown. An incision was made on the labial and the sinus thoroughly curetted, cauterized and filled with bismuth subnitrate paste. The extreme apex of the tooth was curetted away. Fig. 189 is of the same case two weeks after the operation, at which time there were no symptoms of the disease. There is some deposit of new bone—about as much as might be expected in two weeks.

Fig. 190. Case: The lower first and second molars absent. A fistula opening directly mesial to the third molar. The third molar free of carious cavities. I suspected a piece of unremoved root of the missing second molar to be responsible for the suppuration. A radiograph (Fig. 190) was made. It demon-

strates the absence of any piece of tooth root, and shows a large abscess at the apex of the shell-crowned second bicuspid. The bicuspid was opened and an antiseptic solution forced through the tooth and out through the fistulous opening in front of the third molar.

The radiograph does not show the fistulous tract leading from the bicuspid backward toward the third molar. The probable reason for this is that the tract passes along between the bone and periosteum. Therefore, there is very little destruction of bony tissue throughout its course.

Recently the following case presented: Fistulous opening on the labial over the apex of a perfectly sound upper cuspid. The first bicuspid apparently healthy save for a small, faulty, amalgam filling. The proximating lateral shell crowned. I suspected the crowned lateral to be the seat of the trouble. A radiograph was made, and showed, to my surprise, that the lateral was perfectly healthy and its canal well filled. A radiograph of the first bicuspid was made and showed an abscess and unfilled canals. I do not print radiographs of this case, because one of them, the one showing the abscess, has been mislaid. I record the case because it is one the like of which a person may run across any day in practice.

21. In Cases of Alveolar Abscess to Determine the Extent of the Destruction of Tissue—Bony and Tooth

Fig. 191. Case: Shell-crowned, lower first molar. Chronic abscess of several years' standing. The crown was removed, and the tooth treated. The flow of pus stopped. The canals were filled and the crown reset. In about a month there was a recurrence of pus production. A radiograph (Fig. 191) was made, and shows both roots, especially the mesial, badly absorbed. The canal fillings penetrate into the area of diseased bone. Considering the clinical appearance and history of the case, and the great amount of tooth structure destroyed, apicoectomy was not indicated. I therefore advised extraction. A most peculiar fact in this case is the great destruction of tooth structure, and the comparatively slight destruction of the alveolar bone; the reverse of what is usually found. Not only is there little destruction of bone, but bony tissue seems actually to have filled in the space formerly occupied by the tooth roots.

Fig. 192. One of the most perfectly circumscribed alveolar abscesses I have ever seen. The abscess occurs at the apices of the roots of the upper first bicuspid. Notice how the two roots extend into the abscess cavity. The very light shade of bone to the distal of the bicuspid is diseased, somewhat carious, but will regain normal vitality in all probability when thorough drainage

of the abscess is obtained. A case like this should yield to treatment without extraction. Perhaps apicoectomy would be necessary.

A very large abscess involving the upper central and lateral incisors of one side. I am unable to learn what treatment was given in this case. Basing my judgment on the appearance of the radiograph, without any clinical knowl-

Fig. 193.

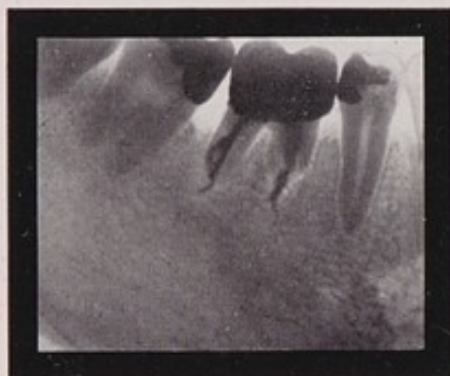


Fig. 191

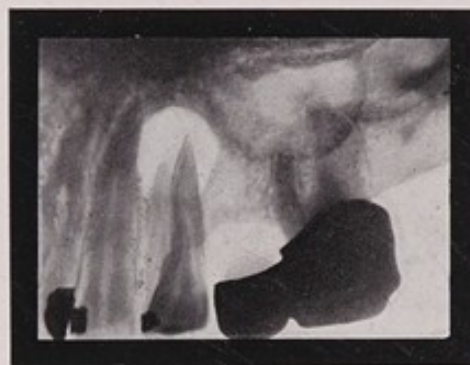

Fig. 192

Fig. 191. Both roots of the shell-crowned, lower, first molar badly absorbed, especially the mesial. Canal fillings extend beyond the ends of the roots.

Fig. 192. An almost perfectly circumscribed abscess about the roots of an upper first bicuspid. Note how the roots extend into the abscess cavity. (Radiograph by Blum, of New York City.)

edge of the case, I would say that the lateral should be extracted, and the opening so made into the abscess cavity enlarged to the distal to such an extent as to permit a thorough curettement of the suppurating sinus. (This would necessitate removal of the bridge from first bicuspid to cuspid.) Or, perhaps an opening sufficiently large to permit thorough curettement and drainage could be made through the external alveolar plate and the lateral conserved. At any rate, knowing that the opening into a pus sinus to drain and curette it thoroughly must vary directly according to the size of the sinus, we can see that, in this case, the opening must be quite large. Such an abscess could not be drained sufficiently well through pulp canals.

Fig. 194.

Fig. 194. shows how utterly futile it would be to attempt to treat, and retain in the mouth, such a tooth as is shown in the radiograph. Such a condition could not have been diagnosed by means other than the use of the X-rays. The small, dark streak through the tooth is a wire. Note the great destruction of the tooth root and the carious condition of the surrounding bone.

Fig. 195.

Case: Sinus opening near the apex of an upper central incisor. The tooth did not yield to treatment. It was treated on the assumption that there was con-

siderable destruction of bone, and powerful stimulating corrosives, like phenolsulphonic acid, were forced beyond the apex. That such treatment was improper is demonstrated by the radiograph (Fig. 195), which shows that there is very little bone destruction. Accordingly the more radical line of treatment was dropped, the sinus injected with bismuth subnitrate paste, a mild antiseptic sealed in the canal, and the tooth allowed to rest unmolested for ten days, at the end of which time all pathological symptoms had disappeared.

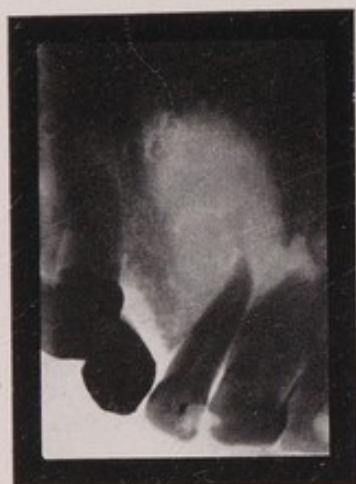

Fig. 193



Fig. 194

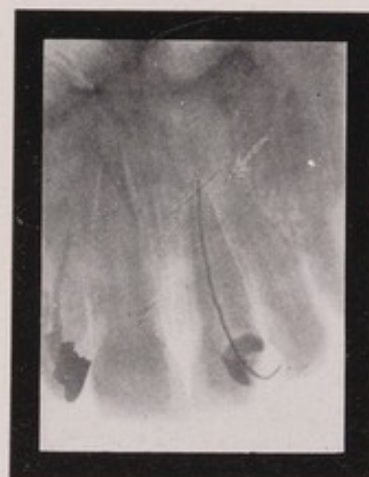

Fig. 195

Fig. 193. Very large abscess involving the lateral and central, and extending almost to the apex of the first bicuspid. (Radiograph by Peabody, of South Orange, N. J.)

Fig. 194. Absorption of the root and surrounding bony tissue. A wire is seen passing into the canal. (Radiograph by Blum, of New York City.)

Fig. 195. A very small abscess cavity at the apex of the central with the wire in it.

22. In Cases of Alveolar Abscess to Learn How Many Teeth are Involved.

Fig. 196.

I recall having treated an abscessed central incisor for a month without effecting a cure, or even much improvement. The apical foramen was well opened, and antiseptic and stimulant washes could easily be forced through the tooth and out through the fistulous opening on the gum, assuring me that I had good drainage. The lateral at the side of the central did not respond to the cold test, but neither did any other tooth in the patient's mouth. Despite the fact that it was a sound tooth, I opened into the lateral, removed the pulp, which, while devitalized, was not badly putrescent, enlarged the apical foramen, and found that washes forced into the lateral came out both the fistula and central. While the case is not the same, the conditions which I then combated in the dark (I did not use the X-rays in my practice at this time), are shown in Fig. 196. An abscess, involving both central and lateral, is shown by the light area

about and above their apices. In this case the canal of the central is only partially filled, and the lateral canal not filled at all.

An abscess pointing in the palate. A radiograph (Fig. 197) was made to determine which tooth was responsible. The central, lateral, cuspid and first bicuspid were suspected. The radiograph shows that all of these teeth

Fig. 197.

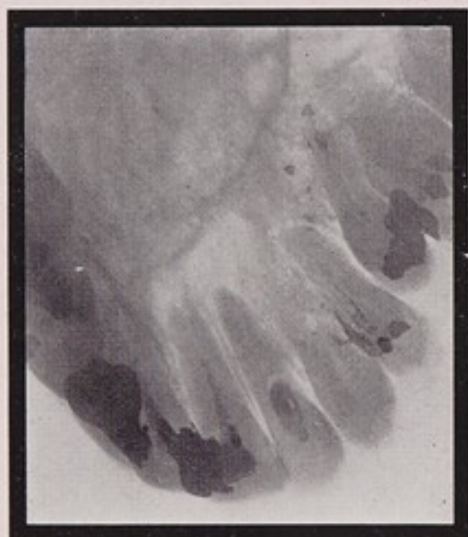

Fig. 196

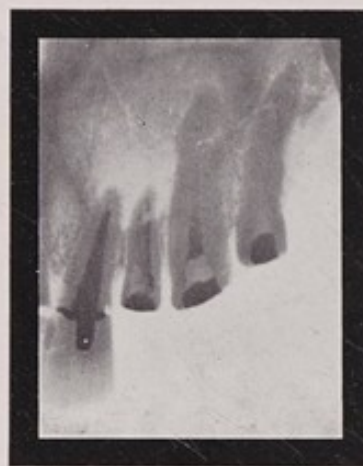

Fig. 197

Fig. 196. Abscess involving the central and lateral incisors. The canal of the central is partially filled. (Radiograph by Lewis, of Chicago.)

Fig. 197. A large abscess involving the central, lateral and cuspid.

except the first bicuspid—*i.e.*, the central, lateral and cuspid—are involved. The abscess was treated through all three teeth, but did not yield to this treatment. It was deemed necessary to curette the sinus. An opening through which the sinus could be curetted was made by extracting the lateral root. Perhaps there are those who will condemn my surgery, saying the tooth should have been conserved and the opening made into the sinus through the external alveolar plate. My reason for extracting the tooth root is that I was quite uncertain as to the exact labial palatal location of the sinus—recollect the abscess pointed on the palate.

23. In Cases of Abscess of Multirooted Teeth, to Learn at the Apex of Which Root the Abscess Exists.

This radiograph shows an abscess at the apex of the mesial root of a shell-crowned, lower first molar. The canals of the tooth are not filled. Without this picture to guide us a great deal of time and energy might be wasted in opening and enlarging the apical foramen of the distal canal, which is worse than unnecessary. Knowing that the abscess is at the

Fig. 198.

apex of the mesial root, we should try to obtain drainage by opening one or both of its apical foramina. This is not always possible, despite loud and angry protestations to the contrary. If, after earnest, conscientious, and prolonged effort the mesial foramina cannot be enlarged, obtain drainage by opening through the buccal alveolar plate, directing the bur towards the mesial root.

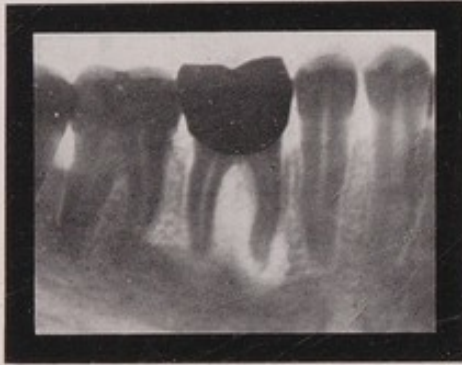


Fig. 198



Fig. 199

Fig. 198. Abscess at the apex of the mesial root of the shell-crowned, lower, first molar. The canals of the tooth are not filled. (Radiograph by Blum, of New York City.)

Fig. 199. Large abscess involving both roots of the lower first molar and probably both roots of the second molar. The distal canal of the first molar is partially filled. (Radiograph by Ream, of Chicago.)

Fig. 199. A large abscess involving both roots of the lower first molar and probably both roots of the second molar. Without a history of the case to guide me, I should say, judging from the appearance of the radiograph, that both the first and second molar need treatment. The apical foramina of the first molar should be opened, and good drainage through the alveolar plate established also. Enlargement of the apical foramina of the second molar would probably be unnecessary.

24. In Cases of Abscess of Crowned Teeth to Learn if the Canals are Properly Filled.

It is a common occurrence in practice to have a patient present with a pus sinus, discharging in the region of the apex of a tooth carrying a crown. If the canals of the tooth are properly filled, we should treat the sinus through the external alveolar plate; if the canals are not properly filled, then the crown should be removed and the case treated through the tooth—perhaps through the external alveolar plate also, depending on the extent of the destruction of tissue. Whether or not the crown should be removed is determined by the use of the radiograph.

See Fig. 188. This radiograph shows that it is quite unnecessary to remove the post-collar crown (an abutment of a bridge) from the abscessed lateral, for the canal is well filled. As formerly recorded, the

treatment of this case was chiefly surgical, through the external alveolar plate, and was effective.

In the third edition of his *Modern Dental Materia Medica, Pharmacology and Therapeutics*, Dr. Buckley prints Fig. 200, and the following description: Fig. 200 "shows the involvement of the upper central and lateral

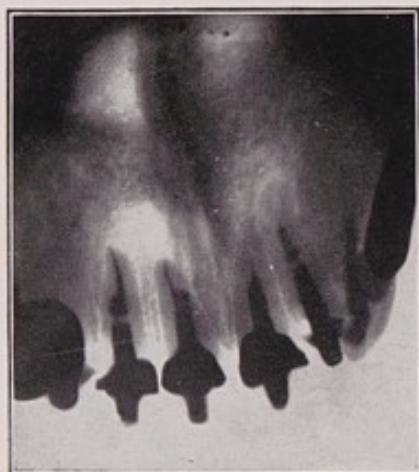

Fig. 200

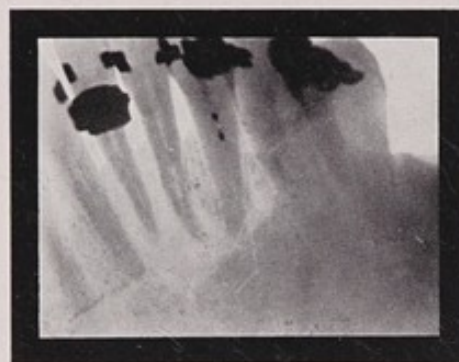

Fig. 201

Fig. 200. Abscess involving the upper central and lateral incisors. There was but one fistulous opening on the labial. Since the canals of central and lateral are both properly filled the treatment should consist simply of curettement of the affected area, which, of course, does not necessitate the removal of the post-porcelain crowns from the teeth. (Radiograph by Ream, of Chicago.)

Fig. 201. Dr. Rhein says of Fig. 201: "This is a typical case of chronic alveolar abscess, which for years had been erroneously treated for pyorrhea."

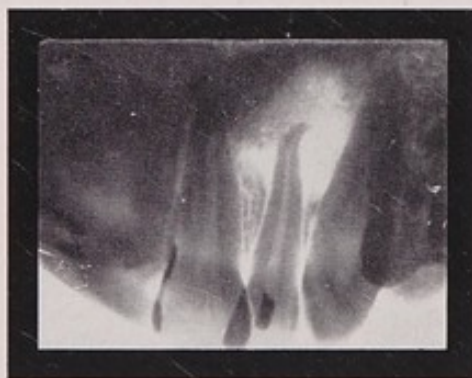

Fig. 202. Alveolar abscess wrongly diagnosed as pyorrhea. (Radiograph by Rhein, of New York.)

incisors in an abscess. Both teeth carried perfectly adjusted porcelain crowns. The skiagraph not only shows the involvement of both teeth, but also that the roots are properly filled. The treatment here is purely surgical, and means the curettement of the affected area." Had the radiograph not been used the operator would, in all probability, have made the laborious and foolish mistake of removing the crowns on the assumption that the canals were not properly filled.

25. As an Aid in Differential Diagnosis Between Chronic Alveolar Abscess and Pyorrhea Alveolaris.

When a chronic alveolar abscess discharges about the neck of a tooth the case so closely simulates calcic pyorrhea alveolaris that, without using the radiograph or opening into the affected tooth, the operator cannot make a definite diagnosis.

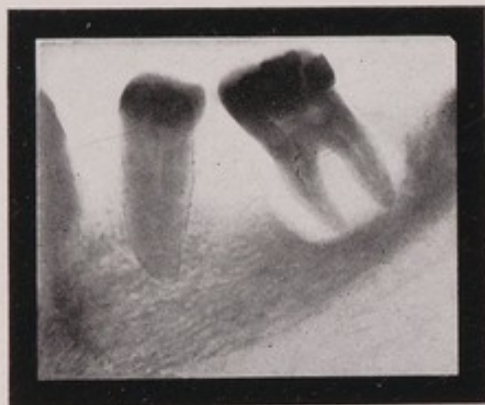

Fig. 203.

Fig. 203. Absorption of the bone around the molar due to pyorrhea alveolaris. The tooth has no bony attachment at all. (Radiograph by Ream, of Chicago.)

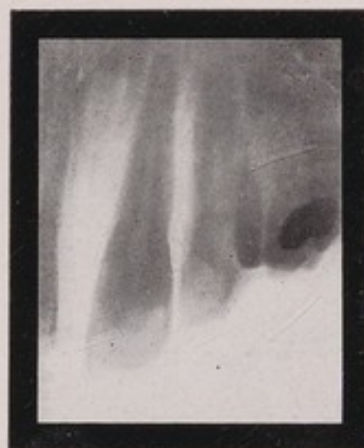

Fig. 204

Fig. 204. Absorption of the bony tissue due to pyorrhea alveolaris. The distortion (elongation) enables us to observe clearly little spiculae of diseased bone. The central has no bony attachment, except at the extreme apex.

This is a case from the practice of Dr. M. L. Rhein, of New York City. Dr. Rhein says: "This is a typical example of a chronic alveolar abscess, which for years had been erroneously treated for pyorrhea."

Fig. 201.

Fig. 202.

Fig. 202 represents another case from the practice of Dr. Rhein, which had been wrongly diagnosticated as pyorrhea. The lateral incisor was supposed to be affected by pyorrhea, but after making a radiograph, Fig. 202, it was seen that the real trouble was an apical abscess, the infection arising from the death of the pulp.

26. To Observe Destruction of Tissue Due to Pyorrhea Alveolaris.

Fig. 203.

Other factors being equal, our chances of curing pyorrhea alveolaris vary inversely according to the amount of destruction of alveolar process surrounding the affected teeth. Fig. 203 demonstrates the futility of treating and attempting to conserve the molar tooth. All of the bone immediately surrounding the tooth is destroyed.

A central incisor affected with pyorrhea. The tooth has no bony attachment except at its extreme apex. Extraction is indicated. The distortion—the elongation—in this picture enables us to observe the diseased bone to the

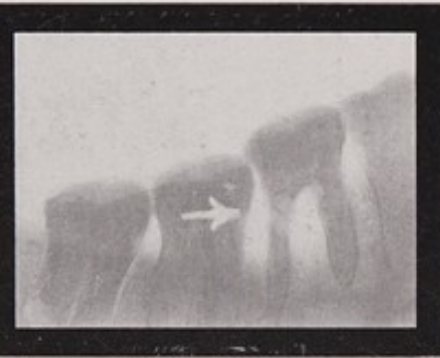

Fig. 205

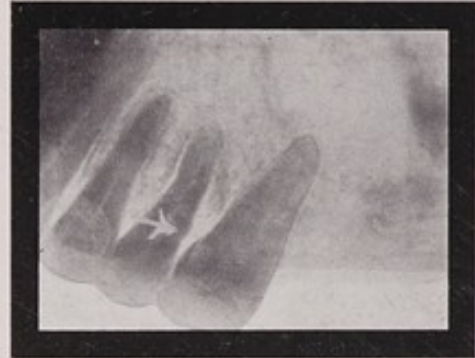

Fig. 206

Fig. 205. The distal root of the first molar has practically no bony attachment and is badly roughened. It was extracted. The arrow points to an absorbed notch in the distal root.

Fig. 206. The arrow points to bit of calculus on the distal of a second bicuspid. The light area above the calculus denotes the destruction of bone and represents a pyorrhea pocket.

left of the central unusually well. In the negative now before me I can see clearly the soft tissue between the centrals. Looking to the mesial and distal, I can distinguish also the enamel of the central. The lingual enamel in the incisal region has been worn away; hence the lighter shadow of the tooth in this region.

A lower first molar affected with pyorrhea. The distal root appears roughened, due to a necrotic condition of its surface and the presence of calculus on it. It has no attachment to bone except at its extreme apex. The alveolar process to the mesial of the mesial root is comparatively healthy. The tissues to the distal of the mesial root are not as healthy as those to the mesial, but not so badly diseased that they cannot regain a healthy vitality. The treatment of this case should be begun with extraction of the distal root. This was done, and the mesial root successfully conserved.

A pyorrhea pocket on the distal of an upper second bicuspid. There is but slight destruction of bone. The most remarkable thing about this picture is that it shows a bit of calculus on the distal of the second bicuspid.

27. In Cases of Pericemental Abscess.

"Pericemental abscesses have been described by numerous writers, one of the best papers on the subject being that by Dr. E. C. Kirk, published in the *Dental Cosmos* for November, 1900. There are various views as to the etiology of this condition, but the main point of interest lies in the fact that pericemental abscess occurs on the root of a tooth in which the

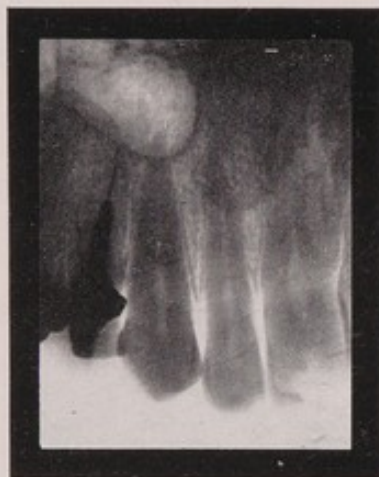

Fig. 207

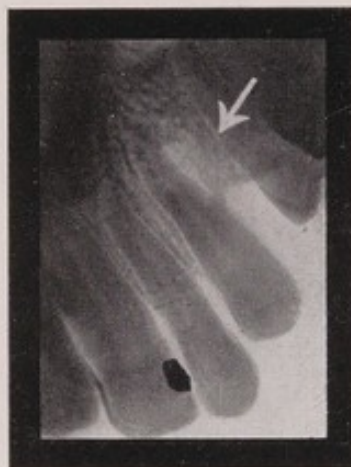

Fig. 208

Fig. 207. Pericemental abscess at apex of upper cuspid. The crowned first bicuspid was suspected, but the radiograph shows an abscess at apex of the cuspid, which was sound and alive.

Fig. 208. The light area to which the arrow points is a pericemental abscess.

pulp is still alive, a fact which renders a true diagnosis sometimes quite complex. For example, a patient might present with a well defined fistula appearing between the roots of two teeth, one of which may be perfectly sound, whereas the other might be just as certainly pulpless. It would be quite reasonable for the operator to conclude that an abscess originated from infection coming from the root of the pulpless tooth, and to treat such a tooth, it might be necessary to remove important and well constructed work, such as an inlay or a bridge abutment. A radiograph, however, will disclose that the abscess involves the pericementum of the living tooth, and thus the dentist would be saved the mortification of unnecessarily destroying the inlay or abutment attached to the pulpless tooth, and the patient would be saved the annoyance and expense involved in such a misconstruction of symptoms.

“From the practice of Dr. M. L. Rhein is a case of this character. The bicuspid is crowned and might have been suspected as the cause of the abscess, especially as in the radiograph only one root canal filling is seen, but the history of the case made this impossible. The tooth was treated

Fig. 207.

twelve years ago for an abscess, and both canals were perfectly filled, as can be seen in other radiographs of the case in the possession of Dr. Rhein, these radiographs being taken at a slightly different angle. The tooth having remained perfectly comfortable during all of these years, the well defined abscess disclosed at the apex of the cuspid tooth was diagnosed as a pericemental abscess. The tooth in question was absolutely sound, having no filling or cavity of any kind, and when opened the pulp was found to be alive. Also there was no taint of pyorrhea in this mouth. This diagnosis was confirmed by the fact that the removal of the pulp from the cuspid and subsequent treatment through the canal effected a perfect cure.*"

Fig. 208. Case: A sinus discharging near the apex of an upper cuspid. The cuspid had no carious cavity in its crown, and responded to the cold test. A radiograph (Fig. 208) was made and shows a pericemental abscess on the distal side near the apex of the cuspid, but not involving the apex, and hence was not involving the pulp.

It would have been a mistake to remove the pulp from the cuspid because it was not involved. An incision was made through the external alveolar plate, the pus sinus was thoroughly curetted and then filled with bismuth paste. The result was a prompt and complete cure.

Buckley, in his last edition of his *Modern Dental Materia Medica, Pharmacology and Therapeutics*, prints a radiograph similar to Fig. 208. Before the radiograph was used, in the case reported by Dr. Buckley, the pericemental abscess was diagnosed as an alveolar abscess, due to a dead pulp. The tooth thought to contain a dead pulp was opened, and a vital pulp found. The operators who handled the case experienced a great deal of difficulty in removing the pulp, nitrous oxygen anesthesia being resorted to finally to accomplish it. After removal of the pulp "the tooth (a central incisor) became dark blue in color." In concluding the report of this case, Dr. Buckley says: "The patient in this instance was a lady, and when we recall that the tooth involved was an anterior one, the seriousness of the mistaken diagnosis becomes all the more apparent."

Compared to the occurrence of alveolar abscesses, as caused by infection from dead pulps, pericemental abscesses are rare.

28. In Cases of Persistent Suppuration Which Do Not Yield to the Usual Treatment.

Fig. 209. Case: Girl eighteen years old, had had a lower second molar extracted two months previous to the time when she presented to me for treatment. The socket from which the second molar had been extracted was an open

*By Dr. R. Ottolengui.

suppurating sore. The patient was poor, and, wishing to spare her the expense of having a radiograph made, a diagnosis was made to the best of my ability by other means—by symptoms and instrumental examination. The diagnosis was infection by some particularly virulent pyogenic organisms and a slight caries of the bone. I was unable to locate any unremoved piece of tooth root. The socket was vigorously curetted and cauterized with phenolsulphonic acid, a mouth-wash prescribed, and the patient instructed to return in three days. When next seen there was



Fig. 209

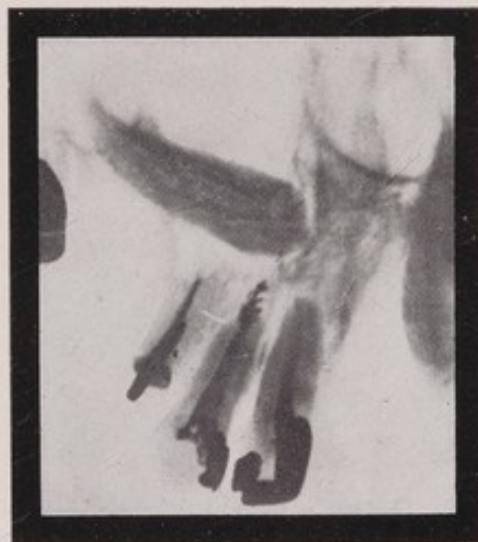

Fig. 210

Fig. 209. An unerupted third molar which caused sufficient irritation to sustain a suppurating wound from where a second molar was extracted.

Fig. 210. A case of persistent suppuration of several years' standing. The radiograph shows the cause—an impacted, malposed upper cuspid. (Radiograph by Lewis, of Chicago.)

but slight improvement in the objective symptoms, and the patient reported that there had been no abatement in pain and soreness. The lesion was washed thoroughly with an antiseptic solution, and the patient instructed to return in three days. When seen again there was no improvement over what had existed before the operation. Wishing to get a more complete and reliable history of the case, I consulted with the patient's physician. He had treated the oral lesion before the case came to me, and was of the opinion that it was tubercular. He suggested the tuberculin treatment. A radiograph (Fig. 209) was made to make sure that there was not a piece of the second molar still in the jaw. As can be seen, there is no piece of tooth root present, but what we do see is an erupting third molar. Perhaps I should have thought of the third molar as a cause for the trouble. But I did not until the radiograph was before me. Believing this tooth, in its effort to erupt, to be responsible for a slight irritation and the consequent suppuration, the soft tissues and the

bone covering it were dissected away. The result was immediate improvement. I regret that I cannot definitely report a complete recovery, but I am sure it occurred. The patient left the city about a week after the last operation, and I have not seen nor heard from her since.

I have already referred to a case of persistent suppuration, reported by Dr. T. W. Brophy, which did not yield to treatment until a radiograph disclosed the presence of a supernumerary tooth, and it was removed. In answer to a letter of mine, asking for a radiograph of the case, Dr. Brophy

Fig. 210.

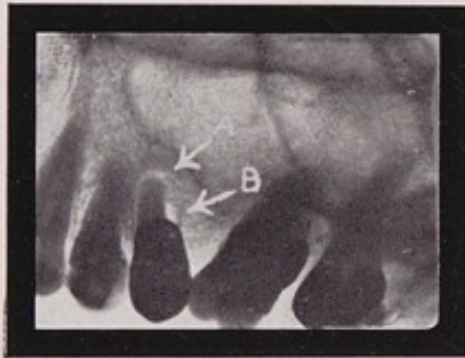


Fig. 211

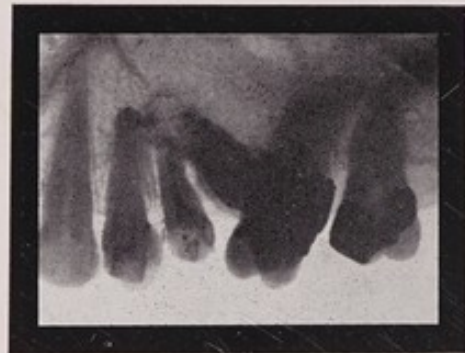

Fig. 212

Fig. 211. Abscess at the apex of the shell-crowned, second bicuspid. It is very difficult to observe either the abscess or the unfilled canal in the bicuspid in the print, though both show clearly in the negative. The arrow A points to the abscess at the apex of the tooth. The arrow B points to an abscess on the side of the root, caused by the ill-fitting shell-crown.

Fig. 212. Same case as Fig. 211. The dark shadow is bismuth paste. It passes from the apex of the upper second bicuspid downward and towards the second molar.

informed me that it could not be found, and enclosed Fig. 210, saying it was a similar case, *i.e.*, a case of persistent suppuration, which did not yield to treatment until the radiograph showed the exciting cause, and it was removed. The history of the case, illustrated in Fig. 210, is about as follows: The upper lateral became abscessed. It was treated, and the canals filled. Pus continued to flow from a fistulous opening on the labial. The abscess was treated through the alveolar plate, but without success. A radiograph was made. I quote Dr. Brophy. "It (the radiograph) exhibits a cavity in the bone, absorption of the apex of the root of the lateral, as well as the apex of the root of the adjacent central tooth. Above is an impacted cuspid lying in a nearly horizontal position. To cure a case of this character calls for most careful study, deliberation and action. The course to pursue is largely dependent upon the condition of the other teeth forming the upper denture. In a young person, the removal of the lateral incisor root, which is crownless and diseased, and the gradual moving downward into its place of the cuspid would be the most desirable procedure. If the patient is in middle life, and the teeth

badly diseased and loose, as the teeth here represented are, I would recommend the removal of the diseased teeth, diseased bone, and impacted tooth. The history of this case, with suppuration extending over a period of several years, so beautifully and clearly illustrated by the use of the Roentgen photograph, impresses us with the inestimable value of this means of reaching a diagnosis."

29. To Observe the Course of the Fistulous Tract.

Dr. Emil Beck, of Chicago, was the first to use bismuth paste* in radiography. The paste is opaque to X-rays. Thus Dr. Beck would inject a fistula and abscess cavity, then, with the paste injected, make a

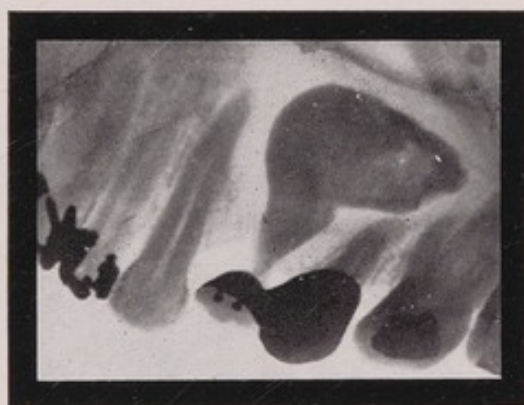


Fig. 213. Bismuth paste injected into fistulous opening just above the first bicuspid dummy and nearly filling a very large abscess cavity. (Radiograph by Ream, of Chicago.)

radiograph. Deep shadows would be cast onto the film or plate by the subnitrate of bismuth, showing distinctly the course of the fistula and the extent of the abscess cavity.

The curative property of bismuth paste was discovered truly by accident. After using the paste to enable him to make better radiographs, Dr. Beck noticed that some bad pus cases recovered.

"Cargentos," a colloidal silver oxid, made by Mulford & Company, can be used as bismuth paste is used, for either radiographic purposes or as a remedy.

When the use "to observe the course of a fistulous tract" suggested itself to me, I had in mind a case which I treated some years ago. It was a case in which a fistula pointed externally at the symphysis. Without going into a detailed history of the case, let it suffice to say that a sound and not very badly impacted lower third molar was finally extracted and the case recovered. Probing to the seat of the trouble was impossible, but had the fistula been injected with bismuth paste and a radiograph made, the connection between the third molar and the fistulous opening

*Bismuth subnitrate, vaseline, paraffine and white wax.

at the symphysis would have been clearly shown. I regret that I have not been able to obtain a radiograph of such a case. I have not, however, and must, therefore, content myself with a report of the only case I have in which bismuth paste was used to trace a fistulous tract.

Figs. 211 and 212. Case: A fistulous opening on the buccal near the apex of an upper second bicuspid; the first molar missing. Another fistulous opening on the buccal just above the gingival line of the second molar. A probe entering the fistula above the bicuspid led to its apex. A probe entering the fistula of the molar seemed to lead to the bifurcation of the roots of the molar. Having at a previous date treated the molar, and so knowing the condition of the canals, I was reluctant to believe that the tooth was abscessed.

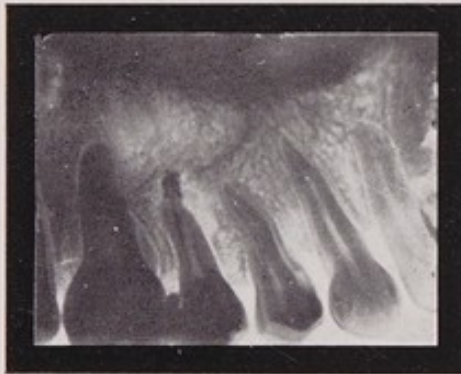


Fig. 214

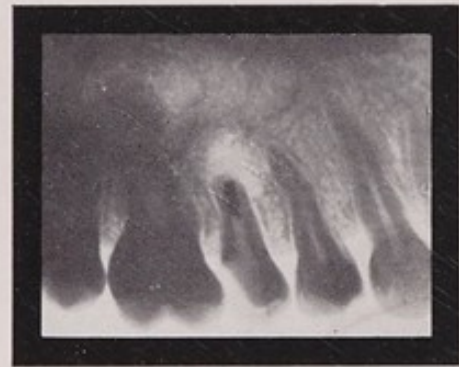

Fig. 215

Fig. 214. Before apicoectomy. Notice the considerable canal filling forced through the apical foramen. (Radiograph by Blum, of New York City.)

Fig. 215. Same case as Fig. 214. After apicoectomy. (Radiograph by Blum, of New York City.)

I entertained the belief that both fistulous openings led to an abscess at the apex of the bicuspid, but I could not verify this belief by probing. A radiograph (Fig. 211) shows the canals unfilled, and an abscess at the apex of the bicuspid. It shows also that there is no abscess at the apex of the molar roots. But it does not show a fistula leading from the bicuspid to the molar. The shell-crown on the bicuspid was removed and phenolsulphonic acid pumped through the tooth and out of the fistula over the bicuspid, but the acid could not be forced through the bicuspid and out at the opening over the molar. The tooth and both fistulous openings were injected with bismuth paste and a radiograph made. (Fig. 212.) I was then able to see that, as I had suspected, the seat of the trouble was at the apex of the bicuspid. The molar did not need treatment. The phenolsulphonic acid could not be forced through the bicuspid and out at the molar fistulous opening, because it traveled the path of least resistance out the nearer opening. The fistulous tract could not be

seen without injection with bismuth paste, because there was so little bone destruction. Throughout most of its course the fistula traveled between bone and periosteum.

Fig. 213. A large abscess arising at the apex of the second bicuspid, and discharging above the artificial first bicuspid. Bismuth paste injected into the fistulous tract. Perhaps the cuspid is involved also. It should be tested for vitality of its pulp.

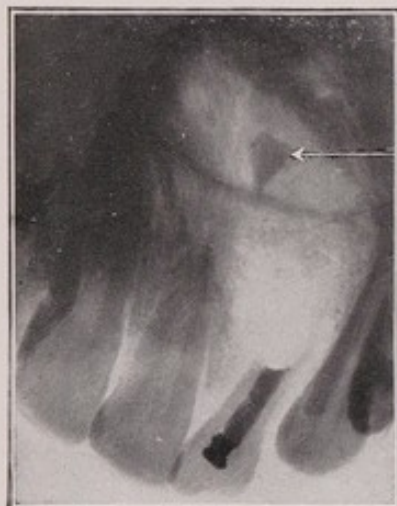

Fig. 216

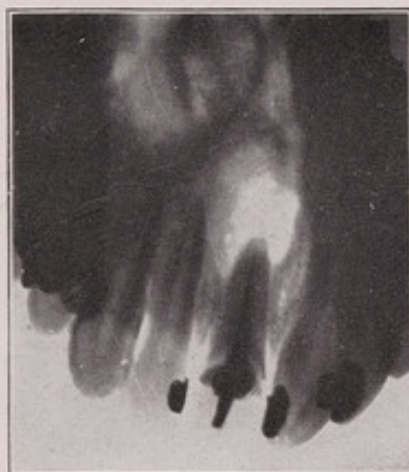

Fig. 217

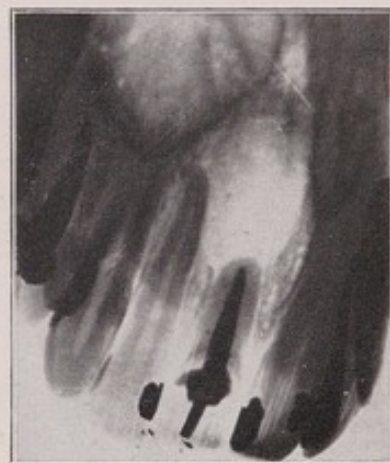

Fig. 218

Fig. 216. The apex of the lateral was cut off, then lost. The radiograph shows its location, so aiding materially in its removal. (Radiograph by Ream, of Chicago.)

Fig. 217. A chronic abscess at the apex of an upper central incisor. The tooth carries a post-porcelain crown and the canal is filled almost to the apex. (Radiograph by Lewis, of Chicago.)

Fig. 218. The same as Fig. 217 four days after the amputation of the apex of the central and curettage of the pus sinus. (Radiograph by Lewis, of Chicago.)

30. To Observe the Field of Operation Before and After Apicoectomy (Root Amputation).

When a tooth fails to respond to less radical treatment, and it is deemed necessary to amputate a portion of the apex of the root, the question naturally arises, how much of the root shall be cut off? A good radiograph will answer this question. Fig. 214 shows that but little of the root need be amputated. Observe that a great amount of canal filling penetrates the apical foramen. Fig. 215 is of the same case illustrated in Fig. 214 immediately after the operation.

Fig. 216. In his work on *Materia Medica and Therapeutics*, Dr. Buckley reports an interesting case of apicoectomy, in which the apex was amputated, then lost. A radiograph was made. (Fig. 216.) Dr. Buckley says: "This radiograph aided materially, as it verified the presence of the root-end and its location."

Radiographs from Dr. Buckley's *Modern Dental Materia Medica, Pharmacology and Therapeutics*.
Figs. 217 and 218. They are exceptionally good pictures taken before and after amputation of the apex.

31. To Locate Foreign Bodies, Such as a Broach in the Pulp Canal or Tissue at the Apex of a Tooth; A Piece of Wooden Toothpick in the Peridental Membrane, Etc.

Fig. 219. Case: A young lady about twenty-five years of age. Abscess pointing near the apex of an upper central incisor carrying a post porcelain crown. I suspected that the canal of the central was not filled properly, and made a

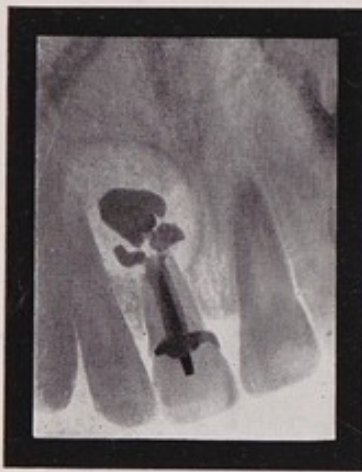

Fig. 219

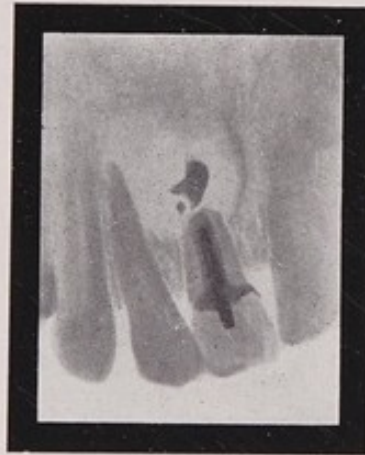

Fig. 220

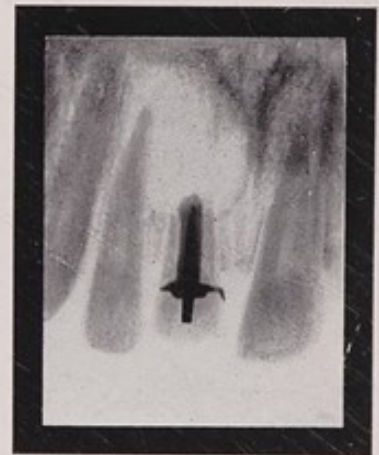


Fig. 221

Fig. 219. Cement and gutta-percha—mostly cement—in an abscess cavity at the apex of a post-porcelain crowned central incisor.

Fig. 220. Same as Fig. 219, after what was thought to be all of the cement and gutta-percha was removed. The radiograph shows both some cement (the larger shadow) and some gutta-percha (the small shadow) still remaining in the abscess cavity.

Fig. 221. The same as Fig. 219, showing the abscess cavity clear of all foreign bodies.

radiograph (Fig. 219) to learn if in this surmise I was correct. The radiograph shows the canal filled. At the apex of the root can be seen a large abscess cavity, with foreign bodies of some nature in it.

Fig. 220. An incision was made on the labial aspect, and what was thought to be all of the foreign material, which proved to be cement and gutta-percha—mostly cement—was removed through the external alveolar plate. A radiograph (Fig. 220) was made, and shows some cement (the larger shadow) and some gutta-percha (the small shadow) still in the abscess cavity.

Fig. 221. These bodies were removed and another radiograph (Fig. 221) made to prove that no foreign irritating body remained in the abscess cavity.

The pus sinus was then curetted, washed, cauterized, injected with bismuth paste, and another radiograph (Fig. 222) made. All of this work was done at one sitting, and consumed about two hours' time. The radiograph (Fig. 222) shows that the bismuth paste does not entirely fill the abscess sinus. It has been my experience that the most vigorous and earnest efforts often fail to "completely fill" an abscess cavity with bismuth paste. The manufacturers of the paste tell us that "every crevice" must be filled

Fig. 222.

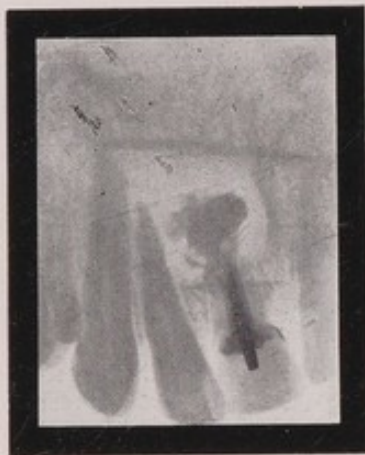

Fig. 222

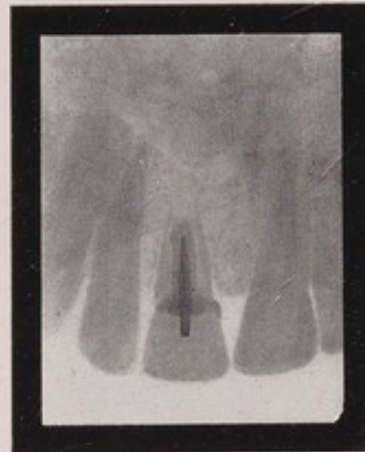


Fig. 223

Fig. 222. Same as Fig. 219. The abscess cavity filled with bismuth subnitrate paste.
 Fig. 223. Same as Fig. 219, three and one-half months after the operation. The abscess cavity is entirely filled with new bone. The new bone is as yet not quite as dense as the surrounding bone.

or the paste will not have the desired curative effect. Every crevice that can be filled should be, I concede. But I am showing you a case now in which the sinus was not quite filled, and, as we shall see presently, the results obtained were ideal. Three days after the operation another injection of bismuth paste was made. At this sitting the paste was not injected under as much force as the previous injection, for I did not wish to break up and destroy any granulation tissue that had formed along the walls of the sinus. Another injection under even less pressure than the second was made at the end of four days. The patient returned one week after the third injection with no symptoms of her former trouble.

Fig. 223.

Three and one-half months after the operation Fig. 223 was made. It shows a most remarkable and gratifying condition. The abscess cavity is entirely filled with new bone. This new bone is as yet not quite as dense as the surrounding bone.

Fig. 224.

Case: Man of middle age had suffered obscure neuralgic pains for about a month. None of the teeth on the affected side were tender to percussion

or pressure. A radiograph (Fig. 224) was made to learn whether or not the canals of the upper second molar were filled. There was a very large amalgam filling in this tooth. The radiograph does not show the roots of the molar well, but it *does* show a dark shadow between the second and third molars just above the cervical margin of the filling in the distal of the second molar. On inquiry it was learned that the patient was in the

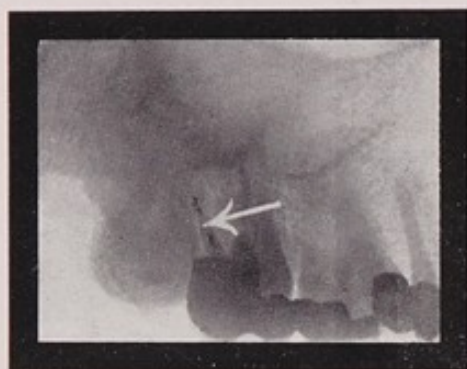

Fig. 224

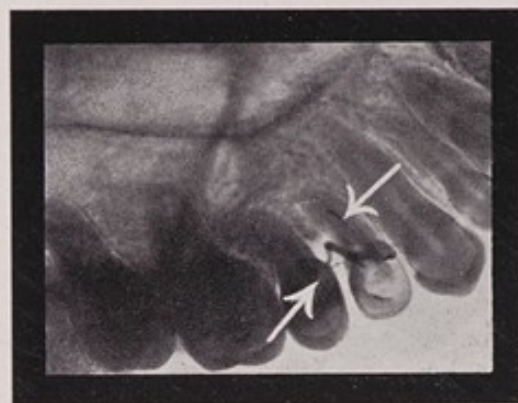


Fig. 225

Fig. 224. The arrow points into a piece of wooden toothpick between the second and third molars.

Fig. 225. The upper arrow points to a piece of broach in the canal of the upper first bicuspid. The lower arrow points to a piece of gutta-percha passing through a perforation to the distal.

habit of using wooden toothpicks. Suspecting the shadow to be a piece of toothpick, an attempt was made to remove it with explorers, canal pluggers and silk floss. The effort met with failure, but, feeling sure that my diagnosis was correct, the third molar was extracted. The piece of toothpick adhered to the extracted tooth. There was an immediate and complete recovery from pain.*

*Immediately after Fig. 224 appeared in the May, 1912, issue of *ITEMS OF INTEREST*, Dr. C. Edmund Kells, Jr., wrote to me saying there must be some mistake, that wood was "absolutely transparent" to the X-rays, and that according to the halftone, Fig. 224, the piece of toothpick cast a denser shadow than the amalgam filling in the molar tooth. I replied, insisting that wood was not "absolutely transparent" to X-rays, explaining that it had been necessary to retouch the print to make the shadow of the pick show at all in the halftone, and enclosing the original negative of the case. I then received two disassociated molar teeth stuck together, side by side, with pink paraffin and wax, and a piece of toothpick in the wax, parallel to the long axis of the teeth. Also a radiographic negative of the teeth and a letter from Dr. Kells, saying he had tried to make a radiograph of the pick and had failed. I glanced at the negative and could see only the teeth—neither the wax nor the piece of pick between them. I made a radiograph of the test specimen Dr. Kells had sent me and succeeded in showing both the wax and that part of the ends of the piece of toothpick which extended beyond the wax. That part of the pick covered with paraffin and wax could not be seen.

I was talking of the experiment and showing my own radiographs to a dental student. The student asked to see Dr. Kells' negative, he examined it and said, "Why, I can see the same thing in this that I see in your picture." And so he could. When examined closely Dr. Kells' negative showed the ends of the piece of toothpick extending beyond the wax. I had not examined it carefully enough before—neither had Dr. Kells.

I appreciate the interest Dr. Kells takes in my work, and I thank him most earnestly for calling my attention to what seemed to be a mistake, but having radiographed a piece of toothpick experimentally, I shall not retract anything said regarding Fig. 224.

Fig. 225. Case: Young woman, had been in the hands of an incompetent dentist, who had treated an upper first bicuspid for several weeks, and had finally advised its extraction, whereupon the patient left him, presenting to me, and asking if the tooth could not be saved. A radiograph (Fig. 225) was made, and shows a piece of broach in the canal and a perforation to the distal through which passes a gutta-percha point. About the end of the point is an abscess. Owing to the position of the tube, which was placed

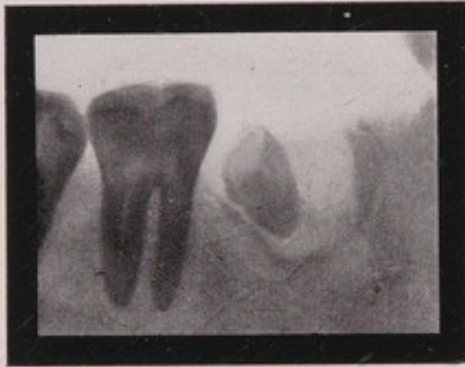

Fig. 226

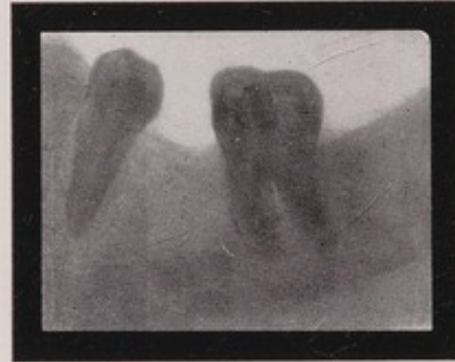

Fig. 227

Fig. 226. Unremoved mesial root of a lower second molar.

Fig. 227. The radiograph proves the absence of an unremoved root of the lower first molar.

too high, the teeth in the picture are too short, and the perforation, which was well above the gum line—too far to be detected—seems to be just at the neck of the tooth.

I agreed with the "incompetent dentist" that the tooth could not be saved. The condition revealed by the radiograph could not have been learned by any other means save extraction and dissection of the tooth.

32. To Determine the Presence or Absence of a Bit of Root Imbedded in the Gum Tissue.

After the extraction of a great number of teeth, or after having been operated upon by some other dentist, a patient will present with the gum tissue highly inflamed and, pointing to the inflamed area, say, "Isn't there a piece of tooth there yet?" Unless the X-rays are used it is necessary to anesthetize the parts and dissect away some of the soft tissues to determine whether the inflammation may be due to an unremoved bit of tooth root, an unresorbed spicula of process, or a bit of process fractured from the jaw. This requires a great deal of time and work, and causes the patient unnecessary pain. The radiograph should be used.

Fig. 226. Case: Much swelling of the face on the affected side. The patient was unable to open the mouth to any extent without considerable pain. Two weeks

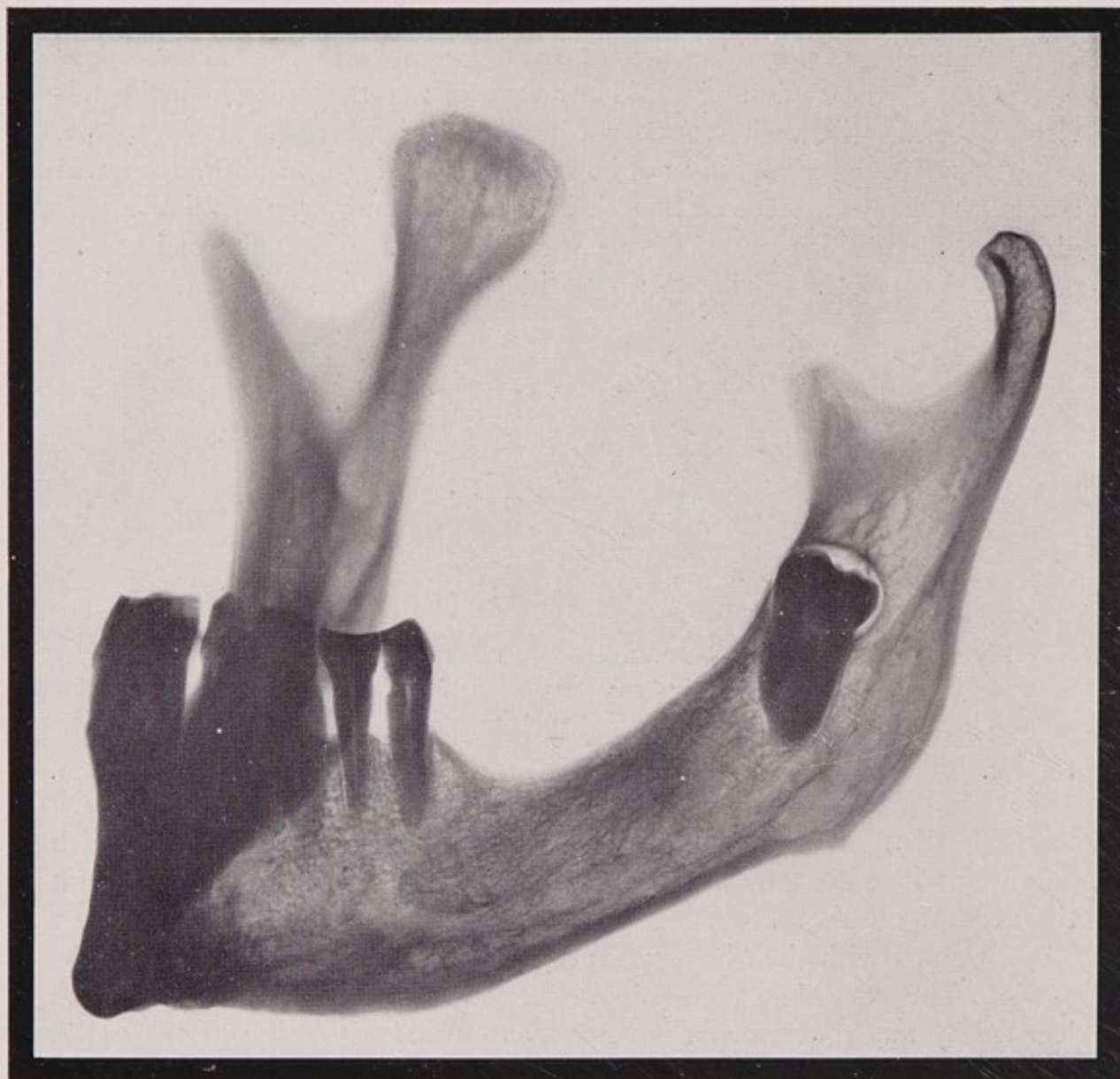

Fig. 228. This radiograph is of a dry subject. Pictures of dry bones show clearly because there are no soft tissues to penetrate. The third molar is badly impacted in the ramus. (Radiograph by Cryer, of Philadelphia.)

previously the lower second molar on the affected side had been extracted (?) by a quack dentist. The question naturally arose, "Has all of the second molar been removed?" A radiograph (Fig. 226) was made, and shows that the mesial root still remains. It was taken out, and the case recovered promptly. The advantages derived from using the radiograph in this case were as follows: It saved the patient the pain of opening the mouth for a prolonged instrumental and ocular examination; and also the pain caused by lancing, dissecting, and probing incident to such an examination. It saved both the patient and the operator time. It showed clearly and exactly how much of the tooth was left, and illustrated its

exact location. It made the extraction of the piece of root decidedly easier for both patient and operator.

Fig. 227 is of a case similar to that shown in **Figs. 227 and 228.** Fig. 226. In this case, however, the second molar had been extracted a year previously, and the radiograph shows no unremoved bit of tooth root. The radiograph fails to disclose a cause for the clinical signs. But let me impress you with this fact: it does show that an unremoved bit of tooth root is *not* the cause, and so aids us very greatly in a diagnosis by elimination. The patient did

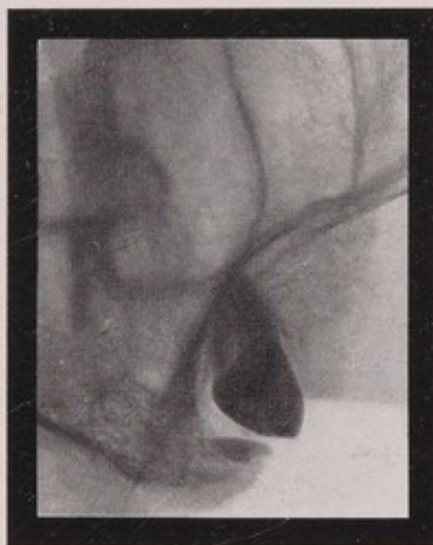

Fig. 229. A piece of tooth root and an impacted cuspid in an otherwise edentulous upper jaw. (Radiograph by Lewis, of Chicago.)

not return after his first visit, so the case was never diagnosed. There may have been a third molar impacted in the ramus. (See Fig. 228.) No one can deny the possibility. We took only the first step toward diagnosis—we eliminated a possible cause.

Though I have been unable to obtain a definite history of this case, it is, in all probability, about as follows: After the extraction of the upper teeth the patient returned with a localized inflammation of the gum tissue in the cuspid region. A radiograph was made to learn if this inflammation was caused by an unresorbed bit of process or a piece of tooth root. The picture shows not only a piece of tooth root, but also an impacted cuspid tooth. It is not unlikely that this patient suffered from obscure neuralgic pains, headache, or other nerve affections.

Notice the bit of root imbedded in the process. **Fig. 230.** My chief reason for exhibiting this picture is because it shows so clearly the gum tissue overlying the process.

Fig. 231. A piece of root, one end of which rests on the edge of an ill-fitting shell crown, the other against the cuspid tooth. The inflammation caused by this root extends up to the apex and to the mesial of the cuspid. In such a position the root could never have dropped down to where it could be seen in the mouth.



Fig. 230

Fig. 230. The arrow points to a bit of tooth root. Notice how clearly the gum tissue shows in this radiograph. (Radiograph by Ream, of Chicago.)

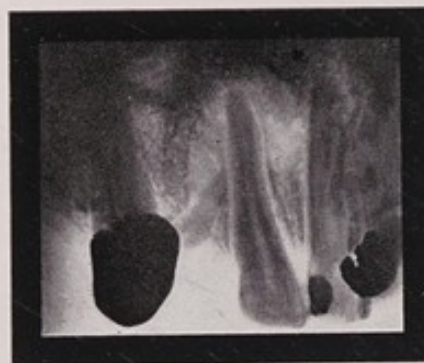

Fig. 231

Fig. 231. A bit of tooth root, one end resting on the edge of an ill-fitting shell crown, the other against the cuspid. The abscess caused by this piece of root extends to the apex and to the mesial of the cuspid. (Radiograph by Blum, of New York City.)

33. To Diagnose Fracture of a Root.

Figs. 232 and 233. Within the same week two cases in which the upper anterior teeth had sustained a severe blow presented at the college clinic for treatment. In one case a lateral incisor (Fig. 232), and in the other case both centrals (Fig. 233) were very loose. Radiograph Fig. 232 shows the root of the lateral fractured. Extraction is indicated. Radiograph Fig. 233 shows that the roots of the centrals are not fractured. Extraction is contraindicated. (As can be seen in the radiograph, both central crowns are broken off, and one lateral is knocked out completely.) It will be appreciated that the radiographic findings in these cases governed completely our course of treatment. I would suggest it as a most rational expedient that radiographs be taken in all cases of traumatism, before treatment is begun.

Fig. 234. Case: Young lady fell on dance hall floor striking the upper centrals and loosening them. Her dentist treated both teeth, removing inflamed pulps. One tooth progressed promptly to recovery, but the other remained loose and sore. After several weeks of treatment the patient presented to Dr. F. B. Moorehead, of Chicago, who had a radiograph made before commencing treatment. The radiograph shows the root of the loose tooth fractured

near the apex. Dr. Moorehead removed the apex of the root through the external alveolar plate, smoothed the end of the broken root, and the case recovered promptly. It is almost superfluous to do so, yet I want to call your attention to the fact that this case, like very many others I have reported, could not have been diagnosed and treated properly without using the radiograph.

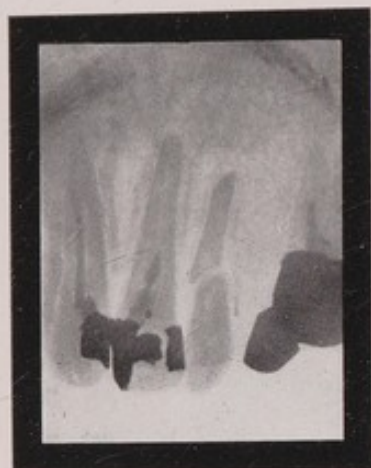

Fig. 232

Fig. 232. Fractured upper lateral incisor. Because of the location of the break extraction is indicated.

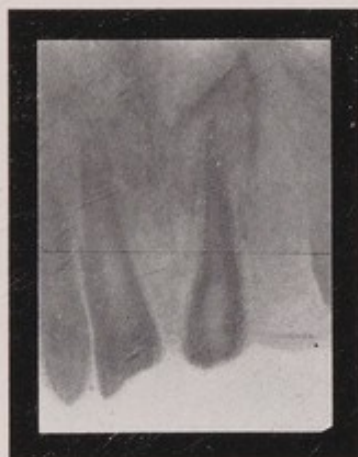

Fig. 233

Fig. 233. It was thought that the roots of the centrals were fractured. The radiograph shows they are not.

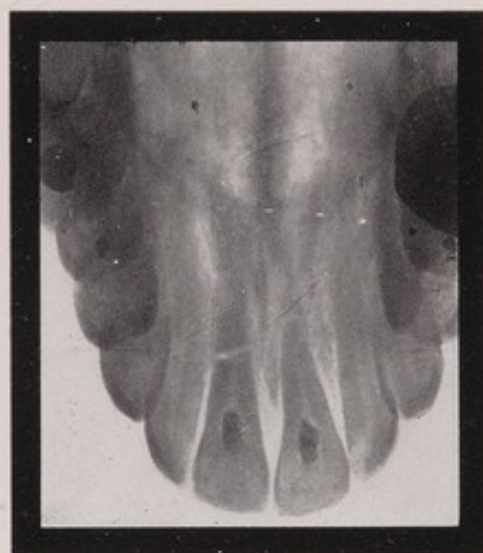

Fig. 234

Fig. 234. Left central fractured near the apex. The case had been treated for alveolar abscess without success for several weeks. The removal of the piece of fractured root-end through the external alveolar plate effected a cure. (Radiograph by Lewis, of Chicago.)

34. To Observe the Size and Shape of Roots of Teeth to be Used in Crown and Bridgework.

Malformed upper laterals—"peg laterals"—occur quite frequently. Their appearance is bad, and, for esthetic reasons, we often crown them. The porcelain jacket crown is difficult to construct and, at best, fragile. If the root of the peg lateral is long enough a post porcelain crown of some kind is indicated in preference to the porcelain jacket. Fig. 235 shows a peg-shaped lateral. In this case the root is long enough to permit of the introduction of a post into the canal a sufficient distance to insure stability of a post crown. The root is somewhat tortuous, but, with the radiograph to guide, the operator should be able to enlarge the canal sufficiently, without danger of making a perforation into the pericemental membrane.

Fig. 235.

Fig. 236.

Before using teeth as abutments for large bridges, it would not be unwise to make radiographs to note the size of the roots. It would be a mistake, I believe, to use such a tooth as the malformed one shown in Fig. 236 as an abutment for a bridge of any extent. It should be borne in mind that unless the pose is exactly right—and we seldom have it so—the teeth, as they appear on the radiograph, do not represent definitely the exact length of the teeth themselves. Nevertheless, the radiograph does give us a fairly definite idea of the relative length of the teeth.

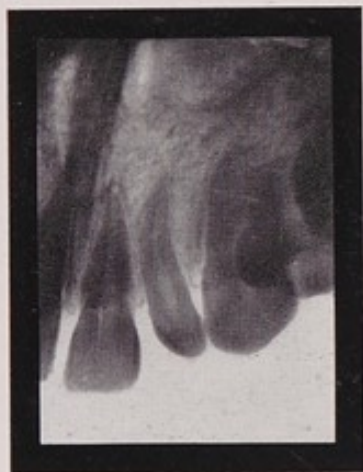**Fig. 235**

Fig. 235. A peg lateral, the root of which is somewhat tortuous. (Radiograph by Blum, of New York City.)

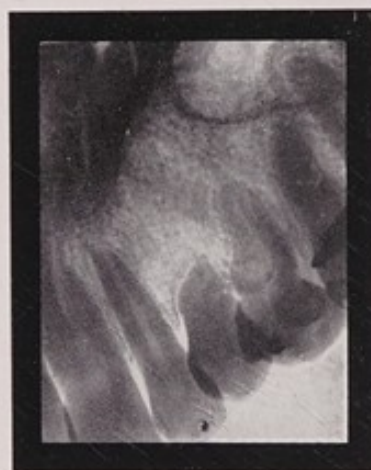**Fig. 236**

Fig. 236. A malformed cuspid tooth. It would be a mistake to use such a tooth as an abutment for a large bridge.

35. As an Aid and Safeguard When Enlarging Canals for Posts.

There are times while enlarging canals for posts when we lose the course of the canal and are much disturbed to know if we are making our enlargement in the proper direction. Place a wire in the canal and make a radiograph. If the enlargement is being made to the mesial or distal, with danger of a perforation, this can be seen in the picture. One might completely penetrate the side of the root towards the labial, or buccal, or lingual, without being warned of the danger by a radiograph, but, bear in mind, perforations made through the side of a root are, with rare exceptions, either to the mesial or distal.

Fig. 237.

In Fig. 237, observe the central carrying a post porcelain crown. The post does not follow the canal. Had the enlargement for it continued in the same direction as was started, the dentist would have penetrated the side of the root. A radiograph of this case would have enabled the operator to see his mistake and correct it.

Fig. 238. This radiograph shows a perforation through the side of the root, to the distal, in an upper second bicuspid. The perforation was made when enlarging the canal for a post. A probe passes through the side of the root, up into an abscess cavity at the apex of the tooth.

The radiograph is an aid not only when we are enlarging canals for posts, but also when we are removing posts from canals. It shows us how long the post is, and how much tissue we can cut away from the sides of it in safety.

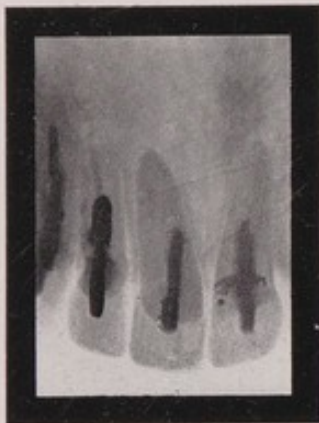

Fig. 237

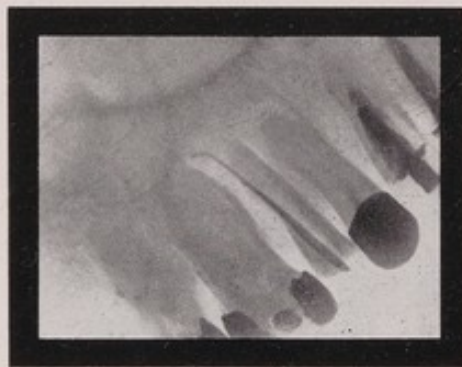

Fig. 238

Fig. 237. The post in the post-porcelain crowned central does not follow the canal. It almost penetrates the side of the root. (Radiograph by Graham, of Detroit.)

Fig. 238. Perforation through the side of the root of an upper second bicuspid. A probe passes through the perforation. (Radiograph by Graham, of Detroit.)

36. To Examine Bridges About Which There Is An Inflammation.

Figs. 239 and 240. At best fixed bridges are not sanitary. For this reason we often find an intense inflammation about them. Thorough depletion by scarifying and the use of an astringent, antiseptic mouthwash will usually give prompt relief. There may be causes for the inflammation other than the simple fact that the bridge is a foreign body in the mouth, making thorough cleanliness impossible. Observe Figs. 129, 239 and 240 as examples. It would be extremely difficult to remove the bit of root shown beneath the bridge in Fig. 239 without removing the bridge. The piece of root shown in Fig. 240 can easily be removed through the external alveolar plate without removing the bridge.

I have recently heard of a case in which a very severe inflammation existed about a bridge which had only been set for about a week. The case was treated for several days, and finally the bridge removed when it was seen that, at the time the bridge was set, a considerable quantity of

cement had been forced into the tissues near a shell crown abutment. Removal of this cement effected a prompt cure. Had a radiograph been made, the cause of the trouble would have been seen immediately, and, depending on the exact location of the cement, removal of the bridge may have been avoided.

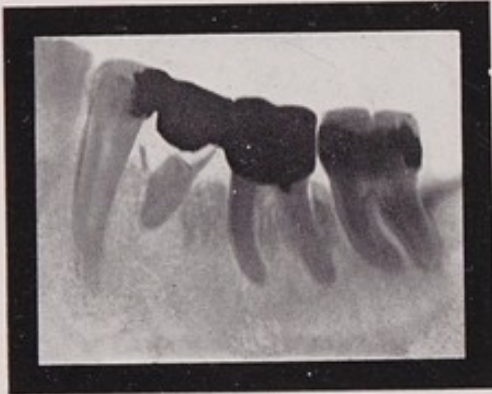

Fig. 239

Fig. 239. A piece of tooth root in the tissues beneath a bridge. (Radiograph by Lewis, of Chicago.)

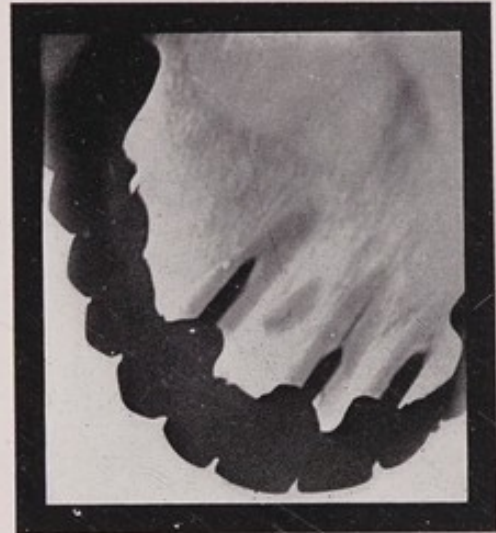

Fig. 240

Fig. 240. A piece of tooth root in the tissues above a very large bridge. It would be easily possible to remove it through the external alveolar plate without removing the bridge. (Radiograph by Lewis, of Chicago.)

37. To Observe the Field Before Constructing a Bridge.

This use of the radiograph has already been illustrated—Figs. 129, 239, and 240. The radiograph will not only disclose the presence of unerupted teeth, and unremoved pieces of tooth roots, but, as has been suggested under another heading, it will also show the operator the size, shape and health of the roots of the teeth he is using for abutments.

38. To Observe Planted Teeth.

Case: One in the practice of Dr. C. Edmund Kells, Jr., Fig. 241, shows a fracture of the root of a lateral, the result of a fall. After the two pieces of the lateral were extracted they were united and held together with an iridio-platinum screw set in cement, and the repaired root then replanted. The radiograph (Fig. 242) was made immediately after the operation. A gold splint is seen covering the crown of the cuspid, lateral and both centrals.

Fig. 243.

A case of replantation of a lower second bicuspid two years and four months after the operation. The root is almost entirely absorbed. Notice how plainly the pericemental membrane can be seen about the roots of the first bicuspid and first molar, appearing as a light line. Notice also the absence of this line about the remaining portion of the root of the replanted tooth.

The theory of the attachment of planted teeth is as follows: The roots of the planted teeth are absorbed at different points, and bone

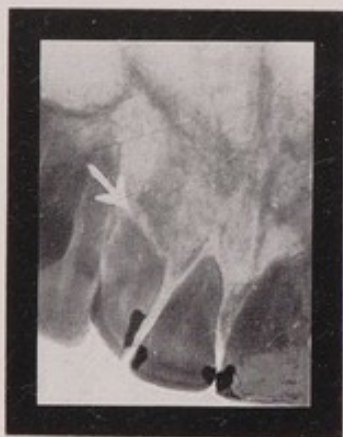

Fig. 241.

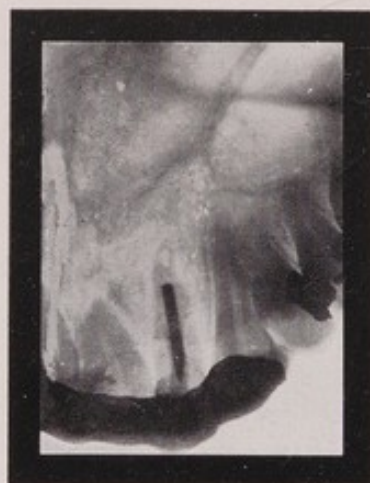

Fig. 242.

Fig. 241. Fracture of upper lateral incisor. (Radiograph by Kells, of New Orleans.)

Fig. 242. Same as Fig. 241 after the removal of the lateral and its replantation. Radiograph by Kells, of New Orleans.)

immediately fills into these places, so holding the tooth. Hence, planted teeth do not have a pericemental membrane. Radiographic findings bear out this theory.

Fig. 244.

Fig. 244 shows an implanted porcelain root. Observe that the root has practically no bony attachment at all, and would drop out save for the manner in which it is splinted to the other central.

Fig. 245.

Dr. E. G. Greenfield, Wichita, Kas., has designed and manufactured a sort of cage-like root of iridio-platinum wire to be used for implantation. So far all forms of artificial roots for teeth have proven failures, but this one bids fair to be a success. Whether it will be a success or not depends on whether or not bony tissue will build in and about the wires. The radiograph (Fig. 245) is introduced more for the purpose of showing the artificial roots than for any other reason. The radiograph has not been made in such a way as to enable us to see whether there is an osseous deposit within the wires or not.

39. In Cases of Cementoma.

Cementomata (or cases of hypercementosis, as they are often called) are sometimes the cause of neuralgia. There are no means at our disposal whereby they (cementomata) can be diagnosed save by the use of the radiograph.

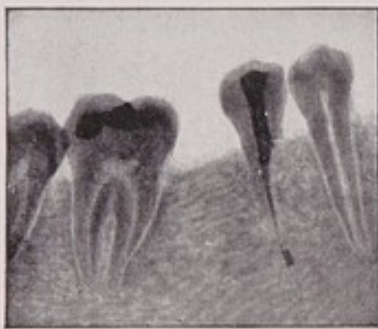

Fig. 243.

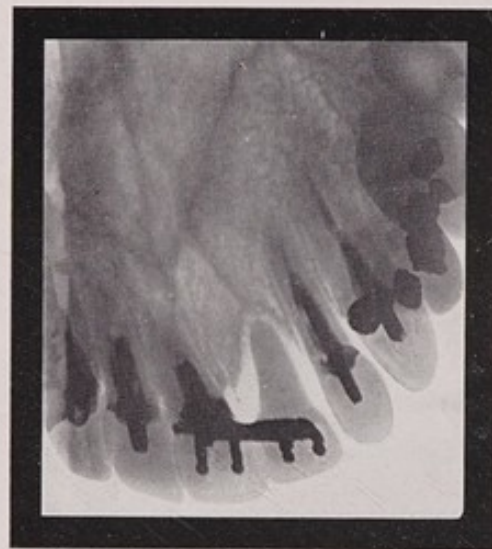

Fig. 244.

Fig. 243. A case of replantation of the lower second bicuspid two years and four months after the operation. The root is almost entirely absorbed. (Radiograph by Kells, of New Orleans.)

Fig. 244. Artificial porcelain root with no bony attachment at all save just at the apex. (Radiograph by Ream, of Chicago.)

Figs. 246 and 247. These radiographs illustrate cementomata, which were responsible for persistent neuralgias. Extraction was necessary in both cases.

40. In Cases of Bone "Whorls."

The term bone whorl is used to designate particularly dense areas of bone occurring in bone. Bone whorls may be caused by a prolonged, mild irritation, like that produced by an impacted tooth, for example. They are sometimes responsible for facial neuralgia. In answer to a letter asking him if he ever found it necessary, or ever expected to find it necessary, to open into the bone and surgically break up whorls to relieve neuralgia, Dr. Cryer replies, "I have found it necessary in several cases to open into the bone and remove the whorls, or hard bone, and I fully expect to do so again." From the nature and location of whorls, it is obvious that they can be found only by the use of the radiograph.

Figs. 248 and 249. A case in the practice of Dr. Cryer. The patient was suffering from pain on one side of the face. A radiograph of the case (Fig. 248) shows an impacted lower third molar. It was thought best to remove the second molar



Fig. 245. Two artificial roots implanted in the upper jaw. (Radiographer not known.)



Fig. 246.

Fig. 246. Cementoma on lower, second, shell-crowned molar. (Radiograph by Ream, of Chicago.)



Fig. 247.

Fig. 247. Cementoma. (Radiograph by Ream, of Chicago.)

first, then the third molar. This was done, and the neuralgia disappeared for about ten days, then pain returned. Another radiograph (Fig. 249) was made which shows a bone whorl in the region from which the second molar had been removed. Another operation was done removing the whorl, after which the neuralgia disappeared altogether.

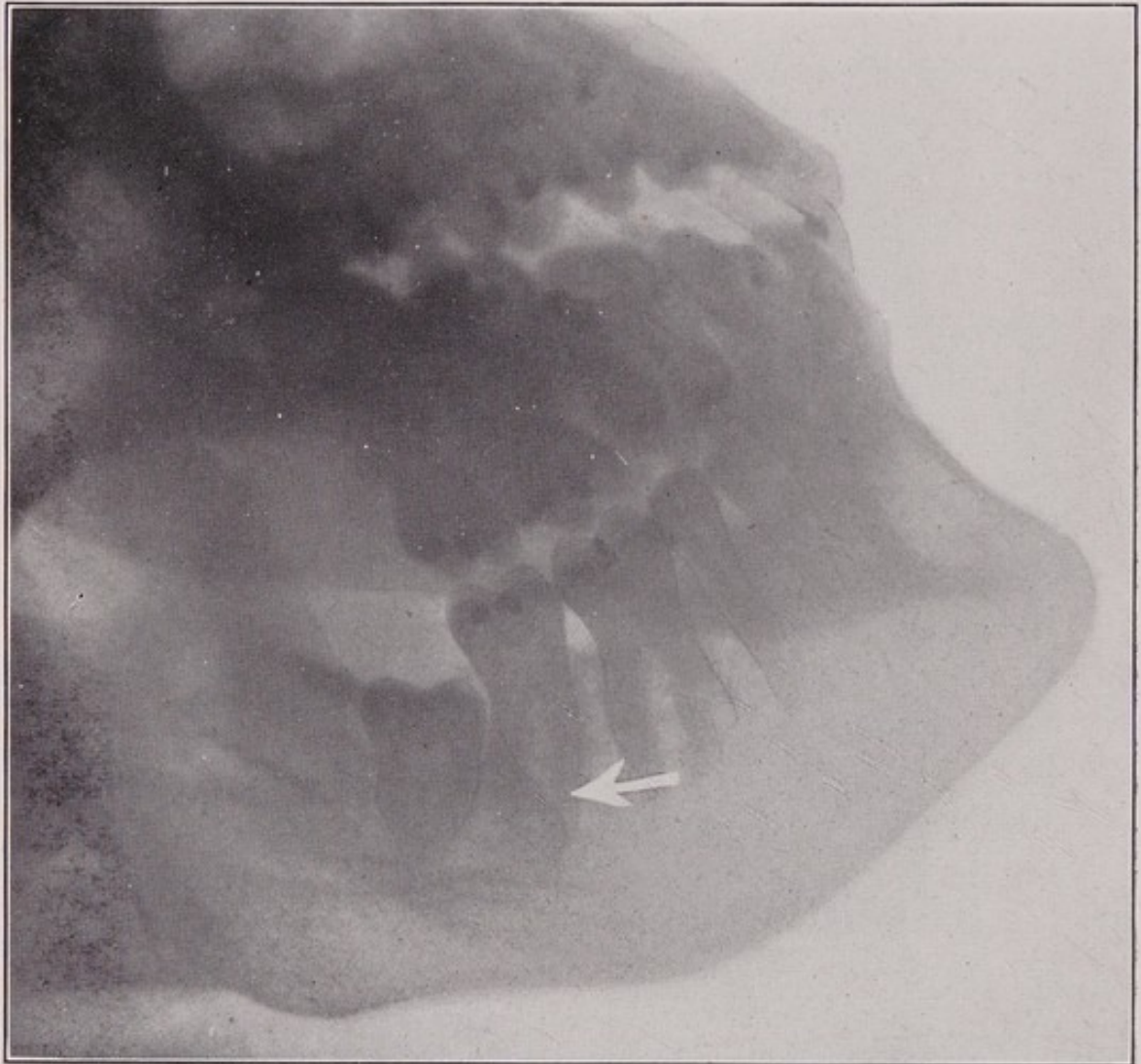

Fig. 248. An unerupted lower third molar. The arrow points to a bone "whorl." (Radiograph by Pancoast, of Philadelphia.)

Fig. 250.

Case in the practice of Dr. Robert H. Ivy, of Philadelphia. "The patient had suffered from neuralgia of the mandibular division of the fifth nerve on the right side, for two years. In February, 1911, she was treated by an alcohol injection of this division, which gave relief from pain for six months, after which the trouble returned, but not so severely as before. In January, 1912, a skiagram was made, showing a dense spot in the region of the first molar tooth, and in close relation to the inferior dental nerve. This is so dense as to appear like a piece of tooth root, but when cut down upon with the surgical engine, nothing but dense bone was found. The patient has been without neuralgia since the operation, though it is too soon yet to say whether the relief will be permanent."

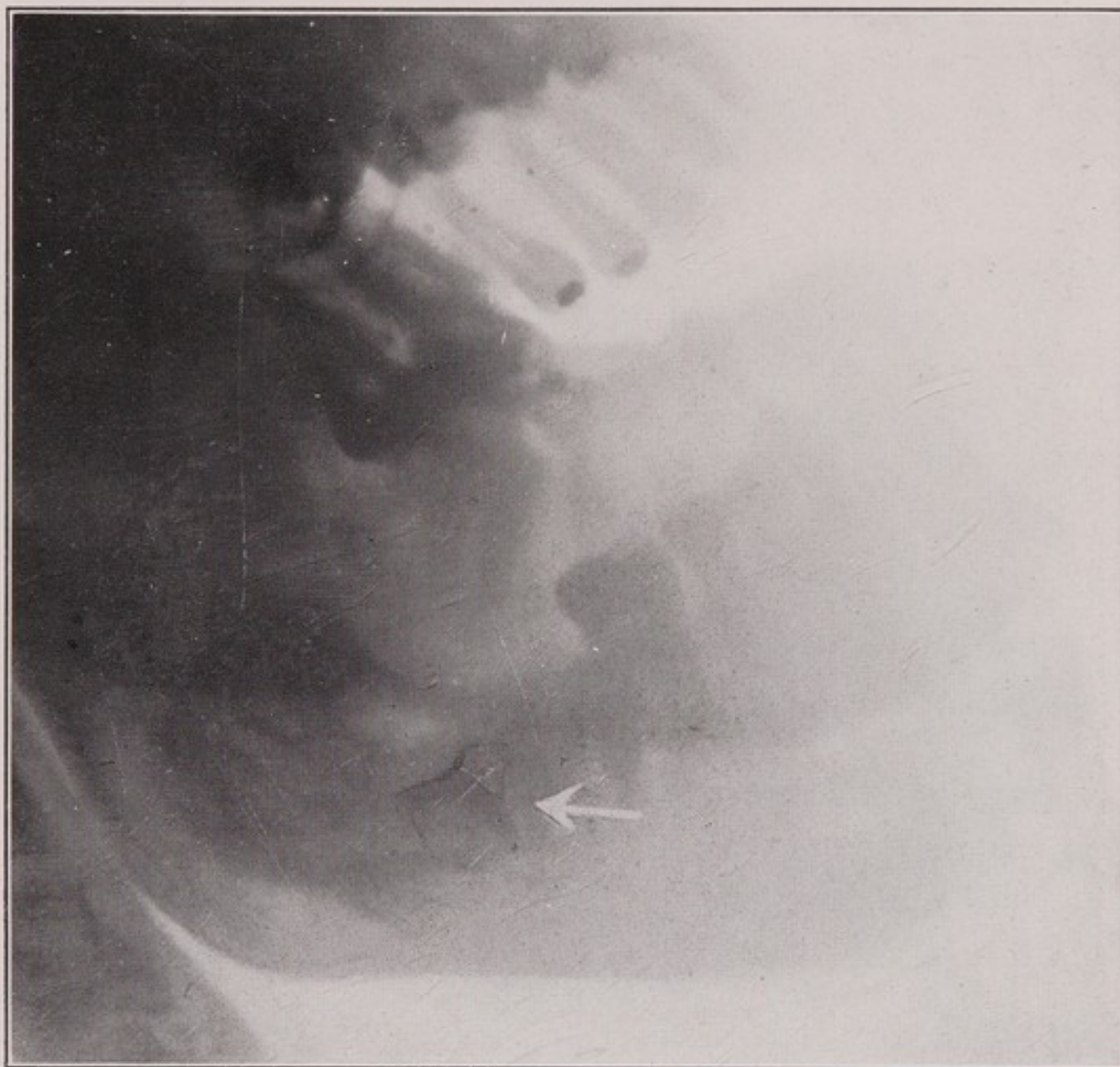

Fig. 249.* The same as Fig. 248 after the extraction of the lower second and third molars. The arrow points to a dark, three-sided shadow—a bone "whorl." The X on the shadow is caused by a scratch on the negative. (Radiograph by Pancoast, of Philadelphia.)

41. To Locate Stones (Calculi) in the Salivary Ducts or Glands.

The history of this case given me by Dr. Sidney Lange, of Cincinnati, Ohio, is as follows: Patient, female, age about forty, suffered recurrent attacks of swelling and pain in the region of the submaxillary gland on one side. The attacks seemed to follow the taking of sour foods. A radiograph (Fig. 251) was made. The arrow points to a stone in the submaxillary duct. Because the patient had had a stone removed from the same duct several years previously, and because the gland was considerably thickened, simple removal of the stone was thought to be contraindicated, and a more radical operation involving the removal of the entire gland was performed.

Fig. 251.

42. In Cases of Bone Cysts.

"A cyst is an organized structure consisting of a sac-like wall together with its contents, especially one of pathological formation or abnormal development."—*Appleton's Medical Dictionary*.

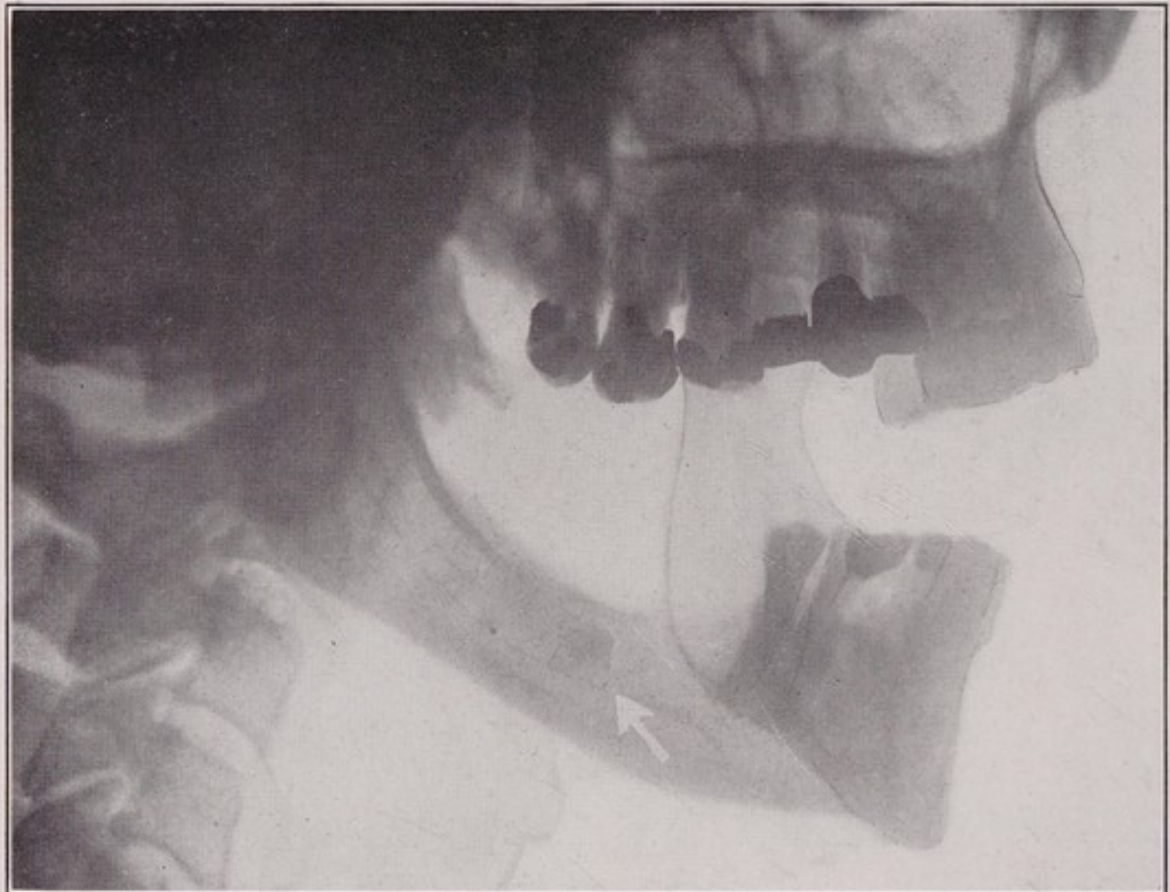


Fig. 250. The dark shadow to which the arrow points is a bone "whorl." (Radiograph by Pancoast, of Philadelphia.)

According to this definition all chronic alveolar abscesses are cysts—bone cysts, because they occur in bone. But the name cyst is usually not applied until the abscess sac assumes a great size. The abscess in Fig. 193 is large enough to be called a cyst, in the generally used sense of the term.

Fig. 252. This radiograph shows a large cyst in the lower jaw. The two roots of the lower first molar are doubtless responsible for the cyst formation.

In cyst cases there is often considerable and disfiguring enlargement of the bone, and such cases are spoken of as cystic tumors, a tumor, of course, being simply an abnormal enlargement or growth.

Figs. 253 and 254. A man, age about thirty-seven, was referred to the college clinic "to have a growth on the lower jaw cut off." There was no "growth" to "cut off." There was a definite enlargement of the bone in the lower first molar region,

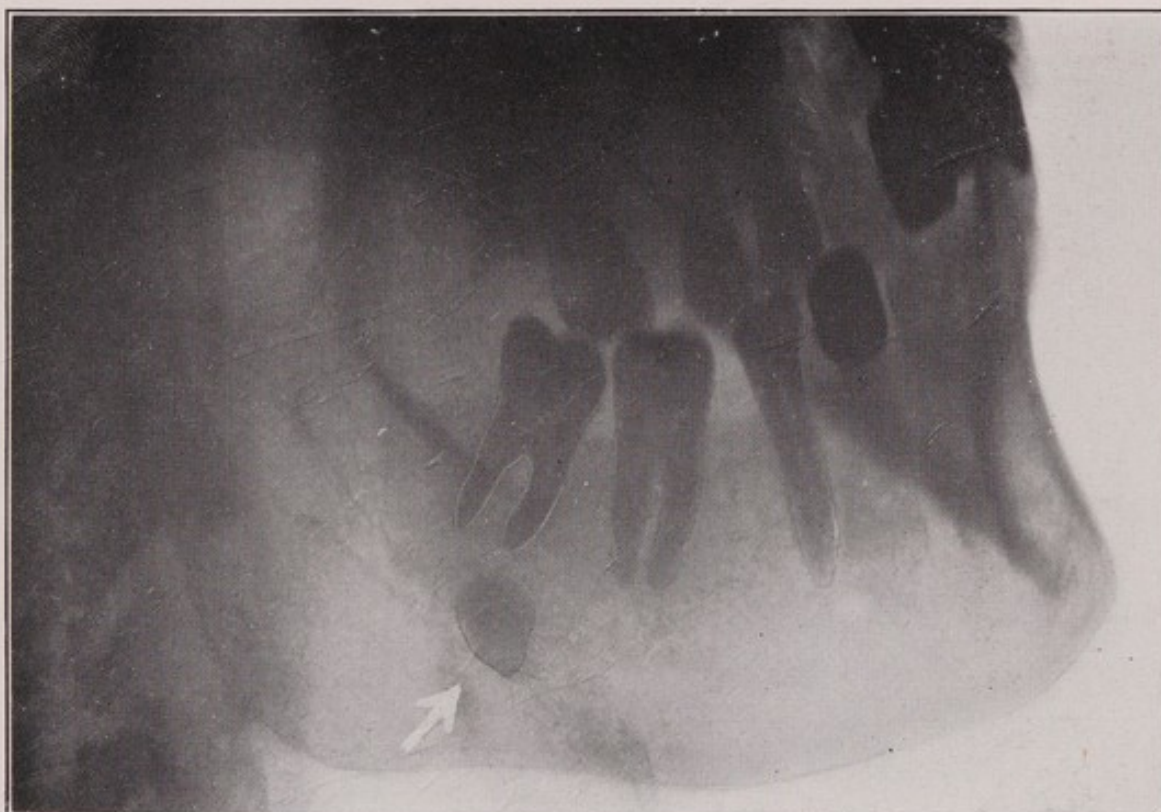

Fig. 251. The arrow points to a stone in the submaxillary duct. (Radiograph by Lange, of Cincinnati.)

giving the man the appearance of carrying a large lump of tobacco in the vestibule of the mouth. The patient suffered local pain, and the involved area was tender to palpation. The first molar tooth was missing from the jaw. A radiograph was made and showed a cyst involving the second bicuspid and second molar. (I regret that the radiograph has been lost.) Neither the second bicuspid nor the second molar had cavities nor fillings in them. Considering the evidence of neglect of the mouth and teeth, it was not deemed worth while to try to conserve the teeth. Accordingly the second bicuspid was extracted, which permitted the escape of considerable watery, brown pus. A doubt then arose as to whether the radiograph showed an involvement of the molar or not. Another radiograph (Fig. 253) was made. It shows that the molar is involved. It was extracted and more serous pus evacuated. Antiseptic solutions

could now be washed from one tooth socket, through the cyst, and out at the other tooth socket. The cyst was curetted, cauterized and packed with sterile gauze. Healing except from within outward was prevented by the use of gauze, and the case recovered. Relief from pain and soreness was

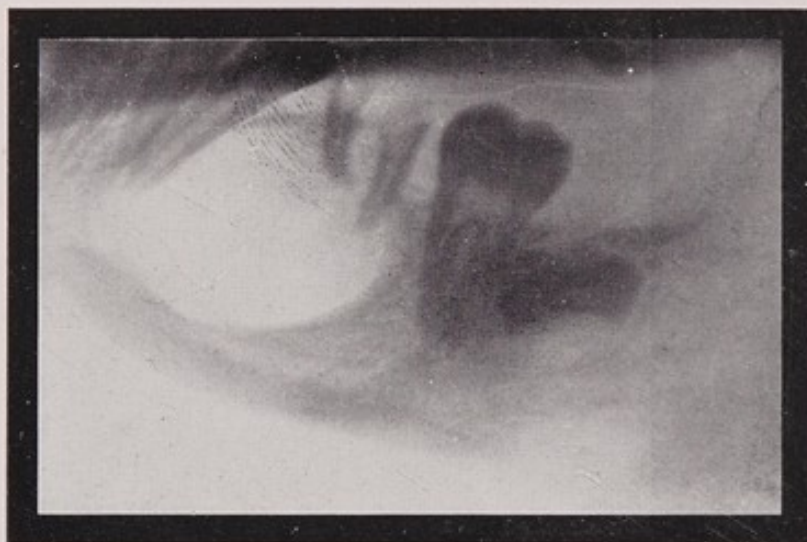


Fig. 252. Large cyst in the lower jaw. The more or less oval-shaped light area represents the cyst. (Radiograph by Lewis, of Chicago.)

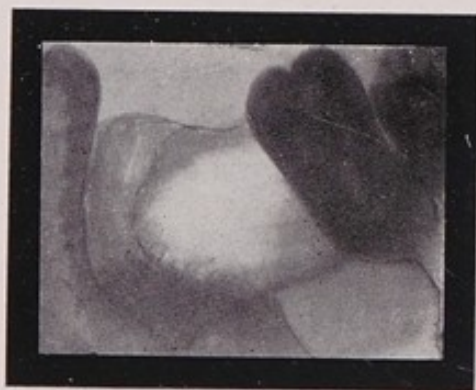

Fig. 253.



Fig. 254.

Fig. 253. A bone cyst in the lower jaw.

Fig. 254. Same as Fig. 253, with the cyst outlined to enable the reader to observe Fig. 253 to better advantage. The circle A is the alveolus from which the second bicuspid was extracted.

immediate. It required two or three months for all of the enlargement of the jaw to disappear.

In my experience as a radiographer I have observed that the general practitioner of dentistry shows great reluctance to extract a tooth, no matter what the condition he is treating may be. On the other hand, the

specialist in oral surgery extracts teeth sometimes without making the slightest effort to conserve them. I believe, however, that the oral surgeon is less often mistaken. A man may make a greater mistake than the extraction of a tooth. For example: failure to extract a tooth which is causing otherwise incurable suppuration, general sepsis, nervous disorders, necrosis or distracting pain.

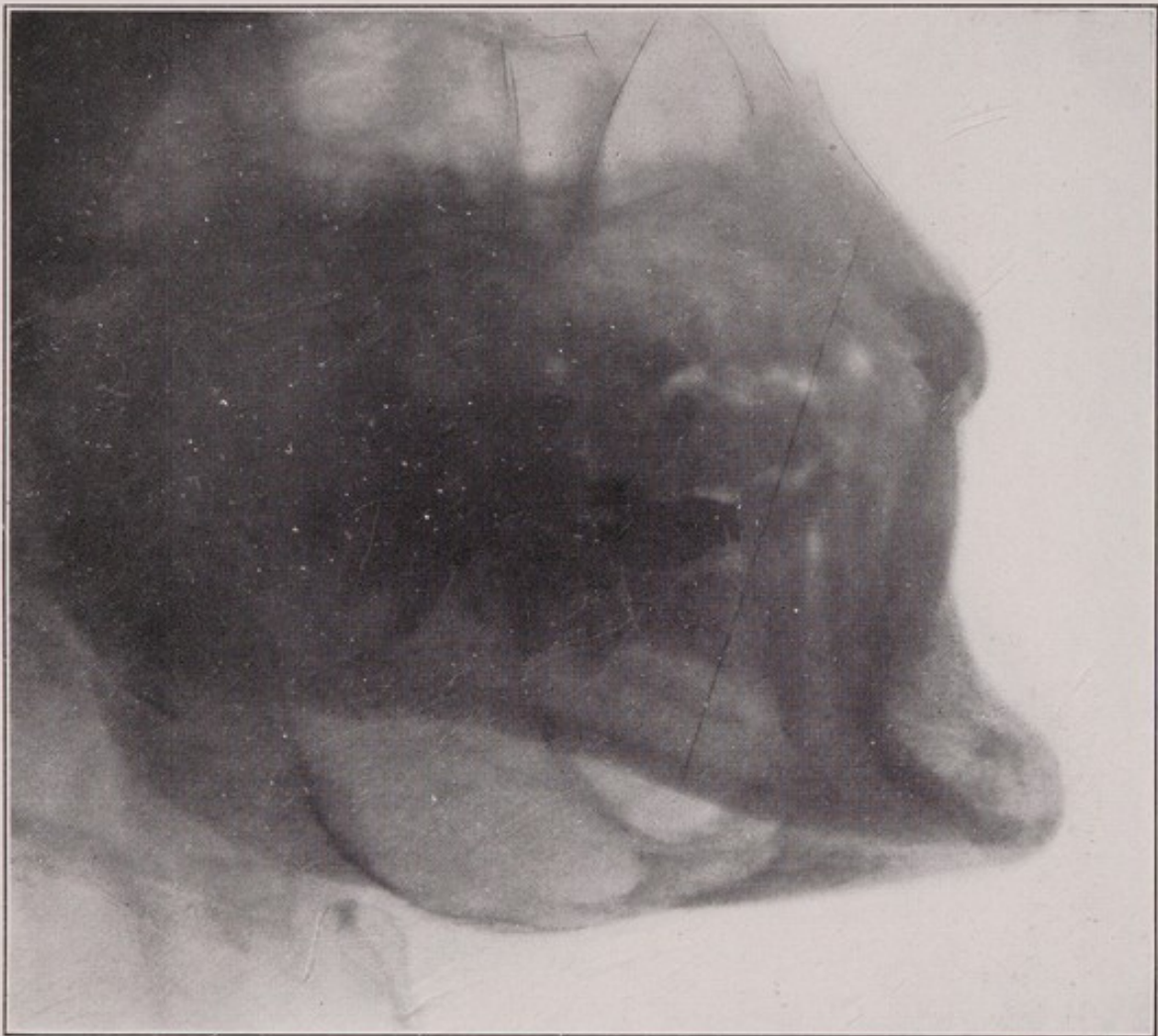


Fig. 255. A very large cyst of the lower jaw. The light area represents the cyst. This radiograph shows the hyoid bone. (Radiograph by Lange, of Cincinnati.)

Dr. Sidney Lange, of Cincinnati, made the radiograph shown in Fig. 255, but did not treat the case. **Fig. 255.** Dr. Lange was, however, able to furnish the following history: Patient, boy, about eighteen. Very large swelling in the lower jaw. No pain or tenderness in the region of enlargement. A radiograph (Fig. 255) was made, and the case diagnosed as a "benign bone cyst." The boy was taken to a hospital and the cyst drained of a straw-

colored fluid, curetted and packed with gauze, through an opening made inside of the mouth to the buccal. The patient left the hospital in a week or two after the operation.

Fig. 256. Case: Male, age about twenty-five. Enlargement of the mandible at the symphysis. Tenderness, intermittent local pains. The radiograph shows a large cyst. Failing to keep an appointment, the patient has not been heard of since the radiograph was made.

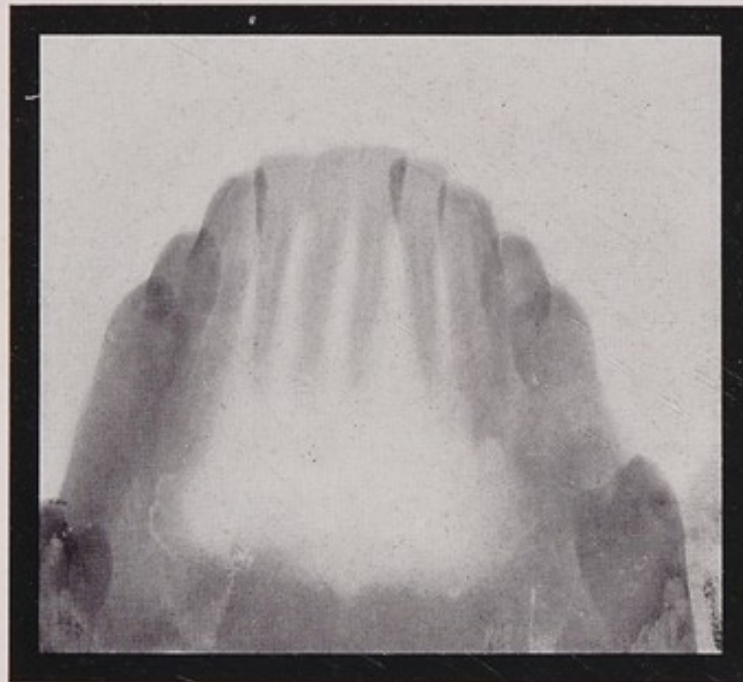

Fig. 256. Bone cyst of the lower jaw.

43. In Cases of Dentigerous Cyst.

Any cyst containing a tooth body, or tooth bodies, is said to be a dentigerous cyst. Dentigerous cyst of the jaws are not uncommon. Their definite diagnosis is possible only when the radiograph is used.

Because the apex of the tooth extends into the pus sac a chronic dento-alveolar abscess is sometimes called a dentigerous cyst. But this use of the term is considered improper.

Fig. 257. Case in the practice of Dr. M. H. Cryer. I quote Dr. Cryer: "The patient, a child of nine, had a swelling of the left side of jaw for about two years. This gradually increased to the size of a hen's egg, causing considerable deformity. A radiograph of the case (Fig. 257) shows a retained de-

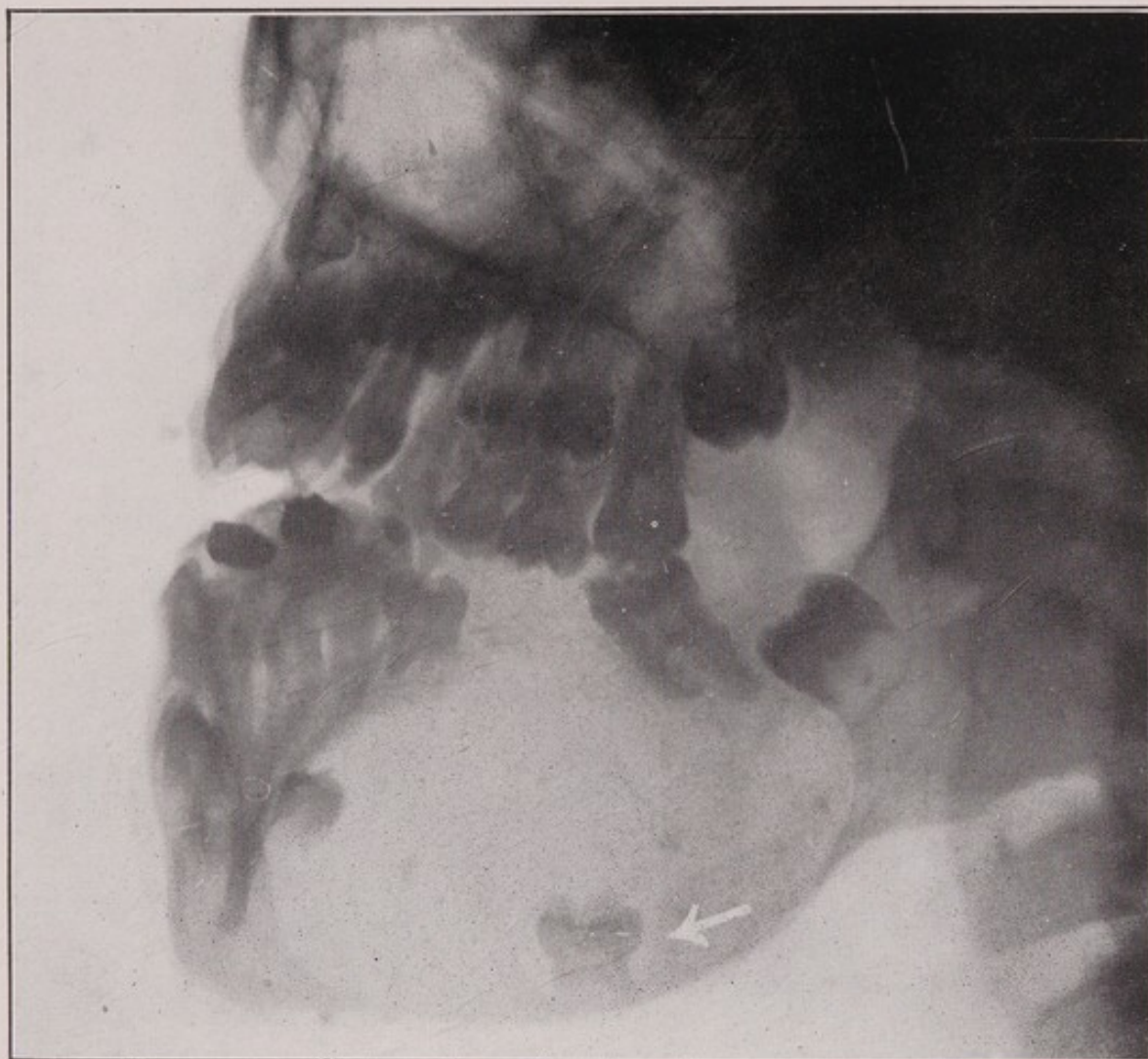


Fig. 257. Dentigerous cyst of the lower jaw in child nine years old. The arrow points to the tooth in the cyst. The light area represents the cyst. (Radiograph by Pancoast, of Philadelphia.)

ciduous second molar tooth at the lower border of the jaw and surrounded by an ovoid clear area. A diagnosis of dentigerous cyst was made.

"At operation through the mouth the shell of bone was found to contain, not the usual fluid, but a resilient mass of pinkish-white tissue surrounded by a sac of darker color. The contents, including the soft tissues, the tooth shown in the picture and the sac, were removed and the cavity lightly packed with gauze. The patient is making an uneventful recovery. The further diagnosis of the case will depend on microscopic examination of the tissue."

Fig. 258 was made for a patient of Dr. J. G. Lane, of Philadelphia. Age of patient, eight. The radiograph shows an unerupted second bicuspid surrounded by a light area representing a dentigerous cyst. The upper wall

Figs. 258 and 259.

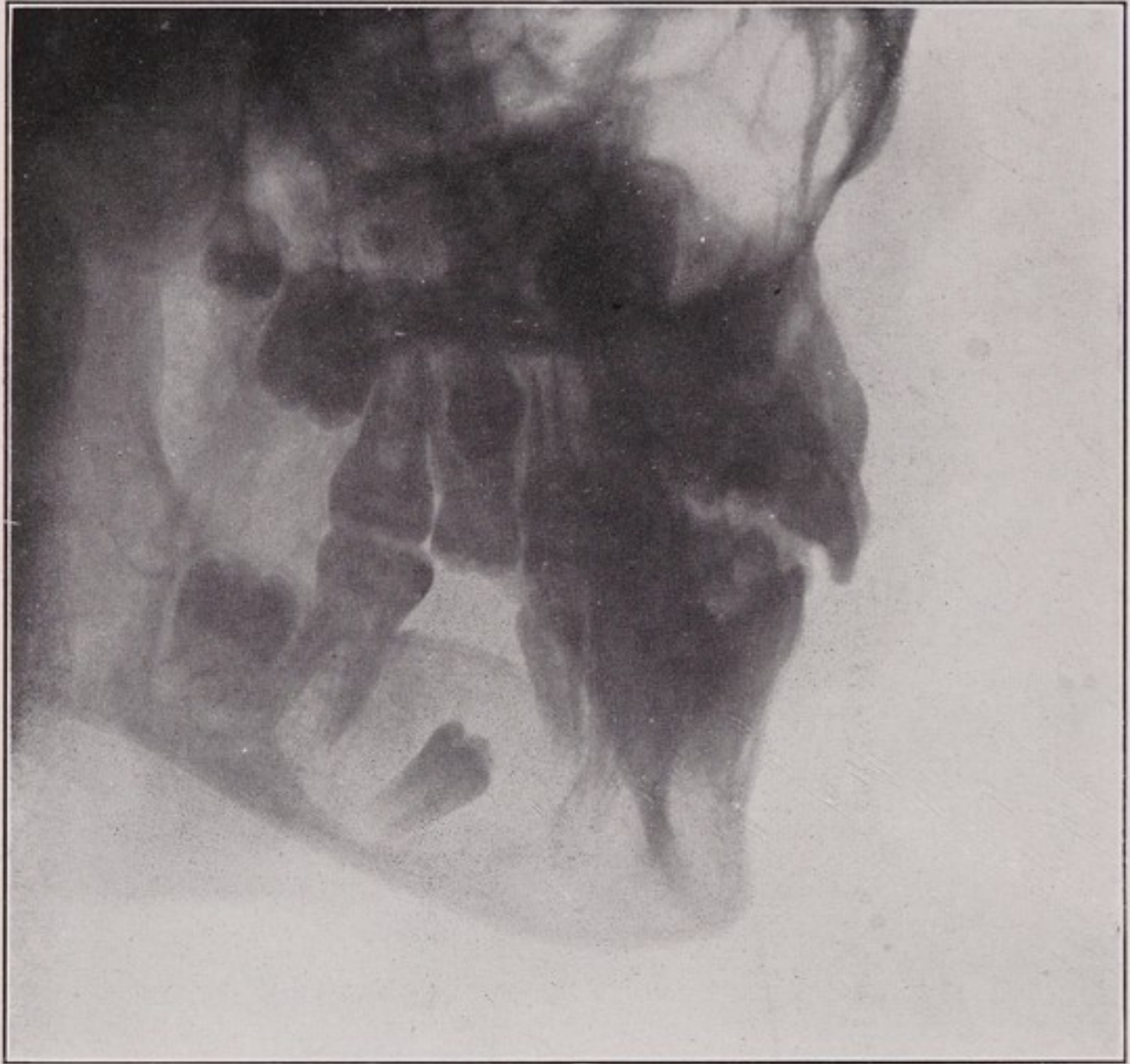


Fig. 258. A dentigerous cyst containing a lower second bicuspid. (Radiograph by Pancoast, of Philadelphia.)

of the cyst and its fluid contents were removed, leaving the tooth in place. A later radiograph (Fig. 259) shows that the tooth is gradually erupting into position. (This history is quoted from a paper by Dr. Cryer.)

44. In Cases of Tumor, Benign or Malignant.

I have already reported a case of cystic tumor, which was referred to the college clinic to have the tumor "cut off." There was nothing to "cut off," and a radiograph showed a cavity in the bone, aspiration of which accomplished a cure.

Fig. 260.

The following cases occurred in the practice of Dr. Cryer: "The two patients were sent by different practitioners from different portions of the State of

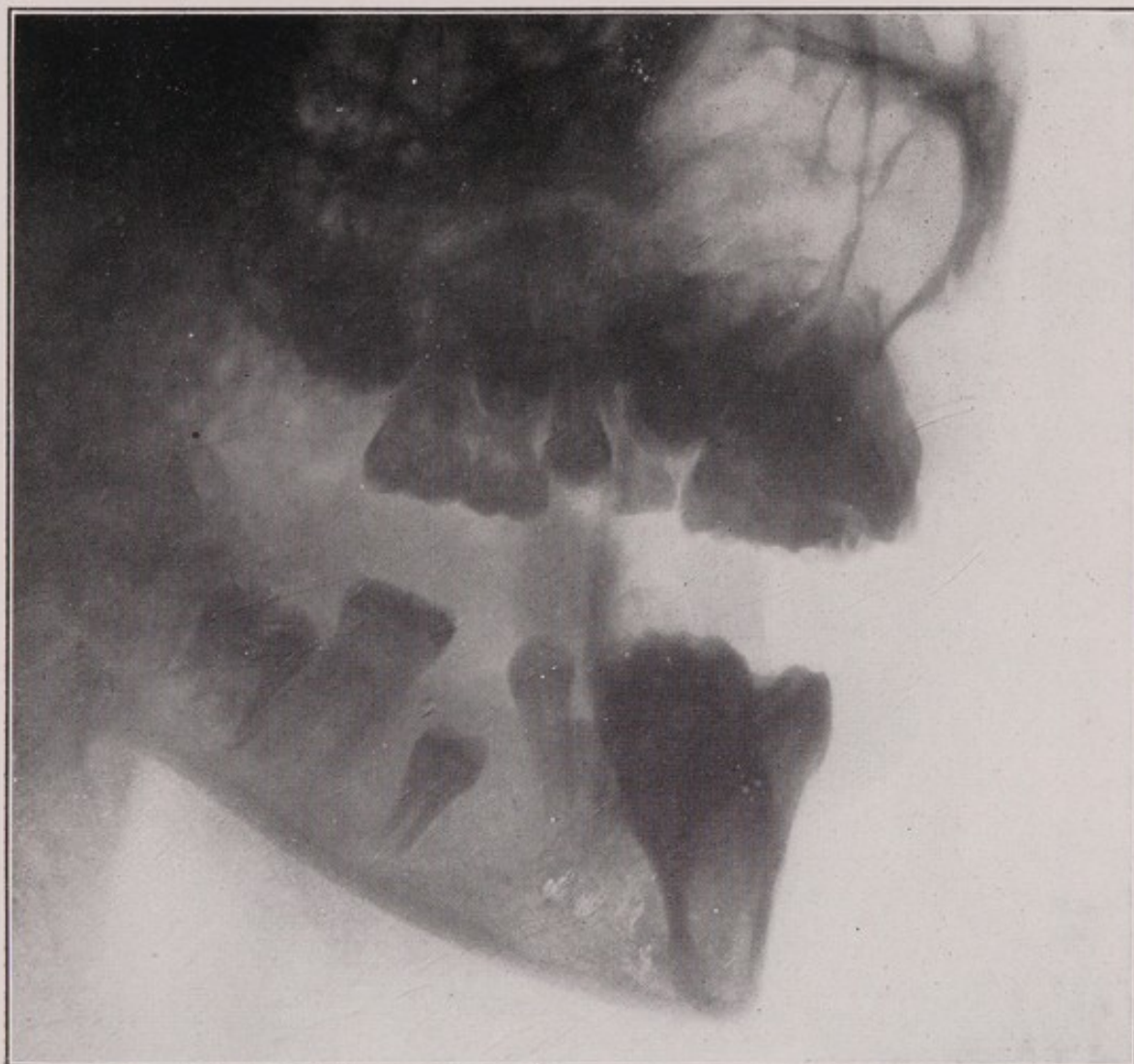

Fig. 259. Same as Fig. 258 after removal of the fluid contents and upper wall of the cyst, showing the second bicuspid erupting into place. (Radiograph by Pancoast, of Philadelphia.)

Pennsylvania, but came for examination on the same day. They were two women patients of about the same age, both wearing full upper artificial dentures and partial lower ones, and both suffering from a similar character of pain, the only difference being that in one patient the pain was located on the left side of the lower jaw, while the other was on the right side of the lower jaw. Physical examination revealed the fact that the right cervical lymphatic glands in one of the patients were slightly enlarged. The history obtained of the cases did not aid in diagnosis. Both patients claimed that the molar teeth on each side had been extracted years ago. X-rays were made of the jaws with the following results:

"Fig. 260 was made from the patient whose cervical glands were

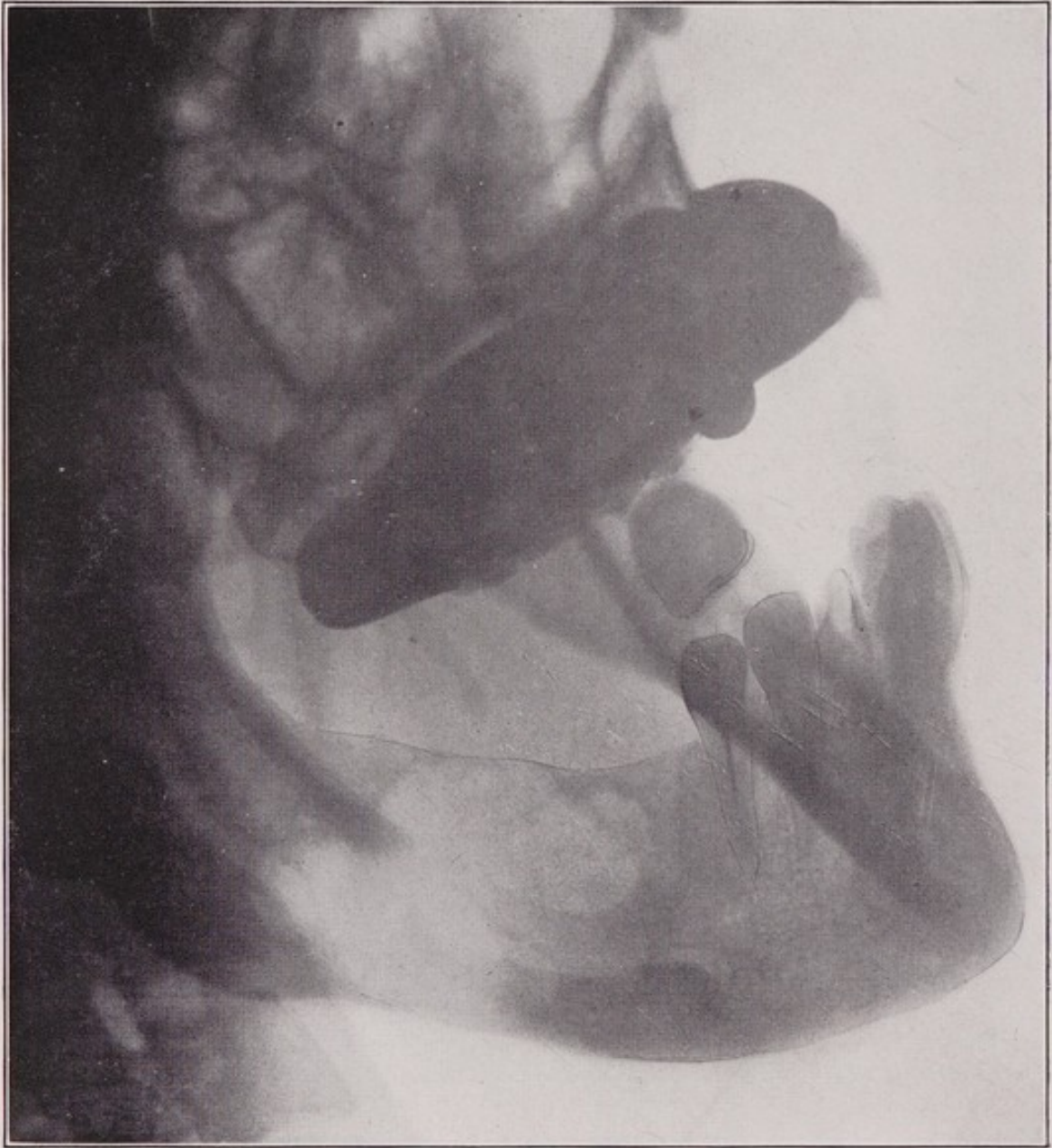

Fig. 260. Myeloid sarcoma of the lower jaw. In appearance it resembles a bone cyst somewhat. (Radiograph by Pancoast, of Philadelphia.)

enlarged. The picture shows a breaking down of the bone, with the two dark shadows indicating abnormal density of the bone in some portions. From this appearance, together with the slight enlargement of the glands, the case was diagnosed as myeloid sarcoma. A microscopic examination of the tissue removed, confirmed the diagnosis."

I do not reproduce the radiograph of the other case because the print I have is not clear enough to permit of a good halftone reproduction. The print before me shows fairly well three impacted lower teeth, one a rudimentary bicuspid, the others a second and third molar.

Dr. Cryer says: "There seemed to be very little difference in these two cases from the history and physical examination, but the wonderful work of the X-rays revealed a very great dissimilarity. On the one hand the skiagraph indicated the sad necessity of removing the entire right side of the jaw and submaxillary lymphatic glands, with the possibility of the disease returning, while in the other case the extraction of the three impacted teeth was the only thing required."

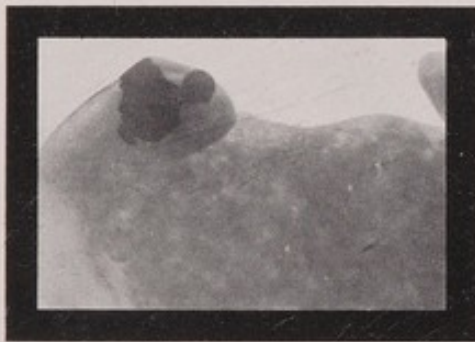

Fig. 261.

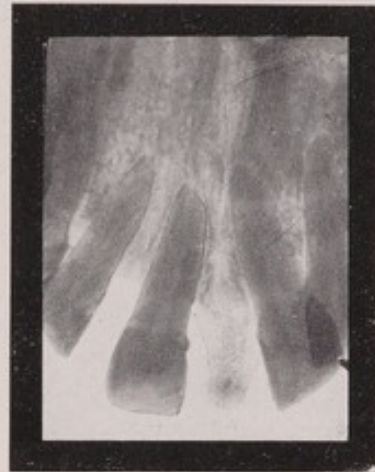

Fig. 262.

Fig. 261. Osteoma (?) of the lower jaw.

Fig. 262. Hypertrophy of the gums and alveolar process. The radiograph shows no irritant cause for the condition, and none was found otherwise.

Fig. 261.

My readers are by this time acquainted with the appearance of normal alveolar process and jaw bone. Fig. 261 shows what I believe to be an osteoma. The patient would not consent to the removal of tissue for microscopical examination. The radiograph shows only that the bone is diseased. The exact nature of the disease must be determined by the microscope.

Fig. 262.

Case: Enlargement of the gums about the upper anterior teeth, causing considerable disfigurement. Fig. 262 shows what was thought to be hypertrophy of the gum tissue and alveolar tissue. Microscopic examination verified the diagnosis. The teeth and the hypertrophied tissue were removed.

Fig. 263.

At the age of thirteen a permanent lateral had failed to erupt. A radiograph was made to learn whether or not it was present in the jaw. Fig. 263 shows the permanent lateral, and shows also why it has not erupted. In

the path of eruption is seen what I believe to be an "epithelial, composite"* odontoma.

Odontomata sometimes assume considerable size. To be absolutely sure in diagnosis, and to be certain of their complete removal, the radiograph should be used.

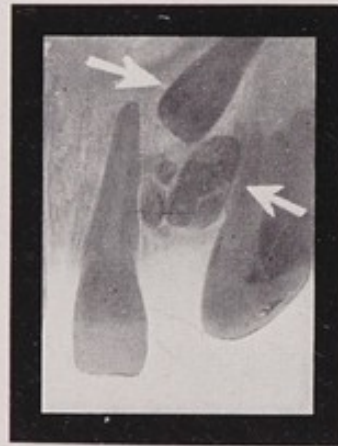


Fig. 263. The upper arrow points to the permanent lateral incisor. The lower arrow points to an odontoma. (Radiograph by Flint, of Pittsburgh.)

Fig. 264.

"The case illustrated in Fig. 264 presents many interesting features from the standpoint of diagnosis and treatment. The patient was a woman about thirty-five years of age, who suffered for a number of years from pains in the ear and the tonsillar region, as well as from difficulty in mastication and deglutition, while her general health had deteriorated to such an extent that she became very anemic, having suffered from malnutrition due, no doubt, to imperfect mastication and the absorption of pus products. In this condition she was referred to the extracting specialist who was unable, from the ankylosis present, to arrive at any definite conclusion as to the possibility of an impacted tooth which was suspected, while the only evidence that pointed in this direction was a free discharge of pus through a fistulous opening in the soft tissues over the third molar region of the right inferior maxillary.

"She was therefore referred to the radiographer when the true condition, as shown in Fig. 264, was revealed. The necessity for removing the displaced second molar, as well as the odontoma, presented a situation which was not a pleasing one to contemplate. The patient, as well as her friends, were informed of the probability of fracturing the mandible in the endeavor to remove the molar and the dental tumor, which together

*Barrett "Oral Pathology and Practice."

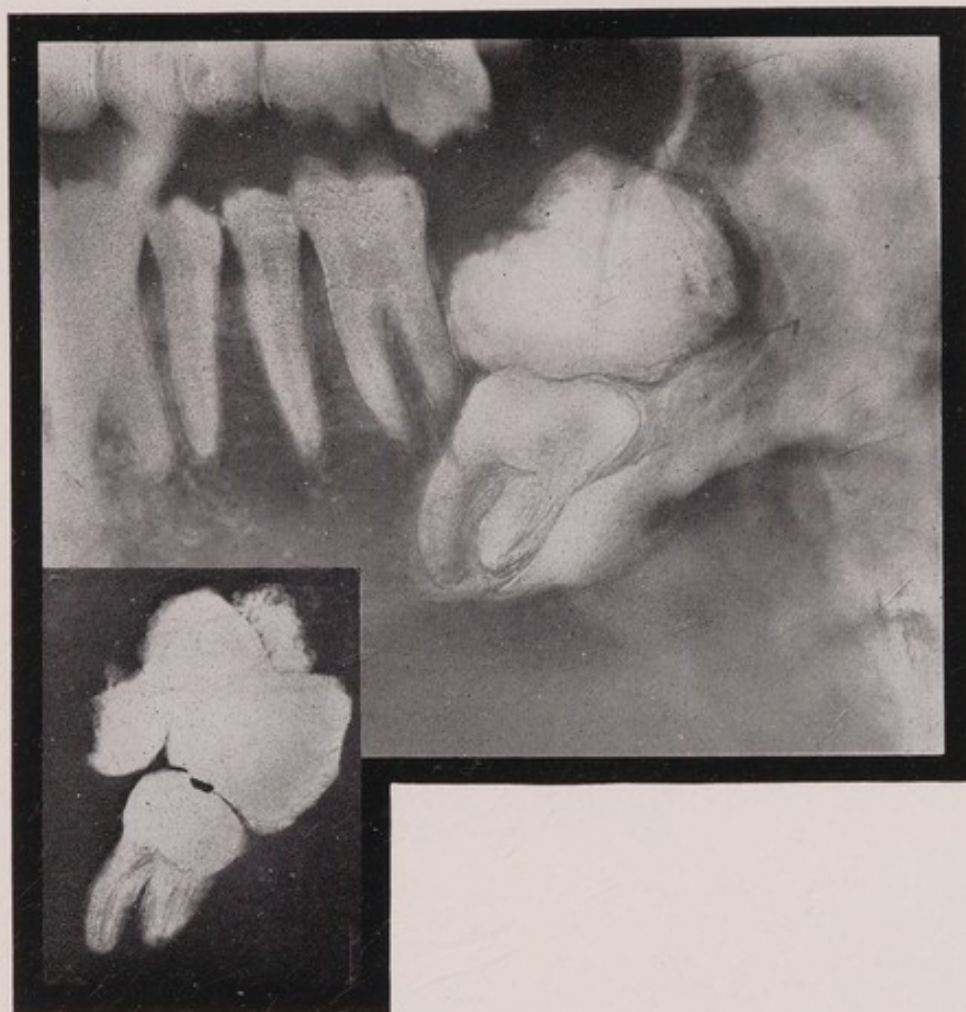


Fig. 264. A large composite odontoma. (Radiograph by Chene, of Detroit.)

occupied almost the entire body of the mandible at the angle of the ramus. Under a general anesthetic of nitrous oxide and oxygen, which was followed by ether, the tumor was removed, as was also the impacted molar, without any great difficulty, but when the circumscribed bony structure about the molar was drilled and chiseled sufficiently to permit of an elevator passing under one corner of it and pressure applied, the expected happened, and a break in the body of the mandible occurred. This accident was of no serious consequence, however, for under an occipito-mental bandage, which a few days later was reinforced by wire fixation, the fracture healed and the case proceeded to an uneventful and speedy recovery, with complete restoration of health. The odontoma was of composite structure, the central part being made up of what may have been the third molar, about which were arranged concentric layers of cementum, and probably some compact bony structures."

For the report of this case I am indebted to Dr. Don M. Graham, of Detroit, Mich.

45. To Observe Anomalous Conditions Such as the Fusion of the Roots of Two Teeth for Example.

Fig. 265. Case: Child about twelve. The crowns of two of the lower incisors seemed fused together. To accomplish regulation of the teeth it became expedient in the opinion of the operator handling the case to extract one of the

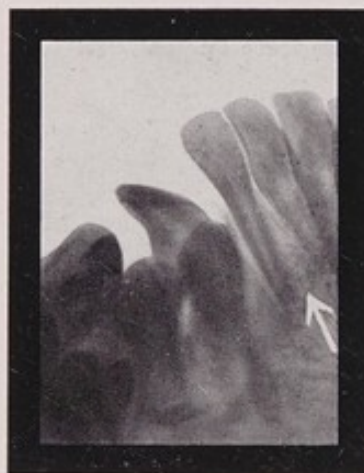

Fig. 265. Shows that the two lower incisors are not fused together.

incisors. The choice of the tooth to extract fell to one of the two which seemed fused together. The question arose: "Are the roots of the teeth fused also?" A radiograph (Fig. 265) shows they are not. It shows further that the crowns are not fused either, though, let me admit, I shared in the mistake of the man who referred the case thinking they were; and failed, as he had, in an attempt to pass a ligature between them. It was not until I had the radiograph before me, showing me that I was not attempting the impossible, that I succeeded in getting a silk ligature between the teeth. One of the teeth was slightly malformed; they were almost mortised together in consequence, and in contact from the incisal edge to beneath the gum margin.

Second and third molars are sometimes fused together. I recall having extracted the upper second and third molars in an effort to remove the third, the roots of the two teeth having been coalesced. Had I used radiographs, and known the condition which existed, I might have conserved the third molar, and so saved the second molar, which latter was a useful tooth. Or, had it been necessary to remove the teeth, I might have saved my patient considerable pain by a more inclusive use of my local anesthetic.

46. To Observe the Location and Extent of a Necrotic or Carious Condition of Bone.

Fig. 266. This radiograph is of a case of arsenical necrosis, which would not yield to the usual treatment of curettement and drug stimulation. The arrow points to the line of demarcation, below which can be seen the sequestrum. The case recovered promptly upon removal of the sequestrum.

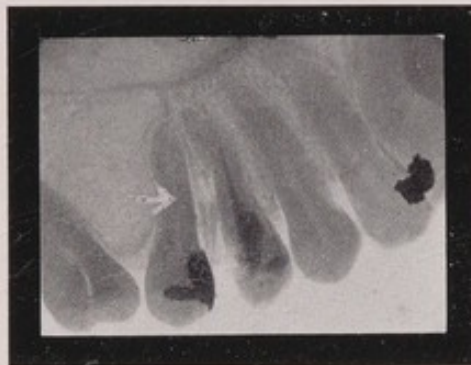

Fig. 266. The arrow points to the line of demarcation, beneath which can be seen the sequestrum.

Figs. 267 and 268. Case: Necrosis of the lower jaw, caused by an abscessed tooth. The patient suffered for a year from recurrence of an abscess in the lower jaw. During this time he made several changes from one dentist or physician to another. At the time the case came under the care of Dr. Gilmer, of Chicago, the symptoms were alarming. There were two external pus sinuses along the lower border of the mandible in the bicuspid region. The patient had been unable to lie down for a period of ten days because of the intense pain which resulted from assuming a recumbent position. The body temperature rose and fell by turns. Stupor and coma occurred.

A radiograph of the case (Fig. 267) shows a sequestrum about the size of the first joint of the thumb along the lower border of the mandible in the bicuspid and cuspid region. The line of demarcation can be seen fairly well in the plate before me. I regret that I was unable to obtain a good print of this case. The negative was an excellent one, but the photographer who made the print from it did poor work.

The operation, done by Dr. Gilmer, of Chicago, was as follows: An external incision was made along the lower border of the mandible in the region of the sequestrum, and the sequestrum removed through it. The bone was curetted, a drainage tube inserted, and the incision sewed up. The first bicuspid and cuspid were extracted.

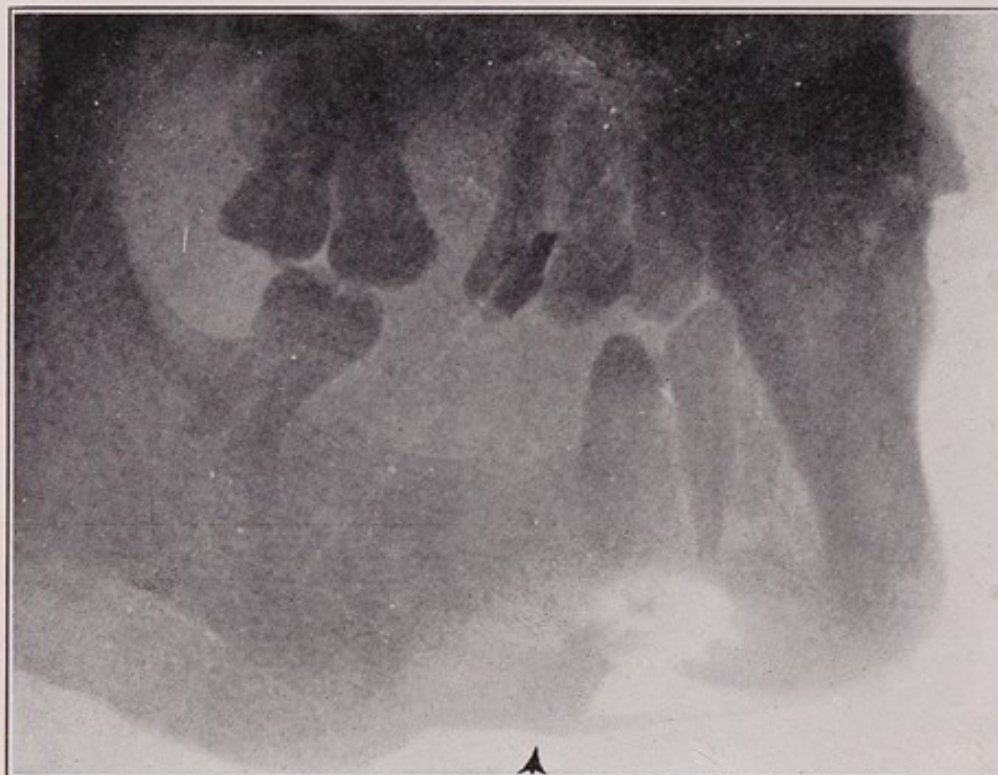


Fig. 267. The arrow points to a sequestrum about the size of the first joint of the thumb.
(Radiograph by Porter, of Chicago.)

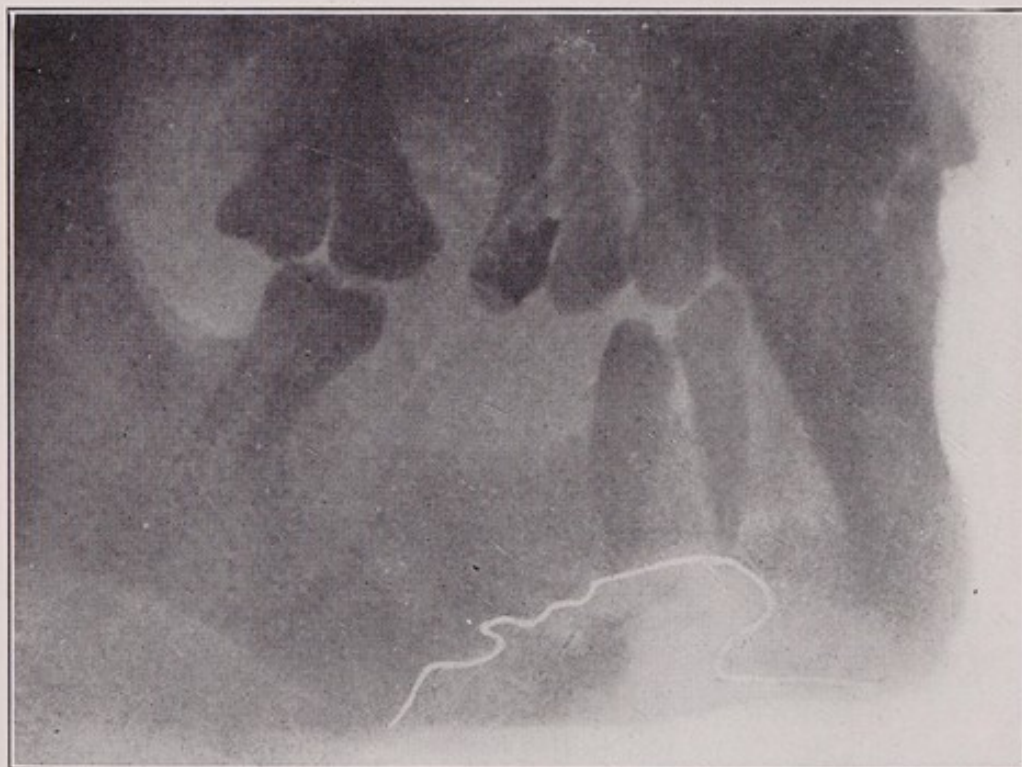

Fig. 268. Same as Fig. 267, with the line of demarcation outlined to enable the reader to observe it better than in Fig. 267.

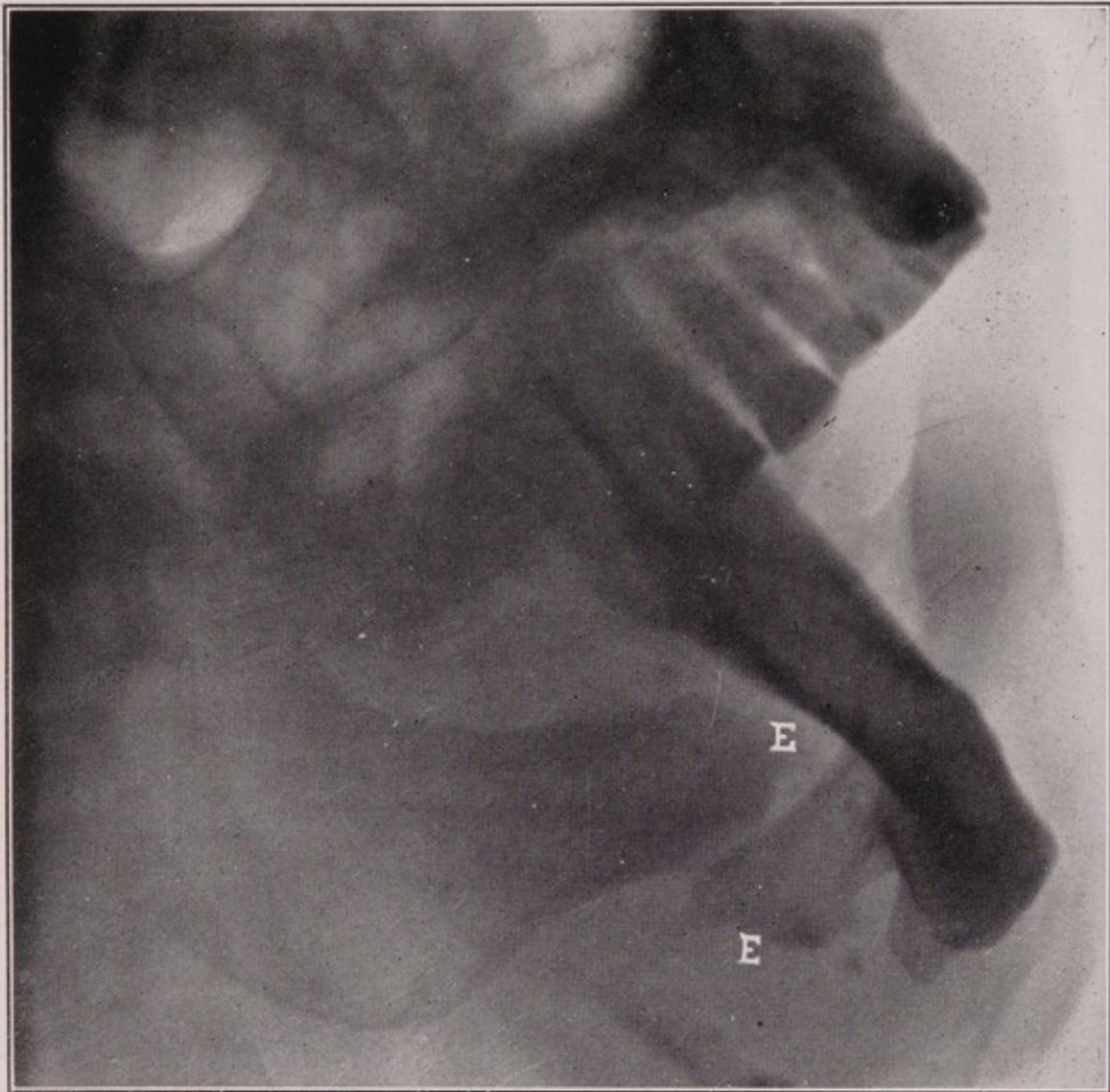


Fig. 269. EE, ends of overlapping bone.

Had the operator not had a radiograph to guide him in his work he could not possibly have performed the operation as quickly, thoroughly, and intelligently as he did, for he would not have known just where, and just how big, the sequestrum was.

Fig. 269.

A case of phosphor necrosis of the lower jaw several years after removal of the sequestrum. The jaw is in two parts, with the ends overlapping.

Fig. 270.

A carious condition of the alveolar process and superior maxillary bone, caused by the retention of a piece of tooth root above the dummies of a bridge.

Curettement and stimulation with drugs might, or might not, be necessary in this case, but it is probable that the carious bone will regain normal health and vitality upon removal of the direct cause of the caries—the bit of tooth root.

47. To Diagnose Antral Empyema.

This radiograph was made from a dry skull. It shows the following: The frontal sinuses AA, the orbits BB, ethmoid cells CC, the nasal cavity DD, and the maxillary sinuses EF. The sinus E is filled with lead shot, the sinus F has a molar tooth in it. The picture is printed to give one an opportunity to study the "landmarks" of such a radiograph, and so enable one to interpret the coming pictures more readily.

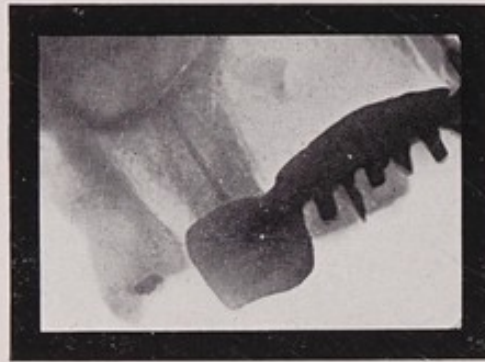Fig. 271.

Fig. 270. Carious condition of the alveolar process and bone, caused by a piece of tooth root above the dummies of a bridge. (Radiograph by Lewis.)

Fig. 272.

To observe pus in the antrum it is necessary to make a radiograph of both antra, that they may be compared. In Fig. 272 the antrum A is filled with pus, the antrum B is healthy. It must be borne in mind that the radiograph alone does not demonstrate to us the presence of *pus* in the antrum. It shows us only that there is *something* in the antrum. The appearance of the radiograph would be about the same, whether that something were pus or a soft, tumorous growth. Such a radiograph as Fig. 272 will show whether the disease is confined to the antrum or involves the ethmoidal cells and frontal sinuses. In this case the disease exists only in the antrum.

Cloudiness of the antrum A indicates a pathological condition. In Fig. 273 the arrows point to a dark shadow, which is an impacted upper third molar tooth. Fig. 274 is a lateral view of the same case, and shows the impacted tooth clearly. Extraction of the tooth effected an immediate cure. (This case was one in the practice of Dr. Cryer.)

Figs. 273 and 274.**48. To Observe the Size, Shape and Location of the Antrum, as an Aid in Opening into It.****Fig. 275.**

Unless a pus-filled antrum is opened at its lowest point, it cannot be perfectly drained. Unless it is perfectly drained the operation cannot result

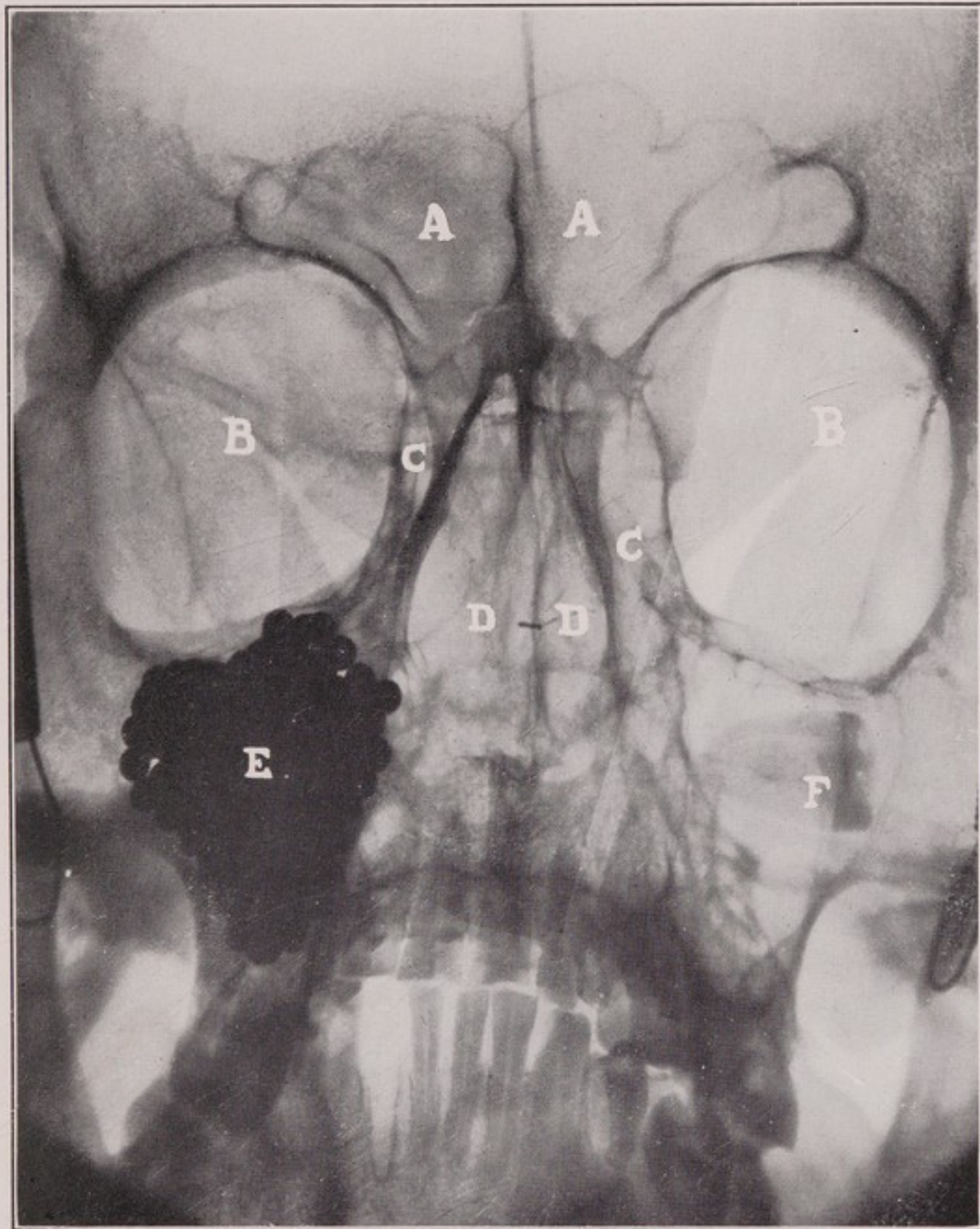


Fig. 271. Radiograph of a dry skull. One antrum is filled with lead shot, the other has a molar tooth in it. This radiograph is clearer than one made from the living subject because there were no soft parts or circulating blood to blot out detail.

in a permanent cure. The size, shape and location of the antrum can best be observed stereoptically. Often, however, a good idea of its size, shape and location can be obtained from a radiograph, like Fig. 276, for example. Radiographs of the antrum made on films held in the mouth

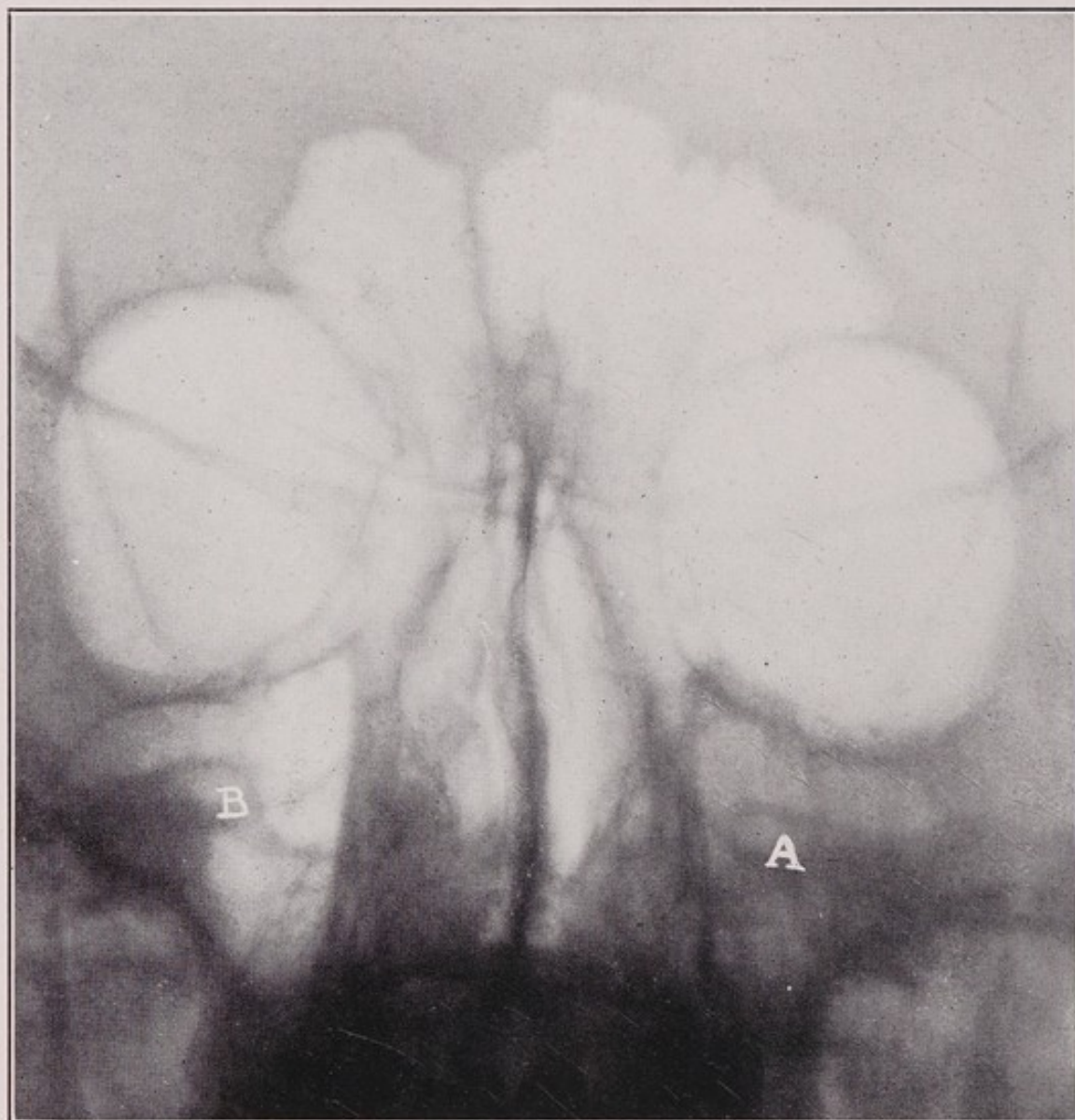


Fig. 272. A, antrum with pus in it. B, healthy antrum. (Radiograph by Carman, of St. Louis.)

are very misleading and confusing, as witnessed in Fig. 275, which was made on a film held in the mouth, and is of the antrum filled with lead shot—illustrated in Fig. 271.

Fig. 276. The dots outline a very large antrum. An opening made at the favorite site for opening into the antrum through the mouth, above their apices, between the second bicuspid and first molar (the first molar has been extracted), would not puncture this antrum at its lowest point. The root of the second molar seems to penetrate the antrum. Whether it actually penetrates the floor of the antrum or not I cannot say definitely, because

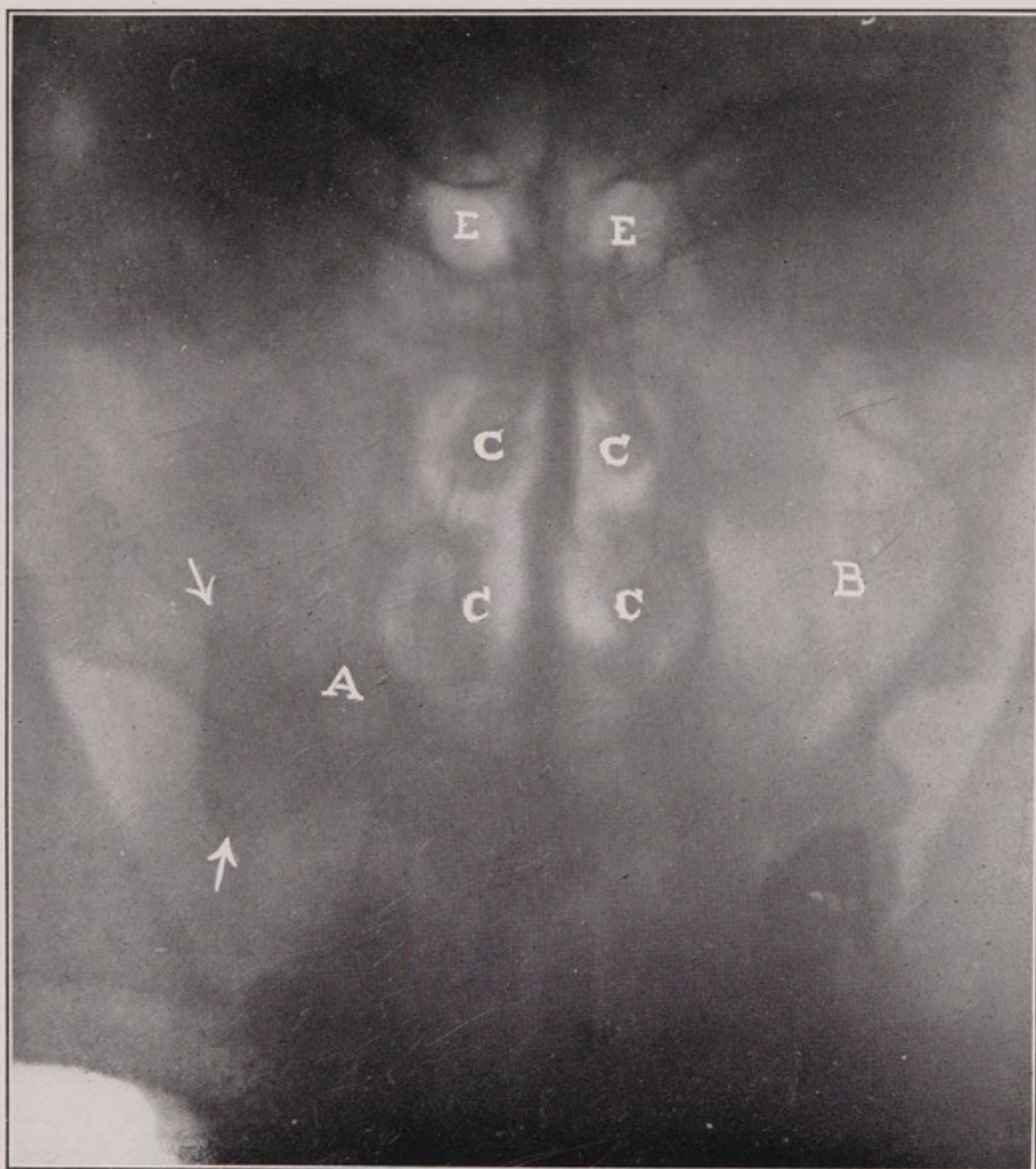


Fig. 273. A, diseased antrum. The shadow pointed to by the arrows is an impacted third molar. B, healthy antrum, CC, turbinate bones, EE, very small frontal sinuses. (Radiograph by Pfahler of Philadelphia.)

of the lack of perspective in the radiograph. I am inclined to think, however, that it does not—the lower part of the antrum and the end of the root overlap, the tooth root passing to the lingual of the antrum.

Because of its unusual size the lower part of the antrum was thought to contain a malignant growth. Dr. Cryer rejected this interpretation, saying that the antrum must have been of the size shown in the radiograph before the formation of the second and third molars, and that the large antrum was responsible for the pinched-together condition of their

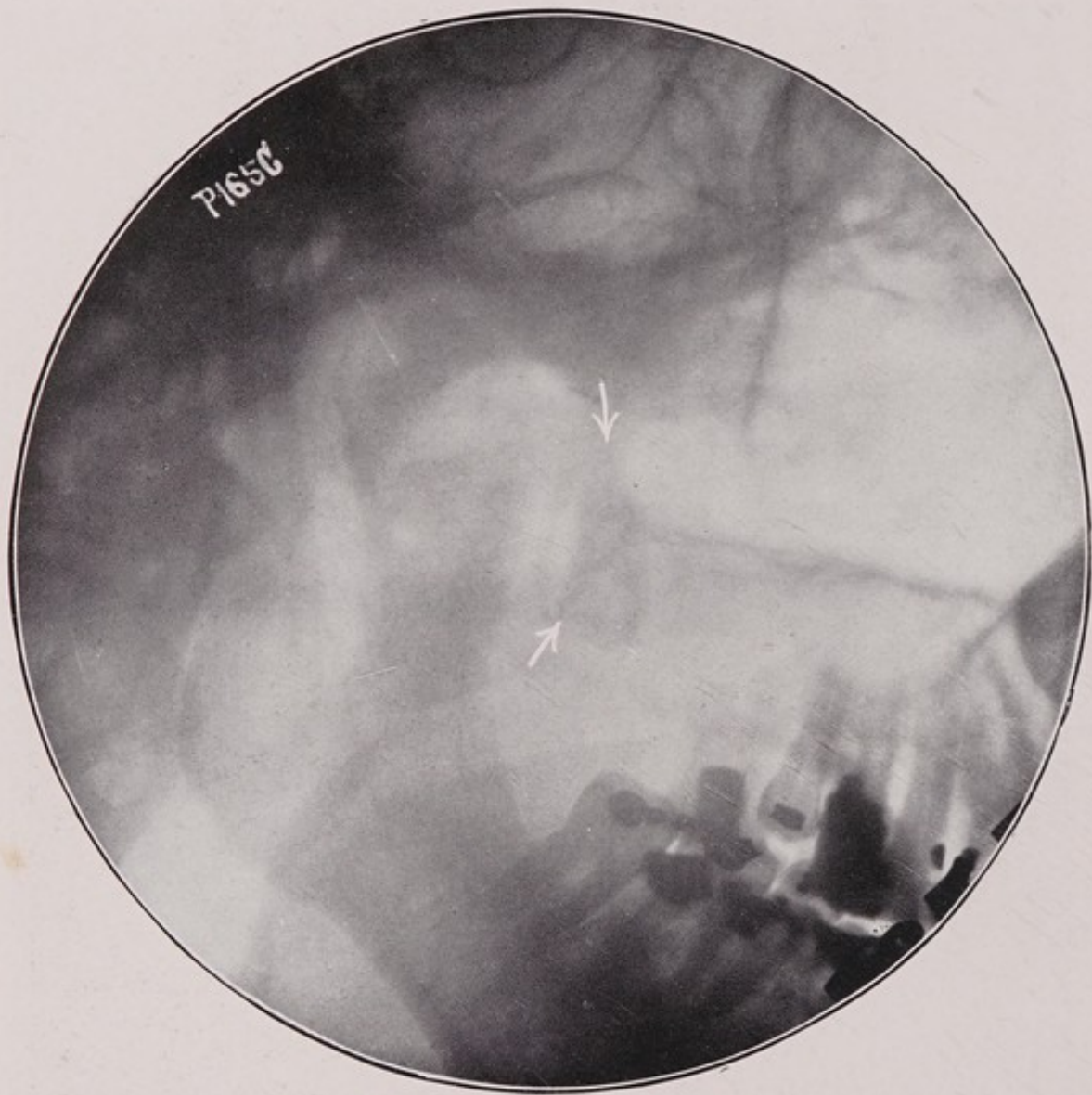

Fig. 274. Lateral view of the same case illustrated in Fig. 273. This radiograph shows the impacted tooth clearly. (Radiograph by Pfahler of Philadelphia.)

roots. He theorized further, accounting for the pain the patient suffered by surmising that the pinched condition of the roots of the third molar was causing pressure on the dental pulp. In his description of the case Dr. Cryer does not mention the faulty canal filling in the second molar as a possible cause for the pain. Both molar teeth were extracted and the patient was freed from neuralgia.

49. To Locate Foreign Bodies, Such as Tooth Roots or Broaches, in the Antrum.

Fig. 277 shows a piece of tooth root in the antrum. It is a portion of the second bicuspid, which had been extracted (?) about a week previous to the time when the patient presented to Dr. Virgil Loeb for treatment. The

Figs. 277 and 278.

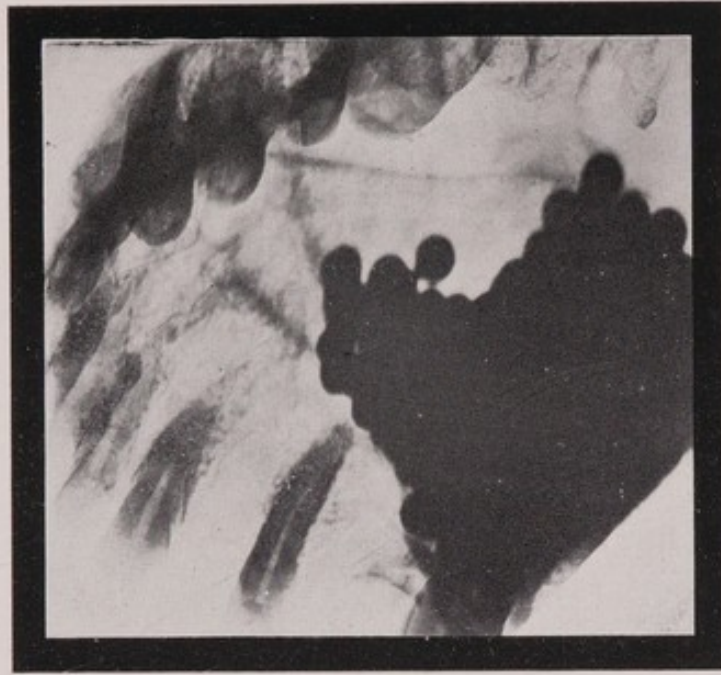


Fig. 275. Antrum filled with lead shot. The same as Fig. 271.

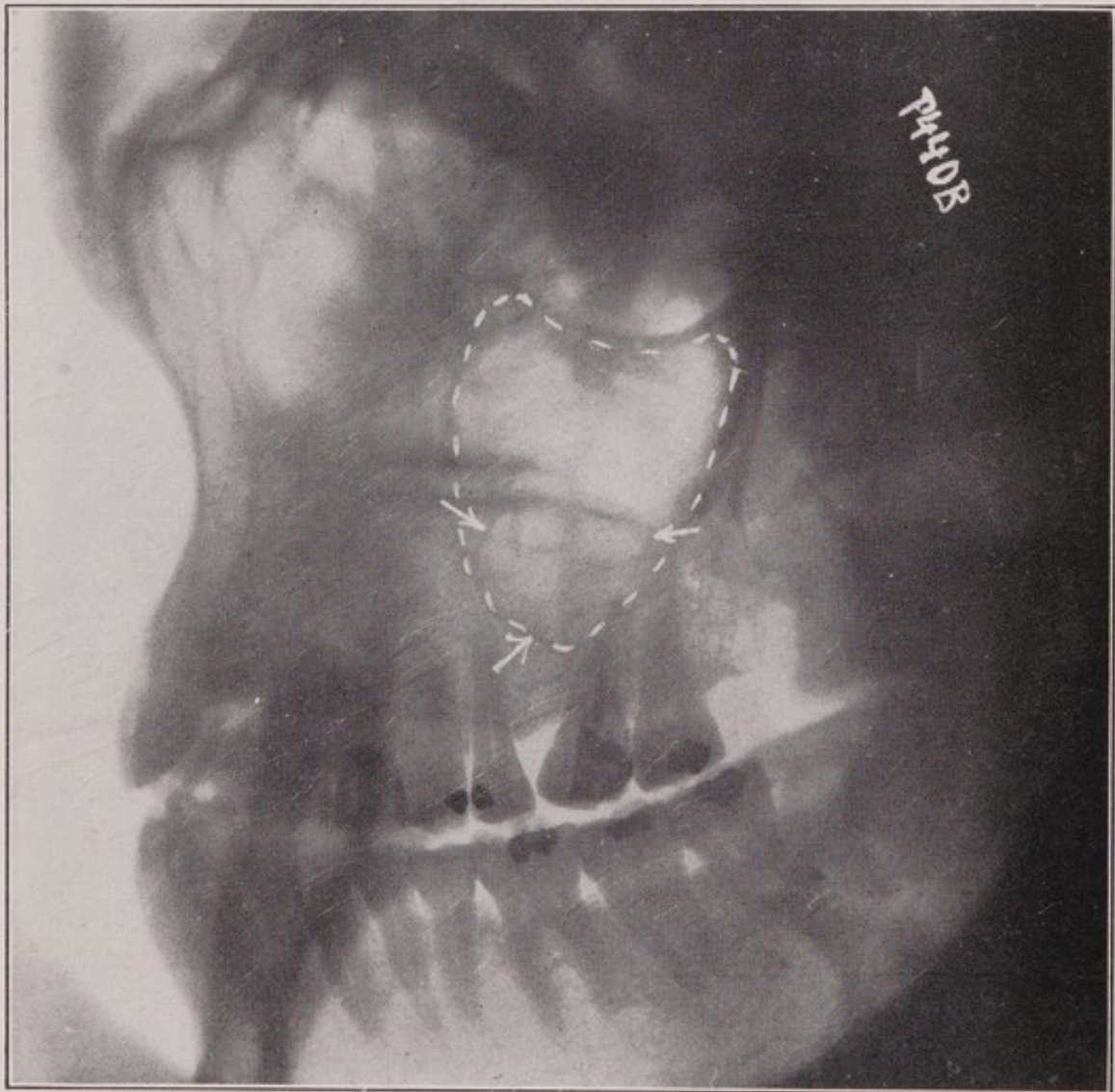

Fig. 276. The dots outline a very large antrum. A septum is seen in this antrum dividing it into two parts. The arrows point to the lower part. (Radiograph by Pfahler, of Philadelphia.)

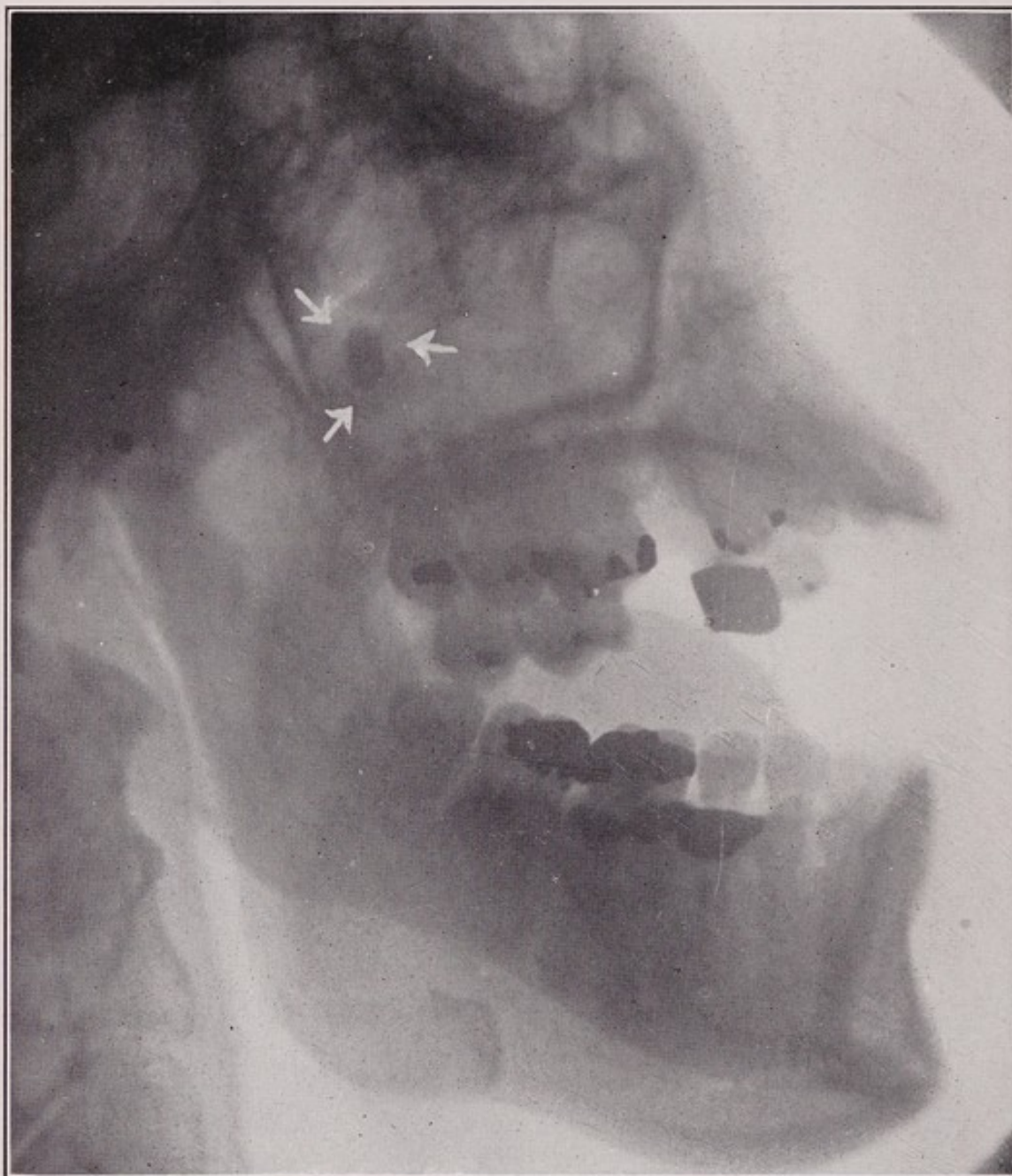


Fig. 277. The arrows point to a piece of tooth root in the antrum. (Radiograph by Carman, of St. Louis.)

first molar was extracted, an opening made into the antrum through one of its alveoli, and the piece of root removed. The object of the operation was to remove the piece of tooth root from the antrum. This was accomplished. And again let me repeat what I have said before: An operator may make a greater mistake than that of the extraction of a tooth—he may conserve the tooth at the expense of the health and happiness of the patient. Conservative dentistry often, all too often, means conservation of disease.

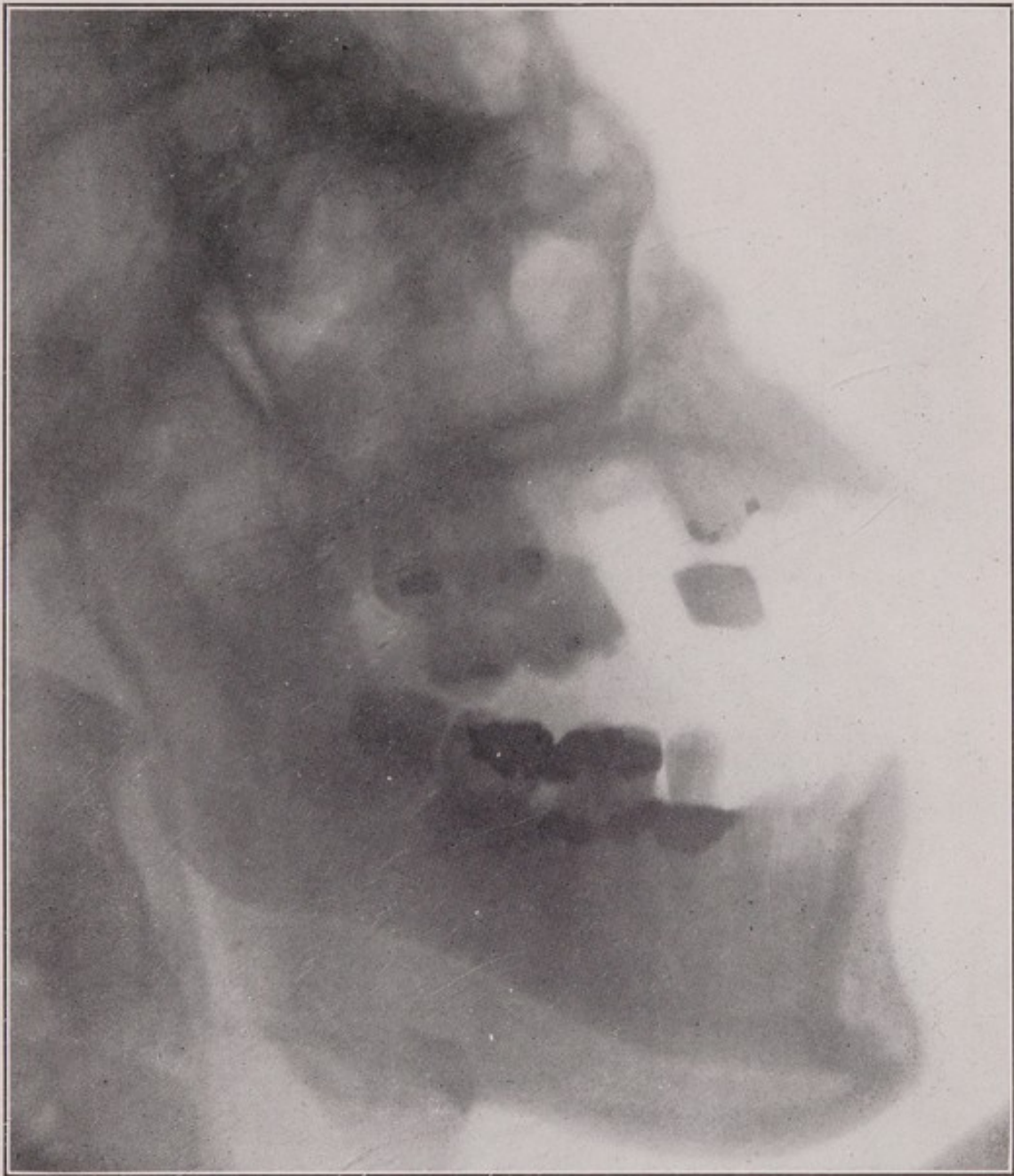

Fig. 278. Same case as Fig. 277 after removal of the piece of tooth root. (Radiograph by Carman, of St. Louis.)

Fig. 279. Dr. Cryer says of Fig. 279: "It is made from a patient who had trouble in the maxillary sinus for some time. The picture demonstrated that a piece of rubber tubing, which had been used for drainage, had slipped into the antrum and become lodged in the region of the ostium maxillare. After its removal and a brief treatment, the part became well."

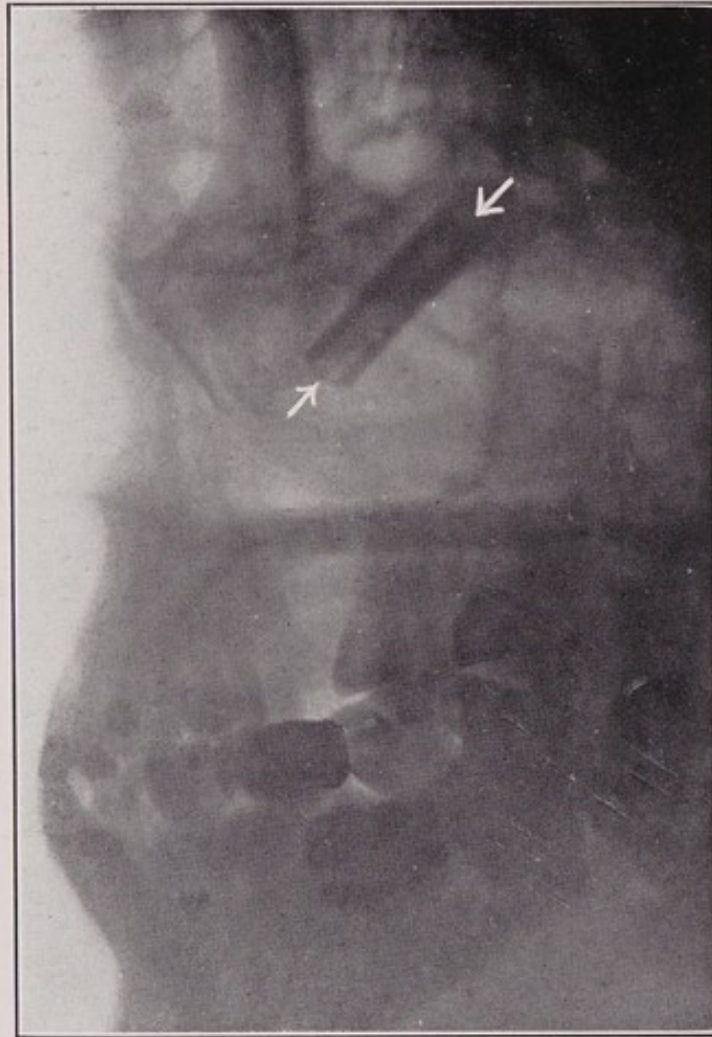


Fig. 279. The arrows point to a piece of rubber tubing in the antrum. (Radiograph by Pancoast, of Philadelphia.)

50. To Observe Cases of Luxation Before and After Reduction.

The symptoms of dislocation of the condyle from the glenoid fossa are so characteristic that, it seems to me, even the most inexperienced should recognize them with ease. It is a fact, however, that the case illustrated in Figs. 280 and 281 was diagnosed dislocation, because I presume the patient could not get the anterior teeth together. The radiographs show two fractures. Fig. 280 near the angle, and Fig. 281, of the other side of the jaw, in the second bicuspid region.

This radiograph is by Tousey, of New York City, and is one of the clearest radiographs of the temporo-mandibular articulation ever made from a living subject.

Fig. 282.

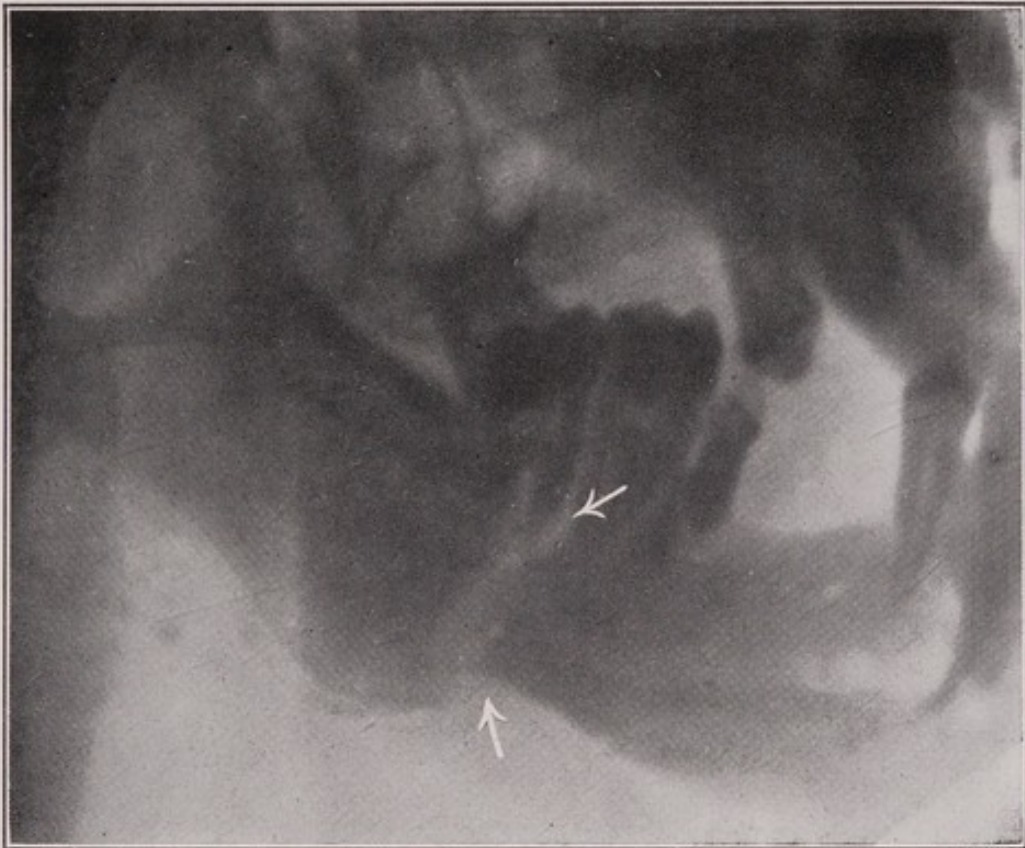


Fig. 280. The arrows point to a fracture of the jaw in the region of the angle. (Radiograph by Cole and Raper.)



Fig. 281. The arrows point to a fracture of the lower jaw just posterior to the second bicuspid. The opposite side of the same jaw radiographed in Fig. 280. (Radiograph by Cole and Raper.)

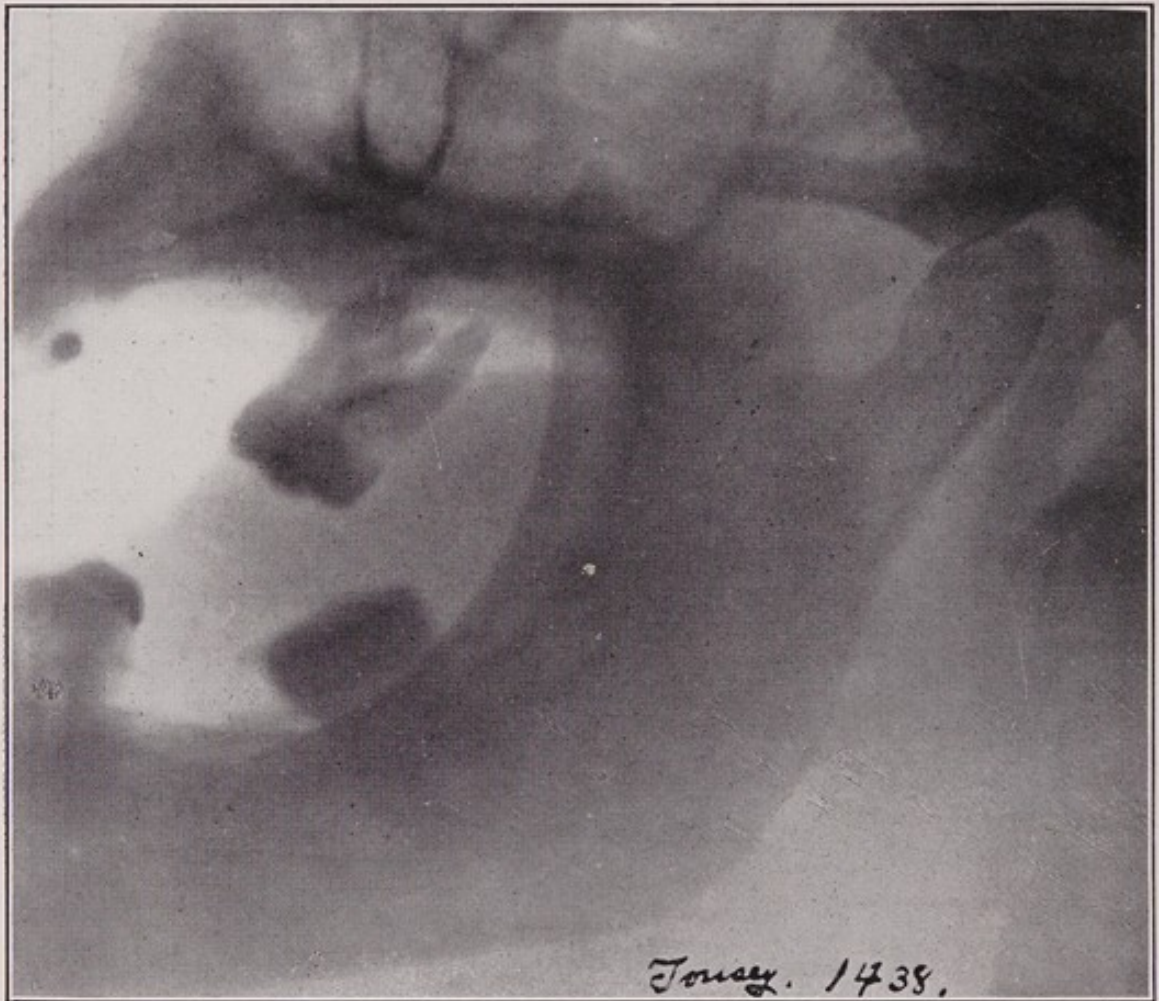


Fig. 282. Excellent radiograph of the temporo-mandibular articulation. Made from a living subject. (Radiograph by Tousey, of New York City.)

Figs. 283 and 284. Case: Dislocation of the condyle from the glenoid fossa. Fig. 283 shows the condyle A anterior to the *eminentia articularis* B. Fig. 284 of the same case after reduction. While it fails to show the condyle itself clearly, it shows the neck of the condyle and demonstrates that, in this picture, the condyle A is on the other side of the *eminentia articularis* B.

51. In Cases of Fracture of the Jaw.

Fracture of the jaw is almost always accompanied by such a great deal of swelling and induration that digital and ocular examination are highly unsatisfactory. The operator who treats a fracture should know just where and what kind of a fracture he is dealing with. If there be displacement of the fragments, he must know how much, and in what direction, the displacement occurs, in order that he may properly readjust the parts. This knowledge can be gained only by the use of radiographs—

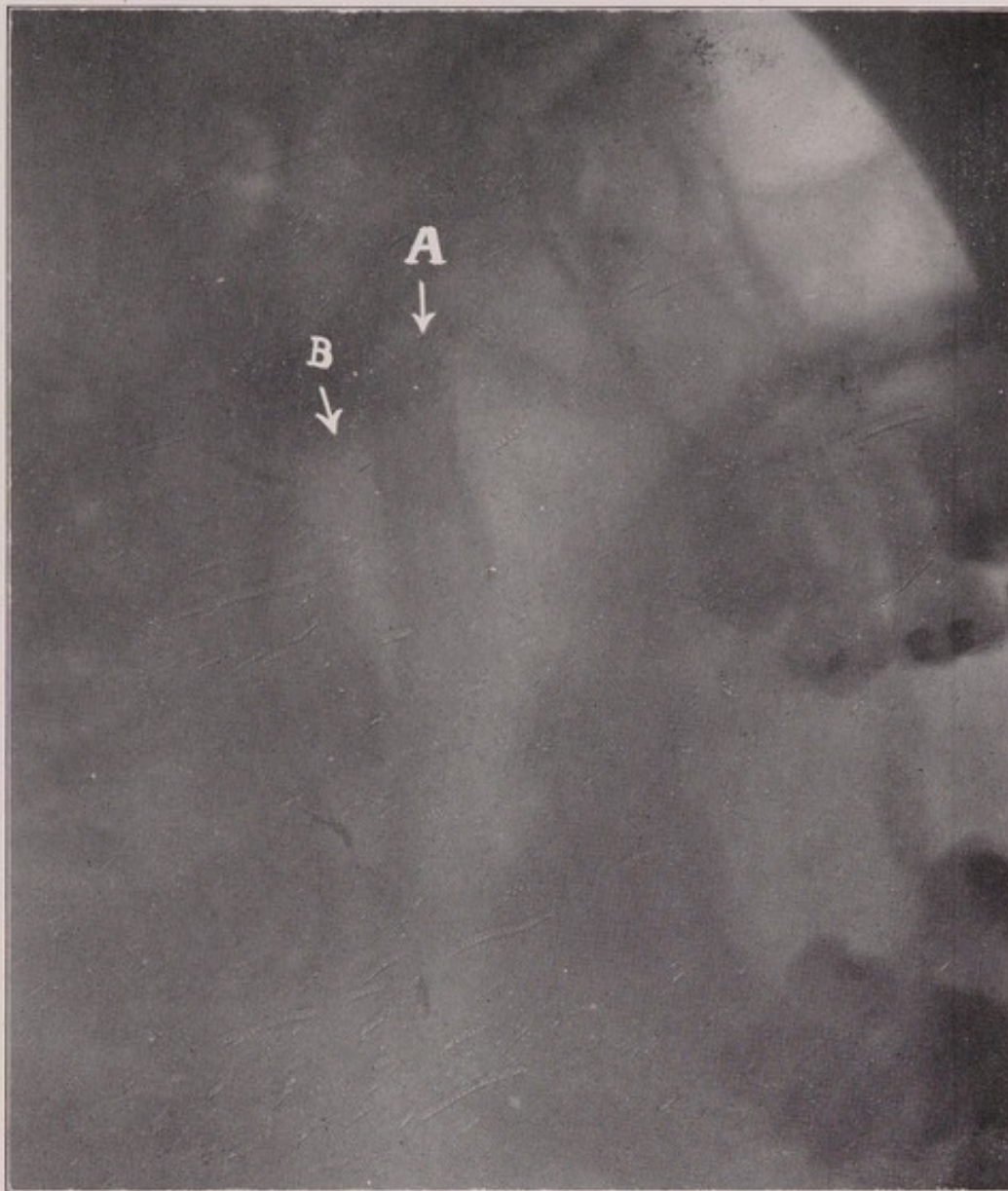


Fig. 283. Dislocation of the condyle from the glenoid fossa. A, condyle. B, eminentia articularis. (Radiograph by Cole and Raper.)

stereoptic radiographs in cases where there is considerable displacement of the fragments.

Fig. 285.

Fracture at the symphysis. The appliance on the teeth is being used as a splint.

Figs. 286 and 287.

Case in the practice of Dr. Cryer. Fig. 286 shows a fracture of the mandible at the angle. The body of the jaw is displaced downward. Fig. 287 is of the same case after reduction and adjustment of an interdental splint. While the apposition of the fractured ends is not perfect yet, there is a

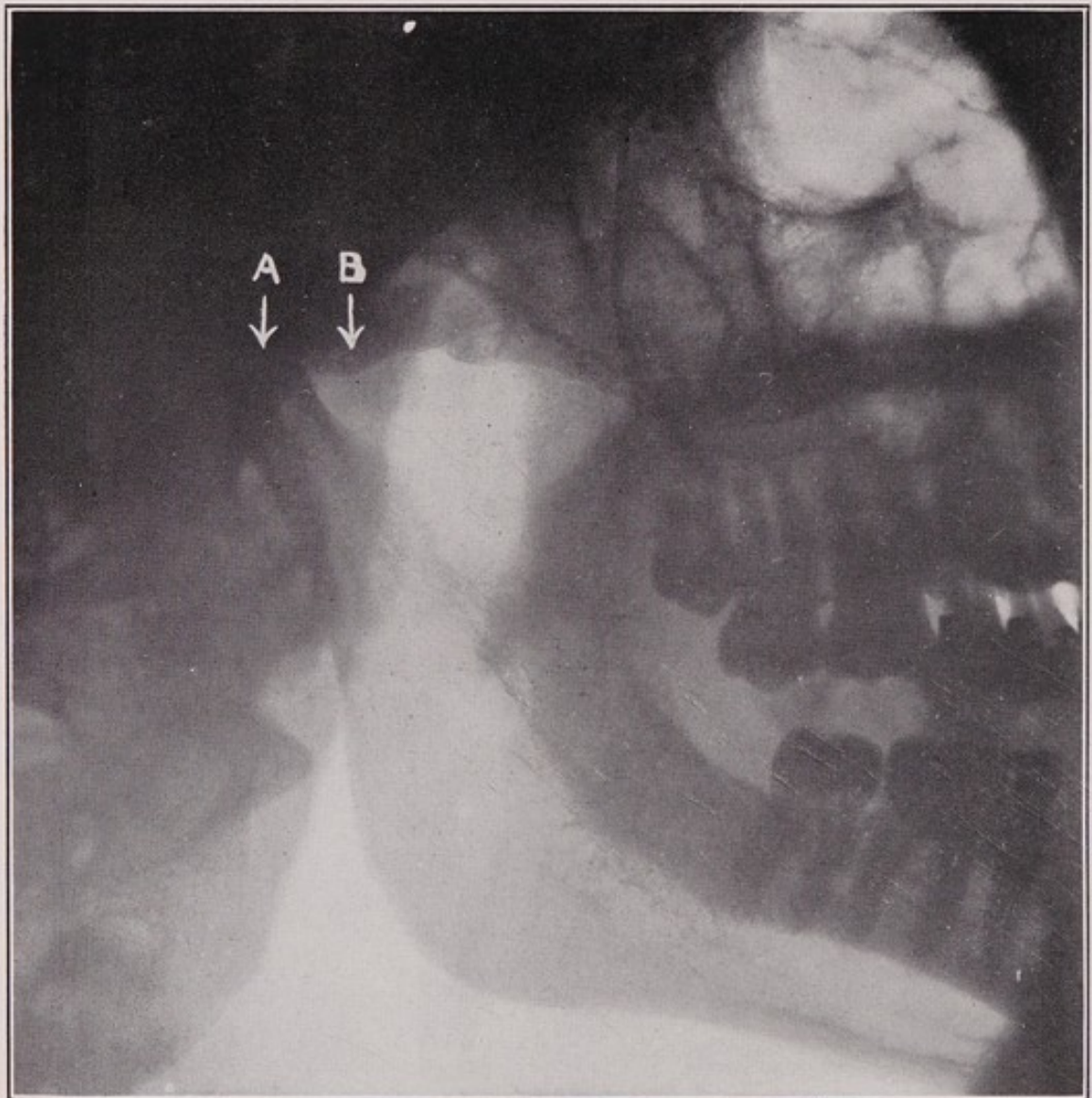


Fig. 284. Same as Fig. 283 after reduction of the dislocation. A, condyle. B, eminentia articularis. (Radiograph by Cole and Raper.)

very great improvement over the condition showed in Fig. 286, and I believe the apposition to be as near perfection as human ingenuity is capable of carrying it.

Just when to remove a splint and bandage from a fracture case is always a problem. The splint shown in Fig. 287 was removed at the end of the eighth week. Dr. Loeb, of St. Louis, Mo., states that radiographs are a great aid in determining just when to remove splints.

Fig. 288.

A double, comminuted fracture of the mandible four months after the accident. The bone in the region of the fracture is necrotic.

52. In Cases of Ankylosis of the Temporo-Mandibular Articulation or the Joint Formed by the Tooth in the Jaw.

The radiograph is of value in cases of ankylosis to observe the cause of the ankylosis.

Fig. 289.

Case: A miner who had sustained a traumatism resulting in ankylosis. The ankylosis had existed for several months at the time Fig. 289 was made. The dots outline the missing parts, *i.e.*, the anterior border of the ramus and

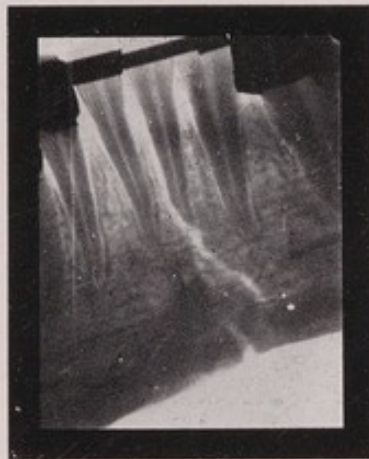

Fig. 285. Fracture of the mandible at the symphysis. (Radiograph by Blum, of New York City.)

the coronoid process. The disease of the bone could not have failed to affect the temporal and masseter muscles. It is my belief that in this case the true muscular tissue was destroyed and replaced with cicatricial tissue, which condition caused a false ankylosis. I consulted two surgeons, but neither was able to suggest a corrective operation.

An orthodontist was unable to move a tooth into proper occlusion. He referred the case to me, thinking perhaps the presence of a supernumerary tooth body was responsible for the immobility of the tooth. A radiograph demonstrated the absence of any such body, and showed that the tooth had practically no peridental membrane at all. There was a condition of partial ankylosis, to overcome which it was necessary for the orthodontist to reinforce his anchorage and exert more force on the refractory tooth. I do not print a radiograph of this case because of the great difficulty of showing the peridental membrane, or the absence of it, in a half tone.

53. To Observe the Field of Operation before and after Resection of the Mandible.

Resection of the mandible is a difficult, radical operation, and one which has been performed comparatively few times. With the exception of Dr. Ballin (*Items of Interest*, June, 1908), operators who have done this operation have not, so far as I am able to learn, availed them-

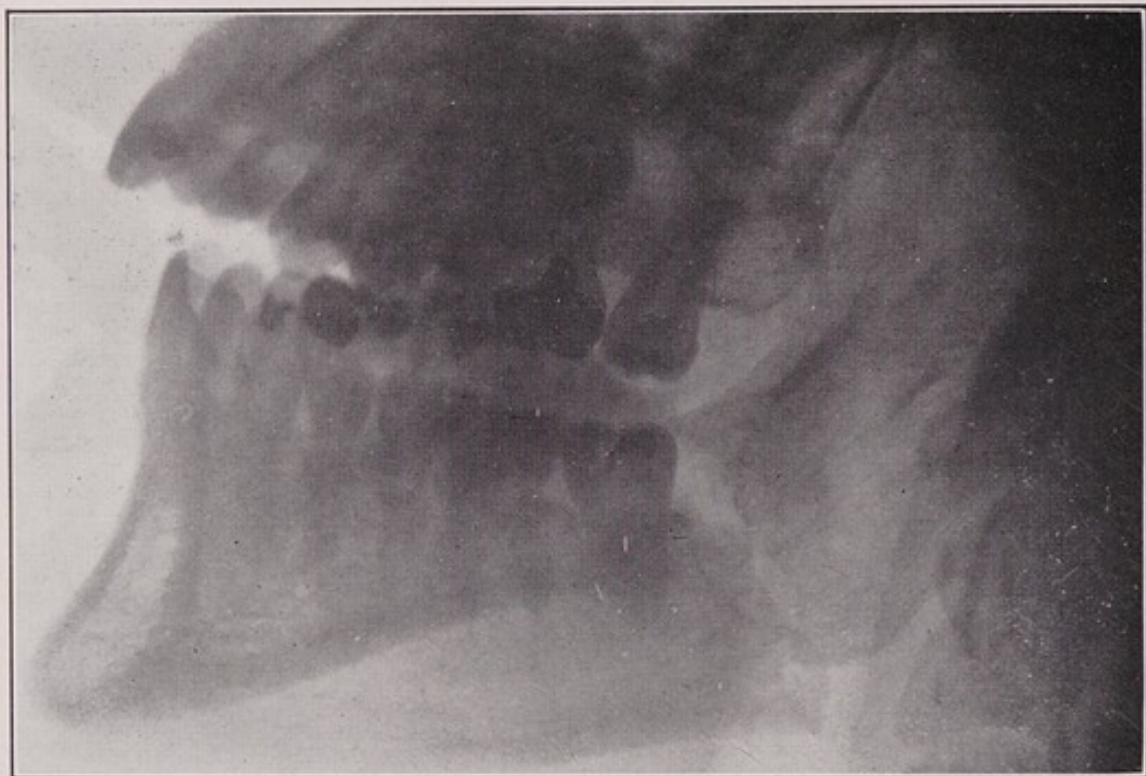


Fig. 286. Fracture at the angle of the mandible. Displacement of fractured ends. (Radiograph by Pancoast, of Philadelphia.)

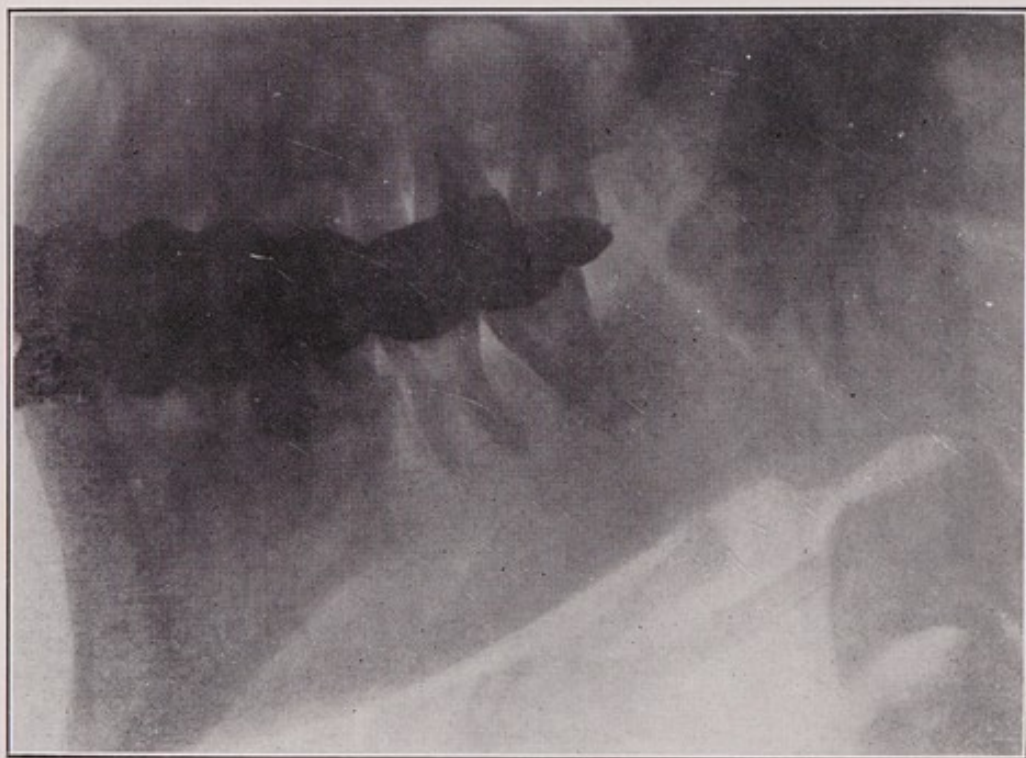

Fig. 287. The same as Fig. 286 after reduction and adjustment of an interdental splint. (Radiograph by Pancoast, of Philadelphia.)

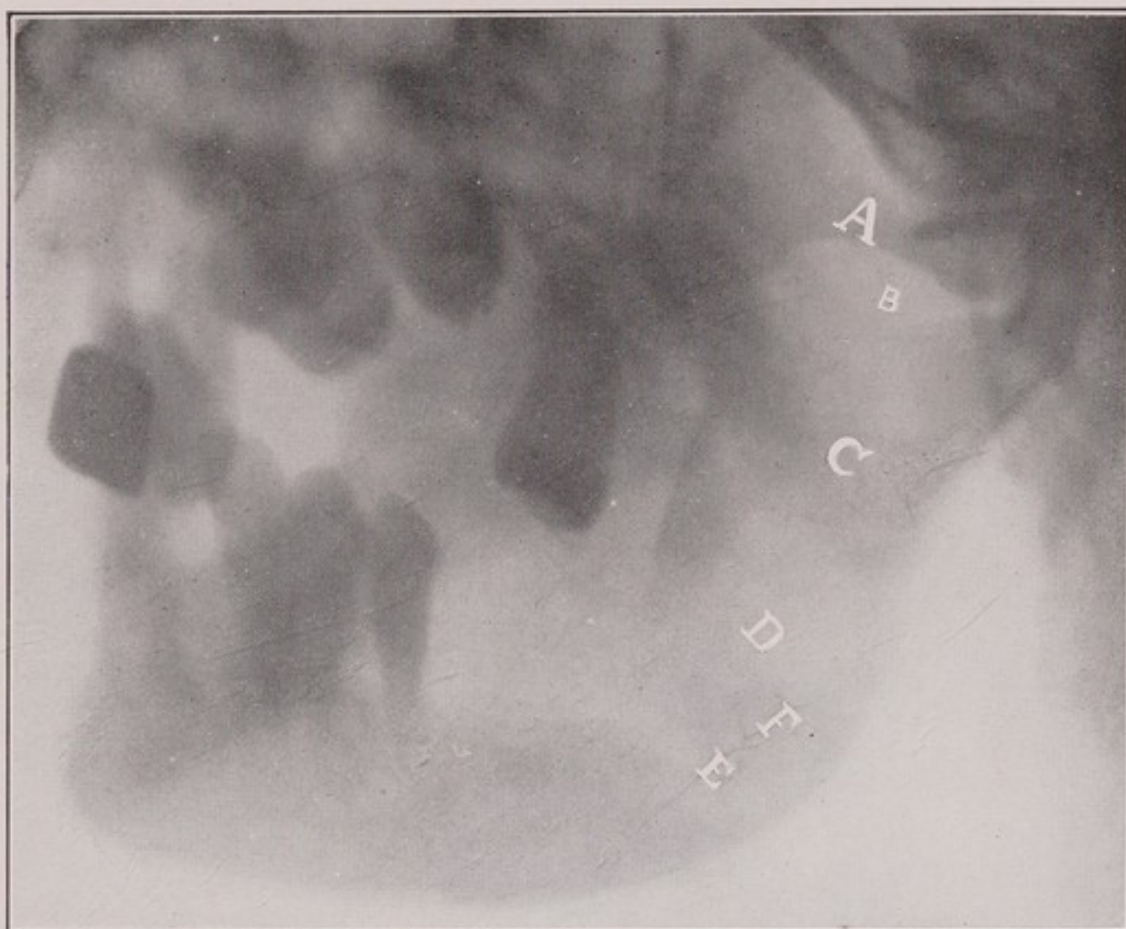


Fig. 288. Double comminuted fracture of the mandible. That the reader may understand the picture, observe the following: A, zygomatic arch; B, sigmoid notch; C, upper part of ramus; D, one fracture; E, the other fracture; F, fragment of bone between fractures.

selves of the assistance which good radiographs of the case would have rendered. Resection of the mandible might become necessary as a result of an existing pathological condition of the bone, or it might be done to correct a bad case of prognathism. For whatever reason the operation may be done, the operation itself is the same, in that a piece of the mandible is removed. Consider the operation for prognathism, for example: A piece of the body of the mandible from each side is cut out and removed. The anterior part is then forced back and the cut ends of the bone (four of them) wired into apposition. That anti- and post-operative radiographs of such a case would be of value is apparent.

54. In All Cases of Facial Neuralgia with an Obscure Etiology.

Cases of facial neuralgia with an obscure etiology, the exciting cause for which was disclosed by the radiograph, have already been described under more specific headings—Figs. 159, 164, 176, 177, 179, 224, 246, 247, 248, 249, 250, 264, and others. Until the exciting cause is found when it then receives a more specific name, any dental pain is likely to be referred to as neuralgia.

When making radiographs to learn the cause of trifacial neuralgia, it is expedient usually to make a large 8 x 10 picture of the affected side. This radiograph can then be studied and, if some lesion is discovered, another radiograph of the particular region of the lesion made on a small film. The second radiograph, on the film, will be clearer than the one on the plate, and will verify or disprove the findings in the larger picture.

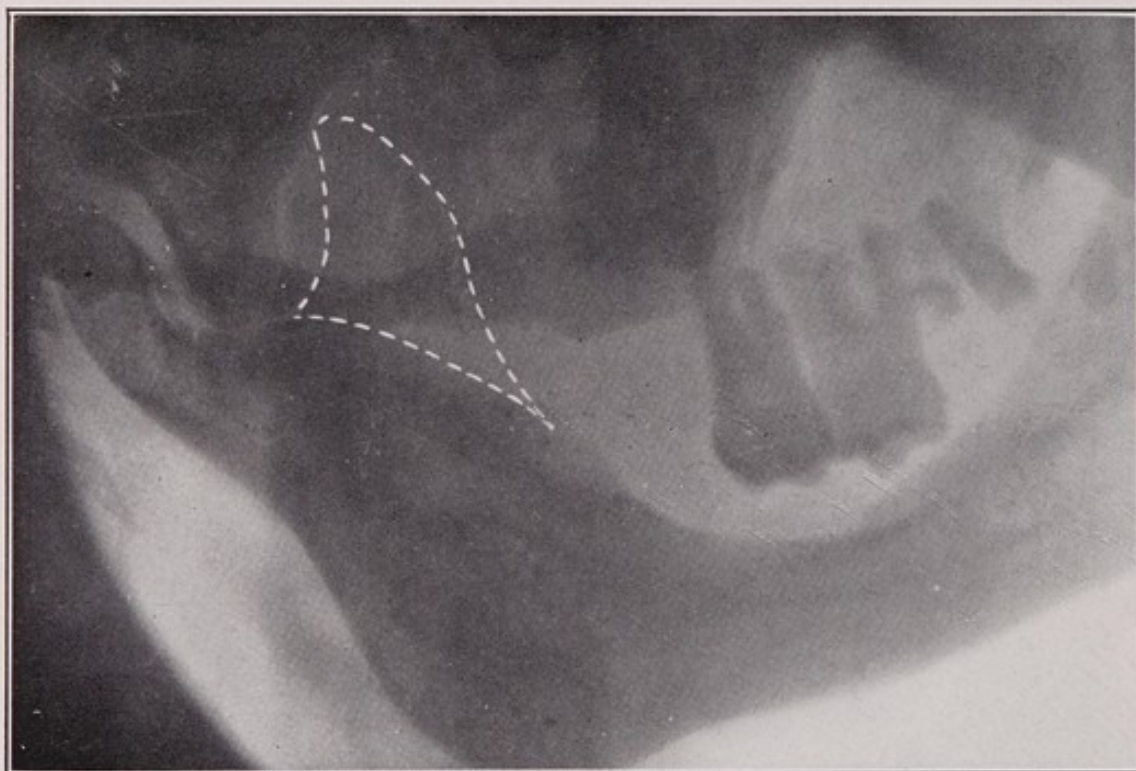


Fig. 289. The dots outline the missing parts—i.e., the anterior border of the ramus and the coronoid process. (Radiograph by Cole and Raper.)

Figs. 290 and 291. Case: Married woman, middle age, suffered from pains in the region of the upper bicuspids. The dentist could find no lesion that might be responsible for the trouble. A radiograph (Fig. 290) was made, but does not show the upper teeth clearly. It does, however, show a shadow in the body of the mandible in the region of the *lower* first molar, which tooth is missing from the jaw. A radiograph (Fig. 291) of the region in which the shadow appeared was made on a small film held in the mouth. The film was not placed in exactly the proper position and, as a result of this mistake, pictures only a part of the lesion. It shows the crown of a supernumerary lower bicuspid with three supernumerary bodies (denticles) above it. Though the lesion in the lower jaw was not at the location in which pain occurred, it was doubtless responsible for the neuralgia.

The patient would not submit to an operation. The case, if not operated upon, will probably progress to a large dentigerous cystic tumor. Evidence of this can already be noticed in Fig. 290 by the lack of normal density of the surrounding bone.

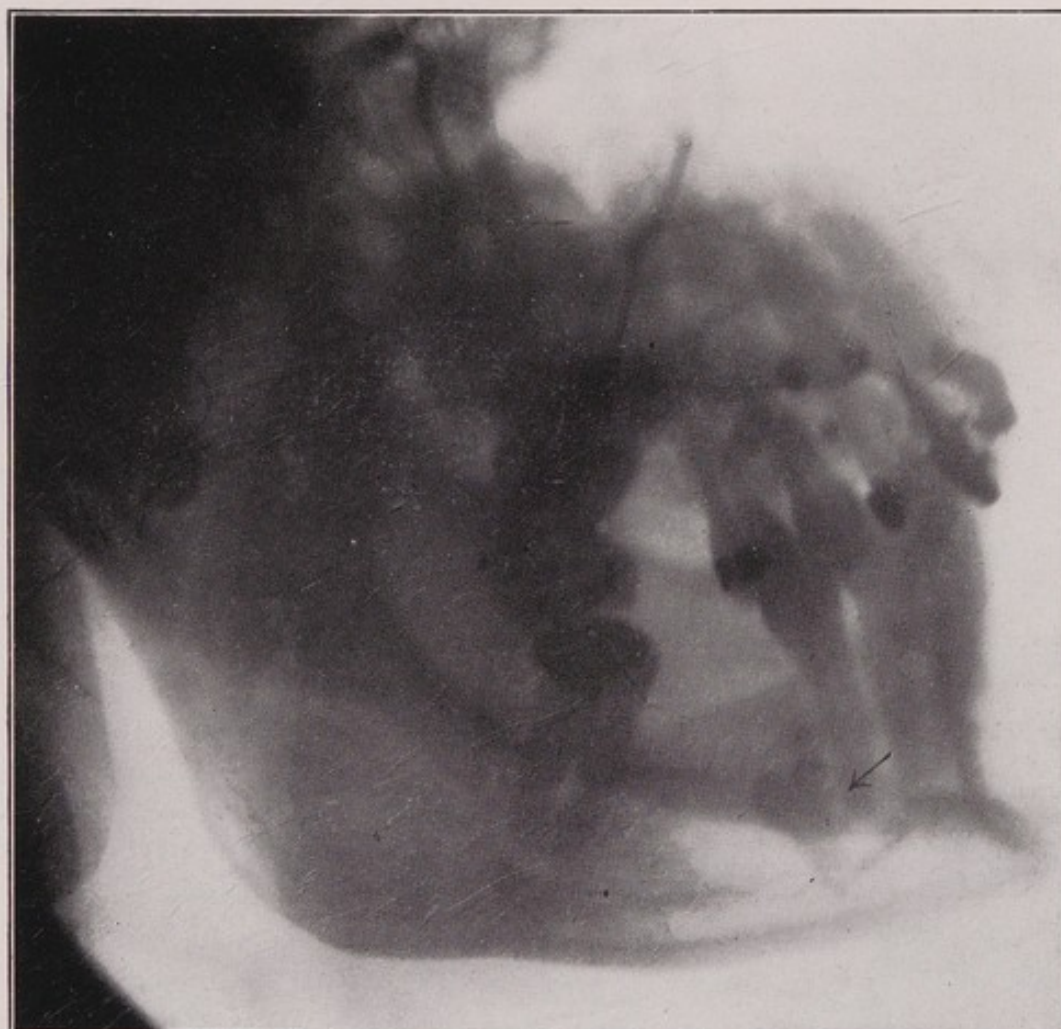

Fig. 290. The arrow points to a shadow in the body of the mandible in the region of the lower first bicuspid. (Radiograph by A. M. Cole, of Indianapolis.)

Fig. 292. Case: Married woman, physician's wife, about forty-eight years old, had suffered for twenty-five or thirty years with attacks of neuralgia occurring four or five times a year, each attack lasting for several days. None save dental operations were performed, though she received palliative treatment for ear, mastoid cells and antrum trouble. No treatment gave relief. She left her home in Indiana and spent one winter in South Carolina, hoping the milder climate would ward off the attacks of pain, but this proved futile. At no time did her temperature rise above normal, prov-

ing, or seeming to prove, that whatever the irritation, there was little or no suppuration attending it. A radiograph (Fig. 292) was finally made, and showed an impacted upper third molar. This tooth was removed, and since then, now over four years ago, she has not had a single attack of neuralgia.

Attention is called to the fact that up to the time of making the radiograph this was a typical case of idiopathic facial neuralgia.

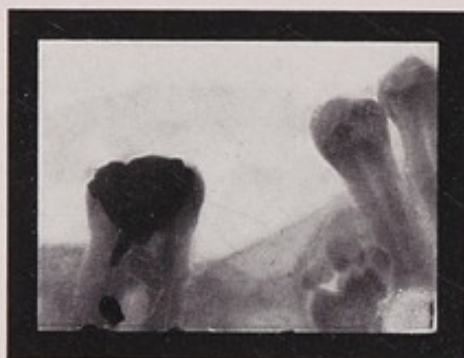

Fig. 291. The same case as Fig. 290. A radiograph of the upper part of "the shadow." It shows the crown of a supernumerary bicuspid with three denticles above it. The white spot at the apex of the second bicuspid is caused by an air "bell" attaching itself to the film in that region at the time it was in the developing solution. (Radiograph by A. M. Cole, of Indianapolis.)

55. To Observe the Inferior Dental Canal.

Often, but not always, we are able to radiograph the inferior dental canal. (See Fig. 190.) To the man contemplating resection of the inferior dental nerve anywhere throughout its course in this canal a radiograph showing the location of the canal would be of value.

Dr. Virgil Löeb, of St. Louis, reports a case of anesthesia of the lower lip, and that part of the face on one side which receives its nerve supply from the nerves passing through the mental foramen. The anesthesia followed the extraction of a lower third molar. A radiograph of the case showed that the roots of the third molar had penetrated the inferior dental canal. Knowing this, it was deduced that, at the time of extraction, the inferior dental nerve had been stretched, and a few fibers torn at the mental foramen. Lately I have personally observed such a case. I do not print radiographs of either Dr. Loeb's or my own case, because they are not clear enough to permit of good half-tone reproduction. Such cases as the ones now under consideration recover slowly, the time required varying from one to several months. Treatment with the high-frequency current may, or may not, hasten recovery slightly. Though slow, complete recovery may be expected.

Immediately after the filling of the canals of a lower second molar a patient suffered most severe pain in the region of the filled tooth. A radiograph was made and showed the canal filling penetrating the apical foramen of the distal root, projecting into the inferior dental canal, and

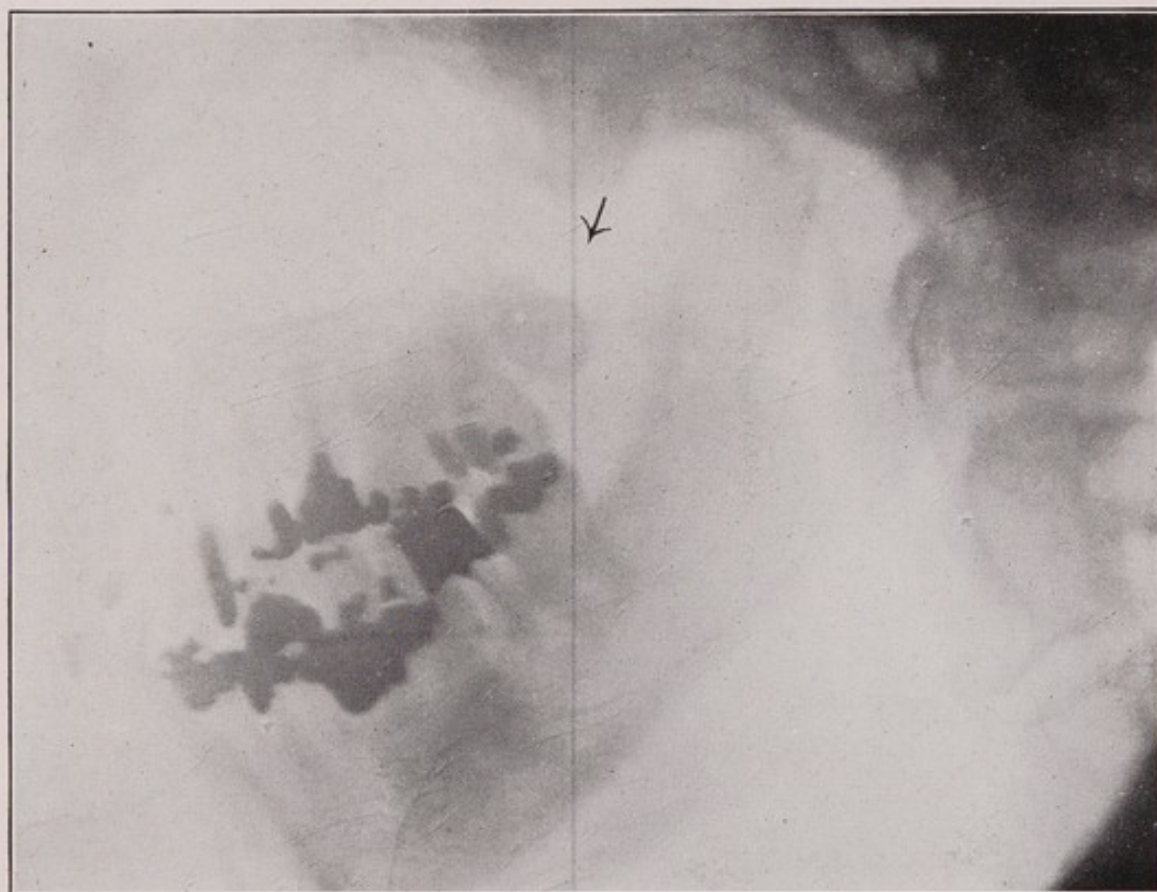


Fig. 292. The arrow points to an impacted upper, third molar, the cause of "idiopathic" neuralgia, from which the patient had suffered recurrently for from between twenty-five to thirty years. (Radiograph by A. M. Cole, of Indianapolis.)

doubtless pressing the inferior dental nerve. An effort to remove the canal filling met with failure, and the tooth was extracted to relieve the patient of the intense pain. Again I do not print radiographs of the case because the prints are not sufficiently clear to permit of good half-tone reproductions.

56. In Cases of Ludwig's Angina.

Angina is defined in Dorland's Medical Dictionary as "any disease or symptom characterized by spasmodic suffocative attacks"; Ludwig's angina as "purulent inflammation seated around the submaxillary gland." Whenever there is a pus sinus opening on the neck in the region of the submaxillary gland, the patient is said to have Ludwig's angina. This is the popular application of the term, and it seems to the writer unfor-

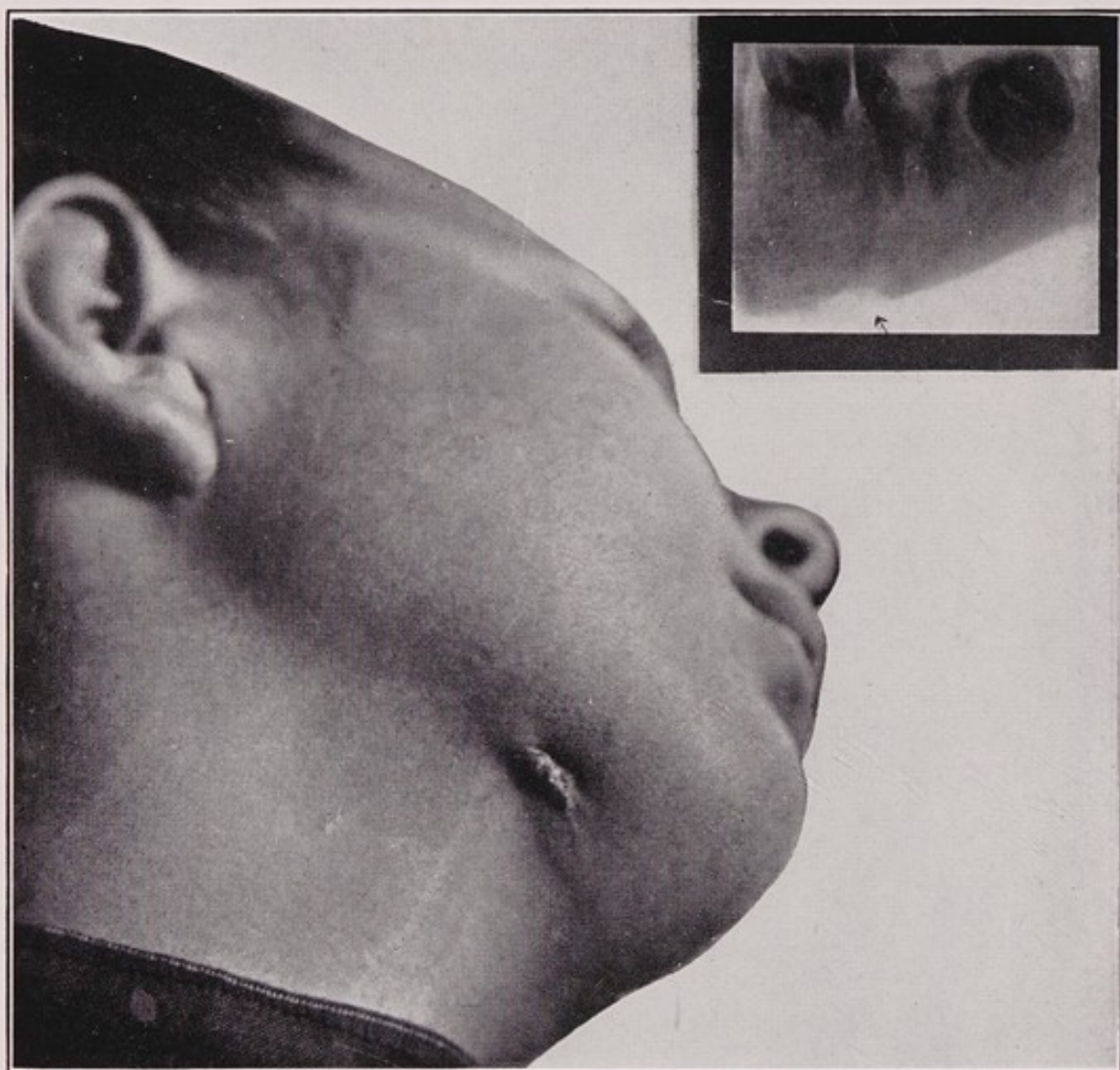


Fig. 293. Photograph of a case of so-called Ludwig's angina. Also a radiograph of the case showing an abscess of the first permanent molar. The fistulous tract cannot be seen.

tunate, for there is seldom angina—*i.e.*, suffocative attacks—in these cases of suppuration of the neck.

Fig. 293 is a photograph of a case of so-called Ludwig's angina occurring in a child ten years of age. The accompanying radiograph of this case shows an abscessed lower first molar, which was responsible for the sinus on the neck. The arrow points to a notch in the lower border of the body of the mandible. Extraction of the lower first molar and curettement of the alveoli was all that was necessary to effect a cure in this case. Had the patient been older, or not so vigorously healthful, the slightly necrotic area pointed to by the arrow would have required curettement through a facial opening. The radiograph happens to demonstrate the congenital absence of a lower second bicuspid.

Dr. H. R. Sparrevohn, of Los Angeles, reported a case of "Ludwig's Angina" in the June number of the *Dental Cosmos*, 1910. The patient was receiving hospital treatment for suppuration of the glands of the neck, when Dr. Sparrevohn examined the case, had radiographs made, and pronounced the trouble due to an impacted lower third molar, which could be seen clearly in the radiograph, and in appearance was similar to Fig. 159. Neither the patient nor the attending physicians could be convinced that his diagnosis was correct. (Had the fistula been injected with bismuth paste and a radiograph made there would have been no chance for dispute.) Dr. Sparrevohn closed his report of the case as follows: "I should be thankful to readers of the *Dental Cosmos* if they would express themselves as to the correctness of my diagnosis. At present I am much discredited, especially by the medical men connected with the case."

Dr. Herbert McIntosh, a physician, answered Dr. Sparrevohn in *Dental Cosmos*, October, 1910. He said in part: "I think there can be scarcely any doubt that the malposed molar, of which very good radiograms were presented, was the cause of the serious symptoms reported. Anyone who has had experience in the skiagraphing and observing of such cases would have no hesitation in suspecting dental irritation as the origin of the symptoms reported in the case. In general, the medical man is too apt to overlook the reflex irritation produced by the teeth. There is evident need of skiagraphy to clear up these obscurities of diagnosis in conditions of the face and cranium. There should likewise be a greater readiness to admit the importance which teeth have in producing pathological conditions of the tissues."

I believe I am safe in saying that about all of the cases of so-called Ludwig's angina are due to dental lesions. Yet, referring to no less than a dozen medical dictionaries and works on the practice of medicine, I find that none of them even mention the teeth as an etiological factor to be considered. These books state that the disease is caused by diphtheria, erysipelas, syphilis, tuberculosis, and that it occurs epidermically and idiosyncratically. It is therefore not surprising that Dr. Sparrevohn's diagnosis was discredited.

As is indicated by the remarks of Dr. McIntosh, many medical men are more enlightened than the authors of the books to which I have referred. But, on the other hand, many of our brothers in the practice of general medicine need education along this line. For example, a physician of my acquaintance, a specialist on the treatment of tuberculosis, treated, and treated without benefiting, a case quite similar in appearance to Fig. 293, giving the usual anti-tubercular treatment, including the administration of bacterine. The patient's mouth had *never* been examined

by a dentist, and radiographs of the case were not made, nor were either of these things done after I suggested them, because the physician thought it so highly improbable that the teeth could cause such a condition.

To illustrate the grave nature of the symptoms in some of these cases permit me to report the following case:

Young man, age twenty-three, suffered from what was diagnosed pharyngeal abscess. Confined to the house for a month, and lost thirty pounds. A change of physicians brought in a man on the faculty of the Indiana Dental College. It became necessary to make an external incision to permit the escape of a great quantity of pus. And let me say that because the incision was made on a line with, instead of at right angles to, the fibers of the muscle, the resultant scar is hardly noticeable. The writer was called in consultation. I did not do radiographic work, nor appreciate its importance at this time, or the doubt in my mind as to the correctness of my diagnosis might have been eliminated. The patient could not open the mouth, but instruments passed along the vestibule of the mouth came in contact with the corner of what I suspected to be an impacted lower third molar. The mouth was opened, the tooth found and removed, and the patient recovered immediately. The impacted tooth was not decayed.

The radiograph should be used in all such cases of suppuration about the face and neck.

The lower third molar, though not badly impacted, not malposed and not decayed, is abscessed. The abscess points externally. The fistulous tract cannot be seen in the radiograph because of the slight destruction of bony tissue throughout its course.

Fig. 294.

57. In Cases of Insomnia, Neurasthenia, Insanity and Kindred Nervous Disorders.

If Dr. Henry S. Upson, of Cleveland, were a dentist, his assertion that dental lesions may, and do, cause insanity, would be met, not altogether unfairly, with the argument that, in the practice of his specialty, Dr. Upson had developed a rare case of myopia, and could no longer see past his especial field and consider other etiological factors. But Henry S. Upson is not Henry S. Upson, dentist; he is Henry S. Upson, M.D., Professor of Diseases of the Nervous System at the Western Reserve University, and Attendant Neurologist to the Lakeside Hospital, Cleveland, Ohio.

The situation as it stands to-day is this: Dr. Upson claims that impacted teeth and chronic alveolar abscesses cause insomnia, neurasthenia and insanity. He gives histories of radiographically illustrated cases, which have been cured by extraction of the impacted or abscessed teeth,

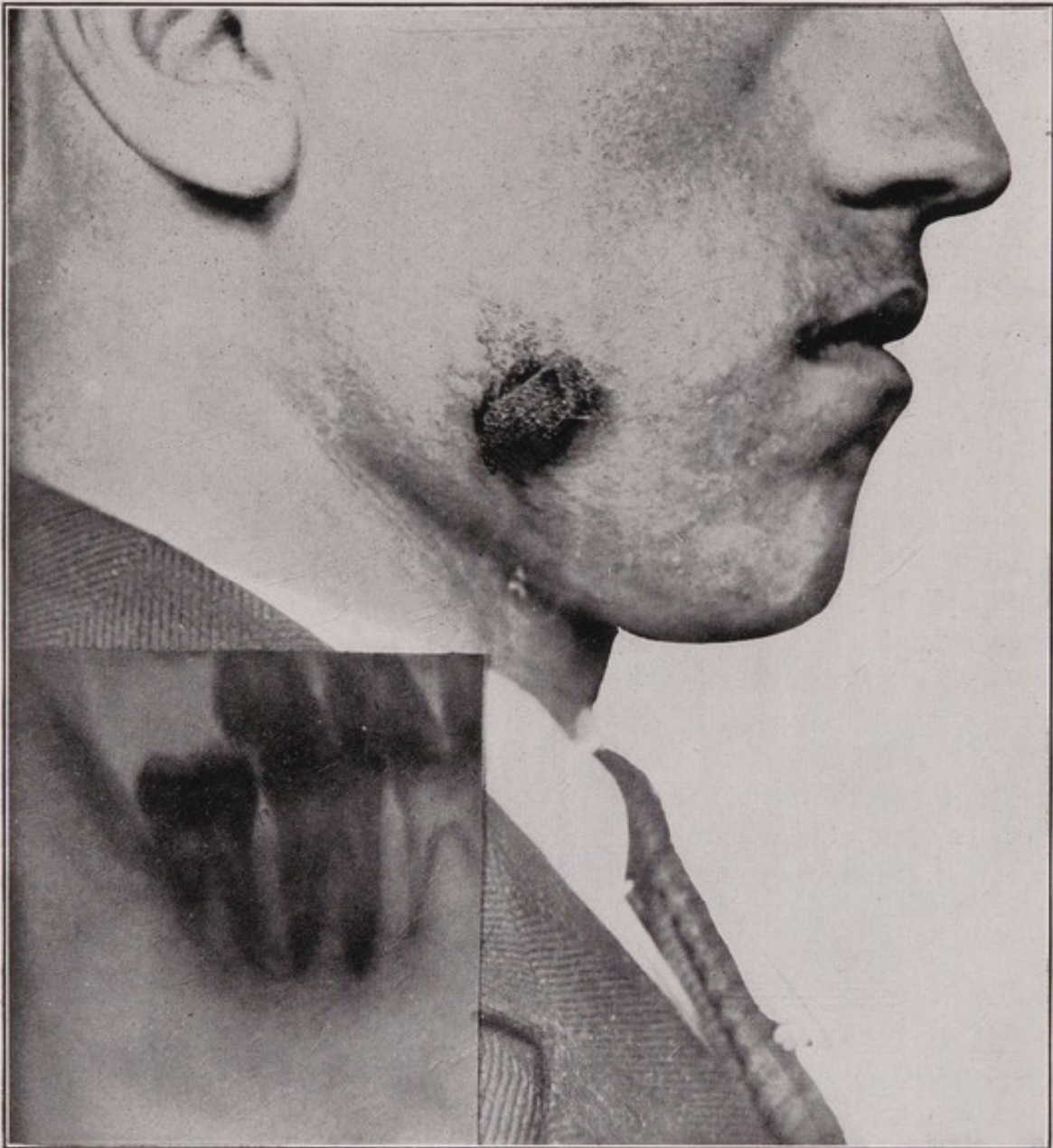

Fig. 294. Alveolar abscess pointing externally. The abscess is caused by the only slightly impacted and not malposed lower third molar.

and he asks a question: "If a diseased uterus can cause insanity (and it is believed that it can), then why not dental disease?" The nervous connection between the teeth and brain is much more intimate than that between the uterus and the brain. No one answers Dr. Upson's question, and so far, no one has in any way tried to prove Dr. Upson wrong in his belief that the teeth are responsible for grave nervous disorders. We must then, in fairness, accept what he says as the truth, until we are able to show wherein he is mistaken.

To give you an idea of the importance of dental lesions as a causa-

tive factor in the neurosis, as promulgated by Dr. Upson, I quote from the doctor's book, "*Insomnia and Nerve Strain*":

"Of the viscera responsible for the more obscure cases of nervous and mental derangement, I have no hesitation in designating the teeth as the most important. This is not only on account of the common, almost universal occurrence of dental diseases, but because these organs move, during the period of their development, through the solid framework of the jaw, highly innervated and clothed by a membrane sensitive to impact and to corrosive toxins."

That Dr. Upson has met with skepticism on the part of his brother practitioners is suggested I believe by the following, quoted again from the book, "*Insomnia and Nerve Strain*":

"There seems to exist among physicians not only a disregard but a distinct, though mild dislike of the teeth as organs to be reckoned with medically, they being, as it were, an Ishmael, not to be admitted to their pathologic birthright. Lauder Brunton's essay on the subject is too little known and heeded, and few such systematic attempts have been made to correlate their disorders with the suffering of the human race, except for the obvious phenomena of pain. Ordinary pain at a distance, as headache or neuralgia, due to the teeth, though well known, is commonly disregarded. Even the various reflex nervous phenomena in children, convulsions, fretfulness, and fever, are not now ascribed to the irritation either of teething or of dental caries, but to digestive disorders. The state of recent opinion, as enshrined in epigram, is that 'The result of teething is nothing but teeth.'"

My readers may ask what has all this to do with dental radiography? Just this: the radiograph should be used more extensively, as Dr. Upson has used it, in a search for dental lesions in cases of the various nerve disorders, for Dr. Upson states "The lesions can seldom be observed by any means save the use of the X-rays."

Though I would like to print a radiograph and history of all of the different neuroses including insomnia, neurasthenia, mania, hysteria, melancholia and dementia, it would hardly be in keeping with a work of this kind, and I shall therefore give but one case, which is more or less typical.

Case: Melancholia and insomnia. "An unmarried woman, twenty-seven years old, a teacher, for a year had been profoundly melancholy with intractable insomnia, delusions of various deadly sins, and entire hopelessness of recovery. Restlessness was extreme, tonic and local uterine treatment were of no avail. As a last resort the teeth were examined. They were apparently in perfect condition. A skiagraph (Fig. 295) showed an impacted upper third molar tooth pressing against the second molar, a con-

Fig. 295.

dition obviously capable of causing irritation. The symptoms, in about a week after the removal of the tooth, began to improve. Recovery was complete in six or eight weeks, and has persisted. There had been at no time pain or other localizing symptoms."

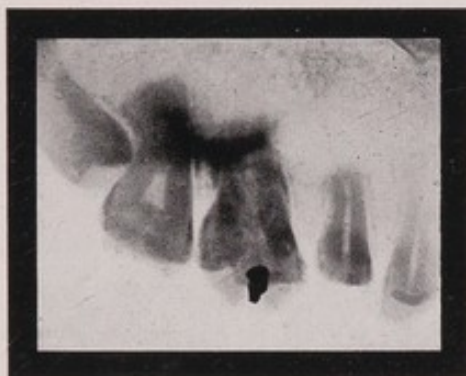

Fig. 295. Impacted upper third molar, causing melancholia and insomnia. (Radiograph by Lodge, of Cleveland.)

In concluding our consideration of this subject, I quote from a recent paper by Dr. Upson:

"The following is a tabulated statement of cases of neurasthenia and the psychoses seen in private practice during about two and a half years, in which skiagraphic examinations of the teeth and jaws were made. These results represent the first stumbling efforts in a new and unknown field, and so do not adequately show what may be accomplished by skill and careful endeavor along the same line:

	Number	Operation	Recovery	Convalescent	Improved	Unimproved	No Data
Manic depressive type.....	11	9	5	..	2	..	2
Dementia precox.....	10	8	5	1	..	2	..
Psychosis	4	4	1	2	1
Insomnia	7	6	2	..	4
Neurasthenia	26	15	1	4	6	1	3
	—	—	—	—	—	—	—
	58	42	14	7	12	3	6

The following is a separate statement of the cases of impaction included above:

	Number	Operation	Recovery	Convalescent	Improved	Unimproved	No Data
Manic depressive type.....	5	3	2	..	1
Dementia precox.....	7	5	4	1
Psychosis	2	2	1	1
Insomnia	3	2	2
Neurasthenia	13	9	..	4	2	1	2
	—	—	—	—	—	—	—
	30	21	7	6	5	1	2

58. In Cases of Periodic Headaches.

Irritation of the trifacial nerve may cause headache. The irritation may be due to such lesions as an impacted tooth, a chronic abscess, or a sementoma, for examples.

“After the removal of the malposed impacted cuspid seen in Fig. 296, severe headaches which she (the patient) had had once or twice a week for many years ceased immediately.”*

Fig. 296.

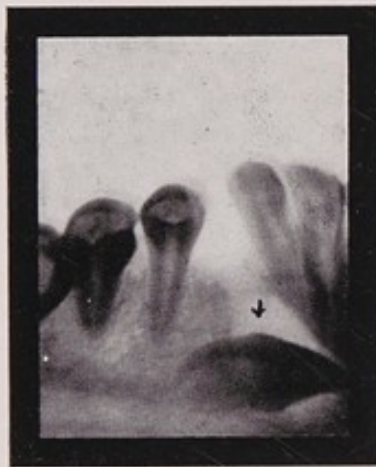

Fig. 296

Fig. 296. Malposed impacted lower cuspid, responsible for periodic headaches. (Radiograph by Thomas, of Cleveland.)

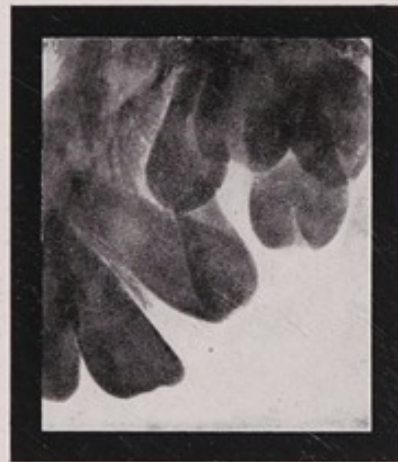

Fig. 297

Fig. 297. An impacted upper cuspid, which caused blinking of the eyes. (After Dr. Varney Barnes.)

59. In Cases of Facial Gesticulatory Tic. (Spasmodic Twitching of a Set of Facial Muscles.)

Fig. 297.

“An impacted upper cuspid which caused blinking of the eyes.”**

Dr. Barnes also reported a case of twitching of the facial muscles on one side. On the corresponding side two supernumerary teeth were found. I have been unable to learn from Dr. Barnes whether removal of the supernumerary teeth effected a cure. Dr. Barnes agrees with Dr. Upson thus far at least: both men are of the opinion that impacted teeth may be responsible for varied and grave nerve disorders. Dr. Up-

*Dr. Henry S. Upson, Cleveland, Ohio.

**Dr. Varney E. Barnes, Cleveland, Ohio.

son's treatment has always been extraction, while Dr. Barnes advocates orthodontic procedures, such as enlarging the dental arches and elevation of the impacted tooth.

60. To Allay the Fears of a Hypochondriac.

Every practitioner of dentistry and medicine has trouble with hypochondriacal patients, patients suffering—and actually suffering—from some imaginary ailment. What these patients need is psychic treatment.

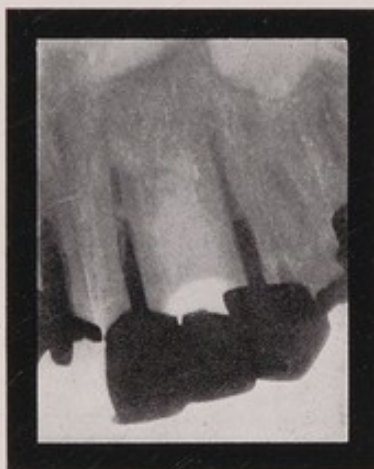

Fig. 298. The radiograph demonstrates the absence of a piece of the lateral root above the lateral dummy and shows the canal of the central and cuspid well filled and the tissues at their apices healthy.

To be sympathized with—or a better way to state it would be to say “understood”—and at the same time shown that their trouble lies, not in any pathologic lesion, but in faulty habits of thought.

Fig. 298. Case: Young lady, age about twenty-three, complained of obscure indefinite pains in the region of a bridge extending from central to cuspid, which pains she declared were due to an unremoved portion of the lateral incisor root. Having seen the lateral root when it was extracted, and superintended the treatment of the central and cuspid, and the making of the bridge, and knowing the patient—in short, knowing the complete history of the case—I was inclined to believe that the trouble with the bridge lay in the diseased imagination of the patient. After treating the case with counter-irritants once or twice, each time conversing freely with the patient concerning her symptoms, and failing to observe any clinical signs of a pathologic lesion, I became convinced that my original surmise was correct, and that the

teeth involved in the bridge were causing no pain. I positively knew there was not a piece of the lateral root above the artificial dummy, as the patient insisted. Having arrived at this conclusion, I proceeded as tactfully and kindly as I could to explain my belief to the patient. Whereupon she broke down and cried, displaying definite symptoms of hysteria. I want it distinctly understood that I did not blame the patient for her condition; that I was not out of patience with her; that I did not tell her there was nothing the matter with her—for there was, though the seat of the trouble was not the bridge. And this I tried to make her understand. After she had recovered somewhat from her crying, I said: "Now I do not want to take that bridge off, for I know there is no root beneath it. I do not need to look and see, as you ask me to. But I know a way of looking at the bridge so we can *both* see it if there is any root there, or if either of the crowned teeth are at all diseased. If I can show you beyond the shadow of all doubt that there is no root there, will you believe that what I have been telling you is perhaps true, that the bridge is all right, and that you are falling into faulty habits of thought?" She said she would.

The radiograph (Fig. 298) shows there is no root above the lateral dummy, that the canals of the central and cuspid are properly filled, and that the tissues at their apices are not diseased. The radiograph of her own case, together with several others showing roots above bridges, abscesses and perforations, were shown and explained to the patient. I did not attempt to force her to admit that I had been right in my diagnosis of her case, nor did she do so verbally; but she has not returned for further treatment, and she still wears the bridge.

61. In Cases Where the Patient Cannot Open the Mouth Wide Enough for an Ocular Examination.

An impacted lower third molar sometimes causes a false ankylosis. We suspect the presence of the impacted tooth, but are unable to demonstrate it except by the use of the radiograph made on a large plate (Figs. 101 and 102) or a film on the outside of the mouth (Fig. 97). With the radiograph to confirm suspicions and show the exact location of the offending tooth, the operator may proceed to anesthetize the patient, force the mouth open with a mouth prop and extract the tooth.

Fig. 299.

Fig. 299 is a case in which the mouth could not be opened because of the inflammation caused by the impacted lower third molar seen in the radiograph.

62. In Research Work to Study Osteology, the Development of the Teeth, Action of Bismuth Paste, Bone Production and Destruction, Changes Occurring in the Tempo-Mandibular Articulation When Jumping the Bite, Blood Supply to Parts, Resorption of Teeth and the Causes for It, Etc.

The value of the radiograph to the man who is looking for the just-how and why of things is clearly apparent. It obviates the necessity of conjecture, and gives us simple, indisputable facts. Many problems now

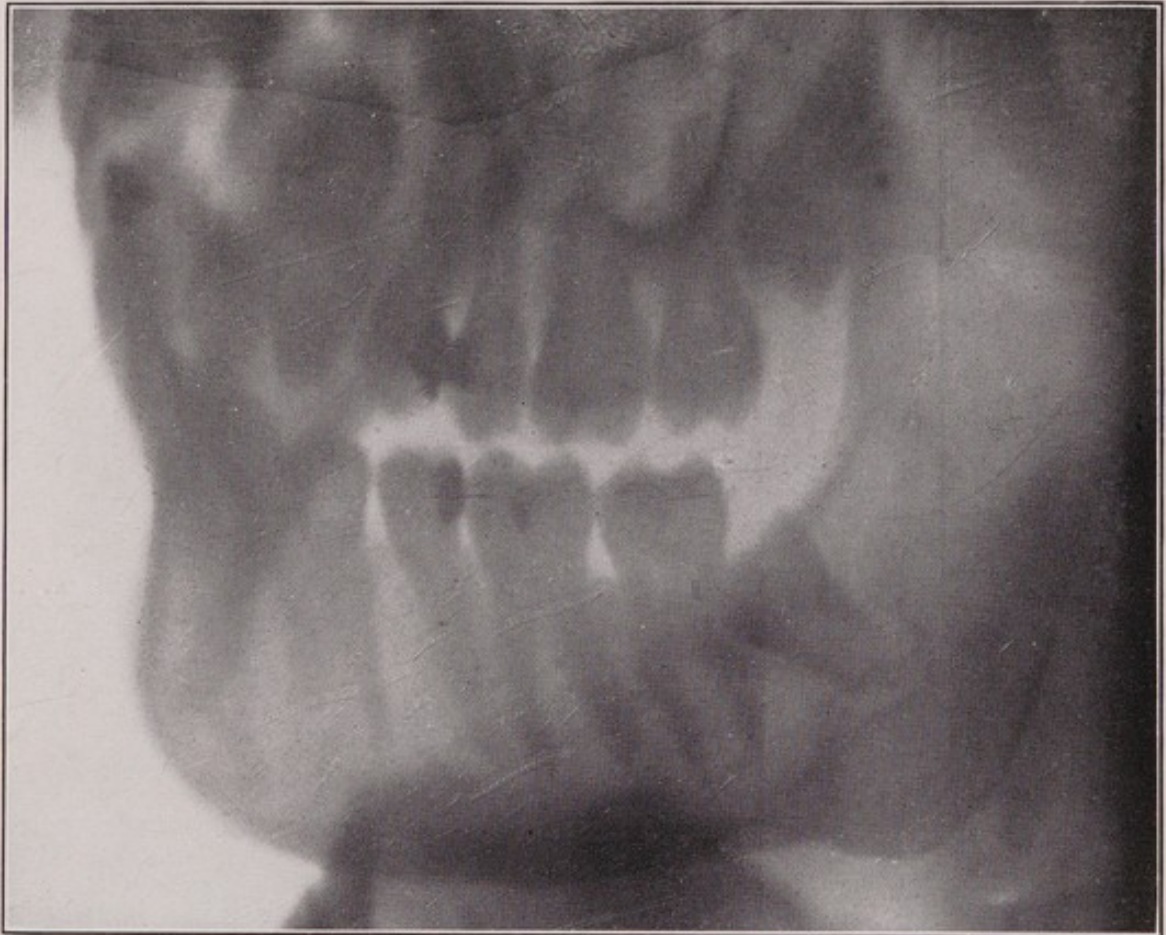

Fig. 299. Impacted lower third molar, causing a false ankylosis. (Radiograph by Graham, of Detroit.)

confronting the dental scientist can be solved only by the intelligent and persistent use of the X-rays.

It is not my intention now to tell of all the different uses to which the radiograph has been and may be put in the broad field of dental scientific research. I could not if I tried. I shall mention but a few.

Dr. Joseph Beck, by the use of the stereoscopic radiographs, is making a comparative study of the pneumatic sinuses of man and the lower animals.

Dr. Johnson Symington and Dr. J. C. Rankin have recently published a book, "*An Atlas of Skiagrams*," illustrating, in twenty radiographs, the development of the teeth and jaws from birth to the age of sixteen years.

I have demonstrated the action of bismuth paste in one case. (Fig. 223.) No definite conclusions should be drawn from this single case. The field of research work along this line is still wide open and inviting investigation.

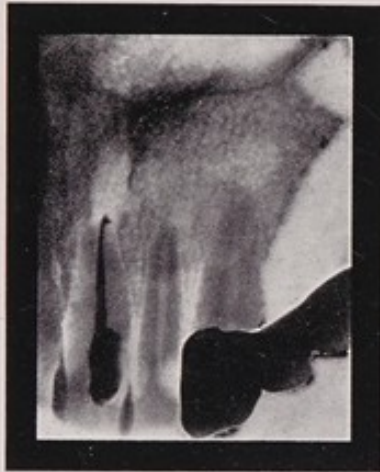

Fig. 300.

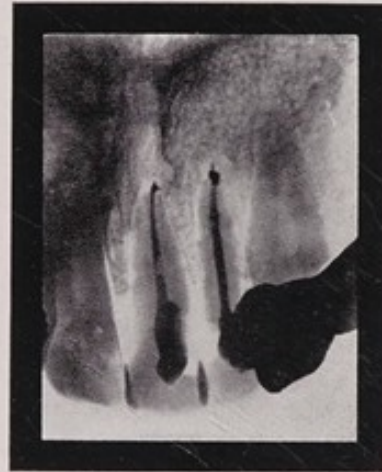

Fig. 301.

Fig. 300. Abscessed upper lateral incisor, causing disintegration of the built-in bone at the apex of the central incisor. (Radiographed by Schamberg, of New York City.)

Fig. 301. The same as Fig. 300 after treatment and filling of the canal of the lateral. Bone is being rebuilt into the abscess cavity at the apex of the central. (Radiographed by Schamberg, of New York City.)

Bone production and destruction in alveolar abscesses is a matter of which we know entirely too little. A systematic radiographic study of the subject is bound to result in the disclosure of interesting and important facts.

A question, the answer to which is of extreme importance is, "Do alveolar abscess cavities become filled with bone after the abscess is cured?" My experience leads me to believe they do; but the new bone is *not* so dense, and it is susceptible to ready disintegration as a result of contiguous inflammation. To elucidate: Observe Fig. 300, a case from the practice of Dr. R. Ottolengui. Note the light areas at the apices of both the central and lateral. A cursory observation of the radiograph, and a failure to consider clinical history, would result in the diagnosis of abscess of both the central and lateral. Observe, please, however, that the canal of the central is well filled, while the canal of the lateral is not filled at all.

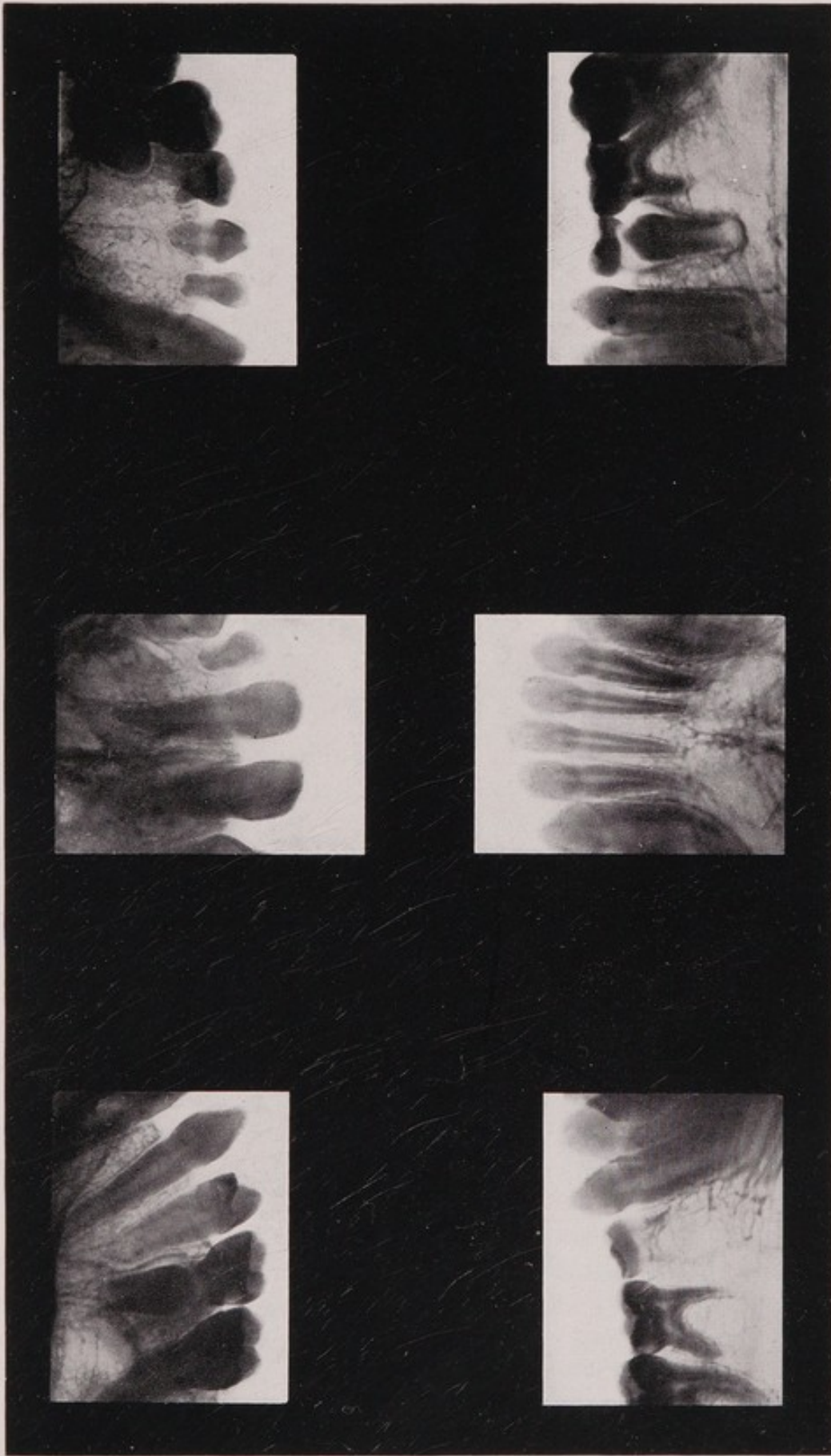

Fig. 302. Radiographs demonstrating the congenital absence of seven secondary teeth. (Radiograph by Schamberg, of New York City. Case: One in the practice of Dr. Ottolengui, of New York City.)

The central had been filled three years previously to the making of the radiograph, and there had been no recurrence of the abscess during that time. The lateral was treated and its canal filled, when all symptoms of abscess disappeared, proving it to be entirely responsible for the trouble. Fig. 301 was made one week after the canal of the lateral was filled. What I shall speak of now I fear cannot be seen in the accompanying half-tone; but it can be observed *easily* in the negatives. At the apex of the central there is a disposition of bone in the old abscess cavity. The bone is not as dense as the surrounding structure, and hence the outline of the old cavity can still be seen; but it is sufficiently dense, so that it can be observed distinctly, and especially well when compared with the cavity at the apex of the lateral, which has not been freed from infection long enough to permit of an osseous formation within it.

Just what changes occur in the temporo-mandibular articulation when "jumping the bite" is still an unsettled question. It is extremely difficult to radiograph this articulation, but it can be done, and it is not unreasonable to expect that some day the radiograph will show us just what occurs. Dr. H. A. Ketcham, of Denver, is, and has been for some time, working in this field of research.

Dr. Cryer, in a recent article on the study of blood supply to the jaws and teeth, printed a radiograph of a disassociated mandible injected with mercury. How well blood supply may be studied by injecting the vessels with bismuth paste, or some other substance opaque to the rays, then making a radiograph is obvious and most encouraging to the student.

The radiographs are of a little girl eleven years of age. They demonstrate the congenital absence of the following teeth: In the upper jaw both lateral incisors, one cuspid and one bicuspid; in the lower jaw three bicuspids, making in all seven permanent teeth congenitally absent from the jaws. Despite the absence of the permanent teeth resorption of the roots of the temporary teeth occurs, showing that the resorption is not dependent on the eruption of the permanent teeth. I do not make the statement that the temporary tooth roots resorb independently of the succedaneous teeth because of what I see in the radiograph in Fig. 302. Fig. 302 but illustrates what has been observed in many other radiographs.

Dr. H. A. Ketcham, with the aid of radiographs, has endeavored to disprove that certain orthodontic procedures caused impaction of the third molars.

The discussion of the orthodontic procedure of "opening the maxillary suture" is one in which the radiograph is yet playing an important rôle. That

this suture can be opened is claimed by Dr. Varney C. Barnes. Figs. 303 and 304 are from the practice of Dr. Barnes. How wide it may be opened, the permanency of the separation of the bones, and the benefits to be derived from the operation I shall not discuss, but radiography will always be a valuable aid in determining the condition, both before and after treatment.

In the discussion of a paper, read at a dental society meeting, Dr.

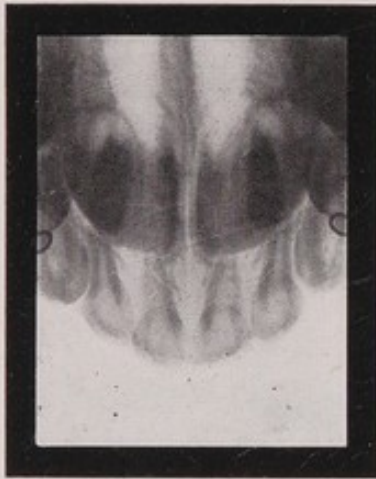

Fig. 303.

Fig. 303. Before attempting to open the maxillary suture. (Radiographed by Lodge, of Cleveland.)

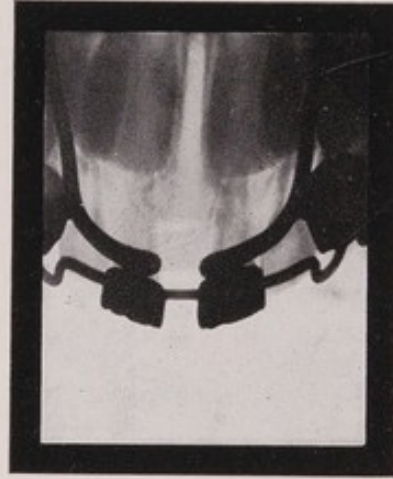

Fig. 304.

Fig. 304. Same case as Fig. 303 fourteen days later, after attempt to open the maxillary suture. (Radiographed by Lodge, of Cleveland.)

Don Graham recently said: "If the radiograph has done nothing else it has proven beyond all doubt that the best canal filling in use to-day is gutta-percha."

Likewise radiographs have shown us that, when filling canals with large apical foramina, we would better force a little gutta-percha through the apex rather than to fall short of reaching the end of the root. Of the two mistakes, filling a little beyond or not quite to the apex, the former seldom causes trouble, while the latter almost always results in the recurrence of the abscess.

The radiograph shows an upper cuspid with a perforation to the mesial through the side of the root into the periodontal membrane. The radiograph was made several weeks after patching the perforation with gutta-percha. There is scarcely any inflammation at all at the point of perforation, showing how well the tissues tolerate gutta-percha.

Fig. 305.

Under this heading of research work allow me to mention the recent

disturbing paper by Dr. William Hunter, of London. Let me say that Dr. Hunter's charge that we, as a profession, practice septic dentistry is well founded. One needs to do but little radiographic work to be fully convinced that the conservative dentistry of which we have been so proud is often a dreadful mistake. It consists all too often of simply treating the case until it becomes a chronic abscess, then, with the abatement of

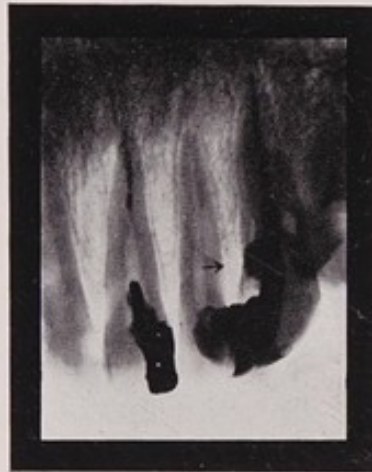

Fig. 305. The arrow points to a perforation, through the side of the cuspid root, which has been patched with gutta-percha.

the acute symptoms, calling the case cured. As a radiographer, a man in a position to make extensive observations, I declare that the root canal work of the majority in our profession is a disgrace and a menace to health. Bad root canal work is not usually the result of inability to do the work properly, so let us have hope. It is nearly always due to the fact that the operator *thinks* he cannot get paid for the work. And it is indeed hard to convince a public, which has received its dental education from advertising quacks, of the necessity of receiving and paying for the proper treatment of its teeth.

I would not be understood as saying that I agree fully with Dr. Hunter. I do not. But the doctor is on the right track. He knows there is such a thing as bad dentistry, septic dentistry, being practiced, as do all observing men, especially radiographers.

63. As a Record of Work Done.

Any sort of a record of work done is always valuable. Radiographic records of canal fillings, extractions and the like are often of the utmost value to the operator. Such records would be of the most gratifying service in the unpleasant event of being tried for malpractice. A patient,

let us say, finds it necessary to go to the hospital for a week after the extraction of a badly impacted third molar. The next thing the operator knows is that suit has been brought against him. He learns that he "broke the jaw-bone," and that the patient is to remain a "helpless invalid for the balance of her life," because of "his lack of skill, his ignorance and brutality." Radiographs of the case showing just what had been done for the patient might prevent the suit or win the case for the operator.

In cases where the patient is seized with a decided disinclination to pay a dental bill the radiograph may sometimes be used to advantage. These patients usually suffer from the loss of memory, and tell the judge that the plaintiff is quite mistaken in imagining that he filled their root canals. Radiographs would go far toward convincing the judge of the validity of the claim.

64. In Cases of Hidden Dental Caries.

The "diagnosis of hidden dental caries by means of radiographs" was suggested and recommended by Drs. H. W. C. and C. F. Bodecker in a short unillustrated paper printed in the *Dental Review*, April, 1912. I quote a paragraph from the article referred to. "The diagnosis of caries in its first stages on the proximal surfaces of molars and bicuspidis is often difficult, and frequently patients complain of sensations at points where we cannot discover caries either with floss silk or explorer. Separation then has to be resorted to, in order to definitely locate the trouble. Sometimes the patient is not able to point out any single tooth in which he notices the sensation; he simply tells us that it is 'somewhere on that side,' and passes the finger over two or three teeth. Another factor which makes diagnosis difficult is reflex pain. Frequently the irritation is in an upper tooth, and the patient experiences the pain in a lower one, and *vice versa*. Therefore, to obviate the useless separation of teeth in locating small carious spots, we have used the Roentgen apparatus. It would, nevertheless, be a useless expenditure of time and work to radiograph two or three teeth in the upper arch, and if no defect had been found to repeat the same in the lower. We have, therefore, constructed a film holder by the aid of which the crowns of the bicuspidis and molars of one side can be photographed at one time."

Personally, I have never put the radiograph to the use suggested by the Doctors Bodecker, but it is my intention to do so.

And so—we have passed over the uses of the radiograph in the practice of modern dentistry, and it has been a long trip. Permit me to repeat what I said at the beginning of the chapter, for you are now better able to understand and believe me. Of the uses for the radiograph enumerated, some are of cases that the general practitioner of dentistry may

not be called upon to diagnose or treat oftener than once or twice in a lifetime, perhaps not at all; but by far the greater number are of cases the like of which we meet almost daily in the practice of dentistry.

There is a popular belief among dentists at large that the use of the radiograph is indicated only in the baffling, the exceptional, the iconoclastic cases in our practice. This is not true. It is a fact that the radiograph, in a spectacular manner, has been responsible for the diagnosis and cure of many baffling cases. But I am tempted to say that this is unfortunate. For the radiograph does not always solve the mysteries of the refractory cases, though practitioners of dentistry and medicine pay it the embarrassing and unfair compliment of expecting it to do so. The radiograph's most potent value in dentistry is in the ordinary, the everyday cases which come to our offices—in cases of impacted teeth as an aid in extraction; in cases where the apical foramen is very large as an aid in filling the canals properly; in cases where apical sensitiveness may be due to a large apical foramen or an unremoved, undevitalized remnant of pulpal tissue; in cases of retained temporary teeth to learn if there be succedaneous teeth present in the jaw; in cases of badly decayed teeth of the secondary set in the mouths of children to learn if the roots of the diseased teeth are fully formed; in cases of abscess to determine which tooth is affected; in cases of traumatism, and so on. It is in these cases, met constantly, that we may use the radiograph and derive the greatest assistance and benefit. In baffling cases we will often be disappointed in our use of the radiograph, but in the ordinary cases, such as I have just enumerated, never, for we know just what to expect, and we do not expect too much.

It should ever be borne in mind when using the radiograph for diagnostic purposes that it is only an *aid*; in many cases the greatest aid we have, but, nevertheless, only an aid in diagnosis. No other methods or means of diagnosis should be forgotten or slighted.

When the use of the radiograph fails to reveal the cause of the trouble it is not fair to look upon its use as of no assistance or value. For example, a patient is suffering from false ankylosis. Judging from the symptoms we suspect an impacted lower third molar to be the active cause. We make a radiograph and fail to find an offending third molar or anything else that might be responsible for the ankylosis. It is natural that we should be disappointed, but we must not feel that the radiograph has been of no service at all, for we now know that an impacted third molar is *not* the cause of the trouble, and we have taken an important step in diagnosis by elimination.

In printing the great number of radiographs, which have appeared in this chapter, it is inevitable that some should not be good. It must be

remembered, too, that *only an idea* of what can be seen in negatives can be learned from half-tones. It has been most discouraging to the writer to observe, at times, the great loss of detail in the printed half-tones, as compared to the original negative. I wish to state most emphatically, however, that with the rarest exception the loss of detail was not the result of incompetency on the part of the makers of the half-tone plates. This most complete collection of dental radiographs ever made has been

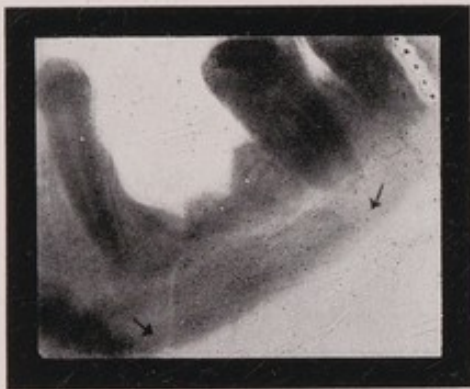

Fig. 306.

Fig. 306. The arrows point to the ends of what might have been mistaken for a line of demarcation.

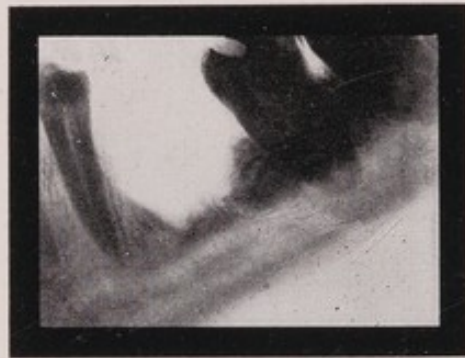

Fig. 307.

Fig. 307. The same case as Fig. 306, proving the line seen in Fig. 306 to be a fault in the film.

transferred from the photographic print to the half-tone in a masterful way, and its failure to be perfect represents only the shortcoming of the process itself.

Misinterpretation of radiographs is one of the easiest things in the world and, for this reason, I can already hear, in imagination, the cries of condemnation of the disappointed ones who will, within the next few years, take up dental radiographic work. I believe that no one who has ever done radiographic work has experienced disappointment more often, or more keenly, than I have. But every radiograph ever made is the product of simple physical and chemical laws, and when misread the fault usually lies in the reader.

Very often it is expedient to make several radiographs of the same part, changing the pose slightly to verify or disprove the findings in the first picture of the part.

Fig. 306 is a case from which a first molar tooth and sequestrum had previously been removed, because of arsenic poisoning. The radiograph was made to learn if all the sequestrum had been removed. It shows to the inexperienced reader what would appear to be a line of demarcation and

Figs. 306 and 307.

a large sequestrum involving the lower border of the mandible. The line, however, has not the typical appearance of a line of demarcation and the sequestrum (?) does not look like diseased bone. Two more radiographs (one of which is shown in Fig. 307) were made and show no line, proving the line on the first picture to be a fault in the film.

When I started this chapter I expected to close it by quoting words of praise for the radiograph, spoken and written by the leading men in the dental profession. I shall not take the space to do this, but shall tell you simply that I could if I wished. I shall quote but one man who, in an impromptu discussion, voiced the sentiments of all. Though he is a specialist in oral surgery, he speaks as well for the orthodontist, the extracting specialist and the general practitioner. Dr. T. W. Brophy said "Now that we have the X-ray picture to help us, I do not see how we could possibly get along without it."

The greatest argument in favor of the use and value of the radiograph, however, does not lie in the enthusiastic and inspiring remarks concerning its value, but in the irrefutable facts set forth and illustrated in this chapter.

Seldom, indeed, is the use of the radiograph in dentistry a matter of life or death to the patient, though it may sometimes be, but often, often indeed, does health and happiness depend on its use.

CHAPTER VIII.

The Dangers of the X-Ray.

A work of this kind would be worse than incomplete, it would be a positive menace to the welfare of the public and the profession, without a chapter devoted to vigorous warning of the evil results that may occur from exposure to the X-rays.

The following unfortunate results have been attributed to the action of the X-rays: dermatitis (*i.e.*, X-ray burn), cancer, leukemia, sterility, abortion, insanity, lassitude and alopecia.

We will now consider each of these foregoing dangers, taking them up in the order named.

X-ray burns are of two kinds, acute dermatitis and chronic dermatitis.

Acute dermatitis* manifests itself anywhere from twenty-four hours to (in rare cases) as long as two or three months after exposure to the rays. The time, however, is usually from three to fifteen days.

Acute Dermatitis.

Itching and redness are the first symptoms to appear. The itching becomes intense, swelling occurs, the skin grows harsh and dry, and has a smooth, glossy appearance.

In mild cases the inflammation subsides gradually after a few days and, depending on the severity of the burn, may or may not be followed by desquamation and loss of hair.

This Elberhart calls an acute dermatitis of the first degree.

In the more severe form of acute dermatitis, termed by Elberhart of the second degree, there will be the formation of a blister with the usual serous exudate and marked neuralgic pains.

*Elberhart "Practical X-Ray Therapy."

In the very severe cases of acute dermatitis, where the deeper layers of the skin and underlying tissues are affected, a slough forms and the destructive condition shows a marked tendency to spread and become malignant. Severe pain in these latter cases is a wellnigh constant symptom.

Chronic Dermatitis. After exposing himself to the X-rays a great number of times, and having had a number of mild attacks of acute dermatitis—or perhaps without ever

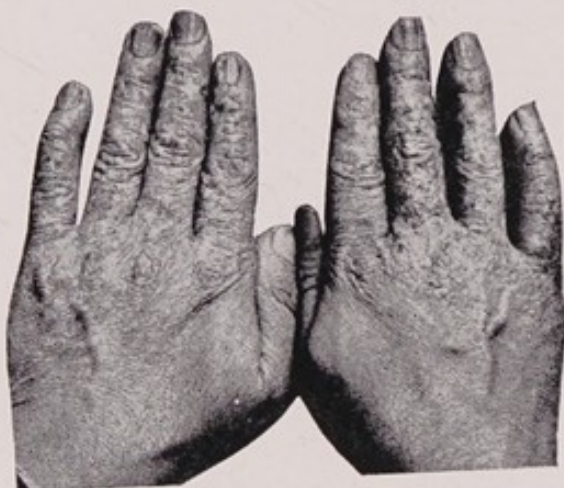

Fig. 308. Chronic X-ray Dermatitis.

having had acute dermatitis—the X-ray operator notices certain tissue changes occurring, usually on the back of the hands, sometimes on the face and chest. The hands, face and chest are most likely to become affected, because these parts are the most exposed to the rays. There is a pigmentation of the skin very similar to tanning, such as sun and wind will produce. Freckles occur in some cases. The skin becomes harsh, dry and wrinkled—the same changes that occur with age. Hair drops out. The fingernails become brittle and thin and ridged longitudinally. Small, hard, scabby growths (keratoses) occur here and there. These growths break down into ulcers, which often become cancerous. (Fig. 308.)

Cancer. There has been a great deal of discussion as to whether X-rays can, or cannot, produce cancer, but in the face of such reports as Dr. C. A. Porter's* I do not see how anyone can dispute it. According to the highest authorities, X-rays can, and have, produced carcinoma. In 1907 Dr. Porter re-

* "The Surgical Treatment of X-Ray Carcinoma and Other Severe X-Ray Lesions, Based Upon an Analysis of Forty-seven Cases."

ported eleven cases of "unquestionable X-ray cancers," six of which proved fatal.

Cancer usually follows a chronic dermatitis, occurring at the site of a former ulcer, though it may result from a very severe acute dermatitis. When cancer follows chronic dermatitis the victim is almost invariably an X-ray operator; when it follows acute dermatitis the victim is usually a patient who has been exposed to the rays for therapeutic purposes.

Even before the formation of cancer, when chronic ulcers appear, operation after operation becomes necessary. These operations consist of

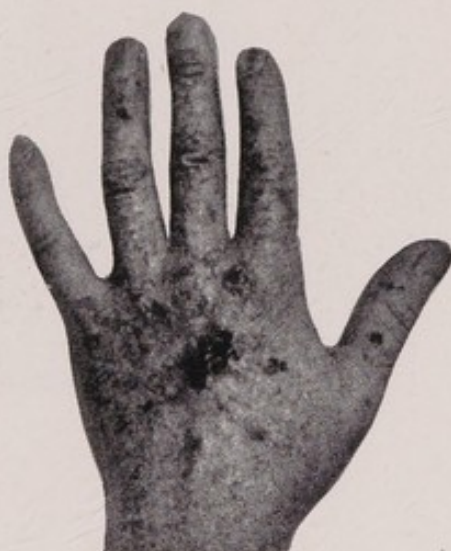

Fig. 309. X-ray Cancer.

a curettement of the ulcer and skin grafting. With the formation of cancer commences amputation. First one finger, then another, then two more, then a hand, both hands, an arm. A welcome death, due usually to the formation of metastatic cancers throughout the vital organs of the body, is the next step of the progressive case.

I print reports here by Dr. Porter of two more or less typical cases of fatality due to X-ray lesions:

"Case XXXI—Man, 32 years old, who, after three years of X-ray work, suffered from severe lesions on both arms, breast, neck and face. In 1901 there began a slowly growing ulceration of the back of the right hand, which, by the middle of 1902, had become a gangrenous epithelioma; glands enlarged at the elbow and in the axilla. Amputation at the shoulder; axillary glands removed, and found full of squamous-celled carcinoma. Sound healing. In December, 1904, a typical cancer of the lower lip and another of the angle of the mouth were excised, as was a suspicious

lesion on the back of the left hand. In March, 1905, a growth of the cheek was removed, which was pronounced by Unna to be a sarcoma. In September, 1905, excision of the right lower jaw for carcinoma. Recurrence, involving the tongue and the adjacent cheek, was present in February, 1906. Death soon followed."

"Case XLVII. Summary: In 1897 began work with the X-rays, testing the tubes for several hours a day. First noticed erythema and

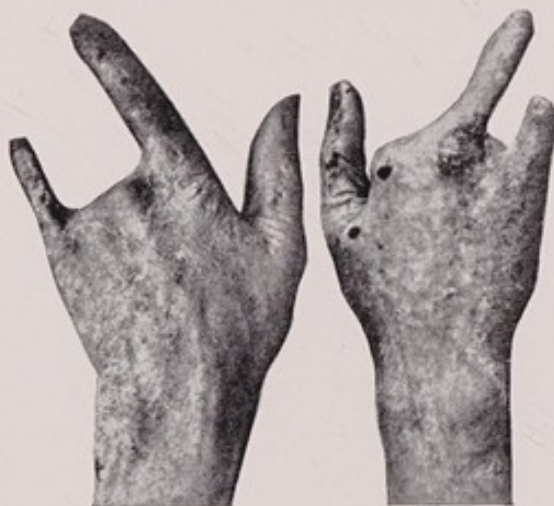

Fig. 310. Hands of X-ray operator after thirty operations.

warty growths in 1900. In 1905, keratoses and warts had formed on both hands, chest and face. First carcinoma developed and required amputation of two fingers of the left hand in April, 1907; similar growth curetted on right hand. By March, 1908, rapid extension of the disease necessitating amputation of left forearm; curettage of epithelioma on right hand. August, 1908, involvement of epitrochlear and axillary glands. August 11, 1908, amputation of fingers of right hand. September 25, 1908, amputation at shoulder. Death on November 7, 1908; general carcinosis." (Fig. 309.)

The report of another case by Porter commences:

"I have operated upon this patient under ether thirty-two times, the operations varying in duration from one hour and a half to three hours. At present there remains of his left hand two joints of the little finger, the forefinger and thumb; of the right hand, the thumb, the middle finger, barring part of the terminal phalanx, and one and a half phalanges of the little finger. More than half of the skin of the backs of both hands consists of Thiersch grafts." (Fig. 310.)

Figs. 308, 309, 310, copied by permission from *The Journal of Medical Research*.

Regarding the pain suffered by these patients, with severe chronic dermatitis and cancer, Porter says: "The amount of pain suffered is variable though usually extreme. From my experience and personal communications with patients, I believe that the agony of inflamed X-ray lesions is almost unequaled by any other disease."

Leukemia. Leukemia is a blood disease characterized by an increase in the number of white blood cells. The cardinal symptoms of the disease are insidious emaciation and lassitude. It is generally fatal. Practically nothing is known concerning its etiology. It is suspected that continued exposure to the X-rays may produce leukemia but, as yet, this supposition has not been scientifically substantiated.

Sterility. X-ray operators of the male sex, who subject themselves to repeated mild exposures to the rays, are often sterile. This sterility is due either to the death of the spermatozoa, or to their complete disappearance from the semen. This condition has no effect one way or the other on the carnal instincts of the individual, and if the victim will discontinue exposing the parts to the X-rays, virility will be regained. Likewise repeated exposures of the ovaries to the X-rays will produce sterility in the female by causing a disappearance of the Graafian follicles; the menses do not cease, and sexual animation remains unaltered. As with the male, the power of reproduction is regained promptly when the parts are no longer subjected to X-radiation.

Abortion. Quoting from Elberhart (Practical X-Ray Therapy): "Fraenkel claims that the Roentgen ray retards the growth of the ovum and tends to produce abortion when the thyroid gland and ovaries are exposed to it."

Fraenkel has in mind the use of the X-rays as a therapeutic agent, and mentions a case of induced abortion after twenty-five exposures of five or ten minutes each every other day.

For the slight radiation required for dental radiographic work pregnancy *cannot possibly* be considered a contra-indication.

Insanity. There is a somewhat popular superstition that X-rays will produce insanity in those who constantly expose themselves to their action. This belief arose, I think, from the fact that a prominent X-ray operator lost his mind a few years ago. So far as I know he is the only X-ray operator, of the thousands engaged in the work, who has met with such a misfortune, and it is as ridiculous to blame the X-rays for it as it would be to claim that his insanity was caused by the suspenders he wore.

There is a belief among operators themselves that X-ray operators develop a "nervous, restless, intense personality." Whether the development of such a personality is due to the electric condition of the atmosphere of the operating room, to the action of the X-rays, or to the enthusiastic interest developed by research work is a matter of conjecture. Personally I do not believe any of these things are responsible for the restless, nervous personality of so many operators. These men were of a restless disposition before they took up X-ray work. In fact, their adoption of the work was but a sign of their restlessness and desire to be progressive.

Lassitude. X-ray operators often complain of a feeling of utter exhaustion. When it is proven that X-rays can produce leukemia, I shall believe that this feeling of extreme lassitude is caused by exposure to the X-rays. Until then I shall hold to the belief that this exhaustion, which unquestionably does occur, is due to the work, physical and mental, the bad air of the dark room, and the depressing disappointments experienced by all conscientious radiographers.

Alopecia. Loss of hair may occur from a severe X-ray burn, but I can find no reliable authority who attempts to prove that the X-rays will produce baldness of the head without dermatitis.

Protection. Knowing now the dangers of the X-rays, how shall we protect ourselves and our patients against them? We shall protect ourselves by never exposing any part of our bodies to the direct or primary X-rays, and our patients by exposing them as short a time as possible.

How can we do radiographic work without exposing ourselves to the X-rays?

Sheet lead one-eighth inch thick is opaque to very penetrating X-rays. Lead glass—a transparent glass containing a great deal of lead silicate—though it would need to be "about two inches thick to totally obstruct very penetrating X-rays," nevertheless offers considerable, and perhaps sufficient, protection in the thickness of one-quarter inch.

The writer was informed that linoleum is opaque to the X-rays. To test the verity of this information Figs. 311, 312 and 313 were made. A study of the illustrations will show that, compared to lead or lead glass, linoleum offers very little resistance to the rays; compared to wood, the resistance is much greater. White linoleum offers more resistance than red, green or blue.

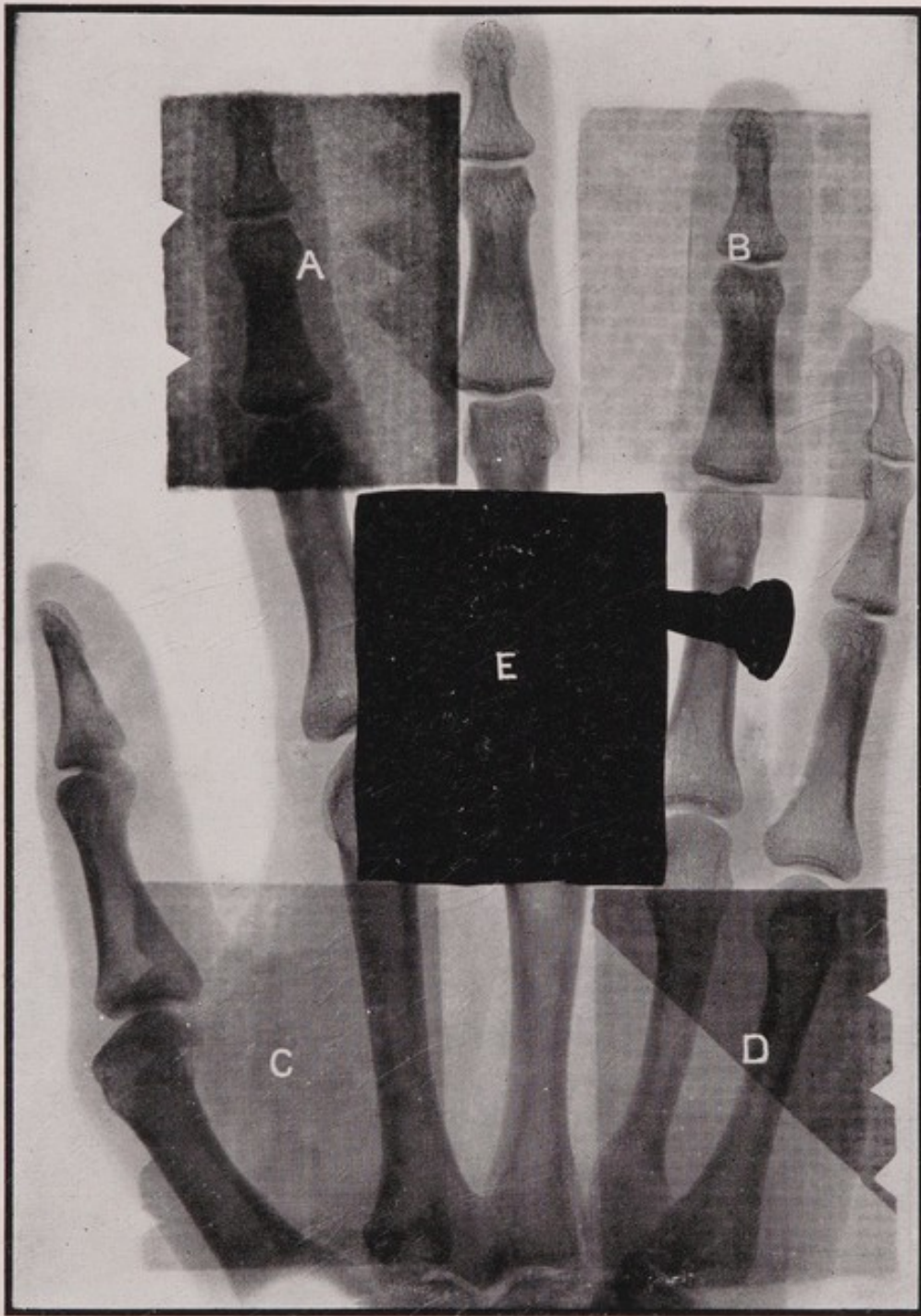


Fig. 311. A, B, C, and D are pieces of linoleum. E, a piece of sheet lead 1-16 inch thick.

**Appliances for
Protection.**

The appliances which may be used for protection against the X-rays are: Protection lead screens (Figs. 314 and 315), protection lead cabinets (Figs. 316 and 317), protection shields for the tube (Figs. 60, 61, 63 and 64, Chapter III, and Fig. 318), protection or safety X-ray tubes (Fig. 319), X-ray proof gloves (Fig. 320), lead glass spectacles (Fig. 321), and protective aprons.

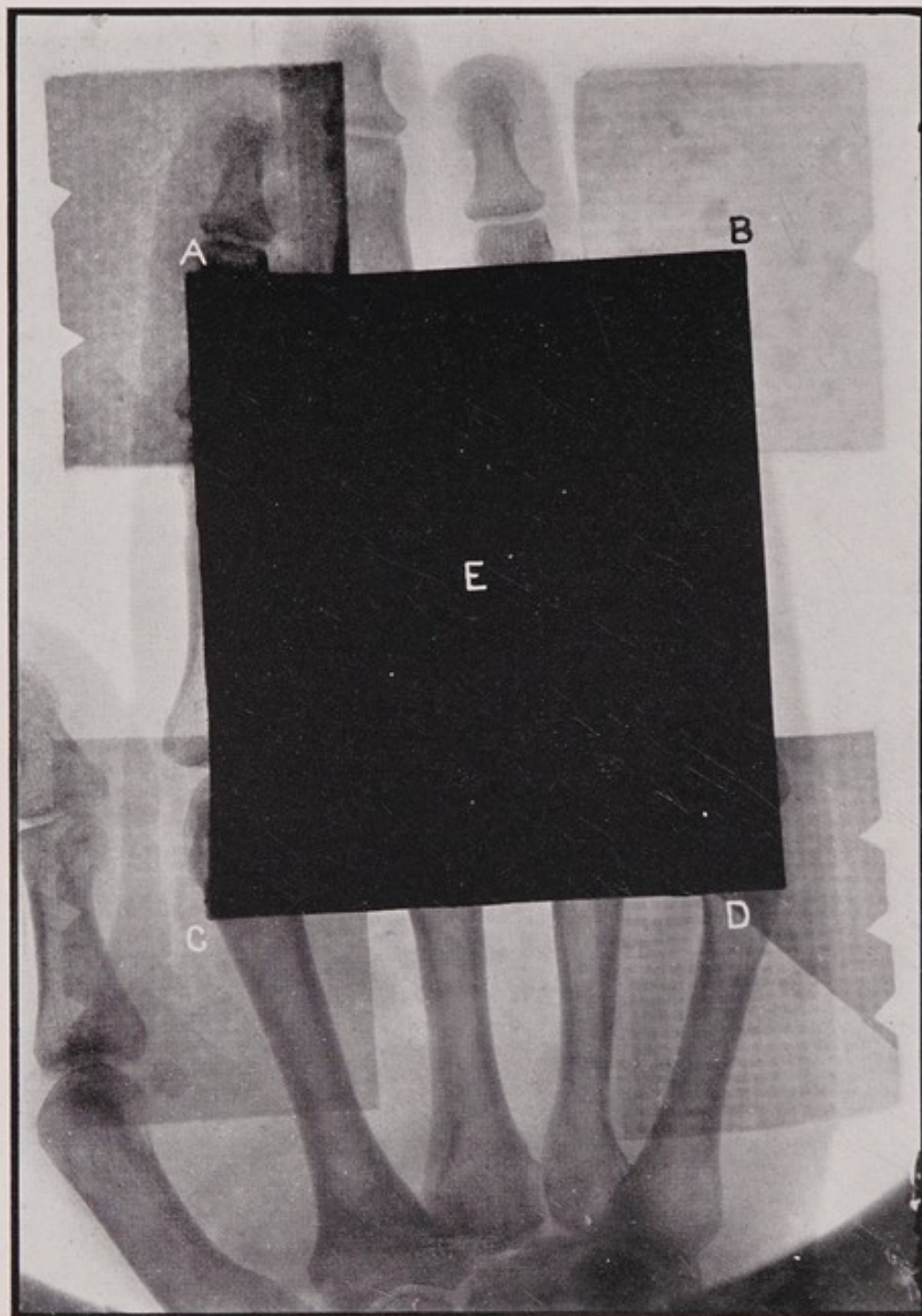


Fig. 312. A, B, C, and D, same as in Fig. 311. E, a piece of lead glass 1-4 inch thick.

The Lead Screen and Cabinet.

From the standpoint of protection for the operator nothing is so efficient as the lead screen or cabinet (Figs. 314, 315, 316 and 317). The use of either makes it possible for the operator to protect himself completely from all direct X-rays.

The lead used in protective screens and cabinets is usually one-six-

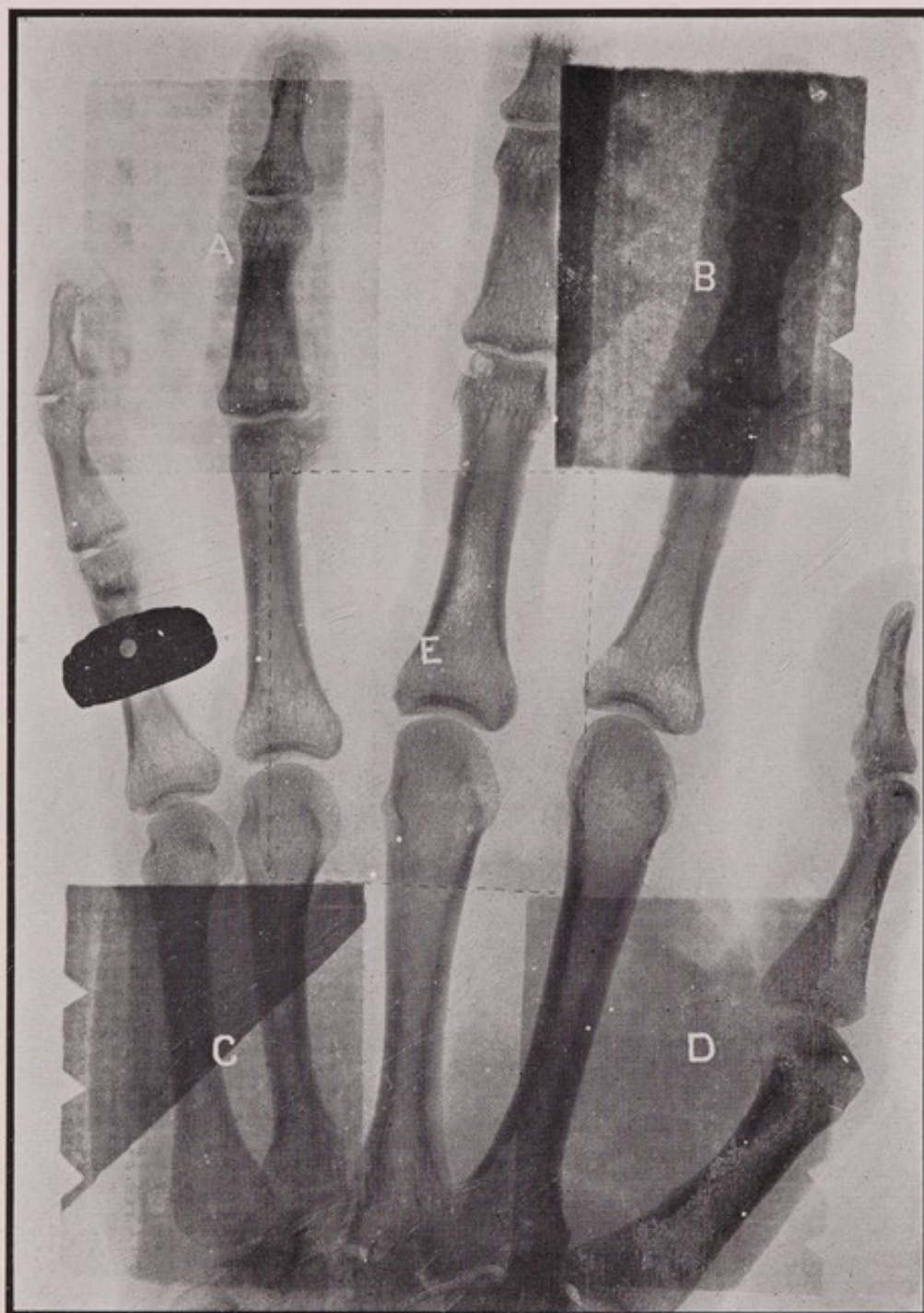


Fig. 313. A, B, C, and D, same as in Fig. 311. E, the dotted lines outline the position of a piece of pine wood 1-2 inch thick.

teenth inch thick. Lead of this thickness does not totally obstruct very penetrating X-rays when the tube is brought close up to it, but at the usual distance of several feet between tube and screen it is doubtful if any X-rays penetrate the latter.

The lead glass used in the windows in protection screens and cabinets is usually one-fourth inch thick. With the tube placed in close proximity




Fig. 314.

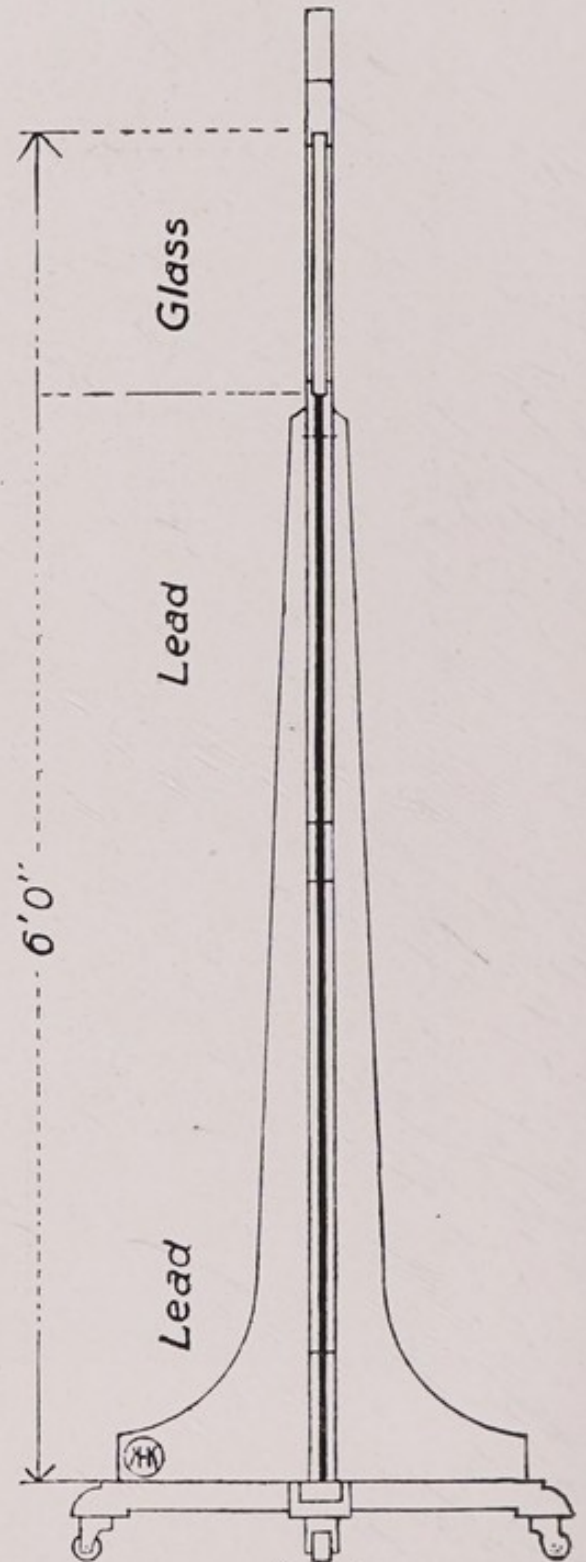


Fig. 315.

Fig. 314. Protective lead screen.

Fig. 315. Protective lead screen, sectional view.




Fig. 316.

Fig. 316. Protective lead cabinet; front view.




Fig. 317

Fig. 317. Protective lead cabinet; rear view.

to the screen, lead glass of this thickness is highly translucent to the X-rays, but with the tube a distance of several feet the rays penetrate the glass but feebly.

Instead of the lead glass window a screen may be covered entirely with lead and mirrors so arranged that the operator may observe his tube and patient from his position back of the screen.

Let it be clearly understood that the man standing behind a lead




Fig. 318. Protective tube shield and stand.

screen is not *completely* protected from *all* X-rays. If the tube is rather close to the screen some of the X-rays may penetrate it—becoming extremely feeble, however, by the time they make the penetration—and he is, of course, exposed to the secondary, tertiary and other sets of feeble rays which fill the room like light. *But he is completely protected from the powerful dangerous rays.*

The protective lead screen, or cabinet, or their equivalent, is a necessity in the practice of modern radiography.

Protection Shields.

Protection shields are of three varieties: those made of lead glass (Figs. 60, 61 and 63, Chapter III), those depending on a sheet of metallic lead for their action (Fig. 64, Chapter III), and those made of rubber impregnated with lead or a salt of lead (in appearance similar to Fig. 64). The X-ray tube fits into the protection shield, which latter protects the patient to a great extent against the action of all X-rays except

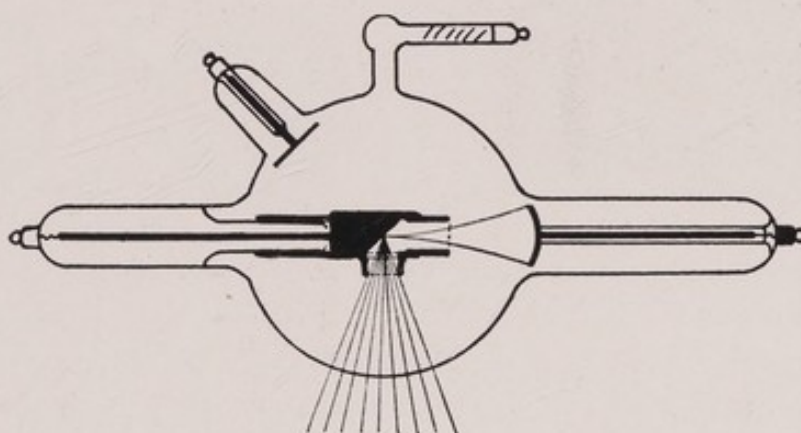


Fig. 319. Protection or safety, X-ray tube.

those which pass through the window of the shield and are being used to make the radiograph. As a matter of fact, the patient does not need this protection in the practice of dental radiography, but it is not inexpedient to use even protective measures that are thought to be unnecessary. The operator is also protected in a degree by the protective shield.

A protection shield calculated to take the place of a lead screen or cabinet is illustrated in Fig. 318. The protective material used is, I judge from its appearance, rubber impregnated with lead or a salt of lead. The manufacturers claim to use a German preparation, the formula of which is not divulged. This material is more opaque to the X-ray than lead glass, less opaque than metallic sheet lead.

Protection X-Ray Tubes.

Protection or safety X-ray tubes are manufactured, some of lead glass save for a window of ordinary glass transparent to the X-rays, and some with an internal protective arrangement which allows the X-rays to be given out from the tube from a limited place or spot only (Fig. 319).

Gloves.
Fig. 320.

The hands of the operator may be protected with X-ray proof gloves. These gloves are usually made of rubber impregnated with lead or some salt of lead. Protective gloves may be made by painting ordinary leather gloves with several coats of white lead. X-ray proof or "opaque" gloves, as they are called, are not really opaque to X-rays; they are, in fact, quite translucent to powerfully penetrating rays.

Gloves should be used when the operator finds it necessary to hold the film in the patient's mouth himself. Seldom, very seldom indeed, is

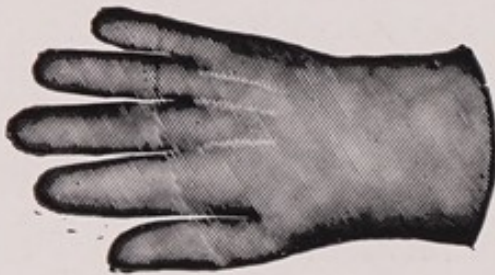


Fig. 320.

Fig. 320. X-ray proof, opaque, or protection gloves.

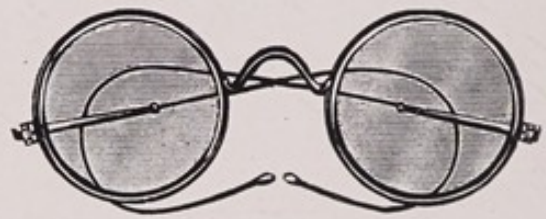


Fig. 321.

Fig. 321. Lead glass spectacles.

it necessary for the operator to do this, and I warn you against the practice with the same feeling that I would cry "Don't!" if I should see you making a plaything of a culture of the bacillus of the white plague.

Spectacles.

Protection lead glass spectacles may be used to protect the eyes (Fig. 321). Not because the eyes are any more susceptible to the ill effects of the X-rays than the skin of the face, but because injury to them is such a serious matter. Operators suffering from chronic dermatitis of the face usually suffer also impairment of vision.

Protection Apron.

Protection aprons of lead-impregnated rubber may be purchased from manufacturers of X-ray supplies. They are used to prevent sterility.

Protection gloves, spectacles and aprons are obviously not needed so long as the operator remains behind a screen.

Efficiency of Protective Measures.

Having now told you of the dangers of the X-rays and shown what measures have been adopted to prevent disaster, the question arises, Have these modern means of protection proven efficient?

So far as I know, no man who has conscientiously and consistently stayed behind a protective lead screen, or in a lead cabinet, has developed either cancer or dermatitis or sterility, or suffered or experienced any other pathological change which could be attributed to the X-rays. And some have been engaged in the work for as long as twelve years.

The severe and fatal cases of dermatitis and cancer have occurred in patients who received prolonged and repeated X-ray treatments for some disease, and in pioneer operators.

As practitioners of dental radiography, we will never be called upon to make such exposures of our patients as are necessary when the X-rays are used as a therapeutic agent.

The pioneer operators whose lives were ruined and destroyed by the X-rays did not protect themselves at all, not knowing that it was necessary. Even without any protection disaster did not manifest itself immediately, as might be imagined. Men worked for months and even years before any trouble developed. Take the case of a well-known manufacturer of X-ray tubes, for example. He exposed himself two or three hours daily, six days in the week, for a little over a year before he noticed any dermatitis. It must be remembered, however, that at that time the machines and tubes could not generate near the same number of X-rays that the improved machines and tubes of to-day can, and the danger was therefore less.

**Efficiency of
Slight Protection.**

As an example of how efficient even slight protection is, Dr. Porter cites a case of dermatitis of the hands, save for the skin protected by a broad gold ring, which remained perfectly normal. The immunity which even light clothing offers is shown by the rarity or slight degrees of dermatitis above the cuffs, or on the other parts of the body protected by clothing.

Before it was known to be dangerous, operators formed the habit of using their hands for penetrometers—observing them through the fluoroscope to learn the power of penetration of the X-rays. This practice has doubtless caused many cases of dermatitis and cancer of the back of the hands. The use of any penetrometer save those of an improved type which enable the operator to “look around a corner” necessitates the exposure of the operator, especially his hands, to the rays, and I object to their use for this reason.

**Summary
of Danger
to Operator.**

Summarizing the danger to the operator, we may say simply this: If he will observe strictly the rule to remain behind a lead screen or in a lead cabinet he may work for a period of ten or twelve years in safety. What the dangers of exceeding this time limit are we do not know. Perhaps there are none. Perhaps all the older X-ray operators will die of leukemia within the next ten years. Who can say? We are entitled to our opinions, but no one really knows. The pioneers in the work are still in danger; we who follow are comparatively safe.

Though the operator need never expose any part of his body to any except the weak, harmless X-rays which fill the room, it is necessary to expose at least that part of the patient being radiographed to the direct rays. The question arises, how long may we expose the patient with perfect safety, without any danger whatever of producing acute dermatitis? Authorities are very reluctant to set this time limit.

The very few cases of serious acute dermatitis due to exposure for radiographic work occurred when the outfits used were so small that the time of exposure reached thirty minutes and longer. Compare such exposures with those of to-day, which range from a fraction of a second to only one minute at most, even with the small suitcase outfits, and the improbability of producing dermatitis will be appreciated.

The first rule regarding the exposure of patients should be, *never expose the patient longer than absolutely necessary.*

And now I shall place myself in line for criticism by authorities, by setting a time limit of exposure of the patient. Even with the smallest apparatus, and where a number of exposures are necessary, the aggregate time of exposure need not and should not exceed two minutes. If it is necessary to use this full time, two minutes in one day, then do not expose the same part of the same patient for a week or ten days. Give the skin a chance to recover from any change produced in it, and so guard against a cumulative effect of the X-rays. I cannot imagine a case in dental radiography which would require an exposure longer than two minutes. And *seldom, indeed*, will it be found necessary to expose the patient, even in the aggregate when several radiographs are made, as long as the time limit set.

Two minutes is a conservative limit—in fact, a five-minute exposure would in all probabilities prove harmless—but keeping inside of it, we may have the assurance that, except in a case of most extraordinary susceptibility, amounting to positive idiosyncrasy, nothing more than a very slight acute dermatitis, no worse in its effect on the health and happiness of the patient than a mild case of sunburn, could possibly occur. And even this slight acute dermatitis is so extremely unlikely to occur that the careful operator need never expect to see it.

Thus I may say, so far as the patient is concerned, X-rays are perfectly harmless if the operator is careful. The danger to patients from infection by instruments is infinitely greater than the danger from the sensible use of the X-rays for radiographic purposes.

“In the early days of the X-rays there was a tendency to attribute X-ray burns, not to the X-rays themselves, but to some accompanying factor, the

**Time Limit for
Exposing Patients.**

**Summary of
Danger to Patient.**

exclusion of which would prevent the occurrence of X-ray burns."* Thus it was suggested that burns were due to an electrical condition surrounding the tube; to chemical conditions surrounding the tube; to bacteria being carried into the tissues by the X-rays; to violet rays, and so on. It is generally conceded to-day, however, that X-ray burns are the result of a specific action of the X-rays themselves on the tissues.

There is a popular theory that for X-rays to have an effect on the skin they must be absorbed by it. Thus, the more penetrating X-rays which pass completely through the derma are less likely to produce dermatitis than rays of less penetration—just enough penetration to be absorbed. Knowing this theory—a theory the writer receives with skepticism—we will now consider the use of a *filter*.

The Filter.

First, however, let us dwell on some points which were not touched upon in Chapter III, when we discussed the generation and nature of X-rays. It was stated in Chapter III that the X-rays from a tube of high vacuum were the most penetrating—that the penetration of the X-rays varied directly according to the degree of vacuum of the tube. Thus the X-rays from a high vacuum tube are very penetrating, the rays from a medium vacuum tube of medium penetration, and the rays from a tube of low vacuum, of low penetration. While this is true, there is something further to be said. Take the high vacuum tube: while most of the direct X-ray given off from it are of high penetration, *some* rays of medium and low penetration are also generated. While the tube of medium vacuum generates X-rays of medium penetration principally, *some* rays of high and low penetration are also generated; and though the X-rays from a tube of low vacuum are by far mostly of low penetration, some few rays of medium and high penetration are given off also.

Since the tube of a high vacuum is the one we use in radiographic work, let us enumerate the different sets of X-rays given off from such a tube. First, are the direct rays of high penetration—these are by far the most numerous; next, the sets of direct X-rays of medium and low penetration—these are comparatively few in number; then secondary X-rays given off from the glass of the tube; and last, if there is any inverse current in the tube, the rays generated by it.

If now the theory of absorption for effect is correct, then it is desirable to expose the patient only to the direct penetrating X-rays, and not to any of a less penetrating nature. In an effort to gain this end the filter is used.

Filters are made of wood, aluminum, leather and various other materials. For example, a piece of sole leather (no definite thickness) is

*Pusley and Caldwell, "Roentgen Rays in Therapeutics and Diagnosis."

placed over the window of the tube shield. The X-rays from the tube pass through it before striking the patient and the leather filters out, absorbs, all (?) of the weaker rays, which might otherwise be absorbed by the skin, and so guards against dermatitis.

The danger of producing dermatitis varies directly according to the number of X-rays which strike the part. Recollect that X-rays emanate from a point, traveling in diverging lines. Thus the greater the distance between the target and the skin the fewer rays strike the latter and the less danger of dermatitis. When the tube is brought very close (within three or four inches) to the part and *no filter is used* the skin is then acted upon not only by a much greater number of the direct penetrating rays, but also by the softer direct rays and by the secondary rays from the glass of the tube, so increasing the danger of burning materially. Thus it will be seen that the use of the filter permits the operator to place the tube close to the patient, so that his film or plate is within range of a greater number of penetrating direct rays, and at the same time protects the patient against the soft rays. (See summary of the conditions under which Fig. 121 was made, Chapter V.)

Theoretically, the use of the filter should aid in obtaining a clear radiograph by cutting out all save the direct penetrating rays. It is not as efficient in this respect, however, as the compression diaphragm. (Figs. 60 and 66.)

The number of direct X-rays generated by a given tube varies directly according to the number of milliamperes sent through it. Thus danger of dermatitis also varies directly according to the number of milliamperes sent through the tube. To elucidate: the distance between the tube and the skin remaining the same, an exposure of one minute with ten milliamperes passing through the tube will have practically the same physiologic effect as an exposure of two minutes with five milliamperes passing through the tube.

There is no such thing known as either acquired or natural immunity to the action of the X-rays. Some are more susceptible than others, but no one is immune. Blondes are reputed to be more susceptible than brunettes. One burn greatly predisposes to another.

Immunity.

Treatment of Acute X-Ray Dermatitis.

The careful practitioner of dental radiography, unless he meets a case of idiosyncrasy, will never have occasion to make use of knowledge regarding the treatment of acute X-ray dermatitis. It is well, however, to have the knowledge even though we are never called upon to use it. The most important thing to know concerning the treatment of acute X-ray burns may be learned from the nursery

rhyme about "Little Bo-Peep" and "her sheep." "*Let them alone.*" So many drugs aggravate the condition that their use is contraindicated. A normal salt solution is, perhaps, the best wash and may be used freely.

There will be men in our profession who will not take up radiographic work, and who will say as an excuse for not doing so that they believe the work "too dangerous." Men who give this excuse are either unacquainted with the facts relative to the real danger or they are deceiving themselves. A disinclination to do necessary work, mental and physical, may lead a man to believe that the reason he does not take up X-ray work is because he believes it to be "dangerous."

Radium Rays.

It is interesting to know that the rays given off by the recently discovered element radium are very similar to the X-rays.

The commercial, so-called, radium is not pure radium. It is a salt of radium, usually radium bromid. So far, radium never has been isolated. Radium bromid is a white crystal.

"In 1896 it was discovered that the metal uranium gave off rays very similar to X-rays. Observing that different pieces of uranium varied greatly in their radio-activity, M. and Mme. Curie, of Paris, working on the hypothesis that uranium itself was not radio-active at all, but derived this property from some impurity incorporated in it, isolated radium bromid from the metal uranium."*

At present radium salts are obtained from uranium oxid, which latter is first obtained from pitchblende, a heavy black material in appearance somewhat similar to anthracite coal. One ton of pitchblende must be treated with approximately five tons of various chemicals and fifty tons of water to obtain one gram of radium bromid. The present market price of one gram of radium bromid ranges from \$1,500 to \$125,000, according to the radio-activity of the salt.

Radium rays, like X-rays, cannot be reflected or refracted. They travel in straight lines, and secondary rays are given off from objects which they strike. They penetrate objects directly according to the density of the object, and act on a photographic plate like light and X-rays. Their physiologic effect on the skin is very similar to X-rays. They produce a dermatitis almost identical to X-ray dermatitis. Becquerel carried a sealed glass tube containing 0.2 gram of radium salt in his shirt pocket for six hours. Fifteen days thereafter a dermatitis closely simulating X-ray dermatitis appeared, then subsided in about thirty days. One case of fatality from leukemia caused, presumably, by radium has been reported.

*Tousey, "*Medical Electricity and Roentgen Rays.*"

CHAPTER IX

Purchasing a Radiograph Outfit.

Before considering the purchase of a radiographic outfit we would better settle the question of who should do dental radiographic work. Should it be done by specialists or the general practitioners of dentistry? Three years ago it was my habit to answer this question unhesitatingly, and say "by the specialist."

My reasons for believing that dental radiographic work should be done by specialists were: (1) I was of the opinion that the radiograph was not particularly useful in the practice of dentistry except in rare cases, and (2) there being no text-book on the subject, proper self-education in the art was difficult, almost to the point of being impossible.

As I see the situation to-day, however, the use of the radiograph is indicated in so many cases that it would be rather impracticable for the general practitioner to refer all radiographic cases to the specialist. A further objection to referring all radiographic cases to the specialist is that, while said specialist may be a very expert radiographer, his knowledge regarding dental subjects may be so meagre that he cannot interpret the radiograph correctly after it is made. Notwithstanding these drawbacks to the practice of referring patients, I can understand the attitude of the *busy city* dentist, who does not care for, or dislikes radiographic work, and therefore would prefer to refer his cases to a dental radiographic specialist.

But no matter how busy he may be nor how much he may dislike the work, the dentist in the smaller cities and towns, where there is no specialist in the same town, should be able to do at least the simpler radiographic work on films himself. Otherwise the work will not be done at all, because of the inconvenience incident to making a trip to the city specialists, and in consequence the best dental services will not be rendered. It is an exceptional case indeed when a general practitioner of dentistry develops a degree of skill and proficiency equal to that attained by the specialists—the man who devotes all of his time to

radiographic work—and the more difficult work on large plates, necessitating a pose in the recumbent position, and stereoscopic work should therefore better be referred to specialists.

My second reason for having formerly been of the opinion that all radiographic work should be referred to specialists—viz., the difficulty of self-education—I hope is no longer a good reason, for I have tried, in this work, to supply a text-book which will enable the man who wishes to take up dental radiography to do so without wasting a great deal of time and energy reading books on electricity, photography and general X-ray work.

Some manufacturers make such statements regarding radiographic work as, "The work is extremely simple and can be mastered in a few minutes; in the time it will take to glance over our instructions which we send with each outfit." As a result of such misrepresentation men have taken up the work in profound ignorance and so have endangered their own and their patient's health and life. Self-education to do the simplest work intelligently, safely and well is not, I assure you, a matter of a few minutes study, but of many hours.

**X-Rays
as a
Therapeutic
Agent.**

In passing let me mention X-rays as a therapeutic agent in dentistry, and condemn them as useless. It is so difficult to measure the dose in X-radiation that it is only by long and usually soul-trying and disastrous experience that a man becomes competent to use X-rays as a therapeutic agent. The work should be done by specialists only. General practitioners of either dentistry or medicine are liable to do more harm than good when attempting therapeutic X-radiation.

X-rays have been employed in the treatment of pyorrhoea alveolaris, but no results have been obtained that have not been gained by the use of the easier used, better known, less dangerous drugs, commonly applied. The incurable cases remain incurable, whether the X-rays are used or not, and, in the cases in which disease is due to local irritants which can be removed, recovery takes place as a result of the universally known methods of treatment—again, whether the X-rays are used or not. X-rays are used also for the treatment of cancer of the mouth and leukoplakia, but such diseases are comparatively rare and if treated with the X-rays, the work should be done by specialists. As far as I know, this is the extent of the therapeutic application of the X-rays to diseases of the mouth—an extremely limited application.

In short, my opinion of the value of the X-rays in the practice of dentistry is this: as a means of making dental radiographs they are invaluable; as a therapeutic agent, they are worse than useless.

Requirements of a Radiographic Outfit.

Of what should a dental radiographic outfit consist? Naming the bare necessities for the simplest work—to which the operator may add, as he does the work and feels the need of expediting apparatus—we have: (1) Photographic paraphernalia and supplies, including a dark-room lantern, trays, a glass graduate, prepared developing powder or solution, prepared fixing powder, and films; (2) an X-ray machine or coil; (3) an X-ray tube; (4) a tube stand; (5) a lead screen.

All the photographic paraphernalia and supplies, except the films, may be purchased at any photographic supply house. Regarding films see page 85. Regarding the dark-room lantern see page 68. Regarding developing solutions see pages 75, 76, 102 and 103. Regarding fixing solutions see pages 78 and 104. The expenditures for photographic paraphernalia and supplies need not exceed \$5 at most.

There are three kinds of X-ray machines for the prospective buyer to choose from: the transformer or interrupterless coil (Figs. 15 and 38), the induction coil (Fig. 13), and the high frequency coil (Fig. 14).

Interrupterless Coils.

The transformers are the most powerful and most expensive X-ray machines on the market. With them small, film radiographs may be made in an exposure of one second or fraction thereof. The finished radiograph from such an exposure is no better than one made with a less powerful machine from a longer exposure. Personally, I can see no *particular* advantage in shortening the exposure beyond two or three seconds. The transformer is for the specialist or general practitioner who is fortunate enough not to have to consider seriously the expenditure of a considerable amount of money. Transformers range in cost from six hundred to over a thousand dollars.

See summary of conditions under which Fig. 117 was made, page 132.

Induction coils are made in various sizes. The largest ones rival the transformers in power, the smaller ones are not nearly so powerful. See summaries of conditions under which Figs. 81, 111, 97, 99, 103, 100, 105, 118, 119, 120 and 121 were made.

Induction Coils.

Induction coils range in price from about \$200 to \$600.

Unless he need not consider the expenditure of money I would advise the general practitioner of

dentistry who wishes to do only the lighter, simpler work on films to buy either a small induction coil or one of the best high-frequency, suitcase coils. If his supply current is direct, I would say choose the induction coil; if alternating, the high frequency coil. My reason for this discrimination is that when the induction coil is operated on an A. C. circuit the current must first be passed through a rectifier (Figs. 27 and 28). The purchase of the rectifier adds to the expenditure, and its use detracts from the efficiency of the coil. When the high-frequency coil is used on the D. C. circuit a rotary converter (Fig. 36) must be used. This also adds to the expenditure and cuts down the efficiency of the coil. Some suitcase coils are advertised to operate on either a direct or alternating current, without a rotary converter for the latter. A vibrator interrupter (Fig. 22) is used on these machines. Less efficiency is lost with the rotary converter than with the vibrating interrupter.

**High Frequency
Coils.**

Most high frequency, suitcase, X-ray coils are built to sell; not to make radiographs. Only the most powerful of the type are capable of doing good dental radiographic work. I would advise the prospective purchaser to insist on a practical demonstration before investing. What may be expected from the more powerful of these coils may be learned from the study of the summaries of the conditions under which Figs. 112, 113, 114 and 115 were made.

The high frequency X-ray coils range in price from about \$150 to \$200.

**X-Ray
Cubes.**

A six-inch X-ray tube is the proper size to do dental radiographic work. Only the tubes with a regulating chamber are popular to-day (see Fig. 44). The price of the six-inch X-ray tube is well standardized and is \$20.

**Tube
Stands.**

There are a great variety of tube stands to choose from (Figs. 59, 60, 61 and 63). They range in price from \$10 to \$150. The small tube stands or holders which are fastened onto the suitcase coils do not permit of a sufficient range of movement to adjust the tube properly, nor are they substantial enough to hold the tube firmly immovable.

**Protection
Screens.**

Lead screens (Figs. 314 and 315) cost from \$10 to \$30. Even the best lead screens are not backed with lead thicker than 1/16 inch. The writer operates back of a "home-made" screen the lead of which is 1/8 inch thick and the 3x3 inch window the lead glass of which

is $1\frac{1}{2}$ inches thick. The material for this screen cost \$15. It is not a particularly beautiful piece of furniture, and if the time spent in building it be considered worth anything, I did not save money, but the finished screen offers more protection than any I know of on the market.

A man may figure from the foregoing approximately what it will cost him to buy the kind of an outfit he wishes to purchase.

Let us take a concrete example of a general practitioner who wishes to make the minimum investment and obtain an outfit with which he may do the lighter work on films, and perhaps occasionally make a large plate radiograph. His photographic paraphernalia costs say \$4. Assuming that his supply current is A. C., he may purchase a high frequency radiographic coil for \$150. An X-ray tube costs \$20, a tube stand \$12. He makes his own screen the material for which costs \$15. He spends \$201 and has an outfit with which he can make small film radiographs in a 10 to 20 second exposure and large plate radiographs in about one minute.

CHAPTER X.

Stereoscopic Radiography.

The word stereoscopic is derived from two Greek words, meaning "solid" and "to see."




Fig. 322. Hand stereoscope in use.

The phenomenon of the stereoscopic picture or radiograph is one very difficult to explain briefly. It is sufficient for us to say here that to gain a stereoscopic effect—that is, to get a picture rich in perspective—we must have two pictures, one for each eye, and observe them with a stereoscope (Figs. 322 and 323). When the two pictures are properly focused in the stereoscope, the observer no longer sees two flat pictures of the same object, but, instead, the single object stands out in clear perspective, just as it would if we looked at the object itself, the two pictures being registered on the retina of either eye and the merging centre of the brain fusing them into one.

To make stereophotographs it is necessary to use a special, double-lens camera (Fig. 324), which takes a picture for each eye simultaneously. Figs. 337 and 338 are stereophotographs.

A moment's consideration of the subject makes it obvious that two radiographs, one for each eye, cannot be made simultaneously. We must




Fig. 323. Large stereoscope made especially for observing stereoradiographs.

place the X-ray tube in the position to make the radiograph for one eye and make the exposure, then shift the tube two and one-half inches (the approximate distance between the eyes), place a new plate or film in exactly the same position occupied by the first plate or film (and this without changing the position of the part being radiographed), and make a second exposure to get the radiograph for the other eye.

**Stereoscopic
Tube Stand.**

To accomplish the proper shifting of the tube a special tube stand or pedestal should be used. There are several such stands on the market known as "stereoscopic tube stands." The one shown in Fig. 61, and again in Figs. 326 and 330, is used by the writer.

**Plate
Changers.**

To accomplish the removal of the first plate after exposure, and replace it with a second plate for the second radiograph, without changing the position of the part being radiographed, it is necessary to use a plate changer (Fig. 325), or a "stereoscopic table" (Fig.




Fig. 324. Double lens camera for making stereophotographs.




Fig. 325. Plate changer.

326), which latter is simply a large plate changer made into a table. The principle of all plate changers is the same. The part being radiographed rests undisturbed on a window of celluloid or thin aluminum, while the plates slide beneath in a tunnel.




Fig. 326. Stereoscopic table and tube stand. H, centering rod.

The plate changer illustrated in Fig. 330, and explained by diagram in Fig. 327, differs from others in that only one five by seven inch plate is used, two pictures, five by three and one-half inches, being made on either end of the plate. A five by seven stereoradiograph (both pictures on the one plate) may be observed with a hand stereoscope (Fig. 322), while all other plate stereoradiographs must be observed with the special stereoscope (Fig. 323).

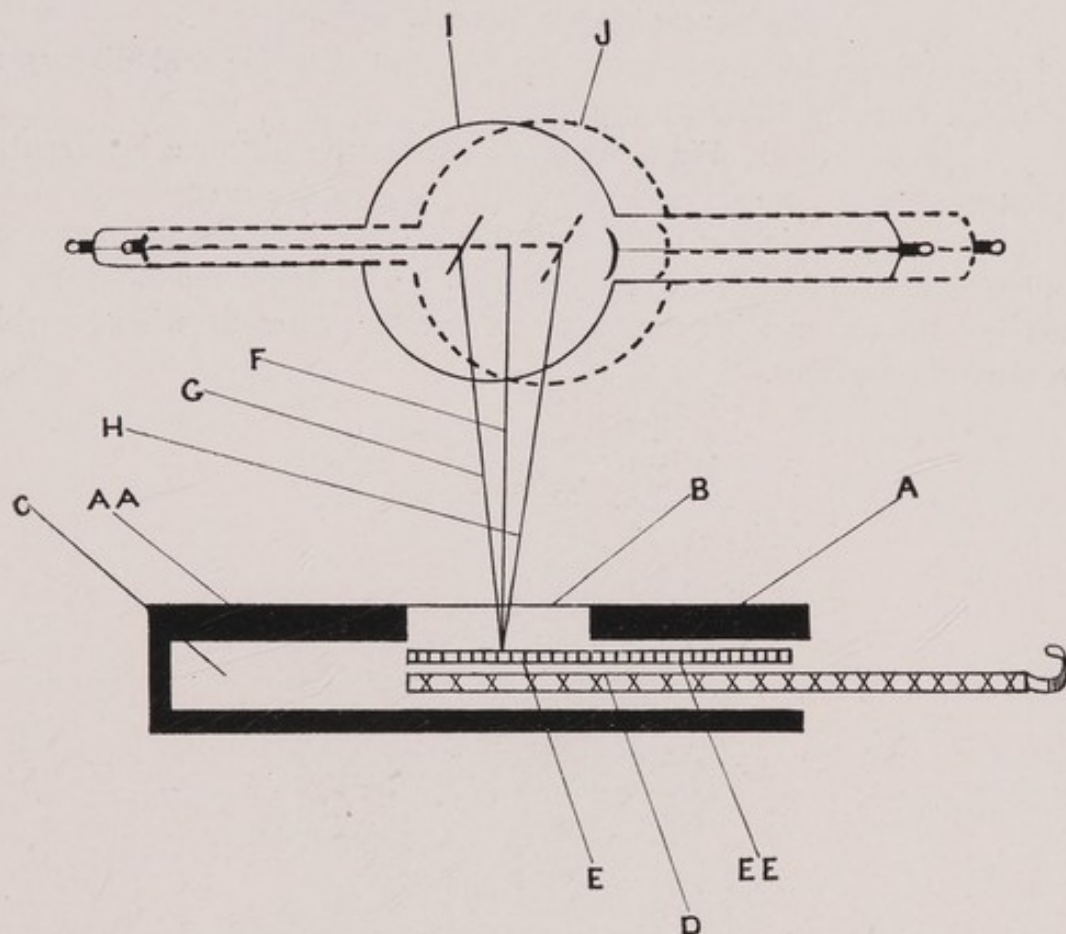


Fig. 327. A and AA, lead which protects the plate against the action of the X-ray. B, window of thin aluminum or celluloid on which the part being radiographed lies. C, end of the tunnel. D, plate carrier. E, end of 5x7 plate on which the first radiograph is made with the tube in position I. EE, end of plate on which second radiograph is made after it is shifted under the window B, and the tube is in position J. F, centering line. G, angle of X-rays with the tube in the first position, I. H, angle of X-rays with the tube in second position, J. The diagram shows the tube being shifted on a line with its long axis. It may be shifted in this manner, or at any angle to its long axis—it makes no difference.




Fig. 328. Compression cones, cylinder and square.

Technic for Making Stereoradiographs.

Let us now take a concrete example and describe and discuss the steps taken in the making of Fig. 339.

Distance. First, what should be the distance between the target and the plate? There are no special rules to follow regulating the distance between the target and the plate when making stereoradiographs. The same results were obtained by the writer with the distance twelve inches as when working at twenty-four inches.

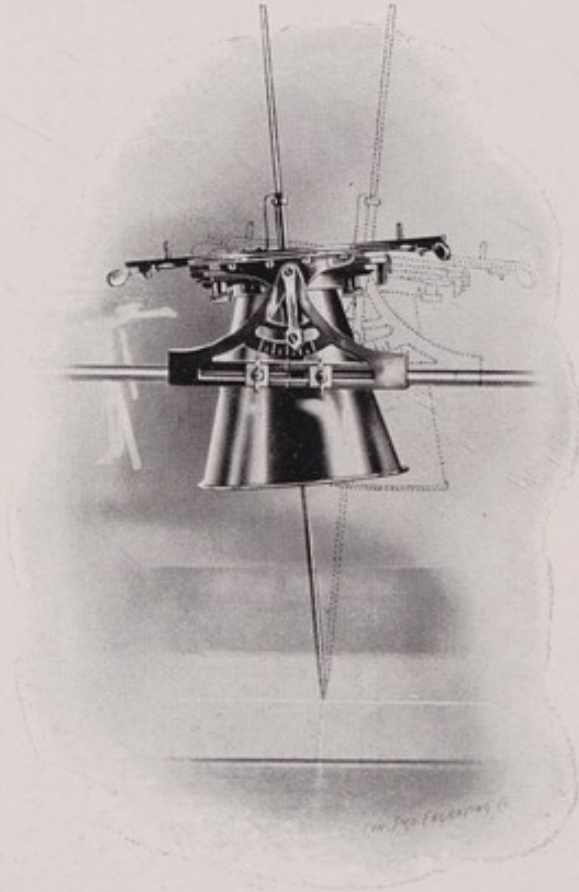


Fig. 329. The lead glass bowl and X-ray tube must be removed while the centering rod is being used. When the stand is "set," the rod is removed and the protection bowl and X-ray tube replaced.

**Setting
Tube Stand.**

The first step is to "centre the tube," to place it so that a line (line F of Fig. 327) drawn from the focal point on the target will strike the plate in the center. This may be done with the greatest accuracy by the use of the centering rod (Fig. 326), but the use of the rod is not imperative unless a compression cone or cylinder (Fig. 328) is to be used, as will be described presently.

After centering the tube, when using a stand like the one in Figs. 326 and 330, the stand is "set" so that the tube may be moved one and one-quarter inch on each side of the center to positions I and J of Fig. 327 (see illustration).



Fig. 330. Pose for making Fig. 344. It is often expedient to have the patient remove the coat and collar for this pose.

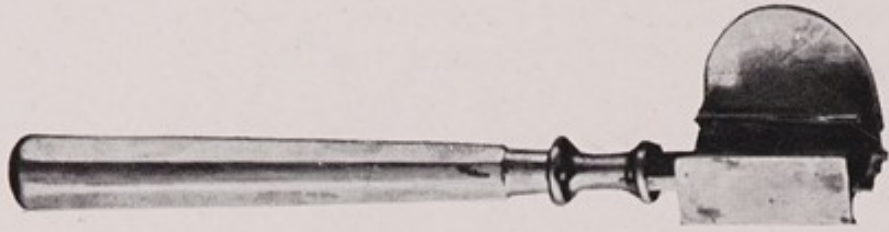


Fig. 331. Modified Kny-Sheerer film holder.

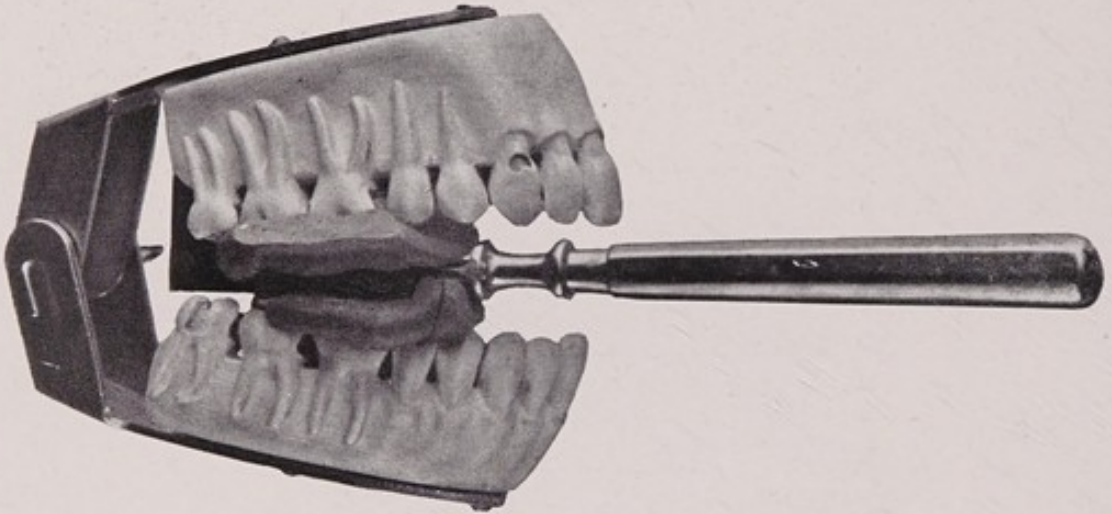


Fig. 332. The film holder shown in Fig. 331 in position.

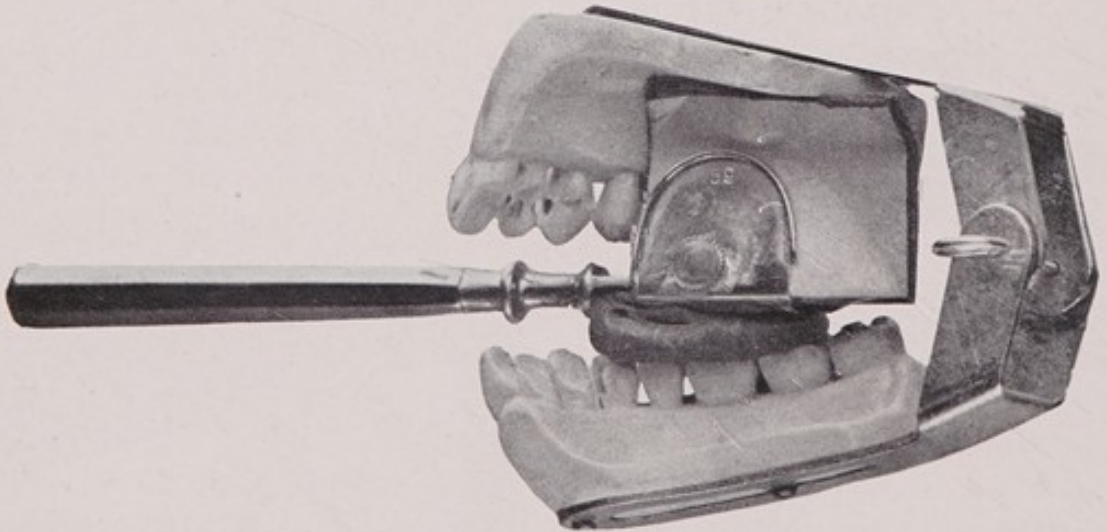


Fig. 333. Another view of the film holder in position.

Tipping the Tube.

It is not necessary to tip the tube, as it is shifted, in order to have the X-rays strike the object and plate at the proper angles—at the angles at which the eyes of an observer would see the object, because the X-rays emanate from the focal point on the target in diverging lines in all directions. So the *same* X-rays are not used to make the second picture that are used to make the first. If they were, it would be necessary to tip the tube to make them strike the object and the plate at the proper angles. (Observe lines G and H of Fig. 327.) When using a compres-

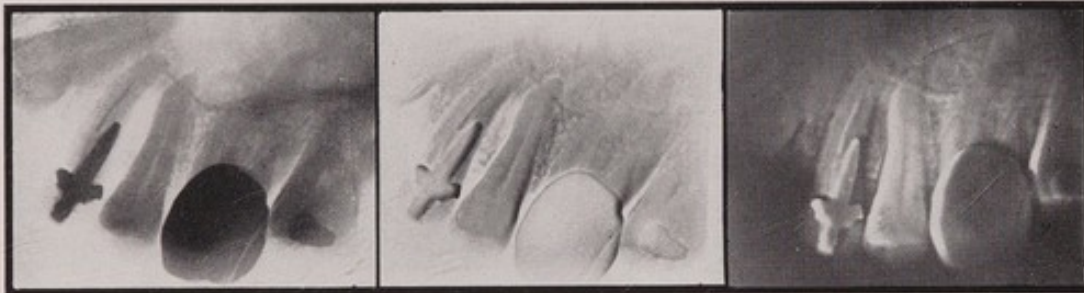

Fig. 334

Fig. 335

Fig. 336

Fig. 334. The photographic print from which this halftone was taken was made from the original negative, or "first picture."

Fig. 335. The same as Fig. 334, except made from "pictures one and two," held together with binding strips.

Fig. 336. The same field as Fig. 334, but made from the "third picture."

sion cone or cylinder we *do* use the same rays to make both radiographs, and hence it becomes necessary to tip the tube as it is shifted. This can be accomplished with accuracy only by the use of the centering rod (see Fig. 329). Thus, if a cone or cylinder is to be used, the tube stand must be "set" not only to shift the tube but to tip it also as it is shifted.

With the tube stand "set," the tube in position I of Fig. 327, and the plate in the position shown in Fig. 327, the first exposure is made. The tube is then shifted to position J, the plate carrier pushed in until the unexposed half of the plate comes under the window B, and the second exposure is made. Since the two radiographs are made on the same plate in this instance, special care should be taken to expose them each the same length of time. Otherwise they will "come up" unequally in the developing solution and radiographs of different densities will result.

If the technic outlined above is followed, it will be found when observing the finished stereoradiograph that we see the part from the position of the tube during exposure. Thus observe Fig. 339, which was taken with the palm of the hand toward the plate, a coin on the back of the hand, a needle under the hand.

If, instead of following the technic as given, the first exposure be made with the tube in position J and the plate as shown in Fig. 327, and the second exposure with the tube in position I, after the plate is shifted; then, when observing the finished stereoradiograph, it is as

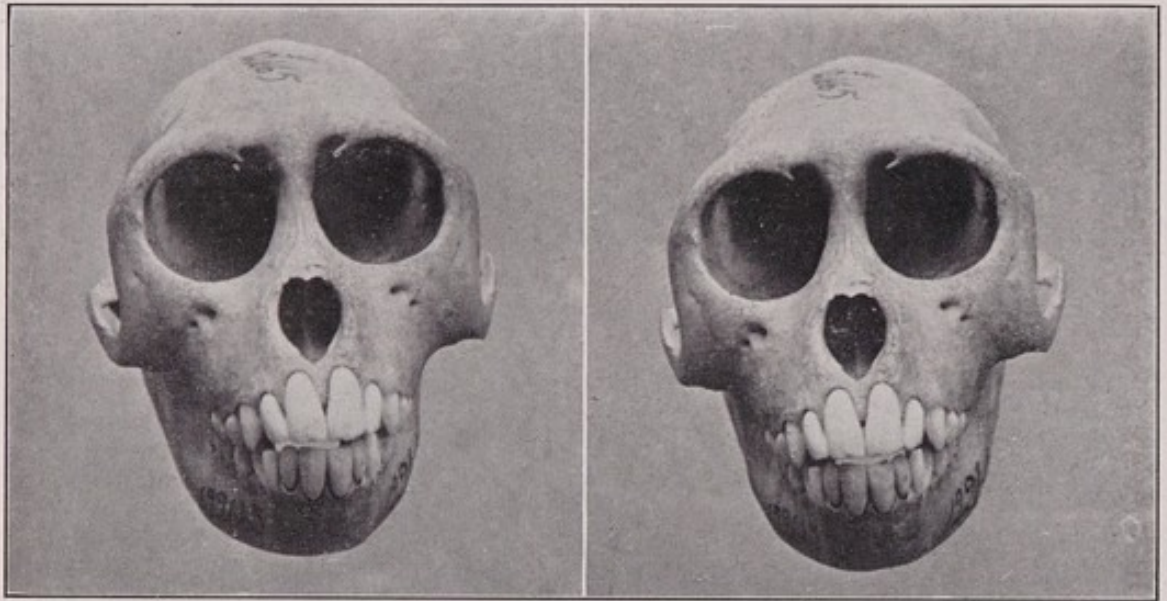


Fig. 337. Stereophotograph of the skull of a monkey, from Dr. John J. Kyle's collection of skulls of vertebrates.

though we saw the part from the position of the plate during its exposure (see Fig. 340).

This changing of position of observation may be accomplished also by interchanging the two radiographs—placing the right on the left and the left on the right. Take Fig. 339, for example; interchange the radiographs and the stereoradiograph is the same as Fig. 340; or take Fig. 340 and interchange the radiographs and the stereoradiograph is the same as Fig. 339. The interchanging of radiographs must be done without inverting them, or the change of position of observation will not be accomplished—the stereoscopic effect will remain the same and the part will simply be viewed upside down.

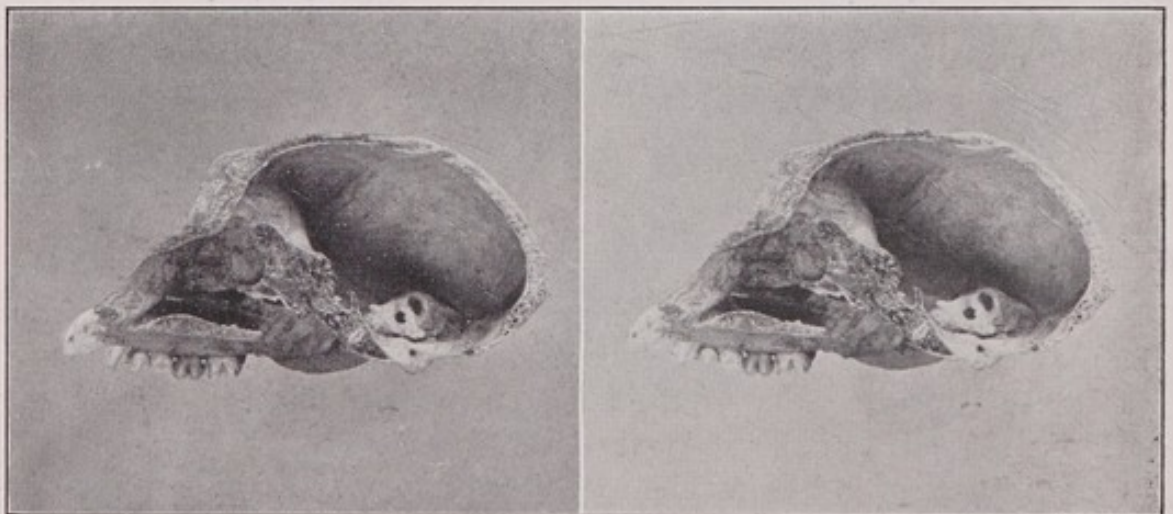


Fig. 338. Sagittal section of the skull of a monkey, from Dr. John J. Kyle's collection of skulls of vertebrates.

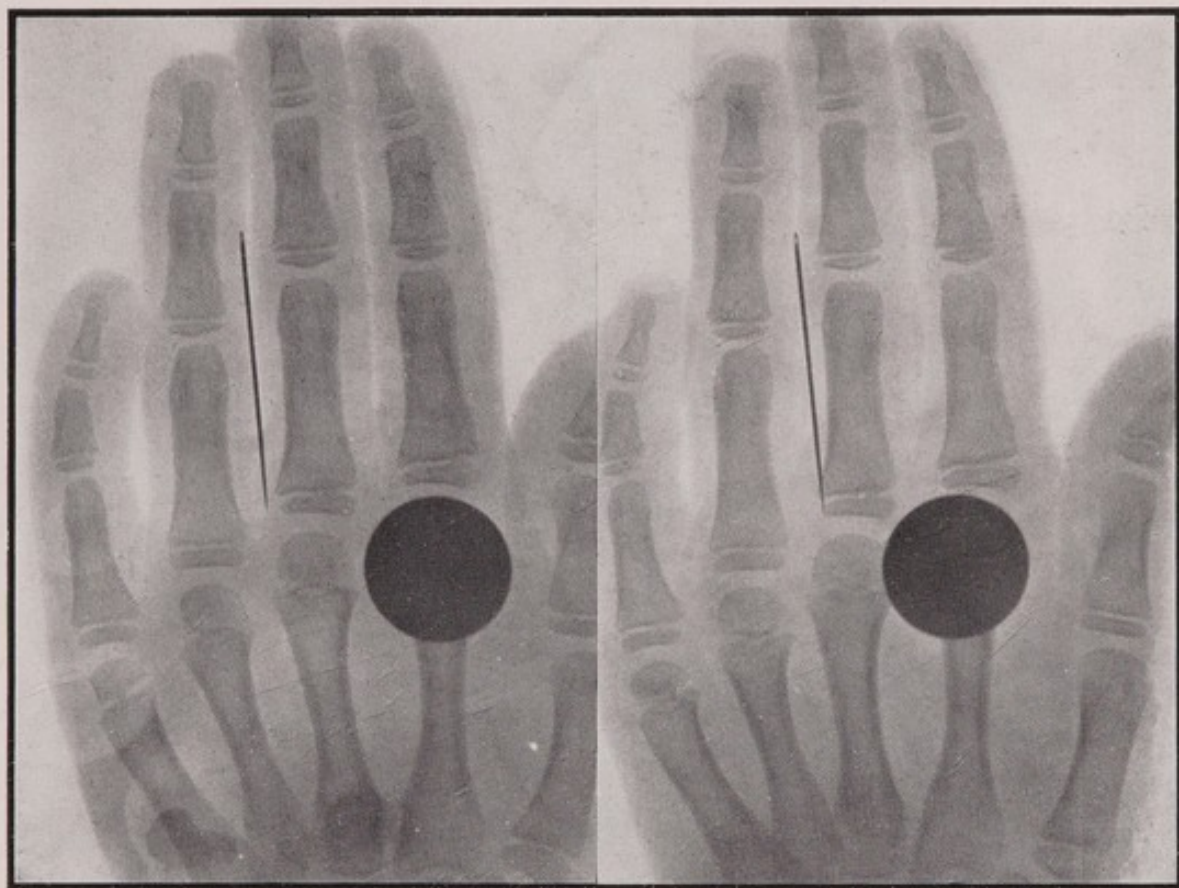


Fig. 339. Showing the coin on one side of the hand, the needle on the other. Here we observe the hand from the position of the tube.

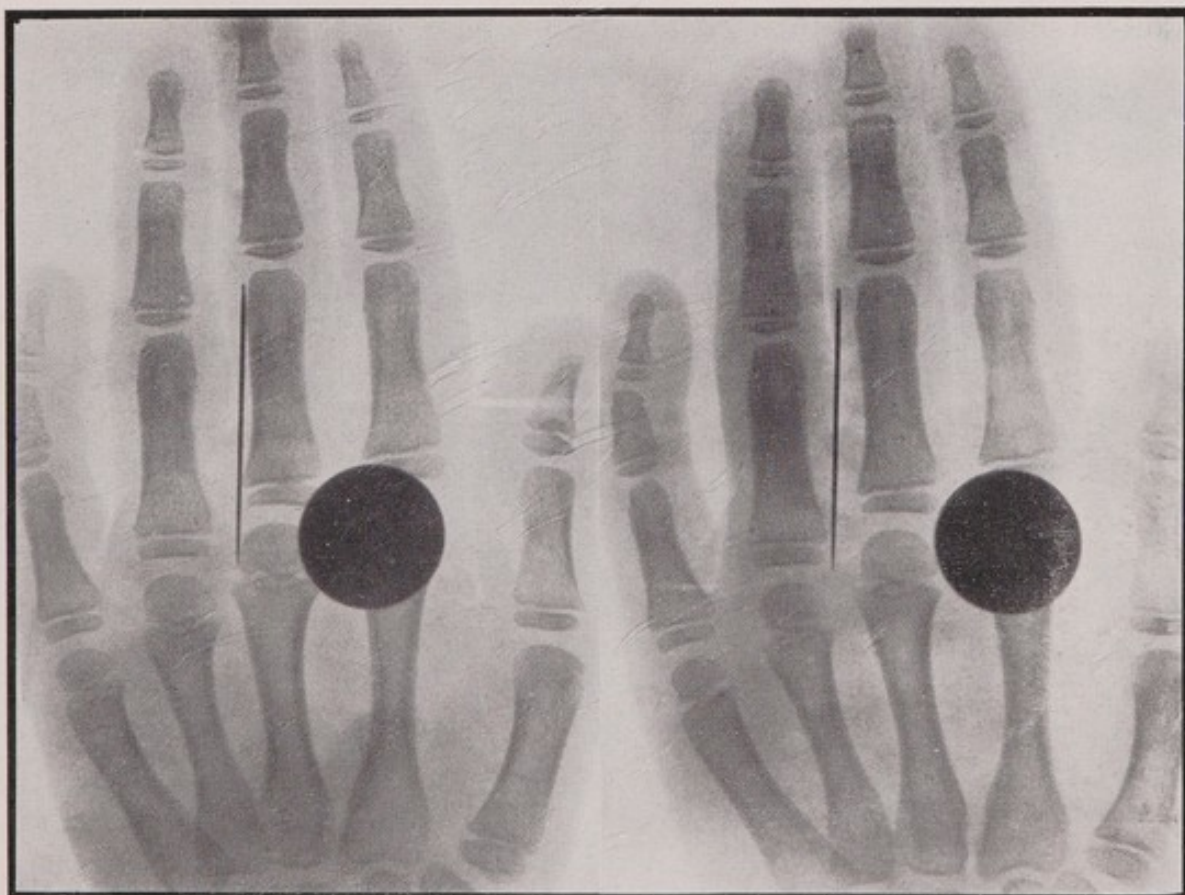


Fig. 340. The same as Fig. 339 except that we observe the hand from the position of the plate during its exposure, instead of the position of the X-ray tube.

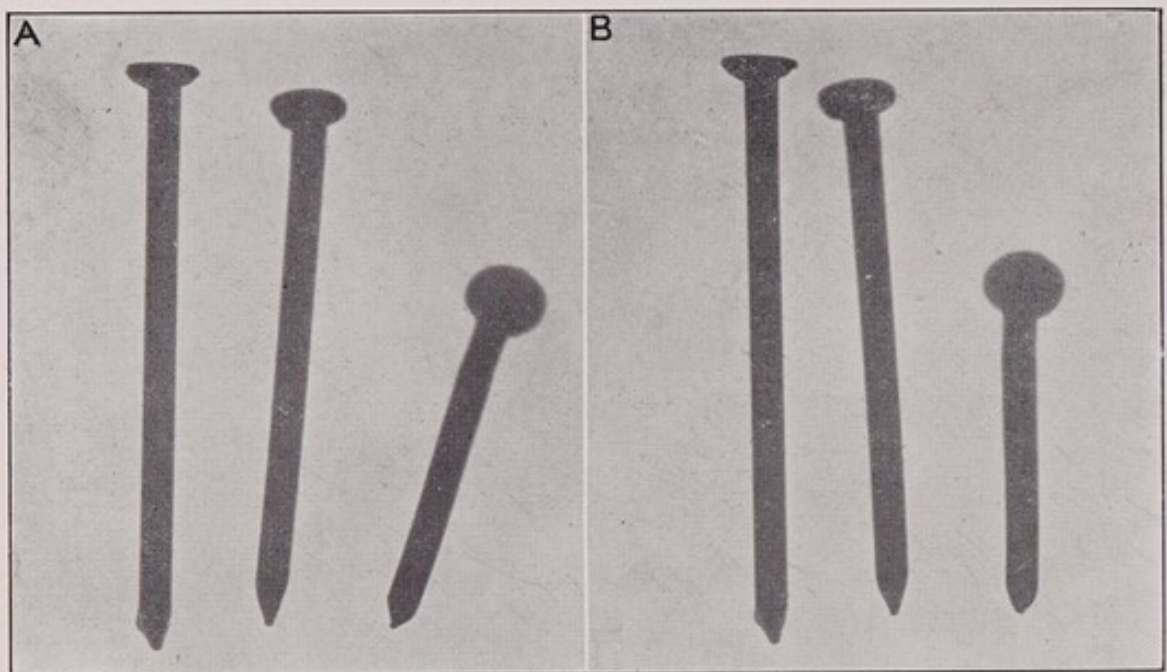


Fig. 341. Three nails of the same size and length. One is in a vertical position, the other two lean toward the observer, at different angles.

Figs. 341, 342 and 343 are the same radiographs mounted differently. No stereoscopic effect at all is seen in Fig. 343, because the tube was shifted at right angles to the long axis of the nails. Had the tube been shifted on a line with the long axis of the nails it would be necessary to observe them as in Fig. 343 to get a stereoscopic effect.

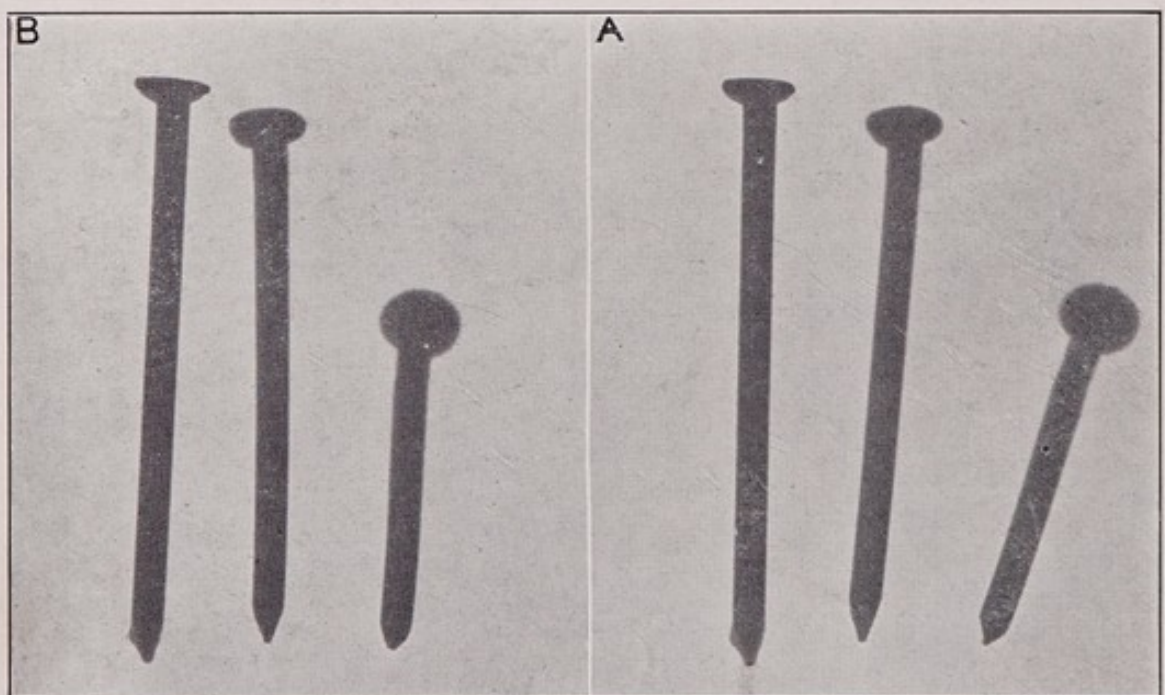


Fig. 342. The same as Fig. 341 except that the individual radiographs are interchanged, the right changed to the left side and the left to the right side. Thus in this stereoradiograph the leaning nails lean away from instead of toward the observer.

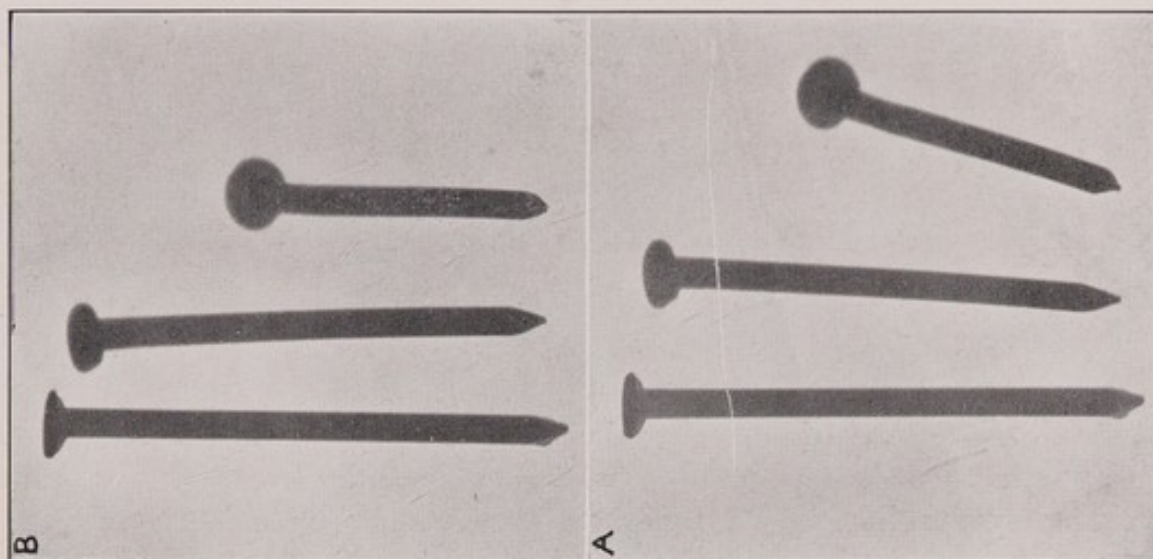


Fig. 343. No stereoscopic effect at all is obtained with the radiographs mounted as in this figure.

**Special Technic
for Dental Stereo-
Radiography.**

We now come to a more definite consideration of dental stereoscopic radiography. Stereoradiographs of the lower teeth may be made on plates using the plate changer illustrated in Fig. 327. Fig. 344 is such a stereoradiograph. Fig. 344 was made from the pose illustrated in Fig. 330.

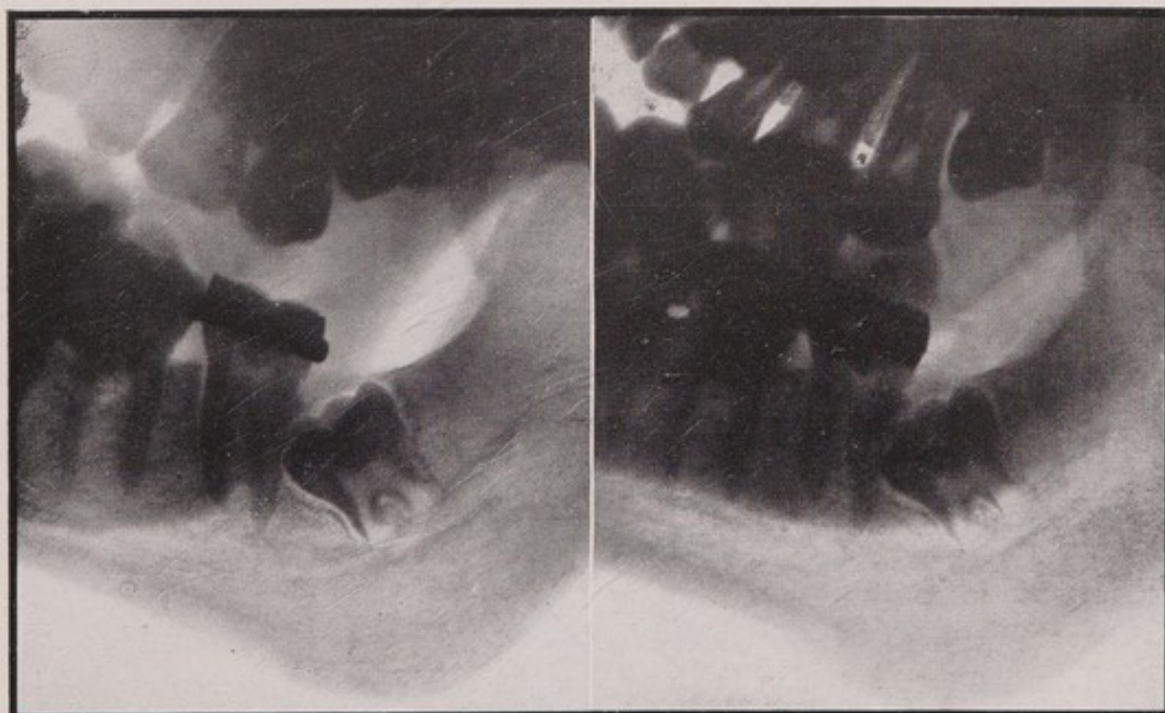


Fig. 344. Though the stereoscopic effect is not very good the figure is representative of what can be done by the method employed to make this stereoradiograph.

When making stereoradiographs on separate plates, like Figs. 345 and 346, it is necessary to use a large plate changer, like Figs. 325 and 326. Figs. 345 and 346 were made on eight by ten inch plates, and the radiographs reduced as shown in the figures, so that they might be observed with the small hand stereoscope. To observe the original negatives it is necessary to use a large stereoscope (Fig. 323).

Dental Film Holder.

When making dental stereoradiographs, on films held in the mouth during their exposure, the problem of replacing the first film, after its exposure, with a second film, which will occupy precisely the same position as the first, is one fraught with great difficulties. In an effort to accomplish this the writer uses a Kny-Sheerer film holder and modeling composition. The film holder, as I use it, is modified almost beyond recognition (see Figs. 331, 332 and 333). Films may be placed in this modified holder in exactly the same position, and, by the aid of the impression of the occlusal surfaces of the teeth in modeling composition, the holder may be replaced in the mouth in the same position. This film holder is applicable to practically any part of the mouth, but especially so to the molar region.

It is not absolutely necessary, but I prefer to have the patients pose in a recumbent position for all dental stereoscopic work, believing they are less likely to move the head while the films are being changed in this position than they would be if sitting in a chair. Thus the pose for making Fig. 347 was a slight modification only of Fig. 330.

Thanks to the work of Dr. C. Edmund Kells, we now know that it is not necessary to have the two films in exactly the same *position* to make a stereoradiograph like Fig. 348. All that is necessary is to have them occupy exactly the same *plane*. Hence no film holder need be used. The film is placed in the mouth as in Figs. 88 and 89.

Preparation of Radiographs for Study with Stereoscope.

After the two film negatives are made, prints may be made from them, and these prints mounted on cardboard to be observed with the hand stereoscope. Or the negatives themselves may be observed stereoscopically by mounting them on transparent glass, sticking them in place with binding strips such as are used in *passé partout* work.

The distance between the radiographs mounted for stereoscopic observation should be approximately two and one-half inches from a given point in one radiograph to the same point in the other radiograph. Great

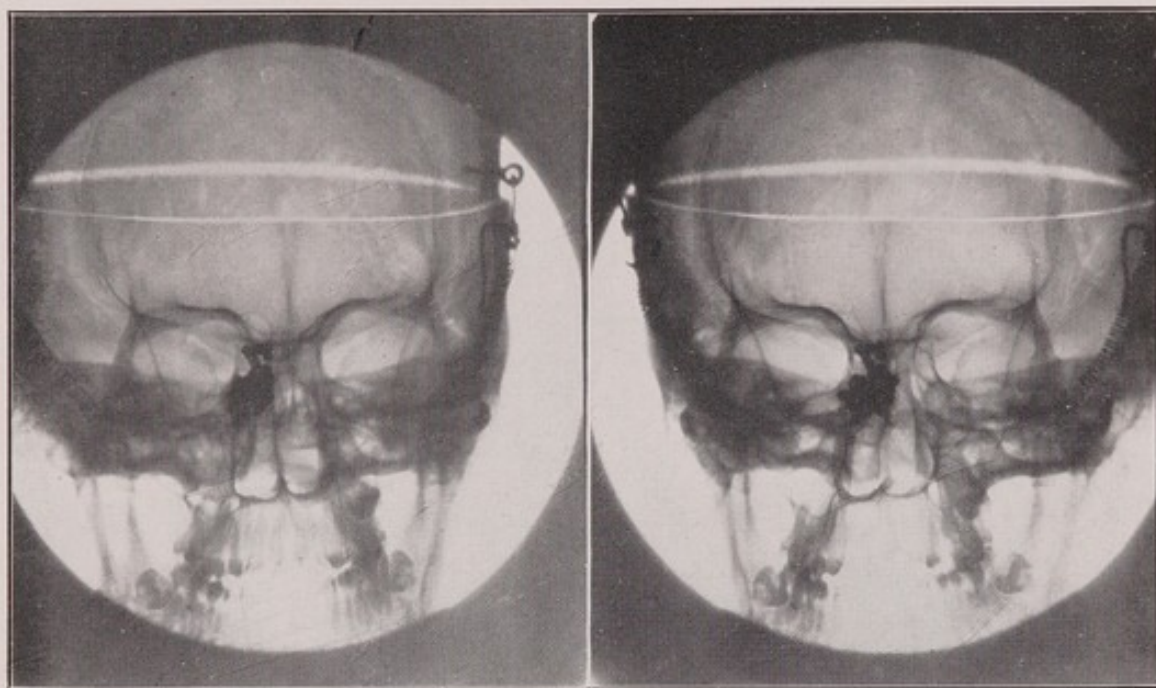


Fig. 345. Antero-posterior view of a dry skull. The right sphenoid sinus is filled with lead shot.

accuracy in mounting the radiographs for stereoscopic study is not necessary though preferable.

Landmarks.

It is always expedient when making dental stereoradiographs to place some landmark, such as an anchor clamp band or a wire, on the teeth. Knowing then that the screw and nut of the clamp band are on the lingual or buccal side, as the case may be, or that the wire is twisted on the lingual or labial side, as the case might be, we may determine immediately, when

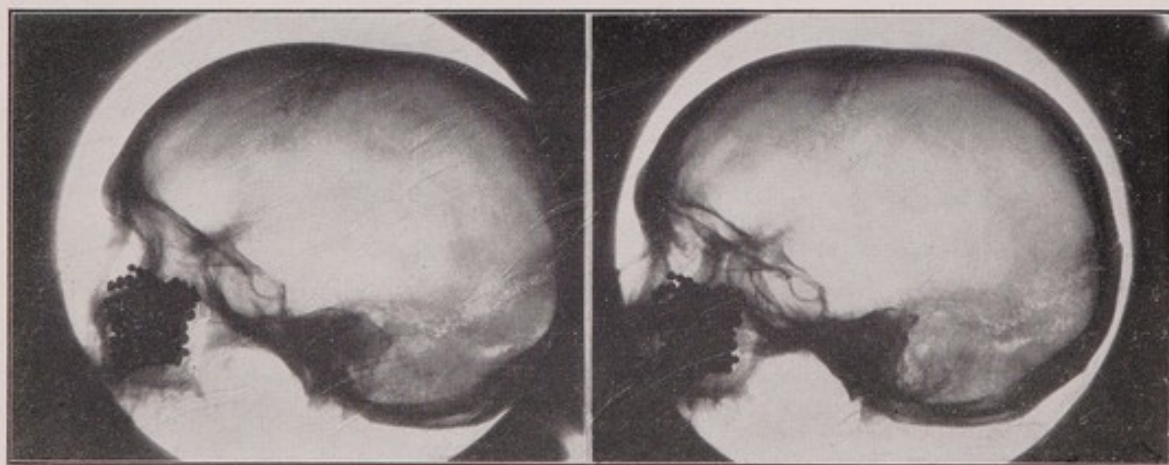


Fig. 346. The reproduction here has lost much of its excellence. When the original negatives were viewed in the illuminating stereoscope, one could look as clearly and directly into the skull as he could into a soap bubble. The dark outline is the antrum nearer the observer filled with lead shot. (Stereoradiograph by A. M. Cole and Raper.)

observing the stereoradiograph, whether we observe the part from the position of the tube or the position of the film.

Dr. Kells states that, as a general proposition, a more perfect stereoscopic effect may be gained if the radiographs are mounted so that the stereoradiograph is observed from the position of the film. This is true, and one reason for it is that, other things being equal, the closer an object

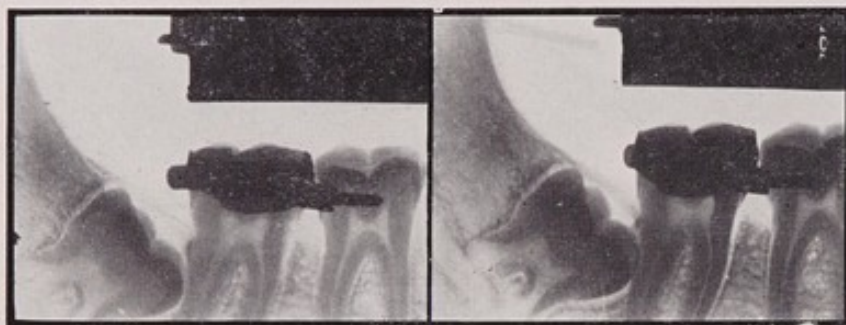

Fig. 347. Impacted lower, left, third molar, viewed from the lingual. The screw and nut of the clamp band are on the lingual.

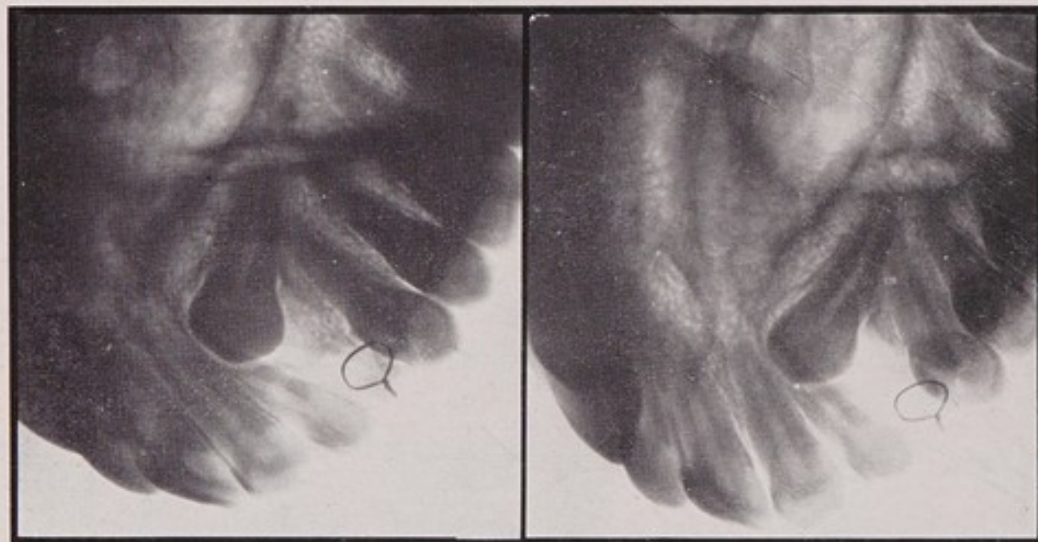


Fig. 348. Viewed from the position of the film—from the lingual. The temporary cuspid is so much decayed and resorbed it can scarcely be seen. The wire around its neck can be seen clearly. The wire is twisted on the labial.

is to the plate or film the clearer it is outlined in the radiograph. Likewise as we look upon a scene, the closer objects are clearer than those at a distance. Hence, when we observe a stereoradiograph from the position of the film or plate during its exposure, those parts of the stereoradiograph seeming to be closer to us are clearer, while those farther away are less clear.

If the film packets used contain two films each, four negatives will be made, and these may be mounted on clear glass, so that the operator

may observe the part from the position of the film and tube also.

**Enlargement
of Dental
Stereoradiographs.**

In direct proportion as things are large or small it is easy or difficult to discern perspective. The parts in dental radiographs are so small that it is difficult to gain perspective. In an effort to overcome this handicap, to an extent at least, Fig. 350 was made. Fig. 350 is an enlargement of Fig. 349. Owing to the loss of

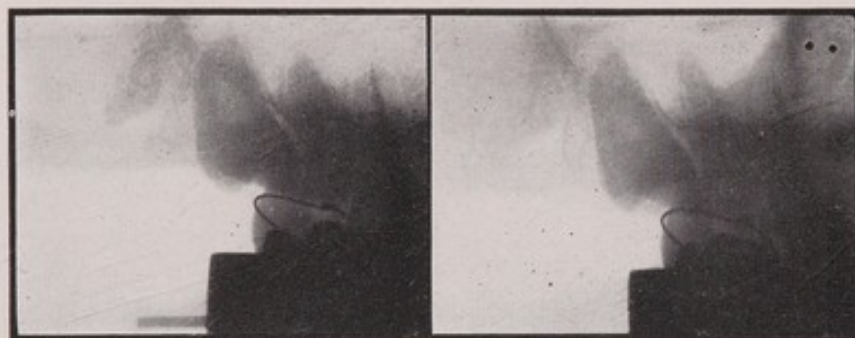

Fig. 349. Impacted upper, third molar, viewed from the position of the tube. The wire passing around the neck of the second molar is twisted on the lingual. The impacted tooth sets to the buccal.



Fig. 350. Same as Fig. 349 enlarged.

detail incident to enlargement there seems little if any advantage in this step. There is none made at the present time, but a magnifying stereoscope would probably be of value for viewing dental stereoradiographs.

**Practical Value
of Dental Stereoc-
radiographs.**

So much for the technic involved in the practice of dental stereoscopic radiography. Let us now consider the results, the practical application and the possibilities of dental stereoscopic radiography. Frankly, the results are discouraging. Considering

the difficulties of practice, and the results obtained at the present time, there is an extremely limited practical application of the stereoradiograph to dentistry. What the future possibilities of dental stereoscopic radiography are I would not attempt to say. My hope is that some day we may be able to stereoradiograph the upper molar roots successfully.

By describing it I think I have proven that the technic involved to do dental stereoscopic work is so difficult that the work should be left entirely to specialists in radiography. Even in the hands of the most skillful it seems, at the present time, that there are several good reasons why it will never be popular. The reasons are: (1) The difficulty, and




Fig. 351. Coins at different distances from a wire screen.

at the same time the necessity, of obtaining two radiographs uniformly rich in detail. (2) The difficulty and necessity of placing two films in the mouth in the same position. (3) The difficulty and necessity of having the patient maintain the same pose while the two exposures are made. (4) The great amount of time consumed to do the work. (5) The parts being so small makes it especially difficult to gain a stereoscopic—a perspective—effect. (6) One of the most important reasons why dental stereoscopic work probably never will be popular, even among specialists, is that we feel no great need of it. The single radiograph is not totally lacking in perspective, and a careful study of it will reveal almost, if not quite, as much as can be seen in the dental stereoradiograph. (7) The stereoradiograph is sometimes misleading. For example, witness Fig. 351. To make this illustration three coins were placed on a piece of wire screening, one directly against the screen, the other two resting on cotton

built up to hold them at different distances from the screen. In the stereoradiograph the coin which rests against the screen seems to stand out from it a short distance.

Some day perhaps we may so modify and perfect our technic that the stereoradiograph will be of indispensable value (1) in observing the three roots of upper molars; (2) in seeing a wire passing through a perforation to the labial, buccal or lingual; (3) in some particular cases

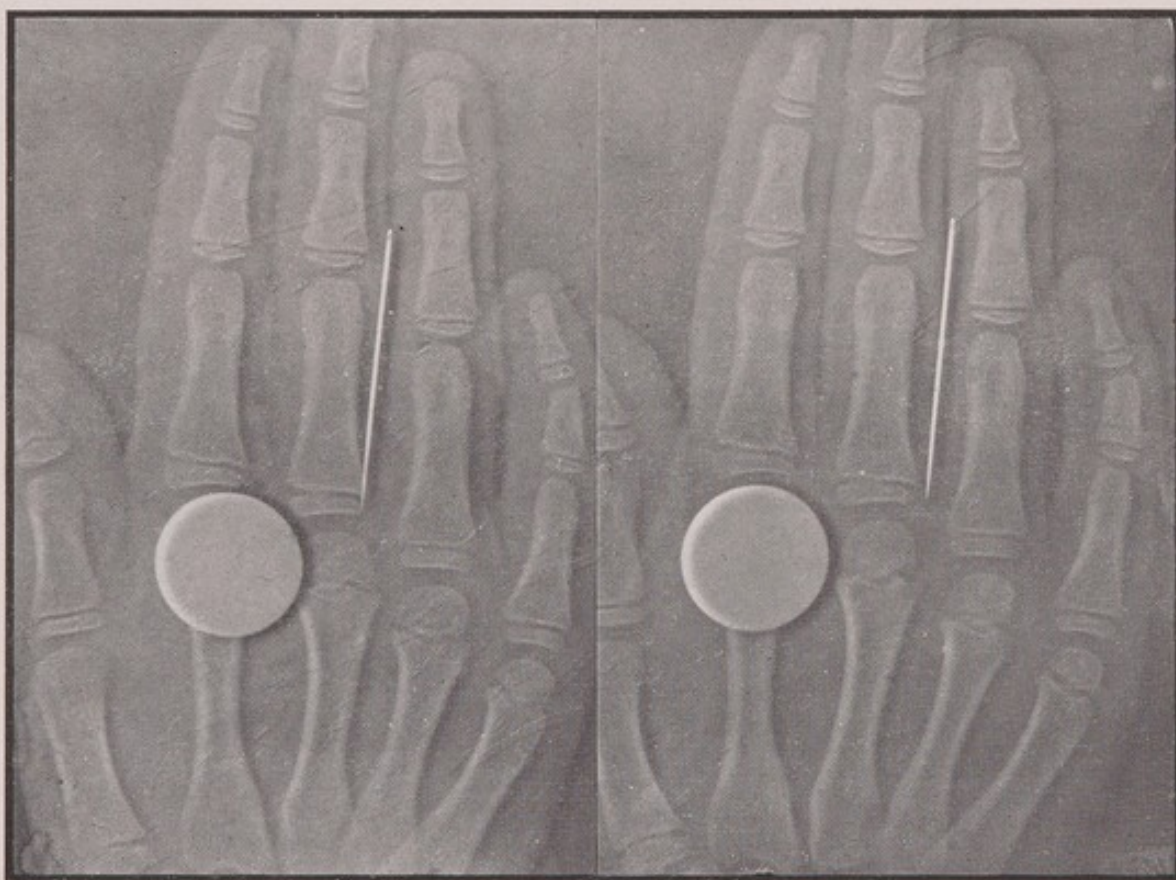


Fig. 352. Same as Fig. 339 made "plastic."

of impacted teeth to show more exactly their location, and so aid in the extraction; (4) in showing the orthodontist when he may move the coming permanent teeth by moving the deciduous teeth; (5) in determining more exactly than can be done with the single radiograph the size and location of a pus cavity or cyst; (6) in cases of fracture of the mandible; (7) in locating exactly bone "whorls," calculi in the glands or ducts of glands and foreign bodies in the antrum; (8) in learning the size, shape and location of the antrum as an aid in opening into it; and (9) in cases of tumor to locate more definitely the offending body.

Plastic Radiography.

There is no one thing which so limits the usefulness of the radiograph as its lack of good perspective. Hence our interest in stereoscopic radiography. Hence, also, our interest in plastic radiography.

Plastic radiography is a method of making radiographs in such a way that the parts stand out in *bas relief*. A better name than plastic

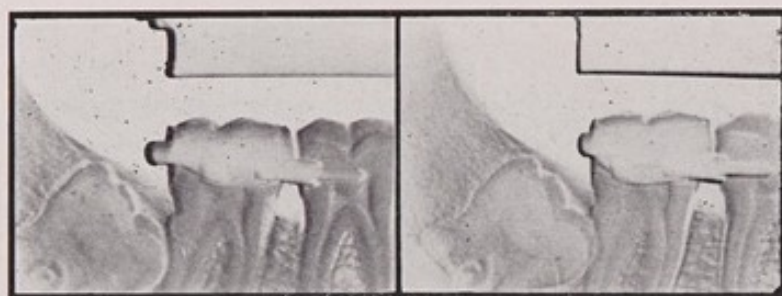

Fig. 353. Plastic reproduction of Fig. 347.

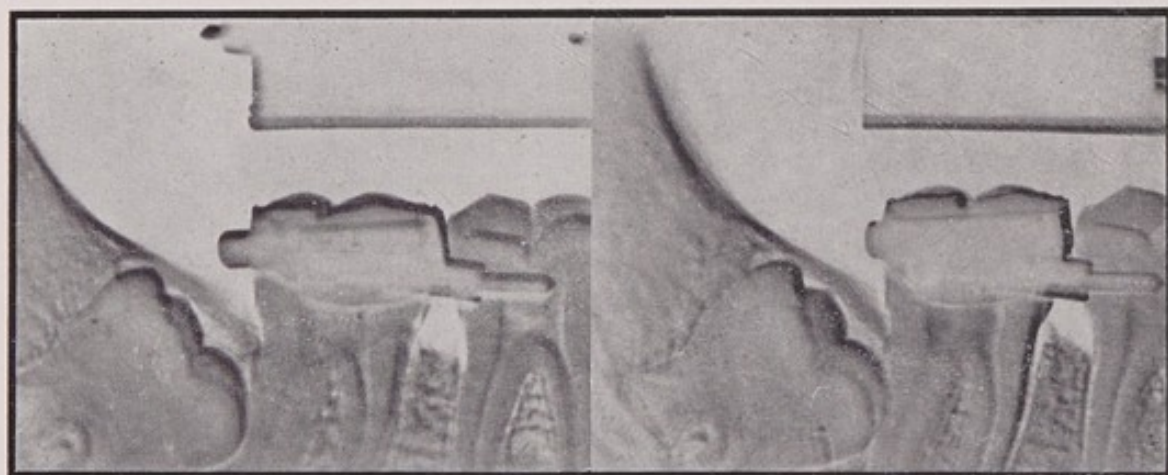


Fig. 354. Fig. 353 enlarged.

radiography would have been trick radiography. I describe the method simply as a matter of interest. It is of no practical value whatever.

**Technic of
Plastic
Radiography.**

The following are the steps in making a plastic radiograph. The negative is made as usual. For convenience in referring to it we shall call the negative the *first picture*. From the *first picture* another picture, the *second picture*, is made on a photographic plate, the technic for doing this being the same as for making lantern slides (see Chap. V). The *first* and *second pictures* are now placed together, non-sensitive sides in apposition, held up to the light and moved about until the parts of the two pictures overlie one another exactly. They are now held immovable while an assistant sticks them together with

paper binding strips. Next, place them in a printing frame and make a photographic print on paper (see Figs. 335, 352, 353 and 354). While the exposure is being made the printing frame must remain immobile and the light must pass through pictures number one and number two and strike the photographic paper at an angle of about ninety degrees.

Instead of allowing the light to pass through pictures one and two and strike the photographic paper at an angle, the same result may be accomplished by allowing the light to pass straight through pictures one and two, if at the time they are stuck together the two pictures are almost, but not quite, in perfect overlying opposition.

Instead of making the print on paper from pictures one and two, another picture, number three, may be made on a plate, and from this *third picture* photographic prints made (Fig. 336).

Plastic radiography is simply a scheme of shading radiographs. Nothing *more* can possibly be seen in the plastic production than could have been seen in the original negative, though, perhaps, something may be seen *more easily*. To the man unacquainted with the reading of radiographs the plastic pictures seem much clearer, but to the man of experience it is not so clear, for there is an unavoidable loss of detail in the making of the plastic reproduction.

Plastic Stereoradiographs. Figs. 352, 353 and 354 are plastic stereoradiographs. It is interesting to pause and consider the number of steps necessary to make Fig. 354. First, the negatives were made; from these the "second picture" of the plastic method, then the prints on photographic paper, from which enlargements were made, and then the halftone.

In concluding let me say that the properly made, intelligently read single radiographic negative is of the utmost importance and value in the practice of dentistry. Let us not forget this, and let us not decry the radiograph because our efforts in stereoscopic and plastic work fail to make it absolutely infallible.

INDEX

Abortion	277	Cabinet, Protective Lead.....	280, 283
Abscess,		Calculus	200
Alveolar	185	Canals of Teeth,	
Dentoalveolar	185	Broach in.....	204, 205
Destruction of Tissue in.....	187	Enlarging	176, 210
Multirooted Teeth.....	190	Filling	175, 176
Number of Teeth Involved.....	189	Finding	172
Of Crowned Teeth.....	191	Cancer	274, 275
Opening on Cheek.....	253	Caries,	
Pericemental	195	Dental	269
Pyorrhea Alveolaris, Differential		Of Bone.....	231
Diagnosis	193	Cathode	41, 42
Absorption of Teeth (See Resorption)		Cathode Stream.....	48, 49, 52
A. C.....	2, 9, 11, 24, 295	Cementoma	214
Acid Fixing Bath.....	78	Circuit, Electric.....	10
Alopecia	278	Coil,	
Alternating Current.....	2, 9, 11, 24, 295	High Frequency (See High Fre-	
Alveolar Abscess.....	185	quency Coil).	
Ammeter or Amperemeter.....	32	Induction (See Induction Coil).	
Ampere	4	Interrupterless (See Interrupter-	
Amputation of Apex of Tooth Root	201	less Coil).	
Angle of X-rays.....	91 to 94	Color of X-ray Tube.....	51, 52
Anode	41, 42	Commutator	9
Ankylosis	247, 262	Compression Cones and Diaphragms,	
Anomalies	230		63, 64
Anti-Cathode	41, 42	Condenser	34, 35, 36
Antrum of Highmore.....	234	Conductors, Electric.....	1
Foreign Body in.....	238	Congenital Absence of Teeth (See	
Pus in.....	234	Missing Teeth).	
Radiographing of.....	108, 114	Converter, Rotary.....	36, 37
Apparatus, Radiographic.....	294	Crowned Teeth.....	181, 191
Apicoectomy	201	Currents	2, 38, 53
Aprons, X-ray Proof.....	286	Cutouts (See Fuses).	
Armature	9	Cutting of Teeth, Delayed.....	148
Arsenical Necrosis.....	231	Cycle	2
Articulation, Temporo-mandibular,		Cyst	
	242, 266	Bone	218
Artificial Roots.....	213	Dentigerous	222
Assistant Anode.....	44	Danger,	
Azo	83, 104	Of Electric Currents.....	32, 38
Baldness	278	Of the X-rays.....	273
Bi-anodal X-ray Tubes.....	44	To Operator.....	287
Bismuth Paste.....	199, 204	To Patient.....	288
Blood Supply.....	266	Dark Room.....	67
Bone "Whorls".....	214	Dark Room Lantern.....	68
Bridgework	209 to 212	D. C.....	2, 9, 11, 19, 295
Bromide Paper.....	116, 118	Death, from X-rays.....	275, 276
Broken,		Deciduous Teeth.....	157, 161, 162, 163
Broach in Canal.....	204, 205	Delayed Eruption of Teeth.....	148
Tooth	205	Densities, Recorded on Radiograph,	
Burn, X-ray (See Dermatitis)			136, 138

Denticles	250	Extraction of Teeth.....	162, 168
Dentoalveolar Abscess.....	185	Eye, Disturbance of.....	172
Dental Radiograph.....	I, 85	Facial Neuralgia (See Neuralgia).	
Dental Stereoradiographs.		Faraday	8
Practical Value of.....	313	Fatality, from X-ray Lesions...	275, 276
Technic for Making.....	309	Ferrotypes	106
Dermatitis	273, 274, 290	Field	9
Developer	74	Filling,	
Choice of.....	102	Canals	175, 176
Hydrochinon	75	Encroaching on Pulp.....	181
M-Q	75	Large	181
Temperature	76	Film,	
Development.		Description of.....	66
Of Negative.....	74, 102	Holder	98, 304, 310
Of Prints.....	83, 104	Methods of Holding in the	
Of Teeth.....	264	Mouth	98, 304, 310
Destruction of Tissue, Bone and		Placing Outside the Mouth.....	106
Tooth	187	Position of and Direction of Rays,	90
Diagram.		Protection of.....	86, 87, 98
Cathode Stream.....	48	Radiographs, Advantages of.....	114
Compression Cone and Diaphragm,		Special X-ray.....	66, 85
High Frequency Coil.....	36, 38, 129	Filter	289
Induction Coil.....	20, 32, 33, 34	Fistula on Face.....	253
Mechanical Interrupter.....	28	Fistulous Tract.....	199
Pose for Radiographs.....	70, 91 to 94	Fixing,	
Rheostat	31	Box	79
Shunt	45	Of Negatives.....	77, 104
Stereoscopic Work.....	301	Of Prints.....	84
Switch	22	Fluoroscope	55, 56, 143, 144
Valve Tube in Use.....	54	Foreign Bodies.....	202
X-rays	48	In Antrum.....	238
X-ray Tubes.....	46	Fracture,	
Diaphragms and Compression Cones,		Of Tooth.....	208
61, 64, 301		Of Jaw.....	244
Differential Diagnosis, Pyorrhea and		Friedlander's Shield.....	63, 64
Abscess	193	Frontal Sinuses.....	234, 235, 237
Differentiation, Primary and Sec-		Fuses	17, 21
ondary Teeth.....	161	Generator	9
Dislocation of Condyle.....	242	Grounding the Current.....	112
Direct Current.....	2, 9, 11, 19, 295	Gloves	286
Distance Between X-ray Tube and		Hair, Loss of.....	278
Patient	97	Headache	260
Drying.		High Frequency Coil,	
Of Negatives.....	80, 103, 104	Description of.....	33
Of Prints.....	84, 106	Diagram of.....	36, 38, 129
Duration of Exposure.....	71, 99	Radiographs Made With...124 to	130
Dynamos	9	Technic Involved in Use of.....	130
Ear, Pain in.....	228	Hydrometer	21
Education in Radiographic Work,		Hypercementosis (See Cementoma).	
292, 293		"Hypo"	78, 79, 261
Electricity	1	Hypochondriac	261
Electrolyte	17, 21	Idiopathic Neuralgia.....	252
Electromagnets	7	Illuminating Boxes.....	136, 298
Elementary Radiography.....	I to 85	Immunity	290
Empyema of Maxillary Sinus.....	234	Impacted Teeth.....	168, 256, 262
Ethmoid Cells.....	234, 235	Induction Coil,	
Exposure.		Description of.....	15
For Prints.....	83, 104	Diagrams of.....	20, 32, 33, 34
Of Patient, Time Limit.....	288		
Time of, for Negatives.....	71, 99		
Exostosis, Dental.....	214		

Radiographs Made With,		Fixing of.....	77, 104
73, 120 to 124, and 133 to	135	Intensification of.....	81
Technic Involved in Use of.....	88	Marking of.....	141
Inferior Dental Canal.....	252	Reducing of.....	81
Inflammation About Bridge.....	211	The Relative Values of Dense	
Insanity.....	256, 277	Areas in.....	136, 138
Insomnia.....	256	Washing of.....	79, 104
Installation.....	15, 36	Neuralgia, Facial.....	249, also 160, 180
Insulation.....	7, 27	Neurasthenia.....	256
Intensifier.....	81	Neuroses.....	256
Intensifying Screens.....	101	Nonconductor.....	2
Interrupterless Coil,		North Pole of Magnet.....	6
Description of.....	39	Odontoma.....	151, 228, 229
Radiograph Made With.....	132	Ohm.....	3
Technic Involved in Use of.....	88	Ondoscope or Oscilloscope (Same	
Interrupters.....	17 to 25	as Oscillimeter).	
Inverse Current.....	53	Oscillimeter.....	54
Jumping the Bite.....	263	Osteology.....	263
Kilowatt.....	5	Osteoma.....	227
Kilowatt-hour.....	5	Pain, of X-ray Lesions.....	277
Kresko.....	104	Paper, Photographic.....	83, 104
Lame Teeth.....	184	Penetration of X-rays.....	56
Lantern Slides.....	118	Penetrometer.....	55
Lassitude.....	278	Perforation of Teeth.....	179
Lead Cabinet.....	280	Pericemental Abscess.....	195
Lead Screen.....	280, 295	Pericementitis, Chronic.....	184
Leukemia.....	277	Perspective.....	142, 144, 297
Life, Loss of.....	275, 276	Photographic Paraphernalia Needed	294
Locked Jaw.....	262	Placing Film Outside the Mouth....	106
Ludwig's Angina.....	253	Planted Teeth.....	212
Luxation.....	242	Plastic Radiography.....	316
Magnetism.....	5	Plastic Stereoradiographs.....	317
Magneto.....	9	Plate Changers.....	299
Making Photographic Prints.....	83, 104	Plates and Films,	
Making Negatives (See Negatives).		Photographic.....	65
Making Radiographs.....	65, 85	X-ray.....	66
Malformed Teeth.....	230	Pose for Making Radiographs,	
Marking Negatives.....	141	Of the Upper Anterior Teeth....	96
Maxillary Sinus (See Antrum).		Of the Antra of Highmore...108, 114	
Maxillary Suture.....	266	Of the Lower Anterior Teeth.100, 108	
Meters.....	32	Of the Lower Anterior Teeth and	
Methods of Holding Film in the		Antra.....	108
Mouth.....	98, 304	Of the Lower Molar and Bicuspid	
Missing First Molar.....	153	Region.....	99
Missing Second Molars.....	155	Of the Upper Molar and Bicuspid	
Missing First, Second and Third		Region.....	92
Molars.....	155	With the Film Outside the Mouth	107
Missing Teeth.....	148, 157, 266	Pose for Making Stereoscopic Den-	
Motor.....	37	tal Radiographs.....	303
Moisture, Protection of Film from,		Position of Film and Direction of	
86, 87		X-rays.....	90
Myelosarcoma of the Lower Jaw... 226		Position of Film in the Mouth,	
Necrosis.....	231	89, 95, 97	
Negatives.....	78, 137, 141	Positive Wire, Test for.....	19
Development of.....	74, 102	Positives.....	83
Drying of.....	80, 103, 104	Potential.....	2, 3
Faults in.....	81, 82	Pregnancy.....	277
		Primary,	
		Current.....	11, 12, 27, 33
		Teeth (See Deciduous Teeth).	
		Winding.....	11, 12, 27, 33

Prints, Photographic.....	137, 138	Amputation of.....	201
Development of.....	83	Fracture of.....	208
Drying of.....	84, 106	Forming.....	160
Exposure.....	83, 104	Fusion of.....	203
Fixing of.....	84	In Antrum.....	238
Toning of.....	105	Radiographed for Bridgework....	209
Washing of.....	84	Rotary Converter.....	36
Probing.....	199	Ruhmkorff Coil (See Induction Coil).	
Protection.....	278		
Apron.....	286	Secondary,	
Cabinets.....	280	Current.....	11, 12, 27, 33
Gloves.....	286	Dentin.....	180
Of Films.....	86, 87, 98	Rays.....	57, 289
Screens.....	280, 295	Winding.....	11, 12, 27, 33
Shield.....	59 to 63, 285	Shield, for X-ray Tube (See Protection Shield).	
Spectacles.....	286	Shunt.....	42
X-ray Tube.....	285	Short Circuit.....	19
Psychoses.....	256	Skiagraph, or Skiagram.....	65
Pulp Nodules, or Stones.....	179	Solio.....	104
Punctured X-ray Tube.....	52	South Pole of Magnet.....	6
Purchasing a Radiographic Outfit....	292	Spark Gap, Terminal,	
Pyorrhea Alveolaris.....	193, 293	20, 28, 35, 36, 40, 43, 44	44
"Pyro".....	76	Current or Coil Regulating....	35, 36
		Inverse.....	51, 53
Radiographic Outfit, Purchasing a..	292	Parallel (Same as Terminal).	
Radiograph or Radiogram.....	65	Series.....	52, 53
Radiographs Made Direct on Photographic Paper.....	116	Tube Regulating.....	46, 47
Radiographs, Preparation of, for Study with Stereoscope.....	310	Spasm, Facial Muscles.....	260
Radiography,		Specialists in Radiographic Work..	292
Elementary.....	1 to 85	Spectacles.....	286
Dental.....	85 to 317	Sphenoid Cells.....	311
Plastic.....	316	Squeegee Board.....	106
Stereoscopic.....	144, 297	Stands, X-ray Tube.....	59, 60, 284, 295
Radium Rays.....	291	Static Machine.....	14
Reading Radiographs.....	136	Stereoradiographs,	
Records,		Technic for Making.....	297
Of Densities in Radiographs..	136, 138	Plastic.....	317
Radiographic Records.....	268	Stereoscope.....	297, 298
Rectifier.....	24	Stereoscopic,	
Reducer.....	81	Radiography.....	144, 297
Reproductions.....	137	Table.....	300
Requirements of a Radiographic Outfit.....	294	Tube Stand.....	303
Research Work.....	263	Sterility.....	277
Resorption of Teeth,		Stones,	
157, 165, 168, 169, 213	266	Pulp.....	179
Resection,		Salivary.....	217
Of Inferior Dental Nerve.....	252	Supernumerary Teeth.....	167
Of Mandible.....	247	Suppuration 168, 196 (See Abscess and Pyorrhea).	
Retained Deciduous Teeth.....	157	Switches.....	17
Rigg's Disease (See Pyorrhea Alveolaris).			
Rheostat.....	25	Technic,	
Rodinal.....	103	For Covering Films.....	86
Roentgen.....	65	For Making Dental Radiographs..	85
Ray (See X-ray).		For Making Plastic Radiographs.	316
Wm. Condar.....	49	For Making Radiographs.....	65
Roots of Teeth,		For Making Stereoradiographs....	297
Absorption of (See Resorption).		For Using a High-Frequency Coil	130
Artificial.....	213	For Using an Induction Coil.....	88
		For Using an Interrupterless Coil.	88

Teeth,	
Abscess of (See Abscess).	
Absorption of (See Resorption).	
Caries of, Hidden.....	269
Canals of (See Canals).	
Crowned	181, 191
Cutting, Delayed.....	148
Deciduous.....	157, 161, 162, 163
Delayed Eruption.....	148
Development of.....	264
Differentiation Between Primary and Secondary.....	161
Enlarging Canals of.....	176, 210
Eruption of, Delayed.....	148
Extraction of.....	162, 168
Filling (See Filling).	
For Bridgework.....	209
Forming Roots of.....	160
Fracture	208
Impacted	168, 256, 262
Lame	184
Malformed	230
Missing	148, 157, 266
Moving	163, 164
Planted	212
Primary (See Deciduous).	
Resorption of, 157, 165, 168, 169, 213, 266	
Retained Deciduous Teeth.....	157
Roots of (See Roots).	
Supernumerary	167
Tumor of.....	214
Temporary Teeth (See Deciduous Teeth).	
Temporo-mandibular Articulation, 242, 266	
Tesla Coil (See High-Frequency Coil).	
Test, For Polarity of Induction Coil... 41 For Polarity of Lead Wires on D. C..... 19	
Therapeutic Agent, X-rays as.....	293
Tic Douloureux (See Neuralgia).	
Tic, Facial Gesticulatory.....	260
Titubator	78
Toning	105
Transformer, II (See also Inter- rupterless Coil).	
Trayrocker	78
Trays, for Developing and Fixing, 74, 102	
Trigeminal Neuralgia (See Neural- gia).	
Tube, Valve.....	54
Tube, X-ray.....	41
And Patient, Distance Between... 97	
Bi-anodal	44
Color of.....	51, 52
Crooke's	41
Hard	42
High	42
High-Frequency	57, 58
Inverse in.....	52, 53
Low	42
Properly Lighted.....	50
Puncture of.....	52
Rack	58
Shield	59 to 63, 285
Soft	42
Stand.....	59, 60, 284, 295
Vacuum	41, 42
Vacuum Regulator.....	45
Target	41, 42
Tumor.....	151, 214, 224 to 229, 250
Turbinates Bones	273
Twitching	260
Uses of the Radiograph in Den- tistry	146
(1) In Cases of Delayed Erup- tion to Determine the Pres- ence or Absence of the Unerrupted Teeth.....	148
(2) In Cases Where Deciduous Teeth are Retained Long After the Time When They Should Have Been Shed, to Learn if the Succedaneous Teeth be Present.....	157
(3) To Learn if the Roots of Children's Teeth are Fully Formed	160
(4) To Determine Whether a Tooth be One of the Pri- mary or Secondary Set....	161
(5) To Determine When to Ex- tract Temporary Teeth....	162
(6) To Show the Orthodontist When He May Move the Coming Permanent Teeth by Moving the Deciduous Teeth	163
(7) To Observe Moving Teeth..	164
(8) In Cases of Supernumerary Teeth	167
(9) In Cases of Impacted Teeth as an Aid in Extraction....	168
(10) To Determine the Number of Canals in Some Teeth... 172	
(11) As an Aid in Filling the Canals of Teeth with Large Apical Foramina.....	175
(12) To Learn if Canals Are Open and Enlarged to the Apex Before Filling and to Observe the Canal Filling After the Operation.....	176
(13) To Determine Whether an Opening Leading from a Pulp Chamber Be a Canal or a Perforation.....	179
(14) In Cases of Pulp Stones (Nodules)	179

(15) In Cases of Secondary Dentin Being Deposited and Pinching the Pulp.....	180	(31) To Locate Foreign Bodies, Such as a Broach in the Pulp Canal or Tissue at the Apex of a Tooth; a Piece of Wooden Toothpick in Peridental Membrane, etc..	202
(16) To Learn if the Filling in the Crown of a Tooth Encroaches on the Pulp.....	181	(32) To Determine the Presence or Absence of a Bit of Root Imbedded in the Gum Tissue	205
(17) In Cases of Teeth with Large Metal Fillings or Shell Crowns Which Do Not Respond to the Cold Test, to Learn if the Canals Are Filled.....	181	(33) To Diagnose Fracture of a Root	208
(18) To Learn if Apical Sensitiveness is Due to a Large Apical Foramen or an Unremoved, Undevitalized Remnant of Pulp.....	183	(34) To Observe the Size and Shape of Roots of Teeth to be Used in Crown and Bridgework	209
(19) In Cases of Chronic Pericementitis (Lame Tooth)....	184	(35) As an Aid and Safeguard when Enlarging Canals for Posts	210
(20) In Cases of Alveolar Abscess to Determine White Tooth is Responsible for the Abscess.....	185	(36) To Examine Bridges About Which There Is An Inflammation	211
(21) In Cases of Alveolar Abscess to Determine the Extent of the Destruction of Tissue—Bony and Tooth...	187	(37) To Observe the Field Before Constructing a Bridge.	212
(22) In Cases of Alveolar Abscess to Learn How Many Teeth are Involved.....	189	(38) To Observe Planted Teeth..	212
(23) In Cases of Abscess of Multirooted Teeth; to Learn at the Apex of Which Root the Abscess Exists	190	(39) In Cases of Cementoma....	214
(24) In Cases of Abscesses of Crowned Teeth to Learn if the Canals Are Properly Filled	191	(40) In cases of Bone "Whorls".	214
(25) As an Aid in Differential Diagnosis Between Chronic Alveolar Abscess and Pyorrhea Alveolaris.....	193	(41) To Locate Stones (Calculi) in the Salivary Ducts or Glands	217
(26) To Observe Destruction of Tissue Due to Pyorrhea Alveolaris	193	(42) In Cases of Bone Cysts....	218
(27) In Cases of Pericemental Abscess	195	(43) In Cases of Dentigerous Cysts	222
(28) In Cases of Persistent Suppuration Which Do Not Yield to the Usual Treatment. (In fact, in all cases that do not yield promptly to the usual course of treatment.)	196	(44) In Cases of Tumor, Benign or Malignant.....	224
(29) To Observe the Course of the Fistulous Tract.....	199	(45) To Observe Anomalous Conditions, Such as the Fusion of the Roots of Two Teeth for Example.....	230
(30) To Observe the Field of Operation Before and After Apicoectomy (Root Amputation)	201	(46) To Observe the Location and Extent of a Necrotic or Carious Condition of Bone	231
		(47) To Diagnose Antral Empyema	234
		(48) To Observe Size, Shape and Location of the Antrum, as an Aid in Opening Into It..	234
		(49) To Locate Foreign Bodies, Such as Tooth Roots or Broaches, in the Antrum...	238
		(50) To Observe Cases of Luxation Before and After Reduction	242
		(51) In Cases of Fracture of the Jaw	244
		(52) In Cases of Ankylosis of the Temporo-Mandibular Articulation or the Joint Formed by the Tooth in the Jaw	247

(53) To Observe the Field of Operation Before and After Resection of the Mandible.	247	Resorption of Teeth and the Causes for It, etc.....	263
(54) In All Cases of Facial Neuralgia with an Obscure Etiology	249	(63) As a Record of Work Done	268
(55) To Observe the Inferior Dental Canal.....	252	(64) In Cases of Hidden Dental Caries	269
(56) In Cases of Ludwig's Angina	253	Vacuum	41, 45, 54
(57) In Cases of Insomnia, Neurasthenia, Insanity and Kindred Nervous Disorders	256	Valve Tube.....	54
(58) In Cases of Periodic Headaches	260	Velocity of Electricity.....	3
(59) In Cases of Facial Gesticulatory Tic (Spasmodic Twitching of a Set of the Facial Muscles.....)	260	Velox	83
(60) To Allay the Fears of Hypochondriac	261	Vibrator	17, 23
(61) In Cases Where the Patient Cannot Open the Mouth Wide Enough for an Ocular Examination.....	262	Villard Tube.....	54
(62) In Research Work to Study Osteology, the Development of the Teeth, the Action of Bismuth Paste, Bone Production and Destruction, Changes Occuring in the Temporo-Mandibular Articulation When Jumping the Bite, Blood Supply to Parts,		Volt	3
		Washing,	
		Of Negative.....	79, 104
		Of Print.....	84
		Watt	5
		Winding,	
		Primary.....	11, 12, 27, 33
		Secondary.....	11, 12, 27, 33
		Wiring for Installation.....	15, 36
		Wires in Canals	
		173, 174, 175, 176, 179, 183	
		X-ray	48, 49
		As a Therapeutic Agent.....	293
		Burn	273, 274, 190
		Dangers of.....	273
		Discovery of.....	49
		Machines	14
		Outfit	294
		Penetration of.....	56
		Proof Box.....	98, 101
		Tubes, 41 (See Tubes).	
		Tube Stand.....	59, 60, 284, 295

