

Infiltration and nerve blocking / by Sheridan C. Waite.

Contributors

Waite, Sheridan C.

Publication/Creation

[Springville] : [Antidolor Manufacturing Co.], [1919]

Persistent URL

<https://wellcomecollection.org/works/krnv9yz2>

License and attribution

This work has been identified as being free of known restrictions under copyright law, including all related and neighbouring rights and is being made available under the Creative Commons, Public Domain Mark.

You can copy, modify, distribute and perform the work, even for commercial purposes, without asking permission.




Wellcome Collection
183 Euston Road
London NW1 2BE UK
T +44 (0)20 7611 8722
E library@wellcomecollection.org
<https://wellcomecollection.org>

**INFILTRATION and
NERVE BLOCKING**

COPYRIGHT

By
SHERIDAN C. WAITE, D.D.S.,



22500472164

Med
K49450



Infiltration and Nerve Blocking

Copyright

1919 PTO.

Nerve Blocking
Inhalation and

Copyright, 1919.

By Dr. R. B. Waite, Springville, N. Y.

WELLCOME INSTITUTE LIBRARY	
Coll.	Wellcome
Coll.	
No.	WU

11332980

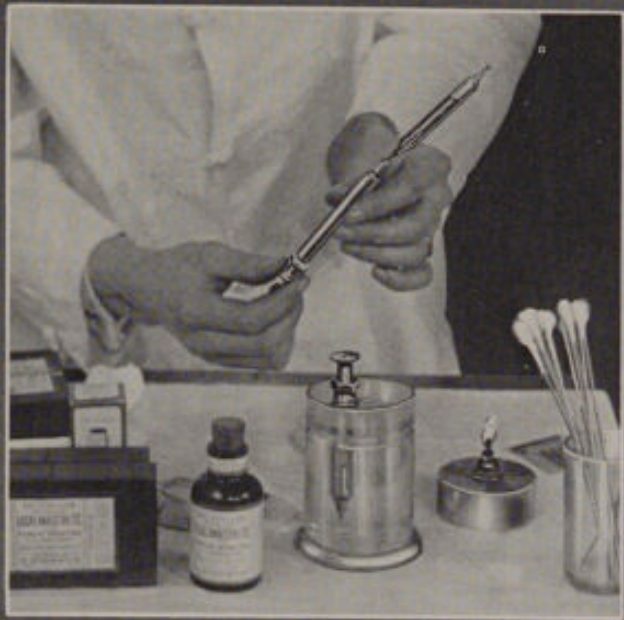UNIVERSITY
COLLEGE LONDON
LIBRARY

~~100136~~

THE ANTIDOLOR MANUFACTURING CO.,
SPRINGVILLE, ERIE CO., N. Y.



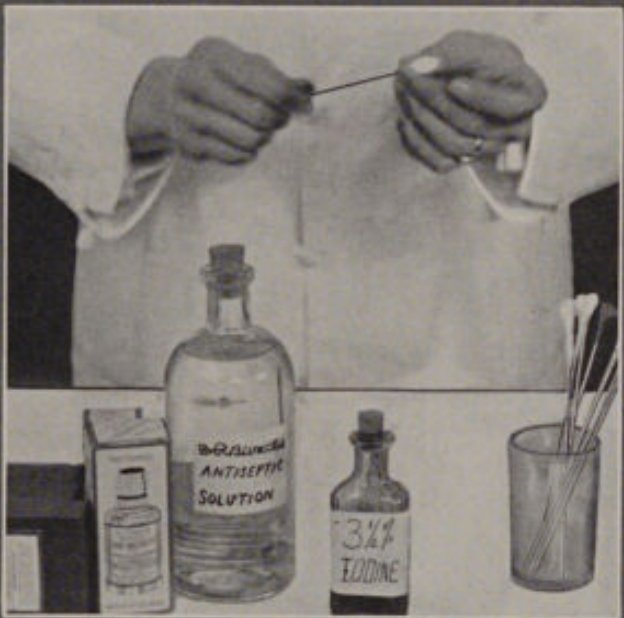Filling syringe both ends of ampule broken.



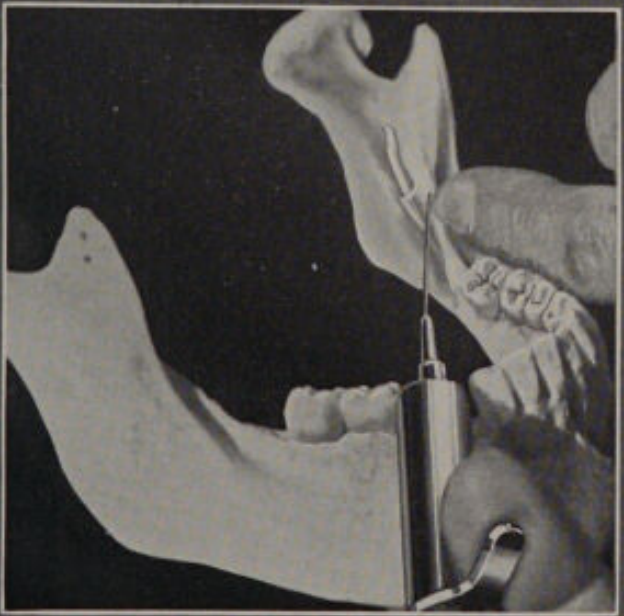Filling syringe one end of ampule broken.



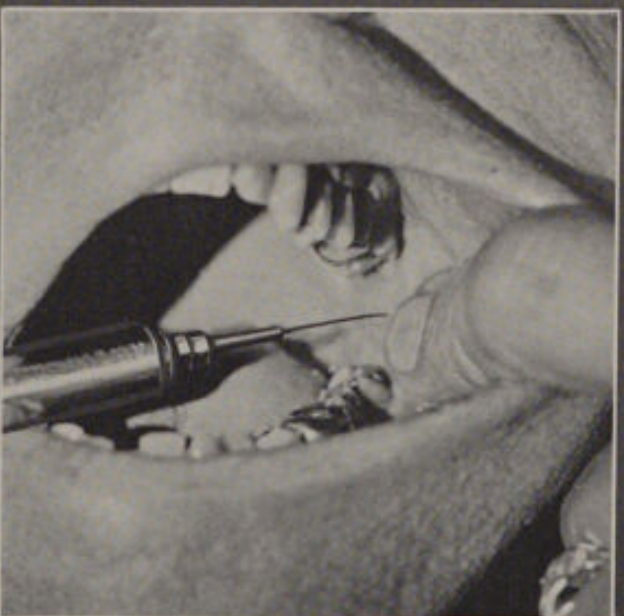
Always pass lip of bottle through flame before pouring anaesthetic into syringe.



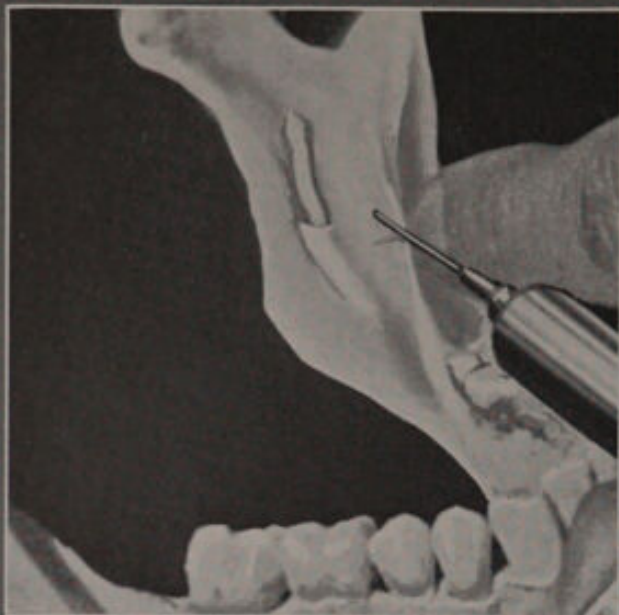Wrapping applicators with cotton.



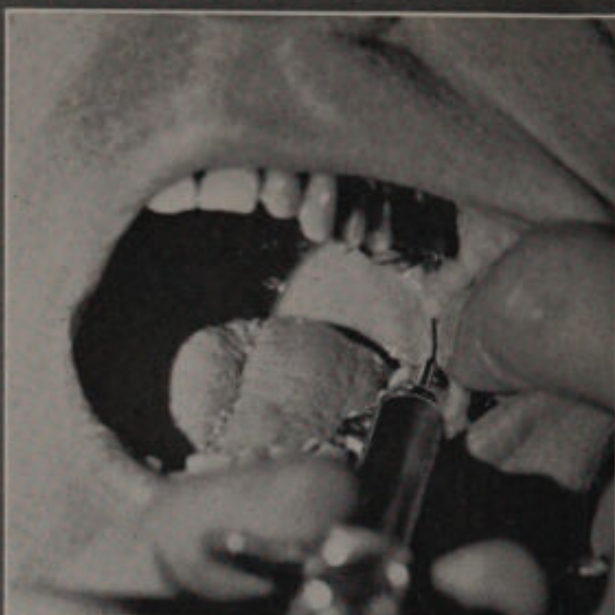
First movement for landmark.



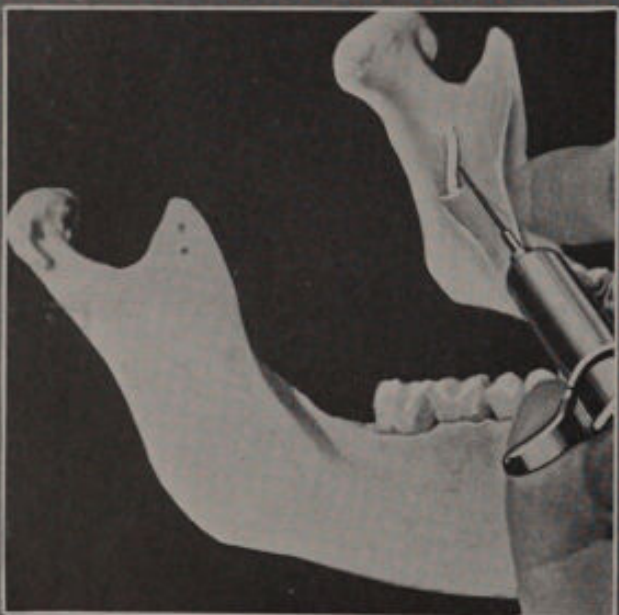First movement for landmark.



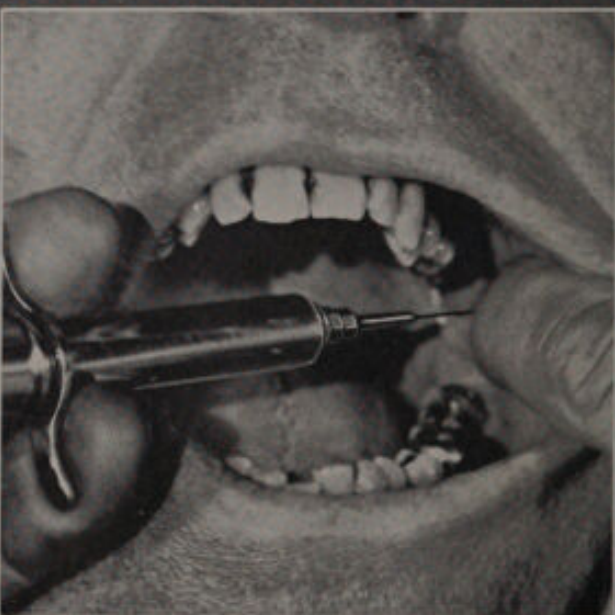
Second movement for Lingual Nerve. Anaesthetises Lingual Mucous Membrane to Median Line.



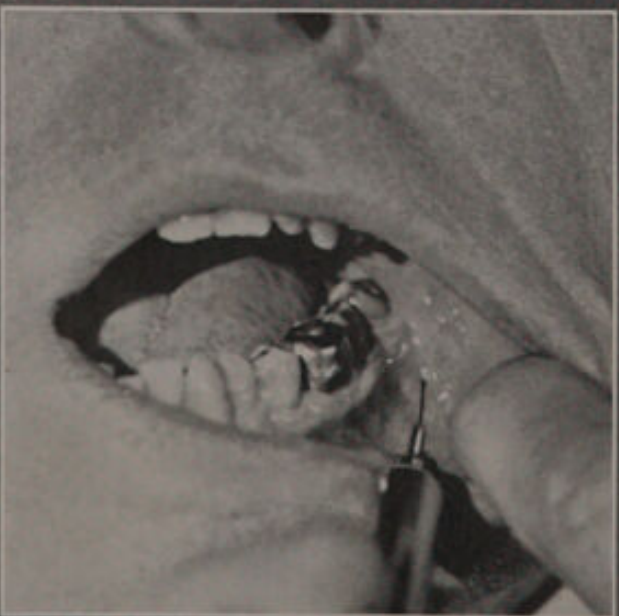Second movement for Lingual Nerve. Anaesthetises Lingual Mucous Membrane to Median Line.



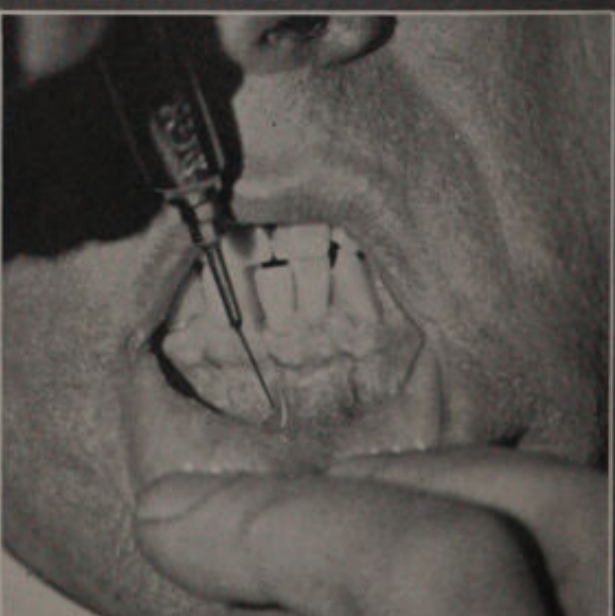
Third Movement for Inferior Dental Nerve. Anaesthetises from 3rd Molar to Central Incisor. (Median Line)



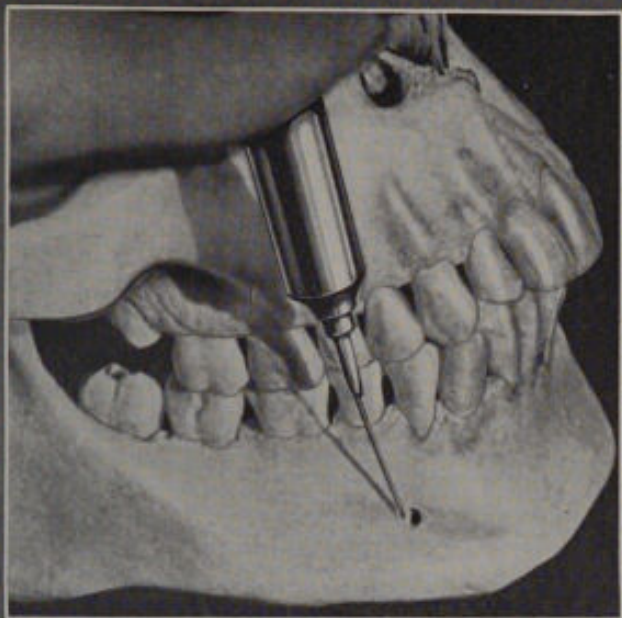Third Movement for Inferior Dental Nerve. Anaesthetises from 3rd Molar to Central Incisor. (Median Line)



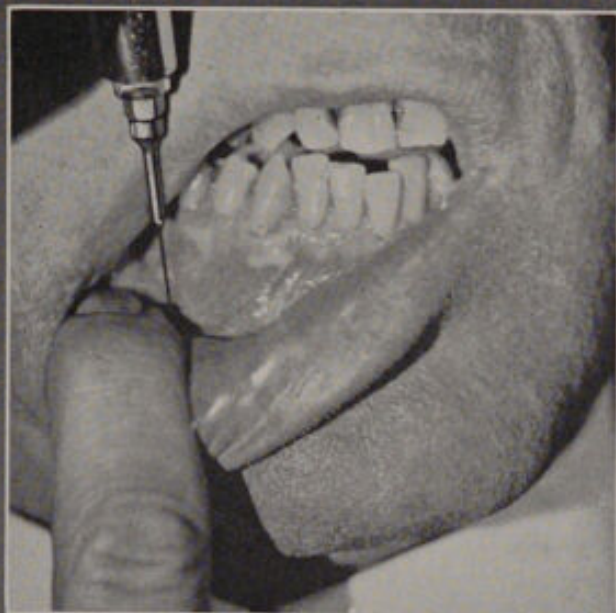Long Buccal Injection. Anaesthetises Buccal Mucous Membrane to First Molar.



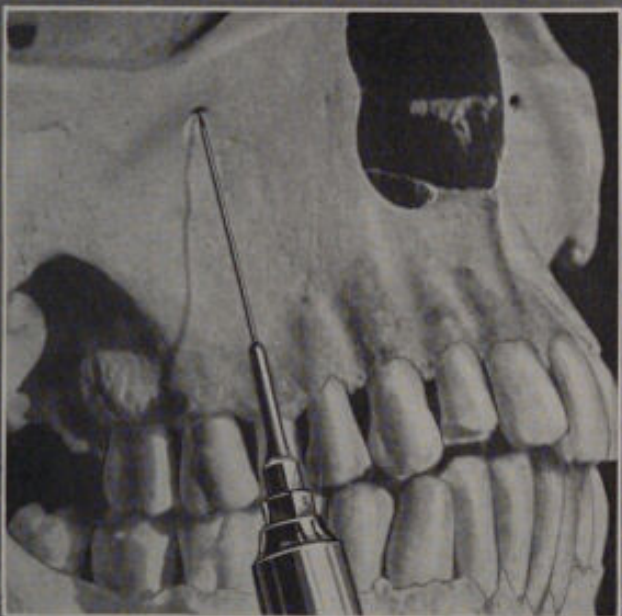
Incisive Injection. Anaesthetises Pulps, Cuspid, Lateral and Central.



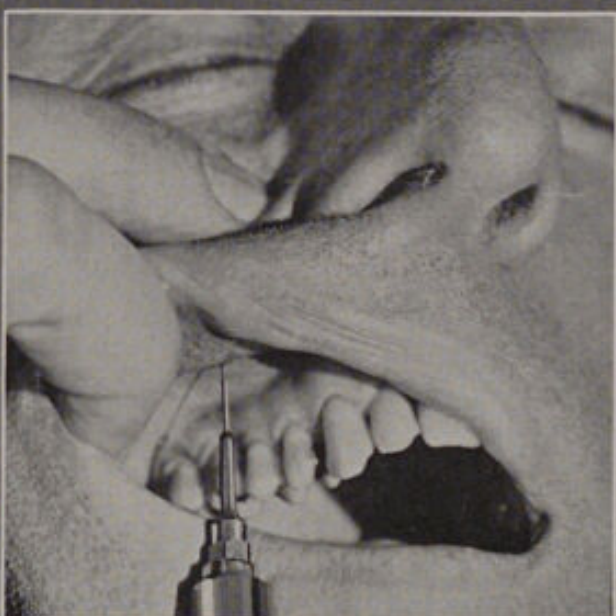
Mental Injection. Anaesthetises Pulps Bicuspids in some cases pulps of the Cuspid, Lateral and Central.



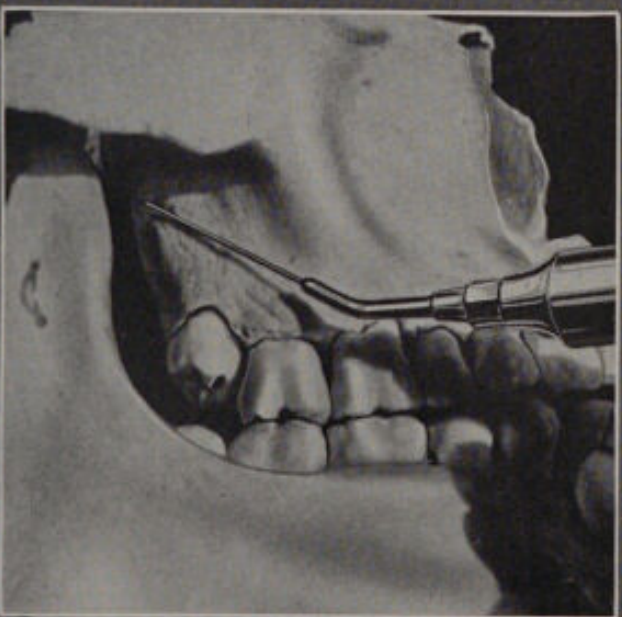
Mental Injection. Anaesthetises Pulps Bicuspids in some cases pulps of the Cuspid, Lateral and Central.



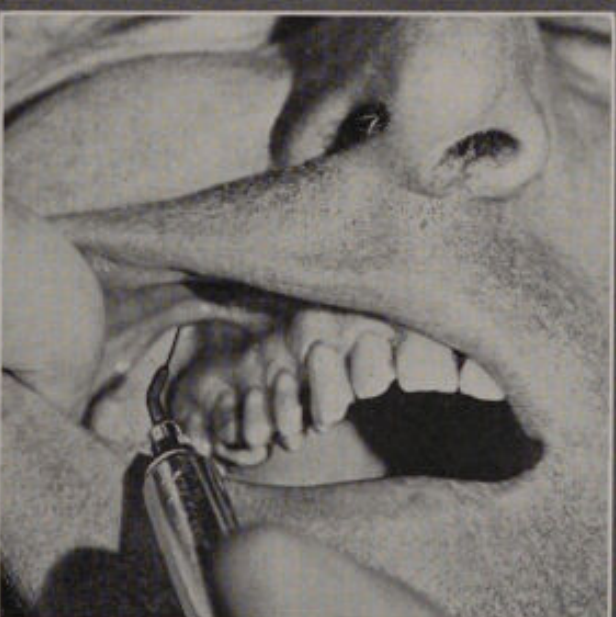Infra-orbital Injection. Anaesthetises Pulps Cuspid Lateral, Central and anaesthetises labial mucous membrane



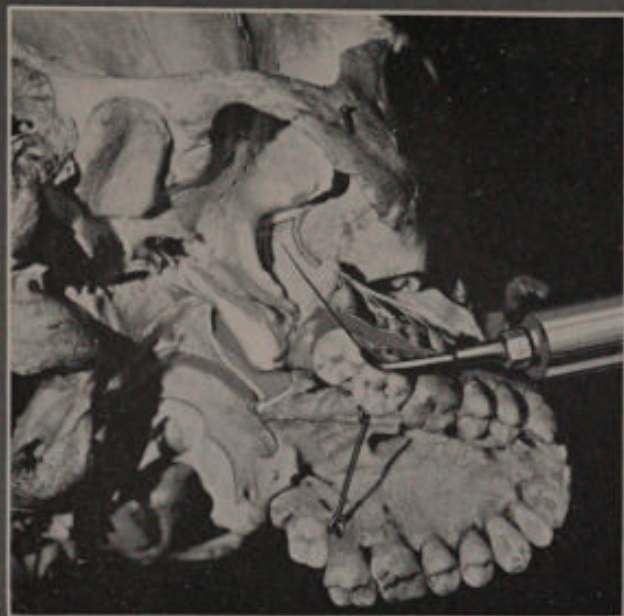Infra-orbital Injection. Anaesthetises Pulps Cuspid Lateral, Central and anaesthetises labial mucous membrane



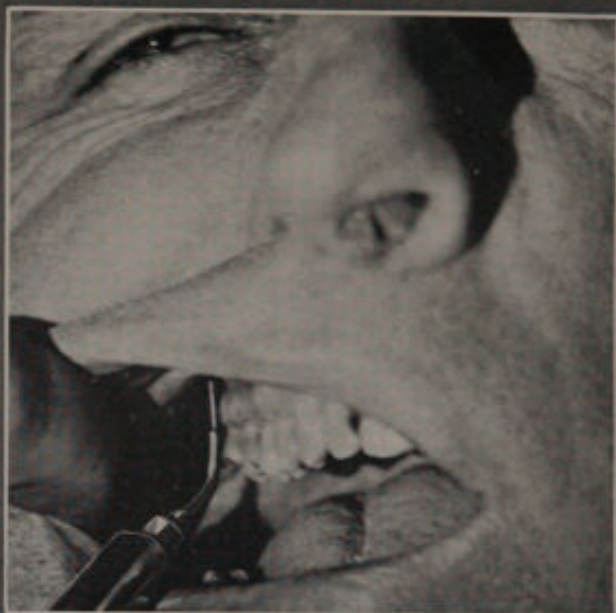Tuberosity Injection. Anaesthetises Pulps of 3d, 2nd Molar also Distal Buccal and Palatal Roots of 1st Molar.



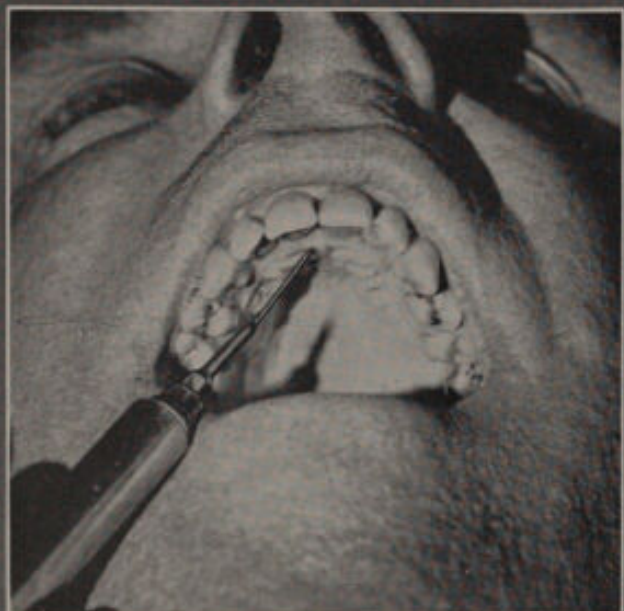
Tuberosity Injection. Anaesthetises Pulps of 3d, 2nd Molar also Distal Buccal and Palatal Roots of 1st Molar.



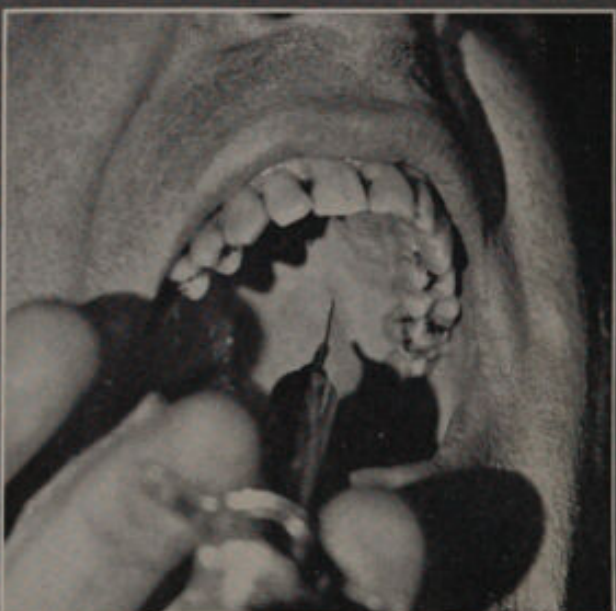
Second Division. Anaesthetises all the entire Superior Maxilla to the Median Line.



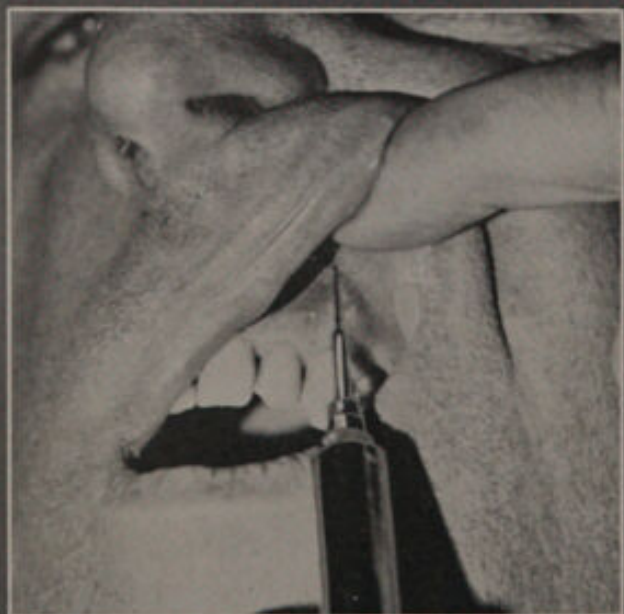Second Division. Anaesthetises all the entire Superior Maxilla to the Median Line.



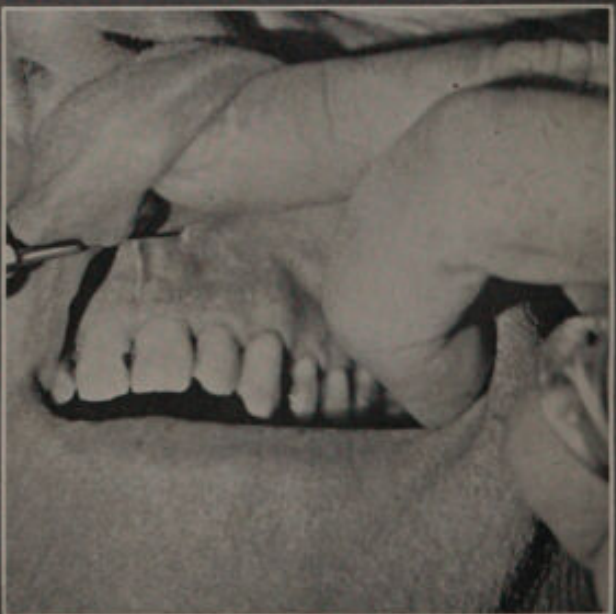Anterior Palatine Injection. Anaesthetises Mucous Membrane from Cuspid to Cuspid.



Anterior Palatine Injection. Anaesthetises Mucous Membrane from Third Molar to Cuspid.



Infiltration for single tooth.



Infiltration for several teeth.

Introduction

Nerve Blocking is one of the greatest subjects of the day and now has a definite place in Dentistry.

Much has been written on the subject, with the result that a great many dentists have absorbed the idea that it is a difficult and complicated subject, which they do not care to handle.

This is a very erroneous idea. There is nothing difficult or complicated about it. All that is necessary is the knowledge of your anatomy, and the use of the ordinary precautions in the matter of Asepsis.

Nerve Blocking has been worked out scientifically by dissecting human specimens, and all of the injections can be made with the utmost ease.

The author of this article has made any number of dissections and thousands of injections, and is confident that if you will simply give a careful reading to this course you will feel confident to make all of these injections and do absolutely painless work.

Think what it will mean to your patients to know that they can have their teeth extracted, pulps removed, cavities prepared, etc., without a suggestion of pain. They will gladly pay extra fees for this service, which is worth so much to them. Not only that, but they will tell their friends of your ability and skill, thereby bringing you new patients. All of this will result to your financial credit, as it will materially increase your profits, to say nothing of your greater prestige as a skillful operator. It will most assuredly be a great asset to you in your profession.

It is the author's intention to give a short description of Asepsis, Osteology of the Superior and Inferior Maxillary Bones, also the Sphenoid Bone, The Fifth Cranial Nerve, General Directions and the following Injections:

- 1—The Mandibular or Lingual and Inferior Dental.
- 2—The Long Buccal.
- 3—The Mental.
- 4—The Incisive.
- 5—The Infra-Orbital.
- 6—The Anterior Palatine.
- 7—The Posterior Palatine.
- 8—Lingual Mucous Membrane.
- 9—The Tuberosity.
- 10—The Second Division.
- 11—Infiltration.
- 12—Intra-Osseous.

As stated above, by simply refreshing your memory on your Anatomy by a careful reading of the following pages, you will find no difficulty in making any of the injections described with ease. Make a few of the injections, and see how easy it is and the painless work you can do.

Asepsis

Asepsis is a condition in which living Pyogenic, or Pus Producing Bacteria are absent.

Sepsis is a condition in which pus producing bacteria are present within the blood or tissues.

Aseptic Surgery is the performance of an operation in a field free from Pyogenic or Septic Germs, with sterilized hands, instruments, towels, gauze, cotton, etc., preventing the introduction of germs from without.

Osteology

The Bones of the Cranium are: The Parietal, Temporal, Occipital, Frontal, Ethmoid and Sphenoid. The Bones of the Face are: The Malar; Lachrymal; Vomer; Nasal; Palate; Superior Maxillary; Inferior Maxillary; Inferior Turbinate and Hyoid.

The Bones which interest us are: The Sphenoid Bone; The Superior Maxillary and The Inferior Maxillary.

THE SPHENOID BONE resembles a bat with its wings spread out, facing you. It is situated in the anterior part of the base of the skull. Two legs hang down behind the Superior Maxillary Bone, called the Pterygoid Processes. The Smaller wings form the middle fossa, which supports the middle part of the brain. The greater wings spread out until they form part of the external surface of the skull, located in front of the Temporal Bones. The Sphenoid Bone contains a great number of openings or foramen, through which the nerves and blood vessels enter and take their exit from the brain. The principal openings or foramen are:

- 1—The Sphenoidal Fissure.
- 2—The Foramen Rotundum.
- 3—The Foramen Ovale.

1—**The Sphenoidal Fissure** is a direct opening between the middle fossa in the skull and the orbit. It transmits the First, or Ophthalmic Division of The FIFTH NERVE.

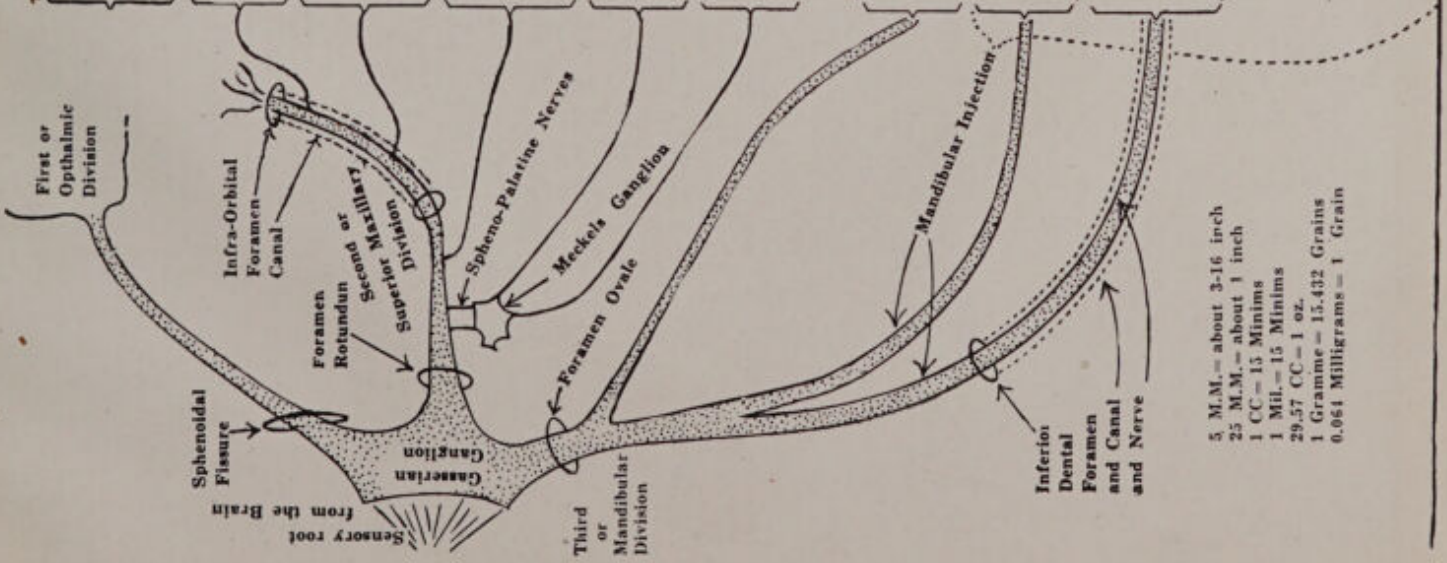
2—**The Foramen Rotundum** connects the middle fossa in the Cranium and the Speno-Maxillary Fossa. It is located in the Sphenoid Bone, about two inches directly back of the Infra-Orbital Foramen. The Foramen Rotundum transmits the Second, or Maxillary Division of The Fifth Nerve. Between the Foramen Rotundum in the Sphenoid Bone, and the entrance of the Infra-Orbital Canal in the Superior Maxillary Bone is first, a small cup-shaped space or fossa, and then a long fissure, called respectively the Speno-Maxillary Fossa and the Speno-Maxillary Fissure.

STRUCTURES ANAESTHETISED

NAME OF NERVE	NAME OF INJECTION	LOCATION OF PUNCTURE POINT	Depth of Needle in the tissues and length of needle	AMOUNT OF SOLUTION	TIME TO WAIT	STRUCTURES ANAESTHETISED
The Second or Superior Maxillary Division	Second Division	In the Mucous Fold—Buccal to Upper Third Molar—Second Molar in the child.	30 M.M. deep 40 M.M. needle Long Right-Angle Hub No. 3½	3 to 4 C.C. or Mills	5 to 20 Minutes	All the Structures supplied by the Anterior Superior Alveolar—Middle Superior Alveolar—Posterior Superior Alveolar—Naso and Anterior Palatine Nerves
Anterior Superior Alveolar	Infra-Orbital	In the Mucous Fold—Near apex of second Bicuspid—Needle parallel with long axis of root	20 M.M. deep 30 M.M. needle Straight Hub No. 1	2 to 3 C.C. or Mills	8 to 10 Minutes	The pulps of the Central Lateral and Cuspid teeth—Alveolar Ridge—Perioesteum—Labial Mucous Membrane—Upper Lip—which has a noticeable droop
Middle Superior Alveolar	Infiltration	In the Mucous Fold—Between Apices of Cuspid and First Bicuspid—Needle carried along bone—above Apices of First and Second Bicuspid. Any tooth may be infiltrated in preference to Nerve blocking.	From 5-20 M.M. deep 30 M.M. needle Straight Hub	1 C.C. or Mil	3 to 5 Minutes	The pulps of the first and second Bicuspids, and in 95% of cases the Mesial Buccal Roots of the Upper first Molar—The Alveolar Ridge—Perioesteum—Buccal Mucous Membrane
Posterior Superior Alveolar	Tuberosity	In the Mucous Fold—Near the apex of the Distal Buccal Root of the Upper Second Molar—First Molar in the child.	20 M.M. deep 30 M.M. needle Long Curved Hub No. 3	2 to 3 C.C. or Mil	8 to 10 Minutes	The Molar teeth—Alveolar Ridge—Perioesteum—Mucous Membrane. In 95% of cases the nerve supplies the third and second Molars and only the Distal Buccal and Lingual roots of the first molar
Naso-Palatine	Anterior Palatine	At the Anterior Palatine Foramen 15 M.M. Palatal to the gum margin of the right and left central. Needle inserted on either side of large Papillae	5 M.M. deep 30 M.M. needle Straight Hub	½ C.C. or Mil	3 to 5 Minutes	The Mucous Membrane and Perioesteum—palatal to upper six anterior teeth—anasomoses with Anterior palatine—palatal to the Cuspid
Anterior Palatine	Posterior Palatine	At the Posterior Palatine Foramen 10 M.M. above the Palatal gum margin of the Upper Third Molar	5 M.M. deep 30 M.M. needle Straight Hub	Only ¼ C.C. or Mil	3 to 5 Minutes	Mucous Membrane—Perioesteum—palatal to upper Molars, bicuspids and anasomoses with Naso—Palatine—palatal to cuspid

Copyright by *DR. B. W. Sprinville*, N. Y. 1919.

Long Buccal	Long Buccal	In the Mucous Fold near the Mesial Buccal Root of the Lower Second Molar	20 M.M. deep 30 M.M. needle Straight Hub	1 C.C. or Mil	3 to 5 Minutes	The Buccal Mucous Membrane—Molars. In some cases as far as bicuspid teeth
Lingual	Lingual	In the Mucous Membrane 10 M.M. above the occlusal surface of the Lower Molars. Needle at center of index finger	10 M.M. deep 30 M.M. needle	1 C.C. or Mil	3 to 5 Minutes	The Lingual Mucous Membrane—Perioesteum. Internal Plate—Anterior 2-3 of tongue
Inferior Dental Terminal Branches	Inferior Dental	Same as for the lingual injection but inject 10 M.M. deeper	20 M.M. deep 30 M.M. needle Straight Hub	2 C.C. or Mills	5 to 15 Minutes	All the teeth on one half of mandible—as far as median line—Alveolar Ridge—Perioesteum—Gum tissue buccal to Bicuspids. Central teeth—lower lip
Mental	Mental	In the Mucous Fold—Near the lower second Bicuspid. Needle parallel with long axis of the tooth	10 M.M. deep 30 M.M. needle Straight Hub	1½ C.C. or Mills	3 to 5 Minutes	The chin and lower lip—Buccal Mucous Membrane—this injection anaesthetises the first and second Bicuspids
Incisive	Incisive	In the Mucous Fold at side of Pre-molar or the Median line of chin	10 M.M. deep 30 M.M. needle Straight Hub	1½ C.C. or Mil	3 to 5 Minutes	The pulps of the lower central, lateral and cuspid teeth—Labial Mucous Membrane—Perioesteum and external plate.



5 M.M. = about 3-16 inch
 25 M.M. = about 1 inch
 1 C.C. = 15 Minims
 1 Mil. = 15 Minims
 29.57 CC. = 1 oz.
 1 Gramme = 15.432 Grains
 0.064 Milligrams = 1 Grain

3—**The Foramen Ovale** communicates between the middle fossa in the cranium and the base of the skull. It is located below and a little outward from the Foramen Rotundum. The Foramen Ovale transmits the Third, or Maxillary Division of THE FIFTH NERVE.

THE SUPERIOR MAXILLARY BONE has the form of a hollow pyramid, with the base forming the wall of the nose, and the apex articulating with the Malar Bone. This hollow space is called the Antrum of Highmore, and conforms to the outward contour and shape of the bone. The Apicies of the Bicuspid, and First and Second Molar Roots are covered with a layer of bone, which forms part of the floor of the Antrum. The principal openings or foramen are:

- 1—The Infra-Orbital Foramen.
- 2—The Posterior Dental Foramen.
- 3—The Anterior Palatine Foramen.
- 4—The Posterior Palatine Foramen.

1—**The Infra-Orbital Foramen** is located 10 M.M. below the Infra-Orbital Ridge of the Superior Maxillary Bone, directly above the Second Bicuspid or below the pupil of the eye.

2—**The Posterior Dental Foramen** is located 20 M.M. directly above the distal gum margin of the Upper Third Molar in the Posterior wall of the Superior Maxillary Bone. It generally consists of several small foramen.

3—**The Anterior Palatine Foramen** is located 15 M.M. palatal to the Upper Central Teeth on the Median Line.

4—**The Posterior Palatine Foramen** is located 10 M.M. palatal to and directly above the gum margin of the Upper Third Molar, or the Second Molar in the child.

THE INFERIOR MAXILLARY BONE, also known as the Mandible, consists of two bones, joining at the Median Line of the Chin. Each half of the Inferior Maxillary Bone consists of a Body and a Ramus.

The Body is that part from the Median Line back to the angle of the Ramus, and holds the lower teeth. The part from the angle to the top of the Condyle is called the Ramus.

The Ramus is the upturned perpendicular extremity of the lower Maxilla on either side and presents three surfaces:

- 1—The Exterior.
- 2—The Anterior.
- 3—The Interior.

1—**The Exterior Surface** is flat and attaches the Masseter Muscle.

2—The Anterior Surface of the Ramus has an External Oblique Line, an Internal Oblique Line and a Base. It is formed by the junction of the Ramus with the body of the Mandible, distal to the Lower Third Molar.

3—On the Interior Surface of the Ramus, at about its center, is a prominence called the Lingula or Spine, to which is attached the Internal Lateral Ligament. Just above this Lingula is located the Inferior Dental Foramen, which is the beginning of the Inferior Dental Canal. This canal runs down through the center of the Ramus, makes a turn at an angle of about 45 degrees or more, and courses horizontally through the body of the Mandible, near the lower margin. The Inferior Dental Canal divides below the apex of the second bicuspid into two canals. One branch, (which is not over $\frac{1}{8}$ " long), turning outward and upward to the surface is called the Mental Canal. The other branch continues through the spongy bone to be lost under the Lateral Incisor. Both these canals are continuations of the Inferior Dental Canal. Between the lower Right Lateral and Lower Left Lateral there is no canal, so the Incisive nerves course through the spongy bone and anastomose at the Median Line.

The Mental Foramen is located below the apex of the Second Bicuspid, halfway between the lower border of the Mandible and the buccal gum margin.

The Incisive Fossa is located below the Lower Lateral and Central Teeth, halfway between the Lower border of the Mandible and the labial gum margin.

Nerves

THE FIFTH NERVE takes its origin from the midbrain and enlarges into the Gasserian Ganglion. There are two Gasserian Ganglions, located in the floor of the Cranium near the Median Line. Each Ganglion taking care of one side of the face and anastomosing at the Median Line.

THE GASSERIAN GANGLION is a flat crescent 10 M.M. long, 20 M.M. wide, and divides into three branches:

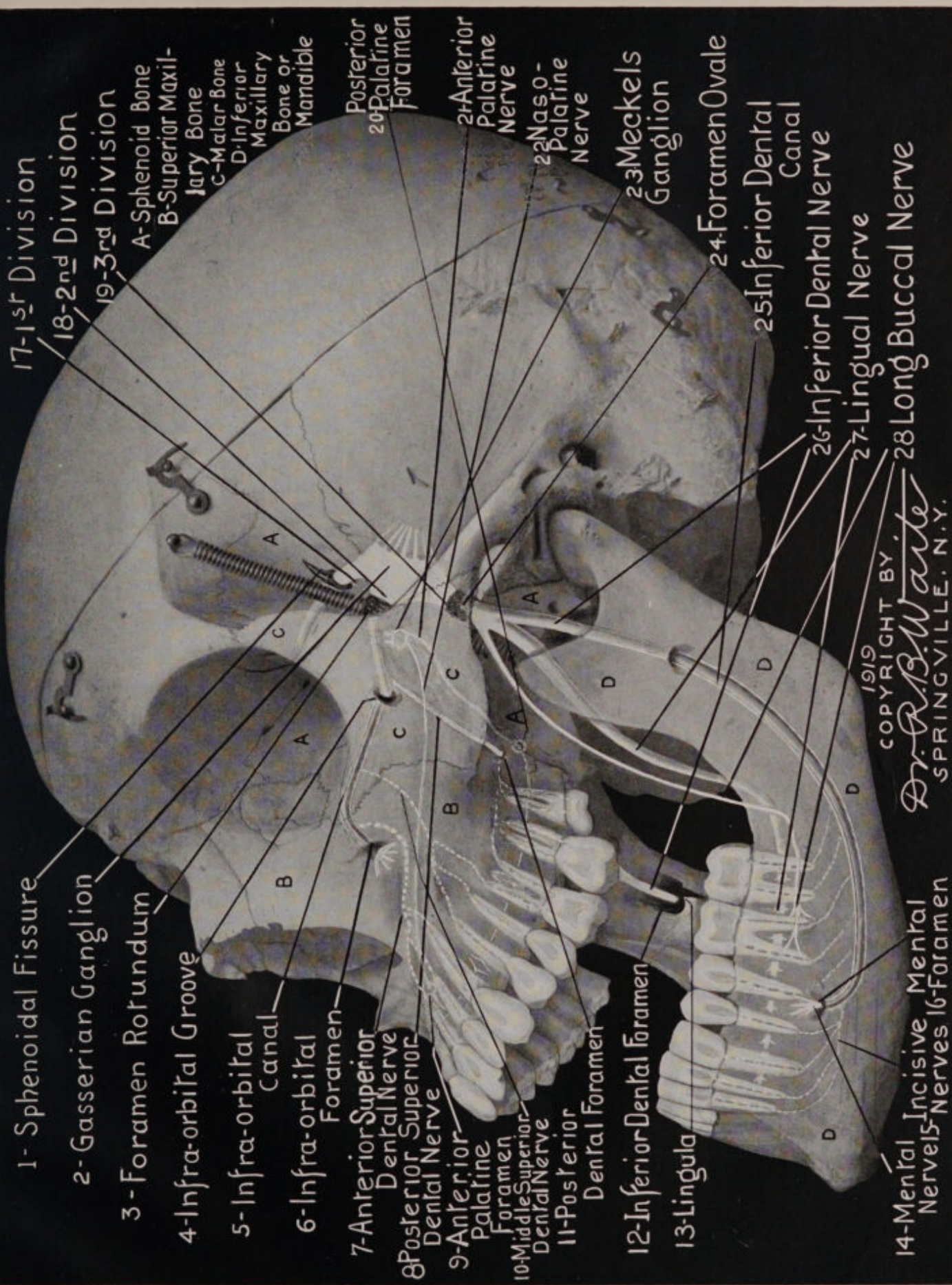
1—The First, or Ophthalmic Division.

2—The Second, or Maxillary Division.

3—The Third, or Mandibular Division.

1—The First, or Ophthalmic Division, is the smallest nerve branch from the Gasserian Ganglion. It takes its exit from the Cranium, through an opening or fissure directly back of the orbit, or socket, of the eye, called the Sphenoidal Fissure. Its branches supply structures within the eye, also the forehead and scalp and does not interest us in a dental way.

2—The Second, or Maxillary Division, supplies the superior Maxilla, or Upper Jaw, such as the Teeth, Alveolar Ridge, Bone, Periosteum, Gum Tissue, The Antrum of



17-1st Division
 18-2nd Division
 19-3rd Division

A-Sphenoid Bone
 B-Superior Maxillary Bone
 C-Malar Bone
 D-Inferior Maxillary Bone or Mandible

20-Posterior Palatine Foramen

21-Anterior Palatine Nerve

22-Naso-Palatine Nerve

23-Meckels Ganglion

24-Foramen Ovale

25-Inferior Dental Canal

26-Inferior Dental Nerve

27-Lingual Nerve

28-Long Buccal Nerve

1-Sphenoidal Fissure

2-Gasserian Ganglion

3-Foramen Rotundum

4-Infra-orbital Groove

5-Infra-orbital Canal

6-Infra-orbital Foramen

7-Anterior Superior Dental Nerve

8-Posterior Superior Dental Nerve

9-Anterior Palatine Foramen

10-Middle Superior Dental Nerve

11-Posterior Dental Foramen

12-Inferior Dental Foramen

13-Lingula

14-Mental Incisive Nerves
 15-Mental Foramen

1919
 COPYRIGHT BY
 Dr. R. B. Waite
 SPRINGVILLE, N.Y.

Highmore, The Upper Lip, Side of the Nose, Lower Eyelid, The Mucous Membrane on the palatal side of upper teeth, The Soft Palate, The Uvula and The Tonsil.

The Second Division takes its exit from the Cranium through the Foramen Rotundum, crosses the Spheno-Maxillary Fossa, follows the Spheno-Maxillary Fissure and enters the Infra-Orbital Canal in the Distal Surface of the Superior Maxilla. The nerve courses from the Foramen Rotundum in the soft tissues outward toward the Malar Bone for about $\frac{7}{8}$ " or 23 M.M. It then passes into the Infra-Orbital Canal, which canal runs forward slightly toward the Median Line, along the base of the orbit in the Superior part of the Maxilla, being about 30 M.M. long. The last 10 M.M. of the canal turns abruptly downward, terminating on the face through an opening called the Infra-Orbital Foramen, located 10 M.M. below the Infra-Orbital, or lower ridge of the Orbit, directly below the pupil of the eye and above the apex of the Second Bicuspid. As the Second Division emerges from the Infra-Orbital Foramen, it becomes known as the Infra-Orbital Nerve, which supplies the Lower Eyelid, the Side of the Nose and the Upper Lip.

The Second, or Maxillary Division gives off the following branches:

a—The Anterior Superior Dental Nerve.

b—The Middle Superior Dental Nerve.

c—The Posterior Superior Dental Nerve.

d—Two short Spheno-Palatine nerves to Meckel's Ganglion, which in turn gives off The Naso-Palatine and Anterior-Palatine Nerves.

a—The Anterior Superior Dental Nerve is given off within the Infra-Orbital Canal, about 5 M.M. distal to the Infra-Orbital Foramen just before the Second Division terminates on the face. The Anterior Superior Dental Nerve descends in a canal in the anterior wall of the Maxilla, to supply the Upper Central, Lateral and Cuspid Teeth, the Labial Mucous Membrane, Periosteum and Alveolus, on one side of the Median Line only.

b—The Middle Superior Dental Nerve is given off about midway within the Infra-Orbital Canal. This nerve passes down through the canal in the outer wall of the Antrum of Highmore and supplies the Upper First and Second Bicuspids, and in 95% of the cases, the Mesial Buccal Root of the Upper First Molar.

c—The Posterior Superior Dental Nerve is given off in the soft tissues of the Spheno-Maxillary Fossa, just before the Second Division enters the Infra-Orbital Canal anterior to Meckel's Ganglion. It follows down the Posterior surface of the Tuberosity of the Superior Maxillary for about 20 M.M., where it enters one, or in some cases several small posterior Dental Foramen. The Posterior Dental Foramen is located 20 M.M. above the distal gum margin of the Upper Third Molar.

The Posterior Superior Dental Nerve supplies the three roots of the Third, Second and First Molars. In 95% of the cases, the Mesial Buccal Root of the Upper First Molar is supplied from the Middle Superior Dental Nerve.

d—**Meckel's Ganglion** lies just below the Superior Maxillary Nerve in the Spheno-Maxillary Fossa, just back of the Posterior Superior Dental Nerve, and is connected to the Second Division by two short nerves, The Spheno-Palatine.

Meckels Ganglion is triangular in shape, about 5 M.M. long and gives off several nerves, only two of which interest us:

a—The Naso-Palatine.

b—The Anterior Palatine.

a—The Naso-Palatine Nerve starts from Meckels Ganglion, courses down along the septum of the Nose and is transmitted through the Anterior Palatine Foramen, located in the Median Line, 15 M.M. palatal to the Upper Central Teeth. Both Right and Left Palatine Nerves come out of the one Anterior-Palatine Foramen. These nerves supply the mucous membrane palatal to the upper six Anterior Teeth, or from Cuspid to Cuspid.

b—The Anterior Palatine Nerve arises from Meckels Ganglion, passes directly down in a canal between one leg of the Sphenoid and the Superior Maxillary Bone, and is transmitted through the Posterior Palatine Foramen, located 10 M.M. above the palatal gum margin of the Upper Third Molar, or above the second molar in the child. It supplies the mucous membrane palatal to the Upper Molars and Bicuspids, and anastomoses with the Naso-Palatine Nerve, palatal to the Cuspid Teeth.

3—**The Third or Mandibular Division** is the largest branch given off from the Gasserian Ganglion. It takes its exit from the Cranium, through an opening called the Foramen Ovale and divides into three branches:

A—The Long Buccal.

B—The Inferior Dental.

C—The Lingual.

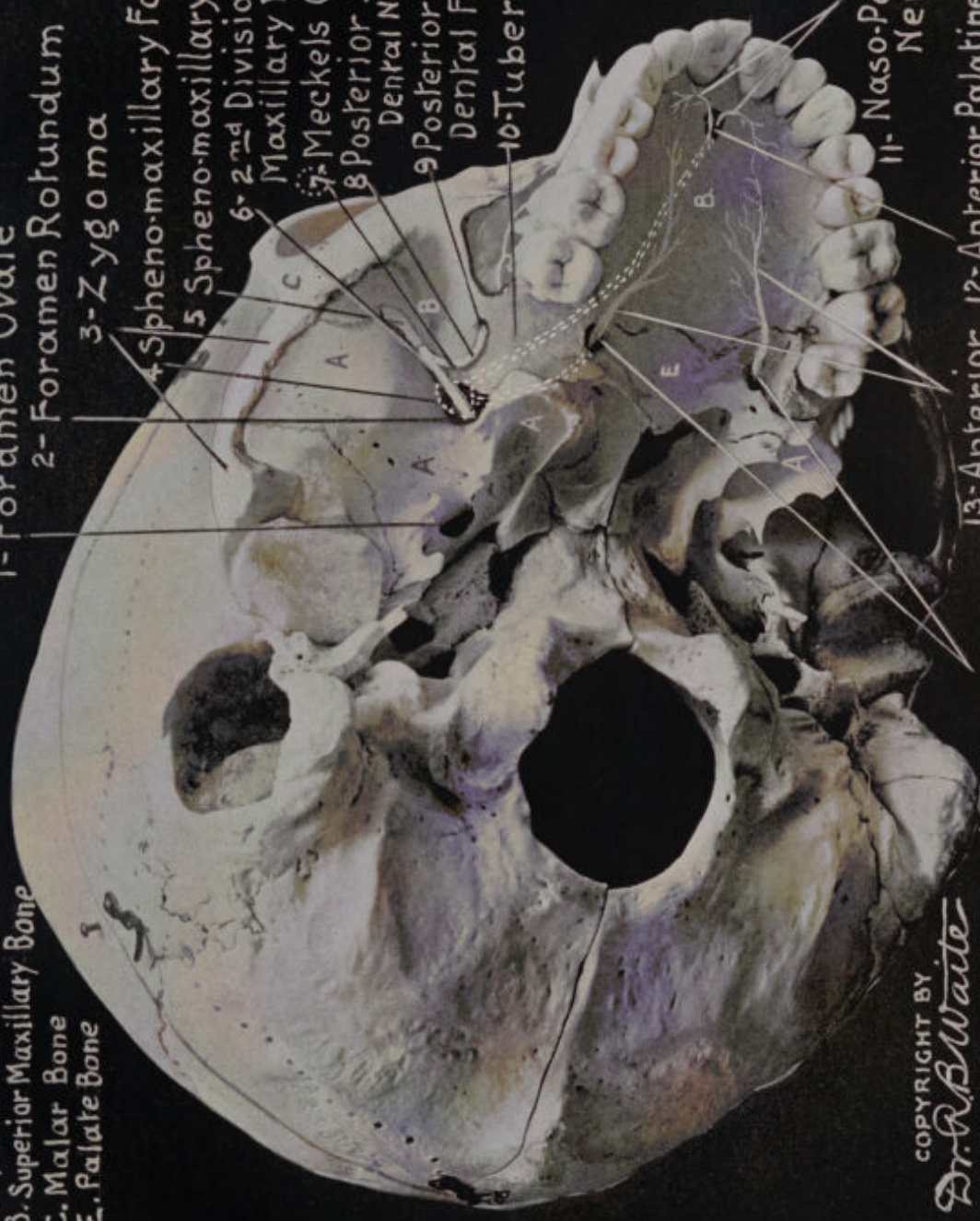
A—**The Long Buccal Nerve** is given off just outside of the Foramen Ovale. It passes forward through muscle tissue and enters the cheek muscle, buccal to the Third Molar, then passes directly down along the cheek and terminates into the Mucous Membrane buccal to the Lower Third Molar, sending off branches as far as the lower First Molar, and in some cases to the Lower Bicuspids. It supplies the buccal mucous membrane with sensation.

B—**The Inferior Dental Nerve** passes down and outward into The Inferior Dental Canal, terminating at the Median Line. It supplies the pulps of the Teeth, the Alveolar Process, Periosteum and Mucous Membrane on the Buccal Surface, except the Buccal Membrane of the Molars, which is controlled by The Long Buccal Nerve. At the

A. Sphenoid Bone
 B. Superior Maxillary Bone
 C. Malar Bone
 E. Palate Bone

1- Foramen Ovale
 2- Foramen Rotundum
 3- Zygoma
 4- Spheno-maxillary Fossa
 5 Spheno-maxillary Fissure
 6- 2nd Division of Maxillary Nerve
 7- Meckels Ganglion
 8- Posterior Superior Dental Nerve
 9- Posterior Superior Dental Foramen
 10- Tuberosity

11- Naso-Palatine Nerves
 12- Anterior Palatine Foramen
 13- Anterior Palatine Nerves
 14- Posterior Palatine Foramen



COPYRIGHT BY
Dr. R. B. Waite
 SPRINGVILLE, N.Y.
 1919

Median Line it anastomoses with the nerve on the opposite side. Below the apex of the Second Bicuspid the Inferior Dental Nerve divides into:

1—The Mental Nerve.

2—The Incisive Nerve.

1—The Mental Nerve branches outward through the Mental Canal and passes out of The Mental Foramen, which is halfway between the gum margin and the lower border of the Mandible. The Mental Nerve supplies the Chin, Mucous Membrane, Periosteum and Lower Lip with sensation.

2—The Incisive Nerve, or the continuation of The Inferior Dental Nerve, terminates on the Chin through seven or eight small Incisive Foramen located below the Lateral Tooth and anastomoses at the Median Line with the nerve from the opposite side.

C—The Lingual Nerve follows the Inferior Dental Nerve for a short distance, then gradually courses Anterior to the Inferior Dental Foramen. It passes about 5 M.M. from the Internal Oblique Line of the Ramus, turns forward in the Mucous Membrane on the Lingual Side of the Lower Teeth, anastomosing with the opposite Lingual Nerve at the Median Line. It also supplies the Anterior two-thirds of the tongue with sensation.

Injections

THE MANDIBULAR, OR LINGUAL AND INFERIOR DENTAL

To Locate The Internal Oblique Line:

The Post Molar Triangle, on the Anterior surface of the Ramus, is formed by the External Oblique Line, The Internal Oblique Line and the Base. The Post Molar Triangle is concave and can be easily felt. The Internal Oblique Line is very pronounced in some individuals, but hard to locate in others.

First: Place your index finger along the buccal Mucous Membrane, with apex of finger buccal to the Lower Second Molar Roots. Now slide the tip of your finger distally along the mucous membrane until you can feel the External Oblique Line. Then rotate your finger over the Post-Molar Triangle and the apex of finger nail will be facing lingually at the Internal Oblique Line, your finger resting on the Occlusal Surface of the Lower Molar Teeth.

In some cases it is difficult to differentiate between the muscle and Internal Oblique Line. When in doubt, instruct the patient to open and close his mouth, keeping your finger over the Post-Molar Triangle. By this method you will be able to detect whether it is bone or muscle. With your finger still in this position, you are ready to insert the needle.

First Movement—For Landmark:

The syringe is held from the opposite side of the mouth, **resting upon the first and second bicuspid teeth**. The point of the needle placed at the center of the tip of the fingernail, bevel of the point toward the bone. This point should be 10 M.M. to 12 M.M. above the Occlusal Plane of the Lower Molar Teeth. Insert the needle through the Mucous Membrane, until you strike the Internal Oblique Line of the Ramus. This acts only as a landmark.

Keep the needle inserted and the syringe resting upon the teeth, always keeping the syringe and needle horizontal with the occlusal plane of the lower teeth.

Second Movement—For Lingual Nerve:

If you are injecting for an extraction, bring the syringe to the opposite side, just outside of the buccal cusps of the lower molars, on a line with the occlusal surface. Insert the needle back a distance of 5 M.M. The side of the needle will be against the Internal Oblique Line of the Ramus and the point of the needle will be near the Lingual Nerve. If needle is inserted too far it will hit the Internal Pterygoid muscle. Inject 1CC of the Anaesthetic.

This nerve supplies the Mucous Membrane on the Lingual Surface of one-half the Lower Teeth with sensation, as far as the Median Line, and the anterior two-thirds of the tongue.

If you are injecting for the removal of a pulp or sensitive dentine, do not inject any anaesthetic at this point. The Second Movement is when you want the Lingual Mucous Membrane anaesthetised.

Third Movement—For The Inferior Dental Nerve:

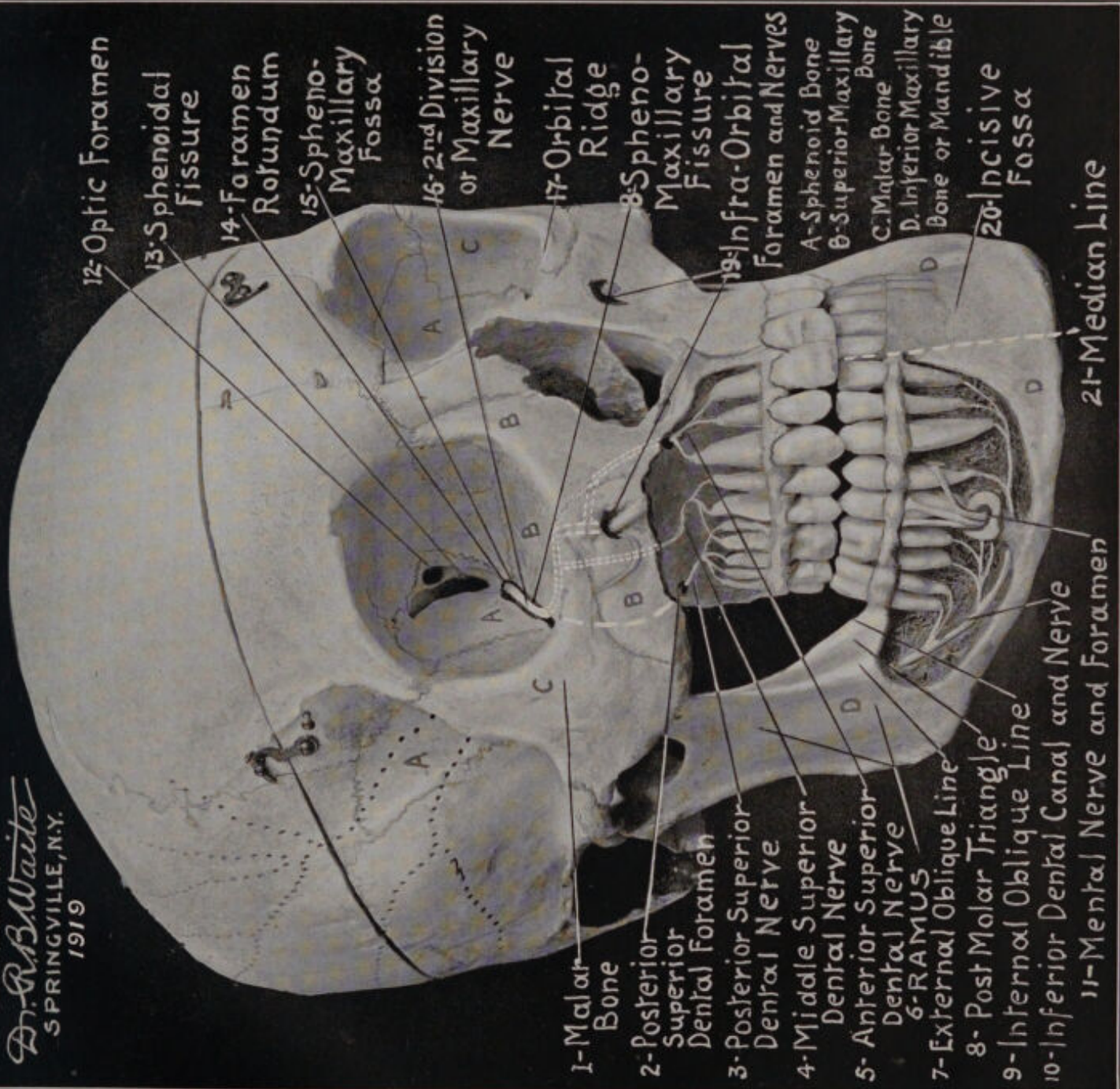
Providing you made the second movement for the Lingual Nerve, bring the syringe back past the Median Line or farther, according to the divergence of the Ramus, the syringe resting upon the teeth. Now, feel your way back, slowly and carefully, by the sense of touch. There should be absolutely no resistance to the progress of the needle. In the majority of cases, you will feel the point of the needle pass over a prominence and strike against the Periosteum of the bone within the Mandibular Fossa. If the needle meets resistance, it may be in the Internal Lateral Ligament which is attached to the Lingula or spine. In such case, withdraw the needle part way and try again a little higher up.

Slowly inject $2\frac{1}{2}$ CC of anaesthetic for removal of pulps and for preparing sensitive dentine. For extracting, slowly inject 2CC.

If you insert your needle too low or too far back, you will deposit the anaesthetic into the ligament or muscle. Injecting into the muscle is one cause of lameness when opening and closing the jaw.

COPYRIGHT BY

Dr. R. B. Waite
SPRINGVILLE, N.Y.
1919



12-Optic Foramen

13-Sphenoidal Fissure

14-Foramen Rotundum

15-Spheno-Maxillary Fossa

16-2nd Division or Maxillary Nerve

17-Orbital Ridge

18-Spheno-Maxillary Fissure

19-Infra-Orbital Foramen and Nerves

A-Sphenoid Bone

B-Superior Maxillary Bone

C-Malar Bone

D-Inferior Maxillary Bone or Mandible

20-Incise Fossa

21-Median Line

1-Malar Bone

2-Posterior Superior Dental Foramen

3-Posterior Superior Dental Nerve

4-Middle Superior Dental Nerve

5-Anterior Superior Dental Nerve

6-RAMUS

7-External Oblique Line

8-Post Molar Triangle

9-Inferior Oblique Line

10-Inferior Dental Canal and Nerve

11-Mental Nerve and Foramen

From the Puncture Point on the Mucous Surface to the bone at the Internal Oblique Line is 5 M.M.

From the Internal Oblique line to Lingual Nerve is 5 M.M., in all 10 M.M. from Puncture Point.

From the Lingual Nerve to the Inferior Dental Nerve is 10 M.M., in all 20 M.M. from Puncture Point.

From Puncture Point to Inferior Dental Nerve is 20 M.M.

Inject from 2½CC to 3CC of anaesthetic for complete injection.

In making a Left Mandibular Injection, stand on the right side of the chair with your left arm around the patient's head. Locate the Internal Oblique Line with the index finger of the left hand.

In making a Right Mandibular Injection, stand in front of your patient and locate the Internal Oblique Line with the Left Index Finger.

When the mouth is open, keep the Occlusal Surface of the Molar Teeth horizontal, or level with the floor by tipping the head back or forward. Then keep the syringe horizontal with the occlusal surface of the Lower Molar Teeth. This is important, otherwise the point of the needle is liable to go below the Inferior Dental Foramen.

The tendency of most dentists is to insert the needle too low.

REMEMBER. Theoretically, the Inferior Dental Nerve only should be injected to obtund Sensitive Dentine for the lower teeth, but most always there is an Anastomosis on the buccal surface from the Long Buccal Nerve, and occasionally on the Lingual surface from the Nerve, consequently if Anaesthesia of the pulps are not complete from the Inferior Dental injection only, then inject 1 CC of Anaesthetic in the Mucous Membrane buccal to the tooth and massage with the index finger. In extreme cases only it is necessary to inject the Lingual Nerve for removal of pulps.

THE LONG BUCCAL INJECTION

The Long Buccal Nerve is given off just outside the Foramen Ovale, from the Third, or Mandibular Division of The Fifth Nerve. It enters the cheek Buccal to the Upper Third Molar, sending branches as far forward as the Lower First Molar and in some cases, The First Cuspid.

Stand in front of the patient and insert the needle in the loose mucous fold at the mesial buccal root of the Lower Second Molar. Instruct the patient to close his mouth, retract the cheek, hold syringe horizontal with the Lower Jaw and insert the needle to a depth of 10 M.M., keeping close to the bone.

As the needle advances, deposit a small amount of anaesthetic until 1CC has been deposited. Withdraw the needle and massage over the Mucous Membrane. This anaesthetises the mucous membrane buccal to the Lower Third, Second and First Molars, and sometimes the First and Second Bicuspid.

MENTAL INJECTION.

Location of Mental Foramen.

The Mental Foramen is located below the apex of the Second Bicuspid, halfway between the lower border of the Mandible and The Buccal Gum Margin.

With your finger, locate the Mental Foramen from the outside by pressing on the face, below the area of the Second Bicuspid. The patient will experience pain because the Mental Nerve is pressed against the bone as it courses out of the Foramen.

Now, with your finger still over the Mental Foramen, stand behind the patient and reflex the lip. Hold your syringe vertical and insert the needle in the buccal mucous fold at the apex of the Lower Second Bicuspid, with the needle parallel to the long axis of the root. Insert down about 10 M.M. until the point enters the Mental Foramen. Deposit slowly 1CC to 2CC of anaesthetic. Remove the needle and massage. This forces the anaesthetic through the Mental Canal, into the Inferior Dental Canal, which anaesthetises the pulps of the lower bicuspid teeth, and in some cases the pulps of the Cuspids, Lateral and Central Teeth, or as far as the Median Line. In some cases the Mental Foramen is located a little Mesial or distal to the apex of the Second Bicuspid.

INCISIVE INJECTION.

Location of the Incisive Fossa:

Below the Lower Central and Lateral Teeth, on both sides of the Median Line, are slight depressions or fossae containing seven or eight small openings called the Incisive Foramen, which transmit terminal branches from the Incisive Nerve and is one of the branches of the Inferior Dental Nerve.

Location of Puncture Point:

Stand behind the patient, locate the Incisive Fossa by feeling with your finger on the outside of the chin. Keep this position and reflex the lip. The needle is then inserted in the mucous fold on either side of the Median Line. The syringe is held in a vertical position. Push the point of needle downward 10 M.M. Inject slowly 1CC to 2CC of anaesthetic. This injection is for the Lower Central, Lateral and Cuspid Teeth.

If the six Anterior Teeth are to be extracted, two incisive injections and two lingual mucous membrane injections would be necessary. After making the first incisive injection, pull the needle nearly out of the mucous membrane, bring the syringe over to the opposite side just past the Median Line, force backward laterally, and downward into the other fossa. In this way you need make only one puncture in the mucous fold.

Inject slowly from 1CC to 2CC of anaesthetic, remove needle and massage. This forces the anaesthetic through the Incisive Foramen and anaesthetises the Incisive Nerve, which supplies the Cuspid, Lateral and Central Teeth, The Labial Mucous Membrane, External Plate and Periosteum.

LINGUAL MUCOUS MEMBRANE INJECTION.

If you make a Mental or Incisive Injection or Infiltration for extracting one or more teeth on the lower jaw, the Lingual Mucous Membrane must be anaesthetised.

2ND Position

3RD Position

1ST Position




Insertion of
Temporal Muscle

Insertion
of Internal
Pterygoid
Muscle

Insertion of
Internal Lateral Ligament

COPYRIGHT BY
Dr. R. B. Waite
SPRINGVILLE N. Y.



Instead of anaesthetising the Lingual Nerve by the Mandibular Injection, inject into the Lingual Mucous Membrane, distal to the last tooth you are to extract. Insert the needle halfway between the lingual gum margin and the apex of the tooth; then carry the point of the needle to the apex of the root and deposit $\frac{1}{2}$ CC to 1CC of anaesthetic.

This will block off the Lingual Nerve from the area of the puncture point to the Median Line. By testing the mucous membrane at the Median Line, you can ascertain how near the anaesthesia extends to the Median Line, or how far the anastomoses extends over from the opposite side.

THE INFRA-ORBITAL INJECTION

Location of the Infra-Orbital Foramen:

The Infra-Orbital Foramen faces downward and is located 10 M.M. below the Infra-Orbital Ridge, directly below the pupil of the eye and above the Second Bicuspid.

Location of the Puncture Point:

Locate the Infra-Orbital Foramen by the sense of touch, with tip of first finger on outside of the face. Keep finger in position and reflex the upper lip.

The syringe is held down along one side of the chin. The needle is inserted in the mucous fold, at the apex of the Upper Second Bicuspid, parallel with the long axis of the tooth. Insert the needle straight up, a distance of about 20 M.M., and the point will enter against the bone forming the upper part of the Infra-Orbital Foramen. Inject slowly from $1\frac{1}{2}$ CC to $2\frac{1}{2}$ CC of anaesthetic. With the finger which has located the Foramen, you can feel the anaesthetic as it is being injected. Remove the needle and massage gently over the Infra-Orbital Foramen. This will force the anaesthetic back into the canal and anaesthetise the Anterior Superior Dental Nerve. It supplies the Upper Central, Lateral and Cuspid Teeth, the Labial Mucous Membrane, External Plate and Periosteum.

If a blood vessel is punctured, it will cause a black eye, or an ecchymosis. This will clear up in a few days.

THE ANTERIOR PALATINE INJECTION.

Location of the Foramen:

This Foramen is located on the Median Line, 15 M.M. lingual to the Upper Central Teeth, and transmits two Naso-Palatine Nerves. The two Superior Maxillary Bones join at the Median Line, forming only one Anterior Palatine Foramen.

Location of Puncture Point:

Hold the syringe against the Lower Lateral Tooth, on the right or left side of the Mandible. It makes no difference on which side you inject. Press the bevel of the needle against the mucous membrane at the side of the large papilla and force the

anaesthetic into the tissue. Then insert the needle. This keeps the anaesthetic ahead of the needle. Then insert the needle into the Foramen a depth of 5 M.M. Deposit $\frac{1}{2}$ CC of anaesthetic. As this injection is painful, first touch the mucous membrane with a little Phenol.

This injection anaesthetises the Mucous Membrane, Periosteum, and Internal Plate palatal to the six anterior teeth, or from Cuspid to Cuspid.

THE POSTERIOR PALATINE INJECTION

Location of the Foramen:

The Posterior Palatine Foramen is located directly above the palatal gum margin of the Upper Third Molar, opening forward a few millimeters anterior to the junction of the hard and soft palates, and transmits the Anterior Palatine Nerves.

Location of the Puncture Point:

Hold the syringe on the opposite side from which you are going to inject. With syringe held at corner of the mouth, and needle point 10 M.M. above the Palatal Gum margin of the Upper Third Molar, insert needle straight through the mucous membrane to the bone. Now, bring the syringe over laterally, or to the opposite side, and insert up and back a distance of 10 M.M. The needle will enter the Posterior Palatine Foramen. Deposit only $\frac{1}{2}$ CC of Anaesthetic. If you deposit a larger quantity of Anaesthetic, you get anaesthesia of the Soft Palate which causes gagging.

The Anterior Palatine Nerve supplies the Mucous Membrane, Periosteum, Internal Plate palatal to the Upper Molars and Bicuspids, and terminates or anastomoses with the Naso-Palatine Nerve, palatal to the Upper Cuspid Teeth.

THE TUBEROSITY, THE ZYGOMATIC OR POSTERIOR SUPERIOR DENTAL INJECTION.

Location of the Foramen:

The Posterior Dental Foramen is located 20 M.M. above the distal gum margin of the Upper Third Molar in the Posterior Surface of The Superior Maxillary Bone. At times, there are several small Foramen instead of one. This Foramen transmits the Posterior Superior Dental Nerve.

Location of the Puncture Point:

Insert the needle in the Mucous Fold, near the apex of the distal buccal root of the Upper Second Molar, or the First Molar in the child. Insert the needle up and back a distance of 10 M.M. You will first pierce the Buccinator, or cheek muscle, and then drop into space. The cheek muscle attaches to the upper and lower buccal alveolar ridge. Now, bring the syringe over laterally to the angle or corner of the mouth and insert the needle up and in 10 M.M. more, keeping the point of the needle close to the

Superior Maxillary Bone. When the needle has been inserted 20 M.M. in all, stop, and the point will be in the region of the Posterior Dental Foramen. Deposit 2CC of Anaesthetic. Use straight 30 M.M. No. 3 needle. Long Curved Hub.

This injection will anaesthetise the pulp of the Third and Second Molars, the Distal Buccal and Palatal Root of the First Molar, Buccal Mucous Membrane, Periosteum, External Plate and Alveolus.

SECOND DIVISION INJECTION.

The Superior Maxillary Nerve or The Second Division, has its beginning at the Gasserian Ganglion, passes through the Foramen Rotundum in the Sphenoid Bone, into a cup-shaped depression or fossa, between the Sphenoid and Superior Maxillary Bones, from which it derives the name, Spheno-Maxillary Fossa. The Foramen Rotundum is about two inches directly back of the Infra-Orbital Foramen.

The Superior Maxillary Nerve then passes outward and forward in a fissure, between the Sphenoid Bone and the Posterior part of the Superior Maxillary Bone, where it enters the Infra-Orbital Canal.

Within the Spheno-Maxillary Fossa, the Second Division or Superior Maxillary Nerve gives off Meckels Ganglion and the Posterior Dental Nerve.

It is about 25 M.M., or one inch from the Foramen Rotundum to the entrance of the Infra-Orbital Canal.

Location of Puncture Point:

In blocking off the Second Division, insert the needle in the mucous fold, buccal to the Upper Third Molar; direct it upward, a little in toward the Median Line, and forward. When you begin to inject, the point of needle will be about two inches straight back of the Infra-Orbital Foramen. The syringe is held an equal distance between the occlusal surface of the Upper and Lower Teeth.

In this injection use a 40 M. M. No. 3½ needle with a right angle curved hub, and insert the needle to a depth of 30 M.M., leaving 10 M.M. exposed. The path of the needle hugs close to the posterior surface of the Superior Maxillary Bone.

This injection is made for Antrum operations, Hair Lip, Cleft Palate, Extracting one-half the Upper Teeth, Root Amputations, etc. The entire Second Division is anaesthetised, including the pulps of the teeth; Alveolar Process; Buccal and Palatal Mucous Membrane as far as the Median Line; the Antrum of Highmore; one-half the Upper Lip; Side of Nose; Lower Eyelid and Meckels Ganglion, which supplies the Palatal Mucous Membrane, soft palate and tonsil.

Deposit from 3CC to 4CC of Anaesthetic. Anaesthesia will be complete in from 5 to 20 minutes.

OPERATIONS THAT CAN BE PERFORMED BY THE SECOND DIVISION INJECTION.

If a patient presents a case for a full upper extraction, only half the teeth are extracted the first day.

First, the Second Division Injection is made. Next, with a sharp knife, cut the gum and Periosteum between the teeth. Then, with your Periosteal Separator, peel back the Periosteum and Mucous Membrane from both sides of the Alveolar Ridge. Next, proceed to extract the teeth from the Central to the Third Molar. Then, with your bone-cutting forceps cut the bone down and smooth the ragged edges. Now, bring the two flaps together and if they are too long, trim them off until they meet. Then wash the parts with warm salt water solution and paint with Tincture of Iodine. Now, bring the Periosteum and gum together and suture in about four places, and paint again with Iodine. Remove sutures in about five days. Then you may operate on the opposite side.

This gives a wonderful looking result. The Periosteum, being brought together, prevents so much absorption, and will make better ridges to hold the artificial dentures.

INFILTRATION.

Infiltration for Upper First and Second Bicuspid:

We depend upon the solution being absorbed through the bone and anaesthetising the pulp. The success of these injections depends on making the injection well above the apex of the roots into the tissues and inserting the point of the needle under the Periosteum.

The needle is inserted in the mucous fold, between the First Bicuspid and Cuspid Teeth, the syringe being held horizontal. The Periosteum, or covering of the bone, is picked up and needle passed along between the Bone and Periosteum. $\frac{1}{2}$ CC of Anaesthetic is deposited slowly about every 5 M.M. Inject 1CC of Anaesthetic. Remove needle and massage. Be sure the injection is made above the apex of the teeth.

Infiltration for Central, Lateral and Cuspid Teeth is done in the same manner, but insert the needle in the mucous fold above the apex of the Central, and force the needle back along the bone a distance of about 10 M.M. Deposit 1CC of Anaesthetic. This anaesthetises the pulps of the Teeth, Buccal Mucous Membrane, Alveolar Ridge, Periosteum and External Plate.

Injection for Palatal Mucous Membrane:

Insert the needle distal to the last tooth to be extracted, into the mucous membrane, halfway between the gingival gum margin and apex of the tooth. Push the needle up along the bone and deposit $\frac{1}{2}$ CC of Anaesthetic in the region of the Apex of the Tooth. The Anterior Palatine Nerve is anaesthetised as far forward as the Cuspid Tooth.

THE INTRA-OSSEOUS INJECTION

This method of injection is used to anaesthetise the Upper Bicuspids, or the Anterior Teeth. Use an obtunding needle, such as was formerly used for Sensitive Dentine, or a heavy gauge hypodermic needle, and an all metal syringe.

Force the point of the needle through the gum, against the process near the apex of tooth, and hold firmly against the process. By pressure the Anaesthetic will be forced through the plate of bone into the spongy bone, causing immediate anaesthesia.

Deposit 1CC of Anaesthetic.

Anaesthesia may also be obtained by drilling through the External Plate of Bone. Then, using a tapered obtunding needle to fit drilled hole, inject the anaesthetic into the spongy process. Quick and lasting anaesthesia will be obtained. This method is not recommended except in extreme cases.

Preparation of the Mucous Membrane

To prepare the mucous membrane for the needle, have the patient rinse his mouth with warm water, or an antiseptic solution, such as Dr. R. B. Waite's ANTI-PY-O Mouth Wash full strength or diluted one-half with water. Then, with cotton wrapped on a long wooden applicator, dry the mucous membrane in the field of the puncture point. Wrap another applicator with cotton, saturate with a 3½% alcoholic solution of Iodine, with which paint the mucous membrane and allow to dry. Then proceed to make your injection.

Instead of using Iodine, you can saturate a very small pledget of cotton, the size of a pin head, with Phenol. Absorb the excess Phenol by touching the saturated pledget to a cloth, cotton roll or gauze, then touch the mucous membrane at the puncture point only. The Phenol acts as an anaesthetic, as well as an antiseptic. Use care to prevent saliva getting on the sterilized mucous membrane. If this should occur, apply more Iodine before proceeding with the injection.

The Iridio-Platinum Needle is sterilized before every puncture of the mucous membrane by passing through the flame, or it can even be heated to a white heat. If, however, you use a Non-Rusting Needle, do not heat same to a white heat. Simply passing the needle through the flame is sufficient to sterilize it. Then force a few drops of the anaesthetic out of the needle. This cools it sufficiently to begin the injection at once. After syringe has been filled with Anaesthetic, never allow sides of hypodermic needle to come in contact with anything, such as cheek, or lips of patient.

Ampules. To remove the anaesthetic from the ampule; first, with a file or carborundum wheel in lathe or engine, scratch the sides of both ends of ampule where you

wish to break it; second, break off one end of ampule; third, with needle on syringe, remove the plunger and hold the broken end of ampule in the syringe; fourth, break off the other end of the ampule and the anaesthetic will run into the syringe.

Or, one end of the ampule can be broken in a towel without previously marking. Then insert the needle in the broken end of ampule, holding in an upright vertical position, and syringe will fill by withdrawing plunger.

It is impossible for the anaesthetic to run out of ampule when only one end is broken, but if both ends are broken, the anaesthetic will run out instantly.

General Directions

Confidence of Patient:

Before making a Nerve Blocking Injection, gain the confidence of your patient by telling him what you are going to do. If it is a Lingual and Inferior Dental Injection, tell the patient the lower lip and tongue will become numb. Make it positive that you are not going to hurt him.

Testing for Anaesthesia:

To test the mucous membrane for anaesthesia, take your cotton pliers and press hard against the gums, or test the cavity in tooth with an excavator. If no sensation is produced, anaesthesia is complete. While testing for Anaesthesia, **ask your patient if it hurts, not if he feels it.** Feeling is different from hurting.

Duration of Anaesthesia:

Anaesthesia will generally last from a short time to several hours.

Mucous Fold:

The Mucous Fold, or Reflection of the Mucous Membrane, is practically devoid of sensation. It is the highest or lowest part of the mucous membrane between the cheek and Alveolar Ridge of the Superior Maxillary and Inferior Maxillary Bones.

Hypodermic Needles:

Every injection should be made with a straight needle.

Don't bend the needle because you are liable to lose the location of the point of a curved needle, and bending any metal causes crystallization, making it liable to break any place. For the Second Division use a straight No. 3½, 40 M.M. needle, with an extra long right angle hub. For the Tuberosity Injection use a No. 3, 30 M.M. straight needle, with an extra long slightly curved hub. For all other injections, use a straight 15 M.M. or 30 M.M. needle. Always keep your needles sharp and be sure the points are free from spurs.

Points to Remember

1—In the Mandibular or Lingual-Inferior Dental Injection, there is soft tissue between the Internal Side of the Ramus and the Internal Pterygoid Muscle, in which tissue there is no resistance to the needle, unless you insert needle low into the Internal Lateral Ligament, which is attached to the Lingula.

2—There are two Posterior Palatine Foramen, transmitting the Anterior Palatine Nerves, and only one Anterior Palatine Foramen, transmitting two Naso-Palatine Nerves.

3—Always remember, in making the Tuberosity, Mandibular, Long Buccal and Infra-Orbital Injections, the length of your needle is **30 M.M.** and the depth of the needle in the tissue is **20 M.M.** Do not go deeper than 20 M.M.

4—The length of the needle in The Second Division is **40 M.M.** The depth of the needle in the tissues is 30 M.M.

5—In the Mental and Incisive Injections the depth of the needle in the tissues is only 10 M.M.

6—Palatal. All the surface within the arch of the upper teeth.

7—Lingual. All the surface within the arch of the lower teeth.

8—Always remember, Asepsis is most important in Nerve Blocking.

9—Soreness is caused by: injecting too rapidly; injecting into muscle; sepsis; too hot a solution; solution not being Isotonic (Hypertonic).

10—Swelling is due to edema, which is an effusion of watery liquid into connective tissue, and will gradually be absorbed.

11—Five Milimeters equal about 3-16".

Ten Milimeters equal about 3-8", (or 1 centimeter).

Twenty-five Milimeters equal about 1".

Thirty Milimeters equal about 1 3-16".

12—Remember, the Lingual Nerves supply the Lingual Mucous Membrane as far forward as the Median Line on the Lower Teeth. The Anterior Palatine Nerve, which comes through the Posterior Palatine Foramen, supplies the Palatal Mucous Membrane in the Superior Maxillary, as far forward as the Cuspid, and the Naso-Palatine Nerve supplies the Palatal Mucous Membrane from the Central to the Cuspid, but the Naso-Palatine Injection anaesthetises from Cuspid to Cuspid.

Lower Injections

I.—To extract the right or left lower first, second or third molars:

- 1—Lingual
 - 2—Inferior Dental
 - 3—The Long Buccal Injection.
- } Mandibular Injection.

II.—To remove the pulp, prepare a sensitive cavity in the molars, bicuspid, or any teeth to the Median Line:

- 1—An Inferior Dental Injection only. **If any sensation, Infiltrate Bucally or Labially.**

III.—To extract one-half the lower teeth to Median Line:

- 1—Lingual Injection.
- 2—Inferior Dental Injection.
- 3—Long Buccal Injection.

IV.—To extract the first and second lower bicuspid:

- 1—Mental Injection.
- 2—Lingual Mucous Membrane Injection at first molar.

V.—To prepare a cavity or remove a pulp in the lower first or second bicuspid:

- 1—Mental Injection or
- 2—Inferior Dental Injection.

VI.—To extract the six Anterior Teeth and the Right First and Second Bicuspid:

- 1—Two Incisive Injections.
- 2—One Mental Injection, right side.
- 3—Lingual Mucous Membrane Injection, Distal to Second Bicuspid, right side.
- 4—Lingual Mucous Membrane Injection, Distal to Left Cuspid.
- 5—Infiltration on Buccal, Distal to Left Cuspid.

Upper Injections

I.—To extract the Upper Third or Second Molars, or both.

- 1—Tuberosity Injection.
- 2—Posterior Palatine Injection.

II.—To extract the Upper Right First Molar, or Upper Right First, Second and Third:

- 1—Tuberosity Injection.
- 2—Posterior Palatine Injection.
- 3—Infiltration above First Molar, (Buccal Side).

III.—To prepare a cavity in a First Molar, or all the Upper Teeth:

- 1—Tuberosity Injection.
- 2—Infiltration above First Molar, (Buccal Side).

IV.—To prepare a cavity, remove a pulp in the Upper First or Second Bicuspid, etc:

- 1—Infiltration on Buccal Side
- 2—Or Intra-Osseous.

V.—For extraction of upper first and second Bicuspids:

- 1—Infiltration on Buccal Side.
- 2—Posterior Palatine Injection.

VI.—To extract the upper right central, lateral and cuspid teeth:

- 1—Buccal Infiltration.
- 2—Anterior Palatine.
- 3—Infiltrate left of Median Line buccally and lingually to block off anastomoses.

Solutions

The requisites for a local anaesthetic are:

- 1—A Sterile Solution.
- 2—A solution that will not deteriorate.
- 3—A solution that is antiseptic, or even germicidal.
- 4—An Isotonic Solution.
- 5—A solution that will produce a quick and lasting anaesthesia.

Always use Dr. R. B. Waite's Antiseptic Local Anaesthetic-With Cocaine, or Dr. R. B. Waite's Improved Local Anaesthetic With Novocain, which meet each and every requirement for The Perfect Local Anaesthetic.

TIME TO WAIT FOR ANAESTHESIA.

1 Minute	3-5 Minutes	8-10 Minutes	5-15 Minutes
Intra-Osseous.	Infiltration.	Infra-Orbital.	Mandibular, or Lingual
	Lingual Injection.	Tuberosity.	Inferior Dental Injection
	Anterior Palatine Injection.		
	Posterior Palatine Injection.		
	Mental Injection.		
	Incisive Injection.		
	Long Buccal Injection.		





