

## **Injuries of nerves and their treatment / [James Sherren].**

### **Contributors**

Sherren, James, 1872-1945.

### **Publication/Creation**

London : James Nisbet, 1908.

### **Persistent URL**

<https://wellcomecollection.org/works/cv5nurc8>

### **License and attribution**

Conditions of use: it is possible this item is protected by copyright and/or related rights. You are free to use this item in any way that is permitted by the copyright and related rights legislation that applies to your use. For other uses you need to obtain permission from the rights-holder(s).



Wellcome Collection  
183 Euston Road  
London NW1 2BE UK  
T +44 (0)20 7611 8722  
E [library@wellcomecollection.org](mailto:library@wellcomecollection.org)  
<https://wellcomecollection.org>

INJURIES OF NERVES  
AND THEIR TREATMENT

JAMES SHERREN





22102129139

H. K. LEWIS,  
136 GOWER STREET,  
LONDON, W.C.

Med  
K35344



5/- net  
4/6

# INJURIES OF NERVES

AND

## THEIR TREATMENT

BY

JAMES SHERREN, F.R.C.S.ENG.

ASSISTANT SURGEON TO THE LONDON HOSPITAL; SURGEON TO THE  
POPLAR HOSPITAL FOR ACCIDENTS; LATE ERASMUS WILSON  
LECTURER, ROYAL COLLEGE OF SURGEONS

London

JAMES NISBET & CO., LIMITED

22, BERNERS STREET, W.

1908

11296028

PRINTED BY ADLARD AND SON  
LONDON AND DORKING

|                               |          |
|-------------------------------|----------|
| WELLCOME INSTITUTE<br>LIBRARY |          |
| Coll                          | weIMOmec |
| Call                          |          |
| No.                           | WL       |
|                               |          |
|                               |          |
|                               |          |

H7



TO

HENRY HEAD, M.D., F.R.S.

IN APPRECIATION OF VALUED HELP, THIS BOOK IS  
DEDICATED



## P R E F A C E

THIS manual is intended as a guide to the examination and treatment of cases of nerve injury. While including all that the author believes to be essential to this, it does not claim to be an exhaustive account of the subject.

A large proportion of the material used has appeared in papers published in 'Brain' (with Dr. Head), in the 'British Medical Journal,' 'Clinical Journal,' and 'Lancet.' The illustrations are, with three exceptions, original. Of these three, two are modified from illustrations given by Cushing, one from a diagram in a paper by Morrison Davies. The photographs have been taken by Mr. Wilson, photographer at the London Hospital, to whom my thanks are due.

JAMES SHERREN.

DEVONSHIRE STREET, W.

*February, 1908*





# CONTENTS

| CHAPTER  | PAGE |
|--|------|
| I. CLASSIFICATION AND METHOD OF PRODUCTION OF NERVE INJURIES . . . . .           | 1    |
| II. SYMPTOMS RESULTING FROM COMPLETE DIVISION OF A PERIPHERAL NERVE . . . . .    | 15   |
| III. SYMPTOMS RESULTING FROM INCOMPLETE DIVISION OF A NERVE . . . . .            | 35   |
| IV. METHOD OF EXAMINATION OF NERVE INJURIES . . . . .                            | 45   |
| V. DIFFERENTIAL DIAGNOSIS . . . . .  | 61   |
| VI. TREATMENT OF NERVE INJURIES . . . . .  | 72   |
| VII. PLASTIC OPERATIONS UPON NERVES . . . . .                                    | 85   |
| VIII. METHOD OF RECOVERY AFTER COMPLETE DIVISION OF A NERVE AND SUTURE . . . . . | 99   |
| IX. METHOD OF RECOVERY AFTER INCOMPLETE DIVISION OF A NERVE . . . . .            | 123  |
| X. PAIN COMPLICATING NERVE INJURIES . . . . .                                    | 132  |
| XI. CRANIAL NERVES . . . . .   | 150  |
| XII. NERVES OF THE CERVICAL PLEXUS AND THE CERVICAL SYMPATHETIC . . . . .        | 178  |
| XIII. THE BRACHIAL PLEXUS . . . . .  | 183  |
| XIV. NERVES SUPPLYING THE MUSCLES OF THE SHOULDER GIRDLE . . . . .               | 211  |
| XV. DIAGNOSIS OF LESIONS OF THE BRACHIAL PLEXUS . . . . .                        | 219  |
| XVI. NERVES OF THE UPPER LIMB . . . . .  | 230  |
| XVII. THE CAUDA EQUINA . . . . .   | 276  |
| XVIII. NERVES OF THE LOWER LIMB . . . . .  | 287  |
| INDEX . . . . .  | 305  |

8



# INJURIES OF NERVES AND THEIR TREATMENT

## CHAPTER I

Classification of Nerve Injuries—Method of Production of Nerve Injuries: (1) by Penetrating Wounds, Accidental or Operative; (2) by Pressure; (3) by Traction—Nerve Injuries complicating (a) Fractures; (b) Dislocations; (c) Surgical Procedures—Gunshot Injuries of Nerves.

INJURY to one of the principal nerves of a limb is an accident of extreme gravity. Its recognition, exact diagnosis and correct treatment is of the utmost importance. Under the most favourable circumstances a period of incapacity results which often extends into months and may necessitate entire change of employment.

It is necessary to be acquainted with the prognosis of the various forms of injury to which each nerve is liable; such injury often affects the future career of the patient, and in many cases the interests of

employers or their representatives are also involved. It may fall to the lot of any medical man to be called upon to state, for example, the probability of a patient after primary suture of one of the nerves of the hand, being able to again follow employment requiring manual dexterity, and at what date.

The subject will be dealt with from the clinical standpoint with these questions in view.

**Classification of nerve injuries.**—All nerve injuries fall into one of two groups: (*a*) Those in which the symptoms indicate complete interruption of continuity; (*b*) those in which the symptoms point to incomplete interruption of continuity. For these two groups I employ the terms (*a*) “complete” and (*b*) “incomplete ‘division,’” the word “division” being used in connexion with the conducting portion of the nerve. This avoids terms such as “concussion,” “contusion,” “laceration,” which are of use in describing the method by which a nerve is injured but do not form the basis of a useful classification; they omit the one fact of importance in treatment and prognosis, whether the separation from the central nervous system of the structures supplied by the injured nerve is complete or incomplete.

But it must be remembered that interruption of conduction, permanent or transitory, complete or incomplete, may result from an injury which leaves the naked-eye continuity of the nerve intact. For this

type of injury I use the term "physiological"; when the injury results in anatomical solution of continuity, "anatomical" division. Hence the complete classification is into—

|                     |                  |
|---------------------|------------------|
| Complete division   | { Anatomical.    |
|                     | { Physiological. |
| Incomplete division | { Anatomical.    |
|                     | { Physiological. |

There is no sign apart from inspection of the nerve by which it is possible to tell into which of the subdivisions (anatomical or physiological) the injury falls. The second part of the classification must therefore often be omitted, or added after operation.

**Methods of production of nerve injuries.**—All nerve injuries may be referred to one of three causes: (1) Wounds, accidental or operative; (2) pressure; (3) traction. These affect the individual nerves in varying frequency. For example, the median and ulnar are most often injured by penetrating wounds, the musculo-spiral as the result of pressure, the brachial plexus as the result of traction.

*Wounds of nerves, accidental and Operative.*—Accidental wounds in the region of the wrist and lower third of the forearm are responsible for a large proportion of the nerve injuries of civil life. They are often complicated by division of tendons and form one of the most serious accidents we are called upon to treat. In the lengthy operation for the



union of the divided tendons the nerve injury is not infrequently overlooked.

Sometimes the nerve is divided through a small punctured wound, and for this reason nerve injury is not suspected.

The nerves which most often suffer in this way are the median and ulnar, alone or together, and the radial.

It is impossible to avoid the division of many small cutaneous nerve-branches during the course of a surgical operation. Such injuries are, as a rule, of little importance ; regeneration and restoration of function follow if the edges of the wound are brought into accurate contact and the wound heal by first intention. In some cases larger branches are divided, of necessity or accidentally, and the symptoms persist.

The nerves most often injured during the course of surgical operations are the branches of the cervical plexus and the spinal accessory in operations upon the neck, and the facial nerve. In operations upon the neck the spinal accessory should be carefully avoided, or if divided, sutured. Its section produces a noticeable deformity of the shoulder (*vide* p. 175), which is more marked if, as usually happens, the branches given to the trapezius from the third and fourth cervical are divided at the same time. Injuries of the sensory branches of the cervical plexus may cause pain and tenderness in their area of distribution. The trunk of the facial nerve is

most often injured in operations upon the mastoid and middle ear, its branches, in operations in the parotid and submaxillary regions.

Next in frequency the nerves of the abdominal wall suffer. Incisions in the linea semilunaris must of necessity divide the lower dorsal nerves supplying the rectus abdominis, and may aid the formation of post-operative ventral hernia. Fortunately it is rarely imperative to open the abdomen through an incision in this situation. In most operations in the upper abdomen the incision should be made through the posterior sheath of the rectus, after pulling the muscle outwards. If this is inadvisable, as in the operation of cholecystostomy, the fibres of the rectus should be separated.

The last dorsal, ilio-hypogastric and ilio-inguinal nerves, particularly the former, are exposed to injury in their course behind the kidney. This injury may be avoided by making all incisions parallel to their course and remembering their position when it is necessary to enlarge the wound. The last dorsal nerve is occasionally included in a ligature with the first lumbar artery. Severe symptoms may be produced by injury to any of these nerves (*vide* p. 144).

The ilio-inguinal nerve, as it lies beneath the structures forming the spermatic cord and passes out at the external abdominal ring, is sometimes cut into or included in a ligature during operations upon inguinal herniæ. This nerve should be always



recognised and carefully preserved. Considerable inconvenience may result from its injury; I have known the pain severe enough to render operation necessary.

In all operations, however simple, the course of the neighbouring nerves should be borne in mind.

*Pressure on nerves.*—The pressure may be momentary or long continued, the result, for example, of a blow or involvement in callus. As an example of the former, a blow on the ulnar nerve behind the internal condyle of the humerus leading to a temporary interference with the functions of the nerve may be cited. Of the latter, involvement of the musculo-spiral nerve in the callus repairing a fracture at the junction of the middle and lower thirds of the humerus.

The musculo-spiral nerve suffers most often from this type of injury. It may be pressed upon during sleep, or by crutches, involved in fibrous tissue or callus, or compressed by a displaced fragment of bone. Less often the brachial plexus is compressed by the dislocated head of the humerus, the external popliteal by the violence producing a fracture of the neck of the fibula or other direct pressure. The median and ulnar nerves may be injured by tight splints or bandages. In Volkmann's ischæmic contracture of the forearm muscles, when, as is usually the case, it results from splint pressure, involvement of these nerves is rarely absent. The pressure of

the strapping used in putting up a fracture of the clavicle by Sayre's method is responsible for some cases of injury to the ulnar nerve leading to a temporary loss of conduction.

*Traction injuries.*—Injuries due to overstretching—traction—affect chiefly the brachial plexus. They form an extremely important group to which attention has recently again been directed. Brachial birth paralyses and injuries of the plexus due to a fall upon the shoulder or violence applied to the side of the head owe their origin to this cause (*vide* p. 187). The great sciatic nerve or its external popliteal division are sometimes injured during the manipulations necessary to the treatment of a congenital dislocation of the hip, or the reduction of a traumatic dislocation.

The overstretching may result in anatomical or physiological division, which may be complete or incomplete. Physiological is more common than anatomical and incomplete than complete division.

**Nerve injuries complicating fractures.**—The nerve may be injured at the moment of the fracture—primary; involved in the process of repair, or pressed upon by the displaced end of the bone—secondary.

The primary injuries fall into two groups, (*a*) in which the nerve injury is caused by the fracture, for example, injury of the musculo-spiral from bruising or laceration by the fragments of the fractured humerus; (*b*) in which the nerve injury



results from the violence producing the fracture, a fall on the point of the shoulder causing a fracture of the clavicle and a traction injury to the brachial plexus, or direct violence applied to the outer side of the leg, a fracture of the neck of the fibula and an injury to the external popliteal nerve.

The nerve may be ruptured, contused, lacerated, or compressed between the ends of the bone. In most cases the symptoms result from pressure and cause weakness or paralysis of muscles accompanied by a loss of sensibility according to the nerve injured and the degree of the injury. Occasionally, when the nerve is lacerated, pain may arise in the distribution of the affected nerve a few days after the injury (*vide* p. 43).

In secondary injury the nerves become involved in fibrous tissue, or compressed by exuberant callus or bone. The musculo-spiral is the nerve most often affected in this way. The interference with the functions of the nerve may arise many years after the fracture, as occurs in the late involvement of the ulnar nerve after fractures in the region of the elbow-joint (*vide* p. 256).

Primary injury is rarer than secondary, but it is difficult to obtain the exact percentage, for it often happens that no examination for nerve injury was made before the limb was put in splints and the fact of the injury is first discovered on their removal; in by far the greater number of cases also, no operation

is necessary, so that the exact condition of the nerve is a matter of conjecture.

In both primary and secondary injuries the division is more often incomplete than complete, and even in the primary form, more often physiological.

In every instance of fracture careful examination should be carried out before the limb is put up.

The musculo-spiral nerve suffers most often in the upper limb, the external popliteal in the lower. Bruns found the order of frequency to be as follows: Out of 189 cases of involvement of nerves in fractures 77 were instances of musculo-spiral, 25 external popliteal, 19 ulnar, and 17 median. All others were rare. These figures correspond to the relative frequency in the patients with nerve injuries complicating fracture which have been treated at the London Hospital.

**Nerve injury complicating dislocations.**—As in the nerve injuries complicating fractures the injury may be primary or secondary. The primary may be caused by the direct pressure of the head of the bone at the moment of dislocation, arise during attempts at its reduction, or may be due to the violence which caused the dislocation.

Secondary involvement occurs only in unreduced dislocations, and is due to the long-continued pressure of the head of the bone, or to inflammatory changes around it.

Both primary and secondary involvement is met



with most often as a complication of subcoracoid dislocation of the humerus, and is by no means an uncommon accident. The brachial plexus or the nerves arising from it are injured, in most cases the plexus itself. The whole plexus may be injured, but it is usually the inner cord alone, or to the greatest degree. The whole plexus sometimes suffers in injudicious attempts at reduction by the "heel in axilla" method. In subglenoid dislocations the circumflex or musculo-spiral nerve may be injured. The ulnar nerve is sometimes injured in dislocations of the elbow, the posterior interosseous in forward dislocations of the head of the radius, and the great sciatic or obturator nerve in dislocations of the hip.

**Nerve injuries complicating surgical procedures.**—It is still by no means uncommon to find a localised paralysis resulting from surgical procedures carried out under a general anæsthetic. The majority of these fall into the group of "post-anæsthetic paralyses," due to the position of the patient. But in a few, the operative manipulations of the surgeon are responsible; such are the injuries to the brachial plexus, following the reduction of a dislocation of the humerus by the "heel in axilla" method, or of the great sciatic or its external popliteal branch from manipulation of a congenital dislocation of the hip, or the reduction of an acquired dislocation, or the large number of injuries resulting from wounds of

nerves. These have already been referred to in their appropriate sections.

The cases in which no manipulative cause can be assigned fall into two groups. The first, which is uncommon, includes the injuries resulting from direct pressure; such are injury to the musculo-spiral, due in most cases to the direct pressure of the edge of the table, or injury to the external popliteal nerve, from the application of a Clover's crutch or Esmarch's bandage.

In the second group are the traction injuries. The brachial plexus of the right side suffers most often, and the muscles supplied by the fifth cervical nerve are usually paralysed alone; if muscles supplied by other nerves suffer as well, those supplied by the fifth are always the most severely affected.

This type of injury can only occur when the patient's arm is abducted from the body or raised above the head; in none of the recorded cases did it follow an operation in which the arms were kept to the side. It most often happens when the right arm has been abducted and externally rotated, and the patient, for the convenience of the surgeon, has been brought to the edge of the table; in this way the weight of the upper limb falls on the brachial plexus and its cords are stretched.

In a few cases the paralysis follows elevation of the arms above the head; in these the nerves may be injured as the result of the direct pressure of the



head of the humerus over which they lie. It has been suggested that the injury is due to the nerves being crushed between the clavicle and first rib or transverse process of cervical vertebræ; this is improbable.

The violence results most often in incomplete physiological division, and the majority of the cases recover without active surgical interference. In all the patients that have come under my notice, spontaneous recovery occurred, and I have been able to find record of one case only in which recovery was incomplete. In this patient the deltoid remained permanently paralysed.

These paralyses occurring after a routine abdominal operation, are a reproach to all concerned, and not to the anæsthetist alone, to whom the blame is often imputed. They are preventable in most cases, and thought must be taken to avoid attitudes which are likely to produce injury to nerves, and particular care exercised to avoid undue abduction or elevation of the arms.

**Gunshot wounds of nerves.**—The recent wars in South Africa and the Far East have added much to our knowledge of these injuries. Makins, in his *Surgical Experiences in South Africa*, states that “the occurrence of these injuries has undoubtedly increased in frequency with the employment of bullets of small calibre.” This was also noticed in the Russo-Japanese war and recorded by Hashimoto and Tokuoka.

It is impossible to give the exact frequency with

which the various nerves were injured, but of those cases needing prolonged treatment or operation the great sciatic suffered most often, next in frequency the musculo-spiral. Thus, out of 38 cases treated by Hashimoto and Tokuoka, 18 were sciatic, 16 musculo-spiral, 2 median, 1 ulnar, and 1 posterior tibial. The comparative frequency agrees fairly well with that of the cases that have come under my observation, with the exception that injuries of the brachial plexus and the nerves arising from it were more often met with.

The sciatic suffered most often from a primary injury, the musculo-spiral in fractures of the humerus in a greater percentage of cases than seen in fractures of this bone in civil life.

In a large number of cases the injury is an incomplete physiological division, primary, or secondary, from involvement in fibrous tissue or callus. The temporary loss of conductivity, complete or incomplete, not uncommonly met with when the track of the bullet passes near one of the peripheral nerves, is an example of primary incomplete physiological division. Complete anatomical division is rare. In many instances the wound does not completely divide the nerve, but the signs of complete division develop later from the resulting fibrosis, and indicate operative treatment. In other cases pain and tenderness (*vide* p. 134) occur, rendering neurectomy necessary.

Several instances have been recorded in which a nerve was penetrated by a bullet, the nerves of the brachial plexus and the great sciatic most often, without producing even complete physiological division. One case has come under my notice in which the median nerve was so affected without any permanent interference with conduction.



## CHAPTER II

Symptoms following the Complete Division of a Peripheral Nerve  
—Changes in Sensibility produced by Division of a Peripheral Nerve—Three Systems of Afferent Fibres—Changes in Sensibility resulting from Division of Posterior Roots—Division of a Nerve “without Sensory Change”—Changes in the Muscles following Complete Division of their Motor Nerve—Paralysis—Electrical Changes—Changes in the Skin, Nails, Hair, Bones, and Joints.

COMPLETE division of a mixed peripheral nerve results in the loss of those forms of sensibility which it “exclusively” supplies, and paralysis of the muscles to which it sends motor fibres.

**Changes in sensibility.**—Section of a sensory nerve enables us to map out its “exclusive” supply, that is, the area to which it alone sends fibres; it gives no information with regard to the much larger area to which it supplies fibres in common with other nerves. To obtain this, its “full” supply, we must study the sensibility remaining after division of the surrounding nerves; this method of residual sensibility or residual æsthesia, first employed by Mr. Jonathan Hutchinson sen., to map out the distribution of the median nerve on the dorsal surface of the fingers, has in the hands of Sherrington given valuable results in experimental work.



The area of full supply deduced from residual sensibility corresponds closely to the extent of skin which becomes tender on stimulation of the trunk of the nerve. This was done experimentally by Weir Mitchell, who, following the example of Waller, stimulated the ulnar nerve behind the internal condyle with a mixture of ice and salt. He experienced an intense burning pain over an area larger than that which later became anæsthetic as the result of the continued action of the freezing mixture. Most peripheral nerves are too deeply seated to admit of this method of stimulation. But after certain incomplete injuries, particularly those due to gunshot wounds (*vide* p. 134), marked tenderness may arise in the territory to which the injured nerve sends fibres. This is always more widespread than the loss of sensibility which results from its therapeutic division and corresponds to its full supply.

After section of a mixed nerve, such as the median at the wrist, if no tendons have been divided at the same time, the patient is, in most cases, able to appreciate those stimuli commonly called tactile; a touch with the finger, a pencil, or a piece of paper may be not only readily distinguished but accurately localised. When pricked with a pin the patient recognises that he has been touched but fails to perceive the sharpness of the stimulus. Anything, in fact, which deforms the skin produces an effect on consciousness. To this form of sensibility

which persists after the division of all the cutaneous nerves supplying the skin, Dr. Head and the author gave the name of "deep sensibility" or "deep touch." The fibres which convey this form of sensibility have widespread anastomoses and run for the most part with the motor nerves to the muscles and along their tendons and other fibrous structures to the bones, periosteum and ligaments. While deep

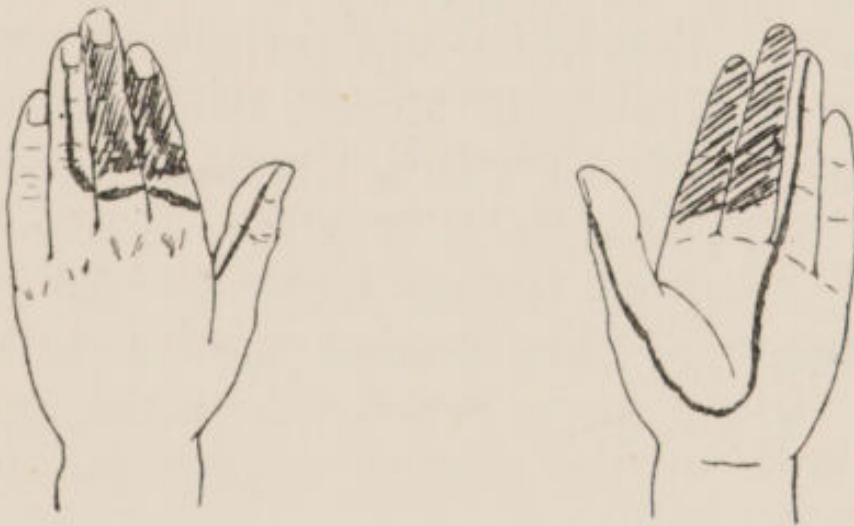


FIG. 1.—To illustrate the loss of sensibility resulting from division of a peripheral nerve. The area of loss of sensibility to light touch is bounded by a line; the shaded portion represents the area of loss of sensibility to prick and all degrees of temperature. The unshaded portion represents the "intermediate zone."

sensibility is present the patient is able to recognise the position into which his joints have been placed. Through this deep system the patient is also able to appreciate increase of pressure and the pain of deep pressure, this being ill defined and often compared by the patient to that produced by bruising a bone.



The sharpness of a stimulus, a prick with a sharp needle and all degrees of temperature are not recognised over an area which varies somewhat from patient to patient (*vide* Fig. 1).

Surrounding this area and corresponding closely to the distribution of the nerve as figured in anatomical text-books is a territory within which the patient is unable to appreciate light touches with cotton-wool and to discriminate between temperatures of about  $22^{\circ}$  C. and  $38^{\circ}$  C. (called minor degrees), and fails to distinguish as two, the points of a pair of compasses when separated to many times the distance necessary over the corresponding part of the sound limb or the unaffected portion of the injured (compass test). The boundary of this loss of sensibility to light touch is well defined and liable to very little variation even when many patients are examined.

Within the area between the border of the loss of sensibility to prick and the loss of sensibility to light touch (called the intermediate zone), the patient is able to appreciate the sharpness of a pin-prick and to differentiate between water below about  $20^{\circ}$  C. and water above about  $45^{\circ}$  C. All stimuli in this zone appear to have an unpleasant tingling, diffuse character. A prick causes a sensation of pins and needles, which radiates widely; the patient often withdraws his hand, describing the sensation as a "numb, tingling pain," or "as if you were

touching a sore place," and rubs the part; this pain may persist for a considerable time. Changes in atmospheric temperature affect this portion of the skin very readily, the slightest coldness in the weather causes the part to become cold and blue, and of this the patient bitterly complains. On palpation it feels definitely colder than the sound portion of the limb.

The boundary of this intermediate zone may be marked out by dragging a sharp needle across the skin from normal towards abnormal parts; immediately the boundary of the loss of sensibility to light touch is reached a marked change in sensibility is noticed by the patient, the sensation provoked having the characteristics just described. This is spoken of as the "line of change to prick" (*vide* also incomplete division, p. 38).

We see, then, that complete division of a mixed or sensory nerve causes a well-defined loss of sensibility to light touch, which varies little from patient to patient and an ill-defined and smaller area of loss of sensibility to prick, which varies within wide limits, sometimes being almost as extensive as the loss of sensibility to light touch, at others falling far short of it. The outline of the area of loss of sensibility to prick may also vary somewhat in the same patient; on a bright, warm day it will be a little smaller than on a cold, damp one, and may vary with the state of the patient's health. But this variation is



slight only, and is easily overlooked unless the condition is charted each time the patient is examined. A loss of sensibility to deep touch may be present if the nerve has been divided above all its motor branches, or if tendons have been severed in addition to the nerve, but is rarely as extensive as the loss of sensibility to prick.

Hence we see that division of a nerve rarely produces an area of loss of all forms of sensibility; deep touch can usually be appreciated everywhere and the only loss of sensibility at all corresponding in extent to that usually assigned to the nerve, is the loss of sensibility to light touch. For these and other reasons the afferent fibres in a peripheral nerve may be divided into three systems, as suggested by Dr. Head and the author. These have the following characteristics :

(1) Those which subserve deep sensibility. These conduct impulses produced by pressure; its gradual increase can be perceived and the pain produced by excessive pressure recognised. Through this system the patient recognises the extent and direction of the movements of joints and muscles. These fibres run mainly with the motor nerves, have widespread anastomoses, and are not destroyed by division of all the sensory nerves to the skin.

(2) Those responding to painful cutaneous stimulation and to the extreme degrees of temperature. To this system of fibres and end organs we gave the

name "protopathic." All sensations evoked by the stimuli to which this system is capable of reacting are badly localised, radiate widely and are accompanied by tingling. It is the form of sensibility which exists in the intermediate zone, between the boundary of loss of all forms of cutaneous sensibility and that of the loss of sensibility to light touch. Reflex movements owe their origin to this system, which produces a rapid response unaccompanied by any definite appreciation of the spot stimulated.

(3) A system of nerve-fibres and end organs responding to light touches with a well-localised sensation. Through it minor degrees of temperature are differentiated and two points discriminated. To this system we gave the name of "epicritic."

In describing the loss of sensibility which results from the division of individual nerves I shall employ these three headings, and use the terms "epicritic" and "protopathic" sensibility as synonymous with sensibility to light touch and to prick. These last two forms of sensibility are differently represented in each peripheral nerve, but in all cases the fibres subserving protopathic sensibility have a much wider overlap than those which subserve epicritic sensibility.

The investigation of the distribution of deep sensibility is beset with many difficulties; it can only be examined in cases in which all cutaneous sensibility is absent. It is impossible at present to formulate any further hypothesis with regard to its distribution.



Much difference of opinion has existed with regard to the loss of sensibility which results from division of a peripheral nerve. It was pointed out by Richet, in 1867, that sensibility may be retained after division of the median nerve; many similar cases have been recorded, and I have known good observers in other branches of surgery overlook the fact of division of this nerve.

The method used by Richet in testing sensibility explains why no loss could be discovered. An account of it has been preserved in a letter written to the *Lancet* by Lockhart Clarke, in which he stated "with a piece of paper rolled up into the form of a stick he (Richet) tickled in the most perplexing way different parts of the fingers and palm supplied by the median nerve. . . . Nevertheless sensibility, though not abolished, was somewhat impaired, as was evident when a pin was used instead of paper to excite the skin. The application of heat and cold was not attended with very satisfactory results." It is quite evident that the ordinary loss of sensibility produced by division of the median nerve was present in this case with retention of deep sensibility. Similar methods of testing have led to similar errors in numberless cases since.

Richet considered that the retention of sensibility was due to the presence of the recurrent fibres described by Claud Bernard. The next year, Savory explained the phenomenon as it occurred after

division of the musculo-spiral nerve by the presence of anastomoses with neighbouring nerves. In the same year Létiévant enunciated his wider theory, that of supplementary sensibility (*sensibilité suppléée*), including in the term not only recurrent sensibility and anastomoses, or, as he expressed it, coarse and fine anastomoses, but also sensibility taken up from an anæsthetic region by the end organs of the neighbouring sound skin, called by him "mediate sensibility," and corresponding in its characteristics to that form of sensibility to which we gave the name of "deep." His researches received apparent confirmation from the researches of Arloing and Tripier, published the following year.

In 1873 Létiévant published his work, *Traité des Sections Nerveuses*, in which he gave an extended account of his doctrine applied to the various nerves. Richelot, and more recently, Laborde, confirmed his observations, while most modern writers on the subject have taken supplementary sensibility as the explanation of the varieties of loss of sensibility met with after division of a nerve. But however widely applied, this fails to explain the well-defined and little varying loss of epicritic sensibility, the varying protopathic loss, the presence of deep sensibility and the curious dissociation of sensibility seen after division of posterior roots and certain nerves of the dorsum of the hand (*vide* p. 241) in which light touch and the minor degrees of temperature can be appre-



ciated over a part insensitive to protopathic stimuli. It also leaves unexplained the method of sensory recovery (*vide* pp. 101, 123). These can be most satisfactorily explained by the theory brought forward by Dr. Head and the author.

The loss of sensibility present immediately after the injury remains unchanged until regeneration of the peripheral end and reunion with the central nervous system takes place. There is no gradual encroachment upon the anæsthetic area by the nerves supplying the surrounding skin. In cases of secondary suture performed some weeks after section, if any improvement in sensibility has taken place, freeing and freshening the ends of the nerve results in the sensory loss becoming identical with that which was present immediately after the accident; all the restoration in sensibility has been due to reunion with the central nervous system. This reunion may be through divided nerve branches in the surrounding tissues and not through its own central end, but this does not take place to any great extent in adults.

**Division of posterior roots.**—The effect of the division of posterior roots throws a further light upon the sensory distribution of the peripheral nerves. A knowledge of the nature of this distribution is of extreme importance in diagnosis.

Division of posterior roots produces an area of loss of protopathic sensibility larger than the area

of loss of light touch (*vide* Fig. 2). A territory, therefore, remains within which the patient is unable to appreciate the sharpness of a prick or the extreme degrees of temperature, but is able to recognise stimulation with cotton-wool, and may be able to discriminate between warm and cool, although totally unable to detect any difference between ice and water at  $55^{\circ}\text{C}$ .

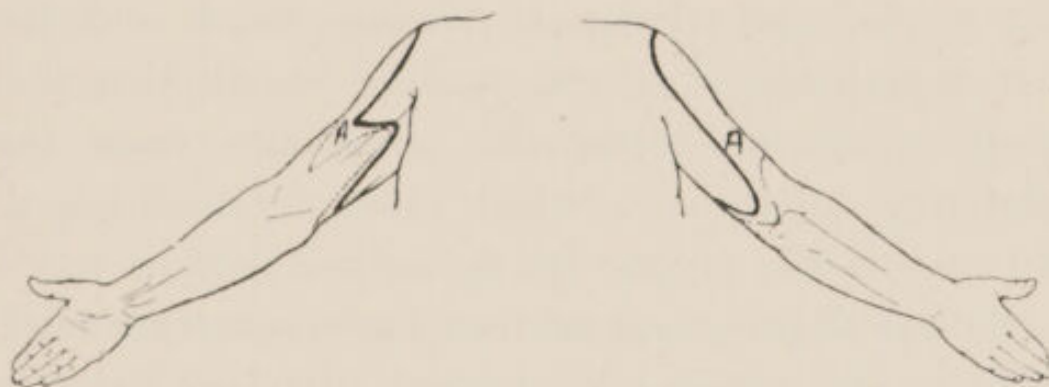


FIG. 2.—To illustrate the loss of sensibility resulting from division of posterior roots. In this patient (Head and Sherren, No. 52) the fifth, sixth, seventh, and eighth cervical, and first and second dorsal posterior roots were divided. The thick continuous line represents the area insensitive to prick; the thin dotted line the area insensitive to light touch. A represents area within which light touches with cotton-wool were appreciated, but painful stimulation was unrecognised.

The peripheral nerve may be looked upon as the unit of epicritic supply, the posterior root as the unit of protopathic supply. The nearer a peripheral nerve represents the supply of one or more posterior roots, the more definite will be the borders of the loss of sensibility to prick produced by dividing that nerve, and the more nearly will the loss of proto-



pathic correspond to the loss of epicritic sensibility. For example, the external popliteal nerve (*vide* p. 297) corresponds closely to the distribution of the fifth lumbar root, its division produces a widespread and well-defined loss of protopathic sensibility corresponding almost exactly to the area of epicritic loss. The median nerve, on the other hand, represents the supply of no single posterior root, but contains sensory fibres from the seventh and eighth cervical, and possibly also from the sixth cervical and the first dorsal nerves; consequently its division will produce loss of protopathic sensibility over the relatively small area to which this nerve carries all the protopathic supply (its exclusive supply).

**Division of peripheral nerves without sensory change.**—There are certain nerves which can be divided in certain situations without producing sensory change that can be appreciated by any of our present methods of testing. These are, the musculo-spiral in the lower third of the arm, that is, below the point at which its external cutaneous branches are given off, the radial nerve in the upper two thirds of the forearm, and certain of the anterior primary divisions of the cervical nerves which enter into the formation of the brachial plexus. These nerves supply no area of skin exclusively with any form of sensibility, hence division of other branches in addition is necessary to produce any sensory loss.

**Motor symptoms.**—Complete division of a nerve



containing motor fibres results in immediate paralysis of the muscles supplied by it. But this paralysis is not always obvious, and its detection may require careful examination. No movement ordinarily employed in daily life is the result of the contraction of one muscle only; in investigating the paralysis of muscles after a nerve injury this must be remembered. It is the action of the individual muscles that must be investigated, not the movements with which their contraction is usually associated. For example, after division of the median nerve at the wrist, the action of the abductor and opponens pollicis muscles must be investigated, not the presence or absence of abduction and opposition, these movements can be imitated by the contraction of other muscles. Again, extension of the fingers in a line with the hand is due to the contraction of the extensors of the fingers, supplied by the musculospiral nerve, of the flexors of the wrist supplied by the median and ulnar, and of the interossei muscles supplied by the latter nerve.\*

That mistakes might arise in this way was first pointed out by Swan in 1834, in recording the results of his experiments. He wrote: "I was at first astonished at seeing how much an animal could move its limb a short time after operation (division

\* Those interested in the subject of muscular movements will find a full account in Dr. C. E. Beevor's *Croonian Lectures*, delivered in 1903.

of sciatic nerve), and concluded that misconceptions have arisen from considering the general motion of the limb as evidence of the regeneration of the nerve." Létiévant, nearly forty years later, developed this and named the movements "supplementary." He speaks of supplementary motility (*motilité suppléée*), meaning thereby the imitation by unaffected muscles of movements usually associated with contraction of the paralysed muscles.

The affected muscles atrophy with a greater or less rapidity according to the means used to keep up their nutrition, and unless care be taken may become converted into a mass of fibro-fatty material devoid of all contractile power.

Unless precautions are taken they become overstretched by the action of the opposing muscles, and these latter become permanently contracted—conditions that seriously interfere with complete recovery.

**Electrical changes.**—Muscles in communication with healthy anterior horn cells respond readily and briskly when stimulated with the interrupted (faradic) and the constant (galvanic) currents. With the former current, when the interruptions are rapid the muscle remains contracted as long as the current is passing; with the latter, a brisk twitch occurs at the moment the current is made or broken, but no contraction is evoked while the current is passing through the muscle. A contraction is produced by



the smallest amount of current when the kathode is used as the testing electrode and the current is closed (K.C.C.), then when the anode is used and the current closed (A.C.C.).

After division of its motor nerve, a muscle ceases to respond to stimulation with the interrupted current applied over its motor point in from four to seven days. At about the tenth day it may be exceedingly difficult to obtain any contraction to the constant current, and at or about this time the muscles respond to this form of stimulation with a sluggish, wave-like contraction starting at the spot stimulated, and a stronger current must be used to call it forth than on the sound side. The contraction appears first at the closing of the circuit, when the anode is used as the testing electrode (A.C.C. > K.C.C.), but this, although usual, is probably not invariable. To loss of irritability to the interrupted current with this specific alteration in the type of the contraction given to stimulation with the constant current the name "reaction of degeneration" (R.D.) is applied. The name should be reserved for this one type of reaction and terms such as "partial R.D." avoided.

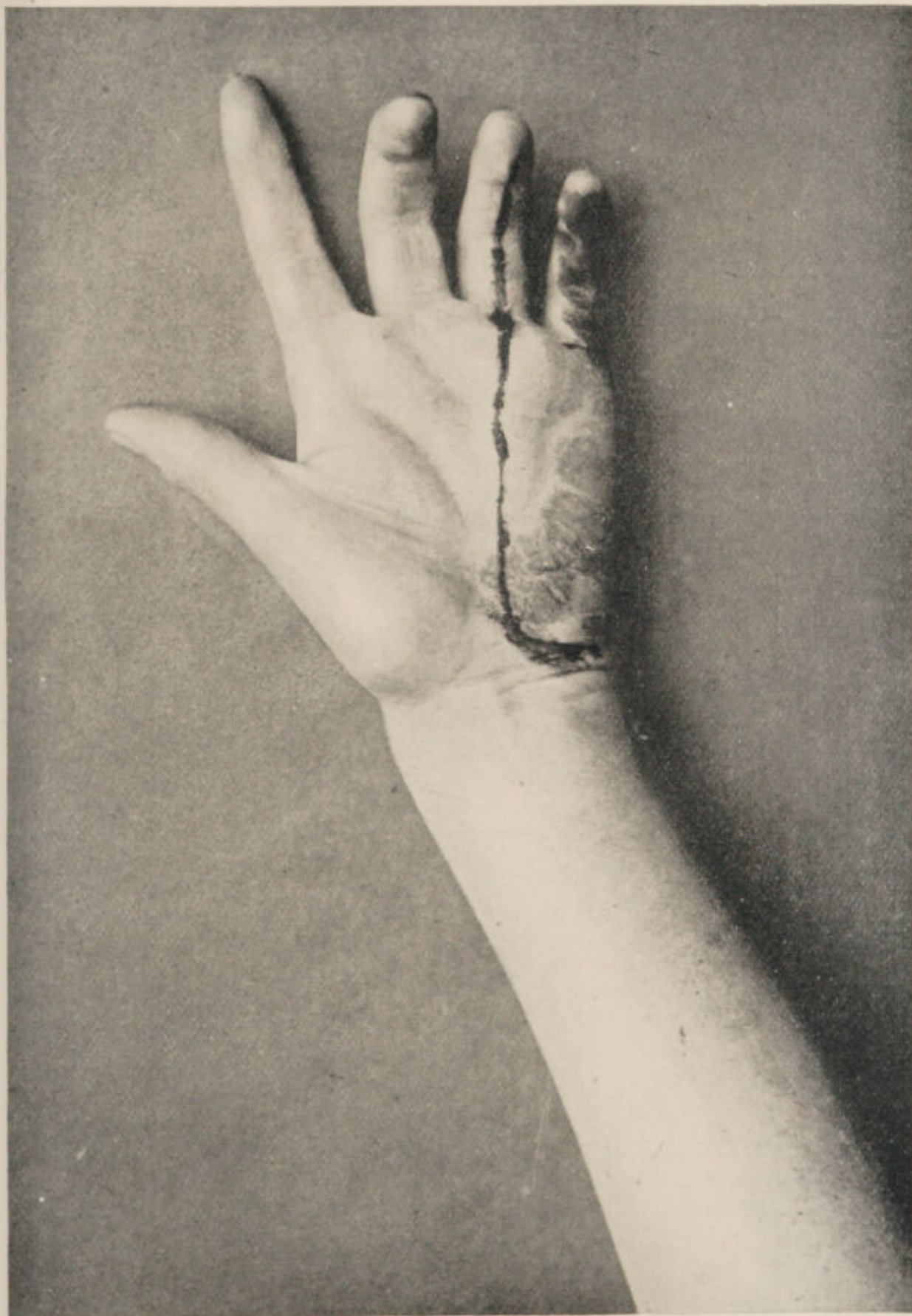The length of time after separation from their anterior horn cells that the muscles retain the power of reacting to stimulation with the constant current varies; so long as contractile substance is present in the "muscles" they will respond to this



stimulus. When once a muscle has lost the power of responding to this current its recovery is impossible. But great care is necessary before coming to this conclusion, for contraction may be evident at one examination and not at another. Purves Stewart has recorded a case in which the muscles responded to stimulation with the constant current sixteen years after separation from its nerve-centre, and I have recently seen a patient in whom the muscles reacted to the constant current, although the musculo-spiral nerve had been divided twenty-three years.

**Changes in the skin.**—When one of the nerves of the palm is divided the superficial layers of the epithelium no longer desquamate so readily over the area of loss of sensibility to prick. This is well seen in a patient who does manual work, and is a striking feature in the progress of a case of primary suture. On removing the first dressing the normal parts of the hand protected by the cotton-wool are soft and the epithelium sodden, but over the abnormal area the epithelium has not been shed and presents a rough, dry layer marking out the affected area (*vide* Plate I). If the hand be well soaked the dry epithelium can be peeled off, exposing wrinkled, pinkish-blue skin, colder than normal. This area does not sweat. A prick bleeds more readily than elsewhere and leaves, as first pointed out by Israel, a red spot or papule, which may persist for many hours, or even days. This is most striking, and the marks of


PLATE I.



Taken three weeks after division of the ulnar nerve to show the delayed desquamation over the ulnar portion of the palm of the hand. The area enclosed by the line represents the area insensitive to light touch.







## PLATE II.

To illustrate the formation of "trophic ulcers."

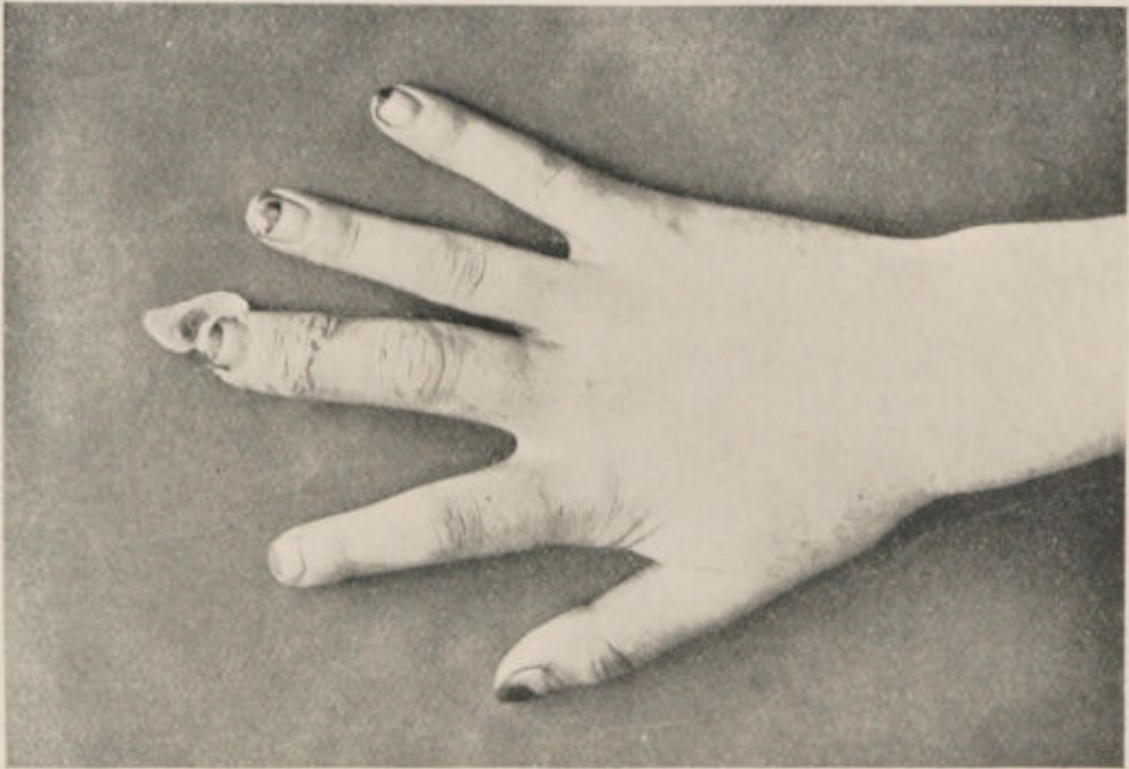


FIG. 1.—Shows a blister on the dorsal surface of middle finger following an injury to the median nerve.

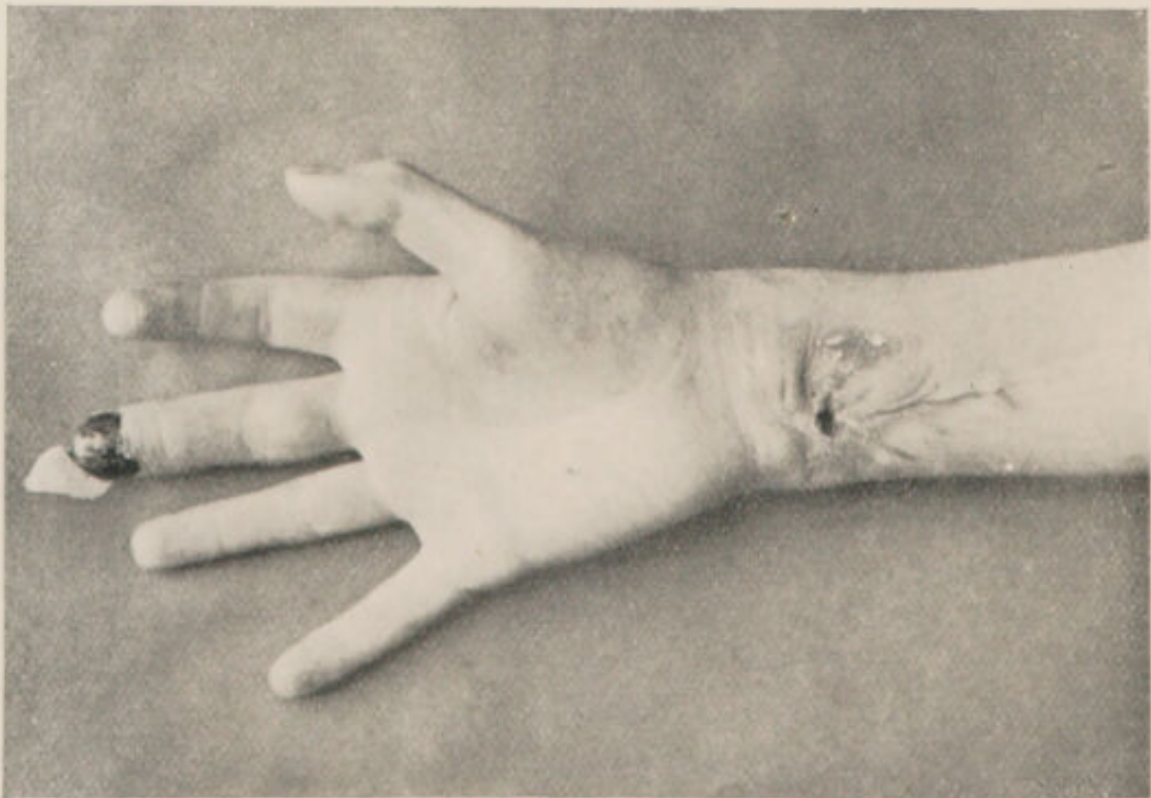

FIG. 2.—The blister is shown separating and leaving a raw, red surface.

the needle used for testing sensibility to prick can often be readily seen the following day.

Changes in the skin of a similar kind, but less marked, occur after division of nerves supplying other parts of the body.

During the time that the skin is insensitive to protopathic stimuli it is peculiarly liable to injury ; a burn or other insult is unperceived, and in this way ulcers may be produced (*vide* Plates II and III), which, from their situation or from the nature of the infection, may lead to the destruction of a considerable portion of the affected member. In many cases the patient continues his work, and one patient who came under my observation, a stonemason, refusing to trouble, ground away the terminal phalanx of his finger against the stone he was sawing.

“Trophic” ulcers usually originate in blisters ; if kept free from infection these dry and form a callosity, which on removal leaves a raw surface. The blisters are produced in many instances by injuries of so slight a nature that no damage results to the neighbouring sound skin from application of the same violence. For example, a patient travelling by train on a winter day felt his hand cold ; when he arrived at his destination he found blisters on the affected fingers. More often water not sufficiently hot to be unpleasant to the sound portion of the hand causes blisters on the affected ; for this reason fomentations must be employed with care in



the treatment of these ulcers. If kept at rest and free from irritation they heal readily and do not spread beyond the analgesic portion of the limb unless complicated by acute sepsis.

Blisters may originate spontaneously; they are often noticed on waking in the morning, and usually occur at a time when sensibility to prick is beginning to return to the affected portion of the limb.

The appearance of the fingers and hand of a patient with an old nerve injury is usually typical. The fingers are thin and tapered towards their points, with wasting of the subcutaneous tissues, particularly at the pulp of the fingers. The skin is of a mottled reddish-blue colour, but in simple non-irritative cases never becomes so red and shiny as to merit the term "glossy skin"; this must be reserved for the condition to which it was originally applied (*vide* p. 42).

**Changes in nails.**—It has been known for many years that changes in the nails follow nerve injuries. The nails become altered in texture, are harder and more brittle and lose their gloss. They also become more highly curved than normal, and ribbed in both the transverse and longitudinal directions. There is often a heaping up of epithelium under the free edge of the nail.

The rate of growth of the nails may be altered. Dr. Head and the author showed as the result of many observations on the nails of the fingers of sound limbs,

### PLATE III.

To illustrate the formation of " trophic ulcers."

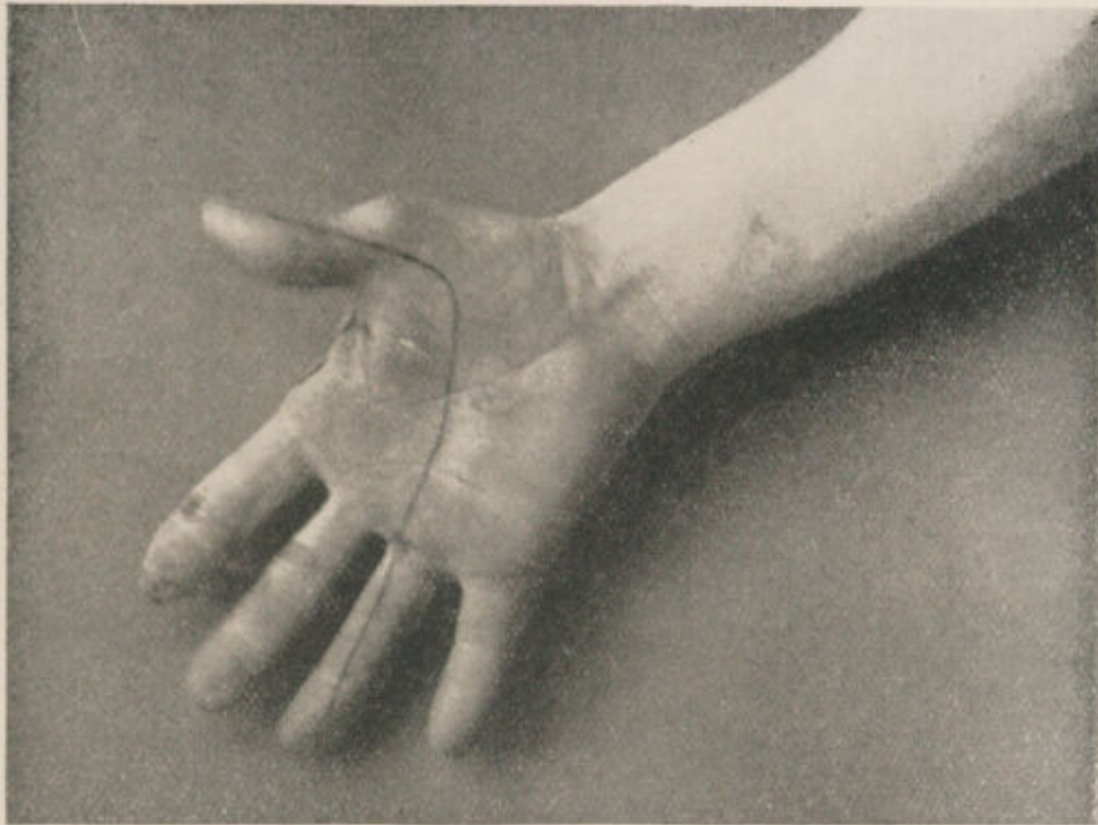

FIG. 1.—Shows destruction of the tip of the index finger by an ulcer. Note the general thickening of this finger and the ulcer on the middle finger.




FIG. 2.—Shows the hand of the same patient two years later, after secondary suture had been performed and protopathic sensibility had been restored. The ulceration spread and necessitated amputation of the terminal phalanx of the middle finger, and destroyed a portion of the tip of the index.





of the fingers of limbs immobilised for the treatment of fractures, and as the result of paralysis due to central causes, as well as in nails of fingers insensitive from the division of nerves but retaining the power of voluntary movement, that want of movement was the cause of the diminished growth of the nails after division of a peripheral nerve.

When the skin becomes insensitive as the result of injury to a nerve, but that injury has not divided tendons or paralysed muscles, the nails do not show any change in growth. The most profound alterations in growth are seen after division of the ulnar nerve; here, owing to the paralysis of the interossei muscles, the middle and index finger-nails are affected as well as the little and ring.

**Changes in hair.**—Changes may occur in the hair as the result of nerve injuries. This is seen most often after an injury dividing the nerves of the dorsum of the hand. The hairs appear irregular, not lying in regular arrangement as seen on the normal hand, but each hair occupying a different position. They may show, in addition, a change in colour and often a change in texture, becoming brittle.

**Changes in bones and joints.**—Acute arthritis following a nerve injury must be a condition of rarity. I have not yet observed it in any of the cases which have come under my notice.

Changes take place in the ligaments and joints

retained in an abnormal position. This is most often seen after division of the ulnar nerve; the thick anterior ligament of the interphalangeal joints becomes contracted and resists full extension. At the same time changes may occur in the joint itself; occasionally fibrous ankylosis takes place, but such intra-articular change is unusual.

Changes in the bones must also be uncommon. I have been unable to find evidence of textural change in recent cases by palpation, the occurrence of spontaneous fracture or the result of X-ray examination. In the case of nerve division in infancy, for example, widespread birth paralysis, there will be deficient growth of the whole limb with alteration in the shape of the bones, the former due to the want of movement, the latter to the abnormal position of the limb.

## CHAPTER III

Incomplete Division of a Peripheral Nerve—Its definition—  
Resulting Loss of Sensibility; of Motion—Changes in Electrical  
Reactions—Causalgia—Changes in Skin and Nails.

UNDER the term “incomplete division” are grouped those cases of interruption or impairment of conductivity which do not lead to degeneration of the whole peripheral end of the affected nerve.

This incomplete division may be anatomical or physiological, the anatomical, due to a wound or partial rupture, the physiological, the result of compression of the nerve by fibrous tissue, extrinsic or intrinsic, by bone, blood-clot, growth or external violence. Although the treatment and prognosis of the different forms varies somewhat with their causation, the symptoms are identical, and for this reason it is well to discuss them together.

It has been found on examining the condition of the part supplied by a nerve which has been incompletely severed by a sharp cutting instrument, that a considerable portion, certainly a third of the trunk, may be divided without producing motor or sensory change or one of a transient nature only. This is most important in connexion with the operation of



nerve anastomosis (*vide* p. 90). In this operation it is essential to divide nerve-fibres in a sound nerve in order that the axis cylinders in the affected nerve may be brought into end-to-end contact with some of those in the sound. I have on several occasions divided one third of the internal popliteal nerve without producing any paralysis, often no sensory change, occasionally a loss of the power of appreciating light touches which returned in a few days. I have also done the same to the hypoglossal without producing more than a temporary paresis of the muscles supplied by it. This was also the experience of Bruandet and Humbert as the result of their experiments upon animals. They came to the conclusion that the fibres in a peripheral nerve which go to make up any branch do not become grouped together until just before it leaves the parent trunk.

But there are exceptions to this rule; it applies only to the trunk of a nerve well above the point at which branches are given off; if the incision cuts into the nerve just above the point of origin of a branch the signs of complete division of that branch are produced. In certain situations also—for example, in the anterior primary division of the fifth cervical nerve—the nerve-fibres are arranged in a well-defined order, and incomplete division of this nerve may entail complete division of those motor fibres which supply the spinati and the deltoid muscles (*vide* p. 199). Again, in the trunk of the

great sciatic nerve, the external and internal popliteal nerves remain separate from their origin in the pelvis, hence incomplete division of the great sciatic may cause complete division of the external or internal popliteal nerve (*vide* p. 292).

But in the accidental wounds of the trunks of nerves, so uncomplicated a section is rare; in addition to the incomplete anatomical division there is usually physiological division, the result of the transient compression of the intact nerve-fibres by the cutting instrument or the effused blood. It must be remembered in this connexion that those fibres which are separated from their nerve centres must degenerate and regenerate before they can again carry on their functions.

Absence of symptoms in many cases is due to the fact that more nerve-fibres are present in the trunk of a nerve than are absolutely necessary to supply the part. When symptoms are present the recovery of function is due to restoration of conduction in the fibres which have suffered an incomplete physiological division. It must, however, be remembered that the injury to the anatomically intact nerve-fibres may be so great that complete physiological division is produced; this may also arise at a later period as the result of compression by fibrous tissue.

It was for long the recognised teaching that incomplete injuries of nerves affected the motor more than the sensory fibres. I showed, in my Erasmus



Wilson Lectures, that this was not the case. Out of nineteen instances of incomplete division of mixed nerves, from various causes (excluding the musculo-spiral), seen at that date, sensibility was affected in all; in six there was no paralysis, and in one it did not affect all the muscles supplied by the injured nerve below the lesion. Since that date I have been able to confirm this by many more observations. Motion is affected alone or to a greater extent than sensation only when the injury affects nerves such as the musculo-spiral or the fifth cervical anterior primary division, which have no exclusive sensory supply, and whose complete division has no demonstrable effect upon sensation.

**Sensory symptoms.**—The first effect of incomplete division of a mixed nerve is upon epicritic sensibility. In many slight cases there is no area of loss of sensibility that can be marked out by stimulation with cotton-wool; this can be appreciated everywhere and minor degrees of temperature discriminated. But the patient is conscious of an area of skin altered in sensibility, and it is usually possible to demonstrate this by the changed sensibility produced at its borders when a piece of cotton-wool or a sharp point is dragged lightly across the skin from sound to affected portions (line of change). If the area of changed sensibility is well marked response to the compass test will be defective.



But in those cases which come under the care of the surgeon, loss of sensibility to cotton-wool is usually absolute, with borders as well-defined as after complete division. Complete loss of epicritic sensibility may be the only sign of the injury, motion may be entirely unaffected. The following is a good example of this type of injury :

“A boy, aged thirteen, was strapped by Sayre’s method for a fractured clavicle. When the limb was taken down he complained of numbness. On examination I found loss of sensibility to light touch over the ulnar area, with no affection of the muscles. Yet it was five months before complete recovery ensued with perfect discrimination of two points.”

When the injury is more severe, impairment or loss of protopathic sensibility results and the sensory loss may resemble exactly that seen after complete division. The following is illustrative of this.

“C. B—, aged twenty-seven years, slipped and cut his wrist with a broken bottle. He came to the London Hospital at once and was seen by me an hour and a half after the accident. An oblique wound was present on the anterior surface of the wrist, running from the tendon of the flexor carpi radialis upwards and outwards for an inch and a half.

“The opponens and abductor pollicis muscles acted well. He was unable to appreciate light touch over the full median area; sensibility to prick was abolished over the terminal two phalanges of index

and middle fingers and an area on the palm at their base.

“I explored the wound at once and found the median nerve swollen with a small incised wound on its ulnar side.”

In this patient the loss of epicritic and protopathic sensibility was as widespread and of as profound a degree as after complete division of the nerve, yet there was no motor affection. As a rule, however, when sensibility is impaired to this degree voluntary power is also affected.

**Motor symptoms.**—Paralysis of some or all of the muscles supplied by the injured nerve may result from incomplete division. It is only after sufficient time (eight to fourteen days) has elapsed, to allow of the development of electrical changes, that the diagnosis of incomplete division can be made in many instances.

In the least severe cases the muscles, though paralysed, retain their irritability to the interrupted current; this is seen most often in crutch and sleep paralyses; rarely—though two such cases have come under my care—the muscles retain the power of voluntary movement, but do not respond to stimulation with the interrupted current. Usually the reactions that I consider typical of incomplete division are present. On about the tenth day after the injury the muscles do not respond to the interrupted current, but react in a characteristic manner



when stimulated with the constant. The strength of current necessary to call forth the contraction is less than on the sound side; the contraction so produced is brisk as compared with that seen when the reaction of degeneration is present, and polar reversal is, as a rule, absent.

When I delivered the Erasmus Wilson Lectures in 1906, I had been able to investigate nineteen cases of incomplete division of nerves associated with paralysis, and in eighteen of these this reaction was present; in the other patient the muscles reacted to the interrupted current. Since that date I have had the opportunity of investigating further cases of this description; in all—some of them patients sent for operation—the diagnosis made by electrical examination was confirmed by the after-history of the case.

**After-results of incomplete division.**—Pain is a more frequent symptom after both anatomical and physiological incomplete division than after complete division, and is often accompanied by tenderness of the skin (hyperalgesia), sometimes by glossy skin and changes in the growth of the nails.

These symptoms only occur as the result of irritation; they rarely arise immediately, a latent period of a few days to three weeks usually being present. The pain is most severe when there has been an incomplete anatomical division, and is most often seen after gunshot wounds. The first case of this nature was reported by Denmark in 1813; the patient was a



soldier wounded at the storming of Badajoz. Later, Paget drew attention to this symptom in injuries in civil life, and his words well describe the condition and the knowledge that was then possessed with regard to it. "Glossy fingers appear to be a sign of peculiarly impaired nutrition and circulation due to the injury of nerves. They are not observed in all cases of injured nerves, and I cannot tell what are the peculiar conditions of the cases in which they are found, but they are a very notable sign and are always associated, I think, with distressing pain and disability. In well-marked cases the fingers which are affected are usually tapering, smooth, hairless, almost devoid of wrinkles, glossy, pink, or ruddy, or blotched as if with permanent chilblains. They are commonly also painful, especially on motion, and the pain often extends from them up the arm." The cases upon which this description was based were instances of incomplete physiological division.

But it is to Weir Mitchell, Morehouse and Keen that we owe the first complete description of this condition named by them "causalgia," based upon their observations of the results of gunshot wounds of nerves during the American Civil War. The following description from Weir Mitchell's book describes the condition with accuracy: "The skin affected in these cases was deep red or mottled, or red and pale in patches. The subcuticular tissues were nearly all shrunken, and where the palm alone

was attacked the part so diseased seemed to be a little depressed and firmer and less elastic than common. In the fingers there were often cracks in the altered skin, and the integuments presented the appearance of being tightly drawn over the subjacent tissues. The surface of all the affected parts was glossy and shining, as though it had been skilfully varnished. Nothing more curious than these red and shining tissues can be conceived of. In most of them the part was devoid of wrinkles and perfectly free from hair. Mr. Paget's comparison of chilblains is one we often used to describe these appearances, but in some instances we have been more strikingly reminded of the characters of certain large, thin, and polished scars."

But, as seen in civil life, the condition is rarely so severe; it may result from penetrating wounds, primary injury in association with fractures, or a direct blow. After a latent period of a few days intense burning pain makes its appearance. The painful area is usually extremely tender and maps out the full distribution of the injured nerve, and may present the skin changes described above, but these are by no means constant and only present in the most severe cases.

Loss of sensibility may be present, varying according to the nerve injured and the degree of that injury; usually the loss is of epicritic sensibility only. The pain soon affects the patient's general condition,



he rapidly loses self-control and becomes "hysterical," often bursting into tears on the suggestion of a local examination.

On exploration the nerve is found locally enlarged and often embedded in fibrous tissue. The condition may perhaps be considered as a neuritis; it occurs most often in gunshot wounds with delayed union, but in several cases which have come under my care the wounds healed by first intention, and it may occur as the complication of a subcutaneous injury (*vide* also p. 134).

The skin changes are different to those seen after complete division. The skin sweats profusely and the affected area may often be marked out by beads of moisture. In some cases the subcutaneous tissues appear to be increased in size, and the nails may become more curved and grow faster than those of the unaffected hand. Blisters may make their appearance and break down to form ulcers; these may appear not only over the area of sensory loss, but often over the area in which there is hyperalgesia but no loss of sensibility.

In cases of incomplete division without irritation the changes in the skin are little marked unless the injury has resulted in protopathic loss, when they may resemble those seen after complete division. As, after complete division, the changes in the nails will depend upon the extent of the loss of movement resulting from the injury.



## CHAPTER IV

Method of Examination and Diagnosis—History—Examination of the Patient—Method of Testing Sensation—Electrical Examination—Diagnosis : in recent cases ; in old cases.

It is necessary to follow some definite plan in the examination of a case of nerve injury or points are omitted which are essential to full diagnosis. The full diagnosis consists in the discovery of the nerve or nerves injured, the anatomical position of the injury and its nature, whether complete or incomplete.

Before commencing the local examination the history should be taken ; much light is often thrown on obscure cases by listening carefully to the patient's account of the accident and his subsequent experiences. The important points to be elicited are, the date of the accident, and, as far as possible, its exact nature ; then, what symptoms pointing to a nerve injury first attracted the attention of the patient, and the time after the accident at which such sensory change, paresis or paralysis, was noticed.

In old cases inquiry should be made for increase

or diminution in the extent or degree of the sensory or motor symptoms. If pain has been present at any time, questions must be put to ascertain the date of its onset, its exact distribution and character, whether neuralgic, burning, etc., if it varies in severity from time to time, if it has spread to areas other than that first affected, or the patient is aware of anything that increases it or can obtain relief from it in any way. Some idea must be formed of its severity, whether keeping the patient awake at night, or affecting his mental condition or general health. If the nerve was injured in a wound, how long the wound took to heal, and the nature of its treatment.

It is useful to conduct the routine examination under the following three headings: (1) General inspection of the part injured; (2) examination of sensation; (3) examination of muscles.

**1. General inspection of the part injured:**

- (a) Position of injured part or limb.
- (b) Wounds, scars, etc.
- (c) Condition of skin—changes in colour, desquamation, blisters, ulcers, alterations in temperature.
- (d) Condition of nails and hair.

**2. Examination of sensation:**

- (a) For tenderness.
- (b) For loss of epicritic, protopathic, and deep sensibility.



### 3. Muscular examination :

- (a) Wasting, general and localised, contractures.
- (b) Paralysis.
- (c) Electrical changes.

1. (a) The position taken up by the injured limb or part may at once reveal the nerve involved ; the drop wrist of musculo-spiral injury, the drop foot of injury to the external popliteal, the ulnar hand and the true claw hand of injury to the median and ulnar are examples.

(b) The presence of wounds and of scars must be noted, their nature and anatomical position. If a scar, whether showing signs of primary union or of healing by granulations, whether free of the deep tissues, or, if adherent, to what structures ? Palpation in the neighbourhood may reveal the presence of bulbous enlargements, or of tenderness accompanied by pain referred to the affected limb.

(c) The condition of the skin should always be investigated ; the desquamating skin seen a few days after the injury, the dry, bluish pink, atrophic skin of a later period or the red glossy skin, often covered with beads of perspiration will all aid in diagnosis. When blisters are present, their exact situation and relation to the area of analgesia, or of epicritic loss. A note should be made as to the mode of onset of the blisters or ulcers, if they originated in response to injury or appeared spontaneously. If the latter, this may point to commencing recovery.



(*d*) The nails should be examined for changes in colour or gloss, for brittleness, growth of epithelium under the free edge, curvatures, ridging, etc.

2. In testing sensation, quiet surroundings are essential. The patient should be comfortably seated with the affected part resting easily, so that no restraint is imposed or muscular effort necessary to maintain the position of the limb. The eyes of the patient should be closed, if necessary, bandaged. He should be told to speak whenever he feels anything, whether a prick, a touch, or any other sensation or change in sensation. No further questions should be asked. The usual method of testing, touching or pricking the patient and saying, "do you feel this, etc.," is more time-consuming and quite untrustworthy.

(*a*) If pain is complained of or the condition of the part is suggestive, the examination should be first conducted to find out if tenderness of the skin is present and its exact extent marked out. This can be done by dragging the point of a pin lightly across the limb from the sound to the affected side, the patient being told to speak as soon as the stimulus becomes painful. Immediately the tender area is reached, the patient withdraws the hand and shows obvious signs of discomfort.

(*b*) Epicritic sensibility should be tested first; it is the system first affected in any injury of peripheral nerves, and the extent of its loss is greater than

that of prick or deep touch. By this form of sensibility light touches are appreciated, temperatures between about  $22^{\circ}\text{C}$ . and  $38^{\circ}\text{C}$ . discriminated, and localisation as tested by the compasses, rendered possible.

For routine clinical work the testing of light touch is usually sufficient, but temperature tests and the compass test are valuable in cases of difficulty or doubt. Light touch is tested by means of cotton-wool rolled up to form a pledget, or a soft camel's hair brush stroked gently over the affected part. This test must be applied with circumspection. Certain parts—for example; the outer part of the thenar eminence—even of a well-kept hand, are relatively insensitive to cotton-wool and over the greater part of the palm of a working man no response may be obtained. Again, if used roughly, or dabbed on at right-angles to the surface, deep touch may be evoked; even when lightly employed over desquamating areas this stimulus may be appreciated by means of deep sensibility. Errors may also arise with this form of stimulation over hair-clad parts in which there is retention or return of sensibility to prick. This is particularly liable to happen over the dorsum of the hand or external popliteal area of the leg, and may lead to errors in diagnosis or to over-estimation of the stage of recovery. But the sensation produced by the cotton-wool in these cases is entirely different from that



given by stimulation of the hairs on a normal part of the limb with cotton-wool ; it possesses the radiating, tingling character associated with protopathic sensibility. On shaving a part in this condition it becomes entirely insensitive to cotton-wool. In all cases of doubt this should be done and the temperature and compass tests applied.

It sometimes happens that epicritic sensibility is altered but not abolished. In these instances the patient is often able to define an area of skin within which sensation is altered ; dragging a piece of cotton-wool across the part from sound to affected portions will also mark it out, and the compass test is in most cases defective.

Within the area of epicritic loss, but retained protopathic sensibility (intermediate zone), a prick and the more extreme degrees of temperature are appreciated, but the patient entirely fails to discriminate water at about  $22^{\circ}$  C. from water at about  $38^{\circ}$  C., and sensibility to the compass test is defective.

Glass test-tubes containing ice and water at  $50^{\circ}$  C. are used for investigating the extreme degrees of temperature ; for the minor degrees similar tubes containing water at about  $24^{\circ}$  C. and  $38^{\circ}$  C. These temperatures should be readily discriminated by the patient as cool and warm over the corresponding sound part, and should be first employed there and not used as tests for epicritic sensibility unless the patient is able readily to distinguish them over



normal parts. So many difficulties surround the testing of the minor degrees of temperature that too much reliance should not be placed on failure to discriminate, and the test should only be used in cases of difficulty.

In applying the compass test the blunt points of a pair of compasses are separated from one another for a measured distance. The skin of the affected portion of the limb is touched, and the patient is asked to say after each stimulation whether he has been touched by one or two points. When they are separated for less than a certain distance, varying with the part of the body under examination, the points no longer appear as two on the normal skin. Dr. Head and the author found that two points could be accurately recognised over any part of the normal palm when separated for 1 cm. and applied transversely. This is more convenient than longitudinal application, for the area available for testing is limited and the points are appreciated at a smaller distance apart when applied in this manner. In carrying out the test the method introduced by us is useful. The patient is touched ten times with one point, ten times with two, each being applied at random. The results are recorded graphically in the following manner. Every time the patient's answer is correct a stroke is made, above a horizontal line if he was touched with one point, below if he was touched with two. An incorrect answer

is recorded by a cross. Thus, if he answers one when touched with two points a cross is placed below the line. A preceding stimulus frequently has an effect upon those which follow it, and to register the order in which the stimuli have been applied is therefore an additional aid to the interpretation of the records. Thus, if the testing began with four double touches correctly answered four strokes would be made below the line. At the point above the line directly over the last of these would begin the record of the subsequent single stimuli; in this way the results of all further stimuli are recorded until the number is complete.

Perfect appreciation of the compass points at a distance of 2 cm. would be represented thus :

$$\begin{array}{r} 2 \text{ cm. } \begin{array}{ccccccc} 1 & \text{III} & & \text{II} & & \text{IIIII} & \\ 2 & \text{IIIII} & \text{III} & & \text{III} & & \end{array} \end{array}$$

If, however, the patient is unable to differentiate the two points at this distance, answering one to every stimulation, the record would stand :

$$\begin{array}{r} 2 \text{ cm. } \begin{array}{ccccccc} 1 & & \text{IIIII} & & \text{II} & \text{IIIII} & \\ 2 & \text{XXX} & & \text{XXX} & \text{X} & & \text{XXXXX} \end{array} \end{array}$$

Such a formula would show that when 2 cm. apart the sensation produced by two points is well below the threshold at which discrimination becomes possible. Less complete failure would be represented by some such formula as—

$$\begin{array}{r} 2 \text{ cm. } \begin{array}{ccccccc} 1 & \text{IIXX} & \text{IX} & & \text{IXXI} & & \\ 2 & & \text{XI} & \text{IX} & & \text{IIXXX} & \end{array} \end{array}$$



where 50 per cent. of the answers are wrong with one point, 60 per cent. with two points. A curious phenomenon is the tendency to appreciate one point as two as soon as the limits of accurate discrimination are passed.

Used in this manner the test becomes a valuable one.

A sharp needle or pin should be used as the test for pain, and care must be taken that the patient understands he is only to speak when he feels the *pain* of the prick, not when he feels pressure or a touch. Unless this precaution is taken mistakes easily occur, particularly after division of the median or external popliteal nerves, when large areas are often present sensitive to pressure but insensitive to prick. If any doubt exists it is easy to discover if sensibility to pain is present by using a painful interrupted current. When the iron core is inserted into the primary circuit of an induction coil, the current possesses a painful character due, as suggested by Dr. Lewis Jones and confirmed by Dr. Head, to the greater duration of the current waves. This painful stimulation is not appreciated over the area where deep sensibility is present but protopathic sensibility is lost.

No temperature sensations can be evoked from an area within which cutaneous sensibility is absent. For testing, tubes containing ice and water at 50° C. should be used, and the patient asked to state the



nature of the stimulation, whether a touch, warm or cold.

Deep sensibility may be tested by means of the pressure of a pencil or other blunt object; no difference in size can be perceived between the point of a pin and the blunt end of a pencil. One patient was unable to recognise the difference between the point of a pin and the end of a cylindrical rod 2 cm. in diameter; both appeared to be pressure. The appreciation of size (*acuæsthesia*) is a property of epicritic sensibility.

It must be remembered that when deep sensibility is present, pain may be produced if the pressure is excessive and corresponds to the amount necessary on the sound side to produce pain. This can be measured by Rivers' modification of Cattell's algometer. To call forth the pain of deep pressure a blunt object must be employed; it is impossible to call it forth by means of the pin or needle used in testing, a pressure of from 2 to 4 kgms. being necessary.

In testing the sense of passive position and movement, the patient, whose eyes are closed, is asked to imitate with the corresponding sound part the movement of the part under examination. For instance, in testing the sense of passive movement and position in the first interphalangeal joint of a finger, the second phalanx is held between the observer's finger and thumb and moved in various directions, the

patient imitating this with the corresponding finger of the sound hand.

3. The method of examination of the affected muscles is important, and mistakes often occur from incompleteness of examination.

(a) The distribution and amount of wasting and the presence and degree of contracture of the opposing muscles should be noted.

(b) I have already pointed out the care which is necessary in this examination to avoid overlooking the paralysis of individual muscles.

(c) It is most important that this should be thoroughly understood, and it should be carried out, if possible, by the surgeon who will be responsible for the treatment of the case. The reactions of the muscles to both constant and interrupted currents must be investigated in most cases. A battery in which both currents are combined, the constant with a galvanometer in the circuit is most serviceable. It is so constructed that with the electrodes attached to one pair of terminals, either the interrupted or the constant current may be used, and the latter reversed. Where electric light is installed the current may be taken from the main and its voltage reduced.\*

The testing electrode should be of the closing type, that is, the current should not pass through it

\* For information on this and on the theoretical side of muscles testing the reader is referred to Dr. Lewis Jones' book on *Medical Electricity*.



until the key is depressed ; it should have a small bulbous end covered with wash-leather. The best form of indifferent electrode is the padded metal plate. The indifferent electrode is attached to the terminal marked +, the testing one to that marked -.

The testing electrode is to be applied to the muscles at or near their motor points. These are situated at or near the point of entry of the motor nerves ; they vary slightly in different individuals, but their general situation is the same and should be learnt by practical muscle testing. The indifferent electrode should be firmly placed against some remote part of the body, where the muscular contractions which may be produced will not interfere with the examination of the affected part. When the legs are being tested, it may be placed in a basin of normal saline which immerses the patient's opposite hand, but this position interferes with the testing of the upper limb. In testing the intrinsic muscles of the hand the best results are obtained when the indifferent electrode is placed on the opposite side of the hand to that under investigation.

Both the electrodes and the parts to be examined, not omitting the corresponding sound limb, must be well soaked in warm normal saline solution before commencing to test.

Begin testing with the interrupted current, using a strength of current just sufficient to contract the muscles of the observer's thenar eminence. Always



use the current from the secondary coil (see that the switch is on S)—that from the primary is more painful.

A good light is essential in order to see that the muscle under observation contracts; in some cases palpation over its tendon of insertion is necessary. If the muscles under examination react to the interrupted current no further investigation is necessary.

If they do not react to this form of stimulation they must be tested with the constant current. Their reactions to this form of excitation are most important, for in many cases we have to rely upon the nature of their response for the diagnosis between complete and incomplete division.

A normal muscle responds to stimulation with the constant current with a brisk twitch when the testing electrode is negative and the current is closed (K.C.C.). In examining, apply the testing electrode to the muscle and close the current by depressing the key in the handle of the electrode, and observe on the galvanometer the current necessary to produce a response, then reverse the current, causing the testing electrode to become positive (A.C.C.), and again note the strength of current necessary under these conditions. In all cases compare the response given by the affected muscles and the current necessary to produce it with that given by the corresponding muscles of the sound side; this must never be omitted.

In children a general anæsthetic is often necessary.

**Examination in cases of recent injury.**—In recent cases the scheme of examination must be somewhat modified. The complete diagnosis cannot be made, apart from exploration, until such time has elapsed as will suffice for the development of electrical changes in the affected muscles. But in a large number of the cases that are seen soon after the accident, the nerve is injured as the result of an incised wound in the region of the wrist, and it cannot be too strongly insisted upon that a thorough examination of the parts below the wound should be carried out on the lines laid down, before any attempt is made to deal with the wound or divided structures under an anæsthetic. Numerous instances have come under the writer's notice in which nerve injuries have been overlooked for want of obeying this simple rule. Before starting a lengthy operation upon recently divided nerves and tendons it is well to know what structures are divided, and not to trust to a chance discovery to enable the correct structures to be found and sutured.

Similarly all cases of fractures and dislocations or falls on the shoulder should be examined for signs of nerve injury before being treated. An instructive case of this nature recently came under my notice. A patient sustained a dislocation of the shoulder, which was treated at a hospital and the dislocation reduced; he obtained compensation for this injury. Some time later he was dissatisfied

Unable to display this page



Unable to display this page

## CHAPTER V

Differential Diagnosis—From Lesions of Spinal Cord and Roots;  
Motor, Sensory—From Hysterical Manifestations; Sensory,  
Motor—From Ischæmic Contracture.

DIFFICULTIES may arise in the diagnosis of lesions of the peripheral nerves from those of nerve roots, of the spinal cord, from hysterical conditions and from Volkmann's ischæmic contracture.

**Spinal cord.**—Difficulties in diagnosis arise in most cases only in injuries of the cervical and sacral regions of the cord due to fracture dislocations of the spine.

When the spinal cord is affected we have to deal not only with the effect of destruction, or interference with, the function of the segment of the spinal cord in which the lesion is situated and of the fibres entering into it at this level, but also with interference with the conduction of impulses passing up and down the cord. The resulting disturbance of motion and sensibility differs very considerably from that seen after a peripheral nerve injury.

*Motion.*—A lower segment lesion, that is, a lesion of the lower motor "neurone," anywhere from its

origin in an anterior horn cell to its distribution in the muscle it supplies, produces a flaccid paralysis accompanied by changes in the electrical excitability of the affected muscle, and if complete, the reaction of degeneration. It should be remembered that the motor fibre may be affected at the anterior horn cells as the result of an injury or anterior poliomyelitis or in the anterior root or peripheral nerve. In all these situations motion may be affected without sensibility; in lesions of anterior horn cells or anterior roots motion is affected alone; in the peripheral nerves sensibility is usually affected at the same time.

The grouping of the affected muscles may at once denote the peripheral or central position of the lesion. For example, the deformity produced by an injury of the ulnar nerve is different from the true claw-hand produced by a lesion of the first dorsal root or segment, and in the same way paralysis of the extensors of the fingers and thumb and the ulnar extensor of the wrist, while the supinator longus and radial extensors of the wrist remain unaffected, at once denotes the root or central position of the lesion.

But the Erb-Duchenne or peroneal group of muscles may suffer as the result of interference with their supply in the anterior horn, root or peripheral nerve. In the former case (Erb-Duchenne) the diagnosis may rest entirely upon the



Unable to display this page

Unable to display this page

temperature is lost, the appreciation of heat or of cold is lost as a whole. The patient may be insensitive to all degrees of temperature and yet be able to appreciate the lightest touch and discriminate the points of a pair of compasses—conditions which can never occur from a lesion of a peripheral nerve only.

*Touch, superficial and deep.*—After division of a nerve or posterior root, light touches with cotton-wool are usually not appreciated, though deep touch (pressure) evokes a response. But when the lesion lies within the spinal cord both forms of touch are affected together.

*Passive movement and position.*—After division of peripheral nerves the recognition of passive movement and of the position into which any part of the limb has been placed (passive position) is associated with the integrity of deep sensibility. But with an intra-medullary lesion it is entirely dissociated. The patient may be able to appreciate passive position and movement although totally insensitive to every other sensory stimulus, or *vice-versa*. In a similar way, a patient may be able to appreciate all varieties of touch perfectly, and yet be unable to discriminate two points (compass test). In lesions of peripheral nerves the compass test is always affected with light touch.

We thus see that a rearrangement of impulses takes place within the spinal cord and that their interruption causes loss of sensibility to pain, heat, cold,



or tactile sensibility as a whole instead of to epicritic, protopathic, and, in some cases, deep sensibility as occurs when the continuity of a peripheral nerve is interrupted.

Put briefly the important points are as follows :

After division of a peripheral nerve or of posterior roots there may be loss of epicritic, protopathic and deep sensibility. After division of a peripheral nerve the loss of epicritic sensibility is greater than the loss of protopathic; after division of posterior roots, the loss of protopathic sensibility exceeds in extent the loss of epicritic. But when the injury affects the spinal cord, pain, temperature appreciation, touch, may be affected separately. Usually light and deep touch are well recognised although sensibility to pain and to temperature is absent.

In unilateral lesions of the spinal cord the appreciation of pain, heat and cold is affected on the side opposed to the lesion, passive movement and position on the side of the lesion and the motor affection.

**Hysterical affections.**—The hysterical limbs of women are well recognised; but occurring in healthy men, complicating, as they may, fractures, dislocations, or even a nerve injury, they are not so often diagnosed. This type of functional nervous disorder may follow any form of injury; thus, I have seen anæsthesia and paralysis of the whole hand follow a burn of the thenar eminence in a woman, and a fracture of the radius in a boy of twelve. It may complicate

recovery from operations; in one case that came under my care paralysis of the upper limb was noticed after the evacuation of a large abscess in the supra-clavicular region, and gave rise to the opinion that the brachial plexus had been injured.

The following is a typical case, in this instance, complicating a fracture of the humerus.

“A seaman, aged forty-four years, fractured his humerus while at sea. It was treated by the master of the ship and kept in splints for six weeks; union was perfect and the position good. When the splints were removed it was found that the limb was ‘completely paralysed.’ He was sent to me as a case of injury to the brachial plexus.

“The patient was a robust man who had followed the sea for thirty years, and had never had any serious illnesses.

“All the muscles of the right upper limb were wasted, the arm, forearm and hand were paralysed and the muscles flaccid. The skin was bluish in colour, and cold.

“Over the whole of the upper limb he was insensitive to all forms of stimulation, including deep touch, and the upper limit of the sensory loss surrounded the limb as a ring (stocking anæsthesia). The distribution and nature of the loss of sensibility at once demonstrated that it could not have resulted from injury to peripheral nerves or spinal cord. On testing the muscles electrically they responded



readily to stimulation with the interrupted current, as is always the case in this affection."

The condition may follow an injury in either sex, but is more often seen in the male. So far as I have been able to ascertain they are usually healthy individuals and may show no other hysterical manifestation. Careful examination will sometimes reveal the typical hysterical change in the field of vision, a contraction of the whole field of vision, more marked on the affected side with contraction of the colour field, appreciation of blue being diminished first in contra-distinction to the diminution of the field of vision for red, seen in patients with organic disease.

As a rule loss of sensibility and paralysis are both present, but either may be found alone, the former more often than the latter. The loss of sensibility is to all forms equally (including deep touch), a variety of loss that does not occur after any peripheral nerve, posterior root, or spinal cord injury; its upper limit usually surrounds the limb, often at the level of a joint, and all forms of sensibility are lost up to the same level. In the upper limb the loss of sensibility may cover the pectoralis major muscle in front and the scapula behind (fore-quarter type).

The paralysis may persist unchanged for years and marked muscular wasting will then occur. It is, as a rule, flaccid, and no attempts are made to throw the affected muscles into action, but occasion-



ally a patient is met with in whom attempts to perform a movement—for example, flexion of the elbow—causes an equal and simultaneous contraction of both flexors and extensors, rendering the diagnosis easy. Contractures may be present, differing from those seen as the result of injuries to nerves, in that all the muscles are affected, not only those on the same side of the limb as the contracture. For example, in a contracture at the elbow of a hysterical limb, not only are the flexor muscles rigid, but any attempt to further flex the forearm is met by contraction of the triceps.

No difficulty should arise in the recognition of most examples of this condition: the loss of sensibility is diagnostic and the flaccid paralysis with retention of electrical reactions typical. But when complicating a nerve injury it gives rise to difficulty. It explains many of the recorded cases of nerve “concussion” in which paralysis of the whole of a limb results from a gunshot injury which may or may not have injured one nerve. In the latter case the widespread symptoms rapidly clear, leaving signs of involvement of one definite nerve.

In Civil practice I have seen several examples of this condition some time after the original accident, but have not yet observed it at the time of infliction of the nerve injury.

Careful attention to symptoms will enable the diagnosis to be made. The paralysis may be wide-

spread and affect muscles central to the site of the nerve injury, but occasionally—for example, after division of the median or ulnar nerves at the wrist—all the intrinsic muscles of the hand are found to be paralysed, and only the electrical examination reveals the functional nature of the paralysis of one group of these. In testing sensibility the remarkable correspondence of the upper limit to all forms of sensibility and the affection of deep sensibility should make the diagnosis, even in these cases, easy.

**Volkmann's ischæmic contracture.**—It sometimes happens that difficulty occurs in connexion with the diagnosis of this condition. Several cases of this nature have been recorded as unusual examples of nerve injury.

The contracture most often results from the injurious pressure of tightly-applied splints, and nerves may suffer as well as muscles. In a typical example, arising after splint-pressure in the forearm, it will be found that the forearm is held pronated, with the wrist and fingers flexed; supination of the forearm and active or passive extension of the wrist or fingers is impossible. The contracted muscles are not paralysed and react normally to both interrupted and constant currents, hence the name "ischæmic paralysis" sometimes given to this condition is a misnomer.

On flexing the wrist, so relaxing the contracted muscles, the fingers can be extended, and on ex-

tension of the wrist they again become flexed, showing that the condition is due to diminution in length of the affected muscles.

The injury to the median and ulnar nerves which so often complicates the condition will affect the intrinsic muscles of the hand; these may be wasted and paralysed and give the reaction of degeneration, and there may be the usual loss of sensibility seen after complete division of these nerves, but as a rule the nerve injury is incomplete.



Unable to display this page

Unable to display this page

Unable to display this page



surgery does slight suppuration interfere so greatly with the success of the operation.

If the nerve is found to be incompletely divided, the gap should be closed by a catgut stitch to bring the cut axis cylinders again into apposition and to prevent the ingrowth of fibrous tissue.

If the nerve is completely divided primary suture must be performed.

*Primary suture.*—The modern operation of primary suture is of comparatively recent date. It is said to have been performed first by Baudens in 1836, who sutured all the nerves of the brachial plexus with the exception of the musculo-spiral, which were divided in a sword cut of axilla. But it is only since 1864 that it has been a recognised method of treatment, Nélaton's being the first of the more recent cases.

In the operation of primary suture it is necessary to bring the divided ends of the nerve into apposition, and to prevent, if possible, the ingrowth of fibrous tissue and adhesion of the junction to surrounding structures.

If the ends of the nerve are lacerated they should be trimmed transversely with a sharp scalpel. Scissors should never be used for the purpose; their crushing action may prevent recovery. It sometimes happens that a nerve is divided at two or more levels, a portion being loose; this should be sutured in. It is unusual to find so great a portion of the nerve

destroyed that it is impossible to bring the ends into apposition; for the treatment of this complication the reader is referred to Chapter VII.

Sterile catgut is the best suture material for nerves. It is not necessary to use hardened gut unless there is tension on the stitch, but if considerable portions of the ends of the nerve have had to be removed on account of laceration, catgut, hardened to resist absorption for at least fourteen days, should be employed. The suture should be passed with a round needle, both needle and suture being as small as possible. The suture should be passed through the whole thickness of the nerve at right angles to its axis and tied with just sufficient force to bring the ends into apposition. It is sometimes said that the catgut should not be passed through the whole substance of the nerve on account of the bad results which would arise if infection were to occur. But paraneurotic suture is an operation involving much more handling of the nerve, if the sheath of a nerve the size of the median or ulnar is to be sutured; in my opinion the method which I have recommended, passing the suture through the whole thickness of the nerve, is the one least open to objection. In most cases it is only necessary to use one stitch. The nerve should be handled with extreme gentleness and the whole end of the nerve never grasped in the forceps; the sheath of the nerve only should be picked up with fine toothed



forceps and the nerve steadied in this way while the suture is being passed.

Silk should never be used as a suture material. It remains as a foreign body in the nerve and may give rise to trouble months after primary suture. In one case that came under my notice, following primary suture of the median nerve, restoration of sensibility was almost complete and motor power had returned to the affected muscles, when the occurrence of inflammation around the silk suture used to unite the ends of the nerve put back the condition of the part to that which was present immediately after the accident; the symptoms again became those of complete division of the nerve. After evacuation of the abscess and removal of the stitch, recovery was exceedingly slow and was not complete many months after the time usually taken in primary suture of the median nerve.

Not only must the ends of the nerve be brought together by suture, but means should be taken to prevent the ingrowth of fibrous tissue between the nerve ends, and the junction from becoming adherent to surrounding parts. For this purpose I use chromicised Cargile membrane. This resists absorption in the tissues certainly for five weeks, and does not cause irritation. I have used it now in many cases of nerve and tendon injury and also in cerebral surgery and have never found it give rise to trouble. Many other substances have been



recommended from time to time—decalcified bone tubes (Vanlair), gelatine tubes (Lotheisen), animal's artery (Foramitti), paraffin wax (Murphy).

After primary suture of a nerve in an accidentally inflicted wound it is always wise to put in a drain for a short time; it can usually be removed in four and twenty hours. After suture of the skin wound the limb must be put up on a splint so arranged that no tension is thrown upon the junction and the paralysed muscles are relaxed. The further treatment is on the lines I have already laid down.

**Treatment of subcutaneous injuries.**—All the signs of complete division may be present as the result of an injury of this nature; there is no sign by which we can tell if the nerve has been ruptured or injured as the result of compression, in other words, if the injury is anatomical or physiological, and in many cases, at first, if it is complete or incomplete.

If seen immediately after the accident, the limb should be put at rest on a splint with the paralysed muscles relaxed. Daily massage should be employed until such time has elapsed as will enable the diagnosis of the degree of the injury to be made. If at the end of a fortnight the reaction of degeneration has developed in the paralysed muscles, the nerve should be exposed. It may be found completely ruptured; more often it is swollen and firm at the seat of the injury. This damaged portion should be

removed and the ends brought into contact. If no change can be discovered in the condition of the nerve, the wound should be closed.

When the division is obviously incomplete, relaxation of the muscles is to be kept up with daily massage until voluntary power returns, when the splint may be discarded and active movements encouraged. The massage should be continued until recovery is complete.

Sometimes a nerve becomes secondarily involved in fibrous tissue, or pressed upon by bone, or in a case of incomplete division, in spite of appropriate treatment the condition does not improve. Exploration should be undertaken in these cases, the nerve freed, the cause of the pressure removed and means taken to prevent the nerve from becoming adherent by surrounding it by one of the substances already mentioned; for this purpose I prefer Cargile membrane.

*Secondary suture.*—This operation is of more recent date than primary suture. Said to have been first performed by Nélaton in 1864, it was first carried out in this country by Jessop in 1871.

Various meanings have been attached to the term "secondary suture"; it has been described as suture after the first twenty-four hours. The author uses the term to mean suture after degeneration has taken place in the peripheral end of the nerve.

Secondary suture should be unknown after injury



to nerves in wounds ; but in the case of subcutaneous injuries it may be unavoidable.

Before proceeding to operation a careful examination is necessary in order to discover how much improvement is likely to ensue as the result of the operation. The time after the injury at which operation is undertaken, certainly up to three years, seems to have little influence on the time of recovery, and there is no reason why success should not be obtained at much longer periods, although no entirely satisfactory case has been recorded. Of more importance than the time after the accident is the nature of the original injury, if an incised wound, its manner of healing ; suppuration in the original wound seriously diminishes the chance of complete recovery.

The condition of the muscles and joints should be investigated. Muscles which have been overstretched for months are unlikely to have their function completely restored, although they may regain voluntary power and electrical excitability as the result of the operation. For example, the ulnar position of the fingers met with after division of the ulnar nerve rarely or never disappears after secondary suture. The interossei muscles have been lengthened, the extensors of the fingers, the ligaments around the metacarpo-phalangeal and inter-phalangeal joints contracted.

The electrical reactions must be tested. If there is no reaction to stimulation with the constant current



it is probable that muscular recovery is impossible, but this opinion must not be given on one examination only, however carefully carried out.

From the point of view of sensation it is always worth while attempting secondary suture, especially if "trophic ulcers" are present, for Dr. Head and the author showed that the fibres upon which the integrity of the trophic condition of the skin depend, regenerate under conditions which render recovery of epicritic sensibility and motor power unlikely.

The operation of secondary suture may be divided into three stages.

- (1) Identification of the ends of the nerve.
- (2) Freeing and freshening the ends of the nerve.
- (3) Re-establishment of anatomical continuity.

(1) The incision should be made over the line of the nerve and be of sufficient length to expose the trunk well above and below the seat of the injury. The nerve should be traced from above and below; any attempt to find it directly at the seat of the injury will only lead, in most cases, to unnecessary damage being inflicted on the nerve.

(2) The bulb with the fibrous tissue, which is usually found surrounding and uniting the two ends, is then well freed and the nerve stretched. After this has been done the bulb on the central end is removed with a sharp scalpel. From the lower end only the fibrous upper extremity need be removed; the whole of the lower end of the nerve is in the

same condition, so that it is useless cutting section after section in the hope of finding something which looks less like fibrous tissue and more like nerve.

(3) Catgut should be used for suture material, and it is best to use catgut hardened to resist absorption for about fourteen days. The junction and the freed portion of the nerve are then surrounded with Cargile membrane.

It often happens that the ends do not come readily into apposition after the necessary amount of nerve ends have been removed; it was for this reason that the preliminary stretching was recommended. This will give fully an inch in the upper limb, and combined with relaxation of all the joints over which the nerve passes, will rarely fail to enable the ends to be brought into contact. If a gap is still left one of the methods described in the following chapter should be adopted.

After closure of the wound the limb should be put up so that there is no tension on the nerve and the paralysed muscles are relaxed. The position necessary to prevent tension on the junction must be maintained until the wound is soundly healed and then very gradually corrected.

**Nerve injuries complicating fractures.**—The nerve may be injured at the time of the accident, ruptured, lacerated, pressed upon by the fractured end of the bone or nipped between the fragments. In primary injury to the musculo-spiral nerve complicating a



fracture of the humerus, operation should be carried out, the condition of the nerve investigated and the appropriate treatment adopted. Means should also be taken to mechanically fix the fracture. The same rule should be followed in primary involvement of the external popliteal in a fracture of the fibula.

In most cases, however, the nerve injury is not discovered until the splints are removed; in many of these the nerve involvement is undoubtedly secondary. The rules for treatment in these cases are simple. If the signs of complete division are present, operation must be performed; the nerve should be exposed above and below the seat of the fracture and traced towards it. The nerve may be found ruptured, but more often involved in callus or fibrous tissue and altered in shape and consistency, usually being thin and fibrous; when found completely divided anatomically, secondary suture should be carried out. In the complete physiological division the damaged portion should be excised and the continuity of the nerve restored, unless the nerve be found little altered, when freeing and wrapping with Cargile membrane may first be tried. If no improvement occurs in a few weeks then the damaged portion must be resected.

When the signs are those of incomplete division, the limb should be kept at rest and the usual treatment carried out. If improvement does not occur the nerve must be cut down upon and the cause of the



pressure removed. It sometimes happens that the involvement comes on some weeks or months after the injury ; in these cases operation should be performed without delay.

**Treatment of gunshot wounds.**—These should be treated upon the lines already laid down, remembering that primary suture is inadvisable in most cases under the conditions obtaining in war time. In other respects the general rules apply. The limb should be kept at rest and the injury treated as if subcutaneous.

Unable to display this page

Unable to display this page



We have therefore the following nomenclature: nerve transplantation, nerve anastomosis, nerve crossing.

**Group 1. *Nerve transplantation.***—It was demonstrated by Phillipeaux and Vulpian in 1870 that a portion of the lingual nerve of a dog could be transplanted into a gap in the hypoglossal, restoration of function occurring in due time. It was at first considered that the transplanted portion of nerve played an active part, and Gluck even spoke of its healing by “primary union,” meaning thereby restoration of function without degeneration in the transplanted portion and peripheral end of the nerve. Tillmans was the first to suggest that a transplanted portion of nerve acted only as a scaffolding for the support of the newly-formed nerve-fibres. Recently Ballance and Purves Stewart came to the same conclusion as the result of their experiments. But it has been pointed out by Merzbacher and confirmed by Marinesco that the changes which take place in an isolated portion of nerve inserted between the cut ends of another nerve differ when the transplant is taken from the same animal (auto-transplantation) or from one of the same species (homo-transplantation) from those which occur when it is taken from an animal of another species (hetero-transplantation). In the last instance death and necrosis occur, in the first two, degeneration, which is a vital process. Forssman found in his experi-

mental work on rabbits, that when the transplant was obtained from another rabbit regeneration took place as rapidly as after primary suture ; but when taken from an animal of another species, regeneration occurred much more slowly, and in some cases no regeneration at all took place.

It appears therefore as the result of experiment that the transplanted portion of nerve plays an active part when it is taken from the same animal or one of the same species, and does not act only as a scaffolding for the new nerve-fibres, but has a definite influence on regeneration through the cells of the nucleated sheath. This is borne out by the clinical evidence.

Nerve transplantation was first employed in treatment by Albert in 1876, who inserted a portion of the posterior tibial nerve of an amputated limb into a gap in the median nerve. Mayo Robson, in 1888, was the first to perform the operation in this country, and his was the first successful case recorded. Into a gap in the median nerve, due to the resection of a portion of the nerve with a neuroma, he transplanted two and a half inches of the posterior tibial nerve from an amputated limb. The affected muscles reacted to stimulation with the interrupted current nine months later and restoration of function was complete three years after operation.

After examining the records of all the published cases of nerve transplantation I came to the conclusion that the clinical results bore out the experimental in-



vestigations of Forsmann, Merzbacher and Marinesco; they were incomparably better when auto- or homo-transplantation had been performed than after hetero-transplantation. Thus although only three out of eight cases of auto- and homo-transplantation are reported at a sufficient interval after operation to admit of recovery, two of these recovered completely; one showed no sign of motor recovery seventeen months after operation. On the other hand, out of twenty-two cases of hetero-transplantation, sixteen are recorded at an interval after operation which would have permitted of recovery. Of these only one can be definitely said to have recovered, that is it is the only case in which a complete report is given, including the electrical reactions of the affected muscles, but perhaps recovery ensued in two of the remainder.

**Group 2.**—There is one operation in this group that must be shortly mentioned to be condemned—that is, the operation of turning flaps of nerve from both ends to bridge over the gap. This method, recommended and employed by Létiévant under the name “*autoplastie nerveuse à lambeaux*,” leaves a complicated wound on both ends of the nerve and on the flaps used as bridging material, which must certainly become adherent to the surrounding structures and favour the ingrowth of fibrous tissue. The results are as unfavourable as the method would lead us to expect.



The other operations in this group aim at the provision of a path, free from fibrous tissue, along which the new axis cylinders may develop. This was first attempted by Assaky in his "union at a distance" with catgut threads, in which the ends of the nerve were brought as near as possible by catgut sutures, which bridged over the gap. It has been improved by the introduction of tubular suture (Vanlair), in which, in addition, the ends of the nerve are surrounded by a tube. Various materials have been used—decalcified bone, aluminium, collodion, and recently, preserved and hardened animals' arteries, and a resected portion of one of the patient's superficial veins. This last seems the best form of tube to employ.

Tubular suture has given results which are a little better than those given by hetero-transplantation.

**Group 3.**—The possibility of the union of motor nerves supplying different groups of muscles attracted the attention of investigators at an early date. Flourens, in 1828, was successful in his attempt to cross the nerves of the brachial plexus of a fowl. But it is from investigations of a more recent date that our knowledge of the subject is obtained. Manasse, in 1898, was the first to experimentally investigate what we now understand as nerve anastomosis; but it is to the work of Kennedy, Kilvington, and Langley and Anderson, that our exact knowledge is due.

It is essential to separate nerve anastomosis from nerve crossing, for in the former an attempt is made to bring the axis cylinders of the affected nerve into end-to-end contact with some of those in the sound; in nerve crossing the peripheral end of the affected nerve is united end-to-end with the central portion of a divided sound nerve. Nerve crossing was first worked out experimentally, but surgery led the way

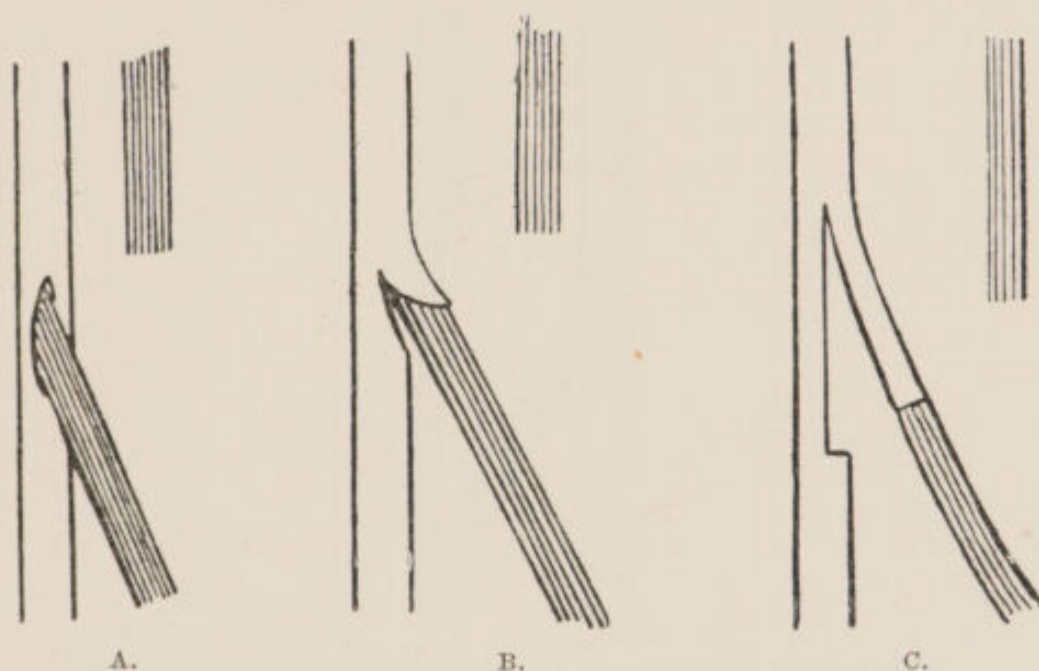


FIG. 3.—Complete peripheral anastomosis, showing the three methods of union. The affected nerve is shaded in all the figures relating to nerve anastomosis. A. Insertion of peripheral end of affected into vertical slit in sound nerve. B. Insertion of peripheral end of affected nerve into a gap in the sound nerve, produced by an oblique incision; C. End-to-end union, with flap raised from sound nerve.

for experimental investigation into the question of nerve anastomosis.

*Nerve anastomosis.*—Létiévant first recommended this operation in 1873 under the name of “greffe nerveuse.” He had, however, no opportunity for

carrying it out. Després (1876) appears to have been the first to perform it, but the case was reported two months after the operation—too early a date to admit of recovery. It was not until 1897 that Sick and Sanger reported the first successful case. Two months after rupture of the musculo-spiral nerve in a compound fracture of the humerus,



FIG. 4.—Partial peripheral anastomosis. Can also be carried out by methods B and C, Fig. 5.

a flap of the median nerve was raised and the peripheral end of the musculo-spiral united end-to-end with it. Twenty-seven months later all the muscles of the forearm except the extensor longus pollicis acted normally, and reacted to stimulation with the interrupted current.

Recently much attention has been directed to operations of this nature by the work of the Ballances



and Purves Stewart on nerve anastomosis in facial paralysis.

The results of the operation of nerve anastomosis have been most encouraging. Out of twelve cases (excluding those in which the operation was carried out for facial paralysis or infantile paralysis) reported



FIG. 5.—Complete central anastomosis. Can also be carried out by methods B and C, Fig. 5.

sufficiently long after the operation, only two were failures, some recovery taking place in all the others, although it is impossible to say from the published reports that recovery was complete in any case.

Several methods of nerve anastomosis are possible. They may be divided into the peripheral and central, the partial and the complete. In peripheral anastomosis (Figs. 3, 4) the whole or part of the peripheral

end of the affected nerve is brought to the sound nerve. In central anastomosis (Figs. 5, 6), the unaffected nerve is divided completely or partially and its central united to the affected nerve.

In some of the recorded cases of nerve anastomosis the peripheral end of the affected nerve was sutured to the sheath of the sound; the failure which

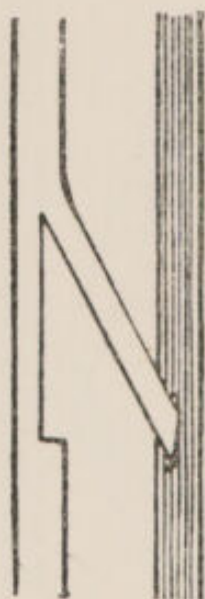


FIG. 6.—Partial central anastomosis. Can also be carried out by methods B and C, Fig. 3.

resulted was to be expected. It should be the aim of the surgeon to bring the cut ends of axis cylinders into contact, for without this, union with the central nervous system is impossible. This end-to-end contact may be brought about in three ways (*vide* Fig. 3); in the case of small nerves, by making a vertical slit in the sound nerve sufficient axis cylinders are divided to ensure a good result; but in larger nerves, a flap should be raised and the

affected nerve sutured in or united end-to-end with it. Raising a flap and uniting it end-to-end with the peripheral end of the affected nerve is the best method to adopt, as it avoids the possibility of the union of one axis cylinder in the central end of the sound nerve with an axis cylinder in each peripheral end.

In cases of nerve injury complete peripheral anastomosis is the variety that must be employed; it is not justifiable to completely divide a sound nerve.

It has been recommended to implant the central end of the divided nerve also into the sound and so use the sound nerve as a path along which new nerve-fibres may make connexion between the two ends. But it has been shown that the axis cylinders in the central end of a divided nerve have no preference for those of its own central end, but will just as readily make connexion with those in the peripheral end of a nerve united to it. The results are therefore likely to be better if the central end is not used, for the cross union of axis cylinders which must result makes the restoration of perfect co-ordination unlikely.

*Nerve crossing.*—This operation was first carried out in the human subject by Drobnik, in 1879, in a case of facial paralysis, the peripheral end of the facial being united end-to-end with the divided external branch of the spinal accessory nerve. It has been employed chiefly in operations upon the



facial nerve, and will be discussed fully in dealing with that condition.

**Method 3.**—This, originally recommended by Löbker, has been carried out successfully by Keen and others in cases of division of the musculo-spiral nerve complicating fractures of the humerus. It is only justifiable in dealing with injuries of this nerve, when, as in one of Keen's cases, non-union of the bone is present in addition to the nerve injury.

The method to be employed to restore continuity will depend upon the nerve injured and the size of the gap. The method of election is undoubtedly auto- or homo-transplantation. This operation is most often necessary in cases of injury to the musculo-spiral nerve. Here the treatment is simple. The incision is prolonged downwards, the radial nerve exposed, and an adequate portion resected and sutured without tension into the gap between the two ends of the musculo-spiral nerve, the whole being surrounded by Cargile membrane or an absorbable tube. The upper two thirds of the radial nerve may be removed without causing any demonstrable effect upon sensation. This operation was, I believe, first suggested and carried out by Mr. Dean at the London Hospital in 1896, but the method was never published. A portion of the patient's own radial nerve, three inches in length, was inserted into a gap in the musculo-spiral. Voluntary

Unable to display this page

Unable to display this page



## CHAPTER VIII

Recovery after Complete Division of a Nerve—"Primary Union"

—Sensory Recovery after complete Division; three stages—

Motor Recovery—Recovery after Primary Suture; Prognosis

—Recovery after Secondary Suture; "Rapid Return of Sensi-

bility"; Prognosis—Complications arising during the Pro-

gress of Recovery—"Trophic" Ulcers—Theories with regard

to Regeneration.

WHEN a nerve is completely divided degeneration follows in the whole peripheral end; before conduction can be re-established regeneration must take place.

"**Primary union.**"—By this term was understood union of the divided ends of a nerve with re-establishment of conduction without the occurrence of degeneration in the peripheral end.

Until 1839 it was considered that function was restored by union of the divided ends of the nerve just in the same way as another tissue. Swan, in 1834, wrote: "There appears to be two modes which Nature employs for effecting the union of divided nerves, one by the effusion of coagulable lymph, the other by granulation." Nasse, in 1839, pointed out that degeneration occurred in the peripheral end of a divided nerve; but it was Waller's classical re-

searches, published in 1852, that gained general acceptance for this view.

In June, 1864, two examples of "primary union" of the median nerve were reported at medical societies in Paris. The first was a patient operated upon by Nélaton, who resected a portion of the nerve with a neuroma: the second, a case of accidental division at the wrist, in which Laugier had performed primary suture. Both were reported, and have since been quoted, as examples of primary union. But of Nélaton's case, it is recorded that he observed retention of sensibility before the operation, but "in spite of his astonishment said nothing": and of the second case, that tests applied fifteen days later revealed the usual loss of sensibility, and that even seventeen months after the operation sensibility was still defective. With foundations as slender as these, other cases have been reported.

All recent experiments have failed to demonstrate the existence of primary union, and the clinical evidence is equally negative. Weir Mitchell, writing on the subject, summed up well when he wrote: "The evidence offered by surgeons is too open to criticism to allow of our admitting that severed nerves may unite by immediate union."

No case has been recorded of immediate return of function in paralysed muscles, with absence of the development of the usual electrical changes; the early "return" of sensibility means retention of sensibility.

Difficulties surround the testing of sensation in cases of accidental nerve section; this, together with a want of appreciation of the distribution of sensibility to deep touch and to prick, gave rise to the error. When every case of nerve division is tested carefully before as well as after suture no more will be heard of primary union.

**Recovery after complete division of a nerve.**—After division of a nerve followed by suture, an interval elapses before restoration of function commences. This interval varies somewhat with the age of the patient, the nerve injured, the method of healing of the wound and the variety of suture, being as a rule more rapid in the young and in cases of primary suture and markedly retarded by inflammation.

*Sensory recovery.*—This may be divided into three stages :

- (1) Restoration of protopathic sensibility.
- (2) Restoration of sensibility to light touch and minor degrees of temperature.
- (3) Restoration of the power of localisation.

In none of the cases of recovery which I have watched did any change in sensibility take place other than that due to regeneration. It is perhaps possible that improvement in the power of appreciation of a prick might take place during the first few days after suture, owing to the "education" of the overlapping fibres from other nerves subserving protopathic sensibility. This was recorded by Létievant,



and was considered by him to be due to the recovery of the "supplementary sensibility" from shock—"local torpor," as he called it. Although I have several times been able to examine the condition of sensibility within four hours of the receipt of the injury, I have not observed it; any loss of sensibility that then existed remained until regeneration commenced. In secondary suture performed several weeks after the injury, if any improvement in sensibility has taken place, freeing and freshening the ends of the nerve always results in the loss of sensibility becoming identical to that which was present immediately after the accident. All the restoration is due to reunion with the central nervous system by means of its own central end or those of divided nerves in the surrounding tissues. I am therefore opposed to the statements made by several writers that "the return of sensibility in a mixed or sensory nerve does not prove that the nerve is regenerating." In cases in which observations are taken immediately after the injury, all sensory recovery will be found to be due to regeneration and union with the central nervous system.

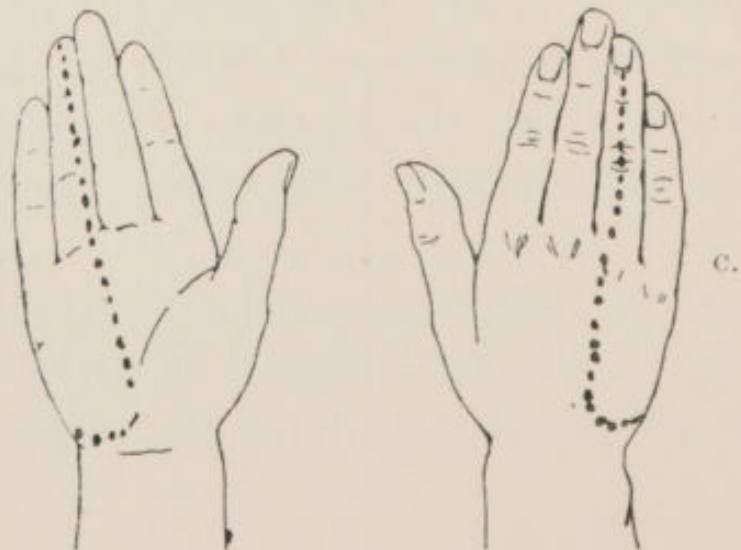
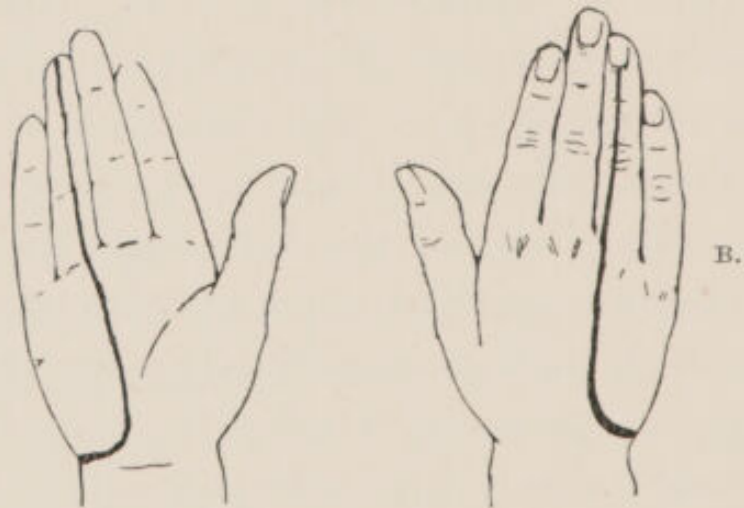
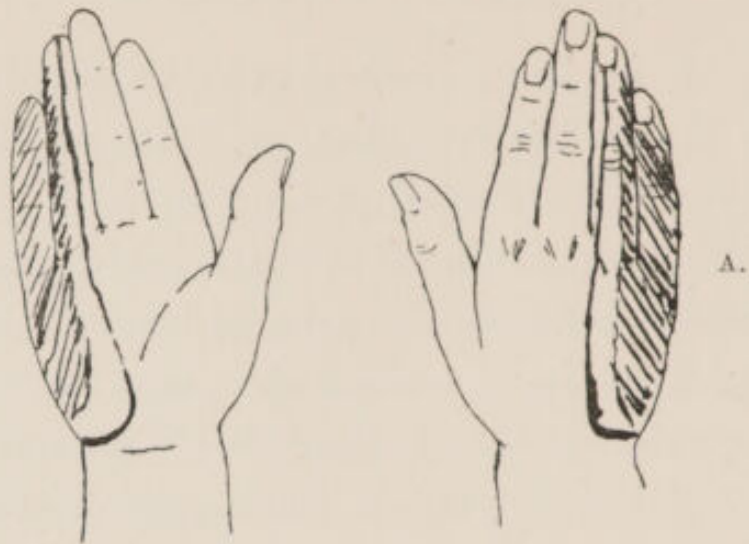
At a period which varies somewhat with the age of the patient and the nerve injured, in uncomplicated cases being from about six to sixteen weeks after suture, the first stage of sensory recovery commences. The area insensitive to prick begins to diminish in extent, and protopathic stimuli are usually everywhere

appreciated in from four to twelve months after suture. This is the first stage of recovery (Fig. 7 B). The whole of the affected portion of the limb is now in a condition resembling that of the intermediate zone which existed between the area of loss of sensibility to prick and the line bounding the area of insensibility to light touch, but the response to all stimuli is more intense. All the stimuli here appreciated have an unpleasant tingling character, and the patient often complains bitterly of discomfort, and massage may have to be omitted for a time. During this stage blisters may appear spontaneously over the analgesic area, but on its completion all ulcers heal and no further blisters make their appearance.

During the whole of the first stage the area of loss of sensibility to light touch remains as extensive and as well defined as immediately after the injury. Gradually its proximal border becomes indefinite and the area slowly diminishes in extent until, at a time varying from about twelve months in the case of primary suture of a nerve at the wrist, to about eighteen months after secondary suture of a similar nerve, the whole of the affected portion is sensitive to light touch and the intermediate degrees of temperature. This concludes the second stage.

The interval between the end of the first and the beginning of the second stage varies with the variety of suture and the distance from the periphery of the

FIG. 7.





Unable to display this page

Unable to display this page

Unable to display this page



The time necessary for perfect recovery varies, and will be discussed more fully under primary and secondary suture.

The observations which it has been possible to make upon the recovery of deep sensibility have been too few to enable rules to be laid down. The extent of the loss and the rapidity of recovery depend in many instances upon the division of structures other than nerves; but in those cases in which deep touch was lost as the result of the division of nerves alone it was restored before the restoration of sensibility to prick.

*Motor recovery.*—At a time varying with the distance of the point of suture from the periphery and the age of the patient, the muscles regain their voluntary power. This return is usually preceded by a change in the electrical reactions of the affected muscles: the contraction given to stimulation with the constant current loses its sluggish character, and is obtained with a current smaller than is necessary to produce a contraction in the corresponding muscles of the sound side, and polar reversal disappears; the reactions become identical with those I have described as typical of incomplete division. Dr. Head and the author found that irritability to the interrupted current is usually present on the same date as the first return of voluntary power is noticed.

**Recovery after primary suture.**—The following conclusions are based upon the personal observation of

over fifty cases of primary suture. In none of these did any early return of sensibility take place. The earliest date at which the first return of sensibility to prick was noticed was 5 weeks, the latest 25 weeks, and the first stage was complete in from 23 to 46 weeks. The second stage commenced in from 19 to 46 weeks. The great prolongation observed in some cases was due to suppuration—difficult to avoid in many cases of accidental wounds.

Restoration of localisation was not, as a rule, complete until more than two years after suture, and often yet longer time was necessary.

After primary suture of one of the nerves of the hand, no matter at what level, restoration of sensibility to prick will commence in from six weeks to four months, and will be appreciated over the whole of the affected area in from four to six months; the end of the second stage of recovery will be reached in about a year.

It has long been the usual teaching that the further the point of section from the periphery, the longer the time necessary for motor return. The unique series of cases of division of the brachial plexus recorded by Etzold proved this: in all, the muscles nearest the seat of the lesion first regained voluntary power. I have been able to confirm these observations after division of nerves in both the upper and lower limbs. It is well illustrated after division of the ulnar nerve. After primary suture of



this nerve at the wrist, motor power returns in about a year; but if divided at the elbow, nearly two years elapse before the intrinsic muscles of the hand are capable of voluntary movement, although the flexor carpi ulnaris recovers at a much earlier date.

The rule can be laid down that after the usual division of nerves at the wrist motor power will be regained in a year; if at the elbow, motor power will not return to the muscles of the hand for two years.

**Prognosis after primary suture.**—By complete recovery is understood the restoration of perfect appreciation of all sensory stimuli and the return not only of voluntary power to the affected muscles, but of perfect function; in other words, the part must regain a condition indistinguishable from the normal.

This may occur after primary suture.

The completeness of the recovery will depend to a large extent, as already pointed out, upon the care taken in the after-treatment: but some recovery is to be expected in all cases, no matter how neglectful the patient may be. In every case of primary suture which I have watched, motor power was regained and the second stage of recovery of sensibility completed. All cases uncomplicated by suppuration which I was able to keep under observation for a sufficiently long period, regained perfect sensation.

I also investigated the condition of as many as possible of the older cases of primary suture per-



formed at the London Hospital, and found that there was only one in which no improvement took place—a patient in whom the wound was infected, leading to a cellulitis which necessitated many incisions.

The prognosis will depend to a certain extent upon the nerve injured, the distance of this injury from the periphery, and the condition of the wound. For example, the musculo-spiral nerve in the lower third of the arm carries no exclusive sensory supply to any part of the forearm or hand, and the muscles it supplies are not so intimately connected with delicate movements of the fingers as, for instance, those supplied by the ulnar; complete recovery will therefore be reached more quickly and in a greater proportion of cases. The further the seat of section from the periphery, the longer the period of necessary after-treatment and the greater the chance of the accidents which hinder complete recovery.

After primary suture of one of the nerves of the forearm uncomplicated by suppuration, recovery will ensue and become perfect if appropriate after-treatment is carried out. Muscular power and irritability to the interrupted current will be restored in from nine months according to the level of the lesion, but three years will probably be necessary to complete sensory recovery.

**Recovery after secondary suture.**—From time to time instances of rapid restoration of sensibility after this variety of suture have been recorded. Of recent

observers Kennedy is the strongest supporter of this possibility. In some of the cases the sensation restored at an early date again became lost.

Experimental work does not throw any light upon these records. Head and Ham have shown in their experimental work on cats, that after secondary suture of a nerve which had been divided for at least two months and consisted of elongated cells, twenty-eight days elapsed before it would conduct impulses. This agrees with the earliest time of return that I have noted in clinical work. In none of my twenty-one cases, in which the suture was performed in patients of various ages, and from four weeks to five years after division, was any restoration of sensibility noticed before the thirtieth day, although carefully looked for. Professor Halliburton, speaking on the subject, suggested that what I have already mentioned as one of the causes of the so-called "primary union," the presence of deep sensibility, has led to similar error here. This is undoubtedly the explanation of most of these cases. My attention has more than once been drawn by Hospital Residents to the "rapid return" of "sensibility to prick," after secondary suture, which, on careful testing in the usual manner, proved to be deep sensibility. In one patient upon whom I had performed secondary suture of the median nerve it was said that sensibility to prick had returned on the day following operation. On testing, I found that he complained of pain on



pressure, but could not distinguish the sharpness of the point of a pin ; it was equally painful and produced the same sensation as pressure with the blunt end of a pencil ; moreover, he was entirely insensitive to the painful interrupted current, and all temperature appreciation was absent. There was no doubt that the pain was that caused by deep pressure, which could be readily evoked before operation.

Before concluding that a rapid return of sensibility has taken place in any patient, sensibility must be carefully tested in all forms and mapped out on charts before and after suture, at first day by day, later week by week, up to recovery. It is evident, however, that a rapid return of sensibility is not to be expected after secondary suture, and that its " occurrence " must be regarded as unusual.

Recovery after secondary suture follows the same general lines as after primary. But much greater variability obtains in the time at which the various stages of sensory recovery begin. Motor recovery follows the same march as after primary suture.

But although motor and sensory recovery follow the same stages as after primary suture, their time of commencement differs. The time necessary for the commencement of the first stage of sensory recovery may be shorter than after primary suture, the changes in the peripheral end necessary to regeneration of the nerve being advanced at the time of suture. But usually the time is much longer



and the interval between suture and the commencement of the second stage of recovery almost double as long. So far I have not yet seen complete sensory recovery follow secondary suture, although I have watched patients for more than five years and seen them at intervals up to fifteen years after suture ; in all the patients some difference could be appreciated between the two limbs, an area of changed sensibility remaining with imperfect appreciation of the compass test. This may be of no moment after suture of the musculo-spiral or external popliteal nerves, but it materially affects the result of secondary suture of the median or ulnar.

Much less variation occurs with regard to motor recovery, but the time necessary is almost always longer.

**Prognosis after secondary suture.**—The first question that arises is, how long after the injury is it possible to perform secondary suture with any hope of success ; unfortunately it is one to which no definite answer can at present be given. Although instances of “successful” operations have been recorded at intervals up to fifteen years after division, the reports are so meagre that no conclusions can be drawn from them. But an interesting series of cases has been recorded by Bowlby. In these, suture was performed at times ranging from twelve years after division downwards. He came to the conclusion that muscular recovery was not likely to be

Unable to display this page

Unable to display this page



Before giving an opinion as to the advisability of operation other factors have to be taken into consideration: the condition of the paralysed muscles as regards their reaction to the constant current, the amount of atrophy and overstretching present and the contracture in the opposing muscles. If great atrophy of the part and deformity has resulted from the nerve injury, complete recovery of function is impossible, although the muscles may regain the power of voluntary movement.

In all cases sensory recovery up to the end of the first stage is to be expected; this is important, as recovery up to this stage abolishes the tendency to the formation of ulcers. Recovery of motor power after long periods is unlikely, for not only have changes taken place in the muscles themselves and in their opponents which render recovery unlikely, but also in the central nervous system; it is probable that in patients in whom the nerve has been divided for a long period and the muscles retain their irritability to the constant current, nerve anastomosis is more likely to be successful than secondary suture.

In conclusion, recovery, both sensory and motor, will take longer after secondary than after primary suture. Up to three years from the accident muscular recovery will probably ensue. Whether it will become perfect depends to a great extent upon the amount of deformity that has taken place, but it may be complete; perfect sensory recovery is unlikely.

**Complications arising during recovery.**—Complications may arise during the progress of recovery. Pain is, as a rule, present in the distribution of the affected nerve during the first two or three days after suture; this is due to irritation of the central end and is rarely of sufficient degree to need treatment. If severe it points to an infective neuritis. The wound should be inspected, and, if necessary, opened up and drained. If this has been done, the condition of the nerve should be explored at a later period when the wound has soundly healed. In cases in which supuration has taken place gradual deterioration of function may occur after a period of improvement, due to involvement of the junction in fibrous tissue; this usually arises after silk has been used as a suture.

Blisters may arise at two periods during the stage of recovery after complete division and suture. Slight injuries pass unnoticed during the stage of complete insensibility to cutaneous stimuli; the patient not infrequently burns himself, or, if engaged in manual labour, injures the limb while at work. To this group belong the so-called perforating ulcers seen after division of the great sciatic nerve. The ulcers so arising heal readily with appropriate treatment. With the first sign of returning sensibility to prick the patient often complains of pain shooting into the affected part, and blisters may arise spontaneously. These may burst, leaving a raw surface,



which, if infected, becomes an ulcer. If protected they dry, leaving a scab under which new epithelium forms.

All tendency to the formation of blisters ceases with the restoration of sensibility to prick. The immunity experienced on the restoration of this form of sensibility is often striking; in spite of work continued under unaltered conditions no further trouble arises. Thus, a carpenter whose median and ulnar nerves had been accidentally divided suffered, both before and after secondary suture, from ulcers caused by burns or blisters from the use of his tools. On the complete return of protopathic sensibility, eight months after suture, all the ulcers healed and no more appeared.

The distribution of these ulcers is further proof of the close association which exists between protopathic sensibility and the nutrition of the skin. Under no circumstances, except when complicated by acute sepsis, do they extend beyond the area of insensibility to prick.

**Theoretical consideration with regard to regeneration.**—Much attention has recently been directed to the method of regeneration, and it will be necessary to discuss this briefly, together with the light thrown upon it by the clinical experience of recovery.

Investigators are divided into two schools—the central and the peripheral. The former, following Waller, believe that regeneration consists in the



downgrowth of axis cylinders from the central end of the nerve into the nerve sheaths of the peripheral end destitute of axis cylinders; the latter, who consider that the new axis cylinders are formed in the peripheral end from the cells of the nucleated sheath. Prominent authors are ranged on the two sides: Mott, Halliburton, Langley and Anderson are strong supporters of the central theory, while Ballance, and Purves Stewart, Kennedy and Bethe are prominent upholders of the peripheral doctrine.

All recent writers, however, are agreed up to a certain point; at a time after division of a nerve, varying with the animal used and its age, whether union with the central nervous system has taken place or not, proliferation of the neurilemma cells leads to the formation of a strand of spindle-shaped cells, called by different observers, "embryonic fibres," "band fibres," or "neuroplastic fibres." It is with regard to the further changes which take place in the peripheral end of a nerve separated from its central end that opinion is so greatly divided. Ballance and Purves Stewart, Langley and Anderson, Bethe and others have found axis cylinders clothed with medulla. Some of these observers considered this as evidence of autogenetic regeneration, but Langley and Anderson showed that the formation of medullated axis cylinders in the peripheral end of a nerve separated from its own central end was due to union with the central nervous system by means of

divided nerves in the tissues around. They found that all the medullated fibres in the peripheral end degenerated when the nerves which run to the tissues near the cut end were divided near the spinal cord. These experiments appear to be conclusive, and to account for the varying results obtained.

It appears certain that no new axis cylinders are formed in the peripheral end of a divided nerve until it again comes into connexion with the central nervous system, through its own central end or through the central ends of small divided nerves in the tissues around. But it seems probable that after suture, regeneration of, at least, the fibres subserving protopathic sensibility takes place peripherally. This is in accordance with the results given by the study of sensory recovery after primary and secondary suture. The first stage of recovery commences at about the same time, no matter at what level the nerve is divided. But the clinical evidence is not so clear with regard to the fibres which subserve sensibility to light touch and those which supply the muscles. I have shown that the first signs of recovery of sensibility to light touch and of voluntary power in the affected muscles are noticed at a later date the farther from the periphery the nerve is divided. But as the same occurs during the recovery of a nerve from the effects of pressure when no regeneration is necessary, the explanation given by Henriksen seems to be correct: "The injured



nerve is a bad conductor; the longer the piece of nerve injured the greater the resistance . . . and thus a higher degree of regeneration must be supposed before it can be expected that an impulse will cause movement. . . . It cannot be taken as evidence that the nerve is growing from the centre."

In conclusion, it appears that the clinical evidence, so far as it is positive, is in favour of the formation of new axis cylinders *in situ*, and that even when it is negative it discloses nothing against this theory. But union with the central nervous system is necessary before the development of axis cylinders takes place. Taken with the experimental evidence, it goes to show that regeneration, at any rate of the fibres subserving protopathic sensibility, is peripheral but not autogenetic.



## CHAPTER IX

Recovery after Incomplete Division of a Nerve—Sensory Recovery,  
Illustrative Cases—Motor Recovery—Prognosis.

AFTER incomplete division of a mixed nerve the loss of sensation and motion may at first resemble that which follows complete division, but the method of recovery is entirely different.

After complete division of a nerve and suture, sensibility to prick becomes everywhere restored before the commencement of the recovery of sensibility to light touch. There is thus an interval before the commencement of the second stage of recovery (restoration of sensibility to light touch) in which the whole affected area is sensitive to protopathic but insensitive to epicritic stimuli. Complete sensory recovery, the disappearance of the area of changed sensibility to prick, and the perfect restoration of sensibility to the compass test often occupies several years.

But after incomplete division sensibility to light touch and to prick are restored together (*vide* Figs. 8 A, B, C), and, unless nerve-fibres have been anatomically divided in considerable number the power

of appreciating two points (the compass test) is soon regained.

Knowledge of this method of sensory recovery, first described by Dr. Head and the author, is a valuable addition to our powers of diagnosis. If both forms of sensibility are recovering together, it is certain that the injury has not been severe enough to produce complete interruption of conduction in the injured nerve, with degeneration of the whole peripheral end.

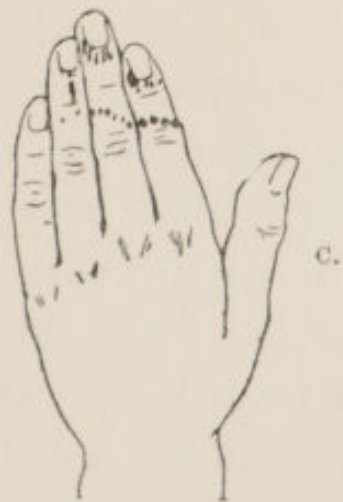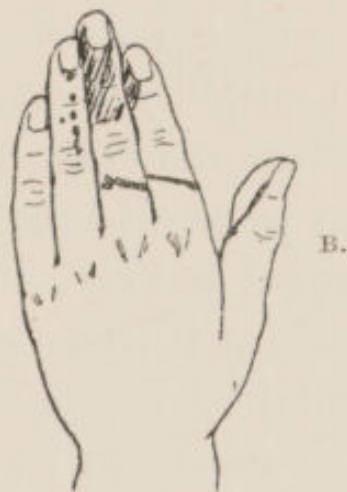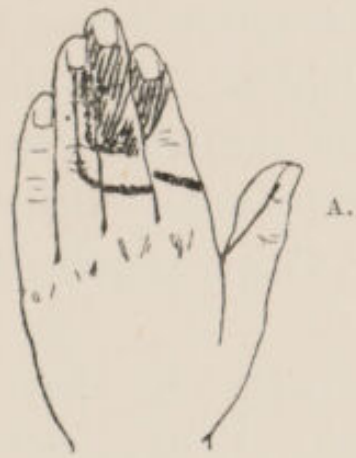
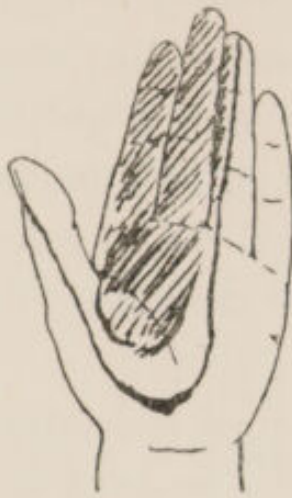The following cases illustrate this method of recovery :

“ A man, aged twenty-seven years, cut his left wrist with a fragment of broken glass, September 20th, 1902. When I saw him two and a half hours later a small incised wound was present over the position of the median nerve at the wrist. The abductor and opponens pollicis muscles acted perfectly, but sensibility was lost over the area shown in Fig. 8 A. Protopathic sensibility was lost over an area somewhat smaller than usual after complete division of a median nerve with such a large exclusive supply—that is, the loss of sensibility to prick did not involve the radial border of the index finger or the palmar surface of the thumb, although an extensive area on the palm

---

FIG. 8.—To show method of recovery after incomplete division of a nerve. A. Loss of sensibility after incomplete division of the median nerve. B and C. Stages in the recovery of both forms of sensibility together. Dotted areas represent ill-defined limits.

FIG. 8.





was affected. The loss of sensibility to light touch was as widespread and as well defined as after complete division. I explored the wound at once, and found the median nerve for half an inch immediately above the annular ligament dark red in colour and swollen, with a superficial incised wound on its ulnar side.

No change in the condition of sensibility took place until six days later, but the muscles lost their irritability to the interrupted current, although they retained the power of voluntary movement. Fourteen days after operation the area of loss of both forms of sensibility began to diminish in extent from above downwards (Fig. 8 B). Over the previously insensitive portion of the palm the compass test was almost perfect at 1 cm., and was completely restored in this position fourteen days later. Three months after the injury the muscles again reacted to the interrupted current. In six months the condition of sensibility was as shown in Fig. 8 C; in nine months it was perfect, except over the terminal phalanges of middle and ring fingers."

A similar method of recovery is shown in Fig. 9 A, B, taken from a patient with an incomplete division of ulnar nerve.

"This patient sustained a fracture of radius and ulna in the lower third of the forearm eight weeks before I saw him. On examination on January 1st, 1906, sensibility was lost over the area in Fig. 9 A.

All the muscles in the hand supplied by the ulnar nerve were paralysed and gave the reactions typical of incomplete division.

"On January 3rd I explored the condition of the

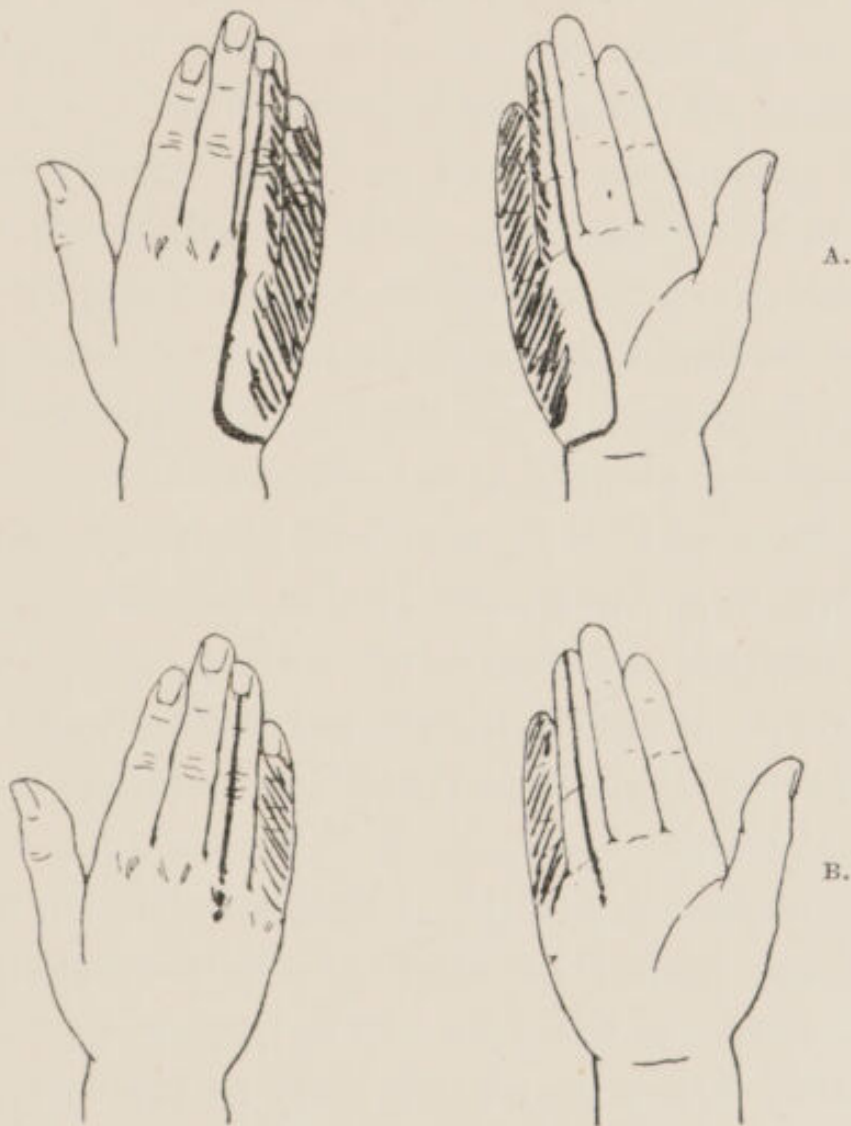


FIG. 9.—A, To illustrate the loss of sensibility following incomplete division of the ulnar nerve. B, Method of recovery, both forms of sensibility together.

nerve. I found it bound down to the ulna through the fibres of the flexor profundus digitorum; on freeing it there were signs on its posterior surface



that it had been wounded by one of the fractured ends of the bone.

"Ten days later both forms of sensibility began to return together, and six weeks after the operation the condition of sensibility was as shown in Fig. 9 B."

Recovery after a less severe form of injury is illustrated by the following case :

"A patient was kicked at football over the inner condyle of the humerus. As a result sensibility to light touch was lost over an area on the palm of the hand corresponding almost to the distribution of the palmar branch of the nerve ; protopathic sensibility was lost over an area almost as extensive. All the movements of the fingers could be performed, but the little finger was weak and tended to assume the ulnar position ; all reacted to the interrupted current. Both forms of sensibility cleared together, and at the end of three weeks sensibility was normal even to the compass test."

Motor recovery after incomplete division follows the same march as after complete—that is, the muscles nearest the seat of the injury first regain voluntary power and excitability to the interrupted current.

In the cases in which the reactions typical of incomplete division are present, voluntary power usually returns before the re-establishment of excitability to the interrupted current.

Occasionally voluntary power is present from



the first, although excitability to the interrupted current is lost. But this is unusual, as pointed out in Chapter III; the least severe form of injury produces paralysis of the muscles supplied by the affected nerve, with retention of irritability to the interrupted current.

In all the cases in which my notes on the subject are complete, voluntary power returned before electrical excitability, often some weeks before. In cases uncomplicated by sepsis or extensive wounds of the surrounding parts, the first return of voluntary power in the upper limb occurred in from about four to ten weeks, and progressed to complete recovery in all the patients. In one instance in which the external popliteal nerve was affected, voluntary power did not return for nine months, and excitability to the interrupted current was not present two months later. In another patient in whom the muscles supplied by the external popliteal nerve, though paralysed, reacted to the interrupted current, voluntary power began to return in three and a half months and was perfect in five. In another patient in whom the reaction of degeneration developed later no recovery took place in two and a half years.

Sensory recovery usually begins in about three weeks and is completely restored in about six months.

But these times of motor and sensory recovery are

Unable to display this page

Unable to display this page



## CHAPTER X

Pain complicating Nerve Injuries—The Involvement of Nerves in Scar Tissue—Symptoms due to Involvement of the Trunk of a Nerve, Paralytic, Irritative—Symptoms due to the Involvement of Terminal Branches—Pain following Nerve Injuries the result of Operations upon the Kidney, upon Herniæ—Amputation Neuromata.

PAIN sometimes arises as the immediate result of nerve injuries, but more often during the after-progress of the case. At the moment of the infliction of the injury pain may be felt in the full distribution of the nerve, but it is never of long duration. When arising within a few days of the injury it is usually the result of infection. Arising later, it is usually due to involvement of the nerve in scar tissue, either in the nerve itself, the so-called interstitial neuritis, or in the tissues around.

The trunk of the nerve or one of its terminal branches may be affected; the symptoms produced in both may bear a superficial resemblance to each other. In both, pain may be present, referred over a large area, accompanied in some instances by hyperalgesia, rarely by glossy skin; muscular wasting and paralysis may also be present. But in the first case

(involvement of the trunk) the pain and tenderness which often accompanies it marks out the full distribution of the affected nerve, and may be accompanied by loss of sensibility and paralysis of muscles, with changes in their electrical excitability; in the latter, the pain and tenderness map out the area of distribution of the root or roots from which the injured twig arises, which, in only a few cases, will at all correspond to the area of distribution of a peripheral nerve; the paralysis is never accompanied by electrical changes in the muscles.

The symptoms vary in severity; in some, slight pain on movement or change in the weather only is complained of, in others, pain of an excruciating nature accompanied by changes in the skin.

**Symptoms due to involvement of the trunk of a nerve.**—The cases in which the trunk of a nerve is involved may be divided clinically into two groups, the non-irritative and the irritative.

*Non-irritative group.*—In this group the functions of the nerve are gradually interfered with by pressure, and the symptoms are due simply to interference with conduction; pain and tenderness are absent, or if pain is present it is slight. The typical example of this form of involvement is seen in the musculospiral nerve, following a fracture of the humerus. The main points are illustrated by the following case:

“A man, aged twenty-eight years, sustained a frac-



ture of the lower third of the humerus. I saw him two weeks after the accident. All the muscles supplied by the musculo-spiral nerve were wasted, paralysed, and gave the reactions typical of incomplete division. At operation, twenty-eight days after the injury, I found the nerve closely bound down by fibrous tissue to the callus. I freed it, and sutured muscle beneath, in order to prevent it from again becoming adherent to bone, and wrapped it to prevent it from forming adhesions to surrounding parts. Recovery began in twelve weeks, and all the muscles supplied by the injured nerve acted voluntarily eight weeks later, and reacted again to the interrupted current six months after the operation."

The treatment of the cases in this group is simple. Neurolysis is followed in a short time by recovery, providing care be taken to avoid the occurrence of compression or reinvolvement in the scar. The nerve must be protected from again becoming adherent; it has often happened that neglect of this precaution has necessitated another operation.

*Irritative group.*—At the end of the first stage of recovery after complete division the part supplied by the affected nerve is sensitive everywhere to prick, but so great is the discomfort produced by this stimulus that it is not infrequently said to be "hyperalgesic." A similar condition is seen in cases of incomplete division with epicritic loss. This tenderness is confined to the area of loss of light touch and



is the expression of protopathic sensibility. But the tenderness associated with irritative involvement occupies the full area of protopathic supply of the nerve and may be accompanied by no loss of sensibility.

The following case illustrates these points :

“L. E—, aged fourteen years, cut his forearm with broken glass. The wound was sutured and healed by first intention. Two weeks later he began to suffer pain, and the wound was reopened without effect ; the pain gradually increased in severity. I saw him fourteen weeks after the accident ; a scar was present on the anterior surface of the forearm, two and three quarter inches above the fold of the wrist. Extending downwards from this the full distribution of the anterior branch of the external cutaneous nerve was mapped out by extreme tenderness. There was no loss of any form of sensibility.

“The nerve branch was exposed at the seat of the injury and found implicated in fibrous tissue and adherent to the scar ; it had evidently suffered incomplete anatomical division. The damaged portion was excised and the ends of the nerve brought together. No loss of sensibility followed the operation, the anterior branch of the external cutaneous nerve of the forearm having no exclusive sensory supply. The patient lost his pain at once and has since remained free.”

Unable to display this page

above the inner condyle of the humerus and came out on the outer side, in front of the elbow-joint. He describes the condition as follows: "I always found him with the forearm bent and in the supine position, and supported by the firm grasp of the other hand." The pain "was of a burning nature and so violent as to cause a continual perspiration from his face. He had an excoriation on the palm from which exuded an ichorous discharge."

This is an excellent description of the pain and of the "trophic" sore, which probably originated as a blister, but no account is given of the other skin changes which may accompany it. These were first described by Hamilton in 1838. He stated that "the pain may be accompanied by redness and swelling resembling the appearance of the skin in inflammation of the fascia or a deep collection of matter."

A fuller description was given by Paget in 1864 (*vide* p. 41), but to Mitchell, Morehouse, and Keen is due the credit of the exact picture of this condition (*vide* Chapter III).

I had the opportunity of examining several such cases, due to bullet-wounds received during the late war in South Africa. The following record illustrates admirably the most important points of these severe cases.

"L. G. H— was wounded at Tweefontein on July 22nd, 1901, by a bullet that entered four and a half



inches below the internal condyle of the humerus and passed across the forearm to the radial side. The arm did not become painful until he had been in hospital three weeks; the pain then gradually increased in severity, and when I saw him with Dr. Head on January 26th, 1902, was constant.

“The skin of the affected hand was smooth, glossy, and of a pinkish blue colour, covered with beads of sweat, the fingers tapered and the nails were thin, long and curved. The hand was intensely tender over a large area occupying the palm, the ulnar half of the thenar eminence, the palmar aspect of the little, ring and middle fingers. Over the dorsal surface this tenderness occupied the ulnar half of the hand and extended to the tendon of the ring finger, and the dorsal surface of the little, ring and middle fingers. The tender skin was intensely sensitive to pinching, to pressure with the head of a pin and to the pin-point. Epicritic sensibility was lost over the usual ulnar area. Sensibility to the extreme degrees of temperature was present everywhere. Operation revealed incomplete anatomical division of the ulnar nerve in the forearm, the ends being intimately bound up in a mass of fibrous tissue. Complete division of the nerve, removal of the damaged portion and re-establishment of continuity completely relieved the pain. Sensibility returned to the hand by the usual stages.”

The latent period which existed in this case

Unable to display this page

symptoms might follow the wounds of small nerves. These cases seem to have been first described by Abernethy. Wardrop, in 1823, recorded a case in which pain in the whole distribution of the radial nerve followed ten days after a wound on the radial border of the thumb. Neurotomy of the affected branch gave immediate relief. Hamilton, in 1838, wrote a paper on the subject, giving instances following injuries to nerve branches from various causes, in some cases due to the operation of phlebotomy. They were accompanied by tenderness of the skin, and in some cases by paralysis or spasm and contracture of the muscles of the limb, and were often accompanied by symptoms now called hysterical. In some of the instances mentioned neuritis may have been the cause, particularly in those that came on in which the symptoms supervened a short interval after the injury, but most were not of this nature, although commonly called neuritis. Very little attention seems to have been paid to these cases of late years. The most modern paper of importance on the subject was written by the late Sir W. Mitchell Banks, in 1869.

Irritation of one of the terminal branches of the fifth nerve may cause pain and tenderness, referred to the whole of the distribution of that branch to which it belongs; this is now a commonplace of medicine. But similar symptoms may follow the involvement of the branch of any nerve in scar tissue,



the result of a wound, or in some cases, a subcutaneous injury.

As occurs when the trunk of a nerve is involved, an interval always elapses between the injury and the first symptom. The pain is usually widespread, extending over the full protopathic distribution of the root or roots involved, and is often accompanied by hyperalgesia. There may be in addition, particularly in the lower limb, paresis or paralysis of the muscles supplied by the corresponding nerve or root.

The following case brings out the important points: "G. L—, aged thirty-six years, crushed his right foot in September, 1902, fracturing the first and second metatarsal bone. At first the pain was entirely local, but in a few weeks it involved the whole of the great sciatic area and increased in severity. All the muscles of the leg supplied by this nerve were weak and wasted. He was admitted to the London Hospital in May, 1903, and treated by rest and massage, various forms of electricity, injections of strychnine, all without success. In September, 1903, one year after the injury, I explored the first metatarsal space and found the branch of the anterior tibial nerve, which runs to the cleft between the great and second toes, involved in fibrous tissue. It was impossible to free it entirely, so I removed the involved portion and performed end-to-end suture. He lost his pain at once, but it was over a year before full power was restored to

the wasted muscles. At the end of this time he was quite well and has remained so since."

These cases are often described as chronic traumatic neuritis. But the symptoms arise in individuals who are otherwise healthy, in injuries that are often subcutaneous, or if open, heal by first intention, and the pain and tenderness disappear immediately after removal of the damaged portion of the nerve. It is obvious, therefore, that the term "chronic neuritis" does not adequately express the condition.

Treatment should be operative; much valuable time is wasted by general treatment. If the condition be recent, and the patient object to operation, absolute rest should be tried; massage and electrical treatment are absolutely useless unless the cause be first removed by operation.

The damaged portion of the nerve must be removed, and communication with the central nervous system restored, if possible, by end-to-end suture or anastomosis. But the size of the nerve involved may render this impracticable—for example, when one of the terminal branches of a digital nerve is involved in scar tissue. The best treatment in these cases consists in excision of the scar, and suture or Wolfe's grafting; in some cases amputation of the affected portion may be necessary.

Although in the recent cases pain and tenderness disappear immediately, cure is not, as a rule, so



rapid in the case of a mixed nerve. The condition of the patient may make him more susceptible to the small area of anæsthesia which may have resulted from the operation, and recovery may be delayed until regeneration has taken place. If the muscles are wasted and paretic, months may elapse before they regain their full power. During the interval the limb should be kept at rest in such a position that the affected muscles are flaccid. The splint should be removed daily for massage, and, if possible, stimulation with the interrupted current, to which the muscles always react. The patient should be encouraged to use the affected muscles, and as soon as voluntary power is re-established, the splint removed.

These cases are not infrequently met with in connexion with claims for compensation; an injury of this nature will certainly, if muscles are affected, incapacitate the patient for a year, even if operated upon early.

The diagnosis of hysteria is often made; undoubtedly in many cases hysterical symptoms supervene, but careful examination will always reveal the nerve affected and lead to the correct treatment.

Occasionally a true chronic neuritis is set up; in these cases removal of the damaged portion of the nerve fails to secure relief, or the relief is transient; nothing remains but excision of the root ganglia corresponding to the roots affected, or intra-dural division of roots.



**Pain following nerve injuries, the result of operations.**—As I have already pointed out in Chapter I, injuries of the smaller nerves during the course of a well-planned operation are soon recovered from. But it occasionally happens that irritative symptoms arise from the involvement of a trunk or terminal branch in fibrous tissue. The last dorsal, ilio-hypogastric or ilio-inguinal nerves may be injured during the course of operations upon the kidney, unless care be taken to make all incisions parallel to their course. In most of these cases no pain is complained of while the patient is in bed, and symptoms appear when the patient first gets up, and increase in severity. Pain and tenderness are complained of below the scar; this may be severe enough to make the pressure of clothes around the waist unendurable.

Examination usually reveals no loss of sensibility, but a well-marked area of tenderness corresponding to the nerve involved. This can be marked out in the usual way by dragging the point of a pin lightly across the skin, from sound to affected parts. It occasionally happens that one of these nerves is completely divided; this may produce a loss of epicritic sensibility, with resultant exposure of protopathic sensibility. All stimuli over the area have then, the unpleasant, painful, radiating character associated with this form of sensibility.

In both cases the injured nerve must be exposed by operation. If it has been cut into and the

symptoms are irritative the damaged portion must be resected and end-to-end suture performed, or, if it is involved in scar tissue only, freed, and precautions taken to prevent its recurrence. If it be found divided an attempt must be made to bring the ends into apposition ; if this fails, anastomosis to one of the parallel nerves must be carried out.

The ilio-inguinal nerve is liable to injury in the performance of radical cure of inguinal hernia. It should always be seen and avoided as it passes out at the external abdominal ring below and to the outer side of the cord. Injury will produce pain and tenderness in its distribution, aggravated by exertion, and may be severe enough to prevent the patient from following his employment. In some cases it is accompanied by pain, referred to the whole first lumbar distribution.

Treatment is on the lines already laid down.

Irritation of terminal branches as the result of involvement in scar tissue may occasionally give rise to difficulties in diagnosis. It arises in its most typical form after amputation of the breast. In this operation the perforating branches of the intercostal nerves are divided, and their involvement may give rise to severe symptoms. If the first or second dorsal be involved, pain is felt radiating down the inner side of the arm and forearm, often accompanied by tenderness.

The following is an example :



"In November, 1905, I carried out the complete operation for mammary carcinoma. The flaps did not come well into contact, and a small area was left at their upper part which healed by granulation. The patient was entirely free from symptoms until early in 1906 pain commenced and increased in severity, bringing her to see me in November of that year. She stated that the pain started in the upper part of the scar and radiated down the inner side of the arm and forearm, and was worse on moving the arm. Over the inner end of the second intercostal space was a tender spot, palpation of which caused the pain to shoot down the inner side of the arm. The skin of the inner side of the arm in the region supplied by the intercosto-humeral nerve was tender to the slightest touch.

"I excised the tender portion of the scar, and after freeing the skin sutured the flaps over Cargile membrane. She lost her pain and tenderness at once and has since remained free."

The rules for the treatment of nerves involved in scar tissue may be summed up as follows :

When the symptoms produced are those of incomplete division, neurolysis and protection of the recently freed portion should be adopted. When irritative symptoms are present and the trunk of the nerve involved, excision of the damaged portion, followed by restoration of continuity. When a



Unable to display this page

and may describe its exact position in space, but unless inflammation occurs pain is absent. The consciousness of the position of the absent member may never be lost, and any irritation of the bulb will cause the pain to be referred to the area of the absent limb which was supplied by the fibres affected. Thus, in a patient in whom symptoms pointing to irritation of the end bulb originated twenty-three years after an amputation of the foot, the reference of the pain to the inner side of the absent limb led to the discovery of the bulb on the stump of the internal saphenous.

The symptoms resemble those described as due to irritation of the terminal branch of a nerve, modified by the absence of a part of the limb. There may be pain widespread in the distribution of the nerve involved, accompanied by tenderness of that portion of the stump supplied by branches from the roots involved, and in some cases accompanied by changes in the skin. The pain may be produced by direct pressure on the bulb, and is often felt with changes of the weather. Muscular twitchings often occur in association with the pain, and hysterical symptoms may be present.

The time after the amputation at which the symptoms first appear is variable, but the longest interval that has come under my notice was in the case just quoted—twenty-three years.

The treatment should be preventive—in every

amputation the nerves should be pulled down and cut short with scissors to prevent their involvement in the fibrous tissue at the scar, and the ingrowth of fibrous tissue. It has been proved experimentally that crushing the end of a nerve prevents the formation of a large end bulb.

When symptoms are present the bulb and three or four inches of the affected nerve must be removed. This has sometimes failed to relieve the pain; in these cases intra-dural division of posterior roots should be performed if the symptoms are severe.



## CHAPTER XI

Method of Injury of Cranial Nerves—Olfactory Nerves: Method of Testing Smell—Optic Nerve—Oculo-motor Nerves—Fifth Nerve: Method of Injury: Loss of Sensibility: Taste Fibres: Taste Tests: Motor Supply of Palatal Muscles: Corneal Changes—Facial Nerve: Varieties of Injury: Anastomosis—Auditory Nerve—Glosso-pharyngeal Nerve—Vagus Nerve—Spinal Accessory Nerve: Paralysis of Trapezius Muscle—Hypoglossal Nerve.

AFFECTIONS of the cranial nerves, with the exception of the facial and spinal accessory, are rare in surgical practice. They are injured most often as the result of operative procedures and fractures of the base of the skull. The facial is the nerve most often injured in the latter way. Rawling found some interference with the functions of this nerve in twenty-four out of sixty patients; Kohler in twenty-two out of forty, although other authors do not give such a large percentage. Next in order of frequency are the auditory, the sixth, optic, third and fourth.

**Olfactory nerves.**—Injury to the olfactory nerves and the bulb into which they pass must be considered together, as the symptoms produced by their injury are identical.

Loss of smell not infrequently complicates a fracture of the anterior fossa of the skull or of the nasal bones, resulting from direct violence, but in only a few of these cases is it due to nerve injury. Anosmia may also follow blows on the back of the head which do not, so far as can be ascertained, cause a fracture of the anterior fossa.

The patient usually complains of inability to taste, less often of the loss of smell. In the majority of cases an immediate diagnosis of nerve injury is impossible; the nasal cavity is filled with blood-clot, and the injury to the roof of the nasal cavity may render testing impossible for a time.

In testing for loss of the sense of smell, irritating and pungent substances which may stimulate the sensory branches of the fifth nerve must be avoided. Aromatic volatile materials, such as oil of cloves, peppermint, and assafoetida should be employed, each nostril being tested separately.

Recovery usually follows loss of smell, complicating fractures of the skull or nasal bones. Permanent anosmia is rare from an injury to the olfactory nerves or bulb.

**Optic nerve.**—This nerve rarely suffers direct injury. It may be injured in penetrating wounds of the orbit or temporal region; gunshot wounds in the temporal region have injured both optic nerves without causing any injury to the eyeball. It is sometimes injured in fractures of the base of the skull,



involved in orbital cellulitis, or the fibrous tissue resulting from it, or pressed upon by growth.

Unilateral blindness has, in rare instances, followed a severe head injury unaccompanied by any evidence of a fractured base. This is usually explained as due to a hæmorrhage into the nerve, but Rawling has suggested that it may result from a fracture through the base of the anterior clinoid process, the fragment exercising direct pressure on the nerve.

A complete division of the nerve causes loss of vision in the affected eye, with more or less dilatation of the pupil. Ophthalmoscopic examination later reveals optic atrophy.

**Oculo-motor nerves.**—These nerves are most often injured in fractures of the base of the skull, next in order of frequency during operations for removal of the Gasserian ganglion as they lie in the outer wall of the cavernous sinus, or by the pressure of orbital tumours. Most of these cases come under the care of the ophthalmic surgeon.

The sixth nerve most often suffers in a fracture of the base by reason of its anatomical position, being implicated as it lies on the side of and grooves the dorsum sellæ, next the third, rarely the fourth. The third nerve is more often affected by causes other than injury.

In examining for signs of involvement of the ocular nerves, the position of the eye should be first



noted, its protrusion or recession, and the presence or absence of squint. The patient should then be asked to follow the movements of the observer's finger in the necessary directions, to detect weakness or paralysis of any muscle. The size, shape and reactions of the pupil to light and accommodation must also be noted.

The patient, in most cases, complains of diplopia, and this may be the only symptom indicative of injury to one of the nerves supplying the ocular muscles. For the investigation of this symptom the reader is referred to works on ophthalmic surgery.

*The third nerve.*—Injury to this nerve is uncommon, although paralysis of some of the muscles supplied by it is by no means rare.

The nerve may suffer injury in fractures of the base of the skull often with other nerves, particularly the first division of the fifth and the optic. Injury to the whole nerve is unusual; in most cases some only of its branches are affected, ptosis and dilatation of the pupil often occurring without external strabismus.

Complete division of the nerve produces ptosis from paralysis of the levator palpebræ superioris with over-action of the frontalis, so that the eyebrow is higher than on the sound side. There is slight exophthalmos and the pupil is dilated and does not react to light or accommodation. External strabismus

is present, and the patient is unable to move the eye upwards, downwards, or inwards.

*Fourth nerve.*—This nerve is rarely injured alone. Its division causes paralysis of the superior oblique muscle, with impaired power of downward movement. This deficient movement is difficult to detect, but the characteristic diplopia on looking downwards and the feeling of giddiness on going downstairs is characteristic.

*Sixth nerve.*—This nerve most often suffers in fractures of the base of the skull. Its injury produces internal strabismus, with inability to turn the eye outwards.

*Fifth nerve.*—Injuries of this nerve or of its branches are uncommon; it acquires its surgical importance chiefly in connexion with trigeminal neuralgia. It may be injured in fractures of the base of the skull or jaws, or from involvement in the products of bone disease, or pressed upon by inflammatory collections or growth in the frontal sinus, maxillary antrum or skull. Involvement of the whole nerve is unusual, one of its branches only being affected in most cases.

Makins has recorded the following facts with regard to gunshot wounds involving this nerve. It suffered most often in fractures of the jaws; a whole division was rarely affected, and the loss of sensibility was, as a rule, temporary.

*Sensory symptoms.*—It must be remembered that



the fifth nerve, when injured, behaves just as any other peripheral nerve; that pressure upon the nerve or involvement in growth will produce a loss of sensibility exactly similar to that produced by pressure upon the median or ulnar nerves. This is especially important to remember in connexion with pain in the distribution of this nerve and its treatment by operation. Interference with the functions of the nerve or one of its branches produces a loss of sensibility, first to light touch, then to pain. If severe pain is being caused as the result of pressure upon the nerve, some alteration in sensibility will be found; on the other hand, in some of the cases of referred pain and in trigeminal neuralgia major no sensory loss is present.

The exclusive supply of the fifth nerve is most readily studied in patients who have undergone the operation of removal of the Gasserian ganglion. Its full supply is shown in cases of division of the sensory branches of the cervical plexus (*vide* Plate VI, p. 178), but as there is very little overlap between it and the cervical nerves, its exclusive and full supply are almost identical.

The exclusive supply was first systematically studied by Krause, and is described in his well-known monograph. But it is largely owing to the researches of Harvey Cushing, confirmed recently in many respects by Morriston Davies, that our knowledge is due.



The loss of sensibility resulting from removal of the Gasserian ganglion is smaller than would have been supposed from reading a description of its supply, as ascertained by dissection. While varying somewhat from individual to individual, it retains in all its peculiar outline.

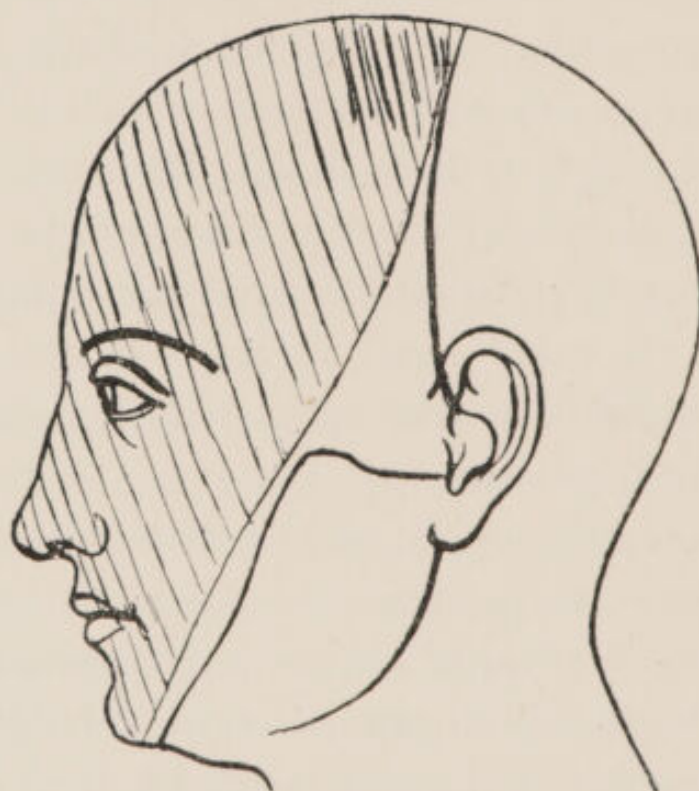

FIG. 10.—To show the loss of sensibility resulting from removal of the Gasserian ganglion.

Sensibility to light touch and to prick are lost over an area which is almost identical, but fails to correspond in the region of the external ear and the nose. Morriston Davies gives an accurate description of the area of epicritic loss, from which the following description is taken. Its anterior boundary is the mid-line of the forehead and chin. Its posterior

border may be described as consisting of three straight lines (*vide* Fig. 10). The upper is almost vertical and extends from a point in the sagittal plane, midway between the nasion and the inion, to the free margin of the tragus at the junction of its middle and lower thirds; thence the second line passes horizontally forwards to a point midway between the external auditory meatus and the outer canthus of the eye; here the third line begins and runs obliquely down to a point on the lower border of the chin vertically below the angle of the mouth.

The posterior boundary of the loss of sensibility to prick runs a much straighter course anterior to the line described above. The anterior wall of the external auditory meatus and the anterior portion of the tympanic membrane are usually insensitive to light touch and to prick.

It seems probable that deep touch is lost over an area corresponding roughly to that of the loss of sensibility to prick, and with it loss of sense of position and movement in the muscles of the face. Cushing found loss of the sense of active movement in the facial muscles when stimulated with the interrupted current, and also loss of the sense of passive position. Joy and Johnson and Spiller have recorded cases in which "deep sensibility" was present. Morriston Davies confirms the absence of the sense of movement and position, and found that although deep pressure was occasionally appreciated it was



badly localised on to adjacent sound parts. "Deep sensibility" of this nature is probably due only to traction on surrounding sound structures; it differs entirely from the deep sensibility seen after division of such a nerve as the median.

True deep sensibility appears to be absent in most patients after complete removal of the Gasserian ganglion.

The mucous membranes supplied by the fifth nerve become insensitive to epicritic and protopathic stimuli. In the mouth the area includes half the tongue, as far back as the circumvallate papillæ, and then passes outwards along their line to the anterior pillar of the fauces, and then along the anterior margin of the soft palate to the tip of the uvula, thence along the centre of the palate to the upper lip. All on the affected side of this line lose sensibility to light touch and prick. The tongue retains its deep sensibility, the fibres conveying which appear to travel by the hypoglossal nerve.

Cushing has confirmed the observations made by Krause, and conclusively shown that taste is not permanently affected by the removal of the Gasserian ganglion. Morriston Davies has exhaustively reviewed the recorded cases and confirmed these observations. The fibres subserving taste in the anterior two thirds of the tongue pass in the chorda tympani, running for a part of its course with the lingual nerve (*vide* also "Facial nerve," p. 165).



Cushing offers the suggestion that the temporary loss of taste seen in some cases after removal of the ganglion may be due to degenerative changes in the lingual nerve affecting the chorda tympani, mechanically or toxically. Horsley has suggested that it might be due to the unilateral furring of the tongue, so often seen after this operation.

It is by no means an easy or rapid matter to test taste perception, and before any conclusion is reached with regard to loss of taste the patient must first have been proved, before operation, to possess the sense of taste in the anterior two thirds of the tongue ; it is not unusual to find that this is absent in elderly people otherwise healthy.

In testing it is better to employ solutions than solids. Solutions of sugar, salt, quinine and acetic acid are used ; these are brushed on to the protruded tongue with a camel's hair pencil or glass rod. The tongue must be kept protruded throughout the test, and as soon as the patient experiences any taste sensation he should make an agreed sign. The mouth must be well washed out between each application.

The nasal mucous membrane on the affected side is anæsthetic, hence the inhalation of irritating substances causes no discomfort or lachrymation, and tickling the affected nostril does not cause sneezing. The sense of smell may be defective owing to dryness of the mucous membrane.

*Motor symptoms.*—Complete division of the fifth nerve or its motor division produces paralysis of the muscles of mastication, the masseter, temporal and pterygoids. But this causes little inconvenience, difficulty in mastication being more due to the food lodging between the cheek and gum owing to their anæsthesia. On opening the mouth the jaw is deflected to the paralysed side from the unopposed action of the sound external pterygoid. The paralysis of the anterior belly of the digastric and the mylo-hyoid muscles, said to be supplied from this nerve, cannot be detected clinically.

Considerable difference of opinion has existed with regard to the motor supply of the muscles of the palate, and it has been stated that they, or perhaps the tensor palati only, are supplied by the fifth nerve. Cushing observed in four of his cases an asymmetry of the palate of a greater degree than, in his opinion, could be accounted for by deflection of the jaw. In one case, also, he was able to obtain twitches in the corresponding side of the soft palate on stimulating the stump of the third division of the fifth during the course of a ganglion extirpation. On the other hand, Horsley was able to detect no movements on similar electrical stimulation in three patients. Krause was of opinion that no alteration of the soft palate was to be seen, and Morriston Davies, from the examination of twenty-six cases, found a slight inequality in five, and came



to the conclusion that "the balance of evidence seems to show that the fifth nerve has nothing whatever to do with the nerve supply of the palatal muscles." It is quite possible that the asymmetry observed was due to a loss of muscle sense. To obtain conclusive evidence electrical examination of the muscles is necessary.

The innervation worked out by Hughlings Jackson, Aldren Turner, Beevor and others, from the accessory portion of the vagus, corresponds with clinical observations. In the few cases that I have had the opportunity of examining, no alteration was present in the palatal muscles. Their motor supply is through the pharyngeal plexus.

Paresis of the facial muscles has been noticed after excision of the ganglion, due to loss of the sense of passive position and movement.

*First division.*—This division may be injured during the course of operations upon the frontal sinus, and may be involved in disease in this situation. It may also suffer in fractures of the anterior fossa of the skull, but the injury is rarely complete, or of the whole division. When involved in disease of the sinus the supra-orbital and supra-trochlear branches are affected; as the result of fractures, anæsthesia of the cornea and conjunctiva alone, followed by subsequent destruction of the cornea, has been recorded. Its nasal branch may be affected in fractures of the cribriform plate.



The first division of the fifth nerve supplies the scalp as far back as the mid-point between the external occipital protuberance and the nasion, together with the conjunctiva of both lids. Deep touch is everywhere present after section of this division.

After removal of the whole ganglion transient changes in the pupil have been noticed; immediately after the operation it is smaller than on the sound side. Cushing observed this in eight cases; it existed for some weeks and was associated with a slight degree of enophthalmos. But in none of the cases recorded by Morriston Davies did it remain for as long as this. No permanent alteration of lachrymal secretion results.

It is well known that after injury of the first division of the fifth nerve changes may supervene in the cornea, leading in some cases to ultimate loss of the eye. It is a rare condition and present in only a small proportion of the cases.

Considerable difference of opinion exists with regard to its causation. One thing seems certain: it does not arise spontaneously in cases in which the ganglion has been completely removed, if care be taken to protect the eye from injury during the course of the operation and the succeeding few days. But in cases of incomplete division of this branch it may do so, thus falling into line with what has been said with regard to "trophic" ulcers elsewhere (*vide*

p. 31). In most of the cases it has been noticed during the first few days following operation—a period at which there is a diminution of lachrymal secretion. The change begins in the corneal epithelium, the cornea becomes dull and its epithelium is shed, infection rapidly ensues and the eye is lost.

Willibrandt and Säger have suggested that it is due to irritation of the peripheral end of the nerve, and this theory has the support of Parsons. But it is obviously untenable in cases of complete division, unless arising within a very short time after the operation, while the fibres in the peripheral end still conduct impulses. I am more in agreement with the experimental work of Turner, Ferrier and Hanau that the corneal change is due to external injuries in all cases in which the ganglion has been completely removed, or the first division completely divided.

*Second and third divisions.*—These are rarely affected. They may be injured in fractures of the petrous bone traversing the cavum Meckelii; the infra-orbital nerve may suffer in fractures of the upper jaw, or be involved in growths or inflammatory affections of the antrum of Highmore. The inferior dental nerve suffers occasionally in fractures of the jaw, and the lingual nerve has been injured in extraction of an impacted wisdom tooth.



The loss of epicritic and protopathic sensibility resulting from injury of either of these divisions or nerves is small ; deep sensibility is unaffected.

**Facial nerve.**—Facial paralysis is one of the most common varieties of peripheral paralysis. But many of the cases are incomplete, and not, strictly speaking, due to injury. In 265 cases of facial paralysis collected by Bernhardt, only 5 or 6 per cent. were due to injury, and 6 to 9 to middle-ear disease ; the remainder belonged to the so-called “rheumatic” type. Much the same percentage existed in the 130 cases collected by Philip and the 135 of Hübschmann. But these figures by no means show the importance of the surgery of the facial nerve, for many cases due to non-traumatic causes come later under the care of the surgeon.

Facial paralysis is occasionally seen in the newly born, usually in cases in which forceps have been necessary ; Libin found facial paralysis 25 times in 1063 forceps deliveries. It is usually unilateral.

*Symptoms.*—The symptoms caused by interference with the functions of the facial nerve differ according to the level of the injury, and fall into three groups owing to the association with it of the chorda tympani nerve between the geniculate ganglion and the lower part of the Fallopiian canal ; here it leaves the facial to cross the tympanic cavity.

Injury to the facial nerve below the point at



which the chorda leaves it results, most often, from penetrating wounds of accidental or operative origin in the parotid and sub-maxillary regions; it also occurs as a birth paralysis.

Its complete division produces flaccid paralysis of all the muscles of the corresponding side of the face, and is at once obvious. The natural furrows are obliterated, leaving the affected side of the face, expressionless and devoid of voluntary or emotional movement. The eye cannot be closed and the lower lid droops, allowing the punctum to fall away from the eyeball; this, with the loss of the suction action of the lachrymal sac from paralysis of Horner's muscle, is responsible for the lacrymation. The conjunctival reflex is abolished through its motor limb. On attempting to close the eye the eyeball moves upwards.

If completely divided where accompanied by the chorda tympani nerve, taste is lost over the corresponding half of the anterior two thirds of the tongue. The nerve may be injured in this situation as the result of operations upon the middle ear or a fracture of the petrous bone, or be affected in otitis media.

When divided above the geniculate ganglion the symptoms resemble those in the first group, but the auditory nerve is usually affected at the same time. It is sometimes stated that a lesion of the facial in this situation produces paralysis of the corresponding

half of the soft palate ; I have been unable to observe this.

In patients in whom the facial paralysis has existed for some time, contractures of the affected muscles may develop. This may cause momentary confusion and difficulty in diagnosis, the healthy side, at rest, appearing to be the affected ; voluntary movement at once reveals the side paralysed.

In investigating a case of facial paralysis, its cause, the site of the injury, and the degree of involvement of the nerve must be discovered. The cause is, as a rule, obvious, and shown by the history of injury or operation.

*Prognosis.*—The prognosis varies with the cause of the injury. A very large proportion of the idiopathic cases recover spontaneously, a few only of the so-called rheumatic type remaining permanently paralysed and needing operative interference. The electrical reactions are of the utmost importance. Complete facial paralysis may entirely disappear in a few days or weeks, or remain permanent. There is nothing except the investigation of the electrical reactions of the affected muscles which will enable a prognosis to be given. If the reactions are those of incomplete division recovery may be confidently expected. If the true reaction of degeneration is present, recovery apart from operation is unusual. In most instances the injury is incomplete and operation is rarely indicated. Facial paralysis,



following an operation on the middle ear is, as a rule, due to incomplete division; recovery takes place in the majority of the cases. In facial paralysis complicating fracture of the base of the skull, whether the involvement is primary or secondary, recovery usually takes place. The partial facial paralysis, paralysis of the lower facial muscles, which is so common as the result of operations in the submaxillary region, is rarely permanent; if apposition of the edges of the wound is accurate and the wound heal without suppuration, recovery is the rule.

*Treatment.*—The lines upon which the treatment of facial paralysis is conducted differ not at all from those laid down in Chapters VI and VII.

If the nerve be completely divided primary suture should be carried out, if possible, but for anatomical reasons this is often impossible. In older cases continuity with the central nervous system must be restored either by means of its own central end, or more often for anatomical reasons, by anastomosis. When the nerve is involved as the result of middle-ear disease operative interference in the antrum or tympanum is indicated.

If the facial nerve has been completely divided in the petrous bone, whether as the result of operation or fracture, the sooner operation is carried out the better the chance of complete recovery. When the injury follows a mastoid operation time must be allowed to permit all inflammation to cease; it is



Unable to display this page

than when the spinal accessory is employed. Nerve anastomosis and not nerve crossing should be carried out. It is unnecessary to sacrifice a sound nerve, emotional movement may be restored without. The complete peripheral operation should be performed, and nerve-fibres divided in the sound nerve, either by making an oblique cut into the nerve, or by splitting off a portion and uniting it end-to-end with the peripheral end of the facial (*vide* p. 91).

Instances of recovery have been recorded after simply inserting the peripheral end of the facial into a vertical slit in the hypoglossal, but the return of voluntary movement is more rapid if axis cylinders are definitely divided.

The primary essential for success in this operation is asepsis. If the wound suppurates recovery will be delayed and imperfect. The greatest care and gentleness of handling is necessary, and the incisions must be made into the nerve with a sharp, thin-bladed tenotomy knife.

In order to carry out the operation of facio-hypoglossal anastomosis a long incision should be made extending from the mastoid at the level of the external auditory meatus down to the great cornu of the hyoid bone. The anterior border of the sterno-mastoid muscle is first defined and pulled backwards, then the posterior belly of the digastric identified and pulled backwards and downwards; if large, it may be necessary to divide some

of the fibres in its upper border. The facial nerve is next sought for; it is most easily found by feeling for the styloid process; the nerve passes out immediately in front of this and enters the parotid gland. The facial nerve should next be freed, and an attempt made, in cases in which it has been injured in the performance of a mastoid operation, to pull the stump out from the stylo-mastoid foramen. If this cannot be done the nerve should be divided in the foramen, as high as possible, with a tenotomy knife. The hypoglossal should next be found; the transverse process of the axis is first felt and serves as a guide to the occipital artery, which runs upwards and outwards across it. The internal jugular vein is identified and retracted inwards; this exposes the vagus and the hypoglossal nerves; the latter is easily distinguished by its relation to the occipital artery. After freeing, it is brought towards the facial and an oblique cut made into its trunk so as to divide about one third of its fibres and the peripheral end of the facial sutured in with fine catgut. If there is any tension on the junction it is better to raise a flap and perform end-to-end union. The raw surface left and the junction should be surrounded with Cargile membrane.

The after-treatment requires care. The nutrition of the muscles must be kept up by massage and stimulation with the constant current until voluntary power is restored. As soon as voluntary power



returns to each group of muscles they must be exercised systematically until the patient regains complete control.

An operation such as I have described inflicts astonishingly little injury on the hypoglossal nerve. At first there may be paralysis of the corresponding half of the tongue, but if the wound heal by first intention it is quite transient, and the slight hemiatrophy which supervenes disappears in a few months.

No improvement in the condition of the facial muscles is to be expected for at least six or eight weeks. About this time it is usually noticed that the lower part of the face at rest is more symmetrical; following this, from three to six months after operation, a return of power in the muscles at the angle of the mouth takes place; those which regain voluntary power last are the muscles around the eye and the frontalis. Preceding the return of voluntary power the muscles show a change in their electrical reactions, the reaction described as typical of incomplete division developing. In some cases, particularly in those following an operation for acute mastoiditis, recovery may be much delayed.

Movement is at first associated with movements of the tongue, but soon becomes dissociated. In a favourable case the patient should be able to perform all movements in from nine months to a year, but emotional movement is restored much later. It is at this stage that the patient is able voluntarily to

throw all the muscles of his face into action, yet in smiling the affected side of the face remains motionless. Emotional movement may take years to be restored, but improvement steadily ensues and may be expected to be perfect in a young patient in whom the wound healed by first intention.

After facio-hypoglossal anastomosis the return of power is, therefore, as follows: First, movements associated with those of the tongue, then dissociated, and finally emotional. In all the cases of facial nerve anastomosis reported sufficiently long after operation, some recovery took place; this commenced earlier and became more complete in cases in which the hypoglossal nerve was used, but up to the present few cases of *perfect* recovery have been recorded.

In any case we can confidently predict great improvement to follow the operation, which may in time restore the condition of the face to normal.

**Auditory nerve.**—This nerve is usually injured in fractures of the middle fossa of the skull, and is associated in 80 per cent. of the cases with a facial paralysis.

Nerve deafness results from its complete division.

**Glosso-pharyngeal nerve.**—No instance of isolated injury to this nerve has been recorded. It is most likely to suffer at the jugular foramen, with the vagus and spinal accessory nerves. But although fractures of the base of the skull frequently involve this region, the nerves usually escape.



The symptoms produced by its injury are: difficulty in swallowing from paralysis of the middle constrictor and stylo-pharyngeus muscles, and loss of sensibility on the posterior third of the tongue and pharynx on the affected side.

**Vagus nerve.**—The vagus during its long course through the neck is exposed to many forms of injury, but rarely suffers complete division. It or its recurrent laryngeal branch may be injured in operations upon the thyroid gland, ligature of the great vessels, or removal of tuberculous or malignant glands. It may suffer in the thorax as the result of the pressure of growths or aneurysms.

It was the belief of the older surgeons that death invariably resulted from division of one vagus nerve, but if it is divided below the point at which the recurrent laryngeal nerve is given off, no symptoms are, as a rule, present, hence the surgeon should not hesitate to sacrifice the nerve if necessary in operations upon malignant disease. In twenty-four cases in which the nerve has been divided during the course of operations in no instance did death result from the nerve injury. Thus, in a case recorded by Rivington, the nerve was divided during the operation of ligature of the internal carotid. No symptoms resulted, and when death occurred later from a cerebral abscess the division was verified.

But when irritated during the course of operations, included in a ligature, pulled upon by retractors,



picked up in pressure forceps, etc., alarming symptoms may result. In cases recorded by Michaux and Tilman the pulse and respiration temporarily ceased from sudden stimulation of the vagus during the course of operations upon the neck.

This nerve carries the motor fibres to the muscles of the soft palate and larynx. The paralysis of the palate is easily recognised if the patient is told to open the mouth and the raphe of the palate be watched; it is seen to be pulled to the sound side when elevated by producing such sounds as "eh."

Hoarseness results from paralysis of one recurrent laryngeal nerve. On laryngoscopic examination the cord of the affected side is seen to be fixed midway between adduction and abduction—the cadaveric position.

In investigating a case of paralysis of the larynx, due to an injury to the vagus nerve or its recurrent branch, it is necessary to discover, if possible, the seat of the injury. The condition of the palate is first investigated; if this is not affected the history of operation or the symptoms of growth will alone reveal the seat of the injury.

Treatment is carried out along the usual lines, primary or secondary suture, or if this is impossible, anastomosis to cervical nerves or spinal accessory.

**Spinal accessory nerve.**—This nerve supplies the sterno-mastoid and the trapezius in conjunction with branches from the cervical plexus. The extent of

the supply of the trapezius from the spinal accessory varies, but as a rule the upper part is supplied by this nerve, the lower by branches from the third and fourth cervical nerves. The spinal accessory is most often injured during the operation of removal of tuberculous glands of neck, and in many of the cases the branches of the third and fourth cervical are also affected and paralysis of the whole trapezius results. It must not be forgotten that the nerve may be involved in the spinal canal and at the jugular foramen, though in the latter position it is rarely affected alone.

Division of the nerve in the anterior triangle of the neck produces paralysis of the sterno-mastoid and upper part of the trapezius. The paralysis of the sterno-mastoid gives rise to no marked symptom. There is no alteration in the position or movements of the head, but the muscle does not become prominent on depressing the head against resistance, or on rotating it to the opposite side. The upper fibres of the trapezius muscle usually suffer alone when the nerve is divided in this situation. This produces an alteration in the contour of the neck (*vide infra*), slight drooping and rotation of the shoulder, but little interference with movement.

Paralysis of the whole trapezius muscle produces considerable deformity and disability, and the greatest care should be taken to avoid this result of operations upon the neck. The patient complains



of weakness of the whole upper limb. The scapula is dropped and rotated forwards (*vide* Plates IV and V), and so tilted that its spine is more horizontal than normal and its lower angle is nearer the mid-line than the upper. There is also slight winging of the scapula, which disappears at once on bringing the serratus magnus muscle into action (*vide* p. 212).

The lower border of the rhomboideus major stands out prominently and becomes more marked when the shoulders are thrown back. The contour of the neck is altered and becomes somewhat irregular from the exposure of the levator anguli scapulæ. The patient is unable to raise the arm above the head after it has been abducted by the deltoid, but can raise it above the head in front of the body, and this may lead to difficulty in diagnosis. When the paralysis of the trapezius has been in existence for some time the patient may learn to raise the arm above the head by a peculiar manœuvre. The arm is abducted by the deltoid muscle and then carried a little forward and rotated outwards by the pectoralis major and carried above the head in this position by the serratus magnus.

Immediate suture should be carried out in all cases in which the nerve is divided during the course of an operation. If not seen until later, an attempt should be made to perform secondary suture. If it is impossible to find the central end or to bring the



## PLATE IV.

Taken from a patient with paralysis of the whole trapezius following an extensive operation upon tuberculous cervical glands.

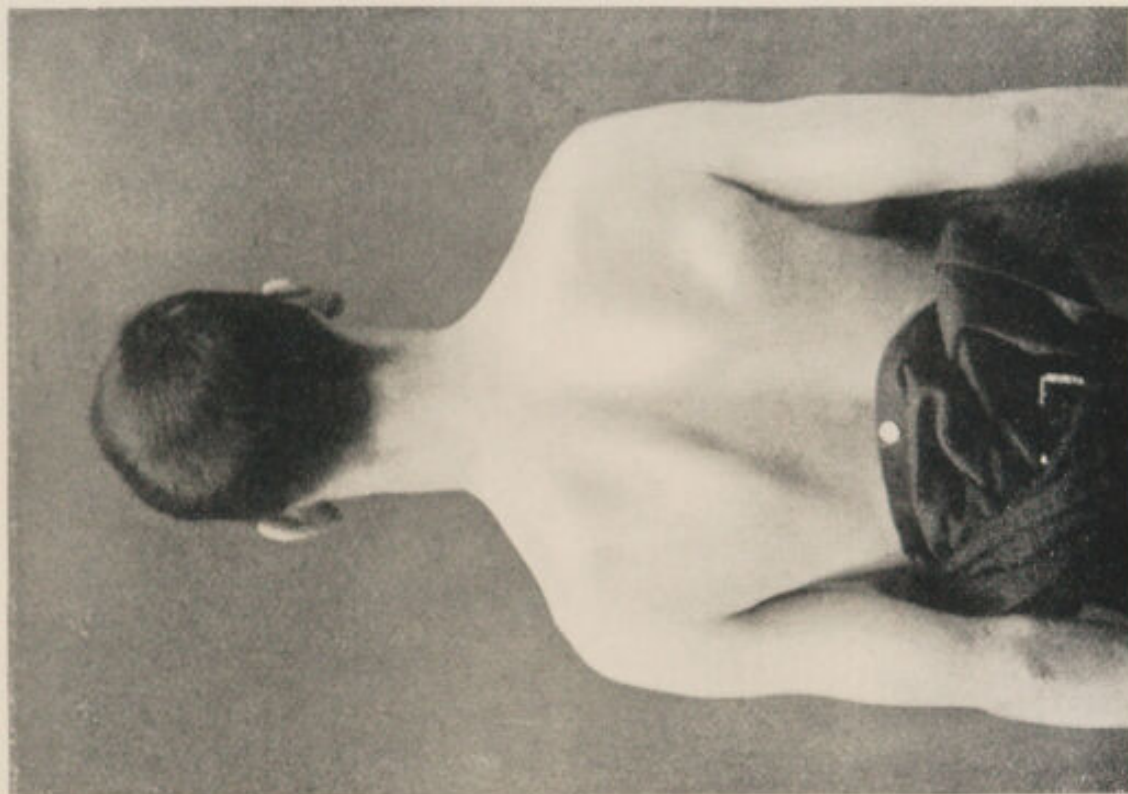

FIG. 1.—The prominence formed by the rhomboideus major and the dropping and tilting of the scapula are well shown.

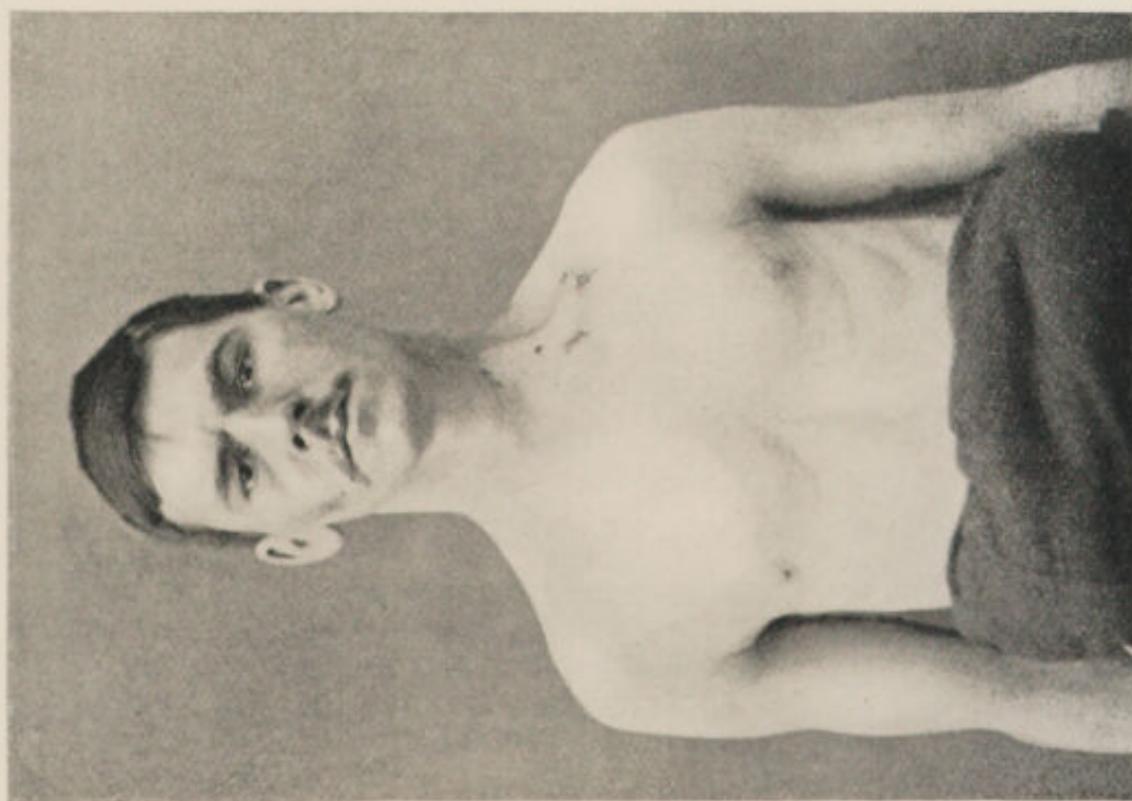


FIG. 2.—Shows the alteration in the contour of the neck.



Unable to display this page



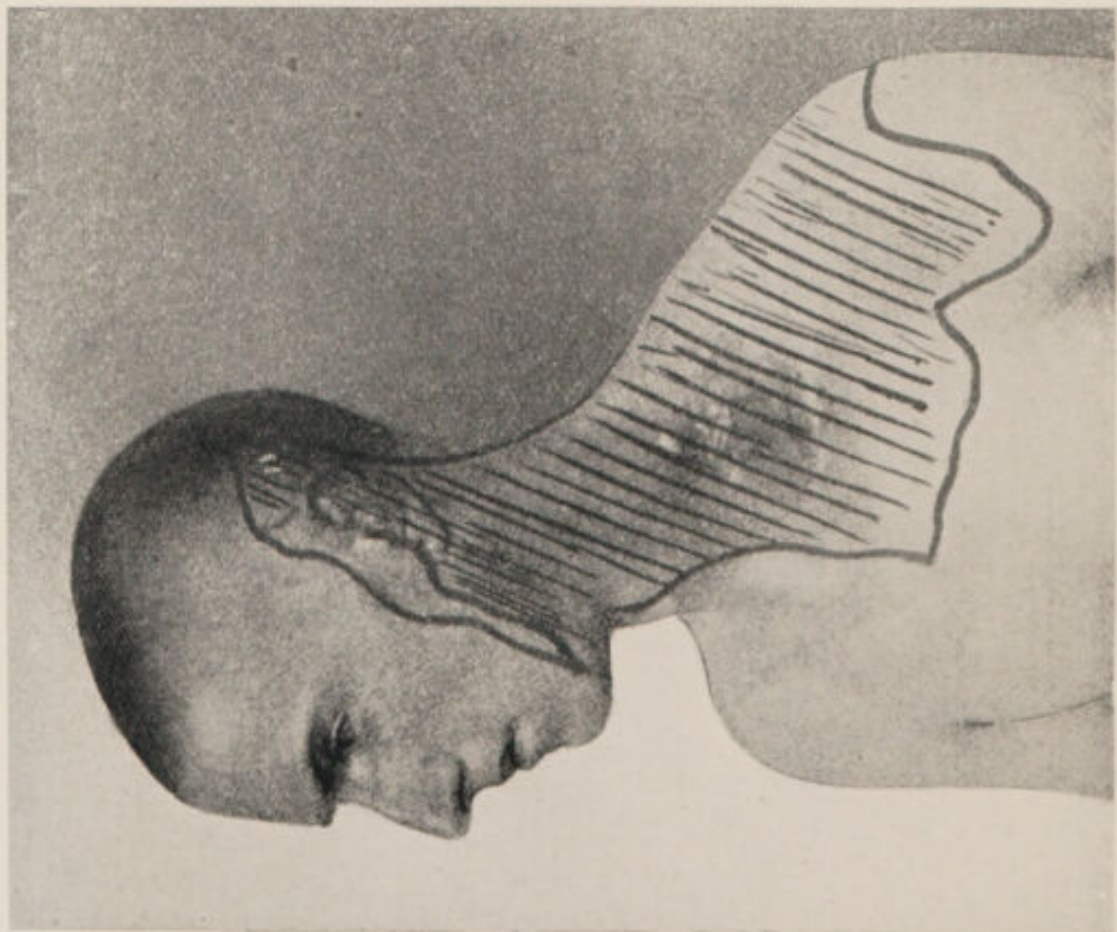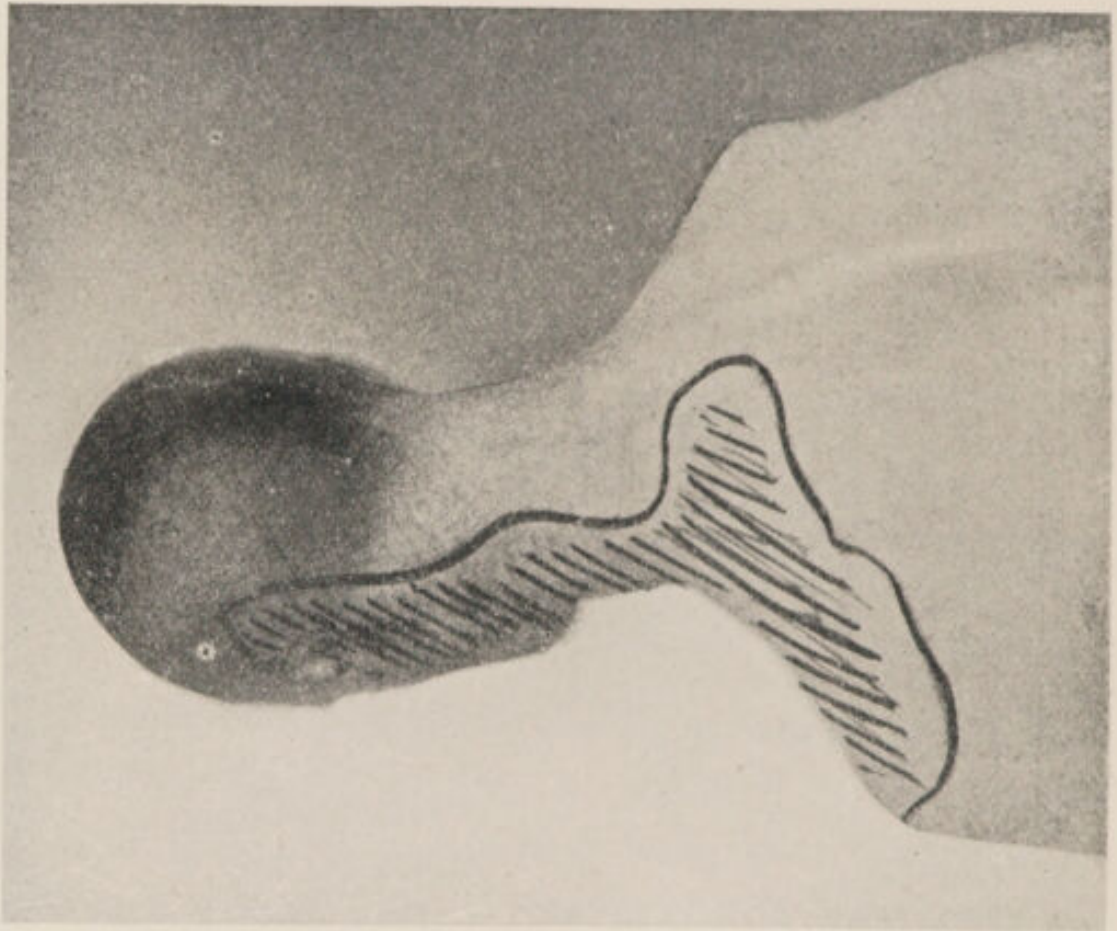
Unable to display this page

Unable to display this page

Unable to display this page







To illustrate the loss of sensibility produced by section of the sensory nerves of the cervical plexus. Modified from Cushing.

which these branches descend should be noted (Plate VI).

When divided during the course of an operation primary suture should be performed, as considerable discomfort may result from non-union.

The most important motor branch of the plexus is the phrenic, which arises mainly from the fourth cervical, but receives in most cases a branch from either the third or fifth; other branches are, to the levator anguli scapulæ and scalenus medius from the third and fourth; the sterno-mastoid and trapezius receive branches respectively from the second and third and the third and fourth in common with those given from the spinal accessory. These have been considered with the spinal accessory nerve.

**Phrenic nerve.**—This nerve may be injured as it lies on the scalenus medius during the progress of operations upon lymphatic glands or upon the supra-clavicular portion of the plexus. It has been injured most often during the operation of ligature of the third part of the subclavian artery, being included in the ligature or divided. In one case recorded by Bransby Cooper violent coughing set in immediately after the operation, and continued until death on the fifteenth day following inclusion of the nerve in a ligature. Erichsen and Reidel also published cases in which death followed a few days after division of this nerve, death being due to pulmonary troubles.



Unable to display this page




PLATE VII.



From a patient who completely ruptured the left brachial plexus as the result of a fall on the point of the shoulder. The pseudo-ptosis and slight enophthalmos are well seen.



It must not be forgotten that the pupillary fibres may be injured in the spinal cord itself.

The pupillary changes seen after injuries of the cervical sympathetic were recorded first by Petit in 1727, but the earliest complete description appears to have been due to Jonathan Hutchinson, who, in 1866, described the effects of its injury with the plexus in a stab wound of the neck, and of its pupil dilating fibres in injuries of the spinal cord.

It is by means of the fibres supplying the eye and orbital muscles that affections of this part of the sympathetic are recognised. It carries, in addition, vaso-motor fibres for the blood-vessels of the face and upper limb, and fibres for the supply of the sweat glands.

Section of the cervical sympathetic produces slight enophthalmos and pseudo-ptosis (*vide* Plate VII); the upper lid droops but can be elevated spontaneously. The pupil affected is smaller than the sound, unless seen in a bright light, when both are equal and contracted. It does not dilate when shaded, or in response to the instillation of cocaine or to pinching the side of the neck (cilio-spinal reflex). The affected side of the face does not flush or sweat and the ear often feels colder to the touch of the observer than the sound one. The area of absence of sweating includes, as first pointed out by Purves Stewart, the whole of the upper limb; this I have been able to confirm. No interference with the heart's action has been recorded.

Stimulation of the sympathetic much more rarely comes under the care of the surgeon; it may occur as the result of the pressure of tumours or aneurysms or the traction of adhesions. It results in exophthalmos, widening of the palpebral fissure, dilatation of the pupil, with, in many cases, flushing and sweating.

The prognosis will depend upon the cause of the injury. Occurring in connexion with injuries of the brachial plexus it is rarely complete; the eye, although remaining contracted on shading, dilates to the instillation of cocaine. These cases usually recover. If the paralysis is complete, recovery is unlikely when injured in association with the brachial plexus, its treatment under this condition is impossible for anatomical reasons.

Its division in the neck should be treated by primary or secondary suture. The work of Langley and Anderson has established the fact that the preganglionic fibres of the sympathetic regenerate just as peripheral nerves. If the ends cannot be brought into apposition nerve anastomosis may be carried out.



## CHAPTER XIII

The Brachial Plexus: Distribution of its Roots to Muscles and Skin—Classification and Causation of its Injuries—Injuries to Whole Plexus; Upper Arm Type; Lower Arm Type; Inner Cord; Outer Cord; Posterior Cord—Treatment and Prognosis of Brachial Plexus Injuries—Brachial Birth Paralysis.

UNDER the term “brachial plexus” is included the anterior primary divisions of the fifth, sixth, seventh and eighth cervical nerves, with varying portions of the first dorsal and fourth cervical, together with the trunks and cords formed by their junction and decussation. The individual named nerves arising from these are not included.

A knowledge of the motor distribution of the various roots entering into the plexus is necessary in order to understand the paralysis resulting from injuries.

Although fibres from more than one root can be traced to most of the muscles of the upper limb, from the clinical standpoint the motor supply depends usually upon one root only.

Stimulation of the anterior primary divisions during the course of operations, and the investigation of the motor affection resulting from accidental



lesions, the exact nature of which is made manifest by operation, are the means by which the extent of their supply is elucidated. These opportunities arise most often in injuries of the upper and lower roots, rarely in those of the middle of the series; the distribution of these latter is, therefore, somewhat uncertain.

Much more difficulty and considerable confusion exists with regard to the sensory distribution of the posterior roots entering into the formation of the plexus, on account of the different methods which have been used. It is very necessary to bear in mind the distinction between areas of full and exclusive supply (*vide* p. 15), and also to separate the areas of supply of the different forms of sensibility. The distribution of the roots entering the plexus to the skin of the upper limb does not, of course, correspond to the area which would become insensitive to cutaneous stimuli on division of that root. The well known figures of Thorburn and Kocher were obtained by various methods, principally from instances of injury to the spinal cord, others from injuries to roots, sometimes the full supply being obtained, at others the exclusive. This probably accounts for the difference seen in the various plates. In most cases, however, the areas seem to be those of the full protopathic supply. The areas given by Dr. Head, obtained from cases of herpes zoster, should also correspond to the full protopathic supply. But it has to be remembered

that the overlap between adjacent roots is considerable in the upper limb ; for example, it is possible to completely divide the anterior primary divisions of the fifth, sixth or seventh cervical nerves containing the cutaneous fibres arising from the posterior roots

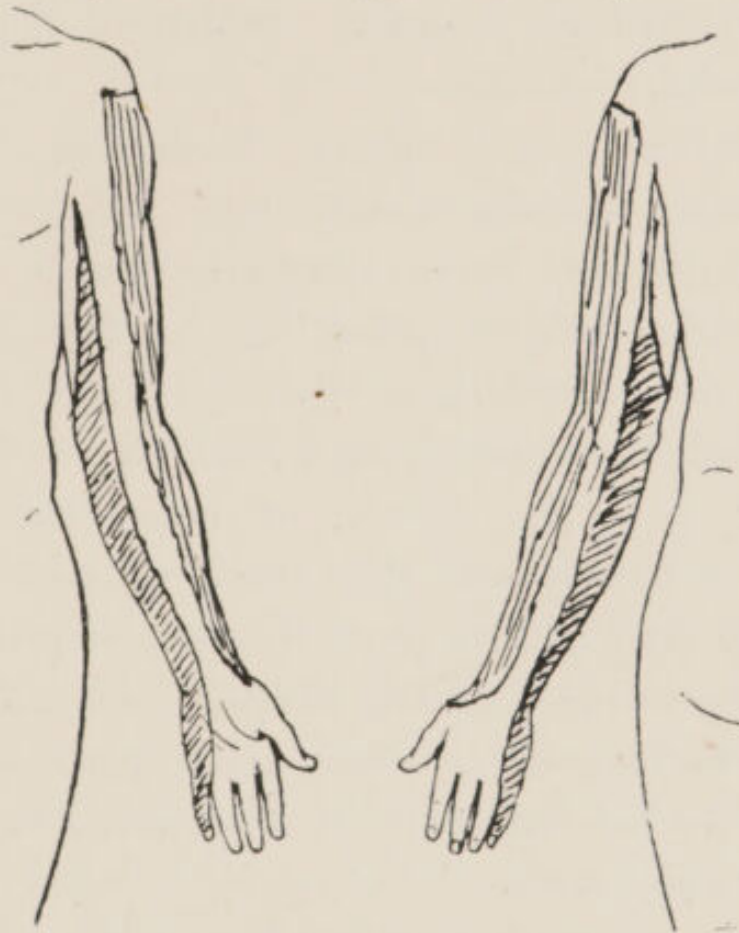


FIG. 11.—Represents the full protopathic supply of fifth cervical and first dorsal posterior roots. Vertical shading : fifth cervical. Oblique shading : first dorsal.

of the fifth, sixth or seventh cervical nerves, without producing any sensory loss that can be discovered by any of the methods at our disposal. It is, therefore, impossible to delineate all the areas supplied by these roots on any one chart of the upper limb. The diagram given (Fig. 11) represents the full



protopathic supply of the fifth cervical and first dorsal nerves, but it must be remembered that the areas of full supply of the sixth and eighth cervical will overlap these considerably. These areas are only of use from the point of view of residual sensibility and in irritative conditions leading to hyperalgesia.

The tables usually given illustrating the root supply to the muscles of the upper limb have been obtained, not only from injuries to nerves, but also from injuries to the spinal cord. The following table differs from those usually given in small details, and is obtained from a study of the paralysis resulting from the section of individual anterior primary divisions and the result of experimental excitation during the course of operative procedures.

*Fifth cervical.*—Deltoid, biceps, brachialis anticus, supinators, rhomboids, usually the spinati, occasionally the radial extensors of the wrist, rarely the pronator radii teres.

*Sixth cervical nerve.*—Pronators, radial extensors of the wrist, clavicular portion of pectoralis major, serratus magnus.

*Seventh cervical.*—Triceps, extensor carpi ulnaris, extensors of fingers, pectoralis major.

*Eighth cervical nerve.*—Flexors of wrist, flexors of fingers.

*First dorsal nerve.*—Intrinsic muscles of hand.

**Classification.**—Lesions of the plexus may be



classified into supra- and infra-clavicular varieties. This is important, for the causation and prognosis of these forms differ in most instances.

**Causation.**—Supra-clavicular injuries result usually from indirect violence, the force being applied to the head or the shoulder ; infra-clavicular, usually from the direct violence of the dislocated head of the humerus.

Taking first the supra-clavicular injuries. In addition to those due to indirect violence they may arise occasionally from the presence of a cervical rib, complicating a fracture of the clavicle, or as the result of a penetrating wound or a fracture of cervical spine.

*Supra-clavicular injuries due to indirect violence.*—The injuries resulting from violence applied to the head or shoulder are due to overstretching of the anterior primary divisions of the cervical nerves ; only in rare cases are the “roots” affected. They fall into the class of traction injuries ; they are not due to the direct pressure of the clavicle as has been suggested by many authors. The traction falls first upon the upper part of the fifth anterior primary division, then upon its junction with six, following this upon the remaining divisions in order from above downwards. The slight amount of pressure necessary to produce overstretching of the plexus in a child can easily be seen by depressing the shoulder ; the cords at once stand out prominently.

Injuries of this type, both in children and in adults, affect usually the fifth or fifth and sixth anterior primary divisions and produce the Erb-Duchenne type of paralysis. There is no reason why the injuries sustained at birth should be separated from those of adult life, both occur as the result of similar violence, the same muscles are affected and the treatment identical. If the traction fall upon the plexus from below—for example, a man in falling from a height endeavours to save himself by clutching at some projection—the injury affects the first dorsal, then the others in order from below upwards. The same may result in infants in breech presentations, with the arms extended, or in certain face presentations.

In both cases recovery takes place from the root last affected, and may leave an Erb-Duchenne or Klumpke paralysis as a terminal lesion when the original affection was more widespread.

The actual method of production of these injuries has been much discussed and many fanciful explanations brought forward, such as the compression of the trunks between the clavicle and first rib, or transverse processes of cervical vertebræ. But it was shown by Horsley as the result of experiment in 1884—although this seems to have been overlooked by most writers on the subject—and later maintained by Duval and Guillain, and demonstrated in infants by Taylor, that the correct cause is traction. It has

Unable to display this page



Unable to display this page

are, as a rule, on one side only—the right. It has been estimated that not more than from 5 to 10 per cent. of those with cervical ribs present symptoms, and that in about two thirds of these they are of a nervous nature. As a rule symptoms do not appear until early adult life, resembling in this way the late involvement of the ulnar nerve after injuries in the region of the elbow in early life.

There may be a general weakness of the whole limb noticed at the end of the day or after severe exertion, accompanied by muscular wasting, or, what is more usual, pain shooting down the inner side of the arm and forearm into the ulnar portion of the hand, described by the patient as neuralgic; this is sometimes accompanied by alterations in sensibility, which are rarely of a greater degree than loss of epicritic sensibility. Wasting and paresis of the intrinsic muscles of the hand is usually present; first noticed and most marked in those of the thenar eminence. The lesion affects the inner cord of the plexus formed of fibres from the eighth cervical and first dorsal nerves; hence there is no interference with the cervical sympathetic, and the flexor muscles of the fingers have been affected in a few instances.

This lesion should always be kept in mind in cases of brachial “neuralgia” and in wasting of the intrinsic muscles of the hand, for many errors in diagnosis have been made.

The treatment of the condition is simple and in most cases satisfactory—removal of the rib. It rarely happens that the nerves themselves have to be dealt with. After removal of the cause the usual after-treatment should be carried out.

*Complicating fractures of the clavicle.*—As a complication of a fracture of the clavicle, brachial plexus injury is uncommon. Taylor, in 1903, was only able to collect ten cases, and I have had one patient with this complication under my care. In most, including the one I have recorded, the nerve injury was due to the violence producing the fracture and not to pressure on, or laceration of, the nerves by the ends of the bone. In some instances the fracture was due to direct violence, often from gunshot wounds, in others, including the case I have recorded, to indirect violence applied to the point of the shoulder, causing a fracture of the clavicle at the junction of its outer and middle thirds and a traction injury of the plexus.

*Penetrating wounds.*—Penetrating wounds involving the plexus are rare. I have reported one such case, in which the fifth anterior primary division was divided together with the descending branches of the cervical plexus, producing a typical Erb-Duchenne paralysis with loss of sensibility over the point of the shoulder.

In military practice injuries of the plexus, due to gunshot wounds, have been by no means uncommon.



*Infra-clavicular injuries of the plexus.*—In its infra-clavicular course, injury most often results from the direct pressure of the dislocated head of the humerus, occasionally from attempts made to reduce it by the heel-in-axilla method, sometimes from fracture of the upper end of the humerus or of the neck of the scapula.

The whole plexus may suffer, but more often the inner cord alone, rarely the outer. In unreduced dislocations of the humerus, pain and tenderness may result from changes in the nerves, due to pressure, and may indicate operation; in other cases paralysis may supervene from the same cause. In attempts at reduction either by manipulation or open operation, plexus injuries have been produced.

**Symptoms produced by injuries of the plexus.**—There are three well-known types of brachial plexus lesion due to supra-clavicular injuries and produced by indirect violence: the whole plexus, the upper arm type (Erb-Duchenne) and the lower arm type (Klumpke). As a permanent affection the upper arm type is the most common; more than 60 per cent. of the patients present this form of paralysis when seen by the surgeon. In many instances the symptoms noticed immediately after the accident diminish in extent; the initial distribution may be the whole plexus, some recovery ensues and the condition remains stationary as an upper arm type of lesion. In other cases muscles supplied by other roots are also affected; these, it is impossible to classify.

In infra-clavicular lesions the inner cord and the whole plexus are the only common types. Here a lesion of the whole plexus often becomes later, one of the inner cord only.

*The whole plexus.*—This results usually from indirect violence applied to the head or shoulder, rarely as the result of a dislocation of the humerus, or from attempts made to reduce it. It is a somewhat uncommon accident, for Bristow, in 1902, was only able to collect twenty-four instances of lesion of the whole plexus due to indirect violence. I have had three cases under observation.

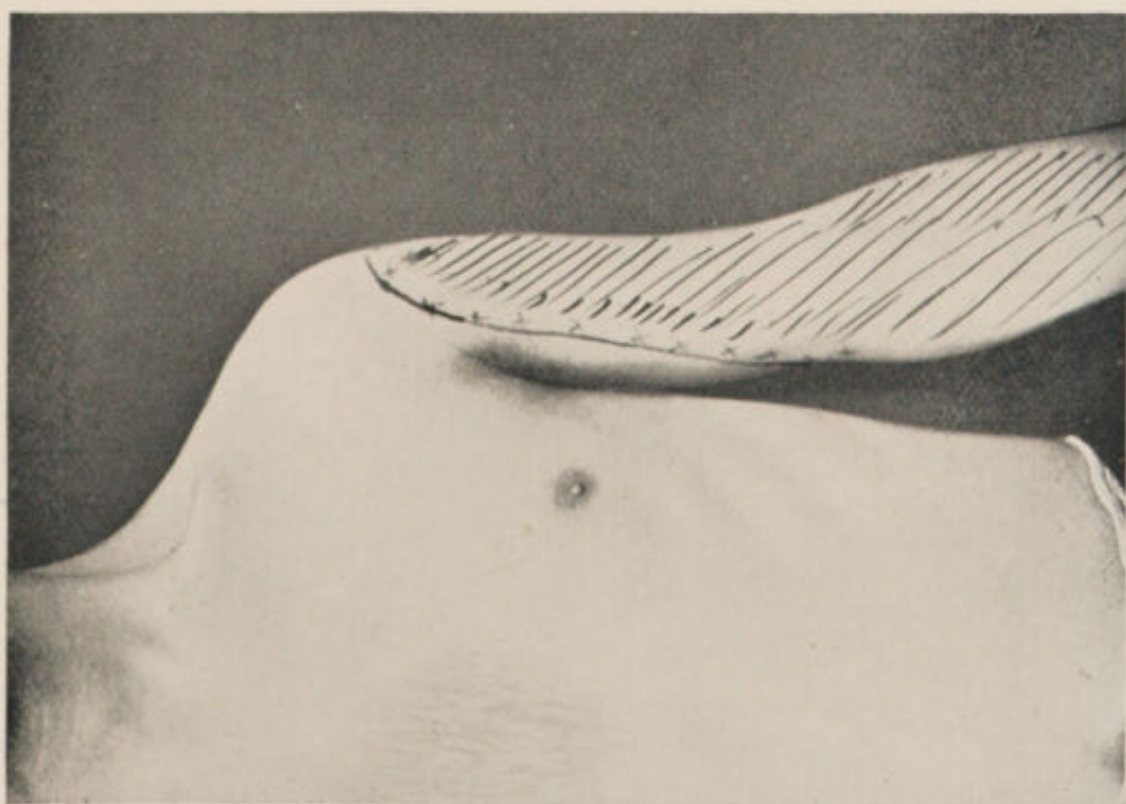
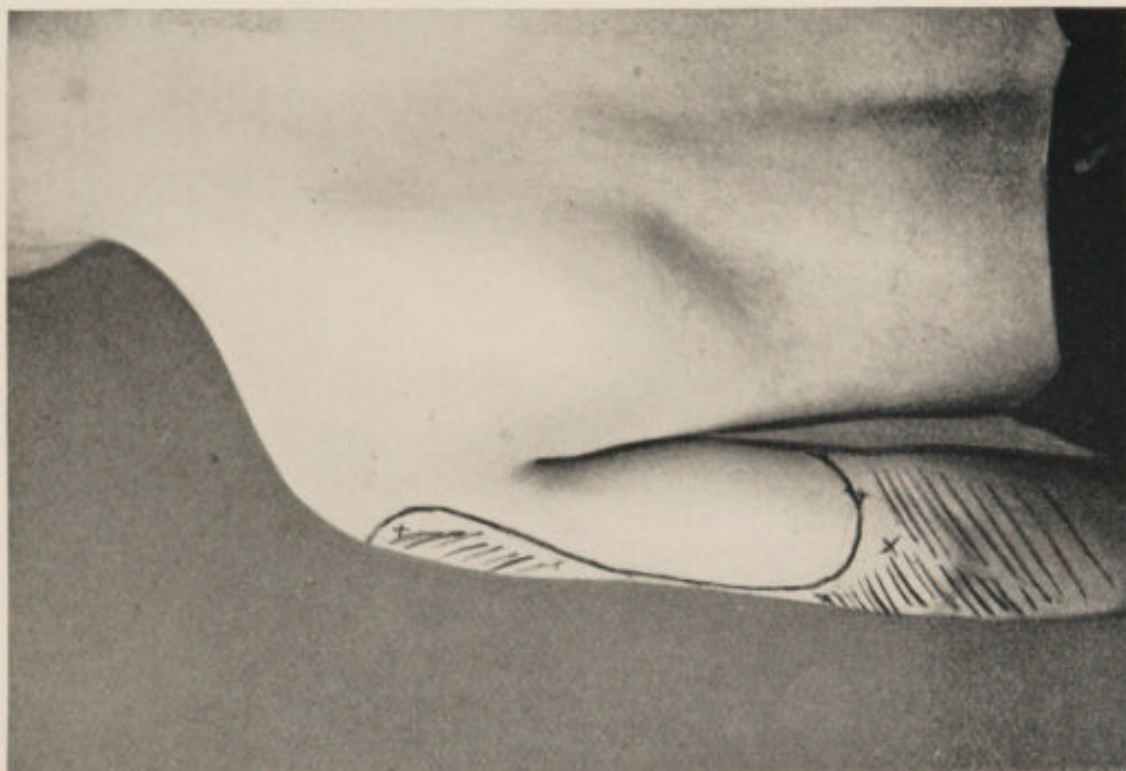
The symptoms produced by division of the whole plexus will depend to a certain extent upon the level of the injury, whether supra- or infra-clavicular, roots, primary divisions or cords. In a supra-clavicular division the loss of sensibility is the same whatever the level of the lesion.

Epicritic and protopathic sensibility are lost over the whole of the forearm and hand and over the outer surface of the arm in its lower two thirds, the area overlapping on to the anterior and posterior surfaces (*vide* Plates VIII and IX). The sensitive area on the point of the shoulder gives the full supply of the descending branches of the cervical plexus, that on the inner side of the arm the portion of skin supplied by the intercosto-humeral and small internal cutaneous nerves. Deep touch is lost over the forearm.

In lesions of this type the sympathetic is usually




PLATE VIII.



From a patient with complete division of the brachial plexus in the supra-clavicular region. To show the boundaries of the loss of epicritic and protopathic sensibility.







Unable to display this page



Unable to display this page

Unable to display this page

arm. The deltoid, spinati, biceps, brachialis anticus and supinators are paralysed. It was pointed out by Harris and Low that the radial extensors of the wrist and the pronator radii teres might be affected. In a patient upon whom I operated and found the fifth anterior primary division torn through, the radial extensors of the wrist were paralysed; this is the only case in which I have observed paralysis of these muscles from this cause, but in one patient with a lesion of the lower divisions they escaped together with the muscles usually supplied by the fifth. So far I have been unable to observe any affection of the pronator radii teres.

A patient with this paralysis is unable to supinate the forearm and to abduct the arm, and in most cases to flex the forearm. But he may regain some power of flexion of the forearm or possess this movement on coming under observation, although no recovery has taken place in the paralysed muscles. Flexion of the fully pronated forearm may be carried out by the muscles arising from the external condyle of the humerus, the extensors of the wrist becoming feeble flexors of the forearm.

There is, as a rule, no loss of sensibility accompanying this form of paralysis. This was first recorded by Duchenne and has been confirmed by all subsequent observers. Even when the fifth and sixth anterior primary divisions are divided together there may be no obvious change, but there is usually



some diminution or loss of epicritic sensibility on the outer surface of the arm and forearm. But although there is no loss of sensibility after division of the fifth, it is not uncommon to have complaint made of peculiar feelings, tickling, pins and needles, over the outer side of the arm. In several of these cases careful examination has revealed no objective change, the compass test was normally appreciated, and minor degrees of temperature accurately discriminated.

After this, as after other nerve injuries, the abnormal position of the limb may persist although the muscles have regained their power of voluntary movement, and these may remain permanently wasted although they react to stimulation with the interrupted current. Such cases have led to errors in diagnosis and probably to unnecessary treatment. Patients have come under my observation as examples of nerve injury suitable for operation, in whom examination revealed the fact that recovery had taken place, but the abnormal position of the limb had remained because of the lack or inefficiency of the after-treatment. In these cases the diagnosis of an old injury to the fifth cervical nerve is obvious, yet all the muscles are acting and react normally.

The injury to the fifth anterior primary division may be incomplete, and this incomplete division may be anatomical or physiological; it is very necessary to bear this in mind. Over-stretching of the fifth nerve may produce a hæmorrhage in its sheath, with

compression of the whole nerve, or, on the other hand, a rupture of some of its fibres. In the former case there is paralysis of all the muscles supplied by the nerve with the typical reactions of incomplete division; in the latter the fibres in the upper part of the nerve supplying the deltoid and spinati suffer, leading to paralysis of these muscles, without affecting the flexors of the forearm and the supinators. The reaction of degeneration may develop in the spinati and deltoid without the biceps and supinator muscles being in any way affected, or after an Erb-Duchenne paralysis the spinati and deltoid may be left as a permanent paralysis, the other muscles having recovered. I have described cases of this nature, upon one of whom I operated, and was able to demonstrate the lesion in the upper part of five, and by stimulation with the interrupted current to obtain contraction in the flexors and supinators, while the deltoid remained flaccid. As this form of paralysis follows a fall on the shoulder great care is necessary in diagnosis; these are the cases that are usually described as caused by an injury to the circumflex from a blow on the shoulder.

*Lower arm type of paralysis.*—This type, usually called after Klumpke, who described it fully, was first mentioned by Flaubert in 1827. It may arise from overstretching of the plexus, as the result of penetrating wounds, sometimes from involvement in growth. When resulting from traction the violence



affects the roots from below, as in falling from a height and grasping at a projection, or from over-flexion or over-extension of the neck; in these last cases it may be bilateral.

In a typical example of this paralysis all the intrinsic muscles of the hand are affected and the hand assumes the true claw shape. Sensibility is usually altered over the inner side of the arm and forearm, sometimes also on the ulnar border of the hand, the loss of sensibility to prick being in most cases larger than that to light touch. In some, the long flexors of the fingers suffer in addition, but it is probable that in these instances the eighth cervical is also injured, but lesions of this nature verified by operation are few, and further study is necessary before coming to any definite conclusion.

Characteristic orbital symptoms are present, due to involvement of the branches given from this nerve to the cervical sympathetic.

*The inner cord.*—Injury to this cord is the most common lesion of the plexus after an Erb-Duchenne paralysis. It is most often produced by a sub-coracoid dislocation of the humerus, and is rarely complete.

The muscles paralysed are those supplied by the ulnar nerve with, in addition, those intrinsic muscles of the hand supplied by the median, *i. e.* all the intrinsic muscles of the hand suffer.

Sensibility is affected over the inner (post axial)



Unable to display this page

**Treatment of brachial plexus injuries.**—Treatment is carried out along the lines already laid down. As most are subcutaneous injuries it is impossible to make the diagnosis of complete or incomplete division until sufficient time has elapsed to allow of the establishment of the reaction of degeneration. If at the end of fourteen days this is present, operation should not be delayed.

In supra-clavicular lesions of the whole plexus, good exposure is given through an incision starting at the posterior border of the sterno-mastoid muscle at the junction of its upper and middle thirds, and carried downwards and outwards to the junction of the outer and middle thirds of the clavicle; in some cases it will be necessary temporarily to divide this bone. When operation is delayed it is usually impossible to identify the individual nerves in the mass of fibrous tissue with which they are incorporated, and to bring ends which have been identified, into apposition after its removal. Patient and careful dissection may bring the upper ends into view; it may be impossible to identify the individual lower ends, and in many cases they have had to be sutured without exact knowledge. It is only when these cases are operated upon early that complete success is likely to ensue. No instance of perfect recovery after secondary suture of the whole plexus has been recorded.

The anterior primary divisions of five and six may be easily exposed through a similar incision. In

deepening this it is important to avoid injury to the descending branches of the cervical nerves. The posterior border of the sterno-mastoid is freed and drawn inwards and the nerves sought as they pass out from under cover of the scalenus anticus. The junction of five and six is brought into view after a little dissection, with the upper trunk formed by their junction and its division into three branches, the supra-scapular and the branches to the outer and posterior cords. Tracing the nerves up from their junction the seat of the injury is easily found. The supra-scapular nerve should always be examined; I have found it divided in addition to the fifth cervical. The phrenic nerve exposed on the anterior surface of the scalenus anticus must be avoided. In the cases in which the deltoid and spinati alone are paralysed and give the reaction of degeneration, the damaged portion may be excised and a portion of the radial nerve inserted, or these upper affected fibres may be anastomosed to the sixth anterior primary division.

In the typical lower arm type of paralysis the lesion is situated in the first dorsal anterior primary division, too high to admit of direct union. Temporary division of the clavicle is necessary to expose it, and anastomosis to the eighth cervical anterior primary division will be necessary in most cases.

In all cases of incomplete division and after suture the usual after-treatment must be persisted



in until recovery ensues, and care must be taken to see that the paralysed muscles do not become overstretched.

**Prognosis of brachial plexus injuries.**—There are a few points that have to be considered in regard to the prognosis of these lesions. The majority of the injuries are subcutaneous, and there is no doubt that these have a much worse prognosis than subcutaneous injuries of peripheral nerves elsewhere, due chiefly to differences in causation. In an important paper on the plexus, published by Warrington and Jones, they came to the conclusion, from the examination of cases under their care, that spontaneous recovery took place only in about 30 to 40 per cent. of the cases. Bruns, in a paper which has been widely quoted, came to a similar conclusion; he found that of cases of injury to peripheral nerves (excluding complete section and suture), treated without operation, 66 per cent. recovered; of plexus injuries, 26 per cent. only. But on looking through the cases on which he has based his figures it is at once obvious how different is their causation in the two groups. It is impossible to compare in this way, for example, a case of paralysis of the musculospiral due to a fractured humerus, or pressure during sleep, with an Erb's paralysis due to overstretching of the plexus. In discussing the reason for this relatively bad prognosis he seems to have lost sight of this difference in causation, and considered that in

many instances there was an injury to anterior horn cells. But there is no evidence that this is of common occurrence in brachial plexus injuries.

In considering the prognosis we have to take into account the cause of the symptoms, and to separate, for this reason, examples of injury above the clavicle from those below. The prognosis has to do first—and this applies to supra- and infra-clavicular injuries—with the distance of the injury from the periphery. To take a simple illustration, division or injury of the ulnar nerve at the elbow is of more serious import than when the injury takes place at the wrist, in the axilla than at the elbow; longer time is necessary before recovery ensues, consequently the greater the chance of permanent damage.

But the nature of the injury bears still more on the question. Situation has to do with time; causation may abolish altogether the possibility of spontaneous recovery. Years must elapse in a case of suture of the brachial plexus before the muscles can again be innervated, and unless the treatment in the interval has been kept up, the nerves find fibrotic and contracted muscles to act upon. Traction injuries make up a large proportion of plexus injuries, and it is easy to understand how little tendency there is in the more severe cases for spontaneous recovery to take place. A complicated scar is produced in which nerve-fibres have been divided at



different levels, hence any recovery that takes place is frequently imperfect.

The prognosis in infra-clavicular lesions is much brighter. These injuries, which result in most cases from dislocation of the humerus, in my experience invariably recover without surgical intervention, although of the cases recorded by Bruns five out of six did not recover power, but the only case reported by Warrington and Jones made an excellent recovery.

**Brachial birth paralysis.**—Although, as already pointed out, these lesions differ in no respect from similar nerve injuries in the adult, yet it will be convenient to discuss them apart.

Our present knowledge of the subject dates from 1872, when Duchenne described four infants who at birth presented what we now call Erb-Duchenne paralysis, without any alteration in sensibility. But these were by no means the first examples of paralysis of the arm described in newborn infants. Smellie, as early as 1768, mentioned its occurrence.

It has been demonstrated beyond doubt that the lesion is, as originally described by Duchenne, due to traction. The operative findings and the microscopical examination of portions of nerve removed by Clark, Taylor and Prout, and the post-mortem examinations recorded by Schmidt and others have settled the question. In all severe cases the cause of the paralysis is over-stretching of the plexus; in



some of the less severe cases the direct pressure of the accoucheur's fingers may be the cause.

The lesion is produced with almost equal frequency in breech and in vertex presentations. Thus, in ninety-three cases collected by Schumacher, fifty were vertex, forty were breech. The whole plexus may be affected or the paralysis may be of the upper or of the lower arm type. The injury is usually unilateral and the left arm is more often affected than the right. In about 80 per cent. of the cases the lesion is of the upper arm type. When the whole plexus is at first affected some spontaneous recovery usually occurs, and, as a rule, a residual upper arm paralysis is left.

Paralysis of the lower arm type is of great rarity, Stransky found it in twelve out of ninety-four cases, and Thomas was only able to collect sixteen examples, but this by no means represents its true frequency; it is much rarer than this, for many of the common upper arm type are not recorded. The lower arm type occurred most often as the result of breech presentations with extended arms, a few after face presentations. Batty Shaw has recorded a case in which it resulted from traction applied to the axilla. As a rule the paralysis is unilateral, but a few cases of bilateral lower arm palsy have been described.

It is not usual, at any rate in hospital practice, to find the lesion recognised at birth. The first

Unable to display this page

of the affected muscles tested. Those cases with marked tenderness rarely recover completely.

If, when the patient comes under observation, the reaction of degeneration is present, complete recovery apart from operation is unlikely.

Spontaneous recovery has taken place in about 70 per cent. of the cases that have come under my observation. In many the paralysis had completely disappeared by the time the child was brought to have its electrical reactions tested at the age of three months. Complete spontaneous recovery rarely takes place if no improvement is noticed by this date.

Brun's figures are more gloomy; he found 26 per cent. only of spontaneous recoveries.

*Treatment.*—These lesions are treated on the same lines as similar injuries of the plexus in the adult. The upper limb is kept at rest with the affected muscles relaxed, and as soon as all tenderness has ceased daily massage and passive movement employed. If relaxation of the affected muscles is not insisted upon permanent deformity may result, although the muscles regain their voluntary power and electrical excitability. The electrical reactions should be tested under an anæsthetic at the end of ten or twelve weeks. If the reaction of degeneration is present operation should be undertaken as soon as convenient. If the health of the child will not permit of operation, delay of a few months will probably affect the final result little, so long as the



correct non-operative treatment is being carried out.

The length of the incision necessary to expose the anterior primary divisions of the plexus will depend upon the extent of the injury. If the lower divisions are involved it will be necessary to divide the clavicle. In the usual upper arm type the junction of five and six is sought. Often the deep fascia is found thickened and adherent to the injured nerves. The supra-clavicular nerve must always be exposed and examined.

In many cases the nerves are found in anatomical continuity, but on palpating five at its junction with six a scar is found ; this must be excised and end-to-end union carried out. In some cases five may be found completely divided anatomically, in others the supra-scapular nerve may be discovered torn through in addition. If end-to-end union is impossible, complete peripheral anastomosis is carried out to a neighbouring nerve.

After closure of the wound the shoulder must be elevated so that no tension falls on the junction, and the limb kept in this position until the wound is soundly healed. For complete success the after-treatment must be faithfully carried out.

## CHAPTER XIV

Injuries to the Nerves supplying the Muscles of the Shoulder  
Girdle—The Long Thoracic Nerve: Winging of the Scapula  
—The Supra-scapular Nerve—The Nerve to the Rhomboids  
—The Circumflex Nerve.

**The long (posterior) thoracic nerve, nerve of Bell.**—This nerve, which supplies the serratus magnus, arises by three roots from the fifth, sixth and seventh cervical nerves, that given from the sixth being the most important; its upper two roots pass through the scalenus medius muscle, and after uniting on its anterior surface lie here for a short distance. The lower root does not perforate the scalenus medius, but passes in front to join the trunk opposite or below the first rib. The upper roots are thus exposed to injury in the neck.

Paralysis of the serratus magnus, the result of injury, is seen most often in males between the ages of twenty-five and forty, commonly on the right side. The nerve suffers in most instances as the result of direct pressure applied to the supra-clavicular region in those whose occupation entails carrying weights on the shoulder. It has been said to be due to compression of the nerve between the

Unable to display this page



cases a combined lesion, due to paralysis of the serratus magnus and lower trapezius, and the symptoms produced are as follows: Pain is often complained of radiating from the supra-clavicular region. There is a conspicuous winging of the scapula; on marking out the spine and lower angle of each scapula and comparing their position, it is seen that in addition to the prominence of the lower angle on the affected side its spine is more horizontal and the lower angle nearer the mid-line than the upper and than the corresponding lower angle on the sound side. The patient is unable to raise the affected arm in front of the body above the level of the shoulder, and to perform any forward pushing movements; any attempt to do so at once increases the winging, and the whole scapula can be pushed away from the thorax by backward pressure on the hand when the arm is raised.

When the serratus is paralysed alone the deformity when the arm is at rest is hardly noticeable, and may be overlooked unless the rule is adopted of marking out the land-marks on the scapula. The patient is unable to raise the arm above the level of the shoulder in front of the body, and to perform forward pushing movements above a horizontal plane passing through the shoulder; attempts to perform this latter movement causes the winging to become more marked. Pushing movements below this plane are possible.

The slight winging of scapula, produced by paralysis of the lower trapezius alone, at once disappears on raising the arm above the level of the shoulder in front of the body, thus throwing the serratus magnus into action. It becomes increased when attempts are made to push below the level of the shoulder.

*Treatment.*—In the large proportion of cases the injury is incomplete and does not call for operative interference. Absolute rest to the limb should be ordered, the elbow being supported. The usual treatment with massage, etc., must be carried out. If the reaction of degeneration develops operation must be considered. Direct suture is out of the question, except in the cases in which the nerve is injured in the course of a surgical operation. In the cases in which the lesion is due to pressure, anastomosis to the posterior cord should be carried out if necessary, or the sterno-costal portion of the pectoralis major transplanted from the arm to the inferior angle of the scapula.

*Prognosis.*—The large proportion of these cases recover without surgical intervention if treatment is carefully carried out.

**The supra-scapular nerve.**—Injury to this nerve alone is an accident of great rarity. Eleven cases have been recorded, most of them due to carrying weights on the shoulder or from falls on the outstretched hand. In two cases of brachial birth



paralysis I found complete rupture of this nerve together with the anterior primary division of the fifth cervical nerve; none of the cases other than these have been verified by operation, and it is probable that in some, the fibres which go to form this nerve were affected as they run in the fifth anterior primary division.

Injury to this nerve affects the spinati muscles. These become wasted and the spine of the scapula unduly prominent. External rotation of the arm, though weak, is still possible, the teres minor and posterior fibres of the deltoid carrying it out. But the spinati muscles are usually affected with the other muscles supplied from the fifth cervical nerve. In these cases external rotation of the arm cannot be performed.

*Treatment.*—An isolated paralysis of the spinati should be treated upon the usual lines; even if completely divided it is hardly of sufficient import to call for operative interference. Electrical examination of the infra-spinatus muscle is easy, but the supra-spinatus is covered by the trapezius; its electrical reactions cannot, therefore, be satisfactorily tested.

**Nerve to the rhomboids.**—Isolated injury to this nerve is almost unknown and is of slight importance; accompanying the paralysis of other muscles, it is an important localising aid.

It may be injured with the serratus magnus and



lower trapezius as the result of direct pressure above the clavicle, in penetrating wounds or divided during the course of operations upon the neck.

The deformity produced by paralysis of the rhomboids is characteristic. On marking out the spines and lower angle of the scapula it is seen that the lower angle is further from the mid-line than the upper, the spine makes a more acute angle with the mid-line than the one on the sound side, and the whole scapula is dropped (*vide* Plate X, fig. 1).

**Circumflex nerve.**—An injury to this nerve is by no means so frequently met with as the accounts in the text-books would lead one to believe. Paralysis of the deltoid muscle, however, following an injury to the shoulder is common, but is due in most cases, as I have shown, to injury to the fibres supplying this muscle as they run in the fifth cervical anterior primary division, and is usually accompanied by paralysis of the spinati muscles. Most of the so-called examples of circumflex injury following a fall or blow on the shoulder are of this nature. In a few the wasting is secondary to disease of the shoulder-joint and examination reveals no paralysis.

The usual explanation given of an injury to the circumflex due to a blow on the shoulder is that the nerve receives an injury in its intra-muscular course; no such case has come under my notice. In miners who lie for long periods on the side the muscle may be paralysed by direct pressure on the

PLATE X.

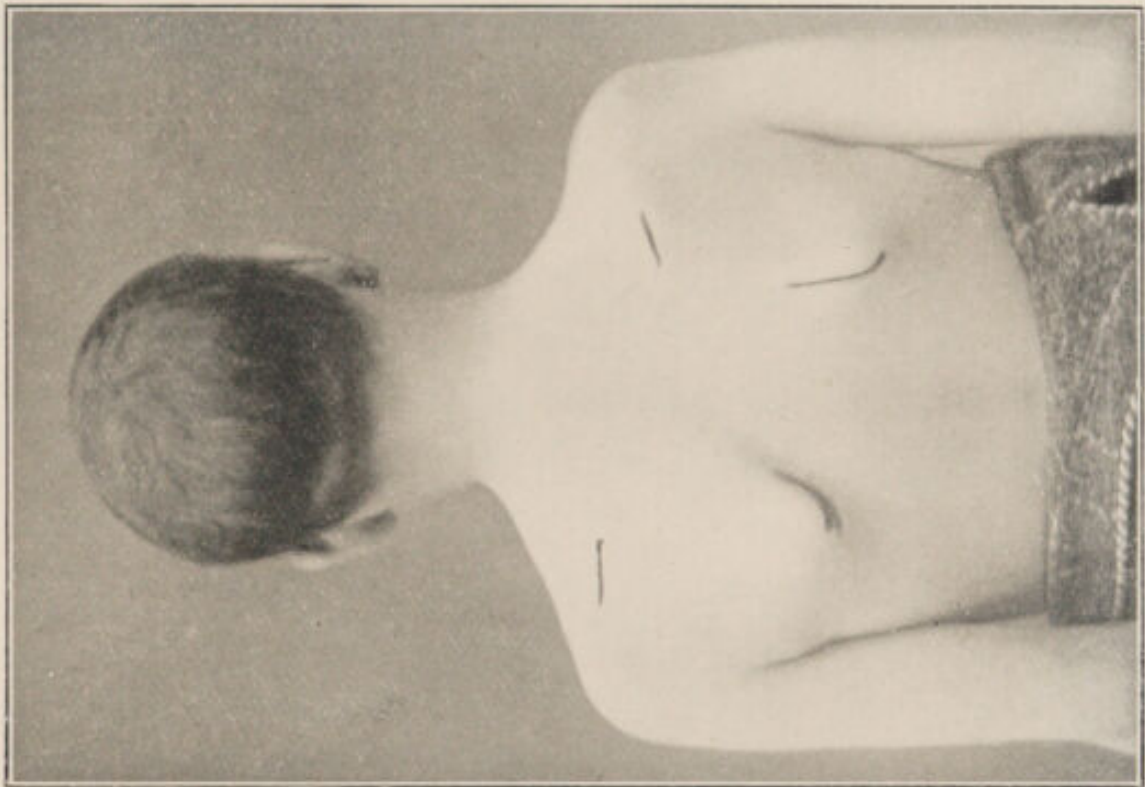

FIG. 1.—To illustrate the deformity produced by division of the nerve to the rhomboids. (R.)

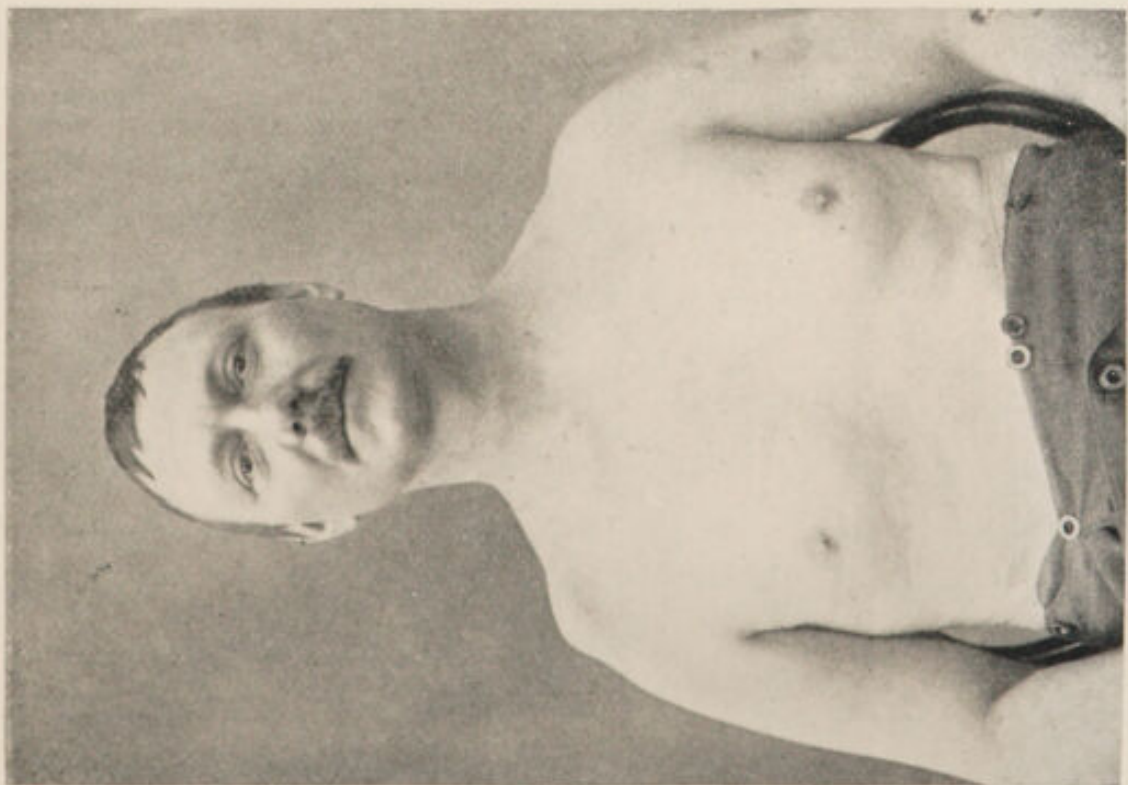

FIG. 2.—To show dropping of humerus in paralysis of the deltoid and spinati muscles.





terminal filaments of the nerve, and the nerve may be involved as the result of inflammation of the sub-deltoid bursa. It is, however, more liable to injury as it passes round the neck of the humerus. Here it may be pressed upon by a crutch, the head of the humerus in sub-glenoid dislocations, or injured in fractures of the neck of the scapula or surgical neck of the humerus.

An injury to this nerve causes well-defined symptoms. The deltoid is wasted and the acromion process prominent, but the head of the humerus does not tend to fall away from the glenoid cavity as it does when the spinati are affected in addition (*vide* Plate X, fig. 2) ; this is an important diagnostic point, but unfortunately it is not always present, the long tendon of the biceps in some cases is able alone to keep the head in position, but in the patient from whom the illustration was taken neither the biceps nor the clavicular fibres of the pectoralis major were paralysed. The paralysis of the deltoid muscle is easy to detect in recent cases ; in old-standing ones it is by no means so simple. As pointed out, first by Duchenne, later by Ross, Kennedy and Kron, other muscles take its place and elevate the arm ; these are the spinati, the clavicular fibres of the pectoralis major and serratus magnus.

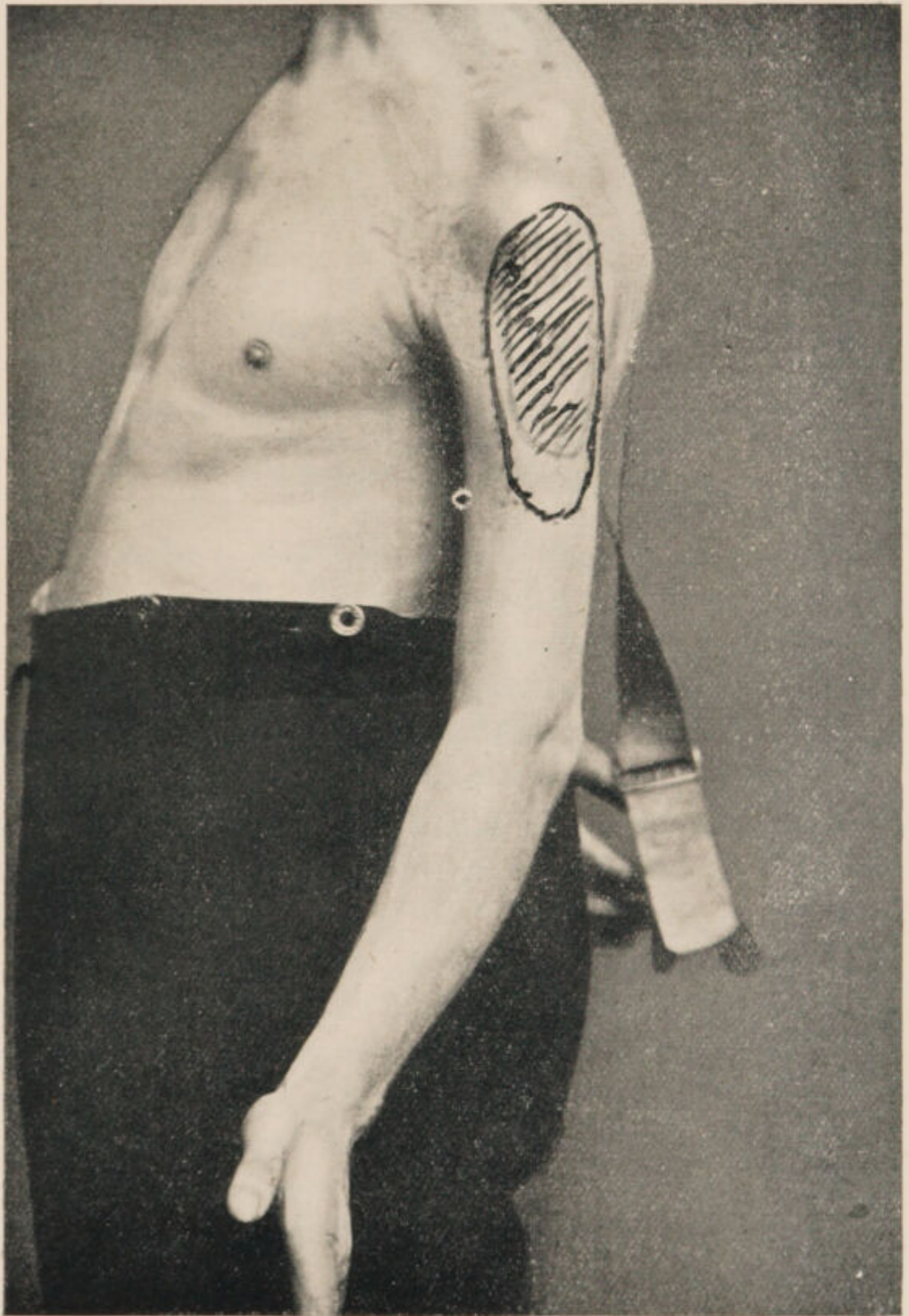
The paralysis of the teres minor cannot always be determined.

Sensory changes always accompany an injury to this nerve of sufficient severity to cause paralysis of the deltoid. Complete division of the nerve produces a loss of epicritic and protopathic sensibility over the area seen in Plate XI. There is, as a rule, no loss of deep touch. In incomplete lesions the loss is correspondingly less and follows the usual rules.

Careful examination is necessary before coming to the diagnosis of an injury to the circumflex nerve. If there is no sensory change this can certainly be excluded. All the muscles of the shoulder girdle must be examined and the condition of the spinati specially noted.


*Treatment.*—The injury is usually incomplete and treatment proceeds on the usual lines. But even if the lesion be complete and the reaction of degeneration present, operation is by no means always necessary. The sensory loss is over an unimportant region and the paralysis may be fairly well compensated by other muscles. The age of the patient and his occupation must be considered. In most cases sufficient abduction is obtained by training the neighbouring muscles to take the place of the deltoid. If, however, perfect abduction is essential, the nerve may be exposed and the condition dealt with by operation. This is best done through an incision parallel to the posterior border of the deltoid muscle.





Loss of sensibility resulting from division of circumflex nerve.





THE END OF THE WORLD

## CHAPTER XV

The Diagnosis of Brachial Plexus Injuries—Alterations in the Position of the Scapula—Diagnosis from Injuries of the Cervical Portion of Spinal Cord—Localising Signs.

IN making a diagnosis the following points have to be ascertained : the situation and nature of the lesion, whether spinal cord or peripheral nerves, whether above or below the clavicle, and its exact position in the plexus. As in the case of all other nerve injuries, the diagnosis of complete or incomplete division must be made from the distribution of the symptoms and the electrical examination of the affected muscles.

Time and patience are needed to make the diagnosis in these cases. It is of the utmost importance to have the patient stripped so as to expose the whole of both upper limbs, including the shoulder girdle muscles, and the routine examination (*vide* p. 45) must be carried out.

The condition of the muscles passing from the trunk to the scapula is important. The midline of the body and the spines and lower angles of the scapulæ must be marked in ; only in this way are

Unable to display this page



clavicular fibres of the pectoralis major and taken up above the head by the serratus magnus.

The winging of the scapula commonly seen, due to pressure above the clavicle, results from paralysis of both serratus magnus and lower trapezius. In these cases the winging is well marked and *all* pushing movements in front of the body are impossible.

The nerve to the rhomboids is rarely injured. The fifth cervical nerve usually suffers after it has given off this branch, but in the patient from whom fig. 1, Plate X, was taken it was divided in a penetrating wound above this point. Its division produces a characteristic deformity of the scapula. The lower angle is further from the mid-line than the upper, and the spine of the scapula makes a more acute angle with the mid-line than on the sound side. Diagnosis should be easy; its recognition is of great importance in localisation.

The position of the upper limb is often indicative of the injury. Dropping of the humerus, with elongation, should always be looked for; it indicates a supra-clavicular lesion. The position seen in Erb-Duchenne paralysis and the abducted arm, when this group is spared, are also characteristic, but it must be remembered, as already pointed out (*vide* p. 62), that certain of these groups may be affected in injuries of the spinal cord. The grouping of the affected muscles is of importance in the diagnosis of

lesions of the plexus from those of peripheral nerves ; for example, paralysis of the Erb group of muscles or the whole of the intrinsic muscles of the hand alone could follow no lesion of one peripheral nerve. But it is of little importance in the differential diagnosis of lesions of the cord from plexus lesions ; both these groups may be due to injury of anterior horn cells ; we must rely on other signs.

The sensory examination must be carried out in every case. Sensibility is always lost, and this loss is obvious to the patient and surgeon, in injuries of the whole plexus, but this is not the case in injuries of single anterior primary divisions, although the patient may complain of alterations in sensibility. In lesions of the spinal cord the patient is often unconscious of any alteration of sensibility on the side of the body opposite to the lesion.

The diagnosis of a lesion of the plexus from one of the spinal cord is important. It is not sufficiently well recognised that a lesion of the cervical portion of the cord may closely simulate a brachial plexus lesion. It has too long been the custom to consider an injury of this part of the cord as almost of necessity fatal, and a broken neck synonymous with sudden death. But a fracture of the cervical spine not infrequently occurs in which, as I have pointed out, no symptoms suggestive of this accident are present at the time of the accident, and it is only later that deformity occurs.



These injuries are usually due to flexion : For example, a man, while carrying a weight on his back, slips, or a weight from a height falls upon his back producing over-flexion of the cervical spine ; they may also arise as hunting accidents or from diving into shallow water. Jonathan Hutchinson as far back as 1866 described typical cases of this nature, but considered that they were due to injury of nerve roots rather than to the cord itself. It is to a great extent owing to the work of Thorburn and Page that we know the nature of these injuries. The former pointed out that an injury to the spinal cord might occur without a fracture from over-flexion of the spinal column, and that it consisted in a hæmorrhage into the grey matter, particularly in the region of the anterior horn.

These cases are by no means uncommon ; several have come under my observation. In most instances there are definite signs of interference with the functions of the cord below the level of the lesion, and the case may at first be considered one of " concussion " of the spinal cord, and it is not until some days have elapsed that the local destructive lesion is manifest. In others—and in these most difficulty arises—the hæmorrhage is small, and may lead to but slight interference with conduction in the cord, and nothing may be noticed beyond increased reflexes in the lower limb of the same side as the lesion.



A typical case of hæmatomyelia illustrates well the points given in Chapter V. There is destruction of a portion of the anterior horn; consequently some muscles, usually the intrinsic muscles of the hand, remain permanently paralysed and may give the reaction of degeneration. The muscles of the same side below the seat of the lesion are more or less spastic. The reflexes are increased and Babinski's sign present and there is loss of pain, heat and cold on the opposite side of the body below the lesion. Of this the patient is often unaware until his attention is drawn to it by accident or testing. It should also be remembered that signs of interference with the cervical sympathetic may be present, the pupillary fibres descending from their centre in the medulla being interrupted in the cord. The following is typical of this group :

"A male, aged forty-one years, came to my out-patient department at the London Hospital in December, 1906, on account of abdominal pain. Noticing that the interossei muscles of his left hand were wasted, I questioned him and found that twenty years previously he had struck his head while diving into shallow water. He lost power in his limbs at once but did not lose consciousness ; power returned slowly to all except the left leg and the left hand. The intrinsic muscles of the left hand were wasted, and except the abductor and opponens pollicis were wasted and paralysed and gave the reaction of

Unable to display this page

Unable to display this page



to raise the right arm from the side. Nine months previously he had fallen on the point of his shoulder.

"The spinati and deltoid were wasted and paralysed and gave the reaction of degeneration. The biceps, brachialis anticus and supinator longus were unaffected. There was no sensory loss.

"On April 4th, 1905, I explored the plexus above the clavicle and found a scar in the upper part of the fifth cervical anterior primary division, just before it joins with the sixth; this scar was adherent to the tissues above. After freeing I stimulated it with the interrupted current, and found that the biceps and supinators contracted vigorously but not the deltoid or spinati."

The paralysis of the spinati in these cases is often overlooked and the condition considered due to an injury to the circumflex nerve. To avoid error the examination must be thorough, and the condition of all the muscles innervated by the fifth cervical nerve investigated. The sensibility of the area on the outer surface of the arm supplied by the circumflex nerve must be tested. The rule can be laid down that paralysis of the deltoid without sensory change is due to interference with the functions of the fifth cervical nerve and not with the circumflex; whenever this nerve is injured there is impairment or loss of sensibility.

The diagnosis between a complete and an incomplete injury of the plexus may not be so simple as in

the case of injury to one peripheral nerve. From the sensory standpoint it must be remembered that isolated injury of an anterior primary division is rarely accompanied by sensory change, consequently we have to rely entirely on our examination of the muscles. It must also be borne in mind that incomplete interruption of continuity of the fifth cervical may lead to complete division of those fibres which supply the spinati and deltoid with resulting reaction of degeneration in these muscles.

A knowledge of the electrical reactions associated with incomplete division is necessary. The following is an illustrative case :

“C. R—, aged nineteen years, was admitted into the London Hospital under my care for operation as a case of traumatic Erb’s paralysis, on November 7th, 1905. Three months previously he had fallen off his bicycle, pitching on to the side of his head. Bruising came out in the neck some days after the accident.

“The upper limb was in the position typical of this injury, and the spinati, deltoid, biceps and supinators were wasted and paralysed. They did not react to the interrupted current, but reacted in the typical manner to the constant, briskly to the normal pole and with a smaller current than was necessary to produce contraction in the muscles of the sound limb.”

Had they given the reaction of degeneration I

should certainly have operated and resected the damaged portion of the nerve. He was treated by massage and exercises, and at the end of nine months from the date of the injury no difference could be told on superficial examination between the two limbs.



## CHAPTER XVI

Nerves of the Upper Limb (excluding Brachial Plexus and those supplying Shoulder Girdle Muscles)—Musculo-cutaneous Nerve—Musculo-spiral Nerve: Method of Injury: Motor Symptoms: Sensory Symptoms: Division without Loss of Sensibility—Radial Nerve—Ulnar Nerve: Method of Injury: Injury in Three Positions: True and False Adduction of the Thumb: Recovery and Prognosis: Injuries in Fractures: recent; old—Dislocation of the Ulnar Nerve—Examination and Diagnosis of Ulnar Injuries—Median Nerve: Method of Injury: Sensory Symptoms: Motor Symptoms: Recovery and Prognosis—Simultaneous Injury of Median and Ulnar: Method of Injury: Symptoms: Method of Recovery and Prognosis.

**Musculo-cutaneous nerve.**—This nerve, which continues the outer cord of the brachial plexus, after the outer head of the median has been given off, supplies the coraco-brachialis and biceps muscles, with the brachialis anticus in part; it then becomes cutaneous and, as the external cutaneous nerve of the forearm, supplies the pre-axial (radial) side of the forearm on its anterior (flexor) and posterior (extensor) surfaces.

Isolated injury of the trunk of this nerve is rare; only fifteen examples have been recorded, and eleven of these were due to injury in the removal of tumours and the result of gunshot wounds. On the

Unable to display this page

individual patients with the size of the lower external cutaneous branch of the musculo-spiral, and fades gradually into the normal sensibility of the post-axial half of the posterior surface.

Section of the anterior or posterior branches of this nerve alone usually fails to produce any alteration in sensibility. I have divided the anterior and the posterior branch in different patients, and failed to produce any sensory loss that could be discovered even with the most careful testing, and the patient suffered from no subjective symptoms.

**The musculo-spiral nerve.**—This nerve is, from the surgical point of view, one of the most important in the body. It shares with the median and the ulnar the distinction of being more often affected by injury than any other nerve. It is also the nerve upon which plastic operations for the restoration of anatomical continuity have to be most often carried out. The result of division of this nerve is striking, and its injury is seldom overlooked.

The nerve is most often involved in the lower third of the arm; only in crutch, anæsthetic, "Saturday-night" paralyse and the rare penetrating wounds is it affected elsewhere.

The majority of the injuries are physiological, usually from direct pressure, the result of fractures of the humerus, and that causing "crutch" and "anæsthetic" paralysis; it is rarely divided by a penetrating wound, but I have known the accident



happen during the course of wiring an ununited fracture of the humerus (*vide* p. 237). Injury to the musculo-spiral nerve sometimes results from a forward dislocation of the head of the radius; one such case has come under my care and a similar one has been recorded by Borchard.

The posterior interosseous branch may suffer in dislocations of the upper end of the radius and in fractures of its neck, and has been divided as it is passing through the supinator brevis in operations upon old dislocations and fractures. The radial nerve may be divided in penetrating wounds in the region of the wrist, usually in association with branches of the external cutaneous.

In hospital practice, sleep and Saturday-night paralyses are common, due to direct pressure upon the nerve. Slight weakness in the muscles supplied by the musculo-spiral nerve and tingling in its sensory distribution are common, and have been experienced by all who have fallen asleep with an arm hanging over the back of a chair. But the discomfort produced is sufficient to arouse a normal individual, and the paralysis is, therefore, rare and transient. But it is otherwise when the patient is under the influence of alcohol; paralysis is, in this condition, common as the result of direct pressure, and constitutes the sleep and Saturday-night paralyses.

Crutch paralysis of the musculo-spiral nerve is often seen; it may be avoided by padding the head

of the crutch and employing cross pieces in order that the weight of the body may be taken by the arms as well as the axilla.

Injury to the nerve as the result of a fractured humerus is common. Bruns found involvement of the nerve in 8 per cent. of all cases of fracture of the humerus, and these figures do not exaggerate its frequency, in my experience, although Reithus found it only in 4 per cent. It suffers most often in fractures involving the lower and middle thirds. It may be injured at the time of the accident—primary, or involved later—secondary; the latter is probably the more common. In the primary cases the injury may be anatomical or physiological, though the latter is the more usual. The nerve may be lacerated, ruptured, pressed upon by, or between, the ends of the bone, or contused; there is no symptom that will tell us which has happened, and, at first, if the injury is complete or incomplete.

In the secondary cases the nerve may be embedded in fibrous tissue or callus, or pressed upon, or stretched over, the displaced end of a bone.

*Motor symptoms.*—The appearance produced by paralysis of the muscles supplied by this nerve is characteristic: the wrist is helpless and dropped, and there is a marked prominence on the dorsum of the hand if the position has persisted for some weeks, due to overstretching of the dorsal ligaments of the wrist and subluxation of the carpus.



The patient is unable to extend the wrist owing to the paralysis of the *extensores carpi ulnaris et radiales*; the paralysis of the *extensor communis digitorum* makes extension of the fingers at the metacarpo-phalangeal joints impossible. On attempting this movement the wrist becomes flexed owing to the synergic action of the carpal flexors, and the fingers often become extended at the inter-phalangeal joints and flexed, and the metacarpo-phalangeal by the unopposed action of the *interossei* and *lumbricales*, which usually act with the common extensor in extension of the fingers. All the extensor muscles of the thumb are paralysed and extension of the terminal phalanx of the thumb is always impossible, but care must be taken in interpreting the movement which takes place at the metacarpo-phalangeal joint; the *abductor pollicis* is attached to the outer side of the base of the first phalanx and often sends a slip to the tendon to the *extensor longus pollicis*, its contraction may produce a movement resembling extension, but palpation over the tendons of the extensors of the thumb will at once reveal its nature. Paralysis of the triceps is unusual, the nerve usually being involved below the point at which its branches of supply are given off.

Paralysis of the triceps is easily recognised; active extension of the forearm is impossible.

*Sensory symptoms.*—It has become one of the commonplaces of surgery that the musculo-spiral



nerve may be divided without causing any loss of sensibility. Savory first recorded this in the following careful manner :

“When testing that portion of the skin of the hand which is supplied by branches of the radial nerve we were not a little astonished to find that it was but little impaired. When the skin . . . was lightly pricked the man cried out sharply. He could distinguish in the same region two points of contact when they were not more than an inch apart, both in the long and in the transverse axis of the hand ; but when they were closer than this on any part of the back of either hand or forearm he confused them, and, indeed, in comparing the sensibility of this region with that of the inner portion of the back of the hand and two inner fingers, or with the corresponding part of the opposite hand, no very striking difference could be detected. All portions, too, of the back and sides of the middle finger appeared to be equally sensitive. He could distinguish also between contact of hot and cold bodies in this region as well as in other parts.”

Many similar cases have been recorded. Among them are two reported by Kennedy, in which the nerve was divided in the lower third of the arm without producing any marked sensory change ; one recorded by Parry, in which two inches of the nerve was destroyed without producing any definite loss of sensibility ; and Ledderhose reported a case in which

the nerve was ruptured as the result of a compound fracture of the humerus. The following is another case of this nature :

“ A boy, aged nine years, came under my care on account of musculo-spiral paralysis following operation on a mal-united fracture of the humerus. At the operation I discovered that the nerve had been completely divided just above its bifurcation. Both before and after I had performed secondary suture I was unable to find any sensory change ; the compass test was perfectly appreciated and minor degrees of heat and cold discriminated and no subjective symptoms were present.”

It is obvious that complete division of the musculo-spiral nerve in its lower third produces no alteration in the sensibility of the forearm and dorsum of the hand, and this is the position in which the nerve is most often injured. But division above the point at which its external cutaneous branches are given off, or division in the lower third together with injury to these branches or to the posterior division of the external cutaneous nerve of the forearm (musculo-cutaneous), produces a definite loss of sensibility on the dorsum of the hand. But the extent and degree of this loss varies according to the relative size of the posterior branch of the external cutaneous. Fig. 12 shows the usual loss resulting from division of the nerve in the upper third of the arm. The diagram was taken from two patients in whom the



nerve was severed in the axilla as the result of a gunshot wound, and corresponds with that recorded by Clement Lucas, Kennedy and Reger.

Thus, division of the nerve above the point at which its external cutaneous branches are given off produces a loss of sensibility on the dorsum of the hand. The loss is of both epicritic and protopathic sensibility, the former slightly larger in extent than

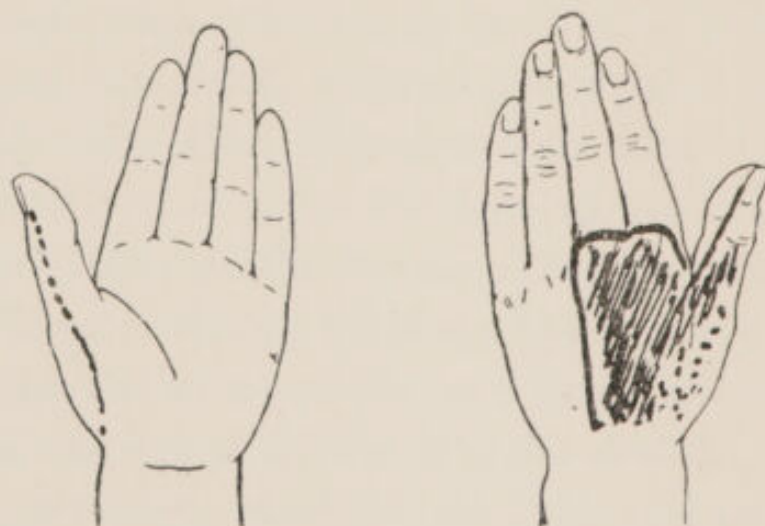


FIG. 12.—Loss of sensibility produced by division of musculo-spiral nerve in the upper third of the arm. Dotted area designates incomplete loss.

the latter, especially towards the radial side of the hand. There is no loss of deep touch. Towards the ulnar side the loss of both forms of sensibility is well defined, but on the radial it fades away into the normal sensibility of the palm. Instances have been recorded in which a loss of sensibility has been present in the forearm; I have not observed this and believe that it only occurs when the posterior



branch of the external cutaneous is divided in addition to the whole musculo-spiral.

**The radial nerve.**—As would be anticipated, section of this nerve in the upper two thirds of the forearm produces no loss of sensibility. I have had the opportunity of examining patients in whom portions of this nerve have been removed for nerve transplantation without causing sensory loss. On the

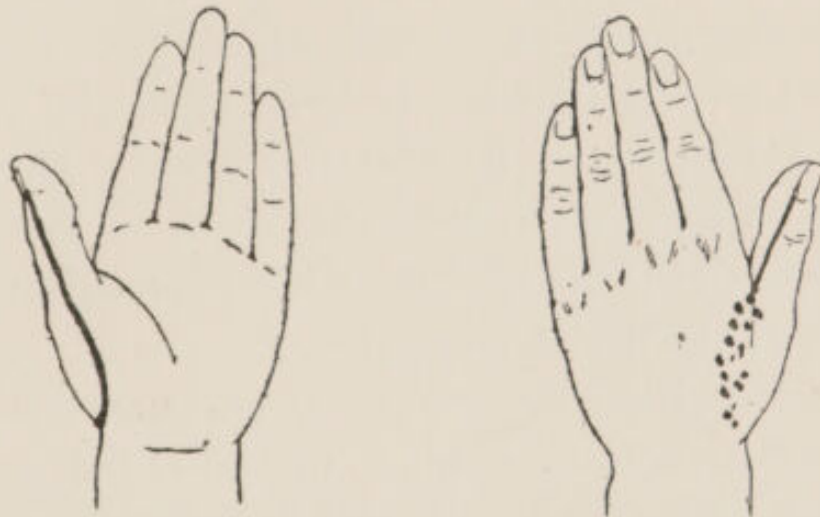


FIG. 13.—To illustrate the loss of epicritic sensibility produced by division of the radial nerve in the lower third of the forearm.

other hand, division in the lower third of the forearm, after it has become associated with branches from the posterior branch of the external cutaneous nerve has a definite effect on sensibility. Fig. 13 is taken from a patient in whom I divided the nerve just after it had passed beneath the tendon of the supinator longus. This produced a loss of sensibility to light touch, with a well-defined border towards

the thenar eminence and on both sides of the thumb, but on the ulnar side, ill-defined, and fading away into the normal sensibility of the dorsum of the hand; there was no loss of protopathic sensibility. This corresponds to the result seen in several examples of accidental section in this situation that have been under my care.

But wounds of the dorsal surface of the wrist and forearm often produce a larger area of loss, a loss of both protopathic and epicritic sensibility, deep sensibility remaining intact. In these cases the external cutaneous nerve or its posterior branch have been divided in addition to the radial, and in some cases also, some of the fibres of the lower external cutaneous branch of the musculo-spiral.

Division of the external cutaneous nerve or of its posterior branch, in addition to the radial, produces an area of loss of epicritic and protopathic sensibility well defined towards the thenar eminence, ill defined and of varying extent towards the ulnar. Fig. 14 was taken from a patient in whom, as the result of an accidental wound, the radial and external cutaneous nerves were divided in the lower third of the forearm, and corresponds exactly to that found when these two nerves were intentionally divided on two occasions. By comparison with Fig. 12 we see the extent of skin usually supplied by the descending branch of the musculo-spiral.

Simultaneous division of the radial and external



cutaneous nerves in any part of their course produces a curious dissociation of sensibility. In Fig. 14 it will be seen that this area is roughly triangular in shape. Prick and the extreme degrees of temperature cannot be appreciated over the whole affected area, but light touches with cotton-wool and the minor degrees of temperature can be recognised over the triangular area by an intelligent patient. The

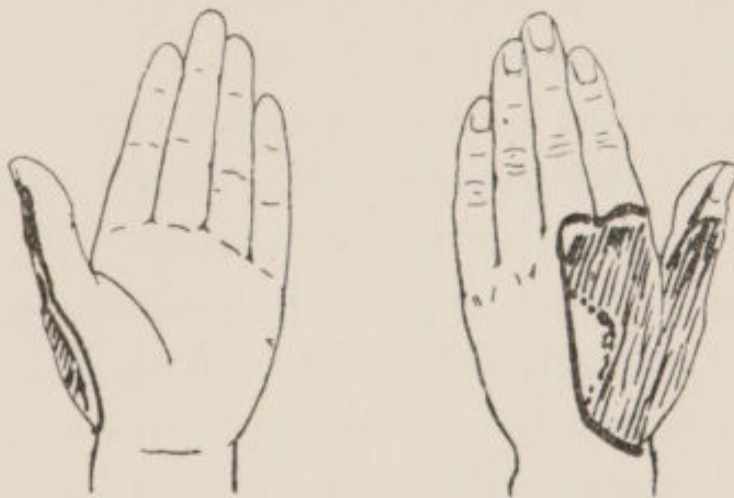


FIG. 14.—To illustrate the loss of sensibility produced by section of the radial and external cutaneous nerves. The triangular area, bounded towards the ulnar side by a continuous line, towards the radial by a dotted line, represents the area sensitive to light touch but insensitive to prick.

lower external cutaneous branch of the musculo-spiral appears, therefore, to supply a larger area with epicritic than with protopathic fibres. This forms no exception to the rules already laid down, that division of a peripheral nerve produces a loss of sensibility to light touch greater in extent than that of sensibility to prick, for when the whole musculo-spiral is divided this is the case.



Unable to display this page

or has lasted for a longer time, the typical reactions of incomplete division are present. Recovery, if the cause has been removed, commences in these cases in from four to twelve weeks. If the reaction of degeneration is present, recovery rarely ensues without resection of the damaged portion and end-to-end suture.

After primary or secondary suture the prognosis is better than after suture of any other nerve of the body. This is probably an accident of supply only; no sensory loss is present after division in the usual situation; in the rare instances in which the nerve is divided above the origin of its external cutaneous branches, the area of altered sensibility is situated over a region where it will in no way impair the efficiency of the hand for work. The muscles supplied by the nerve are not employed in fine movements of the fingers to the same degree as those supplied by the median or ulnar. Perfect recovery may be expected in about a year from the time of suture.

The march of recovery after incomplete division and after complete division and suture is the same. Those muscles nearest the seat of the lesion first regain their voluntary power. When the nerve is divided in the lower third of the arm the supinator longus first recovers, followed in a short time by the extensors of the wrist, then the common extensor of the fingers, and finally those of the thumb.

During the whole period of paralysis the affected muscles must be kept from overstretching; the wrist must not be allowed to remain in the dropped position but supported on a splint. The usual after-treatment must not be neglected.

If the paralysis result from the pressure of crutches suitable crutches must be ordered that will exercise no pressure upon the nerve.

Examination must be made in all fractures of the humerus for the signs of nerve injury. The primary cases, though the less numerous, are the more serious, and should be explored as soon as possible. If this were done the need for nerve transplantation after injury would rarely arise. In most of the cases, however, the paralysis is not discovered until the splints have been removed. If the signs point to a complete division of the nerve operation should not be delayed. The surgeon should be prepared to deal with a gap in the nerve that cannot be bridged over by nerve stretching. In these cases the radial nerve should be used (*vide* p. 96). Resection of bone should be reserved for cases of ununited fracture complicated by division of the nerve, which will necessitate freshening the ends of the bone. The bone should never be divided solely for the purpose of shortening the limb.

In most cases of secondary involvement, and in those cases in which the injury is discovered on the removal of splints, the reactions are those of incom-



Unable to display this page

Unable to display this page

entailing constant movements at the elbow, such as glass-workers, cigarette-makers.

The effect of division of the ulnar nerve must be studied, as it arises in three situations—(1) at or above the point at which the motor branches to the forearm muscles are given off (at the elbow), and at the wrist (2) above and (3) below the point at which its dorsal branch is given off.

*At the elbow.*—Division of the nerve at or above the elbow produces paralysis of the following muscles: the flexor carpi ulnaris, the ulnar half of the flexor profundus digitorum, all the interossei, the two inner lumbricales and the adductors of the thumb.

The hand assumes a characteristic position and it is easy to say the ulnar nerve has been injured, but difficulty is sometimes experienced in discovering the paralysis of the individual muscles. The index and middle fingers are extended at the metacarpophalangeal joints owing to paralysis of the interossei muscles attached to them; the little and ring fingers are hyper-extended at these joints in consequence of paralysis of the lumbricales in addition. All the fingers are flexed at the interphalangeal joints, the flexion being most marked in the little and ring fingers; the little finger is held abducted.

On flexing the wrist the hand is slightly tilted to the radial side. But the paralysis of the flexor carpi ulnaris is often compensated by the action of



the palmaris longus, and careful palpation over the insertion of the former muscle into the pisiform bone may be necessary in order to make the diagnosis. The little and ring fingers can be flexed to a slight degree by the slips of the flexor sublimis attached to them and supplied by the median nerve, but flexion of the *terminal* phalanx of the little finger is always impossible. Little difficulty should be experienced in discovering the paralysis of the intrinsic muscles of the hand supplied by this nerve, but it is not infrequently overlooked. All true movement of abduction and adduction of the fingers is lost, but a false abduction can be carried out by the extensor communis digitorum; this is readily distinguished, for it is always accompanied by extension of the basal phalanges, and palpation reveals the fact that the interossei are flaccid. In palpating the first interosseous space during this movement it must be borne in mind that the first lumbrical muscle, passing on the radial side of the index finger to the dorsal expansion, may be taking part. I have known mistakes to occur from electrical testing also, this muscle reacting to stimulation with the interrupted current and being taken to be the first dorsal interosseous. The adductor muscles of the thumb bring this digit towards the second metacarpal bone in a plane at right angles to that of the palm (*vide* Plates XII and XIII). This movement can be well simulated by means of the long flexor and extensor

Unable to display this page

Unable to display this page



Unable to display this page

Unable to display this page

muscles of the thumb (false adduction) but the movement is always accompanied, in the former case by extension of the terminal phalanx and outward rotation of the thumb, in the latter by flexion and inward rotation. Careful examination will reveal these supplementary movements.

*Sensory symptoms.*—Epicritic sensibility is lost over the little finger and the ulnar half of the ring finger, and that part of the palm and dorsum of the hand to the ulnar side of a line drawn longitudinally through the ring finger and continued upwards. This area is extremely constant and varies little from patient to patient. Its borders are well defined; on passing from the median to the ulnar portion of the palm or in the reverse direction the patient can tell at once when the border is reached, and the result of subsequent stimulations are identical. Protopathic sensibility is lost over an area which varies considerably (*vide* Fig. 15) from patient to patient, in some cases the little finger and the extreme ulnar border of the palm only being affected, in others the area is nearly as large as that over which epicritic sensibility is lost. Between the boundaries of loss of epicritic and protopathic sensibility is the intermediate zone. Deep sensibility is usually lost over an area almost as extensive as that insensitive to prick.

*Division at the wrist.*—Accidental division of the nerve in the lower part of the forearm is rarely



unaccompanied by division of tendons. In most instances the wounds are due to broken glass.

Injuries of this type frequently divide the nerve

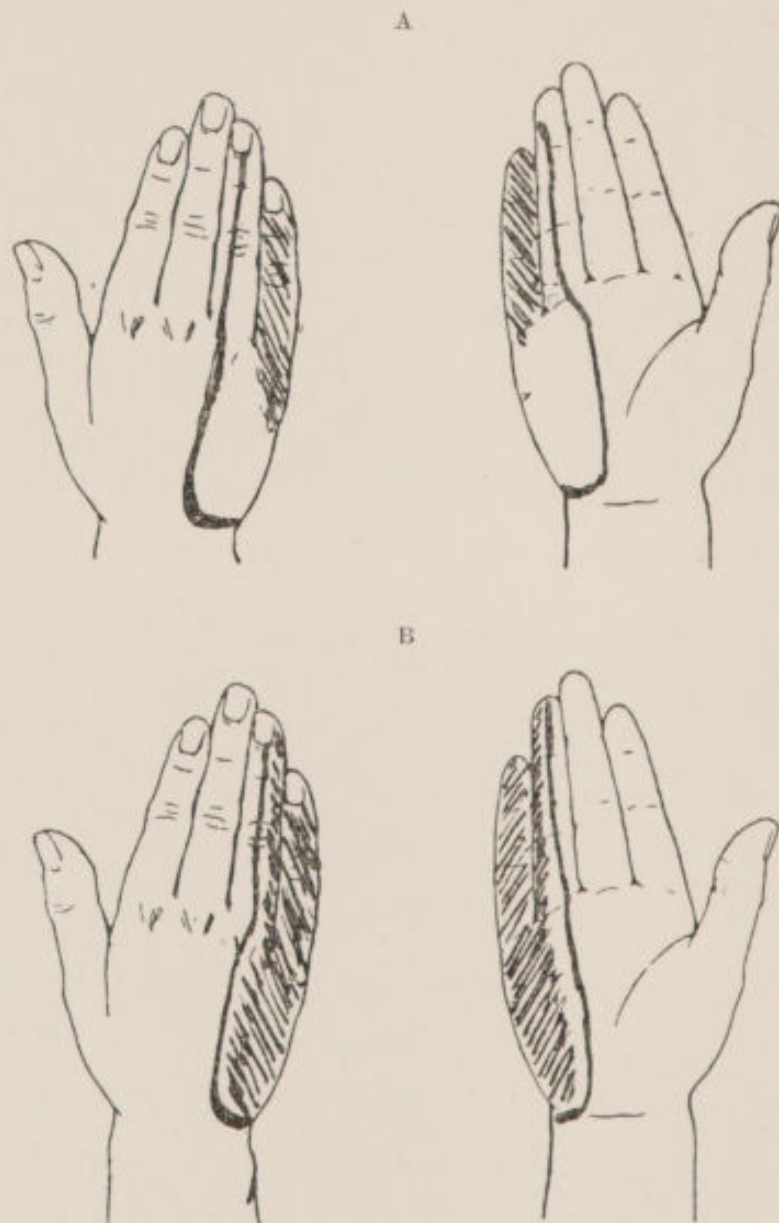


FIG. 15.—Loss of sensibility produced by division of whole ulnar nerve, A with small, B with large exclusive protopathic supply.

below the point at which its dorsal branch is given off. I have found the nerve divided in this situation as often as the whole nerve. Very little attention

has been paid to this form of injury and its effects are often overlooked on account of the slight sensory symptoms produced, the patient coming under observation later, with wasting of the ulnar muscles and typical ulnar paralysis. Among the recent textbooks of surgery and diseases of the nervous system, Rose and Carless and Oppenheim alone draw attention to this.

After injury in both situations (above and below the dorsal branch) all the intrinsic muscles of the hand supplied by the ulnar nerve are paralysed, but on account of the division of tendons which usually co-exists this may be difficult to elicit immediately after the injury. The loss of sensibility after division of the whole nerve at the wrist resembles that seen after division at the elbow (Fig. 15), with the exception that deep sensibility is usually lost in the latter lesion; in an uncomplicated instance of division of the ulnar at the wrist it is usually retained. The extent to which it is lost depends upon the division of tendons; if many are divided, deep touch may be lost over an area as extensive as that of the protopathic loss; when no tendons are divided, it is lost over the terminal phalanges of the little finger at most.

After division of the nerve below the point at which its dorsal branch is given off epicritic sensibility is lost over an area on the palm (*vide* Fig. 16) corresponding exactly to that which is affected after

section of the whole nerve. Its palmar boundary is definite, but at the ulnar border it gradually merges into the normal sensibility of the dorsum of the hand; there is no well-defined boundary here between sensitive and insensitive parts. On the dorsum the terminal two phalanges of the little and half of the terminal two phalanges of the ring fingers usually become insensitive to these stimuli.

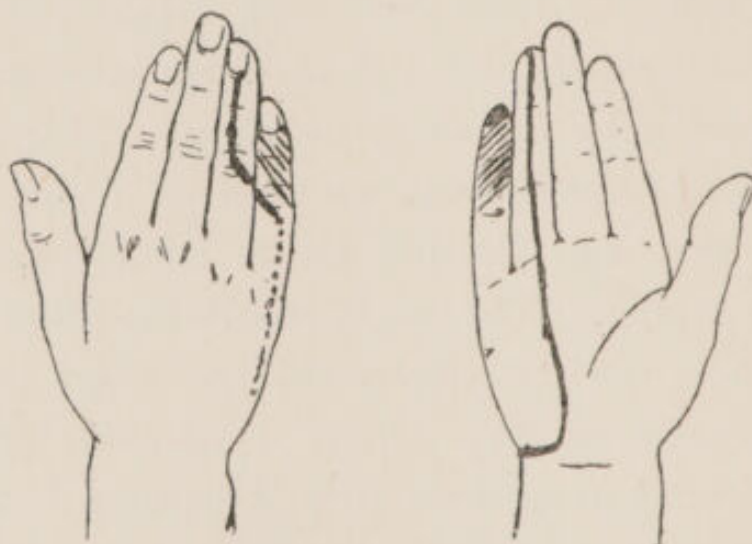


FIG. 16.—To illustrate the loss of sensibility produced by division of the ulnar nerve below its dorsal branch.

Deep sensibility is everywhere retained. The extent of protopathic loss varies within wide limits; usually the terminal phalanx of the little finger only is insensitive, but an area almost as large as that of the loss of sensibility to light touch may be present. This area of protopathic loss may vary in extent from time to time in the same patient. In a patient in whom, at the operation, I discovered that the ends of the nerve had been united to tendons, the



extent of the insensibility to prick had varied from a small area on the palm to one almost corresponding to that of the loss of sensibility to touch. The same phenomenon may occur after division of the external popliteal nerve below its lateral cutaneous branch (*vide* p. 299).

*Full supply of the ulnar nerve.*—As mentioned previously, division of a nerve depicts only the area

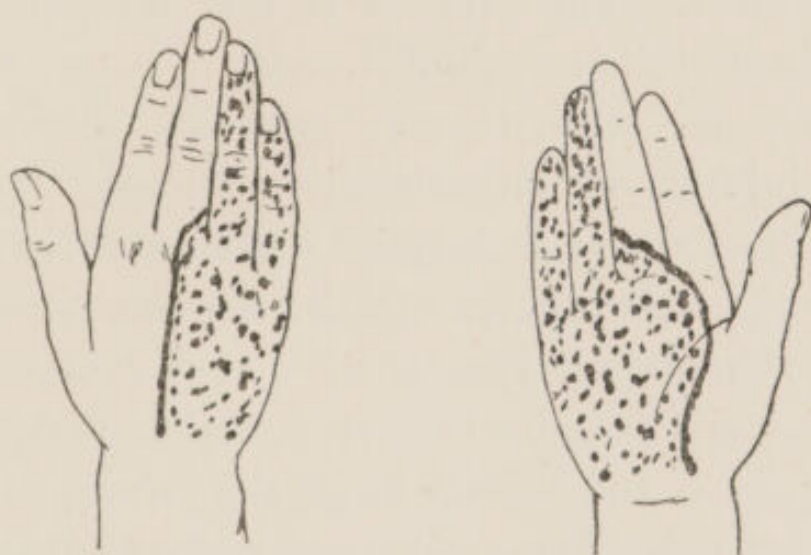


FIG. 17.—To illustrate the full protopathic supply of the ulnar nerve.

exclusively supplied by it. Its full supply can only be obtained from patients in whom surrounding nerves have been divided, leaving intact the area supplied by the nerve we wish to study. Knowledge of the full supply, especially of the nerves of the hand, is necessary in the diagnosis of irritative lesions.

Fig. 17, showing the full protopathic supply of the ulnar nerve, was taken from a patient who

divided all the cutaneous nerves of the hand except the ulnar, and corresponds exactly to the area which became tender in patients with incomplete division of the ulnar nerve and irritation. It must be remembered, however, that as the exclusive area supplied with protopathic sensibility from any one nerve varies, so the full supply must vary.

The full epicritic supply corresponds practically to its exclusive. The overlap in the nerves carrying epicritic stimuli is negligible.

*Treatment.*—Special care must be taken in all ulnar injuries to prevent the deformity from becoming permanent. A splint must be worn, at least during the night time, until the muscles regain their power of voluntary movement. If this is not done the interossei muscles become stretched and changes take place in the ligaments of the inter-phalangeal joints, rendering the recovery of perfect function impossible, although regeneration of the nerve may take place and the muscles regain their irritability to the interrupted current. It is also necessary to institute exercises as soon as voluntary power begins to return.

*Prognosis and method of recovery.*—After complete division of the ulnar nerve in any part of its course followed by primary suture, the first sign of restoration of sensibility to prick will be noticed in from six weeks to three months if the wound heal by first intention, and will be completely restored in

Unable to display this page



the paralysed muscles, but these may remain atrophic if the normal position of the fingers cannot be restored. Careful examination should be made, and the patient informed before operation is undertaken of the amount of success expected.

**Injuries of the ulnar nerve in fractures, recent and remote.**—Injuries of the ulnar nerve in recent fractures or dislocations, either as a primary or secondary affection, are not uncommon, coming next in frequency in the upper limb to injuries of the musculo-spiral nerve in fractures of the humerus. Bruns records that in 188 cases of nerve injuries complicating fractures 19 were ulnar.

The injury occurs in fractures involving the internal condyle and the division is usually physiological and incomplete. Involvement of the ulnar nerve in a recent fracture or epiphysial separation of the lower end of the humerus is an additional indication for operation in these cases. In dislocations the usual treatment for incomplete division should be carried out.

Interference with the functions of the ulnar nerve arising many years after an injury in the region of the elbow which has led to permanent deformity is not so well recognised, and has often led to errors in diagnosis. Attention was first directed to this subject in 1877 by Panas. He recorded three cases of this nature, and stated that the condition had led to errors in diagnosis, and that Duchenne

had at first mistaken such a case, with other eminent physicians, for disease of the spinal cord, but by careful attention to details he had been able to rectify the error. Similar mistakes are still being made.

I have been able to find record of seventeen cases of late involvement of the ulnar nerve after fractures of the lower end of the humerus, and have had five under my care, upon two of whom I operated.

The injury producing the deformity has been, in most cases, a fracture or epiphysial separation of the lower end of the humerus which has led to a marked cubitus valgus, often with obliteration of the ulnar groove behind the internal condyle.

The symptoms appear usually many years after the injury. In most of the recorded instances the accident was in childhood, and in several cases no history of the injury could be obtained. This was the case in one of the patients upon whom I operated, but the physical signs and the radiograph left no doubt as to the origin of the marked cubitus valgus which was present.

The first symptom noticed is generally pain in the distribution of the nerve ; this is soon followed by wasting and weakness in the muscles which it supplies. This may have gone on to complete division, but as a rule the signs are those of incomplete division only. The patient may be unaware of any deformity at the elbow, and it is only on tracing



the nerve upwards in the usual way that the nature of the case is discovered ; but this is unusual.

The ulnar nerve is enlarged into a spindle-shaped swelling behind the internal condyle. This was well marked in the patients upon whom I operated ; the enlargement was smooth and quite free from adhesions to surrounding parts.

The period between the injury and the onset of symptoms varies. The longest of which I have note is twenty-seven years. In some instances it seems that excessive work or a change of occupation has preceded the onset of symptoms ; in most of the patients no such history was obtainable.

I have had the opportunity of carefully examining the portion of nerve removed from one patient. The pathological change was strictly limited to the spindle-shaped swelling. The nerve immediately above was perfectly healthy ; that below showed degenerated fibres with a few small healthy medullated fibres, the degenerated being in the usual "resting" condition. At the seat of the injury was a mass of cellular fibrous tissue in which it was almost impossible to trace any nervous structure. These appearances agree with the only similar examination published, that of Panas, who was able to obtain the specimen after death of the patient from pyæmia. The cause is a local interstitial neuritis, due to repeated friction or pressure upon the nerve, symptoms only appearing when the fibrous tissue has increased



sufficiently to press upon the axis cylinders, and will, if not treated, progress to complete physiological division.

*Diagnosis.*—If the existence of this condition is remembered no difficulty should arise. Dislocation of the ulnar nerve may be suspected but the absence of undue mobility and the gradual onset of symptoms renders differential diagnosis easy. In many of the cases the diagnosis of anterior poliomyelitis was made. Careful attention to the symptoms will prevent this mistake. The typical deformity in the region of the elbow and the spindle-shaped swelling upon the nerve establishes the diagnosis. The degree of involvement must then be settled; in most cases the division is incomplete.

*Treatment.*—In all cases means should be taken to remove the cause of the disease. In the least severe cases, rest will entirely relieve the symptoms for a time, but recurrence inevitably takes place on resuming active use of the forearm.

The nerve should be exposed behind the internal condyle and a groove in the bone chiselled for it; if the cubitus valgus is excessive it may be necessary to remedy this. When the signs are those of incomplete division only, removing the cause of the pressure and protecting the nerve will be sufficient, but when the signs are those of complete division, the spindle-shaped swelling should be excised and end-to-end suture performed in addition.

**Dislocation of the ulnar nerve.**—Abnormal mobility of the ulnar nerve is common and gives rise to no symptoms. Hain, who is confirmed by Cohn, found it in 25 per cent. of men, 13 per cent. of women. It occurs in those individuals in whom the physiological cubitus valgus is more marked than normal. It may also arise in traumatic cubitus valgus. This abnormal mobility, to which the name "subluxation" is given, is the predisposing cause of dislocation, the term "dislocation" being confined to those cases in which the nerve passes forwards over the internal condyle.

Traumatic dislocation of the ulnar nerve can only occur in flexion of the elbow. During this movement the nerve has a tendency to pass inwards like the string of a bow; this tendency is increased in cubitus valgus. A fall on the flexed elbow is given as the cause of this accident in many cases, sudden and violent flexion rupturing the fibres of the fascia which keep it in position.

The symptoms are commonly met with in males between the ages of twenty and thirty. Suddenly, after an injury to the elbow, pain is felt in the distribution of the ulnar nerve, usually accompanied by alteration in sensibility and weakness of muscles. Symptoms are relieved by rest and recur with frequency on resuming use of the arm; the repeated insults to which the nerve is subject in passing over the internal condyle may lead to an interstitial



neuritis, and the formation of a spindle-shaped swelling on the nerve with a gradual deterioration of function up to complete division. Occasionally the dislocation arises without sudden injury (these are the so-called congenital cases); it is probable that here the fascia keeping the nerve in position becomes gradually stretched, and at last allows the nerve to pass over the condyle.

*Treatment.*—Operation is necessary if symptoms are present pointing to interference with the functions of the nerve. A long incision should be made behind the internal condyle to expose the nerve; after freeing the nerve, the groove in the bone should be deepened, if necessary, and the nerve wrapped in membrane to prevent it from forming adhesions, and finally the bony groove converted into a canal by stitching a portion of the fascia of the triceps over it. In neglected cases in which a spindle-shaped swelling is found on the nerve and the signs of complete division are present, it will be necessary to resect the damaged portion; this, however, is rarely required.

*Examination and diagnosis.*—The complete routine examination is necessary in order to form a correct and complete diagnosis. In patients in whom symptoms of involvement of the muscles of the hand supplied by the ulnar nerve, or of alteration in sensibility or pain in the ulnar area are present, especially when no history of injury can be obtained,



some difficulty may be experienced. A lesion of the ulnar nerve has to be diagnosed from one of the first dorsal root or of the inner cord of the plexus. In both these cases *all* the intrinsic muscles of the hand are affected and the hand assumes the true claw shape ; all the fingers are equally hyperextended at the metacarpo-phalangeal and flexed at the interphalangeal joints. In lesions of the ulnar nerve this is not the case : the hyper-extension and flexion is most marked in the little and ring fingers, least in the middle and index, these fingers being kept at their metacarpo-phalangeal joints and slightly flexed at their interphalangeal. In lesions of the inner cord the muscles supplied by the ulnar nerve in the forearm are affected in addition.

The loss of sensibility even in complete lesions of the first dorsal root is, as a rule, ill-defined, and partakes of the character laid down on p. 24 as characteristic of root lesions. The cervical sympathetic may also be affected. In inner cord lesions sensory symptoms will be present in proportion to the muscular changes, and affect the forearm as well as the ulnar area on the hand.

**The median nerve.**—This nerve resembles the ulnar in being most frequently injured through wounds in the region of the wrist made by broken glass ; it may also be wounded in incised wounds in other parts of its course, involved in fractures of the lower end of the humerus or radius, or in fractures of both

Unable to display this page

Unable to display this page



injury. In all uncomplicated cases of division of the median nerve the patient was able to appreciate all stimuli applied to the dorsal surface of the thumb. The line bounding the loss of epicritic sensibility is well defined, the line of transition from æsthetic to anæsthetic portions is abrupt. This area of loss varies within very slight limits only ; on no occasion have I seen the ring finger unaffected. But it is otherwise with the loss of sensibility to prick. This varies within wide limits : it may include not quite the whole of the terminal two phalanges of index and middle fingers (Fig. 18 A), or be almost as widespread as the loss of sensibility to light touch (Fig. 18 B). In the patients from whom these figures were taken the nerve was divided at the wrist, in Fig. 18 B, through a small punctured wound which divided no other structure. In one instance of division of the nerve at the elbow the loss resembled that seen in the latter figure. After division of the median nerve, however, at whatever level it occurs, it is more usual for protopathic stimuli to be appreciated over the palm, and for the loss of this form of sensibility to resemble that seen in Fig. 18 A.

In many of the injuries in the neighbourhood of the wrist, tendons are divided in addition ; this usually results in the appearance of an area insensitive to deep touch almost as extensive as that of the loss of sensibility to prick. In the patient from whom Fig. 18 A was taken, the nerve was divided

Unable to display this page

So far the exclusive supply only of the nerve has been dealt with. Looked at from the standpoint of residual sensibility it will be seen that there can be very little overlap in the fibres subserving sensibility to light touch; its exclusive and full supplies are, therefore, identical. But it is otherwise with protopathic sensibility; the full supply may bear very little relation to the exclusive. Fig. 19, representing the full area supplied by the nerve with protopathic fibres, was obtained from patients in whom the ulnar, radial and external cutaneous nerves were divided. But it is to be remembered that it will vary somewhat from patient to patient. It corresponds closely to the area which becomes tender on stimulation of the nerve.

*Motor symptoms.*—After division at the elbow the patient may experience little discomfort from the paralysis; the impairment of mobility affects chiefly the thumb, and, to a less extent, the index finger. The terminal phalanx of the thumb cannot be flexed owing to the paralysis of the flexor longus pollicis (this is a most important symptom); the index finger can only be flexed at its metacarpo-phalangeal joint by means of the interossei muscles attached to it, both long muscles being dependent on the median for their supply. Pronation of the forearm is feeble, and only possible by the weight of the arm. The principal test of division of the median nerve above the point at which its motor branches to the forearm



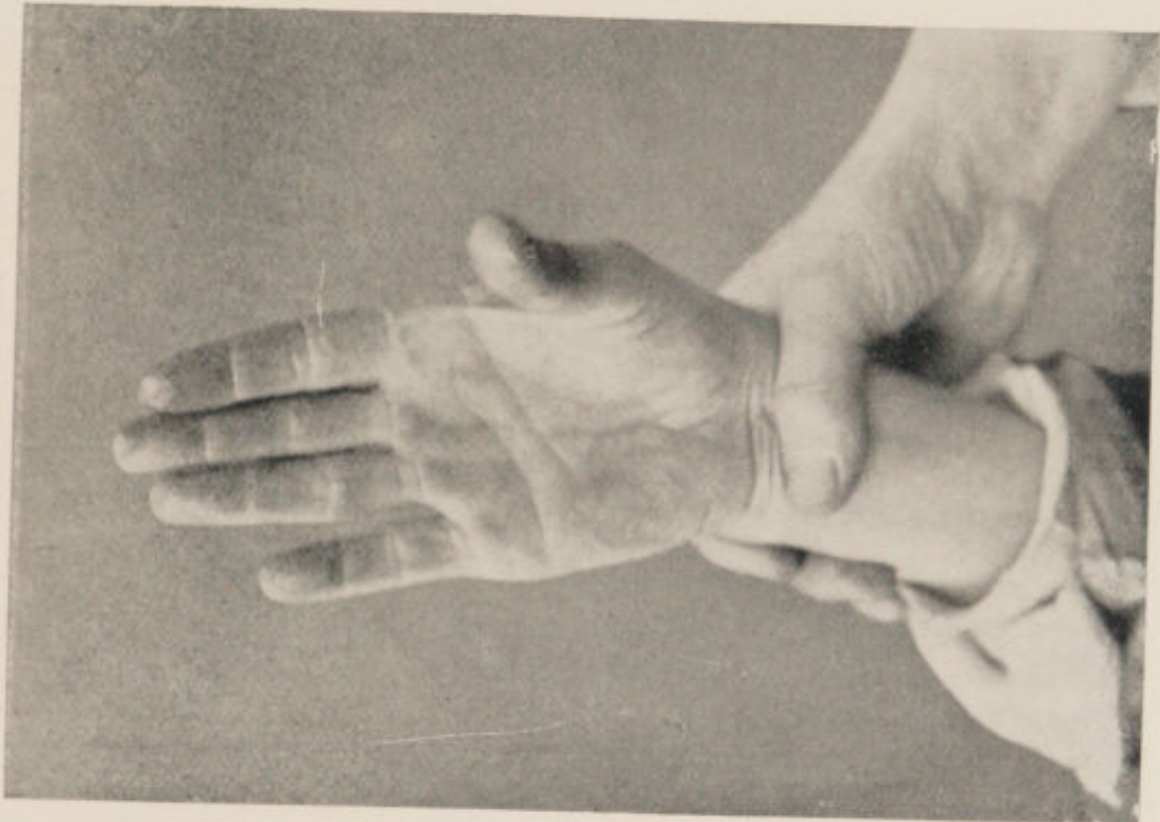muscles are given off, is paralysis of the flexor longus pollicis muscle. It must be remembered that these branches are given off just below the elbow, consequently division in the upper third of the forearm may leave them unaffected.

After division at the wrist the abductor-opponens group of muscles and the outer two lumbricales only are affected. It is essential to understand the action of the abductor and opponens. The abductor pollicis takes the thumb away from the index finger in a plane at right angles to that of the palm—an action that is not one of the ordinary movements of daily life; this is the action which is lost and which can be only feebly imitated by the extensor brevis and ossis metacarpi pollicis (*vide* Plates XIV, XV). In testing the action of the abductor pollicis the patient should be asked to touch a pencil, or the observer's finger held immediately in front of the thumb, the hand being placed with its dorsum on the table.

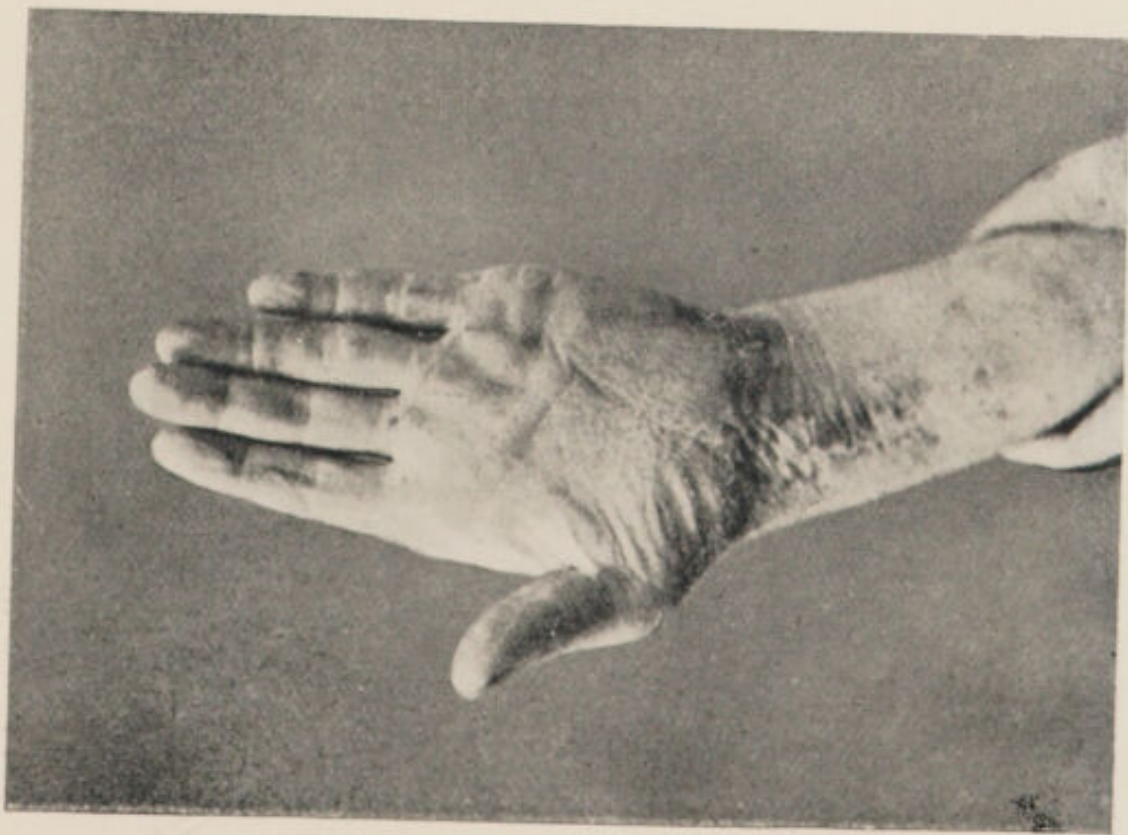In opposition the thumb is rotated so that its palmar surface looks towards the palm (Plate XVI A); for the perfect performance of this movement the action of the opponens pollicis is necessary, but it is often difficult to tell from inspection alone that the movement is being produced by the long flexor of the thumb and the abductor muscles (Plate XVI B). Palpation over the insertion of the opponens to the metacarpal bone of the thumb may be necessary

PLATE XIV.

A



B



To illustrate (A) true abduction of the thumb, (B) false abduction of the thumb; seen from the palmar surface.



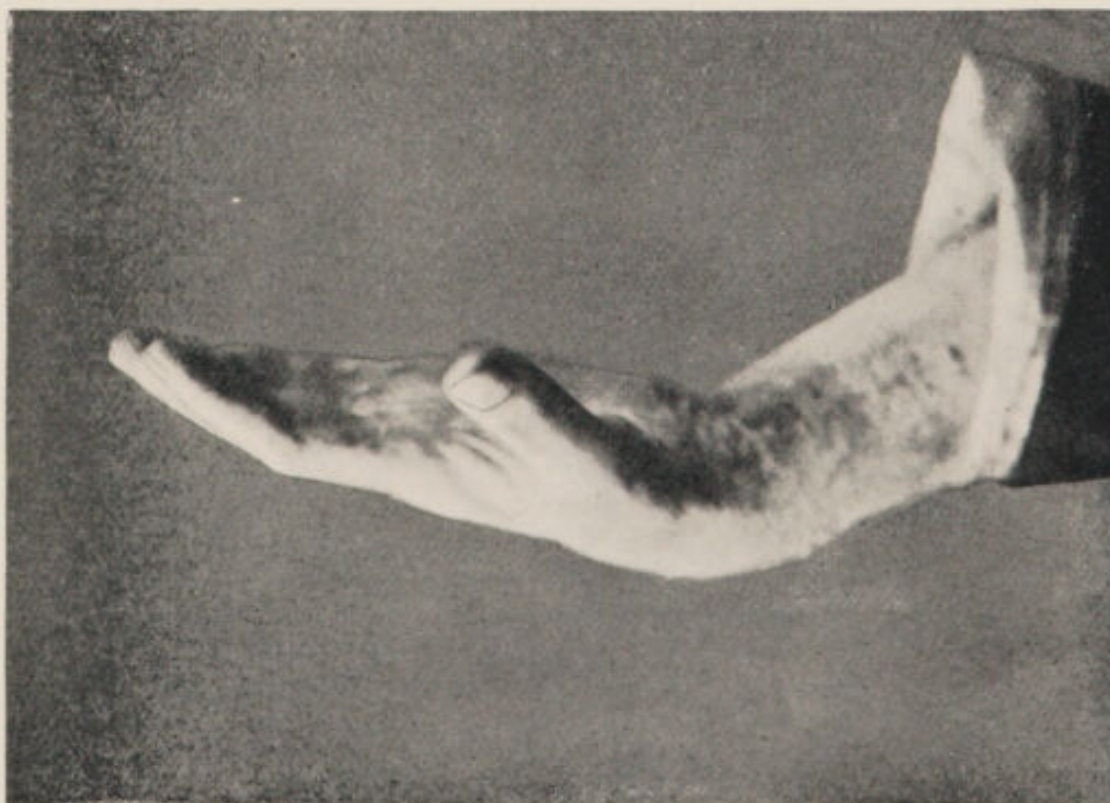


PLATE XV.

A



B



To illustrate (A) true, (B) false abduction of the thumb; viewed from the radial side.

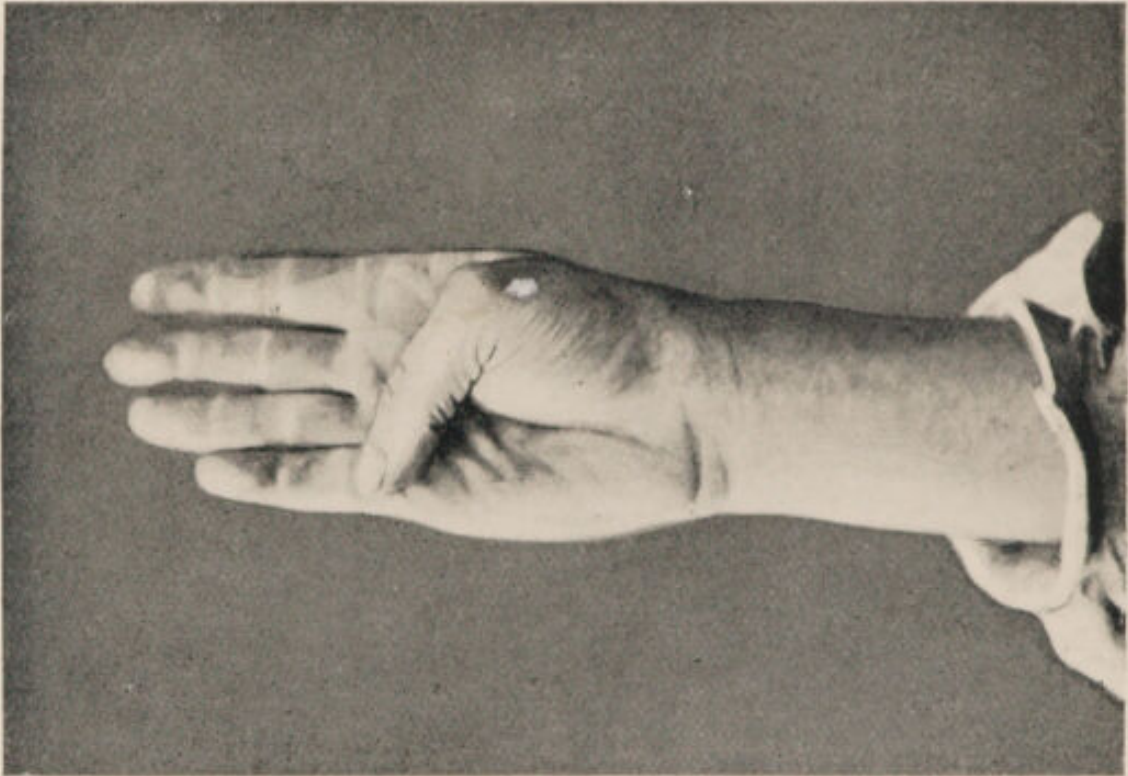

Unable to display this page

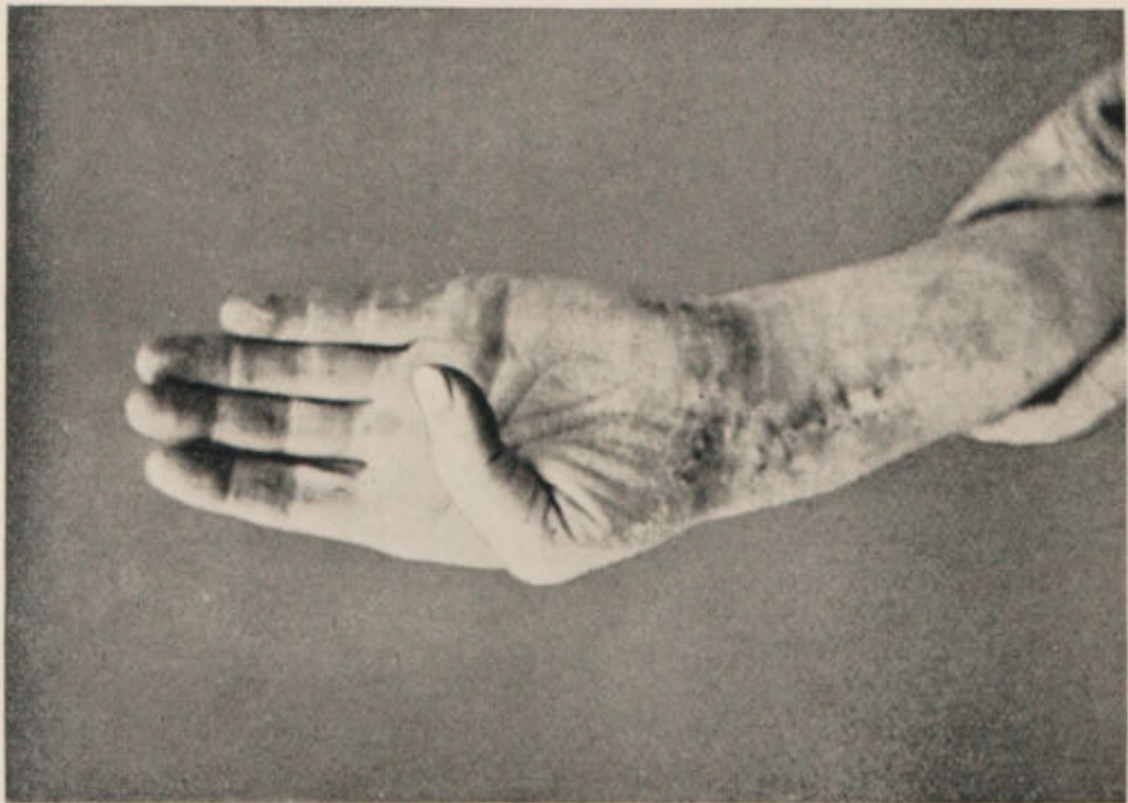

PLATE XVI.

A



B



Showing true (A) and false (B) opposition of the thumb.

before coming to any decision with regard to its paralysis.

The action of the superficial head of the flexor brevis pollicis cannot be separated from that of the abductor, and the paralysis of the outer two lumbricales produce no symptoms that can be recognised.

The branch supplying the abductor - opponens group of muscles may be given off in the lower third of the forearm instead of its usual position immediately below the annular ligament, and so escape injury in division of the median at wrist. I have recorded such an abnormality. In a patient upon whom I performed primary suture at the wrist I could discover no paralysis of the muscles of the thumb before operation. At the operation I found that the branch supplying these muscles was given off in the lower third of the forearm and had escaped injury.

*Diagnosis.*—Injury to the median nerve is still frequently overlooked owing to the retention of deep sensibility, the relatively small loss of protopathic sensibility in many cases, and the absence of any characteristic attitude such as is seen after injury to the ulnar or musculo-spiral, and the relatively slight paralysis resulting from its complete division. I have seen complete division of this nerve overlooked by all the members of a post-graduate class in surgery.

The effect of the division of the median nerve



upon motion and sensation has given rise to much controversy, and had much to do with the establishment and perpetuation of the error with regard to primary union (*vide* p. 100).

It is only by carefully examining in a routine manner all injuries in the region of the wrist that the diagnosis will be made. It is a serious thing for the patient to have a complete division of this nerve missed; the probability is that sensibility will never become perfect after secondary suture; it will certainly become so in an uncomplicated case of primary suture of this nerve in which the after-treatment is faithfully carried out.

*Recovery and prognosis.*—Recovery follows the usual lines. After suture the first sign of restoration of sensibility to prick is noticed in from six weeks to three months. Light touch may be expected to commence to return after suture at the wrist in about nine months, and to be completely restored in about twelve months. When divided nearer the centre a correspondingly longer time is necessary. Complete sensory recovery follows the same course as after division of other nerves.

After suture at the wrist a return of power in the paralysed muscles may be expected in about ten months.

The prognosis after division of this nerve is good, better than after a similar injury to the ulnar; the muscular recovery is not liable to be hindered by



deformity, hence it is more often perfect, even if no after-treatment is carried out.

**Median and ulnar nerves.**—These nerves are not infrequently injured simultaneously, most often in accidentally-inflicted wounds in the region of the wrist, then as the result of tight splints in the treatment of fractures of the forearm; interference with the functions of these nerves is present in many

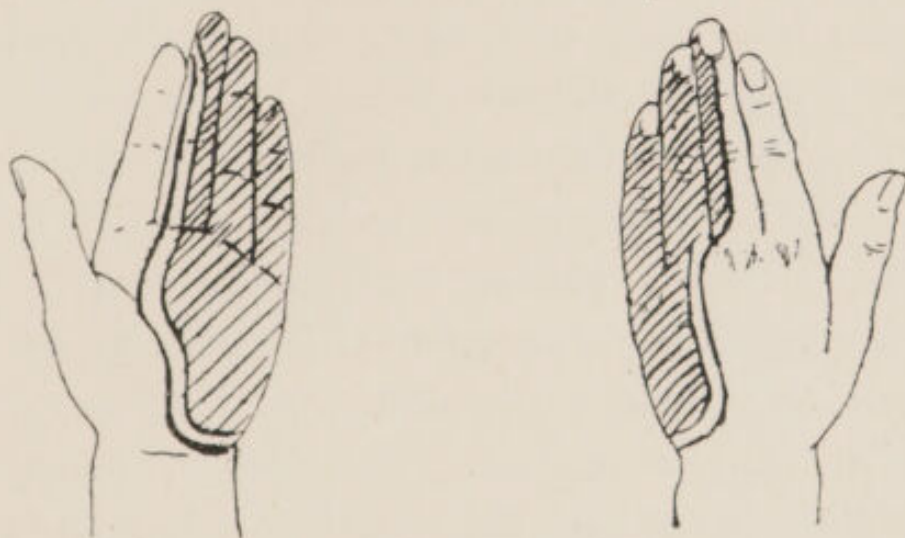


FIG. 20.—Illustrating the loss of sensibility resulting from complete anatomical division of ulnar, incomplete anatomical division of median nerve.

cases of Volkmann's ischæmic contracture of the forearm muscles. They are occasionally involved in fractures or epiphysial separations of the lower end of the humerus or in fractures of the forearm.

When resulting from wounds in the region of the wrist the division of the median is not uncommonly incomplete; a not infrequent accident is—complete anatomical division of the ulnar nerve accompanied by incomplete anatomical division of the median. Fig. 20 represents the loss of sensibility to be expected in cases

of this nature. The injury to the median is usually sufficient to paralyse for a time the intrinsic muscles of the hand which it supplies, and they often develop the reactions typical of incomplete division and demonstrate them well in comparison to the true reaction of degeneration in the muscles supplied by the completely divided ulnar nerve.

When both nerves are completely divided (Fig. 21) the area insensitive to light touch occupies the whole of the palm and palmar surface of the thumb and fingers. Its boundary towards the radial side is that seen after division of the median nerve. On the dorsal as on the palmar surface the loss of light touch corresponds exactly to that produced by division of the ulnar nerve added to that caused by division of the median. The loss of protopathic sensibility varies with the extent to which the radial portion of the palm is supplied with this form of sensibility from the radial and external cutaneous nerves. Usually the loss of sensibility to prick extends from the ulnar side to the cleft between the index and middle fingers ; the palmar surface of all the fingers is affected. On the dorsal surface the area insensitive to these stimuli does not differ from the sum of that which results from division of the nerves separately. In those cases in which the median nerve supplies a large portion of the radial half of the palm and palmar surface of the thumb the loss is correspondingly greater. Fig. 21 also



gives the full supply of the radial and external cutaneous nerves on the palm of the hand.

After the usual accidental division of the median and ulnar nerves with many tendons, deep sensibility is abolished over an area almost as extensive as that which becomes insensitive to prick. To ascertain the extent of insensibility to deep touch from division of these nerves alone a case uncomplicated by division

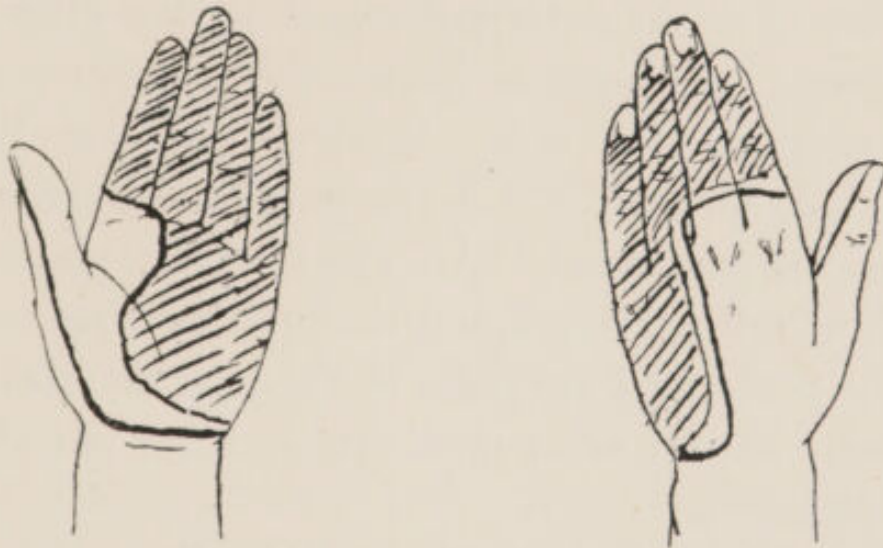


FIG. 21.—Showing the loss of sensibility resulting from complete division of the median and ulnar nerves.

of tendons must be investigated. It is rarely this opportunity occurs as the result of accidental section, but in a patient upon whom secondary suture was performed six months after the injury, the tendons had been united at the time of the accident. Immediately after the operation of secondary suture he could appreciate and localise deep touch correctly over the whole area insensitive to prick, with the exception of the palmar surface of the little finger and the greater part of the dorsum—an area which



becomes insensitive in many cases after division of the ulnar nerve alone.

The ulnar nerve is sometimes divided below its dorsal branch with a corresponding smaller loss of sensibility.

After division of the median and ulnar nerves the hand assumes the true claw shape, with all the fingers hyper-extended at the metacarpo-phalangeal and flexed at the interphalangeal joints; after division above the point at which the forearm muscles are supplied the wrist tends to become hyper-extended, and all the flexor muscles of wrist and fingers are paralysed. All the intrinsic muscles of the hand are paralysed and the only movements that can be performed are those of the long muscles. No difficulty should arise in diagnosis after division in any situation.

*Method of recovery.*—Restoration of sensibility to prick is first noticed in the median area of the palm, and its complete restoration occupies about the same time as when the ulnar alone is divided at the wrist. It seems probable that the restoration of epicritic sensibility requires a longer time than after division of one nerve alone.

The abductor-opponens group always regain voluntary power and excitability to the interrupted current before the muscles supplied by the ulnar nerve.

Division of the median and ulnar nerves is an

accident of great severity ; as a rule many tendons are divided in addition to the nerves. Complete restoration of function is improbable and will certainly not take place unless the after-treatment is carefully carried out ; it will then require at least two years before the recognition of the compass test becomes perfect.

## CHAPTER XVII

The Cauda Equina—Method of Injury—Symptoms Produced—Distribution of Roots, Sensory and Motor—Examination and Diagnosis—Prognosis—Treatment.

THESE injuries acquire their importance from the difficulty which often exists in their diagnosis from injuries of the spinal cord, a diagnosis which is essential to correct treatment.

The spinal cord terminates at the level of the lower border of the first lumbar vertebra in the adult ; in early life it occupies more of the spinal canal.

Below the level of the twelfth dorsal vertebra in the adult the name "conus medullaris" is given to it ; anatomically, this portion of the cord is defined as that below the level of origin of the third sacral roots.

In fracture dislocations or penetrating wounds in the lumbar region the nerves of the cauda equina may be injured alone, or in association with the lower portion of the cord (the conus). The lumbar and sacral nerves arise close together and their roots run downwards inside the dura mater, forming the cauda equina, the points of exit of these roots from the theca being much lower than their place of



origin from the cord. The posterior root ganglia are situated outside the dura mater, so that in injuries of the cauda we are dealing with posterior and anterior roots. It must be remembered that although regeneration of posterior roots may be possible as far as the cord, this is of itself useless, as no regeneration of intra-medullary fibres takes place; therefore, complete division of a posterior root central to its ganglion is irremediable. On the other hand, after complete division of an anterior root recovery proceeds as after division of a peripheral nerve.

Injuries to the cauda equina result most often from a fracture dislocation in the lumbar region, and the nerves may be injured alone or with the conus. Fracture dislocations are extremely common in the dorsi-lumbar region; in fractures below the level of the first lumbar vertebra the injury will, in most cases, affect the cauda alone and spare the conus; up to the level of the eleventh dorsal vertebra it may injure the cauda alone, but as a rule the conus also is affected.

Injury to the cauda alone, or in association with the conus, occasionally results from a fall on the back or buttocks without there being any evidence of bony injury. Such a case has recently been under my care, and several have been recorded.

The symptoms produced in injuries of the cauda equina vary with the extent and degree of the

injury. As first pointed out by Thorburn, when the injury is incomplete the nerves injured are usually lower in the series than those spared: for example, interference with the functions of the bladder and rectum, and alterations of sensibility over an area on the buttocks corresponding to the supply of the third sacral roots and those below it (*vide* Fig. 22), are present in practically all the cases.

The same changes in the electrical reactions of the affected muscles occur as after injuries of peripheral nerves of a corresponding degree of severity.

The sensory loss is of the root type, *i. e.* the area of loss of light touch is smaller than the area of loss of sensibility to prick.

The sphincter ani is paralysed and incontinence of fæces results; retention of urine is present at first, followed in many cases by true incontinence; sexual power is usually absent, but the testes retain their normal sensibility, being supplied from a higher level than the anæsthetic skin of the scrotum. Sherrington and Langley and Anderson have pointed out that the bladder and rectum have a double nerve supply from the last dorsal and upper lumbar roots, and from the sacral roots through the pelvic splanchnics. The exact function of these two sets of fibres has not been worked out, but clinically, lesions of the lower set cause paralysis of the bladder and rectum.

The following illustrates a typical lesion due to a fracture dislocation of the second lumbar vertebra:

Unable to display this page



Unable to display this page

pheral nerve division with a loss of sensibility to light touch larger than that to prick.

This case is in every way typical of the result of an injury to the cauda equina from a fracture of the lumbar vertebræ, at first complete paralysis of the legs, later improving and leaving some permanent disability behind. The muscles of the anterior surface of the thigh and the adductors escape, and there is a sensitive strip on the inner side of the leg, and the anterior, internal and external aspects of the thigh retain their sensibility. The distribution of the loss of motion and sensibility is, however, often asymmetrical.

The conus medullaris may be injured alone or more often with the nerves of the cauda equina. When injured alone, paralysis of the bladder and rectum results with a small patch of alteration of sensibility over the coccyx. When a larger area of loss is present we must assume that the cauda is injured in addition, unless the injury be purely spinal cord.

**Examination and diagnosis.**—In making the diagnosis, the extent of the lesion (the segments or roots involved) and its degree, whether complete or incomplete, must be settled, and its position, whether cord, cauda, or both combined. It must be remembered that a lesion of the conus and cauda combined may, on superficial examination, be mistaken for an injury of the spinal cord at a much higher level, but on a

thorough examination the typical sensory change in the latter case will enable the diagnosis to be made even in a recent case, while if some time has elapsed no doubt can arise from the muscular examination.

The examination follows the lines already laid down. To make the diagnosis of the seat of the lesion and the roots involved it will be necessary to remember roughly the sensory and motor distribution of the sacral and lower lumbar roots.

From the sensory standpoint the landmark to remember is the saddle-shaped area of loss of sensibility on the buttocks corresponding to the third sacral root (*vide* Fig. 23). From the motor side, that the muscles supplied by the external popliteal (with the exception of the tibialis anticus) are those supplied by the fifth lumbar root.

The sensory diagram (Fig. 23) is modified from one given by Cushing. The position originated with Cushing and shows, better than any previously published, the distribution of the various roots. The remarks made in speaking of the distribution of the posterior roots entering into the formation of the brachial plexus apply here, but the overlap is less and the areas on the buttocks may be taken as the exclusive protopathic supply of the sacral roots below and including the third.

The following table gives roughly the distribution of the roots to the various muscles; the remarks



Unable to display this page

Unable to display this page

the sensory loss : if cauda, it has root characteristics. Asymmetry is suggestive of a lesion of the cauda ; improvement of symptoms points in the same direction.

**Prognosis.**—This cannot be said to be good, but may be improved by operation.

Death seldom occurs as the direct result of an injury to the cauda equina ; it will result most often from urinary infection. Complete recovery is rare ; in most of the cases spontaneous recovery is incomplete, as in the case I have quoted.

**Treatment.**—The surgery of the cauda equina is in its infancy. Both in traumatic cases and also as a field for nerve anastomosis after fractures of the spine with involvement of the spinal cord, and in old cases of infantile paralysis, there is great hope of success. The nerves lie close together rendering anastomosis easy.

In fracture dislocation of the spinal cord involving the cauda equina, I consider that operation should be carried out without delay. The spinal canal must be opened up and the dural sheath exposed ; this should not be opened until careful search has been made for signs of pressure external to it. If no satisfactory cause is found for the symptoms, the dura must be opened and the individual roots investigated. The anterior roots can be distinguished by stimulation with the interrupted current for a few days after the injury. After dealing with the con-



dition found the dura is closed; the bone removed in performing the laminectomy should not be replaced.

It is probable that no great harm will result in leaving the patient for a few days and treating as a case of nerve injury elsewhere and watching the reactions of the paralysed muscles, but it is to be remembered that all delay makes operative interference more difficult, and that the long-continued pressure on the roots may lead to their degeneration; if this takes place in the posterior roots complete recovery is impossible. Whether operation is carried out or no the usual after-treatment is to be adopted.

In long-standing cases the rules governing operative interference in long-standing injuries of peripheral nerves must be applied.

When the paralysis of the bladder and rectum is permanent as the result of injury to the conus or sacral nerves supplying the bladder, intra-vertebral nerve anastomosis or nerve crossing may be carried out as advised by Kilvington. In doing this operation sound nerves must be taken *outside* the dura mater to innervate the injured sacral roots. It is possible to divide the twelfth dorsal nerve in its foramen of exit and bring it to the anterior and posterior roots of the second, third and fourth sacral, cut free from the cord.

## CHAPTER XVIII

Injuries to the Nerves of the Lower Limb—Lumbar Plexus—Anterior Crural Nerve—Obturator Nerve—External Cutaneous Nerve: Bernhardt's Disease—Sacral Plexus—Paralysis of Gluteal Muscles—Great Sciatic Nerve: Method of Injury: Motor Symptoms: Prognosis—External Popliteal: Injuries Above and Below its Lateral Cutaneous Branch.—Internal Popliteal Nerve—Anterior Tibial Nerve.

INJURIES to the nerves of the lower limb are, with the exception of the external popliteal, rare, and in most instances, subcutaneous.

Injuries of the lumbar or sacral plexus are uncommon, of the former rare. They have been recorded as a complication of psoas abscess and of operation for its cure, as the result of pelvic operations, prolonged parturition, fractured pelvis and gunshot wounds.

**Anterior crural nerve.**—This nerve is rarely affected. It has been injured as a complication of fractures of the pelvis or femur, as the result of penetrating wounds, during the course of operations upon psoas abscess, and as the result of the abscess, and has suffered from manipulations carried out for the treatment of congenital dislocation of the hip-joint.

Its division is rarely complete.



The most important symptom is the paralysis of the quadriceps extensor cruris. There should be no difficulty in the diagnosis of this; the patient is unable to extend the leg. He can, however, bring it forward in walking by using the adductors after the leg has been everted.

Sensation is affected over an extremely well-defined area in the leg (Plate XVII) and over an ill-defined area on the antero-lateral aspect of the thigh. In the lower two thirds of the leg epicritic and protopathic sensibility are lost over an area which has well-marked borders. At its upper part the boundaries become ill defined and it merges into an area on the anterior and internal aspects of the thigh, in which, as a rule, there is no complete loss of any form of sensibility.

**Obturator nerve.**—Isolated injury of this nerve is less often met with even than an injury to the anterior crural. The lesion is usually incomplete and occurs as a complication of protracted labour, particularly when forceps have been necessary. It may also be injured in thyroid dislocations of the hip and in the rare obturator hernia. Pain may be experienced in its sensory distribution on the inner side of the knee in cases of irritative lesion.

The adductors are paralysed as the result of its injury, with the exception of the flexor portion of the adductor magnus which is supplied by the great sciatic. Its complete division produces no loss of





Showing the loss of sensibility in lower part of the leg after division of the anterior crural nerve.



Unable to display this page



Unable to display this page

Paralysis or weakness of the glutei muscles of both sides as seen in injuries of the cauda equina produces a waddling gait with lordosis. Paralysis of the glutei muscles of one side only is easily diagnosed; the flattening of the buttock and failure of action of the muscles is obvious. The action of the gluteus maximus is best tested by attempts at extension of the thigh or in rising from a stooping position. Paralysis of the gluteus medius and minimus alone is difficult of diagnosis, but weakness of outward rotation of the limb is present, and the paralysis of the tensor fasciæ femoris will enable the diagnosis of an injury to the superior gluteal nerve to be made.

**The great sciatic nerve.**—Injuries to the sciatic nerve are rare in civil practice, but it suffers from gunshot injuries more often than any other nerve. In addition to penetrating wounds, injury may result from the manipulations necessary in the treatment of congenital dislocation of the hip, occasionally as the result of a traumatic dislocation, or its reduction, or it may suffer, with other branches of the sacral plexus, in fractures of the pelvis.

It must be remembered that for surgical purposes the great sciatic nerve consists of two separate nerves, the external and internal popliteal, and that these remain separate up to the point at which they are given off from the plexus. Either nerve may be injured alone in an accident to the great sciatic.

Hence incomplete division of this nerve may differ from that of other nerves. In incomplete injuries of the great sciatic its external popliteal portion suffers more often; this occurs not only in subcutaneous injuries, such as those produced in manipulating congenital dislocations of the hip, but also as the result of a penetrating wound. In the gunshot wounds of this nerve which have come under my notice it was particularly noticeable. This is in agreement with Makins' experience. He states: "The most striking observation with regard to injuries of the great sciatic was the comparatively frequent escape of the popliteal element (internal popliteal) and the severe lesion of the peroneal. This was so pronounced as to amount to as high a proportion of peroneal symptoms as 90 per cent. . . ."

It is therefore obvious that an incomplete injury to the great sciatic nerve may produce a complete division of the external popliteal nerve without affecting the internal.

No satisfactory explanation of this is forthcoming. The exposed position of the fifth lumbar anterior primary division and the posterior position of the external popliteal element of the great sciatic nerve in the thigh may have something to do with this. But we must remember that the external popliteal group of muscles suffers frequently in other nervous conditions; for example, in infantile paralysis it is



the group most often permanently paralysed, and it is often picked out in toxic neuritis. Daus, in a research upon the subject, could arrive at no satisfactory conclusion; he simply states that the nerve is more vulnerable than the internal popliteal, and quotes experiments by Gerardt, jun., in which, after the death of animals the extensor muscles of the leg lost their electrical excitability before the flexors. Hofman came to the conclusion that a difference in their blood supply accounted for the more frequent affection of the external popliteal; it receives a smaller branch from the *comes nervi ischiatici* than the internal. It is difficult to believe that this is the explanation.

Complete division of the great sciatic nerve is uncommon; in sixteen patients that have come under my notice with injury to this nerve in two only was the division complete.

*Motor symptoms.*—After section of the great sciatic nerve all the muscles of the leg are paralysed and all movements of the foot impossible. If divided in the upper part of the thigh the hamstring muscles are paralysed. But although these muscles are not acting, flexion of the leg on the thigh is still possible by means of the *gracilis*; in long-standing cases this muscle becomes hypertrophied and a very efficient flexor. This has led to errors in diagnosis through non-observance of the rule that the action of individual muscles must be investigated, the flexion

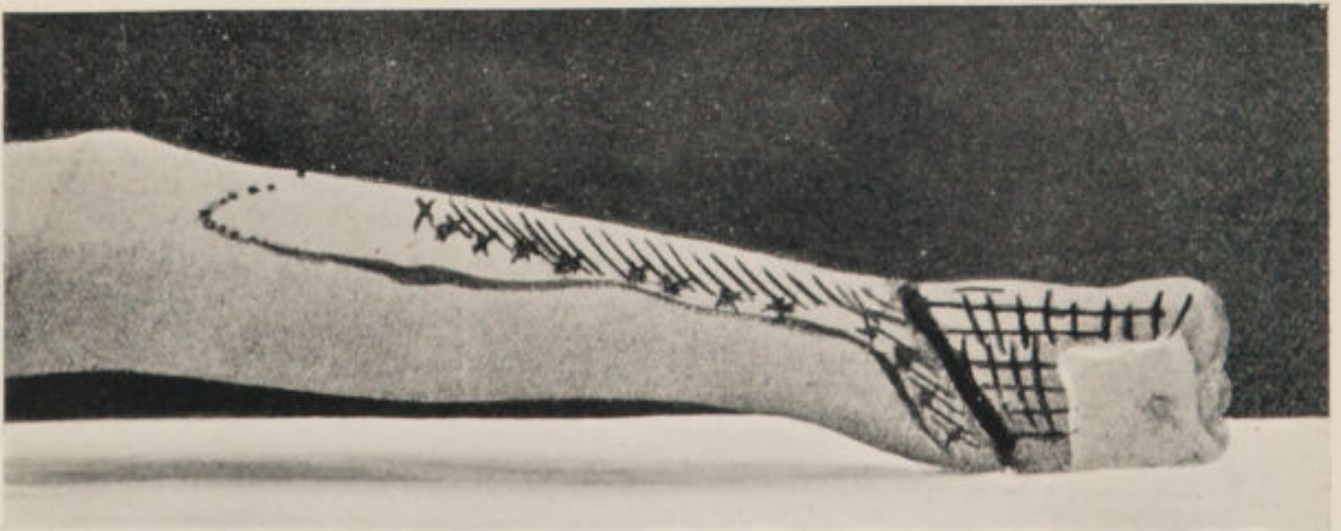
of the leg being considered due to the action of the hamstring muscles supplied by the great sciatic.

*Sensory symptoms.*—There is a widespread loss of sensibility below the knee, a strip on the inner side, the full supply of the internal saphenous alone remaining sensitive. The borders of the area of loss of epicritic and protopathic sensibility are almost co-terminous, except above (*vide* Plates XVIII, XIX), and are well defined. In spite of the widespread loss of sensibility deep touch is affected only over a comparatively small area of the foot. This has led to diagnostic errors. Within the area of loss of protopathic sensibility deep touch may be well developed, the patient recognising pressure immediately and localising it well.

*Prognosis.*—After suture of the great sciatic, months must elapse before the patient regains a useful limb. Sensibility to deep touch is first regained, and the foot should be everywhere sensitive to this form of stimulation in from three to six months. About eight weeks after suture, in an uncomplicated case, the area of loss of protopathic sensibility should begin to improve, but months will elapse before it is everywhere appreciated. No alteration in the extent of the epicritic loss is to be expected before eighteen months.


The first muscles to regain voluntary power and electrical excitability, after suture or after an incom-

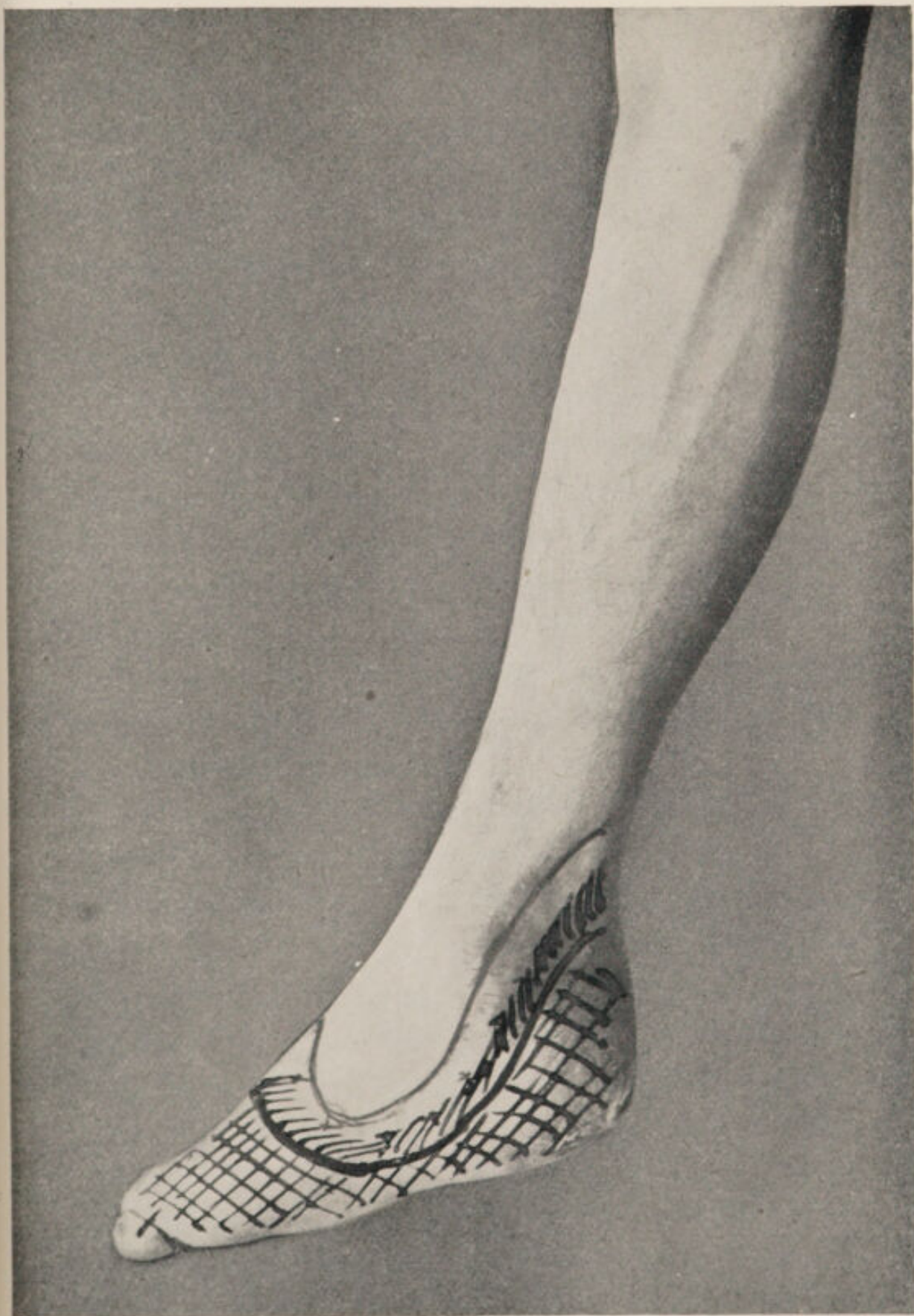




Showing the loss of sensibility resulting from division of the great sciatic nerve. The area of loss of epicritic sensibility is bounded by a thin line, dotted at its upper part; the area of protopathic loss by crosses, the thick line bounds the area of loss of deep touch. The unshaded area is the intermediate zone, the oblique shading the area of loss of epicritic and protopathic sensibility, the area of cross shading that in which all forms of sensibility are absent.







For description see Plate XVIII.





plete injury of the whole nerve in the upper part of the thigh, are the hamstrings. This may be expected in about a year after suture, but two years will probably elapse before any change takes place in the muscles of the leg, and complete muscular recovery is unlikely under three years. The internal popliteal group regains power before the external.


The prognosis in all cases of injury to this nerve is more unfavourable than after injuries of a similar degree affecting nerves of the upper limb. This has chiefly to do with the time which must elapse between suture and recovery; unless the nutrition of the skin and muscles is carefully maintained and care taken to prevent overstretching of the paralysed muscles the result will be poor, even although nerve regeneration has taken place.

*Treatment.*—In dealing with instances of incomplete interruption of continuity in the great sciatic nerve we must be prepared to treat complete division of its external popliteal portion. This must be dealt with as complete division elsewhere; if after an injury to the great sciatic, the reaction of degeneration develops in the external popliteal group of muscles, even although those supplied by the internal popliteal are unaffected, the nerve should be exposed, the damaged portion of the external popliteal found by tracing it up from below, separated from the internal, excised and reunited. During the early stages of recovery the weight of the body must

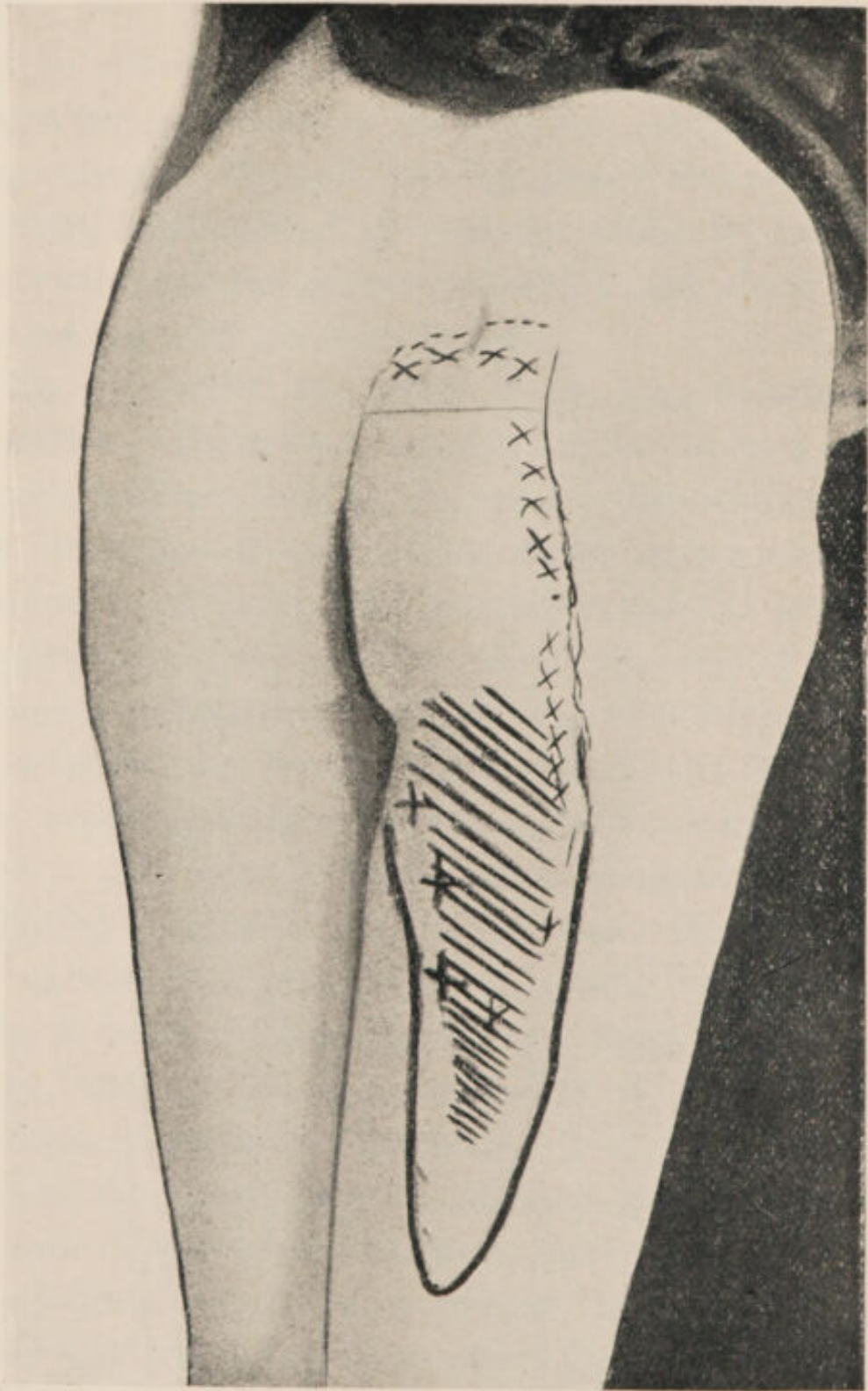
not be allowed to rest on the paralysed foot; perforating ulcers are liable to develop and may necessitate amputation. The foot and leg should be fitted with a light, well-padded poroplastic splint to prevent deformity and the patient allowed to get about on a bucket leg with the limb flexed.

No time after the injury is too long to attempt operation; amputation should not be advised as a routine measure even in old cases. The tendency to the formation of perforating ulcers ceases with the restoration of protopathic sensibility, and this is to be expected in every case in which the wound heals without suppuration. At the end of the first stage of recovery the whole of the sole of the foot is in that condition of sensibility found in the intermediate zone. All stimuli have an unpleasant tingling radiating character, and for this reason the limb may be useless, the patient being unable to bear any weight on it. This will, in most cases, be only a stage, and as epicritic sensibility is restored the tenderness gradually diminishes. If sensory recovery fails at this stage, amputation may be necessary on account of the tenderness and pain; if this is done care should be taken to obtain the flap from the inner side of the leg, from skin supplied with normal sensibility by the internal saphenous.

If complete motor recovery fails a suitable surgical boot should be worn, or athrodesis of the ankle carried out.







To show the loss of sensibility produced by complete division  
of the small sciatic nerve.

**The small sciatic nerve.**—This is rarely injured alone but suffers in lesions of the sacral plexus.

Epicritic and protopathic sensibility are lost as the result of its complete division over the relatively small area shown in Plate XX. Deep sensibility is unaffected.

**The external popliteal nerve.**—This is more often injured than any other nerve of the lower limb. It may suffer when bound up with the internal popliteal to form the great sciatic, or, after it has separated, above or below the point at which its lateral cutaneous branch is given off. Injury in the last position is the most common.

Anatomical division of the nerve is rare, but it has occurred during tenotomy of the biceps tendon and during the forcible straightening of a flexed knee-joint. It suffers most often after it has separated from the internal popliteal, from direct violence and in association with fractures of the neck of the fibula, the nerve injury being primary and caused by the injury producing the fracture. From its exposed position on the neck of the fibula it is exposed to external injury, and suffers not infrequently from the faulty application of Clover's crutch, Esmarch's bandage or puttees. It is occasionally overstretched, and sometimes ruptured, during the forcible extension of a flexed and ankylosed knee. It is occasionally involved in those whose occupation entails work in a crouching attitude.

*Symptoms.*—No difficulty in the diagnosis is likely to arise from the motor side. The foot is in the position of talipes equino-varus, and the tibialis anticus, all the extensors of the toes and the peronei muscles are paralysed. Consequently the foot cannot be flexed or everted and the toes cannot be extended.

Difficulties may arise in the interpretation of the

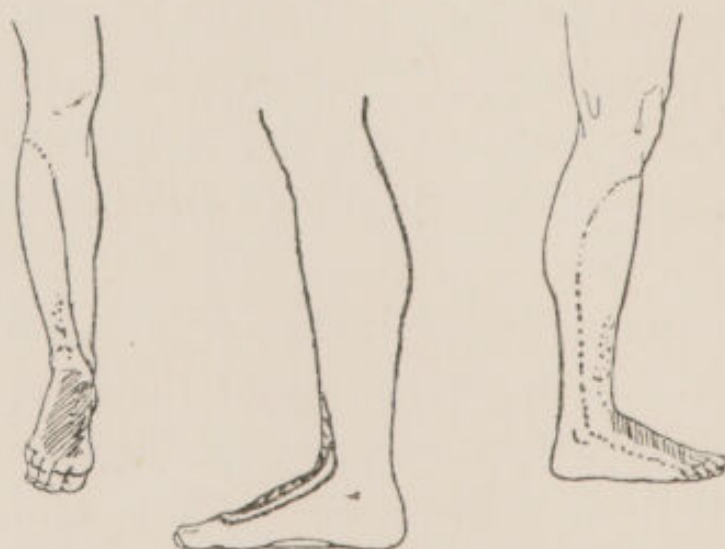

FIG. 24.—Illustrating the loss of sensibility resulting from division of the external popliteal nerve below its lateral cutaneous branch.

loss of sensibility. Deep sensibility is unaffected, and the patient may be able to appreciate and to localise the slightest pressure causing deformation of the skin. Just before the nerve passes round the neck of the fibula it gives off a large lateral cutaneous branch; it is most often injured below this point. The loss of sensibility which results from this lesion is only absolute on the dorsum of the foot and lower third of the leg (*vide* Fig. 24). The anterior



Unable to display this page

Unable to display this page

division usually leaves the tibialis anticus muscle unaffected; in an injury to the lumbo-sacral cord or external popliteal nerve this muscle is paralysed. An injury of the fifth anterior root leaves sensibility unaffected; if the posterior root is affected in addition, the loss of light touch is less extensive than the loss of sensibility to prick. This was beautifully shown in a patient with involvement of these roots in a cauda equina injury, on whom I divided the external popliteal nerve for purposes of anastomosis. Before his operation the loss of sensibility was of the root type; after, it showed the typical features of the loss of sensibility resulting from division of a peripheral nerve.

*Treatment.*—Attention must be directed to the necessity for preventing foot drop. Complete recovery is impossible in a patient whose paralysed muscles have been over-stretched for a considerable time. The foot must be kept at right angles to the leg in a light poroplastic splint; later, the patient may be allowed to walk on the affected limb with a surgical boot fitted with a toe-raising spring. At night the splint should be worn until the muscles have regained voluntary power.

*Involvement in fractures.*—As already mentioned, this nerve is not infrequently injured in fractures of the upper end of the fibula. The injury is, in most cases, physiological, but a case has been recorded by Duplay in which the nerve was found completely



ruptured. The nerve usually passes between the fragments, and unless operation is undertaken the division becomes complete. In all cases of fracture of the upper end of the fibula with involvement of this nerve, if there is any separation of the fragments, primary operation should be undertaken, the nerve freed, and the fragments exposed and wired, or the small upper fragment may be completely removed, care being taken to injure the attachment of the biceps as little as possible. If the nerve be found ruptured, suture, after trimming the ends with a sharp scalpel, should be carried out. When the fragments are in close apposition immediate operation is unnecessary; the usual treatment for a subcutaneous injury should be instituted. In old cases in which the reaction of degeneration has developed, excision of the damaged portion of the nerve must be carried out; neurolysis is useless.

*Recovery and prognosis.*—The tibialis anticus is the muscle which first regains voluntary power and electrical excitability, followed by the extensors of the toes, and lastly the peronei; these latter muscles may remain permanently paralysed.

Recovery will follow in most cases if the appropriate treatment and after-treatment is carried out, and may be expected to become complete in about three years. But if, after suture, no care is taken, complete recovery never takes place.

**Internal popliteal nerve.**—Injury to this nerve is

uncommon ; it has occurred during the forcible straightening of a flexed and ankylosed knee.

The calf muscles, the tibialis anticus and flexors of the toes are paralysed, and the foot takes up the position of talipes calcaneo valgus ; extension of the foot, inversion in the extended position and flexion of the toes are impossible. No difficulty arises in recognising the paralysis of the muscles concerned in these movements.

There is no loss of deep sensibility after complete division of this nerve, but epicritic and protopathic sensibility are lost over the sole of the foot. This area has a well-defined inner border, but the outer border is ill defined owing to its overlap with the external saphenous. The dorsal surface of the outer four toes is insensitive to epicritic stimuli, but there is no loss of protopathic sensibility over their dorsal or plantar surfaces.

**Anterior tibial nerve.**—This nerve is rarely injured alone on account of its deep position, but occasionally it is pressed upon or lacerated in fractures of the tibia, and may give rise to all the symptoms of irritative involvement of a nerve.

Anatomically, filaments of this nerve may be traced to the cleft between the great and second toes, but it has here no exclusive supply. I have on two occasions divided this nerve for therapeutic purposes and failed to produce any loss of sensibility in this situation.





# INDEX

---

- Abduction of thumb, 27, 268
- Acuæsthesia, 54
- Adduction of thumb, 248
- Anastomosis, nerve, 86
  - in cauda equina lesions, 285
  - in facial paralysis, 168
  - in injuries of nerves, 92
  - — spinal cord, 286
  - varieties of, 92
- Anterior crural nerve, 287
  - tibial nerve, 303
  - — — injury in fractures, 43, 141, 303
- Antidromic impulses, 139
- Auditory nerve, 172
- Autoplastie nerveuse, 89
  
- Bernhardt's disease, 289
- Birth paralysis, brachial, 206
  - — facial, 164
- Blisters arising after complete division, 21
  - arising after incomplete division, 44
  - arising during recovery, 73, 103, 118
- Brachial plexus, 183
  - — birth paralysis, 206
  - — distribution of roots entering, 184
  - — injuries of, from cervical ribs, 190
  - — — complete, 194
  - — — infra-clavicular, 193
  - — — inner cord, 200
  - — — localisation of, 225
  - — — outer cord, 19, 201
  - — — post-anæsthetic, 189
  - — — prognosis of, 204
  - — — supra-clavicular, 187
  - — — traction, 197
  - — — with fractured clavicle 192
- Causalgia, 42, 137
- Cauda equina, 276
  - — diagnosis of injuries of, 284
- Cervical nerves, 178
  - ribs, injuries of brachial plexus, associated with, 190
  - sympathetic, 181, 194, 225
  - — injury of, 181, 182

- Cervical sympathetic, injury with  
     brachial plexus, 194, 200  
 Change, line of, 19, 38, 50, 107  
 Chorda tympani nerve, 164  
 Circumflex nerve, 216, 227  
 Classification of nerve injuries, 2  
   — of brachial plexus injuries, 187  
 Compass test, 51  
   — — restoration of, after divi-  
     sion, 107, 124  
 Complications during recovery  
   after complete division, 118  
   — — after incomplete division,  
     132  
 Contractures, 28, 117  
   — hysterical, 69  
   — facial, 166  
   — ischæmic, 70  
 Conus medullaris, 276  
   — — injuries of, 281  
 Corneal changes, 161, 163  
 Crossing, nerve, 86, 95  
   — — in facial paralysis, 169  
 Crutch paralysis, musculo-spiral,  
     232, 234  
   — — circumflex, 217  
  
 Deep sensibility, 17, 20  
   — — recovery of, 108  
   — — tests for, 54  
 Degeneration, reaction of, 28  
 Deltoid muscle, paralysis of, 199,  
     216, 226  
 Diagnosis of nerve injuries, 45, 61  
   — — from hysteria, 66  
   — — from ischæmic contracture,  
     70  
   — — from spinal cord injuries,  
     61, 222  
  
 Diagnosis of brachial plexus in-  
     juries, 219  
 Diplopia, 153  
 Dislocations, nerve injury compli-  
     cating, 9  
   — injury of anterior crural nerve,  
     287  
   — — of brachial plexus, 200  
   — — of musculo-spiral nerve, 233  
   — — of obstructor nerve, 288  
   — — of sciatic, great, 291  
   — — of ulnar nerve, 256  
 Division, anatomical, 2  
   — complete, 15  
   — definition of, 2  
   — in wounds, 3  
   — incomplete, 35  
   — physiological, 2  
 Dorsal nerves, operative injuries  
     of, 5, 144, 146  
 Electrical reactions, in complete  
     division, 28  
   — — in incomplete division, 55  
 Electrical testing, 55  
   — treatment, 73  
 End bulbs, 142  
 Epicritic sensibility, 21  
   — — recovery of, 101, 123  
   — — tests for, 48  
 Erb, see *Paralysis*.  
 Examination, methods of, 45  
 External cutaneous nerve (of  
     forearm), 230, 233  
   — — (of leg), 289  
   — popliteal nerve, 297  
   — — injury with great sciatic,  
     293  
   — — — in fractures, 301  
 Facial nerve, 164

- Facial nerve anastomosis, 169  
 — — birth paralysis of, 164  
 — — distribution, 165  
 — — paresis of muscles after removal of Gasserian ganglion, 161  
 — — prognosis, 166  
 Fifth cranial nerve, 154  
 — — corneal changes after injury of, 162  
 — — distribution, sensory, 154  
 — — — motor, 160  
 — — first division, 161  
 — — second and third division, 163  
 Fractures, injuries of nerves in, 7, 82  
 — — of brachial plexus in, 187, 192  
 — — of external popliteal in, 297, 301  
 — — of musculo-spiral in, 234  
 — — of ulnar nerve in, 256  
 Fracture of base of skull, nerve injury in, 150  
 Fractures of spine, cervical region, 222  
 — — lumbar region, 277  
 Glosso-pharyngeal nerve, 172  
 Glossy skin, 32, 42, 132, 137  
 Gluteal nerve, 290  
 Gunshot wounds, see *Wounds*.  
 Ganglion, Gasserian, removal of, 155  
 — — injuries of nerves in, 152  
 — — posterior root, removal of, 143  
 Horner's muscles, paralysis of, 165  
 Hypoglossal nerve, 177  
 — anastomosis, 169  
 Hyperalgesia, 41, 132  
 Hysteria, 66  
 — diagnosis from nerve injury, 143  
 Injury, nerve, by pressure, 6  
 — — by traction, 7  
 — — by wounds, 3  
 — — in wounds, gunshot, 12  
 — — — operative, 9  
 — — complicating fractures, 7, 82  
 Ilio-hypogastric nerve, 5, 144  
 Ilio-inguinal nerve, 5, 144, 145  
 Inferior dental nerve, 163  
 Internal cutaneous nerve, 245  
 — popliteal nerve, 302  
 — saphenous nerve, 290  
 Intercosto-humeral nerve, 146  
 Joints, changes in, 33  
 Klumpke, see *Paralysis*.  
 Lacrymation after removal of Gasserian ganglion, 162  
 — in facial paralysis, 165  
 Lingual nerve, 163  
 Lumbar plexus, 287  
 — roots, distribution of, 283  
 Massage in nerve injuries, 73, 78, 143  
 Median nerve, 262  
 — — full supply of, 267  
 — — injury, diagnosis of, 270  
 — — — motor symptoms, 267  
 — — — sensory symptoms, 264  
 — and ulnar nerves, 271



- Meralgia paræsthetica, 289  
 Motility, supplementary, 28  
 Musculo-cutaneous nerve, 230  
 Musculo-spiral nerve, 232  
 — — injury in fractures, 234  
 — — treatment, 242
- Nails, changes in, 32, 44  
 Neuritis, 118, 132, 140, 142  
 — of ulnar nerve, 258  
 Neuromata, amputation, 147  
 Neurolysis, 131, 146, 245
- Obturator nerve, 288  
 Operations, nerve injuries caused  
     by, 4, 144, 167, 175  
 — plastic, on nerves, 85
- Pain in nerve injuries, 43, 132  
 — following amputations, 148  
 — treatment of, 139, 142, 145  
 Palate, motor supply of, 160, 166,  
     174  
 Paralysis, brachial birth, 206  
 — diaphragm, 179  
 — Erb-Duchenne, 195, 288  
 — following complete division, 27  
 — — crutch pressure, 6  
 — — incomplete division, 40  
 — — splint pressure, 6  
 — Klumpke, 199  
 — palate of, 160  
 — post-anæsthetic, 10, 189  
 — post-operative, 10  
 — serratus magnus, of, 160  
 — sterno-mastoid, 175  
 — trapezius of, 175  
 Phrenic nerve, 179  
 Primary suture, 75
- Primary suture, recovery after, 108  
 — — prognosis of, 110  
 — union, 99  
 Prognosis of brachial birth para-  
     lysis, 208  
 — of incomplete division, 131  
 — of brachial plexus injuries, 190,  
     204  
 — of post-anæsthetic paralyses,  
     12  
 — of primary suture, 110  
 — of secondary suture, 114  
     See also under *Individual nerve*.  
 Protopathic sensibility, 20  
 — — recovery of, 101  
 — — tests for, 53  
 Pupil, changes in, following injury  
     to cervical sympathetic, 181  
 — removal of Gasserian ganglion,  
     162  
 — spinal cord injury, 224
- Radial nerve, 233, 239  
 — and external cutaneous, 240  
 Reactions, electrical, in complete  
     division, 28  
 — in incomplete division, 48  
 — in testing, 55  
 Recurrent laryngeal nerve, 174  
 — sensibility, 22  
 Recovery, after anastomosis,  
     facial, 171  
 — — for injury, 93  
 — after complete division, 101  
 — after incomplete division, 123  
 — after primary suture, 108  
 — after secondary suture, 112  
 — after transplantation, 89  
 — after tubular suture, 90  
 Regeneration, 119

- Rhomboid muscles, paralysis of, 215, 255
- Roots, nerve, division of, 143, 149  
— loss of sensibility following, 24  
— supply of cervical, 184, 186  
— — of sacral, 286
- Sacral plexus, 287  
— roots, 282
- Scapula, alterations in position, 219  
— winged, 212
- Scars, nerve involvement in, 132, 139
- Sciatic nerve, great, 291  
— — plastic operations on, 97  
— — small, 297
- Sensibility, deep, 17  
— dissociated, 23, 25  
— epicritic, 20  
— protopathic, 28  
— rapid return of, after secondary suture, 113  
— recovery of, 101  
— supplementary, 23  
— tests for, 48
- Serratus magnus, paralysis of, 211, 225
- Sixth cranial nerve, 154
- Skin, changes following complete division, 30  
— — — incomplete division, 42  
— grafting, recovery of sensation after, 106
- Spinal accessory nerve, 175  
— cord injuries, diagnosis of, 61, 222
- Spinati muscles, paralysis of, 214, 225
- Stretching, nerve in secondary suture, 82
- Supra-scapular nerve, 214, 266
- Supply, exclusive, 15  
— full, 15
- Suture, primary, 75, 108  
— secondary, 79, 112  
— tubular, 90, 97
- Sweating, absence of, 30, 181  
— increase of, 44, 139, 182
- Taste, 158  
— nerves of, 165  
— tests for, 159
- Tests, compass, 51  
— electrical, 55  
— for deep touch, 54  
— for light touch, 48  
— for passive position, 54  
— for pain, 53  
— for smell, 151  
— for taste, 159  
— sensory, 48  
— temperature, 49, 53
- Third cranial nerve, 153
- Transplantation, definition of, 85, 86  
— prognosis of, 89  
— varieties of, 87
- Trapezius, paralysis of, 175
- Treatment, 72  
— of amputation neuromata, 149  
— of brachial plexus injuries, 202  
— of brachial birth paralysis, 209  
— of facial paralysis, 167  
— of gunshot wounds, 84  
— of subcutaneous injuries, 73  
— — involvement in fractures, 82

Treatment of scars, 134, 139  
— wounds, 74

Ulcers, "trophic," 31, 44, 81, 118

Ulnar nerve, 246

— — diagnosis of injuries, 261

— — dislocation, 260

— — full supply, 253

— — injuries in fractures, 256

— — prognosis of injuries, 254

— — treatment, 254

Vagus nerve, 173

Volkman's contracture, 70

Wounds of nerves, accidental, 3,  
74

— — gunshot, 12, 42, 84

— — operative, 4, 74

Zone, intermediate, 17, 18





# GALL-STONES AND DISEASES OF THE BILE-DUCTS

BY  
J. BLAND-SUTTON, F.R.C.S.

PROFUSELY ILLUSTRATED

Crown 8vo, 3s. 6d. net (postage 4d.)

*The Lancet* says: "Though the book is small it contains a good deal. The style is simple, and the addition to each chapter of references to works dealing with the subject, enables the reader to look up the matter more fully if he wishes. We are pleased with the book . . . it should prove of value to senior students and to those in practice. If the later volumes are as good as this, the series will have justified its existence."

*The British Medical Journal* says: "The student will find no more admirable outline of the clinical aspects of gall-stone disease, than is presented in the first eight chapters."

---

# CANCER OF THE STOMACH

BY  
A. W. MAYO ROBSON, D.Sc., F.R.C.S.

WITH MANY ILLUSTRATIONS

Crown 8vo, 4s. 6d. net (postage 4d.)

*The Medical Times and Hospital Gazette* says: "We look upon the volume itself as one of the best contributions to the literature of gastric cancer that has appeared in English. It is clearly written, free from padding, and contains just that kind of information which the physician or the surgeon most needs in actual practice. We commend this excellent monograph to the notice of our readers, as well as the series to which this volume forms a valuable addition."

---

JAMES NISBET & CO., LTD.  
22, BERNERS STREET, W.

# ALCOHOLISM

A CHAPTER IN SOCIAL PATHOLOGY

BY

W. C. SULLIVAN, M.D.

Large crown 8vo, 3s. 6d. net (postage 4d.)

C. W. SALEEBY, M.D., in the *Daily Chronicle* says: "This little book embodies one of the most valuable contributions to the study of a monstrous question that has appeared for many years past. The author has gone right to the root of the matter. There is no serious student of the liquor question who can afford to be without this admirable book."

*The Lancet* says: "The present little book is an agreeable surprise. The author has something new to say as to the pathology of alcoholism, and new ideas as to means for controlling some part at all events of the disease. The book may be heartily commended to all who are interested in the study of alcoholic indulgence, and who desire to read a dispassionate scientific study of one side at least of the complex problem."

---

# EXPERIMENTS ON ANIMALS

BY

STEPHEN PAGET

New and Revised Issue, with an Introduction by LORD LISTER

Extra crown 8vo, 4s. 6d. net (postage 4d.)

*The Pall Mall Gazette* says: "This book is of course the standard work on this subject, and the present edition is even better, more complete, and more effective than the last. . . . No one who takes any interest in this subject can do his duty to it or to himself without reading Mr. Paget's admirable book."

*The Medical Press and Circular* says: "An accomplished writer and a vigorous opponent, Mr. Paget has many qualifications for the task, and on the whole he has carried it out well. We are delighted to see the book in its third edition; we only wish it were the thirtieth. To those medical men who at present take no interest in the controversy it becomes almost a duty to make themselves acquainted with its chief features, and we say without fear of contradiction that if they read this book their eyes will be opened."

---

JAMES NISBET & CO., LTD.

22, BERNERS STREET, W.

