

**Army handbook of practical radiography / prepared under the direction of the director-general of Army Medical Services.**

**Contributors**

Great Britain. War Office.  
Great Britain. Army Medical Services.

**Publication/Creation**

London : H.M.S.O., 1963.

**Persistent URL**

<https://wellcomecollection.org/works/jvvt7h83>

**License and attribution**

This work has been identified as being free of known restrictions under copyright law, including all related and neighbouring rights and is being made available under the Creative Commons, Public Domain Mark.

You can copy, modify, distribute and perform the work, even for commercial purposes, without asking permission.



Wellcome Collection  
183 Euston Road  
London NW1 2BE UK  
T +44 (0)20 7611 8722  
E [library@wellcomecollection.org](mailto:library@wellcomecollection.org)  
<https://wellcomecollection.org>

**ARMY  
HANDBOOK  
OF  
PRACTICAL  
RADIOGRAPHY**

Vet Hospital,  
R. A. ... ing  
Centre and Depot.

*[Faint, illegible text]*



Med  
K42175

Vet Hospital,  
R. A. V. C. Training  
Centre and Depot.

THE  
LIBRARY OF THE  
MUSEUM OF MODERN ART  
1900  
1900

ARMY HANDBOOK OF  
PRACTICAL RADIOGRAPHY

ARMY HANDBOOK OF  
PRACTICAL  
RADIOGRAPHY

Supersedes "Field Service Handbook of Practical Radiography" (P.O.  
Order No. 575)  
Approved by the Director of the Department of  
Army Medical Services

LONDON  
HER MAJESTY'S STATIONERY OFFICE  
1942

ARMY HANDBOOK OF  
PRACTICAL RADIOGRAPHY



W.O.  
Code No.

12700

26/Publications/9015

**ARMY HANDBOOK OF  
PRACTICAL  
RADIOGRAPHY**

(Supersedes "Field Service Handbook of Practical Radiography" (W.O.  
Code No. 600))

Prepared under the direction of the Director-General  
of Army Medical Services.

THE WAR OFFICE,  
1963.

*LONDON*  
HER MAJESTY'S STATIONERY OFFICE  
1963



© Crown copyright 1963

Published by  
HER MAJESTY'S STATIONERY OFFICE

To be purchased from  
York House, Kingsway, London, W.2.  
423 Oxford Street, London, W.1.  
13a Castle Street, Edinburgh 2.  
109 St. Mary Street, Cardiff.  
39 King Street, Manchester 2.  
50 Fairfax Street, Bristol 1.  
35 Smallbrook, Ringway, Birmingham 5.  
80 Chichester Street, Belfast 1.  
or through any bookseller.

Price 15s. 6d. net

|                               |          |
|-------------------------------|----------|
| WELLCOME INSTITUTE<br>LIBRARY |          |
| Coll.                         | WeIMOmec |
| Coll.                         |          |
| No.                           | WN       |
|                               |          |
|                               |          |
|                               |          |

7469942

Printed in England for Her Majesty's Stationery Office  
by Blake & Mackenzie, Ltd. Liverpool.

## CONTENTS

|   | PAGE |
|---|------|
| Introduction                                | vii  |
| Abbreviations                               | ix   |
| Radiographic terminology...                 | x    |
| Viewing of radiographs                      | xi   |
| Marking, filing and disposal of radiographs | xii  |
| Exposure factors and technique charts       | xiii |
| kV values of War Department X-ray sets      | xv   |
| Radiation hazards to patients and others    | xvi  |
| Standard positions in radiography           | 1    |
| The hand ...                                | 2    |
| The fingers                                 | 4    |
| The thumb                                   | 6    |
| The wrist ...                               | 8    |
| The forearm                                 | 10   |
| The elbow joint                             | 11   |
| The humerus                                 | 14   |
| The shoulder joint                          | 16   |
| The acromio-clavicular joint                | 17   |
| The clavicle                                | 18   |
| The scapula                                 | 19   |
| The sternoclavicular joints                 | 21   |
| The toes                                    | 22   |
| The foot ...                                | 24   |
| The os-calcis                               | 26   |
| The ankle joint                             | 28   |
| The lower leg                               | 29   |
| The knee joint                              | 30   |
| The patella                                 | 32   |
| The femur, lower two thirds                 | 34   |
| The hip joint and upper third of femur      | 35   |
| The pelvis                                  | 37   |
| The sacrum                                  | 38   |
| The coccyx                                  | 40   |

CONTENTS—*contd.*

|   | PAGE |
|---|------|
| The sacro-iliac joint ... ..            | 41   |
| Lumbo-sacral articulation ... ..        | 42   |
| The lumbar vertebrae ... ..             | 44   |
| The dorsal or thoracic vertebrae ... .. | 46   |
| The cervico-dorsal region ... ..        | 47   |
| The cervical vertebrae ... ..           | 48   |
| The sternum ... ..                      | 51   |
| The ribs ... ..                         | 53   |
| The skull ... ..                        | 56   |
| The cranium ... ..                      | 57   |
| The facial bones ... ..                 | 60   |
| The nasal bones ... ..                  | 62   |
| The nasal accessory sinuses ... ..      | 64   |
| The mastoid air cells ... ..            | 68   |
| The mandible ... ..                     | 71   |
| The temporo-mandibular joints ... ..    | 74   |
| The teeth ... ..                        | 76   |
| The thoracic viscera ... ..             | 79   |
| The abdominal viscera ... ..            | 84   |
| The liver ... ..                        | 87   |
| The diaphragm ... ..                    | 87   |
| The digestive tract ... ..              | 88   |
| The urinary tract ... ..                | 90   |
| The biliary tract ... ..                | 97   |
| Cholecystography ... ..                 | 97   |
| Bronchography ... ..                    | 102  |
| Stereography ... ..                     | 104  |
| Pelvimetry ... ..                       | 108  |
| Localization of foreign bodies ... ..   | 112  |
| Radiographic exposure table ... ..      | 114  |

## INTRODUCTION

### Scope

The scope of this book has been limited to routine practical radiography, showing the routine positioning for each part, with further projections for special circumstances. It is not intended to be a comprehensive textbook on radiographic positioning.

A table showing the kilovoltage values for stud settings of certain War Department X-ray machines have been included, as well as notes on exposure factors and on completion of technique charts.

### General preliminaries to radiographic examinations

As routine radiography is normally carried out by radiographers with no medical officer present, a note should be made in fracture cases as to whether or not splints may be removed by the radiographer. No splint will be removed without first referring to the medical officer in charge.

Before an X-ray examination begins, it may be necessary to remove any articles liable to mask the details of the part under investigation, and, for hospital in-patients, time may be saved by some of these being removed in the wards. The following are examples:—

Garments made of silk or of india-rubber, or embroidered with silk; and those carrying buttons, buckles, hooks and eyes, or other metallic fastenings.

Belts, trusses, waterproof material.

All dressings except dry gauze, lint, cotton wool and bandages. Even these may require removal if they are so bulky as to obscure anatomical landmarks and thus prevent adequate positioning.

Metal or metal mesh splints, unless made entirely of aluminium, will seriously obscure any bone which they cover; and screws or nails in wooden splints sometimes cause similar trouble.

Lead lotion and B.I.P.P are both more radiopaque than bone and may therefore hide it altogether.

Plaster of Paris masks callus and fine detail of bone, but permits the demonstration of position in a case of gross fracture. Adhesive plaster and Elastoplast are less radiopaque than plaster of Paris, but may hide early callus or a crack in a bone, and it is therefore desirable to have cases X-rayed without them. Where opaque dressings may not be removed, slight increase of kV should be applied.

Dentures must be removed before X-ray examination of the face, mouth, skull, nasal accessory sinuses, or neck; and in some cases spectacles give trouble. Before examination of the face or sinuses any artificial eye should be removed.

The new acrylic resin dentures are, however, radiotranslucent, and radiographers should familiarize themselves with the naked eye appearances of such dentures. It is obvious that unless such a denture contains a metallic ridge, radiographic investigation for such a swallowed denture is useless, unless an opaque medium is used.

The taking of any preparations containing radiopaque material, such as bismuth, should be suspended for two days before X-ray examinations of the abdominal region. Before any examination of the abdomen is undertaken, the patient should be adequately prepared in accordance with current instructions.

## ABBREVIATIONS

|          |                                |
|----------|--------------------------------|
| A.I.I.S. | Anterior inferior iliac spine. |
| A.O.     | Anterior-oblique.              |
| A.P.     | Antero-posterior.              |
| A.S.I.S. | Anterior-superior iliac spine. |
| C.R.     | Central ray.                   |
| D.P.     | Dorsi-plantar.                 |
| F.F.D.   | Focus-film distance.           |
| F.O.     | Fronto-occipital.              |
| Lat.     | Lateral.                       |
| L.A.O.   | Left anterior-oblique.         |
| L. Lat.  | Left lateral.                  |
| L.P.O.   | Left posterior-oblique.        |
| Obl.     | Oblique.                       |
| O.F.     | Occipito-frontal.              |
| O.M.     | Occipito-mental.               |
| O.M.L.   | Orbito-meatal line.            |
| P.A.     | Postero-anterior.              |
| P.D.     | Plant-dorsal.                  |
| P.B.     | Potter-bucky diaphragm.        |
| P.O.     | Posterior-oblique.             |
| P.O.P.   | Plaster of Paris.              |
| R.A.O.   | Right anterior-oblique.        |
| R.B.L.   | Radiographic baseline.         |
| R. Lat.  | Right lateral.                 |
| R.P.O.   | Right posterior-oblique.       |
| S.F.D.   | Subject film distance.         |
| S.M.V.   | Sub-mento-vertical.            |

## Radiographic Terminology

**Aspect** denotes the surface view of the subject under scrutiny, in descriptions of human anatomy.

**Anterior aspect** is that seen when viewing the subject from the FRONT.

**Posterior aspect** is that seen when viewing the subject from the BACK.

**Right or left lateral aspects** are those seen when viewing the subject from the R. or L. sides respectively.

The terms Antero-posterior and postero-anterior, describe the DIRECTION OF THE C.R., in relation to the subject:—

**A.P.** indicates projection from anterior to posterior aspects, i.e., the front aspect of the body faces the X-ray tube.

**P.A.** indicates projection from posterior to anterior aspects, i.e., the rear aspect of the body faces the X-ray tube.

The terms anterior oblique and posterior oblique describe the POSITION OF THE SUBJECT IN RELATION TO THE FILM, together with an indication of which side of the subject should be nearer the film:—

**R.A.O.** indicates anterior aspect of subject facing the film, RIGHT side close to film, left side rotated away.

**L.A.O.** indicates anterior aspect of subject facing the film, LEFT side close to film, right side rotated away.

**R.P.O.** indicates posterior aspect of subject facing film, RIGHT side close to film, left side rotated away.

**L.P.O.** indicates posterior aspect of subject facing film, LEFT side close to film, right side rotated away.

The term lateral also DESCRIBES THE POSITION OF THE SUBJECT IN RELATION TO THE FILM:—

**R. Lat.** indicates RIGHT side of subject close to film, with frontal plane perpendicular to film.

**L. Lat.** indicates LEFT side of subject close to film, with frontal plane perpendicular to film.

*Note:*—Limbs and skull are considered with regard to their individual positioning, without reference to related trunk position.

## VIEWING OF RADIOGRAPHS

### Standard Viewing Routine

Radiographs are viewed from the anterior aspect in the correct anatomical position, whether projected A.P. or P.A.

*The only exceptions are:—*

- (a) Hands and wrists—to be viewed from the posterior aspect with the fingers upwards.
- (b) Feet and toes—to be viewed from the dorsal aspect, with the toes uppermost.
- (c) All lateral views—to be viewed as from the tube aspect.

### Standard routine for positioning of markers.

Markers will be placed on the *top left corner of the film*, as related to the anatomical viewing position. The photographic marking masking will always be placed on the *top right corner of the film*.

*Exceptions to this rule will be:—*

- (a) Where the marker is liable to be masked by the dense opacity of the structures under examination.
- (b) Where cone fields are liable to exclude the marker from the field of radiation.

Markers will **always** be placed to read correctly when in position on the film or cassette. Thus, all radiographs, (except as shown above) should be viewed as from the anterior aspect; in P.A. projections the marker will be *viewed reversed*. This appearance serves as a check on the authenticity of the type of projection.

The perfect radiograph should embody the following points:—

- (a) Film size must be correct, just large enough to show structures required and their relationship to adjacent parts. Limbs must include at least one joint, as a guide to position of abnormality and to deviation from correct alignment of structures involved.
- (b) Position must be correct as taught, i.e., A.P., P.A., obl, or lat., free of rotation, correctly aligned and properly centered.
- (c) Exposure factors must permit visibility of parts under consideration.
- (d) The F.F.D. must be correct. This is normally adjusted for least possible distortion of size; but a short F.F.D. is specified in some techniques.
- (e) The cone field, if any, must be properly centered.
- (f) Effects caused by motion, pre-exposure, lack of exposure, grid lines or masking by opaque foreign bodies must not be apparent.
- (g) Artefacts must be identified as such.
- (h) Identification must be complete and properly arranged.



## MARKING, FILING AND DISPOSAL OF RADIOGRAPHS

### Marking

Every radiograph should bear the serial number of the case shown in the B MED 9 X-ray register and should also be marked in the upper right hand corner with the patient's number, name, rank and regiment or corps, and the date and place of examination.

This data can most conveniently be placed on the film by using the photographic marker, now issued to most X-ray departments.

### Filing

All radiographs of each case will be kept together and filed under one of two heads, either NORMAL, i.e. where the radiologist has reported no lesion or abnormality; or ABNORMAL, where a lesion or abnormality has been demonstrated. Each class should be grouped by CALENDAR MONTHS.

The letters "N" or "A" should be entered in the X-ray register against each case, and on the envelope containing the X-ray films to show how the radiograph has been grouped.

When cases have "follow-up" X-ray examination, radiographs taken at previous examinations must be transferred forwards and filed under each new serial number for the case.

Where radiographs leave the department for wards or any other department of the hospital, or where the films are transferred to another hospital with the patient, a separate index book should be used to record the movement of the X-ray films; and a signature should be obtained in each case for their receipt.

### Disposal

- (a) *Normal X-ray films.* All normal class X-ray films one year old should be sent to Officer Commanding, Army Return Electro-Medical Equipment Depot, Repository Road, Woolwich, London, S.E.18.

Films should be parcelled up and despatched monthly as they attain the requisite age. If one month's parcel is insignificant, discretion should be exercised until the amount is large enough for economic despatch.

- (b) *Abnormal X-ray films.* Abnormal X-ray films should be retained for two years and then despatched, in monthly parcels, to Ministry of Pensions and National Insurance, Norcross, Blackpool, Lancs.

## EXPOSURE FACTORS AND TECHNIQUE CHARTS

The correct exposures to produce the best film effects on a radiograph for any region of the body, may be found empirically.

For any particular machine, the values of kV, mAs, and F.F.D. employed may be recorded and tabulated in the form of a technique chart, from which may be read the correct exposure for any part to be examined.

These values will always produce a similar effect if:—

- (a) Conditions between tube and film remain constant.
- (b) Film and/or intensifying screen are of comparable speeds with those employed originally.

Identical values of the kV and mAs will ensure a similar intensity of radiation emitted from the source.

An identical value of the F.F.D. will ensure a similar ratio of loss due to distance from the source.

**Conditions between tube and film** affecting ultimate intensity incident upon the film are:—

- (a) Absorption by tissue.
- (b) Absorption by grid, if used.

- (a) *Absorption by tissues.* This depends on the density and thickness of the part. Values are specified for a subject of average build and weight. Adjustment by increase or decrease of kV should be made where the patient is above or below the specified average.

*Absorption by P.O.P.* Correction is also necessary where P.O.P. casts add to the normal thickness and density of the part. An addition of about 5 kV, or mAs X 2, is usual. If the cast is wet a compensation of + 10 kV should be usual.

- (b) *Absorption by grid.* This depends on the type and construction of the grid. If a grid is used where its employment is not specified, then mAs value quoted should be multiplied by 2 (average), if of stationary type, and by 3 (average) if of moving type (P.B.).

If the grid is not used where its employment is specified, then mAs value quoted is divided by 2 (average) for the stationary type and by 3 (average) for the moving type.

**Speed of film and intensifying screens.** The degree of reaction to a given intensity of radiation indicates the "speed" of the film. Exposure factors are based on the use of one particular grade of non-screen film and one grade of standard film used with intensifying screens.

Employment of different grades in either type necessitates adjustment of quoted mAs in inverse ratio to the different speeds.

The relative speeds of standard types (with intensifying screens) to non-screens types also varies according to grades and factors are therefore based on the assumed use of a particular grade in each type. An average ratio is 4 : 1 standard (with screens) to non-screen.

If standard types with screens are employed where non-screen are specified then quoted mAs should be divided by 4. If the reverse applies, mAs should be multiplied by 4.

Intensifying screens also vary in speed according to grade. Their speed is judged by their intensifying factor, which is the ratio of the exposure required for standard film with screens, to that required for standard film without screens.

Technique charts will therefore give the following particulars in tabulated form:—

|                               | <i>Screens.</i> | <i>Grid.</i> | <i>P.B.</i> |
|-------------------------------|-----------------|--------------|-------------|
| Part position KV. mAs. F.F.D. | Yes or No.      | Yes or No.   | Yes or No.  |

The grades of film used in each type are usually specified in a footnote, which will also quote the intensifying screens in use.

It is also assumed that a particular type of developer is in constant use in the dark-room; some types produce greater density than others from a given exposure.

It is important to emphasize that a technique chart has only been compiled by experience with one particular type of set. It is not always possible, and sometimes not practicable to apply factors quoted for one type when using another type, the more efficient the electrical circuit employed so the greater the emission even for stated values of kV and mAs.

An exposure table is given at App. A. This is only intended to be used as a guide in compiling a technique chart for a new or unfamiliar machine.

| Stud No. where applicable | M.X.2. | M.X.3.  |        |        |        | Mobilix |    | R.II Converted to 4 value unit | R.IV H. V. model |
|---------------------------|--------|---------|--------|--------|--------|---------|----|--------------------------------|------------------|
|                           |        | F.F.    |        | B.F.   |        | kV      | mA |                                |                  |
|                           |        | 15 m.A. | 25m.A. | 40m.A. | 50m.A. |         |    |                                |                  |
| 1                         | 52.5   | 44      | 39     | 33     | 27     | 43      | 60 | 32                             | 54               |
| 2                         | 54     | 47      | 43     | 36     | 31     | 51      | 56 | 35                             | 57               |
| 3                         | 56     | 51      | 47     | 40     | 35     | 59      | 53 | 38                             | 60               |
| 4                         | 58     | 54      | 50     | 43     | 38     | 67      | 50 | 42                             | 63               |
| 5                         | 60     | 57      | 53     | 47     | 42     | 74      | 47 | 44                             | 66               |
| 6                         | 61.5   | 62      | 57     | 51     | 46     | 81      | 44 | 48                             | 69               |
| 7                         | 63.5   | 65      | 61     | 55     | 49     | 88      | 42 | 50                             | 72               |
| 8                         | 65.5   | 68      | 64     | 58     | 53     | 95      | 40 | 53                             | 75               |
| 9                         | 67.5   | 72      | 67     | 63     | 57     |         |    | 56                             | 78               |
| 10                        | 69     | 75      | 71     | 66     | 61     |         |    | 58                             | 81               |
| 11                        | 71     | 78      | 75     | 69     | 64     |         |    | 62                             | 84               |
| 12                        | 72.5   | 85      | 78     | 73     | 68     |         |    | 65                             | 87               |
| 13                        | 74     | 86      | 82     | 77     | 72     |         |    | 68                             | 90               |
| 14                        | 76     | 88      | 85     | 80     | 75     |         |    | 70                             | 93               |
| 15                        | 78     | 92*     | 87     | 83     | 78     |         |    | 72                             | 96               |
| 16                        | 80     | 94*     | 91*    | 86     | 82     |         |    | 75                             | 99               |
| 17                        |        |         |        |        |        |         |    | 78                             | 102              |
| 18                        |        |         |        |        |        |         |    | 80                             | 105              |
| 19                        |        |         |        |        |        |         |    | 82                             | 108              |
| 20                        |        |         |        |        |        |         |    | 85                             | 111              |
|                           |        |         |        |        |        |         |    |                                | 114              |
|                           |        |         |        |        |        |         |    |                                | 117              |
|                           |        |         |        |        |        |         |    |                                | 120              |

\*These values in a ccess of 90kV should not be used

## RADIATION HAZARDS TO PATIENTS AND OTHERS

Radiographers must at all times bear in mind the need to reduce the exposure to radiation of patients and attendants to the minimum. Only those whose presence is essential should be allowed to enter the radiography room with the patient. Attendants who are required to hold a patient, or for other reasons to stay near him, should wear lead rubber aprons and where necessary, lead rubber gloves.


At the moment of exposure, the radiographer and all attendants should be as far away as is practicable from the patient and from the direct line of the X-ray beam behind lead screens where possible.

Careful radiography will eliminate repeat exposures. Cones and diaphragms must be used, to limit the field exposed to the smallest consistent with adequate examination.

Whenever the part to be examined is adjacent to the testes or ovaries, these organs will be protected by suitably placed lead rubber or other devices, except where this would obscure the part under examination.

Projections requiring such protection are marked with an asterisk.

# STANDARD POSITIONS IN RADIOGRAPHY



## THE UPPER EXTREMITY THE HAND

Routine projections: P.A. and A.O.

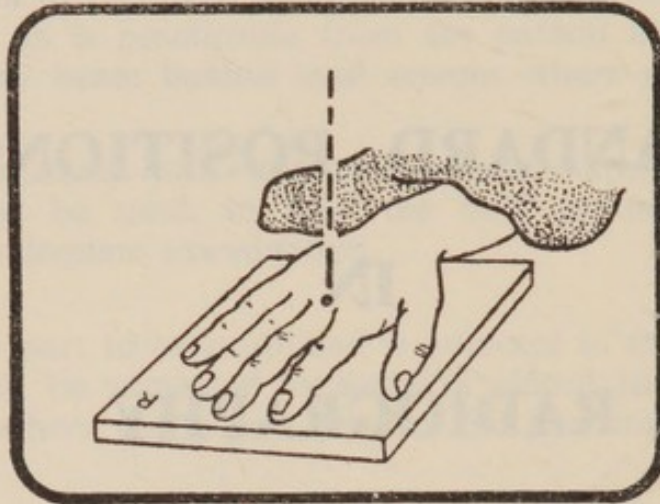
The whole limb should be at couch level if at all possible.

Where splints and/or dressings may *not* be removed, centering points may be estimated by measurement of the normal limb. Limbs examined for comparison must be radiographed under identical conditions.

### Postero-anterior.

Non-screen film recommended.

Fig. 1



**Centre.**

To head of 3rd metacarpal.

Patient to be seated.

Hand with palmar aspect down on film.

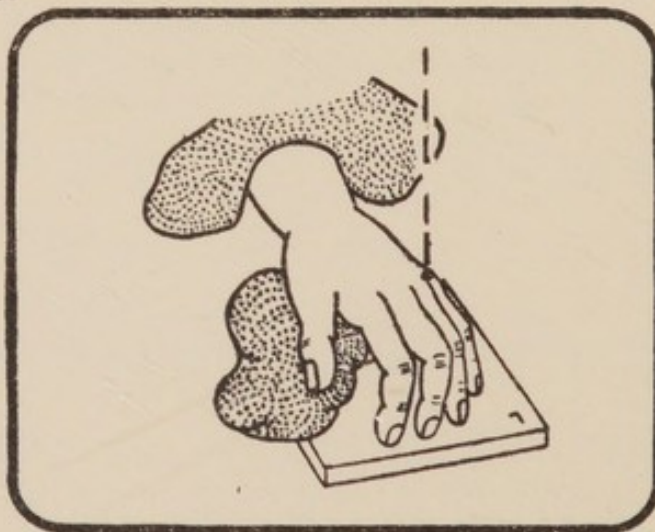
Fingers extended, slightly separated and evenly spaced.

Forearm, wrist and hand in a straight line.

Sandbag over lower third of forearm.

### Anterior-oblique.

Fig. 2



**Centre.**

Over head of 5th metacarpal.  
(The oblique ray projects the metacarpals separately on to the film).

Patient to be seated.

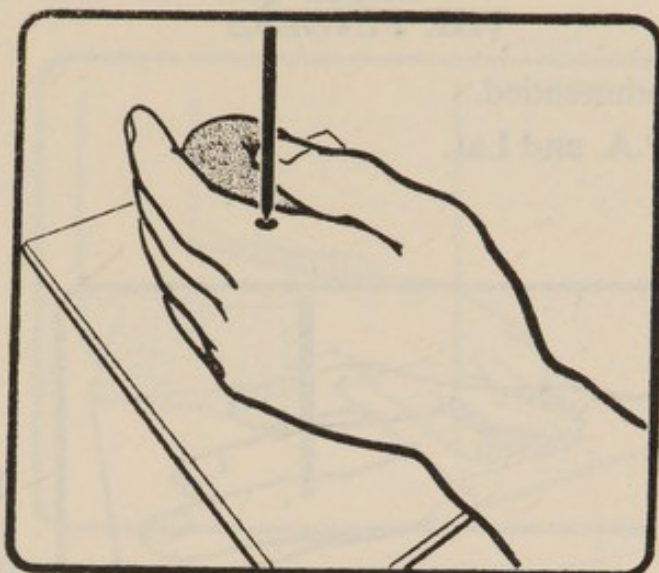
From the P.A. position the hand is supinated until the palmar aspect forms an angle of  $45^\circ$  with the film.

Fingers separated and supported parallel to film.

Thumb separated and supported with non-opaque pad.

**Lateral.**

Fig. 3



**Centre.**

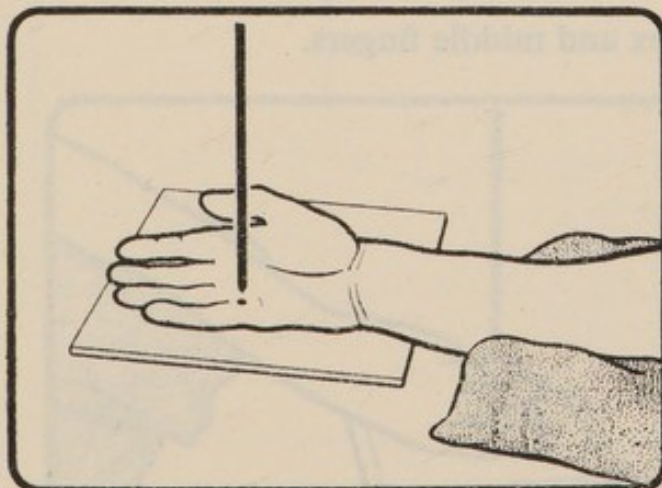
Over head of  
2nd metacarpal.

Patient to be seated.  
Fifth finger and metacarpal on film.  
Palmar aspect at right angles to film.  
Fingers together and extended.  
Thumb separated anteriorly.  
Hand, wrist and forearm in a straight line.  
Non-opaque pad under thumb.  
Sandbag over lower third of forearm.

This projection is of use to show displacement of fragments in fracture cases and also to show position of foreign bodies.  
If these three projections are presented on one film the A.O. projection should always be in the middle of the film.

**Posterior oblique (An alternative to Anterior Oblique).**

Fig. 4



**Centre.**

To head of  
5th metacarpal.

Patient to be seated.  
From the P.A., A.O. or Lat. positions the hand is further supinated until the dorsal aspect of the hand is at 45° to the film.  
Fingers separated and supported.  
Sandbag under forearm to give better support.  
Sandbag over forearm.



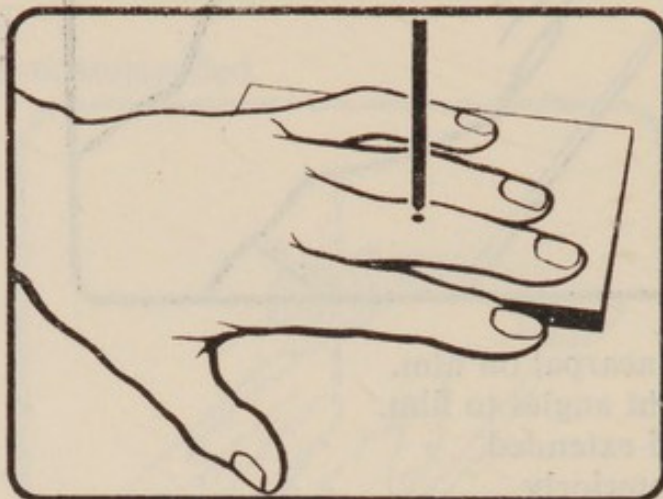
## THE FINGERS

Non-screen film recommended.

Routine positions: P.A. and Lat.

### Postero-anterior.

Fig. 5



**Centre.**

To suspected site of injury over centre of film.

Either thumb or little finger should be included in P.A. view to establish identity of suspected digit.

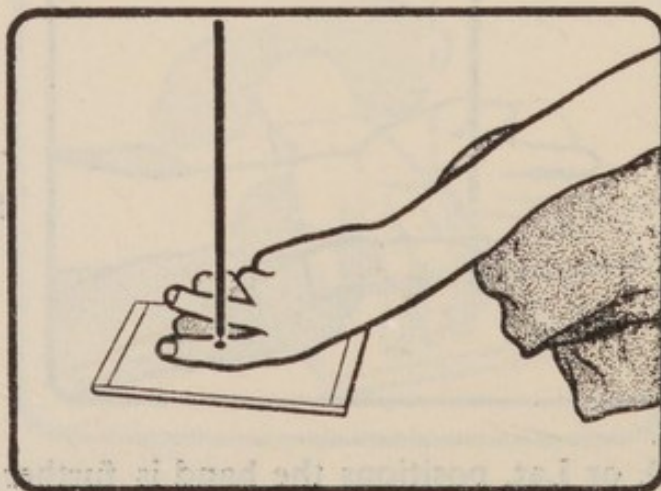
Patient seated.

Palmar aspect of fingers under examination on film.

Fingers separated slightly.

### Lateral (1). For index and middle fingers.

Fig. 6



**Centre.**

To suspected site of injury over centre of film.

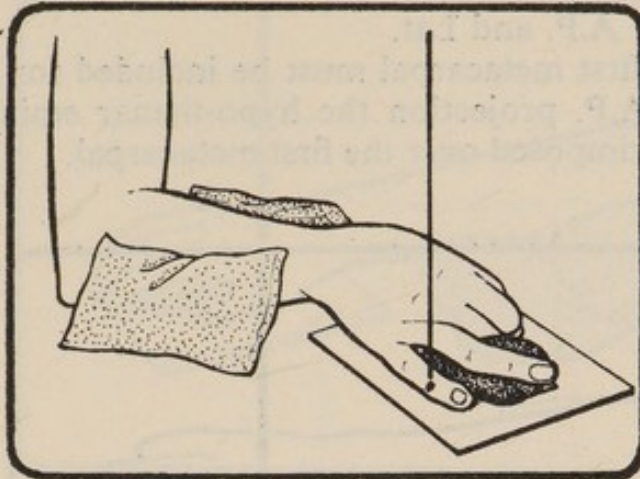
Patient seated.

Hand rotated until lateral border of index finger is in contact with film.

Index and middle fingers extended.


**Lateral (2). For little and ring fingers.**

**Fig. 7**



**Centre.**  
To suspected  
site of injury.

- Patient seated.
- Medial border of hand on film.
- Hand a little inclined to prone position.
- Little and ring fingers extended.
- Other fingers flexed and supported.



Centre  
To suspected  
site of injury

## THE THUMB

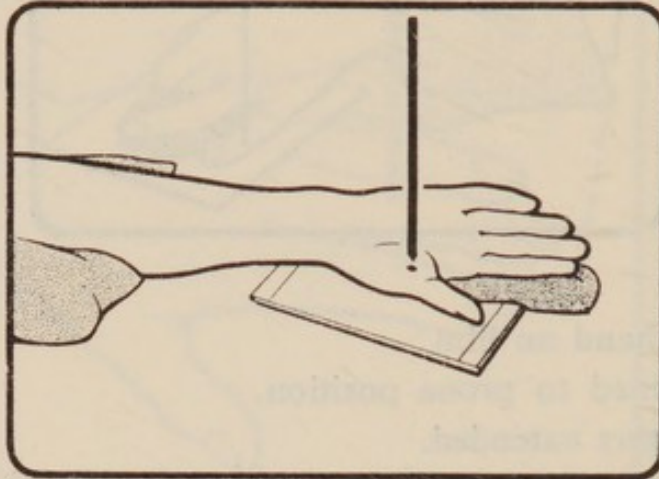
Non-screen film recommended.

Routine positions: A.P. and Lat.

The whole of the first metacarpal must be included for possible Bennett's fracture. In the A.P. projection the hypo-thenar eminence must not be allowed to be superimposed over the first metacarpal.

### Antero-posterior.

Fig. 8



**Centre.**

To metacarpophalangeal joint of thumb.

Patient to be seated.

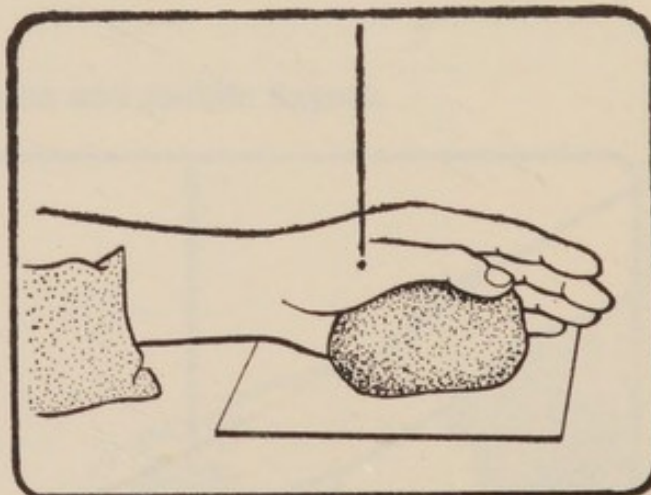
Shoulder at couch level.

Hand, wrist and forearm extended.

Arm rotated medially until posterior aspect of thumb is in contact with the film.

### Postero-anterior (Alternative to A.P.).

Fig. 9



**Centre.**

To metacarpophalangeal joint of thumb.

Patient seated.

Hand, wrist and forearm extended.

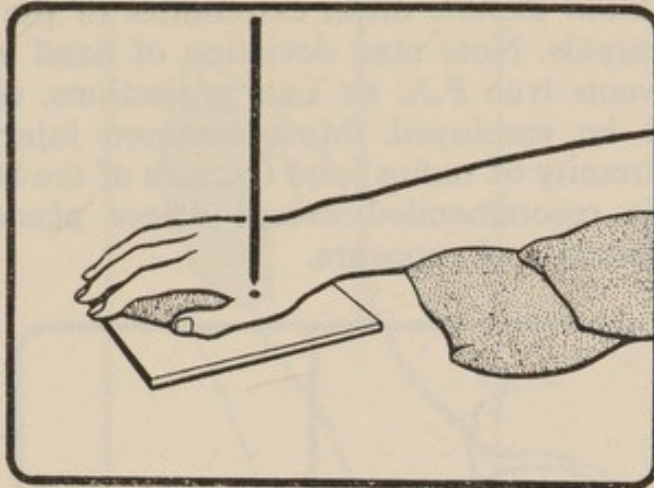
Medial border of hand on film.

Palmar aspect of hand at 45° to film

Thumb extended.

**Lateral.**

Fig. 10

**Centre.**

To metacarpophalangeal joint of thumb.

Patient seated.

Palmar aspect of hand to film.

Thumb separated.

Palm raised on radiolucent pad about 1 in. thick until thumb is in true lateral position.

## THE WRIST

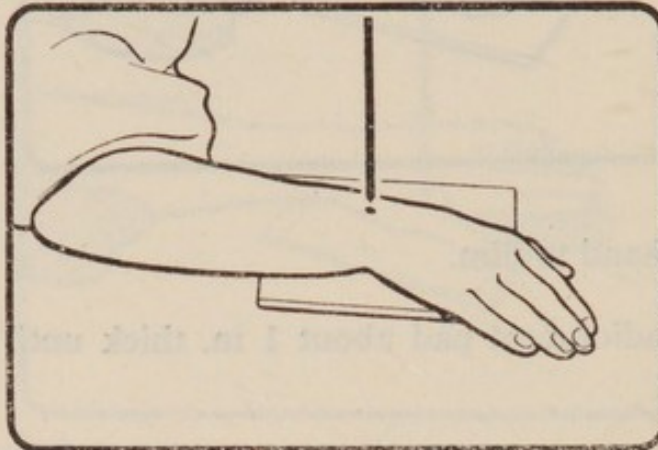
Routine projections: P.A. A.O. P.O. Lat.

The projections should include distal extremities of the radius and ulna, carpals and metacarpals. Note ulna deviation of hand in P.A. projection. Where injury prevents true P.A. or Lat. projections, compensating tube angulation should be employed. Most common injuries are COLLES Fracture (distal extremity of radius) and fracture of the SCAPHOID.

Non-screen film is recommended except where plaster of paris casts necessitate undue increase of exposure.

### Postero-anterior.

Fig. 11



**Centre.**

To mid point  
between  
styloid  
processes.

Patient seated.

Palm, wrist and forearm on film.

Ulna deviation of hand.

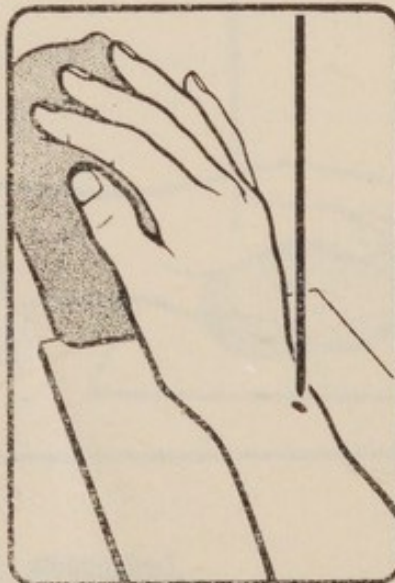
Pad under the metacarpo phalangeal joint, to keep wrist in close contact with film.

Sandbag on forearm and also on fingers.

Shoulders at couch level.

### Anterior-oblique.

Fig. 12



**Centre.**

To styloid  
process of  
ulna.

Patient seated.

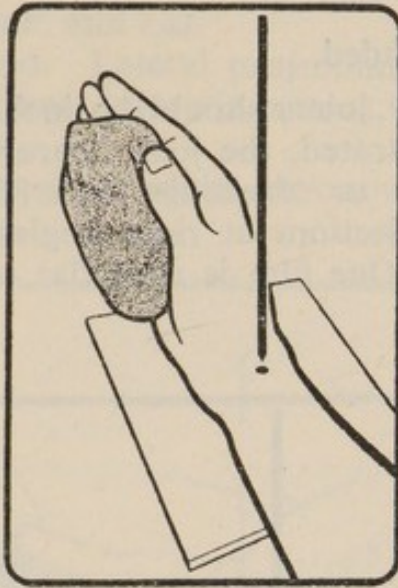
From the P.A. position the hand is rotated until palmar aspect is at 45° to film.

Pad under thumb.

Sandbag over forearm.

**Lateral.**

Fig. 13

**Centre.**

To styloid  
process of  
radius.

From the A.O. position the hand is further rotated so that palmar aspect is at  $90^\circ$  to film.

Hand, wrist and forearm in a straight line.

Fifth finger and medial border of hand on film.

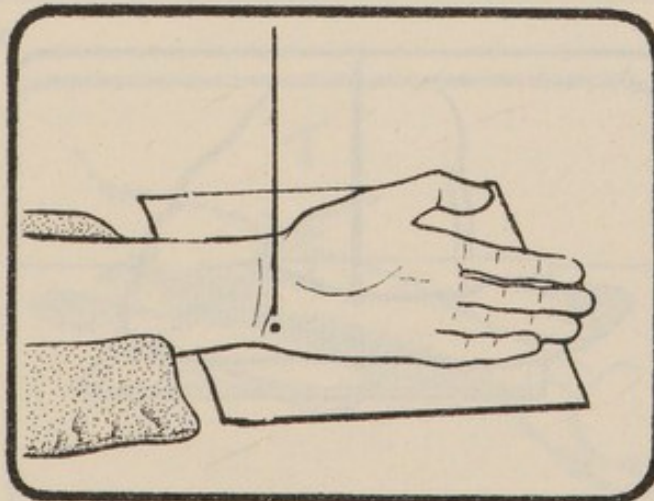
The radius vertically over ulna.

Hand supported by radiolucent pad to maintain position.

Sandbag over forearm

**Posterior-oblique.**

Fig. 14

**Centre.**

To styloid  
process of  
ulna.

From the Lat. position the hand is further rotated until dorsal aspect of hand is at  $45^\circ$  to film.

Hand, wrist and forearm in straight line.

Thumb extended.

Sandbag over forearm.

## THE FOREARM

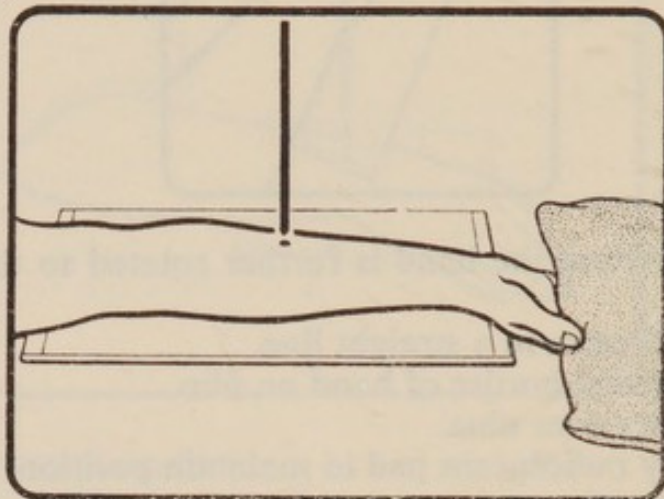
Routine projections: A.P. and Lat.

Non-screen film recommended.

Both the wrist and elbow joints should be included if possible. Where only one joint is demonstrated, the joint nearer the site of injury must be selected. If splints or dressings interfere with STANDARD POSITIONING, two projections at right angles may be taken without movement of the limb. One film is used flat on table and second film at 90° to table top.

### Antero-posterior.

Fig. 15



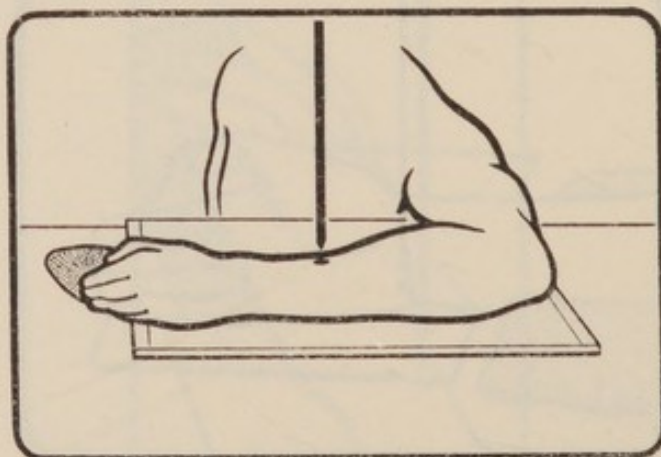
#### Centre.

To mid ulna  
and radius  
between wrist  
and elbow.

Forearm fully supinated.  
Elbow extended.  
Forearm fully touching film.  
Sandbag over palm of hand.

### Lateral.

Fig. 16



#### Centre.

Over radius,  
between wrist  
and elbow.

Shoulder, wrist and hand at same level.  
Opposite shoulder lowered to same level.  
Elbow flexed at 90°.  
Medial border of hand and forearm on film.  
Thumb uppermost.  
Sandbag across upper arm.

## ELBOW JOINT

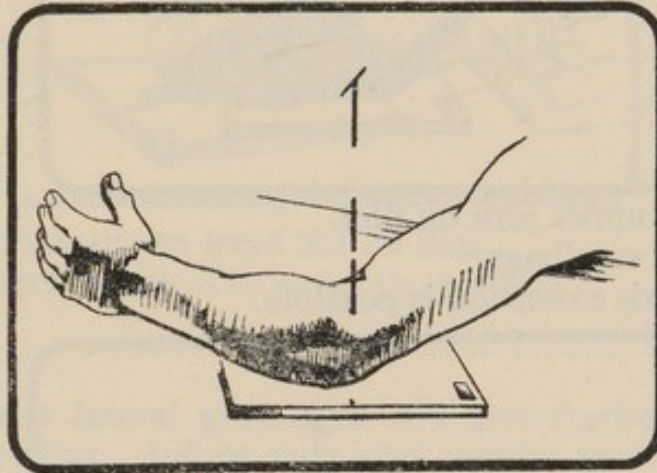
Routine projections: A.P. and Lat.

Patient should be seated. Lateral projection should be taken first as it is usually less painful where injury is present, thus giving more confidence for further examination.

Non-screen film recommended where exposure will not be unduly lengthy.

### Lateral.

Fig. 17



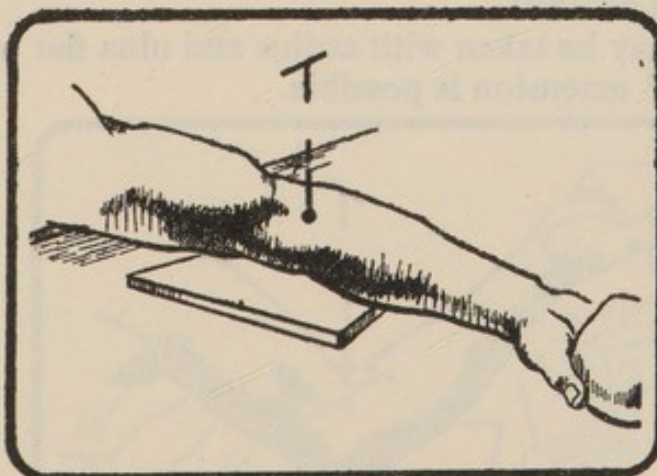
**Centre.**

To lateral  
epicondyle  
of humerus.

Elbow flexed at 90°.  
Medial border of elbow on film.  
Medial border of hand on film.  
Thumb uppermost.  
Shoulder, elbow and hand at same level.  
Opposite shoulder at same level.  
Sandbag over forearm.  
Sandbag over wrist.

### Antero-posterior.

Fig. 18



**Centre.**

To 1 in. distal  
to mid point  
of line join-  
ing epicondyles  
of humerus.

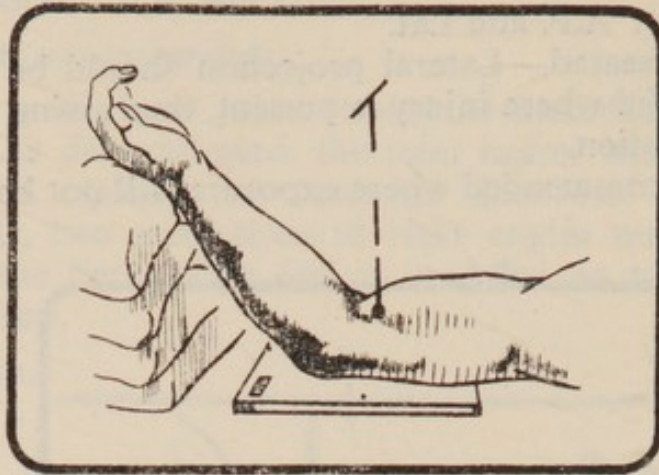
Forearm fully supinated, and resting on film.  
Elbow extended.  
Shoulder at couch level.  
Patient seated sideways to couch.  
Thumb touching couch, if possible.



**Modified A.P. projections of elbow joint**

1. Where elbow cannot be fully extended:—

Fig. 19

**Centre.**

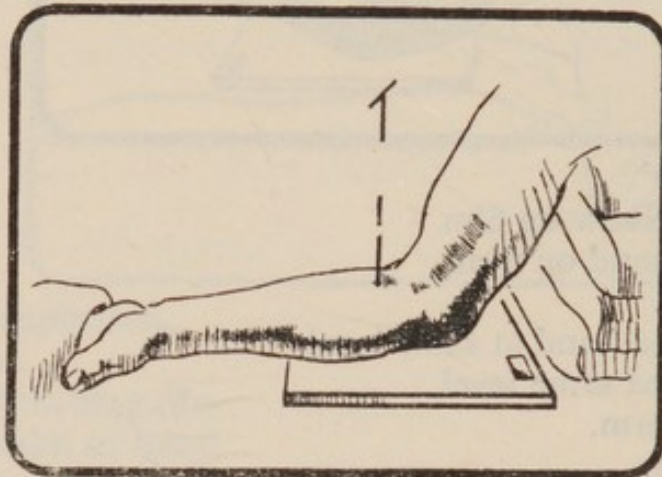
Midway  
between  
epicondyles  
of humerus  
or 1 in. to 2 in.  
proximal to  
joint.

Posterior aspect of upper arm on film.

Wrist supported by sandbags.

2. Where two thirds extension is possible.

Fig. 20

**Centre.**

1 in. to 2 in.  
distal to  
midpoint of  
line between  
epicondyles  
of humerus.

Shoulder raised on sandbags.

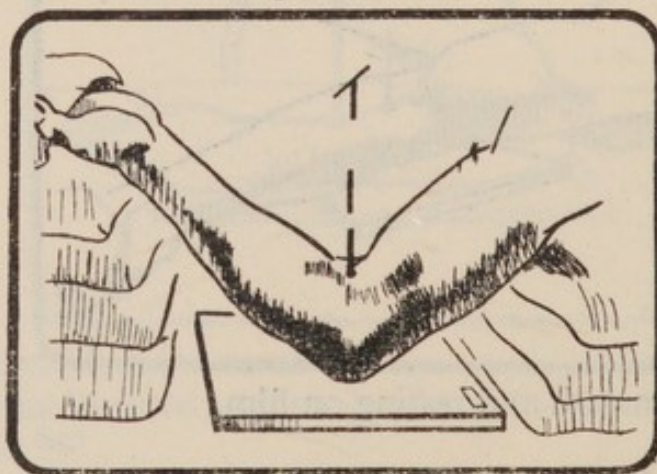
Elbow and posterior aspect of forearm on film.

Sandbag over hand or wrist.

Additional views may be taken with radius and ulna flat on film.

3. Where only 90° extension is possible.

Fig. 21

**Centre.**

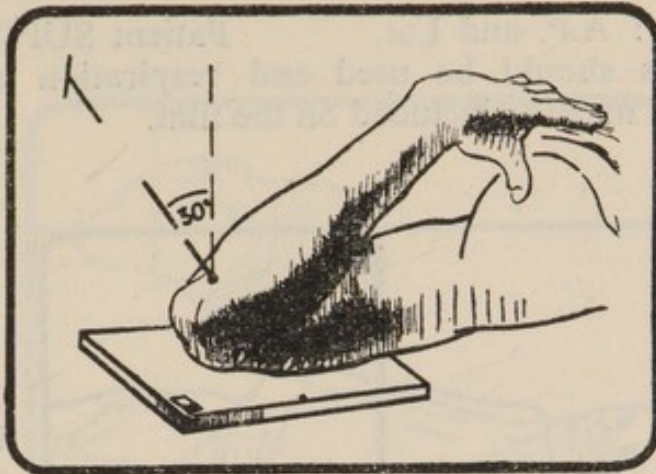
To middle  
of crease of  
elbow.

Olecranon on film so that both upper and lower arms form angle of 45° to film.

Upper and lower arms supported.

4. When elbow is fixed in full flexion.

Fig. 22



**Centre.**  
2 in. distal to  
olecranon  
process.

A.P. projection with humerus fixed flat on film.  
Tube centred 30° from vertical to patient's shoulder.

Modification of true lateral projection will give further information on the head of the radius. Injury may also require some modification of positioning, dependant upon degree of flexion obtainable.

#### Modified lateral for head of radius

1. From the lateral position rotate the hand medially until the palm of hand is in contact with film.
2. Hand further rotated until radial aspect of wrist is in contact with the film.
3. Any intermediate positions between 1 and 2 above.

Fig. 23 Reserved

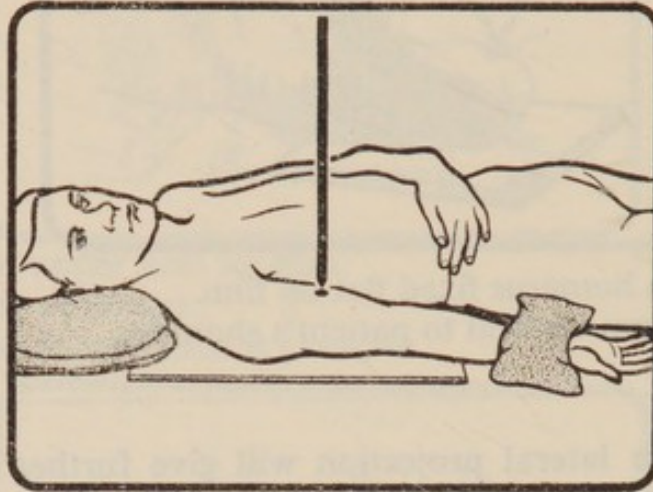


## THE HUMERUS

Routine projections: A.P. and Lat. Patient SUPINE or ERECT.  
Intensifying screens should be used and respiration arrested during exposure. One joint must be included on the film.

### Antero-posterior

Fig. 24



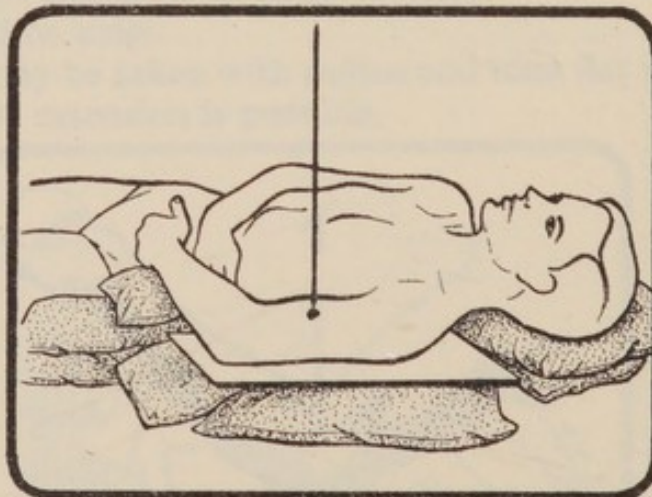
#### Centre.

Midway  
between elbow  
and shoulder  
to anterior  
aspect of  
humerus.

Patient supine or erect, with film under upper arm.  
Body rotated slightly to affected side.  
Posterior aspect of shoulder pressed to film.  
Forearm fully supinated, elbow extended.  
Line joining humeral epicondyles parallel to film.  
Lower arm immobilized by sandbag.

### Lateral

Fig. 25



#### Centre.

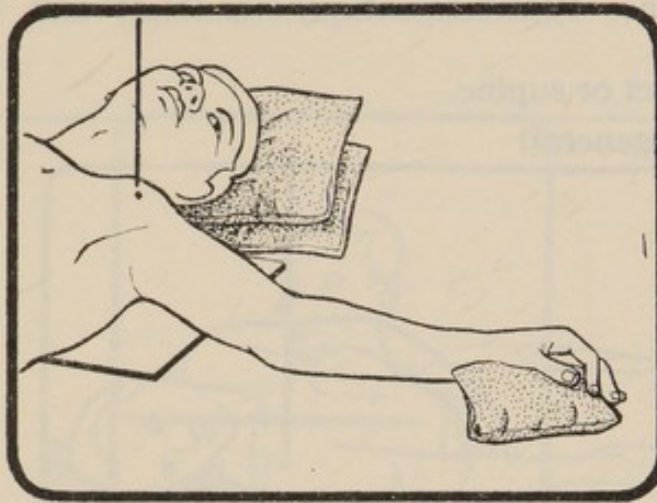
Midway  
between elbow  
and shoulder  
to lateral  
aspect of  
humerus.

Patient supine or erect, with film under upper arm.  
Body rotated slightly to affected side.  
Forearm pronated and humerus rotated medially 90°.  
Line joining epicondyles of humerus at right angles to film.  
Hand placed on abdomen.

## For suspected fracture of surgical neck of humerus

### Antero-posterior

Fig. 26

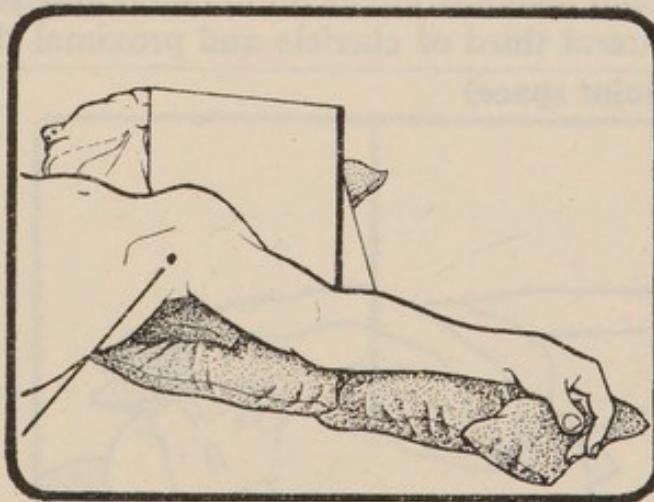


**Centre.**  
To head of  
humerus.

Patient erect or supine.  
Humerus fully abducted.  
Feet apart, in erect position, to stabilize position.

### Lateral

Fig. 27



**Centre.**  
Through axilla  
with central  
ray directed  
horizontally  
and angled  
towards  
shoulder.

Patient erect or supine.  
Humerus fully abducted.  
Head rotated away from injured side.  
Feet apart if taken in erect position.

## THE SHOULDER JOINT

For all examinations of this region, intensifying screens must be used.  
Respiration must be suspended during exposure.

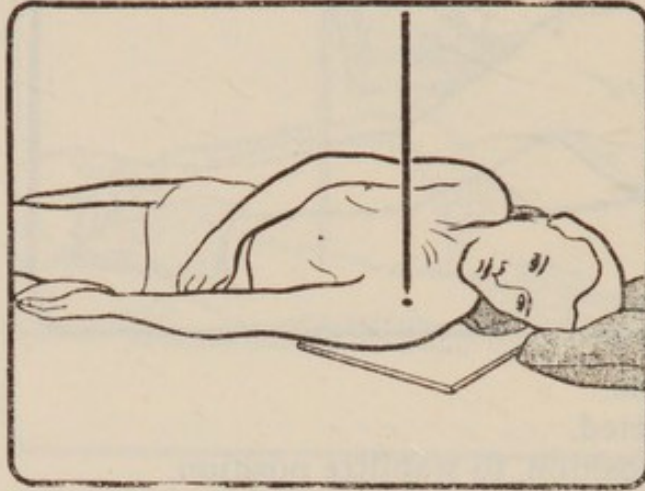
### Shoulder

Routine projections: Posterior-oblique (general) and Posterior-oblique (joint-space).

Patient may be erect or supine.

#### Posterior-oblique (general)

Fig. 28



**Centre.**

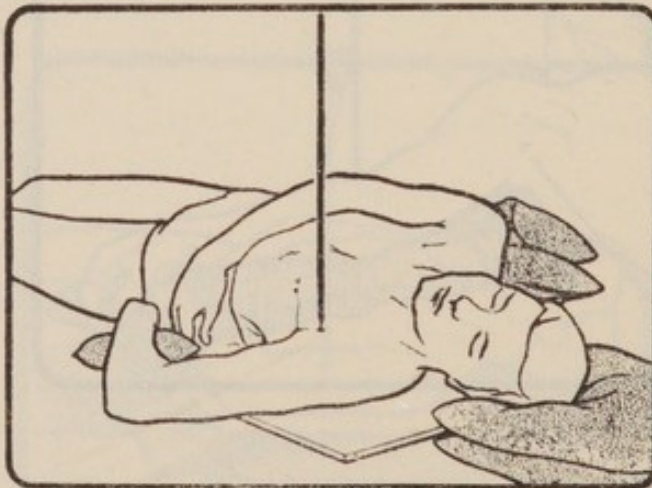To coracoid  
process of  
scapula.

Body slightly rotated to affected side.  
Back of shoulder pressed to film.  
Arm abducted, elbow extended.  
Forearm fully supinated.  
Sandbag on hand.

This projection should demonstrate gleno-humeral and acromio-clavicular articulations; the lateral third of clavicle and proximal third of humerus.

#### Posterior-oblique (joint space)

Fig. 29



**Centre.**

To head of  
humerus.

Unaffected shoulder well raised on sandbags.  
Broad plane of scapula parallel to film. Elbow flexed.  
Forearm supported on sandbags.

*Note.*—Small film to be used as it is only required to include gleno-humeral articulation.

Broad plane of scapula **MUST** be parallel to film for correct body rotation.

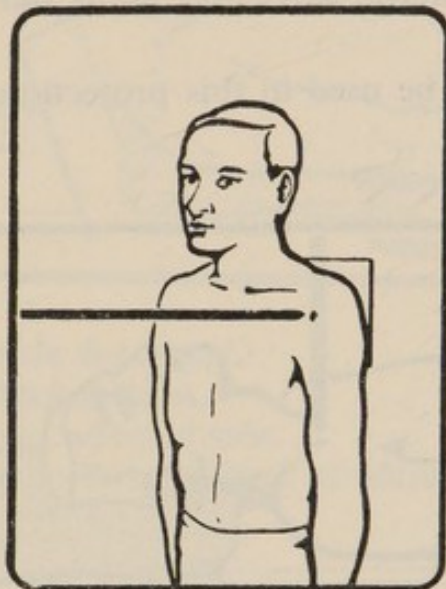
**Acromio-clavicular joint**

Routine projection: Antero-posterior of both joints for comparison.

Patient *ERECT* only—to demonstrate joint spaces at normal tension with weight of arm unsupported.

**Antero-posterior**

Fig. 30

**Centre.**

To head of  
humerus.

Patient erect.

Body slightly rotated to affected side.

Back of shoulder pressed to film.

Both joints for comparison

Feet apart for better balance.

## THE CLAVICLE

Routine projections: A.P. and/or P.A. Additional view: Infra-superior (NON-routine).

Patient ERECT or HORIZONTAL.

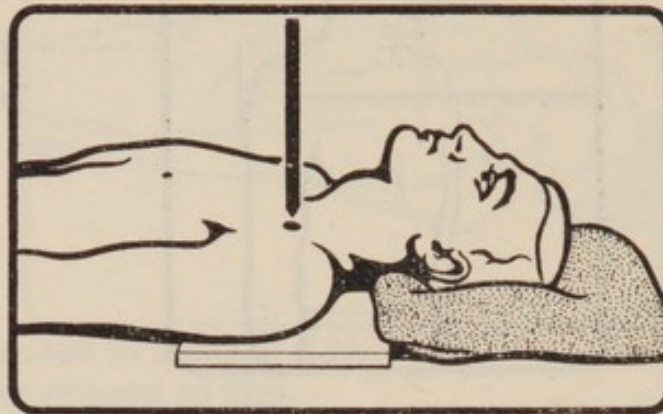
Both above projections should be taken as routine but P.A. (prone) may not be possible due to discomfort.

Acromio-clavicular and sterno-clavicular joints must be included on the film.

Intensifying screens must be used in this projection but the use of a grid is not recommended.

### Antero-posterior

Fig. 31



**Centre.**

To centre  
of clavicle.

Patient supine or erect.

Hands to the sides.

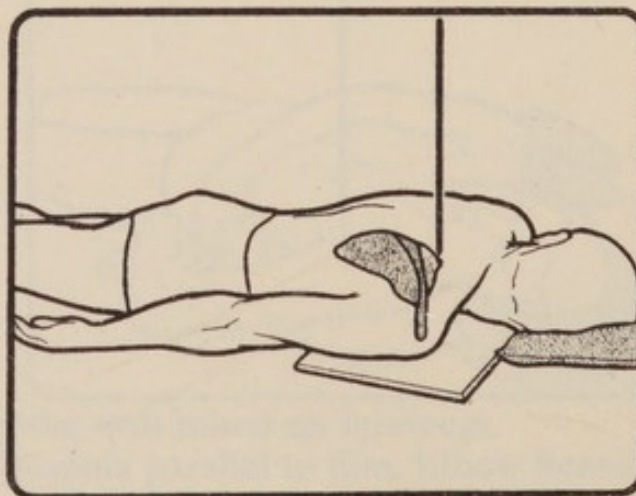
Shoulders braced back.

Upper border of film displaced 2 in. above shoulder level.

No grid.

### Postero-anterior

Fig. 32



**Centre.**

To superior  
angle of  
scapula.

Patient prone or erect.

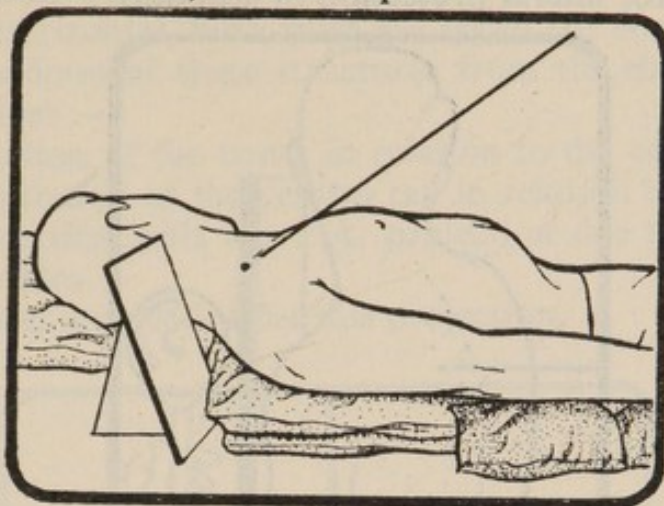
Head turned away from affected side.

Body slightly rotated so that shoulder is in contact with the film.

Arm rotated medially with palmar aspect of hand facing posteriorly.

**THE CLAVICLE****Infra-superior (Non-routine) Patient supine.**

Fig. 33

**Centre.**

1 in. from  
sternal end of  
clavicle with  
central ray  
angled at 35°  
to horizontal  
and 15°  
laterally  
towards  
shoulder.

Patient supine.

Shoulder on affected side depressed.

Arm abducted, hand facing trunk.

Head rotated away from affected side.

Cassette supported to posterior aspect of shoulder and at right angles to central ray.

No grid.

**THE SCAPULA**

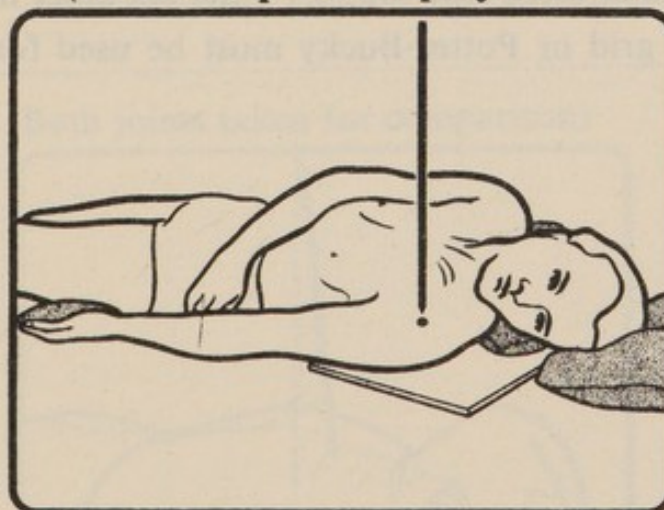
Routine projections: Posterior-oblique and anterior oblique.

Patient **ERECT** or **HORIZONTAL**.

Intensifying screens must be used for these projections.

**Posterior-oblique (for antero-posterior projection of scapula)**

Fig. 34

**Centre.**

To head of  
humerus.

Patient erect or supine.

Body rotated 30° to affected side.

Affected scapula on film.

Arm abducted, elbow extended.

Forearm fully supinated.

Over rotation of trunk will superimpose mid-line thoracic structures on the vertebral border of scapula.

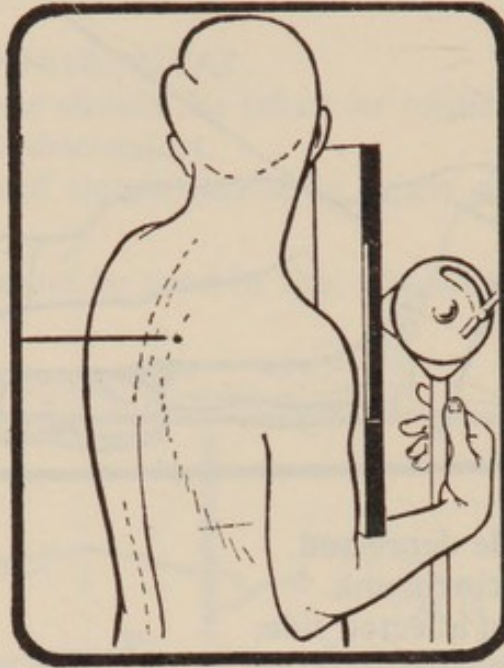
Note use of oblique rays to project thoracic structures as clear as possible of scapula.

The use of a stationary grid is *not* recommended for this projection.



**Anterior-oblique** (for lateral projection of scapula)

Fig. 35

**Centre.**To superior  
angle of  
scapula.

Patient erect or semi-prone.

Affected shoulder and clavicle on film, with unaffected side so rotated that the vertebral border of the scapula is superimposed on the head of the humerus.

Arm abducted, and hand grasps film stand.

Hand and arm of unaffected side support other shoulder in position.

*Note.*—Stationary grid or Potter-Bucky must be used for this projection.

## THE STERNO-CLAVICULAR JOINTS

Routine projections: A.O. and P.A.

Patient erect or horizontal, both sides are taken for comparison.

Separation of shadows of these structures from the shadow of the spine is obtained by either:—

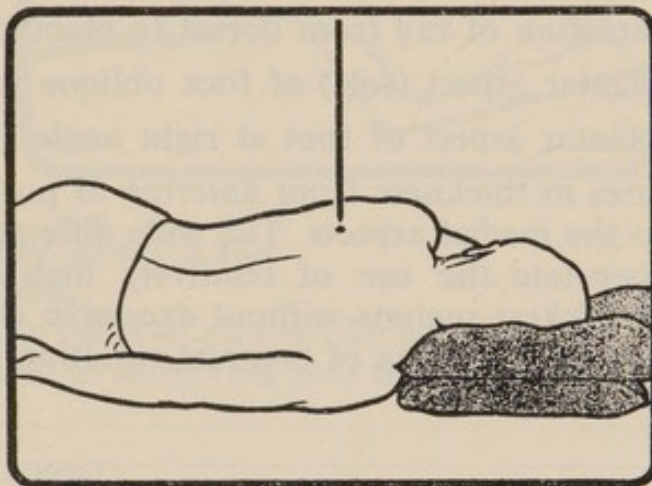
1. Rotation of the trunk in relation to the central ray.
2. Angulation of the central ray in relation to the trunk.

There is less distortion with the P.A. projection due to closer proximity of the part to the film.

Intensifying screens are needed for this projection.

### Anterior-oblique

Fig. 36



#### Centre.

To level of 4th dorsal vertebra, 4 in. from mid-line through side nearer tube, to S.C. joint nearer film.

Patient prone.

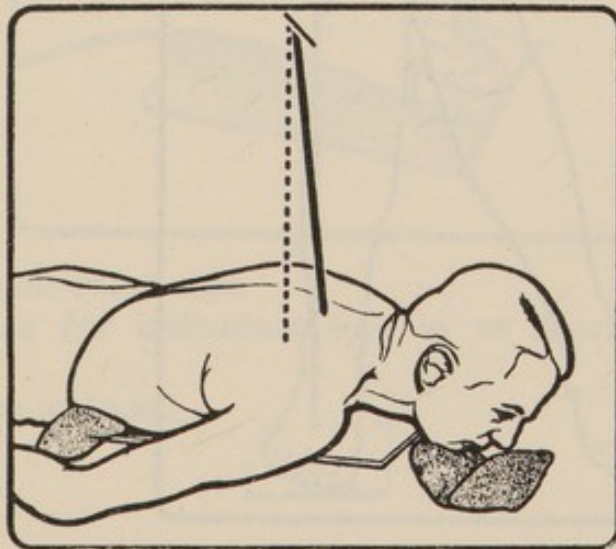
Body rotated 45° to film.

Raised side supported by pillows.

No grid.

### Postero-anterior (Both joints taken for comparison)

Fig. 37



#### Centre.

To level of 4th dorsal vertebra. Tube displaced from mid-line a distance equal to (a)

(a) = thickness of patient measured at level of sternal angle.

Patient prone.

Anode-film distance = 3(a).

Tube tilted 18° towards mid-line.

No grid.

## THE LOWER LIMB

Where sufficiently short exposures are not possible with non-screen film, intensifying screens must be used, as immobilization for the lower limb is more difficult than for the upper extremity.

Positioning in general is carried out with the patient sitting or recumbent on couch, but examination may be conducted (with mobile type of unit), where convenient or necessary, with patient on ward chair or on stretcher trolley.

Variation of normal positioning terminology is used for foot projections.

D.P. :— indicates direction of ray from dorsal to plantar aspect of foot.

Obl. :— indicates plantar aspect (sole) of foot oblique to film.

Lat. :— indicates plantar aspect of foot at right angles to film.

*Note.*—The foot varies in thickness from anterior to posterior and from the lateral to the medial aspects. The wide differences in resultant densities necessitate the use of relatively high kV to produce detail in the thickest regions without excessive contrast or overall blackening and lessening of contrast resulting in the less thick regions.

### THE TOES

Routine projections: D.P. and Lat.

**Dorsi-plantar.**

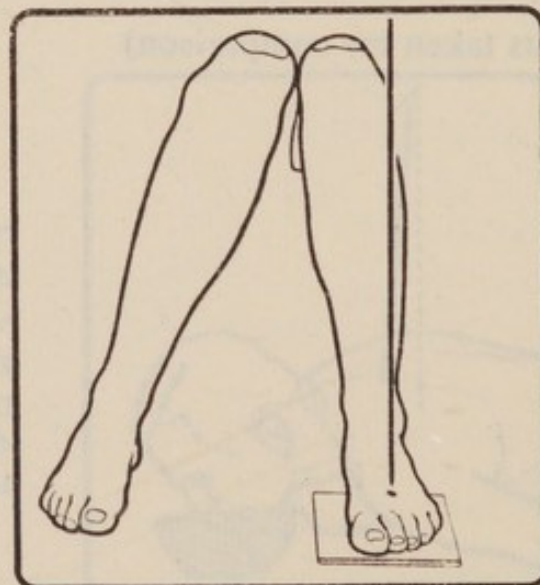


Fig. 38

**Centre.**

To head of  
3rd metatarsal  
or to individual  
toe.

Patient seated.

Knees comfortably flexed.

Toes and plantar aspect of foot on film.

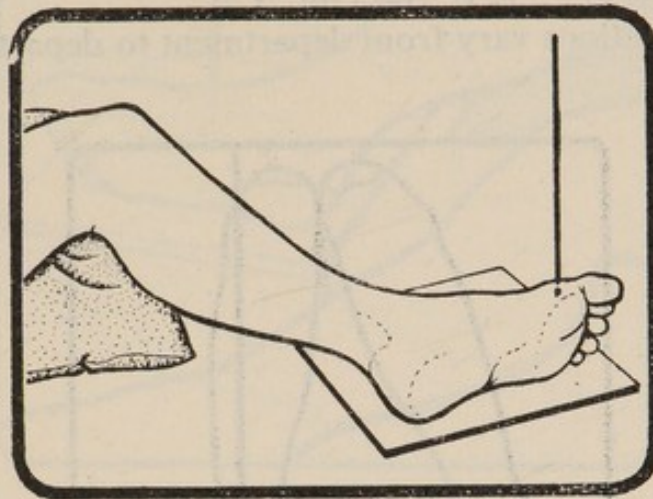
Toes packed straight with cotton wool.

Knee of affected limb supported by unaffected knee.

Max Hospital;  
R. A. V. C. Training  
Centre and Depot.

**Lateral (a) General**

Fig. 39

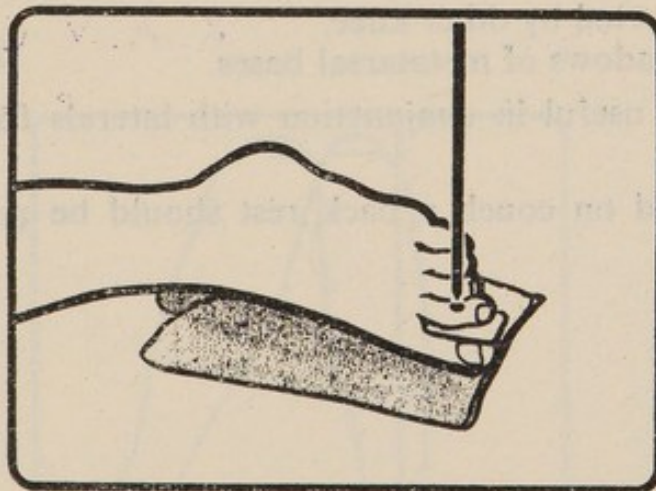


**Centre.**  
To head of  
1st metatarsal.

Patient reclining on affected side.  
Hip and knee flexed.  
Unaffected limb in front of affected limb.  
Knee raised on pad to bring foot into true lateral position.

**Lateral (b) Individual**

Fig. 40



**Centre.**  
To affected toe.

Patient reclining on either side.  
Dental films used for individual toes in as nearly lateral position as possible.  
One joint must be included.

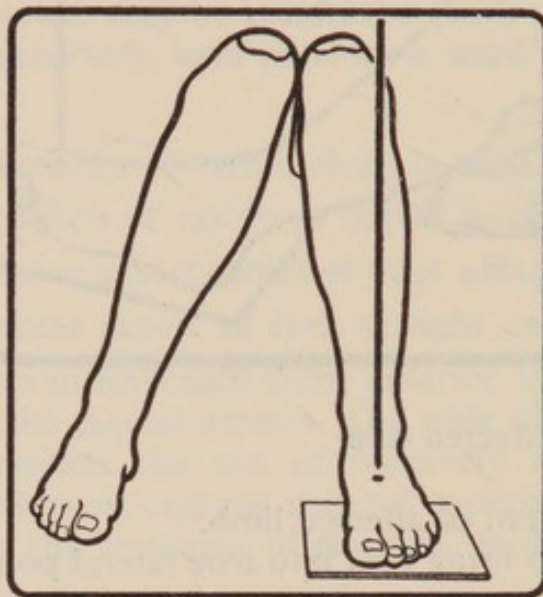
## THE FOOT

Routine projections: D.P., D.P. 2nd Obl., Lat.

These routine projections vary from department to department.

### Dorsi-plantar

Fig. 41



**Centre.**

To mid point  
of mid-tarsal  
joint

Patient seated or semi-recumbent, knees comfortably relaxed and flexed. Toes and sole of foot on the film.

Affected side supported by other knee.

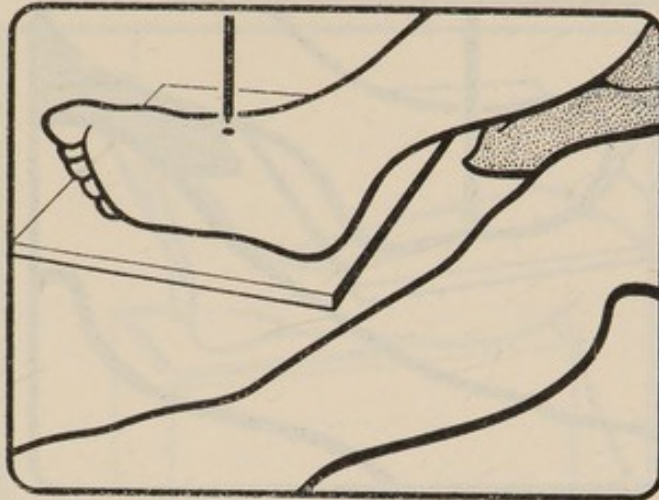
Note overlap of shadows of metatarsal bases.

This projection is useful in conjunction with laterals for localization of foreign bodies.

If patient is seated on couch a back rest should be provided and seat raised.

**Lateral**

Fig. 42



**Centre.**  
To navicular-  
cuboid area.

Patient reclining on affected side.

Hip and knee flexed.

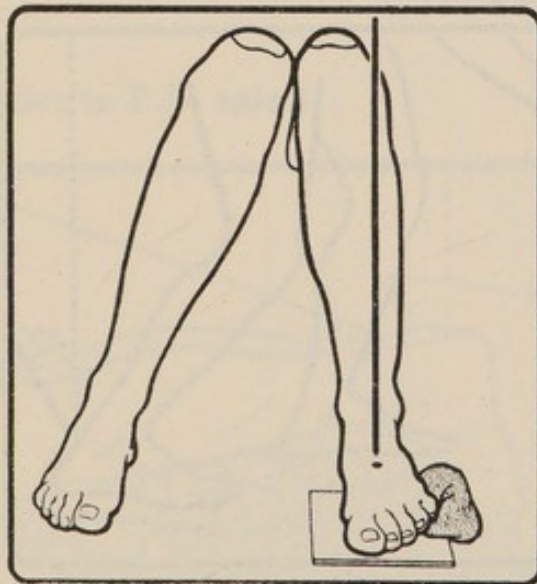
Unaffected limb in front of affected limb.

Knee raised on pad and sole of foot at right angles to film.

Metatarsals overshadow each other in this projection but position of foreign bodies will be indicated when used in conjunction with a D.P.

**1st Oblique (D.P.)**

Fig. 43



**Centre.**  
To mid-tarsal  
region with  
central ray  
angled 15°  
towards ankle  
joint.

Patient seated.

Toes and sole of foot on film.

Knees comfortably flexed.

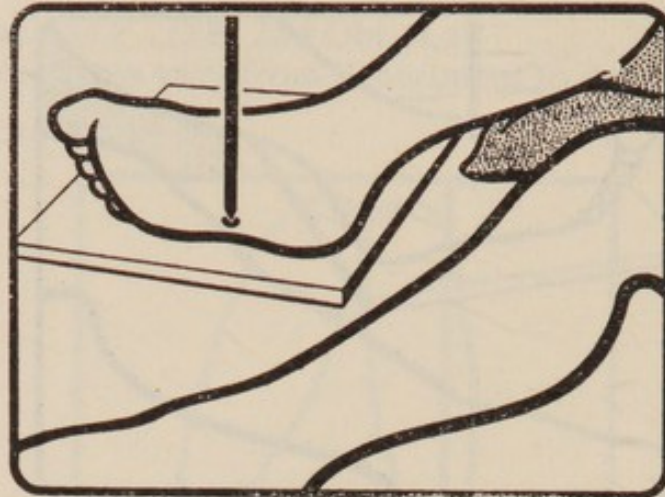
Small non-opaque pad placed under fifth metatarsal to bring dorsum of foot parallel to film.

Knee of affected side supported vertically by other knee.

Overlapping metatarsal bases and tarsal bones seen from another aspect.

**2nd Oblique (P.D.)**

Fig. 44

**Centre.**Over base of  
5th metatarsal.

Patient lying on affected side with hip and knee joint flexed.

Unaffected limb in front of injured limb.

Foot placed obliquely on film.

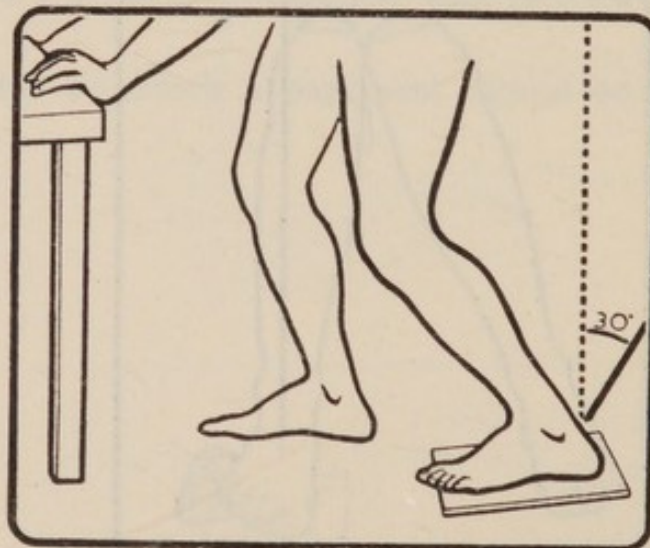
Note the use of oblique rays for better separation of the metatarsals and demonstration of the tarsal articulations.

**THE OS CALCIS**

Routine projections: Axial and Lat. (Both sides for comparison).

**D.P. Axial (For standing patient)**

Fig. 45

**Centre.**To tendo-  
achilles at  
level of  
malleoli.

Patient standing with film under affected heel, the other foot advanced a pace.

Suitable support provided for patient to rest his hands and support himself.

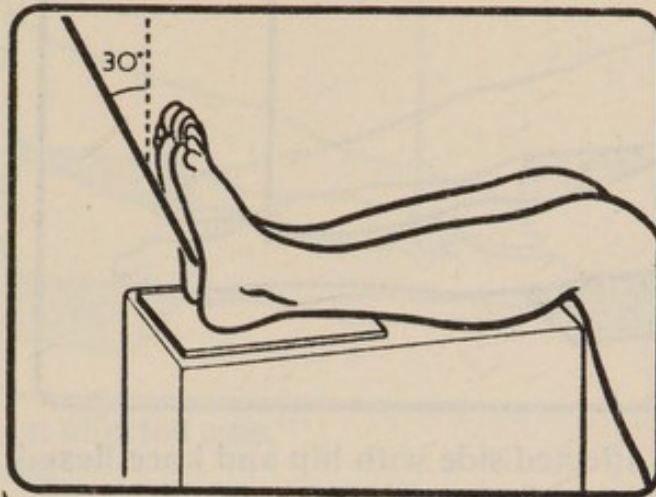
Both knees bent.

Knee of affected side well forward.

Central ray at 30° from the vertical.

**P.D. Axial (For stretcher cases)**

Fig. 46



The diagram gives a modification of the position as described in the text.

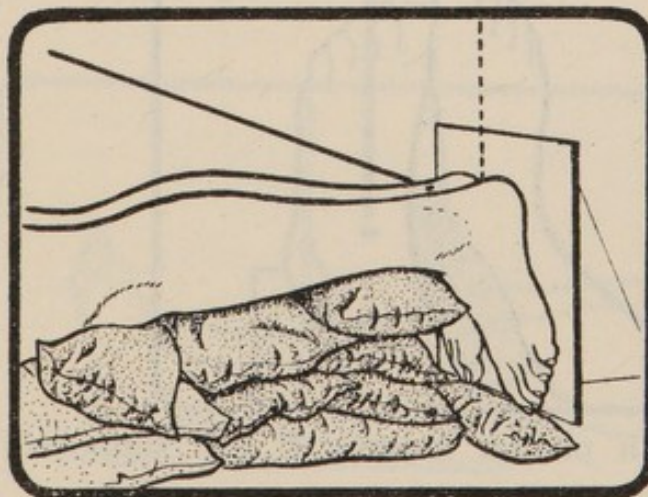
**Centre.**

To film through centre of plantar aspect of foot.

Patient supine with both lower legs extended.  
 Feet held in dorsi-flexion with cord or bandage held by patient.  
 Central ray at  $30^\circ$  cephalic from the vertical.  
 (Both sides taken for comparison). If it is desired to take both projections on one film simultaneously, centre to between feet incorporating above instructions.

**D.P. Axial (Alternative to P.D. axial)**

Fig. 47

**Centre.**

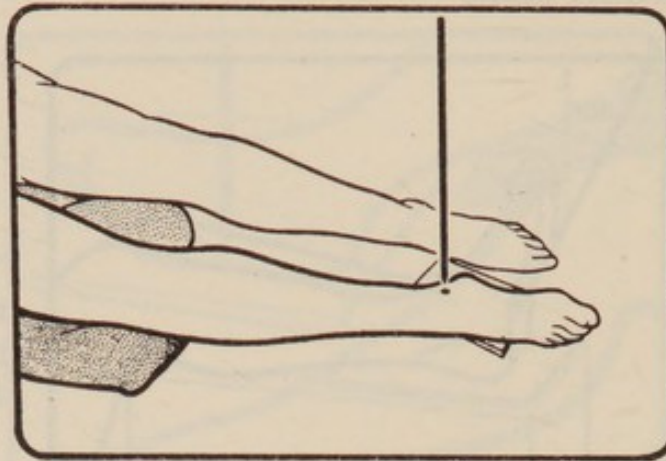
To tendo-achilles with central ray at  $60^\circ$  from the vertical.

Patient prone, and raised on pillows.  
 Plantar aspect of foot/feet in contact with vertically supported film.  
 Centre midway between feet if projections of both feet are to be taken simultaneously on one film.



**Lateral**

Fig. 48

**Centre.**To centre of  
os calcis.

Patient reclining on affected side with hip and knee flexed.  
Unaffected limb in front of affected limb.  
Knee raised on pad to bring foot into true lateral position.  
Both os calcis taken for comparison.

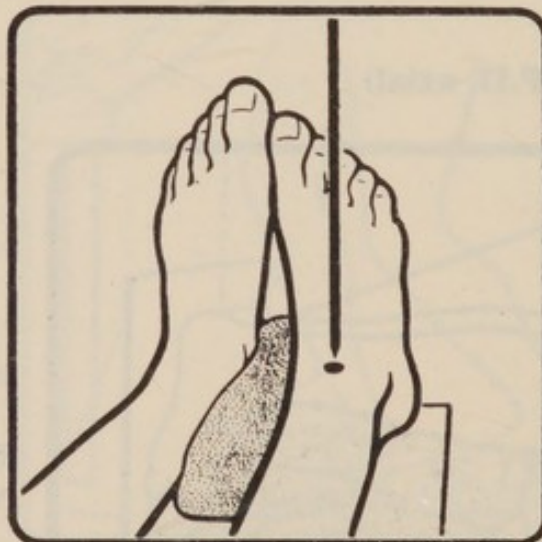**THE ANKLE JOINT**

Routine projections: A.P. and Lat.

Patient seated or supine.

**Anterior-posterior**

Fig. 49

**Centre.**To mid-point  
of inter  
malleolar line  
of affected  
**ankle.**

Legs extended with plantar aspects of feet supported comfortably by sandbags.

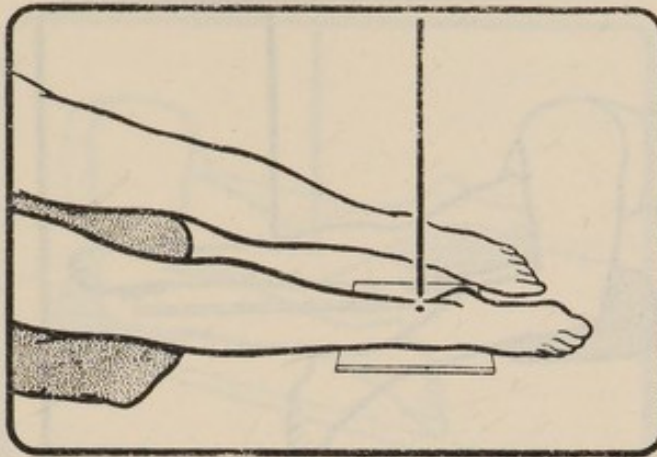
Great toes touching so that plane of malleoli is parallel to film.

Sandbag over lower leg.

Joint space should be at the level of lower third of film. If it is not possible to maintain plane of malleoli parallel to film, the central ray should be directed at right angles to the inter malleolar plane.

**Lateral**

Fig. 50



**Centre.**  
To medial  
malleolus.

Patient reclining on affected side.

Hip and knee flexed.

Unaffected limb in front of affected limb.

Knee raised on pad to bring foot into true lateral position.

Film to include lower third of tibia and fibula, talus and os calcis. The selected kV must be sufficient to demonstrate fibula through the tibia. To avoid turning patient film may be supported vertically to medial aspect of ankle, with patient supine and central ray directed horizontally.

**THE LOWER LEG**

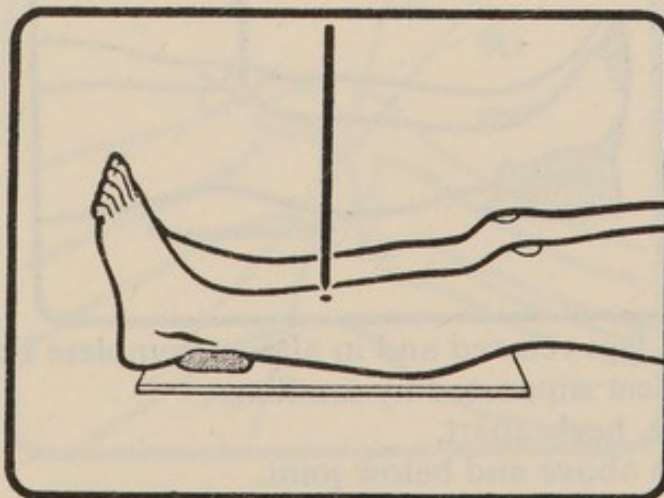
Routine projections: A.P. and Lat.

Patient seated or supine.

For gross injuries the knee and ankle joints will both be included on the film, to show general alignment of bone fragments. If it is not possible to include both joints on one film, two films, with overlap of middle third of limb will be taken. A least one joint will always be included in any one film.

**Antero-posterior**

Fig. 51



**Centre.**  
To mid-point  
of part under  
examination.

Patient supine or sitting.

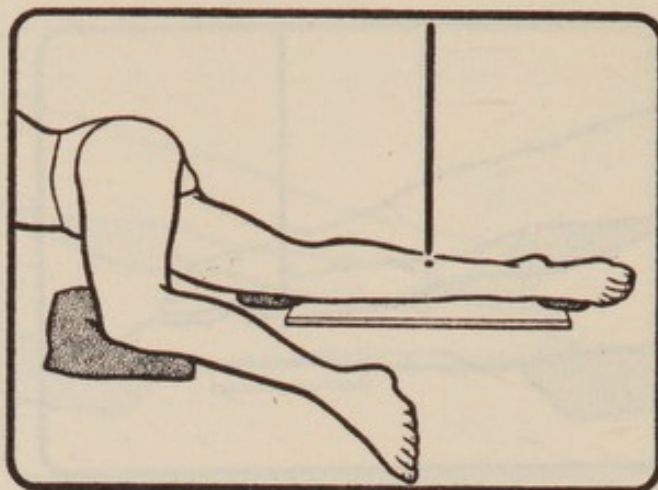
Legs extended.

Plantar aspects of feet supported by sandbags.

Great toes touching, heels apart.

**Lateral**

Fig. 52

**Centre.**To mid-point  
of part under  
examination.

Patient reclining on affected side.

Hip and knees slightly flexed with body rotated so that unaffected leg may be brought over and placed in front of affected limb.

*Note.*—This projection may be performed with the central ray directed horizontally with patient lying supine, i.e., where patient cannot be placed in reclining position.

**THE KNEE JOINT**

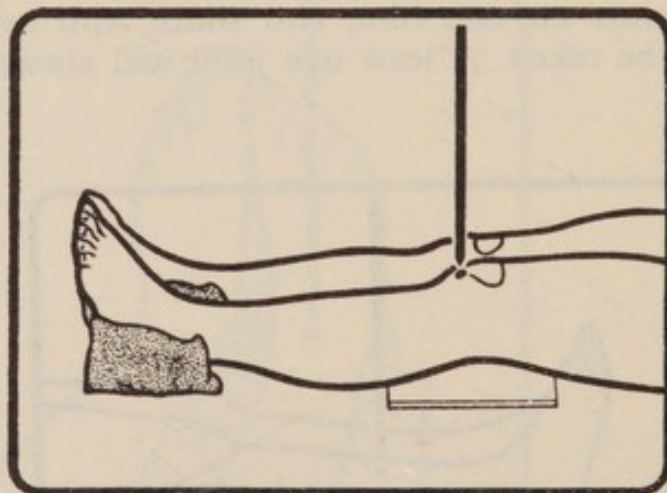
Routine projections: A.P. and Lat.

Additional projections: Modified A.P. for intercondylar notch.

Modified Lat. for proximal tibio-fibula articulation.

**Antero-posterior**

Fig. 53

**Centre.**To middle of  
leg one inch  
below patella.

Patient supine with legs relaxed and in almost complete extension.

Plantar aspects of feet supported by sandbags.

Great toes touching, heels apart.

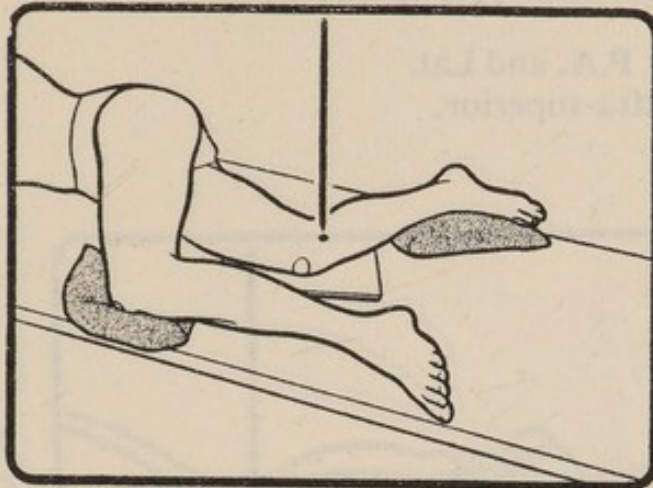
Sandbags over limb above and below joint.

Patella centred between medial and lateral aspects of femur.

Where injury does not permit of the required extension of the limb, the film may be raised and supported in position with sandbags or other suitable material.

## Lateral

Fig. 54



Centre.

Medial  
tuberosity of  
tibia.

Patient reclining on affected side.

Hip and knee slightly flexed.

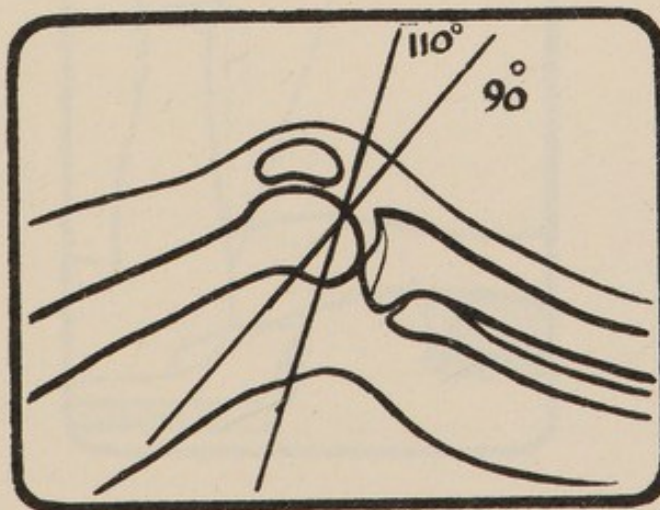
Unaffected limb placed in front of affected limb, but with pad under foot to bring knee to couch level.

*Note.*—The supine position is employed when patient cannot be placed in lateral position. Support film vertically between knees. Plane of femoral condyles at right angles to film. Tibia supported parallel to film.

When TIBIAL TUBERCLE is requested, the projections required will be laterals of both knee joints.

**Modified A.P.** (For demonstration of intercondylar notch.) Non-routine.

Fig. 55



Centre.

To apex of patella with cephalic tilt.  
(a) For anterior part of intercondylar notch at  $110^\circ$  to line of lower leg.  
(b) For posterior part of intercondylar notch at  $90^\circ$  to line of lower leg.

Patient supine.

Affected knee flexed.

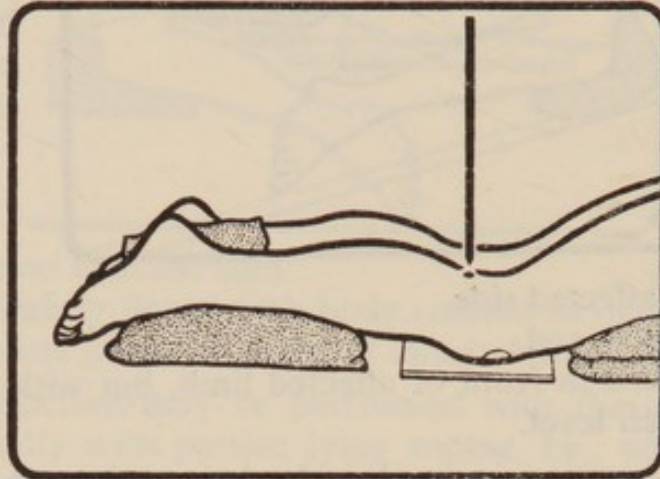
Film placed well up under femur and supported by sandbags or pillows.

## THE PATELLA

Routine projections: P.A. and Lat.  
Additional views: Infra-superior.

### Postero-anterior

Fig. 56



**Centre.**

To middle of  
crease of  
posterior  
aspect of knee.

If patella is badly damaged the patient should be placed in the supine position and the under-couch tube position utilized.  
Otherwise patient prone with knee on film.

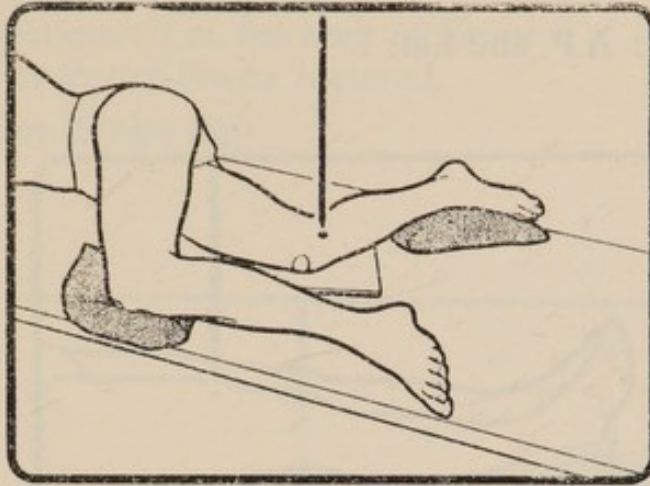
Sandbag under leg above the knee.

Large sandbag under lower legs and ankle region.

Patella centred between medial and lateral aspects of femur.

**Lateral**

Fig. 57

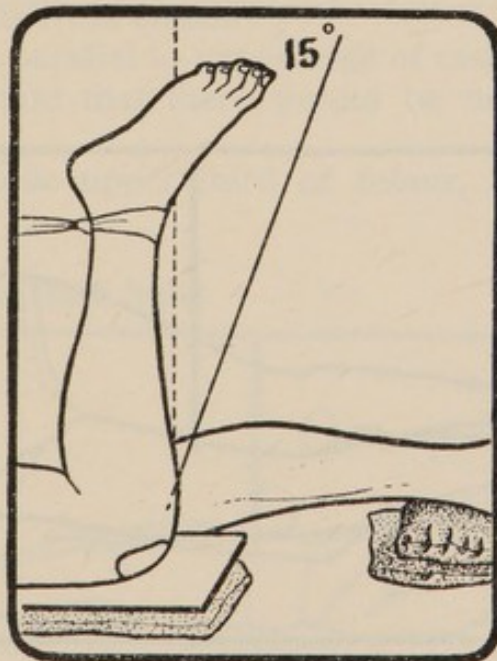**Centre.**To medial  
tuberosity of  
tibia.

Patient reclining on affected side.  
Hip and knee slightly flexed.

Unaffected limb in front of affected limb, and suitably supported.  
Pad under ankle of affected limb to bring knee and patella into true lateral position.

**Infra-superior** (Non-routine) *For posterior surface of patella and adjacent surface of femur.*

Fig. 58

**Centre.**

With 15°  
cephalic tilt  
from vertical  
centre behind  
patella.

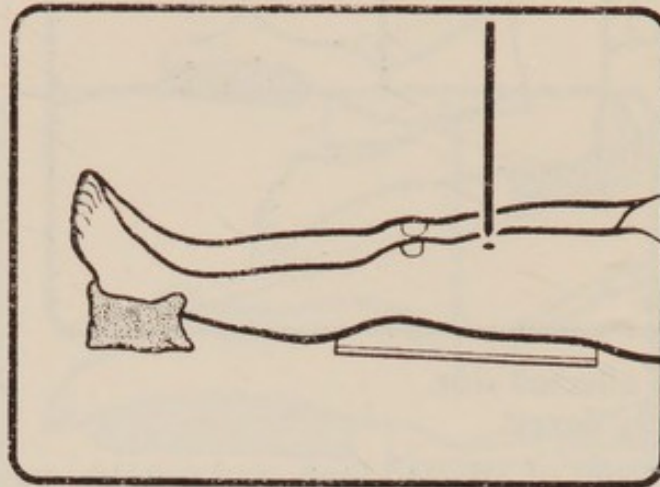
Patient prone.  
Affected knee flexed to 90°  
Foot extended.  
Lower leg supported in flexion by bandage tied to ankle and other end of bandage held by patient or other suitable support.

## FEMUR—LOWER TWO THIRDS

Routine projections: A.P. and Lat.

### \*Antero-posterior

Fig. 59



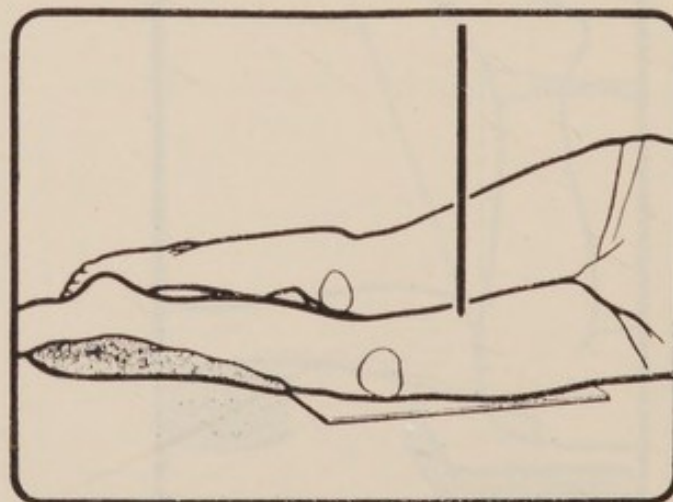
Centre.  
To middle of  
film.

Patient supine with legs extended.  
Great toes touching, heels apart.  
Sandbag over lower legs.  
Thin pads under heels.  
The knee joint must be included.  
Film placed well below knee joint.

*Vet Hospital;  
R.A.V.C. Training  
Centre and Depot.*

### \*Lateral

Fig. 60



Centre.  
To middle of  
film.

Patient lying on affected side.  
Hip and knee flexed with unaffected limb behind affected limb.  
The knee joint must be included.

If the above positioning is impracticable the patient may be supine and the central ray be directed horizontally. The film should be supported against lateral aspect of thigh. Unaffected limb raised and supported.

## HIP JOINT AND UPPER THIRD FEMUR

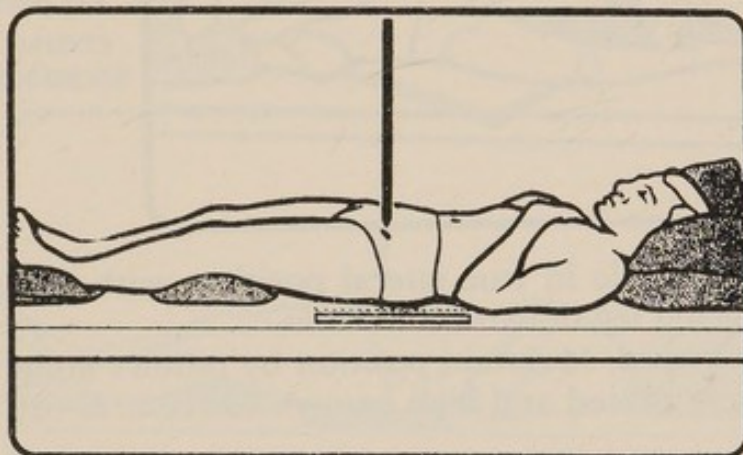
Routine projections: A.P. and Lat.

Additional projections: Lat. for neck of femur.

*Stationary grid or Potter-Bucky required.*

### \*Antero-posterior (Single hip)

Fig. 61



**Centre.**  
1 in. distally  
along the  
perpendicular  
bisection of a  
line between  
the anterior  
superior iliac  
spine (ASIS)  
and the upper  
border of the  
symphysis  
pubis.  
(1 in. inferior  
to the mid-  
point of  
Poupart's  
ligament).

Patient supine, legs extended.

Great toes touching, lower limbs rotated inwards.

A.S.I.S. equidistant from couch.

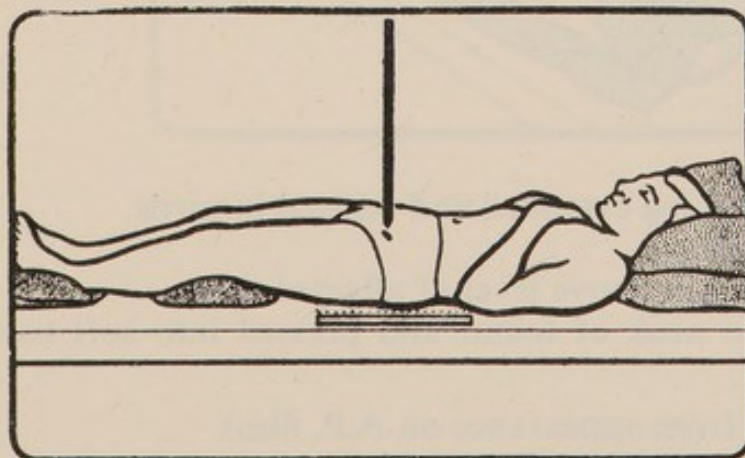
Inter spinous line parallel to upper edge of cassette.

It is most important that there should be no rotation of the trunk or pelvis.

Film should include upper third of femur, A.S.I.S. and the symphysis pubis.

### \*Antero-posterior (Both hips)

Fig. 62



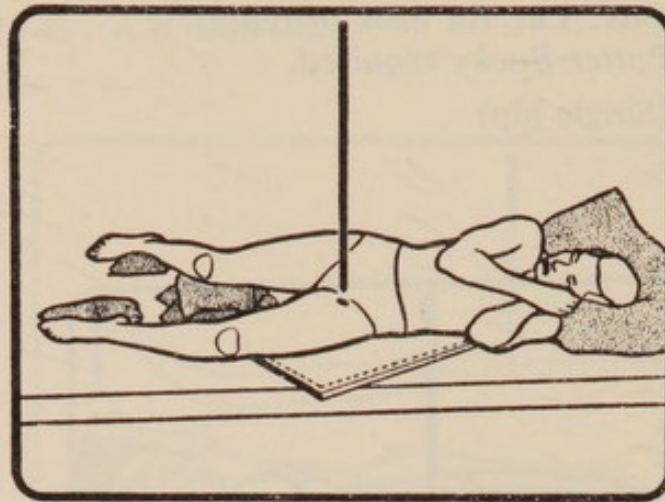
**Centre.**  
To midline of  
body 1 in.  
above upper  
border of  
symphysis  
pubis.

Large film placed transversely with upper edge slightly below iliac crest. Remarks for single hip A.P. apply to this projection with the exception of the centring point.



**\*Lateral**

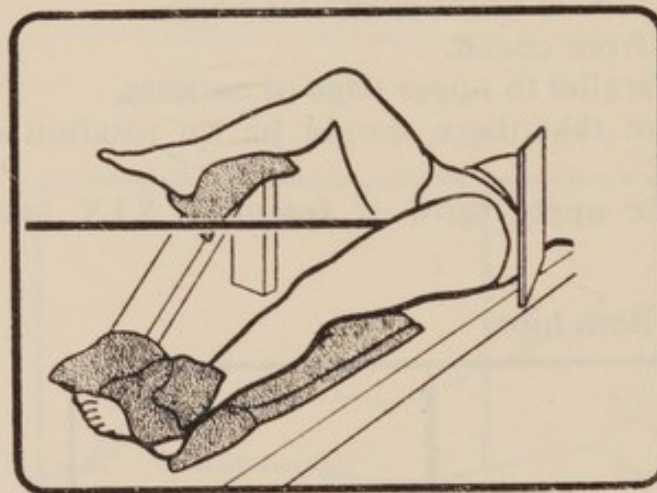
Fig. 63

**Centre.**To just below  
crease of groin.

Patient lying on affected side in true lateral position, with hip and knees slightly flexed. Unaffected leg drawn backwards. Pelvis rotated  $45^\circ$  backward. Maintain position by pillows under buttocks. Ensure film is obliquely placed and high enough for central ray to fall on central portion.

**\*Lateral (For neck of femur)**

Fig. 64

**Centre.**At right angles  
to centre of  
film.

Patient supine, affected leg extended and rotated inwards. Unaffected hip fully flexed. Lower leg supported well above level of affected thigh. Film held parallel to neck of femur and pressed into soft tissues above iliac crest.

(This may be judged from appearance on A.P. film).  
Tube horizontal at level of the affected thigh.

Figs. 65 and 66 reserved.

## THE PELVIC GIRDLE

### THE PELVIS.

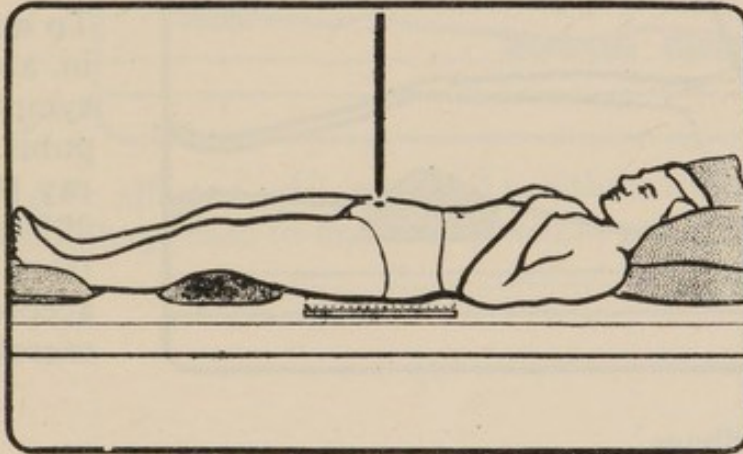
*Note the difference between the male and female pelvis in depth and breadth.*

Routine projection: A.P.

Additional projections: Lat. and P.O. to demonstrate ILIAC FOSSA.  
Stationary grid or Potter-Bucky essential. Expose during arrested respiration.

#### \*Antero-posterior

Fig. 67



#### Centre.

To a point  
2 in. above  
upper border  
of symphysis  
pubis in mid-  
line.

Patient supine, legs rotated inwards.

Toes together, heels apart.

Knees slightly flexed on pads.

Film placed transversely, high enough to include iliac crests.

Hands placed on chest.

A.S.I.S. equidistant from film.

## SACRUM

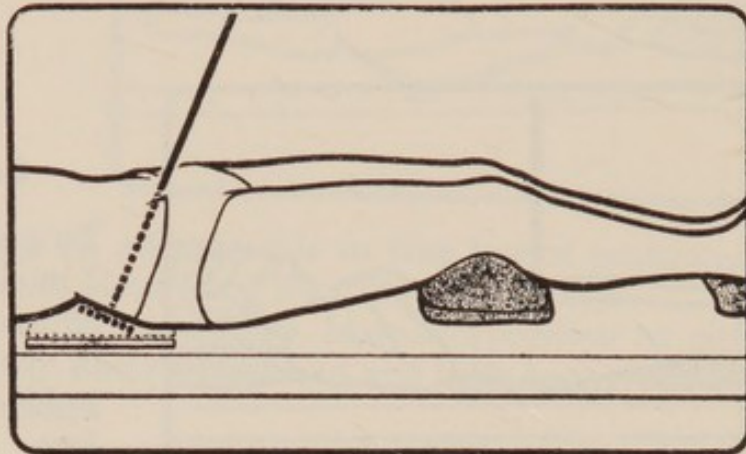
Routine projections: A.P. and Lat.

*Stationary grid or Potter-Bucky essential.* Expose during arrested respiration.

The relative angle of the sacrum varies according to sex and in individuals.

### \*Antero-posterior

Fig. 68



#### Centre.

To mid-line 1 in. above symphysis pubis. Central ray  $10^{\circ}$  to  $20^{\circ}$  cephalic from vertical according to sacral angle.

Patient supine.

Knees flexed on sandbags.

Hands on chest.

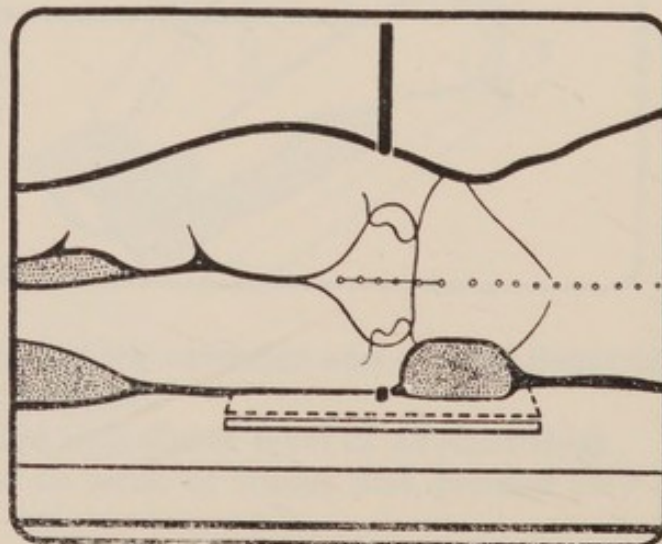
Shoulders raised on pillows.

A.S.I.S. equidistant from film.

Film displaced upwards so that central ray falls on the centre of the film.

### \*Lateral

Fig. 69



#### Centre.

To 2 in. anterior to posterior inferior iliac spine.

Patient in true lateral position.

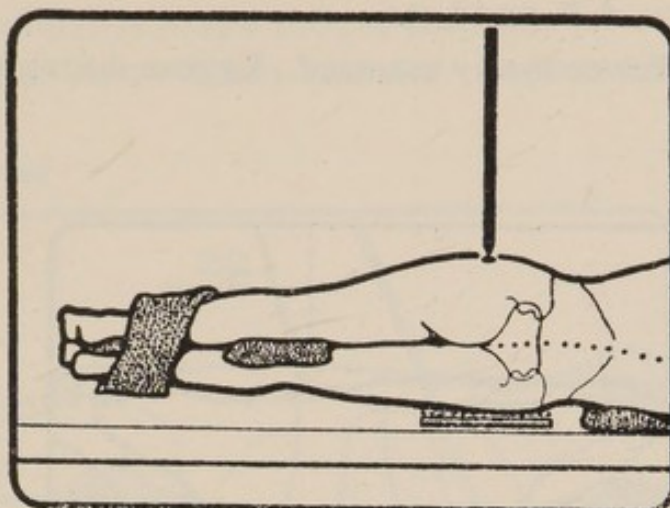
Upper hip and knee slightly flexed.

Compensate for possible lumbar sag by radiolucent padding as illustrated.

An increase of F.F.D. from the normal used is desirable where tube load limitations will permit.

**\*Lateral (Non-routine)**

Fig. 70



**Centre.**  
**Above**  
**trochanteric**  
**dimple.**

Patient placed on affected side, in lateral position with legs extended.  
Pillows and sandbags used to maintain position and for patient's comfort.

---

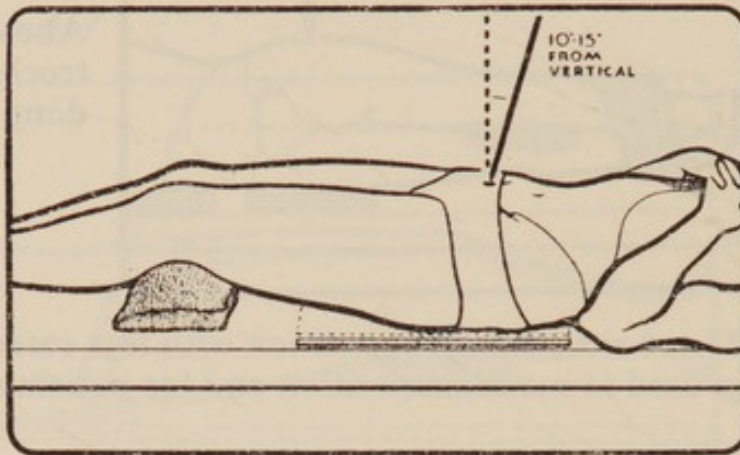
## THE COCCYX

Routine projections: A.P. and Lat.

*Stationary grid or Potter-Bucky essential.* Expose during arrested respiration.

### \*Antero-posterior

Fig. 71



**Centre.**

To mid-line 1 in. above symphysis pubis. Tube angulated 10° to 15° plantar from vertical.

Patient supine.

Hands folded on chest.

Knees flexed on small sandbag.

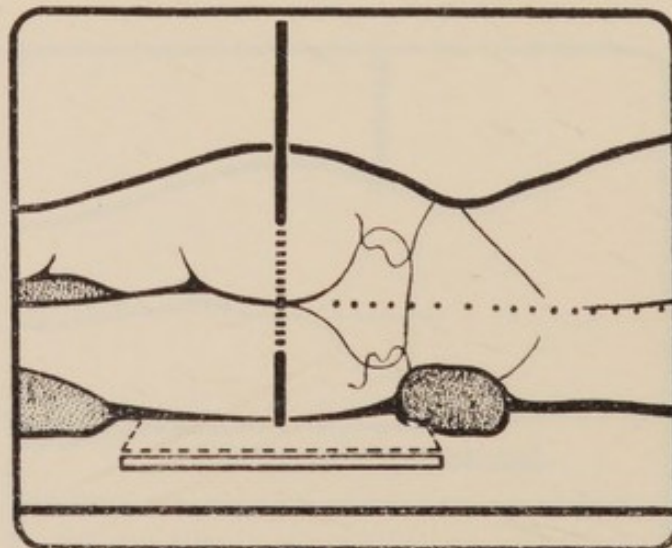
Shoulders raised slightly to flatten spinal curve.

A.S.I.S. equidistant from film.

The tube angulation projects the pubic bones away from the coccyx.

### \*Lateral

Fig. 72



**Centre.**

Over coccyx.

Patient lying in true lateral position.

Upper hip and knee slightly flexed.

Limb nearer tube brought forward and supported at hip level on sandbag.

Film so placed to have coccyx central over film.

An increase of F.F.D. is desirable where tube load limitations will permit.

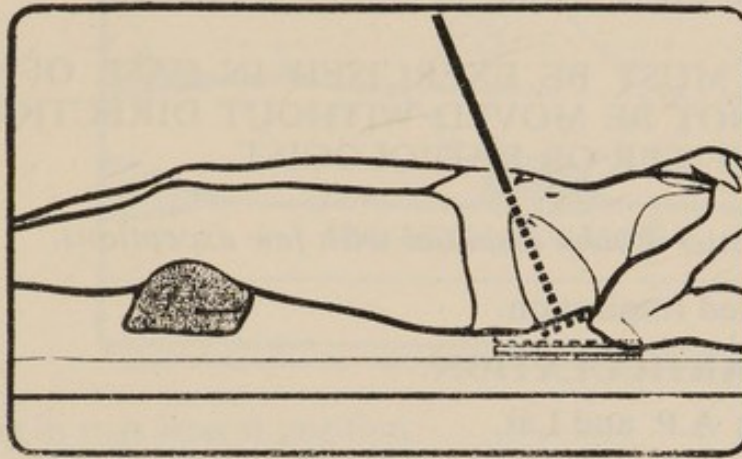
## SACRO—ILIAC JOINTS

Routine projections: A.P. and P.O. of each side for comparison.

*Stationary grid or Potter-Bucky essential.* Expose during arrested respiration.

### \*Antero-posterior

Fig. 73



### Centre.

To mid-line just above symphysis pubis. Central ray 10° to 20° cephalic from vertical to reach plane of sacrum at right angles.

Patient supine.

Knees flexed on sandbags.

Hands on chest.

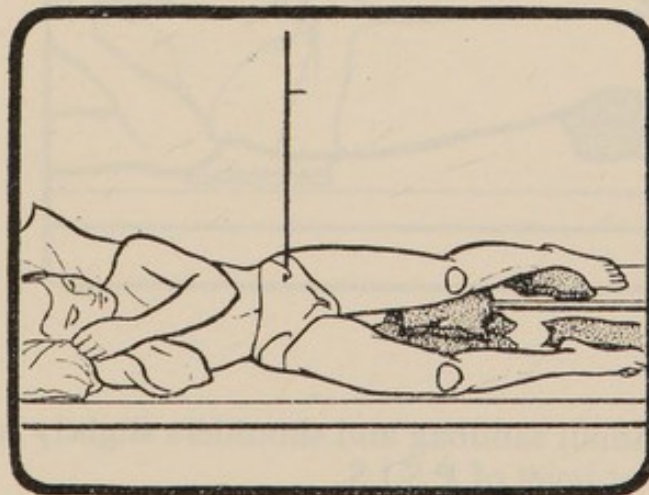
Shoulders raised on pillow.

A.S.I.S. equidistant from film.

Film placed transversely so that central ray falls on middle of film.

### \*Posterior-oblique

Fig. 74



### Centre.

To 1 in. medial to A.S.I.S. on raised side of trunk.

Patient supine.

Patient rotated from supine to side NOT under examination, until trunk is at 30° to couch.

Hands on chest.

Trunk supported by pillows.

An increase of F.F.D. from the normal used is desirable where tube load limitations will permit.

## THE VERTEBRAL COLUMN

In the techniques for the vertebral regions, the main object is the clear demonstration of the intervertebral articulations.

Positioning may be either horizontal or erect. The horizontal position is the more usual except where a study of posture is required.

**EXTREME CARE MUST BE EXERCISED IN CASE OF INJURY. PATIENT MUST NOT BE MOVED WITHOUT DIRECTION FROM THE MEDICAL OFFICER OR RADIOLOGIST.**

*Stationary grid or Potter-Bucky essential with few exceptions.*

Expose during arrested respiration.

### LUMBO-SACRAL ARTICULATION.

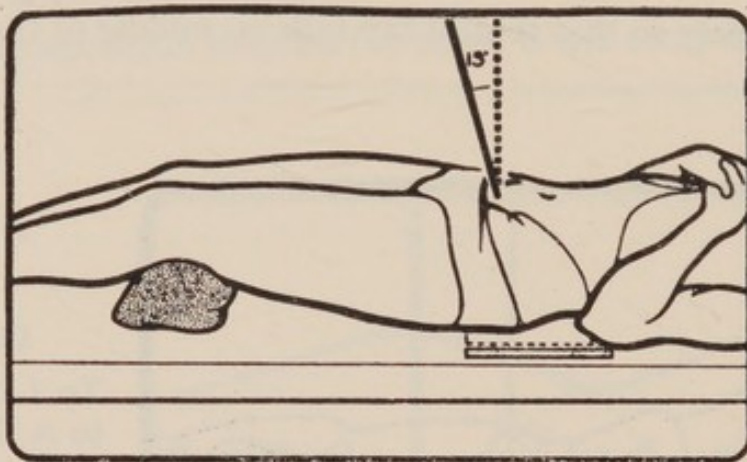
Routine projections: A.P. and Lat.

Alternative projection: P.A.

Additional projection: Posterior obliques.

#### \*Antero-posterior

Fig. 75



#### Centre.

To centre point of the inter-spinous line. Central ray angulation  $10^{\circ}$  to  $15^{\circ}$  cephalic from vertical so as to pass through lumbo-sacral articulation.

Patient supine.

Knees flexed over small sandbag and shoulders slightly raised.

Middle of the film at level of P.S.I.S.

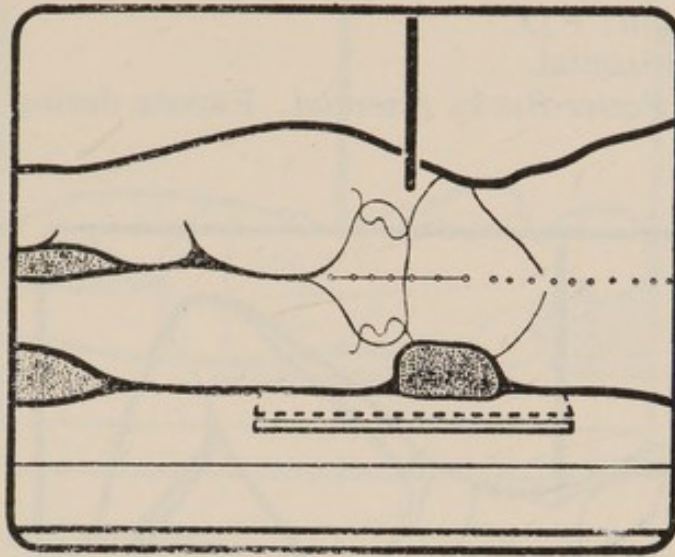
Lumbo-sacral angle noted in calculation of tube angulation.

Ensure that there is no rotation of the pelvis.

The lumbo-sacral articulation is not shown in a satisfactory manner by the lumbar vertebrae projection as the A.P. projection usually shows foreshortening of the fifth lumbar vertebra over the lumbo-sacral articulation.

\*Lateral

Fig. 76

**Centre.**

Three inches  
anterior to  
spinous process  
of 5th lumbar  
vertebra.

Patient lying in true lateral position.

Upper hip and knee slightly flexed.

Middle of film at level of P.S.I.S.

Effects of spinal sag must be avoided either by making spine parallel to film with padding at waist level or by angulation of tube at right angles to line of vertebrae



## LUMBAR VERTEBRAE

Routine projections: A.P. or P.A. and Lat.

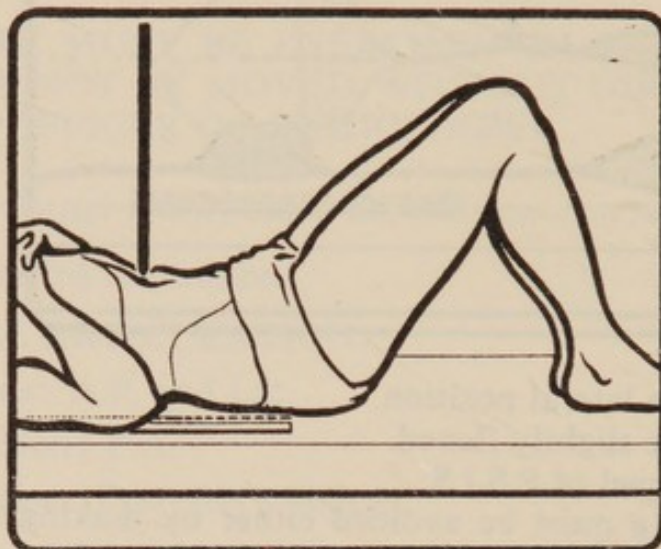
Additional projection: P.O.

Patient erect or horizontal.

*Stationary grid or Potter-Bucky essential.* Expose during arrested respiration.

° Antero-posterior

Fig. 77



**Centre.**

To mid-line at level of lower costal margin, i.e., third lumbar vertebra.

Patient supine.

Knees well raised.

Feet flat on table and immobilized.

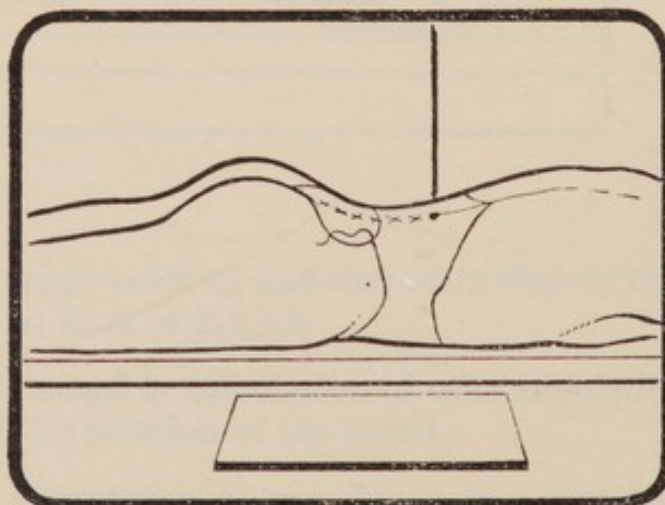
Shoulders slightly raised.

Body straight and no rotation of pelvis.

An increase of F.F.D. from the normal used is desirable where the tube load limitations will permit.

° Postero-anterior

Fig. 78



**Centre.**

To spinous process of third lumbar vertebra, at level of lower costal margin.

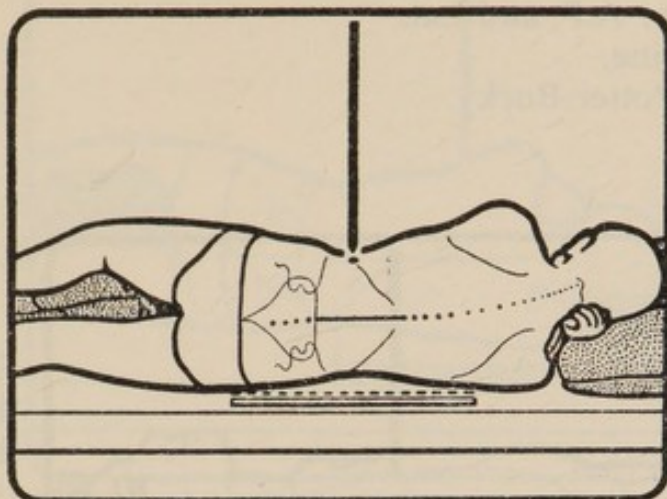
Patient prone.

Head placed in lateral position.

Arms above head.

**\*Lateral**

Fig. 79

**Centre.**

To a point  
4 inches  
anterior to  
spinous process  
of 3rd lumbar  
vertebra.

Patient in true lateral position.

Hip and knees flexed.

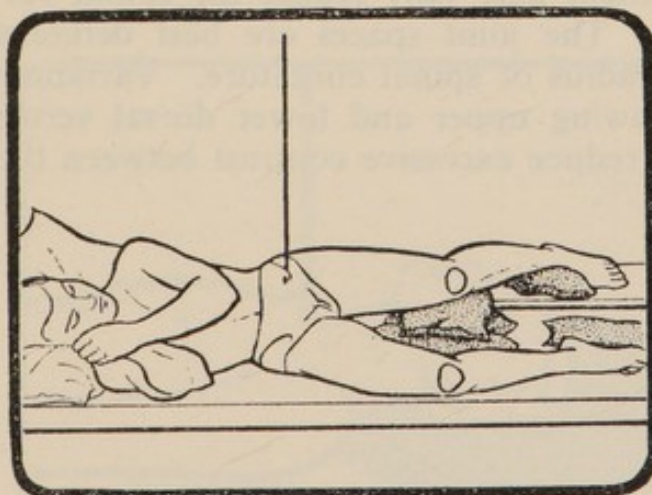
Upper leg and knee supported on pillows.

The ideal is to get the plane of the lumbar vertebrae parallel to the film with the central ray at right angles to both.

Where the plane of the vertebrae cannot be corrected by padding at waist level the tube must be angulated to meet the plane of the vertebrae at right angles.

**\*Posterior-oblique** (*For demonstration of articular processes and laminae with vertebral bodies*) Non-routine.

Fig. 80

**Centre.**

To the level of  
the lower costal  
margin in the  
mid-clavicular  
line.

From the supine position the patient is rotated to an angle of  $45^\circ$  to film.

Raised trunk and thigh supported by pillows.

*Note.*—Both sides should be taken for comparison.

## DORSAL OR THORACIC VERTEBRAE

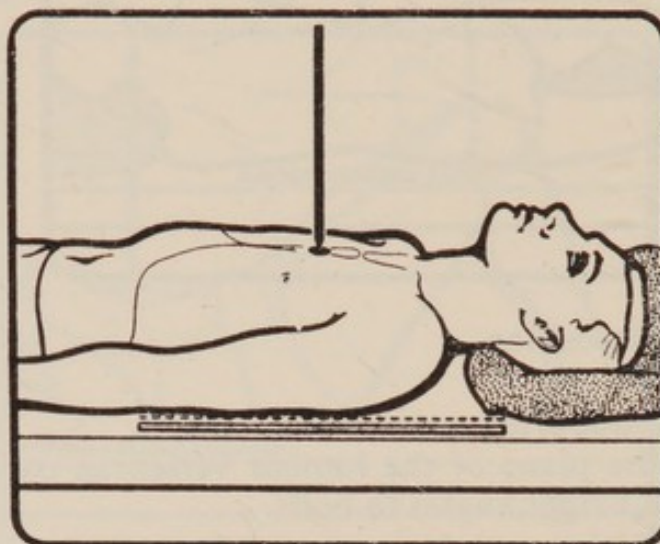
Routine projections: A.P. and Lat.

Patient erect or supine.

Stationary grid or Potter-Bucky.

### Antero-posterior

Fig. 81



### Centre.

To mid-line  
halfway  
between sternal  
angle and  
xiphoid  
cartilage.

Patient supine.

Hands and arms to sides.

Small pillow under head.

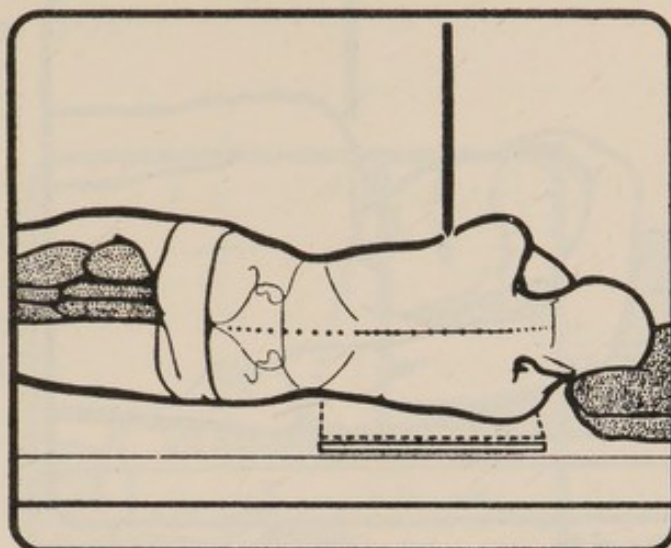
Upper border of film slightly above level of shoulders.

Expose on INSPIRATION to depress level of diaphragm.

Manipulation of patient may only reduce the spinal curve slightly from its normal posture. The joint spaces are best demonstrated when the F.F.D. is equal to radius of spinal curvature. Variations in densities of structures overshadowing upper and lower dorsal vertebrae necessitates a fairly high kV to reduce excessive contrast between these regions.

**Lateral**

Fig. 82

**Centre.**

To a point 2 in.  
anterior to  
spinous process  
of 6th dorsal  
vertebra.

Patient lying in true lateral position with spine parallel to the film.

Arms in front of trunk.

Hands placed on pillow.

When padding cannot bring plane of vertebrae parallel to film tube angulation will have to be resorted to.

Cephalic tilt where upper vertebrae are further from film and plantar tilt where upper vertebrae are nearer the film.

Expose during SHALLOW respiration to diffuse rib shadows.

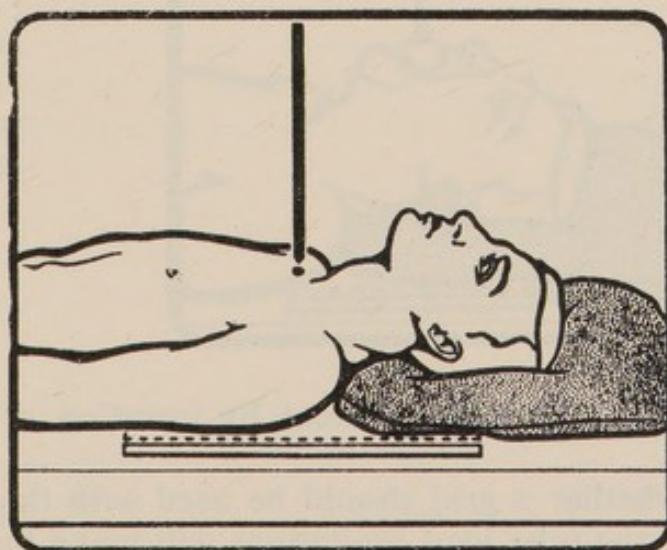
The upper three dorsal vertebrae are overshadowed by dense shoulder structure in this projection and their demonstration is the subject of the cervico-dorsal technique.

**CERVICO—DORSAL REGION**

Routine projections: A.P. and Lat.

**Antero-posterior**

Fig. 83

**Centre.**

1" above  
supra-sternal  
notch

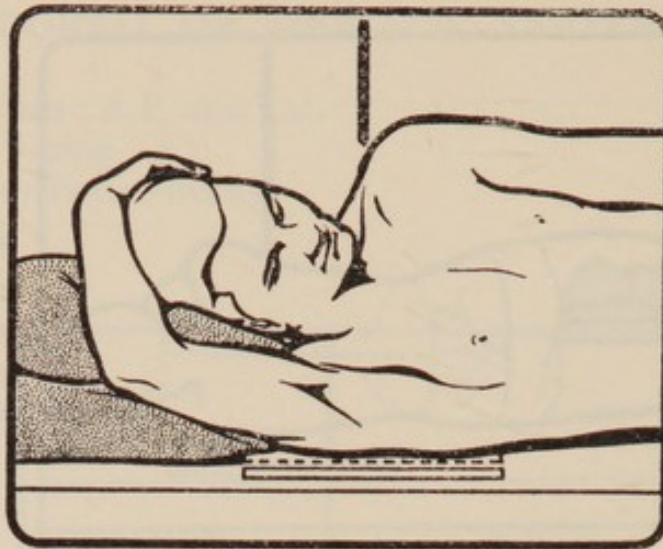
Patient supine, hands to sides.

Medial plane of skull perpendicular to film.

Film reaching from fourth cervical to the fourth dorsal vertebrae.

**Lateral**

Fig. 84

**Centre.**

Through base of neck at side nearer tube to the axilla nearer the film.

Patient lying on right side.  
 Right arm raised above head.  
 Left arm pulled down against left side.  
 Small pad under head.  
 Middle of film below axilla with upper border at level of symphysis menti.

**CERVICAL VERTEBRAE**

Routine projections: A.P. (1-3) A.P. (3-7) Lat. (1-7).

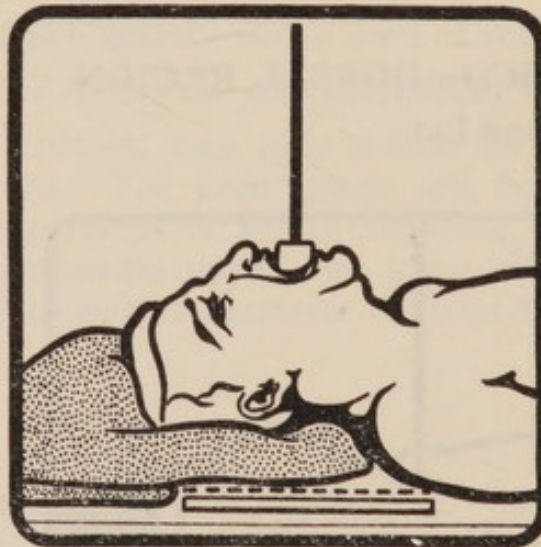Additional projection: Obliques.

Use of stationary grid or Potter-Bucky not essential.

Expose during arrested respiration. Patient erect or horizontal.

**Antero-posterior (1-3)**

Fig. 85

**Centre.**

To centre of open mouth, with central ray parallel to hard palate.

Patient supine or erect.

Mouth is kept open to its fullest extent by insertion of cork or dental film box.


The choice as to whether a grid should be used with this projection will depend on whether the tube load limitations will make the exposure time too long or not.

The projection through the open mouth is to avoid superimposition of anterior skull structures on C.1-3.

Where difficulty occurs in adjusting skull, angulation of the tube will be necessary.

**Antero-posterior (3-7)**

Fig. 86

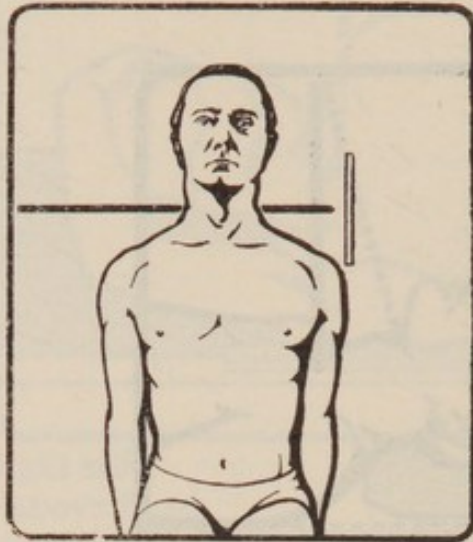
**Centre.**

In midline to 1 in. above suprasternal notch.  
 (A low centring point avoids overshadowing of upper vertebrae by mandible. Incorrect positioning will cause vertebrae to overshadow occipital bone).

Patient supine.

Medial plane perpendicular to long axis of film.

Chin raised to bring lower border of jaw at right angles to film.

**Lateral (1-7)****Fig. 87****Centre.**

1 in. posterior  
to angle of  
the jaw.

Patient erect or seated.

Shoulders as low as possible.

Patient in true lateral position in relation to film with chin raised.

Tip of shoulder in contact with lower border of film.

Use of grid or Potter-Bucky is not essential for this projection. Cassette must be positioned with lower border at shoulder level and shoulders depressed as low as possible. Mandible raised so that angles do not obscure upper vertebrae.

The long subject-film-distance (S.F.D.) in this case requires an F.F.D. of at least 48 in. to reduce size distortion and blur. Where patient cannot be moved the horizontal ray must be employed. The lateral projection should be attempted first and then the radiologist should be consulted as to what extent the patient can be moved for the A.P. projections.

**Posterior-oblique (1-7)**

**Centre.** To a point 1 in. above the level of the suprasternal notch; to the side of the neck nearest the TUBE.

Patient seated facing tube.

Neck extended, chin raised.

Patient rotated 45°.

**Anterior-oblique (1-7)**

**Centre.** To a point 1 in. above the level of the suprasternal notch; to the side of the neck nearest the FILM.

Patient seated facing film.

Neck extended, chin raised.

Patient rotated 45°.

Figs. 88 and 89 Reserved.

## THE THORACIC CAGE THE STERNUM

Routine projections: P.A. or A.O. with Lat.  
Patient erect or horizontal.

Stationary grid or Potter-Bucky should be used for this projection.

### Postero-anterior

This projection employs tube angulation to avoid superimposition of vertebral shadows on the sternum. Tube displacement may be to either side of the vertebral column but displacement to the left is to be desired so that projection is through the heart and possible confusion of lung detail with that of the sternum is thus minimized.

Exposure should be on **SHALLOW RESPIRATION** to diffuse rib and lung detail.

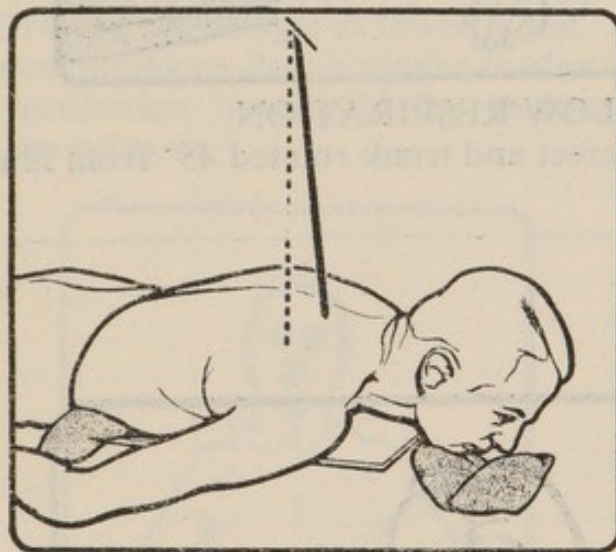


Fig. 90

### Centre.

To level of 4th dorsal vertebra.  
Tube is displaced from mid-line for a distance equal to (a).  
(a) = Thickness of patient measured at level of sternal angle.

Patient prone, head rotated to one side.

F.F.D. should be equal to  $3 \times (a)$ .

Tube is angulated  $18^\circ$  towards mid-line.

An increase in the time element of the exposure is favoured to diffuse unwanted rib and lung shadows.

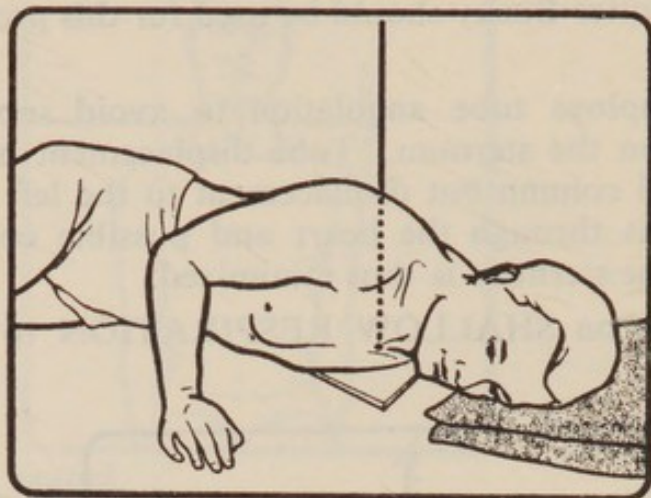


**Anterior-oblique** (Alternative to P.A.).

The body rotation replaces the tube angulation.

Right A.O. projection is used to project heart shadow on to sternal shadow.

Fig. 91

**Centre.**

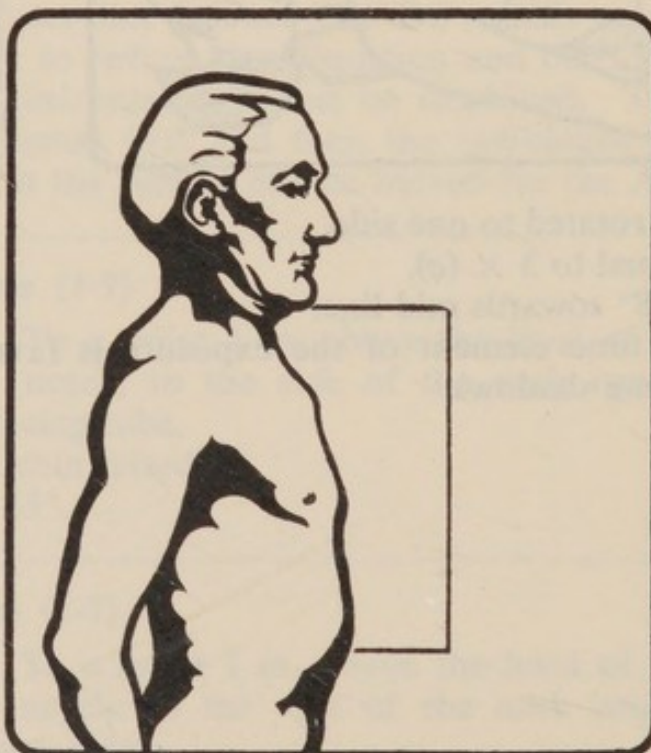
To level of 4th dorsal vertebra, 4 in. from mid-line through side nearer the tube.

Expose during **SHALLOW RESPIRATION**.

Patient horizontal or erect and trunk rotated 45° from film.

**Lateral**

Fig. 92

**Centre.**

To the sternal angle. Long S.F.D. calls for an F.F.D. of at least 48 in. Expose on *ARRESTED INSPIRATION*

Patient erect in true lateral position.

Feet apart, for better balance of patient.

Shoulders back, arms in "at ease" position.

Stationary grid or Potter-Bucky not necessary for this projection.

## THE RIBS

Routine projections: P.A. or A.P.

Additional projections: Obl.

Patient erect or horizontal.

Stationary grid or Potter-Bucky not usually employed except for lower ribs (9-12).

The 1st or 12th rib must always be included.

Any adhesive strapping should be removed but not before reference to medical officer in charge of case.

### Antero-posterior (1-10)

Used for posterior injuries. Employment of a high centring point projects diaphragm to lowest level. Respiration arrested on INSPIRATION, i.e., diaphragm at lowest point.

Difficulty in positioning to clear scapular shadows from lung fields renders this projection unsuitable for regions of the ribs superimposing the scapulae.

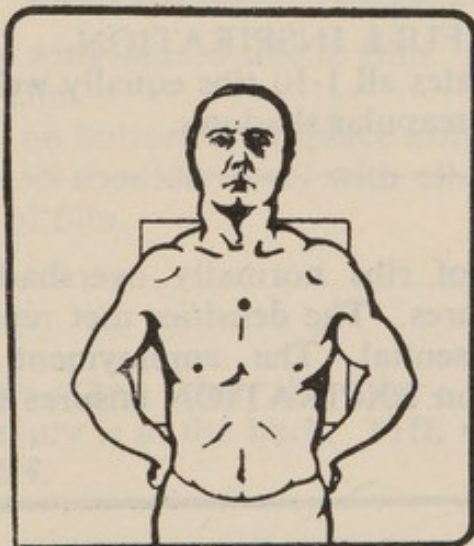


Fig. 93

### Centre.

To mid-line at level of sternal angle. A short F.F.D. (36 in. or less) tends to diffuse anterior rib shadows.

Patient erect or supine.

Back against film with upper border of film 1 in. above root of neck.

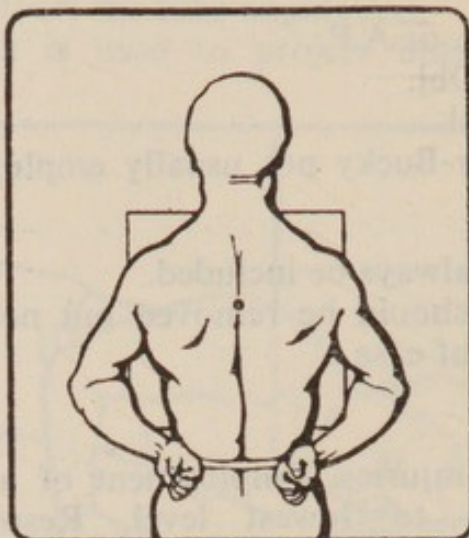
Backs of hands on buttocks, upper arms brought forward.

Respiration suspended in full inspiration.

The erect position is to be preferred as in this case, with the patient at full inspiration, the diaphragm is at its lowest possible level.

**Postero-anterior (1-10)**

Fig. 94

**Centre.**

To mid-line at level of 4th dorsal vertebra. An F.F.D. of at least 48 in. should be used.

Patient erect or prone, but erect position is to be preferred. Neck slightly extended, chin raised, above upper border of film. Shoulders depressed and the upper arms brought forward against film to move scapulae laterally.

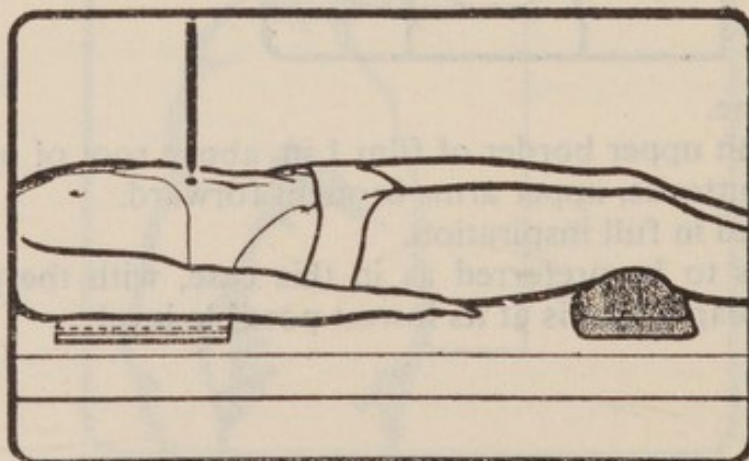
Respiration suspended in **FULL INSPIRATION**.

This projection demonstrates all 1-10 ribs equally well and easier positioning simplifies problem of scapular shadows.

**Antero-posterior (9-12)**

For demonstration of ribs normally overshadowed by diaphragm and overlying structures. The densities met render the use of a grid or Potter-Bucky essential. The employment of a low centring point and exposure on **EXPIRATION** ensures that the diaphragm is projected clear.

Fig. 95

**Centre.**

To mid-line at the level of lower costal margin.

Patient supine with arms comfortably at sides.

The film is placed transversely with lower border of film below subcostal line.

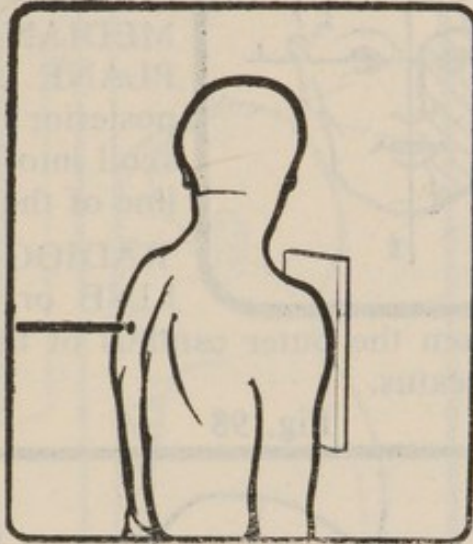
Make sure that the trunk is not rotated.

### Obliques (Anterior or Posterior). Non-routine.

Obliques are projected where injury is localized in the region of the axillary line.

For left anterior oblique, where cardiac shadow intervenes the kV should be raised by 5 kV.

Fig. 96



#### Centre.

To level of 4th dorsal vertebra  
4 in. from mid-line through  
side nearer the  
tube.

Patient erect or lying with injured side to film.

Body rotated 45° to film.

Hand of injured side on buttock to displace arm from chest wall.

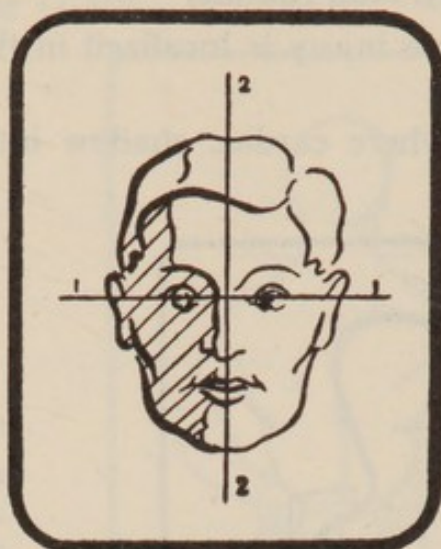
Other arm extended to shoulder level with elbow flexed and arm resting above upper border of film.

### IMPORTANT

Anterior-obliques are taken when the injury is at the front, Posterior-obliques when the injury is at the back. **THE OTHER SIDE IS TAKEN FOR COMPARISON.**

Definitions:—

Fig. 97



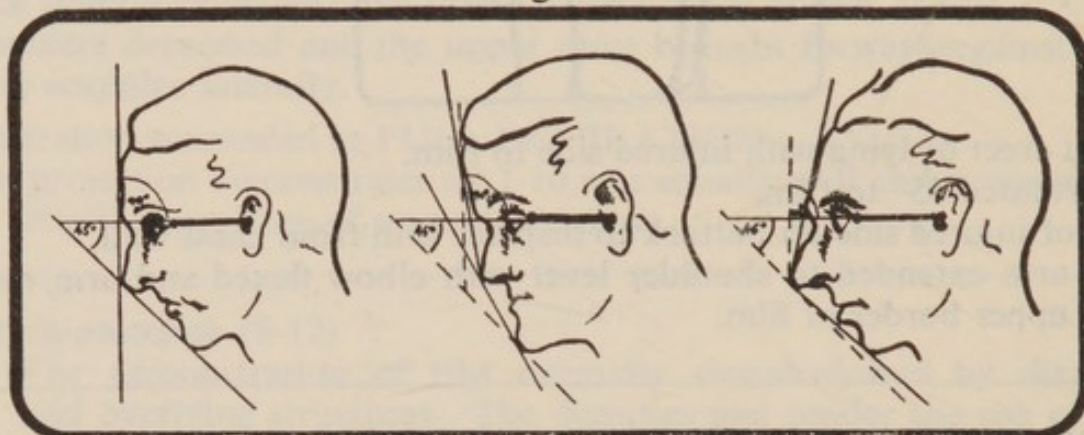
INTERPUPILLARY LINE or INTER ORBITAL LINE is a line drawn between the middle of the pupils when the eyes are looking straight forwards.

MEDIAN or SAGITTAL PLANE is a vertical antero-posterior plane dividing the skull into halves, following the line of the sagittal suture.

RADIOGRAPHIC BASE LINE or ORBITO-MEATAL

LINE is a line drawn from the outer canthus of the eye to the middle of the external auditory meatus.

Fig. 98



The importance of using the RADIOGRAPHIC BASE LINE is shown in the diagram. This view is sometimes erroneously called the nose-chin position. In fact as will be seen from the diagram the placing of the nose and chin in contact with the cassette seldom achieves accurate angulation of this base line to the film, because of the variations in facial contours. *The use of a stationary grid or Potter-Bucky is essential for most skull work.*

Immobilization of the skull is of utmost importance and it is assisted by exposure during arrested respiration.

A long F.F.D. of at least 36 in. is advisable wherever possible. A blurred definition of the side remote from the film occurs when shorter F.F.D. is employed, because of the relatively large S.F.D. of the remote side.

All foreign bodies, such as hair clips, false teeth, etc., must be removed from the head before examination.

Only in rare cases is emergency X-ray examination of the skull regarded as necessary. Treatment for shock or possible brain injury is of primary importance, otherwise patient in such cases may not be amenable to X-ray examination.

For radiographic purposes the examination of the skull is divided into two categories: CRANIAL and FACIAL.

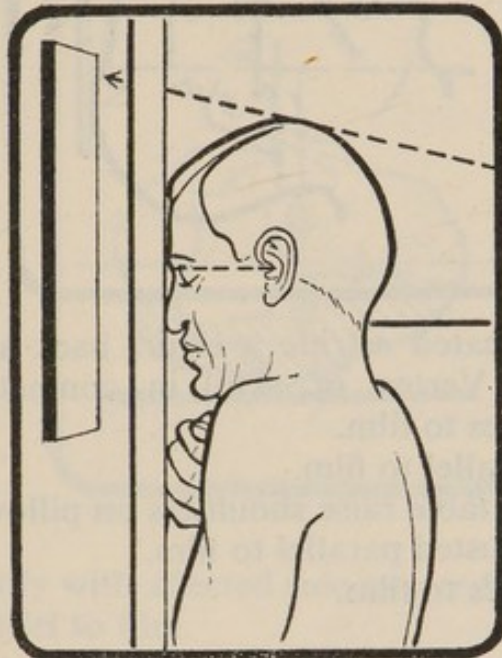
## THE CRANIUM

Routine projections: Selected from, O.F. F.O. S.M.V. 30° F.O. and lateral.  
Patient erect or horizontal.

Stationary grid or Potter-Bucky essential. Expose in arrested respiration.

### Occipito-frontal

Fig. 99



#### Centre.

In the mid-line  $2\frac{1}{2}$ "  
below external  
occipital  
protuberance.

Patient prone or erect.

Median plane at right angles to the film.

Radiographic base line at right angles to film.

Film placed with long axis parallel to long axis of face, with upper border of film two inches above vertex of skull.

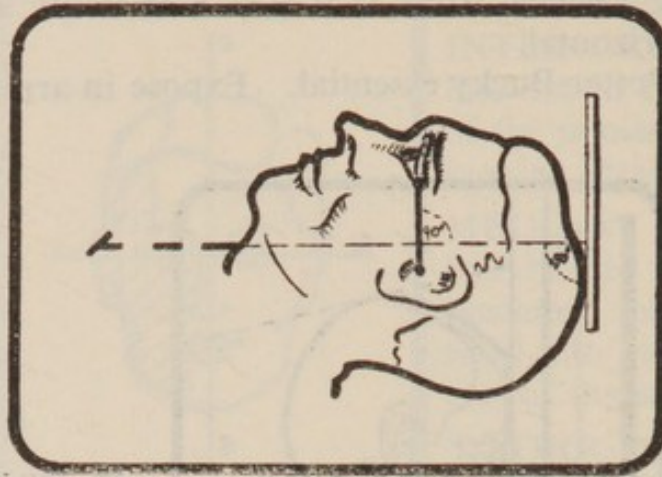
A low centring point enables oblique rays to project maximum area of cranial structures clear of dense basal regions.

---

Fig. 100 Reserved.

**Submento-vertical**

Fig. 101

**Centre.**

To a point midway between the angles of the mandible with central ray at  $90^\circ$  to film.

Patient facing tube and seated astride a chair, back arched and patient gripping back of chair. Vertex of skull in contact with film.

Median plane at right angles to film.

Radiographic base line parallel to film.

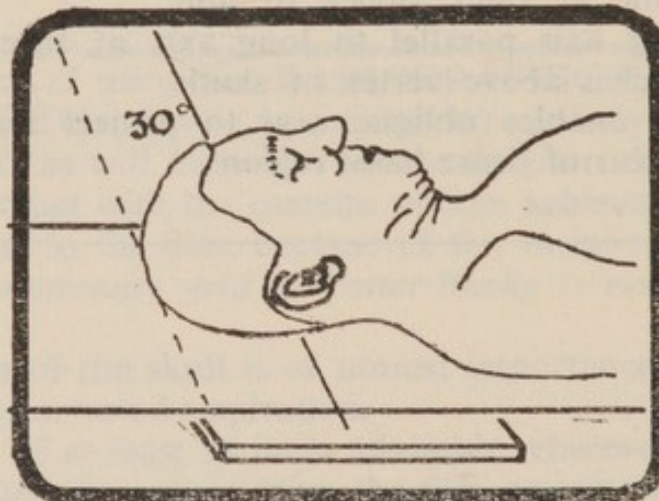
Where patient is supine on table raise shoulders on pillows.

Radiographic base line adjusted parallel to film.

Median plane at right angles to film.

**30° Fronto-occipital**

Fig. 102

**Centre.**

Tube angled  $30^\circ$  caudal from vertical. Central ray through frontal bone to foramen magnum.

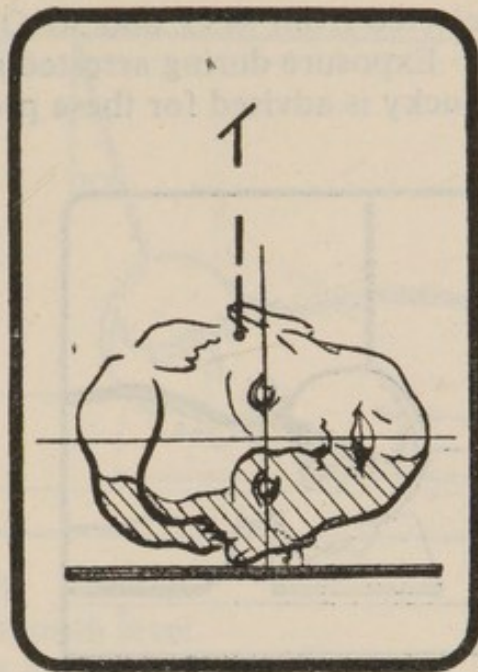
Patient supine, chin well down on chest.

Radiographic base line at right angles to film.

Median plane at right angles to film.

**Lateral**

Fig. 103

**Centre.**

To mid-point  
between  
glabella and  
occipital  
protuberance.

Patient prone.

Head turned laterally with affected side nearer film.

Median plane parallel to film.

Inter-orbital line at right angles to film.

Non-opaque pad under chin if necessary.

Long axis of film parallel to long axis of cranium.

Film displaced  $1\frac{1}{2}$  in. above vertex.

If the median plane cannot be adjusted parallel to film the C.R. must be angulated at right angles to it.

The position is best maintained in the prone position, arm of affected side extended alongside trunk. Opposite arm and elbow flexed and raised on pillow.

If the patient is in the supine position and is not to be moved, raise the head on non-opaque pad. Film placed vertically to lateral aspect of skull and C.R. directed horizontally. Median plane must be parallel to film and inter-orbital line at right angles to it.



## THE FACIAL BONES

Routine projections: O.M. and Lat. (S.I. and Lat. for nasal bones).  
 Additional projections: Selected from M.O. and 30° O.M.  
 Patient erect or horizontal. Exposure during arrested respiration.  
 Stationary grid or Potter-Bucky is advised for these projections.

### Occipito-mental

Fig. 104



#### Centre.

Central ray through vertex of skull to glabella.

Patient prone, or erect.

Nose and chin on film.

Mid-point of chin in mid-line of film.

Mid-point of film at mouth level.

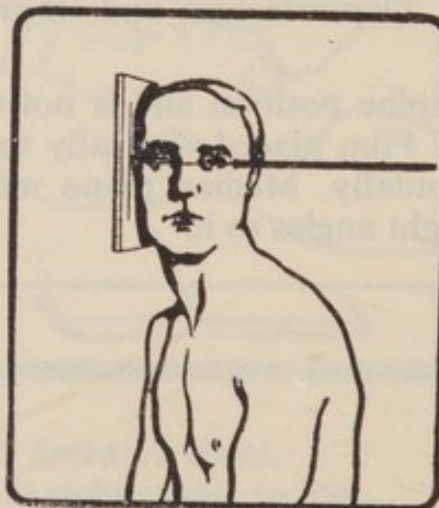Median plane of skull at right angles to film.

Radiographic base line at 45° to film.

The angulation of the head in relation to the centring point enables dense petrous temporals to be projected beneath the lower level of the malar bones.

### Lateral

Fig. 105



#### Centre.

To malar bone at its junction with the external angular process of the frontal bone.

Patient prone or erect.

Head turned laterally so that affected side is against film.

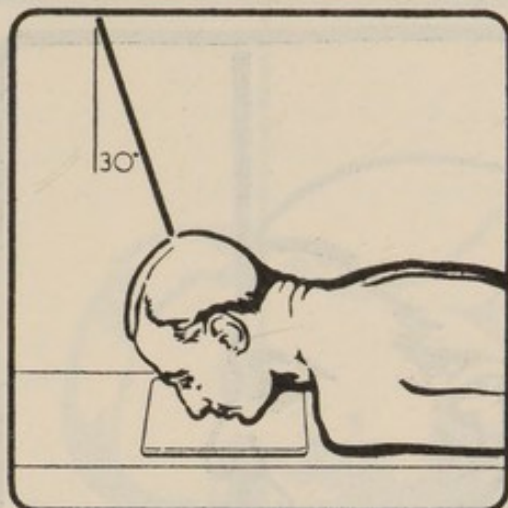
Interorbital line at right angles to film.

Median plane parallel to film.

Stereoscopic projections may be useful.

**30° Occipito-mental**

Fig. 106

**Centre.**

Through middle of mouth to centre of film with tube angulated 30° caudal from vertical Central ray through vertex.

Patient prone or erect.

Mid-point of film at mouth level.

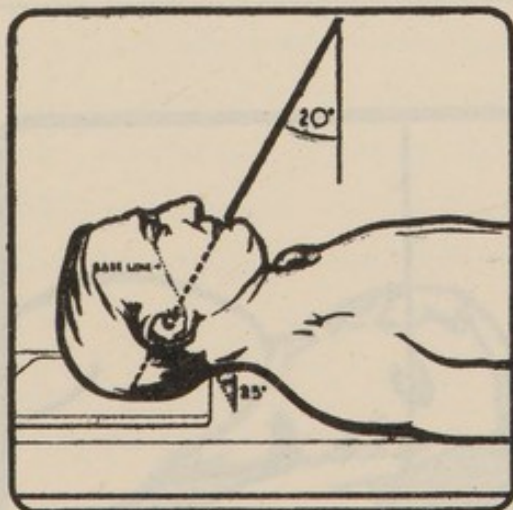
Median plane at right angles to film.

Radiographic base line 45° to film.

This projection is used in conjunction with the routine O.M. to demonstrate the LOWER ORBITAL MARGINS and the adjacent MALAR REGIONS.

**Mento-occipital** (Alternative to O.M. if latter is impracticable).

Fig. 107

**Centre.**

Through middle of mouth with tube angulated 20° cephalic from vertical.

Patient supine.

Radiographic base line at 65° to film.

Median plane at right angles to film.

Middle of film at level of vertex.

This projection projects the facial bones above the basal structures.

## NASAL BONES

### Superior-inferior

Fig. 108



**Centre.**

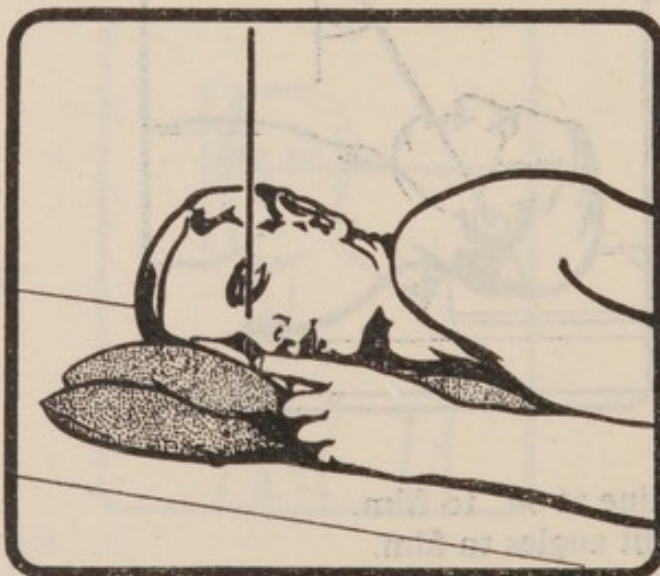Through  
glabella at  
right angles  
to film.

Patient seated with occlusal film placed lengthwise between teeth, with  $\frac{3}{4}$  projecting out of mouth.

It is not always possible to obtain this view satisfactorily where nasal bones are depressed in relation to frontal bones.

### Lateral

Fig. 109



**Centre.**

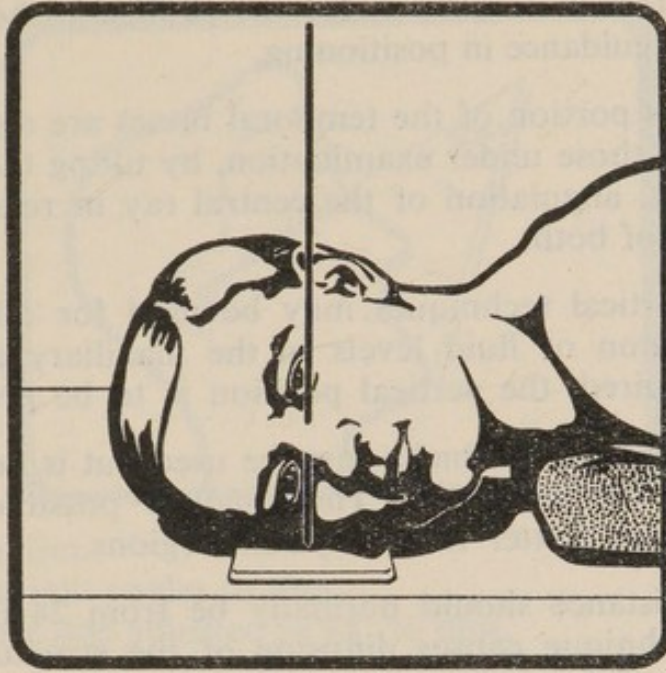
To root of  
nose.

Dental film placed against nasal bones laterally and held parallel to median plane.

Both sides taken for comparison.

**Lateral (Alternative method)**

Fig. 110

**Centre.**To root of  
nose.

Patient prone.

Head in true lateral position.

Median plane parallel to film.

Half-plate film may be used placed at side of head.

*Note.*—Due to the large S.F.D. the F.F.D. should be increased to minimise the resultant distortion

## THE NASAL ACCESSORY SINUSES

The positioning terminology is as for the skull and the same landmarks are employed for guidance in positioning.

The dense petrous portion of the temporal bones are again the regions to be excluded from those under examination, by tilting the head in relation to the central ray, angulation of the central ray in relation to the head, or a combination of both.

Horizontal or vertical techniques may be used for all projections, but where demonstration of fluid levels in the maxillary antra and frontal air sinuses is required, the vertical position is to be preferred.

A stationary grid or Potter-Bucky may be used but is not essential where a fine focal spot is available. The smallest possible cones must be utilized to minimise scatter from adjacent regions.

The focus film distance should normally be from 24 in. to 30 in. This short distance technique causes diffusion of the structures remote from the film in favour of those closer to the film.

Care must be taken to include the marker in the field of the localizing cone and at the same time it must not be superimposed over any relevant detail.

Careful manipulation of the part and satisfactory immobilization is of vital importance.


All foreign opacities must be removed from the part under examination.

The routine projections are selected from the following:—

- |                   |   |
|-------------------|---|
| Occipito-mental   | To demonstrate:—Maxillary antra and frontal sinuses   |
| Submento-vertical | To demonstrate:—Sphenoidal and ethmoidal sinuses      |
| Obliques          | To demonstrate:—Posterior ethmoids                    |
| Lateral           | To demonstrate:—All sinuses but with superimposition. |

**Occipito-mental** (*For antra and frontal sinuses*)

Fig. 111

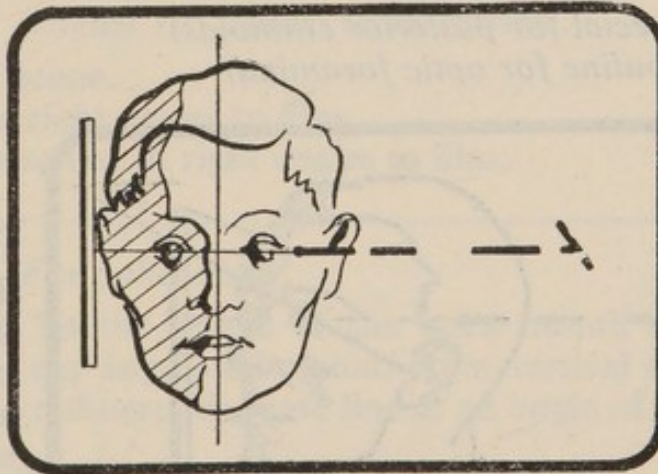
**Centre.**

To the mid-line above the occipital protuberance to bring central ray at level of infra orbital margin.

Point of chin on film.  
Median plane at right angles to film.  
Radiographic base line adjusted to  $45^\circ$  to film.

**Lateral** (*All sinuses with superimposition*)

Fig. 112

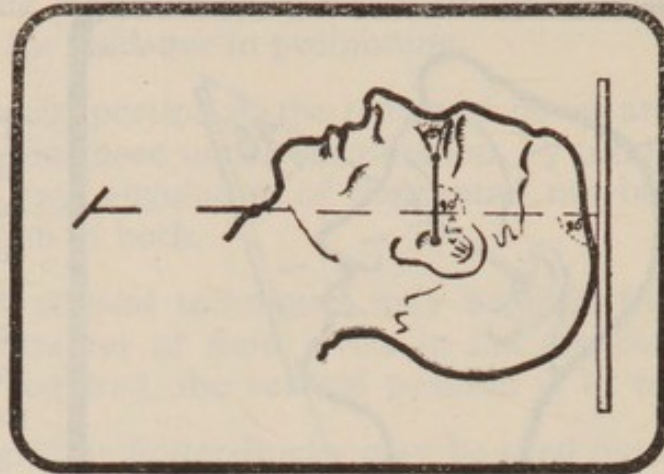
**Centre.**

To radiographic base line 1 in. behind outer canthus of the eye.

Head turned laterally with affected side to film.  
Median plane parallel to film.  
Interorbital line at right angles to film.  
Right and left sides will be superimposed.

**Submento-vertical** (*For sphenoidal and ethmoidal sinuses*)

Fig. 113

**Centre.**

Midway  
between the  
angles of the  
mandible with  
central ray at  
right angles to  
film.

Patient seated on chair and leaning back so that vertex of skull is in contact with the film.

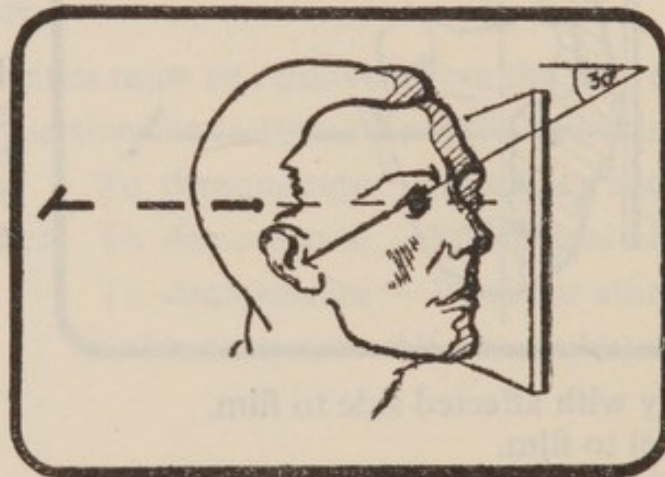
Median plane at right angles to film.

Radiographic base line parallel to film.

Film supported vertically behind head.

**Anterior-oblique** (*Special for posterior ethmoids*)  
(*Routine for optic foramina*)

Fig. 114

**Centre.**

To a point  $2\frac{1}{2}$   
in. above and  
behind external  
auditory  
meatus, to  
centre of orbit.

Nose and forehead placed on film.

Head rotated laterally through  $40^\circ$ .

Face tilted forwards until side of chin touches film.

Radiographic base line  $30^\circ$  angled plantar from horizontal.

Interpupillary line maintained in horizontal position.

Both sides taken for comparison.

## ALTERNATIVE PROJECTIONS FOR SUPPLEMENTARY INFORMATION ON SPHENOIDS AND ETHMOIDS

### **Occipito-frontal (1)** (*For anterior ethmoids*)

Centre: To a point  $1\frac{1}{2}$  in. below occipital protuberance with central ray at  $90^\circ$  to film.

Patient erect or prone.

Median plane at right angles to film.

Radiographic base line at right angles to film.

---

### **Occipito-frontal (2)** (*For sphenoids*)

Centre: To a point 2 in. below occipital protuberance with tube angled  $10^\circ$  caudal from vertical.

Patient erect or prone.

Median plane at right angles to film.

Radiographic base line at right angles to film.

---

### **Occipito-frontal (3)** (*For antra and anterior ethmoids*)

Centre: To a point above occipital protuberance with tube angled  $10^\circ$  caudal from vertical.

Patient erect or prone.

Median plane at right angles to film.

Radiographic base line at right angles to film.

---

### **Vertico-mental** (*For sphenoids*)

Centre: To the centre of the open mouth with the central ray angulated plantar from vertical so as to pass the radiographic base line at an angle of  $70^\circ$ .

Patient erect or prone.

Nose and chin on film.

Radiographic base line adjusted to  $45^\circ$  to film.

Median plane at right angles to film.

Mouth open, assisted if necessary by cork or bandage.

---

*Note.*—To confirm fluid levels.

To confirm the presence of fluid levels in the antra or frontal sinuses, a modified O.M. projection may be taken by deviation of the head to one side or the other. Fluid levels may be demonstrated in horizontal position with patient supine. The film is placed vertically at lateral aspect of the skull and the C.R. directed horizontally. Centre to a point 1 in. from outer canthus of the eye, along the R.B.L.



## THE MASTOID AIR CELLS

These air cells, situated between the external auditory meatus and the occipital bone behind the ears are superimposed in the true lateral position.

Separation of their shadows, from the lateral aspect, is obtained by angulation of the C.R. or by tilting the head.

From anterior to posterior aspects the mastoids are partially overshadowed by adjacent occipital and facial structures, and their projection in profile is obtained by rotation of the head.

For good definition of extremely fine detail a small focal spot should be employed.

A stationary grid or Potter-Bucky may be used but is not essential with a fine focal spot. In many of these projections a grid is impracticable. Both sides are taken for comparison.

The pinna of the ear should be folded forward for lateral projections. Care must be taken to use a cone that will just adequately cover the part under examination and care must also be taken to see that the marker used is inside the cone field.

Routine projections: Selected from Obl/lat., Lat., A.O., P.O. and occasionally a Townes (30° F.O.) is included.

### Lateral

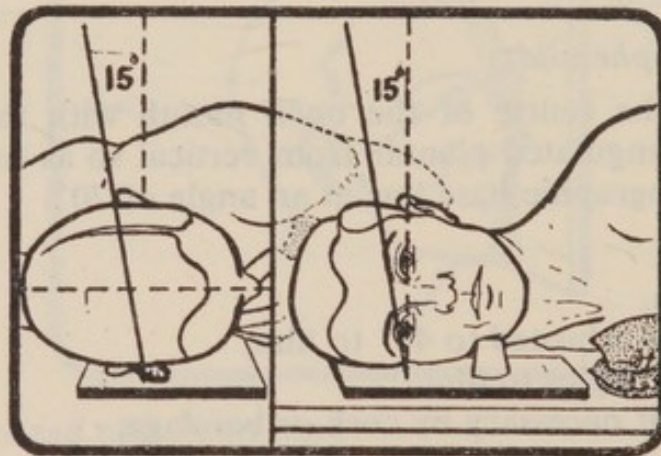


Fig. 115

### Centre.

To a point 2 in. above and behind the external auditory meatus nearer the tube. Central ray directed 15° caudal and 15° facial from vertical.

Patient prone or erect.


Head in the true lateral position.

Interpupillary line at right angles to film.

Median plane parallel to film.

**Oblique-lateral**

Fig. 116

**Centre.**

To a point 2 in. above and behind the external auditory meatus of the side nearer the tube, to mastoid process nearer the film.

Patient prone.

Head in the lateral position and raised on an angle board  $20^\circ$ .

Head rotated until cheek touches the film.

Both sides taken for comparison.

**Anterior and Posterior Obliques**

These projections aim to show the mastoids in profile.


The mastoid process is projected clear of the cervical vertebrae by rotation of the head; and below the occipital bone by:—

Upward tilting of the head (P.O.).

Downward tilting of the head (A.O.).

**Anterior-oblique**

Fig. 117

**Centre.**

To root of mastoid process nearer film, with central ray at right angles to couch.

Patient prone, with pillow under chest.

Vertex lowered over  $20^\circ$  angle board.

Nose and forehead placed on film.

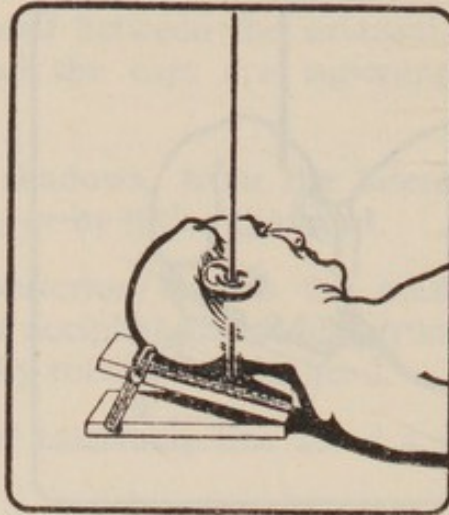
Head rotated  $35^\circ$  towards affected side.

Chin raised on pad.

Both sides taken for comparison.

**Posterior-oblique**

Fig. 118

**Centre.**

To the root of the mastoid process of the side nearer the tube, with central ray at right angles to couch.

Patient supine.

Vertex raised on 20° angle board.

Chin down and head rotated 35° away from affected side.

Both sides taken for comparison.

Figs. 119 and 120 Reserved.

## THE MANDIBLE

With the mandible as with the mastoids, one side is superimposed on the other side, from the lateral aspect.

Head tilting and tube angulation are again employed to affect separation of the shadows of each side.

Choice of techniques will be guided by condition of patient and/or suitability and limitations of the apparatus.

With the exception of projections using angle board techniques, the patient may be examined in either the erect or horizontal positions.

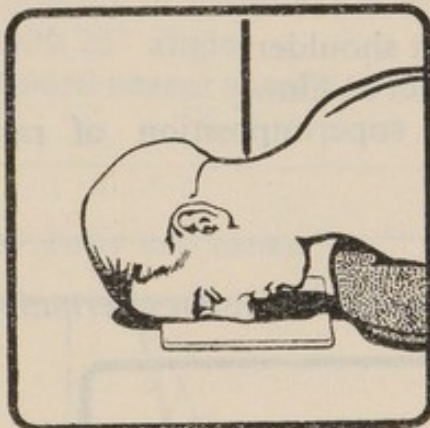
Routine projections: Selected from, P.A., Ant/Obl. and two variations of Lat. and Obl/Lat.

Stationary grid or Potter-Bucky should be used for the P.A. and A.O. projections but it is not essential with the other projections if a fine focal spot is used.

Choice of positions will also be governed by consideration of the part of the mandible to be examined.

### Postero-anterior

Fig. 121



Patient prone or erect.

Nose and/or forehead to film.

Median plane at right angles to film.

Radiographic base line at right angles to film.

Lower border of film placed 1 in. below the chin.

### Anterior-oblique (*For symphysis menti*)

Fig. 122



Patient prone or erect.

Nose and/or forehead to film.

Median plane placed at right angles to film and radiographic base line at right angles to film; then head rotated 20° to affected side.

### Centre.

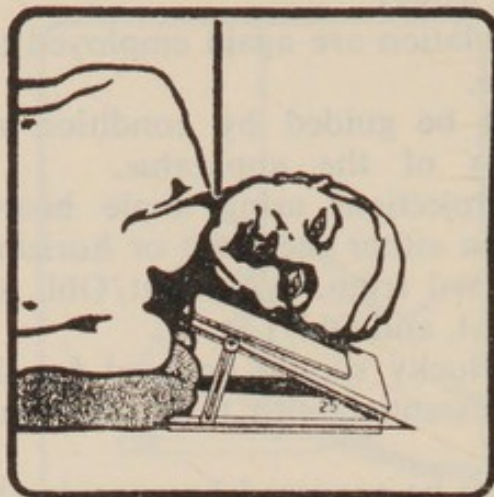To a point 2½ in. below occipital protuberance in mid-line, with central ray at 90° to film.

### Centre.

To symphysis menti with central ray at right angles to film.

**Lateral (1)** (*For Ramus, angle and body*)

Fig. 123

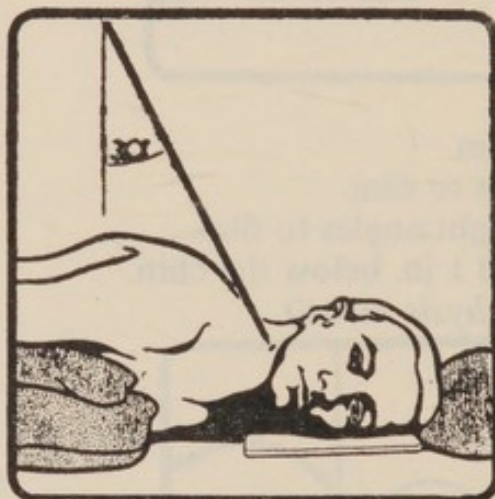**Centre.**

To a point 2 in. below angle of jaw nearer the tube, with central ray at right angles to the couch.

Patient recumbent in lateral position.  
 Head over 25° angle board.  
 Raised edge of board against shoulder.  
 Median plane of head parallel to film.  
 Chin forward to prevent superimposition of ramus on the cervical vertebrae.

**Lateral (2)** (*For ramus, angle and body. An alternative to lateral (1)*).

Fig. 124

**Centre.**

To a point 2 in. below angle of the jaw nearer the tube, with central ray angled 30° cephalic from vertical.

Patient prone.  
 Head rotated to true lateral position.  
 Film flat on table top.

**Oblique-lateral (1) (For body and angle)**

Fig. 125

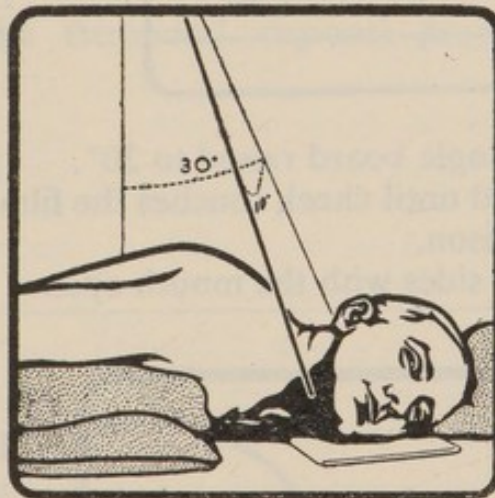
**Centre.**

To a point 2 in. below the angle of the jaw nearer the tube with the central ray angled  $10^\circ$  facial from vertical to symphysis menti.

Patient placed in lateral position.  
 Patient rotated to bring body of mandible in contact with film.  
 Film on angle board with  $25^\circ$  angle.  
 Raised edge of angle board nearer shoulder.

**Oblique-lateral (2) (For body and ramus)**

Fig. 126

**Centre.**

To a point 2 in. below the angle of the jaw nearer the tube, with the central ray angled  $30^\circ$  cephalic and  $10^\circ$  facial from vertical to symphysis menti.

Patient placed in lateral position.  
 Patient rotated to bring body of mandible in contact with film.  
 Film flat on couch top.

## THE TEMPORO—MANDIBULAR JOINTS

The temporo-mandibular joints are situated adjacent to the mastoid air cells, just anterior to the external auditory meatus of each side. Their shadows are separated by similar methods to those used for mastoid and mandible techniques.

Local lack of contrast in these regions makes imperative the use of fine focal spot, the smallest possible localizing cone and stationary grid or Potter-Bucky where practicable.

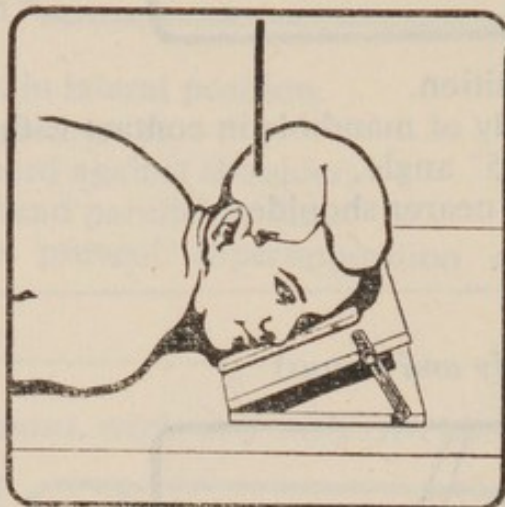
Both sides must be taken for comparison and exposures made with the mouth both open and closed.

Routine projections: Selected from Obl/Lat. and Lat. 1, 2.

Patient recumbent for angle board techniques, erect or recumbent for C.R. angulation techniques.

### Oblique-lateral

Fig. 127



#### Centre.

To a point 2 in. above and behind external auditory meatus of side nearer tube with central ray at right angles to couch top.

Patient prone.

Head in lateral position on angle board raised to 20°.

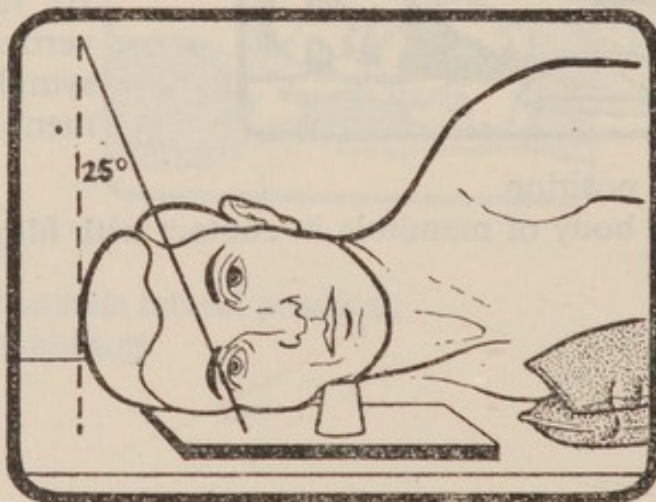
Head raised and chin lowered until cheek touches the film.

Other side taken for comparison.

Position is repeated for both sides with the mouth open.

### Lateral (1)

Fig. 128



#### Centre.

To a point 2 in. above temporo-mandibular joint remote from film to joint in contact with film, central ray angulated 25° caudal from vertical.

Patient prone.

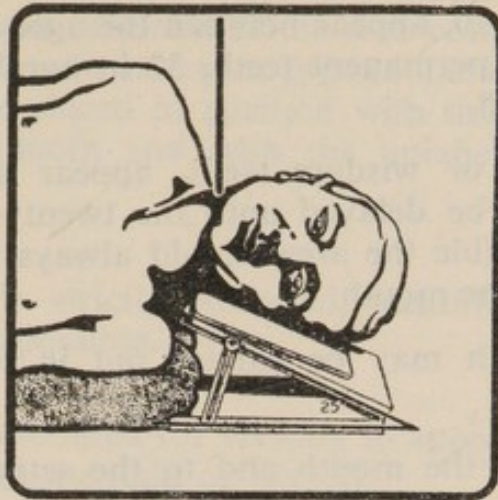
Patient rotated into Ant/Obl. position.

Raised shoulder supported and head in true lateral position.

In this projection the overlying structures are projected below the joint under examination.

**Lateral (2)****Lateral (2) With angle board**

Fig. 129



Patient recumbent in lateral position.  
 Head over 25° angle board.  
 Raised edge of board against shoulder.  
 Median plane of head parallel to film.  
 Interpupillary line at right angles to film.  
 Chin forward to prevent superimposition of ramus on cervical vertebrae.  
 Head rotated 10° backwards.  
 Overlying structures (temporal regions) projected above joint under examination.

Fig. 130 Reserved.

**Centre.**

To a point  $\frac{1}{2}$  in.  
 behind and 1  
 in. below angle  
 of mandible  
 nearer the tube,  
 with central  
 ray at right  
 angles to couch  
 top.



## THE TEETH

The human being develops two sets of teeth. The temporary or deciduous set, numbering 20, appear between the ages of 6 months and 2 years, giving place to the permanent teeth, 32 in number, which develop from the sixth year onward.

The last four molars, or wisdom teeth, appear usually during the eighteenth year but may be delayed until the twenty-sixth year. Even if no wisdom tooth is visible the area should always be included in the complete examination of the mouth.

All positioning for teeth may be carried out in either the erect or horizontal position.

Owing to the shape of the mouth and to the setting of the teeth in the soft gum structures covering the alveolar processes, projection of an undistorted image is rendered difficult. Using an intra-oral technique, a film is placed in the mouth in contact with the crown of the tooth, and is separated from the root or apex of the tooth by the gum. The film is therefore not parallel to the axis of the tooth. The angulation between the tooth and the film varies from subject to subject and according to the region of the mouth under examination. It is most acute in the upper incisor area and in the lower molar regions it is almost negligible.

The aim in projection should be to direct the beam at right angles to the line bisecting the angle formed by the planes of the tooth and film, otherwise foreshortening or elongation occurs. Lateral distortion must also be avoided, as this gives rise to overlapping of tooth shadows. The number of films used to overcome this difficulty will vary with the shape of the mouth but at least ten films are necessary for satisfactory demonstration of each tooth on at least one film.

Where special film holders are not available the patient should be instructed to hold the film in position with the index finger, and must be impressed with the importance of holding it firmly to prevent it slipping.

Should it be necessary to supplement information gained from the intra-oral film projections, as for instance the exact location of unerupted teeth or a dental cyst, then a larger intra-oral film (occlusal film) should be placed between the teeth in the occlusal plane.

For the lower jaw the central ray should be directed at  $90^{\circ}$  to the occlusal film. A true occlusal projection of the upper teeth necessitates the use of intensifying screens, as the beam must be directed through the vertex to the film, but a useful view may be obtained by centring obliquely to the film, in order to avoid dense bony structures and intensifying screens are not then required.

Further information may also be gained by extra-oral techniques as for instance the oblique laterals of the mandible.

## IDENTIFICATION

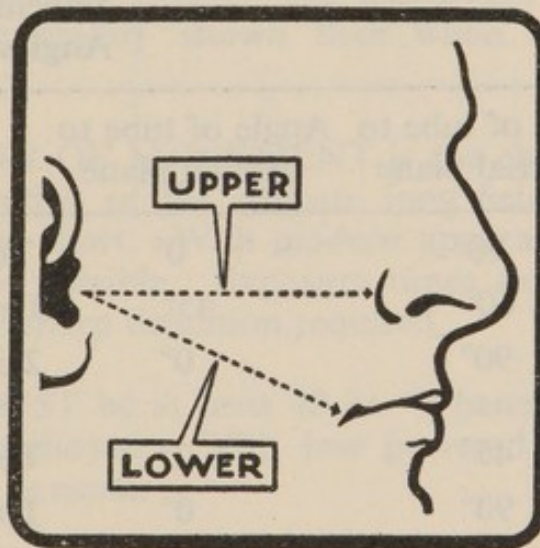
Dental films should never be marked in the dark room. Each film is marked with a small indentation in one corner which corresponds in position to a similar indentation or printed marking on the outer wrapper. The film should be placed in position with this marking placed towards the crown of the tooth and with the unlabelled side of film towards tooth.

If this routine is strictly followed, identification of the teeth after processing becomes possible.

Films should be mounted for viewing to appear as the mouth is seen by the surgeon, i.e., with the right on his left.

### Intra-oral (Upper teeth)

Fig. 131



Patient supine or seated.

Film held in position by *patient's* index finger, forceps or film holder.

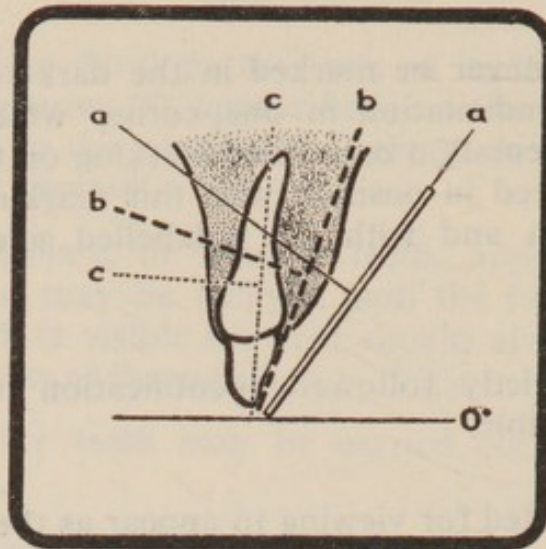
Occlusal plane parallel to floor.

Occlusal plane is taken as being a line between the ala of the nose and the tragus of the ear.

For lower jaw examinations with mouth open the occlusal plane of the lower teeth is taken as being parallel to a line between the corner of the mouth and the tragus of the ear.

The head must be tilted to bring this plane horizontal.

Fig. 132

**Centre.**

Central ray directed perpendicular to a plane bisecting the angle between the plane of the film and the plane of the tooth.

**Extra-oral***See Mandible.***Occlusal**

Patient supine or seated  
Angles as below.

| Examination                        | Angle of tube to occlusal plane | Angle of tube to median plane | Centre                          |
|------------------------------------|---------------------------------|-------------------------------|---------------------------------|
| Upper anterior                     | 70°                             | 0°                            | To point of nose.               |
| Upper oblique                      | 60°                             | 45°                           | To canine fossa.                |
| Lower occlusal<br>(Head well back) | 90°                             | 0°                            | 2 in. below<br>symphysis menti. |
| Lower anterior                     | 45°                             | 0°                            | To symphysis menti.             |
| Lower posterior                    | 90°                             | 0°                            | To root of second<br>molar.     |

**WARNING**

**BECAUSE OF THE SHORT F.F.D. THE RADIATION DOSE TO THE TONGUE AND OTHER STRUCTURES OF THE MOUTH AND FACE IS VERY HIGH. IT IS IMPORTANT TO AVOID REPEAT FILMS AND CARE IN PATIENT POSITIONING IS ESSENTIAL.**

## THE THORACIC VISCERA

The thorax contains the lungs and mediastinum. The mediastinum is the middle portion between the lungs enclosing the heart and cardiac vessels, the oesophagus and trachea.

Radiographic examinations of the lungs and heart are usually the subject of separate techniques but information in respect of both may be gained from the same radiograph. The level of the diaphragm varies with the respiratory movements, being raised with expiration and depressed with inspiration.

The lungs are more translucent radiographically when filled with air and exposures are made normally after **NORMAL INSPIRATION**. Forced or partial inspiration may give rise to misleading appearances. It should be ensured that the shoulders are not raised during inspiration. This is a very common tendency, but must be avoided.

**ERECT TECHNIQUE** should be adopted whenever possible, as the positioning is then simpler, the diaphragm level is lower and fluid levels are more readily shown than when horizontal positioning is employed.

**ELIMINATION OF MOVEMENT** is the chief factor to consider for satisfactory definition of the delicate lung field detail. Exposure times must therefore be short. With modern apparatus, times within 1/30 to 1/100 second are possible. Exposure times exceeding 1/10 second cannot guarantee the sharp definition required.

The F.F.D. **MUST** be at least 48 in. Whenever possible an F.F.D. of 72 in. will be employed. With low powered apparatus a compromise distance of 60 in. is usual.

**QUALITY**. A wide diversity of opinion exists among radiologists as to the ideal quality of the radiographic appearances required for accurate diagnosis of lung conditions. The radiographer must be guided in this matter solely by the requirements of the radiologist.

**IDENTIFICATION**. Right or left markers must be carefully employed, as the possibility of transposition of the organs, although rare, does exist. Abnormal lung conditions, displacement of the heart or generalized opacity of the lung fields will also render identification difficult from anatomical appearances alone.

## THE THORACIC VISCERA

Routine projections: P.A. with Lat. (A.P. and Lordotic projections as necessary).

### Postero-anterior

The P.A. is preferable to the A.P. positioning as the lung fields are then nearer the film and the arms more easily accommodated to make the shadows of the scapulae be projected clear of the lung field shadows. If in spite of correct positioning the apices of the lung fields are obscured by the clavicular shadows, a further small film should be taken with the tube centred over the apices and the C.R. directed at  $20^\circ$  plantar from horizontal.

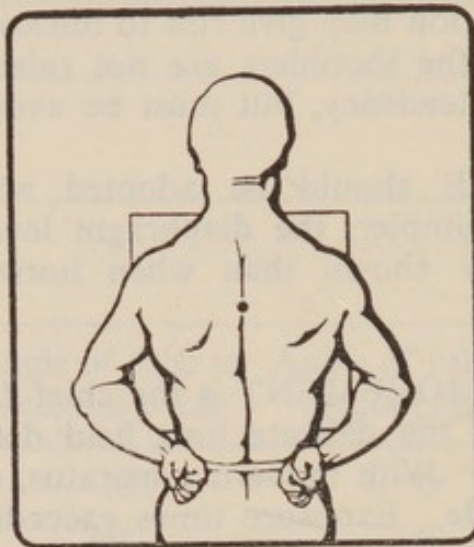


Fig. 133

### Centre.

To a point in mid-line at the level of the fourth dorsal vertebra.

Film with long axis upright, in chest stand.

Patient erect, neck slightly stretched with chin on upper border of cassette.

Back of hands on hips.

Shoulders depressed, and upper arms brought forward against film, to bring scapulae away from medial plane in lateral direction.

Rotation of patient must be avoided.

Respiration suspended in normal inspiration.

*Note.*—The A.P. is usually necessary with bed patients. Centre to sternal angle.

**Lateral** (For assistance in localization of appearances seen in A.P./P.A. views)

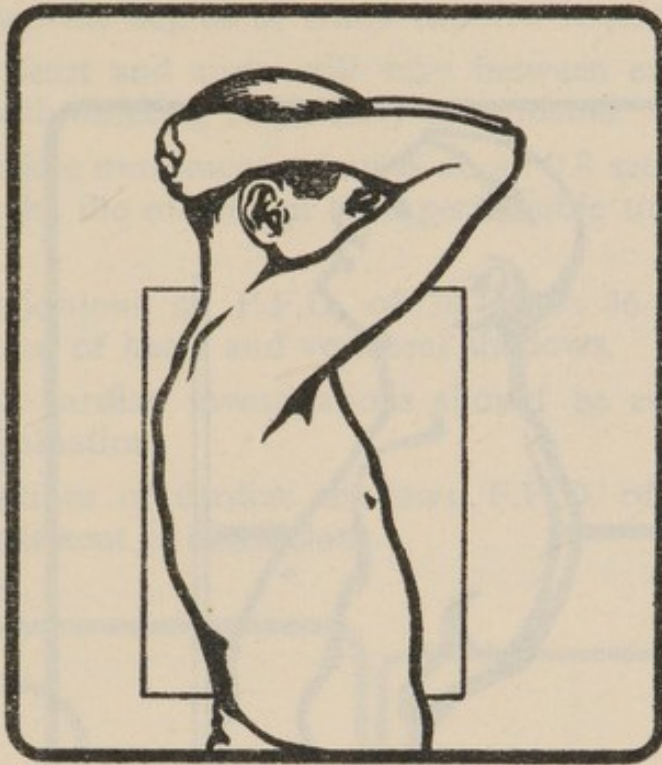


Fig. 134

**Centre.**

Through axilla  
to the middle  
of the film.

Patient erect, hands on head.

Elbows brought forward, affected side placed against film.

Top of film above shoulder level.

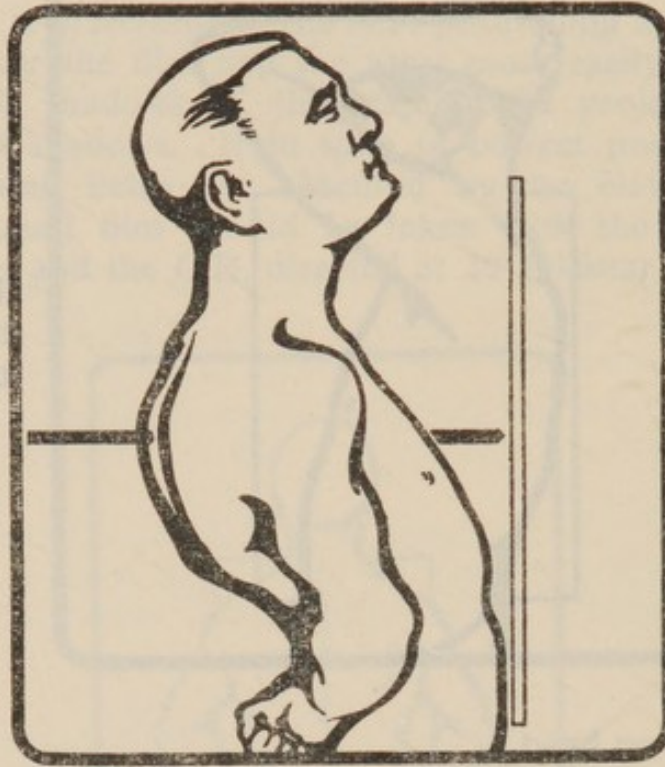
Respiration suspended in inspiration.

Where no indication of affected side is given, place patient in left lateral position as less distortion of heart shadow is presented in this projection.

**Lordotic**

A.P. useful to demonstrate apices. Where pleural conditions in mediastinum or inter-lobar fissure are suspected, a P.A. should be employed.

Fig. 135

**Centre.**

To a point in mid-line at the level of the fourth dorsal vertebra.

Used to show certain types of pleural effusions and to demonstrate abnormalities of the minor interlobar fissure.

Patient positioned as in P.A. but with trunk bent backwards to an angle of  $45^\circ$  towards the floor.

The projection may also be taken by placing patient in the P.A. position and angling the tube  $45^\circ$  plantar from horizontal.

## Obliques

Obliques are taken mainly for information on cardiac conditions and as a general rule should not be taken without prior screening, by the radiologist, to ascertain the degree of trunk rotation required.

Appearance of heart and aorta will vary between erect and recumbent positioning or with differing respiratory movements.

One cycle of cardiac movement occupies about 0.8 second and 0.1 second is considered to be the maximum time permissible to obtain satisfactory results.

For oblique projections an F.F.D. of 30 in. to 36 in. is employed to assist in separation of heart and vertebral shadows.

All radiographic cardiac investigations should be complementary to a fluoroscopy examination.

For P.A. projections of cardiac shadows, F.F.D. of 72 in. is essential for accurate assessment of dimensions.

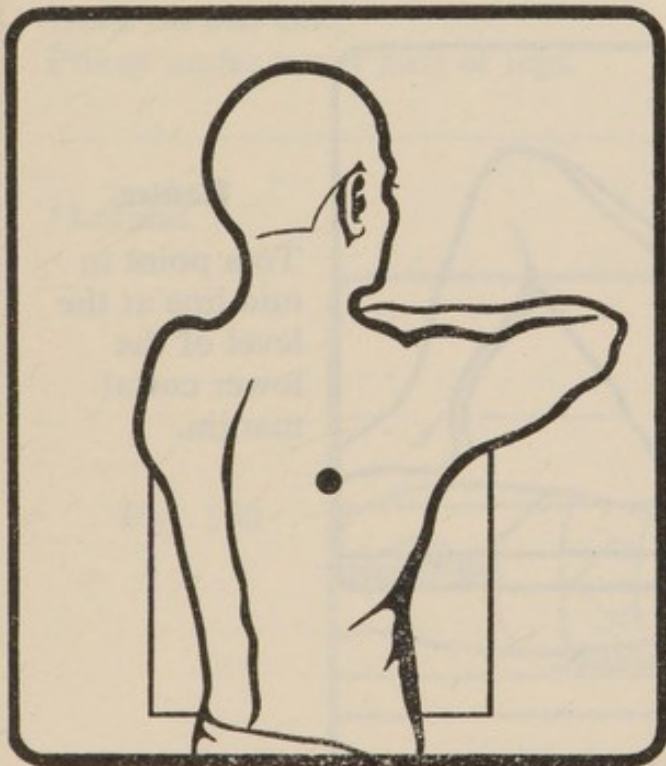


Fig. 136

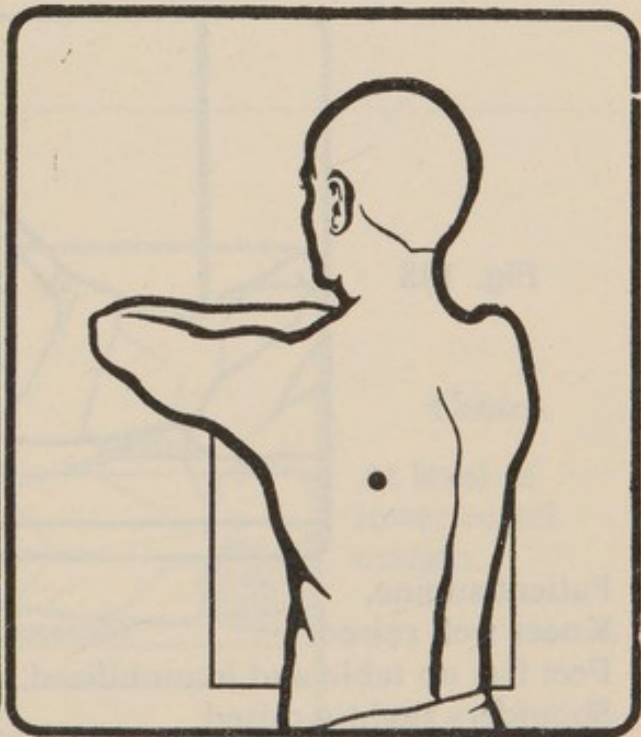


Fig. 137



## THE ABDOMINAL VISCERA

The separate organs in the abdomen are mostly demonstrated radiographically by special techniques with opaque media. Plain views of the abdomen are also of value, and are commonly requested. Gas and faecal shadows obscure much detail, and may be reduced by one or two days' light diet with mild purgation, or by high bowel washout in suitable cases.

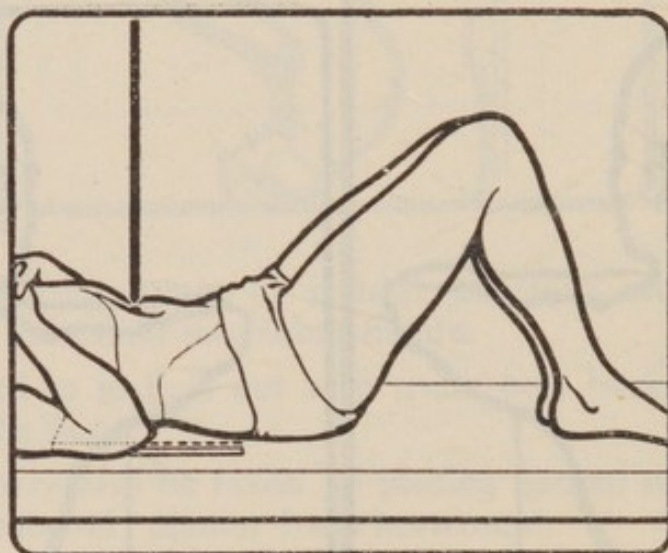
Good plain abdominal films should show the edges of both psoas muscles, and will usually show the renal outlines, liver edge and the lower pole of the spleen.

The routine film is the A.P. Supine. Additional views are the P.A. Prone and Lateral views.

### The abdominal viscera—General

#### \*Antero-posterior

Fig. 138



**Centre.**

To a point in mid-line at the level of the lower costal margin.

Patient supine.

Knees well raised.

Feet flat on table and immobilized.

Shoulders slightly raised.

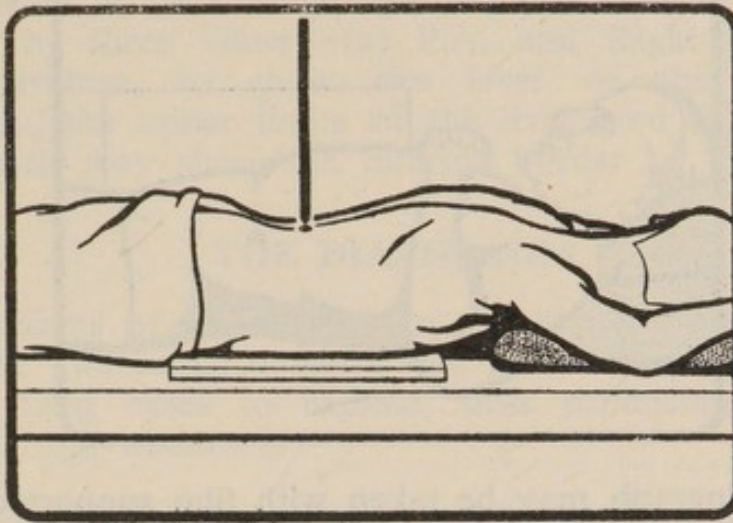
Body straight and no rotation of pelvis.

Film with long axis parallel to long axis of body. Film extending from diaphragm to level of symphysis pubis.

Correctly exposed film should show shadows of the psoas muscles.

**\*Postero-anterior**

Fig. 139

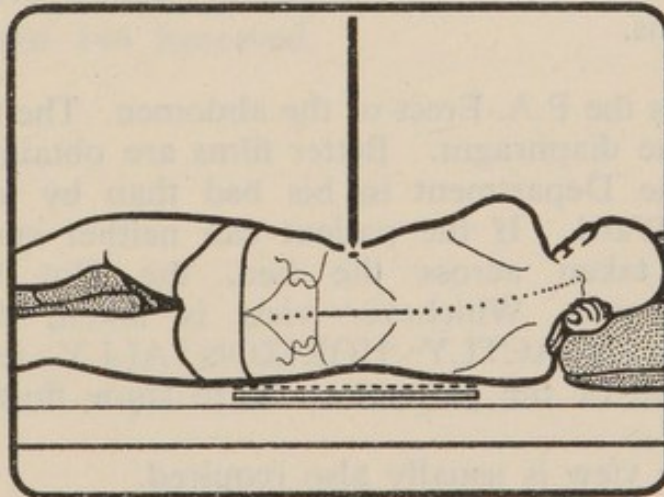
**Centre.**

To spinous  
process of  
third lumbar  
vertebra.

Patient prone with lower border of film extending to symphysis pubis.  
Hands placed above head.  
Head on one side.  
Pillow under lower part of legs.

**\*Lateral**

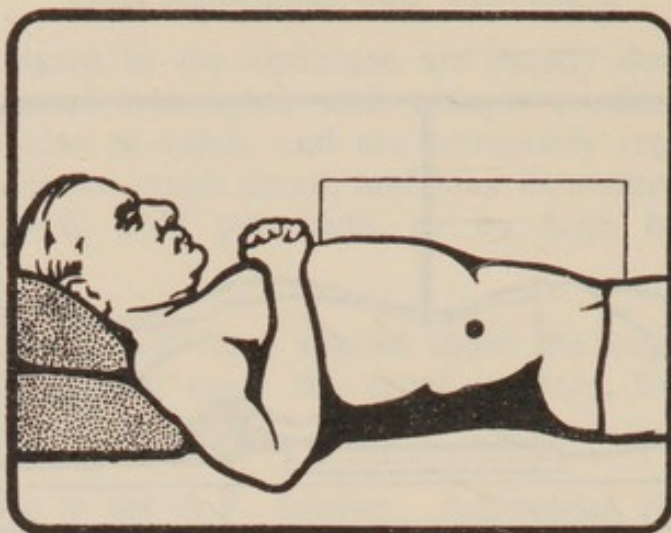
Fig. 140

**Centre.**

At level of  
lower costal  
margin.

Patient lying in true lateral position.  
Film with long axis parallel to long axis of trunk.  
Film placed longitudinally with lower border at level of the  
trochanteric dimple.  
If necessary this projection can be taken with the C.R. horizontal and  
the patient supine.

Fig. 141



If necessary radiograph may be taken with film supported vertically at side; patient lying supine with hands folded on chest.

The X-ray beam is directed horizontally.

### THE 'ACUTE ABDOMEN'

By this term is meant an onset of abdominal pain and malaise arousing a suspicion of severe illness. Such cases commonly require early surgery. Examples are appendicitis, perforated duodenal ulcer and bowel obstruction. The gas and fluid in the gut, or free in the peritoneal cavity, act as contrast media which may produce valuable evidence leading to a definite diagnosis.

The best view is the P.A. Erect of the abdomen. The film **MUST** show both domes of the diaphragm. Better films are obtainable by bringing the patient to the Department in his bed than by taking a portable machine to the Ward. If the patient can neither stand or sit up, a lateral view is taken across the bed, the film being supported vertically at his side. Whichever view is taken, the Central Ray must be directed **EXACTLY HORIZONTALLY** regardless of the possible inclination of the patient, so as to show fluid levels.

An A.P. Supine view is usually also required.

## THE LIVER

The liver is shown as a dense shadow in the right upper abdomen, from the domes of the diaphragm to the coastal margin. It is demonstrated by three views:—(a) P.A. and Right Lateral of chest on full inspiration, to show the level of the domes of the diaphragm, i.e., the upper limits of the liver, and (b) P.A. Abdomen (fig. 139), which may show the inferior border of the liver.

## THE DIAPHRAGM

All examinations of the diaphragm are best performed in the erect position as the abdominal contents can more easily move downwards, allowing the lung bases to expand, thus producing better contrast between chest and abdomen.

The movements of the diaphragm are investigated by fluoroscopy.

The routine projections are P.A. and both Laterals taken as for chest.

A permanent record of the range of movement of the diaphragm can be made by taking two exposures on the same film. The first exposure is made at full EXPIRATION (using  $\frac{2}{3}$ rds normal exposure), the second at full INSPIRATION (using  $\frac{1}{3}$ rd normal exposure without movement of the patient).

Figs. 142, 143, and 144 Reserved.

## THE DIGESTIVE TRACT

No part of this tract is adequately demonstrated without the use of contrast media. The medium used is usually Barium Sulphate ( $\text{BaSO}_4$ ) in various preparations. Only the sulphate must be used, as other salts are soluble and poisonous. The sulphate is insoluble, passing through the tract unabsorbed and unchanged.

Proprietary preparations of Barium Sulphate are supplied in powder or cream form. The powders require careful mixing with water in accordance with the makers' instructions if they are not to precipitate and thus spoil the examination. The creams require only dilution.

The examinations are the Barium Swallow, Meal and Enema. These are carried out by a combination of fluoroscopy and radiography conducted by the Radiologist. Normal screening takes place in dim illumination, as the screen image is not very bright, and the image is only adequately seen if the observer's eyes are 'dark-adapted' by wearing adaption goggles for some ten minutes before beginning to screen. If an Image Intensifier is available the screen image can be seen well in moderate illumination. The radiographer must bear in mind that the patient is unfamiliar with the room and not fully dark-adapted and must be guided and protected from possible injury.

The functions of the radiographer are:—

- (a) to set up the apparatus and test that it is in order,
- (b) to adjust blackout blinds, and test for light leakage,
- (c) to ensure a stock of loaded cassettes is available,
- (d) to prepare the contrast medium and administer it to the patient,
- (e) to manipulate the exposure controls. Each patient must be assessed as to probable radiographic opacity, the radiographer being prepared to change the factors at very short notice to all the positions and degrees of obliquity of the patient; erect, supine and tilted.
- (f) to hand cassettes to the radiologist and receive them from him, and in some cases, to load and unload automatic or hand operated exposure devices,
- (g) to take 'follow-up' films as directed.

All crockery, spoons, tubes, funnels, cans, catheters, etc., used in Barium techniques must be most carefully cleaned with hot soapy water immediately after use, and rectal catheters cleaned for sterilisation. It must be borne in mind that many patients carry infection which might be transferred to other patients or to radiographers.

### **THE BARIUM SWALLOW**

This is used to show the pharynx and the oesophagus, not only for diseases of these structures, but also to assist in heart and mediastinal examinations by showing deviation of the oesophagus from its normal course due to pressure from adjacent structures.

No preparation of the patient is required.

Barium sulphate mixtures of varying consistency may be used, from a thin watery suspension up to a semi-solid bolus. Usually thin cream and thick cream are required.

All positioning is carried out visually by the radiologist and exposures may be required at very short notice.

### **THE BARIUM MEAL**

This examination demonstrates the stomach and small intestine, but does not usually show the colon well.

The patient is prepared by abstaining from both food and drink for twelve hours before the examination. Opaque medicines (principally Bismuth preparations) are discontinued 48 hours before the examination. The patient should be warned that the examination may entail several visits to the Department on the first day, and possibly one or more visits on succeeding days.

About 20 ounces of opaque medium should be prepared, and 4 ounces of thicker medium in a separate container.

Chest screening and Swallow procedure are usually carried out first, followed by the Meal proper. Procedures are highly variable and films may be exposed in any combination of tilt and obliquity of the patient. The radiographer needs a thorough knowledge of the more usual procedures employed by his radiologist and must constantly adjust the exposure factors as the patient is moved.

### **THE BARIUM ENEMA**

This demonstrates the rectum, colon and caecum, and commonly a section of the terminal ileum. The appendix may also be shown.

The patient is prepared by high bowel washout on two occasions, one on the evening prior to the examination and the other about two hours before the examination. Success is dependant upon the careful administration of the washouts, a mere enema being useless.

Certain modern purgatives (e.g., Bisacodyl) may prepare the bowel adequately in some patients, thus obviating overnight admission for washouts.

Six pints of fairly thin barium sulphate suspension are prepared, using water a little warmer than blood heat so that the enema is administered at blood heat. Drugs (Veripaque, tannic acid, etc.) may be added to the fluid to stimulate colonic contraction in the later stages of the examination, thus producing more complete emptying. Whether they are used at all, and their quantities should be decided separately for each patient by the radiologist.

The opaque fluid is run into the rectum from a douche can via rubber tubing and a rectal catheter, using only a 'head' of 18 inches of fluid, unless the radiologist directs that a greater or lesser pressure be required.

The examination is conducted in three phrases, firstly whilst filling and when adequately full, secondly after emptying, and thirdly after subsequent air insufflation.

### THE URINARY TRACT

The urinary tract consists of the kidneys, ureters, bladder and urethra.

The kidneys lie on the posterior abdominal wall, between the levels of the twelfth dorsal and third lumbar vertebrae near the spine and a little obliquely, the upper poles closer than the lower. The left kidney lies  $\frac{1}{2}$ -inch higher than the right. On the medial aspect are the calyces or drainage tubules leading into the renal pelvis.

The ureters lead from the kidney pelves downwards, roughly parallel to the spine near the tips of the transverse processes, entering the bony pelvis near the sacro-iliac joints, curving inwards and forwards to enter the bladder posteriorly.

The bladder when empty lies in the anterior part of the pelvic cavity behind the symphysis pubis, but when full extends up into the abdomen to the level of the sacro-iliac joints.

The urethra runs from the lowest part of the bladder behind and then under the symphysis pubis, to the exterior.

UROGRAPHY and PYELOGRAPHY are terms applied to demonstration of the renal calyces, pelves and ureters

CYSTOGRAPHY is the demonstration of the bladder, and URETHROGRAPHY that of the urethra.

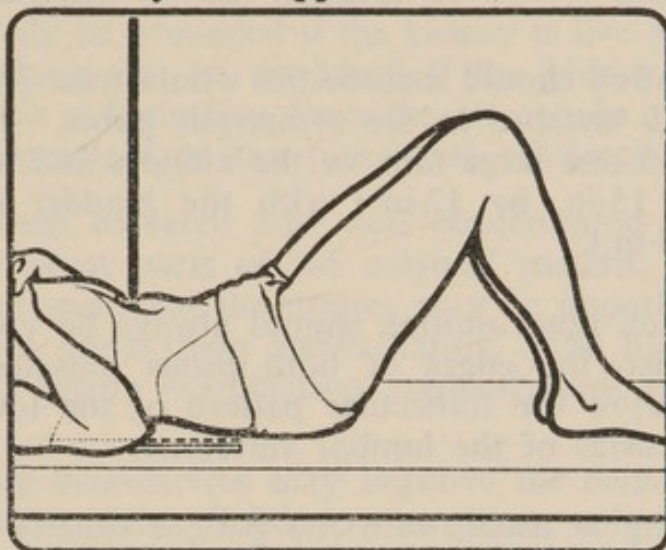
## URINARY TRACT

Routine projections: A.P. and A.P. (30° plantar)

Lateral and right and left posterior obliques for cystography.

### \*Antero-posterior (Kidneys and upper ureters)

Fig. 145



**Centre.**

To a point in mid-line at the level of the lower costal-margin.

Patient supine, knees well raised.

Feet flat on table and immobilized by sandbags.

Shoulders raised slightly on pillows.

Body straight, pelvis horizontal and without rotation.

Hands comfortably placed.

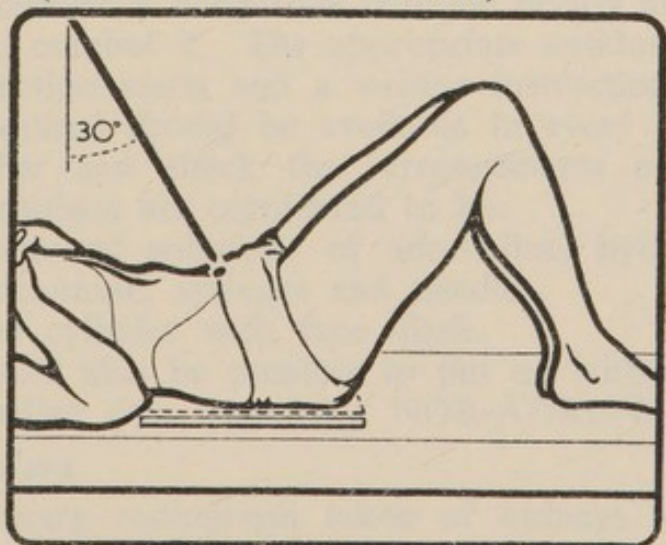
Middle of film at level of lower costal margin and placed with long axis parallel to long axis of patient.

Correctly exposed film should show shadows of the psoas muscles.

Compression should be applied if necessary.

### \*Antero-posterior (Bladder and lower ureters)

Fig. 146



**Centre.**

To a point in mid-line 1 in. above symphysis pubis with central ray angulated 30° plantar from vertical.

Patient placed in position as for A.P.

Film placed with long axis parallel to long axis of patient and with lower border of film 1 in. below level of the trochanters.



Conditions for which demonstration may be required include calculus formation (stone), local destruction or distortion of pattern due to infection, neoplasm and hydronephrosis. The latter term is applied to dilation of renal calyces and pelves by retained urine, due usually to obstruction.

### *Technique*

Routine examination should include the whole tract from the level of the eleventh dorsal vertebra to the symphysis pubis. The whole tract may be included on one large film, or the kidneys and upper ureters on one film (usually 15-in. by 12-in.) with the bladder and ureters on another (10-in. by 8-in.).

Some part of each renal outline should always be visible on a plain film, as should also the edges of both psoas muscles. A correctly exposed film will show the trabecular pattern of the lower ribs and of the transverse processes of the lumbar vertebrae.

Supine positioning is usual, with the patient exactly centred on the long axis of the film. Oblique views are often taken in addition, to separate various shadows from one another. Prone films are not unusual, and occasionally an erect A.P. may be required.

Exposure is normally made in expiration, but separate views may be taken in inspiration and expiration to show renal movement relative to other structures.

Screen film and Potter-Bucky diaphragm is used with the smallest tube focus consistent with the mAs employed.

Two principal forms of urinary tract investigation are the excretion or intravenous pyelogram (IVP) and the retrograde pyelogram.

## INTRAVENOUS PYELOGRAM

The specially prepared drugs (URIODONE, HYPaque, etc.), are supplied as a solution in ampoules. They are complex organic substances containing a high proportion of iodine, and are rapidly excreted into the urine by functioning kidneys. The appropriate dose is injected into a vein, usually in the forearm or elbow region. Radiographic shadows will only be produced if the kidney is live and functioning, and only faint shadows can be produced if the kidney cannot concentrate the drug. This is a distinction from the retrograde pyelogram where the shadow is independent of the functional efficiency of the kidney.

The drug when excreted and well concentrated can cast a shadow even of the smallest parts of the calyceal pattern. The kidney pelves are usually well seen, but the ureters may be imperfectly shown, as the fluid only passes down them intermittently. The bladder, which should be emptied just before examination gradually distends with semi-opaque fluid.

The following manoeuvres may improve the demonstration:

(a) bowel preparation. Solids in stomach or colon may cast obscuring shadows. The patient may be given a purgative (e.g. Dulcolax) 48 and 24 hours before the examination.

(b) fluid restriction. No fluid is given for the last 12 hours before the examination. This leads to a more concentrated urine.

(c) Abdominal compression. This may partially obstruct the ureters, causing the renal calyces and pelves to fill out more fully. A rounded pad is pressed firmly into the abdomen just below the umbilicus by a special compression band or inflatable compression device.

### *Dangers of Urographic Materials*

The vast majority of patients have no ill effects from their injection. A few have minor discomforts such as flushing, nausea and vomiting. Very rarely however a dangerous collapse occurs and urgent measures are required to combat it. The appropriate antidotes must be at hand *before* the injection starts and a written instruction on the drugs and instruments required should be available in every Department, so that the radiographer can check that arrangements are complete. The minimum precautions are considered to be:

- (i) ampoules of solutions of adrenaline, hydrocortisone and an anti-histamine, syringes and needles.
- (ii) oxygen cylinder with face mask.
- (iii) it should also be possible to put up without undue delay, an I.V. saline drip containing NOR-ADRENALINE.

### *Routine Procedure*

- (a) Preliminary radiograph taken of kidneys and bladder region. These are inspected by the radiologist to ensure positioning and factors are appropriate.
- (b) Contrast medium injected.

- (c) A series of films of kidneys is taken at intervals, e.g. 5 minutes, 15 minutes, 25 minutes. A bladder film is taken after the last renal view, and often a further bladder view after micturition.

### RETROGRADE PYELOGRAM

This examination demonstrates the anatomy of the renal collecting system, but does not show whether the kidney is functioning. As the quantity and density of the injected fluid are under control, very high grade pictures should always be obtained. A good opaque fluid is IVP contrast medium diluted to 20% with sterile distilled water.

A preliminary film is usually taken to show the location of the ureteric catheter. After this, contrast medium is injected slowly, at low pressure, up the catheter. 5 mls is adequate to show a normal pelvi-calyceal system, whereas in hydronephrosis up to 50 mls. may be required.

A film is taken as soon as the injection is finished, usually in A.P. supine position. This is inspected by the radiologist or surgeon, and further injection or different positioning carried out if required. It is sometimes of advantage to take a 'late' film, e.g., after 40 minutes, to see to what extent the fluid has been retained.

After general anaesthesia, if the patient is not yet conscious, the anaesthetist should be asked to arrest breathing during the exposure. If the patient is half-awake and uncooperative, it may be best to postpone the injection until he is fully conscious.

#### *Warning on Asepsis.*

It is most important that the renal tract should not become infected by this procedure. Full aseptic routine ('scrub-up', gowns, masks, gloves, sterile towels and swabs) must be used by all concerned with diluting the dye, preparing the syringes, handling the catheter, etc.

### CYSTOGRAPHY

This is the demonstration of the urinary bladder filled with contrast medium. Excreted IVP medium may produce an adequate cystogram, but usually the bladder is catheterised and filled by tube and funnel at a pressure not exceeding 12 inches head of solution, using 150 to 200 mls. Media include 8% sodium iodide solution, and dilutions of pyelographic materials. Too dense a medium may obscure important lesions. A combination of barium sulphate suspension (STERIPAQUE) and air may coat tumours and profile them in the gas shadow.

Routine projections are A.P. with central ray angulated caudally 15° to 25° and 45° and 60° posterior obliques with vertical central ray. Additional views include A.P. with central ray angulated cranially 25° to show base of bladder, and "pelvic outlet view" described under Pelvimetry.

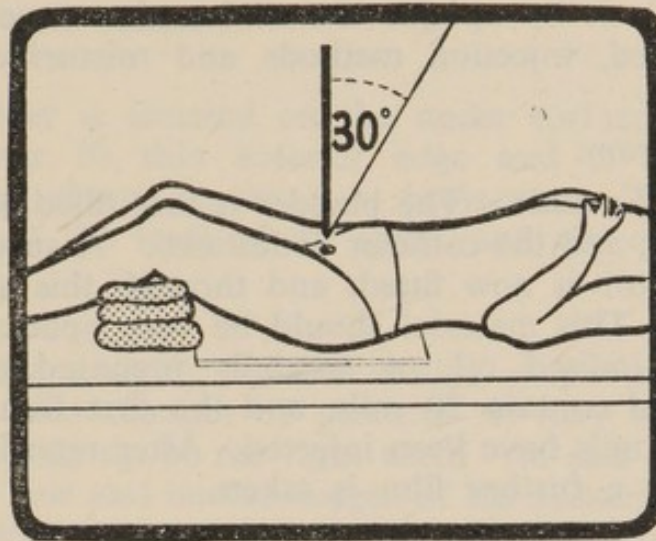
A further film is taken after micturition to show any residual urine.

**THE BLADDER**

Routine projections:—A.P., R. and L., P.O.

**\*Antero-posterior**

Fig. 147

**Centre.**

To a point in mid-line 1 in. above symphysis pubis.

Patient supine.

Knees well raised.

Feet flat on table and immobilized.

Shoulders slightly raised.

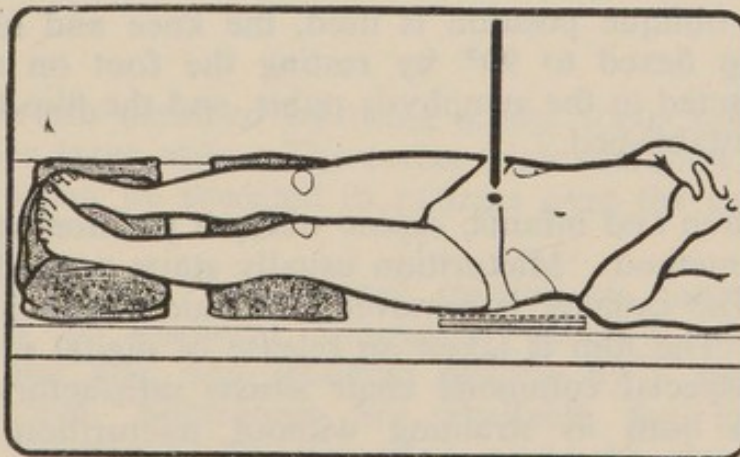
Body straight and no rotation of pelvis.

Film placed longitudinally with lower border 1 in. below the level of the trochanters.

Central ray  $30^\circ$  caudal from vertical to centre as indicated above.

**\*Posterior-oblique**

Fig. 148

**Centre.**

To a point 2 in. inferior and medial to the A.S.I.S. remote from the film.

Patient supine.

Body rotated  $45^\circ$  to side under examination.

Hips and knees flexed and supported with non-opaque pads under pelvis and shoulders.

Hands on chest.

Film displaced to side under examination with upper border 1 in. below the iliac crests.

## URETHROGRAPHY

The urethra is distensible, and its features are not adequately seen unless it is filled out by opaque material under some pressure. Two techniques are used, injection methods and micturition methods.

### *Injection Urethrogram.*

This is used in the male. The bladder is first filled with opaque fluid as for cystography, and the catheter withdrawn. A special penile clamp and urethral adaptor is now fitted, and through this a further opaque material injected. This material should be very opaque and somewhat viscous, such as iodised oil, or specially prepared pastes or jellies. The syringe should contain 20 mils, and the first film is taken during injection when 12 mils have been injected. After repositioning, injection is restarted before a further film is taken.

The patient should be propped up semi-sitting, pelvis related into posterior oblique position, and the hip and knee nearer the table each flexed to  $90^\circ$ , the upper leg being straight. The central ray is directed to the root of the penis. A straight A.P. film may be of value as well as posterior obliques.

### *Micturating Cysto-Urethrograms.*

This technique is used in both sexes, particularly for women and children. The bladder is filled as for cystography and the catheter withdrawn. In the male and in younger children of both sexes, the patient may be willing and able to micturate in the standing position. A  $60^\circ$  posterior oblique position is used, the knee and hip nearer the film holder being flexed to  $90^\circ$  by resting the foot on a block. The central ray is directed to the symphysis pubis, and the film taken as soon as micturition is established.

In young children and infants, supine oblique positioning is often the only practicable method. Micturition usually starts around the catheter during filling. The catheter is removed, and micturition interrupted by digital pressure. The film is taken on release of digital pressure.

In women, a special commode chair assists satisfactory micturition. Films are taken both in straining without micturition, and during micturition.

## THE BILIARY TRACT

The biliary tract consists of the hepatic ducts, common bile duct, cystic duct and gall bladder.

The gall bladder is situated on the under surface of the right lobe of the liver near its thin anterior edge and is therefore relatively anterior and best shown in the P.A. projection. The ducts are more deeply situated, at the level of the spine, and are often better seen in the A.P. view.

The gall bladder is highly variable in size, shape and position, moving with respiration and changes of posture. It may be found anywhere between the anterior tip of the right ninth rib and the iliac crest, and between the mid line and lateral margin of the abdomen. When medially situated its shadow tends to fall on the spinal shadow, which is dense enough to obscure it. In such cases it may be projected clear of the spine by 'off-centring', or by obliquity of the patient.

The principal conditions for which demonstration is required are poor function, obstruction and calculus formation. Biliary calculi (gall stones) may be opaque or non-opaque, but even when opaque may only be visible in films of the highest quality, combining extreme sharpness with adequate contrast.

No part of the normal tract is dense enough to be visible in plain radiographs, which are only taken as preliminary to opaque medium studies.

Best results are obtained by using a fine focus tube, relatively low kV and rather large mAs. The rather high radiation dose involved in the technique can be accepted in patients over the age of 40.

The biliary system is rendered opaque to some degree by the administration of chemical substances specially synthesised to be excreted in the bile, and rendered opaque by a high proportion of combined iodine. Substances are available for taking by mouth (Pheniodol, Telepaque, Biloptin, etc.) or to be given by intravenous injection (Biligradin). They may have unpleasant side effects such as nausea, diarrhoea and urticaria.

The demonstration of the gall bladder is called **CHOLECYSTOGRAM**. Even if the drug as excreted by the liver is too dilute to be shown in the hepatic ducts, the gall bladder may be able to concentrate it sufficiently to give a dense shadow. If the hepatic ducts and common

bile duct are demonstrated, this is called a CHOLANGIOGRAM. The more modern drugs are excreted at higher concentration than older ones, and more likely to show the ducts. The intravenous injection of Biligrafin is at present the most likely to show the ducts, and this is particularly used after the gall bladder has been removed. Even with the older drugs the common bile duct is often well seen when the gall bladder is excreting the drug it has concentrated.

Other forms of demonstration include intra-operative cholangiography, the ducts being injected with an opaque medium (Diodone, Steripaque, etc.) during operation, and the films taken on the operating table; and post-operative cholangiography, the opaque medium being injected into the drainage T-tube left in the bile duct for a few days after cholecystectomy.

Common routines are as follows:—

*Oral Cholecystography*

*First Day* Mild aperient if patient is constipated.

*Second Day* Preliminary radiograph. Breakfast and midday meal to be fairly large, appetising, and to contain fats acceptable to the patient. This is to empty the gall bladder. Evening meal to be light and fat free. Drug taken about 8 p.m. Only water or fruit juice is now allowed up to the time of the examination

*Third Day* Morning. Film of upper abdomen to localise gall bladder shadow. After localisation, subsequent projections must be well coned down. After a satisfactory film has been obtained, a fatty meal (e.g., eggs beaten up in creamy milk) is given, and further radiographs taken at intervals such as 20, 40 and 80 minutes, or as directed by the radiologist.

*Intra-Venous Cholecystography.*

Breakfast (to empty the gall bladder) e.g., tea, buttered toast and egg. Injection of BILIGRAFIN 1½ to 2 hours later. Films at 15, 30 and 45 minutes A.P. (for ducts) and at 2 hours P.A. (for gall bladder). If the gall bladder is well opacified, fatty meal may be given to show emptying.

**CHOLECYSTOGRAPHY**

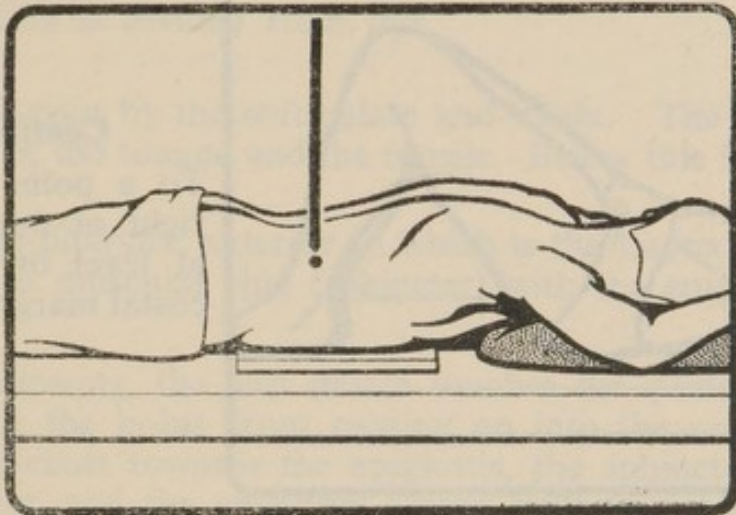
Routine projections: Selecte from P.A., A.P., L.A.O.

Patient erect or horizontal.

**AT LEAST ONE FILM SHOULD ALWAYS BE TAKEN ERECT**

**Postero-anterior**

Fig. 149

**Centre.**

To a point 3 in. to right of spinous process of the 3rd lumbar vertebra.

Patient prone, or erect.

Hands placed on pillow.

Head rotated to one side.

Pillow placed under lower part of legs.

Film displaced to right side of patient with lower edge at level of A.S.I.S.

Expose during suspended respiration on EXPIRATION.

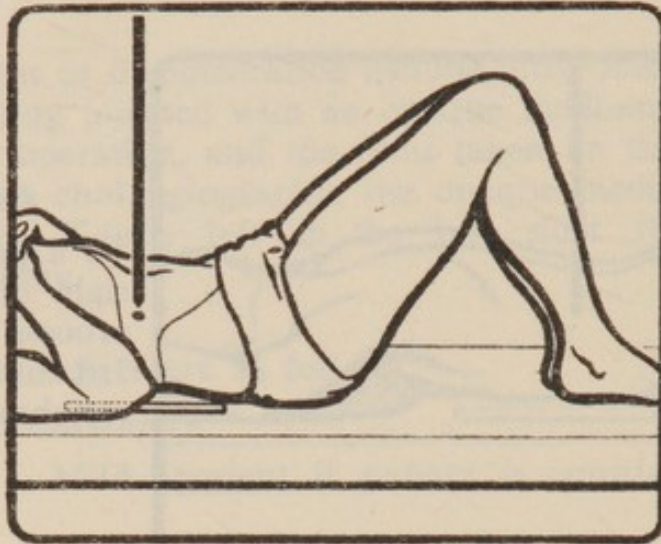
Compression will increase contrast. Absolute immobilization essential. In this position fundus of gall bladder is at lowest level. This is the routine projection for patients of sthenic and hypersthenic types where shadow of gall bladder is not likely to be obscured by the vertebrae. The position may be used for asthenic types by centring well away from the mid-line.

The L.A.O. is an alternative to this "off-centred" view.



**Antero-posterior**

Fig. 150

**Centre.**

To a point 3 in. to right of mid-line at level of lower costal margin.

Patient supine.

Knees well raised.

Feet flat on table and immobilized.

Shoulders slightly raised.

Body straight and no rotation of pelvis.

Expose during suspended respiration on **EXPIRATION**.

This projection is very useful for separation of shadows of any mobile opacities in the gall bladder and is more likely to demonstrate the cystic duct than the P.A. projection as gall bladder lies more nearly horizontally.

## THE AIR PASSAGES

The UPPER air passages consist of the nasal and oral cavities, and behind and below these, the PHARYNX and LARYNX. The PHARYNX is a muscular tube, largely concerned with swallowing, and may be divided for description into three regions.

Naso-pharynx, containing the adenoids and origins of the Eustachian tubes. This is divided from the

Oro-pharynx by the soft palate and uvula. The oro-pharynx contains the back of the tongue and the tonsils. Below this is the

Laryngo-pharynx, anterior to which is the larynx. The entrance to the larynx is a muscular ring (sphincter) with the epiglottis above it.

In swallowing, the soft palate touches the posterior pharyngeal wall, preventing the bolus from passing up into the nose. Then the larynx moves upwards towards the epiglottis, the sphincter closes by muscular contraction, and the epiglottis arches over this closed entrance, so that the bolus passes over it, largely divided into two lateral streams.

The whole pharyngeal region, and interior of larynx and trachea are extremely sensitive to touch, which causes coughing or retching; either of these tending to clear the air passages.

In addition to its primary function of protecting the trachea and lungs, the larynx is also the organ of phonation, i.e., produces the musical notes which the tongue, teeth and lips cut up into speech.

### *Radiography.*

Radiography of the Upper Air Passages is by means of soft tissue lateral views, the contained air acting as a contrast medium. The amount of air present can be increased by the VALSALVA manoeuvre, i.e., closing mouth, holding the nose, and by forcible expiration blowing out both the cheeks and the nasal cavity.

For the naso-pharynx (adenoids, etc.) the central ray is directed at a point one inch anterior to the external auditory meatus, for the laryngo-pharynx, to a point one inch posterior to the most prominent part of the thyroid cartilage.

The pharynx is continuous below the oesophagus, and the larynx continuous with the trachea.

The LOWER air passages consist of the TRACHEA, BRONCHI, BRONCHIOLES and ALVEOLI. The trachea enters the chest, and divides into right and left main bronchi at the level of the fifth thoracic vertebra. The main bronchi enter the lungs, branching into lobar and then segmental bronchi, and after further subdivisions into bronchioli which communicate with the final air-sacs or alveoli.

The trachea is fairly well seen in normal chest radiographs, particularly if these are slightly overpenetrated. The main bronchi are often seen for an inch or so, but beyond this bronchi are seldom seen distinctly in the normal person.

### *Bronchography.*

Bronchography is the radiographic demonstration of the bronchi by means of an opaque medium. The intention is to *coat* the inner surfaces of the bronchi, not to flood them.

### *Opaque Media.*

The older materials include iodised oils (LIPIODOL, NEOHYDRIOL, etc.) which are intensely opaque, and produce excellent bronchograms. They persist in the lungs however, and obscure subsequent changes. New media include crystal suspensions in water or oil of absorbable iodine-containing organic molecules (DIONOSIL, etc.). These are eliminated from the lungs in a few days.

### *Methods.*

Tracheal intubation. A tube is passed through the larynx into the trachea, via the mouth or nose. This requires excellent local anaesthesia or general anaesthesia but, if achieved, produces the best results.

"Over-the-tongue". The medium is poured, a little at a time, on the back of the tongue. The patient breathes in deeply and steadily each time a few mls are poured. Good local anaesthesia is required, and the method may fail with unco-operative patients.

Cricothyroid puncture. A short needle, straight or curved, is thrust through the cricothyroid membrane into the lowest part of the larynx, under local anaesthesia. Through this a little local anaesthetic is sprayed, followed by the opaque medium. This method is quick and simple.

Whichever method is used, the medium is caused to flow to the various bronchi by gravity, tilting the patient into various successive positions. About 20 mls per side can be used in a full grown adult. A tilting table is of value, as the apices may only fill in prone or supine head down positions.

### *Radiography.*

Films may be taken erect or recumbent, PA or AP, plus laterals and obliques. The exposure is greater than for normal chest radiography, and should be judged so as to produce a nearly fully exposed thoracic spine picture. Stationary grid or P.B. may be used.

### *Functions of the Radiographer.*

The anaesthesia, intubation and injection are all carried out by a doctor. The procedure is, however, a team affair, and much delay, and distress to the patient, can be caused by poor arrangements. The radiographer must therefore:

- (a) Ascertain the method to be used, and issue the correct appointment and preparation form to the Ward in good time. The form should contain instructions regarding sensitivity tests, pre-medication, abstention from food, etc.
- (b) lay out trays of appropriate instruments. Any "tray" lists should be checked over with a doctor from time to time.
- (c) have sufficient cassettes immediately available, and the dark room ready to process each film as soon as exposed.
- (d) learn the methods of positioning used, so as to be able to assist smoothly and unobtrusively.

## STEREOGRAPHY

Human binocular vision enables us to perceive depth because each eye views the same object from a different aspect and different images are received by the right and left eye respectively (the parallax effect). The simultaneous visualization of these images, however, does not give us a sensory impression of two separate images. The brain function of the optical system combines them to give us an impression of one image only. The information conveyed to the brain by the parallax effect is utilized to give us a true impression of the relationship of objects in anterior planes to those in posterior planes; and we call this a perception of depth. The conditions which give this effect may be simulated in radiography to give perception of depth in a radiograph. Two separate projections are made in which the position of the object in relation to the film remains unchanged, but the position of the X-ray tube anode is made to differ between the two projections, usually by a dimension which corresponds to the average interpupillary distance in the human adult.

The aspects presented by these two projections are as seen from the tube aspect in each case and when viewed may be regarded as comparable with the aspect visualized by right and left eyes, had they occupied the differing position of the focal spot during each projection. A tube shift to the right of normal centering will project an aspect comparable to that regarded by the right eye from the same position and conversely for a tube shift to the left. If, now, the right shift image may be viewed by the right eye separately from, but simultaneously with the view of the left shift by the left eye the two images will be co-related by the optical brain function to give an impression of depth.

### To prepare stereographs

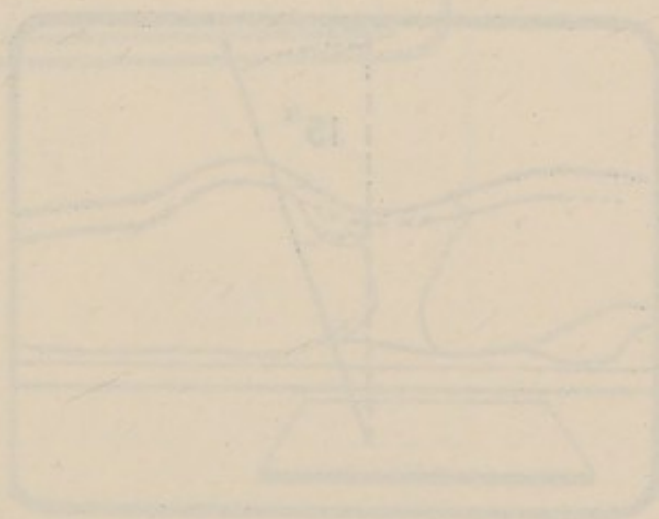
1. A cassette tunnel or a Potter-Bucky is used.
2. Non-reversible marker technique is used.
3. Patient placed in routine position using normal centering.
4. 30 in. focal-film-distance is used.
5. Make a 3 cm. transverse tube shift, that is 3 cm. EAST of the centre with NORTH as the upper edge of the film in the position of normal viewing.
6. Make a normal exposure for the part.
7. Displace the tube 6 cm. in the opposite direction, i.e., WEST or 3 cm. WEST of the original centering.
8. Make a second exposure with a further film in exactly the same position as the first film.
9. Ensure that the two films are processed together so that they will be of the same quality

### Viewing stereographs in a Whetstone stereoscope

1. Verify that the stereographs have been marked so that the NON-REVERSIBLE letters read correctly when looked at from the target or tube side.
2. Place the stereographs vertically side by side so that these letters read normally.
3. Superimpose these radiographs edge to edge and examine them by transmitted light.
4. One image will appear nearer to the right hand than the other. This is the one taken with the left (WEST) tube position, and it must be viewed by the left eye. Place it in the left viewing box.
5. Place the other film in the right viewing box for viewing by the right eye.

### Viewing stereographs with stereoscopic binoculars.

The stereoscopic binocular is an optical device in which each eye observes a separate object by means of a prism in each eyepiece. Thus the stereographs can be set up side by side—right stereograph to the right and left stereograph to the left, and the tube aspect of the films turned away from the observer because the prisms reverse the image—in a pair of ordinary X-ray viewing boxes and then simultaneously viewed with the binoculars. Each eye must see only one radiograph, and when the binoculars are adjusted properly the two images become merged into one three dimensional image.



## FEMALE GENITAL ORGANS

### Warning

The examinations described in this section involve direct radiation of the patient's ovaries, and possibly also whole-body radiation of a foetus. The number of exposures should therefore be restricted to an absolute minimum, and repeat examination avoided by great care in positioning and exposure.

The female genital organs consist of the ovaries, fallopian tubes, uterus and vagina. They are situated within the true bony pelvis, except in pregnancy when the enlarging uterus expands into the general abdominal cavity. None of these structures, if normal, are visible on plain radiographs. In certain pathological conditions, calcification can occur in them, and this may be demonstrated by plain radiography. A "bone-free" view of such calcification may be obtained by a routine bladder view.

When the urinary bladder is empty, the uterus lies fairly close to the symphysis pubis, rising a little above it. If it is required to demonstrate only slightly opaque structures, such as early pregnancy (up to 18 weeks), the patient is positioned **PRONE**, central ray directed in the mid line, towards the upper border of the symphysis pubis, with  $15^\circ$  tube tilt towards the head (Fig. 151).

### Positioning. P.A.

Patient prone  
Support under ankles.

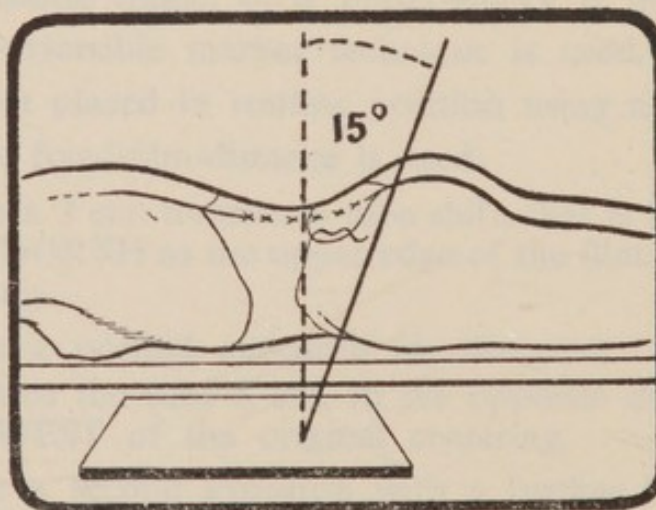


Fig. 151.

**Centre.**  
To distal end of  
coccyx, with tube  
angulated  $15^\circ$  cephalic.

Films to include pelvic region only.  
Expose on expiration.

### *Radiography of the Pregnant Abdomen*

Information about the foetus and placenta is required. For instance foetal age, multiplicity and attitude can be determined, and it may be possible to prove foetal death or congenital anomaly. The placental site may be discernible, particularly in true lateral view.

Standard positions are PA or AP (PA preferred, as the foetus is nearer to film), (Figs. 152, 153) and lateral view. It is said that the foetus is more likely to move if short of oxygen. The mother should therefore, after being positioned, be instructed to take a few deep steady breaths just before the exposure.

#### **Positioning. P.A.**

Patient prone, supported under head and pelvis, with pillows to relieve pressure on abdomen. Head turned to one side.

Hands clasped under chest.

Ankles supported.

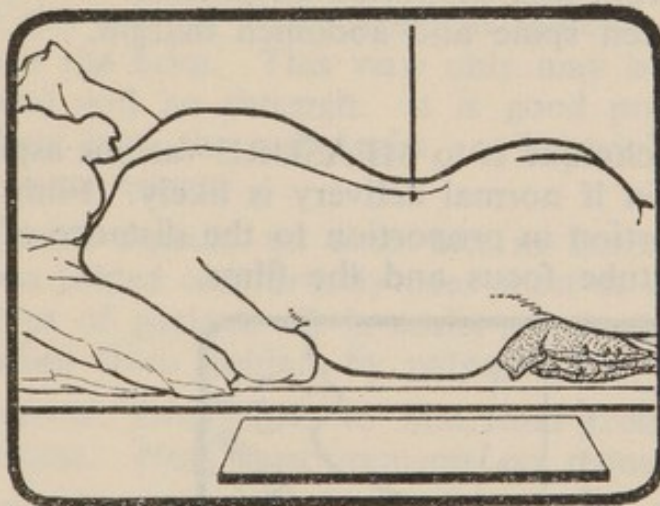


Fig. 152.

**Centre.**  
to apex of abdominal  
curve at level of  
fourth lumbar  
vertebra.

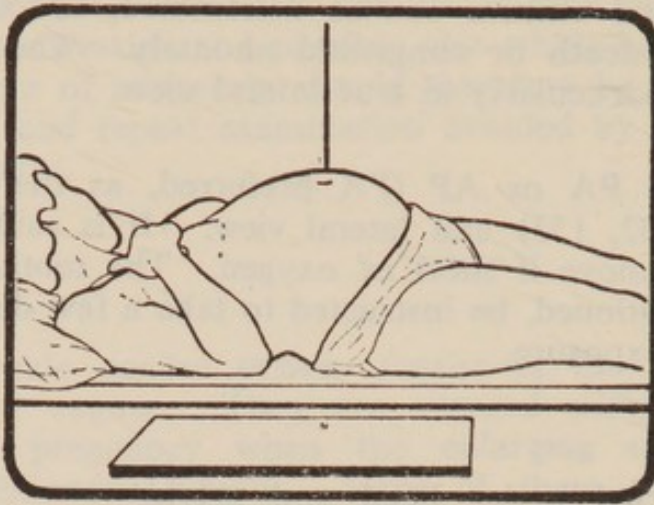
Expose on expiration.



**A.P.**

Patient supine, hands clasped over chest, knees raised over small pillow.

Fig. 153

**Centre.**

To mid line at spinous process of fourth lumbar vertebra.

Expose on expiration.

**Lateral.**

Patient turned on to side which is the more comfortable.

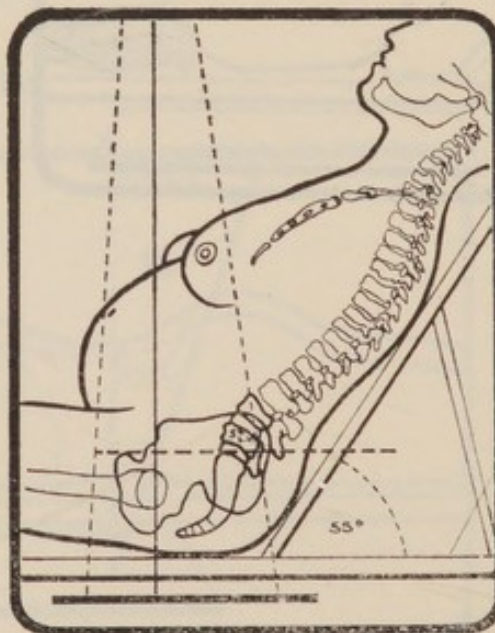
Arm and leg remote from film supported on pillows.

Centre: Midway between spine and abdomen margin.

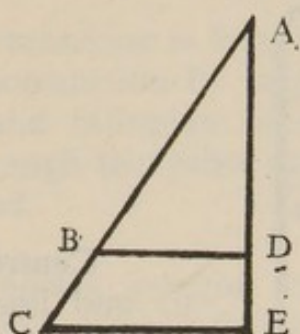
*Pelvimetry*

The purpose of this technique is to MEASURE various aspects of the female pelvis, to ascertain if normal delivery is likely. Films produced show enlargement—distortion in proportion to the distance of the plane radiographed from the tube focus and the films.

Fig. 154.



It is therefore necessary to measure the focus—film distance (NOT focus—table distance), and the focus to selected plane distance. The true size of objects in the selected plane are given by the formula:—



$$BD = CE \cdot \frac{AD}{AE}$$

CE = length of object on film

AD = focus—plane distance

AE = focus—film distance

BD = true length of object

The shape of objects will be best rendered on the film when the selected plane is parallel to the film, and the central ray is at right angles to the centre of this plane.

The more usual views are the lateral, the “brim” or inlet, and the outlet view.

#### *Lateral View.*

This view is best obtained ERECT for two reasons. Firstly, it is easier to be sure the pelvis is not tilted, and secondly, the weight of the foetus and the tone of the abdominal muscles often causes the foetal head to enter the brim. This view only may be sufficient to show that a foetal head will go through. It is good practice to take this view first and show it to the radiologist or obstetrician, who may thereafter require no more views.

Patient stands equally on both feet in lateral position, feet slightly apart. Arms folded comfortably over chest or resting on the back of a chair in front of patient. It is easier to check that patient is in true lateral position from behind, by palpating the posterior iliac spines.

Measurements: from tube to film, and from tube to fifth lumbar spinous process. Note measurements on request form.

Centre: one inch above highest point of greater trochanter of femur nearer to tube.

Patient may breathe quietly during exposure.

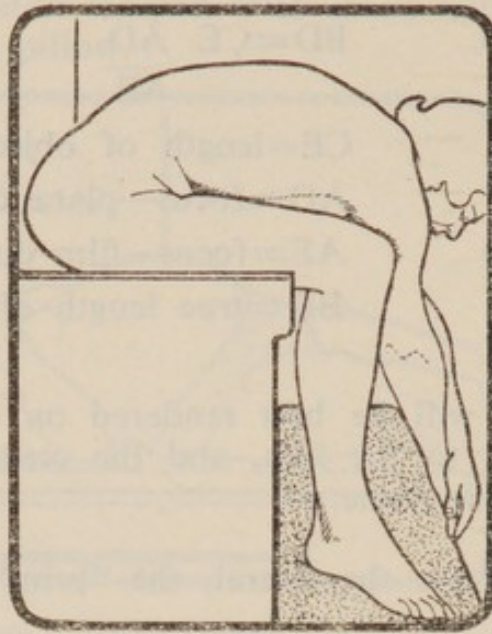
#### *The “brim” view.*

Patient seated on couch or horizontal Potter Bucky stand, over centre of PB. Back supported at an angle of between 55° and 60°. Knees slightly flexed over pillow (couch) or resting on stool (PB stand). The level of the brim can be checked with a special caliper, one end on upper border of symphysis pubis, the other at upper border of 5th lumbar spinous process.

FFD should be long (48 inches or more) and a small cone used.

Measurements: tube—film distance and tube—brim distance.

Fig. 155



**Centre.**  
to mid line  
between the ASIS

The patient may be allowed to breathe quietly during the exposure.

*The outlet view.*

No measurements are required in this case, as the selected plane is nearly in contact with the couch top and the degree of distortion negligible.

Patient seated on couch over PB, knees separated and flexed over side or end of couch, feet resting on a stool. Trunk is flexed forward until the abdomen is as low down as the patient can comfortably get it between the thighs.

With central ray vertical and in mid line, centre to the spinous process of the first sacral vertebra.

Exposure to be made on expiration.

## HYSTERO-SALPINGOGRAPHY

This technique is largely used in the investigation of infertility. It is the demonstration by means of an opaque medium of the lumen of the uterus and fallopian tubes. If the opaque medium can be caused to flow through the tubes and spill into the peritoneal cavity, their patency is proved.

The newer opaque media (SALPIX, PERIODAL) consist of an absorbable water soluble iodine containing substance, plus a further absorbable substance giving the required viscosity. The medium is injected by the gynaecologist either "blind" or under fluoroscopic control.

Positioning and exposure are as for AP pelvis, coned down to a 10 x 8 film. Additional views may include obliques, and "late" films, up to 24 hours. The "late" films may show non-absorption of the medium in diseased tubes, or delayed spill into the peritoneal cavity.

## LOCALISATION OF FOREIGN BODIES (FBs)

Many FBs are not radiopaque. The first stage therefore is to find out whether a suspected FB is demonstrable; by taking two views of the part at right angles. If demonstrable, the approximate position of the FB is now known. If operative removal is contemplated, the patient should be placed in the operation position, and small lead shot applied with clear "scotch" tape over the FB in both AP and lateral position. Further AP and lateral views are now taken, centred through these shot when the relationship of the FB to their surface markers will be known. The positions of the markers should then be indicated by crosses drawn on the skin with indelible dye.

The surface marking of FBs may also be obtained by screening, using an opaque pointer under the screen to mark the skin. If this method is used, the part should be rotated to see in what position the FB is most superficial, and the skin point nearest to the FB is marked.

If a wound can be safely probed, take the film with probe in situ, showing relationship of track to FB.

Elaborate "triangulation" methods with tube shaft are seldom superior to these simpler methods, except possibly for Intra-ocular FB. (IOFB).

### IOFB Detection and Localisation

Even very minute metallic FBs within the eye are of great clinical importance, and must be shown. For preliminary detection, a PA skull view should be taken, centred to the root of the nose, with the radiographic base line tilted up  $25^{\circ}$  anteriorly. This will produce a view of both orbits with the petrous temporal bones just below the orbital margins. The film should then be repeated with a *different cassette*. In each case good screens should be used, and should be dusted before loading. The intention is to eliminate false positive shadows. An FB should appear on both films. A single lateral view is taken of the affected side.

If an FB is detected and is thought to be intra-ocular, it must be accurately localised. Two sets of methods are available, the external markers and the attached corneal markers.

One method of external marker is the McGRIGOR SPECTACLES method, the apparatus being simple and easily portable. It is used with an undercouch tube. The special cross wire spectacles are fitted to the patient and aligned by screening. A dental film is then placed on the cross wires, and two exposures made on the same film, the tube being displaced first 3 cm. to one side of the centre point, and then 3 cm. to the other. The tube-film distance should not be less than 20 inches.

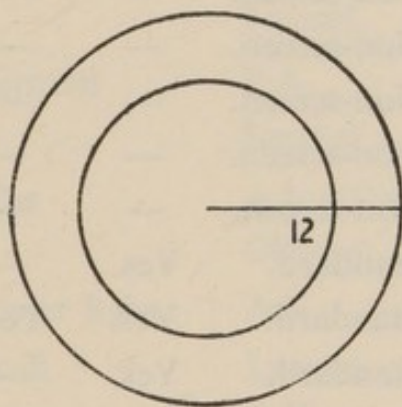
The FB position is obtained from the film by plotting out the shadow measurements on a special chart.

One method of attached corneal marker is a silver ring sewn on to the limbus by the ophthalmic surgeon. Exposures are then made in PA and lateral views with the patient looking up, forward and down. If the FB shadow moves with the ring it is presumably within the eye, and its position in two planes is known.

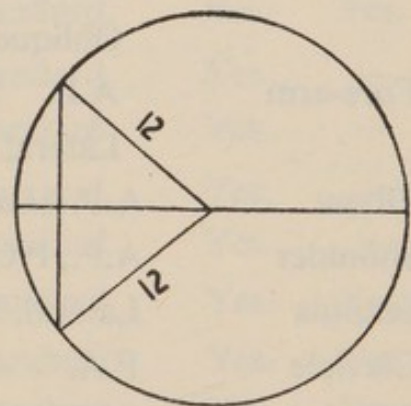
For greater accuracy, the following procedure is used. The PA projection is taken centring through the ring from 30 inches or more. If successful, the view shows the ring as a perfect circle. The lateral projection is also taken from 30 inches or more, centring over the edge of the ring. This shows the ring as a single straight line.

A schematic eye is now drawn on each film (Fig. 156). In the PA film, superimpose a circle of 24 mm. diameter concentric with the ring shadow as in (a), and in the lateral film, making the linear shadow of the ring the chord of a similar circle (b).

The position of the FB relative to the limbus can be estimated by measurement of these two diagrams.



(a)



(b)

Fig. 156.

### RADIOGRAPHIC EXPOSURE TABLE—FOUR VALVE UNIT

**NOTES.** The exposures given in these pages are offered as a guide only, to be used in compiling a technique chart for a new or unfamiliar machine.

All exposures are suitable for average adult subjects and assume standard development.

Where the use of a grid is specified, it is intended that a moving grid be used. If this is not available and a stationary, wafer grid is employed, the mAs figure should be reduced to  $\frac{2}{3}$  of the value given.

| Region & Projections. | kV.           | mAs. | FFD. | Film. | Screens.    | Grid. |      |
|-----------------------|---------------|------|------|-------|-------------|-------|------|
| Hand                  | P.A.          | 60.  | 6.   | 30"   | Non-screen. | —     | —    |
|                       | Lateral.      | 60.  | 12.  | 30"   | Non-screen. | —     | —    |
|                       | Oblique       | 60.  | 9.   | 30"   | Non-screen. | —     | —    |
| Thumb                 | A.P.          | 60.  | 8.   | 30"   | Non-screen. | —     | —    |
|                       | Lateral.      | 60.  | 8.   | 30"   | Non-screen. | —     | —    |
| Wrist                 | P.A.          | 60.  | 8.   | 30"   | Non-screen. | —     | —    |
|                       | Lateral.      | 60.  | 16.  | 30"   | Non-screen. | —     | —    |
|                       | Oblique.      | 60.  | 12.  | 30"   | Non-screen. | —     | —    |
| Fore-arm              | A.P.          | 60.  | 14.  | 30"   | Non-screen. | —     | —    |
|                       | Lateral.      | 60.  | 16.  | 30"   | Non-screen. | —     | —    |
| Elbow                 | A.P.&Lat.     | 60.  | 20.  | 30"   | Non-screen. | —     | —    |
| Shoulder              | A.P., P.O.    | 55.  | 25.  | 36"   | Standard.   | Yes.  | —    |
| Scapula               | Lateral, A.O. | 70.  | 80.  | 36"   | Standard.   | Yes.  | Yes. |
| Clavicle              | P.A.          | 55.  | 25.  | 36"   | Standard.   | Yes.  | —    |
| S.C. Joints           | Oblique.      | 70.  | 25.  | 36"   | Standard.   | Yes.  | Yes. |
| Foot                  | D.P.          | 80.  | 6.   | 30"   | Non-screen. | —     | —    |
|                       | D.P.O.        |      |      |       |             |       |      |
|                       | Oblique.      |      |      |       |             |       |      |
|                       | Lateral.      | 80.  | 8.   | 30"   | Non-screen. | —     | —    |
| Toes                  |               | 60.  | 5.   | 30"   | Non-screen. | —     | —    |
| Great Toe             | D.P.          | 70.  | 6.   | 30"   | Non-screen. | —     | —    |
|                       | Lateral.      | 70.  | 8.   | 30"   | Non-screen. | —     | —    |
| Os Calcis             | Axial.        | 90.  | 18.  | 30"   | Non-screen. | —     | —    |
| Ankle                 | A.P.          | 70.  | 14.  | 30"   | Non-screen. | —     | —    |
|                       | Lateral.      | 70.  | 12.  | 30"   | Non-screen. | —     | —    |

| Region & Projections. |            | kV. | mAs. | FFD. | Film.       | Screens. | Grid. |
|-----------------------|------------|-----|------|------|-------------|----------|-------|
| Knee                  | A.P.       | 60. | 10.  | 36"  | Standard.   | Yes.     | —     |
|                       | Lateral.   | 60. | 8.   | 36"  | Standard.   | Yes.     | —     |
| Hip.                  | A.P.       | 70. | 160. | 36"  | Standard.   | Yes.     | Yes.  |
|                       | Lateral.   | 70. | 200. | 36"  | Standard.   | Yes.     | Yes.  |
| Pelvis                | A.P.       | 70. | 100. | 36"  | Standard.   | Yes.     | Yes.  |
|                       | Lateral.   | 85. | 480. | 36"  | Standard.   | Yes.     | Yes.  |
| Cervical Spine        | A.P. 1-3.  | 55. | 40.  | 30"  | Standard.   | Yes.     | —     |
|                       | A.P. 3-7.  | 65. | 60.  | 36"  | Standard.   | Yes.     | Yes.  |
|                       | Lateral.   | 65. | 80.  | 60"  | Standard.   | Yes.     | No.   |
| Dorsal Spine          | A.P.       | 80. | 70.  | 36"  | Standard.   | Yes.     | Yes.  |
|                       | Lateral.   | 85. | 160. | 36"  | Standard.   | Yes.     | Yes.  |
| Lumbar Spine          | A.P.       | 70. | 160. | 36"  | Standard.   | Yes.     | Yes.  |
|                       | Lateral.   | 85. | 320. | 36"  | Standard.   | Yes.     | Yes.  |
| Sacrum                | A.P.       | 70. | 160. | 36"  | Standard.   | Yes.     | Yes.  |
|                       | Lateral.   | 85. | 400. | 36"  | Standard.   | Yes.     | Yes.  |
| Coccyx                | A.P.       | 70. | 100. | 36"  | Standard.   | Yes.     | Yes.  |
|                       | Lateral.   | 75. | 160. | 36"  | Standard.   | Yes.     | Yes.  |
| Sternum               | P.A.       | 50. | 10.  | 60"  | Standard.   | Yes.     | —     |
|                       | Lateral    | 85. | 30.  | 60"  | Standard.   | Yes.     | —     |
| Ribs                  | A.P.orP.A. | 72. | 8.   | 30"  | Standard.   | Yes.     | —     |
|                       | Oblique    | 70. | 16.  | 30"  | Standard.   | Yes.     | —     |
| Lower Ribs            | A.P.       | 70. | 160. | 36"  | Standard.   | Yes.     | Yes.  |
| Skull                 | Lateral.   | 60. | 140. | 36"  | Standard.   | Yes.     | Yes.  |
|                       | O.F.       | 65. | 140. | 36"  | Standard.   | Yes.     | Yes.  |
|                       | O.M.       | 75. | 140. | 36"  | Standard.   | Yes.     | Yes.  |
|                       | 30°F.O.    | 70. | 160. | 36"  | Standard.   | Yes.     | Yes.  |
| Nasal Bones           | S.I.       | 60. | 45.  | 30"  | Non-screen. | —        | —     |
|                       | Lateral.   | 70. | 6.   | 30"  | Non-screen  | —        | —     |
| Mandible              | Lateral    | 55. | 30.  | 30"  | Standard.   | Yes.     | —     |
|                       | P.A.       | 70. | 50.  | 30"  | Standard.   | Yes.     | Yes.  |
| T.M. Joints           |            | 65. | 16.  | 30"  | Standard.   | Yes.     | —     |
| Lung fields           | P.A.       | 62. | 20.  | 60"  | Standard.   | Yes.     | —     |
|                       | Lateral.   | 82. | 24.  | 60"  | Standard.   | Yes.     | —     |
|                       | Oblique    | 67. | 20.  | 36"  | Standard.   | Yes.     | —     |



| Region & Projections. | kV. | mAs. | FFD. | Film.     | Screens. | Grid. |
|-----------------------|-----|------|------|-----------|----------|-------|
| Alimentary Tract,     |     |      |      |           |          |       |
| Oesophagus R.A.O.     | 77. | 20.  | 36"  | Standard. | Yes.     | —     |
| Stomach P.A.          | 85. | 40.  | 30"  | Standard. | Yes.     | Yes.  |
| Colon P.A.            | 85. | 60.  | 30"  | Standard. | Yes.     | Yes.  |
| Gall-bladder P.A.     | 70. | 100. | 36"  | Standard. | Yes.     | Yes.  |
| Lateral.              | 80. | 150. | 36"  | Standard. | Yes.     | Yes.  |
| Renal Tract A.P.      | 70. | 165. | 48"  | Standard. | Yes.     | Yes.  |
| Urinary Bladder A.P.  | 70. | 80.  | 33"  | Standard. | Yes.     | Yes.  |
| Pregnancy             |     |      |      |           |          |       |
| * (Early) P.A.        | 65. | 100. | 36"  | Standard. | Yes.     | Yes.  |
| Pregnancy             |     |      |      |           |          |       |
| * (Advanced P.A.      | 80. | 100. | 36"  | Standard. | Yes.     | Yes.  |
| * Lateral.            | 90. | 420. | 36"  | Standard. | Yes.     | Yes.  |
| *Pelvimetry           |     |      |      |           |          |       |
| (Advanced             |     |      |      |           |          |       |
| Pregnancy) Brim view. | 95. | 480. | 36"  | Standard. | Yes.     | Yes.  |

**\*Note.** Though all 'pregnancy' exposures assume the use of standard films and standard screens, every attempt should be made to minimize these exposures and the use of ultra-fast films and screens should be considered routine.





