

Neurological surgery of trauma / Prepared and published under the direction of Leonard D. Heaton. Editor in Chief: John Boyd Coates, Jr.; editor: Arnold M. Meirowsky.

Contributors

United States. Army Medical Service.
Coates, John Boyd.

Publication/Creation

Washington : Office of the Surgeon General, Dept., 1965.

Persistent URL

<https://wellcomecollection.org/works/ggrh3y8n>

License and attribution

This work has been identified as being free of known restrictions under copyright law, including all related and neighbouring rights and is being made available under the Creative Commons, Public Domain Mark.

You can copy, modify, distribute and perform the work, even for commercial purposes, without asking permission.



Wellcome Collection
183 Euston Road
London NW1 2BE UK
T +44 (0)20 7611 8722
E library@wellcomecollection.org
<https://wellcomecollection.org>

THE ROYAL SOCIETY OF HEALTH

FOR THE PROMOTION

Founded 1876

LIBRARY REGULATIONS

(a) Books, periodicals and pamphlets may be borrowed by Fellows, Members, Licentiate Members, Associates and Affiliates personally or by a messenger producing a written order. The person to whom such publications are delivered shall sign a receipt for them in a book provided for that purpose.

(b) Publications may be borrowed through the post upon a written order. An acknowledgement of the receipt of such publications must be made on the form provided and returned to the Society immediately. Failing this, it will be assumed that the borrower has received the books, for which he will accordingly be held responsible. The postage of publications returned to the Society shall be defrayed by the borrower.

(c) A borrower may not have more than three publications in his possession at one time.

(d) A borrower will be considered liable for the value of any publication lost or damaged while on loan to him, and, if it be a single volume or part of a set, for the value of the whole work thereby rendered imperfect. Marking or writing in the publications is not permitted, and borrowers are requested to call attention to damage of this character.

(e) Books and pamphlets may be retained for twenty-eight days. Periodicals may be retained for fourteen days. Applications for extension of the loan period must be made in writing before its expiry. This loan period cannot be extended without application being made to the Secretary of the Society whose decision in this matter must be accepted as final and binding.

(f) Books and pamphlets added to the Library will not be lent until after the expiry of one month from the date received. The current number of a periodical may not be borrowed.

(g) Borrowers retaining publications longer than the time specified, and neglecting to return them when demanded, forfeit the right to borrow until they be returned, and for such further time as may be ordered by the Council.

Any borrower failing to comply with a request for the return of a publication shall be considered liable for the cost of replacing it, and the Council, may, after giving due notice to him, order it to be replaced at his expense.

No publication may be reissued to the same borrower until at least seven days have elapsed after its return, neither may it be transferred by one borrower to another.

(h) Publications may not be taken or sent out of the United Kingdom.

(i) Publications returned through the post must be securely packed and adequately protected.

(j) Parcels should be addressed: THE LIBRARIAN,

THE ROYAL SOCIETY OF HEALTH

90 BUCKINGHAM PALACE ROAD, LONDON, S.W.1

O.B., Truro.

—January, 1965



22102105574

Med
K35011

THE ROYAL SOCIETY
FOR THE PROMOTION
OF HEALTH

90 Buckingham Palace Road, London, S.W.1

Class No.....OR/41

Acc. No.....29291

This book is returnable on or before the last date Marked below

--	--



NEUROLOGICAL SURGERY OF TRAUMA



Neurological

Surgery of Trauma

Prepared and published under the direction of
Lieutenant General LEONARD D. HEATON
The Surgeon General, United States Army

Editor in Chief
Colonel JOHN BOYD COATES, JR., MC, USA

Editor
ARNOLD M. MEIROWSKY, M.D.

1128537

THE HISTORICAL UNIT, UNITED STATES ARMY MEDICAL SERVICE

Colonel JOHN BOYD COATES, Jr., MC, USA, *Director*

CHARLES J. SIMPSON, *Executive Officer*

Lieutenant Colonel GILBERT A. BISHOP, MSC, USA, *Chief, Special Projects Branch*

CHARLES M. WILTSE, Ph. D., Litt. D., *Chief, Historians Branch*

ERNEST ELLIOTT, Jr., *Chief, Editorial Branch*

Lieutenant Colonel JEROME RUDBERG, MSC, USA, *Chief, Information Activities Branch*

RODERICK M. ENGERT, *Chief, General Reference and Research Branch*

HAZEL G. HINE, *Chief, Administrative Branch*

WELLCOME INSTITUTE LIBRARY	
Coll.	welM Omec
Call	
No.	WL

Library of Congress Catalog Card Number 64-60013

Authors

MAITLAND BALDWIN, M.D.

Clinical Director and Chief, Surgical Neurology, National Institute of Neurological Diseases and Blindness, National Institutes of Health, Bethesda, Md., and Clinical Professor of Surgery, Georgetown University School of Medicine, Washington, D.C. Commander, MC, USNR, Amphibious Forces Pacific, 1944-46.

JOSEPH C. BARNETT, JR., M.D.

In private practice of neurological surgery, Marietta, Ga.; Faculty member, Emory University Medical School, Department of Surgery, Division of Neurological Surgery, Atlanta, Ga. Formerly First Lieutenant, MC, AUS, Far East Command, 1951-53.

FRANK B. BERRY, M.D.

Professor of Clinical Surgery Emeritus, College of Physicians and Surgeons, Columbia University, New York, N.Y. Brigadier General, USAR (Ret.) Formerly Consultant in Surgery, Seventh U.S. Army, World War II; Assistant Secretary of Defense (Health and Medical), 1954-63.

EDWARD J. BISHOP, M.D.

Chief of Department of Neurosurgery, St. Vincent Charity Hospital and Evangelical Deaconess Hospital, Cleveland, Ohio. Formerly Captain, MC, AUS; Commanding Officer, 160th Mobile Neurosurgical Detachment, Korea, 1951-52; Chief of Neurosurgical Service, Tokyo Army Hospital, Japan, 1952.

ERNEST BORS, M.D.

Chief, Spinal Cord Injury Service, Veterans' Administration Hospital, Long Beach, Calif., and Clinical Professor of Surgery, University of California Medical School, Los Angeles, Calif. Formerly Major, MC, AUS; Chief, Spinal Cord Injury Section, 104th Evacuation Hospital, Camp White, Oreg., 1943-44; Hammond General Hospital, Modesto, Calif., 1944-45; Birmingham Veterans' Administration Hospital, Van Nuys, Calif., 1945-46.

WILLIAM F. CAVENESS, M.D.

Department of Neurology, College of Physicians and Surgeons, Columbia University, New York, N.Y. Captain, MC, USNR (Ret.).

ROBERT A. CLARK, JR., M.D.

Senior staff member and Chief of Neurosurgical Service, Macon Hospital, Macon, Ga.; and Consultant, Veterans' Administration Center, Dublin; 2795th U.S. Air Force Hospital, Robins Air Force Base; Georgia State Department of Health, Crippled Children's Division; and Georgia State Department of Education, Division of Vocational Rehabilitation; Instructor in Surgery (Neurosurgery), Cornell University Medical College, 1948-54. Formerly Lieutenant, MC, USNR; Medical Officer, Neurosurgical Service, Tokyo Army Hospital, Tokyo, Japan; Member, 1st Neurosurgical Detachment (Provisional), Eighth U.S. Army, Korea; Chief, Neurosurgical Service, U.S. Naval Hospital, Yokosuka, Japan; Chief, Neurosurgery Section, U.S. Naval Hospital, Corpus Christi, Tex., 1950-52.

WILLIAM S. COXE, M.D.

Associate Professor of Neurological Surgery, Washington University School of Medicine, St. Louis, Mo. Formerly Captain, MC, AUS, Walter Reed Army Hospital, Washington, D.C., 1953-55.

PHILIP R. DODGE, M.D.

Assistant Professor of Neurology, Harvard Medical School, and Neurologist and Pediatrician, Massachusetts General Hospital, Boston, Mass. Formerly Major, MC, AUS, Neurologist, Tokyo Army Hospital, Japan, 1950-51.

SIDNEY GOLDRING, M.D.

Professor of Neurological Surgery, University of Pittsburgh School of Medicine, Pittsburgh, Pa. Formerly Captain, MC, AUS; Camp Pickett, Va., 1952; Walter Reed Army Hospital, Washington, D.C., 1952-54.

GRIFFITH R. HARSH III, M.D.

Assistant Professor of Neurosurgery, University of Alabama Medical School, Birmingham, Ala. Formerly Captain, MC, AUS, 1st Neurosurgical Detachment (Provisional), Korea.

ROBERT F. HEIMBURGER, M.D.

Professor of Surgery and Director of Neurological Surgery, Indiana University School of Medicine, Indianapolis,

Ind. Formerly First Lieutenant, MC, AUS, 1945-46; Captain, MC, USAF; Consultant in Neurological Surgery, U.S. Air Force in Europe, 1953-54; National Civilian Consultant in Neurological Surgery to The Surgeon General, U.S. Air Force, 1958 to present.

FRANK H. MAYFIELD, M.D.

Assistant Clinical Professor of Surgery, University of Cincinnati, Ohio (on leave to serve as a member of the Board of Directors of the University). Formerly Lieutenant Colonel, MC, AUS; Chief of Neurosurgical Service, Percy Jones General Hospital, Battle Creek, Mich., 1942-46; Oversea Consultant in Neurosurgery to The Surgeon General, U.S. Army, 1956.

BERT H. McBRIDE, M.D.

Assistant Clinical Professor of Surgery, Division of Neurosurgery, University of Cincinnati College of Medicine, Cincinnati, Ohio. Lieutenant (jg), MC, USNR.

ARNOLD M. MEIROWSKY, M.D.

Assistant Clinical Professor, Division of Neurological Surgery, Department of Surgery, Vanderbilt University School of Medicine; on attending staff, Vanderbilt University Hospital, St. Thomas Hospital, Mid State Baptist Hospital, and Nashville General Hospital, all in Nashville, Tenn. Civilian Consultant in Neurosurgery to The Surgeon General, U.S. Army, 1954 to present. Lieutenant Colonel, MC, USAR. Neurosurgeon in field and general hospitals, U.S. Army, in the Zone of Interior and the Pacific combat areas, 1942-46; Chief, Section of Neurological Surgery, 1946-50, and Director, Surgical Research, 1949-50, Veterans' Administration Medical Teaching Group, Kennedy Hospital, Memphis, Tenn.; Consultant in Neurosurgery to the Chief Surgeon, Far East Command, Korea and Japan, 1950-52.

HOWARD C. NAFFZIGER, M.D. (deceased)

Professor of Surgery, 1929-47, Professor of Neurological Surgery, 1947-51, Professor of Neurological Surgery Emeritus, 1951-61, University of California Medical Center, San Francisco; Regent, University of California, 1952-61; President, American College of Surgeons, 1938-39, American Surgical Association, 1953-54, and The Society of Neurological Surgeons, 1929-30; Founder Member of American Boards of Surgery and Neurological Surgery. Lieutenant Colonel, MC, U.S. Army, World War I, and later, Colonel, Medical Corps Reserve; Special Consultant, Office of Scientific Research and Development, 1942-45; Honorary Consultant, Army Medical Library (now National Library of Medicine), 1944-52; Consultant in Neurological Surgery, Far East Command, Korea and Japan, 1951.

MARCUS W. ORR, Ph. D.

Assistant Professor, Department of History, Memphis State University, Memphis, Tenn. Formerly Sergeant, AUS, 42d Infantry Division; Research Associate, Paraplegia Research Unit, Department of Surgical Research, Indiana University Medical Center, Indianapolis, Ind., 1949-52.

THOMAS N. PAGE, M.D., M.P.H.

Deputy Director, Bureau of County Health Services, State Health Department, Montgomery, Ala. Colonel, USA (Ret.). Formerly Director, Public Health and Welfare Sub-Commission of the Allied Commission for Italy, 1945; Surgeon, Eighth U.S. Army, Korea, 1951-52; Chief, Medical Plans and Operations Division, Office of The Surgeon General, U.S. Army, 1955-58.

DAVID L. REEVES, M.D.

In private practice of neurological surgery, Santa Barbara, Calif. Formerly Colonel, MC, AUS; Chief, Neurosurgical Service, Hoff General Hospital, Santa Barbara, Birmingham General Hospital, Van Nuys, and Hammond General Hospital, Modesto, all in California.

HUGO V. RIZZOLI, M.D.

Associate Clinical Professor, Neurological Surgery, George Washington University School of Medicine; Consultant in Neurological Surgery, Walter Reed Army Hospital, Andrews Air Force Hospital, and Bethesda Naval Hospital; attending neurosurgeon, Mt. Alto Veterans' Administration Hospital, all in Washington, D.C., area. Formerly Major MC, AUS, 1944-46.

C. DAVID SCHEIBERT, M.D.

Assistant Clinical Professor, Division of Neurological Surgery, Department of Surgery, Vanderbilt University School of Medicine, Nashville, Tenn. Formerly Lieutenant (jg), MC, USNR, 1946-48; Chief, Section of Neurological Surgery, Kennedy Hospital, Veterans' Administration Medical Teaching Group, Memphis, Tenn., 1951-59.

HENRY G. SCHWARTZ, M.D.

Professor of Neurological Surgery, Washington University School of Medicine, St. Louis, Mo. Formerly Lieutenant Colonel, MC, AUS; Chief of Neurosurgery Service, 21st General Hospital, Mediterranean Theater of Operations, U.S. Army; Consultant in Neurosurgery, Continental Advance Base Section, 1945, and to The Surgeon General, U.S. Army, 1961 to present.

WILLIAM E. SHAMBORA, M.D.

Major General, USA (Ret.). Formerly Chief Surgeon, Army Ground Forces, 1941-44; Surgeon, Ninth U.S. Army,

1944-46; Commandant, Medical Field Service School, 1946-47; Surgeon, Pacific Forces, 1947-50; Surgeon, First U.S. Army, 1950-51; Chief Surgeon, Far East Command, 1951-53; Commanding General, Brooke Army Medical Center, Fort Sam Houston, Tex., 1953-60; Vice President, St. Mary's University, San Antonio, Tex., 1960-62.

R. GLEN SPURLING, M.D.

Professor of Neurosurgery Emeritus, University of Louisville School of Medicine, Louisville, Ky. Formerly Colonel, MC, AUS; Chief, Neurosurgical Section, Walter Reed Army Medical Center, 1942-44; Senior Consultant in Neurosurgery, European Theater of Operations, 1944-45; Consultant in Neurosurgery to The Surgeon General, U.S. Army, 1945-46.

GORDON T. WANNAMAKER, M.D.

Assistant Clinical Professor of Neurosurgery, Medical College of South Carolina, Charleston. Formerly Lieutenant Colonel, MC, AUS; Chief of Neurosurgery, Walter Reed Army Hospital, Washington, D.C.; Tokyo Army Hospital, Japan; Tripler Army Hospital, Honolulu, Hawaii; Brooke Army Hospital, Fort Sam Houston, Tex.

CHARLES S. WISE, M.D.

Professor of Physical Medicine and Rehabilitation, The George Washington University School of Medicine; Chairman, Department of Physical Medicine and Rehabilitation, The George Washington University Hospital; Consultant in Physical Medicine and Rehabilitation, Walter Reed General Hospital, Mt. Alto Veterans' Administration Hospital, St. Elizabeths Hospital, Children's Hospital, all in Washington, D.C., and National Institutes of Health, Bethesda, Md. Formerly First Lieutenant, MC, AUS; Laboratory Service Officer, Air Transport Command, and Liaison Medical Officer, China-Burma-India Theater, September 1942-February 1945.

HANS H. ZINSSER, M.D.

Associate Professor of Clinical Urology, Columbia University, College of Physicians and Surgeons, New York, N.Y. Formerly Major, MC, AUS, 1944-46; Treatment Section Leader, 222d Airborne Medical Company, 13th Airborne Division, European Theater of Operations, U.S. Army; Assistant Chief of Surgery, Walter Reed Army Hospital, Washington, D.C.

Foreword

Several years ago, Dr. Arnold M. Meirowsky visited the Office of The Surgeon General of the Army and discussed with several concerned members of the staff the desirability of preparing and publishing a text devoted to neurological surgery of trauma. During the Korean War, the management of neurosurgical patients had been refined to the point where satisfactory end-results had exceeded even the splendid advances which had been achieved in World War II. Mortality rates were brought to an all-time low.

Doctor Meirowsky spoke with the authority of one who had served as Consultant in Neurosurgery in the Far East Command during most of the Korean War and it was he, together with his colleagues, who had been largely responsible for formulating and carrying out, with the approval of the theater Chief Surgeon, the neurosurgical policies of management and treatment of United Nations Forces involved in that War.

In the discussion which followed, it was agreed that if a volume on this subject could be prepared, as was suggested, it would include a comprehensive presentation of the subject based upon the extensive experiences, both military and civilian, of outstanding neurosurgeons in the various areas of trauma involving neurological surgery. It was considered that such a book, with the advantages which such would have, would be of outstanding quality and prove to be a publication of substantial value to the civilian medical profession as well as to its military counterpart. Trauma is not limited to the battlefield. It occurs daily in civilian life as well.

With the above in mind, approval for this text was given by my predecessor. As a general surgeon realizing the need for such a specialized text, its preparation throughout has had my hearty support. Doctor Meirowsky has assembled an imposing array of nationally and internationally known authors who, in my judgment, have made a superior professional contribution to our present-day knowledge of most, if not all, known aspects of diagnosis and neurological surgery of trauma.

In reading the manuscript, and in reflecting on my own surgical experience, I am particularly impressed with certain important highlights, brought forth clearly, which all physicians who have or may have responsibility thrust on them for the care of the neurosurgical patient should be aware of, heed, and carry out in the course of treatment for which they assume responsibility.

It is an established fact that speedy evacuation to a medical facility where early initial neurosurgical treatment may be provided reduces mortality. In the military, air evacuation is preferable. Further treatment, as soon as feasible, is then indicated in a neurosurgical center where competent and highly skilled neurosurgeons are assembled.

A trained nursing staff must be provided for the care of neurosurgical patients. Nursing personnel must be considered as part of the team complex and are a necessity. Without an intelligent, dedicated, and meticulous nursing service, the best operative care may fail.

It is important both in military and civilian life that medical personnel be adept in improvising needed equipment at medical facilities. Specifically desired commercial equipment is not always available when needed. Simple adjustments or adaptation of equipment or supplies which are within reach can, have been, and will be utilized successfully by alert personnel with imagination, thought, and initiative. Throughout the text, numerous illustrations present this fact to the reader.

Good surgical management dictates the employment of careful debridement. This cardinal principle has been stated many times in the past and is re-emphasized here. The appropriate use of antibiotics as an adjunctive treatment is discussed and recommended.

On the part of the attending surgeon, the need for honest and frank discussion with the patient as to the latter's current or potential neurological deficit is one which must be remembered and be properly timed. In the wisdom of the authors, this personal discussion has proved to be an important aspect of the surgeon's responsibility. Specialized skill in the practice of the art of medicine is required. In this regard, every effort should be made to maintain the patient's morale, as well as that of the medical staff when dealing with these patients. A "don't give up" attitude must be adopted by all.

The chapters devoted to urological management and to physical and vocational rehabilitation are as important as any in the book. These problems deserve constant thought and watchful attention.

As with the book as a whole, the chapters dealing with intervertebral discs are well done and surgically interesting and informative. My own conservative spelling of the word "disc" is perhaps somewhat comparable to the initial conservative management of this condition recommended by the authors.

The final chapters deal quite appropriately with peripheral nerve surgery. The diagnostic measures recommended are clearly described and amply illustrated. These chapters should be extremely helpful to *all* surgeons and medical practitioners, as well as to those who aspire to be.

In times of emergency, it is highly doubtful and probably unreasonable to expect that there will be an abundance of skilled neurosurgeons available in all geographic areas of need. During World War II, and again during the Korean War, well-trained general surgeons were sent to leading civilian medical schools and centers for intensive short courses in the principles of neurosurgical management. This was a wise move, well worth the effort and time. Later, many of these men were responsible for the initial care of neurosurgical patients, and they acquitted themselves in a commendable manner. In my judgment, in any future emergency, a similar training program may be necessary. It is my hope that such emergency will never occur, but, as a prudent measure in the national interest, I strongly encourage all surgeons to acquaint themselves with the knowledge which is admirably presented within the pages of this book.

As with other volumes for which it has been my privilege to write the foreword, it is a pleasure to express my gratitude and appreciation to the authors who wrote this volume, and particularly to Doctor Meirowsky, who spent countless hours planning and technically editing this work; and to the personnel of The Historical Unit of my office who are helping me with the preparation and publication of professional volumes such as this.

LEONARD D. HEATON,
Lieutenant General,
The Surgeon General.

Preface

As this text goes to press, The Historical Unit, United States Army Medical Service, has already published a respectable number of volumes reporting historically, and analyzing scientifically, medicine and surgery as practiced during the course of the Second World War. Among those volumes, two are concerned with the history of Neurosurgery in World War II. The student of those two volumes will obtain an enlightened picture of the practice of all phases of military neurosurgery and its progress during the war years. He will find that, out of those years, new concepts and new methods have evolved which will be guides to further developments in the years to come.

Military neurosurgery is neurological surgery of trauma. While all aspects of the latter apply to peacetime as well, genuine progress in this field is attributable always to the prolonged pursuit of active warfare. The fruits of this pursuit gained momentum in the immediate postwar years when individual men took time to analyze and time to conclude. As the quiet after the storm of war settled, enthusiasm for the enhancement of further knowledge in the field of neurological surgery of trauma died down and made room for the exploration of other and equally important aspects of neurological surgery. When the unexpected war in Korea broke out, the achievements in the management of neurosurgical trauma, which had been reached in the Second World War, had been shelved though not forgotten by all. Shelved and forgotten had been the means of achievement; namely, an adequate organization permitting the application of established concepts and methods in this new type of warfare. This has never been more aptly expressed than in the 1958 manual entitled "Emergency War Surgery, NATO Handbook," as follows:

Success in military medicine, furthermore, has been achieved in spite of the fact that over the ages, many—sometimes most—of the lessons of the past, all of them learned by hard experience, ordinarily lie fallow between conflicts. Almost invariably they have had to be rediscovered, relearned by additional hard experience, and expanded and adapted by succeeding medical generations as new emergencies have arisen.

Those concerned with neurological surgery of trauma in the Korean War had to rediscover and relearn. Out of their rediscovery evolved a system of management adaptable to warfare under varying conditions in varying geographic territory. Out of their rediscovery evolved new concepts and new methods. It was the late Eldridge H. Campbell, Jr.—one of the few neurosurgeons who had expended much effort to keep interest alive in the field of military neurosurgery—who first suggested and urged that the management of war wounds of the brain and spinal cord in the Korean War be documented, analyzed, and published. His suggestion led to the preparation of the present text. This may help to explain why much space and emphasis have been devoted to those sections dealing with neurosurgical trauma incurred in active warfare. Suffice it to say that the accomplishments in behalf of our casualties in the Korean War with wounds of the brain and spinal cord are witness to the efforts and dedication of a small number of young neurosurgeons, most of whom have written individual chapters in this book, and to the unequalled contribution of a small corps of nurses and enlisted technicians.

The reader will find, therefore, considerable space devoted to the documentation of war wounds of the brain and spinal cord. Outstanding men in the field of neurological surgery of trauma have composed those sections of this text which deal with neurosurgical trauma as it may occur in peace and war alike—closed head and spinal cord injuries, disk injuries, and peripheral nerve trauma.

Today, almost 14 years after the onset of the Korean War, responsible men in medicine and surgery are occupied with the formulation of a concept of the management of mass casualties which

may occur in nuclear warfare. The approach to this concept is based on a priority system that automatically gives preference to the wounded who can be returned to immediate activity rather than to those who are seriously or critically injured. This approach is realistic, to say the least, in anticipation of nuclear warfare. Civil Defense authorities have suggested that some 70 target cities could be struck simultaneously, resulting in 10 to 15 million injured in need of professional care, with perhaps an equal number of dead. In such an event, the management of mass casualties demands an approach vastly in variance from the tenets by which American physicians and surgeons in peace and war have been guided to date. What then is the justification of a text on neurological surgery of trauma stressing earliest possible definitive management of penetrating wounds and dealing with minute aspects of the surgical management of every part of the central and peripheral nervous system?

The answer is this: Immediate treatment for those who can be returned to activity, delayed treatment for those who are seriously injured, and expectant treatment for those who are "expected" to die, are the only alternatives left to us, should we be confronted with mass casualties produced by a total nuclear attack. They are not the methods which our natural concept of practicing medicine and surgery dictates. They are alternatives which we cannot adopt whenever circumstances permit us to do differently.

Conventional warfare at large scale permits immediate care by specialized personnel of those who have sustained serious wounds of the central nervous system. This is borne out by experiences in the Second World War as well as in the Korean War and applies also to the civilian disaster which we know today. In the event of all-out nuclear warfare, a different system of priorities will have to be employed. Only those responsible for triage in any type of disaster can decide which course to follow at any given time; there can be no question in our mind that that decision will be in favor of earliest possible definitive treatment of everybody, whenever that is at all feasible. With this in mind, we should like to think that this volume furnishes the information which is essential to neurological surgery of trauma.

ARNOLD M. MEIROWSKY, M.D.

Acknowledgments

On his return to Japan from Korea aboard the U.S.S. *Consolation* (AH-15), in 1952, the late Eldridge H. Campbell, Jr., then Civilian Consultant in Neurological Surgery to The Surgeon General, U.S. Army, suggested that the records of all casualties with wounds of brain and spinal cord be used to document a monograph on war wounds of the central nervous system. His explicit and detailed suggestions formed the foundation for the respective sections of this volume. Campbell's teachings can be found in those pages of this book which are concerned with penetrating trauma. His untimely death prevented his name from appearing on the list of authors.

The late Howard C. Naffziger, in his capacity as Civilian Consultant in Neurological Surgery to The Surgeon General, U.S. Army, visited the Far East Command during the early phase of the Korean War. He gave invaluable advice and helped greatly in formulating policies regarding the management of neurosurgical casualties in the Korean War.

Frank B. Berry, whose visit in the Far East Command contributed essentially to the high standards of surgery in forward and rear echelons, lent substantial support to neurological surgery in the Far East Command. His advice and guidance in the formulation of this book have been invaluable.

The young neurosurgeons and neurologists, who were closely associated with the editor in the management of neurosurgical casualties in the Korean War, have generously contributed to the pages of this text: Joseph C. Barnett, Jr., Edward J. Bishop, William F. Caveness, Robert A. Clark, Jr., Philip R. Dodge, Griffith R. Harsh III, and Gordon T. Wannamaker. The editor is deeply indebted to each and every one of these men, who made a valiant contribution to military neurosurgery in wartime. To each of the other authors, who have contributed so generously of their time and talents, the editor is sincerely grateful.

Col. John Boyd Coates, Jr., MC, USA, Director, The Historical Unit, United States Army Medical Service, has been the heart and soul of this endeavor. It was he who proposed and saw through to its conclusion the preparation of the text. It was he who gave enthusiastic support and guidance. Without his experienced counsel the book could not have been prepared.

I shall always be deeply grateful to Miss Janie W. Williams, Chief, Publication Section, Editorial Branch, The Historical Unit, for the tremendous job which she has done in the final publications editing of this volume and in the preparation of the index. Miss Williams' tireless efforts to check every minute detail is only surpassed by her exacting skill, knowledge, and perseverance.

Mr. Herman Van Cott, formerly Chief, Medical Illustration Service, Armed Forces Institute of Pathology, deserves credit for having made the facilities of his office available. Mr. D. K. Winter, medical illustrator, Armed Forces Institute of Pathology, has done a magnificent job in preparing many of the halftone drawings for this volume. Miss Frances Shultz, medical illustrator, Armed Forces Institute of Pathology, prepared for publication the line drawings of the anatomy of the peripheral nerves. Their cooperation and their skill are greatly appreciated.

The members of the staff of Vanderbilt University Medical Library, Nashville, Tenn., have been generous with their time and with their facilities. Their cooperation has been most helpful.

Mrs. Celeste Brooks, in my office, has made an untiring effort to facilitate the task on hand. Through the years during which this book has been in preparation, she gathered the necessary

references, prepared individual manuscripts for the publications editor, and did all the detailed work essential to completion of this book.

To all, then, who have given so generously and unselfishly of their time and their talent, I shall always be grateful, for they have made this book possible.

ARNOLD M. MEIROWSKY, M.D.

Nashville, Tennessee

8 April 1960

Prologue

Sir Winston Churchill once said: "The further you look back, the further you can look forward."

In "Neurological Surgery of Trauma," Arnold M. Meirowsky and his collaborators fulfill this dictum. They have gone back to the dawn of history to trace the development of neurological surgery. In "The Edwin Smith Surgical Papyrus," 27 observations of head injuries are described. If the surgeon observes the injury to be so severe that the patient is likely to die, he should say "an ailment not to be treated." The historical narrative is carried through Hippocrates, Celsus, and Galen. After this, as is recorded, nothing of true value appeared until the 13th century in the writings of William of Salicet, Theodoric, and Langfranc. All of these wrote excellent treatises on various types of wounds of the head and their teachings were carried forward in the 14th century by Henri de Mondeville and Guy de Chauliac, and then by Ambroise Paré in the 16th century, and Larrey and the English surgeons in the 18th century.

As the author points out, however, our contemporary military neurosurgery really begins with World War I, with the pioneer work of organization and actual neurological surgery directed, and performed in part, by Col. Harvey Cushing, MC. He introduced the neurosurgical team concept and taught that early operation in the forward area would reduce mortality by almost 50 percent. In the Zone of Interior, 12 neurosurgical centers were established.

In World War II further progress was made. This was due in large part to the great advance in and spread of sound residency training for our young surgeons, which was truly in its infancy until the end of World War I and then steadily flourished so that at the beginning of World War II many well-trained surgeons in general surgery and its specialties were available. The result was that mortality in both craniocerebral and spinal wounds was markedly lowered. And not only were there auxiliary neurosurgical teams available, but many of the evacuation hospitals and almost all of the communications zone hospitals had neurosurgical teams of well-trained neurosurgeons. In the Zone of Interior, in addition to the 26 neurosurgical centers, there was a rapid development of rehabilitation centers so that in addition to a considerably lowered mortality, there was also a great increase in the number of men rehabilitated and restored to some form of activity in civilian life.

Although accurate figures are not available, it may be stated that the approximate mortality of craniocerebral wounds was about 13 percent of those operated upon, and the mortality of spinal wounds was in the vicinity of 15 percent. For example, in 14 forward hospitals in the Seventh U.S. Army in its eastern France campaign, there were 1,176 patients admitted with penetrating cerebral wounds. Of these, there were 327 (27.91 percent) deaths; only 949, however, could be brought to surgery, as the others were so seriously injured that they died soon after hospitalization. Of the 949, there were 137 (13.7 percent) deaths.

The story of the Korean experience is exciting and truly fantastic and shows the truth of Sir Winston Churchill's statement. In the early months of the Korean War, all patients with head or spinal wounds were sent to the rear to the Tokyo Army Hospital, forgetting the dictum of Harvey Cushing and also the experience of World War II. When Maj. Gen. William E. Shambora, USA, arrived as Chief Surgeon of the Far East Command, he gave full support to the concept of Lt. Col. Arnold M. Meirowsky, MC, based upon his deep knowledge of the past, his experience in World War II, and his teachings of and his close association with the late Col. Eldridge H. Campbell, Jr., MC, visiting consultant in Korea and Chief Neurosurgeon, 33d General Hospital, Mediterranean (formerly North African) Theater of Operations in World War II, 1943-45. As one reads Colonel Meirowsky's

description of his organization, his thorough planning for the evacuation and further care of patients with craniocerebral and spinal wounds all the way to the Zone of Interior, it is truly an exciting story. As he states in chapter 7, in the 1,105 casualties in Korea with penetrating craniocerebral trauma who reached an Army neurosurgical installation from 1 September 1950 to 31 August 1952, the mortality was only 7.78 percent, an extraordinary record. In chapter 25, and still more impressive, if possible, is the record of 387 penetrating compound wounds of the spinal canal, of which only 14 died, a mortality of 3.6 percent. And not a single case of decubital ulcer developed!

This amazing record in both craniocerebral and spinal wounds was made possible not only because of the extraordinarily fine surgical organization but also because of a new means of evacuation from the front which not only reduced greatly the time between wounding and hospitalization but also assured a very smooth and easy transport—the helicopter.

It was my privilege to visit the hospitals along the front in Korea in the winter of 1951–52. I was particularly interested in the treatment of the neurosurgical cases with the small neurosurgical units complete unto themselves in the forward areas, the larger ones well in the rear of the fighting, and finally the neurosurgical ward in the Tokyo Army Hospital.

The remainder of the volume is a sound exposition of neurosurgery in general, including the surgery of trauma of the peripheral nerves. It includes not only the neurosurgery of war, when such trauma occurs in epidemic and bizarre forms, but also trauma as it is encountered in civilian life. Diagnostic procedures, resuscitation, treatment, and rehabilitation are all carefully described. As such, this is not only a valuable work for the military, but it should be used as a classical textbook of neurosurgical trauma in its entirety.

Every war produces its unique conditions and problems, not only from the type of warfare of any given time but also from the changes and advances in medicine and surgery. Just as World War II was vastly different from World War I, so the Korean War was entirely different from World War II. All of these factors must be considered in evaluating future medical and surgical problems. Meirowsky and his coworkers have demonstrated what superb management and organization, with prompt and expert surgery by a group of master surgeons, can accomplish.

"I would remind you again how large and various was the experience of the battlefield, and how fertile the blood of warriors in rearing good surgeons."—Sir Clifford Allbutt.

FRANK B. BERRY, M.D.

Contents

FOREWORD.....	<i>Page</i> IX
Lieutenant General LEONARD D. HEATON	
PREFACE.....	XI
ARNOLD M. MEIROWSKY, M.D.	
ACKNOWLEDGMENTS.....	XIII
ARNOLD M. MEIROWSKY, M.D.	
PROLOGUE.....	XV
FRANK B. BERRY, M.D.	

Part 1

MILITARY NEUROSURGERY

Historical Notes

Chapter 1

HEAD INJURIES.....	1
MAITLAND BALDWIN	

Chapter 2

SPINAL CORD INJURIES.....	11
MAITLAND BALDWIN	

Management of Neurosurgical Casualties in the Korean War

INTRODUCTORY NOTE.....	15
WILLIAM E. SHAMBORA	

Chapter 3

HISTORICAL DATA.....	17
ARNOLD M. MEIROWSKY AND THOMAS N. PAGE	

Chapter 4

ORGANIZATIONAL DATA.....	25
ARNOLD M. MEIROWSKY, THOMAS N. PAGE, AND JOSEPH C. BARNETT, JR.	

Personnel.....	26
Equipment.....	29
Comment.....	32

Part 2

CRANIOCEREBRAL TRAUMA

Closed Craniocerebral Trauma

Chapter 5

Page

GENERAL CONSIDERATIONS.....	41
-----------------------------	----

FRANK H. MAYFIELD AND BERT H. MCBRIDE

Immediate Care.....	42
Clinical Assessment.....	45
Classification and Effects of Skull Fractures.....	51
Hyperthermia and Hypothermia.....	53

Chapter 6

DIFFERENTIAL DIAGNOSIS AND TREATMENT OF SURGICAL LESIONS.....	55
---	----

FRANK H. MAYFIELD AND BERT H. MCBRIDE

Subgaleal Hematoma.....	55
Subgaleal Hydroma.....	55
Extradural Hemorrhage.....	55
Subdural Hematoma.....	57
Subdural Hydroma.....	61
Subarachnoid Hemorrhage.....	61
Intracerebral Hematoma and Cerebral Swelling.....	61
Anesthesia.....	63

Penetrating Craniocerebral Trauma

INTRODUCTORY NOTE.....	65
------------------------	----

HOWARD C. NAFFZIGER

Chapter 7

GENERAL CONSIDERATIONS AND PREOPERATIVE MEASURES.....	67
---	----

ARNOLD M. MEIROWSKY

Emergency Management of the Unresponsive Patient.....	69
Initial Wound Care.....	69
Antibiotics and Chemotherapy.....	71
Initial Examination.....	71
Roentgenograms.....	72
Preparation for Operation.....	72
Anesthesia.....	73

Chapter 8

SCALP LACERATIONS.....	75
------------------------	----

ARNOLD M. MEIROWSKY

Surgical Technique.....	76
-------------------------	----

*Chapter 9**Page*

COMPOUND FRACTURES OF CONVEXITY OF THE SKULL..... 83

ARNOLD M. MEIROWSKY

Statistics.....	83
Surgical Management.....	85
Surgical Technique.....	94
Compound Fractures of Base of Skull.....	101

Chapter 10

PENETRATING WOUNDS OF THE BRAIN..... 103

ARNOLD M. MEIROWSKY

Statistics.....	104
Surgical Management.....	104
Surgical Technique.....	117

Chapter 11

HEMATOMAS ASSOCIATED WITH PENETRATING WOUNDS..... 131

JOSEPH C. BARNETT, Jr.

Incidence.....	131
Intracerebral Hematoma.....	132
Subdural Hematoma.....	133
Epidural Hematoma.....	133
Intraventricular Hematoma.....	133
Special Considerations.....	134

Chapter 12

INFECTION COMPLICATING PENETRATING CRANIOCEREBRAL TRAUMA.. 135

GRIFFITH R. HARSH III

General Considerations.....	135
Management of Infection.....	136
Surgical Management of Extracranial Infections.....	137
Surgical Management of Intracranial Infections.....	138
Interval Care.....	139
Final Closure.....	140
Surgical Management of Specific Infections.....	141

Chapter 13

TANGENTIAL WOUNDS OF SCALP AND SKULL..... 143

PHILIP R. DODGE

General Pathophysiological Considerations.....	143
Pathological Findings.....	144
Clinical Features.....	145
Management of Tangential Head Injuries.....	147

<i>Chapter 14</i>	<i>Page</i>
THROUGH-AND-THROUGH WOUNDS.....	161
GRIFFITH R. HARSH III	
General Considerations.....	162
Surgical Management.....	163
Surgical Technique.....	164
 <i>Chapter 15</i>	
TRANSVENTRICULAR WOUNDS OF THE BRAIN.....	165
GORDON T. WANNAMAKER	
Definition and Diagnosis.....	165
Statistical Analysis.....	165
Representative Cases.....	167
Treatment.....	174
Factors in Mortality.....	178
 <i>Chapter 16</i>	
WOUNDS OF DURAL SINUSES.....	181
ARNOLD M. MEIROWSKY	
Analysis of Casualties With Wounds of Dural Sinuses Incurred in the Korean War.....	182
Superior Longitudinal Sinus.....	183
Transverse Sinus.....	188
Torcular Herophili.....	189
Sigmoid Sinus.....	190
Inferior Longitudinal Sinus.....	191
Superior Petrosal Sinus.....	191
Straight Sinus.....	191
Discussion.....	191
Surgical Technique.....	195
 <i>Chapter 17</i>	
WOUNDS INVOLVING THE AIR SINUSES.....	203
EDWARD J. BISHOP	
General Considerations.....	203
Types of Wounds.....	204
Associated Wounds.....	204
Antibiotic Therapy.....	204
Time Interval Between Injury and Definitive Surgery.....	204
Sinuses Involved.....	205
Findings at Operation.....	205
Surgical Management.....	205
Routine Sinus Management.....	206
Postoperative Complications.....	206
Mortality.....	207
Discussion.....	209
Surgical Technique.....	210

Chapter 18

CEREBROSPINAL FLUID FISTULA..... 213

C. DAVID SCHEIBERT

Etiology.....	213
Symptoms.....	214
Signs.....	214
Diagnosis.....	214
Preoperative Complications.....	215
Surgical Treatment.....	217
Surgical Technique.....	217
Results.....	218
Discussion.....	218

Chapter 19

POSTOPERATIVE MANAGEMENT..... 221

ARNOLD M. MEIROWSKY

Management of Coma.....	221
Restlessness.....	221
Bladder.....	222
Bowels.....	223
Sedatives and Analgesics.....	223
Feeding.....	225
Antibiotics.....	226
Eye Care.....	226
Skin Care.....	226
Body Temperature.....	226
Dressings.....	226
Flap Taps.....	228
Ventricular Taps.....	228
Lumbar Puncture.....	229
Cerebral Edema.....	229
Ambulation.....	229
Records.....	229

Chapter 20

REPAIR OF CRANIAL DEFECTS..... 233

DAVID L. REEVES

Historical Note.....	233
Materials Used.....	234
Operative Procedures.....	238
Cranioplasty.....	244
Summary and Conclusions.....	254

Posttraumatic Epilepsy

Chapter 21

CLINICAL MANIFESTATIONS..... 257

WILLIAM F. CAVENESS

Introduction.....	257
Incidence.....	257
Diagnosis.....	261
Therapy.....	262
Prophylaxis.....	262

<i>Chapter 22</i>	<i>Page</i>
BASIC MECHANISMS.....	265
WILLIAM F. CAVENESS	
Introduction.....	265
Complexity of Injury.....	265
Reaction to Injury.....	266
The Established Discharging Lesion.....	267
Propagation of the Abnormal Discharge.....	267
Precipitating Factors.....	269
Genetic Factor.....	270
Conclusion.....	270
Part 3	
TRAUMA OF SPINAL CORD	
Closed Spinal Cord Injuries	
<i>Chapter 23</i>	
GENERAL CONSIDERATIONS.....	273
HENRY G. SCHWARTZ, WILLIAM S. COXE, AND SIDNEY GOLDRING	
Review of Pertinent Anatomy and Pathophysiology.....	274
Management Upon Hospital Admission.....	275
<i>Chapter 24</i>	
DEFINITIVE TREATMENT.....	277
HENRY G. SCHWARTZ, WILLIAM S. COXE, AND SIDNEY GOLDRING	
Cervical Lesions.....	277
Thoracic and Lumbar Lesions.....	280
Early Medical Management.....	281
Spinal Fusion.....	284
Muscle Spasms.....	284
Pain.....	284
Penetrating Spinal Cord Injuries	
<i>Chapter 25</i>	
GENERAL CONSIDERATIONS.....	287
ARNOLD M. MEIROWSKY	
The Paraplegic Patient.....	287
Organization of Neurosurgical Care.....	289
Complications of Paraplegic Disorders.....	303
<i>Chapter 26</i>	
NEUROSURGICAL MANAGEMENT.....	307
ARNOLD M. MEIROWSKY	
Indications for Neurosurgical Intervention.....	307
Operative Method of Laminectomy.....	310

*Chapter 27**Page*

ANALYSIS OF WOUNDS INVOLVING THE CERVICAL CANAL INCURRED IN THE KOREAN WAR..... 327

GORDON T. WANNAMAKER

Level of Injury.....	327
Treatment.....	328
Neurosurgical Intervention.....	329
Time of Surgical Intervention.....	330
Sympathetic Blockade, An Acute Cervical Cord Syndrome.....	331
Results.....	331
Factors in Mortality.....	331

Chapter 28

ANALYSIS OF WOUNDS INVOLVING THE THORACIC CANAL INCURRED IN THE KOREAN WAR..... 333

JOSEPH C. BARNETT, Jr.

Associated Injuries.....	333
Surgical Management.....	333
Neurological Deficit.....	335
Followup Data.....	335
Mortality.....	335

Chapter 29

ANALYSIS OF WOUNDS INVOLVING THE LUMBOSACRAL CANAL INCURRED IN THE KOREAN WAR..... 337

ROBERT A. CLARK, Jr.

Initial Evaluation.....	337
Associated Injuries.....	338
Time of Operation.....	339
Findings at Operation.....	339
Short-Term Followup.....	340
Postoperative Problems.....	341
Long-Term Followup.....	341
Preoperative Evaluation and Preparation.....	342
Surgical Technique.....	344
Postoperative Care.....	344

Sequelae

Chapter 30

NEUROSURGICAL ASPECTS OF NEUROGENIC BLADDER..... 345

C. DAVID SCHEIBERT

Chapter 31

UROLOGICAL ASPECTS OF NEUROGENIC BLADDER..... 357

HANS H. ZINSSER

Introduction.....	357
Chronology of the Development of Urological Dysfunction After Central Nervous System Injury..	357
Necessary Studies and Resulting Patterns.....	359
Possible Modes of Treatment After Stabilization Has Been Obtained.....	362

<i>Chapter 32</i>	<i>Page</i>
SYMPATHETIC BLOCKADE, AN ACUTE CERVICAL CORD SYNDROME.....	365
ARNOLD M. MEIROWSKY	
Treatment.....	367
 <i>Chapter 33</i>	
AUTONOMIC HYPERREFLEXIA.....	369
ARNOLD M. MEIROWSKY	
 <i>Chapter 34</i>	
PHYSICAL AND VOCATIONAL REHABILITATION.....	371
ERNEST BORS	
General Considerations: Objectives of Rehabilitation.....	371
Special Considerations: Objectives and Techniques of Rehabilitation.....	372
Results of Rehabilitation.....	392
Epicritic Remarks.....	395
 <i>Chapter 35</i>	
THE PROBLEM OF PARAPLEGIA IN MODERN SOCIETY.....	399
MARCUS W. ORR	
 Part 4	
 SPASTICITY RESULTING FROM TRAUMA	
 <i>Chapter 36</i>	
THE SPINAL CORD AND SPASTICITY.....	403
ROBERT F. HEIMBURGER	
Characteristic Pattern.....	403
Description.....	404
Physiology.....	408
Treatment.....	410
 <i>Chapter 37</i>	
SPASTICITY ARISING FROM LESIONS IN THE BRAIN.....	417
ROBERT F. HEIMBURGER	
Decerebrate Rigidity.....	418
Spastic Hemiplegia.....	422
Extrapyramidal Disorders Resulting From Trauma.....	425
Forced Grasping.....	428

Part 5

ASSOCIATED WOUNDS

Chapter 38

	<i>Page</i>
MULTIPLE WOUNDS ASSOCIATED WITH PENETRATING TRAUMA OF BRAIN AND SPINAL CORD.....	431

FRANK B. BERRY

Physical Examination of the Patient.....	432
Head and Face.....	432
Chest.....	432
Hemorrhage.....	433
Trunk.....	434
Abdomen.....	434
Open Wounds and Fractures.....	435
Preparation for Surgery.....	435
Burns.....	435
Summary.....	436

Part 6

TRAUMA OF THE INTERVERTEBRAL DISK

Chapter 39

LUMBAR DISK.....	437
------------------	-----

R. GLEN SPURLING

Anatomy.....	437
Physiology.....	441
Clinical and Roentgenological Diagnosis of Lumbar Intervertebral Disk Lesions.....	443
Therapy.....	464
Postoperative Management.....	472
Postoperative Lumbar Pain.....	472

Chapter 40

CERVICAL DISK.....	475
--------------------	-----

R. GLEN SPURLING

General Considerations.....	475
Clinical Syndromes of Rupture of the Cervical Disk.....	476
Differential Diagnosis.....	483
Headache of Cervical Origin.....	484
Roentgenological Diagnosis.....	485
Differential Roentgenological Diagnosis.....	485
Myelography.....	487
Management.....	493

Chapter 41

THORACIC DISK.....	501
--------------------	-----

ARNOLD M. MEIROWSKY

Part 7

TRAUMA OF PERIPHERAL NERVES

Chapter 42

ANATOMY OF PERIPHERAL NERVES.....	505
-----------------------------------	-----

HUGO V. RIZZOLI

Component Fibers of Spinal Nerves.....	507
The Brachial Plexus.....	507
The Lumbar Plexus.....	524
The Sacral Plexus.....	528
The Pudendal and Coccygeal Plexuses.....	534

Chapter 43

PATHOLOGY OF PERIPHERAL NERVE INJURIES.....	537
---	-----

HUGO V. RIZZOLI

Peripheral Nerve Structure.....	537
Histological Changes in Nerve Injury.....	540
Pathological Classification of Nerve Injuries.....	543
Clinical Classification of Peripheral Nerve Injuries.....	544

Chapter 44

ELECTRODIAGNOSTIC TESTING OF PERIPHERAL NERVE FUNCTION.....	547
---	-----

CHARLES S. WISE

Response to Galvanic and Faradic Stimulation.....	547
Response to Electrical Currents of Varying Duration and Intensity (Strength-Duration Curve) ...	548
Chronaxie Measurements.....	549
Electrical Skin Resistance Measurements.....	550
Electromyography.....	550

Chapter 45

EXAMINATION AND CLINICAL MANIFESTATIONS OF PERIPHERAL NERVE INJURIES.....	553
---	-----

HUGO V. RIZZOLI

History.....	553
Examination.....	553
Other Clinical Manifestations.....	559

Chapter 46

TREATMENT OF PERIPHERAL NERVE INJURIES.....	565
---	-----

HUGO V. RIZZOLI

Nonoperative Treatment.....	565
Operative Repair of Peripheral Nerve Injuries.....	566
Surgical Exploration.....	566
Neurorrhaphy.....	572
Results.....	576

INDEX.....	581
------------	-----

Illustrations

Figure

Page

1. Methods of trephining in ancient times	2
2. Skull opening by multiple perforations	2
3. Hieroglyphics of Smith Papyrus	3
4. Trephines used by à Cruce in the 16th century	4
5. Diagram to show insertion of catheter, tract of penetrating missile, to locate foreign bodies	6
6. Tripod incision for small irregular wound of vault	7
7. Three-legged incision for larger wound of cranial vault	7
8. Casualty arriving at mobile neurosurgical unit by helicopter	19
9. Helicopter evacuation	20
10. Winter evacuation of neurosurgical casualty	21
11. Litter pods used in subzero temperatures	21
12. Craniotomy set	28
13. Laminectomy set	29
14. Mobile neurosurgical detachment, preoperative, operating, and postoperative ward tents	30
15. Ordnance-made litter stand used as operating table	31
16. "Mayo" stand	33
17. Sterile supplies on shelves in operating tent	33
18. Operating lamp	34
19. Preparation stand for casualties with head wounds	35
20. Postoperative ward tent	36
21. Portable dressing tray	38
22. Litter-turning method for paraplegic patients	39
23. Aspiration of tracheostomy tube	43
24. Bent 18-gage needle provides O ₂ supply	43
25. Chest restraint and padded gloves	47
26. Patient in decerebrate rigidity 2 days after injury and 1 year later	52
27. Delayed ecchymosis, fracture, anterior fossa	53
28. Subdural hematoma	58
29. Molding of brain due to hematoma	60
30. Ectopic subdural clots identified by ventriculography	62
31. Location of exploratory bur holes	63
32. Subtemporal decompression	64
33. Coma position	70
34-39. Surgical technique of scalp lacerations	77
40. S-shaped incision	86
41-42. Coronal flap	88
43. Unilateral flap across forehead	90
44. Dandy's "concealed" flap	91
45. Scalp closure by plastic procedures	92
46. <i>En bloc</i> resection of depressed fracture	93
47. Partial <i>en bloc</i> excision of depressed fracture adjacent to base of skull	94
48-53. Surgical technique of compound fractures of convexity of the skull	95
54. Dural graft	106
55. Facio-orbito-temporal wound; operative approach	109
56. Recovery after facio-orbito-temporal missile wound	110
57. Surgical management of penetrating right frontal wound of brain, with involvement of frontal sinus	111
58. Surgical management of penetrating left fronto-temporo-parieto-occipital transventricular wound of brain	114
59. Surgical management of penetrating parasagittal, biparietal missile wound of brain, with laceration of middle portion of superior sagittal sinus	115
60. Surgical management of penetrating right frontotemporal transventricular wound of brain	116
61-72. Surgical technique of penetrating wounds of the brain	118
73. Hematoma associated with penetrating wound	132
74. Open fungus treatment	140
75. Tangential wounds of scalp and skull	144
76. K-1282 and family 7 years after through-and-through gunshot wound of head	161

Figure	Page
77. Two distinct bony penetrations with intact intervening cranium.....	162
78. Two distinct dural penetrations with bony openings connected by common fracture.....	162
79. Supine position most useful for simultaneous attack on entrance and exit wounds in transverse through-and-through injuries.....	163
80. Lateral recumbent position for anteroposterior through-and-through injuries.....	163
81. Penetrating wound of the left parietal bone, with metallic fragment in left cribriform area.....	166
82. Surgical management of retained intracranial metallic foreign bodies, with <i>no</i> retained bone fragments.	170
83. Wandering metallic foreign body.....	175
84. Diagram with number of cases and location of wounds of dural sinuses.....	183
85. Repair of small laceration of dural sinus by strip of Gelfoam tied with sutures.....	193
86. Sinograms showing muscle occlusion of superior longitudinal sinus posterior to Rolandic vein of monkey.....	194
87-88. Photomicrograph of section of superior longitudinal sinus of monkey.....	195
89. Electroencephalographic and cerebrospinal fluid changes before, during, and after occlusion of sinus of monkey.....	197
90-93. Repair of dural sinus wound with muscle stamp.....	198
94. Wound involving left supraorbital ridge and left frontal air sinus.....	208
95. Intracerebral aerocele.....	216
96. Coma position.....	222
97. Three-cot method for care of restless patient.....	223
98. Application of mitts.....	224
99. Outer attachment for urinary drainage of unresponsive patients.....	225
100. Postoperative dressing with 3-inch Ace bandage.....	227
101. Flap tap tray.....	228
102. "Record Room," postoperative ward tent, 3d Neurosurgical Detachment (Provisional).....	230
103. Head injury card, 3d Neurosurgical Detachment (Provisional).....	231
104. The original Müller-König procedure, outer table graft.....	233
105. Demonstration of the Durante or von Hacker procedure, outer table graft.....	234
106. Double-hinged or cellar-door modification, outer table graft.....	235
107. Usual type of outer table graft.....	236
108. Technique of forming the tantalum plate.....	239
109. Methods of forming the mold and the tantalum plate.....	241
110. The lineator devised by Hemberger.....	242
111. An adjustable lineator devised by the author.....	242
112. Method of cutting out ledge of bone with a Stout No. 3 dental chisel.....	242
113. Perforations in the outer border of bony ledge.....	243
114. Wedge directer for tapping the tantalum wedges into position.....	243
115. Tantalum cranioplasty of congenital defect.....	245
116. Epidural granuloma removed from tantalum plate.....	246
117. Photomicrograph of epidural granuloma.....	247
118. Frontal and lateral photographs of patient after cranial repair 7 months postoperatively.....	248
119. Preoperative and postoperative photographs of defect of right side of skull.....	249
120. Repair of large skull defect.....	250
121. Repair of defect of left frontal region.....	251
122. Large skull defect before and after tantalum cranioplasty.....	252
123. Right fronto-orbital defect before and after tantalum cranioplasty.....	253
124. Defect in parasagittal area before and after tantalum cranioplasty.....	254
125. Closed head injuries—categories I, II, and III.....	258
126. Penetrating head injuries—categories IV, V, and VI.....	258
127. Incidence of posttraumatic epilepsy in World War II and Korean War veterans according to category of injury.....	259
128. Common sites of fracture dislocation in spinal cord injuries.....	274
129. Compression fracture and dislocation accompanied by locked facets.....	278
130. Fracture of odontoid process with atlanto-axial dislocation.....	279
131-132. Compression fracture and dislocation of L1.....	280
133. Paraplegic patient being prepared for evacuation.....	291
134. Helicopter evacuation of paraplegic patient.....	292

<i>Figure</i>	<i>Page</i>
135. Turning of paraplegic patient in operating tent.....	293
136. Position of feet in supine position.....	294
137. Position of feet in prone position.....	295
138. Lifting of quadriplegic patient.....	296
139. Medical record for paraplegic patient.....	298
140-151. Technique of laminectomy in presence of penetrating wound of spinal canal.....	312
152. Frequency of missile wounds involving lumbosacral canal.....	338
153. Paraplegic and his chickens 7 years after sustaining penetrating wound of the spinal canal (T12-L1) in North Korea.....	343
154-155. Differential sacral neurotomy.....	351
156-159. Forms used by the Veterans' Administration in caring for paraplegic patients.....	374
160. Segmental innervation of the movements of the upper and lower limbs.....	381
161. Workbench for paraplegics.....	391
162. Spontaneous flexor spasticity 4 years after spinal cord injury at level of sixth thoracic vertebra.....	406
163. Movements of decerebrate rigidity 24 hours after closed head injury.....	419
164. Right spastic hemiparesis 4 years after avulsion of the left frontoparietal scalp, skull, and cortex...	424
165. Roentgenograms showing the track of .22 caliber bullet.....	427
166. Composite picture, to demonstrate parkinson-like tremor of left hand.....	428
167. Diagrammatic sagittal section through two lumbar vertebrae.....	439
168. Distribution of second recurrent lumbar nerve to region of third and fourth lumbar vertebrae.....	440
169. Diagrammatic presentation of function of intervertebral disk.....	442
170. Typical lumbar deformity (sciatic scoliosis) in patient with ruptured lumbar disk.....	447
171. Typical lumbar deformity in patient with ruptured disk.....	447
172. Reproduction of pain pattern in ruptured intervertebral disk by forcible lateral bending and rotation toward painful side.....	448
173. Reproduction of radicular pain by deep percussion.....	448
174. Jugular compression test.....	449
175. Modification of sciatic-nerve-stretching test of Lasègue by dorsiflexion of foot.....	450
176. Testing of gastrocnemius muscle.....	451
177. Lumbar and sacral dermatomes according to Keegan.....	452
178. Sensory dermatome deficit with rupture of third, fourth, and fifth lumbar disks.....	453
179. Optimal position for eliciting Achilles tendon reflex.....	454
180. Normal Pantopaque myelogram (serial exposures).....	460
181. Pantopaque myelogram showing anterior defect in opaque column at L4-L5 interspace in lateral view.....	461
182. Pantopaque myelogram (serial exposures) showing filling defect characteristic of a ruptured disk at L5-S1 interspace.....	462
183. Pantopaque myelogram (serial exposures) showing characteristic filling defect of a ruptured disk at L5-S1 interspace.....	462
184. Pantopaque myelogram showing large filling defect on left characteristic of tumor of cauda equina...	462
185. Pantopaque myelogram (serial exposures) showing filling defect at L3.....	464
186. Operative field during first stages of exposure of herniated nucleus pulposus at L4-L5 interspace...	470
187. Operative field after exposure of herniated nucleus pulposus at fourth lumbar interspace.....	470
188. Mechanism of root compression by bony spur and outer fibers of annulus fibrosus.....	477
189. Technique of neck compression test.....	478
190. Approximate areas of forearm and hand into which pain or paresthesiae radiate or in which sensation is diminished when nerve roots are compressed.....	479
191. Mechanism of bilateral ventral pressure from central herniation of nucleus pulposus.....	481
192. Mechanism of root compression in lateral herniation of nucleus pulposus.....	482
193. Lateral roentgenogram showing fracture dislocation of C4 on C5 vertebrae.....	486
194. Lateral roentgenogram showing incomplete congenital fusion of C3 and C4 vertebrae.....	487
195. Lateral roentgenogram showing congenital fusion of spinous processes of C2-C3.....	488
196-197. Myelogram of normal cervical spine.....	490
198. Myelogram showing deformity of root sleeve.....	492
199. Myelogram showing minimal deformity of axillary pouch.....	493
200. Patient with ruptured cervical disk in halter traction.....	494
201. Patient in upright position for operation on cervical disk.....	496

<i>Figure</i>	<i>Page</i>
202. Roentgenogram taken at operating table to verify correct level of exposure.....	497
203. Diagrammatic representation of operative field at operation for ruptured cervical disk at C6-C7 level.....	498
204. Pantopaque myelograms showing well-defined defect opposite the T10-T11 interspace on the left...	503
205. Dermatome map.....	505
206. Typical spinal nerve.....	506
207. Brachial plexus.....	508
208. Testing of rhomboid muscles.....	509
209. Testing of serratus anterior muscle.....	510
210. Testing of supraspinatus muscle.....	511
211. Testing of infraspinatus muscle.....	511
212. Testing of pectoralis major muscle.....	512
213. Testing of latissimus dorsi and teres major muscles.....	512
214. Musculocutaneous nerve.....	513
215. Testing of biceps brachii muscle.....	514
216. Axillary nerve, including sensory distribution.....	514
217. Testing of deltoid muscle.....	514
218. Radial nerve.....	515
219. Testing of triceps muscle.....	516
220. Testing of brachioradialis muscle.....	516
221. Testing of extensor carpi radialis longus, extensor digitorum communis, and extensor carpi ulnaris muscles.....	517
222. Median nerve.....	518
223. Testing of pronator teres muscle.....	519
224. Testing of flexor carpi radialis muscle.....	519
225. Testing of flexor digitorum profundus muscle.....	520
226. Testing of flexor pollicis longus muscle.....	520
227. Testing of abductor pollicis brevis muscle.....	520
228. Ulnar nerve.....	521
229. Testing of flexor carpi ulnaris muscle.....	522
230. Testing of flexor digitorum profundus muscle.....	523
231. Testing of abductor digiti quinti muscle.....	523
232. Testing of first dorsal interosseus muscle.....	523
233. Testing of adductor pollicis muscle.....	524
234. Lumbar plexus.....	525
235. Femoral nerve and obturator nerve.....	526
236. Testing of iliopsoas muscle.....	528
237. Testing of quadriceps femoris muscle.....	528
238. Sacral plexus.....	529
239. Sciatic and tibial nerves.....	531
240. Testing of biceps femoris and semitendinosus and semimembranosus muscles.....	532
241. Testing of gastrocnemius muscle.....	532
242. Common peroneal nerve.....	533
243. Section of common peroneal nerve.....	538
244. A higher magnification of a part of a nerve fascicle in cross section.....	539
245. Longitudinal section through a peripheral nerve.....	539
246. Longitudinal sections of peripheral nerves.....	540
247. Diagrammatic representation of various stages of degeneration and regeneration of distal stump of a peripheral nerve.....	541
248. Complete severance of ulnar nerve.....	542
249. Strength-duration curves of electrical excitability.....	549
250. Electromyogram during muscular relaxation.....	550
251. Electromyogram during muscular contraction.....	551
252. Electromyogram showing fibrillation potential of denervation.....	551
253. Electromyogram showing potentials occurring during partial degeneration or regeneration of peripheral nerve.....	551
254. Radial nerve paralysis.....	554
255. Combined median and ulnar nerve paralysis.....	554

Figure	Page
256. Thomas splint for radial nerve paralysis.....	565
257. Skin incision for exposure of brachial plexus.....	569
258. Skin incision for closure of musculocutaneous nerve.....	569
259. Skin incision for exposure of axillary nerve.....	569
260. Skin incision for exposure of proximal third of radial nerve.....	569
261. Skin incision for exposure of radial nerve in lateral aspect of arm.....	569
262. Skin incision for exposure of radial nerve in forearm.....	570
263. Course of median nerve in upper extremity.....	570
264. Terminal branches of median nerve below annular ligament.....	570
265. Skin incision for exposure of the ulnar nerve in upper extremity.....	570
266. Skin incision for exposure of ulnar nerve at wrist and in hand.....	571
267. Anatomical approach to sciatic nerve.....	571
268. Anatomical approach to tibial nerve in calf.....	571
269. Anatomical approach to peroneal nerve.....	572
270. Classical method of end-to-end suture following resection of scarred ends by serial section.....	575
271. Procedure for repair of lateral neuroma.....	575
272. Neurorrhaphy of median and ulnar nerves in the arm.....	576
273. Roentgenograms following neurorrhaphy of median nerve at wrist, showing marking sutures.....	577

Tables

Number	
1.	Provisional table of organization for mobile neurosurgical units, October 1951..... 29
2.	Tentage for mobile neurosurgical unit..... 30
3.	Vehicles for mobile neurosurgical unit..... 30
4.	Type of wounds in 1,105 casualties with craniocerebral injuries, Korean War..... 68
5.	Mode of injury in 226 consecutive cases of compound fractures of the skull..... 84
6.	Intracranial hematomas in 226 consecutive cases of compound fractures of the skull..... 85
7.	Mode of injury in 379 consecutive penetrating wounds of the brain..... 104
8.	Mortality rate of 379 consecutive penetrating wounds of the brain..... 104
9.	Incidence of hematomas in 316 consecutive cases of penetrating wounds..... 131
10.	Relationship between location of wound and formation of hematoma..... 134
11.	Correlation between the site of injury and focal neurological signs in 31 cases..... 145
12.	Tangential scalp wounds in 31 patients..... 148
13.	Site of ventricular penetration in 214 consecutive Korean battle casualties..... 165
14.	Nationality of 214 consecutive Korean battle casualties..... 166
15.	Installation of first surgical treatment of 214 consecutive Korean battle casualties..... 167
16.	Indications for reoperation among the 211 patients who survived initial surgery..... 168
17.	Operative procedure in 214 consecutive Korean battle casualties..... 177
18.	Factors in mortality in the 31 fatal cases among 214 consecutive Korean battle casualties..... 179
19.	Classification of casualties with wounds of dural sinuses, September 1950 through August 1952, Korea... 182
20.	Site of 112 wounds of dural sinuses, September 1950 through August 1952, U.S. Army, Korea..... 182
21.	Type of lesion in 124 dural sinus wounds..... 183
22.	Surgically significant intracranial hematomas in 112 cases with wounds of the dural sinuses..... 184
23.	Incidence of involvement of the air sinuses in 100 consecutive cases of penetrating craniocerebral wounds.. 205
24.	Types of complications in 17 cases with dural penetration..... 205
25.	Types of lesions found in 13 of 16 cases presenting an intact dura at operation..... 205
26.	Types of dural closure used and subsequent development of cerebrospinal fluid fistula..... 207
27.	Posttraumatic epilepsy studies and period of followup..... 257
28.	Fits in relation to mode of injury, Korean War veterans..... 259
29.	Fits in relation to mode of injury, World War II veterans..... 259
30.	Neurological deficit and results of surgical (laminectomy) and nonsurgical treatment of 64 patients..... 332
31.	Characteristics of the acute cervical cord syndrome in 26 patients with cervical cord injuries..... 366
32.	Group classifications for corrective therapy exercises for paraplegics..... 386
33.	Group classifications for corrective therapy exercises for partial quadriplegics..... 387
34.	Functional significance of spinal cord lesion level..... 393
35.	Muscle responses to stimulation by galvanic and faradic current..... 548

MILITARY NEUROSURGERY

Historical Notes

CHAPTER 1

Head Injuries

Maitland Baldwin

In all of our wars and each of our battles, head injuries have been a part of the harsh toll exacted from the fighting forces. Across the years between Concord and Remagen, Champlain and Korea, these serious injuries have occurred in each major action and every theater of war. In the engagements at White Plains, Gettysburg, or San Juan Hill, a serious head injury was almost invariably a fatal injury. In those battles, and in the wars of which they were a part, very few casualties with serious head injuries survived the effects of their wounds. Then, as now, the need for treatment was obvious and urgent. Treatment was usually available and almost invariably ineffective. The men who looked down the slope of Breed's Hill or across the field from Cemetery Ridge knew that a brain wound was usually the last wound. Soldier and surgeon alike regarded brain wounds with a realistic and fatalistic attitude. A saber edge, musket or minié ball, grapeshot or casing fragment in the brain meant the end of a soldier's life. When the initial impact was great, death was quick. If the first blow was less severe, death came slowly with brain herniation, bleeding, delirium, and coma. Some casualties survived to die of sepsis, and a very few lingered on as paralyzed, blind, and foolish cripples. Treatment did not materially alter this grim course. For, in those times, surgeons could not cope with the special and

complicated problems of brain wounds. The problems of cerebral edema, hemorrhage, and sepsis found no adequate solution in contemporary treatment. Certainly, the fatalistic attitude of soldier and surgeon toward these terrible injuries was not without basis in reality. Strangely enough this same attitude, which originated in old experiences, persists today. Yet modern experience (in treatment) does not provide any realistic basis for its continuation. Since the campaigns of 1917-18, methods of treatment have become increasingly effective. Indeed, a soldier who suffered a brain wound while fighting in the Meuse-Argonne had a far better chance of survival than his professional antecedents who received similar wounds at Cold Harbor or Antietam. Moreover, the records of treatment from the campaigns of 1941-45 provide even more evidence for success. In that war the majority of those who survived initial impacts were rehabilitated. However, even this fine record was surpassed in the more recent Korean War. From Pusan perimeter to the Yalu River most casualties with brain wounds that came to definitive treatment survived and many such patients have been successfully rehabilitated.

In the wars before 1917-18, soldiers with brain wounds usually died as a result of their injury. Then, and in later wars, soldiers with brain wounds

often survived. Recently, the morbidity and mortality of these and other combat wounds of the nervous system have fallen steadily. This happy decline is directly related to the development of neurological surgery as a special field. Once this modern specialty began its growth and development, its techniques became available for application in combat and in the further treatment of combat injuries. The applications of neurological surgery in combat areas and in supporting hospital facilities has materially reduced the traditional morbidity and mortality of brain wounds.

Obviously, American military neurosurgery is a modern development. It is, in fact, a development of the 20th century. Yet like its civilian counterpart, military neurosurgery has an ancient lineage. For craniotomy (one of the principal operations of modern neurosurgery) was practiced in one or another form in ancient times. Actually, the crude forms of craniotomy are probably the oldest of all surgical operations. Men of the stone age operated

that the same craftsmen used coca leaves as local anesthetics in scalp wound edges before craniotomy. Apparently, the ancient craniotomies were performed for four reasons: fracture, laceration of the periosteum, acute osteitis, or syphilis. These are the conclusions of Tello (3) who examined 400 prehistoric crania (fig. 2).

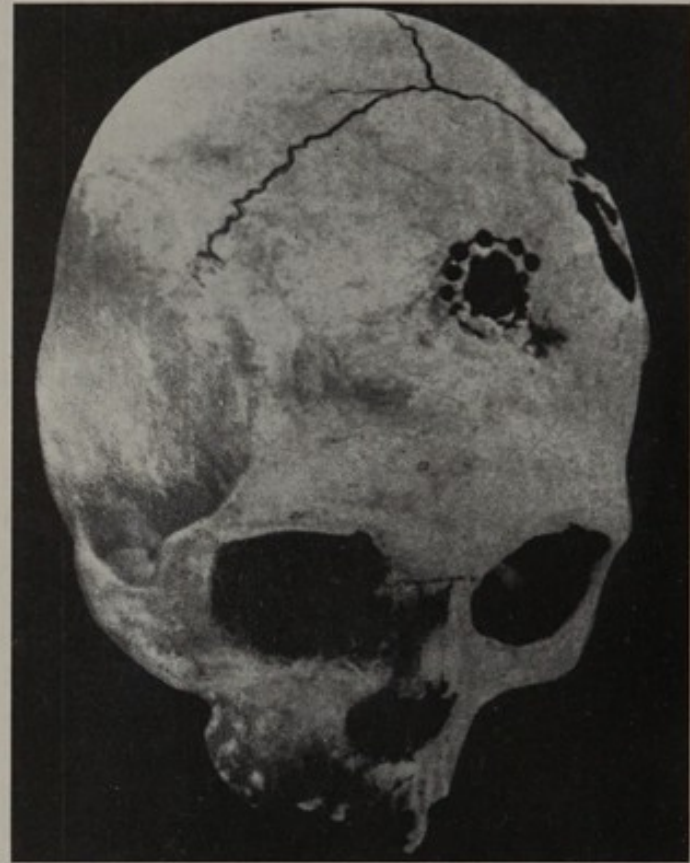


FIGURE 2.—Skull opening by multiple perforations. (From Tello.)

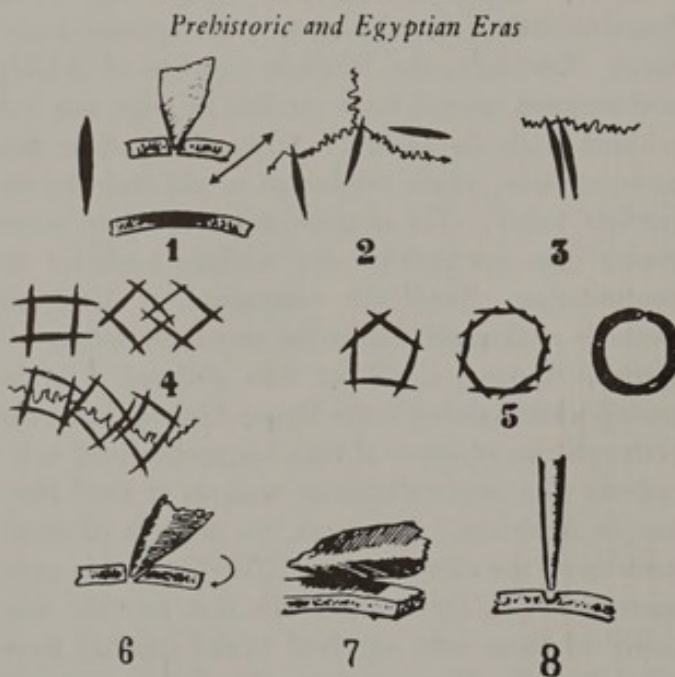


FIGURE 1.—Methods of trephining in ancient times. (From Tello.)

on living heads in various ways (fig. 1). The ancient Incas even developed the art of craniotomy so that it was useful in treatment of combat injuries. According to Cushing (1), these Peruvians not only trephined with some success, but also made successful cranioplasties with silver. Courville (2) says

However, there is no evidence that these ancients knew anything of brain function. Apparently their technical skill (although limited) developed without any knowledge of brain anatomy or function. Yet later, in the early Egyptian writings, there is some evidence for knowledge of brain function, while there is very little evidence of relevant surgical techniques. In the Edwin Smith Surgical Papyrus (4) (circa 1700 B.C.) the meninges and brain convolutions are mentioned. In fact, this Egyptian papyrus probably contains the first mention of the word "brain" in human writings. For example, the writer describes a "gaping wound of the head with compound comminuted fracture of the skull and rupture of the meningeal membranes." Then in his report

of the examination, he says: "If thou examinest a man having a gaping wound in his head, penetrating to the bone, smashing his skull, (and) rending open the brain of his skull, thou shouldst palpate this wound. Shouldst thou find that smash which is in his skull [like] those corrugations which form in molten copper, (and) something therein throbbing (and) fluttering under thy fingers, like the weak place of an infant's crown before it becomes whole—

when it has happened there is no throbbing (and) fluttering under thy fingers until the brain of his (the patient's) skull is rent open—(and) he discharges blood from both his nostrils, (and) he suffers with stiffness in his neck, * * *." Actually this ancient Egyptian writing refers to brain as "marrow of the skull" (fig. 3). This papyrus also provides evidence that the ancient Egyptian surgeons knew something of the relation of cerebral function

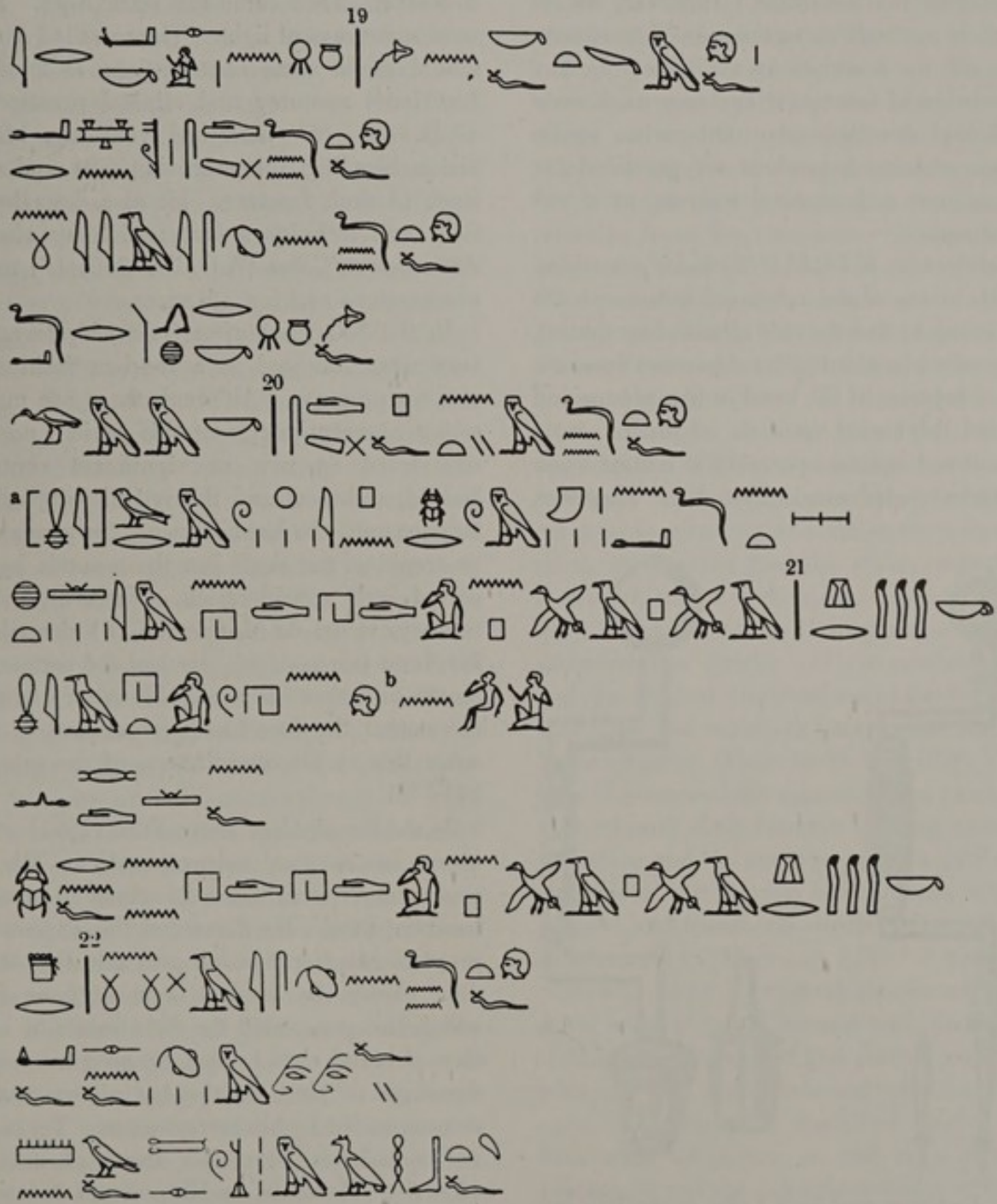


FIGURE 3.—Hieroglyphics of Smith Papyrus which describe meninges and cerebral cortex as they appear in a cranial wound. (Hieroglyphics for brain are underlined.) (From Breasted.)

and surface anatomy. A case of left temporal depressed fracture is described in which the site of injury is related to a speech deficit and a contralateral paralysis. Altogether, there are 27 observations of head injuries in this extraordinary record. It is certainly the oldest written account of combat head injury and its treatment.

Obviously, the Egyptians knew something of the functional anatomy of the brain and its coverings. Apparently, they used this knowledge in selection of head injuries for treatment. However, we do not know their methods or techniques of treatment, since there are no descriptions available. In any age, a knowledge of functional anatomy must come before technical developments. Otherwise, operative practice remains a random art practiced for various emotional and mystical motives, as it was in the stone ages.

Hippocrates (460–357 B.C.) (5) knew something of both. He wrote of the relationship between the side of brain injury and the side of motor symptoms, and he advocated trephining for depressed fracture. He classified injuries of the head in five groups and recommended trephining in some of them. Actually, he cautioned against operation in certain cases which might be treated surgically today. However,

he brought what is now called the scientific method to consideration of these problems. Therefore, his writings are a great landmark in this small area of medicine, as in others. Before and after him, diagnosis and therapy was a peculiar compound of ignorance, mystical conjecture, and tragic error.

After Hippocrates (or the Grecian period), the diagnosis and treatment of head injuries did not flourish for a long time. In this, as in other intellectual pursuits, progress slowly diminished until it ceased. Then came the Dark Ages. Still there were some rays of light. The so-called Alexandrian school made some contributions to knowledge of functional anatomy and clinical practice. Celsus (A.D. 37) (6) described vomiting, blurring of vision, bleeding from cranial orifices, and aphasia as signs of skull fracture. He also described indications and techniques for craniotomy after injury. After Celsus, Galen (A.D. 130–210) (7) made some observations and few advances.

In the 500 years after Galen, hippocratic teachings were followed in a random fashion. There was no progress. Although there are many interesting observations from this period, none can be considered as new or significant contributions. Indeed, technical and theoretical progress was not evident until the Renaissance. Surgeons continued to trephine the skull but the wounds beneath received little consideration. However, in the 13th century, Henri de Mondeville (8) described a test for dural penetration. He had the patient close his mouth and blow his nose. If matter extruded from the wound, the dura had been penetrated. Cushing notes this in his observations of the campaigns in 1917–18.

In the Renaissance years, Paré (1561) (9) towers above his surgical contemporaries. His name is synonymous with some progress in treatment of head injuries. He discarded the ancient ideas of prophylactic trephination and said that this procedure should be used to remove bone fragments which had penetrated the dura mater or in evacuation of blood clots. Also, he used innocuous head dressings in place of the hot oil or cauterization recommended by his predecessors. Yet his trephining techniques were like those of ancient days (fig. 4). However, as Hippocrates before him, he observed the relationship of extremity paralysis to side of brain injury.

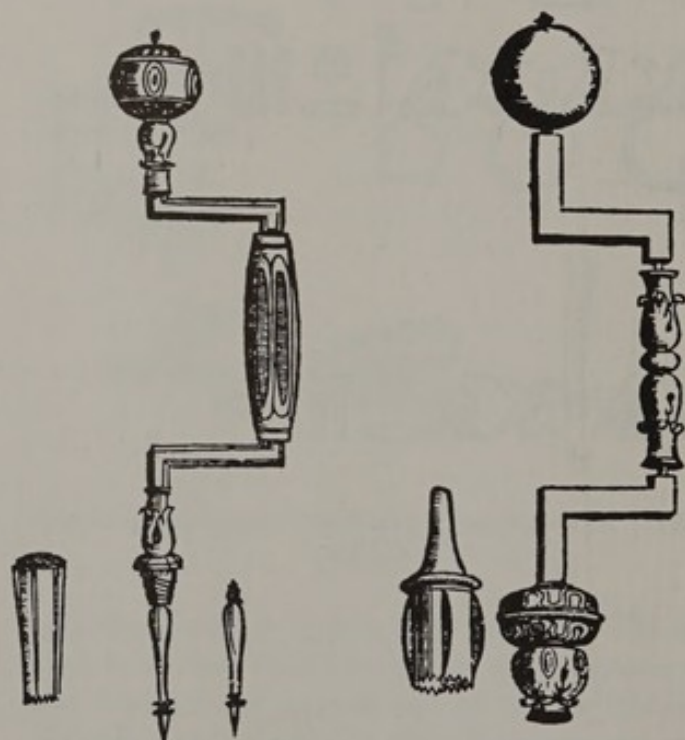


FIGURE 4.—Trephines used by à Cruce in the 16th century. (From Walker, A. Earl: *A History of Neurological Surgery*. Baltimore: Williams & Wilkins Co., 1951.)

Paré and his contemporaries did not emphasize the importance of brain damage in head injury. Percivall Pott (1778) did emphasize the significance of the brain injury and recommended trephining. It was during this period that operative technique extended far beyond its theoretical support. There was a bewildering array of surgical tools available to the hand of a surgeon with temerity. Yet, there was no information on prevention of wound infections and nothing could be done to prevent them. Thus, most craniotomy patients died of sepsis and the operation fell in disrepute. Moreover, little was added to knowledge of functional anatomy, and anesthesia was unknown. Yet there were some successes. Sir Astley Paston Cooper (1768–1841) and a Mr. Hempstead diagnosed and successfully treated (by craniotomy) a case of focal seizures caused by depressed fracture (10).

In general, the military experience of these periods is a reflection of what may be called contemporary civilian practice. The American wars of 1775 and 1812 added nothing to the progress of diagnosis or treatment. Schmucker (11), Surgeon-General in the armies of Frederick the Great, advocated prophylactic trephination. Baron Larrey (12), a surgeon in the Napoleonic Wars (1829), advised craniotomy for all cases of depressed or comminuted fracture, as well as those with impacted foreign body or intracranial hematoma. The War Between the States (1861–65) did not provide any evidence of progress. The arduous campaigns of this war from Fort Sumter to Appomattox were fought before understanding of antisepsis and during the infancy of anesthesiology. Keen (13) states that patients recovered "in spite of our encouragement of infection." He notes that surgical sponges used to wipe the wound were often dropped on the floor, recovered, and used again! The death rate from pyemia of wounds of head, face, and neck was 95.4 percent (14). Nine hundred and eighty-three cases of brain injury (15) were reported in detail. The mortality and morbidity of these cases were forbidding, yet not surprising. Lister did not make his reports on antisepsis until 1867. Moreover, anesthesiology was in its infancy and its uses in neurological cases were not clearly defined. However, anesthetics were widely used, chloroform being the most popular. It is estimated that over 80,000 administrations of anesthesia were required in this

war.

The principles of antisepsis, cerebral localization, and anesthesia were not sufficiently clear in the campaigns of 1861–65 to foster development of neurological surgery. Yet some organizational development did support the beginnings of military neurosurgery, for Weir Mitchell (16) was able to organize the first hospital designed for the care of neurological injuries. This hospital was the legitimate ancestor of both the Neurological Units of the First World War and of the Canadian Neurological Hospital in the Second World War.

During the period of the Civil War, surgeons elsewhere were analyzing the intimate causes and effects of head injury. Likewise, physicians and physiologists were investigating mechanisms of brain function and thus providing a more rational and scientific basis for treatment. Broca (1861) (17) reported a "centre" for speech representation in the third posterior frontal convolution. Later, in 1870, Fritsch and Hitzig (18) described motor centers in the cerebral cortex; 1870 was also the year of the Franco-Prussian War. In this conflict, the antiseptic principles of Lister found their first military applications. Thus, the foundations of modern neurosurgery were being constructed in knowledge of cerebral localization and antiseptic techniques. Indeed, this period saw the embryology of modern cranial operative techniques. Actually, these were born in the last of the 19th century. The scientific discoveries of Ferrier (19) in cerebral localization and the clinical observations of Jackson (20) provided the last essential background for success in brain surgery. Thus, on 25 May 1886, Victor Horsley (21) successfully operated on a young man with a compound skull fracture causing seizures. This operation and the subsequent work of Horsley is an example of the peculiar combination of physiology, asepsis, and anesthesia which characterizes modern neurosurgery. Macewen (22), 2 years later, reported 21 cases of cerebral abscess treated by operation without mortality and with great success.

Military surgeons of this period profited by these advances and made technical contributions of their own. Krönlein (23) described careful aseptic and hemostatic technique, as well as a method of debridement and the conditions under which the dura should be opened.

By the time of the First World War, neurological

surgery was passing its childhood years. Roentgen-ray techniques were added to the growing arsenal of the military neurosurgeon and he had learned the contemporary lessons of asepsis, anesthesia, and cerebral localization. Actually, his work in the years immediately preceding the 1914 conflict already shows the effects of these lessons—for the campaigns in Cuba and South Africa saw the effective use of some antiseptic principles.

However, contemporary military neurosurgery begins with the war of 1914–18. In the United States, the Council of National Defense, through its General Medical Board, selected civilian surgeons for special assignments in neurosurgery. Harvey Cushing, who had already seen experience with the British Expeditionary Force, was a natural choice. He made the most of this opportunity in provision of organizational, scientific, and technical principles which are still applicable today. In June 1918, neurological surgery was made a separate subservice of the general surgical services. Colonel Cushing was appointed as senior consultant. He analyzed the problem, as follows: (1) The immediate care in forward hospitals of more serious cases, and (2) the later care at the base hospitals of the residual paralyses of the main peripheral nerves, the neurosurgical aspects of which were not likely to come into prominence until the complete healing of complicating wounds and fractures (24).

Cushing knew that the previous results of early operations for penetrating wounds of the skull showed an operative mortality of from 50 to 65 percent. This was a grim reminder of the need for more effective organization and application of more efficient techniques. Thus he said that the most urgent organizational need was for officers who had some neurological training in case of penetrating wounds of the skull. These surgeons would be assigned to units in forward areas. In the obvious emergency which existed, Cushing did not consider provision of such personnel in base hospitals. Eventually, he hoped to establish neurological centers in rear areas so that special treatment could be provided after the care in forward zones. The next problem was procurement of special instruments, such as perforators, rongeurs, and drills. This was solved by purchase from French firms, since none were available from U.S. Army sources. Then, detailed instruction was provided to selected surgeons

in various evacuation hospitals. In addition, concise instructions entitled "Directions to Neurosurgical Teams Concerning Craniocerebral Wounds" were prepared. In all this careful organization, Cushing tried to teach one lesson: If craniocerebral cases were operated in forward areas by specially trained teams, the mortality was reduced by 50 per-

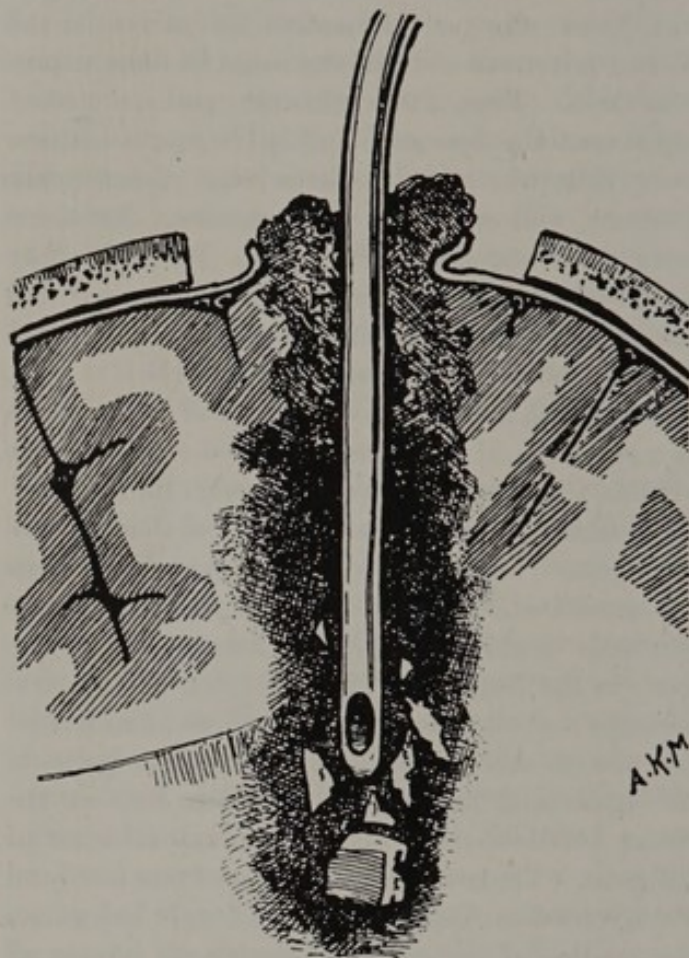


FIGURE 5.—Diagram to show insertion of soft rubber catheter in track of a penetrating missile to locate foreign bodies. (From Cushing.)

cent. He reported that in 200 cases operated on in a forward area, the mortality was 28.5 percent; whereas in a similar series operated on by the same team in a base hospital, the mortality was 45 percent. Despite this and other effective evidence of his system, it was never fully implemented. Commanding officers often reassigned neurosurgical team members to general duty or refused to allow time-consuming neurosurgical procedures when these could be avoided by transfer of cases to rear areas. Nevertheless, by July 1918, Cushing had assigned teams to most evacuation and mobile hospitals.

Meanwhile, he established a school for training replacements. In the Meuse-Argonne operation he was permitted to assign enough neurosurgical teams to evacuation and other mobile facilities so that casualties with craniocerebral trauma received almost continuous operative treatment. This plan compared favorably with four other plans which were advanced, as follows:

1. Operations on craniocerebral wounds by uninstructed surgeons unfamiliar with this special kind of work.
2. Single neurosurgical teams placed in individual hospitals.
3. A number of teams collected in one special hospital.
4. The placing of two teams in larger evacuation hospital centers on the main lines of traffic.

The system worked effectively when properly applied. In about 900 cases of head injury, 23 percent died, 43 percent returned to duty, 26 percent were unfit for military service, and 5 percent were sent to convalescent camps.

Cushing's scientific and technical contributions to military neurosurgery were numerous. He described a technique of debridement of cranial wounds under local anesthesia (fig. 5) and cranioplasty (figs. 6 and 7). His careful investigation of various brain wounds added to future knowledge of treatment and provided invaluable data in pathological anatomy.

After World War I, neurosurgery continued its rapid development. This development was once more a function of various physiological and tech-

nical advances. The particular care of head injury received impetus through development of suction apparatus, the electrocautery, and various hemostatic clips, as well as from administration of blood transfusions. Diagnostic procedures such as electroencephalography and pneumography provided additional aids for study of the aftereffects of brain wounds. Finally, technical and scientific information was coordinated in treatment of special after-effects, such as posttraumatic epilepsy.

World War II brought with it the sulfonamides and the antibiotics, as well as new hemostatic agents in the form of Gelfoam. Cushing's techniques were modified in accordance with these developments, and in addition, new techniques of dural repair were devised. Tantalum cranioplasty was reported by Pudenz (25) and widely used thereafter. There were some significant and important studies on the mechanisms of head injury. All these advances gave vitality and effectiveness to the practice of neurosurgery in the campaigns of 1941-45. Once more, the elements of its success could be found in the principles of cerebral localization and the techniques of hemostasis, antisepsis, and anesthesia. The organizational problems were similar to those faced in World War I. The need for specially trained personnel organized in teams was apparent. This was usually solved by assignment of trained personnel to mobile Army hospitals, such as evacuation and field hospitals. These forward units were supported by neurological and neurosurgical units in base installations. The Canadians solved the problem by establishing a neurological hospital in a rear area which was in support of forward units.

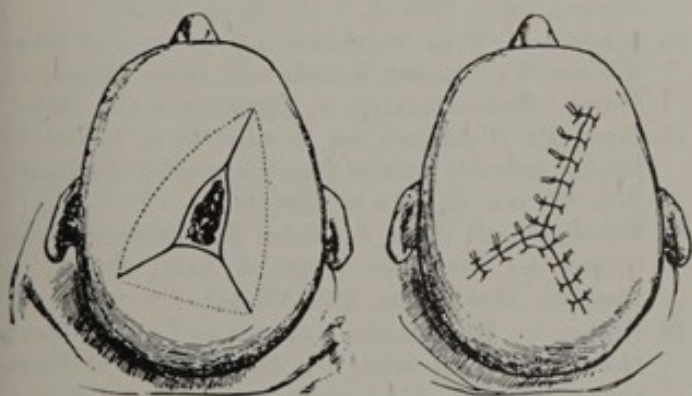


FIGURE 6.—Tripod incision for small irregular wound of vault. Dotted lines indicate area of reflection of flaps. (From Cushing.)

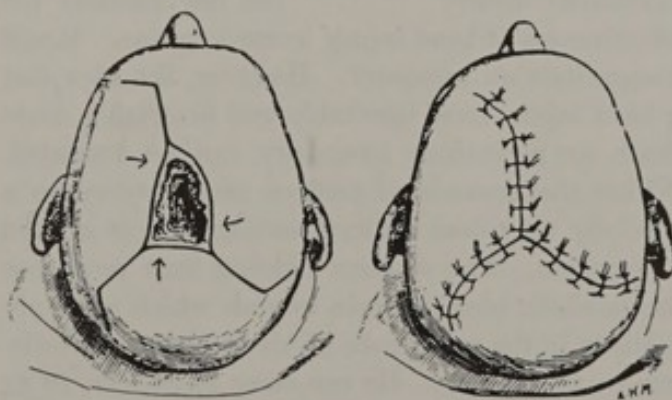


FIGURE 7.—Three-legged (Isle of Man) incision for larger wound of cranial vault. (From Cushing.)

One of the forward units captured in the action before Dunkirk included a British neurosurgical team.

Today, neurosurgery has come of age. In its maturity, it can offer much to the care of combat casualties. This can be done, and indeed, must be done. The doing will be easier and the results more satisfactory if we can learn from the lessons of the past that this is a special field which cannot be left to the uninstructed. Nor can the trained personnel of today function effectively without organization and concentration in special environments. The organization of personnel and the development of special working environments for them are practical in the various military settings. This has been amply demonstrated in several past campaigns. It must be accomplished in the future in order that our casualties receive the high standard of care which they deserve.

The special requirements of neurological surgery are not those of the men who serve it. These requirements are clearly defined, now, in the maturity of neurosurgery by the characteristics of the human brain which it is designed to treat. These characteristics have been defined in numerous scientific investigations which form the essential background of this modern specialty. Moreover, the experience in all the campaigns from Concord to Appomattox has shown that the brain does not tolerate casual or ignorant treatment.

Fighting men have known the effectiveness of a head injury for centuries. Indeed, generations of fighting men understand the advice which John of Gaunt gave to a knight before combat (26): " * * * let thy blows, doubly redoubled, fall like amazing thunder on the casque of thy adverse pernicious enemy * * *." No one contests the effectiveness of head injury in modern war. It will incapacitate an opponent. However, the idea that a head injury must inevitably and invariably cause death or permanent incapacity can be contested. Within the grounds of modern neurosurgery on a specially organized military setting, this is a valid assumption. The modern fighting man must lose the fatalistic idea of brain wounds which was only realistic in the experience of his forebears at Antietam or Gettysburg. He can come to believe, in its modern connotation, the dictum of Galen: "I have seen a wounded brain heal."

REFERENCES

1. Cushing, Harvey: *Surgery of the Head*. In Keen, William W.: *Surgery; Its Principles and Practice*. Philadelphia: W. B. Saunders Co., 1908, vol. III, pp. 17-276.
2. Courville, C. B.: Prehistoric Trepanation. *Bull. Los Angeles Neurol. Soc.* 1: 42-46, 1937.
3. Tello, J. C.: Prehistoric Trephining Among the Yauyos of Peru. *Proc. 18th Internat. Cong. of Americanists*, 1913, London, 2 vols., pp. 75-83.
4. Breasted, James H.: *The Edwin Smith Surgical Papyrus*. Chicago: The University of Chicago Press, 1930, vol. I, pp. 165-166.
5. Adams, Francis: *The Genuine Works of Hippocrates*. London: The Sydenham Society, 1849.
6. Celsus, Aurelius C.: *De Medicina*. English translation by W. G. Spencer. Cambridge, Mass.: Harvard University Press, and London: W. Heinemann, Ltd., 1935-38.
7. Galen: *Medicorum Græcorum operum quæ exstant*. Edited by C. G. Kühn. Leipzig: C. Knobloch, 1821-33.
8. De Mondeville, Henri: *Chirurgie de Maître Henri de Mondeville*. Translated by E. Nicaise. Paris: G. Baillière et Cie., 1893.
9. Paré, Ambroise: *Oeuvres complètes d'Ambroise Paré revues et collationnées sur toutes les éditions avec les variantes*. By J.-F. Malgaigne. Paris: J. B. Baillière, 1840-41.
10. Penfield, Wilder, and Jasper, Herbert: *Epilepsy and the Functional Anatomy of the Human Brain*. Boston: Little, Brown & Co., 1954.
11. Schmucker, Johann L.: *Chirurgische Wahrnehmungen*. Berlin and Stettin: F. Nicolai.
12. Larrey, D. J.: *Surgical Memoirs of the Campaigns of Russia, Germany, and France*. Translated from the French by John C. Mercer. Philadelphia, Carey & Lea, 1832.
13. Keen, William W.: *Surgery; Its Principles and Practice*. Philadelphia: W. B. Saunders Co., 1908, vol. III.
14. *Medical and Surgical History of the War of the Rebellion*. Surgical History. Washington: Government Printing Office, 1883, pt. III, vol. II, p. 859.
15. *Medical and Surgical History of the War of the Rebellion*. Surgical History. Washington: Government Printing Office, 1870, pt. I, vol. II, pp. 35-68.
16. Mitchell, S. Weir, Morehouse, George R., and Keen, William W.: *Gunshot Wounds and Other Injuries of Nerves*. Philadelphia: J. B. Lippincott & Co., 1864.
17. Broca, P.: *Remarques sur le siège de la faculté du langage articulé; suivies d'une observation d'aphémie*. *Bull. Soc. anat. de Paris* 36: 330, 1861.
18. Fritsch, G., and Hitzig, E.: *Ueber die elektrische Erregbarkeit des Grosshirns*. *Arch. f. Anat., Physiol. u. wissensch. Med.*, Berlin, 1870, 300-332.
19. Ferrier, D.: *The Croonian Lectures on Cerebral Localization*. Delivered before the Royal College of Physicians, June 1890. London: Smith, Elder & Co., 1890.
20. Jackson, H.: *On the Anatomical, Physiological and Pathological Investigation of the Epilepsies*. West

- Riding Lunatic Asylum Medical Reports 3: 315-339, 1873.
21. Horsley, V., and Schäfer, E. A.: A Record of Experiments Upon the Function of the Cerebral Cortex. London: Philos. Tr. Roy. Soc. 179B: 1-45, 1888.
22. Macewen, William: Pyogenic Infective Diseases of the Brain and Spinal Cord; Meningitis, Abscess of Brain, Infective Sinus Thrombosis. Glasgow: J. Maclehoſe & Sons, 1893.
23. Krönlein, R. U.: Beiträge zur operativen Hirnchirurgie. Verhandl. d. deutsch. Gesellsch. f. Chir. 30 (pt. 2): 121-124, 1901.
24. The Medical Department of the United States Army in the World War. Washington: Government Printing Office, 1927, vol. XI, pt. 1, pp. 749-758.
25. Pudenz, R. H.: The Repair of Cranial Defects With Tantalum; An Experimental Study. J.A.M.A. 121: 478-481, 13 Feb. 1943.
26. Shakespeare, William: Richard II, Act I, Sc. III.

CHAPTER 2

Spinal Cord Injuries

Maitland Baldwin

On 19 February 1945, at approximately 1100 hours, a Marine Corps radioman was hit in the neck by a machinegun bullet. As he fell among his advancing comrades, his body was hidden by a dense cloud of smoke and volcanic ash. He lay motionless and helpless in the sound and fury of the initial assault on Iwo Jima. As the first wave of marines moved on, two litter bearers and a hospital corpsman reached his side. They died there. Then his platoon leader tried to drag him in the shelter of a shallow ditch. Shrapnel killed the officer and wounded the paralyzed radioman again. Finally, he was carried to the water's edge where he was hit twice more by shell fragments and debris before evacuation to an offshore transport.

Aboard ship, his first clinical examination revealed that he was quadriplegic. More specific sensory testing showed that the level of his lesion was approximately the fifth cervical segment. It was assumed that the gunshot wound (of the neck) was the principal cause. This and the other wounds received preliminary treatment. Then, after some future examination, his bladder, bowels, and skin were given particular care. Eventually, he was returned to a stateside naval hospital where he received definitive treatment. His neck was explored and the spinal cord exposed. The gunshot had partially severed the cord and the local damage was such that functional severance was almost complete. The cervical vertebrae were fused and the wound closed. Then began the long course of aftercare. His bladder was tested and maintained by tidal drainage (1), and his bowels were conditioned to a daily evacuation. His skin received massages and was

cushioned on a special mattress supported by a Stryker frame.

Then, he began a long course of physiotherapy and rehabilitation. Obviously, these various tests and treatments did not restore the function of his severed spinal cord, but they did assure his survival and something more. He learned to manipulate reading devices with his teeth and, because some upper extremity function escaped, he was able to move his right arm. He saw the changing world through the eyes of many friends and on the television screens. Indeed, because of intensive rehabilitation measures, he lived in it for 14 years after his original injury.

As a personal history, this is tragic and heroic. It is also one part of a long professional history. Moreover, as such, it represents considerable professional progress, for all such casualties died soon after injury in the wars before World War II. At Quebec, Jamestown, or Ticonderoga such a wound was fatal. So, in the battles of Champlain, Bull Run, or San Juan Hill, a spinal wound meant death to the recipient. Even in the First World War, these casualties usually died soon after preliminary treatment. However, at the time of the Second World War, professional progress could assure the survival of most spinal injuries.

Knowledge of spinal injury and its care has been acquired slowly over the centuries. Yet, the ancients knew something of the effects of spinal dislocations. In fact, Hippocrates (2) wrote that the limbs below a spinal dislocation were usually paralyzed; however, from Hippocrates to Aretaeus, treatment was directed entirely at the bony cover-

ings of the spinal cord. Essentially, it was a crude attempt to manipulate the vertebrae from without. Actually, what might be called operative treatment was not reported until Paul of Aegina (3) suggested that the fragments of "broken spines" could be removed. Somewhat later, writers such as de Chauillac (4) condemned any attempt at operative intervention; however, Ambroïse Paré (5), who pioneered in so many aspects of military surgery, actually exposed the dura and roots as early as 1549. Later, in 1753, Geraud (6) removed a musket ball from the third lumbar vertebra. According to his report, the patient recovered some of the functions which had been lost. Louis (7) did one successful spinal operation in which a piece of metal was removed from the spinal canal. After this heroic surgery, the patient recovered function in his legs. However, the history of spinal injury in these years is not a happy chronicle.

In the succeeding century, the problem of operation on the spine and spinal cord became a controversial subject. There was disagreement on the advisability of such operations. Some thought that any operations were unduly hazardous because of sepsis and without hope of therapeutic gain. Others advocated a cautious use of available operative technique. In fact, this conflict lasted for a hundred years and is still echoed today. However, the advent of Listerian principles tempered some of the opposition to operative treatment. Then certain principles of surgical therapy gradually became established.

Cushing (8) described most of these principles in 1905. He divided patients with spinal injury in three categories, as follows:

1. Those cases in which operation was contraindicated because it could not help and might harm (by causing hematomyelia).
2. The cases of fracture dislocation, in which operation could do no good because of the almost certain complete transverse lesion of the cord.
3. The cases of partial cord lesion due to pieces of bone or bullet in which operation would very likely be of benefit.

These principles were used in the First World War and, according to Horrax, they are still in use today (9). Certainly they were not sufficient unto themselves alone in the 1914-18 conflict. Despite ra-

tional selection in operative treatment, cases of spinal injury usually died in that war. Indeed, a marine who suffered a wound of the spinal cord while serving at Château-Thierry usually died soon afterwards. Likewise, soldiers at St. Mihiel or Meuse-Argonne whose wounds involved the spinal cord could not look forward to survival. They did not survive because there were no established methods or techniques for paraplegic or quadriplegic care. The skin of the paralyzed victim broke down under the pressure of its motionless body and great festering sores developed. Meanwhile, the partially denervated bladder and bowels became stagnant and often infected. Cystitis, ureteritis, and kidney abscess claimed many lives, for there was no method adequate for irrigation and cleaning of the affected bladder. Since these problems presented (for the time being) insurmountable obstacles, the way toward more complex rehabilitation therapy remained closed.

The care of the bladder, skin, and bowels in patients with spinal injury became systematized and successful during the Second World War. Before hostilities began (1937), Munro had described his "tidal drain" and soon afterwards successful modifications of this device were developed. The technique of "tidal drainage" provided the first answer to the question of how to treat the paralyzed bladder. This signal success pointed the way to others like it, and the urological complications of severe spinal injury were greatly reduced. In this same period, it became possible to rehabilitate veterans after severe spinal injury and thus insure a useful survival period (10). Systematic rehabilitation procedures including skin care, muscle exercises, bladder and bowel conditioning, as well as skill in the use of the wheelchair, brace, and crutch became common. The partially paralyzed veteran was trained to a self-sufficiency after treatment which insured his survival. Those who came before him in the long lines of our wars could well envy his new-found opportunities, for the lack of which so many died.

However, the ultimate treatment of spinal cord injury is not yet. We cannot repair the cord. We can only insure a minimum of secondary disabilities after injury. Perhaps the real future of surgical treatment of spinal cord injuries lies in studies of

capacities for regeneration. It certainly cannot be found in the history of previous therapeutic endeavors.

REFERENCES

1. Munro, D.: The Treatment of the Urinary Bladder in Cases With Injury of the Spinal Cord. *Am. J. Surg.* 38: 120-136, October 1937.
2. Adams, Francis: The Genuine Works of Hippocrates. London: The Sydenham Society, 1849.
3. Paul of Aegina: The Seven Books of Paulus Aegineta. Translated by F. Adams. London: The Sydenham Society, 1844.
4. Guy de Chauliac: La Grande Chirurgie. Revue et collationnée sur les manuscrits et imprimés Latins et Français. Ornée de gravures. Translated by E. Nicaise. Paris: Baillière et Cie., 1890.
5. Paré, Ambroïse: Oeuvres complètes d'Ambroïse Paré revues et collationnées sur toutes les éditions avec les variantes. By J.-F. Malgaigne. Paris: J. B. Baillière, 1840-41.
6. Geraud: Observations sur un coup de feu à l'épine. *Mém. de l'Acad. Roy. de Chir.* 2: 515-517, 1753.
7. Louis: Remarques et observations sur le fracture et la luxation des vertèbres, Memoire lu à la séance publique de l'Académie Royale de Chirurgie le 18 avril 1774. *Arch. gén de méd.* 11 (S-2): 397-429, 1836.
8. Cushing, H.: The Special Field of Neurological Surgery. *Cleveland M. J.* 4: 1-25, 1905, and *Johns Hopkins Hosp. Bull.* 16: 77-87, 1905.
9. Horrax, Gilbert: Neurosurgery: An Historical Sketch. Springfield, Ill.: Charles C Thomas, 1952.
10. Munro, D.: Rehabilitation of Veterans Paralyzed as the Result of Injury to the Spinal Cord and Cauda Equina. *Am. J. Surg.* 75: 3-18, January 1948.

Management of Neurosurgical Casualties in the Korean War

Military surgery is a development within the art and science of surgery which is designed to carry out a specialized, essential, and highly significant mission under the adverse conditions of war. It is distinctive in that, contrary to the usual medical practice, the care of the individual must necessarily become secondary to the military effort whenever a given tactical situation so demands.

On the other hand, neither this realistic and practical necessity nor the additional necessity of haste in caring for a continuous flow of battle casualties requires that military surgery be carried out in an atmosphere of confusion and disorder or that standard principles of treatment be abandoned. On the contrary, as all past medicomilitary history shows, intelligent planning and training, in anticipation of the needs of the emergency, have made possible an enviable record in military medicine.¹

Introductory Note

Historically, the story of military neurosurgery can be traced from the early efforts of Harvey Cushing in World War I. Neurosurgery as a specialty had not gained stature until World War II. Following World War II there was considerable emphasis placed on the residency training programs, both in civilian and military institutions.

The management of neurosurgical casualties in the Korean War had the usual difficulties that are evident in the early phase of any war. Lack of qualified personnel, equipment, and a policy on the handling of cases contributed to the difficulty. This situation was rectified in part by the establishment of a provisional neurosurgical detachment which was attached to a Mobile Army Surgical Hospital. It became evident that for increased efficiency it would be necessary to establish a specialized unit. This was done under the able direction of Arnold M. Meirowsky and Thomas N. Page. The record speaks for itself and is masterfully portrayed in this volume.

The training of Korean surgeons in the tech-

niques of neurosurgery by Meirowsky, and others, deserves the highest praise. The establishment of facilities similar to those of the United States in the Korean Medical Service produced very gratifying results.

The close association with the Navy, especially with William F. Caveness, contributed immeasurably to the successful management of neurosurgical cases.

This story would not be complete if we failed to mention the valuable contributions given by Frank B. Berry and Eldridge H. Campbell. Their praise and encouragement were great stimuli to all. Nor would all of this be possible were it not for the assistance given to the patients by the aidmen, battalion surgeons, and helicopter pilots in the preparation and transportation of casualties to the neurosurgical unit.

Not recorded herein—nor will they ever be—are the anxieties and sleepless nights of the surgeons, and devotion to duty by officers and enlisted men. This account should be a great inspiration to all medical personnel.

WILLIAM E. SHAMBORA

¹ Emergency War Surgery, NATO Handbook. Washington: U.S. Government Printing Office, 1958, p. 1.

CHAPTER 3

Historical Data

Arnold M. Meirowsky and Thomas N. Page

The Korean War found us unprepared. At the outset neurosurgical casualties were evacuated from Korea to Japan without any or without definitive radical debridement and closure. The incidence of meningocerebral infection was 41 percent (1). Fungating cerebritis presented a challenging problem (2) (3). Decubital ulcers prevailed in casualties with spinal cord wounds. In September 1950, when one of the authors (A.M.M.) took charge of neurosurgical problems in the Far East Command, the immediate problem was that of definitive care of those neurosurgical casualties already at Tokyo Army Hospital and of those evacuated to Tokyo Army Hospital during the following months. During the first 30 days, 118 major neurosurgical operations were performed. Many of them were necessitated by the presence of retained bone fragments in the brain, by cerebritis, and by other complications due to the lack of availability of early definitive neurosurgical intervention. The second and much graver problem was that of reorganization of the care of neurosurgical casualties.

"There can be little doubt that, as is the case with thoracic, abdominal, and joint injuries, the earlier a cranial operation is performed, the less likelihood there is of sepsis. The mortality, however, in a hospital near the front is, in the natural course of events, almost certain to be greater than the mortality of operations for similar conditions at the base, for delay always serves to eliminate a certain percentage of desperately injured * * * (4). This was the conclusion which Harvey Cushing reached in 1918. Segregation of neurosurgical casualties and their definitive treatment in mobile neurosurgical teams was first employed in the British Army in October 1942 (5) (6). The splendid

achievements of mobile neurosurgical units with the British Armies overseas in World War II, as documented in articles by Jefferson (7), Schorstein (8), Small and Turner (9), Stewart and Botterell (10), Small, Turner, and Watt (11), Calvert (12), Johnson and Dutt (13), Connolly (14), Ascroft (15), Ascroft and Pulvertaft (16), and Cairns, Calvert, Daniel, and Northcroft (17) represent a milestone in the history of military neurological surgery. The advances which have been made in all aspects of military neurosurgery by our own Armed Forces during World War II have been documented by Spurling and Woodhall and their coauthors (18) (19). In the Okinawa campaign, neurosurgical care in forward areas was made possible by the vision and courage of the Tenth U.S. Army's Surgical Consultant, Col. George G. Finney, MC. The results obtained in that campaign with the treatment of craniocerebral trauma again brought about convincing proof of the necessity of early definitive neurosurgical intervention.

The establishment of first echelon mobile neurosurgical teams in Korea rendering early definitive neurosurgery to all casualties with wounds of the brain and spine was recommended. Direct air evacuation from these teams to a second echelon center in Tokyo, omitting interim hospitalization in installations not neurosurgically staffed and equipped, was added to this recommendation. Initially these proposals were not received with enthusiasm. Dr. Howard C. Naffziger, on the occasion of his visit to the Far East as Consultant to The Surgeon General in the fall of 1950, gave the proposed plan of reorganization his wholehearted support. The importance of Howard Naffziger's visit to the Far East Command at that particular time cannot be

emphasized enough. His help and advice were invaluable.

Nevertheless, reorganization was slow in coming about. In considering a reorganization, which unfortunately could not be based on any existing table of organization and equipment, the command required convincing proof of the necessity of such a reorganization. As Neurosurgical Consultant to the Chief Surgeon, Far East Command, one of the authors (A.M.M.) received orders to visit forward medical installations in the Eighth U.S. Army and in the X Corps sector in order to study management of neurosurgical casualties on the spot and to make formal recommendations on the basis of his observations. The consultant's bulky dufflebag contained almost every neurosurgical instrument necessary for definitive surgery of penetrating wounds of the brain and spinal cord. It also contained Gelfoam, Cottonoids, and a few other practical items. It certainly seemed that this was the time to prove again what had long been established in the First and Second World Wars—the necessity of early definitive neurosurgical intervention.

The condition of casualties returned to the neurosurgical center in Tokyo from the 121st Evacuation Hospital at the time of the fighting at the Chosin (Changjin) Reservoir in 1950 was in striking contrast to those in the earlier days of the Korean War. Experience gained in this phase of the Korean War furnished additional proof for the necessity of reorganization. The plan of forming first-echelon neurosurgical teams in Korea received the support of Maj. Gen. Edgar E. Hume, then Surgeon, Far East Command, Col. Oral B. Bolibaugh, MC, Chief Consultant to the Surgeon, Far East Command, and Col. Chauncey E. Dovell, MC, Surgeon, Eighth U.S. Army. The organization of these teams, however, was impeded by a grave shortage of neurosurgically trained and experienced personnel.

Late in February 1951, the 1st Neurosurgical Detachment (Provisional) was organized in Taegu. A two-echelon system of care of neurosurgical casualties was thus established with the neurosurgical center remaining in Tokyo Army Hospital under the direction of Maj. Gordon T. Wannamaker, MC. The magnificent work which was done by Capt. Griffith R. Harsh III, MC, and by Lt. (jg) Robert A. Clark, MC, USNR, of the 1st Neurosurgical Detachment (Provisional), during the period from 1 March

to 1 August 1951, resulted in a striking reduction of morbidity and mortality. The rate of craniocerebral infection, which had been 42 percent on admission to the Tokyo Army Hospital Neurosurgical Center, was reduced to a figure varying between 2 and 4 percent.

The first mobile neurosurgical unit was assembled and tested during the offensive in the vicinity of Kumsong, Korea, in October 1951, on the instigation of one of the authors (T.N.P.) who was then Surgeon, Eighth U.S. Army. The mobile neurosurgical unit was organized and employed in conjunction with various MASH (Mobile Army Surgical Hospital) units.

The system that evolved for the care of neurosurgical casualties in the Korean War, beginning in October 1951, was so organized as to keep casualties with brain and spinal cord wounds within neurosurgical channels from the time they left the battalion aid station. Evacuation from the aid station was by helicopter (fig. 8). Casualties with brain and spinal cord wounds were taken directly to one of the mobile neurosurgical teams for purpose of neurosurgical intervention and institution of all necessary neurosurgical nursing measures. At time intervals ranging from 3 to 10 days, depending on the condition of the individual patient and on the tactical situation, casualties were evacuated from these mobile units. Evacuation of all neurosurgical casualties from mobile units at the MASH to the nearest airport was by helicopter (fig. 9), and from there by prearrangement directly to Tokyo by C-54 type aircraft, eliminating intermediate hospital admission in installations not specially equipped for the care of neurosurgical casualties, and eliminating ambulance rides on rough roads. The Army Quartermaster's winter evacuation bag permitted helicopter evacuation even at subzero temperatures (figs. 10 and 11). In Tokyo, the neurosurgical center at Tokyo Army Hospital represented the second echelon in this organization. It was the ideal place for prolonged management of critically ill casualties, for secondary operations, and for preparation of all casualties with brain and spinal cord wounds for the long trip home. The mobile neurosurgical team was standardized and employed exclusively in the Eighth U.S. Army under the direction of Maj. Gen. William E. Shambora, Chief Surgeon, Far East Command, who also sponsored



FIGURE 8.—Casualty with penetrating craniocerebral trauma arriving at 3d Neurosurgical Detachment (Provisional). Note litter pod at lower right.

and was instrumental in the organization of a similar team in the ROKA (Republic of Korea Army) in July 1952, under the supervision of Brig. Gen. Yun, Tchi Waang, Surgeon General, ROKA. 1st Lt. Joseph C. Barnett, Jr., MC, commanded the first mobile neurosurgical team. Capt. Yoon, Bog-Yung, MC, ROKA, commanded the first ROKA mobile neurosurgical unit.

During the period September 1950 to September 1952, the overall mortality for all casualties with penetrating craniocerebral trauma was 7.78 percent, the mortality of casualties with penetrating wounds of the spinal canal was 3.6 percent.¹ During the

¹The mortality figures are based on all cases of penetrating craniocerebral trauma (exclusive of uncomplicated scalp wounds) and all cases of penetrating wounds of the spinal canal and its contents seen, treated and operated on by the members of the neurosurgical staff of the U.S. Army in the Far East Command during the period 1 September 1950 to 1 September 1952. Included are all those cases which did not receive early definitive neurosurgical care. Also included are those initially operated on by organizations other than those under U.S. Army control, but reoperated on in an Army installation in the Far East Command because of secondary complications.

period October 1951 to September 1952, the incidence of meningocerebral infection was less than 1 percent (20) (1). Confined intracranial hematomas were encountered and evacuated in 46.2 percent of all casualties with penetrating wounds of the brain because casualties were seen as a rule within 3 to 8 hours after having been wounded (21). Decubital ulcers did not develop in any American or United Nations casualty within the Far East Command during the period October 1951 to September 1952. Such is the record which was established by provisional mobile neurosurgical units that did not even exist on paper, and certainly not in any official table of organization and equipment. Such is the record that was established by a handful of young surgeons—1st Lt. Samuel W. Atkins, Jr., MC, Joseph Barnett, Capt. Edward J. Bishop, MC, Robert Clark, Griffith Harsh, 1st Lt. Milam E. Leavens, MC, and 1st Lt. Jose Nine-Curt, MC. Griffith Harsh commanded the 1st Neurosurgical Detachment (Pro-



FIGURE 9.—Helicopter evacuation of neurosurgical casualty from 3d Neurosurgical Detachment (Provisional) to nearest airport.





FIGURE 10.—(Above) Neurosurgical casualty being prepared for evacuation by helicopter in the Army Quartermaster's winter evacuation bag. (Right) The bag is labeled "Evacuate direct to Tokyo Army Hospital Neurosurgical Center." (Photograph courtesy of *Annals of Surgery*.)

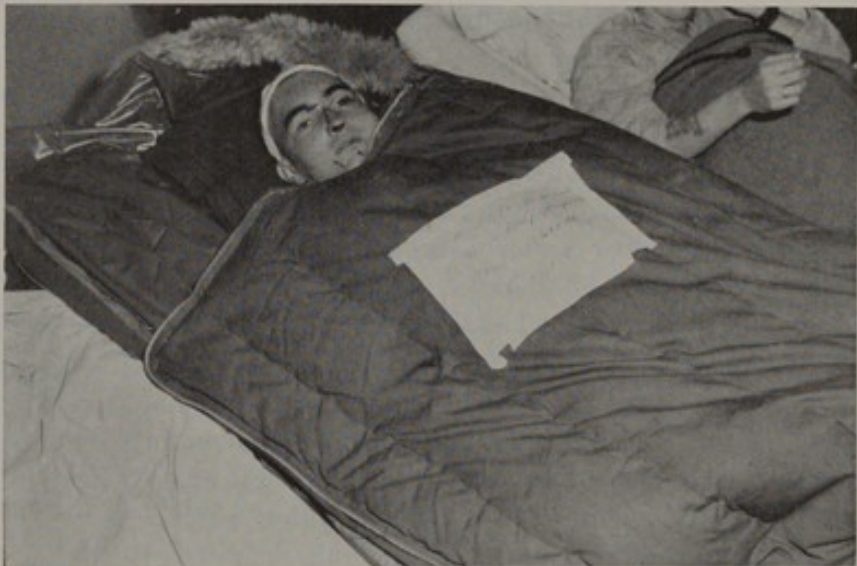

FIGURE 11.—Litter pods were used to protect patients from subzero temperatures.

visional) and shared the load of work during the spring offensive of 1951 and subsequent months with Robert Clark, on loan from the U.S. Navy. Joseph Barnett commanded the first mobile neurosurgical team attached to a MASH. Samuel Atkins was on his team from the outset. The unequalled achievements of some of these men, who at times worked beyond the limits of human endurance, were carried through to success at the neurosurgical center in the rear echelon which was headed by Gordon Wannamaker. During the latter phase of the Korean War, Gordon Wannamaker was assisted in his excellent work by 1st Lt. Paul R. Rosenbluth, MC. Each of the men who worked subsequently in the Korean theater was assigned for a few months to the neurosurgical center in Tokyo. Their efforts were aided in no small measure by the valiant assistance of a handful of qualified and capable nurses and enlisted technicians.

A tremendous stimulus and help to all engaged in neurological surgery in the Korean War was the presence of Dr. Eduard A. V. Busch aboard the hospital ship, *M/S Jutlandia*. Doctor Busch, Denmark's outstanding senior neurosurgeon, and his first assistant, Kjeld Vaernet, contributed generously to the neurosurgical efforts in the Korean War.

A considerable amount of neurological surgery was done aboard our own hospital ships. For a time, direct helicopter evacuation was worked out from the 1st Marine Division to the U.S.S. *Consolation* (AH-15). This system of evacuation offers splendid possibilities for earliest possible definitive neurosurgical care and is of the greatest practical importance, particularly in island warfare. Comdr. William F. Caveness, MC, USNR, and his associates have recorded elsewhere in this account their information on problems related to posttraumatic epilepsy, which were carried out in the field and aboard hospital ships.

During the period September 1950 to September 1952, two civilian neurosurgeons, Dr. Howard Naffziger (in 1950) and Dr. Eldridge H. Campbell (in 1951), visited the Far East Command in the capacity of neurosurgical consultants to The Surgeon General, U.S. Army. A third consultant, Dr. Frank B. Berry (later Assistant Secretary of Defense (Health and Medical)), visited the Far East Command as general surgical consultant to The Surgeon General and contributed greatly to the management

of neurosurgical casualties in the field. In preceding pages, tribute has been paid to Howard Naffziger's contribution to the management of U.S. casualties in the Korean War. The late Eldridge Campbell made an exhaustive study of every aspect of the care of neurosurgical casualties in the first and second echelons of the Far East Command (22) (23) on the occasion of his visit. Dr. Campbell's help and advice, and his support were invaluable. The beneficial effect which the visit of these three men, Berry, Campbell, and Naffziger, had on neurological surgery in the Far East Command cannot be overestimated.

REFERENCES

1. Meirowsky, A. M., and Barnett, J. C.: Mobile Neurosurgical Team. *Ann. Surg.* 138: 178-185, August 1953.
2. Meirowsky, A. M., and Harsh, G. R., III: The Surgical Management of Cerebritis Complicating Penetrating Wounds of the Brain. *J. Neurosurg.* 10: 373-379, July 1953.
3. Wannamaker, G. T., and Pulaski, E. J.: Pyogenic Neurosurgical Infections in Korean Battle Casualties. *J. Neurosurg.* 15 (pt. 5): 512-518, September 1958.
4. Cushing, H.: Notes on Penetrating Wounds of the Brain. *Brit. M. J.* 1: 221-226, 23 Feb. 1918.
5. Cairns, H.: Neurosurgery in the British Army, 1939-1945. *Brit. J. Surg. (War Surg. Supp. No. 1)*, pp. 9-25, June 1947.
6. Cairns, H.: The Organization for Treatment of Head Wounds in the British Army. *Brit. M. Bull.* 3: 9-14, 1945.
7. Jefferson, G.: Head Wounds and Infection in Two Wars. *Brit. J. Surg. (War Surg. Supp. No. 1)*, pp. 3-8, June 1947.
8. Schorstein, J.: An Atlas of Head Wounds Illustrating Standard Operative Technique. *Brit. J. Surg. (War Surg. Supp. No. 1)*, pp. 27-61, June 1947.
9. Small, J. M., and Turner, E. A.: A Surgical Experience of 1,200 Cases of Penetrating Brain Wounds in Battle, N.W. Europe, 1944-45. *Brit. J. Surg. (War Surg. Supp. No. 1)*, pp. 62-74, June 1947.
10. Stewart, O. W., and Botterell, E. H.: Cranio-Facial-Orbital Wounds Involving Paranasal Sinuses; Primary Definitive Surgical Treatment. *Brit. J. Surg. (War Surg. Supp. No. 1)*, pp. 112-118, June 1947.
11. Small, J. M., Turner, E. A., and Watt, A. C.: The Management of Brain Wounds in the Forward Area. *Brit. J. Surg. (War Surg. Supp. No. 1)*, pp. 75-80, June 1947.
12. Calvert, C. A.: Orbito-Facio-Cranial Gunshot Wounds. *Brit. J. Surg. (War Surg. Supp. No. 1)*, pp. 119-141, June 1947.
13. Johnson, R. T., and Dutt, P.: On Dural Laceration Over Paranasal and Petrous Air Sinuses. *Brit. J. Surg. (War Surg. Supp. No. 1)*, pp. 141-167, June 1947.

14. Connolly, R. C.: The Management of the Untreated Brain Wound. *Brit. J. Surg. (War Surg. Supp. No. 1)*, pp. 168-172, June 1947.
15. Ascroft, P. B.: A Survey of Fatal Head Wounds. *Brit. J. Surg. (War Surg. Supp. No. 1)*, pp. 178-182, June 1947.
16. Ascroft, P. B., and Pulvertaft, R. J. V.: The Bacteriology of Head Wounds. *Brit. J. Surg. (War Surg. Supp. No. 1)*, pp. 183-186, June 1947.
17. Cairns, H., Calvert, C. A., Daniel, P., and Northcroft, G. B.: Complications of Head Wounds, With Especial Reference to Infection. *Brit. J. Surg. (War Surg. Supp. No. 1)*, pp. 198-243, June 1947.
18. Medical Department, United States Army. *Surgery in World War II. Neurosurgery. Volume I.* Washington: U.S. Government Printing Office, 1958.
19. Medical Department, United States Army. *Surgery in World War II. Neurosurgery. Volume II.* Washington: U.S. Government Printing Office, 1959.
20. Meierowsky, A. M.: Penetrating Craniocerebral Trauma; Observations in Korean War. *J.A.M.A.* 154: 666-669, 20 Feb. 1954.
21. Barnett, J. C., and Meierowsky, A. M.: Intracranial Hematomas Associated With Penetrating Wounds of the Brain. *J. Neurosurg.* 12: 34-38, January 1955.
22. Letter, Eldridge Campbell, M. D., Civilian Consultant in Neurosurgery, to The Surgeon General, Department of the Army (Attn: Coordinator of Professional Consultant Activities), 11 Feb. 1952, subject: Report of Civilian Consultant in Neurosurgery on Tour of Far East Command.
23. Campbell, E. H.: Recent Notes on Wounds of the Brain and Spinal Cord. *In* Symposium on Treatment of Trauma in the Armed Forces, 10-12 Mar. 1952, Army Medical Service Graduate School, Walter Reed Army Medical Center, Washington, D.C.

CHAPTER 4

Organizational Data

Arnold M. Meirowsky, Thomas N. Page, and Joseph C. Barnett, Jr.

In considering the tactical use of medical troops in combat, several basic principles should be kept in mind. The success of developing procedures for the care of sick and wounded depends on the support of the type of organization currently in being and on the medical support of the tactical doctrine set up by staff officers. It is essential that the command surgeon's hands are not tied by virtue of his physical location in the command channels. The command surgeon cannot function adequately if situated too far to the rear and under a support command commander, rather than the major command commander. Fortunately for all concerned and especially for the wounded man, this was not the case in the Korean War.

The proper tactical deployment of the neurosurgical detachments depends on the type of warfare which such detachments are used to support. In a brush-fire type of war, such as in Korea, our experiences fairly well standardized organization and employment of these units. In warfare of a nuclear nature with troops widely scattered and in some instances surrounded, other methods must be devised to care effectively for the wounded.

In the latter type of warfare all doctors will be at a premium and especially so the specialists. This one factor alone points up the fact that we must make the most efficient use of our meager resources. In that situation we cannot deprive the civilian population of their fair share of trained available medical personnel as their problems will be as great or greater than those of the Armed Forces.

The team concept must be such that the team would be adequate for the job at hand and able to support any type of action decided upon by the

combat commander. To do this, *it must be fully mobile for any type of movement—by air, sea, or land.* It must be able to carry the majority of its own supplies for a specified period of time. *It must be able to augment without interfering with the normal operation of the unit which it supports.* It must be completely competent clinically. Its personnel should be trained in loading properly their supplies and equipment aboard trucks, boats, planes, or railroad cars and be prepared to work under isolated conditions with only infrequent air support. This presupposes the ability to hold and treat postoperatively until relief can be obtained.

In order to accomplish these prerequisites, certain assumptions have to be made:

1. That adequate tables of organization and tables of equipment exist so that quick and effective organization can be accomplished.
2. That ample time is set aside for the required training.
3. That adequate vehicles (land, sea, air) are available and under control of the major command surgeon.
4. That the major command surgeon has complete control of all medical means.
5. That the position of the command surgeon in the command setup is such that he has immediate access to the commander.
6. That the organization of any unit replacing the MASH (Mobile Army Surgical Hospital) be such that neurosurgical teams can work in conjunction with them.
7. That neurosurgical teams be used as far forward as possible so that they can function effectively.
8. That teams must never be permanently assigned

to any hospital or command unit but must remain under the direct control of the command surgeon so that their mobility and capability can be exploited to the utmost.

Air evacuation of casualties from the point of injury to the hospital where neurosurgical teams are available is the method of choice from the standpoint of speed, safety, and comfort. Further air evacuation postoperatively should be available from the point of team treatment to the next echelon to the rear (usually an evacuation hospital). Ground evacuation can, of course, be used in both instances if air evacuation is not available, but should not be used preoperatively for this type of case if it can be avoided. Small fixed-wing aircraft or helicopters are the aerial evacuation vehicles of choice (1) (2).

Neurosurgical teams should be able to accompany or followup as soon as possible movement into an airhead supporting that type of operation. Their small amount of equipment and personnel make them extremely suitable for this type of support.

Mobile neurosurgical units were organized in the Korean War as provisional units without the benefit of a table of organization and equipment. To this day, the only available table of organization and equipment for an autonomous neurosurgical unit is the team provided in T/O & E 8-500 which is inadequate and which does not permit the definitive care of neurosurgical casualties.

In the design of the mobile neurosurgical units (3) which were employed in the Korean War, three basic objectives were sought: Earliest possible neurosurgical management, mobility, and economy.

PERSONNEL

NEUROSURGEONS

The requirement of neurosurgical autonomy presupposes the availability of trained and experienced neurosurgeons. The general surgeon cannot be expected to keep abreast of advances which are being made continuously in distinct surgical specialties. Though he may be thoroughly familiar with the technique of neurosurgical emergency procedure, the necessary intimate knowledge of the behavior of cerebral tissue and other intracranial structures under pathological conditions can only

be gained on the basis of extensive clinical experience. Such knowledge is of fundamental importance in the operative and in the postoperative management of missile wounds of the brain. Policies with regard to surgical and conservative management should be set forth and carried out by well-qualified and experienced neurosurgeons who have devoted protracted time and thought to the study of neurological surgery of trauma.

In the presence of wounds of the brain and of the spinal cord, the margin between life and death and that between recovery and invalidism is narrow at best, necessitating careful selection of the personnel which is to be assigned to a neurosurgical team. In his report to The Surgeon General, Eldridge Campbell emphasized this point particularly, "In general, however, it may be opined that the best men should be in the Far East, that the best men in the Far East should be in Korea, and that the best men in Korea should be in the forward hospitals" (4) (5).

It requires the mature judgment of an experienced neurological surgeon to command a mobile neurosurgical team in the field. The assistant neurosurgeon should have had at least 2 years of formal resident training in neurosurgery, preceded by adequate schooling in the basic principles of general surgery. The assignment of a third junior surgeon can be of real value to the team as it would be to any aspiring young surgeon. The tough proving ground of a neurosurgical team in a forward area with its tremendous turnover of casualties with missile wounds of brain and spinal cord provides an ideal training program in the military aspects of neurological surgery.

ANESTHESIOLOGISTS

Patients suffering from disturbed cerebral physiology require the attendance of a well-informed anesthesiologist. One of the authors (A.M.M.) was forced to do most of his work in the Second World War with local anesthesia. This is not at all desirable when dealing with penetrating missile wounds of the brain. The authors benefited a great deal from an exceptionally good anesthesia regimen in the Korean theater where they had the assistance of highly skilled and experienced anesthesiologists. The mobile neurosurgical unit should have its own

anesthesiologist so as to be able to operate without delay. An experienced nurse anesthetist can fill this position though the physical strain, at times, may be great.

NURSES

Casualties with severe craniocerebral trauma are often as dependent for their very survival on adequate nursing care as on adequate surgery. Such nursing care implies specialized training and also a high nurse-patient ratio. Casualties with spinal cord injuries, by the nature of their disability, require a greater number of hours of nursing care than is ordinarily accorded to them in either civilian or military hospitals. Only by such care can complications be eliminated. In the operating room it is quite feasible, as demonstrated by the 3d Neurosurgical Detachment (Provisional) in Korea, to employ enlisted surgical technicians rather than nurses. Because of the strenuous and fatiguing nature of that work, it would be necessary to employ at least four nurses in the operating room only; this would enlarge the personnel complement of the team unjustifiably. Female personnel, because of the tactical situation, may not be able to advance with the team during the initial phase of an offensive, necessitating in any event the availability of enlisted surgical technicians who are skilled and experienced as scrub nurses, circulating nurses, and as assistants in the operating room. Such was the situation that one of the authors (A.M.M.) experienced during the first few weeks of the Okinawa campaign where he had the benefit of a crew of highly skilled enlisted technicians. Considering 25 to 35 casualties as the average capacity of the described team, 4 nurses can adequately supervise the preoperative and postoperative care, provided that they are specially trained in neurosurgical nursing and that they are supported by a staff of neurosurgically trained and experienced enlisted technicians. A complement of four nurses assigned to the preoperative and postoperative tents of the mobile team will permit regular duty hours and sufficient time off duty to prevent exhaustion and undue fatigue of female officers.

The following comment is from the final report of the Neurosurgical Consultant to the Chief Surgeon, Far East Command (6) :

One of the great assets in the care of neurosurgical casualties in the Korean War was the availability of

specially trained neurosurgical nurses. The nursing care of neurosurgical casualties in the Far East Command has been unexcelled. Inasmuch as neurosurgical nursing differs essentially from nursing procedures in other fields, consideration may be given to the creation of a special MOS number which would serve as an incentive to the individual and which would facilitate finding qualified nurse officers for replacement in neurosurgical installations.

ENLISTED SURGICAL TECHNICIANS

A complement of 10 enlisted surgical technicians, trained in neurosurgical work, is considered the necessary minimum. This complement was used in the provisional neurosurgical detachments of the Eighth U.S. Army and in the neurosurgical team of the Republic of Korea Army. The excellent results which were obtained in the provisional neurosurgical detachments of the Eighth U.S. Army in Korea and the considerable reduction of morbidity and mortality among neurosurgical casualties during the second year of the Korean War may be ascribed largely to the fact that they were afforded the benefits of specialized surgical and nursing care within hours after having been wounded.

Of the 10 enlisted surgical technicians, 4 men were employed in the operating room, each working a 12-hour shift. Of these four technicians, the two most skilled performed the duties of a scrub nurse; the other two worked as circulating nurses or as assistants to the operating surgeon.

Six surgical technicians are required to take care of the preoperative and postoperative work. In the preoperative ward, these technicians must shave and prepare heads for operation, cleanse wounds, administer blood transfusions, give enemas, catheterize patients, insert indwelling catheters, employ intratracheal suction, take blood pressure readings, and record other vital signs. The work in the postoperative ward includes the delicate and tedious management of the comatose patient and the time-consuming care of the paraplegic casualty. (See chapters 21 and 27.)

The following extract from the final report on the care of neurosurgical casualties in the Korean War, during the period September 1950 to August 1952, points out the personnel problems with which a provisional unit can be confronted despite the fact that such a unit may be called upon to perform under duress, carrying the weight of grave responsibility.




FIGURE 12.—Surgical Instrument Set, Supplemental, Brain and Nerve Injuries. Craniotomy set.

During the spring offensive of 1951, the 1st Neurosurgical Detachment (Provisional), under the command of Capt. Griffith R. Harsh III, MC, carried out a total of 126 craniotomies and laminectomies in 26 days.

A complement of 10 enlisted surgical technicians, trained in neurosurgical technician work, is considered the necessary minimum. It is in this complement that the T/O which has been used in the provisional neurosurgical detachments of the Eighth U.S. Army and in the neurosurgical unit of the ROKA, differs from T/O & E 8-500, Section 11, Part 4 * * *. The latter allows for three enlisted technicians only which does not suffice to render adequate pre-operative and postoperative care to the neurosurgical casualties * * *. The drawing of additional enlisted men from the parent unit in order to increase the strength of the enlisted T/O provided by 8-500 has proved unsatisfactory, does not fit the special needs, and it is not economical inasmuch as it necessitates a continuous process of training of new men which interferes with the smooth function of a small unit and with adequate care of patients.

* * * Those enlisted surgical technicians who have

served with the provisional neurosurgical detachments of the Eighth U.S. Army were given a 30-hour course by the staff of those detachments, instructing them in all aspects of the nursing management of casualties with trauma to brain and spinal cord.

* * * * *

The work of the 10 enlisted technicians of the Third Provisional Neurosurgical Detachment which was the pilot unit for mobile neurosurgical teams in the Eighth U.S. Army and which has been used as model and training unit, has been unexcelled. Though these men had been specially trained and were highly skilled in the performance of their specialized work, none of them could be promoted to non-commissioned rank because of the inavailability of an official T/O. In order to do justice to men with such responsible duties, a T/O should be devised which is commensurate with their assignment.

The provisional table of organization, which was used for mobile neurosurgical units as of October 1951, is described in table 1. It was tested in the Korean War and has proved its worth. Such

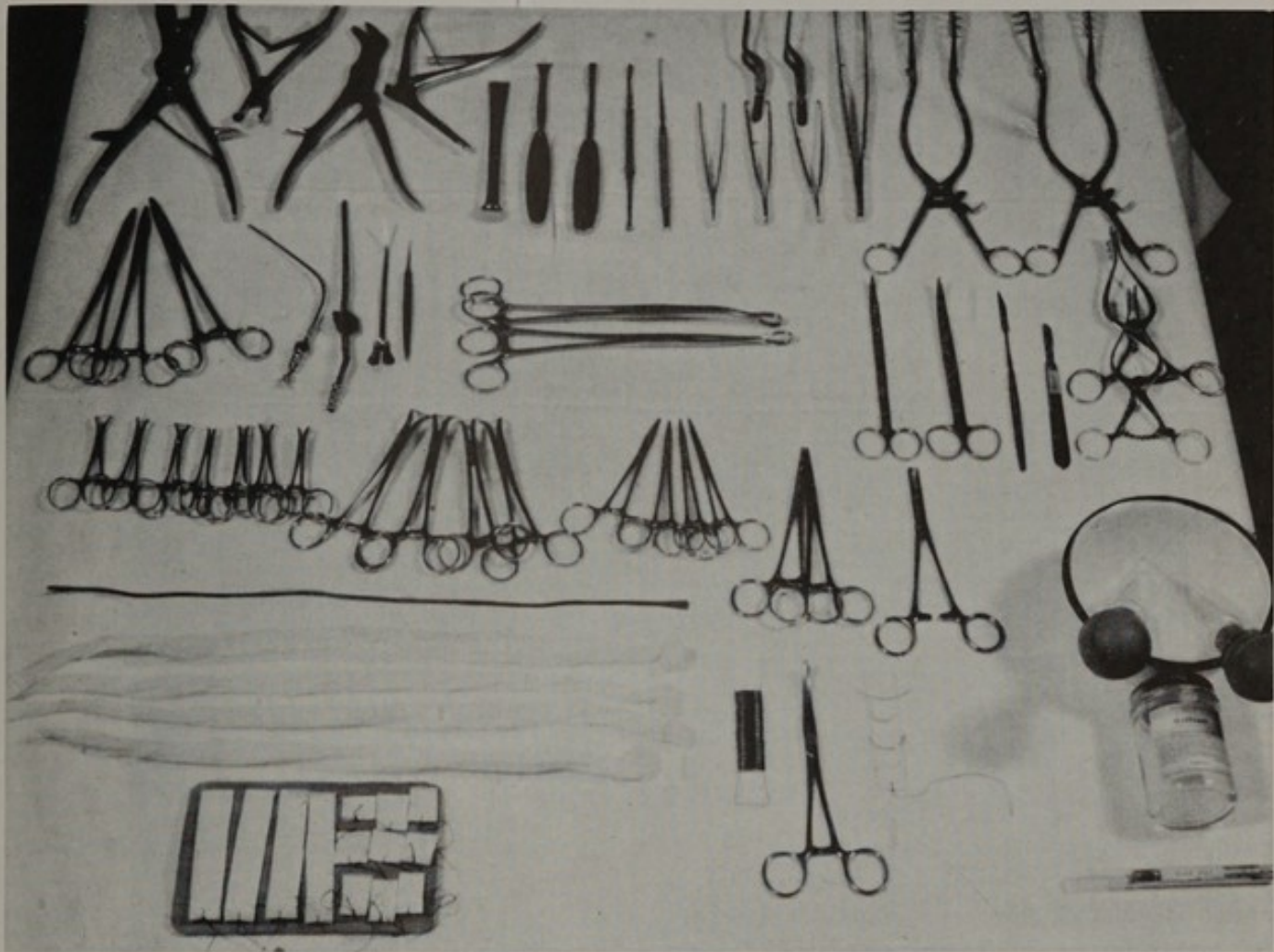

FIGURE 13.—Surgical Instrument Set, Supplemental, Brain and Nerve Injuries. Laminectomy set. (Photograph courtesy of J. B. Lippincott Company.)

TABLE 1.—Provisional table of organization for mobile neurosurgical units, October 1951

Personnel	Military Occupational Specialty	Number
Neurosurgeon.....	B-3131.....	1
Assistant neurosurgeon..	C-3131.....	1
Assistant surgeon.....	D-3131 or D-3150...	1
Anesthesiologist.....	C-3115.....	1
Nurse, operating room..	3443.....	4
Operating room technician.	0861.....	10
Total.....		18

figures as the reduction of meningocerebral infection from 41 percent in the fall of 1950, when mobile neurosurgical units were not available, to less than 1 percent for the first year of functioning of the mobile neurosurgical units, speak for themselves.

To date, no change has been made in that part of T/O 8-500 pertaining to neurosurgical teams. The dire need for this change need not be emphasized.

EQUIPMENT

The Army's "Surgical Instrument Set, Supplemental, Brain and Nerve Injuries" (9-581-200) includes all essential instruments for the performance of neurosurgical operations of any magnitude in the field (figs. 12 and 13). The competent surgeon does not require a wide variety of instruments and can perform craniotomies and laminectomies with this standard Army set. A mobile neurosurgical team should be equipped with three such sets in order to facilitate operating on a 24-hour basis, as is often necessary. A small number of basic general surgical instruments will be needed in addition to



FIGURE 14.—Tentage of mobile neurosurgical detachment at 8063d Mobile Army Surgical Hospital. Preoperative tent at far end, operating tent center, and postoperative ward tent in foreground.

the supplemental neurosurgical set.

A portable electrosurgical unit (3-275-600), a portable Heydbrink anesthesia apparatus (3-010-430), and eight portable suction machines (3-752-750) are essential items on the list of nonexpendable supplies.

Surgical linen, cots, litters, blankets, and various housekeeping items should be furnished by the parent unit to which the team may be attached. The surgical service of that unit can also provide space in the autoclave for the preparation of sterile supplies.

Tentage and equipment (fig. 14, table 2) essential for autonomous functioning of the neurosurgical team can be loaded on one 2½-ton cargo truck. To assure mobility, a neurosurgical team should be assigned one such truck and sufficient vehicle space in addition for the transportation of the entire personnel, allowing sudden independent moves from one sector of the front to another at any given time (table 3).

The employment of tents rather than of available, but usually unsuitable, housing structures provides an organic unit which consists of three closely connected sections. Two hospital tent end sections are used as operating room, providing sufficient space

TABLE 2.—Tentage for mobile neurosurgical unit

Type	Quantity
Tent, hospital, end section No. 1, complete with pins and poles.	5 each.
Tent, hospital, end section No. 2, complete with pins and poles.	5 each.
Tent, hospital, middle section, complete with pins and poles.	4 each.
Tent, squad, complete with pins and poles.	1 each.
Tent, command post, complete with pins and poles.	1 each.

TABLE 3.—Vehicles for mobile neurosurgical unit

Type	Quantity
Truck, 2½ ton, cargo.	1 each.
Truck, ¾ ton, weapon carrier.	1 each.
Truck, ¼ ton.	1 each.
Trailer, ¼ ton.	1 each.

for one or two operating tables and for essential operating equipment. The operating tent is centered between preoperative and postoperative ward tents. One corner of the preoperative tent is used solely for




FIGURE 15.—(Top) Ordnance-made metal litter stand for use as operating table. (Photograph courtesy of *Annals of Surgery*.) (Bottom) Same stand with litter in place.

the preparation of patients for surgery, leaving sufficient space for four cots and for two paraplegia litter beds for casualties awaiting surgery. The postoperative ward should provide space for 25 to 30 patients, requiring two hospital tent end sections and four middle sections. A command post tent is best suited for the preparation and maintenance of records. Additional housing tentage for officers

and for enlisted men should be allocated to the team by the parent unit.

OPERATING TENT

The employment in the field of commercial operating tables is costly and impractical. These tables consume space and interfere with mobility. A sturdy

metal litter stand (fig. 15) lends itself well to the performance of craniotomies and laminectomies. Any ordnance unit in the field can make a similar stand from scrap iron. Craniotomy in the supine and lateral position can be carried out on a padded litter, placed on such a metal stand. The head can be positioned with blankets and secured with adhesive tape. Suboccipital operations and laminectomies require a litter with a circular hole for the face, enabling the anesthesiologist to control the air passages.

A Mayo stand can readily be improvised (fig. 16). Sterile supplies are kept on hand on shelves in the operating tent (fig. 17).

Standard field operating lamps are bulky, consume space, and interfere with mobility. A practical surface light which can be moved on a crossbeam from head to spine, as illustrated in figure 18, can be handmade without difficulty. Supplemented by a headlight or by Frazier lighted retractors for the illumination of deep structures, this lamp has been found effective for use. In the tent for operative patients, a metal litter stand similar to that used in the operating room lends itself well as a preparation stand. Specially adapted litters facilitated thorough preparation of the head, catheterization, and administration of an enema (fig. 19).

The postoperative ward tent can readily be arranged so as to provide the necessary space for head dressings, flap taps, lumbar punctures, oxygen therapy, intratracheal suctioning, and intravenous administrations. The cubicle arrangement has been found most practical, allowing the use of one suction apparatus for four patients and facilitating ward procedures in general (fig. 20). Alternatively cots can be placed in a line, with the heads of the patients facing the middle aisle so as to facilitate the care of head dressings. A portable dressing tray can be utilized to best advantage in the postoperative ward tent (fig. 21).

Considering the fact that the life expectancy of men afflicted with paraplegia can be as good as that of other individuals, so long as such common complications as decubital ulcers, bladder overdistention, bladder infection, and hypoproteinemia are prevented, the importance of immediate availability of proper care for this group of casualties scarcely needs emphasis. The employment of Stryker frames in the field is impractical because of time-consuming

maintenance and because of the space which the frames require; their use by a team in the field would interfere with mobility. During the fighting at the Chosin (Changjin) Reservoir in November 1950, Maj. Clifford P. Goplerud, MC, and Maj. Joseph L. Girardeau, MC, of the U.S. Army employed the litter-turning method on a quadriplegic patient of one of the authors (A.M.M.) for the first time. Further experience led to improvement of this method and its standardization. The exclusive use of the two-hourly litter-turning method in the 3d Neurosurgical Detachment (Provisional) during the period October 1951 to August 1952 was responsible for the fact that decubital ulcers did not develop in any American or United Nations patient. The litter-turning method requires blanket-padded litters which are placed on sawhorses. Two-hourly turnings are effected by placing a second litter on top of the patient and strapping him between the two litters. On completion of the turning, the top litter is removed, cleansed, and aired. For the prone position, the litter is specially prepared with an opening for the face and one for the catheter (fig. 22).

COMMENT

Experiences in the Second World War and in the Korean War have amply demonstrated the need of a special organization for the management of neurosurgical casualties. The two-echelon system which was employed in the Far East Command for the management of all casualties with missile wounds of brain and spinal cord answered that need. The incidence of meningocerebral infection was as high as 41 percent during the early phase of the Korean War when it was necessary to delay specialized neurosurgical care until the patients reached Tokyo. The adoption by the U.S. Army Medical Corps of the two-echelon system with mobile neurosurgical teams rendering definitive treatment at division level reduced the incidence of meningocerebral infection to less than 1 percent.

Of all missile wounds of the brain admitted to the 3d Neurosurgical Detachment (Provisional) during a 10-month period, 46.2 percent had clinically significant intracranial hematomas displacing midline structures sufficiently to have become fatal had they not been removed within a few hours after the




FIGURE 16.—Improvised Mayo stand.



FIGURE 17.—Sterile supplies arranged neatly on shelves in operating tent.



FIGURE 18.—(Top) Handmade operating lamp. (Photograph courtesy of *Annals of Surgery*.) (Bottom) Operating lamp, metal litter stand, and litter. (U.S. Army photograph.)

trauma had been sustained. It is surmised, therefore, that the realization of earliest possible neurosurgical intervention in the second year of the Korean War has spared the lives of many men who could not have survived the trip back to a rear installation. The employment of helicopter evacuation was an essential factor in the successful work of the mobile neurosurgical teams.

The use of substitute Stryker frames (litter-turning

method) for the early care of paraplegic and quadriplegic casualties has eliminated the occurrence of decubital ulcers, a complication which has been largely responsible in the past for the high morbidity among paraplegic patients.

The maintenance of an adequate program for patients with missile wounds of brain and spinal cord in active warfare, in the final analysis, is dependent on the experience, the skill, and the enthusiasm of

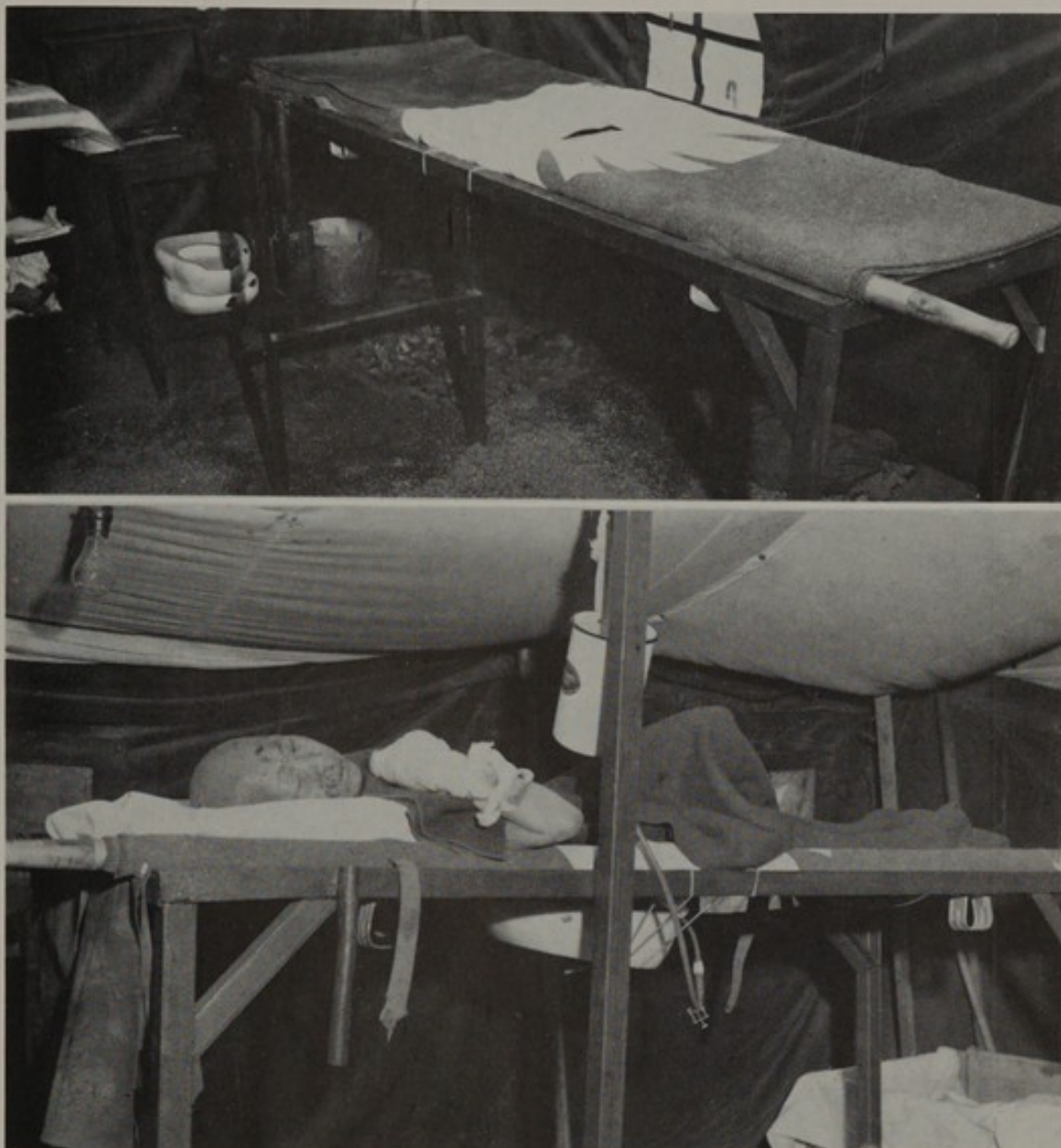


FIGURE 19.—Preparation stand for casualties with head wounds. (Top) Specially prepared litter for administration of enema. (Bottom) Specially adapted litter facilitated thorough preparation of head, catheterization, and administration of enema. (Photograph courtesy of *Annals of Surgery*.)

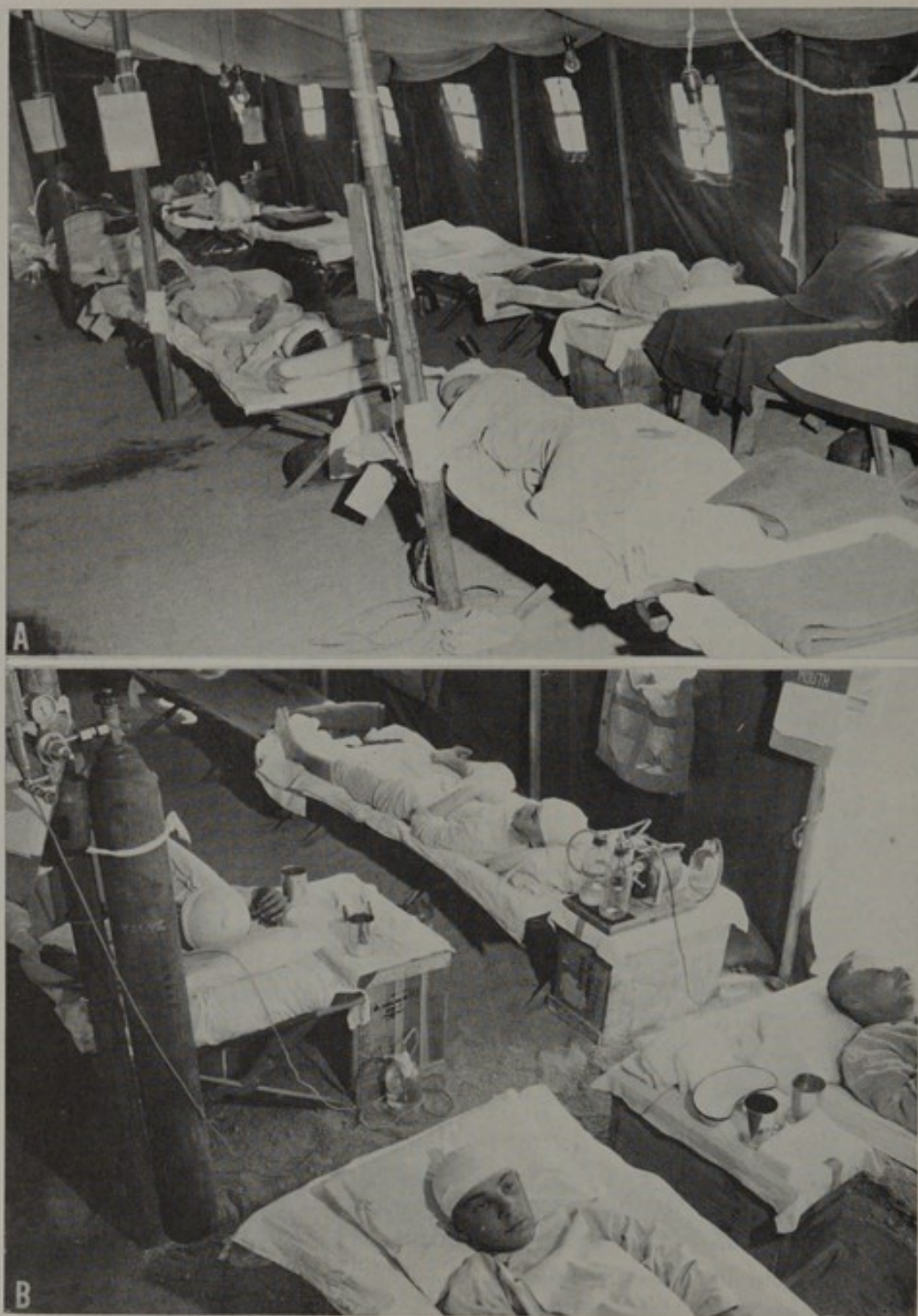

FIGURE 20. (See opposite page for legend.)

the personnel charged with the responsibility for this group of casualties. Military exigencies, however, necessitate a structural organization, centralizing specialized care and special facilities. The mobile neurosurgical teams, which were employed on a provisional basis by the Eighth U.S. Army in Korea and

by the Republic of Korea Army, furnish such structural organization and provide the exceptional care of neurosurgical casualties of which the U.S. Army Medical Corps has proved itself capable (3) (5) (7) (8). Their inclusion in the current table of organization and equipment is essential.



FIGURE 20.—Postoperative ward tent. A. Arrangement of beds does not facilitate the care of head dressings. B. Cubicle arrangement facilitates the care of head dressings and the use of one suction apparatus and one oxygen tank for four patients. (Photograph courtesy of *Annals of Surgery*.) C. Paraplegic casualty on padded litter for purpose of two-hourly turning between litters. D. Paraplegic section. (Photograph courtesy of *Annals of Surgery*.)



FIGURE 21.—Portable dressing tray.

REFERENCES

1. Page, T. N., and Neel, S. H.: Army Aeromedical Evacuation. U.S. Armed Forces M.J. 8: 1195-1200, August 1957.
2. Wing, J. E., and Addison, J. A.: Helicopter Mobile Medical Companies. U.S. Armed Forces M.J. 7: 1802-1808, December 1956.
3. Meirowsky, A. M., and Barnett, J. C.: Mobile Neurosurgical Team. Ann. Surg. 138:178-185, August 1953.
4. Annual Report, Consultant in Neurological Surgery, Far East Command, 31 Dec. 1951.
5. Letter, Eldridge Campbell, M.D., Civilian Consultant in Neurosurgery, to The Surgeon General, Department of the Army (Attn: Coordinator of Professional Consultant Activities), 11 Feb. 1952, subject: Report of Civilian Consultant in Neurosurgery on Tour of Far East Command.
6. Final Report on the Care of Neurosurgical Casualties in the Korean War During the Period September 1950-August 1952, by Lt. Col. Arnold M. Meirowsky, MC, former Neurosurgical Consultant to the Chief Surgeon, Far East Command, 1 Sept. 1952.
7. Sachdeva, D. C.: American Neurosurgical Team. Armed Forces M.J., India 13: 129-143, 1957.
8. Yoon, Bog-Yung: A Statistical Study on Combat Head Injuries. Korea Army M.J. 1: 4-44, 1954.




FIGURE 22.—Steps in litter-turning method for paraplegic patients. A. Blank-padded litter on sawhorse and specially prepared litter with an opening for the face and one for the catheter. B. Supine position. Padded wooden board is used to prevent foot drop. Note blanket under lower legs to keep knees slightly flexed and to prevent pressure on heels. C. As on a Stryker frame, the patients are turned every 2 hours, day and night. Specially prepared padded litter for prone position is being placed on top of patient. D. The two litters are strapped together with the patient still in the supine position. E. Aidmen preparing to turn the patient. F. Upon completion of the turning maneuver, the top litter is removed. Patient is now in prone position. (Photographs of steps B, C, E, and F courtesy of *Annals of Surgery*.)

Part 2

CRANIOCEREBRAL TRAUMA

Closed Craniocerebral Trauma

CHAPTER 5

General Considerations

Frank H. Mayfield and Bert H. McBride

Head trauma, whether occurring with the endemic spread of peacetime or the epidemic concentration of war, will, at the outset, usually place its victims in the hands of relatively inexperienced people. Those who survive the early period will, as a rule, receive more skilled care, yet the ultimate mortality and morbidity are highly dependent on the quality of early management.

Fortunately, attendants, lay and professional, can become rather proficient in the management of patients with head injury, even though they may not be thoroughly versed in anatomy and pathology. A thorough understanding, however, of certain fundamental principles and objectives, a sense of dedication, and considerable optimism are essential to success. Perhaps in no field of medicine is eternal vigilance more important.

Experience has shown beyond question that cerebral anoxia is the most frequent cause of death after head injury, and hence the principal objective of all attendants should, from the outset, be the establishment and maintenance of an adequate airway. In our opinion this takes precedence even over bleeding in order of priority.

It is necessary also for the attendant to understand that cerebral anoxia may result either from contusion or laceration of the brain or from compression of

the brain and that it may be aggravated by changes in parts of the body other than the brain.

It also must be recognized that the patient who has sustained a head injury may survive the effects of contusion and laceration of the brain but that he also may be suffering from compression of the brain due to hemorrhage or swelling and that he may not survive these effects unless they are promptly corrected. It should be apparent therefore that the most urgent responsibility is to provide an adequate and clear airway and then to observe the patient closely so that, if signs of compression of the brain develop, they can be recognized and the cause corrected before irreversible changes can occur.

It follows logically therefore that we first consider the general care of the unconscious patient and then that we consider the signs of progressive cerebral hypoxia, which may indicate the presence of a lesion that requires surgical correction, and lastly that we give attention to definitive differential diagnosis and treatment of surgical lesions.

Perhaps some may wonder that we proceed to the care of the unconscious patient even before discussing assessment of the state of consciousness, but we prefer to give attention to important things first. The physician who is concerned about details of history and examination before determining that the patient

is breathing well, or the nurse, for instance, who, when asked the condition of the patient, hunts the blood pressure chart or gives a record of the pulse before reporting on the level of consciousness seldom has a good grasp of the problems before them.

IMMEDIATE CARE

The prime duty of the first attendant is to assure an adequate airway. The lateral recumbent position with face dependent usually will permit an adequate respiratory exchange (fig. 96). It is difficult to maintain an unconscious patient in this position on a hand litter, and in this instance the prone position with a vent for the mouth is usually more satisfactory.

The airway should be cleared of secretions at the earliest moment. Mechanical suction through a catheter greatly facilitates this but usually is not available at the scene of the injury. Supplemental oxygen administered by nasal catheter is helpful, but again this usually is not available to those who first wait upon the injured patient. Adequate oxygenation usually can be obtained if immediate and unremitting attention is given to the respiratory exchange. We would not, of course, belittle the hazards of external bleeding, which should be immediately controlled, but we are so anxious to emphasize the importance of the immediate establishment of an adequate airway that we place this first.

When the airway is established and any bleeding controlled, one should pause to assess the state of consciousness, for this is by far the most important measure of the patient's condition. If an injured patient has not been rendered unconscious, or if he has quickly regained consciousness and is alert and cooperative, his condition should cause no concern. If he is unconscious but, with the passage of time, responds more readily to stimuli, then the prognosis would appear good. On the other hand, if it is noted that stupor is deepening or that the conscious patient has become confused or that more painful stimuli are necessary to arouse him, it is reasonable to assume that serious impairment of the circulation of the brain is taking place, and it is probably the result of compression of the brain due to either hemorrhage or swelling, which will require surgical correction.

On the other hand, if the onset of coma has been instantaneous and continuous, even though quite deep, the coma is probably the result of contusion and laceration which, as a rule, is not amenable to surgical intervention. In either event, however, if the coma is deep and there is any question of the efficiency of respiratory exchange, a tracheostomy should be done. Tracheostomy improves respiratory exchange by bypassing the relaxed tissues of the nasopharynx and facilitating the removal of mucus and/or blood and also promotes efficiency by reducing the dead space in the respiratory tree by approximately 50 percent. In our wards we proceed generally with the premise that if one wonders if a tracheostomy is needed, it is already overdue. The great benefit which accrues from tracheostomy, however, will be nullified unless it is meticulously cared for. Frequent cleansing of the trachea and tube is essential.

TRACHEOSTOMY

The technique of tracheostomy does not fall within the scope of this chapter but the care of the patient with tracheostomy does and is most important. The tracheostomy tube and trachea must be aspirated frequently. It is best accomplished with a catheter attached to a mechanical sucker. The catheter which must be used for aspiration through the tracheal tube inflicts less trauma if it is attached to a Y-tube (1) (fig. 23). An open-end catheter is better than one with a side-vent. It should be inserted through the tracheostomy tube with one wing of the Y open. When the catheter meets resistance, the open end of the Y is closed with a finger and the open end of the catheter rotated. By changing the position of the head from one side to the other during the aspiration, the trachea as well as both main bronchi usually can be cleaned. Gentleness must be stressed in the execution of this maneuver. Forceful suction often lacerates the mucosa, adding blood to the secretions and also inviting infection.

Mucous plugs form quickly when the respiratory tract dries. They are hazardous and are difficult to remove. They should be prevented. Oxygen has a drying action on the tissues and when given as a supplement through the tracheostomy tube, it should be humidified. It can be applied with a funnel over a tube. The passage of a catheter through the tracheostomy tends to obstruct the tracheostomy,

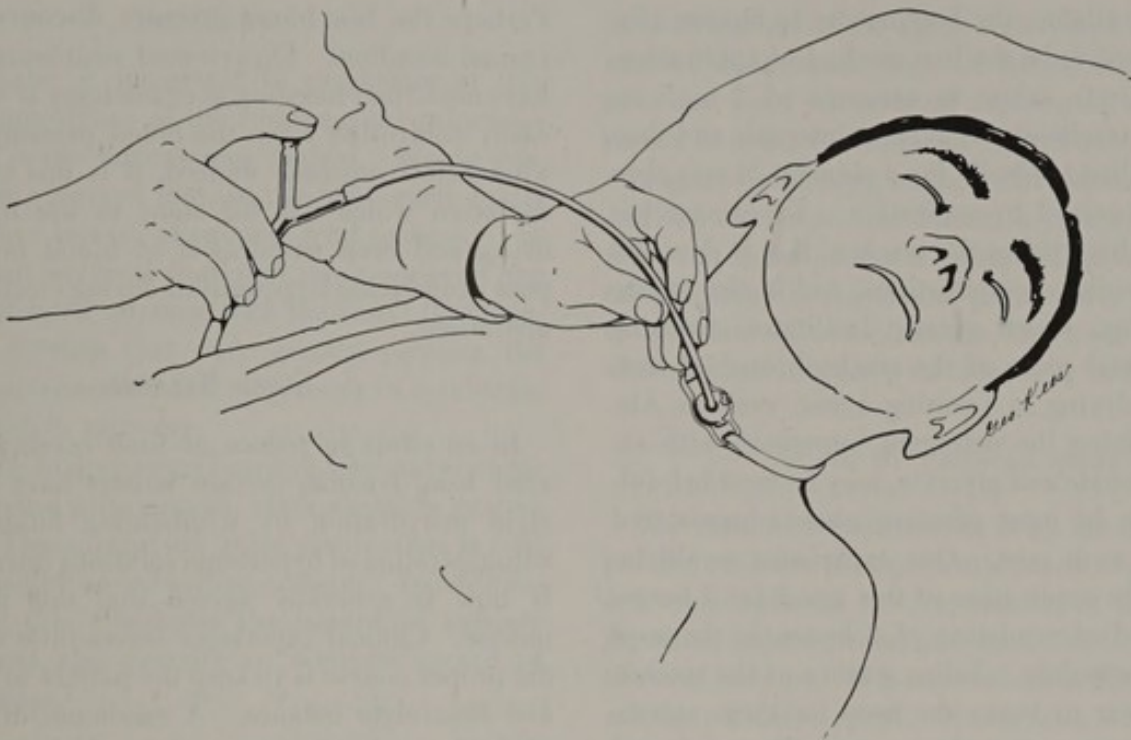


FIGURE 23.—Aspiration of tracheostomy tube with catheter attached to a Y-tube.

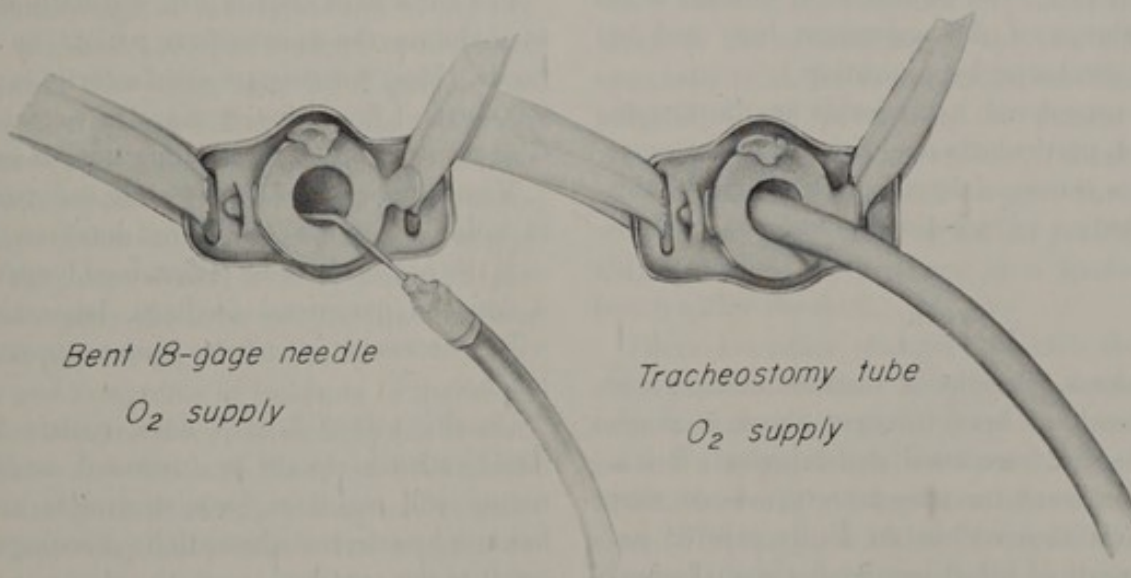


FIGURE 24.—The small bent needle provides adequate oxygen but does not obstruct the airway.

and when available, the bent-needle technique (fig. 24) is believed to be the best method of application.

If one injects saline in amounts of 3 to 5 cc. through the tracheostomy tube at intervals and then allows the saline to "boil" for a moment, it may then be easily recovered by aspiration. Experience has shown that this washes the trachea, that it does not induce pulmonary complications, and it also stimulates coughing, which greatly facilitates cleansing the more distal parts of the tracheobronchial tree. To combat drying, a foaming agent, such as Alevaire, containing the detergent Superinon with sodium bicarbonate and glycerin, may be most helpful. It appears to be most effective when administered periodically as a mist. Our experience would indicate that the application of this agent for 2 hours, with a period of remission of 2 hours, is the most satisfactory schedule. Saline washes of the trachea actually appear to lessen the need for these agents. We believe it important also to wash the mouth and nasopharynx periodically, which is carried out in essentially the same way. Clinical observations would indicate that this maneuver substantially lessens pulmonary complications.

By changing the patient's position from one side to the other at regular intervals, the lungs usually can be kept clear. The objective, of course, is to promote drainage of the uppermost lung and to evacuate its discharge by aspiration.

We have considered it advisable in the unconscious patient, particularly one with a tracheostomy, to maintain a screen of broad-spectrum antibiotics for the prevention of infectious pulmonary complications.

SHOCK

Surgical shock (peripheral vascular collapse) is rarely the result of head injury. Shock is much more apt to occur from associated injuries. It is a fairly common error for attendants to assume that shock which is observed in the badly injured patient is the result of blood loss from a scalp laceration, with the result that internal bleeding from a ruptured viscus, such as the spleen, kidney, or liver, may be overlooked.

When shock is present, it should be treated in the usual manner with blood and intravenous fluids. Intracranial clots of surgical significance are rarely observed in patients who are admitted in shock.

Perhaps the low blood pressure discourages intracranial bleeding. Experienced neurosurgeons long have noted that bleeding at craniotomy is much more easily controlled when the blood pressure is somewhat below normal. Indeed, it is this clinical observation which has led some to use hypotensive drugs and even withdrawal of blood for the purpose of inducing hypotension during elective cranial operations.

FLUID BALANCE

In an effort to reduce or limit cerebral swelling after head trauma, certain writers have advocated rigid dehydration by withholding fluids and the administration of hypertonic solutions intravenously. It now is generally agreed that this premise is unwise. Clinical experience leaves little doubt that the proper course is to keep the patient in both fluid and electrolyte balance. A minimum of 2,000 cc. of fluid per day is necessary for the average adult. Fever or fluid loss elsewhere may raise these requirements. The clinical signs of hydration or dehydration, of which urinary output is the most reliable, usually are adequate measures of fluid balance. A record of intake and output should, of course, be maintained from the start.¹

For a few days after injury, it usually is necessary to maintain the unconscious patient on parenteral fluids. Most patients are satisfactorily supported by 2,000 cc. of fluid (invert sugar in water) each day. Glucose solution (5 percent in water) is satisfactory.

Vomiting or excessive sweating indicates the need of saline solution administered intravenously.

If the patient is to be maintained longer than 3 or 4 days on parenteral feedings, laboratory studies will be necessary in order to insure proper electrolyte balance.

Usually within 3 or 4 days, gastric feeding by nasal catheter should be instituted, and thereafter nature will maintain both electrolyte and protein balance by selective absorption. Feedings should be small at the outset to lessen the chances of diarrhea or vomiting. Occasionally regular bowel action does not develop promptly, and it is important that the lower bowel be inspected manually for the presence of a fecal impaction.

¹ The use of urea is discussed in chapter 19, p. 225-226.—A.M.M.

BED CARE

We consider it important to emphasize at this point the importance of the fundamental principles of nursing in the unconscious patient. We do this, for we have observed that, in the tense early hours after a severe injury, attendants tend to be so concerned about survival that they omit some of the essentials of good nursing, with the result that complications develop that may greatly prolong the ultimate convalescence and may result in a substantial deterrent to recovery.

One who is in deep coma requires frequent changes of position and soft, smooth, clean sheets to protect the skin. The control of urine elimination is best accomplished by an indwelling catheter. In addition to tidiness, this eliminates the hazard of urinary retention and also permits an accurate record of urinary output.²

CLINICAL ASSESSMENT

Trauma to the brain may destroy brain tissue or may initiate certain byproducts that progressively impair the circulation of the brain. These byproducts are the same as with trauma elsewhere; namely, edema or hemorrhage or a combination of the two (2). Since the skull chamber is rigid, hemorrhage or edema within may occur only by displacing the fluid from normal spaces within the brain and skull. These, of course, are the cerebrospinal fluid and the normal blood supply. Displacement of cerebrospinal fluid produces no significant clinical symptoms. On the other hand, interference with the normal blood supply produces profound alterations in the normal physiology of the brain.

The signs and symptoms of ischemia of the brain resulting from compression, particularly due to clot, vary remarkably in relation to the speed with which the intracranial space is encroached upon. A relatively small mass may kill within a few minutes or hours if it develops rapidly. On the other hand, massive space-consuming lesions, such as hematomas or tumors, are tolerated well by the brain for prolonged periods if the mass develops slowly.

Thorough and continuous scrutiny of the patient

in anticipation of the signs and symptoms of intracranial disturbance and, at times, certain special tests and even intracranial exploration may be necessary in order to determine the presence or absence of a space-consuming intracranial lesion.

The most important factor in making this determination is the patient's course. Hence, a carefully taken history is important, particularly as it relates to the state of consciousness, the time of onset of altered consciousness, its duration, and its course.

STATE OF CONSCIOUSNESS

The state of consciousness is by far the most important measure of a patient's condition. One cannot overemphasize the importance of frequent and repeated, indeed almost constant, checks on the state of consciousness. It is our custom ordinarily to first ask the patient to speak. If this fails, we would then endeavor to determine if he will respond accurately to a command, such as protruding the tongue. If no response is initiated by this, painful stimuli should be applied, such as compression of the supraorbital nerve or pinching the skin of the arms or thighs. Quick, purposeful, protective movements by the extremities of each side are favorable signs. On the other hand, if the response to painful stimuli is delayed or the extremities on the two sides respond unequally or if, for example, the movements are not purposeful and protective, the patient should be viewed with serious concern, and if these latter signs have developed subsequent to more favorable signs which were observed in an earlier period, this probably indicates the presence of a space-consuming lesion within the skull.

There are other changes to which the attendant should give attention. The development of involuntary urination (bedwetting), for example, in a patient who previously has been voluntary and continent, is strongly suggestive of cerebral compression. The human is trained from childhood to tidiness and is easily aroused by the stimulus of a distended bladder. To void in bed is an indication that his state of consciousness is substantially impaired. It is not unusual, particularly in the aged with subdural hematomas, for this to be the first sign of impending coma.

It is necessary to interpret the state of consciousness that one observes in relation to the history. If,

² The use of an outer attachment is discussed in chapter 19, p. 223.—A.M.M.

for example, a patient has been conscious after a blow and then becomes unconscious, it should be obvious that the coma is not the result of contusion or laceration but is developing as the result of either hemorrhage or swelling. On the other hand, if the patient has been rendered unconscious at the moment of impact and the coma has persisted, it may be assumed that the initial loss of consciousness was the result of concussion, contusion, or laceration. However, if the unconsciousness persists over a prolonged period, it would be impossible for any examiner to determine with assurance whether intracranial bleeding or swelling were not also taking place, yet it is essential that the determination be made, for the patient may survive the contusion and laceration but be unable to withstand the effects of a space-consuming hemorrhage as well. The knowledge and experience of a skilled surgeon usually are necessary, for special diagnostic tests, such as pneumoencephalography, ventriculography, or angiography, or indeed cranial exploration may be required in order to make the determination. We are pleased when our subordinates—orderlies, nurses, internes, and residents—are alert enough to make the observation that the patient's state of consciousness is deteriorating and call it to our attention, saying, in effect, "It is your move," and indeed it is the surgeon's move.

In most well-organized services, the attending surgeon will see the patient frequently during the day, but the risk to the patient does not lessen with nightfall, and we would have little respect for a surgeon who endeavored to interpret a telephone report without seeing the patient. To do so not only exposes the patient to great risk but also greatly lowers the morale of subordinate attendants.

Restlessness, thrashing about in bed, is a fairly common symptom in patients with cerebral anoxia. It occurs perhaps more often as the result of contusion and laceration of the brain than with compression due to hematoma. Restlessness which develops immediately after injury probably is an expression of contusion and laceration. However, the onset of restlessness in a patient who previously was quiet may be the first clinical expression of the presence of a space-consuming intracranial lesion. One should be particularly concerned with patients who have changed from a state of quiet to one of restlessness or from orientation to confusion. All attendants should recognize that the skills of an ex-

perienced surgeon are needed at this point to determine the course of therapy.

CONTROL OF RESTLESSNESS

The control of restlessness often can be achieved by correction of the cause. Cerebral anoxia is a frequent cause, and attention should be given to this first. On the other hand, a distended urinary bladder, painful bandages, or casts, for example, all induce restlessness. The semicomatose and confused patient will combat restraint. Many will stop thrashing about if these matters are corrected.

The restless patient usually can be prevented from falling out of bed by a chest restraint while permitting free movement of the arms or legs (fig. 25). Encasing the hands in padded dressings (boxing gloves) will protect catheters and dressings and also encourage rest. Only when all of these exigencies have been attended to and have failed is one justified in using drugs for the control of restlessness in a patient who has sustained head trauma.

The use of narcotics, particularly morphine, in the treatment of head trauma has long been condemned. They have been condemned on the premise that they mask changes in the state of consciousness and also in the neurological signs, particularly the pupils, which might permit the correct diagnosis of a surgical lesion of the brain. They also have been condemned on the premise that they tend to depress respirations. For the most part, these objections are hypothetical rather than real, and for the control of pain and shock from associated injuries, we consider the use of reasonable amounts of narcotics justified. Narcotics, however, are not the most satisfactory agents for the control of restlessness which arises directly from disorders of the cerebrum, such as contusion. The derivatives of chlorpromazine hydrochloride, 10 to 25 mg., at intervals of 4 to 6 hours, appear most satisfactory. Paraldehyde and the barbiturates may be used if necessary.

PULSE, RESPIRATIONS, TEMPERATURE, AND BLOOD PRESSURE

Frequent observations and recordings of the pulse, respirations, the temperature, and blood pressure are necessary in order to assess properly the intracranial state. When the intracranial pressure is

raised rapidly, the pulse is slowed, the respirations are slowed, the blood pressure is elevated, and the temperature usually is raised. On the other hand, if the increased intracranial pressure continues or reaches a level sufficient to impair the circulation of the brain, these reactions change. The early period usually is spoken of as the period of compensation and the other of broken compensation.

A slow pulse, slow respirations, elevated blood pressure, and high temperature may accompany increased intracranial pressure so long as the major circulation of the brain is preserved. However, if the major circulation begins to fail as the result of compression, these clinical responses tend to be reversed. The pulse and respirations may become rapid. The blood pressure may fall. The temperature is not ordinarily lowered at this time but tends to rise.

Preceding this break in compensation, which is a morbid development, there is usually a period of rapid fluctuation in the pulse rate. It may be rapid for a few moments and then become quite slow, only to change again to a more rapid rate. Usually

when the pulse becomes quite slow, the patient will be restless and, if conscious, is apt to scream with headache. When these observations are made, immediate surgical intervention may well be necessary or death will ensue. We have observed this repeatedly in hemorrhages of arterial origin, such as extradural clots, acute subdural hematomas, and hemorrhages in the posterior fossa.

HEADACHE AND VOMITING

Headache and vomiting are often symptoms of increased intracranial pressure, and if present and persistent in a patient who is conscious, these symptoms should be viewed with grave concern. Efforts to appraise the significance of vomiting on the basis of whether it is projectile or nonprojectile are futile. Vomiting, in our experience, is a symptom which does not lend itself to subclassification.

CRANIAL NERVES

Changes in the function of certain of the cranial nerves provide most useful information in the assess-

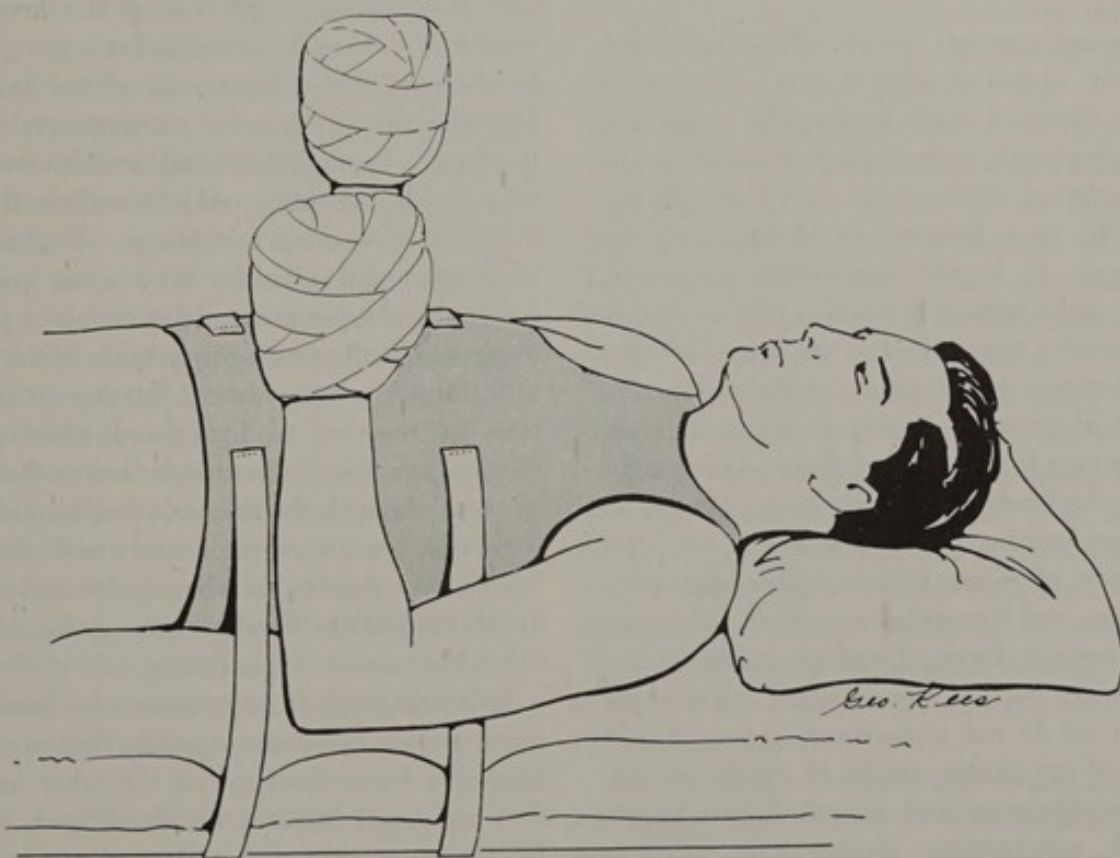

FIGURE 25.—Diagram of chest restraint and padded dressings (boxing gloves) for the restless patient.

ment of the injured patient, and we would like to discuss briefly the clinical evaluation of these.

It is imperative that the status of the cranial nerves be recorded at the time of the initial examination, for abnormal cranial nerve findings that are present immediately after impact usually are the result of laceration of the nerve, a situation that occurs frequently with fractures of the base of the skull. On the other hand, subsequent palsies of the cranial nerves usually reflect the presence of an intracranial clot. For example, if a pupil were dilated or fixed immediately after injury, it usually would be the result of laceration of the third cranial nerve. However, if it developed subsequently, it probably would reflect the presence of an intracranial hematoma.

Olfactory (first cranial) nerve.—The olfactory nerve may be injured as the result of fracture through the anterior fossa of the skull and occasionally by direct contusion or laceration without fracture. The presence or absence of anosmia, however, is of little significance in the acutely injured patient, even though it may be observed as an unpleasant and often permanent residual of head injury.

Optic (second cranial) nerve.—Bilateral blindness is rarely observed after injury. Unilateral blindness is observed with reasonable frequency. If present immediately after impact, it usually is the result of laceration of the optic nerve and is frequently related to a fracture which traverses the optic foramen. It is not correctible surgically. Occasionally amblyopia will develop late as the result of progressive narrowing of the optic foramen at the site of repair of a fracture of the skull. We have not yet observed a patient in whom this occurred. It is rare for significant diagnostic changes to develop in the fundi in the early stages after head trauma. Slow-forming clots, such as the subdural hematoma, may, of course induce papilledema and/or hemorrhages, and it must be recognized, of course, that the hydrostatic force of sudden arrest of the head may induce retinal hemorrhages. For some reason which we do not understand, subarachnoid hemorrhage of traumatic origin is rarely accompanied by papilledema and retinal hemorrhages, whereas with spontaneous hemorrhage, such as occurs with intracranial aneurysms, this is a fairly frequent finding.

Oculomotor, trochlear, and abducent (third, fourth, and sixth cranial) nerves.—Paralysis of the third cranial nerve, particularly progressive dilatation of a pupil, is usually a pertinent clinical finding and reflects, as a rule, the presence of a space-consuming intracranial lesion (3). On the other hand, paralysis of the extraocular muscles, supplied by the fourth (trochlear) and sixth (abducent) nerves, is rarely the result of intracranial hematoma or swelling. The probable explanation for this lies in the fact that the hematoma itself is not directly responsible for the changes in the pupil. Instead, the space-consuming lesion shifts the brain, with the result that the temporal lobe on the affected side tends to herniate through the incisura and thereby compresses the third nerve (4). The fourth and sixth nerves are not so vulnerable to this complication. We should hope that our readers would recognize that the size of the pupil is not directly proportionate to the size of the clot but is determined in large measure by the degree of herniation of portions of the temporal lobe through the incisura. The tendency of the temporal lobe to herniate varies remarkably with anatomical variations of the skull and also with the location of the hematoma. It would, of course, be possible for a person to expire as the result of compression of the brain from a hematoma in any location without causing the pupil to dilate. On the other hand, a relatively small mass may displace the temporal lobe sufficiently in certain individuals to cause herniation. It is necessary to emphasize that all who wait upon patients with serious head injuries should include as a part of their observations the routine inspection of the pupils with a flashlight, comparison of the size of the two and tests of reaction to light, and when progressive changes are noted, one experienced in the assessment of these changes should be called immediately. If these changes are noted in one whose consciousness is also deteriorating or whose pulse and respirations are slowing or the blood pressure rising, for example, immediate action is mandatory.

It is not unusual in patients who have sustained head trauma to observe pupils that are equal but markedly constricted or, on the other hand, pupils that are equal but are widely dilated, and indeed from time to time one notes patients in whom the size of the pupils varies spontaneously but remains equal. Efforts to explain this phenomenon have, in

our opinion, never been entirely successful. It is presumed to be the result of contusion, and more often the contusion is located in the brain stem, yet these changes are not reliable prognostically or diagnostically. In general, patients who are admitted with normal pupillary responses will do better than those who have abnormal responses (5). On the other hand, experience would indicate that patients whose pupils vary in size but remain equal on the two sides seldom require surgical intervention.

In certain patients after severe contusion or laceration of one hemisphere or the other, one may note conjugate deviation of the eyes and occasionally nystagmus. This also is noted with cerebral vascular accidents in one hemisphere or the other. In cortical lesions, the eyes generally are turned toward the lesion, whereas when the brain stem is involved, the eyes tend to turn away from the side of the lesion, but unless these findings are corroborated by other clinical observations, such as hemiplegia, they are not reliable localizing signs.

Trigeminal (fifth cranial) nerve.—The trigeminal nerve may be damaged as the result of fracture of the base of the skull, but it does not lend itself to treatment and is rarely of specific diagnostic value in the assessment of patients with head injury.

Facial (seventh cranial) nerve.—Clinical observations of facial paralysis are interesting. With fractures of the base of the skull, the facial nerve may be lacerated, with the result that paralysis of the face on the affected side develops. It may be instantaneous in onset and involve the entire face, with the result that the patient cannot close the eye or move the muscles of the cheek. Depending on the location of the fracture, taste on the anterior part of the tongue also may be affected.

Facial weakness resulting from lesions that involve the cerebral hemispheres is confined as a rule to the lower half of the face and, to a lesser extent, the eye, presumably because the human has dual innervation to the muscles about the eye. Weakness of the lower face reflects the presence of a lesion in the opposite cerebral hemisphere and, if delayed in onset, often is early evidence of an intracranial hematoma.

Paralysis of the face of the peripheral type may develop a few hours or a few days after an injury. This is more apt to occur in patients who have had bleeding from an ear or other evidence of a fracture

of the base of the skull. It does not reflect the presence of an intracranial clot, and spontaneous recovery usually takes place.

Acoustic (eighth cranial) nerve.—The acoustic nerve is often injured as the result of fracture through the petrous portion of the temporal bone. Bleeding from the ear and at times leakage of cerebrospinal fluid often results from this injury. No local treatment is required. It is important to emphasize, however, that one should not irrigate the canal or insert artificial plugs, such as cotton.

Glossopharyngeal, vagus, spinal accessory, and hypoglossal (ninth, tenth, eleventh, and twelfth cranial) nerves.—Theoretically, the ninth, tenth, eleventh, and twelfth cranial nerves may be affected as the result of trauma, but it is so rare for changes in these nerves to have diagnostic significance that they may be omitted from this discussion. The interested reader should refer to a standard neurological text.

MOTOR SYSTEM

Disturbances of the motor system due to head trauma in the acute phase fall into three general categories: (1) Paralysis or paresis, (2) convulsions, and (3) decerebrate rigidity.

Paresis.—Weakness or paralysis of the muscles on one side of the body results from a lesion on the opposite side of the brain. If the disturbance of power is present from the moment of impact, it almost invariably results from contusion or laceration of the brain. If it develops subsequently, it usually is the result of hemorrhage.

For the most part, paralysis resulting from laceration or contusion will involve the entire side of the body, whereas paralysis due to hematoma is more apt to begin in one part, such as the face, the arm, or the leg. One fairly frequent exception to this rule occurs with local depressed fractures of the skull, particularly fractures produced by smooth, blunt objects traveling at high speed, such as a golf ball. If these occur over the motor strip, focal paralysis is apt to be noted.

All attendants should be able to and should check motor function frequently. This usually can be accomplished by comparing the power of the hand grip on the two sides or by comparing the patient's ability to support the extremities in air or often-

times by the observation that during restlessness one side is moved about more than the other.

Convulsions.—Experience has shown that convulsions which appear in the wake of acute head trauma are associated with intracranial hemorrhage in a high instance of cases. If the seizures are focal (Jacksonian) in character, surgical exploration is mandatory. If the seizures are generalized, it is the obligation of the surgeon to prove that clot is not present by contrast studies or surgical exploration before committing the patient to a program of medical control.

When a surgical lesion has been ruled out, medical therapy should be instituted promptly, for seizures tend to aggravate hypoxia both by inefficient respiratory exchange and by the stimulation of secretions into the respiratory tract. Dilantin sodium (diphenylhydantoin sodium), 15 to 25 mg., combined with phenobarbital, 1 to 3 gr., every 4 to 6 hours usually is adequate to control seizures that are not the result of clot. On the other hand, an occasional patient will present himself in status epilepticus.³ Pentothal sodium (thiopental sodium) administered in a solution of 1 gm. per 1,000 cc. of 5 percent glucose, given as a continuous drip, may be needed.

Decerebrate rigidity.—A clinical syndrome believed to arise from contusion of the brain stem is noted from time to time in patients with acute head injury. The individual is unconscious but responds to painful stimuli with extensor rigidity of all the extremities. Rotation of the head often will induce extension of the extremities of one side but flexion of the opposite side. It resembles the righting reflex of a decerebrate cat. These patients frequently grind their teeth. The pupils usually are equal but fluctuate in size remarkably. There are periodic variations in sweat; at times excessive sweating is present; at other times the skin is dry and flushed.

This syndrome is an indication of a serious injury, but with an adequate airway and nutrition, many can be salvaged (fig. 26).

SPINAL PUNCTURE

Considerable controversy exists in reference to the indications for and the merit of spinal puncture in

the diagnosis and treatment of head injuries. Some have advocated daily spinal punctures as a routine in the treatment of patients with head trauma. Others have been equally opposed to its use. The authors of this chapter consider the routine use of spinal puncture as a therapeutic agent unwise. On the other hand, it is a useful diagnostic tool. The following are considered proper indications for spinal puncture:

A. Diagnostic:

1. To determine the pressure when intracranial clot is suspected.
2. To determine the presence and/or degree of bleeding in the cerebrospinal fluid.

The record of the spinal fluid pressure in a restless patient is, of course, meaningless. In the relaxed and cooperative patient, a spinal fluid pressure above 150 mm. of water should be regarded as suspicious, and pressures above 200 mm. of water are definitely pathological. As the circulation of the brain begins to fail, particularly in the aged, spinal fluid pressures may remain low, even in the presence of massive intracranial space-consuming lesions. This is especially true of the chronic subdural hematoma.

B. Therapeutic:⁴

1. To lower intracranial pressure by withdrawal of fluid as a temporary expedient pending measures directed at more lasting control of intracranial tension, such as surgical evacuation of intracranial clot.
2. Evacuation of bloody fluid when signs of meningismus appear, which is usually within 4 to 8 days after subarachnoid bleeding. Drainage of fluid at this time tends to relieve headache and to speed recovery.

Spinal puncture is best accomplished with the patient in the lateral recumbent position, using the standard spinal puncture needle. The operating surgeon should determine the color of the fluid, the initial pressure, and final pressure and also should record the amount of fluid that was withdrawn. Jugular compression tests should not be carried out unless one suspects injury to the spinal column. These tests give no information of value in reference to the brain. On the other hand, the rise in intra-

³ Dilantin sodium, IV, 250-500 mg., has proved most helpful in the management of status epilepticus.—A.M.M.

⁴ The editor feels that there is no place for a therapeutic spinal tap in the management of closed head injuries. A.M.M.

cranial tension that accompanies jugular compression may be harmful.

Spinal puncture should not be attempted if the patient is uncooperative, for the information obtained is unreliable, and struggling against restraint may induce additional bleeding, or indeed it may be the factor that causes herniation of the brain either through the tentorium or into the spinal column.

CLASSIFICATION AND EFFECTS OF SKULL FRACTURES

It is rare for the course of treatment of one with a closed head injury to be influenced by the presence or absence of a fracture of the skull. Classification of skull fractures, therefore, based on description of the line or indeed of the part of the skull involved is of little value. It is, of course, important to determine whether the fracture is open and also whether the fragments are depressed against the brain, and at times it is helpful to know whether a fracture line has crossed certain major vascular channels.

For the most part, brain injury is more severe when the force applied to the head is sufficient to fracture the skull. Hence, the morbidity and mortality are greater in any group of patients in whom fractures are found. The fracture per se, however, is rarely responsible. If the head is set suddenly in motion by a blunt force, or if the head which is in motion is arrested by contact with a resistant object, the skull absorbs some of the force and may fracture, but much of the force is transmitted to the brain (6). On the other hand, if the head is compressed, as between the jaws of a vise, massive fracturing may occur without trauma to the brain.

LINES OF FRACTURE

The vault of the adult human skull is composed of dense, strong, laminated, and resilient membranous bone. The base of the skull is composed of relatively inelastic cartilaginous bone. The base is not subject to direct force and hence can be fractured only when the vault undergoes considerable deformation (7).

Fractures of the skull tend to form radiating lines from the point of impact to the opposite pole of the skull. This has been repeatedly confirmed by roentgenograms of patients with head trauma, and beauti-

ful experimental confirmation was developed by Gurdjian and his colleagues with stress coat tests (8). Since the base of the skull is fragile and also houses such important structures as the carotid arteries and the medulla, injuries to this part are often serious.

When force is applied rapidly to a small area, local depression of the skull is apt to occur.

The soft, malleable skulls of infants and young children are affected quite differently by trauma than the rigid adult skull, and indeed, because of the malleability of the skull of the child, the blow tends to be cushioned and the brain protected to some extent. As the result of this, fractures of the skull in young children are often overlooked. In fact, it is not unusual for a hematoma or a collection of spinal fluid under the scalp to call the parents' attention to the site of fracture several days or weeks after the blow. We have been impressed that a child's skull seems particularly vulnerable to a blow, such as one by a golf ball, which tends to indent it.

In infancy, the skull may be substantially misshapen by a blow but quickly resume its normal shape, but as the child grows older, the skull bones unite and calcium deposits then occur, which make it more resistant to temporary deformation, but instead it tends to fracture and also to transmit more severe injury to the brain.

These general principles bearing on fractures of the skull are, however, of little value in assessing the individual case, which must be evaluated solely on the basis of actual and potential injury to the brain, as reflected by the clinical signs.

ROENTGENOGRAMS OF THE SKULL

Roentgenographic study of the skull is rarely urgent and, as a rule, should be deferred until more urgent matters, such as the airway, bleeding, shock, and associated injuries, are under control.

Roentgenographic examination usually will reveal fractures of the vault of the skull. Fractures that traverse the base of the skull are more difficult to visualize radiographically. There are certain clinical signs, however, that identify a fracture of the base of the skull which otherwise might not be apparent. Bleeding from the auditory canal or from the nose and mouth without evidence of direct injury to the part usually is an expression of a frac-

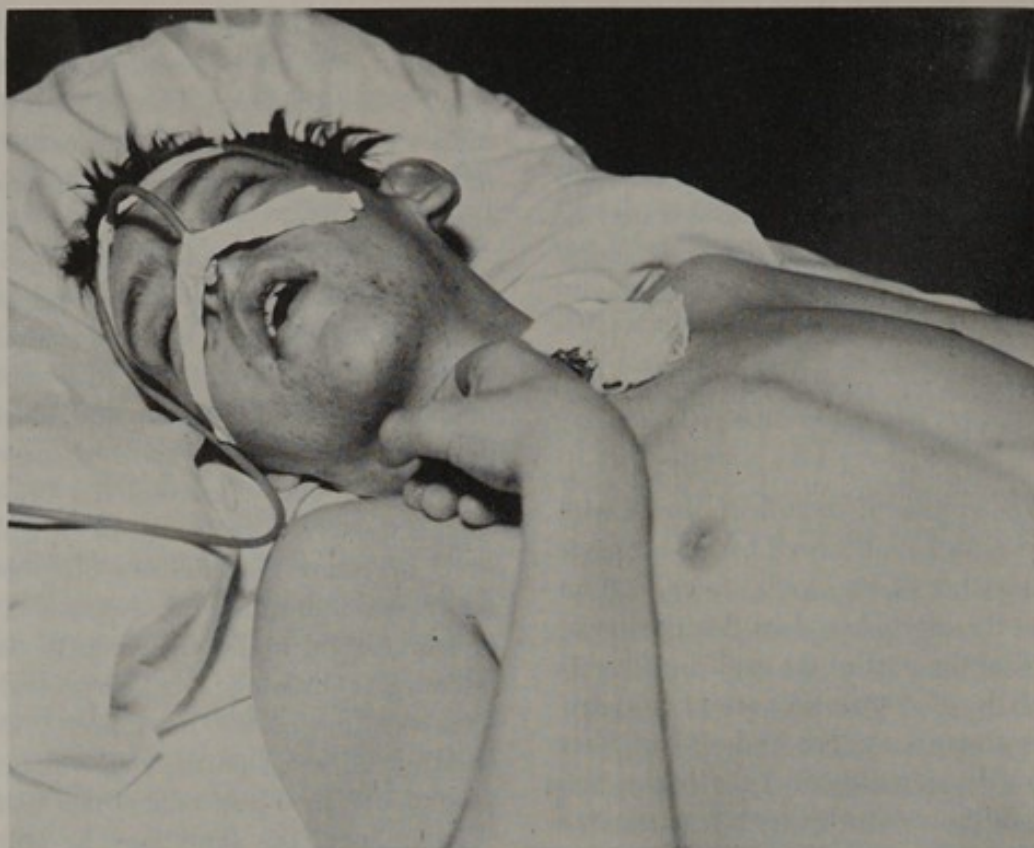

FIGURE 26.—(Top) Patient in decerebrate rigidity 2 days after injury. Note flexion of the right extremity, extension of the left. Same patient 1 year later.

ture of the base of the skull. In order for the membranes lining these passages to be torn, it is necessary that the bones be displaced.

At times ecchymosis may appear over the mastoid (Battle's sign) several days after trauma. This is believed to be the result of bleeding into the tissues about the base of the skull at the site of fracture. The same is true of ecchymosis about the orbits, which appears to result from the extravasation of blood into the tissues about the face after fractures that traverse the anterior fossa (fig. 27).

DEPRESSED FRACTURE

Most depressed fractures are open or compound. Occasionally, however, depression of the skull occurs without open wound of the scalp. A depression of the skull along the course of a linear fracture may occur. Usually these do not exceed 1 to 3 mm. and do not require surgical correction. The comminuted fractures usually are depressed to a greater degree. Under the premise that they were responsible for latent epilepsy, surgical correction of the deformity has been advocated. It seems unlikely that progressive changes will result from depressed fragments, but because of this possibility and for cosmetic reasons, surgical correction should be carried out, but it can be undertaken as an elective procedure.

HYPERTHERMIA AND HYPOTHERMIA

Perhaps the most exciting and promising new developments in our knowledge of cerebral function evolve from studies of body temperature. Contusion and compression of the brain often are accompanied by a marked rise of body temperature. Such a rise is an unfavorable prognostic sign, and many have advocated controlling the body temperature by cooling. The observation was empirical, however, and the object of most clinicians until recently was to prevent a rise of temperature above normal.

From extensive experimental and clinical evidence it now is known that hyperthermia is associated with increased metabolic demands by the brain that often overtax an impaired cerebral circulation, and progressive deterioration of the brain follows. On the other hand, by lowering the body temperature to

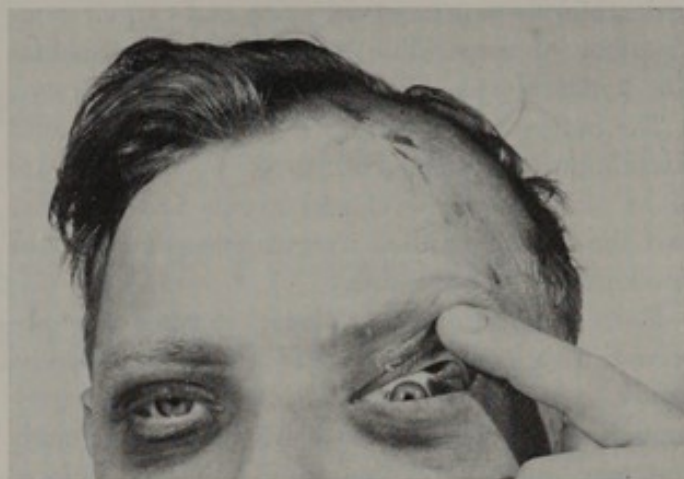

FIGURE 27.—Ecchymosis about periorbital space and subconjunctival space, delayed in onset, from fracture of frontal fossa.

normal or below, the metabolic demands of the brain often can be brought into balance with the blood supply. Moreover, it now is proved that there is substantial collateral circulation in the brain, though it usually is not adequate to sustain life of brain tissue whose prime circulation is lost when the body temperature is normal or increased. It may, however, be quite adequate if the metabolic demands are lowered by hypothermia. Furthermore, this collateral circulation will develop rapidly under hypothermia, so that often within a few days or weeks it will sustain cerebral tissue even when the body temperature has returned to normal.

The results of hypothermia as a mode of therapy in severe head injuries permit considerable optimism, for one now witnesses survival and good functional recovery in many patients whose prognosis formerly appeared hopeless (9).

The induction and maintenance of hypothermia is a procedure of major order and should not be undertaken by inexperienced personnel and fortunately is needed only in the severely injured. The prevention of hyperthermia, however, is an absolute obligation of all who undertake the care of patients with injuries of the brain.

A detailed description of the technique of inducing and maintaining hypothermia is not advisable here, and indeed the ideal technique has not yet been developed. At present we accomplish this by the use of large bags of crushed ice, after the administration of substantial doses of chlorpromazine

hydrochloride to prevent shivering and various combinations of meperidine hydrochloride, promethazine hydrochloride (Phenergan), and barbiturates.

The patient's temperature is lowered slowly over a few hours to a range of 30° to 32° C. This appears to be an adequate level and avoids for the most part the risk of cardiac irregularities that tend to develop at levels below this.

Many interesting physiologic changes are observed with cooling. Usually the patient sleeps gently, breathes deeply and slowly and, strangely enough, often becomes more responsive to stimuli and may move parts that were paralyzed before. Indeed, it is not unusual to observe improvement in state of consciousness and paralysis disappear when the temperature is lowered, but stupor deepens again and paralysis reappears when the body temperature is allowed to rise. This, in turn, may be followed by improvement when hypothermia again is induced.

It is not yet known how long one may be kept safely in a state of hypothermia. We have maintained patients at levels of 30° to 32° C. for periods of 4 to 6 weeks without observing untoward results. Fortunately, in most instances hypothermia for a few days is adequate. Within 4 to 6 hours after active cooling is discontinued, the temperature will

return to normal without adding external heat for rewarming.⁵

REFERENCES

1. Plum, F., and Dunning, M. F.: Techniques for Minimizing Trauma to the Tracheobronchial Tree After Tracheotomy. *New England J. Med.* 254: 193-200, 2 Feb. 1956.
2. Evans, J. P., and Scheinker, I. M.: Histologic Studies of Brain Following Head Trauma; Posttraumatic Cerebral Swelling and Edema. *J. Neurosurg.* 2: 306-314, July 1945.
3. Rand, C. W.: The Significance of a Dilated Pupil on the Hemilateral Hemiplegic Side in Cases of Intracranial Hemorrhage Following Head Injuries: Report of Seven Cases. *Arch. Surg.* 18: 1176-1189, April 1929.
4. Jefferson, F.: Tentorial Pressure Cone. *Arch. Neurol. & Psychiat.* 40: 857-876, November 1938.
5. Blakeslee, G. A.: Eye Manifestations in Fracture of the Skull. *Arch. Ophth.* 2: 566-572, November 1929.
6. Pudenz, R. H., and Shelden, C. H.: Lucite Calvarium—Method for Direct Observation of Brain; Cranial Trauma and Brain Movement. *J. Neurosurg.* 3: 487-505, November 1946.
7. Dandy, Walter E.: *Surgery of the Brain*. Hagerstown, Md.: W. F. Prior Co., Inc., 1945.
8. Gurdjian, E. S., Webster, J. E., and Lissner, H. R.: The Mechanism of Skull Fracture. *J. Neurosurg.* 7: 106-114, March 1950.
9. Grantham, E. G., and Segerberg, L. H.: Hypothermia in Severe Head Injuries. *Medical Science* 4: 263-267, 1958.

⁵ Many hospitals now have hypothermic blankets (Therm-O-Rite) which facilitate greatly maintenance of hypothermia.—A.M.M.

CHAPTER 6

Differential Diagnosis and Treatment of Surgical Lesions

Frank H. Mayfield and Bert H. McBride

Hemorrhage may occur in any of several anatomical areas: (1) The subgaleal space, (2) the extradural space, (3) the subdural space, (4) the subarachnoid space, and (5) within the brain.

It is not unusual for bleeding to be present in more than one of these areas in the same patient, but for clarity it is better to consider the clinical picture and treatment of each separately. Indeed, when the location of the hemorrhage is not obvious or when the blow has produced severe impairment of the level of consciousness, differential diagnosis may be difficult. It may be impossible to make a definite preoperative diagnosis other than intracranial clot. We will consider in a later section the diagnosis and management of ectopic or aberrant hematomas.

SUBGALEAL HEMATOMA

The clinical picture of massive bleeding in the subgaleal space is interesting and at times quite confusing. In the majority of cases the hemorrhage is initiated by a linear fracture of the skull. Occasionally it occurs with wounds that tend to avulse the scalp. The writer recalls two in which the hair was caught in a mechanical device and the scalp pulled loose from the pericranial attachments. It is more frequent in children than adults. With rare exceptions it is not noted within the first few hours or days after injury, but then the patient or its parents will note a fluctuant mass under the scalp. On the day that it is noted, one is apt to observe swelling of the tissues of the face. In the majority

of instances spontaneous absorptions will take place, though the absorption is quite slow. As absorption begins, systemic changes are often noted, with high fever and intense pain and tenderness. Indeed, the clinical picture of subgaleal abscess is simulated. Surgical incision at this time is inadvisable, lest infection actually be introduced through the drainage site. Hence, it is advisable to treat the patient in this state with aspirations through a large (10 or 12 gage) needle.

SUBGALEAL HYDROMA

Occasionally cerebrospinal fluid will be discharged under the scalp through a fracture site and will be mistaken for subgaleal bleeding. It is properly described as a subgaleal hydroma and rarely requires any treatment except a pressure bandage.

EXTRADURAL HEMORRHAGE

The most common cause of an extradural hematoma is laceration of a branch of the middle meningeal artery due to a fracture. The fracture is generally linear in type. The middle meningeal artery enters the skull through the foramen spinosum and lies within a groove in the inner table of the temporal bone. This position renders the vessel quite vulnerable to injury.

It is, of course, possible for bleeding to be present in the extradural space as the result of lacerations

of the dural sinuses. Fractures which cross over the superior sagittal sinus or the transverse sinus are particularly prone to cause extradural bleeding.

By far the most common story is that of a blow to the head, most often in the temporal area. The blow may or may not be sufficient to render the patient unconscious. If the brain is not otherwise affected, the patient will regain consciousness and may appear symptom-free for a time, or at least the symptoms may be mild enough that they are disregarded. Within a short period, which may vary in duration from a few minutes to several hours, headache of increasing intensity will develop. It may be followed by vomiting. This usually is accompanied by slowing of the pulse, perhaps a rise in blood pressure, and then weakness of the face, arm, and leg on the opposite side. Perhaps there will be convulsions. These are apt to be Jacksonian in nature. With these changes, some dulling of consciousness and dilatation of the pupil on the affected side will be noted. When the latter changes appear, the patient usually is in extremis.

It is one of the tragedies of medicine that this lesion, which lends itself so well to complete and permanent cure, should still carry a mortality rate of 30 to 50 percent. The reason, of course, is that many are not recognized until irreversible changes in the brain have occurred.

Blows received in athletic contests are prone to induce rapid intracranial bleeding. A batter hit by a baseball is a very typical case. The clots that develop after this type of impact are more apt to go unrecognized than those that follow more violent accidents, such as an automobile crash. The victims of the automobile crash arrive at the hospital with the ambulance throttle and siren open, and all who see them are aware that they may have been seriously injured. On the other hand, the athlete is apt to be regarded as having sustained a trivial injury and is sent home.

Several psychological factors seem to account for this. The competitor wishes to minimize his complaint lest he distract his teammates or be regarded as unmanly. The coach also is apt unintentionally to fall into this psychological trap, and the audience, first seized by fear, is relieved when the competitor gets to his feet and turns its attention again to the contest.

In our experience, no patient who has an extra-

dural clot or, in fact, any rapidly expanding intracranial clot, ever has a symptom-free interval. All complain of headache from the outset. Posttraumatic headache that is not relieved by aspirin should be viewed with grave concern. Moreover, these patients are not entirely lucid mentally. They tend to be confused. Even though they may converse, they are apt to sleep if left alone. They have a peculiar staring expression and give the examiner the impression that they may be in shock, for the skin is cold and clammy. The pulse, however, is usually slow and bounding and the blood pressure normal or elevated.

Careful examination at this stage usually will show some neurological abnormalities. The earliest signs would be increased reflexes on the opposite side with perhaps a Babinski sign and clonus elicited, and thereafter irregularity of the pupils is noted.

This is one occasion where roentgenograms are valuable. A patient who has received a blow on the head but is conscious and who complains of headache should have roentgenograms in search of fracture which may cross the middle meningeal artery. The absence of a fracture, however, does not rule out an extradural hemorrhage.

Surgical attack prior to the loss of consciousness usually will permit complete cure. On the other hand, the mortality rate, even after surgical evacuation, is high if surgery is undertaken after coma has ensued.

It is generally assumed that the arterial bleeding is initiated by the fracture and that the force of the arterial stream progressively separates the dura from the skull. This in turn is believed to open new bleeders, with a progressively increasing hematoma mass. To the writers it appears more likely that the dura is separated from the skull by the deformation that occurs at the moment of impact and that the size of the clot is therefore predetermined in most instances. Moreover, it appears likely that the hemorrhage reaches its maximum size within a few moments and that the progressive signs that are noted arise from secondary edema and ischemia.

We have not been able to produce extradural hematoma experimentally without first separating the dura. The hemorrhage tends to limit itself to one side of a fracture line, and postoperative clots, with rare exceptions, are limited to the area of dural separation. Perhaps this is of academic interest only,

but if one proceeds under the premise that progressive bleeding is necessary for the production of this syndrome, early symptoms are apt to be overlooked.

The surgical treatment of an extradural hematoma depends, of course, upon its location. The hematoma usually will be found beneath a fracture and more often where the fracture crosses the course of the middle meningeal artery, and hence the site of crossing should be the site of initial exploration. If roentgenograms are not available, the surgeon may be guided to the site of fracture by the area of contusion on the scalp.

Occasionally patients are admitted in extremis, with the history and findings indicating the presence of an extradural clot. In this instance, one is justified in placing a drill hole through the scalp in the suspected area without being concerned about technique—indeed, without shaving the scalp. After a clot is identified and the opening is enlarged to perhaps the size of a twenty-five-cent piece, large amounts of clot will extrude spontaneously, usually in sufficient amounts to permit restoration of the circulation of the brain and usually without significant fresh hemorrhage. At this point the patient can be transferred to the operating room, where removal of the remaining portion of the clot, hemostasis, and tidy closure can be achieved. This will salvage an occasional case. The establishment of an adequate airway in certain instances is the only step which takes precedence over an emergency opening.

Since the majority of extradural clots occur in the temporal area, this should be the site of the initial exploration. A bur hole is made to permit exploration of both sides of the fracture line. If a clot is identified, the bony opening is then enlarged to permit its evacuation, which can be accomplished by suction, scoops, and irrigation.

It will be necessary to control many bleeding points, and the process is tedious and time consuming, but, having relieved the pressure on the brain, speed is not important. It may be necessary to coagulate the middle meningeal artery or even to plug the foramen spinosum with bone wax, a wooden applicator, Oxycel (oxidized cellulose), or cotton. There are many steps, such as suturing the dura to the pericranium, which the experienced surgeon utilizes to lessen the likelihood of secondary bleeding, but these cannot be learned from a text.

It is advisable to nick the dura in order that the

subdural space may be investigated for subdural hematoma as well. Moreover, it is advisable in the patient who is operated upon in extremis to explore the inferior surface of the temporal lobe to determine if the temporal lobe is herniated through the incisura and, if so, to restore it to its normal location. Evacuation of the hematoma without correcting the herniation of the temporal lobe is not adequate. Indeed, it is necessary in an occasional instance to section the tentorium in order to insure correction of this state.

SUBDURAL HEMATOMA

The symptoms which develop as the result of bleeding in the subdural space depend in large measure on the speed and magnitude of the initial hemorrhage. It is obvious that arterial bleeding in the subdural space will cause changes similar to those of extradural bleeding of arterial origin and indeed may be more fulminating, and this, of course, will be classified as an acute subdural hemorrhage. In contrast to this, there is an unusual disorder known as chronic subdural hematoma, which is initiated by trauma but whose symptoms develop so insidiously that it may not be recognized for weeks or months (1). It should be apparent therefore that in between these two extremes may be hemorrhages of any size and extent and speed, and it has become customary to classify subdural hematomas as (1) acute, (2) subacute, and (3) chronic.

ACUTE SUBDURAL HEMATOMA

The symptoms of acute subdural hematoma are similar in many respects to those of extradural hematoma. They may arise from arterial bleeding. Even though the patient may not have sustained significant cerebral contusion or laceration, the mortality and morbidity of acute subdural hematomas is high. Since it is necessary that the bleeding be massive in order that acute symptoms appear, and since the subdural space is so extensive, it is often difficult to identify the bleeding point and control the bleeding, even if the initial hematoma is identified and evacuated. In general, the symptoms and signs of acute subdural hematoma are those of rapid and massive compression of the brain developing after head trauma. Oftentimes the patient will have

been explored for extradural clot and none found, but when the dura is opened, the subdural hematoma is visualized.

The surgical approach to these lesions varies substantially with different surgeons and in particular with the individual patient. In the acute subdural hematoma, active bleeding is taking place, and hence evacuation of the clot is not sufficient. The bleeding points must be visualized and controlled, and in order to do this, extensive exposure is necessary.

On the other hand, in the subacute or chronic subdural hematoma, evacuation of the clot is all that is necessary, for the bleeding will have ceased spontaneously.

In patients suspected of acute subdural hematoma, we would place a single drill opening in the superior temporal area on each side, and if, on opening the dura, an acute hematoma is identified, we would then reflect an extensive bone flap, one that permitted exposure of the entire cortex if necessary. The hematoma would be evacuated and the field kept clean with irrigation and suction until all bleeding points had been visualized and controlled. If one attempts only to evacuate the hematoma but makes

no serious effort to visualize the bleeding points, blood will continue to well into the field, and death will ensue from cerebral compression.

It is suggested that several hours may be necessary in order to effect hemostasis. Many patients with acute subdural hematomas will be salvaged in this way. It is tempting, after a prolonged period of irrigation and suction but with bleeding still active, for one to resort to hypotension, and indeed this may be useful, but it does not obviate the necessity of visualizing and sealing the bleeding points. A continuous spinal drainage facilitates exposure. Roentgenograms of the skull and the location of points of contusion on the scalp may guide the surgeon to the bleeding point. It is a condition that requires courage, prompt action, and patience, and the skills of the most experienced surgeon available are necessary to cope with this state successfully.

SUBACUTE SUBDURAL HEMATOMA

The diagnosis of subacute subdural hematoma usually is arrived at by finding blood in the subdural space in a patient who is explored solely because he

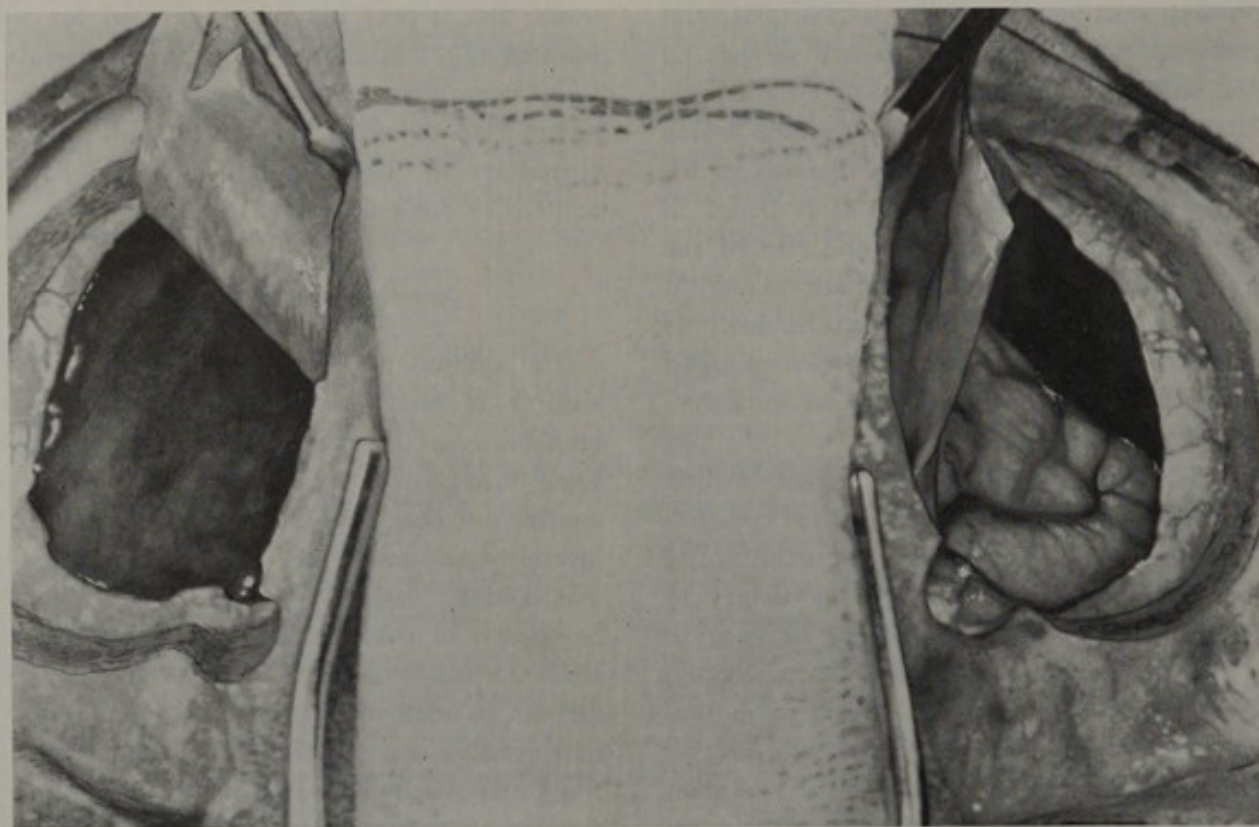


FIGURE 28.—Surgical field showing bilateral subdural hematoma exposed through 2-inch trephine openings. Partial removal on one side, the clot in place on the other.

is deteriorating and not because of any specific localizing signs. Hematomas which produce symptoms and findings that require surgical correction within 4 to 10 days after injury are spoken of as being subacute. It is believed that the majority occur as the result of bleeding from veins which traverse the subdural space. They often are associated with contusion and laceration of the brain, and in the majority the initial symptoms of hematoma are masked by the signs of contusion and laceration.

The surgical correction of such lesions, of course, consists first in their identity by exploring through a drill opening. We prefer to place the opening in the superior temporal area in the region just above the ear, first on one side and then on the other. This is necessary since hemorrhage in the subdural space is bilateral in at least 25 percent of cases. When the hematoma is identified, we would prefer to make a larger opening, such as a 2-inch trephine (fig. 28), and evacuate the remainder of the clot. Fortunately, since in these cases the initial injury has occurred several days before, active bleeding usually is not a problem. Many operating surgeons prefer to make multiple openings. The choice of operative exposure is, of course, a matter of personal experience, and there is no substantial evidence to indicate that a single opening on either side as compared to multiple openings is either better or worse than the other.

CHRONIC SUBDURAL HEMATOMA

The chronic subdural hematoma is a most unusual lesion. Indeed, it appears to have no counterpart in medicine. The lesion that now is recognized as a chronic subdural hematoma was originally described by Virchow (2) as "pachymeningitis hemorrhagica interna" and was thought to be the result of inflammatory disease. However, since the writings of Trotter (3), it has been known that the chronic subdural hematoma is, virtually without exception, the result of trauma. Strangely, the trauma may appear quite trivial and is often overlooked or forgotten by the patient, yet weeks or months afterward a massive collection of liquified hematoma will be found covering one or both hemispheres of the brain. The blood is encased in a membrane. The outer membrane, which is attached to the dura, is thick and opalescent and is composed in part of the coagulum of the blood and in part of mesothelial tissue that is thrown out

by the dura. The inner membrane is thin and translucent and, as a rule, is avascular and appears to be composed almost entirely of the coagulum of the blood. Within this membrane is hematoma, which usually is in part liquified and in part organized, solid clot. It has been shown that this membrane is semipermeable and that fluid dialyzes from the surrounding tissues into the hematoma, which has a higher osmotic tension, with the result that the hematoma slowly expands. The majority of evidence would indicate that, as a rule, the hemorrhage results from trauma to one of the vessels that bridge from the cortex to the sagittal sinus and that the bleeding, being venous in origin and hence of low pressure, is controlled spontaneously before it attains sufficient size to cause serious compression of the brain. It may, of course, arise from arterial bleeding and is observed occasionally after spontaneous rupture of an aneurysm, but the majority are believed to be venous in origin and, after becoming encapsulated, will continue to expand, unless recognized and evacuated, until death occurs or the osmotic tension within the hematoma equalizes and the hematoma ceases to grow. Because of the slow and insidious development, mental aberrations, usually in the form of subdued alertness, are a major symptom, and a substantial number of these lesions are found at post mortem in the wards of mental institutions where the senile are housed.

The patient should be suspected of having a subdural hematoma when dulling of consciousness occurs, particularly if a history of trauma is elicited. The trauma may, of course, be violent, but these lesions often follow what is regarded by the patient as a minor blow. The authors have in their records several patients who sustained trauma in which the head was accidentally bumped on some household object such as a shelf, a blow which the patient ignored, except that he had more headache with it than would be expected, and who then gradually deteriorated, with dulling of consciousness and the development of signs of cerebral compression in the form of focal paralysis and papilledema. Since many occur in the aged, roentgenograms of the skull will visualize the pineal gland to be shifted. Spinal fluid pressure may or may not be elevated. It is not unusual in the aged to find normal spinal fluid pressure in the presence of massive bilateral or unilateral hematomas.

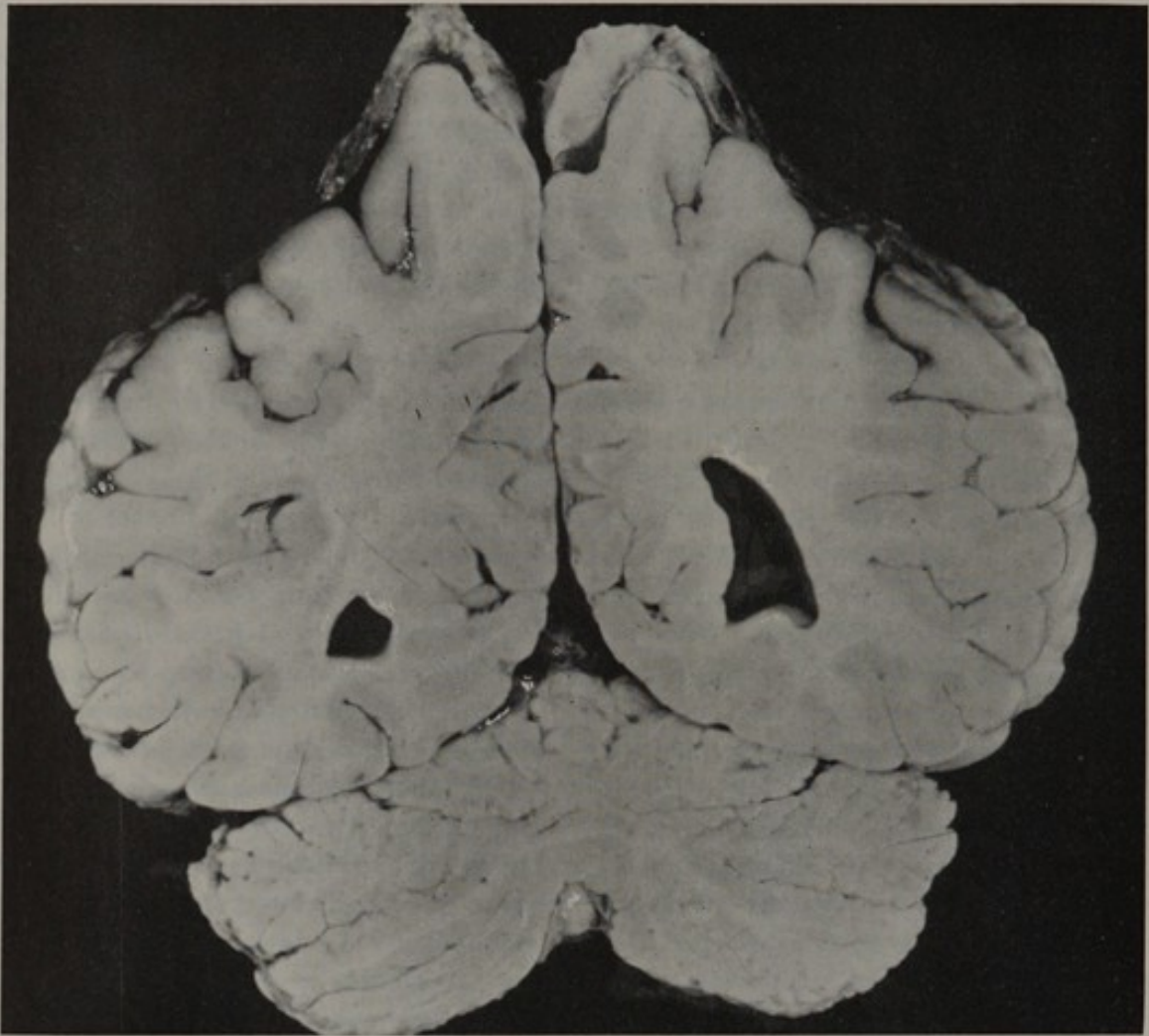


FIGURE 29.—Cross section of brain showing severe molding due to hematoma. Brain did not expand after evacuation.

As a rule, patients with subdural hematoma will complain of headache. They may develop vomiting. Some complain of diplopia. All experience a gradual dulling of consciousness and finally evidence of cerebral compression. They often are suspected of having a tumor and the lesion is found incidentally as ventriculography is being undertaken for the visualization of tumor.

TREATMENT

If one suspects the presence of a chronic subdural hematoma, it is advisable to place a bur hole in the superior temporal area, first on one side and then on the other, and nick the dura in order to inspect the subdural space. It was our custom for a long time to enlarge this opening, to open the outer membrane and evacuate the liquid portion of the clot, and then to make multiple openings in order

to permit irrigation of the subdural space, whereupon the operation was terminated after the opposite side had been explored. More recently, however, we have preferred to make larger openings in order to permit evacuation of some of the membrane, though its entire removal does not appear to be necessary in the adult. The majority of patients will recover after evacuation of the liquid content of the hematoma; however, repeated fluid accumulation will necessitate formal craniotomy with resection of membranes. Special consideration should be given to the matter of the membrane in children, since there is some evidence which indicates that the membrane may be sufficient to arrest brain growth in a child.

The principal problem which confronts the surgeon in the treatment of chronic subdural hematoma is the failure of the brain to expand after evacuation of the clot. It is not unusual for a patient to im-

prove after the evacuation of a hematoma through one or multiple openings and then to deteriorate after a day or two, with the result that recurrent bleeding is suspected. Reopening the wound, however, will often reveal that the brain has failed to expand (fig. 29) because sufficient molding as the result of longstanding compression has impaired substantially the intrinsic circulation.

Efforts to expand the brain by posture, by the administration of hypotonic solutions intravenously, have failed. Within the past few years, however, it has been pointed out by LaLonde and Gardner (4) that the brain could be expanded satisfactorily by the insertion of a spinal puncture needle and the introduction of saline into the spinal (lumbar) subarachnoid space while the craniotomy wound is still open. This is done slowly, and the authors now have observed many patients in whom consciousness was regained abruptly and completely after this maneuver was carried out, and we feel that in any in whom the brain fails to expand it should be undertaken. It is necessary to emphasize that the cranial opening should be at the most elevated point, lest air or fluid be trapped in the subdural space. The wound is not closed until the brain is completely expanded.

SUBDURAL HEMATOMA IN INFANTS

Because of the growing brain and the flexible skull, the clinical picture and treatment of subdural hematomas in infants vary substantially from those in which the cranial vault is already closed. Many can be handled by aspiration through the fontanel. The decision to attempt surgical removal of the hematoma and its membrane requires considerable experience and judgment and will not be considered here.

SUBDURAL HYDROMA

Cerebrospinal fluid may accumulate in the subdural space. It is believed to be due to a ball-valve rent in the arachnoid, with the result that cerebrospinal fluid is discharged from the subarachnoid into the subdural space. These patients complain of headache and show signs of progressive compression of the brain. They usually are suspected of having

subdural hematomas, and the fluid is identified and removed by surgical exploration. It usually is sufficient to permit the fluid to escape through a bur hole, after which it will continue to drain into the subgaleal tissues.

SUBARACHNOID HEMORRHAGE

Blood in the spinal fluid is a common finding with head injuries. Any of the vessels which traverse the subarachnoid space may contribute to this. If it arises from one of the large arteries, such as the carotid, rapid fatal termination is usual. On the other hand, large amounts of blood within the subarachnoid space may be tolerated well and require no specific treatment. We have felt that spinal drainage is rarely of benefit. Oftentimes patients with blood in the subarachnoid space will, after 8 or 10 days, show signs of meningismus, and spinal drainage at this time lessens symptoms and perhaps speeds convalescence.

INTRACEREBRAL HEMATOMA AND CEREBRAL SWELLING

The group of patients who are unconscious from the moment of impact and then deteriorate or the group of patients who develop progressive stupor without focal signs are difficult to evaluate and carry a high mortality and morbidity rate. On the other hand, careful management will salvage many. Hemorrhage may occur in any part of the brain. Hematomas may form in unusual locations within the subdural space or indeed in the extradural space over the posterior fossa (5) (fig. 30).

It is not unusual for patients to sustain head trauma as the result of a fall that has been initiated by a spontaneous cerebral vascular accident (stroke).

None of these presents a characteristic clinical picture. It is necessary therefore to develop an orderly plan of procedure in order that a correct diagnosis be arrived at and appropriate therapy instituted.

In a patient who is deteriorating and who seems in eminent danger of death but who shows no significant focal signs, we would first explore the superior

temporal area on either side, then the frontal area, then the parietal area, and then the posterior fossa (6) (fig. 31), with the hope that either a subdural or extradural hematoma would be visualized. If none was found, we would then inject air into the ventricles through the posterior parietal openings for ventriculograms. On the other hand, if the patient was deteriorating but did not appear in eminent danger of death, or if there was a problem of differential diagnosis between cerebral vascular accident and a space-consuming hematoma, we would do a limited pneumoencephalogram. Air injected into the subarachnoid space in quantities of 10 to 15 cc., with the patient on the roentgen table, usually

will confirm or disprove the presence of a hematoma. If it was confirmed, of course, immediate surgical removal would be undertaken. If the ventricular system was normal in pattern, it would be reasonable to assume that surgical attack would not be of benefit.

An occasional patient will show marked increased intracranial pressure and appear in eminent danger of death without presenting focal neurological signs or deformity of the ventricular system. These usually are patients who have suffered extensive bitemporal and subfrontal contusion. The operation of subtemporal decompression has been used for this, but in our experience it is seldom adequate (fig. 32).

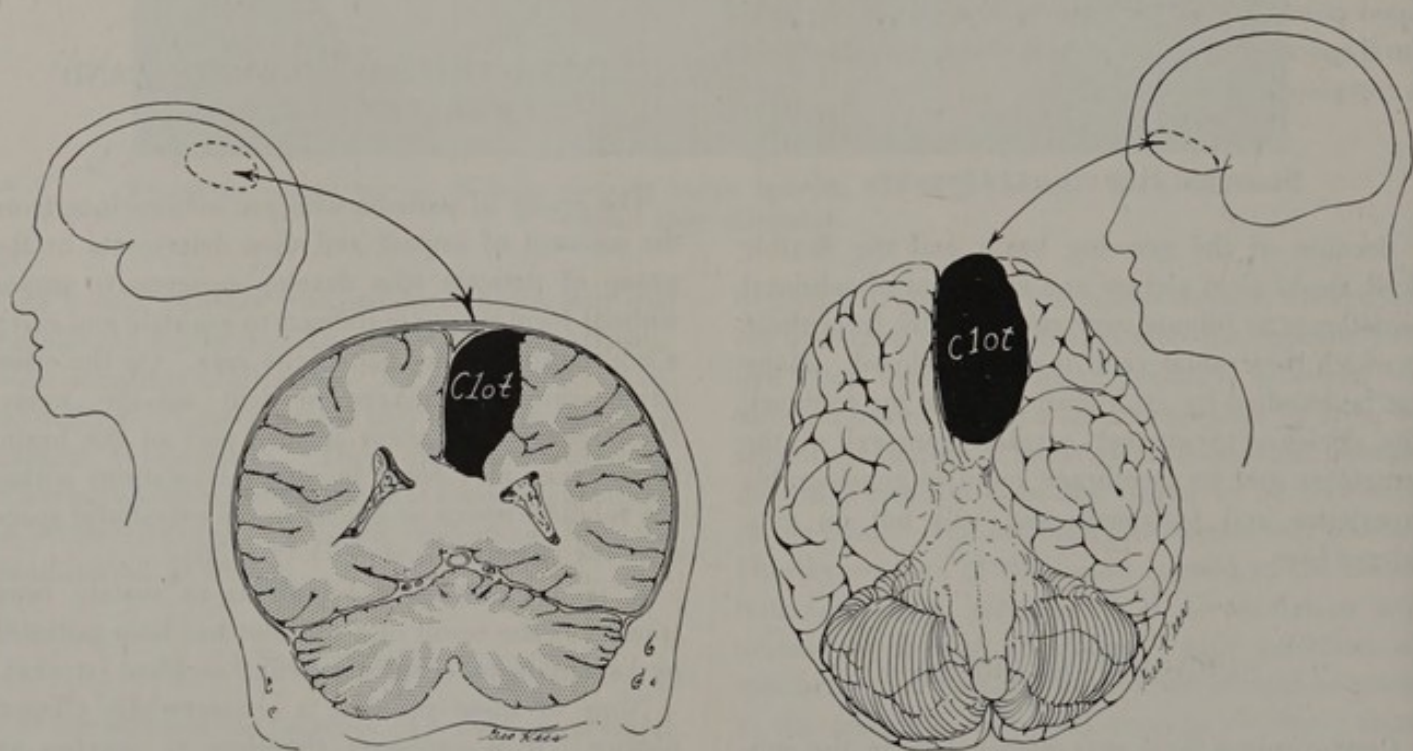


FIGURE 30.—Diagrammatic representations of ectopic subdural clots identified by ventriculography.

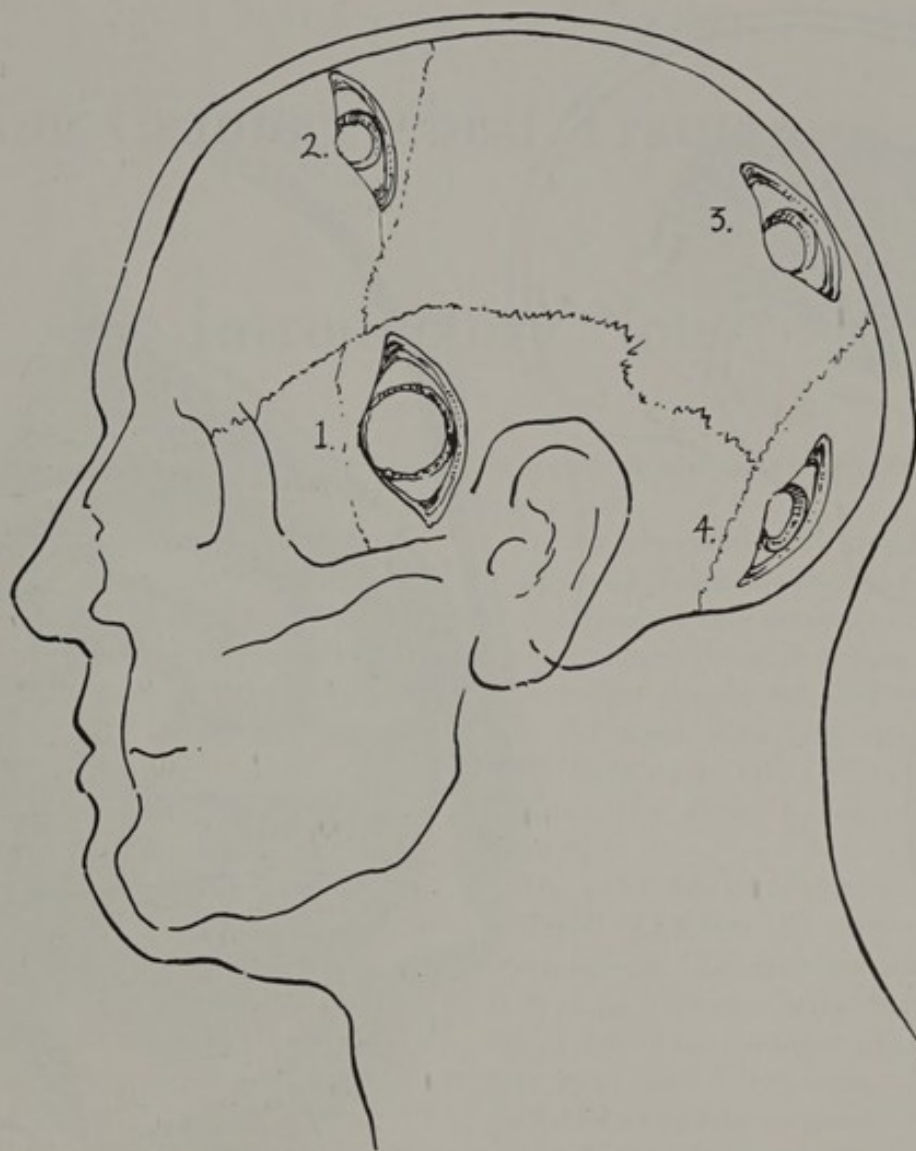


FIGURE 31.—Location of exploratory bur holes, numbered in the order of their placement.

Botterell (7) has recommended internal decompression by amputating the nondominant temporal lobe, and our experience would confirm his observation that this may be a lifesaving procedure. Many of these patients will be suffering from herniation of the uncus, and, if possible, one should explore the incisura before amputating the lobe, as it may be possible to incise the tentorium and thereby correct the herniation. On the other hand, amputation of the lobe may be required in order to obtain exposure of the incisura.

ANESTHESIA

The indications for anesthesia are the same whether the lesion is open or closed. Local anesthesia is preferable except in the restless patient. In this case intravenous Pentothal sodium (thiopental sodium) supplemented with oxygen is entirely adequate. There is, however, no contraindication to any general anesthetic agent. The injured brain tolerates anesthesia well if adequate oxygenization is maintained.

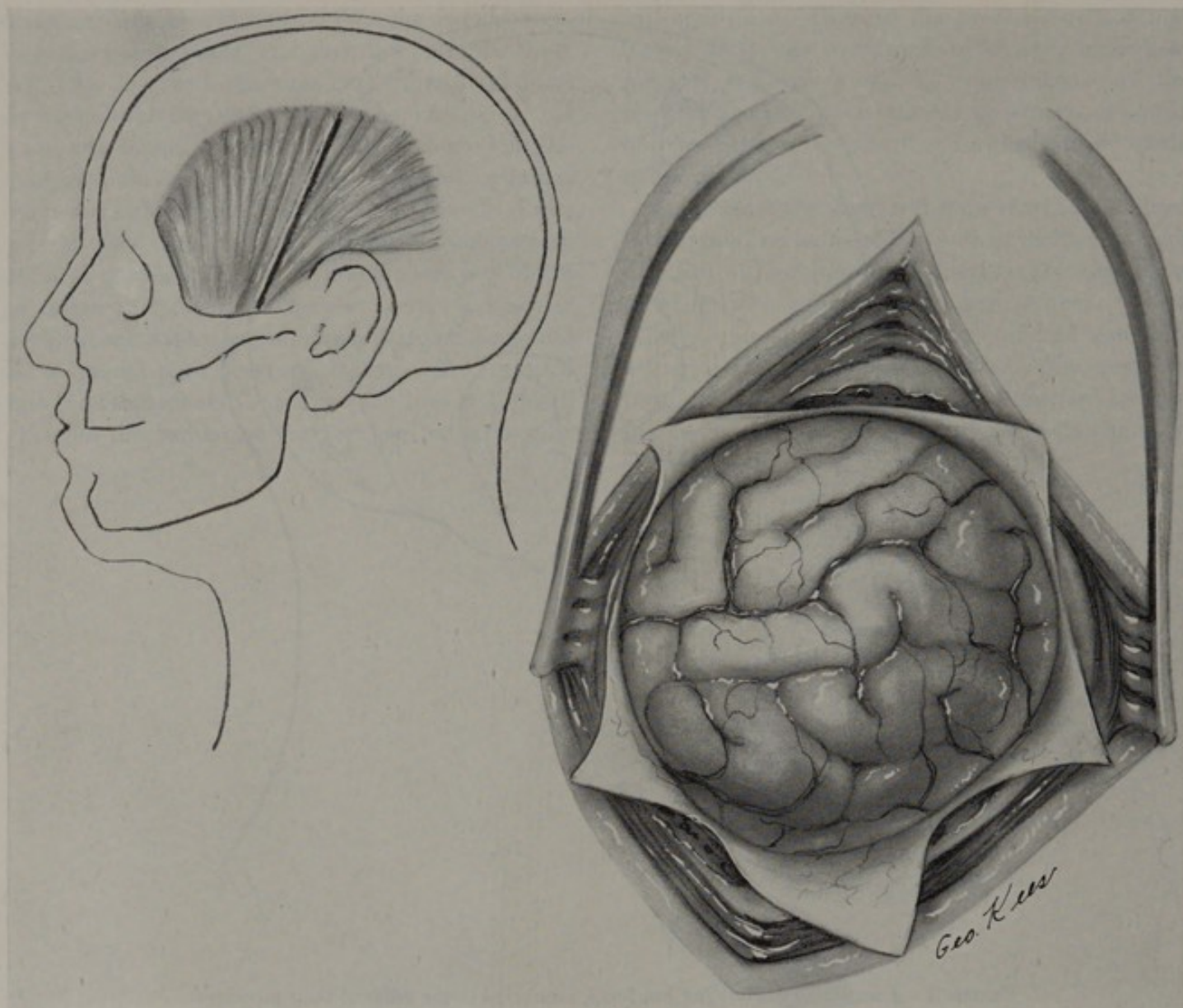


FIGURE 32.—Technique of subtemporal decompression.

REFERENCES

1. Gardner, W. J.: Traumatic Subdural Hematoma, With Particular Reference to Latent Interval. *Arch. Neurol. & Psychiat.* 27: 847-858, April 1932.
2. Virchow, R.: Das Hämatom der Dura mater. *Verhandl. psych-med. Gesellsch. Würzburg* 7: 134-144, 1857.
3. Trotter, W.: Chronic Subdural Hemorrhage of Traumatic Origin and Its Relation to Pachymeningitis Hemorrhagica Interna. *Brit. J. Surg.* 2: 271-291, October 1914.
4. LaLonde, A. A., and Gardner, W. J.: Chronic Subdural Hematoma; Expansion of Compressed Cerebral Hemisphere and Relief of Hypotension by Spinal Injection of Physiologic Saline Solution. *New England J. Med.* 239: 493-496, 30 Sept. 1948.
5. Coleman, C. C., and Thomson, J. L.: Extradural Hemorrhage in the Posterior Fossa. *Surgery* 10: 985-990, December 1941.
6. Schneider, Richard C.: Craniocerebral Trauma. In Kahn, Edgar A., Bassett, Robert C., Schneider, Richard C., and Crosby, Elizabeth Caroline: *Correlative Neurosurgery*. Springfield, Ill.: Charles C Thomas, 1955, pp. 275-326.
7. Botterell, E. H.: Disruption of the Frontal and Temporal Lobes as a Cause of Secondary Coma Following Head Injuries. Paper read at the meeting of the Harvey Cushing Society, 14 Nov. 1947. Cited by Evans, Joseph P.: *Acute Head Injury*. American Lecture Series No. 60, American Lectures in Surgery. Springfield, Ill.: Charles C Thomas, 1950.

Penetrating Craniocerebral Trauma

Introductory Note

The writer has appraised this section on penetrating cranial wounds from three viewpoints: First, as a consultant on patients returning from Korea during the early days of the war, second, as a consultant in Japan and Korea during the period of active hostilities, and third, in viewing the late results on casualties following their return to the United States. A remarkable improvement in management became evident. From such a background a review of this publication has been of deepest interest.

Proper systematization of neurosurgical care as presented here did not occur until facilities for definitive surgical care at the front were developed under Lt. Col. Arnold M. Meirowsky, MC, and his associates in 1951. Prior to that time the Tokyo General Hospital received wounded from many sources many days after injury and following varying sorts of preliminary care.

One cannot fail to be amazed at the reduction in the incidence of infection, the lessened mortality, and the improvement in overall results from World War I to World War II and on through the Korean War.

Mechanical aids, anesthesia, antibiotics, and larger numbers of specially trained personnel have made the average care far better than that possible in the best hands at earlier times. The improvement

in transport and earlier definitive care also played a large part.

In this presentation of methods and results one must read between the lines to realize the dedicated round-the-clock care devoted to these patients. The frequent observations, dressings, spinal taps, and the attention to general care involve continuous effort day and night, with little rest for the personnel. These have served above all to produce remarkable results. The ability to learn from experience is evident.

The writer has been impressed with these factors in Japan and Korea and portrayed in these modest presentations. Comparative results are presented. It is to be earnestly hoped that later additions to knowledge in the treatment of casualties will not be dependent upon future wars. However, it is from such sources that the surgeons being developed today must rely for directions in the principles and manner of treatment.

In these chapters this information is readily available in well-presented, concise form, and they should be in the hands of all surgeons. The systematic outlines of technique and the steps in care are helpful additions. Wide circulation and careful perusal of this text will pay large dividends in the future.

HOWARD C. NAFFZIGER

Fracture of the cranium is more difficult than the other fractures of bones, and its forms are manifold and varied according to the diversity of the circumstances in which the fracture occurs. For one type occurs from a rapier striking, or a broad-sword cutting, or some other similar thing cleaving the whole bone until it reaches the meninges. Another does not reach the meninges but only cuts into the outer table, and the wound may be large or small; and among these there is the occult fracture in bone which the ancients call hairline. Another occurs from a spear, an arrow, a sharp pointed sword or something similar, and is the more difficult of the fractures since it penetrates more deeply, and its wound is slight and occult. Another results from a fall or the blow of a stone or something similar, so that the bone is depressed, and this, according to most observers, occurs in children's heads because of the softness of their bones; or it is not depressed but is split like a hairline fracture, which may or may not penetrate to the membrane. These wounds are sometimes small and sometimes without any [scalp] wound at all.

However, all types of fractures are determined by diligent examination with the probe. And they are determined by enlarging the incision and by separating the skin from the cranium. (Campbell, Eldridge, and Colton, James (translators): *The Surgery of Theodoric* ca. A.D. 1267. New York: Appleton-Century-Crofts, Inc., 1955, vol. I (Books I and II), pp. 106-107.)

CHAPTER 7

General Considerations and Preoperative Measures

Arnold M. Meirowsky

In the 1951 spring offensive in Korea, a 19-year-old U.S. Marine Corps corporal (K-32) was struck in the back of the head and neck by an unidentified missile. On admission to the 1st Neurosurgical Detachment (Provisional), he did not give any signs of recognition or response. Dilated, staring pupils, which did react to light, and fixation of the eyes in left inferior conjugate deviation gave him an almost lifeless appearance. His neck was hyperextended. His legs were flaccid and motionless. Deep tendon reflexes and plantar responses could not be elicited in the lower extremities. There were a few purposeless movements of the left arm and intermittent irregular tonic contractions of the right arm. Blood pressure was 140/90 mm. Hg. Pulse was thready and irregular. The pulse rate was 120 per minute. Respiratory excursions were shallow and irregular. The respiration rate was 52 per minute.

Examination of the head revealed a huge, gaping, and grossly contaminated laceration reaching frominion to midportion of neck. Administration of oxygen and whole blood transfusions served to stabilize vital signs, except for the respiration rate which remained 52 per minute. Neurological signs suggested compression of brain stem and mesencephalon with possible damage to the posterior third of the superior longitudinal sinus. Neurosurgical intervention was decided upon, despite the seemingly grave prognosis. Extensive comminution and depression of the occipital and suboccipital bones were encountered. A large bone fragment had torn the torcular Herophili. This tear extended into the gaping superior longitudinal sinus and into both transverse

sinuses. The lacerated portions of the venous sinuses and the entire torcular appeared to be incompletely thrombosed. Repair was accomplished with absorbable gelatin sponges (Gelfoam). Because of the precarious condition of the patient, resection of the cerebellar hemisphere was postponed for a second procedure.

Extraocular movements returned 4 hours after operation. There was some recovery of motor power in the right leg and in both arms within 4 days during which time the patient began to respond, but seemed to be blind. Within 1 week he became more and more responsive; at the end of the first week, he appeared to be fully oriented. In a second operation, a subtotal resection of the right and a partial resection of the left cerebellar hemispheres were performed. The patient continued to improve and began to ambulate in a walker 3 weeks after having been wounded. At time of his return to the United States, he still had considerable motor weakness affecting right arm and left leg. Vision had remained poor, but he could count fingers with either eye at a distance of 4 feet.

Two years later, the patient was reexamined by Dr. Charles E. Brackett, Jr., University of Kansas Medical School, Kansas City, Kans. Doctor Brackett related that the patient is employed as a mimeograph operator. He is free of headaches and dizziness. He does not walk with a limp, but has noted some clumsiness of the right hand. His vision is serviceable for getting about, but he does not see well enough to read print.

Doctor Brackett's examination revealed a smooth

skull defect overlying the torcular with normal pulsations. Visual fields were characterized by a right homonymous hemianopia with macular sparing. Both optic nerves showed a moderate degree of atrophy. There was no impairment of extraocular movements. Gait appeared normal, except for slightly decreased associated movements of the right arm. Station was normal. The Romberg sign was not elicited. Other coordination tests were normal, except for slight hesitancy in finger to nose test on the right. Doctor Brackett did not find any motor weakness or abnormal reflexes. The only other neurological deficit found was reduction of sensation to all stimuli to the left leg below the groin. The electroencephalogram taken by Doctor Brackett 2 years after the injury was normal.

It used to be the general consensus that once a man was shot in the head all powers would be lost except those of vegetation. The preceding story and many other stories like it point to the fallacy of such a conclusion which could readily lead to a "do nothing" policy. The teachings of Harvey Cushing and of many American, British, and Canadian neurological surgeons who served in the European and African theaters in World War II were reconfirmed in the Korean War. Earliest possible definitive neurosurgical intervention is the single most pertinent factor in the successful treatment of penetrating craniocerebral trauma. Simultaneously available and carefully applied specialized nursing care will prevent many of the complications that may kill outright a man with a penetrating wound of the brain.

In the Korean War, 1,105 casualties with pene-

trating craniocerebral trauma reached an Army neurosurgical installation in the Far East Command during the period from 1 September 1950 to 31 August 1952. Of these 1,105 casualties, 86 died, a mortality of 7.78 percent (table 4).

The overall incidence of the KIA (killed in action) with penetrating craniocerebral trauma is not definitely established. Figures compiled by the Wound Ballistics Research Team under the command of Lt. Col. Robert H. Holmes, MC, give an excellent idea as to the high incidence of head trauma among the KIA (1) (2) (3). The regional frequency chart of KIA wounds in KIA personnel as compared to body surface area reveals an incidence of head wounds of 27 percent. The prime purpose of the present publication is aimed at an improvement of neurosurgical management of casualties with penetrating wounds of the head. Advancements of military neurosurgery which will be presented in these chapters and which have produced the low mortality figure, just quoted, reflect improvement. Much could be added to this improvement, if new measures preventing trauma to the head could be employed in warfare. The Wound Ballistics Research Team came to the conclusion "that any further appreciable reduction of casualty rate lies in 1) use of body armor, 2) faster salvage of casualties from the battlefield" (1) (2) (3). The latter has been discussed in detail in chapter 4, pp. 25-39. Inasmuch as an appreciable number of penetrating wounds were due to low velocity missiles, perhaps of 1,000 f.p.s. or less, many of these wounds could have been prevented or their severity been reduced had a helmet been worn (1) (2) (3) (4).

Experiences in the Second World War in the Pacific Area and particularly experiences in the Korean War show a varying degree of discipline with regard to wearing the helmet in combat. The high incidence of missile wounds of the brain in participants of patrol actions, during which the wearing of the helmet was not always mandatory, is only one but a shining example of the need of better protection. It would be desirable if a combat helmet could be devised that consists of one piece rather than helmet and separate liner. If it were feasible to devise a one-piece plastic helmet without loss of protective value, it would at least be impossible for the men to go into action with a helmet liner as the only protection, as was a common occurrence in the Korean

TABLE 4.—*Type of wounds in 1,105 casualties with craniocerebral injuries, Korean War, 1 September 1950-31 August 1952*

Type of wound	Number of cases	Deaths	
		Number	Percent
Compound, comminuted, depressed fractures.	226	2	0.88
Penetrating wounds of the brain.	879	84	9.55
Total.	1,105	86	7.78

War (2) (3). The shape of the helmet in use by the U.S. Army during the Korean War did not afford sufficient protection for the frontal and temporal regions. The chinstrap then in use did not only prove to be impractical but dangerous. The Naval Medical Field Research Laboratory, Camp Lejeune, N.C., has carried out extensive research work and has presented the results of this work in the report entitled "Military Helmet Design" (4).

Every case of penetrating craniocerebral trauma requires neurosurgical intervention. Earliest possible neurosurgical intervention is essential so as to:

1. Relieve compression of cerebral structures and interference with cerebral blood flow in the high percentage of penetrating brain wounds with associated intracranial hematoma.
2. Reduce the incidence of meningocerebral infection.
3. Make specialized neurosurgical nursing available to unresponsive patients in order to reduce mortality and lessen the incidence of complications.

EMERGENCY MANAGEMENT OF THE UNRESPONSIVE PATIENT

Because of existing intracranial tension, patients with penetrating craniocerebral trauma exhibit various degrees of depression of mental alertness. Other signs that may be seen are restlessness, nausea, vomiting, incontinence, bradycardia, hypertension, depression, irregularity of respiration rate, and elevation of body temperature. Unable to care for himself, the unresponsive patient's survival depends on the efficacy of emergency measures that are taken by those charged with his care.

Maintenance of an open airway is the single most important emergency measure in behalf of an unresponsive patient with penetrating craniocerebral trauma. Mechanical obstruction of air passages is a common cause of early death in the presence of coma. Such obstruction can be overcome and prevented by frequent intratracheal suction and by positioning of the patient. Intratracheal suction will rid the airways of mucous plugs. It should be done through the nostrils so as to prevent the patient from biting off the suction tubing or from clamping down on it during a seizure. Effective suctioning will

keep the airways open. To avoid aspiration of vomitus, the stomach should be washed out thoroughly as an early preventive measure.

More important yet is the proper positioning of the patient in coma. Preoperatively, the patient should be kept on his side at all times. This is necessary to facilitate drainage and to prevent aspiration of mucus and vomitus. It is inadvisable to keep an unconscious patient on his back. The coma position, which is described in detail under postoperative care (chapter 19, pp. 221-232) should be used preoperatively as well (fig. 33).

In managing the vast majority of casualties with penetrating craniocerebral trauma incurred in the Korean War, tracheostomy proved to be unnecessary as long as the coma position was employed and frequent suctioning carried out. Tracheostomy was reserved for a few isolated cases of brain wounds associated with maxillofacial injuries and then proved to be a lifesaving measure.

While tracheostomy is advocated by a majority of surgeons, this author feels that it should not and need not be employed routinely in the handling of comatose patients. The experience of the Korean War certainly proves that proper nursing measures almost always suffice to prevent mechanical impairment of respiration.

INITIAL WOUND CARE

Initially, a wide area about the site of penetration should be shaved and the scalp thoroughly cleaned. A dressing consisting of dry gauze squares and a bandage should then be applied. The use of adhesive bandage on the head can usually be avoided. In fungating wounds, with brain tissue presenting at the surface of the scalp, gauze fluffs may be used, and care should be taken not to apply the bandage too tightly. Debridement of the superficial layers of the scalp, an integral part of definitive surgery, is deferred until such can be effected. Only if there is profuse bleeding from a galeal or any other exposed and readily accessible vessel, should hemostasis be carried out during the process of initial wound care.

Blood replacement must be carried out as rapidly as feasible. It represents a vital step in the preoperative preparation. Whole blood should be administered whenever the red blood cell count is

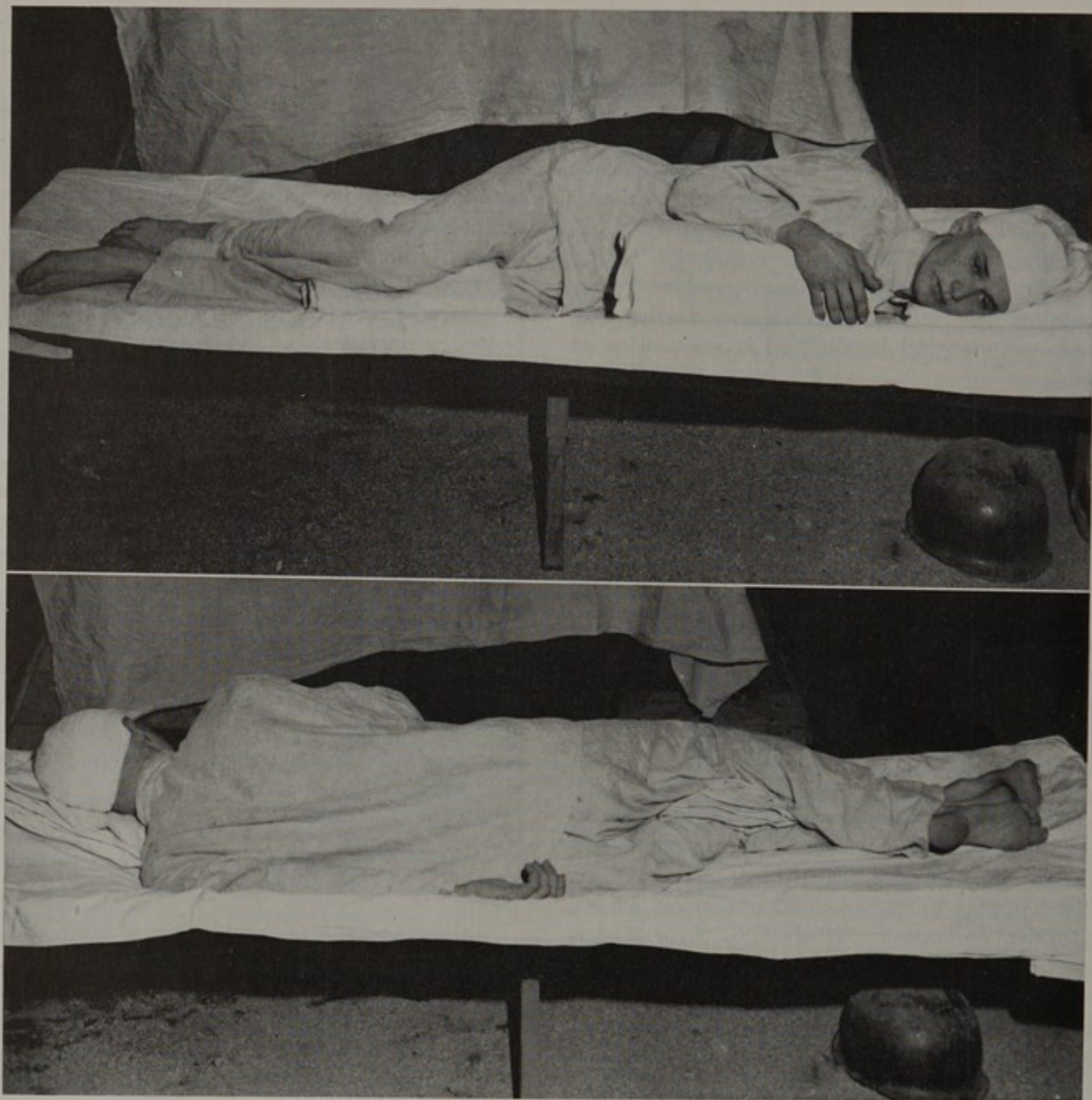


FIGURE 33.—Coma position.

below 4 million and the hemoglobin level below 14 grams.

ANTIBIOTICS AND CHEMOTHERAPY

Immediate preoperative prophylactic administration of broad spectrum antibiotics is indicated in the care of every patient with penetrating craniocerebral trauma. During the Korean War, penicillin and streptomycin were administered prophylactically prior to surgery as a routine measure. Streptomycin cannot be used safely for longer than 5 days, however, because of possible vestibular damage.

INITIAL EXAMINATION

Inspection of the head, a brief neurological examination, and roentgenograms of the skull will usually suffice to rule out a simple laceration of the scalp without associated intracranial damage. In assaying the extent of any penetrating head wound, determination of the patient's responsiveness is essential for the direction of future management. In recording the patient's responsiveness, we would do well to heed Schorstein's plea—

* * * that the traditional terms referring to states of consciousness—e.g., coma, stupor, unconsciousness, confusion, etc.—be abandoned * * *. It might be better to speak of "responsiveness" rather than consciousness, and to record briefly the patient's behaviour, his responses to the stimulation of questioning, being given a drink, the physical examination, and, where necessary, to pain. Too often one sees notes which describe in detail the force of the tendon reflexes, but dismiss the patient's behaviour, the most important single indication of the function of the central nervous system, in one inaccurate word (5).

The steps in the initial examination of a casualty with penetrating craniocerebral trauma are as follows:

1. Determination of the level of consciousness by appraisal of the degree of responsiveness is the first step in the examination of a man with penetrating craniocerebral trauma. In the responsive patient, this determination also permits recognition of aphasic manifestations. Decreasing responsiveness under observation points to increasing intracranial pressure which may well be due to an intracranial hematoma or progressive cerebral edema.

2. The second step in the examination consists of thorough inspection of the head. Topography of entrance and exit wounds is determined. The appearance of each wound is described. Information is needed as to extent of contusion of scalp tissue surrounding the wound. It is also necessary to note any discharge of blood, fluid, or pulped brain tissue from the wound. A galeal bleeder may require occlusion at time of initial examination so as to prevent unnecessary blood loss. Recognition of a coexisting cerebrospinal fluid fistula by way of ear or nostril, presence of spectacle hematoma or Battle's sign may point to involvement of basilar skull structures.

3. Determination of "vital signs," blood pressure, pulse, and respiration, will help to establish a baseline. Their course may give valuable information with regard to increase of intracranial tension. Matson looks at respirations as one of the most reliable guides to the extent of central nervous system injury (6). Slow, deep, stertorous breathing and irregular respirations of Cheyne-Stokes variety may be indicative of a grave prognosis. Slowing respirations point to increased or increasing intracranial pressure. Rapid shallow respirations are more commonly the sequel of associated wounds. Reflection on vital signs of compensation of intracranial tension by the systemic circulation is well understood (7). Surgical shock is rarely seen as the result of penetrating craniocerebral trauma (8). An extensive scalp wound, of course, may produce considerable blood loss and secondary surgical shock. This is rare. Whenever surgical shock occurs in the presence of penetrating craniocerebral trauma, a thorough search should be made for associated systemic wounds or injuries.

4. The neurological examination should be sufficiently thorough to render relevant information with regard to all neurological systems. Of the cranial nerves the functions of the second, third, fourth, and seventh nerves are of particular interest. Pupillary dilators should be avoided. A reasonably accurate funduscopic examination can be carried out without the benefit of dilated pupils. Close observation of size, inequality, and reaction of pupils is most informative. Changes in the equality of pupils for instance may set forth priority for neurosurgical intervention when dealing with large numbers of casualties, which otherwise may not have been

considered.

5. Any available information as to handedness should be recorded. The presence of hemiparesis or paraparesis should be noted and reference should be made in the record as to flaccidity and spasticity. The early, almost immediate, onset of progressive spasticity following wounds of the superior longitudinal sinus represents but one striking example of the importance of such observations (9).

6. Examination of physiological reflexes and determination of the presence of pathological reflexes are essential. Additional information should be listed with regard to sensory perception and coordination. The presence or absence of meningeal signs, such as photophobia and Kernig, Brudzinski, or Leichtenstern signs, may give information with regard to traumatic subarachnoid or subdural hemorrhages over the convexity or at the base. A thorough search for associated injuries completes the examination. Priority evaluation and management of multiple injuries can only be made by a thorough appraisal of all pathological findings (10). (See chapter 38, pp. 431-436.)

ROENTGENOGRAMS

Prior to neurosurgical intervention, roentgenograms should be available. Casualties with obvious craniocerebral trauma need not be submitted to roentgenological examination prior to arrival at an installation at which definitive neurosurgical intervention will be carried out. To take skull films on any patient with obvious penetrating craniocerebral trauma prior to arrival at the place of definitive treatment is deemed inadvisable. Time consumed in the preparation of roentgenograms will delay evacuation; transportation of wet films is unsatisfactory. It is essential, however, that roentgenological examination be performed prior to operation.

Preoperative roentgenograms will give information about the bony defect, number and location of indriven bone fragments, and location of metallic fragments. Retained bone fragments are the commonest single cause of posttraumatic brain abscess. Their removal is essential and can only be done with the help of adequate roentgenographic studies.

It is mandatory to examine roentgenographically all patients with scalp wounds that appear uncompli-

cated in order to detect otherwise obscure intracranial trauma. The story of K-595 illustrates this necessity.

This U.S. Army private was wounded by a metallic fragment on 20 October 1952 by enemy action in North Korea. He was admitted to an evacuation hospital where the scalp wound in the right suboccipital region was debrided and closed. Roentgenograms were not taken. For convalescence, the patient was transferred to another evacuation hospital where he continued to complain of severe headaches. When a decrease in responsiveness was noted, roentgenograms of the skull were taken revealing a depressed, comminuted fracture of the right suboccipital bone and a metallic fragment lodged in the right middle fossa. It was then, 6 days after having been wounded, that this patient was transferred to the 3d Neurosurgical Detachment (Provisional) where he was operated upon without further delay. A right suboccipital craniectomy was performed, revealing a right cerebellar abscess and a transventricular wound with the metallic foreign body lodged in the right temporal lobe. If roentgenograms could have been taken prior to debridement and closure of the suboccipital scalp wound, this man could have had the benefit of immediate, radical neurosurgical intervention with probable prevention of infection.

Routine roentgenograms should include anteroposterior, posteroanterior, and lateral views. Stereoscopic films are most helpful for the accurate localization of comminuted bone fragments and/or metallic fragments.

Air studies, such as ventriculography or pneumoencephalography, and arteriographic studies have no place in the management of acute penetrating craniocerebral trauma.

It is of the utmost importance to take postoperative roentgenograms in all instances of craniocerebral trauma. They should also include anteroposterior, posteroanterior, and lateral views—preferably stereoscopically (11). This will assure recognition of all retained comminuted bone fragments that may have been overlooked at time of primary operation. The knowledge of such bone fragments is essential inasmuch as secondary craniotomy is indicated in every instance of retention of comminuted bone fragments even if only one such fragment has been retained. This is necessary in order to prevent meningitis, cerebritis, and brain abscess.

PREPARATION FOR OPERATION

The emergency measures which have been discussed include many of the steps that are essential

for the preparation for surgery of a man with penetrating craniocerebral trauma.

Bleeding and clotting time are determined and the blood cross matched and typed. Not less than two pints of whole blood should be available for the surgery of any penetrating wound of the brain. When a dural sinus wound is suspected, two pints might not suffice.

Oral intake should be discontinued 8 hours prior to surgery. Stomach lavage, carried out preoperatively on unresponsive patients, is an effective measure in protecting them postoperatively against aspiration.

Time permitting, a cleansing enema should be given preoperatively in order to prevent spontaneous bowel movements during the immediate postoperative period and in order to prevent straining with the first postoperative enema because of an excessive amount of hard feces.

Constricting rings and false teeth should be removed before transporting the patient to the operating room. Pulse, respiration, blood pressure, and temperature should be checked and recorded prior to leaving the preoperative ward. It must also be ascertained at that time that the patient has emptied his bladder.

Atropine, $\frac{1}{150}$ gr., is used as the only premedication in men with penetrating craniocerebral trauma. Scopolamine is poorly tolerated in the presence of increased intracranial pressure. Analgesics and hypnotics are contraindicated as premedication for the same reason that they are contraindicated in the preoperative and postoperative management. Carefully controlled endotracheal anesthesia can be effectively administered with atropine as the only premedication.

The hair of the entire scalp should be clipped. This may be done immediately prior to operation or a few hours in advance of operation. Shaving should be done immediately prior to surgery. In dealing with penetrating craniocerebral trauma, it is essential to shave the entire head, face, and neck. Only the eyebrows should not be shaved unless there are some exceptional reasons. It has long been known that eyebrows either grow back very slowly or not at all after being shaved (12). Upon completion of a close shave of the head, the entire scalp should be washed for 10 minutes with soap and water (13). In an effort to produce a sterile field

and to prevent infection, thorough washing of the scalp with soap and water is more effective than any one or any combination of fancifully colored antiseptics.

ANESTHESIA

A detailed discussion of anesthesia problems is beyond the scope of this book. Suffice it to say that the administration of Pentothal sodium (thiopental sodium) intravenously in conjunction with endotracheal nitrous oxide and oxygen is the method of choice for the operative management of craniocerebral trauma (14). This type of anesthesia was used almost exclusively for the surgery of penetrating wounds of the brain during the Korean War.

During the Second World War, in the Pacific, this author was forced to use local anesthesia quite frequently simply because anesthesiologists were extremely scarce. Local anesthesia is not desirable in the management of compound wounds and should not be used unless special circumstances necessitate it. During the Korean War, U.S. mobile neurosurgical teams in Korea and at the Center in Tokyo had the benefit of highly skilled, capable, and enthusiastic anesthesiologists who deserve credit for having saved many lives and whose help has been invaluable.

REFERENCES

1. Report, Wound Ballistics Survey, Korea, 15 November 1950-5 May 1951, Surgeon General's Office, Department of the Army, Medical Research and Development Board, Washington, D.C.
2. Beyer, James C., Enos, William F., and Holmes, Robert H.: Personnel Protective Armor. In Medical Department, United States Army. Wound Ballistics. Washington: U.S. Government Printing Office, 1962, pp. 641-689.
3. Herget, Carl M., Coe, George B., and Beyer, James C.: Wound Ballistics and Body Armor in Korea. In Medical Department, United States Army. Wound Ballistics. Washington: U.S. Government Printing Office, 1962, pp. 691-767.
4. Naval Medical Field Research Laboratory, Camp Lejeune, N.C., Research Report, NM 810109.1, Special Report, "Military Helmet Design," June 1958.
5. Schorstein, J.: Intracranial Haematoma in Missile Wounds. Brit. J. Surg. (War Surg. Supp. No. 1), pp. 96-111, June 1947.
6. Matson, Donald D.: The Treatment of Acute Craniocerebral Injuries Due to Missiles. American Lecture Series

- No. 22. American Lectures in Surgery. Springfield, Ill.: Charles C Thomas, 1948.
7. Cushing, H.: Some Experimental and Clinical Observations Concerning States of Increased Intracranial Tension. The Mütter Lecture for 1901. *Am. J. Med. Sc.* 124: 375-400, September 1902.
8. Campbell, E., and Whitfield, R. D.: Incidence and Significance of Shock in Head Injury. *Ann. Surg.* 138: 698-705, November 1953.
9. Meierowsky, A. M.: Wounds of Dural Sinuses. *J. Neurosurg.* 10: 496-514, September 1953.
10. Glenn, F.: Symposium on Skeletal Trauma; Priority Evaluation and Management of Multiple Injuries. *Am. J. Surg.* 85: 461-467, March 1953.
11. Gurdjian, Elisha Stevens, and Webster, John Elliott: Head Injuries, Mechanisms, Diagnosis, and Management. Boston: Little, Brown & Co., 1958.
12. Schmeiden, Victor, and Peiper, Herbert: Operationen am Kopfe. In Stich, Rudolf, and Makkas, Matthias (editors): Fehler und Gefahren bei chirurgischen Operationen. 2d edition. Jena, Germany: Gustav Fischer, 1932, pp. 1-87.
13. White, J. C.: Care of the Severely Injured Patient—Neurosurgical Injuries. *J.A.M.A.* 165: 1924-1930, 14 Dec. 1957.
14. Jansen, M. T.: Anesthesia in Acute Craniocerebral Trauma. In Symposium on Military Medicine in the Far East Command, September 1951, pp. 88-89. A supplementary issue to the Surgeon's Circular Letter, Medical Section, General Headquarters, Far East Command, Supreme Commander for the Allied Powers (Japan), and United Nations Command.

CHAPTER 8

Scalp Lacerations

Arnold M. Meirowsky

* * * every scalp wound [no matter how trifling] must be regarded as a potential penetrating lesion of the brain.—Harvey Cushing.

Wounds of the scalp comprise uncomplicated, small lacerations, perforating lacerations, contused lacerations with a varying degree of devitalization of surrounding tissue, and massive avulsions. The wide range of pathology produced by scalp wounds leaves one common denominator: Scalp wounds are compound wounds. They require earliest possible and radical debridement and closure. In order to rule out an obscure penetrating wound of the brain, however, roentgenograms should always be taken prior to debridement and closure of the scalp laceration. (See "Roentgenograms," chapter 7, p. 72.)

The devastating sequelae of improper treatment of scalp lacerations point to the surgical significance of these seemingly minor wounds. Secondary infection of a scalp laceration may lead to subgaleal abscess, to osteomyelitis, and to intracranial infection (1) (2) (3) (4) (5). Immediate debridement and primary closure of a scalp laceration are also necessary because of the possibility of delayed appearance of a neurological deficit necessitating neurosurgical intervention. Harvey Cushing was the first to stress the importance of careful surgical management of every scalp wound because of the high incidence of cortical pathology in the presence of scalp wounds without bone damage (6). The tangential bullet wound of the scalp without associated bone injury, but with extradural, subdural, intracortical, subcortical hemorrhage, or with localized encephalomalacia represents but one striking example (7). This is well illustrated by the story of—

X-20, a 20-year-old Marine sergeant who sustained a superficial scalp laceration on the left side of the forehead in the

Okinawa campaign. The laceration was caused by a tangential bullet. He had not been unconscious and was admitted to the minor surgery section of an advanced field hospital. The scalp laceration was not debrided, but simply dusted with sulfonamide powder and pulled together with an adhesive strip. Twenty-four hours later, the patient began to vomit, complained of severe headaches, and became increasingly drowsy. When seen the next day, he could barely be aroused from his stupor. He understood questions, but answered hesitantly and with incorrect and slurred pronunciation. The scalp laceration in the left frontal area was grossly infected. The left pupil was dilated. There were bilateral papilledema and right hemiparesis. Roentgenograms did not show a fracture. The necessary operation, which was made hazardous by the grossly infected scalp laceration, revealed an extradural and a subdural hematoma over the cerebral hemisphere. The craniotomy wound healed in 4 days; the scalp laceration in 4 weeks. Radical debridement and layer closure of the wound initially would have prevented the threat of meningitis and brain abscess.

Debridement of the individual layers of the scalp should be as radical as the tissue damage requires. A minimal excision of skin from the wound margins is the method of choice (8); however, all devitalized skin must be resected. The debridement should then be carried through all layers of the scalp inclusive of the periosteum. Hemostasis is temporarily accomplished by digital pressure on the wound margins and ultimately by the galeal suture line. Lacerations and avulsions in temporal and occipital regions require more radical surgical measures than lacerations in other regions of the scalp, primarily because of contamination and devitalization of muscle tissue. *En bloc* resection with the cutting current far into healthy muscle tissue is the method of choice.

Liberal use of saline irrigation throughout the process of debridement will assure removal of foreign substances and clots from the site of laceration.

Closure should be done in individual layers with interrupted silk sutures. Through-and-through sutures should only be used in instances of secondary closure. Hemostasis depends on the galeal suture line. The galeal sutures should be tied tightly with the knot placed parallel to the wound margin. Cutting the silk sutures close to the knot will prevent secondary infection and "spilling" of sutures. The skin sutures should not be tied tightly making allowance for postoperative edema of scalp tissue. There are no indications for incomplete closure and drainage of a properly debrided scalp wound. A drain, unnecessarily, delays and complicates healing;

it may even induce infection. The occasional subgaleal hematoma which may develop postoperatively can be adequately removed by aspiration through a No. 18 gage spinal puncture needle.

There are many different ways of carrying out adequate debridement and closure of a scalp laceration. There are other methods which may be ingenious, but considerably less adequate and effective. On record is a patient who had been treated elsewhere for a scalp laceration. Inspection revealed the wound edges neatly approximated by strands of hair tied across the laceration. Ingenious as this method may be, it can scarcely be recommended.

SURGICAL TECHNIQUE

The steps in the surgical technique of scalp lacerations are:

1. Shaving of wide area surrounding laceration (fig. 34).
 2. Cleansing of skin surrounding laceration with soap and water (fig. 35).
 3. Preparation of skin surrounding laceration with two coats of thimerosal and two coats of alcohol.
 4. Draping with sterile towels.
 5. Excision of entire skin edge with scalpel (fig. 36).
 6. Excision of narrow margin of all exposed layers of scalp and resection of periosteum (fig. 37).
 7. Individual inspection of all exposed layers of scalp and additional resection of devitalized tissues.
 8. Wide *en bloc* excision of exposed temporal or occipital muscle with cutting current.
 9. Inspection of denuded bone for fracture lines, small foreign bodies, or evidence of interosseous hematoma.
 10. Irrigation of wound with warm sodium chloride solution (fig. 38).
 11. Undermining of scalp (fig. 38).
 12. Primary closure *without drainage* in two individual layers (fig. 39).
 13. Closure of galea with interrupted sutures of No. 00 silk.
- The individual suture is to be tied tightly and the knot placed parallel to the wound margins. Sutures are to be cut short (fig. 39a-e).
14. Closure of skin without drainage with interrupted sutures of No. 0000 silk.
- The sutures may be tied quite loosely (postoperative edema of scalp) (fig. 39 f-g).
15. Collodion dressing.
 16. Removal of skin sutures after 48 hours.

REFERENCES

1. Cairns, H.: Gunshot Wounds of the Head in 1940. J. Royal Army M. Corps 76: 12-22, January 1941.
2. Evans, Joseph P.: Acute Head Injury. American Lecture Series No. 60. American Lectures in Surgery. Springfield, Ill.: Charles C Thomas, 1950.
3. Meirowsky, A. M., and Harsh, G. R. III: Treatment of Penetrating Craniocerebral Trauma. In Symposium on Military Medicine in the Far East Command, September 1951, pp. 85-88. A supplementary issue to the Surgeon's Circular Letter, Medical Section, General Headquarters, Far East Command, Supreme Commander for the Allied Powers (Japan), and United Nations Command.
4. Meirowsky, A. M.: Penetrating Craniocerebral Trauma; Observations in Korean War. J.A.M.A. 154: 666-669, 20 Feb. 1954.
5. Jefferson, G.: Head Wounds and Infection in Two Wars. Brit. J. Surg. (War Surg. Supp. No. 1), pp. 3-8, June 1947.
6. Cushing, H.: A Study of a Series of Wounds Involving the Brain and Its Enveloping Structures. Brit. J. Surg. 5: 558-684, April 1918.
7. Dodge, P. R., and Meirowsky, A. M.: Tangential Wounds of Scalp and Skull. J. Neurosurg. 9: 472-483, September 1952.
8. Matson, Donald D.: The Treatment of Acute Craniocerebral Injuries Due to Missiles. American Lecture Series No. 22. American Lectures in Surgery. Springfield, Ill.: Charles C Thomas, 1948.

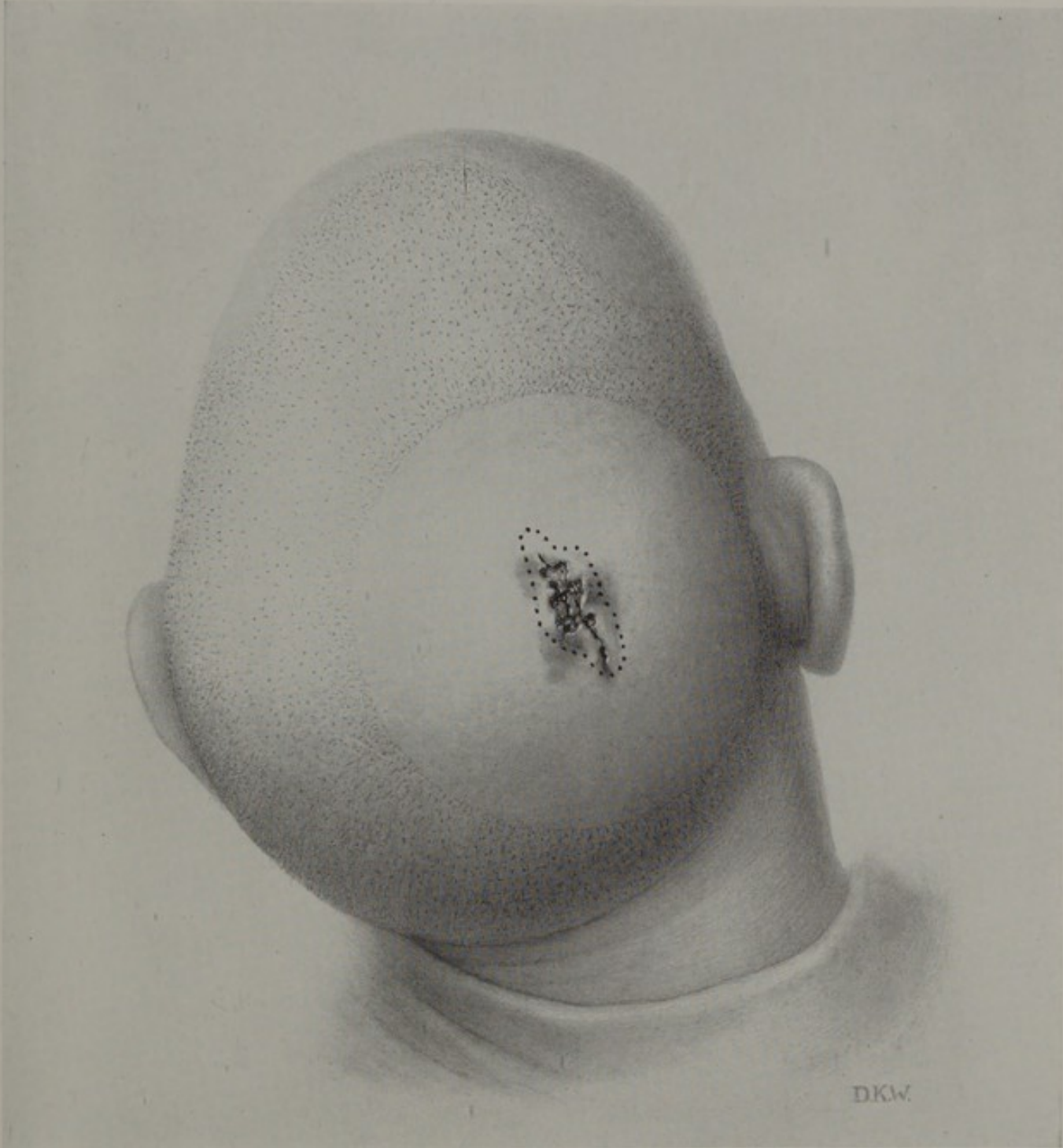


FIGURE 34.—Shaving of wide area surrounding laceration.

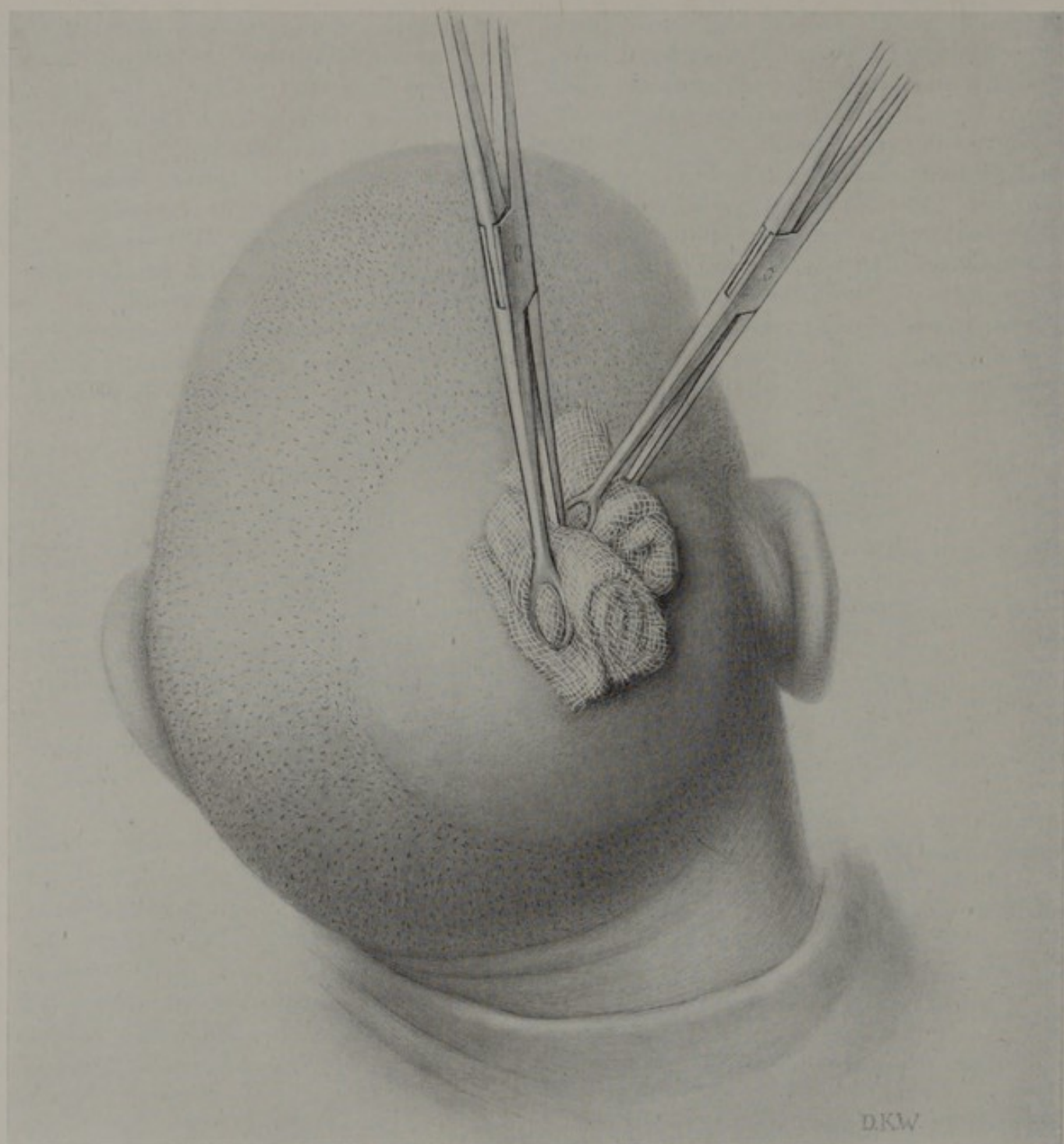


FIGURE 35.—Cleansing of skin surrounding laceration with soap and water.

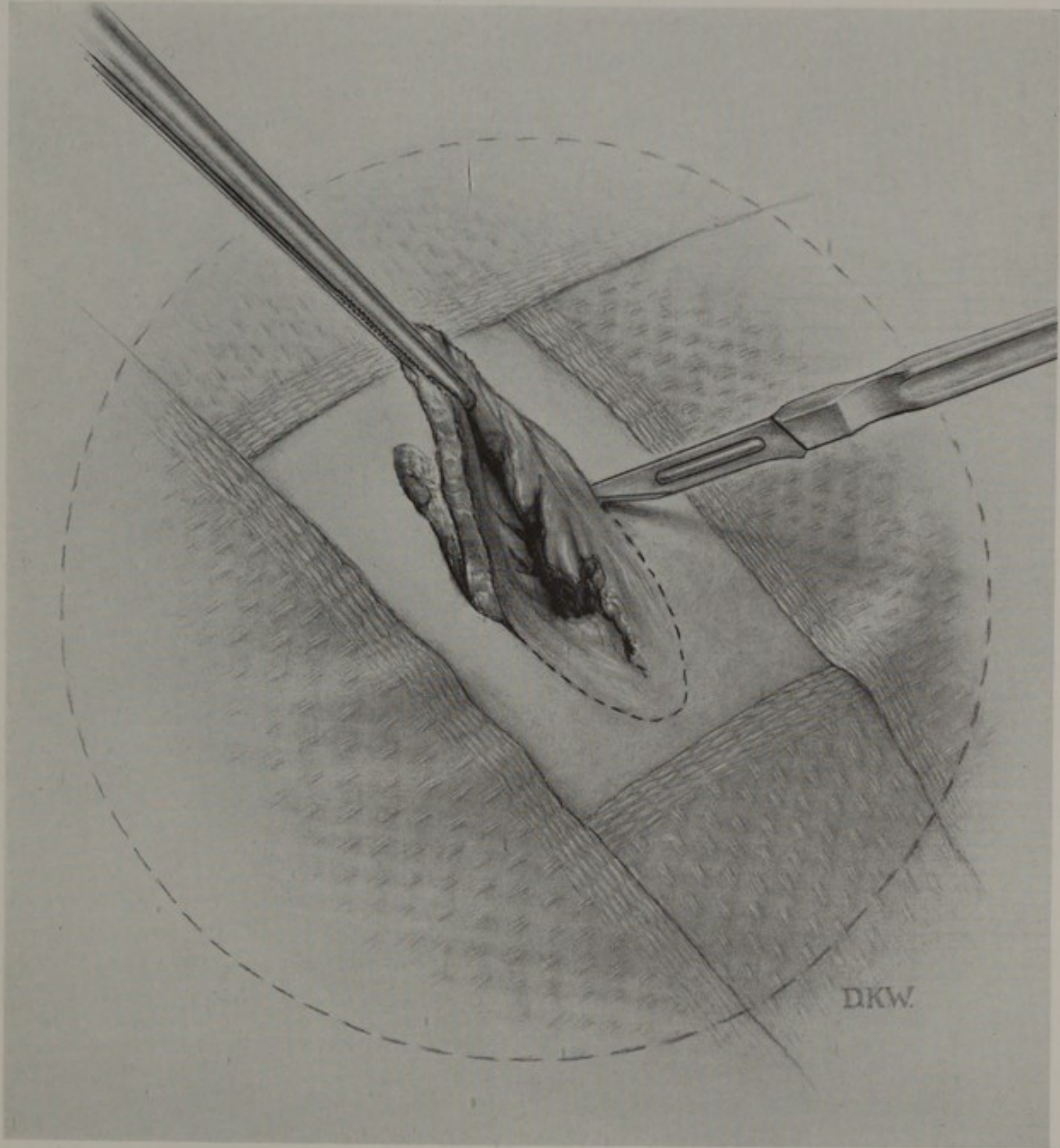


FIGURE 36.—Excision of entire skin edge with scalpel.

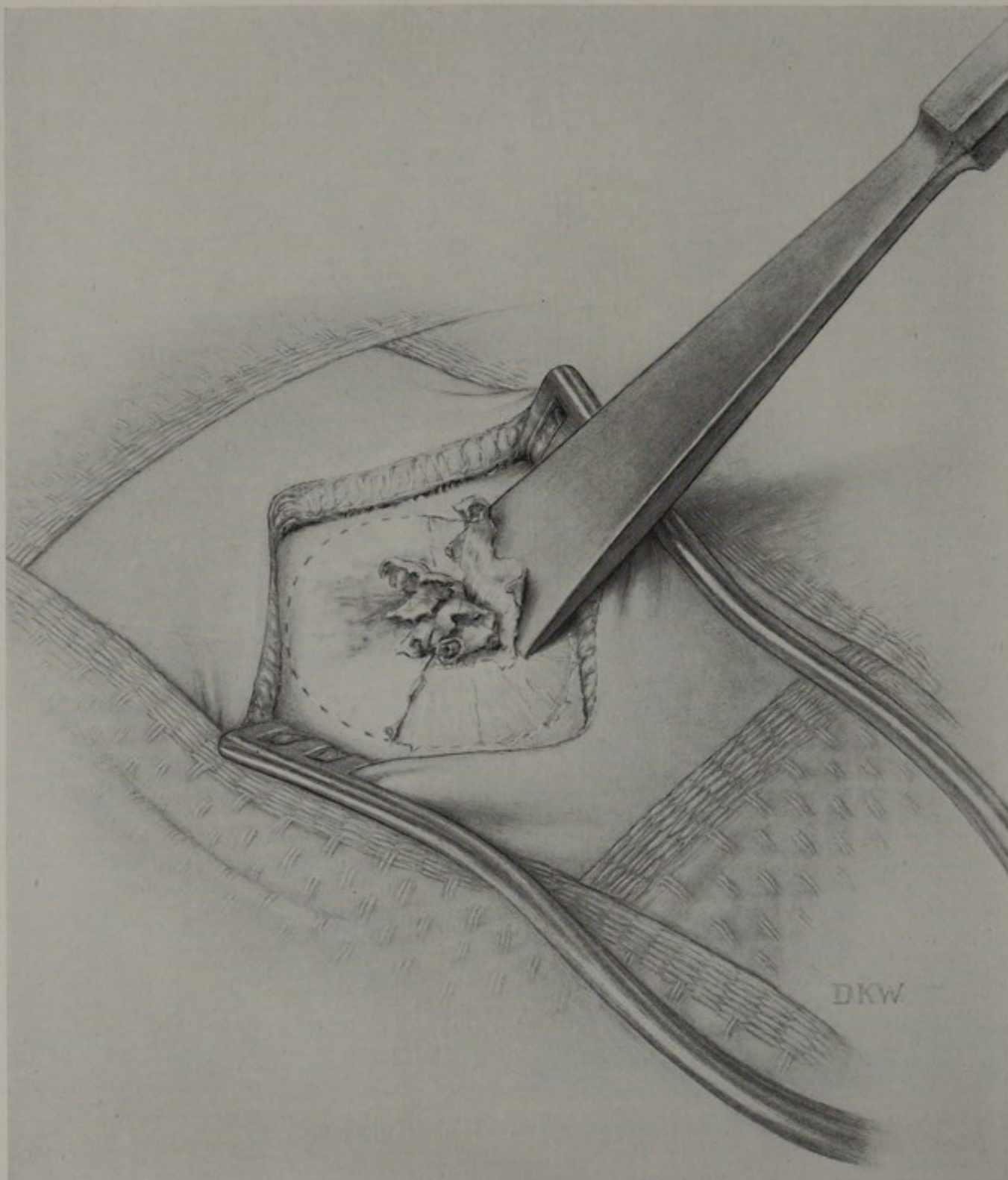


FIGURE 37.—Resection of contaminated periosteum.

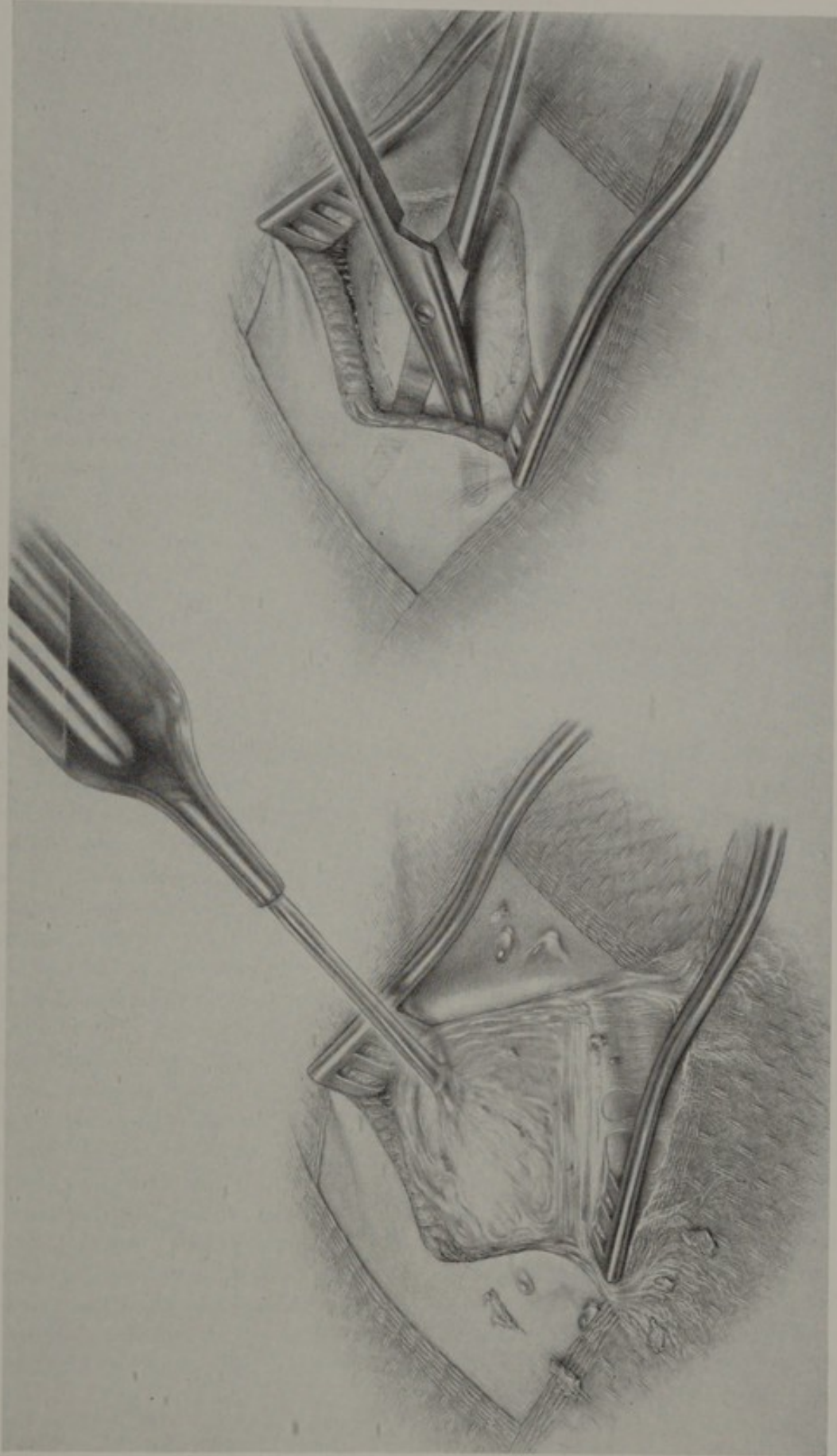


FIGURE 38.—(Left) Irrigation of wound with warm sodium chloride solution. (Right) Undermining of scalp.

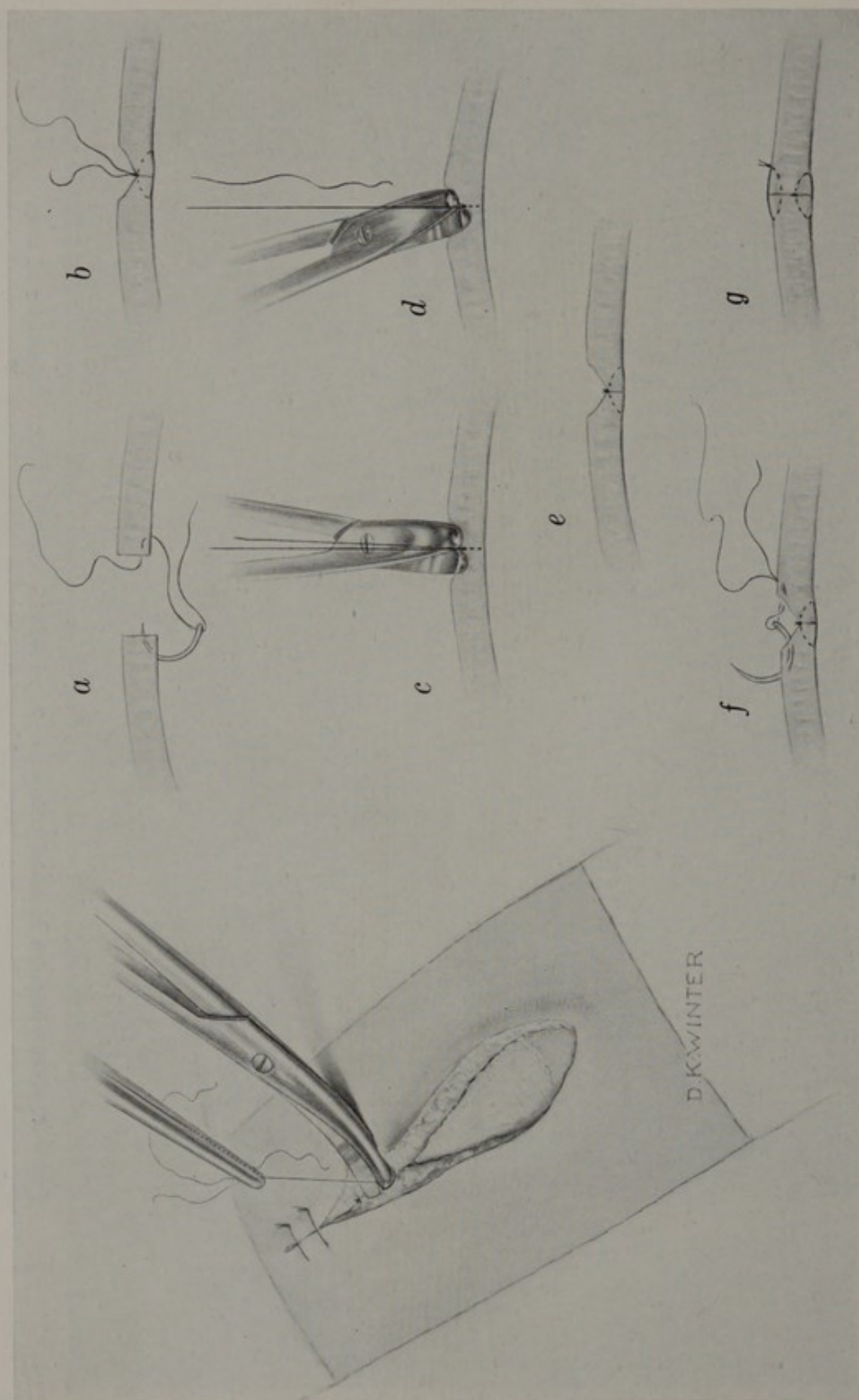


FIGURE 39.—Closure of galea and skin in individual layers. Note method of cutting galeal sutures immediately adjacent to knot.

CHAPTER 9

Compound Fractures of Convexity of the Skull

Arnold M. Meirowsky

The setting of a broken bone ought not to be delayed in summer time beyond the seventh day, and in winter it should not go past the tenth day; yet this is not tolerable when the dura mater has been indented or punctured, since a puncture may perhaps produce hot abscess and spasm, and perchance lead to apoplexy. Therefore it is necessary that that bone should be removed immediately, and then, if there should be apoplexy, consciousness will return to the senseless patient. But if there should be an open wound then one should make special haste; but if the skull is fractured and its surrounding membrane is torn, then it is necessary to make haste to cut out and remove skull fragments, nor ought one to put this off beyond the second day. Therefore if skull fragments should have to be removed, let as much be speedily removed as seems best and most desirable in order that bad symptoms and harmful tendencies may not arise; and it is necessary to remove the bone fragments widely so that the poison may have an opportunity to escape.¹

Definition: Fractures of convexity underlying scalp wound in presence of intact dura.

Neurosurgical intervention is indicated in the management of all compound fractures of the convexity of the skull. Infection can be prevented only by earliest possible surgical measures. A contaminated scalp wound requires primary surgical debridement and closure. If the underlying fracture is linear, surgical debridement need not go beyond the scalp in an effort to prevent infection. Depressed and comminuted bone fragments beneath the scalp wound, however, require craniectomy. Retained bone fragments represent the single most important causative factor in posttraumatic infection. The neurological deficit will clarify the indications for cranial surgery in the presence of a compound linear fracture. The astounding incidence of intracranial hematomas and of localized areas of encephalomalacia suggests that intracranial surgery is frequently indicated in the presence of compound linear skull fractures. This is borne out

by the statistics of compound fractures of convexity of the skull incurred in the Korean War and, particularly, by an analysis of tangential wounds of scalp and skull. (See chapter 13, pp. 143-159.)

STATISTICS

Korean War (September 1950 to September 1952)

The following statistical data include neurosurgical casualties who were cared for by U.S. Army mobile neurosurgical teams and/or in the neurosurgical center at Tokyo Army Hospital. Among the latter group were casualties who had received neurosurgical care prior to admission to the center in Tokyo, either aboard hospital ships or, in a few instances, at other installations. The statistics include neurosurgical casualties of the U.S. Army, U.S. Navy, U.S. Marine Corps, U.S. Air Force, United Nations troops, and Republic of Korea Army. The statistics are for the period from September 1950 to September 1952. The Army's first neurosurgical team was not launched until late in February 1951. As discussed elsewhere (chapter 12, pp. 135-142),

¹ Campbell, Eldridge, and Colton, James (translators): *The Surgery of Theodorica* ca. A.D. 1267. New York: Appleton-Century-Crofts, Inc., 1955, vol. I (Books I and II), p. 122.

TABLE 5.—Mode of injury in 226 consecutive cases of compound fractures of the skull

Mode of injury	Number	Percent
Metallic fragments.....	86	38.1
Missiles.....	59	26.1
Vehicular accidents.....	45	19.9
Blunt objects.....	26	11.5
Unknown.....	10	4.4
Total.....	226	100.0

the incidence of intracranial infection was considerably higher before March 1951 (1). The incidence of intracranial hematoma was considerably higher after March 1951 because patients were seen more rapidly (2). The following figures represent overall data which do not make allowance for the factors just mentioned.

There were 226 casualties with compound depressed fractures of the vault, on all of whom operation was performed. Shell fragments were responsible for the depressed fractures in 86 cases (38.1 percent) and missiles in 59 cases (26.1 percent). Forty-five men (19.9 percent) sustained a compound depressed fracture in vehicular accidents. Blunt objects were responsible for the depression in 26 instances (11.5 percent). In 10 casualties, the mode of injury remained undetermined (table 5).

Of the 226 casualties with compound depressed fractures of the vault, 2 died; a mortality rate of 0.88 percent. The records of the fatal cases are briefly summarized.

K-1201 was wounded in action by metallic fragments at midnight on 21 November 1951. Admitted to mobile neurosurgical team, 22 November, 6:00 p.m. Comatose, responded to pain stimuli by movements of left arm and leg. Head: Multiple lacerations, left occipital and suboccipital area. Neck: Through-and-through wound with small entrance wound left anterolateral aspect of neck and ragged exit wound in left posterolateral aspect of neck. Right hemiplegia. Bilateral Babinski. Roentgenograms of the skull revealed a compound depressed fracture in the suboccipital region. Prior to craniotomy, exploration of left carotid artery was done inasmuch as a pulsating hematoma was increasing in size. The carotid artery was found to be lacerated and ligated. The scalp lacerations were connected with each other and radically debrided. All metallic fragments were removed. A bur hole was placed distally to the site of depressed and comminuted fracture. An *en bloc*

incision was carried out of the bone. Three depressed fragments of moderate size were encountered. The dura was not penetrated; however, it was tense and bluish discolored. It was opened. A considerable amount of encephalomalacic tissue and subdural and subcortical clots exuded under pressure. The patient's condition was extremely poor at that time and craniotomy was limited to relief of severely increased intracranial pressure by the liquefied encephalomalacic tissue and the subdural and subcortical clots in the posterior fossa. Patient died approximately 18 hours after operation.

Comment.—This patient's neurological deficit represents the sequela of the impairment of the blood supply to the left side of the brain. In addition, the patient had severely increased intracranial pressure for a long period of time. For tactical reasons, evacuation of this patient had been delayed.

K-746 was injured at an air force base in Japan at 6:00 p.m., 18 November 1951, when a B-29 loaded with 500-pound bombs exploded. Sustained multiple lacerating wounds of face and scalp as well as contusions of body. Was rendered unconscious immediately. Apparently considerable loss of blood in transport. Arrived at neurosurgical center, Tokyo Army Hospital, 6 hours after having been injured. Comatose, in shock. Blood pressure: 48/12. Responded to pain stimuli in all four extremities. Pupils equal, conjugate deviation to the left. Right central facial weakness. Multiple lacerations of face, upper and lower lips, left ear, and scalp. Roentgenograms revealed compound comminuted depressed fracture in left frontal region with metallic foreign body embedded in tissues in left supraorbital region. After blood transfusion had been administered and patient was out of shock, a left frontal craniectomy was performed. Site of fracture was removed. Underlying dura was intact. When opened, a large subdural hydroma as well as clots of blood and liquefied brain tissue exuded under marked pressure. No subdural hematoma was encountered. Primary closure of dura and scalp was performed. Following operation, patient remained comatose. There was evidence of a widespread missile-blast injury. Blood was obtained from stomach by gastric suction. Urine was bloody. Twelve hours after craniectomy, systolic blood pressure rose to 200 and breathing became labored. Patient was returned to operating room. A bur hole was made on the right side and a large right subdural hematoma was evacuated. The underlying brain appeared severely contused and soft. Patient did improve for a while. After prolonged episodes of artificial respiration and stimulants, a bitemporal decompression was performed but to no avail. Patient died 23 November 1951.

Comment.—1. Extreme increased intracranial pressure from cerebral edema as sequela of blast injury is not uncommon. 2. Bilateral bur holes should be made regardless of the neurological deficit. Immediate relief of the right subdural hematoma might have helped to reduce cerebral edema. 3. Availability now of Urevert (lyophilized urea and travert solution) might help considerably in patients with massive cerebral edema following blast injury.

Postoperative infection occurred in five cases (2.21 percent). Of these five casualties, one developed an extradural abscess and four developed superficial scalp infection. The story of K-1129 illustrates this complication:

This 26-year-old corporal was wounded by metallic fragments in Korea on 10 February 1951, sustaining a penetrating wound of scalp and skull in the right parieto-occipital region. Craniectomy was performed aboard a U.S. Navy hospital ship on 13 February 1951. The scalp was debrided, bone fragments were removed, the dura was not opened. On admission to neurosurgical center, Tokyo Army Hospital, 3 days later, patient appeared alert but was disoriented as to time and place. He complained of headaches. The 13 cm. transverse occipitoparietal laceration was edematous and tender to palpation. Wire sutures were still in place. Hemiparesis, left; Babinski, left; left homonymous hemianopsia. Jacksonian seizures 48 hours after admission to the center, involving left face, left arm, and leg. Immediate reoperation decided upon. A large extradural venous hematoma, an equally large subdural venous hematoma, as well as liquefied encephalomalacic tissue intermingled with clots, were resected. Initial recovery appeared good. Five days following surgery, skin separation occurred with oozing of fibropurulent material. Neurological examination was essentially negative at that time. Patient had another seizure with head and eyes turning to the left and twitching of left side of the face. Reoperation was decided upon. An extradural abscess was evacuated. The organism was hemolytic staphylococcus which was sensitive to Aureomycin. A postoperative superficial infection of scalp tissue was treated with Aureomycin as well as with 6-hourly irrigations for 48 hours. Subsequently, dressings with a mixture of plasma and penicillin were applied. At time of evacuation to the Zone of Interior, patient did not have any noticeable neurological deficit. The scalp wound was healed. Followup report from Walter Reed Army Hospital, where patient was hospitalized upon arrival in the Zone of Interior is summarized as follows:

Admission examination revealed a 4- by 2-cm. depressed skull defect in right parietal region which was pulsating normally. There was a small area in the scalp which was draining. This responded to hot compresses and bacitracin. Electroencephalography revealed basic frequency of 9 per second with irregularly recurring slow waves in right temporoparietal leads. In the middle of May, the scalp area again broke open with infection. Hot soaks were applied and antibiotics were used. On 13 September 1951, patient was taken to the operating room with the preoperative diagnosis of chronically infected scalp wound. A scarplasty and debridement of the initial wound of the right parieto-occipital area was performed. The old scar was excised, followed by removal of fibrotic tissue. The dura was not opened. No areas of pus collection were noted but two black silk sutures embedded in chronic infected fibrotic tissue were removed. The edges of the incision were sharpened and adequately closed with wire sutures. The patient withstood the proce-

TABLE 6.—*Intracranial hematomas in 226 consecutive cases of compound fractures of the skull*

Intracranial hematomas	Number	Percent
Extradural.....	44	19.5
Subdural.....	44	19.5
Subcortical.....	36	15.9
Total.....	124	54.9

dure well. He was discharged from the Army without any evidence of infection.

An intracranial hematoma was found at time of first operation in 124 of the 226 cases, an incidence of 54.9 percent. Of these, 44 (19.5 percent) were extradural hematomas, 44 (19.5 percent) were subdural hematomas, and 36 (15.9 percent) were subcortical hematomas (table 6).

In 25 (11.1 percent) of the 226 cases, subdural hydromas were encountered. Localized encephalomalacia underlying the site of fracture was found in 89 cases (39.4 percent).

SURGICAL MANAGEMENT

SCALP

The surgical approach to the scalp wound in compound fractures depends on the topography of the latter and on its extent. Debridement of the scalp wound should be carried out in accordance with the same principles employed when dealing with scalp lacerations. It should be as radical as the direct damage to individual layers of the scalp necessitates. Limitation of debridement in an effort to preserve tissue, more often than not, results in sloughing when poorly vascularized scalp tissue is retained or in infection unless all contaminated tissue is resected.

Wounds involving temporal or occipital muscle require special consideration. Secondary infection is a common sequela of a wound involving temporal or occipital muscle unless radical resection of the muscle has been performed. It is better to sacrifice an entire temporal muscle as a preventive measure rather than to risk an extensive scalp infection which can spread rapidly into muscle tissue. Electrosurgical resection of the entire muscle or *en bloc* resec-




FIGURE 40.—Complete S-shaped incision.

tion of the muscle far into healthy tissue is indicated in every instance of muscle penetration.

The surgical approach of choice can best be determined by inspection of the shaved head prior to positioning on the operating table. Preoperative neurological and roentgenological data have to be taken into consideration. Scalp exposure should be planned to permit free access to the entire area of

fracture and surrounding intact bone and to facilitate *en bloc* craniectomy. Consideration should also be given to the cosmetic result. Extensive scars outside the hairline can usually be avoided. Their presence adds to the psychological trauma and enhances unnecessarily selfconsciousness. In this world of ours in which the spirit of competition prevails, the ultimate goal of rehabilitation can only be

achieved if attention is paid to such seemingly minor points of reference.

Small wounds not requiring extensive debridement may be excised elliptically and the incision extended in linear fashion proximally and distally. By undermining the scalp beneath the galea, closure can readily be accomplished without tension.

The tripod incision should be avoided whenever possible. Its shortcomings were recognized early in the Second World War by Eldridge H. Campbell (3): "When employed, acutely angled flaps should be avoided, and the narrowest angle placed on the side of the best blood supply. Great gentleness should be exercised in handling the flaps, particularly their apices. If apical sutures are necessary, they must be tiny and nonconstricting. Accurate closure without tension is essential."

Wounds of moderate size and large wounds of the convexity, particularly if caused by shell fragments, can be exposed by debridement of the actual scalp wound and a curvilinear, S-shaped, extension of the incision proximally and distally. A complete S-shaped incision, in which the wound is included in the central limb, affords ideal exposure of all vertex wounds (fig. 40). The modified as well as the complete "S" facilitates extensive undermining of the scalp which in turn permits closure without tension. Martin and Campbell (4) stressed the need for generously long incisions to distribute the tension over a wide area. As pointed out by Matson (5), undermining of the scalp should always be carried out in the areolar layer over the pericranium, inasmuch as the galea is freely movable in this layer while it is firmly attached to the skin.

The coronal flap affords by far the best exposure of a penetrating wound of the forehead or of the anterior temporal region (fig. 41). Wounds which fall in line with the coronal incision can readily be debrided and extended into it. Penetrating wounds anteriorly to the coronal flap require independent debridement and closure (fig. 42). In outlining the incision for a coronal flap, care must be taken to place it well behind the hairline. It is best to swing the flap along the natural curves of the hairline, but 1 to 2 cm. behind it.

In some instances, Dandy's "concealed" flap may afford as good exposure as the coronal flap. Its preparation and closure are not as time consuming as that of the coronal flap. The latter is the method

of choice in bifrontal wounds and in those which are situated in the anterior midfrontal region. The employment of a unilateral flap extending across the forehead, as shown in figure 43, is undesirable for cosmetic reasons. Its employment is unnecessary inasmuch as the coronal flap, which is always concealed behind the hairline, or Dandy's "concealed" flap affords entirely adequate exposure (fig. 44) (6).

While virtually all convexity wounds are handled best by curvilinear (S-shaped) incisions, the inclusion of the wound within a large horseshoe flap may provide advantageous exposure in the presence of high-velocity missile wounds.

Debridement of the scalp wound is the same as that of an uncomplicated scalp laceration. As soon as debridement of the scalp wound has been completed, the instruments used for this purpose are discarded. The scalp wound is then extended proximally and distally so as to expose the site of comminution and depression and the surrounding intact bone in a radius of 3 to 4 centimeters.

Galeal hemostasis can be accomplished by Michel's clamps. The latter are well tolerated by edematous skin while heavy scalp clips frequently lead to skin necrosis when used in conjunction with contused skin and scalp.

Primary tight closure of the scalp in individual layers without tension is essential in order to avoid secondary infection of subcutaneous tissue with the threat of subsequent extradural abscess, osteomyelitis, and meningitis. By making liberal use of curvilinear (S-shaped) incisions, with extensive undermining of the scalp, primary closure can be accomplished in the vast majority of instances without tension on the suture line. In cases of secondary closure, through-and-through sutures are indicated.

Whenever there is extensive loss of scalp substance, it becomes necessary to resort to plastic procedures. In peacetime and in civilian injuries, plastic closure of scalp wounds in the presence of extensive loss of scalp substance is the domain of the plastic surgeon. When it comes to the management of craniocerebral trauma in active warfare, earliest possible radical and complete neurosurgical intervention in the combat zone becomes mandatory. With the rare exception of cases of fungating cerebritis, for which we advocate open treatment (7), primary closure of the scalp overlying the site of



FIGURE 41.—Frontal and lateral views 8 years after penetrating wound of brain. No neurological deficit. K-453 was wounded in action by a shell fragment on 7 December 1951. He sustained a left frontal penetrating wound involving the brain. Left frontal craniectomy by coronal flap was carried out by the 3d Neurosurgical Detachment (Provisional). K-453 has graduated from college since the Korean War and now holds a responsible position with a radio station.

craniectomy is essential in order to prevent secondary infection of extracranial and intracranial structures. This closure must be accomplished without tension.

When the loss of scalp substance is too great to permit closure without tension, plastic procedures are indicated (fig. 45). Matson (5) does not recommend the use of relaxing incisions for closure of scalp wounds. The author used relaxing incisions extensively for closure of scalp wounds in the Pacific area during the Second World War and avoided using them whenever possible during the Korean War. The author concurs with Matson who states that “* * * It is almost always preferable to

elevate a flap of scalp and slide or rotate it across a defect rather than attempt to relax one or both margins of the defect and approximate them directly over the underlying wound.” The base of rotation or sliding flaps should be directed toward the blood supply. The flap should be large enough to cover the entire defect, and to allow closure in individual layers without tension. Matson suggests that the flap be about three times the size of the defect to be covered. It is of prime importance that the entire site of craniectomy be covered at time of initial surgery. When using pedicle flaps, the pericranium should be left intact. In many instances, it is, of

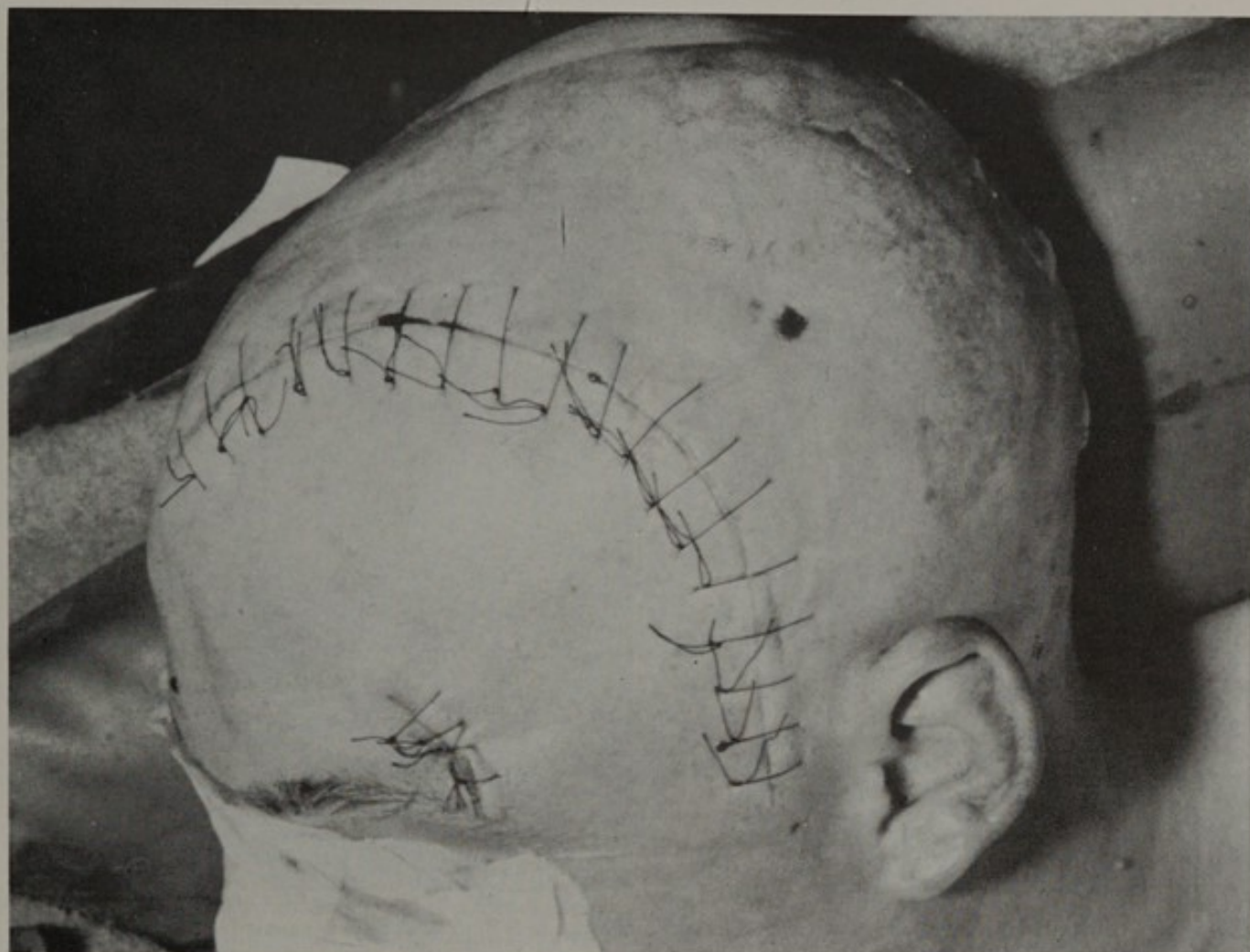


FIGURE 42.—Independent debridement and closure of penetrating wound. Coronal flap used for exposure. Note lateral limb of flap extending to zygoma.

BONE

Compound linear fracture of convexity of skull.—

In the absence of a neurological deficit suggesting intracranial pathology, compound linear skull fractures do not require surgical intervention other than debridement and closure of the scalp wound. The importance of the latter has already been stressed. Signs and symptoms of increasing intracranial pressure may not manifest themselves for some time after the injury. As illustrated by the story of X-20 (chapter 8, p. 75), intracranial surgery can be gravely complicated by a neglected scalp wound.

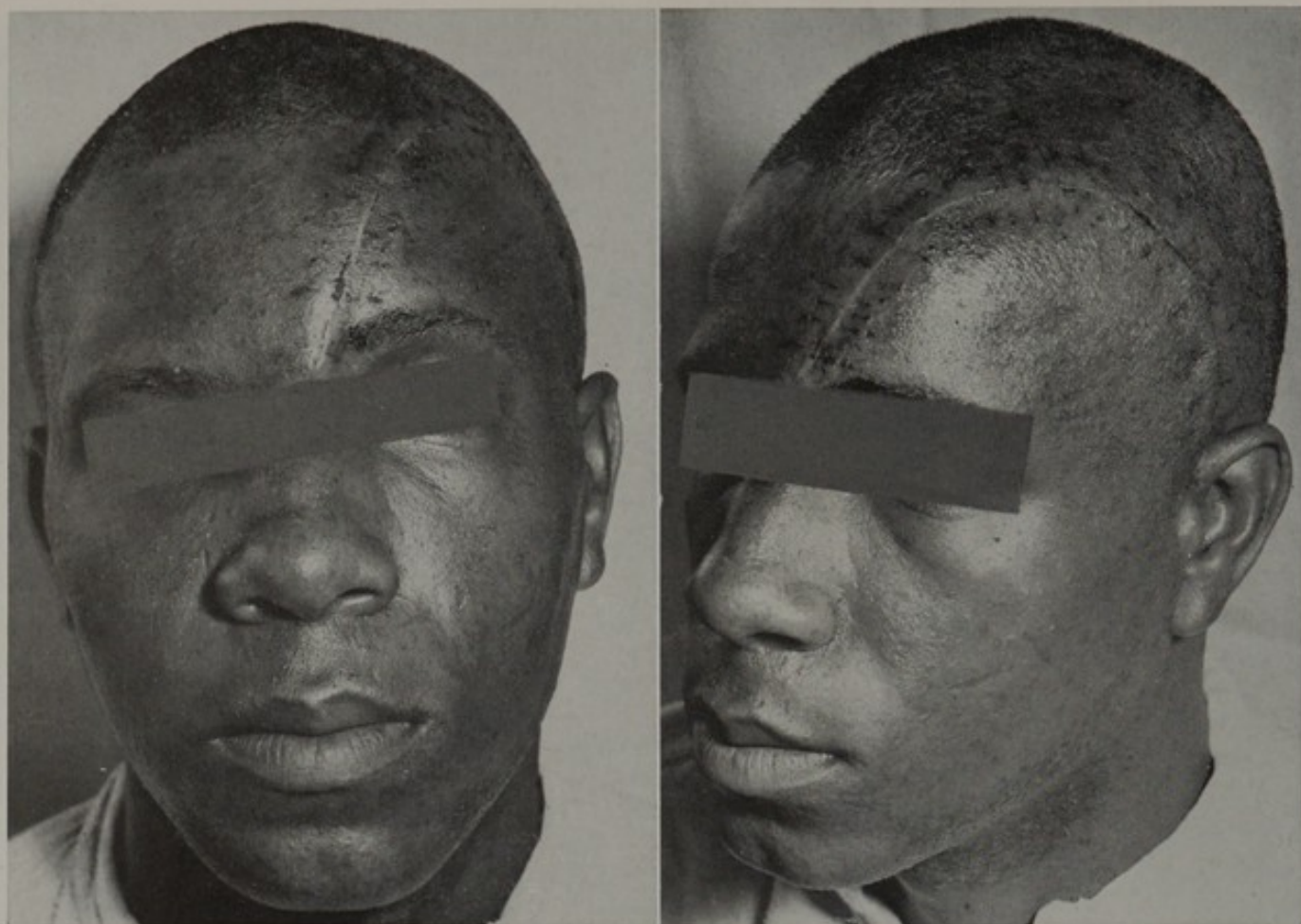


FIGURE 43.—Views of unilateral flap across forehead. It is undesirable for cosmetic reasons.

Whenever initial neurological examination suggests the remote possibility of an intracranial hematoma, exploratory bur holes should be made at time of debridement of the scalp wound. The story of K-1835 illustrates that point:

This 21-year-old U.S. Army private, first class, sustained a right parietal shell wound on 24 October 1951 at 12:00 noon. He was tagged at 2:30 p.m., and admitted to the 2d Neurosurgical Detachment (Provisional) at 8:00 p.m. Though drowsy, he could be aroused and showed some aphasic manifestations. Blood pressure: 130/60. Pulse: 68. Respiration rate: 14. *LEFT*-handed. Inspection of the head revealed a dirty, stellate laceration in the right posterior parietal region, measuring 6 centimeters. Roentgenograms showed an underlying linear fracture without depression or comminution. There was no neurological deficit other than a Babinski response on the left.

Immediate right parietal craniectomy was performed under local infiltration anesthesia. A bur hole was made posterolaterally to the fracture line. The intact dura was opened. Clotted blood escaped under pressure. A moderately large subdural hematoma was evacuated. The

underlying cortex was contused. A small area of liquefied cortical tissue was resected. Primary closure was performed. On admission to the center in the second echelon 7 days later, the patient was alert and oriented. He did not have any aphasia. The neurological deficit was limited to hyperactivity of the left deep tendon reflexes, absence of the left abdominal reflexes, and a Babinski response on the left.

Compound comminuted depressed fracture of convexity of skull.—Debridement with proximal and distal extension of the scalp wound affords exposure of the site of depression and comminution. This exposure should include intact bone surrounding the site of fracture in a radius of 4 centimeters. The periosteum covering this area of intact bone must be resected. A wide variety of comminuted depressed fractures may be encountered. Almost invariably comminution and depression of the inner table are more extensive than those of the outer table. To the naked eye, there may be a negligible

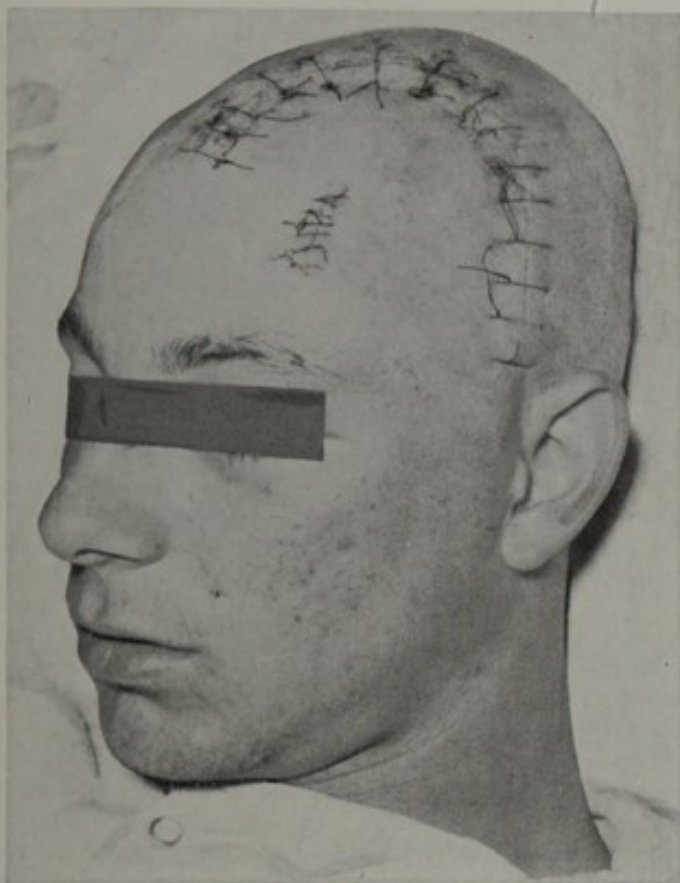


FIGURE 44.—Dandy's "concealed" flap.

depression of the outer table associated with exceedingly extensive comminution and depression of the inner table. Roentgen films may fail to convey the true extent of comminution and depression unless stereoscopic views are available. The routine employment of stereoscopic views of all craniocerebral wounds is tremendously helpful in preparation for surgery (8).

The principle underlying the surgical management of a compound comminuted depressed fracture of the convexity, regardless of its extent, is that of total resection of the site of fracture, which is contaminated and potentially infected. For that reason, elevation of a compound and depressed fracture is not indicated under any circumstances. *En bloc* resection of the site of depression and comminution is the surgical method of choice (9). Earliest possible decompression is not only essential in order to prevent infection but also an effort to prevent permanency of a neurological deficit (10). The story of K-95, a 22-year-old U.S. Army corporal, demonstrates prevention of permanent cortical blindness by decompression of the visual cortex.

A through-and-through bullet wound of the scalp resulted in depression and comminution of occipital and suboccipital bones. When first seen a few hours after having been wounded, he was drowsy, but could be aroused. He was restless and complained of severe headaches. He was unable to recognize objects placed in front of the eyes, but did see the glare from a flashlight. Inasmuch as he was first seen in an area where craniectomy could not be performed, he was taken by plane to the 1st Neurosurgical Detachment (Provisional), causing a delay in definitive treatment. During the plane ride he became increasingly drowsy, complained of headaches and nausea, vomited several times, but continued to recognize the glare of a flashlight although he was unable to see the outline of a canteen of water that was offered him. At operation, which was performed 16 hours after the patient had been wounded, extensive comminution and depression of occipital and suboccipital bones were encountered, producing compression and contusion of the torcular Herophili. The dura was not torn. Subdural inspection revealed contusion but no evidence of liquefaction of the occipital and cerebellar cortex. Postoperatively the patient fared well and experienced recovery of vision. In a letter written by the patient 21 months after having been wounded, he stated that his "vision has been restored to what it was before I was wounded."

Craniectomy should never be started from the center. Comminuted and depressed bone fragments should not be rongeured toward the periphery. In dealing with contaminated and potentially infected wounds, it is essential to prevent spread of infection into clean areas. Centripetal *en bloc* resection serves to prevent such spread of infection. Four or even five bur holes are made into intact bone surrounding the site of fracture. A DeVilbiss rongeur is used to connect the individual bur holes, and to permit removal of the comminuted depressed bone plate *en bloc* (fig. 46). Two blunt instruments such as periosteal elevators are used to lift up one side of the plate. Intactness of the dura is ascertained before prying the plate loose in its entirety. Comminuted bone fragments and clots, attached to the inner table and dura, are freed with a blunt instrument. The force of the blunt instrument is directed toward the inner table of the bone plate to avoid cortical contusion through the intact dura. The bone plate is then lifted out *en bloc*.

In some areas, it is not feasible to surround the site of fracture with bur holes. This applies particularly to depressed fractures of the convexity adjacent to the base of the skull and to those in the

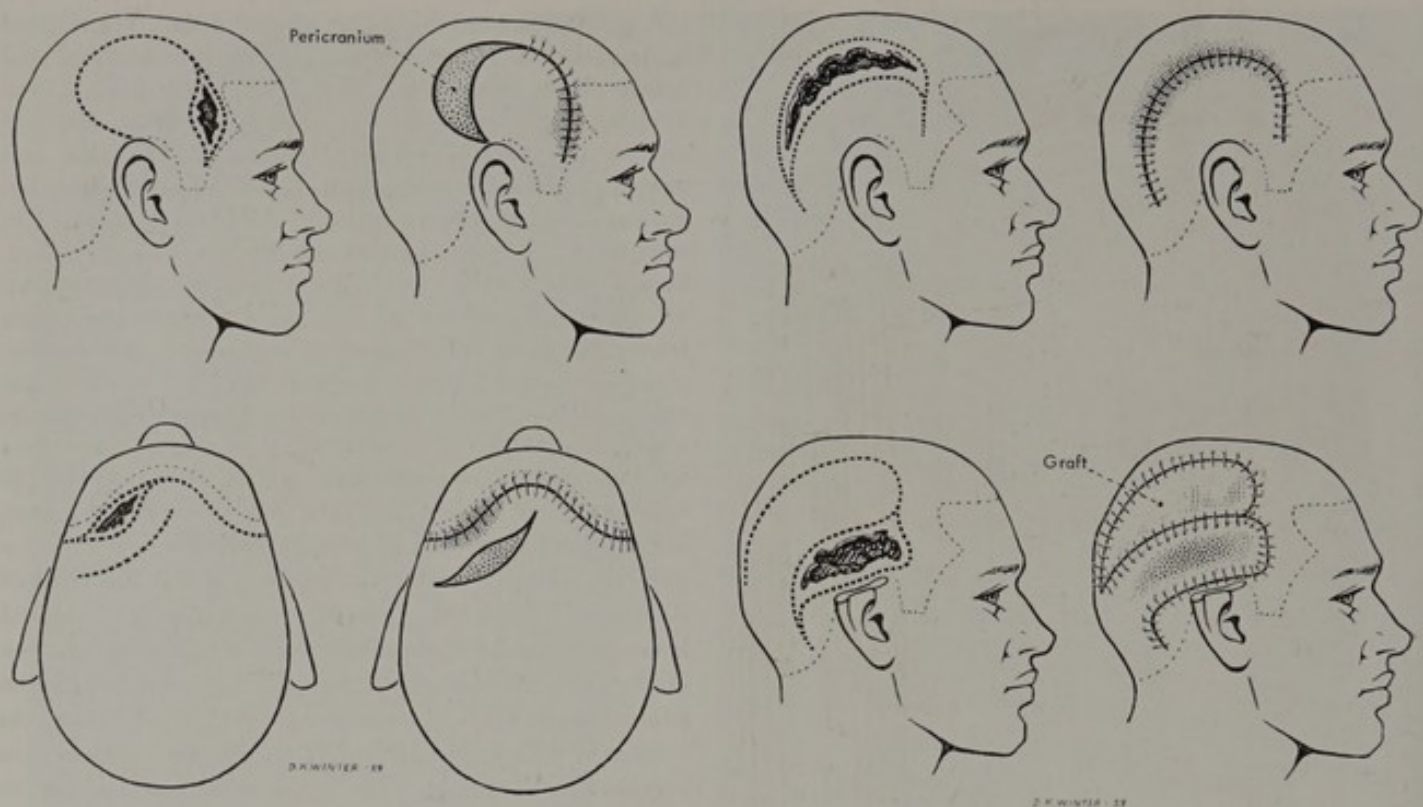


FIGURE 45.—Scalp closure by plastic procedures. (Modified from Matson.)

proximity of the frontal air sinuses. In lieu, one or two distal bur holes can be made (fig. 47) and *en bloc* excision can be carried out with DeVilbiss rongeur by starting the craniectomy at this bur hole. Upon completion of the actual craniectomy, the operative site is thoroughly washed out with warm saline solution and bone bleeders are controlled by use of bone wax of firm consistency. An existing extradural hematoma can now be evacuated without difficulty. If venous in nature, hemostasis can be accomplished by electrocoagulation of epidural venous bleeders. If the hematoma is the result of a tear in one of the branches of the middle meningeal artery, definitive occlusion of that vessel must be accomplished. This may necessitate tracing the artery into the foramen spinosum and occluding it there not only by electrocoagulation but also by plugging of the foramen with bone wax.

The dura underlying the depressed fracture is usually very vascular. Coagulation of epidural vessels may not suffice to achieve lasting hemostasis. In order to prevent postoperative extradural bleeding, the dura should be secured to the periosteum or to the galea by interrupted silk sutures.

The incidence of subdural and intracerebral pa-

thology in compound fractures with an intact dura is so high that the necessity of opening the dura in every instance cannot be stressed too emphatically. This is borne out by the overall statistics of compound fractures incurred in the Korean War. It is also borne out by an analysis of tangential wounds of scalp and skull (11). (See also chapter 13, pp. 143–159.) Without exception the dura should be opened, the subdural space searched for possible hematoma or hydroma, and the cortex underlying the site of fracture inspected for encephalomalacia.

In the presence of increased intracranial pressure with or without localizing signs, with or without the finding of an intracranial hematoma on the side of the fracture, an exploratory bur hole should be made on the opposite side to rule in or out a contre-coup hematoma. The need for an exploratory bur hole on the opposite side is best illustrated by K-746 (p. 84), one of two fatal cases in this series of 226 compound comminuted depressed fractures.

The statistics of the Korean War have led us to conclude that opening the intact dura is a step of paramount importance in the surgical management of compound fractures. The following clinical histories illustrate this point:

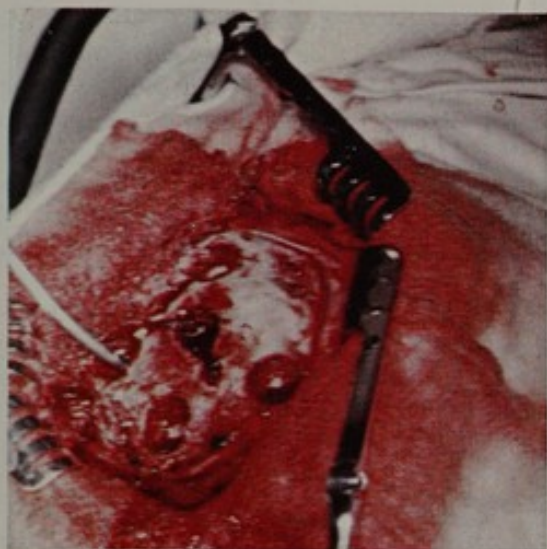

FIGURE 46.—*En bloc* resection of depressed fracture.

K-1963, a 23-year-old U.S. Army corporal, sustained a shell fragment wound of the right parietal area on 28 March 1951, resulting in avulsion of the scalp and depression and comminution of the right parietal bone. On admission, he was lethargic and disoriented. He had a left hemiparesis, involving face, arm, and leg. There was complete paralysis of the left leg. *En bloc* craniectomy was performed. The intact dura was opened. A sizable subdural and a large subcortical hematoma were evacuated. Liquefied encephalomalacic tissue was resected and primary closure was performed. Recovery was uneventful. At time of evacuation to the second echelon in Tokyo, 10 days after having been wounded, he was alert and oriented. The hemiparesis persisted. Complete followup examination was furnished by the commanding officer of Percy Jones Army Hospital where patient was discharged in December 1951:

"Examination at this time reveals a completely healed, nontender, 10-cm. scar over the right parietal region parallel to and just to the right of the midline. The underlying bony defect is adequately covered with the plastic plate and the cosmetic result is satisfactory. The patient is fully ambulatory without abnormality in gait. The Romberg is negative. He stands equally well on either foot, but is clumsy and hesitant in hopping on the left leg. The strength of all extremities is adequate and equal without spasticity or rigidity. The deep tendon reflexes are brisk and somewhat more hyperactive on the left. The superficial reflexes are present and equal bilaterally. No pathological reflexes are obtained, and there is no demonstrable clonus. The cranial nerves are intact. There is no defect in coordination and no sensory deficit. The patient's speech is hesitant and slow, but there is no evidence of specific aphasia. He writes legibly and well. The patient's only subjective complaint at this time is that of slight weakness and tremor of the left lower extremity after prolonged walking or standing. There have been no convulsive episodes."

A letter written by the patient on 6 April 1958, 7 years after having been wounded, states: " * * * My arm doesn't bother me. But the leg does bother me once in a while

when I am working or tired. Some time in the winter when it is cold. I don't have seizures or convulsions. But I do get dizzy spells, but not too often. I work in a papermill as a truck driver. I got married after I got discharged from the Army. I have two boys and one girl * * *."

Comment.—This case represents a gratifying result of early, radical neurosurgical intervention. In the light of the pathology, it is interesting that this patient did not develop an epileptic focus. The absence of such a focus might be explained by radical evacuation of a large subcortical hematoma and a clean resection of the surrounding area.

K-2205, a Puerto Rican private, wounded in action, sustained a shell fragment wound in the right frontal area on 29 August 1952. When admitted to the 2d Neurosurgical Detachment (Provisional), he was drowsy but responded when spoken to. Shell fragment wound had produced an angular laceration of the right frontal region anteriorly to the hairline, measuring 5 centimeters. Skull roentgenograms revealed a depressed fracture in the right frontal region. Neurological examination failed to reveal any deficit. Right frontal craniectomy was performed by means of a Dandy "concealed" flap. A bur hole was placed laterally to the site of depression and comminution and *en bloc* excision was performed starting at this bur hole by use of the DeVilbiss rongeur. The underlying dura was intact although contused. Opening of the dura revealed a moderate degree of encephalomalacia. The softened and liquefied cortical tissue was resected. The subdural space was irrigated in all directions. No subdural hematoma was encountered. The Dandy "concealed" flap was closed. Subsequently, the scalp laceration in the right anterofrontal region was radically debrided and closed in individual layers. Patient made an uneventful recovery.

K-156, a 22-year-old U.S. Army corporal, sustained a bifrontal shell fragment wound on 7 March 1952 at 10:15 a.m., when a fuse exploded while he was attempting to remove it from a mortar shell. He was tagged at 11:00 a.m. and was admitted to the 2d Neurosurgical Detachment (Provisional) on 7 March 1952 at 1:30 p.m. He did not lose consciousness, appeared drowsy but could easily be aroused on admission. Blood pressure: 140/80. Pulse: 80. Respiration rate: 20. Inspection of the head revealed laceration of the globe of the right eye, a 2- by 2-cm. punctate laceration in the midanterofrontal region and a 4- by 5-cm. laceration of the right supraorbital region. Neurological examination revealed the cranial nerves to be intact with the exception of total loss of vision in the right eye. Motor system: Equal as to tone and strength. Sensory system: No abnormalities. Reflexes: The deep tendon reflexes appeared hyperactive on the left. There were no pathological reflexes. Roentgenograms of the skull: Comminuted depressed fracture, right frontal bone involving right and left frontal sinuses. Large metallic foreign body lodged posteriorly and inferiorly to the floor of the right orbit. Prior to neurosurgical intervention, the right eye was enucleated by Captain Aalpoel. At time of enucleation, the metallic foreign

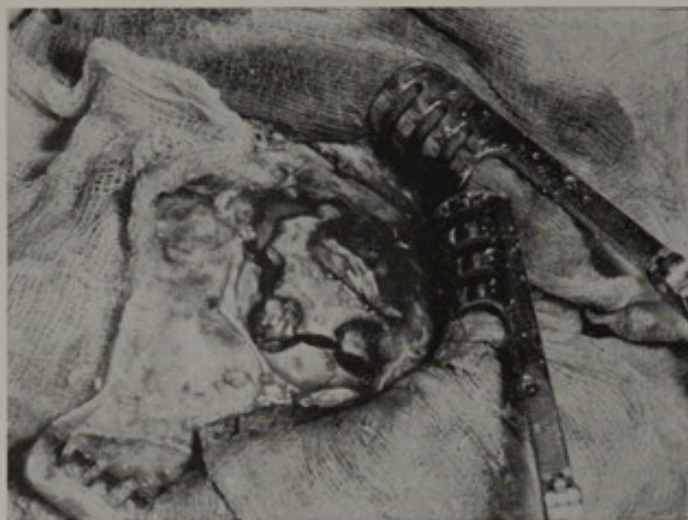

FIGURE 47.—Partial *en bloc* excision of depressed fracture adjacent to base of skull.

body was removed from the orbit. Under sodium pentothal anesthesia, a coronal flap was turned down. The site of depression and comminution included both frontal sinuses. A wide craniectomy was performed with total resection of the remaining portions of the frontal sinuses. Dura appeared contused but not lacerated. The dura was opened on both sides. Moderate sized subdural hematomas covering the entire frontal pole were evacuated from both sides. Coronal flap was closed and the lacerations of the forehead were then radically debrided and closed. Patient made an uneventful recovery and was evacuated to the neurosurgical center at Tokyo Army Hospital on 17 March 1952. On admission, he was alert and had no neurological deficit other than that caused by the loss of the right globe. He did not have any evidence of cerebrospinal fluid fistula.

K-805, a U.S. Army private, sustained a bullet wound of the right frontal region on 30 November 1950 in North Korea. He was knocked unconscious and came to when captured by Chinese communists. After escaping, he was taken to the 121st Field Hospital on 6 December 1950 when he was first seen neurosurgically. At that time he was alert, oriented, and did not show any neurological deficit. In the midfrontal region at the hairline there was a poorly debrided, but sutured, laceration. Roentgenograms showed a depressed comminuted fracture of the right frontal bone. The bullet lay directly beneath the right inner table. The site of bullet entrance was thoroughly redebrided and resutured. A coronal flap was then turned in the midfrontal area. *En bloc* resection of the comminuted depressed fracture was performed. The *en bloc* specimen showed an interosseous hematoma. There were a few, clinically insignificant, epidural clots. The dura appeared bruised, bluish-gray, extremely tight. Anterolaterally, the bullet was stuck between dura and frontal bone. It had bruised the dura; however, there was no dural tear. The bullet was removed. Epidural vessels were cauterized. The dura was then opened and the anterior pole of the right frontal lobe exposed. There was a small localized subdural hematoma which was evacuated. Postoperatively, patient fared well, was evacuated directly to the neurosurgical center at Tokyo Army Hospital 4 days later, on 10 December 1950. On admission he was alert, oriented, and cooperative. Operative wound was healed. There was no neurological deficit. Patient was evacuated to the Zone of Interior.

In a letter dated 16 April 1958 from this patient to the author, he stated that he does have seizures but not as frequently now as he did have. "I still have the headaches and dizzy spells and I have difficulty in speech * * *." He has been traveling quite extensively throughout the West Coast, was formerly employed, but is not working at present.

SURGICAL TECHNIQUE

The steps in the surgical technique of compound fractures of convexity of the skull are:

- 1-8. See steps 1 through 8 in the surgical technique of scalp lacerations, p. 76.
9. Discarding of instruments used for debridement.
10. As indicated by topography of wound:
 - a. Extension of scalp wound by a curvilinear, S-shaped or "S," incision (fig. 48).
 - b. Extension or inclusion of wound into horseshoe or coronal flap.
 - c. Closure of scalp wound and separate exposure of site of depression by flap.
11. Exposure of site of depression and radius of 4 cm. of intact bone surrounding site of fracture.
12. Resection of periosteum covering intact bone surrounding site of fracture (fig. 49).
13. *En bloc* resection of site of depression, as indicated by topography of wound.
 - a. Four or five bur holes are made into surrounding intact bone at safe distance from site of depression (fig. 50). (Consider that the inner table depression is almost invariably more extensive than the exposed outer table depression.) The bur holes are connected with each other by the use of a DeVilbiss or Montenovesi rongeur.
 - b. One bur hole is made distally to site of fracture. Starting at this bur hole, bone is rongeuired away in circular fashion, excising site of fracture with a DeVilbiss or Montenovesi rongeur (fig. 51).

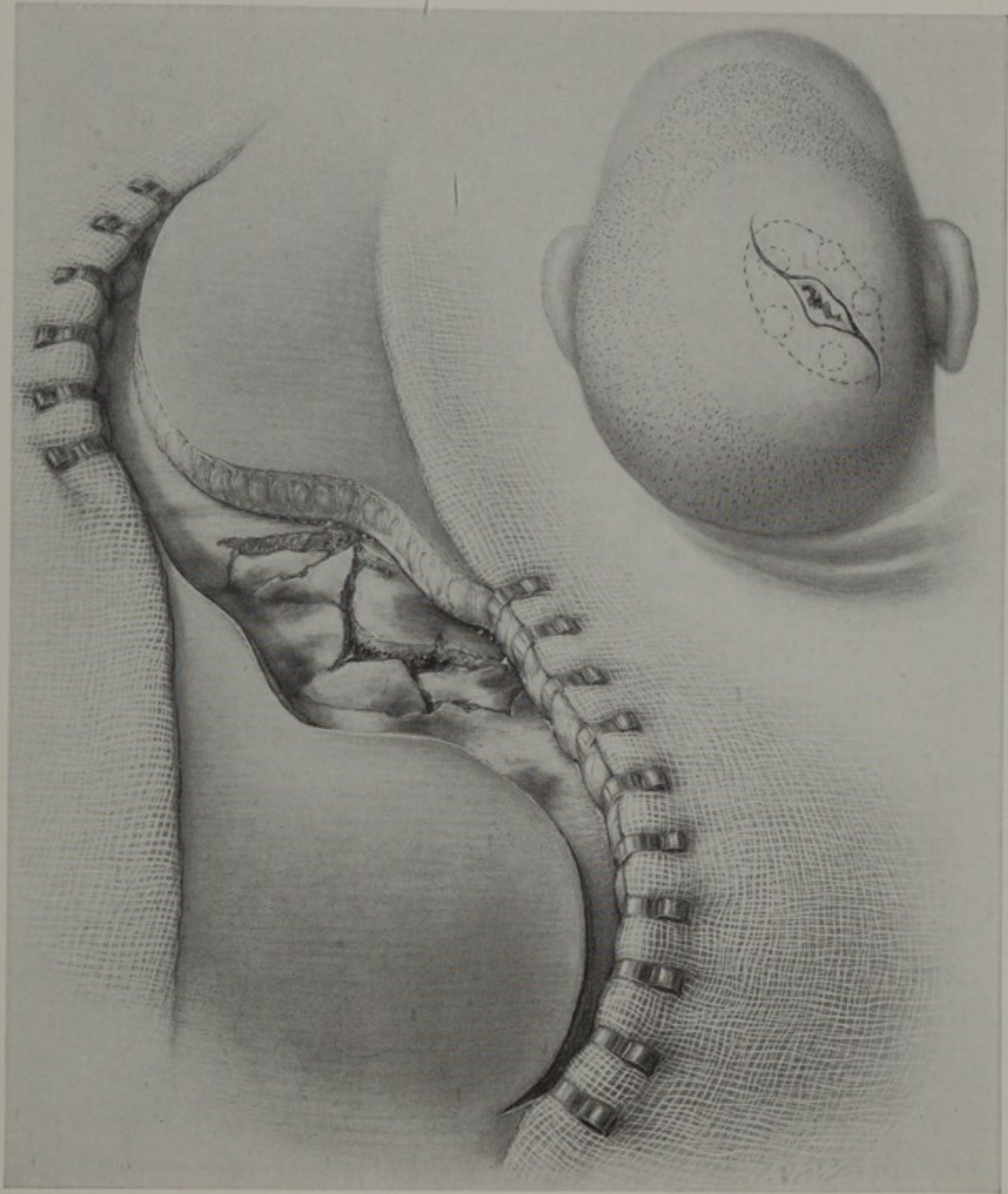


FIGURE 48.—Extension of scalp wound by a curvilinear or S-shaped incision.

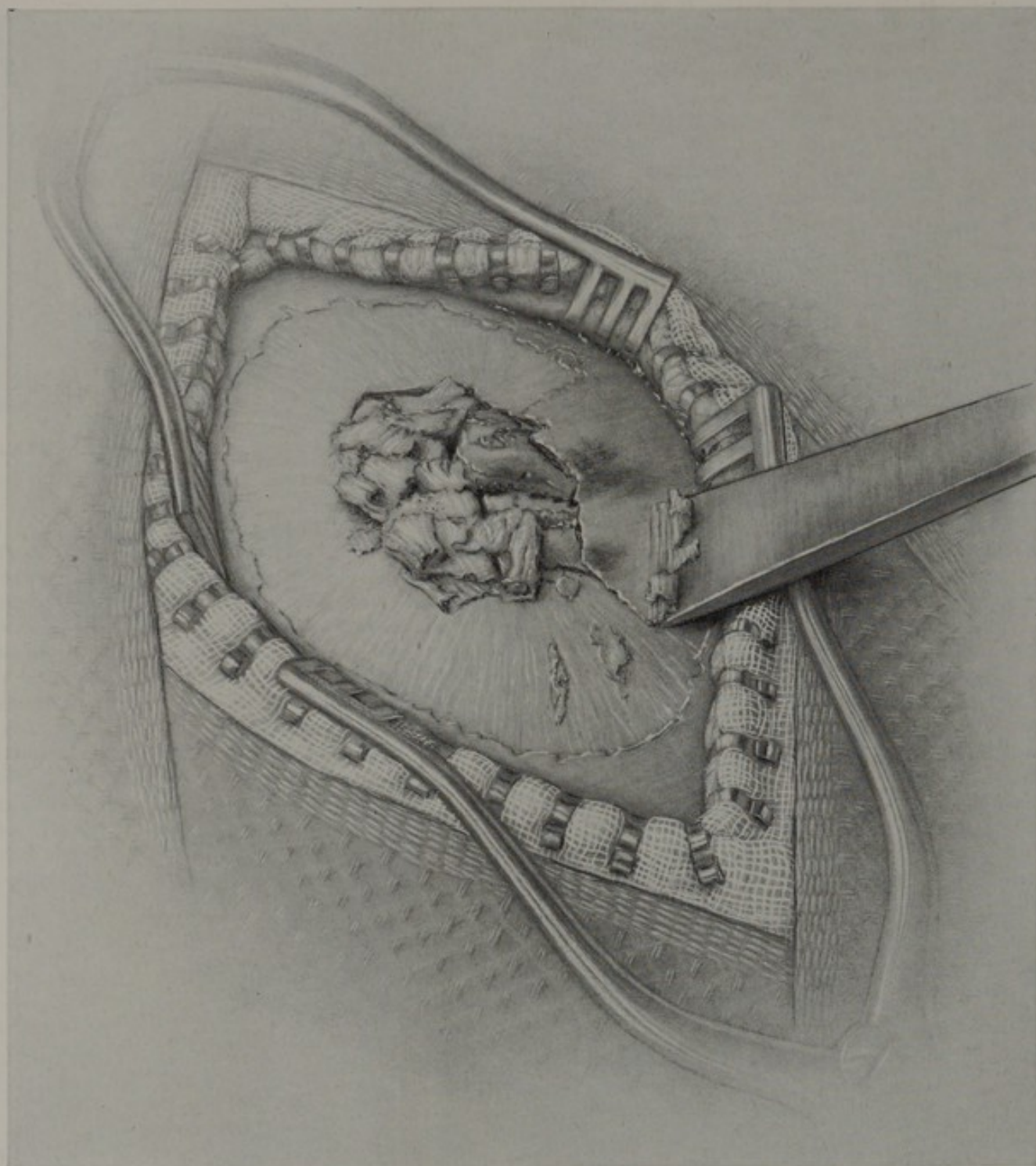


FIGURE 49.—Centripetal resection of periosteum covering intact bone surrounding site of fracture.

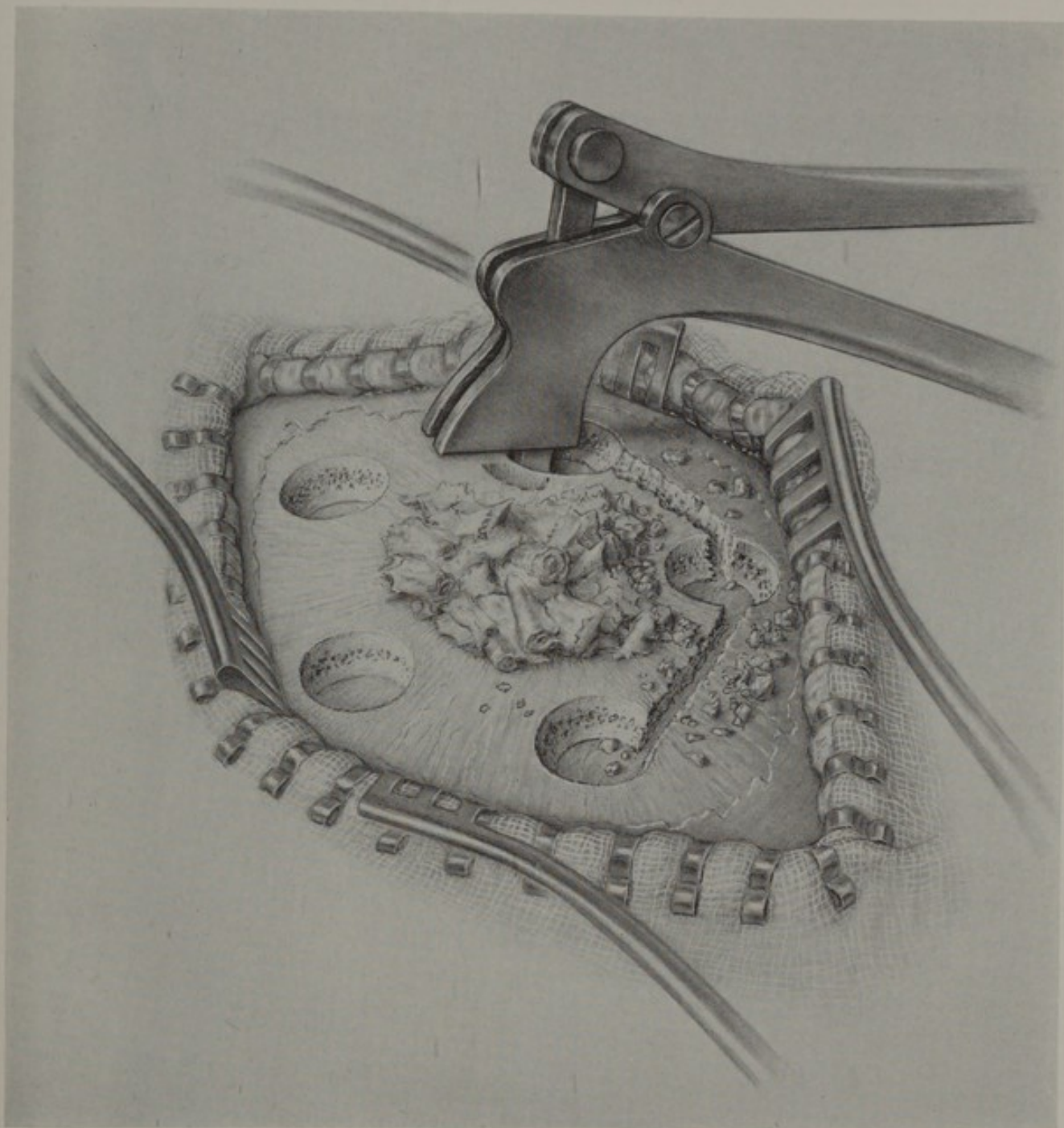


FIGURE 50.—*En bloc* resection.

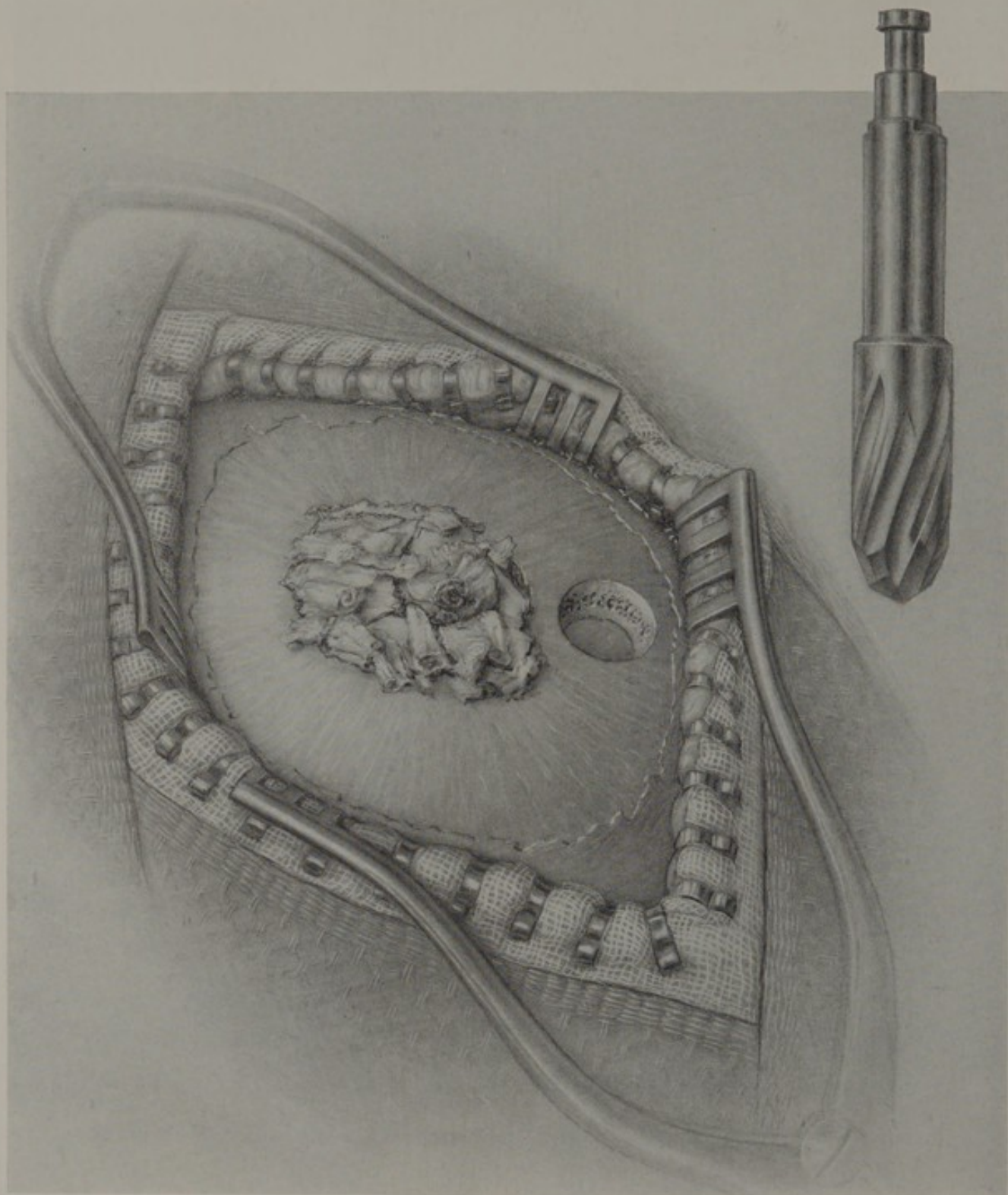


FIGURE 51.—Single bur hole distal to site of fracture.

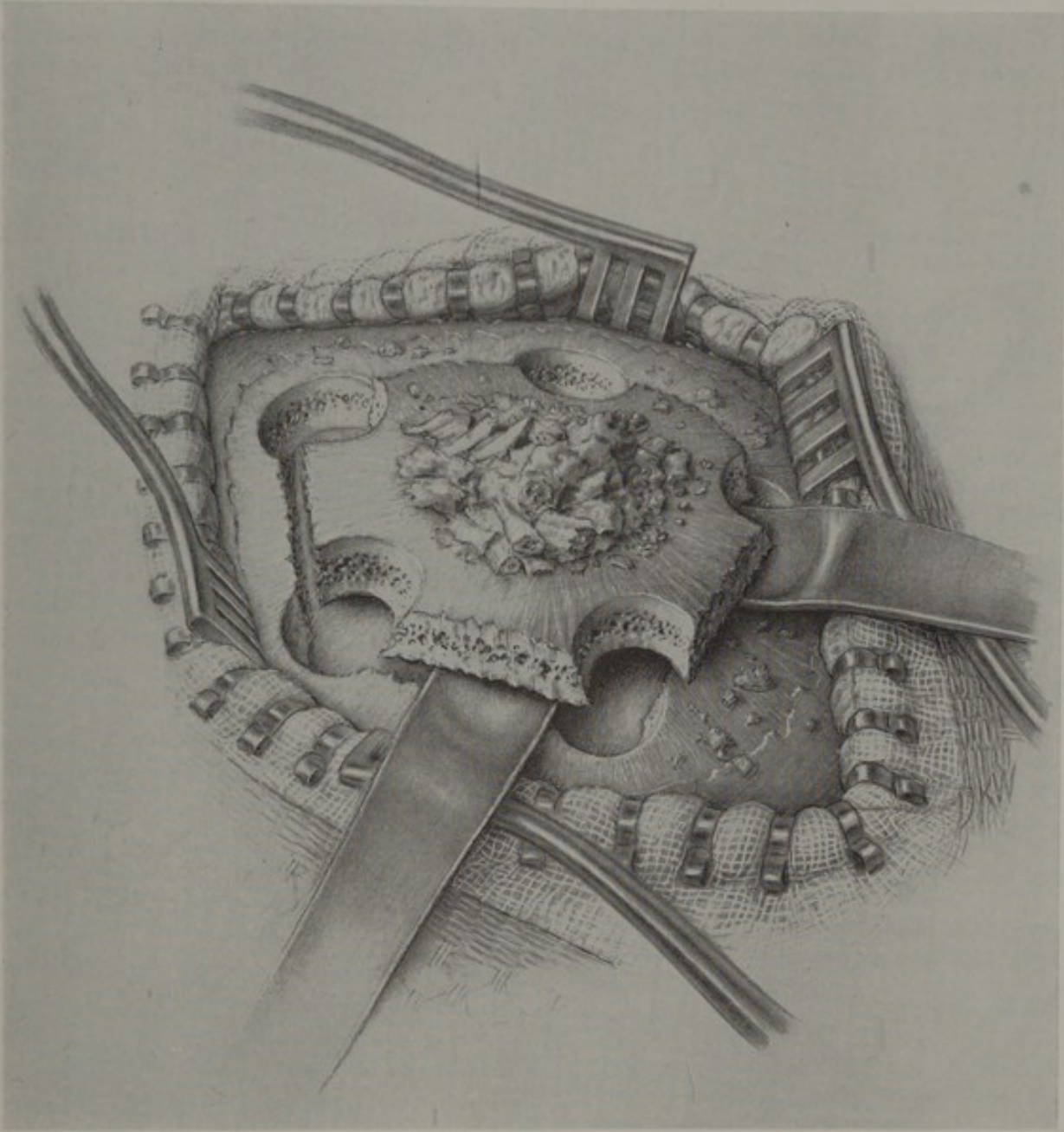


FIGURE 52.—Gradual *en bloc* lifting of entire bone plate with blunt periosteal elevators, separating depressed inner table from dura.

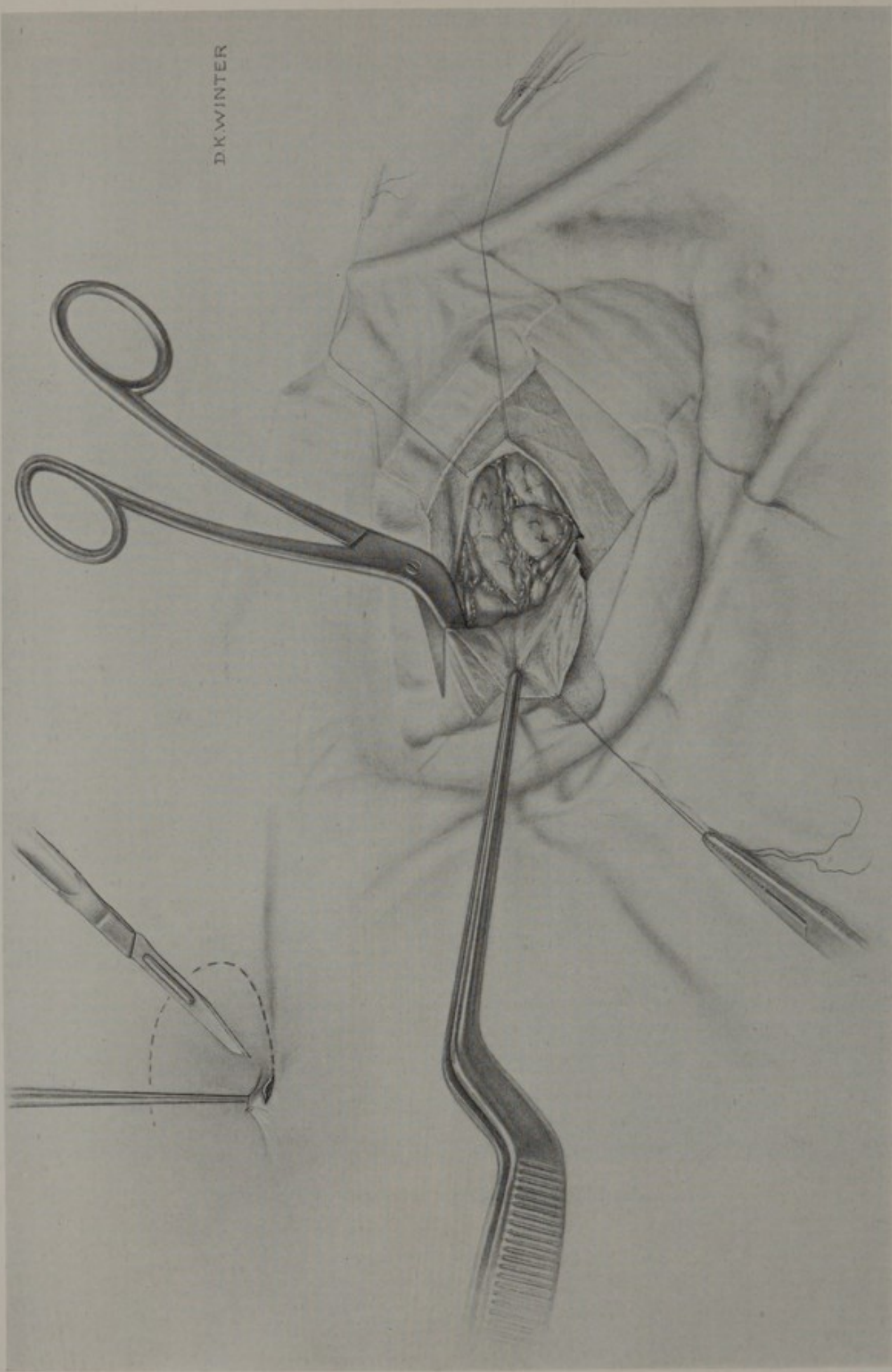


FIGURE 53.—Opening of dura.

14. Gradual *en bloc* lifting of entire bone plate with blunt periosteal elevators, separating depressed inner table from dura (fig. 52).
15. Irrigation with saline solution.
16. Hemostasis with bone wax.
17. Hemostasis of epidural vessels with coagulating current.
18. OPENING OF DURA (fig. 53).
19. Four directional search and evacuation of subdural hematoma and/or hydroma.
20. Resection by "clip-and-cut" method of liquefied, softened, or otherwise devitalized cortical and subcortical tissue.
21. Search for and evacuation of subcortical hematoma.
22. Hemostasis of cortical vessels with silver clips and Gelfoam. SPARING use of coagulating current because of possible secondary devitalization of traumatized tissue.
23. Irrigation with saline solution.
24. Watertight closure of dura.
25. Closure of scalp. See steps 11 through 13 in the surgical technique of scalp lacerations, p. 76.
26. Exploratory bur hole on side opposite fracture to rule in or out a contre-coup hematoma.

COMPOUND FRACTURES OF BASE OF SKULL

Unless complicated by intracranial hematoma or by cerebrospinal fluid fistula, these fractures require conservative management. In an effort to prevent intracranial infection, broad spectrum antibiotics are an essential part of this conservative management. The management of intracranial hematomas which may complicate a compound basilar skull fracture has been discussed in detail in chapter 6.

The management of cerebrospinal fluid fistula is discussed from all aspects in chapter 18. Those compound basilar fractures which accompany penetrating wounds of the brain are discussed in chapter 10.

REFERENCES

1. Meirowsky, A. M.: Penetrating Craniocerebral Trauma; Observations in Korean War. J.A.M.A. 154: 666-669, 20 Feb. 1954.
2. Barnett, J. C., and Meirowsky, A. M.: Intracranial Hematomas Associated With Penetrating Wounds of the Brain. J. Neurosurg. 12: 34-38, January 1955.
3. Campbell, E. H., Jr.: Compound, Comminuted Skull Fractures Produced by Missiles; Report Based Upon 106 Cases. Ann. Surg. 122: 375-397, September 1945.
4. Martin, J., and Campbell, E. H., Jr.: Early Complications Following Penetrating Wounds of the Skull. J. Neurosurg. 3: 58-73, January 1946.
5. Matson, Donald D.: The Treatment of Acute Craniocerebral Injuries Due to Missiles. American Lecture Series No. 22. American Lectures in Surgery. Springfield, Ill.: Charles C Thomas, 1948.
6. Dandy, Walter E.: Surgery of the Brain. Hagerstown, Md.: W. F. Prior Co., Inc., 1945.
7. Meirowsky, A. M., and Harsh, G. R., III: The Surgical Management of Cerebritis Complicating Penetrating Wounds of the Brain. J. Neurosurg. 10: 373-379, July 1953.
8. Gurdjian, Elisha Stevens, and Webster, John Elliott: Head Injuries, Mechanisms, Diagnosis, and Management. Boston: Little, Brown & Co., 1958.
9. Cushing, H.: A Study of a Series of Wounds Involving the Brain and Its Enveloping Structures. Brit. J. Surg. 5: 558-684, April 1918.
10. Campbell, E. H.: Recent Notes on Wounds of the Brain and Spinal Cord. In Symposium on Treatment of Trauma in the Armed Forces, 10-12 Mar. 1952, Army Medical Service Graduate School, Walter Reed Army Medical Center, Washington, D.C.
11. Dodge, P. R., and Meirowsky, A. M.: Tangential Wounds of Scalp and Skull. J. Neurosurg. 9: 472-483, September 1952.

CHAPTER 10

Penetrating Wounds of the Brain

Arnold M. Meirowsky

And very often the dura mater is torn, and sometimes the pia mater, too, and the above mentioned symptoms do not appear; on the contrary, the membranes are repaired, and the patient is cured. Wide experience gives us confidence in this regard, for we have seen many cases with both membranes broken, and some from which no small quantity of the brain tissue had issued, become completely cured. We are as certain of this as we are of death. We have seen many more, too, which had some of the above mentioned symptoms, restored to their original state of health.¹

Definition: Penetrating craniocerebral trauma with dural tear.

Neurosurgical intervention is indicated in the management of all penetrating wounds of the brain. Earliest possible definitive surgical measures must be applied for the same reasons that hold for the management of compound fractures of the convexity of the skull. Prevention of infection depends on rapid and radical resection of all devitalized and devitalizing tissue, on removal of all foreign bodies and retained comminuted bone fragments, and on primary closure by graft of the meninges. Retention of devitalized brain tissue (pulp) serves to increase intracranial pressure, produces secondary cerebral edema, and may bring about a shift of midline structures. Subdural and subcortical hematomas, frequently associated with penetrating wounds of the brain, are life endangering. These hematomas produce increased intracranial pressure, as they do in closed craniocerebral injuries. More often than not their prolonged presence results in a shift of midline structure. The early restoration of venous channels may be a lifesaving procedure and one that will lead almost always to considerable de-

gree of recovery of function.

General aspects of surgical management of penetrating wounds of the brain can readily be standardized. Such standardization, however, is necessarily limited in scope inasmuch as there are certain specific types of penetrating wounds of the brain requiring special management. Among those are transventricular wounds, through-and-through wounds, dural sinus wounds, air sinus wounds, and others. All will be dealt with in separate chapters.

Of prime importance to the surgical management of all penetrating wounds of the brain is prevention of infection and removal of expanding intracranial lesions. As proved again during the Korean War, the incidence of infection of penetrating wounds of the brain can be reduced to a virtually inconsequential figure by earliest possible definitive neurosurgical intervention. The reduction of the incidence of infection from 41 percent to less than 1 percent in the Korean War was accomplished by the organization of mobile neurosurgical teams making definitive neurosurgical intervention feasible within hours after men had been wounded. Such expanding intracranial lesions as subdural and subcortical hematomas were encountered and surgically removed at a much higher rate in these forward installations than had been done previously.

¹ Campbell, Eldridge, and Colton, James (translators): *The Surgery of Theodorica ca. A.D. 1267*. New York: Appleton-Century-Crofts, Inc., 1955, vol. I (Books I and II), pp. 108-109.

STATISTICS

Korean War (September 1950 to September 1952)

The following statistical data include neurosurgical casualties who were cared for by U.S. Army mobile neurosurgical teams and/or in the neurosurgical center at Tokyo Army Hospital. Among the latter group were casualties who had received neurosurgical care prior to admission to the center in Tokyo aboard hospital ships and, in a few instances, in other installations. The statistics include neurosurgical casualties of the U.S. Army, U.S. Navy, U.S. Marine Corps, U.S. Air Force, United Nations troops, and Republic of Korea Army. The statistics cover the period from September 1950 to September 1952. The U.S. Army's first neurosurgical team in Korea was not launched until late in February 1951. The Army's first mobile neurosurgical team functioning at division level did not go into action until October 1951. As just mentioned, the incidence of meningocerebral infection was much higher before March 1951. The incidence of intracranial hematoma associated with penetrating wounds of the brain was considerably higher after February 1951. The following figures represent overall data which do not make allowance for these facts.

There were 879 consecutive casualties with penetrating wounds of the brain on whom operation was performed. Shell fragments were responsible for penetrating wounds in 409 cases (46.53 percent), missiles in 264 cases (30.03 percent), and penetrating objects other than missiles or shell fragments were responsible for penetrating brain lesions in 206 cases (23.44 percent) (table 7).

Of these 879 casualties, 84 died (9.55 percent). Of the 409 casualties who had been wounded by shell fragments, 33 died (8.06 percent). Of the 264

TABLE 7.—*Mode of injury in 879 consecutive penetrating wounds of the brain*

Mode of injury	Number	Percent
Shell fragments	409	46.5
Missiles	264	30.0
Other	206	23.5
Total	879	100.0

TABLE 8.—*Mortality rate of 879 consecutive penetrating wounds of the brain*

Mode of injury	Number	Deaths	
		Number	Percent
Shell fragments	409	33	8.1
Missiles	264	31	11.7
Other	206	20	9.7
Total	879	84	9.6

casualties who had been wounded by a missile, 31 died (11.7 percent). Of the 206 casualties in whom penetration resulted from a cause other than missile or shell fragment, 20 died (9.7 percent) (table 8).

SURGICAL MANAGEMENT

SCALP

The surgical approach to the scalp in penetrating wounds of the brain is identical with that employed in management of compound fractures (pp. 85-89).

BONE

The surgical approach to the depressed fracture associated with the penetrating wound of the brain is identical with that used in the management of isolated compound depressed fractures (pp. 89-94).

DURA

The necessity of opening the dura underlying a compound depressed fracture has been stressed and documented in the chapter dealing with the surgical management of depressed fractures of the skull. Penetrating wounds of the brain are associated with a tear in the dura. This tear may be punctate, it may be of moderate size, but with ragged edges, or it may be an extensive laceration producing a large gap. The existing dural tear requires debridement of its edges which have been contaminated by the foreign body that has produced the brain wound and by comminuted pieces of bone that have been forced through the dural tear. Not infrequently,

minute but contaminated pieces of bone become adherent to the dura. Necrotic and grossly contaminated portions of the dura should be excised with a No. 11 Bard-Parker blade or with a pair of dural scissors. Debridement of the dural defect can be completed then by resection of a narrow edge of dura with dural scissors. Insertion of dural stay sutures will prevent spontaneous retraction of the dural edges. The dural tear should be enlarged sufficiently to afford adequate exposure of the site of penetration and of a wide area of intact cortex surrounding the site of penetration. The mode of enlargement of the dural tear depends on the topography of the wound. Enlargement of the debrided tear by an S-shaped incision in which the original tear becomes situated in the central limb of the S is almost always advantageous.

The mode of management of the dura in penetrating wounds of the brain, which is here presented as our method of choice, has not been generally accepted heretofore (1) (2). Early experiences with radical dural debridement in penetrating wounds seen in the Pacific areas during World War II have convinced me of the importance of this surgical step. Dural debridement, as here described, was policy in the management of penetrating craniocerebral trauma during the Korean War. It is the author's feeling that liberal debridement of the dura has been a contributing factor in the reduction of infection which will be discussed elsewhere.

Primary closure of the dura is carried out with interrupted sutures of No. 0000 nonabsorbable suture material. This closure must be watertight. If primary watertight closure is impossible, closure must be perfected by graft.

REPAIR OF DURAL DEFECTS BY GRAFT

Treatment of the dural defect produced by a penetrating wound of the brain has been a matter of controversy for a long time. Opinions range from unequivocal opposition to the repair of a dural defect by graft to the school of strict adherence to the principle of watertight closure of the meninges in every instance (2 through 11).

An analysis of a consecutive series of 540 penetrating wounds of the brain in which the dural defect was closed with a graft has served to clarify a surgical policy for the repair of dural defects which

cannot be closed primarily (12). These 540 penetrating wounds were incurred in the Korean War during the period from September 1950 to September 1952. Many of these grafts were inserted by mobile neurosurgical teams in forward areas at time of primary closure of the penetrating wound.

A total of 590 grafts were used in 540 cases. Of these, 489 grafts were inserted at time of primary craniectomy and 64 grafts were inserted at secondary craniectomy. In 37 instances, grafts had to be reinserted or replaced in secondary operations. Cerebrospinal fluid fistula, retained bone fragments, subdural hematoma, or seizures necessitated secondary operation.

Types of grafts.—Homografts were used exclusively as tissue grafts. Fascia lata was used 198 times, temporal or occipital fascia 186 times, and pericranium 155 times. Gelfilm was employed as a dural substitute in 19 cases and in conjunction with a tissue graft in 8 cases. The use of Gelfilm in conjunction with a tissue graft presents inviting possibilities. It seems to offer all the advantages of plastic and of tissue grafts while it minimizes the disadvantages of each substance. Gelfilm used in this manner helps to prevent adhesions between cortex and natural graft. It does not lend itself readily to adequate fixation with sutures for purpose of watertight closure. The latter can only be effected by a tissue graft which is secured with closely spaced interrupted sutures (fig. 54). In several instances, Gelfilm was employed as a temporary measure in cases necessitating two-stage surgery (13). In the second stage, a tissue graft was inserted in lieu of the plastic material.

Surgical evaluation.—It was possible to inspect surgically the condition of the graft in 144 instances. The graft was found to be viable 90 times. In addition, there were 25 viable grafts in which a defect was found: either a pinpoint opening or an opening along the suture line. The latter usually resulted from placing sutures too far apart or from sutures' pulling loose. In 20 cases the graft was not viable, as witnessed by necrosis and discoloration. The type of tissue used for the graft did not seem to influence the ultimate viability. Gelfilm was noted to be displaced in 5 instances and in place in 4 instances. Of the 563 tissue grafts, when inspected secondarily, the graft was found to be nonviable in only 20 instances (3.6 percent).

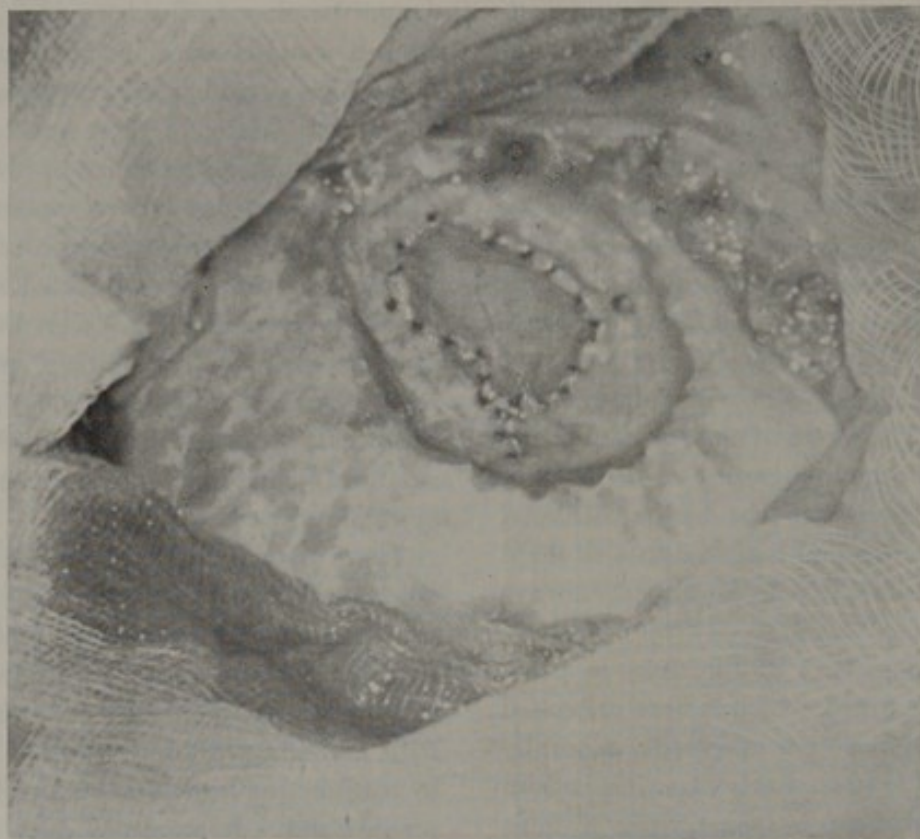

FIGURE 54.—Watertight dural closure by fascia lata graft.

The postoperative occurrence of focal seizures may indicate cortical herniation through a small dural defect produced by an incompletely closed graft. The story of K-212 illustrates this complication.

This 23-year-old private sustained a through-and-through bullet wound on 20 May 1951. The entrance wound was in the left naso-orbital angle. The exit wound was cephalad and posteriorly to the right ear. The patient was drowsy on admission, but could be aroused. The neurological deficit was limited to a seventh nerve paralysis of the lower motor neuron type. Blood pressure was 104/58; pulse was 64. Roentgenograms revealed 11 comminuted bone fragments within the right temporal lobe.

Right temporal craniotomy permitted evacuation of an extensive subdural hematoma from the middle fossa. The temporal lobe was lacerated. There was a tear in the dura underlying a defect in the temporal bone. Fourteen comminuted bone fragments were removed from the lacerated temporal lobe. Necrotic brain tissue was resected. A piece of fibrin film was inserted subdurally to cover the dural defect. It was weighted down with strips of Gelfoam. Primary closure of the scalp was performed in individual layers.

On the 3d postoperative day, the patient developed focal seizures without syncope, involving the left side of the face only. Vital signs remained stable. The patient appeared rational and well oriented. The flap did not bulge. These

seizures recurred frequently during the next 5 days. On the 5th day, the patient had a focal seizure with syncope. Because of the possibility of a subdural hematoma, secondary craniotomy was decided upon. The dural suture line was found to be intact. It was partially opened. There was no subdural hematoma. The pathology which readily explained the occurrence of focal seizures was found at the site of the dural tear corresponding to the exit wound. The Gelfilm which had been used to cover the dural defect was found extradurally. Through the dural defect a small area of soft and discolored temporal lobe cortex had herniated. The herniated cortex was in the proximity of the face area. A piece of pericranium was used as a graft to cover the area of herniation after this portion of temporal lobe was allowed to fall back in place. Routine closure was performed.

Recovery was uneventful. Seizures did not recur.

BRAIN

The surgical debridement of the brain wound proper requires adequate exposure. As already mentioned, enlargement of the dural tear is almost always necessary in order to expose the site of penetration and a wide margin of surrounding intact cortex. Retraction of debrided dural edges with stay sutures weighted down with mosquito clamps

helps to add to this exposure. Pulped liquefied brain tissue, intermingled with clots, hair, dirt, and comminuted pieces of bone may exude in sizable quantities through the dural tear. That amount of pulped tissue which presents itself may be readily removed with irrigation and suction in order to clear the operative field. It is well to remember that pulp exuding under pressure presents but a small portion of the brain tissue which has been devitalized by the impact of the missile or metallic fragment. It is also important not to overlook the fact that exuding comminuted bone fragments represent but a minimal portion of the number of comminuted pieces of bone which may have been scattered around within the confines of the wound.

Clearing the surface of the brain of pulp, debris, clots, and surface dirt makes the subdural space surgically accessible. Thorough irrigation of the subdural space will not only serve to clean it of additional debris, but may also reveal sizable subdural clots situated distal to the site of penetration. Comminuted bone fragments likewise may have found their way into the subdural space where they could produce a subdural abscess. Irrigation of the subdural space is best carried out with a No. 8 soft rubber catheter until clear fluid returns. The actual process of surgical debridement of the brain wound proper can be started only after the site of penetration and its surrounding cortex have been adequately exposed and the subdural space cleared of clots and debris. The debridement of the brain wound proper should be carried out centripetally. It must include resection of devitalized tissue, removal of all comminuted bone fragments, removal of presenting metallic foreign bodies, and evacuation of intracerebral clots.

The cortex at site of penetration requires radical debridement because of gross devitalization and contamination. Cortical resection should include the entire discolored portion of the cortex as well as a narrow surrounding margin of intact cortex. The fear of losing functioning brain tissue leads more often than not to inadequate debridement which may well result in much greater tissue loss because of subsequent infection. Minute bone fragments may be found adherent to torn and thrombosed cortical vessels. It is safest to resect these bone fragments together with that portion of the vessel to which they are attached.

The "clip-and-cut" method of cortical resection is a precise method of debridement which leaves a relatively clean scar. After selecting the cortical area to be excised, clips are placed on the corresponding cortical vessels which are divided between two silver clips by a No. 11 Bard-Parker blade. The cortex is cut with a No. 11 Bard-Parker blade so as to produce a well-defined and fresh cortical margin. The resected brain tissue is best removed by the centripetal use of a brain spatula. Occasionally, a cortical vessel may require coagulation. In that case, the vessel should be picked up with a bayonet forceps and coagulated with a low current. Use of cutting current for cortical debridement and resection is inadvisable as it results in greater tissue loss than necessary and may produce a considerable degree of local edema. Small and Turner (14) recommend subpial resection of the cortex surrounding the site of penetration, hoping thus to minimize posttraumatic epilepsy.

Whenever technically feasible, subpial resection of the cortex seems desirable. It is, however, necessary to resect discolored cortical tissue which would otherwise undergo delayed liquefaction. This can best be done by the described "clip-and-cut" method.

Resection of the cortex surrounding the site of penetration should be followed by saline irrigation of the newly created surface and of the exposed track. In the past, surgeons have warned against forceful saline irrigation of a track for fear that contaminated material may be disseminated into uninvolved tissue (2) (15), while others seem to feel that careful washing of the walls and floor of the wound track under direct vision is a safe and useful procedure (9). We have employed routinely forceful saline irrigations between each step of debridement of a penetrating brain wound, considering it an important and irreplaceable part of the entire process of debridement. Contaminated material may, of course, be disseminated into softened brain tissue which has already gone through the process of devitalization. That tissue must be resected. To disseminate contaminated material by saline irrigation into firm intact brain tissue does not seem a likely possibility. Having employed saline irrigations routinely in the surgical management of penetrating brain wounds, we have been impressed by the fact that these irrigations often will serve to "force out" of the track residual pulp, debris, and loose

comminuted bone fragments.

Inspection of the missile track can best be carried out with a headlamp or with a Frazier lighted retractor. Retained bone fragments may denote themselves by a closing track. The same applies to a subcortical hematoma which may be situated adjacent to the track (14). Removal of such a hematoma readily results in relaxation of the wall of the missile track revealing its true size. It is of the utmost importance to observe a missile track after completion of debridement for at least a few minutes in order not to miss a closing missile track. The author has found this ingenious observation by Small and Turner to be applicable in every instance of retention of a subcortical hematoma adjacent to the missile track.

In the past, warnings have been issued frequently against digital inspection of a missile track (1). It is essential that the walls of each missile track be carefully palpated for retained bone fragments. The high incidence of infection occurring around retained bone fragments, which has been encountered and described by many observers, was again experienced in the early phase of the Korean War (4) (9) (10) (14) (16) (17) (18).

A retained bone fragment which has been discovered within the wall of the missile track by a palpating finger can best be removed under direct vision with a bayonet forceps. If this fragment should be attached to a vessel, the latter should be coagulated or its distal end resected with the sliver of bone attached and secured with a silver clip. A careful check of preoperative roentgenograms almost always reveals all scattered bone fragments.

Matson (9) has pointed out that no attempt need be made to do block excisions of a wound track by electrosurgical dissection. We also did not find that necessary. Radical debridement of the missile track, as has been described, should suffice to eliminate retention of pulp or hematoma and to remove all retained bone fragments. Whenever postoperative roentgenograms reveal a residual bone fragment, secondary craniotomy should be carried out for purpose of removal of that fragment even though the patient may be doing well clinically. We are convinced that rigid adherence to that policy has played a considerable part in the reduction of meningo-cerebral infection in Korean casualties from 41 per-

cent initially to less than 1 percent ultimately. Lewin and Gibson (19) in a survey of British casualties in the Korean War comment on the incidence of re-exploration (10 of 51 casualties) and conclude that this rigorous policy was justified by the fact that not one brain abscess was encountered among the British troops.

While the removal of each and every indriven comminuted bone fragment is mandatory (20), a somewhat more liberal attitude has been adopted in general with regard to indriven metallic fragments. The consensus once was that the heat of the missile rendered it sterile and that contaminated material carried in adherent to the foreign body itself also might be sterilized by the heat of the missile (9). Often metallic fragments penetrate deeper than any other material, allowing the missile track to seal behind them. The surgeon is justified in leaving the metallic fragment in place if it is inaccessible and cannot be removed without danger of damage to seemingly intact brain. Whenever accessible, however, metallic fragments should be removed, be they large or small. Metallic fragments should be considered accessible when they are within the operative field. They should also be considered accessible when they are situated close to the surface even though they may be outside the operative exposure. This applies particularly to missiles or metallic fragments lodging subcortically opposite the site of entrance. Their removal by separate craniotomy is necessary particularly in view of the frequent occurrence of subdural hematomas overlying such a missile (21). Bullets should be removed always inasmuch as they are large, have a tendency to wander, and to cause considerable damage (22). The same applies to large metallic fragments.

What has been said so far about metallic fragments essentially represents the policy followed during the Korean War. A close review of case reports from that War and followup studies, however, suggest that it may well be advisable in the future to make an all-out effort to remove all metallic fragments wherever they may be unless their removal would endanger the patient. More often than not these fragments carry other foreign material with them and are a potential source of infection for years to come. There is certainly evidence that the old tenet of absolute sterility of a metallic fragment does not

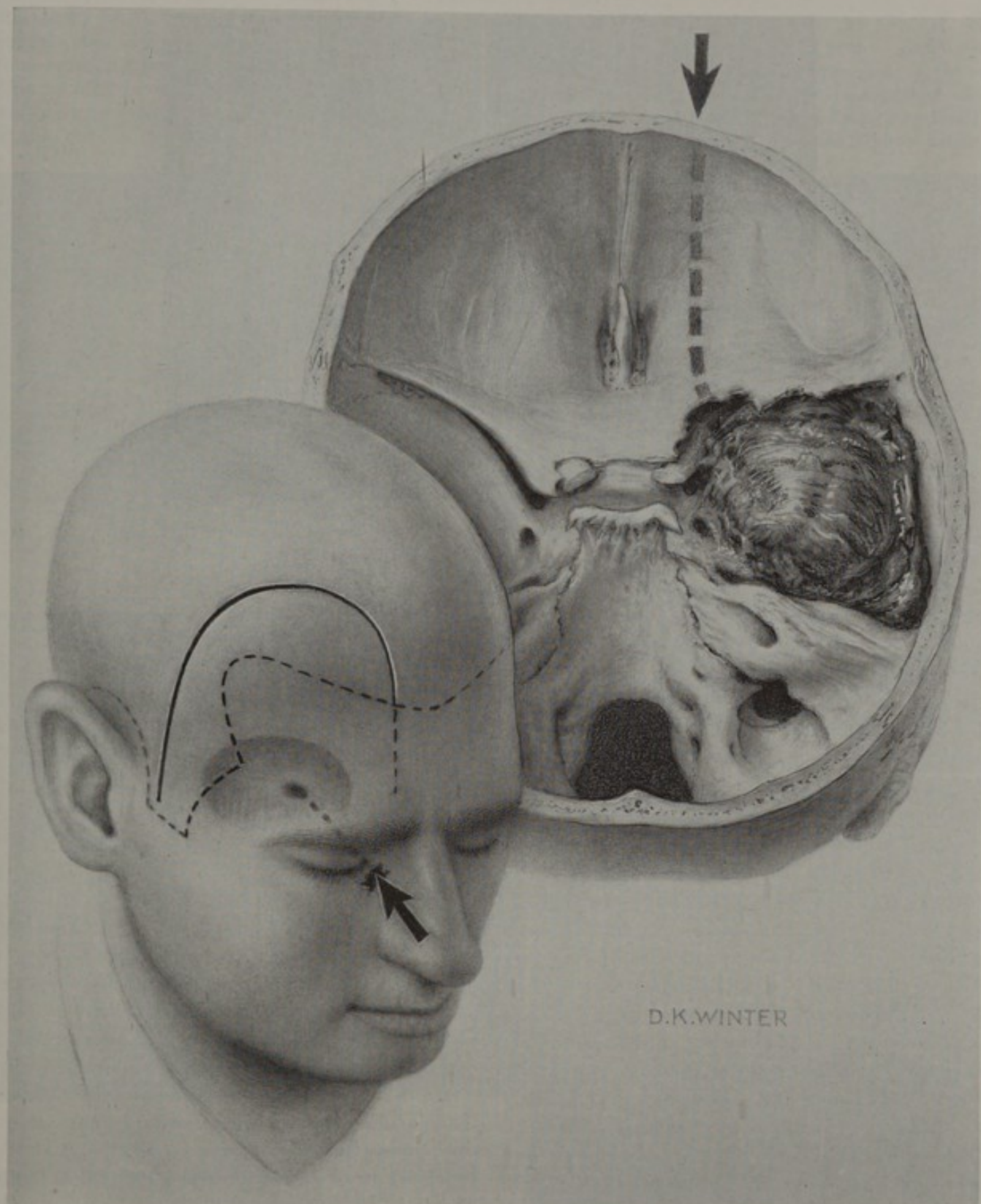


FIGURE 55.—Penetrating wound of middle fossa with site of entrance wound infra-orbitally.

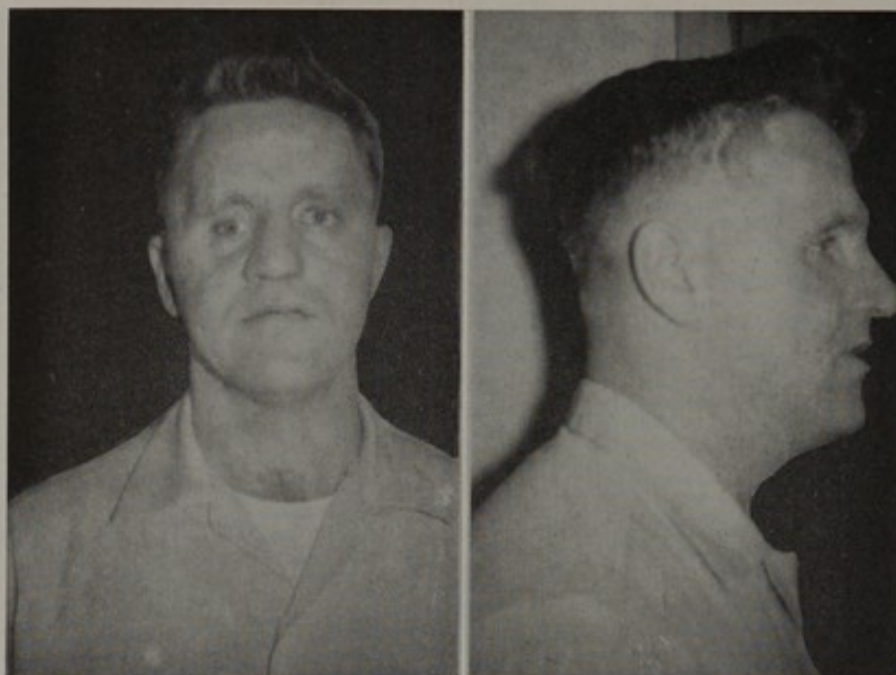


FIGURE 56.—Frontal and lateral views of K-211, 8 years and 4 months after facio-orbito-temporal missile wound.

hold. For that reason and because of the irritative phenomena which metallic fragments may cause, they should be removed whenever feasible.²

Application of the "clip-and-cut" method of resection will serve to prevent secondary hemorrhage from the debrided cortex as well as from the debrided subcortical area. There may be at times an oozing surface at the depth of the missile track after the latter has been thoroughly debrided. Such an oozing surface is best controlled by application of Gelfoam strips which can be safely left in place.

Wounds involving dural sinuses, air sinuses, and other special structures require niceties of surgical judgment and surgical technique that are worthy of detailed discussion. Special chapters are devoted to these wounds. To this discussion of the surgical technique of penetrating brain wounds in general, we should only like to add some comments on those faciocranial wounds which bypass the air sinuses, but enter the cranial cavity through the floor of the anterior or middle fossa. Calvert (23) has described in some detail pertinent aspects of these types of brain wounds, subdividing them into facio-orbito-

frontal and facio-orbito-temporal gunshot wounds. In contradistinction to the penetrating wounds of the vault, facio-orbito-frontal and facio-orbito-temporal wounds require craniotomy rather than craniectomy. Almost invariably these wounds result in destruction of the eye, not infrequently necessitating its enucleation. Because of the outward obscurity of the concomitant cerebral damage, facio-orbitocranial wounds may not always come to the attention of the neurological surgeon immediately, and yet, they are particularly prone to infection. They are also characterized by a high incidence of associated subdural and intracerebral blood clot formation. In order to ward off a fatal outcome due to compression of midbrain and brain stem by hematoma and to prevent infection, these wounds require a high neurosurgical priority. Craniotomy should be performed in every instance of a facio-orbito-frontal or facio-orbito-temporal wound within hours after its incurrence (fig. 55).

The story of K-211 illustrates the typical findings that may be encountered in a facio-orbito-temporal missile wound:

This 21-year-old U.S. Army sergeant, first class, was wounded in action on 1 September 1951, sustaining a missile wound of the head. A metallic foreign body had entered the skull at the left nasolabial fold, passed through the left nostril fracturing the inferior turbinate, passed through the middle turbinate, the right maxillary sinus and the right

² This has been borne out by recent studies carried out at Lackland Air Force Base, Tex. (Robertson, James T., Maj., MC, USAF: Tissue Toxicity in Certain Metallic Wounds of the Nervous System. Presented at the 16th Annual Meeting of the Southern Neurosurgical Society, St. Louis, Mo., 20-22 Feb. 1964.)

orbit, entering the right middle fossa of the cranial cavity through the outer wing of the right sphenoid. He was drowsy and disoriented, and answered questions incoherently. Vision was lost in the right eye. There was no other cranial nerve deficit. Reflexes were equally active throughout. There was a Babinski response on the left. The ophthalmological con-

sultant advised against enucleation of the eye. Right frontal craniotomy was decided upon. Right Dandy "concealed" flap. Osteoplastic bone flap. Tight dura with many distended epidural veins. Decompression effected by aspiration of fluid from right lateral ventricle. Dural flap turned with base to midline. Localized subdural hematoma.

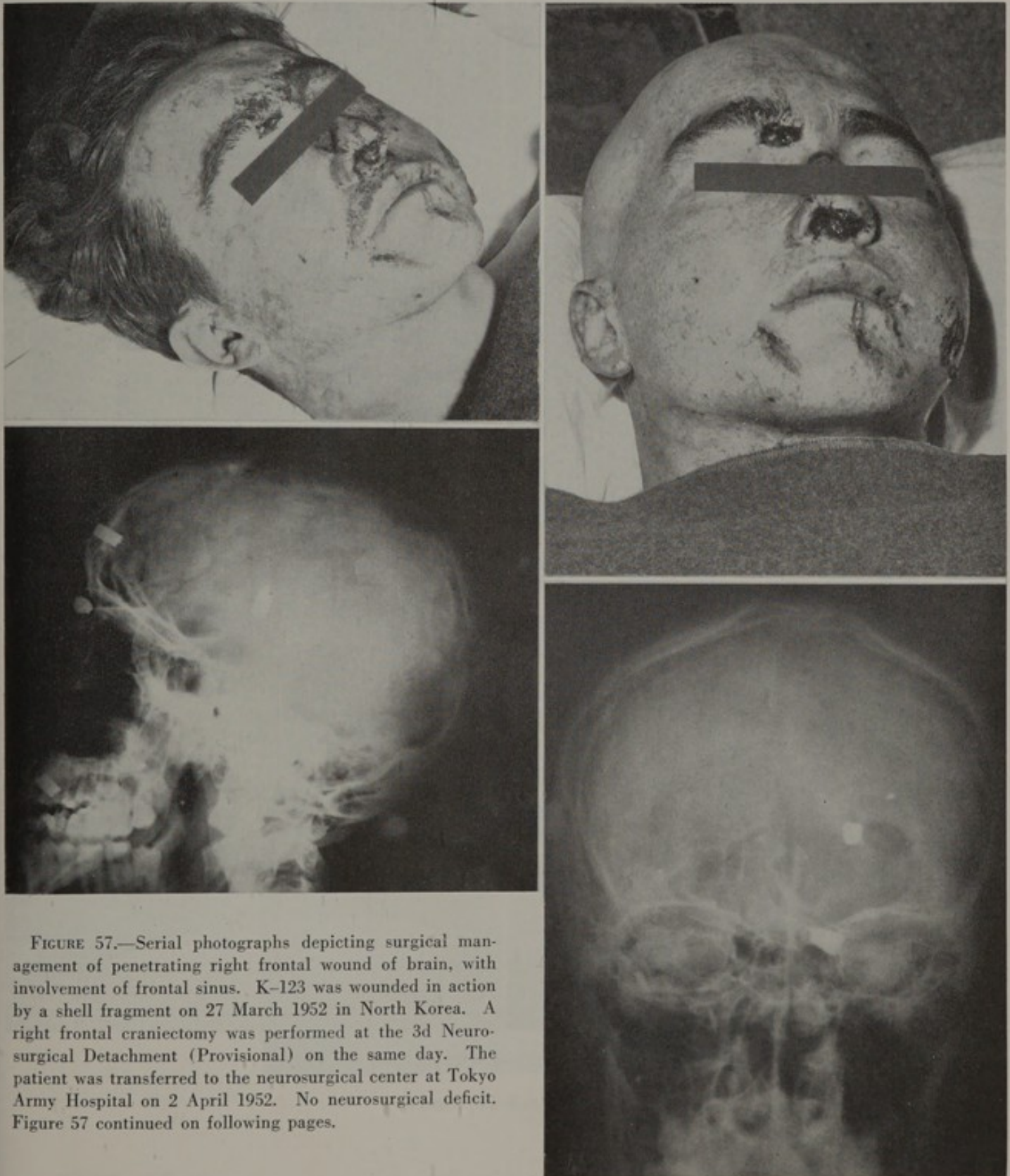


FIGURE 57.—Serial photographs depicting surgical management of penetrating right frontal wound of brain, with involvement of frontal sinus. K-123 was wounded in action by a shell fragment on 27 March 1952 in North Korea. A right frontal craniectomy was performed at the 3d Neurosurgical Detachment (Provisional) on the same day. The patient was transferred to the neurosurgical center at Tokyo Army Hospital on 2 April 1952. No neurosurgical deficit. Figure 57 continued on following pages.

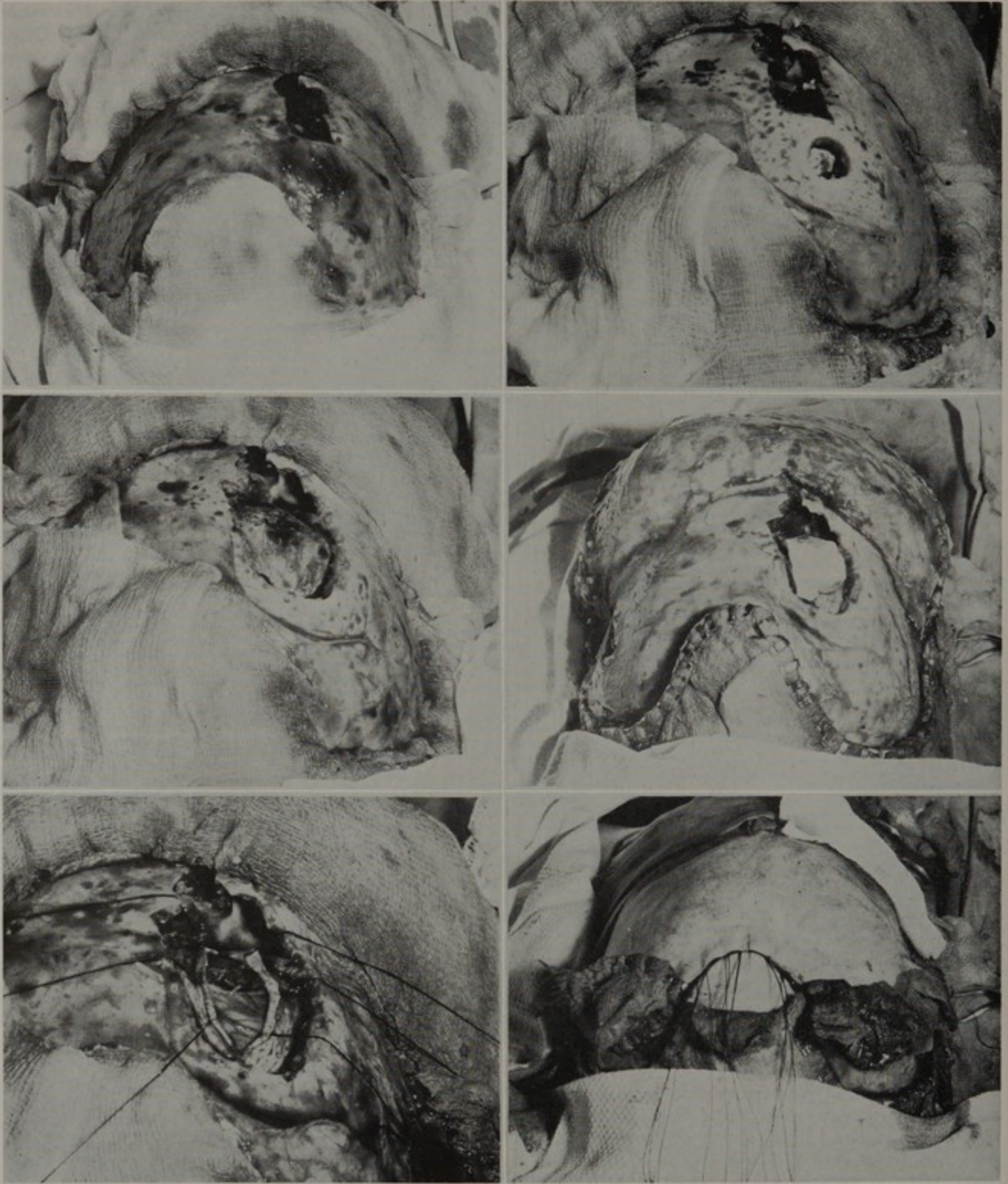


FIGURE 57.—Continued.

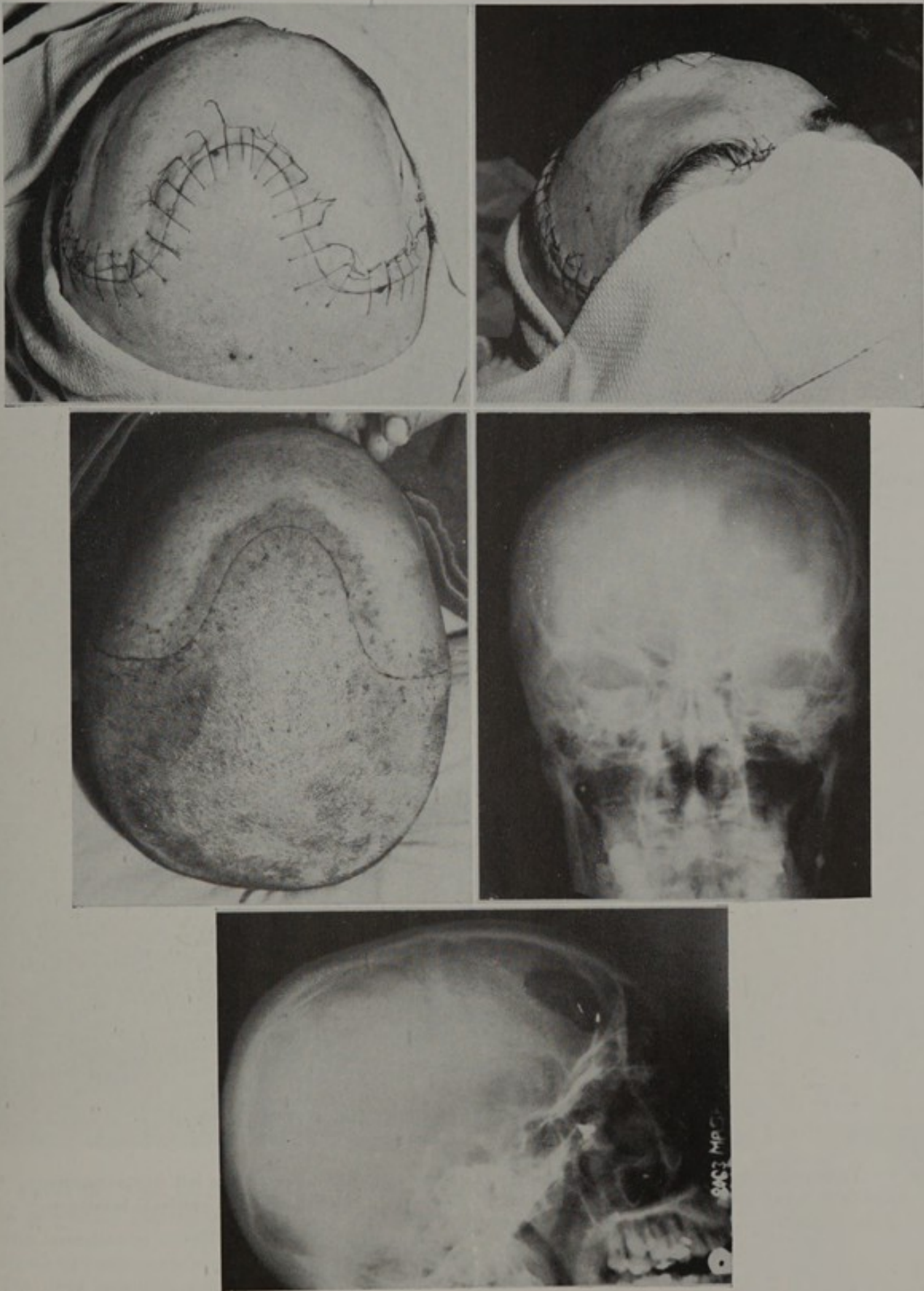


FIGURE 57.—Continued.

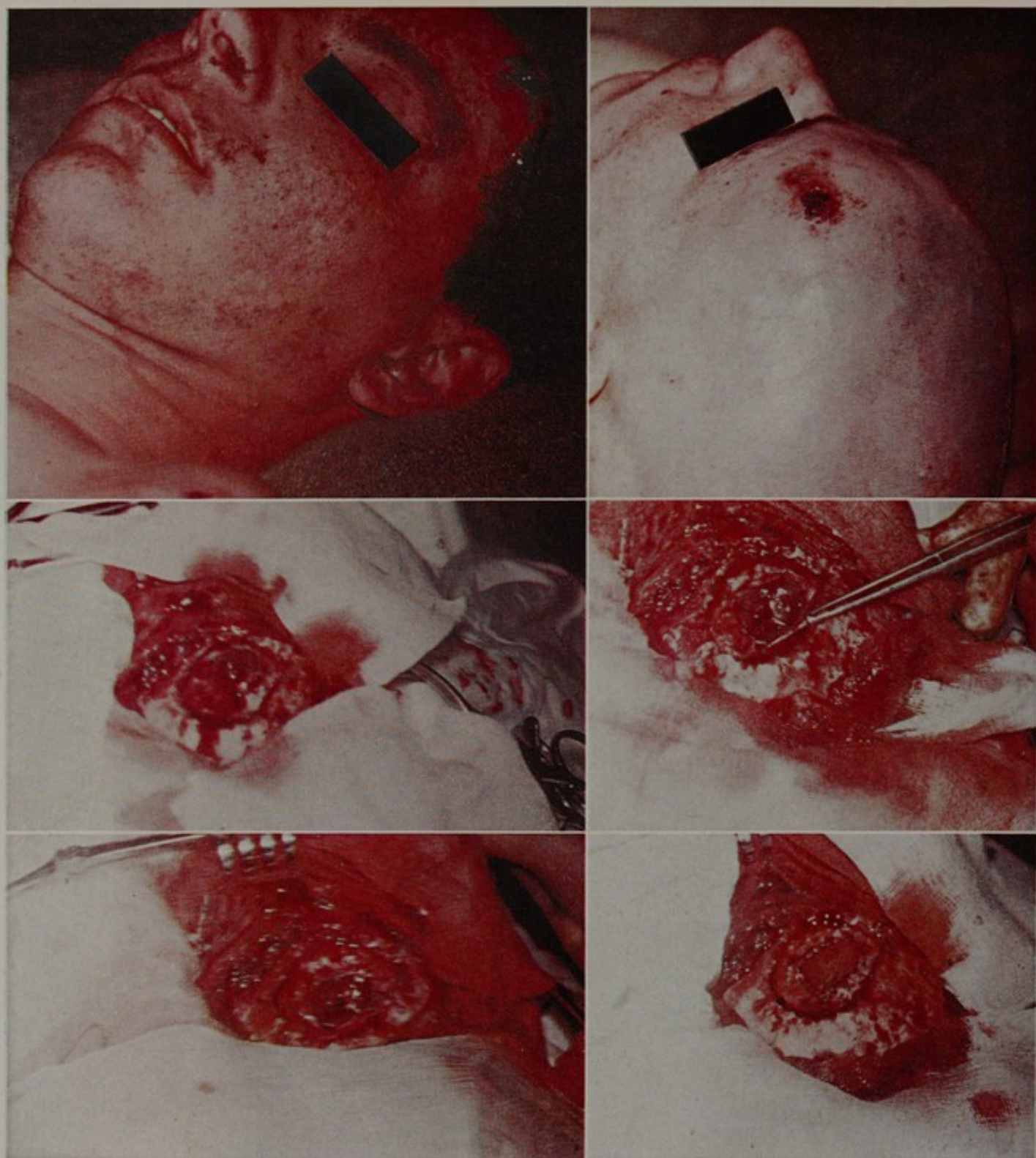


FIGURE 58.—Serial photographs depicting surgical management of penetrating left fronto-temporo-parieto-occipital transventricular wound of brain. There was a subcortical and a subdural hematoma. A left frontotemporal craniectomy was performed on K-413 on 6 May 1952.

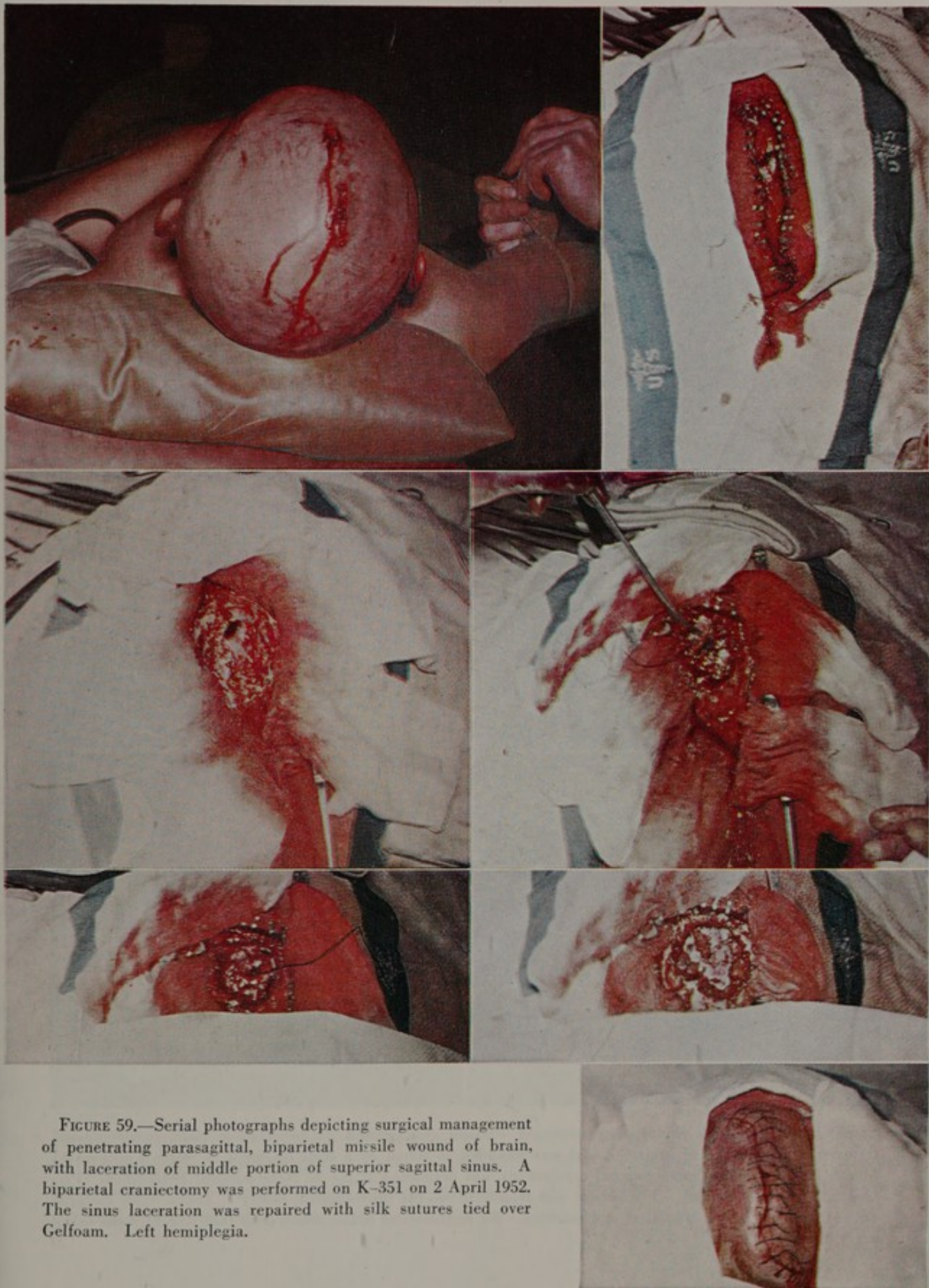


FIGURE 59.—Serial photographs depicting surgical management of penetrating parasagittal, biparietal missile wound of brain, with laceration of middle portion of superior sagittal sinus. A biparietal craniectomy was performed on K-351 on 2 April 1952. The sinus laceration was repaired with silk sutures tied over Gelfoam. Left hemiplegia.

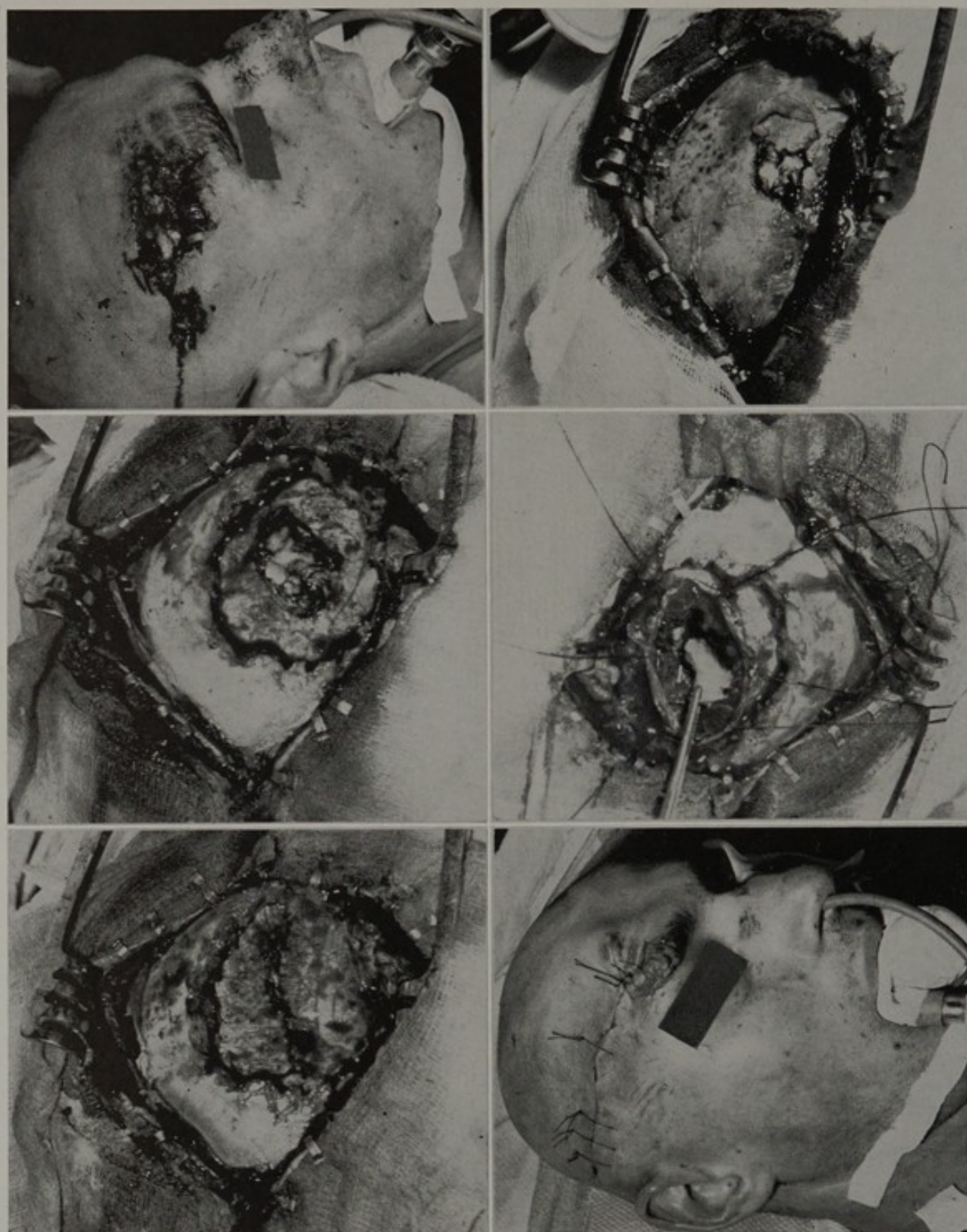


FIGURE 60.—Serial photographs depicting surgical management of penetrating right frontotemporal transventricular wound of brain. K-234 was wounded in action by a shell fragment in North Korea on 31 March 1952. A right frontotemporal craniectomy was performed at the 3d Neurosurgical Detachment (Provisional) on the same day. The patient was transferred to the neurosurgical center at Tokyo Army Hospital on 10 April 1952. He was alert and oriented. No neurological deficit other than that due to right radial nerve injury.

Undersurface of posterior aspect of right frontal lobe macerated, liquefied, and intermingled with intracerebral clots. Resection of devitalized portion of frontal lobe and evacuation of clots produced excellent exposure of sphenoid wing and base of middle fossa. Entrance wound identified in outer wing of sphenoid. Large hematoma at base of middle fossa evacuated. Liquefied and macerated portion of antero-temporal lobe resected. Four pieces of comminuted bone removed from middle fossa. Dural closure with temporal fascia. Primary closure of osteoplastic and skin flap.

Patient made an uneventful recovery and returned to his prewar job as a zinc plater after discharge from active duty.

In one of his rare letters to this author, dated 30 November 1959, K-211 wrote: "I would rather face the North Koreans again than to sit down and write a letter. Like hell I would!" He said that he didn't have headaches unless he became unduly hungry. He never has seizures or falling out spells. Vision is 20/20 in the left eye (the right eye is totally blind). Sense of smell is impaired slightly but otherwise he is in good health. He is married and has two children (fig. 56).

The following serial pictures (figs. 57, 58, 59, and 60) depict surgical management of penetrating wounds of the brain of Korean War casualties.

SURGICAL TECHNIQUE

The steps in the surgical technique of penetrating wounds of the brain are:

- 1-8. See steps 1 through 8 in the surgical technique of scalp lacerations, p. 76.
- 9-17. See steps 9 through 17 in the surgical technique of compound fractures of convexity of the skull, p. 94-101.
18. Debridement of dural tear: Excision of necrotic and grossly contaminated dural edges (fig. 61). Resection of comminuted bone adherent to dura. Resection of narrow dural edge (fig. 62).
19. Enlargement of debrided tear (fig. 63).
20. Retraction of dural edges with stay sutures.
21. Removal of exuded brain pulp by irrigation and suction.
22. Inspection and irrigation of subdural space.
23. Centripetal cortical debridement by "clip-and-cut" method: Resection of entire discolored portion of cortex and of narrow surrounding margin of intact cortex (figs. 64 and 65).
24. Saline irrigation of newly created brain surface and of exposed track (fig. 66).
25. Inspection of track with headlamp and/or Frazier lighted retractor (figs. 67 and 69).
26. Removal of clots from track (fig. 68).
27. REMOVAL OF ALL BONE FRAGMENTS (figs. 68, 69, and 70).
28. Removal of metallic fragments whenever feasible.
29. Hemostasis of subcortical vessels by coagulation or application of silver clips.
30. Observation for "closing track" denoting residual subcortical hematoma.
31. Saline irrigation of track (fig. 71).
32. Control of oozing surface at bottom of track by application of Gelfoam strips.
33. Primary watertight closure of dura or—
34. Watertight closure of dura by graft:
 - a. Fascia lata.—Horseshoe flap, lateral aspect of thigh. Excision of fascia lata with scalpel (fig. 72, inset). Primary closure of skin flap on thigh in two layers. Insertion of fascia lata into dural defect with CLOSELY spaced interrupted sutures of No. 0000 non-absorbable suture material (fig. 72). It is inconsequential which side of the graft faces the cortex.
 - b. Temporal, occipital fascia.—Suitable for medium and small defects. Must be obtained from exposed areas that are not contaminated. Insertion in similar fashion as fascia lata.
 - c. Pericranium.—Suitable for small defects. Must be obtained from exposed area that is not contaminated. Insertion in similar fashion as fascia lata.
 - d. Gelfilm.—Should be used only in conjunction with tissue graft. Subdural insertion of Gelfilm and fixation to dura with a couple of sutures. Watertight closure by superimposed tissue graft.
35. Closure of scalp. (See steps 11 through 13 in the surgical technique of scalp lacerations, p. 76.)

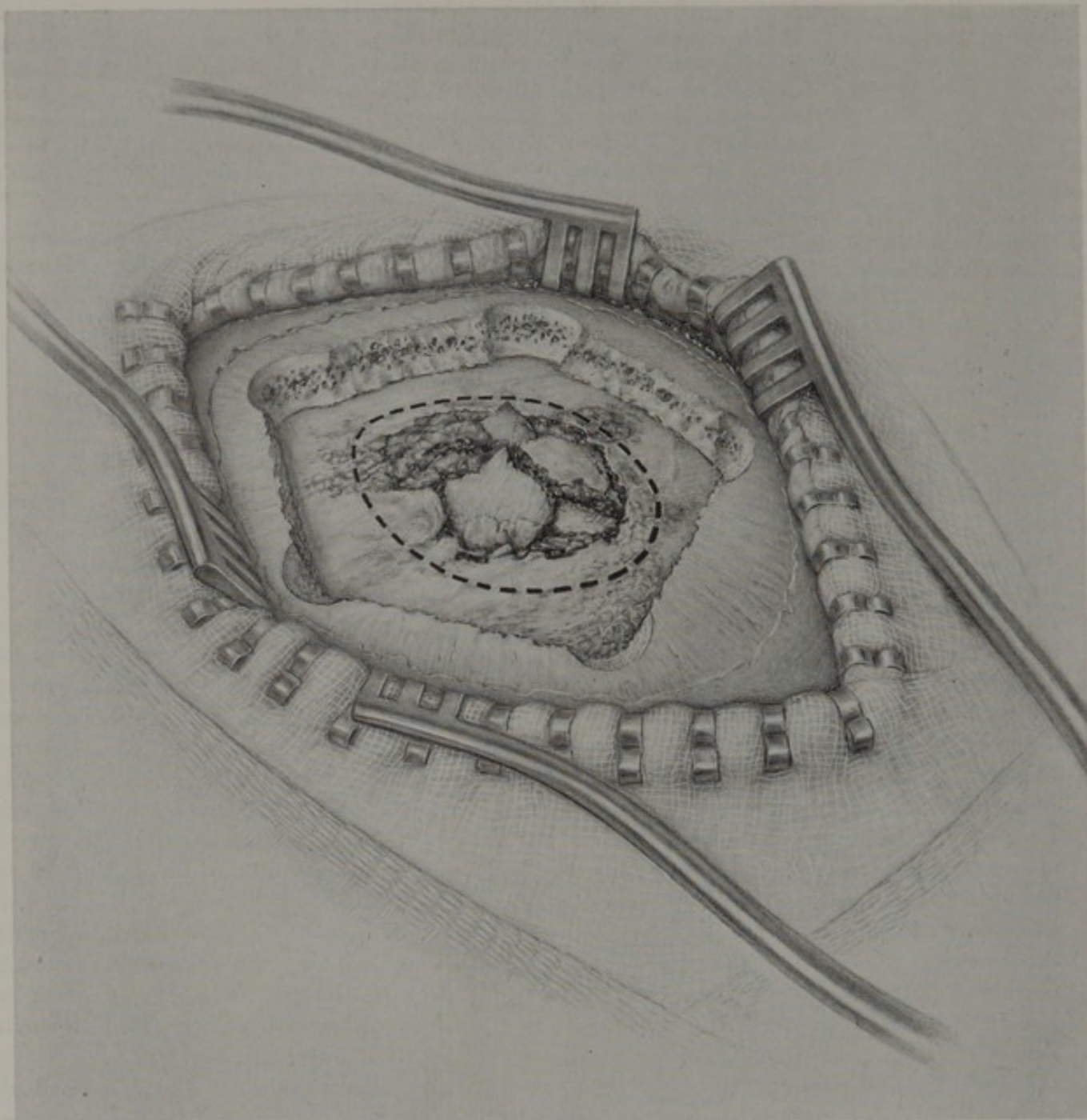


FIGURE 61.—Penetrating wound of brain after *en bloc* resection.

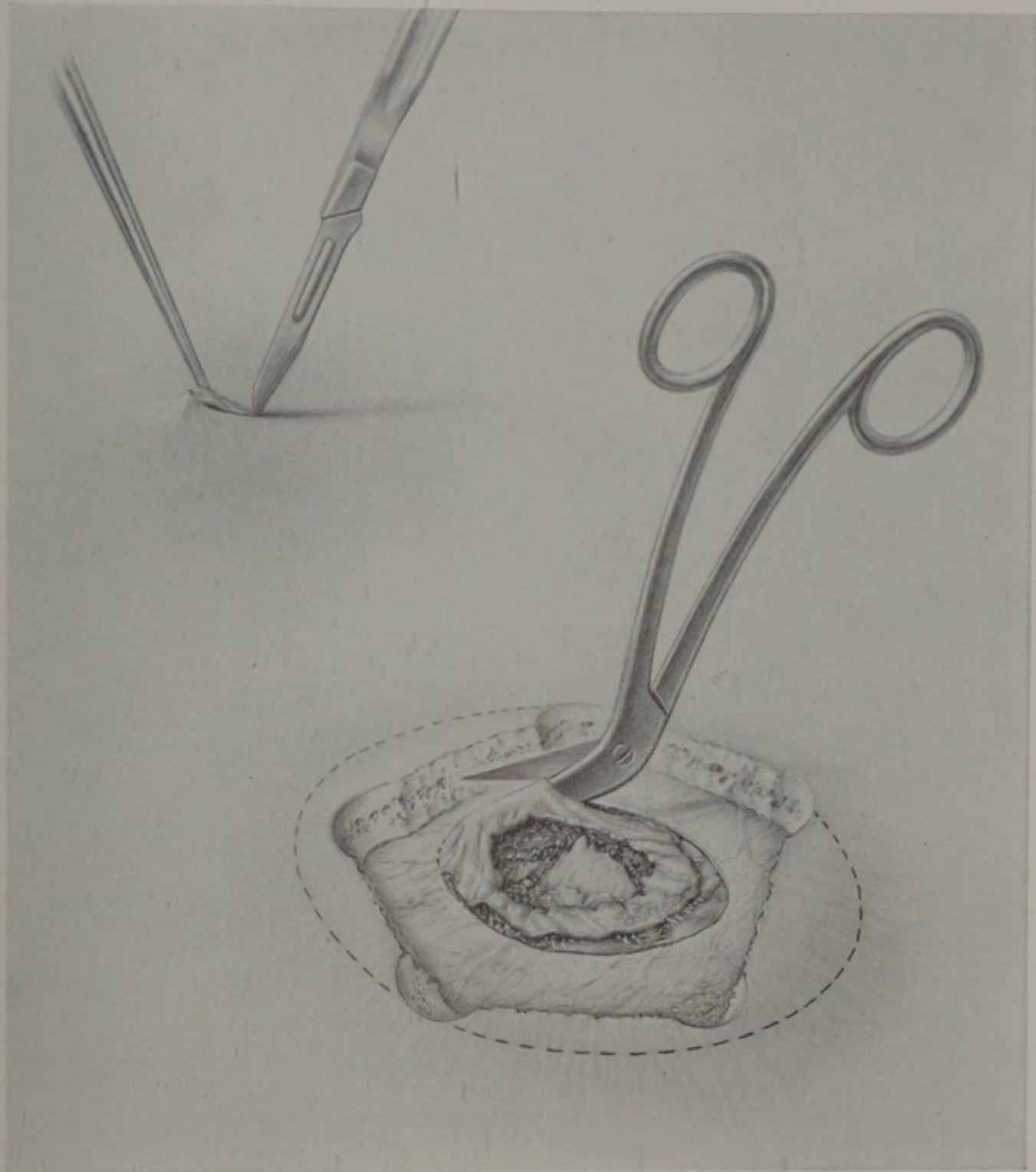


FIGURE 62.—Debridement of dura.

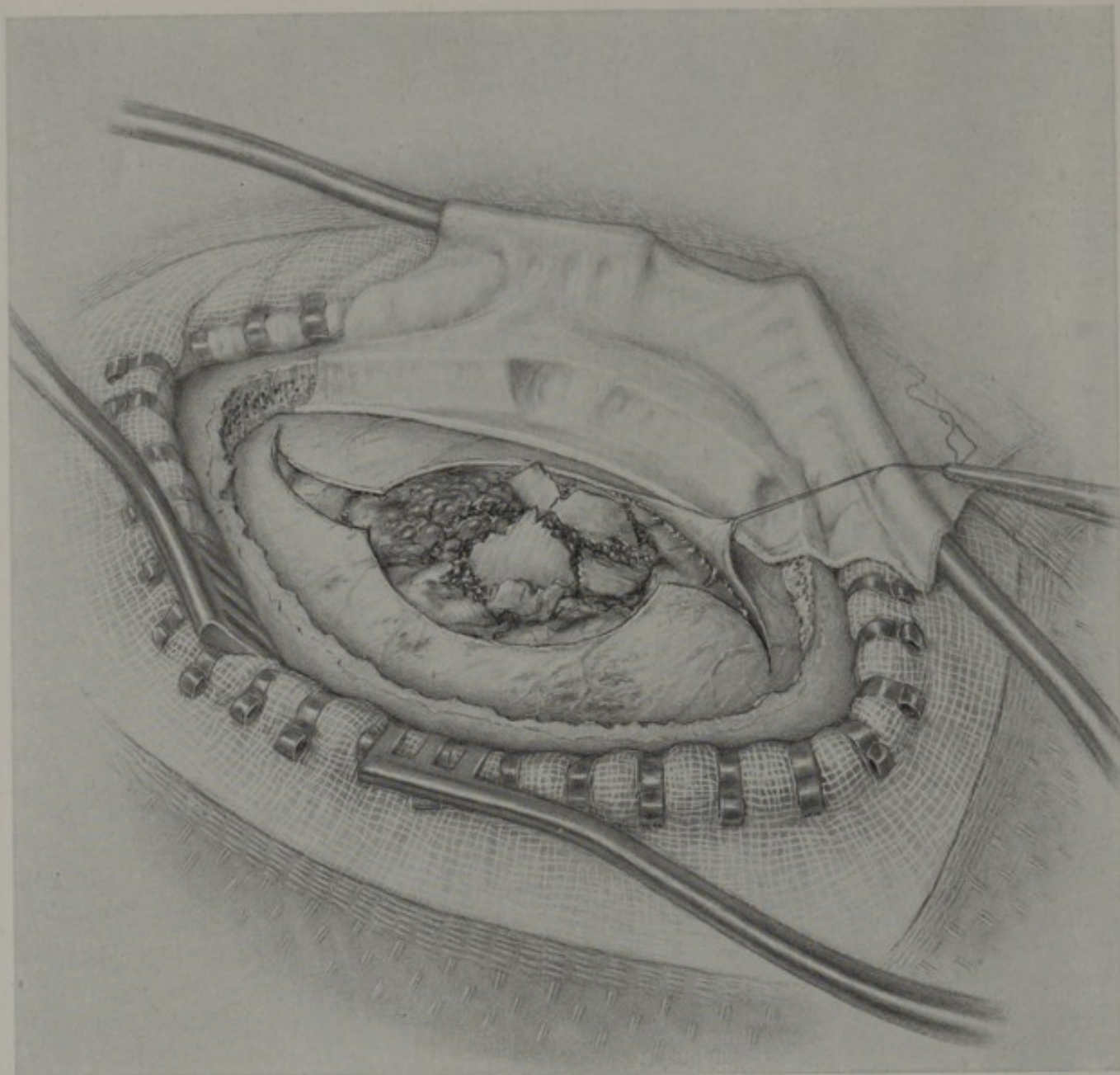


FIGURE 63.—Enlargement of debrided tear.

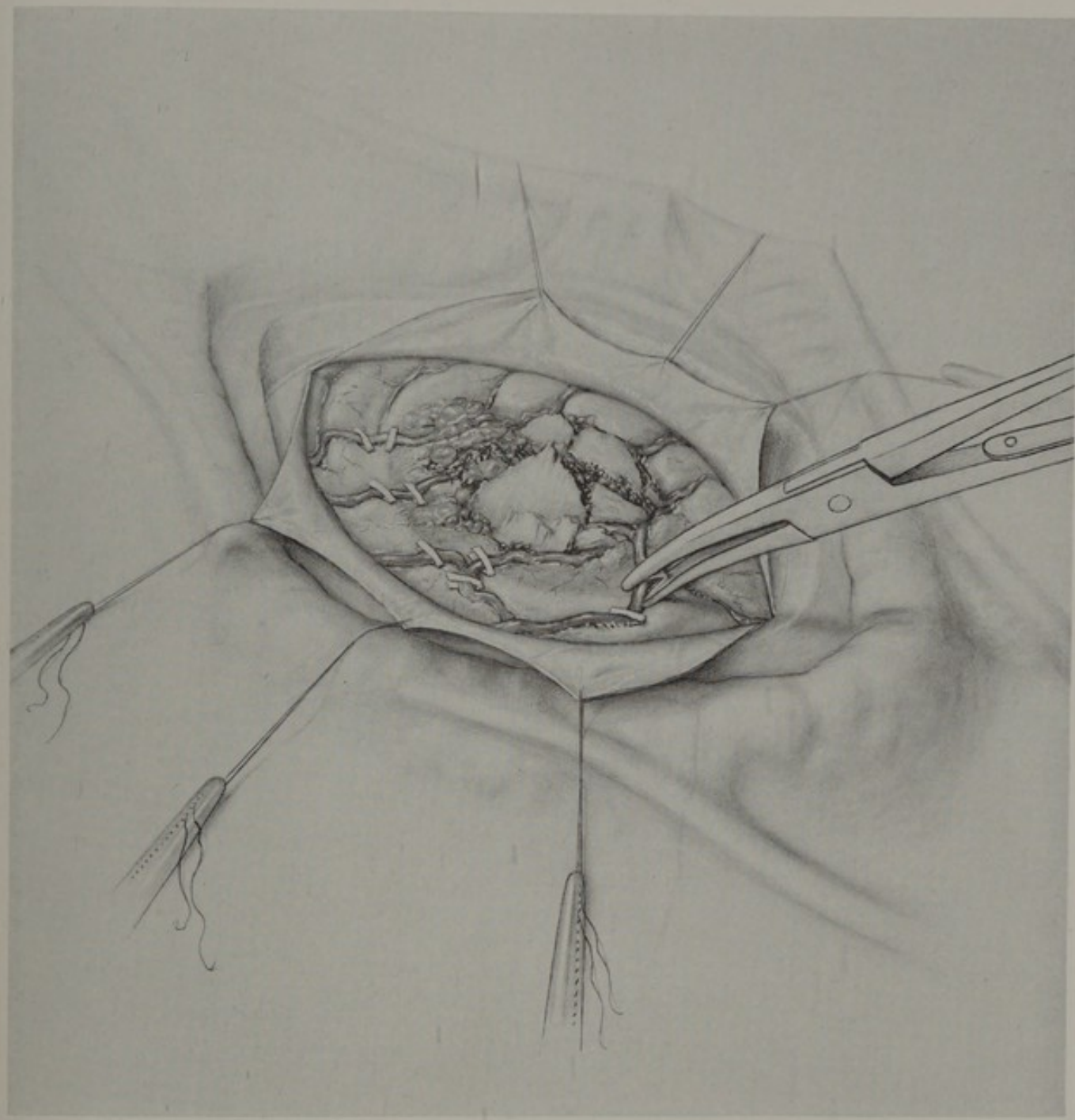

FIGURE 64.—Centripetal cortical debridement by “clip-and-cut” method.

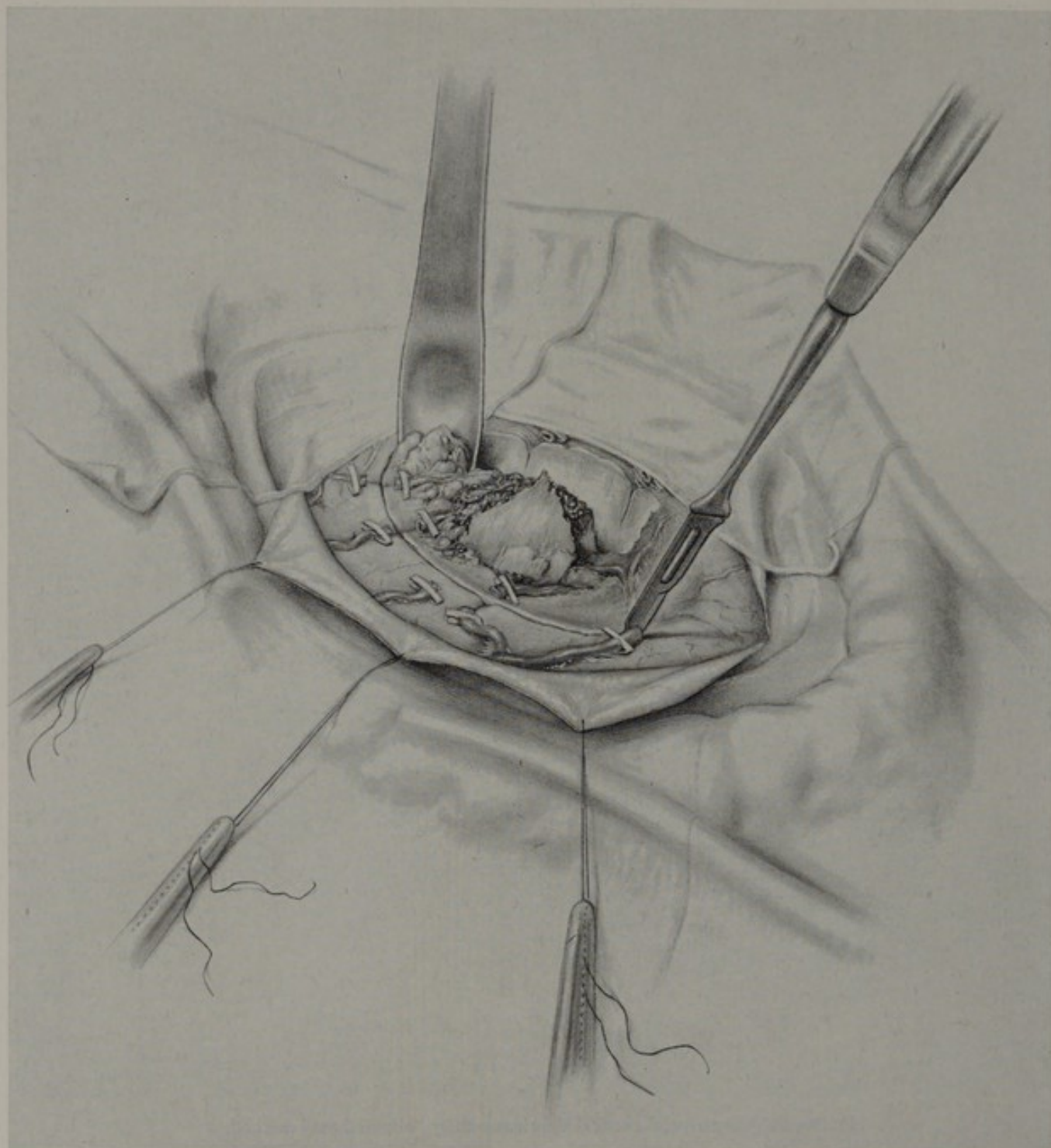


FIGURE 65.—Centripetal cortical debridement by "clip-and-cut" method.

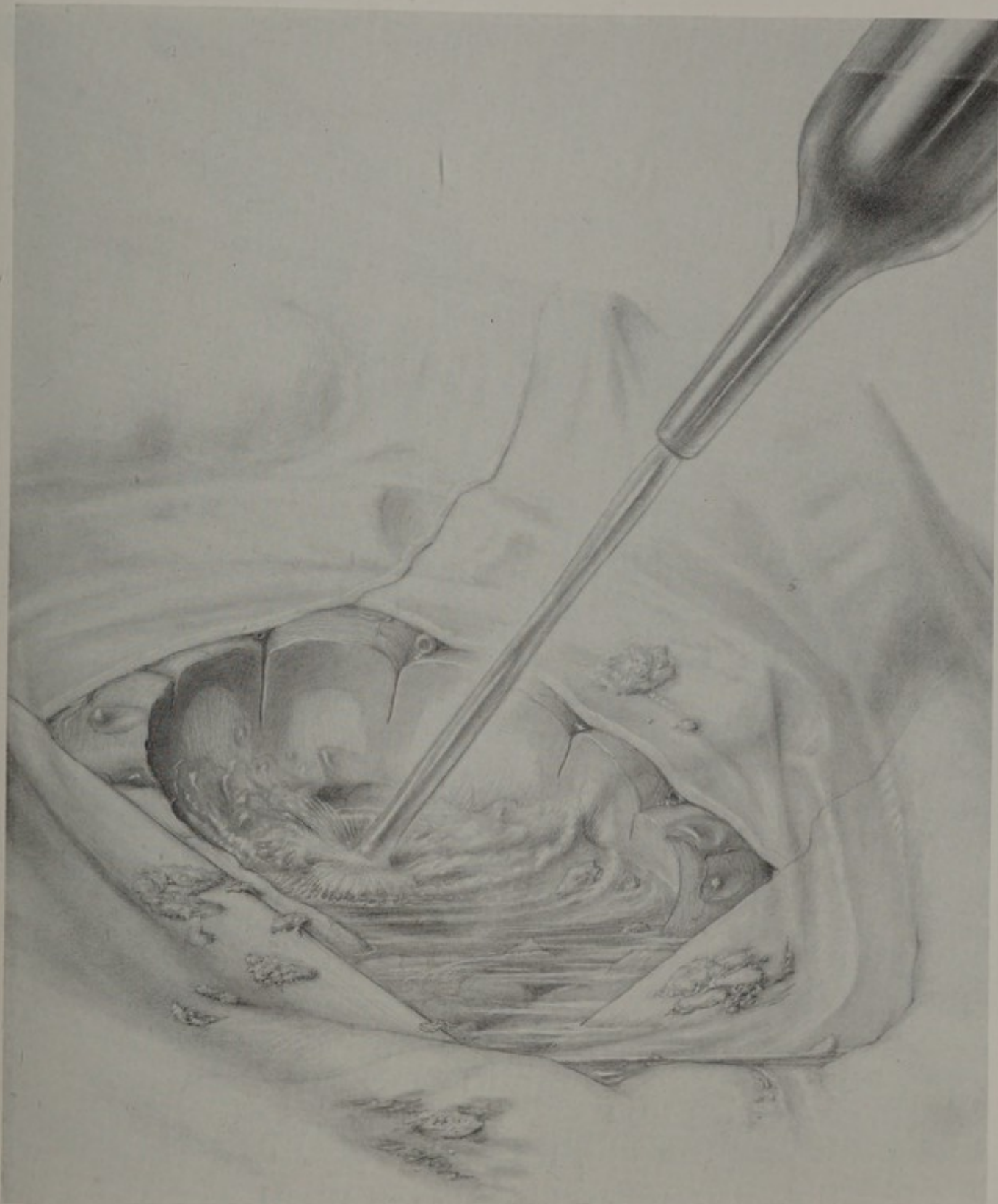


FIGURE 66.—Saline irrigation of newly created brain surface and of exposed track.

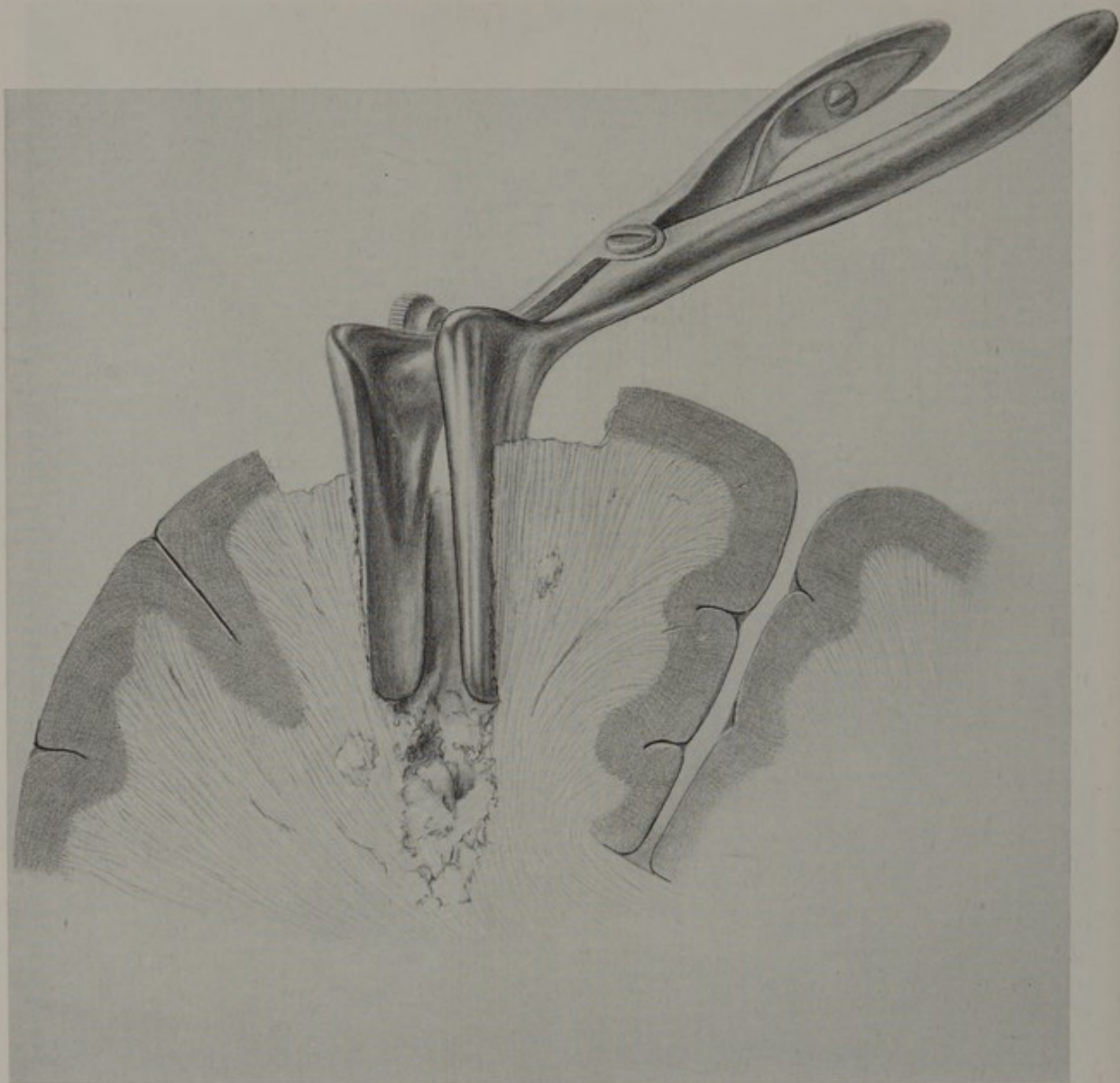

FIGURE 67.—Inspection of missile track through nasal speculum.

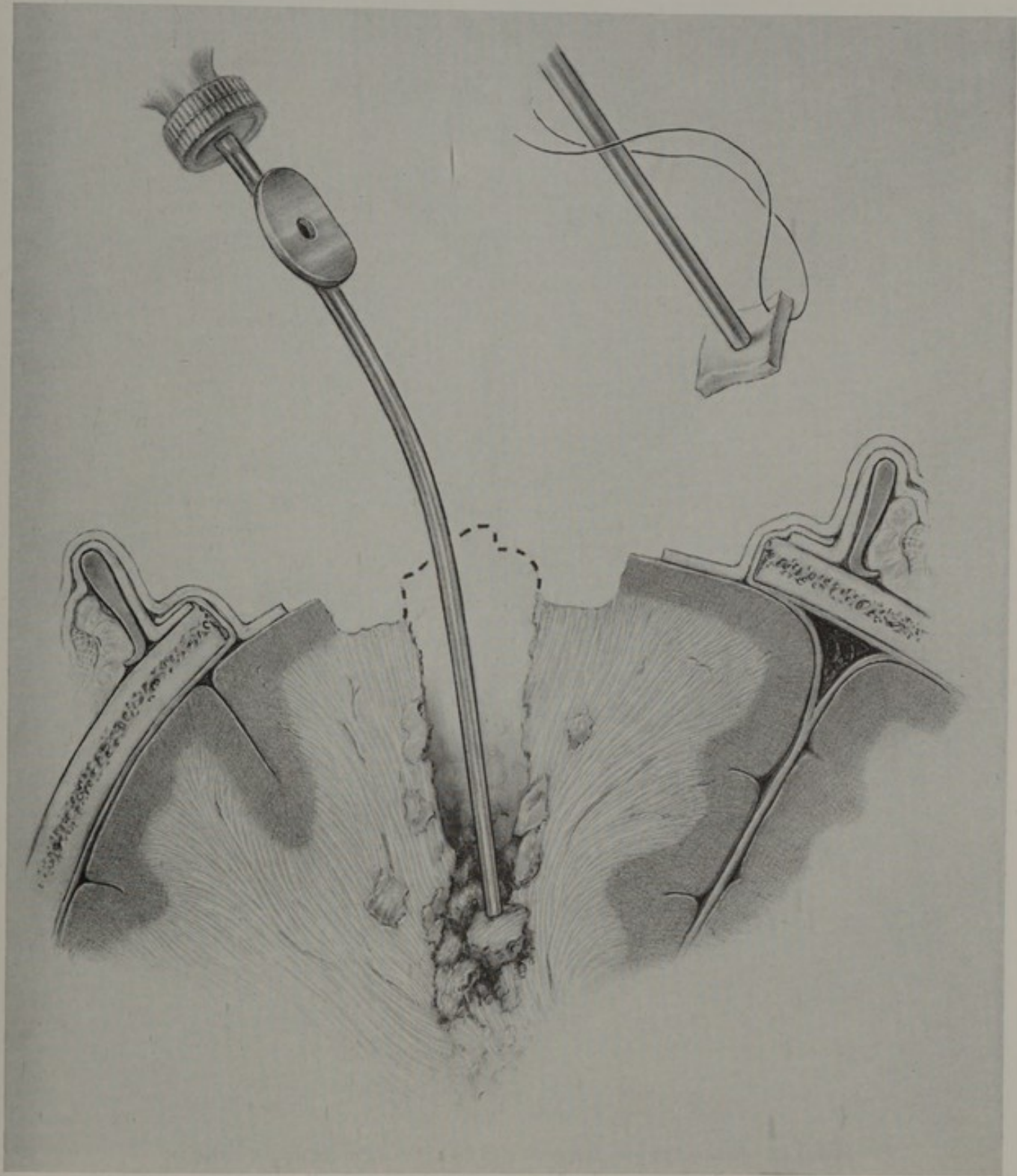


FIGURE 68.—Resection of pulp and clots within missile track.

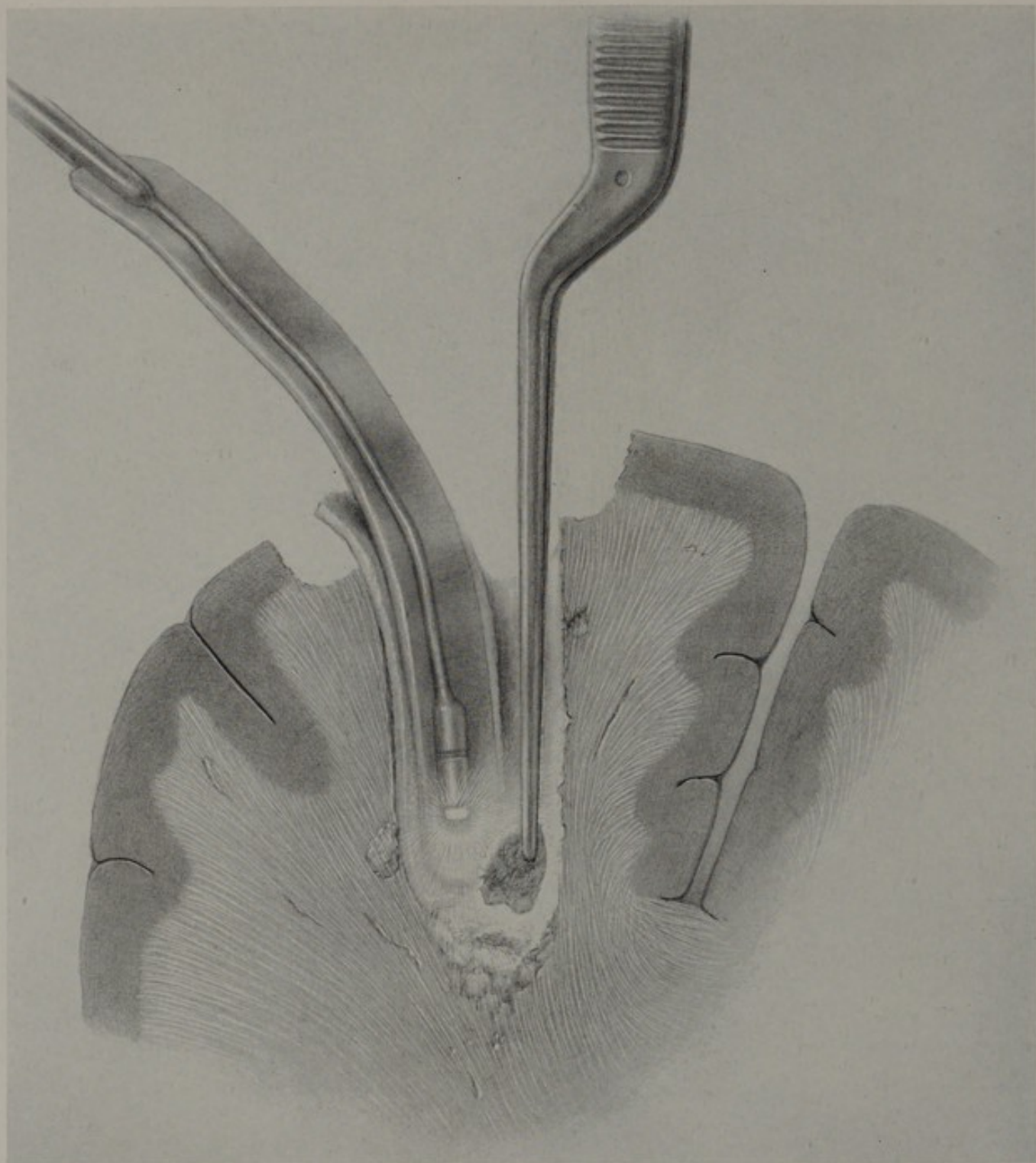


FIGURE 69.—Removal of bone fragment with the aid of a Frazier lighted retractor.

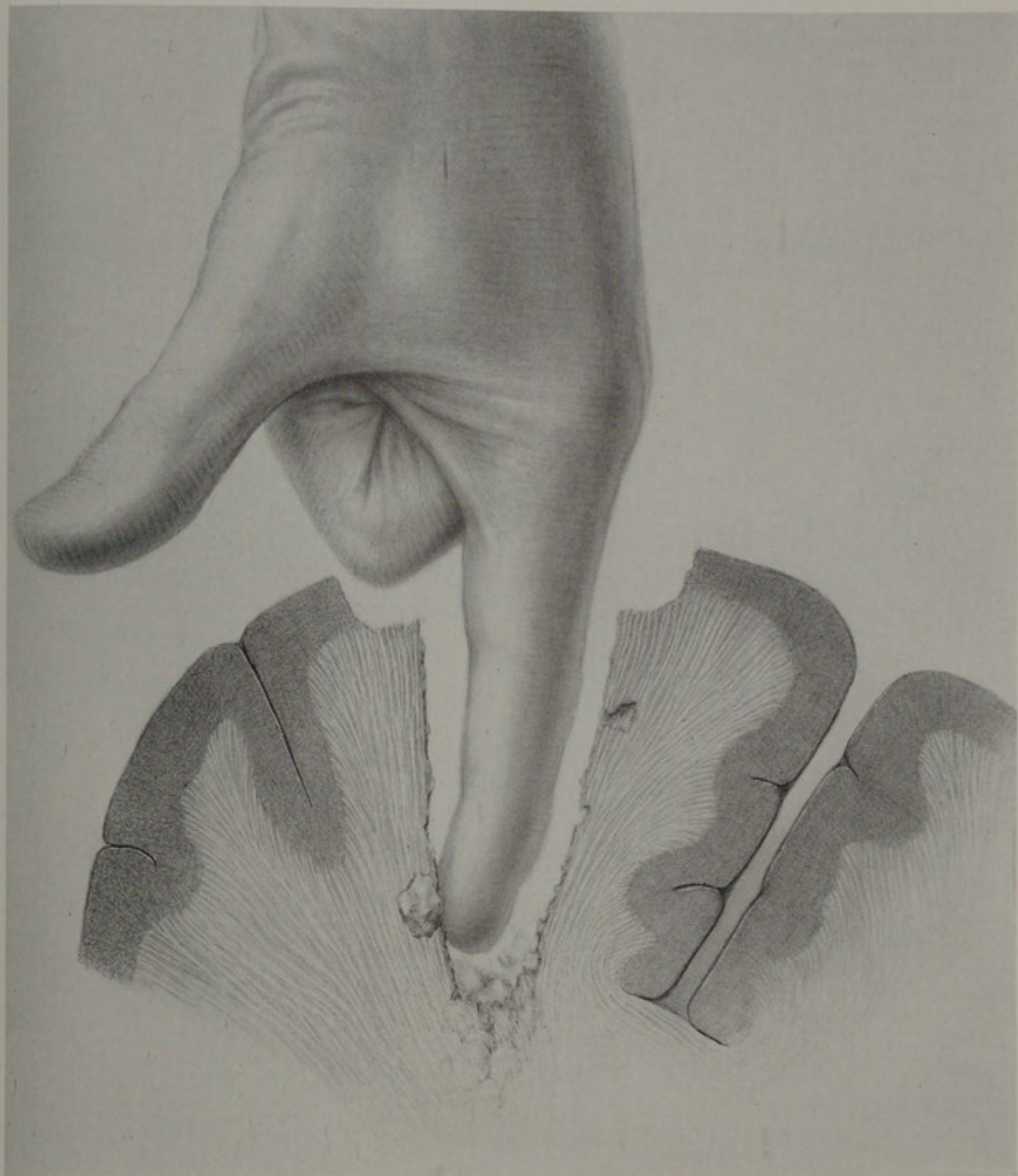


FIGURE 70.—Digital palpation for embedded bone fragment.

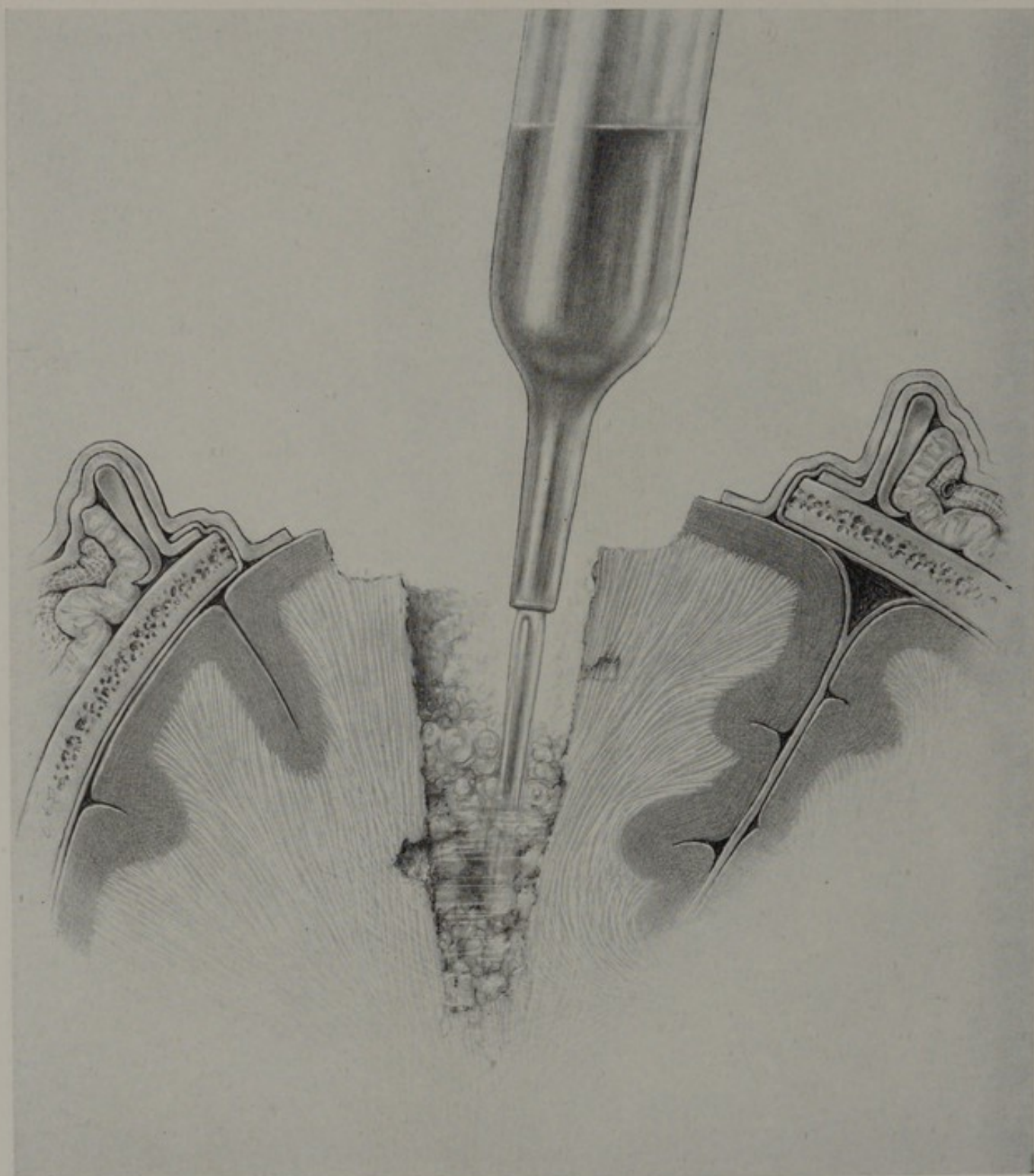


FIGURE 71.—Saline irrigation of track.

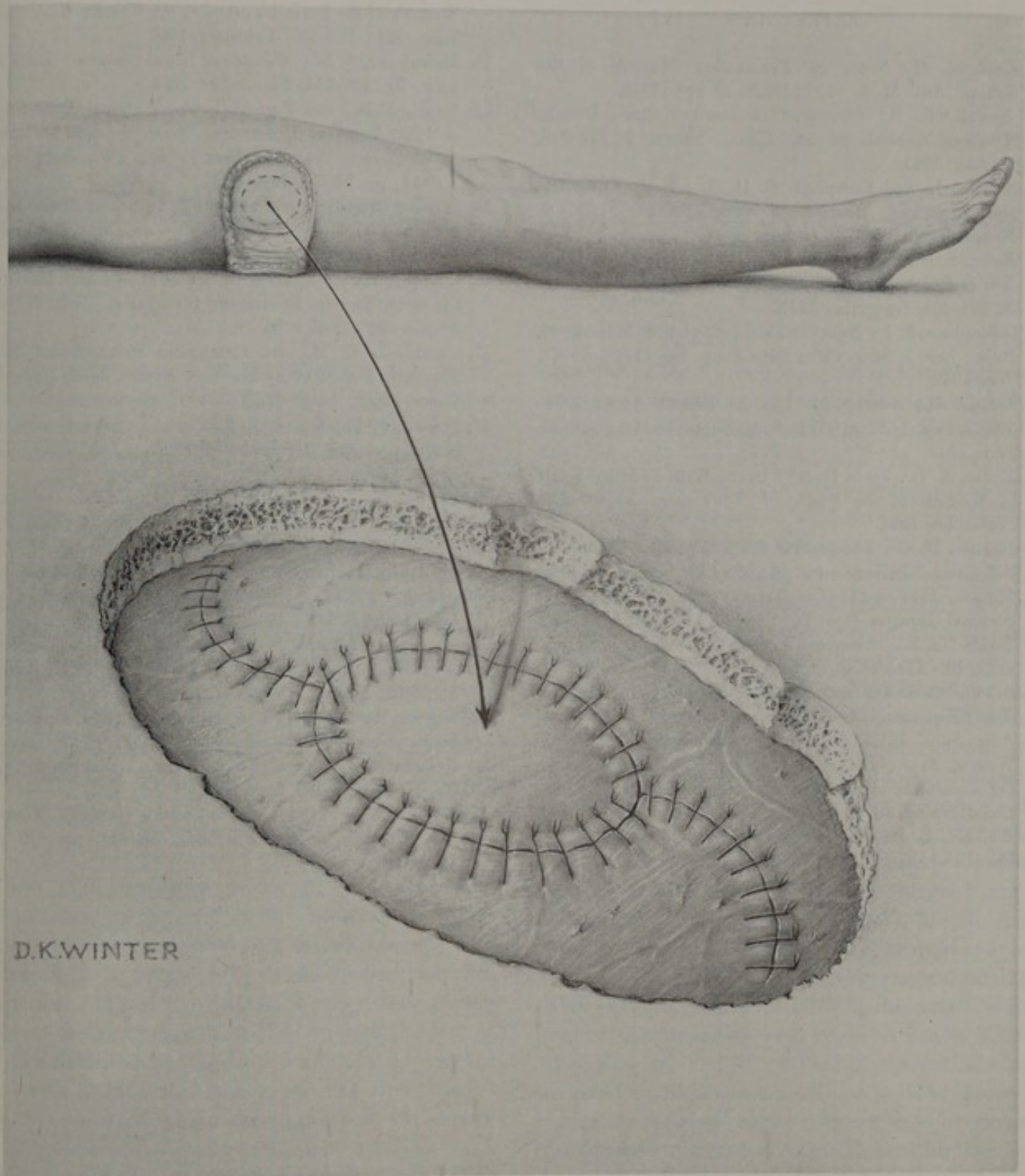


FIGURE 72.—Watertight closure of dura by fascia lata graft. Inset shows horseshoe flap, lateral aspect of thigh, for obtainment of fascia lata.

REFERENCES

1. Cushing, H.: Notes on Penetrating Wounds of the Brain. *Brit. M. J.* 1: 221-226, 23 Feb. 1918.
2. Ascroft, P. B.: Treatment of Head Wounds Due to Missiles; Analysis of 500 Cases. *Lancet* 2: 211-218, 21 Aug. 1943.
3. Martin, J., and Campbell, E. H., Jr.: Early Complications Following Penetrating Wounds of the Skull. *J. Neurosurg.* 3: 58-73, January 1946.
4. Rowe, S. N., and Turner, O. A.: Observations on Infection in Penetrating Wounds of the Head. *J. Neurosurg.* 2: 391-401, September 1945.
5. Gillingham, F. J.: Neurosurgical Experiences in Northern Italy. *Brit. J. Surg. (War Surg. Supp. No. 1)*, pp. 80-87, June 1947.
6. Cairns, H.: Neurosurgery in the British Army, 1939-1945. *Brit. J. Surg. (War Surg. Supp. No. 1)*, pp. 9-25, June 1947.
7. Ecker, A. D.: Tight Dural Closure With Pedicled Graft in Wounds of the Brain. *J. Neurosurg.* 2: 384-390, September 1945.
8. Haynes, W. G.: Penetrating Brain Wounds; Analysis of 342 Cases. *J. Neurosurg.* 2: 365-378, September 1945.
9. Matson, Donald D.: The Treatment of Acute Cranio-cerebral Injuries Due To Missiles. American Lecture Series No. 22. American Lectures in Surgery. Springfield, Ill.: Charles C Thomas, 1948.
10. Schwartz, H. G., and Roulhac, G. E.: Craniocerebral War Wounds; Observations on Delayed Treatment. *Ann. Surg.* 121: 129-151, February 1945.
11. Weaver, T. A., Jr., and Frishman, A. J.: A Report on the Treatment of Craniocerebral Wounds in an Evacuation Hospital. *J. Neurosurg.* 3: 148-156, March 1946.
12. Wallace, P. B., and Meirowsky, A. M.: The Repair of Dural Defects by Graft; An Analysis of 540 Penetrating Wounds of the Brain Incurred in the Korean War. *Ann. Surg.* 151: 174-180, February 1960.
13. Meirowsky, A. M.: Wounds of Dural Sinuses. *J. Neurosurg.* 10: 496-514, September 1953.
14. Small, J. M., and Turner, E. A.: Surgical Experiences of 1,200 Cases of Penetrating Brain Wounds in Battle, N. W. Europe, 1944-45. *Brit. J. Surg. (War Surg. Supp. No. 1)*, pp. 62-74, June 1947.
15. Munro, Donald: Cranio-Cerebral Injuries: Their Diagnosis and Treatment. New York, Toronto, and London: Oxford University Press, 1938.
16. Cushing, H.: A Study of a Series of Wounds Involving the Brain and Its Enveloping Structures. *Brit. J. Surg.* 5: 558-684, April 1918.
17. Campbell, E. H., Jr.: Compound Comminuted Skull Fractures Produced by Missiles; Report Based Upon 100 Cases. *Ann. Surg.* 122: 375-397, September 1945.
18. Schwartz, H. G., and Roulhac, G. E.: Penetrating Wounds of the Cerebral Ventricles. *Ann. Surg.* 127: 58-74, January 1948.
19. Lewin, W., and Gibson, R. M.: Missile Head Wounds in the Korean Campaign; Survey of British Casualties. *Brit. J. Surg.* 43: 628-632, May 1956.
20. Botterell, E. H.: Brain-Injuries and Complications. In *British Surgical Practice*. London: Butterworth & Co. (Publishers), Ltd., 1948, vol. 2, pp. 349-384.
21. Matson, D. D., and Wolkin, J.: Hematomas Associated With Penetrating Wounds of the Brain. *J. Neurosurg.* 3: 46-53, January 1946.
22. Cairns, H., Calvert, C. A., Daniel, P., and Northcroft, G. B.: Complications of Head Wounds, With Especial Reference to Infection. *Brit. J. Surg. (War Surg. Supp. No. 1)*, pp. 198-243, June 1947.
23. Calvert, C. A.: Orbito-Facio-Cranial Gunshot Wounds. *Brit. J. Surg. (War Surg. Supp. No. 1)*, pp. 119-141, June 1947.

CHAPTER 11

Hematomas Associated With Penetrating Wounds

Joseph C. Barnett, Jr.

Early surgical care for the traumatic neurosurgical patient has long been stressed, but, in reference to penetrating wounds and the incidence of associated intracranial hematoma, there has been some divergence of thought as expressed in the available literature (1) (2) (3) (4) (5). Campbell and Kuhlenbeck, however, in a study of mortal brain wounds noted that hematoma formation was most common in the cerebral wound and that many of the missile-track clots grew to large size and thus doubtlessly hastened death (6). It was observed by Schorstein (5), in his study of World War II casualties, that three-quarters of the penetrating cerebral injuries presenting a small wound of entry were associated with intracranial hematoma.

INCIDENCE

The high incidence (table 9) of intracranial hematomas associated with penetrating brain wounds was a realization that evolved from a constant effort to bring early definitive neurosurgical care to the casualty. Primarily, other basic principles of surgical care motivated this effort, but as earlier definitive care became feasible, the incidence of acute intracranial hematoma rose significantly. As was observed within the confines of our experi-

ence during the Korean War, the incidence of hematomas was directly related to the time factor involved in the patient's reaching a facility capable of rendering definitive neurosurgical care (7). During the early phase of the action, neurosurgical casualties were evacuated to Japan for definitive care, and the usual time required for transportation of the patient was from 1 to 3 days. In reviewing the data gathered from this group of penetrating wounds, there was a 7-percent incidence of intracranial hematoma. Some months later, when it was possible to offer major surgical facilities within Korea, a neurosurgical team was established at the evacuation hospital level and the time required for evacuation at this level ranged from 12 to 36 hours. Review of data from this group of penetrating wounds yielded a 24-percent incidence of hematoma. With later developments in the tactical situation, it was possible to establish an Army mobile neurosurgical unit in Korea (8) which was attached to a Mobile Army Surgical Hospital. This provided the most proximal location attainable offering major surgical facilities. With definitive care available at this level, 39 percent of the casualties were received within 3 hours after first aid and 78 percent of the patients were received within 8 hours. In this latter group of patients receiving earliest possible neurosurgical care, there was a 46-percent incidence of intracranial hematoma associated with penetrating wounds. Taking into consideration our varied experience as to the incidence of intracranial hematomas associated with penetrating cerebral wounds, it seems that proximity as a function of time required for the patient to reach a point where definitive care is available is the most important factor and that, with variations in this factor, a wide variation of incidence is possible.

TABLE 9.—Incidence of hematomas in 316 consecutive cases of penetrating wounds

Site of hematoma	Number of hematomas	Incidence (percent of series)
Epidural.....	13	4.1
Subdural.....	77	24.4
Intracerebral.....	87	27.5
Intraventricular.....	2	.7

INTRACEREBRAL HEMATOMA

The most commonly encountered intracranial hematoma complicating the penetrating craniocerebral wound was found to be the intracerebral hematoma. This is further defined as the missile-track hematoma, lying within the path or trajectory of the missile or indriven elements and confined within the cerebral substance (fig. 73). Twenty-seven percent of penetrating cerebral wounds were complicated by an intracerebral hematoma which was of sufficient volume to be of definite clinical and surgical significance.

K-1898 was admitted to a neurosurgical unit approximately 8 hours following multiple shell fragment wounds of the left trunk and extremities with single penetrating left temporal wound. Aphasia, right homonymous hemianopia. Increasing drowsiness. Roentgenograms revealed small metallic fragment in left posterior parietal region, near falx, with several intracerebral indriven bone fragments. Temporal craniectomy and radical debridement carried out with evacuation of large missile-track hematoma. Bone fragments removed, metallic fragment not recovered. Layer closure. Aphasia cleared almost completely in 2 weeks. Right homonymous hemianopia persisted. Uneventful postoperative course.

This case (K-1898) illustrates a large hematoma as was classically encountered within the path of the metallic missile and indriven bone fragments. It must be brought out that, at times, the path of the missile and the path of the indriven bone fragments or other debris are somewhat divergent. Although in most instances of penetrating cerebral wounds an intracranial foreign metallic body was identifiable, there were instances of tangential or glancing wounds of the skull wherein the metallic fragment did not penetrate the skull but led to an explosive penetration of cranial bone fragments, on occasions to a depth of several centimeters. Effectually, the indriven bone fragments act as individual agents and may lead to an intracerebral hematoma actually distant from the metallic trajectory. This was encountered on several occasions; thus the value of preoperative films in relation to both the metallic fragment as well as the bone fragments became well established. Also of great value was the impression gained at the time of surgery as to intracranial tension. Following a thorough debridement of the missile canal with or without the findings of a significant hematoma, should the brain remain tense,

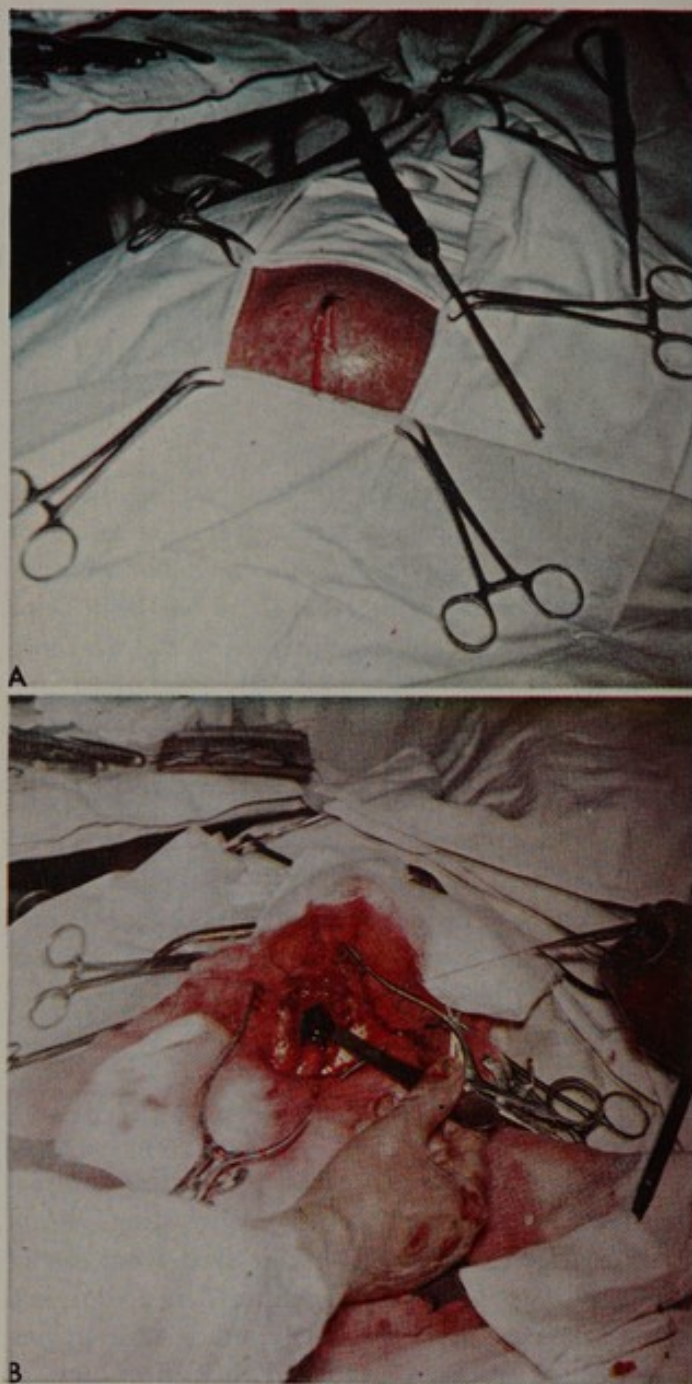


FIGURE 73.—K-396. Wounded in action, 5 April 1952. Shell fragment. Wound, penetrating, brain, parietal, right transventricular. Right parietal craniectomy, 5 April 1952. Hematoma, subdural, right. Hematoma, subcortical, parietal, right. Residual astereognosis, left arm and leg. A. Entrance wound draped for operation. B. Subcortical hematoma (exposed).

further exploration for a distant hematoma must be considered, particularly should there be a distant bone fragment or smaller metallic fragment not within the confines of the major missile path. Small and Turner (9) have pointed out how a previously unsuspected blood clot, usually in relation to the

missile and possibly at some distance from the point of entry, may denote itself by a closing track. This has certainly also been our experience in the Korean War.

In 38 percent of those wounds presenting a clinically significant intracerebral hematoma, there was a complicating subdural or epidural hematoma which was also of sufficient volume to be of surgical significance. Although, in all instances, the epidural clot was readily evacuated at the time of craniectomy, the subdural clot was discovered on occasion only by purposeful exploration.

SUBDURAL HEMATOMA

A subdural hematoma was found to complicate 24 percent of penetrating craniocerebral injuries, though small subdural clots were associated with almost all penetrating wounds, large hematomas were less frequently encountered. Campbell (10) has reported a 10-percent incidence in penetrating wounds, but, there again, the difference in echelon of definitive care could be of importance.

K-1194 was admitted to a neurosurgical unit approximately 24 hours following multiple shell fragment wounds of face and upper extremities and small penetrating left frontal wound. Roentgenograms revealed metallic fragment left parietal lobe and indriven bone fragments within missile path. Partial aphasia, mild right hemiparesis. At craniectomy, the meningocerebral penetration was defined, dura tense and darkly discolored. Sizable subdural hematoma evacuated, no significant intracerebral clot. Debridement and layer closure. Discharged from service without neurological deficit 1 month after injury.

This case (K-1194) demonstrates the simple feature of an accompanying subdural hematoma principally confined within the immediate area of penetration. Instances have been encountered, however, where the bulk of the clot lay distant, usually dependent, from the actual site of penetration. This experience cautions against skimpy exposure and only cursory examination of the subdural space. In 15 instances in which the metallic fragment was located near a cortical surface opposite the wound of entrance or within the line of trajectory of the missile, exploratory trephination over the area of suspected opposite cortical involvement in 6 of these revealed a significant subdural hematoma. This observation was reported by Matson and Wolkin (11). In some instances, there was evidence that

the metallic fragment had glanced from the opposing inner table of the skull, inflicting a cortical injury with subsequent hematoma formation but without sufficient force to effect a through-and-through type injury. In missile wounds, therefore, there exists the potentiality of multiple cerebral injuries sustainable from a single missile. In 30 percent of those wounds presenting a clinically significant subdural hematoma, there was an accompanying intracerebral or epidural hematoma which, too, was of sufficient volume to be significant.

EPIDURAL HEMATOMA

The epidural hematoma was less frequently encountered than the intracerebral or the subdural hematoma and occurred at an incidence rate of only 4 percent in penetrating craniocerebral wounds.

K-1982 was admitted to a neurosurgical unit approximately 12 hours after injury, having sustained penetrating missile wound right parietal area. During initial phase of evacuation reportedly ambulatory but admitted as stretcher patient with left hemiparesis. Roentgenograms revealed several small metallic fragments and bone fragments right parietal lobe. Right parietal craniectomy and radical wound debridement revealed an extensive epidural hematoma. Cerebral missile track debrided, no significant subdural or intracerebral clot. Layer closure. Postoperatively, patient had two left focal seizures. Wound healed primarily. Hemiparesis cleared.

This case (K-1982) was thought to represent the venous type of epidural hematoma, primarily arising from bone bleeding rather than of meningeal origin. There were instances, however, in which meningeal radicles were torn and identifiably responsible for the epidural hematoma. In all such instances, the wounds were located temporally within the area of the major middle meningeal radicles. Approximately one-third of those cases presenting primarily an epidural hematoma were complicated by a surgically significant intracerebral or subdural hematoma.

INTRAVENTRICULAR HEMATOMA

Those patients demonstrating, at the time of surgery, an identifiable intraventricular clot comprised less than 1 percent of the series chosen for statistical consideration. In all instances, the wounds were of transventricular type (12), were associated with large hematomas within the missile

canal, and very likely represented a spillage of the intracerebral clot into the ventricular cavity. Evacuation of the clot was attempted in all instances.

SPECIAL CONSIDERATIONS

In the group of 316 consecutive penetrating wounds which were studied in detail, 90 percent were injuries sustained by fragments from mortars, mines, grenades, or artillery shells. The actual size of the fragment varied from a few millimeters in diameter to several centimeters, thus the wounds of entrance were usually comparable to the size of the metallic missile and accounted for the fact that 82 percent of the injuries primarily or superficially involved only one cerebral lobe. The large avulsive-type craniocerebral wounds were less frequently encountered and, because of the nature of this type of wound in which precipitated hemorrhage can easily escape from the open wound, confined intracranial hematomas were even less frequently encountered.

Consideration of the site of the penetrating wound in respect to the likelihood of an intracranial hematoma (table 10) seems to bear some anatomical relationship to arterial and venous supply. Frontal and parietal lobe penetrations were least commonly associated with hematoma formation. The temporal lobe penetrations presented a relatively high incidence, possibly bearing some relationship to the middle cerebral complex. The occipital lobe and cerebellar penetrations also presented a relatively high incidence, probably bearing some relationship to the proximity of large dural venous sinuses.

Signs of increasing intracranial pressure and progressive neurological deficit should form a basis of surgical priority and operative management, particularly in the management of multiple casualties. In the group of patients found to have a significant confined hematoma, 20 percent presented signs of increasing deficit and pressure despite rapid definitive management of the penetrating wounds. The penetrating cerebral wound does not present the problem of decision as to the necessity or advisability of surgical intervention since that indication is already existent. The concomitant possibilities of a developing intracranial hematoma would lend further urgency to the earliest possible definitive care. In the light of progressive neurological deficit with signs

of increasing intracranial pressure, the penetrating craniocerebral wound is quite likely harboring an intracranial hematoma.

TABLE 10.—*Relationship between location of wound and formation of hematoma*

Location of wound	Number of wounds
Frontal.....	149
Temporal.....	75
Parietal.....	94
Occipital.....	25
Cerebellum.....	12

REFERENCES

1. Craig, W. M.: Neurosurgery in World War II. U.S. Armed Forces M.J. 3: 1-13, January 1952.
2. Finlayson, A. I.: Penetrating War Injuries of Brain; Desirability of Early Definitive Surgery. Bull. U.S. Army M. Dept. (No. 87), pp. 61-69, April 1945.
3. Meierowsky, A. M.: Penetrating Craniocerebral Trauma; Observations in Korean War. J.A.M.A. 154: 666-669, 20 Feb. 1954.
4. Meierowsky, A. M., and Harsh, G. R., III: Treatment of Penetrating Craniocerebral Trauma. In Symposium on Military Medicine in the Far East Command, September 1951, pp. 85-88. A supplementary issue to the Surgeon's Circular Letter, Medical Section, General Headquarters, Far East Command, Supreme Commander for the Allied Powers (Japan), and United Nations Command.
5. Schorstein, J.: Intracranial Haematoma in Missile Wounds. Brit. J. Surg. (War Surg. Supp. No. 1), pp. 96-111, June 1947.
6. Campbell, E. H., and Kuhlenbeck, H.: Mortal Brain Wounds; A Pathologic Study. J. Neuropath. & Exper. Neurol. 9: 139-149, April 1950.
7. Barnett, J. C., and Meierowsky, A. M.: Intracranial Hematomas Associated With Penetrating Wounds of the Brain. J. Neurosurg. 12: 34-38, January 1955.
8. Meierowsky, A. M., and Barnett, J. C.: Mobile Neurosurgical Team. Ann. Surg. 138: 178-185, August 1953.
9. Small, J. M., and Turner, E. A.: A Surgical Experience of 1,200 Cases of Penetrating Brain Wounds in Battle, N.W. Europe, 1944-45. Brit. J. Surg. (War Surg. Supp. No. 1), pp. 62-74, June 1947.
10. Campbell, E. H., Jr.: Compound, Comminuted Skull Fractures Produced by Missiles; Report Based Upon 100 Cases. Ann. Surg. 122: 375-397, September 1945.
11. Matson, D. D., and Wolkin, J.: Hematomas Associated With Penetrating Wounds of the Brain. J. Neurosurg. 3: 46-53, January 1946.
12. Wannamaker, G. T.: Transventricular Wounds of the Brain. J. Neurosurg. 11: 151-160, March 1954.

CHAPTER 12

Infection Complicating Penetrating Craniocerebral Trauma

Griffith R. Harsh III

GENERAL CONSIDERATIONS

Prevention of infection is the primary purpose of most efforts in the management of penetrating cranio-cerebral wounds. Early, thorough, meticulous cleansing and resection of damaged tissues and foreign matter, followed by accurate layer approximation of wounds, is undoubtedly the key to prevention of suppuration. Consideration of factors known to be related to the development of infection will perhaps clarify the management of the infected wound. That earliest possible surgical attack on the cranio-cerebral wound is of the utmost importance was clearly redefined during the Korean War. In the initial phases of combat, neurosurgical care was available only in the intermediate zone (Tokyo Army Hospital). Of all neurosurgical casualties admitted to this installation, 41 percent were infected (1) (2). Some of these wounds had been treated surgically—though often inadequately—others had not been touched. Most had received antibiotics (penicillin and/or streptomycin) which usually were instituted at the battalion aid station. Delay between wounding and definitive neurosurgical therapy varied from less than 1 to 23 days. Nine months after the outset of the war, a neurosurgical installation was established in Korea. Subsequently, the percentage of infected neurosurgical wounds admitted to Tokyo Army Hospital was reduced from 41 percent to less than 1 percent (3).

Initial therapy must be thorough and complete as well as early. As pointed out by Schwartz and Roulhac (4), simple debridement and closure of

scalp wounds over an underlying cranial or cerebral injury can only be condemned. A primarily healed scalp incision has all too often concealed a shaggy, necrotic, contaminated, subjacent missile track which subsequently abscessed. Repeated experience with such tragic results of both delayed and improper or inadequate therapy of compound cranio-cerebral injuries has led to the firm conviction that facilities for complete neurosurgical care must be established as close to the combat area as militarily feasible.

Even with the neurosurgical unit most ideally situated, the surgeon is occasionally confronted with a compound brain injury, perhaps previously unrecognized, which is several days old. Though the chances for late infection following surgery are greater in such wounds, nothing can be gained by further delay in therapy. Complete resection and closure should be immediately undertaken.¹

The actual mechanics involved in surgical therapy of compound cranio-cerebral wounds have been accurately described and need not be reiterated here. Several factors, however, demand emphasis. In a random series of 110 secondarily (postoperative) infected cranio-cerebral wounds handled during the Korean War, 54 had retained bone fragments. In five others, the presence or absence of fragments was not recorded. In 44 primarily infected wounds, retained bone fragments were present in 30 instances. The presence of retained bone fragments is *prima facie* evidence of inadequate debridement. The

¹ A possible exception is, of course, the grossly infected fungating wound which should be managed by resection with creation of an artificial fungus, as elucidated later.

tendency to abscess formation around retained bone fragments is so great that it has become routine to perform postoperative roentgenographic examination of all penetrating wounds. If bone fragments are demonstrated, re-operation for their removal is considered mandatory. As the incidence of secondary infections increases directly in proportion to the number of multiple procedures, complete definitive therapy is, of course, desirable with the initial surgical attack.

Metallic fragments have generally been considered less hazardous than bone fragments and other debris (5). A somewhat greater potential for infection around retained low-velocity missiles (shell fragments, and so forth) than in the vicinity of high-velocity missiles (small caliber bullets) has been suggested; however, suppuration frequently has been encountered originating around even small metallic fragments, and it is the opinion of the author that diligent search for them should be made where feasible.

Importance of dural closure in the prevention and management of infection cannot be overemphasized (6). Without dural closure in a penetrating wound, formation of a subgaleal and, at times, superficial (external) cerebral fungus is almost inevitable. Strangulation of the herniating brain (be it subgaleal or superficial) surely leads to necrosis. The presence of this devitalized tissue in a contaminated wound is an excellent enhancement to suppuration. In a significant number of instances in our experience, superficial infection of the scalp, with or without subgaleal spread, has been restricted from intracranial extension by an intact dural graft. In no instance has a tight dural closure seemed to induce or abet intracranial infection.

Layer closure of the properly debrided and cleansed scalp in a compound injury is essential. In such a wound the advantage of buried (inverted) nonabsorbable sutures in promoting primary healing far outweighs any potential danger from foreign body reaction.² Scalp closure under tension enhances necrosis, wound separation, and infection. The use of wide undermining rotation flaps and, occasionally, judiciously placed relaxing incisions is well known.

² Layer closure of the contaminated but noninfected wound is in sharp contrast to through-and-through closure as is considered best in the already infected wound.

Wounds encroaching on accessory air sinuses may be associated with a higher incidence of infection. Complete removal of all depressed and devitalized bone fragments is mandatory. Mucous membranes must be completely exenterated and the external ostia sealed with muscle stamps. Additional sealing with Gelfoam pledgets soaked in antibiotic solution has been felt to be advantageous. Tight dural closure is especially important to preclude cerebrospinal fluid fistula formation and its attendant danger of infection.

Among those factors responsible for infection in compound craniocerebral injury, ignored or unrecognized wounds are important. In the initial phases of the Korean War, it was standard policy to consider as nonsurgical all small fragment penetrations of the middle fossa from low in the face. These were treated with antibiotics and "expectant observation." The resultant high incidence of middle fossa suppuration evoked a much more aggressive approach in the latter phases. All such injuries should be debrided as soon as possible through appropriate osteoplastic craniotomy. In a few instances, penetrating brain wounds, caused by small missile fragments, were unrecognized and untreated until tragically announced by the appearance of signs of intracranial infection (7). Unrecognized cranial wounds occur most often in multiple fragment injuries in which small scalp and facial lacerations are thought to be only superficial. Routine thorough roentgenological examination of the skull in all such instances (with or without signs of intracranial damage) will preclude such oversight.

MANAGEMENT OF INFECTION

Early recognition of the presence of infection is of primary importance. Persistence of infection leads only to increased neurological deficit and mortality. Superficial suppuration in dehiscent wounds is, of course, obvious. Cryptic infection may be indicated by persistent low-grade fever or recurrent bouts of meningitis. Bulging scalp flaps over underlying bone defects, with or without other evidence of increased intracranial pressure, may herald a developing cerebritis or brain abscess. A small superficial draining sinus is frequently the only clue to a low-grade, but deadly, deep cerebritis. Cere-

brospinal fluid, otorrhea or rhinorrhea, or cutaneous fistulas are considered precursors of infection. If persistent for more than 10 days, they must be treated forthwith by appropriate dural repair.

It is well established that sustained aggressive treatment is the *sine qua non* of successful management of craniocerebral infection. Upon admission of a patient with an infected wound a preconceived plan of action is immediately begun. Complete physical examination and evaluation of the patient is mandatory. An added burden of associated injury and debilitation significantly increases the incidence of and the ravages attendant to craniocerebral infection. Maintenance of body nutrition is essential in combating infection. In the comatose or anorectic patient, tube feedings must be instituted promptly.

Initial laboratory investigation must include peripheral blood and urine assessment. Body resistance to infection is greatly decreased by anemia. Transfusion is essential in those patients with blood depletion. Bacteriological evaluation of all infected wounds is implemented by admission smear and culture with sensitivity studies as indicated. Experience in Korea has substantiated that in previous wars (7) the common skin contaminants were the usual offending organism. In Korea, all patients with compound craniocerebral trauma routinely received penicillin and streptomycin, which were continued until the wound had been healed for 10 days or bacteriological sensitivity study dictated a change to other antibiotics. Successive cultures as wound healing progresses often indicate different bacterial dominance necessitating alteration of the antibiotic program.

SURGICAL MANAGEMENT OF EXTRA-CRANIAL INFECTIONS

SCALP LACERATIONS

Successful surgical management of an infected wound depends on aggressive mechanical cleansing with soaks and irrigation, surgical debridement, and wound closure at an appropriate time. It is in the choice of the latter that the greatest surgical judgment is required. Preliminary preparation necessarily includes wide shaving of the involved and

adjacent area, followed by standard field preparation with soap and water. The soap and water scrub includes the laceration itself. Forceful irrigation of the contaminated area and finger palpation for possible retained foreign bodies are beneficial. Previously placed sutures, if still present, are removed. The surrounding area up to the edges of the laceration should be further cleansed with a disinfectant, such as alcohol or zephiran chloride (benzalkonium chloride). The entire wound is then dressed with a fluffy moist dressing. Twice daily irrigation of the wound greatly enhances the efficacy of the soaks. This regimen is continued until the wound has begun to have a clean healthy appearance. Immediate debridement and closure is then in order. Ideally, an infected laceration is ellipticated and completely excised. If the laceration overlies bone, the elliptical incision is carried down to the bone and all superficial tissue is discarded. Should the laceration overlay intact temporal or suboccipital fascia, the excision need extend only to these layers. Suppurating lacerations extending into temporal or occipital muscles necessitate wide muscle resection. In the event the infected laceration is more an avulsion or is too large for excision, piecemeal debridement of the devitalized edges is the procedure of choice. The now thoroughly cleansed wound is again irrigated and reapproximated with through-and-through sutures. In closure of previously infected wounds, the scalp is closed without buried sutures.

SUBGALEAL ABSCESS

Localized subgaleal abscess underlying a healed scalp laceration may on occasion be effectively managed by simple needle aspiration and irrigation followed by antibiotic instillation. If suppuration continues after a few such attempts, more radical therapy is necessary. The wound must be re-opened and irrigated. Foreign bodies and necrotic tissue must be removed and the wound treated as described in the chapter, "Scalp Lacerations." The wound is packed with moist gauze which should be changed at least twice daily. Each dressing is accompanied by a few minutes forceful irrigation. Time utilized in twice daily dressings is more than repaid in speed of wound cleansing. Subsequent closure is effected as just described. In the event of more generalized subgaleal infection covering larger areas of the head

(subgaleal empyema) opposing parallel incisions are effective for drainage. This is followed by through-and-through irrigation and indwelling through-and-through drains. Should the subgaleal infection occur following craniectomy, the infection is actually an extradural abscess. In the presence of an intact dura (or dural graft), the infection is frequently confined extracranially and may be managed as described. If the dura has not been closed, the existence of cerebritis is inevitable and must be managed as described below. Of course, the patient with subgaleal infection who also manifests signs of intracranial pressure or infection must be considered as having cerebritis or brain abscess until proved otherwise.

Frequently, subgaleal-extradural infection is encountered in the untreated compound comminuted depressed skull fracture. In such instances, the soft tissue is treated, as described previously, for 24 hours. Craniectomy and closure are then effected. Wide craniectomy must include careful search for evidence of osteomyelitis and removal of any bone so involved.

SURGICAL MANAGEMENT OF INTRACRANIAL INFECTIONS

MENINGITIS

In the absence of other infection, meningitis is treated with massive antibiotics of appropriate spectra and occasionally sulfadiazine. Resistant cases may be benefited by intrathecal administration of an appropriate drug.³ When meningitis is secondary to cerebrospinal fluid fistula (cutaneous or air sinus), appropriate dural repair is essential. Closure of the fistula is preferably effected during a quiescent interval but occasionally must be undertaken in the presence of continuing activity. In all instances of unexplained and particularly recurrent meningitis, diligent search must be made for sources of seeding, such as small abscesses around bone or metal fragments.

The story of K-1447 illustrates a common mechanism of infection which can readily be prevented by earliest possible definitive surgical attack on a brain wound. This 35-year-old

private, first class, sustained a penetrating wound of the left occipitoparietal area on 17 August 1950 when a prisoner of war at Waegwan, Korea. He was shot with his hands tied behind his back and left to die. He was recovered by U.S. infantrymen and evacuated. Subsequent medical records were incomplete but somewhere in the evacuation chain the wound was "explored and debrided." Upon arrival at an army general hospital, chills, fever, psychotic behavior, and a positive malaria smear led to his transfer to a psychiatric hospital and antimalarial therapy. Meningismus and subsequent lumbar puncture revealed the presence of meningeal infection which responded to Aureomycin. Following two quiescent interludes and three bouts of meningitis, he was seen in neurosurgical consultation. Examination revealed a right homonymous hemianopia without other neurological deficit. Roentgenograms of the skull revealed retained comminuted bone fragments in the left occipital lobe. At craniotomy on 23 September 1950, 11 bone fragments were found within the partially necrotic occipital lobe. A small, well-delineated abscess was found adjacent to the posterior horn of the left lateral ventricle. A 12th bone fragment, surrounded by the abscess, was found to have pierced the wall of the ventricle and protruding into the ventricular cavity. Occipital lobe and abscess were radically resected. All 12 bone fragments were removed. Dura and scalp were closed. The postoperative course was uneventful. There were no recurrences of meningitis during a 7-month followup period.

SUBDURAL ABSCESS

Subdural suppuration most often exists concurrently with infection in other areas, though occasionally it is confined solely to the subdural space. If so, evacuation of the pus, followed by careful search and removal of foreign body material, prolonged forceful irrigation, and closure without drainage will frequently suffice. When infection persists, cerebritis is again almost inevitable and must be handled as described below.

CEREBRITIS AND BRAIN ABSCESS

Among the infective complications of penetrating craniocerebral trauma none requires a more aggressive and yet perspicacious therapeutic approach than brain abscess and cerebritis. In the Korean War, truly encapsulated brain abscesses were only occasionally encountered. Intracerebral infection was far more frequently manifested as free pus within a missile track. Partially or poorly formed walls in an adjacent area of cerebritis were, of course, almost constant concurrents. The surgical management of these disheartening sequelae of unbridled intracra-

³ Intrathecal penicillin in instances of partial spinal subarachnoid block (associated cord injury) is contraindicated because it may be attended by the development of "status spasticus."

nial infection is the same whether they appear primarily in untreated wounds or secondarily in previously treated wounds. Radical resection of all infected or necrotic material as well as removal of all foreign bodies is mandatory. At operation, radical extracerebral debridement with wide resection of the involved portions of the scalp, bone, and dura mater is performed. In previously treated wounds, when the infection is confined within an intact dura, though further extracranial soft tissue resection may be unnecessary, additional craniectomy is almost always mandatory. The core of cerebritis surrounding a missile track whether primarily or secondarily infected is invariably of larger diameter than the bone perforation. Resection of friable necrotic brain tissue in the presence of inadequate exposure is dangerous and fruitless.

The infected track is exposed widely and any free pus removed with a suction. Gentle digital palpation helps to determine the tissue consistency and is essential to assure removal of all foreign bodies. Wide sucker resection of all the surrounding area of cerebritis is then effected until healthy though sometimes still edematous brain is encountered. *En bloc* resection of such infected tissue with the "clip-and-cut" method is of course desirable but (due to the longitudinal extent of many of the infected cavities) is seldom feasible. The extreme urgency of complete hemostasis and the value of frequent copious saline irrigations in resection of cerebritic tissue cannot be sufficiently emphasized. Division of meningocortical adhesions at the periphery of the wound facilitates brain retraction and more thorough resection. Direct inspection of subdural spaces precludes hydroma or hematoma retention and subsequent tendency to brain herniation.

When the rare encapsulated abscess is encountered, care is taken to maintain the integrity of the capsule to avoid further contamination. Aspiration of the contents of the abscess through a small-gage needle may facilitate removal of the capsule. There is no place for simple aspiration and injection of traumatic encapsulated abscesses (if indeed there is in nontraumatic ones!). The capsule is more often than not associated with bone fragments or other foreign bodies and total excision is mandatory. When resection and hemostasis are complete, the operating surgeon is faced with two choices for further procedure: (1) Tight dural and through-and-

through scalp closure, or (2) institution of open fungus treatment (8). In the author's opinion there is no indication for rubber-dam or catheter drainage of such a resected bed. Definitive closure of the dura (with a suitable graft) and scalp is most desirable but not always feasible. It is in making the decision as to which of the two courses to follow that the surgeon's perspicacity is most severely taxed. In general, use of the open fungus method is reserved for patients presenting with old (4 to 5 days) untreated craniocerebral wounds who manifest frank fungating cerebritis and for patients who have had previous resection and closure, but who for one reason or another have developed cerebritis with cerebral fungus formation.

OPEN FUNGUS TREATMENT

Following resection as just described, lumbar puncture will facilitate further retraction of the cerebrum. Withdrawal of 60 to 80 cc. of fluid is usually sufficient. The new brain surface is then thoroughly irrigated with saline and covered with a square of pure, fine mesh autoclaved silk cloth soaked in saline or penicillin solution. The moist, nonirritating piece of silk is covered with strips of petrolatum-impregnated gauze. Gauze fluffs are incorporated in the dressing which is held together by a 5-yard gauze roll (fig. 74).

INTERVAL CARE

The wound is redressed, inspected, and irrigated 4 and 8 hours after the initial resection. The frequency of dressings thereafter is determined by the appearance of the cerebral surface. Irrigation every 8 to 12 hours is usually necessary to decrease the accumulation of the products of progressive necrosis. Each dressing is carried out with the same precautions as those used in the operating room. The wound is exposed, the scalp edges are cleaned with thimerosal (Merthiolate), and the entire field is draped with sterile towels. Reshaving may be necessary every 2 to 3 days. The surface of the brain is thoroughly irrigated with a continuous stream of saline from an Asepto Syringe. Often, 8 to 12 hours after the initial resection, the brain may begin to protrude above the surface of the skull, forming a true cerebral fungus. This is not dis-

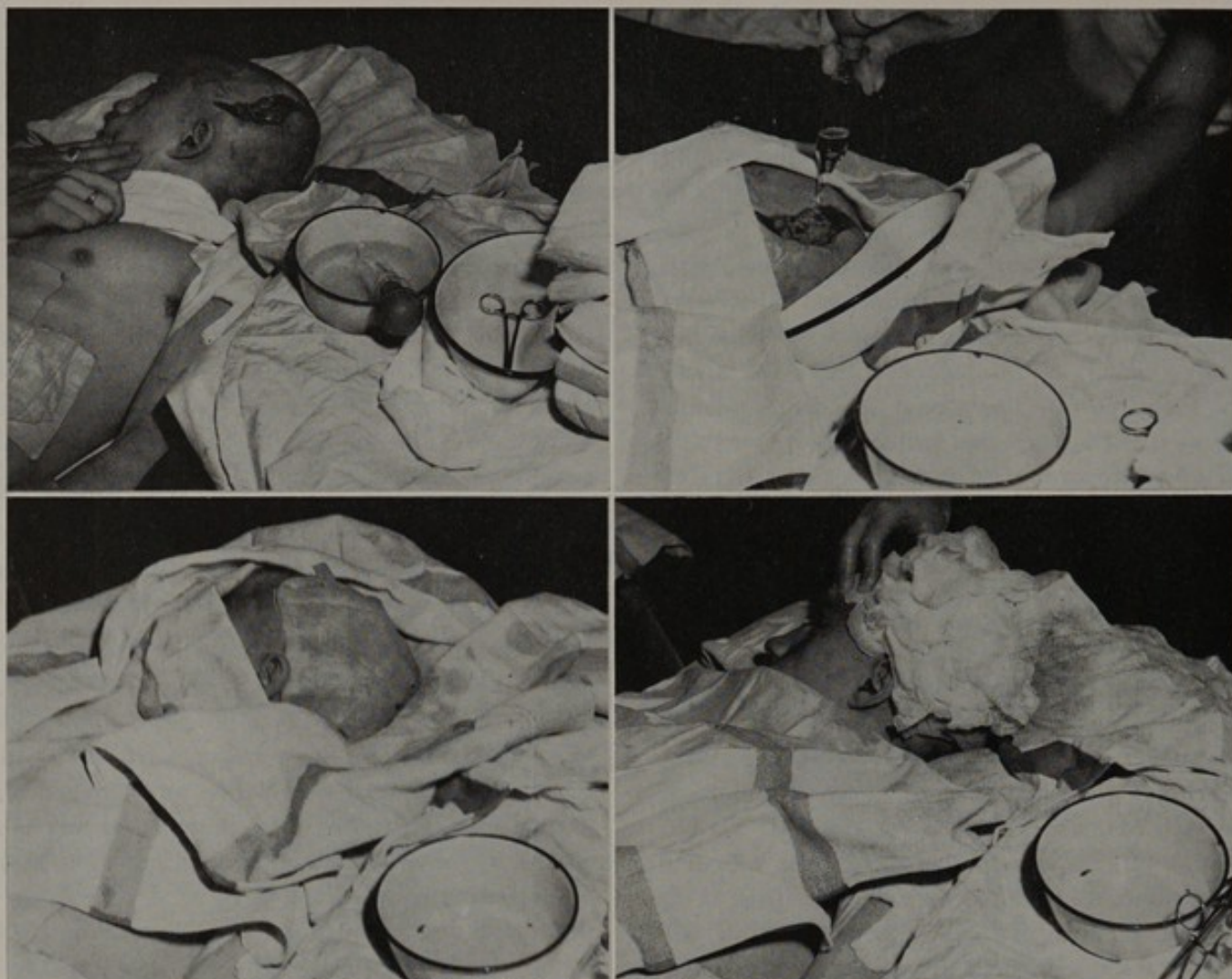


FIGURE 74.—Open fungus treatment.

astrous, the causative edema being less damaging if the brain is allowed to expand than if it is confined within the cranium by some artificial means. Excessive herniation may be controlled by lumbar punctures judiciously repeated whenever the progression of herniation is rapid. In such cases, it may be necessary to separate the scalp edges bluntly from the underlying cortical surface and irrigate the subdural space. Duration of open treatment depends on the appearance of the cerebral surface and on the clinical response of the patient. As infection subsides and debris and exudates are washed away, the surface of the brain assumes a pinkish-gray appearance and takes on a firm consistency. This is usually accompanied by cessation of progressive fungation, indicating that the infection has subsided completely and that it may be safe to perform secondary closure.

FINAL CLOSURE

The patient is prepared for secondary craniotomy. The edges of all layers of the scalp are freshened. The cerebral surface is cleanly resected by sharp dissection, employing silver clips for hemostasis. The dural edges are freed from the cortex and the dural defect is repaired with a fascia lata graft which is secured with interrupted sutures of fine silk. The scalp is closed in layers without tension, using whatever plastic procedure may be feasible in the individual case. Cranioplasty is deferred for at least 12 months.

This method of treating fulminating fungating cerebritis was utilized in Korea in 28 instances. The employment of this method has been associated with the reduction of mortality and morbidity and has been felt to be an essential factor in lessening

the ultimate neurological deficits in instances of severe infection.

An 18-year-old American soldier (K-1673) sustained a penetrating missile wound of the left parietal lobe on 15 September 1950. A craniectomy was performed at a forward surgical installation with "evacuation of clots, debridement of cortex, and removal of depressed bone fragments." Two days later, at a station hospital, the wound was revised and the dural defect was closed. On admission to the neurosurgical center at Tokyo Army Hospital 7 days later, the patient appeared lethargic, but could be roused. He had a mixed aphasia. There was marked right hemiparesis with right hyperreflexia. Roentgenograms of the skull revealed numerous retained bone fragments.

First operation.—Reoperation was effected with removal of an extensive subdural hematoma, retained bone fragments, and frank pus at the depth of the missile track.

Course.—Seven days later, the wound began to separate. After 11 days, a large cerebral fungus presented on the surface.

Second operation.—The fungus and the surrounding cerebritic cortex were resected.

Course.—Open therapy was instituted. After 3 days, the surface of the brain appeared clean and had assumed a firm consistency. There was no increasing protrusion of brain substance.

Third operation.—The presenting cerebral surface was again resected and the dural defect closed with a fascia lata graft. Scalp was closed without drainage.

Course.—Postoperatively, the patient fared well except for slight separation of the skin edges without evidence of infection. This healed spontaneously. At time of evacuation to the Zone of Interior 2 months later, the scalp was well healed. The patient had regained considerable motor power on the right side. A right upper quadrantal field defect persisted. There was minimal residual dysphasia.

A followup letter, received 26 months after the initial injury, revealed that there had been complete recovery from the neurological deficit. On phenobarbital medication, the patient had had one seizure. He also reported that cranioplasty was postponed for 15 months because of intermittent drainage from the superficial layers of the scalp. There had been no infection since then. Following discharge from the Army in October 1952, the patient was employed in the vehicle storage division of an Air Force base.

SURGICAL MANAGEMENT OF SPECIFIC INFECTIONS

A. Infected scalp lacerations:

1. Wide shave followed by thorough soap and water scrub of area and laceration.
2. Forceful irrigation and finger palpation search for foreign bodies.
3. Twice daily moist dressings.
4. Interval excision (or debridement) of contaminated area.
5. Irrigation and closure with through-and-through suture.

B. Localized subgaleal abscess:

1. Aspiration, irrigation, and antibiotic instillation often sufficient.
2. With persistent suppuration, wound opened and managed as infected laceration.
3. With complicating compound depressed skull fracture, soft tissue cleansing as described, followed by wide craniectomy and through-and-through closure.

a. Widespread subgaleal abscess (subgaleal empyema):

- (1) Parallel incisions.
- (2) Thorough irrigation and through-and-through drains.

C. Meningitis:

1. Search for and removal of contributing causes (bone or metallic fragments, cerebrospinal fluid fistula).
2. Antibiotics and chemotherapy.

D. Subdural abscess:

1. Surgical evacuation, irrigation, removal of foreign bodies, and closure.
2. If persistent, management as cerebritis.

E. Brain abscess and cerebritis:

1. Abscesses usually free pus rather than encapsulated.
2. Wide resection of soft tissue and cranium, if previously untreated.
3. Wound extension and additional craniectomy, if scalp healed.
4. Track cleansing with suction, irrigation, and palpation.
5. Resection of surrounding infected brain and abscess capsule, if present.
6. Meticulous hemostasis.
7. Tight dural and scalp closure.

F. Open fungus treatment:

1. Only in old untreated wounds presenting

- frank fungating cerebritis or recurrent cerebritis and fungus formation after other previous resection.
2. Extracranial and intracranial resection as described above.
 3. Fine mesh silk cloth covering for brain surface and fluffy moist dressing.

4. Frequent (8 to 12 hours) aseptic dressings with irrigation and forceps debridement of brain surface.
5. Control of brain herniation with interval lumbar puncture.
6. Ultimate definitive resection followed by dural and scalp closure.

REFERENCES

1. Annual Report, Consultant in Neurological Surgery, Far East Command, 31 Dec. 1951.
2. Final Report on the Care of Neurosurgical Casualties in the Korean War During the Period September 1950-August 1952, by Lt. Col. Arnold M. Meirowsky, MC, former Neurosurgical Consultant to the Chief Surgeon, Far East Command, 1 Sept. 1952.
3. Meirowsky, A. M.: Penetrating Craniocerebral Trauma; Observations in Korean War. *J.A.M.A.* 154: 666-669, 20 Feb. 1954.
4. Schwartz, H. G., and Roulhac, G. E.: Craniocerebral War Wounds; Observations on Delayed Treatment. *Ann. Surg.* 121: 129-151, February 1945.
5. Matson, Donald D.: The Treatment of Acute Craniocerebral Injuries Due to Missiles. American Lecture Series No. 22. American Lectures in Surgery. Springfield, Ill.: Charles C Thomas, 1948.
6. Wallace, P. B., and Meirowsky, A. M.: The Repair of Dural Defects by Graft. An Analysis of 540 Penetrating Wounds of the Brain Incurred in the Korean War. *Ann. Surg.* 151: 174-180, February 1960.
7. Wannamaker, G. T., and Pulaski, E. J.: Pyogenic Neurosurgical Infections in Korean Battle Casualties. *J. Neurosurg.* 15 (pt. 5): 512-518, September 1958.
8. Meirowsky, A. M., and Harsh, G. R., III: The Surgical Management of Cerebritis Complicating Penetrating Wounds of the Brain. *J. Neurosurg.* 10: 373-379, July 1953.

CHAPTER 13

Tangential Wounds of Scalp and Skull

Philip R. Dodge

In a tangential head injury, the missile does not penetrate the skull but merely glances or grazes it. The scalp is lacerated and the cranium may be only guttered or depressed and fragmented. The dura may be pierced by bony spicules or remain intact whether or not a fracture has been induced. Regardless of the extent of damage to the overlying skull, contusion of the underlying brain is common.

The principal error committed in management of patients with tangential head injury is underestimating its seriousness for, beneath a seemingly simple scalp laceration, there may be considerable disruption of cerebral tissue with prominent clinical symptoms and signs. It is this aspect of the glancing or grazing injuries, in particular, that has stimulated the interest of several students of trauma and prompted them to report on their experiences (1) (2) (3) (4). Our analysis of the acute syndrome in a small series of such patients studied during the Korean War has been reported elsewhere (5). These findings along with experiences gained from a larger group of similar cases, including a 7-year followup study, form a basis for the following remarks.

GENERAL PATHOPHYSIOLOGICAL CONSIDERATIONS

Response of the skull and underlying brain tissue to local impact has been studied in experimental models and in animals (6) (7). It is clear from these studies that depression of bone develops locally at the point of contact and that the distorting force is transmitted to the underlying brain which is, as a

consequence, compressed (fig. 75, A1). If the elasticity of bone is barely exceeded, the inner table of the skull alone may break (fig. 75, A2); but, if the force is greater, the structural integrity of both inner and outer tables will be lost (fig. 75, A3). Fractures so induced may be linear but are more often stellate in shape.

Contusion and laceration of the brain are frequent in tangential injury, but experimental and clinical observations suggest that some of the immediate cerebral dysfunction that follows such an injury has the characteristics of a local concussion; the symptoms and signs being too transient to be explained by contusion alone (5) (8) (9). For example, a glancing blow over the left motor-hand area may result in a transient hemiparesis and hemisensory defect in the absence of generalized concussion. This disturbance of function may persist for minutes or hours leaving a minimal amount of residual arm and finger weakness. Serial electroencephalographic studies during the immediate postinjury period, in such patients and in animals, by Meyer and Denny-Brown (9), have revealed diminished electrical activity in the region of injury. This is observed before the expected high-voltage delta activity develops and coincides in time with the transient clinical symptoms and signs. As a result of experimental studies, Meyer and Denny-Brown state that trauma induces reversible damage to the neural membrane and conclude that this constitutes the essential disturbance in both localized and general concussion. This appears not to be a consequence of anoxia or vascular change, and there need not be any significant histological lesions associated with the concussive blow. However, in contusion, Meyer (10)

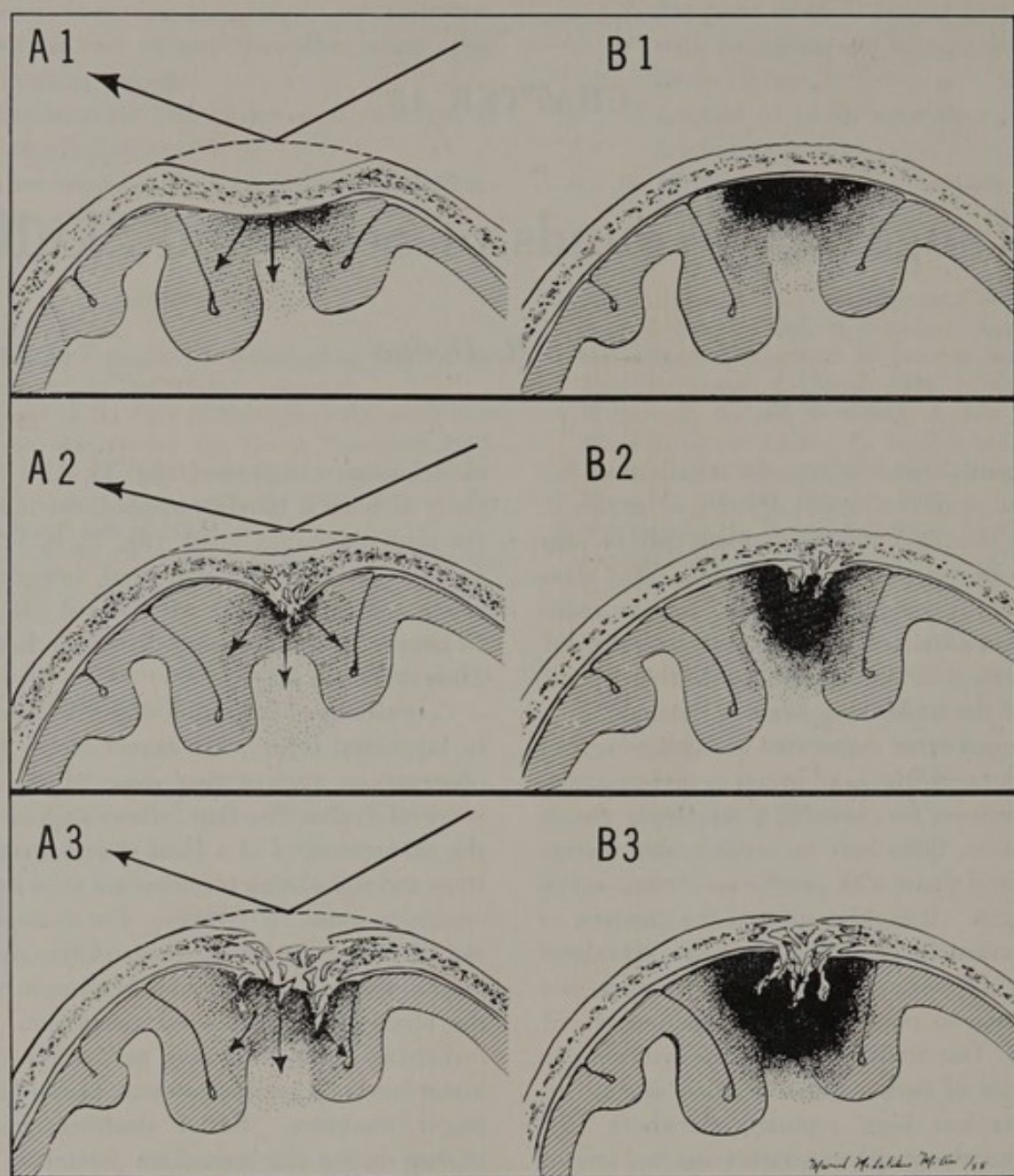


FIGURE 75.—The arrows depict the course of the missile. The manner in which bone, dura, and brain may be distorted immediately after impact is shown in views A1, A2, and A3. The resultant injuries are illustrated in views B1, B2, and B3.

reports physiological evidence of localized impairment in circulation and hypoxia developing within a few minutes of impact and coinciding with the development of petechial hemorrhages. Whether anoxia induces these hemorrhages is uncertain. If a blow applied to produce the concussion or contusion disrupts the continuity of pial vessels, more extensive intracerebral and subarachnoid hemorrhages may result. This is common in laceration though

this type of lesion may, on the other hand, be relatively avascular.

PATHOLOGICAL FINDINGS

A missile striking the head tangentially almost invariably damages the cerebrum immediately beneath the point of contact. Contusion and laceration of

the brain are usual; all but 1 of 19 operative cases in our original series demonstrated such findings (5). At operation, the dura may appear plum colored when there has been bleeding associated with contusion and laceration. In fact, frank intracerebral clots from 10 to 12 ml., usually admixed with pulped brain, were found in 9 of the original 19 operative cases (fig. 75, B1, B2, B3). In the early days or weeks after injury, the diseased region is often so devitalized, necrotic, and edematous that it will extrude spontaneously through a lacerated or surgically incised dura. In addition to intracerebral clots, four subdural and three epidural hematomas of compressive proportions developed and produced symptoms and signs of an expanding intracranial mass on two occasions in our original series.

CLINICAL FEATURES

Most glancing or tangential injuries in wartime result from shells, grenades, mortar fragments, or from high-velocity missiles discharged from rifles, carbines, machineguns, and other automatic weapons. Occasionally, a flying rock will inflict a similar blow. In most instances (87 percent), the nature of the fighting at time of injury permits the soldier to say with fair certainty what caused his injury. In our followup study, 30 (77 percent) of 39 patients queried concerning this point stated that they were wearing helmets when injured. However, replies to this type of question are difficult to evaluate since there is understandable concern on the part of the patient, despite reassurance to the contrary, that he might be penalized in compensation matters for neglecting to wear this protective covering. Whether in a given case an injury might have been more severe in the absence of a helmet cannot be answered, but we suspect this to be true. On the other hand, of course, there is no doubt that fragments as well as high-velocity missiles can penetrate a steel helmet and then graze the scalp and skull.

Examples of fractures discussed earlier have been encountered in patients with tangential head injury whom we have studied. However, even if grooving of the outer table is included in the fracture group, only 25 percent of the patients had a fracture.

There was no loss of consciousness in 41 percent

of our patients with tangential head injury even if contusion or laceration were sustained. Posttraumatic amnesia when it occurs is usually briefer in these patients and many can describe the experience of being struck. These last two facts indicate that extreme acceleration and deceleration of the head, as occur so commonly in blunt head injury, are lacking in most tangential injuries. There was no significant difference in the incidence of concussion that could be related to the type of missile or the intactness of skull and dura. The seriousness of focal neurological signs could not be correlated with disturbance in consciousness since some patients who had not received a concussion had extensive focal signs and vice versa.

Since damage to the brain was usually local and restricted to the region immediately beneath the point of impact of the missile, the focal neurological symptoms and signs were easily relatable to the injury. As would be expected, focal signs were most prominent when the wound overlay a region of cortex, damage to which produced readily recognizable evidence of cerebral dysfunction. Thus, focal signs were nearly universal from wounds overlying the motor and sensory cortices. In contrast, wounds of the anterior frontal region were usually silent. The correlation between site of scalp injury and focal neurological signs in the 31 cases previously studied is presented in table 11. It is seen that 22 (71 percent) of the 31 patients had focal symptoms or signs. The patients without focal signs were injured in the frontal, posterior parietal, occipital, and nondominant temporal lobes. The neurological signs when present are often strikingly focal or re-

TABLE 11.—*Correlation between the site of injury and focal neurological signs in 31 cases*

Site of injury	Number of cases	Number with focal signs
Anterofrontal	5	0
Frontoparietal	17	¹ 16
Occipital	4	3
Temporal	3	² 1
Frontotemporal	1	1
Temporoparietal	1	1
Total	31	22

¹ The case without focal signs had a postparietal injury.

² Both cases without focal signs had nondominant hemisphere injuries.

stricted, so that quadratic field defects and motor or sensory dysfunction limited to a limb or part of a limb are not uncommon. In this regard, as one might anticipate, patients with extensive, depressed fractures tend to have greater loss of brain tissue and more global signs. Bilateral sensory and motor signs are usual in parasagittal injuries, even in the absence of fracture. The phenomenon of local concussion, mentioned previously, was noted in at least five patients whom we studied.

Progression of focal neurological signs is unusual in tangential injury and was encountered only twice in our reported series. In one instance there was a large subcortical hematoma and in the other instance a subdural hematoma. In every operative case, sufficient contusion and/or laceration was found to explain all but the most transient signs.

In the original series, 9 of 12 patients who answered the questionnaire still had focal signs 7 years after injury. When our larger series of 44 cases (including the original 12) is considered, it is found that 6 (46 percent) of 13 cases without fracture, 14 (74 percent) of 19 cases with fracture but without dural laceration, and 10 (83 percent) of 12 cases with fracture and dural laceration reported persistent focal signs and symptoms some 7 years after injury. As would be anticipated, focal neurological signs persisted most often in those patients who had sustained the most extensive initial cerebral damage.

Evidence of a generalized increase in intracranial pressure was uncommon in our experience with tangential head injury. Some depression in state of consciousness and blurring of optic disk margins with associated engorgement of veins was seen occasionally. We observed the progress of these signs in two patients prior to surgery.

Either localized or generalized headache was complained of in 85 percent of the patients immediately following tangential head injury. Some of these were probably related to increased intracranial pressure, but this was certainly not so in a majority of cases. Similar headaches were reported in 33 (85 percent) of 39 cases 7 years later. Thus, headache represents the most common persisting complaint. Only two of these patients admitted to having had headaches prior to injury. A great many types of headache are complained of and although the description suggests a psychiatric causation in some, the majority would seem not to be so explained.

Pain in the region of the injury on exposure to extremes of heat was commented upon a few times and could be explained, in some instances, by the presence of a metallic prosthetic plate.

Seizures may occur within the first few days after a tangential head injury and always reflect injury, albeit slight, to the cortex (5). This was true of 6 (19 percent) of 31 cases that we studied, and from 2.5 to 5.0 percent of a larger series studied by others (3) (11). Extensive cortical injury and involvement of the sensorimotor cortex increases the likelihood of seizures. Fits may be Jacksonian, focal, or generalized but more often than not their nature suggests a discharging focus near the site of injury. In most instances, seizures will recur during the immediate postinjury period, but the mechanism of their production is probably different from that of late posttraumatic epilepsy and no significant relationship between these early and late posttraumatic seizures exists (12). Unfortunately, we have been able to secure followup information from only three of six patients with early posttraumatic seizures included in our original report; none has developed posttraumatic epilepsy or received anticonvulsant medication. On the other hand, six of the nine patients remaining in the original group from whom followup reports are available have developed late posttraumatic seizures (table 12, pp. 148-159).

The incidence of late epilepsy in our followup group of 44 cases (including the 12 from the original series) of tangential injury is 6 (46 percent) of 13 cases without fracture or dural laceration, 11 (58 percent) of 19 cases with fracture but no dural laceration, and 10 (83 percent) of 12 cases with fracture and dural laceration. Thus, 27 (61 percent) of 44 cases have experienced late posttraumatic seizures! This is an extraordinarily high incidence and may reflect some selection, since individuals with such difficulties may be more likely to answer the questionnaire. If one assumes that all patients with late posttraumatic seizures are included in the questionnaires received, the incidence would still be 20 percent.

An operation was performed on all but one, and the contused and necrotic cerebrum was evacuated in all but three of the patients who developed posttraumatic epilepsy. Careful debridement of the contused cortex would appear not to lessen materially the liability to posttraumatic epilepsy. The liabil-

ity to seizures may be somewhat greater in patients with extensive cerebral damage as contrasted with milder injuries, but the number of cases is too small to permit a definite conclusion.

MANAGEMENT OF TANGENTIAL HEAD INJURIES

The scalp laceration must be treated with meticulous care in the manner described in chapter 8, "Scalp Lacerations." Prompt craniotomy is indicated if there are progressing neurological signs, if there is evidence of increasing intracranial pressure, or a depressed skull fracture. The operative technique is essentially as outlined in chapter 10, "Penetrating Wounds of the Brain." If the primary consideration for surgery is a depressed fracture and no dural penetration is found, some observers in the past have debated the necessity of opening the dura.¹

In addition to the preceding indications for surgery, we usually explored the brain in all patients with seizures and in all patients with focal neurological signs persisting with minimal or no improvement for several days. In these situations, as in each of the preceding ones, we incised the dura and removed any clots and devitalized cerebral tissue by a combination of suction and irrigation with copious amounts of saline. Often the adjacent contused tissue has been resected sharply to normal brain tissue. We have not and do not believe that simple contusions should be tampered with. Hemostasis is accomplished with silver clips and electrocautery. In every instance the dura should be closed with interrupted sutures of fine black silk and the scalp closed without drainage.

The wisdom of exploring the brain in the absence of a depressed fracture or of nonprogressive cerebral disease may be open to question, but epidural, subdural, and subcortical hematomas of compressive proportions have been encountered often enough in our experience to lead us to err in this direction. Furthermore, the desirability of removing devitalized tissue is difficult to assess. Cairns (13) has emphasized that the neurological symptoms and signs from superficial cerebral injury tend to im-

prove spontaneously, and with this we agree. However, our impression is that recovery may be hastened by this procedure, although crucial data to prove this point are lacking. It has been suggested in the past that the liability to posttraumatic epilepsy is lessened by removal of necrotic debris but this appears unlikely on the basis of our findings.

It should be noted that no secondary brain abscesses were encountered in our initial series. Meningitis developed months or years later in four patients in the larger series and one patient suffered twice from this complication. Three of these four patients had wounds involving the frontal air sinuses.

REFERENCES

1. Cushing, H.: A Study of a Series of Wounds Involving the Brain and Its Enveloping Structures. *Brit. J. Surg.* 5: 558-684, April 1918.
2. Horrax, G.: Observations on a Series of Gunshot Wounds of the Head. *Brit. J. Surg.* 7: 10-54, July 1919.
3. Jefferson, G.: Gunshot Wounds of the Scalp With Special Reference to the Neurological Signs Presented. *Brain* 42: 93-112, June 1919.
4. Gamlen, H. E., and Smith, S.: A Study of the Interrelation Between the Radiography and Surgery of Gunshot Wounds of the Head. *Arch. Radiol. & Elec.*, 22: 240, January 1918; 270, February 1919.
5. Dodge, P. R., and Meierowsky, A. M.: Tangential Wounds of Scalp and Skull. *J. Neurosurg.* 9: 472-483, September 1952.
6. Coe, G. B., MacNamee, J. K., and Herget, C. M.: Brain Injury From Local Impact Without Skull Fracture. *Mil. Surgeon* 111: 428-432, December 1952.
7. Gurdjian, E. S., Webster, J. E., and Lissner, H. R.: The Mechanism of Skull Fracture. *J. Neurosurg.* 7: 106-114, March 1950.
8. Russell, W. R.: Transient Disturbances Following Gunshot Wounds of the Head. *Brain* 68: 79-97, June 1945.
9. Meyer, J. S., and Denny-Brown, D.: Studies of Cerebral Circulation in Brain Injury. III. Cerebral Concussion. *Electroencephalog. & Clin. Neurophysiol.* 7: 529-544, November 1955.
10. Meyer, J. S.: Studies of Cerebral Circulation in Brain Injury. III. Cerebral Contusion, Laceration and Brain Stem Injury. *Electroencephalog. & Clin. Neurophysiol.* 8: 107-116, February 1956.
11. Wagstaffe, W. W.: Gunshot Wounds of the Head. *In* History of the Great War, Based on Official Documents; Medical Services, Surgery of the War. Edited by W. G. Macpherson and others. London: His Majesty's Stationery Office, 1922, vol. 2, pp. 1-39.
12. Denny-Brown, D.: The Clinical Aspects of Traumatic Epilepsy. *Am. J. Psychiat.* 100: 585-592, March 1944.
13. Cairns, H.: Gunshot Wounds of the Head in 1940. *J. Royal Army M. Corps* 76: 12-22, January 1941.

¹ In the Korean War, opening the dura in the presence of a depressed fracture was policy. The necessity of opening the dura in all instances of depressed fractures has been discussed in detail in chapters 9 and 11.—A.M.M.

TABLE 12.—*Tangential scalp*

Patient	Time elapsed from injury until seen by surgeon	Time elapsed from first examination until operation	Period of hospitalization	Wounding agent	Loss of consciousness prior to admission	Area of scalp lacerated	Helmet worn	Initial focal neurological signs and symptoms	Early seizures	Roentgenographic findings
K-201 . . .	Days 33	Days 2	Days 13	High velocity missile.	No	Right parietal, near midline.	Yes . . .	Immediate paralysis legs and left arm; complete recovery right leg in 1 day; gradual recovery left hemiparesis until on admission residual paralysis below left knee which had persisted unchanged since injury; hyperreflexia and extensor plantar response, left; equivocal Babinski, right; absent cortical sensation below left knee.	None	Outer table of skull grooved under scalp laceration.
K-1466 . . .	55	8	34	do	5 mins . . .	Left mid-parietal.	Yes . . .	Paresis, right arm for 1 day; history suggesting cortical sensory defect, several weeks; no objective abnormalities.	6 sensory seizures progressing from right trunk to arm, hand, face, and occasionally leg.	Depressed fracture under scalp laceration.
K-292 . . .	8	0	32	do	No	Left parietal.	Yes . . .	No weakness, but difficulty in using fingers of right hand, fine movements; this persisted for a few days.	Several seizures; 3 observed to begin with movements of right side and to become generalized.	None
K-925 . . .	7	2	20	do	30 mins . .	Left occipital.	No . . .	No symptoms, but right upper quadrant visual field defect on examination.	None	No fracture . . .

wounds in 31 patients

Operative procedure and surgical pathology	Clinical course in hospital in early postinjury period	7-year followup questionnaire							
		Residual focal neurological signs and symptoms	Late post-traumatic seizures	Menigitis since injury?	Are you well?	What bothers you?	Headaches?	Working status	Discharge from Army because of injury?
Right parietal craniectomy; skull grooved; cortical contusion and laceration under distended rolandic vein; liquefied cortex removed by suction and irrigation.	Alert and oriented on admission; occasional bitemporal headaches; no papilledema; lumbar puncture not done; 75% recovery in motor function within 1 day after operation; on transfer to Zone of Interior, slight residual paresis; partial recovery in cortical sensation.	Weakness of left leg.	Occasional focal motor seizure of left leg; no medication.	No....	No....	Headaches, difficulty with left leg.	Yes.....	Full time.	Yes.
Left parietal craniectomy; depression both tables of skull; cortical contusion and meningocortical adhesions; adhesions freed; Gelfilm placed between meninges and cortex.	Alert and oriented on admission; right frontal headaches; no papilledema, C.S.F. pressure normal; slow wave focus over site of injury on EEG; no seizures following operation but temporary cortical sensory defect, right hand; neurological examination negative and no headaches on transfer to Zone of Interior.	Occasional dragging of right leg when tired.	None.....	No....	Yes....		No.....	Regular Army.	No.
Left parietal craniectomy; skull intact; cortical contusion and subcortical hematoma; clot evacuated by suction and irrigation.	Confused, lethargic on admission (? postictal state); no headaches; no seizures postoperatively; temporary right facial weakness; P.E.G. normal; abnormal EEG with nonfocal, generalized bursts of 4 to 6 per sec., moderately high amplitude slow waves; neurological examination negative on transfer to Zone of Interior.	None.....	do....	No....	Yes....		Yes.....		No.
Left occipital craniectomy; skull intact, cortical contusion; contused area resected.	Alert and oriented on admission; severe left occipital and generalized headaches; no papilledema; C.S.F. pressure 230 mm.; fluid blood-tinged; total protein 25.5 mg. %; visual field defect persisted after operation; no headaches at time of transfer to Zone of Interior.	Persistent field defect.	Rare "black-out spells" until present time; no medication.	No....	No....	Headache and "black-outs."	Yes, 2 to 3 mos. in right frontal region.	Full time.	Yes.

TABLE 12.—*Tangential scalp*

Patient	Time elapsed from injury until seen by surgeon	Time elapsed from first examination until operation	Period of hospitalization	Wounding agent	Loss of consciousness prior to admission	Area of scalp lacerated	Helmet worn	Initial focal neurological signs and symptoms	Early seizures	Roentgenographic findings
K-1836...	14	No operation.	33	Metallic fragment.	Few secs.	Left parietal, near midline.	(?).....	Immediate numbness both legs, lasting few secs.; paralysis, right leg, for 1 hour; paresis of flexors of right hip and knee on examination; reflexes and sensory system intact.do.....do.....
K-1914...	15	6.....	26	High velocity missile.	Few secs.	Right parietal.	(?).....	No symptoms, but questionable left upper motor neuron-type facial weakness.do.....	Depressed fracture under scalp laceration.
K-845....	35	16.....	28	Metallic fragment.do.....	(?).....	Immediate onset left hemiparesis and numbness which cleared partially until on admission spastic paresis and cortical sensory loss left leg; Babinski sign on left.do.....	No fracture...
K-820....	2	6 (1st operation).	30do.....	5 hrs.....	Left occipital.	Yes....	No focal neurological symptoms, but on examination slight weakness left arm, increased deep tendon reflexes left, with left extensor plantar; slightly dilated left pupil and suggestive cerebellar signs.do.....	No fracture; calcified pineal in midline (prior to 1st operation).
		18 (2d operation).								
K-319....	6	6.....	22	Left parietal.	(?).....	No neurological deficit until 1 day after injury when dysphasia and right facio-brachial monoparesis developed; no reflex or sensory abnormalities.	Several generalized clonic seizures; reported not to have lost consciousness.	No fracture...

wounds in 31 patients—Continued

Operative procedure and surgical pathology	Clinical course in hospital in early postinjury period	7-year followup questionnaire							
		Residual focal neurological signs and symptoms	Late post-traumatic seizures	Menigitis since injury?	Are you well?	What bothers you?	Headaches?	Working status	Discharge from Army because of injury?
No operation.....	Alert and oriented on admission; generalized headaches becoming localized over right eye on admission; retinal veins slightly engorged; disks hyperemic; EEG borderline abnormal, 2 bursts 20 to 22 per sec., bifrontal sharp waves; neurological examination negative and no headaches on return to duty.								
Right parietal craniectomy; depression both tables of skull, cortical contusion, subcortical hematoma; clot evacuated by suction and irrigation.	Alert and oriented on admission; no headaches; slight blurring of optic disks; C.S.F. pressure 270 mm.; fluid crystal clear, 7 RBC per cu. mm.; total protein 37 mg. per 100 ml.; rapid recovery after operation; neurological examination negative at time of transfer.								
Right parietal craniotomy; skull intact; cortical contusion and laceration in leg area; needle aspiration for intracerebral clot.	Alert and oriented on admission; no papilledema; C.S.F. pressure 178 mm.; postoperative course unremarkable, only slight improvement in neurological signs at time of transfer.								
1st operation: Left occipital trephination and ventricular tap; left suboccipital craniectomy; contusion left cerebellar hemisphere inspected.	Oriented but responses slow; optic disk margins blurred; C.S.F. pressure 240 mm. and 290 mm. after 1st operation; generalized, intermittent mild headaches. Following second operation, patient's signs cleared slowly.	Poor balance; deaf, left ear.	None,....	No....	No....	Deafness and ringing in left ear.	Infrequent, last one day, in area of injury.	Regular Army.	No.
2d operation: Bifrontal trephination; 40 cc. left frontal hydroma evacuated.									
Left parietal craniectomy; skull intact; dura tense, cortical contusion; large subcortical hematoma, evacuated by suction and irrigation.	Confused and dysphasic (? postictal) on admission; apparent progression of signs; no papilledema; C.S.F. not recorded, P.E.G. revealed 3d ventricular shift to right and slight depression of left lateral ventricle; no seizures postoperatively and no abnormal neurological findings on transfer to Zone of Interior.	None.....	do....	No....	No....	Headache.	Yes; not described.	Not reported.	Yes.

TABLE 12.—*Tangential scalp*

Patient	Time elapsed from injury until seen by surgeon	Time elapsed from first examination until operation	Period of hospitalization	Wounding agent	Loss of consciousness prior to admission	Area of scalp lacerated	Helmet worn	Initial focal neurological signs and symptoms	Early seizures	Roentgenographic findings
K-1959...	1	0.....	24+	High velocity missile.	No.....	...do.....	(?).....	Immediate paralysis, right arm, numbness, right side; examination revealed severe paresis, right arm, increased deep tendon reflexes without extensor plantar, right; cortical sensory loss, right.	None.....	Outer table of skull grooved under scalp laceration.
K-780.....						Left temporo-parietal.	(?).....	Severe dysphasia and right hemiparesis on admission to field hospital.	...do.....	
K-1390...	4	30.....	40	Metallic fragment.	Left occipital.	(?).....	No neurological symptoms, but questionable right upper quadrant visual field defect on examination.	3 seizures observed beginning with deviation of eyes to right, vocal arrest and clonic movements of arms.	No fracture...
K-1515...	3	No operation.	26	Few secs	Right parietal.	(?).....	Immediate paralysis legs, return of function right leg in several hours, persistent weakness and numbness left leg; left hemiparesis and cortical sensory deficit (leg involved more than arm) on examination.	None.....	...do.....
K-1105.....			17			Left posteroparietal.	(?).....	None.....	Generalized seizure beginning right side.	Inner table fracture with depression under scalp laceration.

wounds in 31 patients—Continued

Operative procedure and surgical pathology	Clinical course in hospital in early postinjury period	7-year followup questionnaire							
		Residual focal neurological signs and symptoms	Late post-traumatic seizures	Menigitis since injury?	Are you well?	What bothers you?	Headaches?	Working status	Discharge from Army because of injury?
Left parietal craniectomy; skull grooved; dura tense, cortical contusion, subcortical hematoma (8 to 10 cc.) removed by suction and irrigation.	Patient dazed on admission, generalized headache; no papilledema; lumbar puncture not done; gradual improvement postoperatively; slight 4 to 6 per sec. slow wave focus in left parietal area on EEG after operation; no headache, but mild residual spastic paresis of right arm and unchanged sensory deficit on transfer.	Slight weakness, right face.	Occasional focal motor, right face; no medication.	No....	Yes....	"Nothing."	No.....	Regular Army.	No.
Left temporoparietal craniectomy; skull intact; dura tense, cortical contusion, distended cortical vein, large subcortical hematoma removed by suction and irrigation.	Patient operated upon at field hospital and adequate followup is lacking.								
Left occipitoparietal craniectomy; skull intact; cortical contusion; cannula aspiration for intracerebral clot.	Alert and cooperative on admission; generalized headaches and pain behind eyes; preoperative P.E.G. normal; no papilledema; C.S.F. pressure 290 mm., fluid normal; no seizures postoperatively during 10-day period of observation prior to transfer to Zone of Interior.								
No operation.....	Alert and oriented on admission; no papilledema; lumbar puncture not done; gradual recovery; left arm normal on transfer to Zone of Interior, although residual weakness and cortical sensory deficit present in left leg.								
Left parietal craniectomy, crease outer table and depression inner table of skull; dura tense; 30 to 40 cc. subdural hematoma and 10 cc. subcortical hematoma, cortical contusion; clots evacuated by suction and irrigation.	Patient drowsy on admission, no papilledema; lumbar puncture not done; uneventful recovery with no seizures following operation; no neurological findings on transfer to Turkey.								

TABLE 12.—*Tangential scalp*

Patient	Time elapsed from injury until seen by surgeon	Time elapsed from first examination until operation	Period of hospitalization	Wounding agent	Loss of consciousness prior to admission	Area of scalp lacerated	Helmet worn	Initial focal neurological signs and symptoms	Early seizures	Roentgenographic findings
K-2257...	4	1.....	25	High velocity missile.	Several mins.	Left parietal.	(?).....	Right hemiparesis with slight spasticity of long flexors of fingers; deep tendon reflexes increased on right but plantar flexor; cortical sensory deficit over ulnar side of right hand.	None.....	No fracture...
K-1040...	3	2.....	16	Metallic fragment.	No.....	Right parietal.	(?).....	Immediate paralysis, left leg which was complete and spastic on admission; deep tendon reflexes increased on left with extensor plantar; cortical sensory deficit, left leg.	Multiple focal sensory seizures involving left abdomen, trunk, arm, hand, and face.do.....
K-1113...	2	1.....	16	High velocity missile.	Right frontal.	(?).....	None.....	None.....	Depressed fracture under scalp laceration.
K-94.....	8	1.....	15	Left parietal, near midline.	Yes.....	Right hemiparesis, increased deep tendon reflexes, right, and diminished sensation over right trunk and leg (? quality); some questionable difficulty using left leg.do.....do.....
K-1807...	8	3.....	41	Metallic fragment.	Left frontal.	Yes.....	Depressed state of consciousness after injury and no history available; on examination, ptosis, left eye; eye directed downward and outward, pupils equal.do.....	No fracture...
K-1792...	7	1.....	55do.....	Left parietal.	Yes.....	Early symptoms not recorded; on examination, sensory dysphasia and slight right hemiparesis; no reflex or sensory abnormalities.do.....do.....

wounds in 31 patients—Continued

Operative procedure and surgical pathology	Clinical course in hospital in early postinjury period	7-year followup questionnaire							
		Residual focal neurological signs and symptoms	Late post-traumatic seizures	Menigitis since injury?	Are you well?	What bothers you?	Headaches?	Working status	Discharge from Army because of injury?
Left parietal craniectomy, skull intact; venous epidural hematoma (6 cm. diameter); subcortical hematoma (3 to 4 cm. diameter); clots evacuated by suction and irrigation.	Alert and oriented on admission; bifrontal headache, blurring of optic disk margins; gradual improvement in hemiparesis postoperatively but persistence of cortical sensory deficit on evacuation to Zone of Interior; fundi normal.								
Right parietal craniectomy, skull intact; cortical contusion and encephalomalacia; cannula aspiration for intracerebral clot.	Alert and oriented on admission; retinal veins engorged, disk margins blurred; lumbar puncture not done; no seizures postoperatively and considerable return of motor power, left leg; increased spasticity and persistent sensory deficit on transfer to Zone of Interior; fundi normal.								
Right frontal craniectomy; depression inner table skull; subdural hematoma, cortical contusion, encephalomalacia and subcortical hematoma; clots and encephalomalacia removed by suction, irrigation, and resection.	Lethargic but oriented on admission; headache localized at injury site; no papilledema; lumbar puncture not done; patient remained neurologically negative postoperatively; alert with no headache on transfer to Zone of Interior.								
Left parietal craniectomy, depression both tables of skull overlying sagittal sinus; cortical contusion, inspection only.	No papilledema; lumbar puncture not done; following operation persistent weakness, right leg, with foot-drop; deep tendon reflexes remain increased in right leg; question of cortical sensory loss in both legs on transfer to Zone of Interior.	Weakness right leg.	None.	No.	No.	Weakness, right leg.	No.	Full time.	Yes.
Bifrontal and left parietal trephinations; skull intact; large subdural hematoma in left frontoparietal region; clot removed by suction and irrigation.	Lethargic and disoriented on admission; fundi normal; lumbar puncture not recorded; rapid clearing in state of consciousness postoperatively; recovery of third nerve paresis in several months' time; return to limited duty.	None.	Yes, psychomotor.	No.	No.	Headache. .	Frequent, frontal.	Regular Army.	No.
Bifrontal trephinations and left parietal craniectomy; skull intact; venous extradural hematoma, cortical contusion and large subcortical hematoma removed by suction and irrigation.	Lethargic and apathetic on admission; slight engorgement retinal veins; lumbar puncture not recorded (lumbar puncture at another hospital said to have shown increased C.S.F. pressure and bloody fluid); gradual improvement following operation and no neurological abnormalities on transfer to Zone of Interior.	Subjective weakness right side.	None.	No.	No.	Headache, sore neck.	Yes.	Full time.	Yes.

TABLE 12.—*Tangential scalp*

Patient	Time elapsed from injury until seen by surgeon	Time elapsed from first examination until operation	Period of hospitalization	Wounding agent	Loss of consciousness prior to admission	Area of scalp lacerated	Helmet worn	Initial focal neurological signs and symptoms	Early seizures	Roentgenographic findings
K-1731...	5	4.....	27	(?) min., hrs.	Left temporal.	Yes....	Early history not available; dysphasia with right hemiparesis on examination.do.....	Depressed fracture under scalp laceration.
K-2258...	20	No operation.	22	High velocity missile.	No.....	Right parietal, near midline.	(?).....	Immediate onset left hemiparesis, arm and face recovered in few minutes; persistent weakness left leg and, on examination, spastic paresis with increased deep tendon reflexes, left leg; left plantar response, less active flexor than right; sensation normal.do.....	No fracture...
K-2259...	11	...do.....	25	...do...	No.....	Right temporal.	(?).....	None.....do.....	...do.....
K-2260...	112	...do.....do...	No.....	Left parietal.	(?).....	Immediate onset numbness and weakness right arm and face; face recovered in few days; on examination, slight weakness intrinsic muscles right hand; all sensation diminished over ulnar side, right hand.do.....	...do.....
K-977....	11	...do.....	34	Metallic fragment.	No.....	Left parietal at vertex.	No....	Immediate onset paralysis right leg below knee; on examination paresis right leg, paralysis right foot; increased deep tendon reflexes right leg with right extensor plantar; cortical sensory deficit right foot.do.....	...do.....

wounds in 31 patients—Continued

Operative procedure and surgical pathology	Clinical course in hospital in early postinjury period	7-year followup questionnaire							
		Residual focal neurological signs and symptoms	Late post-traumatic seizures	Meningitis since injury?	Are you well?	What bothers you?	Headaches?	Working status	Discharge from Army because of injury?
Left frontotemporal craniectomy, depression both tables skull; large venous extradural hematoma, cortical contusion and encephalomalacia; clot removed by suction and irrigation.	Lethargic on admission; retinal veins engorged, no lumbar puncture recorded; rapid recovery in state of consciousness, hemiparesis and dysphasia postoperatively; no neurological abnormalities on transfer to Zone of Interior.	Weakness, right arm and leg.	Yes, generalized; "taking pills."	No....	No....	Frontal headache daily.	Yes.....	Part-time.	Yes.
No operation.....	Alert and oriented on admission; no headaches; no papilledema; C.S.F. pressure normal; fluid acellular, total protein 64 mg. %; 4 to 7 per sec. slow waves from both parietal regions on EEG; slight weakness left lower leg on return to limited duty.								
do.....	Alert and oriented on admission; no papilledema; persistent headache, site of injury; C.S.F. pressure 125 mm., fluid normal; EEG normal; headache cleared spontaneously; evacuated to France.								
do.....	Alert and oriented on admission, several months after injury; throbbing left-sided headache; no papilledema; lumbar puncture not done; gradual recovery without treatment; disposition uncertain.								
do.....	Alert and oriented on admission; bifrontal headache; no papilledema; C.S.F. pressure normal; slight dilatation and elevation left lateral ventricle suggesting atrophy on P.E.G.; biparietal 3 to 4 per sec. slow wave foci (more prominent on right) on EEG; progressive improvement in all neurological signs; evacuated to Zone of Interior.	Weakness, right foot; ringing, both ears.	Yes, focal motor of eyes.	No....	No....	"Sharp" headache frequent.	Yes.....	Full time.	

TABLE 12.—*Tangential scalp*

Patient	Time elapsed from injury until seen by surgeon	Time elapsed from first examination until operation	Period of hospitalization	Wounding agent	Loss of consciousness prior to admission	Area of scalp lacerated	Helmet worn	Initial focal neurological signs and symptoms	Early seizures	Roentgenographic findings
K-2261...	14	...do....	67	High velocity missile.	5 to 10 mins.	Right frontal.	(?)....	None.....	...do.....	...do.....
K-2262...	10	...do....	10	...do....	Few mins.	...do....	(?)....	...do....	...do....	...do....
K-2263...	15	...do....	10	...do....	2 to 3 mins.	Right temporal.	(?)....	...do....	...do....	...do....
K-2236...	5	...do....	Few mins.	Right fronto-temporal.	(?)....	...do....	...do....	...do....
K-2264...	12	...do....	29	...do....	No.....	Occipital (Ext. occ. prot.).	(?)....	...do....	...do....	...do....
K-2265...	3	...do....	22	Few mins.	Left frontal.	(?)....	...do....	...do....	...do....

wounds in 31 patients—Continued

Operative procedure and surgical pathology	Clinical course in hospital in early postinjury period	7-year followup questionnaire							
		Residual focal neurological signs and symptoms	Late post-traumatic seizures	Menigitis since injury?	Are you well?	What bothers you?	Headaches?	Working status	Discharge from Army because of injury?
do	Alert and oriented on admission; left occipitotemporal headache lasting few hours at time; no papilledema; C.S.F. pressure 180 mm., fluid normal; EEG normal; headache cleared and returned to duty.								
do	Alert and cooperative on admission; right frontal headache developing into generalized tension headache, severe posttraumatic anxiety state; no lumbar puncture, no papilledema; transferred to neuropsychiatric hospital.								
do	Alert and oriented on admission; severe tension headache and posttraumatic anxiety state; no papilledema; lumbar puncture not done; transferred to neuropsychiatric hospital.								
do	Alert and oriented on admission; intermittent right frontal headache of short duration; no papilledema; no lumbar puncture recorded; EEG normal; developed postconcussion anxiety symptoms which gradually cleared; disposition unknown.								
do	Alert and oriented on admission; persistent right occipitoparietal headache, no papilledema; C.S.F. pressure normal, fluid normal; EEG normal (poor dominant rhythm); gradual clearing of headache; returned to duty.								
do	Alert and oriented on admission; no headache, no papilledema; C.S.F. pressure 176 mm., fluid normal; EEG: Amplitude asymmetry with apparent depression in normal activity over left anterior temporal region; remained asymptomatic; returned to duty.								

CHAPTER 14

Through-and-Through Wounds

Griffith R. Harsh III

Of 65 patients with through-and-through injuries of the head admitted to the neurosurgical service during the Korean War, 51 survived. Though late followup of many of these has not been effected, it is known that some are leading useful, productive lives as illustrated by a summary of patient K-1282.

A 27-year-old first lieutenant was wounded in action in Korea, 20 May 1951, sustaining a through-and-through gunshot wound of the head. Entrance was in the right posterior parietal area, exit from the left posterior temporal region. On admission to the 1st Neurosurgical Detachment (Provisional), 21 May 1951, cerebrum was exuding from both wounds. The patient was comatose with no response to pain. Both pupils were fixed to light, the left being larger than the right. There were spontaneous movements of both upper and the left lower limbs. These movements usually terminated in spastic extension of the lower limbs with alternating flaccidity and spastic extension of the uppers. There were bilateral ankle cloni, bilateral Babinski and Hoffmann signs. The neck was rigid. Blood pressure was 110/84; pulse, 140, and respiration, 28.

Roentgenograms of the skull revealed bone fragments driven deeply into the right posterior parietal area. There were comminuted, elevated bone fragments in the left posterior temporal region. Because of evidence of markedly increased intracranial pressure and the precarious condition of the patient, palliative operation was elected.¹ The dilated left pupil and the greater right-sided deficit dictated initial attack on the exit wound. A left temporal craniectomy was effected with removal of a large subcortical hematoma. Fibrin film closure of the dural defect and layer closure of the scalp were effected. Postoperatively, the patient manifested rapid improvement and, 24 hours later, definitive operation was decided upon. A right parietal craniectomy was effected with removal of indriven bone fragments and debridement of the missile track to the falx.

This was followed immediately by secondary left temporal craniectomy and retrograde debridement of the missile track to the falx. Fascia lata closure of the dural defect was effected on both sides. Postoperatively, the patient was confused, but manifested progressive improvement. There was transient blindness, aphasia, and a left peripheral facial paralysis. The patient subsequently improved progressively and was evacuated through channels. Recent communication indicates that the patient has almost completely recovered (fig. 76). He is described by his wife as being in "normal physical condition with the use of all his extremities." There is impaired vision in his left eye and normal acuity in his right eye though the visual field is somewhat reduced. Speech is described as grossly normal.

Fifty-one survivors of sixty-five patients with through-and-through head injuries is in sharp contrast with the widely accepted belief that such injuries are almost always hopeless. Statistical analysis of these patients will provide a matrix for elaboration of a mode for care of patients with through-and-through wounds.

In this text, "through-and-through wound" is used to imply a penetrating injury of the brain in which a



FIGURE 76.—K-1282 and family 7 years after through-and-through gunshot wound of head. (Permission to print granted in personal letter to author and editor by patient.)

¹ Because of the apparent increased incidence of infection with multiple procedures, this approach is undertaken as a calculated risk and only in the presence of an unusually precarious clinical condition. Complete definitive surgery at the initial operation is usually the procedure of choice.

missile (or part of it) has passed into and out of the cranial cavity. There may be (1) two distinct bony perforations with intact cranium between them (fig. 77), or (2) two separate dural penetrations with the bony openings connected by a common fracture (fig. 78). The more usual through-and-through scalp wound with gutter-type bone and dural laceration is not included.

In 36 patients, the missile traversed more than one cranial compartment in a side-to-side fashion. In 22, two or more compartments were involved in an anteroposterior direction without crossing the midline. In seven, the through-and-through wound traversed only one cranial compartment.

In all, there were 14 deaths. Three of these patients died without operation. One (unoperated) had associated abdominal injuries. Eleven patients died following operation, an operative mortality of 17 percent. Five of these postoperative deaths occurred in patients with side-to-side penetrations, six with front-to-back. No deaths occurred in those with only one cranial compartment involved.

Fourteen patients manifested infection either before or after operation, an incidence of 21.5 percent. As would be expected, this was somewhat higher than the overall figure for infection in patients with compound craniocerebral trauma (pp. 136-137). Five

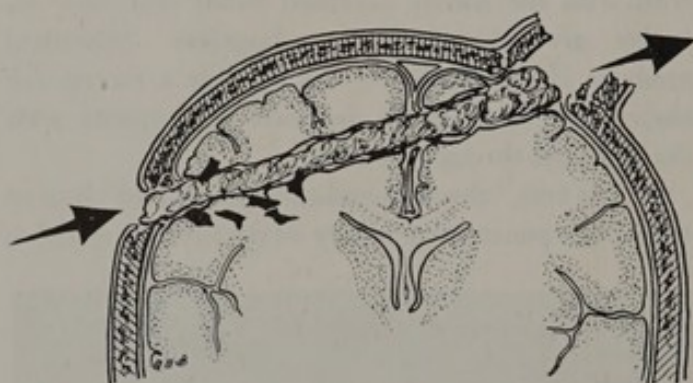


FIGURE 77.—Two distinct bony penetrations with intact intervening cranium.

had cerebritis, five abscesses (either intracerebral or extracerebral), and four had evidence of active meningitis. Only one of the patients with infection died.

Analysis of residual neurological deficit in this series of patients is inadequate at best, for few late followups are available. Yet 17 of the patients were described as having no gross neurological deficit postoperatively. Five had only blindness or other

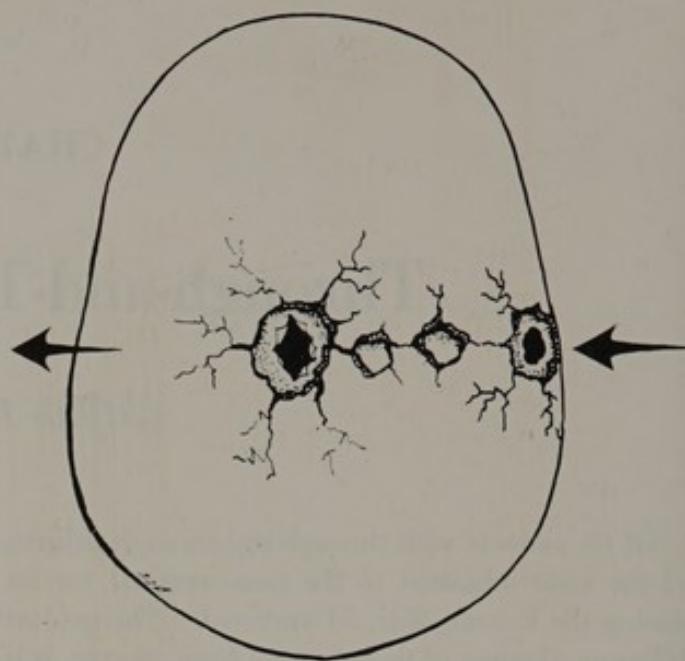


FIGURE 78.—Two distinct dural penetrations with bony openings connected by common fracture.

partial cranial nerve loss. The remaining 29 patients (at the time of evacuation to the Zone of Interior) manifested various degrees of motor, sensory, and intellectual impairment according to the cerebral areas involved. There were three who were described as being aphasic only. Thirteen manifested a combination of aphasia and hemiplegia. Three of the latter were said to be improving. Of nine patients manifesting hemiplegia only, the deficit was receding in two of them.

GENERAL CONSIDERATIONS

The basic principles of care of through-and-through wounds are as described in the introductory chapter concerning penetrating wounds. Several factors, however, require special consideration. Of prime importance is the necessity for a diligent search for both entrance and exit wounds. Failure to recognize an exit (or entrance) wound may lead to delayed treatment of one or the other with an attendant increased incidence of infection. In this regard, special emphasis should be placed on missiles entering (or exiting) the cranial cavity from low in the face; thus, entering through the anterior or middle fossa and exiting elsewhere. Because bone fragments at such wounds are often not visualized, or if present, are small, they are frequently over-

looked. This has often led to late infection and, on occasions, has been responsible for failure to recognize hematomas in the fossa of entrance (pp. 110) (1). These wounds, which are not usually approachable by craniectomy at the site of bony penetration, must be attacked and debrided through an appropriate osteoplastic craniotomy. The opposite wound (exit or entrance) is, of course, managed with appropriate craniectomy. In a search for the concealed middle fossa wound, stereoscopic roentgenograms are of considerable value.

Positioning, when feasible, should allow access to both the entrance and exit wounds from the same sterilely prepared and draped field. This can be accomplished in most instances with the patient in the supine position and with sandbags under the head (fig. 79). With endotracheal anesthesia, as is commonly used, respiratory obstruction from excess flexion of the neck is usually not a problem. In fronto-occipital wounds, two separate positions may be required, though many can be simultaneously

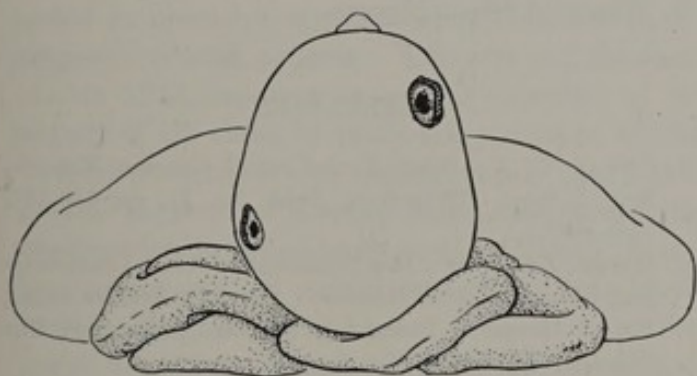


FIGURE 79.—Supine position most useful for simultaneous attack on entrance and exit wounds in transverse through-and-through injuries.

attacked with the patient in the lateral recumbent position (fig. 80). As it frequently becomes necessary or desirable to connect the two wounds surgically, it is mandatory that the entire head be shaved and sterilely prepared. Occasionally, simultaneous approach to the entrance and exit wounds through a single field is technically impossible. In such cases two separate, though immediately successive and complete, procedures are necessary. The temptation, in the face of a heavy casualty load, to treat the more severe wound and delay the other for a secondary procedure, can only be condemned.

In the experience of this author, preference in

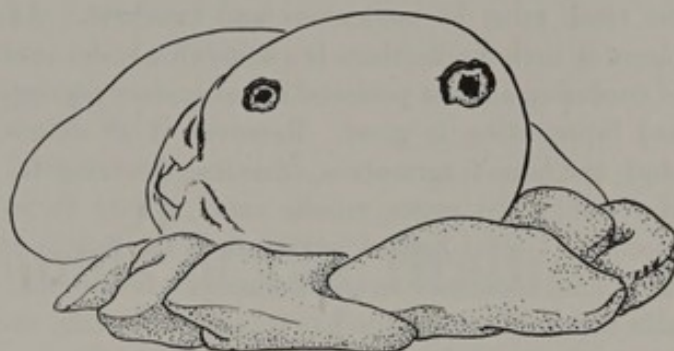


FIGURE 80.—Lateral recumbent position for anteroposterior through-and-through injuries.

treating the entrance or the exit wound has seldom been of importance. In the presence of an obvious lateralized hematoma, the appropriate location deserves primary consideration. In this regard, Matson has pointed out a somewhat higher incidence of hematoma at the wound of exit (2).

SURGICAL MANAGEMENT

The surgical technique employed in through-and-through wounds is, with a few amplifications, essentially that previously described for all penetrating craniocerebral injuries.

SCALP AND BONE

In the majority of instances, it is desirable to handle the two scalp wounds as separate entities with two distinct soft tissue excisions. Occasionally, proximity of the wounds demands simultaneous handling with a connecting incision. Such a plan is mandatory when the sites of bony penetration are united by a common fracture. Soft tissue exposure then allows total craniectomy and adequate inspection of the entire, usually shallow missile track. This complete visualization is essential when a superficially coursing missile traverses the midline and may involve the sagittal sinus. It is well established that both the scalp and bone injury may be more extensive at the exit wound, requiring wider resection.

MISSILE TRACK

Because through-and-through wounds are frequently caused by high-velocity missiles, resection of

the track must be meticulous and extensive. Adjacent to such tracks, there is a somewhat wider zone of contusion and the potential for secondary necrosis and liquefaction is great. Removal of all debris, clots, and bone fragments is, of course, fundamental. If feasible, the entire missile canal should be inspected. Use of lighted retractors in the depths of the wound facilitates an often otherwise insurmountable task. If the missile has traversed the falx, the penetration may be enlarged to allow inspection of the contralateral track.³ When "transfalx" cleansing

³ This maneuver is of value in wounds which are not through-and-through wounds, but in which the missile has traversed the falx and lodged in the opposite hemisphere of the brain. In such injuries (not included in the above statistics), large missile fragments or contralateral hematomas may necessitate removal through an osteoplastic flap on the opposite side.

is not possible, visualization to the falx from both wounds is desirable. If both the entrance and exit wounds are approached through one surgical field, through-and-through irrigation of the track is feasible and valuable.

DURA

Management of the dural tears in through-and-through injuries differs in no particular from that in single injuries. Watertight closure of the dura (after appropriate debridement), either by primary suture or by graft, is perhaps even more important in view of a possible greater potential for ventricular tears and subsequent cerebrospinal fluid fistula.

SURGICAL TECHNIQUE

Considerations applicable to through-and-through wounds:

1. Diligent search for both entrance and exit wounds—stereoscopic roentgenograms.
2. a. Positioning to allow for simultaneous approach to wounds, if feasible.
- b. Two separate, complete and successive procedures if simultaneous approach is not possible.
- c. Low anterior or middle fossa wounds approached through appropriate craniotomy.
3. Connecting scalp incision for closely situated wounds.
4. Wider debridement at exit wound.
5. "Total" craniectomy for penetrations with a common fracture.
6. Wide brain-track resection.
7. Complete track visualization whenever feasible.
8. Watertight dural closure.

REFERENCES

1. Calvert, C. A.: Orbito-Facio-Cranial Gunshot Wounds, *Brit. J. Surg.* (War Surg. Supp. No. 1), pp. 119-141, June 1947.
2. Matson, Donald D.: The Treatment of Acute Craniocerebral Injuries Due to Missiles. American Lecture Series No. 22. American Lectures in Surgery. Springfield, Ill.: Charles C Thomas, 1948.

CHAPTER 15

Transventricular Wounds of the Brain

Gordon T. Wannamaker

This report is based on an analysis of 214 consecutive Korean battle casualties of verified transventricular wounds of the brain, treated by Army neurosurgeons at various installations in Korea and Japan from September 1950 through October 1952. The overall mortality rate was 19.1 percent. Harvey Cushing (1), in World War I, reported a mortality of 73 percent among 30 patients with transventricular wounds. Haynes (2), in 1945, reported an operative mortality of 33.7 percent in 77 surgically treated patients. Schwartz and Roulhac (3), in 1948, reported an overall mortality of 30 percent in 50 cases of penetrating wounds of the cerebral ventricles. An earlier paper (4) based on 105 consecutive Korean battle casualties with transventricular wounds treated at Tokyo Army Hospital reported an overall mortality of only 10.47 percent. Cognizance was taken of the fact that the Tokyo report was based primarily on the second echelon of treatment and reflected, therefore, an unusually low mortality figure.

DEFINITION AND DIAGNOSIS

Wounds of the ventricle in this series were produced by missiles or foreign bodies passing through or into the ventricular system. Actual visualization of the opening into the ventricle at surgery or autopsy was the basis for diagnosis. There was no definite clinical syndrome characteristic of transventricular wounds even though most of the patients had high temperatures and stiff necks. The physical findings depended upon the area of the brain involved. A diagnosis of ventricular penetration was

TABLE 13.—*Site of ventricular penetration in 214 consecutive Korean battle casualties*

Site	Number
Right lateral ventricle	96
Left lateral ventricle	95
Third ventricle	7
Fourth ventricle	1
Both lateral ventricles	10
Bilateral and third ventricles	1
Right lateral and third ventricles	4
Total	214

suspected when roentgen films showed evidence of the missile canal, outlined by bone fragments, passing through the position normally occupied by the ventricles. The lateral ventricles were most frequently involved. The third ventricle alone was penetrated in seven instances and in association with a lateral ventricle in an additional five. There was one case of penetration of the fourth ventricle (table 13).

STATISTICAL ANALYSIS

The 214 consecutive battle casualties were of a variety of nationalities, as listed in table 14. The greater majority were Americans.

Before the establishment of a neurosurgical team in Korea in February 1951, the majority of patients were operated upon at various installations in Korea and Japan, frequently without the benefit of a neuro-

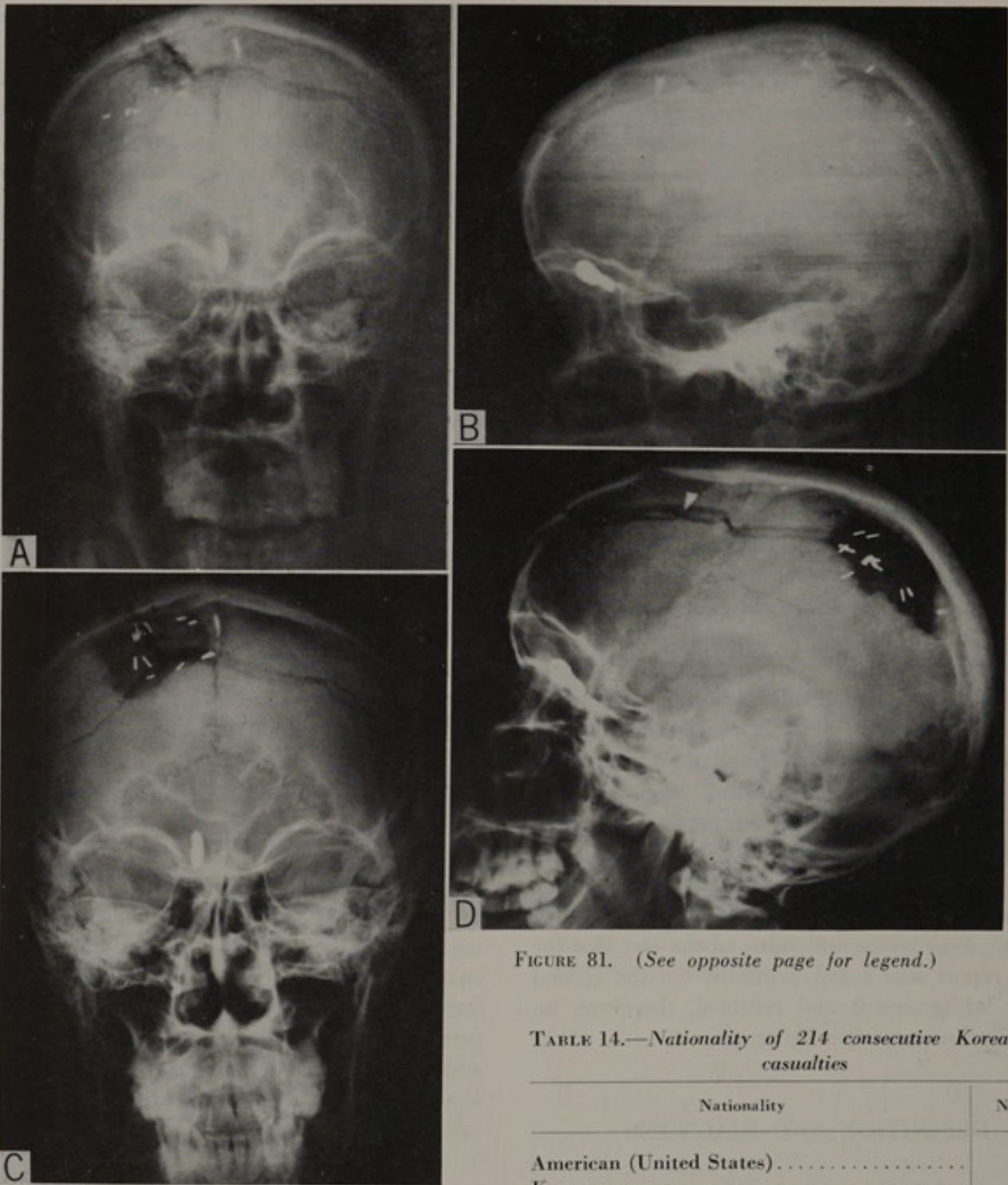


FIGURE 81. (See opposite page for legend.)

TABLE 14.—*Nationality of 214 consecutive Korean battle casualties*

Nationality	Number
American (United States)	164
Korean	21
British	8
French	4
Puerto Rican	4
Turkish	3
Greek	2
Australian	2
Philippine	2
Colombian	1
Belgian	1
Thai	1
Canadian	1
Total	214

surgeon. The value of early definitive neurosurgery was again demonstrated. As Eden (5) aptly put it, "There is no doubt that the surgeon who first operates on an open brain wound makes or mars it. There is no useful first aid operation—ideally, the initial operation should be the final and complete one. Failure to obtain primary union or inadequate removal of indriven bone fragments, all too frequently spells a vicious circle of cerebral fungus,

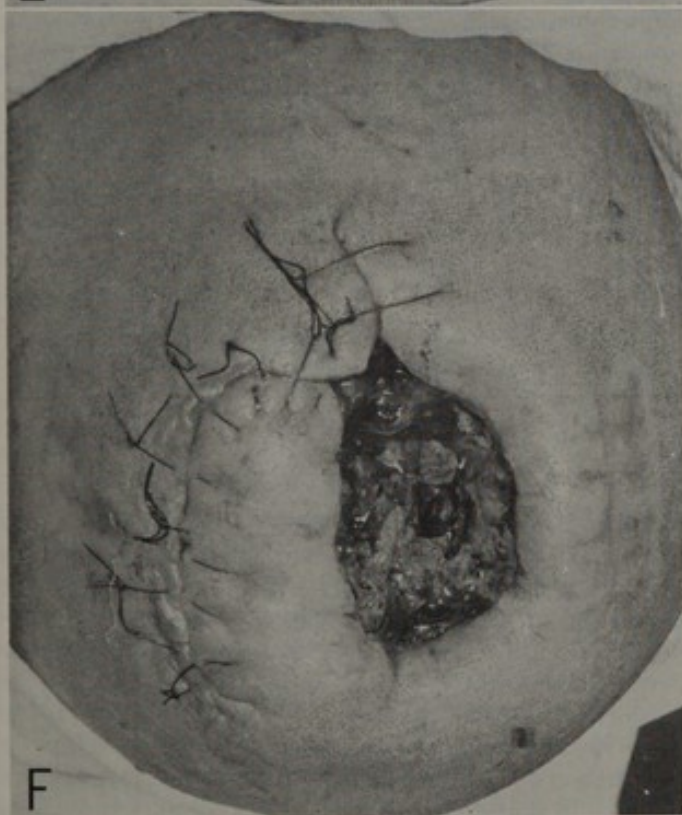
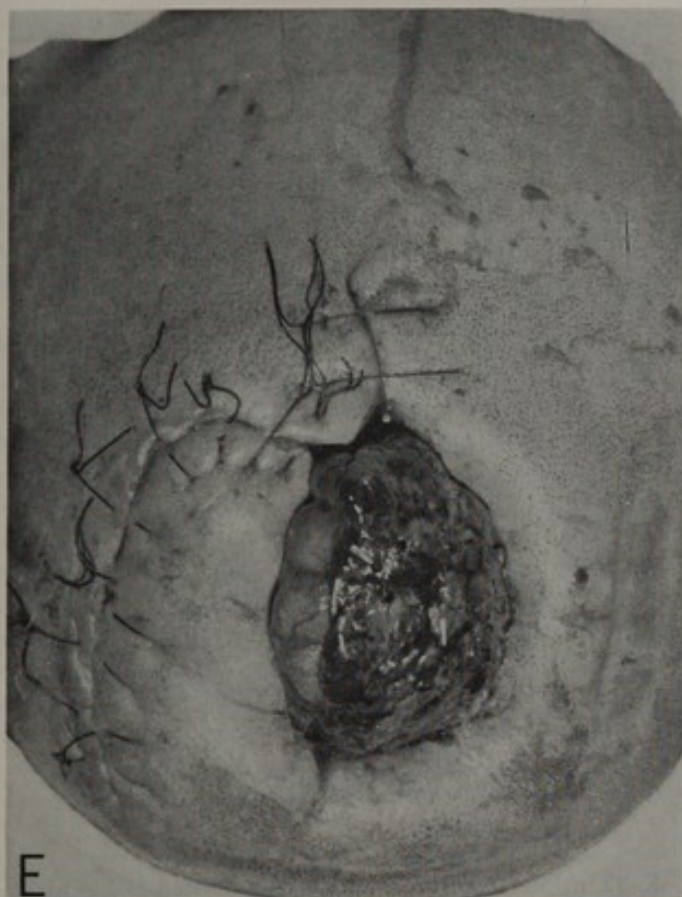


FIGURE 81.—K-80. Penetrating wound of the left parietal bone, with metallic fragment in the left cribriform area. A. Anteroposterior roentgenogram of skull prior to surgery. Note imbedded bone fragments. The linear fractures radiate to both parietal regions and the left frontal area. B. Lateral roentgenogram, preoperative. C. Anteroposterior roentgenogram of skull at time of admission at Tokyo Army Hospital following surgery in Korea. The bony defect has been enlarged to extend to the midline. All indriven bone fragments have been removed. The silver clips from previous surgery are in evidence. D. Lateral roentgenogram at time of admission to Tokyo Army Hospital. E. Persistent herniation of the brain through bone and scalp defect in left parietal, parasagittal area. Note that the narrow-based skin flap in the left parietal area has been debrided and resutured. The scar of the original relaxing incision in the right parasagittal area can be seen. F. Photograph taken the same day as E, but immediately following a spinal tap. The release of spinal fluid temporarily reduces the cerebral fungus and partially opens the missile track, exposing the opening into the ventricle.

abscess, and meningitis." It is the wise surgeon, however, who readily recognizes his mistakes and attempts to correct them. The medical facility at which the patients received the first surgical procedure is listed in table 15.

In this series, 212 patients were operated upon. Two patients died while awaiting surgery. Another died on the operating table. Of the 211 patients who survived the initial surgical procedure, 79 (37.44 percent) required one or more reoperations for the various causes listed in table 16.

REPRESENTATIVE CASES

To illustrate some of the factors leading to reoperations, the following case reports are given:

TABLE 15.—*Installation of first surgical treatment of 214 consecutive Korean battle casualties*

Medical facility	Number of patients
Army neurosurgical team, Korea.....	158
U.S. Navy hospital ships, Korea.....	22
Tokyo Army Hospital.....	15
Other Army hospitals, Korea and Japan.....	15
Danish hospital ship, Korea.....	2
Died preoperatively.....	2
Total.....	214

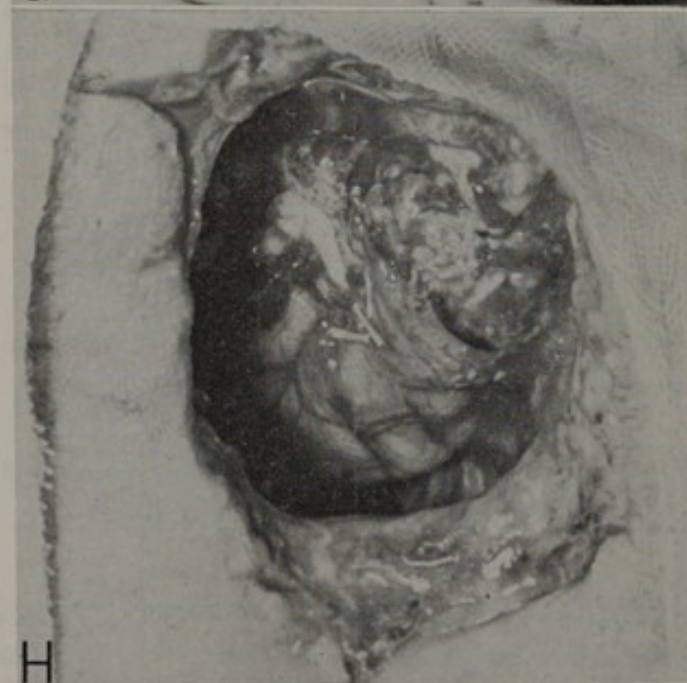
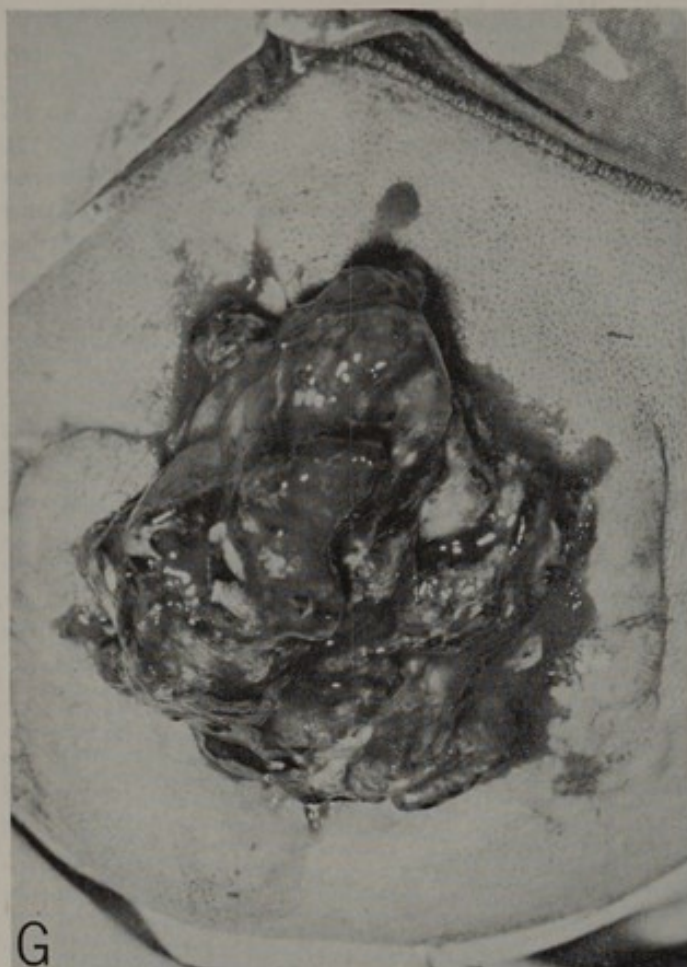


FIGURE 81.—Continued. Photographs at surgery, 16 February 1952. G. Herniated fungating brain with recent hemorrhage on the surface of the brain and associated with fresh hemorrhage in the subdural space. H. After evacuation of the subdural hematoma and radical resection of all devitalized cerebral tissue, only a small amount of the left cerebral hemisphere remained. This procedure proved to be the last resection necessary for controlling brain herniation and swelling. The wound was closed 4 days later, view I.

Photographs following closure of the wound. I. After watertight closure of the dura by means of a fascial graft, a large skin flap was made in the right parietal area and rotated to the left to cover the bony opening. The scar of the previously made relaxing incision had to be incorporated in the rotation flap. A split-thickness graft was applied to the periosteum which was exposed after rotating the flap. The old skin flap in the left parietal area had to be sutured to prevent it from reopening. J. Ten days later, showing good coverage of bony defect by rotation flaps which are healing well. The split-thickness graft over the periosteum shows only a partial "take." K. Two weeks prior to discharge. Patient sitting up. Scalp wounds well healed.

K-80, a Puerto Rican soldier, was admitted to the neurosurgical detachment at the 8063d Mobile Army Surgical Hospital in Korea on 20 December 1951, 7 hours after having been wounded in action. He was comatose and triplegic.

There was a 7-cm. laceration in the left parietal, parasagittal region of the scalp through which necrotic brain tissue and blood clots were exuding. Roentgen films of the skull (fig. 81 A and B) showed a comminuted fracture

TABLE 16.—*Indications for reoperation among the 211 patients who survived initial surgery*

Indication for reoperation	Number of patients
Retained bone fragments	39
Brain abscess formation	11
Cerebral fungus formation	12
Cerebrospinal fluid fistula at site of wound closure	7
Persistent coma	2
Subcortical clots	2
Large metallic foreign body, mobile	2
Obstruction of third ventricle by Gelfoam	1
Revision of skin closure	3
Total	79

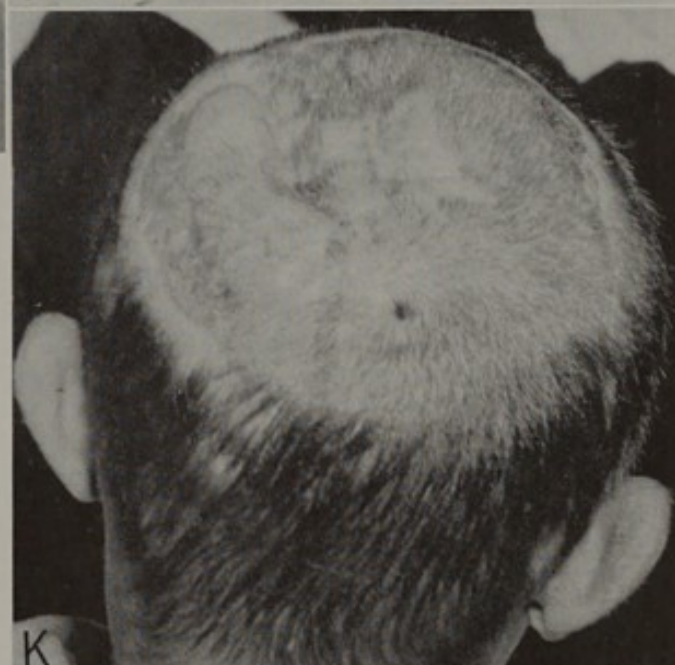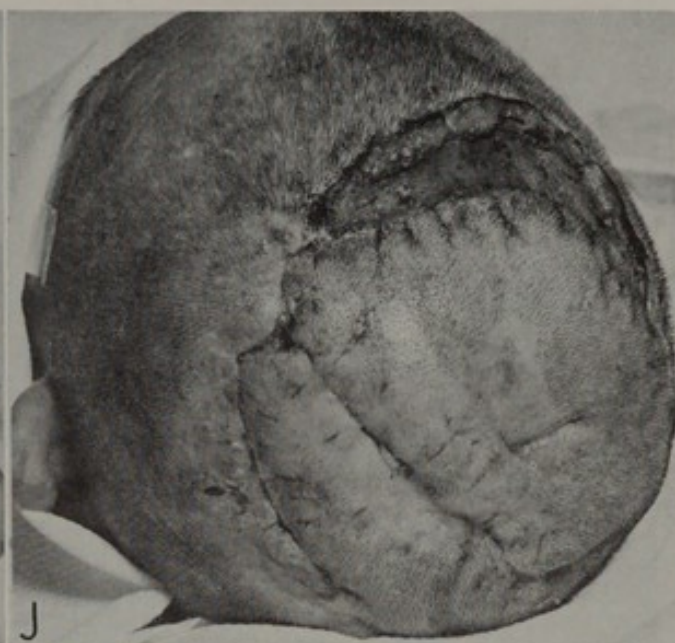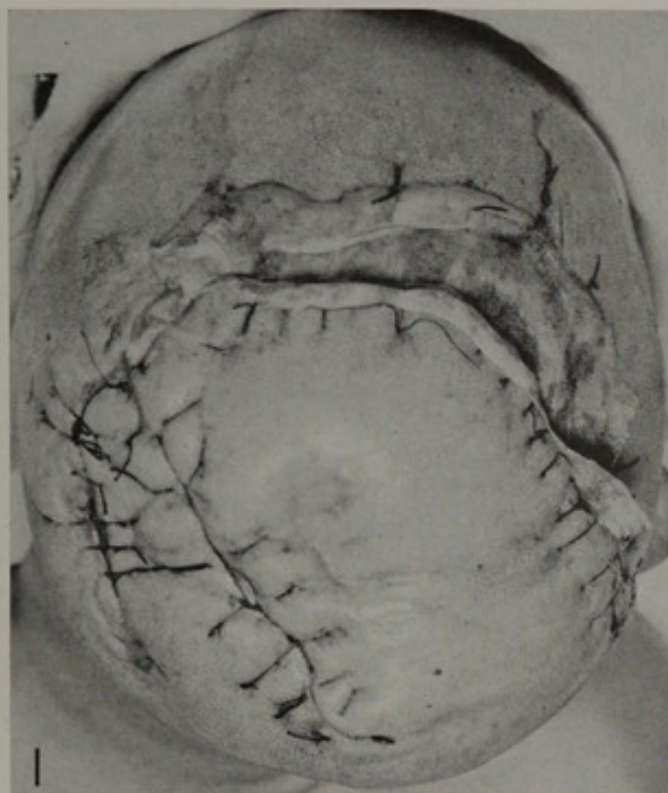


FIGURE 81.—Continued.

in the left midparietal, parasagittal area which radiated anteriorly. There were many indriven bone fragments and a large metallic foreign body in the floor of the left anterior fossa at the region of the cribriform plate. Associated injuries included compound fractures of the left radius, and the third and fourth metacarpals, right. The neurological findings were best explained on the basis of occlusion of the superior sagittal sinus at its mid or posterior third. On painful stimuli, the patient was paralyzed in all extremities except the upper left.

Shortly after admission, a left parietal craniectomy was carried out. The wound was found to be transventricular. Apparently, the large metallic fragment which was lodged in the floor of the anterior fossa had passed through the left lateral ventricle. The metallic fragment was not readily accessible and was allowed to remain in place. Debridement of devitalized brain tissue, bone fragments, dirt, and debris was carried out. The superior longitudinal sinus was found to have been lacerated and thrombosed at the junction of its mid and posterior thirds. The sinus laceration was sealed with a muscle stamp. The dural opening was closed with a fascial graft. Closure of the skin under tension was accomplished with the aid of relaxing incisions. The first postoperative week was rather stormy, but by 6 January 1952, the patient's vital signs became stable and he had regained consciousness. There was return of some function in the left lower extremity. However, the scalp wound which was closed under tension had a separation of its

edges, and on 7 January, a revision of the scalp closure was carried out, employing a rotation skin flap from the left parietal area over toward the midline to cover the bony defect and exposed dural graft. A split-thickness graft was applied to the periosteum of the donor site. Postoperatively, the patient was noted to have Jacksonian seizures involving the right side of the face. Dilantin medication was started, and on 9 January, 20 days after being wounded, he was evacuated to Tokyo Army Hospital.

On admission to Tokyo Army Hospital, the second echelon of treatment, roentgenograms of the skull (fig. 81 C and D) showed the bony defect in the left parietal region and the retained metallic fragments. Pus was present beneath the rotated scalp flap which was necrotic on its distal tip.

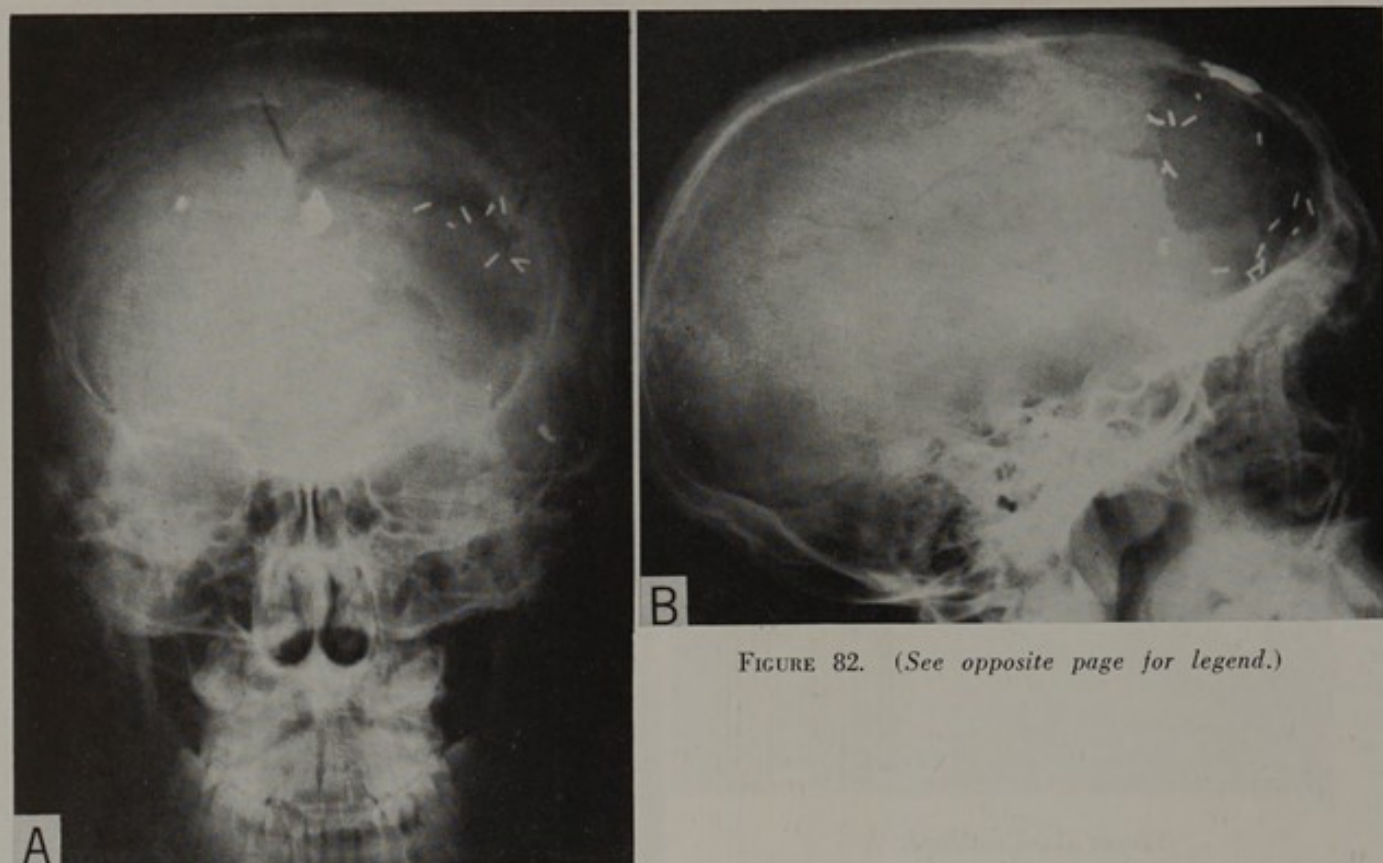


FIGURE 82. (See opposite page for legend.)

Culture of the pus yielded a gram-positive coccus which was sensitive to Aureomycin and a gram-negative rod which was sensitive to Chloromycetin. The patient was placed on large doses of both of these antibiotics. Because of his triplegia, he was treated on a Stryker frame. On 13 January, the rotation flap was elevated and its necrotic tip resected. The epidural abscess was evacuated. The wound was allowed to remain open in the hope that the infection would not spread intracranially. However, on 21 January, it became evident that there was underlying cerebritis which necessitated opening the dural graft and treating the infection by the open fungus technique. The cerebritic process continued (fig. 81 E), and the brain herniation was partially controlled by means of frequent repeated spinal taps (fig. 81 F). During the next 3 weeks, five operations with resection of fungating brain on each occasion (fig. 81 G) were required before the infection was brought under control and the residual left cerebral hemisphere remained sunken well within the cranial vault (fig. 81 H). By 18 February, cultures taken from spinal fluid, brain, and skin were sterile. The wound was closed, employing a fascial dural graft and rotation of a broad-based skin flap from the right parietal area toward the left to meet the narrow flap which had previously been raised on the left. A split-thickness graft was applied to the periosteum of the donor site (fig. 81 I). There was a "poor take" of the split-thickness graft (fig. 81 J); re-grafting with pinch grafts was necessary on 19 March. During April, the patient made good progress and became ambulatory with assistance, even though he had a marked right hemiparesis. The wound eventually healed well (fig. 81 K). His aphasia improved to the point that he could express

himself in simple sentences, but he remained a marked behavior problem from the standpoint of emotional lability. By 21 May 1952, 5½ months and 11 operations after being wounded, all evidence of infection had subsided, his general condition was good, and he was evacuated to a state-side neurosurgical center for further observation and therapy.

COMMENTS

The initial complicating factor in this case (K-80) was the breakdown of the skin closure. The infection spread readily from the subgaleal space to the intracranial contents. The sagittal sinus thrombosis and resultant venous congestion of the brain added to the therapeutic problem of controlling infection. Only after repeated resections of the cerebritic tissue was a sterile wound achieved and closure became possible.

K-53, a 19-year-old infantry private was wounded in action in Korea on 5 November 1951, sustaining a penetrating shell fragment wound to the left frontal region of the brain. Several hours after injury, he was admitted to the neurosurgical detachment at the 8076th Mobile Army Surgical Hospital. Examination revealed a gaping 8- by 5-cm. laceration of the scalp in the left frontal region. Softened, necrotic brain tissue and blood clots exuded through the separated skin edges. The wound was grossly

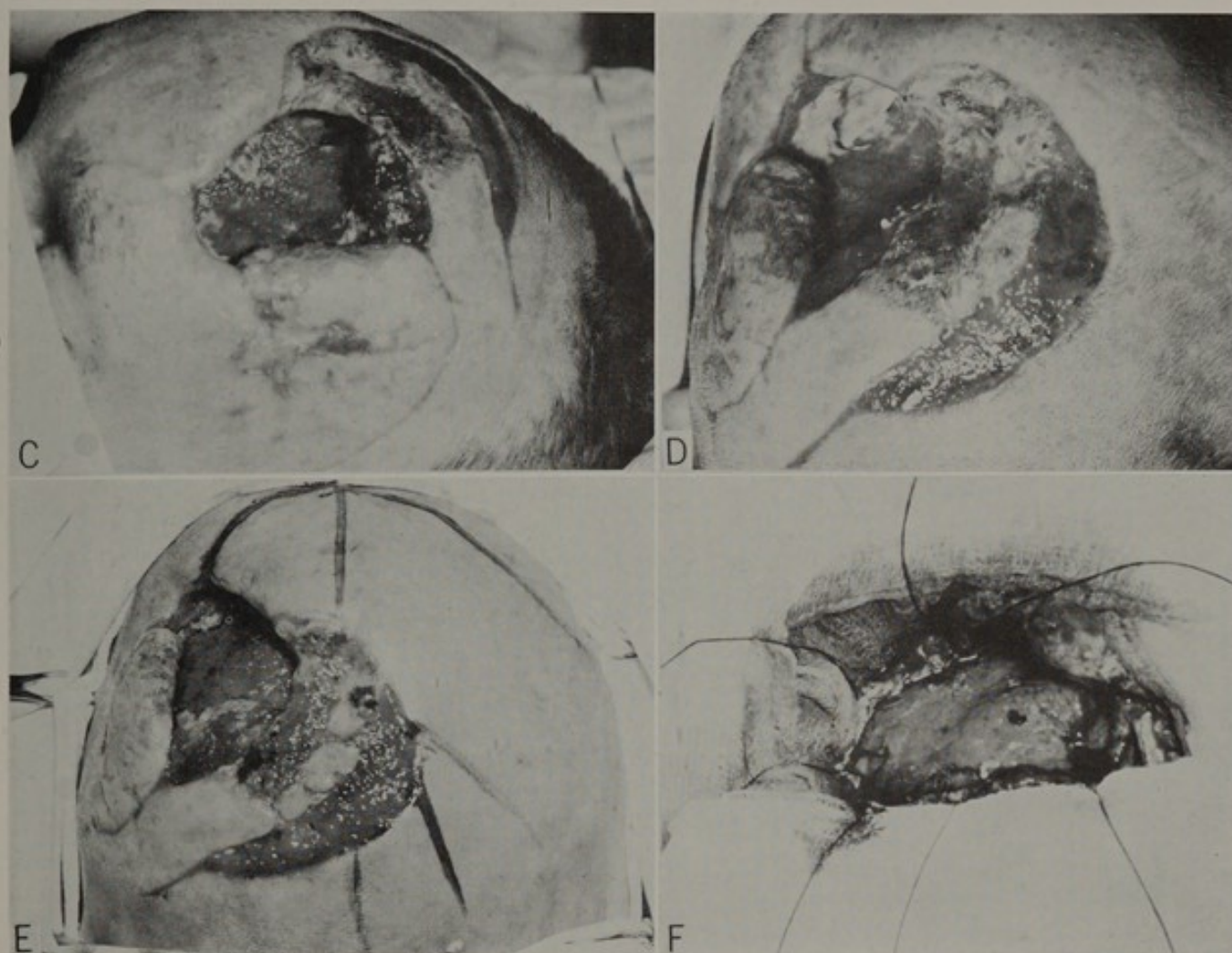


FIGURE 82.—K-53. Anteroposterior (A) and left lateral (B) roentgenograms showing condition of the skull on admission to Tokyo Army Hospital, 28 November 1951. There are several small retained intracranial metallic foreign bodies (shell fragments) and silver clips from previous surgery, no retained bone fragments. The larger shell fragment overlying the sagittal sinus was subsequently removed. C. Left frontolateral view taken 10 days after debridement at Tokyo Army Hospital, showing large skin and dural defect with exposure of the underlying brain. Near the midline, an opening into the anterior pole of the left lateral ventricle can be noted. D. Top of head, taken at the same time as view A, showing the narrow base of the skin flaps, granulations over the periosteum at the sites from which the skin flaps were rotated, and the large gaping hole in the left frontal region. At this time, cultures of the wound were sterile. E. Head prepared and draped for surgery, the following day. The skin has been marked from the wide-based flap to rotate over the existing defect. F. The remainder of the wound has been drapped and attention directed to identifying the rim of normal dura subjacent to the bony opening. Stay sutures have been applied to the dura.

contaminated with soil, hair, debris, and comminuted bone fragments. Roentgenograms of the skull showed extensive damage with many indriven bone fragments and a basilar skull fracture of the anterior fossa on the left extending into the roof of the orbit and cribriform plate. Initial surgery was performed several hours after injury. The fungating portion of the left frontal lobe, back to the region of the sphenoid ridge and anterior horn of the lateral ventricle, was resected. A bleeding point in the inferior sagittal sinus was sealed with a muscle graft. A direct communication with the nasal passage was present because of extension of the basilar skull fracture into the frontal

and ethmoid sinuses. The frontal sinus was debrided, and pieces of fascia lata were used to seal the dural defect in the floor of the anterior fossa as well as the convexity. The scalp was closed primarily, but under tension. Post-operative roentgenograms of the skull revealed the presence of three retained bone fragments in the brain substance. A second operation was performed to remove these fragments on 10 November, 5 days after the original surgery. The scalp wound was reclosed; however, the suture lines separated requiring a third operation to close it by means of a rotation skin flap to cover the exposed dural graft. This skin flap failed to cover the area adequately and a second

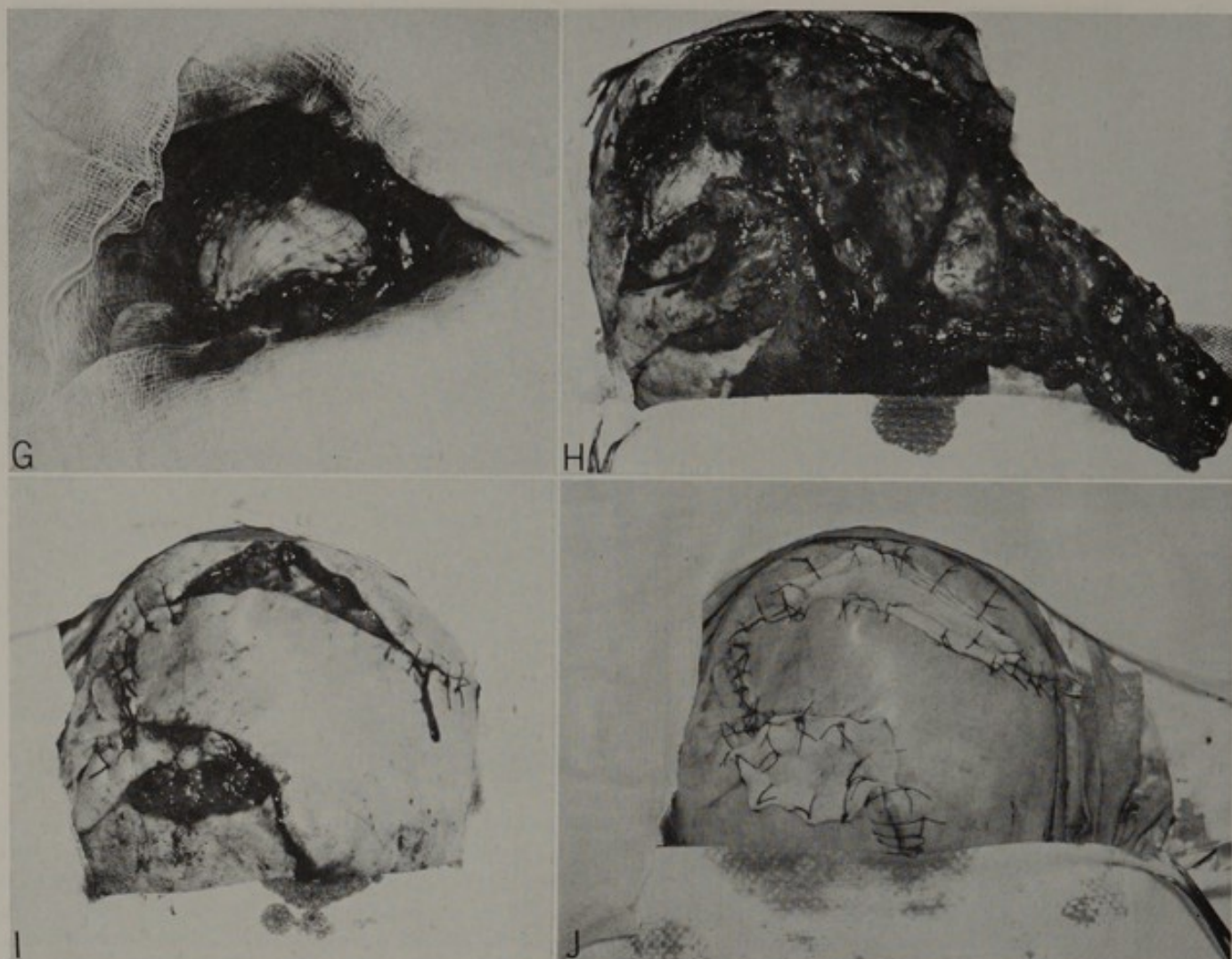


FIGURE 82.—Continued. G. Autogenous fascia lata obtained from the patient's thigh was used as a dural graft. A watertight closure was obtained. H. The large skin flap from the forehead has been raised and turned back on its base. The shiny white dural graft can be seen on the left. I. The skin flap has been rotated so that its distal portion completely covers the bony opening and the dural graft. The periosteum over the intact bone in the supra-orbital area has been very carefully preserved to serve as a base for a split-thickness skin graft. J. Split-thickness skin grafts from the nonhairy lateral thoracic wall have been sutured over the exposed periosteum in the supraorbital area and to the granulations overlying the periosteum in the coronal region.

skin flap had to be rotated to achieve closure. Postoperatively, the rotated skin flaps became necrotic in their distal thirds, and the patient was transferred to the neurosurgical center at Tokyo Army Hospital on 28 November.

On examination at Tokyo Army Hospital, the distal thirds of the rotated skin flaps were noticed to be gangrenous. There was infection of the exposed underlying dural graft and a small cerebral fungus was presenting through the partially gaping dura. The neurological examination showed no deficit except for meningeal irritation and loss of effect. Roentgen films of the skull (fig. 82 A and B) showed a bony defect in the left frontal bone, several small intracranial metallic foreign bodies, and silver clips from previous surgery. Cultures of the exposed brain and adjacent tissue showed the presence of beta hemolytic staphylococcus and a *Proteus* organism, sensitive only to Chloromycetin. The

patient was started on Chloromycetin therapy. The fourth surgical procedure was performed on 30 November. Debridement of the necrotic tips of the previously rotated skin flaps, infected dural graft, and underlying cerebritic tissue was accomplished. The wound was allowed to remain open. Over the course of the next 10 days the wound dressing was changed every 8 hours and the wound cleansed with pHiso-Hex and saline. By 10 December, all superficial and intracranial infection had subsided (fig. 82 C and D) and cultures taken from the wound had been sterile for 3 days. The fifth surgical procedure was performed on 11 December (fig. 82 E, F, G, H, I, and J). Fascia lata was used as a dural substitute and the dural opening was closed. A large skin flap was raised from the forehead region and rotated to cover the dural graft and scalp defect in the left frontal region. Split-thickness skin grafts were placed over the remaining exposed

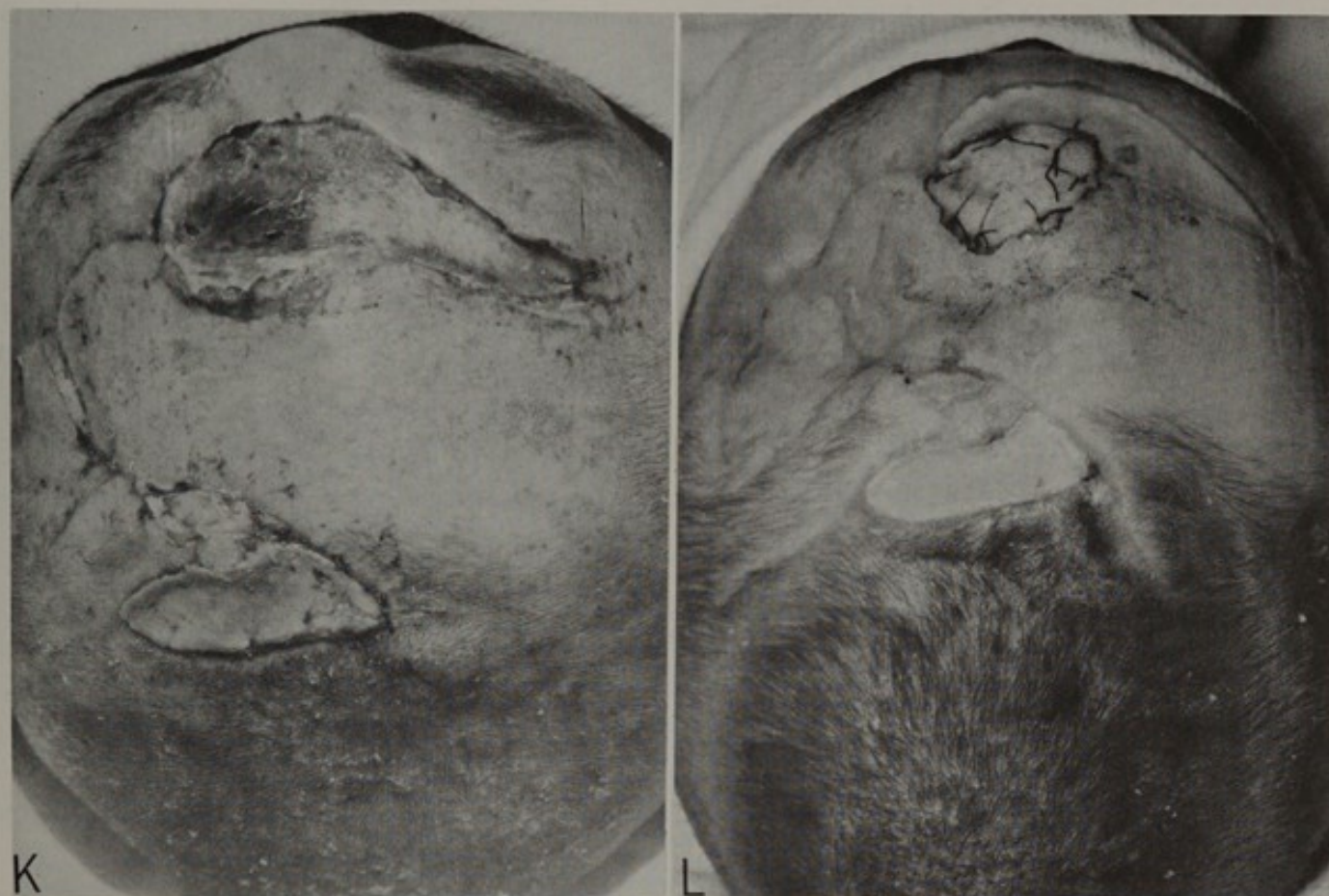


FIGURE 82.—Continued. K. Seven days subsequent to plastic repair revealed that the rotation flap and coronal skin grafts were well vascularized and healing nicely. Nine-tenths of the supraorbital split-thickness graft has "taken," but in the left corner the area of blackness denoted necrosis of the graft. L. The area of "poor take" was regrafted.

periosteum. Seven days later, examination revealed (fig. 82 K) that the rotation flap and skin grafts were healing nicely except for a small grafted area in the mid forehead. This latter region was regrafted (fig. 82 L). Six weeks after surgery all wounds were well healed (fig. 82 M, N, and O). The patient was ambulatory without neurological deficit. He was transferred to the United States by air evacuation as an ambulatory patient on 25 February 1952, for subsequent cranioplasty and cosmetic repair of the scalp in the forehead region.

COMMENTS

This case (K-53) demonstrates some of the common pitfalls in treating transventricular wounds of the brain. Had there been complete removal of all indriven bone fragments at the first operation, perhaps the subsequent series of events requiring intensive therapy and prolonged hospitalization would not have been brought about. Closure of the scalp wound under tension is another factor which led to two attempts at rotation flaps, which, however, be-

cause of their relatively narrow base, became necrotic. To maintain viability of the skin flap, a wide base with good blood supply as was finally used is essential. From a purely cosmetic point of view, it is not desirable to use the skin of the forehead as a rotation flap, but sometimes it is the only immediate available means of producing a closed wound, thus, saving the patient's life by sealing out infection.

It has been shown that, as in penetrating wounds in other parts of the body, the earlier the initial complete debridement, the lower the postoperative infection rate. Penicillin and streptomycin were used routinely in practically all cases in Korea. Culture and sensitivity tests became readily available at Tokyo Army Hospital in January 1951. It was then possible to identify within a 24- to 36-hour period the type of organism involved and to administer the specific antibiotic indicated. Practically all patients who were infected on admission to Tokyo Army Hospital had organisms that were resistant to penicillin and streptomycin (6). The employment of

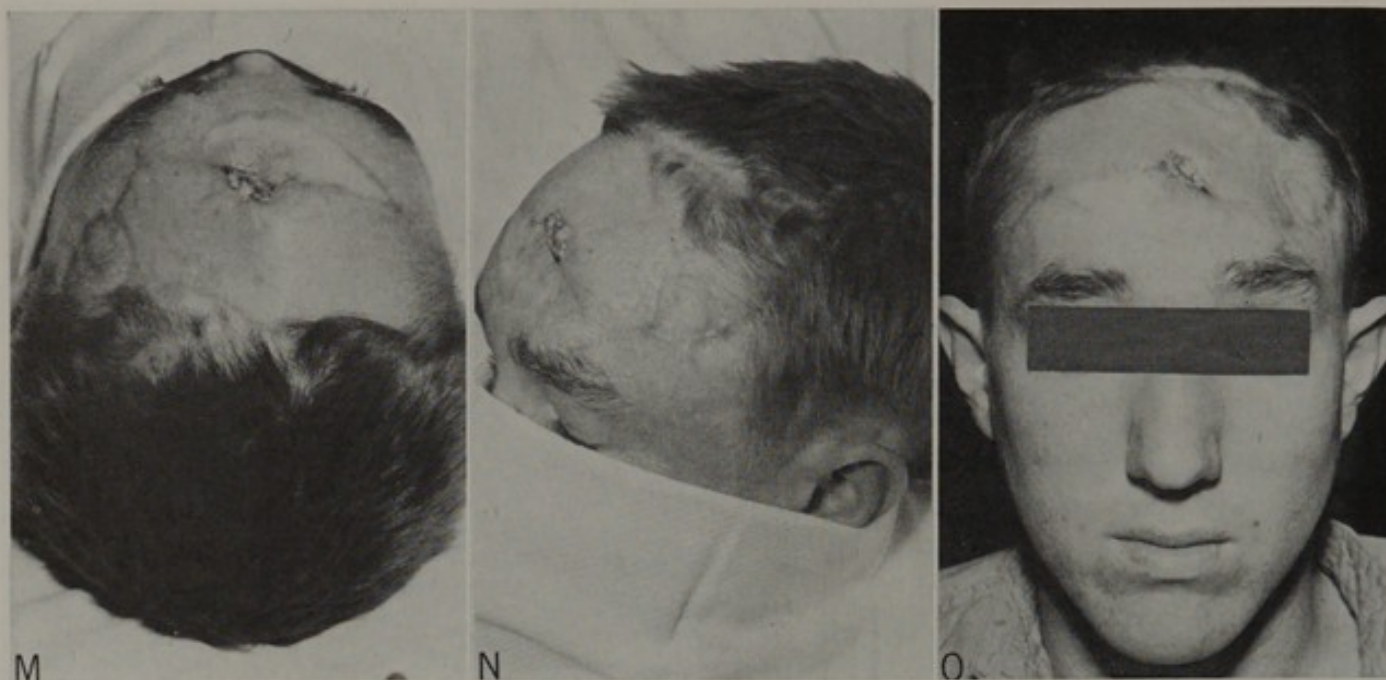


FIGURE 82.—Continued. M, N, and O. Six weeks postoperatively. All wounds healed. Patient ambulatory, without complaints.

Aureomycin (chlortetracycline), Terramycin (oxytetracycline), and Chloromycetin (chloramphenicol), no doubt, saved many patients with ventriculitis and meningitis who would have died. The goal of a high percentage of recoveries from penetrating wounds of the brain as anticipated by Cushing in 1918, with early definitive surgery and appropriate antibiotics, is now approaching the realm of achievement.

TREATMENT

A comparison with other penetrating wounds of the brain treated during this period, and reported elsewhere in this text (chapter 10), shows that the patients with ventricular wounds were the sickest and carried the highest mortality incidence.

PREOPERATIVE

The preoperative management of penetrating wounds of the head has been adequately described elsewhere and will not be detailed here. Emphasis again must be placed upon the importance of preoperative roentgenograms, preferably stereoscopic views, with accurate localization of intracranial bone fragments and foreign bodies. However, with field

equipment requiring long exposure time, this was practically impossible at the advance units.

OPERATIVE

The principles of radical debridement of the brain with removal of devitalized cerebral tissue, clots, bone fragments, pieces of helmet lining, hair, dirt, and so forth, have been established. The metallic foreign body (missile) is removed, if it can be readily reached without further destruction of vital areas of the brain. Superficial metallic fragments near the cortical surface of the brain at a site distant to the point of penetration are occasionally associated with hematoma. In this series, there have been only two cases of complication resulting from a retained metallic foreign body. These were quite large and moved about within the missile canal, causing further brain damage. They were subsequently removed. One case (K-1696) is illustrated in figure 83.

The open method of debridement through an adequate craniectomy with direct visualization of the missile track was the method used in this series. Pentothal (thiopental sodium) induction with endotracheal nitrous oxide-oxygen anesthesia was employed routinely. There were no deaths or complica-

tions from the anesthesia, which was maintained in a light plane. The scalp, muscles, and pericranium were adequately debrided. It was necessary to perform a craniectomy of such size as to allow for debridement of the dura mater and superficial cortical tissue as well as visualization of the missile canal. A craniectomy of 4 to 5 cm. in diameter was usually found to be the minimum that could be used. Silver clips were the method of choice for obtaining hemostasis of cortical vessels. The cautery was used sparingly to lessen additional thrombosis and necrosis. No unusual foreign body reaction was noted about

the silver clips in patients subsequently reoperated upon. The softened walls of the missile canal were removed by suction. The canal was inspected with a Frazier lighted retractor and gently palpated for foreign bodies. The subdural space was inspected in all cases as occasionally a subdural clot was encountered. Intraventricular clots and foreign bodies were removed under direct vision when present. All wounds were copiously irrigated. Following evacuation of all clots, debridement of devitalized tissue, and removal of foreign bodies, the missile canal remained well retracted. This, no

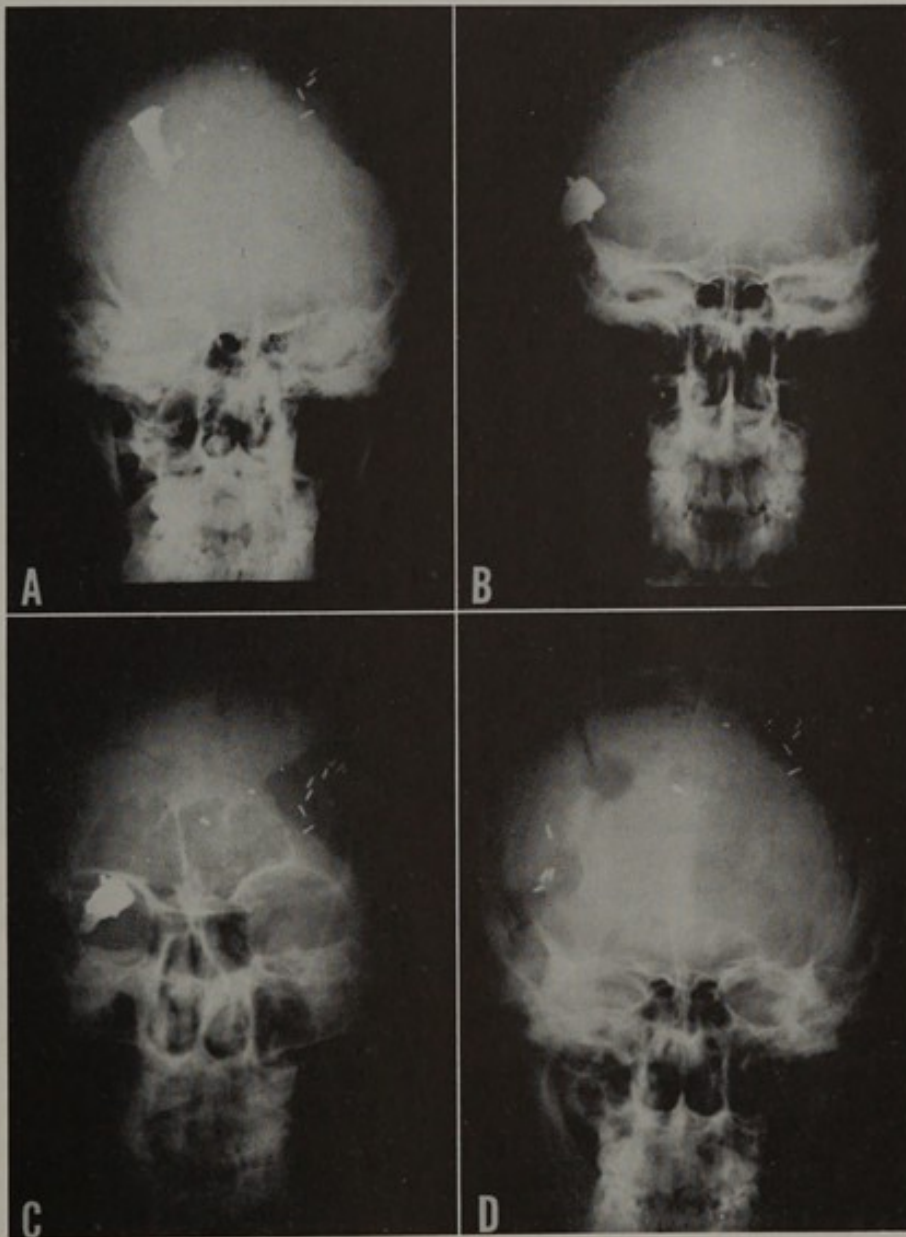


FIGURE 83.—K-1696. Illustrative case of large wandering metallic foreign body. The missile entered the head in the left parietal region. It was not removed at the time of initial surgery. Subsequent roentgenograms (A, B, and C) showed that the heavy missile moved about within the right lateral ventricle. D. Missile has been removed.

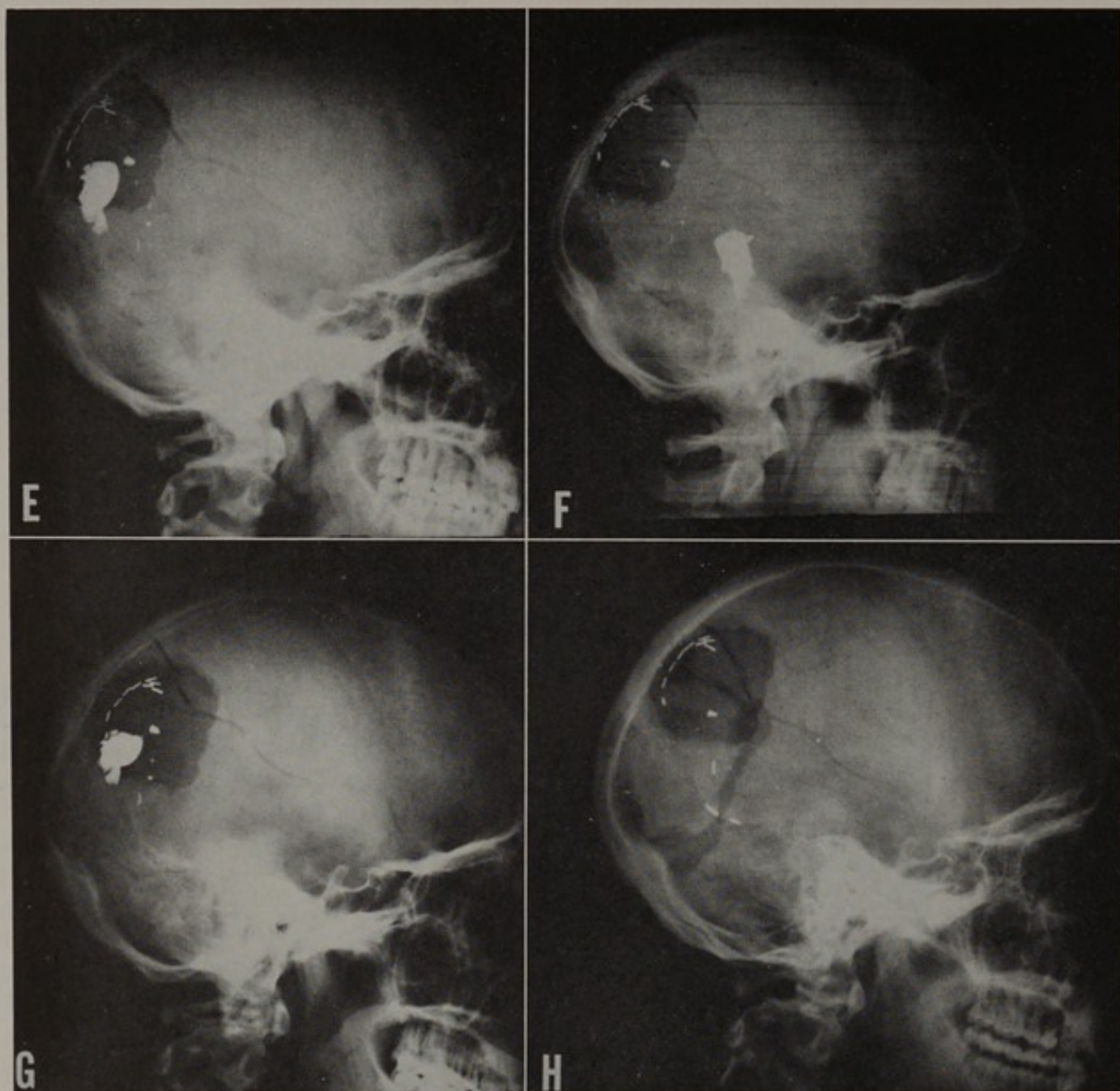


FIGURE 83.—Continued. E, F, and G. Lateral roentgenograms, before removal of wandering metallic foreign body. H. After removal.

doubt, was also aided by the opening into the ventricular system with free drainage of ventricular fluid. However, if active cerebritis was present with associated edema, there was less tendency for the walls of the missile track to remain widely separated.

All wounds were closed tightly following debridement unless active cerebritis was present. In many of the latter cases, the wounds were left open and the cerebral tissue was repeatedly irrigated with sterile saline solution (chapter 12). Cerebral herniation was controlled with repeated spinal taps.

Appropriate antibiotics were given systemically. No intrathecal or intraventricular medications were used. After the cerebritis had subsided, usually in 4 to 6 days, intracranial toilet was accomplished in the operating room and dural closure was achieved with fascial graft or by other means.

Gelfoam was used in the missile track in 23 of our early cases to seal off the opening into the ventricle. In several reoperative cases, the Gelfoam was encountered floating about freely in the pseudoporencephalic cyst that communicated with the lateral

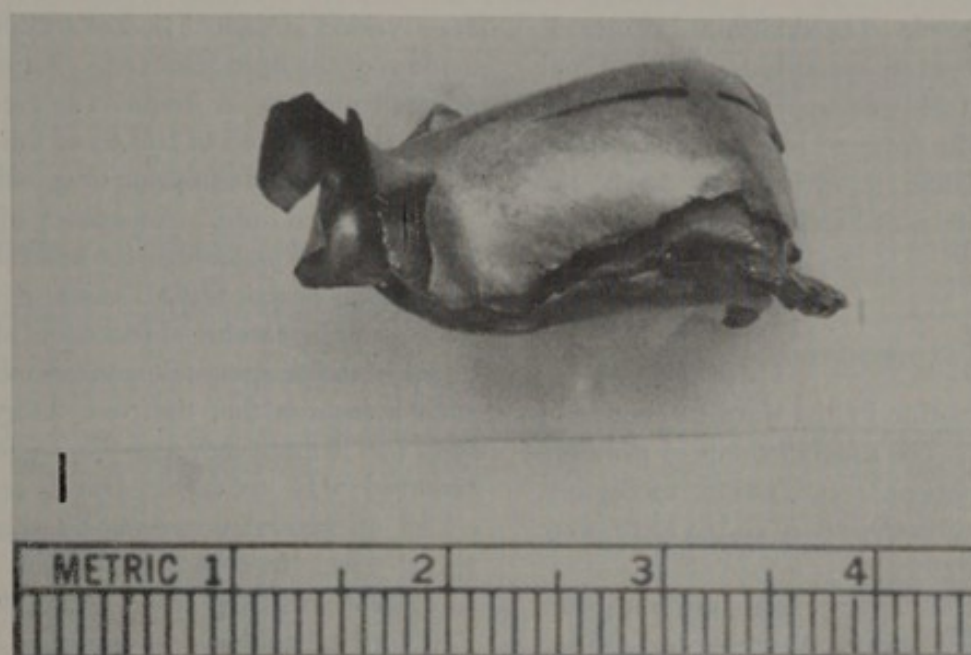

FIGURE 83.—Continued. I. Excised metallic foreign body.

ventricle. The possibility of a loose fragment of Gelfoam blocking the foramen of Monro or the cerebral aqueduct was thought in retrospect to have been the cause of transitory bouts of increased intracranial pressure in some of the postoperative cases. The possibility of Gelfoam acting as an avascular focus for infection was also considered and its use as a seal in the ventricular opening was discontinued. Its value as a hemostatic agent during surgery has been well established, and for this purpose, it was utilized freely in our series.

Dural closure was of great importance in the surgical treatment of transventricular wounds. Fascia lata graft was used in 102 cases, temporal fascia in 40, pericranial in 15, and occipital fascia in 3 (table 17). Primary dural closure was used in four cases and muscle stamp for associated dural-blood sinus tear in one case. In two cases the dura mater was not repaired. In these two, a direct skin graft was applied on the granulating cerebral tissue, much by the same technique as has been described by Webster. Early in our series, Gelfilm or fibrin film for dural closure was attempted in 14 cases of transventricular wounds. One sealed without difficulty, three sealed following repeated scalp flap and spinal taps, and ten required reoperation because of cerebral herniation or persistent fistulous formation. In seven of these cases, the dura mater was closed with a fascial graft; in the remaining three, it was

TABLE 17.—Operative procedure in 214 consecutive Korean battle casualties

Dural closure	Number of patients
Pericranial graft	15
Temporal fascia graft	40
Fascia lata graft	102
Occipital fascia	3
Primary dural closure	4
Muscle stamp	1
Gelfilm closure	14
Dura not closed (split-thickness graft applied to brain granulations)	2
Galeal graft	0
Not clearly recorded (unknown)	30
No surgery (died preoperatively)	2
Died during surgery	1
Total	214

reclosed with Gelfilm and subsequently sealed after repeated scalp flap and spinal taps.

Primary closure of the scalp was also of great importance, particularly when dural grafting had been done. We saw several cases in which necrosis of the dural graft, fistulous formation, and cerebritis developed because of inadequate scalp closure. Rather than accomplish closure under tension, rotation of a scalp flap with a wide base from an area

of intact bone was used. The skin flap was rotated to cover the entire operative craniectomy defect and a split-thickness graft was applied to the intact periosteum at the site from which the rotation flap was raised. We found it advisable to apply the split-thickness graft immediately rather than as a delayed procedure.

POSTOPERATIVE

Meticulous observation by the ward surgeon is of utmost importance. The usual methods of positioning the comatose patient, resuscitation, suctioning, changing position, catheterization, and so forth, were employed.

In cases of infection, appropriate antibiotics were administered systematically. A great deal of importance was placed on culture and sensitivity reports that could be obtained within a 24-hour period. Penicillin was not used in conjunction with Aureomycin, Chloromycetin, and Terramycin, because of their alleged antagonistic actions. Intravenous fluids were given to the comatose patients for a period of from 24 to 48 hours, postoperatively. Then nasogastric tube feedings were employed. When this stage was reached, all antibiotics were administered by this method. Antibiotics were administered for 10 days to patients without obvious infection, and for at least 3 weeks to those with infection. In the latter, this included a period of at least 10 days after there was no gross evidence of infection as determined by spinal taps with cell count and culture studies.

All head dressings were changed approximately 4 to 6 hours after surgery, utilizing sterile technique and individual sterile dressing sets. The dressings were changed one or two times a day until complete healing had resulted. At the time of each changing, the scalp over the craniectomy site was inspected and palpated. Subgaleal fluid collection was treated by aspiration under sterile technique.

Spinal taps were frequently employed in the management of postoperative transventricular wounds. The actual palpation of the skin flap over the craniectomy defect was the deciding factor. Individual

cases varied in regard to frequency of taps and the amount of the fluid removed. We saw no untoward results from taps as frequent as every 8 hours with removal of from 60 to 100 cc. of fluid, provided that the flap tap was done prior to spinal tap when there was extradural fluid. A tendency of overproduction of spinal fluid was noted for several days following surgery in practically all cases of transventricular wounds. By careful observation of the scalp flap, graded, serial spinal punctures were employed in such a fashion that the time interval between the taps was lengthened and the amount of the fluid removed was reduced. Dural graft leaks were sealed on several occasions by combined flap and spinal taps. In cases of infection, cell counts, cultures, and sensitivity tests were done at least once a day until all evidence of infection had subsided.

Superficial scalp sutures were removed within 48 hours in most cases, thus depending on the buried galeal sutures for closure. The patients were maintained on bed rest for a period of 4 days following surgery. Then they were started on sitting up, ambulation, and physiotherapy.

Hemoglobin and hematocrit values were maintained at a level above 14 and 40 gm. percent, respectively.

Postoperative skull roentgenograms were taken on the fourth day. Retained bone fragments were indicative of further operative procedures.

Evacuation of the patient to his homeland was made upon completion of all definitive therapy except cranioplasty, physiotherapy, and rehabilitation.

FACTORS IN MORTALITY

A review of the records in the 31 fatal cases in this series shows that the cause of death was primarily infection in 14, intraventricular hemorrhage in 3, and severe generalized diffuse brain damage in 7. The cause of death is unknown in seven instances. Two patients died preoperatively, one died during surgery, and four died within 10 days following surgery (table 18).

TABLE 18.—*Factors in mortality in the 31 fatal cases among 214 consecutive Korean battle casualties*

Patient	Initial surgery delay	Initial surgery	Survival from injury	Cause of death	Died—
			<i>Days</i>		
K-4.....	12 hours.....	Hospital ship.....	25	Cerebritis.....	6 days following 3d operation.
K-1693.....	24 hours.....	Station hospital, Korea.	74do.....	40 days following 3d operation.
K-325.....	36 hours.....	Tokyo Army Hospital.	25do.....	1 day following 3d operation.
K-1223.....	12 hours.....	Station hospital, Japan.	75do.....	12 days following 3d operation.
K-1377.....	72 hours.....	Tokyo Army Hospital.	52do.....	Unknown.
K-1521.....do.....	Hospital ship.....	99do.....	6 days following 7th operation.
K-99.....	30 hours.....do.....	30do.....	12 days following 3d operation.
K-1549.....	48 hours.....	Tokyo Army Hospital.	84do.....	22 days following 5th operation.
K-1002.....	18 hours.....	Neurosurgical detachment, Korea.	18	Dural leak, postoperative hemorrhage.	3 days following 2d operation.
K-261.....	12 hours.....	Mobile Army Surgical Hospital, Korea.	74	Cerebritis.....	8 days following 8th operation.
K-2233.....	20 hours.....	Neurosurgical detachment, Korea.	13	Ruptured brain abscess.	2 days following 2d operation.
K-407.....	24 hours.....	Norwegian Mobile Army Surgical Hospital, Korea.	62	Hemorrhage.....	1 day following 5th operation.
K-681.....	15 days.....	Neurosurgical detachment, Korea.	19	Peritonitis, cerebritis, subdiaphragmatic abscess.	4 days postoperatively.
K-590.....	12 hours.....do.....	10	Sagittal sinus transection increased pressure.	10 days postoperatively.
K-972.....do.....do.....	8	Hypothalamic.....	1 day following 2d operation.
K-1018.....	<12 hours.....do.....	1	Postoperative hemorrhage.	<1 day postoperatively.
K-1020.....do.....do.....	1	Hyperthermia.....	11 hours postoperatively.
K-950.....do.....	None.....	<1	Unknown.....	Preoperatively.
K-353.....do.....	Neurosurgical detachment, Korea.	<1do.....	During surgery.
K-375.....do.....do.....	3do.....	3 days postoperatively.
K-389.....do.....do.....	5	Hypothalamic.....	4 days postoperatively.
K-56.....do.....do.....		Unknown.....	Within 3 days postoperatively.
K-2244.....do.....do.....	1	Brain damage.....	1 day postoperatively.
K-1471.....do.....do.....	9	Unknown.....	9 days postoperatively.
K-1581.....	>24 hours.....do.....	3	Brain damage.....	2 days postoperatively.
K-427.....	<12 hours.....do.....	66	Cerebritis.....	3 days following 3d operation.
K-1629.....do.....do.....	7	Unknown.....	7 days postoperatively.
K-1611.....	48 hours.....	None.....	2do.....	Preoperatively.
K-1756.....	>12 hours.....	Neurosurgical detachment, Korea.	9	Cerebritis.....	8 days postoperatively.
K-100.....	12 days.....do.....	148do.....	18 days following 10th operation.
K-496.....	<12 hours.....do.....	7	Hyperthermia.....	7 days postoperatively.

REFERENCES

1. Cushing, H.: A Study of a Series of Wounds Involving the Brain and Its Enveloping Structures. *Brit. J. Surg.* 5: 558-684, April 1918.
2. Haynes, W. G.: Transventricular Wounds of the Brain. *J. Neurosurg.* 2: 463-468, November 1945.
3. Schwartz, H. G., and Roulhac, G. E.: Penetrating Wounds of the Cerebral Ventricles. *Ann. Surg.* 127: 58-74, January 1948.
4. Wannamaker, G. T.: Transventricular Wounds of the Brain. *J. Neurosurg.* 11: 151-160, March 1954.
5. Eden, K.: Mobile Neurosurgery in Warfare; Experiences in Eighth Army's Campaign in Cyrenaica, Tripolitania, and Tunisia. *Brit. J. Surg.* 31: 324-328, April 1944.
6. Wannamaker, G. T., and Pulaski, E. J.: Pyogenic Neurosurgical Infections in Korean Battle Casualties. *J. Neurosurg.* 15 (pt. 5): 512-518, September 1958.

CHAPTER 16

Wounds of Dural Sinuses

Arnold M. Meirowsky

The principle of earliest possible neurosurgical intervention applies to wounds of dural sinuses as it applies to all penetrating wounds of the brain. Harvey Cushing's observations during the First World War (1) advanced the idea that operation might serve to prevent the serious sequelae of progressive sinus thrombosis in wounds involving the major venous channels within the cranial cavity. On the basis of his experiences in World War II, Donald D. Matson was the first to sum up the principles of modern surgical management of dural sinus wounds (2).

The analysis of 112 consecutive casualties with penetrating wounds of the brain involving dural sinuses, incurred in the Korean War, might serve as a basis for discussion of neurological sequelae and surgical management. The analysis of neurological sequelae will be inadequate at best; for in the vast majority of cases, the disturbances of venous circulation were associated with gross cerebral lesions. Critical contemplation of the surgical treatment of these wounds might serve to suggest a feasible pattern to follow.

This analysis is limited to cases of trauma of dural sinuses and does not include in the statistics wounds affecting their tributaries. As evidence of the impact of impairment of venous circulation, however, a case (K-201) is cited which is not among the 112 discussed here because the wound affected a tributary vein and not the sinus itself (3).

K-201. Eight-centimeter scalp laceration in right parasagittal parietal region, caused by high-velocity missile. No unconsciousness. Immediate paralysis of both legs and left arm. Within minutes, onset of return of movements in right leg which was functioning normally within 24 hours. Repair of scalp laceration on day of injury.

Thirty-three days later, when first examined by us, complete paralysis below left knee and mild spastic hemiparesis of entire left side excluding face. Increased deep tendon reflexes, absent abdominal reflexes, and extensor plantar response on the left. Absent position sense, left great toe; impaired recognition of number writing, left foot.

Roentgenograms of skull: Grooving of outer table beneath healed scalp laceration.

Right parietal craniectomy, 2 days after initial examination, 35 days after injury. Dura intact, meninges firmly adherent to underlying tissue. Dissection revealed area of encephalomalacia within postcentral gyrus and markedly distended rolandic vein. The latter could be compressed up to its entrance into the sinus. Removal by suction of liquefied necrotic area, measuring 2 by 3 centimeters. Rolandic vein remained dilated.

Within 24 hours after operation, 75 percent return of motor power in left leg (virtually no return of motor power below left knee in 35 days prior to operation). At time of evacuation 11 days later, only slight footdrop. No return of sensation in left foot.

Personal letter addressed to the author written by this patient 3 years after having been wounded is quoted, in excerpt, as follows:

"* * * I am still in the Army and am stationed at Camp * * *, Japan, way up north a few miles from Sendai. I am with the * * * Corps and do I have me an easy job. I work in Post Headquarters in the Message Center. Sir, you asked about my left leg and foot. Well, Sir, the feeling has come back to me and I can walk as good as anybody, but I can't judge just where I am going to set it when I am walking. I can step on rocks and what have you and I can't tell it unless I am looking at what I am doing. I do not have headaches at all from my wound and there has never been any blacking out for me * * *."

Comment.—The permanent loss of body image, as far as the contralateral leg is concerned, can best be explained by the encephalomalacia involving a small portion of the parasagittal parietal area (4) (5).

We surmise that the impaired venous outflow from the leg area was responsible for the persistence of

motor paralysis below the knee. Surgically, only two steps were taken: (1) Resection of liquefied cortical tissues, and (2) freeing of meningeal adhesions, conceivably obstructing venous drainage. It is quite possible that a partial thrombosis was present at the site of entrance into the sinus. The postoperative return of function suggests facilitation of flow distally to the partially obstructed lumen.

ANALYSIS OF CASUALTIES WITH WOUNDS OF DURAL SINUSES INCURRED IN THE KOREAN WAR (6)

Selection of cases.—During the 23-month period from September 1950 through August 1952, 112 consecutive casualties with penetrating wounds of the brain involving dural sinuses were treated at the neurosurgical detachments of the Eighth U.S. Army in Korea and at the neurosurgical center of Tokyo Army Hospital, Japan Logistical Command. They were U.S. soldiers and marines, members of the United Nations Forces, and of the Republic of Korea Army.

The following criteria were used to select cases for inclusion in this report:

1. Transection of a sinus.
2. Laceration of a sinus wall perforating the entire thickness of the wall.
3. Contusion and compression of the sinus (in all but four cases manifested by abrasions of the outer wall with multiple bleeding points).
4. Thrombosis of an anatomically intact sinus evidenced by surgical inspection and digital palpation.

Of 112 consecutive operative cases, 7 were multiple dural sinus injuries, resulting in a total of 124

TABLE 19.—*Classification of casualties with wounds of dural sinuses, September 1950 through August 1952, U.S. Army, Korea*

Classification	Total
Number of consecutive cases	112
Fatal cases	13
Mortality percent	11.6
Patients with multiple sinus wounds	7
Number of dural sinus wounds	124

TABLE 20.—*Site of 112 wounds of dural sinuses, September 1950 through August 1952, U.S. Army, Korea*

Site	Total cases	Total deaths	
		Number	Percent
Superior longitudinal sinus	78	10	12.8
Transverse sinus	¹ 27	3	11.1
Torcular Herophili	7	0
Sigmoid sinus	5	² 1	20.0
Inferior longitudinal sinus	2	0
Superior petrosal sinus	2	0
Straight sinus	1	0
Total	112	13	11.6

¹ There were 29 wounds—2 cases with involvement of right and left transverse sinus.

² Also listed as fatal case under "Transverse sinus."

individual sinus wounds. There were 13 deaths, a mortality of 11.6 percent (table 19).

The penetrating wounds of the brain involving dural sinuses were caused by shell fragments in 65 cases and by high-velocity missiles in 32 cases. Two patients were struck by a rock and two by a blunt object. Four patients were involved in a vehicle accident. In seven instances, the mode of injury remained unknown. Thirty of the 112 patients had associated wounds of the body. There were 78 patients with a wound of the superior longitudinal sinus. The transverse sinus was involved 29 times, but 2 patients had an injury of both the right and left transverse sinus. There were seven wounds of the torcular Herophili. The sigmoid sinus was involved in five, and the inferior longitudinal and superior petrosal sinus each in two cases. One wound of the straight sinus was encountered (fig. 84) (table 20).

Transection of the sinus occurred in nine cases, in six of which the sinus was found to be thrombosed. Laceration of the wall of the sinus, of varying degree, occurred 87 times; a thrombus was encountered at time of surgery at the site of laceration 14 times. Twenty-two cases were classified as contusion and compression; in 19 of these, the contusion was manifested by abrasions of the outer wall of the sinus with multiple bleeding points. A thrombus was diagnosed on the basis of surgical inspection in 1 of the 22 cases. Thrombosis of an intact sinus

was encountered in six penetrating wounds of the brain (table 21).

Surgically significant intracranial hematomas occurred in 28 of the 112 cases (25 percent) (table 22).

SUPERIOR LONGITUDINAL SINUS

(78 Cases, 10 Deaths, 12.3 Percent Mortality)

Of the 78 cases in this group, 3 had trauma of adjacent sinuses. Seventeen patients had trans-ventricular wounds. In seven cases, the injury involved the frontal air sinuses.

TABLE 21.—Type of lesion in 124 dural sinus wounds

Lesion	Number of cases	Associated thrombosis
Transection.....	9	6
Laceration.....	87	14
Contusion and compression....	22	1
Thrombosis.....	6	
Total.....	124	21

In 6 patients, the injury resulted in transection of the sinus, while it was found to be lacerated in 50 patients. Seventeen lesions were classified as con-

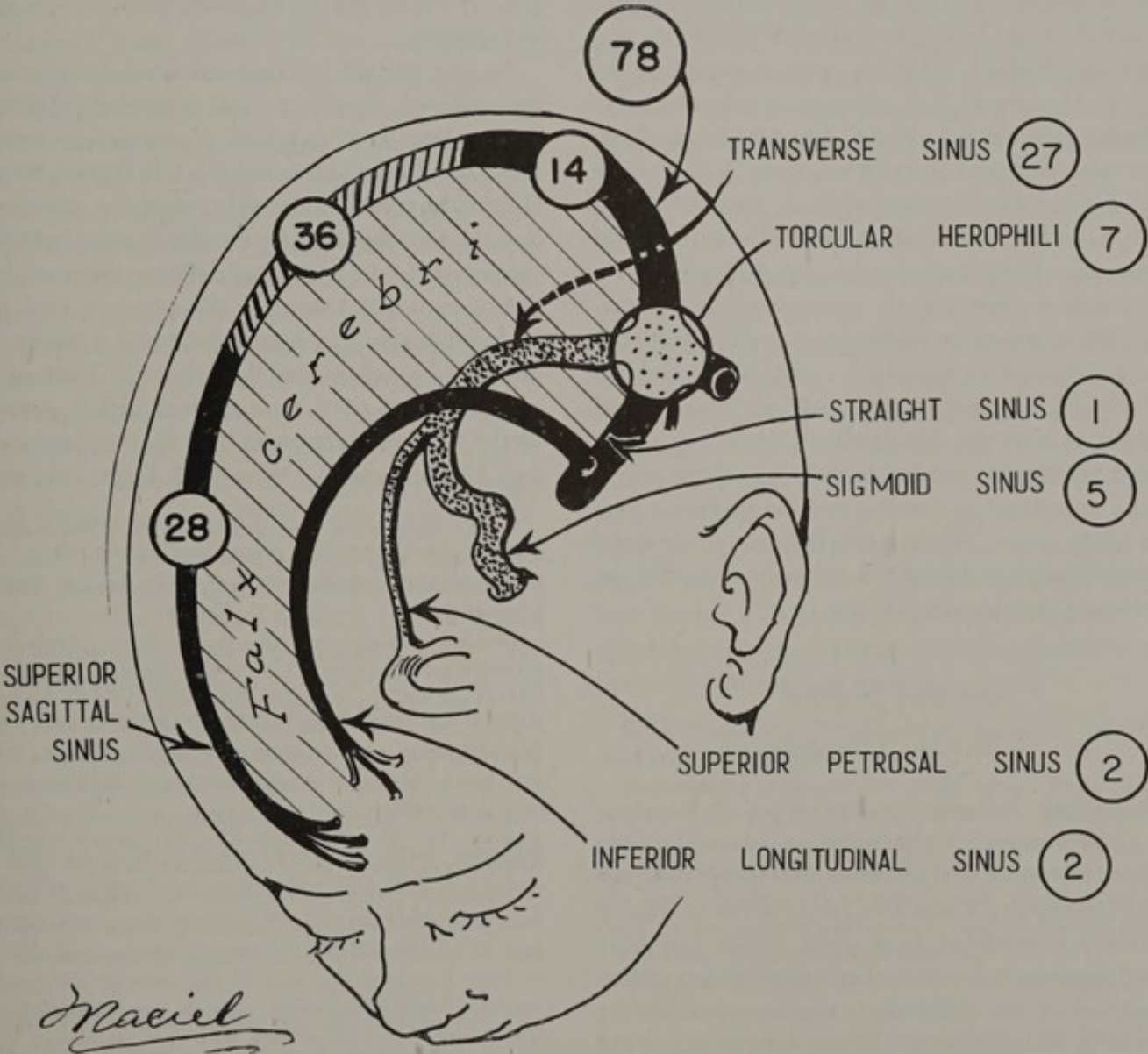


FIGURE 84.—Schematic drawing showing number of cases and location of wounds of dural sinuses, U.S. Army, Korea, September 1950 through August 1952. (Drawing courtesy of *Journal of Neurosurgery*.)

TABLE 22.—*Surgically significant intracranial hematomas in 112 cases with wounds of the dural sinuses*

Type	Number
Subdural hematoma, homolateral.....	10
Subdural hematoma, bilateral.....	2
Extradural hematoma, homolateral.....	5
Intracerebral hematoma.....	11
Total.....	28
Percent of total.....	25

tusion and compression, and in five instances, thrombosis in the presence of an intact sinus wall was diagnosed on the basis of surgical inspection.

Meningocerebral infection was a complicating factor in 11 patients, 3 of whom succumbed to overwhelming cerebritis. Eight patients reached an Army neurosurgical installation from 5 to 7 days after having been wounded and had advanced meningocerebral infection at time of neurosurgical admission. Three patients developed meningocerebral infection despite early neurosurgical intervention. There were five instances of scalp infection.

In an attempt to facilitate a critical analysis of methods of surgical repair and of neurological sequelae of superior longitudinal sinus wounds, it seemed practical to subdivide them into those affecting the anterior, the middle, and the posterior portions of the sinus. By this definition, we understand the middle portion to include all wounds within the province of the rolandic outflow.

ANTERIOR PORTION

(28 Cases, 3 Deaths)

This group includes 3 transections of the sinus and 17 lacerations. Thrombosis was encountered in all three instances of transection and in the presence of one laceration; it was also encountered at time of secondary craniotomy in a sinus which had been ligated apparently because of an extensive laceration.

Surgical repair of the sinus was accomplished by ligation in two instances. Eleven lacerations of the sinus were repaired with silk sutures tied over Gelfoam or fibrin foam, and 1 was repaired with silk

sutures only. Surgical removal of a thrombus was not attempted in any case.

As far as can be determined, all patients were rendered unconscious initially. Except for three of them, all were unresponsive to a varying degree at time of admission to a neurosurgical installation. In six cases, there was no detectable neurological deficit, and in four cases, the deficit was fairly insignificant. Varying degrees of hyperactivity of deep tendon reflexes or diminished or absent abdominal reflexes, suggestive of unilateral frontal lobe pathology, were noted in four cases. Hemiparesis or hemiplegia, accompanied by the usual reflex changes, was encountered eight times, but only four of these patients had fully developed spastic hemiplegia. One of the three fatal cases had a spastic paraparesis.

In one patient, a large subdural hematoma was encountered despite normal neurological findings. This patient had sustained a penetrating wound of the frontal lobe involving the left frontal air sinus. Operation revealed a small tear in the anterior portion of the superior longitudinal sinus which was thrombosed. In four other patients, the neurological deficit could be traced to the presence of a homolateral extradural, a homolateral and a bilateral subdural, or a subcortical hematoma. None of these patients retained a neurological deficit postoperatively. It is of interest to note that all four patients had involvement of one or both frontal air sinuses.

K-28. 23-year-old U.S. Army private. Penetrating left frontal shell wound caused by a trip flare, 9 February 1952, involving left frontal air sinus, simultaneously destroying left eye.

Drowsy on admission 2½ hours later. Avulsed scalp wound from upper lid of left eye to helix of left ear. Left frontal air sinus and macerated portion of left frontal lobe exposed in area measuring 8 by 8 centimeters. Entire wound grossly contaminated with hair and debris. Roentgen films: Extensive comminution and depression of left frontal bone, left frontal air sinus, and left orbit. Blood pressure 110/70. Pulse rate 82. Respiration rate 24. No neurological deficit except for destruction of left optic nerve.

Immediate craniectomy under endotracheal anesthesia with pentothal induction. Upon resection of macerated portion of left frontal lobe, a large bone fragment was found to have lacerated the wall of the anterior portion of the superior longitudinal sinus. Repair was accomplished with interrupted fine silk sutures tied over Gelfoam. Primary closure with fascia lata as dural substitute and layer closure of the scalp.

Uneventful recovery. Ambulatory on admission to neuro-

surgical center in Japan. Neurological deficit: Partial right seventh nerve palsy of central type.

Fatal cases.—In two of the three fatal cases, the patients were decerebrate on admission. One patient (K-56) died 24 hours after operation. Surgical inspection revealed thrombosis of a transected sinus in the presence of extensive bifrontal damage. The course of the other patient (K-38) was complicated by a postoperative hemorrhage, removal of which did not alter his neurological status. He never responded after admission, intermittent bouts of extensor rigidity and hyperthermia developed, and he died 8 days after having been wounded. The third patient (K-57) was not moribund on admission. Bifrontal craniectomy revealed a subdural hematoma overlying the right frontal lobe. Bloody and liquefied brain tissue was removed from the right lateral ventricle. There was extensive destruction of the left frontal lobe, an intracerebral hematoma, laceration of the anterior horn of the left lateral ventricle, and a tear of the anterior portion of the superior longitudinal sinus. The sinus hemorrhage was controlled with silk sutures tied over Gelfoam. The patient did well for 24 hours after operation, when signs suggestive of a progressive sinus thrombosis developed, an impression that was confirmed by the appearance of the brain at secondary exploration.

Discussion.—The neurological deficit seen with wounds of the anterior portion of the superior longitudinal sinus does not follow any specific pattern. In all but the three fatal cases, that deficit could have been the sequel of any penetrating wound of the frontal lobe. The exception to this is best illustrated by two of the fatal cases (K-56 and K-57). The neurological developments in these two cases are comparable to those seen with thrombosis of the mid-portion of the sinus, presenting the picture that Holmes and Sargent (7) have described as the "superior longitudinal sinus syndrome." We presume that in each of these two cases (and possibly also in the third fatal case (K-38)) the thrombus extended far posteriorly. None of the other 25 cases in this group presented similar neurological changes.

In two of the fatal cases (K-38 and K-57), we believe, a thrombosis developed subsequent to repair of a bleeding sinus tear with sutures tied over Gelfoam.

MIDDLE PORTION

(36 Cases, 6 Deaths)

This group includes all wounds within the province of the rolandic outflow. Among them were 3 transections and 21 lacerations. Thrombosis was encountered in the presence of two transections and six lacerations.

The sinus was ligated in one instance. Twelve lacerations were repaired with sutures tied over Gelfoam or fibrin foam. In two of these, the thrombus was removed prior to repair. One laceration was closed with silk sutures and one small tear was sealed with silver clips. A muscle stamp was used in three instances.

Nine patients were oriented at time of neurosurgical admission. Among them was one with a left parietal missile wound from which brain tissue exuded and who had a spastic triplegia. Ten patients showed varying impairment of responsiveness. Twelve were admitted in semicoma or coma. Records of five others did not contain adequate information.

There was no detectable neurological deficit before or after surgery in three patients, and in two others, the deficit was limited to fairly insignificant changes. One patient had a monoplegia. Seven were admitted with hemiplegia or hemiparesis which was associated with a varying degree of hypertonicity. There were four instances of paraplegia or paraparesis with spasticity present in one of them. Spastic triplegia or tri paresis occurred in 13 patients with flaccid paralysis of the arm and spasticity of both legs in one. Two patients were quadriplegic. One showed pronounced flaccidity of all extremities while the other had marked spasticity.

K-70. 27-year-old French soldier. Biparietal penetrating shell wound, 7 March 1951.

Stuporous on admission 24 hours later. Blood pressure 150/40. Pulse rate 74. Respiration rate 30. Macerated, contaminated wound extending diagonally across vertex with liquefied brain tissue exuding. Spastic tri paresis, sparing left arm. Withdrawal to pain stimuli of all extremities. Deep tendon reflexes hyperactive. Left abdominal reflexes diminished. Moderate nuchal rigidity.

Immediate biparietal craniectomy revealed extensive depression and comminution of both parietal bones. Comminuted fragments had torn the superior wall of the longitudinal sinus for a distance of 3 centimeters. Removal of the thrombus, which filled the entire gap, resulted in hemorrhage. Repair of the lacerated sinus was accomplished with in-

interrupted silk sutures tied over Gelfoam. Nineteen bone fragments were removed from the missile track, which was traced to a point 2 cm. caudad to the inferior margin of the falx. Resection of liquefied and necrotic brain tissue did not define a precise zone of demarcation. Anticipating the necessity of a second-stage resection, the dural defect was not grafted, but a piece of Gelfilm was inserted extradurally and primary closure of the scalp was performed.

Prior to secondary craniotomy 13 days later, the wound edges had separated and necrotic brain tissue presented at the surface. There was a clearly defined zone of demarcation. No retained bone fragments or residual hematoma were encountered. The missile track contained xanthochromic fluid. Evacuation of this fluid revealed a tear of the third ventricle which had not been recognized at preceding operation. Fascia lata was used as dural substitute. The scalp was closed in layers. Subsequent scalp infection necessitated frequent saline irrigations and treatment with plasma powder. The scalp defect was allowed to granulate over. Meningitis did not develop.

On admission to neurosurgical center 49 days later, patient was alert and oriented. No aphasia. Spastic tripareisis with virtual paralysis of right arm, but only moderate weakness of left leg, persisted. No evidence of meningocerebral infection.

Within 3 weeks, the patient had two focal seizures and was placed on Dilantin Sodium. He had no further seizures until his return to France, where he did not receive Dilantin Sodium.¹

Followup data are based on numerous letters received from the patient and from members of his family. Four years after injury, he walked without assistance and had recovered some use of his right arm. His letters were intelligent and well coordinated. His handwriting was neat and legible. He had traveled on several occasions without being accompanied.

Comment.—The neurological picture presented by this patient (K-70) shortly after having been wounded is essentially that of Holmes and Sargent's (7) "superior longitudinal sinus syndrome." The temporary postoperative change from tripareisis to virtual triplegia is of interest in view of the fact that the thrombus was removed at time of first operation. The decrease and eventual disappearance of spasticity is in keeping with the classical observation of Holmes and Sargent.

Continued liquefaction subsequent to initial surgery has been observed in many instances of trauma of the midportion of the superior longitudinal sinus and also in some wounds of the posterior portion of the sinus. More often than not, continued liquefaction and delayed demarcation necessitate a second-

stage operation. Optimum time for secondary resection may lie between 4 and 7 days. Postponement for 13 days as in case K-70 could have resulted in meningocerebral infection and may have been responsible for the slow initial recovery.

Surgical removal of the thrombus as was done in case K-70 may well be indicated whenever technically feasible. Its removal may be an essential factor in the prevention of bloodstream infection. Restoration of the sinus wall subsequent to removal of the thrombus may lead to the reestablishment of adequate venous drainage.

Fatal cases.—In three of the six fatal cases of wounds of the midportion of the superior longitudinal sinus the patients died of extensive meningocerebral infection. They did not receive definitive neurosurgery until 11 to 17 days after having been wounded (K-4, K-99, and K-100). Two patients died within 12 hours following surgery. One (K-43) had dilated and fixed pupils and a spastic paraplegia on admission. Operative findings included an almost completely thrombosed superior longitudinal sinus. The other (K-45) also had fixed and dilated pupils and a spastic triplegia on admission. The lacerated sinus was completely obstructed in its midportion by a solid thrombus.

In one patient (K-9), who exhibited a spastic triplegia on admission, thrombosis of the sinus with extensive liquefaction of both hemispheres developed subsequent to repair of a large sinus tear with sutures tied over Gelfoam. He died 6 days after having been wounded.

Post mortem inspection revealed thrombosis of the superior longitudinal sinus at the site of surgical repair with extensive softening of both hemispheres. No residual hematoma was encountered.

The patient's death must be ascribed to thrombosis of the sinus which developed subsequently to its repair with silk sutures tied over Gelfoam. It is of interest to note that this patient exhibited Holmes and Sargent's syndrome when first seen despite the fact that a thrombosis was not noted initially.

Discussion.—As anticipated, wounds of the midportion of the superior longitudinal sinus involving the rolandic outflow are accompanied by a greater mortality and by a much more devastating neurological deficit than any other sinus wounds. Although, in the majority of cases in this group, the disturbances of venous circulation were associated

¹ The Overseas Division of Parke, Davis & Company has now donated Dilantin Sodium (diphenylhydantoin sodium) to this soldier in order to enable him to continue treatment.

with gross cerebral lesions, the high incidence of paraplegia, triplegia, and quadriplegia with prevailing spasticity points to the specific syndrome that has been described by Holmes and Sargent (7). Cerebral edema and actual liquefaction were striking features in these cases. More often than not, such liquefaction may continue for some days after sinus repair, suggesting a two-stage operation as the surgical method of choice in the management of wounds of the midportion of the superior longitudinal sinus.

Our figures relative to the incidence of thrombosis in this entire series may not be correct. In some of the cases, lacunar thrombosis as suggested by Holmes and Sargent (7) may well have been present despite bleeding from the lumen of the sinus. Also, inspection and digital palpation of an intact or contused and abraded sinus wall is not entirely reliable. We may, therefore, have failed to recognize existing thrombosis in cases that are analogous to that of K-118.

K-118. 26-year-old U.S. Army sergeant. Left parietal parasagittal, penetrating, tangential missile wound with necrotic brain tissue exuding on admission, same day. Alert, oriented, no aphasia. Right homonymous hemianopia. Spastic triplegia, sparing left arm (no facial paresis). Bilateral Babinski. Absent abdominal reflexes. Right hemisensory deficit.

Roentgen films of skull: Depressed, comminuted fracture, left parietal bone, parasagittal. Comminuted bone fragments outlining vertical track alongside the falx.

Left parietal craniectomy: Resection of necrotic brain tissue, debridement of track, and removal of indriven bone fragments. Sinus wall contused and abraded. Coagulation of multiple bleeding points over the sinus wall. Pericranium as dural graft. Primary closure in individual layers and primary healing.

Neurological deficit persisted at time of evacuation to Zone of Interior, approximately 3 weeks later. (Postoperatively, the patient also had a mild facial weakness on the right.)

That severe compression of the midportion of the sinus need not always be accompanied by permanent occlusion, may be illustrated by case K-90.

K-90. Korean civilian woman, struck over vertex with undetermined object. Conscious and alert when seen 3 days later. Sutured biparietal scalp laceration without evidence of infection. Cranial nerves intact. No papilledema. Flaccid paralysis of both legs. Left patella reflex absent, right patella reflex hypoactive. Ankle reflexes equally active. Babinski, right. Abdominal reflexes absent.

Roentgen films of the skull: Depressed comminuted biparietal fracture.

Biparietal craniectomy through "S" incision. One comminuted bone fragment had torn the superior wall of the sinus for a distance of 2 centimeters. Proximally and distally the sinus was fully compressed and the sinus wall abraded by comminuted bone fragments. A frank sinus hemorrhage was encountered from the posterior portion of the tear. There was some bleeding also from the anterior margin of the tear, suggesting the possibility of a partial thrombosis. A thrombus, however, was not identified at operation and there was bleeding from the contused sinus wall anteriorly to the laceration. The laceration of the sinus was repaired with sutures tied over Gelfoam. The sinus wall anteriorly and posteriorly to the laceration was so friable that it was necessary to control bleeding from the abraded wall with fine silk sutures. The underlying parietal cortex was reddened and edematous. There was no liquefaction. No subdural hematoma. Primary closure in individual layers.

Within 24 hours, the patient regained some motion in the legs. Two days postoperatively, she was taken home in a ricksha without our knowledge. She was never reexamined, but reliable observers have seen her walk on the streets of her hometown on her own power and without apparent limp.

POSTERIOR PORTION

(14 Cases, 1 Death)

This group includes all wounds posterior to the rolandic outflow. There were 12 lacerations and 2 contusions with bleeding abrasions of the sinus wall. Thrombosis was encountered three times in the presence of a sinus laceration. Injury extended to adjacent sinuses in the three cases.

Surgical repair was accomplished by direct suture of the sinus wall in one case and by sutures tied over Gelfoam or fibrin foam in three cases. Three sizable lacerations were sealed with muscle stamps. Gelfoam without suture was employed five times.

Two patients did not experience unconsciousness when wounded; a third man was rendered unconscious momentarily. The remaining 11 patients showed marked impairment of their responses on neurosurgical admission. Four of them were deeply comatose; six also exhibited excessive restlessness.

There was no motor weakness in any of these patients. Hyperactive deep tendon reflexes were found in three cases with impairment of the abdominal reflexes in two of them. In three cases in this group, there was bilateral impairment of air conduction.

As anticipated, visual disturbances were predominant in this group, but such impairment could in-

variably be traced to embarrassment or to direct damage of the visual cortex. Subjective blurring of vision was the only disturbance in the presence of one sinus tear caused by an indriven bone fragment. Vision was initially limited to light perception in three patients but was restored at time of evacuation, except for persisting homonymous hemianopia in two of them. Two men had a homonymous hemianopia on admission, and there was no change in the visual fields after operation. Four patients were rendered totally blind. At time of evacuation from the neurosurgical center in Tokyo, one could count fingers at a distance of 1 foot and one at a distance of 4 feet. The third retained a homonymous hemianopia. Only one patient remained blind.

K-104. 21-year-old U.S. Marine Corps, private, first class. Penetrating left occipital shell fragment wound with exuding necrotic brain tissue, 7 December 1950. Associated wounds included frostbite of toes and fingers.

Stuporous and exceedingly restless on admission, same day. Blood pressure 124/60. Pulse rate 42. Respiration rate 16. Pupils equal, fixed to light. No motor impairment. Bilaterally hyperactive deep tendon reflexes. Bilateral Babinski response. Absent abdominal reflexes.

Bioccipital craniectomy revealed extensive destruction of brain tissue and penetration of bone fragments to a depth of 7 centimeters. Posterior portion of superior longitudinal sinus was covered by a large blood clot which contained many comminuted bone fragments. Continuous ooze of venous blood from this area suggested sinus laceration which came into sight after removal of clot. Two bone fragments partially sealed the large sinus tear. Their removal resulted in frank hemorrhage. The tear in the sinus was sealed with a muscle stamp from the leg. Closure was performed in layers, deferring radical resection for a second-stage operation. This was accomplished 8 days later. A third bone fragment, which had been overlooked at time of first operation, was found to be lodged in the sinus wall anterior to the previously described tear. Its removal resulted again in hemorrhage from the sinus, clearly indicating that preceding muscle repair had not resulted in thrombosis. The old muscle stamp was replaced by another piece of muscle, sealing the sinus laceration, which measured approximately 4 centimeters. Additional debridement also revealed a laceration of the posterior horn of the right lateral ventricle.

Though there was primary wound healing, the patient had a stormy postoperative course. He was mentally confused for about 1 month but was rational and oriented at time of evacuation, 2 months after having been wounded. He remained blind.

In a letter typed by the patient 2 years later he gave an account of his activities at that time. He was undergoing

training for a civil service job as a typist transcribing from a dictating machine. He engaged in dancing and swimming and lived an active life. His only complaint was of occasional mild headaches. To date he had had no seizures.

Comment.—Muscle repair of a large laceration of the sinus did not result in thrombosis, as proved by second-stage operation.

Fatal case.—In the only fatal case in this group (K-66), the patient had sustained a close-range gunshot wound resulting in extensive laceration and thrombosis of the sinus. On admission, 3 hours after having been wounded, he was in profound coma and exhibited intermittent respiratory failure as well as disturbances of temperature regulation. He died 2 hours postoperatively.

TRANSVERSE SINUS

(27 Cases, 3 Deaths, 11.1 Percent Mortality)

The transverse sinus was involved unilaterally in 25, and bilaterally in 2 cases. In seven patients, the missile wound was also responsible for damage to adjacent sinuses; six of these had involvement of the torcular Herophili. The seventh patient had a separate laceration of the sigmoid sinus and is mentioned as the one fatal case in that section. There was one transventricular wound in this group.

Meningocerebral infection was a complicating factor in five cases; in two, the infection was present at the time of neurosurgical admission.

In 3 cases, injury resulted in transection, and in 21 instances, in laceration of the transverse sinus. Depressed bone fragments produced contusion and abrasions of the sinus wall with multiple bleeding points in three patients. Thrombosis was encountered in two transections and in two lacerations. One transected sinus was ligated. Two lacerations were repaired with silk sutures, 11 with sutures tied over Gelfoam or fibrin foam, and 4 with muscle stamps. Gelfoam pledgets were employed seven times. Three patients did not require repair because of existing thrombosis, and in one, the mode of repair is not known.

Because of their topography, missile wounds of the transverse sinus produced varying neurological deficits. Impairment of vision was particularly common. Cerebellar damage occurred in some, and

motor and sensory changes in others. In each case, there was definite relation between the neurological deficit and the gross cerebral or cerebellar lesions. None of the neurological changes could be ascribed, with certainty, to the lesion of the transverse sinus itself.

K-65. U.S. Army second lieutenant with penetrating left occipital shell wound. Momentary loss of consciousness with subsequent complaint of severe headaches and blurring of vision. Debridement of the wound was carried out in an intermediate station but no details were available until admission to neurosurgical center in Japan 17 days later. He was then alert and oriented. Neurological deficit was limited to right homonymous hemianopia.

Roentgen films: Perforation of left suboccipital bone. Comminuted bone fragments lodged in plane of tentorium. Metallic foreign body within left occipital lobe.

Left occipital and suboccipital craniectomy revealed an extradural hematoma overlying the cerebellar hemisphere and the left occipital lobe. One bone fragment was lodged in the transverse sinus. Its removal resulted in sinus hemorrhage which was controlled by sutures placed through the torn edges of the sinus wall. Two of these sutures were tied over a pledget of fibrin foam. No subdural hematoma was encountered. Primary closure without drainage.

Except for persistent right homonymous hemianopia, the patient made an uneventful recovery.

Comment.—The bone fragment was lodged within the sinus wall for 17 days without producing thrombosis of the sinus. This patient is one of very few in whom meningocerebral infection did not develop despite incomplete initial debridement.

Fatal cases.—K-20 was admitted with fungating cerebritis in the presence of a transventricular wound. Operation revealed a 3-cm. tear of transverse sinus, which was thrombosed. Subsequent ventriculostomy did not result in improvement. Autopsy revealed extensive basilar meningitis with obstructive hydrocephalus. The author, who operated on this patient, failed to institute open treatment, a method which has proved beneficial in the management of cerebritis complicating penetrating wounds of the brain (8).

K-40 had a through-and-through, fungating, left parietal-left suboccipital wound with subdural hematoma in posterior fossa and over left cerebral hemisphere. The transverse sinus was transected and thrombosed. Patient died of respiratory failure 2 days postoperatively.

The third fatal case (K-82) will be discussed in the section on the "Sigmoid Sinus."

TORCULAR HEROPHILI

(7 Cases, 0 Death)

The torcular Herophili was involved seven times. Only one isolated laceration of the confluence of the sinuses was seen. The other six patients also had involvement of one or more adjacent sinuses. In one instance, the lacerated torcular Herophili was thrombosed. Shell fragments were responsible for six cases. One man sustained a through-and-through gunshot wound resulting in comminution and depression of occipital and suboccipital bones. This did not produce a frank laceration of the torcular Herophili, but an extensive contusion of the wall of the confluens with multiple bleeding points on its braded surface. None of the patients died. Meningocerebral or superficial scalp infection did not complicate recovery.

In one instance, the torcular Herophili was repaired with silk sutures tied over Gelfoam. Pledgets of Gelfoam were used in four cases; in one of these, the pledget was replaced by a muscle stamp in the second-stage operation. Similar muscle stamps were used in two other instances.

Only two patients showed motor impairment. One had mild weakness of the lower extremities but regained all function. The other (K-32) was triplegic but recovered.

There were no visual disturbances in one case. Two patients had only light perception when first seen: one recovered full vision, the other retained a right homonymous hemianopia. One man could recognize objects prior to surgery. At time of evacuation, he had fair vision, sufficient to get about the ward. Two, or possibly three, patients were blind initially; within 2 weeks after the first operation, one could count fingers at 1 foot. The other was able to count fingers at 4 feet within 3 weeks. Visual fields checked at a visual angle of 3/330 and 6/330 did not reveal a defect at that time. The third patient was too disturbed mentally to permit determination of his visual status.

In all cases, the pupillary light reflex was intact when the patients were first seen; reaction to light and to accommodation was intact in all of them at time of evacuation. One patient showed left inferior conjugate deviation and paralysis of upward gaze. The conjugate movements were fully restored

at time of evacuation. Nystagmus was seen in one instance. Papilledema did not develop in any patients. While all seven showed various degrees of impairment of the conscious level initially, only one patient remained disoriented at time of evacuation.

Comment.—Analysis of the seven wounds of the torcular Herophili reveals a striking paucity of neurological changes except in K-32. The deficit in that particular case was probably the sequel of existing compression of brain stem and mesencephalon.

Predominant in all but one of the cases was the impairment of vision, which could be explained on the basis of direct cortical contusion. The possibility exists, however, that defective venous drainage was responsible for dysfunction of the visual cortex and that subsequent restoration of vision was facilitated by collateral circulation. It might also have been brought about by the reestablishment of venous flow after surgical repair of the venous channels. Free flow of venous blood was seen at second operation in two cases even though one of them revealed initially a thrombosis of the torcular Herophili.

It was Dandy's impression (9) that thrombosis of the torcular Herophili may not be compatible with life because of insufficient collateral circulation for both the longitudinal and straight sinuses. This analysis seems to indicate that temporary occlusion of the confluens can be tolerated, an argument in favor of repair of a lacerated torcular Herophili after surgical removal of the thrombus.²

SIGMOID SINUS

(5 Cases, 1 Death, 20.0 Percent Mortality)

The sigmoid sinus was involved five times. There were four isolated lacerations. In one patient, a .45 caliber bullet, after lacerating the sigmoid, transected the transverse sinus and traversed the cerebellar hemisphere. A German 8 mm. submachinegun

("burp gun" in American parlance) was responsible for one of the sigmoid sinus lacerations. The remaining three were caused by shell fragments. Meningocerebral and superficial scalp infections were not complicating factors in any of the cases.

In one instance, the laceration was repaired with interrupted silk sutures; in two cases, a muscle stamp was used. One laceration was repaired with silver clips covered with a Gelfoam strip. In the fifth case, the method of sinus repair is not known.

Because of the topography of the entrance wound, a peripheral facial palsy of varying degree was encountered in three out of five cases. Nerve deafness was found in two instances. Motor paralysis was not seen. In line with the associated cerebellar damage, a considerable deficit was encountered in four out of five cases.

K-114. 24-year-old U.S. Army corporal with penetrating right temporo-occipital shell wound.

Drowsy, but oriented on admission 24 hours later. Headaches, vomiting. Blood pressure 110/60. Pulse rate 96. Respiration rate 22. Questionable right seventh nerve palsy. No acoustic perception on the right.

Roentgen films: Depression and comminution of inferior portion of right temporal and occipital bones and right mastoid and petrous bones. Innumerable comminuted bone fragments at base of posterior portion of middle fossa. One metallic fragment within comminuted area of petrous bone.

Operation revealed dural tear at base of middle fossa. Liquefied brain tissue, clots, and comminuted bone fragments encountered extradurally. Intradurally, a substantial clot and five comminuted bone fragments were removed together with liquefied brain tissue. The metallic fragment had pierced the wall of the sigmoid sinus, occluding it temporarily. Its removal resulted in profuse hemorrhage. Repair was effected with silver clips and Gelfoam pledgets.

Primary healing and uneventful recovery. Reexamination at the neurosurgical center in Japan revealed no neurological deficit, except for complete loss of hearing on the right and a peripheral seventh nerve palsy on that side.

Comment.—This is the only instance in which the author has used silver clips for the repair of a sinus laceration. It is not an entirely satisfactory method because of the relative danger of secondary hemorrhage.

Fatal case.—In K-82, the operative findings included a transected and thrombosed transverse sinus and a separate laceration of the sigmoid sinus. The patient died of postoperative pulmonary complications 7 days after having been wounded. In the 13 fatal cases in this entire series, he was the only patient to succumb to pulmonary pathology.

² Shortly after conclusion of the consecutive series of dural sinus wounds here presented, two casualties with penetrating wounds of the brain caused by shell fragments and lacerations of the torcular Herophili were encountered in the 2d Neurosurgical Detachment (Provisional). These patients were cared for and operated on by Dr. Joseph C. Barnett, Jr., Atlanta, Ga., and by Dr. Jose Nine-Curt, Puerto Rico, respectively. Available followup reports indicate that both patients made a satisfactory recovery.

INFERIOR LONGITUDINAL SINUS

(2 Cases, 0 Death)

One laceration of the inferior longitudinal sinus and one thrombosis in the presence of an intact sinus wall was seen.

K-53, U.S. Army corporal, sustained a shell wound of the left forehead resulting in a huge gaping laceration, measuring 8 cc. in diameter, and in destruction of the anterior portion of the left frontal lobe.

At operation, a hematoma was encountered covering the floor of the left anterior fossa. Its removal revealed laceration of the inferior longitudinal sinus which was repaired with a muscle stamp.

The postoperative neurological deficit was limited to personality changes of frontal lobe type.

SUPERIOR PETROSAL SINUS

(2 Cases, 0 Death)

Of the two cases in which the superior petrosal sinus was involved, one is reported here as a representative case.

K-117, U.S. Army private, first class, sustained a right temporo-occipital, through-and-through bullet wound. Debridement was performed at an intermediate station but details of the extent of the operation are not on record.

On admission to neurosurgical center in Japan, 7 days later, patient was irrational and exceedingly restless. He had a left hemiparesis and mild nuchal rigidity. Examination of the head revealed a sutured linear incision in right posterior temporal region, overlying a bulging and poorly pulsating defect. Cerebrospinal fluid was noted to leak through the approximated skin edges which were reddened and edematous.

Roentgen films: Bony defect in right temporo-occipital area. One cluster of bone fragments in temporal area; a second cluster intracerebrally just cephalad to the plane of the tentorium.

Right temporo-occipital craniectomy was performed 2 days following admission, after patient had been placed on antibiotic therapy. Upon opening the scalp incision, large amounts of necrotic and partially liquified brain tissue exuded through a tear in the dura mater. The entire necrotic portion of the temporal lobe was resected. A large hematoma was encountered in the vicinity of the fractured petrous bone. Within this hematoma, three comminuted pieces of bone were found, all of which had pierced the wall of the superior petrosal sinus. Their removal resulted in frank hemorrhage which was controlled by a piece of muscle. Gelfilm was used in lieu of a dural graft.

In a second-stage operation, 7 days later, the exit wound in the anterior temporal region was exposed and 19 extradural bone fragments were removed. As posteriorly, Gelfilm was used in lieu of a dural graft.

Recovery was slow but steady. Left hemiparesis subsided and the patient was ambulatory at time of evacuation to the United States.

STRAIGHT SINUS

(1 Case, 0 Death)

Following is the only case in this series in which the straight sinus was involved.

K-84. The patient sustained a penetrating left occipital missile wound. He did not receive neurosurgical attention until admitted to the neurosurgical center in Japan.

He appeared lethargic and restless. Inspection of the head revealed three separate penetrations of the scalp in the left occipital area near the midline. Necrotic brain tissue and clots exuded spontaneously from all three wounds. The neurological deficit was limited to a right homonymous hemianopia. There was no papilledema.

Roentgen films: Depression and comminution of both occipital bones with intracerebral bone fragments in medial aspect of left occipital lobe.

Bioccipital craniectomy revealed a narrow longitudinal defect involving both occipital bones. Necrotic brain tissue (with a foul odor), clots, and comminuted bone fragments exuded through the bony defect after the scalp had been retracted. The dura mater was widely torn. The left occipital lobe was macerated and had to be resected. Granulation tissue and organized clots covered medial aspect of falx and tentorium. Removal of clots resulted in massive hemorrhage from a tear in the straight sinus. The tear was repaired with a muscle stamp which was covered with strips of fibrin foam.

Because of existing cerebritis, secondary resection was anticipated and primary closure was performed without dural graft.

Reopening of the scalp incision, 13 days later, revealed a well delineated fungating mass which was resected. Fascia lata was used as dural substitute.

Primary closure resulted in uncomplicated recovery. At time of evacuation to the United States, 40 days later, the neurological deficit consisted of marked anomia, cortical sensory loss, and right homonymous hemianopia.

Comment.—Matson (2) has reported one case of laceration of the straight sinus. His patient sustained a penetrating transventricular missile wound of the left occipital lobe. The missile track extended below the falx and contained many comminuted bone fragments. A profuse hemorrhage from the straight sinus was controlled with silver clips.

DISCUSSION

The surgical repair of dural sinus wounds requires consideration of certain individual factors

which should be discussed in the light of newly gained experiences.

Proper positioning on the operating table of patients with dural sinus wounds has been stressed by many neurosurgeons. Small and Turner (10) advocate a reclining position. Matson (2) recommends elevation of the head during debridement to reduce the pressure in the large venous channels unless a falling blood pressure demands otherwise. Evans (11) points to the grave danger of fatal air embolism if the head is elevated at time of operation and prefers lowering the head despite increased bleeding from such positioning. A tragic complication of this kind was experienced by the author during the Okinawa campaign. Three separate tears were encountered in the superior longitudinal sinus. The patient died suddenly on the operating table after two lacerations had been repaired. Autopsy revealed air embolus as the cause of death. There can be no doubt that the reclining position provides a considerable degree of safety. We have found it satisfactory to employ a neutral (horizontal) position and have not encountered air embolism in this series.

Pentothal sodium (thiopental sodium) induction, with employment of an endotracheal tube and gas, has been our anesthesia of choice. The necessity of maintaining a normal blood pressure before, during, and after operation with whole blood transfusions is of prime importance. The use of artificial hypotension in suspected wounds of dural sinuses is not advisable.

The cardinal principle of management of sinus injuries, not to disturb the point of laceration of the dura until the area has been well exposed, has been stressed by Matson (2). It is also important to evacuate all clots which may obscure a sinus laceration and to remove all comminuted bone fragments which may have lodged in the wall or in the lumen of the sinus. This is necessary for the sake of radical debridement in order to prevent infection; it is equally necessary for the restoration of the lumen of the sinus. The tendency toward rapid reestablishment of venous circulation in a repaired dural sinus has been demonstrated by Sir Hugh Cairns and his associates (12).

The management of a thrombosed sinus wound is worthy of reevaluation. In the presence of a transection, of course, collateral circulation will have to

be depended upon. The removal of a thrombus from the transected ends of a sinus is indicated only as another measure to prevent infection. It permits debridement of the sinus wall which will have to be followed by ligation. To our knowledge, there is no satisfactory method of functional repair of a transected sinus. With the advent of plastic prosthesis for blood vessel repair, reestablishment of the continuity of a severed sinus may well be within the realm of possibility in the future.

Primary thrombosis of a lacerated sinus, which was encountered 14 times in this series, presents an interference with venous circulation which can be eliminated. In two patients (K-70 and K-77), a thrombus which fully occluded the lumen at the site of laceration was removed. The degree of functional return in both of these cases seemed to indicate the establishment of adequate venous drainage. We believe that the surgical removal of an obstructing thrombus from a lacerated sinus is warranted. After placing interrupted fine silk sutures through the torn edges of the sinus, the thrombus can best be evacuated with strong suction. Repair of a small laceration is then completed by insertion of a muscle stamp into the lumen.

A suitable technique for the repair of small lacerations is the use of interrupted fine silk sutures on eye needles, placed through the edges of the tear. The laceration in the sinus wall can be firmly occluded by tying these sutures over a strip of Gelfoam (figs. 85 and 59, p. 115).

Insertion of muscle into the lumen of the torn sinus is the method of choice for the repair of moderate sized and large lacerations. As pointed out by Sir Hugh Cairns (12), the establishment of adequate venous drainage in cases similar to K-104 (p. 188) suggests that a large muscle stamp does not necessarily interrupt the flow of blood through a sinus so repaired. Experimental studies on the monkey,³ based on clinical experiences in the Korean War, confirmed these clinical impressions (13). Insertion of skeletal muscle into the lumen of the sinus in the monkey resulted in complete obstruction which was demonstrated by sinography 1 week following occlusion. Relief of the obstruction and recanalization had taken place in all five

³ These studies were supported by the Research and Development Division, Office of The Surgeon General, Department of the Army, under Contract No. DA-49-007-MD-522.

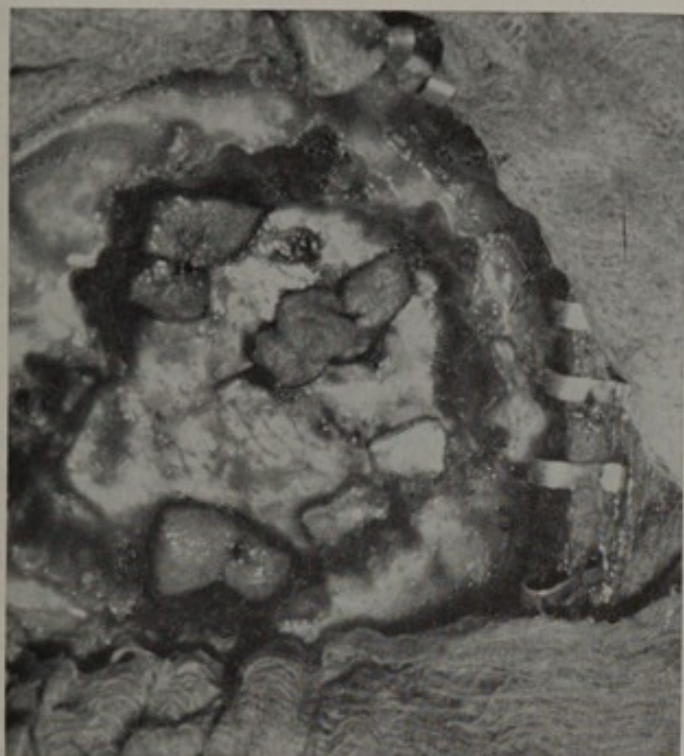

FIGURE 85.—Repair of small laceration of dural sinus by strip of Gelfoam tied with sutures. (Photograph courtesy of *Journal of Neurosurgery*.)

animals when sinography was repeated 2 weeks after occlusion. During these 2 weeks, no demonstrable neurological deficit developed. The sinus was then resected at the site of muscle insertion for purpose of histological studies. It was of interest to note that ligation of the sinus proximally and distally did not produce a neurological deficit (fig. 86).

Histological studies revealed conversion of the muscle into collagenous scar tissue which was firmly adherent to the wall of the sinus except at the site of recanalization. These sites were characterized by islands of partly degenerated muscle fibers surrounded by spaces which were lined with endothelial cells and which contained blood elements. Large spaces between scar tissue and wall of the sinus appeared to be continuous with the sinus. There was no evidence of thrombus formation (figs. 87 and 88).

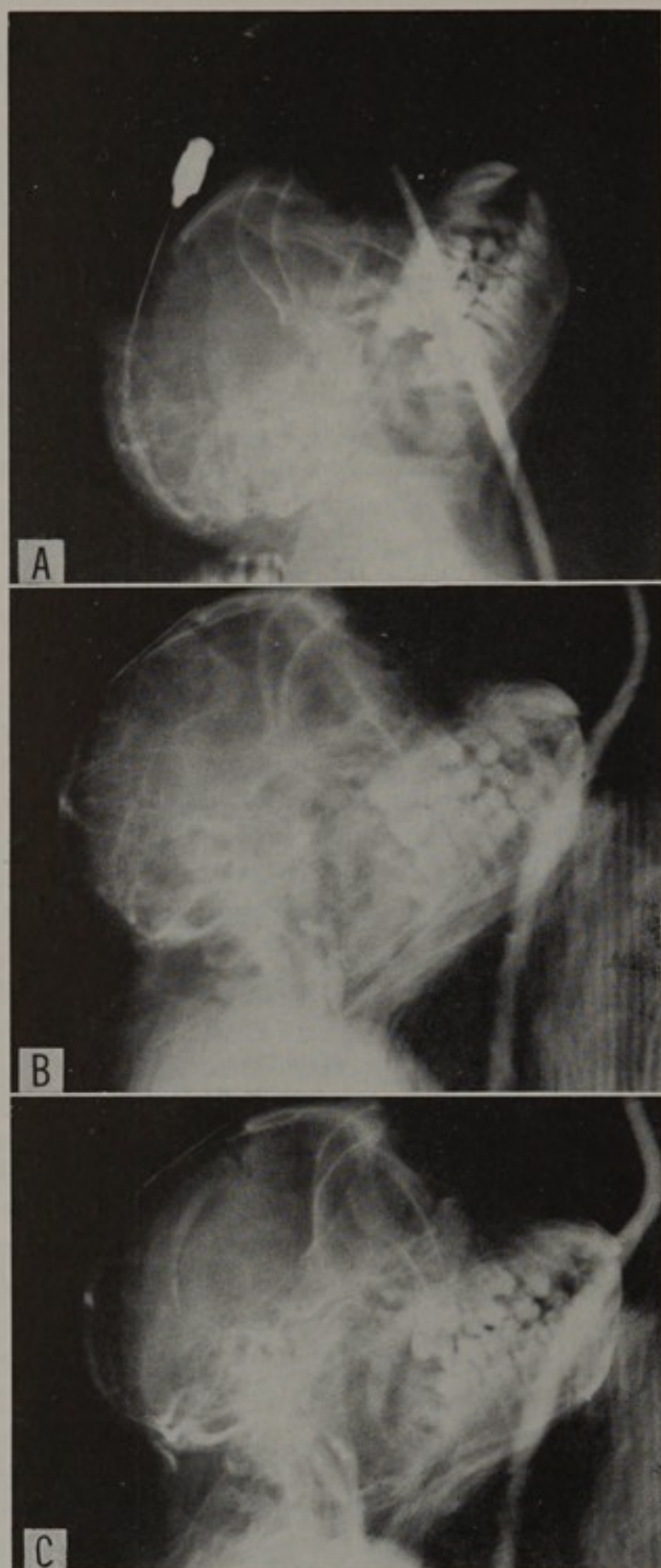
These experiments in the monkey clearly demonstrate the process of recanalization which takes place in the sinus which has been repaired with a muscle stamp.

The muscle stamp, best obtained from the lateral aspect of the thigh, should be at least four times the diameter of the laceration. It should measure from

1 to 2 cc. in thickness. This permits insertion of a small portion of the stamp through the lacerated sinus wall into the lumen of the sinus. The external portion of the muscle stamp prevents oozing and has a cushioning effect on the contused sinus wall surrounding the laceration. Occasionally, it may be necessary to secure the muscle stamp to the dura with a few interrupted silk sutures or to seal it peripherally with a strip of Gelfoam.

In 3 of 42 lacerations repaired with silk sutures which were tied over Gelfoam or fibrin foam, secondary thrombosis developed. The same was observed in 1 of 15 lacerations that were repaired with a muscle stamp. Thrombosis may, of course, have developed in other instances without manifesting itself clinically. We are inclined to believe, however, that the occurrence of secondary thrombosis depends not so much on the method of repair as on the maintenance of systemic blood volume and pressure before, during, and immediately after operation. Anticoagulant therapy was not employed in brain wounds in the Far East Command. It may well be a valuable adjunct in dural sinus surgery and may serve to prevent instances of secondary sinus thrombosis following surgical repair of a dural sinus tear.

In man, the analysis of neurological sequelae to occlusion of dural sinuses or their tributaries has been complicated by associated gross cerebral lesions and simultaneous pathological alterations of collateral routes. Nevertheless, Holmes and Sargent (7) have been able to define a neurological syndrome occurring in man with occlusion of the superior longitudinal sinus posterior to the rolandic veins. Merwarth (14) described the syndrome of the rolandic vein. The recent observations of Swanson and Fincher (15) throw additional light upon the nature of the neurological deficit resulting from obstruction of the superior longitudinal sinus. There is agreement that the superior longitudinal sinus can be ligated with impunity anterior to the point of entrance of the rolandic veins. This is confirmed by the analysis of 112 wounds of the dural sinuses incurred in the Korean War (6). There is considerable evidence, in that analysis and in Swanson and Fincher's observations, that the dire neurological sequelae to occlusion of the superior longitudinal sinus posterior to the rolandic veins may be temporary, and that extent and duration of the



neurological deficit may depend on the local damage that has been produced.

Studies with experimental occlusion of dural sinuses on the monkey (13) which were stimulated by the experiences with dural sinus wounds in the Korean War not only confirmed the concept of recanalization but also brought to light electroencephalographic changes as well as cerebrospinal fluid pressure changes secondary to artificial occlusion of dural sinuses in the monkey. In five monkeys, electroencephalographic studies and determinations of changes in cerebrospinal fluid were carried out in order to obtain further information on the effect of sudden alteration of venous outflow. In each instance, slow waves of high amplitude (200 to 300 volts, 3 to 5 per second) occurred instantaneously and returned gradually, within 20 to 90 seconds, to the baseline pattern (fig. 89). Associated with the appearance of the slow waves of high amplitude was a rise in cerebrospinal fluid pressure, with increases ranging from 70 to 100 mm. of water. A plateau of from 70 to 100 mm. of water above the preocclusion pressure was reached in each monkey within 1 to 2 minutes. These levels remained unchanged at termination of the experiments 4 hours later.

The experimental evidence of cortical swelling and venous engorgement associated with an increase in cerebrospinal fluid pressure and with changes in the encephalographic pattern indicates temporary alterations in the monkey similar to those expected in man. The apparently rapid development of collateral venous outflow as demonstrated in the monkey seems to prevent permanent alterations.

FIGURE 86.—Monkey No. 7. A. Sinogram immediately following muscle occlusion of superior longitudinal sinus posterior to rolandic veins. B. Sinogram 9 days following occlusion. Note appearance of diodrast distal to site of occlusion. C. Sinogram at time of excision of superior longitudinal sinus containing muscle for purpose of histological studies. (Photographs courtesy of *Journal of Neurosurgery*.)

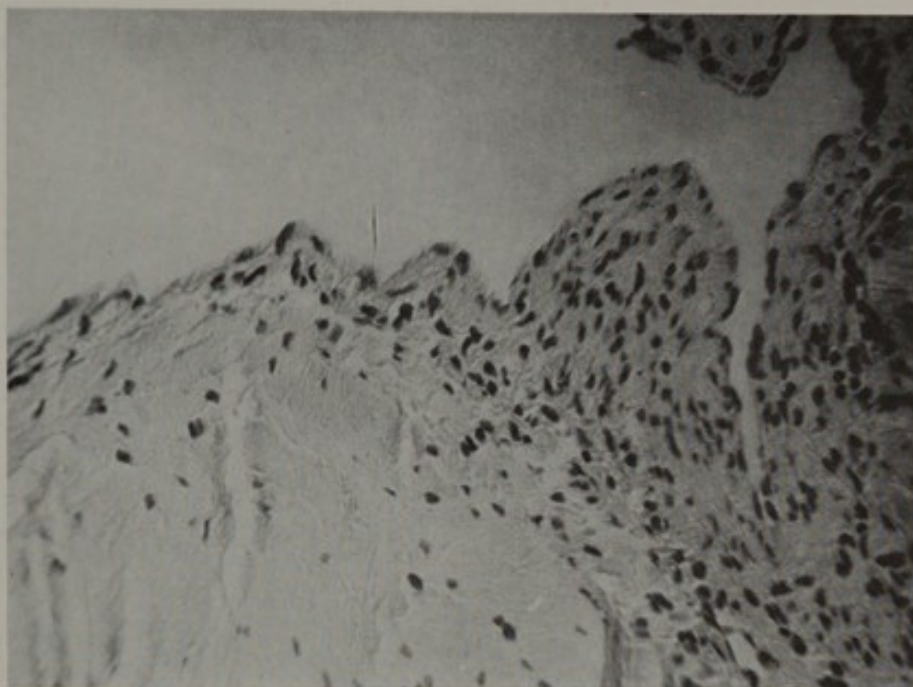


FIGURE 87.—Monkey No. 7. Section through superior longitudinal sinus demonstrating endothelial lining of muscle tissue inserted 3 weeks previously producing initial occlusion. Area to right is contracted, fibrosed, striated muscle. (Photograph courtesy of *Journal of Neurosurgery*.)

SURGICAL TECHNIQUE

Inspection of site of wound after complete shave and study of roentgenograms in two planes will lead frequently to anticipation of a dural sinus wound.

A. Preoperative steps:

1. Maintenance of horizontal position.
2. Typing, cross matching: 3 to 4 pints of whole blood.
3. Intravenous cut-down.
4. Priority for neurosurgical intervention.
5. Endotracheal anesthesia.
6. Horizontal positioning on operating table.

B. Operative steps:

1. Placing of scalp incision so as to afford wide exposure. "S"-shaped incision usually affords best exposure (fig. 90).
2. Debridement of scalp and periosteum.
3. Bur hole at safe distance from site of depression and comminution.
4. Starting from the distal bur hole, a wide craniectomy is performed by rongeur bone away cautiously. Comminuted bone fragments and clots suspected to seal dural sinus lacerations are kept in place until wide craniectomy has been performed making venous sinus surgically accessible (fig. 91).

5. In case of transection of sinus:

- a. Ligation of proximal and distal ends with silk sutures.
- b. A thrombus may be left undisturbed unless it is intermixed with comminuted bone fragments situated within lumen of sinus. In that case, resection of bone fragments and evacuation of thrombus by suction become necessary.

6. In case of laceration of sinus:

- a. Full exposure of sinus laceration by removal of extradural clots and extradural bone fragments or foreign bodies covering laceration.
- b. Debridement of sinus laceration by resection of all minute bone fragments from the lumen of the sinus.
- c. Resection of sealing thrombus from lumen of sinus by use of suction.
- d. Closure of small laceration with interrupted sutures of No. 0000 silk tied over Gelfoam.
- e. Closure of moderate-sized or large laceration.



FIGURE 88.—Monkey No. 130. Photomicrograph of section of superior longitudinal sinus showing muscle infiltrated with red blood cells and enlarging channels. Sinus excised 2 weeks following occlusion with muscle. (Photograph courtesy of *Journal of Neurosurgery*.)

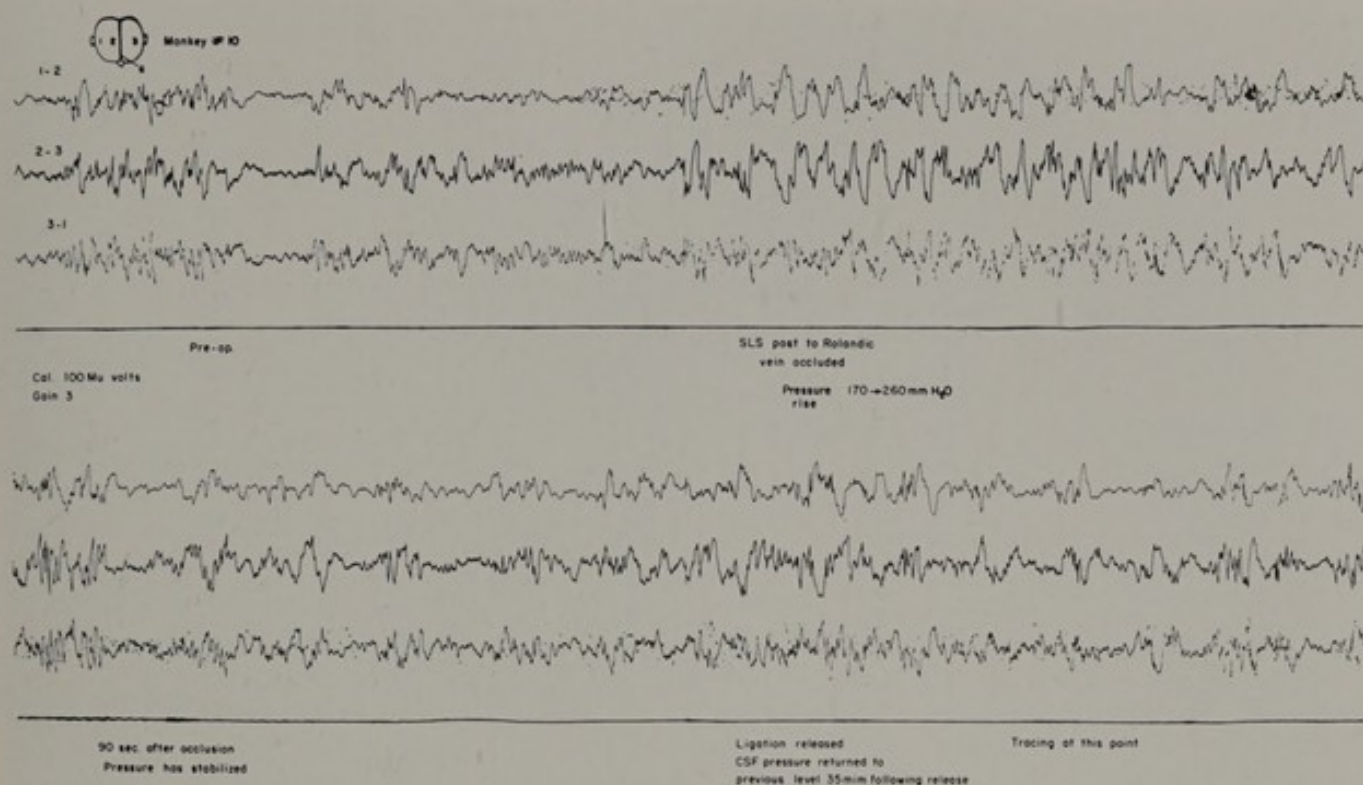


FIGURE 89.—Monkey No. 10. Electroencephalographic and cerebrospinal fluid changes before, during, and after occlusion of the superior longitudinal sinus posterior to rolandic inflow. (Photograph courtesy of *Journal of Neurosurgery*.)

ation by insertion of muscle stamp (figs. 92 and 93):

- (1) Resection of large piece of muscle from lateral aspect of thigh.
- (2) Insertion of small portion of muscle into lumen of sinus as thrombi or comminuted bone fragments are removed.
- (3) That portion of muscle stamp not within the lumen remains resting ex-

tradurally, fanlike, on top of sinus laceration. The extradural portion of the muscle stamp can be readily fixed by a few silk sutures to the dura.

7. In case of contusion of sinus with multiple small bleeding points:

Control oozing by—

- a. Packing with Gelfoam pledgets.
- b. Packing with small muscle stamp.

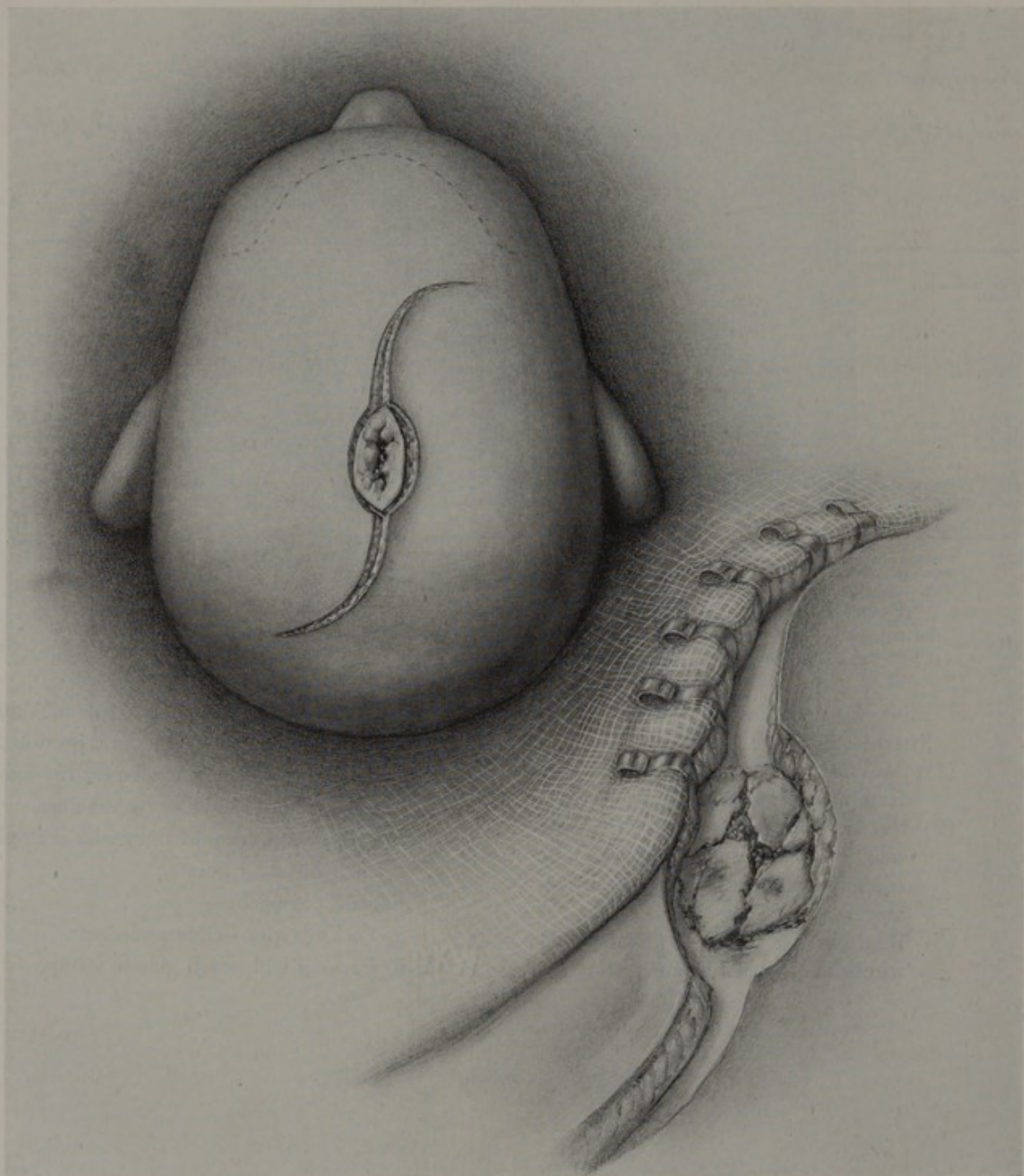


FIGURE 90.—Repair of dural sinus wound with muscle stamp.

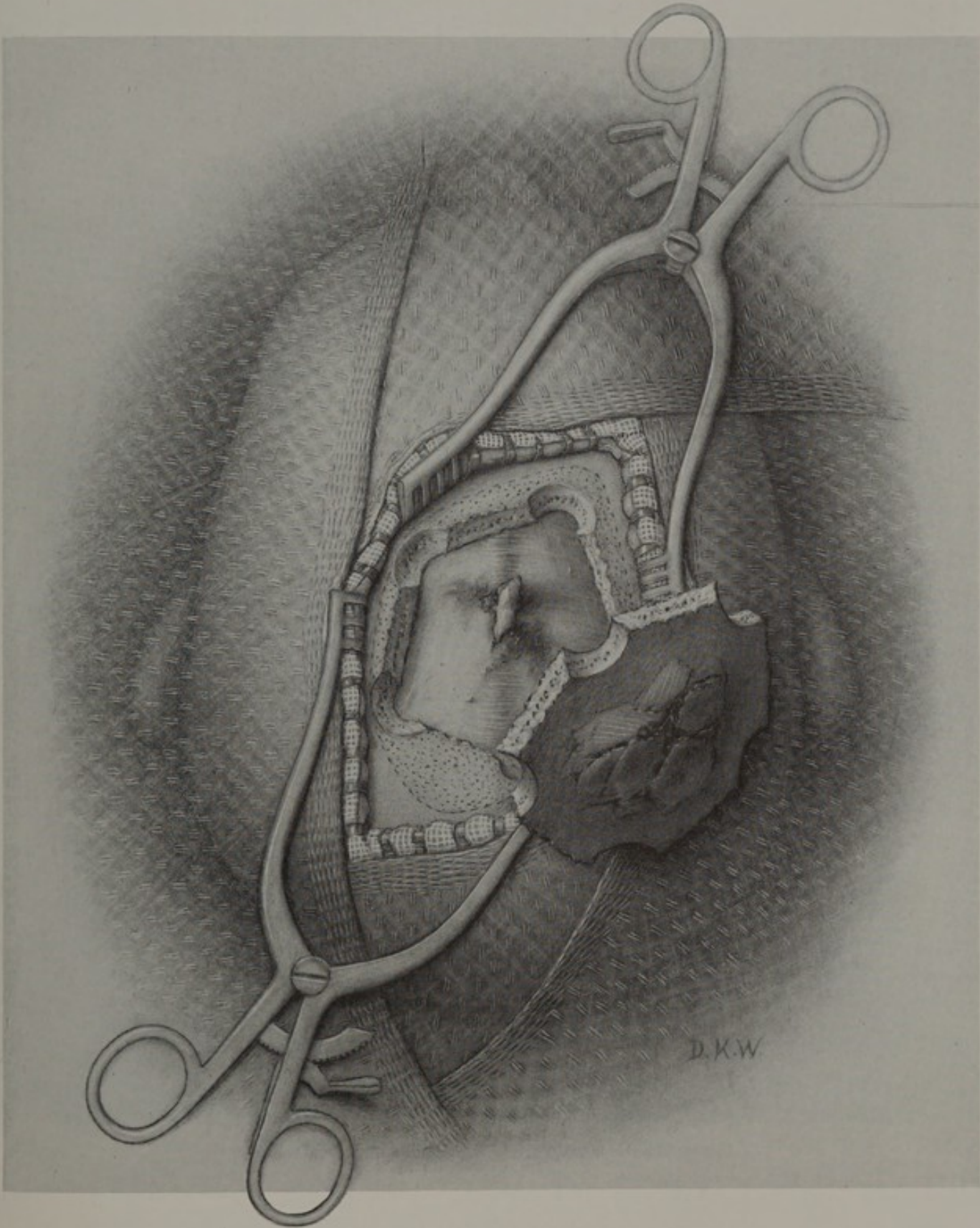


FIGURE 91.—Repair of dural sinus wound with muscle stamp.

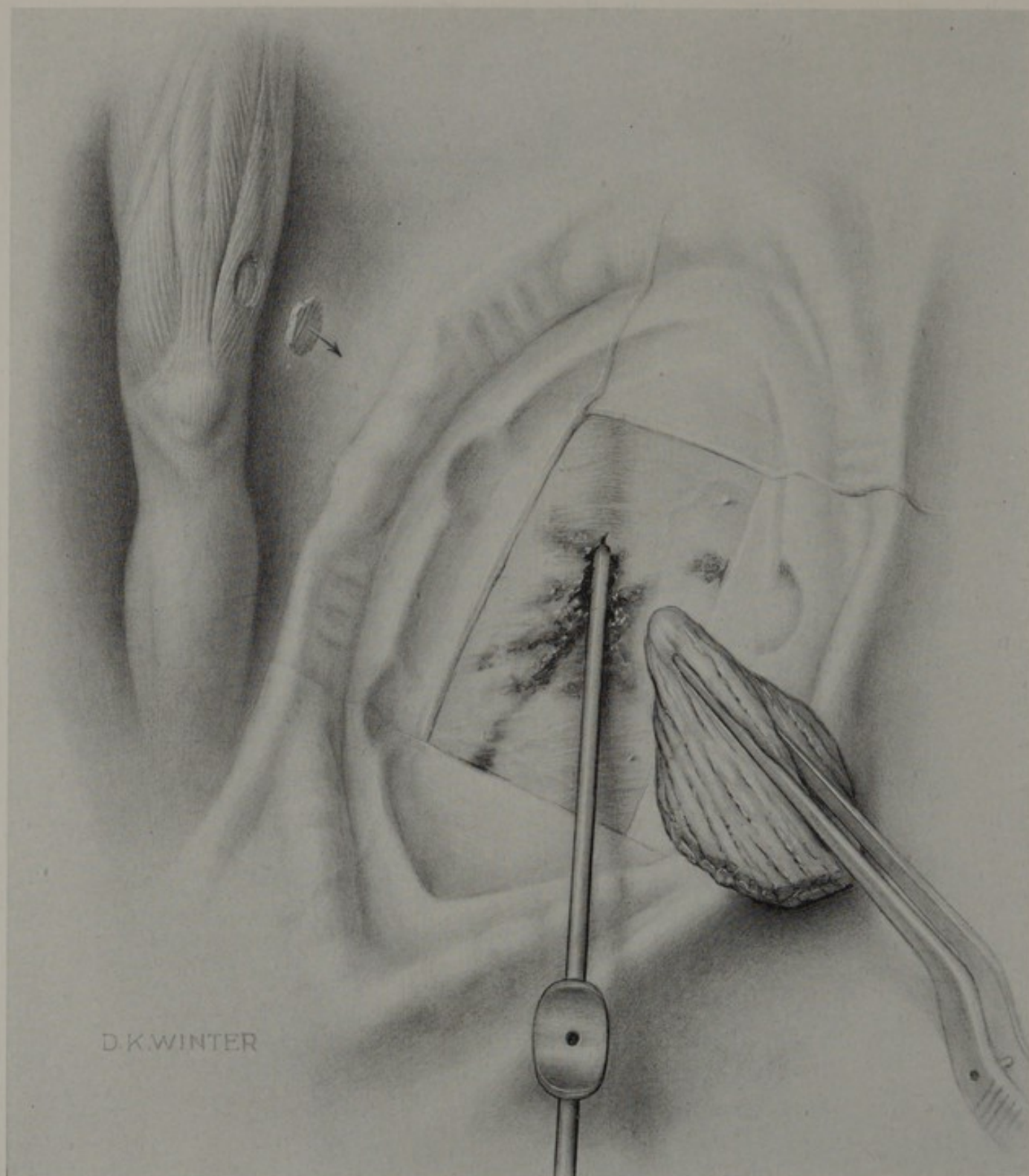


FIGURE 92.—Repair of dural sinus wound with muscle stamp.

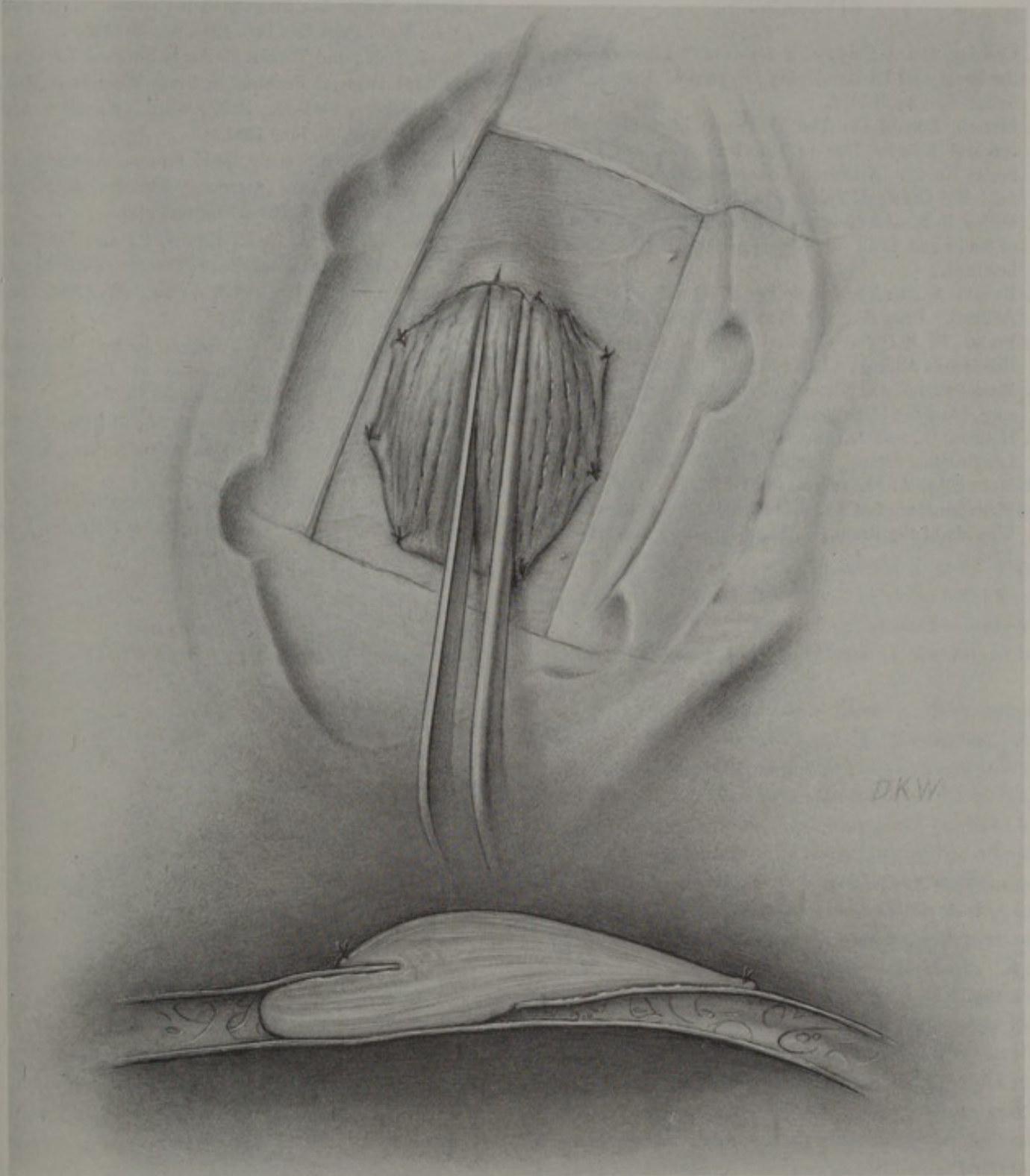


FIGURE 93.—Repair of dural sinus wound with muscle stamp.

REFERENCES

1. Cushing, H.: A Study of a Series of Wounds Involving the Brain and Its Enveloping Structures. *Brit. J. Surg.* 5: 558-684, April 1918.
2. Matson, Donald D.: The Treatment of Acute Cranio-cerebral Injuries Due to Missiles. American Lecture Series No. 22. American Lectures in Surgery. Springfield, Ill.: Charles C Thomas, 1948.
3. Dodge, P. R., and Meirowsky, A. M.: Tangential Wounds of Scalp and Skull. *J. Neurosurg.* 9: 472-483, September 1952.
4. Russell, W. R.: The Physiology of Memory; President's Address. *Proc. Roy. Soc. Med.* 51: 9-15, January 1958.
5. Brain, W. R.: The Cerebral Basis of Consciousness; President's Address. *Brain* 73: 465-479, December 1950.
6. Meirowsky, A. M.: Wounds of Dural Sinuses. *J. Neurosurg.* 10: 496-514, September 1953.
7. Holmes, G., and Sargent, P.: Injuries of the Superior Longitudinal Sinus. *Brit. M. J.* 2: 493-498, 2 Oct. 1915.
8. Meirowsky, A. M., and Harsh, G. R., III: The Surgical Management of Cerebritis Complicating Penetrating Wounds of the Brain. *J. Neurosurg.* 10: 373-379, July 1953.
9. Dandy, Walter E.: *Surgery of the Brain*. Hagerstown, Md.: W. F. Prior Co., Inc., 1945, pp. 427-428.
10. Small, J. M., and Turner, E. A.: A Surgical Experience of 1,200 Cases of Penetrating Brain Wounds in Battle, N.W. Europe, 1944-45. *Brit. J. Surg. (War Surg. Supp. No. 1)*, pp. 62-74, June 1947.
11. Evans, Joseph P.: Acute Head Injury. American Lecture Series No. 60. American Lectures in Surgery. Springfield, Ill.: Charles C Thomas, 1950.
12. Cairns, H., Calvert, C. A., Daniel, P., and Northcroft, G. B.: Complications of Head Wounds, With Especial Reference to Infection. *Brit. J. Surg. (War Surg. Supp. No. 1)*, pp. 198-243, June 1947.
13. Owens, G., Stahlman, G., Capps, J., and Meirowsky, A. M.: Experimental Occlusion of Dural Sinuses. *J. Neurosurg.* 14: 640-647, November 1957.
14. Merwarth, H. R.: The Syndrome of the Rolandic Vein (Hemiplegia of Venous Origin). *Am. J. Surg.* 56: 526-544, June 1942.
15. Swanson, H. S., and Fincher, E. F.: Experiences Involving the Superior Longitudinal Sinus and Rolandic Veins. *Neurology* 4: 801-810, November 1954.

CHAPTER 17

Wounds Involving the Air Sinuses

Edward J. Bishop

GENERAL CONSIDERATIONS

Penetrating wounds involving the air sinuses have engendered considerable interest in neurosurgeons dealing with this type of injury, in both military and civilian practice, as evidenced by pertinent publications by Adson (1), Baker and MacLean (2), Cairns (3) (4), Coleman (5), Gurdjian and Webster (6), Matson (7), McKenzie (8), Schorstein (9), and Stewart and Botterell (10). Of all penetrating craniocerebral wounds, those involving the air sinuses demand particularly specialized care and meticulous surgical repair. The missile passes from the external environment through a usually contaminated and often infected passage into the intracranial cavity, and in cases of meningeal laceration, into the subarachnoid space, cerebrospinal fluid, and the brain. The net result is that, in addition to the seriousness of an ordinary penetrating craniocerebral wound, there is the added threat of infection through and from the sinuses involved. The importance of preventing infection in these cases is brought into sharp focus by the observations of Matson (7) and Schorstein (9). Usually, the neurological deficit is limited to the frontal lobes. Consequently, if infection is prevented, the overall long-term outlook for rehabilitation of the patient with this type of wound is much more favorable than, for instance, that of the patient with a much smaller, less complicated wound in the temporal or parietal region.

Utilizing the proved surgical principle that the incidence of infection in a contaminated wound lessens as the time between contamination and complete surgical debridement is shortened, a concerted

effort must be made to reduce to an absolute minimum the time interval between injury and complete definitive surgical treatment.

This time interval can be reduced under combat conditions by placing well-equipped and well-trained neurosurgical teams as close to the battlefield as possible and by evacuating patients directly from aid stations to the neurosurgical units by helicopter. In civilian practice, it can be accomplished only by regarding and treating this type of wound as an emergency of the highest order.

In attacking the problem from another angle, routine antibiotic therapy must be initiated as soon as the patient is received in the battalion aid station and maintained in the chain of evacuation for as long as indicated. Detailed bacteriological studies, inclusive of determination of sensitivity of the offending bacterial organisms to the various antibiotics, should be carried out as soon as possible so that infections may be treated more accurately and effectively by utilizing the appropriate drug. Approaching the problem from still another direction, every effort must be made to insure complete debridement and isolation of the intracranial cavity from the constantly contaminated nasal cavity and, in certain instances, from the involved sinus itself. In order to accomplish this objective, careful adherence to elements of operative technique peculiar to this type of wound must be observed. These points will be considered specifically later in this chapter under the heading "Routine Sinus Management."

The importance of having an ophthalmological surgeon working in close cooperation with the neurosurgeon will often be proved, inasmuch as penetrat-

ing wounds of the air sinuses are frequently complicated by involvement of the eyes and orbits. The primary benefit of having this specialized care and advice is the preservation of vision whenever possible in injuries of the globe and orbit. Of secondary but not inconsiderable value to the neurosurgeon is the ophthalmological surgeon's opinion regarding the advisability of enucleation. In cases of penetrating wounds of the sinuses through the orbit when enucleation is indicated, it may be advantageous to perform enucleation immediately prior to cranial surgery. In many instances, palpation of the orbital walls following enucleation and prior to cranial surgery by the neurosurgeon is extremely helpful in determining the point of entrance of the missile into the cranial cavity and its exact course, especially in those cases in which the point of entry is near the midline. With this additional information, it is possible to choose more accurately the optimum side for reflecting the osteoplastic bone flap.

The content of this chapter is the distillation of the composite experiences of neurosurgeons who treated wounds involving the air sinuses during the Korean War. The statistics quoted are based upon a series of 100 consecutive cases of penetrating craniocerebral wounds of this type, which were incurred during the period from September 1950 to September 1952.

TYPES OF WOUNDS

In the group of 100 consecutive cases of penetrating wounds involving the air sinuses, 78 percent were caused by high-velocity missiles; that is, bullets from rifles, carbines, machineguns, and other automatic weapons. The wounds in the remaining 22 percent were caused by metallic fragments; that is, fragments from grenades, mortars, and high explosive shells.

ASSOCIATED WOUNDS

In 68 percent of the cases, there were associated wounds. Of these, exactly one-half presented wounds of the orbit. Of the 34 patients with orbital wounds, 27 had unilateral ocular damage and 7 had bilateral ocular damage. In general, in those

cases of penetrating sinus wounds with associated severe wounds of the abdomen or chest, laparotomy or thoracotomy was carried out first, and if the operating time was not too lengthy, cranial surgery was carried out under the same anesthesia.

ANTIBIOTIC THERAPY

In this series of 100 cases of wounds involving the air sinuses, antibiotic therapy was started as soon as possible after injury. As a rule, antibiotic therapy was initiated in the battalion aid station, usually less than 6 hours after injury. However, actual record of this is not available in the case histories on which this chapter is based. Upon admission to the neurosurgical unit, each patient was given penicillin, 300,000 units, and streptomycin, $\frac{1}{2}$ gm., twice a day. In the following calculation of time elapsed before initiation of antibiotic therapy, the time of admission to the neurosurgical unit is used as a baseline. In 95 cases, antibiotic therapy was started less than 24 hours after injury, 79 of which were started on therapy less than 12 hours after injury. Therapy was begun 36 hours after injury in one case and 72 hours after injury in another case. The time factor is unknown in three cases. Routinely, patients were continued on this medication for 2 weeks following surgery. If then afebrile, medication was discontinued. The patients were observed for 1 week without antibiotic therapy. If still afebrile at the end of 1 week, they were evacuated to the Zone of Interior. Antibiotic therapy was given for a period of 14 days following surgery to 58 percent of these patients; 42 percent required more prolonged antibiotic therapy because of intracranial infection or infection of wounds in other parts of the body.

TIME INTERVAL BETWEEN INJURY AND DEFINITIVE SURGERY

In these 100 cases, 75 came to definitive surgery less than 48 hours after injury. Of these, 67 were operated upon less than 24 hours after injury. Twenty-three cases came to surgery more than 48 hours after injury, and in 2 cases, the time interval is unknown.

SINUSES INVOLVED

Table 23 illustrates the incidence of involvement of the various air sinuses. It is of interest to note the extremely high incidence of involvement of the frontal sinus, 82 percent. This figure is much higher than the figure (47 percent) quoted by Matson (7).

FINDINGS AT OPERATION

CASES WITH DURAL PENETRATION

Of the 100 cases in this series, 84 presented penetration of the dura at operation. Of the 84, 67 (80 percent) showed the usual sinus penetration with varying degrees of comminution and depression along with a relatively uncomplicated cerebral track. There were complications in 17 (20 percent) of the 84 cases with dural penetration (table 24).

CASES WITH INTACT DURA

Of the 100 cases, 16 presented an intact dura at operation. The dura was opened in all 16 cases. The results of the intradural explorations are as follows:

1. Nine cases (56 percent) presented surgically remediable lesions.

TABLE 23.—Incidence of involvement of the air sinuses in 100 consecutive cases of penetrating craniocerebral wounds incurred during the Korean War, September 1950 to September 1952

Sinus involved	Number of cases	Mortality
Frontal.....	82	3
Frontal and ethmoid.....	5	0
Frontal and maxillary.....	3	0
Frontal, ethmoid, and maxillary..	2	0
Frontal, ethmoid, and sphenoid...	1	0
Ethmoid.....	3	0
Ethmoid and maxillary.....	2	1
Ethmoid, maxillary, and sphenoid.	1	1
Ethmoid and sphenoid.....	1	0
Total.....	100	5

TABLE 24.—Types of complications in 17 cases with dural penetration

Complication	Number of cases
Transventricular missile track.....	8
Subdural hematoma.....	7
Intracerebral hematoma.....	1
Subdural and intracerebral hematoma.....	1
Total.....	17

2. Four cases (25 percent) revealed gross cerebral pathology which was not surgically remediable (table 25).
3. Three cases (19 percent) resulted in negative intradural explorations.

SURGICAL MANAGEMENT

ANESTHESIA

Anesthesia consisted of endotracheal nitrous oxide and oxygen, supplemented by intravenous thiopental sodium (Pentothal sodium) in 2.5-percent solution. Intubation was accomplished by utilization of a small amount of intravenous thiopental sodium in conjunction with 2 cc. of 5 percent cocaine, administered transtracheally.

TABLE 25.—Types of lesions found in 13 of 16 cases presenting an intact dura at operation

Lesion	Number of cases
Surgically remediable:	
Subdural hygroma.....	4
Subdural hematoma.....	3
Intracerebral hematoma.....	2
Total.....	9
Not surgically remediable:	
Marked cerebral liquefaction.....	3
Marked cerebral contusion.....	1
Total.....	4
Grand total.....	13

APPROACH TO THE WOUND

In the majority of wounds, especially those with a small rent in the frontal scalp (from 1 to 3 cm.), the wound of entry should be debrided and a coronal scalp flap reflected anteriorly (p 87). The galeal surface of the wound of entry should then be debrided and closed. Following intracranial debridement and closure of the coronal incision, plastic closure of skin edges of the wound of entry should be carried out. This method is superior to debridement and repair of the wound through the wound of entry. In many instances, it will be found that the area of fracture of the sinus is larger than the wound of entry. Consequently, complete debridement of the sinus, and in many instances the roof of the orbit, is extremely difficult, if not impossible, without enlarging the wound of entry. If at operation it is found that the fracture extended into the ethmoid sinuses with "scissors" laceration of the overlying dura, the technical problem of sealing this dural defect with a fascia lata graft is much simpler and the closure more likely to be successful with the full exposure afforded by reflecting a coronal scalp flap and bone flap than by attempting the repair through the wound of entry. In scalp wounds large enough to permit adequate debridement and dural repair, this procedure may be carried out in preference to reflecting a coronal flap.

ROUTINE SINUS MANAGEMENT

The program of routine sinus management of penetrating wounds involving the air sinuses incurred during the Korean War consisted of application of the following principles of surgical technique at time of initial operation:

1. Complete debridement of scalp edges and underlying periosteum.
2. Removal of all comminuted bone fragments.
3. Removal of all debris and mucous membrane from the sinuses.
4. Cauterization of the walls of the sinuses, especially at points of attachment of the mucous membrane.
5. Bone wax and/or penicillin-soaked Gelfoam barricade of the sinus ostia.

6. Complete debridement of cerebral wound with attempt at watertight dural closure.

Evaluation of the efficacy of routine sinus management in the 100 consecutive cases in this series, with reference to the incidence of postoperative infection, reveals the following data:

1. Among the 97 percent who received routine sinus management, 10.3 percent developed postoperative infection. Two patients died. Meningitis was the cause of death in both cases.

2. All of the 3 percent who did not receive routine sinus management developed postoperative infection. In these cases, the sinuses were incompletely debrided and allowed to remain open from 1 to 10 days. One patient died. The cause of death was meningitis.

Analysis of these results suggests the value of complete debridement of the sinuses and isolation of the intracranial cavity from the nasal cavity.

POSTOPERATIVE COMPLICATIONS

In this discussion of complications, and elsewhere in this chapter, the term "postoperative" is applied to that period following operation during which the patient was under direct observation and for which records are available. The average postoperative period was 33 days; the shortest and longest periods were 8 and 120 days, respectively.

There were no cases of osteomyelitis in this series of wounds involving the air sinuses. Of the 100 cases, 26 developed one or more of the following complications.

INFECTIONS

(13 Cases, 3 Deaths)

All of the 13 cases in this group developed postoperative infection. In all, the dura was found to be penetrated at time of operation. In 12 cases (92 percent), routine antibiotic therapy was started less than 24 hours after injury, and in the remaining case, between 24 and 36 hours after injury. Ten cases (77 percent) received definitive surgical therapy less than 24 hours after injury, two (15 percent) between 24 and 48 hours, and one between 48 and 72 hours. Statistical breakdown of the complicating infections reveals that—

1. There were seven cases of meningitis and three deaths. (A cerebrospinal fluid fistula was not present in any of the fatal cases.)

2. There was a brain abscess present in two cases. Both patients recovered. (In one case, the abscess was surrounding a retained metallic foreign body which had not been removed at initial surgery. In the other case, the abscess was around several small retained bone fragments which, likewise, had not been removed at initial surgery.)

3. There were two cases of cerebritis and meningitis. Both patients recovered. (These patients were treated by the open fungus method (11).)

4. There was an extradural abscess present in two patients. Both recovered.

CEREBRAL FUNGUS

(2 Cases, 0 Death)

Two cases were due to faulty scalp closure over a fascia lata graft which, when exposed, broke down with resultant fungus formation. Both patients were successfully treated by the application of secondary fascia lata grafts, followed by proper scalp closure.

EXTRADURAL AIR FISTULA

(1 Case, 0 Death)

The fistula sealed itself spontaneously and uneventfully after 2 weeks.

CEREBROSPINAL FLUID FISTULA

(10 Cases, 0 Death)

Three patients developed meningitis. All three were treated successfully with sulfadiazine and/or the appropriate antibiotic medication following sensitivity tests. The fistula sealed itself spontaneously in four cases. Surgical repair utilizing either fascia lata or temporal fascia grafts was necessary in six cases. Primary closure is the method of choice in securing a watertight seal of the dural defect. This is impossible in many cases because of loss of dural tissue. The defect must be tightly closed with a dural substitute.

The various types of dural closures used and the subsequent development of cerebrospinal fluid fis-

tulas are shown in table 26. The figures in the table give one the impression that the incidence of cerebrospinal fluid fistulas was lower when the dura was closed primarily and when temporal fascia was used than when fascia lata was used. It should be borne in mind, however, in interpreting these figures, that the fascia lata was usually utilized when the dural defect was very large—often extending posteriorly along the floor of the anterior fossa to the sphenoid ridge where watertight closure was extremely difficult and often impossible. In cases of this type, a large piece of fascia was sutured tightly as far posteriorly as possible and the remainder weighted down with Gelfoam.

MORTALITY

The mortality rate was 5 percent for this entire series of wounds involving the air sinuses. A brief resume of each of the five fatal cases follows:

TABLE 26.—Types of dural closure used and subsequent development of cerebrospinal fluid fistula

Type of closure	Number of cases	Cerebrospinal fluid fistula
Primary dural closure.....	32	3
Fascia lata graft.....	29	5
Periosteal graft.....	10	1
Temporal fascia graft.....	10	0
Type of graft unknown.....	3	1
Total.....	84	10

K-169. Penetrating missile wound, right frontal, through the right frontal sinus; metallic foreign body in right parietal region. Antibiotic therapy started within 12 hours after injury; definitive surgery less than 24 hours after injury. Routine sinus therapy was employed. There were no retained bone fragments. Metallic foreign body was not removed. On the 10th postoperative day, after satisfactory postoperative course and still on routine antibiotic therapy, the patient precipitously developed signs of acute meningitis, and the spinal fluid became cloudy with 500 polymorphonuclear cells per cubic millimeter. The patient became progressively worse and, as a last resort, because of signs of increasing intracranial pressure the left lateral ventricle was tapped. Relatively clear ventricular fluid was obtained. The right lateral ventricle was then tapped and cloudy ventricular fluid was obtained. The patient's condition deteriorated and he died the following day.

Comment.—There is no autopsy report recorded, but the clinical course strongly suggests rupture of a cerebral abscess into the right lateral ventricle with resultant fatal meningitis.

K-189. Penetrating missile wound, right frontal sinus. Started on routine antibiotic therapy less than 24 hours after injury. Initial debridement was started less than 24

hours after injury. The operation was not completed. The wound was packed open with petrolatum-impregnated gauze and the patient was evacuated to a neurosurgical unit. Routine sinus therapy and debridement of the wound was carried out within 48 hours after injury, but the patient developed severe meningitis and, in spite of intensive antibiotic therapy, died 37 days after injury. Autopsy revealed extensive basal meningitis.

Comment.—This case was not properly handled at initial surgery at which time debridement was incomplete and the wound allowed to remain open for an additional 24 hours before coming to complete definitive debridement and closure. Death was due to meningitis.

K-204. Penetrating missile wound through the right maxillary, ethmoid, and sphenoid sinuses into the middle fossa. Antibiotic therapy was started 18 hours after injury and the patient received definitive surgery 20 hours after injury. General condition was good. Patient was afebrile on routine antibiotic medication. The right maxillary wound developed purulent drainage which persisted from the postoperative period. Debridement and closure of the right maxillary wound of entry was carried out on the 20th day after injury. Twenty-four hours after closure of the maxillary wound, the patient's temperature rose abruptly and he became comatose. He died 18 days later of beta hemolytic streptococcal meningitis, which failed to respond to intensive antibiotic and sulfadiazine therapy. Autopsy report revealed basilar meningitis and marked softening of the brain stem.

Comment.—This patient was making a satisfactory recovery and was afebrile 20 days after initial surgery. A severe meningitis developed within 24 hours after closure of the antral wound of entrance which had been draining purulent material. Death ensued 18 days later. In all probability, closure of the wound resulted in an accumulation of pus under considerable pressure, which, when it became great enough, burst through or around the edges of the fascia lata graft used to barricade the intracranial cavity from the sphenoid and ethmoid sinuses.

K-220. Penetrating missile wound, left frontal sinus. Metallic foreign body crossed the midline and lodged in the right parietal region. The patient was comatose preoperatively. Antibiotic therapy was started 12 hours after injury; definitive surgery, 14 hours after injury. The missile track was palpated inferior to the falx. On the second postoperative day, the patient developed extensive rigidity and Cheyne-Stokes respiration. Condition deteriorated and death ensued on the fourth postoperative day. Autopsy revealed no hematoma in the missile track.

Comment.—Death in all probability was due to progressive thrombosis and softening of the midbrain, secondary to direct trauma by the missile.

K-223. Penetrating missile wound with entry through the right maxillary and ethmoid sinuses, exit left frontal temporal region. The patient was comatose and presented a dilated fixed left pupil preoperatively. Antibiotic therapy and definitive surgery 4 hours after injury. At operation, marked cerebral edema was noted and a large subdural hematoma encountered and removed. Patient died several

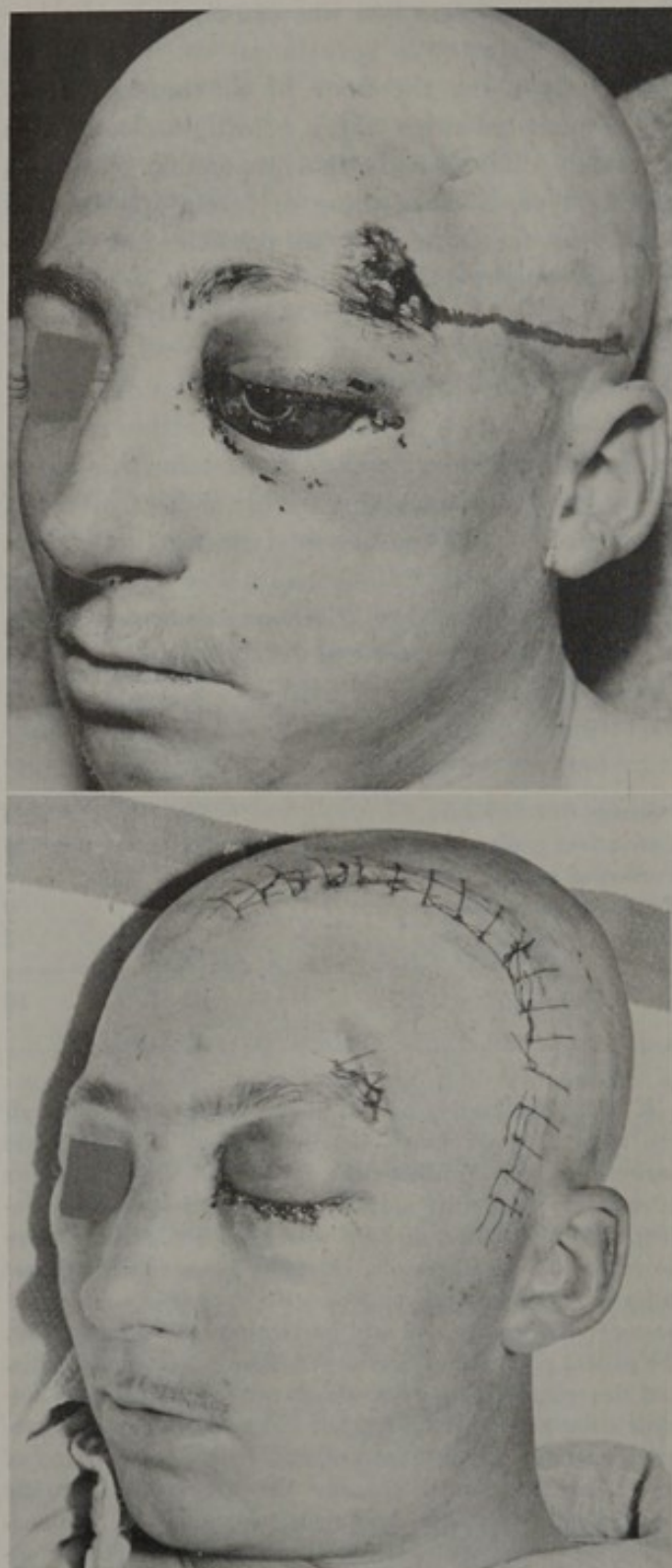


FIGURE 94. (See opposite page for legend.)

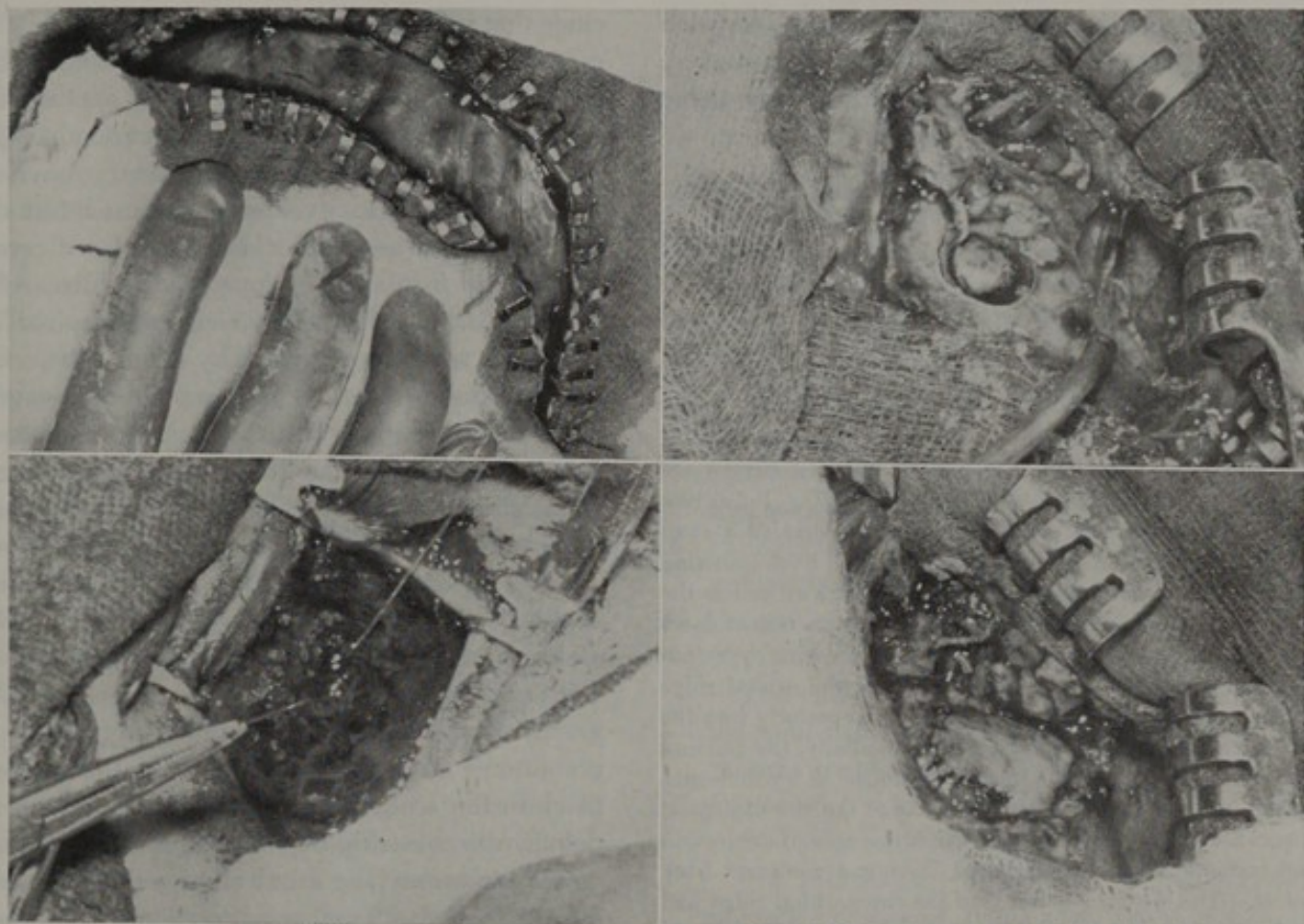


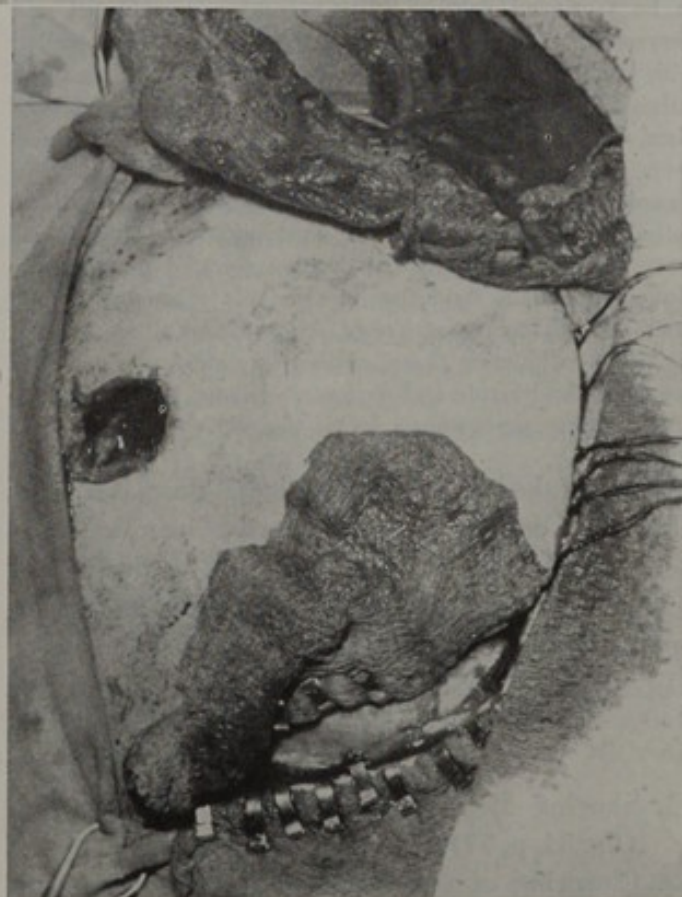
FIGURE 94.—K-122. Fracture, skull, compound, comminuted, depressed, involving left supraorbital ridge and left frontal air sinus. Complicated by left subdural hematoma.

hours after operation with signs of increasing intracranial pressure. Death was due to severe generalized cerebral contusion and edema.

DISCUSSION

Analysis of the percentage incidence of the various involved sinuses indicates that there is no great difference in mortality of wounds involving the frontal sinuses and those involving the other air sinuses. Of deaths in this series, 60 percent occurred in cases involving the frontal sinuses alone; this group of wounds comprised 82 percent of the total series.

The question of whether the dura should be opened when found intact at time of operation in this type of wound has been the subject of considerable debate among neurosurgeons. All 16 cases in which intact dura was encountered were explored



intradurally. Of these, 9 (56 percent), revealed surgically remediable lesions which were removed. The story of K-122 illustrates such a remediable lesion in the presence of an intact dura.

K-122. This 22-year-old British gunner was wounded in action by mortar fire at 2:45 a.m. on 26 March 1952 near Kumwa, Korea. On admission to the 3d Neurosurgical Detachment (Provisional), 6 hours later, he was drowsy but responded rationally when aroused. Inspection of the head revealed a 2-cm. punctate-type laceration above the lateral aspect of the left eyebrow. The left globe was collapsed and proptosed. Outside of loss of vision on the left, the cranial nerves were intact. Motor system was equal as to tone and strength. No abnormalities in the sensory system; no abnormalities in reflexes. Blood pressure 130/72. Pulse rate 72. Respiration rate 80. X-rays of skull revealed a comminuted depressed fracture of the left frontal bone involving the left orbital roof and left supraorbital ridge as well as the left frontal sinus. A Dandy concealed flap was turned down on the left side and inspection of the skull revealed comminution and depression of the medial half of the orbital ridge with extension of the depressed fracture superiorly into the anterior portion of the frontal bone. Medially, the fracture line extended into the left frontal air sinus. A bur hole was placed into the frontal bone superiorly to the site of depression. Starting at this bur hole, the entire area of depression and comminution was rongeuired leaving a moderate bony defect. The medial two-thirds of the supraorbital ridge had to be sacrificed because it was grossly comminuted and depressed. The opening in the left frontal sinus was sealed with bone wax. The underlying dura was intact but tight, bulging, and bluish in color. Upon opening it, a *moderate-sized subdural hematoma* of mixed type exuded under pressure. After the concealed flap had been turned back and closed in individual layers, the scalp lacerations were radically debrided and closed. Postoperative course was uneventful. Patient did not develop elevated temperature. No cerebrospinal fluid fistula. He was evacuated to the neurosurgical center at Tokyo Army Hospital on 2 April 1952. On admission there, patient was alert, had no cerebrospinal fluid fistula and no fever. Except for the absence of the left eye, there was no deficit (fig. 94).

None of the 16 patients with intact dura at time of operation developed postoperative infection and none died. In view of the high incidence of remedial lesions encountered and the paucity of postoperative complications, it seems legitimate to con-

clude that intradural exploration is indicated in each case of this type, except possibly when evidence of gross infection is present at the time of operation and the tension and appearance of the dura do not suggest an underlying hematoma. The story of K-122 illustrates the necessity of opening an intact dura.

Of the 90 cases which did not develop a cerebrospinal fluid fistula, 6 developed meningitis. Of the 10 cases which did develop a cerebrospinal fluid fistula, 3 were complicated by meningitis. Comparison and evaluation of these figures suggest a direct relationship between the occurrence of cerebrospinal fluid fistula and the increased incidence of meningitis, a point which serves to reemphasize the importance of securing a watertight dural closure.

Both cases of cerebral fungus were due to deterioration of a dural graft following dehiscence of the scalp wound. It is of extreme importance to secure a firm two-layer closure of the scalp over the dural graft, especially whenever craniectomy rather than craniotomy has been carried out. If it is impossible to close the scalp wound because of a large scalp deficit, a sizable scalp flap must be rotated in order to cover adequately the craniectomy site and area of dural closure. The donor site should then be covered with a split-thickness graft, preferably at a later date when clean granulation tissue has covered the exposed periosteum.

The one case in this series in which the wound was packed open with petrolatum-impregnated gauze at the time of initial surgery resulted in fatal meningitis. Schorstein (9) reported four cases of penetrating wounds of the brain involving the air sinuses and the orbits incurred during the Second World War in which the cerebral wound was packed open with soft paraffin gauze after debridement. There were no fatalities. This mode of surgical therapy, however, renders the wound relatively vulnerable to infection. Watertight closure of dura and scalp should be the method of choice even though the operating time may be slightly greater.

SURGICAL TECHNIQUE

The steps in the surgical technique of wounds involving the air sinuses are:

1. Shaving of wide area surrounding laceration (fig. 34, p. 77).
2. Cleansing of skin surrounding laceration with soap and water (fig. 35, p. 78).
3. Preparation of skin surrounding laceration with two coats of thimerosal and two coats of alcohol.

4. Draping with sterile towels.
5. Excision of entire skin edge with scalpel (fig. 36, p. 79).
6. Excision of narrow margin of all exposed layers of scalp, including periosteum (fig. 37, p. 80).
7. Individual inspection of all exposed layers of scalp and additional resection of devitalized tissues.
8. Wide *en bloc* excision of exposed temporal or occipital muscle with cutting current.
9. Inspection of denuded bone for fracture lines, small foreign bodies, or evidence of interosseous hematoma.
10. Irrigation of wound with warm sodium chloride solution (fig. 38, p. 81).
11. Starting from a bur hole placed 1 cm. from bony wound of entry or from farthest point of fracture depression, utilizing a duckbill rongeur, remove all depressed fragments, proceeding from the periphery of the depressed area toward the center.
12. Upon encountering sinus mucous membrane, care must be taken to remove this structure completely. Coagulation with electrocautery of any points of mucous membrane attachment to wall of the sinus.
13. Open the dura through a small incision to check for possible subdural hematoma. If none is

present, the dural opening should be closed with interrupted sutures of No. 0000 black silk. During the previous maneuver, care should be exercised to drape any exposed sinus mucous membrane from the dural opening, preferably with a large piece of Cottonoid.

14. Barricade the opening from the sinus into its appropriate draining area with either bone wax, if the opening is small enough, or with large pieces of Gelfoam, if larger. The Gelfoam should be soaked in an aqueous solution of penicillin.
15. Irrigation of the wound with warm normal saline solution.
16. Primary closure *without drainage* in two individual layers (fig. 39, p. 82).
17. Closure of galea with interrupted sutures of No. 00 silk.

The individual suture is to be tied tightly and the knot placed parallel to the wound margins. Sutures are to be cut short (fig. 39a-e, p. 82).

18. Closure of skin without drainage with interrupted sutures of No. 0000 silk.

The sutures may be tied quite loosely (post-operative edema of scalp) (fig. 39f-g, p. 82).

19. Collodion dressing.
20. Removal of skin sutures after 48 hours.

REFERENCES

1. Adson, A. W.: Cerebrospinal Rhinorrhea; Surgical Repair of Fistula: Report of Case. Proc. Staff Meet., Mayo Clin. 16: 385-387, 18 June 1941.
2. Baker, G. S., and MacLean, A. R.: Cerebrospinal Rhinorrhea Associated With Pneumocephaly, Pneumococcic Meningitis and Abscess of the Brain: Report of Case. Proc. Staff Meet., Mayo Clin. 16: 746-750, 19 Nov. 1941.
3. Cairns, H.: Injuries of Frontal and Ethmoidal Sinuses With Special Reference to Cerebrospinal Rhinorrhea and Aeroceles. J. Laryng. & Otol. 52: 589-623, September 1937.
4. Cairns, H.: Gunshot Wounds of the Head in the Acute Stage. Brit. M.J. 1: 33-37, 8 Jan. 1944.
5. Coleman, C. C.: Fracture of Skull Involving Paranasal Sinuses and Mastoids. J.A.M.A. 109: 1613-1616, 13 Nov. 1937.
6. Gurdjian, E. S., and Webster, J. E.: Surgical Management of Compound Depressed Fracture of Frontal Sinus, Cerebrospinal Rhinorrhea and Pneumocephalus. Arch. Otolaryng. 39: 287-306, April 1944.
7. Matson, Donald D.: The Treatment of Acute Cranio-cerebral Injuries Due to Missiles. American Lecture Series No. 22. American Lectures in Surgery. Springfield, Ill.: Charles C Thomas, 1948.
8. McKenzie, D.: Head Injuries Involving the Air Sinuses. Brit. M.J. 1: 652-654, 13 May 1944.
9. Schorstein, J.: Gunshot Wounds of the Fronto-Orbital Region. Lancet 1: 44-47, 8 Jan. 1944.
10. Stewart, O. W., and Botterell, E. H.: Cranio-Facial-Orbital Wounds Involving Paranasal Sinuses; Primary Definitive Surgical Treatment. Brit. J. Surg. (War Surg. Supp. No. 1), pp. 112-118, June 1947.
11. Meierowsky, A. M., and Harsh, G. R., III: The Surgical Management of Cerebritis Complicating Penetrating Wounds of the Brain. J. Neurosurg. 10: 373-379, July 1953.

CHAPTER 18

Cerebrospinal Fluid Fistula

C. David Scheibert

External communication of the cerebrospinal fluid spaces requires prompt treatment and repair if infection of the central nervous system and its complications are to be avoided.

The first recognition and description of cerebrospinal rhinorrhea, according to Jobson (1), is credited to Thomas Willis. Lillie and Spar (2) point out that S. Vander Weil in 1727 reported clear watery fluid escaping from the ear in cases of head injury. Hirsch (3) recorded that Hans Chiari in 1884 described an intracranial aerocele found during post mortem examination.

It is the purpose of this chapter to present the experience gained during the management of 41 patients with cerebrospinal fluid fistulas, to weave it with the reports of others, and to extract suggestions which will aid in the treatment of the problem.

The incidence of cerebrospinal fluid fistula with head injury is fairly uniform among various sources. Gage (4) quotes Coleman as stating that rhinorrhea occurred in approximately 2 to 5 percent of patients suffering skull fractures with the same experience reported by Adson and Uihlein (5). Oldberg (6) found otorrhea four to five times more common than rhinorrhea, but he had never witnessed a persistent otorrhea that did not cease spontaneously. In reviewing 1,731 cases of head injury, with skull fractures in 655, Calvert (7) described 128 with fractures involving the sinuses, and of these patients, 21 had developed rhinorrhea. In a study of 1,000 nonmissile head injuries admitted to a hospital, Lewin (8) found 72 with fractures into the paranasal air sinuses with 18, or almost 2 percent, developing rhinorrhea. Among the 879 casualties of the Korean War with penetrating cranio-

cerebral trauma, 23 required operative treatment for cerebrospinal fluid fistulas, the incidence of otorrhea being twice that of rhinorrhea in both missile and metallic fragment injuries.

ETIOLOGY

The foremost etiology of cerebrospinal fluid fistulas is trauma to the head, both blunt external and penetrating. The creation of a fistulous tract by operative procedures has been noted by Dandy (9) and by Woodhall and Cramer (10). Spontaneous cerebrospinal rhinorrhea has been described by Rand (11) and by Coleman and Troland (12) and may be due to congenital defects in the cribriform plate of the ethmoid bone (13) or nasal meningoceles. Norsa (14) has presented the occurrence of rhinorrhea in conjunction with brain tumors, more frequently with those of the pituitary than any other type. Ventricular fistulas with hydrocephalus have been described by Walker (15). Inflammatory processes causing rhinorrhea are listed by MacDonald (16). Teed (17) and Cushing (18) have shown the importance of sinus osteomata in producing rhinorrhea and intracranial aeroceles.

Experience gained from the treatment of 41 patients with external communication of the cerebrospinal fluid pathways forms the basis of this report. Of these 41 patients, 25 suffered penetrating head injuries—10 of which were caused by high-velocity missiles and 15 by metallic fragments. One patient in each group was a veteran of World War II; the remaining 23 patients were injured during the Korean War. An additional 13 patients suffered

external blunt trauma—12 World War II veterans and 1 Korean War veteran. The three remaining patients were World War II veterans; two suffered from spontaneous onsets of rhinorrhea and one had an osteoma of the left frontal sinus with resulting intracerebral pneumatocele.

SYMPTOMS

In the 25 patients with acute penetrating craniocerebral trauma, the symptoms were those of the acute injury itself, and the cerebrospinal fluid loss through the nose, ear, or wound was noted in all less than 4 days after injury. By contrast, in the 13 patients suffering external blunt trauma, cerebrospinal rhinorrhea was a presenting symptom in half, but onset was usually quite delayed after the time of injury. The onset of rhinorrhea varied from the day of injury to 10 years following injury, and in four patients, the onset of rhinorrhea was first noticed more than 1 year after injury. In the other half of the patients suffering external blunt trauma, the presenting symptoms were those of meningitis. Acute meningitis caused the admission of the two patients who had suffered a previous spontaneous onset of rhinorrhea. The one patient having an osteoma of the frontal sinus sought hospitalization because of the sudden onset of right hemiparesis and partial aphasia precipitated by blowing the nose.

SIGNS

The cardinal sign of a fistula—external loss of cerebrospinal fluid—was present in all but 1 of the 25 patients with penetrating craniocerebral wounds, manifesting itself by rhinorrhea in 8, otorrhea in 14, and loss of cerebrospinal fluid from the wound in 2. The rhinorrhea was bilateral in five of the eight patients so affected. The fistula was unilateral in the remaining 19 patients with penetrating wounds. In spite of two episodes of meningitis in one patient following penetrating head injury, external loss of cerebrospinal fluid was never noted. Of 13 patients with blunt external trauma, 12 had rhinorrhea and 3 of these were bilateral. In one of these patients, the rhinorrhea was due to a cerebrospinal fluid fistula through the middle ear with external loss of

fluid through the eustachian tube and thence out the nares. Unilateral rhinorrhea was present in both patients suffering spontaneous onset of a cerebrospinal fluid fistula, but the patient with osteoma of the frontal sinus never gave evidence of external drainage of cerebrospinal fluid. Thus, it is seen that 39 of 41 patients had external loss of fluid as evidence of the fistula. The incidence of otorrhea was twice as frequent in those patients with penetrating craniocerebral injury, with rhinorrhea present in all but one of the patients with blunt external trauma.

Other neurological signs noted and equally distributed among the various causes for the fistula were loss of smell in 7 patients, loss of hearing in 7, loss of vision in 11, additional cranial nerve loss (particularly those of extraocular motor function) in 11, and additional neurological loss (such as decerebrate rigidity, coma, and hemiplegia) in 14. Accurate neurological tests were not or could not be carried out in all patients, particularly those with acute penetrating wounds of the brain.

DIAGNOSIS

The diagnosis of a cerebrospinal fluid fistula is established by the presence of external loss of cerebrospinal fluid. Collection of this fluid and analysis for protein, sugar, or mucin promotes accurate identification and differentiates it from other body fluids. It is felt that the subarachnoid injection of dyes or radioactive tracer substances is not necessary for definite diagnosis and possible hazards of such diagnostic measures can be avoided. One must always be aware that rhinorrhea may occur on the side opposite an anterior fossa fistula site, but as pointed out earlier, all cases in this study gave evidence of external cerebrospinal fluid loss on the side of the fistula. Ecker (19) has documented rhinorrhea occurring by way of the eustachian tube, resulting from a fistula site in the middle of posterior fossa. This pitfall in localization can be avoided by observing for a fluid level behind the tympanic membrane and observing the orifice of the eustachian tube for drainage of fluid.

Roentgenography of the skull and sinuses may give further diagnostic information. On roentgenographic visualization carried out in the majority of

these 41 patients, 23 were found to have fractures. Of the 13 suffering blunt external trauma, 11 had roentgenographic evidence of fracture involving the frontal bone, sinuses, and/or floor of the anterior fossa of the skull. The presence of intracranial air is further evidence of fistulous communication of the subarachnoid pathways. Three patients were noted to have subarachnoid air, and one of these also had filling of the ventricular system. Three patients had intracerebral aerocoles. Of 3 patients with a fistulous site through the sphenoid sinus in the 13 suffering blunt external trauma, 1 was found on roentgenographic examination to have an identifiable fluid level in the sphenoid sinus. Since fistulas through the sphenoid sinus, particularly in the anterior wall of the sella turcica, are difficult to identify, special upright skull roentgenograms with a horizontally directed roentgen beam may give valuable preoperative information when such a fluid level is present. An unexplained meningitis, of other than meningococcic etiology, should always alert one to the possibility of exteriorization of the brain or subarachnoid space.

PREOPERATIVE COMPLICATIONS

Certain preoperative complications other than the extent of cerebral injury warrant mention. Preoperative seizure occurred in only one of the patients suffering penetrating craniocerebral injury. Two of the thirteen patients suffering blunt external trauma and one of the two patients with spontaneous onset of rhinorrhea had seizures prior to surgery. Only one patient of the entire group had a subdural hematoma, this being identified in one of the patients suffering a high-velocity missile injury.

The most important preoperative complications were infections of bacterial origin. Of the 41 patients, 12 suffered 22 episodes of meningitis. One patient suffered six episodes of meningitis prior to surgical control of the cerebrospinal fluid fistula. One of the most important revelations of this presentation is that only 1 of the 23 patients suffering acute penetrating craniocerebral injury in the Korean War developed meningitis. In only 2 of the 12 patients with meningitis was definitive surgery for the cerebrospinal fluid fistula carried out in less than 2 months after the onset of the fistula. No

stronger argument can be presented for the early adequate surgical treatment of cerebrospinal fluid fistulas. This is borne out by comparing two illustrative cases—one of early definitive repair without infection (case 1) and the other with late repair after suffering complications of meningitis and pneumocephalus (case 2).

Case 1 (K-233), a 24-year-old, right-handed male infantry lieutenant, sustained in action on 11 January 1951, a missile wound of the head entering the left suboccipital area and exiting just superior and anterior to the left ear. There was initial unconsciousness, followed by confusion and left headache.

On admission to Tokyo Army Hospital on 14 January 1951, the patient was conscious with a mild nominal speech defect, loss of hearing in the left ear, and a Babinski response on the right. There was a crusted punctate wound in the left suboccipital region and a linear wound in the left temporal scalp with macerated cerebrum and cerebrospinal fluid from the latter wound as well as the external auditory canal.

Immediate left temporal craniotomy confirmed the roentgen impression of multiple bone fragments in the left temporal lobe of the brain. After resection of the involved dura and temporal lobe including the in-driven bone fragments and the shattered left petrous ridge, middle and inner ear were visualized. After application of bone wax, a large piece of Gelfilm was placed intradurally over the petrous ridge and temporal dura and routine closure was performed in layers.

The postoperative course was smooth with no otorrhea after 12 hours. On evacuation to the Zone of Interior on 5 February 1951, there was loss of hearing in the left ear, a minimal speech defect, and hypalgesia over the maxillary division of the left trigeminal nerve.

Followup examination on 4 November 1959 revealed a normal 32-year-old male whose only neurological deficit was severe loss of hearing in the left ear. There had been no further otorrhea or seizures.

Case 2 (Kennedy VA Hospital No. 130534), a 23-year-old veteran of the Korean War, was injured in an automobile accident on 2 July 1956, sustaining facial injuries, loss of smell and loss of left vision. Within 8 days after injury, bilateral rhinorrhea was noted and continued. Meningitis due to *Staphylococcus aureus* became obvious on 16 August 1956, and transfer to the Veterans' Administration Medical Teaching Group Hospital, Memphis, Tenn., was effected on 25 August 1956. Roentgenograms revealed fractures of the left orbit and maxilla and a large collection of air in the left frontal lobe of the brain (fig. 95A).

On 31 August 1956, after partial control of the meningitis, bifrontal craniotomy was done and three dural openings were closed with intradural free grafts of temporal fascia and periosteum. These openings were in the right cribriform plate, left ethmoid sinuses, and the left frontal sinus, the latter illustrated by operative photograph of the intradural exposure (fig. 95B). Rhinorrhea ceased, but 2 weeks later, there was an exacerbation of meningitis which was finally

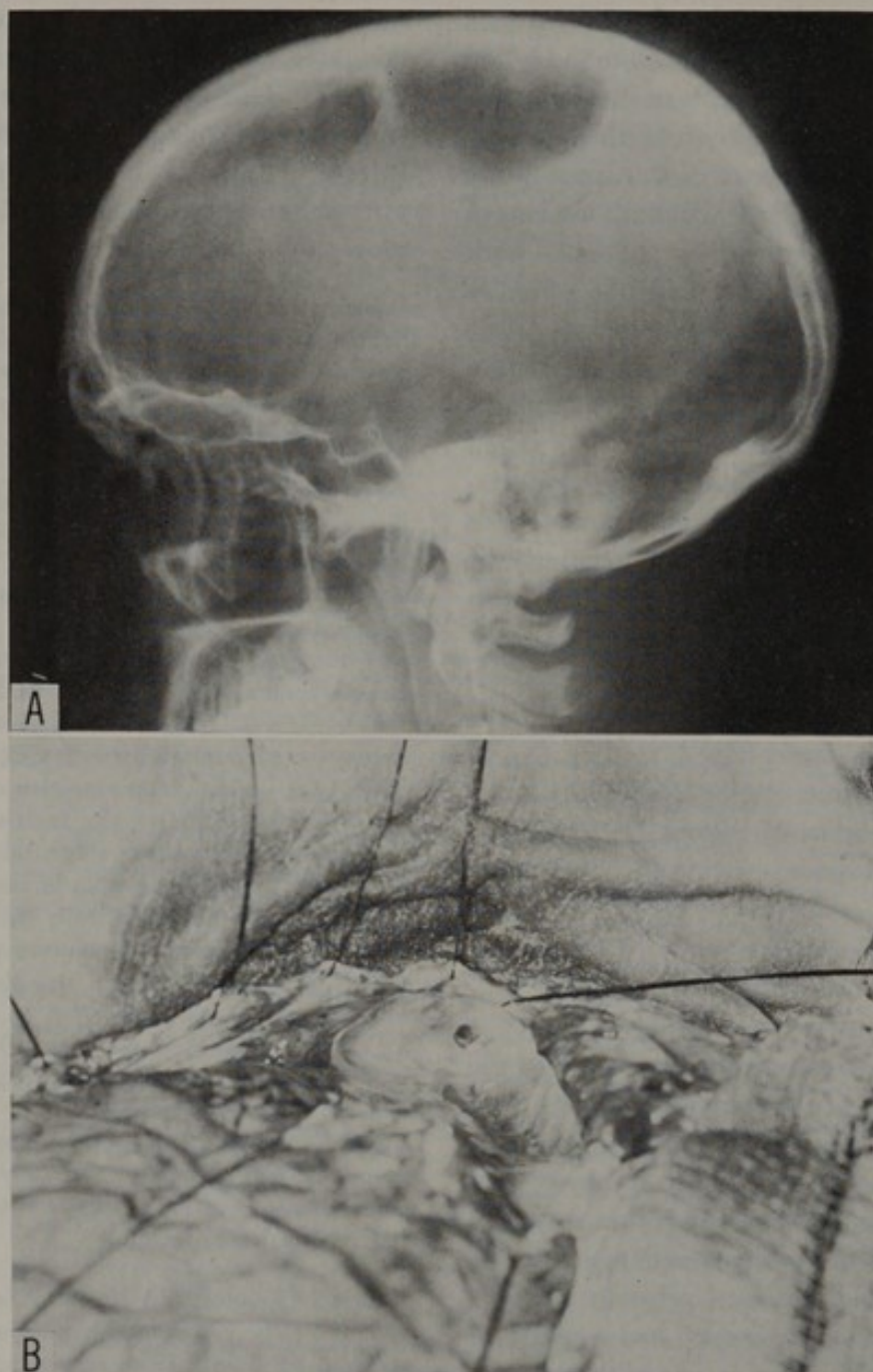


FIGURE 95.—A. Intracerebral aerocele resulting from traumatic defect of posterior wall and dura over left frontal sinus. B. Intradural exposure through left frontal craniotomy, showing small fistulous defect in dura over posterior left frontal sinus.

controlled with novobiocin. The patient made an uneventful recovery and was well and had married when last checked 3 years later. The severe episode of *Staph. aureus* meningitis and pneumocephalus might well have been avoided by earlier surgical therapy. The exacerbation of meningitis 2 weeks after surgery was due to incomplete eradication of infection prior to use of novobiocin.

Of the 13 patients having fistula as the result of blunt external trauma, 7 suffered a total of 10 episodes of meningitis, all but 1 episode occurring

more than 2 months after the onset of the cerebrospinal fluid fistula and as late as 6 years after injury. Hospital admission for the two patients with spontaneous onset of rhinorrhea was occasioned in each instance by an acute meningitis which occurred 9 weeks and 2 years, respectively, after the spontaneous onset of rhinorrhea. In only one instance was meningitis responsible for postoperative death in spite of successful surgical closure of the fistula.

This occurred in the one patient who suffered extensive frontal metallic fragment injury in the Korean War in spite of the initial debridement and closure of the cerebrospinal fluid fistula on the second day after injury. The patient died 5 weeks later of a mixed basilar meningeal infection due to *Staphylococcus aureus*, *Pseudomonas aeruginosa*, and *Proteus*. In only one patient was the meningitis due to meningococcus. This occurred in one patient with the spontaneous onset of rhinorrhea. The remaining meningeal infections were due to *Staph. aureus* in 3, pneumococcus in 11, and streptococcus in 1, with the offending agent undiscovered in the 5 remaining episodes. In all but the one patient with the mixed meningeal infection, these episodes of meningitis were successfully combated with sulfonamide and antibiotic drugs. In spite of this good fortune, it appears obvious that prevention of meningitis by early surgical treatment was much more to be desired. After the successful closure of a cerebrospinal fluid fistula, there were no recurrences of meningitis.

Only three patients had abscess formation. All 3 were among the 15 patients with penetrating injuries caused by metallic fragments. One patient had an extradural and a subdural abscess, one patient had a subdural abscess, and one patient had an intracerebral abscess. In each instance, the abscess formation was successfully combated by surgical treatment and antibiotic therapy. The incidence of intracranial air has been discussed previously and was of importance as a complication in that intracerebral aerocele was responsible for neurological loss in two of the three patients in which it occurred.

Analysis of the interval from onset of cerebrospinal fluid loss to surgical correction reveals that the 23

patients suffering penetrating wounds of the brain in the Korean War had repair of the fistula in less than 4 weeks, only 4 patients exceeding a period of 9 days. Of the remaining 18 patients, only 3 underwent repair of the fistula in less than 1 month, due to, usually, the delayed or unnoticed onset of rhinorrhea in patients suffering nonpenetrating injury; one persisted 8 years before reaching surgical attention. Of the 15 patients going more than 1 month before surgical correction, 11 suffered one or more attacks of meningitis. The high incidence of meningitis associated with delay indicates that surgical repair of a fistula should not be postponed more than 2 weeks. Meningitis, when present, should be controlled preferably prior to operation, but does not contraindicate immediate surgery.

SURGICAL TREATMENT

When external loss of cerebrospinal fluid is noticed at the time of definitive surgery for a compound craniocerebral wound, the fistula may be controlled by adequate dural closure at the same time. The principles outlined in chapter 10, "Penetrating Wounds of the Brain," are to be followed. Of the 23 casualties suffering penetrating cranial wounds during the Korean War, all (2) with cerebrospinal fluid drainage from the wound and all (14) with otorrhea had successful closure through the wound at time of surgical repair. Of the seven with rhinorrhea due to penetrating wounds, three had correction via the wound and four by frontal craniotomy. Approach by craniotomy was utilized in the remaining 18 patients who did not have acute penetrating injury.

SURGICAL TECHNIQUE

The following technique has been employed for the correction of rhinorrhea by elective craniotomy:

1. With the patient in the supine position under general anesthesia, a frontal coronal incision behind the hairline is reflected in an extra-periosteal plane.
2. A small, low, osteoplastic bone flap is turned on the side of the fistula. Bilateral flaps may be utilized.
3. An intradural approach is usually used through a dural incision parallel to the supraorbital ridge.
4. Open air sinuses may be handled as noted in chapter 17.
5. Ventricular puncture or lumbar drainage will allow any necessary brain relaxation.
6. The Cottonoid-protected frontal lobe is elevated,

dividing the olfactory tract, if necessary, but sacrificing as few of the anterior superior cerebral veins as possible.

7. Thorough inspection of the posterior wall of the frontal sinus and floor of the anterior fossa usually reveals the opening, using a probe in the olfactory groove and anterior sella if necessary. Adhesions may be present at or near the fistula.

Extradural exposure was used in only four instances in this series. The fistulous opening was always found to be on the side of injury and the side of cerebrospinal fluid loss. Ten of the patients, all with rhinorrhea—usually bilaterally—had multiple sites, the most being three. The locations of the cerebrospinal fluid fistulas and the number of times involved were as follows: Frontal sinus in 18, ethmoid in 8, sphenoid in 3, petrous ridge and mastoid in 12, and cribriform plate in 8. The substances used for dural grafts were fascia lata in 12, temporal fascia in 14, periosteum in 10, Gelfilm in 7, primary suture in 3, and fascia of undisclosed origin in 3 additional cases. With the exception of persistent meningitis due to *Staph. aureus* in two patients and pneumatocele in three, associated pathology at the time of operation was limited to the penetrating injuries and consisted of transventricular wounds in four, subdural hematoma in one, and abscess in three cases divided equally into extradural, subdural, and intracerebral abscess. The presence of an abscess usually necessitated a second delayed procedure for cerebrospinal fluid fistula repair.

Contrary to expectations, wound infections and aggravation of meningitis did not occur in the series of 41 patients. Infection was eliminated by adequate surgery. Four patients suffered convulsive seizures during the preoperative period while two of these and nine additional cases had seizures at some time during the postoperative course. The occurrence of meningitis did not seem to affect the incidence of seizures.

RESULTS

Successful closure of the cerebrospinal fluid fistula was obtained in 40 of 41 patients. The only failure occurred in a patient with traumatic rhinorrhea via the eustachian tube. This patient had a

8. An ample free intradural stamp graft of temporal fascia, periosteum, or fascia lata is placed over the defect and covered with Gelfoam.
9. Ventricular fluid may be replaced with routine dural and two-layer scalp closure.
10. Nose blowing must be avoided for at least 1 month.

previous negative extradural middle fossa exploration elsewhere, a negative intradural posterior fossa exploration, and then refused an intradural middle fossa approach so that the site of fistula was never identified. In 10 patients, multiple procedures were necessary to cope with the fistula successfully. One patient with a high-velocity missile injury to the cribriform plate required three operations for closure. Thus, in spite of some variation in operative technique and substance utilized for repair, the 40 patients in whom the fistulous site was identified were cured.

Reasons for failure consist of inability to identify the dural tear as may occur with communication of the sphenoid sinus through the anterior sella turcica or rhinorrhea via the eustachian tube, faulty surgical technique, or possible necrosis of a fascial graft due to infection. In spite of 22 episodes of predominantly pneumococcus and *Staph. aureus* meningitis, death occurred in only six patients with missile wounds, five of these from the extent of brain injury and the sixth from injury and a chronic basilar meningitis.

DISCUSSION

While the majority of the patients underwent intradural exposure of the cerebrospinal fluid fistula with fascial repair as described by Eden (20), it is obvious that the extradural approach and use of other materials such as Gelfilm and suture are likewise successful. Adson (21) enthusiastically supported a bilateral extradural operation, and the various methods of surgical repair have been well reviewed by German (22). Preference for the intradural route is based on the following reasons: (1) Better visualization of the sphenoid sinus area as described by Lewin and Cairns (23), (2) better chance of a viable graft and less danger of produc-

ing fresh dural tears as proposed by Calvert (24), (3) elimination of dead space, (4) less chance of disturbing infected tissue, and (5) better possibility of sparing the olfactory nerve and tract.

More important than method of repair is the prompt surgical correction of rhinorrhea in order to insure a minimum of complications and good results as presented by Rizzoli, Hayes, and Steelman (25). Morley and Hetherington (26) have emphasized the incidence of meningitis delayed up to 9 years as the first evidence of dural rupture. There is much evidence presented by Lewin (8) to commend the surgical exploration of patients who have only temporary rhinorrhea. The importance of the prompt correction of a cerebrospinal fluid fistula in preventing meningitis and other complications has been well documented by this study of 41 patients and the preceding reports of others.

REFERENCES

1. Jobson, G. B.: Spontaneous Cerebrospinal Rhinorrhea. *Pennsylvania M.J.* 44: 1275-1276, July 1941.
2. Lillie, H. I., and Spar, A. A.: Escape of Cerebrospinal Fluid Into the Wounds of Operations on the Temporal Bone. *Arch. Otolaryng.* 46: 779-788, December 1947.
3. Hirsch, O.: Successful Closure of Cerebrospinal Fluid Rhinorrhea by Endonasal Surgery. *A.M.A. Arch. Otolaryng.* 56: 1-12, July 1952.
4. Gage, E. L.: Traumatic Otorrhea, Rhinorrhea and Pneumocephalus. *West Virginia M.J.* 51: 193-197, July 1955.
5. Adson, A. W., and Uihlein, A.: Repair of Defects in Ethmoid and Frontal Sinuses Resulting in Cerebrospinal Rhinorrhea. *Arch. Surg.* 58: 623-634, May 1949.
6. Oldberg, E.: Cerebrospinal Fluid Rhinorrhea. *Postgrad. Med.* 16: 1-5, July 1954.
7. Calvert, C. A., and Cairns, H.: Discussion on Injuries of Frontal and Ethmoidal Sinuses. *Proc. Roy. Soc. Med.* 35: 805-810, October 1942.
8. Lewin, W.: Cerebrospinal Fluid Rhinorrhea in Closed Head Injuries. *Brit. J. Surg.* 42: 1-18, July 1954.
9. Dandy, W. E.: Treatment of Rhinorrhea and Otorrhea. *Arch. Surg.* 49: 75-85, August 1944.
10. Woodhall, B., and Cramer, F. J.: Extradural Pneumatocele Following Tantalum Cranioplasty. *J. Neurosurg.* 2: 524-529, November 1945.
11. Rand, R. W.: Spontaneous Cerebrospinal Rhinorrhea. *Bull. Los Angeles Neurol. Soc.* 18: 74-83, June 1953.
12. Coleman, C. C., and Troland, C. E.: The Surgical Treatment of Spontaneous Cerebrospinal Rhinorrhea. *Ann. Surg.* 125: 718-728, June 1947.
13. Love, J. G., and Gay, J. R.: Spontaneous Cerebrospinal Rhinorrhea; Successful Surgical Treatment. *Arch. Otolaryng.* 46: 40-44, July 1947.
14. Norsa, L.: Cerebrospinal Rhinorrhea With Pituitary Tumors. *Neurology* 3: 864-868, November 1953.
15. Walker, A. E.: Spontaneous Ventricular Rhinorrhea and Otorrhea. *J. Neuropath. & Exper. Neurol.* 8: 171-183, April 1949.
16. MacDonald, R.: The Occurrence of Spontaneous Cerebrospinal Rhinorrhea in the Literature, the Experience of the Writer and Other Diplomates of American Boards of Otolaryngology and Neurosurgery. *Laryngoscope* 55: 552-586, October 1945.
17. Teed, R. W.: Primary Osteoma of Frontal Sinus. *Arch. Otolaryng.* 33: 255-292, February 1941.
18. Cushing, H.: Experiences With Orbito-ethmoidal Osteomata Having Intracranial Complications, With Report of Four Cases. *Surg. Gynec. & Obst.* 44: 721-742, June 1927.
19. Ecker, A.: Cerebrospinal Rhinorrhea By Way of the Eustachian Tube; Report of Cases With Dural Defect in Middle or Posterior Fossa. *J. Neurosurg.* 4: 177-178, March 1947.
20. Eden, K. C.: Traumatic Cerebrospinal Rhinorrhoea; Repair of Fistula by Transfrontal Intradural Operation. *Brit. J. Surg.* 29: 299-303, January 1942.
21. Adson, A. W.: Results Following Surgical Repair of Craniosinus Fistula for Cerebrospinal Rhinorrhea; Abstract of Published Paper With Comment on Subsequent Experience. *Proc. Staff Meet., Mayo Clin.* 17: 281-286, 6 May 1942.
22. German, W. J.: Cerebrospinal Rhinorrhea—Surgical Repair. *J. Neurosurg.* 1: 60-66, January 1944.
23. Lewin, W., and Cairns, H.: Fractures of the Sphenoidal Sinus With Cerebrospinal Rhinorrhoea. *Brit. M.J.* 1: 1-6, 6 Jan. 1951.
24. Calvert, C. A.: Orbito-Facio-Cranial Gunshot Wounds. *Brit. J. Surg. (War Surg. Supp. No. 1)*, pp. 119-141, June 1947.
25. Rizzoli, H. V., Hayes, G. J., and Steelman, H. F.: Rhinorrhea and Pneumocephalus; Surgical Treatment. *J. Neurosurg.* 11: 277-283, May 1954.
26. Morley, T. P., and Hetherington, R. F.: Traumatic Cerebrospinal Fluid Rhinorrhea and Otorrhea, Pneumocephalus and Meningitis. *Surg. Gynec. & Obst.* 104: 88-98, January 1957.

CHAPTER 19

Postoperative Management

Arnold M. Meirowsky

MANAGEMENT OF COMA

Meticulously planned and exacting systematic postoperative care is a decisive factor in the management of penetrating craniocerebral trauma. Many postoperative measures are designed to reduce mortality and morbidity, to prevent complications, and to hasten recovery. Some of them apply to the care of any comatose patient. Others represent specific technical steps applicable to patients with brain wounds only.

The management of the comatose patient, be it in a field hospital in a combat zone, in an Army hospital in the rear echelon or Zone of Interior, or in a civilian hospital, should be so standardized as to make such management most effective.

Of prime importance is the maintenance of an open airway. As has been mentioned in chapter 7, this can be accomplished by positioning and suctioning. Mechanical obstruction of the air passages can be prevented by frequent intratracheal suctioning and by positioning of the patient. Intratracheal suctioning with evacuation of mucous plugs should be done through the nostrils so as to prevent the patient from biting off the suction tubing or from clamping down on it during a seizure. The suction tube should be inserted all the way into the trachea until it produces a cough reflex. Effective suctioning will keep the airways open.

More important yet is the proper positioning of the patient in coma. This is necessary in order to facilitate drainage and to prevent aspiration of mucus and vomitus. The most effective position consists of placing the patient on his side with hips and knees flexed, the dependent arm behind the

back, the chest supported by a blanket roll, and the head slightly anteflexed but aligned with the spine (fig. 96). In such a position, mucus and vomitus cannot be aspirated into the bronchial tree. In order to oxygenate each lung to an equal extent, the patient must be turned from right to left at least every 2 hours.

The patient with an acute surgical intracranial disorder, either preoperative or postoperative, should not be turned by less than three people. Two attendants should place themselves on one side of the patient in order to prepare the turn. They will put their arms under the patient before the actual turning is done. A third person will take hold of the head, supporting it and turning it in the same plane as the body is turned.

RESTLESSNESS

Because of coexisting increased intracranial pressure, patients with penetrating craniocerebral trauma, even postoperatively, may show a considerable degree of restlessness. This may well present a nursing problem. Such restlessness cannot be combated with sedatives or analgesics lest the patient be harmed or clinical developments be masked.

Restraints should not be used inasmuch as the otherwise unresponsive patient tends to fight those restraints subconsciously which in turn will serve to increase the intracranial tension further.

It is best to allow the patient to toss around. In so doing, he will tire readily and make restless movement only at intervals. It is, of course, necessary to protect the patient from possible injury.

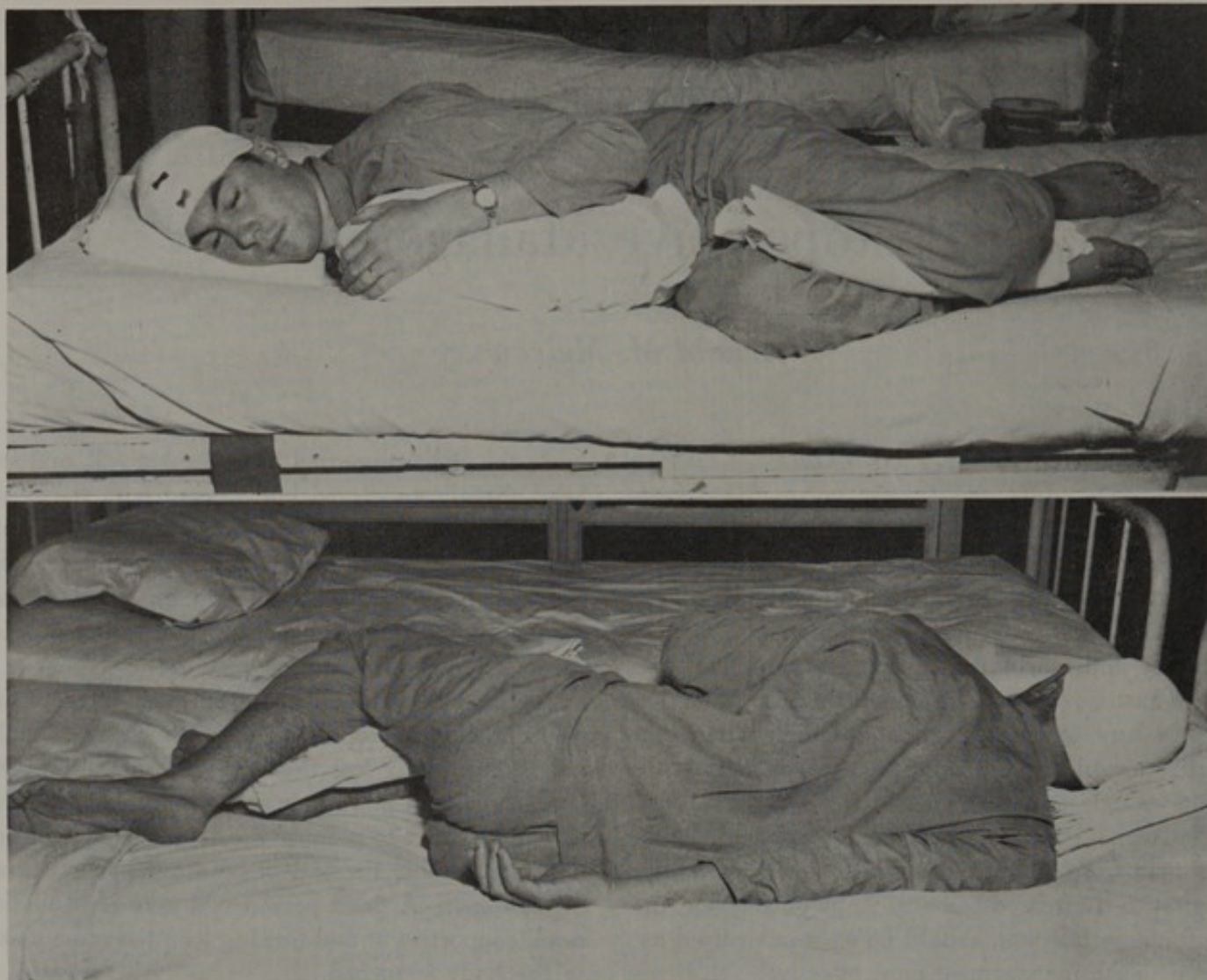

FIGURE 96.—Coma position.

Sides made of heavy netting as devised by Ernest Sachs (1) (2) afford by far the best protection. Side rails or side boards, as commonly used, may lead to additional injury of the patient unless they are carefully padded. In the field or in combat zones when neurosurgical casualties were cared for on Army cots, the three-cot method (fig. 97) was a helpful aid in the care of the restless patient.

To prevent the irrational patient from pulling out feeding tubes, catheters, outer attachment, or intravenous needles, it is best to apply mitts to both hands. Prior to application of the mitts, hands should be thoroughly washed, dried, and liberally powdered with talcum. Padding should be applied over volar and dorsal surfaces of the hand and be-

tween each two fingers (fig. 98). These mitts should be changed every 48 hours. At that time, the skin of the hands, particularly between the fingers, should be inspected for possible abrasions. Hands should be washed, dried, and powdered again prior to reapplication of the mitts.

BLADDER

Many comatose patients are incontinent for urine. A small number of patients with penetrating wounds of the brain may, however, have urinary retention for which all of them must be examined. This applies particularly to bifrontal and bifrontoparietal

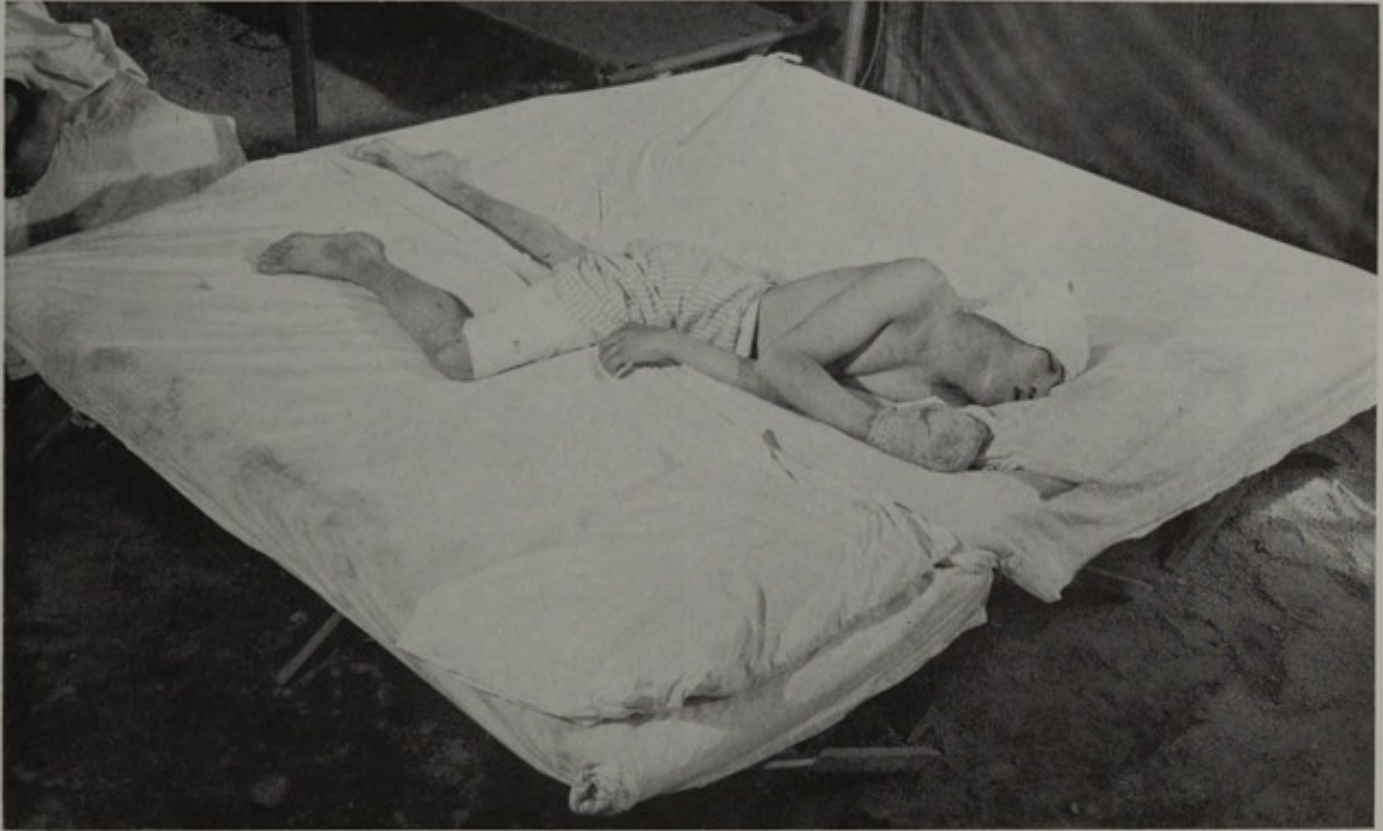

FIGURE 97.—Three-cot method for care of restless patient.

wounds. Restlessness, though commonly caused by an expanding intracranial lesion, may be due to bladder distention in the unconscious patient. If urinary retention is present, catheterization is in order and should be repeated every 8 hours. An indwelling catheter is usually not necessary inasmuch as urinary retention rarely presents a lasting problem in the management of patients with craniocerebral wounds.

A practical method of caring for the incontinent patient was first used during the Okinawa campaign in 1945 and again proved its expedience in the Korean War. The patient is fitted with a condom, the tip of which is attached to a tube leading into a bottle on the floor (fig. 99). This prevents soiling of blankets and sheets, protects the patient's skin from exposure to urine, and facilitates exact determination of the patient's urinary output.

BOWELS

Spontaneous bowel movements should be prevented by regular enemas, since straining may lead to secondary intracranial hemorrhage.

SEDATIVES AND ANALGESICS

The use of sedatives and analgesics in the presence of craniocerebral trauma is contraindicated for three reasons:

1. Those agents that are sufficiently potent to produce sedation and to relieve pain have a tendency to interfere with intracranial dynamics and to depress respiration.
2. All sedatives and analgesics have a masking effect. Any one of them may impede the establishment of indications for neurosurgical intervention.
3. The narcotic effects of these drugs may delay early surgery and may thus contribute to the degree of irreparable loss of function.

In depriving the patient temporarily of rest and of relief from pain, it should be understood that restlessness and irrationalism may well be the direct sequelae of the expansion of a space-occupying intracranial lesion. This condition can be relieved only by surgical intervention.

Increased intracranial pressure also depresses the rate of respiration. Morphine, for instance, has a

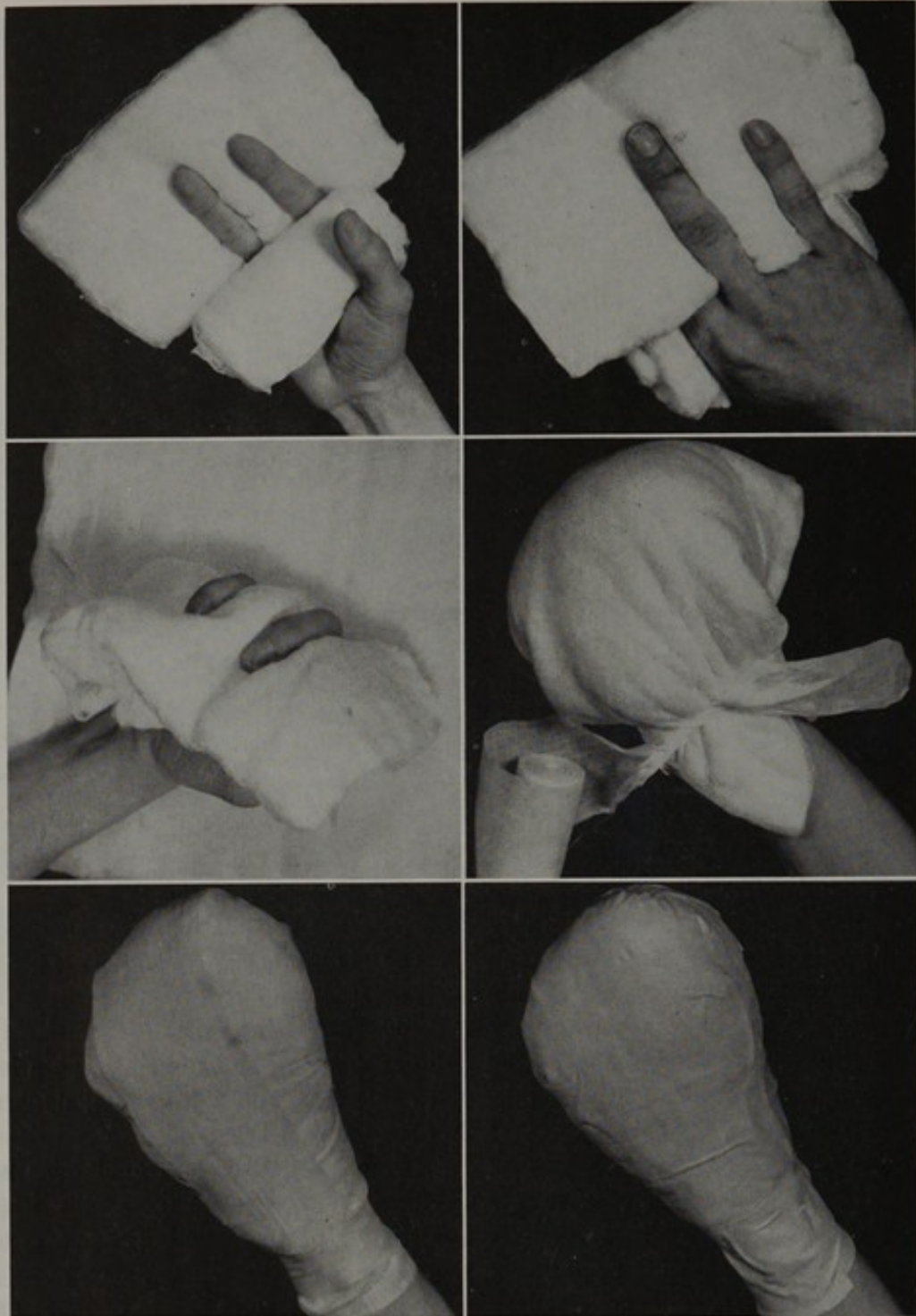


FIGURE 98.—Application of mitts.

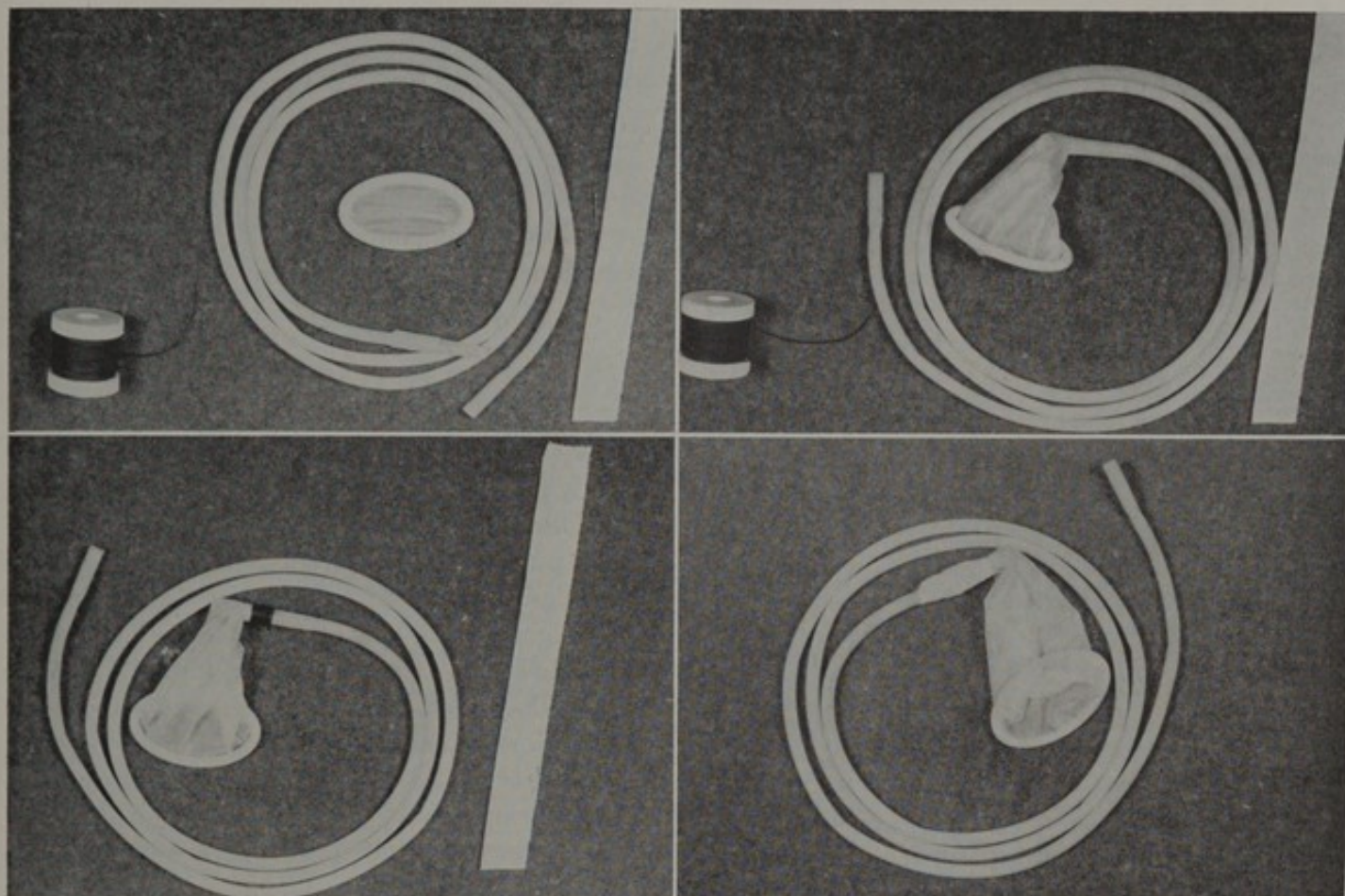


FIGURE 99.—Outer attachment for urinary drainage of unresponsive patients.

similar effect on the respiratory rate that may be embarrassed catastrophically by the combination of the two factors. The irrational or unresponsive patient is not sufficiently aware of pain to require relief. The conscious patient with penetrating craniocerebral trauma who complains of headache should be reassured and given an explanation why his headaches cannot be relieved until the necessary surgery has been performed.

FEEDING

The comatose patient should be maintained in a normal state of hydration. An average of 2,500 cc. of fluid every 24 hours is adequate for an average-sized person under average climatic conditions. In the event that this fluid has to be administered intravenously, sodium chloride solution should not be used in more than 1,000 cc. of the 24-hour total. Postoperatively, it is best to get away from intra-

venous fluids as rapidly as possible and substitute tube feedings. This can almost always be done without untoward effects 1 or 2 days after operation.

Only autoclaved Levin tubes are to be used for feeding. The tube is to be inserted through one nostril and fastened to the face by a narrow strip of adhesive tape. The tube should be changed every 5 to 6 days. Upon insertion of the tube and before each feeding, the stomach should be aspirated to ascertain that the tube is in place.

The unresponsive patient can live for weeks or months on a well-balanced tube feeding formula supplemented by sufficient fluid intake. It is essential that small feedings be given at frequent regular intervals.

The unresponsive patient should be given 200 cc. of formula plus 50 cc. of water every 4 hours (8 a.m., 12 m., 4 p.m., 8 p.m., 12 p.m., 4 a.m.). Two hours after each feeding of formula (10 a.m., 2 p.m., 6 p.m., 10 p.m., 2 a.m.), the patient should be given 200 cc. of fruit juice and water. In the neurosurgi-

cal center at Tokyo Army Hospital during the Korean War, the following tube feeding formula was used:¹

	<i>Protein</i>	<i>Fat</i>	<i>Carbo- hydrate</i>
Canned strained meat (beef, two 7 oz. cans).....	34.3	7.7	
Strained liver (1 oz.).....	4.6	1.0	
Milk (24 oz.).....	24.0	30.0	36.0
Casec (2 oz.).....	52.0	1.0	150.0
	114.9	39.7	186.0
Calories.....			1,554.7
Water.....percent..			82.5
Volume.....cubic centimeter..			960.0
Equivalent fluid value...cubic centimeter..			792.0

The formula must be prepared fresh daily and kept in a refrigerator. It should be heated to body temperature before using.

ANTIBIOTICS

A broad-spectrum antibiotic should be given in large doses prophylactically to every patient with penetrating craniocerebral trauma and should be administered postoperatively for a period of at least 5 to 6 days. The ever-changing picture of available antibiotics does not make it feasible to make specific suggestions as far as prophylactic management is concerned. Streptomycin cannot be safely used for longer than 5 days because of possible vestibular damage. Sulfonamide drugs should be reserved for treatment of specific meningeal and intracerebral infections.

EYE CARE

In order to protect the eyes of an unconscious patient, it is necessary to irrigate them regularly. This can be done with saline solution or with 1-percent boric acid eye irrigations. The irrigations should be carried out from the inner angle of the eye to the outside. These irrigations should be followed by insertion of one drop of sterile castor oil in each eye. Following frontal and temporal craniotomies, it is best to use routinely cold saline compresses in order to hold down postoperative edema of the lids.

¹ This formula was prepared by Lt. Col. Bernard I. Copple, MC, USA.—A.M.M.

SKIN CARE

Special skin care must be given to each unconscious patient so as to prevent occurrence of bedsores. The skin should be kept dry and well powered. Frequent turning, as outlined before, is an additional and important safeguard against the development of decubital ulcers.

BODY TEMPERATURE

Moderate elevation of temperature, as occurs frequently following penetrating craniocerebral trauma and following operative procedures, can be combated with the administration of aspirin. Rapid high elevation of temperature must be combated more vigorously. This can best be done by sponging with alcohol. Such sponging is only effective if the skin is hot. In the presence of a cold skin with high temperatures, sponging with iced alcohol is ineffective. The most practical measure of bringing the temperature down with iced alcohol consists of the use of 20 to 30 gauze squares which have been soaked in iced alcohol. These gauze squares are rapidly applied to the skin surface. As the entire body surface is covered with gauze squares, the first applied squares are removed, soaked again, and replaced with new ones. Rapidly, over a period not exceeding 20 to 30 minutes, the gauze squares soaked in iced alcohol are applied, removed as soon as they have become warm, and replaced by new iced alcohol gauze squares. After the temperature has thus been effectively lowered, the body is carefully dried. Maintained hypothermia is far superior. The hypothermic blanket (Therm-O-Rite) greatly facilitates maintenance of hypothermia which has a definite place in the postoperative management of patients with craniocerebral trauma.

DRESSINGS

Upon conclusion of the operation, a 3-inch Ace bandage should be applied snugly in an effort to prevent postoperative oozing into the subgaleal space (fig. 100). Because of postoperative edema, the tight Ace bandage will have to be loosened to

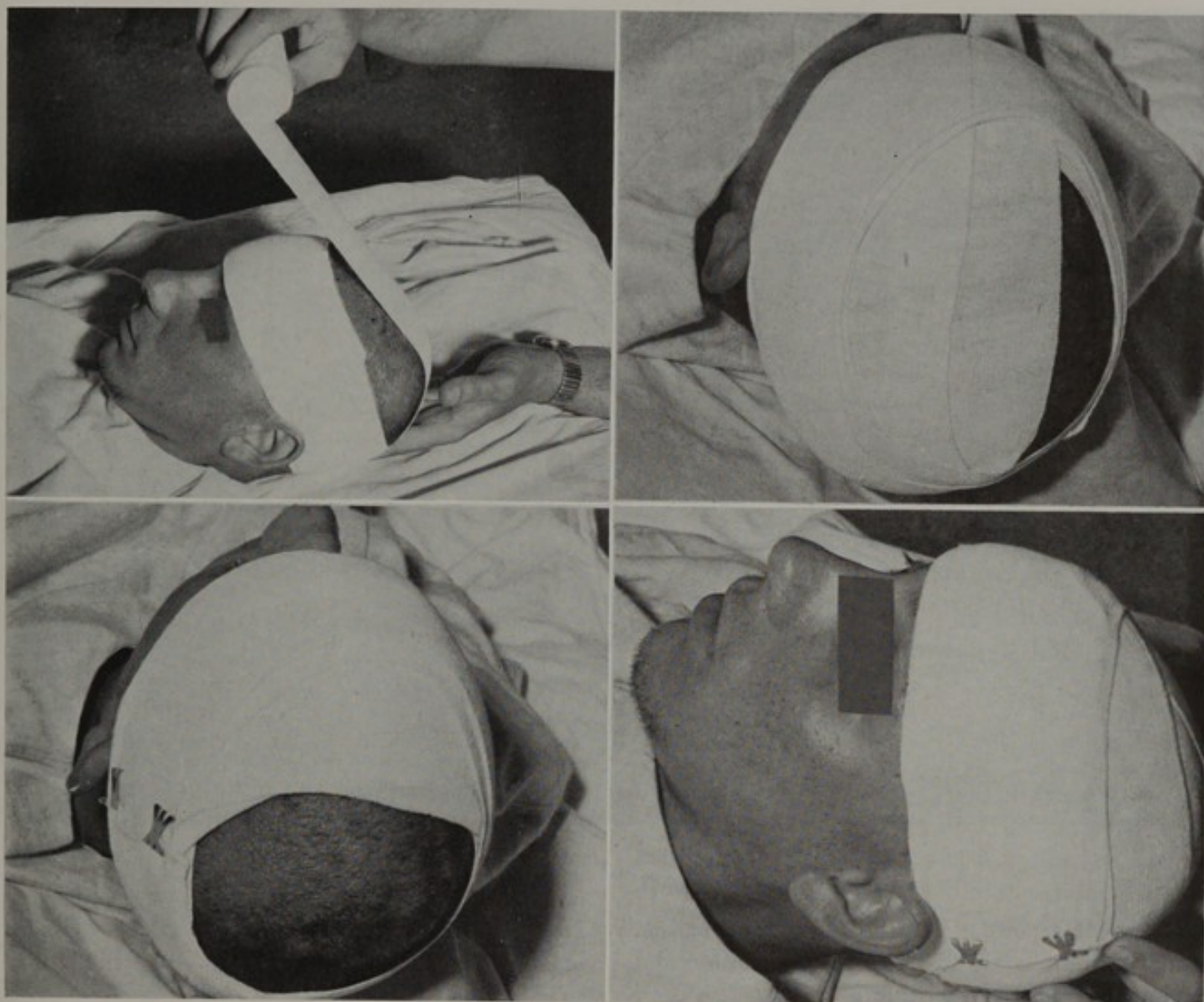


FIGURE 100.—Postoperative dressing with 3-inch Ace bandage.

some extent within a few hours after the operation. The wound should be inspected from 6 to 8 hours after operation, then again after 12 hours, and subsequently not less than every 24 hours for the first 2 or 3 postoperative days. Skin sutures can usually be removed 24 to 48 hours after operation. A stockinette cap may be used in lieu of the Ace bandage as soon as the flap is properly healed.

Frequent change of dressings serves to prevent complications. It gives the surgeon an opportunity to follow wound healing with his own eyes and to help it along by aspiration of fluids that may have accumulated under the flap. Inasmuch as surgery of penetrating craniocerebral trauma is concerned with craniectomy rather than craniotomy, direct ob-

servation of the flap during the immediate postoperative phase facilitates recognition of a postoperative hematoma or development of increased intracranial pressure.

The need of frequent change of dressings cannot be overemphasized. In some circles, there still appears to be a great fear of changing dressings for several days postoperatively because of danger of infection. The advantages of postoperative sterile dressing changes outweigh by far any conceivable dangers.

Occasionally, separation of wound edges may be noted during the early postoperative phase. Secondary "through-and-through" sutures can readily be applied in that case. If it does not seem desirable to suture the wound secondarily, the ap-

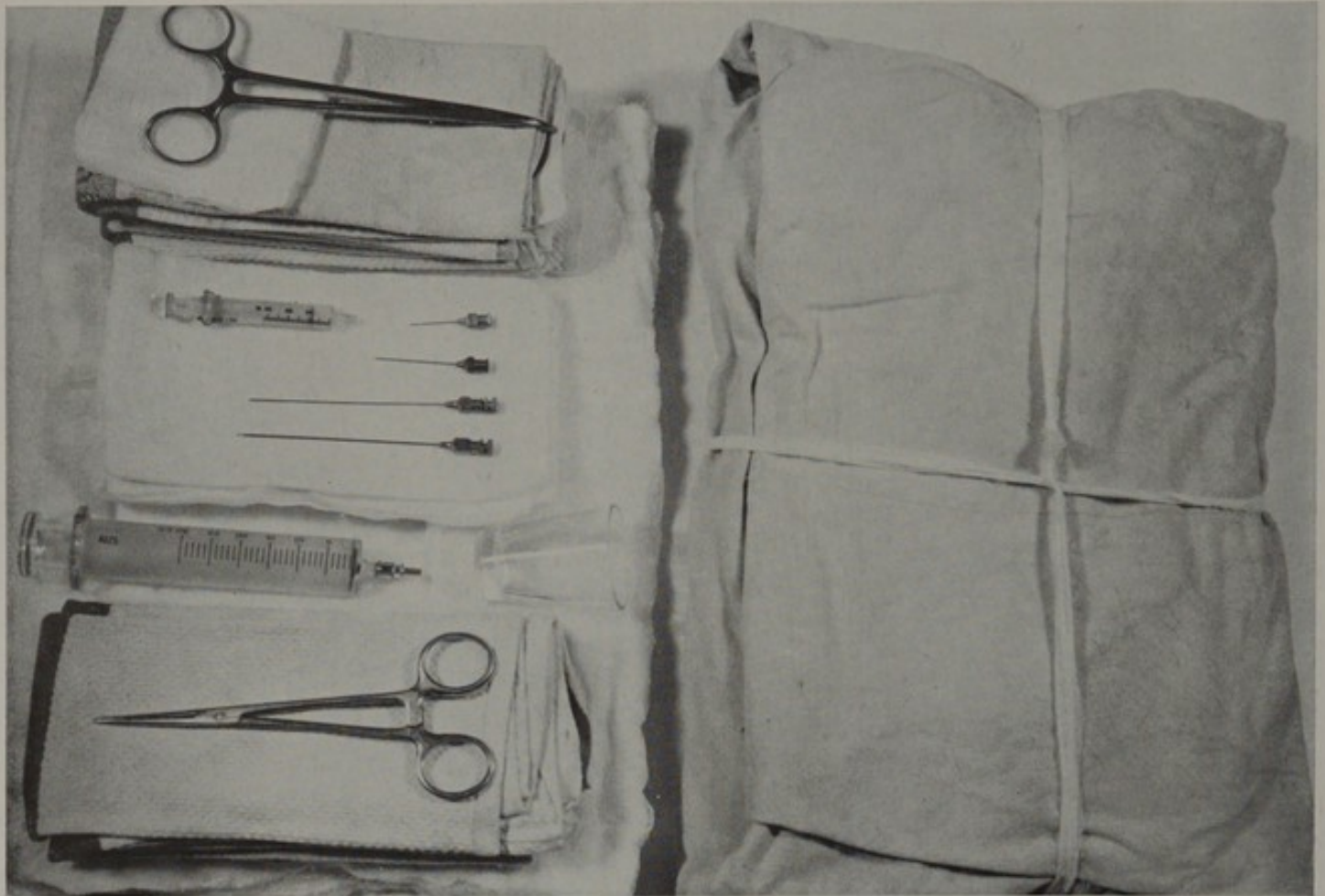


FIGURE 101.—Flap tap tray.

plication of a powder prepared by mixing plasma with penicillin serves to stimulate granulation and healing by secondary intention.

FLAP TAPS

A flap tap is indicated whenever the flap is fluctuating. Prior to the flap tap, it will be necessary to reshape the area through which the aspirating needle is to be inserted. Under sterile precautions, a No. 18 gage lumbar puncture needle is inserted distally to the line of incision and thereby distally to the cranial defect. The needle is then advanced toward the center of the cranial defect and fluid is aspirated with a syringe.

In the care of large numbers of casualties with penetrating trauma, it has been practical to set up special flap tap trays. Such a tray should contain 4 by 4's, sterile towels, sterile gloves, one No. 18

gage lumbar puncture needle, one 20 cc. syringe, one medicine glass, and one culture tube (fig. 101).

VENTRICULAR TAPS

In the presence of rapidly increasing intracranial pressure, repeated ventricular taps may be indicated. They can be carried out through a bur hole (or existing bony defect) in the anterofrontal area or in the posteroparietal area. Sterile precautions must be used during ventricular taps. The area must be reshaved and thoroughly prepared. Insertion of the ventricular cannula is then carried out in routine manner. In the management of large numbers of casualties with penetrating craniocerebral trauma, it is practical to have sterile ventricular tap trays on hand. Such trays should contain 4 by 4's, sterile towels, sterile gloves, two ventricular cannulae, medicine glass, and culture tube.

LUMBAR PUNCTURE

In the postoperative management of penetrating craniocerebral trauma, therapeutic lumbar punctures can be used to good avail. They are reasonably safe inasmuch as craniectomy has produced a wide area of decompression. Postoperative use of lumbar puncture is of particular importance whenever the dural suture line is not entirely watertight. Repeated lumbar punctures may serve to keep the pressure off the dural suture line allowing it to heal firmly. The tremendous importance of postoperative use of lumbar punctures in the management of transventricular wounds has been discussed in chapter 15.

CEREBRAL EDEMA

Penetrating wounds of the brain invariably produce edema of the surrounding brain tissue. Surgical intervention may result in a temporary increase in cerebral edema. Whenever venous drainage has been impaired, such as is the case in many wounds of dural sinuses or their tributaries, posttraumatic and postoperative edema may take on formidable proportions.

In the past, hypertonic solutions have been used intravenously in an effort to ward off progressive edema. This has been long abandoned inasmuch as its effect is not only transitory but also because a compensatory rise in intracranial pressure often follows the initial reduction of edema.

The methods mentioned in the preceding paragraphs—decompression by flap taps, ventricular taps, or even spinal tap (in the presence of a large bony decompression)—have been used in the management of casualties in the Korean War.

The advent of urea which has been introduced by Javid and his coworkers (3) (4) (5) (6) (7) represents a milestone in the historical development of neurological surgery. While urea was not available in the Korean War, it is now readily accessible. In the future management of craniocerebral trauma, urea will have a definite and important place. It may well be advisable to plan on intravenous administration of urea immediately prior to operation for those penetrating wounds of the brain which are productive of extensive cerebral edema. Its

use prior to and during operation may ward off progressive postoperative edema; however, additional amounts of intravenous urea may well be given during the immediate postoperative phase (8).

AMBULATION

Following surgery for penetrating craniocerebral trauma, patients are taken out of bed, put in a chair, and permitted to ambulate at the earliest possible time. This is of tremendous importance from a circulatory point of view. More rapid clearing of the sensorium has frequently been observed concomitant with early ambulation. The role of physical therapy during the immediate posttraumatic and postoperative phase cannot be overemphasized.

RECORDS

Even mobile neurosurgical teams in combat zones can maintain adequate records without too much difficulty (9). Detailed analysis of special wounds, as can be found in these pages, could not have been prepared if it had not been for the maintenance of adequate records in the field during the Korean War (fig. 102). Figure 103 shows the type of form that was used to record head injuries during the Korean War. Its employment as official record in future warfare has been recommended. While this type of field record does not come up to the standards of records that must be maintained in stationary installations, it has proved its value for use in combat zones.

The ultimate goals in the treatment of casualties with wounds of the brain are restoration of the greatest possible degree of function and rehabilitation (10). The achievement of these goals rests with the availability of earliest possible definitive neurosurgical treatment and simultaneously applied specialized nursing care. Physical therapy, speech retraining, and every other applicable source of help must be employed in an effort to restore the wounded man to function in a society to which to belong and in which to function are his sacred rights.

The story of X-95 who was wounded in 1945 in the Okinawa campaign might serve as a proving re-



FIGURE 102.—“Record Room,” postoperative ward tent, 3d Neurosurgical Detachment (Provisional), Eighth U.S. Army, Korea.

minder that rehabilitation can be achieved. Shell fragments had destroyed this 19-year-old's (Marine Corps, private, first class) left temporal lobe rendering him hemiplegic and aphasic. His speech had been reduced to one word—possibly the code word which was last on his lips when the shell fragments struck. For weeks after having been wounded, he could only cry out the single word “X-ray, X-ray, X-ray.” Recovery was a slow process of surgery and corrective surgery, physical medicine, and speech retraining. Today, 14 years later, the same man has written and published a most embracing and authoritative thesis on language retraining (11), devoting his lifetime to the rehabilitation of those afflicted in the same manner as he was many years ago.

REFERENCES

1. Sachs, E., and Bradley, F. R.: How to Handle Head Injuries. *Mod. Hosp.* 57: 49-50, November 1941.
2. Sachs, Ernest: *The Care of the Neurosurgical Patient Before, During and After Operation.* St. Louis: C. V. Mosby Co., 1945.
3. Javid, M.: Urea; New Use of an Old Agent; Reduction of Intracranial and Intraocular Pressure. *Surg. Clin. N. America* 38(4): 907-928, August 1958.
4. Javid, M., and Settlege, P.: Effect of Urea on Cerebrospinal Fluid Pressure in Human Subjects; Preliminary Report. *J.A.M.A.* 160: 943-949, 17 Mar. 1956.
5. Javid, M., Settlege, P., and Monfore, T.: Urea in the Management of Increased Intracranial Pressure. *Proceedings of 42d Clinical Conference of the American College of Surgeons, San Francisco, Calif., October 1956. Surgical Forum* 7: 528-532, 1957.
6. Javid, M., and Settlege, P.: Clinical Use of Urea for

APD _____

HEAD INJURY CARD

Name

Branch

Date of Admission

How

When

Where

Mental Status

Head

Cranial Nerves

Motor System

Sensory System

Reflexes

Meningeal Signs

BP

Associated Injuries

Remarks

Rank

Home Address

Nearest of Kin

Handedness

ASN

P

RESP

TEMP

OPERATIVE NOTE

Operation

Date of Operation

Anesthesia

Procedure

Operator

OPERATIVE NOTE (contd)

Diagnosis

Recommendations

Disposition Date

Signature _____

FIGURE 103.—“Head Injury Card,” 3d Neurosurgical Detachment (Provisional), Eighth U.S. Army, Korea.

- Reduction of Intracranial Pressure. 82d Annual Meeting. Tr. Am. Neurol. A., pp. 151-153, 1957.
7. Javid, M., and Anderson, J.: The Effect of Urea on Cerebrospinal Fluid Pressure in Monkeys Before and After Bilateral Nephrectomy. J. Lab. & Clin. Med. 53 (No. 3) : 484-489, March 1959.
 8. Javid, M.: Urea in Intracranial Surgery. A New Method. J. Neurosurg. 18: 51-57, January 1961.
 9. Campbell, E. H.: Recent Notes on Wounds of the Brain and Spinal Cord. In Symposium on Treatment of Trauma in the Armed Forces, 10-12 Mar. 1952, Army Medical Service Graduate School, Walter Reed Army Medical Center, Washington, D.C.
 10. Russell, W. R.: Rehabilitation After Gunshot Wounds of Brain. Brit. J. Surg. (War Surg. Supp. No. 1), pp. 252-255, June 1947.
 11. Norrix, James M.: Language Rehabilitation of the Brain-Injured Adult in the United States Since 1914. Thesis submitted to faculty of University of Utah, Salt Lake City, Utah, August 1958.

CHAPTER 20

Repair of Cranial Defects

David L. Reeves

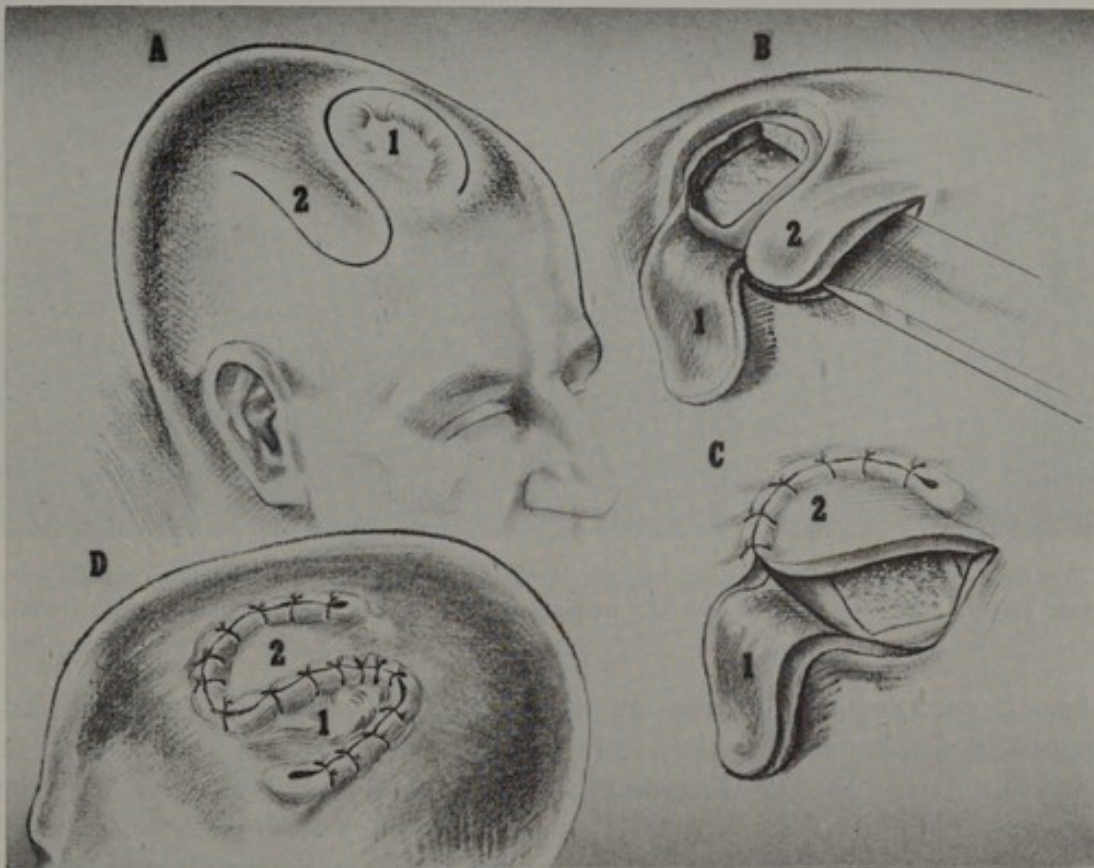


FIGURE 104.—The original Müller-König procedure. A. The incision. B. The flaps with the scalp freed from the defect and the dermatoperiosteal flap. C. The transposition of the flaps. D. The closure.

HISTORICAL NOTE

The casualties of war, which include many cranial defects requiring repair, invariably provoke a renewed interest in materials and methods. Previous work in this field has been well covered by Grant and Norcross (1), Woolf and Walker (2), and Reeves (3) (4). In addition to the skull defects caused by

the increasing number of civilian accidents, cranioplasty has been necessary to correct the deformities resulting from osteomyelitis, the removal of infected bone flaps, and the excision of hyperostosing tumors.

From a historical point of view, the surprising success with the variable methods and materials employed in the repair of cranial defects is striking. The different kinds of materials used have included

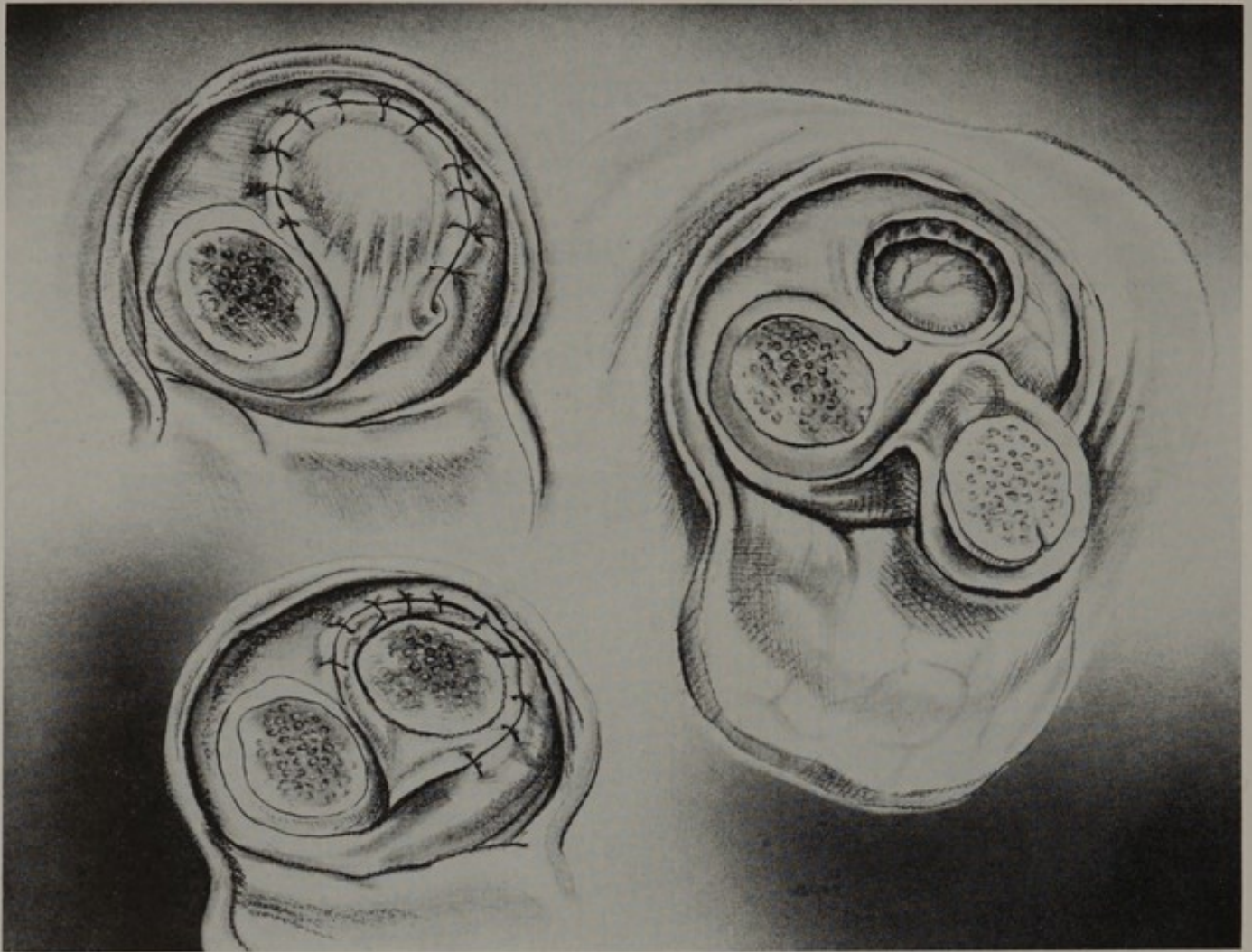


FIGURE 105.—Demonstration of the Durante or von Hacker procedure with the single scalp flap and hinged graft (right) which is sutured with the periosteum on the external or internal surface (left).

autogenous, homogenous, and heterogenous grafts as well as numerous alloplastic materials outside the animal kingdom.

MATERIALS USED

BONE GRAFTS

Autogenous grafts

The outer table graft represents one form of autogenous graft. In the Müller-König method (5) (6), twin flaps of scalp, one containing the skin and what was left of the pericranium from the site of the defect, and the other the skin, pericranium, and outer table taken from an adjacent area in such a way that the bases of the flaps were opposite to each

other and could be transposed (fig. 104).

The osteoperiosteal graft and its variations, employed first by Durante (7) in 1900, have been used frequently. In this procedure, a single scalp flap and hinged graft are employed (figs. 105 and 106). In 1905, Keen (8) used chips of bone from the adjacent outer table. In 1907, Söhr (9) was the first to use the type of outer table graft most commonly employed. The graft is cut entirely free of the pericranium and held in place by means of periosteal sutures. The graft may be obtained from an area on the opposite side of the skull or immediately adjacent to the cranial defect (fig. 107).

Rib grafts were used first by Kappis (10) in 1915, and split-rib grafts were used in 1917 by Brown (11). They are still employed with good results.

The cancellous bone from iliac grafts has been found dependable and satisfactory for correction of

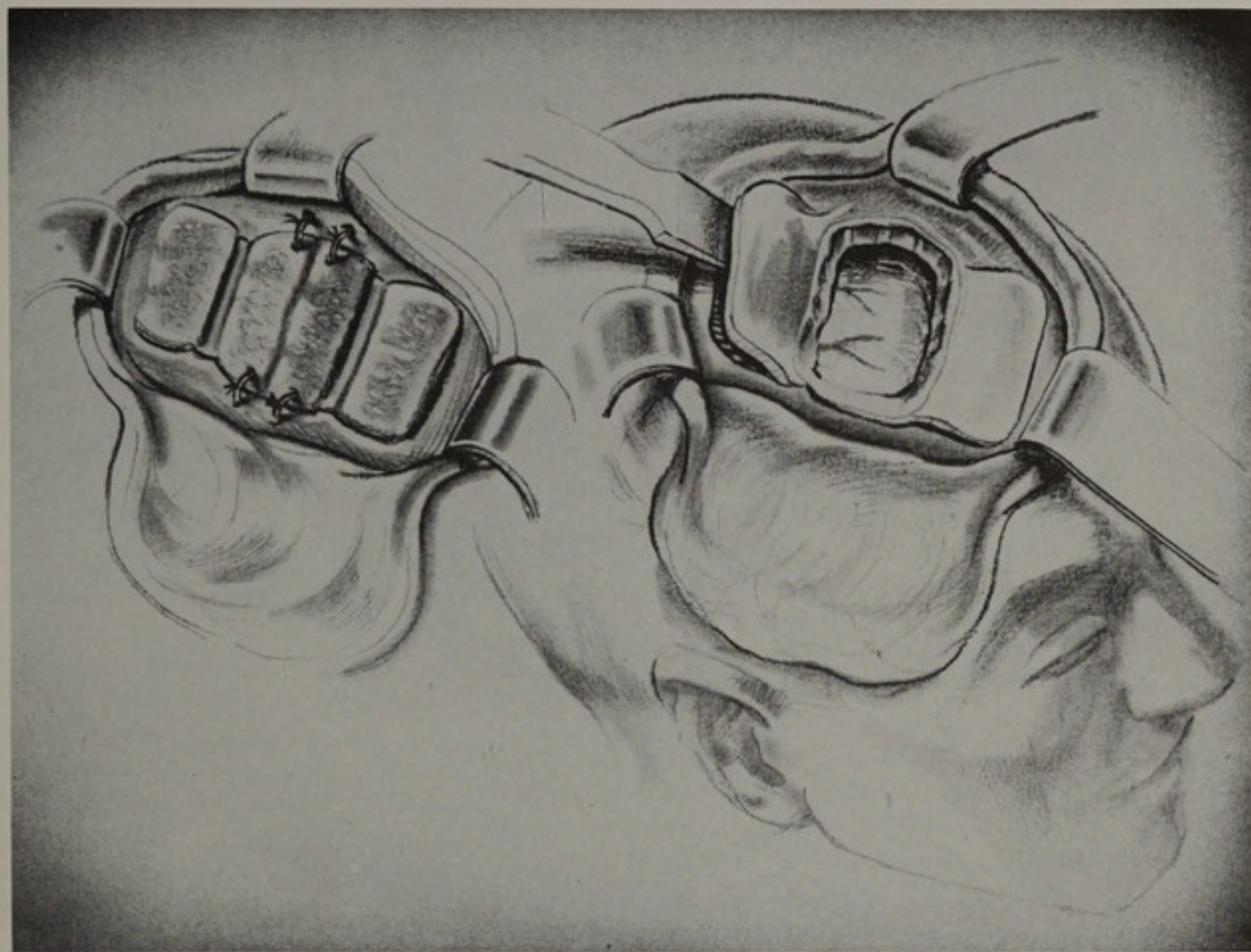


FIGURE 106.—Double-hinged or cellar-door modification. The periosteal flaps are cut on each side of the defect.

contour defects and bony losses in facial structures (12).

Replacement of boiled bone flaps has occurred with successful results, but many have been removed because of infection and absorption, and more frequently with delayed replacement (13). Autogenous bone preserved in a sterile frozen state has also been successfully reimplanted (14).

Homogenous grafts

Woodhall has used, with satisfaction, preserved human homogenous cartilage in the repair of supra-orbital and other small cranial defects.

Bush (15) concluded that homogenous bone could be transplanted under the same conditions as, or in conjunction with, autogenous bone and could be obtained from a bone bank. That such homogenous

bone could be employed satisfactorily as a large bone plate or for the replacement of a large bone defect seems dubious.

Heterogenous grafts

Insofar as heterogenous grafts are concerned, it would seem that these can only be considered from the standpoint of historical interest.

ALLOPLASTIC GRAFTS

Nonmetallic grafts

Of the nonmetallic alloplastic grafts, Celluloid was used as early as 1890 by Fraenkel (16), but because of the reports in which the graft had softened and become ineffective, the use of Celluloid would no longer appear justified.

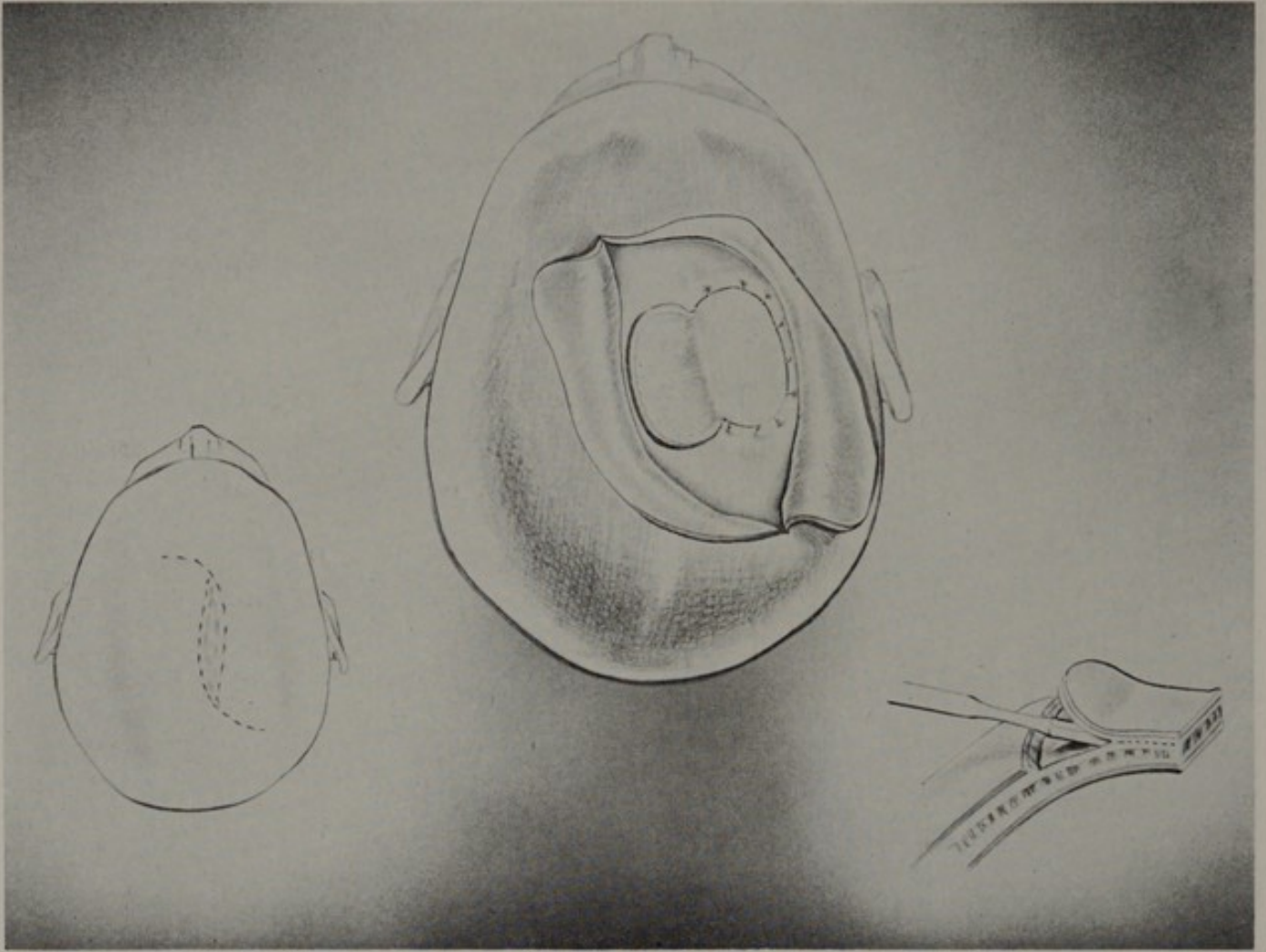


FIGURE 107.—The usual type of outer table graft. Ordinarily, the graft is cut entirely free of the pericranium and held in place by means of periosteal sutures. The graft may be obtained from an area on the opposite side of the skull or immediately adjacent to the cranial defect.

The plastics

Methyl methacrylate is known by such trade names as Vitacrylate, Lucite, Plexiglas, and Crystalite.

In recent years, the acrylic resins have become the material of choice for repair of many defects. In 1940, Kleinschmidt (17) successfully inserted plates of Plexiglas into the skull defects of rabbits. Plexiglas was employed first for human cranioplasty in October 1940 by Zander (17). In 1943, Gurdjian, Webster, and Brown (18) described their method of repairing large skull defects with acrylic and reported that one case was in excellent condition with no evidence of deleterious reactions, at the end of 15 months. In 1944, the material was used experimentally as observation windows in the skull of monkeys by Shelden, Pudenz, Restarski, and Craig (19).

In 1946, Elkins and Cameron (20) reviewed their experiences with 70 cases of skull defects repaired with methyl methacrylate between June 1943 and January 1945. It was their conclusion that the material produced a minimum of foreign-body reaction in the tissues and afforded excellent cosmetic results. In comparison with the metallic materials, they emphasized that acrylic was neither subject to the physical effects of temperature change nor to the effects of electric phenomena, and that it did not interfere with any pneumoencephalographic films and lateral arteriographic tracings that might be taken.

Spence (21) has simplified the technique of preparation of the plastic material so that the previous objections to its nonmalleability and prolonged preparation have been eliminated and its usefulness greatly increased.

Jackson and Hoffman (22), in 1956, reported an instance of a depressed comminuted fracture of a large plastic (methyl methacrylate) cranioplasty following a minor head injury and cautioned against its use to cover large cranial defects.

Metallic grafts

While various kinds of metals have been successfully used in the repair of cranial defects (3) (4), the inertness and strength of Vitallium, Ticonium, stainless steel, and tantalum leave little reason for the employment of other metallic materials unless

their properties are found to be similar. Vitallium and stainless steel have the disadvantage of not being malleable. It would, therefore, seem that Ticonium and tantalum would be the metals of choice.

In 1936, Lluema-Uranga (23) described the use of silver wire mesh to fill in defects, and in 1945, Boldrey (24) published an article on the use of stainless steel wire mesh in the repair of small cranial defects. The author of this chapter has found this material excellent for this purpose. More recently, Scoville (25) has used heavier stainless steel wire mesh for the repair of moderate-sized defects with excellent results.

Frequently, those performing cranioplasties become enthusiastic concerning the material and method with which they are familiar. There are, nonetheless, a number of substances which have proved satisfactory and some are more suited for certain types of cranioplasty than others. Certainly, autogenous bone or cartilage (derived from the outer table of the skull, the ribs, ilium, scapula, or tibia) continues to offer an adequate means for the repair of the smaller skull defects and especially those involving the frontal sinuses and the region of the glabella. It may also be found that stored homogenous bone from a bone bank will prove satisfactory in many instances. At the same time, it seems likely that plastic repair of extensive skull defects with autogenous bone or cartilage or with homogenous bone from a bone bank will not be feasible.

The recent experiences with Vitallium, stainless steel, Ticonium, and tantalum leave little reason for the employment of other metallic materials, and at the present time, most of those familiar with the subject consider tantalum the metal of choice for the repair of the large defects. Heavy stainless steel wire mesh has proved satisfactory in the repair of the smaller defects.

Methyl methacrylate plates have proved quite satisfactory in the repair of the small and moderately large cranial defects and have certain advantages in lacking the physical effects of temperature change and inertness to any electric phenomena. The potential danger of short-wave diathermy in patients with metals embedded in their tissues has been discussed and mentioned as a contraindication in the use of metallic grafts. Etter, Pudenz, and Gersh (26) planted surgical metals in experimental animals

in a manner simulating their use in human patients. Short-wave diathermy was administered to animals with tantalum skull plates, tantalum cuffs around nerves, tantalum and stainless steel plates lying next to the femur, and tantalum wire in the subcutaneous tissues. They found that there was no significant difference between the temperature on the side containing the metal and that on the control side, irrespective of the diathermy machine used, the method of application of the short-wave energy, or the nature of the metal used. Moreover, histological examination of tissues adjacent to the metals showed no significant destructive effects from the diathermy contributable to the presence of the metal. The major blood supply was anatomically intact in all of the experimental animals. Etter, Pudenz, and Gersh believed it conceivable that tissue damage might occur by the use of diathermy if the circulation was impaired. They referred to the work of Peet and Braden as confirming in general terms their own results.

Lion (27) has shown, under conditions of short treatment with strong fields, that the field concentrations provoked by implanted metals might well rise up to values dangerous to the tissue contiguous to the metal.

OPERATIVE PROCEDURES

BONE GRAFTS

Autogenous grafts

Osteoperiosteal grafts.—Osteoperiosteal grafts from the outer table of the skull can be obtained from an area immediately adjacent to the cranial defect or from the opposite side of the skull. Usually, exposure is made through the original scalp scar which is excised at the same time. The excess scar tissue about the dura is freed from the inner surface of the skull. The edges of the defect are beveled by means of a chisel, a gouge, or the use of dental burs on an electric motor.

A pattern of the deformity is then marked on appropriate material a few millimeters larger than its actual size. A mosaic of the outer table with its pericranial covering is chiseled out. Necessary adjustments in size and shape can be made and the graft fitted against the bevel or into a ledge of bone,

after which closure is performed in the usual manner. Many variations of such a technique can be used, though without any significant advantage being evident.

Although the ilium and the scapula are well suited for the plastic repair of skull defects, the prolongation of the operative procedures necessary for the exposure and preparation of such grafts hardly justifies a technical discussion of them and the same may be said to apply to osteoperiosteal grafts obtained from the tibia. Macomber (12) has described the technique for the use of grafts from cancellous iliac bone.

Split-rib grafts.—The split-rib graft, with or without periosteum, has proved satisfactory for restoration of larger defects. Exposure of the 9th and 10th ribs in the posterior axillary line has been the usual procedure. After elevation of the periosteum, a piece the proper length is resected, and the ribs are then split by hand with a sharp thin chisel so that the two pieces, one concave and the other convex toward the cut surface, are available. During exposure of the defect, these are placed in saline solution. At the opposite sides of the defect, a ledge is prepared to support the ends of the ribs. Small holes are drilled in the ledge and ends of the ribs for fixation with steel or tantalum wire. Fixation by means of tantalum or Vitallium screws can also be used. After closure, protection of the region of repair is advisable until the subsequent period of stabilization has occurred.

Cartilage grafts.—Cartilage grafts can be used advantageously for the repair of the small deforming defects of the supra-orbital ridges and the region of the glabella, but they are not as strong as bone grafts and remain as cartilage. The defect is exposed by plastic excision of the overlying scar. A rectangular transplant obtained from rib cartilage is cut into shape and placed over the residual skull margin. Its anterior free borders are adjusted to conform to the desired curve of the region affected. Fixation of the transplant is obtained by overlocking sutures or by pressure of overlying soft tissues.

In the use of cancellous iliac bone grafts, Macomber (12) uses an incision parallel to and just below the iliac crest to the depth of the bone. The ilium is unroofed and its outer table turned down like a trapdoor by means of a wide chisel. The desired amount of bone is removed and the application



FIGURE 108.—The skull defect is filled with modeling clay in forming the tantalum plate.

of the graft to the defect not unlike that carried out with cartilage.

ALLOPLASTIC GRAFTS

Metallic grafts

Tantalum.—Descriptions of the formation of tantalum plates, similar to those used for other alloplastic materials, have been published by Mayfield and Levitch (28), Woodhall and Spurling (29), Hemberger, Whitcomb, and Woodhall (30), Woodhall (31), and Reeves (3) (4). The one-stage or the indirect or primary method is more commonly

used. The two-stage or the direct or secondary procedure requires a direct impression with later insertion of the plate after it has been prepared.

A dental impression compound such as Kerr's red compound for the indirect method and the green compound for the direct method are employed with modeling clay or a hydrocolloid material, such as Truloid, often used in the preparation of the multi-contoured deformities of the frontal region. After the patient's scalp has been shaved, the defect is outlined with an indelible pencil, with an allowance of a centimeter overlap. Mineral oil is then applied, and the defect filled in with the dental compound, which has been softened in warm water and worked manually until pliable (fig. 108). In order

to retain the dental stone or the plaster of paris, the compound is applied beyond the area of the defect. Cold wet towels are used for hardening. When the impression is removed, the outline and depth of the skull defect is revealed as an elevated mass. The sides of the dental compound are then built up with wax strips or boxing wax to contain the dental stone or plaster of paris, which is then poured in to form a model. The depressed area within the dental stone or plaster, which represents the depth and extent of the bony defect, is filled in with dental wax which is contoured with a heated spatula to correspond to the surrounding scalp outline. Before the defect is built up with dental wax, a crossmark is scraped into the bottom of the defect to prevent movement of the wax restoration. Tin-foil is then used to fill in the defect so that the dental wax can be more easily removed.

A mold is then made with one of the molding sands. The mold includes the wax restoration and an adequate mass of the adjacent skull contour and a die poured with zinc, or in the case of the larger defects, with Hydromite. The surface of the die is painted with a solution of alcohol and talc after it has cooled, and a soft clay, such as Moldine, is formed about the circumference of the zinc die to act as a mold for the counterdie of poured lead. When Hydromite is used, a similar procedure is employed. The tantalum plate is then cut to approximate contour with an increased diameter of approximately 1 centimeter. With the use of a handpress or hydraulic press, the plate is then swaged between the die and the counterdie. When the molding has begun, the plate is removed and inspected for marginal wrinkles in the metal. Any furrows or wrinkles are obliterated with a ball-peen hammer and the edges of the excess metal trimmed off. For drainage, one or more holes may be punched in the dependent portion of the plate and the plate re-swaged. Many neurosurgeons prefer plates preformed with numerous small perforations.

A modification of the method of forming the plate prior to operation has been described by Baker (32), who uses the female die and a heavy rubber pad in the pressing cylinder. He fills in the skull defect with modeling clay, covers its surface with clear fingernail polish, and then places the dental stone on the calvarium to form the identical mold. The nail polish prevents the clay from sticking to the

stone. The plate can be hammered out on the mold until it has been shaped. The mold is then placed in a steel cylinder, surrounded by more dental stone until it is held firmly in position, and the plate swaged into the desired contour by the pressing method, using the rubber pad (fig. 109).

The hydrocolloid type of impression material is preferred for more accurate reproduction of detail in the multicontoured and difficult frontal defects. The following formula has been very satisfactory in the preparation of the hydrocolloid impression material:

Agar	gram..	62
Green soap	gram..	5
Magnesium sulfate	gram..	3
Cellulose fibers from 2 sanitary napkins		
Truloid	tubes..	5
Water	cubic centimeter..	1,500

After the mixture has been heated in a double boiler until it is of a smooth consistency, it is cooled to about 120° F. for impression over the scalp. The mixture is painted over the defect and the surrounding contour with a soft brush to the thickness of about 1 inch. After cooling with towels soaked in ice water, it can be reinforced further with a layer of plaster of paris. The impression is then poured in dental stone. The rest of the preparation is no different from that described with the dental compound.

Secondary repair of a skull defect may be necessary after the debridement of bone in acute injuries of the skull or following the removal of a skull tumor.

In the two-stage procedure, a bone ledge is prepared around the defect and a direct impression made with subsequent restoration of the defect with the tantalum plate. Such a direct impression can be made by the use of sterilized dental compound, usually Kerr's green compound which softens more readily and at a lower temperature than the red compound. The hydrocolloid impression material can be similarly used after autoclaving and cooling to 98.6° Fahrenheit.

Less complex methods of forming the tantalum plates have been used with excellent results. These include the fabrication of the plates about a basic model of the skull, the hammering of plates with the use of preformed dental-cement molds or a basic metallic model, and the similar preparation of the plate at the operating table by hammering from a basic model. It is surprising how skillful a surgeon

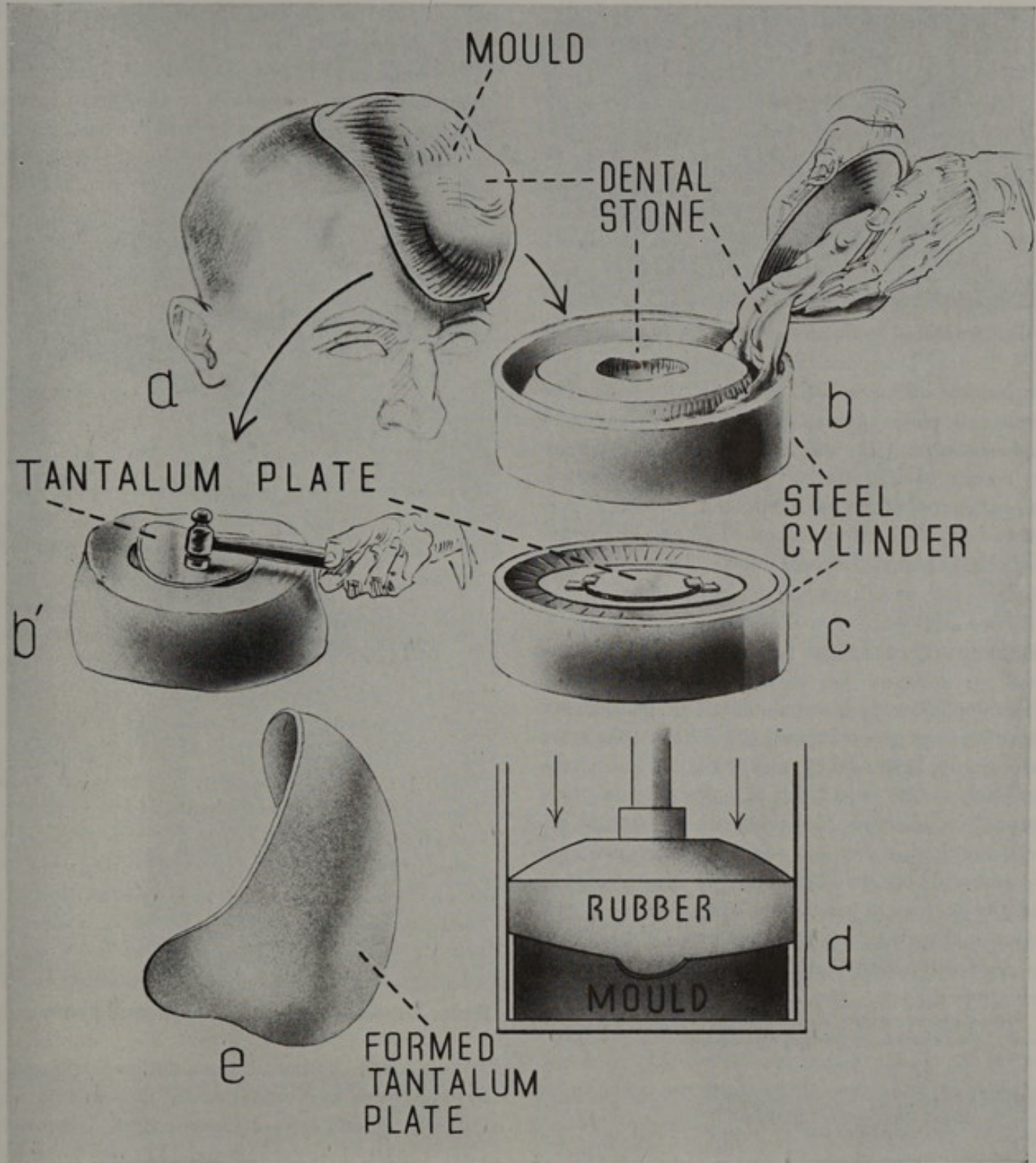


FIGURE 109.—Methods of forming the mold and the tantalum plate.

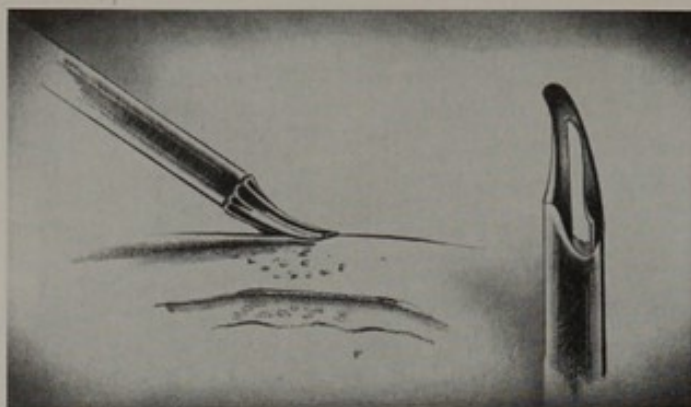


FIGURE 110.—The lineator devised by Hemberger.

can become by using such methods. By fitting the hammered plate against the patient's defect until it appears correct, the surgeon can readily determine the results of his efforts. Additionally, commercially prepared plates are available for different portions of the skull affected, and these can be altered or similarly adjusted as necessary.¹

OPERATIVE FIXATION OF TANTALUM PLATE

Cranioplasties with tantalum can be carried out under local or general anesthesia. The scalp scars have usually been of the linear variety, allowing the approach to the defect through the original scar. Coronal incisions are desirable for the frontal defects, and the usual craniotomy incision is preferred for temporal bone defects because the mass of muscle and the increased vascularity after injury in this region make direct exposure difficult. Broad, thin scalp scars adherent to underlying tissues should be

¹ Stainless steel or tantalum preformed templates have been used successfully by the author in the repair of cranial defects.

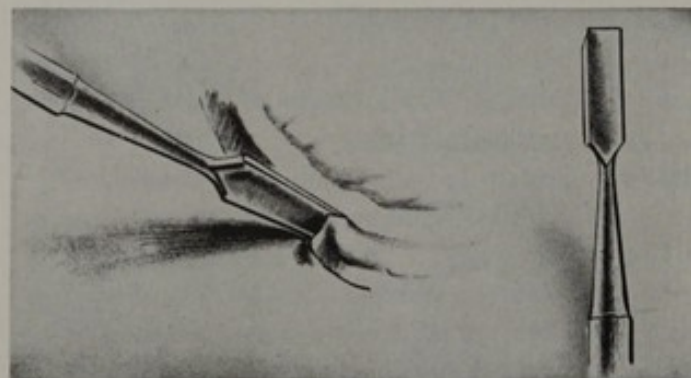


FIGURE 112.—Method of cutting out ledge of bone with a Stout No. 3 dental chisel.

revised plastically before cranioplasty, and grafting may be required.

The metallic plate can be applied to the calvarium either by the inlay method or the onlay method. Metallic wires, wedges, or screws have been used for the fixation. In the inlay procedure, after the skull defect is exposed, the tantalum plate is placed over the defect and its margins cut so that it overlaps the margins of the defect for approximately 0.5 centi-

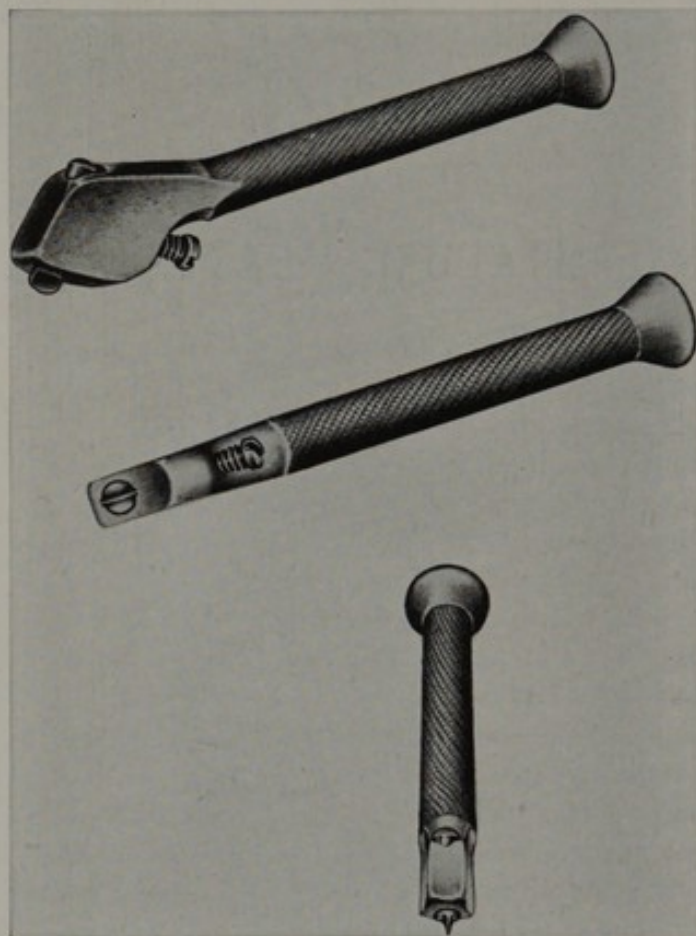


FIGURE 111.—An adjustable lineator devised by the author.

meters. This border is then outlined with an instrument such as a dental scaler and cut to a depth of about 2 mm. with a lineator or a dental chisel (33) (34) (7) (figs. 110 and 111). A bone ledge is then cut out along this circumferential outline to a depth of about 2 mm. with a Stout No. 3 dental chisel (fig. 112). The additional use of dental burs in an electrically driven motor has been found helpful. The preformed plate is adapted to this ledge, the necessary adjustment being made with contour pliers, scissors, or hammering on a basic model of metal. Fixation is then secured by tantalum wedges, the perforations into the outer border of

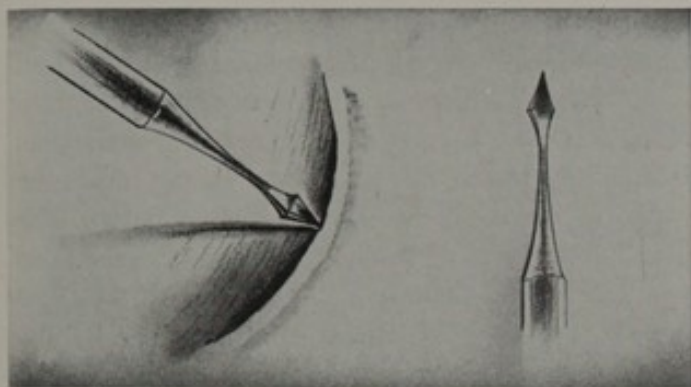


FIGURE 113.—Perforations are made in the outer border of the bony ledge with the perforator.

the bony ledge being made with the perforator (fig. 113). The tantalum wedges are tapped into position by the wedge director (fig. 114), in the same manner a glazier immobilizes a glass windowpane before applying putty about its border, and then turned over the edge of the plate. Ordinarily four to six wedges are sufficient for a plate. If tantalum screws are used, it is advisable to have perforations made along the edge of the plate to accommodate them.

The tantalum screws are very useful in the fixation of the tantalum plate in the onlay procedure. Often a combination of the onlay and inlay methods is desirable. In such instances, the inlay method is carried out at a location which might reveal an overlying plate, and the onlay method continued over the calvarium, where the plate would not be noticeable. In large defects over the calvarium, the onlay method, with the use of tantalum screws, allows a very rapid and satisfactory fixation of the plate that otherwise might be time consuming and tedious and without any significant justification.

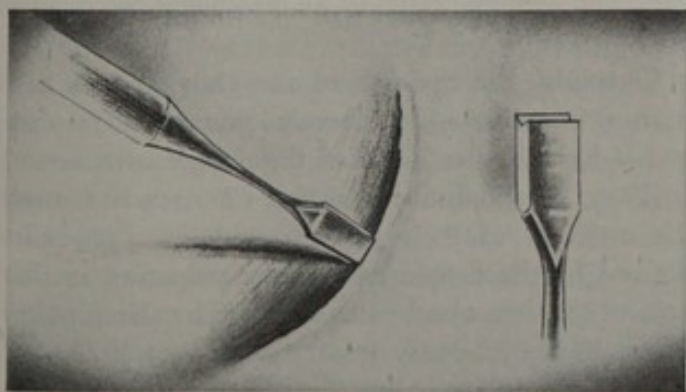


FIGURE 114.—Wedge director for tapping the tantalum wedges into position.

Vitallium (35) (36).—The most adaptable method of using Vitallium is that of employing Vitallium strips which come in stock lengths and widths with slight contouring quite suggestive of the split-rib graft. The use of the necessary number of strips will cover the majority of defects over the convexity.

Because Vitallium is not malleable, casts must be made from impressions obtained by either the direct or indirect method. In view of the satisfaction with tantalum and its malleability, this has not proved feasible. Fixation of the Vitallium has been best obtained with Vitallium screws.

Ticonium (37) (38).—The work done on Ticonium would indicate that its arrangement and contouring are similar to that already described for tantalum.

Nonmetallic grafts

The acrylic resins.—The direct or indirect method can be employed in the preparation of acrylic plates. Gurdjian, Webster, and Brown (13) have used this material by the indirect or primary method, the preparation being carried out in much the same manner used for the tantalum plate. The desired amount of acrylic is heated gently over a Bunsen burner until it is soft and pliable. It is then adapted to the outer surface of the mold. Holes are drilled into the edges for the purpose of fixing the graft into position by means of wire sutures.

Elkins and Cameron (20) have described the direct method they used. An impression of the bony defect is taken by inserting a sterile impression tray containing an inner coating of wax into the wound. The tray is removed, and if the impression is satisfactory, it is placed in a pan of cold water for hardening and sent to the dental laboratory. The retractors are removed from the incision, and a sterile dressing is applied to the wound without disturbing the drapes.

In the dental laboratory, the tray and its impression are then embedded in an ordinary dental stone in the lower half of a Pryor injector flask. After the stone has hardened, it is coated with silex. The upper half of the flask is filled with dental stone, and the halves are placed together. The lid of the flask is then placed in position, and the plunger is adjusted to the estimated top of the tray. The pressure plunger is removed after 5 minutes and the

halves of the flask are separated. The wax impression material is boiled out and the tray is removed, after which the impression matrix is lined with tin-foil and packed with acrylic resin in sufficient quantity for packing pressure and for an allowance of about 20-percent shrinkage. The top of the injector flask and the pressure plunger are reinserted, and the plunger screw is adjusted until the indicator is one-fourth inch above the housing. The flask is placed in boiling water for about 35 minutes for curing; in this process, the plunger screw will require several readjustments. After a cooling period of 10 minutes, the parts of the flask are separated, and the acrylic plate is removed for polishing. Several small holes are drilled around the edges of the plate for wiring, and two larger holes are perforated in the center for drainage. Cold solution sterilization is then carried out. Elkins and Cameron estimated that an average of about an hour and a half is required for completion of the procedure.

Either inlay plates the full thickness of the skull or onlay plates 2 to 3 mm. in thickness can be prepared by variations in the impression technique. Fixation of the onlay plate is preferably by screws.

Spence (21) has developed a method of rapidly repairing cranial defects in which the plastic material is molded into the cranial defect at the time of operation. The cranioplastic kit contains three vials of liquid monomer and three packages of powder polymer of methyl methacrylate together with the necessary polyethylene bags in which the mass is placed after mixing. The powder and liquid are sterile, but their containers together with the polyethylene bags must be soaked in cold sterilization prior to the operation. One unit of the powder and liquid is usually sufficient for most cranial defects.

After the preparation of the bony defect, the surgeon mixes one volume of liquid monomer to two volumes of powder polymer of methyl methacrylate, and when this has formed a doughy mass, it is dropped into a sterile polyethylene bag. This soft plastic is then rolled on a flat surface into the desired shape, with its thickness approximating the depth of the skull edges. A sterile test tube, syringe barrel, or other round object can be used although a stainless steel roller is preferred because of its weight and ease of operation.

The soft cranioplastic in the polyethylene bag is then placed over the skull defect, and by pressing

lightly with the end of the fingers, it is fitted into the missing skull area. The plastic bag is stretched by assistants as the surgeon molds the plate into the defect and forms an overlapping bevel edge. This is done to keep the plate from falling inside the skull. When the heat of combination begins, the plate is lifted out of the bony wound and removed from the polyethylene bag.

When the material is cool enough to handle, excesses are trimmed away with bone rongeurs or cut with a saw. A sterile carborundum wheel attached to an electric bone saw is also used to smooth the rough spots and to bevel the edges so that the plate will blend gradually with the skull. Screws or sutures of wire or silk may be used to hold the plate in position. Spence has indicated that mixing of the plastic and fitting of the plate requires about 5 to 10 minutes, hardening about 8 minutes, autoclaving about 5 minutes and, depending on the size of the plate, a total time of about 20 to 25 minutes.

CRANIOPLASTY

INDICATIONS

Grant and Norcross (1), in summarizing the indications for cranioplasty in their classical paper, included the following:

1. The revision of deforming and unsightly defects.
2. The danger of trauma at the site of the defect.
3. Pulsating or painful defects.
4. Headaches and other symptoms of the syndrome of the trephined, including discomfort at the site of the defect, a feeling of apprehension, dizziness, and intolerance to vibration.
5. The assumed relief of an associated convulsive state.

Certainly, the revision of unsightly defects has been productive of uniformly gratifying results, and it has likewise obviated the danger of trauma. In 1945, Woodhall and Spurling (29) reported that the majority of their patients with head wounds noticed localized tenderness upon palpation in the area of the defect and complained of localized pain, which had a tendency toward spontaneous resolution. Cranioplasty relieved these subjective complaints. Vertigo and generalized headache were less common symptoms and seemed unaffected by crani-

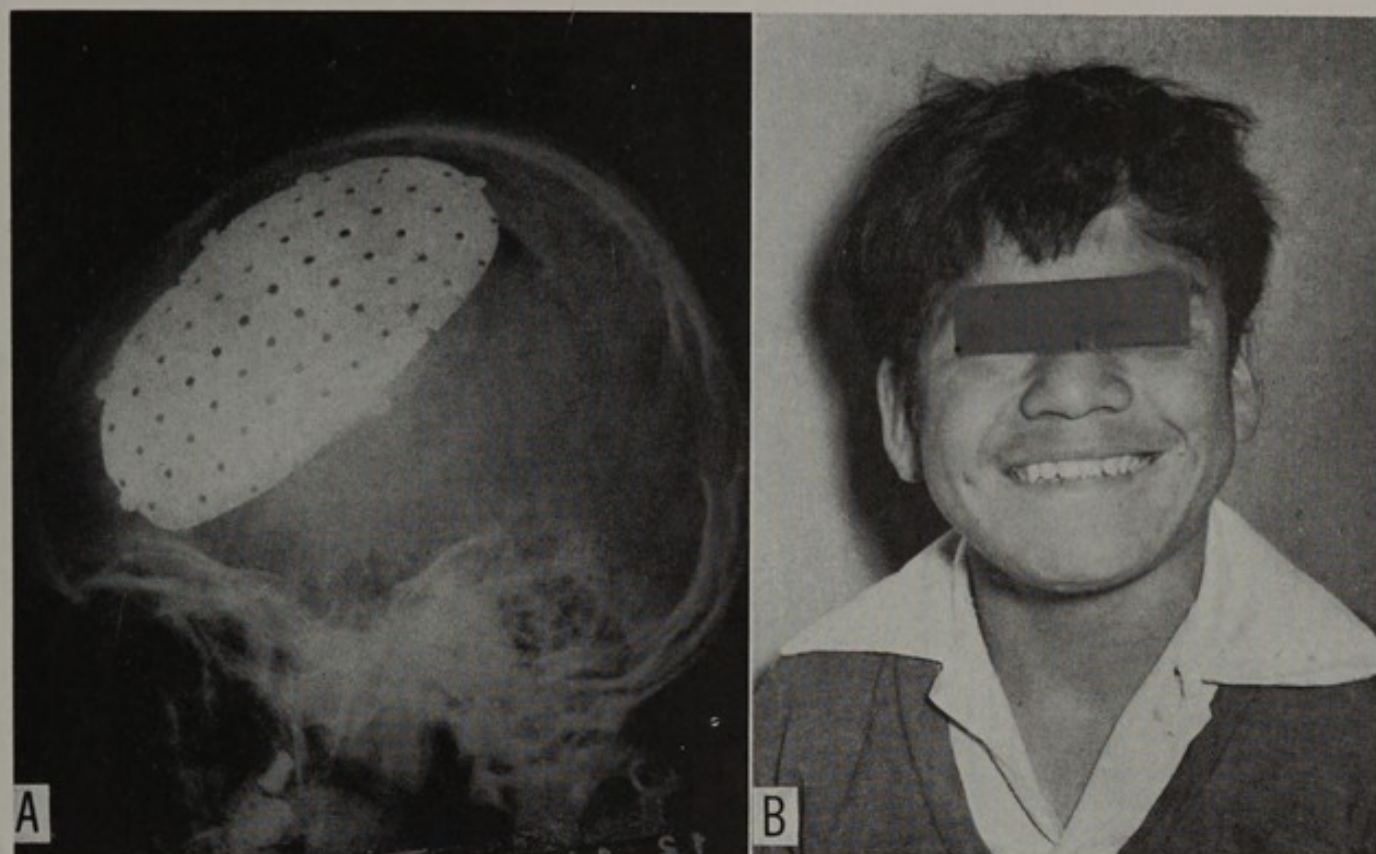


FIGURE 115.—A. Postoperative lateral roentgenogram showing tantalum cranioplasty of the congenital defect, 11 December 1946. The onlay method with tantalum screw fixation was used. B. Photograph of 11-year-old Mexican boy taken on 14 July 1947.

oplasty; in all probability, they represented sequelae of the cerebral injury. The most striking relief of a painful defect following tantalum cranioplasty occurred after repairing a large congenital defect of the left frontoparietal area overlying a porencephalic cyst in an 11-year-old Mexican boy with mental retardation and a right hemiparesis (fig. 115). Preoperatively, he would not allow palpation of the defect and complained of its tenderness. Postoperatively, he was relieved of his symptoms and had no objection to palpation of the scalp.

Grant and Norcross (1) noted that most surgeons who made any reference to epilepsy reported that a certain number of patients were either entirely relieved or improved. Nonetheless, they admitted there had been an insufficient number of accurate surveys to enable one to judge exactly the results of the operation. In a study of the effect of cranioplasty upon the electrical activity of the brain in 26 cases, Woodhall and Spurling (29) found no subsequent change in the character of the cortical electrical activity in 12. In 10, there was evidence of improvement in an abnormal electroencephalogram, and in

4, the abnormal activity became even more manifest with the development of epileptogenic foci.

Bradford and Livingston (39) did not believe that the cranial defect was the cause of convulsive seizures or that its repair would significantly alter the incidence of convulsions. This is the opinion generally accepted.

COMPLICATIONS

One of the complications influencing cranioplasty is the presence or absence of infection. As has been well pointed out by Bradford and Livingston (39), secondary intervention for tantalum plating in the presence of infection or immediately following wound healing cannot be justified on the basis of scattered successes. If frank infection has been present, it was their opinion that secondary operation to cover a cranial defect should be delayed for a minimum period of 3 months after primary healing. Campbell (33) and Meirowsky (40), as a result of experience in the Korean War, believe that cranioplasty should be delayed 6 months for all uncomplicated cases of penetrating craniocerebral

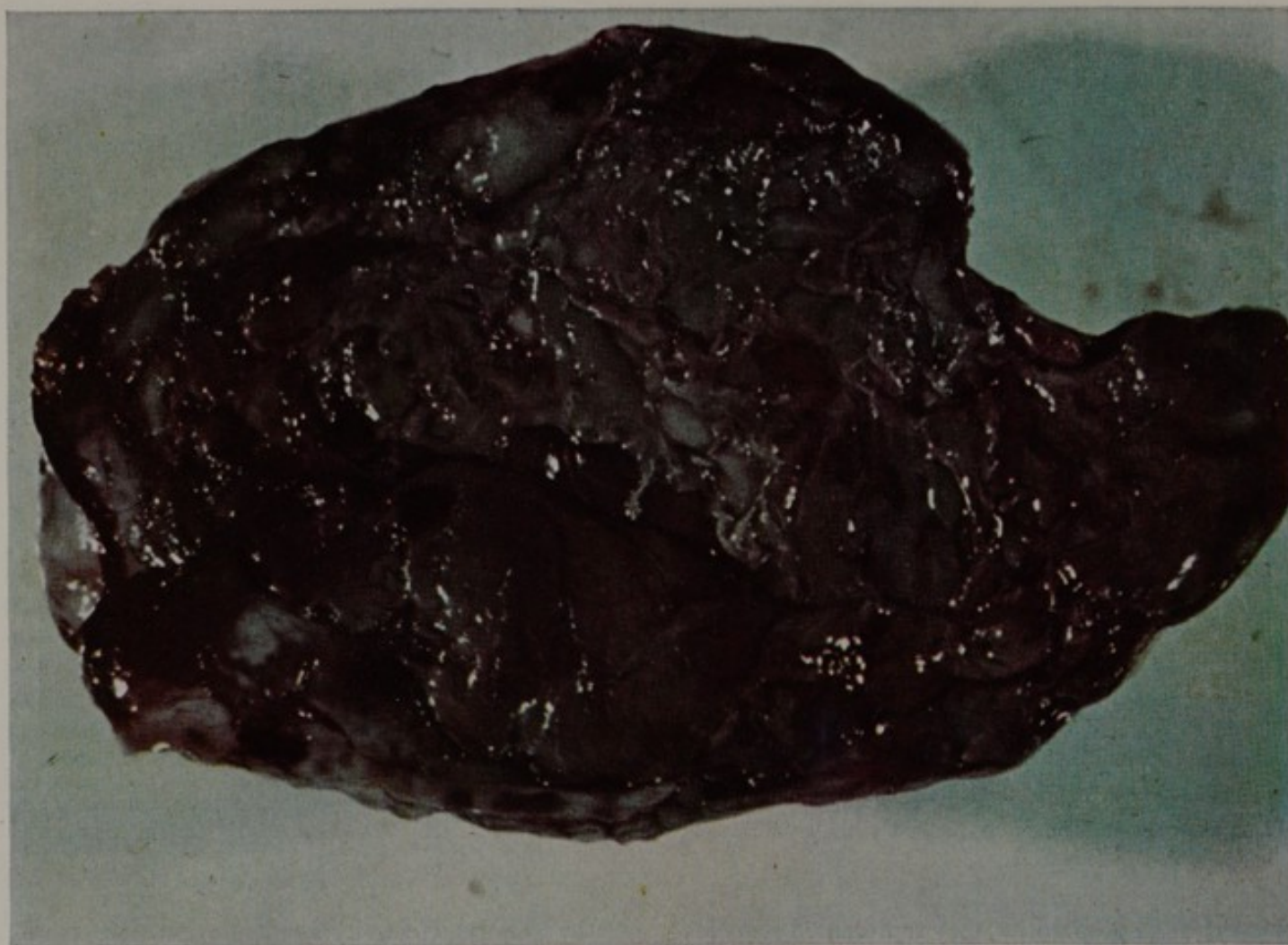


FIGURE 116.—Epidural granuloma removed from tantalum plate. (Photograph courtesy of Veterans' Administration Medical Teaching Group Hospital, Memphis, Tenn.)

trauma, from 9 to 12 months for cases involving the air sinuses, and 12 months after clearance of infection in all infected cases.

Bradford and Livingston (39) concluded that treatment of cerebral hernia should be directed toward that pathological process and not toward the mechanical blocking of the escaping cerebral mass. As has been appreciated by those working with this problem, complete coverage with good scalp is necessary for successful cranioplasty with tantalum, and that, if cranioplasty with tantalum is unsuccessful, the plate should be removed promptly.

Lane and Webster (41) surveyed some 115 Veterans' Administration hospitals and learned that 49 tantalum plates had been removed by April 1947. Moreover, it was their discovery that such conservative measures as aspiration, catheter drainage, and instillation of penicillin in the presence of an in-

fecting cranioplasty invariably failed and that success by such methods were but temporary. A continuing recurrence of infection finally required removal of the plate after which the wound healed. Such findings are entirely in accord with this author's experience. Lane and Webster also found that 50 percent of the removed plates had been inserted in the frontal area, and that in 35 percent of the total, the cranial defect involved the frontal sinuses.

In 1945, Woodhall and Cramer (42) reported two instances of extradural pneumatocele which were dependent upon a fistulous tract extending from the frontal sinus into the characteristic fibrous envelope that surrounds a tantalum plate after fixation in a skull defect.

Meirowsky (43) encountered 11 cases of epidural granulomas in the presence of tantalum plates necessitating their removal (figs. 116 and 117).

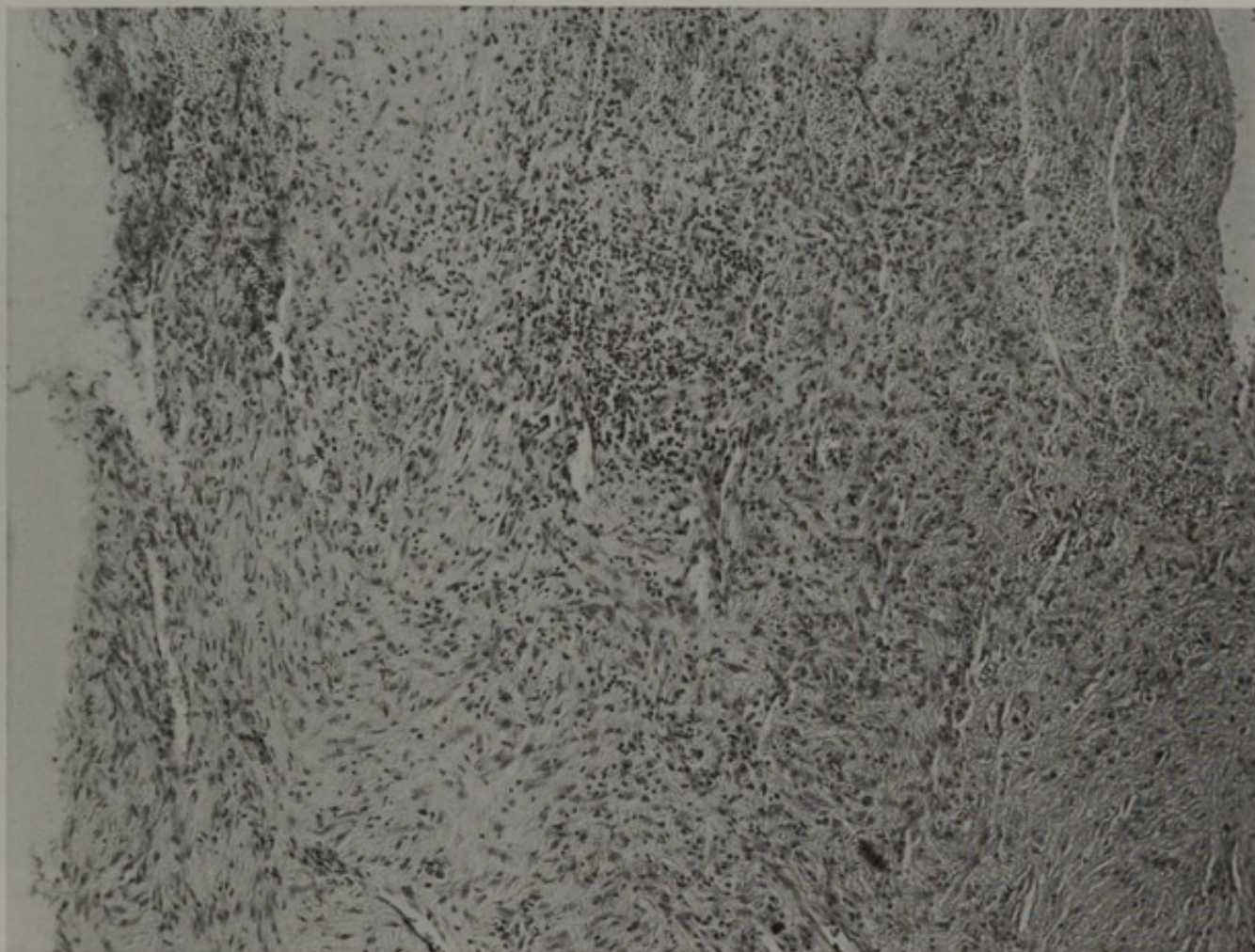


FIGURE 117.—Photomicrograph of epidural granuloma removed after tantalum cranioplasty. (Photograph courtesy of Veterans' Administration Medical Teaching Group Hospital, Memphis, Tenn., and the *Journal of Neurosurgery*.)

As a result of reviewing statistics from neurological surgeons in charge of neurosurgical centers in the Army and Navy during World War II, as well as those from Veterans' Administration hospitals, James C. White (cited by Reeves (3)) concluded that complications from plates made of tantalum, Vitallium, and Lucite occurred in practically the same proportion of cases. He also learned that thin, scarred, and inadequately vascularized scalp frequently broke down over a plate. The scalp not infrequently was found eroded by poorly fitted plates or those not securely fixed. He discovered the triangular metal wedges on occasion caused this complication whereas the screws were found superior. Plates perforated to allow underlying fluid exchange and better fixation proved superior to the unperforated plate. It was likewise discovered that

plates inserted over the frontal sinuses or mastoid areas usually had to be removed in the presence of acute infection or air leakage. In agreement with others, White concluded that primary repair was inadvisable, and in the presence of infection, plating should be deferred for at least 6 months or more.

From a review of the statistics, White saw no reason for returning to grafts with autogenous bone. He pointed out their difficulty of insertion and the fact that the cosmetic result after covering extensive defects or complicated repairs of the frontal bone was never as satisfactory. Additionally, after an apparently successful take, these grafts occasionally soften and lose their shape. White concluded that when the cranial defect involved the frontal sinus, however, a return to the use of grafts of living bone was recommended.

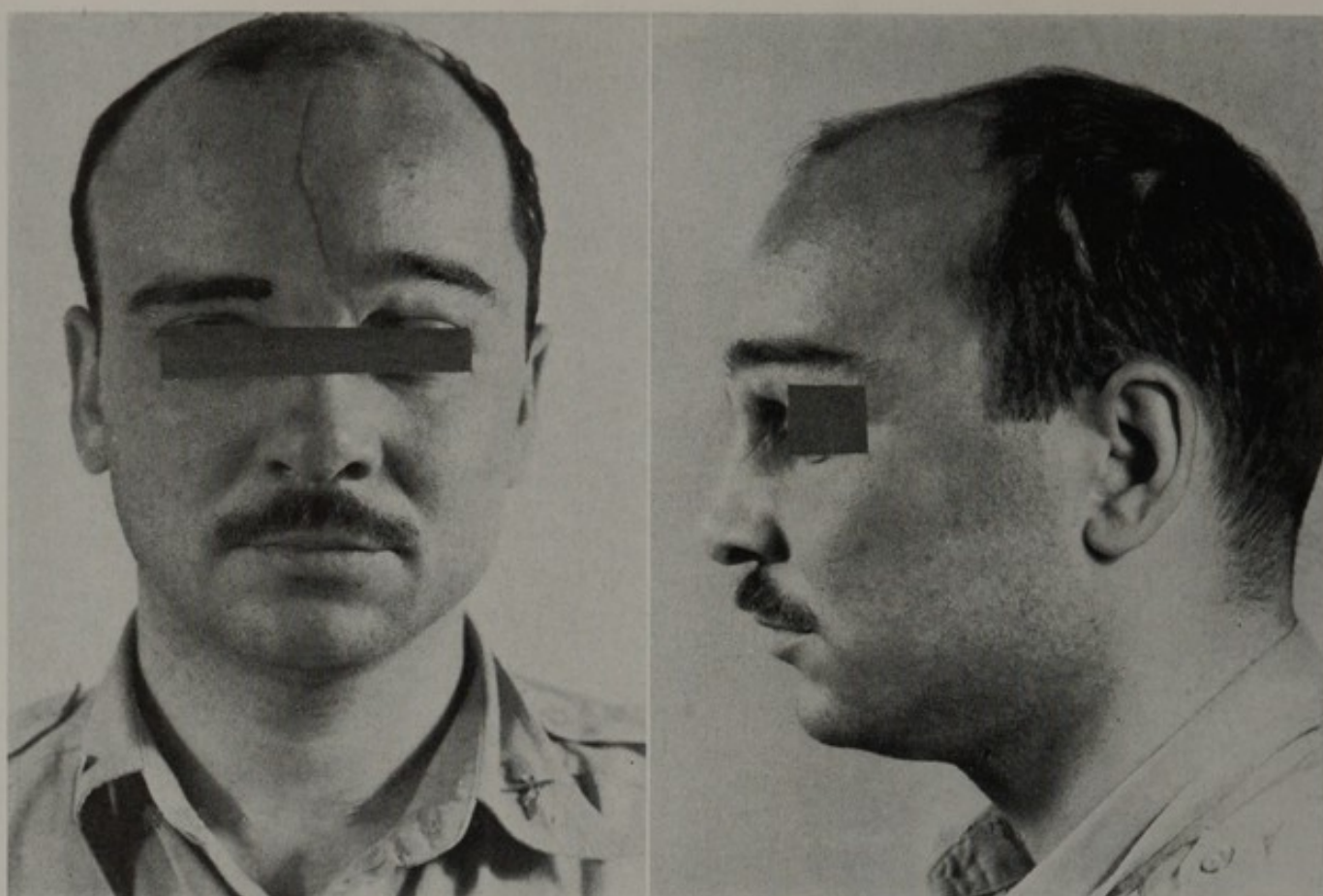


FIGURE 118.—Frontal and lateral photographs 7 months postoperatively.

ILLUSTRATIVE CASES

B.B.B., a second lieutenant in the Army Air Forces, was admitted to Hoff General Hospital, Santa Barbara, Calif., 21 September 1943, because of a large skull defect in the left frontoparietal region. He had been struck in the left naso-orbital region by a shell fragment from an anti-aircraft battery while acting as a navigator on a bombing mission, 13 June 1943, in an overseas theater of war. On his return to the base, depressed bone fragments, metallic fragments, and embedded pieces of his oxygen mask were removed from the wound. Later, he was returned to the United States for further treatment and observation.

The patient had a large frontoparietal cranial defect measuring 3 by 5 inches, with $1\frac{1}{2}$ inches of the left orbital bone destroyed. Redundant granulation tissue and slight drainage were noted in the left naso-orbital area of the incision as well as its posterior margin in the left temporal area. The patient said that these drainage areas often closed and then reopened. Fortunately, he had no aphasia or hemiparesis, but his memory was not good, and there was marked impairment of vision in the left eye. He also had anosmia.

Because of the redundant granulation tissue and roentgenographic evidence of retained foreign bodies, the old incision was reopened on 15 October 1943. The dense scar tissue overlying the skull defect was excised, and the an-

terior portion of the left frontal lobe explored with the removal of five small pieces of bone and one small piece of rubber which was a fragment of the patient's oxygen mask. A small piece of metallic fragment was also removed. Portions of devitalized and lacerated cerebral tissue in the anterior portion of the left frontal lobe were excised. At the time of operation, an outline of the skull defect was obtained with a piece of sterile cellophane. The patient's postoperative course was gratifyingly uneventful, and the wound healed without further drainage.

Roentgenograms taken on 31 October 1943 no longer revealed the presence of the bone fragments or the metallic fragment. The cranial defect was repaired on 23 February 1944. An accurate tantalum plate of the defect was prepared by means of impressions, molds, and models. When the skull defect was exposed, the scar tissue and dura had regenerated over the brain and were surprisingly normal in appearance. The tantalum plate was wired in place with tantalum wire. The patient's postoperative convalescence was uneventful and the cosmetic result good (fig. 118). The patient had developed Jacksonian convulsions which were fairly well controlled with anticonvulsive medication. An exact date of the onset of the convulsions was not obtained, but it was prior to his operations in the United States. This was one of our early cases, and at that time adequate appreciation of the technique of the direct or secondary method of cranioplasty had not occurred. The

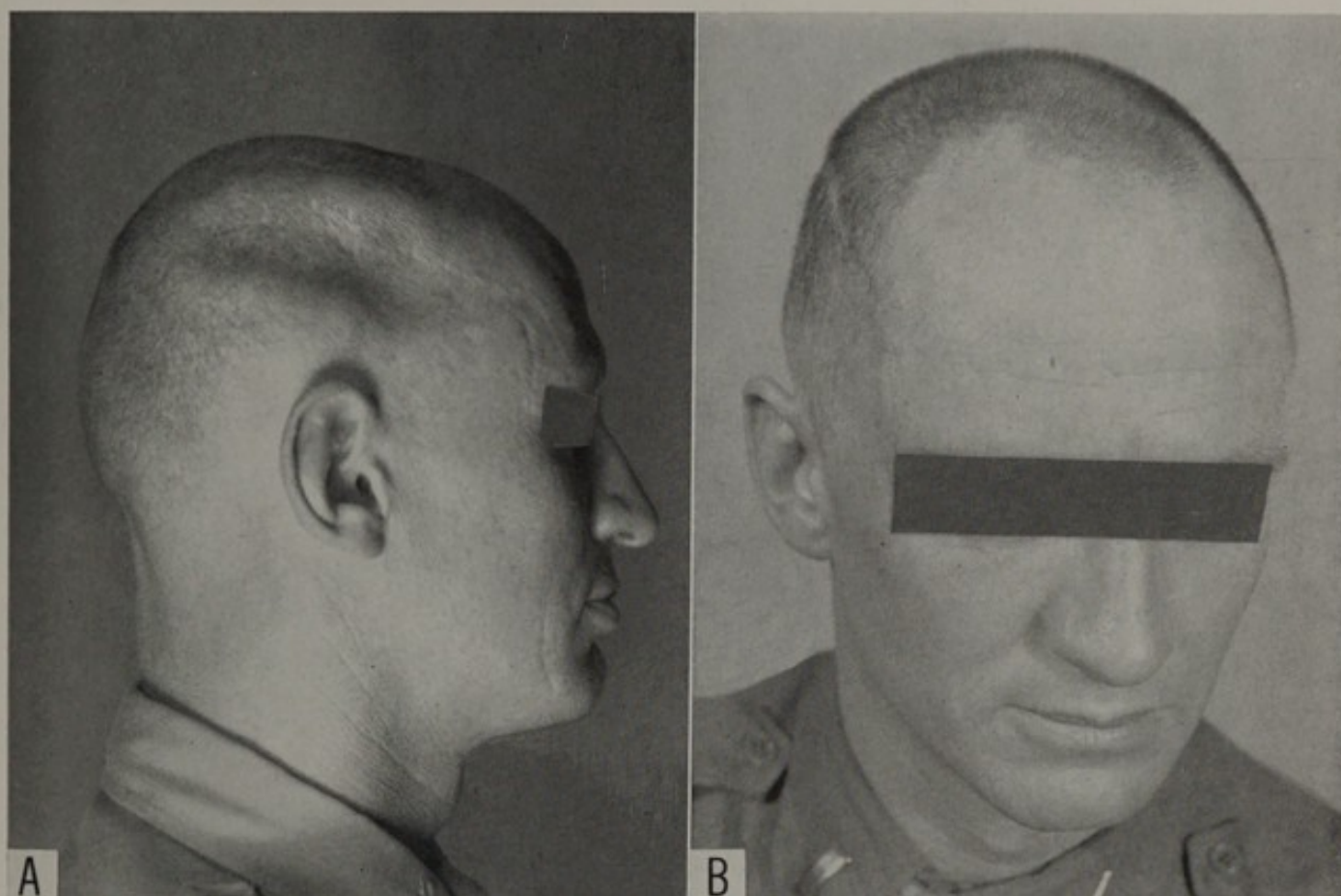


FIGURE 119.—A. Preoperative photograph showing large defect of the right side of the skull. B. Frontal view 15 days postoperatively.

patient was seen last on 3 November 1956. He has had difficulty adjusting to life and an occupation but has been well except for a convulsion every few months. On 1 February 1950, he fell, striking the area of the defect, but it remained intact in spite of a slight bend in its contour which, if anything, gave the involved area of the scalp a less artificial appearance.

R.A.A., a 34-year-old captain, sustained a skull defect of the right parietal region when that area was struck by machinegun bullets on 16 April 1945, in Germany, when the machinegun in the hands of an enlisted man accidentally discharged. This caused a severe, lacerating wound involving the scalp, skull, dura, and brain with an associated left hemiparesis and a compound, comminuted, fracture of the skull which led to the large skull deformity.

Roentgenograms of the skull revealed a right parietal deformity measuring 11 by 5 by 4 cm., with evidence of old fracture lines extending into the lateral border of the right orbit. A tantalum cranioplasty was completed on 16 October 1945 by means of the inlay technique along the upper portion of the plate and the onlay method elsewhere. Tantalum wedges were used for the fixation of the plate. The patient made an uneventful recovery, and the cosmetic result was satisfactory (fig. 119). He was last heard from in December 1958.

M.R.P., a 33-year-old sergeant, sustained a severe penetrating wound of the right frontoparietal region of the skull and brain as a result of an enemy shell fragment received on 14 November 1944, in Germany. There was an associated open comminuted fracture which resulted in a large residual skull defect (fig. 120 A). After debridement of the wound with removal of the bony fragments, 14 November 1944, at the 25th Evacuation Hospital, he ultimately was admitted to the Hammond General Hospital at Modesto, Calif., 29 January 1945. A left hemiparesis gradually improved. Roentgenograms demonstrated a skull defect in the right parietal area near the midline measuring 7 by 8 cm. (fig. 120 B and C). While at home on a furlough, the patient had a convulsive episode. A tantalum cranioplasty with the use of the onlay technique and fixation by means of tantalum wire was performed on 5 April 1945. The plate had been preformed by the indirect method and hammered out on the dental cement mold. His postoperative course was uneventful, and the cosmetic result satisfactory (fig. 120 D).

A letter from the patient dated 1 May 1947 revealed complete satisfaction with the cranioplasty. He said he was continuing to have occasional convulsive episodes.

W.B.G., a technician, fifth grade, was injured on 23 April 1944 near Anzio, Italy, when a Very pistol he was holding exploded in his face. This resulted in an open com-

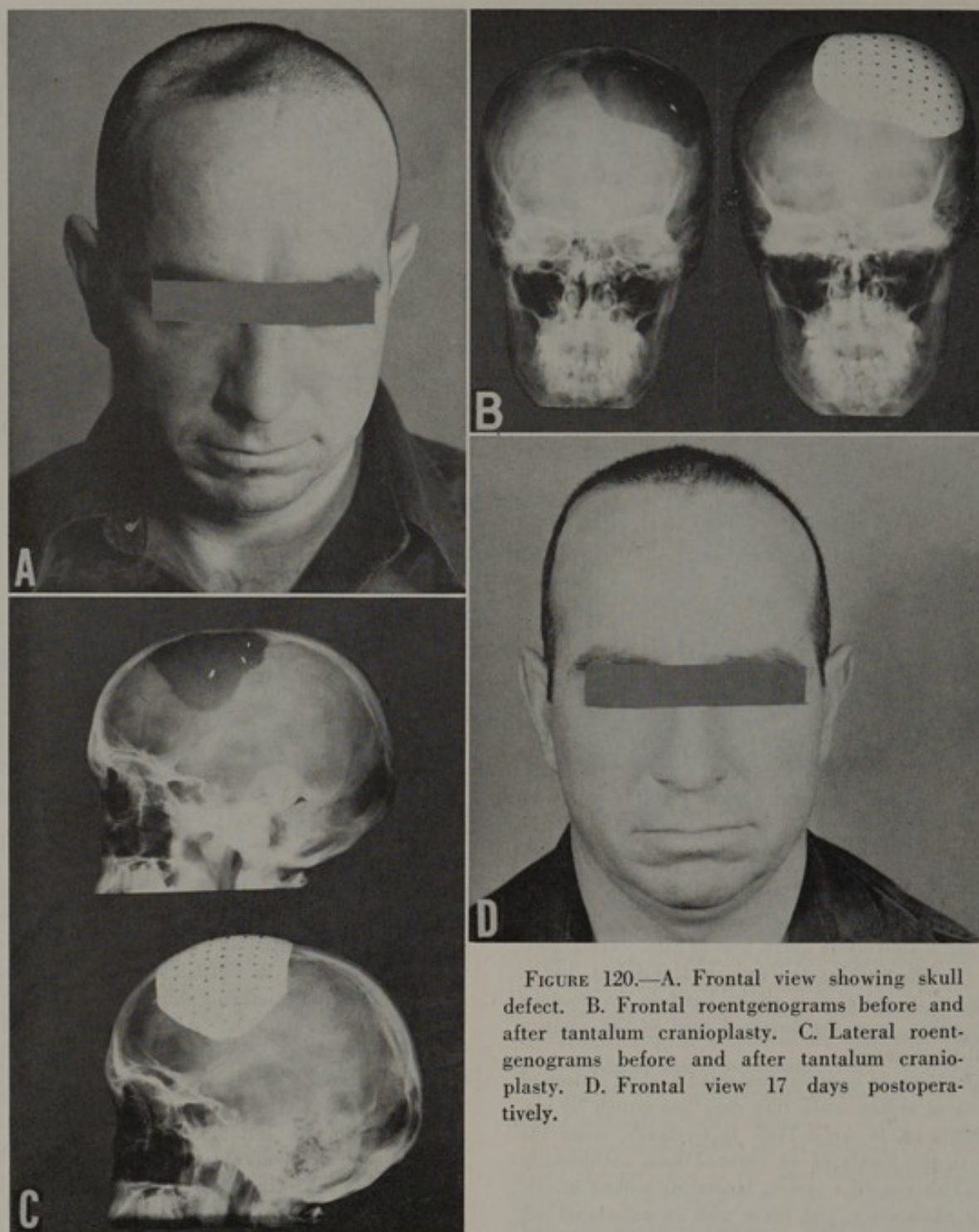


FIGURE 120.—A. Frontal view showing skull defect. B. Frontal roentgenograms before and after tantalum cranioplasty. C. Lateral roentgenograms before and after tantalum cranioplasty. D. Frontal view 17 days postoperatively.

minuted fracture of the left frontal bone with contusion and laceration of the underlying frontal lobe. He was operated on at the 38th Evacuation Hospital and then transferred to the 21st General Hospital. The patient was admitted to the Hammond General Hospital, Modesto, Calif., on 29 May 1945. Except for the skull defect in the left supra-orbital region (fig. 121 A), the examination failed to disclose anything noteworthy. When he returned from an oversea furlough, a cranioplasty with tantalum was carried out on 8 August 1945. The plate was inlaid and held in position by means of tantalum wedges. His course postoperatively was uneventful, and no comment concerning

convulsive episodes was included in the hospital discharge summary. The patient was given a certificate of disability for discharge in October 1945. Figure 121 B shows roentgenograms taken before and after cranioplasty, and figure 121 C and D show the cosmetic result 12 days postoperatively.

G.T., a private, was wounded in action by a rifle bullet in the left parietal region on 28 August 1944, in France. He received an open comminuted fracture of the left parietotemporal region with laceration of the underlying brain and an associated aphasia and right hemiplegia. Debridement was performed within 24 hours (fig. 122 A).

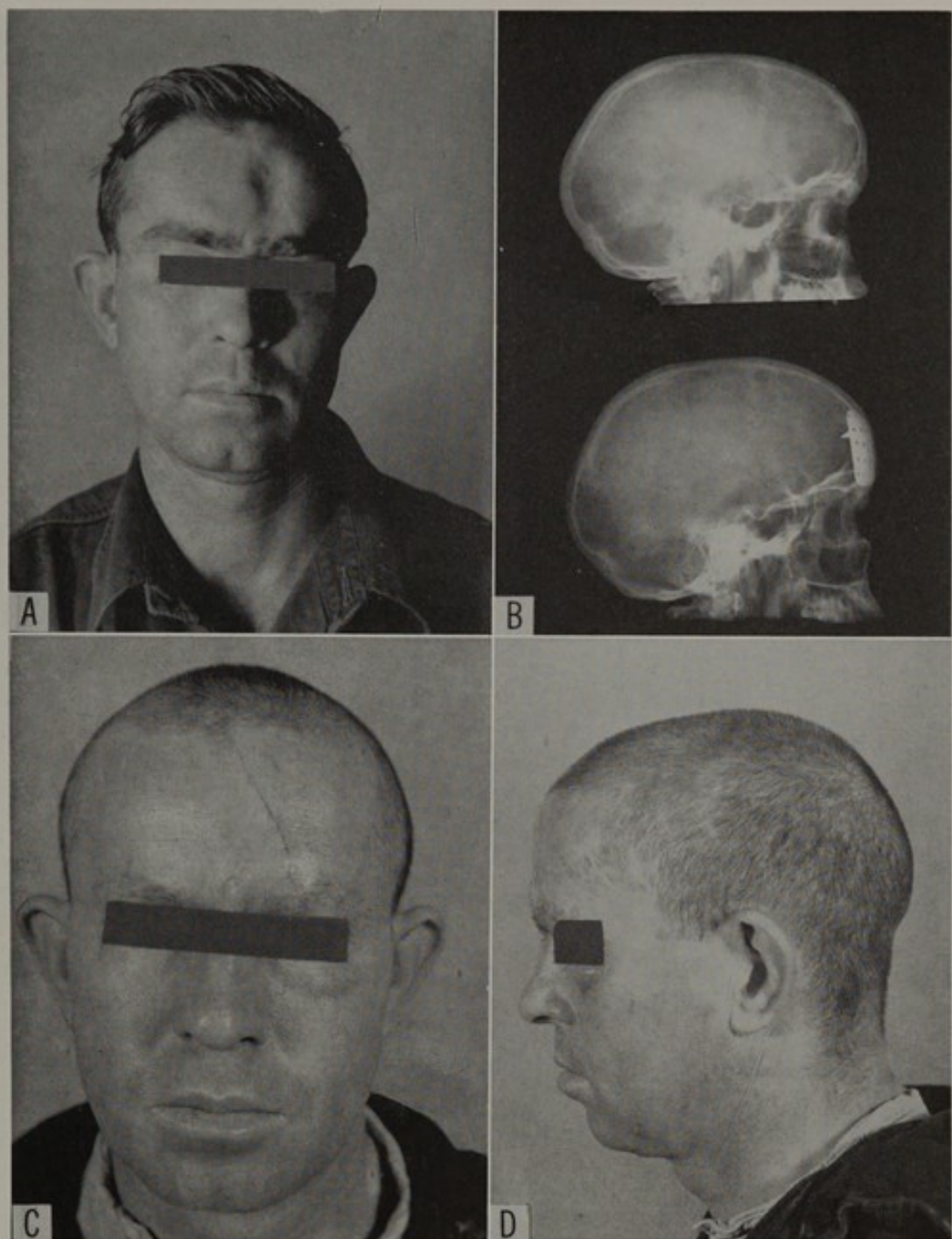


FIGURE 121.—A. Preoperative photograph showing defect of the left frontal region. B. Lateral roentgenograms before and after tantalum cranioplasty. C. Frontal view 12 days postoperatively. D. Lateral view 12 days postoperatively.

A tantalum cranioplasty was completed on 25 January 1945 by means of the onlay technique and fixation with tantalum wires. Preparation of the plate was by the indirect method and the employment of a basic dental cement mold (fig. 122 B). His postoperative course was uneventful. The hemiplegia partially improved, and progress with the aphasia was made with the aid of a speech training program (fig. 122 C).

E.L.F., sergeant, first class, sustained a deformity of the right fronto-orbital region with the loss of the right eye

as the result of an open comminuted depressed fracture of that area from a shell fragment wound incurred during combat in an overseas theater of operations (fig. 123 A and B).

A plastic repair of the defect was completed on 16 August 1945 by means of a tantalum plate, preformed by the indirect method and hammered out on the dental mold. The inlay technique with fixation by means of tantalum wedges was used. The patient recovered without incident, and a satisfactory cosmetic appearance resulted (fig. 123 C and

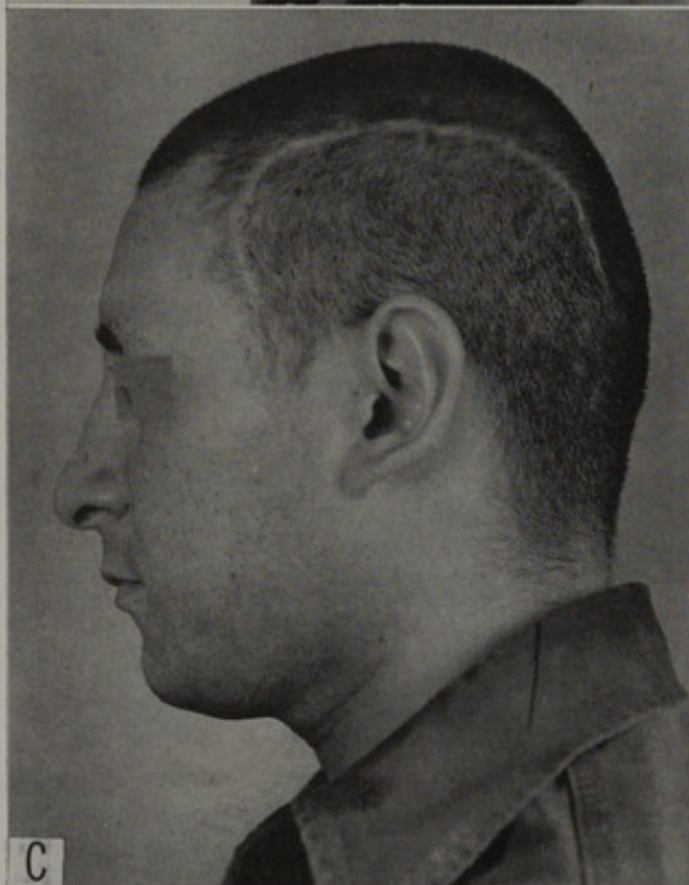
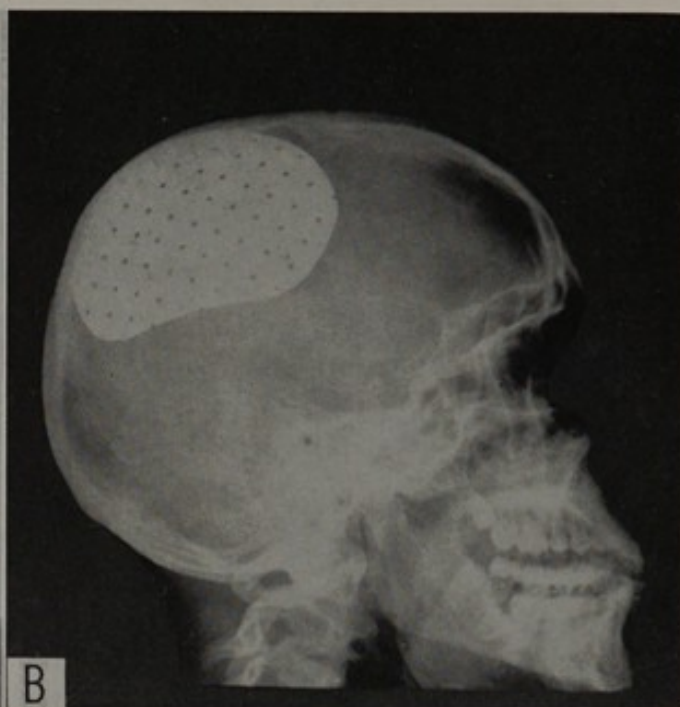
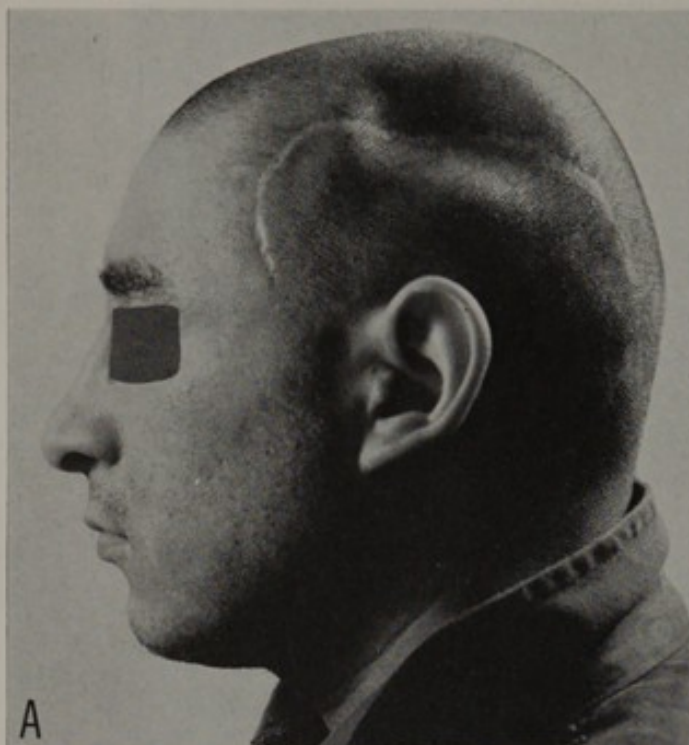


FIGURE 122.—A. Lateral photograph showing large skull defect. B. Lateral roentgenogram after tantalum cranioplasty. C. Lateral photograph after tantalum cranioplasty.

D). Subsequently, he was transferred elsewhere for completion of work on an artificial eye, and no further record was available.

V.E.H., technician, fifth grade, sustained a bomb fragment injury on 24 September 1943, in New Guinea, with a resultant open comminuted fracture of the skull and underlying laceration of the parasagittal region of the brain (fig. 124 A). Debridement was completed overseas. A tantalum cranioplasty with the inlay technique and fixation by means of tantalum wires was performed on 22 May 1944. The scalp overlying the defect was rather thin in two areas, but at this stage of experience with cranioplasty, the likelihood of pressure atrophy subsequently was not sufficiently appreciated. The plate was removed on 19 July 1944. Interestingly, the granulation tissue had filled in the dead space beneath the tantalum plate and also had filtered through the perforations in the plate, holding it firmly in position (fig. 124 B).

A second repair was attempted on 3 October 1944. Previously, it was believed skin grafting would be necessary. Eventually, the condition of the scalp improved sufficiently to make this seem unnecessary. The patient recovered uneventfully, and it appeared that the procedure was successful (fig. 124 C). Sometime prior to cranioplasty, the patient developed convulsive seizures. He received a certificate of disability for discharge on 18 January 1945, and about 1 month later, an area of necrosis in one of the thin areas of the scalp developed which necessitated his return to a veterans' hospital.

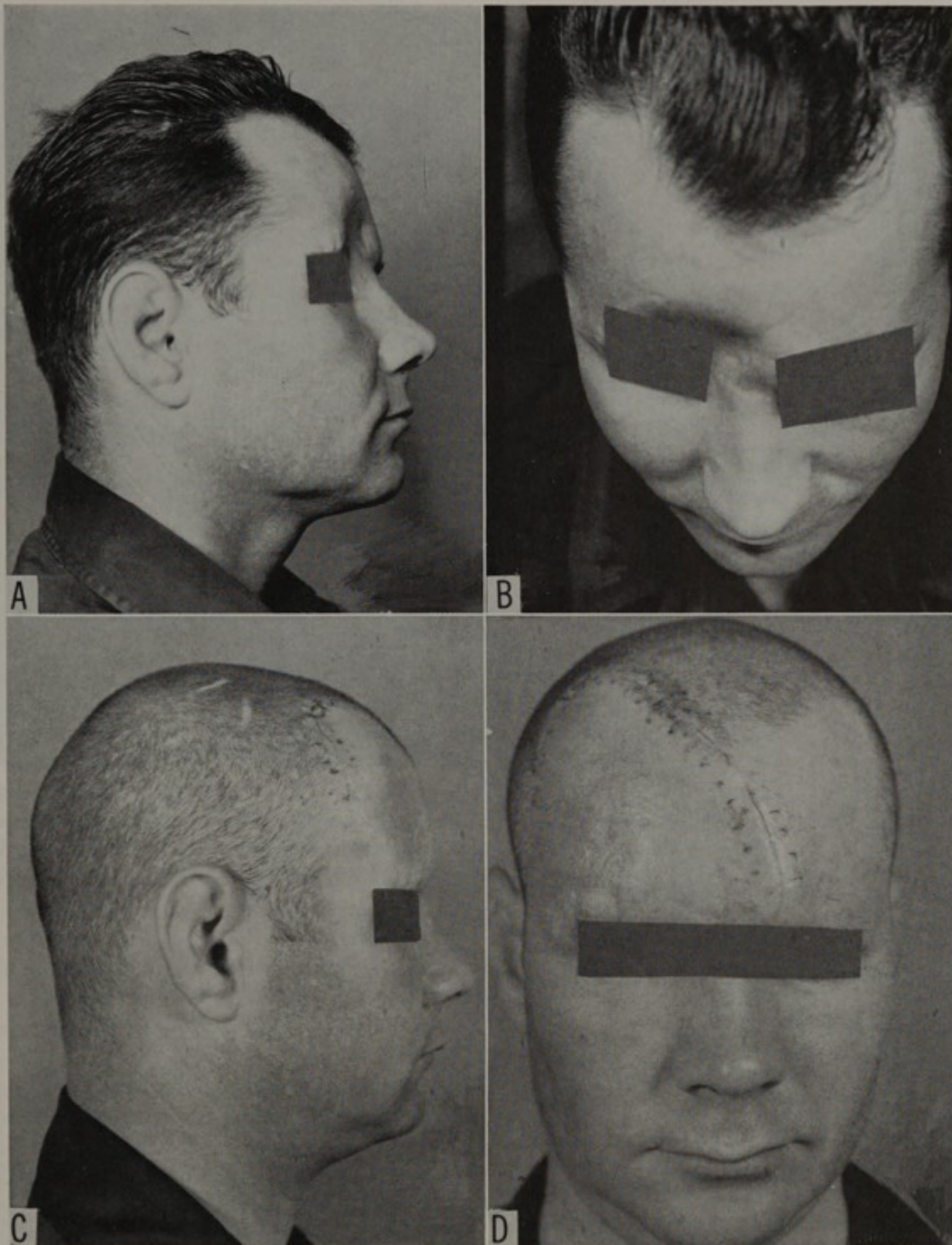

FIGURE 123.—A. Lateral view showing fronto-orbital defect of right side. B. Frontal view. C. Lateral view 8 days after tantalum cranioplasty. D. Frontal view 8 days postoperatively.

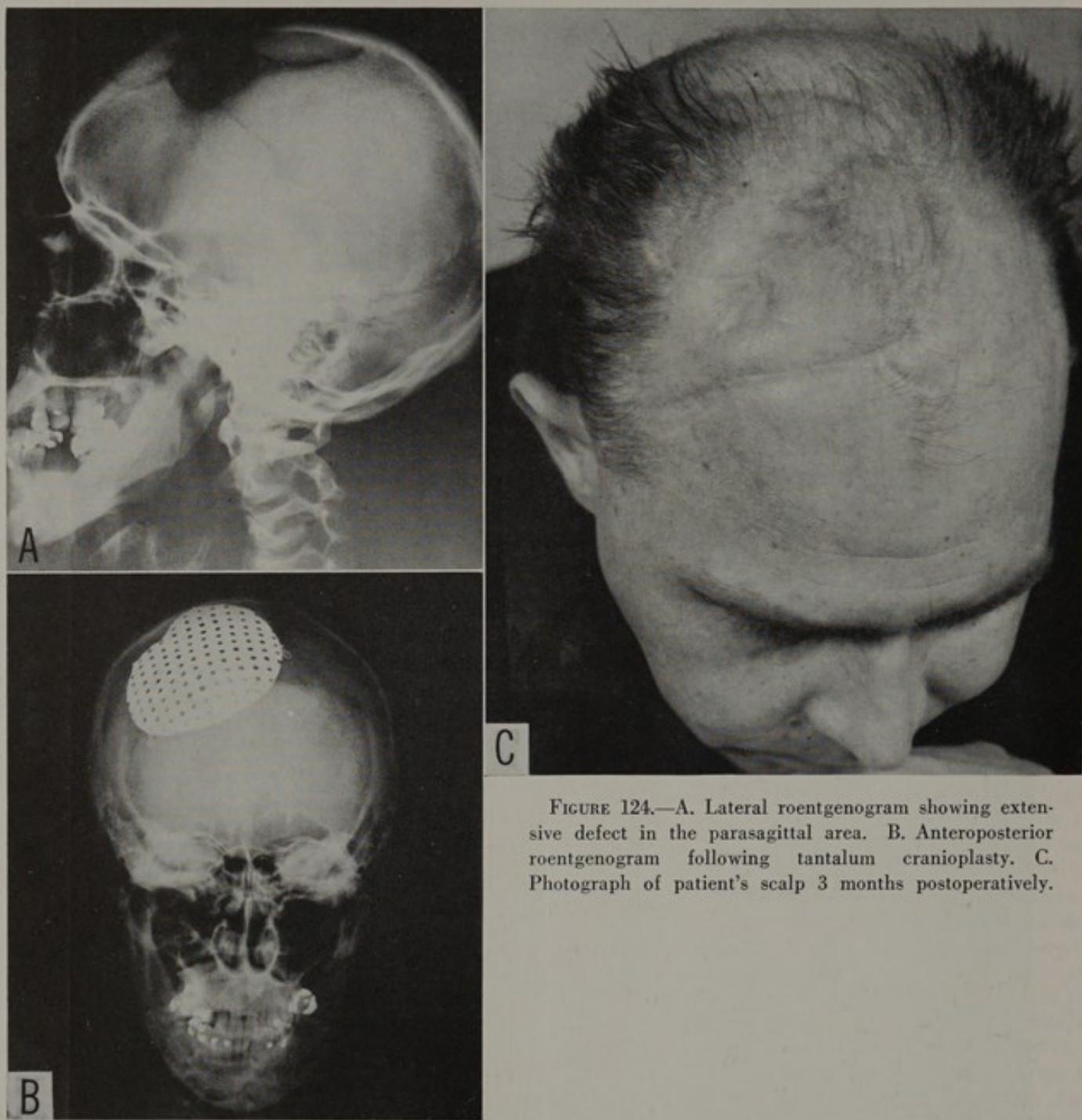


FIGURE 124.—A. Lateral roentgenogram showing extensive defect in the parasagittal area. B. Anteroposterior roentgenogram following tantalum cranioplasty. C. Photograph of patient's scalp 3 months postoperatively.

SUMMARY AND CONCLUSIONS

The increased number of cranial defects resulting from the casualties of war invariably stimulates interest in an intriguing subject which at other times is neglected. The experience concluded recently is no exception. A review of the literature reveals surprising success in the past with variable materials and methods.

Before the introduction of such alloplastic materials as Vitallium, Ticonium, and tantalum, it was

rather generally agreed that wherever possible an autogenous bone graft was the procedure of choice, and of these, outer table and rib grafts were preferred. Of the alloplastic materials employed prior to this time, the results obtained with the use of gold appeared to be superior to any of the others.

The recent experience with Vitallium, Ticonium, tantalum, and stainless steel, including tantalum and stainless steel wire mesh, leaves little justification for the use of other metallic materials unless newer metals with superior qualities are uncovered.

At the present time, most of those familiar with the subject consider tantalum the metal of choice for the repair of the larger defects. Acrylic plates have certain advantages in lacking the physical effects of temperature change and being inert to electric phenomena. Improvement in the technique of preparation of plates for repair of cranial defects has largely obviated the previous disadvantage of a more difficult preparation and has made their use more popular. Use of metal or acrylic will no doubt be determined to some extent by the personal choice of the operating surgeon who is more familiar with and enthusiastic about one than the other. Autogenous bone or cartilage continues to offer an adequate means for the repair of the smaller skull defects, particularly those involving the frontal sinuses and the region of the glabella.

A description of the operative technique for the various types of cranioplasty is given. Inasmuch as tantalum and acrylic were the two alloplastic materials most frequently employed by the armed services, the procedures necessary for their preparation and insertion were described and discussed in greater detail.

It has been agreed rather generally that the indications for cranioplasty include: (1) The revision of deforming and unsightly defects, (2) the danger of trauma at the site of the defect, (3) pulsating and painful defects, and (4) headaches and other symptoms of the syndrome of the trephined, including discomfort at the site of the defect. There has also been considered the relief of an associated convulsive state. It is believed, however, that the cranial defect is not the cause of convulsive seizures nor that its repair alters the incidence of them appreciably.

Among the complications influencing reparative surgery is that of infection. Secondary intervention for tantalum plating in the presence of infection or immediately following wound healing cannot be justified on the basis of scattered successes. It is believed still wise to consider a minimum delay of 6 months after primary healing before a secondary procedure to cover a cranial defect is performed and 12 months after healing if frank infection has been present. Complete coverage with good scalp is essential to successful tantalum cranioplasty, and unsuccessful tantalum plates should be removed promptly.

The soundness of the policies of complete debridement, repair of dural defects, and careful primary closure of lacerations was well established as a result of World War II, and had, of course, an important bearing on the time and success of cranioplasty (4).

Shell fragments, as might have been anticipated, represented the most frequent cause of the defect, suggesting a failure to survive the impact of the higher velocity missiles of rifle and machinegun fire.

The most frequently associated permanent neurological defect was that of hemiplegia.

Seven representative cases of tantalum cranioplasty of the traumatic variety have been presented from a total number of 196 which, except for a few operated upon in civilian practice, were under the author's supervision during military service at the neurosurgical centers of Hoff General Hospital, Santa Barbara, Calif., Birmingham General Hospital, Van Nuys, Calif., and Hammond General Hospital, Modesto, Calif.

The mortality and morbidity rates in cranioplasty with tantalum have been surprisingly low. No operative or postoperative deaths occurred in our series of 196 patients. The results of the procedure have been gratifyingly successful.

REFERENCES

1. Grant, F. C., and Norcross, N. C.: Repair of Cranial Defects by Cranioplasty. *Ann. Surg.* 110: 488-512, October 1939.
2. Woolf, J. I., and Walker, A. E.: Cranioplasty; Collective Review. *Internat. Abstr. Surg.* 81: 1-23, 1945; in *Surg., Gynec. & Obst.*, July 1945.
3. Reeves, David L.: Cranioplasty. American Lecture Series No. 39. American Lectures in Surgery. Springfield, Ill.: Charles C Thomas, 1950.
4. Reeves, David L.: Cranioplasty. In *Medical Department, United States Army. Surgery in World War II. Neurosurgery. Volume I.* Washington: U.S. Government Printing Office, 1958, pp. 261-278.
5. Müller, W.: Zur Frage der temporären Schädelresektion an Stelle der Trepanation. *Zentralbl. f. Chir.* 17 (No. 4): 65-66, January 1890.
6. König, F.: Der knöcherne Ersatz grosser Schädeldefekte. *Zentralbl. f. Chir.* 17 (No. 27): 497-501, July 1890.
7. Durante, Francesco: *Trattato di patologia e terapia chirurgica, generale e speciale.* Roma: Società editrice Dante Alighieri, vol. 3, 2d ed., 1904-06.
8. Keen, W. W.: Filling Defects of the Skull by Bone Chips From the Outer Table of the Neighboring Bone. *Ann. Surg.* 42: 296-298, July-December 1905.

9. Söhr, O.: Zur Technik der Schädelplastik. *Beitr. z. klin. Chir.* 55: 465-483, 1907.
10. Kappis, A.: Zur Deckung von Schädeldefekten. *Zentralbl. f. chir.* 42 (No. 51): 897-898, 18 Dec. 1915.
11. Brown, R. C.: The Repair of Skull Defects. *M.J. Australia* 2: 409-411, 17 Nov. 1917.
12. Macomber, D. W.: Reconstruction of Bony Defects of Face, With Special Reference to Cancellous Iliac Bone. *Surg., Gynec. & Obst.* 83: 761-766, December 1946.
13. Ray, B. S., and Parsons, H.: The Replacement of Free Bone Plates in Routine Craniotomies. *J. Neurosurg.* 4: 299-308, July 1947.
14. Odom, G. L., Woodhall, B., and Wrenn, F. R., Jr.: The Use of Refrigerated Autogenous Bone Flaps for Cranioplasty. *J. Neurosurg.* 9: 606-610, November 1952.
15. Bush, L. F.: The Use of Homogenous Bone Grafts; Preliminary Report on Bone Bank. *J. Bone & Joint Surg.* 29: 620-628, July 1947.
16. Fraenkel, A.: Ueber Deckung von Trepanationsdefecten am Schädel durch Heteroplastik. *Wien, klin. Wchnschr.* 3 (No. 25): 475-476, 19 June 1890.
17. Kleinschmidt, O.: Plexiglas zur Deckung von Schädel-lücken. *Chirurg.* 13: 273-277, 1 May 1941.
18. Gurdjian, E. S., Webster, J. E., and Brown, J. C.: Impression Technique for Reconstruction of Large Skull Defects. *Surgery* 14: 876-881, December 1943.
19. Shelden, C. H., Pudenz, R. H., Restarski, J. S., and Craig, W. M.: The Lucite Calvarium—A Method for Direct Observation of the Brain. I. The Surgical and Lucite Processing Techniques. *J. Neurosurg.* 1: 67-75, January 1944.
20. Elkins, C. W., and Cameron, J. E.: Cranioplasty With Acrylic Plates. *J. Neurosurg.* 3: 199-205, May 1946.
21. Spence, W. T.: Form-Fitting Plastic Cranioplasty. *J. Neurosurg.* 11: 219-225, May 1954.
22. Jackson, I. J., and Hoffmann, G. T.: Depressed Comminuted Fracture of a Plastic Cranioplasty. *J. Neurosurg.* 13: 116-117, January 1956.
23. Lluésma-Uranga, E.: Las filigranas de hilo de plata en cranioplastia. *Rev. de cir. de Barcelona* 11: 155-158, February 1936.
24. Boldrey, E.: Stainless Steel Wire-Mesh in the Repair of Small Cranial Defects. *Ann. Surg.* 121: 821-825, June 1945.
25. Seoville, W. B.: Discussion of Plastic Neurosurgical Procedures on the Scalp and Skull. Phoenix, Ariz., The American Academy of Neurological Surgery Meeting, 8-10 Nov. 1956.
26. Etter, H. S., Pudenz, R. H., and Gersh, I.: The Effects of Diathermy on Tissues Contiguous to Implanted Surgical Metals. *Arch. Phys. Med.* 28: 333-344, June 1947.
27. Lion, K. S.: The Effect of the Presence of Metals in Tissues Subjected to Diathermy Treatment. *Arch. Phys. Med.* 28: 345-347, June 1947.
28. Mayfield, F. H., and Levitch, L. A.: Repair of Cranial Defects With Tantalum. *Am. J. Surg.* 67: 319-332, February 1945.
29. Woodhall, B., and Spurling, R. G.: Tantalum Cranioplasty for War Wounds of the Skull. *Ann. Surg.* 121: 649-671, May 1945.
30. Hemberger, A. J., Whitcomb, B. B., and Woodhall, B.: Technic of Tantalum Plating of Skull Defects. *J. Neurosurg.* 2: 21-25, January 1945.
31. Woodhall, Barnes: Cranioplasty. In Bancroft, Frederic W., and Pilcher, Cobb (editors): *Surgical Treatment of the Nervous System*. Philadelphia: J. B. Lippincott Co., 1946, pp. 63-74.
32. Baker, G. S.: Cranioplasty With Tantalum Plate: A New Method of Forming the Plate Prior to Operation. *Proc. Staff Meet., Mayo Clin.* 21: 177-182, 1 May 1946.
33. Campbell, E. H.: Recent Notes on Wounds of the Brain and Spinal Cord. In *Symposium on Treatment of Trauma in the Armed Forces*, 10-12 Mar. 1952, Army Medical Service Graduate School, Walter Reed Army Medical Center, Washington, D.C.
34. Courville, C. B.: Some Notes on the History of Injury to the Skull and Brain. *Bull. Los Angeles Neurol. Soc.* 9: 1-16, March-June 1944.
35. Venable, C. S., and Stuck, W. G.: Three Years' Experience With Vitallium in Bone Surgery. *Ann. Surg.* 114: 309-315, August 1941.
36. Geib, F. W.: Vitallium Skull Plates. *J.A.M.A.* 117: 8-12, 5 July 1941. *Correction*, 117: 306, 26 July 1941.
37. Campbell, E., Meierowsky, A., and Hyde, G.: Studies on Use of Metals in Surgery; Comparative Determinations of Cytotoxicity of Certain Metals in Fibroblast Culture. *Ann. Surg.* 114: 472-479, September 1941.
38. Campbell, E. H., Meierowsky, A., and Tompkins, V.: Studies on Use of Metals in Surgery; Experiments on Use of Ticonium in Cranial Repair. *Ann. Surg.* 116: 763-775, November 1942.
39. Bradford, F. K., and Livingston, K. E.: Failure in Early Secondary Repair of Skull Defects With Tantalum. *J. Neurosurg.* 3: 318-328, July 1946.
40. Meierowsky, A. M.: Penetrating Craniocerebral Trauma; Observations in Korean War. *J.A.M.A.* 154: 666-669, 20 Feb. 1954.
41. Lane, S., and Webster, J. E.: A Report of the Early Results in Tantalum Cranioplasty. *J. Neurosurg.* 4: 526-529, November 1947.
42. Woodhall, B., and Cramer, F. J.: Extradural Pneumatocele Following Tantalum Cranioplasty. *J. Neurosurg.* 2: 524-529, November 1945.
43. Meierowsky, A. M., Hazouri, L. A., and Greiner, D. J.: Epidural Granulomata in the Presence of Tantalum Plates. *J. Neurosurg.* 7: 485-491, November 1950.

Posttraumatic Epilepsy

CHAPTER 21

Clinical Manifestations

William F. Caveness

INTRODUCTION

One of the most dramatic and often most troublesome sequela of head trauma is epilepsy. Recognized by Hippocrates and feared through the ages, it is not yet fully understood. The purpose of this chapter is to outline the useful existing clinical knowledge and report in part the findings from the Korean War.¹

INCIDENCE

The reported incidence of posttraumatic epilepsy has been influenced by the definition of injury, recognition of seizures, adequacy and length of followup, and character of the sample. The range in young adult males from the Armed Forces is represented in the studies from World Wars I and II and the Korean War (1) (2) (3) (4) (table 27).

DEGREE OF INJURY

Of primary consideration in the development of posttraumatic epilepsy is the severity of injury. As a measure of severity, head trauma has traditionally been separated into closed and penetrating injuries, with the dura mater usually the line of demarcation. Ascroft (2) found epilepsy in 23 percent of those

TABLE 27.—*Posttraumatic epilepsy studies and period of followup*

Author	Number of men	Number with fits	Percent with fits	Period of followup (years)
World War I:				
Credner ¹	1,990	775	38.0	10-14
Ascroft ²	317	107	34.0	7-20
World War II:				
Walker and Jablon	739	207	28.0	6-9
Korean War:				
Caveness and Liss	407	97	23.8	5

¹ German study.

² British study.

with injury to the scalp and skull with the dura intact. It is of interest that almost one-third of these had focal signs. With penetration of the dura, the incidence rose to 45 percent. At the Head Injury Advice Bureau, Oxford, England, in a followup study of 500 men whose injury had left the dura intact, Phillips (5) found epilepsy in 6 percent. Russell and Whitty (6), at the same facility, found epilepsy in 43 percent of 820 men with the dura penetrated. Walker and Jablon (3), following U.S. Army personnel, have found epilepsy in 14.2 percent of those without and in 35.8 percent of those with dural penetration. In the present study of U.S. Navy and Marine Corps casualties, 15.7 percent with closed head injuries and 40.3 per-

¹ Combat Head Injury Project, Follow-Up Phase, Columbia University, New York, N.Y., sponsored by the Office of Naval Research, Nonr 266 (26): A Study of Head Injuries Incurred by U.S. Navy and Marine Corps Personnel During the Korean War.

cent with penetrating head injuries have developed seizures in the first 5 years following injury.

The authors just mentioned have recognized that the figures for closed head injuries may be weighted by depressed fractures, focal signs, and other indications of underlying brain damage. Further, the

penetrating injuries may afford a higher incidence when there are retained foreign bodies, significant hemorrhage, or infection. These each reflect a greater degree of brain damage. Intracerebral hemorrhage and brain abscess probably warrant added consideration, as Kaplan (7) has shown a

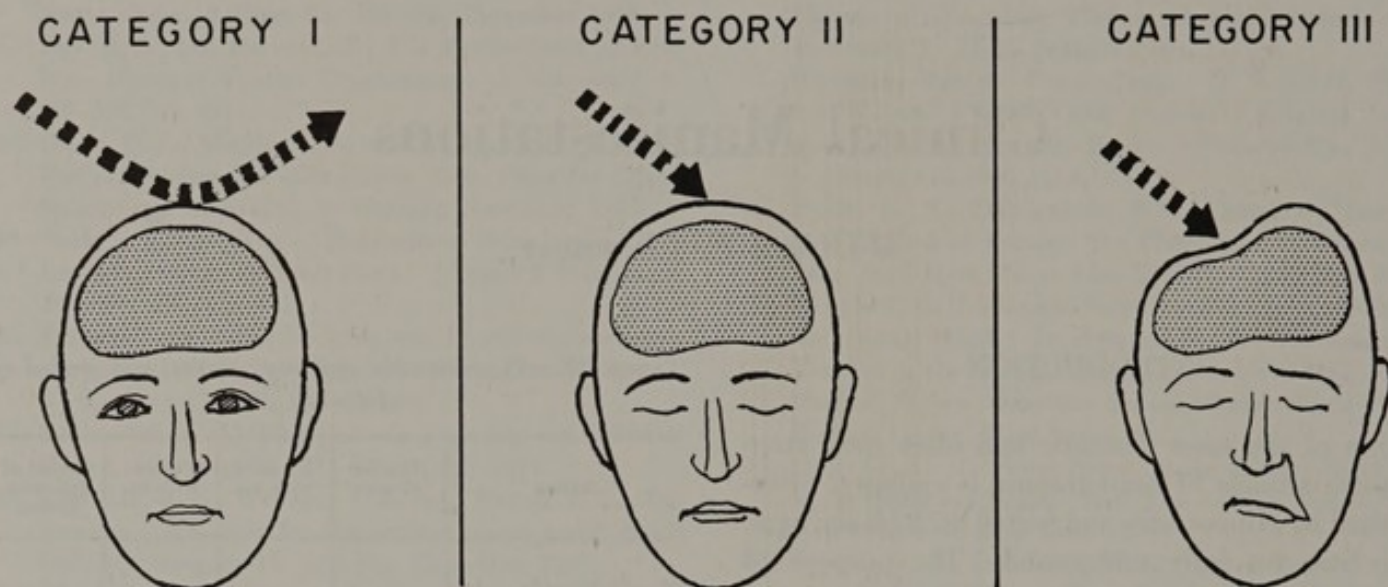


FIGURE 125.—Closed head injuries. *Category I.* Blow to head without apparent neurological significance. No unconsciousness. Confusion is permitted. *Category II.* Blow to head with concussion. Four subcategories, including loss of consciousness up to 12 hours. Complete recovery is assumed. Minimal transient neurological signs are permitted. *Category III.* Blow to head without penetration of dura but with overt evidence of underlying damage to brain. Revealed by direct inspection or reflected by neurological deficit. Loss of consciousness may be present up to or beyond 12 hours.

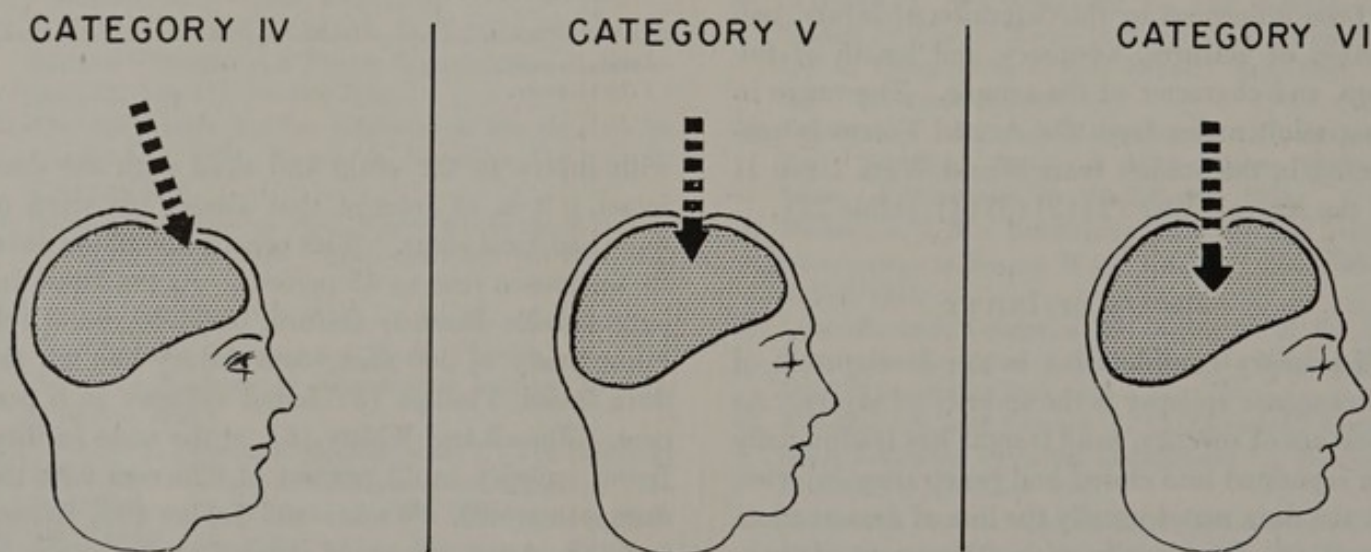


FIGURE 126.—Penetrating head injuries. *Category IV.* Dural penetration with no loss in consciousness and no overt neurological deficit. Penetration is substantiated by direct inspection or by laboratory findings. *Category V.* Dural penetration with evident neurological deficit. Concussion may or may not be an accompaniment. *Category VI.* Dural and brain penetration of profound degree or with significant complications. Ventricular involvement. Brain stem involvement. Perforation. Appreciable epidural, subdural, or intracerebral hemorrhage. Retained foreign bodies. Meningitis, abscess. Prolonged coma.

30-percent incidence of seizures in spontaneous intracerebral hemorrhage and Jooma and his associates (8) have shown an incidence of 50 percent in brain abscess unrelated to trauma.

In an attempt to subdivide injuries into degrees of brain damage, without and with penetration of the dura, the criteria indicated in figures 125 and 126 have been set up. These six categories are arbitrary and not exactly graded, but they are relatively easy to recognize and may further clarify the relation of severity of brain damage to seizure development.

When the Korean War veterans under study are

TABLE 28.—Fits in relation to mode of injury, Korean War veterans

Category of injury	Number of men	Number with fits	Percent with fits
Closed head injuries:			
Category I.....	70	6	8.6
II.....	117	14	12.0
III.....	86	23	26.7
Penetrating head injuries:			
Category IV.....	23	4	17.4
V.....	38	13	34.2
VI.....	73	37	50.7

placed in the six categories, the sequela of epilepsy is seen in the relation shown in table 28.

With the kind permission of Walker and Jablon, their figures from World War II veterans have been cast into the same six categories (table 29), insofar as their data permitted it, and therefore do not agree with the total figures presented in table 27.

A more direct comparison of the two sets of figures is afforded by figure 127. Of interest is the small but not inconsequential incidence in the mildest injuries, category I. There is a striking similarity in the most severe of the closed and in the most severe of the penetrating injuries, one-quarter of category III

TABLE 29.—Fits in relation to mode of injury, World War II veterans

Category of injury	Number of men	Number with fits	Percent with fits
Closed head injuries:			
Category I.....	60	4	6.7
II.....	143	25	17.5
III.....	60	15	25.0
Penetrating head injuries:			
Category IV.....	31	9	29.0
V.....	199	72	36.2
VI.....	133	68	51.1

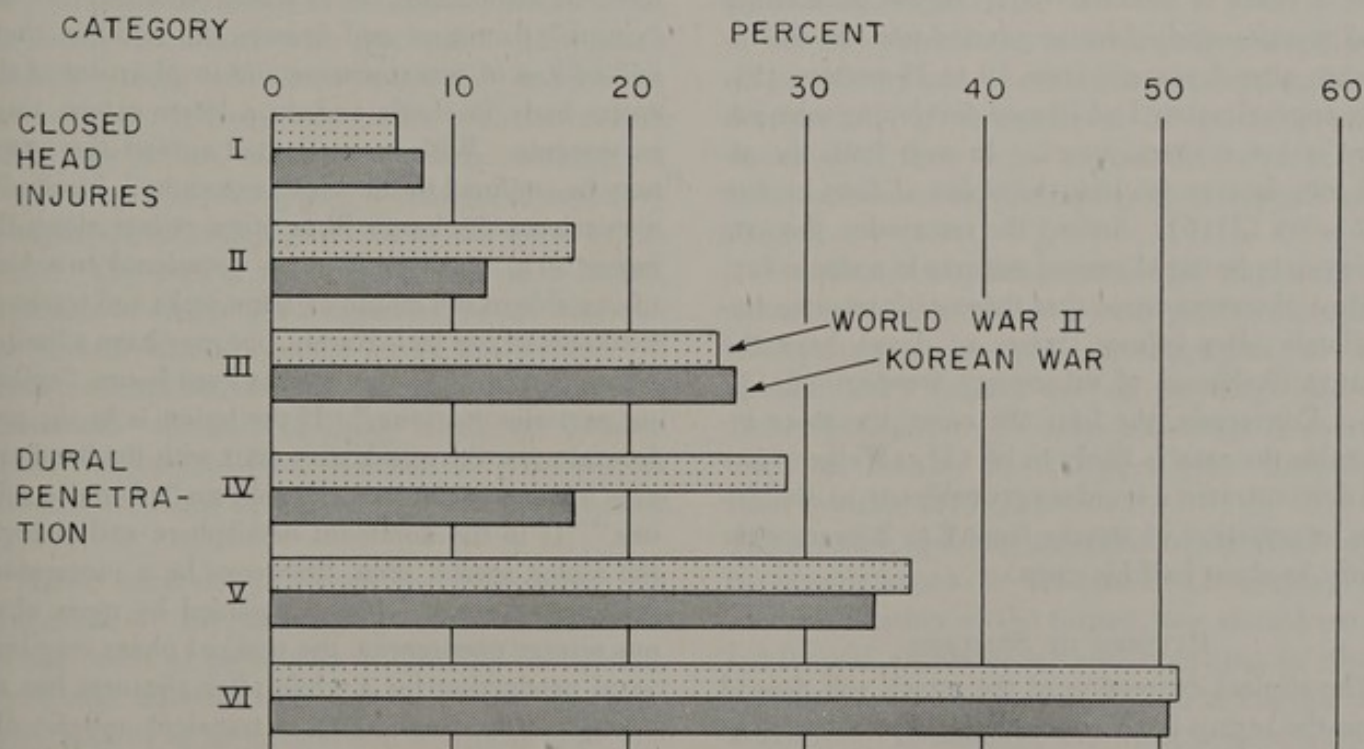


FIGURE 127.—Incidence of posttraumatic epilepsy in World War II and Korean War veterans according to category of injury.

and one-half of category VI in both series having developed seizures.

SITE OF INJURY

The complexity of forces acting upon the brain when the head is struck makes it difficult to adjudge the exact location and extent of injury playing a part in the subsequent fits. It is probably more widespread than formerly thought. If one considers the site of initial entry in penetrating head injuries of limited depth, it is apparent that any part of the brain may yield fits, but the incidence is greater in the central region than at either pole (3) (6). This may be due in part to the easier recognition of focal fits from the sensorimotor cortex.

ONSET, FREQUENCY, AND CESSATION OF SEIZURES

The highest incidence is within the first few months of injury. This is followed by a sharp decline and, with minor fluctuations, a low incidence over many years. The time gradient of men developing fits is roughly from 50 to 60 percent in the first 6 months, 70 to 75 percent in the first year, 15 to 20 percent in the second year, and from 1 to 4 percent in subsequent years (2) (3) (6). In closed head injuries, the peak in onset is earlier, within the first 3 months; the decline is sharper; and the onset after 5 years is minimal (5). In the penetrating head injuries studied for protracted periods, the incidence after 5 years is from 10 to 15 percent (9).

In approximately 1 of 10 men developing seizures, there is but a single attack. In over half, the attack rate is very low, on the order of four or five in 2 years (3) (6). Among the remainder, the rate varies up to bursts of several seizures in a single day.

Most observers agree that those with seizures immediately after injury (hours or days) have the greatest likelihood of subsequent freedom (2) (3) (6). Conversely, the later the onset, the more intractable the case is likely to be (5). Walker (10) has demonstrated a spontaneous tendency to diminution or cessation of attacks from 2 to 3 years after injury in about half his cases.

PATTERN OF SEIZURES

The clinical expression of the attack will depend upon the region from which the epileptic discharge is originating, plus the rapidity and extent of its spread. From this, it is evident that a wide variety

of seizures is possible. A few more usual examples will be described in order of their recognition.

Major generalized seizures.—Major generalized seizures occur in well over half the cases (3) (6). An even greater proportion is found in closed head injuries alone (5). The seizure may be heralded by a cry or a blank stare. The body stiffens, falls, and jerks rhythmically, though not always symmetrically, for a minute or more. The face is suffused, breathing noisy. The tongue may be bitten or sphincter control lost. The movements subside. Coma gives way to sleep or confusion and finally full awareness. A "warning" is recalled by some of the patients, the major portion of the fit by none. The aftermath usually includes headache, drowsiness, fatigue, or aching muscles, particularly of the back. The appearance of these convulsions prompts the designation "grand mal." One surmises that the discharging lesion is close to the midline or if near the cortex it is capable of bringing about sudden widespread and massive excitation in a manner that obscures focal phenomena.

Focal motor seizures.—Focal motor seizures may present a typical "Jacksonian" fit. Given a discharging lesion in the hand area of the motor cortex, the attack may begin with rhythmic movements of the contralateral thumb, with progressive involvement of hand, arm, face, trunk, and leg. If the "march" continues and crosses the midline, there will be loss of consciousness and involvement of the entire body in clonic and, to a lesser extent, tonic movements. With more limited spread the attack may be confined to the upper extremity. Similarly, a restricted discharge from other points along the motor strip may result in an occasional twitching of one side of the mouth or a few jerks and transient weakness of one leg. Rarely, one may have a limited attack persisting for minutes or even hours, "epilepsia partialis continua." If the lesion is in the prefrontal area, the attack may start with the head and eyes turning to the opposite side, an "adversive seizure." If in the dominant hemisphere and close to the motor speech area, there can be a momentary inability to speak. If accompanied by more obvious seizure phenomena, the postictal phase may lack word production for a while after alertness has returned. Other, more subtle, transient aphasic difficulties may arise from discharging lesions in the temporal or parietal lobes.

Focal sensory seizures.—Focal sensory seizures from the sensory cortex may follow the pattern of Jacksonian seizures with aberrant sensation in place of abnormal movements. The rate of spread is usually faster than that in the focal motor attacks. There may be a tingling or numbness in a limb (simulating impaired circulation), a sensation of warmth or cold, or of wind blowing over a part, or a strange sense that a member is shriveling. Attacks arising from the occipital lobe may be experienced by the patient as flashing lights, balls of color, or other crudely formed visual phenomena. There may be an unpleasant smell or, uncommonly, a whirring noise from lesions in the uncinate and superior temporal gyri, respectively. There may be admixtures of the preceding focal motor and sensory seizures and any may progress to a generalized seizure. These local, spreading, and admixed attacks are found in about one-third of the cases.

Psychomotor seizures.—Psychomotor seizures arise from a discharge mainly within the temporal lobe or lobes. Rarely is the spread sufficient to cause a generalized seizure. Clinically, psychomotor attacks may begin with altered perception of the environment. Objects or sounds will seem too distant or the converse, a place too familiar or the opposite. There may be formed visual or auditory patterns unrelated to the environment but occasionally identified with the past. The motor activity varies and is not usually recalled by the patient. It frequently begins with movements about the mouth, such as smacking, sucking, or swallowing, but principally, it consists of repetitive semipurposeful action of a part or the whole of the body. The patient may simply pick at a button, continue to stamp out a cigarette, or he may run for several blocks. In the attack the patient will seem confused but may not be impervious to outside commands—the sort of thing Hughlings Jackson called “mental diplopia.” Recognized psychomotor seizures are found in less than one-sixth of the cases (3) (6).

Minor seizures.—It should be remembered that fragments of any attack may occur naturally or as the result of incomplete control by medication. Petit mal attacks, with classical repetitive, brief interruptions in awareness and a typical spike and dome electroencephalographic pattern, have not been seen in the Korean War veterans under study.

DIAGNOSIS

The more precise the knowledge of the injury and the neurological deficit, if one is apparent, the better able one is to anticipate and recognize a seizure pattern arising from the injured area. Similarly, one is better prepared to discount a “spell” from other causes.

A lucid *subjective* and *objective* description of the attack pattern is of signal importance. Major convulsions are hard to miss and focal motor seizures, particularly with progression of clonic movements, are easily recognized by patient and observer alike. A rare, brief inability to pronounce a word or a fleeting tingling in the side of the face may be discounted by the patient and unnoticed by family or friend.

Transient epileptic alterations in consciousness may be confused with syncopal attacks. Giddiness, blurring of vision, and loss of consciousness may accompany the vasomotor instability that not infrequently follows head trauma for a limited period. The posture of the patient, the setting in which the attack occurs, and the manner of recovery are often helpful in making this distinction. An increase in muscular tone, labored respiration, loss of sphincter control, or postictal headache would be against vasovagal cause.

Psychic phenomena, without proper attention to its periodicity and repetition in pattern, may be misinterpreted. If accompanied by gustatory movements or if there is an extension into more overt motor phenomena, the epileptic interpretation is clearer.

The electroencephalogram is firm diagnostic confirmation when it shows a focal paroxysmal abnormality that correlates with the attack pattern. Less specific abnormalities are of no diagnostic aid. Nonepileptics show the same percentage of aberrant electrical activity as epileptics after comparable head injuries (11) (12).

Idiopathic epilepsy unrelated to the head injury may rarely have to be differentiated from this group. In consideration of the former, one should remember its peak incidence is around puberty, its clinical pattern is classically symmetrical, a familial incidence is not uncommon, and when present, a typical spike and dome electroencephalogram is confirmatory. Against it would be a focal electroencephalo-

graphic abnormality or focal fit pattern. Symptomatic epilepsy from other cause should not be missed because of overattention to the injury. The most serious error in this regard would be to overlook a brain tumor, an important etiological factor in epilepsy as midlife is approached.

It will have been noted that a single seizure following brain injury has been included in this consideration of posttraumatic epilepsy. Some will wish to reserve the term "epilepsy" for clinically expressed "tendency to recurrent seizures" with the lower limits of frequency being set at two attacks, three attacks, or more. This may well be of value for sociological reasons or therapeutic guidance. The author and others (3)(6) feel that single or multiple attacks following injury are part of the same process. With this, it must be pointed out that the precipitating factors in the attacks immediately after injury may be quite different from those that occur at a later date.

THERAPY

Posttraumatic epilepsy must be seen in its relation to the total sequelae of brain damage. The management should be a part of the overall rehabilitation of the patient. Specific to it will be medical or, less commonly, surgical therapy and a few restrictions on activity.

At present there are many anticonvulsant drugs. The most effective are phenobarbital and Dilantin Sodium (diphenylhydantoin sodium). In general, one may employ phenobarbital, 0.1 to 0.4 gm. a day, in those cases of low attack frequency. For the more difficult problems, Dilantin Sodium may be used in doses of from 0.3 to 0.6 gm. a day. If this fails, both drugs may be tried at maximum levels of tolerance (13). In psychomotor seizures, commonly the most intractable, Mysoline (5-phenyl-5-ethylhexahydropyrimidine-4,6-dione (Primidone)) may be added to one or both of these compounds at 1.0 to 1.5 gm. a day. The side effects that may limit the tolerance to these drugs are: For phenobarbital, drowsiness; for Dilantin Sodium, nystagmus, blurring of vision, ataxia, or skin eruption; and for Mysoline, gastric disturbance or somnolence.

With such drug therapy, faithfully carried out,

control or marked reduction of seizures can be expected in 60 to 70 percent of the cases. The remainder will be all but refractory to these and newer compounds. When attacks have been controlled for 2 years, gradual elimination of the medication may be attempted.

Status epilepticus, a succession of major attacks without intervening recovery of consciousness, is occasionally the first expression of posttraumatic epilepsy. This must be treated as a medical emergency. Sodium phenobarbital, 0.4 to 0.6 gm., or paraldehyde, 0.3 to 0.6 cc., by vein may interrupt the attacks.² To use less medication by other routes is but to temporize and with frequent repetition will complicate the problem with drug intoxication. Comprehensive supportive therapy with attention to a free airway, oxygen supply, fluids, nutrients, and electrolyte balance, increases the possibility of a spontaneous remission.

Surgery, with intent to remove the epileptogenic focus, should be contemplated only in cases with incapacitating attacks after failure of a trial, for at least a year, of optimum medication. Given a demonstrated locus of the discharging lesion in a part of the brain that may be spared, precise removal should provide better control of the attacks in about half the cases.

Those activities in which a seizure would endanger the life of the patient or others should be prohibited. The most hampering restriction is that of operating a motor vehicle. Obviously, the possibility of accident will be greater in some than in others. The patient with one seizure a year, always coincident with sleep, even though it be a major convulsion, is less a hazard than one who has unexpected momentary confusional episodes each week. Ordinary work and recreational activity should not be restricted. The more active the patient, the less likely he is to have a seizure. Alcohol, the effects of which may precipitate individual attacks, is to be avoided.

PROPHYLAXIS

Prevention of posttraumatic epilepsy should begin at the moment of injury. Prompt and definitive

² The administration of intravenous or intramuscular Dilantin Sodium has been helpful in our hands in combating status epilepticus.—A.M.M.

surgical and medical care is essential in limiting the destructive processes of the injury. In the future, a better understanding and correction of metabolic derangement incident to injury should be a valuable adjunct to the present management.

Anticonvulsant prophylaxis for a limited period following injury is a reasonable precaution in the more seriously injured. Of choice would be phenobarbital for its relative freedom from side effects, at a level of from 0.1 to 0.3 gm. a day for a period of 12 to 18 months. This can be no more than an enlightened guess, as the amount and type of drug varies with individual needs. No reliable data are yet available on the effectiveness of such prophylaxis. If employed, there should be supervision to insure its continuance and to detect masked or partially controlled seizures.

REFERENCES

1. Credner, L.: Klinische und soziale Auswirkungen von Hirnschädigungen. *Ztschr. f. d. ges. Neurol. u. Psychiat.* 126: 721-757, 1930.
2. Ascroft, P. B.: Traumatic Epilepsy After Gunshot Wounds of the Head. *Brit. M.J.* 1: 739-744, 17 May 1941.
3. Walker, A. E., and Jablon, S.: A Follow-Up of Head-Injured Men of World War II. *J. Neurosurg.* 16: 600-610, November 1959.
4. Caveness, W. F., and Liss, H. R.: Incidence of Post-Traumatic Epilepsy. *Epilepsia (Amster)* 2: 123-129, June 1961.
5. Phillips, G.: Traumatic Epilepsy After Closed Head Injury. *J. Neurol. Neurosurg. & Psychiat.* 17: 1-10, February 1954.
6. Russell, W. R., and Whitty, C. W. M.: Studies in Traumatic Epilepsy; Factors Influencing the Incidence of Epilepsy After Brain Wounds. *J. Neurol. Neurosurg. & Psychiat.* 15: 93-98, May 1952.
7. Kaplan, H. A.: Management of Craniocerebral Trauma and Its Relation to Subsequent Seizures. *Epilepsia (Amster)* 2: 111-116, June 1961.
8. Jooma, O. V., Pennybacker, J. B., and Tutton, G. K.: Brain Abscess: Aspiration, Drainage, or Excision? *J. Neurol. Neurosurg. & Psychiat.* 14: 308-313, November 1951.
9. Baumm, H.: Erfahrungen über Epilepsie bei Hirnverletzten. *Ztschr. f. d. ges. Neurol. u. Psychiat.* 127: 279-311, 1930.
10. Walker, A. E.: Prognosis in Post-Traumatic Epilepsy; A Ten-Year Follow-Up of Craniocerebral Injuries in World War II. *J.A.M.A.* 164: 1636-1641, 10 Aug. 1957.
11. Williams, D.: Neurological and EEG Aspects of Head Injury. *Electroencephalog. & Clin. Neurophysiol.* 7: 495, 1955.
12. Marshall, C., and Walker, A. E.: The Value of Electroencephalography in the Prognostication and Prognosis of Post-Traumatic Epilepsy. *Epilepsia (Amster)* 2: 138-143, June 1961.
13. Merritt, H. Houston: A Textbook of Neurology. Philadelphia: Lea and Febiger, 1955, pp. 658-664.

CHAPTER 22

Basic Mechanisms

William F. Caveness

INTRODUCTION

It is a sobering thought that epilepsy as a reported sequela of head injury has not been materially reduced since the First World War (1) (2) (3) (4). This can be explained in part by lack of uniformity in earlier studies, by more effective present-day methods of followup, by recognition of seizure phenomena not previously delineated, and by a greater salvage of the more seriously injured. But this sustained high incidence, in spite of these signal advances in medicine and surgery, is a forceful reminder that we have not yet mastered the basic mechanisms, a prerequisite for more effective prevention of posttraumatic epilepsy. This chapter will attempt to put the problem in perspective, with attention to some of the difficulties, observations, and suppositions of workers in this field. At the outset further attention will be directed to the nature of the injury.

COMPLEXITY OF INJURY

PRIMARY INJURY

When the head is struck, the brain, in its semi-rigid, uneven housing, is subjected to varying degrees of acceleration, deceleration, rotation, compression, expansion, and swirling motions about its attachments. As a result, there may be diffuse neuronal injury, contusion, laceration, or all three. When the dura is penetrated, brain structure can be ruptured by indriven bone fragments or the agent of injury. If the agent is a missile traveling at high

velocity, radial force is added to the direct trauma. As major vessels are torn, ventricles traversed or the brain stem encroached upon, the gravity and complexity of the injury is accentuated.

SECONDARY INJURY

Following the impact, and depending roughly on the site and extent of the injury, secondary physical and biochemical changes, local or general, extend the brain damage. So-called physiological injuries can progress to death without the development of epiphenomena (5). More apparent changes include brain anoxia, swelling, stasis, acidosis, and electrolytic imbalance. These may be augmented by subsequent hemorrhage or sepsis. General changes in respiration, circulation, endocrine function, and temperature can take place from impaired regulatory centers and wound products (6) (7). Concurrent injuries elsewhere in the body can add to these adverse influences.

REPAIR

If the wound cycle is interrupted either naturally or by medical or surgical intervention, the destructive processes recede as the reparative processes begin to deal with the disordered brain tissue. In the mild injury, there is rapid recovery in function with no apparent metabolic defect or structural discontinuity. In the more severe injury, resolution takes place at a slower pace with an uneven deficit in neurons and alteration in glial elements. When necrosis is extensive, more time is required and there is further distortion as the dead tissue is removed

and the wound consolidated by gliosis, fibrosis, and cyst formation. The loss and alteration in structural design has its less exact counterpart in loss and alteration in functional pattern.

CHANGE IN BRAIN ORGANIZATION

The brief recapitulation of factors just described that may play a part in craniocerebral trauma emphasizes the varied possibilities of damage capable of bringing about focal and general, transient and protracted changes in brain organization.

REACTION TO INJURY

As one of the reactions to injury in an evolving process, the seizure may have different contributing causes at different times. It follows that the attacks accompanying the early more violent phases of the reaction are less likely to persist than those that are a part of the eventual steady state. This should be less true if the pre-injury seizure threshold is low, thus permitting attacks to appear in many if not all the phases. The point in the injury cycle at which the first seizure occurs has attracted interest but received uneven study.

At the moment of impact.—An immediate seizure from mass excitation of the brain by trauma is rare in man. On the contrary, there is usually an abrupt loss in activity. However, brilliant flashes of light may be experienced from occipital blows and occasional brief tremors of an extremity may result from blows about the vertex. Very infrequently a convulsion occurs when a man's head strikes a curbstone or the ice of a hockey rink. Experimental confirmation of such direct neuronal reaction has been obtained in cats and less regularly in monkeys (8).

Within the first few minutes or hours.—A humoral mechanism as a probable significant factor in the very early seizures is suggested by the following:

Bornstein, in 1946 (9), demonstrated the free release of acetylcholine into the cerebrospinal fluid following experimental head trauma. Its direct excitatory effect on the cerebral cortex had been shown previously by Brenner and Merritt in 1942 (10). The detection of acetylcholine in the cerebrospinal fluid in human beings after trauma was reported by Tower and McEachern in 1949 (11), and the acti-

vation of human epileptogenic foci by its topical application was demonstrated by Purpura in 1953 (12). Thus a substance is released in trauma that has a potent excitatory effect, particularly on damaged cortex.

In the convulsion that takes place prior to recovery of consciousness, a possible factor of another sort is the release of a "recruiting response" (13) from nonspecific thalamic and diencephalic afferents by temporary lack of restraint from the mesencephalic reticular system.

Within the first few hours or days.—Brain contusion and laceration are implicated in early attacks, according to most observers. These are important as a measure of the mass density of neuronal injury and of the accompanying metabolic flux.

Complications are common within this period. Venous sinus thrombosis accentuates stasis and anoxia. Subdural hemorrhage through continuing compression adds to brain instability by forwarding changes already underway (14) and possibly creates local irritation when there are subpial collections (15). Intracerebral hematoma, independently capable of producing physical and chemical changes favorable to fits (14), understandably augments this tendency in trauma. In a developing brain abscess, this is true to an even more pronounced degree (1) (16).

Within the first few weeks.—The multiple causes outlined in the preceding paragraphs may still operate, particularly in the more severe injuries, but in those patients farther along in the recovery phase, another process may come into play as the dominant mechanism. An explanation of this has been carefully developed by Phillips (17) whose principal tenet is the hyperexcitability of the recovery neuron, a unit that has been incapacitated but is capable of recovery and reintegration with other neurons. Just prior to reestablishment of normal function, this neuron is thought to have "super-normal" activity from a Sherrington-like rebound and lack of restraint from proper integration. For a fit to eventuate, there must be an appropriate accumulation of such units in this critical stage of their recovery. In support of this attractive, if not yet established concept, Phillips stresses the contour of the seizure incidence curve following trauma. Excepting the early steep rise and irregular plateau, he believes the smooth decline from 3 to 18 months

to be consistent with a single process and that process to be the rapidly diminishing population of "recovering" cells from which seizures can originate.

Within the first few months or years.—Seizures from the mechanism just described should disappear as unstable cells continue to full recovery. As this is taking place, stubbornly recurrent attacks begin to appear from more permanently established neuronal instability. It is this last type of instability that has commanded most attention, both clinically and experimentally. In fact, many consider it the only true form of posttraumatic epilepsy. Something of its mechanism will be discussed in the following section.

THE ESTABLISHED DISCHARGING LESION

FRAMEWORK

Perhaps the greatest work on the epileptogenic focus, and certainly the clearest framework for ultimate understanding, has been provided by Penfield and his associates, Jasper, Rasmussen, Kristiansen, and Erickson (18) (19) (20) (15). Elaborating the legacy from John Hughlings Jackson, they have systematically extended the knowledge of the functional anatomy of the brain and the epileptic reflection from lesions in its various parts. This contribution, in the main, has resulted from painstaking observations in the course of surgical therapy for recurrent seizures in patients with established brain lesions.

ELECTRICAL SUBSTRATE

The "occasional, sudden, excessive, rapid and local discharge" surmised by Hughlings Jackson from the intrinsic pattern of the fit has been given intrinsic electrical definition by electroencephalography and electrocorticography and by direct stimulation of the brain.

ANATOMICAL SUBSTRATE

Local aberrant activity was found to arise, after a "silent period of strange ripening" (21), from areas of brain parenchyma adjacent to all manner of scars, cysts, abscess formations, chronic hematoma, and other pathological residuum from trauma. An optimum site was next to a meningocerebral cicatrix.

The appearance of the cells in the discharging zone, with destruction or sclerotic alteration in neurons, phagocytosis by neuroglia, disappearance of oligodendroglia, and multiplication and fibrillation of astrocytes, prompted the conclusion that the hyperirritability was the result of long-continued subtle injury, possibly from mechanical stress but most likely from altered blood supply.

But as Penfield subsequently notes, these structural changes do not provide the full explanation, for they may produce epilepsy in one individual and not in another, epileptic discharge in one area of a widely injured brain and not in another (21).

CHEMICAL SUBSTRATE

The nature of the epileptogenic zone was given another dimension when Tower and Elliott demonstrated a "biochemical lesion" in the areas with the electrical and morphological changes just described. The principal defects were in acetylcholine, glutamic acid, and potassium metabolism (22) (23).

THE DISCHARGING CELL AND ITS PROCESSES

A finer definition of the epileptogenic focus has been afforded by the study of individual neurons. It is now recognized that the discharges of cell body, dendrite, and the axon have distinct electrical features, with the potentials of the apical dendrites being that most apparent in the electroencephalogram (24). Schmidt, Thomas, and Ward, with microelectrodes, have demonstrated abnormal, high-frequency bursts of electrical activity from single cells in the epileptogenic zone. They attribute this autonomous activity to a relatively enduring dendritic depolarization, with a resultant difference in potential between cell body and dendritic network. The cause is thought to be pathological changes in the dendrites from the mechanical stress of scar tissue (25).

PROPAGATION OF THE ABNORMAL DISCHARGE

CORTICAL ACTIVITY

The beginning of propagation is the progressive involvement of interlocking cortical elements via

the dendritic meshwork. The advancing depolarization in the dendritic mantle, influenced by the related abnormal cells but retaining a measure of independence, is reflected at the surface by high amplitude negative spikes (26). Whether it proceeds beyond this point to the activation of neurons in the deeper layers of the cortex is dependent upon a number of factors, among which are its magnitude, location, and the state of the surrounding brain. Obviously, an overwhelming dendritic buildup, whatever its location and however intact the surrounding brain, will detonate increasing numbers of pyramidal cells until successive subcortical circuits are activated to a degree that will be expressed in a clinical seizure.

PREFERENTIAL CIRCUITS

From clinical experience, areas near the central sulcus are more susceptible to abnormal activity than those at either pole. It is of interest that in man electrical stimulation of the frontal pole evokes little if any response, and Russell has found a protracted delay in the development of epilepsy from traumatic lesions in this area, in contrast to those more centrally located. In the established seizures with focal onset, he has noted the rapidity with which a developing sensory "march" can bring in a motor expression and the almost complete lack of the opposite "spread" from the slower motor march to sensory phenomena (27). With electrical stimulation of the monkey brain, French, Livingston, and their coworkers (28)(29) found well-delineated areas of hyperexcitability scattered over the cortex but gathered in clusters along the precentral gyrus and at the tip of the temporal lobe. They further noted that these preferential areas have equally preferential direction in their subcortical spread.

Walker (30), in a more extensive study of the subcortical structures that subserve a discharging lesion in the monkey, assigns a regular relationship in systems: "From the frontal cortex, these involve the caudate nucleus and the midline higher brain stem; from the central cortex, the putamen, thalamus, subthalamus, and cerebellum as well as the pyramidal pathways; from the temporal and cingular cortex, the amygdala, hippocampus, hypothalamus, and higher brain stem." One circuit may function in *epilepsia partialis continua*. More than one is

brought into play with the march of a Jacksonian seizure, or all with a generalized convulsion. Any may be activated cortically or subcortically. Additional findings from depth recordings in patients complement this recognition of preferential subcortical pathways.

From the preceding, it is evident that the proximity of the discharging lesion to such circuit systems is an important determinant in the development of recurrent seizures. In an extension of this, one might expect that the more exactly the discharging lesion is a part of a preferential system, the more intractable the attacks will be. If it is at a distance, there would be "a flickering hypersynchrony around a scar" for minutes or hours without any clinical manifestations.

INTEGRITY OF THE SURROUNDING BRAIN

Hughlings Jackson (31) postulated that normal brain cells are swept into abnormal activity by the local unruly discharge. This is demonstrably true, but the ability of normal brain to block or "snuff out" the aberrant discharge is equally true.

It is not surprising then that loss in brain substance enhances the liability to epilepsy. Organization, essential to normal stability, is thus overtly impaired. The degree of impairment is related to the extent and, more particularly, to the location of the loss. Russell and Whitty (3) have stressed the importance of even limited destruction in the parietal region.

The sensitization of neuronal structures by denervation, recognized since Claude Bernard, led Cannon to formulate his "law of denervation" (32) and, subsequently, has been demonstrated experimentally throughout the neuraxis. Fisher and Stavaky (33) showed that destruction or ablation of one portion of the cerebrum rendered descending chains of neurons from that hemisphere supersensitive to injection of acetylcholine. Spiegel and Szekely (34) demonstrated hypersensitivity of the sensory cortex of the cat following partial deafferentation by lesions in the ventral posterior thalamic nuclei. Henry and Scoville (35) observed spontaneous bursts of paroxysmal activity from partially undercut human cortex. Echlin (36) observed similar but more pronounced spontaneous activity from the chronically isolated or partially isolated cortex in

man and experimental animals. In the latter, the supersensitive local response to acetylcholine prompted the conclusion that "chronic partial isolation of cerebral neurons * * * is an important factor—if not the basic factor—in the causation of focal epilepsy." Eidelberg (37), by circumsection of a cortical area in the monkey, severing lateral connections but leaving long tracts intact, found hyperexcitability to develop in the contralateral homotopic area. Further, this augmented response remained in the remote focus after procainization or excision of the circumsected area or section of the corpus callosum.

From the preceding, it follows that any relatively large brain injury may cause some change in the sensitivity of neurons at a distance and over wide areas. Thus, cortical areas ordinarily refractive may be brought into abnormal activity. Injury in more than one part of a preferential circuit should greatly facilitate the initiation and diffusion of an epileptic discharge. The latter would be especially true if the basal ganglia and brain stem nuclei of more than one preferential complex were implicated. It is not surprising that the precise alterations in function seen in laboratory demonstrations become blurred in the clinical manifestations of war injuries. Nevertheless, from both come the realization that a defect in organization, a particular imbalance between excitatory and inhibitory influences, provides the precarious state of the epileptic brain.

Recent physiological and biochemical investigations of the intricate systems of checks and balances in neuronal activity make clearer the significance of their disruption. According to Phillips (38), a discharging Betz cell has its own collateral feedback that, by activating small inhibitory interneurons, limits the axonal discharge and the depolarization of apical dendrites. Damage to a nerve network made up of such units, particularly if there is a disproportionate loss in the smaller elements, should result in focal instability at this cellular level. The extracellular graded potentials of the dendritic network receive facilitory and inhibitory afferents from the brain stem. Damage to the latter, by altering the excitatory level of the dendritic mantle, could forward the depolarization of an epileptic discharge. In general support of this are the experimental observations of O'Leary, Goldring, and Cox (39). With direct current recording, the den-

droitic negative spike is shown to be followed by a positive deflection and a slower negativity. The latter, a separate excitatory process, is exaggerated prior to the onset of a seizure. Both the primary spike and the slower negative potential may be accentuated by subcortical stimulation and by pharmacological agents.

The biochemical reactions in neuronal function are in part structurally organized within the cell, in part acting in the synaptic transmission of excitation and inhibition, and in part influencing the general level of neuronal activity by diffuse action in interstitial fluids. In the developing understanding of these reactions, acetylcholine has been associated with excitatory transmission (40) and gamma aminobutyric acid with inhibitory influence (41). The possible effect of the former in seizure production after injury has been discussed. Gamma aminobutyric acid, not a transmitter substance but widely dispersed in the central nervous system, probably plays an essential role in restraining abnormal activity. In rupture of the brain parenchyma, the loss or accumulation of gamma aminobutyric acid, no longer confined by the blood brain barrier, should affect the excitability of the damaged area.

PRECIPITATING FACTORS

As a sequela of head injury these may be less apt homeostatic controls, evidenced clinically by greater vulnerability to physical and emotional stress, alteration in sleep pattern, diminished tolerance to alcohol, and other indications of endocrine or metabolic dysfunction. Thus, there are many possible precipitants if the seizure threshold is low.

Of theoretical interest and perhaps of greater practical importance than is currently recognized is the ability of afferent stimuli, external and internal, to activate seizures. It is tempting to speculate on the increased effectiveness of this factor when there is injury to the brain. The exaggerated response of the damaged cortex to ordinary afferents has been implied. Injury to the brain stem reticular system could influence the effectiveness of sensory receptors as well as alter the level of cortical excitability (42). Injury to the thalamus and diencephalon could not only impair the filtering and

distribution of incoming stimuli through specific projection systems but could augment the general responsiveness through diffuse nonspecific systems. For example, two Korean casualties with overt brain stem signs showed prolonged bursts of extremely high amplitude electroencephalographic activity upon stretching a hollow viscus (enema) or upon sharp auditory or tactile stimulus.

GENETIC FACTOR

None of the preceding factors explains why one casualty does not develop epilepsy when another with apparently the same brain injury and repair is subject to uncontrollable attacks. Part of the explanation could be our inability to discern significant differences in clinically similar cases.

At present there are no convincing data to support the importance of heredity in posttraumatic epilepsy, yet one must still suspect a pre-injury constitutional deficit, beyond our present methods of appraisal.

CONCLUSION

It is probable that more questions have been raised than answered in this discussion. But it is hoped that the readers of this volume in their observations, reflections, and investigations will help resolve the areas of ignorance.

REFERENCES

1. Ascroft, P. B.: Traumatic Epilepsy After Gunshot Wounds of the Head. *Brit. M.J.* 1: 739-744, 17 May 1941.
2. Caveness, W. F., and Liss, H. R.: Incidence of Post-Traumatic Epilepsy. *Epilepsia (Amster)* 2: 123-129, June 1961.
3. Russell, W. R., and Whitty, C. W. M.: Studies in Traumatic Epilepsy; Factors Influencing the Incidence of Epilepsy After Brain Wounds. *J. Neurol. Neurosurg. & Psychiat.* 15: 93-98, May 1952.
4. Walker, A. E.: Prognosis in Post-Traumatic Epilepsy; A Ten-Year Follow-Up of Craniocerebral Injuries in World War II. *J.A.M.A.* 164: 1636-1641, 10 Aug. 1957.
5. Jefferson, G.: The Nature of Concussion. *Brit. M.J.* 1: 1-5, 1 Jan. 1944.
6. Moore, Francis D.: Metabolism in Trauma: The Meaning of Definitive Surgery—The Wound, The Endocrine Glands, and Metabolism. In *The Harvey Lectures*; Delivered under the auspices of The Harvey Society of New York, 1956-1957. New York: Academic Press Inc., 1958, pp. 74-99.
7. Howard, John M. (editor): *Battle Casualties in Korea: Studies of the Surgical Research Team, Army Medical Service Graduate School, Walter Reed Army Medical Center, Washington: U.S. Government Printing Office, 1955-56, 4 vols.*
8. Walker, A. E., Kollros, J. J., and Case, T. J.: The Physiological Basis of Concussion. *J. Neurosurg.* 1: 103-116, March 1944.
9. Bornstein, M. B.: Presence and Action of Acetylcholine in Experimental Brain Trauma. *J. Neurophysiol.* 9: 349-366, September 1946.
10. Brenner, C., and Merritt, H. H.: Effect of Certain Choline Derivatives on Electrical Activity of the Cortex. *Arch. Neurol. & Psychiat.* 48: 382-395, September 1942.
11. Tower, D. B., and McEachern, D.: Acetylcholine and Neuronal Activity; Cholinesterase Patterns and Acetylcholine in Cerebrospinal Fluids of Patients With Craniocerebral Trauma. *Canad. J. Research, Sect. E* 27: 105-119, April 1949.
12. Purpura, D. P.: Activation of Epileptogenic Foci by Topical Application of Acetylcholine to the Exposed Cerebral Cortex of Man. *Electroencephalog. & Clin. Neurophysiol., Supp.* No. 3, August 1953, p. 46.
13. Dempsey, E. W., and Morison, R. S.: The Electrical Activity of a Thalamocortical Relay System. *Am. J. Physiol.* 138: 283-296, January 1943.
14. Kaplan, H. A.: Management of Craniocerebral Trauma and Its Relation to Subsequent Seizures. *Epilepsia (Amster)* 2: 111-116, June 1961.
15. Penfield, Wilder, and Erickson, Theodore C.: *Epilepsy and Cerebral Localization: A Study of the Mechanism, Treatment and Prevention of Epileptic Seizures.* Springfield, Ill.: Charles C Thomas, 1941.
16. Joona, O. V., Pennybacker, J. B., and Tutton, G. K.: Brain Abscess: Aspiration, Drainage, or Excision? *J. Neurol. Neurosurg. & Psychiat.* 14: 308-313, November 1951.
17. Phillips, G.: Traumatic Epilepsy After Closed Head Injury. *J. Neurol. Neurosurg. & Psychiat.* 17: 1-10, February 1954.
18. Penfield, Wilder, and Jasper, H. H.: *Epilepsy and the Functional Anatomy of the Human Brain.* Boston: Little, Brown & Co., 1954.
19. Penfield, Wilder, and Rasmussen, Theodore: *The Cerebral Cortex of Man: A Clinical Study of Localization of Function.* New York: The Macmillan Co., 1950.
20. Penfield, Wilder, and Kristiansen, Kristian: *Epileptic Seizure Patterns: A Study of the Localizing Value of Initial Phenomena in Focal Cortical Seizures.* Springfield, Ill.: Charles C Thomas, 1951.
21. Penfield, W.: Symposium on Post-Traumatic Epilepsy. *Epilepsia (Amster)* 2: 109-110, June 1961.
22. Tower, D. B., and Elliott, K. A. C.: Activity of Acetylcholine System in Human Epileptogenic Focus. *J. Appl. Physiol.* 4: 669-676, February 1952.

23. Tower, D. B.: Biochemical Abnormalities in Epileptogenic Cerebral Cortex. In XIX International Physiological Congress, Montreal, August 31 to September 4, 1953, Abstracts of Communications, pp. 834-835.
24. Bishop, G. H., and Clare, M. H.: Responses of Cortex to Direct Electrical Stimuli Applied at Different Depths. *J. Neurophysiol.* 16: 1-19, January 1953.
25. Schmidt, R. P., Thomas, L. B., and Ward, A. A., Jr.: The Hyper-Excitable Neurone; Microelectrode Studies of Chronic Epileptic Foci in Monkey. *J. Neurophysiol.* 22: 285-296, May 1959.
26. Brazier, M. A. B.: Neuronal Structure, Brain Potentials and Epileptic Discharge. *Epilepsia* 4: 9-18, November 1955.
27. Russell, W. R., and Whitty, C. W. M.: Studies in Traumatic Epilepsy; Focal Motor and Somatic Sensory Fits: Study of 85 Cases. *J. Neurol. Neurosurg. & Psychiat.* 16: 73-97, May 1953.
28. French, J. D., Gernandt, B. E., and Livingston, R. B.: Regional Differences in Seizure Susceptibility in Monkey Cortex. *A.M.A. Arch. Neurol. & Psychiat.* 75: 260-274, March 1956.
29. Livingston, R. B., French, J. D., Konigsmark, B., Richland, K. J., and Abdullah, A. F.: Experimental Studies in Cortical Epileptogenesis (In press.)
30. Walker, A. Earl: Posttraumatic Epilepsy—An Inquiry into the Evolution and Dissolution of Convulsions Following Head Injury. In *Clinical Neurosurgery; Proceedings of The Congress of Neurological Surgeons, San Francisco, Calif., 1958*. Baltimore: Williams & Wilkins Co., 1959, pp. 69-103.
31. Taylor, James, Holmes, Gordon, and Walshe, F. M. R. (editors): *Selected Writings of John Hughlings Jackson. Volume I. On Epilepsy and Epileptiform Convulsions*. London: Hodder & Staughton, Ltd., 1931.
32. Cannon, W. B.: A Law of Denervation (Hughlings Jackson Memorial Lecture). *Am. J.M. Sc.* 198: 737-750, December 1939.
33. Fisher, S. M., and Stavsky, G. W.: The Effects of Acetyl-Beta-Methylcholine in Human Subjects With Localized Lesions of the Central Nervous System. *Am. J.M. Sc.* 208: 371-380, September 1944.
34. Spiegel, E. A., and Szekely, E. G.: Supersensitivity of Sensory Cortex Following Partial Deafferentiation (Lesion of Ventral Posterior Thalamic Nuclei). *Electroencephalog. & Clin. Neurophysiol.* 7: 375-381, August 1955.
35. Henry, C. E., and Scoville, W. B.: Suppression-Burst Activity From Isolated Cerebral Cortex in Man. *Electroencephalog. & Clin. Neurophysiol.* 4: 1-22, February 1952.
36. Echlin, F. A.: The Supersensitivity of Chronically "Isolated" Cerebral Cortex as a Mechanism in Focal Epilepsy. *Electroencephalog. & Clin. Neurophysiol.* 11: 691-722, November 1959.
37. Eidelberg, E., Konigsmark, B., and French, J. D.: Electrocortical Manifestations of Epilepsy in Monkey. *Electroencephalog. & Clin. Neurophysiol.* 11: 121-128, February 1959.
38. Phillips, C. G.: Actions of Antidromic Pyramidal Valleys on Single Betz Cells in the Cat. *Quart. J. Exper. Physiol.* 44: 1-25, January 1959.
39. O'Leary, J. L., Goldring, S., and Coxe, W. S.: Experimental Evidence Relating to the Pathogenesis of Post-traumatic Epilepsy. *Epilepsia (Amster)* 2: 117-122, June 1961.
40. Nachmansohn, David: *Chemical and Molecular Basis of Nerve Activity*. New York: Academic Press, 1959.
41. Elliott, K. A. C.: γ -Aminobutyric Acid—An Inhibitory Factor in Brain. In *Proceedings of the Fourth International Congress of Biochemistry, Vienna, 1958, vol. III; Symposium III, Biochemistry of the Central Nervous System*. New York: Pergamon Press, 1959, pp. 251-267.
42. Magoun, H. W.: Recent Contributions to Seizure Activation. *Epilepsia* 1: 69-82, November 1952.

TRAUMA OF SPINAL CORD

Closed Spinal Cord Injuries

CHAPTER 23

General Considerations

Henry G. Schwartz, William S. Coxe, and Sidney Goldring

As recently as 1940, Elsberg (1) made the following statement: "The patient with a complete transverse lesion of the cord, if he lives for any length of time, is fully incapacitated from work for the remainder of his or her life." In another treatise of the same subject, antedating Elsberg's paper by several years, Mixter (2) wrote, "with cord transection or softening there is no hope of return of function and death from urinary sepsis usually comes in a few months." Such dire prognostications no longer hold, and antibiotics, in addition to other general measures, have undoubtedly made the difference (3) (4) (5) (6).

Unfortunately, definitive surgical treatment in most instances of spinal cord trauma is rarely productive of recovery of function. Indeed, to this date, there is still no uniformity of opinion regarding specific indications for surgical intervention. In the majority of cases, therefore, prognosis is dependent upon symptomatic care and rehabilitation. The value of these measures should not be minimized for many patients are returned to useful, productive lives if complications are prevented and physical and moral rehabilitation is accomplished. Specifically, restoration of a compromised airway following a cervical injury, early attention to bladder and skin care, maintenance of nutritional requirements, institution of physical therapy, and

proper education of the patient, so that he can satisfactorily cope with the demoralizing diversities of this affliction, are the critical factors which need attention.

Cord damage and consequent neurological deficit may occur without demonstrable injury of the spine (7). However, in the majority of instances, there is accompanying fracture and dislocation of the vertebrae. Conditions which result in nonpenetrating fracture dislocations are those which produce indirect injury to one or more vertebrae by a transmitted mechanical force from a point of distant impact. Examples are cervical injuries from diving accidents, and thoracic and lumbar spinal trauma consequent to falls in which the patient lands on his heels or buttocks. Accidents resulting in violent flexion and hyperextension of the trunk are also responsible for a significant number of fracture dislocations. The most frequent sites of injury are the 5th, 6th, and 7th cervical and the 12th thoracic and 1st lumbar vertebrae (fig. 128). In all probability, the latter observations can be explained by the increased range of mobility of the vertebral column in these locations.

Cervical and thoracolumbar injuries each present their own problems of management and will be discussed independently. Also, important features of medical care, which seriously influence prognosis

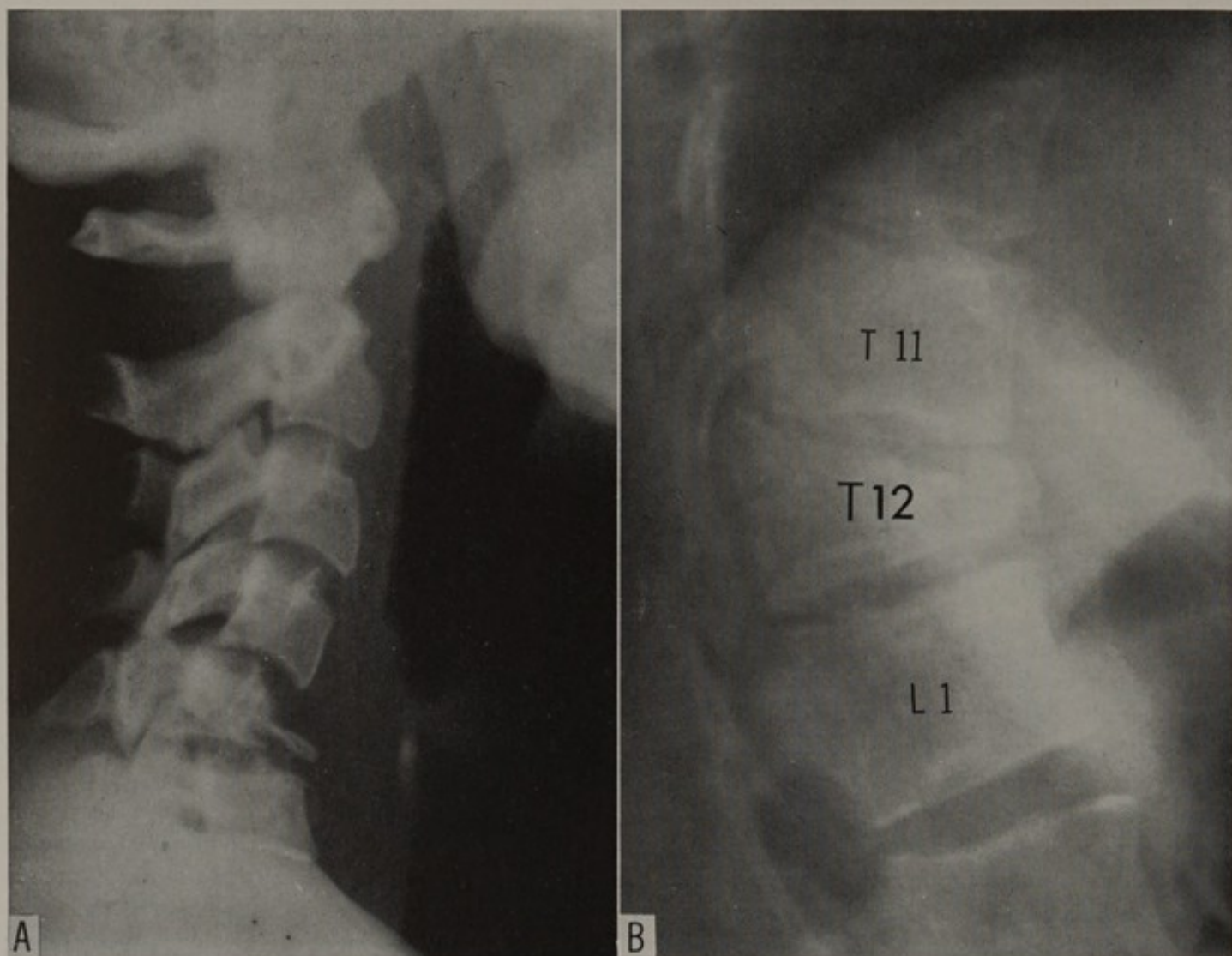


FIGURE 128.—Common sites of fracture dislocation in closed spinal cord injuries. A. Compression fracture and dislocation of C6 resulting from a diving accident. B. Compression fracture and dislocation of T12 sustained in an automobile accident.

and are common to all spinal cord injuries, will be treated under separate headings. In addition, the special problems of atlanto-axial dislocations, injuries accompanied by extruded intervertebral disk, indications for spinal fusion, muscle spasm, and pain will be given separate consideration. However, before proceeding to these specific topics, important anatomy, pathophysiology, and essentials of early management will be reviewed.

REVIEW OF PERTINENT ANATOMY AND PATHOPHYSIOLOGY

In the adult, the cord usually ends at the level of the first lumbar vertebra, the remainder of the

dural sac being occupied by the sensory and motor roots or cauda equina. Therefore, with injury in the lumbar region one deals with root rather than cord involvement. From a functional viewpoint, the same is true for a lesion of T12. Many spinal segments are crowded into the distal portion of the conus medullaris; the 12th thoracic and 1st lumbar vertebrae overlying the lower lumbar and all of the sacral segments. With injury in this region, therefore, no isolated cord remains distal to the lesion and reflex behavior in the involved body segments is not possible.

A complete lesion of the spinal cord or cauda equina produces the same functional loss in the early period after injury. The constellation of signs

which develop are popularly referred to as spinal shock. There is loss of bowel and bladder function, loss of all modalities of sensation, absent deep tendon reflexes, and flail limbs with total paralysis below the level of the lesion. In the case of injury of the cauda equina, this picture is permanent except for the bladder. If care is taken to avoid overdistension with consequent irreversible damage to muscle fibers, patients may develop automatic bladder function and effect micturition with the help of the Credé maneuver. As just mentioned, a similar clinical picture results with low conus lesions.

With higher injuries a different series of events takes place. Flaccid paraplegia resulting from spinal shock is ultimately replaced by spastic paralysis. In the usual case, unless overwhelming pulmonary or systemic infection is present, about 2 to 3 weeks after injury, nocuous stimulation of the plantar surface of the feet results in extension of the great toe (Babinski sign). In the ensuing days, deep tendon reflexes return, and with passage of time, they become hyperactive. The bladder develops an exaggerated response to stretch, resulting in a small vesical capacity with frequent and ineffective micturition. The sensory area from which an extensor toe sign can be elicited expands, and in many patients stroking a cutaneous area anywhere below the level of the lesion is an adequate stimulus. There is a commensurate irradiation of the motor response and stroking the thigh may result in flexion of the leg and thigh with urination and defecation—the mass reflex.

Knowledge of a few neuroanatomical fundamentals enables one to satisfactorily localize cord lesions. Recall that there are three major ascending sensory systems and one major descending motor tract. Fibers carrying pain and temperature establish synaptic junction upon cord entry, cross almost immediately, and travel rostrally in the ventral half of the cord. Those conveying touch have a more diffuse distribution, some crossing to ascend in the ventral cord quadrant and others coursing uncrossed in the posterior funiculus, a fact accounting for the preservation of touch, unless there is an extensive cord lesion. Axons serving proprioception ascend without crossing in the dorsal columns. Finally, the descending motor fibers decussate in the lower medulla and stream downward in the dorsolateral

half of the cord.

Other anatomical salients pertinent to spinal cord injuries and worthy of recapitulation are the 4th cervical segment innervating the diaphragm, the juxtaposition of the 2d thoracic and 4th cervical dermatome approximately 2 inches below the clavicle, and the 1st and part of the 2d thoracic segments having their distribution in the upper extremity. Clinical clues to the level of cord injury may at times be elicited rapidly on the basis of reflex activity. For example, presence of biceps reflex, with absence of triceps function, suggests integrity of the 6th cervical and loss of the 7th cervical nerve. Beevor's sign (rostral movement of the umbilicus) is found in lesions between the 10th and 11th thoracic nerves.

MANAGEMENT UPON HOSPITAL ADMISSION

In transporting patients with spinal cord injuries, movement of the involved region is painstakingly avoided. Thorough physical examination will define the anatomical location and severity of the lesion, and in addition, will establish the presence or absence of associated trauma. Signs of peripheral vascular collapse may accompany spinal fracture dislocations. However, if there is evidence of shock, it is important to search for contributing factors other than the vertebral injury, for example, ruptured viscus, fractured femur, hemothorax.

With cervical injuries there may be embarrassment of the airway. If pooled secretions cannot be handled adequately by prudent suctioning, a tracheostomy is performed.

It goes without saying that discovery of a distended bladder dictates institution of continuous catheter drainage. Even in the absence of distention, with demonstration of significant neurological deficit, it is wise to anticipate impaired function and insert a urethral catheter. Prolonged overdistention may lead to irreversible damage of bladder musculature and preclude rehabilitation of function.

Roentgenograms consisting of anteroposterior and lateral views are obtained as soon as possible, and once again, it is important to stress avoidance of indiscreet manipulation of the patient. *A physician*

should be in constant attendance to supervise the movement and positioning. This job cannot be delegated to a conscientious technician who may unwittingly compromise the patient's welfare to improve the technical quality of the roentgenograms. Stereoscopic views or laminagrams are very helpful in determining the possibility of cord compression by a fractured laminar fragment.

A lumbar puncture with cuff manometrics is a useful examination and aids in estimating the degree of cord compression or swelling. The information derived is particularly helpful when there is neurological deficit but only minimal to moderate compromise of the spinal canal is demonstrated roentgenographically. However, it is well to recall that this test has a limiting factor, which is the size of the needle. If an extraparenchymal space no larger than the cross sectional area of the bore of the needle is present, the test will fail to uncover any abnormality. If spinal puncture is to be done, it is obvious that extreme caution must be exercised in moving or positioning the patient.

The procedures and examinations just described are performed with dispatch, the results colligated, and a decision of proper treatment reached as soon as possible.

REFERENCES

1. Elsberg, Charles A.: Injuries of the Spinal Cord and Nerve Roots. In Brock, Samuel (editor): *Injuries of the Skull, Brain and Spinal Cord: Neuro-Psychiatric, Surgical, and Medico-Legal Aspects*. Baltimore: Williams & Wilkins Co., 1940, pp. 495-536.
2. Mixter, J. M.: Fracture and Dislocation of the Spine. In Lewis, Dean DeWitt (editor): *Practice of Surgery*. 12th edition. Hagerstown, Md.: W. F. Prior Co., Inc., 1932, vol. I.
3. Botterell, E. H., Aberhart, C., and Jousse, A. T.: Treatment of Traumatic Paraplegia. *Univ. Toronto M.J.* 29 (No. 2): 53-62, November 1951.
4. Munro, D.: Rehabilitation of Veterans Paralyzed as the Result of Injury to the Spinal Cord and Cauda Equina. *Am. J. Surg.* 75: 3-18, January 1948.
5. Pool, J. Lawrence: The Neurosurgical Treatment of Traumatic Paraplegia. American Lecture Series No. 83. *American Lectures in Surgery*. Springfield, Ill.: Charles C Thomas, 1951.
6. Schneider, Richard C.: Trauma to the Spine and Spinal Cord. In Kahn, Edgar A., Bassett, Robert C., Schneider, Richard C., and Crosby, Elizabeth Caroline: *Correlative Neurosurgery*. Springfield, Ill.: Charles C Thomas, 1955, pp. 327-354.
7. Naffziger, Howard C., and Boldrey, Edwin B.: Surgery of Spinal Cord. In Bancroft, Frederic W., and Pilcher, Cobb (editors): *Surgical Treatment of the Nervous System*. Philadelphia: J. B. Lippincott Co., 1946, pp. 357-373.

CHAPTER 24

Definitive Treatment

Henry G. Schwartz, William S. Coxe, and Sidney Goldring

Before proceeding with a detailed discussion of specific treatment for spinal cord compression, it is well to review the recent studies of Tarlov and his collaborators (1)(2). They precipitated sensorimotor paralysis in dogs by applying acute extradural compressive forces. Balloons were employed and inflated to effect complete sensorimotor paralysis by large, intermediate, and minimal compressive forces. They also produced both cord (T5-T9) and cauda equina (L5) compression. To obtain full recovery in cord experiments, large compressive forces had to be released within 1 minute, intermediate ones in 30 minutes, and minimal ones in 2 hours. In cauda equina studies, complete sensorimotor paralysis by maximal compressive forces for as long as 5 hours was compatible with full functional return. With an incomplete sensorimotor deficit (cord or cauda equina) restoration of function was observed in animals in which compression was maintained for as long as 1 week.

The results of these animal experiments, therefore, portend a bleak outlook for almost all cases of complete cord lesions. Although functional restoration by decompression is possible, the time interval in which it must be accomplished is too short to be of practical benefit. However, surgery might offer a favorable outcome in cauda equina cases treated shortly (within hours) after injury and in patients with cord compression who have some preservation of neurological function.

Clinical experience tends to confirm such a prognosis (3)(4). Decompressive laminectomy in patients who developed immediate and complete sensorimotor paralysis following injury has rarely if ever resulted in significant functional recovery.

However, it is not at all uncommon to see almost complete return of function following surgery if the neurological lesion was incomplete.

CERVICAL LESIONS

We feel that skeletal traction (5) is the treatment of choice in fracture dislocation of the cervical spine. Surgery in the acute stages following injury is hazardous and may actually increase the neurological deficit. As soon as examination establishes the presence of a cervical lesion, a canvas head halter with from 15 to 20 pounds of traction is applied, and lateral and anteroposterior roentgenograms are obtained. The patient is then taken to the operating room with halter traction in place and Crutchfield or Vinke tongs expeditiously inserted. The weights are connected to the tongs for skeletal traction, and roentgenograms are repeated. If dislocation is still present, 10 pounds of weight are added, and after a 30-minute period, roentgenograms are made again. At times, one may have to use as much as 40 to 50 pounds of weight before effecting reduction—spasm of the cervical paraspinal muscles offering considerable resistance to realignment of the vertebrae. In recalcitrant cases, sedation, analgesics, and local procaine infiltration are often helpful in reducing the spasm. Once reduction is established, the weight is reduced from 8 to 10 pounds and the patient maintained in skeletal traction from 6 to 8 weeks. If there is significant neurological deficit, the patient is kept on a Foster or Stryker frame, otherwise he may remain in bed.

Occasionally, realignment of the dislocated vertebrae cannot be accomplished in spite of adequate

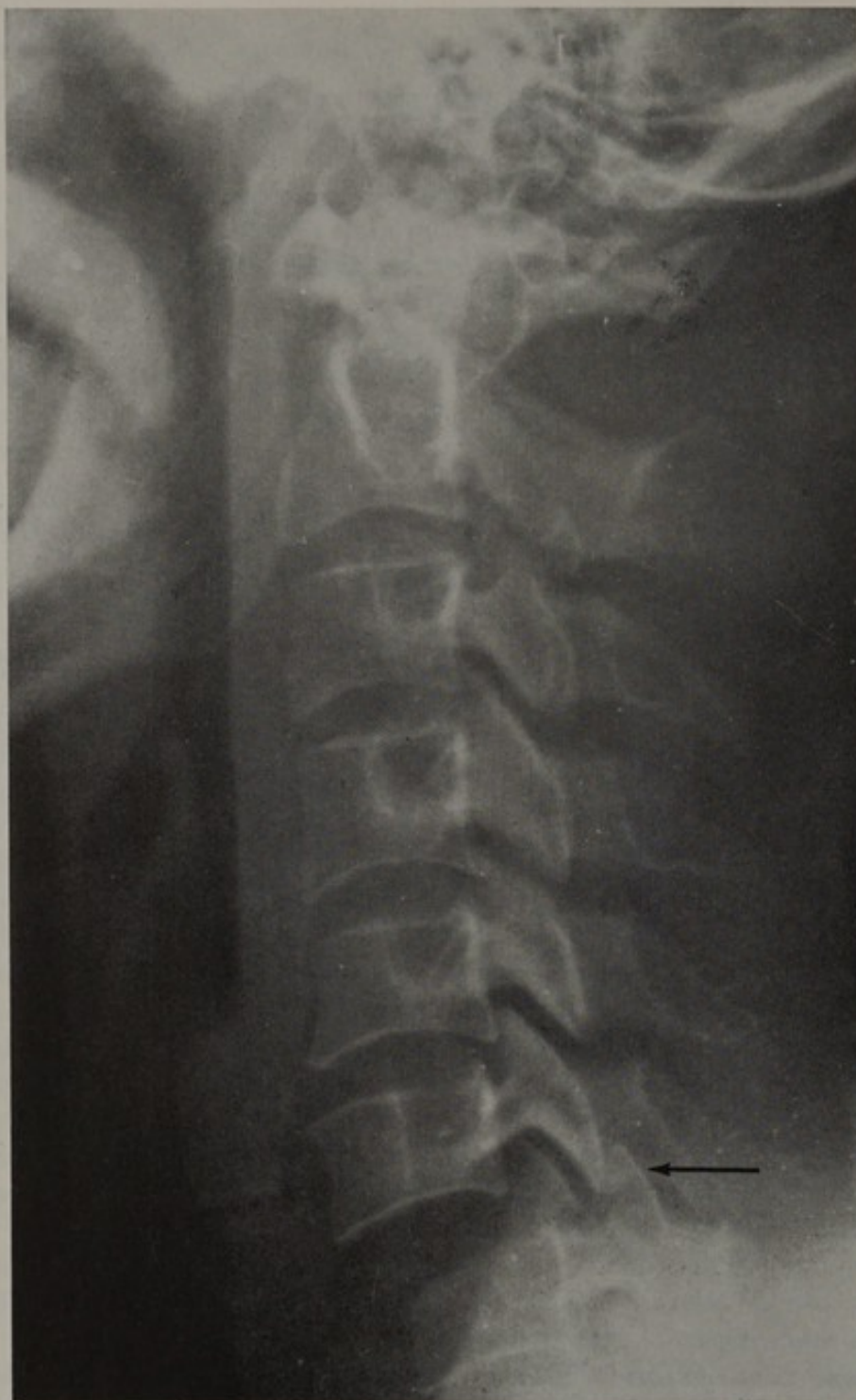

FIGURE 129.—Compression fracture and dislocation accompanied by locked facets. Note the superior facet of C7 overriding and locked on the inferior facet of C6 (arrow). Patient fell from a scaffold and struck pavement head on.

skeletal traction. In such cases, examination of roentgenograms will usually reveal overriding and locking of the articular facets—the superior facet of the lower vertebra riding over the inferior facet of the upper one (fig. 129). In this situation, it is necessary to perform a laminectomy and unlock

the facets surgically in order to obtain reduction. The other indications which we have used for surgical intervention in the cervical region are compromise of the spinal canal by a bony fragment and extrusion of an intervertebral disk.

A special case in cervical spine injuries is atlanto-

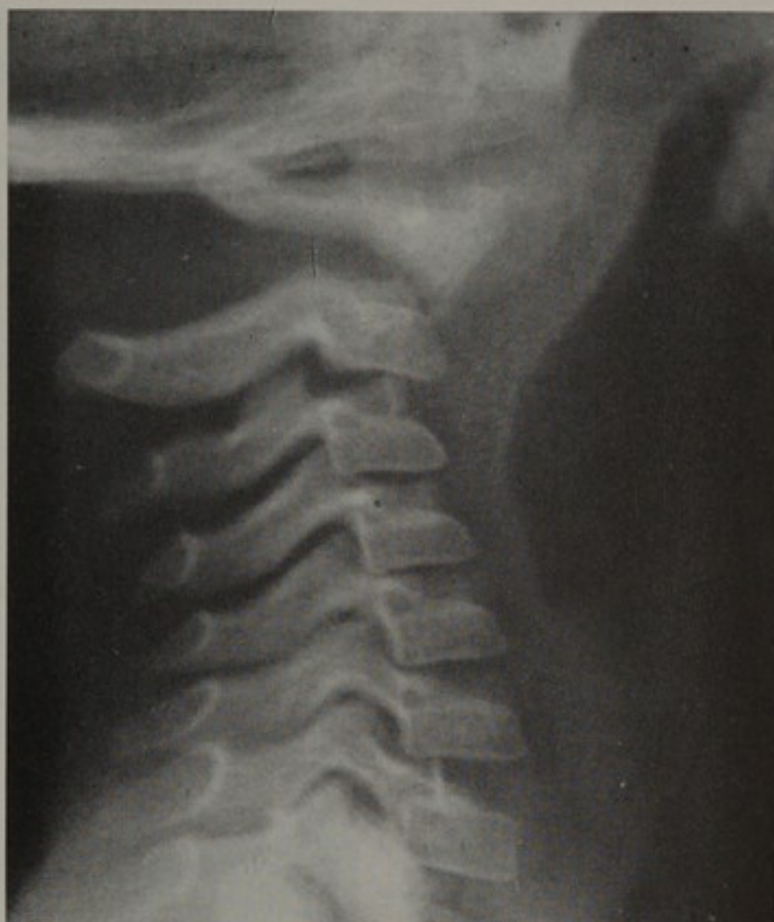

FIGURE 130.—Fracture of the odontoid process with atlanto-axial dislocation, sustained in an automobile accident. Patient is a 2½-year-old child who complained only of cervical pain. Neurological examination was negative.

axial dislocation with or without fracture of the odontoid process. It is obvious that many of these injuries will never come to the attention of the neurosurgeon, since trauma at this level resulting in significant cord injury is not compatible with life. Surprisingly, many of the patients in whom the diagnosis is made are ambulatory complaining only of pain and stiffness of the neck. In addition, the trauma may be relatively insignificant. An example is a 2½-year-old child who entered St. Louis Children's Hospital, St. Louis, Mo., complaining of neck pain. Several days earlier, she was involved in an automobile accident in which it was felt she had not incurred any injury. Neurological examination was entirely negative, yet roentgenograms revealed a fractured odontoid with atlanto-axial dislocation (fig. 130). Although patients with dislocation at this level may be asymptomatic initially, late neurological complications are not an uncommon occurrence (6). It is generally agreed that reduction and solid healing are essential for the prevention of neu-

rological sequelae. This may be accomplished by skeletal traction followed by prolonged immobilization in brace or cast or by spinal fusion. In their excellent review of atlanto-axial dislocation, Alexander, Forsyth, Davis, and Nashold (6) describe a method of spinal fusion of C1, C2, and C3. They feel that fusion shortens the disability period and offers greater assurance of solid union. They employ ribs (from a bone bank) or fresh iliac bone, laying the grafts on either side of the spinous processes along the laminae of C1, C2, and C3. At each vertebra, the graft is secured by a stainless steel wire which has been passed beneath the lamina. In addition, the lamina of C1 is anchored to the spinous process of C2 by wire. This technique has worked very well in their hands and appears to be a satisfactory way of dealing with the problem. In young children, we have had good results without grafts, utilizing heavy wires running from the arches of C1 to the laminae of C3 with the C2 arch as a fulcrum.

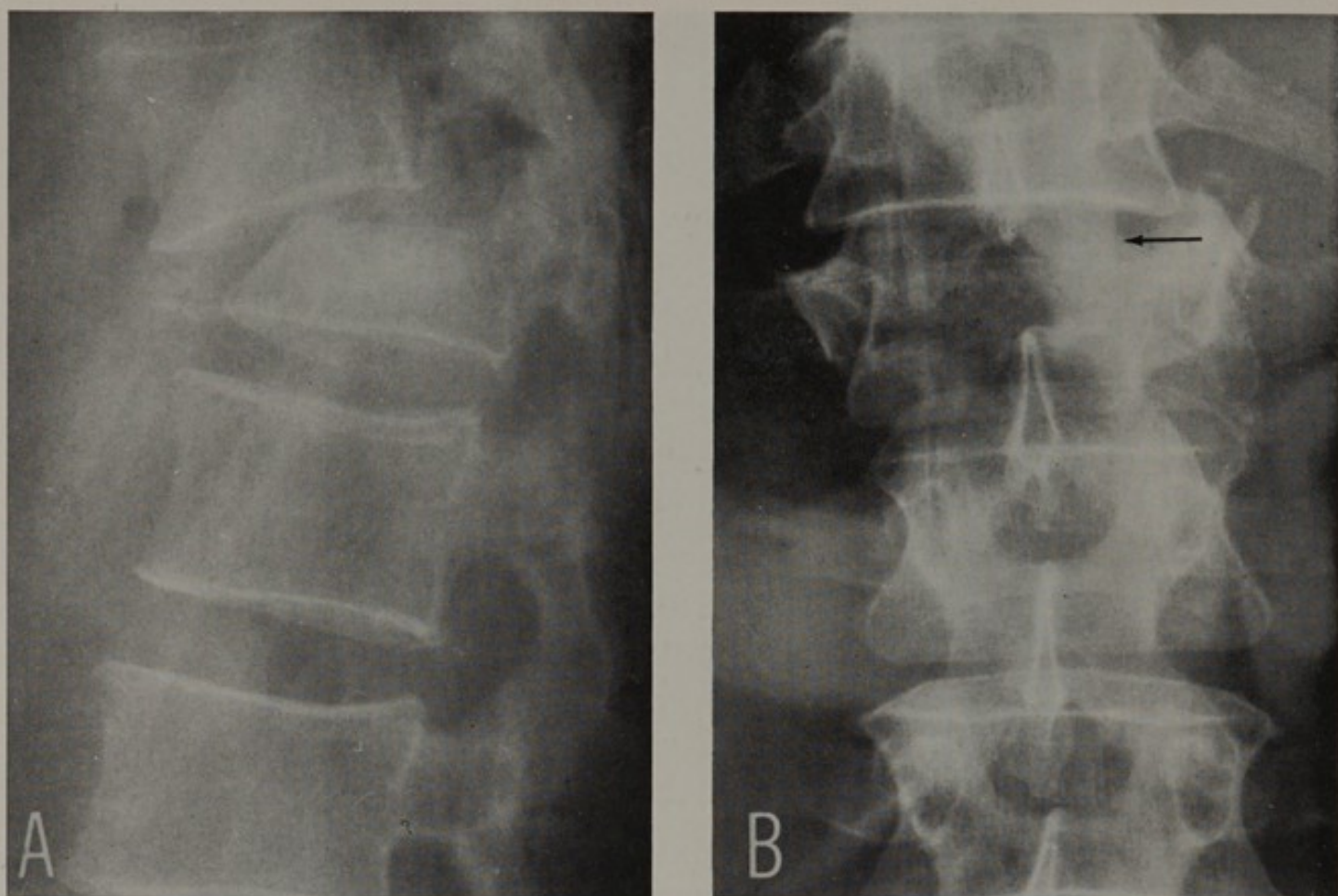


FIGURE 131.—Compression fracture and dislocation of L1 in a 47-year-old farmer who was pinned under a tractor. A. Lateral view. B. Anteroposterior view. Note encroachment on spinal canal by right inferior articular facet of T12 (arrow).

THORACIC AND LUMBAR LESIONS

In injuries of the thoracic and lumbar vertebrae, early treatment usually consists of decompressive laminectomy followed by a period of 6 to 8 weeks on a frame or omission of surgery and maintenance of the patient in mild hyperextension for a similar time interval. As mentioned earlier, indications for exploration and decompression in spinal injuries vary among neurosurgeons. We have considered the following findings as indications for surgical intervention:

1. Radiological evidence of a bony spicule compromising the spinal canal.
2. A progressively developing neurological deficit.
3. Failure of rapid progressive neurological improvement when there is a complete lesion, but no indication of fracture or dislocation in roentgenograms.
4. An incomplete neurological lesion, with a complete block.

5. Same as category 4, but without complete block and failure of improvement in the neurological picture.

Not infrequently, we also explore patients with fracture dislocations who have complete lesions and come under our care in the early hours or days following injury. This is done with full realization of the dismal prognosis. Perhaps it is wishful thinking, but by going ahead with laminectomy we feel we are offering the patient the benefit of the doubt. We have not seen any recovery of function following operation in completely paralyzed patients with thoracic fractures accompanied by lateral dislocation of the vertebral bodies. Similar lesions at the thoracolumbar junction or in the lumbar spine offer more hope with surgery.

The value of decompression appears more definite in patients who have a complete block, but show some preservation of neurological function. Admittedly, when postoperative improvement does oc-

cur, it is often difficult to be certain that the same result might not have been achieved without surgery. However, there are many instances in which surgical intervention appeared to have been the decisive factor in effecting a favorable outcome. The following case history is an example.

On 25 October 1958, a 47-year-old farmer was admitted to Barnes Hospital. At 1:00 p.m. that day, he was pinned under his tractor which literally jackknifed his body. He immediately lost use of his lower extremities and his legs felt numb; however, he was able to perceive painful sensation. Upon examination 6 hours after injury, he had total motor paralysis and areflexia of his lower extremities. Position sense was virtually absent in his toes and feet, and he had hypesthesia and hypalgesia to T12 with touch more diminished than pinprick sensation. He was unable to void, and a retention catheter was inserted. Roentgenograms revealed a compression fracture of L1 with posterior and lateral dislocation; the right inferior articular facet of T12 being displaced medially and encroaching upon the spinal canal (fig. 131). Surgery was begun 9 hours after injury at which time there had been no change in the neurological picture. The right inferior articular facet of T12 was found pinning the right half of the dural sac against the body of L1. The left half was distended and displaced to the left without any visible pulsations. Following removal of all bony compression, the dura ballooned out to its normal contour and pulsated freely. Since surgery, the patient has regained bladder function, cutaneous and deep sensation have returned to normal, and there has been progressive recovery of motor function in the limbs.

From the findings at operation, it is difficult to believe that this man could have recovered any useful function without the benefit of decompression.

Occasionally, patients with fracture dislocation may also have an extruding intervertebral disk, which contributes significantly to their neurological deficit.

A 16-year-old boy was involved in an automobile accident on 21 March 1958. He suffered multiple rib fractures, renal contusion, and was unconscious for several hours. Six days after injury, he noted weakness of the right lower extremity. The weakness progressed, and he was admitted to Barnes Hospital on 31 March 1958. Upon examination, there was marked weakness of the right quadriceps, tibialis anticus, and peroneal muscles. The right knee jerk could not be elicited, and there were hypalgesia and hypesthesia of L2 and L3. Roentgenograms revealed fracture of the body and pars interarticularis of L1 with lateral displacement of L1 to the right (fig. 132). At surgery, the L1 lamina which was compressing the dural sac was removed, and in addition, a laminectomy of L2 was performed. Following this, it was observed that the dura was displaced

upward on the right side at the L1-L2 interspace. Upon retraction of the dura medially, a fractured annular ring with loose fragments of disk material were disclosed. The free disk fragments were removed and the remaining disk material in the interspace evacuated. A spinal fusion was then performed. After surgery, there was progressive recovery of neurological function, and upon readmission to the hospital for removal of his body cast 4 months later, neurological examination was entirely normal.

The case just cited also demonstrates the value of surgical exploration in patients who show progressive neurological deficit.

The question of whether one should open the dura at the time of decompressive laminectomy is an unsettled issue. There are those who caution that the dura should never be opened for fear of herniation of edematous cord (4), and there are those who recommend opening the dura and performing a dorsal myelotomy if significant swelling is evident (7). Frequently, we open the dura, making an effort to preserve the arachnoid, although we have not made it a practice of incising the dorsal columns. If significant cord swelling is found, we do not hesitate to explore the cord with needle and syringe for an intramedullary clot.

EARLY MEDICAL MANAGEMENT

Here we are concerned with the 6 to 8 weeks' period which follows injury. Management during this time has been discussed in many excellent reviews and we will recapitulate the essentials only. The areas upon which we focus our attention are the skin, bladder, nutrition, morale, and physical therapy.

Skin.—The combination of immobility and absent sensation predispose the patient with cord injury to the dreaded complication of decubital ulcer. Sustained and imperceptible pressure in denervated areas produce ischemia and tissue necrosis and an ulcer follows. The time required for development of irreversible changes is relatively short, and we have seen infarcted areas appear in poorly managed patients within 6 hours. The Foster and Stryker frames have been valuable aids in handling this problem. They permit the patient to be turned as if he were a board and he lies on his abdomen and back alternately for short periods of time (from 1 to 2 hours). The skin of the patient and the sheets

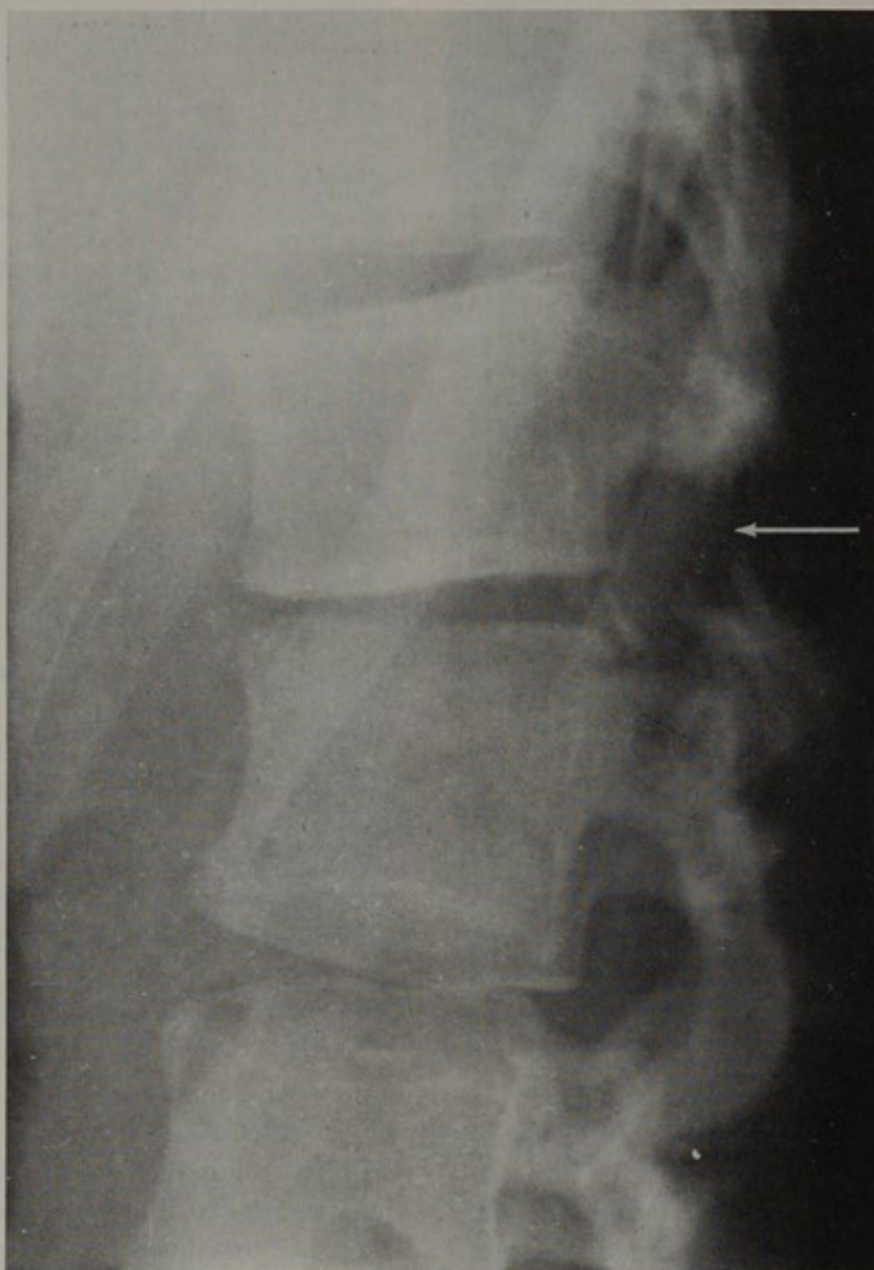

FIGURE 132.—Compression fracture and dislocation of L1. Note also fracture of pars interarticularis (arrow). Extrusion of the L1-L2 intervertebral disk was found at surgery. Patient was a 16-year-old boy who developed progressive weakness of his right lower extremity several days following an automobile accident.

covering the frame or bed should be kept well powdered to prevent abrasions on movement. Even with brief periods of intermittent pressure, decubital ulcers may still develop in areas of the skin overlying bony prominences which are poorly protected by adipose tissue. Therefore, pillows or similar supports must be placed strategically to protect such vulnerable areas as the heels, sacrum, anterior superior iliac spines, patellae, and tibiae. We have become increasingly aware of the necessity of protecting the fibular head and avoid hyperextension

at the knee to prevent peripheral peroneal palsy.

One of the most treacherous problems posed by decubital ulcers is the insidiousness with which infection and abscess formation may take place beneath an eschar in an inadequately treated ulcer. Superficially, a sacral lesion may appear benign and healing, but upon removal of the eschar, an abscess is encountered which may extend to the rectum. Indeed, in some cases a rectal fistula has made the infection known.

Of course, the best treatment of lesions is their

prevention. However, once they appear, adequate debridement, avoidance of further pressure, and allowing reparative processes to proceed from the bottom up are the principles which govern treatment. In a few fortunate instances, a clean base can be obtained quickly and rotation of skin flaps may then be successfully attempted.

Bladder.—In both cord and cauda equina lesions, it is possible ultimately to dispense with catheter drainage. This potential goal can be achieved only through the happy combination of dedicated attendants and the maintenance of interest and effort to the patient. With cord involvement, the bladder behaves like spastic somatic musculature. There is paresis and an exaggerated response to stretch. Reflex contraction occurs with a partially filled (from 75 to 150 cc.) bladder, and detrusor weakness results in an incompletely emptied viscus. Where the residual urine is small, patients may "get along" with such reflex micturition. However, many times transurethral resection of the vesical neck resulting in a decreased peripheral resistance is necessary to establish effective bladder emptying. When bladder spasticity is marked, conversion of the reflex bladder to an automatic one by differential sacral neurotomy as proposed by Meirowsky, Scheibert, and Hinchey (8) (9) may eliminate the indwelling catheter.

As mentioned earlier, patients with cauda equina lesions, resulting in totally denervated bladders, may develop automatic control because of the inherent tone in the smooth muscle viscus (10). With the aid of abdominal compression, complete evacuation of the bladder may be accomplished.

However, reflex and automatic micturition can be effected only if the bladder has not been irreversibly damaged. Therefore, the principle which guides management is preservation of the integrity of bladder musculature. It follows then, that a retention catheter must be inserted before significant overdistention results in permanent muscular atony. The catheter is not allowed to drain continuously for this predisposes to the development of a small capacity, contracted viscus. Therefore, it is distended intermittently to its normal capacity. This may be accomplished by intermittent distention with from 250 to 300 cc. of saline, 1/4-percent acetic acid, or a similar solution, employing tidal drainage as described by Munro (11), or by releasing a clamped catheter

periodically. If the latter method is employed, the bladder is also irrigated with one of the aforementioned solutions two or three times daily. Infection is an ever-present threat with the use of an indwelling catheter, and it is the other contributing cause of a contracted and fibrotic viscus. Every effort should be made to minimize its appearance. All irrigations are performed under sterile conditions, a new catheter is inserted weekly, and the patient is placed on prophylactic doses of one of the urinary chemotherapeutic agents. In addition, a daily fluid intake of no less than 3,000 cc. should be maintained.

In the male, common complications with an indwelling catheter are periurethral abscess, prostatitis, and epididymo-orchitis. Obviously, any temperature elevation merits thorough examination of the external genitalia.

Nutrition.—It is well established that patients immobilized by cord injuries have a negative nitrogen balance. Weight loss is almost always evident and edema may develop. A high protein, high caloric diet is essential and serial determinations of serum proteins and hemoglobin are helpful in following the patient. Reduction of the circulating hemoglobin is a sign of severe depletion. It is the last protein reservoir to be tapped by the body metabolism, and in cases where it is significantly reduced, whole blood transfusions are indicated. Once again, we call attention to the necessity for a high fluid intake. In this instance, however, for a reason other than combating urinary tract infection. Very soon after injury, there is an increase in urinary calcium excretion. With immobilization and absence of stress, the protein matrix of bone fails to bind calcium and the latter is excreted in the urine. Unless the urinary output is kept high, the increased calcium concentration predisposes to the formation of calculi.

Morale.—The stark realization of the presence of permanent limb paralysis and impaired bladder, bowel, and sexual function is one of the most demoralizing situations experienced by man. One cannot overemphasize the importance of properly informing the patient of his condition. The timing and the method of this communication are a test of the art of the physician. The patient must not be misled by encouragement of futile aspirations. After a factual and sympathetic appraisal of his handicap he is made aware of what he has to look forward to. Encouragement should be along realistic lines of

what proper medical care and rehabilitation has done for others and may do for him. Indeed, all is not lost, and in many instances, the patient may anticipate earning his own livelihood. Today, there are numerous paraplegics and some quadriplegics who support their families and are active in civic affairs. In spite of this ray of hope, most patients will intermittently become depressed. Frequent conversations and bolstering of their morale, therefore, are essential.

Physical therapy.—The details of physical rehabilitation are beyond the scope of this chapter. However, we wish to stress the importance of the early institution and maintenance of a vigorous program of physical therapy. Recovery of neurological function is of no consequence if muscular atrophy and contracture have been permitted to occur. In addition, in some patients, prostheses, braces, and muscle training have been of inestimable value in rehabilitation. The attending physician must continue to be on the alert for possible complications. We have had the unhappy experience of having a patient succumb from pulmonary embolism during overzealous physiotherapy of a paralyzed limb containing a deep femoral thrombus.

SPINAL FUSION

Whether spinal fusion should be performed is a problem only if significant neurological recovery is anticipated. With permanent, complete, neurological lesions stability of the spine is not essential. With fracture dislocations in the upper thoracic vertebrae, fusion is also unnecessary since the rib cage will stabilize the spine in most instances. In patients who are expected to be ambulatory and who have injuries in the cervical, thoracolumbar, and lower lumbar regions, fusion probably offers the best assurance of spine stability and prevention of further neurological deficit. In the majority of such patients, we have recommended fusion 3 to 6 weeks after injury.

MUSCLE SPASMS

Involuntary flexion contractions of the lower limb musculature is a frequent problem in cord lesions. They are a manifestation of the mass reflex and an

example of the inefficiency of isolated, uninhibited cord function. At times, the spasms may be so precipitous and severe that the patient is literally jerked from his frame to the floor. If the contractions are frequent and allowed to continue untreated, contractures develop and the patient assumes a permanent posture of paraplegia in flexion. This makes skin care difficult and a vicious cycle of decubital ulcers and further contractures may be initiated. Spasms appear to occur more frequently in the presence of malnutrition and infection. Therefore, attention to the principles of management outlined in the section on "Early Medical Management" minimizes their appearance. In addition, intensive physical therapy is good insurance against the development of contractures. Drugs have not been of any significant help.

In cases which do not respond to time and good medical management, other measures have to be employed. For patients with complete neurological lesions, Munro has advocated anterior rhizotomy from T10 through S1 (12). This procedure has proved satisfactory and we have employed it in preference to subarachnoid alcohol injection. Recently, MacCarty (13) has carried out cordectomies with satisfactory results. He recommends this as a simple and effective way of eliminating spasm. Of course, where contractures have already developed, the procedures just mentioned have to be combined with a tenotomy.

PAIN

Pain of minor significance is frequently encountered following closed spinal cord injuries—symptoms varying from local muscle discomfort to transient, radicular complaints. Fortunately, development of severe and persistent painful states is an uncommon occurrence, and from 3 to 10 percent of the patients require surgical intervention for intractable pain (14) (15) (16) (17). The latter statistics include penetrating injuries, but our own experience with closed spinal trauma corresponds with these figures. Of the last 80 cord and cauda equina injuries admitted to Barnes Hospital, St. Louis, Mo., only 5 cases underwent surgery for the relief of pain.

The majority of pain problems result from injuries of the conus and cauda equina. Cervical

cord lesions seldom pose any difficulty, and in our series, there was only one case whose pain was of any significance. This was a patient with fracture dislocation of C5-C6, in whom persistent disabling root pains required posterior rhizotomy.

Painful situations frequently encountered.—Root pain at the level of the lesion is most commonly observed with cervical and high thoracic injuries. Its character is well known and needs no description here. In most instances it is transient, rarely requiring definitive treatment. When it persists and is disabling, posterior rhizotomy is indicated and will abolish the pain.

Paroxysmal episodes of nausea, flushing, excessive heat, abdominal cramps, sweating, and severe headaches are frequently observed. Hypertension in conjunction with distention of bladder and bowel may occur during these periods (p. 369). Though these sensations might not be considered "painful," they are almost always self-limiting and disappear with time. However, there are reports of cases which required surgical procedures. Lower thoracic ganglionectomy, bilateral spinothalamic tractotomy, lumbosacral posterior rhizotomy, and lower thoracic cordectomy (8) (13) (18) have been performed with beneficial results.

Pain referred to areas of impaired or absent sensation presents the most difficult problem. It may or may not be radicular in character. Depending upon the intellect and previous experience of the patient, the pain is variably described as "crushing," "viselike," "tearing," "electric shock," "like a bad toothache," "sharp," "stabbing," and "burning." Some neurosurgeons feel that burning pain has a separate etiology, impairment of sympathetic function being invoked (14). They point out that the burning sensation is characterized by its constancy and vague reference.

The majority of patients with pain of the type just described have injuries of the conus and cauda equina and constitute most of the cases in which painful sequelae require surgical intervention. Again, as in the other painful states, subsidence of symptoms with passage of time is the rule. However, a significantly larger number of these patients develop intractable symptoms. Fortunately, these cases have responded to surgical intervention and bilateral high thoracic cordotomy (T1-T2; lateral spinothalamic

tractotomy) has proved to be the procedure of choice (14) (15) (16) (18). In the four patients in whom we carried out cordotomy, all had significant and lasting relief of their symptoms.

In patients who have not had a previous decompressive laminectomy, we recommend exploration of the injury site prior to consideration of cordotomy. We have encountered patients whose painful symptoms have been alleviated by decompression of cord and roots. In addition, it is also valuable to perform extradural or controlled spinal anesthesia prior to cordotomy. This procedure gives some indication of the results one might expect. However, failure to abolish all pain should not deter one from going ahead with cordotomy. We have recently alleviated all pain with bilateral thoracic cordotomy in a patient in whom preoperative spinal anesthesia failed to eliminate symptoms. Envelopment of injured roots by impenetrable adhesions appears to be a plausible explanation for this observation.

Finally, we emphasize the importance of adherence to the principles, outlined under "Early Medical Management," in handling painful sequelae of spinal injuries. Pain compounded by pressure sores, ravages of urinary tract infection, poor nutrition, and morale is virtually an insurmountable problem. On the other hand, a patient free from these demoralizing complications can usually tolerate his discomfort while time does the trick. In no instance should one resort to the administration of narcotics. They are rarely of any lasting help and addiction is a real threat.

REFERENCES

1. Tarlov, I. M., Klinger, H., and Vitale, S.: Spinal Cord Compression Studies. I. Experimental Techniques to Produce Acute and Gradual Compression. *A.M.A. Arch. Neurol. & Psychiat.* 70: 813-819, December 1953.
2. Tarlov, I. M., and Klinger, H.: Spinal Cord Compression Studies. II. Time Limits for Recovery After Acute Compression in Dogs. *A.M.A. Arch. Neurol. & Psychiat.* 71: 271-290, March 1954.
3. Schneider, Richard C.: Trauma to the Spine and Spinal Cord. In Kahn, Edgar A., Bassett, Robert C., Schneider, Richard C., and Crosby, Elizabeth Caroline: *Correlative Neurosurgery*. Springfield, Ill.: Charles C Thomas, 1955, pp. 327-354.
4. Tarlov, I. M., and Herz, E.: Spinal Cord Compression Studies. IV. Outlook With Complete Paralysis in

- Man. A.M.A. Arch. Neurol. & Psychiat. 72: 43-59, July 1954.
5. Crutchfield, W. G.: Further Observations on Treatment of Fracture Dislocations of the Cervical Spine With Skeletal Traction. Surg. Gynec. & Obst. 63: 513-517, October 1936.
 6. Alexander, E., Jr., Forsyth, H. F., Davis, C. H., Jr., and Nashold, B. S., Jr.: Dislocation of the Atlas on the Axis; The Value of Early Fusion of C1, C2, and C3. J. Neurosurg. 15: 353-371, July 1958.
 7. Freeman, L. W.: Injuries of the Spinal Cord. Surg. Clin. N. America 34: 1131-1146, August 1954.
 8. Meirowsky, A. M., Scheibert, C. D., and Hinchey, T. R.: Studies on the Sacral Reflex Arc in Paraplegia. I. Response of Bladder to Surgical Elimination of Sacral Nerve Impulses by Rhizotomy. J. Neurosurg. 7: 33-38, January 1950.
 9. Meirowsky, A. M., Scheibert, C. D., and Hinchey, T. R.: Studies on the Sacral Reflex Arc in Paraplegia. II. Differential Sacral Neurotomy, An Operative Method. J. Neurosurg. 7: 39-43, January 1950.
 10. Lapidus, J.: Observations on Normal and Abnormal Bladder Physiology. J. Urol. 70: 74-83, July 1963.
 11. Munro, D., and Hahn, J.: Tidal Drainage of Urinary Bladder; Preliminary Report of This Method of Treatment as Applied to "Cord Bladders" With a Description of the Apparatus. New England J. Med. 212: 229-239, 7 Feb. 1935.
 12. Munro, D.: The Rehabilitation of Patients Totally Paralyzed Below the Waist, With Special Reference to Making Them Ambulatory and Capable of Earning Their Living. I. Anterior Rhizotomy for Spastic Paraplegia. New England J. Med. 233: 453-461, 18 Oct. 1945. *Correction*, 233: 731, 13 Dec. 1945.
 13. MacCarty, C. S.: The Treatment of Spastic Paraplegia by Selective Spinal Cordectomy. J. Neurosurg. 11: 539-545, November 1954.
 14. Freeman, L. W., and Heimbürger, R. F.: Surgical Relief of Pain in Paraplegic Patients. Arch. Surg. 55: 433-440, October 1947.
 15. Botterell, E. H., Callaghan, J. C., and Jousse, A. T.: Pain in Paraplegia; Clinical Management and Surgical Treatment. Proc. Roy. Soc. Med. 47: 281-288, April 1954.
 16. White, James C., and Sweet, William H.: Pain: Its Mechanisms and Neurosurgical Control. Springfield, Ill.: Charles C Thomas, 1955.
 17. Kahn, E. A., and Peet, M. M.: Technique of Anterolateral Cordotomy. J. Neurosurg. 5: 276-283, May 1948.
 18. De Saussure, R. L., Jr.: Lateral Spinothalamic Tractotomy for Relief of Pain in Cauda Equina Injury. Arch. Neurol. & Psychiat. 64: 708-714, November 1950.

Penetrating Spinal Cord Injuries

CHAPTER 25

General Considerations

Arnold M. Meirowsky

THE PARAPLEGIC PATIENT

Rehabilitation is the ultimate goal of surgical, medical, and nursing treatment of a paraplegic patient. The long-held tenet that wounds of the spinal cord invariably produce permanent paraplegia, usually leading to death within a few weeks or months, is a dictum of the past. The life expectancy of an adequately treated paraplegic patient is as good as that of the average individual. There are today a great many World War II veterans who, though permanently paraplegic, perform well at steady jobs, live satisfactory family lives, and are valuable members of society. They have reached the goal of rehabilitation toward which our neurosurgical efforts must be directed in every instance of paraplegia (1) (2) (3).

Four hundred and seventy-five men sustained wounds or injuries of the spinal canal and its contents in the Korean War during the period from 1 September 1950 to 1 September 1952, resulting in temporary or permanent paraplegia or quadriplegia. Of these, 387 were penetrating, compound wounds. It is this latter group with which we are concerned in the pages to follow. Of the 387 men, 14 died, a mortality of 3.6 percent.

Penetrating wounds, spinal canal:

Agent:	Number of men
Missile	219
Shell fragment	103
Other (or not listed)	65
Total	387

Closed injuries, spinal canal:

Region:

Cervical	30
Thoracic	16
Conus medullaris	20
Cauda equina	22
Total	88
Grand total	475

The essence of management of patients with wounds of the spinal canal and spinal cord lies in the prevention of complications. I should like to begin this discussion of paraplegia, quadriplegia, and of the problems which they present to all of us with the stories of three men, all of whom sustained battle wounds in the Korean War.

The first, an American soldier, K-2033, became a casualty in the late fall of 1950. He sustained a missile wound of the spinal canal at the level of T12 and L1 that rendered him paraplegic. The missile had transversed the retroperitoneal space and lacerated one kidney. Comminuted bone fragments had compressed and contused, but not transected, the conus medullaris. A minimal degree of motor function was preserved caudad to the level of injury, but sensory perception was not preserved. Bowel and bladder function were impaired. A laminectomy was performed 4 days later.

When we first saw this patient, about 2 weeks post-operatively, his face was ashen gray and he showed evidence of excessive weight loss. His laminectomy wound had broken down. He had an extradural abscess. There were multiple decubital ulcers. The bladder was grossly infected.

He died on the 143d day after having been wounded. He died because of an infection about the spinal cord wound that could not be controlled by antibiotics, bladder

and kidney infection, decubital ulcers, and concomitant hypoproteinemia. He died because the sum total of all these complications prohibited early ambulation that could have prevented the formation of kidney stones. The latter was the ultimate cause of death; a urethral stone had blocked the remaining healthy kidney and he died of uremia. Actually, a vicious cycle of complications was the true cause of death. This soldier had a partial spinal cord lesion, any of the effects of which may well have been reversible if complications could have been prevented.

The second story is that of K-764, a 19-year-old U.S. Army private, first class, who was wounded in action by machinegun fire on 14 September 1950. He sustained a compound wound of the cervical canal resulting in quadriplegia. Roentgenographic examination revealed comminution and depression of the seventh cervical lamina. Stryker frame care was instituted with 2-hourly turning and special skin care. A retention catheter was inserted and connected with a tidal drainage apparatus. At operation, a shattered seventh cervical spinous process and depression and comminution of the seventh cervical lamina were found. Complete laminectomy of the sixth and seventh cervical and the first thoracic laminae was performed. An extradural hematoma was encountered and evacuated. Inspection of the cord after opening of the intact dura revealed moderate edema of the cord but no discoloration. The exposed nerve roots were decompressed surgically. The dura was closed. Postoperative course was uneventful. The patient was cared for on a Stryker frame with 2-hourly turning, special skin care, regular enemas, and tidal drainage. He was evacuated to the Zone of Interior still quadriplegic, but with improvement in motor and sensory deficit. In a letter to the author dated 29 October 1958, 8 years after having been wounded, the patient wrote: " * * * my legs returned almost to normal. I don't have too much strength in my arms especially the left one * * *. My bladder seems to be normal. I have some trouble with the bowels. Other than these I am doing very well. I am married and have a daughter four years old * * *."

The third story is that of a U.S. Army major, K-1632, who was wounded in action by a sniper's bullet in September 1950. The missile entered above the collarbone and passed through to his back, fracturing the second thoracic vertebra and resulting in immediate paraplegia. He was operated on on 26 September 1950 in the neurosurgical center, Tokyo Army Hospital. The laminae of T2 were found to be comminuted and depressed. The spinous process of T2 was shattered. The spinal cord was found to be transected at T2. Postoperatively, the patient did not develop any complications. He was returned to the Zone of Interior after having been apprised of the fact that his spinal cord was transected.

Followup information revealed that the patient was hospitalized subsequently at Letterman Army Hospital for a period of 3 months, then was sent to Long Beach Veterans' Administration Hospital. He was discharged from military service on 1 December 1951. Since that time, he has led a remarkably well adjusted civilian life. Though in a wheelchair, he returned to his former occupation as a teacher and

has been most active in his spare time in the Boy Scouts and in other civic affairs. In a spontaneous letter to the author, written Christmas 1957, he said: " * * * Now after two years of full-time teaching, and given a select group of top fifth and sixth graders to develop to their fullest capacities, I couldn't ask for more. I have had the finest cooperation from school officials, fellow teachers, parents, and pupils. * * * To say the least, I am enjoying every day. * * * Had I not had the frank explanation after my operation in Tokyo, I might have let the adversities get me down. Paraplegia is an attitude as much as a condition."

Here, then, are three stories—one of a man with complete paraplegia. Prevention of complications from the outset, early orientation, and development of insight into the nature of the permanent physical handicap put this man on the road to full rehabilitation, which he has achieved. One is the story of a man with an incomplete cervical cord lesion who did not develop any complications and who made a virtually complete recovery. And one is the story of a man with a partial and potentially reversible lesion who succumbed to a vicious cycle of complications to which the paraplegic patient is prone, the only treatment of which is prevention.

Trauma to the spinal cord, or to the cauda equina, may result in complete permanent paralysis below the level of injury; it may result in initially complete paralysis with gradual return of all, or of some, function; or it may result in partial paralysis with continued gain in functional return. A prognosis as to the latter cannot always be made before the cord has been inspected; it certainly cannot be made before operation.

Trauma to the spinal cord does not manifest itself solely by the pathological changes in and about the cord at the site of injury. Such trauma has a profound effect on the entire physiology of the body. It may interfere with motion and with sensation, with function of the bladder, bowels, and other visceral organs, with the circulatory system, with the sweat apparatus, with the endocrine system, and with the electrolyte balance. The management of wounds of the spinal cord is, therefore, concerned with the local pathology and with the effect which this pathology may have on distant organs and on physiological mechanisms. Last but not least, consideration must be given to the interference with equanimity which the conscious experience of sudden motor and sensory loss may cause.

The task awaiting those who are charged with the care of casualties with injury to the spinal cord presents a genuine challenge. The *laissez faire*, *laissez aller*, resulting in therapeutic nihilism, has become an attitude of the past for which an all-out effort toward rehabilitation has been substituted. From the battalion aid station to the mobile neurosurgical team in the combat zone, to the neurosurgical centers in the communications zone and the Zone of Interior, clearly defined responsibilities for medical care must be assumed by doctors and nurses, by corpsmen and ambulance drivers, and by helicopter pilots and Air Force personnel in charge of evacuation. Ultimately, only the combined efforts of all will suffice to meet that challenge and will serve to prepare the way for complete rehabilitation. The same applies to the "chain of command" in civilian practice. Clearly defined responsibilities must be assumed by those in charge of the emergency room of the hospital to which the man with a penetrating wound of the spinal canal is first admitted. What has been accomplished by an efficient organization in combat zones for the care of men with wounds of the spinal canal can be duplicated in civilian practice.

Extensive experience in the management of trauma to the spinal canal and its contents has shown that early mistakes in judgment, nursing care, and bladder management are expensive in terms of delayed and curtailed recovery. An adequate program for a patient with trauma to the spinal cord must be designed to include an array of preventive measures in order to eliminate, or to reduce to a minimum, all possible complications. Medical or nursing measures which are basic in the management of any paraplegic disorder should be adhered to strictly to prevent such detrimental complications as overdistention of the bladder, infection of the genitourinary tract, decubital ulcers, infection at the site of entrance of the missile wound, anemia, hypoproteïnemia, weight loss, despondency, drug addiction, and cachexia (4). In setting forth any program for the management of casualties with trauma to the spinal cord, it must be borne clearly in mind that many injuries of the cord or *cauda equina* may prove to have been partial, permitting considerable or total recovery, and that even those with complete destruction of the spinal cord may be rehabilitated.

To attain the maximum possible return of func-

tion and to prevent detrimental complications, earliest possible neurosurgical intervention with simultaneous application of specialized nursing measures is mandatory. Based on this principle, there evolves a pattern of handling spinal cord wounds which is concerned with many details, the sum total of which brings us closest to the ultimate goal: rehabilitation (1 through 10).

The student of trauma to the spinal cord will find a wealth of individual papers and publications from which he may gather additional information. Some of these are listed among the references to this chapter. Three most informative publications stand out among the current contributions to the problem on hand: (1) Based on his extensive personal experiences, Freeman (2) published two consecutive papers on the treatment of paraplegia resulting from trauma to the spinal cord in 1949. (2) The monograph entitled "*Les traumatismes de la moelle épinière*" by Mahoudeau (11) represents a most comprehensive and searching study of the subject to date. (3) A wealth of information on the management of paraplegic patients as it evolved from the experiences in the Second World War can be found in Spurling and Woodhall's most recent second volume on neurosurgery which is part of the series on the history of the U.S. Army Medical Department in World War II (6).

Ernest Bors, Chief, Paraplegia Service, Veterans' Administration Hospital, Long Beach, Calif., has dedicated his entire professional life to the problems that paraplegia presents. He and his coworkers have made an unequalled contribution with their broad studies of many phases of spinal cord pathology.

ORGANIZATION OF NEUROSURGICAL CARE

EVACUATION

Experience gained in World War II and in centers for the care of paraplegic patients during the postwar period was a decisive factor in the formulation of a new program for the management of Korean War casualties with penetrating injuries of the spinal canal. This experience had made it increasingly clear that prevention of complications had to be achieved during the acute phase of paraplegia and

quadriplegia in order to effect reduction of morbidity and mortality.

In a sense, the Korean War offered "an opportunity" to try out a system of preventive measures which began at the battalion aid station. It is this system which led, in the latter phase of the Korean War, to the elimination of decubital ulcers, to the reduction of bladder infection and kidney stone formation, and to the improvement in general health of men in the acute phase of spinal cord injury. Added to this was the feasibility of early neurosurgical intervention promoting prevention of infection and recovery of function whenever that was anatomically possible.

In active warfare, medical aims and principles must be coordinated with tactical considerations. The days, however, in which "field conditions" were a deterrent rather than a stimulus to major surgery, have long passed. The employment in the Korean War of mobile neurosurgical teams, attached to Mobile Army Surgical Hospitals at division level, first instituted in 1951, had made possible early neurosurgical intervention and the application of specialized nursing measures in the field during the first postoperative days (4) (8) (12) (13). These teams represented the first echelon of definitive care of neurosurgical casualties and were staffed and equipped so as to render specialized operative and nursing treatment within hours after injury. Their function was enhanced immeasurably by the employment of helicopters for the transport of casualties (figs. 133 and 134). Beginning in October 1951, this mode of evacuation from the battalion aid station directly to the mobile neurosurgical unit was used in the Korean War. After 3 to 7 postoperative days, paraplegic casualties were taken to the nearest large airstrip by helicopter and flown from there directly to the neurosurgical center in the communications zone which was situated at Tokyo Army Hospital in Japan. Poorly tolerated ambulance rides on rough roads in the field were thus eliminated. Interim admissions en route, to hospitals not equipped to care for paraplegic casualties, were avoided.

The neurosurgical center in the communications zone represented the second echelon for the care of neurosurgical casualties. Its mission was to provide the paraplegic patient with all those medical and nursing measures which are essential in the preven-

tion of complications and in the rapid attainment of maximum possible restoration of function.

Having completed the acute convalescent period in the communications zone, casualties with spinal cord wounds were then transferred to centers for the care of paraplegics in the Zone of Interior. Their transport was effected by air aboard C-97 planes. Personnel especially trained in the nursing care of paraplegic patients was employed by the Military Air Transport Service aboard these planes. The use of the litter-turning method and the employment of Stryker frames aboard the planes eliminated, for all practical purposes, the occurrence of decubital ulcers en route; twice-daily bladder irrigations aboard the plane reduced the incidence of bladder infection to a minimum.

Special consideration which is due all casualties with trauma to the spinal cord begins in the battlefield where the medical aidman has the first opportunity to identify the nature of the injury and to employ precautions concerned with position and transportation. Thorough indoctrination of doctors and corpsmen at company, battalion, regimental, and divisional levels, of ambulance drivers and helicopter pilots, and of all medical department personnel dealing with paraplegic casualties, and in civilian life, their counterparts, is of the utmost importance and has a direct bearing upon the ultimate degree of recovery of the individual patient.

GENERAL MEASURES

Wound care.—Debridement of the site of penetration may be deferred as long as it is certain that the patient will reach a neurosurgical installation within 24 hours. Cleansing the skin about the wound and application of a protective dry dressing is all that needs to be done at the forward aid station. Associated wounds of the chest, abdomen, or of the great vessels may delay neurosurgical intervention. (See chapter 38.) In those instances, surgical debridement of the site of penetration in accordance with general surgical principles is indicated. If the wound is situated in the center, overlying the site of penetration of the spinal canal, radical debridement and primary closure are justified and desirable in order to facilitate earliest possible laminectomy. A large gaping wound, as such, does not present

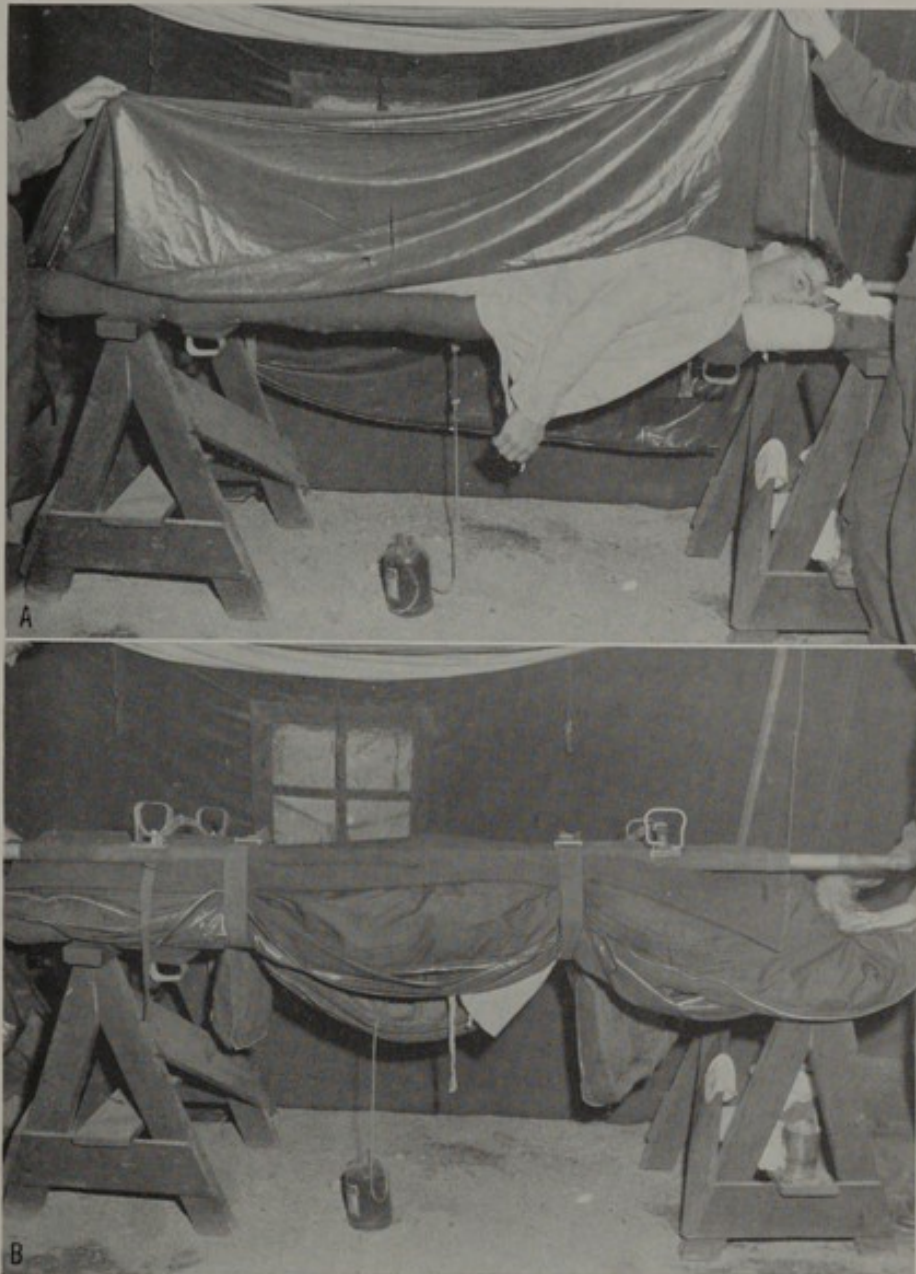

FIGURE 133.—A. Paraplegic patient being prepared for evacuation in winter weather. B. Patient strapped between two litters for turning to supine position before being placed in helicopter. (Photographs courtesy of J. B. Lippincott Company.)

a contraindication to laminectomy. Debridement and closure can be carried out at time of neurosurgical intervention provided that laminectomy is performed early. It must be borne in mind that infection of the soft tissue wound, overlying the site of proposed laminectomy, makes the latter prohibitive for weeks and may deprive the patient of valuable future gains (10).

Transportation and position.—The safest method of transporting casualties with penetrating wounds of the spinal cord consists of litter transport in the

supine position. Care must be taken to make certain that the transport litter is well padded with blankets, thus avoiding contact of the skin with rough surfaces. In the presence of trauma to the cervical cord, the head should be immobilized with small sandbags on each side of the face and neck.

The position of a patient with a penetrating wound of the spinal cord should be prone or supine. To prevent the development of decubital ulcers, the patient must be turned every 2 hours. Rather than placing the paraplegic or quadriplegic patient on




FIGURE 134.—Helicopter evacuation of paraplegic patient.

a cot, he is best cared for on a litter which has been padded amply with blankets. The litter-turning method (fig. 22) has proved to be most advantageous in installations in which the use of Stryker or Foster frames would be impractical.

During the fighting at the Chosin (Changjin) Reservoir in November 1950, the author temporarily interrupted a consultant's visit to various hospitals in order to take care of neurosurgical casualties which had been evacuated from the Reservoir to the 121st U.S. Army Evacuation Hospital, then located in the vicinity of Hamhung. When the problem arose as to how best to care for a casualty with a spinal cord wound, two Medical Corps Reserve offi-

cers, then on the staff of the 121st Evacuation Hospital, but obstetricians and gynecologists in civilian life, rose to the occasion by devising an ingenious method of care which was solely responsible for the elimination of decubital ulcers during the remainder of the Korean War. Maj. Joseph L. Girardeau, MC, and Maj. Clifford P. Goplerud, MC, employed the litter-turning method on a quadriplegic patient for the first time in November 1950. Further experience led to improvement of this method and its standardization. The exclusive use of the 2-hourly litter-turning method in the 3d Neurosurgical Detachment (Provisional) during the period from October 1951 to August 1952, inclusive, was respon-




FIGURE 135.—Demonstration of the use of padded litters for turning of paraplegic patient in operating tent. (U.S. Army photographs.)

sible for the fact that decubital ulcers did not develop in any American or United Nations patient (8) (12).

For the prone position, the padded litter has been specially prepared and an opening for the face as well as for the catheter has been provided. The patient's position is changed every 2 hours by placing a second padded litter on top of him and turning him between the two litters which have been strapped together (fig. 135).

In fixed installations, the positioning, turning, and nursing of the paraplegic and quadriplegic patient is facilitated greatly by the use of Stryker, Foster (14) (15), or Circoletric frames. The Stryker frame is covered with five or six soft pillows placed transversely on the frame. Pillow padding (see fig. 138) has proved to be a great deal more satisfactory than the use of foam or air mattresses or any of the other available commercial supplies. Padding should be used between the inner surfaces

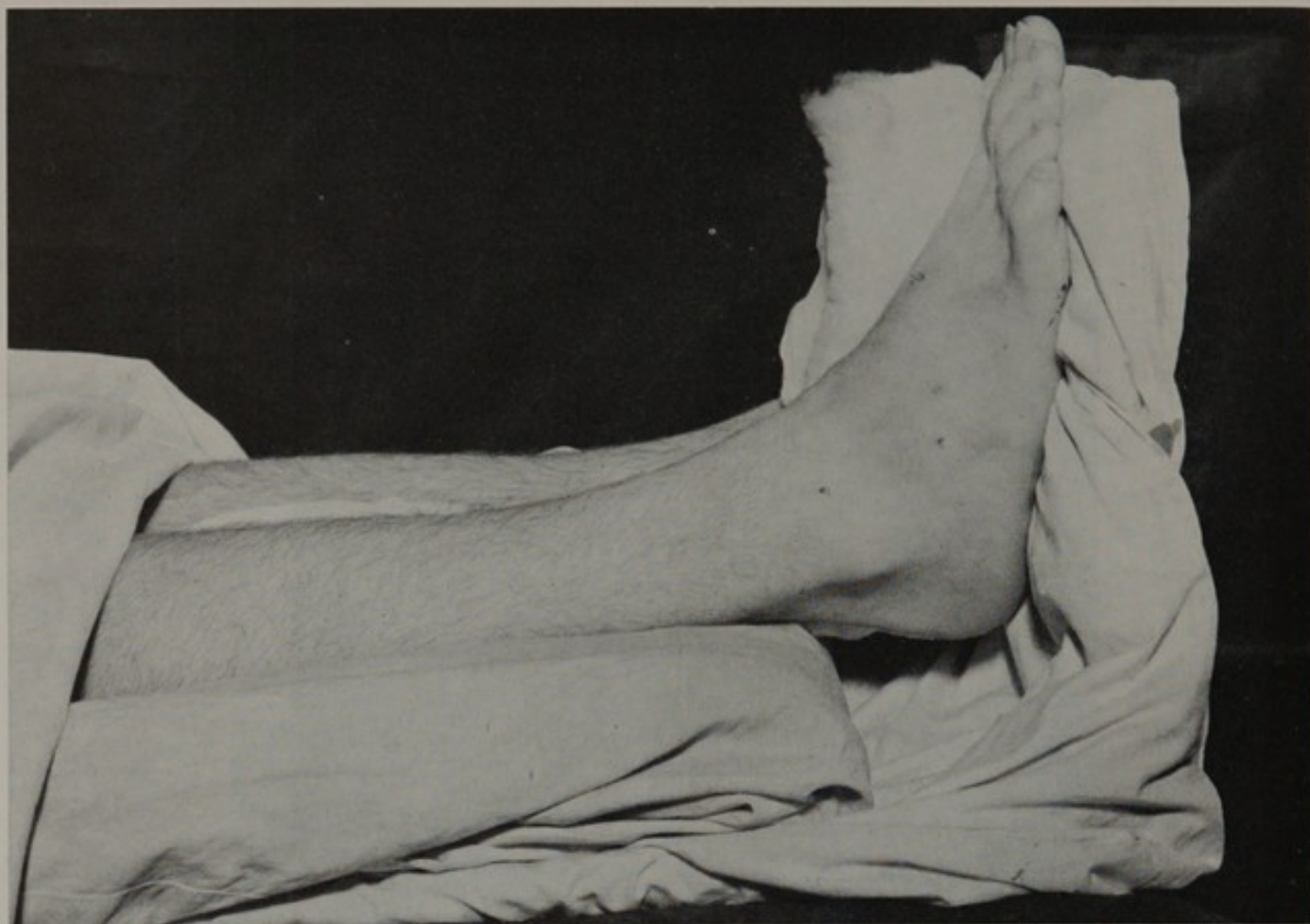

FIGURE 136.—Position of feet in supine position. (Photograph courtesy of J. B. Lippincott Company.)

of the ankles and knees; in the supine position, the lowermost pillow should end at the level of the ankle, allowing the heels to hang freely (fig. 136). The use of a standard footboard will serve to prevent maintained plantar flexion. In the prone position, the lower pillow and canvas frame should end just above the ankle to allow the feet to hang perpendicularly to the floor (fig. 137).

Consideration should be given to the fact that temperature regulation is disturbed caudad to the level of the spinal cord injury. In winter, body heat must be conserved. The problem is even greater in hot summer climate, because large portions of the body have been deprived of their sweat mechanism. For that reason, plaster of paris casts are contraindicated; also, decubital ulcers may develop under a cast within a very few hours. For a long trip, the use of a well-padded half-shell may occasionally be in order in cases requiring a high degree of immobilization; it should, however, be avoided whenever possible. Aboard planes and

trains, the litter-turning method has proved to be advantageous, providing sufficient immobilization as a rule.

The lifting of a patient with trauma to the spinal cord requires certain precautions. The lift should be performed by three or four men. Two or three men place themselves on one and the same side of the patient, pushing their arms under the patient with the elbows almost fully extended and with the forearms in a supine position. One man holds the patient's head, supporting it and applying a moderate degree of traction at the same time. In lifting the patient from transport litter to frame (which should be placed at a right angle to the litter), the attendants will turn around the axis of the man supporting the patient's head, lifting the patient on the frame without flexing his spine (fig. 138).

Initial bladder care.—Urinary retention with overflow exists in the majority of patients with injury to the spinal cord. The ultimate development of a

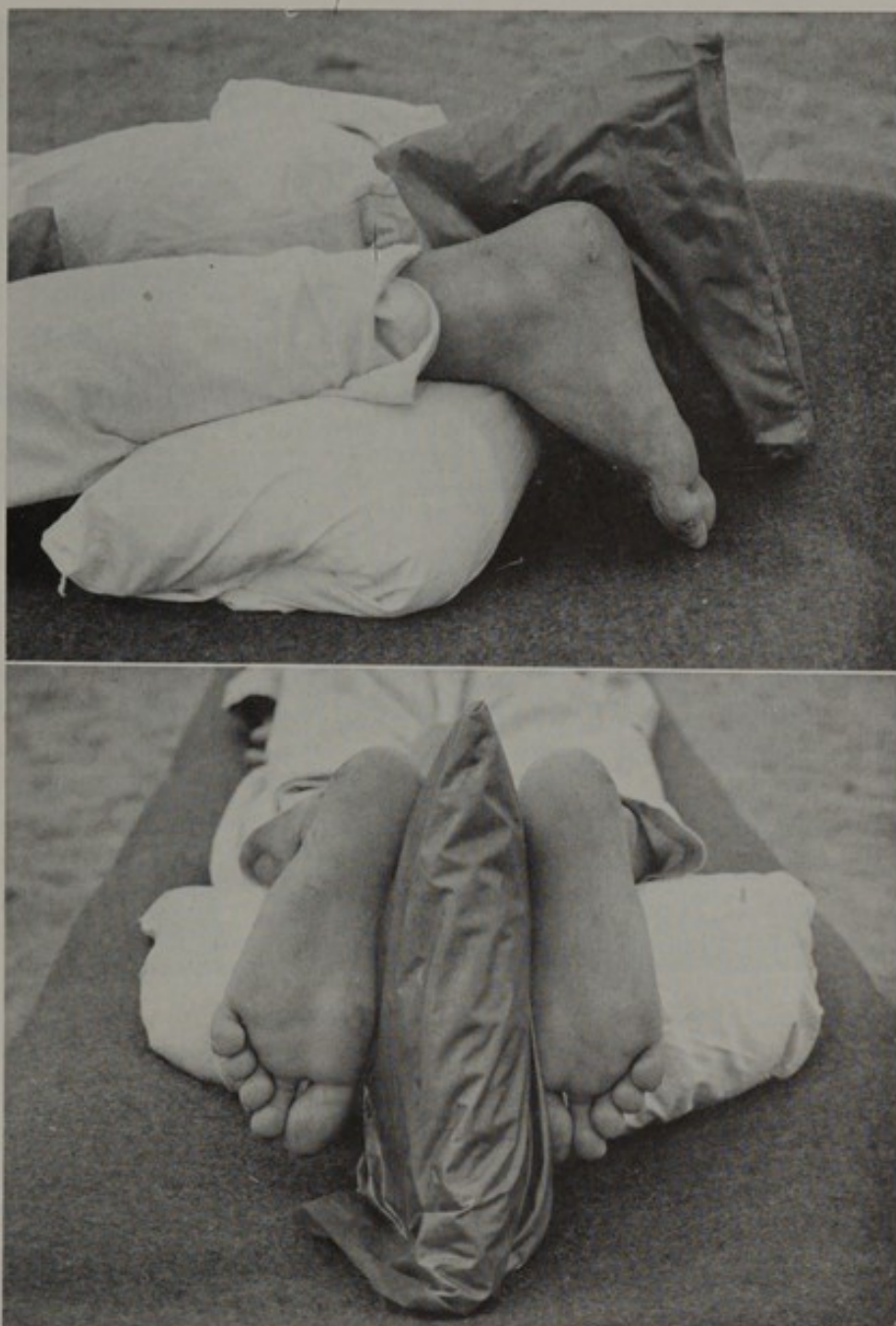


FIGURE 137.—Position of feet in prone position. (Photographs courtesy of J. B. Lippincott Company.)

reflexly functioning bladder or the surgical establishment of an automatic bladder depends on the efficacy of early management of the neurogenic bladder. If the rational method of bladder care as outlined by Munro (16) (17) (18) is followed, it may be possible, in many instances, to discard the catheter as early as 6 weeks after injury. Should Munro's bladder training method fail to result in a reflexly functioning bladder, surgical establishment of bladder automaticity can often be accomplished by differential sacral neurotomy or rhizo-

tomy (19) (20) (21) (22). This has been discussed in detail elsewhere in this volume (pp. 345-355). To succeed with any of these methods, overdistention of the bladder must be avoided from the onset of paraplegia, bladder tone must be maintained, and bladder and ascending urinary tract infection must be prevented.

A No. 16 or 18 French Foley catheter with a 5-cc. retention bag or, if this type is unavailable, any soft catheter of the same size or smaller should be inserted under sterile precautions at the first medical

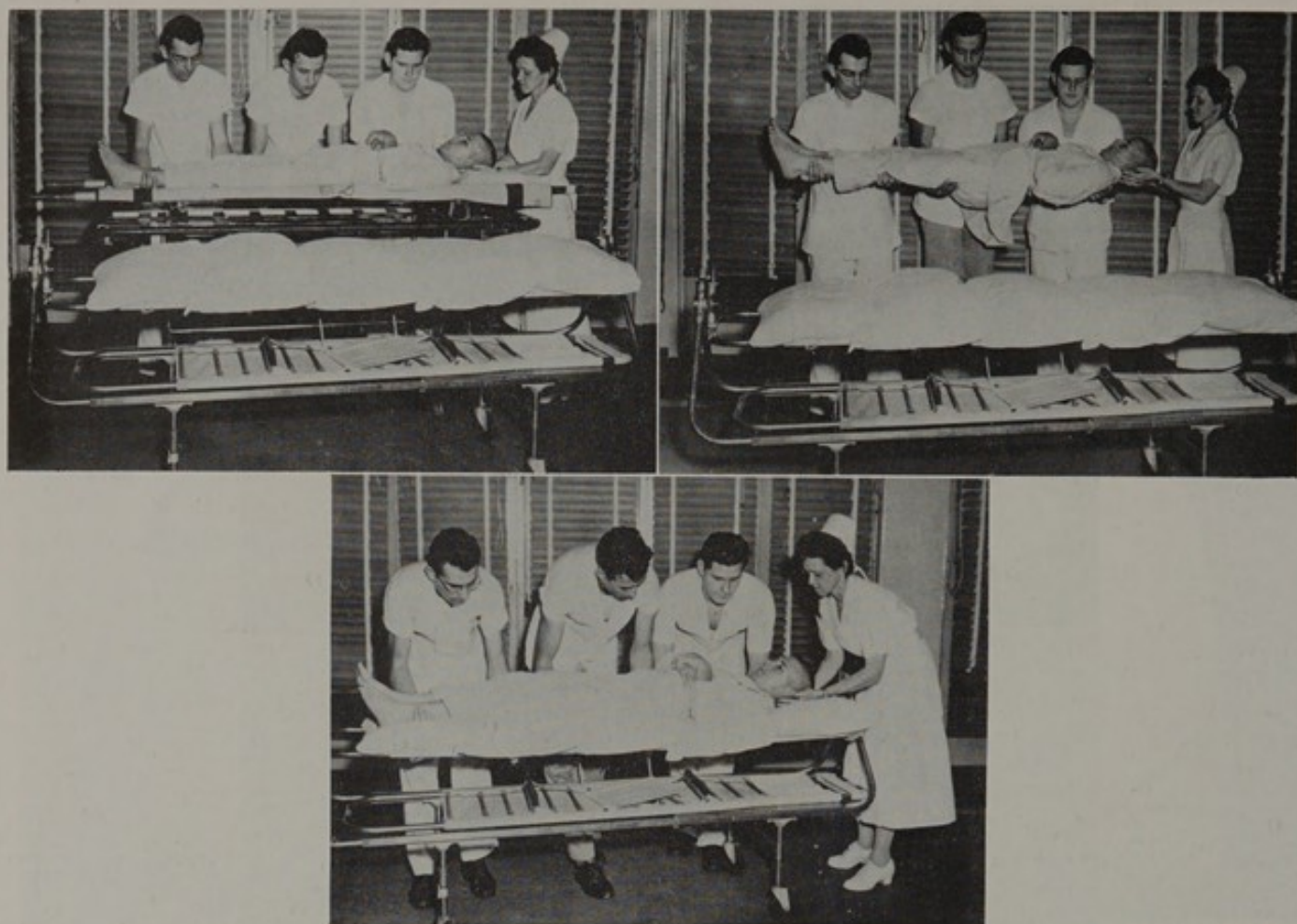


FIGURE 138.—Lifting of quadriplegic patient.

installation to which the patient is admitted. The use of a larger catheter may prevent egress of fluid from the bulbourethral, ejaculatory, and prostatic ducts and produce edematous closure. The resulting stasis may cause epididymitis. Twice-daily irrigations will serve to keep the catheter patent and to prevent infection. The irrigating fluids used include Solution G,¹ Solution M² (23) (24), 2 percent boric acid solution, and normal saline. According to Freeman (2), Solution G is probably the best all-around solution, although Solution M has the advantage of a more favorable pH (5.0) after the first few days of irrigation. Solution G may produce inflammatory changes after prolonged use. The catheter should be changed twice weekly. Permanent removal of the retention catheter should not be done until repeated tests have shown that

the residual urine amounts to less than 30 cubic centimeters.

Munro's tidal drainage (16) (17) represents the treatment of choice of the acute neurogenic bladder. It should be substituted for straight catheter drainage within a few days after the onset of paraplegia (18). Only in the presence of urinary tract infection may it be necessary to discontinue tidal drainage temporarily and to use straight catheter drainage. Suprapubic cystostomy as a method of treatment of the uncomplicated neurogenic bladder is outdated and contraindicated. Even its temporary use interferes with the restoration of a functioning reflex bladder. Suprapubic cystostomy makes it virtually impossible to produce bladder automaticity surgically because of its grave interference with intrinsic bladder tone.

The penis should be kept loosely taped to the abdominal wall to prevent kinking of the urethra on the catheter at the penoscrotal junction, thus pre-

¹ Solution G: Citric acid, 32.25 gm., magnesium oxide, 2.92 gm., and sodium bicarbonate (anhydrous), 3.84 gm. per liter of distilled water.

² Solution M: Citric acid, 32.25 gm., magnesium oxide, 2.92 gm., and sodium bicarbonate (anhydrous), 8.84 gm. per liter of distilled water.

venting periurethral abscess formation and resulting urethrocutaneous fistula (10).

Initial examination.—As soon as the presence of paraplegia or quadriplegia has been ascertained in a newly admitted casualty, the initial examination should be interrupted and a catheter inserted into the bladder. This step should take precedence in order to prevent overdistention of the bladder with its irreparable consequences.

Subsequent examination should include an evaluation of the sensory loss for superficial pain and light touch. The degree of motor loss can be determined readily. Accurate recording of partially retained motor and sensory function will help considerably in the future evaluation of the patient. Deep tendon and superficial reflexes, as well as pyramidal tract signs, should be tested and recorded although their interpretation in the acute spinal cord injury might lead to fallacious conclusions. A rectal examination is most helpful for the evaluation of the degree of loss of sphincter tone. It will also rule out fecal impaction.

The general physical examination must be painstaking and thorough. Common associated injuries such as pulmonary hemorrhages, intestinal perforations, and retroperitoneal hemorrhages should be detected at once, for they may require surgical priority. Associated peripheral nerve injuries may be overlooked. Head injuries are usually recognized before detection of the cord injury. Cervical cord injuries may go undetected when occurring in conjunction with parasagittal craniocerebral trauma.

Roentgenological studies should include anteroposterior and lateral views of the involved area of the spinal column so as to determine the extent of the bony damage and the position of the missile. Stereoscopic views are advantageous. In order to expedite evacuation, roentgenological studies should not be performed before the patient is admitted to a neurosurgical installation. Chest X-rays are taken routinely on all patients with injury to the cervical and thoracic segments of the spinal cord.

While it is advantageous to have preoperative knowledge of the presence of a partial or complete block of the spinal fluid pathways in closed injuries of the spinal canal, this is of no particular help in the management of penetrating wounds of the spinal canal. Every compound wound of the spinal canal requires neurosurgical intervention in order to pre-

vent infection. The presence or absence of a block does not alter indications for surgery. As a rule, therefore, a preoperative spinal tap is unnecessary.

Records.—Accurately prepared, detailed records are of prime importance to the paraplegic patient who may have to undergo prolonged hospitalization in various institutions. It is essential that such a record be initiated when the patient is first seen neurosurgically. In combat zones, the initial record should be established in the first neurosurgical echelon and supplemented successively in every hospital throughout the chain of evacuation. A transcript of the entire record should accompany the patient upon transfer to a Veterans' Administration facility so as to expedite his rehabilitation program. The importance of preparation of detailed records cannot be over emphasized (12). The initial record should include data which are shown in figure 139.

A neurological examination with particular emphasis on motor and sensory findings should be performed and recorded at each hospital to which the patient is admitted. The physiotherapy and physical reconditioning record should be attached to the patient's chart.

Bowel care.—In the presence of paraplegia or quadriplegia, the bowels lose their reflex function. In the early stages, an actual ileus may exist. In cervical and high thoracic cord injuries, this may be of serious consequence. The diagnosis of an ileus can readily be made by percussion and auscultation of the abdomen. Ileus requires immediate attention and can best be alleviated by enema, rectal tube, Wangensteen decompression from above, and Prostigmine Methylsulfate (neostigmine methylsulfate). One cubic centimeter of neostigmine methylsulfate 1:4,000, given every 1 to 2 hours for three to six doses, followed by insertion of a rectal tube for 20 minutes after each injection will usually resolve the ileus (25) (26).

An enema should be given at the earliest possible time after injury providing the patient is not in surgical shock. It should always be given preoperatively. Freeman (2) recommends a warm enema. Because of paralysis of the intestines, it is important to give the enema as a colonic irrigation and to siphon out the enema fluid. An enema should be given every other day. Fecal impactions occur commonly in the presence of a paraplegia disorder and should receive prompt attention. Digital rectal

Name	Rank	Serial Number	
Organization	Home Address		
How:			
When:			
Where:			
General Condition:			
Pulse	Respiration	Blood Pressure	Temperature
Hb.	PCV	Urine Analysis	
Description of Wound:			
Motor System:			
Sensory System: (Diagram)			
Reflexes:			
Rectal Examination:			
Roentgenological Examination:			
Description of Associated Wounds:			
Indications and Timing of Surgery:			
OPERATIVE REPORT			
Anesthesia:	Surgeon:		
Findings and Procedure:			
OPERATIVE REPORT (Contd)			
Recommendations for Immediate Follow-Up Care:			
Final Diagnosis: (Based on operative findings with individual listing of bony, cord and root pathology.)			

FIGURE 139.—Suggested initial medical record for the paraplegic patient.

examinations, therefore, need to be done at regular intervals.

As soon as the paraplegic patient becomes ambulatory in a wheelchair, a bowel control program should be instituted. Freeman (2) advises the following regimen:

As soon as the patient can sit up, enemas are given in that position. Laxatives should be given in the form of 5 to 15 cc. of liquid petroleum and/or 2 to 6 cc. of cascara sagrada given the previous day. In a short time, the patient should be given the duty of administering his own enemas and doing his own digital examinations for possible impactions. The patient then starts a schedule of liquid petro-

tum and cascara sagrada each evening, judging the dosage by the consistency of the stools. Every morning, at exactly the same time, a glycerin suppository should be inserted up to fifteen minutes before the patient gets on the stool. A full hour should be spent before the trial at evacuation is ended. If no stool has resulted, the patient should take 2 cc. of cascara sagrada and go about his daily activities. The usual laxative is taken at bedtime. On the following morning, the procedure is repeated. If no stool results from this effort, an enema should be taken. The entire procedure is then begun again. In a few weeks, regular daily bowel movements will be established and enemas will be needed rarely. Foods are briefly outlined to the patient in regard to their effect on stool consistency ("looseners"—prunes, fruits, and roughage; "binders"—cheese, meat, beans, and other protein-rich foods). * * * There need be no acceptable end result in regard to bowel function other than full control with regular evacuations.

Fluid maintenance.—The output should approximate 2,000 cc. daily. This can be accomplished, as a rule, with a 24-hour fluid intake of 4,000 cubic centimeters. Allowances have to be made for climate, fever, and other special situations requiring adjustments of a fluid maintenance schedule. In the event that the maintenance fluid should have to be administered intravenously, saline should not be used in excess of 1,000 cc. of the 24-hour total. All saline, Ringer's lactate, glucose and saline, salt by mouth, and one-half of blood or plasma should be counted as saline (27). An accurate statistic of the 24-hour total intake and output is essential for the maintenance of a proper fluid balance.

The diet should have a high protein, high vitamin, and high caloric content. As a between feeding, Kleinman and Sprinz (28) have found that the following formula is helpful in obtaining a high protein intake: Powdered skimmed milk, 315 cc.; skimmed milk, 473 cc.; egg whites, 6; and sugar, 15–30 cubic centimeters. This formula provides 92 gm. carbohydrate, 70.5 gm. protein, and 2 gm. fat for each quart, a caloric content of 665 calories per quart.

Blood.—An abnormal blood picture develops frequently in the early phase of cord injury. This is characterized by a sharp drop in serum proteins, followed by reduction of hemoglobin, and by a decrease in red cells. Reduction of hemoglobin may represent use of this protein reservoir by body metabolism. Poorly cared for paraplegic patients with decubital ulcers and bladder infection may

reach a serum protein level below 5.0 gm., a hemoglobin level below 10 gm., and may develop a reversal of the albumin-globulin ratio. Decubital ulcers, not already present at that time, are most likely to develop under those circumstances. Prevention of these changes in the blood picture constitutes an important aspect of the treatment of a paraplegic patient. Maintained anemia and hypoproteinemia may readily set off a vicious cycle leading ultimately to cachexia and to death. To prevent these changes in the blood, whole blood should be administered whenever the hemoglobin is below 14 gm. and whenever the red cell count is lower than 4 million. It is generally calculated that 1 pint of whole blood should be given for every 0.5 gm. that the hemoglobin is found to be below 14 grams. The intravenous administration of plasma, serum, or protein digests does not suffice to combat the reversal of the normal blood picture; their administration is not warranted. The administration of whole blood is the treatment of choice (2) (29).

Skin care.—Decubital ulcers constitute a life endangering complication of a paraplegic disorder. The loss of serum proteins from the ulcer surface accentuates the already existing tendency towards hypoproteinemia. In turn, hypoproteinemia predisposes to the development of decubital ulcers. The presence of an ulcer interferes with positioning and 2-hourly turning of the patient; almost invariably, one decubital ulcer leads to multiple ulcerations of the skin. A vicious cycle is readily set up, leading to cachexia and, if not brought to a standstill, to death. Decubital ulcers are always infected and will attack mercilessly any underlying bone and joint structures. Ambulation, which is so vitally important for the patient's physical rehabilitation and for the prevention of calculus formation, atrophy, and ankylosis, may have to be postponed for months because of the presence of decubital ulcers. The old and outdated tenet that wounds of the spinal cord almost invariably lead to death was based on the once so common picture of the paraplegic lying motionlessly in bed, infested with decubital ulcers, and riddled with infection. It has been proved beyond doubt that intelligent early management eliminates those complications which form a threat to life.

The treatment of decubital ulcers consists of their prevention. The skin does not tolerate prolonged

periods of pressure with concomitant ischemia. The reflex moving response preventing exposure of the skin to prolonged periods of ischemia, ordinarily, is lost in the presence of a paraplegic disorder because of the destruction of normal sensory impulses. Turning of the paraplegic patient every 2 hours and positioning him properly constitutes, therefore, the most important part of the care of his skin. It is also necessary that the skin be kept dry and clean. The perineal areas are frequently neglected and should receive special attention. The use of adhesive tape on skin which has been deprived of its innervation is contraindicated. Hypoproteinemia must be prevented.

Even though proper early management of the paraplegic patient eliminates the occurrence of decubital ulcers, the physician should be aware of the fact that he will be confronted occasionally with the problem of treating an existing ulcer. For specific details, the reader is referred to the excellent writings of Freeman (2) (30) (31), Bors and Comarr (32) (33) (34), and Comarr (35). Generally speaking, the treatment of choice consists of radical debridement, daily irrigations, and daily dressings with dry plasma powder. More important, however, than the selection of the various available external medications is the meticulous wound care which must be applied in order to facilitate early surgical closure of the ulcer. This wound care should be supported by a high protein diet. Of the various surgical methods, total excision of the ulcer with plastic closure by means of a rotation flap is the method of choice. Existing spasticity of any appreciable degree must be relieved surgically by anterior rhizotomy before surgical closure of an ulcer is undertaken (4) (12) (36) (37) (38) (39).

Antibiotics and chemotherapeutic agents.—The ever-changing picture of available antibiotics makes it inadvisable to set forth a specific program of prophylactic dosages of specific antibiotics. Suffice it to say that broad-spectrum antibiotics should be used in liberal dosages as a prophylactic measure in all compound wounds involving the spinal canal and spinal cord. During the Korean War, 600,000 units of penicillin and 0.15 gm. of streptomycin were administered by intramuscular injection four times during a 24-hour period for 2 weeks. The administration of streptomycin was limited to a 5-day

period because of its potential toxic effect on the vestibular apparatus. In the presence of infection, of course, respective antibiotics were given in accordance with cultures and sensitivity studies. To this, Gantrisin (sulfisoxazole) or Furadantin (nitrofurantoin) should be added for the prevention of urinary tract infection. The sulfonamide drugs (other than Gantrisin) should be reserved for actual infection and should not be used prophylactically.

Antibiotics and the sulfonamide drugs should not be administered intrathecally. The presence of a partial or complete block within the subarachnoid space forms a strict contraindication to the intrathecal administration of antibiotics (12). In the presence of partial or complete obstruction of spinal fluid pathways, intrathecal administration of antibiotics may lead to *status spasticus* which is one of the most formidable complications of spinal cord pathology. The author has had the misfortune of seeing and treating two paraplegic patients in *status spasticus*. One died within 48 hours. The other survived.

KE-24191 was 24 years of age when he sustained a fracture dislocation of T5 and T6 and a myelopathy at that level in an automobile accident on 11 November 1948. He was rendered paraplegic. A decompressive thoracic laminectomy was performed on 15 November 1948 at Winter Veterans' Administration Hospital in Topeka, Kans. On 3 January 1949, this man was transferred to Kennedy Veterans' Administration Hospital, Memphis, Tenn., where he first came to our attention. Because of minimal return of function and progressive spasticity, mostly involving flexor groups, pneumomyelography and subsequent pantopaque myelography were carried out, revealing a complete block at T8. Following myelography, the patient developed an elevation of temperature, general malaise, and increasing meningeal signs. Four days after myelography, a lumbar puncture was done, revealing xanthochromic, cloudy spinal fluid with 10,000 red blood cells and a protein of 256 mg. percent. Smear and culture were negative. The latter information was not on hand as yet, when 15,000 units of penicillin in 4 cc. of normal saline were introduced intrathecally. Two hours later, the patient developed excessive, continuous spasms of all muscles receiving their innervation caudad to T5. Breathing difficulties ensued. In rapid succession, flexor spasms continued without letup, putting the entire muscular system caudad to T5 through the full range of motion at rapid speed. The patient was "bathed" in perspiration, losing strength rapidly. The record of medications administered in an effort to interrupt and bring to a standstill this *status spasticus* is sufficiently impressive to warrant citing:

11:30 p.m. (Two and one-half hours after intrathecal injection of penicillin, one-half hour after onset of status spasticus.)

Sodium luminal, grains 2.

12:55 a.m. Morphine, grains $\frac{1}{8}$ (h).

1:15 a.m. Procaine, 180 mg. intrathecally.

2:10 a.m. Sodium amytal, grains $5\frac{1}{2}$ intravenously.

3:00 a.m. Procaine, 200 mg. intrathecally.

3:15 a.m. Sodium amytal, grains 3, intravenously.

4:00 a.m. Spasms of entire musculature caudad to T5 occurred now only in intervals with approximately 3 minutes between paroxysms. Therefore, no further medication was administered until 7:15 a.m. when 200 mg. procaine were given intrathecally. Subsequently, spasms could be elicited by stimuli, but did not recur spontaneously.

10:00 a.m. Spasms recurred with increasing intensity and persistence. Breathing difficulties developed again.

3:55 p.m. Sodium amytal, grains 6, was administered intravenously. Status spasticus did not recur.

Within 24 hours, the patient's neurological status was that prior to the onset of status spasticus. His flexor spasms were of the same degree as before. Anterior rhizotomy (T12-S1) was carried out with complete and permanent relief of spasticity. The patient has fared well ever since then.

The other patient, who was seen with status spasticus, had a posttraumatic myelopathy at T1. Despite immediate institution of a regimen similar to the one just described, this man died. Post mortem examination revealed ascending myelomalacia from T3 to C1.

The experiences and observations which have been related clearly show that intrathecal administration of antibiotics is contraindicated in the presence of a partial or complete blockage of the subarachnoid pathways.

Analgesics and sedatives.—The use of habit-forming drugs is contraindicated in the presence of a paraplegic disorder. Invariably, paraplegic patients will have to undergo prolonged hospitalization. Until they are convinced of their rehabilitation potential and have overcome the grave mental shock and anguish which is concomitant with sudden trauma to the spinal cord and its sequelae, they are quite prone to succumb to the tragic dangers of addiction. Every effort must be made from the first to prevent the patient from becoming exposed to addiction which is incurable. In high cervical cord injury, the use of morphine is also contraindicated because of the proximity of the respiratory center

in the medulla. The dangers of the use of any type of analgesic outweigh its advantages by far.

The habit of administering sedatives to patients who have to undergo prolonged hospitalization cannot be condemned strongly enough. Long-range contact with a vast number of paraplegic patients during the early, subacute, and late phase of their hospitalization has convinced us that these drugs are unnecessary and damaging as well. He who cares for paraplegic patients, and assumes responsibility for their welfare, must establish rapport with each individual patient and orient him to the fullest extent as to the nature of his disorder. The paraplegic patient who suffers from a chronic hang-over due to the regular use of sedatives will be unable and unwilling to rehabilitate himself physically and mentally. Regular night rounds conducted over a period of years on a paraplegic service on which sedatives were simply not used have convinced us beyond doubt that the paraplegic patient can sleep just as well as any other individual as long as he knows that he does not have any access to sedative drugs. The judicious use of tranquilizers in doses not obstructing physical and vocational rehabilitation may prove to be an adjunct in the management of paraplegic and quadriplegic patients in the early phase.

Pain.—The complex problem of pain in the presence of paraplegic disorders has been reviewed by many authors (11) (40) (41) (42) (43) (44) (45). Freeman and Heimbürger (40) differentiate between somatic, sympathetic, and psychic pain. Somatic pain is essentially root-type pain which occurs most commonly in patients with injury to the cauda equina, but may also be present in cervical cord trauma. The pain is paroxysmal, lancinating, and intractable and conforms invariably to a dermatome pattern. While it occurs in its severest form in partial lesions, it is also common in the presence of a transected cauda equina, and will then affect anesthetic dermatomes.

Burning pain and other types of dysesthesia are present at one time or the other, and to varying degrees, in all paraplegic disorders. This burning pain has been classified by Freeman and Heimbürger as sympathetic pain. The so-called visceral pain also falls into this group. It seems likely that this entire syndrome is vascular in origin. While

the psychogenic overlay is a matter of degree in any kind of pain, it does not seem necessary to classify as pain psychic disturbances which may express themselves in unpleasant subjective sensations. A series of paraplegic patients was tested on the author's service at Kennedy Veterans' Administration Hospital, Memphis, Tenn., with the Hardy-Wolff-Goodell machine (43). An increased threshold for perception of pain and prolongation of reaction time was found which points to the true organic nature of burning pain and dysesthesia in the presence of paraplegia.

Surgical intervention must be considered in the presence of intractable root pain as caused by cauda equina lesions. Early laminectomy seems to prevent the occurrence of this pain in a considerable number of patients. Decompressive laminectomy and foraminotomy may relieve intractable root pain due to root compression, even when it had been present for some time. If not caused by depressed bone fragments, root pain usually becomes persistent and intractable unless it disappears within the first week or two after trauma. Therefore, earliest feasible surgical relief is not only justifiable, but urgently warranted so as to prevent the otherwise inevitable addiction to narcotics. Drug addiction must be prevented in the paraplegic patient because today total rehabilitation is a reality and life expectancy can be the same as that of any individual. The contraindications for the use of habit-forming drugs have been discussed in the preceding paragraphs. In search for a cure of intractable root pain, our experiences have convinced us that only bilateral lateral spinothalamic tractotomy at a high cervical or a high thoracic level can bring about such a cure. The validity of this conviction has been confirmed by a review of all paraplegic patients so treated on my service at Kennedy Veterans' Administration Hospital (46) and by subsequent experience.

Lateral spinothalamic tractotomy, carried out in accordance with the technique outlined by Kahn and Peet (47), is the treatment of choice for intractable root pain as may be caused by trauma to the cauda equina or by compression of individual roots in the thoracic or cervical spinal canal. It should be employed before the need for habit-forming drugs becomes apparent. In the Korean War, we employed lateral spinothalamic tractotomy

in a few isolated cases as early as 2 weeks after trauma.

True burning pain is usually quite well tolerated although, in occasional instances, it may become intractable. Thorough indoctrination of the patient, active and passive ambulation, swimming, physiotherapy and, most of all, regular occupational aid in the adjustment to this pain syndrome should be the treatment of choice prior to consideration of surgical intervention. Burning pain is not relieved by sympathectomy. It used to be the consensus that lateral spinothalamic tractotomy would not relieve this type of pain either. Scheibert, however, has performed bilateral high thoracic spinothalamic tractotomy in eight patients with burning pain. Four were completely relieved, three partially relieved, and one was not benefited. Such operative measures as prefrontal lobotomy, which might afford relief, are certainly contraindicated in the presence of any paraplegic disorder inasmuch as they deprive the patient of his initiative to rehabilitate himself.

Psychological factors (12).—A casualty suffering from trauma to the spinal cord experiences consciously the sudden loss of motor and sensory function. This experience is shocking and frightening, and the initial dismay at the discovery of paraplegia is inevitably followed by despondency. The patient tends to adjust easier and more adequately if fully informed as to the nature of his disorder at the earliest feasible time. It is necessary to be candidly truthful with him so as to enlist his intelligent cooperation during the prolonged postoperative process of rehabilitation. It is the surgeon's obligation to explain to the patient the true nature of his injury prior to operation. It is also advisable to discuss the potentialities of the injury, the purpose of the operation, possible results and, particularly, those modes of rehabilitation which may have to be chosen if an anatomical transection should be encountered. Within a few days after the operation, findings and prognosis should be discussed frankly with the patient. In the presence of an anatomical transection of the spinal cord, he should be told then that he will not regain the voluntary use of his legs. At the same time, it can be pointed out to him that modern therapeutic measures will permit, in many instances, the restoration of bladder function. The

paraplegic patient should be fully informed as to the various means of ambulation in long-leg braces and on crutches. Adjustment will be enhanced and facilitated if the tremendous success in regard to full rehabilitation of paraplegic veterans is discussed and if concrete examples are given of various modes of rehabilitation (48).

COMPLICATIONS OF PARAPLEGIC DISORDERS

The complications of paraplegic disorders which can be avoided or minimized by general measures are:

1. *Infection of the genitourinary tract. Formation of urinary calculi. Urethrocuteaneous fistula.*

Measures:

- a. Prevention of bladder overdistention.
- b. Observation of sterile precautions in catheterization.
- c. Use of French Foley catheter, No. 16 or 18, but not larger, with 5-cc. retention bag.
- d. Adequate maintenance of retention catheter: Twice-daily irrigation of catheter with Solution G or Solution M. Change of catheter twice a week.
- e. Frequent check of patency of bladder drainage.
- f. Frequent urinalysis.
- g. Maintained acidity of urine.
- h. Institution of tidal drainage in accordance with Munro's principles at the earliest feasible time, but not later than 1 week after onset of paraplegia.
- i. Adequate fluid balance with a minimum output of 2,000 cc. every 24 hours, usually necessitating a minimum intake of 4,000 cubic centimeters.
- j. Earliest possible regular ambulation to prevent formation of calculi.
- k. Early recognition of existence of urinary calculi by roentgenograms: Flat plate of abdomen once a month. Microscopic examination of urine.
- l. Periurethral abscess formation and resulting urethrocuteaneous fistula can be prevented by taping the penis loosely to the abdominal wall to prevent kinking of the

urethra on the catheter at the penoscrotal junction.

2. *Development of decubital ulcers.*

Measures:

- a. Positioning and turning: Padded litter, litter-turning method in mobile installations. Stryker, Foster, or Circoelectric frame in fixed installations. Turning every 2 hours day and night.
- b. Proper positioning to prevent pressure on heels and other bony prominences. Padding between inner surfaces of knees and between inner malleoli.
- c. Smooth, soft pillows placed transversely on the frame.
- d. Maintenance of dry, clean skin. Skin care every 2 hours immediately after turning. Special attention to perineal area.
- e. Prevention of hypoproteinemia.
- f. High vitamin, high protein, high caloric diet. High protein formula as "between meal" feeding.
- g. Maintenance of normal hemoglobin and normal red cell count.

3. *Fecal impaction. Abdominal distention. Reflex ileus.*

Measures:

- a. Carefully supervised enema every other day with total evacuation of all fecal material from lower bowels by use of high colonic irrigations.
- b. Repeated, regularly performed digital examinations of rectum with digital removal of impacted fecal material.
- c. Frequent use of rectal tube.
- d. Use of rectal tube and Wangensteen drainage in patients with high thoracic and cervical cord lesions.
- e. Occasional use of Prostigmine Methylsulfate (neostigmine methylsulfate).
- f. Omission of gas-forming foods and liquids.

4. *Ankylosis of joints. Tendon contractures.*

Measures:

- a. Early physiotherapeutic measures with passive (and active) exercises.
- b. Positioning of joints: Use of footboard in supine position. Fifteen-degree flexion of knee joints in supine position. Feet perpendicularly to the floor in supine position,

with lower pillow and canvas reaching to the ankles only. Use of orthopedic appliances for finger and wrist joints even prior to ambulatory status.

REFERENCES

1. Covalt, D. A.: The Rehabilitation of the Veteran With Severe Spinal Cord Injury; A Modern Medical Triumph! *Occup. Therapy* 25: 187-190, October 1946.
2. Freeman, L. W.: Treatment of Paraplegia Resulting From Trauma to the Spinal Cord. *J.A.M.A.* 140: 949-958, 16 July 1949; 1015-1022, 23 July 1949. *Correction*, 141: 275, 24 Sept. 1949.
3. Munro, D.: Rehabilitation of Veterans Paralyzed as the Result of Injury to the Spinal Cord and Cauda Equina. *Am. J. Surg.* 75: 3-18, January 1948.
4. Meirowsky, A. M.: The Management of the Paraplegic Patient. *J. Tennessee M.A.* 47: 431-435, November 1954.
5. Munro, D.: The Treatment of Patients With Injuries of the Spinal Cord and Cauda Equina Preliminary to Making Them Ambulatory. *Clinics* 4: 448-474, August 1945.
6. Medical Department, United States Army. *Surgery in World War II. Neurosurgery. Volume II.* Washington: U.S. Government Printing Office, 1959.
7. Meirowsky, A. M.: Neurosurgery and Paraplegia. *The Paraplegia News* 5: 4-5, January 1951.
8. Meirowsky, A. M.: Treatment of Penetrating Wounds of the Spinal Cord. In *Symposium on Military Medicine in the Far East Command*, September 1951, pp. 91-94. A supplementary issue to the Surgeon's Circular Letter, Medical Section, General Headquarters, Far East Command, Supreme Commander for the Allied Powers (Japan), and United Nations Command.
9. Bors, E.: The Challenge of Quadriplegia; Some Personal Observations in a Series of 233 Cases. *Bull. Los Angeles Neurol. Soc.* 21: 105-123, September 1956.
10. Scheibert, C. D.: The Management of Patients With Spinal Cord Injury. *Memphis M.J.* 34: 103-109, March 1959.
11. Mahoudeau, Daniel: *Les traumatismes de la moelle épinière.* Paris: Masson et Cie, 1952.
12. Campbell, Eldridge, and Meirowsky, Arnold: Penetrating Wounds of the Spinal Cord. In *Surgery of Trauma.* Edited by Warner F. Bowers. Philadelphia: J. B. Lippincott Co., 1953, pp. 121-149.
13. Aring, C. D. (editor): Neurological Clinical Pathological Conference of the Cincinnati General Hospital. *Dis. Nerv. System* 14: 24-29, January 1953.
14. Stryker, H.: Device for Turning Frame Patient. *J.A.M.A.* 113: 1731-1732, 4 Nov. 1939.
15. Skinner, G.: Nursing Care of a Patient on a Stryker Frame. *Am. J. Nursing* 46: 288-292, May 1946.
16. Munro, D.: The Rehabilitation of Patients Totally Paralyzed Below the Waist, With Special Reference to Making Them Ambulatory and Capable of Earning Their Living. II. Control of Urination. *New England J. Med.* 234: 207-216, 14 Feb. 1946.
17. Munro, D., and Hahn, J.: Tidal Drainage of Urinary Bladder; Preliminary Report of This Method of Treatment as Applied to "Cord Bladders" With a Description of the Apparatus. *New England J. Med.* 212: 229-239, 7 Feb. 1935.
18. Munro, D.: The Rehabilitation of Patients Totally Paralyzed Below the Waist, With Special Reference to Making Them Ambulatory and Capable of Earning Their Living. III. Tidal Drainage, Cystometry and Bladder Training. *New England J. Med.* 236: 223-235, 13 Feb. 1947.
19. Meirowsky, A. M., Scheibert, C. D., and Hinchey, T. R.: Studies on the Sacral Reflex Arc in Paraplegia. I. Response of Bladder to Surgical Elimination of Sacral Nerve Impulses by Rhizotomy. *J. Neurosurg.* 7: 33-38, January 1950.
20. Meirowsky, A. M., Scheibert, C. D., and Hinchey, T. R.: Studies on the Sacral Reflex Arc in Paraplegia. II. Differential Sacral Neurotomy, An Operative Method. *J. Neurosurg.* 7: 39-43, January 1950.
21. Meirowsky, A. M., and Scheibert, C. D.: Studies on the Sacral Reflex Arc in Paraplegia. III. Clinical Observations on Inhibitory Impulses Within the Sacral Reflex Arc. *Exper. Med. & Surg.* 8: 437-448, May-November 1950.
22. Meirowsky, A. M., Scheibert, C. D., and Rose, D.: Indications for Neurosurgical Establishment of Bladder Automaticity in Paraplegia. *J. Urol.* 67: 192-196, February 1952.
23. Suby, H. I., and Albright, F.: Dissolution of Phosphatic Urinary Calculi by the Retrograde Introduction of a Citrate Solution Containing Magnesium. *New England J. Med.* 228: 81-91, 21 Jan. 1943.
24. Herger, C. C., and Sauer, H. R.: Treatment of Alkaline Incrustations of Urinary Tract With Solution G. *J. Urol.* 53: 696-701, May 1945.
25. Marden, P. A., and Williamson, E. G.: The Use of Prostigmin Methylsulfate in the Prevention of Postoperative Intestinal Atony and Urinary Bladder Retention. *Surg., Gynec. & Obst.* 69: 61-64, July 1939.
26. Gordon, E. J.: The Treatment of Postoperative Abdominal Distention With Prostigmin. *Surgery* 7: 686-695, May 1940.
27. Copple, B. I.: Fluids and Electrolytes in the Acute State. In *Symposium on Military Medicine in the Far East Command*, September 1951, pp. 26-27. A supplementary issue to the Surgeon's Circular Letter, Medical Section, General Headquarters, Far East Command, Supreme Commander for the Allied Powers (Japan), and United Nations Command.
28. Kleinman, A. M., and Sprinz, H.: Problems of Nutrition. In *Transactions of Conference on Spinal Cord Injuries*,

- Second Service Command, held at Halloran General Hospital, Staten Island, N.Y., 19 Oct. 1945, and at Thomas M. England General Hospital, Atlantic City, N.J., 20 Oct. 1945, pp. 60-69.
29. Elman, R.: Maintenance of Nitrogen Balance by Intravenous Administration of Plasma Proteins and Protein Hydrolysates. *Physiol. Rev.* 24: 372-389, July 1944.
 30. Freeman, L. W.: Solving a Problem . . . Decubitus Ulcers—Cause, Prevention, and Cure. *Quart. Bull. Indiana Univ. M. Center* 11 (No. 2): 34-39, April 1949.
 31. Gibbon, J. H., Jr., and Freeman, L. W.: The Primary Closure of Decubitus Ulcers. *Ann. Surg.* 124: 1148-1164, December 1946.
 32. Bors, E., and Comarr, A. E.: Ischial Decubitus Ulcer. *Surgery* 24: 680-694, October 1948.
 33. Bors, E., and Comarr, A. E.: The "Buried Epidermis" Graft. *Surg., Gynec. & Obst.* 87: 68-70, July 1948.
 34. Comarr, A. E., and Bors, E.: Radical Ischialectomy in Decubitus Ischial Ulcers Complicating Paraplegia; Report of 100 Cases. *Ann. West. Med. & Surg.* 5: 210-213, March 1951.
 35. Comarr, A. E.: Ischial Decubitus Ulcer With Atypical Features. *J. Internat. Coll. Surgeons* 13: 233-237, February 1950.
 36. Freeman, L. W., and Heimbürger, R. F.: The Surgical Relief of Spasticity in Paraplegic Patients. I. Anterior Rhizotomy. *J. Neurosurg.* 4: 435-443, September 1947.
 37. Munro, D.: The Rehabilitation of Patients Totally Paralyzed Below the Waist, With Special Reference to Making Them Ambulatory and Capable of Earning Their Living. I. Anterior Rhizotomy for Spastic Paraplegia. *New England J. Med.* 233: 453-461, 18 Oct. 1945. *Correction*, 233: 731, 13 Dec. 1945.
 38. Meirowsky, A. M.: Neurochirurgische Methoden in der Behandlung wichtiger Spätkomplikationen bei traumatischer Paraplegie. *Zentralbl. Neurochir.* 10: 199-210, 1950.
 39. Munro, D.: Care of Back Following Spinal Cord Injuries; Consideration of Bed Sores. *New England J. Med.* 223: 391-398, 12 Sept. 1940.
 40. Freeman, L. W., and Heimbürger, R. F.: Surgical Relief of Pain in Paraplegic Patients. *Arch. Surg.* 55: 433-440, October 1947.
 41. Davis, L., and Martin, J.: Studies Upon Spinal Cord Injuries. II. The Nature and Treatment of Pain. *J. Neurosurg.* 4: 483-491, November 1947.
 42. Munro, D.: Two-Year End-Results in the Total Rehabilitation of Veterans With Spinal-Cord and Cauda Equina Injuries. *New England J. Med.* 242: 1-16, 5 Jan. 1950.
 43. Hazouri, L. A., and Mueller, A. D.: Pain Threshold Studies on Paraplegic Patients. *Arch. Neurol. & Psychiat.* 64: 607-613, November 1950.
 44. White, James C., and Sweet, William H.: Pain: Its Mechanisms and Neurosurgical Control. Springfield, Ill.: Charles C Thomas, 1955.
 45. Gillingham, F. J.: The Problem of Pain in Paraplegia. In *Proceedings of the Seventh World Congress of the International Society for the Welfare of Cripples*, 22-26 July 1957, Planning for Victory Over Disablement. Exeter, England: W. Chudley & Son, Ltd., pp. 437-442.
 46. De Saussure, R. L., Jr.: Lateral Spinothalamic Tractotomy for Relief of Pain in Cauda Equina Injury. *Arch. Neurol. & Psychiat.* 64: 708-714, November 1950.
 47. Kahn, E. A., and Peet, M. M.: The Technique of Anterolateral Cordotomy. *J. Neurosurg.* 5: 276-283, May 1948.
 48. Heyl, H. L.: Some Practical Aspects in the Rehabilitation of Paraplegics. *J. Neurosurg.* 13: 184-189, March 1956.

CHAPTER 26

Neurosurgical Management

Arnold M. Meirowsky

INDICATIONS FOR NEUROSURGICAL INTERVENTION

EARLY LAMINECTOMY

Neurosurgical intervention is indicated in the immediate management of every penetrating wound of the spinal canal and of the spinal cord. There are no contraindications to laminectomy, although associated injuries may delay at times surgical debridement and decompression (1).

The aim of early neurosurgical intervention is threefold:

1. To relieve spinal cord, cauda equina, or individual spinal roots of pressure produced by comminuted bone fragments, blood clots, and foreign bodies.

2. To debride and close the wound in such a manner as to give maximum assurance of primary wound healing.

3. To determine the extent of the neuroanatomical deficit.

Clinical and laboratory examinations, which are at our disposal today, do not suffice to estimate the permanency of any given spinal cord lesion. Such information as a history of sudden onset of paraplegia, absence of deep tendon reflexes, or a roentgenologically demonstrated missile within the spinal canal does not furnish proof for the existence of an anatomical transection. While physiological transection occurs with greater frequency in the thoracic cord and cervical cord than in the cauda equina, decompressive laminectomy should be done in every case so as to give the patient every possible opportunity to regain whatever function can be regained.

In cervical cord injury, the function of one or two pairs of cervical roots above the level of transection may be interfered with by depressed bone fragments. Restoration of function of those roots, as can be accomplished frequently by decompression, may make the difference between permanent quadriplegia or permanent paraplegia. The same principle applies to lesions of the cauda equina. Compression of the cord at any level by intraspinal hematoma may lead to permanent paraplegia at a level higher than the initial trauma, or it may result in irreversible paraplegia in spite of an initially partial lesion, unless it is removed at the earliest possible time.

To prevent soft tissue infection, extradural abscess, and meningitis, radical debridement of all missile wounds of the spinal canal is essential. The debridement includes the soft tissue layers, the bone as it is involved in the missile wound, and the meninges if they have been penetrated. A gaping soft tissue wound overlying the site of proposed laminectomy should not constitute a contraindication to neurosurgical intervention which can be carried out at the same time as debridement of the soft tissue is performed. To debride such a wound, and to leave it wide open, exposes the patient to the grave hazards of secondary infection with the threat of meningitis. This may endanger the patient's life or it may deprive him of function which could have been regained by early laminectomy, a procedure which cannot be carried out in the presence of frank, purulent infection.

An exact knowledge of the extent of the neuroanatomical deficit helps immeasurably in the orientation of the patient and makes it possible to direct his intentions toward the rehabilitation which he should

achieve. It becomes also of importance when advising the patient as to necessary surgical measures in combating such late complications as intractable root pain or spasticity of the lower extremities and bladder.

As soon as the patient's general condition permits, debridement and decompressive laminectomy should be performed. It should be done as early as feasible in order to obtain the maximum possible restoration of function, in order to prevent ascending myelopathy from prolonged compression, and in order to prevent infection with its threat of ascending myelitis and meningitis.

Factors necessitating postponement of early laminectomy, but not omission of operative intervention, are surgical shock, cardiorespiratory imbalance, lower nephron syndrome, and associated wounds of the abdomen, chest, or great vessels. As vitally important and as urgent as a decompressive laminectomy may be for the patient with a missile wound of the spinal cord, it is not primarily a lifesaving measure; laceration of the carotid artery, intestinal perforations, or sucking wounds of the chest—all of which may be associated with missile wounds of the spinal canal—must be given surgical priority. (See chapter 38.)

Localization of penetrating wounds of the spinal cord rarely presents a problem. Stereoscopic roentgenograms are of value in the determination of the extent of fractures involving lamina or facet. The initial sensory deficit may be found at a level higher than the site of penetration and may not at all represent the deficit which corresponds to the level of direct trauma to the cord. Often, this is due to concomitant hematoma; occasionally, this phenomenon represents the sequela of edema, or of thrombosis of one of the spinal arteries.

LATE LAMINECTOMY

There has been considerable variance of opinion about the value of late laminectomy, and even of its justification. From what has been said in the preceding paragraph, the question of late laminectomy should become the exception rather than the rule. Early laminectomy is today the generally accepted treatment of missile wounds of the spinal cord, eliminating the necessity for delayed decompression.

After World War II, we saw a great many patients with missile wounds of the spinal canal who had never had the benefit of a laminectomy and who confronted us with the question as to whether anything could be gained by late decompression. The experience with several hundred of these patients who were operated on months, and often years, after the initial trauma has been invaluable in that regard (2).

Quadriplegia.—Laminectomy performed as late as 3 and 4 years after the initial trauma occasionally resulted in return of function of individual cervical roots. Whenever these roots were responsible for the nerve supply to arm, hand, or finger muscles, benefit was derived from the operation. In isolated instances, it was possible to convert quadriplegia into paraplegia. At times, it was possible to restore function in the fifth, sixth, or seventh cervical roots, bringing about functional return of important finger and hand muscles.

In many instances, the associated root compression was caused by comminuted bone fragments; scar tissue, binding the roots down, or frank adhesive arachnoiditis often represented the sole cause of the existing root compression.

Improvement of circulation, impaired by compression, might well be the cause of operative reduction of the neurological deficit in clinically partial lesions. In the presence of degenerative changes of the cord itself, of course, late laminectomy did not alter the complete neurological deficit. It is in this group of cases, however, that nerve roots above the site of physiological transection may be compressed so that these patients may benefit from late surgical intervention.

In making the decision for late cervical laminectomy, stereoscopic roentgenograms, particularly lateral and oblique views, are of great value. The presence or absence of a partial or complete block might aid in making that decision. The interpretation of the Queckenstedt test should be made on the basis of quantitative readings, particularly in view of the fact that spinal fluid flow may be maintained in the presence of a pinpoint passage in the subarachnoid space. Mere manual compression of the jugular veins is a rather useless maneuver. Graded and timed application of pressure on the jugular veins by employment of a blood pressure

cuff and simultaneous manometric readings should serve to detect a minimal degree of blockage suggesting interference with the function of nerve roots or, in clinically partial lesions, of the cord itself.

Paraplegia (caused by lesions of the thoracic cord or the conus medullaris).—Return of function of individual thoracic roots is not of sufficient clinical or practical value to warrant late laminectomy for that purpose. In clinically partial lesions, it may well be possible to reduce the existing neurological deficit by delayed decompressive laminectomy, particularly if the impairment is caused by mildly depressed bone fragments or by a localized adhesive arachnoiditis. In those clinically partial lesions in which the quantitative Queckenstedt test does reveal some degree of blockage, delayed surgical removal of the block is warranted although it may not bring about clinical improvement. It does not seem possible to accomplish any return of function by late laminectomy in clinically complete lesions of the thoracic cord.

Paraplegia (caused by lesions of the cauda equina).—Laminectomy performed as late as 5 years after the initial trauma resulted in return of function of individual roots which had been compressed by bone fragments. Late laminectomy is always warranted when roentgenographic studies reveal bony compression of the cauda equina or when the quantitative Queckenstedt test suggests partial compression of the roots. There is no clinical test, short of operation, which will prove without fail the presence of an anatomical transection of the cauda equina. Even if the latter should be encountered at operation, decompression of roots above the site of transection may be well worthwhile. The value of neurolysis of cauda equina roots remains open to question. Extensive arachnoiditis binding the roots together may respond to neurolysis temporarily only to recur within a few weeks after the operation. There have, however, been some encouraging results even with this procedure, justifying late neurosurgical intervention in almost every cauda equina lesion.

In view of the preceding comments, it becomes clear that the indications for late laminectomy must be based on careful study and competent evaluation of each individual case. The hazards of the operation, if carried out by an experienced and cautious neurological surgeon, are not significant. The gains

may be sufficiently great as to alter essentially the patient's whole life.

The percentage of casualties with missile wounds of the spinal cord in which function can be restored remains small at this time. There comes a ray of hope from Freeman's laboratory (3) (4) (5) and from the work done by Campbell and his associates (6) suggesting that, under certain conditions, not only nerve roots but also spinal cord tissue is capable of regeneration. Once this work exceeds the laboratory stage, the entire issue of late laminectomy in the presence of paraplegia will have to be reexamined.

A discussion of the indications for neurosurgical intervention in the presence of missile wounds of the spinal cord would be incomplete without a brief comment on two surgical procedures which are advocated by some, but which may grossly interfere with the aims of those neurosurgical measures which have been discussed and recommended in the preceding paragraphs.

SUPRAPUBIC CYSTOSTOMY

The first of the two procedures is suprapubic cystostomy, an operation which no longer has a place in the rational treatment of an uncomplicated neurogenic bladder. Carefully planned and executed management of the paralyzed bladder, as it has been outlined by Munro and Hahn (7), Munro (8), Freeman (9), and others (10) (11), should reduce the incidence of bladder infection of clinical significance to a mere minimum and should do so more dependably than a suprapubic cystostomy could accomplish. The real contraindications for the latter procedure, however, are based on the gross interference with muscle tone which is bound to be caused by the use of a suprapubic tube. Following a suprapubic cystostomy, it will rarely be possible to establish a reflexly functioning bladder by tidal drainage. It is almost impossible to achieve good results with surgical measures for the establishment of bladder automaticity after the musculature of the bladder has been permanently damaged by suprapubic cystostomy.

AMPUTATION

The second procedure is the amputation of paralyzed limbs, a medieval operation which has been

revived of late in a few institutions. The indications for the amputation of limbs should remain in the hands of the orthopedic surgeon who will make the decision on the basis of bone or joint pathology. To amputate paralyzed, but otherwise healthy, limbs only because they are paralyzed, is unsound, unphysiological, and contraindicated. The deplorable psychological effect which this operation has on the paraplegic individual cannot be overestimated. Its employment also annihilates the vitally important ambulation program and makes impossible total rehabilitation, which is our goal.

OPERATIVE METHOD OF LAMINECTOMY

PREOPERATIVE MANAGEMENT

After the indications for surgical intervention have been established, the patient is entitled to be fully informed as to the nature of his injury, the possible sequelae, and the potential restoration. Absolute frankness is of paramount importance if the maximum degree of rehabilitation is to be achieved in the end. Preoperative discussions with the patient should not only cover the rationale of the proposed operation, but should also outline whatever may or may not be accomplished by surgical intervention. It might be advisable to use this first opportunity to begin acquainting the patient with the many acceptable aspects of the life of a man who is deprived of the controlled use of his legs, and with the achievement that can be his, in spite of the handicap.

Preoperative laboratory data should include urinalysis, crossmatching and typing of blood, and determination of the packed-cell volume. Besides stereoscopic roentgenograms of the site of lesion, marker films will help considerably in the precision of the operative approach.

A high colonic enema, followed by digital examination, is of importance in an effort to avoid such postoperative complications as a reflex ileus.

The back should be shaved and then washed for 10 minutes with soap and water. It is also advisable to seal the anal region against the operative field by use of oil silk. The entrance and exit wound, unless situated in the line of incision, should be sealed against the operative field. The indwelling catheter should not be clamped off during the operation.

We have found it practical to use a Stryker or Foster frame in lieu of the operating table. In the field, the padded litter prepared for the prone position, as described previously, is the most suitable operating table. Care is taken to have the patient in a supine position during the last 2 hours prior to operation, so that he will not miss the 2 hourly turning routine.

ANESTHESIA

Cervical laminectomy.—Local anesthesia with 1 percent procaine infiltration is the method of choice. The patient is best premedicated with Nembutal (pentobarbital sodium). Morphine should not be used preoperatively, but it can be employed intravenously after the decompression has been completed so as to relieve the patient of possible pain while closing the wound. Demerol (merperidine hydrochloride) should not be used in any paraplegic or quadriplegic patient because of its adverse effects on the genitourinary tract.

The advantages of local anesthesia in acute cervical cord injury are twofold. In the presence of facet damage, it may be quite hazardous to manipulate the patient sufficiently to permit introduction of an endotracheal tube. Without the use of an endotracheal tube, general anesthesia would not be safe. Reference is made to the acute cervical cord syndrome with bradycardia, hypotension, low temperature, confusion state, and potential interference with the state of consciousness (chapter 32). Because of its fairly frequent occurrence in the acutely injured, general anesthesia would be hazardous at best and would also make it difficult to interpret accurately the course of events. The experienced operating surgeon will certainly not take longer than 1 or 1½ hours for the entire operation. Under those circumstances, local anesthesia is well tolerated except for isolated cases that develop a reaction to Novocain (procaine hydrochloride). In the face of the latter, the risk of a general anesthetic will have to be taken.

Thoracic laminectomy.—In the presence of an associated chest wound, endotracheal anesthesia with Pentothal sodium (thiopental sodium) induction and the administration of nitrous oxide and oxygen is the method of choice. It affords control over respiration and permits thorough suctioning of the bronchial tree before and after operation. In the

uncomplicated thoracic laminectomy, the use of a local infiltration agent is perfectly in order, although because of the potential of infection in the presence of a penetrating wound, we prefer general anesthesia.

Lumbar laminectomy.—Pentothal sodium induction with endotracheal tube and the administration of nitrous oxide and oxygen is the method of choice. The reasons are twofold. First, the same principle for thoracic laminectomy applies. In dealing with penetrating wounds, it seems safer to avoid local infiltration in order to prevent infection. Second, manipulation of the caudal roots may be exceedingly painful and anesthesia of the roots cannot be obtained by local infiltration. This principle applies to lumbar laminectomies at all levels. While the anatomy books list the level of the tip of the conus medullaris in the midportion of the second lumbar lamina, we have found a number of cases in which the cauda equina originates at the level of L1 or even T12. Sherrington (12) refers to this finding as a "prefixed" cauda equina. In view of the fairly common occurrence of such a prefixed cauda equina, one may wonder whether a higher level must not be considered a normal finding.

Spinal anesthesia is considered contraindicated in the presence of acute spinal cord injury.

TECHNIQUE OF OPERATION

There are many different ways of performing a laminectomy in the presence of a penetrating wound of the spinal canal, each of which has its own merits. The following is a description of the technique which is preferred by the author.

In accordance with the marker film, a longitudinal incision is centered over the spinous process of the involved lamina or laminae, and is extended sufficiently to expose at least one intact lamina cephalad and one caudad to the lesion (fig. 140). This incision is carried through skin, subcutaneous tissue, and superficial fascia down to the tips of the spinous processes. Towels are then fastened to the skin edges with Michel clips. Usually, this affords sufficient hemostasis, although occasionally some large vessels may have to be cauterized. The junction of the deep fascia with the interspinous ligament is then severed sharply by cutting along the lateral

borders of the tips of the spinous processes (fig. 141). The paraspinal muscles are resected subperiosteally with a chisel or osteotome of 1 cm. in width. Starting at the uppermost portion of the incision, the chisel is placed obliquely against the corresponding spinous process at the severed junction of the supraspinal ligament and the deep fascia (fig. 142). Scraping the spinous process in a posteroanterior movement and the lamina in a lateral direction will yield a good subperiosteal resection. The latter move is completed just as soon as the osteotome reaches the facet. The osteotome is held in that position, retracting the paraspinal muscles laterally, until an assistant has inserted an unfolded 4-by-8 gauze sponge, the tip of which should be placed firmly against the lamina (fig. 143). The osteotome is then withdrawn and reinserted in a similar manner just below the resected area until the entire paraspinal musculature covering the operative site has been dissected away from the lamina (figs. 144 and 145). In the immediate area of comminution and depression, it is often necessary for safety reasons to dissect the muscles away sharply. The sponges are then withdrawn and two self-retaining Beckman retractors are inserted so as to expose the laminae fully. The entire bony exposure is a rapid procedure taking a great deal less time than a sharp dissection necessitating hemostasis of each individual vessel. After the bony damage has been surveyed, the interspinous ligaments are severed sharply (fig. 146). The spinous processes of the involved laminae and of one intact lamina above and one below are taken off with a bone cutter (fig. 147). With the same instrument, the two spinous processes adjacent to the site of laminectomy, one above and one below, are flattened obliquely (fig. 148). This is particularly important so as to prevent pressure from beneath on the skin overlying the site of laminectomy. The operative site is thoroughly washed with warm saline solution after any missile tracks within the paraspinal muscles have been debrided with a cutting current.

The intact lamina immediately above the site of fracture is then removed with a duckbill rongeur. The ligamentum flavum is cut transversely and at an oblique angle with a No. 15 blade (fig. 149).

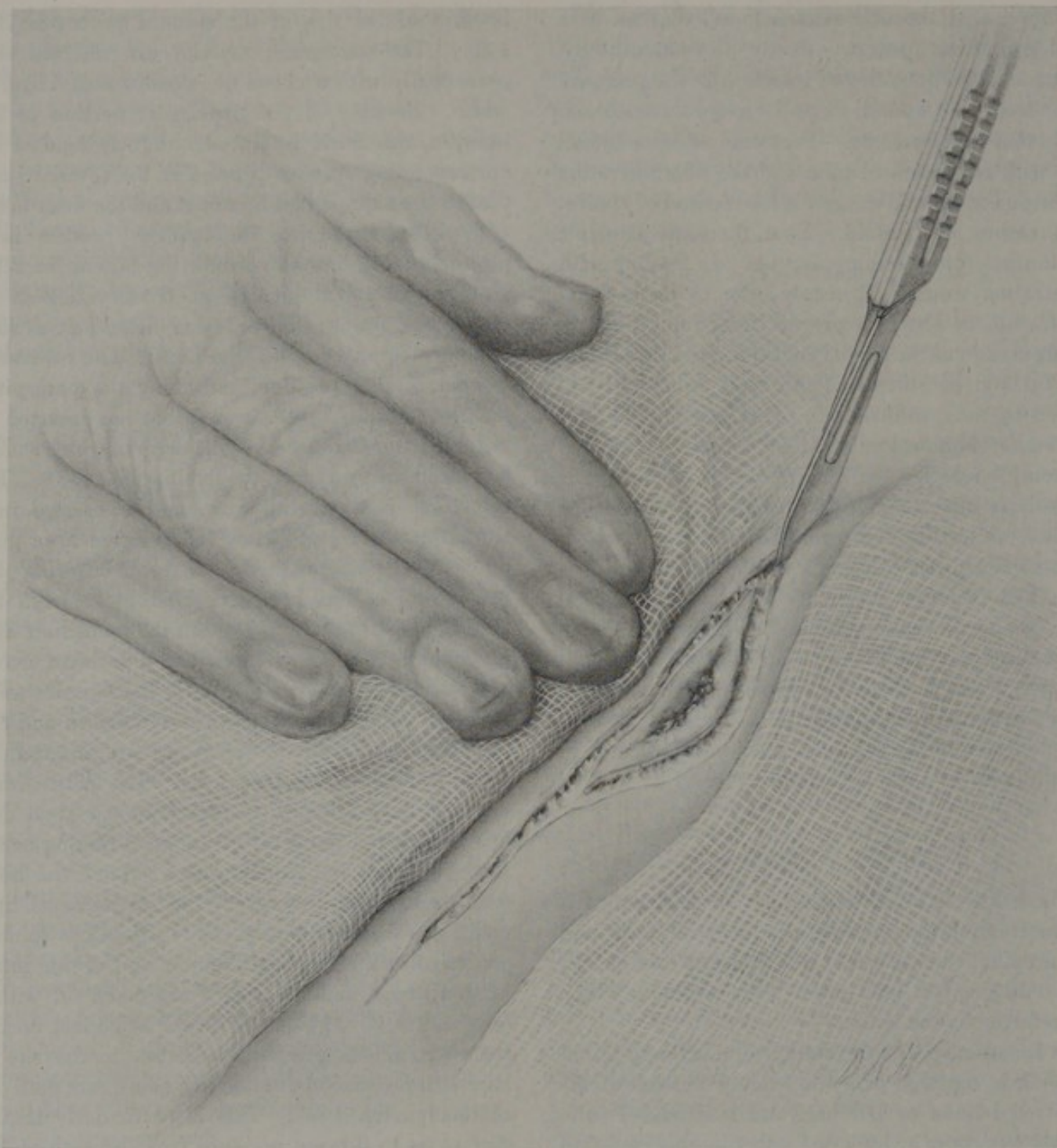


FIGURE 140.—Longitudinal incision centered over spinous processes exposing one intact lamina cephalad and caudad to the lesion. Site of skin penetration is excised.

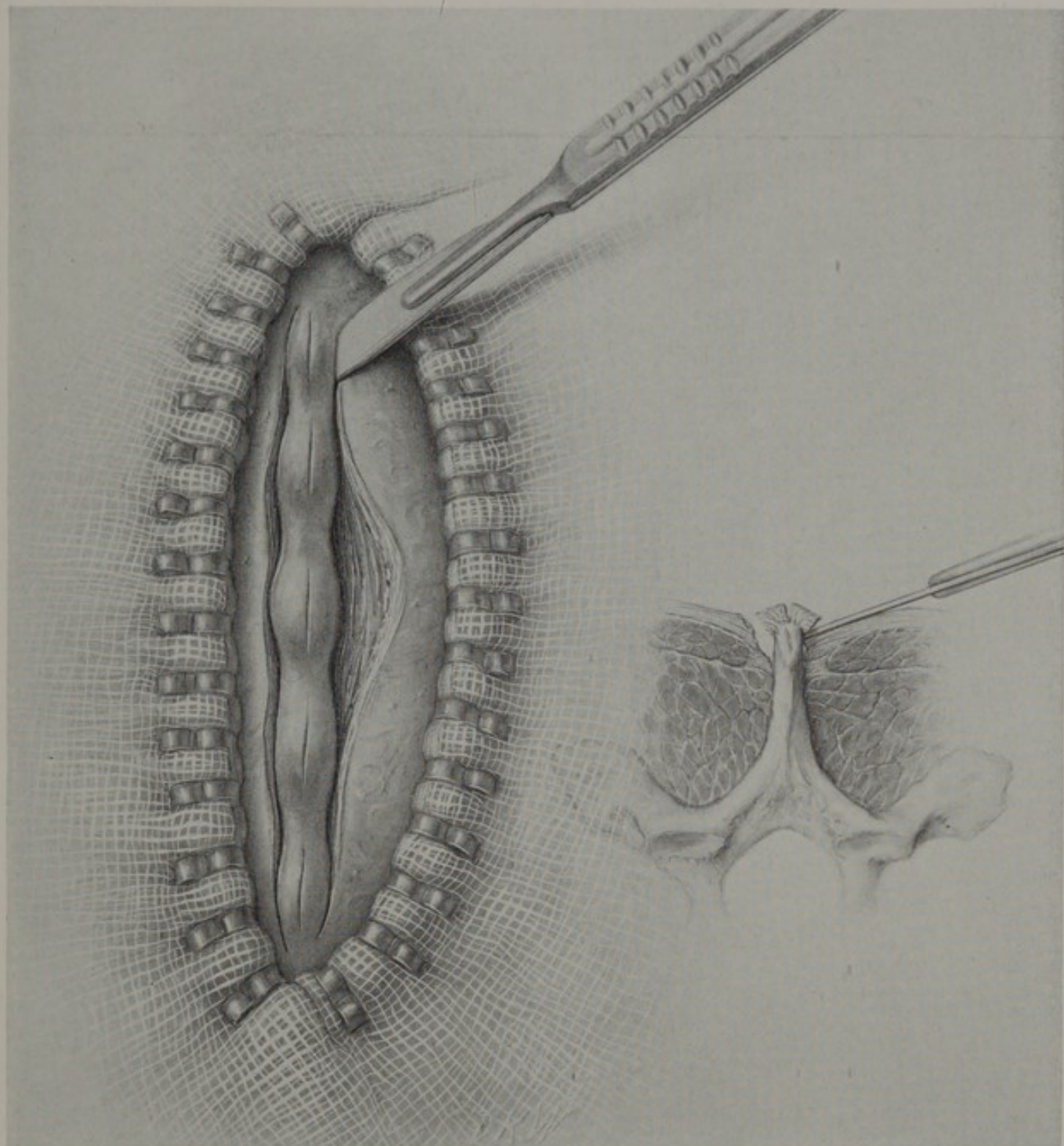


FIGURE 141.—Severance of deep fascia from interspinous ligament.

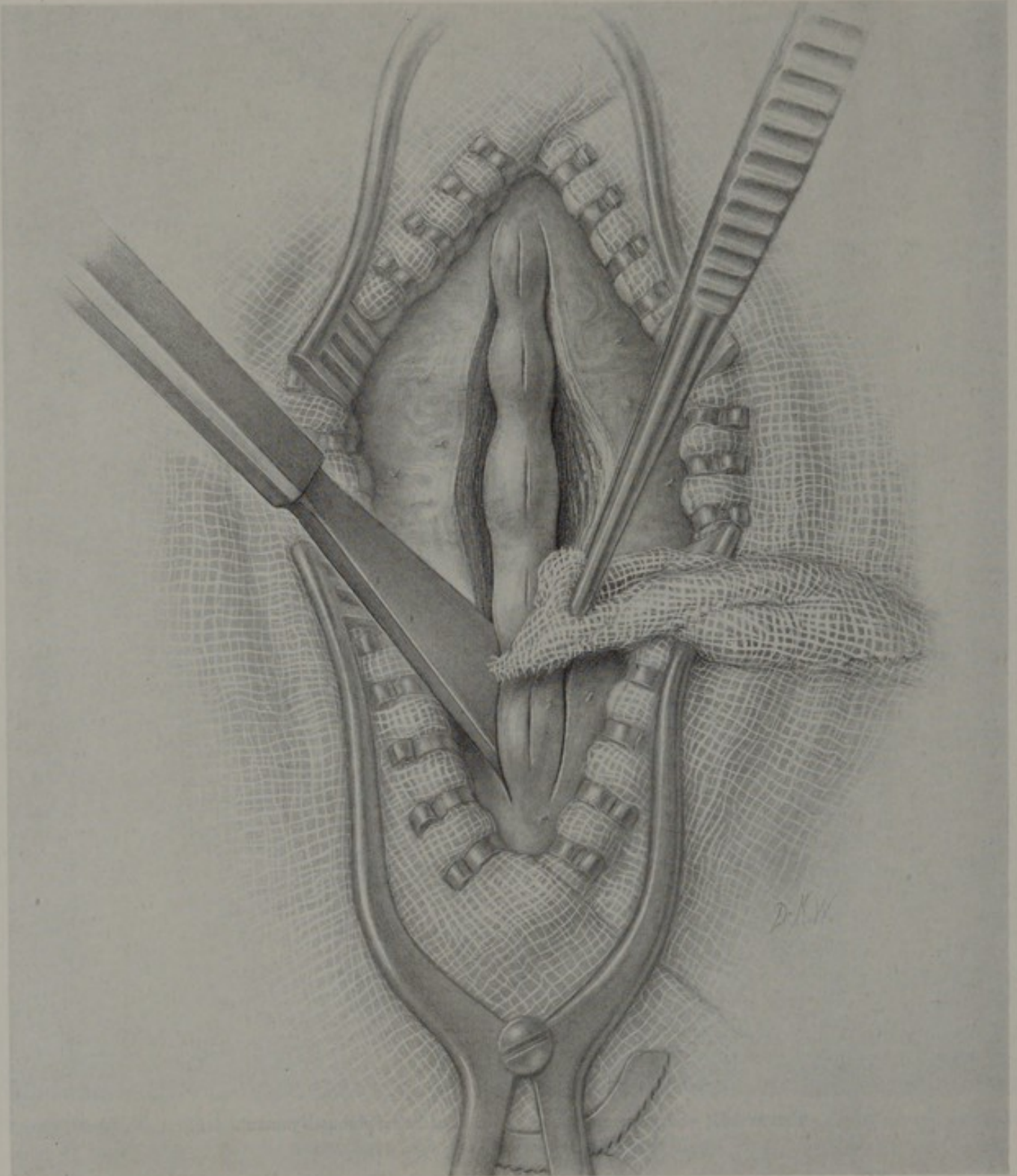


FIGURE 142.—Subperiosteal resection of paraspinal musculature.

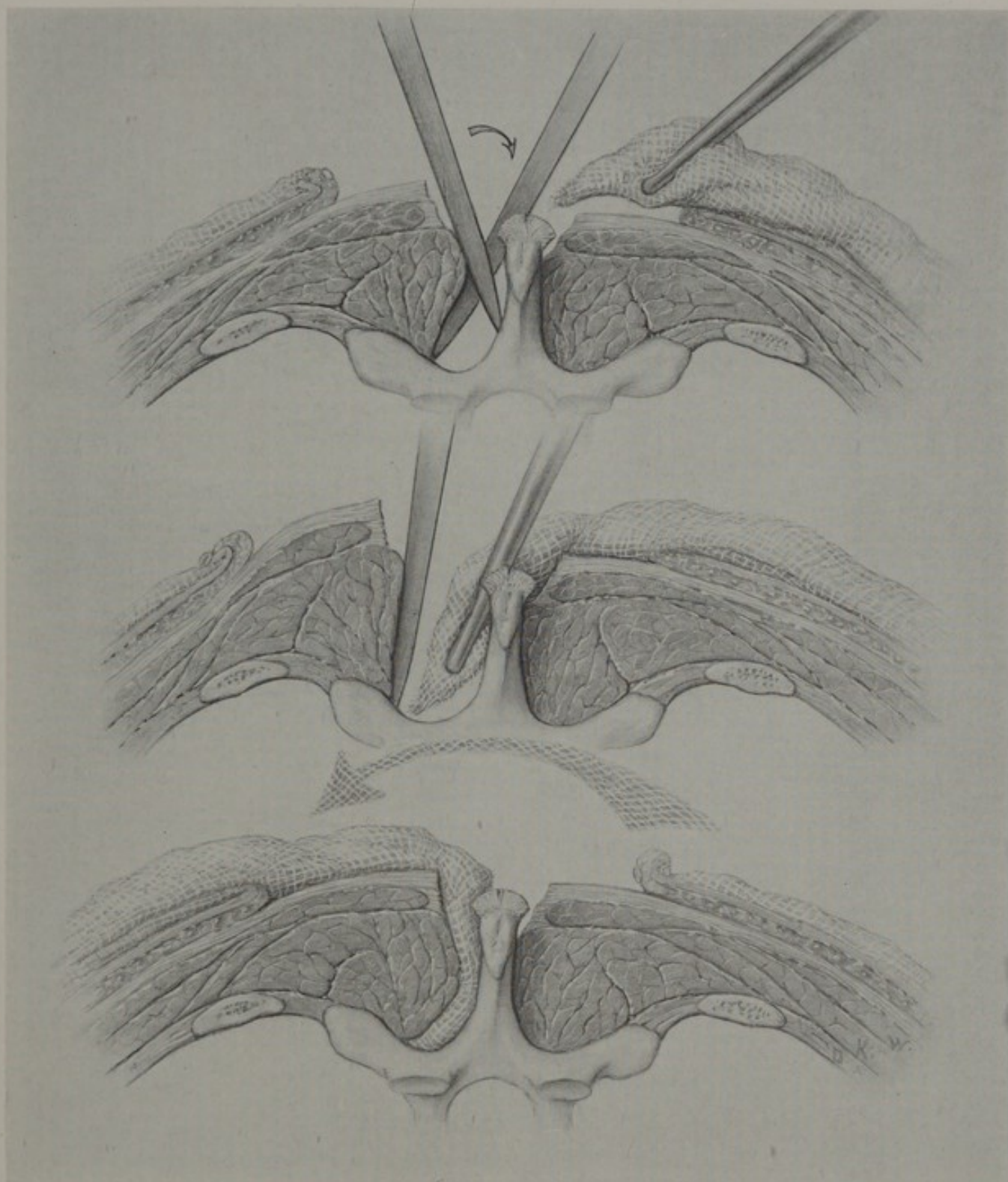


FIGURE 143.—Insertion of tamponading gauze strips as subperiosteal resection of muscles is performed.

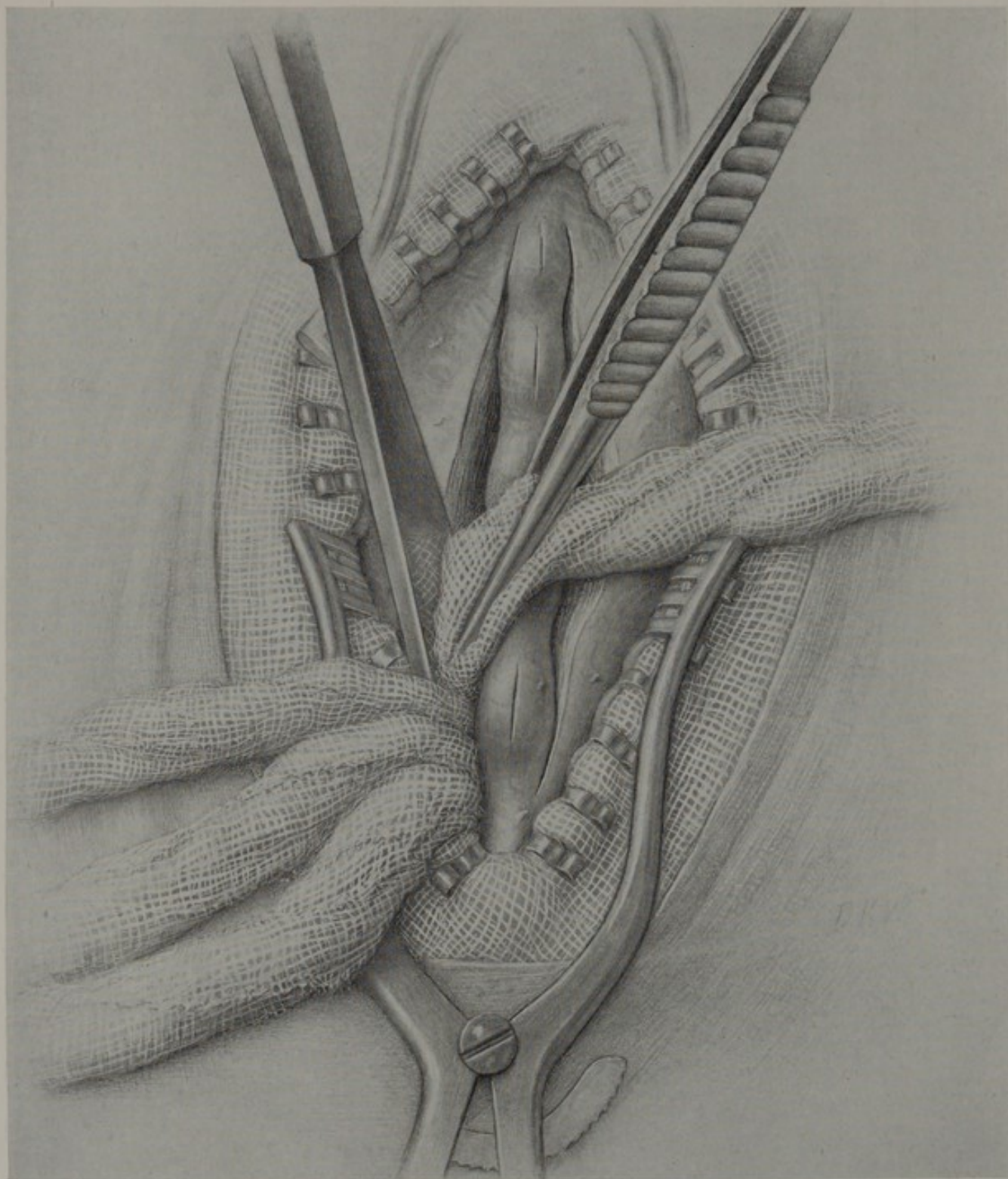


FIGURE 144.—Subperiosteal resection of paraspinal musculature.

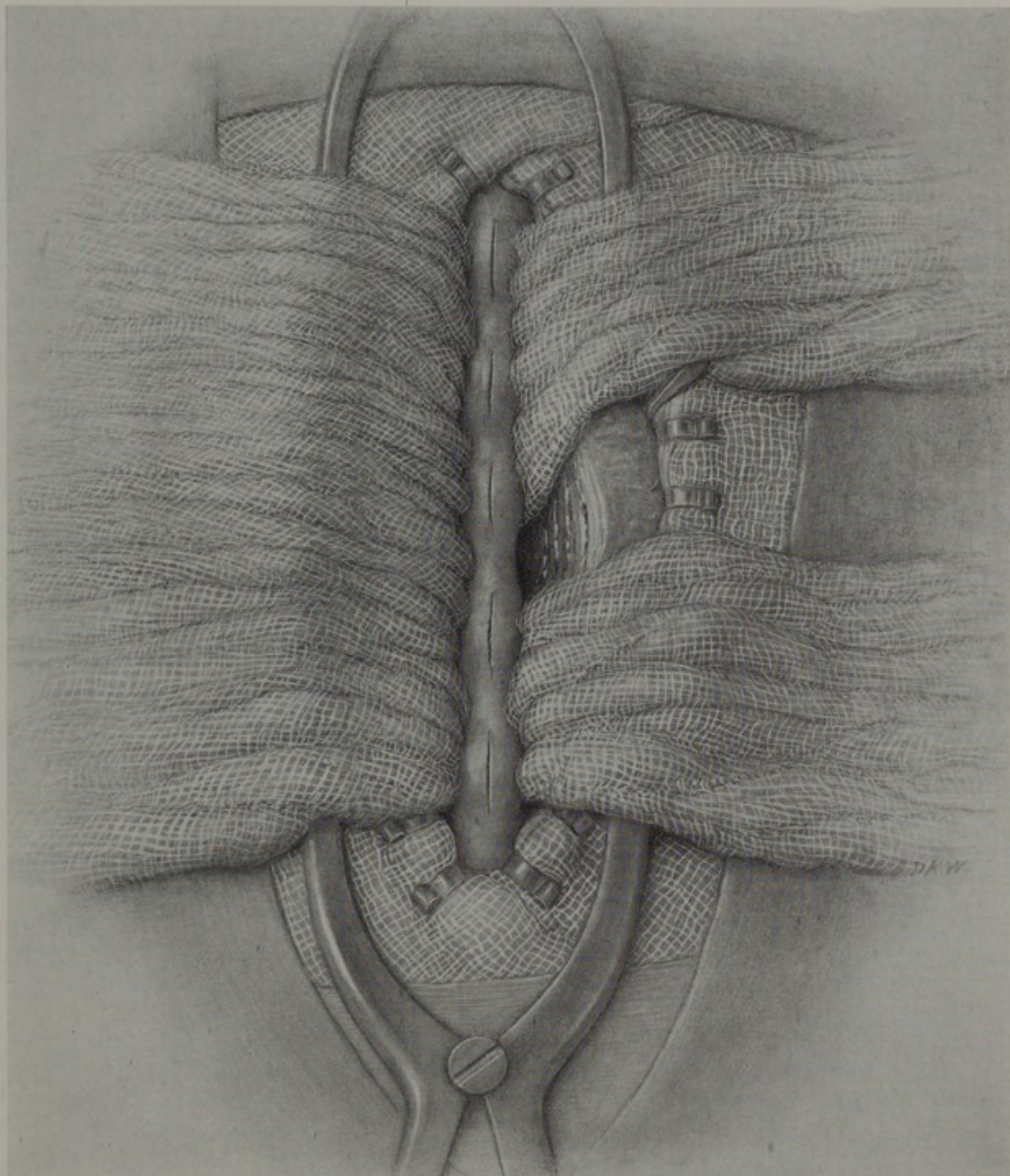


FIGURE 145.—Subperiosteal resection of musculature completed. Tamponading gauze in place.

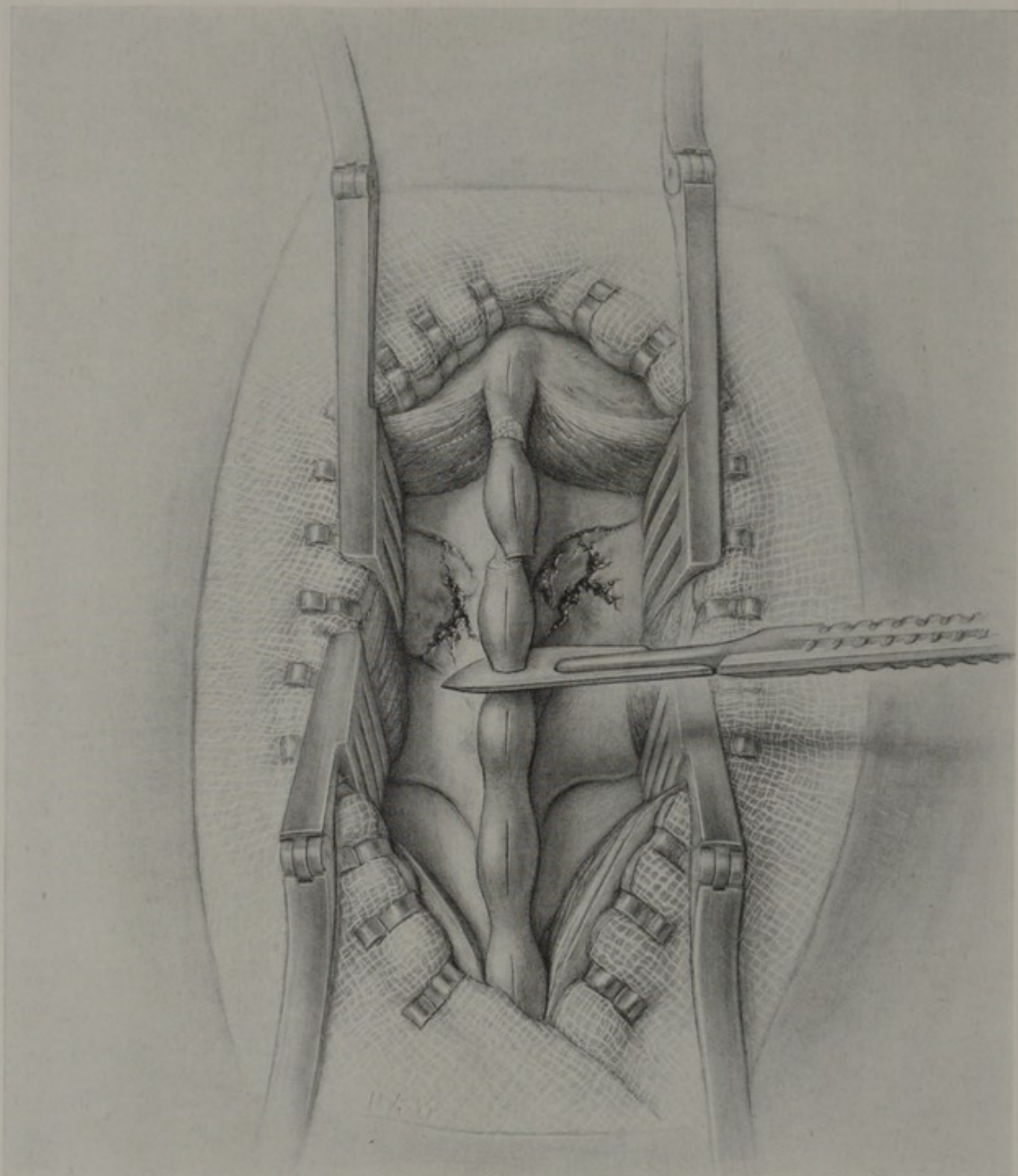


FIGURE 146.—Laminae exposed with self-retaining retractor in place. Section of interspinous ligaments.

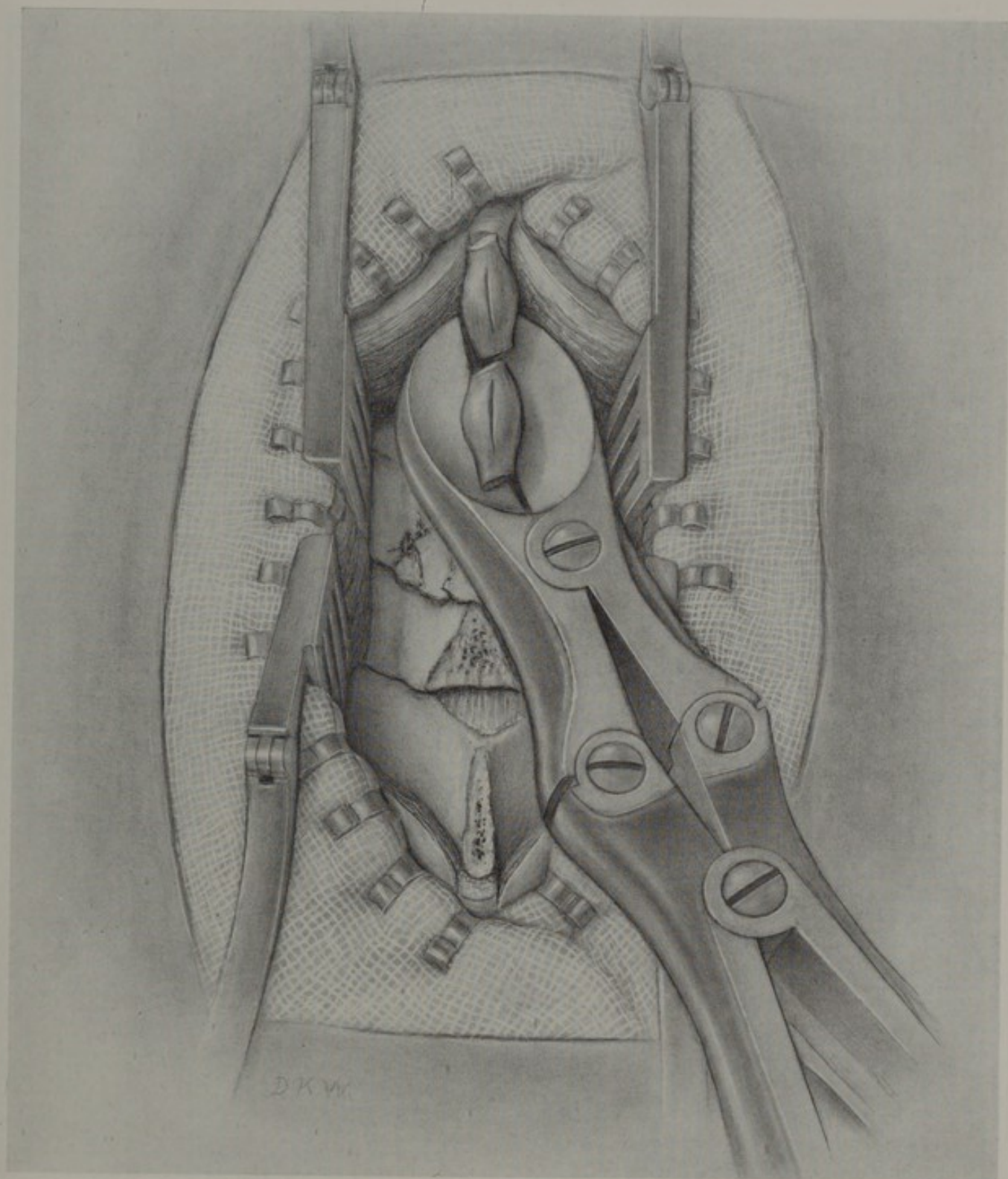


FIGURE 147.—Resection of spinous processes with a bone cutter.

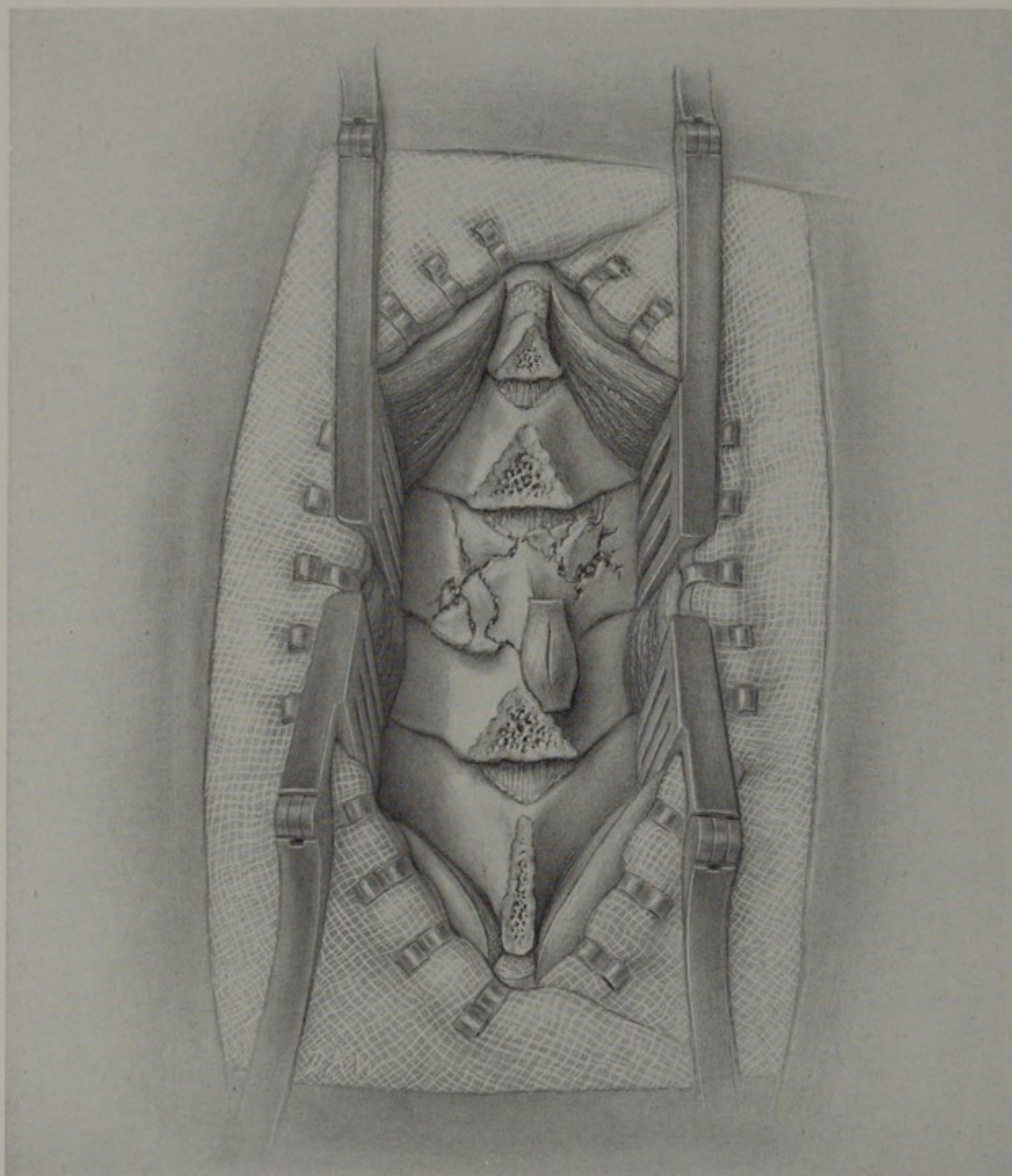


FIGURE 148.—Exposure of comminuted depressed lamina after resection of spinous processes. Note oblique resection of processes caudad and cephalad.

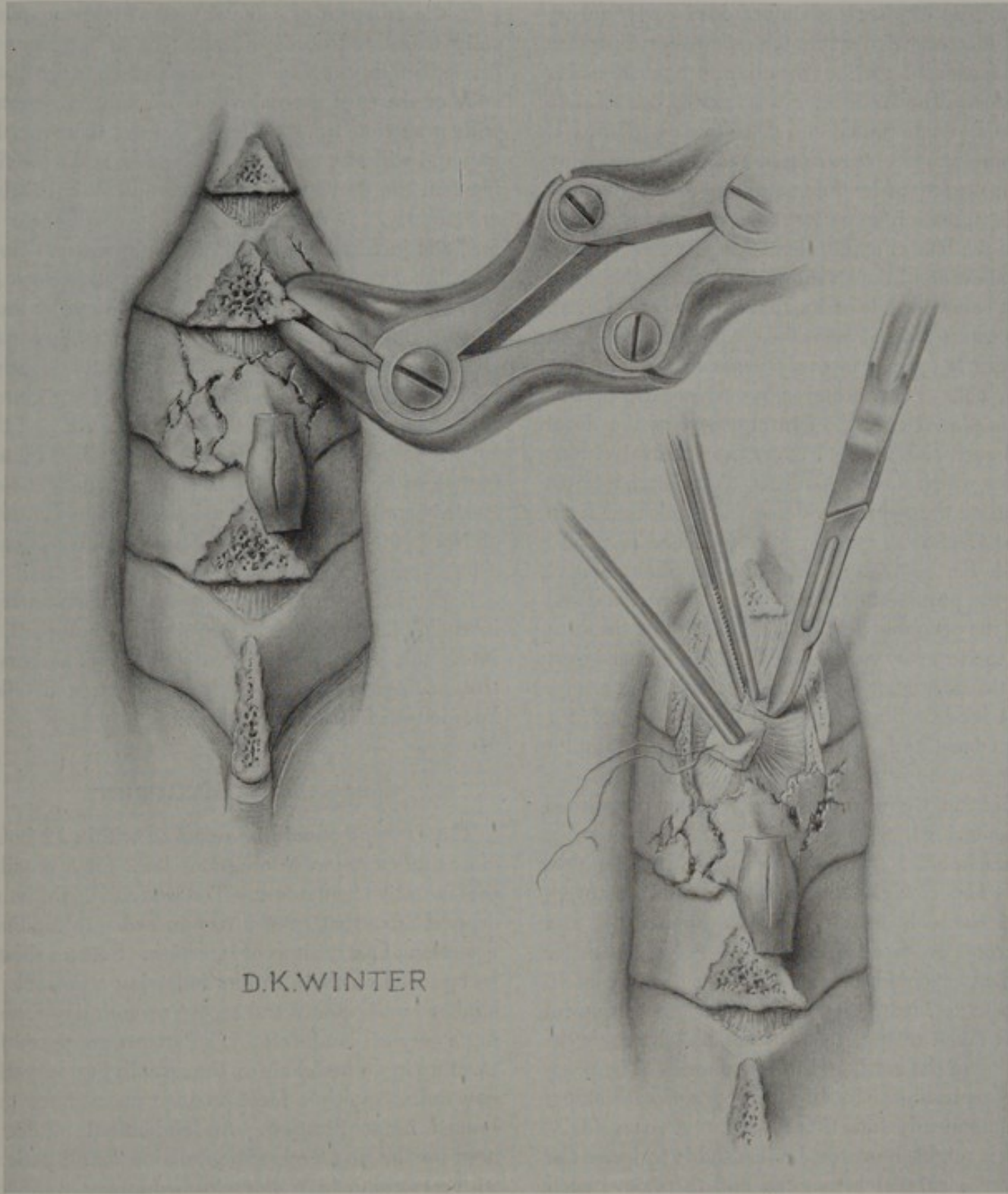


FIGURE 149.—Laminectomy with a duckbill rongeur (left) and resection of ligamentum flavum (right).

This affords exposure of intact dura early during the laminectomy and makes the removal of depressed and comminuted portions of adjacent laminae easier and safer. The laminectomy is carried out so as to include all comminuted and depressed portions. If at all possible, facets are spared and the laminectomy is not made any wider than necessary for the purpose of decompression so as to avoid unnecessary exposure of the lateral epidural venous plexuses. Pending evaluation of the extent of the damage, the intact lamina below the site of fracture is likewise removed.

The exposed dural sac is then inspected (fig. 150). The dura is opened in every instance whether it is torn or not. First, however, a narrow strip of Gelfoam is placed over the lateral aspect of the dural sac on each side so as to cover the epidural venous plexuses which have a tendency to hemorrhage just as soon as the spinal fluid has been released from the subarachnoid space. A stay suture is placed through the outer layer of the dura about 3 mm. above the proximal end and 3 mm. below the distal end of the proposed dural incision. Pulling the dura up on the two stay sutures, a longitudinal incision is made through outer and inner layers of dura with a No. 11 blade. Stay sutures are placed through the dural edges and weighted down with mosquito clamps so as to retract the dural edges laterally over the epidural Gelfoam strips and to prevent blood from entering the subarachnoid space (fig. 151). The arachnoid is opened separately whenever possible. The cord is inspected, clots are removed, pulped tissue is resected with a suction tip, and nerve roots are freed if indicated. A No. 8 catheter is pushed cephalad and caudad for a distance of 10 cm. so as to identify additional blockage. Careful note is taken of the status of the blood vessels, of the color of the cord, and of its volume. The practice of aspirating a freshly injured and edematous, but anatomically intact, cord does not seem advisable. It might, however, be justifiable to incise the pia over a subpial hematoma and to remove such hematoma gently with cotton pledgets. After having washed the operative site thoroughly with warm saline solution, the stay sutures are removed and the dural incision firmly closed with interrupted sutures of No. 0000 silk. Care is taken to prevent blood from entering the subarachnoid space while closing the dura; this can best be accomplished by holding the dural edges up on the uppermost dural sutures.

In the presence of a dural tear with an anatomically transected cord, debridement of the dura is carried out thoroughly. The proximal and the distal ends of the cord are debrided; all pulp is resected with a suction tip. Gelfoam is used to cover the gap and will also suffice to seal a dural tear providing that the deep fascia closure is done thoroughly and tightly. A dural graft with a small piece of fascia is justifiable, but not always necessary; however, the occurrence of a spinal fluid fistula must be prevented. This can best be accomplished by thorough and tight layer closure. The paraspinal muscles are approximated with mattress sutures using No. 0000 silk. The deep fascia is closed with interrupted sutures of No. 00 silk. Tight sealing of the superficial fascia is obtained by closely spaced interrupted sutures of No. 00 silk. The subcutaneous tissue is approximated with a few interrupted sutures of No. 0000 silk. The use of wire sutures is considered unnecessary.

A detailed operative report should be prepared in each of these cases. Decisions with regard to future surgical procedures and subsequent conservative management are largely based on a detailed knowledge of the original lesion.

POSTOPERATIVE MANAGEMENT

The dressing should be removed within 12 hours after the operation in order to check for a possible postoperative hematoma. The wound should be redressed after that once a day in order to facilitate detection of early signs of infection. Sutures should be removed on the fifth day following a thoracic or lumbar laminectomy and on the seventh day following a cervical laminectomy. Patients are permitted to sit up in a wheelchair on the seventh postoperative day unless multiple facet damage necessitates prolonged immobilization. An abdominal binder is used for the first week of ambulation on all patients with cervical or high thoracic cord injury to prevent hypotension. Cervical patients are also fitted with a simple neck brace which should be worn for a period of 6 weeks when sitting up. For thoracic and high lumbar levels of injury, a Taylor back brace is used during the first 6 weeks whenever there is any instability of the spine. Following a low lumbar or sacral laminectomy, a sacroiliac belt may be employed occasionally. Only those patients who have

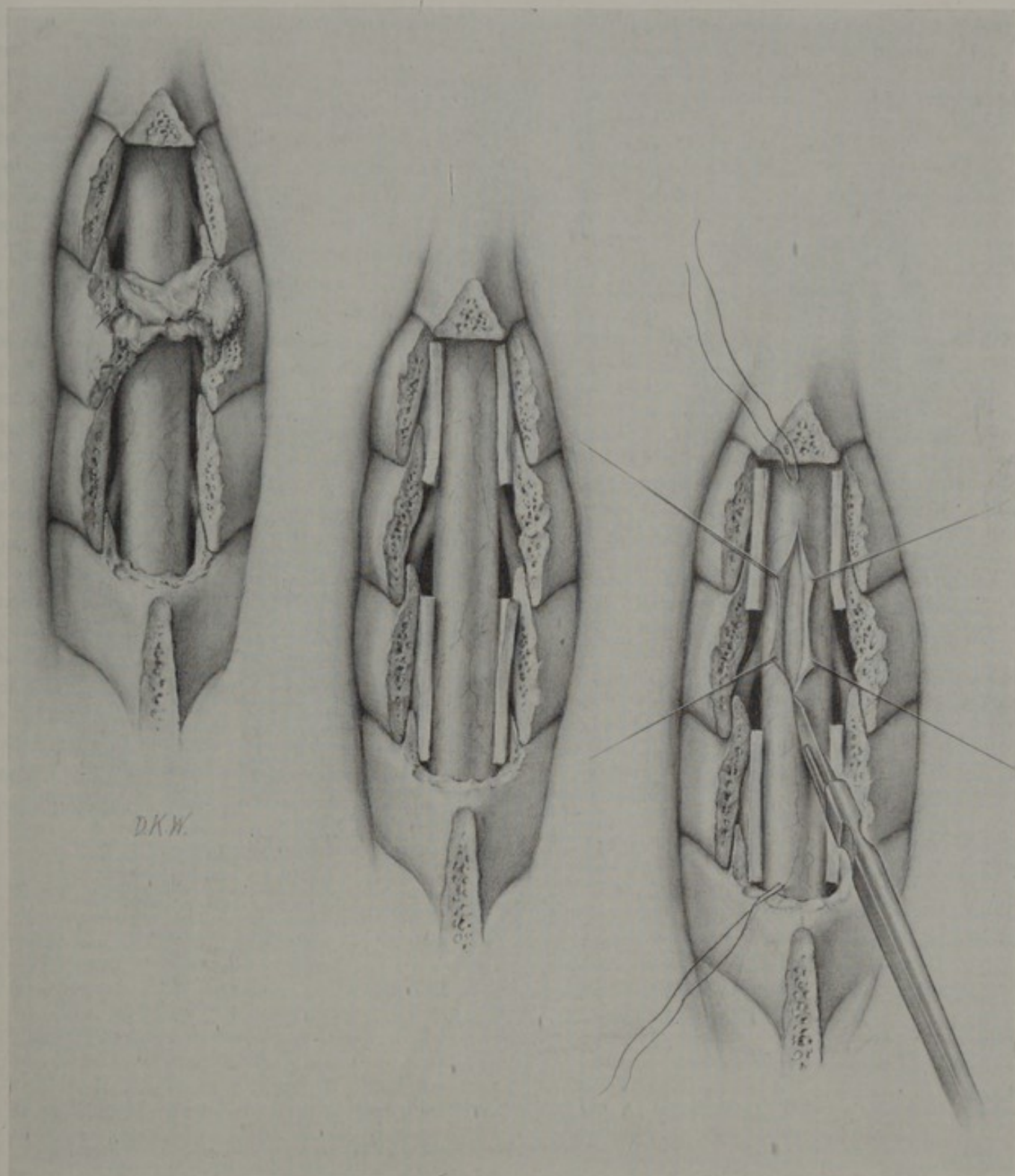


FIGURE 150.—Exposure of dural sac with depressed fragments still in place (left), dural sac exposed with Gelfoam soaked in thrombin inserted extradurally (center), and opening of dura (right).

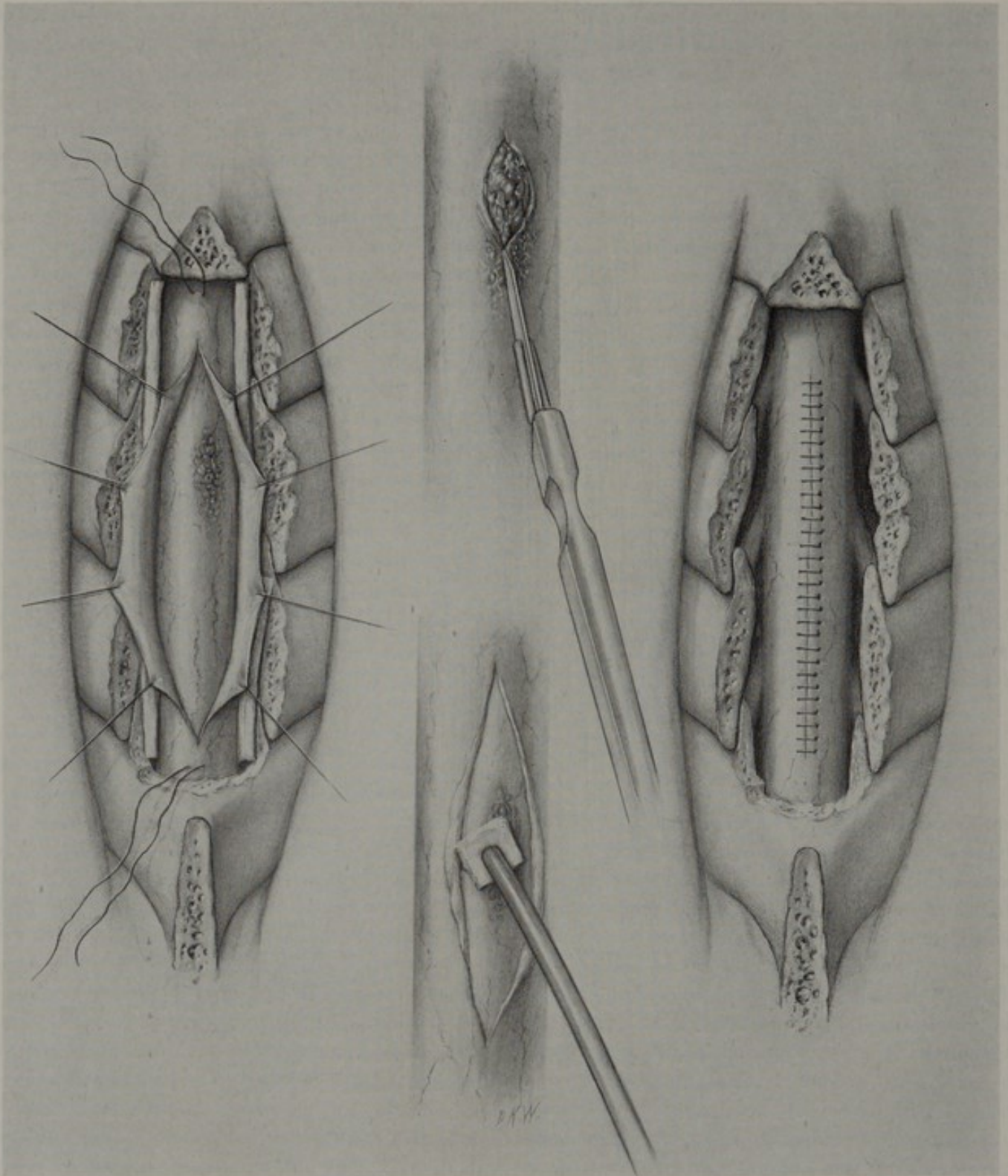


FIGURE 151.—Dural edges retracted with stay sutures to prevent blood from entering the subarachnoid space. Cord exposed, showing subpial hemorrhage in upper third (left), opening of pia and evacuation of subpial hematoma (center views), and watertight dural closure with No. 00000 silk sutures (right).

extensive bilateral facet damage will require a fusion.

Physiotherapy should be started in bed on the second postoperative day and should consist of active and passive exercises. The employment of a whirlpool bath and a Hubbard tank should be started as soon as the patient becomes ambulatory in a wheelchair.

The painstaking application during the postoperative period of all those general measures, which fall under the heading "paraplegia care" and which have been discussed at length in a preceding section (chapter 25), will take the patient safely through the postoperative period. Ambulation, physical reconditioning, and reeducation should be started immediately thereafter. Thorough indoctrination of the patient with full information as to the degree of permanency of the neurological deficit is of immense value in the process of physical and vocational rehabilitation. It is necessary for the paraplegic and quadriplegic patient to have a thorough understanding of all aspects of his disability. Two journals, *The Paraplegia News* (13) and the *Caliper* (14) and such pamphlets as "Paraplegia and You" (15) and the "Handbook for Paraplegics and Quadriplegics" (16) have done much to put paraplegic and quadriplegic men on the road to physical and vocational rehabilitation.

REFERENCES

1. Wannamaker, G. T.: Spinal Cord Injuries; A Review of the Early Treatment in 300 Consecutive Cases During the Korean Conflict. *J. Neurosurg.* 11: 517-524, November 1954.
2. Scheibert, C. D.: The Results of Laminectomy for Traumatic Myelopathy. *Proceedings of Fifth Annual Clinical Paraplegia Conference, Veterans' Administration*, 16-18 Oct. 1956, pp. 35-38.
3. Freeman, L. W.: An Early Report . . . Functional Regeneration of Spinal Nerve Roots. *Quart. Bull. Indiana Univ. M. Center* 11 (No. 3): 43-46, July 1949.
4. Freeman, L. W.: Observations on Spinal Nerve Root Transplantation in Male Guinea Baboon. *Ann. Surg.* 136: 206-210, August 1952.
5. Freeman, L. W.: Return of Function After Complete Transection of the Spinal Cord of the Rat, Cat and Dog. *Ann. Surg.* 136: 193-205, August 1952.
6. Campbell, James B., Bassett, C. Andrew, Husby, J., and Noback, Charles R.: Axonal Regeneration in the Transected Adult Feline Spinal Cord. *In Surgical Forum. Volume VIII. Forty-third Clinical Congress*, October 1957. Chicago: American College of Surgeons, 1958, pp. 528-532.
7. Munro, D., and Hahn, J.: Tidal Drainage of Urinary Bladder; Preliminary Report of This Method of Treatment as Applied to "Cord Bladders" With a Description of the Apparatus. *New England J. Med.* 212: 229-239, 7 Feb. 1935.
8. Munro D.: The Rehabilitation of Patients Totally Paralyzed Below the Waist, With Special Reference to Making Them Ambulatory and Capable of Earning Their Living. III. Tidal Drainage, Cystometry and Bladder Training. *New England J. Med.* 236: 223-235, 13 Feb. 1947.
9. Freeman, L. W.: Treatment of Paraplegia Resulting From Trauma to the Spinal Cord. *J.A.M.A.* 140: 949-958, 16 July 1949; 1015-1022, 23 July 1949. *Correction*, 141: 275, 24 Sept. 1949.
10. Campbell, Eldridge, and Meirowsky, Arnold: Penetrating Wounds of the Spinal Cord. *In Surgery of Trauma*. Edited by Warner F. Bowers. Philadelphia: J. B. Lippincott Co., 1953, pp. 121-149.
11. Scheibert, C. D.: The Management of Patients With Spinal Cord Injury. *Memphis M.J.* 34: 103-109, March 1959.
12. Sherrington, C. S.: Notes on the Arrangement of Some Motor Fibres in the Lumbo-Sacral Plexus. *J. Physiol.* 13: 621-722, 1892.
13. *The Paraplegia News*. Official organ of the Paralyzed Veterans of America and the National Paraplegia Foundation, Northvale, N.J.
14. *The Caliper*. Journal of the Canadian Paraplegic Association, Toronto, Canada.
15. Scully, J. J. (editor): *Paraplegia and You*. California Paralyzed Veterans Association, Long Beach, Calif., ca. 1955.
16. Frost, A., and Frost, R.: *Handbook for Paraplegics and Quadriplegics*. New York, N.Y., 1951.

CHAPTER 27

Analysis of Wounds Involving the Cervical Canal Incurred in the Korean War

Gordon T. Wannamaker

Sixty-four United Nations battle casualties of the Korean War sustained penetrating wounds of the cervical spinal canal with neurological involvement.

LEVEL OF INJURY

The majority of penetrating injuries of the cervical spinal canal occurred caudad to level of C4. Most patients with lesions cephalad to this level had incomplete long-tract involvement or cervical root involvement only.

<i>Vertebral level of injury</i>	<i>Number of patients</i>
C1	3
C1 and C2	1
C2	2
C2 and C3	1
C3	1
C3 and C4	1
C4	4
C4 and C5	5
C5	6
C5 and C6	4
C6	7
C6 and C7	16
C7	4
C6, C7, and T1	2
C7 and T1	7
Total	64

Representative case, K-1896.—Penetrating wound to cervical canal, C1, incomplete paralysis. Good recovery.

This 20-year-old corporal was admitted to the 1st Neurosurgical Detachment (Provisional) in Korea on 4 June 1951, several hours after having been wounded in the neck.

Examination revealed a conscious but disoriented and irrational patient with a slow pulse rate and low blood

pressure. There was a penetrating wound to the neck just to the left of the midline at the level of C1. The right pupil was slightly dilated. The left arm was flaccid and the left leg quite weak. The right arm showed moderate, generalized weakness. Normal strength was present in the right lower extremity. Analgesia was present on the right below C3, and position sense was absent on the left below C3. Deep tendon reflexes were hyperactive. Babinski's sign was elicited bilaterally. The abdominal reflexes were absent bilaterally. Roentgenograms of the cervical spine showed a metallic foreign body just to the left of the midline above and behind the lamina of C1. Roentgenographic studies of the head were normal.

On 5 June, approximately 9 hours after having been wounded, a bilateral laminectomy of C1 was performed. No evidence of fracture was noted. The arch of C1 was removed. The dural sac pulsated freely. The metallic foreign body lay extradurally just above C1 on the left. It was removed. The dura was not opened.

Postoperatively, the patient did well and was evacuated to the neurosurgical center at Tokyo Army Hospital on 9 June, the fourth postoperative day. By this time, his vital signs were normal. He had Brown-Séquard syndrome, manifested by weakness in the left arm and leg and hypalgesia below T4 on the right. The patient's stay was complicated by the formation of a cerebrospinal fluid fistula from a traumatic meningocele which developed at the site of a small opening in the dura on the right side at the level of C1. This was corrected by secondary operation. At the time of evacuation to the United States on 18 August 1951, the patient was able to void without residual urine, had good strength in both legs and in the right upper extremity. The left arm remained weak. Sensation was normal.

This patient (K-1896) apparently suffered from the concussive effect of a low-velocity missile with damage to the spinal cord, predominantly on the

left, at the level of C1. The missile did not enter the dural sac, nor was there a fracture of the lamina of C1. A small tear was probably made in the dural sac on the right at time of initial laminectomy. This is the only patient in this series who required secondary operation for closure of a spinal fluid fistula. The fistula was sealed by enlarging the dural opening, placing a small piece of Gelfoam intradurally, and resuturing the dural opening. Gelfoam was then laid over the suture line. The cervical cord syndrome, characterized by mental confusion, hypotension, bradycardia, and hypothermia, was noted in other patients with wounds of the cervical spine.

There were no patients who had complete respiratory paralysis on admission requiring artificial respiration; however, two patients died postoperatively, presumably from ascending involvement of the cord producing respiratory paralysis.

Representative case, K-1679.—A young U.S. Marine Corps corporal was admitted to the 121st Evacuation Hospital in Korea on 7 December 1950, approximately 4 hours after having suffered a through-and-through gunshot wound of the neck.

Examination revealed the patient to be in profound shock. His skin was cold, blood pressure was unobtainable, and pulse rate was thready but slow. The patient was unresponsive except to painful stimuli. Sensory examination revealed absence of sensory perception for superficial pain and light touch below C3 bilaterally. The patient had diaphragmatic breathing but complete motor paralysis below C4. Roentgenograms of the cervical spine showed fracture of the laminae of C3 and C4.

Preoperative management consisted of an attempt to stabilize and improve his condition. Whole blood was administered with resultant rise in blood pressure to 80 mm. Hg systolic and 50 mm. Hg diastolic and at times as high as 100/60. The peripheral pulse rate remained around 34 to 50 beats per minute throughout the afternoon. The patient became conscious and rational. Spinal tap revealed an initial pressure of 230 mm. H₂O with partial block on Queckenstedt test. Toward night, the patient's skin became warm and the blood pressure stabilized. The bradycardia persisted. The patient was placed on a litter which was specially prepared with an opening for the face so that he could be maintained in a prone position for 2 hours at a time. A second litter, also specially padded, was prepared for use in the supine position. Turning was effected every 2 hours by using the two litters strapped together and turning them in a fashion similar to the Stryker frame. Though the bradycardia persisted, the vital signs remained fairly stable. An intake and output fluid balance was established, and by noon the following day, it did seem that the patient could stand the proposed operation. The previously prepared litter, which had been used whenever the patient was in a prone position, was used in lieu of the operating table.

Operative inspection revealed comminution and depression of the fourth cervical lamina and linear fracture of the third lamina. Removal of the comminuted fragments revealed that two fairly large pieces of bone had penetrated through the dura and had transected the cord just at the inferior border of C3. There was pulpy, partially liquefied cord tissue and hematoma which exuded upon removal of the two bone fragments leaving a gap between the proximal and distal ends, measuring approximately 2 centimeters. The anterior dural wall could be recognized clearly. A small piece of muscle tissue was placed between the ends of the transected spinal cord for hemostasis. The dura was only partially closed over the defect. The muscles and skin were closed in layers. Vital signs had remained stable throughout the procedure.

Postoperatively, the patient was transferred to a naval hospital ship, as it was necessary at that time to evacuate all patients from the 121st Evacuation Hospital because of the tactical situation. Followup report revealed that he died 48 hours later.

This patient (K-1679) suffered from a through-and-through wound of the neck with production of quadriplegia and blood loss superimposed on a syndrome which was later recognized as an acute sympathetic blockade, thus accounting for the low blood pressure with bradycardia. After the blood loss had been replaced by transfusions, the blood pressure remained low and the bradycardia persisted. The administration of atropine would probably have resulted in lessening of the vagal effect. Exigency of war made it necessary to transport this patient while in a critical condition. His death was apparently due to persistence of the sympathetic blockade and respiratory paralysis.

TREATMENT

The keystone of treatment during this early phase of paraplegic care (average 4 to 6 weeks) was to salvage as much neurological function as possible and to prevent infection, the formation of decubital ulcers, and other complications that would retard rehabilitation (1). All penetrating wounds of the cervical spine were debrided and closed primarily (2).

As soon as the patient reached a neurosurgically equipped medical facility, a complete physical examination was done, as penetrating wounds of the cervical cord were frequently associated with damage to additional structures in face and neck or elsewhere in the body. Five patients had associated fractures of the mandible, five had fractures of the long bones of the extremities, four had pneumothorax, four had

scalp lacerations, and two had lacerations of the esophagus and trachea. Another two had fractures of the cranial vault. One had a penetrating wound through the eye and mastoid process.

The establishment of two-echelon neurosurgical care of quadriplegic casualties in the Korean War resulted in a striking change with regard to the occurrence of complications. Mobile neurosurgical units at division level, a center for spinal cord wounds in the communications zone, and helicopter and plane evacuation served to lessen incidence and severity of the previously common complications. After the establishment of two-echelon care, there were no patients who developed decubital ulcers while under the care of U.S. Army neurosurgeons in the Far East Command. This was achieved by turning the patient every 2 hours, either by using the double-litter method (3) or the Stryker frame, and thus avoiding the use of a body cast. This turning was also continued during air evacuation of the patient to his homeland. Bladder infections were the exception rather than the common finding. No patients in this series received suprapubic cystostomies, as employment of such procedures would retard subsequent development of a reflexly or automatically functioning bladder. The McKenna type of tidal drainage apparatus was used (4). Dietary restrictions were practically eliminated by starting early weight bearing on a tilt table (5). Most of the patients with penetrating wounds of the neck had very little bony instability. By use of long back braces with cervical extension, they were able to start sitting in a chair 10 days following laminectomy. None of the patients in this series received a fusion as it was considered unnecessary. Tracheostomies were done on five patients whose associated injuries resulted in partial obstruction of the upper respiratory passage. Whole blood transfusions were given when indicated, and blood substitutes such as plasma were not used. The availability of the newer mycin antibiotics and the disk method of culture and sensitivity studies (6) made the treatment of infections easier than in prior wars.

NEUROSURGICAL INTERVENTION

As soon as practical after admission, the penetrating wound of the neck was debrided and lami-

nectomy accomplished. We encountered practically no difficulty with wound healing or infection in those patients with penetrating wounds who received initial debridement, laminectomy, and primary closure of the wound without drainage as late as 48 to 72 hours after injury. Only one patient in this series had an infected wound. He had been treated for 1 month aboard a hospital ship in the Korean theater prior to transfer to the neurosurgical center at Tokyo Army Hospital.

Of the 64 patients, there were 61 who had sustained penetrating wounds of the neck showing evidence of spinal cord or cervical nerve root involvement with roentgenographic evidence of fracture of cervical vertebrae or their processes. One patient (K-1839) in this group died prior to surgery. All others received debridement of the wound including decompressive laminectomy and intradural exploration.

Representative case, K-980.—Penetrating wound to cervical canal, C5, with immediate quadriplegia. Subsequent recovery.

This 19-year-old private, first class, was admitted to Tokyo Army Hospital on 23 September 1950. History revealed that he had sustained a penetrating wound to the neck 2 days previously in Korea. There was immediate paralysis of the upper and lower extremities following the gunshot wound. Within several hours, he regained a minimal degree of motor power in his legs. He was evacuated to the neurosurgical center at Tokyo Army Hospital.

Examination revealed marked weakness in all four extremities, greater in the upper than in the lower. Some muscle function was present in all muscle groups. Marked hypesthesia was present caudad to C6 bilaterally. The deep tendon reflexes were hyperactive with bilateral ankle clonus and Babinski responses. Roentgenograms demonstrated presence of a fracture of the lamina of C5 with a retained metallic foreign body. A quantitative Queckenstedt test revealed the presence of a partial block.

On 1 October, a bilateral laminectomy of C5-C6 was performed. A small organized extradural hematoma was removed. Intradural examination was essentially normal.

Postoperatively, the patient regained normal sensation in upper and lower extremities. Bladder function reverted to normal. He became ambulatory with assistance. On 17 October 1950, he was evacuated to the United States for further rehabilitation.

This patient (K-980) was fortunate in having sustained only a mild contusion of the cervical spinal cord. The rapid recovery was apparently facilitated by evacuation of the epidural hematoma and by decompressive laminectomy.

Representative case, K-924.—Penetrating wound, C6, with fracture. Laminectomy date of trauma. Subsequent recovery.

An Australian infantryman was admitted to the 2d Neurosurgical Detachment (Provisional) in Korea on 2 July 1952, several hours after having sustained a penetrating wound of the neck.

Examination revealed a small penetrating wound to the right of the midline just lateral to the thyroid cartilage. There was no wound of exit. Motor examination revealed bilateral paralysis of the upper extremities and paralysis of the left lower extremity. The right lower extremity showed fair to moderate function. Sensory examination revealed generalized hyperesthesia on the right side of the trunk and right lower extremity. On the left side, there was hypesthesia to complete anesthesia in the left trunk and left lower extremity. Bilateral Babinski responses were elicited.

The patient was taken to the operating room shortly after admission. A bilateral laminectomy of C6-C7 was performed. The dura was intact. It was opened, and marked discoloration was noted on the left side of the spinal cord in the region of C6.

Postoperatively, the patient showed gradual improvement. There was return of normal motor function in the right upper extremity. The right lower extremity retained its normal motor function. There was some early return of function in the left lower extremity. The left upper extremity remained weak. There was a reversal in the sensory pattern postoperatively. There was moderate hyperesthesia on the left and mild hypesthesia on the right caudad to C7. The patient was evacuated to Tokyo Army Hospital 3 days after surgery in Korea. He subsequently was evacuated to Australia arriving there on 10 August 1952. By 28 August, he was ambulatory with assistance and allowed to go on convalescent leave.

There were an additional three patients who came to the attention of the neurosurgical service who had fractures of the tips of the spinous process without evidence of bony compression of the spinal cord. These patients had complaints of neck pain which subsided spontaneously. The wounds were debrided. Laminectomy was not done.

The results of treatment of the 64 patients with penetrating wounds of the cervical spinal canal are summarized in the following tabulation:

Results	Number of patients
Improved	50
Unimproved	11
Died	3
Total	64

Among the 50 patients whose condition was improved by neurosurgical treatment, 8 recovered completely. The cause of death in two patients was cer-

vical cord syndrome preoperatively and cervical cord syndrome postoperatively. There was inadequate followup of the third patient who died, but death was presumably caused by respiratory paralysis.

Representative case, K-892.—Perforating wound through both shoulders and base of the neck. Fracture of the spinous processes, C6-C7. No neurological deficit.

This 23-year-old private, first class, was wounded in action in Korea by a grenade fragment on 3 September 1951. He received debridement of the wounds of entrance and exit at the 8076th Mobile Army Surgical Hospital, located in the vicinity of the 7th Medical Battalion, in Korea on the day of injury. Roentgenograms showed comminuted fracture of the spinous processes of C6 and C7, but there was no obvious spinal cord damage. The patient was evacuated to the neurosurgical center at Tokyo Army Hospital 2 days later.

On examination, the patient's general condition was fair. He complained of a great deal of pain in both upper extremities and the neck, particularly in the region of the shoulders. Reflexes were present and physiological throughout. There was no abnormal reflex. Sensory examination was essentially normal except for the base of the neck where there was increased sensitivity to pain. Motor examination revealed weakness in the upper extremities secondary to pain; no actual motor paralysis.

A secondary closure was performed at the site of the previously debrided neck wounds. After the pain in the neck subsided the patient had full range of motion of the upper extremities, and the neurological examination remained normal. Laminectomy was not deemed to be indicated in this case.

TIME OF SURGICAL INTERVENTION

There were 46 patients with penetrating wounds of the neck who received laminectomy in Korea. An additional 14 were operated on at Tokyo Army Hospital after having been evacuated from Korea. Of the 60 patients with penetrating wounds, 20 received surgery within 24 hours after having been injured. The remaining 40 laminectomies for penetrating wounds were done at a later date. Laminectomies were not performed on four patients. Had neurosurgical teams been established in Korea during the first 8 months of war, perhaps the incidence of immediate laminectomy would have been higher. However, at times, because of the large influx of casualties, serious penetrating wounds of the brain were given surgical priority over spinal cord injuries, thus delaying the time of laminectomy. In general, spinal cord injuries were considered surgical emergencies and laminectomy was done as soon after admission as possible.

SYMPATHETIC BLOCKADE, AN ACUTE CERVICAL CORD SYNDROME

The symptoms of bradycardia, hypotension, and hypothermia and the disturbances in the level of consciousness and orientation constituted a syndrome which was present in 16 (25 percent) of the 64 patients with penetrating neck injuries. An additional 13 patients had some but not all of the features of the syndrome (7). Practically all patients who had this syndrome also had gastric distention and ileus. In most cases, the patients were rendered quadriplegic immediately following the initial trauma.

Representative case, K-1839.—Penetrating neck injury, cervical cord syndrome, died 4 days after injury.

This 20-year-old private was admitted to the 1st Neurosurgical Detachment (Provisional) in Korea on 30 March 1951. He had sustained a penetrating wound to the neck several hours earlier.

Examination revealed a penetrating wound of the neck. The patient was cold and his blood pressure was low. He responded in an apathetic fashion. There was complete motor paralysis below C5. Anesthesia was also present below C5. The abdomen was markedly distended. Breathing was purely diaphragmatic. Roentgenograms showed a shell fragment in the spinal canal at C5.

Due to the low blood pressure (the exact figures are not recorded), hypothermia, and bradycardia, an attempt was made to prepare him for surgery by the administration of blood transfusions and the use of hot water bottles. The patient failed to improve. The following day, the respiratory rate was noted to be embarrassed by the marked distention of the abdomen. A Levin tube was inserted with release of much foul smelling black liquid and gas. The patient continued to fail and died at 5:00 a.m. the following day.

This patient (K-1839) was one of the first in the series. Surgery was delayed awaiting the patient's recovery from shock. He received several blood transfusions in an attempt to combat shock. This succeeded only in further loading an inert peripheral vascular pool secondary to the acute sympathetic blockade and did not raise the blood pressure. Neurosurgeons subsequently learned to operate on these patients in spite of the slow pulse rate and low blood pressure. Frequently, the blood pressure would return to normal immediately after the cord was decompressed.

There were three patients in this series who exhibited the cervical cord syndrome postoperatively. One case (K-1679) has already been described.

The other two cases (K-2119 and K-2215) will be described in the following paragraphs.

Representative case, K-2119.—Penetrating wound of neck, C4-C5, with postoperative cervical cord syndrome. Recovered.

This 24-year-old private, first class, was admitted to the 1st Neurosurgical Detachment (Provisional) in Korea on 25 April 1951, after having sustained a penetrating wound of the neck the previous day.

Examination revealed the wound of entry on the right side of the neck. He had a complete flaccid quadriplegia below C5 bilaterally and anesthesia below C4 on the right and C3 on the left. Deep tendon reflexes were absent in all extremities. Blood pressure was 85 mm. Hg systolic and 65 mm. Hg diastolic. The pulse rate was 42 beats per minute. Roentgenograms of the cervical spine revealed multiple metallic foreign bodies in the neck, several of which were situated just posteriorly to C4. There was a fracture of the dorsal spine of C4.

Under local anesthesia, 1-percent procaine, a cervical laminectomy of C4 and C5 was done on 25 April 1951. The metallic foreign bodies and comminuted bone fragments were removed. The intact dura was opened. The cord appeared somewhat hyperemic but grossly normal.

Postoperatively, the patient improved for 24 hours, then became disoriented. Bradycardia, hypotension, and hypothermia continued for 72 hours during which the patient remained semiconscious and confused. Intermittent clonic movements of the neck were noted. Lumbar puncture revealed normal pressure and dynamics. Supportive measures including atropine, ephedrine, application of Ace bandages to all extremities, Wangenstein drainage, rectal tube, and neostigmine were added to his routine paraplegic care. Over the course of the next several days, the vital signs reverted to normal. Disorientation, confusion, and bowel distention subsided. The patient was evacuated subsequently to Japan where he was started on a rehabilitation program.

RESULTS

The overall results of all patients treated are shown in table 30. Penetrating wounds of the cervical spine proved to be fatal in 3 (4.7 percent) of the 64 patients. One patient died preoperatively. Three patients did not receive laminectomy. Two of the 60 patients who received laminectomy died, giving an operative mortality of 3.3 percent. An additional 12 patients failed to show improvement in the neurological deficit. Of the 64 patients, 49 showed improvement, 8 of which had complete recovery of neurological function.

FACTORS IN MORTALITY

The cervical cord syndrome was implicated in the death of all three patients. Ascending paralysis re-

TABLE 30.—*Neurological deficit and results of surgical (laminectomy) and nonsurgical treatment of 64 patients with penetrating cervical cord injuries*

Neurological deficit	Number of cases	Treatment					
		Surgical (laminectomy)			Nonsurgical		
		Unimproved	Improved	Complete recovery	Unimproved	Improved	Complete recovery
Transitory long-tract signs or cervical root involvement....	13	10	2	1
Neck pain only (neurological examination normal).....	3	1	2
Partial lesions with spinal cord involvement.....	15	13	2
Complete loss of function below level of injury.....	33	¹ 14	17	1	² 1
Total.....	64	14	40	6	1	1	2

¹ Two patients died.² Patient died.

sulting in respiratory paralysis was, however, the primary cause of death in the two postoperative cases: (1) K-1839 died prior to laminectomy, cervical cord syndrome, (2) K-1679 died 2 days following laminectomy at C3-C4, and (3) K-2215 died on first postoperative day, penetrating wound, C6.

Representative case, K-2215.—Penetrating wound to cervical canal, C6. Died 1 day after surgery.

This patient was admitted to the 2d Neurosurgical Detachment (Provisional) in Korea on 29 July 1952. History revealed that the patient had sustained a penetrating wound to the neck 8 hours previously. He suffered immediate complete paralysis from the neck down.

Examination revealed a penetrating wound in the lower posterior neck from which spinal fluid was draining. There was complete motor and sensory paralysis at C5 and below. Roentgenograms of the cervical spine revealed comminuted fractures of C6 and C7. Blood pressure was 90 mm. Hg systolic and 78 mm. Hg diastolic. The pulse rate was 48 beats per minute and the respiration rate, 10.

On 29 July, approximately 10 hours after having been wounded, a bilateral laminectomy of C6 and C7 was performed. There was a dural tear along the left lateral margin of the spinal canal. The spinal cord was partially transected at the upper level of C6. The proximal stub of the spinal cord was severely contused. The dural defect could not be closed and was packed with Gelfoam. The remaining soft tissues were closed in layers.

Postoperatively, the patient had an acute cervical cord syndrome characterized by hypothermia, hypotension, bradycardia, and periods of disorientation. He was treated with ephedrine and atropine sulfate intravenously which tended

to improve the vital signs. However, he developed acute respiratory paralysis and died the day following surgery.

This was the second patient (K-2215) in this series who died postoperatively. The cause of death was probably due to ascending thrombosis of the anterior spinal artery with resultant complete paralysis of the cervical roots supplying the phrenic nerves.

REFERENCES

1. Wannamaker, G. T.: Spinal Cord Injuries; a Review of the Early Treatment in 300 consecutive Cases During the Korean Conflict. *J. Neurosurg.* 11: 517-524, November 1954.
2. Campbell, Eldridge, and Meirrowsky, Arnold: Penetrating Wounds of the Spinal Cord. *In* *Surgery of Trauma*. Edited by Warner F. Bowers. Philadelphia: J. B. Lippincott Co., 1953, pp. 121-149.
3. Meirrowsky, A. M., and Barnett, J. C.: Mobile Neurosurgical Team. *Ann. Surg.* 138: 178-185, August 1953.
4. McKenna, W. F.: Simple, Efficient, Automatic Tidal Drainage Apparatus. *Urol. & Cutan. Rev.* 52: 18-21, January 1948.
5. Freeman, L. W.: The Metabolism of Calcium in Patients With Spinal Cord Injuries. *Ann. Surg.* 129: 177-184, February 1949.
6. Wannamaker, G. T., and Pulaski, E. J.: Pyogenic Neurosurgical Infections in Korean Battle Casualties. *J. Neurosurg.* 15 (pt. 5): 512-518, September 1958.
7. Rosenbluth, P. R., and Meirrowsky, A. M.: Sympathetic Blockade, An Acute Cervical Cord Syndrome. *J. Neurosurg.* 10: 107-112, March 1953.

CHAPTER 28

Analysis of Wounds Involving the Thoracic Canal Incurred in the Korean War

Joseph C. Barnett, Jr.

Following the establishment of facilities for definitive neurosurgical care within the Far East Command during the Korean War, 191 instances of penetrating thoracic spinal canal and cord injuries were treated. These patients came under neurosurgical care by a process of indirect evacuation through forward hospital facilities or by direct evacuation as was possible following the establishment of the mobile neurosurgical units (1). This series includes only instances of missile-induced penetrating wounds. The high-velocity missiles (including bullets from rifles, carbines, machineguns, and other automatic-type weapons) comprised 69 percent of the injuries, whereas the metallic fragment wounds (including fragments from grenades, mortars, and high explosive shells) comprised 31 percent of the injuries.

ASSOCIATED INJURIES

In 65 percent of these penetrating thoracic spinal canal injuries there was a major associated injury which at least temporarily precluded definitive neurosurgical management. The high incidence of serious accompanying injury frequently called for combined thoracic, surgical, general surgical, or occasionally urological evaluation. In many instances, definitive management of the coexistent problem took precedence in terms of urgency, thus, in some instances, considerably delaying definitive management of the thoracic spinal cord injury. The problem of an accompanying chest penetration with associated pneumothorax, hemothorax, or pneumo-

hemothorax presented in 53 percent of the casualties. In 9 percent of the casualties there presented the problem of multiple combined injuries involving the chest, abdomen, as well as serious extremity wounds, and there was a 3 percent incidence of combined chest and abdominal injuries requiring early surgical management.

SURGICAL MANAGEMENT

The primary considerations in the surgical management of these compound wounds of the thoracic spinal canal were (1) prevention of contamination and infection by thorough debridement and closure of the wound as expeditiously as possible, (2) decompression of the spinal cord, and (3) inspection of the cord from which an anatomical estimate of damage might be made.

K-1487 was wounded by mortar fire sustaining a large avulsive laceration of the posterior chest wall extending from the level of the 9th rib on the left to the right posterior shoulder. Initial total paraplegia reported. Wound debrided upon arrival at neurosurgical unit 12 hours following injury. Films revealed spinous process and laminar fractures T4 and T5. Lung fields clear and no other significant injuries. Neurological examination revealed some return or preservation of tactile and position sense, absent deep tendon reflexes, complete motor paresis. Debridement and exploration under anesthesia revealed depressed laminar fractures T4 and T5 and fracture spinous processes T3 through T6. Laminectomy T4 and T5 revealed intact dura, cerebrospinal fluid blood tinged, no gross damage to cord. Layer closure of the entire wound accomplished. Three weeks following surgery, discernible sensory improve-

ment, some abdominal and pelvic motor return, improved rectal sphincter tone, some bladder sensation. Wound healed per primam intentionem.

This case (K-1487) presents a relatively uncomplicated case in which a large avulsive-type wound accompanied by depressed laminar fractures and profound neurological deficit demanded immediate closure without accompanying injuries contraindicating immediate laminectomy and spinal cord decompression.

K-674 sustained multiple shell fragment wounds of back presenting large sucking wound of the posterior chest, severe radicular pain both lower extremities with complete motor paresis, unable to void. Lumbar puncture (LP) reportedly revealed no block. Chest situation treated, arriving neurosurgical unit 3 weeks following injury. Examination revealed considerable improvement neurologically over that originally noted. Marked weakness in lower extremities but able to stand and walk with assistance, voiding without residual, hyperactive deep tendon reflexes, only minor sensory findings. Incomplete block on repeat LP. Roentgenograms revealed laminar fractures T10 and T11. Small draining wound region spinous process T11 (?CSF), thought to be wound of entrance. Laminectomy with radical debridement of wound accomplished (in line of incision). Findings of slightly depressed laminar fractures T10 and T11, dural sleeve and root laceration T9 right, mild cord contusion, complete dural repair and layer wound closure. By third postoperative week walking well, voiding without residual.

This case (K-674) presents a single major complicating injury (open chest wound) which required immediate attention, postponing definitive neurosurgical care which in this instance consisted of a decompressive laminectomy and debridement and closure of the compound spinal canal wound.

K-1847 sustained a penetrating shell fragment wound of left lower posterior chest wall, missile located intra-abdominally on the right. Left hemothorax. Laparotomy revealed laceration right kidney and liver with missile implanted within liver. Right nephrectomy and liver repair accomplished, hemothorax evacuated and wound of entrance closed. Admitted neurosurgical unit findings of total paraplegia below T10. Roentgenograms: Fractures T10, T11, T12. Laminectomy fourth postinjury day revealing severe comminuted and depressed laminar fractures T10, T11, T12; dural laceration and anatomical transection of cord level T10. Developed right bilio-pleural fistula fourth postinjury week which subsided following repeated chest taps. At sixth postinjury week condition good, no neurological return.

This case (K-1847) demonstrates a complicated surgical problem presenting an acute chest and ab-

dominal problem requiring immediate surgical attention. In this instance, the wounds of entrance and exit referable to the spinal canal were sufficiently remote as to be cared for by other specialty teams.

K-599 sustained a penetrating missile (bullet) wound entry left deltoid area and exit right posterior chest wall. Left brachial plexus handicap, massive left pneumohemothorax, total paraplegia below level T6 resulted. Roentgenograms: Comminuted lamina fracture T6. Admitted neurosurgical unit. Lumbar puncture revealed complete manometric block. Laminectomy third postinjury day revealed extensive comminuted and depressed fracture of T6, dura intact, cord contused on the left but pia intact. Developed causalgia left upper extremity (incomplete brachial plexus injury) cervicodorsal sympathectomy accomplished with good relief. At the seventh postinjury month left brachial plexus handicap completely cleared, no neurological improvement in regard to paraplegia. Admitted to Veterans' Administration hospital for final rehabilitation phase.

This case (K-599) demonstrates two neurological problems as occurring simultaneously together with an urgent chest problem.

The surgical technique utilized in accomplishing the laminectomy has been dealt with elsewhere in this volume (pp. 311-322). Some consideration might be given, however, to the wound most proximal to the cord injury be it the wound of entrance or wound of exit. Although a great variety of circumstances may exist by the nature of such wounds, any wound within reasonable proximity and communicating with the spinal canal was thoroughly debrided and closed. In instances where the wound of entrance was in or near the midline, the debridement was carried out to include this wound within the laminectomy incision, radically debriding the skin and underlying soft tissues of the wound. In instances where the wound of entrance or exit was several inches from the midline, the debridement and closure of the wound was accomplished immediately prior to or following the laminectomy, combining the two procedures. In instances of large avulsive wounds (K-1487) of the back, it was often possible to accomplish the laminectomy within the debrided wound. Remote or distant wounds of the abdominal or chest wall were generally dealt with at the time of thoracotomy or laparotomy, these procedures usually preceding laminectomy.

The time elected for laminectomy in those operated cases varied between a few hours following in-

jury to, in one instance, 90 days following injury. A number of factors were influential in the timing of laminectomy. The condition of the patient, particularly referable to major associated injuries, as well as the availability of definitive neurosurgical care, were the two primary factors. Twenty-three percent of the patients underwent laminectomy within the first 24 hours following injury and 53 percent were operated by the tenth postinjury day.

NEUROLOGICAL DEFICIT

Upon first careful neurological evaluation, 18 percent of the patients presented an incomplete neurological deficit below the level of the injury. In evaluating the most recent known neurological evaluation of the entire group of patients, 20 percent were found to have significant neurological improvement in comparison with their original neurological evaluation.

At the time of surgical exposure, 46 percent of the operated cases demonstrated either a partial or complete anatomical transection of the thoracic cord. Discernible evidence of cord contusion was found in 47 percent of the cases, and in 7 percent, there was no discernible evidence of cord damage. Those patients demonstrating either a partial or total transection of the cord had no significant return in neurological function with three exceptions. These exceptions comprise three instances of incomplete transection at the level of the lower thoracic cord (T11 and T12) and this significant return in neurological function was attributable to the remaining intact portion of the conus medullaris and cauda equina. Attempting to correlate the findings at the time of surgery with return in neurological function, only in those instances in which some contusional damage was noted, or in which no discernible gross damage was definable, was there a significant return in function. In comparing the neurological return seen in both the initially incomplete and complete physiological cord lesions, only 34 percent of those

lesions designated as incomplete improved further to the point of an evaluated significant improvement in their neurological deficit. The group of casualties designated as physiologically complete on original neurological examination demonstrated a 3 percent incidence of significant improvement following laminectomy.

FOLLOWUP DATA

It should be brought out that in this series of casualties there is considerable variance in the followup period. Available recorded information in all instances is complete up to the point of evacuation of the casualty to the United States or the patient's homeland. Beyond this point information is often incomplete or lacking. The followup period then varies from a few weeks to 2 years with only 23 percent of the group having begun their final phase of rehabilitation. Despite the limited number of final reports, 14 percent of the casualties are now ambulatory, either with or without braces and other prosthetic appliances. Seventeen percent have developed either normally or reflexly functioning bladders.

MORTALITY

The mortality for this series of patients insofar as available records indicate is 4 percent. Four deaths were attributable to an acute severe bronchopneumonia, one patient succumbed to acute hepatitis, one died during an acute attack of asthma, and one patient developed an acute recurrent massive hemothorax as a complication of an associated chest injury. In this series there were no operative (laminectomy) mortalities, and as to morbidity, a single postoperative wound infection is recorded.

REFERENCE

1. Meirowsky, A. M., and Barnett, J. C.: Mobile Neurosurgical Team. *Ann. Surg.* 138: 178-185, August 1953.

CHAPTER 29

Analysis of Wounds Involving the Lumbosacral Canal Incurred in the Korean War

Robert A. Clark, Jr.

There were 120 casualties in the Korean War who sustained injuries involving the lumbosacral canal. Of the total, 104 (87 percent) were due to penetration or perforation by high-velocity missiles or metallic fragments and 14 (13 percent) were injuries produced by acute flexion resulting in fracture or dislocation of the spine. These patients represent 23.4 percent of all the spinal injuries cared for during the period from 1 September 1950 to 1 September 1952. This analysis deals only with wounds produced by ballistic missiles.

The patients were predominantly U.S. Armed Forces personnel and included 94 enlisted men of the Eighth U.S. Army, 9 U.S. Army officers, and 1 U.S. Marine Corps enlisted man. The remaining 16 patients included 5 British, 4 Korean, 2 French, 2 Canadian, and 1 each Greek, Thai, and New Zealand soldiers.

Of the group comprising those with penetrating injuries, 97 (93 percent) were wounded in action against the enemy and 7 (7 percent) sustained their injuries accidentally. (Half of the 14 patients with closed fracture dislocations were wounded in action. The mechanism of injury in the wounded-in-action group included one due to an airplane crash, one due to enemy bombing, three from collapse of a bunker because of a direct hit, one parachute jump, and one patient who jumped down a bank during a withdrawal. Six of the remaining seven were accidentally injured, five in vehicular accidents and one in jumping from a burning barracks; in the one remaining case, the mode of injury is not known. There were two cases in

which neither the mode of injury nor the type of injury was recorded. These cases will not be included in the statistical analysis.)

All of these patients were operated upon by the author or his associates in mobile neurosurgical teams in Korea or in the neurosurgical center at Tokyo Army Hospital. Several patients that came under the surveillance of the medical group caring for neurosurgical casualties are not included because they were either operated on by others and their treatment varied somewhat from the standard procedure discussed here, or they were so ill from associated injuries that they died before laminectomy could be carried out.

The frequency of wounds involving the various levels of the lumbosacral canal is shown in figure 152.

INITIAL EVALUATION

Preoperative and postoperative care of these patients was essentially the same as for the spinal canal injured group as a whole. When first seen, complete general physical and neurological examinations were carried out and the pathological findings were recorded. Because of the high incidence of associated wounds, frequent use was made of available consultants in general and thoracic surgery in an effort to detect possible intra-abdominal or intrathoracic injuries. A joint decision was then made as to whether immediate laparotomy, thoracotomy, or thoracentesis should take precedence over laminectomy or whether all surgery should be de-

FREQUENCY

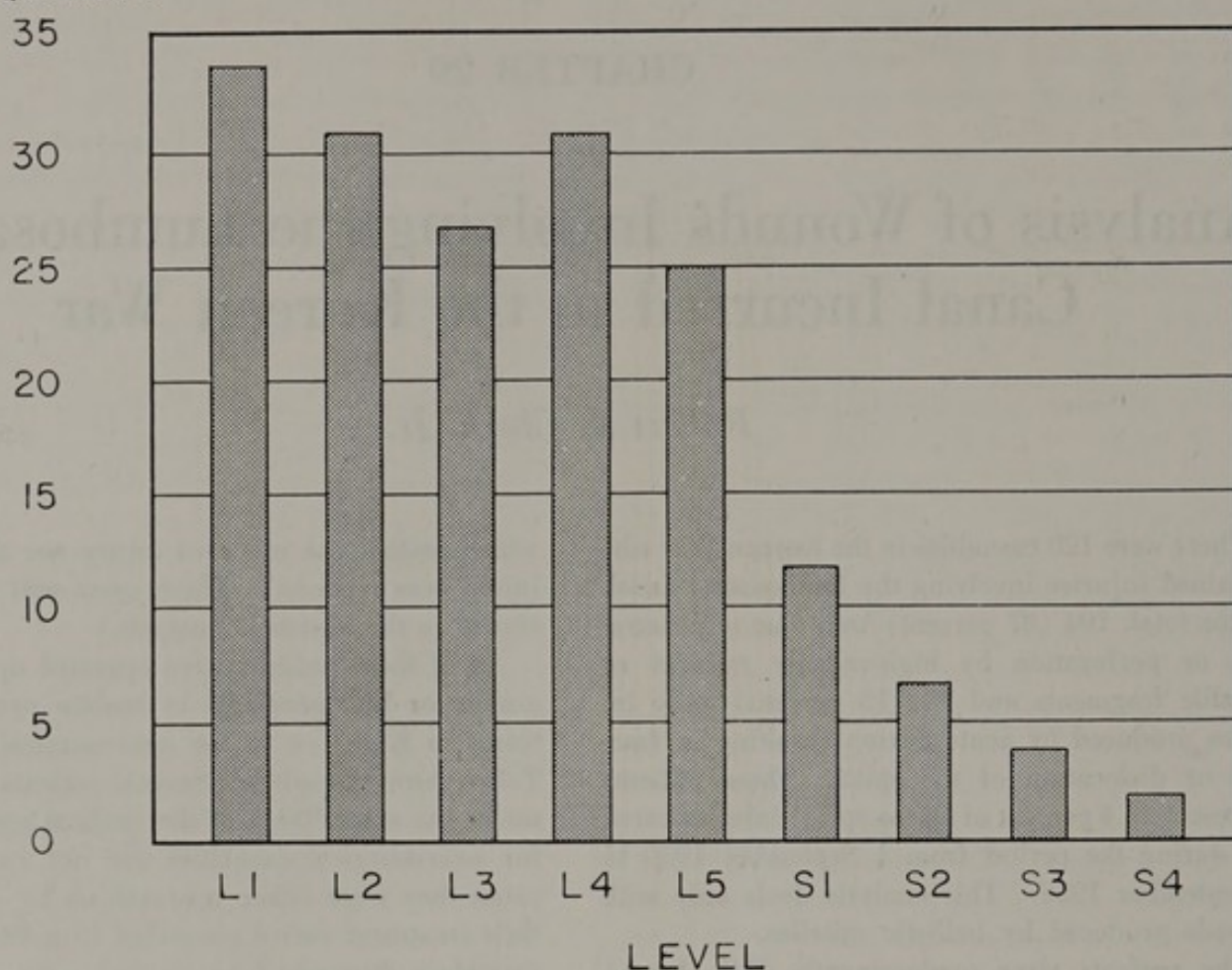


FIGURE 152.—Frequency of missile wounds involving the various levels of the lumbosacral canal.

ferred and the patient simply observed, if the decision as to the presence or absence of an associated injury could not be made on initial examination. The virtue of such close liaison between multiple medical disciplines is attested by the fact that there was only 1 immediate postoperative death in the 120 patients on whom operation was performed.

A hemoglobin and hematocrit determination was obtained on admission to an installation where definitive treatment of the spinal injury could be done, and blood replacement was carried out if indicated. Appropriate roentgenograms of the spine and chest were also obtained. Assessment of the patient's urinary status was immediately made. If he was in retention and a catheter had not already been inserted, this was done immediately, preferably using a No. 16 French Foley catheter or a smaller one. In the field, where neurosurgical teams cared for these casualties, simple dependent drainage was used for the few days they were there. In the neuro-

surgical center in the rear area, Tokyo Army Hospital, where all casualties were cared for until they were ready for evacuation to the Zone of Interior, continuous tidal drainage was used on all patients.

In the field, patients were turned every 2 hours by the litter-turning method. At the neurosurgical center in Tokyo they were placed on a Stryker frame and turning continued on a 2-hourly basis. On this regimen, urinary complications were kept to a minimum, and no patient developed a decubitus ulcer while under the care of the author or his associates.

ASSOCIATED INJURIES

As briefly alluded to, associated injuries were high in the lumbosacral group of missile wounds. There were 30 cases in which they were known to have been injured by a high-velocity missile. Of these, 19 had associated wounds, and 4 were sus-

pected of having an intra-abdominal injury, therefore requiring a period of several days, observation before laminectomy could be carried out. Forty-four of the casualties were known to have been injured by metallic fragments. Of these, 15 had associated injuries, and 2 were suspected of having an intra-abdominal injury. In the remaining 30 cases, the type of missile was not specified; 23 had associated injuries. By associated injuries is meant those which delayed laminectomy, and not injuries such as soft tissue wounds, peripheral nerve injuries, or fractures of the long bones. As might be expected, most of these were penetrating abdominal wounds in which a combination of hollow viscus, liver, spleen, or kidney lacerations and retroperitoneal hematomas were encountered. Several patients had a combination of chest and abdominal injuries while one had a tracheal laceration and one had a penetrating brain wound. One patient's surgery was delayed by the presence of pneumonia on arrival without any associated chest wound.

TIME OF OPERATION

Surgery was carried out as soon as it was feasible. There was considerable delay between injury and laminectomy when the group is compared to the head injury cases. The average timelag was 11 days between wounding and operation for the lumbosacral spine injury group. Only 17 of the 104 penetrating wound cases were operated on the day of injury; the longest interval was 44 days. (In the 14 closed fracture dislocations, the average time interval between trauma and surgery was 4 days, 5 being operated on the day of injury, and the longest interval being 22 days.)

Factors contributing to delay in laminectomy included logistic problems in which there was a delay in getting the patient from the site of injury to a medical facility where laminectomy could be done, urgencies of the times when the influx of head casualties was so great that spine injuries had to be deferred until brain wounds could be definitively treated, gross infection of the wound requiring a period of local care before laminectomy was practical, and lastly the presence of associated injuries. The latter was by far the most frequent cause of delayed laminectomy.

It is interesting to note that while the incidence of wound infection at the time of surgery in head wounds was staggeringly high after 48 hours, there were only 17 (16 percent) of the 104 penetrating lumbosacral spine wounds that were infected at time of operation, even though definitive treatment was delayed an average of 11 days after wounding. The most obvious explanation for this discrepancy lies in the distance that the missile travels in the head versus spine injuries before it reaches nervous tissue and its bony housing. In the former, it is only a centimeter or so, and the contaminated, in-blown material—hair, clothing, and all—is lodged within the brain tissue. In the latter, the missile usually traveled many centimeters before encountering the spine. Most of the dirty, in-blown material was left in the superficial part of the wound of entry. This points up only the difference in the incidence of infection. In no sense does it imply that one may assume a casual attitude toward time of laminectomy. Delay forced upon many of the cases by the more immediate life-imperiling associated wounds unquestionably added to the degree of permanent neurological deficit; unfortunately, this increased deficit is not subject to statistical analysis. The laminectomy incision was, as a rule, some distance from the wound of entrance or exit of the missile. After thorough debridement at all indicated levels, the laminectomy wounds were all, save one, closed tightly with appropriate drainage of any abscesses (flank or retroperitoneal space) through a stab wound if they communicated with the epidural space. Following this principle, only two wounds failed to heal per primam. While it was not possible to do definitive neurosurgery within 24 hours in all cases in this series, this should be the aim in the future.

FINDINGS AT OPERATION

PENETRATING WOUNDS

Depressed fractures of the lamina.—Among the 104 patients with wounds involving the lumbosacral canal, 77 had fractures with significant depression and comminution of the bone. Six patients had simple fractures without depression. A fracture was not found in seven. In the remaining 14

cases, no mention was made of the lamina in the field record of the operation.

Pedicle fractures.—Fractures of the pedicles had been noted in the operative reports of 34 patients. A specific statement was made to the effect that the pedicles were intact in 29 operative reports. In 37 cases, no mention was made of the condition of the pedicles; it seems reasonable to assume that in most, if not all, of this group a pedicle fracture was not seen. The injury was limited to the sacral spine in six patients, and therefore, no apophyseal joints could have been involved.

Epidural hematomas.—Although hemorrhage into the fat and small clots were found in the epidural space in most cases, there were only two patients in whom the epidural hematoma occurred as the sole evidence of trauma external to the dural and neural elements, and it was compressing these structures.

Dural penetrations.—The dura was markedly torn in 26 cases. In 13 additional cases, it was torn in one or more small areas, making the total number of dural penetrations 39. The dura was intact in 55 patients. In all of these patients, except in the presence of gross infection, the dura was opened for inspection of the neural elements; in several instances, the intact dura belied the extensive damage seen inside, thus emphasizing the wisdom of opening the dura if feasible. Three of the wounds occurred below the caudal end of the dural sac, and in seven cases, no mention was made in the field record of the condition of the dura.

Conus medullaris.—The lumbosacral spine was involved below the L2 level in 59 instances and, therefore, involved the cauda equina only. The L1 and/or L2 level was involved in 45 cases. In this group, the conus was grossly normal in seven; in an additional seven, the cauda equina was prefixed. The conus was contused in six patients, transected in four, softened and necrotic in one, and undergoing cystic degeneration in one. In the 19 remaining cases, at the L1–L2 level, no mention was made of the condition of the conus; in this group, it is quite probable that the conus was not seen because of a prefixed cauda equina, bringing the total number of instances of prefixed cauda equina to 26 or nearly half the cases. This suggests that in the living state our concept of the level at which the conus ends may require revision.

Cauda equina.—Seven wounds were above the level of the cauda equina. In five additional cases, the cauda equina was not adequately inspected because of wound infection and fear of contamination of the subarachnoid space. The condition of the cauda equina was not mentioned in three cases. A grossly normal situation was encountered in 28 instances. Thirty of the cases were found to have a contused but anatomically intact cauda. The cauda equina was partially transected in 20 cases and completely transected in 16 cases.

MORTALITY

There was one death in the 104 cases of wounds involving the lumbosacral canal, a mortality of 0.96 percent. This case (K-2033) has been described and discussed in a preceding chapter (pp. 287–288).

SHORT-TERM FOLLOWUP

An attempt has been made to analyze the neurological aspects of these injuries according to the type of missile. This is possible only to a limited degree, for in 74 cases the type of metallic foreign body was specified. In the remaining 30, the term “missile” must be used because the type was not indicated on the record. In deciding on whether significant improvement occurred postoperatively the following criteria were used: Drop in the sensory level at least 3 dermatomes below the level of injury or unequivocal return of motor power below the level of injury. Motor or sensory return in the dermatomes or myotomes at or above the level of injury was not considered to be significant return of function.

On initial examination, there was complete loss of neurological function below the level of injury in 53 of the 104 cases (36 high-velocity missiles, 17 metallic fragments). In 40 instances, the lesion was incomplete by neurological examination (22 high-velocity missiles, 18 metallic fragments). In 11 cases the initial neurological assessment was negative or almost completely so (2 high-velocity missiles, 9 shell fragments).

The followup interval from time of injury to evacuation to the Zone of Interior averaged 4½ weeks, the shortest time interval was 1 week, and

the longest 16 weeks. One could not correlate the improvement seen with the length of followup, at least for this short period, nearly as much as with the findings at operation and with the completeness of the physiological injury preoperatively.

Eleven of the patients with penetrating wounds did not show an appreciable neurological deficit. Surgery in this group was motivated by the presence of a metallic foreign body within the spinal canal as demonstrated by roentgenograms or by root pain with evidence of partial or complete manometric block on spinal tap.

Of the 59 high-velocity missile wounds, 24 had significant improvement, 17 had no improvement, and in 18 cases, no mention was made of the postoperative status. One can surmise that, in this latter group, there was for the most part insufficient change to be worthy of comment. In the shell fragment group (44 patients), 19 showed significant change for the better in their neurological status following operation. Twelve patients showed no return of function, and in 13, no information is available regarding their postoperative neurological examination.

POSTOPERATIVE PROBLEMS

To record in detail the niceties of management of this group of patients following surgery would simply be a repetition of the points already adequately covered. There are several problems unique to spinal injuries at the lumbosacral levels which perhaps need to be discussed here.

Intractable postoperative pain.—As one would expect, there was a very high incidence of radicular pain in the lower extremities in those cases in which the cauda equina was contused or partially severed. Meticulous debridement of the depths of the wound—removing all clots and bone fragments enmeshed in the nerve roots—is the single most important factor in the prevention of intractable pain. The inevitable consequences of intractable pain include (1) narcotic addiction which leads to complete demoralization of the patient with consequent poor food and fluid intake leading to further exaggeration of the negative nitrogen balance which these patients always experience and (2) decreased urinary output with resultant increase in the problems of urinary

infection. Prevention of intractable pain is therefore mandatory. In extreme cases, pain surgery is indicated. In two patients, laminectomy and lateral spinothalamic tractotomy were carried out early after injury. An additional two patients are known to have undergone this procedure shortly after arrival in the Zone of Interior. Considering the number of patients with severe preoperative pain, this is perhaps not a high incidence of intractable pain requiring cordotomy. It certainly points toward the efficacy of radical debridement and decompression in reducing the incidence of intractable pain.

Ambulation.—Earliest possible ambulation is indicated in all cases of penetrating trauma to the lumbosacral canal. In case of multiple but unilateral destruction of pedicles, or in case of single bilateral destruction of pedicles, ambulation without the use of braces can be initiated readily within 1 week after operation. Adequate bracing usually facilitates early ambulation in patients with more extensive damage to multiple facets.

LONG-TERM FOLLOWUP

It is unfortunate that it has not been possible as yet to obtain in some way a systematic long-term followup on the large number of casualties with trauma to the central nervous system incurred in the Korean War. The subsequent well-being of the patients under discussion, freedom from complications, and longevity have been directly proportional to the medical skill and interest with which they have been handled, the mental attitude of these men toward their infirmity, and the degree of return of neurological function. The following two cases in which the eventual outcome is known amply confirm the points alluded to.

K-2000.—This 19-year-old enlisted man of the French Brigade was admitted to the neurosurgical center of Tokyo Army Hospital on 24 January 1951, having been wounded in action in Korea on 13 January 1951. He had sustained a penetrating missile wound of the abdomen and vertebral column. Exploratory laparotomy had been carried out in Korea several hours after injury. At operation, a badly lacerated right kidney was removed and a portion of ascending colon that was perforated was exteriorized. When his abdominal problem had allowed, he was transferred to Japan without having had definitive treatment of his spinal wound.

Since injury and on arrival at Tokyo Army Hospital the

patient had had, and still had, severe burning pain in his feet. Though he had had weakness and numbness of his lower limbs, he had been able to void. Admission examination revealed a healed transverse abdominal incision, a functioning right upper quadrant colostomy, and a gaping dirty wound in the midline, midlumbar region, draining purulent material. Neurologically, he exhibited profound paraparesis. All deep tendon reflexes were absent in the lower limbs. There was a sensory deficit caudad to L1 bilaterally. Over the L4, L5, and S1 dermatomes, there was hyperesthesia with hypesthesia noted elsewhere. Roentgenograms of the lumbosacral spine demonstrated fracture of the laminae of L2 and of the transverse processes of L2, L3, and L4 on the right.

Laminectomy had to be deferred for 6 days in order to clean up the wound overlying the spine. This was done by giving penicillin, Streptomycin, and Chloromycetin and by irrigating the wound every 6 hours with penicillin solution. On 31 January 1951, a laminectomy of L1 and L2 was carried out under general anesthesia. The wound overlying the spine was debrided and extended cephalad and caudad to afford exposure of the spine. Severe comminution with depression of the laminae of L2 was found. The lamina of L1 was also fractured but not depressed. The right L1-L2 apophyseal joints were fractured. All epidural clots and all comminuted fragments were removed. When this had been completed, a No. 8 French Foley catheter was passed freely caudad and cephalad. The dura had not been torn. It was opened. The conus medullaris did not extend down to this level. The roots comprising the cauda equina appeared contused but were intact anatomically. After thorough irrigation of the wound with saline, it was closed tightly in layers with silk sutures.

The patient's postoperative course was uncomplicated. His wound healed per primam. He was cared for on a Stryker frame and turned every 2 hours. Tidal drainage was instituted. Patient did not develop any decubital ulcers. He had gratifying relief of the pain in his lower limbs, and the neurological deficit regressed steadily. Six weeks postoperatively, he was evacuated to France. He was still paraparetic and had not as yet been put in long-leg braces for purpose of ambulation.

Over a year later, the patient volunteered for another tour of duty in Korea. When examined by one of us after his return to Korea, he walked without limp and had normal

bladder and bowel function. The only neurological deficit demonstrable was a small area of hypesthesia over the lateral aspect of each thigh.

K-1088.—This 24-year-old U.S. Army private, first class, was wounded in action in Korea on 10 March 1951, sustaining a perforating missile wound with wound of entry in the left paravertebral region and wound of exit in the right lateral lower thoracic region. An exploratory laparotomy was done in Korea shortly after injury at which time he was found to have a perforation of the hepatic flexure of the large bowel and a laceration of the liver and the right kidney. The perforated bowel was exteriorized; the liver and kidney lacerations were drained through a right flank stab wound. The patient was transferred to Japan as soon as his general condition permitted and arrived at the neurosurgical center, Tokyo Army Hospital, on 17 March 1951.

On admission, he had a low-grade fever. There was dullness to percussion and absence of breath sounds over the right lower lung field. Chest consultation was obtained. Thoracentesis failed to yield any blood or air, and clearance for laminectomy was given. The patient had a physiological transection, on examination, caudad to L2-L3.

On 18 March 1951, laminectomy of T12, L1, and L2 was carried out under general anesthesia. Marked comminution and depression of T12 and L1 were found. The apophyseal joints between the vertebrae had been destroyed. The underlying dura was lacerated on the right. The cauda equina was badly contused—approximately one-third of the roots on the right side being transected.

Postoperative course was uncomplicated. Meticulous paraplegia care was instituted. He was transferred to the Zone of Interior approximately 3 weeks after laminectomy. After operation, the patient was apprised of the extent of his injury. His mental outlook was excellent.

In the spring of 1958,¹ the *Birmingham News*, Birmingham, Ala., published a human interest story concerning the excellent adjustment this man had made to his paraplegic life, as he had never realized any useful return of function (fig. 153). He had graduated from college, recently married, and presently owned and operated a successful poultry farm. Throughout the interview, he reiterated how helpful it had been to have been early acquainted with the extent of his permanent deficit. He, therefore, found it easier to plan his life accordingly.

PREOPERATIVE EVALUATION AND PREPARATION

The steps in the preparative evaluation and preparation of patient with wounds involving the lumbosacral canal are:

1. Assessment of neurological deficit including evaluation of integrity of all lumbosacral dermatomes.
2. Search for associated wounds taking precedent over immediate laminectomy. Use of available consultants in allied specialties. Avoidance of combined procedures.
3. Immediate institution of paraplegic care:
 - a. Stryker frame (substitute litter).
 - b. Insertion of French Foley catheter.
 - c. Skin care.
4. Estimation of hemoglobin and hematocrit. Preoperative blood replacement.
5. Antibiotic regimen.

¹ Carter, Lane: Paraplegic Is Happy With His Chickens. *Birmingham News Magazine*, Sunday, 9 Mar. 1958.



FIGURE 153.—K-1088. Wound, penetrating, spinal canal, T12-L1, North Korea, 10 March 1951. Photograph taken 7 years later. (Photograph courtesy of *Birmingham News*, Ed Jones, photographer.)

SURGICAL TECHNIQUE

The steps in the surgical technique of wounds involving the lumbosacral canal are:

1. General endotracheal anesthesia. Pain consequent to manipulation of cauda equina roots makes employment of local anesthesia undesirable.
2. Use of Stryker frame or substitute litter in lieu of operating table. Turning to supine position immediately prior to surgery.
3. Meticulous preparation of skin overlying spinal injury with soap and water.
4. Midline incision extended sufficiently above and below site of depression and comminution permitting starting point of laminectomy in intact area.
5. Avoidance of entrance and exit wounds if off midline. Excision and inclusion of entrance and exit wounds if in midline or adjacent to it.
6. Dissection of soft tissue and laminectomy, as described in chapter 26, under the heading "Technique of Operation" (pp. 311-322).
7. Careful evaluation of pedicle and posterior joint involvement. (To aid in determining earliest possible ambulation.)
8. Removal of all intraspinal clots and of all comminuted depressed bone fragments to minimize the postoperative development of intractable root pain.
9. Opening of intact dura (unless there is gross infection of epidural space).
10. Coverage of extradural nerve roots and dural defects with Gelfoam soaked in Hydrocortone (hydrocortisone) (in hopes of reducing perineurial scar formation and subsequent intractable radicular pain).
11. Repair of dural defect whenever feasible with fascia graft (prevention of spinal fluid fistula).
12. Tight closure of wound in individual layers with interrupted sutures of nonabsorbable suture material.
13. Drainage of abscess in or communicating with the epidural space through separate stab wound.
14. Separate surgical preparation of wound of entrance and exit if situated away from midline. Radical surgical debridement. Secondary closure of entrance and exit wounds.

POSTOPERATIVE CARE

The steps to be taken in the postoperative care of the patient with wounds involving the lumbosacral canal are:

1. Routine paraplegia care as outlined in chapter 25, pp. 278-305.
2. Early appreciation of the problem of intractable radicular pain with consideration of necessary surgical measures for the relief of intractable pain in an all-out effort to prevent narcotic addiction.
3. Ambulation within 10 days after laminectomy in the absence of pedicle involvement.
4. Ambulation 6 weeks following laminectomy in a Knight brace with pectoral horns in the presence of pedicle involvement.

CHAPTER 30

Neurosurgical Aspects of Neurogenic Bladder

C. David Scheibert

The care of the urinary tract is one of the most important facets of the complex problems resulting from spinal cord injury. While Kessler's (1) survival statistics gathered from the experience in the Veterans' Administration reflect a tremendous improvement in life expectancy over the last 40 years, a mortality study reveals that disease of the urinary tract retains its leading role as a cause of death in the patient with injury to the spinal cord. Dietrick and Russi (2) determined that renal disease was the greatest single cause of death in 20 percent of a 10-year series of 55 autopsies performed on paraplegic patients at the Veterans' Administration Hospital, Richmond, Va., and that urinary tract disease of some form existed in 90 percent of those studied. Zankel, Burney, and Sutton (3) in the course of a year's study at the Veterans' Administration Hospital, Cleveland, Ohio, found that urinary tract infections were responsible for 73 percent of the morbidity among the patients with spinal cord injury and that 64 percent of the surgical procedures on this group were urological in nature. The enormity of the importance of the urinary tract in the paraplegic or quadriplegic patient is further emphasized by U.S. Public Health Service estimates of almost 100,000 such patients in the United States.

The goals of good treatment are the preservation of a healthy upper urinary tract and the establishment of a socially acceptable catheter-free, continent bladder which empties with negligible residual at the desire of the patient.

Knowledge of the innervation of the bladder, the

physiology of micturition, and the effect of neurological injury will aid in giving a clearer understanding of this presentation. Learmonth (4) and Bors (5) have, with many others, contributed succinctly to the understanding of innervation and physiology of the urinary bladder. The smooth muscle of the detrusor is activated by visceral efferent fibers (parasympathetic) from a lower motor neuron in the sacral spinal cord via the anterior roots of S2 through S4 (predominantly S3) (6). Somatic efferent fibers originating from the same level innervate the striated muscle of the vesical neck and pelvic floor. Visceral efferent neurones (sympathetic) from the lower thoracolumbar outflow go to the lower ureter, trigone, and vesical neck by way of the hypogastric and pelvic nerves and have little action other than maintenance of vesical neck tone.

Lapides and others (7) have demonstrated that urination can be initiated and stopped by direct cortical control over the detrusor and smooth muscle of the bladder. With an upper motor neuron lesion above the conus medullaris or sacral spinal cord, cerebral or voluntary control is lost. This leaves the segmental innervation or the lower motor neuron in the sacral cord and the bladder united by an intact sacral reflex arc.

Although sacral reflex activity may begin within a day of spinal cord injury, as determined by the bulbocavernosus and gluteal reflexes, the flaccid state referred to as spinal cord shock usually persists for weeks to months before forceful detrusor emptying contractions with coordinated vesical neck and pel-

vic floor relaxation occur. These successive phases of recovery of the bladder have been well described by Holmes (8).

With a lower motor neuron lesion destroying the sacral spinal cord or the sacral roots of the cauda equina, the sacral reflex arc is broken, and an essentially flaccid paralysis of the detrusor and pelvic floor persists. Micturition then depends not on detrusor contractions but on increasing intravesical pressure by contraction of the muscles of the diaphragm and abdominal wall. Sacral nerve block of S2, S3, and S4 bilaterally or spinal anesthesia acutely converts an upper motor neuron lesion with segmental bladder innervation into a lower motor neuron lesion.

The integrated action of the detrusor, vesical neck, and pelvic floor with effective voiding is the ultimate goal of the management of the urinary tract. Experience in the spinal cord injury centers of the Veterans' Administration (9) (10) has shown that about 70 percent of patients can dispense with catheter drainage.

Overdistention of the bladder is detrimental since it delays the return of detrusor tone and action, and may enhance ureterovesical junction incompetency with resulting ureteral reflux. Early intermittent suprapubic pressure (Credé's maneuver) is to be condemned, as well as early suprapubic cystostomy, in favor of the immediate use of a retention Foley-type urethral catheter about a size 14 French. This smaller size catheter prevents total occlusion of the urethral lumen so that all periurethral glands can readily drain into the urethra without danger of obstruction and resulting infection. The catheter should be changed aseptically at least each week. In the male patient, loosely taping the penis to the abdominal wall in the erect anatomical position helps to eliminate the acute urethral necrosis, resulting abscess, and urethrocutaneous fistula so common in this location.

The intake of copious fluids of at least 4,000 cc. per day helps to maintain a dilute urinary output, thus aiding in preventing infection and the precipitation of the increased excretion of calcium salts. Urinary acidifying agents are of little help in significantly decreasing the pH of the urine. Intermittent aseptic irrigation of the bladder at least several times daily by the closed gravity or syringe

method promotes mechanical cleansing. One may use sterile isotonic saline solution for irrigation or any number of acid or antiseptic solutions. Prophylaxis against infection may also be promoted, particularly in the early days of catheter drainage, by the alternating use of the nitrofurans, long-acting sulfonamides, and mandelic acid.

Following an upper motor neuron lesion, some degree of activity may reestablish itself in the sacral reflex arc within a few hours, as evidenced by return of the bulbocavernous reflex. Significant detrusor tone and contractability may, however, not develop for several weeks or even months following trauma. In the patient with a lower motor neuron lesion, only a very weak degree of intrinsic detrusor contractions occur with much less tone regained in the bladder wall. Cystometry gives information as to bladder tone and contractions at various volumes and determines at what level the tidal drainage overflow should be set, if such a device is utilized. Excretory cystometry, as described by Comarr (11), is certainly more physiological, but the author has used only retrograde cystometry which is described as follows:

1. The catheter is removed for a period of approximately 1 hour.
2. The patient attempts to void, this probably being done best in the sitting position when ambulation is permissible, taking care to avoid pressure against the perineum.
3. Aseptic catheterization is carried out and residual urine volume determined.
4. Determination of sphincter resistance with bladder empty is done by the retrograde method. With the catheter pulled out into the urethra and with external pressure applied to prevent external drainage, warm saline solution is slowly introduced into the urethra with the catheter connected to a calibrated water manometer. The pressure is measured at the point at which fluid overcomes sphincter resistance, with flow into the bladder.
5. A cystometrogram is then performed, using a Munro tidal drainage apparatus or other appropriate instruments.

- a. The catheter is reinserted into the bladder.
- b. At a rate of approximately 150 drops or 10 cc. per minute, warm saline is introduced into the bladder.

c. Pressure readings are taken on the manometer at every 50 cc. while the flow is temporarily stopped.

d. The procedure is stopped at a volume of 300 cc., or sooner if sustained high pressures continue or symptoms of autonomic hyperreflexia occur.

6. Sphincter resistance is again determined with bladder full, as just described.

7. The patient attempts to void, measuring the amount and noting any incontinence.

8. Residual urine is determined.

The optimum level of the tidal drainage overflow siphon permitting bladder filling with emptying at a volume of approximately 300 cc. can readily be determined by cystometry. It is advisable to delay the use of tidal drainage until the detrusor is regaining some tone in order to reduce the danger of overdistending a flaccid bladder. Cystometric study may be repeated at intervals of several weeks in order to adjust the height of the overflow siphon as bladder tonus and spasticity may progressively return, allowing continued bladder filling to approximately 300 cc. before emptying. If and when tidal drainage is not possible, the same process of filling and emptying the bladder may be brought about by intermittent clamping of the catheter, with emptying at such intervals as to prevent the bladder from being distended in excess of 400 cubic centimeters. This alternate clamping and emptying may be carried out during the day with straight drainage at night; however, tidal drainage has the additional advantage over this method of introducing an irrigating medium of one's choice constantly into the bladder so that an acid environment may be maintained if desired. Although maintenance of bladder capacity by these two previously described methods is very desirable, it must also be realized that studies by Comarr (12) have shown that approximately the same percentage of bladders can be brought around to catheter-free existence merely by the use of straight drainage, with removal of catheter when efficient emptying occurs. In the presence of chronic infection, continued maintenance on straight drainage may facilitate the development of a small contracted bladder which then can no longer act as a suitable reservoir.

When cystometry or trial voidings indicate that the patient is able to empty the bladder with a 100-

cc., or preferably less, residual, catheter drainage may be dispensed with. If the patient is then unable to void, or if obvious distention occurs with inefficient emptying, the catheter should be replaced. For patients with lesions above the ninth thoracic segment, there may be little warning of bladder filling. A regulated hourly intake of fluids during the day, with regular voiding periods of at least every several hours, may prove helpful. If initial daily residual determinations indicate that the bladder continues to empty well, preferably with a decreasing residual, one may feel fairly confident of persisting good bladder function. It should be remembered that the patient with an upper motor neuron lesion usually has reflex contractions of the detrusor which act primarily in emptying the bladder along with an external aid by straining. On the other hand, patients with a lower motor neuron lesion must produce micturition by pressure brought to bear on the bladder by straining. If emptying of the bladder, although efficient, is unpredictable, the male patient will be helped greatly by the application of a condom-type urinal apparatus. This may be fastened to the penis with 1-inch Elastoplast bandage loosely applied just behind the glans penis or by Rutzen facing cement (No. 474). This device should be reapplied daily.

Certain roentgenological procedures are also of value in following the course of the neurogenic bladder. Intravenous urography gives much valuable information, as described by Zinsser in chapter 31. This may be performed at regular 3-monthly intervals during the early course, and later, yearly if desired. The use of a flat plate of the abdomen showing the kidneys, ureters, and bladder will be helpful at 3-monthly intervals during the early course to aid in the discovery of calculus formation. Cystography is a valuable aid in determining the presence of ureteral reflex as well as defining the bladder vesical neck and urethra. Cystography may be performed much in the way as cystometry with the exception that a radiopaque solution is used to fill the bladder; roentgenograms are taken at various stages of filling and after attempt at emptying. One must always bear in mind that distending the bladder, by either the retrograde or excretory method, in a patient with infected urine and ureteral reflux may result in an episode of acute pyelonephritis. In such patients, prophylactic anti-

biotic coverage at the time of such procedure, including cystometry, will be of help and one might also introduce a small amount of neomycin with the fluid filling the bladder to further decrease the chance of precipitating a urinary tract infection.

Prevention of complications is another very important function of the previously described early bladder management. It is usually true that proper care of the lower urinary tract insures the health of the upper tract which must always be tantamount. Strict adherence to the principles aimed at promoting good general health and preventing complications in other organ systems, as well as early ambulation, cannot be overemphasized in their importance in facilitating the health of the urinary tract and an earlier return to a catheter-free existence. In spite of the best management, however, complications involving the urinary tract may ensue early in the post-spinal-cord-injury course. These complications consist of infection, calculosis, penoscrotal fistula, or diverticulum and vesicoureteral reflux, sometimes associated with hydronephrosis. Prevention is far superior to need for treatment of these complications.

While the presence of a catheter promotes infected urine, clinical infection of the bladder and kidney may be kept at a minimum by strict adherence to steril technique, generous intake of fluids, cleansing irrigation, and the use of prophylactic chemical agents early in the catheter course as already described. These preventive measures also become therapeutic in the presence of infection. Good drainage of the urinary tract is likewise important, and broad-spectrum chemotherapeutic agents should be used particularly in the presence of an acute pyelonephritis. If prompt remission of a moderately severe septic course is not forthcoming within 48 hours, ureteral obstruction due to calculus or infection should be ruled out by intravenous urography and, when present, may be treated by drainage of the renal pelvis by ureteral catheter. Epididymitis may cause a particularly septic course and failure to respond to antibiotic therapy, or formation of abscess, may require surgical removal. This is also to be considered in the presence of recurrent epididymitis rather than vasotomy.

Calculosis may be kept at a minimum by maintaining a copious urinary output, preventing infection of the urinary tract, and using an acid bladder irrigation medium. The importance of early ambula-

tion in reversing the increased calcium excretion must always be kept in mind. Urinary acidifying agents and acetylsalicylic acid are possibly of some help. The use of sodium phytate or sodium alginate, as described by Zinsser in chapter 31, may prove very helpful, particularly in the chronic stone-former. The treatment of a calculus problem, once developed, falls into the hands of the urological surgeon.

The complications of periurethral abscess and diverticulum can be much decreased by the measures already mentioned; namely, the use of a small caliber catheter to allow good drainage of the periurethral glands and the taping of the penis to the abdominal wall in anatomical position to decrease the penoscrotal angulation in the presence of a catheter. The prevention is more desirable than the necessity of treatment, the various forms of which fall into the domain of a urological surgeon.

Vesicoureteral reflux, with or without dilatation of the upper urinary tract, may occur early or late in the course of spinal cord injury. The factors leading to its development are not as yet clearly understood, but its presence and extent are best determined by cystography. Although this condition may be found in as many as 25 percent of patients with spinal cord injury, it frequently is clinically insignificant, unless evidenced by repeated upper urinary tract infections and progressive dilatation of the upper urinary tract. In that case, straight catheter drainage is the treatment of choice. Distention of the bladder is to be avoided. As efficient micturition becomes possible, allowing catheter removal, particular attention must be given the prevention of progressive dilatation or repeated urinary tract infections.

In spite of excellent early management of the urinary tract, some 25 to 30 percent of patients are unable to dispense with catheter drainage; however, one must not be too eager to carry out destructive or irreversible procedures since good bladder function and removal of catheter have been possible in some patients as long as 4 years after injury or even longer. Three fairly simple reversible procedures are to be considered in facilitating catheter removal. The first of these is the use of chlorpromazine hydrochloride in doses of approximately 25 mg. by intramuscular injection every 4 to 6 hours. Such medication allowed voiding in all but 3 of 22 patients up

to 10 years after injury, as presented by O'Hare (13) who is carrying out further studies on this procedure.

A second innocuous aid in the removal of the urinary catheter is the use of intravesical Pontocaine as described by Bors and Blinn (14). Vesical mucosa anesthesia was achieved by the intravesical instillation of from 60 to 90 cc. of 0.25-percent solution of tetracaine hydrochloride (Pontocaine) in distilled water with drainage 10 minutes later. Sphincterometry and cystometry were then carried out. Although personal experience has not been as rewarding, Bors and Blinn report that in 49 patients subjected to 122 such examinations, functional bladder improvement occurred in 51 percent; and 4 patients of this series, along with 2 others, benefited with permanent catheter removal following repeated mucosal anesthesia. This procedure was also noted to result in a pronounced suppression or inhibiting function on the hyperactive sacral reflex arc, as manifested by the effect of ice water and the bulbocavernous reflex in a patient with an upper motor neuron lesion.

A third reversible, and increasingly important, procedure which may allow removal of the catheter in an otherwise resistant patient is nerve block of two types, namely pudendal and sacral blocks.

Bors, Comarr, and Moulton (15) have described the technique and earlier results of pudendal nerve anesthesia, and Bors (16) later discussed the results in approximately 400 patients with traumatic myelopathy. The pudendal block is performed by having the patient in a prone position and holding the thumb at the junction of the sacrotuberous ligament and ischial tuberosity. The needle is then introduced under the ligament, pointing medially, and 30 cc. of 1-percent intracaine solution containing 150 units of hyaluronidase is introduced on one or both sides as desired. Successful injection results in a patulous anal sphincter and absence of the bulbocavernous reflex. Vesical sphincter resistance is usually lower, residual urine decreases in about two-thirds of the patients and vesical capacity and detrusor activity remain essentially the same in the majority of cases so tested. In performing such studies, Bors and his coworkers noted that about 30 percent of the patients responded temporarily or permanently to pudendal nerve anesthesia with improvement of bladder function. Although this last-

ing beneficial effect could not be explained, it led to performance of repeated pudendal nerve anesthesia in order to bring about permanent catheter removal and avoidance of surgical interruption of the pudendal nerves.

Sacral nerve blocks, as well as spinal anesthesia, have been performed by the author in approximately 150 patients suffering traumatic myelopathy. Sacral nerve block is performed with the patient in the prone position and the needles are introduced into the respective posterior sacral foramina aimed in a medial direction. The second sacral foramen lies approximately one fingerbreadth below the inferior border of the posterior superior iliac spine, the third sacral foramen about one and one-half fingerbreadths inferior to the second, and the fourth, an equal distance below the third. Each pair of posterior sacral foramina, moving caudad, is more superficial and closer to the midline. The needle usually impinges the posterior aspect of the sacrum and, on palpation with the needle point, can be felt to fall into the foramen, taking care that the needle is introduced no more than 1 cc. to avoid encountering the rectum. Needle position can be accurately checked by roentgenograms. Not more than 2 cc. of 1 percent lidocaine hydrochloride (Xylocaine) or 2 percent procaine hydrochloride (Novocain) are introduced at each site. Block of the third and fourth sacral nerves, or the second, third, and fourth sacral nerves, bilaterally, proves to be the most successful combination and should result in relaxation of the anal sphincter and absence of the bulbocavernous reflex in addition to the relaxation of the detrusor, which can be determined on the subsequent cystometrogram and residual trials. There is usually a decrease in urethral sphincter resistance and an increase in vesical capacity. Forty percent of patients with catheters so tested and with upper motor neuron lesions from 3 months to 10 years after injury showed decrease in residual urine to less than 50 cubic centimeters. The results are better in the lower thoracic and conus medullaris lesions since voluntary increase of intra-abdominal pressure is necessary to facilitate evacuation of urine.

As in the case of pudendal nerve anesthesia, it was noted that the beneficial effect of the sacral nerve block might persist for a period of days or permanently. This observation also led to the repeated utilization of sacral nerve anesthesia to facilitate

permanent catheter removal and thus avoid the need for surgical section of the sacral nerves to establish permanent bladder automaticity. Permanent catheter removal has been accomplished in almost two-thirds of the patients showing good micturition under the influence of sacral block. Sacral neurotomy has been employed in the remaining one-third. Thus it is seen that, with the use of chlorpromazine hydrochloride, intravesical Pontocaine, and sacral or pudendal nerve anesthesia, catheter removal can be facilitated in an appreciable number of the 30 percent of patients who do not respond to bladder training, therefore avoiding pudendal or sacral nerve division in patients who, earlier, had been subjected to such surgical procedures.

Bors (17), in 1954, described the results of subarachnoid alcohol injections in 52 patients with traumatic cord lesions. While all of these were not done with bladder function specifically in mind, it was found that in 34 of the patients, good bladder function with removal of catheter was possible, although 9 of these regressed due to ureteral reflux or penoscrotal fistula. Twenty-five patients, or approximately one-half, were freed from the catheter. Transurethral resection was coupled with the alcohol injection in 16 of the patients. Although the use of intrathecal alcohol to interrupt the sacral nerves is a simpler method, the author prefers the more selective operative method of sacral neurotomy for sacral nerve interruption. The use of intrathecal alcohol for improving vesical function has also been decreased, just as has pudendal or sacral neurotomy, by the previously described reversible procedures consisting of repeated nerve block studies and use of chlorpromazine hydrochloride or intravesical Pontocaine.

While Bors and Comarr (18) described the effect of pudendal nerve operations in 1954, the need for such neurotomy has lessened through the use of nonsurgical measures. The technique of the procedure and the pitfalls, such as multiple branches of the pudendal nerve, have been outlined by Bors and Comarr. In 32 patients undergoing pudendal nerve section, 9 of these having only unilateral section, there were good results in bladder function, with catheter removal in 24; 8 had poor results. Additional interventions were carried out in two-thirds of these 32 patients, consisting of transure-

thral resection, usually done prior to pudendal nerve operation, and later sacral neurotomy in 3, 2 of whom obtained good results. Bors and Comarr feel that the indications for pudendal nerve section are as follows:

1. An upper motor neuron lesion with inability to dispense with urethral catheter drainage.
2. Severe abdominal spasticity must not be present in the paraplegic patient.
3. The quadriplegic patient must have a detrusor capable of reliable and strong voiding contraction.
4. Organic obstructive uropathy must not be present at the vesical neck.
5. Severe urinary infection with or without calculi must not be present.
6. Each of a series of pudendal nerve blocks must produce satisfactory but only temporary benefit on micturition.
7. When erection is preserved, unilateral severance is preferable, usually done on the side controlled by the major cerebral hemisphere.
8. Bilateral pudendal nerve section is recommended in two stages.

Ross and Damanski (19), in 1953, presented good results with pudendal nerve interruption in 8 of 11 patients, and by 1956 (20), the number of patients so treated approximated the series of Bors and Comarr.

Sacral nerve section is another operative approach to the establishment of a catheter-free bladder. Indications for this procedure have been described by Meirowsky, Scheibert, and Rose (21). The indications are as follows:

1. A successful series of sacral nerve block studies which produce temporary ability to void completely by straining at will without incontinence.
2. An upper motor neuron lesion, preferably at or below the mid-thoracic level.
3. Absence of organic obstruction of the vesical neck.
4. Absence of calculosis, severe urinary tract infection, and severe ureteral reflux.

In patients fulfilling these criteria, sacral neurotomy may be performed as described by Meirowsky, Scheibert, and Hinchey (22) utilizing a midline sacral incision to expose the posterior sacral foramina of S2 through S4 bilaterally (fig. 154). Preoperative sacral nerve block studies have indi-

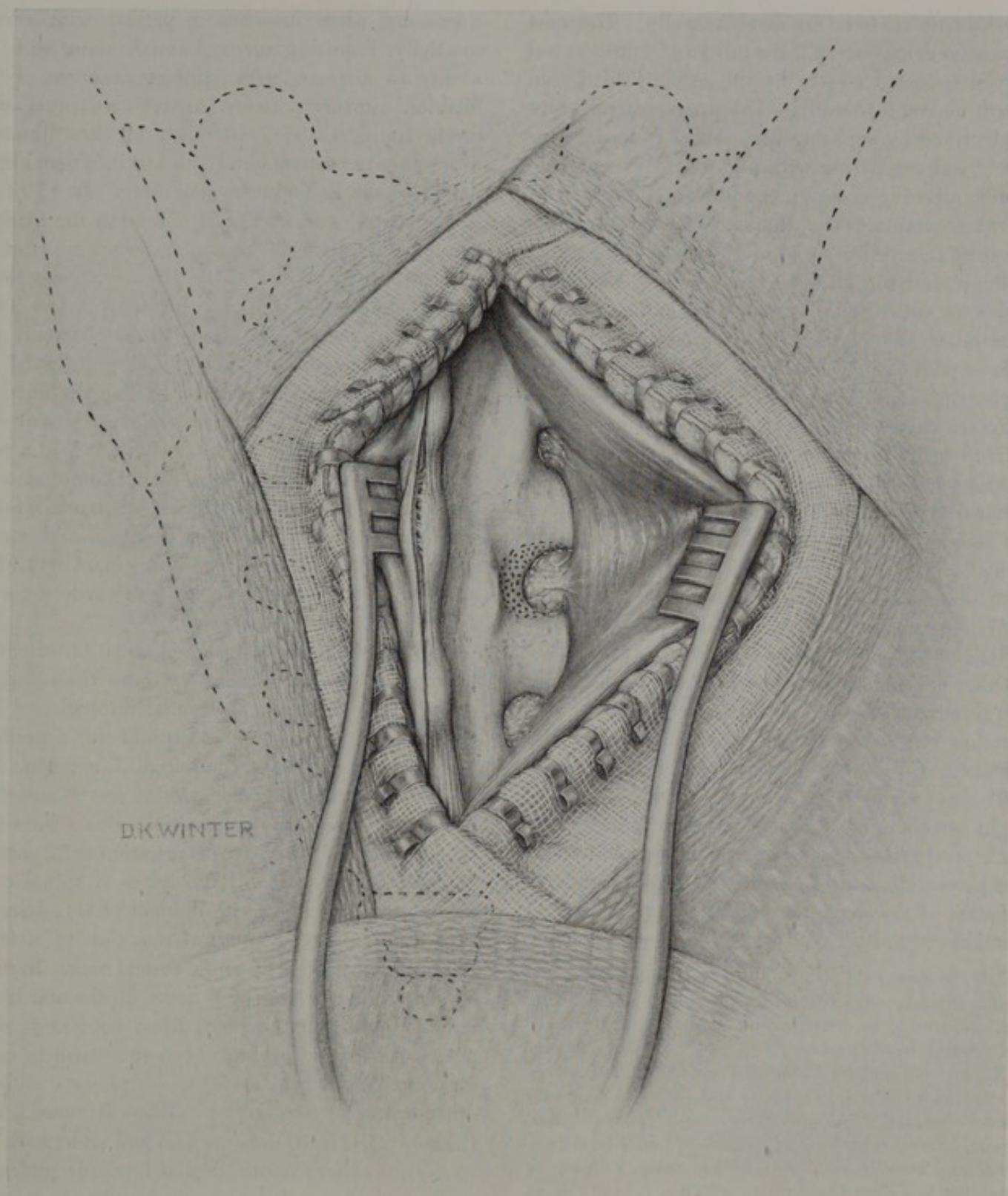


FIGURE 154.—Exposure of posterior sacral foramina, S2 through S4.

cated the nerves to be divided bilaterally. The most successful combination is the third and fourth sacral nerves, followed closely by the second, third, and fourth nerves bilaterally. The proper sacral nerve is identified by exposing the sacrum to its inferior aspect and comparing with preoperative roentgenograms, allowing accurate counting of the posterior sacral foramina. The indicated sacral foramina are then enlarged and the sacral nerve is identified in the underlying fat-filled canal. Care is taken to divide the entire nerve between clips at the indicated level bilaterally (fig. 155), avoiding anatomic pitfalls as pointed out by Meredith (23). Postoperatively, catheter drainage can be discontinued.

Sacral nerve section has been performed in 22 patients with traumatic myelopathy, fulfilling the previous criteria, with successful permanent catheter removal in 17 of the 22 patients. The majority of the failures occurred in the early patients in the series. Favorable results with sacral nerve section have also been described by Patton and Schwartz (24), Brendler and his coworkers (25), Meredith (23), and Alexander, Garvey, and Boyce (26).

Other beneficial effects of sacral nerve blocks and sacral neurotomy on rectal, sexual, and sensory function have been described by Meirowsky and Scheibert (27). Experimental work in monkeys (28) has suggested that good bladder function might be obtained almost immediately after traumatic myelopathy by anterior sacral rhizotomy. A case presentation will illustrate the possible superior diffusion of the local anesthetic agent at the time of sacral block study.

E. H., a 40-year-old male with a physiologically complete twelfth thoracic traumatic myelopathy of 10 months' duration, was unable to dispense with urethral catheter drainage. Sacral block studies of S3 and S4 bilaterally and of S2, and S3, and S4 bilaterally resulted in detrusor relaxation with increase in capacity and ability to empty the bladder completely at will by straining, without incontinence. Sacral neurotomy of S3 and S4 under local anesthesia was initially successful in permitting catheter removal, but in a short time urinary retention began to occur. This could be corrected by Novocain injection of the second sacral nerve bilaterally. Later surgical division of the second sacral nerve on each side resulted in immediate and lasting good bladder function, as indicated by the preoperative sacral block studies.

Another operative approach to the establishment of good bladder function is the use of lumbosacral

rhizotomy when one has a patient with severe spasticity, requiring surgical relief, along with inability to dispense with catheter drainage of the bladder. In such patients, preoperative spinal anesthesia studies will give fairly accurate determination of whether the patient will be able to void with elimination of the lumbosacral reflex arc. In 11 of 13 such patients with beneficial effects on the bladder through spinal anesthesia study, permanent bladder automaticity was established by employing total lumbosacral rhizotomy or cordectomy below T11; however, it must be realized that occasionally the classical anterior rhizotomy of T11 through S1 bilaterally may result in good reflex bladder function, which had not been present previously. Meirowsky, Scheibert, and Hinchey (29) have described a portion of the just noted series of patients and total lumbosacral rhizotomy has a place when one is faced with the problem of catheter drainage and severe spasticity of the lower extremities. MacCarty (30) has described the beneficial effect of cordectomy on the bladder in four patients.

Another surgical aid in the elimination of catheter drainage of the bladder has been transurethral resection to eliminate obstructive uropathy at the vesical neck. Discussion and use of this procedure belong primarily to the urological surgeon, but radical resection is to be avoided lest it interfere with continence and other possible aids. Bors and Comarr utilized transurethral resection in 22 percent of their approximately 1,200 cases of spinal cord injury and they, along with Reingold (31), describe experience with transurethral resection of striated fibers at the anterior lip of the vesical neck. In their hands, the use of pudendal nerve blocks and intravesical Pontocaine coupled, when necessary, with anterior lip resection have been successful in catheter removal in the majority of patients without other operative intervention. Ross, Damanski, and Gibbon (32), in 10 patients who had undergone unsuccessful subarachnoid alcohol block or pudendal neurectomy for catheter removal, utilized resection of the external urethral sphincter with relief of urinary retention in the 8 surviving cases. Emmett, Albers, and Anderson (33), as well as many others, have reported on the results of transurethral resection for the cord bladder. In spite of all the described aids in catheter removal and with the advent

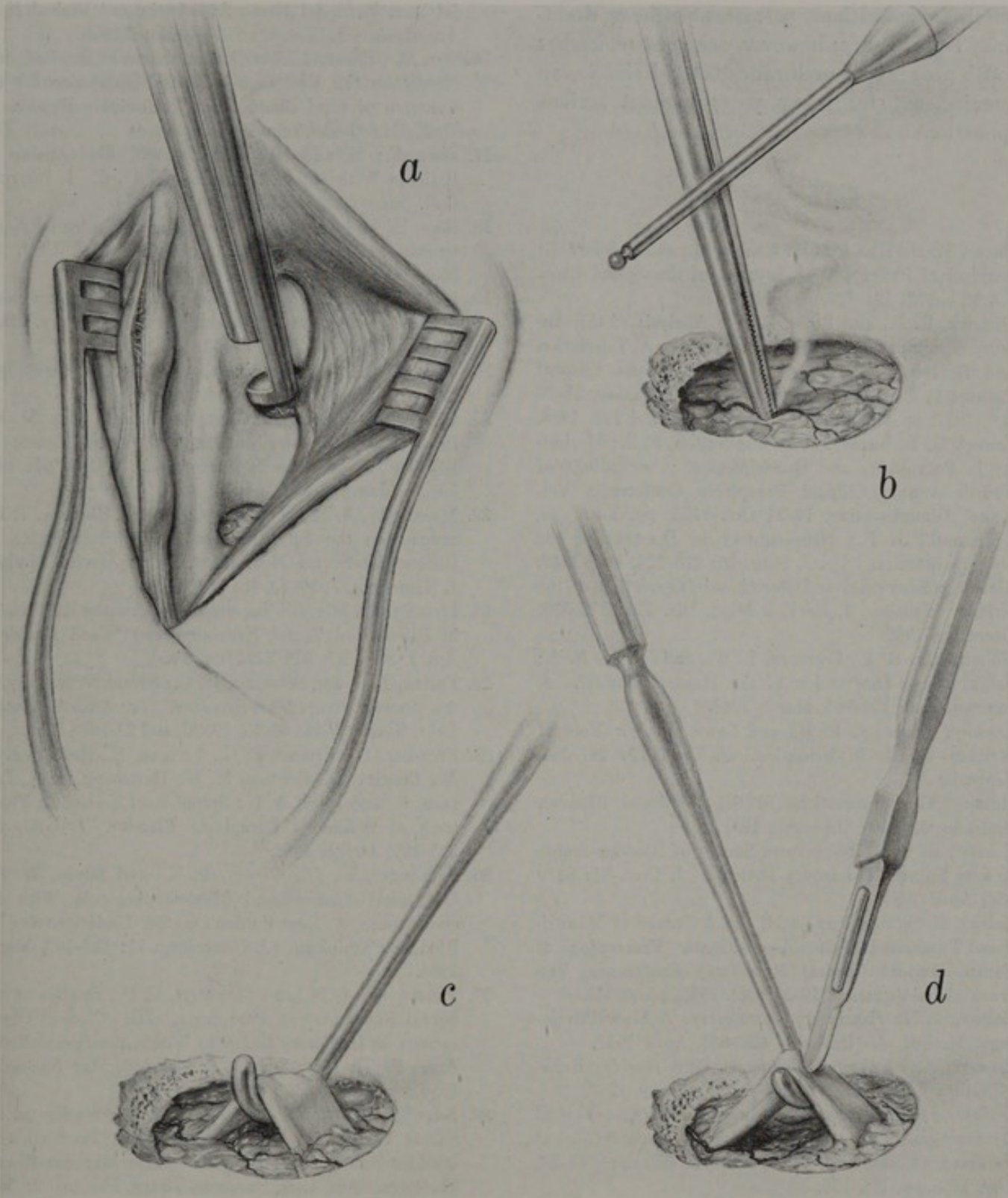


FIGURE 155.—Exposure and section of individual sacral nerve.

of certain complications, permanent catheter drainage may be necessary; however, one must remember that with proper care urethral catheter drainage can be carried out for many years without serious complications.

REFERENCES

- Burke, M. H., Hicks, A. F., Robins, M., and Kessler, H.: Survival of Patients With Injuries of the Spinal Cord. *J.A.M.A.* 172: 121-124, 9 Jan. 1960.
- Dietrick, R. B., and Russi, S.: An Analysis of the Autopsy Findings in Fifty-five Paraplegics—A Tabulation and Review. *Proceedings of Sixth Annual Clinical Paraplegia Conference, Veterans' Administration*, 22-24 Oct. 1957, pp. 93-96; *J.A.M.A.* 166: 41-44, 4 Jan. 1958.
- Zankel, H. T., Burney, T. E., and Sutton, B. B.: Morbidity in Paraplegics and Quadriplegics. *Proceedings of Fourth Annual Clinical Paraplegic Conference, Veterans' Administration*, 19-21 Oct. 1955, pp. 1-6.
- Learmonth, J. R.: Neurosurgery in Diseases of the Urinary Bladder. *Am. J. Surg.* 16: 270-274, May 1932.
- Bors, E.: Segmental and Peripheral Innervation of the Urinary Bladder. *J. Nerv. & Ment. Dis.* 116: 572-578, December 1952.
- Heimbürger, R. F., Freeman, L. W., and Wilde, N. J.: Sacral Nerve Innervation of the Human Bladder. *J. Neurosurg.* 5: 154-164, March 1948.
- Lapides, J., Sweet, R. B., and Lewis, L. W.: Role of Striated Muscle in Urination. *J. Urol.* 77: 247-250, February 1957.
- Holmes, G.: Observations of the Paralyzed Bladder. *Brain* 56: 383-396, December 1933.
- Comarr, A. E.: A Long-Term Survey of Bladder Status Among Spinal Cord Injury Patients. *J. Urol.* 81: 537-538, April 1959.
- Talbot, H. S., and Romsey, E. J.: A Survey of Micturitional Function in Follow-Up Patients. *Proceedings of Fourth Annual Clinical Paraplegia Conference, Veterans' Administration*, 19-21, Oct. 1955, pp. 40-41.
- Comarr, A. E.: Excretory Cystometry: A More Physiologic Method. *J. Urol.* 77: 622-633, April 1957.
- Comarr, A. E.: The Problems of Cord Bladder Rehabilitation. *J. Urol.* 77: 232-237, February 1957.
- O'Hare, J. M.: Chlorpromazine in Neurogenic Vesical Dysfunction. *Proceedings of Seventh Annual Clinical Paraplegia Conference, Veterans' Administration*, 18-20, Nov. 1958, pp. 155-158.
- Bors, E. H., and Blinn, K. A.: Spinal Reflex Activity From the Vesical Mucosa in Paraplegic Patients. *A.M.A. Arch. Neurol. & Psychiat.* 78: 339-354, October 1957.
- Bors, E., Comarr, A. E., and Moulton, S. H.: The Role of Nerve Blocks in Management of Traumatic Cord Bladders: Spinal Anesthesia, Subarachnoid Alcohol Injections, Pudendal Nerve Anesthesia and Vesical Neck Anesthesia. *J. Urol.* 63: 653-666, April 1950.
- Bors, E.: Effect of Electric Stimulation of the Pudendal Nerves on the Vesical Neck; Its Significance for the Function of Cord Bladders: A Preliminary Report. *J. Urol.* 67: 925-935, June 1952.
- Bors, E.: Bladder Disturbances and Management of Patients With Injury to the Spinal Cord. *J. Internat. Coll. Surgeons* 21: 513-527, April 1954.
- Bors, E., and Comarr, A. E.: Effect of Pudendal Nerve Operations on the Neurogenic Bladder. *J. Urol.* 72: 666-670, October 1954.
- Ross, J. C., and Damanski, M.: Pudendal Neurectomy in the Treatment of the Bladder in Spinal Injury. *Brit. J. Urol.* 25: 45-50, March 1953.
- Ross, J. C.: Treatment of the Bladder in Paraplegia. *Brit. J. Urol.* 28: 14-23, March 1956.
- Meirowsky, A. M., Scheibert, C. D., and Rose, D. K.: Indications for the Neurosurgical Establishment of Bladder Automaticity in Paraplegia. *J. Urol.* 67: 192-196, February 1952.
- Meirowsky, A. M., Scheibert, C. D., and Hinchey, T. R.: Studies on the Sacral Reflex Arc in Paraplegia. II. Differential Sacral Neurotomy, An Operative Method. *J. Neurosurg.* 7: 39-43, January 1950.
- Meredith, J. M.: The Importance of Anatomic Precision in Differential Sacral Neurotomy for "Cord Bladder." *Am. J. Surg.* 87: 819-823, June 1954.
- Patton, J. F., and Schwartz, H. G.: Sacral Neurotomy for the Spastic Neurogenic Bladder. *Tr. Am. A. Genito-Urin. Surgeons* 44: 40-43, 19, 20, and 21 June 1952.
- Brendler, H., Kruger, E. G., Lerman, P., Harper, J. G. M., Bradley, D., Berman, M. H., Hertzberg, A. D., Lerman, F., and Dean, A. L.: Spinal Root Section in Treatment of Advanced Paraplegic Bladder. *J. Urol.* 70: 223-229, August 1953.
- Alexander, E., Jr., Garvey, F. K., and Boyce, W. H.: Congenital Lumbosacral Myelomeningocele With Incontinence: A Contribution to the Understanding of Bladder Physiology. *J. Neurosurg.* 11: 183-192, March 1954.
- Meirowsky, A. M., and Scheibert, C. D.: Studies on the Sacral Reflex Arc in Paraplegia. III. Clinical Observations on Inhibitory Impulses Within the Sacral Reflex Arc. *Exper. Med. & Surg.* 8: 437-448, May-November 1950.
- Scheibert, C. D., and Meirowsky, A. M.: Studies on the Sacral Reflex Arc in Paraplegia. VI. Production of Bladder Automaticity in Quadriplegic Macacus Rhesus Monkeys. *Am. Coll. Surgeons (Surg. Forum)* 2: 363-369, November 1951.
- Meirowsky, A. M., Scheibert, C. D., and Hinchey, T. R.: Studies on the Sacral Reflex Arc in Paraplegia. I. Response of the Bladder to Surgical Elimination of Sacral Nerve Impulses by Rhizotomy. *J. Neurosurg.* 7: 33-38, January 1950.
- MacCarty, C. S.: The Treatment of Spastic Paraplegia

- by Selective Spinal Cordectomy. J. Neurosurg. 11: 539-545, November 1954.
31. Bors, E., Comarr, A. E., and Reingold, I. M.: Striated Muscle Fibers of the Vesical Neck. J. Urol. 72: 191-196, August 1954.
32. Ross, J. C., Damanski, M., and Gibbon, N. O. K.: Resection of the External Urethral Sphincter in the Paraplegic—Preliminary Report. J. Urol. 79: 742-746, April 1958.
33. Emmett, J. L., Albers, D. D., and Anderson, R. E.: Statistical and Analytic Review of the Final Results of Transurethral Resection for Cord Bladder. J. Urol. 65: 36-59, January 1951.

CHAPTER 31

Urological Aspects of Neurogenic Bladder

Hans H. Zinsser

INTRODUCTION

The urological complications of injury to the nervous system cannot be overemphasized in their importance for long-range mortality. Immediately after the First World War, it became apparent that urological diseases were accounting for the major portion of the mortality secondary to spinal cord injury (1). Precise definition of the rates of mortality following World War II and the Korean War are difficult to state simply (2) (3), but it is comforting to realize that tremendous strides have been made in the control of long-range urological complications (4). The strides that have been made are due in large part to better understanding of renal physiology in general and of stone formation in particular. The role of antibiotics is difficult to assess, but certainly control of some urea-splitting genitourinary invaders has played a major role in the reduction in such infections, subsequent instigation of stone formation, and urinary obstruction.

The long-range aim for the treatment of all urological dysfunction following nervous system injury should be to restore the patient to tube-free effective motor function of both the upper and lower urinary tracts under voluntary control. The means of achieving these aims on the theoretical basis exist for all patients. The practical achievement of this aim takes the full services of a team providing not only expert urological and neurological care but also psychiatric and physiotherapy assistance on a continuous integrated basis. Scrupulous attention to the performance of individual tests by sympathetic and interested personnel is essential to the

rehabilitation of these patients. Sexual rehabilitation has recently been reviewed (5).

Similar problems have been encountered in the treatment of poliomyelitis cases with bladder involvement (6) (7). It is likely that in this disease, however, the primary lesion is bladder sphincter spasticity without primary involvement of the extrinsic detrusor innervation itself (8) (9). As a result, however, of overdistention, severe disorganization of the myoneural and intrinsic neural network in the detrusor leads to atony.

CHRONOLOGY OF THE DEVELOPMENT OF UROLOGICAL DYSFUNCTION AFTER CENTRAL NERVOUS SYSTEM INJURY

The maintenance of free urine flow in the early phases immediately after injury can be best accomplished by small-caliber indwelling balloon-type catheters and judiciously chosen antibiotic therapy. It cannot be overemphasized in considering the acute onset of central nervous system damage affecting the bladder, that in the initial phases of total or partial cord transection, while bladder tone itself may not be disturbed, the imbalance of tone between the detrusor and the spastic external sphincter may well produce complete bladder neck obstruction. This is most strikingly seen in the early phases of poliomyelitis. In the spastic striated muscle phase of the irritative lesion, the external sphincter shares in the spastic situation and irreparable damage can be done to the bladder, which is unable to counteract the obstructive sphincter by itself.

Damage to the cerebral cortex can have several effects, the most important being complete loss of inhibitory impulses normally responsible for controlling inherent detrusor contraction at given pressures (10). This results in an essentially infantile voiding pattern on an automatic basis which can immensely increase the nursing problem under some circumstances. With incomplete cord lesions, it may be a matter of many months or even years before the final stabilized pattern of overall damage is established. The policy of early decompression of the cord has done much to make early definitive therapy more logical. Occasionally, in blast injuries to the cord, diffuse or scattered hemorrhagic areas within the substance of the cord may lead to disturbances over many years.

As stabilization proceeds, one of two rather broad categories of bladder paralysis manifests itself. The first of these, resulting from massive destruction of the nerves in the region of S2 and below, effectively destroys the entire structure of the reflex arc of the bladder and leaves the bladder entirely dependent on its intrinsic innervation for the performance of the voiding function. These bladders are normally devoid of sensation and depend for what continence persists, on the remaining tone of the internal vesical sphincter. The bladder musculature itself tends to show a reduction in tone over the normal, even with conscientious care through the immediate posttraumatic period. Occasionally with spotty injuries, sensation may be retained and motor innervation lost or the converse. In general, these bladders, when first seen in the early phases of stabilization, have been subjected to prolonged catheter or suprapubic drainage, and the bladder itself may be of very small capacity unless tidal drainage has been instituted. Return of normal bladder function is not to be anticipated, but if sensory function is retained, judicious use of external pressure and cautious removal of a portion of the bladder neck by transurethral resection may result in satisfactory voiding performance (11). If by a combination of circumstances the external sphincter retains its normal innervation with the loss of all sensory components, the external sphincter itself may be treated by selective neurectomy, as will be described further.

The large proportion of neurogenic bladders seen after spinal cord injury are a result of massive de-

struction of the cord above the level of the first sacral segment. With complete cord transection, the lower reflex arcs of the bladder are left intact and reflex voiding takes place, usually with visceral warning sensations which may take bizarre forms (12). A more important result of the intactness of the reflex arc than the warning of impending voiding which these patients may have is the variety of maneuvers to initiate voiding that the reflex makes possible. Most important of these has been the discovery that dilatation of the rectal sphincter manually in these patients will often initiate a detrusor reflex of considerable completeness to a small residual urine volume. Other trigger areas such as the inner aspect of the thigh, the lower abdominal quadrants, or the glans penis have occasionally been of value. It is this group in which the best long-range function may be anticipated if early irreversible damage secondary to bladder distention can be avoided. While subsequent operative procedures may be necessary to establish proper balance between the detrusor tone and sphincter tone, excellent results have been achieved in many of these patients.

The pathology of distortion of the lower and even the upper urinary tract depends on many variables of both injury and management, but in general, the sequence of events is fairly clear. With increasing lower tract obstruction the bladder at first hypertrophies and then eventually goes into decompensation and becomes dilated. Under these circumstances, incompetency of the ureterovesical valves occurs and dilation of the upper tract supervenes (13). Eventually very significant reductions in renal function subsequent to the increased back pressure can be detected. With the frequent manipulations attendant on the management of the neurogenic bladder, infection with a variety of micro-organisms occurs and produces severe pyelonephritis. If these are not properly combated with judiciously selected antibiotic therapy, severe irreversible renal damage occurs. Should these infections have the capacity to split urea in the urine, the high urinary pH's resulting from the splitting of urea to ammonia, produce precipitation of magnesium ammonium phosphate on the bacterial debris, and in addition, on the surface of any drainage system utilized in conjunction with the treatment of these patients. Calculi of magnesium ammonium phosphate are respon-

sible for a large proportion of the post spinal injury complications and account for a large proportion of the mortality of these people. The urea-splitting capacities of these organisms can be quite readily blocked with the use of very small oral doses of mercurial diuretics (14)(15). The consequent diuretic effect of the diuretics is not of prime consideration as long as salt balance is watched scrupulously. Occasionally, low sodium or low potassium states can be induced with continuous medication of this character, but the urine can always be kept at a low pH which will prevent the formation of magnesium ammonium phosphate stones and even dissolve small ones already formed (16).

In the first phases of immobilization of all neurological injuries a tremendous amount of wasting, both muscle and bone, takes place, and the calcium excretion levels may rise as high as from 1,500 to 2,000 mg. per day (17). This calcium load even with optimum control of pH is enough to cause precipitation of calcium phosphate or calcium oxalate in the urine at normal fluid loads. It is imperative at this time to exert all efforts to diminish the oral intake of calcium by careful dietary selection, and to increase urine volumes to as much as 6,000 cc. a day by whatever means are necessary to produce it. The role of passive exercise and of the upright position cannot be minimized in diminishing this calcium diathesis. The adjunct of oral preparations designed to sequester calcium within the intestinal tract should be added if other measures have failed (18)(19). The most thoroughly tested of these is sodium phytate, which, unfortunately, produces diarrhea in many individuals, which can lead to both salt deficiencies and complications of nursing. Perhaps somewhat less effective, but of considerable secondary value, is sodium alginate, which will absorb up to 60 mg. of calcium from the intestinal tract per gram of fed material. It is essentially a stool softener that has no irritative properties, and it can withdraw up to a gram of calcium a day from the intestinal tract of these patients and minimize the renal load necessary to keep the patients in essentially stone-free condition. Attempts to limit the phosphate excretion by dietary regulation in the presence of massive tissue destruction secondary to inanition, trauma, and infection have thus far not been of value (20).

With judicious fluid replacement, ample drainage, and scrupulous attention to infection, spinal injuries should be kept urologically asymptomatic and without stones in the future.

Final therapy and even some phases of the definitive study of the neurogenic bladder must await final stabilization of external neurological signs. Return of normal bladder function has been seen even years after a spinal lesion and it is far simpler to do additional procedures later than to undo procedures done too soon. It is imperative that the extent of the permanent damage be definitely ascertained before any final decisions as to reconstructive work are made.

NECESSARY STUDIES AND RESULTING PATTERNS

The studies which define the status of a neurogenic bladder problem are time consuming but extremely rewarding. It has been estimated that it takes approximately 48 man-hours to accomplish a proper workup and in many instances originally inconclusive studies must be repeated on several widely spaced occasions to achieve definite information.

In the acute phase of injury, it is often mandatory to have roentgenograms taken to define the nature of the spinal bony injuries and injuries to other parts of the body. Among the studies often most useful is an intravenous urogram which will give sufficient detail in the anteroposterior spine films to define much that may be necessary for future management. It also demonstrates unequivocally the degree of renal function that the patient retains and rules out the not inconsiderable 10 percent of the population with anomalous derangement of their urinary organs (21). It will rule out the presence of foreign bodies or of stones preexisting in the patient before management is undertaken. It will demonstrate the muscular competence of the renal pelvis, ureters, the ureteral vesical junction, and the bladder itself. If taken in conjunction with postvoiding films, it gives a totally innocuous, safe method of determining residual urine volume. In many instances, it will demonstrate a dilated obstructed bladder not previously found on physical

examination and will demonstrate damage to the bony pelvis which might otherwise have escaped notice. It is to be remembered that in conjunction with fractures of the bony pelvis, there are almost inevitably changes in the urinary tract which may be of tremendous seriousness. Intravenous urograms should be ordered routinely at least every 3 months in the course of management of a patient with a spinal injury, to rule out the development of subsequent urinary complications. In many instances, with the high urine volumes necessary for safety of these patients, it will be found that larger doses of intravenous dye must be given in order to give good visualization. Doses up to 75 cc. of 75 percent contrast media can be given safely if adequate precautions are taken to counteract circulatory disturbances secondary to the injection of such a large quantity of hypertonic fluid (22). It is vastly preferable to give additional dye rather than subject these patients to a period of dehydration preliminary to taking the films.

A urethrogram will in many instances demonstrate abnormalities of the urethra such as strictures secondary to prolonged indwelling catheterization with catheters of too large a caliber (23). It may demonstrate the incompetence of the valves of the ejaculatory ducts, and with accurate varied projections, may delineate sphincter abnormalities of considerable usefulness at a later date. In the acute phase of injury they probably are not justified, as the agents used can cause considerable reaction if there is damage to the integrity of the lining of the urethra.

With the advent of fluorescence intensifying methods, much dynamic information about the upper and lower urinary tracts can be derived by the study of voiding films by conventional or motion picture techniques. Much of our fundamental understanding of the movements of the trigone associated with normal voiding, both in the male and in the female, have been derived from this method and should be of increasing value in the paraplegic patient (24).

It is important in extensive roentgenographic investigation that medicolegal precautions as far as shielding the genitalia of these patients are carried out. Many of the upper motor lesions are still capable both of erection and ejaculation and have been moderately to highly fertile if the ejaculatory

ducts have not been damaged by overly prolonged indwelling catheter drainage.

Dynamic studies involve hydraulic and electrical instrumentation. The standard cystometry can be performed manually with very simple equipment, but if a large number have to be done a recording cystometer such as the Lewis will be found to be invaluable. It is essential that the equipment be assembled without letting in air, which gives false compensation within the recording system, and that, in the course of bladder filling (to obtain a pressure record of the detrusor itself), scrupulous sterile techniques be utilized and the competency of the ureterovesical valves be proved by simultaneous radiography, using a radiopaque agent for the initial filling of the bladder. If ureterovesical reflux occurs, it can usually be diagnosed by a discontinuity in the cystometrogram and may lead to serious disturbances in the renal function of the patient in the course of the study. In some instances, it may be advisable to add an essentially non-tissue-irritating antibiotic to the filling fluid (such as streptomycin in high concentration) so as to preclude the initiation of a retrograde pyelonephritis. In general, it has been found advisable to have such diagnostic equipment in the charge of one competent technician whose sole duties are to perform the tests and to keep the equipment in perfect condition. At least three cystometrograms should be done as a base line before any definitive diagnostic studies are performed, so that the range of normal variation of that particular patient, the equipment, and the operator can be obtained. Provision should be made for unusually large volumes of filling fluid to be administered, as in some instances with poor care the bladder capacity may be as high as 2,500 cubic centimeters.

In general, the lower cord lesion cystometrograms will show an essentially flaccid bladder curve with a sharp rise at the elastic limit of the bladder tissue itself. The upper motor lesions treated without tidal drainage, but with continuous catheter or suprapubic drainage, will show a small reduced capacity with hypertrophic musculature raising the pressure curve at unusually small volumes to extremely high limits. Bladders that have received adequate care and have tidal drainage over a considerable period of time may show an essentially normal record.

Our methods of measuring sphincter tone are by no means ideal. The construction of double lumen catheters with a recording balloon placed within the prostatic urethra to measure internal and external sphincter tone give inconstant and sometimes erroneous results. Measurement of the so-called breakaway pressure, by overfilling the bladder to the point of spilling of urine around the balloon catheter placed for the cystometrogram, gives one a rough idea of the breakthrough pressure necessary under some circumstances. That these represent closely the pressures necessary with the sphincter unobstructed by an indwelling catheter is open to considerable argument. The breakthrough pressures obtained by suprapubic injection of fluid into the bladder, either through a previously placed cystostomy tube or by trocar penetration, are probably more valid, but carry the following dangers:

1. Indwelling suprapubic catheters inevitably lead to bladder infection regardless of how scrupulous sterile technique may be.
2. Trocar penetration of a distended bladder in a patient with severely reduced resistance may lead either to fistula formation or to subsequent infection of the trocared area.
3. The procedure cannot be readily duplicated.
4. The breakthrough pressure even with the sphincter unobstructed may well not be a true measure of what integrated coordinated voiding may accomplish.

Studies of the mechanics of the normal pelvis and ureter can be done with ureteral balloon catheters, but, because of the long fluid column necessary and the small caliber of the instruments, such studies are likely to yield only integrated values without the fine details which would be so essential for our understanding of the physiology.

Electrical methods so useful in the estimate of striated muscle function in these patients have been relatively disappointing in the study of detrusor and external sphincter function. Bipolar electrodes placed in the external sphincter have demonstrated, indeed, that striated muscle discharges can be elicited by stimulation of appropriate nerves but recordings from the detrusor itself have led to equivocal results (25) (26) (27), and in some instances, undoubtedly, much of the record has been electrode artifact (28). Until the normal patterns have been more clearly defined, it is unlikely that direct study

of smooth muscle action potentials within the urinary tract will be of much diagnostic or therapeutic value (29).

Very useful results indicating the directions for further neurosurgical intervention have been accomplished by successive local blocking techniques. These give a clear view of what a total ablative procedure may accomplish in an otherwise confused diagnostic situation.

The first step in all such diagnostic approaches should involve complete spinal anesthesia. Following spinal anesthesia, there should be no reflex activity on bladder filling, but graded external pressure can produce voiding through the essentially unrestricted outlet secondary to complete relaxation of the external sphincter. One thus obtains a good measure of internal sphincter tone, and if this is excessive, it may lead one to think of transurethral resection of a portion of the internal sphincter to rectify the situation. Caudal anesthesia yields somewhat similar information but occasionally disturbs detrusor contractions themselves and can be somewhat more misleading than spinal anesthesia if the lesion is not too low to permit a spinal to be done. Pudendal block done either unilaterally or bilaterally can demonstrate again by selective reduction of external sphincter tone, with a minimal disturbance of the remainder of the bladder innervation, the potential usefulness of pudendal neurectomy in lessening bladder neck obstruction. It is important to realize that once pudendal crush has been accomplished it should be important to leave a marking clip in the location where the crush is performed so that subsequent permanent division can be carried out by external diathermy.

By all means the most powerful method has been that of blocking the sacral nerves directly in the sacral foramina (30). This procedure is not difficult to accomplish technically, and if carried out in conjunction with stimulation studies, to be described shortly hereafter, can give pinpoint information as to the minimum nervous interruption necessary to accomplish the desired results (31). These techniques have been extensively described elsewhere and have led to rehabilitation of a large number of patients.

Almost as powerful a tool is direct stimulation of the sacral segmental nerves within the sacral foram-

ina with needle electrodes. In many high cord lesions stimulation of S2 or S3 either unilaterally or bilaterally can result in initiation of quite normal reflex voiding. The innervation of this area is, however, quite variable, and several combinations of stimulation may have to be tried before the proper pattern for that patient can be found. The long-range possibility of implantation of electrodes in this area, and external electrical stimulation without transcutaneous leads, would seem to be very real. If transcutaneous leads must be left in place, then braided zirconium leads by all means are the least likely to form a channel for subsequent passage of infection to the area of implant. The braiding of the zirconium wire allows free growth of connective tissue and even epithelial cells through the meshes of the lead, which can be insulated with very thin layers of a variety of nonreactive plastics. The possibility of tumor formation in conjunction with plastics of any kind designed to be left in the body over long periods of time, of course, cannot be forgotten (32). Stimulation of various cutaneous areas, in an attempt to elicit a voiding reflex, is occasionally extremely rewarding and all possible areas should be explored with the stimulating electrode in the course of study (33). Portable stimulators run on a dry cell can be devised in such fashion that, even without the use of the arms, selective stimulation of an area of skin can be accomplished by the paraplegic.

Intracystic stimulation with a variety of current outputs, including high voltage direct current, has thus far been unsuccessful in initiating detrusor contraction. The reason for this is not clear, but it seems entirely likely that any stimulation of the bladder mucosa initiates a pain reflex which inhibits detrusor contraction before contraction can take place as a result of direct muscle stimulation. So puzzling has this problem been that even playing back recorded smooth muscle contraction action potentials into the bladder itself has been tried without success.

Pudendal stimulation, occasionally, is useful to derive figures as to maximal external sphincter tone available (34). Stimulation is certainly useful to locate the pudendal nerves in the course of exploration for pudendal neurectomy or crush. Locating the pudendal nerves in patients with severe injuries to the perineum (including previous exploration)

may be difficult. Under these circumstances the subgluteal approach can be carried out with a minimum of mutilation, and under these circumstances successive stimulation is the only real way of locating those fibers primarily concerned with pudendal function.

POSSIBLE MODES OF TREATMENT AFTER STABILIZATION HAS BEEN OBTAINED

The great enemy to long-range survival of the patient with a neurogenic bladder is the bladder neck. Excessive sphincter tone, scarring sequelae to indwelling catheterization or incomplete emptying of the bladder for a variety of causes leads to the pattern of infection, stone formation, and subsequent renal destruction. It has even been suggested that complete ablation of the bladder neck by conscientious resection of all bladder neck tissue (such as to destroy both sphincters) and the substitution of an artificial sphincter would be the method of choice for the treatment of these patients. Ingenious sphincters have been devised, and valves used in other areas in neurosurgery certainly are deserving of investigation. The most intriguing suggestion is an inflated ellipsoidal balloon with a permanent magnet in its base. This would be drawn and locked in place by the closure of the detrusor itself, forcing it into a bed in the bladder neck previously cleared by transurethral resection. It would be displaced from this position in order to make voiding possible by the application of an external magnetic field, such as to pull it out of its bed in the bladder neck, whereupon it would float to the dome of the bladder, until complete contraction of the detrusor had forced it back to rest in its bed. The difficulty with all such prosthetic inlying material lies in the fact that stone formation on the surface of any plastic within the urinary tract will occur in the presence of urea-splitting infections. The possibility of incorporation of the urease antagonists within the body of the plastics is still under investigation (35), and it is to be hoped that eventually such long term useful plastics will be available for reconstructive surgery. Repair of incompetent ureterovesical valves has been attempted, although results with existing procedures have been far from happy (36) (37).

Some procedures are performed as matters of ex-

treme urgency and should be regarded as disastrous in the management of these patients, notably, the application of indwelling nephrostomy tubes, ureterostomy tubes, or cystostomy tubes. Ureteral intestinal transplant in an effort to make intestinal smooth muscles take over for an incompetent bladder, or the substitution of an intestinal pouch for the bladder itself, have been in use too short a time to justify our endorsement. Only subsequent years will tell whether these procedures have long-range value.

REFERENCES

1. Hinman, Frank: Abdominal and Genito-Urinary Injuries. Philadelphia: W. B. Saunders Co., 1942.
2. Spurling, R. G.: Second Statistical Analysis of Neurosurgical Data From United Kingdom Base Section, 13 Dec. 1944.
3. Burke, M. H., Hicks, A. F., Robins, M., and Kessler, H.: Survival of Patients With Injuries of the Spinal Cord. *J.A.M.A.* 172: 121-124, 9 Jan. 1960.
4. Talbot, H. S.: The Management of the Spastic Bladder in Paraplegia. *J. Urol.* 79: 759-766, April 1958.
5. Talbot, H. S.: The Sexual Function in Paraplegia. *J. Urol.* 73: 91-100, January 1955.
6. Blossom, R. A., and Affeldt, J. E.: Chronic Poliomyelitic Respirator Deaths. *Am. J. Med.* 20: 77-87, January 1956.
7. Brady, L., and Wilson, W. J.: Major Urological Surgery on Poliomyelitic Patients Confined to Respirators; Discussion of Etiology, Prophylaxis Against and Treatment of Calculi in Recumbent Patients. *J. Urol.* 60: 381-388, September 1948.
8. Pierce, J., and Zinsser, H. H.: Early Bladder Dysfunction in Poliomyelitis. Presented before Clinical Congress of American College of Surgeons, Atlantic City, N.J., 15 Nov. 1954.
9. Clarke, B. G.: A Clinical Study of the Motor Paralytic Bladder in Poliomyelitis. *J. Urol.* 76: 66-69, July 1956.
10. Muellner, S. R., Loman, J., and Alexander, L.: The Urinary Bladder in Multiple Sclerosis. *J. Urol.* 68: 230-236, July 1952.
11. Comarr, A. E.: Transurethral Vesical Neck Resection; An Adjunct in the Management of the Neurogenic Bladder. *J. Urol.* 72: 849-859, November 1954.
12. Bors, E.: Segmental and Peripheral Innervation of the Urinary Bladder. *J. Nerv. & Ment. Dis.* 116: 572-578, December 1952.
13. Hutch, J. A.: Vesico-Ureteral Reflex in Paraplegic: Cause and Correction. *J. Urol.* 68: 457-469, August 1952.
14. Wahlberg, C.: The Purification and Properties of Bacterial Urease. Doctoral Dissertation, University of Southern California, Los Angeles, 1956-57. (Obtainable in microfilm.)
15. Zinsser, H. H., and Wahlberg, C.: Urease Inhibitors in Urological Infections: Stone Prevention and Resistance Changes. Scientific Exhibit: Urology. 108th Annual Meeting, American Medical Association, Atlantic City, N.J., 8-12 June 1959, p. 390. ("Struvite Stone Syndrome," distributed in connection with exhibit.)
16. Moyer, J. H., Handley, C. A., and Seibert, R. A.: Report to Lakeside Laboratories: Results on Three New Mercurial Diuretics Over a Two-Year Period Administered Orally to Patients With Cardiac Failure, March 1952. (Unpublished data obtainable from Lakeside Laboratories, Milwaukee, Wis.)
17. Albright, Fuller, and Reifenstein, Edward C., Jr.: The Parathyroid Glands and Metabolic Bone Disease; Selected Studies. Baltimore: Williams & Wilkins Co., 1948.
18. Vermeulen, C. W., Lyon, E. S., Gill, W. B., and Chapman, W. H.: Prevention of Phosphate Stones by Phytate, Phosphate and Hexametaphosphate: Experimental Urolithiasis XV. *J. Urol.* 82: 249-255, August 1959.
19. Veenema, R. J., and Zinsser, H. H.: Sodium Alginate for Hypercalcuria. Presented at Meeting of American Urological Association, Chicago, Ill., 16-19 May 1960.
20. Shorr, E.: The Possible Usefulness of Estrogens and Aluminum Hydroxide Gels in the Management of Renal Stone. *J. Urol.* 53: 507-520, April 1945.
21. Campbell, Meredith: Clinical Pediatric Urology. Philadelphia: W. B. Saunders Co., 1951.
22. Zinsser, H. H., Lloyd, N., and Jacobsen, G. J.: The Quantitative Urogram. (Abstract of paper presented before Western Section of the American Federation of Clinical Research, Carmel, Calif., 29 Jan. 1953.) *Clin. Res. Proc.* 1: 36, April 1953.
23. Damanski, M., and Kerr, A. S.: The Value of Cysto-Urethrography in Paraplegia. *Brit. J. Surg.* 44: 398-407, January 1957.
24. Hinman, F., Jr., Miller, G. M., Nickel, E., Steinbach, H. L., and Miller, E. R.: Normal Micturition; Certain Details as Shown by Serial Cystograms. *California Med.* 82: 6-7, January 1955.
25. Slater, G. S.: Electrocystography: A Study of Bladder Contractions Measured by Differences of Electropotential. *J. Urol.* 69: 626-631, May 1953.
26. Boyce, W. H.: Bladder Electromyography: A New Approach to Diagnosis of Urinary Bladder Dysfunction. *J. Urol.* 67: 650-671, May 1952.
27. Baker, R., and Huffer, J.: Ureteral Electromyography. *J. Urol.* 70: 874-883, December 1953.
28. Brunstig, C. D.: An Interpretation of the Urinary Bladder "Electrocystogram" as Artifact. *J. Urol.* 79: 165-170, January 1958.
29. Butcher, H. R., Jr., and Sleator, W. J., Jr.: A Study of the Electrical Activity of Intact and Partially Mobilized Human Ureters. *J. Urol.* 73: 970-986, June 1955.
30. Meirowsky, A. M., Scheibert, C. D., and Rose, D. K.: Indications for the Neurosurgical Establishment of Bladder Automaticity in Paraplegia. *J. Urol.* 67: 192-196, February 1952.

31. Patton, J. F., and Schwartz, H. G.: Sacral Neurotomy for the Spastic Neurogenic Bladder. *J. Urol.* 70: 230-233, August 1953.
32. Oppenheimer, B. S., Oppenheimer, E. T., Stout, A. P., and Danishefsky, I.: Malignant Tumors Resulting From Embedding Plastics in Rodents. *Science* 118: 305-306, 11 Sept. 1953.
33. Hutch, J. A.: A Study of the Hyperactive Autonomic Reflex Initiated by Bladder Distention in Patients With Lesions in the Cervical and High Thoracic Cord. *J. Urol.* 73: 1019-1025, June 1955.
34. Bors, E.: Effect of Electric Stimulation of the Pudendal Nerves on the Vesical Neck; Its Significance for the Function of Cord Bladders: A Preliminary Report. *J. Urol.* 67: 925-935, June 1952.
35. Arouni, T. J., Schwartz, R., and Zinsser, H. H.: Inhibition of Stone Formation I: Prevention of Incrustation on Plastics in the Infected Bladder. *Trans. Am. Soc. For Artificial Internal Organs* 5: 319-324, 12-13 Apr. 1959.
36. Hutch, John Albert: *The Ureterovesical Junction; The Theory of Extravesicalization of the Intravesical Ureter.* Berkeley, Calif.: Univ. California Press, 1958.
37. Kohler, F. P., and Murphy, J. J.: A Mechanical Ureteral Valve. *Surg. Gynec. & Obst.* 109: 703-708, December 1959.

CHAPTER 32

Sympathetic Blockade, An Acute Cervical Cord Syndrome

Arnold M. Meirowsky

The acute cervical cord syndrome is characterized by disorientation, unresponsiveness, hypotension, bradycardia, and hypothermia. It was first observed during the 1951 spring offensive in Korea at the 1st Neurosurgical Detachment (Provisional) by Robert A. Clark, Griffith R. Harsh III, and the author (1). The components of the syndrome can best be illustrated by summarizing the story of K-2119 who sustained a high-velocity missile wound of the neck in North Korea on 24 April 1951. Depression and comminution of the laminae of C4 and C5, and physiological transection of the cord at that level had resulted in flaccid quadriplegia with areflexia, analgesia, and anesthesia caudad to C3 on the left and to C4 on the right. When first seen, this 24-year-old U.S. Marine Corps private, first class, appeared alert and oriented. His blood pressure was 80 mm. Hg systolic and 65 mm. Hg diastolic. He had a bradycardia of 42. Examination of the head and of all neurological systems failed to reveal any evidence of craniocerebral trauma. Decompressive laminectomy was performed under 1 percent procaine hydrochloride (Novocain) infiltration anesthesia. The dura was intact and the cord had an ischemic appearance. Bradycardia and hypotension persisted postoperatively, and hypothermia developed. During the first 48 hours postoperatively the patient was disoriented, but remained responsive. He then developed clonic extensor movements of the neck, following which he became unresponsive. It was our impression then that the entire syndrome had been brought about by total loss of

sympathetic impulses and the resultant loss of parasympathetic antagonists. Lumbar puncture revealed normal pressure in the absence of a subarachnoid block. Treatment consisted of the application of external heat, administration of ephedrine and atropine, immobilization of the cervical region, turning every 2 hours (to prevent the development of decubital ulcers), and complete nasopharyngeal toilet. The vital signs gradually improved. By the end of the first postoperative week, they had reverted to normal. The patient regained consciousness 1 week after operation and was evacuated to the neurosurgical center at Tokyo Army Hospital where he was placed on a Stryker frame and rehabilitation was initiated. He remained completely quadriplegic, but did not suffer recurrent disorientation. Subsequently, this patient has been under the care of Dr. Ernest H. J. Bors in the Veterans' Administration Hospital, Long Beach, Calif. In 1954, 3 years after injury, Doctor Bors related that this man had developed a severe autonomic hyperreflexia with paroxysmal hypertension. Differential sacral neurectomy abolished the paroxysmal hypertension.

Subsequently, a review of 46 consecutive cases of cervical cord injury was undertaken (2). Of 46 patients with cervical cord injuries who were operated upon, 26 manifested all or a part of the "acute cervical cord syndrome." In all but the first patient, the syndrome occurred preoperatively.

Surgical shock was ruled out in all cases by hematocrit, red blood cell count, and hemoglobin determinations.

TABLE 31.—*Characteristics of the acute cervical cord syndrome in 26 patients with cervical cord injuries*

Case ¹	Level	Injury	Disorientation	Hypotension	Bradycardia	Hypothermia
1.....	C4	Contusion....	Extreme.....	Extreme.....	Extreme....	Extreme.
2.....	C6	Transection...	do.....	do.....	do.....	Do.
3.....	C6	do.....	do.....	do.....	do.....	Do.
4.....	C5	Contusion....	Moderate....	do.....	do.....	Moderate.
5.....	C5	Transection...	do.....	Moderate....	do.....	Do.
6.....	C4	Contusion....	do.....	do.....	Moderate..	Do.
7.....	C5	do.....	Extreme.....	do.....	do.....	Do.
8.....	C7	Transection...	do.....	Extreme.....	do.....	Do.
9.....	C3	do.....	do.....	do.....	Extreme....	Extreme.
10.....	C6	Contusion....	do.....	do.....	do.....	Do.
11.....	C5	do.....	Moderate....	Moderate....	Moderate..	Moderate.
12.....	C7	do.....	do.....	Extreme.....	do.....	Mild.
13.....	C5	do.....	Extreme.....	do.....	Extreme....	Extreme.
14.....	C4	do.....	Intermittent.	Absent.....	Absent....	Absent.
15.....	C5	do.....	Extreme.....	do.....	do.....	Do.
16.....	C4	do.....	Moderate....	do.....	do.....	Do.
17.....	C6	do.....	Mild.....	Mild.....	Mild.....	Do.
18.....	C7	Concussion...	Moderate....	Absent.....	Absent....	Do.
19.....	C5	Contusion....	do.....	Extreme (renal shutdown).	Mild.....	Mild.
20.....	C5	do.....	Extreme.....	Moderate....	do.....	Extreme.
21.....	C5	do.....	Convulsions..	Absent.....	Absent....	Absent.
22.....	C7	Transection...	Moderate....	do.....	do.....	Do.
23.....	C1	Contusion....	Extreme.....	do.....	do.....	Do.
24.....	C7	do.....	do.....	do.....	do.....	Do.
25.....	C6	do.....	Moderate....	Moderate....	do.....	Do.
26.....	C5	do.....	Nocturnal....	Absent.....	do.....	Do.

¹ Two patients died: Case 9 (transection at C3 level) and case 20 (injury complicated by severe third-degree burns). All patients demonstrated absence of shivering and sweating below the level of the lesion and showed a moderate amount of abdominal distention.

Source: Rosenbluth, P. R., and Meierowsky, A. M.: Sympathetic Blockade, An Acute Cervical Cord Syndrome. *J. Neurosurg.* 10: 107-112, March 1953.

In 13 of the 26 patients with sympathetic blockade, the syndrome was complete; in the other 13, not all features were present (table 31).

The components of the syndrome are best considered individually as they present certain diagnostic and therapeutic pitfalls.

DISORIENTATION, STUPOR, AND COMA

Psychic changes are marked immediately after injury and may represent interruption of sympathetic components of emotional expression initiated in the hypothalamus (3) (4). Such manifestations may lead to an erroneous diagnosis of cerebral concussion or psychiatric disorder. In one instance, a soldier with a penetrating gunshot wound of the neck, a comminuted, depressed fracture of C6 and

C7, and contusion of the seventh cervical cord segment was evacuated quadriparetic through the first echelon of neurosurgical care. Disorientation and facetious euphoria were the most prominent features of his clinical picture (case 24, table 31). After transportation without cervical support and with the diagnosis of conversion hysteria, lumbar puncture and review of the roentgen films demonstrated a partial subarachnoid block from the cervical injury. The acute anxiety which one might expect in quadriplegia with sudden threat of complete and permanent immobility is frequently absent and replaced early by passive, jocular, bland indifference. Stupor, coma, and generalized convulsions occurred in a few patients with contusion of the cervical cord without associated head injury.

BRADYCARDIA

The slowing of the pulse rate is probably caused by interruption of preganglionic impulses to the cardiac accelerator nerves. The resulting sympathetic blockade may lead to unchecked parasympathetic activity. A 2:1 ratio between heart rate and peripheral pulse rate during the early phase of the syndrome has been observed in a few cases. The bradycardia may be misinterpreted as a reflection of increased intracranial pressure. One of the patients in this series was subjected to diagnostic bur holes because of such misinterpretation (case 10, table 31).

HYPOTENSION

Loss of peripheral vascular resistance secondary to the alleviation of sympathetic vascular tone was responsible for the hypotension. An initial impression of "shock" without concomitant blood loss may lead to ill-advised, rapid transfusions which succeed only in further loading an inert peripheral vascular pool without raising the blood pressure. Electrocardiographic tracings obtained from these patients from 7 to 10 days after injury show normal conduction patterns with sinus bradycardia.

HYPOTHERMIA, SHIVERING, AND SWEATING

Sherrington observed that shivering and pilo-erection in dogs with spinal transection occurred only in regions innervated above the level of cord section (5). The weather in Korea was cold during some of the bitterest fighting. Because of the absence of shivering and movements caudad to the level of lesion, patients with cervical injuries rapidly became chilled and were admitted with body temperatures as low as 92° F. The oral temperature may be a degree or two higher than the rectal temperature, but usually both are markedly depressed. Since sweating too is absent caudad to the lesion, these patients may rapidly become hyperthermic during the summer months.

GASTRIC DISTENTION AND ILEUS

Temporary neurogenic ileus is a common complicating feature of quadriplegia. Hyperactivity of

the bowel following this type of preganglionic ablation of the sympathetic enteric supply has not been observed by this author.

TREATMENT

Treatment begins with recognition of the syndrome. These patients tolerate evacuation poorly. Care by emergency stabilization of the neck with litter support and an improvised cervical brace can be lifesaving. Temperature should be checked frequently and controlled by external heat or, in summer, by cooling. Brisk rubbing of the skin in hyperthermic patients may cause sufficient cutaneous dilatation to effectively cool by convection. Frequently, the level of injury may be plotted on the skin by flush and sweating above the lesion, and dry, mottled, cyanotic skin below. Care must be exercised in treatment with heat, or in sponging, to keep the skin intact. Burns or abrasions in quadriplegic patients are notoriously slow to heal and may be the precursors of large decubiti. With quadriplegics, care on a Stryker, Foster, or Circoelectric frame with frequent position change, tidal bladder irrigation, and meticulous skin care is mandatory. It is felt that surgical decompression of the spinal cord is indicated at the earliest possible instance (6). The occurrence of the syndrome does not contraindicate surgery. All of these patients were operated upon under local anesthesia on Stryker frames. Occasionally, the vital signs dramatically revert to normal after decompression of the cervical cord. More often, there is a gradual return to normal over a period of days. Return to normal of body temperature occurs in some cervically transected animal preparations by acceleration of the basal metabolic rate (7). This was not true of those in this series who had basal metabolic rate determinations after injury (two cases). No effort was made to test response of these patients to temperature change after injury since it was not considered in the best interest of the patients to do so in the early convalescent stage. Clark has shown that cats with transection of the lower cervical cord are unable to make the adjustments necessary for maintaining a normal body temperature when there is a sudden fall in the environmental temperature (7).

Clinically, the syndrome appears to be a reflex-

tion of the blockade of sympathetic efferent pathways in the cervical spinal cord. Since unbalanced parasympathetic function may accentuate the signs and symptoms, atropine in small doses (0.4 mg.) has been used intravenously in the treatment of some of these patients. No effect on temperature or blood pressure resulted. Striking improvement in the sensorium was reported after atropine administration in one patient who had a complete transection at the C6 level (case 2, table 31). Atropine frequently increased the peripheral pulse rate. In patients with a 2:1 ratio between heart and radial pulse rate, atropine renewed the normal ratio, but relative bradycardia persisted.

REFERENCES

1. Meierowsky, A. M.: Treatment of Penetrating Wounds of the Spinal Cord. *In* Symposium on Military Medicine in the Far East Command, September 1951, pp. 91-94.
2. Rosenbluth, P. R., and Meierowsky, A. M.: Sympathetic Blockade, An Acute Cervical Cord Syndrome. *J. Neurosurg.* 10: 107-112, March 1953.
3. Wang, S. C., and Ranson, S. W.: Autonomic Responses to Electrical Stimulation of Lower Brain Stem. *J. Comp. Neurol.* 71: 437-455, December 1939.
4. Wang, S. C., and Ranson, S. W.: Descending Pathways From the Hypothalamus to the Medulla and Spinal Cord; Observations on Blood Pressure and Bladder Responses. *J. Comp. Neurol.* 71: 457-472, December 1939.
5. Sherrington, C. S.: Notes on Temperature After Spinal Transection, With Some Observations on Shivering. *J. Physiol.* 58: 405-424, May 1924.
6. Campbell, Eldridge, and Meierowsky, Arnold: Penetrating Wounds of the Spinal Cord. *In* Surgery of Trauma. Edited by Warner F. Bowers. Philadelphia: J. B. Lippincott Co., 1953, pp. 121-149.
7. Clark, G.: Temperature Regulation in Chronic Cervical Cats. *Am. J. Physiol.* 130: 712-722, October 1940.

CHAPTER 33

Autonomic Hyperreflexia

Arnold M. Meirowsky

A clinically significant mass autonomic reflex may be seen in patients with myelopathy cephalad to the sixth thoracic dermatome. The symptoms which have been referred to as pressor phenomena are severe throbbing headache, sweating and cutis anserina above the level of myelopathy, occasional dyspnea, palpitation, and nasal congestion. Head and Riddoch (1) have described excessive sweating of patients with spinal cord injury. Autonomic reflexes in the spinal cord of man have been described (2) (3) (4) (5). Satisfactory surgical relief by posterior rhizotomy of T9 through S5 has been reported by Bors and French (6) in seven cases. C. David Scheibert's study of autonomic hyperreflexia (7) has served to throw much light on the overall problem. Scheibert found that sympathetic block with procaine hydrochloride (Novocain) of the sacral nerves or spinal anesthesia relieved headache and hypertension resulting from cystometry of paraplegic patients with a poorly functioning bladder. Stimulation of areas supplied by the sacral nerves and particularly of the bladder may produce autonomic hyperreflexia. For study and subsequent surgery, Scheibert selected only patients with extremely severe hypertension and persistent headache or sweating in response to bladder irrigation or catheterization. A total of 13 patients were studied and operated upon. They had in common myelopathy at or above T4 which was physiologically complete in all except three. Bladder distention resulted in marked elevation of blood pressure, bradycardia, headache, decrease in skin temperature as much as 8° F. in fingers and toes, constriction of blood vessels, dilatation of pupils, cardiac arrhythmias with rates as low as 36, and the following

changes usually above the level of myelopathy: Cutis anserina, blotchy redness of skin, and marked decrease in skin resistance with profuse perspiration. Seven patients underwent sacral rhizotomy or neurotomy (8) of S1 or S2 through S5. Total rhizotomy with conus amputation was performed in four patients. Posterior rhizotomy was performed in one case and thoracic chordectomy in one case. Autonomic hyperreflexia was completely eliminated by operative intervention in 11 cases and almost completely abolished in the 2 remaining cases.

His preoperative and postoperative studies led Scheibert to conclude that bilateral sacral neurotomy or rhizotomy of S2 through S5 is the surgical method of choice for the relief of autonomic hyperreflexia (7). He stresses the fact that this operative approach should only be employed whenever conservative measures such as hexamethonium, which was first successfully used by Bors and Kurnick (9) (10), fail to relieve pressor phenomena.

REFERENCES

1. Head, H., and Riddoch, G.: The Automatic Bladder, Excessive Sweating and Some Other Reflex Conditions, in *Gross Injuries of the Spinal Cord*. Brain 40: 188-263, November 1917.
2. Guttmann, L., and Whitteridge, D.: Effects of Bladder Distention on Autonomic Mechanisms After Spinal Cord Injuries. Brain 70: 361-404, December 1947.
3. List, C. F., and Pimenta, A. deM.: Sweat Secretion in Man. VI. Spinal Reflex Sweating. Arch. Neurol. & Psychiat. 51: 501-507, June 1944.
4. Pollock, L. J., Boshes, B., Chor, H., Finkelman, I., Arieff, A. J., and Brown, M.: Defects in Regulatory Mechanisms of Autonomic Function in Injuries to Spinal Cord. J. Neurophysiol. 14: 85-93, March 1951.

5. Thompson, C. E., and Witham, A. C.: Paroxysmal Hypertension in Spinal-Cord Injuries. *New England J. Med.* 239: 291-294, 19 Aug. 1948.
6. Bors, E., and French, J. D.: Management of Paroxysmal Hypertension Following Injuries to Cervical and Upper Thoracic Segments of Spinal Cord. *A.M.A. Arch. Surg.* 64: 803-812, June 1952.
7. Scheibert, C. D.: Studies on the Sacral Reflex Arc in Paraplegia. V. Surgical Therapy of Autonomic Hyperreflexia in Cervical and Upper Thoracic Myelopathy. *J. Neurosurg.* 12: 468-474, September 1955.
8. Meirowsky, A. M., Scheibert, C. D., and Hinchey, T. R.: Studies on the Sacral Reflex Arc in Paraplegia. II. Differential Sacral Neurotomy; An Operative Method. *J. Neurosurg.* 7: 39-43, January 1950.
9. Kurnick, N. B.: Drug Therapy of Autonomic Hyperreflexia in Patients With Spinal Cord Lesions. Presented at the Third Annual Paraplegia Conference, Veterans' Administration, 12-14 Oct. 1954.
10. Bors, E.: Sacral Neurotomy or Low Subarachnoid Alcohol Block in Autonomic Hyperreflexia. A discussion of Dr. Kurnick's paper, reference 9, above. Presented at the Third Annual Paraplegia Conference, Veterans' Administration, 12-14 Oct. 1954.

CHAPTER 34

Physical and Vocational Rehabilitation

Ernest Bors

Until World War II, the fate of patients with spinal cord injuries was dismal, with few exceptions. The exceptional patients were those under the care of Munro (1) (2) (3) who, since the late twenties, had attempted to help them not only to survive, which was then an achievement in itself, but also to be reintegrated into productive society.

With the advent of new drugs and methods of treatment in the early forties, the scope of rehabilitation of paraplegic men has been widened to such a degree that, at present, it is spoken of as total rehabilitation. While the methods since that time have remained essentially the same, the ultimate goal has undergone a change, in that the emphasis has shifted from the initial cry "they shall walk again" to the objective of maintaining morale, nutrition, and general health (4), and to the aim that "with physical rehabilitation and adequate support, the disabled person can learn to live and work with what he has left" (5).

GENERAL CONSIDERATIONS: OBJECTIVES OF REHABILITATION

Abramson and Ebel (6), Dinken (7) (8), Guttman (9), Gutmann and Guttman (10), Lowman (11), Newman (12 through 17), Nyquist (18) (19) (20), and others have formulated the goals of rehabilitation during the past 10 years, have discussed principles, and have described methods and results. Nyquist (18) has stressed succinctly that the patient with spinal cord injury is not being rehabilitated, but rehabilitates himself according to his physical potential and personality; the profes-

sional team contributes guidance, encouragement, and the tools offered by the various branches and subbranches of physical medicine.

Efforts at rehabilitation start with the admission of the patient to a hospital where definitive treatment is carried out. It consists of medical, nursing, physical, and vocational reconditioning efforts to maintain the precarious homeostasis of spinal man. In many instances, these efforts overlap and are complementary to one another: Proper nursing care means correct positioning of the limbs to prevent contractures, edema, venous stasis, and phlebotrombosis in almost 60 percent of these patients. Disuse atrophy of one extremity may lead to general metabolic repercussions, culminating in nitrogen loss from muscles and bones, a lowered creatinine tolerance, liberation of calcium, and increased calciuria which, in turn, tends to favor urinary calculus because of increased pH of the urine and reduction of citric acid by the activity of urea-splitting micro-organisms. These events are counteracted by the prevention of deconditioning with the aid of muscle exercise and early weight bearing in the upright position, either with the aid of a tilt table or braces. The upright position enhances urinary drainage from kidneys to bladder, improves bladder function by increasing intravesical pressure, and benefits bowel activity and regulation.

The prevention of decubital ulcer is a primary responsibility of the medical and nursing team. Ulcers can be prevented by prescribing a proper diet, administering blood transfusions and anabolic agents (such as testosterone), and by ultraviolet radiation treatments of the body. Once decubital ulcers develop, brine baths in a tank, followed by

local treatment with ultraviolet rays, may lead to spontaneous healing, sparing the patient major reconstructive surgery.

Pain problems, according to their etiology, may require local heat treatment, massage, and exercise. This approach may make neurosurgical intervention unnecessary in some instances, particularly when psychological factors play an etiological part. Occupational therapy, the teaching of self-dependence by corrective therapy, motivation by vocational counseling, and manual arts therapy are of additional benefit.

The reduction of spasticity, with its exteroceptive, interoceptive, and proprioceptive stimulation pattern, is another target for remedial conservative therapy before resorting to neurosurgical or orthopedic intervention. The use of heat in its various applications and muscle fatigue achieved through electrotherapy or exercise, possibly in combination with muscle relaxants, may help to reduce spasticity. This applies especially to patients who fail to respond to the removal of the external somatic (decubital ulcer) or internal visceral (urinary calculus) stimulus with an adequate reduction of spasticity. The decrease of spasticity becomes still more important because the perpetrating mechanism of the proprioceptive feedback may originate from an individual muscle, from muscle groups, or from the musculature of the entire extremity.

The instability of blood pressure is a common phenomenon in patients with lesions above the T4-T6 level. One of its manifestations, postural hypotension, is of interest here. In addition to medical management by administration of an adrenergic agent before rising and compression of the abdomen by a binder, exercises, either of the sling suspension type (9), or with a tilt table at a gradually increasing angle, are of great value.

It is a well-recognized fact that spinal cord injury leads to an initial, usually self-limited, mental depression which may in some cases require psychological and psychiatric assistance. The support given by the representatives of the various branches of physical medicine cannot be stressed enough. By aiding the patient's self-dependence, they are often able to mitigate the psychological impact of the injury. The available methods for helping paraplegic and quadriplegic patients attain self-dependence include a gamut of procedures, from teaching the per-

formance of physical demands of daily living (21) (fig. 156), to locomotion in a wheelchair, driving a car, using self-aid devices, occupational therapy, vocational advisement, and job retraining.

It is evident that many facets of physical medicine and rehabilitation aid the members of the medical team—the neurologist, neurological surgeon, urologist, internist, plastic surgeon, psychiatrist—in their attempts to prevent and to manage complications.

Physiatry at a paraplegia center also seeks the cooperation of the community, industry, and social and welfare agencies, which are indispensable in reaching the goal of total rehabilitation (6).

SPECIAL CONSIDERATIONS: OBJECTIVES AND TECHNIQUES OF REHABILITATION

The medical literature is replete with the aims and methods of the subbranches of physiatry as applied to patients with spinal cord injury. Although the experience of others will be incorporated in this presentation, its bulk will be supplied by personal observations based upon approximately 1,300 cases of traumatic paraplegia during a period of 12 years. Physical medicine and rehabilitation forms one section of the Paraplegia Service of the Veterans' Administration Hospital, Long Beach, Calif.¹

After level and extent of injury have been determined at the initial examination, plans are made for the medical management, including physiatric treatment. As quickly as the patient's condition permits, physical, corrective, and occupational therapy is started. Vocational counseling is instituted as soon as permanent disability can be estimated. All activities start at the bedside and continue in the respective clinics as the patient becomes ambulatory in a wheelchair. The physiatric treatment is gradually increased from a gentle beginning to a full schedule, occupying the paraplegic or quadriplegic patient up to 5 hours a day (22). It is essential that the physiatric bedside program be

¹ The Physical Medicine and Rehabilitation Section is headed by Roy H. Nyquist, who has improved old methods and introduced new procedures, either alone or with the cooperation of other members of the paraplegic staff. The assistance of all of these, as well as that of the supervisors of the respective subsections of the general Physical Medicine and Rehabilitation Service in providing valuable technical information, is gratefully acknowledged.

continued during the time of confinement to bed or wheeled litter following surgical intervention for various complications, in order to prevent a complete lapse of activities with consequent rapidly ensuing regression. The activities offered by the subbranches of physical medicine and rehabilitation will be discussed in the frame of reference of their special application.

PHYSICAL THERAPY

Physical therapy has essentially four objectives; namely, evaluation of the extent of disability, prevention of deconditioning, initiation of reconditioning, and administration of special supportive therapy. Evaluation of sequelae is self-evident. Prevention of deconditioning pertains to the avoidance of atrophy (skin, muscle, joint, and bone) and to the avoidance or correction of deformity. Reconditioning includes muscle reeducation, utilizing fully any vestige of remaining function by remedial exercise, and teaching proper breathing and relaxation. The administration of special supportive therapy concerns itself with the management of decubital ulcer and spasticity.

Testing

Muscle and sensory tests are done and the results entered in the appropriate clinical record (figs. 157, 158, and 159). The grading of muscle loss as to strength and function ranges from normal to zero, allowing for "good" (almost normal except for easy fatigue), "fair" (performance against gravity possible but weak), "poor" (performance against gravity impossible), and "trace" (only slight contraction of parts of the muscle).

In some cases, electric testing is necessary, either by studying the reaction of degeneration with faradic and galvanic currents or by electromyography. The latter is useful to differentiate upper from lower motor neuron lesions when clinical reflex testing remains equivocal (testing of the bulbocavernosus reflex; that is, contraction of the sphincter ani upon squeezing the glans penis) or to assess objectively the efficacy of relaxant drugs (23). The range of voluntary joint motion is tested according to Last's segmental innervation pattern (fig. 160).

Sensory tests include examinations by all modal-

ities. They should be performed from the paralyzed areas cephalad. The upper thoracic dermatomes should be explored along the lateral chest wall progressing toward the axilla (following the axillary line). This will prevent the erroneous diagnosis of two different levels in cases of cervical cord damage, by mistaking an apronlike area of the infraclavicular chest region, supplied by the supraclavicular nerves of the cervical plexus, for a thoracic dermatome.

Thermotherapy

Heat can be applied in various forms and serves several purposes; it is used for the relief of pain, for muscle-joint relaxation (treatment of spasticity), and for increase of circulation (treatment of decubital ulcer). The effect is obviously expedient for the "warming up" period preceding passive or active exercise.

Heat can be applied externally (dry, radiant, moist) and internally (diathermy). In all forms of heat application, extreme caution must be observed in the paralyzed areas in order to prevent burns. No metallic foreign bodies must be present in regions where diathermy is used.

Hot packs, electric pads, or hot water bottles are applied to painful or contracted joints and secondarily contracted muscles. The infrared lamp, the baker, and the heat cradle are used under similar conditions.

Two forms of hydrotherapy—the Hubbard tank and therapeutic pool—are valuable adjuncts to thermotherapy in that the temperature (from 94° to 100° F.) produces relaxation and hyperemia. Also, the brine tank, at the same temperature, the third form of hydrotherapy, is a valuable adjunct to the treatment of decubital ulcers or infected sinus tracts for a period of from 15 to 20 minutes.

The paraffin bath, administered chiefly to the hands of tetraplegics, has a longlasting effect, as heat is retained for several hours, because the encasing paraffin cast prevents heat loss. The temperature of the paraffin bath is higher (close to 120° F.) than that of any other medium. The paraffin bath is used prior to massaging, exercising, and stretching contracted joints of the wrists or fingers, and it also has a beneficial effect on the skin because it makes the skin more pliable.

MY OWN SCORE

NAME _____

DIAGNOSIS _____

DISABILITY _____

DATE OF INITIAL TEST _____

ACTIVITIES	DATE (A)	RECORD			DATE (D)
		(B)	(C)	(E)	
1 Moving from place to place in bed. 1 min.					
2 Changing position in bed. 1 min.					
3 Manipulating the bedpan. 2 min.					
4 Taking off pajamas 2 min.					
5 Putting on clothing. 15 min.					
6 Tying shoestrings. 1 min.					
7 Tying tie. 1 min.					
8 Moving from bed to wheel chair. 1 min.					
9 Controlling footrests of wheel chair. 20 sec.					
10 Propelling the wheel chair. 1 min.					
11 Opening and closing door while in wheel chair. 1 min.					
12 Moving from wheel chair to chair. 1 min.					
13 Moving from chair to wheel chair. 1 min.					
14 Moving from wheel chair to toilet. 1 min.					
15 Moving from toilet to wheel chair. 1 min.					
16 Moving from wheel chair to bathtub. 1 min.					
17 Moving from bathtub to wheel chair. 1 min.					
18 Going through motion of shaving or make-up. 15 sec.					
19 Going through motion of brushing of teeth. 15 sec.					
20 Going through motion of washing self. 20 sec.					
21 Going through motion of combing or brushing hair. 15 sec.					
22 Going through motion of eating. 20 sec.					
23 Going through motion of drinking. 20 sec.					
24 Writing "This is how I write." 20 sec.					
25 Turning light on and off. 15 sec.					
26 Using telephone. 1 min.					
27 Opening and closing desk drawer. 20 sec.					
28 Moving from wheel chair to floor. 1 min.					
29 Moving 20 feet on floor in other than erect position. 1 min.					
30 Ascending three stairs without braces and crutches. 1 min.					
31 Descending three stairs without braces and crutches. 1 min.					
32 Moving from floor to wheel chair. 1 min.					
33 Moving from wheel chair to automobile. 1 min.					
34 Moving from automobile to wheel chair. 1 min.					
35 Moving from wheel chair to bed. 1 min.					
36 Undressing. 10 min.					
37 Putting on pajamas 2 min.					

38 Putting on braces. 7½ min. ea.				
39 Putting on clothing with braces. 15 min.				
40 Moving from bed to erect position. 1 min.				
41 Walking 30 feet. 30 sec.				
42 Opening and closing door in erect position. 30 sec.				
43 Walking backward 3 feet. 1 min.				
44 Walking sideward 3 feet. 1 min.				
45 Moving from erect position to wheel chair. 1 min.				
46 Moving from wheel chair to erect position. 1 min.				
47 Moving from erect position to chair. 1 min.				
48 Moving from chair to erect position. 1 min.				
49 Moving from erect position to toilet. 1 min.				
50 Moving from toilet to erect position. 1 min.				
51 Getting into auto from erect position. 1 min.				
52 Getting out of auto into erect position. 1 min.				
53 Moving from erect position to bed. 1 min.				
54 Removing braces. 10 min.				
55 Walking up ramp, 4 feet. 30 sec.				
56 Walking down ramp, 4 feet. 15 sec.				
57 Going up three standard stairs, using one handrail. 1 min.				
58 Going down three standard stairs, using one handrail. 1 min.				
59 Going up three standard stairs without aid of handrail. 1 min.				
60 Going down three standard stairs without aid of handrail. 1 min.				
61 Stepping down curb. 5 sec.				
62 Stepping up curb. 5 sec.				
63 Going up bus steps. 10 sec.				
64 Going down bus steps. 10 sec.				
65 Getting down on floor. 1 min.				
66 Getting up from floor. 1 min.				
67 Walking 300 feet with valise. 5 min.				
68 Crossing street, 48 feet. 20 sec.				
69 Maintain sitting position. For 3 hr.				
70 Keeping braces on. For 10 hr.				
71 Traveling 1 mile by standard vehicle.				
72 Driving car.				

REMARKS:

VA FORM 10-2555
APR 1946

(Signature)

(Title)

(Location)

FIGURE 156.—"My Own Score," a form used by the Veterans' Administration in aiding paraplegic patients attain self-dependence.

Standard Form 528
Revised October 1953
Promulgated
By Bureau of the Budget
Circular A-32 (Rev.)

CLINICAL RECORD										MUSCLE AND/OR NERVE EVALUATION—MANUAL AND ELECTRICAL: UPPER EXTREMITY									
DIAGNOSIS AND BRIEF CLINICAL HISTORY																			
LEFT										RIGHT									
										← (Insert type of test given) →									
										EXAMINER'S INITIALS									
										DATE									
										SPINAL ACCESSORY NERVE									
										Sternocleido- } —Stern. C2-3									
										mastoid } —Clav. C2-3									
										Trapezius—Upper C2-4									
										—Middle C2-4									
										—Lower C2-4									
										DORSAL SCAPULAR NERVE									
										Rhomboids C4-5									
										LONG THORACIC NERVE									
										Serratus Anterior C5-7									
										THORACO DORSAL NERVE									
										Latissimus Dorsi C6-8									
										UPPER SUBSCAPULAR NERVE									
										Subscapularis C5-6									
										LOWER SUBSCAPULAR NERVE									
										Teres Major C5-7									
										ANT. THORACIC NERVE									
										Pect. Maj.—Clav. C5-7									
										—Stern. C6-8, T1									
										SUPRASCAPULAR NERVE									
										Supraspinatus C4-6									
										Infraspinatus C4-6									
										AXILLARY NERVE									
										Deltoid—Ant. C5-6									
										—Middle C5-6									
										—Post. C5-6									
										Teres Minor C5-6									
										MUSCULOCUTANEOUS NERVE									
										Biceps Brachii C5-6									
										Coracobrachialis C5-6									
										Brachialis C5-6									
										RADIAL NERVE									
										Triceps C6-8, T1									
										Brachioradialis C5-6									
										Supinator C6									
										Ext. Carp. Rad. C6-7									
										Ext. Carp. Uln. C7									
										Ext. Dig. Quinti C7									
										Ext. Ind. Prop. C7									
PATIENT'S LAST NAME—FIRST NAME—MIDDLE NAME										REGISTER NO.					WARD NO.				

16-61503-2

(NAME OF HOSPITAL OR OTHER MEDICAL FACILITY)

MUSCLE AND/OR NERVE EVALUATION—
MANUAL AND ELECTRICAL:
UPPER EXTREMITY
Standard Form 528

FIGURE 157.—Form used by the Veterans' Administration for recording results of muscle and nerve evaluation—upper extremity—of paraplegic patients.

LEFT										← (Insert type of test given) →										RIGHT									
										EXAMINER'S INITIALS																			
										DATE																			
										Ext. Dig. Com.—1 C6																			
										—2																			
										—3																			
										—4																			
										Ext. Pol. Long. C7																			
										Ext. Pol. Brev. C7																			
										Abd. Pol. Long. C7																			
										MEDIAN NERVE																			
										Pronator Teres C6																			
										Palmaris Long. C6-8, T1																			
										Flex. Carpi Rad. C6																			
										Flex. Dig. Sub.—1 C7-8, T1																			
										—2																			
										—3																			
										—4																			
										Flex. Dig. Prof.—1 C8, T1																			
										—2																			
										Flex. Pol. Long. C8, T1																			
										Flex. Pol. Brev. C6-8																			
										Abd. Pol. Brev. C6-7																			
										Opp. Pollicis C6-8, T1																			
										Lumbricales—1 C7-8																			
										—2																			
										ULNAR NERVE																			
										Flex. Carpi Uln. C8																			
										Flex. Dig. Prof.—3 C8, T1																			
										—4																			
										Add. Pollicis C8																			
										Abd. Dig. Quinti C8, T1																			
										Opp. Dig. Quinti C8, T1																			
										Flex. Dig. Quinti C8, T1																			
										Interossei (dor.)—1 C8																			
										—2																			
										—3																			
										—4																			
										(palm.)—1																			
										—2																			
										—3																			
										Lumbricales—3 C8																			
										—4																			

Key to Manual Muscle Evaluation:

100% 5 N Normal : Complete range of motion against gravity with full resistance
 75% 4 G Good : Complete range of motion against gravity with some resistance
 50% 3 F Fair : Complete range of motion against gravity
 25% 2 P Poor : Complete range of motion with gravity eliminated
 10% 1 T Trace : Evidence of contractility but no joint motion
 0 0 0 Zero : No evidence of contractility
 S Spasm } If spasm or contracture exists place S or C after the
 C Contracture } grade of a movement incomplete for this reason

Key to Electrical Evaluation:

(Insert key used locally)

SIGNATURE OF PHYSICIAN

DATE

Standard Form 529
Promulgated May 1950
By Bureau of the Budget
Circular A-32 (Rev.)

CLINICAL RECORD										MUSCLE EVALUATION—TRUNK, LOWER EXTREMITY, FACE																			
DIAGNOSIS AND BRIEF CLINICAL HISTORY																													
LEFT										RIGHT																			
GAL.					FAR.					VOL.					VOL.					FAR.					GAL.				
DATE																													
Diaphragm C3-5																													
Intercostals T1-11																													
Neck Extensors C1-3																													
Erector Spinae C1-S3																													
Quadratus Lumborum T12, L1-3																													
Rectus Abdominis T5-12																													
Obl. Ext. Abd. T5-12																													
Obl. Int. Abd. T7-12, L1																													
Ext. Rot. Hip L2-5, S1, 2																													
Int. Rot. Hip L4, 5, S1, 2																													
Iliopsoas L1-4																													
INF. GLUTEAL NERVE																													
Glut. Max. L5, S1, 2																													
SUP. GLUTEAL NERVE																													
Glut. Med. L4, 5, S1																													
Glut. Min. L4, 5, S1																													
Tens. Fas. Lat. L4, 5, S1																													
FEMORAL NERVE																													
Sartorius L2-4																													
Rect. Fem. L2-4																													
Vast. Med. L2-4																													
Vast. Lat. L2-4																													
Vast. Intermed. L2-4																													
OBTURATOR NERVE																													
Adductors L2-4																													
Gracilis L2-4																													
SCIATIC NERVE																													
Biceps Femoris L5, S1-3																													
Semitendinosus L4, 5, S1, 2																													
Semimembranosus L4, 5, S1, 2																													
POST. TIBIAL NERVE																													
Gastrocnemius S1, 2																													
Soleus L5, S1, S2																													
Tib. Post. L4, 5, S1, 2																													
Flex. Dig. Long. L5, S1, 2																													
Flex. Dig. Brev. L5, S1																													
Flex. Hal. Long. L5, S1, 2																													
Flex. Hal. Brev. L5, S1																													
Abd. Hal. L5, S1																													
Abd. Dig. Quinti L5, S1-3																													
PATIENT'S LAST NAME — FIRST NAME — MIDDLE NAME										REGISTER NO.					WARD NO.														

(NAME OF HOSPITAL OR OTHER MEDICAL FACILITY)

10-61527-1

MUSCLE EVALUATION
Trunk, Lower Extremity, Face
Standard Form 529

FIGURE 158.—Form used by the Veterans' Administration for recording results of muscle evaluation—trunk, lower extremity, face—of paraplegic patients.

LEFT						RIGHT					
GAL.		FAR.		VOL.		VOL.		FAR.		GAL.	
						DATE					
						Interossei S1-3					
						Lumbricales L5, S1, 2					
						COM. PER. NERVE					
						Tib. Ant. L4, 5, S1					
						Ext. Dig. Long. L4, 5, S1, 2					
						Ext. Dig. Brev. L4, 5, S1, 2					
						Ext. Hal. Long. L4, 5, S1, 2					
						Peroneus Tert. L4, 5, S1					
						Peroneus Long. L4, 5, S1					
						Peroneus Brev. L4, 5, S1					
						MUSCLES OF FACE					
						Frontalis CR7					
						Corrugator CR7					
						Orb. Oculi. CR7					
						Procerus CR7					
						Quad. Lab. Sup. CR7					
						Risorius CR7					
						Zygomaticus CR7					
						Orb. Oris CR7					
						Mentalis CR7					
						Quad. Lab. Inf. CR7					
						Triangularis CR7					
						Platysma CR7					
						Deglutition CR 9, 10					
						Speech CR 9, 10					
						Tested by					

Key to Voluntary Test:

- 100% Complete range of motion against gravity with full resistance.
 75% Complete range of motion against gravity with some resistance.
 50% Complete range of motion against gravity.
 25% Complete range of motion with gravity eliminated.
 10% Evidence of slight contractility with no joint movement.
 0 No evidence of contractility.

S—Spasm C—Contracture.

Key to Electrical Test:

- N—Normal contraction.
 SN—Subnormal contraction.
 SL—Sluggish contraction.
 O—No contraction.
 +—Hyperactive response.

REMARKS:

Standard Form 531
 PROMULGATED MAY 1950
 BY BUREAU OF THE BUDGET
 Circular A-32 Rev.

CLINICAL RECORD	SENSORY EXAMINATION—SUPERFICIAL AND DEEP		
INSTRUCTIONS	Shade in area of sensory involvement indicating severity by intensity or darkness of shading. Where involvement consists of an increase in sensation, indicate that fact by a notation next to the involved area.		
<div style="display: flex; justify-content: space-around;"> <div style="width: 45%;"> <p style="text-align: center; font-weight: bold;">TOUCH</p> </div> <div style="width: 45%;"> <p style="text-align: center; font-weight: bold;">PAIN</p> </div> </div>			
<div style="display: flex; justify-content: space-around;"> <div style="width: 45%;"> <p style="text-align: center; font-weight: bold;">TEMPERATURE</p> </div> <div style="width: 45%;"> <p style="text-align: center; font-weight: bold;">POSITION VIBRATION</p> </div> </div>			
PATIENT'S LAST NAME—FIRST NAME—MIDDLE NAME		REGISTER NO.	WARD NO.

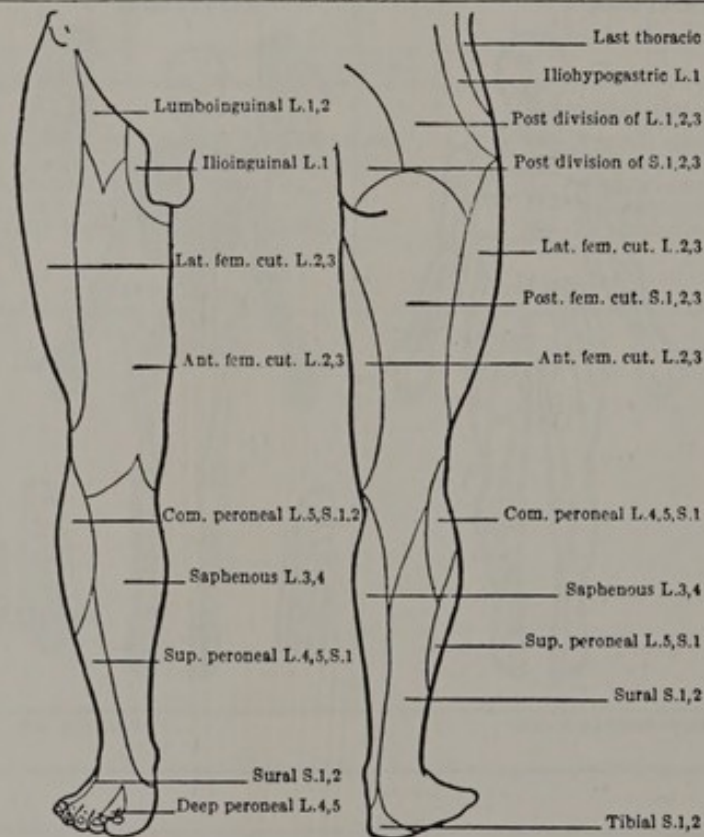
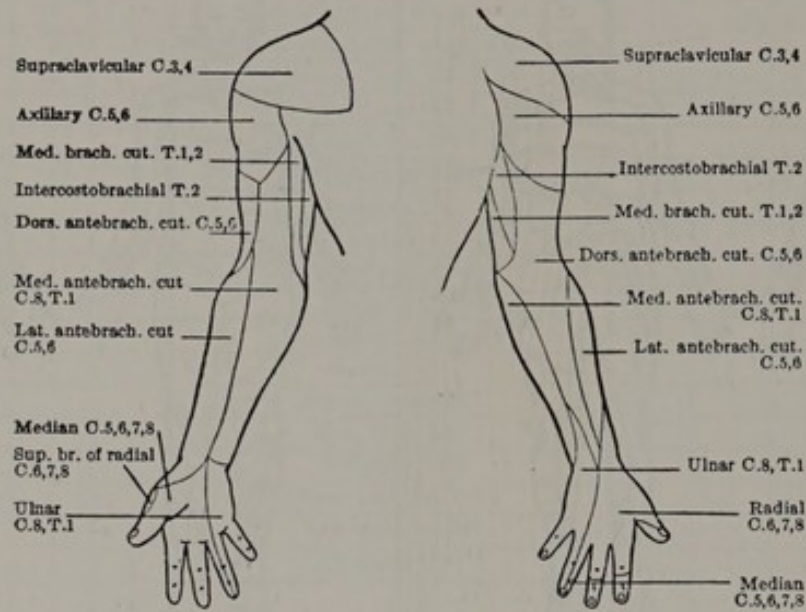
(NAME OF HOSPITAL OR OTHER MEDICAL FACILITY)

16-61924-1

SENSORY EXAMINATION
 Standard Form 531

FIGURE 159.—Form used by the Veterans' Administration for recording sensory distribution of paraplegic patients.

CUTANEOUS SENSORY DISTRIBUTION



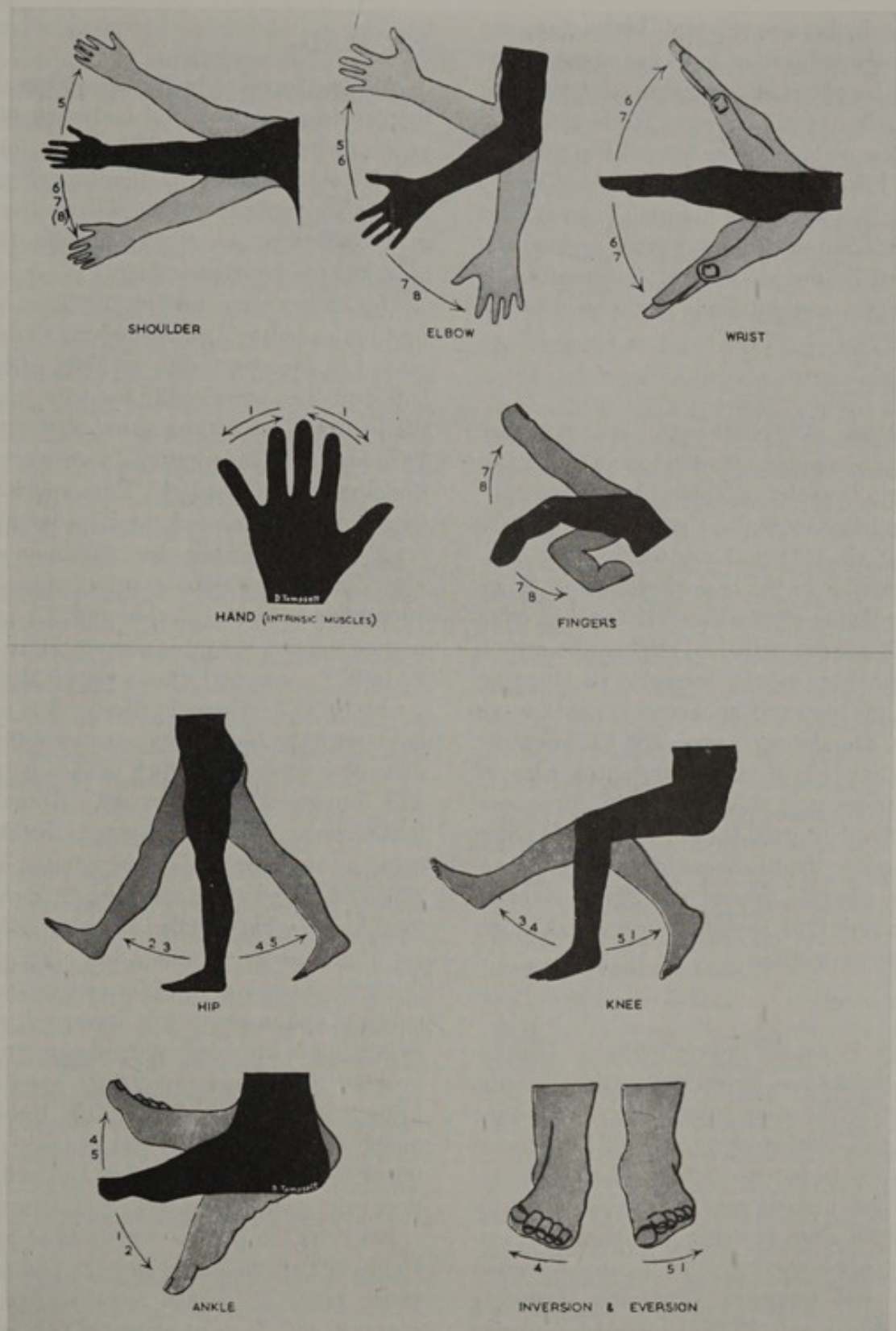


FIGURE 160.—The segmental innervation of the movements of the upper and lower limbs. (From Last, R. J.: Innervation of the Limbs. J. Bone & Joint Surg. 31 B: 452-464, August 1949.)

Short-wave diathermy, although useful for pain relief and muscle relaxation by virtue of its hyperemic effect, is beneficial in the treatment of decubital ulcers, especially those with sinus tracts extending into periosteum or bone. The microwave has been used on the Physical Medicine and Rehabilitation Service, Long Beach veterans hospital, in an attempt to treat urethral fistulae resulting from periurethral abscess caused by the pressure of an intraurethral catheter at acute urethral angle of the penoscrotal junction.

Heliotherapy

Several forms of heliotherapy are available. Their effects are similar with the exception of natural sun, the ultraviolet rays of which are complemented simultaneously by heat and exposure of the body to fresh air. Natural sun treatment is a relaxant, in addition to the bacteriostatic and hematopoietic stimulating effect which it shares with other sources of ultraviolet radiation, such as the carbon arc lamp, the low voltage mercury (hot) vapor quartz lamp, the high voltage mercury (cold) vapor quartz lamp, and the sunlamp. The bacteriostatic and granulation tissue stimulating properties of local application of a cold quartz mercury-vapor lamp are utilized in combination with a preceding brine tank bath in the treatment of decubital ulcers. The curative effect of natural sun is very satisfactory for treatment of superficial decubital ulcers and some sinus formations.

Massage

A massage is usually given following thermotherapy for the sake of its sedative, pain relieving, relaxing, and locally stimulating effect. Effleurage (superficial and deep stroking) should be done in such a manner as not to elicit spastic muscle responses. It may precede passive exercises generally and may benefit cases of dependent edema particularly. Effleurage is also indicated in cases of muscular stiffness and soreness. Pétrissage (kneading and compression) and friction massage (circular and lifting movements with fingertips) are helpful in the treatment of contractures of joints and mobilization of adherent scars. The latter procedure is of importance in surgery of decubital ulcer. Tapotement (percussion) is seldom used in cases of paraplegia.

Hydrotherapy

All three forms of hydrotherapy have in common the provision of heat and buoyancy of the water, which are beneficial for relief of pain, for relaxation, and for obliteration of the limiting effect of gravity on the paralyzed parts of the body. The three forms of hydrotherapy are the brine bath, the Hubbard tank, and the therapeutic pool.

This author was introduced to brine bath therapy by Charles LeRoy Lowman of the Orthopedic Hospital, Los Angeles, Calif., in 1946, where the brine bath had been successfully used for many years in the treatment of various cases of infected wounds, including joint suppurations, with astounding functional result. Since 1947, Bors and his colleagues have continuously used this type of treatment for cases of deep, necrotic, and phlegmonous decubital ulcers and various sinus tract formations. The brine (5 percent sodium chloride and 2.5 percent magnesium sulfate) is kept at a temperature of from 94° to 100° F., and performs a chemical debridement, owing to its hygroscopic effect. It is amazing how large necroses become demarcated without the least trauma, a procedure which cannot be reduplicated with instrumental debridement. Granulation tissue is stimulated. Nyquist heightens the local effect by using an underwater Jacuzzi agitator, the spout of which is placed approximately 12 inches from the local lesion. The agitated brine expedites the process of cleansing. It seems that other properties of the brine bath are anabolic and invigorating; circulation and appetite are increased, a feeling of well-being is provided, while the accompanying relaxation is an asset in cases of spasticity. When brine is used as a medium in the Hubbard tank, a double effect is scored in that two methods are combined to treat simultaneously two different conditions: decubital ulcers and contractures.

Based on the general principles of hydrotherapy, Hubbard tank treatment permits and facilitates the entire range of motion from passive to resistive exercises and the management of pain and spasticity. The temperature is kept between 94° and 100° Fahrenheit. Hubbard tank treatment is indicated in patients who cannot receive equivalent treatment in a therapeutic pool because of skin lesions, suppuration, or uncontrollable incontinence.

The therapeutic pool has several objectives. Its

temperature (from 90° to 95° F.) is relaxing and provides, in conjunction with buoyancy of the water and its lessened gravity effect, a reduction of muscle tension. These properties assist in the treatment of spasticity as well as in the training of coordination and balance. The upright position and gait training can be started earlier in the pool than on land and without the impeding factor of the cumbersome weight of braces. This is especially conspicuous in those cases of incomplete spinal cord damage in which the actual range of volitional movements is occasionally camouflaged by spasticity. In no other medium does the paraplegic patient feel as free and independent as in a therapeutic pool in which he is able to move least handicapped by his disability. This sense of freedom and security has a most beneficial psychological impact which is augmented when the patient is allowed to swim and to participate in water games. All forms of exercises are possible on plinths, combining the benefits of physical and corrective therapy of muscle reeducation with prevention of overstretching. The invigorating metabolic effect of all these activities and of the warm bath is self-evident in its importance for the maintenance of homeostasis.

Electrotherapy

The indications for electrotherapy are manifold. Based upon experimental research, electrical exercise has been used for the treatment of lower motor neuron lesions from 7 to 10 days after injury and was applied in gradually increasing numbers of contractions (200-600 to each muscle group) in the hope of forestalling rapid atrophy of the deltoid, quadriceps, and glutei muscles (9).

Another purpose of electrotherapy, using galvanic-sinusoidal current, is the retraining of partially paralyzed muscles. Newman, however, considers this "at best a poor substitute for the physiological nerve impulses."

By far the most practical application of electrotherapy is found in the management of spasticity. (See chapters 36 and 37 for a detailed discussion of the problems of spasticity.) Although extrinsic and intrinsic (visceresthetic, proprioceptive) stimuli can be found frequently as triggers of spasticity, the true spinal mechanism of spasticity is not fully understood (24). The quest for means of counteracting spasticity is still in progress and successful methods

are more or less empirical in nature, although some of the known theoretical aspects have been taken into consideration. This applies to the use of drugs, of which the group of tranquilizers exerts a braking effect centrally (brain and spinal cord) and peripherally (myoneural junction). Among these drugs, phenobarbital and meprobamate have been found efficacious in a fair number of cases (23). These drugs, used alone or in conjunction with methods of fatiguing the muscles, form the conservative armamentarium, while peripheral neurotomies, myotomies, tenotomies, rhizotomies, and subarachnoid alcohol injection constitute a more radical, destructive approach to the problem. Muscle fatigue can be induced by exercise without and with weight bearing and bracing. This reduces proprioceptive feedback by utilizing the reciprocal reflex relaxation of the antagonist upon stimulation of the protagonist and by electrotherapeutic hyperstimulation.

Electrotherapeutic hyperstimulation was introduced by Lee and his associates (25) who first applied tetanizing currents and later sinusoidal currents for relief of spasm in 27 patients with a subsequent relaxation in 40 percent for 4 hours and in 90 percent for 10 hours, respectively. Sinusoidal currents were then reported to carry a risk of burns not observed with the application of faradic currents. Newman, Arieff, and Wasserman (26) noticed a decrease of spasm and spasticity of the homolateral extremity in 66 percent and of the contralateral extremity in 50 percent of their patients. This effect lasted from 30 minutes to 24 hours, but the average was usually less than 5 hours. Newman and his associates treated their patients for 20 minutes, gradually increasing the galvanic (direct) current to 25 volts (occasionally increased to 35 or 40 volts) while the faradic (alternating) current was increased from 60 to 100 cycles per second in order to secure a firm tetanic contraction without burns. Nyquist uses galvanic-sinusoidal current for 20 to 30 minutes, at a frequency ranging between 40 and 80 waves per minute and a milliamperage which the patient will tolerate; the results are generally satisfactory. Group stimulation is achieved by placing the 2- by 3-inch electrodes on muscles with greatest spasticity. Following such treatment, passive exercise can be more readily accomplished.

Levine, Knott, and Kabat (27), basing their thera-

peutic efforts upon the concept of reciprocal innervation, stimulated with good results the antagonistic muscles with faradic current (100 cycles per second), thus achieving a tetanic contraction. They observed within several seconds such a degree of relaxation of the protagonist as to permit passive movement through the full range of motion.

Exercise therapy

Before enumerating the various methods of exercise, it should be stressed that remedial exercises as done in physical therapy and those performed in corrective therapy will be presented separately, but this does not reflect the generally accepted attitude of the profession. In many places here and abroad, these two fields are not sharply demarcated from each other. That they belong together functionally is perhaps best illustrated by the bed-bicycle of Guttmann, which serves to move passively the paralyzed lower extremities by activating the transmission to the pedals with the arms, working against a load, permitting buildup of arm and trunk musculature simultaneously. Exercise therapy is designed to reduce muscle atrophy with its detrimental repercussions on nitrogen and calcium metabolism, osteoporosis, and shrinking of collagen tissue of the tendons, ligaments, and joint capsules, which eventually result in contractures.

It may be timely to mention some of the principles of the neuromuscular mechanism which explain the effect of some of the exercise methods. "Contraction [of the muscle fiber] consists of a tensional and a dimensional part. Relaxation is caused by mechanical energy of elasticity. * * * Myotatically induced [reflex] contraction is essential for tonus, locostation, and locomotion. The muscle spindle is essential for the myotatic reflex * * * [which] * * * is the master motion and the muscle spindle the master key" (28). Although the cerebral cortex activates gamma fibers to the muscle spindles, it is known that afferents from the muscle spindles activate or summate impulses from higher centers (cerebellum and reticular activating substance), a principle which is utilized by the movement pattern techniques of Fay (29) (30) and Kabat (31) (32), and which applies essentially to incomplete lesions of the spinal cord. Even with complete cord lesions the pattern of mass movements can be applied by using the unlocking

reflexes of Fay (33). These "unlocking reflexes refer to positions and movements of the neck or extremities which cause automatic release or relaxation of hypertonic (spastic) muscles or muscle groups" (33) (34). In his classical articles on the origin of human movement and reflex therapy, Fay deals with the phylogenic evolution of movement from the two-dimensional on-the-ground to the three-dimensional off-the-ground pattern of land reptiles which can be observed in early infancy. Thus, "'normal' and 'pathological' reflexes * * * [are] * * * holdovers of an ancient past * * * [and the] * * * phase from birth to walking [12 to 14 months] covers an evolutionary period of 200 million years" (33) (34).

This principle of utilizing the reflex activity of spinal man for exercise can be used for purpose of relief of spasticity and for active (involitional) spinal exercise. In "unlocking" adductor spasticity, the Marie-Foix withdrawal reflex (flexing the toes) is used, allowing hip flexion with abduction and outward rotation. Continuation of this exercise from 5 to 10 minutes will diminish spasticity, permitting passive exercise of the hip. With simple help, a "walking pattern" can be elicited providing active spinal exercise. The withdrawal reflex is induced by flexing the toes passively and pressing on the ball of the foot; the extension thrust is then elicited by extending the toes passively, simultaneously either pressing the knee inward and down or tapping the knee tendon. Thus a complete stepping cycle is performed by proper activation of spinal reflexes. Utilization of clonus, Babinski, and other pathological toe signs is also proposed by Fay in order to achieve a reflex exercise by activating the feedback mechanism. If repeated many times in succession, these methods improve muscle tone and power and facilitate passive exercise because of reduced spasticity.

Passive exercises with or without stretching of joints (9) prevent contractures, increase circulation, and decrease spasticity by induced muscle fatigue. Passive exercises should be initiated at the very earliest time following injury in order to maintain the range of motion of the joints. Active assistive exercises consist of helping the patient's insufficient volitional strength to take the extremity through the entire range of motion. Whenever active exercises are performed (be they assistive active, active, or resistive), some general principles must be

remembered: Muscle power (against a load) is maximum on the first day; then it declines gradually to the fifth day, and returns on the sixth day to the strength of the first day (35). Only a gradual, rather than a rapid increase of the load will produce progressive increase of strength. A full exercise value is achieved if a muscle is contracting through its full range with optimum load (36). The optimum load is defined as from two-thirds to three-fourths the maximum load; even this contraction against optimum load should be attained gradually by using a warmup period to increase muscle temperature and blood flow. Brisk overexercise must be avoided in order to prevent muscle tear.

Assistive active exercises take the extremity through the range of motion, aiding the residual volitional movement; in active exercises, the patient moves his extremity against gravity through the entire range of motion without the help of a therapist.

The purpose of resistive exercises is to increase muscle strength. Muscle reeducation attempts to retrain weak muscles and to enhance coordination. Especially suited for cases of incomplete lesions, Kabat (32) has introduced his techniques of central facilitation. He seeks to achieve the highest possible level of excitation at the anterior horn cell synapse which results from the summation of proprioceptive stimuli (elicited peripherally by resistance and stretch) and cortical facilitatory impulses. He advocates the utilization of the pattern of mass movement which can be brought about not only by the facilitation of overflow from proximal muscles but also in the reverse. Primitive patterns of mass movements are present in chopping wood, running, shoveling, throwing a ball, and swimming. These patterns are diagonal and spiral rather than straight, as illustrated, for example, by the sequence of movements necessary to roll in bed from supine to lateral position. In his detailed description of resistive exercises, Kabat (31) (37) stresses the importance of the reversal of the antagonistic muscles, for example, in tennis the antagonist's action precedes that of the protagonist. He achieves this by (1) rhythmic stabilization, that is, a rapid alternation, of the isometric contraction, (2) isotonic reversal of antagonists against maximal resistance, (3) isotonic reversal of antagonists with isometric contraction done against maximum resistance with repeated alternation of antagonists, and (4) quick reversal

of antagonists whereby an active motion is slowly carried through the range against maximum resistance with a sudden reversal of motion.

CORRECTIVE THERAPY

The task of corrective therapy is to prepare the patient for locomotion (wheelchair, ambulation, car driving) and self-care. Corrective therapy shares the achievement of these objectives with physical therapy and occupational therapy. Corrective therapy starts immediately after admission of the patient, at the bedside, and is continued at the gymnasium as soon as the patient's condition permits. Nyquist (18) has summarized a program for paraplegics and partial quadriplegics which is presented in tables 32 and 33.

In preparing the patient for locomotion, overdevelopment of certain muscle groups, coordination (balance), and readjustment of the vasomotor equilibrium, in spinal cord injuries cephalad to T6, are essential. The muscles of interest are those of the upper extremity and trunk: Finger flexors, wrist flexors and extensors, triceps, deltoideus, teres major, serratus anterior, pectoralis major and minor, trapezius, and latissimus dorsi. The latissimus dorsi is especially important because its attachment to the lumbosacral fascia prevents jackknifing and makes the use of pelvic bands unnecessary (6). A special exerciser (38) is used for training the latissimus dorsi muscles. It consists of a belt, which is placed around the patient's hips and connected to a pulley system with a 4-foot cable and a weight, which is gradually increased from the initial 2 pounds to a maximum of 80 pounds. The apparatus which is used while the patient is standing between parallel bars is also suitable for treatment of abdominal spasticity. Hip swaying is controlled by tensing the shoulders alternately. This method is more advantageous because it needs a minimum of supervision (timesaving) and eliminates some mat exercises which may cause the development of bedsores.

The usual equipment for corrective therapy consists of hand bells, bar bells, tension springs, pulleys, and weights. When the handgrip is insufficient, a mitten (39) (40) to which the respective equipment can be attached becomes necessary. Special boots with sole weights have been devised by Jahn and Nyquist (41) for quadriceps exercise. Most of these

TABLE 32.—*Group classifications for corrective therapy exercises for paraplegics*

Classification	Activities	Objectives
Group I (P). Bedlying, Stryker frame or Foster bed.	<ol style="list-style-type: none"> 1. Breathing exercises. 2. Assistive exercises to upper extremities if necessary. 3. Light resistive exercises to upper extremities. 4. Free active exercise. 5. Initial self-care activity. 	<ol style="list-style-type: none"> 1. Increase circulation. 2. Stimulate respiratory action. 3. Improve muscle tone. 4. Prevent deconditioning. 5. Help prevent contractures. 6. Improve morale.
Group II (P). Gradual bed sitting to wheelchair or guernsey.	<p>Review Group I (P) exercises</p> <ol style="list-style-type: none"> 1. Sitting balance exercises. 2. Progressive resistive exercises to upper extremities. 3. Progressive self-care activity. 4. Wheelchair activity. 	<ol style="list-style-type: none"> 1. Increase upper extremity, neck, and trunk control. 2. Improve general strength and metabolism. 3. Achieve additional self-care. 4. Improve vascular tone and help prevent abdominal pooling of blood.
Group III (P). Gymnasium exercises.	<p>Review Groups I and II (P) activity</p> <ol style="list-style-type: none"> 1. Graded resistive exercise to upper extremities. 2. Body control activity. 3. Short crutch exercise. 4. Teach method of putting on and removing braces. 5. Self-care techniques. 	<ol style="list-style-type: none"> 1. Increase strength and balance. 2. Introduce mild endurance. 3. Check home problems in self-care.
Group IV (P). Pre-ambulation.	<ol style="list-style-type: none"> 1. Free to light resistive upper extremity warmup exercise. 2. Parallel bar balance exercises. 3. Posture exercises. 4. Stepping coordination exercises. 5. Arm support exercises. 6. Continue practice brace care and removal in chair without assistance. 7. Self-care continued. 	<ol style="list-style-type: none"> 1. Improve organic function. 2. Increase strength and endurance. 3. Total body coordination.
Group V (P). Ambulation.	<ol style="list-style-type: none"> 1. Repeat balance exercises. 2. Crutch work, emphasizing balance exercise. 3. Gait training. 4. Self-care activity emphasized. 	<ol style="list-style-type: none"> 1. Coordination and balance in ambulation. 2. Emphasize self-care.
Group VI (P). Advanced skills.	<ol style="list-style-type: none"> 1. Review balance exercise and gait training. 2. Teach staircase work and ambulation on ramps, curbs, and rough terrain. 3. Teach methods of getting from chair to car and to conventional chairs. 4. Teach and demonstrate methods of falling and regaining standing position. 5. Teach therapeutic swimming and sport skill. 	<ol style="list-style-type: none"> 1. To reach a final goal of complete self-care within the patient's limitations and to attain an attitude of complete confidence. 2. To assist with planning home exercise area.

TABLE 33.—*Group classifications for corrective therapy exercises for partial quadriplegics*

Classification	Activities	Objectives
Group I (Q). Bedlying, Stryker frame or Foster bed.	<ol style="list-style-type: none"> 1. Breathing exercises. 2. Assistive exercise to upper extremities. 3. Free active exercise to upper extremities. 4. Light resistive exercise to upper extremities. 5. Initial self-care activity. 	<ol style="list-style-type: none"> 1. Stimulate respiratory action and increase vital capacity. 2. Increase circulation. 3. Improve muscle tone, prevent deconditioning, and prevent contractures. 4. Improve morale.
Group II (Q). Gradual bed sitting to wheelchair.	<p>Review of Group I (Q)</p> <ol style="list-style-type: none"> 1. Sitting balance exercises. 2. Progressive resistive exercises to upper extremities. 3. Gradual increase in time in sitting in bed or wheelchair with the use of abdominal binder and insert pillow to prevent fall in blood pressure. 4. Beginning wheelchair activity and instruction. 5. Progressive self-care activity. 	<ol style="list-style-type: none"> 1. Increase upper extremity, neck, and upper thorax control. 2. Improve general body metabolism. 3. Improve vascular tone and prevent abdominal pooling of blood. 4. Achieve additional self-care.
Group III (Q). Guerney, wheelchair, or mat.	<p>Review of Groups I and II (Q)</p> <ol style="list-style-type: none"> 1. Gradual tilt table standing. 2. Increased progressive resistive exercises for upper extremities with exercise gloves, dumbbells, weights and pulleys, light bar weights, shoulder wheel, etc. 3. Initial resistive neck exercises. 4. Further self-care techniques. 	<ol style="list-style-type: none"> 1. Introduce mild endurance. 2. Increase strength, speed, coordination of upper extremities. 3. Improve balance of head. 4. Reduce home problems in self-care.
Group IV (Q). Standing in air and activities in water.	<p>Review Groups I, II, and III (Q)</p> <ol style="list-style-type: none"> 1. Tilt table standing. 2. Activity in therapeutic pool, floating with rubber ring around neck and backstroking. 3. Standing in long braces with abdominal binder and insert pillow if necessary in a walker with crutch supports to axillae and strap supports to trunk. 	<ol style="list-style-type: none"> 1. Improve organic functions (diaphragm, blood pressure, vascular tone, circulation, calcium metabolism, urinary drainage from kidneys and bladder). 2. Increase strength and endurance. 3. Improve range of motion of shoulders and expansion of chest. 4. Reduce spasticity.

Source: Nyquist, R. H.: Functions of a Physical Medicine Section for a Paraplegia Service. *Proceedings of Second International Congress of Physical Medicine*, København, 1956, pp. 386-394.

implements can be applied while the patient is still bedfast. Others, such as the punching bag, wheel, and bicycle, are for ambulatory use. Excepted is the "Stoke Mandeville Bed Cycle" (42) which serves the dual purpose of training the upper extremities and trunk and of providing passive movements for the lower extremities.

The attainment of coordination and balance also starts at the bedside, continues in the wheelchair, and culminates in the upright position with or without ambulation. A medicine ball plays an important part in these exercises. Some recommend the visual aid of mirrors (9) (42). The perceptual point of gravity shifts cephalad with the level of the lesion, so that the patient feels very tall, in the upright position, as if standing on stilts. The length of these "stilts" increases with the length of the distal cord segment.

The adjustment of the vasomotor regulation concerns patients with spinal cord injury cephalad to T6 who suffer from orthostatic hypotension because of the impairment of splanchnic control. Changes of position by elevating the head of the bed, tilt table, and stall bars (19) are used in order to ameliorate this situation. In England, swinging in the Guthrie-Smith frame combined with breathing exercises is done for the same purpose. Abdominal binders and sympathomimetic drugs support these efforts of corrective therapy.

Self-care comprises a gamut of activities. Corrective therapy concerns itself with the teaching of dressing and undressing, in bed or in a wheelchair, and with instructing the patient in the methods of transfer from bed to wheelchair, to toilet, to bath, and to car. Even quadriplegic patients can be taught, within the frame of their limitation, to assist themselves into and out of a car by using the car-gutter hook (43). It is generally true, however, that the ability of self-care depends on the level of the lesion, declining rapidly with the ascent of the level above T2. Self-propulsion in a wheelchair is impossible for the patient with a complete lesion at C4, and extremely cumbersome for one with a C5 lesion. Transfer exercises from mat to wheelchair require full use of the upper extremities and upper trunk musculature. The list of self-care activities employed by the Veterans' Administration paraplegia centers is shown in figure 156.

In most instances, ambulation will serve as an exercise rather than as an efficient means of locomotion. Only the patient with either a very low lesion that may require the wearing of foot drop braces, or with an incomplete lesion, will depend upon ambulation for fast locomotion. The main achievement of ambulation as an exercise is the pressure which the body weight brings to bear on the epiphyses of the long bones, providing adequate stimulus for protein formation at the matrix with its favorable effect on calcium metabolism. Even as an exercise, ambulation must be prescribed carefully, taking into consideration the patient's body build, age, and level of lesion. Adiposity, bulky muscles, advanced age, and severe spasticity are unfavorable factors for ambulation. They must be considered in prescribing ambulation judiciously, which should range from moderate to hard work, requiring energy which is "3.5 times and often 5.5 to 8 times the basal metabolic rate" (44).

The various techniques of ambulation have been described and illustrated in detail by Deaver and Brown (45) (46) (47) (48), by Hoberman and Cienia (49) (50) (51) (52), and by Sanders (53) (54). The reader is referred to these explicit series of publications. It is self-evident that preparation for ambulation starts with balancing exercises in bed and ultimately on braces and crutches. Short crutch exercises on floor mats form a preparatory phase to the use of long crutches.

Leg swinging, sidestepping, and forward and backward stepping are best practiced between parallel bars in preparation for crutch walking. For the beginner, the swing-to and shuffle is a convenient gait pattern, using at first an alternate or simultaneous tripod technique until the true swing-to with lifting the body can be accomplished. The same applies to patients with lesions cephalad to T10. As a rule, we do not teach a swing-through technique because of the hazard of falling backward. Other gait patterns practiced at the Veterans' Administration Hospital, Long Beach, Calif., include the four-point and two-point alternate crutch gaits, suited for patients with lesions caudad to T10 and L1, respectively. As ambulation progresses, the patient learns to open and close doors, to sit down and get up from his wheelchair, standard chair, and toilet, to go up and down stairs, to clear curbs, and to ambulate on

rough surfaces. In some instances, he will be able to clear the high steps of public transportation vehicles. One of the most difficult tasks is to teach falling techniques, which must be done first from a sitting position, exclusively on soft mats, mattresses, or heavily sodded spots. Later, the patient should be taught to fall from a kneeling and eventually from an upright position. For the latter, mats have to be piled knee high. The teaching of backward-falling requires a sense for acrobatics on the part of the patient and is considered too dangerous.

Although athletics are not under supervision of corrective therapy, their value for rehabilitation must be stressed here. Sports and competitive games are today recognized all over the world as part of the armamentarium of rehabilitation. They have a beneficial effect on morale, self-assurance, muscle function, and coordination. The direction of sports and competitive games belongs to the athletic instructors. Outdoor and indoor sports are equally popular. Among them are darts, table tennis, archery, javelin throwing, wheelchair golf, volleyball, water polo, and basketball. Basketball was started at the Veterans' Administration Hospital, Long Beach, in 1946 and has grown into a popular national sport. A good number of associations and clubs have been formed and tournaments are held annually. In England, the "Paralympics" is an annual sport competition which was introduced on 25 July 1952 by Guttmann (9) at Stoke Mandeville where teams from all over the world have met ever since.

ORTHOPEDIC APPLIANCES

Planning and manufacturing orthopedic appliances is a combined effort shared by the physician, physical therapist, corrective therapist, occupational therapist, orthopedist, bracer, and attending physician. Prosthetic appliances may be employed for posture and correction, substitution, self-aid, locomotion, and occupation. Obviously, many prosthetic devices serve more than one purpose (55 through 62).

Postural and corrective appliances comprise braces. The Spicer-type brace is used for cervical and the Taylor-type brace for thoracolumbar lesions at the Veterans' Administration Hospital at Long

Beach. Long and short leg braces serve both postural and locomotive purposes. Cockup splints, knuckle-breakers, outrigger splints, extensor gloves for the fingers, and turnbuckle splints for elbows and knees tend to prevent or correct threatening or existing contractures, respectively. Various models of tilt tables have in common the objective of correcting posture.

To the substitutional appliances belong braces with springs substituting the function of the paralyzed muscle (39). Of interest are the prosthetic devices which aim to correct the lack of prehension of the hand of a tetraplegic patient. One of them offers grasp and release by a form-fitting glove, impregnated by plastic, which is activated from the shoulder muscles with a cable (37). Another is the splithook, the prehensile function of which has been studied by Nyquist (19) who found various types most suited for patients with complete lesions at C5 and C6. These patients have sufficient strength left in the muscles of the shoulder girdle to operate the cable harness activating the prehensile action of the hook. The splithook can be used for heavier objects, but is clumsy for holding a cigarette, pencil, or paintbrush. The principle of the Bisgrove splinting device consists of using the forearm musculature for prehension, in that dorsiflexion of the wrist causes flexion of the fingers. It is of psychological interest that many quadriplegic patients are interested initially in substitution devices for prehension, but only a few remain enthusiastic at a later date. Most of them discard the prosthesis and prefer to use trick or substitution movements rather than to admit the need for a prehensile device.

Self-help devices are primarily intended to serve the quadriplegic patient. According to the neurological deficit, some are being operated by mouth, such as a pageturner or a typing stick. Others are fastened to the wrist or fit a cockup splint, or can be attached to the metacarpus by halfrings or to the fingers by several connected individual rings. The last four self-help devices are for daily use, such as eating, combing hair, brushing teeth, shaving, writing, and typing. Whenever any prehensile power of the hand is preserved, self-help devices are equipped with large handles. A universal "prosthesis for tetraplegics" has been devised (63) permitting the interchangeable attachment of all instru-

ments for daily living. The principle of the rocking knife has been found practical for cutting food (39). Overhead reading frames, hand attachments to fit parallel bars, and the previously mentioned exercise mitten and car-gutter hook are other assistive features. For smoking, a cigarette holder fastened in the center of an ashtray and connected by a long tube to a mouthpiece is popular with tetraplegic patients. When traveling, some paraplegic patients carry portable toilet seats. A series of reports on self-help devices has been published by the New York University Bellevue Center in recent years. These contain a wealth of information.

Modern principles of leg bracing for locomotion deserve attention, especially in regard to pelvic bands or corsets for preventing jackknifing, which are but exceptionally used. In their stead, trapezius and latissimus dorsi exercises are recommended because these muscles remain innervated even in cases with low cervical and high thoracic cord lesions (the respective nerve supply originates from C3-C4, the spinal accessory nerve, and C6-C8). By transmission through their respective insertions on spinous processes and fascial connections, this muscle action reaches down to the sacrum (6). Stirrup braces are preferred to calipers for functional as well as safety reasons. A useful temporary brace, the canvas-wood combined Keystone splint, was recently proposed as an expeditious appliance (64) for selected cases.

The main vehicle of locomotion remains the wheelchair, which is selected to fit the patient's need in a joint conference of the physiatrist, the wheelchair expert of the orthopedic shop, and the physical, corrective, and occupational therapists. Winding the rims with rubber hose, plastic, or attaching spokes makes driving easier for the tetraplegic patient. Elongation of the brake handles with bamboo sticks helps him to apply the brakes.

A number of hand control models for car driving are available today. These are routinely used by paraplegic and by some quadriplegic patients, who, in addition, use a hand attachment and a button on the steering wheel. The psychological impact which the independent driving of a car has on anyone with a spinal cord injury is self-evident.

Workbenches have been invented to which modified long leg braces can be attached. These benches

permit the patient to stand at work, eliminating the hazard which prolonged sitting carries for the ischial region, and provide for freedom of movement of the upper extremities (fig. 161). Suspension slings permit tetraplegic patients to use their upper extremities more easily and effectively.

OCCUPATIONAL THERAPY

The work of the occupational therapist has many facets extending into the fields of the psychotherapist, physiotherapist, corrective therapist, manual art instructor, and vocational counselor. The objectives are achieved by graded activities which are diversional as well as physiological and functional. The occupational therapist raises the patient's interest through interviews and demonstrations. Lessening anxiety and emotional stress through diversion may motivate him for future, even gainful, activities. The activities in the occupational therapy clinics are kinetic and prevocational. The quadriplegic patient's residual muscle function is strengthened by braiding, kneading clay, fingerpainting, or other activities, which combine the use of substitution movement through proximal muscle groups and the remaining reduced muscle strength of the periphery. The occupational therapist is not only the main source of producing self-help devices, but is also the main instructor in their use. Many crafts—leather, wood, plastic, metal, ceramics, weaving—are being taught in the occupational therapy clinic, some of which may be accepted by the patient as a gainful hobby or as a form of prevocational training. The performance of the patient gives the therapist a clue as to his aptitude, work habits, and work tolerance, which is welcome and useful information for the vocational counselor and manual arts instructor. The therapist solicits occasionally the paraplegic patient's ideas and assistance to manufacture equipment for the quadriplegic patient and thus achieves a dual objective—psychological and functional—satisfying the patient's ego by recognizing his ability, strengthening his self-confidence, and making him work physically at the same time. It is of great value to have the clinics for occupational, physical, and corrective therapy located in close proximity because it facilitates the cooperation which is desired by the workers in these fields.

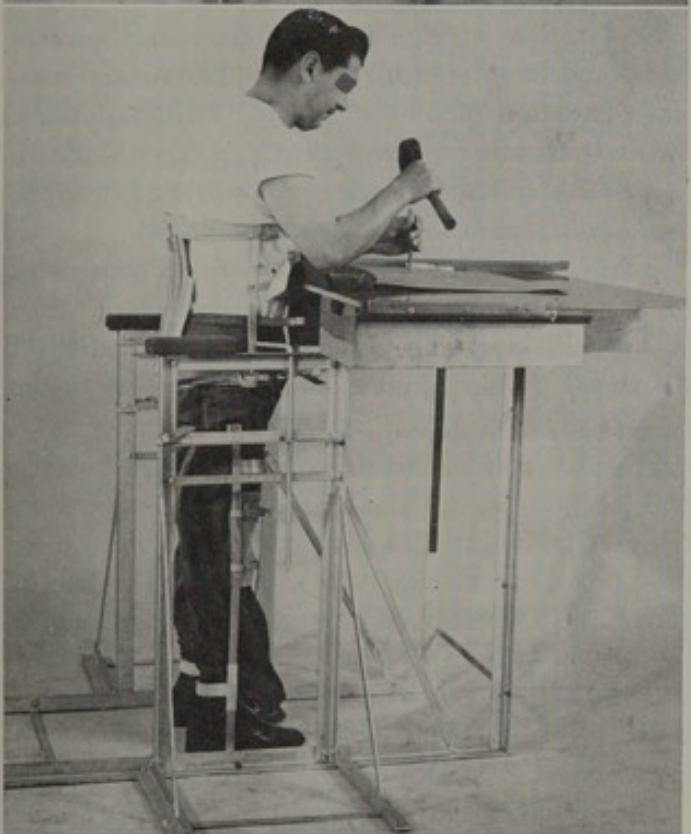
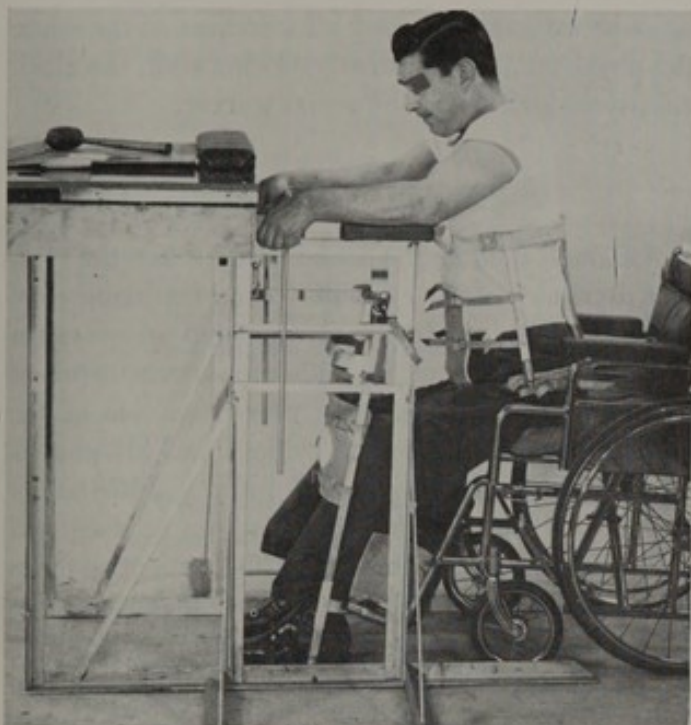
FIGURE 161.—Workbench for paraplegics designed and constructed by John Russey, Veterans' Administration Hospital, Long Beach, Calif.

EDUCATIONAL THERAPY

The objectives of educational therapy are the prevention of mental deconditioning and the preparation for a livelihood compatible with the patient's mental ability and physical disability. Intrahospital teaching comprises subjects of grammar and other subjects of high school level. The latter is achieved by affiliation with a local high school. During the past 10 years, about 200 high school diplomas have been issued to our patients. Among other courses are languages (French and Spanish), higher mathematics, and instruction in typing and shorthand. Typing is of dual importance for the quadriplegic patient. It has a vocational as well as a physical value. The American Legion Auxiliaries have defrayed expenses for paraplegics to take extension courses at the University of California, Los Angeles. These courses offer instruction in various academic and vocational occupations.

MANUAL ARTS THERAPY

The functions of manual arts therapy consist not only of teaching the basic principles of various trades and crafts, but also of providing motivation and of assisting vocational counseling. The latter is achieved by a process of elimination, namely, having the patient try various trades, which amounts to a practical aptitude and interest test. The goal of manual arts therapy is not to produce a finished journeyman, which has to be accomplished at a vocational school. The goal is to provide instruction in and knowledge of basic principles and experience to qualify him for a job in industry based upon skill in a respective trade. A watchmaker can learn up to 80 percent of this trade at the hospital before enrolling in one of the watchmaking schools such as Bulova; a future stock clerk may acquire sufficient mechanical comprehension to qualify him for his work. Among the trades which are taught at Long Beach veterans hospital are watchmaking, photography, metalwork (lathe, sheetmetal, welding, soldering, silver), woodwork, drafting and blueprinting, and basic electricity (radio, television, and "ham" activity for an amateur's license). Manual arts therapy has liaison with representatives of various agencies for job placement, such as the Veterans Advisement, Veterans Employment, and State Employment Agencies.

VOCATIONAL COUNSELING

The objective of vocational counseling is the determination of the type of work for which the patient is suited and of the arrangement of on-the-job training or job placement. Vocational counseling should start as soon as the acute phase of the injury has passed permitting medical assessment of the degree of permanent disability. In most instances the attending physician will be able to ascertain in his first interview the patient's pretraumatic work experience, his schooling, family and social background. Thus, based upon this information, valuable clues can be given to the vocational adviser, even before he starts his own study. Paraplegic patients do not pose any problems, with the exception of motivation, to the adviser. Difficulties arise in dealing with the more extensive neurological deficit of those quadriplegic patients (65) who are not equipped to substitute intellectually for the loss of physical function. Motivation is another difficulty which may face the vocational adviser in any instance of spinal cord injury. Time seems to play a role occasionally. There are patients who will accept work only years after injury, contrary to the majority who do so immediately after discharge from the hospital.

Technically, the adviser prepares a profile composed of test results which serve to confirm information received through interview. They consist of interest tests, personality inventory tests, general mental ability tests, college aptitude tests, achievement tests, mechanical comprehension tests, motor dexterity tests, special relation, art aptitude, and clerical aptitude tests. It may be of interest that quadriplegic patients keep the interest tests in abeyance for longer periods (up to 1 month) before completion than paraplegic patients, which may have to do with difficulty of writing or other reasons of hesitation yet to be investigated. Personality inventory tests are usually covered by the clinical rather than by the vocational psychologist. Some of the achievement tests are supplied by the educational therapist, and art aptitude tests are supplied by the occupational therapist. Difficult advisement problems are discussed in joint meetings between the vocational adviser, the clinical psychologist, and the social worker. Generally, vocational advisement

must be integrated among all members of the team, the physician, the physical medicine staff, the clinical psychologist, and the social worker.

SOCIAL SERVICE ASSISTANCE

Although neither the social worker nor the clinical psychologist, or even the vocational counselor, belongs administratively to the staff of physical medicine, they are nevertheless important members of the rehabilitation team. Since the role of the clinical psychologist is self-evident and his goal is obviously the mental adjustment and psychic homeostasis of the patient, his task shall not be discussed here. The social worker offers the patient psychological help as well as tangible assistance. The function of the social worker on a paraplegia service is exploratory, advisory, and planning-assistive (66).

Exploration of the patient's past and present social and familial history, parental home and marriage situation, procures valuable information for the understanding of the patient's reaction to his injury. This function of the social worker is complementary to that of the clinical psychologist.

Advisory activity of the social worker consists of disclosing and explaining to the patient the laws and benefits applying to his case. The function of the social worker is complementary to that of the contact officer at a veterans hospital.

Planning and assistive functions concern housing and job placement. The latter complements the activity of the vocational adviser. The social worker may provide financial help with the assistance of community, State, Federal, and private agencies.

RESULTS OF REHABILITATION

The results of physical and vocational-industrial rehabilitation have been satisfactory. Rusk (4) (5) saw benefits from rehabilitation in 90 percent of 204 patients and found in another series that 100 of 130 patients were retrained. Long and Lawton (67) (table 34) have attempted to correlate the potential physical and vocational performance with the level of the lesion. Although one may not share all of their views, their outline presents a valuable

TABLE 34.—*Functional significance of spinal cord lesion level*

Activities	C5	C6	C7	T1	T6	T12	L4
Self-care: eating.....	—	±	+	+	+	+	+
dressing.....	—	—	±	+	+	+	+
toileting.....	—	—	±	+	+	+	+
Bed independence: rolling over; sitting up.	—	±	+	+	+	+	+
moving about in bed: supine and sitting..	—	—	±	+	+	+	+
Wheelchair independence: transfer from (to) wheelchair.....	—	±	±	+	+	+	+
Ambulation: functional (includes to stand- ing position).....	—	—	—	—	±	+	+
Attendant: lifting.....	+	+	±	—	—	—	—
assisting.....	+	+	+	±	±	—	—
Homebound work with hands.....	—	—	+	+	+	+	+
Outside job.....	—	—	—	±	±	+	+
Private car.....	—	—	—	±	+	+	+
Public transportation.....	—	—	—	—	—	±	+
Braces or devices.....	Hand	Hand	Hand LLPS	LLPS	LLP ±S	LL ±P	Sh

Hand: hand devices (splints, slings, etc.); Braces: *LL*: double long brace; *P*: pelvic band; *S*: spinal attachment; *Sh*: short leg brace.

Source: Long, C., II, and Lawton, E. B.: Functional Significance of Spinal Cord Lesion Level. Arch. Phys. Med & Rehab. 36: 249-255, April 1955.

prognostic guide. While the physical handicap of paraplegia, severe as it may be, permits independent activity, quadriplegia is dependent on outside assistance. Investigating the self-care and exercise activities of 89 patients, the following was found (68):

Feeding:	Number
Without assistance, without device.....	10
With assistance, without device.....	30
With assistance, with device.....	35
Entirely dependent on outside help.....	14

Only 16 percent were unable to perform the hand-to-mouth movement which in man is essential for self-feeding because of the loss of the snout. It is peculiar that the spinal centers for this vital movement and the others for the movement of the dia-

phragm are in such proximity that those "who cannot feed can rarely breathe" (68).

	Number
Brushing teeth:	
Without device.....	35
With device.....	26
Combing hair:	
Without device.....	42
With device.....	18
Shaving:	
Without device.....	38
With device.....	20
Writing:	
Without device.....	36
With device.....	29
Typing:	
Without device.....	11
With device.....	27

The following activities could be performed according to physical fitness by patients of the same group:

Activity:	Number
Standing frame.....	73
Long leg braces (ambulating).....	2
Long leg braces (standing).....	3
Walker (standing).....	2
Neither brace nor crutch (ambulating).....	3
Neither brace nor crutch (standing).....	2

It is obvious that the few patients with ability to ambulate or to stand without orthopedic appliances had rather incomplete lesions enabling them also to do better in other activities.

Sixty-five patients could propel their wheelchair over short distances and low inclines, and 26 of 89 were able to drive a car. Transfer from wheelchair to car could be done without assistance by only 5 patients; 35 needed one and 49 needed two persons for help. Transfer from wheelchair to bed was done unassisted by 5 patients; 46 needed one and 37 needed two attendants. Five patients could get into the bathtub from the wheelchair without help, but 10 needed one and 74 needed two assistants. Most difficult among the performances are those which require muscular power to lift or support the body weight with the aid of the upper extremities.

The figures of gainful occupation are encouraging, although again the extent and level of the injury are determinants. Surveys conducted at the Veterans' Administration Hospital, Long Beach, with the assistance of the social service (66) in 1948 and 1950 and the Paralyzed Veterans Association in 1953 and 1957, disclosed the following figures:

1948:	
Number of questionnaires sent.....	300
Number returned.....percent..	51
Gainful occupation or school.....percent..	60
1950:	
Number of questionnaires sent.....	400
Number returned.....percent..	48
Gainful occupation or school.....percent..	60
1953:	
Number of questionnaires sent.....	756
Number returned.....percent..	46
Gainful occupation or school.....percent..	71
1957:	
Number of questionnaires sent.....	825
Number returned.....percent..	60
Gainful occupation or school.....percent..	61

¹ Only 460 or 55 percent of the questionnaires returned were evaluated.

The 1957 survey showed that among the 284 working patients there were 25 tetraplegics (9 percent) and 259 paraplegics (91 percent). The 460 patients who were evaluated consisted of 86 (19 percent) tetraplegics and 374 (81 percent) paraplegics. Employment figures related to tetraplegia and paraplegia would, therefore, be 29 and 69 percent, respectively. This apparently high incidence of any type of work among tetraplegics is largely due to the incompleteness of some lesions, permitting the patients to perform well physically. This was also shown in an earlier study in 1956 when, of 233 patients with cervical cord lesions, 36 (16 percent) were working, but only one-half of these (8 percent) could be truly classified as quadriplegics. The following interesting distribution of gainful occupations among these 18 "true" quadriplegic patients was found: Nine patients did office work—accounting, bookkeeping, secretarial work, insurance work, journalism; two were artists (oil and water color); two were aircraft workers; two were mechanics; two did radio repair work, and one was a radio commentator. Recently, Clifton (65) has shown how quadriplegic patients can be trained for mechanical work if the supervisor of the manual arts therapy section has sufficient interest to assist with the adjustment of physical working conditions. The utilization of the voice of the severely handicapped (our radio commentator has a C4-C5 lesion) should be and has been advocated.

Compared with quadriplegics, the paraplegic patient rarely encounters serious difficulties in finding work compatible with his disability. Kidwell (69), in analyzing the vocational rehabilitation of 66 paraplegic patients in 1949, came to the conclusion that "with proper counseling and training facilities * * * paraplegic patients can enter and pursue vocational training in nearly all occupational groups and types of training, achieving standards of performance comparable to that of nondisabled individuals." Kidwell's prognostic statement has been recently confirmed in a large series of 466 paraplegic patients whose occupations were listed in detail in VA Pamphlet 7-12, entitled "Occupations of Paraplegic Veterans of World War II and Korea" (70). The distribution of 480 jobs among 466 paraplegic patients, using Part IV of the Dictionary of Occupational Titles for Classification, was as follows:

Professional, technical, and managerial work.....	224
Clerical and sales work.....	12
Agricultural, marine, and forestry work.....	17
Mechanical work.....	103
Manual work.....	34

Each of these categories is broken down into subdivisions and individual case histories are presented. This study, however, includes also cases of poliomyelitis and does not confine itself to traumatic paraplegia. Four physicians are listed therein, two of them well known to this author. Both have post-traumatic paraplegia with complete thoracic lesions. One, a former patient on our service, is continuing his busy practice in a smaller town and even performs surgery at a specially constructed operating table. The other is professor and chairman of the department of physical medicine and rehabilitation of a university medical school.

EPICRITIC REMARKS

Looking at the results of treatment and rehabilitation of patients with spinal cord trauma over the past 15 years or so, it appears that these results, encouraging as they are, could be improved upon. The greatest asset for the rehabilitation team is the fact that the spinal cord lesion per se is a nonprogressive condition and, therefore, provides a solid basis for plans of reconstruction. This advantage over other progressive conditions (arteriosclerosis, multiple sclerosis, neoplasms) should be fully appreciated. Although it is recognized that the homeostasis of spinal man is precarious, the restitution of the lost equilibrium is facilitated by the stability of the basic condition. The improvement of ultimate results, reintegration of the individual as a productive member of society, will require the continuous cooperation of all team members with their respective staffs, be they neurological surgeons (71), urologists, psychiatrists, physiatrists, orthopedists, or other specialists. Viewed from the standpoint of the physiatrist, three unsolved problems will challenge him in the future, as they did in the past: Spasticity, bracing, and—last but not least—motivation of his patient. The foundations have been laid, but much work remains to be done in order to complete the building.

REFERENCES

1. Munro, D.: Two-Year End-Results in the Total Rehabilitation of Veterans With Spinal-Cord and Cauda-Equina Injuries. *New England J. Med.* 242: 1-16, 5 Jan. 1950.
2. Munro, Donald: *Injuries to the Nervous System*. Philadelphia: W. B. Saunders Co., 1952, pp. 56-170.
3. Munro, D.: The Rehabilitation of Patients Totally Paralyzed Below the Waist, With Special Reference to Making Them Ambulatory and Capable of Earning Their Living. V. End-Result Study of 445 Cases. *New England J. Med.* 250: 4-14, 7 Jan. 1954.
4. Rusk, H. A.: Rehabilitation Pays Dividends; Chairman's Address. *J.A.M.A.* 150: 837-840, 1 Nov. 1952.
5. Rusk, H. A.: Total Rehabilitation. *J. Nat. M.A.* 45: 1-16, January 1953.
6. Abramson, A. S., and Ebel, A.: Symposium on Prolonged Illness; Rehabilitation in the Management of Prolonged Illness. *M. Clin. North America* 37: 915-932, May 1953.
7. Dinken, H.: War Injuries of the Vertebral Column and Spinal Cord, With Special Reference to Physical Treatment. *M. Clin. North America* 27: 1077-1090, July 1953.
8. Dinken, H.: Physical Treatment and Rehabilitation of Paraplegic Patient. *J.A.M.A.* 146: 232-234, 19 May 1951.
9. Guttmann, L.: The Principles of Physiotherapy in the Treatment of Spinal Paraplegia. *Physiotherapy, Lond.* 35: 157-164, October 1949.
10. Guttmann, E., and Guttmann, L.: The Effect of Galvanic Exercise on Denervated and Re-innervated Muscles in the Rabbit. *J. Neurol. Neurosurg. & Psychiat.* 7: 7-17, January-April 1944.
11. Lowman, E. W.: Rehabilitation of the Paraplegic Patient. *Arch. Neurol. & Psychiat.* 58: 610-619, November 1947.
12. Newman, L. B.: Rehabilitation of Patients With Spinal Cord Injuries. *Arch. Phys. Med.* 28: 85-93, February 1947.
13. Newman, L. B.: Special Hand Splints for the Disabled. *Arch. Phys. Med.* 28: 770-772, December 1947.
14. Newman, L. B.: The Role of Physical Medicine and Rehabilitation in Chronic Medical Diseases. *Am. Pract. & Digest Treat.* 7: 47-60, February 1956.
15. Newman, L. B., and Jameson, E. L.: Assistive Devices for the Disabled. *Occup. Therapy* 30: 8-13, February 1951.
16. Newman, L. B., and Tenner, N. N.: Assistive Devices for Ambulation. *J. A. Phys. & Ment. Rehab.* 10: 114-115, July-August 1956.
17. Newman, L. B., and Popell, I. R.: Educational Therapy in the Veterans Administration Rehabilitation Program. *Arch. Phys. Med.* 33: 477-485, 1952.
18. Nyquist, R. H.: Functions of a Physical Medicine Section for a Paraplegia Service. *Proceedings of Second*

- International Congress of Physical Medicine, Copenhagen, 1956, pp. 386-394.
19. Nyquist, R. H.: Exoskeletal Splinthook Prostheses for Patients With Traumatic Tetraplegia; Preliminary Experience With Their Use for Upper Extremities. *J.A.M.A.* 160: 761-763, 3 Mar. 1956.
 20. Nyquist, R. H.: Special Sling for Hoisting Quadriplegic Patients. U.S. Veterans' Administration Department of Medicine and Surgery, Physical Medicine and Rehabilitation Service, Information Bulletin 10-99, 12 Apr. 1957, pp. 56-57.
 21. Deaver, George G., and Brown, Mary Eleanor: Physical Demands of Daily Life: An Objective Scale for Rating the Orthopedically Exceptional. *Studies in Rehabilitation*, No. 1. New York: Institute for the Crippled and Disabled, 1945.
 22. Sverdlik, S., and Rusk, H. A.: Rehabilitation of the Quadriplegic Patient. *J.A.M.A.* 142: 321-324, 4 Feb. 1950.
 23. Nyquist, R. H., Comarr, A. E., and Bors, E.: A Comparative Study of Antispasmodic Drugs in Patients With Spinal Cord Injuries. Presented at the 35th Annual Session, American Congress of Physical Medicine and Rehabilitation, 10 Sept. 1957, Los Angeles, Calif.
 24. Abramson, A. S., and Hirschberg, G. G.: Studies on Spasticity. II. The Role of the Contraction of Certain Muscle Groups and the Effect of Its Elimination on the Over-All Spasticity in Patients With Transverse Spinal Cord Lesions. *Bull. Hosp. Joint Dis.* 13: 164-172, April 1952.
 25. Lee, W. J., McGovern, J. P., and Duvall, E. N.: Continuous Tetanizing (Low Voltage) Currents for Relief of Spasm; Clinical Study of 27 Spinal Cord Injury Patients. *Arch. Phys. Med.* 31: 766-770, December 1950.
 26. Newman, L. B., Arieff, A. J., and Wasserman, R. R.: Present Status in the Management of Spasticity and Spasm; Preliminary Report. *Arch. Phys. Med.* 35: 427-436, July 1954.
 27. Levine, M., Knott, M., and Kabat, H.: Relaxation of Spasticity by Electrical Stimulation of Antagonist Muscles. *Arch. Phys. Med.* 33: 668-673, November 1952.
 28. Mautner, H. E.: The Relationship of Function to the Microscopic Structure of Striated Muscle: A Review. *Arch. Phys. Med.* 37: 286-292, May 1956.
 29. Fay, T.: The Origin of Human Movement. *Am. J. Psychiat.* 111: 644-652, March 1955.
 30. Fay, T.: Rehabilitation of Patients With Spastic Paralysis. *J. Internat. Coll. Surgeons* 22: 200-203, August 1954.
 31. Kabat, H.: Restoration of Function Through Neuromuscular Reeducation in Traumatic Paraplegia. *A.M.A. Arch. Neurol. & Psychiat.* 67: 737-744, June 1952.
 32. Kabat, H.: Central Facilitation; Basis of Treatment for Paralysis. *Permanente Found. M. Bull.* 10: 190-204, August 1952.
 33. Fay, T.: The Use of Pathological and Unlocking Reflexes in the Rehabilitation of Spastics. *Am. J. Phys. Med.* 33: 347-353, December 1954.
 34. Fay, T.: Basic Considerations Regarding Neuromuscular and Reflex Therapy. *Spastics Quart.* 3: 5-8, 1954.
 35. Kraus, H.: Muscle Rehabilitation by Active Motion. *Arch. Phys. Therapy* 24: 151-157, March 1943.
 36. Ebel, A., and Abramson, A. S.: General Principles of Exercise Therapy. *J. A. Phys. & Ment. Rehab.* 5: 2-4, March-April 1952.
 37. Kabat, H., and Rosenberg, D.: Device for Grasp and Release by the Completely Paralyzed Hand. *Arch. Phys. Med.* 32: 462-464, July 1951.
 38. Braun, L.: A Latissimus Dorsi Exerciser for Use With the Paraplegic and Other Neurological Patients. U.S. Veterans' Administration, Department of Medicine and Surgery, Physical Medicine and Rehabilitation Service, Information Bulletin 10-58, June 1954, pp. 20-21.
 39. Shear, H. R., and Comarr, A. E.: Eating Devices for the Paraplegic Patient. *Occup. Therapy* 28: 154-158, July 1949.
 40. Shear, H. R., and Comarr, A. E.: A Triceps-Substitute Brace for Quadriplegics. *Arch. Phys. Med.* 31: 518-520, August 1950.
 41. Jahn, R., and Nyquist, R. H.: Quadriceps "Shoe" Boots. *J. A. Phys. & Ment. Rehab.* 7: 17-18, January-February 1953.
 42. Bell, D. T.: Principles and Techniques of Physiotherapy in the Treatment of Spinal Paraplegia. *Phys. Therapy Rev.* 35: 235-237, May 1955.
 43. Nyquist, R. H., and Nims, R. P.: Car-Gutter Hook With Swiver-Sling for Quadriplegic Patients. U.S. Veterans' Administration, Department of Medicine and Surgery, Physical Medicine and Rehabilitation Service, Information Bulletin 10-99, 12 Apr. 1957, pp. 48-51.
 44. Gordon, E. E., and Vanderwalde, H.: Energy Requirements in Paraplegic Ambulation. *Arch. Phys. Med.* 37: 276-285, May 1956.
 45. Deaver, G. G., and Brown, M. E.: The Challenge of Crutches. I. Methods of Crutch Management. *Arch. Phys. Med.* 26: 397-403, July 1945.
 46. Deaver, G. G., and Brown, M. E.: The Challenge of Crutches. II. Crutch-Walking; Muscular Demands and Preparation. *Arch. Phys. Med.* 26: 515-525, August 1945. *Correction*, 26: 597, September 1945.
 47. Deaver, G. G., and Brown, M. E.: The Challenge of Crutches. III. Standard Crutch Gaits and How to Teach Them. *Arch. Phys. Med.* 26: 573-582, September 1945.
 48. Deaver, G. G., and Brown, M. E.: The Challenge of Crutches. V. Daily Activities on Crutches. *Arch. Phys. Med.* 27: 141-157, March 1946.
 49. Hoberman, M., and Cicien, E. F.: Rehabilitation Techniques With Braces and Crutches, I. *Occup. Therapy* 30: 203-216, August 1951.
 50. Hoberman, M., and Cicien, E. F.: Rehabilitation Techniques With Braces and Crutches, II. *Occup. Therapy* 30: 282-295, October 1951.
 51. Hoberman, M., and Cicien, E. F.: Rehabilitation Tech-

- niques With Braces and Crutches, III. *Occup. Therapy* 30: 377-383, December 1951.
52. Hoberman, M., and Cicienia, E. F.: Rehabilitation Techniques With Braces and Crutches. IV. Methods of Falling and Getting Down and Up From the Floor. *Am. J. Phys. Med.* 31: 21-30, February 1952.
53. Sanders, E. M.: Mobilization of Paraplegics. I. The Early Stage. *Occup. Therapy* 27: 353-370, October 1948.
54. Sanders, E. M.: Mobilization of Paraplegics. II. Wheel Chair and Mat Exercises. *Occup. Therapy* 28: 340-363, August 1949.
55. Bastable, A. D.: Typewriter Frame and Mouthstick for the Quadriplegic With Neck Involvement. *Am. J. Occup. Therapy* 10: 7-12, January-February 1956.
56. Bisgrove, J. G.: A New Functional Dynamic Wrist Extension—Finger Flexion Hand Splint—A Preliminary Report. *J. A. Phys. & Ment. Rehab.* 8: 162-163, September-October 1954.
57. Climo, S.: The Erect Position as an Aid in the Care of the Paraplegic; A Useful Mechanical Aid. *Plastic & Reconstruct. Surg.* 13: 65-69, January 1954.
58. Fowlks, E. W.: Plastic Splints for Neurological Conditions. *J.A.M.A.* 156: 1154-1156, 20 Nov. 1954.
59. Nyquist, R. H., and Clifton, E.: An Overhead Reading Device. *Arch. Phys. Med.* 32: 595-597, September 1951.
60. Nyquist, R. H., and Clifton, E.: A Portable Toilet Seat for Paraplegic Patients. U.S. Veterans' Administration, Department of Medicine and Surgery, Physical Medicine and Rehabilitation Service, Information Bulletin 10-99, 12 Apr. 1957, pp. 52-55.
61. Willhite, C. S., Russey, J. C., and Bors, E.: The Quadriplegic Standing Frame. *Arch. Phys. Med.* 35: 236-239, April 1954.
62. Wise, C. S., and Letterman, G. S.: Coordination of Plastic Surgery and Physical Medicine in the Paraplegic Patient. *Arch. Phys. Med.* 34: 616-620, October 1953.
63. Bedbrook, G. M., and Doyle, W. A.: A Prosthesis for Tetraplegics. *J. Bone & Joint Surg.* 39 B: 132-133, February 1957.
64. Doman, R. J., and Doman, G. J.: A Useful Aid in Early Paraplegia Training. *Phys. Therapy Rev.* 36: 595-598, September 1956.
65. Clifton, E.: Quadriplegics Can Work. *Am. Arch. Rehab. Therapy* 4: 230-238, December 1956.
66. Gafford, T.: Social Work Activities in Paraplegia. *Proceedings of Second Annual Clinical Paraplegia Conference, Long Beach, Calif., 25-27 Aug. 1953*, pp. 82-89.
67. Long, C., II, and Lawton, E. B.: Functional Significance of Spinal Cord Lesion. *Arch. Phys. Med.* 36: 249-255, April 1955.
68. Bors, E.: The Challenge of Quadriplegia; Some Personal Observations in a Series of 233 Cases. *Bull. Los Angeles Neurol. Soc.* 21: 105-123, September 1956.
69. Kidwell, C. E.: An Analysis of the Vocational Rehabilitation of Paraplegic Veterans. *Occup. Therapy* 28: 423-434, October 1949.
70. VA Pamphlet 7-12, Occupations of Paraplegic Veterans of World War II and Korea. U.S. Veterans' Administration, Department of Veterans' Benefits, June 1957.
71. Heyl, H. L.: Some Practical Aspects in the Rehabilitation of Paraplegics. *J. Neurosurg.* 13: 184-189, March 1956.

CHAPTER 35

The Problem of Paraplegia in Modern Society

Marcus W. Orr

Medical sociology has as one of its tasks the study of problems involving more effective relations between medicine as a developing social institution and other functional organs of an improved society. The organization of a comprehensive program for the treatment and rehabilitation of paraplegics and quadriplegics during the years of World War II has provided a unique opportunity for the sociologist to examine a concrete instance of a new and imaginative medical advance the execution of which has involved broad and concerted social action. It has been suggested in several places that World War II itself gave rise to this significant medical and social achievement. This is, in a sense, true, though perhaps it was not clearly the war which caused the creation of this new accomplishment. It seems more logical to see the phenomenon as an imaginative development brought about through intelligent efforts to organize more effectively the means of an advanced civilization to the ends of realizing meaningful purpose. The war reached its purpose in the destruction of vast areas of organized cultural life, whereas creative intelligence succeeded to a great degree in improving the conditions necessary to medical and social advance in spite of the war.

It is, of course, a medical commonplace that paraplegics at the time of World War I seldom survived for longer than a few months or a few years and were never in any sense spoken of as rehabilitated or restored to a productive and happy life. The few instances of survival in some state above the level of mere existence appear as more or less freak occurrences which must be explained through some particular circumstances. Certainly, the paraplegic of 40 years ago, whatever the source of his condi-

tion, was never seen in relation to anything but a life of pain and general decline.

However, some 10 years before the spectacular success of experiments in all aspects of the rehabilitation of World War II paraplegics, Munro had demonstrated major advances in the neurosurgical handling of such cases and in the treatment of the cord bladder (1) (2). Thus, some basis for later progress existed in practical medical and surgical procedures, in techniques of crutch ambulation, and even in broader areas of rehabilitation. With the new ground afforded by developments in drug therapy, Munro's insistence that the paraplegic patient had some concrete claim to a future in the world of adult activity became clearly a valid assertion rather than an "impractical notion."

The vigorous expansion and further refinement of Munro's determined foundations only awaited the larger organization of facilities and skills which characterized the paraplegia rehabilitation program of the Armed Forces and the Veterans' Administration. This ambitious undertaking probably reached its peak medically and surgically from 1945 to 1948, was reevaluated and extended by the Veterans' Administration's continued support, and reached even further refinement in work carried on during the Korean War. Even in 1945, there still existed some dissension as to whether the paraplegic should count on an essentially domiciliary future or should be led to attempt total rehabilitation in the resumption of active relations with family, education, work, and other facets of an effective life (3). However, general approaches to techniques and procedures of the treatment phase were agreed upon and the giant program was centered in

six hospital facilities scattered throughout the United States. These were Halloran General Hospital, Staten Island, N.Y., McGuire General Hospital, Richmond, Va., Cushing General Hospital, Framingham, Mass., Vaughan General Hospital, Hines, Ill., Kennedy General Hospital, Memphis, Tenn., and Birmingham General Hospital, Van Nuys, Calif. With few exceptions, all paraplegic and quadriplegic patients were transferred to these centers of specialized equipment and trained personnel. The eventual transition from management by the Armed Forces to that of the Veterans' Administration was marked by an increase in the standardization of all procedures, more consensus in the definition of total rehabilitation as the end in view, and more clearly organized attention to research on the many problems involved in medical and paramedical fields.

This vast treatment program with its large variety of brilliant contributions to a unified concept of paraplegia rehabilitation has yet to find its definitive historian, but any familiarity with the medical literature must recognize the significant work of Bors, Covalt, Freeman, Heimburger, Meirowsky, Munro, Rusk, Talbot, Thompson, and many others. The problems of pain, spasticity, decubital ulcers, the cord bladder, and so forth were met systematically under conditions of clinical work which, in many ways, approached the ideal. The integration of medical specialties with ancillary functions proceeded to a high level of coordinated practice, and the body of literature shaped by this determined experiment claims relation with basic problems in physiology as well as with the immediate problems of everyday living for the paraplegic.

Principles brought to focus by the World War II effort were further tested and critically expanded by Meirowsky and others (4) (5) during the Korean War. Of particular importance here was the significant reduction of casualties through early medical and surgical treatment and the promotion of shorter periods of hospitalization and rehabilitation through the tightening of efficiency in evacuation, medical handling, and nursing care.

Taken as a whole, the American effort in establishing a ground plan for the rehabilitation of the paraplegic patient has produced an achievement of the first magnitude. It provided implications to the improvement of many basic procedures in medical prac-

tice, offered significant suggestions for future scientific research, and centered attention on the need to redefine and restructure the entire concept of rehabilitation.

The interdependence of medical and surgical procedures with the broader aspects of rehabilitation is particularly clear in the instance of paraplegia. Some idea of the types of future activity in various life situations must enter into, and at times may largely determine, the path initial medical handling must take. Pain, spasm, bowel and bladder function, orthopedic problems, and care of the skin are all inevitably related to what the patient does in formulating plans for education, work, family life, and recreation. The Armed Forces and Veterans' Administration's program recognized this fact in bringing into its scope such services as physical and occupational therapy, clinical psychology, social work, vocational counseling, plans for economic compensation and subsidized housing, and programs of advanced education. Careful training in the principles of self-care, coupled with assurance as to availability of efficient clinical facilities, significantly decreased the likelihood of chronic illness for the paraplegic veteran.

Followup studies on critical samples of the 2,500 paraplegic veterans treated under the Veterans' Administration program have provided cogent evidence that the bid for total rehabilitation was justified by the high degree of well-being among subjects as long as 10 years following discharge from hospital centers (6). Such studies have had, and could continue to have, primary importance in the reconstitution of existing treatment programs and all the techniques and procedures which they involve. The necessarily experimental nature of the original organization destined it to innumerable errors and shortcomings, but the basic concept of the possibility of total rehabilitation seems to be an established fact, given certain conditions. The old life open to a paraplegic, the life of inactivity and decline, has been shown to be an unnecessary and impractical state for a normally intelligent person in modern society. Neither is the old concept of invalidism a practical thing for a social order which depends for its healthy functioning on the maximum development of latent abilities in each of its members.

Some social psychologists and sociologists have

been critical of the development of the rehabilitation theory, arguing that it has been too stringently patient-centered and has thus, in practice, tended to overemphasize the medical and psychological aspects of disability and to ignore the action that the institutions of society must take if rehabilitation is to be firmly embodied as an integral part of modern life. It is noticeably true that the literature concerning the rehabilitation of the paraplegic is strongest in its attention to medical problems and to the mind states of the individual patient. Professional attention to problems involved in the paraplegic's relation to the larger society is sadly lacking. The concern of psychologists, psychiatrists, social workers, and vocational counselors has produced insights of great value which are entitled to stand in the same high company with medical contributions; but properly to prepare a patient for reentry into an active world presupposes that the world is ready to utilize him to the fullest.

More recent thought in the broad field of rehabilitation has called for a critical examination of the role of the community in supporting and stabilizing the basic work of medicine and its allies in the definition of fresh possibilities for the lives of the severely disabled (7). However, this emphasis needs some clarification in the form of a working definition of the community, especially as to the nature of its organs and their best function relative to the problems total rehabilitation poses. It is suggested that medical sociology can be of service here, and can thus help the institution of medicine to see its advances continued to some practical realization in terms of their meaning to the larger society.

Of course, this is not to suggest that significant relations with other social organs have not been established already by such developments as the paraplegia program to which we have been referring. Indeed, it might be reiterated here that the unique feature of this program as compared to prewar paraplegia rehabilitation efforts has been its achievement to some functional relation with educational institutions, organs such as insurance and compensation agencies for patients, family service, industry, housing, public recreation facilities, public transportation, and so on. However, some studies have indicated that the major stumbling block to the realization of total rehabilitation for paraplegics of the

present day lies in the apathetic "attitudes" of the larger society. Beginnings have been made, but it is important to understand their nature and to improve their scope and quality.

More specifically, it might be recalled that the impetus to organization of facilities for the broad rehabilitation of paraplegics (as well as many other disabilities) came, to a great degree, from war veterans constitutive of a private interest group. The number of veteran paraplegics in this country is the smallest fraction of the full paraplegic population which, in fact, numbers far in excess of 100,000 persons. It is particularly clear to medical people that though the bulk of progress in paraplegia rehabilitation has come from efforts in this country, the more comprehensive facilities and programs of the essentially public domain are available only to war veterans. Several other nations in the democratic Western World, faced with a similar uncomfortable situation, have opened their valuable "war-built" facilities to the public use. Quite obviously, this has several advantages. First, it keeps research and development alive through the maintenance of a healthy clinical environment necessary to their survival. Second, it incorporates vital cultural developments into the life of a country, therefore, making meaningful use of past endeavors rather than relegating them to the scrap heap of "war surplus." Third, it provides for a great reduction in strain on the medical profession, the patient and his family, and indeed every aspect of the social community.

The practice of establishing communities for the disabled has been frowned upon in American rehabilitation literature, but nowhere does one find a thoroughly critical examination of the idea in theory, or even an empirical study of its effectiveness in countries where it has been tried. Certainly, it seems logical that, in terms of disabled persons who are unable to function in any meaningful capacity alone and unaided, the community plan offers more of an opportunity to relate to a larger productive life than does the isolated "backroom" existence. Such communities could conceivably justify themselves if they only served as transition points in the individual's journey to integration with some more "normal" environment. The chief objection to the establishment of such facilities here has been that "disability is not a valid basis in itself for interpersonal relations."

Though this may be true, it does not necessarily follow that a community of the disabled need have disability as its basic principle of organization. It might be a community of work, study, family life, health maintenance, recreation, and all other aspects of a well-rounded cultural unit. It could even be integrated into the life of major universities, certain types of industrial settlements, or other orders of existing social fact which hold relatively obvious possibilities for the efficient utilization of disabled persons. A person, after all, finds his true individuality in the quality of his relations with a living, working world, and not merely in his superficial "differences" from his fellow creatures.

The increased development of health and disability insurance programs in the United States offers at least a sensible beginning for serious considerations as to the solution of economic problems involved in the handling of such a complex and expensive disability as paraplegia. Some constructive research in this area could surely come up with better suggestions than the private charity or "fund appeal" for the relief of suffering which, if appropriate to a medieval society, are certainly too inefficient and untrustworthy for the highly organized and effective action complex which is modern society. Medical people have, for many years, been painfully aware that serious neurological problems, of which paraplegia is only one, are far too expensive for the most efficient treatment and rehabilitation. Most often the brunt of expense falls on the physician, or the hospital, where it can no more be borne than by the average family or community unit.

As the paraplegic has become more mobile, even to the degree of living alone and maintaining an active relation with work and education and recreation, the adjustment of public facilities to accommodate him as an efficient "wheelchair person" is more and more of a necessity. In places where movements to attend to such minor problems as the construction of ramps into public buildings, on streets, and so forth have been undertaken, the success has been great if not instantaneous. The amendment of building codes to include ramped exits, the clarification of fire regulations in relation

to strong and agile wheelchair people, the creation of parking facilities, and the like do not necessarily require the use of formal legislation in the sense of imposing unwanted and hateful changes on a recalcitrant society. It has, in many places, been just as effective to provide sensible suggestions to the proper authorities in order to achieve these relatively minor but important additions to community function. However, the basic idea of law is to define the best pathways to proper functioning for the whole community. It seems no more undemocratic or authoritarian to institute laws for the more effective integration of rehabilitation into the larger community than it does to provide for the safety, education, and chance to pursue a good life on the part of our children. Any action, or action situation, which retards such effective integration is, after all, only an aspect of blind custom and drift, an instance of the perversion of true law. In an orderly and well-functioning society, each finds his own realization to the degree that just opportunity prevails. It were better, perhaps, not to insist that the disabled individual has the "right" to largess from society, but to ask whether society can afford to founder and confuse the fine possibilities produced by its own integrity.

REFERENCES

1. Munro, D.: Care of Back Following Spinal Cord Injuries; Consideration of Bed Sores. *New England J. Med.* 223: 391-398, 12 Sept. 1940.
2. Munro, D.: The Cord Bladder—Its Definition, Treatment and Prognosis When Associated With Spinal Cord Injuries. *J. Urol.* 36: 710-729, 19 Dec. 1936.
3. Conference on Spinal Cord Injuries, Second Service Command, held at Halloran General Hospital, Staten Island, N.Y., 19 Oct. 1945, and at Thomas M. England General Hospital, Atlantic City, N.J., 20 Oct. 1945.
4. Meirowsky, A. M.: The Management of the Paraplegic Patient. *J. Tennessee M.A.* 47: 431-435, November 1954.
5. Meirowsky, A. M., and Barnett, J. C.: Mobile Neurosurgical Team. *Ann. Surg.* 138: 178-185, August 1953.
6. Orr, M. W.: Problems in the Social Adjustment of Paraplegic Veterans; A Study of 109 Persons. Unpublished M.A. thesis, University of Illinois, Urbana, Ill., 1952.
7. Allan, W. Scott: Rehabilitation, A Community Challenge. New York: John Wiley & Sons, Inc., 1958.

Part 4

SPASTICITY RESULTING FROM TRAUMA

CHAPTER 36

The Spinal Cord and Spasticity

Robert F. Heimbürger

Spasticity of skeletal muscles is a symptom of damage to the central nervous system. Its most common manifestation is increased muscular resistance to manipulation (1), but it may also appear as sudden involuntary muscular contractions. Even though the muscular resistance and involuntary contractions are extremely strong, the voluntary control of spastic muscles invariably is weakened or absent.

The terms rigidity, mass reflexes, reflex excitability, and increased tonus have been used to describe spasticity. The spasticity which arises from trauma to the central nervous system usually cannot be distinguished from spasticity caused by other lesions of the brain and spinal cord. Although this discussion will be primarily about spasticity which arises from trauma, the statements may also be applicable to spasticity arising from other causes. Local trauma to bones, joints, muscles, and ligaments causes muscle spasms. Usually the history, local examination, and roentgenograms of the part indicate whether the spasms are from local lesions or spasticity arising from lesions in the central nervous system. Occasionally, some difficulty may occur in differentiating the source of muscle spasms. When this occurs observation for a period of time is helpful, as muscle spasms from local trauma subside after a few days or weeks, and those from lesions in the central nervous system last considerably longer.

Skeletal muscles that lose all their nerve connections with the central nervous system become flaccid and atrophic. Spastic muscles retain tone indicating that some of the nerve fibers and anterior horn cells which control them are intact. As voluntary control of spastic muscles is weakened or absent, it is safe to assume that there is damage somewhere in the nervous system. The damage must be proximal to the anterior horn cells. The anterior horn cells and the axons connecting them to the muscles remain intact. Spasticity of skeletal muscles can arise from damage to any of the pathways which carry impulses to the anterior horn cells in the spinal cord. Although this series of pathways is a continuum which is not anatomically separated into components, it is easier for discussion and description to separate spasticity into several types. Fortunately, the spastic phenomena fall into clinically separable forms which fit anatomical or pseudoanatomical groupings. These forms or groupings are the spasticity which arises from damage to the spinal cord, the brain stem, the basal ganglia, and the cerebral hemisphere.

CHARACTERISTIC PATTERN

A characteristic pattern of spastic motor activity develops as a constant result of damage to the spinal cord. The severity and the pattern of spastic move-

ments in human subjects with spinal cord damage varies slightly with the level and extent of the lesion producing it. In spite of minor variations, the overall picture is surprisingly similar from one spinal cord damaged individual to another. Neither the etiology of the spinal cord lesion, whether compressive, traumatic, or degenerative, nor the spinal cord level involved, nor the completeness of the lesion appreciably alters the characteristic pattern of spastic motor activity. The time elapsed since the lesion was inflicted and the nutritional and emotional status of the patient appear to have a greater influence on the severity of spasticity than does the nature and extent of the lesion. These factors alter the magnitude, but do not appreciably alter the pattern of the spastic activity. To produce spasticity, a spinal cord lesion must be cephalad to the conus medullaris. Lesions involving the conus medullaris or the cauda equina distal to it are similar to peripheral nerve lesions. These low spinal cord lesions cause flaccidity as they separate the muscles from their anterior horn cells.

DESCRIPTION

The onset of spasticity arising from spinal cord damage in man is gradual regardless of the type of lesion. In slowly, progressive spinal cord lesions, gradually increasing spasticity is often the first symptom. Sudden traumatic injury is always followed by a period of complete flaccidity of the muscles caudad to the lesion. The flaccidity is followed by gradually increasing spasticity. The flaccid state following spinal cord injury has long been termed "spinal shock." This is an inappropriate term as the patient is seldom in a state of peripheral vascular shock. It is meaningful only because of its long accepted usage. "Decreased spinal reflex activity" (2) or "reflex depression" (3) are more appropriate terms. The period of "spinal shock" or "decreased spinal reflex activity" lasts from 3 to 6 weeks. A rare somatic muscular response can be obtained with noxious stimulation, but the muscles remain toneless and unresponsive a majority of that time.

During the period of "spinal shock," there is retention of urine and feces, indicating that tonic contraction of the sphincters persists (4). Tem-

porary relaxation of the bladder sphincter can be achieved by injecting sacral nerve roots, indicating that the impulses which cause the retention arise in the spinal cord rather than the presumably uninjured sympathetic chain (5). The bulbocavernous (2) (3), ischiocavernous (2), and anal (3) reflexes can usually be elicited very soon after severe spinal cord trauma. Penile erection may appear immediately following injury to the cervical spinal cord and remain present for several hours or until the bladder is emptied with a catheter. Erection does not occur following injuries below the upper thoracic spinal cord. During the period of flaccidity, sweating is decreased or absent caudad to the level of injury. Vasomotor responses are sluggish and edema occurs with dependency (3). This alteration of skin tone increases the danger of decubital ulcers. Decubiti (bedsores) are troublesome complications of spinal cord injury and have a greater tendency to appear during the period of decreased reflex activity.

Response to plantar stimulation may be first elicited from 1 to 24 hours after injury (3). When this reflex appears, it is usually a plantar (flexor) (downward) contraction, but in a few days or weeks following injury becomes extensor (upward). In 1915, Gordon Holmes was of the opinion that "no serviceable recovery can be expected if the plantar responses are flexor following spinal cord injury" (6).

The transition following spinal cord damage, from the state of "reflex depression" (spinal shock) to that of "reflex excitability" (spasticity), is gradual, taking several days or weeks. The average time for the appearance of spasticity (reflex excitability) was found by Martin and Davis (2) to be 11½ months in 80 cervical spine injuries and 21½ months in 292 thoracic spine injuries. These authors did not find any correlation between the severity of the lesion and the duration of the flaccid (spinal shock) period. In most instances, reflex excitability is at a maximum about 2 years after spinal cord injury and gradually diminishes during the subsequent years. Spasticity never completely disappears unless the patient becomes moribund or surgical treatment for the relief is undertaken.

Considerable variation occurs following spinal cord trauma in the speed of onset of spasticity and

the sequence of muscles involved. Usually, the first indication of spasticity is the alteration of plantar flexion of the toes following stimulation of the sole of the foot to dorsiflexion (Babinski's response). This change is followed by weak withdrawal of the lower extremities from noxious external stimuli. The weak withdrawal is manifest by contractions of the dorsiflexors of toes and feet and the flexor muscles of the knee and hip. The muscular responses to stimulation spread during days or weeks from distal to proximal muscle groups, rather than from proximal to distal groups which is the common pattern in hemiplegia (7). As time goes on, the spastic movements increase in strength, involve more and more muscle groups, and become increasingly complicated (8). The contractions of the various muscles involved in the spasms are coordinated by synchronous relaxation of antagonistic muscles during the contraction of the muscles which give rise to the movement. The pattern of the spastic movements does not differ greatly with variations in the spinal cord level or the severity of the lesion. Patients who eventually regain voluntary control of the lower extremities following spinal cord injury invariably go through a period of involuntary flexor spasticity before voluntary function appears.

Spasticity after spinal cord injury is present almost exclusively in the lower extremities and only occasionally appears in the upper extremities of individuals with cervical spinal cord injuries. The lack of upper extremity spasticity is usually due to the destruction of the anterior horn cells which are responsible for upper extremity movements because they are at the site of the lesion. Spasticity does not appear in the upper extremities until it has become fairly well established in the lower extremities. It may be in the nature of a tic-like contraction of small hand muscles or a wild flopping movement of the shoulder girdle with laughter or abrupt changes of body position. It is rarely possible to produce spasms in the upper extremities by noxious stimulation. The musculature of the upper extremities and shoulder girdle usually becomes flaccid and atrophic following cervical spinal cord injury. Depending on the level and extent of the lesion, a variety of mild spastic movements are produced in the arms and hands. Since they are almost never a concern or handicap to the patient, spastic movements of the

upper extremities are rarely discussed in conjunction with spasticity due to spinal cord damage. The remainder of this chapter concerns spasticity of the lower extremities.

Spontaneous spasms appear most frequently in patients with cervical lesions and least frequently in those with lower thoracic cord lesions (9). As the number of muscles involved in spastic movements produced by external noxious stimuli increases, there is also an increase in the frequency of the spontaneous involuntary contractions. Although the term "spontaneous" has been applied to these involuntary movements, they are always produced by internal stimuli. Proprioceptive stimuli frequently trigger involuntary spasms when the patient shifts position, takes a deep breath, or sets his diaphragm. Internal noxious stimuli such as a full bladder or bowel increases spontaneous spasms. Infections which increase the irritability of the bladder mucosa increase spontaneous spasms, as does the stimulation of multiple pain fibers by a decubital ulcer. Often these complications of spinal cord damage produce such severe spontaneous spasms that the patient must be tied in his bed or wheelchair. It is only when spasticity becomes this severe that it can be considered a complication of spinal cord damage. Mild spontaneous spasticity is always present in uncomplicated spinal cord damage and can be expected as part of the pattern of development. Spasticity rarely becomes annoying in healthy paraplegic individuals. It decreases or prevents muscular atrophy by maintaining muscular tone.

The involuntary movements which characterize the spasticity of a large majority of the individuals with severe spinal cord damage are stereotyped. They start with quick, sometimes violent contractions of the abdominal and psoas musculature. This is followed almost simultaneously by flexion of the hips and knees and firm adduction of the thighs (fig. 162). A slightly slower dorsiflexion of the feet is followed by extension of the great toes and fanning of the other toes. The contracted muscles relax partially, and there are usually three or four flexor jerks before the extremities resume their usual extended position. This series of movements occurs when the patient is lying supine and may appear in part when the patient is seated. If it occurs when

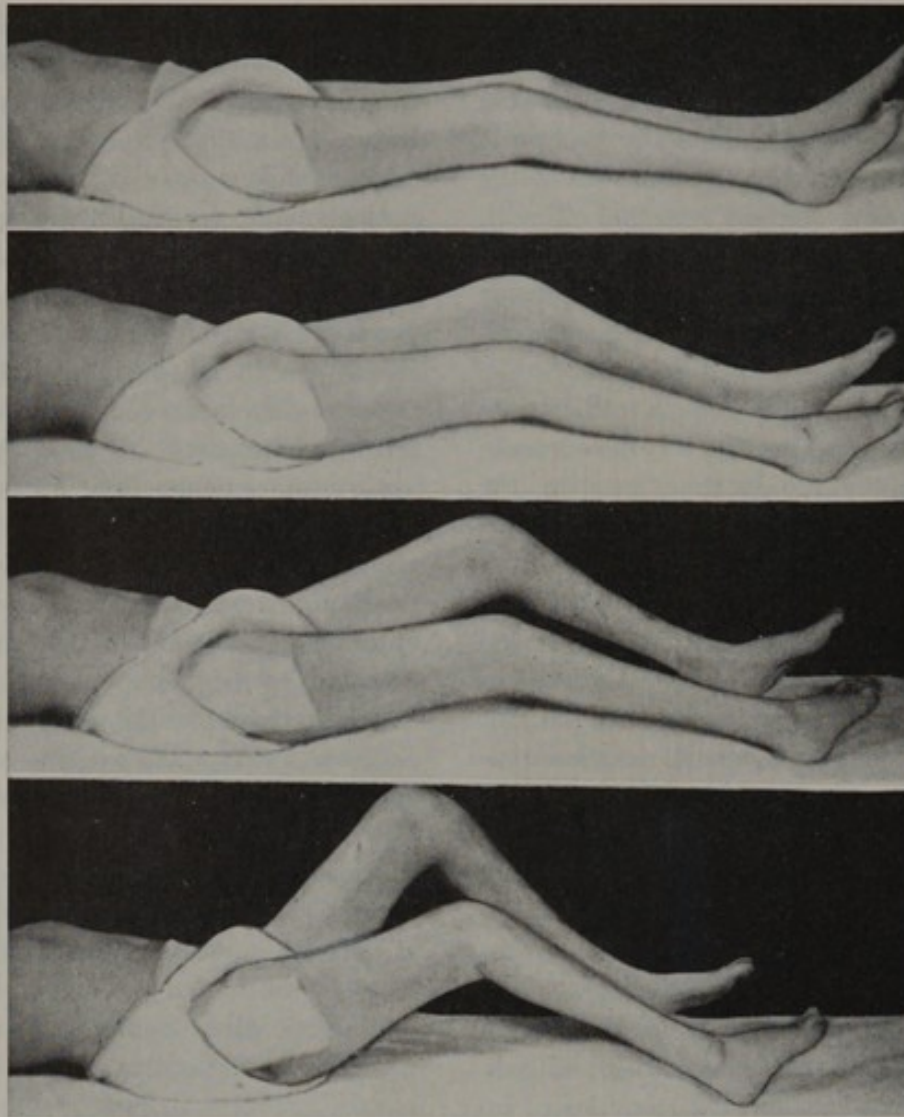


FIGURE 162.—Spontaneous flexor spasticity 4 years after spinal cord injury at the level of the sixth thoracic vertebra. The flexion of thigh and legs with extension of feet takes $\frac{1}{3}$ of a second. (From Departments of Illustrations, Veterans' Administration Hospital and Indiana University Medical Center, Indianapolis, Ind.)

the patient is seated, the feet are often plantar flexed rather than dorsiflexed. A similar reaction of the hip flexors occurs with the patient in the prone position, but the amplitude of the movements is diminished by the patient's weight.

Pollock and his associates (10) made a study of involuntary muscle contractions in paraplegic and quadriplegic patients with their bodies and extremities in various positions and after sudden changes of position. They found a complex system of involuntary muscular actions similar to the tonic neck reflexes of the decerebrate animal. The movements produced by changes of posture varied slightly from patient to patient, but showed a great deal of similarity when a given change of position

was executed. The patients themselves learn about such reflex phenomena and use them as aids in some of their activities. Many paraplegic individuals learn that by contracting the diaphragm or stimulating the skin of the abdomen or groin they can produce flexion of the hip and knee which allows them to put on shoes or trousers. By various maneuvers such as lifting the weight off their buttocks or sliding forward in their wheelchairs a reflex extension of the lower extremities occurs. This can be used to thrust their feet onto the floor of an automobile in preparation for swinging the rest of the body to the seat.

If a paraplegic person reclines from a sitting to a supine position while the legs are flaccidly ex-

tended, there is usually forcible extension of the lower extremities. When the sitting position is resumed there is often flexion at the hips and knees (10). By changing the body positions of paraplegic patients while they were floating in warm water, Pollock and his associates (10) found crossed extensor-flexor responses. Usually the upper leg was flexed and the lower extended when the patient's trunk was rotated from the supine to either lateral position. These phenomena were more easily produced in patients with thoracic than in those with cervical spinal cord injuries. On the basis of this observation, the authors suggest that the cervical portion of the spinal cord exerts an inhibitory action on the postural reflexes of the spinal cord.

Noxious stimuli applied to various skin areas prove effective in producing spastic movements. The following skin areas were found by Pollock and his associates (9) to produce involuntary flexor contractions of the lower extremity in decreasing order of effectiveness—sole of the foot, outer leg, inner leg, inner thigh, external malleolus, anterior thigh, and outer thigh. The decreasing order of effectiveness for the noxious stimulus used was scratch, deep pressure, repetitive pinprick, brush, and single pinprick. Martin and Davis (2) found that midline genital and perineal stimuli frequently bring on bilateral muscular responses, while stimulation of one foot causes a more prompt response which is likely to be unilateral. Many physiotherapists find that pinching, pulling, and flicking the second toe, as in Gonda's maneuver, is the most effective method for producing involuntary flexor spasms in the lower extremities. The response to this stimulus may be unilateral or bilateral depending on the strength of the stimulus. A painful stimulus produced by sharply bending the second toe, but sustained for several seconds, will often stop a series of spastic movements of the lower extremities and produce a brief period of flaccidity. This maneuver is discovered independently by most of the people who attend paraplegic patients. They use it as an aid in dressing very spastic patients. The maneuver for producing temporary flaccidity was described in 1893 by Gowers (11).

Spasticity in the lower extremities of a healthy patient with spinal cord damage is occasionally annoying, but does not become serious unless complications of paraplegia are allowed to develop.

Usually abrupt change in weather or cold, damp atmosphere will increase spasticity, whereas warmth and sunshine will often diminish it. Emotional tension of all sorts—laughing, anger, grief, or apprehension—will increase the spastic phenomena. Spasticity becomes a serious problem only when the spinal reflex centers are constantly bombarded by noxious stimuli from decubital ulcers or urinary tract infections. A vicious circle is usually established in paraplegic patients who have insufficient care. These unfortunate individuals develop decubiti and bladder infections which increase spasticity. The spasticity decreases the patient's appetite because of frequent contractions of the abdominal muscles. They interfere with his sleep. They aggravate his decubital ulcers both through malnutrition and the friction caused by constant movements of the extremities. Flexor contractions develop and become so severe that the anterior thighs rub against the chest wall and the heels against the buttocks to produce decubital ulcers on the eight apposed skin surfaces. The term "paraplegia in flexion" was applied to patients in this condition by Babinski (12) in 1899, and it was also used by Walshe in 1914 (13).

The term "mass reflex" is applied to the involuntary contractions of the lower extremities and truncal muscles in unhealthy paraplegic patients. Autonomic discharges with emptying of the bladder and bowel, piloerection, and profuse perspiration, frequently accompany these violent contractions. The piloerection and sweating ends abruptly at the dermatome level where anesthesia ends and sensation begins. In some cases, only a few dermatomes at the upper end of the anesthetic area are involved in the autonomic discharge. In some individuals, penile erection and even ejaculation will accompany the "mass reflex." These autonomic sexual discharges may occur while the patient is in the prone position and having frequent spasms of the hip flexor muscle. They may even occur during sleep. Some authors refer to this as a primitive "copulatory" reflex, but the muscular activity does not differ from the hip flexor spasms which occur with the patient supine.

In 1893, Gowers (11) made the statement that flexor spasms following spinal cord injury appeared later in the course of development than extensor rigidity and carried a bad prognosis. During World War I, this statement was amplified and probably

misconstrued (13) so that it became customary to predict the mildness or severity of trauma to the spinal cord by the type of spasticity that was observed. If the spastic activity was predominantly flexor in nature, the spinal cord was said to be completely transected. If the muscular action was primarily extensor, an incomplete transection was diagnosed and a better prognosis given. When more accurate data were obtained as the result of frequent surgical explorations of the spinal cord during World War II, it became apparent that these assumptions were false. No statistical correlation exists between the severity of injury and the type of spastic movements which occur in the extremities (2) (10). Freeman was able to produce both flexor and extensor movements of the lower extremities in patients with proved spinal cord transections. At least one patient with constant severe flexor contractions for more than a year following cervical spinal cord trauma developed enough voluntary muscular control to learn to walk without braces and crutches. No lesion could be seen on gross inspection of this patient's spinal cord at surgery. Marshall (14) found that with the proper stimuli both flexor and extensor responses can be elicited from all patients with sufficient spinal cord damage to produce spasticity. Neither the type nor the pattern of spasticity which a patient with spinal cord damage exhibits will indicate whether or how many of the nerve fibers of the spinal cord are severed. An estimate of the intact nerve tissue can be only determined at the time of surgical exploration.

PHYSIOLOGY

The spasticity arising after spinal cord transection has long been a subject of great interest to neurophysiologists. It is well established that this spasticity results from isolation of the distal segment of the spinal cord from the stimuli which arise in higher nervous system centers. The feature of spinal cord spasticity which holds the greatest interest for neurophysiologists is the long delay which takes place between the injury and the development of spasticity. This period of diminished reflex activity following spinal cord injury was described in 1843 by Marshall Hall (15). He called the phenom-

enon "spinal shock." This terminology was also used by Goltz in 1892 (16) who felt that the areflexia following spinal cord injury was in fact "shock" or inhibition due to the irritation of the trauma. Sherrington (17) reasoned that if trauma caused the inhibition of reflexes following spinal cord transection it would be manifest "headward" as well as "arborally." He thought that a lack of impulses from higher centers must be the basis for the areflexia which follows spinal cord transection since the lesion produces little or no effect on functions which are controlled cephalad to the cut but has profound effect on those caudad to it.

The duration of "spinal shock" is one of its interesting features. In reptiles and lower mammalian forms, spasticity arises a few minutes after spinal cord transection, while in monkeys and man, it does not appear until 3 to 6 weeks have elapsed. Sherrington thought that this increased duration of "spinal shock" indicates an increasing control by the higher nervous system centers over spinal cord functions as the evolutionary tree is ascended (17).

During the period of "spinal shock," a reorganization of neuronal functions must take place. It is apparent that "inhibition" is present, but it is hard to believe that inhibitory impulses can act continuously over a period of from 3 to 6 weeks. Scarff and Pool (18) believe that there is a progressive scarring of the severed distal stump of the spinal cord causing irritation similar to that found in an "epileptogenic focus" in the cerebral cortex. Brown-Séquard likened spasticity following spinal cord transection to "spinal epilepsy" (11).¹ This theory does not hold up, however, because spasticity returns unaltered a few hours after the scarred cephalad end of the distal portion of the spinal cord is resected. Following a second transection of the spinal cord, the spastic pattern reappears in a few hours which is much more rapid than scar tissue can be expected to reform (17).

After a single spinal cord transection, the transition from "spinal shock" to a state of spasticity is a gradual one progressing from the appearance of a faint plantar response to rapid integrated movements of the entire lower extremity. This indicates

¹ Status spasticus has been observed in two instances following intrathecal injection of penicillin in the presence of a subarachnoid block (chapter 25).—A.M.M.

that there is a slowly progressive alteration going on in the isolated portion of the spinal cord. Sherrington (17) found that a second transection in the distal portion of the spinal cord will produce a transient areflexia which lasts only a fraction of the time occupied by the original areflexia. This observation has been confirmed many times by subsequent investigations in human subjects as well as experimental animals (18). The spasticity which reappears so quickly following a second transection of the distal spinal cord is identical to that which took days or weeks to develop following the first transection. These findings indicate that the neurons in the isolated distal segment of the spinal cord establish an independent pattern of function to create spasticity. This independent pattern of neuronal function is not governed by the neurons at the cephalad end of the distal segment of the spinal cord as the removal of those neurons does not affect the spasticity.

Liddell (19) found a progressive increase in the resistance to inhibitory stimuli in the lower extremities of cats with transected spinal cords. With the progressive resistance to inhibition there was a progressive destruction of the smaller neurons in the distal segment of the spinal cord. The anterior horn cells were not destroyed. Van Harreveld and Marmont (20) were able to shorten the period of "spinal shock" in cats by exerting hydrostatic pressure on the distal segment of the spinal cord to asphyxiate it. They also observed a progressively severe degeneration of the internuncial neurons as the duration of asphyxia was increased. The anterior horn cells were the most hardy of the neurons in this experiment and were the last to show degenerative changes from asphyxia. These reports of progressive degeneration of small neurons make it apparent that the histological pattern is not constant in the distal segment of a transected spinal cord. The loss of internuncial neurons added to the loss of impulses from higher nervous system centers must markedly alter the pattern of impulses which reach the anterior horn cells. The only stimuli which can reach the anterior horn cells are afferent sensory stimuli from undamaged posterior nerve roots and the impulses which the remaining neurons in the isolated spinal cord themselves produce. Förster (21) performed posterior rhizotomies to reduce the

spasticity arising from spinal cord damage on the theory that it was a reflex response. By reducing the sensory stimuli reaching the isolated spinal cord, he thought he could reduce spasticity.

After spinal cord transection, neither the inhibitory nor the facilitatory impulses coming from the reticular formation (22) and elsewhere in the brain (23) (24) reach the internuncial neuron pool of the isolated segment of cord. This greatly decreases the number of impulses impinging on each anterior horn cell and must decrease its threshold of excitability. This in part explains the period of flaccidity following spinal cord transection, but does not account for its long duration.

Spinal cord transection leads to degeneration of descending tracts and internuncial neurons in the isolated spinal cord and a decrease in the number of synapses which reach each remaining neuron. Recent attention to the regeneration of axons within the spinal cord (25) (26) (27) (28) indicates that not only degeneration of neurons and axons but also regeneration of axons takes place in the spinal cord during the period of "spinal shock." The decrease in number of synapses reaching each anterior horn cell stimulates the remaining neurons to send out additional processes (26) and establish new synapses. Spasticity probably arises only after a sufficient number of synapses have reached the anterior horn cells to produce enough facilitation so that they can fire. The prolonged period of reflex inactivity called "spinal shock" which follows spinal cord injury is probably occupied by the degeneration of long tracts and internuncial neurons and the regeneration of axons and synapses to reestablish the facilitation of the anterior horn cells.

Under these circumstances of regeneration, the reflex arc, from sensory endings to motor end-plates, involves fewer neurons than would be involved in an intact spinal cord. The reflexes become less complex, and the spastic activity becomes somewhat stereotyped. In the healthy individual with spinal cord damage, postural and other proprioceptive changes cause minor alterations in the spastic pattern. This probably indicates that many internuncial neurons are still intact. Individuals with severe complications of paraplegia have spasticity that is more violent and stereotyped, indicating that there has been greater destruction of internuncial neurons.

The decreased number of neurons in the isolated segment of spinal cord stimulates each of the remaining intact neurons to send out a greater number of new processes. This leads to a closer synaptic relationship between the neurons than would be expected if a larger number were present. The paucity of neurons decreases the amount of inhibition that would be expected from a larger neuronal pool. A greater facilitation of each sensory stimulus is produced as it is carried to the anterior horn cell. A greater number of impulses reach the anterior horn cells simultaneously because many more of the synapses which carry them come from the same internuncial neuron, and a repetitive stereotyped spastic pattern is produced.

TREATMENT

The most important treatment of the spasticity which arises from spinal cord damage is prevention. Adequate care of the urinary tract and skin will minimize the violence of the spasticity by decreasing the volume of noxious stimulation which bombards the isolated spinal cord. Adequate care must be started within a few hours of the onset of paraplegia or many months will be wasted in treating decubiti and urinary tract infections. Prevention of these complications must be continued throughout the patient's life. The normal spasticity which is present in most healthy paraplegic individuals does not require treatment except for reassurance that it will be neither harmful nor painful. A constant vigil must be maintained to prevent complications of paraplegia so that normal spasticity will not increase to become harmful.

Adequately cared for individuals with spinal cord damage require no treatment for spasticity except that it be explained to them. The appearance of spasticity cannot be regarded as an indication of the return of voluntary muscular control nor does it mean that voluntary control can never return. If spasticity appears within 2 to 3 days after injury, it gives greater hope for the return of voluntary muscular control than if it appears after 3 to 6 weeks. Usually no really useful voluntary motor function returns unless there is some evidence of its presence within a few days of the time of injury, but this again is not a hard and fast rule as there are oc-

casional exceptions. Very careful explanation to the patient of the importance of spasticity is necessary so that hopes of return of voluntary control are not encouraged. It also is not wise to use the appearance of spasticity as the sign that no return is possible. Explanation of the onset of spasticity must be handled carefully as it is a very important psychological issue during a time of severe emotional trauma.

The patient should be encouraged to observe the changes which bring on spastic movements. Taking a deep breath, changing position of the body, or certain skin stimuli will usually produce involuntary spastic movements. The recognition and use of trigger mechanism for these spasms may be helpful to the patient in some of his daily tasks, such as getting out of bed, emptying his bladder, getting into an automobile, and so forth. By synchronizing a voluntary attempt to perform the same movement as is produced by the involuntary spasm, it is sometimes possible to achieve some voluntary control of the spastic group of muscles.

Neglected patients with spinal cord damage frequently develop spasticity which harms general health. In these patients, spontaneous flexor spasms of the legs become more and more frequent, and contractures of the spastic muscle groups develop. Finally, they lie constantly in the flexed position. Muscle and joint contractures make it impossible to place the patient in a position that will relieve pressure on the decubiti. The patient becomes cachectic and pain ridden. It is at that time that heroic measures for the relief of spasticity become mandatory to preserve life.

Between the two extremes, the healthy paraplegic individual with occasional spasm and the individual with "paraplegia in flexion," lie a large number of patients with some spasm. Moderately severe spasticity may disturb a patient's sleep, keep him from ambulating with braces and crutches, require him to be strapped in bed or wheelchair, or cause frequent small discharges of urine. It is toward this group that most of the therapy for spasticity is directed.

Drugs have been disappointing in the control of spasticity arising from spinal cord damage. Freeman and Heimburger have administered curare to the point of producing diplopia without appreciably decreasing involuntary muscle spasms. Some of

the newer antispasmodic drugs—Robaxin¹ (methocarbamol), Equanil (meprobamate)—even when given in large doses do not alter spinal cord spasticity to any great extent. The reduction of spasticity following the intravenous administration of chlorpromazine has been claimed to reduce spasms (29). The benefit does not continue with repeated intravenous injection or with oral administration. Even the use of anticonvulsant drugs, to combat the irritation of the scarred proximal end of the isolated spinal cord, has no effect (18). Nonspecific antigens (Piromen) have been ineffectual in relieving spasticity (30). The ingestion of alcoholic beverages appears to cause temporary alleviation of spasticity. When this treatment is tried over long periods, however, serious complications of paraplegia arise and counteract any beneficial action of the alcohol. Sedatives and opiates produce temporary relief also, but must be administered in increasingly larger doses to produce an effect. Most paraplegic individuals are very susceptible to drug addiction, which in turn increases the incidence of decubiti and urinary tract infections.

Förster (21) was the first surgeon to attempt the alleviation of spasticity which follows spinal cord damage. The surgical procedure he used was based on his theory that spasticity is a reflex phenomenon requiring the input of afferent impulses and the outflow of efferent impulses. He performed posterior rhizotomies to decrease the number of afferent impulses reaching the anterior horn cells in the isolated portion of the spinal cord. This operation was subsequently abandoned because it produces only temporary relief of spasticity. Posterior rhizotomy is probably not effective because it is nearly impossible to isolate the spinal cord from afferent impulses as relatively little sensory input is required to produce a massive efferent discharge from the damaged distal segment of spinal cord. Groves reported some success from posterior rhizotomy in 1911 (31), but found that there had been considerable damage to the anterior horn cells of the spinal cord following his procedure. Probably direct damage to these neurons during his surgery or indirect damage through ischemia produced by occluding the blood supply which enters the spinal cord with posterior roots produced the desired relief of spasticity.

In 1945, Munro suggested the use of anterior rhizotomy (32) to diminish troublesome spasticity

and speed up and improve the rehabilitation of paraplegic individuals. Since his report, anterior rhizotomy has been the most widely used surgical procedure for the treatment of spasticity due to spinal cord damage. Subsequent articles have appeared to modify the technique and state the indications more clearly (33) (34). Since anterior rhizotomy is a destructive procedure which precludes any return of voluntary muscular control, it should be done only with the clearest of indications and with the complete consent of the patient. Individuals suffering from "paraplegia in flexion" need anterior rhizotomy as a lifesaving measure. It can be done quite safely under local anesthesia for the most debilitated patients. Often it is necessary to carry out this procedure on individuals with spasticity less severe than "paraplegia in flexion" in order to permit them to obtain adequate sleep at night, to sit comfortably in a wheelchair, to participate more actively in ambulation exercises, or to decrease the formation of decubital ulcers by relaxing muscle contractures to permit more variation of body positioning. Except in very unusual circumstances, anterior rhizotomy should not be carried out until paraplegia has been present for at least 2 years. Some motor return has developed as late as 2 years after injury. Often spasticity decreases spontaneously about 2 years after the onset of paraplegia.

In a majority of instances, anterior rhizotomy (34) can be most satisfactorily performed by using local injection or no anesthesia. This permits testing of the spastic muscles during the procedure so that the surgeon can be sure of cutting all the required anterior nerve roots. Usually the operative site is in an area made anesthetic by the original spinal cord damage. The vertebral levels of T12 and L1 are marked roentgenographically prior to surgery, and these two laminae are removed. This usually exposes the conus medullaris, but if it does not, the laminectomy must be extended to make its complete visualization possible. The dura mater is opened longitudinally in the midline; the arachnoid is incised laterally. The last firm dentate ligament (usually T12) is grasped and severed so that the spinal cord can be rotated to reveal the anterior nerve roots. The exit of the nerve root of T12 from the dural sac is used as a point of orientation. The anterior roots are counted from T12 and sectioned individually between silver clips. The occasional

large blood vessel which accompanies an anterior root is separated from the root and left intact. By counting nerve roots, it is possible to section the desired ones and leave intact those which preoperative sacral nerve blocks have shown must be spared to preserve good bladder function. The anterior roots arise from the spinal cord as a continuous group of small rootlets, which gather together to form a bundle of fibers shortly after they emerge from the anterolateral sulcus of the spinal cord. Sometimes it is difficult to be sure that all the nerve fibrils have been severed, so it is desirable to be able to test the spastic muscles during surgery so that any missed roots or fibrils can be found and sectioned. Anterior rhizotomy has had to be repeated on a few occasions because nerve roots have been missed and annoying spasticity has persisted.

Following anterior rhizotomy, it is necessary to watch the patient's skin more carefully as decubital ulcers form more easily just as they did for several weeks after the initial spinal cord injury.

Removal of the distal neuroma from the spinal cord to decrease the irritation of the scarred cephalad stump of traumatized spinal cords, as advocated by Scarff and Pool (18), has been completely abandoned for the treatment of spasticity as it produces very temporary relief, sometimes lasting only a few hours.

Usually only certain of the spastic movements interfere with rehabilitation or cause annoyance, and the other involuntary movements are easily tolerated. Particularly annoying are hip flexor and adductor spasms. Spasms of the thigh and knee extensor muscles are usually welcomed as they aid brace and crutch ambulation. Peripheral neurectomies are often used to reduce spasms in specific muscle groups (35). Obturator neurectomy is frequently used to reduce thigh adductor spasms while femoral or sciatic nerve sections are used less frequently to reduce hip flexor and foot extensor spasms. Obturator neurectomy is used to reduce constant adductor spasms of the thighs. It helps improve ambulation, gives comfort in a wheelchair or bed, and increases the ease of maintaining personal cleanliness. Often relaxation of adductor spasms will not only abolish "scissoring" of the lower extremities but produces other benefits such as decreasing spontaneous, forceful bladder evacuations by diminishing the pressure of the pelvic muscles on the bladder. This simple

procedure will occasionally reveal voluntary muscular control which was masked by the severe adductor spasticity. Neurectomy of the obturator nerve may be carried out through an intrapelvic or extrapelvic approach (36).

Intrapelvic obturator neurectomy is carried out by making bilateral 4-cm. incisions parallel to and 1 cm. above the inguinal ligament, about half way between the anterior superior iliac spine and the pubic symphysis. The peritoneum is exposed and separated from the obturator muscles. As this is done, the obturator nerve can be palpated as it emerges from the obturator muscle and crosses the retroperitoneal space parallel to the long axis of the body. The nerve is identified by the obturator artery which accompanies it. Both structures emerge from the obturator foramen in its superior medial portion. When the nerve and artery can be easily visualized, they are separated and a segment of the nerve removed between silver clips. Occasionally, it is desirable to crush rather than sever the obturator nerve so that it will regenerate in 6 to 12 months.

Extrapelvic obturator neurectomy is carried out by making a 4-cm. incision along the medial border of the adductor longus muscle starting at the pubis about 2 cm. lateral to the symphysis. The adductor longus muscle is retracted laterally to expose the adductor brevis. The obturator nerve divides as it emerges from the posterior surface of the pubis ramus. The anterior division courses over the anterior surface of the adductor brevis muscle, while the posterior division courses over the medial surface of the adductor brevis to lie between it and the adductor magnus. Both divisions of the nerve are severed. In case the adductor muscles are contracted, their tendon attachments to the pubis can be severed during this operation.

The extrapelvic method of sectioning or crushing the obturator nerve and its branches as it crosses the adductor muscles in the thigh produces a less complete denervation of the adductor muscles than the intrapelvic approach. General or spinal anesthesia is required to reach the medial thigh in the patient with severe adductor spasm. The retroperitoneal approach requires only local anesthesia or none at all if the paraplegic sensory level is T10 or above.

Femoral neurectomies to decrease the strength of flexor spasms at the hip are occasionally carried out,

as are sciatic neurectomies to decrease equinus deformities of the foot. Both of these procedures are used only to improve ambulation. Sciatic neurectomy might be carried out to allow the wearing of shoes without undue friction on the skin of the foot because of gastrocnemius muscle spasms. Achillogenotomy is used to decrease equinus, but it is less satisfactory as it does not abolish the spastic movements of the foot and the skin friction continues.

Femoral neurectomy is carried out by making a 3-cm. incision parallel to and 1 cm. below the inguinal ligament, centered over the lateral portion of the femoral canal. By palpating the femoral artery, it is a relatively simple matter to find the nerve which lies just lateral to it. No branches have come off the nerve at this point, so it can be sectioned, crushed or sectioned, and sutured, depending on how long the effect is desired. If the nerve is to be sutured, it is wise to place two guide sutures before it is sectioned so that the approximation can be brought into good alignment.

Sciatic neurectomy (35) is a relatively simple procedure to carry out as the sciatic nerve can be easily exposed through a longitudinal incision from 4 to 5 cm. over the cleft between the vastus medialis and lateralis of the hamstring muscles, 10 cm. above the popliteal space. By separating the muscles through fascial planes the nerve can be exposed, sectioned, crushed or sectioned, and sutured.

A number of chemicals have been injected into the spinal canal in an attempt to relieve spasticity. The commonly used spinal anesthetic agents injected both intrathecally or extradurally will relieve spasms during the time that they are active. They have been used continuously for as long as 3 days with the idea that a prolonged period of flaccidity might break up some "cycle" that produces spasticity. No lasting benefit was achieved by this method. Spinal and epidural anesthesia is useful as a test to determine how many anterior nerve roots need to be sectioned to produce satisfactory relief of spasticity. This determination is particularly important when it becomes necessary to relieve spasticity in the abdominal musculature. Although spasms of the abdominal muscles are extremely annoying to the patient, it is better for them to have some abdominal tone as flaccid abdominal musculature makes breathing in the seated position difficult and increases the tendency for bowel impaction. Epidural blocks are

more effective than spinal anesthetics in this type of testing as the level of the block can be gradually raised while observations of spasticity are made. When satisfactory relief of spasticity has been achieved, the number of anterior roots to be sectioned for permanent control of the spasticity is determined by the level of the block. Palpation of muscle tone is the only method of determining the level of the block as it is carried out in an anesthetic area.

Alcohol has been used in a number of ways to stop spasms. The most frequent method is intrathecal injection of 95 percent alcohol (37) (38) (39). It is possible to relieve spasticity over limited periods by this technique, but spasms return after several months to 2 years. For this reason, it is used when a few months of flaccidity are needed in the care of paraplegia due to metastatic carcinoma. In the treatment for the spasticity of traumatic paraplegia, a period of many years of relief is usually needed, so that anterior rhizotomy is the procedure of choice. The operative risk of anterior rhizotomy and intrathecal alcohol injection is approximately the same; the desired duration of flaccidity should be, therefore, the major factor in choosing between the two procedures. The major disadvantage to intrathecal alcohol injection is that both anterior and posterior nerve roots are destroyed, and occasionally, the nerve destruction rises above the desired spinal cord level to produce unwanted and occasionally dangerous sequelae.

The intrathecal injection of alcohol must be carried out with the patient on his side. In this position, a small gage (No. 20) lumbar puncture needle is easily introduced into the low lumbar region. Jugular compression will usually show whether the subarachnoid space is patent or blocked at the site of the spinal cord lesion. If it is blocked, there need be less fear that the alcohol will migrate cephalad in the spinal canal to produce a higher level than is desired. When a free flow of spinal fluid has been established, the patient is turned to the prone position and the legs and buttocks elevated about 45 degrees above the horizontal position. Absolute or 95 percent alcohol is slowly injected in 1-cc. doses while spasticity is being tested. When enough alcohol has been injected to abolish the spasms, the injection is discontinued. The patient must remain in the feet-up position for an hour to be sure that the

alcohol is all absorbed and none is free to travel further cephalad in the canal when the patient is flattened to a horizontal position. As much as 10 to 15 cc. of alcohol may be needed to produce the desired result. A frequent check on sensation is also valuable as the alcohol should not rise above the paraplegic level of anesthesia.

Sometimes, due to arachnoidal adhesions and other barriers, it is not possible to get the alcohol to reach all the desired nerve roots. It may be necessary to repeat the alcohol injection, introducing the needle at a different vertebral level to produce the desired flaccidity. It is possible to treat unilateral spasticity by injecting alcohol while the patient lies in a lateral position with the spastic side up and the buttocks elevated above the head. The alcohol then rises to destroy the uppermost nerve roots. Some surgeons prefer to decrease the chance of undue spread of the alcohol by treating the spasticity on one side at a time. With this unilateral technique, a smaller volume of alcohol can be used, thus decreasing the risk.

Joshua Spiegel has injected alcohol directly into the spinal cord in an attempt to relieve spasticity. When this technique is used, it is necessary to make injections at several levels along the isolated distal segment of the spinal cord. If all the anterior horn cells in the distal portion of the spinal cord are not destroyed, spasticity will return from 2 to 6 months after intramedullary injection. If a single alcohol injection is made into the isolated spinal cord, spasticity usually returns in a few days. The procedure is considerably less satisfactory for permanent relief of spasticity than intrathecal alcohol injection or anterior rhizotomy.

Various tracts in the spinal cord have been sectioned in an attempt to relieve spasticity. Ventromedial cordotomy has been used for the treatment of spastic diplegia (40). Since the spasticity which follows spinal cord damage results from the release of the anterior horn cells from higher nervous system centers, it cannot be expected that further sectioning of the tracts from these centers will bring about permanent relief. When "spinal shock" from such a procedure has been overcome, the remaining intact neurons will reestablish their own reflex autonomy and spasticity will continue. Since spinothalamic tractotomy for relief of pain can be com-

pared to ventromedial cordotomy, it can be reported that this procedure often increases spasticity in paraplegic individuals even though pain has been abolished.

Corpectomy of all or part of the isolated distal portion of the spinal cord has been carried out in an attempt to relieve spasticity (41). This therapy is carried out to eliminate the isolated distal portion of the spinal cord which is thought to be similar to the "spastic epileptogenic hemisphere" in infantile hemiparesis. A more satisfactory automatic bladder, as well as relief of spasticity, is the supposed advantage of this procedure. Corpectomy can be justified for removal of an intramedullary tumor, but there are so many procedures which can relieve spasticity and improve bladder control more simply than by the long laminectomy required for corpectomy.

A great many physiotherapeutic measures are used to relieve spasticity due to the spinal cord damage. At best, they are of only temporary benefit. Heat, massage, whirlpool baths, diathermy, and ultrasound are very useful in decreasing the contractures and joint ankylosis which result from spasticity. Spasticity itself is temporarily diminished by these methods, particularly when heat is applied. Patients who have become accustomed to physiotherapy find that only a few days without it are followed by a marked increase of spasticity. Combined with crutch and brace ambulation, physiotherapy is justified up to 2 years after spinal cord injury. After 2 years, crutch and brace ambulation alone is usually sufficient to maintain joint mobility and general health. Most individuals are able to carry out a physiotherapy program at home. If troublesome spasticity does not start to subside about 2 years after injury, one of the surgical techniques mentioned should be considered.

Various physical means to control spasms have been tried. During World War II, a group of 30 to 40 paraplegic patients at one of the military hospitals had boxlike wooden splints applied to their legs and hips. Some were bound in these splints so that spastic movements were not possible for as long as 18 months. When the splints were removed, spasticity was present in all of the patients treated by this method. In some, the spasticity was more severe than in similar patients who had had more

conventional physiotherapy. The splinted group of patients had the additional problem of an increased incidence of decubital ulcers.

An intriguing therapeutic method which has achieved some success in the relief of spasticity is hypnosis and posthypnotic suggestion (42). Although the study was carried out on a small group of patients and the results were not entirely conclusive, the occasional dramatic relief of spasticity with posthypnotic suggestion brings up a great deal of interesting speculation and warrants further investigation. One wonders what connections exist between the psyche and the isolated distal portion of a damaged spinal cord to permit the decrease of spasticity during posthypnotic suggestion. The possibility of sympathetic neuronal connections or hormonal controls must be considered. Perhaps more realistic is the probability that in only a few instances of traumatic spinal cord damage are all the neural connections in the spinal cord severed. In many cases, the traumatized cord appears normal a few hours after injury. If the cord is explored again many months after injury, it may again appear grossly normal. From these observations, it seems probable that some neural elements are still anatomically connected. Is it possible that inhibitory impulses can traverse these otherwise inactive pathways during hypnosis, just as some normal individuals can perform impossible feats of strength under similar circumstances? Of course, the decrease in spasticity during posthypnotic suggestion could be entirely coincidental.

REFERENCES

1. Magoun, H. W., and Rhines, Ruth: Spasticity: The Stretch-Reflex and Extrapyramidal Systems. American Lecture Series No. 9, American Lectures in Surgery. Springfield, Ill.: Charles C Thomas, 1948.
2. Martin, J., and Davis, L.: Studies Upon Spinal Cord Injuries. III. Altered Reflex Activity. *Surg., Gynec. & Obst.* 86: 535-542, May 1948.
3. Riddoch, G.: The Clinical Picture of Complete Transverse Division of the Spinal Cord. *Medical Science* 5: 44, October 1921.
4. Riddoch, G.: The Reflex Functions of the Completely Divided Spinal Cord in Man, Compared With Those Associated With Less Severe Lesions. *Brain* 40: 264-402, November 1917.
5. Heimburger, R. F., Freeman, L. W., and Wilde, N. J.: Sacral Nerve Innervation of the Human Bladder. *J. Neurosurg.* 5: 154-164, March 1948.
6. Holmes, G.: The Pathology of Acute Spinal Injuries. Goulstonian Lectures on Spinal Injuries of Warfare. *Brit. M. J.* 2: 769-774, November 1915.
7. Kuhn, R. A., and Macht, M. B.: Some Manifestations of Reflex Activity in Spinal Man With Particular Reference to the Occurrence of Extensor Spasm. *Bull. Johns Hopkins Hosp.* 84: 43-75, January 1949.
8. Pollock, L. J., and Schaeffer, B. S.: Spasticity, Pseudospontaneous Spasms and Other Reflex Activities Appearing Late After Injury to the Spinal Cord. *Arch. Neurol. & Psychiat.* 63: 674-675, April 1950.
9. Pollock, L. J., Boshes, B., Finkelman, I., Chov, H., and Brown, M.: Spasticity, Pseudospontaneous Spasms, and Other Reflex Activities Appearing Late After Injury to Spinal Cord. *A.M.A. Arch. Neurol. & Psychiat.* 66: 537-560, November 1951.
10. Pollock, L. J., and others: Body Reflexes Acting on the Body. *A.M.A. Arch. Neurol. & Psychiat.* 74: 527-533, November 1955.
11. Gowers, Sir William Richard: A Manual of Diseases of the Nervous System. 2d edition. London: J. & A. Churchill, 1892, vol. I.
12. Babinski, M. J.: Sur une forme de paraplégie spasmodique consécutive à une lésion organique et sans dégénérescence du système pyramidal. *La Presse Médicale* 24: 118, March 1899.
13. Walshe, F. M. R.: The Physiological Significance of the Reflex Phenomena in Spastic Paralysis of the Lower Limbs. *Brain* 37: 269-336, October 1914.
14. Marshall, J.: Observations on Reflex Changes in the Lower Limbs in Spastic Paraplegia in Man. *Brain* 77: 290-304, June 1954.
15. Hall, Marshall: New Memoir on the Nervous System. London: Hippolyte Braillière, 1843.
16. Goltz, F.: Der Hund ohne Grosshirn. Siebente Abhandlung über die Verrichtungen des Grosshirns. *Pflüger's Arch. f. d. ges. Physiol.* 51: 570-614, March 1892.
17. Sherrington, Charles Scott: The Integrative Action of the Nervous System. New York: C. Scribner's Sons, 1906, pp. 240-248.
18. Scarff, J. E., and Pool, J. L.: Factors Causing Massive Spasm Following Transection of the Cord in Man. *J. Neurosurg.* 3: 285-293, July 1946.
19. Liddell, E. G. T.: Spinal Shock and Some Features in Isolation-Alteration of the Spinal Cord in Cats. *Brain* 57: 386-400, December 1934.
20. van Harreveld, A., and Marmont, G.: The Course of the Recovery of the Spinal Cord From Asphyxia. *J. Neurophysiol.* 2: 101-111, March 1939.
21. Förster, O.: Über eine neue operative Methode der Behandlung spastischer Lähmungen mittels Resektion hinterer Rückenmarkswurzeln. *Zeitschrift für Orthopädische Chirurgie* 22: 203-223, April 1908.
22. Suda, I., Koizumi, K., and Brooks, C. McC.: Reticular Formation Influences on Neurons of Spinal Reflex Pathways. *J. Neurophysiol.* 21: 113-123, March 1958.
23. Lloyd, D. P. C.: Spinal Mechanism of the Pyramidal System in Cats. *J. Neurophysiol.* 4: 525-546, November 1941.

24. Bernhard, Carl Gustaf: The Corticospinal System. Transactions of the Fifth Conference on Nerve Impulse. New York: Josiah Macy, Jr. Foundation, 1954, pp. 95-134.
25. McCouch, G. P., Austin, G. M., and Liu, C. Y.: Sprouting of New Terminals as a Cause of Spasticity. *Am. J. Physiol.* 183: 642-643, December 1955.
26. Liu, Chan-Nao, and Chambers, W. W.: Intraspinous Sprouting of Dorsal Root Axons. *Arch. Neurol. & Psychiat.* 79: 46-61, June 1958.
27. Freeman, L. W.: Return of Function After Complete Transection of Spinal Cord of Rat, Cat and Dog. *Ann. Surg.* 136: 193-205, August 1952.
28. Turbes, C. C., and Freeman, L. W.: Peripheral Nerve-Spinal Cord Anastomosis for Experimental Cord Transection. *Neurology* 8: 857-861, November 1958.
29. Basmajian, J. V., and Szatmari, A.: Chlorpromazine and Human Spasticity. An Electromyographic Study. *Neurology* 5: 856-860, December 1955.
30. Nyquist, R. H., and Bors, E.: Effect of Piromen on Spasticity in Cases of Spinal Cord Injury. *Arch. Phys. Med.* 36: 567-570, September 1955.
31. Groves, E. W. H.: On the Division of the Posterior Spinal Nerve Roots. (I.) For Pain; (II.) For Visceral Crises; (III.) For Spasm. *Lancet* 2: 79-85, July 1911.
32. Munro, D.: The Rehabilitation of Patients Totally Paralyzed Below the Waist, With Special Reference to Making Them Ambulatory and Capable of Earning Their Living. I. Anterior Rhizotomy for Spastic Paraplegia. *New England J. Med.* 233: 453-461, 18 Oct. 1945. *Correction*, 233: 731, 13 Dec. 1945.
33. MacDonald, I. B., McKenzie, K. G., and Botterell, E. H.: Anterior Rhizotomy; The Accurate Identification of Motor Roots at the Lower End of the Spinal Cord. *J. Neurosurg.* 3: 421-425, September 1946.
34. Freeman, L. W., and Heimbürger, R. F.: The Surgical Relief of Spasticity in Paraplegic Patients. I. Anterior Rhizotomy. *J. Neurosurg.* 4: 435-443, September 1947.
35. Freeman, L. W., and Heimbürger, R. F.: The Surgical Relief of Spasticity in Paraplegic Patients. II. Peripheral Nerve Section, Posterior Rhizotomy, and Other Procedures. *J. Neurosurg.* 5: 556-561, November 1948.
36. Speed, J. S., and Knight, Robert A. (editors): *Campbell's Operative Orthopaedics*. 3d edition. St. Louis: C. V. Mosby Co., 1956, vol. II, pp. 1901, 1903-1905.
37. Stellar, S.: Subarachnoid Injection of Alcohol in Treatment of Spasticity in Paraplegia. *A.M.A. Arch. Neurol. & Psychiat.* 69: 343-349, March 1953.
38. Sheldon, C. H., and Bors, E.: Subarachnoid Alcohol Block in Paraplegia; Its Beneficial Effect on Mass Reflexes and Bladder Dysfunction. *J. Neurosurg.* 5: 385-391, July 1948.
39. Cooper, I. S., and Hoen, T. I.: Intrathecal Alcohol in the Treatment of Spastic Paraplegia. *J. Neurosurg.* 6: 187-190, May 1949.
40. Bucy, P. C.: Studies on the Human Neuromuscular Mechanism. II. Effect of Ventromedial Chordotomy on Muscular Spasticity in Man. *Arch. Neurol. & Psychiat.* 40: 639-662, October 1938.
41. MacCarty, C. S.: The Treatment of Spastic Paraplegia by Selective Spinal Cordectomy. *J. Neurosurg.* 11: 539-545, November 1954.
42. Chappell, Dorothy T.: The Use of Hypnosis in the Reduction of Spasticity in Paraplegia. Dissertation Abstracts 13: 430-431, 1953. Doctoral Dissertation, University of Michigan, Ann Arbor, Mich.

CHAPTER 37

Spasticity Arising From Lesions in the Brain

Robert F. Heimbürger

The number and complexity of nuclei and tracts in the brain suggest that a large variety of different patterns of spasticity might arise as the result of severe brain trauma. More variation appears in the involuntary movement patterns resulting from brain injury than from injury of the spinal cord, but again there is a surprising uniformity in the majority of cases. As in the case of spinal cord injury, an alteration in the nerve impulses which finally reach the anterior horn cells following brain injury is responsible for the altered muscular activity which develops. Considering the number of facilitatory, inhibitory, and integrative factors that affect a motor impulse from its point of origin to its final stimulation of the anterior horn cells, it is rather amazing that only a few patterns of spasticity result from trauma to the brain with any regularity.

Brain trauma has been found to produce only five of the many involuntary movement patterns which arise as the result of brain damage (1). Two of these, spastic hemiparesis and decerebrate rigidity, are by far the most common. They comprise more than 97 percent of the cases that develop spasticity following severe brain injury. The other three, parkinsonism, chorea, and forced grasping and sucking, appear as the proved result of trauma (with the possible exception of birth injury), but only occur rarely.

Patterns of spasticity which arise from brain trauma are similar to those that arise from the spinal cord in that a limited number of involuntary movement syndromes develop. They differ somewhat in that diseases which damage the spinal cord produce a pattern of spasticity which is almost identical to that which arises from trauma, while diseases of the

brain can produce involuntary movement syndromes that are not mimicked by brain trauma. In a majority of cases, brain disease produces decerebrate rigidity or spastic hemiparesis which is identical to that produced by trauma. Usually, the actual cause of the involuntary movements, cerebral edema and hemorrhage, are the same for brain disease and brain trauma. An occasional involuntary movement pattern is produced by brain disease that does not occur as the result of brain trauma, unless it is birth trauma. Hemiballism and dystonia musculorum deformans are among these.

The spasticity that develops from brain damage is a reflex phenomenon requiring a sensory input to maintain it, as is true for spasticity from spinal cord damage (2). The spasticity which arises both from spinal cord and brain damage is much diminished or absent during sleep when the sensory input is decreased.

A large lesion can exist in the brain without producing spastic hemiparesis or decerebrate rigidity indicating that the two spastic phenomena arise from damage to specific brain areas. Since these two abnormal motor patterns are very common following severe brain trauma, one must conjecture that two areas of the brain are most vulnerable to damage. Trauma to the head causes the brain to ballot within the skull. This places a great strain on the brain stem as well as damaging the cortical areas which strike the inner tables of the skull. Damage to the brain stem can produce decerebrate rigidity or spastic hemiparesis. Usually, these spastic phenomena do not appear for many hours after injury. This lag of development of spasticity may be due to shock or reflex inhibition from the irritation of the trauma.

More likely the lag occurs because the lesions which give rise to spastic hemiparesis, decerebrate rigidity, or both, do not develop until several hours after the injury has taken place. These two spastic phenomena usually arise as a sequel to cerebral edema rather than as the result of direct trauma to a given part of the brain. This helps to explain why there is such infrequent variation in the two spastic patterns which develop following head injury. Cerebral edema invariably follows trauma to the brain regardless of the cause of the trauma. If the edema is mild, transient or no spastic movements may be observed.

Severe brain edema may affect only one cerebral hemisphere to displace the brain and exert traction on the cerebral peduncles and internal capsule. If this traction exists for a prolonged period, spastic hemiparesis results. The hemiparesis is reversible if the edema subsides before irreversible damage occurs, but permanent if it does not. If the edema increases or spreads to both cerebral hemispheres, the medial portion of both temporal lobes (uncus) or superior portion of the cerebellum is forced through the incisura of the tentorium. This exerts pressure on the brain stem to produce decerebrate rigidity. Decerebrate rigidity is also reversible if pressure on the brain stem is relieved in time. Because the vicious cycle of cerebral edema, brain stem compression, more cerebral edema, and so forth occurs, there is a grave threat to the life of a patient when severe cerebral or cerebellar edema develops. Inflammatory and hemorrhagic diseases of the brain also produce edema. Spastic hemiparesis and decerebrate rigidity, which cannot be distinguished from that produced by trauma, frequently develop during the course of these diseases.

DECEREBRATE RIGIDITY

Decerebrate rigidity arises as the result of damage to the brain stem. The prognosis for life is not good when it develops, but some individuals do recover. A patient who recovers from decerebrate rigidity is usually left with a rather severe intellectual deficit.

DESCRIPTION

Decerebrate rigidity does not usually appear for several hours following brain trauma. It occurs

most commonly after closed head injury in which no demonstrable break occurs in the scalp. Bleeding from the nose or ears is frequently present suggesting that the base of the skull has been fractured.

The first finding to indicate the development of decerebrate rigidity is adduction of the arms at the shoulders and extension at the elbows. This movement is often brought on by noxious stimulation, such as nasopharyngeal aspiration. Although the spastic movement may be unilateral at the start, it is usually bilateral from the start, or soon involves both arms.

The extensor movements of the upper extremities at the onset of decerebrate rigidity are followed rather promptly (a few minutes to several hours) by strong extension of the lower extremities. This usually starts with adduction of the thighs and extension at the knees followed by plantar flexion of the feet and toes with inward rotation of the ankles.

As the leg movements develop, the extensor movements of the arms increase to involve strong pronation of the hands and clenching of the fists. Unless the palms are protected, the fingernails may excoriate them.

The paravertebral muscles soon become involved in the extensor activities so that the head is extended and the gluteal muscles are tightly contracted. The head is thrown back and the irises of the eyes roll toward the top of the head. The paravertebral muscles contract to bow the back in an increasingly severe opisthotonos. Extension of the spine may become so pronounced that the vertex of the head almost touches the buttocks (fig. 163).

The movement pattern of decerebrate rigidity usually occurs in paroxysms which are induced by noxious stimuli such as pain, noise, or even bright light. Between paroxysms, there is relative relaxation of the extensor muscles, but they still have an increased extensor tonus. It is difficult to flex the elbows and knees. If they are forcibly flexed, they gradually return to the extended position.

Profuse sweating, most marked about the face, often accompanies a paroxysm of decerebrate rigidity, particularly if the extensor spasms are prolonged. Piloerection is usually pronounced. Defecation and spurts of urination may occur, but penile erection does not seem to be a part of the "mass reflex" as it is in the spasticity which follows injury to the upper portions of the spinal cord. The jaws are usually

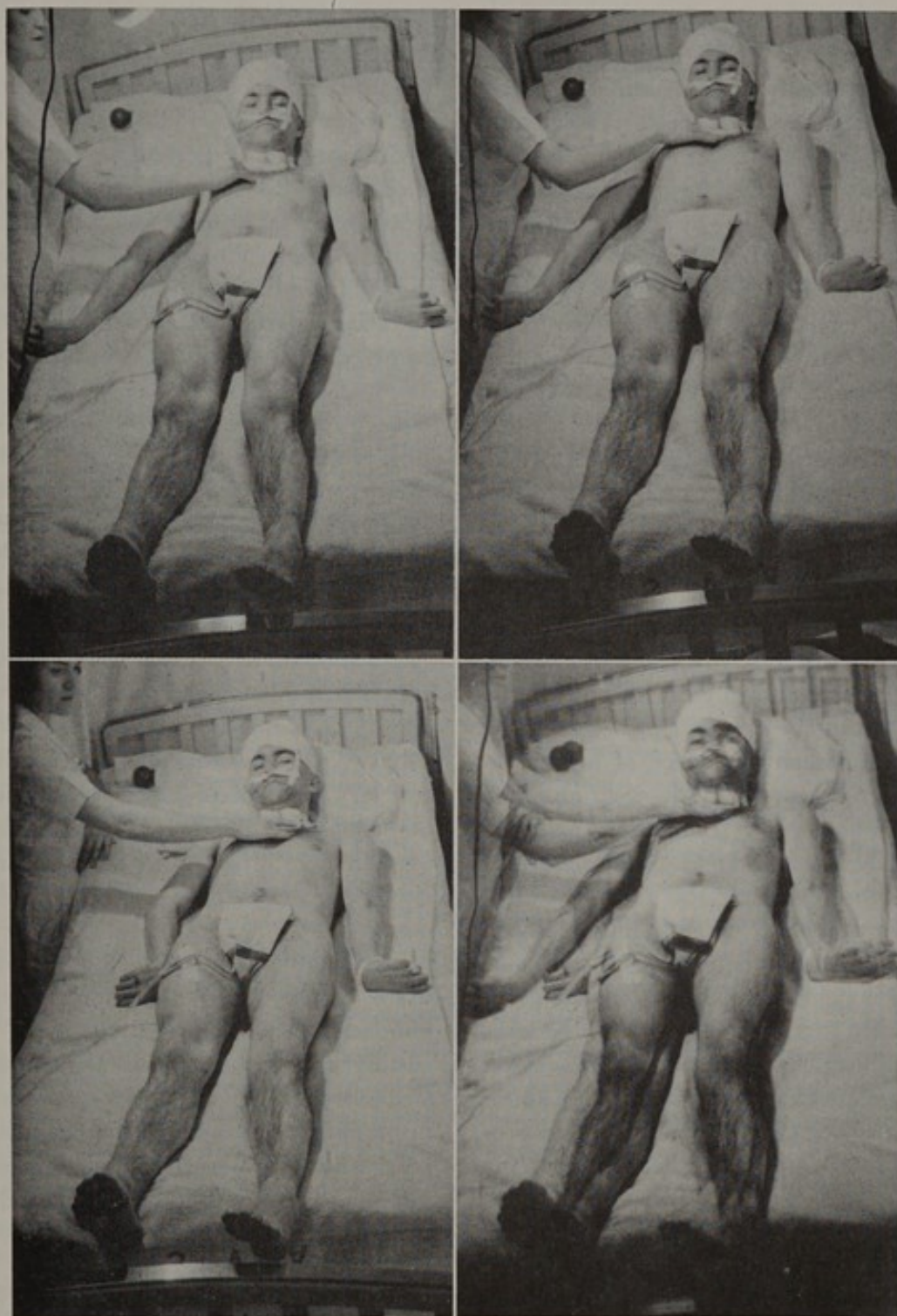


FIGURE 163.—Movements of decerebrate rigidity 24 hours after closed head injury. Stimulation of the sternum causes external rotation and adduction of the arms with volar flexion of the wrist and fingers. The legs and feet are extended and internally rotated. Autopsy 5 days later revealed a large pontine hemorrhage. The fourth picture is a composite to accentuate the appearance of movement. (From Department of Illustration, Indiana University Medical Center, Indianapolis, Ind.)

clenched, but there are no movements of the tongue. Sucking reflexes may be elicited in decerebrate individuals, but do not usually appear until the other manifestations of rigidity have been present for some time.

Postural reflexes can sometimes be elicited in patients with decerebrate rigidity by turning the head to one side or the other (3). These reflexes were first described by Magnus and de Kleijn (4) and usually go by their name. When the face is turned to the right, the left extremities slowly flex while the right ones are extended more vigorously. If the face is then turned to a neutral position, all the extremities are extended. When the face is turned to the left, the right extremities flex slowly and the left extremities become more extended. These "tonic neck reflexes" cannot usually be elicited in patients with severe decerebrate rigidity because the strength of the extensor tone cannot be overcome. They are obtained most easily when the extensor tonus is not very severe and in children with brain stem damage.

No consciousness or any evidence of awareness can be observed during a period of decerebrate rigidity. Individuals who recover from it lose many of the decerebrate movements and most of the abnormal extensor tonus before consciousness returns. Consciousness does not return if decerebrate rigidity is prolonged even though optimum care may prolong life for months or even years. The cases that recover do not usually develop extensive opisthotonos, and the decerebrate phenomena persist for only a few hours. There are exceptions, and it is possible for recovery of consciousness to occur after pronounced decerebrate rigidity has been present for many days.

The author has observed one patient who was decerebrate for 3 weeks and another for 4 weeks. These patients recovered consciousness during succeeding months and were able to walk, with some incoordination of the lower extremities. Both of these patients were young men, and both were left with a severe intellectual deficit. One of the two had paroxysms of spasticity with severe opisthotonos with his decerebrate rigidity.

Wilson (3) found that "fragmentary types" of decerebrate rigidity occur in which the "postural attitudes of decerebrate rigidity may be adopted

involuntarily with full consciousness." He made these findings in patients with chorea and athetosis. The injuries which occur very early in life also give rise to these two conditions. They must resolve themselves over a period of years to permit consciousness while extensor spasticity persists. The presence of some consciousness and a part of the pattern of decerebrate rigidity is seen commonly enough in patients with chorea and athetosis. It has not been reported where damage to the brain stem occurred months or years after birth.

PHYSIOLOGY

Extensor spasticity was first produced in animals by Sherrington in 1896 (5). He found that removal of the cerebral hemispheres gave rise to a phenomenon which he named "decerebrate rigidity." The pattern of involuntary movements which humans develop after brain stem damage as just described is very much like Sherrington's experimentally produced "decerebrate rigidity" (5). Walshe (6) and Davis (7) have attempted to separate the human counterpart of decerebrate rigidity into more than one category. Since such separations do not help the clinician to determine more accurately the location or severity of the lesion, they will not be discussed here.

Sherrington (8) was of the opinion that decerebrate rigidity is a reflex phenomenon requiring afferent as well as efferent impulses. He found that cutting sensory roots will abolish it. Bazett and Penfield (9) believed that decerebrate rigidity is produced by "release" of the brain stem and spinal cord from impulses arising in higher centers. In 1914, Weed (10) found that the cerebellum and red nucleus were essential to production of decerebrate rigidity. Later, Sherrington (11) demonstrated that the phenomenon persisted even after the cerebellum was removed and the dorsal columns of the spinal cord cut. Although a slight change occurred in the pattern when Bazett and Penfield (9) removed the red nucleus, the essential features of decerebrate rigidity were not altered. Sherrington (8) also reported that transection of the brain stem just caudad to the medulla oblongata produces flaccidity of all the extremities.

These findings from animal experimentation make

it possible for us to place the lesion producing decerebrate rigidity in man just caudad to the red nucleus, which lies at the incisura of the tentorium. The lesion must be above the end of the medulla oblongata (or bulb) which lies at the foramen occipitale magnum. Patients who die with decerebrate rigidity after trauma have extensive hemorrhage in the pons usually extending down into the medulla oblongata. The same finding may be present following diseases that produce decerebrate rigidity. Individuals who do not succumb presumably have less extensive lesions in the same area.

Direct trauma to the brain stem area is not often compatible with life. Indirect trauma to the brain stem causes most cases of decerebrate rigidity. Open head injuries produce much local trauma, but the impact is usually dissipated before the brain stem is damaged. Closed head injuries produce more shift of the intracranial contents and more indirect trauma to the brain stem. The contour of the intracranial space is such that the tentorium provides a sharp edge of dura mater just at the level of the red nucleus. When the head is struck a blow by an object that does not enter it, the intracranial contents ballot about, throwing the brain stem against the edge of the tentorium. This causes contusion and hemorrhage from the small veins which enter the brain stem (12).

A closed head injury in which the brain stem is balloted against the edge of the tentorium would be expected to produce decerebrate rigidity within a few minutes. Often the extensor spasms do not develop for 8 to 24 hours after the injury, and at autopsy, severe cerebral edema is present with transtentorial herniation of brain tissue. Apparently, cerebral edema is the most frequent direct cause of decerebrate rigidity following both trauma and other etiological factors. Scheinker (12) has demonstrated that transtentorial herniation causes stretch and bleeding from the plexus of small veins about the brain stem leading to petechial and larger hemorrhages in the pons.

TREATMENT

No treatment can be successful in alleviating decerebrate rigidity in those unfortunate individuals who develop it as the result of direct trauma. The

lesion can be prevented from becoming worse by treatment instituted to combat cerebral edema.

Since cerebral edema is the major cause for many cases of decerebrate rigidity, measures to prevent or decrease it should be instituted vigorously to treat or preferably to prevent decerebrate rigidity. As in the treatment of all head injuries, the physician's first concern should be to establish an adequate airway so that intracranial pressure will not be increased by labored respirations. A tracheostomy is often the most satisfactory method for producing and maintaining an adequate airway. There should be no hesitation in performing a tracheostomy in the treatment of a severe head injury. The intravenous administration of hypertonic solutions, such as glucose and urea, is discussed elsewhere in this volume, but must be thought of in the treatment of decerebrate rigidity. Subtemporal decompression may also aid in decreasing the pressure of brain tissue against the incisura of the tentorium to aid in the treatment of decerebrate rigidity. The herniated uncus may be mechanically lifted from the incisura of the tentorium to relieve pressure on the brain stem. The tentorium can also be cut to prevent the uncus from herniating again and producing a recurrence of decerebrate rigidity.

On occasion, a suboccipital decompression will relieve upward pressure of the cerebellum on the tentorium. This can increase blood flow to the brain stem and help to diminish its edema. Suboccipital decompression is not always successful, but will occasionally bring about rapid decrease in the decerebrate pattern of movements in patients who have been comatose and decerebrate for several weeks.

Hypothermia is favored for treatment of decerebrate rigidity by many neurological surgeons. Maintaining body temperature at 30° to 32° C. (90°-93° F.) is often successful in decreasing decerebrate rigidity and permitting normal brain physiology to be restored. Several days to several weeks of hypothermia may be required. Chlorpromazine, 25 mg., every 2 hours, to diminish shivering, is needed initially to lower body temperature to the desired level. The desired lower temperature level usually stabilizes in 12 to 24 hours and the chlorpromazine dosage can be decreased or stopped. Hypothermia is maintained until the vital signs stabilize or signs of arousal develop. Body temperature

may then be permitted to rise toward normal. If the vital signs and conscious state continue stable or improve further, the temperature is allowed to return to normal. If evidence of increasing intracranial pressure resumes, it is necessary to lower the temperature again. Continued control of temperature is required for hours or days after it has been returned to normal to prevent it from going above normal and produce a recurrence of brain edema and decerebrate rigidity. Several trials may be needed before the body's own control mechanisms recover sufficiently to maintain a normal temperature without external assistance. Meticulous care of the nasopharynx and trachea are required during hypothermia as pneumonia is an ever-present threat. Feeding by stomach tube maintains more normal nutrition during prolonged hypothermia, and may be instituted a few days after injury, even while decerebrate rigidity is still present.

Application of ice and alcohol sponges is an effective and time-honored method for inducing hypothermia. It is difficult to maintain a constantly low temperature with these techniques, and wide fluctuations are the rule. Ingenious refrigerating devices have been developed during the past few years that are capable of maintaining body temperature plus or minus 1° C. (2° F.) of the desired level. These mechanisms "sense" temperature fluctuation in esophageal or rectal thermocouples, and reverse the temperature trend, before they are manifest by an actual gross fluctuation of body temperature. The time and effort required in nursing patients under hypothermia is much diminished by these devices, several of which are commercially available.

The most effective treatment of decerebrate rigidity is *excellent nursing care* for the comatose patient. These are probably the most difficult of patients to nurse. A second essential to successful treatment of decerebrate rigidity is a firm optimism which does not relinquish hope for many weeks after brain trauma.

SPASTIC HEMIPLEGIA

Spastic hemiplegia develops less frequently following nonmilitary brain trauma than does decerebrate rigidity. It appears more frequently following penetrating head injuries or one in which brain

tissue is destroyed by depressed skull fractures. It is, therefore, more common in brain injuries which occur during warfare. Although present, the threat to life from injuries which produce hemiplegia is not as great as it is from injuries which produce decerebrate rigidity.

The spastic pattern of decerebrate rigidity can be produced only by a lesion in a circumscribed area of the upper brain stem while spastic hemiplegia can be produced by one or more lesions in widely scattered brain areas. Hemiplegia can develop from severe cerebral edema, as is commonly the case in decerebrate rigidity. However, hemiplegia usually occurs as the result of direct injury of a penetrating missile or an indriven spicule of bone. Hemiplegia can usually be demonstrated soon after the injury but may also delay its appearance for several hours as is the usual case with decerebrate rigidity. The development of spastic hemiplegia cannot be used as a clue to the eventual recovery or degree of intellectual deficit which will be the residual of severe brain trauma. Occasionally, hemiplegia will be followed in a few hours by decerebrate rigidity. This indicates that focal brain damage has occurred followed by severe cerebral edema which pushes the uncus through the incisura of the tentorium to compress the brain stem.

Hemiplegia may be transient following brain trauma, subsiding with the cerebral edema in 2 or 3 days. Usually, an increase in the reflexes of the affected extremities persists as a reminder of the hemiplegia. This is not the only residual, as a fairly severe intellectual deficit may remain when a right hemiplegia improves. The loss of intellect may be due to damage of the language areas in the left cerebral hemisphere. Just as severe a loss to intellect can occur in association with a left hemiplegia from damage to the right cerebral hemisphere (13). The intellectual deficit which accompanies spastic hemiplegia is not usually as severe as that which is seen following the recovery from decerebrate rigidity.

As with all neurological deficits, there is gradation of functional loss with hemiplegia. Voluntary control of an arm and leg on the same side of the body may be slightly impaired and the condition is called hemiparesis. The complete loss of voluntary control of one side of the body is designated as hemiplegia.

DESCRIPTION

Hemiplegia shows its greatest effect in the extremities on one side of the body. Even though the body has the appearance of marked asymmetry, the face is usually symmetrical, betraying muscular weakness only in the presence of emotion or when a voluntary attempt is made to distort the features. By careful observation, it may be possible to see a lag in movements of the eyelid on the affected side when compared to the unaffected side. There is usually no weakness of movements of the forehead, but there is frequently the complaint of difficulty in chewing on the affected side. A slight droop is seen in the corner of the mouth on the paralyzed side. The weakness of the buccal musculature is most noticeable during talking, expressions of emotions, and voluntary attempts to produce symmetrical facial movements. Weakness of the corner of the mouth is often most noticeable when the patient is asleep, and the force of his breathing is strong enough to allow air to escape only from the affected side of the closed mouth. The tongue is usually not weakened if the lesion is in the cerebral cortex, but may deviate toward the side of paralysis if the lesion is in the pyramidal tracts. The head often remains rotated toward the unaffected side of the body because the homonymous hemianopsia which accompanies hemiplegia makes peripheral vision on the affected side impossible. The extraocular muscles are not affected but the eyes may be held toward the unaffected side to improve vision.

The head of a hemiplegic patient is often turned toward the unaffected side to aid vision and because of weakness of the neck muscles on the hemiplegic side. The weakness of the trapezius muscle allows a slight droop of the hemiplegic shoulder. In spite of the droop, the hemiplegic shoulder usually is raised above the normal shoulder as the hemiplegic leg is brought forward in walking.

The hemiplegic arm is held in a characteristic posture with only minor variations from patient to patient. The upper arm is internally rotated at the shoulder and held close to the trunk. The elbow is flexed and the forearm pronated. The wrist is kept in slight volar flexion, and the palm and fingers are cupped. The thumb is adducted and flexed so that it lies in the palm. The index finger is usually

more strongly flexed than the other fingers (3) (14) (15).

Posture of the hemiplegic arm remains, as just described, most of the time, but alters with changes in body position. Brain (15) found that the elbow and wrist extend when the back and hips of a hemiplegic individual are flexed. The fingers assume the posture that the fingers of an ape use while walking on all fours. If the hips are flexed while the patient is supine, the elbow becomes more flexed. Yamshon (14) found that "if the arm is elevated 90 degrees or above, it can be noted that the tone will shift from the flexors to the extensors." The position of the head also influences tone in hemiparetic muscles (16). Strength of both the flexor and extensor muscles of the hemiplegic arm is increased by turning the head toward the paralyzed side. The strength is slightly increased with the head turned away from the paralyzed side and is minimal when it is in neutral position.

The hemiplegic leg has not undergone as much study as the hemiplegic arm, but the pattern which it presents also is quite similar from patient to patient. It remains slightly flexed at the hip and knee while the foot is slightly plantar flexed and internally rotated at the ankle. There is usually more return of muscle strength and voluntary control of the lower extremity than in the upper, so that walking is often possible even though there is very little voluntary control of the arm. The most characteristic aspects of the hemiplegic leg are its movements during walking. These are usually described as a "circumduction gait" which is very descriptive. The hemiplegic lower extremity remains fairly flexed at the knee and ankle during walking, making a slight flexion at the hip and a tilt of the pelvis necessary to elevate the affected hip. This permits it to be brought forward in a circular movement without dragging the toes (fig. 164).

Reflex activity in the paralyzed extremities is usually absent shortly after the brain injury is inflicted. The arm and leg are flaccid and the corner of the mouth droops even at rest. No resistance is offered against movements of the muscles. As the patient recovers from the general effects of the brain injury, some tone returns to the muscles and attempts to move the extremities are accompanied by resistance and pain. Reflex activity returns and some

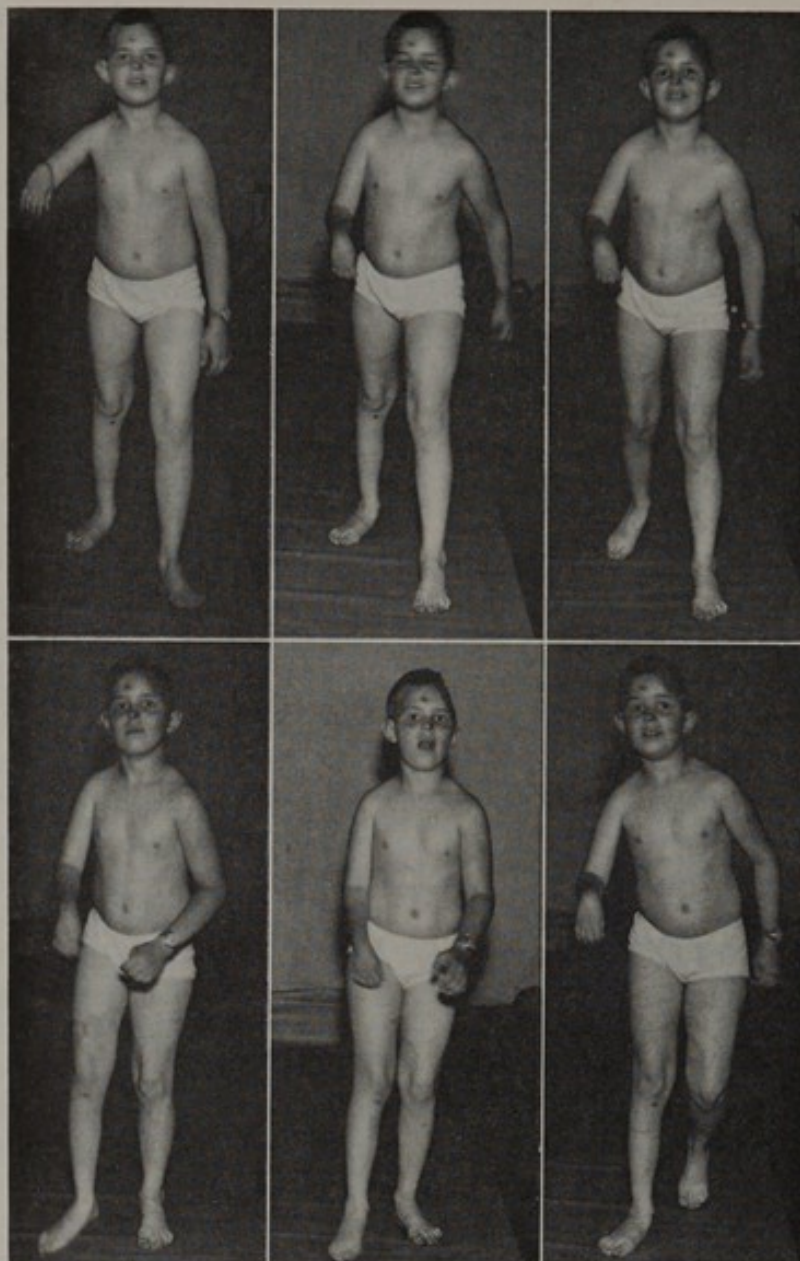


FIGURE 164.—Right spastic hemiparesis 4 years after avulsion of the left frontoparietal scalp, skull, and cortex when this child fell from a moving car. The right elbow, wrist, and fingers are held in a flexed position. There is a decreased swing of the right shoulder as compared to the left. The circumduction and external rotation of the right lower extremity is demonstrated best in the fourth picture where the right foot passes the left. (From Department of Illustration, Indiana University Medical Center, Indianapolis, Ind.)

voluntary movements may appear. These usually appear first in the proximal muscles in the shoulder and hip rather than in the distal muscles of fingers and toes as is the case with function after spinal cord injury. Soon the reflexes become hyperactive, Babinski's and Hoffman's reflexes appear, and clonus can be produced upon proper stimulation. If considerable voluntary control of movements is returned, there is a progressive diminution of hyperreflexia.

PHYSIOLOGY

Animal experimentation on spastic hemiplegia has been extensive. This has shown fairly conclusively that ablation of Brodmann's area 4 yields transient, flaccid hemiplegia. Removal of area 6 produces transient, spastic hemiplegia while removal of areas 4 and 6 produces permanent spastic hemiplegia (17) (18) (19) (20). In like manner, lesions

which affect the anterior limb of the internal capsule give rise to spastic hemiplegia while those that affect the middle portion usually give rise to flaccid hemiplegia (17). Lesions in the pons which do not destroy the pyramidal tracts but are lateral to the midline produced contralateral spastic hemiparesis (21).

There are some apparent differences in the localization of lesions that produce spastic and flaccid hemiplegia in man and in monkeys. Although monkeys show flaccidity and atrophy of muscles following ablation of area 4 (17), this has not been observed in man (22). Fairly large lesions of Brodmann's areas 4 and 6 may give rise to flaccid paralysis in man (22), but always produce spastic paralysis in primates (17). Atrophy of muscles of the contralateral side of the body may occur from lesions in the parietal lobe or thalamic area in man (22). Flaccid paralysis may result after pyramidal tract damage if the lesion extends to involve the medial lemniscus or cerebellar pathways in the medulla.

Spastic hemiparesis following head injury usually develops from direct destruction of brain tissue by a penetrating injury. It may arise secondary to hemorrhage from a torn blood vessel or from ischemia when an artery has been disrupted. Edema of one cerebral hemisphere following trauma may yield spastic hemiplegia because of compression of the ipsilateral cerebral peduncle. This usually progresses to decerebrate rigidity or subsides with some recovery of the paresis. Subdural and epidural hematomas may give rise to spastic hemiplegia which may recover when the hematoma is evacuated.

TREATMENT

Meirowsky's (23) and Barnett and Meirowsky's (24) magnificent work during the Korean War demonstrated that penetrating and depressed wounds of the skull should receive definitive neurosurgery as soon as possible. The complications which arise from brain injury can be greatly decreased (23). The debridement of cerebral tissue should be judicious. It must be enough to decrease cerebral edema, but not so much that more neurological deficits are produced. Evacuation of epidural, subdural, and intracerebral hematomas is particularly

important in the prevention of spastic hemiplegia (24).

When the spastic hemiplegia has become established, physiotherapy is helpful in decreasing ankylosis of joints and contractures of muscles. It is helpful in the process of relearning coordinated functions. The regain of voluntary muscular control in hemiplegic patients is best during the first 2 months after the hemiplegia is acquired (25). For this reason, rehabilitation activities should start as soon as the patient can obey simple commands. Even though it is practical to utilize professional assistance for rehabilitation from a few weeks to a few months, part of the training should be directed toward a continuation of the rehabilitation program on the patient's own initiative. The patient's own rehabilitation efforts with the help of his family should continue for the remainder of his life no matter how long that might be.

EXTRAPYRAMIDAL DISORDERS RESULTING FROM TRAUMA

Many patients with extrapyramidal disorders, and their relatives, relate the onset of involuntary movements to a head injury. Careful questioning usually demonstrates that the trauma is merely coincidental. For this reason, reports of extrapyramidal disorders resulting from trauma are viewed with suspicion, and only a few well-authenticated cases have been recorded in medical literature.

Leonhardt (1) examined the records of 2,500 brain injured individuals after World War II. Only 66, 0.225 percent, had extrapyramidal disorders. In his opinion, in only 26, 0.105 percent, of these was the trauma directly responsible for the extrapyramidal disorder. He concludes, after his own observations and a review of the literature, that of the extrapyramidal disorders only parkinsonism and chorea can result from brain trauma which is inflicted after birth. Levy (26) also concluded that the tremor and rigidity of parkinsonism can be produced by brain trauma, but this occurs rarely.

DESCRIPTION

The two clinicians (1) (26) who have discussed the occurrence of extrapyramidal disorders have

given much detail regarding their cases. It is not known what type of head injury is most likely to produce an extrapyramidal disorder, although one would conjecture that they are more commonly produced by penetrating wounds. The time which elapses between the injury and the appearance of the extrapyramidal type of spasticity is not known. The similarities and differences between the extrapyramidal disorders which result from trauma and those that are produced from other causes have not been discussed. Because of the rarity of this condition and the paucity of detailed information, it is not possible to present a description of extrapyramidal disorders produced by trauma to the brain.

PHYSIOLOGY

A variety of lesions stereotactically placed in the brains of animals has produced some of the signs and symptoms of parkinsonism (27). None of these lesions has been in the substantia nigra, so some doubt has been cast on the theory that parkinsonism is produced by a lesion in that nucleus. Study of human material continues to point to lesions in the substantia nigra as the cause of the symptoms to parkinsonism (28). Chorea has not been produced experimentally, and no definitive location of the lesion which produces it in humans has been discussed. It is possible that chorea is the result of rather widespread brain damage.

The author has seen one patient in which trauma to the brain has produced many of the symptoms of parkinsonism. As there is not much doubt that trauma produced the extrapyramidal disorder, the case will be reported in some detail, as follows:

Thirteen-year-old boy received left frontal gunshot wound. Comatose 20 days. Right arm strongly flexed and right leg strongly extended. Voluntary movement in right extremities and speech returned. Able to go to school. Tremor of left hand developed 8 months after injury and was accompanied by rigidity. Controllable left-sided convulsions started 6 years after injury. Finished school and working daily.

J.H.D., R152820, a 13-year-old boy was admitted to the James Whitcomb Riley Hospital on 13 January 1951, 3½ hours after he had been shot in the head by a .22 caliber rifle. The bullet entered the left frontal region of the head, and he became comatose immediately.

Past history revealed that he had been well except for a broken arm at the age of 5 and the usual childhood illnesses.

Family history revealed that the patient's father died in

1939 at the age of 48 of a "heart attack." Mother and six siblings were living and well.

Examination on admission revealed a well developed and nourished boy in deep coma with two small penetrating wounds in the left frontal region 5 cm. from the midline at the level of the coronal suture line. The child's body, including his neck, was in rigid extension. There were occasional short bursts of generalized tonic convulsive movements. No response could be produced with noxious stimulation. No weakness was noted in any muscle group. The pupils were alternately pinpoint in size and extremely dilated. The eyes wandered aimlessly. No weakness or paralysis of the extraocular muscles was observed. There were occasional long periods of apnea. The respiration rate was 10 beats per minute and the pulse rate, 44. Blood pressure was 135 mm. Hg systolic and 80 mm. Hg diastolic.

Roentgenograms of the skull were made (fig. 165) and revealed a bullet track which traversed the brain in a straight line. It probably crossed the midline just above the third ventricle and just posterior to the foramen of Munro. One fragment of the bullet lodged in the area of the posterior right thalamus, the other in the far posterolateral portion of the right occipital lobe.

Surgery was carried out a short time after admission. Through an osteoplastic frontal craniotomy, the brain was found to be edematous, tense, and without pulsation. A thin layer of clotted blood lay over the cortex. The bullet track was debrided to a depth of about 5 cm. and numerous small fragments of metal, hair, and bone were removed. The dura mater could not be closed. A bur hole over the right frontal area revealed normal brain with little or no edema or tension and normal pulsations. No attempt was made to remove the large metallic fragments near the base of the brain.

Postoperatively, the child remained comatose for 20 days. During this period, he had spiking fever to 102.6° daily, but normal blood pressure, pulse, and respiration. His left arm and leg relaxed partially, but the right arm remained firmly flexed at the elbow, adducted at the shoulder, and flexed at the wrist and fingers. The right leg remained rigidly extended. The head and eyes deviated forcefully to the right. Toward the end of the 20 days, restless, purposeless movements of the left extremities developed.

Twenty days after the injury, he showed a dramatic improvement. The restlessness subsided. He started to move his head and eyes from the position of right deviation. The right arm and leg relaxed somewhat and some voluntary movement appeared. The patient started to recognize people and say a few words. He responded very rapidly to physiotherapy and speech therapy and was discharged from the hospital on 23 February 1951 with slight weakness and hyperactive reflexes in the right extremities. He had no deficit in peripheral vision.

He returned to school and performed fairly well. About 8 months after injury, a fine, rhythmical tremor developed in his left hand (fig. 166). This was more pronounced when he was nervous, when he tried to control the tremor, or tried to use the left hand while being observed. The tremor was

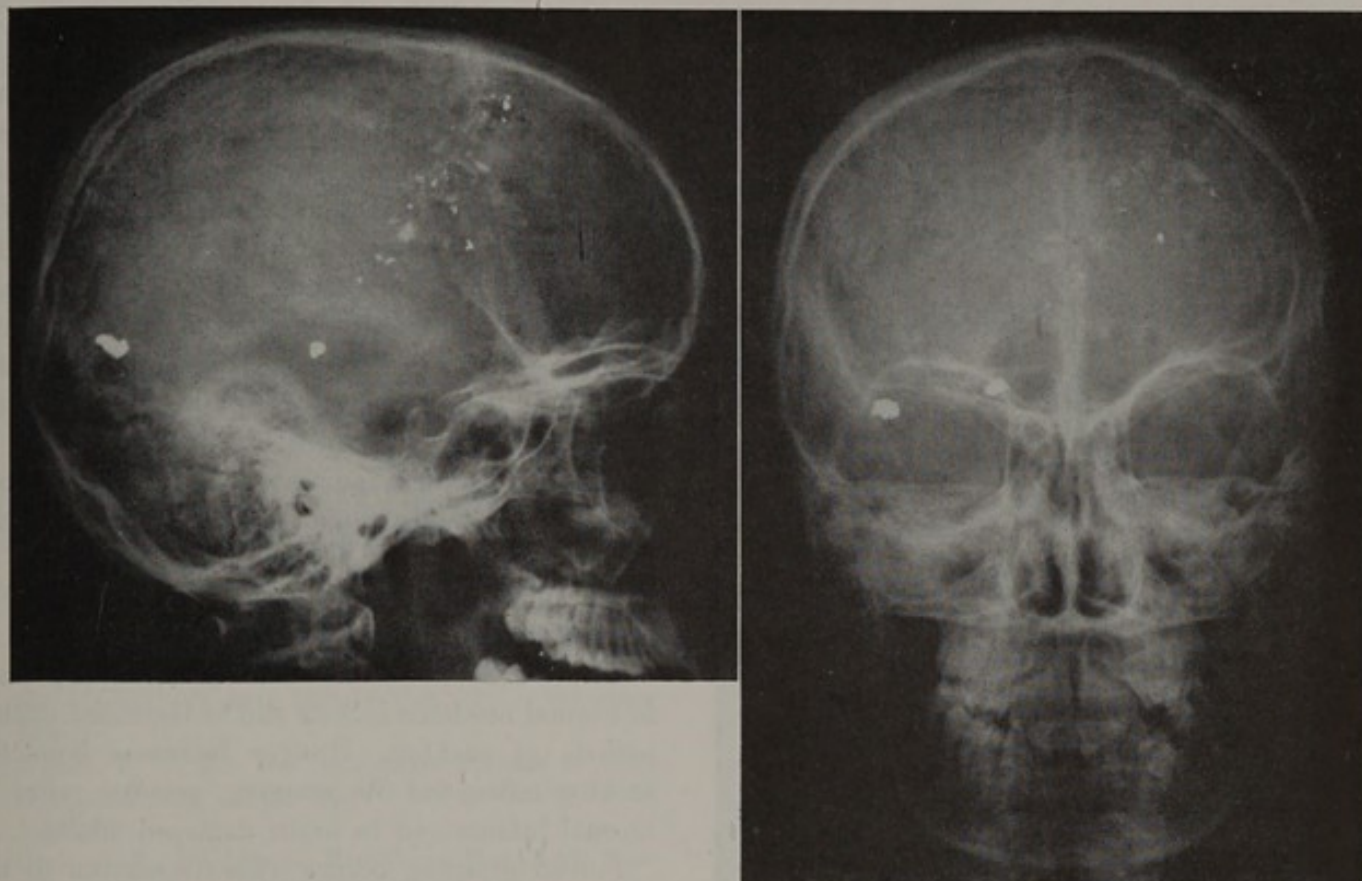


FIGURE 165.—Lateral and anteroposterior roentgenograms showing the track of a .22 caliber bullet. The patient developed a parkinson-like tremor and rigidity in the left hand and arm 9 months after the injury. The metallic fragments passed through the basal ganglia. They lodged in the right occipital lobe and probably the right posterior thalamus. (From Department of Illustration, Indiana University Medical Center, Indianapolis, Ind.)

not particularly troublesome to him and did not interfere with his schoolwork. There was minimal rigidity of the left arm, but none in the left leg. Gait was not typical of parkinsonism, but speech and other activities were markedly slow for a 13-year-old boy.

Several episodes of transient visual loss and hemiparesis developed. These were not thought to be convulsive until November 1956, when he had a left-sided seizure. He has had several convulsions since, but they have been controlled with anticonvulsant drugs. Antiparkinsonian drugs have not aided his tremor or rigidity.

There seems to be little or no progression of the patient's parkinsonian symptoms from the time of onset until his last out-patient visit on 2 December 1958. He has not developed festination of gait. He does have masklike facies, bradykinesia, and rigidity and tremor limited to the left hand and forearm. Chemopallidectomy has been suggested, but he still is not sufficiently troubled by the tremor and rigidity to consider it.

There is very little doubt that the bullet wound produced the signs and symptoms of parkinsonism in this patient. It is interesting to speculate regarding the location of the lesion which produced the

tremor and rigidity. Undoubtedly, the bullet fragments traversed the anterior limb of the internal capsule on the left and probably came very close to the middle portion of the internal capsule on the right. The area of damage must have been in or close to the posterior portion of the right globus pallidus. One large metallic fragment came to rest in the posterior portion of the thalamus on the right. The fact that the tremor did not develop for 8 months after injury indicates that it may have resulted from some scarring and irritation caused by the metallic and bony fragments that remained in the brain. Apparently no infection occurred in the wound or the depths of the brain.

Speculation is that the piece of metal in the posterior thalamus on the right is responsible either directly or indirectly for the parkinsonian tremor and rigidity. This thalamic location for the lesion agrees with the location of lesions that have produced parkinsonism in animals (27).

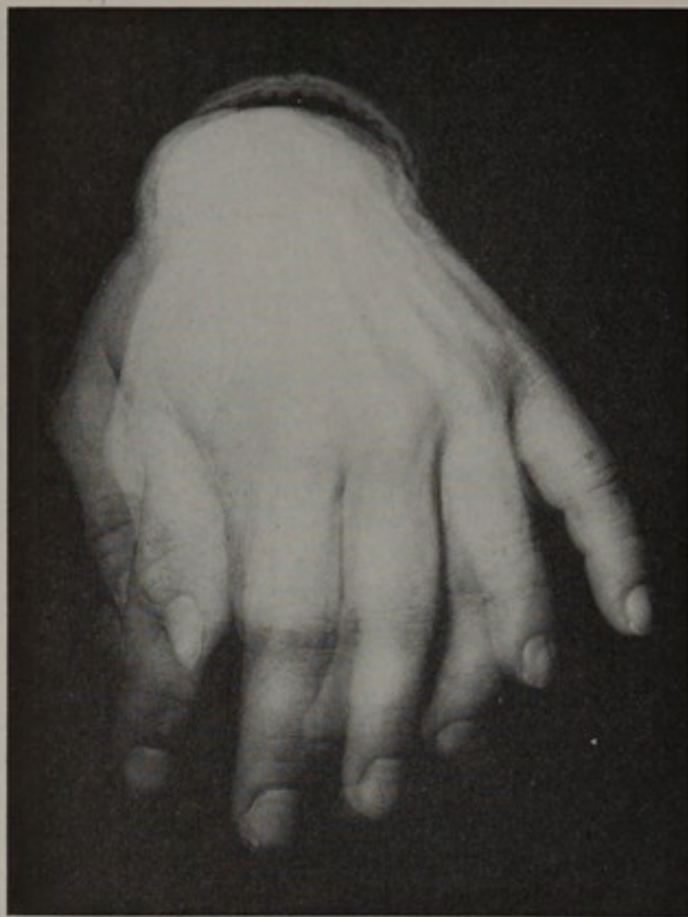


FIGURE 166.—Composite picture, to demonstrate the parkinson-like tremor of the left hand produced by a .22 caliber bullet which passed through the basal ganglia of a 13-year-old boy. (See figure 165 for path of bullet.) (From Department of Illustration, Indiana University Medical Center, Indianapolis, Ind.)

TREATMENT

Treatment of extrapyramidal disorders that result from trauma should be no different from the treatment suggested for parkinsonism and chorea that arise from other causes. No accurate study on the effect of drugs on parkinsonism resulting from trauma has been made. In our patient, antiparkinsonism drugs had no effect on tremor and rigidity. The available drugs should be tried in the treatment of posttraumatic parkinsonism. No reports have been made of the treatment of posttraumatic parkinsonism or chorea by chemopallidectomy or other stereotactic approaches. There is no theoretical reason to indicate that it will be less effective in this group than it is in postencephalitic or arteriosclerotic parkinsonism.

FORCED GRASPING

Forced grasping is a type of spasticity which has long been associated with damage of the frontal lobes (29) (30). Adie and Critchley (29) thought that both the pyramidal and extrapyramidal motor systems must be intact in order for it to occur. They conjectured that "forced grasping and groping" are produced by damage to the cerebral cortex in Brodmann's area 6. Animal experimentation has also produced forced grasping with lesions in the region of area 6.

Bucy (31) reports four cases that exhibited forced grasping that were found to have tumors in the posterior fossa or occipital lobes. From this, it appears that forced grasping may be a symptom of severe widespread brain damage.

Bieber (32) found that forced grasping is present in normal newborn infants and is increased during periods of sucking. Hunger increases both the sucking reflex and the grasping, groping reflex in normal infants and in brain damaged adults.

Forced grasping occurs with stimulation to the palm of the hand. The stimulating object is firmly grasped and it is released with difficulty. Some patients have wandering movements of their hands, grasping and firmly holding objects that they encounter. Patients who exhibit this phenomenon appear to have little or no awareness of their surroundings. They may react briefly to painful or auditory stimuli but do not obey simple commands.

A variety of patterns of spasticity can be produced by damage to the central nervous system. Some of the spastic patterns result from irritation of neurons in the central nervous system. More often spasticity of central nervous system origin can be best described by Hughlings Jackson's term "release phenomenon" (33), in which excess activity of some groups of neurons occur because other neurons are not functioning. Considering all of the nuclei and tracts which compose the central nervous system, it is surprising that only a few patterns of spasticity develop from trauma, or any other type of damage to the brain. It is even more surprising that only three of the possible patterns of spasticity occur with any regularity following central nervous system trauma. These are, in the order of frequency,

spastic paraplegia, decerebrate rigidity, and spastic hemiplegia.¹

REFERENCES

- Leonhardt, W.: Hirntrauma und extrapyramidale Erkrankungen. *Fortschr. Neurol. Psychiat.* 21: 341-354, July 1953.
- Magoun, H. W., and Rhines, Ruth: Spasticity: The Stretch-Reflex and Extrapyramidal Systems. American Lecture Series No. 9, American Lectures in Surgery. Springfield, Ill.: Charles C Thomas, 1948.
- Wilson, S. A. K.: On Decerebrate Rigidity in Man and the Occurrence of Tonic Fits. *Brain* 43: 220-268, November 1920.
- Magnus, R., and de Kleijn, A.: Die Abhängigkeit des Tonus der Extremitätenmuskeln von der Kopfstellung. *Pflüger's Arch. f. d. ges. Physiol.* 145: 455-548, May 1912.
- Sherrington, C. S.: On Reciprocal Innervation of Antagonistic Muscles. Third Note. *Proc. Roy. Soc. London* 60: 414-417 (23 Apr. 1896-18 Feb. 1897), December 1896.
- Walshe, F. M. R.: The Decerebrate Rigidity of Sherrington in Man. *Arch. Neurol. & Psychiat.* 10: 1-28, July 1923.
- Davis, L. E.: Decerebrate Rigidity in Man. *Arch. Neurol. & Psychiat.* 13: 569-579, May 1925.
- Sherrington, C. S.: Decerebrate Rigidity and Reflex Coordination of Movements. *J. Physiol.* 22: 319-332, February 1898.
- Bazett, H. C., and Penfield, W. G.: A Study of Sherrington Decerebrate Animal in Chronic As Well As Acute Conditions. *Brain* 45: 185-265, October 1922.
- Weed, L. H.: Observations Upon Decerebrate Rigidity. *J. Physiol.* 48: 205-227, May 1914.
- Sherrington, Charles Scott: The Integrative Action of the Nervous System. London: Cambridge University Press, 1947, pp. 299-307.
- Scheinker, I. Mark: Neurosurgical Pathology. Springfield, Ill.: Charles C Thomas, 1948, pp. 25-26.
- Reitan, R. M.: Intelligence and Language Functions in Dysphasic Patients. *Dis. Nerv. System* 15: 131-137, May 1954.
- Yamshon, L. J.: Position of the Arm in Spastic Hemiplegia. *Arch. Phys. Med.* 31: 658-660, October 1950.
- Brain, W. R.: Significance of Flexor Posture of Upper Limb in Hemiplegia, With Account of Quadrupedal Extensor Reflex. *Brain* 50: 113-137, June 1927.
- Yamshon, L. J., Machek, O., and Covalt, D. A.: The Tonic Neck Reflex in the Hemiplegic; Objective Study of Its Therapeutic Implication. *Arch. Phys. Med.* 30: 706-711, November 1949.
- Kennard, M. A., and Fulton, J. F.: The Localizing Significance of Spasticity, Reflex Grasping, and the Signs of Babinski and Rossolimo. *Brain* 56: 213-225, July 1933.
- Fulton, J. F., and Kennard, M. A.: A Study of Flaccid and Spastic Paralysis Produced by Lesions of the Cerebral Cortex in Primates. *Assoc. for Research in Nerv. and Ment. Dis.* 13: 158-210 (Proceedings of the 28th and 29th of December 1932), 1934.
- Hines, M.: The Anterior Border of the Monkey's (Macaca Mulatta) Motor Cortex and the Production of Spasticity. *Am. J. Physiol.* 116: 76, June 1936.
- Welch, W. K., and Kennard, M. A.: Relation of Cerebral Cortex to Spasticity and Flaccidity. *J. Neurophysiol.* 7: 255-268, September 1944.
- Tower, S. S.: The Production of Spasticity in Monkeys by Lesions in the Pons. *Anat. Rec.* 82: 450-451, April 1942.
- Davison, Charles: The Precentral Motor Cortex: Pathology. University of Illinois, Urbana, Ill., pp. 430-431, 1944.
- Meirowsky, A. M.: Increased Intracranial Pressure in Penetrating Craniocerebral Trauma. *Mil. Med.* 118: 488-492, May 1956.
- Barnett, J. C., and Meirowsky, A. M.: Intracranial Hematomas Associated With Penetrating Wounds of the Brain. *J. Neurosurg.* 12: 34-38, January 1955.
- Van Buskirk, C.: Return of Motor Function After Hemiplegia. *Neurology* 4: 919-928, December 1954.
- Levy, F.: Posttraumatic Parkinsonism. *Progr. Med.* Paris 82: 515-520, December 1954.
- Les méthodes stéréotaxique, Rapports et discussions. First International Congress of Neurosurgery, pp. 85-187, 1957.
- Hassler, R.: Rapports and Discussions. Premier Congress International des Sciences Neurologiques, Première Journée Communé, pp. 49-56, 1957.
- Adie, W. J., and Critchley, M.: Forced Grasping and Groping. *Brain* 50: 142-170, June 1927.
- Viets, H. R.: Forced Grasping in Man and Its Localizing Significance. *New England J. Med.* 210: 675-678, 29 Mar. 1934.
- Bucy, P. C.: Reflex-Grasping Associated With Tumors Not Involving the Frontal Lobes. *Brain* 54: 480-491, December 1931.
- Bieber, I.: Grasping and Sucking. *J. Nerv. & Ment. Dis.* 91: 31-36, January 1940.
- Wagley, P. F.: A Study of Spasticity and Paralysis. *Bull. Johns Hopkins Hosp.* 77: 218-273, September 1945.

¹ The author wishes to acknowledge the help received through hours of discussion with Doctors Leslie W. Freeman, Arnold M. Meirowsky, Russell Meyers, Paul C. Bucy, C. David Scheibert, and Calvin C. Turbes in the development over many years of the ideas that have gone into this chapter.

ASSOCIATED WOUNDS

CHAPTER 38

Multiple Wounds Associated With Penetrating Trauma of Brain and Spinal Cord

Frank B. Berry

In the management of the severely injured, the preservation of life takes top priority. Life-endangering qualities of an injury or injuries demand quick recognition and the institution of therapy. * * *

The relative urgency of the life-endangering physiological derangements * * * sets the priorities in acute multiple injuries. In all situations, those causes of asphyxia take first priority in efforts to save life. Known hemorrhage ranks high for measures to arrest it and to replace the blood loss. In conscious patients, hidden hemorrhage or hollow abdominal viscous injuries may be diagnosed and they are the next urgent. Debridement of extremity and trunk wounds comes last but even in the last place, it remains a lifesaving preventive surgical measure. In unconscious patients, intra-abdominal life-endangering injuries may be suspected but diagnosis is difficult although not impossible. The unconscious state does not temper the demand for a lifesaving laparotomy if the indication can be determined.

Only when there are signs and symptoms of an increasing intracranial pressure does a head injury assume tremendous relative importance in determining therapeutics. Of course, such a situation will enter the setting of priorities. It cannot, however, demand attention until the dangers of asphyxia and massive hemorrhage have been obviated (1).

These just cited paragraphs have been taken from an article by Hampton and form an admirable summation for the questions propounded by the title of this chapter, because neither in war nor in civilian life, unfortunately, are wounds and injuries always confined to one area of the body. In the severely wounded, the mortality rises in direct proportion to the number of wounds. When there are injuries

within the abdomen, it increases directly with the number of viscera injured.

As we turn to common causative agents in civilian life, we might postulate also that the mortality of automobile accidents, for example, increases directly with the speed of the car. Likewise, it is an established fact that although there has been a very marked decrease in airplane accidents, nevertheless, in major accidents involving jet aircraft the mortality rate for crew members has increased. In almost all of these civilian accidents there is a high incidence of multiple injuries.

In World War II, in a report of the 2d Auxiliary Surgical Group, in a series of 454 penetrating wounds of the head, about 30 percent had multiple injuries and the associated injuries in about one-third were considered to be serious (2). With the automobile and airplane today, serious trauma of the head, neck, and chest probably predominate.

The absence of shock in intracranial injuries per se has been stressed by Campbell and Whitfield (3). Hence, it may be assumed that if severe shock is present its cause should be sought elsewhere. This naturally becomes more difficult in the unconscious patient as the search is perforce blind, particularly in the absence of any open wound. It may, therefore, be assumed that the shock associated with head injuries alone is due primarily to loss of blood from the scalp wounds, which may be readily com-

bated by surgery and blood transfusions. As a rule, however, when severe shock is present, the surgeon should look for other injuries.

In all instances, whether the patient is conscious or unconscious, a careful examination in a good light is essential. If no open wound is present, diagnosis becomes more difficult. Here initial and subsequent blood pressure readings are of great importance and, together with the pulse rate, are of great value in determining possible injuries elsewhere. Other factors that may be noted on examination are, of course, evidence of fractures of the long bones, rib cage, spine, pelvis, and major subluxations.

PHYSICAL EXAMINATION OF THE PATIENT

Prior to examination, all clothing should be removed and the patient should be supine on a flat table or bed with a board under the mattress, or prone if there is possible concomitant fracture of the spine. Occasionally, because of respiratory difficulty or pain, it may be necessary to maintain the patient in a semi-erect position for adequate respiration. Following physical examination, if there is any question of injury to the chest, much can be gained by simple fluoroscopy. This may be done either with the patient lying flat or in a sitting position, if possible. In the chest areas, collections of air or fluid and displacement of the trachea and heart may be seen; and the suspicion aroused, and sometimes even definite knowledge obtained, as to herniation of abdominal viscera through the diaphragm.

HEAD AND FACE

From the standpoint of priority surgery, we are primarily concerned with injuries or burns of the face and neck which interfere with the airway, such as fractures about the nose and jaws, lacerations of the lower face, and injuries to the neck either to the cervical spine or in the region of the larynx and trachea. We may be able to correct these immediately by positioning the patient, by the use of an endotracheal tube, or by tracheostomy. Tracheostomy should be done promptly and not considered as a last-gasp measure. Moreover, this will prevent

secretions from accumulating in the trachea and bronchi, which might well result in certain areas of atelectasis with resulting areas of pneumonitis. Naturally, such injuries call for immediate surgery of reparative nature so that a normal respiratory mechanism may be restored as soon as possible.

CHEST

Much may be ascertained from complete examination of the chest: First, the presence of fractured ribs and tissue crepitus; second, the type of respiration and expansion of the chest and abdomen and the use of the accessory muscles; third, the displacement of the trachea to one side or the other which may indicate an accumulation of fluid, pneumothorax, or herniation of abdominal viscera through the diaphragm; and fourth, the information that may be obtained from percussion and auscultation. If good lung sounds are heard throughout both sides, there may be little immediate concern. As to the heart itself, physical examination is sometimes difficult in fat patients or those with considerable emphysema. Nevertheless, examination of the heart combined with the pulse rate and blood pressure reading may lead one to suspect cardiac tamponade—the silent heart—or perhaps direct cardiac injury as by severe contusion, which might well be suspected by marked irregularities of the pulse and altered heart sounds. In many individuals with multiple rib fractures, as in “steering wheel” injury with rib fractures occurring along each side of the sternum, tracheostomy should be performed early. This reduces the normal dead space of pharynx, larynx, trachea, and major bronchi, obstruction due to eddies within the larynx and also facilitates greatly the suction of secretions from the trachea and larger bronchi. In such instances, this will be a lifesaving measure. In wartime, one does not have to consider the age factor as in civilian trauma. Even relatively minor injuries of the chest become of serious import in the stout, flabby individual and in the elderly patient with arteriosclerosis and emphysema. This becomes all the more important if there is a history of a coronary attack or angina. Pain is relieved by intercostal nerve block; treatment of the dilated stomach should be instituted promptly; and provi-

sion made for maximum oxygenation with free airway and easy ability to cough. Parenteral fluids should be restricted as much as possible with these patients.

The same care, and only to a slightly less degree, applies to patients with serious abdominal and back injuries. This latter group is very prone to marked distention and postoperative pneumonitis, and these same complications are also frequent with retroperitoneal hemorrhage and fracture of the bodies of the vertebrae. As to other preexisting disease, the presence of tuberculosis is always important and an unrecognized diabetes may get completely out of hand and coma develop rapidly without causing suspicion on the part of the attending surgeon. Again, if the patient is known to be a diabetic and on insulin this should be recognized. In the presence of an active or subacute tuberculosis, there may be an immediate exacerbation with spread.

In less urgent injuries of the chest, the initial treatment should be conservative. Pain is relieved by intercostal injections of 1 or 2 percent procaine hydrochloride. If there is a defect in the chest wall and an open pneumothorax, this is debrided and repaired, the lung reexpanded as rapidly as possible, and closed drainage established. A tension pneumothorax may be relieved by repeated aspiration or by insertion of a large catheter through the second interspace. Cardiac tamponade is treated first by aspiration, which may be repeated, but if this does not bring about the desired improvement, surgical repair of the laceration of the heart will be necessary. On auscultation of the left side of the chest, particularly, one might also hear borborygmi indicative of herniation of intestines through the diaphragm.

The attending surgeon should never forget the value of and information to be obtained from a fluoroscopic examination. This can readily be done with the patient in a prone or supine position and will immediately clarify doubts the surgeon may have from ordinary physical examination—the condition of the lungs, diminished cardiac contractions, possibility of diaphragmatic hernia with displacement of viscera into the chest, and fluid in the chest, encapsulated, or small collections of air and fluid. If at all possible, and if the patient is not too ill, a postero-anterior and a lateral chest roentgenogram should be made with patient sitting erect. This last examination is, of course, frequently impossible; but much

can be ascertained by fluoroscopy alone by gently rotating the patient.

HEMORRHAGE

Next to the prevention of asphyxia and correction of such interference with respiration as immediately threatens life, the arrest and treatment of massive hemorrhage occupies the second position of priority in emergency surgery. In the control of hemorrhage from the larger vessels of the extremities, a tourniquet may have provided adequate temporary treatment or the hemorrhage may have been so extensive that the blood pressure has been greatly lowered and the bleeding has ceased because of exsanguination. In these instances, prompt transfusion of blood is urgent and, initially, it may be necessary to start one to three units simultaneously. In such instances, group O low titer, universal donor, blood should be given. Because of the dangers from repeated transfusions where there may be differences in subgroups, it is best to crossmatch succeeding transfusions directly with the recipient whenever possible.

Apart from the obvious hemorrhage that may have resulted from an open wound, as from one involving the larger blood vessels, the chest, abdomen, and thighs may be the sites of massive concealed hemorrhage which at times cannot be arrested without immediate surgery, and the traumatic shock thus present will not be corrected until this is performed. True shock may result from the loss of extracellular fluid as well as from hemorrhage or from a combination of both, as is seen in massive injury of the thighs without an external wound.

One should always be suspicious of the thigh, particularly if there is fracture of the femur or crushing injury with no external wound. For example, the average thigh of normal circumference may accumulate approximately 2,200 cc. of blood and fluid with an increase in circumference of only 2 inches (1). If there is also an injury to the chest or abdomen with similar accumulation of blood and fluid, a sufficient amount may accumulate in these hidden areas so that a true picture of severe traumatic shock is produced, which, unless corrected, will result in death. In addition to the necessary surgery, therefore, proper fluid replacement be-

comes immediately necessary. Inasmuch as both blood and electrolytes are lost, treatment should consist primarily of blood transfusions, but electrolyte fluids are also needed and are probably best supplied by $\frac{1}{6}$ molar sodium lactate, Ringer's, or some such similar solution. Overenthusiastic transfusions of blood alone may result in a pulmonary edema which is extremely difficult to correct. Likewise, when multiple transfusions are given, precautions must be taken to guard against citrate poisoning.

TRUNK

When there is any suspicion of a back, abdominal, or pelvic injury, catheterization should be performed; furthermore, this should be done to all unconscious and comatose patients. In wounds of the buttocks, rectal examination should always be performed and the examining finger wiped on a piece of white paper or cloth to determine the presence of blood. If necessary or if there is further suspicion of local injury, the patient may be rolled gently to one side and a proctoscopic examination performed.

ABDOMEN

The abdomen may or may not present initially any evidence of internal injury. Not infrequently in blunt trauma, even with a small tear of the spleen or with complete transection of the small intestine, there may be no signs whatsoever for the first few hours. Just as when an artery is completely severed, if the small intestine is completely divided following blunt injury, there is sometimes tight contraction of the two ends and it is only after later relaxation of the smooth musculature that there will be leakage and evidence of peritoneal irritation. Also with the spleen and kidneys it may be extremely difficult to determine signs of hemorrhage for several hours even if there is a moderately severe tear of the spleen. A traumatic rupture of the diaphragm may give no signs at all at first or, on the other hand, may seriously interfere with life, particularly when the left diaphragm is ruptured with sudden major displacement of the viscera into the left side of the chest. The stomach may dilate and cause serious embarrassment of cardiorespiratory physiology, which, if not

recognized, can result in death, or sudden volvulus or strangulation of the intestine may occur. The urinary bladder may be ruptured with or without accompanying fracture of the pelvis, and in the unconscious patient, there would be little evidence of this. As already stated, any unconscious patient should always be catheterized not only from the standpoint of ascertaining possible injury or retention, but also to ascertain whether unsuspected diabetes may also be present. In the absence of initial signs, in all injuries of the abdomen or chest, repeated examinations at hourly intervals should be performed for the first 6 hours.

In patients in shock from evident or suspected abdominal trauma, initial resuscitation should consist of making sure that the stomach is empty and also of parenteral therapy, especially blood transfusion. No other fluid takes the place of whole blood. If blood is not available, a hepatitis virus-free plasma preparation, albumin, or plasma expander should be given until blood becomes available, although it should be recognized that any fluid other than blood still further dilutes an already reduced red cell volume. Therefore, every effort should be made to administer whole blood.

In the presence of cranial and thoracic injuries, however, overhydration and overtransfusion are to be avoided. The amount of fluid to be given will obviously depend upon the estimated blood loss from any external wound or the extent of internal hemorrhage or fluid loss. Usually after the administration of two to four units of blood, the blood pressure will stabilize temporarily around 80 to 90 mg. of mercury. If the patient still remains in severe shock, the chances are that there is continuing hemorrhage or an overwhelming gross infection in the peritoneal cavity, in which case the surgeon should proceed at once with surgery accompanied by continuing transfusions. In further treatment of such patients, norepinephrine may be of great benefit.

OPERATIVE TECHNIQUE

The quickest approach to the peritoneal cavity is by a long median or paramedian incision. The intestines should be immediately delivered out of the peritoneal cavity and the likely areas for hemorrhage sought—spleen, liver, retroperitoneal vessels. Once the bleeding is arrested, then a careful exploration

of the intestinal tract must be made for such repair as is necessary. In civilian practice, the decision to carry out temporary cecostomy or colostomy must be left with the individual surgeon, although, whenever in the slightest doubt, such an operation should be performed. During wartime, all wounds of the large intestines are exteriorized whenever possible and proximal colostomy performed. On the right side of the colon when the wound is small or exteriorization is not possible, repair is made and a proximal cecostomy performed. In wounds of the lower sigmoid and rectum, temporary proximal colostomy should always be performed.

Wounds of the urinary bladder should be repaired and the patient left with a temporary suprapubic cystostomy. Here again in civilian life an indwelling Foley-type catheter may be left in place. In injuries of the urethra in the male, there will be leakage and spread in the fascial planes of the lower abdomen and perineum. Unless this is recognized and immediate surgery performed, serious infection and local tissue necrosis will supervene.

OPEN WOUNDS AND FRACTURES

In the case of open wounds and fractures accompanying intracranial and intraspinal injuries, debridement and repair of the wounds should be planned (1). If the wounds are clean and the patient remains in the hospital and surgery is performed, the wounds may be sutured immediately following debridement. In disasters or war it is far wiser, and infection will be prevented, if such wounds are left open for closure 4 to 7 days later. In fractures of the long bones, adequate splinting and traction of itself forms an important part of the treatment of the initial shock. When such a fracture is present, traction should be applied before further physical examination.

PREPARATION FOR SURGERY

Each patient must be considered as an individual and as an entity and no general rules can be prescribed which will cover all cases. Much will depend upon the time interval between the injury and when the patient is first seen. Timing procedures in the

case of an individual seen 18 hours after wounding may be quite different from the comparable schedule of the injured person brought directly to the hospital within a few hours of his trauma. There must be complete cooperation and frequent consultation between the neurosurgeon and the general surgeon to determine the parenteral and antimicrobial therapy and the timing of the various surgical procedures that may be necessary. In the unconscious or uncooperative patient, or in any patient being prepared for surgery following trauma for that matter, the stomach had best be lavaged through a large tube. Many injured patients have eaten a large meal accompanied by more or less fluid, and it is essential that the stomach be emptied to relieve distention and also to minimize the dangers of vomiting and aspiration of gastric contents.

Certainly, in the presence of an intrathoracic wound with embarrassed respiration or severe hemorrhage, these conditions must be corrected. By the arrest of hemorrhage and prompt repair of the chest with restoration of cardiopulmonary physiology to normal, as far as possible, the patient will become a better risk for surgery in other sections of the body.

After the intrathoracic damage is repaired, it may be possible at the same time to handle the abdominal problem if such is present, either through the diaphragm or by separate incision at the completion of thoracic surgery. If the latter procedure is chosen, the patient is then carried through with a clean, intact thorax, with the lungs expanded under intratracheal anesthesia, and the required abdominal surgery can be completed without hurry and frequently with progressive improvement in the condition of the patient.

BURNS

In extensive burns accompanying head and spinal cord injuries, the same principles of treatment apply. First, an adequate airway must be established. This is particularly important in those burns involving the face and neck, and tracheostomy may be life-saving. Second, there must be adequate fluid therapy. If over 20 percent of the body has been burned, this is especially important. According to Artz (4), an adequate formula for intravenous fluid in the first 24 hours is 1.5 cc. of fluid times the

percentage of body area burned times kilograms of body weight. This may be all Ringer's solution or probably better still, 1,000 cc. should be blood. In addition, if possible, 2,000 cc. of glucose and water should be taken by mouth. On the second day, the amount of intravenous fluid should be halved and this should all be Ringer's solution. Although this is a general formula for severe burns, for those patients with severe intracranial trauma, particularly if accompanied by intrathoracic injury or multiple rib fractures, the administration of fluids will have to be watched very carefully to avoid overdosage. This may be gaged by urine excretion, which should be maintained at from 30 to 50 cc. per hour.

SUMMARY

All wounds or trauma of any sort, whether in the young and healthy individual or in the aged with preexisting disease, produce a profound immediate disturbance of bodily metabolism so that quite apart from the treatment of the injuries themselves, we must think also of the biological reactions that are going on within the organism. We know, for instance, that for the first few days following trauma there is a negative nitrogen balance and that sodium is stored and potassium is lost. These factors become of increasing moment in the elderly patient with constitutional disease, particularly when food must be withheld. Therefore, the serum levels of sodium and potassium should be followed closely and treated accordingly. These may be checked by blood determinations and urinary excretion, but when such a patient is oliguric or anuric, the administration of electrolytes and all fluids must be handled with extreme care. So, when blood is administered in large quantities, one must bear in mind the possibility of citrate intoxication, and also of the administration of undue amounts of potassium, particularly if the

blood has been stored for over 1 week. The longer it is necessary to maintain such patients by intravenous administration of fluids, the more care is required; in the unconscious patient who remains in that state for days, this becomes a most acute problem.

In summation, there are several important points to bring out. First of all, first things must come first in patients with multiple wounds:

1. Assurance of an adequate airway.
2. Arrest of hemorrhage.
3. Traction and immobilization of fractures.
4. Adequate debridement of large wounds, especially those accompanying fracture.
5. Repair of major arteries whenever possible.
6. Adequate preparation for necessary surgery.

It may be quite possible to accomplish some of these procedures at the same time that surgery required for intracranial or intraspinal injury is being performed. Of the utmost importance is the timing of these given procedures and this may be ascertained only by careful appraisal of the patient's injury and his condition, almost from hour to hour, and here cooperation between neurosurgeon, general surgeon, and competent internist is of the utmost importance.

REFERENCES

1. Hampton, O. P., Jr.: Priorities and Life-Saving Measures in Multiple Injuries. *South. M.J.* 47: 141-146, February 1954.
2. Forward Surgery of the Severely Wounded (A History of the Activities of the 2d Auxiliary Surgical Group), 1942-1945, vol. II, pt. I, pp. 656-682.
3. Campbell, E., and Whitfield, R. D.: Incidence and Significance of Shock in Head Injury. *Ann. Surg.* 138: 698-705, November 1953.
4. Artz, C. P., and Soroff, H. S.: Modern Concepts in the Treatment of Burns. *J.A.M.A.* 159: 411-417, 1 Oct. 1955.

TRAUMA OF THE INTERVERTEBRAL DISK

CHAPTER 39

Lumbar Disk

R. Glen Spurling

ANATOMY

The average length of the vertebral column in the male is 71 centimeters. The cervical portion measures 12.5 cm., the thoracic 28 cm., the lumbar 18 cm., and the sacral and coccygeal portions 12.5 cm. each. The average length of the vertebral column in the female is 61 cm., and the component measurements are proportionately smaller than in the male. The vertebral column is large and triangular in the cervical and lumbar portions, where there is the greatest freedom of movement, and small and oval in the thoracic portion, where movement is more limited.

The vertebral bodies vary in thickness according to their location in the spinal canal. They increase in thickness from the second cervical to the first thoracic vertebra. The first three thoracic vertebrae are somewhat thinner, after which there is a progressive increase in their thickness until the sacrum is reached.

The curves of the vertebral column also vary at different levels. In the cervical and lumbar portions, the convexity is anterior because of the greater anterior thickness of the cervical and lumbar intervertebral disks. These curves first become apparent when the child first holds up his head and then assumes the upright posture and begins to walk. The shape of the cervical and lumbar intervertebral disks is, therefore, modified during the postnatal period. They become thicker anteriorly than posteriorly at this time, so that the spine may become adapted to the upright posture. In the thoracic and

pelvic portions, the convexity is posterior because of the greater posterior thickness of the vertebral bodies in this region. These curves, unlike the cervical and lumbar curves, are present during fetal life. In adults there is usually, though not invariably, a slight lateral curvature with the convexity to the right in the right-handed individual and to the left in the left-handed individual.

The vertebral bodies, in addition to being attached to each other by intervertebral disks, are also attached to each other by three other structures, as follows:

1. *The anterior longitudinal ligament.*—This is a strong band of tissue which increases in thickness and width from above downward and which is attached to the lips of the vertebral bodies and to the anterior surfaces of the intervertebral disks.

2. *The posterior longitudinal ligament.*—This is a much weaker ligamentous structure, which is attached posteriorly to the vertebral bodies and intervertebral disks just as the anterior longitudinal ligament is attached anteriorly. The posterior ligament decreases in size from above downward. It has a dentated appearance because it widens to some extent opposite each disk. This ligament is thinnest in the lateral extremities of its attachment to the posterior annulus fibrosus, a circumstance which probably accounts for the fact that by far the greatest number of ruptures of the intervertebral disk occur at these points.

3. *Other lateral bands or sheaths of fibrous tissue.*—These bands, which appear on the lateral as-

pects of the vertebral bodies, are connected with the attachments of the muscles to the spinal column. Although they consist of well-developed fibrous tissue, they are somewhat thinner than the anterior longitudinal ligament. The whole series of vertebral bodies and intervertebral disks which make up the spinal column constitute a flexible column ensheathed in a tough fibrous covering. The fibrous sheath, while it adds to the toughness and strength of the disks, does not interfere with movement because it blends with their outer layers.

The 23 intervertebral disks which are present in the vertebral column from the second cervical to the first sacral vertebra constitute a quarter of the length of the column. The cervical and lumbar disks, which, like the vertebral bodies in these regions, are thicker than the thoracic disks, constitute a third of the length of the lumbar spine.

The ligamenta flava, which are bilateral structures, are attached to the anterior surfaces of the laminae above and to the posterior surfaces and upper margins below. It is the elasticity of these ligaments which helps to maintain the body in the upright posture without voluntary muscular effort. They increase progressively in thickness from the cervical through the lumbar region. Spurling, Mayfield, and Rogers (1), whose observations were confirmed by Horwitz (2), showed by anatomical studies that these ligaments range in thickness from 2 to 7 mm. at the interlaminar spaces from the third lumbar vertebra to the sacrum. At each intervertebral disk, the lower half of the bony foramen is occluded by a groove formed by the ligamentum flavum and the intervertebral disk.

The interspinal ligaments blend anteriorly with the ligamenta flava and posteriorly with the supraspinous ligaments and the ligamenta nuchae.

Each intervertebral disk is composed of three distinct anatomical parts; namely, the cartilage plates, the annulus fibrosus, and the nucleus pulposus.

Cartilage plates

The cartilage plates, which are composed of hyaline cartilage, are cemented to the intervertebral surfaces of the superior and inferior vertebral bodies by a thin layer of calcified cartilage. The cortex on these surfaces is so extremely thin that in many places the bone marrow can reach the surface of the plates through openings in the spongy bone.

Except at its posterior extremity, where closure is incomplete, the bony epiphyseal ring forms the margin of the vertebral body. The ring is about 3.0 mm. wide and from 1.5 to 2.0 mm. high. The cartilage plate abuts on it anteriorly and laterally. Posteriorly, where the ring is defective, the plate extends to the margin of the vertebral body.

On the intervertebral face of each cartilage plate is a fibrocartilaginous layer, which is intimately blended with the plate and which keeps the nucleus pulposus from actual contact with it. The lack of contact is important in only one respect: The anlage of the intervertebral disk produces the fibrocartilaginous envelope from which arise the fibers and cartilage cells that eventually convert the embryonic nucleus pulposus from its original composition of notochord cells into the adult type of structure. The cartilage plate, in contrast, is the unossified remainder of the cartilaginous vertebral body. By proper dissection and preparation (fig. 167), it is easy to show the relationship between the nucleus pulposus and the annulus fibrosus.

Annulus fibrosus

The annulus fibrosus, which is a fibrocartilaginous envelope surrounding the nucleus pulposus, binds the adjacent vertebral body to the cartilage plate, as well as to the bony epiphyseal ring by means of Sharpey's fibers. The bundles of fibers which compose the annulus fibrosus cross one another as they pass obliquely between the vertebral bodies, the arrangement contributing to its elasticity. The numbers of layers composing the annulus fibrosus cross one another as they pass obliquely between the vertebral bodies; this arrangement likewise contributes to its elasticity. The numbers of layers composing the annulus fibrosus differ according to the level of its location in the spinal column. In the lumbar region, according to Joplin (3), there are from 10 to 12 layers.

Nerve supply

Jung and Brunschwig (4) found no nerve endings within the intervertebral disk. They have been misquoted to the effect that nerve fibers are limited to the anterior spinal ligament. Actually, Jung and Brunschwig stated that they have found nerve fibers in small numbers in the lateral extension of the anterior spinal ligament as well as in the posterior

longitudinal ligament. Nerve fibers were present between the annulus fibrosus and the spinal ligaments, but did not enter the disk. This work was done in 1932. In 1940, Roofe (5), using the new technique described by Bodian (6), demonstrated multiple nerve endings in both the posterior annulus fibrosus and the posterior longitudinal ligament.

distributed to the ligamentous structures in the anterior spinal canal and extended to the two vertebrae below their point of origin (fig. 168).

Nucleus pulposus

The nucleus pulposus in the adult lies within a fibrocartilaginous envelope which is not a distinct

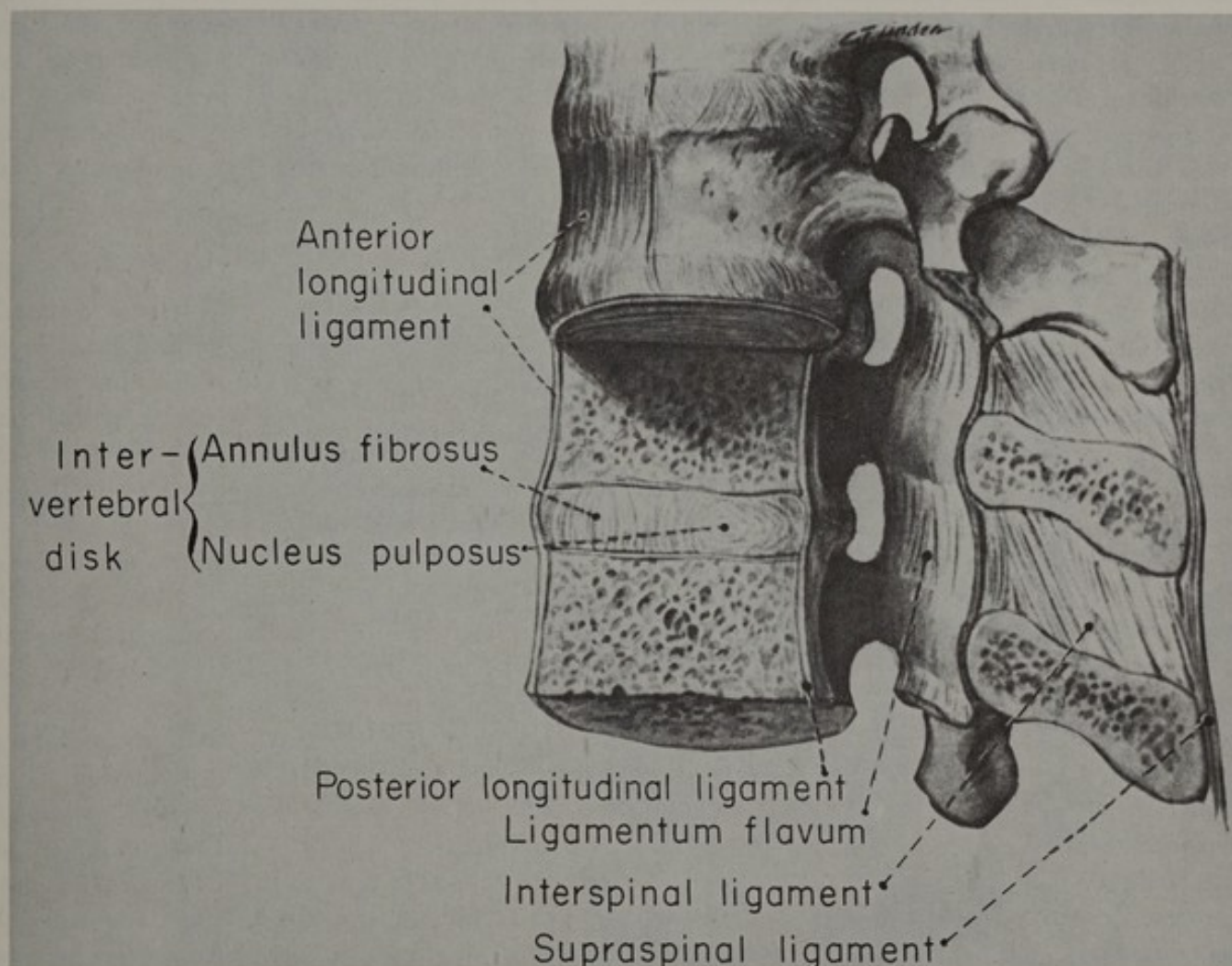


FIGURE 167.—Diagrammatic sagittal section through two lumbar vertebrae, showing relationship between intervertebral disk and other important regional anatomical structures. (From Thorek, Philip: *Anatomy in Surgery*. Philadelphia: J. B. Lippincott Co., 1951.)

Although he could not identify specialized end organs, the type of terminal arborization which he observed would indicate that these nerve endings are probably pain fibers.

In Gray's "Anatomy," there is a recurrent nerve described which originates distal to the dorsal ganglion and enters the spinal canal through the intervertebral foramen. It is stated that it supplies only the dura. Roofe (5), by gross dissection, was able to demonstrate similar recurrent nerves which were

layer but which merges with the annulus fibrosus enclosing the nucleus peripherally. This envelope also separates the nucleus from the hyaline cartilage plates superiorly and inferiorly.

The nucleus pulposus must not be conceived of as a structure lying free within these boundaries. Instead, as already pointed out, it is formed by fine interlacing fibers which extend from the fibrocartilaginous envelope and which are interspersed with cartilage cells. These cells frequently occur in pairs

or in tetrads. The gelatinous matrix in which these structures are embodied is the original mucoid material formed from the notochord cells as they underwent degeneration. An occasional notochord cell is still present in it. According to Keyes and Compere (7), this mucoid material is the permanent matrix of the fibrocartilaginous elements of the nucleus

Histology

Microscopic examination of the cartilage plates reveals that they are composed of true hyaline cartilage, which undergoes a transition to fibrocartilage in the area immediately adjacent to the nucleus pulposus.

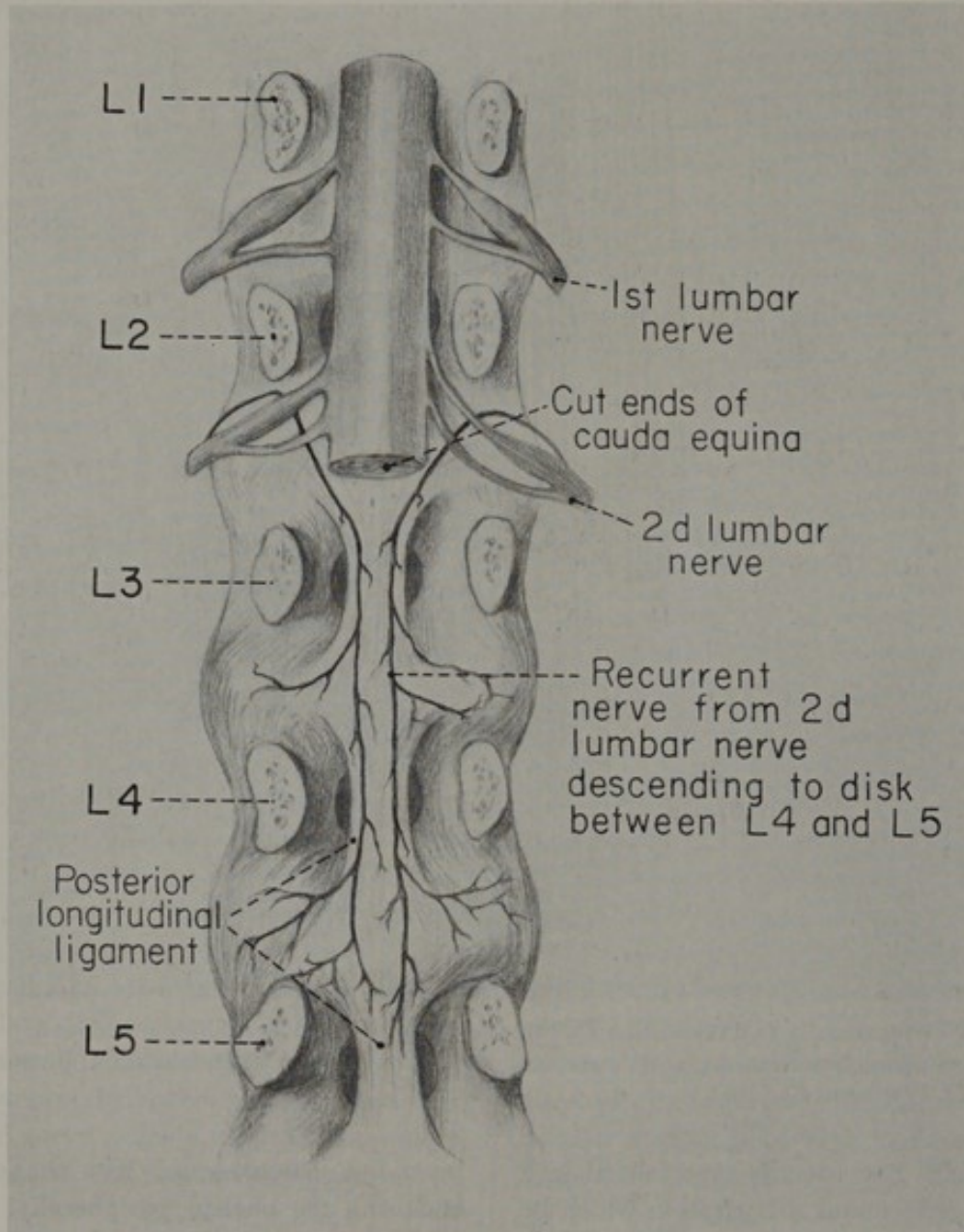


FIGURE 168.—Distribution of second recurrent lumbar nerve to region of third and fourth lumbar vertebrae and intervertebral disks. (From Roofe (5).)

pulposus. It seems more reasonable to conceive of it as modified by diffusion and by the elements which it contains, so that it becomes a special medium in which the fibrocartilaginous components of the nucleus are continuously bathed.

The annulus fibrosus consists of dense bundles of connective tissue fibers embedded in a matrix of cartilage, the cartilaginous component, as just noted, being prominent only in the inner layers. The layer of annulus fibrosus to which the nucleus pulposus

is attached is the fibrocartilaginous envelope which, as also previously noted, constitutes a zone rather than a definite layer.

The fine connective tissue fibers in the nucleus pulposus interlace in all directions. There is also a slight admixture of elastic fibers. In the fluid matrix are found fusiform or spindle-shaped connective tissue cells, groups of cartilage cells, and occasionally, in young persons, clear vacuolated cells which are thought to represent surviving notochord cells. Toward the periphery, the fibrous network gradually becomes denser and finally assumes an orderly arrangement in the thick, curving bundles of the annulus fibrosus.

Changes with age

Certain changes occur in the structures of the intervertebral disk as age advances. Püschel (3), and Keyes and Compere (7), working independently, found that the water content becomes progressively less. Smith (9) described a number of other alterations. In the third decade, although fibrous invasion of the nucleus continues, its elasticity is not affected. Even at this period of life, its color may be distinctly yellow. The number of cartilage cells is increased and they occur in larger groups than during infancy and childhood. In the fourth decade, the continued invasion of fibrous tissue finally begins to affect the elasticity of the nucleus pulposus, which is now tougher and less fluid. During the fifth decade, fibrous tissue is present in whorls.

As the years pass, there is some obliteration of the cellular elements of the nucleus, which appear to be degenerated. The fine fibrous structure tends to become more amorphous and eventually only a diffuse, pink-staining matrix is left. Finally, a brown pigment, the nature of which is not understood, accounts for more or less marked degrees of discoloration in the senile disk.

The alterations which occur with age in the annulus fibrosus can be chiefly attributed to the additional wear and tear to which it is subjected when the nucleus pulposus has ceased to function as efficiently as it did in youth.

PHYSIOLOGY

The physiology of the intervertebral disk will be more clearly understood if some simple comparisons

are made. The annulus fibrosus can be compared to a strong, but still somewhat elastic, membrane which firmly binds the vertebral bodies together. The nucleus pulposus is frequently compared to wet blotting paper, and in appearance it does resemble it, but otherwise the comparison is not valid. In consistency, this structure is a moderately tough, highly plastic tissue, which can easily be shaped between the fingers. Probably the best comparison is with moist fascia, of the nontendinous type. In the process of herniation, when it is torn into various shapes and thicknesses, it actually resembles fragments of fascia of irregular thickness and contour.

The nucleus pulposus can also be compared to a fluid, since, in the limited degree of displacement to which it is subjected in movements of the vertebral column, it behaves as a fluid.

The fluid (plastic) structure—that is, the nucleus pulposus—distends the elastic structure—that is, the annulus fibrosus—so that there is a positive pressure which tends to displace the nucleus whenever the membrane which contains it (that is, the annulus) is cut. This is true even when no weight is placed on the vertebral body. Middleton and Teacher (10) found that the nucleus pulposus could be displaced if the intervertebral disk between the adjacent vertebral bodies was compressed in the jaws of a vise. Barr (11), in 1937, using the same experimental method, found that he could repeatedly cause marked distention of the annulus fibrosus by compressing the intervertebral disk, but that the annulus returned to its normal shape after the vise was released. If, however, the annulus fibrosus was pierced with a needle while the disk was compressed, rupture occurred at the point of penetration, and herniation of the nucleus pulposus followed. Whenever this occurred, the intervertebral disk lost its elasticity and there was no return to its former normal state.

Although Sashin (12) has made the statement that the nucleus pulposus is highly expansile, actually, this is not true. This structure, because of its plastic nature, obeys the laws of fluids and is neither compressible nor expansile. It is the tension of the elastic annulus fibrosus which keeps it under pressure even when the intervertebral disk is not bearing weight.

Even more important than the shock-absorbing function of the intervertebral disk is its function of equalizing the pressure over the entire interverte-

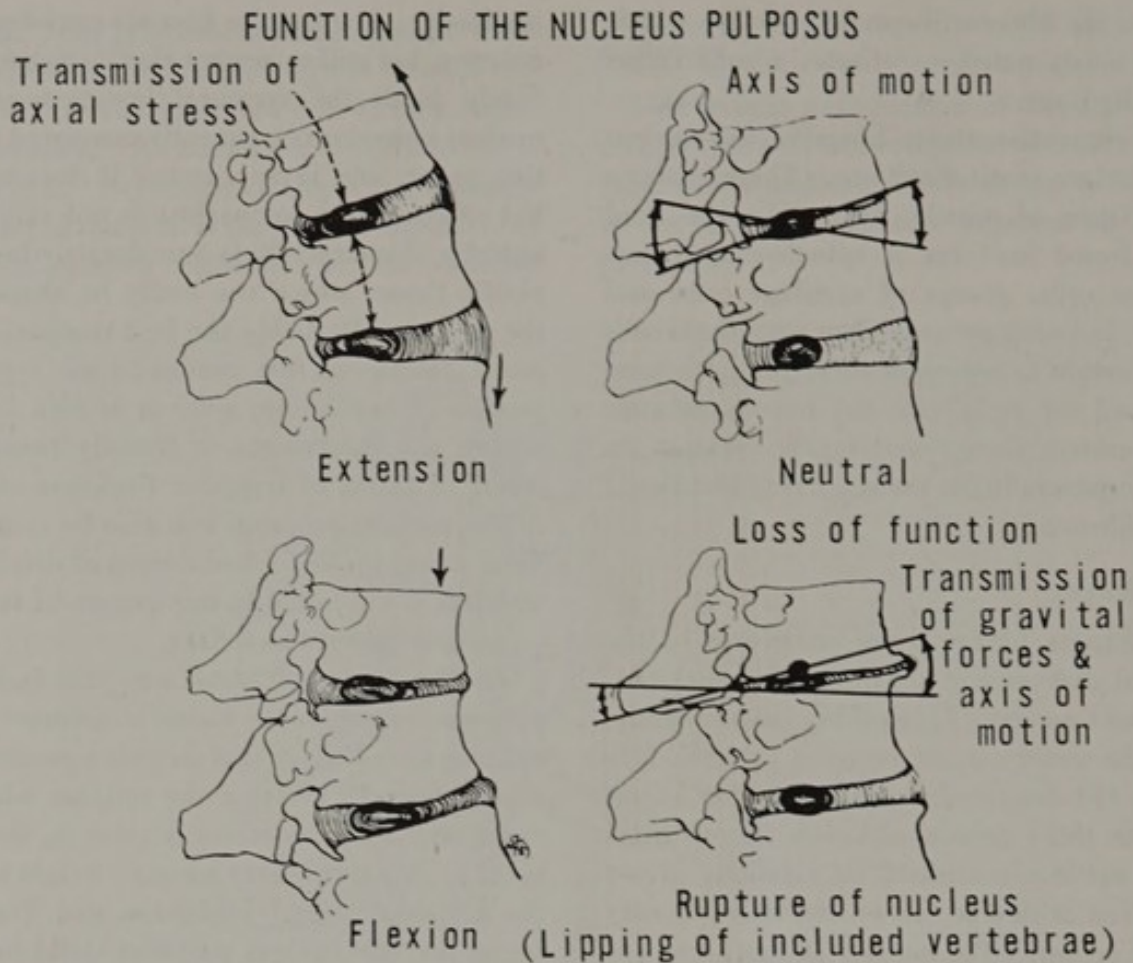


FIGURE 169.—Diagrammatic presentation of function of intervertebral disk. (From Keyes and Compere (7).)

bral surface of each vertebra. Since the pressure through a fluid (plastic) medium is always uniform, any force thus transmitted is distributed equally over the intervertebral surface of each vertebral body. If there were not such a center in each intervertebral disk, transmitted force would be perfectly distributed only when the vertebral bodies remained in a straight line. If these bodies were wedge shaped, the transmitted force would be equally transmitted to them only while they remained arranged in the particular curve for which the degree of wedging was suitable. Since, however, the disks have fluid (plastic) centers, transmitted force is equally distributed to the intervertebral surfaces of the vertebral bodies in a wide range of motion in all directions (fig. 169). Only when angulation is sufficient to displace all fluid medium from one extremity of the cavity to other portions, so that the walls at the point of displacement become apposed, does the distribution of the force become unequal. When this happens,

the effect is borne disproportionately by the area from which the fluid material has been displaced and the cavity has become obliterated.

It is true that a solid intervertebral disk with elastic properties would serve to distribute the transmitted force because elasticity implies a limited degree of fluid. The range of motion, however, would be narrow. Only by means of a fluid or plastic nucleus pulposus could force be transmitted with an even distribution through a wide range of spinal movements.

From what has been said, it is evident that the annulus fibrosus must resist the pressures which would otherwise displace the nucleus pulposus. The annulus also has another function, to help prevent excessive angulation at any single articulation. This function is based on the fact that it binds the margins of the vertebral bodies firmly together. In other words, the annulus fibrosus must withstand both pressure, which tends to distend it, and tension,

which acts in a direction parallel to the vertebral column. Its anatomical configuration equips it to withstand both of these forces.

Another situation arises when injury to the annulus fibrosus or to the laminae of the hyaline cartilage plates has allowed the nucleus pulposus to escape. Then the annulus is subjected to alien forces and becomes little more than a washer resisting direct force. When the fluid medium, which transmits force evenly, is eliminated, movements bring force to bear on small areas of the intervertebral disk at one time (fig. 169), and the disk is then in a position to be ground between opposing vertebral bodies. If a vertebral body is weakened by disease, it, too, may be ground away. If it is not, it will at least become sclerosed and is likely to produce spurs to resist the unusual and poorly distributed forces to which it is subjected.

Still another physical consideration plays a part in this matter: The fluid nucleus pulposus can distribute transmitted force evenly only when the intervertebral surfaces of the vertebral bodies are moderately flat, so that the force can pass from one portion of the enclosed cavity to another. Its passage is relative rather than absolute, since the nucleus pulposus is attached to the annulus fibrosus and the laminae of the cartilage which encloses it.

CLINICAL AND ROENTGENOLOGICAL DIAGNOSIS OF LUMBAR INTERVERTEBRAL DISK LESIONS

HISTORY AND SYMPTOMATOLOGY

There are few clinical entities in which a well-recorded history is so essential in arriving at an accurate diagnosis as it is in a rupture of an intervertebral disk in the lower lumbar region. The history is so informative, in fact, that if the patient is observant, and if he relates his symptoms in chronological order, as well as with regard to chronological intensity, an experienced physician can make a tentative diagnosis, which usually proves to be correct, from a telephoned account.

If the patient is a man, and if he is in an occupation which involves heavy lifting and bending, the

likelihood that the condition is a ruptured lumbar disk is considerably enhanced. The predominance of ruptured disks in males, the average being three males to every female, is conceded by all observers. The proportion varies from the 70 percent reported by Spurling and Grantham (13) to the 87.5 percent reported by Barr (14). The male predominance is probably to be explained by the influence of repeated minor trauma in occupations which require heavy lifting and bending.

Pain

With very infrequent exceptions the first symptom of a ruptured lumbar disk is pain in the back, which is of two types. The most usual story is that the patient, when bending forward in order to lift a heavy object, felt a sudden slip or catch in his back. Then, when he tried to straighten up afterward, the movement was attended with excruciating pain in the lumbar region. The acute pain associated with the acute episode was later succeeded by dull, aching discomfort in the same region.

Direct trauma to the spine is seldom a factor in the production of a ruptured lumbar disk. There are some cases, however, which, in a broad sense, can be considered of traumatic origin. They occur in the large group of persons, usually men, whose occupations require continuous heavy work in the bent-forward position. As a result, there is constant wear and tear upon the lumbosacral spine, and, as a further result, there is an increasing predisposition to rupture of the intervertebral disks at the points of greatest flexibility in the spine, that is, the fourth and fifth lumbar vertebrae. These patients frequently present characteristic symptoms of disk rupture, and the heavy work in which they must engage while they are in a special position can be considered fairly as attended with occupational hazards.

Characteristics of pain

The severity of the initial pain is a prime consideration in the diagnosis of ruptured lumbar disk. In the initial episode, as well as in subsequent acute episodes, both the lumbar and the sciatic pain are characteristically incapacitating. On the other hand, it is of great importance in the evaluation of the patient's story to determine his tolerance for pain. A neurotic person is likely to exaggerate

what may be little more than discomfort, while a stoic person may be inclined to minimize pain which is extremely severe.

Partial or complete remission of symptoms is characteristic of lumbar herniations of the nucleus pulposus. The usual history is of recurrent attacks with freedom, or relative freedom, from pain during the intervals. Most often, there is some degree of pain present between the attacks, usually slight and sometimes best described as soreness, though it is entirely possible for the patient to be perfectly well. Days or weeks may elapse before acute pain recurs. The second episode is frequently ushered in by a second indirect injury, which is often trivial.

Variations in the severity of pain in herniated nucleus pulposus are open to two possible explanations. One is that even in organic lesions, in which the pathological process is steadily progressive, pain is sometimes more severe than at other times. The other possible explanation is that the relationship of the offending mass to the compressed nerves alters to some degree with every bodily movement. The reasoning is logical: The position of the disk changes with each movement, and the position of the mass, which is an integral part of the disk, changes with it.

An outstanding characteristic of the lumbar pain of a ruptured disk is what may be termed its mechanical origin: that is, the pain is characteristically intensified by movement and weight bearing. The patient himself is usually fully aware of the movements which cause an intensification of the pain. Standing may be more comfortable than sitting. The recumbent position, particularly after a period of time, may be extremely uncomfortable, and the patient tends to discover for himself the position in bed in which he has the least discomfort. Bending forward is especially difficult, and it will be observed that in picking up an object from the floor he tends to bend his knees and to keep his back straight. There is seldom any difficulty in distinguishing between this type of pain and the nagging, constant backache, unrelated to movement, which occurs in certain types of visceral disease.

Associated sciatic pain

In the occasional case, pain in the back and sciatic pain occur simultaneously, but, as a rule, there are several attacks of lumbar pain before sciatic pain

ensues. The interval is sometimes measured in years. In the meantime, the patient may have been repeatedly incapacitated by attacks of so-called lumbago. A patient who is presently incapacitated by sciatic pain will sometimes deny that he has ever had previous bouts of low back pain, and will even deny that lumbar pain is associated with his present sciatic pain. This is easily disproved. When the physical examination is carried out, the usual signs of lumbago will be evident, chiefly sciatic scoliosis and local tenderness on percussion. A patient who gives this sort of history will usually be found to have a herniation far lateralward in the annulus fibrosus and projecting directly into the intervertebral foramen.

The distribution of sciatic pain in herniated nucleus pulposus is essentially the same whether the herniation occurs at the fourth lumbar disk or at the lumbosacral disk. There is usually some pain along the entire course of the sciatic nerve, and areas of maximum intensity are frequently present in the gluteal region, the upper posterior thigh, the back of the knee and calf, and the external malleolus. This distribution is readily explained by the fact that involvement of nerve roots that are components of the sciatic nerve may cause radiation along the nerve, exactly as would occur in nerve involvement anywhere else in the body. As a rule, the pain is unilateral and is constant in the same extremity. It is only occasionally bilateral. Very occasionally, it may shift from one limb to the other during the first or successive episodes.

Mild pain in the distribution of the sciatic nerve is probably best explained by slight posterolateral herniation of the nucleus pulposus. This supposition is supported by the fact that many patients who are later incapacitated by ruptured lumbar disks have stories of similar but mild symptoms years before, presumably of the same origin. It is also supported by Andrae's discovery (15) of small posterior herniations, which presumably were symptomless during life, in about 15 percent of routine examinations of the spine at autopsy.

It would not be accurate to explain the slightness of sciatic nerve pain by the small size of the herniations per se, because small herniations frequently give rise to serious symptoms. Fulminating symptoms, for instance, may result from a small protrusion of the disk if it is directly beneath a nerve root

or in the intervertebral foramen. It does seem reasonable, however, to attribute the less severe types of pain observed in the sciatic distribution in many cases to what might be called subsurgical herniations of the nucleus pulposus which do not directly involve the nerve roots. Cases of this kind, in which operation is undertaken with little or no objective evidence of true root involvement, provide innumerable disappointments for both patient and surgeon.

A patient with severe sciatic pain will find that any bending movement, any exercise, and even the sitting position will increase it. Coughing, straining to empty the bowels, or sneezing intensifies it, particularly during acute episodes. He usually keeps the leg flexed and finds it difficult to get his heel to the floor. Slight flexion of the leg and thigh brings some relief because in this position the pull on the sciatic nerve is relaxed. Elevation of the heel of the shoe also may furnish some relief.

The complete remissions of sciatic pain which may occur with relief of the lumbar pain are more difficult to explain. They are observed in about 40 percent of all cases. Deucher and Love (16) have advanced the theory, based on the known propensity of the nucleus pulposus to swell when it is immersed in water, that intermittent edema of the herniated material is responsible for the recurrent episodes of pain, while the disappearance of the edema brings relief. Observers who have studied large numbers of specimens microscopically have not been able to verify this theory.

There are also more convincing explanations, based upon sound theory and verified by clinical experience, for the intermittency of symptoms. It has long been known, for instance, that patients with certain neurological defects, of which an absent ankle jerk is the commonest, will tell a story of former severe sciatic pain, which is no longer present. Neurosurgeons are often consulted for other conditions by patients who present permanent, but no incapacitating, neurological deficits and who supply a history of incapacitating sciatic pain which terminated many years earlier. Such observations clearly indicate that herniation of the nucleus pulposus sometimes ceases to be painful because the nerves involved in the process have undergone physiological destruction. If only one spinal nerve is involved, the neurological deficit will be slight. If two of the lower spinal nerve roots are damaged

(the fifth lumbar and first sacral, for instance), the deficit will be greater, ranging from permanent loss of sensation in the affected dermatome and reflex changes to paralysis of muscle groups controlling the movements of the foot and toes. If the herniated mass becomes larger, or if its position is shifted so that a different root or roots become involved, pain, naturally, will recur.

Mauric's theory (17) is based on the assumption that herniation occurs by degrees rather than en masse. When the herniation is still small, the stretched nerve root can gradually adapt itself to its new and more circuitous course, and pain eventually ceases as adaptation becomes complete. As more of the nucleus pulposus herniates, adaptation is no longer possible and pain persists.

Still another theory is based on Chandler's observation (18) that when lumbosacral fusion is performed in selected instances of low back pain and sciatic pain, the sciatic pain disappears more slowly than the lumbar pain. This might be expected. The lumbar pain disappears because motion ceases as the disk is fixed by the fusion operation. The sciatic pain does not cease immediately after operation because it is caused by herniation of the nucleus pulposus. If it ceases later, as it frequently does, the outcome can be attributed to adaptation of some sort on the part of the involved nerve or nerves as the result of the fixed position of the intervertebral disk. The same chain of events may explain the termination of pain in some conservatively treated cases in which osteoarthritic bridging has produced the same result spontaneously which is produced surgically by spinal fusion.

Love and Walsh's suggestion (19), that relief of symptoms sometimes occurs when practitioners of manipulative therapy are able to force the disrupted mass back into the disk, is not universally applicable, for most patients who experience relief have not been subjected to such manipulation. There is no denying the fact that many patients with excruciating low lumbar pain do obtain relief following various kinds of manipulative therapy, in which should be included the maneuvers performed during the physical examination of a stiff lumbar spine. On the other hand, it is doubtful that manipulations can reduce the herniation into the disk unless the tear in the annulus fibrosus is unusually large. The small rent most often seen at the operat-

ing table would scarcely readmit the herniated mass, regardless of the manipulation employed, because no force could be brought to bear upon the disk which would diminish the pressure within it. If, however, the annulus fibrosus is badly torn, and if, as a result, the opening through which the herniation has occurred is large, it is within the bounds of possibility that manipulation might reduce the size of the herniated mass. We have observed one such case at operation: A large mass of protruding disk elements presented within the spinal canal when the lumbar spine was in moderate flexion but was appreciably reduced in size when the position was changed to extension. In another case, also observed at operation, it was possible to press the protruding mass back into the disk through a large tear in the annulus fibrosus.

NEUROLOGICAL SYMPTOMS AND SIGNS

Localized numbness and paresthesia (tingling) are often of diagnostic significance. The precise area affected in the leg or foot should be noted, since it may serve to identify the particular nerve root or roots which are affected by pressure of the intraspinal herniation of the ruptured disk. There is some doubt that pressure on a single nerve root produces demonstrable sensory loss to the usual stimuli. Paresthesia in the affected dermatome, on the other hand, is readily produced by minor degrees of pressure, the tingling produced in the little and ring fingers by pressure upon the ulnar nerve at the elbow being the most familiar example. In our own opinion, paresthesiae in the affected dermatome are of greater diagnostic and localizing significance than demonstrable sensory loss.

A history of generalized muscular weakness of the affected extremity is usually of little diagnostic help because patients are so often inclined to confuse weakness with pain. Localized palsies referable to special muscles of the leg are not open to this objection and are of diagnostic value. Foot drop is the most usual manifestation. Sphincteric disturbances, such as are commonly seen where there is severe compression of the cauda equina by neoplasms, are seldom associated with herniation of the nucleus pulposus, though a ruptured disk may occasionally so completely block the lumbar spinal

canal that a true transverse lesion with associated sphincteric incontinence will be produced.

Pain is referred to the dermatomes of the affected spinal nerves at some time in the course of almost every proved case of herniated nucleus pulposus. This fact probably accounts for the high incidence of pain in the lateral aspect of the limb, which is supplied by the fifth lumbar and first sacral nerves. In Barr's series (20) of several hundred patients, 90 percent were thus affected. Unless hypesthesia or paresthesiae are present, localization of pain is not reliable in identifying the nerve roots involved.

The soreness often present in the gluteal, hamstring, or leg muscles, regardless of whether the fifth lumbar or first sacral nerve is involved, can be explained by the multiple innervation of these muscles. The spinal nerves, it must be remembered, are mixed nerves and therefore supply sensation as well as motor power to the muscles. It is not surprising, therefore, that pain and tenderness are often present when only one or two roots are involved, while the remaining normal roots continue to furnish adequate motor power, and paresis does not occur. Furthermore, nerve involvement may well cause pain even when it is not of sufficient degree to produce motor or sensory paralysis.

PHYSICAL EXAMINATION

Physical examination is carried out with the patient completely undressed. It begins with observation of his posture and gait, the general alignment of the lower extremities with the trunk, the position of the feet, and the mobility of the small joints of the hands and feet.

Spasticity of the lumbar muscles, with some reduction, complete obliteration, or even reversal of the normal lumbar curve, is characteristic of patients with ruptured lumbar disks. Most of them, in addition, show a listing away from the side of the sciatic pain (fig. 170), while the pelvis is almost always higher on the affected side. Lumbar (sciatic) scoliosis is common. The convexity may be either toward or away from the side of the sciatic pain. Occasionally, a patient is encountered with so-called alternating scoliosis; that is, he is able to change the pelvic list from one side to the other by bending laterally or forward. It must be emphasized

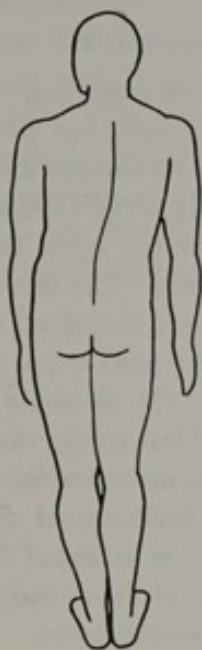

FIGURE 170.—Typical lumbar deformity (sciatic scoliosis) in patient with ruptured lumbar disk on left side. Note elevation of pelvis on left. (From Spurling, R. G., and Thompson, T. C.: Notes on Diagnosis of Herniated Nucleus Pulposus in Lower Lumbar Region. *Surgery* 15: 387-401, March 1944.)

that while a spinal deformity is characteristic of herniated nucleus pulposus, it is not pathognomonic; there are many other pathological processes which affect the spine and in which it may appear.

Movements of the lumbar spine, especially flexion, are usually limited and extension is often painful. Bending toward the side of the lesion is likely to be more painful than bending away from it (fig. 171), though in certain midline disk lesions the reverse may be true.

Intensification of the pain in the back and leg during rotary extension of the lumbar spine (fig. 172), with numbness or tingling in the foot or toes, in our experience, is pathognomonic of ruptured disk. During this examination, the patient stands erect with knees straight and both heels firmly planted on the floor. The examiner grasps his shoulders and slowly extends the lumbar spine, trying at the same time to make him bend toward the painful side.

SPECIAL TESTS

Percussion test

In the percussion test, the patient is directed to bend forward to the point of intensification of the

usual pain in the back or leg. While he stands in this position, light percussion strokes (or digital pressure) are made over the spinous process until the precise point of tenderness is identified. When this point is found, a deep percussion stroke is made on the painful side lateral to the process presumably involved (fig 173). The test is recorded as positive when this maneuver causes sharp pains to radiate into the hip, down the back of the thigh, or into the leg. Our experience is that a positive result is almost pathognomonic of a ruptured intervertebral disk. We have sometimes found it possible to differentiate accurately between lesions of the fourth and the fifth disk by the production of radiating pain with a blow at one level but not at another. The explanation of the pain is the transmission, through the muscles of the back and the ligamentum flavum, of waves of force to the affected nerve root.

Jugular compression test

The jugular compression test devised by Viets (fig. 174) is performed by simultaneous compression of the internal and external jugular veins, for a period of 2 minutes or more, to determine possible exaggeration of the pain pattern. The test may be performed with the patient in either the supine

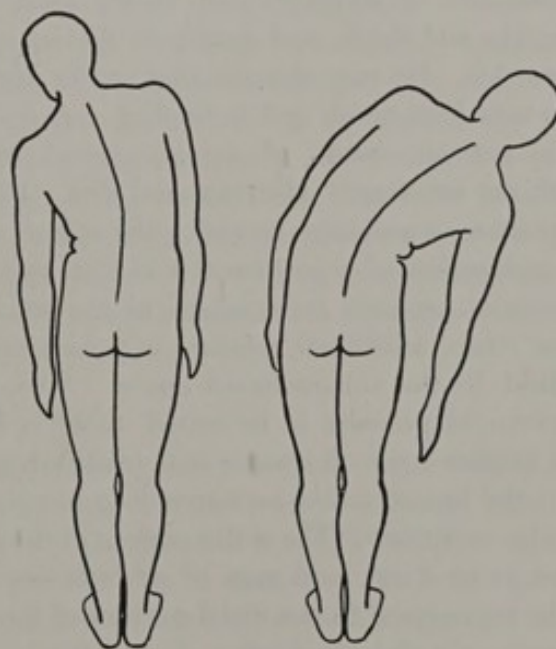


FIGURE 171.—Typical lumbar deformity in patient with ruptured disk on left side. (Left) Restricted lateral bending toward painful side. (Right) Unrestricted lateral bending away from painful side. (From Spurling and Thompson, op. cit.)

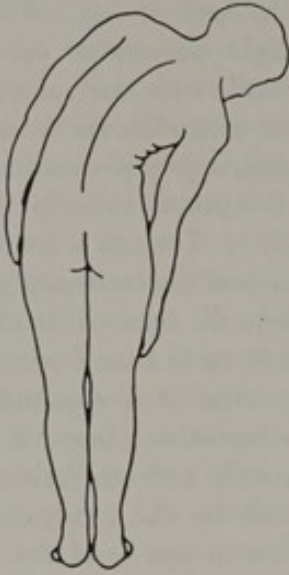

FIGURE 172.—Reproduction of entire pain pattern in back and leg in ruptured intervertebral disk in lower lumbar region by forcible lateral bending and rotation toward painful side. (From Spurling and Thompson, *op. cit.*)

or the upright position. The venous return is impeded until the patient complains of a distinct feeling of fullness in the head and says that his eyes feel as if they were popping out of their sockets. The test should not be listed as negative until the venous return has been impeded for at least 2 minutes. When it is positive, the patient, without prompting, will complain of increased pain in the back, then in the hip and thigh, and finally in the leg down to the ankle. He may also say that one or another of the toes feels numb and is tingling. A positive test is pathognomonic of an intraspinal lesion, though not necessarily of a ruptured disk. It may also point to a neoplasm involving the spinal roots. The explanation of a positive test is that when the intracranial pressure is increased as the result of venous stasis, additional pressure is transmitted to the fluid in the subarachnoid space. When the subarachnoid pressure is increased, there is additional tension upon the nerve root involved at the site of the lesion, and a corresponding increase in radicular symptoms. The entire pattern of the pain, as just pointed out, and even of paresthesiae may thus be reproduced in the distal portion of the dermatomes. Careful observation during the jugular compression test often permits accurate localization of the lesion in addition to clinical confirmation of its presence.

Sciatic-nerve-stretching test

The sciatic-nerve-stretching test devised by Lasègue (21), in 1864, has proved useful in the diagnosis of ruptured lumbar disk. It is performed by flexing the thigh at right angles to the trunk and then extending the leg upon the thigh while the patient is recumbent.¹ The test is considered positive if the maneuvers described cause pain. Opinions differ as to the mechanism of the pain. Danforth and Wilson (22) attribute it to stretching of the components of the sciatic nerve. Freiberg and Vinke (23) suggest three possible explanations: (1) Movement of the lumbosacral or sacroiliac joints, (2) stretching of the irritated hamstring muscles, and (3) tightening of the already spastic piriformis muscle against the sciatic nerve.

In his original description of the sciatic-nerve-stretching test, Lasègue (21) noted that patients who suffered from severe sciatic pain held the ankle plantar-flexed and that dorsiflexion caused severe pain. Many years later, Viner (24) and Purves-Stewart (25) both suggested that the Lasègue test be amplified by dorsiflexing the foot, which stretches the tibial portion of the sciatic nerve as much as 2 centimeters. These observations suggested a further modification of the Lasègue test based upon the

¹ This is not at all the same as the test in which the leg is raised straight up, without flexion, though it is often described as if it were.—R.G.S.

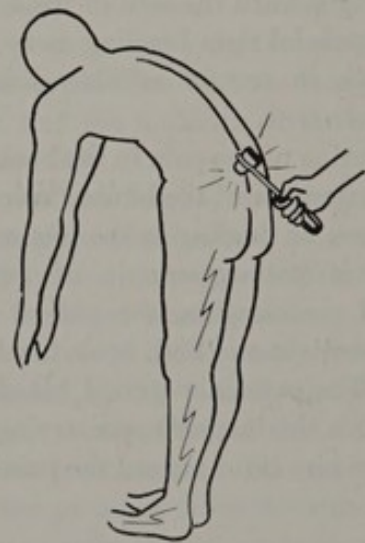


FIGURE 173.—Reproduction of radicular pain by deep percussion (or digital pressure) about 1 inch from spinous process on affected side at level of disk lesion. (From Spurling and Thompson, *op. cit.*)

sensitivity of the sciatic nerve to stretching. It is performed as follows: With the patient lying supine, the thigh is flexed at right angles with the trunk, as in the original test. The leg is then extended upon the thigh, also as in the original test, but only until the patient complains of pain in the gluteal or hamstring region. At this time, without further manipulation of the leg or thigh, without movement

protective muscle spasticity may cause such resistance to the Lasègue maneuver that the sciatic nerve, although it is sensitive to stretching, cannot be brought under tension sufficient to stretch it by dorsiflexion of the foot. Sometimes irritation of the sciatic nerve is so extreme that it is not necessary to flex the thigh to produce a positive result. Mere dorsiflexion of the foot while the patient lies supine with leg ex-

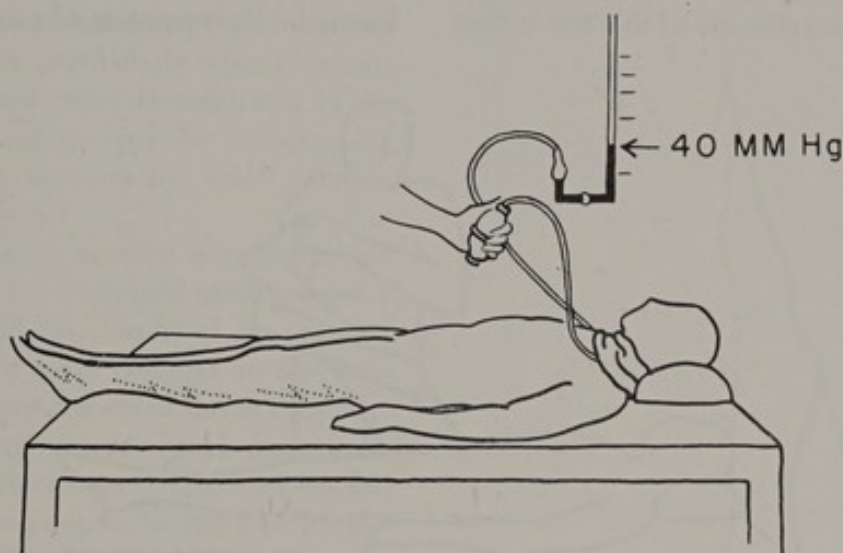


FIGURE 174.—Jugular compression test of Viets with patient supine. This test may also be performed in the upright position, with the examiner using his hands to occlude the venous return from the head. (From Spurling and Thompson, *op. cit.*)

of the hips, pelvis, or lumbar spine, and without putting further strain on either the gluteal or the hamstring muscles, the foot is suddenly dorsiflexed (fig. 175). A marked pull on the tibial nerve, and therefore on the sciatic nerve, is thus effected without the influence of any movement in any other structure. If this test, which we have named the sciatic-nerve-stretching test, is positive, pain is increased in the course of the sciatic nerve above the knee and it is assumed that the nerve is sensitive to a degree of stretching which would not cause pain in a normal nerve.

When the sciatic-nerve-stretching test is performed by the technique just described, it will be negative in a number of diseases of the lumbar or pelvic articulations in which the straight-leg-raising test is uniformly positive. The sciatic-nerve-stretching test, however, is practically always definitely positive in lateral herniations of the nucleus pulposus. There is almost never any doubt of the results except in the occasional case in which pro-

tended may cause excruciating pain.

Turyn (26) described an even more subtle modification of the basic dorsiflexion test—dorsiflexion of only the great toe while the patient lies supine with both legs extended. When sciatic nerve involvement is extensive, this maneuver may cause pain in the gluteal region. The explanation is that stretching of the nerve occurs through its connection with the posterior tibial and plantar nerves which supply the great toe.

Motor tests

Motor testing has proved far more helpful in the diagnosis of herniated nucleus pulposus than it was originally thought that it would be. The segmental motor pattern, as a matter of fact, appears to be somewhat more constant than the segmental sensory pattern. Since, as a rule, only one nerve root is involved, or is severely involved, in the pathological process, the paresis which results is usually so mild that it cannot be detected by examining manually for

weakness. Testing the muscles of the leg under weight bearing is far more useful (fig. 176).

The achilles group of muscles is tested by having the patient walk briskly on his toes. A tendency to drop the heel to the floor is obvious evidence of weakness. Inability to hop on the toes or to spring briskly to them while standing on one foot indicates a slighter degree of weakness. For finer testing, the patient is directed to keep the knee straight while rising on the toes. The rationale of this test is that

of the proximal phalanges. Inability to withstand the pressure is an indication of weakness.

Other muscles of the lower extremities are also tested, but changes in their strength are not nearly so apparent as in the muscles just mentioned. When they are tested by the techniques described, weakness is clearly evident in many patients with lumbar herniations, but the results must be clearcut to be of any value. Equivocal changes in strength should be ignored. Most patients who present loss of the ankle

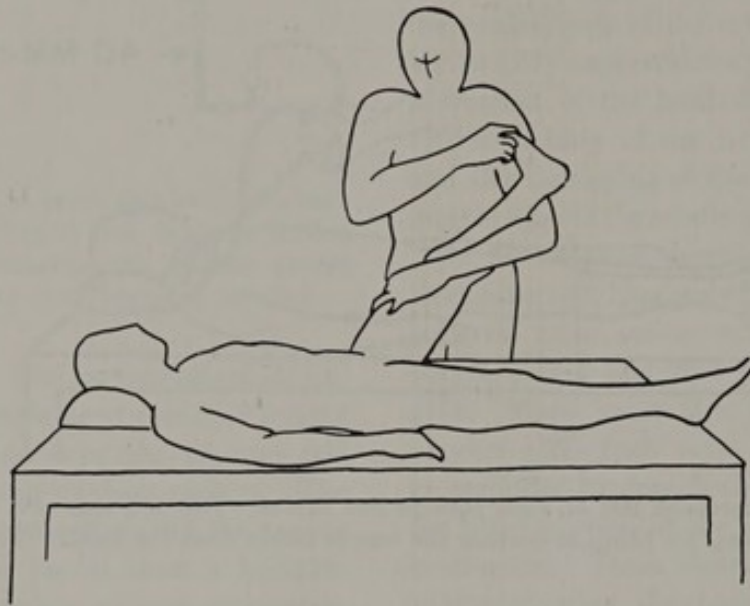


FIGURE 175.—Modification of sciatic-nerve-stretching test of Lasègue by sudden dorsiflexion of foot after leg has been elevated to point of pain. This maneuver puts additional tension upon the sciatic nerve and causes acute pain if any components of the sciatic nerve are irritated. (From Spurling and Thompson, *op. cit.*)

flexion brings the center of gravity over the ball of the foot and there is thus less tension on the tendo achillis.

The anterior tibial is tested by having the patient walk on this heels. Toe slapping is an indication of weakness. Finer testing is carried out by having the patient push his toes against the floor while he supports his whole weight on one heel. During this test he may hold on to something with his hands to maintain his balance.

Weakness of the long extensors of the toes, which is among the commoner of the isolated pareses caused by disk lesions, is most apparent when the ability to extend the great toe is tested. While the patient stands and dorsiflexes both great toes as forcibly as possible, the examiner attempts to depress them to the floor by pressure on the distal ends

jerk will also present demonstrable weakness of the achilles group, usually as the result of lumbosacral herniation. Of much greater diagnostic value is weakness of the extensor hallucis or anterior tibial muscle, which occurs in herniations of the fourth lumbar intervertebral disk, the reason being that at this segmental level there is no reliable tendon reflex.

A search for muscular fibrillations should be part of every motor study. Atrophy, which accompanies many cases of herniated nucleus pulposus, is of no localizing value if it is generalized. It is more often the result of disuse than of paralysis of the motor nerves.

Sensory tests

We do not share the opinion of many observers concerning the great importance of the sensory ex-

amination in accurate localization of a ruptured lumbar intervertebral disk. On the contrary, as our experience has increased with the years, we have come to rely less and less upon the so-called typical pattern of sensory deficits found in this lesion. In well over half of all cases, variations in the patterns of the dermatomes, as the result of multiple root involvement and overlap in innervation of skin areas, make the results confusing rather than helpful. This does not mean, of course, that sensory patterns can be ignored in diagnosis, particularly when they correspond to areas of paresthesiae demonstrated by the lateral bending test and the jugular compression test. It merely means that not too much reliance must be placed upon them.

For a really satisfactory sensory examination of the lower extremities, the examiner must possess a thorough knowledge of the limits of the various dermatomes, which are more complex in the lumbosacral distribution than anywhere else in the body. Foerster (27) regards the extent of each dermatome as much greater than the extent determined by Tilney and Riley (28) because he includes in his determination the entire areas in which stimuli can be detected. In his investigation, Foerster isolated each of the lumbosacral roots by performing posterior rhizotomy upon several of the roots above and several below the particular root to be studied. He then determined the response to stimuli in this area and described the entire area in which stimuli could be detected as constituting the total dermatome.

From his studies, Foerster (27) drew the following conclusions:

1. The third lumbar nerve supplies the medial aspect of the lower half of the thigh, the knee, and the leg down to the internal malleolus.
2. The fourth lumbar nerve supplies the medial surface, and part of the anterior surface, of the knee, leg, and ankle, and the medial aspect of the dorsum of the foot and of the great toe.
3. The fifth lumbar nerve supplies the anterior half of the leg, the anterior half of the dorsum of the foot, the anterior half of all the toes, and the plantar surface of the third, fourth, and fifth toes.
4. The first sacral nerve supplies the sole of the foot, the plantar surface of the toes, in some instances the dorsal surface of the toes, and the lower half of the posterior aspect of the leg.

5. The second sacral nerve supplies the posterior aspect of the thigh and leg, the sole of the foot, and the plantar surfaces of the toes.

The patterns described by Keegan (29) differ in many respects from those described by certain other observers, including Foerster (27) and Tilney and Riley (28). Keegan's painstaking clinical studies were made on hundreds of patients with confirmed ruptured disks, with special reference to the size and

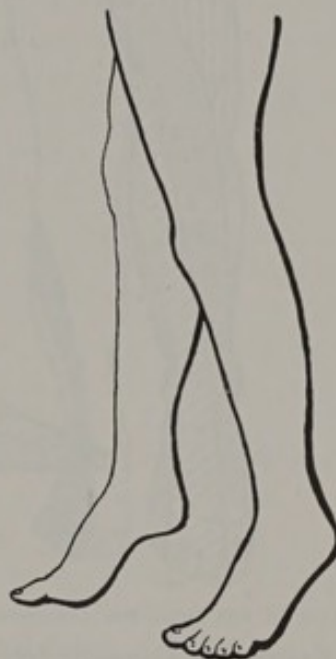


FIGURE 176.—Testing strength of gastrocnemius muscles by having patient walk with heels elevated from floor. Any significant degree of weakness in this muscle group will be manifested by failure to raise the heel from the floor, or to maintain the elevation, while walking.

form of the lumbar and sacral dermatomes (fig. 177). His sensory patterns, however, which are based on the level of the disk lesion, are also based upon the assumption that only a single nerve is involved at the affected level. It is highly doubtful that this assumption is justified. The possibility of multiple nerve root compression must be considered in every patient with a herniated nucleus pulposus. For that reason, Foerster's studies, which were based solely upon root section, seem to us more plausible than Keegan's. If Keegan's dermatome patterns were designated simply according to the anatomical location of the ruptured disk, without any attempt to name the root in relation

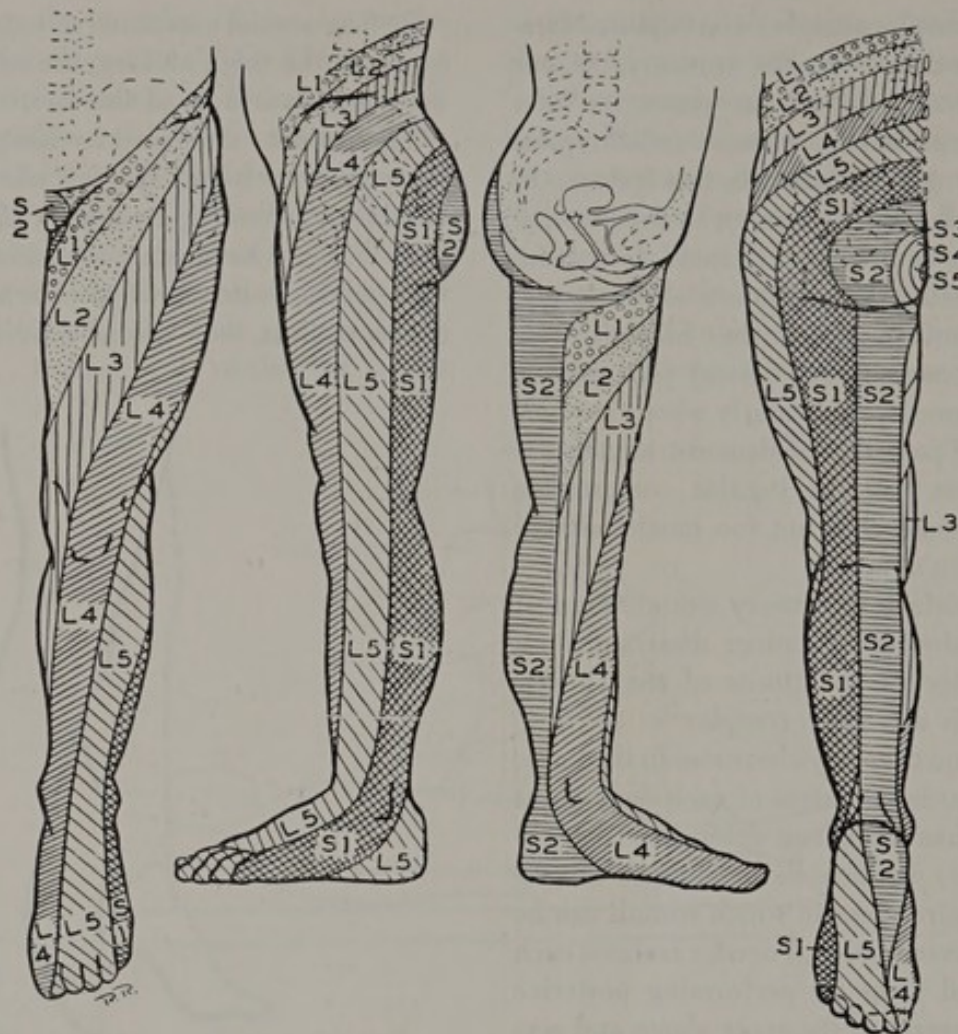


FIGURE 177.—Composite drawing of lumbar and sacral dermatomes according to Keegan (29).

to the dermatome, his work would probably withstand any criticism.

Our own experience, which covers many years of painstaking examinations of the dermatomes in lesions of the lumbar disk, has led us to a practical solution of the problem of sensory examinations. It is now our practice to examine routinely only the distal portions of the dermatomes, that is, the leg and the foot. We make no attempt to name the nerve root most seriously involved. Instead, we refer to the sensory involvement usually found with lesions of the third, fourth, and fifth lumbar disks. Thus, a ruptured disk at the third lumbar level characteristically shows a sensory deficit on the medial aspect of the leg from just below the knee to the dorsum of the foot, with perhaps some involvement of the median aspect of the great toe (fig. 178). A ruptured disk at the fourth lumbar interspace characteristically shows disturbance of sensation on the anterior aspect of the leg, the dorsum

of the foot, the great toe, and perhaps a portion of the second toe. A ruptured disk at the fifth lumbar (lumbosacral) interspace characteristically shows disturbance of sensation of the lateral aspect of the leg and of the foot, and of the third, fourth, and fifth toes, with maximum involvement of the fifth toe.

The areas just mentioned are not constantly deficient, but sensory examination in instances of ruptured disk at these levels will reveal these to be average areas of sensory loss. In our experience, furthermore, these areas of deficit correspond more closely to the areas of numbness and tingling produced by the body rotation test and the jugular compression test than do any of the sensory patterns previously described.

Testing with pinprick and cotton is usually sufficient to demonstrate sensory deficits. If the results of these methods are doubtful, hot or cold test tubes can be employed. Great care must be used during

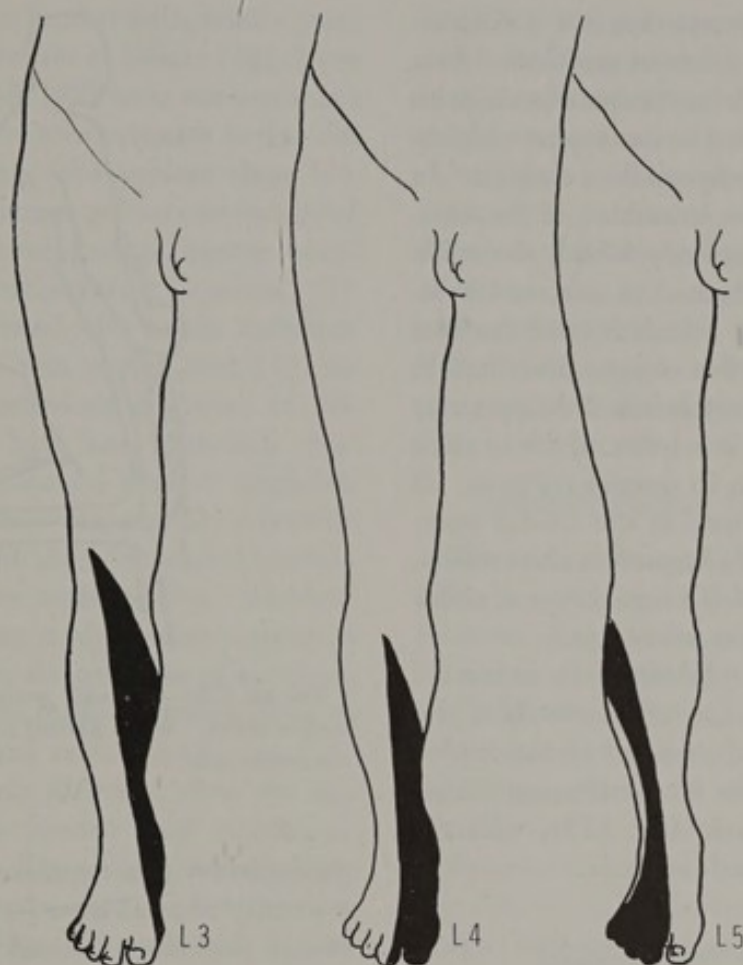


FIGURE 178.—Usual skin areas in which sensory changes (hypalgesia or paresthesiae) are most apt to occur with rupture of third, fourth, and fifth lumbar intervertebral disks.

the sensory examination to avoid suggesting results. Not infrequently, a patient develops hypesthesia of the entire painful lower extremity during the testing. This is unfortunate, for it makes the detection of localized hypesthesia impossible.

When hyperesthesia is observed, as it occasionally is, especially in observant patients, it may be an extremely useful finding. Light stimuli are most effective. Stimulation of the affected area, which usually includes one or two dermatomes, causes a stinging, burning, or prickling pain which spreads to the whole area and which is not unlike the discomfort of causalgia. The phenomenon is probably to be explained on the basis of an incomplete nerve injury, which is a frequent occurrence in herniated nucleus pulposus.

Reflex tests

The reflexes are difficult to test satisfactorily, but the effort is well worthwhile. Their accuracy and

reliability in the diagnosis of disk lesions have been demonstrated upon thousands of patients by large numbers of observers. Neurologists, for the most part, place implicit confidence in them. If other physicians who are interested in this problem will also study them and learn to evaluate them, they will find that the difficulties presented by the clinical diagnosis of rupture of the intervertebral disk will be greatly simplified.

The knee reflex may be increased or decreased in this lesion according to the position which the patient assumes in an effort to be comfortable, and to the muscle spasm associated with his disability. An increase is seldom of neurological significance. A decrease will be observed if the fourth lumbar or the third and fourth lumbar nerves (third lumbar disk) are affected.

The ankle (Achilles) reflex, because of its lower segmental innervation, is of much more importance in disk lesions than the knee jerk. A unilateral al-

teration, in fact, is so important that it is well to attempt to elicit it in several different positions. As a rule, it is readily obtained when the patient sits with his legs hanging free, or when he lies supine with hip and knee flexed, or when he kneels on a cushion. In normal subjects, voluntary contraction of the anterior tibial muscle will completely inhibit the ankle jerk. This reflex is also diminished or absent in lesions at the fifth interspace which involve the first sacral nerve. The only reflex change described in lesions of the fourth interspace is loss of the posterior tibial tendon reflex. This is a reflex which to elicit consistently is difficult even in normal subjects. It is commonly absent in lesions at the L4-L5 interspace. This is an extremely important observation, since about 95 percent of disk lesions occur at either the fourth or the fifth lumbar interspace.

It is difficult to elicit the Achilles jerk unless the examiner is thoroughly familiar with methods of producing relaxation and reinforcement of the tendon jerks. The optimal position for reinforcing the reflexes is kneeling on a chair (fig. 179), with the patient's hands grasping back of chair.

LOCALIZATION OF DISK LESIONS

As has already been pointed out, most patients with ruptured lumbar disks present two chief symptoms; namely, lumbar pain and disability and pain in the distribution of the sciatic nerve. In many instances, localization of the lesion is possible merely on the basis of clinical observation. The characteristic points of differentiation for the various levels are as follows:

Lesions of the third lumbar interspace are characterized by: (1) Tenderness to percussion at the third spinous process, (2) radiating pain produced by percussion on the painful side of this process, (3) a positive jugular compression test, with tingling produced by the maneuver on the medial aspect of the leg and foot, (4) a normal ankle jerk, but a diminished or absent knee jerk, (5) weakness or atrophy of the quadriceps femoris muscles, and (6) hypesthesia on the medial aspect of the leg and foot.

Lesions of the fourth lumbar interspace are characterized by: (1) Tenderness to percussion at the fourth spinous process, (2) radiating pain produced by percussion on the painful side of this process, (3) a positive jugular compression test, with tingling

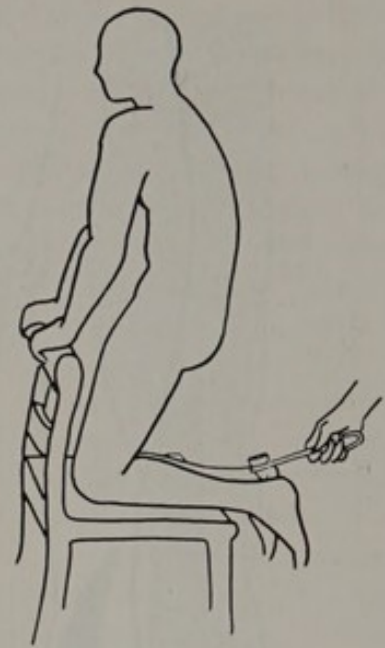


FIGURE 179.—Optimal position for eliciting Achilles tendon reflex. When patient squeezes back of chair, reflexes are reinforced.

produced by this maneuver into the great toe, (4) a usually normal knee jerk and ankle jerk, though one or the other is occasionally diminished if there is multiple root involvement, (5) an absent or diminished posterior tibial reflex, (6) weakness or atrophy of the muscles supplied by the peroneal nerve, and (7) *hypesthesia* on the anterior aspect of the leg and great toe.

Lesions of the fifth lumbar interspace are characterized by: (1) Tenderness to percussion at the fifth spinous process, (2) radiating pain produced by percussion on the painful side of this process, (3) a positive jugular compression test, with tingling produced by this maneuver on the lateral aspect of the leg, the superior aspect of the foot, and the third, fourth, and fifth toes, (4) a normal knee jerk, but a diminished or absent ankle jerk, (5) weakness or atrophy of the gastrocnemius and soleus muscles, and (6) hypesthesia on the lateral aspect of the leg and foot and the third, fourth, and fifth toes.

DIFFERENTIAL CLINICAL DIAGNOSIS

Incidence

Although many observers have attempted it, no one has yet been able to determine the true incidence of primary pathological changes in the intervertebral

disk as responsible for low lumbar pain, sciatic pain, or both. Even such authorities as Mixter (30), Love (31), and Craig and Walsh (32) have done no more than hazard a guess. Our own estimate is that the great majority of patients who present these two complaints are suffering from a primary pathological process in one of the lower lumbar intervertebral disks, though two qualifications must be added: (1) The low back pain associated with sciatic radiation must be severe or have been severe, and (2) the various diseases which introduce problems of differential diagnosis must have been excluded. Statistics to support our opinion are not now available, and it is doubtful that they can ever be collected: Relatively few patients with these complaints are submitted to operation or to myelography. Furthermore, a long-term followup study of such a group of patients would not answer the question of incidence because many persons with these symptoms go on to recovery under nonsurgical management.

The situation is entirely different when the discussion is limited to low lumbar pain (lumbago) without sciatic radiation. The same typical low lumbar disability produced by herniation of the nucleus pulposus is also produced by other pathological processes involving the vertebrae, particularly when the articular facets, the spinal ligaments, and the paraspinal muscles and fascia are involved. Lumbar pain, without sciatic radiation, can, of course, be caused by disorders of the disks, as we have shown by clinical studies of patients operated on under regional procaine hydrochloride (Novocain) analgesia. After the sciatic pain has been relieved by direct injection of the involved spinal root, we have been able to reproduce the identical low lumbar pain by mechanical stimulation of the posterior annulus fibrosus. When, however, the annulus and the posterior longitudinal ligaments were also infiltrated with procaine hydrochloride, further stimulation of the area was painless.

What all of these observations amount to is that rupture of the intervertebral disk is probably the commonest cause of low lumbar pain, with or without sciatic radiation. The abdominal surgeon knows that an acute abdominal condition has more chance of being acute appendicitis than anything else because acute appendicitis is the commonest of all surgical diseases of the abdomen. The situation is less clearcut in herniated nucleus pulposus, partly be-

cause it is a more recently recognized clinical entity, partly because, as has just been pointed out, its true incidence is unknown. Fewer diagnostic and therapeutic errors, however, will be made by physicians called upon to diagnose and treat patients with low lumbar pain, with or without sciatic radiation, if they bear the comparison with acute appendicitis in mind, and if, to paraphrase what Deaver said of acute appendicitis, they think of ruptured intervertebral disk "first, last and all the time" as a possible cause of low lumbar pain.

DIFFERENTIATION FROM OTHER DISEASES

The clinical diagnosis of ruptured lumbar disk can often be made correctly during the first attack. The tentative diagnosis is seldom incorrect in a patient who has had repeated episodes of acute lumbar pain with sciatic radiation, followed by remission of symptoms and complete or almost complete relief until the next attack. On the other hand, this disease, like many other diseases, is subject to so many variations in symptoms and signs that in some cases the differential diagnosis may be difficult. Also, no matter how certain the physician may be of the correctness of his diagnosis, he must always bear in mind the possibility that some other disease may perhaps be responsible for the clinical picture and must know the diseases which may simulate lesions of the intervertebral disk. These diseases are not necessarily of neurological origin or located in the spinal canal. Young (33), for instance, observed 10 patients with typical symptoms of ruptured lumbar disk who had, variously, osteoid osteoma of the femur (4 cases), glomus tumor of the leg, twisted ovarian cyst, multiple myeloma of the spinal canal, eosinophilic granuloma of the pelvis, chondromyxosarcoma of the femur, and tuberculous arthritis of the sacroiliac joint.

Most often, however, the differential diagnosis includes other diseases of the spine, as follows:

Rheumatoid spondylitis

In our experience, the disease from which ruptured lumbar disk must most frequently be differentiated is rheumatoid spondylitis (Marie-Strümpell disease). This disease, the etiology of which is still poorly understood, often begins as an inflammatory reaction in the lumbosacral spine and sacroiliac

joints. The chief symptoms are the same as those of ruptured intervertebral disk; namely, low lumbar pain and unilateral or bilateral sciatic radiation. The pain of Marie-Strümpell arthritis is insidious in onset and progressive in its course. The differential points are that the initial pain is not abrupt and severe, as is the initial pain of a disk lesion, and that remissions between attacks do not occur, as they do in disk lesions.

Other types of arthritis

Other types of arthritis, particularly hypertrophic osteoarthritis, may also require differentiation from rupture of the lumbar disk. Arthritic spurs in or around the intervertebral foramen may cause compression of the spinal roots, with resulting intractable sciatica, in addition to a stiff, painful back. In arthritis, however, the low back disability is, as a rule, only part of the clinical picture because the disease tends to involve many joints at the same time. This is another disease in which remissions are seldom as clearly defined as they are in rupture of the intervertebral disk.

Trauma

If low lumbar pain and sciatic pain are initiated by injury, particularly if the trauma is severe, the resulting fracture of the spine or pelvis often gives rise to symptoms which clinically are identical with those of the initial episode of intervertebral disk injury. The differential diagnosis depends upon the roentgenological findings. Clinical differentiation is impossible.

Neoplasms

Primary and secondary neoplasms of the spine may produce symptoms much like those characteristic of ruptured disk. There are two chief points of differentiation. The first is the unremitting character of the pain in malignant disease. The second is the absence of relief from recumbency and rest, in contrast to the frequent relief thus secured in ruptured lumbar disk.

Metastatic disease of the spine should always be considered as a possible cause of symptoms if there is a recognized primary malignancy in the prostate, rectum, pelvic viscera, adrenal glands, thyroid, or lungs.

Neoplasms of the cauda equina may also produce

symptoms and signs almost identical with those caused by herniated nucleus pulposus. Three points of differentiation are helpful: (1) The pain caused by a neoplasm is likely to be exaggerated by rest and relieved by exercise, (2) the neurological signs produced by such neoplasms are more widespread than the neurological signs of ruptured disks, and (3) spasm of the lumbar muscles, obliteration of lumbar lordosis, and sciatic scoliosis are characteristic of ruptured disk but are not usually associated with tumors of the cauda equina.

Anomalies

Many observers have stated that anomalies of the spine, particularly spondylolisthesis, are productive of symptoms similar to those of ruptured intervertebral disk. This has not been our experience. Indeed, if we find a patient with spondylolisthesis who presents a history and physical findings typical of ruptured disk, we always suspect that, in addition to this disease, there is also a lesion of the disk either above or below the congenital anomaly. In a number of instances in which we have removed a ruptured disk from the fourth lumbar interspace, we have observed also a well-defined spondylolisthesis involving the fifth lumbar and the first sacral vertebrae. Almost always these patients have recovered quite as normally as patients without these congenital anomalies, though they are sometimes left with backache of varying degrees of severity. Spinal anomalies characteristically produce backache, but associated sciatic radiation is not typical.

Hypertrophy of the ligamentum flavum

Hypertrophy of the ligamentum flavum was once considered to be a frequent cause of low lumbar pain and sciatic pain. It is often observed at operations for ruptured disk, but most observers now regard it as a coincidental finding. When it is present, it undoubtedly increases the severity of the symptoms. It also reduces the intraspinal space available for the herniating or bulging disk material to push the spinal root posteriorly. Structural changes in the ligamentum flavum, however, are never an etiological factor in low back pain and sciatic pain.

Infection

Tuberculosis and other infections of the spine may simulate the disk syndrome rather closely. We

have observed one instance of early tuberculosis of the fourth lumbar disk in which no change in the contiguous bone was demonstrable by roentgenography. The incidence of such cases, however, must be extremely low; this was the single instance we encountered in more than a thousand cases in which the diagnosis of ruptured disk was confirmed. We thought that this particular patient had a disk lesion and made the correct diagnosis only after a thin layer of posterior annulus fibrosus had been opened and creamy pus had extruded into the wound.

Primary sciatic neuritis

It is difficult to accept without question such reports as that by Alpers, Gaskill, and Weiss (34), who argue that primary sciatic neuritis is the explanation of severe, persistent sciatic pain accompanied by objective radicular findings. They ignore the fundamental consideration that this disease, far from being frequent, is a true clinical curiosity. Adequate investigation in the great majority of all such cases would reveal that some organic lesion in the lumbar spine or pelvis was responsible for the symptoms and that, in most instances, the lesion would prove to be a ruptured disk.

ROENTGENOLOGICAL EXAMINATION

Adequate roentgenography is an essential part of the examination of all patients suffering from low back pain and sciatic pain. No matter what the disease, early pathological changes in the bones and joints of the lumbosacral spine and pelvis cannot be demonstrated without films of high technical quality. In every such case, the routine examination should include a true anteroposterior roentgenogram of the entire lumbar spine, sacrum, and pelvis, together with a true lateral film of the same areas. If the routine films are lacking in detail or show any apparent abnormality in the sacroiliac joints, special films of this region are made. Similarly, if extensive changes indicative of hypertrophic arthritis are noted in the anteroposterior and lateral films, oblique films showing the intervertebral foramina are secured. Finally, if there are suggestive changes in the region of the pedicles or the laminae, three-dimensional stereoscopic films are made of the suspected areas.

Although many roentgenologists and orthopedic surgeons do not share our opinion, we found that plain films of the lumbar spine, made according to the plan just outlined, are of more differential diagnostic value in the investigation of ruptured lumbar disks, with or without herniation of the nucleus pulposus, than they are of diagnostic value per se. It has been our experience that in most patients who go on to surgery, the roentgenograms reveal little more than elimination (loss) or reduction (incomplete loss) of the normal lumbar lordosis, presumably as the result of associated muscle spasm. When the symptoms are of long standing, thinning of the involved disk, with localized hypertrophic changes in the bony margins of the adjacent vertebral bodies, may sometimes be found also. Since, in most instances, disk degeneration is eventually followed by proliferative changes in the margins of the adjacent vertebrae, it is necessary to secure films of the intervertebral foramina to determine whether bony spurs may be projecting into them. Anteroposterior films would not show them. It is most important that these spurs be identified or excluded, since they must be removed at operation if they are present. If this is not done, a poor postoperative result is extremely likely.

DIFFERENTIAL DIAGNOSIS

The characteristic roentgenological findings in the various conditions most likely to be confused with herniated nucleus pulposus may be summarized, as follows:

Rheumatoid spondylitis

In rheumatoid spondylitis (Marie-Strümpell disease) roentgenological changes are first evident in the sacroiliac joint. In the early stages, loss of definition is characteristic. In the later stages, a moth-eaten appearance in the region of the articulations is equally characteristic.

Trauma

In trauma involving the spine and pelvis there is usually deformity of the vertebrae with displacement of the bony fragments, though no loss of bony detail is apparent. Old injuries may be associated with localized proliferative changes, with or without spur formation.

Neoplasms

In neoplasms of the spine, whether they are primary or metastatic, bone destruction is characteristic and is often associated with collapse of one or more of the vertebral bodies. If bone destruction is suspected on study of the plain films, stereoscopic examination of the suspected area is usually of great value. It goes without saying that, whenever such a situation arises, there must be an immediate and thorough search for the primary site.

In early tumors of the cauda equina there are usually no roentgenological changes which point directly to the diagnosis. Later, destruction of a pedicle or widening of the interpeduncular space may be the only demonstrable roentgenological abnormality. Neurofibroma, meningioma, and chordoma are the most common primary tumors of the cauda equina.

Anomalies

Routine plain films usually permit a prompt diagnosis in spondylolisthesis and other anomalies of the spine. Spinal anomalies are not likely to be confused clinically with ruptured disks, though, as has already been intimated, the fact that an anomaly is present should not deter the neurosurgeon from a further search to confirm or exclude the coincident presence of a ruptured disk.

Infections

In infections of the spine and bony pelvis, roentgenological changes are usually promptly apparent and the diagnosis is readily made when the films are studied in conjunction with the history and laboratory data.

MYELOGRAPHY

Myelography is an interesting phase of the story of the recognition and clinical understanding of the new clinical entity known as rupture of the lumbar intervertebral disk with herniation of the nucleus pulposus. It is not too much to say that, without this diagnostic tool, neither the diagnosis nor the therapy of this condition would have advanced to its present status. The information obtained from this method in the early stages of investigation of herniated nucleus pulposus was enormously helpful. It is somewhat paradoxical, therefore, to be

obliged to add that, since Mixter and Barr (35) published their classical clinical description of this lesion, emphasis on diagnostic methods has gradually shifted from laboratory data to subjective and objective clinical findings. Myelography is still an extremely important part of the diagnostic routine in selected cases, but its use at this time is limited to special indications.²

The first myelographic studies were made with Lipiodol, which is an unstable iodized oil, of high viscosity. Its characteristics make it a meningeal irritant and it proved a far from ideal substance to introduce into the spinal subarachnoid space. A number of investigators then used air, with a considerable degree of success technically. Air, however, has two serious disadvantages as a contrast medium: (1) The poor contrast between air and bony shadows often makes the roentgenograms difficult to interpret accurately, and (2) if air is used, a headache is inevitable when the patient is shifted from the supine to the upright position.

Thorotrast was tried in a limited number of cases, with satisfactory results from the technical standpoint, but the meningeal reaction which invariably occurred was far too severe to make it a safe medium and it never had more than a limited application.

The introduction of ethyl iodophenylundecylate (Pantopaque³) for clinical use by Strain, Plati, and Warren (36), in 1940, seems to have solved the problem of myelography in ruptured lumbar disks. At the end of 12 years, during which time many workers have used it in the investigation of many thousands of patients, it may fairly be said that it is now a universally accepted contrast medium for intraspinal use and that, when it is correctly employed, by trained personnel, it is as safe as it is efficient.

² We have had no experience with the method of roentgen visualization of the intervertebral disk originated by Lindblom and recently reported on, inconclusively, by Gardner and his associates.

³ Pantopaque (the trade name used by the Eastman Kodak Co. for ethyl iodophenylundecylate) is a combination of isometric esters. It contains 30.5 percent iodine and has a density of 1.26 at 20° Celsius. Its coefficient of viscosity at 25° C. is 0.37. At this temperature, it has one-twenty-second of the viscosity of poppyseed oil, the base used in the preparation of Lipiodol, which was formerly used for myelography. At body temperature, the comparative viscosity of Pantopaque is one-seventeenth.

Pantopaque is a colorless liquid which does not deteriorate on standing unless it is exposed to light; then iodine is liberated and the color changes. No changes occur on autoclave sterilization.

Pantopaque has the theoretical advantage of being absorbed from the spinal subarachnoid space, but absorption is very slow and is associated with a mild degree of toxicity. For this reason, aspiration of the material is recommended after roentgenograms are completed.

Indications

With increasing experience we have found that when the clinical findings in a patient with low lumbar pain and sciatic pain are clearcut and unequivocal, and when other conditions which might give rise to these symptoms have been eliminated, myelography is seldom indicated. Many others share this point of view. On the other hand, we always use myelography in a patient who is incapacitated by severe low lumbar pain and sciatic pain, who does not respond favorably to appropriate conservative measures, and whose neurological signs are too equivocal to permit localization of the lesion.

In other words, it is our practice to make the diagnosis of ruptured disk on clinical data alone whenever this is possible and to reserve myelography for use as a localizing procedure. In a recent series of 378 herniations of the nucleus pulposus treated in our clinic and verified by surgery, myelography was used in only 174 cases, less than half. In the other 204 cases, the diagnosis, including accurate localization of the lesion, could be made by clinical means alone.

As might be expected, the incidence of negative and false-negative examinations will be considerably greater when myelography is limited to doubtful cases than it would be if the method were used only to verify typical lesions. On the other hand, if clinical as well as myelographic findings are carefully evaluated, the number of false-positive diagnoses will be few. It cannot be emphasized too often that myelography, important as it is in the cases in which it is indicated, is still only one part of the clinical investigation.

Technique

Myelography is performed with the patient prone on the tilting fluoroscopic table, with a small pillow beneath the abdomen. Spinal puncture is just as simple in this position, when one becomes accustomed to it, as it is in the conventional position. The needle is preferably inserted distal to the fourth or the fifth lumbar spinous process. If there is any suspicion that the lesion is at a higher level, the puncture can be made below the third spinous process. Puncture at this level, however, has the disadvantage that removal of the Pantopaque after the films are made is more difficult than when the needle

is inserted distal to the fourth or the fifth lumbar spinous process. The puncture should not be made higher than the third spinous process, for fear of injury to the conus.

It is important that the needle be inserted in the midline and that it be introduced slowly, millimeter by millimeter, after the ligamentum flavum has been reached. When cerebrospinal fluid has been obtained, the needle is advanced for another 2 mm. before the Pantopaque is injected. As a rule, 3 cc. are sufficient, though the occasional patient whose roentgenograms show a large spinal canal, with an unusually broad terminal subarachnoid space, may require an additional 3 cc. in order to fill the terminal sac completely. After the injection has been completed, a stylet is placed in the needle and the whole field is covered with a sterile towel. The patient is now ready for fluoroscopy.

Pantopaque, because of its low viscosity, can be easily balanced at any desired level in the spinal canal merely by tilting the fluoroscopic table. Because it is heavier than spinal fluid, it always seeks a dependent position in the subarachnoid space. As a result of these properties, the column, when the table is tilted, passes upward or downward over each lumbar intervertebral disk, and serial spot films show the state of the disk at each level. The most satisfactory films are made with a very narrow, relatively long shutter which opens without a grid. The detail is usually remarkably good. The dural sleeves and axillary pouches (fig. 180) are outlined, and not infrequently the whole course of the nerve root is shown at each level. When the findings arouse suspicion, it is often helpful to supplement the spot films with oblique or lateral roentgenograms made with a portable unit.

When the lesion has been demonstrated and spot films have been made of all suspected areas, the column of Pantopaque is localized by fluoroscopy, about the point of the needle, by tilting the table into the desired position. The needle is then introduced for an additional 2 mm., so that aspiration may be accomplished as close as possible to the anterior wall of the spinal canal. A syringe is attached to the needle and gentle aspiration is begun. If the column has been properly localized about the point of the needle, pure Pantopaque is obtained at once and almost the whole amount can be recovered before cerebrospinal fluid begins to bubble through

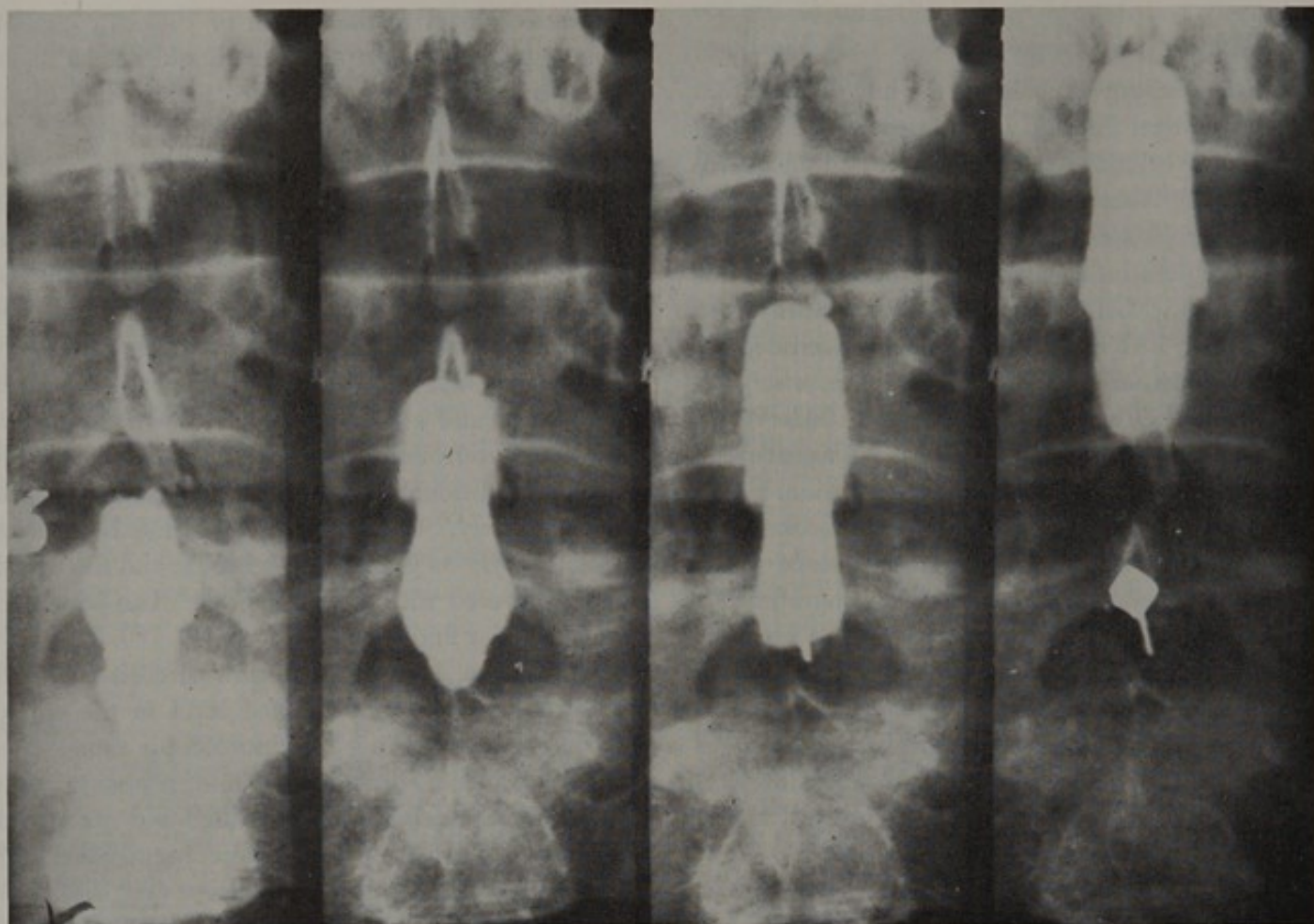

FIGURE 180.—Normal Pantopaque myelogram (serial exposures). Reading from left to right, note smooth column and symmetrical axillary pouches at L5, L4, L4, and L3. Lumbar puncture needle is at L5-S1 interspace.

the oily mixture. When once cerebrospinal fluid is obtained, the syringe is detached, the stylet is reintroduced, and fluoroscopic localization is again accomplished by tilting the table until whatever Pantopaque remains again collects about the point of the needle.

When the examiner has become experienced, the entire examination, by the technique described, does not require more than 15 or 20 minutes, this period including the time used in injection of Pantopaque and its subsequent aspiration.

The technique of myelography sounds deceptively simple. It is not difficult for an experienced neurosurgeon, working with an experienced roentgenologist, to obtain satisfactory results, though considerable practice on the part of both is required. Since myelography is purely a supplementary procedure in the final diagnosis of a ruptured disk, it should be performed only by a neurosurgeon qualified to op-

erate upon the lesion if roentgenological observations confirm the clinical impression.

Interpretation

Myelographic findings must be interpreted with the greatest caution. Even when clinical findings are inconclusive and examination with Pantopaque is indicated, roentgenological observations must be evaluated in relation to the clinical picture. In reading the films, it must be constantly borne in mind that they may be misleading. A very slight variation from the normal in the column of contrast medium may be the only roentgenological evidence of a definite herniation of the nucleus pulposus, while obvious irregularities may simply indicate disks that are more than usually prominent but are otherwise normal. If the anteroposterior myelogram is not clear, it is possible, as already mentioned, to balance the contrast medium at the level of the suspected

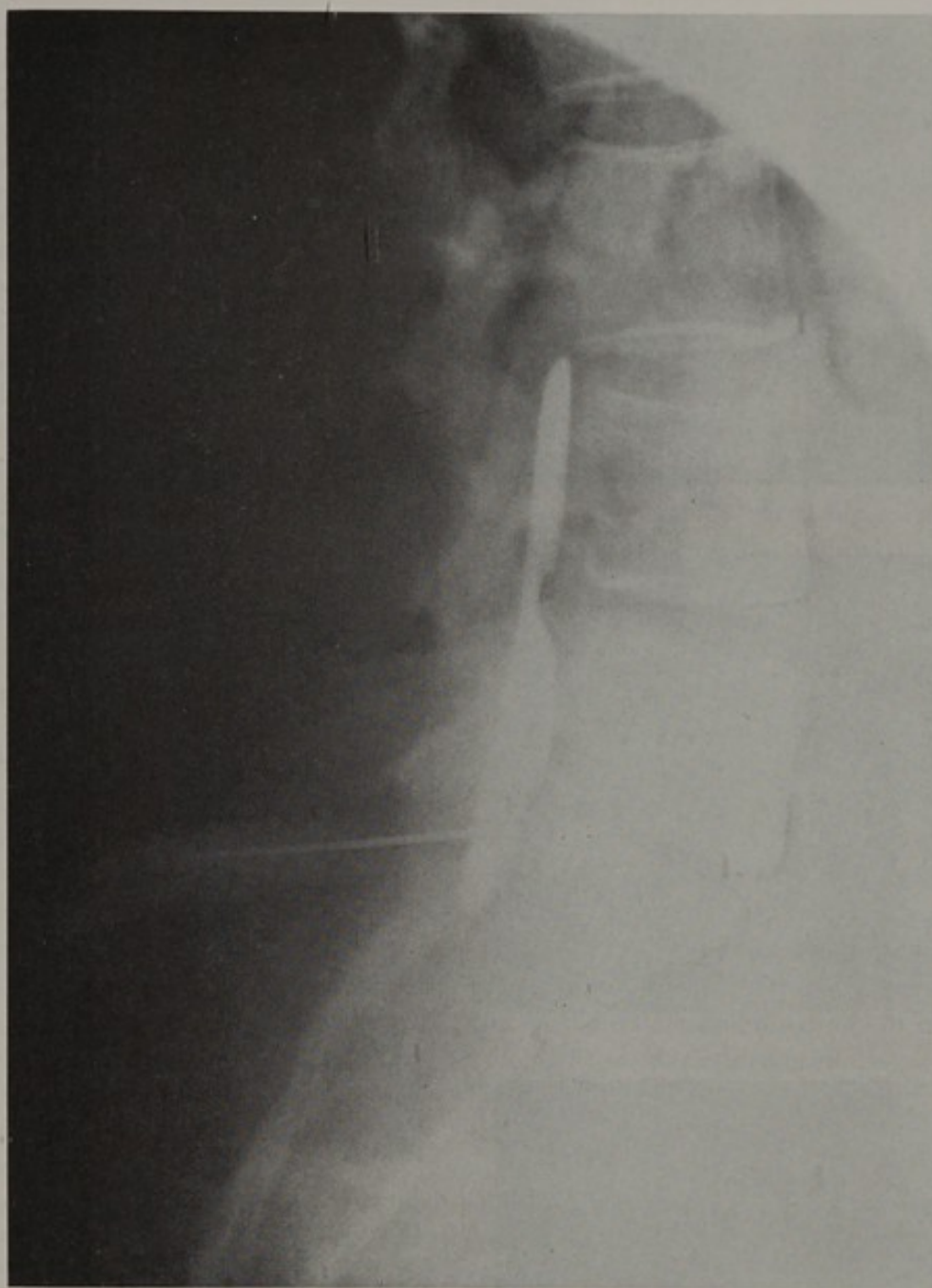


FIGURE 181.—Pantopaque myelogram. Lateral view showing anterior defect in opaque column at L4-L5 interspace and narrow lumbosacral disk. Lumbar puncture needle is at L5-S1 interspace.

disk while a lateral roentgenogram is made with the portable apparatus (fig. 181). Furthermore, whenever a possible defect is observed, it is a good plan to bring the Pantopaque to the suspected area from above or below the disk several times, to determine whether the filling defect is constant.

In our earlier experience with Pantopaque, when we did not aspirate it from the spinal canal after the examination, repetition of the examination some time later often showed a freer flow of oil than

at the original examination. We now believe that this phenomenon was probably the result of subdural injection, with subsequent passage of the contrast medium from the subdural to the subarachnoid space.

A possible, though infrequent, error in myelography is the extradural injection of the iodized oil. When this happens, the mistake is readily detected because the contrast material is irregularly distributed and is fixed. A more frequent technical

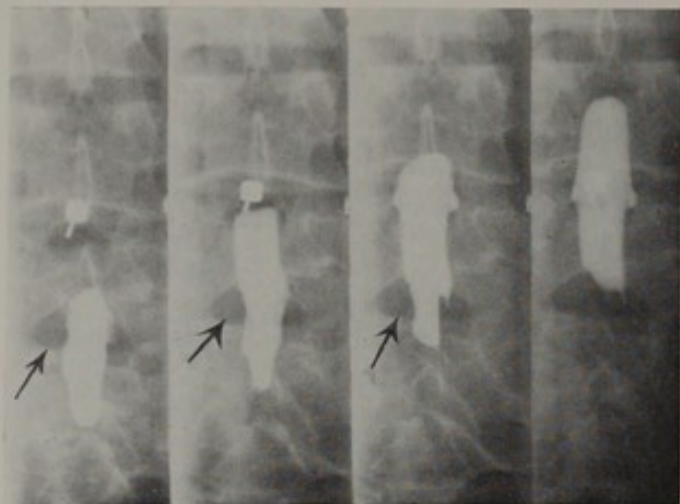


FIGURE 182.—Pantopaque myelogram (serial exposures). Arrow indicates filling defect characteristic of a ruptured disk at L5-S1 interspace. Note smooth column and normal symmetrical axillary pouches at L4-L5 interspace. Lumbar puncture needle is at L4-L5 interspace.

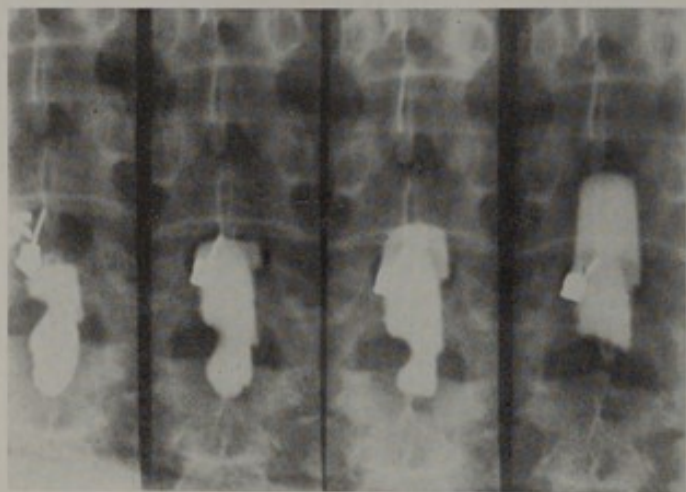


FIGURE 183.—Pantopaque myelogram (serial exposures) showing characteristic filling defect of a ruptured disk at L5-S1 interspace. Lumbar puncture needle is at L4-L5 interspace.

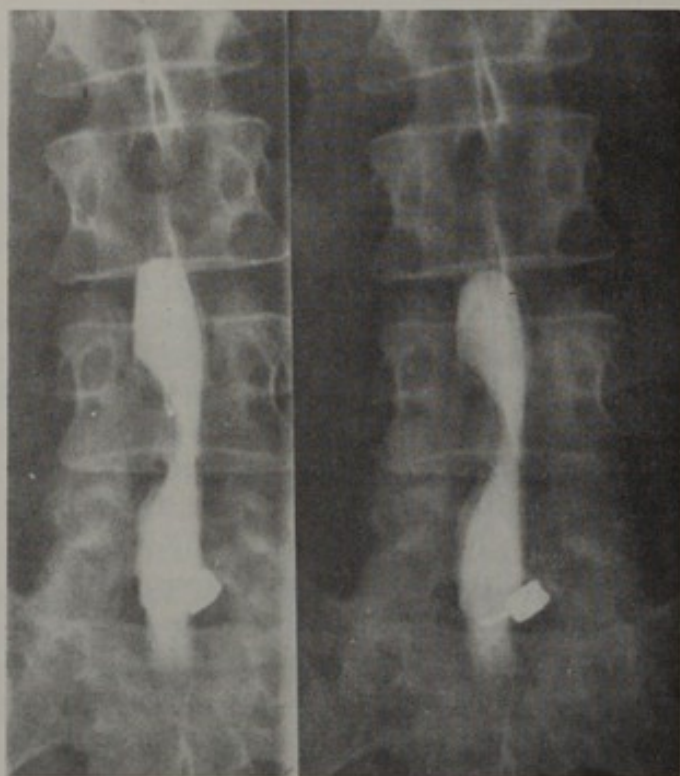


FIGURE 184.—Pantopaque myelogram showing large filling defect on left characteristic of tumor of cauda equina. The neoplasm proved to be a neurofibroma.

error is subdural (extra-arachnoid) injection, which may be quite confusing. Subdural injection is of no diagnostic aid in herniation of the nucleus pulposus, and has the additional disadvantage of interfering with visualization of the subarachnoid space when a satisfactory injection of that space is accomplished later. When oil has been injected into the subdural space, it usually flows less freely than in the subarachnoid space and does not usually pass beyond the upper lumbar or lower thoracic region. Inferiorly, it may flow almost to the end of the dural sac, but the characteristic appearance of sub-

arachnoid filling of the caudal sac is lacking. Part of the contrast medium may remain fixed.

The typical unilateral filling defect (figs. 182 and 183), without indentation of the contralateral side, almost invariably indicates the site of herniation of the nucleus pulposus. Such a defect always partially overlies the intervertebral disk. If no part of the defect overrides the disk, it is unlikely that the lesion is a herniated nucleus pulposus, and some other lesion, such as a neoplasm or arachnitis, should be suspected (fig. 184).

Defects which occur opposite the fourth lumbar disk are usually larger than those opposite the lumbosacral disk, for the reason that the fifth lumbar nerve is impinged upon at the fourth disk before it leaves the dural sac. At the lumbosacral disk, the first sacral nerve has left the dural sac and may be compressed by a disk lesion which impinges little, if at all, upon the sac proper. At either of these levels, the nerve root may occasionally be compressed near the intervertebral foramen without causing any deformity of the column of Pantopaque.

A midline filling defect (fig. 185), while unusual, has in our experience been entirely reliable in indicating herniation when part of the nucleus pulposus was in the midline. This type of defect does not occur in a normal lumbar canal. The diagnosis of herniations which are entirely in the midline, in contrast to lateral herniations, is chiefly by roentgenological investigation. In such cases, symptoms are chiefly limited to the back, and characteristic radicular findings are lacking.

Although a complete subarachnoid block may be produced by a herniated nucleus pulposus, we observed it in only 3 instances in 643 verified ruptured lumbar disks. Whether it is demonstrated by myelography or by the Queckenstedt test, with the usual associated spinal fluid findings, it is more likely to be found in patients with tumors of the cauda equina.

The hourglass type of defect is frequently without significance, though this is not invariably true. A herniated nucleus pulposus lying transversely across the spinal canal may produce it. The column of Pantopaque is sometimes divided transversely by the protrusion, but if one point in the herniation is somewhat lower than the remainder of the lesion, the two pools of iodized oil may be joined and an hourglass appearance will result.

Termination of the dural sac above the lumbosacral disk is an anomaly which is infrequent and is without pathological significance. The symmetrical termination of the sac, with its evenly distributed axillary pouches, is readily differentiated from an obstruction at the same level caused by an encroaching lesion. If the subarachnoid space terminates above the lumbosacral disk, contrast roentgenograms are of no help in determining that a herniated nucleus pulposus is present at this level. Antero-posterior films showing iodized oil in the tip of the dural sac often, because of projection, give the false impression of a shortened caudal sac. If this impression is created, lateral films will clarify the difficulty by showing the normal termination of the sac at the level of the second sacral vertebra.

LABORATORY INVESTIGATIONS

Urinalysis, blood counts, and blood chemical determinations are part of the preoperative study of a patient with a ruptured lumbar disk, just as they would be part of the investigation of any other surgical patient. As a rule, they provide no data of positive diagnostic value. The blood sedimentation rate is determined routinely. It is of no help in the diagnosis of herniated nucleus pulposus, but is useful in the differential diagnosis of early rheumatoid spondylitis (Marie-Strümpell disease), in which it is frequently elevated, whereas it is consistently normal in an uncomplicated ruptured disk.

Lumbar puncture was part of the diagnostic routine in the first series of ruptured lumbar disks to be reported in medical literature. At that time, it was regarded as significant, which was scarcely logical, for in most of the confirmed cases the fluid was normal in all respects. The only useful information which investigation of the cerebrospinal fluid supplies, in fact, is that in about half of all cases the total protein is elevated, the average values being from 50 to 100 mg. percent. Now that the clinical symptoms and signs of ruptured lumbar disks are better understood, fewer and fewer punctures are being performed. They are chiefly useful in cases in which a spinal cord tumor is an important part of the differential diagnosis.

When lumbar puncture and myelography are both indicated, it is better practice to defer removal of the cerebrospinal fluid for examination until the com-

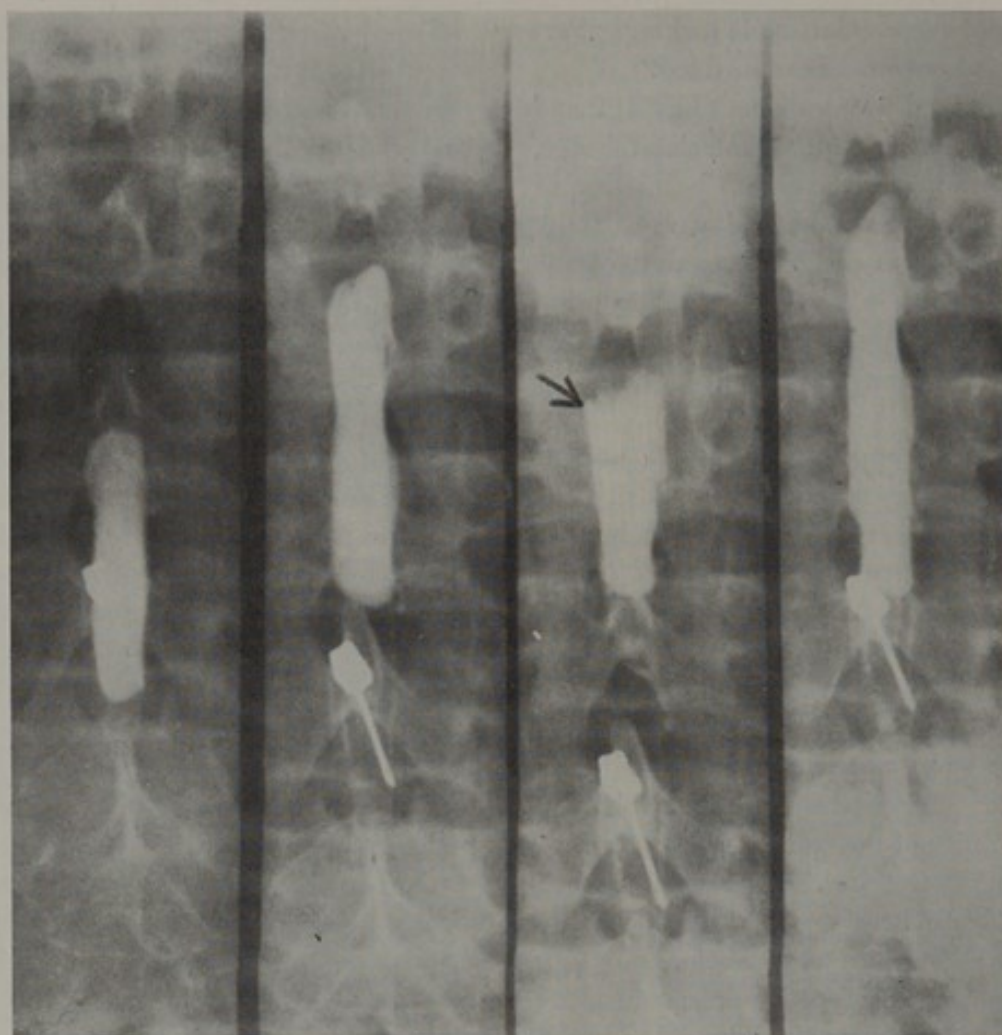


FIGURE 185.—Pantopaque myelogram (serial exposures). Arrow shows filling defect at L3 as column progresses upward. Note that the filling defect is obliterated when the L2-L3 interspace is completely covered with opaque material. Lesion proved to be a ruptured intervertebral disk at L2-L3 interspace. Lumbar puncture needle is at L5-S1 interspace.

pletion of the myelography. If this order must be reversed for any reason, then myelography should not be attempted for 1 week or 10 days after the lumbar puncture. Continuous fluid drainage through the needle hole in the arachnoid after the first puncture often produces sufficient subdural fluid to make another puncture difficult or impossible until at least this period of time has elapsed. Failure to observe this precaution is the most frequent cause of failure of injections of Pantopaque into the arachnoid space, as well as of erroneous injections into the subdural and extra-arachnoid spaces. If the puncture is done within a matter of hours before myelography, the injection of the contrast medium is much more difficult than it would be otherwise because the arachnoid sac frequently collapses.

THERAPY

A detailed review of the innumerable procedures which have been seriously proposed for the treatment of intractable low lumbar and sciatic pain would be of only academic interest. Injections of foreign proteins, direct injection of the sciatic nerve, injection of the epidural space with various solutions, stretching of the sciatic nerve, and the indiscriminate removal of presumed infectious foci attracted considerable attention at one time or another in the past. Some of these methods, even though they were utterly lacking in rationale, actually seemed effective. This is readily explained. In herniated nucleus pulposus, the same situation prevails as in such a disease as multiple sclerosis,

for which, incidentally, almost as many treatments have been proposed. Both diseases are subject to spontaneous remissions, and whenever that is true, therapy is difficult to evaluate. Too often, improvement in symptoms is credited to the method of treatment, by post hoc ergo propter hoc reasoning, and no allowance is made for the natural course of the disease, which includes periods of improvement even in the absence of any treatment at all.

Today, when there is a clear understanding of the pathogenesis and pathological process, most of the treatments proposed in the past for herniation of the nucleus pulposus are practically obsolete. Now, all therapeutic efforts are directed at the real source and origin of the physiological disturbances which give rise to the symptoms. Some patients respond to conservative therapy. If they do not, and surgery must be resorted to, the technique has been so refined that the possibility of weakening important weight-bearing structures in the lower spine is no longer an important consideration. Originally, with this fear in mind, it was the practice to perform wide laminectomy and open the dura mater and arachnoid to identify the lesion. Removal of the cartilaginous mass was accomplished through an incision in the anterior wall of the dural sac. Today, the herniated disk is usually removed without the sacrifice of any significant portion of the lamina at the level of the lesion, and without even disturbing the protective layer of fat which surrounds the dura mater. It is entirely possible that the methods presently employed in the management of disease of the intervertebral disk will be modified and improved in the future. It is fair to say that, at the present time, they are highly satisfactory and represent a great improvement over the methods used in the past.

CONSERVATIVE THERAPY

Before surgical measures are considered, every patient with acute low lumbar pain, with or without sciatic radiation, should have the benefit of a reasonable period of conservative orthopedic treatment by one or another of the following measures:

There is no doubt that postural changes are sometimes responsible for low lumbar and sciatic pain, and that a change of posture, with exercises to correct postural deformities, may relieve the symptoms.

These measures should certainly be tried. It is highly doubtful, however, that poor posture alone is often responsible for pain throughout the sciatic distribution and for the sensory and reflex changes likely to be noted in association with it. Hauser (37) in 1934, described a group of patients with sciatic pain which he termed reflex neuralgia and which he explained as caused by muscular insufficiency. All of these patients, he reported, were cured by correction of muscular imbalance, but the uniformly successful results which he attained have not been duplicated by others who have employed the same method.

The application of heat by means of an electric pad, infrared lamp, or diathermy is often of temporary benefit but is obviously of no permanent curative value.

Excellent results are often secured by keeping the patient on a flat, unyielding surface. He often discovers for himself that he is more comfortable on the floor than in bed. A heavy old-fashioned ironing board can be inserted between the mattress and springs, or a plywood board, cut to size, can be used.

The sacroiliac belt has been recommended for many years for patients with low lumbar pain, although, as Williams (38) pointed out in 1937, most such devices are quite inadequate for the purposes for which they are intended. The much more satisfactory brace which Williams himself devised is now in general use by orthopedic surgeons, as part of the conservative treatment of herniations of the intervertebral disk. It is effective in immobilizing the lower spine, it is very comfortable, and it produces particularly good results when low lumbar pain is the only symptom or the major symptom.

Massage, although sometimes helpful, often exaggerates the pain. Similarly, many patients report relief of symptoms by manipulative therapy, although others are made worse by it. Our own observation is that the patients who are benefited by this measure for the most part suffer only low lumbar pain. Those who also have sciatic pain are seldom relieved, and not infrequently those who have never had sciatic radiation before experience it after manipulative therapy. The anatomical explanation is simple. Manipulation puts an additional stress on an incomplete tear in the annulus fibrosus, the tear becomes complete, and a condition is thus created

which actually hastens herniation of the nucleus pulposus into the spinal canal. Manipulative therapy, in short, while it has a certain theoretic justification, must be used with a great deal of discretion if it is not to do actual harm.

The application of a plaster jacket, with the lumbar curve obliterated as completely as possible, has been recommended by some observers. Buck's extension or plaster fixation of the affected lower extremity is another conservative method which is sometimes useful, though in a number of our own cases the pain recurred when weight bearing was resumed, and operation was required for relief.

These are all measures designed for permanent relief, which they may or may not achieve. For immediate relief of painful muscular spasm, the administration of a muscle relaxant is recommended.

One or more of these measures, as has already been pointed out, should be used in every instance of acute low lumbar pain, with or without sciatic radiation, before surgery is considered. Even patients with sensory changes and altered tendon reflexes sometimes respond to them promptly, and while in many instances the relief is transient, there is always the possibility that it may be permanent. There is no justification, therefore, for immediate surgery, at least in the absence of special indications, until it has been determined that good results cannot be secured by conservatism. How long conservative treatment should be continued is, however, a matter which must be determined individually.

INDICATIONS FOR SURGERY

The only absolute indication for immediate surgery in herniation of the intervertebral disk is the sudden appearance of severe neurological disturbances, as a result of involvement of the cauda equina in a large herniation into the spinal canal. Paralysis of the quadriceps femoris, anterior tibial, or gastrocnemius muscle groups and disturbances of the bladder or rectal sphincter furnish imperative indications for prompt surgery if permanent damage is to be prevented.

In addition to immediate surgery in patients who present neurological disturbances, we also advocate prompt operation, without a trial period of conservative therapy, for the bedridden patient who is completely disabled by low lumbar pain and whose

sciatic pain recurs with every attempt at ambulation. It is seldom necessary to urge a patient in this condition to submit to surgery. He usually demands operation himself.

When the clinical history and neurological findings are clearcut, it is our custom to proceed to operation without myelography. If, however, a patient, even though incapacitated with pain, fails to show the clearcut neurological signs essential for the accurate localization of the lesion, then operation should be deferred until myelography can be carried out with Pantopaque. We regard it as better surgical practice to perform it in all questionable cases than to find ourselves, at operation, confronted with the necessity of exploring two or even three interspaces before identifying the lesion.

Even if the physical and roentgenological indications for surgery are indubitable, operation must not be undertaken without a careful consideration of certain other matters, as follows:

1. The surgical treatment of a ruptured lumbar disk is essentially elective surgery. It is seldom a lifesaving procedure. It is ordinarily done for the relief of pain. From the patient's point of view, there are few organic disorders which can be more incapacitating. The pain of *tic douloureux* is often no more disabling and no more intolerable than the pain many patients experience during acute episodes caused by herniations of intervertebral disks. On the other hand, what the operation involves must also be considered. The operation for ruptured disk, like posterior section of the trigeminal nerve for *tic douloureux*, is essentially a destructive procedure. In the latter, a numb face, often with troublesome paresthesiae, is the price paid for relief of agonizing pain. In the former, an important weight-bearing structure of the spine is left in a fragmented state. If the patient does not respond to conservative measures, and if his pain is truly incapacitating, then the price paid is justified. But the surgeon must be very sure of his facts before he recommends surgery.

2. Before operation is even suggested, there must be a careful evaluation of the patient as a whole, with particular reference to his mental and emotional attitudes and his overall personality. Persons with functional nervous disorders, such as psychoneuroses, neuroses, or hysteria, should be operated upon only as a last resort and only when there are

unequivocal neurological defects. The experience of numerous observers also makes it clear that in compensation cases in which legal action is pending, it is best, whenever possible, to delay surgery until the case is settled.

3. When operation is advised, the patient (with his family) is entitled to a frank statement of the chances of relief, the chances of failure, and the period of postoperative disability. We have found such frankness the best policy. We explain to the patient, in words that he can understand, that no amount of effort or skill on the part of the surgeon can give him a normal disk to replace the one that has ruptured, but that it is equally impossible for natural processes to restore the disk to its original state of integrity. All that the surgeon can do is to remove the detached portion of the disk which is pressing upon the nerve roots and causing pain, together with the spongy interior of the disk, which would be likely to produce future symptoms if it were left behind. Natural healing processes and a compensatory readjustment of function in the lower back must then compensate for the loss of disk structure. We also emphasize that while the patient is likely to secure prompt relief of severe sciatic pain, it is just as likely that his back will be sore and stiff for weeks and sometimes months, just as the abdominal wall remains tender for a period of time after many abdominal operations.

We tell the patient that with the proviso that no operation is free from some element of risk, or some unexpected complication, this is a safe operation. We also explain that the ultimate result is good in 75 percent or more of all surgical cases; that it is extremely unusual not to achieve considerable relief, even if the operation is not entirely successful; and that, barring the hazards over which a surgeon has no control, a competent surgeon never makes a patient with a ruptured disk worse, even if he fails to relieve him at all.

Armed with these details the patient is left to make his own decision, after weighing the facts of his present suffering and disability against the relative chances of success and failure following surgical intervention. Our records show that, since we adopted this policy, our results, analyzed in terms of patient satisfaction, have been progressively better.

4. It is of the greatest importance not to operate for ruptured intervertebral disk during periods of remission. The patient must be having severe pain when he is hospitalized for surgery. Otherwise, it may be difficult or actually impossible to localize the lesion accurately by either clinical examination or myelography. If we recommend operation during a remission, we defer its execution until another acute attack occurs. Then the patient enters the hospital for preoperative studies, which are usually followed by prompt surgery. Failure to adhere strictly to this rule accounts for many negative explorations and many dissatisfied patients.

5. Finally, the modern surgery of ruptured lumbar intervertebral disk is not simple. It should not be lightly undertaken. No surgeon should attempt it unless he is intimately acquainted with the regional anatomy and has been thoroughly trained in the technique of intraspinal surgery. Many of the failures which follow operations for herniations of the nucleus pulposus occur because these criteria have not been met.

ANESTHESIA

Whatever variety of anesthesia the surgeon may prefer personally is suitable for disk operations. The prejudice which we ourselves once entertained against spinal analgesia we now do not believe was justified. We have therefore replaced local analgesia, which we once used routinely, with spinal analgesia, supplemented by an analgesic dose of Pentothal sodium (thiopental sodium). We regard this method as the anesthesia of choice.

If local analgesia is preferred, the usual paravertebral injection is made with 1 percent procaine hydrochloride at the levels of the fourth and fifth lumbar interspace and the fifth lumbar and first sacral interspace. This injection usually permits painless dissection until the nerve roots within the spinal canal are manipulated. Then direct injection of the roots with the same agent usually eliminates sensation until the annulus fibrosus is manipulated. The pain in the back experienced at this time can be relieved by the direct injection of procaine hydrochloride into the annulus fibrosus, but it is not intolerable and the manipulations which cause it occupy so little time that it is usually possible to accomplish them without additional analgesia.

SURGICAL TECHNIQUE

Position

Operation is performed with the patient prone on the table, with the face turned to one side, or with the head resting on a cerebellar headrest. The lumbar spine is flexed, preferably by one or another of the mechanical devices attached to a modern operating table, which permit breaking the table or adjusting the built-in kidney rest. This type of table also has a device to put the patient into the Trendelenburg or reverse Trendelenburg position or to rotate him laterally so that the operative field can be more efficiently illuminated by spot lamps. If an adjustable table is not available, spinal flexion may be achieved by the use of a small inflated rubber pillow between the abdomen and pelvis. Air is released from it when lumbar flexion is no longer required.

Some surgeons prefer to operate with the patient in a sitting position, on the ground that it facilitates exposure. We have not employed it, as we have found the prone position perfectly satisfactory.

Incision

A midline incision, about 3 inches long, is centered directly over the suspected disk. If it does not prove long enough, it can be extended, though this is not usually necessary. It is important that the incision be centered as described. The tendency is usually to place it too high (it is seldom placed too low), particularly in obese patients with large buttocks. A line drawn between the iliac crests usually passes through the upper part of the spinous process of the fourth lumbar vertebra and is useful for orientation. It is also well to review the anteroposterior lumbosacral roentgenograms before making the incision, to be certain that localization is absolutely accurate.

The subcutaneous fat is dissected free from the lumbar fascia on the side on which the patient experiences pain. The erector spinae muscles are exposed close to the midline by a linear incision into the fascia, about 1 cm. from the spinous processes. The strip of fascia attached to these processes is drawn toward the midline by silk retraction sutures to facilitate exposure. The muscular attachments to the laminar and interlaminar structures are separated by blunt dissection. A Semmes hand re-

tractor, which is similar to the Hibbs retractor, is used to displace the muscles laterally and expose the ligamentum flavum.

At this point, after the muscles have been retracted, an additional aid in localization is to insert the index finger into the wound and identify the sacrum by palpation. Once it has been found, it can be used as a landmark to identify the desired interspace.

Whether exposure of the interlaminar structure is easy or difficult is determined by anatomical variations in the individual case. The amount of room between each inferior articular process and each spinous process varies, and, as might be expected, exploration of the anterior spinal canal is easier when the space is wider than when it is narrow.

Laminectomy at the lumbosacral interspace

The technique of laminectomy differs according to whether it is performed at the lumbosacral or at the third or the fourth lumbar interspace.

In most operations done at the lumbosacral interspace there will be found a wide space between the inferior articular process and the spinous process of the fifth lumbar vertebra. The laminae of the fifth lumbar vertebra are narrow, and for that reason the ligamenta flava between the fifth lumbar and the first sacral lamina are much broader than they are at other levels. It is often quite simple to dissect the ligament on the affected side from its attachments at the fifth lumbar and the first sacral vertebrae without disturbing the vertebrae in any way.

After the ligament has been cut at the level of the inferior articular facet, its lateral extension beneath the facet can be removed with a nasal punch, and more adequate exposure of the first sacral root can be secured. If, however, this maneuver does not afford sufficient room, the rim of bone to which the ligament is attached should be removed from the fifth lumbar and the first sacral lamina with the Kerrison modification of the sphenoidal punch or some similar instrument. Since exposure accomplished by this method does not usually afford sufficient room for digital palpation of the anterior spinal canal, a blunt instrument is introduced and carefully maneuvered so that any bulge in the canal will readily be appreciated.

Large extradural veins are frequently encountered at this stage of the operation and care and gentle-

ness are necessary to avoid damage to them. If they are torn, the troublesome bleeding which ensues can usually be controlled by the application to the bleeding area of a small piece of Gelfoam saturated with thrombin. The best way to prevent vascular damage is to protect exposed veins with cotton pledgets, to which black silk strands are attached for purposes of identification. Again, the utmost gentleness is necessary.

The surgical field is then isolated by cotton pledgets placed above and below the involved disk. When the bulging herniated nucleus pulposus is demonstrated, the nerve root is cautiously dissected from the superior aspect of the mass and is retracted medially. It may separate easily but may be extremely adherent to the protruding mass.

The herniated mass has sometimes completely disrupted the posterior longitudinal ligament and lies free in the spinal canal. More often the capsule, which consists of the outer layers of the annulus fibrosus, will be found intact over the bulging mass. When the capsule is intact, a linear incision is made in the bulging mass. Almost at once, nuclear material will herniate spontaneously through the opening, though the amount is usually relatively small, the total mass seldom being larger than a small olive. It is teased out of the opening in the annulus fibrosus, either en masse or in many small fragments. The material is tough and semi-elastic, with a general resemblance to crabmeat. After it has been removed, the ragged edges of the torn annulus fibrosus are easily visualized.

A pituitary rongeur or some similar biting instrument is then inserted through the annular defect and piecemeal evacuation of all loose disk material still in situ is begun. It is essential during this part of the procedure that the anterior rim of the annulus fibrosus be identified each time the instrument is inserted into the interior of the disk, particularly before its jaws are opened to grasp the disk material. Failure to observe this precaution has resulted in piercing of the anterior annulus fibrosus by the instrument used, with serious injuries to the major blood vessels which lie immediately adjacent to it. The medical literature contains no information concerning the number of deaths which have followed this accident, but we are aware of six fatalities, five in Army neurosurgical centers during World War II, and one in a Veterans' Adminis-

tration hospital after the war.⁴ Undoubtedly, there have been other cases. This is a grave and constantly present danger which can be avoided only by most careful attention to every detail involved in the evacuation of the nuclear material from the interior of the disk.

In spite of the risk, evacuation of the nuclear material is a part of the operation which must be carried out completely. The dangers attending it should not deter the surgeon. Simple removal of the protruding mass is not enough to effect a lasting cure. If this step of the operation is slighted, additional nucleus pulposus will be pushed through the tear in the posterior annulus fibrosus as soon as weight bearing is resumed, and the original chain of circumstances will be set up. We therefore make it a practice to excise all the nucleus pulposus and fragmented posterior annulus fibrosus which we can bring out with pituitary rongeurs and curettes. Thorough curettage of each cartilage plate is also a routine part of every disk operation. The surgical specimen thus obtained measures from $\frac{3}{4}$ to 1 fluid ounce.

Laminectomy at the L3-L4 interspace

When the involved disk is at the level of the third or the fourth lumbar interspace, the spaces between the inferior articular processes and the spinous processes are usually too narrow, and the laminae are usually too broad, to permit satisfactory exploration of the spinal canal without excision of a portion of the lateral laminar margins. During this procedure, care must be taken to preserve the facets. Lateral exposure is accomplished by careful dissection of the ligamentum flavum from beneath the ridge of the lamina (figs. 186 and 187). Otherwise, the management of the protruded mass and of the disk is by the technique described for operation at the lumbosacral interspace.

Special points of technique

A lateral herniation which extends to the midline can be removed extradurally if ample space is provided laterally by the removal of the ligamentum flavum. After this step has been carried out, the dural sac can be elevated and the herniation removed

⁴ The reader is also referred to the article by De Saussure, R. L.: Vascular Injury Coincident to Disc Surgery. *J. Neurosurg.* 16: 222-228, March 1959.—A.M.M.

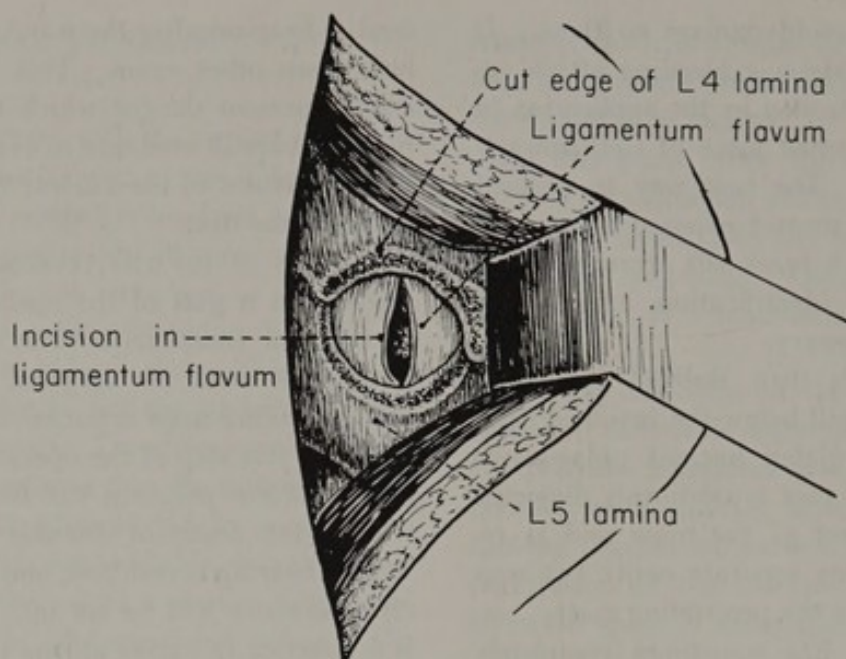


FIGURE 186.—Operative field during first stages of exposure of herniated nucleus pulposus at L4-L5 interspace.

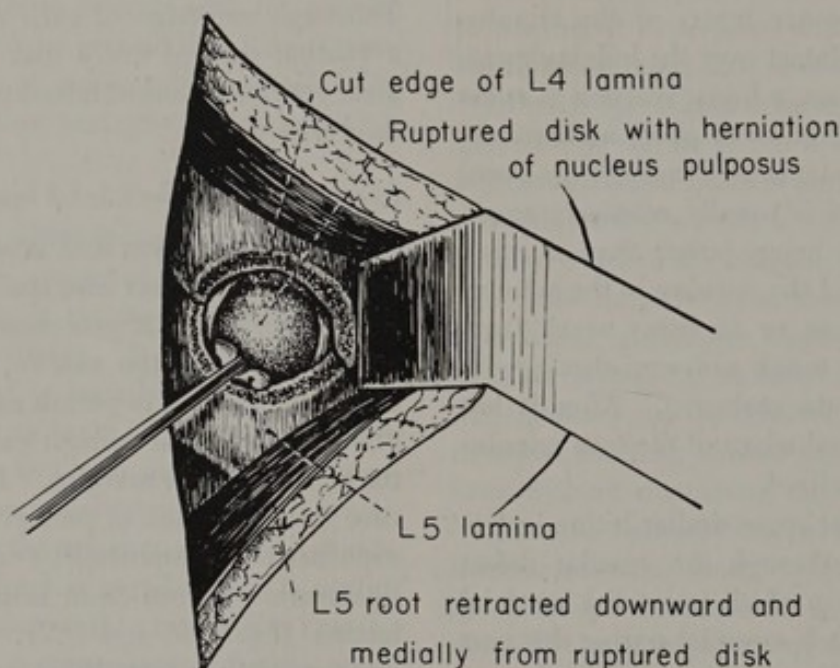


FIGURE 187.—Operative field after exposure of herniated nucleus pulposus at L4-L5 interspace. Note that the root of the L5 nerve has been retracted downward and medially from the ruptured disk.

from beneath it without excessive medial retraction of the dura and nerve roots.

If a frankly bulging mass of herniated disk is not found beneath the nerve root at the suspected level, the disk should be carefully exposed by traction on the dura toward the midline, after which the disk is thoroughly examined by means of a blunt instrument. Often, because the tear is incomplete, the bulging mass will be found located more toward the

midline than in its usual lateral position. Often the instrument used for palpation will slip into the tear in the annulus at this site. As a rule, the mass will also be found to be very soft and nonresilient. The finding of the tear is positive evidence of rupture of the disk and justifies the performance of the complete radical operation.

On the other hand, one is occasionally confronted with a case in which there is no tear in the annulus

fibrosus nor any demonstrable area of weakness. The disk may be somewhat soft to palpation, but it is not possible to demonstrate an actual rupture or a weakened area. There is never any justification for opening such a disk. If a frank rupture cannot be identified either above or below the area first explored, the wound should be closed and the exploration listed as negative. Before closure, however, the suspected nerve root (roots) should be well decompressed by removing the posterior rim of bone and the ligamentum flavum of the intervertebral foramen.

Similarly, if arthritic changes have been demonstrated around the suspected disk by roentgenology, the nerve root is provided with more room in the intervertebral foramen by removal of the posterior rim of bone, as just described.

Closure

Closure of the wound is accomplished in tiers, by a series of interrupted silk or cotton sutures in the deep fascia, the superficial fascia, and the integument. Drainage is never required.

SPINAL FUSION

Whether spinal fusion should be performed with disk surgery is still being debated. As followup data have accumulated, and it has become possible to compare the end results of operation for ruptured lumbar disk with and without spinal fusion, practically all neurosurgeons, and some orthopedic surgeons as well, have come to the conclusion that spinal fusion is not indicated either as a primary procedure or as a routine adjunct to disk surgery. Many orthopedic surgeons, however, believe that in certain instances removal of the disk should be combined with spinal fusion. Thus, Ghormley and his associates (39), in 1940, recommended the combined operation whenever sciatic pain is present in association with spondylolisthesis, spondylolysis, or lumbosacral arthritis, or with a combination of these processes. Smith, Deery, and Hagman (40), in 1944, extended the indications to include "an unstable joint, as determined by the roentgenograms." Barr (14), in 1947, said that "it appears probable that the trend is toward fusion of the spine at the time of laminectomy, in an increasing number of these cases."

We do not accept these indications. In our own clinic we never employ fusion as a primary procedure in ruptured intervertebral disk for at least two reasons, as follows:

1. In the great majority of cases, the disk operation alone is adequate to relieve the patient, and the performance of spinal fusion would therefore subject him to an unnecessary operation. It is impossible, of course, to determine in advance of the disk operation in which cases spinal fusion will later be required, but the number is so small that the risk of secondary surgery is well worth taking.

2. It would mean division of responsibility with the orthopedic surgeon, which is not in the patient's best interests. If the disk operation alone fails to correct intractable low lumbar pain, then spinal fusion can be done as a deferred, secondary procedure. A properly performed disk operation will not interfere in any way with the orthopedic operative field if spinal fusion should later be necessary.

We have not been impressed with the argument that spinal fusion should be performed whenever congenital anomalies of the spine are present, because we have never believed that anomalies of this type play any important role in the disk syndrome. In at least 12 cases (8 in Army practice and 4 in private practice) in which we have removed a ruptured disk at the fourth lumbar interspace, we have found a well-defined spondylolisthesis at the fifth interspace. Only the disk operation was performed, and in all instances, the patients recovered as normally and as satisfactorily as patients without congenital anomalies.

We have also never considered localized arthritis an indication for primary spinal fusion. Arthritic spurs at the site of a diseased disk probably represent nature's effort to fuse the vertebrae, and good bony fusion is likely once this progress is complete. We believe, however, that the finding of spurs in the region of the intervertebral foramina requires some modification of the routine surgical technique.

Spinal fusion, in our opinion, should be carried out at the same time as the disk operation in only one set of circumstances; namely, when the orthopedic surgeon considers that a patient requires it for intractable low lumbar pain but also feels that the disk should be explored before the orthopedic operation is done. The neurosurgeon examines the sus-

pected disk and confirms or excludes herniation of the nucleus pulposus. If a rupture is discovered, the usual disk operation is performed. If it is not, fusion may be undertaken by the orthopedic surgeon with complete assurance that the primary cause of the pain is an orthopedic, not a neurosurgical, problem.

POSTOPERATIVE MANAGEMENT

The patient who has been operated on under spinal analgesia is kept supine for the first 4 to 6 hours after operation. He is then turned from side to side at 4-hour intervals to prevent pulmonary complications. The usual inflated air mattress is used for paralyzed patients. For normal subjects, a special resilient hair and rubber mattress has been found to be more satisfactory.

Pain during the first day or two is controlled by intramuscular injection of dihydromorphine hydrochloride (Dilaudid) (0.002 gm.) or an equivalent amount of some other opiate. Thereafter, acetylsalicylic acid (0.7 gm.) and codeine (0.03 gm.) by mouth will usually be adequate. Pentobarbital sodium (0.1 to 0.2 gm.) is given for sleeplessness.

A patient who finds it difficult to void recumbent can be helped to a sitting or standing position for this purpose within 8 to 12 hours; we have done this repeatedly, with no bad effects. If, however, this does not seem desirable, carbamylcholine chloride (Doryl) can be given in doses of 0.00012 gm. (12 mg.) or 0.00025 gm. (25 mg.) if its use is not contraindicated. In our experience, the use of this drug has greatly reduced the need for postoperative catheterization provided that it is administered before overdistention of the bladder has occurred.

If the patient is comfortable and free from abdominal distention, an enema is not given until at least the third postoperative day. Thereafter, enemas and mineral oil are employed as necessary.

A full diet is given as soon as the patient desires it. In this and other details, the usual postoperative regimen is followed.

How long a patient should be kept at bedrest after a disk operation is something of a problem. No doubt the annulus fibrosus would heal better (that it ever heals completely is doubtful) if he were kept

recumbent for 2 or 3 months. On the other hand, the debilitating effects and actual risks of prolonged recumbency would far outweigh the possible advantages of this regimen.

Our own practice is to limit the period of bedrest, depending upon the circumstances of the individual case, to from 5 to 14 days. We have frequently observed that patients who are allowed up early do just as well as those kept recumbent for longer periods, and sometimes do better. Since it is unlikely that the lacerated annulus fibrosus undergoes significant repair within such brief periods of time, it seems reasonable to permit sitting, standing, walking, and similar forms of mild activity.

Whenever the annulus fibrosus has been found to be extensively lacerated, the patient is fitted with a Williams' low back brace before he leaves the hospital. The objective is to protect the disrupted intervertebral disk rather than the lumbosacral structures, which have not been significantly weakened by the operation.

Patients whose occupations do not require heavy lifting or straining are allowed to return to work after 4 weeks. Those whose occupations are more strenuous are not permitted to return for a period of 12 weeks.

O'Connell (41) advises a somewhat different postoperative regimen. He gets his patients out of bed on the 8th postoperative day and begins spinal exercises on the 10th day. These exercises include flexion, and most patients, O'Connell states, "are discharged, able to touch their toes, three weeks after operation." He considers it most important that the routine of exercises be continued indefinitely.

POSTOPERATIVE LUMBAR PAIN

Certain patients after operation suffer excruciating pain in the back, often associated with marked muscle spasm and a list of the pelvis. They are usually comfortable while they are in bed, though the onset and development of the pain does not appear to be affected in any way by the duration of bedrest immediately after operation. This complication of lumbar disk surgery responds promptly in most cases to oral steroid therapy. The patient should be at complete bedrest during the first week

of drug treatment. After that, ambulation can then be started cautiously. Occasionally, an extremely stubborn case will require the application of a light body cast before ambulation can be resumed in comfort.

We have observed intractable sciatic pain in three patients who failed to respond to every known neurosurgical and orthopedic measure. In each instance cordotomy, which was done bilaterally once, furnished complete relief. This is a more satisfactory operation in such cases than rhizotomy, particularly if the patient has already had a spinal fusion. To take down a successful spinal fusion is a major surgical procedure, and the scarring in the area is so intense that identification of the nerve roots is very difficult indeed.

Every neurosurgeon, no matter how experienced he may be, occasionally encounters what might be termed the chronic disk invalid. These patients furnish a real problem. Sometimes their complaints are real. Sometimes they are imaginary. Most often they are both real and imaginary. No surgeon has any right to be unsympathetic with them, for, despite his best efforts, no ruptured disk ever regains its normal anatomical structure and reassumes its normal physiological functions. There is, therefore, no way for him to disentangle real from imaginary complaints. With the passage of time, patients with real pain usually secure relief. Those whose pain is imaginary can be helped by proper psychiatric guidance. The latter group will be small if the neurosurgeon has carefully weighed the emotional stability and the threshold of pain of each of the patients under his care before he advises surgical therapy for a ruptured disk.

REFERENCES

1. Spurling, R. G., Mayfield, F. H., and Rogers, J. B.: Hypertrophy of the Ligamenta Flava as a Cause of Low Back Pain. *J.A.M.A.* 109: 928-933, 18 Sept. 1937.
2. Horwitz, T.: Lesions of the Intervertebral Disc and Ligamentum Flavum of Lumbar Vertebrae; An Anatomic Study of 75 Human Cadavers. *Surgery* 6: 410-425, September 1939.
3. Joplin, R. J.: The Intervertebral Disc; Embryology, Anatomy, Physiology and Pathology. *Surg., Gynec. & Obst.* 61: 591-599, November 1935.
4. Jung, A., and Brunschwig, A.: Recherches histologiques sur l'innervation des articulations des corps vertébraux. *Presse méd.* 40: 316-317, 27 Feb. 1932.
5. Roope, P. G.: Innervation of Annulus Fibrosus and Posterior Longitudinal Ligament; Fourth and Fifth Lumbar Level. *Arch. Neurol. & Psychiat.* 44: 100-103, July 1940.
6. Bodian, D.: A New Method for Staining Nerve Fibers and Nerve Endings in Mounted Paraffin Sections. *Anat. Rec.* 65: 89-97, 25 Apr. 1936.
7. Keyes, D. C., and Compere, E. L.: The Normal and Pathological Physiology of Nucleus Pulposus of the Intervertebral Disc; An Anatomical, Clinical, and Experimental Study. *J. Bone & Joint Surg.* 14: 897-938, October 1932.
8. Püschel, J.: Der Wassergehalt normaler und degenerierter Zwischenwirbelscheiben. *Beitr. z. path. Anat. u. z. allg. Path.* 84: 123-130, 14 Feb. 1930.
9. Smith, N. R.: The Intervertebral Discs. *Brit. J. Surg.* 18: 358-375, January 1931.
10. Middleton, G. S., and Teacher, J. H.: Injury of the Spinal Cord Due to Rupture of an Intervertebral Disc During Muscular Effort. *Glasgow M. J.* 76: 1-6, July 1911.
11. Barr, J. S.: "Sciatica" Caused by Intervertebral-Disc Lesions; A Report of 40 Cases of Rupture of the Intervertebral Disc Occurring in the Low Lumbar Spine and Causing Pressure on the Cauda Equina. *J. Bone & Joint Surg.* 19: 323-342, April 1937.
12. Sashin, D.: Relation of Pathologic Changes of the Intervertebral Disks to Pain in the Lower Part of the Back. *Arch. Surg.* 32: 932-944, June 1936.
13. Spurling, R. G., and Grantham, E. G.: The End-Results of Surgery for Ruptured Lumbar Intervertebral Discs; Follow-Up Study of 327 Cases. *J. Neurosurg.* 6: 57-64, January 1949.
14. Barr, J. S.: Ruptured Intervertebral Disc and Sciatic Pain. *J. Bone & Joint Surg.* 29: 429-437, April 1947.
15. Andrae, R.: Ueber Knorpelknötchen am hinteren Ende der Wirbelbandscheiben im Bereich des Spinalkanals. *Beitr. z. path. Anat. u. z. allg. Path.* 82: 464-474, 20 Sept. 1929.
16. Deucher, W. G., and Love, J. G.: Pathologic Aspects of Posterior Protrusions of the Intervertebral Disks. *Arch. Path.* 27: 201-211, February 1939.
17. Mauric, G.: Le disque intervertébral: Physiologie, pathologie, indications thérapeutiques. Paris: Masson & Cie, 1933.
18. Chandler, F. A.: Spinal Fusion Operations in the Treatment of Low Back and Sciatic Pain. *J.A.M.A.* 93: 1447-1450, 9 Nov. 1929.
19. Love, J. G., and Walsh, M. N.: Protruded Intervertebral Disks; A Report of 100 Cases in Which Operation Was Performed. *J.A.M.A.* 111: 396-400, 30 July 1938.
20. Barr, J. S.: Low-Back and Sciatic Pain; Results of Treatment. *J. Bone & Joint Surg.* 33-A: 633-649, July 1951.
21. Lasègue, C.: Considérations sur la sciatique. *Arch. gén.d. Méd.* 2: 558-580, 1864.
22. Danforth, M. S., and Wilson, P. D.: The Anatomy of the Lumbo-Sacral Region in Relation to Sciatic Pain. *J. Bone & Joint Surg.* 7: 109-160, January 1925.

23. Freiberg, A. H., and Vinke, T. H.: Sciatica and the Sacro-Iliac Joint. *J. Bone & Joint Surg.* 16: 126-136, January 1934.
24. Viner, N.: The Lipiodol Test for Patency of the Cerebrospinal Canal in a Case of Sciatica (?) With Unusual Features. *Arch. Neurol. & Psychiat.* 13: 767-771, June 1925.
25. Purves-Stewart, James: *The Diagnosis of Nervous Diseases*. 7th edition. London: Edward Arnold & Co., 1931.
26. Turyn, F.: Ein neues Ischiaszeichen. *München. med. Wchnschr.* 76: 834, 17 May 1929.
27. Foerster, O.: The Dermatomes in Man. *Brain* 56: 1-39, March 1933.
28. Tilney, Frederick, and Riley, Henry Alsop: *The Form and Functions of the Central Nervous System*. 3d edition. New York: Paul B. Hoeber, Inc., 1938.
29. Keegan, J. J.: Dermotome Hypalgesia Associated With Herniation of Intervertebral Disk. *Arch. Neurol. & Psychiat.* 50: 67-83, July 1943.
30. Mixter, W. J.: Rupture of the Lumbar Intervertebral Disk; An Etiologic Factor for So-called "Sciatic" Pain. *Ann. Surg.* 106: 777-787, October 1937.
31. Love, J. G.: Protrusion of the Intervertebral Disk (Fibrocartilage) Into the Spinal Canal. *Proc. Staff Meet., Mayo Clin.* 11: 529-535, 19 Aug. 1936.
32. Craig, W. M., and Walsh, M. N.: Diagnosis and Treatment of Low Back and Sciatic Pain Caused by Protruded Intervertebral Disk and Hypertrophied Ligaments. *Minnesota Med.* 22: 511-517, August 1939.
33. Young, H. H.: Non-Neurological Lesions Simulating Protruded Intervertebral Disk. *J.A.M.A.* 148: 1101-1105, 29 Mar. 1952.
34. Alpers, B. J., Gaskill, H. S., and Weiss, B. P.: The Problem of Primary Sciatic Neuritis (Analysis of 55 Cases). *Am. J. M. Sc.* 205: 625-636, May 1943.
35. Mixter, W. J., and Barr, J. S.: Rupture of the Intervertebral Disc With Involvement of the Spinal Canal. *New England J. Med.* 211: 210-215, 2 Aug. 1934.
36. Strain, W. H., Plati, J. T., and Warren, S. L.: Iodinated Organic Compounds as Contrast Media for Radiographic Diagnoses. I. Iodinated Aracyl Esters. *Am. Chem. Soc.* 64: 1436-1440, June 1942.
37. Hauser, E. D. W.: Sciatic Neuralgia: A Clinical Entity; Its Symptoms, Diagnosis and Treatment, With Report of 60 Cases. *J.A.M.A.* 102: 1465-1467, 5 May 1934.
38. Williams, P. C.: Lesions of the Lumbosacral Spine; Chronic Traumatic (Postural) Destruction of Lumbosacral Intervertebral Disc. *J. Bone & Joint Surg.* 19: 690-703, July 1937.
39. Ghormley, R. K., Bickel, W. H., and Dickson, D. D.: Study of Acute Infectious Lesions of Intervertebral Disks. *South. M.J.* 33: 347-353, April 1940.
40. Smith, A. DeF., Deery, E. M., and Hagman, G. L.: Herniation of the Nucleus Pulposus; A Study of 100 Cases Treated by Operation. *J. Bone & Joint Surg.* 26: 821-828, October 1944.
41. O'Connell, J. E. A.: The Indications for the Results of the Excision of Lumbar Intervertebral Disc Protrusions: A Review of 500 Cases; Hunterian Lecture. *Ann. Roy. Coll. Surgeons England* 6: 403-412, June 1950.

CHAPTER 40

Cervical Disk

R. Glen Spurling

GENERAL CONSIDERATIONS

The clinical diagnosis of a ruptured cervical intervertebral disk is usually made without difficulty. This is because, in most instances, the rupture occurs into a lateral recess of the spinal canal and the resulting mass compresses only one cervical nerve root. Therefore, the clinical picture is uncomplicated. When, however, the mass presents in the midline of the spinal canal, or just to one side of the midline, the clinical symptoms and signs may become exceedingly complex and a final diagnosis can be made only with the aid of supplementary laboratory studies.

In his 1928 discussion of the lesions which he called ventral extradural cervical chondromas but which are now known to be ruptured cervical intervertebral disks, Stookey (1) recognized that these masses could produce three basic clinical syndromes, depending upon their location in the spinal canal, as follows:

1. Midline lesions, which compress the ventral aspects of the spinal cord, cause bilateral spinal cord signs, with or without root pressure.
2. Ventrolateral lesions, which compress one lateral aspect of the spinal cord and the ipsilateral nerve root, cause unilateral cord signs and radicular symptoms.
3. Lateral lesions, which compress only the nerve root and spare the spinal cord, cause only radicular symptoms.

Stookey considered that the first and second of these lesions occurred most frequently. Now, more than 35 years after his observations were made, experience has established beyond question that, con-

trary to his original conclusions, the third (lateral) lesion is by far the most frequent.

Theoretically, any of the cervical disks may rupture and may produce either any single one of the clinical syndromes described by Stookey, or any combination of these syndromes. To date, there seems to have been no recorded instances of acute rupture of the cervical disk above the C3-C4 level.

Considerations common to all three clinical syndromes.—Before discussing the three principal cervical disk syndromes, certain considerations common to all of them may logically be considered, as follows:

There is probably some underlying fault, the nature of which is at present unknown, which accounts for the early decadence of the intervertebral disk in certain persons. The occurrence of characteristic disk symptoms in both the cervical and the lumbar region in the same patient is far too frequent to be merely coincidental.

The role of trauma, as the exciting cause of rupture of the cervical intervertebral disk, is difficult to assess unequivocally. Less than 30 percent of the patients in our series told a clear-cut story of a traumatic episode immediately preceding the onset of symptoms.

Numerous patients, after being interrogated in detail, were able to recall some injury to the neck weeks or months or years earlier, but it is extremely doubtful that a remote history of this kind should be accepted as related to recently presenting symptomatology unless there is roentgenological evidence of an old injury of the bone to substantiate it.

Far more common is the history of a crick in the neck, felt upon arising in the morning and followed,

a few hours or a few days later, by typical radicular symptoms. It may be argued, perhaps with considerable justification, that these episodes of morning wryneck can, in fact, be explained on the basis of trauma incidental to certain stress movements of the head and neck during sleep.

One type of traumatic episode predisposing a rupture of a cervical disk is so common that it deserves special consideration. This is a sudden, forcible flexion of the neck such as is experienced when a parked car or a slowly moving car is rammed from behind. Trauma of this kind may produce a true fracture of a vertebra (the so-called whiplash fracture) or an injury of the cervical disk. If a disk has been ruptured in an accident of this kind, the pain in the neck is immediate and severe. After an hour or two, it usually subsides to a dull ache. By the following morning the neck is usually stiff and painful, and radicular symptoms, if they have not occurred immediately, will be manifest within the next 24 hours. Occasionally, they do not appear for a few days; in the meantime, the patient continues to complain of a stiff neck.

Any traumatic episode which is superimposed upon preexisting spinal damage due to spondylosis may produce symptoms which in every way may suggest an acute rupture of a cervical disk. Barnes (2) and Brain, Knight, and Bull (3), among others, have noted that the danger of severe cord damage from a cervical injury seems to be greater in a patient with preexistent cervical spondylosis than in a patient with a normal spine.¹

One point cannot be emphasized too strongly. The diagnosis of rupture of a cervical disk can be established clinically only in patients who present symptoms and signs corresponding to anatomical patterns. *Neck pain alone does not warrant the diagnosis of ruptured cervical disk.* This is a fact of the utmost importance in cases in which legal evaluation may be necessary.

¹ The reader is also referred to the excellent writings of R. C. Schneider and his associates, particularly to the following papers: (1) — Cherry, G. R., and Pantek, H.: The Syndrome of Acute Central Cervical Spinal Cord Injury. With Special Reference to Mechanisms Involved in Hyperextension Injuries of Cervical Spine. *J. Neurosurg.* 11: 546-577, November 1954. (2) — Thompson, J. M., and Bebin, J.: The Syndrome of Acute Central Cervical Spinal Cord Injury. *J. Neur., Lond.* 21: 216-227, August 1958. (3) — Schemm, G. W.: Vertebral Artery Insufficiency in Acute and Chronic Spinal Trauma, With Special Reference to the Syndrome of Acute Central Cervical Cord Injury. *J. Neurosurg.* 18: 348-360, May 1961.—A.M.M.

Occasionally, one encounters patients with verified acute ruptured cervical disks (the typical soft disk) who have had little, if any, cervical disability. They have never suffered from cricks or significant stiffness of the muscles of the neck, although they have pain in the arm or shoulder which is increased by certain movements of the neck. It is difficult to explain the freedom from neck pain after disk rupture except by the speculation that in these cases there is a congenital absence of the sensory fibers which supply the posterior annulus fibrosus through the recurrent nerve. We have observed similar situations in patients with ruptured lumbar disks. The patients suffer from the unilateral sciatica typical of a ruptured lumbar disk but have never experienced low back pain or limitation of motion of the lumbar spine.

Some patients are also remarkably free of disability referable to the neck, even when a localized cervical spondylosis is present and is manifested by spurs extending into the intervertebral foramen, or by a calcified bar which replaces the posterior annulus fibrosus, or by both. The statement is warranted that, as a general rule, the acute soft disk produces more disabling symptoms in the neck than does the hard disk. This is perhaps one explanation of why so many lesions of the cervical disk are incorrectly diagnosed as amyotrophic lateral sclerosis, syringomyelia, primary lateral sclerosis, multiple sclerosis, and other degenerative diseases of the spinal cord.

CLINICAL SYNDROMES OF RUPTURE OF THE CERVICAL DISK

It is possible, in most instances of rupture of the cervical disk, to localize the probable level of the lesion with some degree of certainty, particularly when the spinal nerve root is compressed and there is no involvement of the cord. To accomplish this result requires very exacting neurological examination.

SYNDROME OF ROOT PRESSURE

Symptoms

When, as most often happens, the posterior annulus fibrosus of a cervical disk has ruptured in its

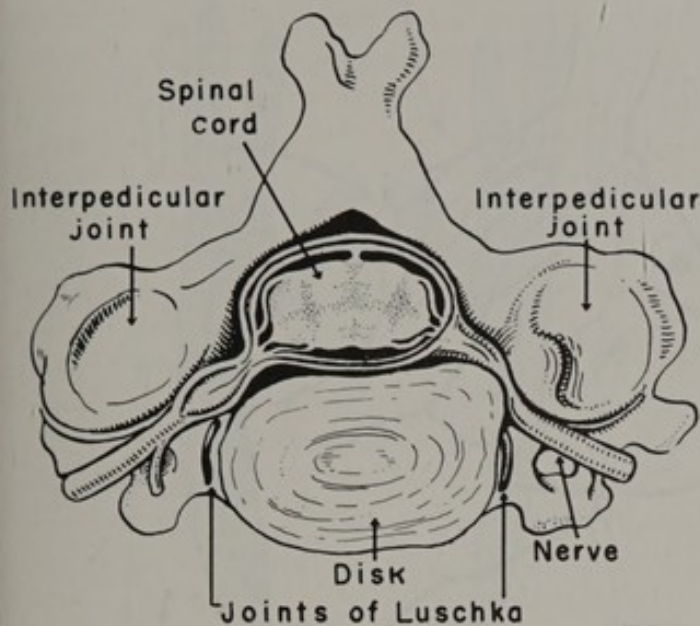


FIGURE 188.—Mechanism of root compression by bony spur and outer fibers of annulus fibrosus. (From Spurling, R. G., and Segerberg, L. H.: *Lateral Intervertebral Disk Lesions in Lower Cervical Region*. J.A.M.A. 151: 354-359, 31 Jan. 1953.)

lateral extremity, there is so little substance present to herniate through the tear that the only result is simple pressure upon the nerve root as it issued from the foramen (fig. 188). If there has been no fragmentation of other structures of the disk, such as the cartilage plates or the annulus fibrosus, the herniated mass will remain small and the chances of damage to the spinal cord are slight.

With the sudden disruption of the posterior annulus fibrosus, the patient usually complains of neck pain of varying intensity. Most often he describes it as a severe crick in the neck. Root symptoms appear only after the nucleus pulposus has herniated through the tear in the annulus fibrosus.

Root symptoms of the so-called soft disk may be acute or insidious in onset. When there is a clear-cut history of trauma, they characteristically appear early and are severe. In fact, in cases of this kind, a clinical diagnosis of fracture of one of the lower cervical vertebrae seems highly probable. Exacerbations and remissions are the rule whether radicular symptoms are acute or are insidious in their onset.

When the lesions are of the hard type, the sequence of events may be quite different. Repeated episodes of neck pain ordinarily precede radicular symptoms by months or even by years. Since hard

lesions are likely to occur at a single vertebral level, in contrast to the usually multiple lesions of spondylosis, the clinical symptoms are usually unilateral and, once symptoms referable to the nerve root appear, the clinical course thereafter resembles that of a soft disk lesion.

When the lesion is at either the C5-C6 or C6-C7 level, at which almost 95 percent of ruptures of the lower cervical disk are located, the chief symptom is almost invariably pain in the lower part of the neck, which is promptly overshadowed by pain radiating into the shoulder and arm, and often into the scapular and precordial regions as well. The pain is usually described as aching and boring in quality. It is likely to be most intense in the deep tissues of the arm, midway between the shoulder and elbow. While it occasionally radiates into the forearm, more often there is a complaint of numbness and tingling below the elbow, particularly on the radial aspect of the hand and the fingers.

The pain is usually intensified by movements of the neck and by coughing, sneezing, and straining. It is worse at night and often interferes with sleep. Frequently it can be relieved, at least to some degree, by assumption of the upright position and ambulation. Raising the arm above the head sometimes brings relief. In some instances, the patient obtains relief by flexion of the neck, but more often this movement aggravates the discomfort. Because he has found that certain movements of the head increase the pain, he is likely to hold the head in a fixed position.

The pain of a ruptured cervical disk is sometimes so intense over the pectoral and precordial regions that a false diagnosis of angina pectoris may be made. We have observed one patient whose episodes of pain were so typical of angina pectoris that their true nature could be established only by the therapeutic test of the administration of nitroglycerin.

Physical findings.—The most usual objective findings are as follows:

1. Relative fixation of the cervical spine in response to passive movements, with reduction or elimination of the cervical lordosis.

2. Reproduction or intensification of the pain by forceful movements of the head downward, backward, or laterally on the neck compression test (fig. 189).

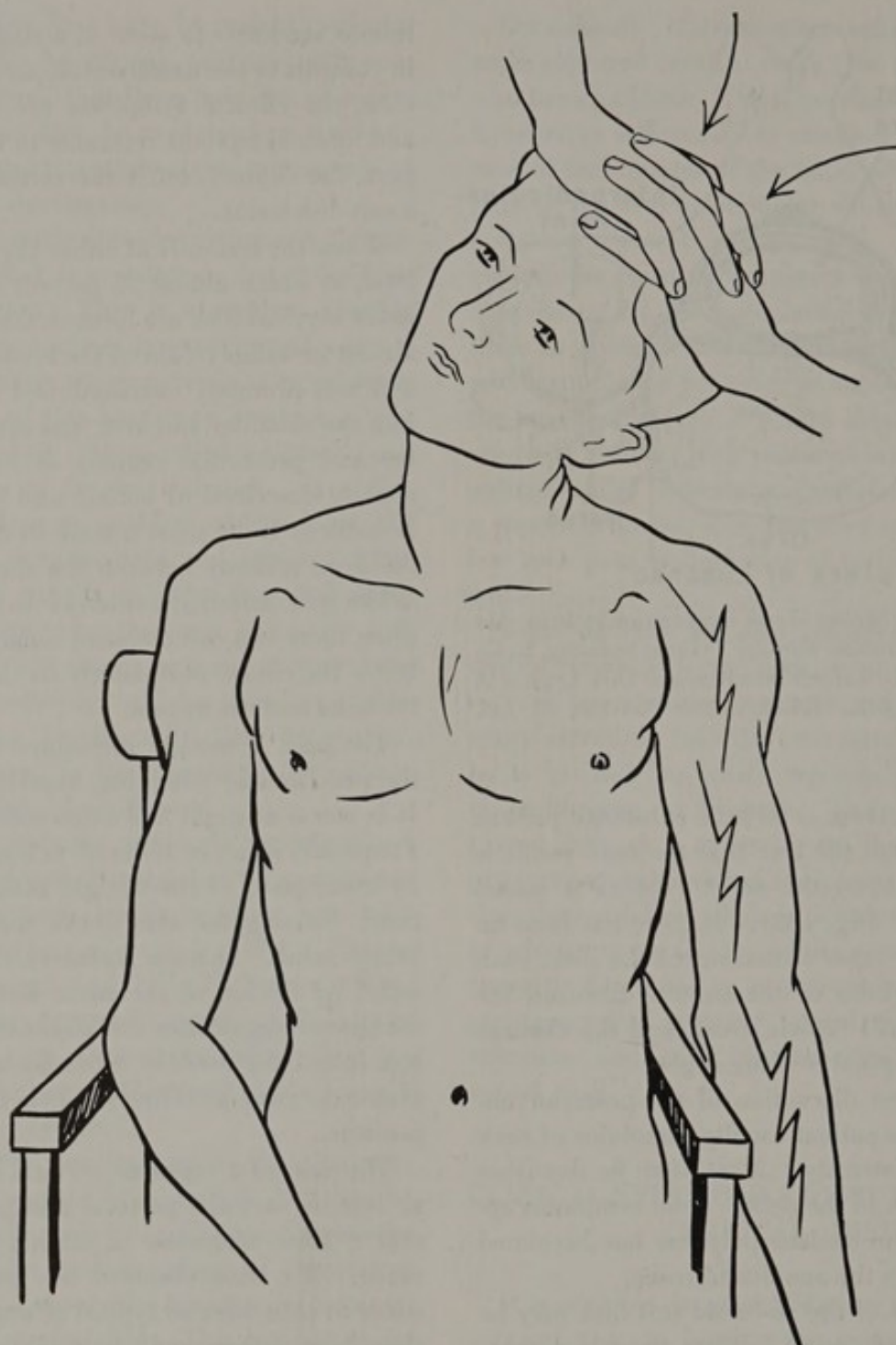


FIGURE 189.—Technique of neck compression test. (From Spurling and Scoville (5).)

3. Relief of pain by manual extension of the head in a straight line with the spinal axis.

4. Local tenderness on pressure over the brachial plexus, in the neck and axilla, and over the scapulo-vertebral region on the affected side.

5. Sensory changes, in the form of either hypesthesia to touch or pinprick, or hyperesthesia in the distal parts of the dermatome of the root involved (fig. 190).

6. Motor weakness or fasciculation of the muscles supplied by the compressed cervical nerve. This is not a frequent finding, and measurable atrophy is the exception rather than the rule.

7. Alternation in the tendon reflexes. These changes were present in approximately 80 percent of our 61 verified cases, a percentage in agreement with the larger series (120 cases) reported by Davis, Odom, and Woodhall (4).

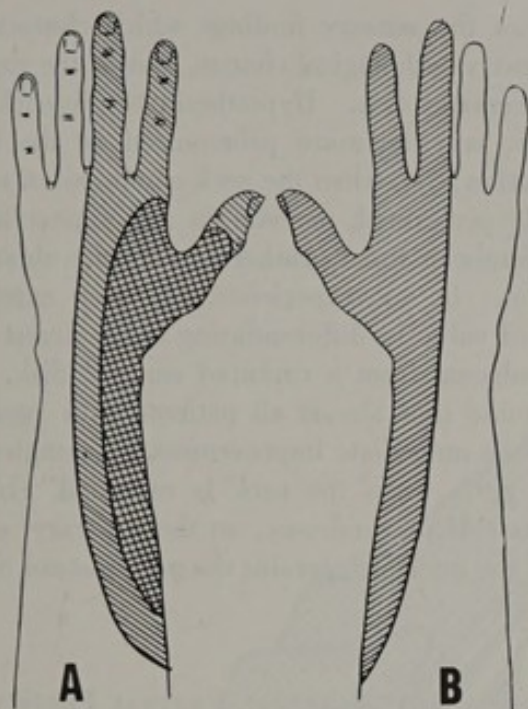


FIGURE 190.—Approximate areas of forearm and hand into which pain or paresthesiae radiate or in which sensation is diminished when nerve roots are compressed. A. Dorsal view of left forearm and hand showing areas affected when sixth and seventh cervical nerve roots are compressed. B. Ventral view of left forearm and hand showing areas affected when seventh cervical nerve root is compressed.

Clinical location of the lesion.—Localization of the lesion on the basis of clinical observations has proved to be less reliable than is indicated in the original reports of Spurling and Scoville (5), among others. There is a difference, which is statistically significant, in the incidence of the signs at the two principal levels of involvement, but the marked individual variations which occur make it unwise to put too much reliance upon these differences.

In general, the following are the important clinical findings in the majority of cases at the principal levels of involvement, as well as the findings at less important levels:

The C5–C6 disk (sixth cervical nerve compression):

1. Reproduction of the pain pattern by the neck compression test, with numbness and tingling into the thumb and radial aspect of the hand.
2. Hypesthesia in the distal portions of the sixth cervical dermatome, particularly on the dorsal and

lateral aspects of the thumb and the radial aspect of the hand (fig. 190).

3. Weakness, atrophy, and fasciculations of the biceps muscle.

4. Depression or absence of the biceps tendon reflex.

The C6–C7 disk (seventh cervical nerve compression):

1. Reproduction of the pain pattern by the neck compression test, with numbness and tingling into the index and middle fingers and the dorsum of the hand.

2. Hypesthesia of the distal portion of the seventh cervical dermatome, particularly of the index and middle fingers and the dorsum of the hand (fig. 190).

3. Weakness, atrophy, and fasciculations of the triceps muscle.

4. Depression or absence of the triceps tendon reflex.

The C3–C4 disk (fourth cervical nerve compression):

In all reported series of cervical disk lesions, the incidence of disease at the C3–C4 level is so small that any attempt to establish a pattern of neurological signs is impossible. The largest series of cases of cervical spondylosis at this level was reported by Brain (6), in his comprehensive study of neurological signs in this disease, but he could not derive, from his 7 single and 13 multiple protrusions, a clinical pattern which would be helpful in localizing lesions at this level. Since cervical spondylosis characteristically produces more spinal cord symptoms and fewer radicular symptoms than lesions at other levels, it is easy to understand why clinical localization is more difficult in this disorder than in other lesions of the cervical disk.

The C4–C5 and C7–T1 disks (fifth and eighth cervical nerve compression):

Enough single disk lesions, uncomplicated by spinal cord compression, have been reported at the C4–C5 and C7–T1 levels to establish fairly reliable clinical patterns.

At the C4–C5 level:

1. The pain pattern involves the base of the neck, the tip of the shoulder, and the anteroposterior surface of the arm down to the elbow. This pattern

should be reproduced by the neck compression test and relieved by extension of the neck.

2. Hypesthesia over the deltoid region may be demonstrable, although the finding is inconstant.

3. Weakness, atrophy, and fasciculations affect the deltoid or biceps brachialis muscles or both.

4. The biceps tendon reflex is depressed or absent. At the C7-T1 level:

1. The pain pattern involves the ulnar distribution and the inferior medial aspect of the arm, forearm, and hand, with numbness and tingling extending into the little finger and half of the ring finger. This pattern should be reproduced by the neck compression test and relieved by extension of the neck.

2. Hypesthesia is demonstrable in the distal portions of the eighth cervical dermatome, that is, the fourth and fifth digits.

3. Weakness, atrophy, and fasciculations affect the intrinsic muscles of the hand.

4. No reflex changes are demonstrable in the upper extremities.

SCALENUS ANTICUS SYNDROME

The scalenus anticus syndrome is very frequently observed in all types of acute lesions affecting the neck and shoulder girdle. It is not uncommon, in fact, to have a patient with symptoms of an acute ruptured cervical disk also exhibit all the usual signs of compression within the scalenus angle, including scalenus tenderness, ulnar hypesthesia, or paresthesia with vascular deficit. The same findings are observed in inflammatory lesions about the shoulder joint.

Our own opinion is that the scalenus anticus phenomenon should be regarded as an overlay of the primary pathological change in any pathological condition of the cervical spine or shoulder girdle. In our experience, primary scalenus compression, in the absence of a cervical rib or the equivalent of a cervical rib (congenital fibrous bands), or with a long seventh cervical transverse process, is an extremely uncommon clinical entity. It seems reasonable to assume that spasm of the scalenus anticus is no more the cause of pain in the upper extremity than spasticity of the sacrospinalis muscle is the cause of sciatica.

The constancy of the scalenus overlay often makes it extremely difficult for the examining physician to

bring out the sensory findings which characterize the primary pathological change, that is, the rupture of the cervical disk. Hypesthesia to pinprick, for instance, may be more pronounced in the ulnar distribution; yet, when the neck compression test is properly performed, paresthesia will appear in the index finger or thumb rather than in the ulnar distribution. In our experience, the neck extension test is of value in differentiating the scalenus anticus syndrome from a ruptured cervical disk. We have found that almost all patients with ruptured disks have immediate improvement, or complete relief of pain, when the neck is extended. In the scalenus anticus syndrome, on the contrary, extension of the neck exaggerates the pain instead of improving it.

SYNDROME OF BILATERAL VENTRAL PRESSURE

When the mass which occupies the spinal canal, whether it consists of herniated nucleus pulposus or a calcified bar of cervical spondylosis, is so situated that bilateral ventral pressure is exerted upon the spinal cord (fig. 191), one would expect the clinical picture to be that of a ventral neoplasm of the spinal cord. This is not true. Although the lesion is rather uniform in both size and location, the symptoms and signs show no constancy in any area.

NECK

In our experience, patients with lesions of the median disk have had strikingly trivial symptoms referable to the neck. Attacks of severe neck pain, although they are unusual, did occur in one of our patients.

Although pain is not the rule, there is usually some limitation of the motion of the neck in extreme extension and flexion. In three of our patients, acute flexion of the neck produced a sensation described by the patients as like an electric shock in the neck, back, and lower extremities.

UPPER EXTREMITIES

If the lesion involves one or more of the lower four cervical disks, motor symptoms are to be expected in the upper extremities as a result of the involvement of anterior horn cells or motor roots

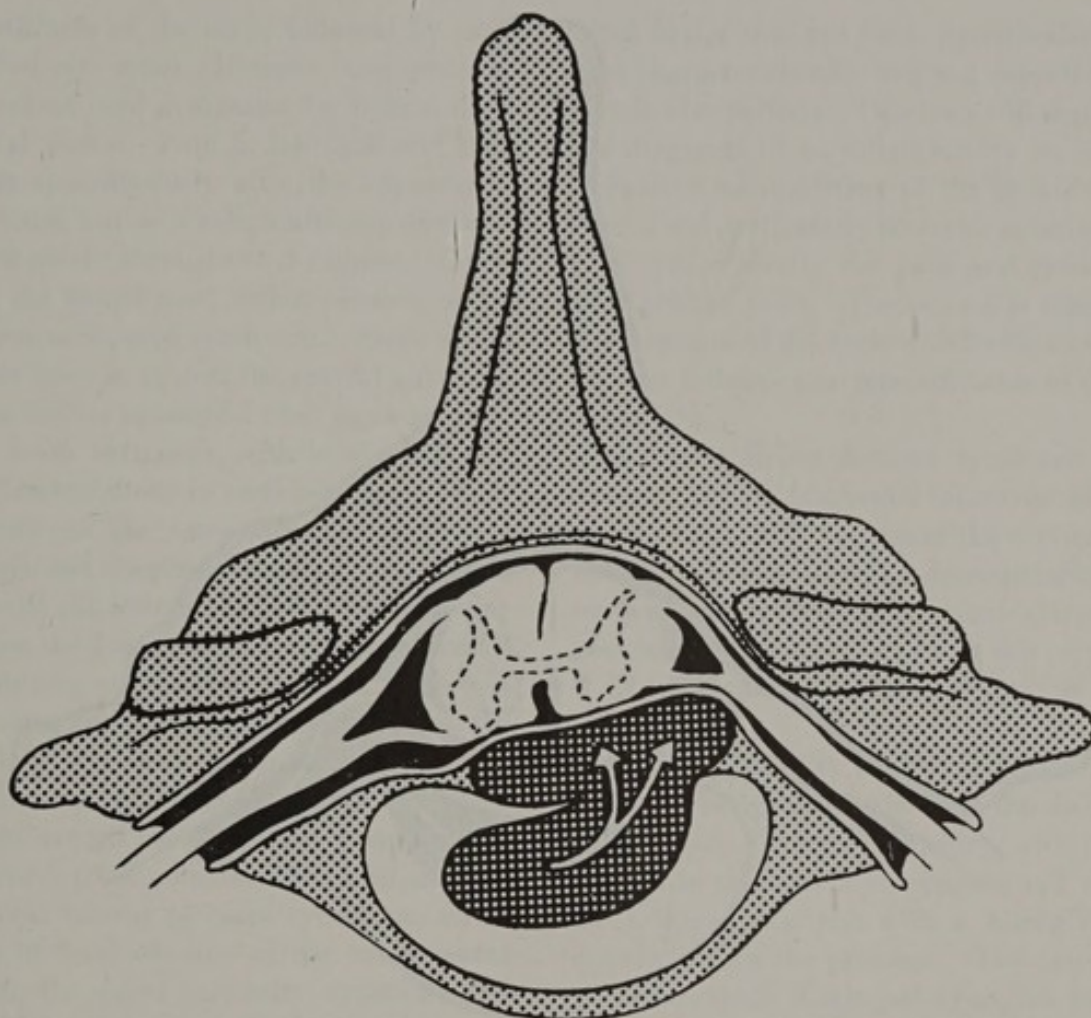


FIGURE 191.—Mechanism of bilateral ventral pressure from central herniation of nucleus pulposus. (After Kristoff and Odom.)

or both at the level of the lesion. If, as frequently happens, the lesion takes the form of a bony ridge, which is characteristic of spondylosis, and if foraminal osteophytes are present as well, then radicular symptoms, both motor and sensory, may accompany paraplegic symptoms. When motor symptoms are present in the upper extremities, the paralysis is of the flaccid type and is accompanied by atrophy and fasciculations. The atrophied muscles, however, as has been pointed out already, do not always reflect the actual anatomical level of the lesion.

The point to remember is that, in midline cervical disk lesions, there may be few, if any, symptoms and signs in the upper extremities. Failure to bear this fact in mind has been responsible for much of the confusion that still exists in the differentiation of disk lesions from degenerative diseases of the spinal cord.

LOWER EXTREMITIES

The most striking part of the neurological picture in midline lesions of the cervical disk is the muscular spasticity of the lower extremities. Muscular weakness is usually minimal and is overshadowed by spasticity and hyperreflexia. The gait is awkward and uncertain. There is difficulty in ascending and descending steps. In late stages, equilibrium seems to be affected out of all proportion to the objective sensory findings.

Signs of pyramidal tract involvement are usually consistent, including hyperactive reflexes, ankle clonus, positive Babinski's sign, and loss of abdominal and cremasteric reflexes. Sphincteric control is usually disturbed but is not usually lost.

Sensory disturbances are extremely variable in degree but not in pattern. Because of the involve-

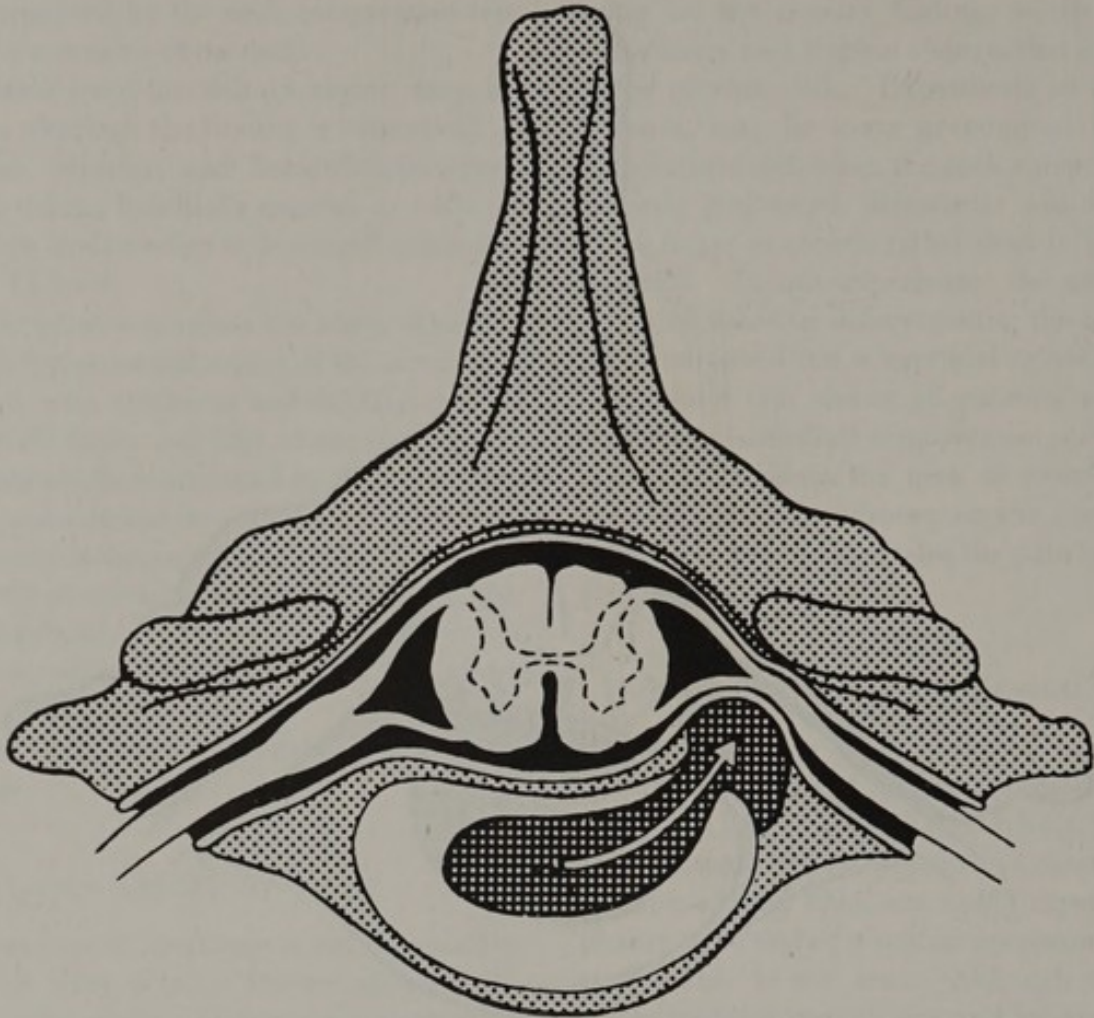


FIGURE 192.—Mechanism of root compression in lateral herniation of nucleus pulposus.

ment of the spinothalamic tract, pain and temperature sensations are most consistently affected. The upper border of sensory disturbance is apt to be considerably lower than one might expect, in view of the level of spinal cord compression. There may be some blunting of tactile sensation, but bone, joint, and vibratory sensations (posterior columns) are usually spared.

Perhaps the most characteristic sensory symptoms of which patients complain are the paresthesiae which affect one or all of the extremities. They consist of temperature phenomena, such as coldness, almost as if the extremity were encased in ice, or a burning sensation, almost as if the skin were on fire.

If root pressure accompanies a midline disk lesion, as often happens in spondylosis, it is frequently possible to demonstrate an area of hypesthesia in the dermatome of the compressed cervical nerve. Under these circumstances, there is no dis-

sociation of sensation, because all sensory fibers of the cervical nerve are equally affected.

SYNDROME OF UNILATERAL VENTRAL PRESSURE

Unilateral involvement of the spinal cord usually occurs in combination with the root compression syndrome and simply indicates that a larger than usual herniation of disk substance has occurred through a tear in the lateral portion of the posterior annulus fibrosus (fig. 192). As has been mentioned earlier, the volume of the nucleus pulposus is not, in itself, sufficient to compress the spinal cord severely, but a mass of considerable size may be formed when bits of annulus fibrosus and cartilage plates are extruded along with it. This, also as already mentioned, is the type of lesion described by surgeons as a soft disk. It is doubtful that a true unilateral cord syndrome ever occurs with a hard disk or with extensive cervical spondylosis.

Pain and stiffness of the neck, followed by pain and weakness of one upper extremity, may precede the onset of spinal cord symptoms by several days or even several weeks. Pain in the neck and arm may disappear spontaneously after the appearance of cord symptoms, but as a rule, radiculopathy and the cord deficit persist throughout the illness. Characteristically, the spinal cord deficit consists of an incomplete Brown-Séquard syndrome. Since direct pressure of the mass is against the ventral quadrant of the cord, unilateral pyramidal tract signs are produced in the lower extremity, with local weakness, atrophy, and fasciculations in certain muscles of the upper extremity on the same side as the lesion. Changes in pain and temperature sensation occur on the side opposite the lesion, at a level three or four segments below the focal motor signs, as the result of pressure on the spinothalamic tract. There is also a slight blunting of tactile discrimination on the side of the body opposite the lesion. Since tactile localization, and muscle, bone and joint, and vibratory sensations are all carried in the posterior columns of the cord, these columns remain unaffected.

The unilateral ventral pressure syndrome, therefore, consists of focal atrophy of the lower motor neuron type in the upper extremity, spasticity and other pyramidal tract signs of the upper motor neuron type in the lower extremity below the level of the lesion and on the same side, and dissociated sensory changes on the opposite side of the body.

It should be emphasized again that, not infrequently, bizarre clinical findings are observed and cannot be reconciled with simple unilateral pressure of a small mass against one side of the spinal cord.

DIFFERENTIAL DIAGNOSIS

Although lesions of the cervical disk which produce the syndrome of root pressure are, as a rule, relatively simple to diagnose, they may be confused with the following conditions:

1. Inflammatory lesions in and around the shoulder joint, including subdeltoid and subacromial bursitis, fibrositis, and fibrous ankylosis. These conditions must be excluded first, for they are the entities most commonly confused with lateral rupture of a lower cervical disk.

Many bizarre neurological patterns are encoun-

tered in the arm, but pain, paresthesiae, and numbness characteristically follow a vascular rather than a radicular pattern. Two tests will usually establish the diagnosis of an inflammatory lesion. The first is passive manipulation of the shoulder; all movements, and particularly posterior rotation and abduction, will intensify the pain and cause fixation at the shoulder joint. The second is manipulation or compression of the neck, which either causes no pain at all or fails to cause intensification of the symptoms in the arm.

2. The scalenus anticus syndrome, as already pointed out, is frequently observed as an overlay phenomenon in all lesions of the cervical disk. Unless there is also present a demonstrable cervical rib or an unusually long seventh cervical transverse process, there is little likelihood that this syndrome, when it is associated with a disk lesion, is the primary condition.

3. The possibility of angina pectoris often leads to confusion, particularly when the disk lesion is on the left side. A careful history, with particular attention to the effects of exercise and rest, followed by a therapeutic test with a nitroglycerin tablet, usually settles the problem. The cases of cervical disk incorrectly diagnosed as angina pectoris which have come under my personal observation have usually been explained by the simple fact that the physicians who had diagnosed them apparently failed to remember the existence of lesions of the cervical disk.

4. Neoplasms at the apex of the lung (suprasulcus) may cause brachial neuropathy because of their direct pressure upon the plexus. Diagnosis rests on two chief considerations, that the pain is more diffuse than that associated with a ruptured disk, since all the cords of the plexus are involved, and that there is usually an associated Horner's syndrome.

5. Tumors of the cervical cord, particularly those which arise from the nerve roots (neurinomas) may, in the early stages, produce symptoms identical to those of a ruptured cervical disk. In some instances, differentiation is impossible before operation.

Lesions of the cervical disk which produce the syndrome of unilateral ventral pressure offer no particular problem in diagnosis, although localization is not always easy. If the Brown-Séquard syndrome is reasonably clear cut, and particularly, if it

is associated with radicular pain, the problem is to differentiate between a neoplasm and a disk lesion. The dynamics of the spinal fluid, together with its chemical analysis, will usually supply the data required to make the differentiation.

The midline disk lesion, which produces the syndrome of bilateral ventral pressure, creates the most diagnostic confusion. This type of lesion may simulate any one of the common degenerative diseases of the central nervous system, including amyotrophic lateral sclerosis, multiple sclerosis, primary lateral sclerosis, and syringomyelia. This author is in complete agreement with Bucy's unqualified statement (7) that every patient with spastic paraplegia and marked disturbances of gait, with little or no involvement of the upper extremities, and with no abnormalities in the domain of the cranial nerves, requires extensive investigation and consideration before he is considered to be suffering from a hopeless degenerative disease of the spinal cord and is condemned to a life of invalidism. Every such patient, as Bucy further states, should undergo a careful examination of the spinal canal under the fluoroscope after the intraspinal injection of Pantopaque, since this is the only possible means of making the differential diagnosis.

HEADACHE OF CERVICAL ORIGIN

Headaches secondary to diseases of the cervical spine have been recognized and described for at least 50 years. Originally, the underlying pathological process was considered to be arthritis, spondylitis, tuberculosis, or some other inflammatory process affecting the cervical vertebrae.

In 1926, Barré (8) called attention to a typical pain pattern frequently associated with cervical arthritis. It consisted of occipital neuralgia, vertigo, tinnitus, otalgia, facial pain which could be relieved by pressure over one of the branches of the trigeminal nerve, and paroxysmal vasomotor disturbances in which the face would become flushed. Barré explained the disturbances as caused by osteophytes which compressed the vertebral artery, the perivascular sympathetic plexus, or both, and called the disorder the posterior cervical sympathetic syndrome. Later, the disorder became known as the Barré-Lieou syndrome. Many authors discussed

it in the differential diagnosis of cephalalgia, but few agreed with either the clinical findings or with Barré's anatomical explanation of them.

Raney and Raney (9), in 1948, and again, with Hunter (10), in 1949, undertook a comprehensive investigation of the problem and concluded that almost every patient with a ruptured cervical intervertebral disk, whether it was of the soft or the hard variety, had at some stage of his illness suffered from headaches of a fairly distinctive pattern. In some instances, it was promptly forgotten once radicular symptoms had appeared. As Raney and Raney expressed it, "because the patient has a tendency to label as headache most discomforts of the head and nuchal region, headache may be regarded as 'lumbago' of the cervical region."

The essential features of the pain pattern in headaches of cervical origin are as follows: The pain begins in the occipital region, usually unilaterally but sometimes on both sides. After a few hours, it radiates anterior to the homolateral eye, forehead, temple, and, occasionally, the maxillary regions. The pain is usually described as a dull ache or a nagging pain but sometimes is described as throbbing, especially when it is retro-orbital. The pain may last from several hours to several days, then may disappear dramatically, without treatment. Characteristically, these headaches are episodic, just as the radicular pain of a cervical disk is subject to remission and exacerbations.

In my own experience, incapacitating headaches which can be traced to lesions of the cervical disk are relatively uncommon. When they are observed, however, they follow the general pattern described by Raney and his associates. They are almost never part of the acute cervical disk syndrome. The cases observed in our clinic were all associated with osteophytosis of the cervical spine, demonstrable by roentgenograms, and usually more pronounced above the C6-C7 level.

Certain physical findings are pathognomonic, as follows:

1. The neck compression test reproduces and intensifies the pain pattern.
2. Manual extension of the neck in a straight axial plane improves or completely relieves the pain.
3. Pressure over the greater or lesser occipital nerves is always painful and usually duplicates the pain pattern in the head and face.

ROENTGENOLOGICAL DIAGNOSIS

Adequate roentgenography of the cervical spine is an essential part of the examination of all patients suffering from pain in the neck in association with pain in the arm or shoulder or in both areas. No matter what the disease, early pathological changes in the bones and joints of the cervical spine cannot be demonstrated without films of high technical quality.

In every instance, the routine examination should include (1) a true anteroposterior projection, (2) a true lateral projection, and (3) both right and left oblique projections to show each one of the intervertebral foramina. If the patient is short and stocky and the neck is apparently short, the radiological technician must exert considerable ingenuity in order to secure a good lateral view of the seventh cervical vertebra.

Brain (3) has emphasized the importance of lateral views, made in full extension and flexion, to reveal unsuspected abnormalities of movement or lack of movement at particular intervertebral levels. We have never been impressed with the value of films made in this manner, for two reasons: The first is that most patients with disease of the cervical spine have a reduction or loss of cervical lordosis as the result of muscle spasm. The second reason is that an attempt at full extension or flexion, in view of these changes, amounts to no more than nodding movements of the head, and these are accomplished by movements in the articulations between the head and the atlas, not by movements of the lower cervical vertebrae.

If the plain films reveal any suspicious areas of increased density in the region of the pedicles or laminae, three-dimensional stereoscopic films are made of these areas. Both primary and metastatic neoplasms characteristically produce localized changes of this kind, and it is essential that they be recognized promptly.

DIFFERENTIAL ROENTGENOLOGICAL DIAGNOSIS

Plain roentgenograms are particularly helpful in the differential diagnosis of the following conditions:

Trauma

Fractures of the body, laminae, or articular processes of a cervical vertebra may produce symptoms identical with those of a ruptured disk, and the differentiation must be made by roentgenograms (fig. 193). Old injuries of the cervical spine are frequently associated with localized proliferative changes which may include spur formation.

Neoplasms

Neoplasms, whether primary or metastatic, characteristically cause bony destruction, which may be associated with collapse of a vertebral body. Therefore, as just pointed out, destructive changes call for an immediate determination of the nature of the malignant lesion. If it is apparently secondary, there must be an immediate and thorough search for the primary tumor.

Anomalies

Congenital anomalies of the cervical spine are not at all uncommon. They are often of questionable clinical significance, though, as some observers have speculated, any congenital lesion may perhaps interfere with normal movements, thus throwing additional stress and strain upon the normal joints and predisposing to early degenerative changes.

The following anomalies are among the common congenital lesions:

1. Complete or incomplete fusion of two vertebral bodies (fig. 194). These are the so-called block vertebrae described by Schmorl (11).
2. Fusion of two or more spinous processes, the vertebrae being otherwise normal (fig. 195).
3. The Klippel-Feil type of deformity, which is sometimes confused with fusion of the vertebrae. In the case first described by Klippel and Feil (12), only four cervical vertebrae were present and they were fused into a mass whose contour was similar to that of the dorsal vertebrae. The numerous variations include more or less complete fusion of two or more vertebral bodies, often accompanied by spina bifida and other abnormalities.

Some observers believe that the undescended scapula originally described by Sprengel (13) is usually part of the Klippel-Feil deformity. In this condition there is a characteristic external deformity, consisting of a short neck, with lowering of the

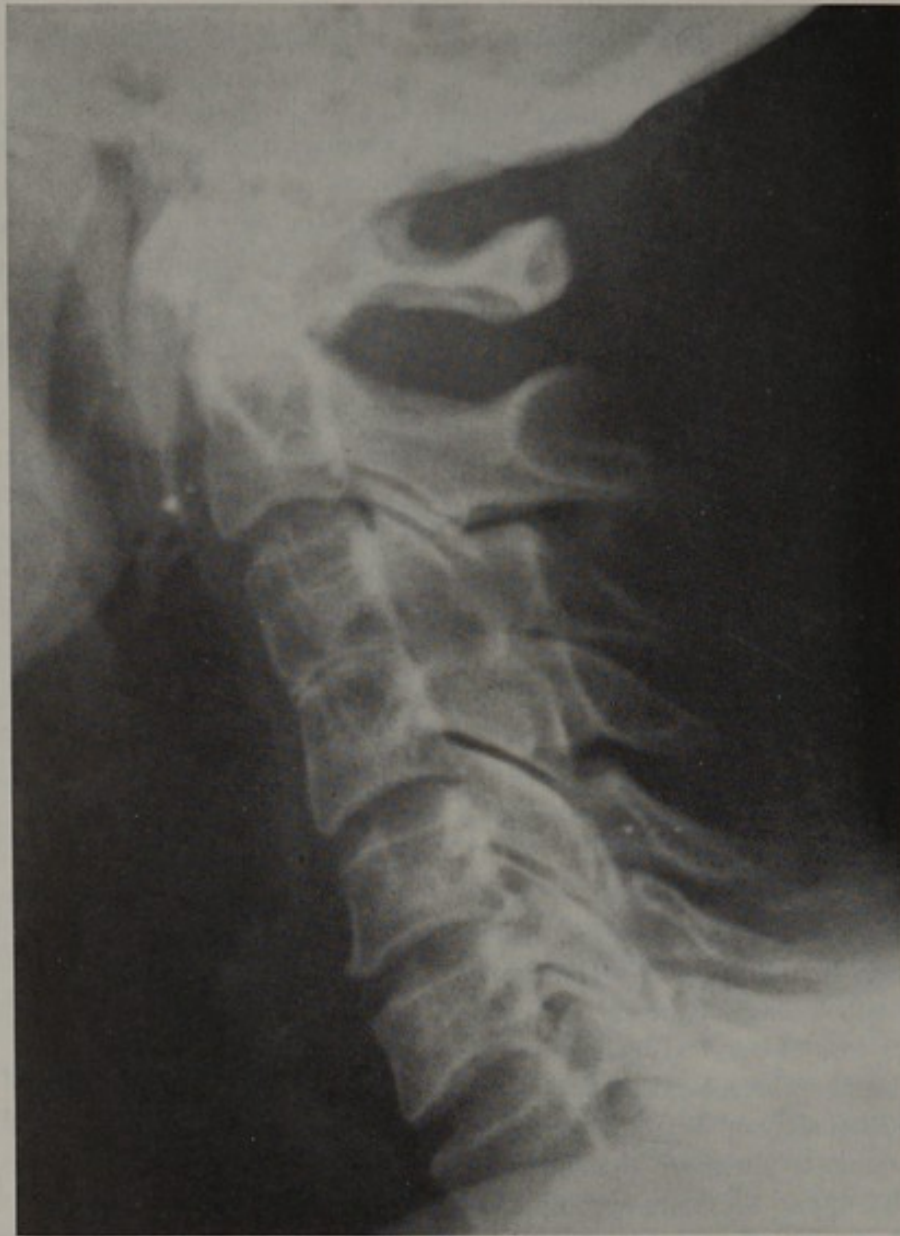

FIGURE 193.—Lateral roentgenogram showing fracture dislocation of C4 and C5 vertebrae. This patient's only symptoms were a still, painful neck and pain radiating into both shoulders. At no time did he have signs or symptoms indicative of spinal cord damage.

hairline on the back of the neck, and limitation of cervical motion.

4. Spina bifida, the failure of fusion of one or more posterior arches, which may or may not be associated with meningocele, is much less common in the cervical than in the lumbosacral spine. Unless it is associated with meningocele, cervical spina bifida has little or no clinical significance.

Anterior spina bifida, the failure of fusion of one or more vertebral bodies, is an even more infrequent phenomenon. If it occurs in the cervical region, a sac may project forward and change the retropha-

ryngeal space into an area of considerable volume, which can interfere with both respiration and swallowing.

Rheumatoid spondylitis

Rheumatoid spondylitis (Marie-Strümpell disease) does not usually involve the cervical spine until after the disease has been present, and has manifested itself symptomatically, for months or even years. Its telltale course, the destructive changes present in the sacroiliac joints, and the increased sedimentation rate all constitute data which

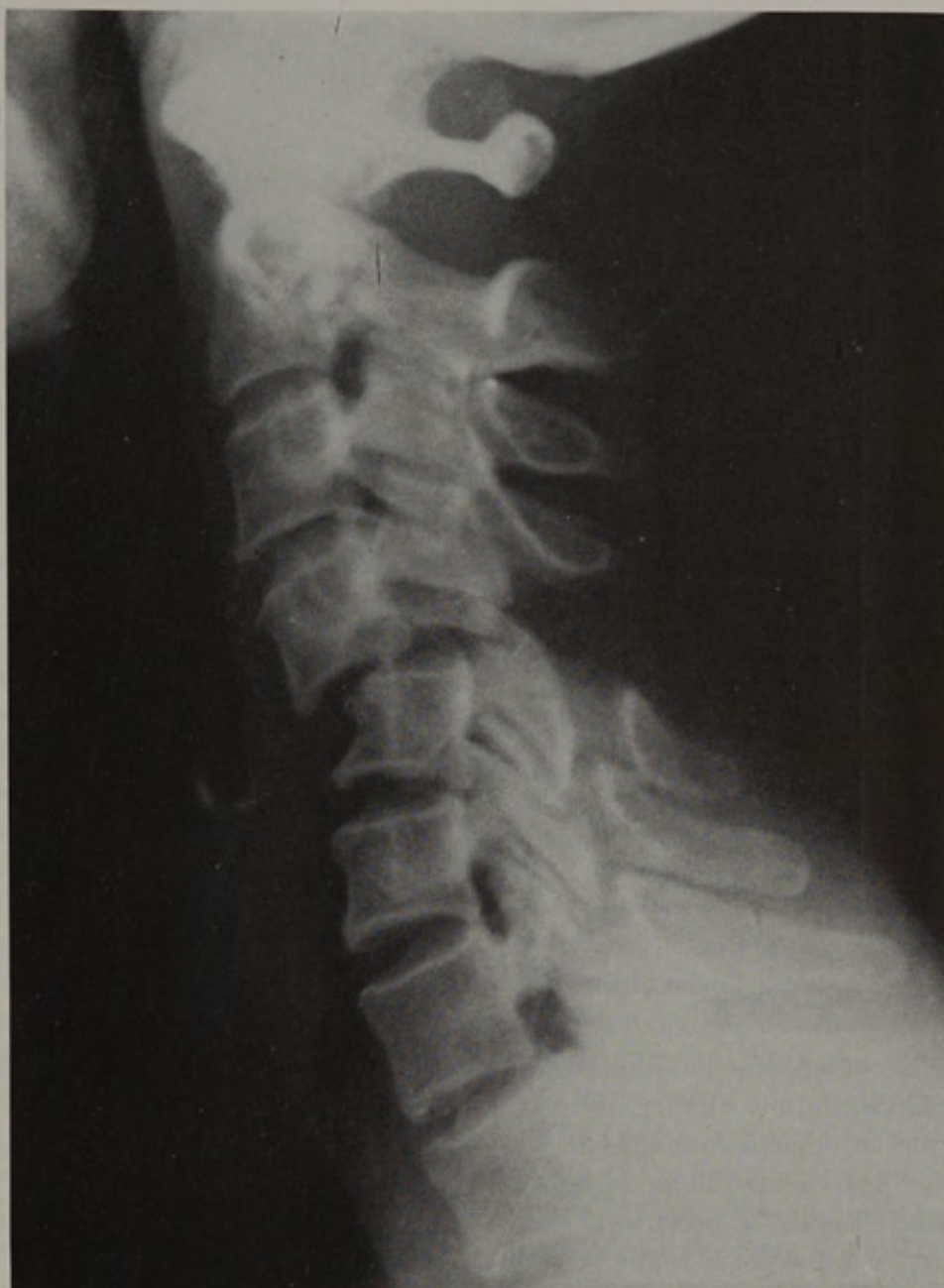

FIGURE 194.—Lateral roentgenogram showing incomplete congenital fusion of C3 and C4 vertebrae (block vertebrae).

are essential in the differential diagnosis and which can be obtained without difficulty.

MYELOGRAPHY

Myelography with Pantopaque is now the standard routine in all American clinics and, for that matter, in most of the other clinics throughout the world.

There have been some adverse reactions, it is true, but those which have been reported to me have

invariably been traced to errors in technique: The ampules of Pantopaque were not handled correctly in sterilization, the instruments used were improperly prepared, and there were errors in the performance of the lumbar puncture.

It is now generally agreed, both by anesthesiologists and by surgeons, that all instruments and all drugs put-up in ampules which are used for spinal puncture or in spinal anesthesia should be sterilized by autoclaving. The former practice of using phenyl-containing solutions or other antiseptic solu-

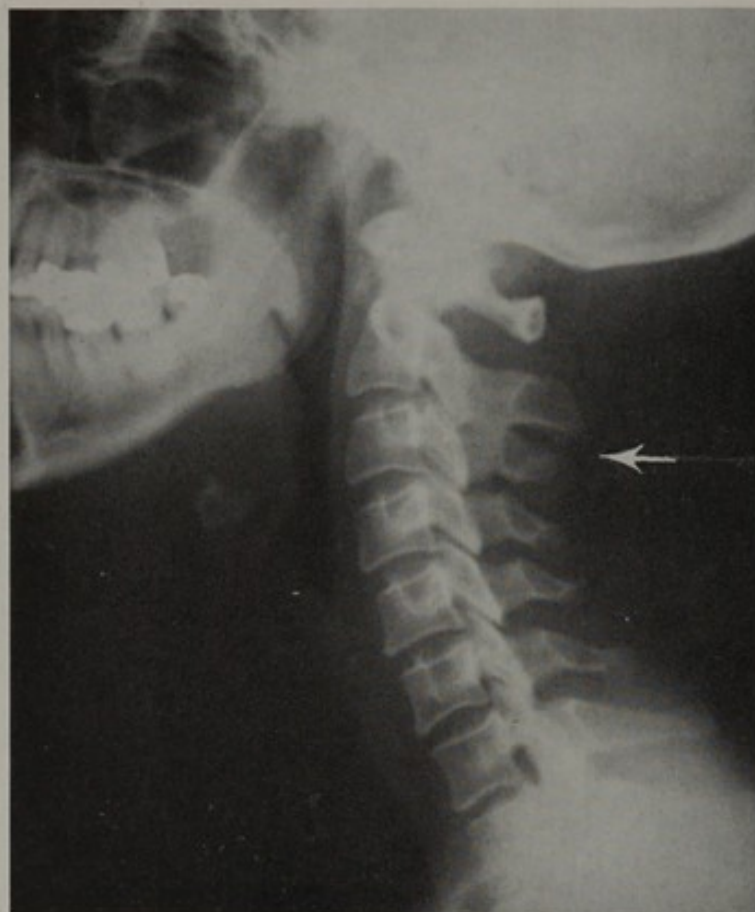


FIGURE 195.—Lateral roentgenogram showing congenital fusion of spinous processes of C2-C3. Note that the vertebrae are otherwise normal.

tions for the sterilization of ampules and needles has long since been abandoned in this country, because of the proved danger of introducing foreign material into the spinal canal. As to the technique of spinal puncture, this procedure should be performed with the same exacting aseptic technique as would be employed in a craniotomy.

Indications

The clinical diagnosis of certain lesions of the cervical disk, particularly those which compress the spinal cord, may be a very difficult problem. The clinical localization of lesions of the cervical disk is also much less accurate than the localization of similar lesions in the lumbar area. For these reasons, myelography plays a far more important role in both the diagnosis and the localization of lesions in the cervical region than it does in similar lesions of the lumbar spine.

Myelograms should be made whenever a patient is encountered who has symptoms indicating a spinal cord deficit and who might reasonably be suspected

of having a lesion of a cervical disk. This generalization is particularly true of patients whose symptoms and signs are referable exclusively to the spine and who are thought to have such degenerative diseases as multiple sclerosis, amyotrophic lateral sclerosis, primary lateral sclerosis, or syringomyelia.

Myelography is also indicated in any case in which conservative treatment, instituted on the clinical diagnosis of lateral rupture of the cervical disk, has not been successful and surgery is recommended. Operation should not be undertaken without accurate localization of the lesions by myelograms. Exploration of more than one interspace in the search for a ruptured disk is a much more hazardous procedure in the cervical than in the lumbar region, in which it is also highly undesirable.

Myelography is also useful, in certain special cases, in the decision for or against surgical treatment. A patient with a severe neurological deficit in an upper extremity, with rapidly progressive symptoms, should be examined by this technique to determine the size and position of the presumable

encroaching lesion. If the defect obliterates the axillary pouch and causes a deformity in the main column of Pantopaque, operation without a test of conservative treatment is justified. If the deformity produced by the defect is confined to the axillary pouch, as is characteristic of hard disks, a trial period of conservative treatment is permissible.

In our own clinic, we routinely perform myelography before surgery for any lesion of a cervical disk, regardless of the clarity of the neurological or plain roentgenological findings. We have been misled too often in the past by assuming that localized spurs in a foramen at one level indicated the site of root pressure, only to find, at operation, a soft disk one segment higher or one segment lower.

Technique

When myelography with Pantopaque was first introduced, the cisternal route of injection was used because of the difficulties of placing the patient in a head-down position, to permit the Pantopaque, which is heavier than spinal fluid, to descend and collect in the cervical region. Complicated halers, slings, shoulder rests, and other equipment were devised to accomplish this purpose, but almost invariably, unless there was a complete or partial subarachnoid block in the cervical region, the Pantopaque would flow into the basal cisternae of the skull before the roentgenologist had time to return the table to the horizontal level.

During and after World War II, working in collaboration with Joseph C. Bell, M.D., Professor of Roentgenology at the University of Louisville School of Medicine, Louisville, Ky., this author was able to devise a method for cervical myelography which requires no special equipment and no more assistance than one would normally have in the fluoroscopic room during lumbar myelography.

The only roentgenological equipment required in this technique is a tilting fluoroscopic table, with its power unit, and a quick switch for exposing films. We have not found it necessary to use a serial plate changer in order to make the required number of roentgenograms.

The patient is placed in the prone (face-down) position on the tilting table, with the abdomen supported by two pillows, to reduce the lumbar lordosis. Since most roentgen units tilt in only one direction, it is also necessary to place him head downward on

the table, so that sufficient tilting will occur to permit the Pantopaque to flow upward into the cervical region.

Spinal puncture is performed, whenever possible, at the lumbosacral interspace, in order to facilitate aspiration of the Pantopaque at the conclusion of the examination. When a free flow of fluid has been obtained, 6 cc. of Pantopaque are injected into the subarachnoid space. This must not be done, however, until it is certain that spinal fluid can be readily aspirated. After the injection has been made, the stylet is reinserted into the needle and the whole lumbar area is covered with a sterile towel which is held in place by adhesive straps.

At this point, the surgeon takes charge of the patient's head and does not relinquish his firm hold upon it until, at the end of the examination, the position is changed for withdrawal of the contrast material. The head is held with the chin extended as far as possible. It does not make any difference if the cervical lordosis is lost because of muscle spasm. If the chin is kept extended, and if reasonable care is exercised in the maneuvers, the Pantopaque will not enter the cisterna magna. This step of the procedure is essential. No one except the surgeon should be responsible for managing the head in the head-down position to prevent the Pantopaque passing into the basal cisternae. When the opaque substance once enters the cisternae, it can seldom be recovered.

The table is slowly tilted to the head-down position, with the surgeon supporting the patient's head, a nurse holding his feet and legs against the table, the patient grasping the shoulder support with his hands, and the roentgenologist following the cephalad-ward progress of the Pantopaque with the fluoroscope. The table is tilted just enough to allow the opaque material to flow over the dorsal kyphotic curve. When this has been accomplished, the table is quickly returned to the horizontal level. The Pantopaque droplets will then readily collect in a column in the cervical region, and from this time onward, only slight variations of the level of the table from the horizontal position are necessary. The examination of every interspace can be accomplished without haste, spot films being taken at frequent intervals to verify and record the fluoroscopic observations.

During this part of the examination, the patient's chin is elevated or lowered as necessary to remove the

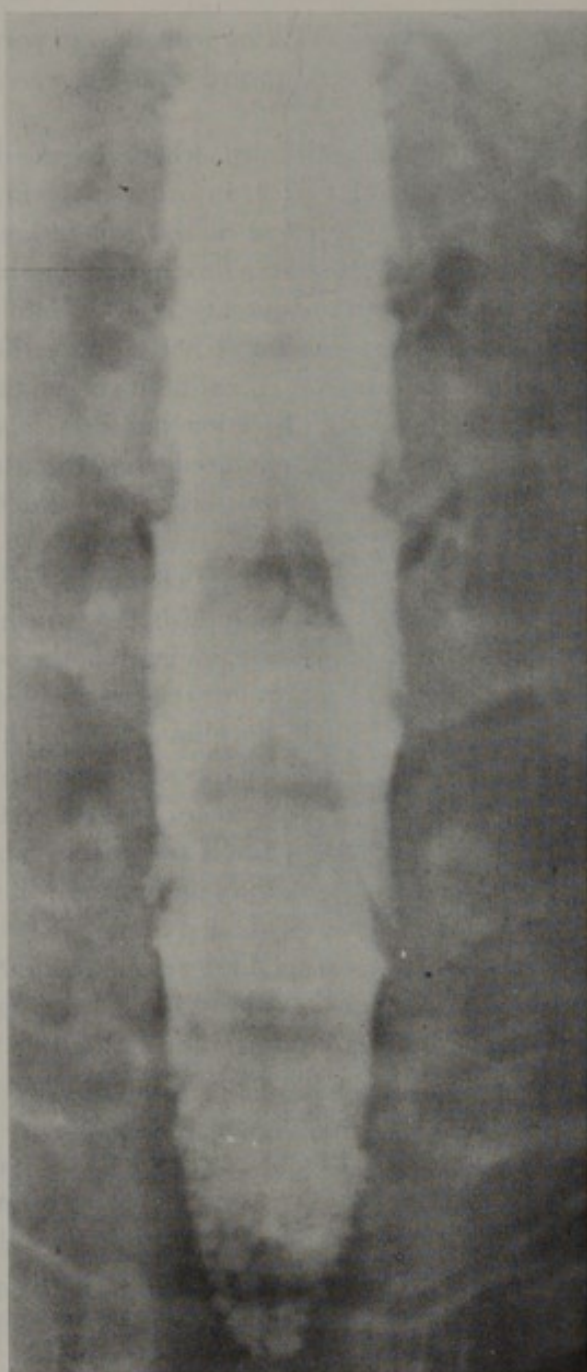

FIGURE 196.—Myelogram of normal cervical spine showing entire cervical subarachnoid space from the second cervical level. Note the symmetrical form of the axillary pouches at each interspace.

occipital bone from the field of vision and to permit clear definition of the upper cervical segments. Lateral films are taken when there is a separation, or partial separation, of the opaque column, and when there is delay in filling any one of the segments. Under these circumstances, posterior displacement of the opaque column would be a most important finding.

When the films have been inspected and found to be of the desired quality, the patient's position is reversed, his feet being now placed at the foot of the table. The prone position is maintained throughout. Care is taken during this maneuver to hold the head with the chin extended.

The table is now tilted downward until the patient is supporting himself on his feet. Meantime, the progress of the Pantopaque downward into the sacral sac is followed with the fluoroscope.

The roentgenologist then centers the column about the point of the needle which has been left in place throughout the examination and the Pantopaque is withdrawn by gentle aspiration.

Myelography by the technique described can be performed within a 15-minute period, with negligible discomfort to the patient.

Interpretation

A cervical myelogram of a normal subject (fig. 196) shows the entire contour of the anterior subarachnoid space, including the arachnoidal extensions over each cervical root (the so-called root sleeves or axillary pouches). The column of Pantopaque is much broader in the cervical than in the lumbar area, because the cervical spinal canal is wider in this region, to accommodate the cervical enlargement of the spinal cord. It is chiefly because of this enlargement that a larger amount of Pantopaque (6 cc.) is used for cervical myelography while an injection of 3 cc. is usually ample for lumbar myelography.

As in all myelographic examinations, it is important to follow every movement of the column under the fluoroscope and to detect delays in filling at any level. Whenever such a delay is observed, a spot film should be made at once. Filling of the root sleeves is more difficult to follow under the fluoroscope in the cervical area because a Bucky diaphragm cannot be used as it can be in the lumbar area. It is therefore essential that satisfactory roentgenograms be made, with concentration of the opaque column at each interspace under suspicion, before the examination is concluded.

In about 10 percent of all myelographic examinations, the Pantopaque, for reasons still not clarified, will form in droplets as it is collected in the cervical region (fig. 197). When this phenomenon occurs, some of the value of the examination may be lost,

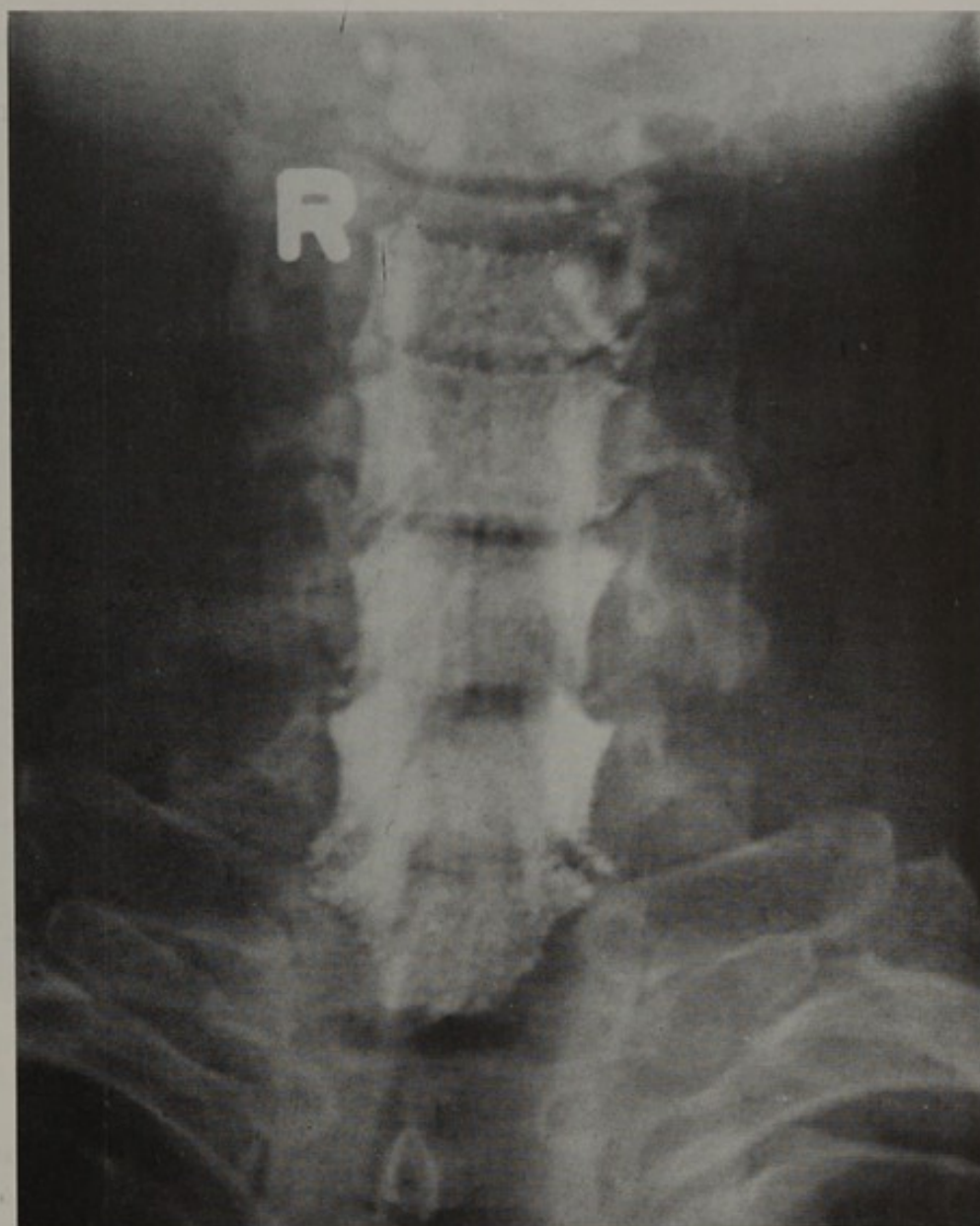

FIGURE 197.—Myelogram of normal cervical spine from fourth cervical to first dorsal vertebra. Note width of Pantopaque column. Note also droplet formation in contrast medium which, in this film, does not detract from the accuracy of the examination.

for the root sleeves are not clearly shown. Any gross filling defect in the column can, however, be shown accurately, whether the column is composed of many small droplets or is a smooth homogenous mass.

On occasion, we have overcome the disadvantages of droplet formation by allowing the Pantopaque to re-collect in the lumbosacral area and to remain there for 5 or 10 minutes before it is again allowed to pass upward into the cervical region.

The presence of a soft lateral ruptured disk is characteristically shown by a small indentation in

the Pantopaque column, with complete obliteration of the root sleeve (fig. 198).

Osteophytes compressing a nerve root in the intervertebral foramen do not produce any defect or only a minimal defect in the myelogram. If the spurs are situated on the central lip of the foramen, there will be obliteration of the root sleeve (fig. 199). If they are located in the foramen proper, no deformity of the Pantopaque column will be apparent. Paradoxically, however, such a myelogram may be just as important in determining the proper management of the case as a myelogram

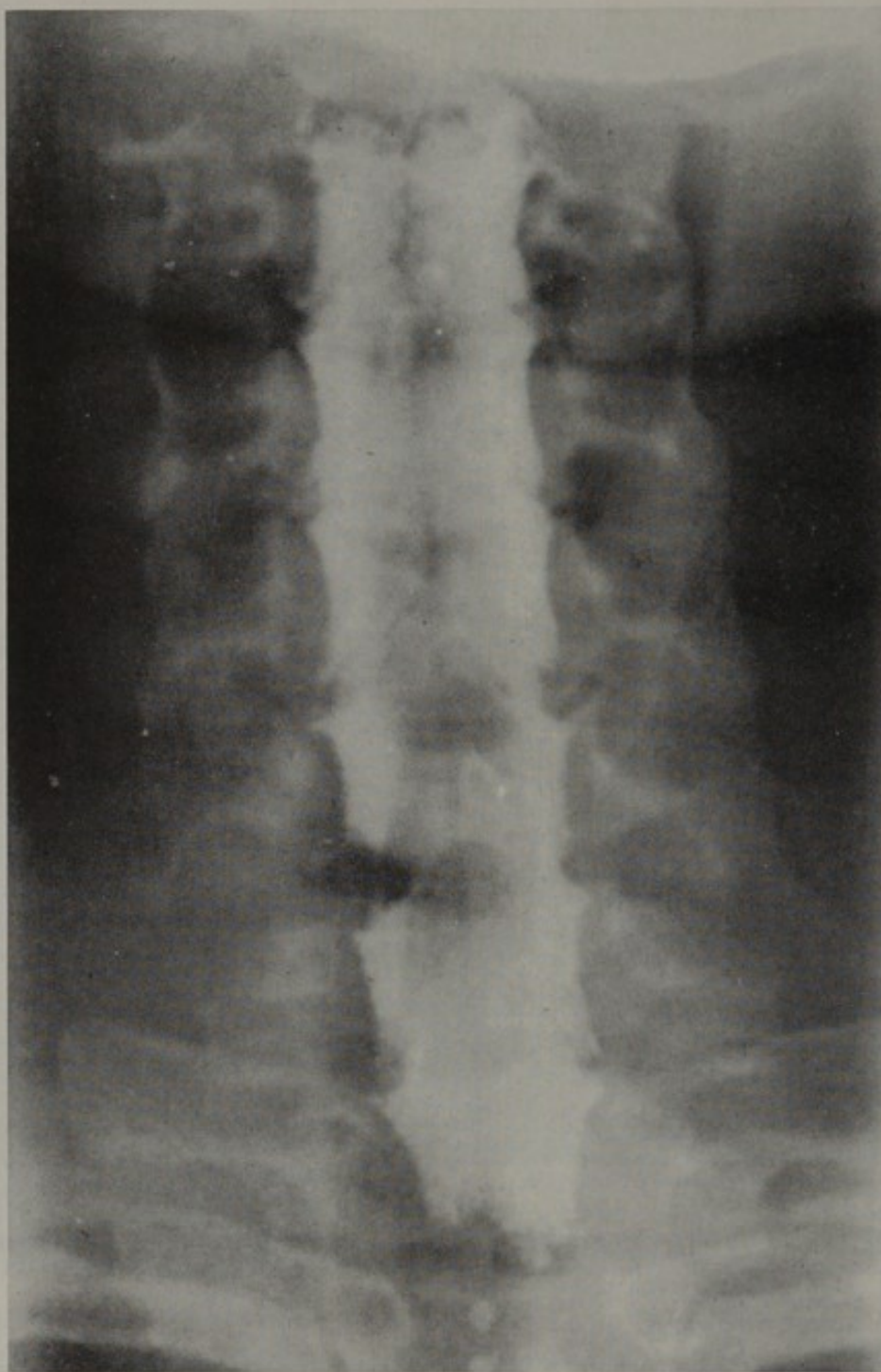


FIGURE 198.—Myelogram showing deformity of root sleeve, which is characteristic of soft lateral disk lesions.

which shows a clear-cut defect. In cases of this kind, plain roentgenograms will have shown the osteophytes in the foramen, the neurological examination will have shown the motor and sensory deficits, and the myelogram eliminates the possibility of a soft disk, at another level. The osteophytes are obviously responsible for the symptoms, and the management of the whole case is clarified.

Complete subarachnoid block, as demonstrated by either the Queckenstedt test or myelography, does not often occur with lesions of a cervical disk. When it is observed, the most probable cause is a neoplasm. In most instances, what appears, at first, to be a complete block at the site of a midline lesion of a disk will usually prove to be a complete separation of the column, with the Pantopaque trickling

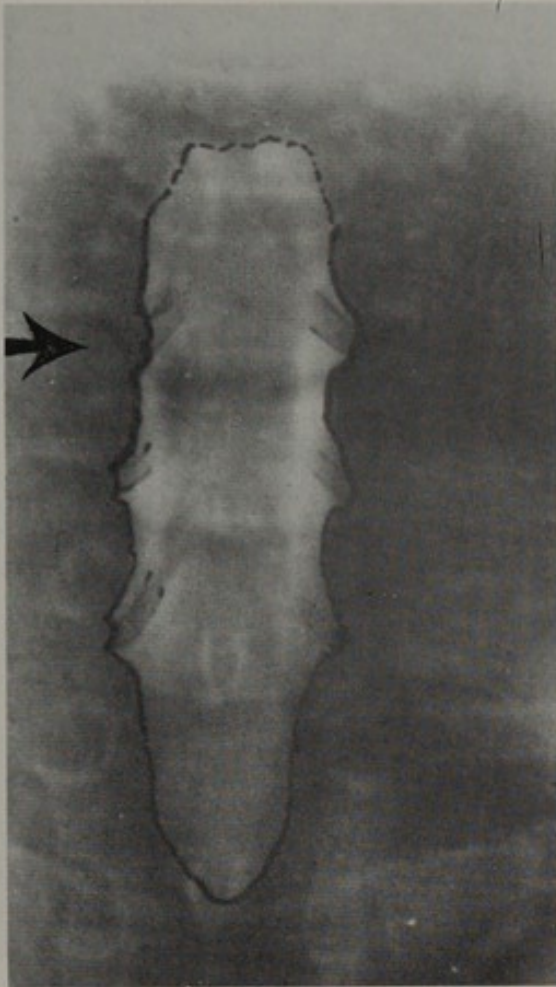


FIGURE 199.—Myelogram showing minimal deformity of axillary pouch (indicated by arrow).

upward around the edges of the subarachnoid space. After the opaque material has been collected above the lesion, the same break will be observed when manipulation of the table sends the dye column in a caudad direction.

In cases of cervical spondylosis associated with multiple bars across the spinal canal, lateral films will show multiple indentations in the anterior border of the opaque column.

MANAGEMENT

With the single exception of the presence of a severe neurological deficit, the policy in our clinic has always been to treat lesions of the intervertebral disk conservatively, whether they occur in the lumbar or the cervical region of the spine. The experience of each passing year has further convinced us of the soundness of this policy.

The presence of a severe neurological deficit, of course, completely alters the picture and furnishes a positive indication for immediate surgical intervention. Such deficits include signs and symptoms of cervical cord compression of any degree and severe weakness and atrophy of muscles of the arms, shoulder girdle, or both. We operate at once when this clinical picture presents itself, either totally or in part. We do not regard radicular pain and numbness and paresthesia in the arm, hand, or both, whether or not they are associated with disturbed tendon reflexes, as indications for surgical intervention until conservative management has proved futile.

CONSERVATIVE MANAGEMENT

Traction, applied in one form or another, is the mainstay of the conservative management of lesions of the cervical disk. It must be emphasized, however, that this form of treatment is only as good as the exacting care with which it is applied and supervised.

The first step in its efficient application is to hospitalize the patient. It is scarcely ever possible to work out an efficient initial routine in the patient's home. To get the maximum benefits from traction, it is essential that he remain in bed from 5 to 7 days and that during this time he be taught the principles of management of the rather complicated apparatus which must be employed. Once he has learned these principles, it is frequently—though not always—possible for him to set up a satisfactory routine in the environment of his own home, so that mild recurrences of symptoms do not necessitate a return to the hospital.

Technical considerations

The use of the head halter is the simplest method of applying cervical traction, which is often entirely satisfactory. The most efficient of the several available methods is unquestionably the application of skeletal traction by the use of Crutchfield tongs. This is the method preferred by many experienced neurosurgeons. This technique, however, requires a surgical incision in the scalp, with insertion of the points of the tongs into the outer table of the skull, and the risk of infection and necrosis is too real to warrant its routine use.

No matter what method of traction is used, a

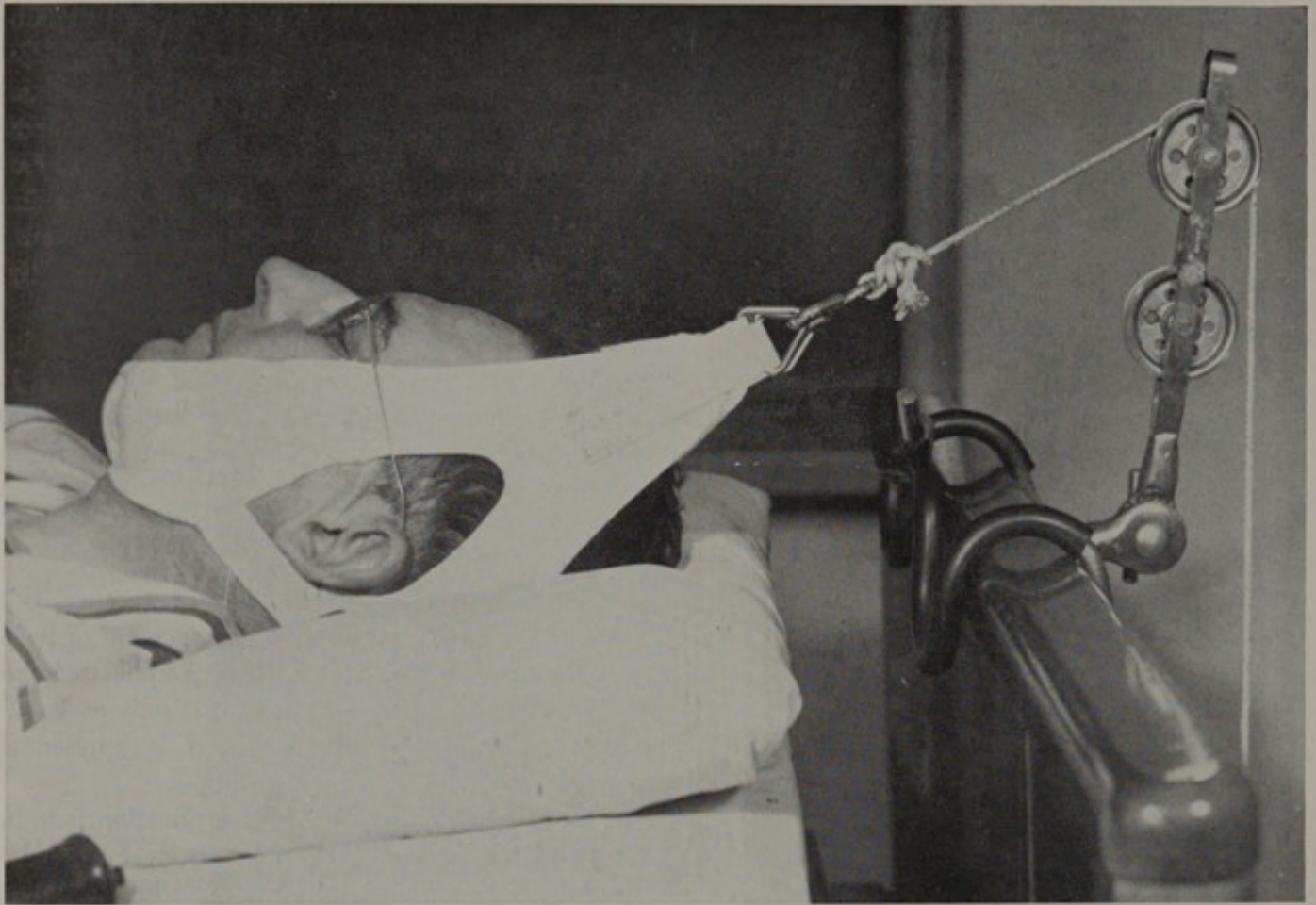


FIGURE 200.—Patient with ruptured cervical disk in halter traction. Note adjustment of collar and pulleys, so that pull is equally distributed between chin and occiput.

fundamental principle of its application is that the pull be in a straight line with the axis of the spine, so that all parts of the intervertebral joints are evenly separated.

Most patients, provided that the apparatus is properly adjusted, tolerate halter traction applied in the horizontal position remarkably well. For a number of years we have been using the Forrester head type of traction collar, which has a number of advantages. It is easily adjusted and is highly efficient. It is inexpensive. It washes readily. Finally, it comes in three sizes.

The criterion of successful halter traction depends upon equal distribution of the pull between the chin and the occiput. When this balance has been achieved, there is minimum discomfort at the points of traction. This equal distribution, however, can be accomplished only by careful adjustment of the pulleys carrying the traction cord and the lateral straps of the head collar (fig. 200). The adjust-

ment requires the attention of the surgeon. It is not a task for the nursing staff.

Once the traction is in proper balance, the patient immediately recognizes the correct feel and soon learns to make his own correction of a faulty pull. The amount of weight used varies with the size and muscular development of each patient. As a rule, 6 pounds is the minimum and 12 pounds the maximum.

An inflexible routine should be established for every patient. This is essential. Satisfactory results can be accomplished only by the full cooperation of the patient with the nursing staff. Our own routine is as follows:

1. Traction is applied uninterruptedly for 2 hours, then is released for an hour, and then is reapplied.
2. It is disconnected at night (for 8 hours), while the patient is asleep.
3. During the first 48 hours of traction therapy, the patient is encouraged to remain completely bed-

fast, without even lifting his head. This is highly desirable but is not always possible.

4. If the pain and discomfort are promptly relieved with the application of traction, the patient is allowed bathroom privileges on the third day and thereafter. Otherwise, the original routine is continued for a minimum of 7 days, and preferably for 10 days.

5. The original routine of 2 hours in traction and 1 hour out of traction must be continued as long as the patient is hospitalized. It is usually a matter of only a few hours before he is convinced of the value of this form of treatment. As a consequence, he is often tempted to overdo the periods of traction, with the invariable result that the skin of the chin and cheeks becomes chafed and treatment is retarded for the next several days.

6. Attention to a few simple details of nursing care contributes to the comfort of the patient as well as to the success of traction therapy, as follows:

a. The bed must be comfortable but also must be firm; the two requirements are perfectly compatible. The use of an innerspring or foam rubber mattress, with bedboards between the mattress and the springs, provides a flat surface which is perfectly comfortable.

b. The bed must be made up so that the patient can lie with his head at the foot. It is almost impossible to attach the traction apparatus to the head of the ordinary hospital bed.

c. A small, soft pillow (about a quarter the size of a regular pillow) is placed under the neck and helps to maintain both head and neck in the correct position.

d. Protective rubber sheets are not used unless the patient is incontinent.

e. If the collar irritates the skin of the chin, small strips of foam rubber are placed at the traction point, and a soothing lotion is applied whenever the traction is not in use.

f. The sheets should be kept free of wrinkles. This simple precaution adds greatly to the comfort of a patient in traction.

g. Alcohol back rubs are given morning and night. One of the major complaints of every patient in traction is lumbar backache, which is probably to be explained by the long periods necessarily spent recumbent.

h. During the period that the patient is entirely bedfast, which means for the first 48 hours at least, his feeding must be the business of the nursing staff.

We have found that the use of one of the muscle relaxants promotes more efficient skeletal traction and adds considerably to the patient's comfort.

SURGICAL MANAGEMENT

If a spinal cord deficit exists, surgical intervention, as already mentioned, is essential and urgent. In all other cases, the emotional stability of the patient must be established before operation is recommended. A patient with a functional overlay should be advised to continue with conservative treatment. Patients with functional nervous disorders, such as psychoneuroses, neuroses, or hysteria, should be operated on as a last resort, and then only when unequivocal neurological deficits are present.

Technique

Position.—In spite of our recognition of certain dangers inherent in the upright position during operations on the cervical spine (fig. 201), we prefer to employ it, using, at the same time, great care in all details to minimize these dangers. The most serious complication encountered in this position is air embolism. We are aware of a number of deaths which have occurred from it, but during the 10 years we have employed the upright position routinely for operations on the cervical spine and the posterior fossa of the skull, we have encountered no serious complications of any sort.

The greatest care is employed through the operation to secure hemostasis, particularly when the extradural veins are disturbed, as they must be during any operation upon the cervical intervertebral disks. Venous bleeding is best controlled by the application of small pieces of Gelfoam to the bleeding point. If anything more efficient is required for hemostasis, we prefer to use tantalum clips, since the electrocautery is a dangerous instrument to use on extradural spinal veins.

Syncope is another possible complication of the upright position. We have encountered it on only three occasions, in none of which it proved serious. The possibility can be materially reduced by wrapping the patient's legs with elastic bandages and ap-

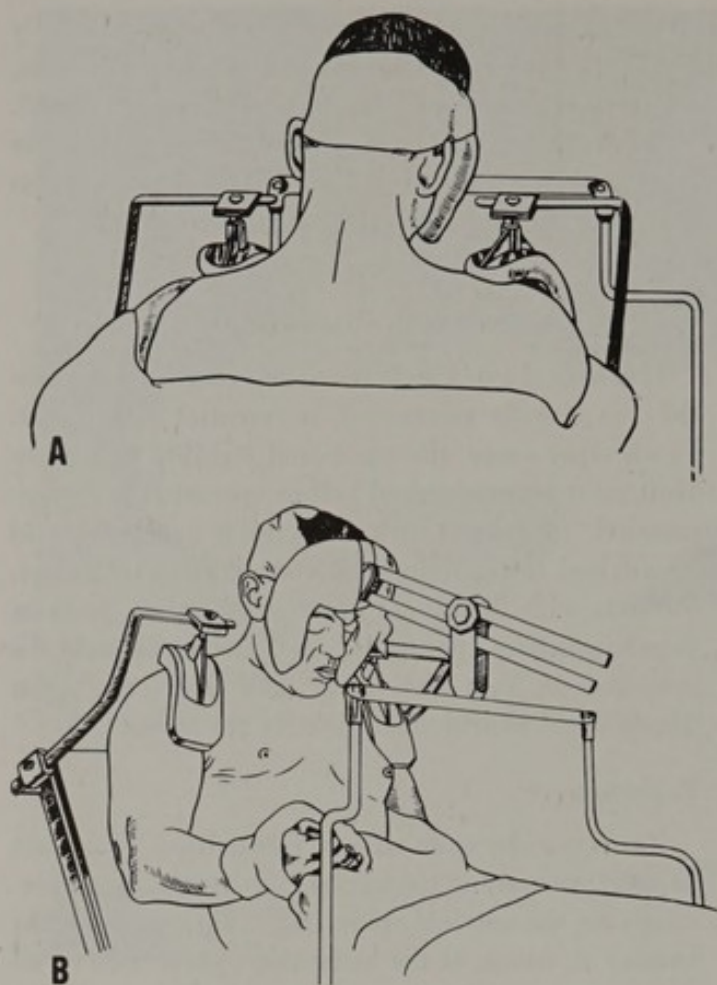


FIGURE 201.—Patient in upright position, ready for operation on cervical disk (lower cervical hemilaminectomy). A. Posterior view. Line of operative incision. B. Oblique view. The headrest employed in this technique was devised by Winchell McK. Craig, M.D., of the Mayo Clinic, Rochester, Minn.

plying an abdominal pressure bandage before the operation is begun.

Anesthesia.—The anesthesia of choice is a mixture of nitrous oxide and oxygen; induction is accomplished with the use of intravenous thiopental sodium (Pentothal sodium). The endotracheal technique is used, again with full recognition of its dangers. Our anesthesiologists are thoroughly familiar with the possible risk of inserting an endotracheal tube in a patient with a disk lesion, and they avoid any unnecessary manipulations of the neck, especially hyperextension, while accomplishing this procedure. We prefer this form of anesthesia because it permits better observation of the vital signs under all circumstances.

Determination of the level of spinal involvement.—Determination of the level of the spine at

which the pathological process lies is one of the major problems of surgery on cervical intervertebral disks. The bony landmarks, particularly bifid spinous processes, are not reliable guides. Accurate orientation is possible by the making of lateral roentgenograms after the soft tissue wound is open, with the tip of a thumb forceps or a metal probe placed on the suspected interspace (fig. 202). The film is readily made and the 5 minutes which it takes to process it is time well spent.

Surgical approach.—Laterally placed lesions of the intervertebral disks require an entirely different operative approach from the approach used in lesions which primarily affect the midline. Lateral lesions are easily dealt with through a unilateral approach and only a minimal amount of the laminae above and below the lesion need be removed. To deal satisfactorily with midline lesions requires a conventional cervical laminectomy, with removal of all the laminae of the spinous processes above and below the level of the lesion.

Unilateral approach.—The steps of this procedure are as follows:

1. The skin incision is made longitudinally, in the midline, with its center at the site of the suspected disk lesion.
2. A linear incision is made in the deep fascia, about half a centimeter lateral to the spinous processes. Leaving a good attachment of fascia to the spinous processes greatly simplifies wound closure.
3. The muscular attachments are dissected free and the paravertebral muscles are retracted laterally with a hand retractor (fig. 203).
4. A partial hemilaminectomy is then accomplished above and below the level of the involved root, with removal of the bony rim of the intervertebral foramen. Small rongeurs and a nasal punch are used, and great care is taken throughout this stage of the procedure to secure perfect hemostasis.
5. Most of the lateral extensions of the ligamentum flavum will have remained intact during the removal of the bone. When it is excised, the entire nerve root, with its covering of dura mater, will be exposed, the exposure extending from the intraspinal origin of the nerve to its entrance into the fascial planes of the neck.
6. The disk lesion usually presents itself immediately anterior to the nerve root. To expose it, the root must be gently retracted.

7. Once the mass is exposed, its characteristics can usually be determined by palpation with a blunt instrument. If it is stony hard, no attempt should be made to remove it, for two reasons: The first is that trauma to the nerve root by the chiseled dissection necessary in these circumstances probably does more harm than good. The second reason is that experience has shown that decompression of the root gives very satisfactory results in hard lesions.

8. If the mass is soft, an incision is made in the capsule and all the loose nucleus pulposus and fragmented annulus fibrosus are removed piecemeal with blunt forceps. Contrary to our practice in operations on lumbar disks, we do not attempt to enter the cervical intervertebral space for removal of additional disk substance which may be present in it. The amount of material removed varies con-

siderably from case to case. Occasionally, a fairly large mass is found, deforming not only the nerve root but also the lateral recess of the dural sac. In such circumstances, the specimen may consist of fragmented disk material as large as a red cherry. Ordinarily, however, the mass is considerably smaller and consists of nothing more than a few strands of dehydrated nucleus pulposus. In occasional cases in which the mass is particularly large, evacuation can be more readily accomplished by a lateral transdural approach, but in most instances, soft disks can be removed completely by leaving the dura mater intact.

9. The wound is closed in layers, with interrupted black silk sutures.

Two separate unilateral approaches are used in cases of bilateral pain in the arms caused by the presence of osteophytes on both anterior margins of the intervertebral foramina. This technique avoids sacrifice of spinous processes and of all the laminae in the region of the lesion, which would otherwise be necessary. It gives equally satisfactory end results. The period of disability is shorter. The cosmetic effect is also superior because dimpling of the wound, inevitable when the spinous processes are removed, does not occur.

This approach, however, must not be employed unless either clinical or myelographic examination has excluded midline involvement.

Bilateral approach.—Bilateral laminectomy is necessary in midline disk lesions with spinal cord deficit, whether or not radicular pain is associated. The spinous processes and the laminae are removed above and below the level of the lesion, the entire posterior aspect of the spinal canal thus being exposed.

A midline incision is made in the dura mater, and the spinal cord, after it is carefully inspected, is gently retracted to one side, to expose the dentate ligament. After the ligament has been cut and the cord has been retracted, the anterior dural space can be inspected.

The bulging disk lesion will at once be apparent and can be palpated with a blunt instrument to determine its consistency and resiliency. If it is stony hard, the lesion is the typical mass of bone and fibrocartilage commonly associated with cervical spondylosis. If it is soft and resilient to pressure, it probably represents the typical herniated nucleus

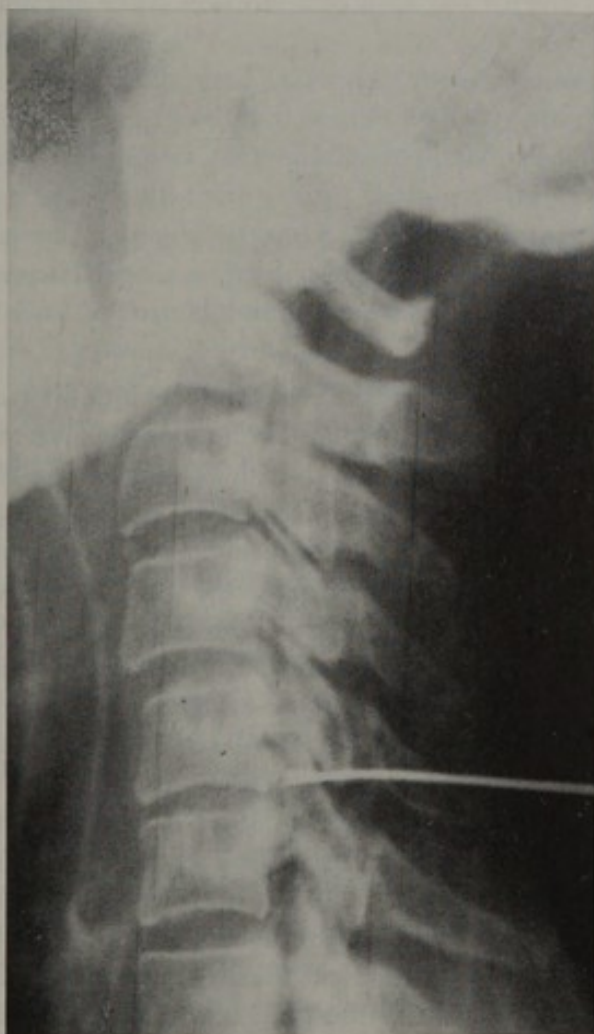

FIGURE 202.—Roentgenogram taken at operating table to verify correct level of exposure. Note point of metal probe, the position of which indicates, unmistakably, the C5-C6 interspace.

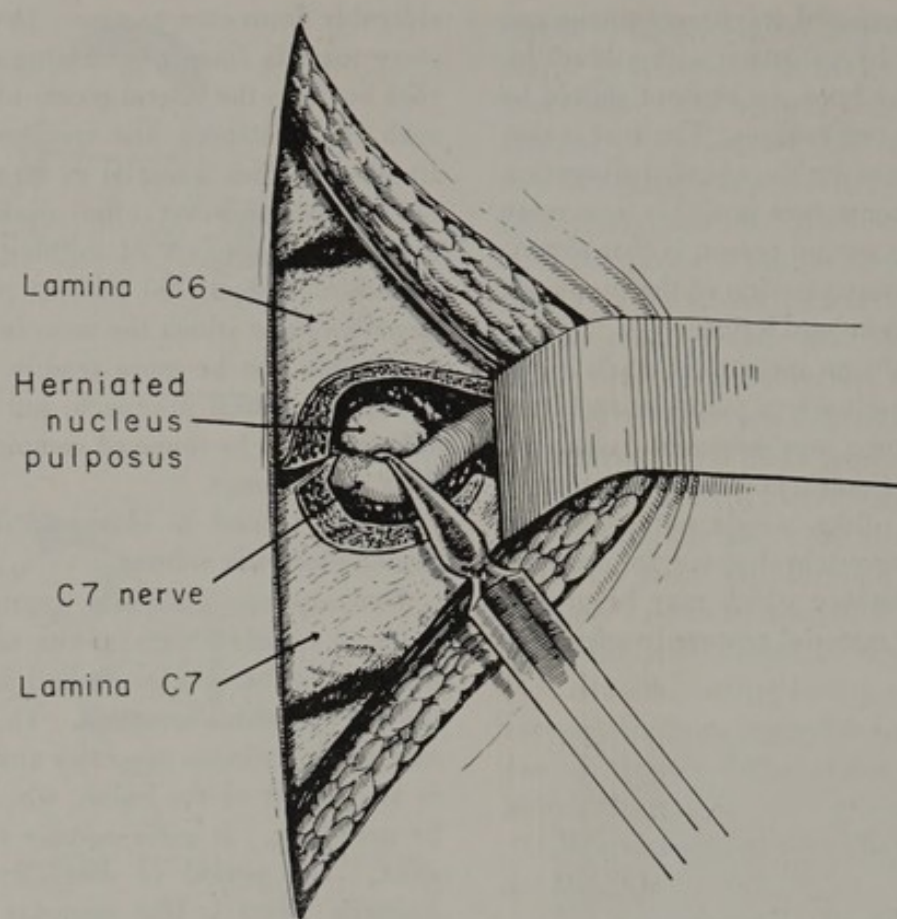


FIGURE 203.—Diagrammatic representation of operative field at operation for ruptured cervical disk at C6-C7 level. The seventh cervical nerve root has been thoroughly decompressed and retracted downward to expose a lateral ruptured disk.

pulposus which occurs after posterior rupture of the annulus fibrosus.

When clinical evidence, roentgenograms and myelograms indicate involvement at multiple levels, the same procedure is carried out at each pathological level.

When the mass is soft and resilient, incision of the anterior dural covering usually results in prompt extrusion of disk material; whatever is not extruded spontaneously can be removed by gentle, piecemeal dissection. No attempt should be made to enter the disk for complete curettement, as is customary in operations on the lumbar disk. If there is still some backward bulging of the dura mater after all free disk material is removed, the two dentate ligaments above and the two below the lesion on each side of the spinal cord should be divided to provide for intradural decompression.

If the mass is hard and has no resiliency when it is palpated with an exploring instrument, the operation should be limited to intradural and extradural

decompression according to the technique of Kahn (14). No attempt should be made to remove these bony bars surgically, even if there is only one present. Any such attempt, as most experienced neurosurgeons will testify, simply invites the disaster of cord damage. Furthermore, the simple and safe procedure of cervical decompression yields very satisfactory results if operation is undertaken before irreversible changes in the cord have occurred.

Kahn's explanation of the role of the dentate ligaments in anterior extradural spinal masses, with his discussion of the mechanism of intradural and extradural decompression, is, in my opinion, the most important contribution to the subject of the cervical intervertebral disk since Stookey's (15) classical description of the clinical features of this entity.

If, in addition to the presence of an intraspinal bar, the intervertebral foramina are grossly narrowed by osteophytes, careful root decompression, according to the technique employed in the unilateral approach, should be combined with spinal cord de-

compression. When the combined procedure is necessary, it is best to remove all bone and ligamentum flavum before the dura mater is opened.

POSTOPERATIVE MANAGEMENT

As might be expected, different routines of postoperative management are required for the different types of operation just described for the treatment of lesions of the cervical intervertebral disk.

Unilateral laminectomy

When unilateral laminectomy is employed, for laterally placed disk lesions, no special postoperative precautions are necessary. Ambulation is permitted as soon as is desired, and the patient is usually fully ambulatory after the first day. Skin sutures are removed on the fifth postoperative day, and the usual hospital stay does not exceed 7 to 10 days.

Pain in the arm is almost always improved, if not completely relieved, within 24 hours after operation. The neck, as would be expected, remains stiff and sore until there is firm healing of the operative wound. Numbness and paresthesia may persist for several weeks. Tendon reflexes may or may not return to normal, but permanent loss of a tendon reflex is consistent with complete clinical recovery.

Most patients are able to return to sedentary work within 2 weeks after operation and to heavy activity within 4 to 5 weeks.

Bilateral laminectomy

The postoperative management of a patient submitted to bilateral laminectomy which is employed for midline disk lesions, particularly those associated with spondylosis, depends upon his physical state before operation. If there are no preoperative symptoms of spinal cord compression, the postoperative routine is essentially the same as the routine after unilateral laminectomy. Patients who require bilateral laminectomy are, however, usually paraplegic to some degree, because of preoperative compression of the spinal cord. The degree of preoperative helplessness determines the salient features of postoperative care.

If sphincteric involvement has been present before operation, it is usually worse for the first few days of the postoperative period. An indwelling catheter

is the simplest and best solution of this problem, though exacting urological care is required to prevent ascending infection of the genitourinary tract.

The care of the skin on pressure points is, as always, of prime importance in paraplegic patients. The position in bed must be shifted every 2 hours, day and night. The skin at pressure points must be kept clean and dry. We are now employing foam rubber mattresses, in preference to the air or water mattresses formerly used.

Improvement of neurological signs, both motor and sensory, is usually manifested within 24 hours after operation. Relief is sometimes reported soon after the patient rouses from the anesthetic. Progressive improvement can be expected to continue for at least 6 months, no matter how long paraplegic symptoms may have been present.

After the first 12 hours, when careful observation is necessary to exclude bleeding, the neck requires no special attention. As soon as the patient can move about in bed without pain, he is allowed to sit upright in bed, or in a chair if he prefers, and to bear the full weight of his head. When cord damage has been minimal, ambulation is permitted within 3 to 5 days after operation.

Pain in the neck may be severe for the first day or two after operation, but pain is never the problem which it sometimes is after abdominal surgery. If pain is unusually severe, it is well for the first few days to immobilize the neck with sandbags after each change of position.

Most patients require no support for the neck after bilateral laminectomy, though occasionally a molded leather collar or similar support is useful if severe pain continues.

Theoretically, it would seem that such an extensive operative procedure upon the cervical spine as is required for spondylosis should leave the patient with an unstable neck, with considerable limitation of motion. Actually, since these operations are, for the most part, done in the lower cervical region, disability is surprisingly slight. The range of motion, once wound healing has occurred, is practically normal and we have never observed postoperative dislocation of vertebrae. There are two explanations for these good results: The first is that in most of these cases the articular facets have not been disturbed during operation and the danger of dislocation is therefore very materially decreased. The

second explanation is that in spondylosis, for which most bilateral laminectomies are performed, partial bony fusion has already been accomplished by the formation of spurs and osteophytes on the edges of the involved vertebrae.

REFERENCES

1. Stookey, B.: Compression of the Spinal Cord Due to Ventral Extradural Cervical Chondromas; Diagnosis and Surgical Treatment. *Arch. Neurol. & Psychiat.* 20: 275-291, August 1928.
2. Barnes, R.: Paraplegia in Cervical Spine Injuries. *J. Bone & Joint Surg.* 30B: 234-244, May 1948.
3. Brain, W. R., Knight, G. C., and Bull, J. W. D.: Discussion on Rupture of the Intervertebral Disc in the Cervical Region. *Proc. Roy. Soc. Med.* 41: 509-516, August 1948.
4. Davis, C. H., Jr., Odom, G. L., and Woodhall, B.: Survey of Ruptured Intervertebral Disks in the Cervical Region. *North Carolina M.J.* 14: 61-66, February 1953.
5. Spurling, R. G., and Scoville, W. B.: Lateral Rupture of Cervical Intervertebral Discs; A Common Cause of Shoulder and Arm Pain. *Surg. Gynec. & Obst.* 78: 350-358, April 1944.
6. Brain, W. R., Northfield, D., and Wilkinson, M.: Neurological Manifestations of Cervical Spondylosis. *Brain* 75: 187-225, June 1952.
7. Bucy, P. C., Heimburger, R. F., and Oberhill, H. R.: Compression of the Cervical Spinal Cord by Herniated Intervertebral Discs. *J. Neurosurg.* 5: 471-492, September 1948.
8. Barré, J. A.: Le syndrome sympathique cervical postérieur. *Rev. neurol.* 33: 248-249, 1926.
9. Raney, A. A., and Raney, R. B.: Facial Neuralgia and Headache. *Ann. West. Med. & Surg.* 2: 169-175, April 1948.
10. Raney, A. A., Raney R. B., and Hunter, C. R.: Chronic Posttraumatic Headache and the Syndrome of Cervical Disc Lesion Following Head Trauma. *J. Neurosurg.* 6: 458-465, November 1949.
11. Schmorl, G.: Zur Kenntnis der Wirbelkörperperiphyse und der an ihr vorkommenden Verletzungen. *Arch. f. klin. Chir.* 153: 35-45, 1928.
12. Klippel, M., and Feil, A.: Un cas d'absence des vertèbres cervicales, avec cage thoracique remontant jusqu'à la base du crane (cage thoracique cervicale). *Nouvelle iconographie de la salpêtrière* 25: 223-250, 1912.
13. Sprengel, D.: Die angeborene Verschiebung des Schulterblattes nach oben. *Arch. f. klin. Chir. Berl.* 42: 545-549, 1891.
14. Kahn, E. A.: The Role of the Dentate Ligaments in Spinal Cord Compression and Syndrome of Lateral Sclerosis. *J. Neurosurg.* 4: 191-199, May 1947.
15. Stookey, B.: Compression of Spinal Cord and Nerve Roots by Herniation of the Nucleus Pulposus in the Cervical Region. *Arch. Surg.* 40: 417-432, March 1940.

CHAPTER 41

Thoracic Disk

Arnold M. Meirowsky

Compared with the widespread attention which has been given to disk problems in the cervical and lumbar regions, herniation of the thoracic intervertebral disk has only received scant recognition. Love and Kiefer's analysis (1) of 17 thoracic disks which were verified by operation at the Mayo Clinic, Rochester, Minn., during the period from 1922 to 1948, represents the first detailed study of the syndrome of the herniated disk in the thoracic region. In 1945, Bradford and Spurling (2) reported an instance of thoracic disk pressure resulting in paralysis. In 1946, Young (3) reported four cases with thoracic disk pathology. More recent discussions of the thoracic herniated disk syndrome by Epstein (4), Abbott and Retter (5), Kite, Whitfield, and Campbell (6), and Peck (7) have served to clarify some of the problems which this syndrome presents. Kite, Whitfield, and Campbell point out that a single well-defined syndrome, such as one sees with the herniation of a cervical or a lumbar disk, is not the rule. They conclude that—

Compression of the spinal cord appears to be much more frequent with herniation in the thoracic than in the cervical spine, so that early diagnosis and early removal of this compression is more imperative with a thoracic disc than with one in any other location. The urgency of early removal is made even greater by the fact that, whereas benign cord tumors produce slowly increasing compression with relatively good recovery following removal, the thoracic disc is subject to sudden additional herniation or extrusion subsequent to the onset of the disease.

To facilitate diagnosis, it is helpful to recognize that herniation of the nucleus pulposus in the thoracic region may produce radicular symptomatology only, it may produce radicular impairment in conjunction with cord compression and, in isolated in-

stances of central herniation, it may produce myelopathy without radicular symptomatology. The variation in signs and symptoms which the herniated thoracic disk may produce can readily be explained by its topography.

While reports in the medical literature emphasize the relative frequency of central and posterolateral herniation with resulting myelopathy, often preceded by inconstant radicular symptomatology, lateral herniation of the thoracic disk, productive of radiculopathy only, escapes recognition more readily.

In an attempt to delineate the symptomatology, Abbott and Retter have divided thoracic disk pathology into three separate entities. In the first group, they have placed those herniated thoracic disks which are productive of long-tract signs with pain and dysesthesia in the back and lower extremities due to central compression of the cord cephalad to the conus medullaris. The second group is characterized by pain in the back and lower extremities with loss of sphincter control, motor weakness in sacral and lumbar segments, and saddle anesthesia with subsequent involvement of lumbar segments. This syndrome is produced by central protrusion of a nucleus pulposus in the region of the T11 or T12 interspaces. The third group comprises all laterally herniated disks producing radicular pain and corresponding dermatome changes.

From a practical point of view, it may suffice to classify thoracic disk pathology into two distinct groups: (1) Central or central and posterolateral herniation of the nucleus pulposus with resulting myelopathy of varying degree, and (2) lateral herniation of the nucleus pulposus with resulting unilateral radiculopathy.

The predominance of long-tract impairment producing progressive paraparesis points toward central herniation of a thoracic disk. Coinciding unilateral root pain and dermatome sensory changes at the corresponding level would suggest central and posterolateral herniation of a thoracic disk. Bilateral root pain may be produced by a central herniation dislodging the dural sac posteriorly and putting traction on the posterior roots. Such bilateral radiculopathy manifests itself usually by hyperalgesia and dysesthesia in the corresponding dermatomes. The presence of hypalgesia and hypesthesia usually indicates actual root compression. Even though there may not be any history of impairment of micturition, a high residual urine commonly occurs in the presence of central and posterolateral disk herniation.

In the differential diagnosis, neoplastic disease within the spinal canal has to be considered foremost. More often than not, a definitive diagnosis cannot be established on clinical grounds. Roentgenograms may or may not show calcification at the involved interspace. A mild, old compression fracture at site of symptomatology, which may have been considered clinically insignificant, helps in the establishment of thoracic disk diagnosis. This was the case in one of our patients (N-2216) in whom root pain could be reproduced or intensified by percussion of the T6 spinous process. Roentgenograms revealed a mild, old compression fracture at that level. Operation was performed without preceding myelography. Removal of the herniated nucleus pulposus at T6-T7 interspace produced complete relief of symptoms. As a rule, however, myelography with 12 cc. of Pantopaque is necessary in order to set forth the indications for neurosurgical intervention. While the indications for surgery can be readily made on clinical and roentgenological grounds, it is not always possible to differentiate between tumor and disk before operation.

In the presence of a central or central and posterolateral thoracic disk herniation, bilateral laminectomy of the lamina cephalad and of the lamina caudad to the diseased interspace is indicated. Opening of the dura permits visualization of cord, nerve roots, and vessels during the extradural excision of the herniated disk. Kahn (8) has demonstrated the value of section of the dentate ligaments in the presence of cord compression. Bilateral posterior foram-

inotomy should be done routinely after the protruding disk has been excised. If the entire protrusion is represented by a hard disk, decompression by laminectomy, section of dentate ligaments, and foraminotomy usually suffice to relieve symptoms.

The root compression syndrome which is produced by lateral herniation of the disk is well defined. The pain is unilateral, limited to one or two dermatomes, and occurs usually in paroxysms. It is described as a "sharpshooting," "cutting," and "stinging" pain. It is frequently intensified by coughing and straining. Neck or trunk flexion, or any other movements that have a stretching effect on the meninges, may accentuate or reproduce the pain. While lateral herniation of a thoracic intervertebral disk is not an uncommon occurrence, it is not as readily diagnosed as might be expected. The classical and well-defined signs and symptoms of lateral herniation of a thoracic disk are often interpreted as intercostal neuralgia. Visceral or intrathoracic disease (5) enters into the differential diagnosis. More often than not, the diagnosis of psychoneurosis is made falsely without the benefit of neurosurgical studies.

Examination usually reveals point tenderness over the diseased interspace. Percussion of the corresponding spinous process or of a point 1 cm. laterally to the interspace reproduces or intensifies almost always the existing root pain. Changes in sensory perception in the corresponding dermatome occurs invariably. They may consist of hyperalgesia and dysesthesia or hypalgesia and hypesthesia. Spasms of the paraspinal musculature are always present. The paucity of clinical signs despite clearly defined symptoms may account for the infrequency with which the diagnosis is made.

The establishment of a definitive diagnosis of lateral thoracic disk herniation depends on Pantopaque myelography.

That the symptomatology caused by lateral herniation of a thoracic intervertebral disk may remain limited to a single root compression syndrome is illustrated by the story of N-1839, as follows:

On 1 August 1958, this 34-year-old office manager was seized by extremely severe shooting pain in the left thoracolumbar region radiating anteriorly around the chest wall, while reaching up with his left arm to pull a drawer out of a filing cabinet. The pain remained persistent and was intensified by movements of the trunk, anteflexion of the head, coughing, sneezing, and straining. Movements of the trunk,

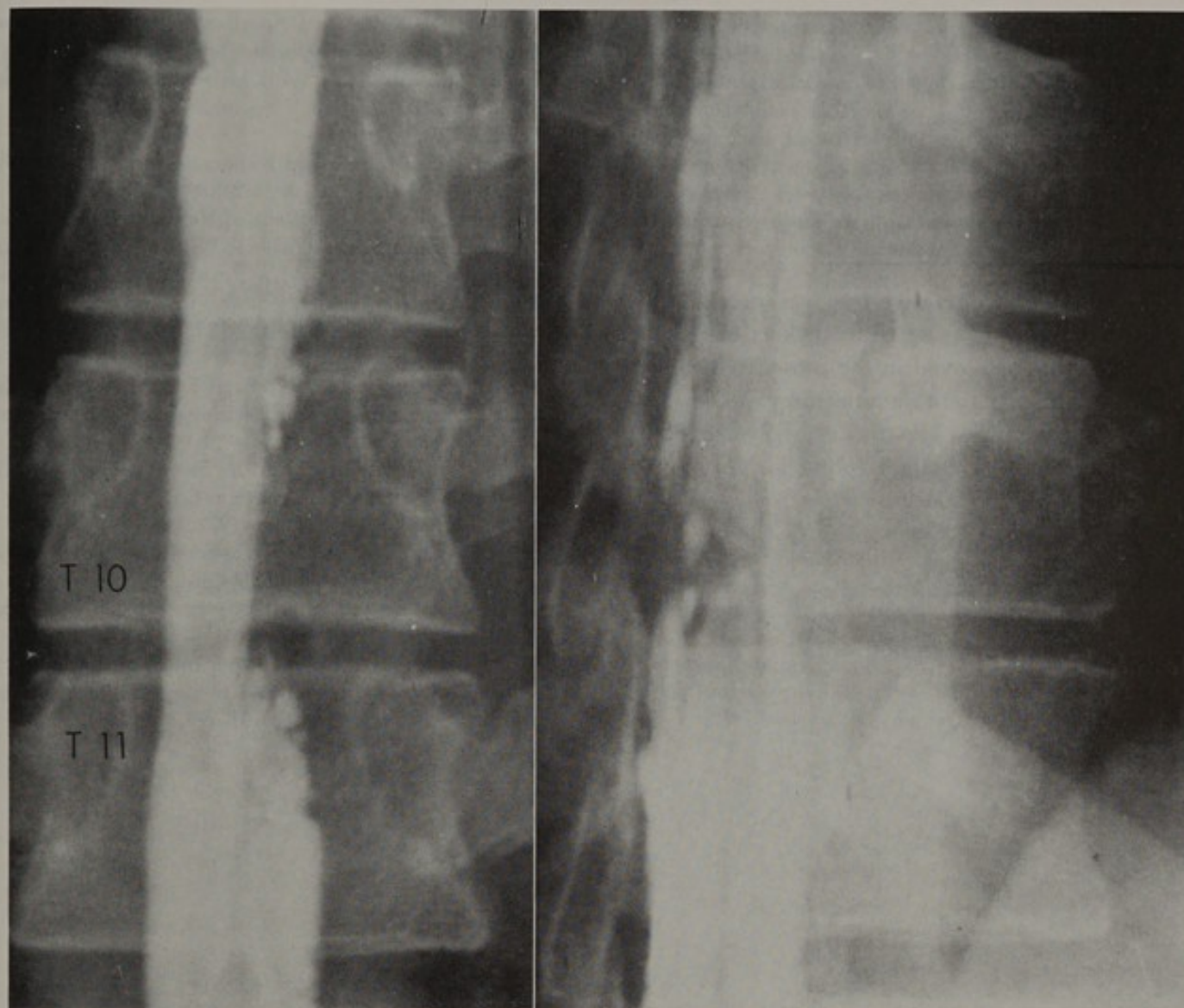


FIGURE 204.—N-1839. Frontal and lateral Pantopaque myelograms showing well-defined defect opposite the T10-T11 interspace on the left.

walking, and simple changes of position intensified the pain to such an extent as to fully disable the patient.

The patient related two similar episodes: Fourteen years prior to the present attack when filing papers into the bottom drawer of a cabinet, he was seized by a pain which was identical in distribution and character. This pain was also disabling; however, it subsided spontaneously after 3 days. For 8 years, the patient remained entirely asymptomatic. Eight years ago, while playing basketball, he hit the ground and experienced a momentary pain in the same distribution. This pain subsided within minutes, only to recur after 3 days while patient was sitting at his desk and reaching up with his left arm to grab some papers. Again, the pain was identical in character and distribution to the present attack, but subsided spontaneously after 3 days.

This man was first seen and examined on 8 August, 6 days after onset of symptoms. He was in extreme pain, unwilling to make any unnecessary movements with head, neck,

or trunk. In putting this man through various maneuvers during the course of examination, he broke out in profuse sweat. Examination revealed an intelligent male, intent on cooperating, and showing no hypochondriacal tendencies. The paraspinal musculature in the thoracolumbar region was boardlike. Exquisite tenderness to palpation was limited to the spinous process of T10. Percussion of the T10 spinous process resulted in intensification of left radicular pain. Anteflexion of the head produced severe radicular pain. Anteflexion of the trunk was impossible because of radicular pain. Trunk rotation intensified the pain which was traveling around the left flank into the left abdominal region. The Naffziger test, as evidenced by increase of intensity of pain on bilateral jugular compression, was strongly positive. Sensory examination revealed hyperalgesia and hyperesthesia in the distribution of the left tenth and eleventh dermatomes. Roentgenograms of the thoracic spine failed to reveal any bony abnormalities.

Spinal fluid examination showed a total protein of 40 mg. percent. Pantopaque myelography revealed a well-defined defect in the dye column opposite the interspace of T10-T11 on the left (fig. 204). Thoracic laminectomy was performed on 8 August. A fully extruded disk was found in the extreme left lateral position between T10 and T11. It was excised. The patient was free from radicular pain upon awakening from anesthesia. He made an uneventful recovery and has been asymptomatic since operation.

The technique of operative removal of a laterally herniated thoracic intervertebral disk is essentially the same as that employed in the presence of a central herniation. Bilateral laminectomy, however, is not always necessary. The disk can be removed by hemilaminectomy. Unilateral posterior foraminotomy should always be done.

REFERENCES

1. Love, J. G., and Kiefer, E. J.: Root Pain and Paraplegia Due To Protrusions of Thoracic Intervertebral Disks. *J. Neurosurg.* 7: 62-69, January 1950.
2. Bradford, F. Keith, and Spurling, R. Glen: *The Intervertebral Disc With Special Reference to Rupture of the Annulus Fibrosus With Herniation of the Nucleus Pulposus.* 2d edition. Springfield, Ill.: Charles C Thomas, 1945.
3. Young, J. H.: Cervical and Thoracic Intervertebral Disc Disease. *M.J. Australia* 2: 833-838, 14 Dec. 1946.
4. Epstein, J. A.: The Syndrome of Herniation of the Lower Thoracic Intervertebral Discs With Nerve Root and Spinal Cord Compression; A Presentation of Four Cases With a Review of the Literature, Methods of Diagnosis and Treatment. *J. Neurosurg.* 11: 525-538, November 1954.
5. Abbott, K. H., and Retter, R. H.: Protrusions of Thoracic Intervertebral Disks. *Neurology* 6: 1-10, January 1956.
6. Kite, W. C., Jr., Whitfield, R. D., and Campbell, E.: The Thoracic Herniated Intervertebral Disc Syndrome. *J. Neurosurg.* 14: 61-67, January 1957.
7. Peck, F. C., Jr.: A Calcified Thoracic Intervertebral Disk With Herniation and Spinal Cord Compression in a Child; Case Report. *J. Neurosurg.* 14: 105-109, January 1957.
8. Kahn, E. A.: The Role of the Dentate Ligaments in Spinal Cord Compression and the Syndrome of Lateral Sclerosis. *J. Neurosurg.* 4: 191-199, May 1947.

TRAUMA OF PERIPHERAL NERVES

CHAPTER 42

Anatomy of Peripheral Nerves

Hugo V. Rizzoli

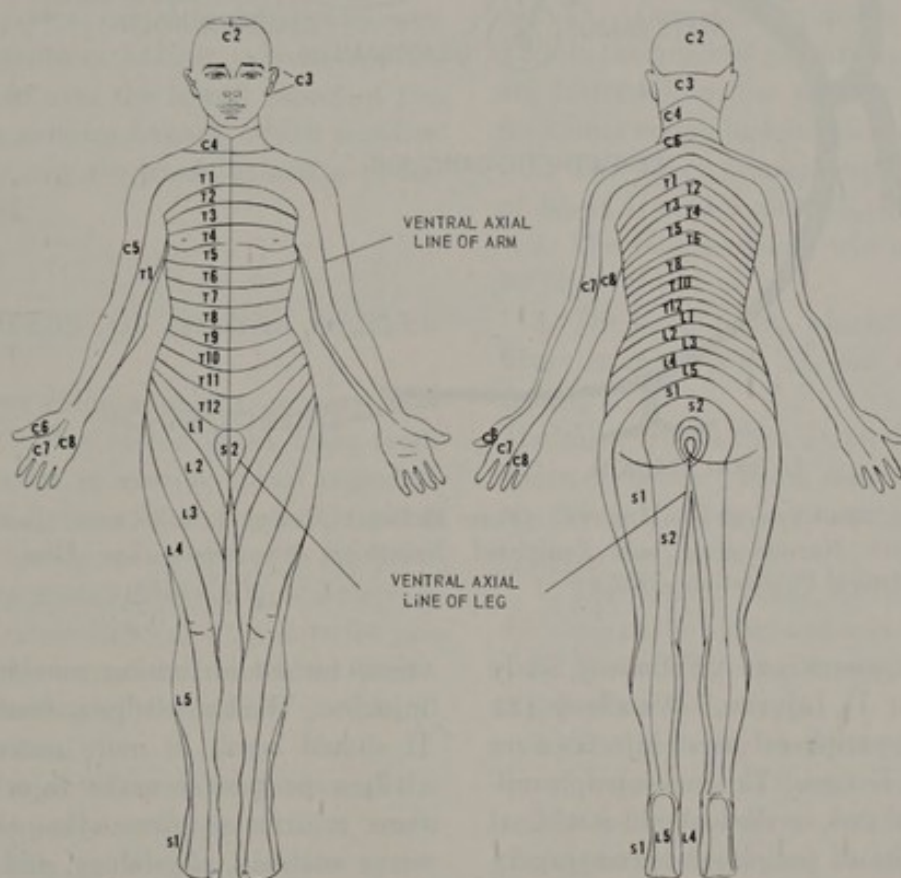


FIGURE 205.—Dermatome map. (From Keegan, J. J., and Garrett, F. D.: The Segmental Distribution of the Cutaneous Nerves in the Limbs of Man. *Anat. Rec.* 102: 409-437, December 1948.)

The high incidence of peripheral nerve wounds in warfare is well documented. In his monograph on nerve wounds, Tinel (1) stated, "Lesions of the nerve trunks in traumatism of the limbs cannot be estimated at less than 18 to 20 percent." During World War I, he encountered 639 cases of nerve injuries, two-thirds of which occurred in the upper

extremity, the remaining cases in the lower extremity. Thirty-six percent of the upper extremity nerve injuries he encountered involved the radial nerve. Unfortunately, long-term studies of nerve injuries incurred during World War I were not done.

In the Veterans' Administration monograph

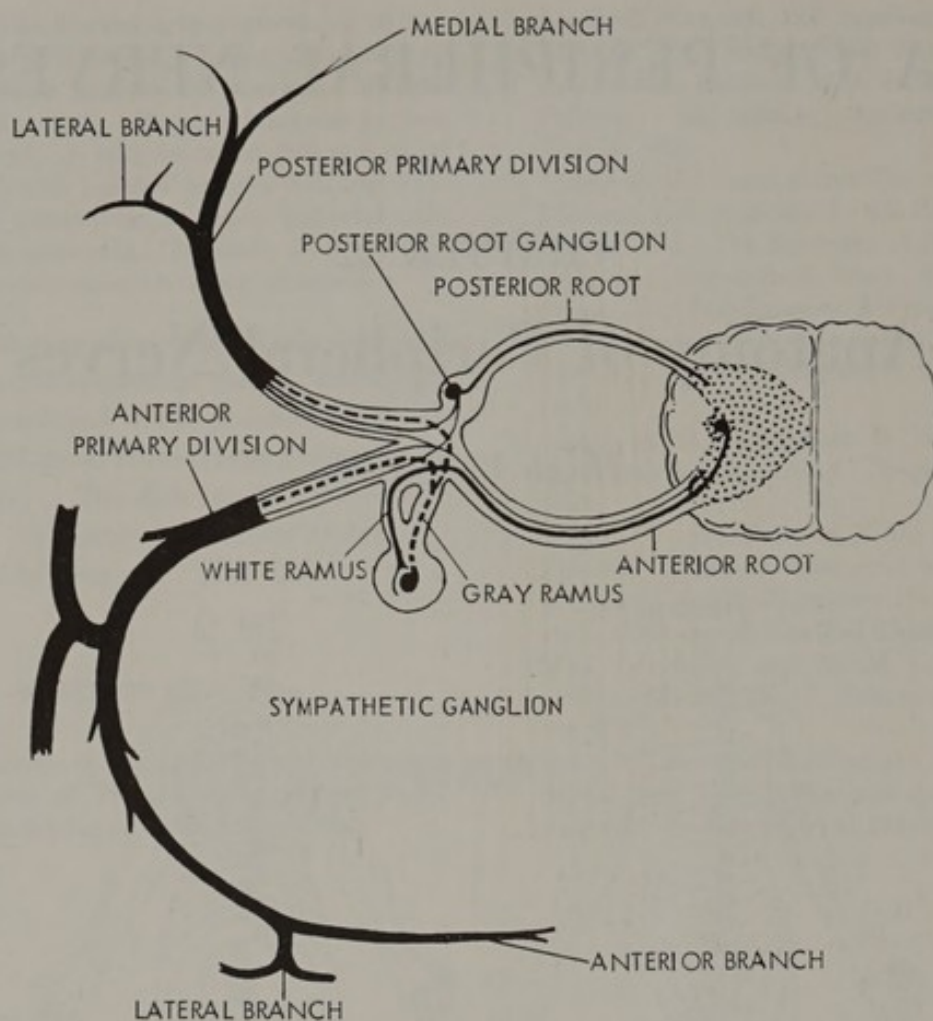


FIGURE 206.—Typical spinal nerve. (Form McDonald, Joseph J., and Chusid, Joseph G.: *Correlative Neuroanatomy and Functional Neurology*, 6th edition. Los Altos, Calif.: Lange Medical Publications, 1952.)

"Peripheral Nerve Regeneration: A Follow-up Study of 3,656 World War II Injuries," Woodhall (2) estimates that 40,000 peripheral nerve injuries were incurred by the U.S. Forces. This monograph represents a monumental task in clinical and statistical followup of the results of peripheral nerve surgery done during World War II. Conceived by Barnes Woodhall, the project started with the establishment, by The Surgeon General of the U.S. Army, of the Peripheral Nerve Registry in November 1944. About 1 year later, 7,050 nerve sutures and 67 nerve grafts had been registered. Later, the program was taken up by the Veterans' Administration and the National Research Council.

When compared with war wounds, peripheral nerve injuries in civilian life are relatively uncommon. However, widespread use of greater mechanical power in industry, travel, and other factors ac-

count for an increasing number of civilian nerve injuries. The knowledge gained during World War II should result in more successful treatment of civilian peripheral nerve injuries. Treatment of these injuries requires a knowledge of peripheral nerve anatomy, physiology, and pathology, and the ability to evaluate these lesions clinically. The examiner must determine whether surgery is necessary and, if so, at what stage it should be performed and what can be accomplished by it.

The peripheral nerves may be classified, according to their site of origin from the central nervous system, into two main groups: (1) Cranial nerves, those originating in the brain, and (2) spinal nerves, those originating in the spinal cord (fig. 205).

Each spinal nerve arises from the spinal cord by two roots, the posterior root (sensory) and the anterior root (motor). The 31 pairs of spinal nerves

originate from segments of the spinal cord as follows: Cervical, 8; thoracic, 12; lumbar, 5; sacral, 5; coccygeal, 1.

The typical spinal nerve (fig. 206), after it emerges from the intervertebral foramen, divides into the posterior primary division and the anterior primary division. The posterior primary division deals with the innervation of skin and the longitudinal muscles posteriorly situated. This, in turn, divides into a medial branch, usually sensory, and a lateral branch, which is mainly motor. The anterior primary division, the larger of the two divisions, forms the cervical, brachial, and lumbosacral plexuses. In the thoracic region, the anterior primary division of the intercostal spinal nerves divides into (1) the lateral cutaneous branch, which supplies sensation to the skin over the lateral aspect of the trunk, and (2) the anterior branch, which supplies sensation anteriorly over the trunk, as well as to the muscles of the trunk.

COMPONENT FIBERS OF SPINAL NERVES

Each spinal nerve contains motor, sensory, and sympathetic fibers. The motor fibers arise from the anterior horn cells in specific spinal segments and leave the cord by way of the anterior spinal roots, traveling within the spinal nerves to the skeletal muscles. Those motor fibers which innervate the muscles of the extremities enter the anterior primary divisions and by way of the brachial or lumbosacral plexuses reach the individual peripheral nerves of the extremities.

The sensory fibers, or afferent components of the spinal nerves, arise peripherally in various nerve endings and, traveling proximally with the motor fibers, leave the mixed spinal nerve via the posterior root, where the fibers join their cell bodies in the posterior root ganglion. After leaving the posterior root cell bodies, the fibers enter the spinal cord and ascend the spinal cord with the various afferent tracts.

The sympathetic fibers (efferent fibers) arise from cells in the lateral column of the spinal cord. The preganglionic sympathetic fibers enter the anterior spinal roots of nerves T1 and L2, leave each of these spinal nerves by way of the white ramus

communicans, and travel to the sympathetic ganglionated chain. Each segmental nerve receives postganglionic sympathetic fibers through a gray ramus communicans from the sympathetic ganglionated chain. These fibers then travel with the branches of the segmental nerves to innervate blood vessels and sweat glands in the sensory distribution of the specific segmental nerve.

THE BRACHIAL PLEXUS

The brachial plexus is formed by the anterior primary divisions of spinal nerves C5, C6, C7, C8, and T1. Occasionally, fibers derived from C4 or T2 join the brachial plexus (fig. 207). Three trunks are formed from the anterior primary divisions of the spinal nerves just mentioned:

1. The upper trunk, which is formed by union of fibers from C5 and C6, and occasionally C4.
2. The middle trunk, which is constituted solely by fibers of C7.
3. The lower trunk, which is formed by union of fibers from C8 and T1, and occasionally of fibers from T2.

The three trunks then divide into anterior and posterior divisions. From these divisions, three cords are formed. They are named by their relationship to the axillary artery:

1. The lateral cord, formed from the anterior divisions of the upper and middle trunks.
2. The medial cord, formed from the anterior division of the lower trunk.
3. The posterior cord, formed by union of posterior divisions of all three trunks.

The following nerves, which supply function to the upper extremity and shoulder girdle, arise from the brachial plexus.

A. Nerves arising from the roots:

1. Phrenic nerve, with some fibers arising from C5 and others arising from C3 and C4.
2. Dorsal scapular nerve (motor nerve to the rhomboid muscles), arising from C5.
3. Long thoracic nerve, arising from C5, C6, and C7, supplying the serratus anterior muscle.

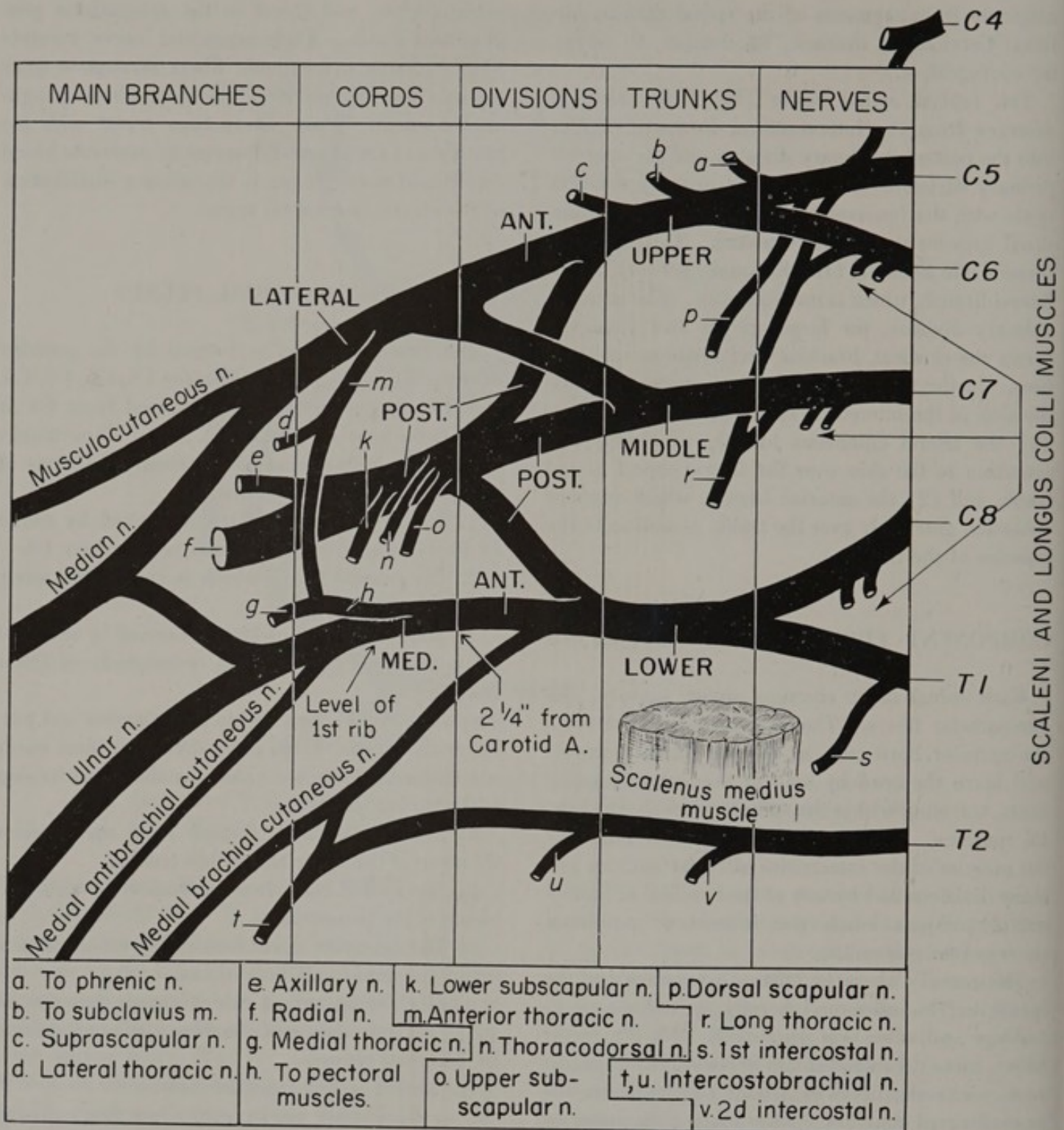


FIGURE 207.—Brachial plexus.

4. Motor branches, arising from C6, C7, and C8, supplying the scapular and longus colli muscles.

B. Nerves arising from the trunks:

1. Nerve supply to subclavius muscle, arising from the upper trunk.

2. Suprascapular nerves, arising from upper trunk, supplying the supraspinatus and infraspinatus muscles.

C. Nerves arising from the cords.

1. Lateral and medial thoracic nerves, arising from the lateral and medial cords,

respectively, and supplying the pectoralis major and minor muscles.

2. Subscapular nerves, arising from the posterior cord:
 - a. Upper subscapular nerve, supplying the subscapularis muscle.
 - b. Thoracodorsal nerve (middle subscapular nerve) supplying the latissimus dorsi muscle.
 - c. Lower subscapular nerve, supplying the teres major and subscapularis muscles.
3. Musculocutaneous nerve, arising from the lateral cord.
4. Median nerve, arising from fibers from the lateral and medial cords.
5. Axillary and radial nerves, arising from the posterior cord.
6. Ulnar nerve, arising from the medial cord.
7. Medial cutaneous nerve of the forearm (sensory supply to the medial surface of the forearm), arising from the medial cord.
8. Medial cutaneous nerve of the arm (sensory supply to the medial surface of the arm), arising from the medial cord.

Dorsal scapular nerve

The dorsal scapular nerve arises from the anterior primary division of the C5 root. It travels caudally behind the brachial plexus to the medial border of the scapula, where it innervates the rhomboid muscles and partially innervates the levator scapulae muscle. The rhomboid muscles adduct and rotate the scapula so the inferior angle moves medially.

MUSCLE TESTING

Rhomboidei.—The patient is asked to place his hand on his hip and to rotate his arm and shoulder backward against the examiner's resistance, applied to the patient's elbow (fig. 208). When function is normal, contraction of the rhomboid muscles can be palpated.

Long thoracic nerve (nerve of Bell)

The long thoracic nerve arises from the anterior primary divisions of C5, C6, and C7. It descends

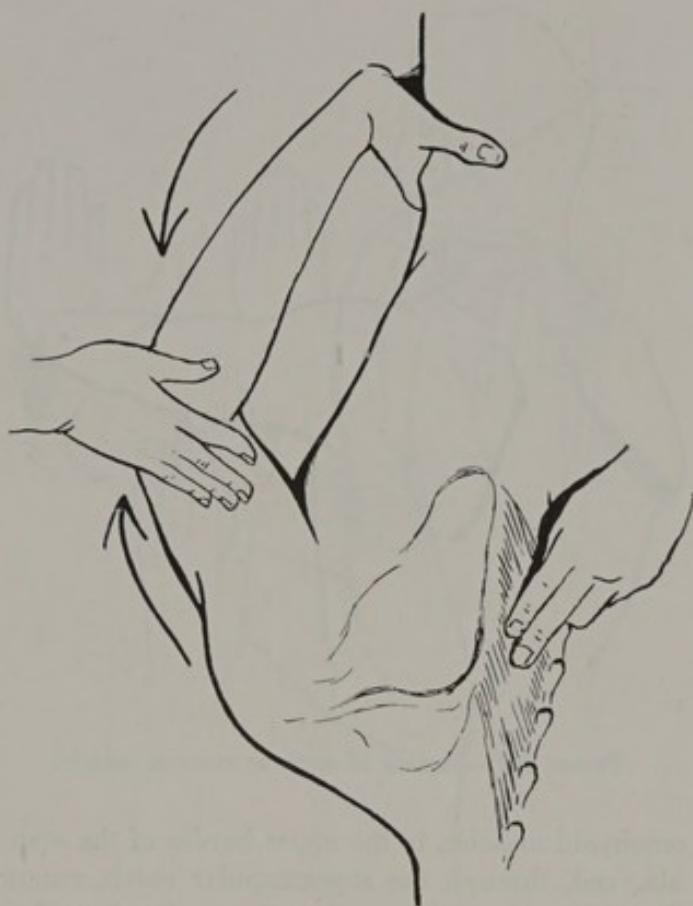

FIGURE 208.—Testing of rhomboid muscles.

behind the brachial plexus and traverses the medial aspect of the axilla on the medial wall of the chest to reach the serratus anterior muscle.

Normally, the serratus anterior muscle keeps the scapula close to the chest wall and rotates the inferior angle of the scapula laterally when the arm is elevated anteriorly, as in pushing movements. When this muscle is paralyzed, there is "winging" of the scapula, and the vertebral border of the scapula moves posteriorly away from the chest wall.

MUSCLE TESTING

Serratus anterior.—The patient is asked to push his hands against a wall, with arms stretched out before him at shoulder level (fig. 209). If paralysis exists, "winging" of the scapula is easily identified.

Suprascapular nerve

The suprascapular nerve arises from fibers which traverse C4, C5, and C6 roots and emerge from the upper trunk of the brachial plexus. It proceeds laterally and backward, beneath the trapezius and

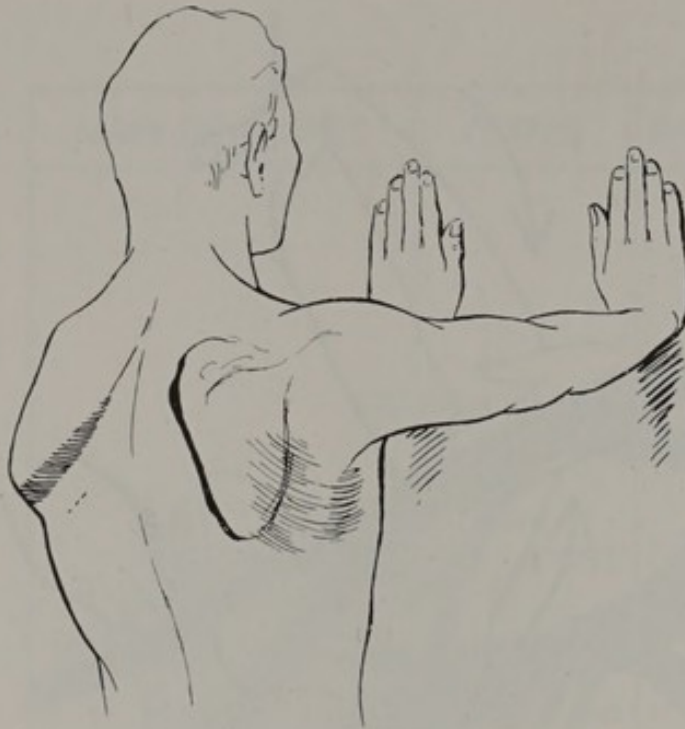


FIGURE 209.—Testing of serratus anterior muscle.

omohyoid muscles, to the upper border of the scapula, and, through the suprascapular notch, enters the supraspinatus fossa, where it supplies branches to the supraspinatus muscle; it then passes downward, beneath the supraspinatus muscle, and curves around the lateral border of the spine of the scapula to the infraspinatus fossa, where it innervates the infraspinatus muscle. Paralysis of this nerve produces obvious atrophy of the supraspinatus and infraspinatus muscles. The supraspinatus muscle helps the deltoid muscle abduct the arm at the shoulder. The infraspinatus muscle functions with the teres minor muscle as an external rotator of the arm.

MUSCLE TESTING

Supraspinatus.—The patient is instructed to tilt his head to the side being tested (in order to relax the trapezius) and to abduct the arm against resistance (fig. 210); contraction of the supraspinatus muscle can be palpated when it is functioning.

Infraspinatus.—The patient is asked to hold his arm at his side, with his elbow against his body and the forearm flexed at the elbow. He is then instructed to rotate the arm externally against the examiner's resistance (fig. 211). When function is present, contraction of the infraspinatus muscle can be felt and often seen.

Subclavian nerve

The subclavian nerve emerges from the upper trunk and is derived from fibers from C5 and C6. It descends in the posterior triangle of the neck, in front of the subclavian artery, to reach the subclavian muscle. This muscle acts as a depressor of the lateral end of the clavicle, draws the clavicle medially toward the sternum, and helps prevent subluxation of the sternoclavicular joint.

Anterior thoracic nerves

There are two anterior thoracic nerves; the medial anterior thoracic nerve, with fibers from C8 and T1, arises from the medial cord, and the lateral anterior thoracic nerve, with fibers from C5, C6, and C7, arises from the lateral cord. These two nerves, usually united by a loop about the axillary artery, innervate the pectoralis major and minor muscles. Paralysis of the pectoralis major muscle results in atrophy which is readily visible on inspection.

MUSCLE TESTING

Pectoralis major.—Function of the pectoralis major muscle is best demonstrated by having the patient stand, with the arm abducted at the shoulder. The patient is then instructed to adduct the arm against the examiner's resistance (fig. 212). When function is present, contraction of this muscle is palpable and visible.

Subscapular nerves

All three subscapular nerves arise from the posterior cord. (1) The upper or short subscapular nerve is composed of fibers from C5 and C6; it passes downward to supply the subscapular muscle. (2) The middle or long subscapular nerve, also known as the thoracodorsal nerve, contains fibers from C7 and C8; it follows the course of the subscapular artery along the posterior wall of the axilla to the latissimus dorsi muscle, which it innervates. (3) The lower subscapular nerve derives its fibers from C5 and C6; it passes laterally and downward, ending in the teres major, also supplying the lower part of the subscapularis muscle.

MUSCLE TESTING

Subscapularis and teres major.—The subscapularis and teres major muscles, when functioning nor-

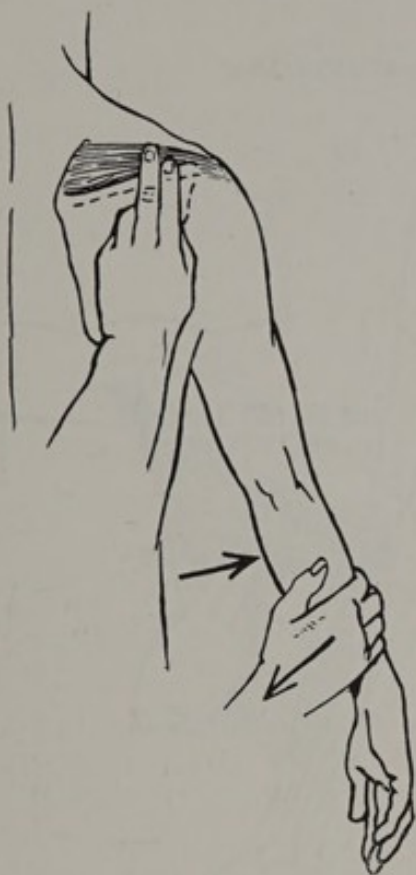

FIGURE 210.—Testing of supraspinatus muscle.

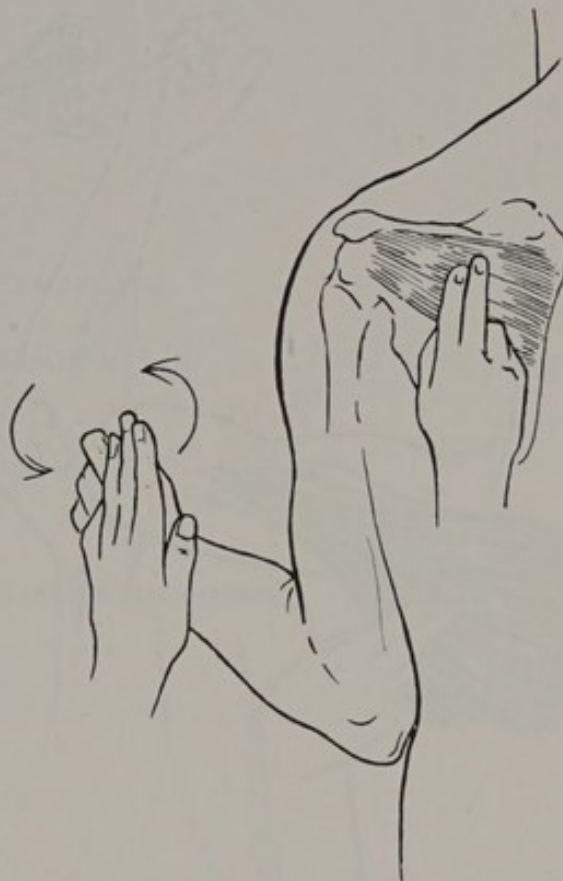

FIGURE 211.—Testing of infraspinatus muscle.

mally, allow internal rotation of the arm at the shoulder. Their function can be tested by having the patient flex his forearm at the elbow and internally rotate the upper arm at the shoulder, while the examiner applies resistance opposing this action.

Latissimus dorsi.—The latissimus dorsi can be tested by grasping the muscle in the region of the inferior angle of the scapula and instructing the patient to cough. Contraction of the normally innervated muscle is palpable.

Latissimus dorsi and teres major.—The latissimus dorsi and teres major can be tested together by testing the adduction of the horizontally abducted arm. The patient is asked to abduct the arm at the shoulder to 90° , the forearm is flexed at the elbow to 90° , and he is then asked to adduct the arm against the examiner's resistance, applied at the elbow (fig. 213).

Medial cutaneous nerve of the forearm

The medial cutaneous nerve of the forearm is a sensory nerve arising from the medial cord with fibers from the C8 and T1 roots, supplying sensation to the medial surface of the forearm. This nerve

runs down the ulnar side of the arm, medial to the brachial artery.

Medial cutaneous nerve of the arm

The medial cutaneous nerve of the arm is a sensory nerve arising from the medial cord of the brachial plexus and derives its fibers from the C8 and T1 roots. It passes through the axilla, at first lying behind and then medial to the axillary vein. It descends along the medial side of the brachial artery to the middle of the upper arm, and supplies sensation to the skin on the medial surface of the upper arm.

Musculocutaneous nerve

The musculocutaneous nerve arises from the lateral cord of the brachial plexus and derives its fibers from the C5 and C6 cervical roots (fig. 214). It pierces the coracobrachialis muscle and passes obliquely, between the biceps and the brachialis muscles, to the lateral side of the arm. Just above the elbow, it pierces the deep fascia lateral to the biceps tendon and continues into the forearm as the lateral cutaneous nerve of the forearm. It supplies motor function to the coracobrachialis, the biceps,

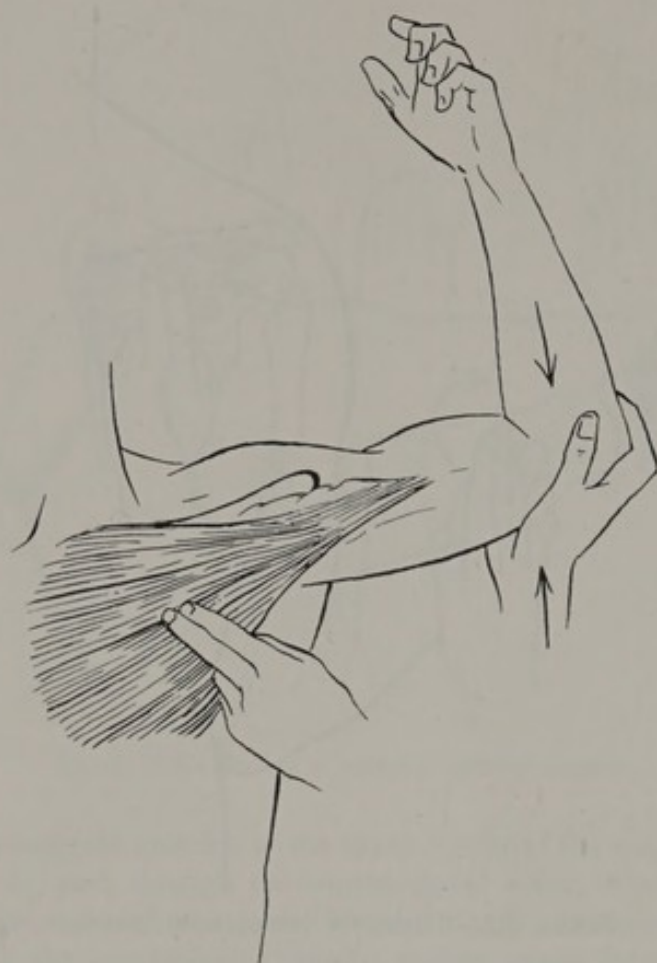

FIGURE 212.—Testing of pectoralis major muscle.

and the brachialis muscles. The lateral cutaneous nerve of the forearm passes behind the cephalic vein and divides at the elbow joint into a volar and a dorsal branch. These branches supply sensation to the skin over the lateral half of the volar and dorsal surfaces of the forearm.

When paralysis has been present for some time, atrophy of the biceps muscle is visible. The biceps reflex is absent when this muscle is paralyzed. Sensory examination reveals some loss of sensation over the skin on the volar surface of the lateral aspect of the forearm.

MUSCLE TESTING

Coracobrachialis.—The coracobrachialis provides flexion of the shoulder. This flexion can be tested by instructing the patient to flex the shoulder with the elbow completely flexed, the humerus in slight external rotation, and the forearm supinated against the pressure of the examiner, who places his hand

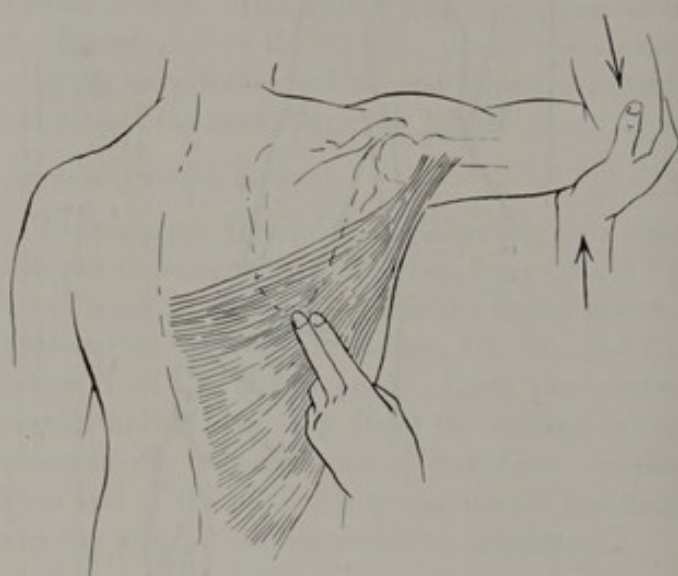


FIGURE 213.—Testing of latissimus dorsi and teres major muscles.

over the anteromedial surface of the lower end of the humerus in a downward and slightly outward direction.

Biceps brachii.—Biceps muscle function is easily tested by having the patient flex the supinated forearm at the elbow, as the examiner resists by attempting to straighten the arm (fig. 215); biceps contractions can be seen and felt.

Axillary nerve

The axillary nerve arises from the posterior cord of the brachial plexus and is composed of fibers from the 5th and 6th cervical roots (fig. 216). It passes downward behind the axillary artery, and at the lower border of the subscapularis muscle it leaves the artery by passing backward, with the posterior circumflex artery of the humerus, through the quadrilateral space bounded by the humerus, subscapularis, long head of the biceps, and the teres major. It then travels around the surgical neck

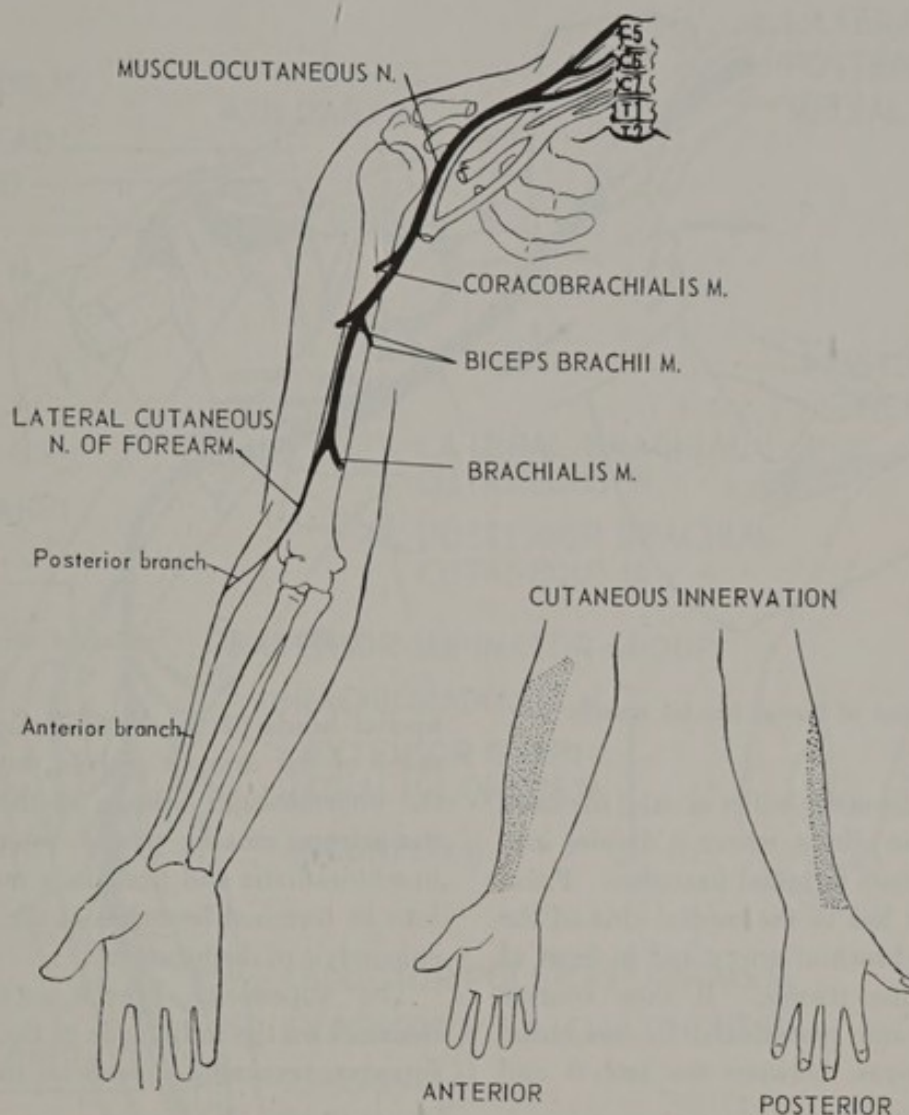


FIGURE 214.—Musculocutaneous nerve. (From Haymaker, Webb, and Woodhall, Barnes: *Peripheral Nerve Injuries; Principles of Diagnosis*. 2d edition. Philadelphia: W. B. Saunders Co., 1953.)

and terminates in the deltoid muscle. The auxiliary nerve supplies motor function to the deltoid and teres minor muscles. A cutaneous branch, the lateral cutaneous nerve of the arm, passes obliquely, distally, and forward from beneath the deltoid, becoming superficial at its posterior border. It supplies the skin over the proximal third of the lateral aspect of the upper arm.

Isolated paralysis of the axillary nerve, though rare, does occur. When paralysis is present for any length of time, there is usually visible atrophy of the deltoid muscle with a concave contour of the shoulder. With paralysis of this nerve, sensory loss over the lateral aspect of the upper arm can usually be demonstrated.

MUSCLE TESTING

Deltoideus.—Function of the deltoid muscle is best tested by asking the patient to abduct the arm at the shoulder against resistance (fig. 217). When the muscle functions normally, contraction can be seen and palpated.

Radial nerve

The radial nerve arises from the fibers of the C6, C7, C8, and T1 roots and is a direct continuation of the posterior cord (fig. 218). It is the largest branch of the brachial plexus. In the axilla, it lies behind the axillary artery and in front of the subscapularis, teres major, and latissimus dorsi

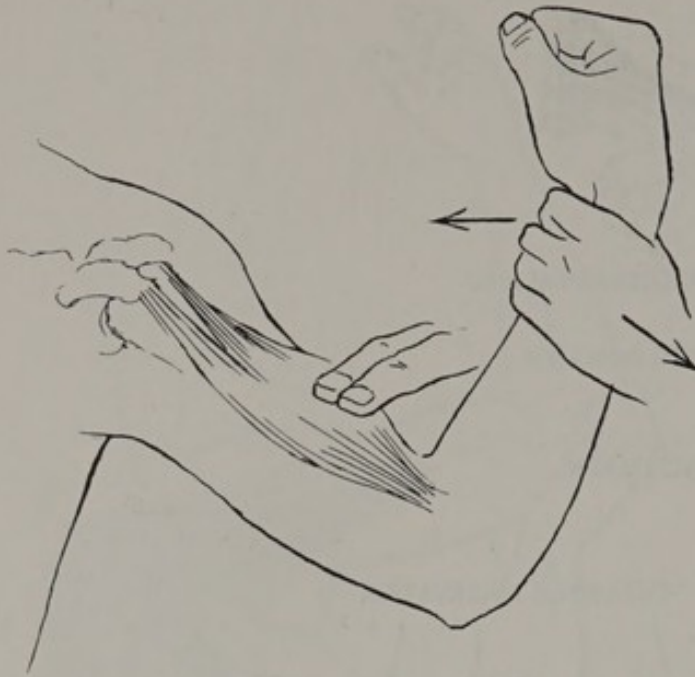

FIGURE 215.—Testing of biceps brachii muscle.

muscles. It extends from the axilla around the back of the humerus to the elbow, where it divides into the superficial and deep terminal branches. Proximally in the arm, it lies to the medial side of the humerus, behind the brachial artery and in front of the long head of the triceps. It then courses obliquely, laterally, and posteriorly, in the radial groove of the humerus, between the lateral and

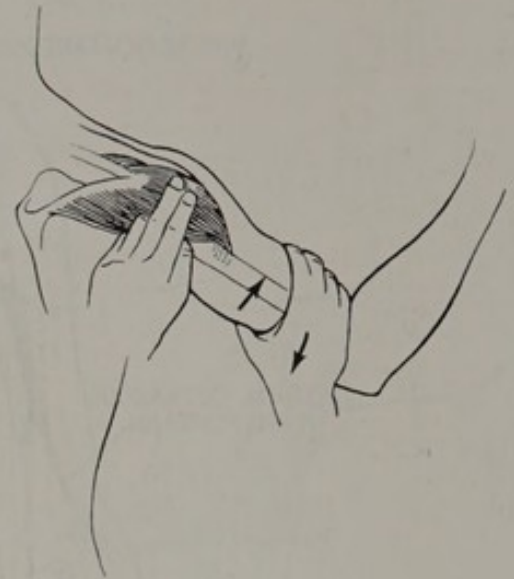

FIGURE 217.—Testing of deltoid muscle.

medial heads of the triceps muscle. In the distal third of the arm, it pierces the proximal part of the intermuscular septum at the lateral border of the triceps muscle, passes anteriorly between the brachioradialis and brachialis muscles, and divides into its terminal branches at the level of the lateral epicondyle of the humerus.

The superficial branch, a cutaneous nerve, descends on the radial side of the volar aspect of the forearm, becoming superficial in the distal part of

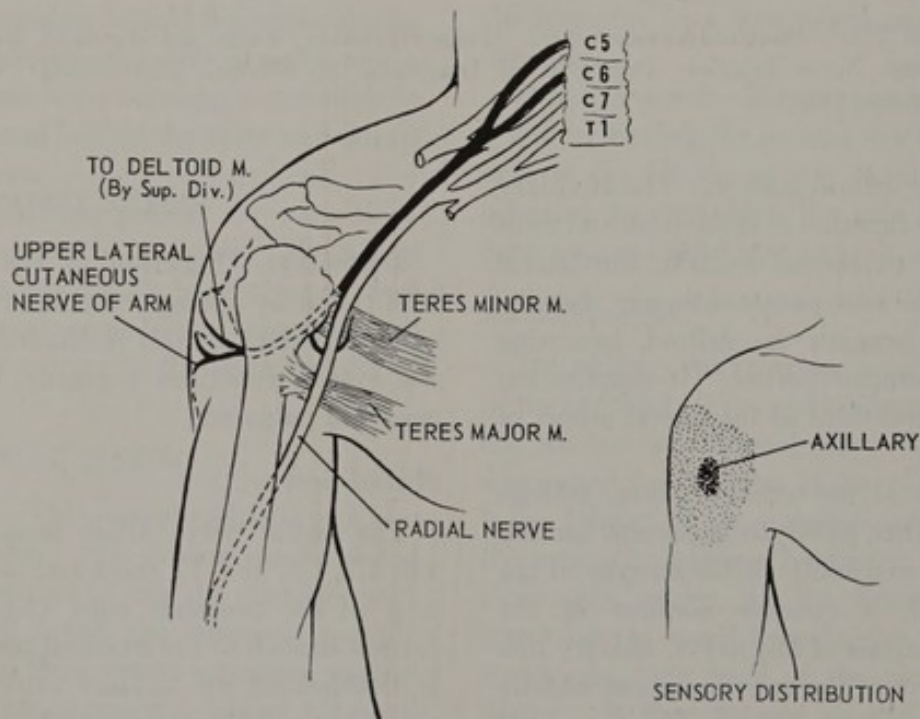


FIGURE 216.—Axillary nerve, including sensory distribution.

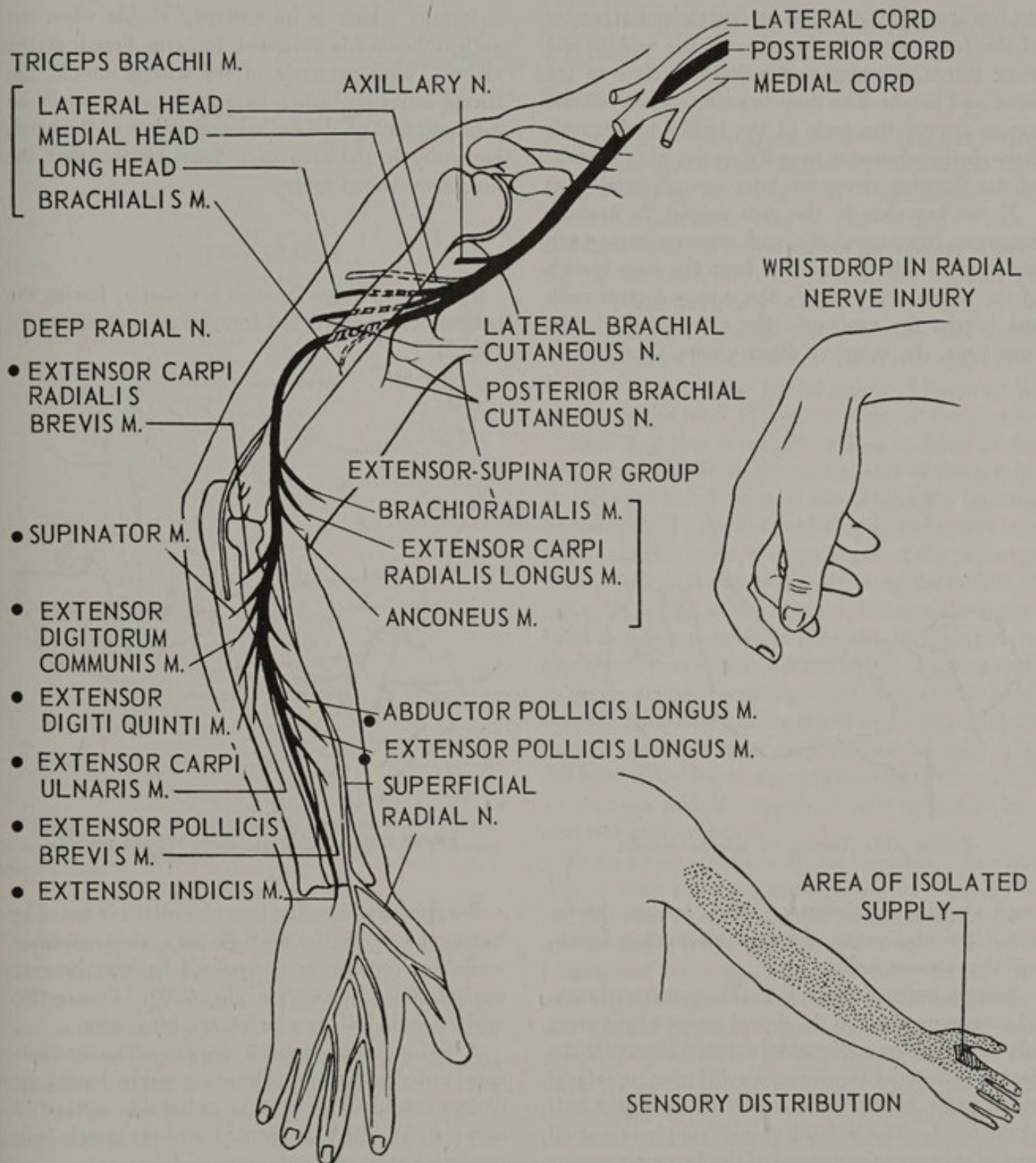


FIGURE 218.—Radial nerve.

the forearm. It then bends around the radial border of the forearm at the junction of the middle and distal thirds, coursing to the dorsal surface of the wrist and hand. The deep branch, entirely motor, passes around the neck of the radius and travels through the supinator muscles on the dorsal aspect of the forearm along the interosseous membrane.

Motor branches in the arm supply the triceps, anconeus, brachioradialis, and extensor carpi radialis longus. Motor branches from the deep branch of the radial nerve supply the extensor carpi radialis brevis, the supinator, the extensor digitorum communis, the extensor digiti quinti, the extensor

deformity which is immediately visible when the patient holds his pronated forearm flexed at the elbow. With paralysis of the triceps muscle, the triceps reflex is absent. Sensory loss can usually be demonstrated on the radiodorsal aspect of the hand, especially in the area of isolated supply, over the first interosseous space.

MUSCLE TESTING

Triceps.—Triceps function is tested by having the patient extend the flexed forearm against resistance (fig. 219).

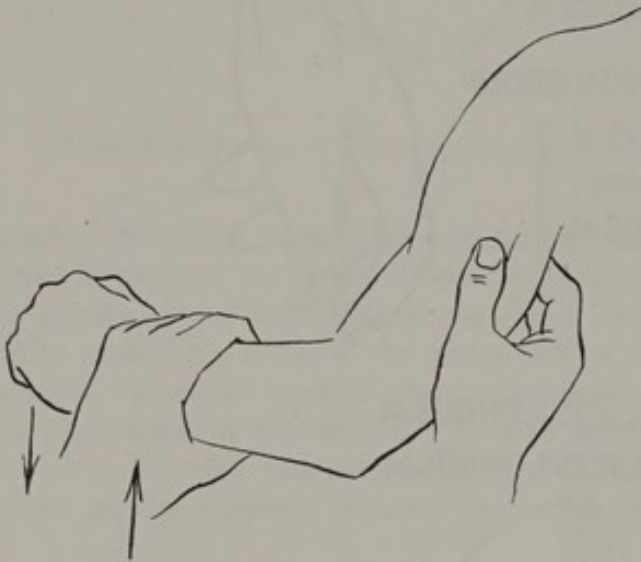


FIGURE 219.—Testing of triceps muscle.

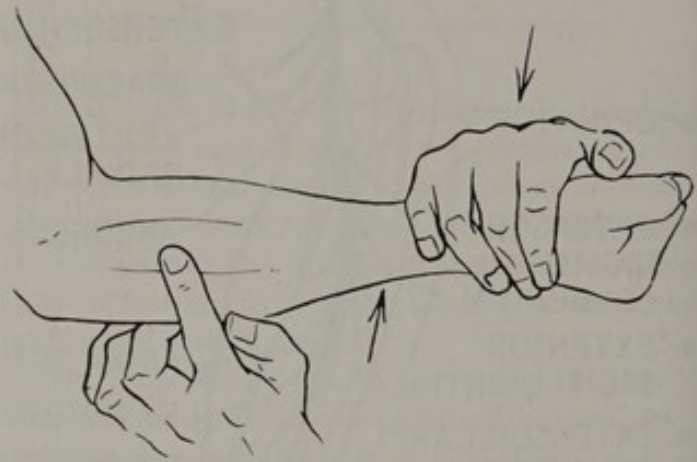


FIGURE 220.—Testing of brachioradialis muscle.

carpi ulnaris, the abductor pollicis longus, the extensor pollicis longus, the extensor pollicis brevis, and the extensor indicis.

Sensory nerves include: (1) The posterior brachial cutaneous nerve to the dorsal aspect of the arm; (2) the posterior antibrachial cutaneous nerve to the dorsal surface of the forearm; (3) the superficial radial nerve to the dorsal aspect of the radial half of the hand. The isolated area of supply is a small area of skin over the dorsum of the first interosseous space.

SIGNS OF PARALYSIS

Clinical evidence of paralysis is easily demonstrated on examination. The number of muscles paralyzed will depend on the level of nerve injury. Typical of radial nerve paralysis is the wristdrop

Brachioradialis.—The brachioradialis is tested by having the patient flex his forearm against resistance while the forearm is maintained halfway between supination and pronation (fig. 220). Contraction of the muscle belly can be felt and often seen.

Extensor carpi radialis longus.—The extensor carpi radialis longus can be examined by having the patient extend his wrist to the radial side, against resistance (fig. 221A); contraction of the muscle belly can be felt and sometimes seen.

Supinator.—The supinator can be tested with the patient standing or sitting, with arm extended at his side. The patient is then asked to resist the examiner's attempt to pronate the forearm.

Extensor digitorum communis.—The extensor digitorum communis is tested by having the patient place his forearm on a table and resist the exam-

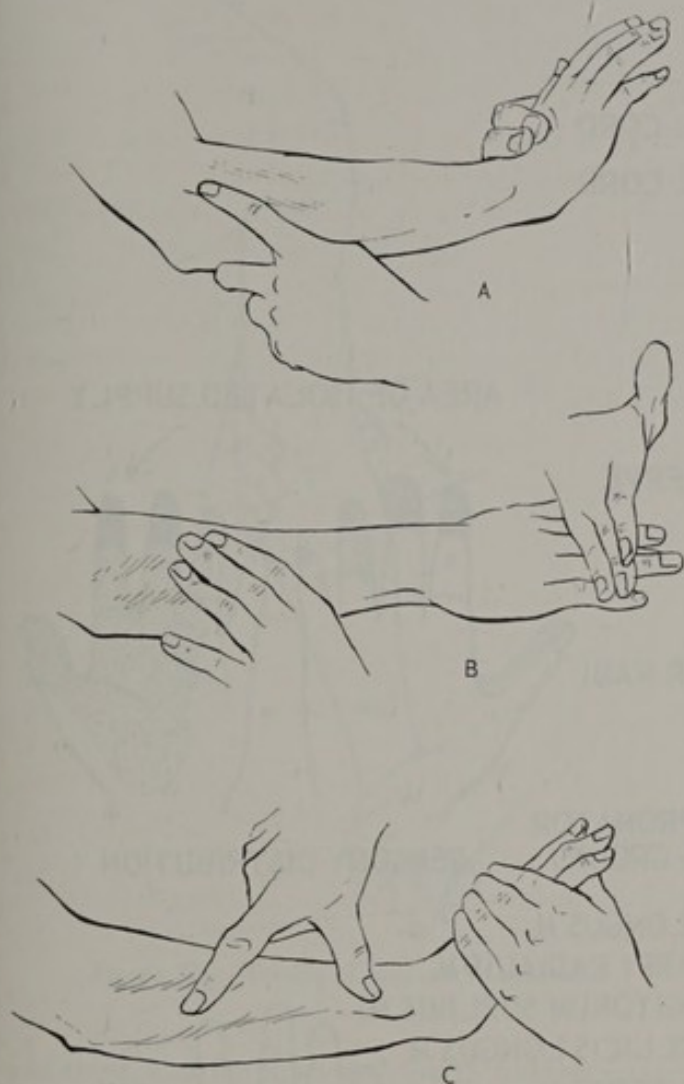


FIGURE 221.—Muscle testing. A. Extensor carpi radialis longus. B. Extensor digitorum communis. C. Extensor carpi ulnaris.

iner's attempt to flex the fingers at the metacarpophalangeal joints (fig. 221B).

Extensor carpi ulnaris.—The extensor carpi ulnaris is tested by having the patient extend the wrist to the ulnar side against resistance (fig. 221C). Contraction of this muscle can be palpated.

Abductor pollicis longus.—The abductor pollicis longus can be tested by having the patient abduct the thumb against resistance in a plane at right angles to the palm.

Extensor pollicis brevis.—The extensor pollicis brevis is tested by having the patient resist the examiner's attempt to flex the thumb at the metacarpophalangeal joint.

Extensor pollicis longus.—The extensor pollicis longus is tested by having the patient resist the exam-

iner's attempt to flex the thumb at the interphalangeal joint.

Median nerve

The median nerve arises from the brachial plexus by two heads, one from the lateral cord and the other from the medial cord (fig. 222). The lateral head, fibers of which come from the C5, C6, and C7 roots, descends along the lateral side of the axillary artery; the medial head, with fibers from the C8 and T1 roots, crosses anteriorly to the axillary artery, at the level where the brachial artery begins, and unites with the lateral head in the proximal part of the arm. It descends, along the lateral aspect of the brachial artery, to the level of the insertion of the coracobrachialis, where it usually crosses in front of the artery and travels on the medial side of the artery. In the antecubital fossa, it lies behind the lacertus fibrosus and the median cubital vein, and passes into the forearm between the two heads of the pronator teres muscle. It travels distally along the middle of the volar aspect of the forearm, between the superficial and deep muscles, to the wrist, becoming more superficial as it approaches the wrist. Passing deep to the transverse carpal ligament, it enters the hand between the tendons of the flexor digitorum sublimis medially and the flexor carpi radialis laterally. In the hand it divides, in a plane posterior to the palmar aponeurosis and the superficial volar arch, into several terminal branches.

In the upper arm there are no branches. In addition to small articular branches, the nerve supply to the following muscles arises in the antecubital space: The pronator teres, flexor carpi radialis, palmaris longus, and flexor digitorum sublimus. In the forearm arise branches to the flexor digitorum profundus (radial portion), flexor pollicis longus, and pronator quadratus. In the distal third of the forearm, a small cutaneous branch arises. It travels superficially to the deep fascia, to supply the palm of the hand. In the hand, a muscular branch arises, just distal to the transverse carpal ligament, and enters the thenar eminence, supplying branches to the abductor pollicis brevis, opponens pollicis, and flexor pollicis brevis. There are usually five cutaneous branches. Three separate branches supply sensation to each side of the thumb and the lateral side of the index finger. The two remaining branches subdivide, at the clefts between the second

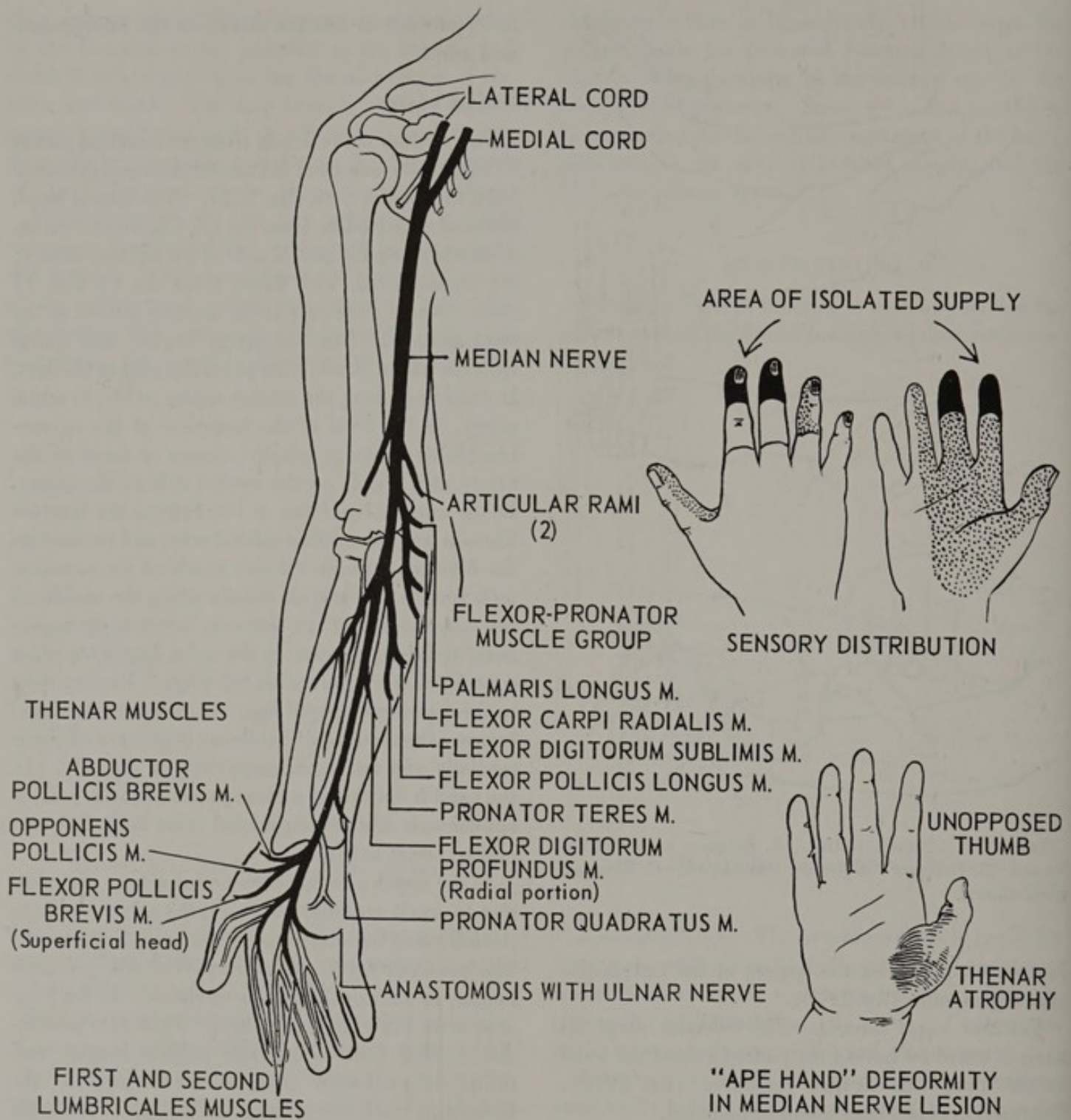


FIGURE 222.—Median nerve

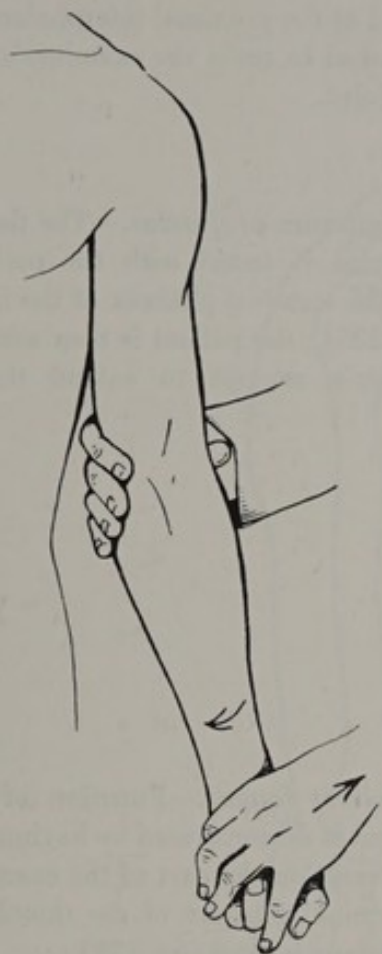

FIGURE 223.—Testing of pronator teres muscle.

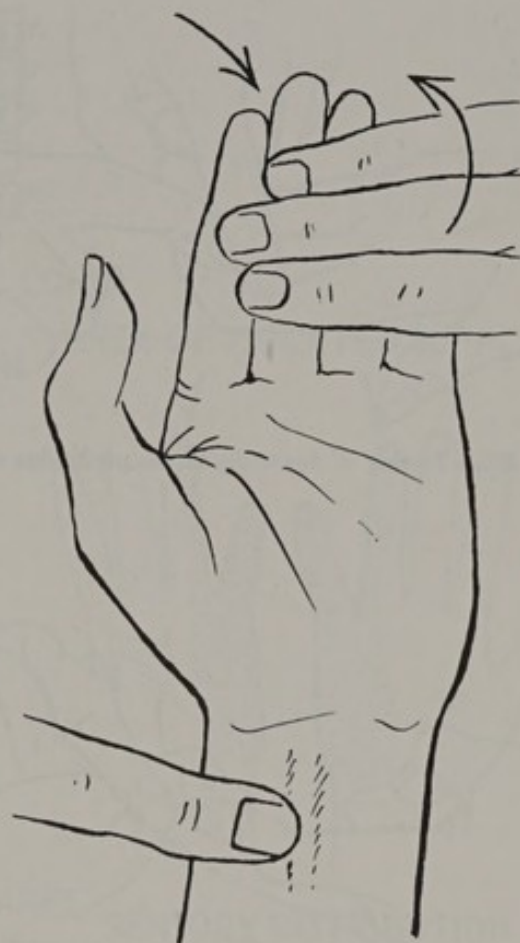

FIGURE 224.—Testing of flexor carpi radialis muscle.

and third, and the third and fourth fingers, respectively, into branches which supply adjacent sides of these fingers. Muscular branches arise from these nerves to supply the first and second lumbricales.

SIGNS OF PARALYSIS

Paralysis of the median nerve above the elbow produces paralysis of the flexor, pronator, and thenar muscles. In the forearm, pronation is weak or lost. At the wrist, there is weakness of flexion and abduction; the hand tends to deviate to the ulnar side. "Ape hand" deformity results because the thumb seems to be in the same plane as the hand, and because of the atrophy of the thenar eminence. There is inability or weakness to oppose or flex the thumb and inability to abduct the thumb in a plane perpendicular to the palm. There is inability to flex the distal phalanx of the thumb and index finger (never supplemented). Sensory loss is variable.

It may involve the entire volar aspect of the radial side of the hand, including the first three fingers. The area of isolated supply is limited to the tip of the index finger.

MUSCLE TESTING

Pronator teres—The pronator teres is tested by having the patient extend the arm at his side and resist the examiner's attempt to supinate the hand (fig. 223). Contraction of the pronator muscle belly can be felt and often seen.

Flexor carpi radialis.—Function of the flexor carpi radialis is tested by having the patient flex the wrist toward the radial side of the forearm against resistance (fig. 224). Contraction of the muscle belly can be palpated.

Flexor digitorum sublimis.—The flexor digitorum sublimis is tested by having the patient place his hand on a table, in a supine position, with one of the

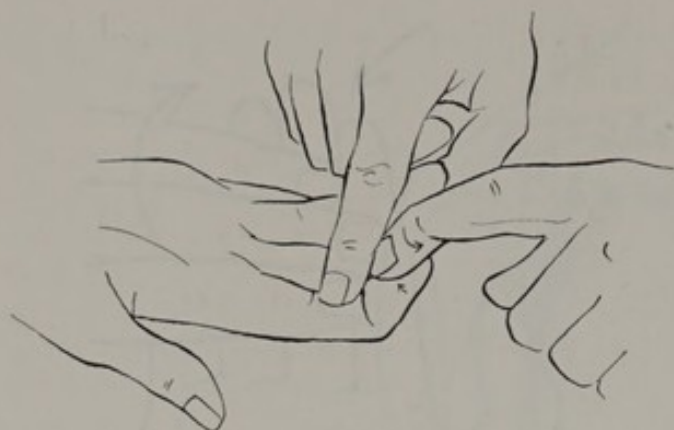

FIGURE 225.—Testing of flexor digitorum profundus muscle.

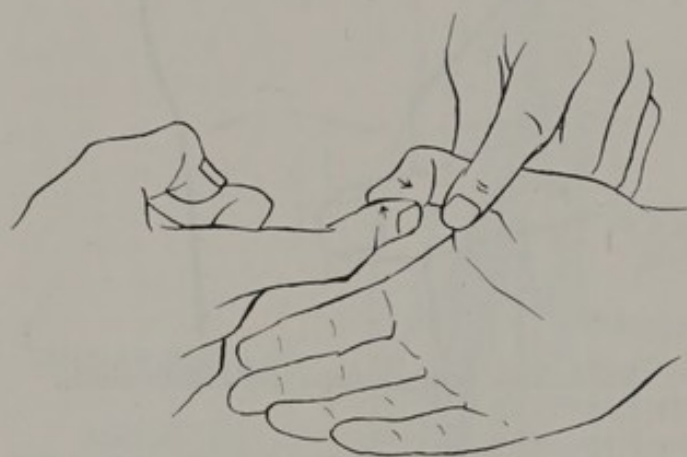

FIGURE 226.—Testing of flexor pollicis longus muscle.

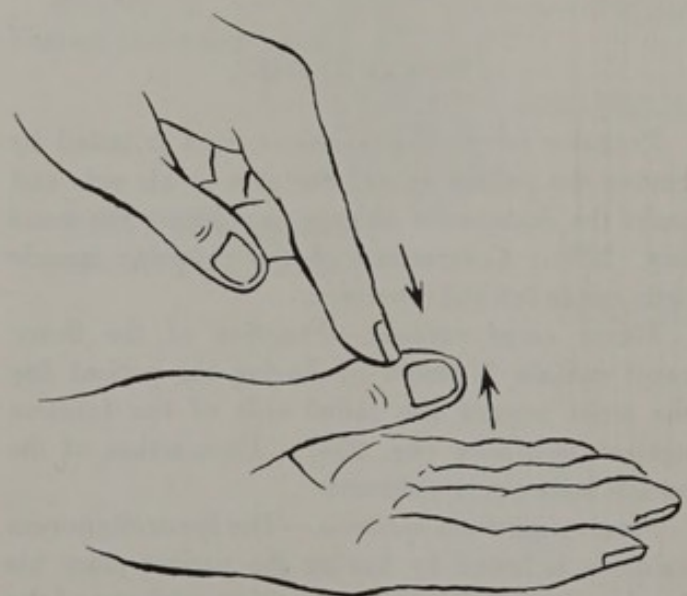


FIGURE 227.—Testing of abductor pollicis brevis muscle.

fingers flexed at the proximal interphalangeal joint; he is then asked to resist the examiner's attempt to extend this joint.

Flexor digitorum profundus.—The flexor digitorum profundus is tested with the patient's hand supine and the terminal phalanx of the index finger flexed (fig. 225); the patient is then asked to resist the examiner's attempt to extend the terminal phalanx.

Flexor pollicis longus.—Function of the flexor pollicis longus is demonstrated by having the patient resist an attempt on the part of the examiner to extend the terminal phalanx of the thumb while the proximal phalanx is fixed (fig. 226).

Abductor pollicis brevis.—The abductor pollicis brevis is tested by placing the patient's thumb in a plane at right angles to the plane of the hand and asking the patient to abduct the thumb, in this plane, against resistance (fig. 227).

Opponens pollicis.—The opponens pollicis is tested by asking the patient to touch the thumb to the tip of the fifth finger against resistance, while the thumbnail remains in a plane parallel to the palm.

Ulnar nerve

The ulnar nerve arises from the medial cord of the brachial plexus (fig. 228). It receives fibers from the C8 and T1 roots and descends on the

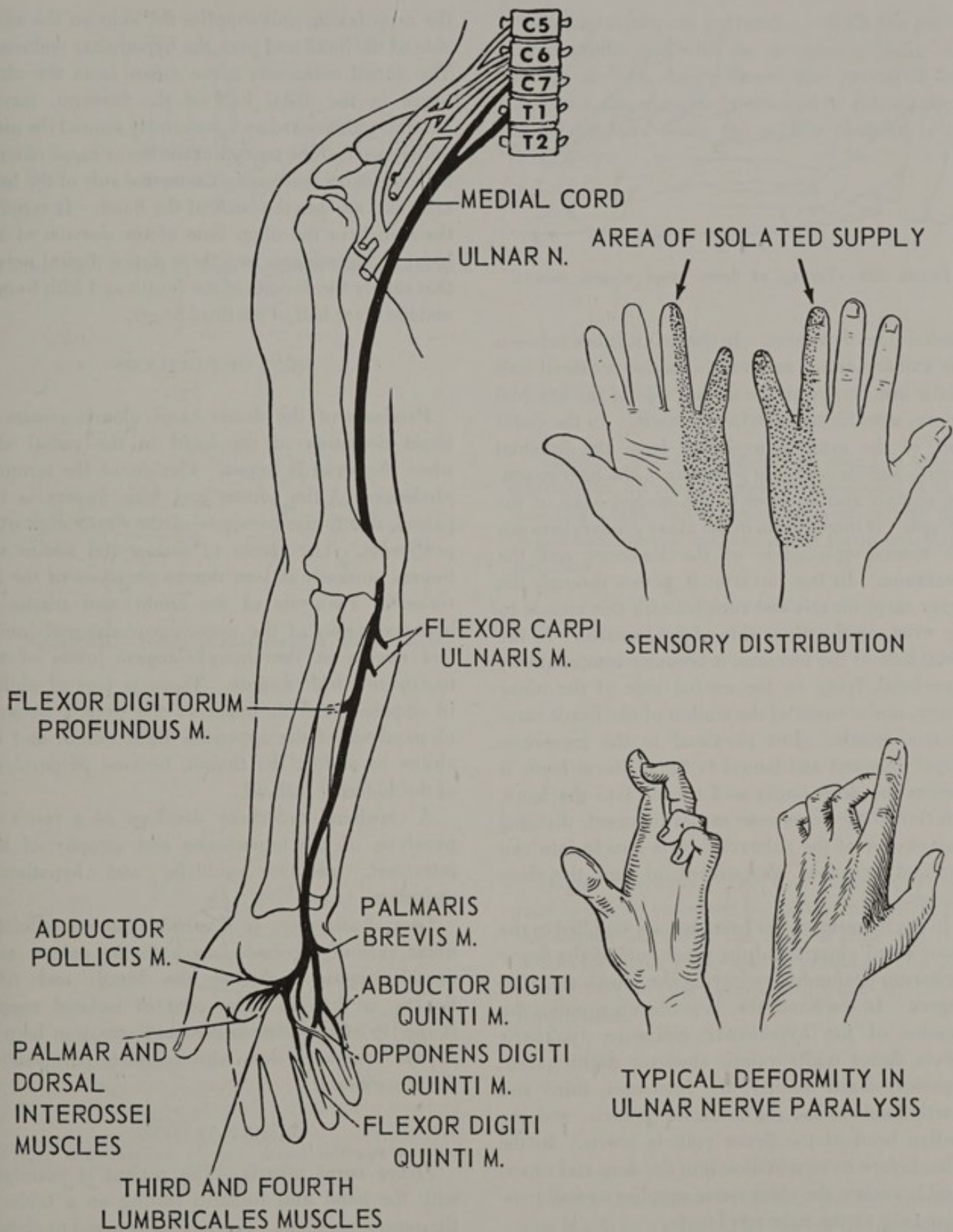


FIGURE 228.—Ulnar nerve.

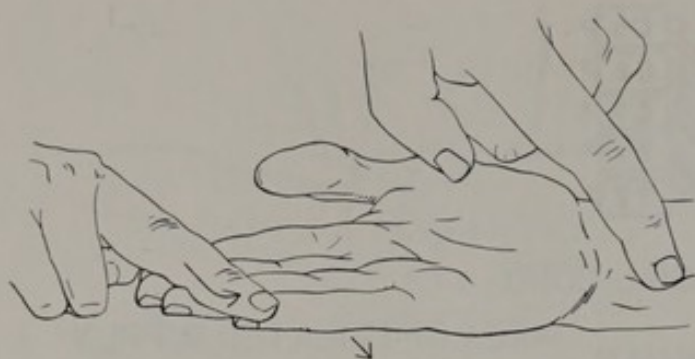

FIGURE 229.—Testing of flexor carpi ulnaris muscle.

medial side of the arm. In the axilla, it lies between the axillary artery and vein. In the proximal half of the arm, it lies on the medial side of the brachial artery, anterior to the triceps muscle. In the distal half of the arm, it separates from the brachial artery, and its course is posterior to the intermuscular septum and anterior to the medial head of the triceps. It then travels in the ulnar groove, between the medial epicondyle of the humerus and the olecranon. In the forearm, it passes through the flexor carpi ulnaris and runs beneath this muscle to the wrist, on the ulnar side of the forearm. In the distal half of the forearm, it becomes comparatively superficial, lying on the medial side of the ulnar artery, under cover of the tendon of the flexor carpi ulnaris muscle. Just proximal to the transverse carpal ligament and lateral to the pisiform bone, it pierces the deep fascia and travels into the hand, anterior to the transverse carpal ligament, dividing under cover of the palmaris brevis muscle into two terminal branches, the superficial and the deep branch.

In the forearm, motor branches are supplied to the flexor carpi ulnaris and the ulnar half of the flexor digitorum profundus, supplying the fourth and fifth fingers. In the hand, the deep branch supplies the muscles of the hypothenar eminence (palmaris brevis, flexor digiti quinti, abductor digiti quinti, opponens digiti quinti), the interossei, third and fourth lumbricales, the adductor pollicis, and the median head of the flexor pollicis brevis. In the palm, before its termination into the deep and superficial branches, the ulnar nerve supplies a small muscular twig to the palmaris brevis.

There are two sensory branches arising from the ulnar nerve in the forearm. The palmar cutaneous nerve arises in the distal third of the forearm, pierces

the deep fascia, and supplies the skin on the ulnar side of the hand and over the hypothenar eminence. The dorsal cutaneous nerve arises from the ulnar nerve in the distal half of the forearm, travels obliquely ulnarward and posteriorly around the ulna, under cover of the tendon of the flexor carpi ulnaris, becomes subcutaneous on the medial side of the forearm, and reaches the back of the hand. It supplies the skin over the ulnar side of the dorsum of the hand and terminates into three dorsal digital nerves that supply the dorsum of the fourth and fifth fingers and the ulnar half of the third finger.

SIGNS OF PARALYSIS

Paralysis of the flexor carpi ulnaris results in slight deviation of the hand to the radial side when the wrist is flexed. Flexion of the terminal phalanges of the fourth and fifth fingers is impaired, due to the paralysis of the flexor digitorum profundus. The ability to abduct and adduct the fingers normally is lost, due to paralysis of the interossei. Paralysis of the lumbricales results in hyperextension of the metacarpophalangeal joints, and flexion at the interphalangeal joints of the fourth and fifth fingers. There is loss of ability to oppose the fifth finger to the thumb, because of paralysis of the opponens digiti quinti, and inability to adduct the thumb, because of paralysis of the adductor pollicis.

A clawhand deformity develops as a result of paralysis of the lumbricales and atrophy of the interossei, adductor pollicis, and hypothenar eminence.

Loss of sensation, to a variable degree, over the ulnar side of the hand, on both the palmar and dorsal aspects, including the fourth and fifth fingers, is present. The area of isolated supply is the tip of the fifth finger, and sensation here is always completely lost with complete paralysis of the ulnar nerve.

MUSCLE TESTING

Flexor carpi ulnaris.—The patient is examined with the hand and forearm resting on a table in the supine position. The patient is asked to abduct the fifth finger against the examiner's resistance (fig. 229). When this muscle is functioning, tendon contraction can be felt and usually seen.

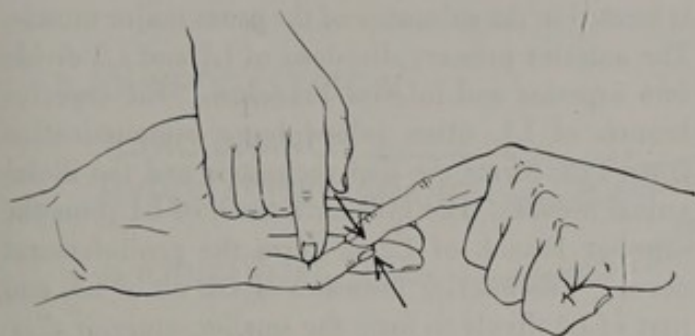


FIGURE 230.—Testing of flexor digitorum profundus muscle.

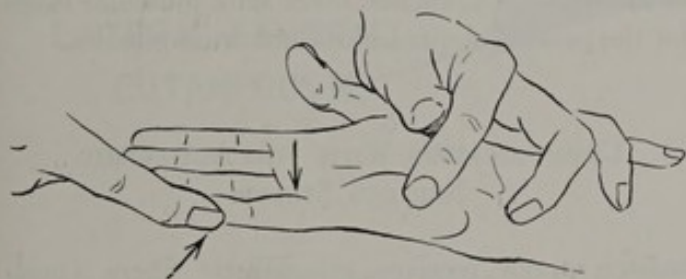

FIGURE 231.—Testing of abductor digiti quinti muscle.

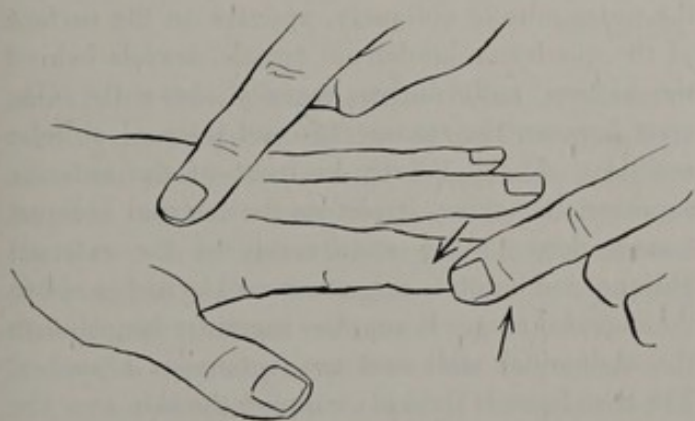


FIGURE 232.—Testing of first dorsal interosseus muscle.

Flexor digitorum profundus.—With the patient's hand supine and with the terminal phalanx of the fourth or fifth finger flexed, the patient is asked to resist the examiner's attempt to extend the terminal phalanx while the middle phalanx is fixed (fig. 230).

Abductor digiti quinti.—The patient is asked to abduct the fifth finger against resistance, with his hand on a table in the supinated position (fig. 231). When functioning, contraction of the muscle can be palpated.

Dorsal interossei.—The first dorsal interosseus muscle can be examined by having the patient place the fingers and palm flat upon a table and try to abduct the index finger against resistance (fig. 232). Contraction of the muscle belly can be felt and usually seen.

Palmar interossei.—The first palmar interosseus muscle can be evaluated by having the patient place his fingers and hand flat upon a table; he is asked to bring the abducted index finger to the neutral position against resistance.

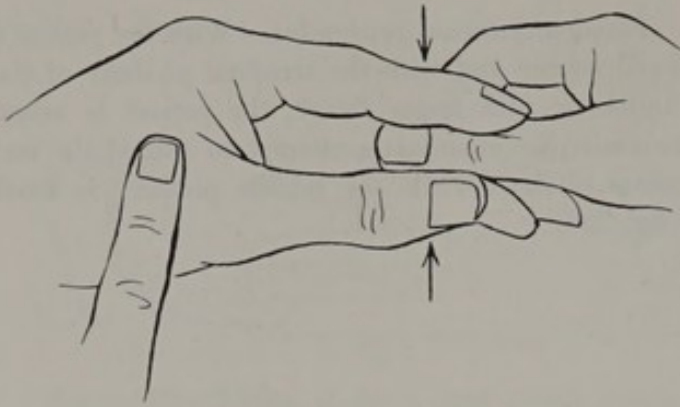


FIGURE 233.—Testing of adductor pollicis muscle.

Adductor pollicis.—With the thumb lying in a plane perpendicular to that of the palm of the hand (the nail of the thumb is in a plane at right angles to the palm), the patient is asked to compress the examiner's thumb between his thumb and index finger (fig. 233). Contraction of the adductor muscle can be seen and felt.

Opponens digiti quinti.—The wrist is supported in a neutral position by allowing it to rest on a table. The first metacarpal is held firmly by the examiner. Pressure is then exerted by the examiner along the fifth metacarpal in a downward and outward direction, and the patient tries to oppose the fifth finger toward the first metacarpal. When functioning, this muscle pulls and rotates the fifth metacarpal so as to cup the hand. Contraction of the muscle can often be seen and felt.

Lumbricales.—The examiner stabilizes the wrist in slight extension. The patient is asked to flex the fingers at the metacarpophalangeal joints and extend the fingers at the interphalangeal joints. Resistance can be applied by the examiner against the palmar surface of the proximal phalanges, and subsequently against the dorsal surfaces of the distal and middle phalanges, in order to test the degrees of strength demonstrated by the patient on flexion of the metacarpophalangeal joints and on extension of the interphalangeal joints.

THE LUMBAR PLEXUS

The lumbar plexus is formed by the anterior primary divisions of the L1, L2, and L3 roots and part of the L4 root (fig. 234). It often receives a communicating branch from the T12 root. It

is located in the substance of the psoas major muscle. The anterior primary divisions of L1 and L2 divide into superior and inferior branches. The superior branch of L1, often joined by a communication from T12, forms the iliohypogastric and the ilioinguinal nerves. The inferior branch of L1 joins the superior branch of L2 to form the genitofemoral nerve. The inferior branches of L2, all of L3, and part of L4 divide to form the smaller, anterior divisions of the lumbar plexus and the larger posterior divisions. The anterior divisions join to form the obturator nerve. The posterior divisions unite to form the femoral nerve. From fibers arising from the posterior divisions of L2 and L3, arises the lateral femoral cutaneous nerve. Near the origin of the terminal branches, there arise muscular twigs for the psoas and quadratus lumborum muscles.

COMMUNICATION WITH THE AUTONOMIC NERVOUS SYSTEM

Each nerve receives sympathetic fibers (post-ganglionic) by means of gray rami communicantes. The first two lumbar roots, and occasionally the third lumbar root, are connected to the ganglionated chain by white rami communicantes (preganglionic fibers).

Iliohypogastric nerve

The iliohypogastric nerve (T12, L1) traverses the psoas muscle obliquely, appears on the surface of the quadratus lumborum muscle, travels behind the kidney, and courses laterally above the iliac crest between the transversus and internal oblique muscles. About 1 inch in front of the anterior superior iliac spine, it pierces the internal oblique, travels deep to the aponeurosis of the external oblique, and becomes subcutaneous 1½ inches above the inguinal ring. It supplies muscular branches to the abdominal wall and two cutaneous branches. The iliac branch (lateral) supplies the skin over the upper lateral part of the thigh, and the hypogastric branch (anterior) descends anteriorly to innervate the skin over the symphysis pubis.

Ilioinguinal nerve

The ilioinguinal nerve arises from the L1 root. Not infrequently, this nerve travels in a common

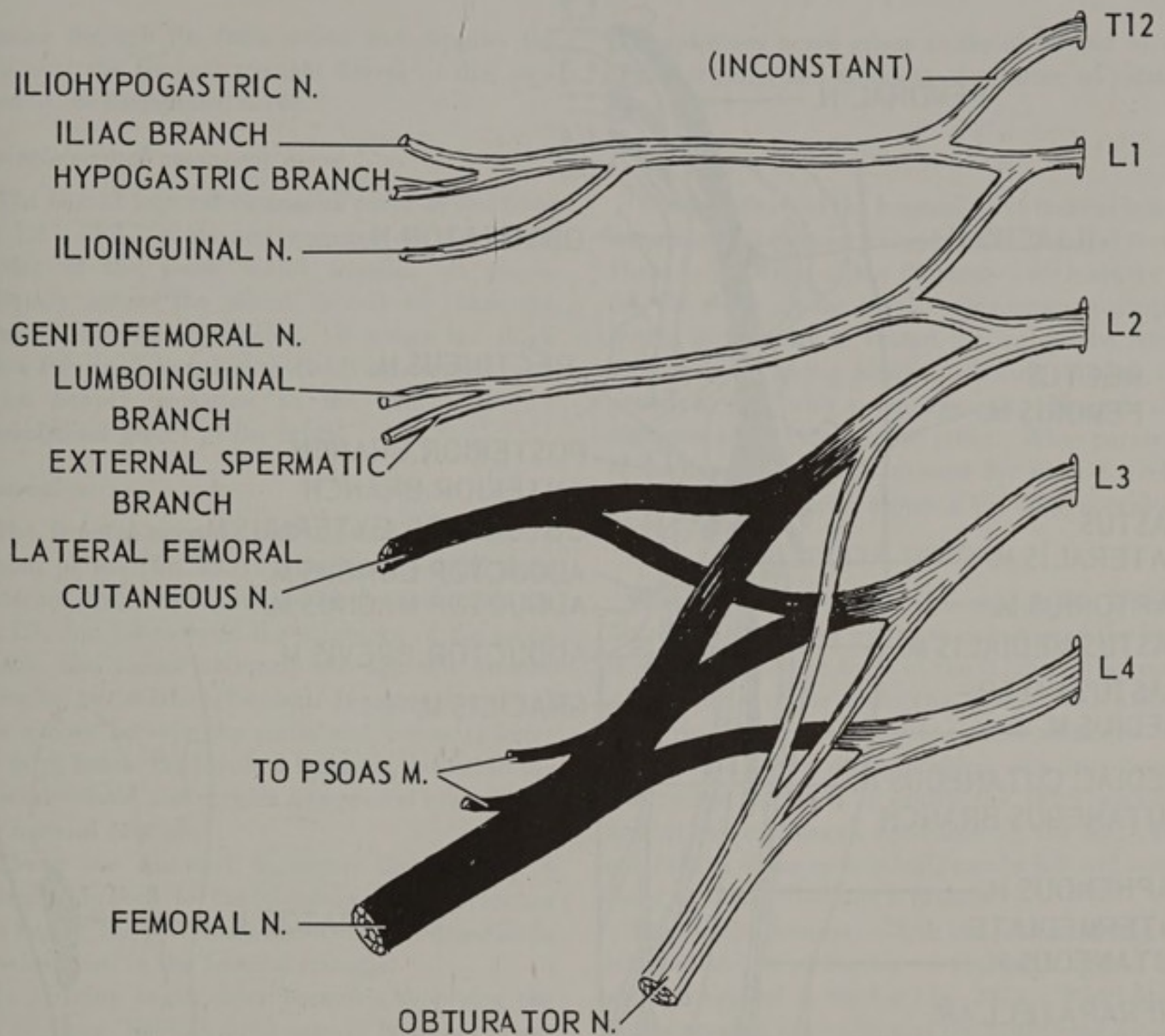


FIGURE 234.—Lumbar plexus.

trunk with the iliohypogastric. When separate, it takes a course similar to that of the iliohypogastric nerve and pierces the internal oblique muscle farther forward and lower down than does the iliohypogastric nerve. It continues forward deep to the external oblique, just above the inguinal ligament, passing through the external subcutaneous inguinal ring. It supplies muscular branches to the abdominal wall and sensory branches to the skin of the upper medial part of the thigh, the root of the penis, and the scrotum (or mons pubis and labium majus in the female).

Genitofemoral nerve

The genitofemoral nerve arises from the L1 and L2 roots and emerges on the anterior aspect of the

psaos muscle. It pierces the psaos fascia and extends downward on the lateral aspect of the common and external iliac vessels, behind the ureter, to the inguinal ligament, where it divides into two branches, the external spermatic nerve and the lumboinguinal nerve.

The external spermatic nerve travels through the inguinal canal with the testicular and the external spermatic vessels. It supplies the branches to the skin of the scrotum and the adjacent area of the thigh. In the female, it accompanies the round ligament to the labium majus. This nerve provides motor supply to the cremasteric muscle. The lumboinguinal nerve passes into the thigh, below the inguinal ligament, and lies on the lateral aspect of the femoral artery. It becomes subcutaneous by

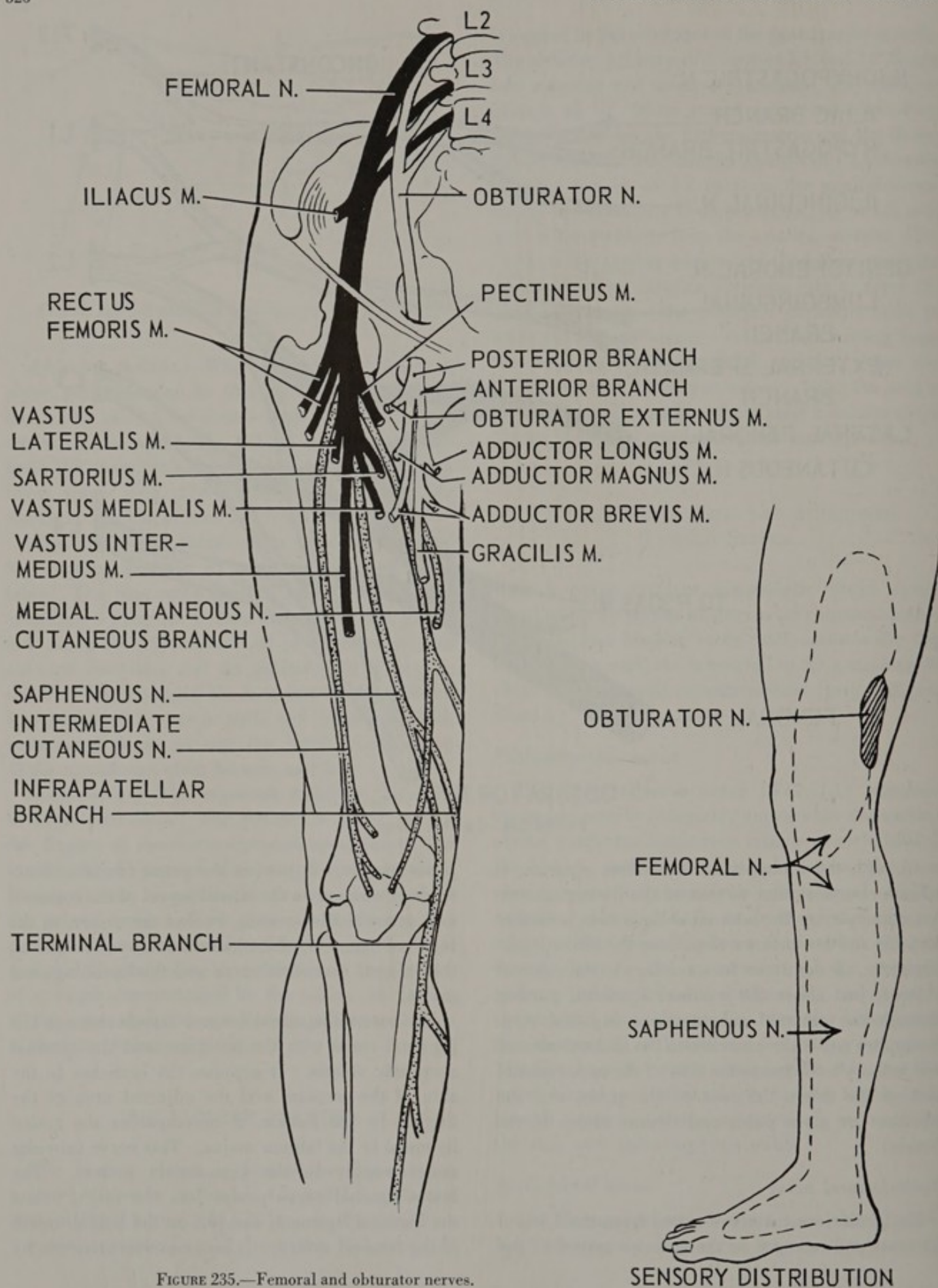


FIGURE 235.—Femoral and obturator nerves.

passing through the fossa ovalis and supplies the skin over the femoral triangle lateral to that supplied by the ilioinguinal nerve.

Lateral femoral cutaneous nerve

The lateral femoral cutaneous nerve arises from the L2 and L3 roots and emerges on the lateral border of the psoas major muscle. It passes obliquely across the iliacus muscle to reach the anterior superior iliac spine. It enters the thigh below Poupart's ligament to divide into several rami which supply sensation to the skin over the anterolateral aspect of the thigh.

Femoral nerve

The femoral nerve is the largest branch of the lumbar plexus (fig. 235). It arises from the three posterior divisions of the plexus derived from the L2, L3, and L4 roots in the substance of the psoas muscle, and passes obliquely through this muscle, emerging at the lateral border. It passes downward in a groove between the psoas and iliacus to enter the thigh below the inguinal ligament, lateral to the femoral vessels, and divides into several branches in the femoral triangle.

Above the inguinal ligament, there arises a muscular branch to the iliopsoas. The branches that supply the pectineus, sartorius, and quadriceps muscles arise in the femoral triangle.

In addition to articular branches supplying the hip and knee, the following sensory branches arise: (1) The intermediate cutaneous nerve which supplies the skin and fascia over the anterior aspects of the thigh. (2) The medial cutaneous nerve which supplies the skin and fascia of the distal two-thirds of the medial aspect of the thigh. (3) The saphenous nerve, which may be considered as the terminal branch of the femoral nerve, extends distally along the femoral vessels. In the canal it passes obliquely in front of the femoral artery, from the lateral to the medial side, then courses anterior to the tendon of the adductor magnus muscle and becomes cutaneous by passing between the sartorius and the gracilis muscles. It then proceeds distally with the great saphenous vein, traveling in front of the medial malleolus and terminating at the middle of the medial border of the foot. The skin and fascia over the medial side of the leg and foot are supplied by the saphenous nerve. (4) The infrapatellar branch of

the saphenous nerve arises at the distal end of the adductor canal and enters the formation of patellar plexus.

SIGNS OF PARALYSIS

With paralysis of the femoral nerve there is loss of sensation in the sensory supply of the femoral nerve. There is paralysis of the iliopsoas with inability to flex the thigh on the trunk. Quadriceps paralysis results in inability to extend the leg on the thigh. This makes walking forward difficult, causing the patient to walk with a steppage gait. There is also disappearance of the patellar reflex. When paralysis of the femoral nerve is present for several weeks, atrophy of the anterior aspect of the thigh is evident.

MUSCLE TESTING

Iliopsoas.—The patient lies supine, the knee is flexed and supported by the examiner, and the limb is positioned so the angle of the thigh on the trunk is less than a right angle (fig. 236). The patient then tries to flex his hip joint against resistance.

Sartorius.—In a sitting position with knee flexed, the patient is asked to rotate the thigh outward against the examiner's resistance on the leg. The contraction of the muscle belly can be felt and sometimes seen when function is present.

Quadriceps femoris.—With the patient sitting, he is asked to extend the leg on the thigh against resistance applied to the leg (fig. 237). When function is present, contraction of the quadriceps muscle is seen and felt.

Obturator nerve

The obturator nerve arises from the three anterior divisions of the L2, L3, and L4 nerve roots (fig. 235). It emerges from the medial border of the psoas major muscle, behind the common iliac vessels and on the lateral side of the ureter and the hypogastric vessels. It travels in contact with the upper part of the obturator internus muscle to the groove of the obturator foramen, through which it reaches the thigh. In the obturator groove, it divides into the anterior and posterior branches. The anterior branch supplies sensory branches to the hip joint and to a small area of skin on the medial aspect of the lower thigh; it supplies muscular branches to the adductor longus, gracilis, and adductor brevis. The posterior branch supplies muscular branches to the

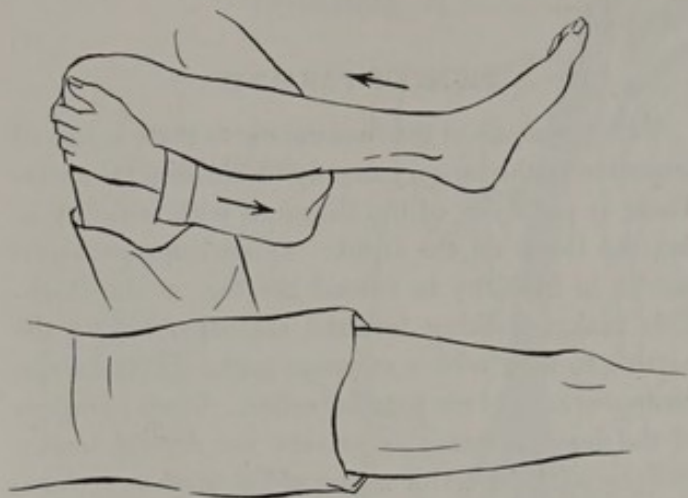


FIGURE 236.—Testing of iliopsoas muscle.

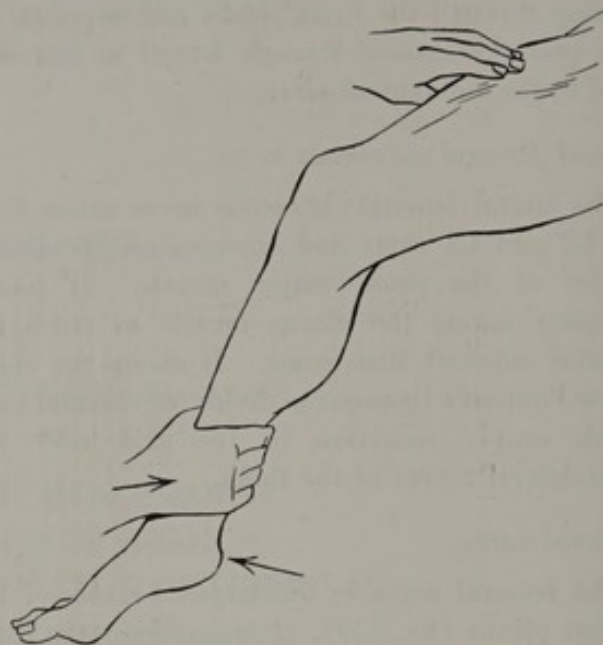

FIGURE 237.—Testing of quadriceps femoris muscle.

obturator externus and adductor magnus, and articular branches to the knee joint.

SIGNS OF PARALYSIS

With paralysis, there is impairment of external rotation and adduction of the thigh, and difficulty in crossing the legs. In addition, there is a small area of sensory loss on the medial aspect of the thigh.

MUSCLE TESTING

Adductors.—With the patient lying on his back, he is asked to adduct the extended limb against resistance. Contraction of the muscle bellies can be felt and often seen when function is present.

THE SACRAL PLEXUS

The sacral plexus is formed by the anterior primary divisions of L5 and S1 and parts of L4, S2, and S3 (fig. 238). Each of these nerves is connected to the sympathetic ganglionated chain by gray rami communicantes (postganglionic fibers), and parasympathetic preganglionic fibers are carried in the S2, S3, and S4 nerves.

The sacral plexus is situated on the posterior wall of the pelvis, between the parietal pelvic fascia and the piriformis muscle. The nerves of the plexus converge toward the inferior part of the greater sciatic

foramen, forming the sciatic nerve and several collateral branches.

Each of the portions of the anterior primary divisions of L4, L5, S1, S2, and S3 nerves which form the sacral plexus divides into an anterior and posterior division. The upper four posterior divisions (L4, L5, S1, S2) join to form the common peroneal nerve. All five anterior divisions (L4, L5, S1, S2, S3) join to form the tibial nerve. The posterior division of S3, with branches from the anterior divisions of S2 and S3, contributes to the pudendal plexus.

A. Branches from the anterior divisions:

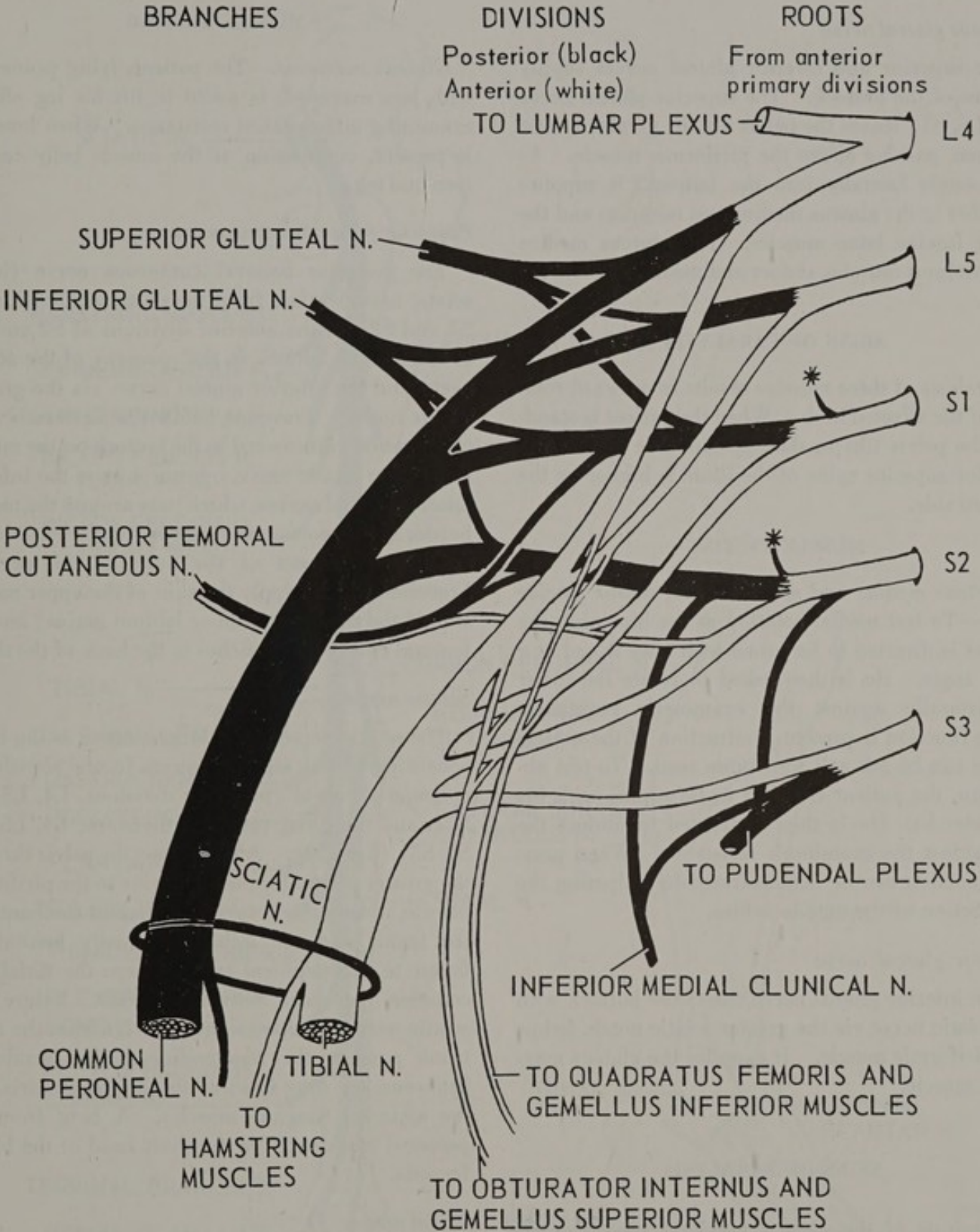
1. Tibial nerve (L4, L5, S1, S2, S3).
2. Nerve to the quadratus femoris and gemellus inferior muscles (L4, L5, S1).
3. Nerve to the obturator internus and gemellus superior muscles (L5, S1, S2).

B. Branches from the posterior divisions:

1. Common peroneal nerve (L4, L5, S1, S2).
2. Superior gluteal nerve (L4, L5, S1).
3. Inferior gluteal nerve (L5, S1, S2).
4. Inferior medial clunical nerve (S2, S3).

C. Branches from both anterior and posterior divisions:

1. Posterior femoral cutaneous nerve (lesser sciatic nerve) (S1, S2, S3).



* NERVES TO PIRIFORMIS M.

FIGURE 238.—Sacral plexus.

Superior gluteal nerve

The superior and inferior gluteal nerves supply muscles of the buttock. The superior gluteal nerve (L4, L5, S1) leaves the pelvis via the greater sciatic foramen, passing above the piriformis muscle. As it proceeds laterally into the buttock, it supplies branches to the gluteus medius and minimus and the tensor fasciae latae muscles. The gluteus medius and minimus muscles abduct and medially rotate the thigh.

SIGNS OF PARALYSIS

Paralysis of these muscles results in outward rotation of the affected limb. When the patient is standing, the pelvis tilts to the opposite side so that the anterior superior spine of the ilium is higher on the affected side.

MUSCLE TESTING

Gluteus medius and minimus, and tensor fasciae latae.—To test medial rotation at the hip joint, the patient is directed to lie prone with knee flexed at a right angle. He is then asked to rotate the lower leg laterally against the examiner's resistance. When function is present, contraction of the muscle bellies can be felt and sometimes seen. To test abduction, the patient is asked to lie supine with his leg extended. He is then instructed to abduct the leg against the examiner's resistance. When present, function can be demonstrated by palpating the contraction of the muscle bellies.

Inferior gluteal nerve

The inferior gluteal nerve enters the buttock with the sciatic nerve via the greater sciatic notch, below the piriformis muscle. It supplies the gluteus maximus muscle.

SIGNS OF PARALYSIS

Paralysis of the gluteus maximus muscle interferes with extension at the hip, making it difficult for the patient to rise from a seated position, run, jump, or climb stairs. The infragluteal fold tends to disappear due to sagging of the muscle. In time, atrophy of the buttock occurs.

MUSCLE TESTING

Gluteus maximus.—The patient, lying prone and with legs extended, is asked to lift his leg off the examining table against resistance. When function is present, contraction of the muscle belly can be seen and felt.

Posterior femoral cutaneous nerve

The posterior femoral cutaneous nerve (lesser sciatic nerve) arises from the posterior divisions of S1 and S2 and the anterior divisions of S2 and S3. It reaches the buttock in the company of the sciatic nerve and the inferior gluteal nerve, via the greater sciatic notch. Traveling below the piriformis muscle, it courses downward in the buttock on the medial side of the sciatic nerve. From it arise the inferior lateral clunical nerves, which pass around the medial border of the gluteus maximus to supply sensation to the inferior aspect of the buttock; the perineal branches, which supply the skin of the upper medial side of the thigh, scrotum or labium majus; and the femoral cutaneous branches to the back of the thigh.

Sciatic nerve

The sciatic nerve is the largest nerve in the body, consisting of two separate nerves in one sheath, the common peroneal (posterior divisions, L4, L5, S1, S2), and the tibial (anterior divisions, L4, L5, S1, S2, S3) (fig. 239). After leaving the pelvis through the greater sciatic foramen anterior to the piriformis muscle, it descends between the greater trochanter of the femur and the ischial tuberosity behind the femur to the popliteal space, where the tibial and common peroneal nerves separate. Before the sciatic nerve terminates, motor twigs from the tibial trunk pass to the semitendinosus and semimembranosus, the long head of the biceps femoris, and the adductor magnus muscles. A twig from the peroneal trunk supplies the short head of the biceps femoris.

Tibial nerve

The tibial nerve begins its independent course in the upper part of the popliteal space and descends in the middle of the popliteal space (fig. 239). On its way to the upper level of the soleus muscle, it gives off branches to the gastrocnemius, plantaris, soleus,

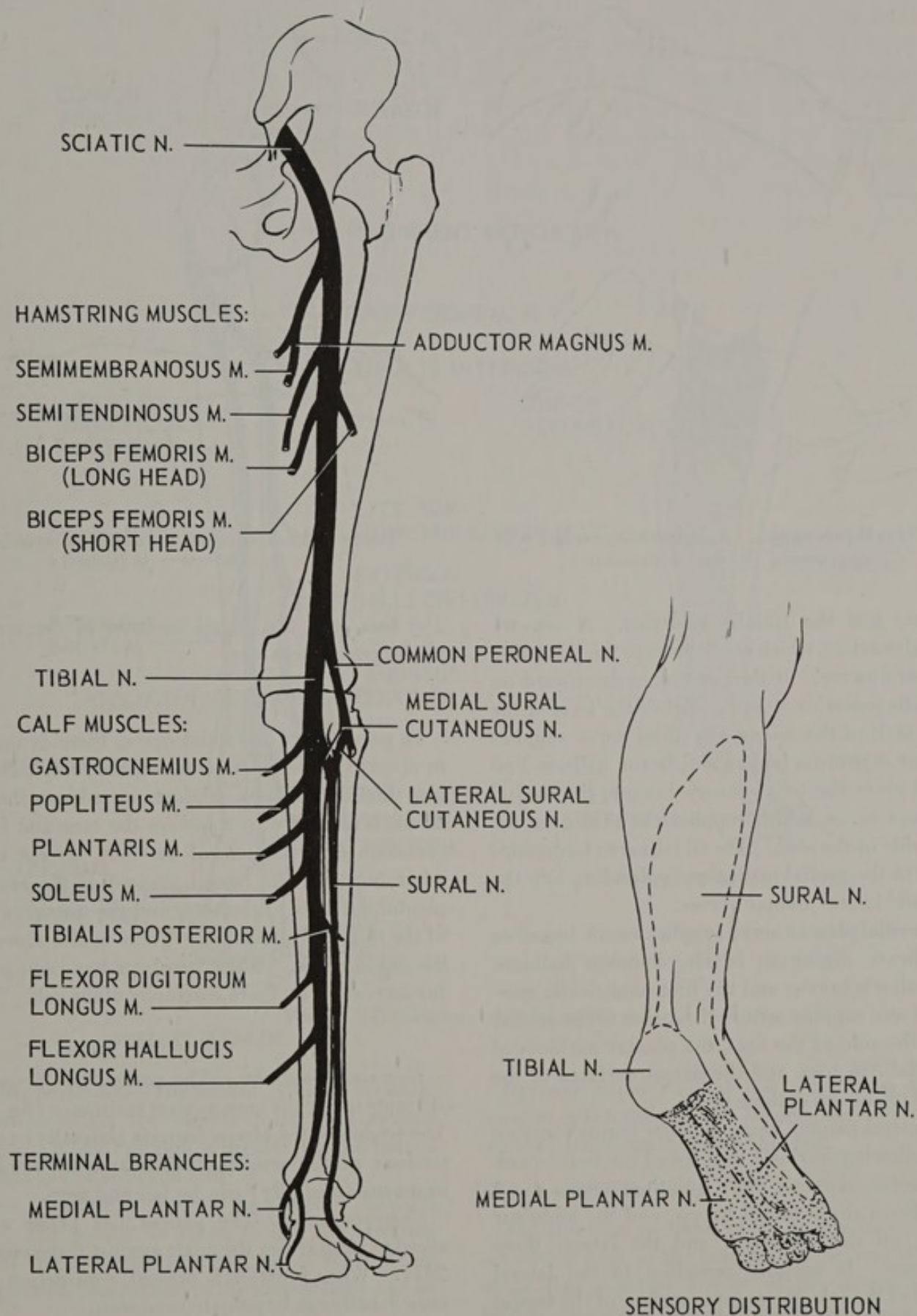


FIGURE 239.—Sciatic and tibial nerves.

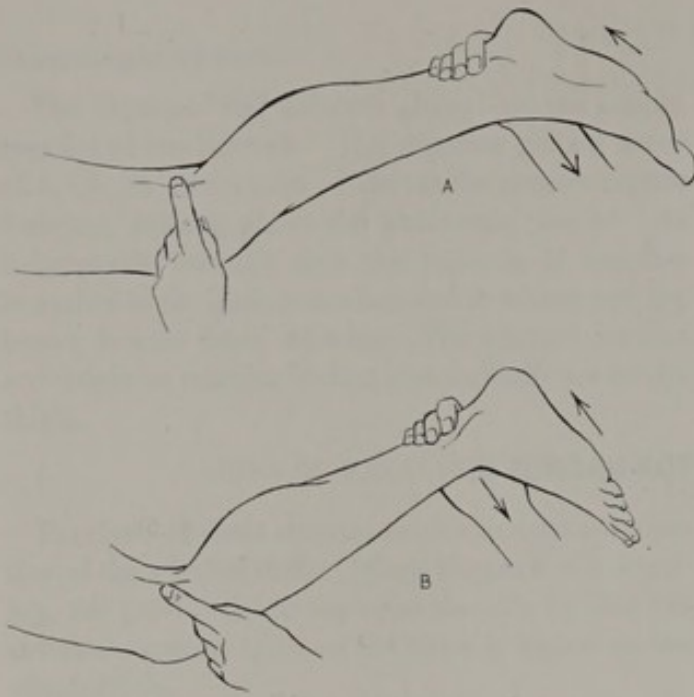


FIGURE 240.—Muscle testing. A. Semitendinosus and semimembranosus. B. Biceps femoris.

popliteus, and the tibialis posterior. A sensory branch also arises, which contributes to the formation of the sural nerve. It then continues downward on the tibialis posterior muscle. Below the level of the fibrous arch of the soleus, the tibial nerve supplies the flexor digitorum longus and flexor hallucis longus and gives rise to a sensory branch, the medial calcaneus nerve, which supplies the skin over the medial side of the heel. The tibial nerve terminates inferior to the medial malleolus by dividing into the medial and lateral plantar nerves.

The medial plantar nerve supplies motor branches to the flexor digitorum brevis, abductor hallucis, flexor hallucis brevis, and the first lumbricalis muscles. It also supplies sensory branches to the medial side of the sole of the foot, the plantar surfaces of the medial $3\frac{1}{2}$ toes, and the dorsal surfaces of the terminal phalanges of these toes.

The lateral plantar nerve supplies motor function to the following intrinsic muscles of the foot: quadratus plantae, abductor digiti quinti, opponens digiti quinti, flexor digiti quinti brevis, and the adductor hallucis, all the interossei, and the lateral three lumbricales. It supplies sensation to the lateral portions of the sole, the plantar surface of the lateral

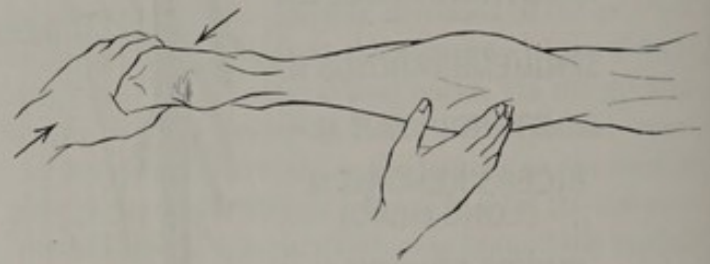

FIGURE 241.—Testing of gastrocnemius muscle.

$1\frac{1}{2}$ toes, and the dorsal surfaces of the terminal phalanges of these toes.

SIGNS OF PARALYSIS

In paralysis of the tibial nerve, there is inability to plantar-flex, adduct, or invert the foot. There is also inability to flex, abduct, or adduct the toes. There is inability to stand on the toes and loss of sensation over the sole of the foot (except on the inner border), the lateral surface of the heel, the plantar surfaces of the toes, and the dorsal surfaces of the terminal phalanges. There is also absence of the ankle reflex. When paralysis has been present for several weeks, there is atrophy of the calf.

MUSCLE TESTING

Hamstring muscles.—The patient lies prone and attempts to flex the knee against resistance (fig. 240). The tendon of the biceps femoris (laterally) and the tendons of the semitendinosus and the semimembranosus (medially) can be felt and seen.

Gastrocnemius.—The patient lies prone and is asked to plantar-flex the ankle against resistance (fig. 241). When function is present, contraction of the muscle belly can be palpated and seen.

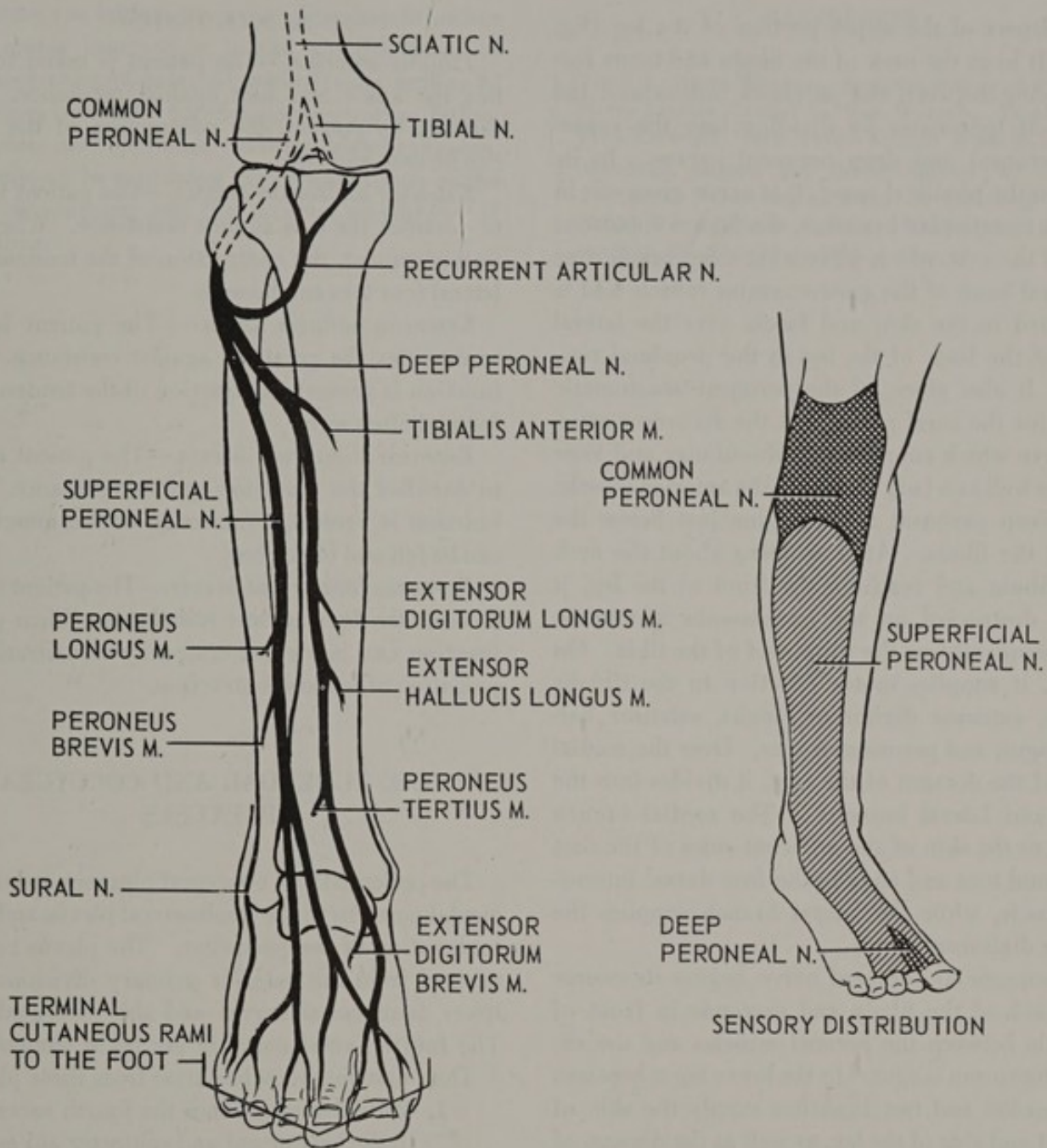


FIGURE 242.—Common peroneal nerve.

Tibialis posterior.—The patient, lying on his back, is asked to invert the plantar-flexed foot against resistance. When function is present, contraction of the tendon can be seen and felt.

Flexor digitorum longus and flexor hallucis longus.—The patient is asked to flex the terminal joints of the toes against resistance. When function is present, contraction of the muscle belly can be felt.

Intrinsic muscles of the foot.—Function of these muscles, when present, can be demonstrated by having the patient cup the sole of his foot.

Common peroneal nerve

The common peroneal nerve begins its independent course high in the popliteal space, and descends along the posterior border of the biceps femoris tendon diagonally across the popliteal space to the

lateral aspect of the upper portion of the leg (fig. 242). It hugs the neck of the fibula and turns forward, lying between the peroneus longus and the fibula. It terminates by dividing into the superficial peroneal and deep peroneal nerves. In its course in the popliteal space, this nerve gives off, in addition to articular branches, the lateral cutaneous nerve of the calf, which pierces the deep fascia over the lateral head of the gastrocnemius muscle and is distributed to the skin and fascia over the lateral aspect of the back of the leg in the proximal two-thirds. It also gives off the peroneal anastomotic branch for the sural nerve, and the recurrent articular nerve which supplies the tibiofibular and knee joints, as well as a twig to the tibialis anterior muscle.

The deep peroneal nerve begins just below the head of the fibula. After winding about the neck of the fibula and reaching the front of the leg, it courses downward on the interosseous membrane and subsequently on the distal end of the tibia. On its way, it supplies motor function to the tibialis anterior, extensor digitorum longus, extensor hallucis longus, and peroneus tertius. Over the medial aspect of the dorsum of the foot, it divides into the medial and lateral branches. The medial branch extends to the skin of the adjacent sides of the first and second toes and ends in the first dorsal interosseus muscle, while the lateral branch supplies the extensor digitorum brevis.

The superficial peroneal nerve begins its course at the neck of the fibula and descends in front of the fibula between the peronei muscles and the extensor digitorum longus. In the lower leg it becomes subcutaneous and two branches supply the skin of the front and side of the leg, as well as the dorsum of the foot. In addition, this nerve supplies motor function to the peroneus longus and brevis muscles. The sensory supply of this nerve to the dorsum of the foot and anterolateral aspect of the lower leg tends to be variable.

SIGNS OF PARALYSIS

In patients with paralysis of the peroneal nerve a drop-foot deformity occurs, causing the patient to walk with a steppage gait. There is inability to extend (dorsiflex) the foot or toes and inability to evert and abduct the foot. Sensory paralysis of this nerve results in loss of sensation over the dorsum of the foot and over the outer side of the lower leg.

MUSCLE TESTING

Tibialis anterior.—The patient is asked to dorsiflex the ankle and foot against resistance. When function is present, the contraction of the muscle can be seen and felt.

Extensor digitorum longus.—The patient is asked to dorsiflex the toes against resistance. When function is present, the contraction of the tendons to the lateral four toes can be seen.

Extensor hallucis longus.—The patient is asked to dorsiflex the great toe against resistance. When function is present, contraction of the tendon can be felt and often seen.

Extensor digitorum brevis.—The patient is asked to dorsiflex the great toe against resistance. When function is present, contraction of the muscle belly can be felt and often seen.

Peroneus longus and brevis.—The patient is asked to evert the foot against resistance. When present, function can be demonstrated by visualization and palpation of tendon contraction.

THE PUDENDAL AND COCCYGEAL PLEXUSES

The pudendal and coccygeal plexuses are the most caudal portions of the lumbosacral plexus and supply innervation of the perineum. The plexus roots are derived from the anterior primary divisions of the lower four sacral nerves and the coccygeal nerve. The fourth sacral nerve is the main component.

The following branches arise from these plexuses:

1. Muscular rami from the fourth sacral nerve to the levator ani and sphincter ani externus.
2. Pudendal nerve (S2, S3, S4).
3. Small sensory branches from S4, S5, and C, which supply skin in the region of the coccyx.

Pudendal nerve

The pudendal nerve (S2, S3, S4) travels through the greater sciatic foramen and enters the perineum through the smaller sciatic foramen where it divides into: (1) The inferior hemorrhoidal nerve to the external anal sphincter and adjacent skin, and (2) the perineal nerve which arises near the base of the urogenital diaphragm and immediately divides into superficial and deep branches. The superficial branches are distributed to the skin over

the scrotum (or labium majus). The deep branches supply motor innervation to the anterior parts of the levator ani and external sphincter, as well as to the perinei muscles, the ischiocavernosus, bulbo-cavernosus, and sphincter urethrae membranaceae, and terminate in supplying the erectile tissue of the corpus cavernosum and the mucous membrane of the urethra.

REFERENCES

1. Tinel, J.: Nerve Wounds. Symptomatology of Peripheral Nerve Lesions Caused by War Wounds. Translated by Fred Rothwell. New York: William Wood & Co., 1917.
2. Woodhall, Barnes, and Beebe, Gilbert W. (editors): Peripheral Nerve Regeneration. A Follow-up Study of 3,656 World War II Injuries. Washington: U.S. Government Printing Office, 1956.

CHAPTER 43

Pathology of Peripheral Nerve Injuries

Hugo V. Rizzoli

Adequate and successful treatment of peripheral nerve injuries requires a knowledge of the pathology and an understanding of the processes of degeneration and regeneration following nerve injuries.

PERIPHERAL NERVE STRUCTURE

A peripheral nerve is made up of numerous nerve fibers contained in a cylindrical, tubelike structure. Each nerve fiber (axis cylinder or axon) is part of a neuron whose cell body is situated in the anterior horn of the spinal cord (motor or efferent), in a posterior root ganglion (sensory or afferent), or in a sympathetic ganglion.

The structural unit of the nervous system is the neuron. The neuron doctrine assumes that the neuron is a cellular unit capable of independent existence. It consists of a cell body whose cytoplasm extends into processes known as either dendrites or axons (axis cylinders). When divided, these processes degenerate distally, and regenerate from the proximal end of the divided process. The dendrites receive impulses from other neurons and transmit them to their cell bodies; the axons carry the impulses away from their cell bodies to other neurons or end organs. The neuron theory predicates a functional polarity in the transmission of impulses. An impulse travels from the axon of one neuron to the dendrite of another neuron, through the cell body, to the axon of this related cell. A neuron may have many dendrites, but it has only one axon.

Both the motor and sensory nerve fibers encountered in peripheral nerves are referred to as

axons, despite the fact that those fibers transmitting afferent impulses to the posterior root ganglion cells are, in reality, dendrites.

The axon or axis cylinder is thought to consist of fine fibrils embedded in a jellylike substance, the axoplasm, which seems to be a direct continuation of the cytoplasm. A limiting membrane, the axolemma, has been demonstrated on the axonal surface. Many axons are surrounded by an obvious myelin sheath; these axons are known as myelinated fibers. Those fibers which have no myelin sheath demonstrable by present techniques are referred to as amyelinated fibers. Myelin sheaths are composed of layers of lipoids between layers of protein. At variable distances of from 50 to 1,000 $m\mu$., the myelinated fibers show constrictions known as nodes of Ranvier. The segment between nodes is designated the internode. Each internode has a single tubular Schwann cell wrapped about the myelin. External to the Schwann cell is a continuous, thin, tubular sheath, the neurilemma, which travels across the nodes of Ranvier without interruption and seems to hold in place the underlying Schwann cells. Together they play an important role in axonal regeneration. The neurilemmal sheath is absent in the central nervous system and begins a short distance after the fibers leave, or before they enter, the brain or spinal cord.

A sheath of connective tissue, the endoneurium, surrounds the neurilemma of each axon. Mucoid in appearance, fibrous in nature, the endoneurium contains fibroblasts, macrophages, and small vessels. It has a tendency to proliferate and contract upon degenerated nerve tubules. It forms trabeculae between the nerve fibers, and at times tends to

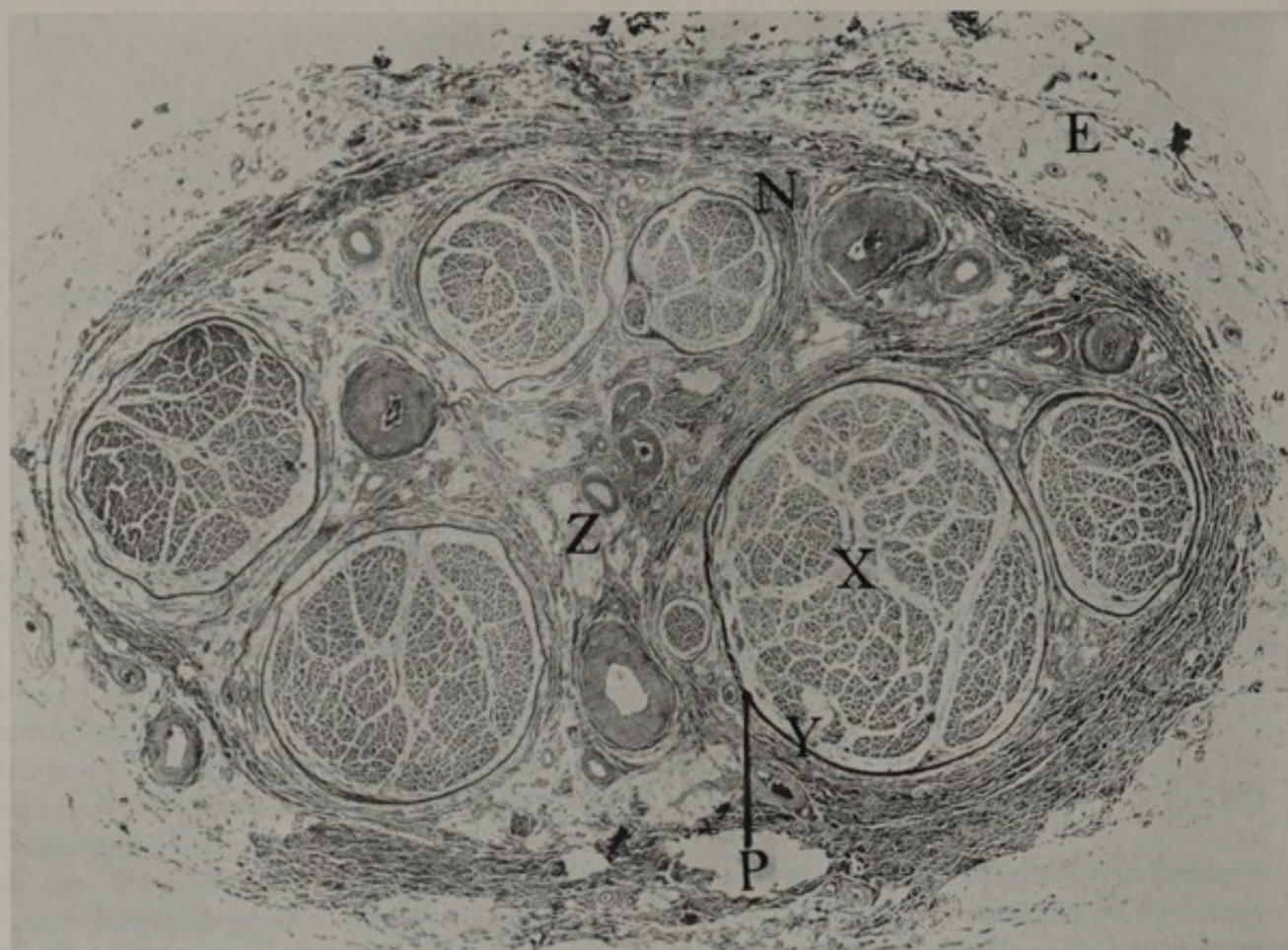

FIGURE 243.—This section of a common peroneal nerve has been chosen to demonstrate cross-sectional topography because its markings are accentuated by the vascular pathology and the intrafascicular edema. The fascicles of varying size are composed of secondary bundles of individual fibers which appear as minute dots in cross section. Separating these secondary bundles are endoneural trabeculae (X) of a light fibrous nature which send fine reticular sheaths within the secondary bundles to surround each nerve fiber. At the periphery of the fascicle or primary bundle and just within the thin perineurial sheath (P), a well-demarcated, perifascicular fluid space is seen (Y). This is continuous with the smaller spaces around the secondary bundles. Some of the fascicles have thicker and tougher sheaths (U) surrounding the true perineurial membranes and these blend with the interfascicular tissue (Z) and the epineurium (E). These sheaths are especially well shown at points where a large nerve gives off branches and are continuous with the epineurium of the branch. Although there is a great variation in the amount of adipose tissue in different parts of any nerve and in similar regions of different nerves, the amount seen here is considered to be a fair average and its distribution in the epineurium and interfascicular tissue is a very common one. Examples of small fascicles not completely incorporated within an accompanying larger one, and others running independently, are also present. A large fascicle such as seen here may contain 10,000 or more nerve fibers and so a sciatic nerve with as many as 80 fascicles may carry approximately 1 million axons. (X 22.5) (From Lyons and Woodhall.)

separate groups of nerve fibers into secondary bundles.

Groups of nerve fibers and their endoneural coverings are ensheathed by a thin, but relatively strong, and slightly elastic tissue, the perineurium. This membrane is composed of large fibroblasts embedded in collagen. A bundle of fibers surrounded by perineurium is known as a fascicle and is discernible on cross section of a nerve (figs. 243

and 244). Fascicles vary in size and may contain as many as 10,000 nerve fibers (axons).

A network of connective tissue, the interfascicular tissue, binds the fascicles and supports the larger vessels of the nerve. Groups of fascicles, ranging from a few to as many as 80, when surrounded by a tough tubular sheath of connective tissue known as the epineurium, constitute a peripheral nerve (figs. 245 and 246).

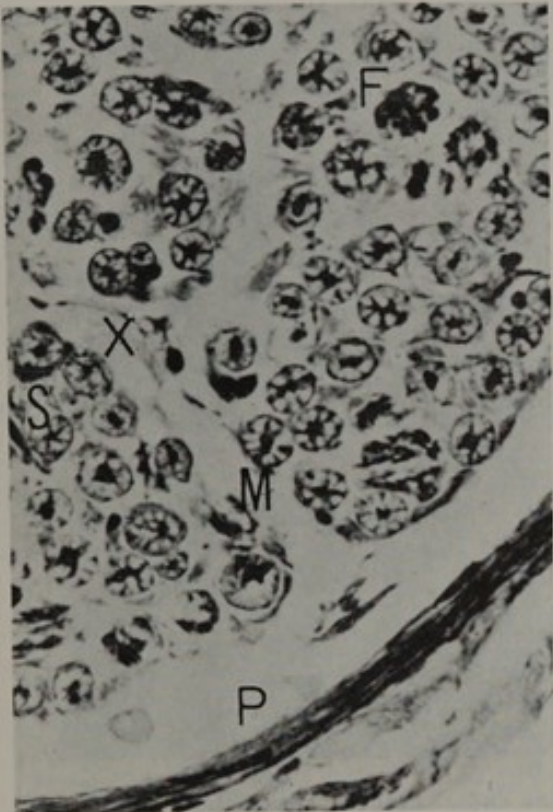

FIGURE 244.—A higher magnification of a part of a nerve fascicle in cross section, showing the thin perineurium composed of fibroblasts and connective tissue fibers (P); the endoneurium (X) dividing the fascicle into secondary bundles and surrounding the nerve fibers; intrafascicular blood vessels; myelinated (M), and clusters of amyelinated nerve fibers (F). Radiating out from the axis cylinder at the center of the myelinated fibers to meet the neurilemma may be seen the neurokeratin of the myelin sheath in wheel-spoke arrangement. In a few places the Schwann cells (S) are seen around the myelinated fibers. (X 600) (From Lyons and Woodhall.)

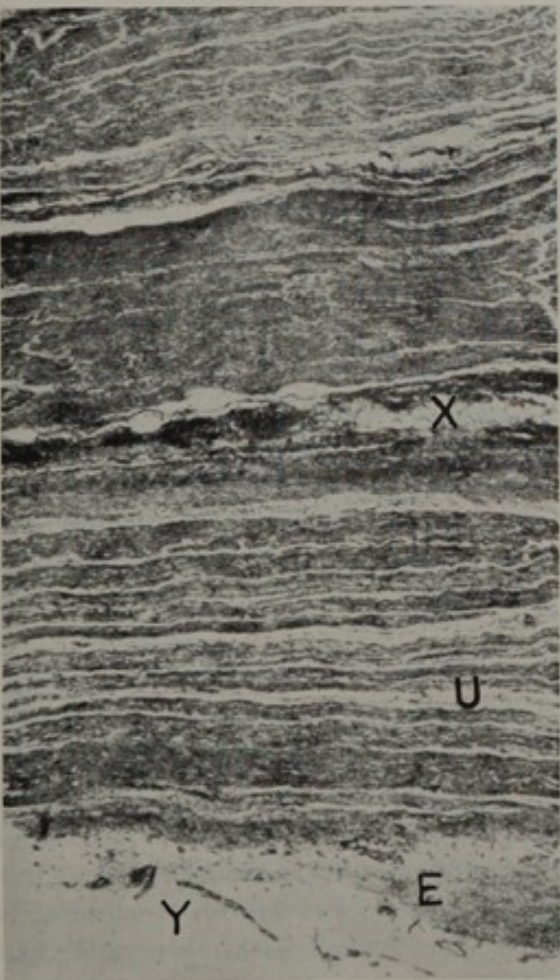


FIGURE 245.—A longitudinal section through a peripheral nerve showing the fatty (Y) and fibrous epineurium (E), and the perineurial membranes blending with the fibrous, fatty, and vascular interfascicular tissue (X). The fascicles show separation into secondary bundles (U). The individual myelinated fibers may be seen better with a hand lens. (X 24) (From Lyons and Woodhall.)

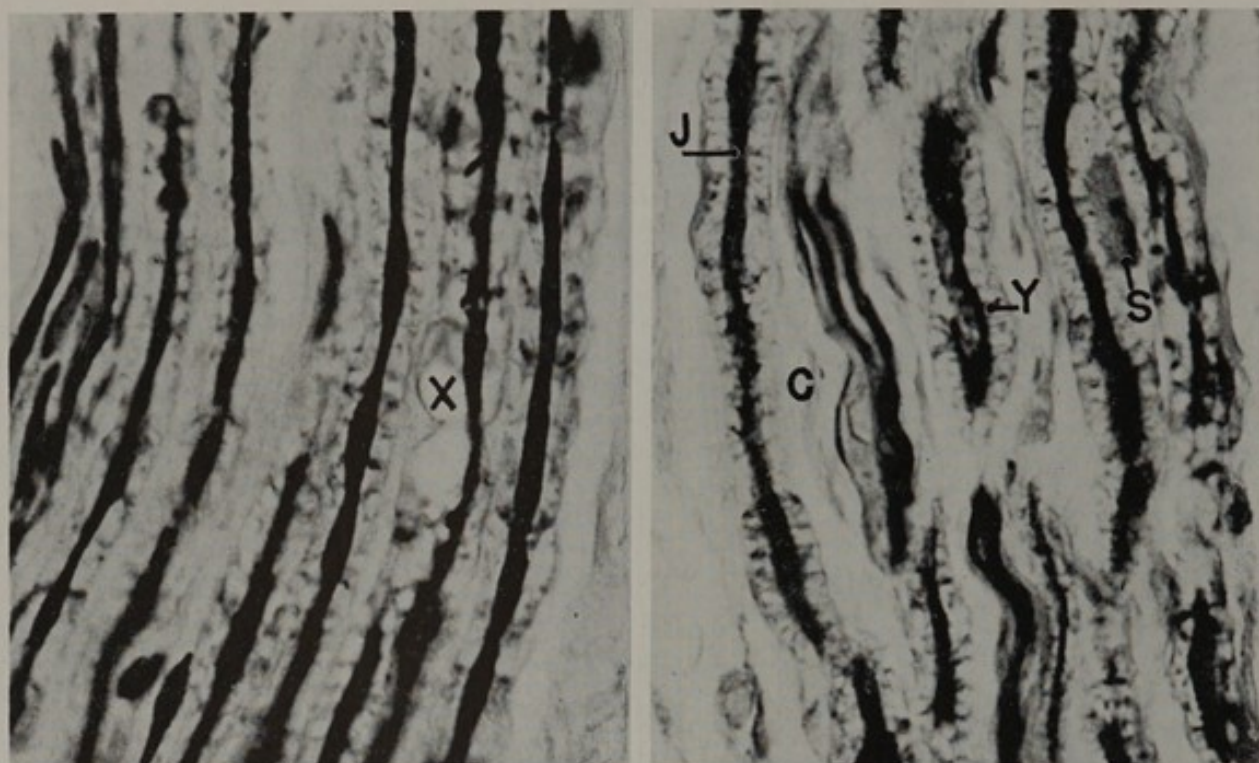


FIGURE 246.—Longitudinal sections of peripheral nerves showing endoneurium (C), Schwann cells (S), a node of Ranvier with a continuous neurilemma (X), axons (J), and neurokeratin (Y). The slight irregularity in the girth of the axons seen here is not unusual in normal nerves. (X 1000) (From Lyons and Woodhall.)

HISTOLOGICAL CHANGES IN NERVE INJURY

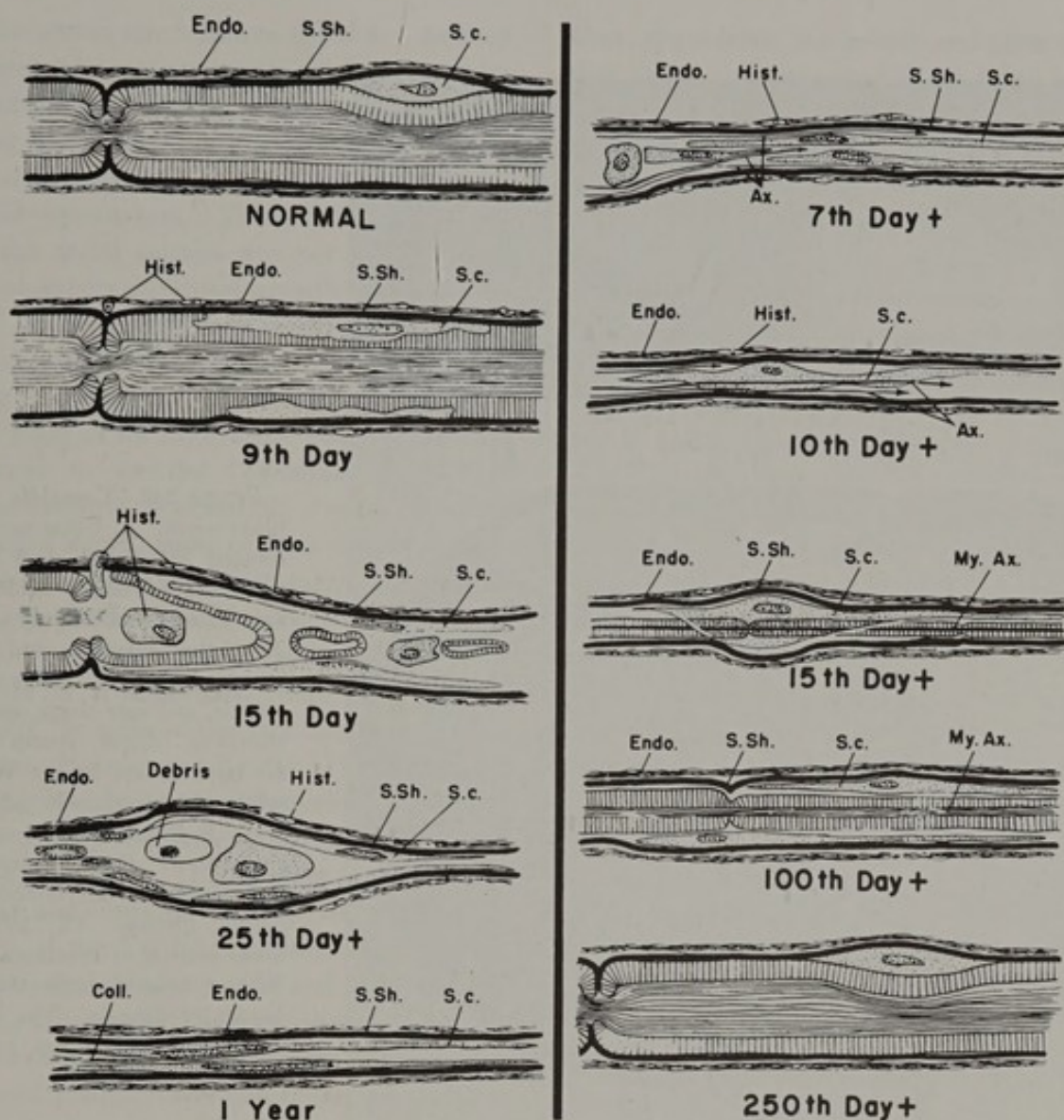
When nerve fibers are divided, a well known sequence of events occurs. These reactions have been listed by Lyons and Woodhall (1) in their "Atlas of Peripheral Nerve Injuries" as follows:

1. Degeneration of axons and myelin sheaths in that part of the proximal stump in the range of trauma.
2. Degeneration of all axons and myelin sheaths throughout the distal nerve trunk and the end organs.
3. Early regrowth with multiple sprouting of the axons of the proximal segment in an attempt to regain the old endings.
4. Degeneration of the Schwann cells coming under the immediate influence of the injurious agent in both stumps.
5. Multiplication of Schwann cells as an accompaniment to the axonal proliferation in the proximal segment.
6. An overgrowth of these same cells in the tubules of the distal segment left without viable axons, but anticipating the ingrowth of new ones.
7. A persistence of atrophic Schwann cells and neurilemmal sheaths for years in the distal stump and end organs.
8. An infiltration of macrophages into the degenerating nerve fibers for the purpose of clearing away the myelin and axonal fragments.
9. A braiding or thickening of the new axonal sprouts and their subsequent myelination or simple enclosure by neurilemmal cells and sheath.

10. A fibrous replacement of the evacuated parts of degenerated Schwann tubules in the event that axonal sprouts do not reoccupy them.

The histological changes are visible in contused segments of injured nerves, regardless of whether or not the nerve is severed. In the proximal stump these pathological changes occur only in the vicinity of injury; whereas, in the distal stump, there is, in addition to local changes, wallerian degeneration to the peripheral nerve endings. There is local degeneration of myelin and axons with phagocytosis of the debris. In addition, there is proliferation of the cells of Schwann with connective tissue proliferation involving the endoneurium, perineurium, and epineurium (2).

Changes occurring in the proximal stump.—In a completely divided nerve, there is early proliferation of the axons in the proximal stump, with axonal sprouting. The proximal axon has great regenerative capacity. Following injury, retrograde axonal degeneration proceeds only to the first node of Ranvier proximal to the site of injury. Instead of regenerating as a single axon, each regenerating axon sprouts into as many as 40 new axons, and they



AFIP 101365

FIGURE 247.—Diagrammatic representation of various stages of degeneration and regeneration of the distal stump of a peripheral nerve, taken largely from data of Holmes and Young (1942) in experimental studies on rabbits. In the first column are represented stages of degeneration in an unsutured nerve, and in the second column, stages of regeneration after the ingrowth of new axons. The cell of Schwann is indicated by S.c., the sheath of Schwann by S.Sh., the endoneurium by Endo., histiocytes by Hist., regenerating axons by Ax., myelinated regenerating axons by My. Ax., and collagen by Coll. The days indicated for the various stages of degeneration and regeneration are to be regarded as only approximate.

First Column. By the 9th day the Schwann cells have become activated in response to degenerative changes in the axons and myelin. Subsequently, the myelin and axis cylinders disintegrate, histiocytes enter the nerve to phagocytose the debris, the Schwann tubules collapse, and the Schwann cells elongate and move distalward. After a year, the Schwann tubules are of much reduced caliber and are filled with elongated Schwann cells, between which there is an accumulation of collagen.

Second Column. Beginning at about the 7th day after immediate end-to-end suture of a divided nerve, newly formed axons advance into the most proximal portion of the distal segment. ("7th Day+" refers to the axons, not the nerve fiber as a whole, which is at approximately the 25-day stage of degeneration.) One of the axons becomes surrounded by Schwann cytoplasm, increases in caliber, and on about the 15th day, myelination occurs in the most proximal part of the distal segment. Maturation of the nerve proceeds slowly, Schwann cells being compressed as the diameter of the newly developing nerve increases, and by the 250th day, the nerve usually has regenerated completely. (From Haymaker.)

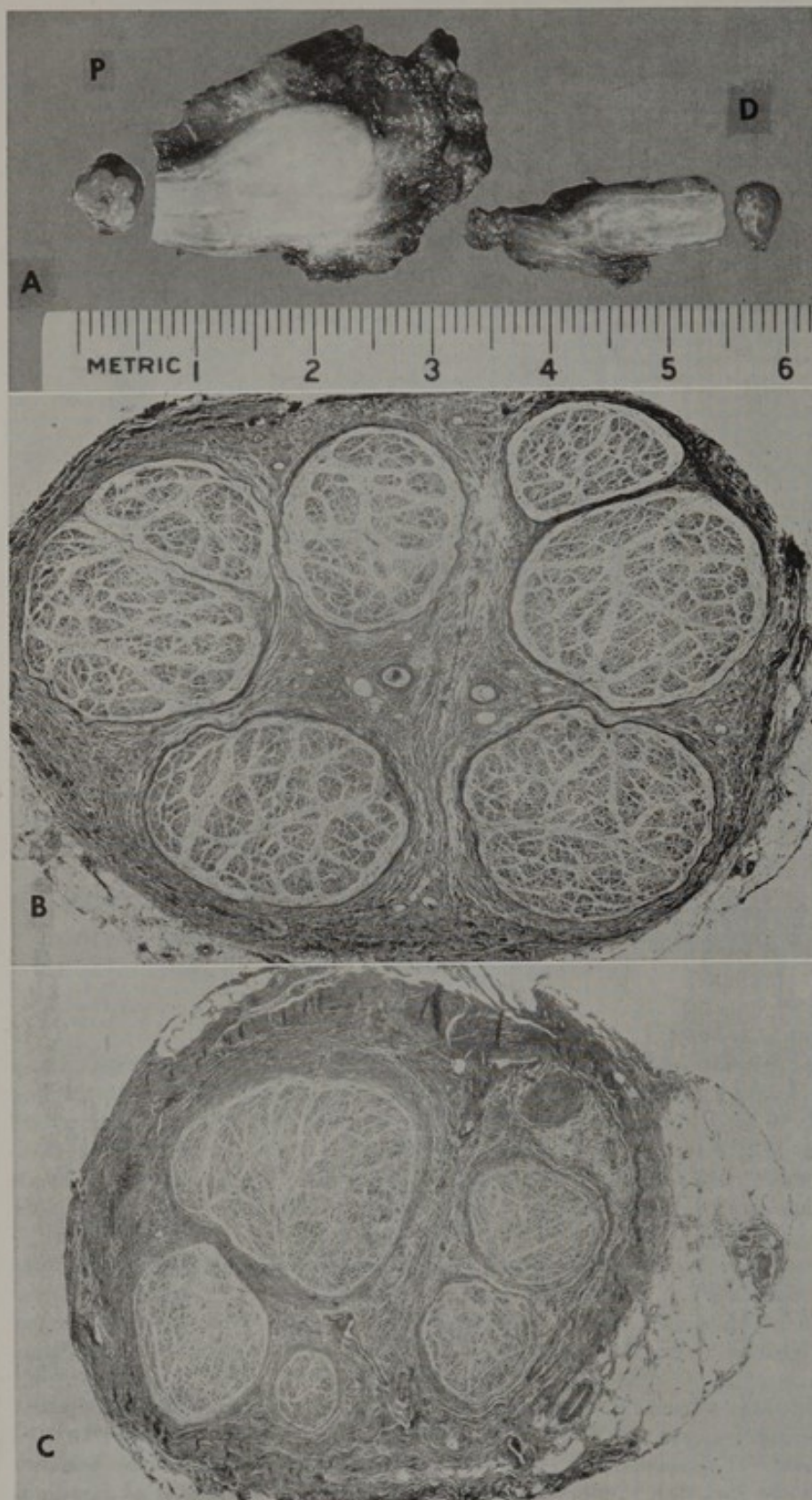


FIGURE 248.—Complete severance of ulnar nerve. A. Ulnar nerve completely severed by mortar shell fragment 8 $\frac{3}{4}$ months previously. (Soldier was prisoner of war in Germany for 7 months.) Note the enlarged and neuromatous proximal stump (P) surrounded by fat, muscle, and scar tissue, and the slightly shrunken distal stump (D). The fascicles shown in the proximal cross section are extremely edematous. (X 1.5) B. Proximal cross section of nerve shown in A. Note intrafascicular edema and moderate interfascicular and epineurial fibrosis. (X 20) C. Distal cross section of specimen shown in A. Note epineurial, perineurial, and interfascicular fibrosis. The small fascicle at the upper left has become almost obliterated. (X 20)

grow distally within the Schwann tubules. / As they reach the area of greatest contusion, the fascicular arrangement becomes disorganized with clusters of regenerating axons growing out of the tubules and fascicles and at times beyond the limits of the perineurium and epineurium. This tendency is much greater if the distal tubules are not patent, or if scar tissue obstructs the distal growth of regenerating axons. In the presence of obstruction, the numerous regenerating axons grow in whirls, twisting and turning and forming a grossly visible swelling or bulblike mass at the end of the proximal stump, often referred to as the "proximal neuroma." Though this swelling is primarily due to the mass of regenerating axons, some of it is due to edema.

Changes occurring in the distal stump.—The distal stump in a completely divided nerve, by contrast, is usually not edematous or swollen, but tends to be shrunken. It is traditionally referred to as the distal "glioma" in spite of the fact that this is not a suitable term. Holmes and Young (3) showed that in the rabbit, while the axons and myelin in the distal segment are undergoing degeneration, the Schwann cells become activated. This is most marked about the ninth day and continues through the third week. Proliferation of the fixed histiocytes begins on the 8th day after section of a nerve and they tend to recede by the 25th day. Phagocytosis of the debris results in the emptying of the Schwann tubules. As the process of phagocytosis continues, the tubules become narrowed and, after several months, shrink to about half their original diameter (figs. 247 and 248).

After neurorrhaphy, there is growth of new axons into the distal stump. This is first noted on or about the seventh day after suture. The rate of regeneration in animals was found to be 3.5 mm. per day (4). Following neurorrhaphy in man, rates of from 1 to 3 mm. a day have been reported. Seddon, Medawar, and Smith (5), in a study of 25 cases (18 involving the radial nerve), reported an average rate of growth of 1.5 mm. per day after suture. The regenerating fibers continue distally into the tubules of Schwann. Only one fiber in each tubule enlarges as the others disappear. Myelination occurs proximally simultaneously and begins as early as the 15th day.

Reinnervation of muscles.—Restoration of motor function does not occur until maturation of the regenerating fibers is complete. As a regenerating

fiber approaches the motor end-plate of a muscle that has been denervated for a brief period, it re-enters the motor end-plate and reinnervates it, and soon these end-plates appear as before. In cases of longstanding paralysis, atrophy and connective tissue proliferation occur; the Schwann tubules become occluded with collagen, making it difficult or impossible for regenerating axons to enter the end-plates. If no new contact is made, atrophy of the muscle becomes progressive.

With increasing periods of denervation, the number of old end-plates which become reinnervated is progressively reduced. The regenerating fibers escape from original terminal nerve bundles and Schwann tubules, and travel between muscle fibers. Some of these axons make contact with the sarcoplasm and new atypical end-plates are formed. The effectiveness of reinnervation is decreased by prolonged denervation.

PATHOLOGICAL CLASSIFICATION OF NERVE INJURIES

The histological changes encountered in peripheral nerve injuries are variable. Tinel (6) has discussed them under the following three headings:

1. *Section.*—It is estimated that about half of the injured nerves in World War II were found to be completely severed. Anatomic nerve division presents the simplest features for histological study. One finds a terminal neuroma on the central end (proximal neuroma), composed of regenerating axons. The distal end also presents a small swelling (distal glioma), always smaller than the proximal neuroma, and composed of excessive proliferation of cells of the sheath of Schwann. Of course, with anatomic division, wallerian degeneration takes place distally.

2. *Complete interruptions without break of continuity of the nerve.*—This group consists of those nerve injuries produced by a crushing or contusion of the nerve, with interruption of the nerve fibers but without actual division of the nerve. This type of lesion results in a neuroma in continuity. Tinel describes three different zones in this neuroma: A middle zone of nerve destruction in a fibrocontractile tissue acting as an obstacle to the regenerating axons; a proximal zone in this neuroma where the

regenerating axons are piled up proximal to the obstruction; and a distal zone of neuroglial proliferation where the cells of the sheath of Schwann form a cellular mass with degenerated nerve fascicles. In reality, however, these three zones are not usually distinct.

3. *Pseudoneuroma resulting from bruising.*—This group has also been referred to as lesion in continuity with transient physiological block. This type of lesion occurs after minor trauma producing minimal pathological changes. There is no disruption of the endoneurium, perineurium, or epineurium, and in its purest form there is usually no division of axons or wallerian degeneration. One may find a simple swelling or fragmentation of the myelin about some of the axons. There may be some interstitial infiltration of the nerve by connective tissue and some proliferation of the cells of the sheath of Schwann. There may be small interstitial hemorrhages, with thickening of the epineurium, perineurium, and endoneurium, which may result in an elongated pseudoneuroma. Clinically, these lesions produce an incomplete and temporary paralysis with spontaneous recovery.

In 1943, Seddon (7) introduced three terms to describe the grades of damage encountered in 650 cases of peripheral nerve injury. Though these terms were meant to serve as a clinical classification, they have proved more useful as a pathological classification.

His terms and definitions follow:

1. *Neurotmesis* (a "cutting," which implies a separation of related parts) describes the state of a nerve in which all essential structures have been sundered. There is not necessarily an obvious anatomical gap in the nerve; indeed, the epineural sheath may appear to be in continuity, although the rest of the nerve at the site of damage has been completely replaced by fibrous tissue. But the effect is the same as if anatomical continuity had been lost. Neurotmesis is therefore of wider applicability than [nerve] division.

2. *Axonotmesis.*—Here the essential lesion is damage to the nerve fibres of such severity that complete peripheral degeneration follows; and yet the epineurium and more intimate supporting structures of the nerve have been so little disturbed that the internal architecture is fairly well preserved. Recovery is spontaneous, and of good quality, because the regenerating fibres are guided into their proper paths by their intact sheaths.

3. *Neurapraxia* (non-action) is used to describe those cases in which paralysis occurs in the absence of peripheral degeneration. It is more accurate than *transient block*

in that the paralysis is often of considerable duration, though recovery always occurs in a shorter time than would be required after complete wallerian degeneration; it is invariably complete.

Mixed lesions.—Lesions in continuity present the most complex problem clinically. One encounters cases in which all portions of the nerve are not insulted to the same degree; therefore, some fibers may have relatively normal function, and others may be completely divided (neurotmesis). Some fibers may undergo wallerian degeneration without disruption of the endoneurium (axonotmesis), while still others may be anatomically intact but may show transient physiological block without axonal degeneration (neurapraxia). In general, all the fibers in any given fascicle tend to be injured to the same degree, and therefore the practical unit to consider in discussion of peripheral nerve injuries is the fascicle with its perineural covering.

CLINICAL CLASSIFICATION OF PERIPHERAL NERVE INJURIES

Sunderland (8) originally classified peripheral nerve injuries according to degree. Traction injuries and injuries due to widespread ischemia were not included. A modification as provided by Haymaker and Woodhall (9) follows:

First degree injury.—This group includes those cases with loss of conductivity of the axis cylinders at the site of injury, without disruption of the various sheaths or of the axons. Wallerian degeneration does not occur (neurapraxia). This type of injury may be produced by instantaneous violence, as in missile wound or fracture, or by compression, as in crutch paralysis. It is said to result from ischemia, interstitial hemorrhages, or mechanical deformation of the axon. Clinically, it is characterized by motor paralysis. Sensory function is usually impaired to a lesser degree, and pain and touch often remain intact. Proprioceptive function (position and vibratory sense) is more apt to be affected. Spontaneous return of function may occur in a few minutes with minor insults, but with the more severe injuries it may not occur for several weeks.

Second degree injury.—In second degree injury, the endoneural tubules remain intact, but the axons are disrupted and wallerian degeneration occurs

(axonotmesis). Excellent spontaneous recovery occurs. Clinically, there is complete sensory and motor paralysis. Because regeneration of the axons must occur, restoration of function does not occur as rapidly as it does with first degree injury. The most proximal muscles are naturally the first to show evidence of return of function.

Third degree injury.—In third degree injury, the degree of insult is such as to cause a disorganization of the internal structure of the fasciculi with disruption of the endoneural tubules with axonal severance and wallerian degeneration. The epineural and perineural sheaths may be intact. Resulting intrafascicular fibrosis and endoneural fibrosis block the path of regenerating axons and cause some to be misdirected into foreign tubules. Clinically, the rate of regeneration is slower than in second degree injuries and functional restoration more variable and less perfect. Prior to regeneration, there is complete loss of motor and sensory function.

Fourth degree injury.—In this group there is disruption of the epineurium, perineurium, and endoneurium, as well as the axons, but continuity of the nerve persists. The injured segment is often converted into a narrowed cord of tissue with connective tissue, proliferating sheaths of Schwann cells, and regenerating axons. This type of injury results in complete motor and sensory paralysis. Regeneration is less perfect than in third degree injuries, since there is more obstruction to the peripheral growth of regenerating axons, and even more chance of misdirection of regenerating fibers. Usually, significant spontaneous regeneration does not occur without neurorrhaphy.

Fifth degree injury.—This group comprises those cases with complete anatomic division, with a proximal neuroma and a distal glioma and, occasionally, a fibrous strand connecting the two. Obviously, all the cases in this group show complete motor and sensory paralysis. There is even less chance of spontaneous regeneration than in fourth degree injuries and certainly no chance of any degree of functional restoration without neurorrhaphy.

REFERENCES

1. Lyons, William R., and Woodhall, Barnes: Atlas of Peripheral Nerve Injuries. Philadelphia: W. B. Saunders Co., 1949, p. 51.
2. Haymaker, W.: Pathology of Peripheral Nerve Injuries. *Mil. Surgeon* 102: 448-459, June 1948.
3. Holmes, W., and Young, J. Z.: Nerve Regeneration After Immediate and Delayed Suture. *J. Anat.* 77: 63-96, October 1942.
4. Gutmann, E., Guttmann, L., Medawar, P. B., and Young, J. Z.: The Rate of Regeneration of Nerve. *J. Exper. Biol.* 19: 14-44, May 1942.
5. Seddon, H. J., Medawar, P. B., and Smith, H.: Rate of Regeneration of Peripheral Nerves in Man. *J. Physiol.* 102: 191-215, 30 Sept. 1943.
6. Tinel, J.: Nerve Wounds. Symptomatology of Peripheral Nerve Lesions Caused by War Wounds. Translated by Fred Rothwell. New York: William Wood & Co., 1917, pp. 8-14.
7. Seddon, H. J.: Three Types of Nerve Injury. *Brain* 66: 237-288, December 1943.
8. Sunderland, S.: A Classification of Peripheral Nerve Injuries Producing Loss of Function. *Brain* 74: 491-516, December 1951.
9. Haymaker, Webb, and Woodhall, Barnes: Peripheral Nerve Injuries: Principles of Diagnosis. 2d edition. Philadelphia: W. B. Saunders Co., 1953, pp. 123-132.

CHAPTER 44

Electrodiagnostic Testing of Peripheral Nerve Function

Charles S. Wise

Electrodiagnostic tests have a long history of usefulness in the clinical evaluation of peripheral nerve function. In 1868, Erb (1) described in detail the responses of normal and denervated muscles to electrical stimulation. In the years that have followed, continuing improvement in apparatus and techniques has led to more sensitive and quantitative methods of electrodiagnosis. The most useful methods employed today include (1) response to galvanic and faradic stimulation, (2) response to electrical currents of varying duration and intensity, (3) chronaxie measurements, (4) electrical skin resistance measurements, and (5) electromyography.

RESPONSE TO GALVANIC AND FARADIC STIMULATION

Technique.—A wide variety of electrical stimulators are available supplying galvanic (direct) and faradic (alternating) current. The stimulators permit convenient adjustment of the strength of the applied current and reversible polarity in the case of the direct current circuit. A large electrode pad is connected to one outlet and a small stimulating electrode to the other. The large pad serves as an indifferent electrode and is placed over a portion of the trunk or extremity not being tested. The active or stimulating electrode is applied over the muscle to be tested. Both electrodes are moistened to reduce skin resistance. The type of current may be varied by a selector switch. "Make and break" switch on

the stimulating electrode controls the application of the electrical stimulus.

Interpretation.—The normally innervated muscle will respond to an adequate galvanic stimulus by a brisk twitch. It will respond only during the "make" and "break" of the electrical circuit. In clinical practice, only the "make" response is employed. Normally, the "make" or closing response to the cathodal (negative) pole is greater than the response to the anodal (positive) stimulus; that is, cathodal closure contraction (CCC) is greater than anodal closure contraction (ACC). During the passage of the galvanic current, the normal muscle accommodates to the stimulus and remains relaxed. When higher strengths of current are used, the normal muscle may remain partially contracted (galvanotetanus), but the intensities of current required are painfully strong and are usually not well tolerated by the patient.

The location of the stimulating electrode over the muscle which permits maximal contraction with a minimum of current is called the motor point. In normal muscle, this point usually is located over the middle of the muscle belly where the motor nerve enters the muscle tissue. In denervated muscle, the motor point is shifted toward either the origin or the insertion of the muscle being tested.

When a motor nerve degenerates, about 14 to 21 days are required for wallerian degeneration to become complete. Responses to faradic stimulation may persist, although diminished, until the anatomical degeneration is complete. After this occurs, a

TABLE 35.—*Muscle responses to stimulation by galvanic and faradic current*

Interpretation	Responses	
	Galvanic current	Faradic current
Normal reaction.....	Brisk twitch, normal motor point (CCC>ACC).	Tetanic contraction.
Partial reaction of degeneration..	Diminished response.....	Diminished response.
Full reaction of degeneration....	Sluggish response, abnormal motor point (ACC>CCC).	No response.
Absolute reaction of degeneration. ¹	No response.....	Do.

¹ Absolute R.D. indicates loss of contractile tissue such as occurs with fibrosis following prolonged denervation.

denervated muscle responds with a characteristic reaction of degeneration (R.D.). The response to a galvanic stimulus in this case is characterized by a slow vermicular contraction as compared to the normal brisk twitch. When denervation is complete, the muscle may remain contracted during the flow of current (galvanotetanus) when comparatively low intensities of current are employed. The galvanotetanus ratio (2) is sometimes used as an index of the degree of denervation present. It is defined as the minimum current required, using cathodal stimulation, to produce a sustained contraction divided by the strength of current required for a threshold contraction. In normally innervated muscle, this ratio may be six or higher; in denervated muscle, the ratio approaches unity.

Faradic current, or alternating current with a frequency of 60 cycles per second or more, produces a sustained tetanic contraction when applied to normally innervated muscle. In disease or injury to the peripheral nerve, when sufficient time has elapsed to allow complete anatomical degeneration, the muscle will not respond to faradic or alternating current. The denervated muscle may respond, however, to alternating current if the frequency is below 50 cycles per second and the current intensity sufficiently high.

The various responses of a muscle to stimulation by galvanic and faradic current (table 35) permit a fairly accurate qualitative estimate of the state of the peripheral nerve. The chief diagnostic value of galvanic-faradic testing is to give objective evidence of a lesion in the lower motor neuron. It is useful in proving or disproving functional disorders, such as hysteria, which may simulate an organic periph-

eral nerve lesion. The tests are limited by lack of quantitative measurements in instances of early or minimal involvement of the motor nerve.

RESPONSE TO ELECTRICAL CURRENTS OF VARYING DURATION AND INTENSITY (STRENGTH-DURATION CURVE) (3)

Technique.—A suitable electronic circuit is employed which permits the application of electrical stimuli of varying strength and duration. The strength of the stimulus, ranging between 0 and 25 ma., is recorded on a milliammeter; the duration of the stimulus is varied by suitable electronic circuits and a selector switch to produce current flow durations from 0.1 to 1,000 milliseconds. A moist cathodal stimulating electrode is placed over the motor point of the muscle to be tested, and a larger indifferent electrode is placed elsewhere on the extremity. A current duration of 1,000 msec. is selected and the number of milliamperes of current required for a threshold response is recorded. By successive steps the current duration is shortened, and for each duration the current required for a threshold response is observed. A strength-duration curve of electrical excitability is charted on a semi-logarithmic graph (fig. 249).

Interpretation.—The normally innervated muscle will respond to currents of shorter duration and lower strengths than the denervated muscle. The normal curve of electrical excitability is represented as almost a straight horizontal line between stimuli ranging from 1,000 to 1 msec. in duration. In this range the normal muscle requires about 2 to 5 ma.

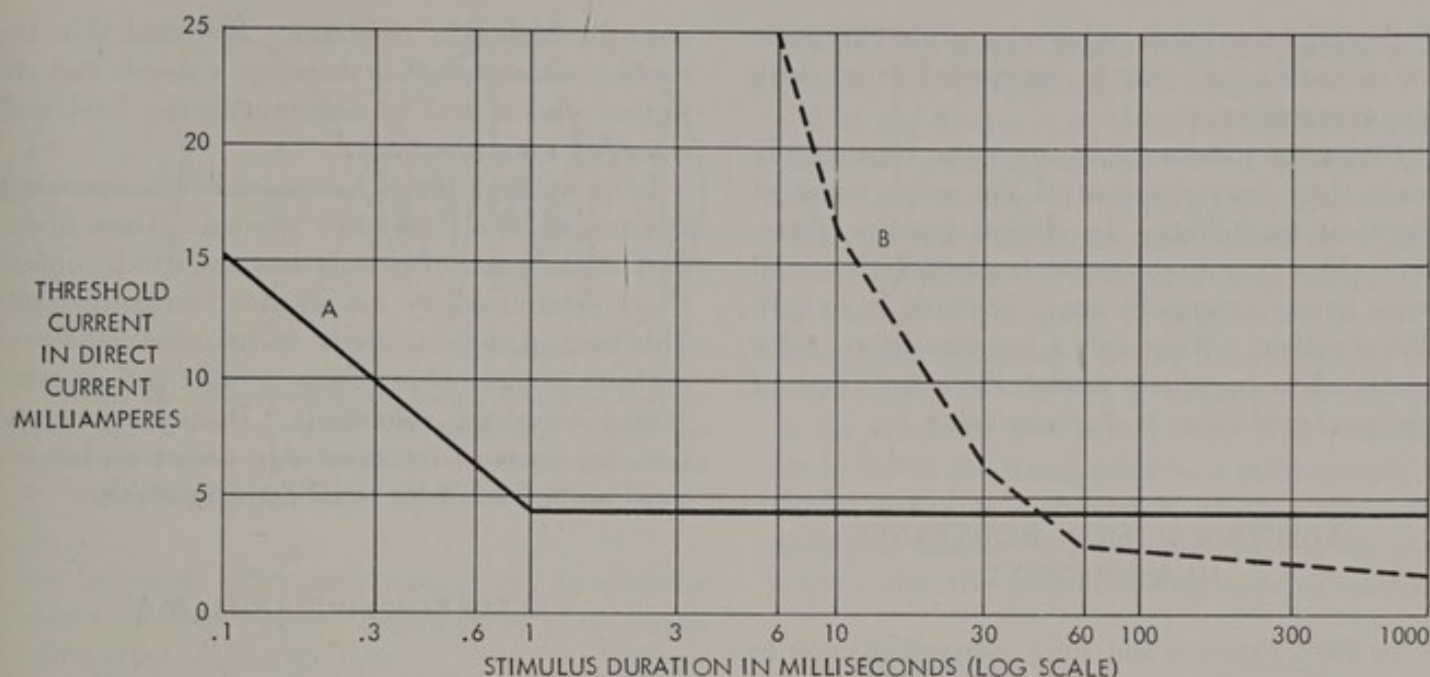


FIGURE 249.—Strength-duration curves of electrical excitability. A. Normally innervated muscle. B. Denervated muscle.

of current for a visible threshold contraction. With current durations of less than 1 msec., the normal muscle will require somewhat higher strengths for a response.

In the denervated state, muscles require stronger electrical currents for threshold responses when impulses of short duration are employed. This is characterized by a shift of the curve upward and to the right. In partially denervated muscle or during early degeneration or reinnervation, the curve of electrical excitability lies somewhat between the two extremes. Early evidence of reinnervation may be detected by the shifting of the curve toward the left or the presence of discontinuities in the curve of electrical excitability. In comparison to the galvanic-faradic testing of peripheral nerve function, the strength-duration curve is a more sensitive and more quantitative measurement of the degree of denervation present. Changes in the curve may also be used as an early prognostic sign for reinnervation.

CHRONAXIE MEASUREMENTS (4)

The chronaxie of a muscle is defined as the duration of a stimulus required for a threshold response using twice the rheobase current. In 1909, Lapique first defined the rheobase as the threshold of stimulus

intensity. In seeking an index of nerve function, he found it necessary to double this threshold intensity and then find the minimum duration of this stimulus required to evoke a response. It is therefore an arbitrary value and indicates only one point on the curve of electrical excitability.

Technique.—Complex electromechanical devices were required in the past for chronaxie determinations. In more recent years, chronaximeters are available employing electronic circuits, making them accurate and convenient for clinical use. In practice, the chronaxie is determined by first finding the rheobase value. The negative electrode is applied over the motor point of the muscle being tested, and the threshold curve is determined, using a duration of 1,000 milliseconds. The stimulating current is then increased to double the rheobase value. By use of appropriate selector switches, the duration of the stimulus is increased from 0.1 msec. to a point where the first visible muscle contraction occurs. The duration of this impulse is recorded as the chronaxie.

Interpretation.—In normally innervated muscle in man, the chronaxie is always 1 msec. or less. Values higher than this indicate some degree of denervation. In complete denervation, chronaxies of 30 msec. may be observed. In partial lesions of the peripheral nerve, chronaxies are usually below 10 milliseconds.

Following nerve repair, a lowering of the chronaxie on successive tests may be interpreted as an early sign of regeneration.

Chronaxie measurements are more conveniently made than determinations of the entire curve of electrical excitability. In clinical practice, therefore, chronaxie measurement is particularly useful when numerous muscles are to be tested in an individual patient. When only a few muscles are to be evaluated in any single patient, the entire curve of electrical excitability is of greater value.

ELECTRICAL SKIN RESISTANCE MEASUREMENTS

In 1907, Peterson and Jung observed changes in the resistance of the skin to the passage of electrical current which were associated with emotional changes. Numerous investigators have employed this psychogalvanic reflex in physiological studies since that time. Richter (5) used the study of electrical skin resistance as a measure of abnormal nerve function.

Technique.—Skin resistance is measured by a dermatometer employing a 9-volt direct current source, a variable resistance, and a microammeter. The disk of an indifferent electrode is covered with electrode paste to reduce skin resistance to a minimum, and the electrode is then clipped to the patient's ear lobe; a second, or exploring, electrode, consisting of a dry polished metallic disk attached to an insulated handle, is touched to the part to be tested. This provides a rapid and technically easy method of scanning the entire body for areas of high or low electrical resistance. Arbitrary values on the microammeter are recorded for symmetrical areas of the body, with particular attention to areas of high skin resistance.

Interpretation.—Richter mapped out the normal variations in electrical skin resistance and observed that areas rich in sweat glands had lower resistance than areas with fewer sweat glands. The axillae, palms of the hands, and soles of the feet normally were found to have a low resistance to the passage of direct current. Skin resistance is greatly increased, however, when normally acting sweat glands are sparse or absent. Following sympathectomy, the denervated area does not sweat and has ab-

normally high skin resistance. Electrical skin resistance measurement is therefore a simple and effective clinical tool in determining the level and extent of sympathectomy.

In peripheral nerve lesions, the accompanying sympathetic fibers are often affected. These fibers parallel the areas of sensory loss and can be objectively determined by use of skin resistance tests. This method is particularly useful when objective evidence is required in infants or other patients who cannot cooperate voluntarily. During reinnervation, the areas of increased skin resistance fall toward normal levels on serial determinations.

ELECTROMYOGRAPHY (6)

The early experimental work in the recording and interpreting of electrical potentials by means of electromyography was carried out by Adrian in 1925. Since that time considerable improvement in apparatus and techniques has led to numerous applications of this tool in research and clinical investigation.

Technique.—Modern electromyographic equipment includes suitable pickup electrodes, a grade amplifier with a frequency response from 40 to 6,000 cycles, and a recording device. The electrode may consist of a fine needle insulated down to its tip with an indifferent electrode placed on the skin surface, or a coaxial needle electrode whereby both poles are inserted into the area to be tested. The amplifier is usually coupled to a cathode ray oscilloscope where the potentials are viewed and to a loudspeaker where characteristic electrical potentials

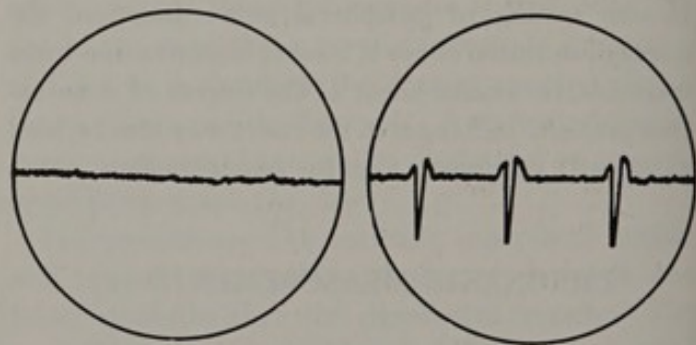


FIGURE 250.—Electromyogram during muscular relaxation. (Left) Muscle at rest, showing electrical silence. (Right) Incomplete relaxation, showing motor unit activity.

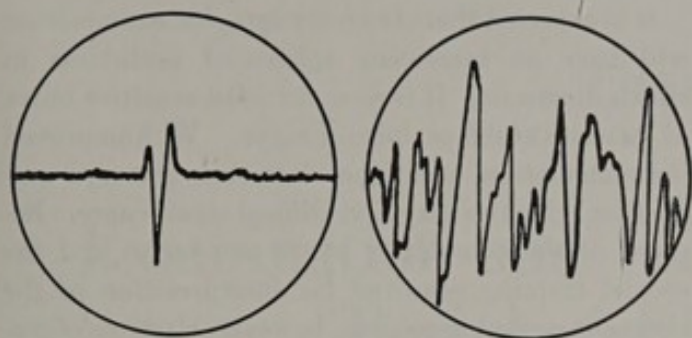


FIGURE 251.—Electromyogram during muscular contraction. (Left) Normal motor unit potential. (Right) Interference pattern—summation of numerous motor unit potentials during vigorous muscular contraction.

can be heard. Permanent records can be made by means of magnetic tape recording or photographs taken of the oscilloscope tube.

Interpretation.—The normally innervated muscle is electrically silent at rest (fig. 250). Upon insertion of the needle, an outburst of electrical activity may be observed which subsides rapidly if the muscle is at rest. These “insertion” motor-unit-action potentials have no clinical significance. With attempted minimal voluntary contraction, normal motor units appear (fig. 251). These are repetitive polyphasic spikes having a magnitude from 100 to 3,000 μ v. (microvolts), a duration of 5 to 10 msec., a wave form of 1 to 6 spikes, and a frequency of 5 to 30 waves per second. On the loudspeaker they are heard as a sharp thumping sound. As voluntary contraction increases in tension, additional motor units are recorded, creating a highly irregular interference pattern across the entire oscilloscope tube. In some unusually apprehensive patients, however,

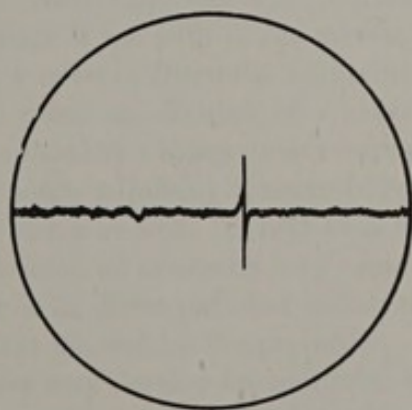


FIGURE 252.—Electromyogram showing fibrillation potential of denervation.

as well as in certain postural muscles, complete relaxation may be impossible to obtain.

With any disease or injury to the lower motor unit associated with degeneration of the anterior horn cell or any portion of the peripheral motor nerve fiber, the electromyogram may record the characteristic potentials of fibrillation (fig. 252). The wave shape of fibrillation of denervation usually is monophasic or diphasic, having a duration of 1 to 2 msec., a frequency of 2 to 20 waves per second, and an amplitude of 100 μ v. or less. The potentials are heard on the loudspeaker as a characteristic irregular series of high-pitched, sharp clicks. The finding of fibrillation-action potentials is the most positive objective clinical finding denoting interrup-

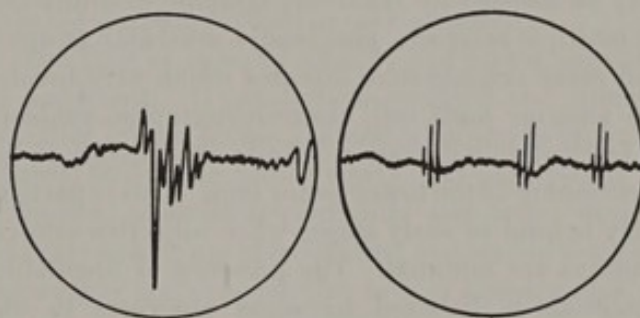


FIGURE 253.—Electromyogram showing potentials occurring during partial degeneration or regeneration of a peripheral nerve. (Left) Complex polyphasic potential. (Right) Nascent polyphasic potential.

tion of the peripheral motor nerve. Following nerve injury, approximately 14 to 21 days are required before fibrillation potentials are observed. Very often, numerous areas in the muscle must be sampled before these potentials are discovered. The fibrillation potentials tend to disappear shortly before nerve regeneration occurs, and they may diminish as fibrosis of the muscle takes place after long periods of denervation.

Regeneration of a peripheral nerve can be accurately followed by serial electromyographic examinations. The earliest sign of recovery may be diminution in the amount of fibrillation activity. The first positive observation, however, is the appearance of small polyphasic action potentials (nascent motor units) with attempted voluntary contraction (fig. 253). As regeneration progresses, these units become larger until the typical polyphasic motor unit potentials associated with nerve regenera-

tion are observed. These may have 10 to 25 spikes, a duration of 10 to 20 msec., and amplitudes varying from 25 to 5,000 microvolts. They are distinguished on the loudspeaker by a rough crackling sound of variable pitch.

As nerve regeneration becomes more complete, the polyphasic potentials are replaced by more and more normal motor units. Even after complete clinical reinnervation has occurred, however, it usually is possible to find occasional areas in which the polyphasic motor units persist.

Other clinical uses.—Aside from its value in following the course of peripheral nerve degeneration and repair, the electromyogram is finding increasing usefulness in neurological diagnosis. The diagnosis of various types of spinal cord diseases may be assisted by electromyographic examination. In multiple sclerosis, progressive muscular atrophy, and other degenerative diseases which may involve the anterior horn cell, electromyographic evidence of fasciculation denotes a definite abnormality in the functioning of the lower motor unit. This is particularly helpful in early stages when objective clinical findings are minimal. The presence of fibrillation potentials is believed by some observers to distinguish the neuropathies from the muscular dystrophies. In the former the disease is primarily in the anterior horn cell, and fibrillations as well as fasciculations are observed. In the muscular dystrophies true fibrillations are believed to be only rarely present.

It is expected that electromyographic examination will have an increasing sphere of usefulness in electrodiagnosis. It is now our most sensitive index of the state of the peripheral nerve. With improved instrumentation, additional data such as nerve conduction velocities may find clinical significance. Because of the complexity of the apparatus and the special training required for interpretation of the electromyographic records, however, electromyography will probably not replace the older electrodiagnostic tests.

REFERENCES

1. Erb, W.: Zur Casuistik der Nerven- und Muskelkrankheiten. *Deutsches Arch. klin. Med.* 4: 242-249, 1 May 1868.
2. Pollock, L. J., Golseth, J. G., and Arieff, A. J.: Galvanic Tetanus and Galvanic Tetanus Ratio in Electrodiagnosis of Peripheral Nerve Lesions. *Surg. Gynec. & Obst.* 81: 660-666, December 1945.
3. Pollock, L. J., Golseth, J. G., and Arieff, A. J.: The Use of the Height of the Whole Strength-Duration Curve of Muscle as a Diagnostic Procedure in Experimentally Produced Lesions of the Sciatic Nerve in the Cat. *Quart. Bull. Northwestern Univ. M. School* 19: 169-180, 1945.
4. Erdman, W. J., II: Clinical Uses of Chronaxie Determinations. *Arch. Phys. Med.* 35: 638-642, October 1954.
5. Richter, C. P., and Katz, D. T.: Peripheral Nerve Injuries Determined by the Electrical Skin Resistance Method; Ulnar Nerve. *J.A.M.A.* 122: 648-651, 3 July 1943.
6. Marinacci, Alberto A.: *Clinical Electromyography: A Brief Review of the Electrophysiology of the Motor Unit and Its Application to the Diagnosis of Lower Motor Neuron Diseases, Peripheral Neuropathy and the Myopathies.* Los Angeles: San Lucas Press, 1955.

CHAPTER 45

Examination and Clinical Manifestations of Peripheral Nerve Injuries

Hugo V. Rizzoli

The nature of a peripheral nerve lesion must be ascertained before one can determine whether surgery is indicated. A detailed history of the injury, a physical examination to determine functional loss, and the results of electrical tests are important in the evaluation of a nerve injury. Multiple examinations at intervals may be necessary to determine whether there is satisfactory spontaneous regeneration.

HISTORY

An accurate, detailed history of the nerve injury is an important diagnostic aid. The date of injury, the location of the wound, the causative agent, the subjective symptoms—especially sensory and motor abnormalities noted by the patient immediately after injury—as well as subsequent changes in symptoms, and operative findings and procedures (if previous surgery has been done) are all very significant.

A large shell fragment will produce extensive nerve damage if the path of the missile crosses the course of a nerve. Often the nature of the injury alone will predicate division of a nerve trunk. A wound produced by a sharp cutting instrument which divides tendons adjoining a nerve is very likely to divide the nerve as well. A high-velocity projectile passing through an extremity may cause injury to a nerve not in its direct path but within range of the energy wave created by the projectile. Motor and sensory loss may develop immediately, though pain and touch are much less affected than proprioceptive

sensibility. When such injuries are mild (first degree), concussion is said to have occurred.

The time of onset of sensory and motor paralysis is important. If paralysis is complete and immediate after injury, severe anatomical injury is probable (third, fourth, or fifth degree). If paralysis is incomplete, anatomical continuity and lesser degrees of nerve injury are present (first and second degree). Secondary compression due to scar tissue, callus, or aneurysm may be responsible in cases of progressive loss of function.

The length of time that has elapsed since injury and whether definite return of function has occurred are important points to consider. If function is returning at a satisfactory rate, surgery is probably not indicated. The level of injury with respect to the proximal muscle branch must be considered. If the proximal muscle branch comes off the main trunk 3 or 4 cm. distal to the site of injury, one expects earlier return in function of this muscle than if it comes off 6 or 7 cm. distal to the site of the lesion.

EXAMINATION

Inspection of the site of injury will often give valuable information. Injuries of the adjacent tissues, such as bones, tendons, and vessels, should be carefully noted. Many peripheral nerves are easily palpable. Palpation along the course of the nerve may disclose a neuroma, or may elicit a "hot spot" indicative of one, and thus help localize the exact

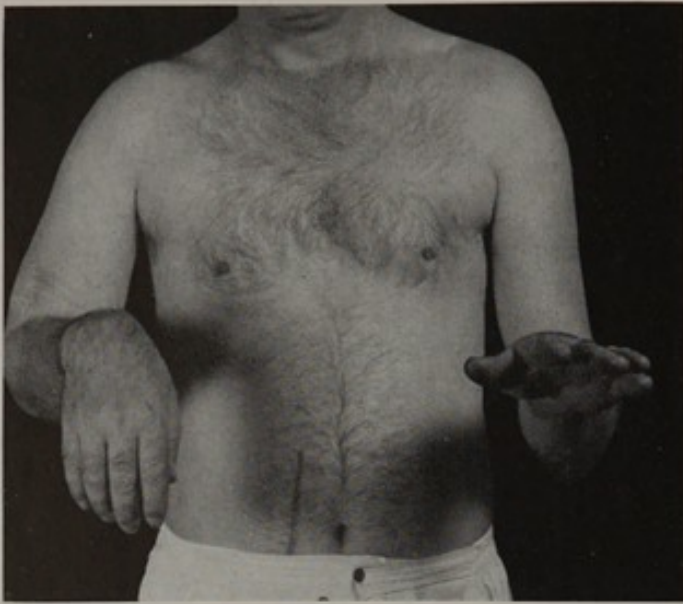

FIGURE 254.—Radial nerve paralysis.

position of nerve injury. An aneurysm, if present, can also be palpated. In perforating wounds, accurate localization of the path of the missile is possible, thus allowing one to determine whether a particular nerve could have been divided. In penetrating wounds, the exact course of the missile is more difficult to trace unless it leaves a radiopaque path.

Deformity.—Typical deformity of the extremity helps to establish evidence of nerve paralysis. Ra-

dial nerve paralysis results in a wristdrop, easily identified when the arm is held flexed at the elbow with the forearm pronated (fig. 254). Median nerve paralysis produces an "ape hand" deformity with marked atrophy of the thenar eminence; ulnar nerve paralysis produces a "claw hand" deformity, due to atrophy of the hypothenar eminence and of the interossei, with flexion deformities of the fourth and fifth fingers at the interphalangeal joints (fig. 255). In sciatic nerve paralysis there is a flail ankle. In peroneal nerve injuries there is a drop-foot deformity with slight inversion of the foot.

Tinel's sign.—While studying World War I nerve injuries, Tinel (1) noted that upon percussion over an injured nerve trunk, formications (often described by the patient as an electric shock sensation) were elicited in the region of the sensory supply of the nerve. He realized this sensation was due to the stimulation of regenerating axons at the point of percussion. This sign can be elicited 4 to 6 weeks after nerve injury or suture. The test is performed by gentle percussion with one finger over the course of a nerve trunk, beginning distally and proceeding centrally until electric shocklike sensations are experienced by the patient in the sensory distribution of the involved nerve. The most distal point at which this sign is elicited is indicative of the most distal point to which regenerating axons

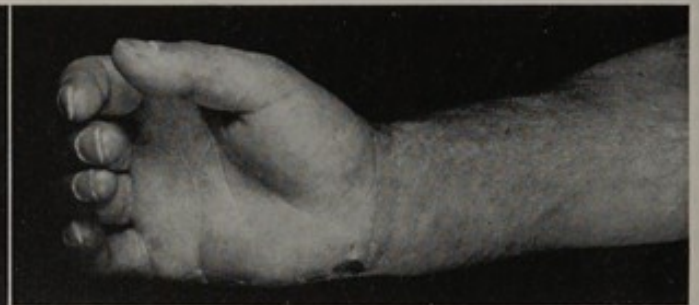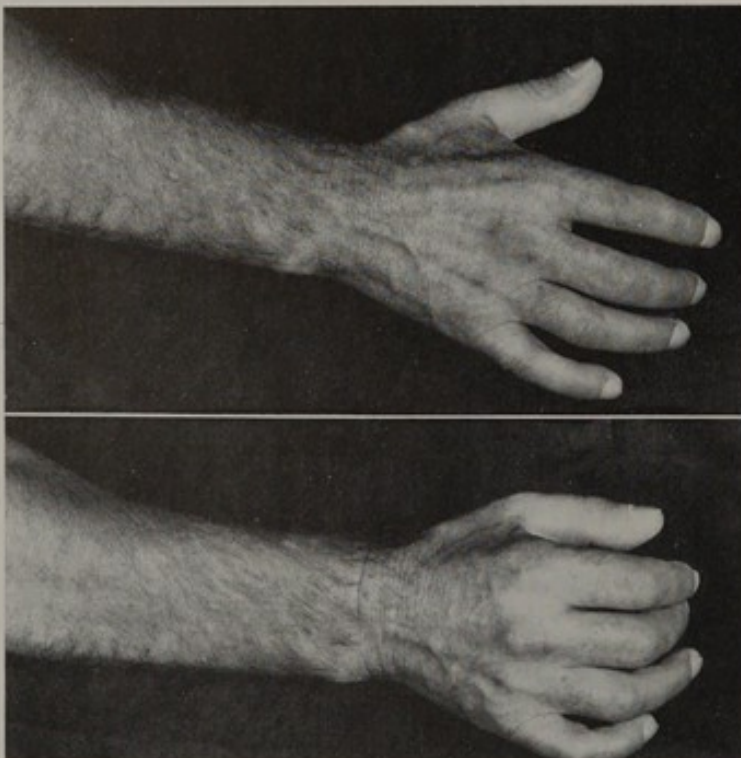


FIGURE 255.—Combined median and ulnar nerve paralysis.

have grown. Advance of the Tinel sign indicates progressive growth of regenerating axons. The intensity of the sensation experienced by the patient is directly proportional to the number of regenerating axons which have reached this most distal point of regeneration. In performing this test, care must be exercised not to stimulate the neuroma, if one is present, or the escaping fibers from the neuroma at the site of injury. At the level of a neuroma, the sign is usually more strongly positive and is responsible for the so-called "hot spot." This is helpful in localizing the level of injury and may be especially valuable where there are multiple levels of injury. The Tinel sign is probably most useful in following the progress of regeneration after surgical repair of a peripheral nerve. Several months after maturation of the regenerated axons, the Tinel sign disappears distally, but percussion over the neuroma may continue indefinitely to produce some pain. Though one sees progressive distal advance of the Tinel sign, satisfactory regeneration may not occur, since too few regenerating axons may be responsible for the positive sign. However, advance of the Tinel sign 2 to 4 mm. a day and, in addition, one that is strongly positive, is often indicative of satisfactory regeneration.

Motor function.—In addition to noting the presence or absence of typical deformities that peripheral nerve lesions produce, individual muscles must be examined. Examination of muscle function can be difficult. It requires patience and a knowledge of the action of each muscle or muscle group, the origin and insertion of individual muscles, and the level of nerve supply. The examiner must be certain that he either sees or feels the muscle belly contract before he is convinced a muscle is functioning. This is important because there are several "trick" or substituted muscle movements by synergistic muscles which at first glance might mask paralysis of other muscles. The brachioradialis may accomplish flexion of the elbow with complete paralysis of the biceps brachii; energetic contraction of the finger flexors, and occasionally the pronator teres, may extend the wrist and tend to mask a wristdrop in radial nerve paralysis. In addition, the possibility of anomalous innervation, especially of the intrinsic muscles of the hand, must be kept in mind. During World War II there

were many examples of complete lesions of the ulnar nerve at the elbow with no apparent paralysis of the intrinsic muscles of the hand. Anomalous branches have been visualized in the lower forearm with fibers from the median to the ulnar nerve. The ulnar nerve is always responsible for flexion of the distal phalanx of the fifth finger. The only motor function always and solely allotted to the median nerve is flexion of the distal phalanx of the index finger.

Muscle function on the injured side should always be compared with that on the opposite side to determine the degree of atrophy and weakness. This also enables the examiner to determine whether the patient has thoroughly understood his instructions. Woodhall and Beebe (2) give the following list of standard followup groups of muscles repeatedly tested by the peripheral nerve study centers. They include representative muscles from the proximal and distal groups which are most reliably tested.

Ulnar Nerve

- Flexor carpi ulnaris
- Flexor digitorum profundus (fourth and fifth fingers)
- Abductor digiti quinti
- Adductor pollicis
- First dorsal interosseus

Median Nerve

- Flexor carpi radialis
- Flexor digitorum profundus (index finger)
- Flexor pollicis longus
- Abductor pollicis brevis
- Opponens pollicis

Radial Nerve

- Triceps
- Brachioradialis
- Extensor carpi radialis
- Extensor digitorum communis
- Extensor carpi ulnaris
- Abductor pollicis longus
- Extensor pollicis longus
- Extensor pollicis brevis

Sciatic Nerve

- Proximal
 - Biceps femoris
 - Semimembranosus
 - Semitendinosus

Sciatic Nerve—Continued

Distal

Tibial nerve

Gastrocnemius-Soleus

Tibialis posterior

Flexor digitorum longus

Flexor hallucis longus

Intrinsic foot muscles (cupping of sole of foot)

Peroneal nerve

Tibialis anterior

Extensor digitorum longus

Extensor hallucis longus

Peroneus longus

Musculocutaneous Nerve

Biceps brachii

Axillary Nerve

Deltoideus

Femoral Nerve

Quadriceps femoris

A record should be kept to compare the function of representative muscles from time to time. The presence of slight degrees of muscle function may not be demonstrable if the movement has to be executed in an unfavorable position. For example, function in a weakened biceps brachii may be demonstrated if gravity is overcome by positioning the upper arm in abduction at the shoulder; the patient is then instructed to flex the forearm at the elbow from a vertical position. Failure to execute a prescribed movement may be caused by joint restriction or by contractures of the antagonists. At times, the apparent muscle paralysis is not on an organic basis, particularly when the prescribed movement is not accompanied by contraction of synergistic muscles. This can be verified by electrical stimulation tests.

Muscle atrophy.—Muscle atrophy following peripheral nerve injury occurs rather slowly, appearing after 2 or 3 weeks and becoming progressive over a period of months. Atrophy is best evaluated by comparison with the normal side. Progression of the atrophy can be followed to some degree by repeated measurements of the circumference of the limb. In the intrinsic muscles of the hand, atrophy is more striking and occurs earlier than in the larger muscles. It appears more rapidly and is more pronounced in nerve section than in nerve compression. Peripheral nerve lesions result in hypotonia, which

is less apt to occur with nerve compression. Nerve section causes total loss of muscle tone.

Reflexes.—Interruption of the reflex arc with flaccid paralysis, hypotonia, and loss of the tendon reflexes results from peripheral nerve lesions. The biceps reflex disappears in musculocutaneous nerve paralysis; the triceps reflex is lost in high radial nerve injuries; the Achilles reflex is lost in sciatic nerve paralysis; and the patellar reflex is absent in femoral nerve paralysis.

Sensation.—Tactile, painful, thermal, and deep sensibilities are involved in peripheral nerve injuries. Cotton wool is the most convenient means of testing touch; however, von Frey's hairs are more reliable for experimental work. Pain is most conveniently tested with a sharp pin or needle, although spring elgesimeters are used in experimental studies of pain sensation. Thermal sensibility can easily be evaluated with two metal tubes, one containing warm water and the other, cold water. In the clinical examination of peripheral nerve injuries, testing of temperature appreciation adds little to what has been learned from testing the appreciation of pain.

Deep sensibility can be tested with a blunt stylus. Position sense can be evaluated by determining whether the patient can distinguish varying degrees of passive flexion or extension of the joint. With single nerve injury, there is very little disturbance of position sense because of considerable overlap. Median nerve paralysis causes loss of position sense only in the interphalangeal joints of the middle and index fingers; ulnar nerve paralysis causes loss of joint sensibility only in the fifth finger. Radial nerve paralysis causes no demonstrable loss of position sense. With total brachial plexus paralysis, position sense is involved to the same degree as the superficial sensibilities. In partial brachial plexus injuries, joint sensibility may be impaired to a greater degree than the superficial sensibilities. Sciatic nerve paralysis produces loss of joint sensation in the foot and toes. Individual paralysis of either the peroneal or tibial nerve does not cause impairment of position sense in the foot or toes.

The fact that the zones of sensory supply of various cutaneous nerves overlap is well established. The area of isolated supply (autonomous zone) varies greatly from person to person. The sensory loss with radial nerve injuries is usually over the radio-dorsal aspect of the hand, including the thumb. In

some individuals, however, there may be no demonstrable sensory loss. The area of isolated supply for the ulnar nerve may be so small as to involve only the terminal phalanx of the fifth finger. In this area, sensation is always mediated by the ulnar nerve. The autonomous zone of median nerve sensation always includes the distal phalanx of the index finger and on rare occasions may not extend much beyond this area. Variations in areas of sensory supply are due to overlap of sensory innervation and to anomalous innervation. There is a greater degree of overlap for pain than for tactile or thermal sensation; therefore, the autonomous zone for pain is smaller than the area of tactile or thermal anesthesia. The area about the zone of total anesthesia, which is contained by the border outlining the zones of thermal and tactile anesthesia, is known as the intermediate zone.

Sympathetic function.—In addition to motor and sensory deficits, peripheral nerve division results in loss of sympathetic function. Sympathetic paralysis results in loss of sweating, vasomotor control, and pilomotor response. In general, the area of sympathetic denervation coincides with the anesthetic area. Following section of a peripheral nerve, the anesthetic area will be pink and will show elevation of skin temperature for about 2 weeks. Later, vasoconstriction occurs, and the temperature is lowered. In partial nerve injuries, there may be prolonged vasomotor disturbances with mottling of the skin and decrease of skin temperature. Alleged areas of sensory loss following peripheral nerve injury can be verified objectively by demonstrating the absence of sweating. In complete paralysis, there will be loss of sweating (anhidrosis) in the anesthetic area. Increase in sweating can occur with partial lesions or following the onset of regeneration. Lack of sweating is obvious when adjacent areas are sweating visibly; on palpation, the area which has been deprived of sympathetic supply feels drier than the adjacent skin. Absence of sweating can be detected objectively by either of the following tests.

Guttmann dye test (3).—The patient is given 10 gr. of aspirin and a cup or two of hot coffee or tea. The area of skin to be tested is dusted with a powder containing sodium salt of chinizarin-2-6-disulfonic acid. The extremity being tested is warmed in a hot air cradle. In 15 to 30 minutes, when profuse sweat-

ing occurs, the light-gray powder becomes a deep red purple. The area which has been deprived of its sympathetic innervation will remain uncolored.

Skin resistance test.—Richter (4) has shown that because of the absence of sweating, an area of skin without sympathetic innervation is highly resistant to passage of a direct current. Such an area can be rapidly outlined with a dermatometer.

Vasomotor and trophic disturbances.—That vasomotor and trophic changes can occur following nerve injury has been known since the observations of Mitchell, Morehouse, and Keen (5). However, it is still unknown whether these changes are due to disturbance of some specific trophic function exerted by a nerve, or whether they are secondary to motor, sensory, and sympathetic disturbances. While vasomotor and trophic changes do not invariably accompany nerve injury, with certain nerve injuries (median and tibial) they seem to occur more frequently. Many observers have maintained that trophic changes occur more frequently in the partial lesions. The British study of World War II injuries (6), however, indicates that the incidence of trophic and vasomotor changes is significantly greater in total transection as compared with incomplete lesions.

Changes in skin temperature.—According to the British series, patients with peripheral nerve injuries usually complained that the affected limb felt colder than the normal limb; however, for a short period immediately following nerve injury the affected skin was warmer. In some cases the area of decreased temperature coincided with the area of sensory supply of the nerve involved, but often the entire extremity was said to be cold. This symptom occurred more frequently with lesions of the upper extremity than with those of the lower extremity. Only rarely did patients complain of increased temperature; when this was the case, the nerve injury was either of recent origin or associated with causalgic pain. Objective skin temperature measurements disclosed a decrease in temperature in half of the patients. It has been found also that the lower temperature was more common in complete lesions and more frequent with upper extremity lesions. Increase in temperature was noted much less frequently (20 percent); no difference was noted in the complete versus the incomplete lesions, but increased temperature

occurred three times as frequently with lower extremity lesions. In some cases there was no difference in temperature between the normal and abnormal extremities during the summer months, whereas striking differences were noted during the winter months.

Color changes.—Cyanosis and redness were noted in about half of the patients in the British series. These changes were usually confined to the areas of sensory loss and were only slightly more frequent in complete lesions. Pallor was uncommon and tended to occur in the foot in cases of sciatic nerve injury.

Texture of skin.—Changes in the texture and general appearance of the skin supplied by an injured nerve occur frequently. Soon after nerve injury, this area shows a tendency to scaliness and desquamates readily, leaving a smooth atrophic area.

Nails.—Changes in the growth and appearance of the nails are frequently observed several months following injury. Typically, the nails become lusterless, dry, and brittle, and there is an increase in the curvature of the nail. Irregularities, such as ridges and grooves, also occur occasionally. Usually nail growth is retarded.

Digital atrophy.—Atrophy of subcutaneous tissue of the terminal phalanges of the digits is common in median nerve injuries. A tapered index finger is often characteristic of median nerve injury. Digital atrophy with ulnar nerve lesions is less common. With lesions in the lower extremity, atrophy of the toes is less marked and less common.

Trophic ulcers.—Denervated skin is particularly prone to ulceration. About one-fourth of the patients with nerve injury show some trophic lesion, such as ulcer, blister or scar resulting from burns, paronychia, and other trauma to the anesthetic skin. These lesions are most frequent during the early months following injury; subsequently, patients learn to protect the insensitive areas.

EVIDENCE OF REGENERATION

Woodhall and Beebe (2) list the following signs as definite evidence of regeneration.

1. *Voluntary motor function.*—The presence of motor function in the proximal muscle below the site of injury is almost certain evidence of regeneration.

2. *Preservation or recovery of sensation.*—Motor function is usually present when there is preservation or recovery of sensation. In cases of contusion due to high-velocity missiles in which only motor function is lost, recovery of motor function is certain to occur. Sensation in the autonomous zone is indicative of anatomical continuity.

3. *The preservation of sweating.*—Sweating in the autonomous sensory zone is also indicative of anatomical continuity.

4. *Motor response on nerve stimulation.*—Electrical nerve stimulation can be performed and may be of help in demonstrating return of function before voluntary motor contraction is visible. Woodhall and Beebe state:

The type of current utilized to stimulate the nerve trunk is unimportant so long as it is of adequate intensity to cause maximal nerve stimulation and is still easily tolerated by the patient. For stimulation of the underlying nerve trunk through the intact skin, the usual operating room stimulator or the machine in use in the physical therapy department will be adequate, utilizing simple galvanic shock or bursts of alternating or faradic current applied through a moistened unipolar electrode of 1 cm. in diameter. Points where the various nerve trunks are in a location easily accessible to stimulation from the skin surface are illustrated in current monographs. The nerve trunk must be stimulated proximal to the branches innervating those muscles whose contractions will be a measure of innervation through the lesion. It does not matter, except in the first week after injury, whether the point stimulated is proximal or distal to the lesion since any axons conducting the stimulus to the muscle must be intact from muscle to anterior horn cell. The efficacy of the stimulus can be tested on the opposite normal limb in a symmetrical location. It must be realized that response in a muscle close to the point of stimulation can be the result of direct stimulation of the muscle rather than nerve conduction. When there is no motor response on nerve stimulation, or the intensity must be raised to a point where neighboring nerves and muscles begin to respond, resort must be made to more direct stimulation of the nerve. This is accomplished by inserting two hypodermic needles at 1-cm. distance into the close proximity of the nerve and applying current to these two needle electrodes to secure a confined bipolar stimulation of the nerve trunk. This has been referred to as a bipolar-intraneural stimulation but the needles need not actually impinge upon the nerve trunk although no harm results when they do. The intensity of stimulus required for maximal stimulation of the nerve trunk through needle electrodes in its close proximity is very small and the make-and-break shock delivered by two 1½-volt flashlight batteries is adequate. Intensity can be regulated by a simple rheostat * * *.

Motor response on nerve stimulation has the same signifi-

icance for regeneration as does voluntary contraction. However, voluntary contraction frequently does not become evident for several weeks after the first response of the muscle to nerve stimulation but the patient will ultimately always learn to initiate a voluntary contraction of the same strength that is demonstrated by artificial nerve stimulation * * *.

UNCERTAIN EVIDENCE OF REGENERATION

Woodhall and Beebe list the following tests and signs as uncertain evidence of regeneration.

1. *Tinel's sign*.—Although a rapid distal advance of the Tinel sign is evidence of distal growth of regenerating axons, one cannot be certain that a sufficient number of axons are regenerating to result in satisfactory spontaneous recovery.

2. *Shrinkage of the area of sensory loss*.—A diminishing area of sensory loss may be only the result of sensory overlap rather than evidence of regeneration. On the other hand, return of sensation in the autonomous zone is certain evidence of regeneration, but the autonomous zone is the most distal area of sensory loss and therefore function here returns last.

3. *Improvement in the usefulness of the extremity*.—Woodhall and Beebe point out that most patients, as the result of compensatory use of uninjured muscles, show gradual improvement in the use of the injured extremity before nerve regeneration occurs.

4. *Electromyography*.—Motor unit potentials on voluntary muscle contraction and action potentials in response to nerve stimulation, as obtained by EMG testing, are unequivocal evidence of motor innervation. In a study of 300 cases discussed by Woodhall and Beebe, however, this test afforded uncertain evidence of regeneration when muscle function could be demonstrated only by this means.

5. *Chronaxie*.

6. *Galvanic tetanus ratio*.

EVIDENCE OF UNSATISFACTORY REGENERATION

1. *Lack of advance of Tinel's sign*.

2. *Lack of motor function*.—Evidence of unsatisfactory regeneration is present when motor response does not occur on nerve stimulation and there is no voluntary contraction in the proximal muscle after sufficient time has elapsed, based on axonal regeneration at the rate of 1 mm. per day.

OTHER CLINICAL MANIFESTATIONS

CAUSALGIA

Causalgia, a term coined in 1864 by Mitchell and his associates (5), refers to a phenomenon which fortunately is rarely seen with peripheral nerve injuries. Characterized by intense burning pain, located in the hand or foot, causalgia is almost always aggravated by both physical and emotional stimuli. Noise, high notes, grating sounds, and even such activities as watching highly exciting movies or reading provocative news items, novels, or stories may produce paroxysms of pain. The patient invariably guards the injured extremity, permitting no movement of the joints. Only after a great deal of reassurance will the patient allow examination of the hyperesthetic hand or foot. Often the patient will drape a moist cloth over the involved appendage to obtain some degree of relief. The pain may persist unimproved for months, but in many cases there is a tendency to spontaneous improvement over a period of time. Many of these patients show trophic changes and joint restriction due to disuse; old, desquamated skin is often seen over the involved digits, while the nails, too painful to cut, grow long and curved.

The incidence of causalgia is reported as ranging from 2 to 5 percent. Most frequently, causalgia develops within a week after injury. In some cases it has been reported as being first noted immediately after injury; however, it may not occur for several weeks. Invariably, causalgia occurs with incomplete nerve injuries. It is more common with proximal than with distal nerve injuries and more likely to occur with median and tibial nerve injuries and with multiple nerve injuries in the same extremity.

The causalgic syndrome can usually be relieved by sympathectomy. In the early stages, repeated sympathetic blocks may result in complete and permanent absence of pain. Resection of the injured nerve with neurorrhaphy has resulted in relief of causalgia, but usually the degree of nerve function present is such as to make this procedure inadvisable.

Numerous theories have been proposed to explain the pathogenesis of causalgia, none of which seems to explain all the observed facts. One interesting theory is based on a contribution by Granit, Leksell, and Skoglund (7), which postulates the establish-

ment of an artificial synapse at the level of nerve injury between the sympathetic and somatic afferent fibers, the efferent sympathetic impulses short-circuiting to the sensory fibers where they travel both centrally and peripherally.

MINOR CAUSALGIA

Less painful syndromes, not particularly aggravated by emotional or physical stimuli, are referred to as minor causalgias. The pain is usually restricted to the sensory distribution of the involved nerve and is variously described as throbbing, tingling, and "pins and needles" sensations. Often the burning pain typical of causalgia is less marked or absent.

NEUROMAS

Neuromas are normally quite painful when stimulated by pressures such as bumping, rubbing, and so forth. Stimulation often produces paresthesia in the sensory distribution of the nerve. Digital neuromas can be extremely painful and incapacitating. Strangely enough, some patients have little or no difficulty, while others may be decidedly handicapped in the use of the involved extremity. These neuromas are often invincible. Resection may result in only temporary relief, since the lesions tend to recur. Stretching of the proximal segment of the nerve, or alcohol injection of the proximal end, may be of help in preventing recurrence. Less severe cases may respond to repeated Novocain (procaine hydrochloride) blocks.

NEUROVASCULAR LESIONS

One would expect combined vascular and nerve lesions in many cases because of the anatomical relationships. Woodhall and Beebe (2) report that 16 percent of 3,656 nerve lesions had associated injuries to major arteries in the same limb. They were more common in the upper extremity (24.4 percent) than in the lower extremity (2.8 percent). In some cases, vascular injury alone occurs at the time of trauma, the nerve injury occurring secondarily either as a result of ischemia or as a result of traction by an aneurysm. In other cases, the nerve and blood vessel are injured simultaneously; here the nerve injury

is due primarily to trauma and is not secondary to the vascular lesion.

ISCHEMIC PARALYSIS

Tinel (1) wrote of the syndrome of ischemic paralysis. It is known to occur following occlusion of any one of the large arteries of the extremities. Gangrene of an extremity may occur following occlusion if the circulation of the extremity is compromised sufficiently. This usually implies obstruction of the collateral circulation as well as occlusion of a major vessel. Fortunately, most cases do not progress to gangrene. Following ligation of major vessels, gangrene occurs in about 6 to 12 percent of cases (Makins (8)), but in missile wounds the incidence may be as high as 20 percent. Occlusion of major vessels may result from trauma, external pressure on the vessels from casts, hemorrhage within the extremity, or embolus. Since Volkmann's contracture (ischemic contracture) does not occur invariably when vascular occlusion is present, the mechanism is not completely clear. The presence or absence of collateral circulation must be a deciding factor.

Two phases are noted clinically. First, marked edema of ischemic origin develops rapidly, and the extremity becomes cold and cyanotic. Active movement is slight, and passive movement is possible but resisted. The patient complains of a severe, deep, burning pain, and there is some degree of hyperesthesia and/or segmental hypesthesia. In the second phase, there is fibrous replacement of the necrotic muscle. Induration results, and the skin becomes smooth and shiny. The nails become talonlike, and trophic ulcers are frequently present. Active and passive movements tend to disappear, and loss of sensation becomes more complete. At this time, pain also tends to disappear. Flexion contracture usually results. The nerves in the affected area usually degenerate with endoneurial collagenous replacement of the axons. Occasionally, necrosis of the nerve has been observed. Though more common in the upper extremity, Volkmann's contracture is seen occasionally in the lower extremity. It occurs in association with fractures, supracondylar fractures of the humerus being the most common type.

ANEURYSMS

Some vascular injuries result in the formation of aneurysms. Elkin (9) reported 450 aneurysms due to trauma. Of these, 340 were of the arteriovenous type, and 110 were false arterial aneurysms. At least 25 percent of traumatic aneurysms of the extremities are associated with nerve injury. Pain is often present. Large aneurysms can be recognized by noting a bulging, pulsating mass. Small aneurysms can be discovered by palpation and auscultation. Arteriovenous aneurysms are characterized by a continuous thrill and a loud, continuous murmur with systolic intensification. False aneurysms produce either a systolic murmur or a murmur with a pause between the systolic and diastolic phases.

TRACTION PARALYSIS

Stretch or traction injuries of peripheral nerves vary in severity from first degree (transient loss of conductivity of axons) to fifth degree (anatomic disruption). In cases of permanent functional loss not due to anatomic division of the nerve, the deficit is due to scarring of the nerve, secondary to injury of the neurilemmal sheath and blood vessels. Stretch paralysis is seen most commonly in the upper extremity, and often the brachial plexus is involved. Stretch paralysis may occur as the result of injury at birth; however, it is not uncommon following other forms of trauma. Stretch paralysis may also occur after fractures and dislocations. The axillary nerve can be involved in dislocation of the shoulder; the ulnar nerve may be injured with fractures of the medial condyle of the humerus; the peroneal nerve may sustain stretch injury with dislocation of the knee.

ASSOCIATED BONE OR JOINT INJURIES

Woodhall and Beebe (2) report an associated bone or joint injury in 47.4 percent of upper extremity nerve injuries, and in 30.1 percent of lower extremity nerve injuries. Civilian-type nerve injuries are less frequently associated with bone or joint trauma. Seddon (10) reports only two serious and five minor nerve injuries in association with 102 fractures treated by a general accident service. Brooks, as cited by Seddon (6), reports a 32.1 percent inci-

dence of fractures in association with nerve lesions in 2,969 nerve injuries seen by the British during World War II. However, 81 percent of the combined fracture and nerve injury cases were due to missile wounds. Only 180 cases (6 percent of the total group) were associated with fracture not due to gunshot wounds.

Nerve injury may occur at the time of fracture or at a later date. Nerve injury incurred at the time of fracture is due to traction, immediate compression, or division. In nerve injuries occurring at a later date, a variety of mechanisms may be involved. In tardy ulnar palsy with fracture of the medial condyle of the humerus, compression or friction may be involved. In fractures of the humerus with open reduction, injury may be a result of surgery; in closed reduction, the nerve may be compressed in the line of fracture, or it may be compressed by subsequent callus formation. Nerve injury can result from a poorly fitting splint or cast: axillary nerve palsy can result from a body cast improperly fitted in the armpit; the common peroneal nerve may be paralyzed from compression of the nerve against the head of the fibula by a tight cast or bandage.

The mechanism responsible for nerve injury is not always readily recognized. In dislocation of the shoulder, the axillary nerve may be injured by displacement of the nerve by the head of the humerus; this could be due to either compression or traction. The differentiation between compression and traction injuries may be important since severe injuries due to compression, being more localized than severe traction injuries, may be amenable to neurorrhaphy. Compression is usually the cause of paralysis in cases of fracture of the long bones. With angulation of the fragment, the nerve may be compressed or actually divided by a jagged fragment. Spontaneous recovery following severe traction injuries is rather rare, whereas spontaneous recovery following radial nerve injuries in association with fractures of the humerus occurs in 70 percent of the cases.

TARDY ULNAR NERVE PARALYSIS

Ulnar nerve paralysis may occur months or even years after injury to the elbow, either because of callus formation or the development of an abnormal

carrying angle. The ulnar nerve may be stretched or injured following repeated flexion of the elbow. This type of paralysis is slowly progressive and insidious in onset.

CARPAL TUNNEL SYNDROME

This syndrome is due to compression of the median nerve as it travels through the carpal tunnel. Compression can be the result of an old fracture of the wrist, arthritis of the wrist, or a congenital anomaly of the carpal tunnel. When due to arthritis or a congenital anomaly, the syndrome may be bilateral. Pain, paresthesia, atrophy of the thenar eminence, and sensory loss in the median nerve distribution may occur. Often there is some swelling over the volar surface of the forearm, just above the wrist. Decompression can be effected by incising the transverse carpal ligament parallel to the course of the nerve. The nerve is usually found to be swollen just proximal to the point of compression.

ERB-DUCHENNE PARALYSIS (UPPER BRACHIAL PLEXUS INJURY)

This is the most common type of brachial plexus injury. It is often the result of birth injuries and is due to compression, stretching, or tearing of C5 and C6 roots. Paralysis and atrophy of the deltoid, biceps, brachialis, and brachioradialis muscles result, with loss of abduction and external rotation of the arm, weakness of flexion, and supination of the forearm. There is sensory loss in the deltoid area and on the radial surface of the forearm in the C6 root distribution.

KLUMPKE'S PARALYSIS (LOWER BRACHIAL PLEXUS INJURY)

This injury is less common and occurs with the arm in abduction at the time of injury. It may result from cervical rib, birth injury, or other trauma. It is characterized by paralysis and atrophy of the intrinsic muscles of the hand and flexors of the wrist, with sensory loss in the ulnar distribution. Occasionally, there is an associated Horner's syndrome.

ANTERIOR TIBIAL SYNDROME

In most cases this syndrome occurs in young men and develops slowly either during, or shortly after, strenuous use of the muscles of the lower extremities. There is severe pain and swelling, with inability to dorsiflex the foot or toes. Ischemic necrosis of the muscles of the anterior tibial compartment and contracture of these muscles develop, so drop foot becomes minimal. The peronei muscles are not involved.

MERALGIA PARAESTHETICA

This syndrome is due to involvement of the lateral femoral cutaneous nerve at the level of the anterior superior iliac spine where it traverses the inguinal ligament. The nerve may be compressed by scar tissue, a thickened ligament, corsets, or belts, or by traction on the nerve in obese individuals with pendulous abdomens. It is characterized by paresthesiae numbness, and pain in the area of cutaneous distribution of the lateral femoral cutaneous nerve, on the lateral aspect of the thigh. Symptoms are aggravated by walking, and to a lesser degree by lying in bed with legs extended; patients are most comfortable when sitting. This syndrome is occasionally seen bilaterally.

REFERENCES

1. Tinel, J.: *Nerve Wounds. Symptomatology of Peripheral Nerve Lesions Caused by War Wounds.* Translated by Fred Rothwell. New York: William Wood & Co., 1917.
2. Woodhall, Barnes, and Beebe, Gilbert W. (editors): *Peripheral Nerve Regeneration. A Follow-Up Study of 3,656 World War II Injuries.* Washington: U.S. Government Printing Office, 1956.
3. Guttmann, L.: *Topographic Studies of Disturbances of Sweat Secretion After Complete Lesions of Peripheral Nerves.* *J. Neurol. & Psychiat.* 3: 197-210, July 1940.
4. Richter, C. P.: *Nervous Control of the Electrical Resistance of the Skin.* *Bull. Johns Hopkins Hosp.* 45: 56-74, July 1929.
5. Mitchell, S. Weir, Morehouse, George R., and Keen, William W.: *Gunshot Wounds and Other Injuries of Nerves.* Philadelphia: J. B. Lippincott & Co., 1864.

6. Seddon, H. J. (editor): *Peripheral Nerve Injuries*. Medical Research Council Special Report Series No. 282. London: Her Majesty's Stationery Office, 1954.
7. Granit, R., Leksell, L., and Skoglund, C. R.: Fibre Interaction in Injured or Compressed Region of Nerve. *Brain* 67: 125-140, June 1944.
8. Makins, George H.: On Gunshot Injuries to the Blood-Vessels, Founded on Experience Gained in France During the Great War, 1914-1918. Bristol: J. Wright & Sons, 1919.
9. Elkin, D. C.: The Treatment of Aneurysms and Arterio-venous Fistulas. *Bull. New York Acad. Med.* 22: 81-87, February 1946.
10. Seddon, H. J.: Nerve Lesions Complicating Certain Closed Bone Injuries. *J.A.M.A.* 135: 691-694, 15 Nov. 1947.

CHAPTER 46

Treatment of Peripheral Nerve Injuries

Hugo V. Rizzoli

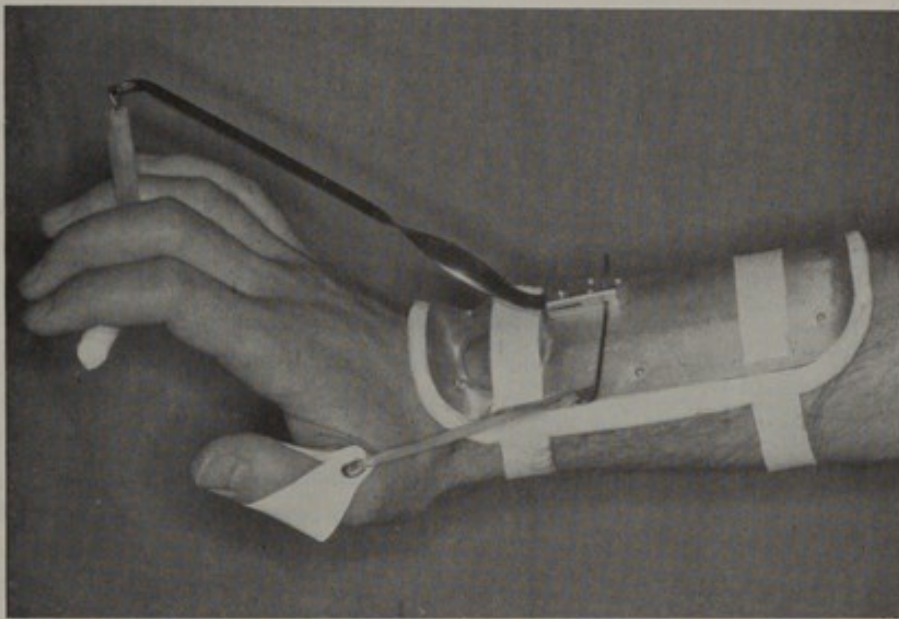


FIGURE 256.—Thomas splint for radial nerve paralysis.

NONOPERATIVE TREATMENT

Following the initial examination of peripheral nerve injuries and during the course of observation, certain principles of treatment should be instituted. The usual surgical principles govern the immediate treatment of the fresh wound. Nerve repair is best deferred for 3 weeks in most cases (1) (2), even when anatomical division is known to be present. Atrophy can be kept at a minimum by vigorous physical therapy in the form of heat, massage, whirlpool treatments, exercise, and galvanic stimulation of the paralyzed muscles. This treatment improves the circulation and also helps prevent fibrosis. Deformity results from contractions in unopposed muscles with stretching of the

paralyzed muscles. With proper mobilization-type splints and physical therapy of the involved joints, deformity and atrophy are kept at a minimum. Overstretching of paralyzed muscles must be prevented. The Thomas- or Oppenheimer-type splints for radial nerve paralysis (fig. 256), and the spring-type foot drop splint for peroneal nerve paralysis are commonly used. Immobilization-type splinting may be necessary for brief periods soon after injury to allow for wound healing, and following neurorrhaphy to prevent disruption of the suture site. If deformity and ankylosis occur, vigorous physical therapy should be instituted. Ankylosis of the elbow or knee, in extension, makes it impossible to overcome even a small gap at the time of neurorrhaphy. Ideally, physical therapy is employed daily.

OPERATIVE REPAIR OF PERIPHERAL NERVE INJURIES

DEFERRED VERSUS IMMEDIATE REPAIR

When neurorrhaphy is indicated, it should be undertaken as soon as it is feasible; however, immediate or primary repair at the time of emergency treatment of the wound has proved unwise for the following reasons:

1. Nerve repair usually requires mobilization of the nerve and enlargement of the wound; the opening of fascial planes is not desirable in the presence of potential infection.

2. The epineurium of the freshly injured nerve is friable and does not hold sutures well.

3. Woodhall and Lyons (3) have demonstrated that immediately after injury one is unable to determine accurately the extent of the zone of interstitial damage in the proximal and distal segments. A 3-week delay permits the injured proximal and distal segments to demarcate and reveal the extent of damage, thus allowing adequate resection of the distal and proximal ends before neurorrhaphy.

4. Neurorrhaphy, being time consuming and requiring meticulous performance and thorough knowledge of the anatomy, is best done as an elective procedure rather than as an emergency.

It is generally agreed that nerve suture should be done as soon as possible after a preliminary waiting period of 3 weeks (1) (2). Suture 1 month following injury produces a better functional result than suture after 3 months, and a much better result than suture after 6 months. Woodhall and Beebe (4) state that one can expect a 30-percent reduction in motor recovery when neurorrhaphy is done 6 months following injury. After 6 months, the degree of motor return lessens progressively; in general, delays of more than 3 months should be avoided. When definite evidence of regeneration is lacking 3 months after injury, surgical exploration is justifiable, especially in cases associated with open wounds. Statistics show that there is a 50-percent chance of finding anatomical division. In cases of closed injury with fracture, especially if there is evidence of satisfactory progressive advance of the Tinel sign, nerve exploration may be deferred in individual cases for more than 3 months (but

not more than 6 months) if the lesion is so high above the proximal muscle branch that one would not expect evidence of regeneration. In these cases, the lesion, statistically, is usually an axonotmesis, and excellent spontaneous recovery is frequent. In fracture cases, evaluation of peripheral nerve defects or surgery should not await completion of the orthopedic treatment, and whenever the fracture site is to be exposed for orthopedic reasons, the nerve should be explored in order to ascertain the nerve pathology present.

SURGICAL EXPLORATION

The basic requirements for successful surgery include (1) familiarity with the history of the case and the course of events since injury, (2) a knowledge of the neurological deficits and the results of electrical tests, and (3) a thorough knowledge of the anatomy of the area about to be explored.

Preparation.—The appropriate extremity is shaved completely and scrubbed with pHisoHex on the evening preceding surgery; it is common practice in many clinics to wrap the extremity in sterile towels. In the operating room, any accepted method of preparing the skin for surgery is used; the fingers or toes must be carefully prepared and covered with a sterile glove, since often part of the hand or foot is left undraped to observe the effect of nerve stimulation. Preparation of the entire extremity is advisable, for frequently it becomes necessary to extend the exposure for a considerable distance and to posture joints in flexion during surgery. After towel-draping the most proximal end, the prepared extremity is inserted through the opening in a laparotomy sheet and is then covered with a stockinet sleeve which, of course, must be cut in line with the proposed skin incision.

Equipment for surgery should include an electrical stimulator. When one is not available, a simple but effective stimulator can be made from an ophthalmoscope handle which has built-in receptacles for banana-type plugs and an ordinary lamp-cord wire with banana plugs at one end; the naked wires on the other end can be used as the stimulating electrodes. It is essential that the patient not be given any curare-like muscle relaxants during surgery,

since these drugs block the transmission of the stimulus at the myoneural junction.

Most upper extremity nerve explorations are done with the patient supine and with the arm abducted on an arm board. For sciatic nerve exploration, the patient must be prone on the operating table. Although a tourniquet makes for a bloodless field, routine use of one is not advised, for it prevents initial surgical exposure under local anesthesia, interferes with sensory stimulation studies, and may hamper proper draping of the extremity. If a tourniquet is used, however, it should not be allowed to remain inflated for more than an hour on the upper extremity, or more than an hour and a half on the lower extremity.

Anesthesia.—In most cases of upper extremity lesions, local anesthesia is preferred to general anesthesia. Since these exploratory procedures may be long and tedious, general anesthesia would increase the operative risk, and it would also make sensory reaction to direct nerve stimulation unavailable. The use of 0.5-percent procaine containing 1:200,000 Adrenalin (epinephrine) proves quite successful; up to 400 cc. can be injected with impunity (sensitive patients excepted). Premedication is effected with Demerol (meperidine hydrochloride) or morphine. If necessary, further sedation may be used during the course of the operation. At times, intravenous Nembutal (pentobarbital sodium) is helpful during the course of surgery. If the patient is uncooperative, or when isolation of the lesion and electrical stimulation studies have been completed, the surgeon may elect to continue with the patient under general anesthesia obtained with intravenous Pentothal sodium (thiopental sodium).

Lesions of the lower extremity can be handled similarly. During World War II, it was common practice to insert a catheter or spinal needle for continuous spinal anesthesia. The operation was usually begun with local anesthesia, and later, when the lesion was isolated and stimulation studies completed, spinal anesthesia was used.

Exposure.—Skin incisions longitudinally directed along the course of the nerve allow maximum exposure. Of course they must not cross flexor creases at right angles, for subsequent contracture will result. At the level of a flexion crease, the incision can be curved laterally to avoid the crease, or it can be

taken to the opposite side of the extremity by a horizontal extension in the flexion crease in a Z-shaped fashion. Seletz (5) has used multiple incisions at various levels along the course of the nerve, some vertical and others horizontal, to avoid crossing flexion creases. In the case of the radial nerve, it is best to avoid a spiral incision along the anatomical course of the nerve in the upper arm; if exposure is required in the proximal portion as well as in the distal half of the upper arm, it is best done with two incisions—one high on the medial aspect of the upper arm and the other on the lateral aspect of the lower half of the upper arm. Crossmarking the planned incision facilitates approximation of the skin, particularly if the wound is to be closed while one of the joints is postured in a flexed position. It may be advisable to plan the course of the incision to excise previous scars. At times, it is necessary to reroute the incision about the periphery of a broad, thin scar. When making incisions in the vicinity of scars, great care must be exercised not to divide a nerve which may have been displaced from its normal bed and become adherent to the undersurface of the scar. Typical incisions for exposure of peripheral nerve injuries are shown in figures 257–269.

The next step is to isolate the distal segment of the nerve in normal tissue by sharp dissection via normal fascial planes. The nerve is easily identified and isolated in normal tissue. A thin rubber tape is slipped around the nerve to permit very gentle traction, if necessary, during further dissection of the nerve. Sensory stimulation data are now obtainable by stimulation around the entire circumference of the nerve. (After these studies are obtained, surgery can be continued with general anesthesia.) A strongly positive sensory response indicates the presence of many intact sensory fibers traversing the level of the lesion. A weak sensory response does not rule out anatomical division, since escaping fibers from a proximal neuroma may have found their way to the distal stump.

Isolation of the normal nerve proximal to the site of injury is accomplished next. Evaluation of motor response to electrical stimulation can now be done. Lack of motor response does not necessarily indicate anatomic division, or that neurorrhaphy is required. In the case of axonotmesis which will go on to satisfactory and spontaneous recovery,

enough time may not have elapsed to allow for re-innervation of the proximal muscles. However, if enough time has elapsed, the findings are significant. Obviously, a good motor response on electrical stimulation in the muscles supplied by the nerve is very significant.

The next procedure is isolation and exposure of the lesion. Care is exercised not to damage normal fascicles and nerve branches in the scarred area of the wound; the use of the electric stimulator is of great help in this portion of the dissection. The lesion is best exposed by first isolating normal nerve on either side and then dissecting the lesion from the adjoining scarred area. Anatomical disruption may exist despite the fact that there may be a fibrous strand joining the proximal and distal ends. In these cases, the need for neurorrhaphy is obvious.

Lesion in continuity.—This type of lesion may present a dilemma to the surgeon. The nerve may appear fairly normal and show only slight thickening of the epineurium, yet the lesion may be the result of a traction injury and may not go on to satisfactory and spontaneous recovery. On the other hand, it may represent a case of simple axonotmesis which will result in spontaneous recovery. A soft fusiform swelling of the nerve at the site of injury may represent a lesion with interfascicular damage with good chance of spontaneous recovery. This may not be the case with a very firm neuroma. In some cases a lateral neuroma may be present which, if not unusually hard, may result in spontaneous recovery. One may find that only a half or a third of the fibers are divided on one of the lateral aspects of the nerve, with a proximal neuroma and a distal glioma involving only a portion of the fibers. Here, dissection of the functioning fascicles from the nonfunctioning fascicles may be possible—especially with sciatic, median, and ulnar nerve injuries—and a partial suture may be feasible.

In dealing with lesions in continuity, all information concerning the case must be considered: The length of time since injury, the mechanism of injury, existing evidence of regeneration, the appearance of the lesion, and results of stimulation studies. If enough time has elapsed to allow peripheral growth of the regenerating axons to the proximal muscles at a rate of 1 mm. per day (approximately 1 inch per month) and this has not occurred, resection of the lesion and nerve suture would be indicated. If, how-

ever, the distance from the lesion to the proximal muscle is 4 inches, and exploration is being carried out 2 months following injury, one should tend to be conservative. A nicety of judgment is required in lesions high on the sciatic nerve, in the axilla, and in the brachial plexus. At these levels it is especially important to do an early neurorrhaphy because regenerating fibers have so far to grow before the proximal and other muscles are reinnervated. A late suture may result in a very poor degree of functional recovery. On the other hand, early sutures at these levels do not produce the degree of functional recovery that would occur in more distal lesions. Therefore, it is especially important that a lesion at a high level not be resected unless one is certain that spontaneous recovery will not occur. When in doubt, one should tend to be more conservative and to be satisfied with lysis of the nerve in the more proximal lesions; whereas, with distal lesions, resection and suture should be done when the criteria for satisfactory regeneration are not fulfilled. Yahr and Beebe (*In Woodhall and Beebe (4)*, pp. 71–201.) arrived at the following conclusions, after statistical study of motor recovery following nerve suture in World War II:

- a. Motor recovery is better after low lesions than after high, but in the upper extremity the advantage is greater in the most proximal muscles and doubtful in the most distal.
- b. In the upper extremity the advantage of the lower lesions is less a matter of the ability of muscles to contract than of actual strength of movement.
- c. The advantage of the tibial over the sciatic-tibial lesions is chiefly a matter of ability to contract rather than strength of movement, but the peroneal exceed the sciatic-peroneal cases not only in regard to the proportion contracting but also in strength of movement for those able to contract.

In some instances, more information may be obtained by incision of the epineurium longitudinally and dissection between the fascicles. This may reveal enough gross scar tissue to warrant resection and suture. The value of neurolysis is highly debatable; however, if insufficient time has elapsed to evaluate the criteria for satisfactory regeneration, one must be satisfied with this conservative approach until the earliest time when more significant evaluation is possible.

The dilemma is usually not as great with civilian-type injuries as with high-velocity missile injuries encountered in warfare. In civilian injuries, early surgical exploration of the nerve lesion associated

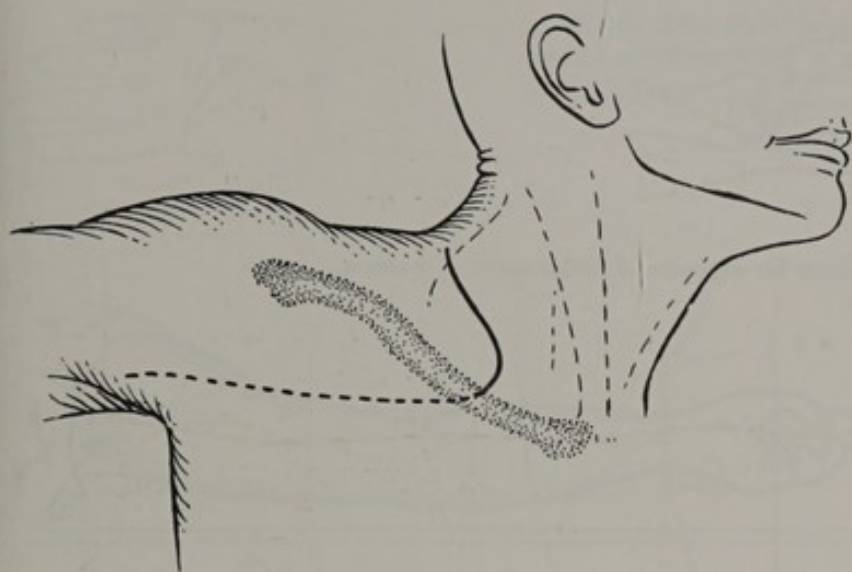


FIGURE 257.—Skin incision for exposure of brachial plexus. Dotted line represents extension.

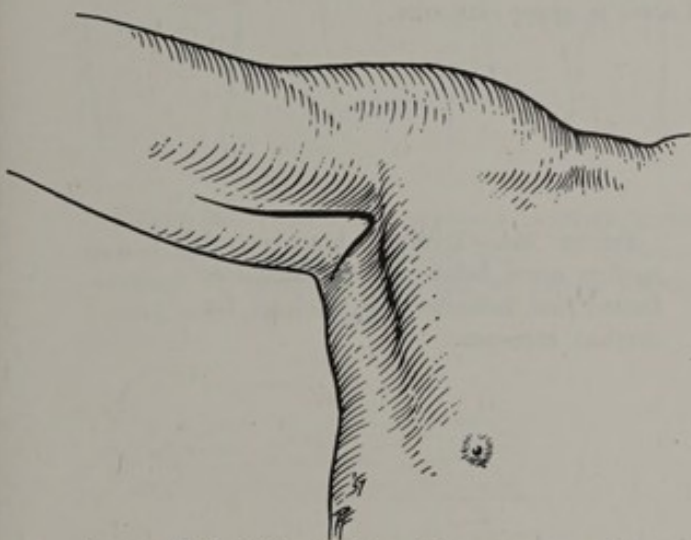


FIGURE 258.—Skin incision for exposure of musculocutaneous nerve.

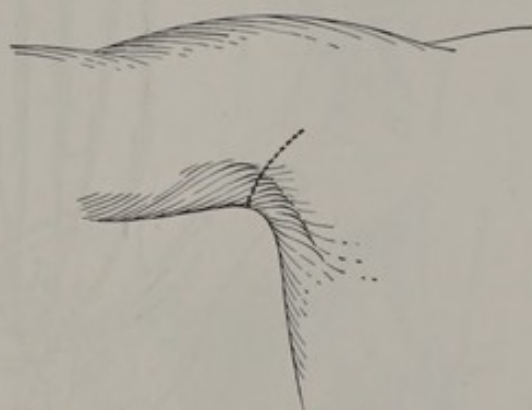


FIGURE 259.—Skin incision for exposure of axillary nerve.

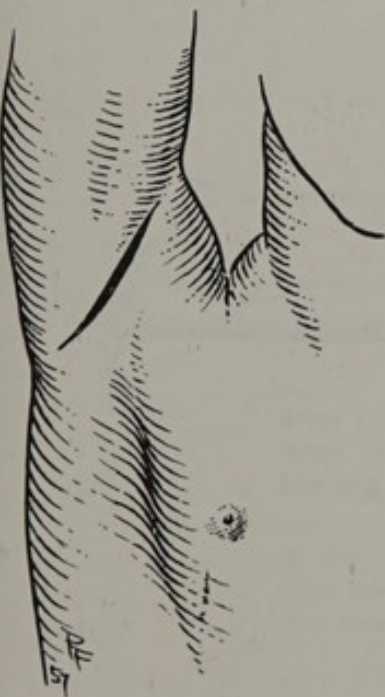

FIGURE 260.—Skin incision for exposure of proximal third of radial nerve.

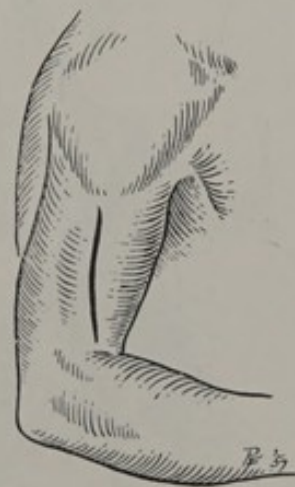

FIGURE 261.—Skin incision for exposure of radial nerve in lateral aspect of arm.

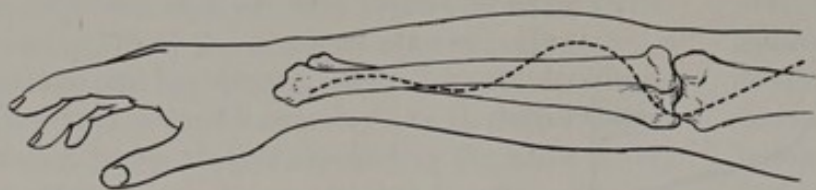


FIGURE 262.—Skin incision for exposure of radial nerve in forearm.

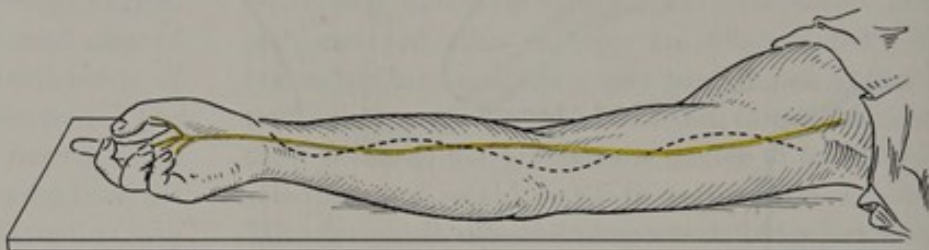


FIGURE 263.—Course of median nerve in upper extremity.

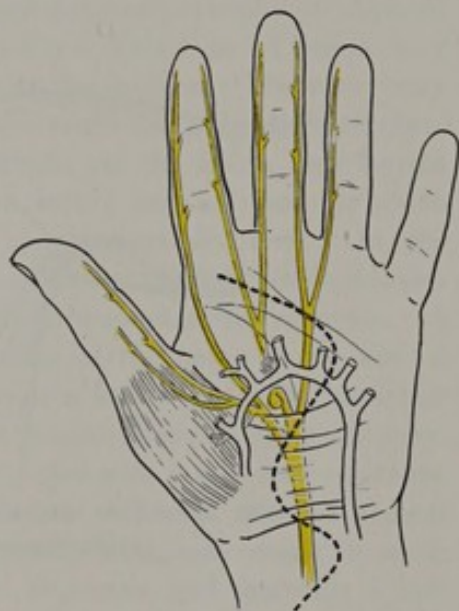
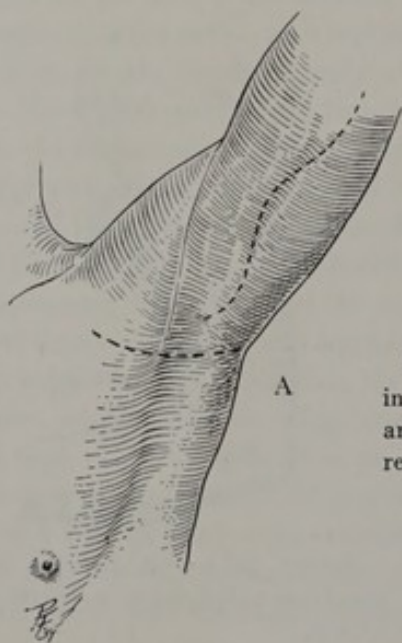
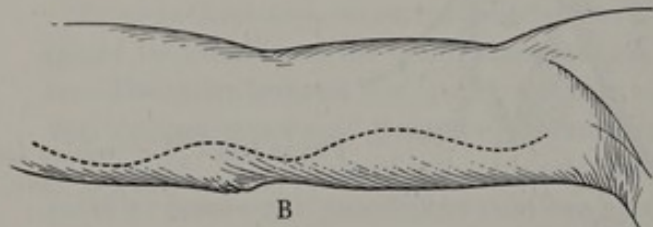


FIGURE 264.—Terminal branches of median nerve below annular ligament. Dotted line indicates skin incision for surgical exposure.



A

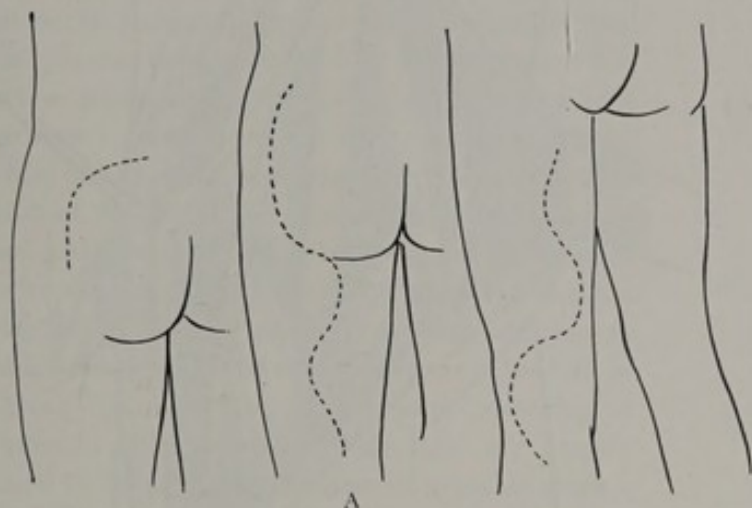


B

FIGURE 265.—Skin incision for exposure of ulnar nerve in upper extremity. A. Exposure in axilla and upper arm. B. Continuation of skin incision in lower arm and region of medial epicondyle.

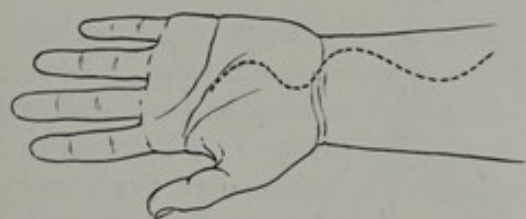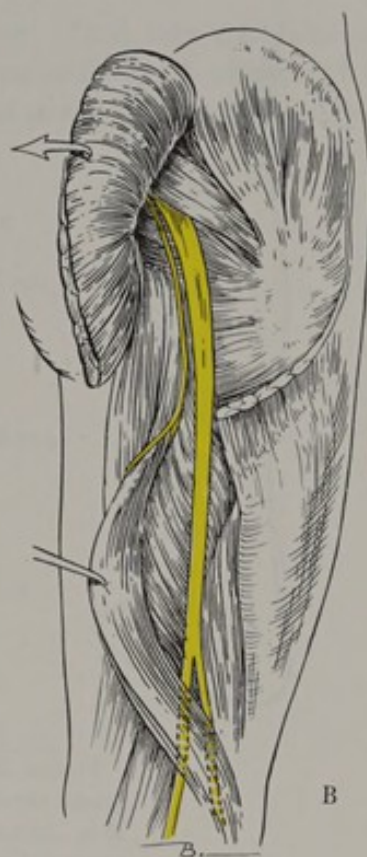


FIGURE 266.—Skin incision for exposure of ulnar nerve at wrist and in hand.

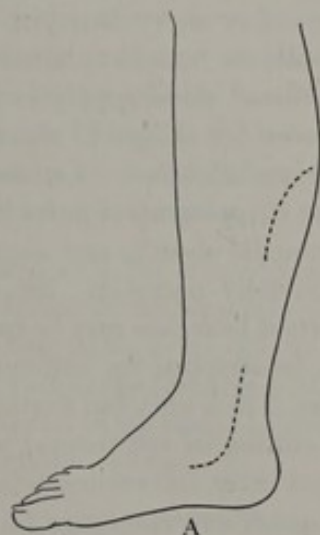
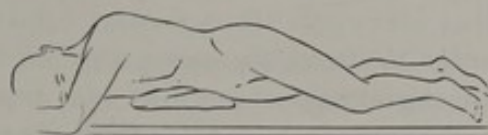

A

FIGURE 267.—Anatomical approach to sciatic nerve. A. Outline of skin incisions in hip and thigh. B. Division of gluteus maximus at tendinous insertion to expose sciatic nerve in buttock and upper thigh.

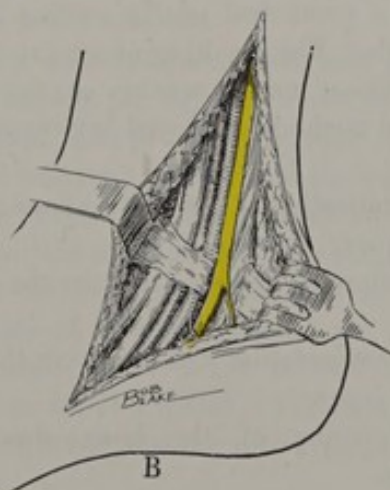
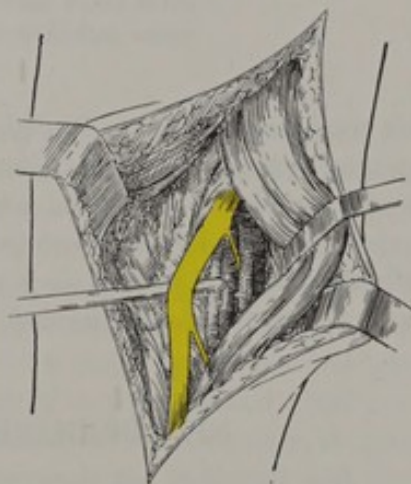


B



A

FIGURE 268.—Anatomical approach to tibial nerve in calf. A. Position of patient and outline of skin incisions. B. Simultaneous exposure of tibial nerve in lower calf and ankle through window incision.



B

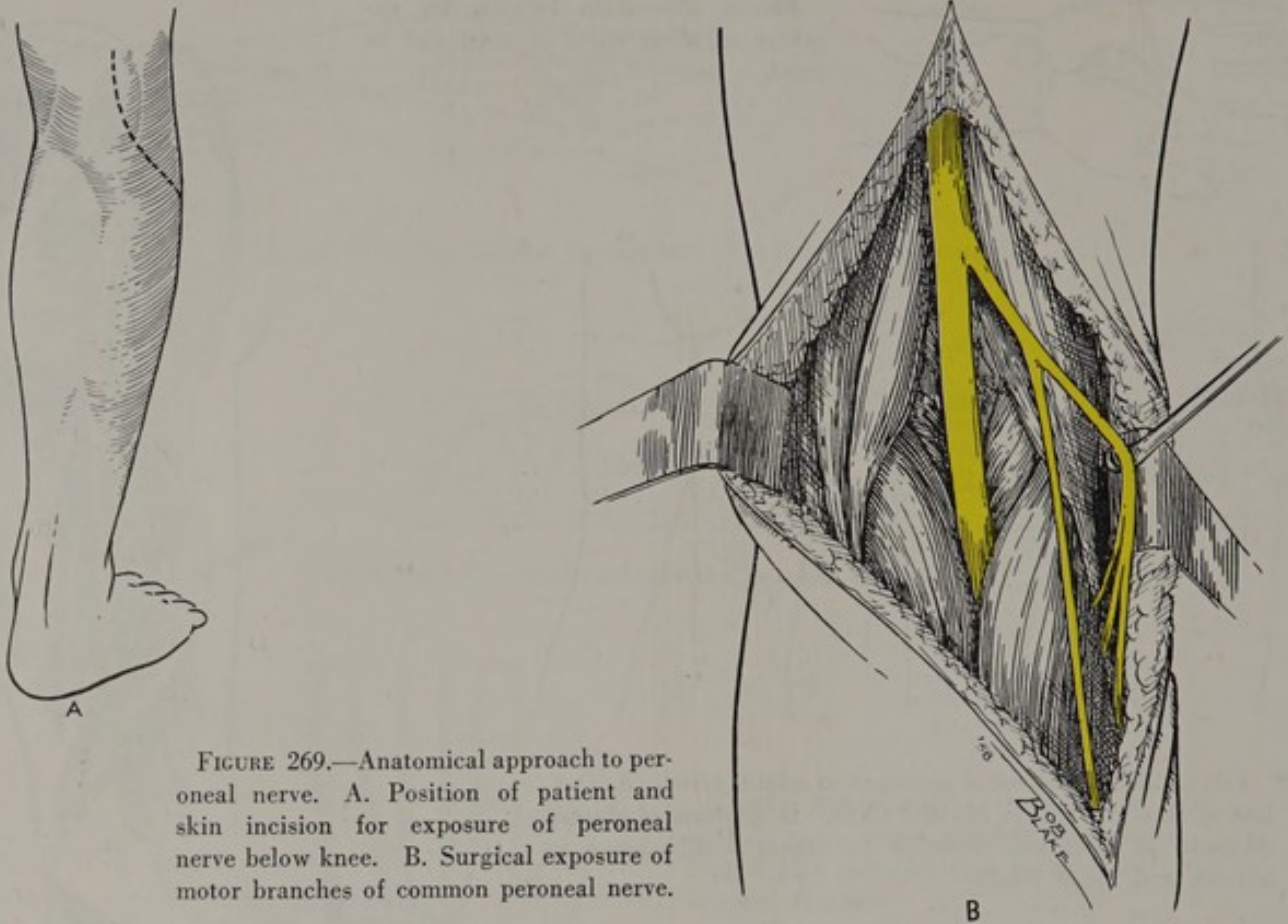


FIGURE 269.—Anatomical approach to peroneal nerve. A. Position of patient and skin incision for exposure of peroneal nerve below knee. B. Surgical exposure of motor branches of common peroneal nerve.

with total paralysis is indicated, since here nerve damage is produced by laceration and nerve paralysis will usually be associated with anatomical disruption. Suture is done when the nerve is anatomically divided, and neurolysis is usually done when the nerve is not obviously divided.

NEURORRHAPHY

Overcoming the gap.—The result of nerve suture depends a great deal on the cutting back to good nerve ends. The resulting nerve gap must be overcome without undue tension at the anastomosis. The usual methods employed in overcoming the gap are:

1. Mobilization of the nerve above and below the site of injury.
2. Flexion of joints to shorten the course of the nerve.
3. Transplantation and rerouting the nerve along a shorter course.
4. Shortening of the bony structure of the extremity.

5. Bulb suture to stretch the nerve.
6. Autogenous grafting.

Mobilization, joint posturing, and transplantation.—The dissection of a nerve from its bed involves interference with the collateral blood supply. However, the longitudinal blood supply is profuse, and there is no evidence for failure of regeneration because of extensive mobilization. Extensive mobilization may require stripping up of nerve branches by splitting the epineurial sheath, and on rare occasions, if it is absolutely necessary, the division of relatively unimportant branches may be indicated. These branches can be stripped up without injury over a length of from 3 to 5 cm., but further stripping often requires cutting of intraneural plexuses, since there are changes in the intraneural topography at various levels where fibers rearrange to prepare for exit from a nerve via its branches. Mobilization alone may help to shorten the gap as much as 2 to 3 centimeters. Usually, flexion of the proximal or distal joint is necessary to allow nerve suture without tension. Therefore, mobilization often has to be extended to the nearest joint. In lesions of the ulnar and median nerves at the wrist, where

the gap would require 90° flexion of the wrist in order to overcome the defect, one should mobilize to the elbow and make up some of the gap by flexion of the elbow. To position the wrist in 90° flexion may result in limitation of dorsiflexion, or possibly disruption of the suture. Similarly, in posterior tibial nerve lesions, near the ankle, no more than 10° of plantar flexion of the foot is advisable. The defect is made up by proximal mobilization and, if necessary, flexion of the knee. Defects in the brachial plexus in the upper arm are overcome by adduction of the arm at the shoulder, as well as mobilization. At times, mobilization has to be continued to the elbow with posturing of the elbow in flexion. Sciatic nerve defects may require, in addition to mobilization, extension of the hip and flexion of the knee. Sutures that require joint posturing at the knee or elbow of more than 100° are usually destined to failure, both because of possible disruption of the suture site and because of subsequent traction injury to the nerve when the cast is removed and the flexion deformity is corrected.

The course of some nerves can be shortened by transplantation. The ulnar nerve is often transplanted anterior to the elbow; the radial nerve may be transplanted anterior to the humerus; the median nerve may be transplanted anterior to the pronator teres muscle. When transplantation is done, stripping of the nerve branches proximally from the main nerve trunk and mobilization distally into the muscles innervated by branches may be necessary.

Babcock (6) gives the following anatomical gaps that can be overcome by mobilization, joint posturing, and transplantation:

1. Median in the arm—15 cm.
2. Median in the forearm—23 cm.
3. Ulnar in the arm—16 cm.
4. Ulnar in the forearm—12.5 cm.
5. Radial in the arm—15 cm.
6. Sciatic—14 cm.

These figures, however, are not of real significance, since certain physiological limitations come into play when a nerve is unusually shortened, even if disruption does not occur. The anastomosis must be under tension, and as the flexion deformity of the extremity is overcome, traction injury of the nerve may result.

Zachary (*In Seddon (7)*), lists the following critical gap lengths compatible with significant recovery after a study of peripheral nerve injuries in World War II.

1. Ulnar nerve
High—10 cm.
Intermediate—13 cm.
Low—10 cm.
2. Median nerve
High—7 cm.
Intermediate—8.5 cm.
Low—7 cm.
3. Radial nerve
High—8 cm.
Intermediate—8 cm.
Low—7.5 cm.
4. Peroneal nerve
High—9 cm.
Intermediate—8.8 cm.
Low—9 cm.
5. Tibial nerve
High—11.5 cm.
Intermediate—11 cm.
Low—8 cm.

Bone shortening.—Shortening of a bone is occasionally practical and has been used in the case of upper arm injuries of median and ulnar nerves, especially when nonunion is present and combined bone and nerve surgery is being done. On very rare occasions, one might consider shortening a normal humerus in order to make up an unusual gap in combined injuries of the median and ulnar nerves, and possibly the radial nerve. Certainly, shortening of the intact humerus is not indicated with simple radial nerve paralysis. Tendon transplanting would seem to be a better solution.

Bulb suture.—On rare occasions, bulb suture can be used to stretch the injured nerve in order to shorten the gap. The procedure consists of suturing the proximal neuroma to the distal glioma, with the extremity in flexion, and subsequent stretching of the nerve (starting immediately after surgery), controlled by a turnbuckle incorporated in a plaster cast. The rate of extension should not exceed 3° per day; thus a joint flexed to 90° should be straightened in about 1 month. Following this, the wound is reexplored and the neurorrhaphy is done

in the usual fashion, after resection of the proximal neuroma and distal glioma. Attempting to overcome gaps greater than 11 cm. by this method, or too rapid stretching of the bulb suture, is usually unsuccessful because of traction injury to the nerve.

Nerve grafting.—Sherren (8) reported a collection of 30 cases of nerve grafting. There was definite evidence of significant improvement in two cases, those of Robson in 1888 and Dean in 1896. Bunnell (9) established autogenous grafting as a reliable method of repair for digital nerves. Ballance and Duel (10) reported on repair of the facial nerve in the fallopian canal by grafting. Bunnell and Boyes (11) and Klar (12) reported cases of injury to main nerve trunks in the limbs with significant recovery following repair by grafting. Heterogenous nerve grafting has not been successful. Fresh and stored homografts have not yet proved satisfactory.

A major limitation in the clinical use of grafts is the difficulty of obtaining sufficient peripheral nerve tissue to allow repair of a large gap in a major nerve trunk. The aim is to implant a graft, or multiple grafts, with a cross sectional area at least equal to that of the distal stump. The supply of autogenous grafts is limited. The usual sources of the grafts are:

1. Cutaneous nerves used for repair of digital and facial nerve defects. Where used for repair of a major nerve trunk, cable grafts (multiple transplants) are necessary. Only that portion of the cutaneous nerve proximal to where its branches come off is useful. The cutaneous nerves ordinarily used are the medial cutaneous nerve of the forearm proximal to its bifurcation at the elbow, the superficial radial nerve, the sural nerve, the saphenous nerve, the lateral femoral cutaneous nerve proximal to the anterior iliac spine, and the small sciatic nerve above the gluteal fold. Cable grafts may be sutured, or the plasma clot technique can be used for anastomosis.

2. A segment of the main nerve trunk, where two main nerves have been damaged so severely that neither can be repaired by simple suture. In these cases a segment of the proximal end of the less important nerve is used for the graft of the more important nerve. This can be done as a free graft, but it is often done as a pedicle graft in two stages. In the first stage, the proximal end of the recipient nerve is sutured to the proximal end of the donor

nerve. The donor nerve is then partially divided proximal to the point of suture (the longitudinal blood supply, however, is left intact), at a distance from the proximal end corresponding to the length of the graft to be taken. At a later date, the partial division of the donor nerve is completed, and this end now becomes the distal end of the graft and is sutured to the distal stump of the nerve to be grafted. Seddon (7) reported useful return of function in 68 percent of 67 cases of nerve grafting.

Resection of lesion.—The degree of functional return depends a great deal on suturing of satisfactory nerve ends. In completely divided nerves the proximal neuroma and the distal glioma must be resected, and in lesions in continuity all the injured portion of the nerve must be resected. Gentle tension must be exerted on the nerve as the cuts are made. This is best done by grasping the pathological portion of the nerve. Serial sections perpendicular to the nerve are made with a sharp razor until satisfactory fascicles are encountered over the entire cross section of the nerve (fig. 270). When dealing with a soft neuroma on the proximal end, one may skimp somewhat as the resulting nerve defect is nearing a critical limit, since the neuroma itself is evidence of regenerating axons; otherwise, the line of proximal resection is at the junction of the neuroma with normal nerve. The distal end is resected serially until relatively normal fascicles are seen. There can be no skimping in the resection of the distal end. To compromise here is to invite failure.

Suture.—Scar tissue should be removed from the nerve bed. If this is not possible, transfer of the nerve to another fascial plane may be feasible. At this stage, just prior to performing the anastomosis, partial closure of the wound at its extremities is worth while and can be done while awaiting cessation of bleeding at the nerve ends. Temporary application of Gelfoam to the nerve ends helps to control bleeding.

The anastomosis is accomplished with a fine, non-absorbable suture material. Atraumatic needles swaged on the suture material are best. Fine 6-0 or 5-0 ophthalmic or arterial silk is generally available. Tantalum wire, 0.003, with atraumatic needles, was commonly used during World War II, but this material is quite difficult to work with. Its only significant advantage is its radiopacity, which permits X-ray evidence of the integrity or disruption

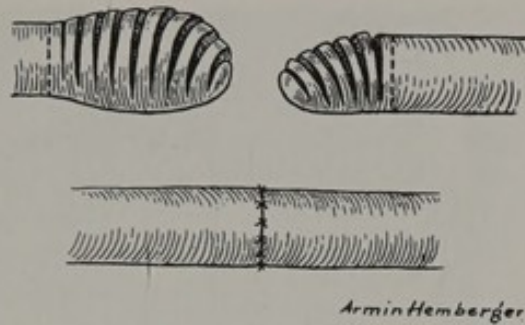


FIGURE 270.—Classical method of end-to-end suture following resection of scarred ends by serial section.

of the anastomosis. This advantage can also be obtained by placing single fine metallic sutures through the epineurium, 1 cm. from the suture line, on both proximal and distal nerve segments. It is of value to attempt to line up the distal end with the proximal end so that the cross sectional topography approximates the normal. With lesions in continuity, marking sutures can be placed on one of the lateral aspects of the nerve on both the distal and proximal segments, so that after resection they can be used as a guide in the alinement of the nerve ends. With lesions not in continuity, study of the cross sectional anatomy following resection of the nerve ends may give further information of the internal topography so that the fascicles can be alined accurately.

The anastomosis is accomplished with multiple interrupted epineural sutures. The lateral sutures are placed first and at least one end on each side is left uncut to permit easy rotation of the nerve. The interrupted sutures on the anterior surface of the nerve are then placed. The nerve is then rotated and the posterior sutures are placed. Great care

must be exercised in the placement of sutures; they must not go deeper than the undersurface of the epineurium and they must be loose enough to allow for some swelling of the nerve ends. The number of sutures used should be the fewest possible to allow for neat apposition of the epineurium (figs. 271 and 272). Wrapping the suture line with tantalum foil or other material has now been discontinued and should not be done.

Closure of the wound is then completed. If possible, the deep fascia is closed. Subcuticular interrupted sutures, placed and tied so the knot is inverted, allow early removal of the interrupted skin sutures. A plaster cast or plaster shell is applied to maintain the degree of flexion required in accomplishing the anastomosis without tension. In sciatic nerve sutures, and in some peroneal nerve sutures at the knee, the application of a hip spica with the hip in slight extension and flexion of the knee may be necessary. Joints that do not need immobilization are not included in the cast. Velpeau's bandage is usually required for lesions in

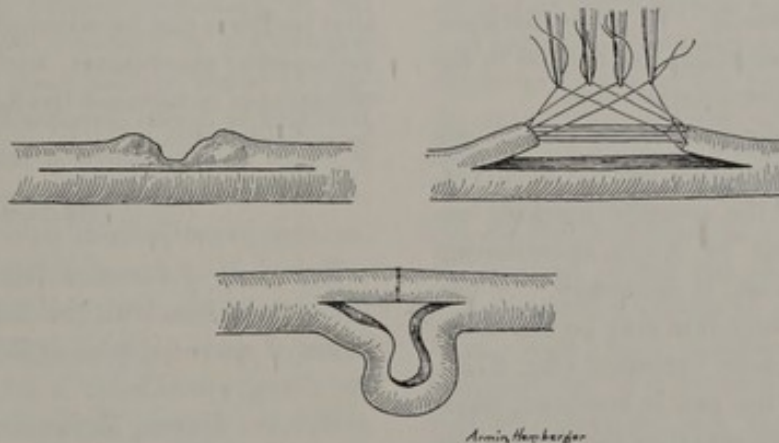


FIGURE 271.—Procedure for repair of lateral neuroma. Note that the injured fascicles are split from the remaining normal nerve before sectioning and suture.

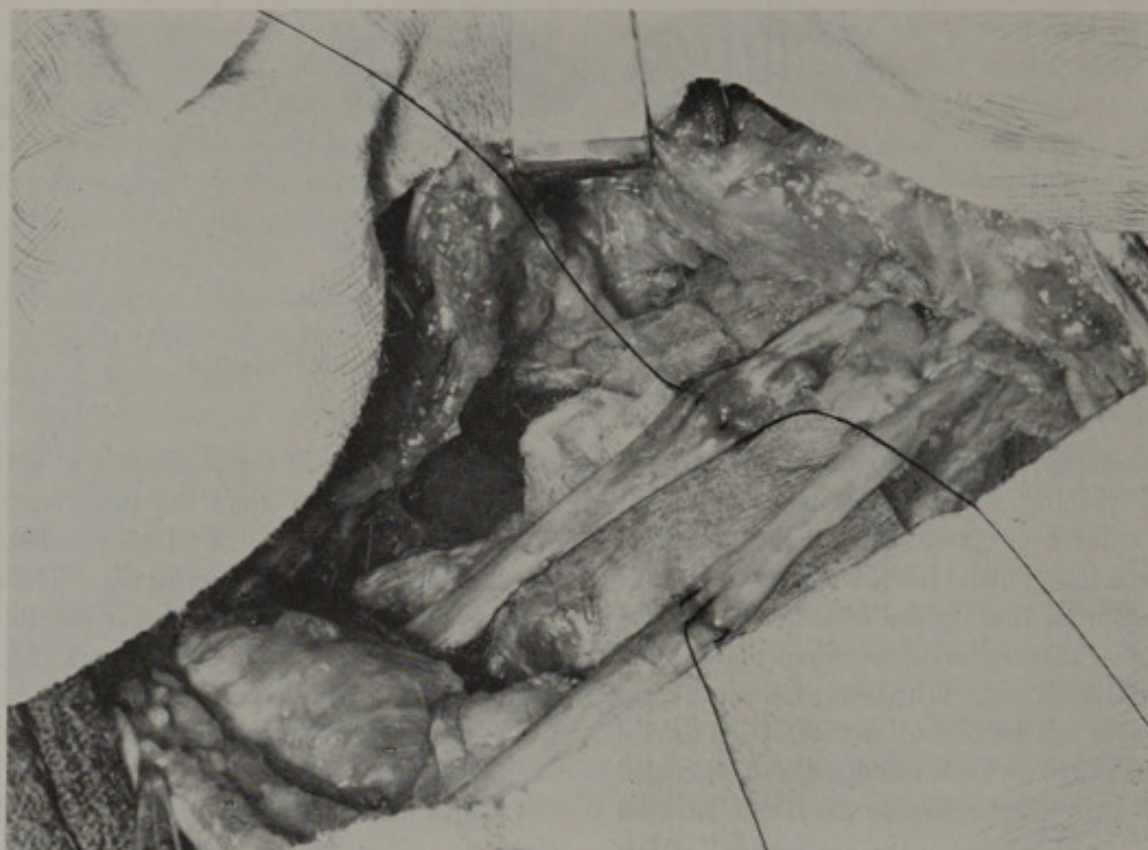


FIGURE 272.—Neurorrhaphy of median and ulnar nerves in the arm.

the axilla or brachial plexus. Immobilization is maintained for 3 weeks; occasional cases which require hip spicas are immobilized for 4 weeks.

The immediate postoperative course does not present unusual problems. Circulation must be checked frequently. Patients should be encouraged to exercise joints that do not require immobilization. Following high sciatic nerve sutures, surgical shock may occur insidiously because of postoperative bleeding under the gluteus muscle. In these patients, routine hematocrit determinations are helpful in the early recognition of postoperative bleeding.

Following removal of the cast, X-ray studies are made to be certain that disruption has not occurred. However, the position of the metallic marking sutures can be demonstrated by X-ray examination prior to removal of the cast, if necessary. A second observation of the suture line may be advisable after the flexed joint has been extended (fig. 273).

Rehabilitation.—When the cast is removed, physical therapy is instituted to mobilize the flexion deformity gradually over a period of from 3 to 5 weeks. Galvanic stimulation and massage of the paralyzed muscles, as well as mobilization of all joints, are

continued, so that neurotization will result in the best possible function. Regeneration is useless if the muscles have been replaced by fibrous tissue and the joints are ankylosed. When function returns, active exercise is initiated. Occupational therapy is useful in helping the patient obtain optimum function from his injured extremity. Postoperative mobilization-type splints for radial and peroneal nerve injuries may be necessary. When it is determined that no more can be accomplished by nerve surgery, orthopedic procedures, such as fusion or tendon transplants to increase the functional recovery, must be considered.

RESULTS

Recovery of function following nerve suture has been studied in both the British and the American series of nerve injuries of World War II.

UPPER EXTREMITY INJURIES

A hand is not useful unless it has active innervation of a variety of movements and satisfactory sensation in the median nerve distribution.

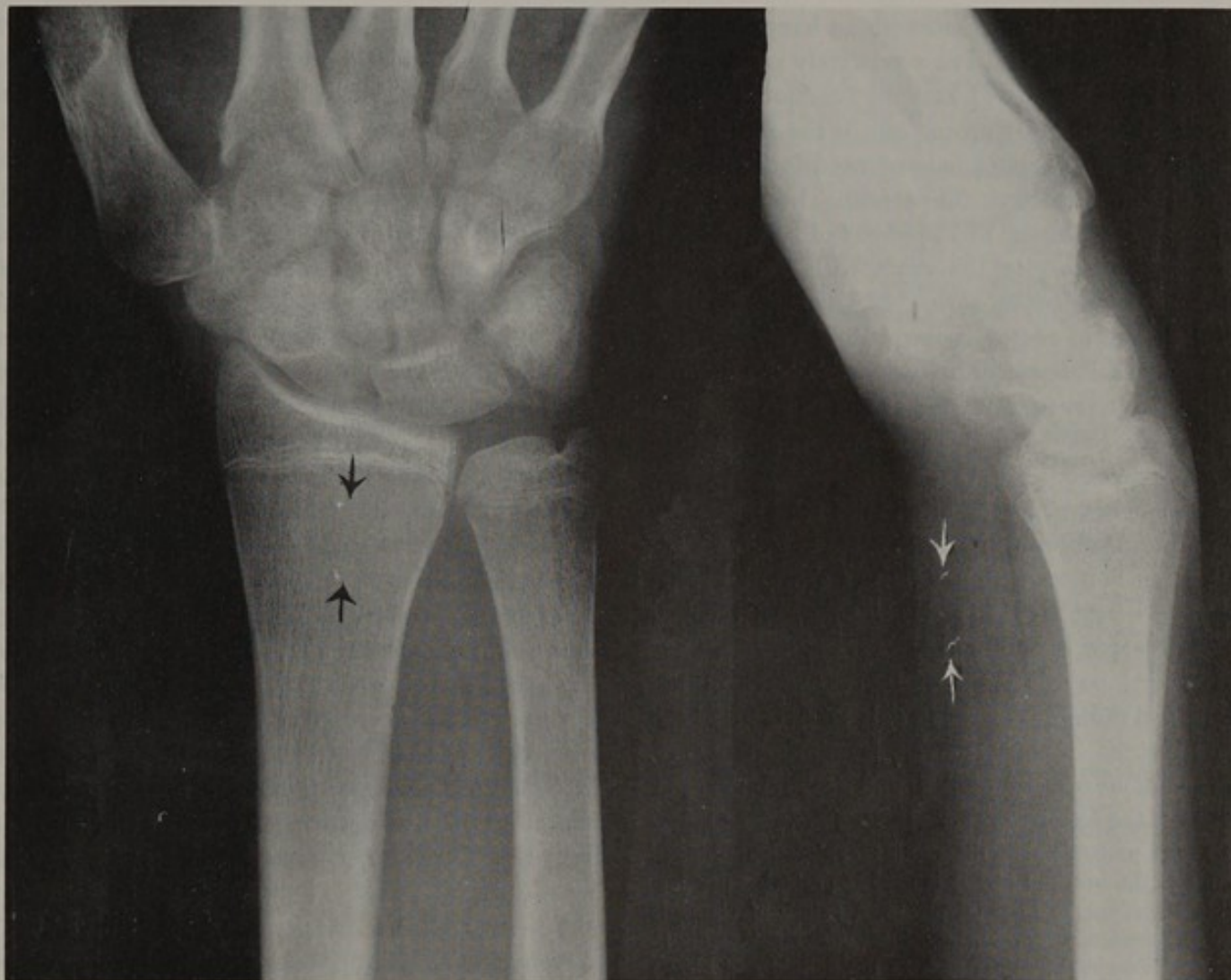


FIGURE 273.—Roentgenograms following neurorrhaphy of median nerve at the wrist, showing marking sutures.

Median nerve.—Both motor recovery and sensory recovery are important. Thirty-two percent in the British series achieved satisfactory recovery of the long flexors and strong palmar abduction of the thumb. After low suture, recovery is not considered satisfactory unless good palmar abduction returns. However, in high sutures, return of function to the long flexors is worth while even if there is little or no return of function in the thenar muscles. In the British series of high median nerve sutures, only 19 percent experienced recovery of both the long flexor and thenar muscles. Almost 90 percent, however, reached a useful grade of recovery. Fifty-three percent experienced a satisfactory grade of sensory recovery and thirty-eight percent reached a higher grade of sensory recovery in which overreaction had disappeared. When only the early low sutures were considered, 52 percent reached the

higher grade of sensory recovery and 68 percent made useful recoveries. In the American series, the average percent of normal function obtained by all median nerve sutures was 59 percent.

A patient with median nerve sutures should not be discharged until he has regained useful sensation in the autonomous sensory zone, unless poor regeneration must be accepted because of the extent of the lesion. In addition, the patient should be able to oppose the thumb to the tips of the index and middle fingers; if this has not occurred as a result of regeneration, it should be provided by tendon transfers. With high median nerve lesions, tendon transfers can be considered early, since it is unlikely that this function will occur as a result of nerve suture. If sensory recovery is not progressing at a satisfactory rate, reexploration of the median nerve may be indicated.

Ulnar nerve.—The patient with an irreparable ulnar nerve paralysis still has a relatively good hand. Woodhall and Beebe (4) rate the functional ability of such a hand at 60 percent, and if the fourth and fifth fingers can be extended and used for grasping, the function is rated at 80 percent. In the American series, an average of 73 percent of normal function was obtained in the cases with ulnar nerve suture. In the British series, 78.5 percent made a useful degree of motor recovery, but only 16 percent regained independent movements of the fingers. Sensory recovery was judged useful in 46 percent; 30 percent reached a grade of sensory recovery without over-reaction.

Radial nerve.—Regeneration is of the highest order in radial nerve injuries. In cases of poor regeneration, tendon transfer operations are quite satisfactory. In the British series, 89 percent reached a useful degree of motor recovery. However, finer control and coordination of the extensors of the fingers and thumb occurred in only 36 percent of the sutured cases. Sensory recovery is unimportant.

Brachial plexus.—Woodhall and Beebe stated after a study of the American series:

It seems probable that the routine exploration of open wounds of the brachial plexus is neither profitable nor justifiable since, in the brachial plexus, a suture of elements supplying the forearm and hand seldom adds significantly to function. Proximal muscles such as the deltoid and biceps do occasionally secure useful recovery through suture.

The statistical study of the American series reveals the following, when the results are classified according to practical functional recovery.

Sutured nerve:	Average (median) percent of normal function
Median	59
Ulnar	73
Radial	78
Sciatic-peroneal	60
Sciatic-tibial	60
Peroneal	60
Tibial	76

LOWER EXTREMITY INJURIES

Functional recovery in the lower extremity, as analyzed in the American series, is measured largely by the distance the patient is able to walk comfortably. In individual cases, the degree of regeneration may bear no direct relationship to the functional re-

covery, as it does in the upper extremity; a patient with no anatomical regeneration after a high sciatic suture may be classified as having a 60-percent functional ability if he is free of foot ulceration and is able to walk satisfactorily in a padded shoe with a brace to prevent foot drop at the ankle. On the other hand, patients with good degrees of regeneration may have paresthesiae that make walking difficult even for short distances, despite adequately padded shoes. However, the correlation between functional ability and nerve regeneration is not so poor as to make sciatic nerve suture inadvisable. In uncomplicated sciatic nerve division, amputation must not be considered because of the lack of regeneration following sciatic suture.

Tibial nerve, including sciatic portion.—In the the British series, the ability of calf muscles to contract against gravity and resistance was considered a useful grade of motor recovery, and 56 percent of the cases in this series achieved this grade of recovery. Return of function to the flexors of the toes was very rare. Of the patients in the British series, 80.5 percent recovered sufficient sensation to show some response to pinprick on the sole of the foot, but only 27 percent demonstrated evidence of tactile sensibility.

Peroneal nerve, including sciatic portion.—A satisfactory recovery requires the ability to dorsiflex the foot against gravity. In the British series, 36 percent achieved this degree of recovery, whereas only 13 percent were able to dorsiflex the foot against gravity and resistance. In ideal cases, in which low lesions requiring small resections were treated early, 59 percent made useful recoveries and 32 percent were able to dorsiflex against gravity and resistance.

Factors influencing recovery

In general, a useful degree of recovery following war injury occurs in 50 percent of all nerve suture cases. A somewhat higher degree of recovery can be expected in civilian-type injuries. Various factors influence the degree of recovery:

1. *Delay before repair.*—This is probably one of the most important factors in motor recovery. In the American series, it was estimated that the final level of motor recovery is greatest where suture is done early and that subsequent delay results in a

loss of 1 percent of maximal performance for every 6 days of delay. The earliest sutures (done within 19 days of injury) did as well as other early sutures (done within 20 to 49 days of injury), but half of them required resuturing.

2. *Level of injury.*—The level of injury is quite significant. The more proximal lesions give a lower degree of functional recovery.

3. *Nature of lesion.*—Wounds produced by high-velocity projectiles damage the nerve stumps more extensively than wounds produced by sharp cutting objects. A badly fibrosed distal segment often results in a poor degree of functional recovery. Attempts to overcome an unusually large gap may result in disruption of the anastomosis or traction injury to the nerve. Small lesions in continuity do better than more extensive lesions. In these cases the fascicular pattern is less disturbed, less stretching of the nerve is required, and it is possible to cut back to good distal ends.

4. *Preoperative and postoperative treatment.*—Functional recovery is prejudiced by allowing contracture with fibrotic ankylosis of the joint and extreme degrees of muscle atrophy to occur. Proper physical therapy before and after surgery can greatly enhance functional recovery.

5. *Age and general health.*—To some degree, age and general health influence the functional result. Perfect recovery following nerve suture does not occur. The results obtained in children, especially in radial and median nerve injuries, have occasionally approached perfection.

REFERENCES

1. Spurling, R. G., and Woodhall, B.: Experiences With Early Nerve Surgery in Peripheral Nerve Injuries. *Ann. Surg.* 123: 731-748, May 1946.
2. Haymaker, W.: Pathology of Peripheral Nerve Injuries. *Mil. Surgeon* 102: 448-459, June 1948.
3. Woodhall, B., and Lyons, W. R.: Peripheral Nerve Injuries; The Results of "Early" Nerve Suture; A Preliminary Report. *Surgery* 19: 757-789, June 1946.
4. Woodhall, Barnes, and Beebe, Gilbert W. (editors): *Peripheral Nerve Regeneration. A Follow-Up Study of 3,656 World War II Injuries.* Washington: U.S. Government Printing Office, 1956.
5. Seletz, Emil: *Surgery of Peripheral Nerves.* Springfield: Charles C Thomas, 1951.
6. Babcock, W. W.: A Standard Technique for Operations on Peripheral Nerves, With Especial Reference to Closure of Large Gaps. *Surg. Gynec. Obst.* 45: 364-378, September 1927.
7. Seddon, H. J. (editor): *Peripheral Nerve Injuries.* Medical Research Council Special Report Series No. 282. London: Her Majesty's Stationery Office, 1954.
8. Sherren, J.: Some Points in the Surgery of the Peripheral Nerves. *Edinburgh Med. J. (New Series)* 20: 297-332, 1906.
9. Bunnell, S.: Surgery of Nerves of the Hand. *Surg. Gynec. Obst.* 44: 145-152, February 1927.
10. Ballance, C., and Duel, A. B.: Operative Treatment of Facial Palsy by the Introduction of Nerve Grafts into Fallopian Canal and by Other Intratemporal Methods. *Arch. Otolaryng.* 15: 1-70, January 1932.
11. Bunnell, S., and Boyes, J. H.: Nerve Grafts. *Am. J. Surg.* 44: 64-75, April 1939.
12. Klar, E.: Über Erfahrungen und Erfolge bei Anwendung der plastischen Überbrückung von Defekten in peripheren Nerven. *Ztschr. f. d. ges. Neurol.* 176: 533-555, 20 Dec. 1943.

Index

- ABBOTT, K. H., 501
- Abdomen:
- examination of, in multiple wounds, 434-435
 - repair of, in multiple wounds, 435
- Abdominal injuries, 333, 334, 339
- ABRAHAM, A. S., 371
- Abscess(es):
- craniocerebral, 136, 138-139, 147, 207
 - bone fragments, etiological factor of, 72, 135
 - epilepsy in relation to, 226
 - extracerebral, 162
 - extradural, 85, 87, 138, 207, 217, 218
 - incidence of, 103, 162, 259
 - intracerebral, 162, 217, 218
 - prevention of, 71, 72, 103, 135, 226
 - subdural, 107, 217, 218
 - surgical management of, 138
 - subgaleal, 55, 75
 - surgical management of, 137-138
 - treatment of, 5, 136-139, 141-142
 - flank, 339
 - in retroperitoneal space, 339
 - periurethral, 296-297, 348, 382
 - spinal canal, 289
 - extradural, 287, 307, 339
 - prevention of, 291, 300, 307
 - urethral, 346
- Acetylsalicylic acid, 472
- Achilles reflex, 453-454
- Achilotenotomy, 413
- Acrylic cranioplasty, 237, 255
 - mold formation for, 243-244
 - plate formation for, 243-244
- Acrylic resins, 237, 243-244
- ADIE, W. J., 428
- Adrenalin, 567
- ADSON, A. W., 203, 213, 218
- Aidmen, preparation of casualties by, 15
- Airway, adequate:
 - establishment of, 57, 435-436
 - in decerebrate rigidity, 50
 - maintenance of:
 - in head injuries, 41, 42
 - mechanical suction in, 42
 - oxygen administration in, 42
- Airway, open:
 - maintenance of, 69
 - intratracheal suction in, 69, 221
 - positioning of patient in, 221
- ALBERS, D. C., 352
- Alcohol, 137
 - in posttraumatic epilepsy, 262, 269
- Alcohol block, subarachnoid, for catheter removal, 352
- Alcohol injections:
 - for catheter removal, 350
 - intramedullary, 414
 - intrathecal, 413, 414
 - technique of, 413-414
 - subarachnoid, 383
- Alevaire, 44
- ALEXANDER, E., Jr., 279, 352
- Alloplastic grafts, 234, 235-238, 254, 255
 - mold formation for, 239-244
 - plate formation for, 239-244
- ALPERS, B. J., 457
- Amblyopia, 48
- Ambulation, 229, 298, 299, 302-303
 - in paraplegia, 388
 - techniques of, in paraplegia, 388
- American Legion Auxiliaries, 391
- Amnesia, 137
 - posttraumatic, 145
- Amputation, of paralyzed limbs, 309-310
- Anal reflex, 404
- Anastomosis, 572, 573, 574, 575, 579
- Anatomy, of—
 - brachial plexus, 507-524
 - lumbar plexus, 524-528
 - peripheral nerves, 505-535
 - puddendal and coccygeal plexuses, 534-535
 - sacral plexus, 528-534
 - vertebral column, 437-441
- ANDERSON, R. E., 352
- ANDRAE, R., 444
- Anemia, in paraplegia, 289, 299
- Anesthesia, 5, 65, 242
 - administration of, 5
 - caudal, 31
 - endotracheal, 73, 163, 174, 192, 205, 310-311
 - epidural, 413
 - for cervical intervertebral disk operations, 496
 - for lumbar intervertebral disk operations, 467-468
 - general, 63, 310, 412
 - in cervical laminectomy, 310
 - in closed craniocerebral trauma, 63
 - in Korean War, 26
 - in lumbar laminectomy, 311
 - in modern neurosurgery, 5
 - in penetrating craniocerebral trauma, 73
 - in thoracic laminectomy, 310-311
 - in World War I, 6
 - in World War II, 26
 - local, 7, 26, 63, 242, 310, 411, 412
 - in penetrating craniocerebral trauma, 73
 - mucosal, for catheter removal, 349
 - portable apparatus, 30
 - principles of, in Civil War, 5
 - puddendal nerve, for—
 - catheter removal, 349-350
 - traumatic myelopathy, 349
 - spinal, 311, 361, 369, 412, 413, 487
 - for traumatic myelopathy, 349
 - technique of, 7
- Anesthesiologists, 26-27, 32, 73
- Anesthesiology, infancy of, 5
- Anesthetics, use of, 5
- Aneurysm(s), 554, 561
 - intracranial, 48
 - rupture of, 59
- Angina pectoris, 477, 483
- Angiography, in closed craniocerebral trauma, 46
- Ankle reflex, 445, 450, 532
 - See also Achilles reflex.
- Ankylosis, 565
 - in paraplegia, 299
- Annulus fibrosus, 438, 439, 444, 445, 446, 465, 467, 469, 470-471, 472, 477, 482, 498
 - anatomy of, 438
 - changes with age in, 441
 - histology of, 440-441
 - physiology of, 441-443
 - posterior, 437, 438, 455, 457, 469, 476, 477, 482
 - removal of, 497
- Anomalies, of spine, 456, 458, 471, 485-486
- Anosmia, in closed craniocerebral trauma, 48
- Anoxia, 144
 - cerebral, 41
 - cause of restlessness, 46
- Anterior longitudinal ligament, 437-438

- Anterior spinal ligament, 438-439
See also Anterior longitudinal ligament.
- Antibiotics:
 craniocerebral wounds, 65
 local, 139
 prophylactic, 71, 135, 137, 203, 204, 226
 therapeutic, 136, 137, 138, 173-174, 176, 178, 207, 217
 intraspinal wounds, 300
 status spasticus, produced by intrathecal injection of, 300
 urological complications, treated with, 357, 358-359, 360
- Anticonvulsant drugs, 262
- Antietam, battle of, 1, 8
- Antisepsis:
 Lister's knowledge of, 5
 principles of, in Civil War, 5
 technique of, 7
 understanding of, 5
- Antiseptic principles, in World War I, 6
- Antiseptic techniques, knowledge of, 5
- "Ape hand" deformity, 519, 554
- Aphasia, 162, 214
- Appendicitis, 455
- Appomattox, battle of, 5, 8
- Arachnitis, 463
- Arachnoiditis, 308, 309
- Arachnoid membrane:
 evacuation of, 60
 in adults, 60
 in children, 60
- ARETAEUS, 11
- ARIEFF, A. J., 383
- Arm:
 paralysis of, 185
 weakness of, due to extradural hemorrhage, 56
- Armed Forces, paraplegia rehabilitation program, 399-400
- Arteriographic studies, in penetrating craniocerebral trauma, 72
- Arteriosclerosis, 432
- Artery:
 axillary, 507, 510, 513, 517, 522
 brachial, 511, 514, 517, 522
 femoral, 527
 subscapular, 510
 subclavian, 510
 ulnar, 522
- Arthritis, 471
 cervical, 484
 hypertrophic, 457
 of spine, 456
- ARTZ, C. P., 435
- ASCROFT, P. B., 17, 257
- Asepsis, in—
 modern neurosurgery, 5
 World War I, 6
- Aseptic technique, 5
- Asepto Syringe, 139
- Aspirin, 56, 226, 557
- Assistant Secretary of Defense (Health and Medical), 22
- Associated wounds, multiple, 431-436
 with craniocerebral trauma, closed, 44
 with craniocerebral trauma, penetrating, 71, 137, 162, 190, 204
 with peripheral nerve injuries, 553
 with spinal cord injury, closed, 275
 with spinal cord injury, penetrating, 298, 308
 cervical, 328
 lumbosacral, 338
 thoracic, 333
See also Craniocerebral trauma, penetrating; Spinal cord injuries, penetrating.
- Asthma, 335
- Athetosis, 420
- ATKINS, 1st Lt. S. W., Jr., 19
- Atlas of Peripheral Nerve Injuries*, 540
- Atrophy, 371, 373, 383
 in paraplegia, 299
 muscle, 384
 muscular, 450
- Atropine, 73, 328, 368
- Aureomycin, 174, 178
- Autogenous bone grafts, 237, 247, 254, 255
- Autogenous grafts, 234-235, 574
 operative procedure, 238-239
- Autonomic hyperreflexia, 369-370
- Axonotmesis, 544, 545, 566, 567, 568
- Axons, 537, 540, 543, 544, 545, 554, 559, 560, 568, 574
- BABCOCK, W. W., 573
- BABINSKI, M. J., 407
- Babinski's reflex, 56, 275, 384, 424, 481
- BAKER, G. S., 203, 240
- BALDWIN, M., 1, 11
- BALLANCE, C., 574
- Barbiturates, in—
 closed craniocerebral trauma, 46
 hypothermia, 53-54
- Bard-Parker blade, 105, 107
- Barnes Hospital, 284
- BARNES, R., 476
- BARNETT, 1st Lt. J. C., Jr., 19, 22, 25, 131, 190n, 333, 425
- BARR, J. S., 441, 443, 446, 458, 471
- BARRÉ, J. A., 484
- Barré-Lieou syndrome, 484
- Battalion aid station, 289, 290
- Battle sign, 71
- BAZETT, H. C., 420
- Bed care, in closed craniocerebral trauma, 45
- Bedsore, 385
See also Decubital ulcers.
- BEEBE, G. W., 555, 558, 559, 560, 561, 566, 568, 578
- Bevor's sign, 275
- BELL, J. C., 489
- Benzalkonium chloride, 137
- BERNARD, C., 268
- BERRY, F. B., 15, 22, 431
- Betz cell, 269
- BIEBER, I., 428
- Birmingham General Hospital, 255, 400
- Bisgrove splinting device, for prehension, 389
- BISHOP, Capt. E. J., 19, 203
- Bitemporal contusion, 62
- Bladder:
 distention of, 348
 drainage of, 12, 347, 357
 effects of cerebral cortex damage on, 358
 irrigation of, 346
 overdistention of, 32, 289, 294-295, 297, 346
 reflex arcs of, 358
 stabilization of, 358, 359
 straight drainage of, 347, 348
 tidal drainage of, 283, 296, 346, 347, 358, 360
 urinary, 345
- Bladder capacity, maintenance of, 347
- Bladder care:
 complications in male, 283
 in closed spinal cord injuries, 12, 273, 275, 283
 in penetrating craniocerebral trauma, 222-223
 in penetrating spinal cord injuries, 12, 294-297
- Bladder infection, 290, 299
 due to indwelling catheter, 283
 in paraplegia, 32
- Bladder management, prevention of complications in, 348
- Bladder paralysis, 358
- Bleeding:
 external, control of, 42
 internal, 44
 intracranial, 44, 46, 56
 extradural, 56, 57
 cause of, 56
 postoperative, 92
 subdural, 57, 58, 59, 61
 subgaleal, 55
See also Hemorrhage.

- Blindness, 162, 188
 bilateral, 48
 cortical, 91
 unilateral, 48
- BLINN, K. A., 349
- Blood, in—
 spinal fluid, 61
 subarachnoid space, 61
- Blood pressure:
 in closed craniocerebral trauma, 46–47, 48, 56
 in penetrating craniocerebral trauma, 71, 73, 192
 in penetrating spinal cord injuries, 369
 instability of, 372
 low, 44
- Blood supply, in closed craniocerebral trauma, 45
- Blood transfusions, 329
 administration of, 7
 in paraplegia, 299
 in closed spinal cord injuries, 283
 in multiple wounds, 433–434, 436
 in penetrating craniocerebral trauma, 192
- BODIAN, D., 439
- Body temperature:
 below normal, 53
 increased, 53
 in head injury, 53
 in penetrating craniocerebral trauma, 69
 normal, 53
See also Hyperthermia; Hypothermia; Temperature.
- BOLDREY, E., 237
- BOLIBAUGH, Col. O. B., 118
- Bone:
 compound comminuted depressed fracture of convexity of skull, 90–92
 compound linear fracture of convexity of skull, 89
- Bone flap(s), 58, 206
 boiled, 235
 osteoplastic, 204
 removal of infected, 233
- Bone fragment(s), 105, 107, 108, 136, 138, 139, 162, 165, 174, 178, 188, 189, 191, 207, 427
 comminuted, 308
 depressed, 302, 307, 309
 indriven, 132–133
 inspection of, 108
 removal of, 83, 91, 103, 107, 108, 117, 135, 136, 164, 173, 174, 192
 retained, 72
 causing infection, 108, 135–136, 166, 207
 denoting closing track, 108
- Bone grafts, 234–235
 operative procedure, 238–239
- Boric acid solution, for bladder irrigation, 295–296
- BORNSTEIN, M. B., 266
- BORS, E., 289, 300, 345, 349, 350, 352, 369, 371, 382, 400
- BOTTERELL, E. H., 17, 63, 203
- Bowel care, in—
 penetrating craniocerebral trauma, 223
 penetrating spinal cord injuries, 297–298
 spinal cord injuries, 12
- BOYCE, W. H., 352
- BOYES, J. H., 574
- Brachial plexus, 561, 568, 573, 576, 578
 anatomy of, 507–524
 injury of, 562
- BRACKETT, C. E., Jr., 67, 68
- BRADEN, 238
- BRADFORD, F. K., 245, 246, 501
- Bradycardia:
 in penetrating craniocerebral trauma, 69
 in penetrating spinal cord injuries, 310, 328, 331, 365, 367, 369
 sinus, 367
- Brain:
 anatomy of, 5, 267
 ancient Incas' knowledge of, 2–4
 Celsus's knowledge of, 4
 early Egyptian knowledge of, 2–4
 Hippocrates' knowledge of, 4
 chronic subdural hematoma, 60
 circulation of, 42, 47, 50, 57, 61
 collateral circulation in, 53
 compression of, 41, 42, 45, 46, 53, 59, 60, 190
 due to subdural hydroma, 61
 concussion of, 46
 contusion(s) of, 41, 46, 49, 53, 59, 143, 144, 145, 147, 266
 edema of, in closed craniocerebral trauma, 45
 expansion of, 60, 61
 function of:
 ancient Incas' knowledge of, 2
 Celsus's knowledge of, 4
 early Egyptian knowledge of, 2–4
 Hippocrates' knowledge of, 4
 mechanism of, 5
 hemorrhage, 41, 45, 46, 55
 herniation of, 51, 136
 injury of:
 Hippocrates' knowledge of relationship of motor symptoms to, 4
 morbidity of, 5
 mortality of, 5
 Paré's knowledge of relationship of extremity paralysis to, 4
 ischemia of, in closed craniocerebral trauma, 45
 laceration(s) of, 41, 45, 46, 49, 59, 143, 144, 266
 metabolic demands of, 53
 missile track in:
 debridement of, 108
 inspection of, 107, 108
 retained bone fragments in, 17, 108, 135–136, 166, 207
 spasticity arising from lesions in, 417–429
 surgery of, Jackson's background for success in, 5
 trauma, clinical assessment, 45–51
 tumor(s), 45, 213
 wound(s) of, 1, 26, 34–36, 131, 229
 aftereffects of, 7
 anticoagulant therapy in, 193
 Cushing's investigation of, 7
 incidence of, 32–34
 in Civil War, 1
 inspection of, missile track in, 164
 management of, 26
 missile, 68
 morbidity of, before World War I, 1–2
 mortality of, before World War I, 1–2
 pathological anatomy of, 7
 penetrating, 26–27, 68, 73, 103–117, 131, 147, 149, 161, 162, 181, 182–183, 189, 217, 339, 431–436
 analysis of, 105, 181
 debridement of, saline irrigations in, 107
 definition of, 103
 incidence of infection of, 18, 103, 135
 mortality of, 104, 182
 statistics of, 104
 surgical debridement of, 106, 107
 surgical management of, 103, 104–117
 surgical technique of, 110, 117
 wounding agent in, 104, 136, 182
 through-and-through, 103
 transventricular, 103, 133–134, 165–178
 case reports of, 167–174
 debridement of, 174, 175, 176
 definition of, 165
 diagnosis of, 165
 incidence of, 165
 missile track in, 174
 mortality of, 165, 167, 174, 178

- Brain—Continued
 wound(s)—Continued
 transventricular—Continued
 statistical analysis of, 165
 treatment of, 174–178
 treatment of, 7
See also Head injuries.
- Brain stem:
 compression of, 110, 190
 contusion of, 50
- BRAIN, W. R., 423, 476, 479, 485
- Breed's Hill, battle of, 1
- BRENDLER, H., 352
- BRENNER, C., 266
- Brine bath(s), 371, 373, 382
- British Army, mobile neurosurgical teams in, 17
- British Expeditionary Force, 6
- British neurosurgical team, at Dunkirk, 8
- BROCA, P., 5
- Brodmann's areas, 424–425, 428
- Bronchopneumonia, 335
- BROOKS, 561
- BROWN, J. C., 237, 243
- BROWN, M. E., 388
- BROWN, R. C., 234
- BROWN-SÉQUARD, C. E., 408
- Brown-Séguard syndrome, 483
- Brudzinski's sign, 71
- BRUNSCHWIG, A., 438–439
- Bucky diaphragm, 490
- BUCY, P. C., 428, 429n, 484
- Bulbocavernous reflex, 345, 346, 349, 404
- Bulbourethral duct, 295–296
- BULL, J. W. D., 476
- Bull Run, battle of, 11
- Bulova watchmaking school, 391
- BUNNELL, S., 574
- BURNEY, T. E., 345
- Burns, in multiple wounds, 435–436
- BUSCH, E. A. V., 22
- BUSH, L. F., 235
- Cable grafts, 574
- Cachexia, 289, 299
- CAIRNS, H., 17, 147, 192, 203, 218
- Calculosis, of urinary tract, 348
- Calculus formation, in paraplegia, 299
- Caliper*, 325
- CALVERT, C. A., 17, 110, 213, 219
- CAMERON, J. E., 237, 243, 244
- CAMPBELL, E. H., 15, 22, 26, 87, 131, 133, 245, 431, 501
- CAMPBELL, J. B., 309
- Canadian Neurological Hospital, 5
- Cancellous iliac bone grafts, 234–235, 238–239
- CANNON, W. B., 268
- Carbamylcholine chloride, 472
- Cardiac arrhythmias, in penetrating spinal cord injuries, 369
- Cardiac tamponade, 432, 433
- Cartilage grafts, 237, 255
 operative procedure for, 238–239
- Cartilage plates, 438, 469, 477, 482
 anatomy of, 438
 history of, 440–441
- Cauda equina:
 compression of, 446
 tumors of, 456, 458, 463
- Causalgia, 453, 559
 minor, 560
- CAVENESE, W. F., 15, 22, 257, 265
- Cecostomy, 435
- Celluloid cranioplasty, 235
- CELSUS, A. C., 4
- Cemetery Ridge, battle of, 1
- Cerebral compression, 45, 58, 60
 signs of, 59
- Cerebral cortex:
 debridement of, 107, 108
 motor centers in, 5
 resection of, 107
 “clip-and-cut” method for, 107, 110
 saline irrigation in, 107
 subpial resection of, 107
 “clip-and-cut” method for, 107
- Cerebral fungus, 207, 210
- Cerebral hernia, after cranioplasty, 246
- Cerebral localization:
 in World War I, 6
 knowledge of, 5
 principles of, 7
 in Civil War, 5
- Cerebral swelling, 61–63
 morbidity in, 61
 mortality of, 61
- Cerebral vascular accident, 61, 62
- Cerebritis, 17, 136, 138–139, 162, 176, 177, 188, 207
 fungating, 17, 87, 139, 140, 189
 prevention of, 72
- Cerebrospinal fluid, 55, 136, 137, 194
 acetylcholine in, 266
 in closed craniocerebral trauma, 45
 in subdural space, 61
 loss of, 214
 incidence of, 214
- Cerebrospinal fluid fistula, 72, 105, 136, 138, 164, 207, 210, 213–219
 incidence of, 213–214
 location of, 218
 preoperative complications of, 215
 surgical technique of repair of, 218
 surgical treatment of, 217
- Cerebrospinal rhinorrhea, 213, 214
 spontaneous, 213
- Cervical cord syndrome, 310, 328, 330, 331–332
 acute:
 characteristics of, 365, 366–367
 in cervical cord injuries, 365–366
 treatment of, 367–368
- Cervical disk, 475–500
 syndromes of, 475–476
- Cervical intervertebral disk lesions:
 anesthesia in, 496
 at C3–C4 level, 479
 at C4–C5 level, 479–480
 at C5–C6 level, 477, 479
 at C6–C7 level, 477, 479, 484
 at C7–T1 level, 479, 480
 clinical syndromes of, 475–483
 conservative management of, 493–495
 determination of level of involvement in, 496
 differential diagnosis in, 483–484
 differential roentgenological diagnosis of, 485–487
 false diagnosis of, 476, 477
 general considerations of, 475–476
 headaches in, 484
 indications for myelography in, 488–489
 interpretation of myelographic findings in, 490–493
 management of, 493–500
 myelography in, 487–493
 operative position in, 495–496
 pain in, 477–480
 postoperative management of, 499–500
 roentgenological diagnosis of, 485
 surgical approach to, 495–499
 surgical management of, 495–499
 survival technique in, 495–499
 symptoms of, in lower extremities, 481–482
 symptoms of, in neck, 480
 symptoms of, in upper extremities, 480–481
 technique of myelography in, 489–493
- Champlain, battle of, 1, 11
- CHANDLER, F. A., 445
- Changjin Reservoir, 18, 32, 292
- Château-Thierry, battle of, 12
- Chest:
 examination of, in multiple wounds, 432–433
 injuries of, 333, 334, 339
 repair of, in multiple wounds, 435
- Cheyne-Stokes respiration, 71
- CHIARI, H., 213
- Chief Consultant to Surgeon, Far East Command, 18
- Chloramphenicol, 174
- Chloroform, 5

- Chloromycetin, 174, 179
 Chlorpromazine, 410-411, 421
 Chlorpromazine hydrochloride—
 for catheter removal, 348, 350
 in closed craniocerebral trauma, 46
 in hypothermia, 53-54
 Chlortetracycline, 174
 Chordectomy, thoracic, 369
 Chorea, arising from brain lesions, 417,
 420, 425, 426, 428
 Chosin Reservoir, 18, 32, 292-293
 CICIENIA, E. F., 388
 Circoletric frame, 292-293, 367
 Civil War, 5
 brain wounds in, 1
 head injuries in, 1
 CLARK, G., 367
 CLARK, Lt. (jg) R. A., Jr., 18, 19, 22,
 337, 365
 "Claw hand" deformity, 554
 CLIFTON, E., 394
 Clinical syndromes of rupture of the
 cervical disk, 476-483
 Clonus sign, 384
 Clot(s):
 epidural, 133
 extradural, 56, 58
 surgical treatment of, 57
 intracerebral, 110, 132, 133-134, 145
 removal of, 107
 intracranial, 55, 56
 intramedullary, 281
 intraventricular, 133-134, 175
 missile-track, 131
 removal of, 91, 164, 174
 subdural, 110, 133, 175
 removal of, 107
 Codeine, 472
 Cold Harbor, battle of, 1
 COLEMAN, C. C., 203, 213
 Colostomy, 435
 Coma, 45-46, 69, 185, 214
 due to extradural hemorrhage, 56
 in head injuries, 42
 in penetrating spinal cord injuries, 366
 management of, 221
 patient in:
 positioning of, 221
 turning of, 221
 positioning of patient in, 69
 profound, 188
 COMARR, A. E., 300, 346, 347, 349, 350,
 352
 Comatose patient(s), 137, 178, 187, 422
 catheterization of, 434
 feeding of, 225-226
 management of, 27, 221
 positioning of, 178
 respiration in, 69
 for depressed bone fragments, 83
 primary, 105
 secondary, 105
 technique of, 91, 92
 Craniocerebral infection, incidence of,
 18, 103, 135
 Craniocerebral injuries:
 closed, 103
 penetrating, incidence of, 133
 Craniocerebral trauma:
 casualties with, treatment of, 6-7
 closed, 41-63
 acute subdural hematoma in, 57-58
 anesthesia in, 63
 bed care in, 45
 blood pressure in, 46-47, 56
 cerebral swelling in, 61-63
 chronic subdural hematoma in, 59-
 61
 classification of skull fractures in,
 51
 clinical assessment of, 45-51
 consciousness in, 56
 control of restlessness in, 46
 convulsions in, 56
 differential diagnosis of surgical
 lesions in, 55-63
 effect of skull fractures in, 51
 extradural hemorrhage in, 55-57
 fluid balance in, 44
 function of cranial nerves in, 47-49
 headache in, 47, 56
 hyperthermia in, 53-54
 hypothermia in, 53-54
 immediate care of, 42-45
 intracerebral hematoma in, 61-63
 management of, 41-42
 motor system in, 49-50
 pneumoencephalogram in, 62
 pulse in, 46-47, 56
 pupils in, 56
 respiration in, 46-47
 roentgenograms of skull in, 51-53,
 56, 57
 shock in, 44, 56
 spinal puncture in, 50-51
 state of consciousness in, 45-46
 subacute subdural hematoma in, 58-
 59
 subarachnoid hemorrhage in, 61
 subdural hematoma in, 57, 61
 subdural hydroma in, 61
 subgaleal hematoma in, 55
 subgaleal hydroma in, 55
 temperature in, 46-47
 tracheostomy in, 42-44
 treatment of surgical lesions, in 55-
 63
 unconsciousness in, 61
 COMPERE, E. L., 440, 441
 Concord, battle of, 1, 8
 CONNOLLY, R. C., 17
 Consciousness:
 in closed craniocerebral trauma, 48, 56
 level of, in—
 chronic subdural hematoma, 60, 61
 closed craniocerebral trauma, 55
 extradural hemorrhage, 56
 head trauma, 59
 penetrating craniocerebral trauma,
 71
 penetrating spinal cord injuries, 331
 state of:
 assessment of, 41-42
 clinical assessment of, 45
 in closed craniocerebral trauma, 45-
 46
 in penetrating spinal cord injuries,
 310
 neurological signs in, 46, 145, 146
 Conus medullaris, 345
 lesions of, 349
 Convulsions:
 due to extradural hemorrhage, 56
 due to head trauma, 49, 50
 incidence of, 245, 255
 in penetrating spinal cord injuries,
 366
 Convulsive seizures, 218
 Convulsive state, 244, 255
 COOPER, A. P., 5
 Corpectomies, spinal, 284
 Corpectomy:
 for intramedullary tumor, 414
 for spasticity, 352, 414
 lower thoracic, 285
 Cordotomy, 285, 341, 473
 bilateral thoracic, 285
 ventromedial, for spastic diplegia, 414
 Cottonoid, 18
 Cotton pledgets, 469
 Council of National Defense, General
 Medical Board, 6
 COURVILLE, C. B., 2
 COVALT, D. A., 400
 COXE, W. S., 269, 273, 277
 CRAIG, W. M., 237, 455
 CRAMER, F. J., 213, 246
 Cranial defects, repair of, 233-255
 Cranial nerves, 47-48, 71, 214
 See also Nerves.
 Cranial wounds, Cushing's debridement
 technique of, 7
 Craniectomy, 87, 88, 110, 133, 138, 163,
 174, 178, 210, 227
 bifrontal, 185
 en bloc, 86
 for comminuted bone fragments, 83

Cranioerebral trauma—Continued

- closed—Continued
 ventriculograms in, 62
 vomiting in, 47, 56
 weakness of arm in, 56
 weakness of face in, 56
 weakness of leg in, 56
 nursing care of casualties with, 27
 penetrating, 65–256
 ambulation in, 229
 analgesics in, 73, 223–225
 anesthesia in, 73
 antibiotics in, 65, 71, 135, 136, 137, 138, 139, 173–174, 176, 178, 203, 204, 207, 217, 226
 basis of mortality figures on, 19
 bladder care in, 222–223
 blood pressure in, 71, 73
 body temperature in, 69, 226
 bowel care in, 223
 bradycardia in, 69
 brain abscess in, 138–139
 care of, 65, 69, 139
 case report of, 67–68
 cerebral edema in, 229
 cerebritis in, 138–139
 chemotherapy in, 71
 clinical features of, 145–147
 dressings for, 226–228
en bloc resection of, 75, 139
 eye care in, 226
 flap taps in, 228
 general considerations in, 65–73
 hematoma(s) in, 131–134
 hypertension in, 69
 hypnotics in, 73
 incidence of, 68, 214
 incontinence in, 69
 infection complicating, 135–142
 initial examination of, 71–72
 initial wound care in, 69
 in Korean War, 69
 lumbar puncture in, 229
 maintenance of open airway in, 69
 management of, 65, 69, 87, 105, 135, 136–137
 meningitis in, 138
 mental depression in, 69
 mortality of, 19–22, 65, 68
 multiple wounds associated with, 431–436
 nausea in, 69
 open fungus treatment of, 139
 pathological findings of, 144–145
 pathophysiological considerations of, 143–144
 postoperative management of, 221–230
 preoperative measures in, 65–73
 preparation for operation in, 72–73
 prevention of, 68
 pulse in, 71, 73
 pupils in, 71
 recordkeeping in, 229–230
 resection of, 139
 respiration in, 71, 73
 respiration rate in, 69
 restlessness in, 69, 221–222
 roentgenograms in, 72, 75
 scalp lacerations in, 75–76, 137
 sedatives in, 223–225
 skin care in, 226
 subdural abscess in, 138
 subgaleal abscess in, 137–138
 surgical management of, 163–164
 surgical shock in, 71
 surgical technique of, 76
 temperature in, 73
 through-and-through, 161–164
 tracheostomy in, 69
 treatment of, 68
 ventricular taps in, 228
 vomiting in, 69
 wounding agents in, 134
 posttraumatic epilepsy in, 257–262, 265, 270
 treatment of, 17
 Craniocerebral wounds, directions concerning, 6–7
 Cranioplastic kit, 244
 Cranioplasty, 140, 178, 233–256
 acrylic resins, 237, 243–244
 alloplastics, 235–238
 bonegraft:
 autogenous, 234, 235, 238
 homogenous, 235
 by ancient Incas, 2
 celluloid, 235
 complications of, 245–247, 255
 Cushing's technique of, 7
 indications for, 244–245, 255
 stainless steel, 237
 tantalum, 7, 237, 239–243
 ticonium, 237, 243
 vitallium, 237, 243
 Craniotomy (ies), 108, 110, 147, 184, 210, 217, 227, 488
 by ancient Incas, 2
 Celsus's knowledge of, 4
 control of bleeding in, 44
 Cooper's knowledge of, 5
 development of, by ancient Incas, 2
 for prevention of—
 brain abscess, 72
 cerebritis, 72
 meningitis, 72
 frontal, 226
 in chronic subdural hematoma, 60, 61

- instruments for, 29–30
 Larrey's knowledge of, 5
 number of, 27–28
 osteoplastic, 136, 163
 performance of, 31–32
 secondary, 108, 140
 indications for, 72
 temporal, 226
 Credé's maneuver, 275, 346
 Cribiform plate, 213, 218
 CRITCHLEY, M., 428
 Crutchfield tongs, 493
 in skeletal traction, 277
 Crystalite, 237
 Cuba, campaign in, 6
 Curare, 410, 566
 Cushing General Hospital, 400
 CUSHING, H., 2, 4, 6, 7, 15, 17, 75, 165, 174, 181, 213
 contributions to military neurosurgery by 7
 principles of, 6
 teachings of, 68
 Cystitis, as cause of death, 12
 Cystography, 347, 348
 Cystometrogram(s), 349, 360, 361
 Cystometry, 346, 347, 349, 360, 369
 excretory, 346, 347
 in paraplegia, 369
 retrograde, 347–348
 description of, 346
 Cystostomy, suprapubic, 435
 DAMANSKI, M., 350, 352
 DANDY, W. E., 87, 190, 213
 DANFORTH, M. S., 448
 DANIEL, P., 17
 DAVIS, C. H., Jr., 279, 478
 DAVIS, L. E., 404, 407, 420
 DEAN, 574
 DEAYER, G. G., 388, 455
 Decerebrate rigidity, 214, 428–429
 arising from brain disease, 417, 421
 arising from brain lesions, 417–422, 425
 description of, 418–420
 physiology of, 420–421
 treatment of, 421–422
 due to closed head injury, 418, 421
 due to head trauma, 49–50
 due to open head injury, 421
 "mass reflex" in, 418–420
 nursing care of patient in, 422
 sucking reflexes in, 418–420
 DE CHAULIAC, G., 12
 Decubital ulcer(s), 17, 19–22, 289, 290, 291–292, 294, 299–300, 372, 404, 405, 407, 410–411, 412, 414–415
 closure of, 300

- in closed spinal cord injuries, 281, 282, 284
 in Korean War, 292-293
 in paraplegia, 32
 in paraplegic casualties, 34
 in penetrating spinal cord injuries, 328, 329, 338
 in quadriplegic casualties, 34
 in unconscious patient, 226
 management of, 373
 prevention of, 371
 short-wave diathermy for, 382
 treatment of, 373, 382
- DEERY, E. M., 479
- Dehydration, after head trauma, 44
- DE KLEIJN, A., 420
- Demerol, 310, 567
- DE MONDEVILLE, H., 4
- Dendrites, 537
- DENNY-BROWN, D., 143
- Dermatomes, studies of, 451-452
- DEUCHER, W. G., 445
- DeVilbiss rongeur, 91, 92
- Diabetes, 433, 434
- Diarrhea, after head trauma, 44
- Diathermy, 373
 external, 361
- Dictionary of Occupational Titles for Classification, 394
- DIETRICK, R. B., 345
- Dihydromorphinone hydrochloride, 472
- Dilantin sodium, 262, 262n
 to control seizures, 50
- Dilaudid, 472
- DINKEN, H., 371
- Diphenylhydantoin sodium, 262
- Diplopia, due to chronic subdural hematoma, 60
- "Directions to Neurosurgical Teams Concerning Craniocerebral Wounds," 6
- Disorientation:
 in penetrating spinal cord injuries, 365, 366
- Diverticulum, vesical, 348
- DODGE, P. R., 143
- Dorsal myelotomy, 281
- Doryl, 472
- DOVELL, Col. C. E., 18
- Dressing tray, portable, 32
- Drop-foot deformity, 534, 554
- Drug addiction, 289, 301, 302, 410-411
- Drugs, sympathomimetic, 388
- DUEL, A. B., 574
- Dunkirk, 8
- Dura, 145
 cause of separation from skull, 56
 closure of, 136, 139, 147, 176, 177, 207
 watertight, 164, 210
- debridement of, method of, 5
 exposure of, 11-12
 intact, 138, 139, 205
 exposure of, 311-321
 opening of, 92, 209, 210
 management of, 105
 opening of, 5, 58, 60, 104, 147, 281, 321-322, 502
 penetration of, 205
 De Mondeville's test for, 4
 primary closure of, watertight, 105
 suturing of, 57
 tear of, 104
- Dural defect(s):
 closure of:
 by graft, 105
 watertight, 207
 primary closure of, 105
 repair of:
 by graft, 105-106
 surgical evaluation of, 105-106
 types of grafts for, 106
- Dural repair, technique of, 7, 105-106
- Dural tear, 322
 debridement of, 104, 105, 106, 107
 enlargement of, 105, 106
 surgical management of, 164
- Dura mater, 177
 debridement of, 175
- DURANTE, F., 234
- DUTT, P., 17
- Dysesthesia, in paraplegia, 301-302
- Dystonia musculorum deformans, 417
- Ear, bleeding from, 49
- EBEL, A., 371
- Ecchymosis:
 about orbits, after trauma, 53
 over mastoid, after trauma, 53
- ECHLIN, F. A., 268
- ECKER, A., 214
- Edema, 371, 382, 404
 cerebral, 71, 176, 187, 229, 417-418, 421-422, 425
 secondary, 103
 of brain, 45
 of cerebral cortex, 107
 of skull, 45
 postoperative, 226
 of scalp, 76
 pulmonary, 434
 secondary, of skull, 45, 56
- EDEN, K., 166
- EDEN, K. C., 218
- Edwin Smith Surgical Papyrus, 2
- EIDELBERG, E., 269
- Eighth U.S. Army, 18, 27, 182, 337
 mobile neurosurgical teams in, 34-36
- Ejaculation in paraplegia, 407
- Ejaculatory duct(s), 295-296, 360
- Elastoplast bandage, 347
- Electrocautery, development of, 7
- Electrocystography, 361
- Electrodiagnostic testing of peripheral nerve function, 547-552
- Electrodiagnosis, methods of, 547-552
- Electrolyte balance, in closed cranio-cerebral trauma, 44
- Electrolyte fluids, in multiple wounds, 433-434, 436
- Electromyography, in--
 paraplegia, 373
 peripheral nerve injuries, 559
 testing peripheral nerve function, 550-552
- Electrosurgical unit, portable, 30
- Electrotherapeutic hyperstimulation, 383
- Electrotherapy, 372, 383-384
- ELKIN, D. C., 561
- ELKINS, C. W., 237, 243, 244
- ELLIOTT, K. A. C., 267
- ELSBERG, C. A., 273
- Embolism, air, 495
- Embolus, air, 192
- EMMETT, J. L., 352
- Emphysema, 432
- Empyema, subgaleal, 137
- Encephalomalacia, 181
 localized, 75, 92
 incidence of, 83, 85
- Endoneurium, 537, 540, 544, 545
- Enlisted surgical technicians, 27-29
- Epididymitis, 295, 348
- Epilepsy, 245
 late:
 due to depressed skull fracture, 53
 incidence of, 146
 posttraumatic, 7, 22, 107, 146, 147
 basic mechanisms in, 265-270
 categories of head injury in, 259-260
 cessation of seizures in, 260
 clinical manifestations in, 257-262
 complexity of injury in, 265-266
 degree of injury in, 257-260
 diagnosis of, 261-262
 established discharging lesion in, 267
 genetic factor in, 270
 frequency of seizures in, 260
 incidence of, 257-261
 onset of seizures in, 260
 pattern of seizures in, 260-261
 precipitating factors in, 269-270
 propagation of the abnormal discharge in, 267-269
 prophylaxis in, 262-263

- Epilepsy—Continued
 posttraumatic—Continued
 reaction to injury in, 266–267
 site of injury in, 260
 therapy in, 262
- Epileptogenic foci, 266, 267, 408
- Epileptogenic zone, 267
- Epinephrine, 567
- Epineurium, 538–539, 540, 543, 544, 545, 567, 568, 575
- EPSTEIN, J. A., 501
- Equanil, 410–411
- Equipment and supplies, for mobile neurosurgical units, 29–32
- ERB, W., 547
- ERICKSON, T. C., 267
- Ethyl iodophenylundecylate. *See* Pantopaque.
- ETTER, H. S., 237, 238
- Euphoria, facetious, in penetrating spinal cord injuries, 366
- Evacuation, 178, 203, 329, 335, 338, 340–341
 air, 18–19, 26
 of neurosurgical casualties, 17–18
 helicopter, 18–19, 22, 26, 32–34
 of casualties, 26
 of paraplegic patients, 289–290
- Evacuation Hospital, 121st—18, 292–293
- Evacuation hospitals, trained personnel in, 7
- EVANS, J. P., 192
- Examination and clinical manifestations of peripheral nerve injuries, 553–562
- Extradural air fistula, 207
- Extrapyramidal disorders resulting from trauma, 425–428
 case report of, 426–427
 description of, 425–426
 physiology of, 426–427
 treatment of, 428
- Eye(s):
 in wounds involving the air sinuses, 203–204
 irrigation of, 226
 paralysis of, 49
 weakness of, 49
- Face:
 examination of, in multiple wounds, 432
 paralysis of, 49
 weakness of, 49
 due to extradural hemorrhage, 56
 wounds of, 162
 death rate from, 5
- Facial palsy, 190
- Faciocranial wounds, 110, 136
- Facio-orbito-cranial wounds, 110
- Facio-orbito-frontal wounds, craniotomy for, 110
- Facio-orbito-temporal wound(s):
 case report, 110
 craniotomy for, 110
- Far East Command, 17, 18, 19, 22, 32, 193, 329, 333
 neurosurgical problems in, 17–22
- Fascia lata grafts, 105, 140, 177, 206, 207, 218
- Fascial graft, 176, 177
- FAY, T., 384
- FEIL, A., 485
- Femoral nerve section, 412
- FERRIER, D., 5
- Fibrin film, 177
- Fibrin foam, 184, 185, 187, 188, 193
- Field hospitals, trained personnel in, 7
- FINCHER, E. F., 193
- FINNEY, Col. G. G., 17
- 1st Marine Division, 22
- 1st Neurosurgical Detachment (Provisional), 18, 19–22, 27–28, 67, 365
- FISHER, S. M., 268
- Flap tap(s), 178, 228, 229
- Fluid balance, in closed craniocerebral trauma, 44
- Fluoroscopic examination, 432, 433
- FOERSTER, O., 451, 452
- Foot drop, 578
 in lumbar intervertebral disk lesions, 446
- Foot drop splint, 565
- Foramen of Monro, 177
- Foramen spinosum, 55, 57, 92
- Foraminotomy, 302
 bilateral posterior, 502
 unilateral posterior, 504
- Foreign bodies, 104, 136, 137, 139, 174, 190
 bullets, 136
 removal of, 108
 impacted, 5
 metallic, 107, 207, 373
 intracranial, 132, 133
 removal of, 174
 metallic fragment(s), 107, 133, 134, 136, 138, 204, 213, 217, 333, 337, 339, 340, 427
 removal of, 108
 missile(s), 107, 136, 162, 165, 204, 213, 255, 333, 337, 338–339, 340
 removal of, 108
 removal of, 103, 138, 139, 175
 retained, 108, 257
 shell fragment(s), 87, 136, 189, 255
- Forrester traction collar, 494
- FÖRSTER, O., 409, 411
- FORSYTH, H. F., 279
- Foster frame, 277, 281, 291–293, 310, 367
- Fort Sumter, battle of, 5
- FRAENKEL, A., 235
- Franco-Prussian War, 5
- Frazier lighted retractors, 32, 175
- Frederick the Great, 5
- FREEMAN, L. W., 289, 296, 297, 298, 300, 301, 302, 309, 400, 408, 410, 429n
- FREIBERG, A. H., 448
- FRENCH, J. D., 268, 369
- FRI TSCH, C., 5
- Fronto-occipital wounds, 163
- Furadantin, 300
- GAGE, E. L., 213
- GALEN, 4, 8
- Ganglionectomy, lower thoracic, 285
- Gantrisin, 300
- GARDNER, W. J., 61
- GARVEY, F. K., 352
- GASKILL, H. S., 457
- Gastric distention, in penetrating spinal cord injuries, 367
- Gelfilm, 177, 218
 as dural substitute, 105
- Gelfoam, 18, 67, 176, 177, 184, 185, 186, 187, 188, 189, 193, 207, 321–322, 328, 469n, 495, 574
- Gelfoam pledgets, 136, 188, 189
- Gelfoam strip(s), 110, 190, 192, 193, 321–322
- GERAUD, 12
- GERMAN, W. J., 218
- GERSH, I., 237, 238
- Gettysburg, battle of, 1, 8
- GHORMLEY, R. K., 471
- GIBBON, N. O. K., 352
- GIBSON, R. M., 108
- GIRARDEAU, Maj. J. L., 32, 292
- Glabella, repair of, 237, 238, 255
- Glioma, 543, 545, 568, 573, 574
- Glucose, 421, 436
- Gluteal reflex, 345
- Glycerin, 44
- GOLDRING, S., 269, 273, 277
- GOLTZ, F., 408
- Gonda's maneuver, 407
- GOPLERUD, Maj. C. P., 32, 292
- GOWERS, W. R., 407
- GRANIT, R., 559
- GRANT, F. C., 233, 244, 245
- GRANTHAM, E. G., 443
- Granuloma, after cranioplasty, 246
- Gray's "Anatomy," 439
- GROVES, E. W. H., 411
- GURDJIAN, E. S., 51, 203, 237, 243
- Guthrie-Smith frame, 388
- GUTMANN, E., 371
- GUTTMANN, L., 371, 384, 389, 557

- HAGMAN, G. L., 471
HAHN, J., 309
HALL, M., 408
Halleran General Hospital, 400
Halter traction, 493, 494-495
Hamhung, 292
Hammond General Hospital, 255
HAMPTON, O. P., Jr., 431
"Handbook for Paraplegics and Quadriplegics," 325
Hardy-Wolff-Goodell machine, for pain tests in paraplegia, 302
HARSH, Capt. G. R., III, 18, 19, 28, 135, 161, 365
HAUSER, E. D. W., 465
HAYES, G. T., 219
HAYMAKER, W., 544
HAYNES, W. G., 165
Head, examination of, in multiple wounds, 432
HEAD, H., 369
Headache(s):
 as indication for cranioplasty, 244-245, 255
 due to chronic subdural hematoma, 60
 due to extradural hemorrhage, 56
 due to subdural hydroma, 61
 in closed craniocerebral trauma, 47
 in penetrating craniocerebral trauma, 146
 in penetrating spinal cord injuries, 369
 of cervical origin, 484
 posttraumatic, 56
Head injuries, 1-8, 297, 339
 causes of, 5
 cerebral anoxia, cause of death in, 41
 death rate from, 5
 effects of, 5
 incidence of, 213
 in Civil War, 1
 neurological signs in, 145, 146, 147
 statistics, 6-7
 tangential:
 management of, 143, 147
 through-and-through:
 case report of, 161
 definition of, 161
 incidence of, 161-162
 mortality of, 162
 principles of care of, 162-163
 surgical management of, 163-164
 treatment of, 4, 5
 early Egyptian knowledge of, 2-4
 in Civil War, 1
 Paré's knowledge of, 4
 wounding agent, 1, 145
 in Civil War, 1
 in Korean War, 104
Head Injury Advice Bureau, 257
Heart, examination of, 432
HEIMBURGER, R. F., 301, 400, 403, 410, 417
Helicopter evacuation, Army Quartermaster's winter evacuation bag for, 18
 See also Evacuation.
Helicopter pilots, transportation of casualties, 15
Heliotherapy, 382
Helmet:
 design of, 68, 69
 wearing of, 68-69, 145
Hematoma(s), 163, 164, 174, 186, 210
 aberrant:
 diagnosis of, 55
 management of, 55
 associated with penetrating cerebral wounds, 131-134
 incidence of, 131
 bilateral, in subdural space, 59
 cause of paralysis, 49
 compression of brain from, 48
 concomitant, 308
 contre-coup, 92
 ectopic:
 diagnosis of, 55
 management of, 55
 evacuation of, 60
 extradural, 57, 61, 62, 133, 145, 147, 329, 340, 425
 cause of, 55
 homolateral, 184
 incidence of, 85, 133
 in spastic hemiplegia, 425
 produced experimentally, 56-57
 removal of, 92
 surgical treatment of, 57
 intracerebral, 61-63, 132-133, 185, 266
 incidence of, 132-133
 in spastic hemiplegia, 425
 morbidity, 61
 mortality, 61
 intracranial, 5, 48, 49, 69, 71, 89, 92, 134, 183
 incidence of, 19-22, 32-34, 83, 85, 104, 131, 134
 intraspinous, 307
 intraventricular, incidence of, 133-134
 missile-track, 132
 debridement of, 132, 134
 postoperative, 227, 322
 retroperitoneal, 339
 space-consuming, 62
 subcortical, 103, 146, 147, 184
 incidence of, 85
 removal of, 103, 108
subdural, 45, 47, 48, 57, 61, 62, 92, 103, 105, 107, 139, 145, 146, 147, 184, 185, 215, 218, 425
 acute, 57-58
 hemostasis in, 58
 morbidity of, 57
 mortality of, 57
 signs of, 57
 surgical approach to, 58
 surgical treatment of, 58
 symptoms of, 57
 bilateral, 184
 chronic, 50, 57, 58, 59-60
 treatment of, 60-61
 homolateral, 184
 incidence of, 85, 133
 in infants, 61
 in spastic hemiplegia, 425
 removal of, 103
 subacute, 57, 58-59
 surgical treatment of, 59
 unilateral, 59
 subgaleal, 55, 76
 subpial, 321-322
HEMBERGER, A. J., 239
Hemianopia, homonymous, 188, 189, 423
Hemiballism, 417
Hemilaminectomy, 504
Hemiparesis, 184, 185, 214, 245, 422
 infantile, 414
 in penetrating craniocerebral trauma, 71
Hemiplegia, 49, 162, 185, 214, 255, 404-405
 spastic, 184
Hemorrhage:
 bilateral, in subdural space, 59
 brain, 41, 42, 45-46, 55
 cerebral, 417
 control of, in multiple wounds, 433-434, 435
 extradural, 55-57, 75
 cause of, 56
 hemostasis in, 57
 mortality of, 56
 in closed craniocerebral trauma, 49
 intracerebral, 144
 incidence of, 259
 intracortical, 75
 intracranial, 50
 secondary, 223
 intraventricular, 178
 petechial, 144
 postoperative, 185
 pulmonary, 297
 retinal, 48
 retroperitoneal, 297, 433
 secondary, 190
 subarachnoid, 48, 55, 61, 71, 144

- Hemorrhage—Continued
 subcortical, 75
 subdural, 55, 71, 75, 266
 acute, 57
 subgaleal, 55
- Hemostasis, 140, 175, 495, 496
 galeal, 87
 in penetrating craniocerebral trauma, 69, 75, 139, 147
 of epidural vessels, 92
 technique of, 7
- Hemostatic agent(s), 177
 in World War II, 7
- Hemostatic clips, 7
- Hemostatic technique, 5
- Hemothorax, 333, 335
- HENRY, C. E., 268
- Hepatitis, acute, 335
- Herniation:
 brain, 139, 140
 cerebral, 176, 177
 cortical, case report, 106
 of temporal lobe, 48, 57
 uncus, 63
- Heterogenous grafts, 234, 235
- Heterogenous nerve grafts, 574
- HETHERINGTON, R. F., 219
- Heydrick anesthesia apparatus, portable, 30
- Hibbs retractor, 468
- HINCHEY, T. R., 283, 352
- HIPPOCRATES, 4, 11, 257
- HIRSCH, O., 213
- Histology, of intervertebral disk, 440–441
- HITZIG, E., 5
- HOBERMAN, M., 388
- Hoff General Hospital, 255
- HOFFMAN, G. T., 237
- Hoffman's reflex, 424
- HOLMES, G., 185, 186, 187, 193, 346, 404
- HOLMES, Lt. Col. R. H., 68
- HOLMES, W., 543
- Homeostasis, 392, 395
 maintenance of, 271, 383
- Homogenous bone grafts, 237
- Homogenous grafts, 234, 235
- Homografts, 105, 574
- Horner's syndrome, 483, 562
- HORRAX, G., 12
- HORSLEY, V., 5
- HORWITZ, T., 438
- Hospital ships, neurological survey aboard, 22
- Hospitals, in—
 World War I, 5
 World War II, 5
- Hubbard tank, 373, 382
- HUME, Maj. Gen. E. E., 18
- HUNTER, C. R., 484
- Hyaline cartilage plates, 439, 443
See also Cartilage plates.
- Hydration, after head trauma, 44
- Hydrocephalus, 213
 obstructive, 189
- Hydroma:
 subdural, 61, 92, 139
 incidence of, 85
 subgaleal, 55
- Hydromite, 240
- Hydronephrosis, 348
- Hydrotherapy, 373, 382–383
- Hyperesthesia, in—
 cervical intervertebral disk lesions, 478
 peripheral nerve injuries, 560
- Hyperreflexia, 424
- Hypertension, in penetrating craniocerebral trauma, 69
- Hyperthermia, 185
 in closed craniocerebral trauma, 53–54
 prevention of, in brain injuries, 53
- Hypertonic solutions, intravenous administration of, 421
- Hypertrophy, of ligamentum flavum, 456
- Hypesthesia, in—
 cervical intervertebral disk lesions, 478, 479, 480, 482
 lumbar intervertebral disk lesions, 446, 452–453
 peripheral nerve injuries, 560
- Hypoproteinemia, in paraplegia, 32, 289, 299–300
- Hypotension:
 in penetrating spinal cord injuries, 310, 328, 331, 365, 367, 368
 orthostatic, 388
- Hypothalamus, 366
- Hypothermia, 226, 421
 duration of, 54
 in closed craniocerebral trauma, 53–54
 in penetrating spinal cord injuries, 310, 328, 331, 365, 367
 physiologic changes in, 54
 technique of, 53–54
- Hypotonia, 556
- Hypoxia, 50, 144
 cerebral, 41
- Ileus, 297, 331
 in penetrating spinal cord injuries, 367
 reflex, 310
- Incisura, 48, 57, 63
- Incontinence, in penetrating craniocerebral trauma, 69
- Infections of spine, 456–457, 458
- Instruments, surgical:
 for mobile neurosurgical unit, 29–30
 procurement of, 6–7
- Insulin, 433
- Internal decompression, 63
- Intervertebral disk:
 anatomy of, 438–441
 changes with age in, 441
 histology of, 440–441
 nerve supply of, 438–439
 physiology of, 441–443
 trauma of, 437–473, 475–500, 501–504
- Intestinal perforations, 297
- Intracranial infection, incidence of, 83
- Ischemia, 411, 425
 in paraplegia, 299–300
 of brain, 45
 of skull, 56
- Ischiocavernosus reflex, 404
- Iwo Jima, assault on, 11
- JABLON, S., 257
- JACKSON, I. J., 237
- JACKSON, J. H., 5, 261, 267, 268, 428
- Jacksonian convulsions, 56
- Jacksonian seizures, 50, 146, 260, 261, 268
- Jacuzzi agitator, 382
- JAHN, R., 285
- Jamestown, battle of, 11
- Japan, 65, 131, 165
 evacuation of neurosurgical casualties to, 17
See also Tokyo Army Hospital.
- Japan Logistical Command, 182
- JASPER, H. H., 267
- JAVID, M., 229
- JEFFERSON, G., 17
- JOHNSON, G. B., 213
- John of Gaunt, 8
- JOHNSON, R. T., 17
- JOOMA, O. V., 259
- JOPLIN, R. J., 438
- Jugular compression, 413–414
- Jugular compression test, 50–51, 450–451, 452
 for lumbar intervertebral disk lesions, 447–448
- JUNG, A., 438, 439, 550
- Jutlandia*, 22
- KABAT, H., 383, 384, 385
- KAHN, E. A., 302, 498, 502
- KAPPIS, A., 234
- KEEGAN, J. J., 452
- KEEN, W. W., 5, 234, 557
- Kennedy General Hospital, 400
- Kennedy Veterans' Administration Hospital, 301, 302
- Kernig sign, 71
- Kerr's compounds, 239, 240
- KESSLER, H., 345
- KEYES, D. C., 439, 440, 441

- Keystone splint, 390
- Kidney abscess, as cause of death, 12
- Kidneys:
- in multiple wounds, 434
 - rupture of, 44
- KIDWELL, C. E., 394
- KIEFER, E. J., 501
- KITE, W. C., Jr., 501
- KLAR, E., 574
- KLEINMAN, A. M., 299
- KLEINSCHMIDT, O., 237
- Klippel-Feil deformity, 485
- KLIFFEL, M., 485
- KNIGHT, G. C., 476
- KNOTT, M., 383
- KÖNIG, F., 234
- Korea, 25, 34, 36, 65, 67, 131, 137, 140, 165, 173, 182, 330
- acute cervical cord syndrome in, 365, 367
 - evacuation of neurosurgical casualties from, 17
- Korean Medical Service, establishment of facilities in, 15
- Korean surgeons, training of, 15
- Korean War, 1, 26, 27, 32, 65, 68, 69, 71, 73, 83, 88, 92, 103, 104, 105, 108, 117, 133, 135, 136, 138, 143, 193, 194, 206, 213, 215, 217, 223, 226, 229, 287, 300, 357, 399
- analysis of wounds involving cervical canal in, 327-332
 - analysis of wounds involving lumbosacral canal in, 337-344
 - analysis of wounds involving thoracic canal in, 333-335
 - British casualties in, 108
 - care of quadriplegic casualties in, 329
 - cranioplasty in, 245-246
 - head injuries in, 1
 - head injury study in, 257-262
 - incidence of cerebral hematomas in, 131
 - lateral spinothalamic tractotomy in, 302
 - management of casualties in, 289-290
 - management of neurosurgical casualties in, 15, 17-22
 - neurosurgical casualties in, 83
 - opening of dura in, 147
 - posttraumatic epilepsy in, 257
 - prevention of spastic hemiplegia in, 425
 - rehabilitation of paraplegics in, 400
 - spinal cord injuries in, 287
 - through-and-through head injuries in, 161-162
 - wounds of dural sinuses in, 181, 182-183
- Korean War veterans, posttraumatic epilepsy in, 261
- KRISTIANSEN, K., 267
- KRÖNLEIN, R. U., 5
- KUHLENBECK, H., 131
- Kumsong, 118
- LaLonde, A. A., 61
- Laminectomy(ies), 290, 291, 329, 330, 334, 337, 339, 341, 414, 465
- at L3-L4 interspace, 469-471
 - at lumbosacral interspace, 468-469
 - bilateral, 497-500, 502, 504
 - cervical, 329
 - decompressive, 277, 281, 285, 302, 307, 308, 309, 329, 334
 - case reports, 281
 - indications for, 280-281
 - surgical priority over, 308
- delayed, 339
- early, in penetrating spinal cord injuries, 307-308
- for locked facets, 278
- for penetrating wounds, 330
- instruments for, 29-30
- late, in penetrating spinal cord injuries, 308-309
- number carried out, 27-28
- operative method of, 210-325
- operative technique of, 311-322
- performance of, 31, 32
- physiotherapy after, 322
- postoperative management of patient, 322-325
- preoperative management of patient, 310
- surgical technique of, 334
- timing of, 334, 355
- unilateral, 496-497, 499
- LANE, S., 246
- Laparotomy, 204, 334, 337
- LAPICQUE, L., 549
- LAPIDES, J., 345
- LARREY, D. J., 5
- LASÈGUE, C., 448, 449
- Last's segmental innervation pattern, 373
- LAWTON, E. B., 392
- LEARMONTH, J. R., 345
- LEAVENS, 1st Lt. M. E., 19
- LEE, W. J., 383
- Leg(s):
- paralysis of, 181, 182
 - spasticity of, 185
 - weakness of, 189
 - due to extradural hemorrhage, 56
- Leichtenstern sign, 71
- LEKSELL, L., 599
- LEONHARDT, W., 425
- Lesions, surgical:
- different diagnosis of, 55-63
 - treatment of, 55-63
- LEVINE, M., 383
- LEVITCH, L. A., 239
- LEVY, F., 425
- LEWIN, W., 108, 213, 218, 219
- LIDDELL, E. G. T., 409
- Lidocaine hydrochloride, in sacral nerve block, 349
- LILLIE, H. I., 213
- LION, K. S., 238
- Lipidol, 458
- LISTER, J., 5
- Litter stand, 31, 32
- Litter-turning method, 32, 34
- Liver, rupture of, 44
- LIVINGSTON, K. E., 245, 246
- LIVINGSTON, R. B., 268
- LLUESMA-URANGA, E., 237
- Lobotomy, prefrontal, 302
- LONG, C., II, 392
- LOUIS, 11
- LOVE, J. G., 445, 446, 455, 501
- Lower extremity injuries, 578-579
- peroneal nerve, including sciatic portion, 578
 - tibial nerve, including sciatic portion, 578
- Lower motor neuron lesion(s), 346, 347, 373
- treatment of, 383
- Lower thoracic lesions, 349
- LOWMAN, C. L., 382
- LOWMAN, E. W., 371
- Lucite, 237, 247
- Lumbago, 444, 455
- Lumbar disk, 437-473
- Lumbar intervertebral disk lesions:
- anesthesia in, 467-468
 - associated sciatic pain in, 444-445
 - characteristics of pain in, 443-445
 - clinical and roentgenological diagnosis of, 443-464
 - closure of operative incision, 471
 - conservative therapy in, 465-466
 - differentiation of, 457-458
 - differentiation from other diseases, 455-465
 - history and symptomatology of, 443
 - incidence of differential clinical diagnosis of, 454-455
 - indications for myelography in, 459
 - indications for surgery in, 466-467
 - interpretation of myelographic findings in, 460-463
 - laboratory investigations in, 463
 - localization of, 454
 - myelography in, 458

- Lumbar intervertebral disk lesions—
Continued
neurological symptoms and signs, 446
operative incision, 468
operative position in, 468
pain in, 443
physical examination in, 446–447
postoperative lumbar pain, 472–473
postoperative management of, 472
roentgenological examination of, 457
special tests for, 447–454
spinal fusion in, 471–472
surgical technique in, 468–471
technique of myelography in, 459–460
- Lumbar plexis, anatomy of, 524–528
- Lumbar puncture, 139, 140, 229
in closed spinal cord injuries, 276
in lumbar intervertebral disk lesions, 463–464
- Lumbosacral arthritis, 471
- Lumbosacral fusion, 445
See also Spinal fusion.
- Lumbosacral reflex arc, 352
- Lungs, drainage of, 44
- LYONS, W. R., 540, 566
- MACCARTY, C. S., 284, 352
- MACDONALD, R., 213
- MACEWEN, W., 5
- MACLEAN, A. R., 203
- MACOMBER, D. W., 238
- Magnesium ammonium phosphate stones, 359
- MAGNUS, R., 420
- MAHOUEAU, D., 289
- MAKINS, G. H., 560
- Mandelic acid, 346
- Marie-Strümpell disease, 455, 457, 463, 468
- MARMONT, G., 409
- MARSHALL, J., 408
- MARTIN, J., 87, 404, 407
- MASH. *See* Mobile Army Surgical Hospital.
- Massage, 382
- MATSON, D. D., 71, 87, 88, 108, 133, 163, 181, 191, 192, 203
- MAURICE, G., 445
- Maxillofacial injuries, associated with brain wounds, 69
- MAYFIELD, F. H., 41, 55, 239, 438
- Mayo Clinic, 501
- Mayo stand, 32
- McBRIDE, B. H., 41, 55
- McEACHERN, D., 266
- McGuire General Hospital, 400
- McKENNA, W. F., 329
- McKENZIE, D., 203
- MEDAWAR, P. B., 543
- Medical Corps Reserve Officers, 292
- Medical troops, in combat, 25
See also Personnel.
- MEIROWSKY, A. M., 15, 25, 65, 67, 75, 83, 103, 181, 221, 245, 246, 283, 287, 307, 350, 352, 365, 369, 400, 425, 429n, 501
- Meningeal artery:
middle, 57, 92, 133
hemorrhage in relation to fracture of, 56, 57
laceration of, 55
- Meningeal infection, mixed basilar, 217
- Meninges, 307
closure of, 103
watertight, 105
- Meningismus, due to subarachnoid hemorrhage, 61
- Meningitis, 87, 136, 147, 162, 174, 206, 207, 210, 214, 215, 216, 218, 307, 308
basilar, 189, 218
incidence of, 217
management of, 138
prevention of, 72
- Meningocerebral infection, 69, 186, 188, 189, 190
incidence of, 17, 19–22, 28–29, 32, 104
reduction of, 108
- Meningococcus, 217
- Mental depression, in penetrating craniocerebral trauma, 69
- Meperidine hydrochloride, 310, 567
in hypothermia, 53–54
- Meprobamate, 383, 410–411
- Meralgia paraesthetica, 562
- MEREDITH, J. M., 352
- MERRITT, H. H., 266
- Merthiolate, 139
- MERWARTH, H. R., 193
- Mesencephalon, compression of, 190
- Metallic grafts, 237–238
mold formation for, 239, 243
plate formation for, 239–243
- Methocarbamol, 410–411
- Methyl methacrylate cranioplasty, 237
- Meuse-Argonne, battle of, 1, 7, 12
- MEYER, J. S., 143
- MEYERS, R., 429n
- Michel's clamps, 87
- Midbrain, compression of, 110
- MIDDLETON, G. S., 441
- Military Air Transport Service, 290
- "Military Helmet Design," 69
- MITCHELL, S. W., 5, 557, 559
- MIXTER, J. M., 273
- MIXTER, W. J., 455, 458
- Mobile Army hospitals, trained personnel in, 7
- Mobile Army Surgical Hospital(s), 15, 18, 19, 22, 131, 290
- Moldine, 240
- Monoplegia, 185
- Morale, in closed spinal cord injuries, 273, 283
- MOREHOUSE, G. R., 557
- MORLEY, T. P., 219
- Morphine, 301, 310, 567
in closed craniocerebral trauma, 46
- Motor system:
convulsions, due to head trauma, 49
decerebrate rigidity, due to head trauma, 49
paralysis, due to head trauma, 49
paresis, due to head trauma, 49–450
- Motor tests in lumbar intervertebral disk lesions, 449–450
- MOULTON, S. H., 349
- Mouth, cleansing of, 44
- Mucous plugs:
evacuation of, 221
prevention of, 42–44
- MÜLLER, W., 234
- Multiple wounds, procedures for care of patient, 436
- MUNRO, D., 283, 284, 294, 295, 296, 309, 371, 399, 400, 411
- Muscle(s):
abdominal, 346, 407, 413
achilles group, 450
abductor hallucis, 532
adductor brevis, 412
adductor longus, 412
adductor magnus, 412
antagonistic, 384, 385, 404, 405
anterior tibial, 450
deltoid, 383, 385
detrusor, 345
diaphragm, 346
extensor digitorum brevis, 534
extensor digitorum longus, 534
extensor hallucis, 450
extensor hallucis longus, 534
extensor, of arm, 423
extraocular, 423
finger flexors, 385
flexor digitorum brevis, 532
flexor digitorum longus, 532
flexor hallucis brevis, 532
flexor hallucis longus, 532
flexor, of arm, 423
gastrocnemius, 412, 413, 530
gluteal, 383, 418, 446, 448, 449, 576
gluteus medius, 530
gluteus minimus, 530
hamstring, 413, 446, 448, 449
iliopsoas, 527
infraspinatus, 508
intrinsic—
of hand, 555, 556

- of foot, 532
 - latissimus dorsi, 385, 390, 509
 - leg, 446
 - longus colli, 508
 - lumbricalis, 532
 - obturator, 412
 - occipital, 137
 - en bloc* resection of, 85
 - paravertebral, 418
 - pectineus, 527
 - pectoralis major, 385, 509
 - pectoralis minor, 385, 509
 - peroneus brevis, 534
 - peroneus longus, 534
 - peroneus tertius, 534
 - piriformis, 448
 - protagonist, 384, 385
 - quadriceps, 383
 - quadriceps femoris, 527
 - reinnervation of, 543
 - rhomboid, 507
 - sartorius, 527
 - scaleni, 508
 - serratus anterior, 385, 507
 - subclavius, 508
 - subscapularis, 509
 - supraspinatus, 508
 - temporal, 137
 - en bloc* resection of, 85
 - tensor fasciae latae, 530
 - teres major, 385, 509
 - tibial, 453, 454
 - tibialis anterior, 534
 - tibialis posterior, 532
 - trapezius, 385, 390, 423
 - triceps, 385
 - vastus medialis, 413
 - wrist extensors, 385
 - wrist flexors, 385
 - See also* Muscle testing.
- Muscle spasms, in closed spinal cord injuries, 274, 284
- Muscle testing, 555
- abductor digiti quinti, 523
 - abductor pollicis, 524
 - abductor pollicis brevis, 520
 - abductor pollicis longus, 517
 - adductors, 528
 - biceps brachii, 512
 - brachioradialis, 516
 - coracobrachialis, 512
 - chronaxie measurements in, 549-550
 - deltoideus, 513
 - dorsal interossei, 523
 - electromyography in, 551-552
 - extensor carpi radialis longus, 516, 517
 - extensor carpi ulnaris, 517
 - extensor digitorum brevis, 534
 - extensor digitorum communis, 516-517
 - extensor digitorum longus, 534
 - extensor hallucis longus, 534
 - extensor pollicis brevis, 517
 - extensor pollicis longus, 517
 - flexor carpi radialis, 519
 - flexor carpi ulnaris, 522
 - flexor digitorum, 533
 - flexor digitorum profundus, 520, 523
 - flexor digitorum sublimis, 519-520
 - flexor hallucis longus, 533
 - flexor pollicis longus, 520
 - gastrocnemius, 532
 - gluteus maximus, 530
 - gluteus medius, 530
 - gluteus minimus, 530
 - hamstring, 532
 - iliopsoas, 527
 - infraspinatus, 510
 - intrinsic, of foot, 533
 - latissimus dorsi, 511
 - lumbricales, 524
 - opponens digiti quinti, 524
 - opponens pollicis, 520
 - palmar interossei, 523
 - pectoralis major, 510
 - peroneus longus, 534
 - pronator teres, 519
 - quadriceps femoris, 527
 - responses to electrical currents of varying duration and intensity, 548-549
 - responses to stimulation by galvanic and faradic current, 547-548
 - rhomboidei, 509
 - sartorius, 527
 - serratus anterior, 509
 - subscapularis, 510, 511
 - supinator, 516
 - supraspinatus, 510
 - tensor fasciae latae, 530
 - teres major, 510, 511
 - tibialis anterior, 534
 - tibialis posterior, 533
 - triceps, 516
- Myelitis, ascending, 308
- Myelography, in—
- cervical intervertebral disk lesions, 487-493
 - lumbar intervertebral disk lesions, 454-455, 458
 - thoracic intervertebral disk lesions, 502
- Myelopathy:
- ascending, 308
 - autonomic reflex in, 369
 - traumatic, 349, 352
- Myotomies, 383
- Mysoline, 262
- NAFFZIGER, H. C., 17, 22, 65
- Napoleonic Wars, 5
- Narcotic addiction, 341
- Narcotics, in closed craniocerebral trauma, 46
- NASHOLD, B. S., Jr., 279
- Nasopharynx, 42
 - care of, 422
 - cleansing of, 44
- National Research Council, 506
- Nausea, in penetrating craniocerebral trauma, 69
- Naval Medical Field Research Laboratory, 69
- Neck compression test, 477, 479, 480, 484
- Neck extension test, 480
- Neck wounds:
 - case report, 11
 - death rate from, 5
 - through-and-through, 328
- Necrosis:
 - in head injuries, 175, 177
 - urethral, 346
- Nembutal, 310, 567
- Neomycin, 347
- Neoplasm(s), 485
 - of lung, 483
 - of spine, 446, 447-448, 456, 458, 463, 480, 484, 485
- Neostigmine methylsulfate, 297
- Nerve(s):
 - abducent, 48-49
 - accessory, 49
 - acoustic, 49
 - anterior thoracic, 510
 - axillary, 509, 512-513, 556, 561
 - common peroneal, 528, 530, 533-534
 - cranial, 47-49, 506
 - dorsal scapular, 507, 509
 - eighth cranial, 49
 - eleventh cranial, 49
 - facial, 49
 - femoral, 524, 527, 556
 - fifth cranial, 49
 - fifth lumbar, 446
 - first cranial, 48
 - first sacral, 446, 453-454
 - fourth cranial, 48-49, 71
 - fourth lumbar, 453
 - genitofemoral, 524, 525-527
 - glossopharyngeal, 49
 - hypogastric, 345
 - hypoglossal, 49
 - iliohypogastric, 524
 - ilioinguinal, 524-525
 - inferior gluteal, 528, 530
 - inferior hemorrhoidal, 534
 - inferior lateral clunical, 530

Nerve(s)—Continued

- inferior medial clunical, 528
 - lateral cutaneous, of forearm, 511-512
 - lateral femoral cutaneous, 524, 527, 562
 - lateral thoracic, 508
 - long thoracic, 507, 509
 - lower subscapular, 510
 - medial cutaneous:
 - of arm, 509, 511
 - of forearm, 509, 511
 - medial thoracic, 508
 - median, 509, 517-520, 555, 562, 572, 573, 577
 - middle subscapular, 509, 510
 - musculocutaneous, 509, 511-512, 556
 - ninth cranial, 49
 - obturator, 412, 524, 527-528
 - oculomotor, 48-49
 - olfactory, 48, 219
 - optic, 48
 - pelvic, 345
 - perineal, 534
 - peroneal, 561, 573, 575, 576
 - phrenic, 507
 - plantar, 449
 - posterior femoral cutaneous, 528, 530
 - posterior tibial, 573
 - pudendal, 534-535
 - radial, 505, 509, 513-517, 555, 556, 573, 576, 578
 - recurrent, 439
 - sciatic, 444-445, 448, 454, 528, 530, 555, 568, 573, 575
 - second cranial, 48, 71
 - seventh cranial, 49, 71
 - sixth cranial, 48-49
 - spinal, 446, 506-507
 - accessory, 49
 - component fibers of, 507
 - subclavian, 510
 - subscapular, 509-510
 - superior gluteal, 528, 530
 - suprascapular, 508-510
 - tenth cranial, 49
 - third cranial, 48-49, 71
 - third lumbar, 453
 - thoracodorsal, 509, 510
 - tibial, 448-449, 528, 530-533, 573
 - transplantation of, 573
 - trigeminal, 49
 - trochlear, 48-49
 - twelfth cranial, 49
 - ulnar, 446, 509, 520-524, 555, 557, 561, 572, 573, 578
 - upper subscapular, 509, 510
 - vagus, 49
- Nerve block, intercostal, for pain, 432, 433
- Nerve roots, exposure of, 11-12
- Nerve supply, of intervertebral disk, 438-439
- Neuralgia, intercostal, 502
- Neurapraxia, 544
- Neurectomy (ies), 358, 369
 - femoral, 412-413
 - technique of, 413
 - obturator, 412
 - extraplevic, 412
 - intrapelvic, 412
 - technique of extrapelvic, 412
 - technique of intrapelvic, 412
 - peripheral, 412
 - sciatic, 412-413
 - technique of, 413
- Neurilemma, 537
- Neurinomas, 483
- Neurogenic bladder:
 - diagnostic approach, 361
 - dynamic studies of, 360
 - management of, 294-295, 358-359
 - necessary studies of, 359, 362
 - neurosurgical aspects of, 345-354
 - roentgenographic studies of, 359-360
 - roentgenological procedures in, 347-348
 - stimulation studies of, 361-362
 - stone formation in, 357, 362
 - treatment after stablization, 362-363
 - treatment of, 296
 - urological aspects of, 357-363
- Neurological centers, establishment in rear areas, 6-7
- Neurological signs:
 - abnormalities, 56
 - effect of narcotics on, 46
- Neurological surgeons. *See* Neurosurgeons.
- Neurological surgery:
 - development of, 5
 - requirements of, 8
 - training program in, 26*See also* Neurosurgery.
- Neurological symptoms and signs, in lumbar intervertebral disk lesions, 446
- Neurolysis, 568, 572
 - of cauda equina roots, 309
- Neuroma (s), 543, 545, 553, 555, 560, 568, 573, 574
- Neurophysiologists, 408
- Neurorrhaphy, 543, 545, 565, 566, 567, 568
 - bone shortening in, 573
 - bulb suture in, 573-574
 - mobilization, joint posturing, and transplantation, 572-573
 - nerve grafting in, 574
 - overcoming gap in, 572
- rehabilitation after, 576
- resection of lesion in, 574
- suture in, 574-576
- Neurosurgeon(s), 203-204
 - qualifications of, 26
- Neurosurgery:
 - advances in World War II, 7
 - as a special field, 8
 - development of, 7
 - foundations of modern, 5
 - military, 1-39
 - beginning of, 5-6
 - Cushing's contributions to, 7
 - head injuries, 1-8
 - historical notes, 1-13
 - management of casualties in Korean War, 15, 25-36
 - management of neurosurgical casualties in Korean War, 11-22
 - spinal cord injuries, 11-13*See also* Neurological surgery.
- Neurosurgical casualties:
 - care of, 27-28
 - definitive care of, 17, 26, 133
 - early definitive neurosurgical care of, 131
 - early definitive neurosurgical intervention, 17, 18, 32-34
 - evacuation of, 18-19, 131
 - management of, 32
 - morbidity of, 27
 - mortality of, 27
 - reorganization of care of, 17-18
 - statistics, 83-85, 104
 - study of care of, 22
 - system of care of, 17-19
- Neurosurgical centers, 289
- Neurosurgical Consultant to the Chief Surgeon, Far East Command, 18, 27
- Neurosurgical detachment (provisional), establishment of, 15
- Neurosurgical detachments, deployment of, 25
 - See also* Neurosurgical teams; Neurosurgical units.
- Neurosurgical personnel:
 - availability of, 26
 - shortage of, 18
- Neurosurgical teams, 203, 338
 - British, at Dunkirk, 8
 - command channels for, 25-26
 - establishment of, 131
 - forward use of, 25-26
 - in evacuation hospitals, 6-7
 - in forward areas, 6-7
 - in mobile hospitals, 6-7
 - in rear areas, 6-7
 - instructions for, 6-7
 - mobile, 105, 229, 289, 290, 337

- command channels for, 25
- concept of, 25
- establishment in Korea, 17-18, 83, 104, 135, 165
- in British Army, 17
- in Eighth U.S. Army, 18-19
- in Korea, 73
- in Tokyo, 73
- organization of, 25-36, 103
- U.S. Army, 83, 88, 104
- organization of, 25-26
- prerequisites, 25-26
- selection of personnel for, 26-29
- table of equipment for, 25-26
- table of organization for, 25-26
- training of, 25-26
- vehicles for, 25-26
- Neurosurgical units:
 - in base installations, 7
 - mobile, 329, 333
 - anesthesiologist in, 26-27
 - arrangement of postoperative ward tent in, 32
 - enlisted surgical technicians in, 27
 - equipment and supplies for, 29-32
 - establishment in Korean War, 131
 - female nurses in, 27
 - nurse anesthetist in, 26-27
 - objectives of, 26
 - operating tent for, 31-32
 - organization in Korean War, 26
 - organization in Republic of Korea Army, 18-19
 - personnel problems in, 27-28
 - provisional table of organization for, 28-29
 - table of organization and equipment for, 26, 28-29
 - vehicles for, 30
- See also Neurosurgical teams; Neurosurgical detachments.
- Neurotmesis, 544
- Neurotomies, peripheral, 383
- New York University Bellevue Center, 390
- NEWMAN, L. B., 371, 383
- NINE-CURT, 1st Lt. J., 19, 190
- Nitrofurans, 346
- Nitrofurantoin, 300
- Nitrogen balance, in multiple wounds, 436
- Nitroglycerin, 477
- Nitroglycerin tablet, 483
- Nitrous oxide, endotracheal, 73
- Nodes of Ranvier, 537, 540
- Nonmetallic grafts, 235
 - mold formation for, 243-244
 - plate formation for, 243-244
- NORCROSS, N. C., 233, 244, 245
- Norepinephrine, 434
- NORSA, L., 213
- NORTHCROFT, G. B., 17
- Novocain, 310, 369, 455
 - in sacral nerve block, 349
- Novocain blocks, 560
- Nuclear warfare:
 - deployment of neurosurgical detachments in, 25
 - trained medical personnel in, 25
- Nucleus pulposus, 438, 439-440, 482
 - anatomy of, 439-440
 - cervical herniation of, 477, 480
 - changes with age in, 441
 - herniation of, 497-498
 - histology of, 440-441
 - lumbar herniation of, 444, 445, 446, 447, 449-450, 452, 453, 456, 457, 458, 459, 460-461, 462, 463, 464-466, 467, 469, 471-472
 - physiology of, 441-443
 - removal of, 497
 - thoracic herniation of, 501-504
- Nurses, 27
 - Nutrition:
 - in closed spinal cord injuries, 273, 283
 - in decerebrate rigidity, 50
 - maintenance of, 137
- NYQUIST, R. H., 371, 373n, 382, 383, 385, 389
- Nystagmus, 49, 190, 262
- Occipital fascia grafts, 105, 177
- O'CONNELL, J. E. A., 472
- ODOM, G. L., 478
- O'HARE, J. M., 349
- Okinawa campaign, 27, 192, 223, 229
 - neurosurgical care in, 17
- OLDBERG, E., 213
- O'LEARY, J. L., 269
- Open wounds and fractures, examination in multiple injuries, 435
- Operating lamps, 32
- Operating tent, for mobile neurosurgical units, 31-32
- Ophthalmological surgeon, 203-204
- Opisthotonos, 418, 420
- Oppenheimer splint, 565
- Orbits, in penetrating craniocerebral trauma, 203-204
- Orthopedic appliances, 389-390
- Orthopedic Hospital, Los Angeles, 382
- Orthopedic surgeon, 309-310
- ORR, M. W., 399
- Osteoarthritis, 445, 456
- Osteoma, sinus, 213, 214
- Osteomyelitis, 75, 87, 138, 206, 233
- Osteoperiosteal graft(s), 234
 - operative procedure, 238
- Osteophytosis, of cervical spine, 484
- Otorrhea, 137, 217
 - incidence of, 213, 214
- Outer table graft, 234
- Oxycel, 57
- Oxygen:
 - administration of, 42
 - administration of, in tracheostomy, 42-44
 - endotracheal, 73
- Oxytetracycline, 174
- Pacific Area, 69, 88, 105
- PAGE, T. N., 15, 25
- Pain, in—
 - cervical intervertebral disk lesions, 477-480
 - closed spinal cord injuries, 274, 284-285
 - lumbar intervertebral disk lesions, 443-446
- Pantopaque, 458n, 459, 460, 461, 463, 464, 466, 484, 487, 489, 490, 491, 492, 502
- Papilledema, 48, 59, 190
- Paraffin bath, 373
- Paraldehyde, 262
 - in closed craniocerebral trauma, 46
- "Paralympics," 389
- Paralysis:
 - ascending, 331-332
 - below level of injury, 288
 - due to head trauma, 49
 - due to hematoma, 49
 - Erb-Duchenne, 562
 - focal, 59
 - ischemic, 560
 - Klumpke's, 562
 - of axillary nerve, 513, 561
 - of biceps brachii muscle, 555
 - of biceps muscle, 512
 - of brachial plexus, 556
 - of extraocular muscles, 48
 - of facial nerve, 49
 - of femoral nerve, 527, 556
 - of foot and toes, 445
 - of gluteus maximus muscle, 530
 - of gluteus medius muscle, 530
 - of gluteus minimus muscle, 530
 - of median nerve, 519, 554, 556
 - of musculocutaneous nerve, 556
 - of obturator nerve, 528
 - of pectoralis major muscle, 510
 - of peroneal nerve, 534, 556, 561, 565
 - of radial nerve, 516, 554, 555, 556, 565, 573
 - of sciatic nerve, 554, 556

Paralysis—Continued

- of tensor fasciae latae muscle, 530
- of third cranial nerve, 48
- of tibial nerve, 532, 556
- of ulnar nerve, 522, 554, 556, 561, 578
- respiratory, 328, 330, 332
- sensorimotor:
 - animal experiments in, 277
 - clinical experience in, 277
 - spastic, due to spinal shock, 275
 - traction, 561
- Paralyzed Veterans Association, 394
- Paraparesis, 185
 - in penetrating craniocerebral trauma, 71
 - spastic, 184
- Paraplegia, 32, 185, 187
 - bowel care in, 297–298
 - complications of, 303–304
 - decompressive laminectomy in, 307
 - due to metastatic carcinoma, 413
 - flaccid, due to spinal shock, 275
 - incidence during Korean War, 287
 - late laminectomy for, 309
 - management of, 12
 - prevention of complications in, 287, 288, 289, 290
 - problem in modern society, 339–402
 - spastic, 186, 428–429
 - traumatic, spasticity of, 413
- "Paraplegia and You," 325
- "Paraplegia in flexion," 407, 410, 411
- Paraplegia News, The*, 325
- Paraplegics:
 - analgesics for, 301
 - antibiotics for, 300–301
 - blood changes in, 299
 - care of, 27
 - chemotherapeutic agents for, 300–301
 - corrective therapy for, 385–389
 - educational therapy for, 391
 - electrotherapy for, 383–384
 - employment of, 394
 - exercise therapy for, 384
 - heliotherapy for, 382
 - hydrotherapy for, 382–383
 - initial examination of, 297
 - involuntary muscle contractions in, 406–408
 - lifting of, 294
 - litter-turning method for, 290, 291–292
 - maintenance of fluid balance in, 299
 - manual arts therapy for, 391
 - massage for, 382
 - "mass reflex" in, 407
 - morale of, 283–284
 - morbidity of, 34
 - muscle testing of, 373
 - number in United States, 345

- occupational therapy for, 390
- orthopedic appliances for, 389–390
- pain problem of, 301–302
- physical and vocational rehabilitation of, 371–395
- position of, 291, 294
- psychological factors of, 302–303
- records for, 297
- rehabilitation of, 287–303, 309–310
- results of rehabilitation of, 392–395
- sedatives for, 301
- sensory testing of, 373
- skin care of, 299–300
- social service assistance for, 392
- spasticity in, 405
- thermotherapy for, 373–382
- transportation of, 291–294
- treatment of, 287–289
- vocational counseling for, 392
- wound care of, 290–291

PARÉ, A., 4, 5, 12

Paresis, due to head trauma, 49–50

Paresthesia, in—

- cervical intervertebral disk lesions, 480, 482, 483, 493
- cervical intervertebral lesions, 499
- lumbar intervertebral disk lesions, 446, 447–448, 450–451, 466
- peripheral nerve injuries, 560

Parkinsonism, 417, 425, 426, 427, 428

Pathology, of peripheral nerves, 537–545

PATTON, J. F., 352

Paul of Aegina, 12

PECK, F. C., Jr., 501

Pedicle graft, 574

PEET, M. M., 238, 302

PENFIELD, W., 267, 420

Penicillin, 71, 135, 137, 138n, 139, 173–178, 204, 246, 300

Penile erection, in—

- decerebrate rigidity, 418–420
- paraplegia, 407
- spinal cord injury, 404

Penoscrotal fistula, 348, 350

Pentobarbital sodium, 310, 472, 567

Pentothal sodium, 63, 73, 174, 192, 205, 310, 311, 467, 496, 567

to control seizures, 50

Percussion test, for lumbar intervertebral disk lesions, 447

Pericranial graft, 177

Perineurium, 538, 540, 543, 544, 545

Periosteal grafts, 105, 218

Peripheral nerve function:

- electrodiagnostic testing of, 547–552
- evidence of regeneration in, 558–559
- evidence of unsatisfactory regeneration in, 559

uncertain evidence of regeneration in, 559

Peripheral nerve injuries, 297, 339

- aneurysms in, 561
- anterior tibial syndrome in, 562
- associated bone or joint injuries in, 561
- carpal tunnel syndrome in, 562
- causalgia in, 559–560
- changes in skin temperature in, 557
- changes of nails in, 558
- chronaxie in, 559
- clinical classification of, 544–545
- color changes in, 558
- deferred versus immediate repair of, 566
- deformity in, 554
- digital atrophy in, 558
- electromyography in, 559
- Erb-Duchenne paralysis in, 562
- examination and clinical manifestations of, 553–562
- examination of, 553–559
- factors influencing recovery, 578–579
- galvanic ratio in, 559
- Guttmann dye test in, 557
- histological changes in, 540–543
- history of, 553
- improvement in usefulness of extremity in, 559
- ischemic paralysis in, 560
- Klumpke's paralysis in, 562
- lesion in continuity, 568–572
- meralgia paresthetica in, 562
- motor function in, 555–556, 559
- motor response on nerve stimulation in, 558
- muscle atrophy in, 556
- neuromas in, 560
- neurorrhaphy in, 572–576
- neurovascular lesions in, 560
- nonoperative treatment of, 565
- operative repair of, 566
- other clinical manifestations of, 559–562
- pathological classification of, 543–544
- physical therapy in, 565
- preservation of sweating in, 558
- preservation or recovery of sensation in, 558
- reflexes in, 556
- results of treatment of, 576–579
- sensation in, 556–557
- shrinkage of area of sensory loss in, 559
- skin resistance test in, 557
- surgical anesthesia in, 567
- surgical exploration in, 566–572
- surgical exposure in, 567–568

- surgical preparation in, 566-567
 sympathetic function in, 557
 tardy ulnar nerve paralysis in, 561
 texture of skin in, 558
 Tinel's sign in, 554, 559, 566
 traction paralysis in, 561
 treatment of, 565-579
 trophic ulcers in, 558
 vasomotor and trophic disturbances in, 557
 voluntary motor function in, 558
Peripheral Nerve Regeneration, 506
Peripheral Nerve Registry, 506
 Peripheral nerves:
 anatomy of, 505-535
 chronaxie measurements of, 549-550
 classification of, 506-507
 electrical skin resistance measurements of, 550
 electromyography in testing of, 550-552
 pathology of, 537-545
 response to galvanic and faradic stimulation, 547-548
 response to electrical currents of varying duration and intensity, 548-549
 structure of, 537-539
 trauma of, 505-579
 Peritoneal cavity, operative technique, 434-435
 Personnel, 65, 289, 290, 372, 390, 395, 400, 407, 408
 anesthesiologists, 26
 for neurosurgical units, 26-29
 neurosurgeons, 26
 nurses, 27
 social workers, 392
 vocational counselors, 392
 PETERSON, 550
 Petrolatum-impregnated gauze, 139, 210
 Phagocytosis, 540, 543
 Phenobarbital, 262, 263, 383
 to control seizures, 50
 PHILLIPS, G., 257, 266, 269
 Phlebothrombosis, 371
 Photophobia, in penetrating craniocerebral trauma, 71
 Physiatry, in paraplegia, 372
 Physical examination, in—
 lumbar intervertebral disk lesions, 446-447
 multiple wounds, 432
 Physical Medicine and Rehabilitation Service, 372n, 382
 Physical therapy, 178, 229
 in closed spinal cord injuries, 273, 284
 Physiology—
 in modern neurosurgery, 5
 of intervertebral disk, 441
 Physiotherapists, 407
 Piloerection, in decerebrate rigidity, 418-420
 Piromen, 411
 Plantar flexion, 404-405
 Plantar reflex, 404
 Plastic grafts, 236-237, 238
 PLATI, J. T., 458
 Plexiglas, 237
 Pneumatocele, after cranioplasty, 246
 Pneumocephalus, 215
 Pneumococcus, 217, 218
 Pneumoencephalography, in—
 closed craniocerebral trauma, 45-46, 62
 penetrating craniocerebral trauma, 72
 Pneumonia, 339, 422
 Pneumonitis, 432, 433
 Pneumothorax, 333, 432, 433
 Poliomyelitis:
 bladder involvement in, 357
 bladder neck obstruction in, 357
 POLLOCK, L. J., 406, 407
 Pontocaine, intravesical, for catheter removal, 349, 350, 352
 POOL, J. L., 408, 412
 Porencephalic cyst, 245
 Posterior longitudinal ligament, 437, 438-439, 455, 469
 Posttraumatic epilepsy. *See* Epilepsy, posttraumatic.
 POTT, P., 5
 Primidone, 262
 Procaine, 567
 Procaine hydrochloride, 310, 349, 369, 433, 455, 467, 560
 Proctoscopic examination, in wounds of buttocks, 434
 Promethazine hydrochloride, in hypothermia, 53-54
 Prostatic duct, 295-296
 Prostigmine Methylsulfate, 297
 Protein balance, in closed craniocerebral trauma, 44
Proteus, 217
Pseudomonas aeruginosa, 217
 Pseudoneuroma, 544
 Psychoneurosis, 502
 Pudendal and coccygeal plexuses, anatomy of, 534-535
 Pudendal block, 361
 Pudendal nerve block, for catheter removal, 349, 352
 Pudendal neurectomy, 361, 362
 for catheter removal, 352
 Pudendal neurotomy:
 for catheter removal, 350
 indications for, 350
 Pudendal plexus, 528
 PUDENZ, R. H., 7, 237, 238
 Pulmonary complications:
 broad-spectrum antibiotics for prevention of, 44
 in closed craniocerebral trauma, 44
 Pulmonary embolism, in closed spinal cord injuries, 284
 Pulse, in—
 closed craniocerebral trauma, 46-47, 48, 56
 penetrating craniocerebral trauma, 71, 73
 PULVERTAFT, R. J. V., 17
 Pupils:
 dilated, 186
 after injury, 48
 due to extradural hemorrhage, 56
 in penetrating spinal cord injuries, 369
 examination of, in—
 closed craniocerebral trauma, 48-49
 penetrating craniocerebral trauma, 71
 fixed, 186
 after injury, 48
 in decerebrate rigidity, 50
 irregularity of, due to extradural hemorrhage, 56
 PURPURA, D. P., 266
 PURVES-STEWART, J., 448
 Pusan perimeter, battle of, 1
 PÜSCHEL, J., 441
 Pyelonephritis, 358
 acute, 347, 348
 retrograde, 360
 Pyemia, death rate from, 5
 Quadriplegia, 185, 187, 328
 acute anxiety in, 366
 bowel care in, 297-298
 decompressive laminectomy in, 307
 incidence during Korean War, 287
 late laminectomy for, 308-309
 management of, 12
 prevention of complications in, 287, 289-290
 problem in modern society, 399-402
 treatment of, 11
 Quadriplegics:
 involuntary muscle contractions in, 406
 litter-turning method for, 32, 292-293
 morale of, 283-284
 number in United States, 345
 physical and vocational rehabilitation of, 371-395
 Quebec, battle of, 11
 Queckenstedt test, 308, 309, 463, 492

- RAND, R. W., 213
 RANEY, A. A., 484
 RANEY, R. B., 484
 RASMUSSEN, T., 267
 Recordkeeping, 229-230
 REEVES, D. L., 233, 239, 247
 Reflex tests, in lumbar intervertebral disk lesions, 453-454
 Rehabilitation, 178
 importance of athletics in, 389
 in penetrating craniocerebral trauma, 230
 objectives of, 371-392
 of hemiplegics, 425
 of paraplegics, 287-303, 322-325, 328
 of partially paralyzed veterans, 12
 physical, 371-395
 results of, 392-395
 sexual, 357
 technique of, 372-392
 vocational, 371-395
 results of, 392-395
 REINGOLD, I. M., 352
 Remagen, battle of, 1
 Renal physiology, in neurogenic bladder, 357
 Republic of Korea Army, 83, 104, 182
 mobile neurosurgical team in, 34-36
 enlisted surgical technicians in, 27
 organization of neurosurgical team in, 18-19
 Respiration:
 Cheyne-Stokes, 71
 in closed craniocerebral trauma, 46-47, 48
 in penetrating craniocerebral trauma, 69, 71, 73
 RESTARSKI, J. S., 237
 Restlessness:
 chest restraint for, 46
 in closed craniocerebral trauma, 46
 in penetrating craniocerebral trauma, 69, 187, 221-222
 padded dressings for, 46, 222
 Resuscitation, in multiple wounds, 434
 RETTER, R. H., 501
 Rheumatoid spondylitis, 455-456, 457, 463, 486-487
 Rhinorrhea, 137, 214, 216-217, 219
 bilateral, 214
 incidence of, 213
 traumatic, 218
 unilateral, 214
 Rhizotomy (ies), 294-295, 383, 473
 anterior, 284, 300, 413, 414
 for severe spasticity, 352
 technique of, 411-412
 anterior sacral, for traumatic myelopathy, 352
 lumbosacral, for severe spasticity, 352
 lumbosacral posterior, 285
 posterior, 285, 369, 409, 411, 451
 sacral, 352, 369
 Rib grafts, 234, 254
 RICHTER, C. P., 550, 557
 RIDDOCH, G., 369
 RILEY, H. A., 451, 452
 Ringer's lactate, 299
 Ringer's solution, 434, 436
 RIZZOLI, H. V., 219, 505, 553, 565
 Robaxin, 410-411
 ROBSON, 574
 ROGERS, J. B., 438
 ROKA. *See* Republic of Korea Army.
 Rolandic outflow, 184, 185, 186, 187
 Rolandic veins, 193
 ROOFE, P. G., 438, 439
 ROSE, D. K., 350
 ROSENBLUTH, 1st Lt. P. R., 22
 ROSS, J. C., 350, 352
 Rotation flap, 178
 ROULHAC, G. E., 135, 165
 Ruptured cervical intervertebral disk.
 See Cervical intervertebral disk lesions; Nucleus pulposus, cervical herniation of.
 Ruptured lumbar intervertebral disk.
 See Lumbar intervertebral disk lesions; Nucleus pulposus, lumbar herniation of.
 Ruptured thoracic intervertebral disk.
 See Thoracic intervertebral disk lesions; Nucleus pulposus, thoracic herniation of.
 RUSK, H. A., 392, 400
 RUSSELL, W. R., 257, 268
 RUSSI, S., 345
 Rutzen facing cement, 347
 SACHS, E., 222
 Sacral nerve block(s), 346, 361, 411-412
 for catheter removal, 349-350, 352
 in traumatic myelopathy, 349
 Sacral neurotomy, 294-295
 for catheter removal, 350, 352
 indications for, 350-352
 in traumatic myelopathy, 352
 technique of, 352
 Sacral plexus, anatomy of, 528-534
 Sacral reflex arc, 345, 346, 349, 358
 St. Louis Children's Hospital, 279
 St. Mihiel, battle of, 12
 SANDERS, E. M., 388
 San Juan Hill, battle of, 1, 11
 SARGENT, P., 185, 186, 187, 193
 SASHIN, D., 441
 Scalenus anticus syndrome, 480, 483
 Scalp:
 closure of, 136, 139, 173
 contusion of, 57, 58
 infection of, 184, 189, 190
 laceration(s) of, 44, 136, 137, 147
 closure of, 75, 76, 137
 debridement of, 75, 76, 85, 137
 en bloc resection of muscle in, 75
 incomplete closure of, 76
 in penetrating craniocerebral trauma, 75-76
 primary closure of, 75
 roentgenograms of, 75
 secondary closure of, 75
 secondary infection of, 75
 surgical management of, 137
 surgical technique of, 76
 wound(s) of:
 closure of, 87, 88, 89, 137
 debridement of, 85, 87, 89, 90
 missile tract in, 163-164
 plastic closure of, 87, 88
 primary closure of, 87, 177
 secondary closure of, 87
 surgical approach, 86, 87
 surgical management of, 85-89, 104
 tangential, 83, 92, 143-147
 through-and-through, 163-164
 Scalp flaps, 136, 177, 178, 206, 210
 SCARFF, J. E., 408, 412
 SCHEIBERT, C. D., 213, 302, 345, 350, 352, 369, 429n
 SCHEINKER, I. M., 421
 SCHMIDT, R. P., 267
 SCHMORL, G., 485
 SCHMUCKER, J. L., 5
 SCHORSTEIN, J., 17, 71, 131, 203, 210
 Schwann cells, 537, 540, 543, 544, 545
 Schwann tubules 541, 543
 SCHWARTZ, H. G., 135, 165, 273, 277, 352
 Sciatic nerve, 444-445, 448, 454
 Sciatic nerve sections, 412
 Sciatic-nerve-stretching test, in lumbar intervertebral disk lesions, 448-449
 Sciatic neuritis, primary, 457
 Sciatic scoliosis, 444, 447
 Scopolamine, 73
 SCOVILLE, W. B., 237, 268, 479
 2d Auxiliary Surgical Group, 431
 2d Neurosurgical Detachment (Provisional), 190
 SEDDON, H. J., 543, 544, 561, 573, 574
 Seizures:
 posttraumatic, 146-147
 preoperative, 215
 SELETZ, E., 567
 Semmes hand retractor, 468

- Sensory tests, in lumbar intervertebral disk lesions, 450-453
- Sepsis, 12
as cause of death, 5
- SHAMBORA, Maj. Gen. W. E., 15, 18
- SHELDEN, C. H., 237
- SHERREN, J., 574
- SHERRINGTON, C. S., 311, 367, 408, 409, 420
- Shivering, in penetrating spinal cord injuries, 367
- Shock:
in closed craniocerebral trauma, 44, 56
in closed spinal cord injuries, 275
in intracranial injuries, 431-432
in multiple wounds, 433-434, 435
treatment of, 44
- Short-wave diathermy, 237, 238
- Sick and wounded, in combat, 25-36
- Silver wire mesh cranioplasty, 237
- Sinus(es):
air, 203-212
accessory, 136
ethmoid, 206, 218
frontal, 92, 147, 184, 205, 218
complications of cranioplasty in wounds involving, 246, 247
cranioplasty of wounds involving, 237, 246, 247, 255
paranasal, 213
sphenoid, 215, 218
wound(s) of, 103, 110, 203-211
antibiotics in, 204
approach to, 206
mortality of, 207, 209
postoperative complications of, 206-207, 210
routine management of, 206
surgical management of, 205-206
surgical technique of, 210-211
- dural, 134, 181-201
confluence of, 189-190
experimental studies of, 192-194
inferior longitudinal, wounds of, 182
incidence of, 191
mortality of, 191
lacerations of, 56
longitudinal, 190
sagittal, 59, 163, 170
sigmoid, wounds of, 182, 188, 189
incidence of, 190
mortality of, 190
straight, 190
wounds of, 182
incidence of, 191
mortality of, 191
- superior longitudinal, 192, 193
wounds of, 71, 182
analysis of, 184-188
anterior portion, 184-185
incidence of, 183-188
middle portion, 185-187
mortality of, 183-188
posterior portion, 187-188
- superior petrosal, wounds of, 182
incidence of, 191
mortality of, 191
- superior sagittal, fracture in relation to, 56
- torcular Herophili, 189-190
incidence of, 189
mortality of, 189
- transverse:
fracture in relation to, 56
wound(s) of, 182, 190
incidence of, 188-189
mortality of, 188-189
- wound(s) of, 103, 110, 181-197, 229
air embolus in, 192
analysis of, 182-183
neurological sequelae of, 193, 194
repair of, 192, 193
silk suture tied over Gelfoam, 192, 193
muscle, 192, 193
surgical technique of, 195, 197
positioning in, 192
blood pressure maintenance during operation in, 192
exposure in, 192
thrombosed sinus wound, 192
thrombosis in, 192
surgical management of, 192
- Skeletal traction, 493, 495
in closed spinal cord injuries, 277, 278, 279
- Skin care, in—
closed spinal cord injuries, 273, 281-283
spinal cord injuries, 12
- Skin flaps, 173, 178
rotation of, 283
- Skin graft, 177
- Skin temperature, in penetrating spinal cord injuries, 369
- SKOGLUND, C. R., 559
- Skull:
compound comminuted depressed fracture of convexity of, 90-92
en bloc excision of, 91
surgical management of, 91
compound fractures of convexity of, 83-101
definition of, 83
management of, 83, 103
- statistics of, 83-85
surgical management of, 85-92
surgical technique of, 94-101
- compound linear fracture of convexity of, 89
- depressed fracture, surgical management of, 104
- fracture(s) of, 49, 51, 55
classification of, 51
comminuted, 53
compound comminuted depressed, 138
compound depressed:
fatal cases of, 85, 92
mortality rate of, 84
statistics of, 84-85
wounding agent in, 84
- compound linear, 83
depressed, 53
effects of, 51
incidence of, 213
in adults, 51
in children, 51
in infants, 51
line of, 51
roentgenograms of, 51-53, 58, 71
mortality of penetrating wounds of, 6-7
roentgenograms of, 136, 214-215
- separation of dura from, 56
- wound(s) of:
missile track in, 163-164
tangential, 83, 92, 132, 133, 143-147
through-and-through, 163-164
- SMALL, J. M., 17, 107, 108, 132, 133, 192
- SMITH, A. DeF., 471
- SMITH, H., 543
- SMITH, N. R., 441
- Social service assistance for paraplegics, 392
- Sodium alginate, 348, 359
- Sodium bicarbonate, 44
- Sodium phytate, 348, 359
- SÖHR, O., 234
- Solution G, for bladder irrigation, 295-296
- Solution M, for bladder irrigation, 295-296
- South Africa, campaign in, 5-6
- SPAR, A. A., 213
- "Spastic epileptogenic hemisphere," 414
- Spastic hemiparesis—
arising from brain disease, 417
arising from brain lesions, 417-418, 425
from lesions in the pons, 424-425

- Spastic hemiplegia, 428-429
 animal experimentation on, 424-425
 arising from brain lesions, 422-425
 description of, 423-424
 physiology of, 424-425
 treatment of, 425
- Spasticity:
 arising from brain lesions, 417-429
 characteristic motor pattern of spinal cord, 403-404
 description of spinal cord, 404-408
 drugs in control of, 410-411
 forced grasping in, 417, 428-429
 from central nervous system damage, 403, 428-429
 hypnosis in relief of, 415
 in lumbar intervertebral disk lesions, 447
 management of, 373, 382, 383
 of lower extremities, 405-415
 of skeletal muscles, 403
 patterns of, arising from brain lesions, 417-418, 428-429
 physiology of spinal cord, 408-410
 physiotherapeutic measures, 414-415
 posthypnotic suggestion in relief of, 415
 reduction of, 372
 relief of, 384
 resulting from trauma, 403-415, 417-429
 sucking reflex in, 417
 treatment of, 373, 382, 383, 385
 treatment of spinal cord, 410-415
- Special tests, for lumbar intervertebral disk lesions, 447-454
- Speech retraining, 229, 230
- SPENCE, W. T., 237, 244
- Sphincterometry, 349
- SPIEGEL, E. A., 268
- SPIEGEL, J., 414
- Spina bifida, 486
- Spinal canal, basis of mortality figures on penetrating wounds of, 19-22
- Spinal cord:
 trauma of, 273-402
 spasticity from, 403-415
 wounds of, 26, 34-36
See also Spinal cord injuries.
- Spinal cord and spasticity, 403-415
- Spinal cord compression, animal experiments in, 277
- Spinal cord injuries, 11-13
 broad-spectrum antibiotics in, 300
 cervical, 404, 405, 406-408
 closed, 273-283
 anatomy in, 274-275
 antibiotics in, 273
 cervical lesions in, 277
 definitive surgical treatment of, 273-274, 277-285
 early medical management in, 281-284, 285
 hospital management of, 275-276
 level of injury in, 275
 lumbar lesions in, 280-281
 pathophysiology in, 274-275
 roentgenograms in, 276, 277
 thoracic lesions in, 280-281
 De Chauillac's knowledge of, 11-12
 future surgical treatment of, 12-13
 Geraud's knowledge of, 11-12
 Hippocrates' knowledge of, 11-12
 in World War I, 11, 12
 in World War II, 11
 case report, 11
 Louis' knowledge of, 11-12
 mortality of, 11
 nursing care of casualties with, 27
 operative treatment of, 11-12
 Listerian principles of, 12
 Paré's knowledge of, 11-12
 Paul of Aegina's knowledge of, 11-12
 penetrating, 287-303
 acute cervical cord syndrome in, 310, 365-368
 ambulation in, 341
 amputation of paralyzed limbs in, 309-310
 analysis of wounds involving cervical canal in, 327-332
 analysis of wounds involving lumbosacral canal in, 337-344
 analysis of wounds involving thoracic canal in, 333-335
 associated injuries in, 333, 338-339
 autonomic hyperreflexia in, 369
 case reports of, 287-288, 327-328, 329, 330, 331, 332, 333-334, 341-342, 352, 365
 cervical cord syndrome in, 328
 complications of, 307-308
 depressed fractures of lamina in, 339-340
 dural penetrations in, 340
 epidural hematomas in, 340
 factors in mortality from, 331-332
 followup data in, 335
 indications for neurosurgical intervention in, 307-310
 initial evaluation of, 337-338
 intractable postoperative pain in, 341
 level of injury in, 327-328, 337
 long-term followup of, 341-342
 management of, 287-303
 medicomilitary care of, 289
 mental depression in, 372
 mortality in, 335
 mortality of, 340
 multiple wounds associated with, 431-436
 neurological deficit in, 335
 neurological examination in, 340-341
 neurosurgical aspects of neurogenic bladder in, 345-354
 neurosurgical intervention in, 329-330
 neurosurgical management of, 307-325
 operative findings in, 339-340
 organization of neurosurgical care of, 289-303
 paraplegia due to, 287-303
 paraplegia problem in modern society, 399-402
 pathological changes in, 288
 pedicle fractures in, 340
 physical and vocational rehabilitation in, 371-395
 postoperative care in, 344
 postoperative problems in, 341
 preoperative evaluation and preparation in, 342
 results of neurosurgical treatment of, 330, 331
 results of nonsurgical treatment of, 331
 roentgenograms in, 297, 308-309
 sequelae of, 345-354
 short-term followup of, 340-341
 suprapubic cystostomy in, 309
 surgical management of, 333-335
 surgical technique in, 344
 time of operation in, 339
 time of surgical intervention in, 330
 treatment of, 328-329
 urological aspects of neurogenic bladder in, 357-363
 wounds of cauda equina in, 340
 wounds of conus medullaris in, 340
 thoracic, 404, 406-407
 treatment of:
 before World War II—11
 Cushing's principles of, 12
 urological complications of, 12
 wounding agent in, 11
See also Paraplegia; Quadriplegia.
- Spinal drainage, acute subdural hematoma, 58
- "Spinal epilepsy," 408
- Spinal fluid fistula, 322, 328
- Spinal fluid pressure, 59

- Spinal fusion, 473
 in closed spinal cord injuries, 274, 284
 in lumbar intervertebral disk lesions, 471-472
 method of, 279
- Spinal puncture, 178
 diagnostic, in closed craniocerebral trauma, 50
 in closed craniocerebral trauma, 50-51
 in closed spinal cord injuries, 276
 therapeutic, in closed craniocerebral trauma, 50
- Spinal shock, 404, 408-409, 414
- Spinal subarachnoid space, 61
- Spinal tap(s), 65, 176, 177, 178, 229
 in closed spinal cord injuries, 297
 in penetrating spinal cord injuries, 297
- Spinal trauma, 456, 457-458, 485
- Spleen:
 in multiple wounds, 434
 rupture of, 44
- Split-rib grafts, 234, 243
 operative procedure, 238
- Split-thickness graft, 178, 210
- Spondylitis, 484
- Spondylolisthesis, 456, 458, 471
- Spondylolysis, 471
- Spondylosis, 481, 482
 cervical, 476, 477, 479, 480, 482, 493, 497, 499, 500
- SPRENGEL, D., 485
- SPRINZ, H., 299
- SPURLING, R. G., 17, 239, 244, 245, 289, 437, 438, 443, 475, 479, 501
- Stainless steel cranioplasty 237, 254
- Stainless steel wire mesh cranioplasty, 237, 264
Staphylococcus aureus, 217, 218
- State Employment Agencies, 391
- Status epilepticus, 50, 262n
- Status spasticus, 138, 300-301, 408n
 case report of, 300-301
- STAVRAKY, G. W., 268
- STEELMAN, H. F., 219
- Stereoscopic films, 72, 91
- Stereoscopic roentgenograms, 163, 174
- STEWART, O. W., 17, 203
- Stoke Mandeville, 389
- "Stoke Mandeville Bed Cycle," 388
- Stone formation, in neurogenic bladder, 357, 359, 362
- STOOKEY, B., 475, 498
- STRAIN, W. H., 458
- Streptococcus, 217
- Streptomycin, 71, 135, 137, 173, 204, 226, 300, 360
- Stryker frame(s), 11, 32, 34, 277, 281, 290, 291-293, 310, 329, 338, 367
- Stupor, in penetrating spinal cord injuries, 366
- Subfrontal contusion, 62
- Suboccipital decompression, 421
- Subtemporal decompression, 63, 421
- Suction apparatus, 32
 development of, 7
- Suction machines, portable, 30
- Sulfadiazine, 138, 207
- Sulfisoxazole, 300
- Sulfonamide drugs, 7-8, 217, 226, 300, 346
- SUNDERLAND, S., 544
- Superinone, 44
- Supplies. *See* Equipment and supplies.
- Suprapubic cystostomy, 296, 309, 329, 346
- Surgeon General, ROKA, 19
- Surgeon General, The, U.S. Army, 22, 26, 506
- Surgeon(s):
 battalion, 15
 civilian, selection of, 6
 Eighth U.S. Army, 18
 Far East Command, 18
 military, 6-7
- Surgery, preparation for, in multiple wounds, 435
- Surgical Consultant, Tenth U.S. Army, 17
- Surgical Instrument Set, Supplemental, Brain and Nerve Injuries, 29-30
- Surgical management, of—
 specific infections, 141-142
 wounds of thoracic canal, 333-335
- Surgical technique—
 for correction of rhinorrhea, 217-218
 of compound fractures of convexity of skull, 94-101
 of dura sinus wounds, 195-201
 of penetrating wounds of brain, 117-129
 of scalp lacerations, 76-82
 of through-and-through wounds, 164
 of wounds involving air sinuses, 210-211
 of wounds involving lumbosacral canal, 344
- SUTTON, B. B., 345
- SWANSON, H. S., 193
- Sweating:
 excessive, after head trauma, 44
 in decerebrate rigidity, 50
 in penetrating spinal cord injuries, 367
- Sympathectomy, 302
- Sympathetic block, autonomic hyperreflexia, 369
- Sympathetic blockade, 328
 acute cervical cord syndrome, 331, 365-368
- Syndrome of bilateral ventral pressure, 480, 484
- Syndrome of root pressure:
 clinical location of lesion in, 479-480
 physical findings in, 477-478
 symptoms of, 476-480
- Syndrome of unilateral ventral pressure, 482-483
- SZEKELY, E. G., 268
- Table of Organization and Equipment 8-500-26, 28-29
- Table of organization and equipment, for mobile neurosurgical units, 34-36
- Taegu, 18
- TALBOT, B. S., 400
- Tantalum clips, 495
- Tantalum cranioplasty, 7-8, 237, 247, 254, 255
 case reports on, 248-251, 255
 complication of, 245-247
 mold formation for, 239-243
 morbidity in, 255
 mortality of, 255
 operative fixation of, 242-243
 plate formation for, 239-243
 removal of, 255
- Tantalum screws, 238, 242-243
- Tantalum wire, 574
- TARLOV, I. M., 277
- Taylor back brace, 322
- TEACHER, J. H., 441
- TEED, R. W., 213
- TELLO, J. C., 2
- Temperature, in—
 closed craniocerebral trauma, 46-47
 penetrating craniocerebral trauma, 73
- Temporal fascia grafts, 105, 117, 207, 218
- Tendo achillis, 450
- Tenotomy(ies), 383
 in treatment of spasticity, 284
- Tentage, for mobile neurosurgical unit, 30-31
See also Operating tent.
- X Corps, 418
- Tenth U.S. Army, 17
- Tentorium, section of, 57
- Terramycin, 174, 178
- Testosterone, 371
- Tetracaine hydrochloride, for catheter removal, 349

- Tetraplegics:**
 employment figures on, 394
 locomotion of, 390
 paraffin baths for, 373
 prosthesis for, 389
 suspension slings for, 390
See also Quadriplegics.
- Therapeutic pool**, 373, 382
- Therapy:**
 corrective, 372, 383, 384, 385-389, 390
 exercise, 384-385
 for lumbar intervertebral disk lesions, 464-472
 hypothermia, 53
 manipulative, for low lumbar pain, 445-446
 manual arts, 391
 occupational, 372, 385, 390
 physical, 372, 373-385, 390
- Thermotherapy**, 373-382
- Thimersol**, 139
- Thiopental sodium**, 174, 205, 310-311, 467, 496, 567
- 3d Neurosurgical Detachment (Provisional)**, 27, 32, 292-293
- THOMAS, L. B.**, 267
- Thomas splint**, 565
- THOMPSON, G. T.**, 400
- Thoracentesis**, 337
- Thoracic disk**, 501-504
- Thoracic intervertebral disk lesions**, 501-504
 diagnosis of, 501-502
 differential diagnosis of, 502
 myelography in, 502
 operative technique for, 504
 pathology of, 501-502
- Thoracotomy**, 204, 334, 337
- Thorotrast**, 458
- Thrombin**, 469
- Thrombosis:**
 ascending, 332
 in head injuries, 170, 175
 lacunar, 187
 of dural sinus, 181, 182, 192
 of inferior longitudinal sinus, 191
 of spinal artery, 308
 of superior longitudinal sinus, 184, 185, 186, 187, 188
 of torcular Herophili, 189, 190
 of transverse sinus, 188, 189, 190
 sinus, 182, 185, 193, 266
- Thrombus**, 182, 185, 186, 193
 removal of, 184, 186, 190, 192
- Ticonium** 237, 243, 254
- Ticonderoga**, battle of, 11
- Tidal drainage of bladder**, 12
- TILNEY, F.**, 451, 452
- TINEL, J.**, 505, 543, 554, 560
- Tinel's sign**, 554, 559
- Tissue grafts**, 105
- T/O & E.** *See* Table of Organization and Equipment.
- Tokyo**, 32, 89, 104, 188
- Tokyo Army Hospital**, 17, 18, 19, 65, 83, 104, 135, 165 173 182 226 290, 329, 330, 337, 338
- Tongue**, paralysis of, 49
- Torcular Herophili**, wounds of, 182, 188
 incidence of, 189-190
 mortality of, 189-190
- TOWER, D. B.**, 266, 267
- Trachea:**
 aspiration of, 42-44
 care of, 422
 cleansing of, 42, 44
- Tracheostomy (ies)**, 329, 421, 432, 435
 bent-needle technique in, 42-44
 in closed craniocerebral trauma, 42-44
 in closed spinal cord injuries, 275
 in penetrating craniocerebral trauma, 69
 mechanical suction in, 42
 oxygen in, 42-44
 technique of, 42-44
- Traction**, in cervical intervertebral disk lesions, 493-495
- Tractotomy:**
 bilateral high thoracic spinothalamic, 285, 302
 lateral spinothalamic, 285, 302, 341
 spinothalamic, 414
- Tranquilizers**, 383
 in paraplegia, 301
- Transurethral resection**, 358, 361, 362
 for catheter removal, 350
 for obstructive uropathy, 352
- Trauma.** *See* specific types.
- Treatment of peripheral nerve injuries**, 565-579
- Trephination:**
 exploratory, 133
 prophylactic, 4, 5
- Trephined**, syndrome of, 244, 255
- Trephining:**
 by ancient Incas, 2
 Hippocrates' knowledge of, 4
 of skull, 4
 Pare's techniques of, 4
 Pott's recommendation of, 5
- Triparesis**, 185, 186
- Triplegia**, 187, 189
 spastic, 185, 186
- TROLAND, C. E.**, 213
- TROTTER, W.**, 59
- Truloid**, 239
- Trunk**, examination of, in multiple wounds, 434
- Tuberculosis**, 433, 456-457, 484
- Tumor(s)**, 60
 brain, 428
 hyperostosing, 233
- TURBES, C. C.**, 429n
- TURNER, E. A.**, 17, 107, 108, 132, 192
- TURYN, F.**, 449
- UIHLEIN, A.**, 213
- Unconscious patient(s):**
 care of, 41-42, 45
 catheterization of, 434
 fluid balance in, 44
 gastric feeding of, 44
 position of, 42, 44, 69
 protein balance in, 44
 pulmonary complications in, 44
See also Coma; Comatose patient; Unresponsiveness; Unresponsive patient.
- Unconsciousness**, in—
 closed craniocerebral trauma, 61
 penetrating craniocerebral trauma, 184, 187
- United Nations Forces**, 83, 104, 182, 337
- United States**, 65, 67, 335
 insurance programs in, 402
 paraplegic population in, 401
- U.S. Air Force**, 83, 104
- U.S. Army**, 69, 89, 105, 247
- U.S. Army Medical Corps**, 32, 34-36
- U.S. Army neurosurgeons**, 329
- U.S. Marine Corps**, 67, 83, 104, 257
- U.S. Navy**, 15, 83, 104, 247, 257
- U.S. Public Health Service**, 345
- U.S.S. *Consolation* (AH-15)**, 22
- University of California**, Los Angeles, 391
- University of Kansas Medical School**, 67
- University of Louisville School of Medicine**, 489
- Unresponsiveness**, in penetrating spinal cord injuries, 365
- Unresponsive patient**, management of, 69
- Upper extremity injuries**, 576-578
 brachial plexus in, 578
 median nerve in, 576-577
 radial nerve in, 578
 ulnar nerve in, 578
- Upper motor neuron lesion(s)**, 345, 346, 347, 349, 373
- Urea**, 229, 420
- Ureteral reflux**, 346, 347, 350
- Ureteritis**, cause of death, 12

- Ureterovesical reflex, 360
 Urethral fistulas, 382
 Urethrocutaneous fistula, 296-297, 346
 Urethrogram, 360
 Urinalysis, 310
 Urinary bladder, in multiple wounds, 434, 435
 Urinary calculus, 372
 Urinary output, 44, 45
 Urinary retention, 222
 Urinary tract infection(s), 348, 407, 410-411
 incidence of, 345
 Urination, involuntary, 45
 Urine, calcium load in, 359
 Urography, intravenous, 347, 348, 359
 Urological complications:
 antibiotics in, 357, 358-359, 360
 magnesium ammonium phosphate stones in, 358-359
 mortality from, 357
 Urological dysfunction:
 chronology of development after central nervous system injury, 357-359
 treatment of, 357
 Urological surgeon, 348, 352

 VA Pamphlet 7-12-394
 VAERNET, K., 22
 VANDER WEIL, S., 213
 VAN HARREVELD, A., 409
 Vasotomy, 348
 Vaughan General Hospital, 400
 Vehicles, for mobile neurosurgical teams, 25-26, 30
 Vein:
 axillary, 511, 522
 cephalic, 512
 great saphenous, 527
 median cubital, 517
 Velpeau's bandage, 575
 Venous stasis, 371
 Ventricular fistulas, with hydrocephalus, 213
 Ventricular system, in closed craniocerebral trauma, 62
 Ventricular taps, 228, 229
 Ventriculitis, 174
 Ventriculography, 60
 in closed craniocerebral trauma, 45-46, 62
 in penetrating craniocerebral trauma, 72
 Ventriculostomy, 189
 Vertigo, as indication for cranioplasty, 244-245
 Vesicoureteral reflux, 348
 Veterans' Administration, 297, 346
 followup study of peripheral nerve injuries by, 505-506
 paraplegia rehabilitation by, 399-400
 study of urinary tract disease by, 345
 Veterans' Administration hospitals, 246, 247, 289, 372, 394, 469
 autopsies on paraplegic patients at, 345
 basketball in, 389
 gait patterns for paraplegics practiced at, 388
 orthopedic appliances at, 389
 self-care activities for paraplegics at, 388
 study of urinary tract infections at, 345
 trades taught at, 391
 Veterans Advisement Agencies, 391
 Veterans Employment Agencies, 391
 VIETS, 447
 VILNER, N., 448
 VINKE, T. H., 448
 Vinke tongs, in skeletal traction, 277
 VIRCHOW, R., 59
 Vitacrylate, 237
 Vitallium, 237, 243, 247, 254
 Vitallium screws, 238, 243
 Vocational counseling, 372, 392
 Volkmann's contracture, 560
 Vomiting—
 after head trauma, 44
 due to chronic subdural hematoma, 60
 due to extradural hemorrhage, 56
 in closed craniocerebral trauma, 47, 56
 in penetrating craniocerebral trauma, 69
 WALKER, A. E., 213, 233, 257, 260, 268
 Wallerian degeneration, 540, 543, 544-545, 547
 WALSH, M. N., 445, 455
 WALSHE, F. M. R., 407, 420
 Wangenstein decompression, 297
 WANNAMAKER, Maj. G. T., 18, 22, 165, 327
 WARD, A. A., 267
 War of 1775-5
 War of 1812-5
 WARREN, S. L., 458
 WASSERMAN, R. R., 383
 WATT, A. C., 17
 WEBSTER, J. E., 177, 203, 237, 243, 246
 WEED, L. H., 420
 WEISS, B. P., 457
 "Whiplash" fracture, 476
 WHITCOMB, B. B., 239
 White Plains, battle of, 1
 WHITE, J. C., 247
 WHITFIELD, R. D., 431, 501
 WHITTY, C. W. M., 257, 268
 WILLIAMS, P. C., 465, 472
 WILLIS, T., 213
 WILSON, P. D., 448
 WILSON, S. A. K., 420
 WISE, C. S., 547
 WOLKIN, J., 133
 WOODHALL, B., 17, 235, 239, 244, 245, 246, 289, 478, 506, 540, 544, 555, 558, 559, 560, 561, 566, 568, 578
 WOLF, J. I., 233
 World War I, 1, 4, 6, 12, 15, 18, 65, 181, 357
 anesthesia in, 5-6
 antiseptic principles in, 5-6
 asepsis in, 5-6
 brain wounds before, 1-2
 cerebral localization in, 5-6
 epilepsy since, 265
 head injuries in, 1
 neurological surgery in, 5-6
 neurological units in, 5
 paraplegics in, 399
 posttraumatic epilepsy in, 256
 roentgen-ray techniques in, 5-6
 reflex phenomena in spastic paralysis in, 407-408
 spinal cord injuries in, 11
 Cushing's principles of management of, 12
 study of peripheral nerve injuries, 554
 World War II, 1, 7, 15, 17, 18, 26, 32, 65, 68, 73, 87, 88, 105, 131, 181, 210, 213, 246, 255, 308, 357
 American study of peripheral nerve injuries in, 576-579
 British study of peripheral nerve injuries in, 557, 561, 576-579
 Canadian Neurological Hospital in, 5
 experience with paraplegic patients in, 289-290
 extrapyramidal disorders after, 425
 fatalities in Army neurosurgical centers in, 469
 head injuries in, 1
 incidence of multiple wounds in, 431
 method for cervical myelography in, 489-490
 paraplegics in, 414-415
 treatment of, 399
 posttraumatic epilepsy in, 257

World War II—Continued

- quadriplegics, treatment in, 399
- reflex phenomena in spastic paralysis, 470-408
- rehabilitation of paraplegics in, 371, 399, 400
- rehabilitation of quadriplegics in, 399
- spinal cord injuries in, 11
- U.S. Army Medical Department in, 289
- veterans of, 287

Wound Ballistics Research Team, 68

Wounds. *See* specific types.

Wristdrop, 555

deformity, 516, 554

Xylocaine, in sacral nerve block, 349

Yahr, 568

Yalu River, battle of, 1

Yamshon, L. J., 423

Yoon, Capt. B.-Y., 19

Young, H. H., 455

Young, J. H., 501

Young, J. Z., 543

Yun, Brig. Gen. T. W., 19

Zachary, 573

Zander, 237

Zankel, H. T., 345

Zephiran chloride, 137

Zinsser, H. H., 347, 348, 357

Zone of Interior, 221, 289, 290, 338 340

341







