

## **The Medical and scientific archives of the Adelaide Hospital. no. 3.**

### **Contributors**

Adelaide Hospital (Adelaide, S. Aust.)

### **Publication/Creation**

[Adelaide, S. Aust.] : [R.E.E. Rogers, Government Printer], [1924]

### **Persistent URL**

<https://wellcomecollection.org/works/hz4er37t>

### **License and attribution**

This work has been identified as being free of known restrictions under copyright law, including all related and neighbouring rights and is being made available under the Creative Commons, Public Domain Mark.

You can copy, modify, distribute and perform the work, even for commercial purposes, without asking permission.



Wellcome Collection  
183 Euston Road  
London NW1 2BE UK  
T +44 (0)20 7611 8722  
E [library@wellcomecollection.org](mailto:library@wellcomecollection.org)  
<https://wellcomecollection.org>

*(Supplement to the Annual Report of the Adelaide Hospital  
for the Year 1923.)*

---

THE  
MEDICAL AND SCIENTIFIC ARCHIVES  
OF THE  
ADELAIDE HOSPITAL.

---

No. 3.

---

EDITORIAL COMMITTEE :

J. BURTON CLELAND, M.D., Honorary Pathologist.  
C. T. C. DE CRESPIGNY, M.D., M.R.C.P., Honorary Physician.  
ARTHUR M. CUDMORE, M.B., F.R.C.S., Honorary Surgeon.

---

(Supplement to the Annual Report of the Adelaide Hospital  
for the Year 1923)

Digitized by the Internet Archive  
in 2019 with funding from  
Wellcome Library

<https://archive.org/details/b32156789>



# CONTENTS.

I. HYDATID DISEASE—	PAGE.
Commentary .. .. .	4
(1) Recurrent Hydatid Disease of the Liver .. .. .	5
(2) Recurrent Hydatid Disease (?) of the Liver .. .. .	5
(3) Hydatid Cyst of the Liver .. .. .	6
(4) Hydatid Cyst of the Liver .. .. .	6
(5) Hydatid Cyst of the Liver .. .. .	6
(6) Hydatid Cyst of the Liver (?) .. .. .	7
(7) Recurrent Hydatid Disease of the Abdomen .. .. .	7
(8) Hydatid Cysts of the Lungs with Hydro-pneumothorax .. .. .	8
(9) Hydatid Cysts of the Spleen .. .. .	9
(10) Hydatid Cyst of the Pelvis .. .. .	9
(11) Hydatid Cysts of the Pelvis, Liver, and Abdominal Cavity .. .. .	10
(12) Obsolete Hydatid Cyst of the Subcutaneous Tissues of the Back .. .. .	11
(13) Degenerated Hydatid Cyst of the Liver .. .. .	11
(14) Degenerated Hydatid Cyst of the Liver .. .. .	11
(15) Obsolescing Hydatid Cyst of the Liver .. .. .	12
References to Records of Australian Cases of Hydatid Cysts affecting the Pelvis and Urinary Organs .. .. .	12
II. CASES RESEMBLING TYPHUS FEVER (Brill's Disease ?) .. .. .	20
III. NERVOUS SYSTEM—	
(1) Monkey and other Inoculations from Cases of Acute Poliomyelitis and Acute Encephalitis with the Record of a Case of Acute Encephalitis, .. .. .	33
IV. MEDICAL CASES—	
(1) Acute Gastric Ulcers. Suicide .. .. .	37
(2) Typhoid Fever with Perforation of an Ulcer and Infarcts in the Spleen .. .. .	37
(3) Amœbic Dysentery and Abscess of the Liver, Subphrenic Abscess and Purulent Pericarditis .. .. .	38
(4) Ulcers in the Small and Large Intestine with a Purpuric Rash and Streptococcal Septicæmia .. .. .	39
(5) Fibrosing Tuberculosis of the Pleura suggesting Scirrhus Carcinomatous Deposits .. .. .	40
V. DISEASES OF THE SKIN—	
(1) A Fatal Case of Iodide Idiosyncrasy with Facial Granulomata .. .. .	41
VI. SURGICAL CASES—	
(1) Death Following a Superficial Wound possibly from Diphtheritic Intoxication .. .. .	43
(2) Horseshoe Kidney in a Deaf and Dumb Patient. .. .. .	44
(3) Pneumococcal Abscess following Pneumonia .. .. .	44
VII. NEOPLASMS—	
(1) Extensive Rodent Ulcer involving the Skull .. .. .	44
(2) Lymphosarcoma of the Small Intestine with Involment of the Supra-renal Glands .. .. .	45
(3) Carcinoma of the Prostrate with Deposits in both Suprarenal Glands, Ribs, Pericranium, and Dura Mater .. .. .	46
(4) Reticular Lymphatic Permeation in Secondary Carcinomatosis of the Lungs .. .. .	47
VIII. TUBERCULOSIS—	
(1) Notes on Cases of Pleurisy with Effusion and its Relation to Tuberculous Infection .. .. .	50



# CONTENTS

1	1. Introduction
2	2. The History of the
3	3. The History of the
4	4. The History of the
5	5. The History of the
6	6. The History of the
7	7. The History of the
8	8. The History of the
9	9. The History of the
10	10. The History of the
11	11. The History of the
12	12. The History of the
13	13. The History of the
14	14. The History of the
15	15. The History of the
16	16. The History of the
17	17. The History of the
18	18. The History of the
19	19. The History of the
20	20. The History of the
21	21. The History of the
22	22. The History of the
23	23. The History of the
24	24. The History of the
25	25. The History of the
26	26. The History of the
27	27. The History of the
28	28. The History of the
29	29. The History of the
30	30. The History of the
31	31. The History of the
32	32. The History of the
33	33. The History of the
34	34. The History of the
35	35. The History of the
36	36. The History of the
37	37. The History of the
38	38. The History of the
39	39. The History of the
40	40. The History of the
41	41. The History of the
42	42. The History of the
43	43. The History of the
44	44. The History of the
45	45. The History of the
46	46. The History of the
47	47. The History of the
48	48. The History of the
49	49. The History of the
50	50. The History of the
51	51. The History of the
52	52. The History of the
53	53. The History of the
54	54. The History of the
55	55. The History of the
56	56. The History of the
57	57. The History of the
58	58. The History of the
59	59. The History of the
60	60. The History of the
61	61. The History of the
62	62. The History of the
63	63. The History of the
64	64. The History of the
65	65. The History of the
66	66. The History of the
67	67. The History of the
68	68. The History of the
69	69. The History of the
70	70. The History of the
71	71. The History of the
72	72. The History of the
73	73. The History of the
74	74. The History of the
75	75. The History of the
76	76. The History of the
77	77. The History of the
78	78. The History of the
79	79. The History of the
80	80. The History of the
81	81. The History of the
82	82. The History of the
83	83. The History of the
84	84. The History of the
85	85. The History of the
86	86. The History of the
87	87. The History of the
88	88. The History of the
89	89. The History of the
90	90. The History of the
91	91. The History of the
92	92. The History of the
93	93. The History of the
94	94. The History of the
95	95. The History of the
96	96. The History of the
97	97. The History of the
98	98. The History of the
99	99. The History of the
100	100. The History of the

THE  
MEDICAL AND SCIENTIFIC ARCHIVES  
OF THE  
ADELAIDE HOSPITAL.

---

The appearance of the third issue of these Archives may be looked upon as indicating their secure establishment as an annual event. Already the records of cases, which have thus been made available, have proved of definite value in the practice of the Adelaide Hospital itself, and it is hoped that others, outside this relatively narrow sphere, have found them of interest and of use.

The year 1923 has seen the appointment of a full-time Registrar to the staff of the Hospital. As a consequence, the individual case-sheets of the patients have been much more fully kept, thus facilitating the preparation of the Archives. It has been part of this officer's duty to collect during the year suitable material for publication, and the Editorial Committee desires to express its appreciation of this assistance. It is impossible, however, for a single registrar to carry out all the duties appertaining to such an office in a Hospital the size of the Adelaide Hospital. The Editorial Committee, in the interests of fuller records of the work done at the Adelaide Hospital, hopes in the near future to see the appointments of Medical, Surgical, and Obstetrical Registrars and of a Resident Pathologist to the staff of the Hospital. Only when a senior resident staff is thus fitly represented will the fullest supervision of individual cases be possible, will the records be as full and accurate as they should be, will all the necessary complicated examinations be carried out, and will the fullest use be made of the experiences gained in the wards.

The arrangement of the cases reported this year in the main follows that of the preceding year. The various cases of hydatid infestation that have occurred are again reported, and a new departure has been made in this issue of summarising previous Australian records of hydatid cysts in a certain location, following the reporting of an interesting case of this nature. Further cases of the typhus-like disease have occurred and are reported. No definitely diagnosed cases of cerebral tumors were met with.

The Committee have pleasure this year in presenting another new feature of the Archives, consisting of the inclusion of illustrations. In the present issue an excellent sketch is presented of a rare and severe type of rash due to idiosyncrasy to iodides. The Committee would like to express their appreciation of the hearty support accorded to these Archives by the Inspector-General of Hospitals and the Members of the Board of Management of the Adelaide Hospital.



## I.—HYDATID DISEASE.

During the year 1923, 12 cases of hydatid disease were operated on at the Adelaide Hospital. One of these patients died and an autopsy was held on the body, and in three other autopsies, in patients dying from other diseases, degenerating hydatid cysts were found in the liver.

Of the eleven cases operated on, six (Nos. 1, 3, 4, 5, 10, and 11) at least had cysts in the liver. In four of these the liver was apparently involved alone; daughter cysts were present in three of these and absent in one, and the contents were bile-stained in one. In Case No. 6, hydatid membrane was passed by the bowel and the patient was considered to have a cyst in the liver, but at operation this was not detected. In Case No. 10, a large retrovesical and extraperitoneal cyst was found and evacuated at operation, and at the autopsy a much degenerated cyst was found on the under surface of the liver—it seems likely, from the appearance presented by this cyst, that at one time it had ruptured with resulting seeding of the most dependant part of the abdominal cavity, the recto-vesical pouch, and that the daughter cyst so located had finally, as it grew, become buried in the subperitoneal tissues. In Case No. 11, the cyst in the liver was one of several in the abdominal cavity.

The case (No. 8) of hydatid cysts of the lung is interesting as presenting a hydro-pneumothorax with collapse of the lung. Apparently one cyst had burst into the pleural cavity, discharging its contents, including small daughter cysts, therein. In addition, through a valve-like communication with a small bronchiole, a pneumothorax with positive pressure developed.

Hydatid cysts of the spleen are rare, and the symptoms and signs associated with such a condition in Case No. 9 are probably unique. One of the cysts indented the stomach and, in consequence, with the further assistance of an adhesion across the body of the stomach to the under surface of the liver, that organ, as shown by a barium meal, presented an hour-glass appearance.

The hydatid cyst of the pelvis in Case No. 10 was of long-standing, as shown by a very thick adventitious capsule. It formed a swelling, naturally mistaken for an enlarged bladder, rising 5in. above the pubic bone. By its pressure it had given rise to great symmetrical dilatation of both ureters with double hydronephrosis.

Hydatid cysts in the subcutaneous tissues (Case No. 12) are also uncommon.

Amongst just over 700 autopsies performed at the Adelaide Hospital during the years 1920 to 1923 hydatid cysts have been the cause of death in four cases, and have been found accidentally, usually in a degenerated condition, in nine other cases in which death has been due to diseases unconnected with the cysts. During the year 1923, hydatid cysts were found at autopsy in five cases out of 208 *post-mortem* examinations. In two the cysts were directly responsible for death. In the other three cases the patients had died from other diseases, and the presence of the cysts was quite unsuspected. (In Case 5, the cyst in the liver was found accidentally during an operation for fibro-myoma of the uterus.) In these particular autopsy cases the cysts were degenerating, and no further increase in size could have occurred. As the patients who come to autopsy in the Adelaide Hospital may be looked on as representing average samples of the adult population of South Australia, it may be suggested that probably nearly 2 per cent. of the adults dying in this State are infested with hydatid cysts, and that in more than half of these cases such cysts have given rise to no obvious inconvenience. This, of course, does not imply that 2 per cent. of the population are so



infested. Unsuspected hydatid cysts are, however, unquestionably common, and it is well to bear this frequency in mind when carrying out the hydatid complement fixation test, so as not to be misled into interpreting the symptoms presented necessarily to the presence of the cyst.

Of the 12 cases of hydatid disease coming to operation, in two the diagnosis was not made beforehand, the presence of a cyst being unsuspected. Nine of the 12 cases had complement fixation tests performed on the blood. In five of these the test was positive (55 per cent.) and in the remaining four it was negative. In one of the four cases giving a negative test the cyst was obsolescent, but in the others mature and living cysts were found.

#### (1) RECURRENT HYDATID DISEASE OF THE LIVER.

(Under the care of Dr. Cudmore, Hon. Surgeon. Notes by Dr. I. B. Jose, Registrar.)

(Continuation notes of Case 6 reported in the Medical and Scientific Archives of the Adelaide Hospital, No. 1, 1921, p. 27.)

H. H., a male, *æt.* 51, was admitted to the Adelaide Hospital on August 14th, 1923, complaining of a salt taste in his mouth, attacks of coughing, shortness of breath, and a feeling of fullness under the lower ribs. These symptoms had been present for a few weeks. Since the last report he had undergone an operation for hydatid disease in the right iliac region of the abdomen in March, 1923.

On examination a swelling was found in the epigastrium extending down from the under surface of the liver for about 3in., and continuous with it. The hydatid complement fixation test was positive, eosinophiles 3.5 per cent. X-ray showed a circular opacity above the right diaphragm; also denser shadows, probably calcified areas in the healed hydatid cyst walls in the vicinity.

On August 17th an epigastric incision was made. Numerous adhesions were present in the abdominal cavity as a result of past operations. The mass previously palpated was found to be a portion of the liver, which had been distended by an hydatid cyst situated in its substance. The cyst was evacuated of its fluid through a trocar. The cyst was then opened—there were no daughter cysts present. The cyst wall was removed and the cavity sutured. It is probable that the supra-diaphragmatic opacity was due to another hydatid cyst.

#### (2) RECURRENT HYDATID DISEASE (?) OF THE LIVER.

(Under the care of Dr. Mainwaring, Hon. Surgeon. Notes by Dr. I. B. Jose, Registrar.)

E. G., a female, *æt.* 35, was admitted to the Adelaide Hospital on March 23rd complaining of a pain in the upper part of the abdomen and vomiting. These had lasted a week. The pain on a few occasions had suddenly become more severe and radiated to the left shoulder and the back of the chest. Twelve years previously she had had a series of operations for hydatid disease of the liver, and had a persistent sinus in the site of an old abdominal scar. She had had several attacks of pain since her previous operation, but had had none for the last six months. She stated that one brother had coughed up an hydatid of the lung some time ago.

On examination of the abdomen the liver could be felt 2in. below the coastal margin, but no tumor was palpable. The hydatid complement fixation test was negative. X-ray examination showed a dome-shaped bulging of the right cupola at the cardio-phrenic angle.



A differential blood count showed 3 per cent. of eosinophiles. No operation was performed. The patient is still being kept under observation.

### (3) HYDATID CYST OF THE LIVER.

*(Under the care of Dr. Mainwaring, Hon. Surgeon. Notes by Dr. I. B. Jose, Registrar.)*

J. G., a male, *æt.* 26, was admitted to the Adelaide Hospital on March 30th, 1923, complaining of an attack of severe pain in the upper abdomen. This radiated to the back, and was followed by vomiting, which did not relieve the pain. There had been no jaundice. He had had a similar attack of pain seven years ago, accompanied by jaundice, and had had many attacks since then, the longest free interval being about one year.

On examination of the abdomen, tenderness and rigidity were found in both hypochondria and the epigastrium. No tumor was palpable. The hydatid complement fixation test was positive. X-ray examination showed a rounded projection upwards of the normal shadow of the right lobe of the liver.

Laparotomy was performed. The right lobe of the liver was found depressed, enlarged, and hard. A small vertical incision was made in the right flank beneath the coastal margin and a pair of long forceps were introduced through this opening and pushed into the substance of the liver, where a large hydatid cyst was found containing many daughter cysts and bile-stained fluid. The contents and membrane were evacuated, and the cavity washed out with saline, and drained through a tube stitched to the skin.

During convalescence there was a free drainage of bile from the tube, or sinus—after the tube had been removed on the third day—for six weeks.

### (4) HYDATID CYST OF THE LIVER.

*(Under the care of Dr. Newland, Hon. Surgeon. Notes by Dr. I. B. Jose, Registrar.)*

D. R., a male, *æt.* 64, born in Mount Gambier, was admitted to the Adelaide Hospital on September 19th, 1923, complaining of a tumor in the right lumbar region, which he had noticed for a month. Four years previously he had been operated on for hydatid disease of the kidney through a lumbar incision, and he had a large post-operative hernia. The tumor was painful at times, and occasionally he passed foul-smelling urine. The tumor was of smooth outline and was apparently an hydatid cyst, arising either from the anterior surface of the kidney or the under surface of the liver. The hydatid complement fixation test was negative.

On September 22nd an incision was made over the lower end of the tumor, which was found to be an hydatid cyst arising from the under surface of the liver. The cyst was evacuated, and a large amount of clear fluid, hydatid membrane, and daughter cysts were removed. The cavity was washed out with 1 per cent. formalin and closed. Convalescence was normal.

### (5) HYDATID CYST OF THE LIVER.

Found accidentally during Laparotomy for Uterine Fibro-myoma.

*(Under the care of Dr. T. G. Wilson, Hon. Gynecologist. Notes by Dr. I. B. Jose, Registrar.)*

R. C., a female, *æt.* 43, was admitted to the Adelaide Hospital complaining of dysmenorrhœa and menorrhagia. She stated that about a



year previously she had an attack of epigastric pain, radiating to the shoulder. It came on soon after food. She had had a few attacks since, but not for several months.

During operation for supra-vaginal hysterectomy, a large hydatid cyst 6in. in diameter was found projecting from the under surface of the liver. This was marsupialized, opened, drained of many daughter cysts, the endo-cyst removed, and the cavity drained. Convalescence was normal. The hydatid complement fixation test was not performed.

#### (6) HYDATID CYST OF THE LIVER (?).

*(Under the care of Dr. Cudmore, Hon. Surgeon. Notes by Dr. I. B. Jose, Registrar.)*

E. V., a female, *æt.* 39, was admitted to the Adelaide Hospital on October 25th, 1922, complaining of epigastric pain, which was of the nature of a colic, and frequent vomiting. A diagnosis was made of gallstones, and on October 27th laparotomy was performed, and the gall bladder was found to contain biliary sand. No large stones were present. Cholecystectomy was performed. Her symptoms were relieved, and she was discharged well on November 19th, 1922.

On January 27th, 1923, she was readmitted with a return of epigastric pain of the same nature as before, and accompanied by vomiting. This was relieved by medical treatment, and she was again discharged on March 1st.

On April 14th she was readmitted, having had another severe attack of pain in the upper abdomen and between the shoulder blades, accompanied by vomiting and slight jaundice. She had also noticed a swelling in the epigastrium. She stated that since last leaving hospital she had not been well, and had suffered from occasional attacks of less severe pain; also that she had noticed cysts in her motions occasionally for about two years. (This she had not mentioned before.)

On examination of the abdomen the liver was found to extend downward into the epigastrium to within 2in. of the umbilicus. Her blood showed a weak positive complement fixation test, and portions of hydatid membrane and several small daughter cysts were found in the fæces. Vomiting and the attacks of pain continued, with an occasional rigor. On April 20th another laparotomy was performed and the right lobe of the liver was found greatly enlarged. It was explored with a trocar and cannula, and although the point of the trocar appeared to enter a cavity, no fluid or other material was obtained. Next day a portion of hydatid membrane was passed with an enema.

Convalescence from the operation was normal, and she was discharged on June 22nd, 1923.

#### (7) RECURRENT HYDATID DISEASE OF THE ABDOMEN.

*(Under the care of Dr. Newland, Hon. Surgeon. Notes by Dr. I. B. Jose, Registrar.)*

E. H., a female, *æt.* 49, was admitted to the Adelaide Hospital on February 19th, 1923, complaining of a discharging sinus, which had followed on an operation for hydatid disease 10 months before. About six weeks before admission two pieces of membrane (probably hydatid) were discharged from the sinus, prior to which she had been vomiting frequently after food. She had also previously had an operation for hydatid disease in 1921.



On examination a tumor was felt below the right costal margin, passing down to within an inch of the umbilicus and continuous above with the liver. This was tender on palpation.

On February 28th laparotomy was performed by Dr. Newland. Just prior to making the incision, as the tumor was being palpated it was felt to burst. On opening the abdomen, a burst hydatid cyst was found in the transverse meso-colon. This was removed entirely, and the abdominal cavity cleaned out. The old sinus was excised and a calcareous plaque removed from the inner extremity of the sinus.

Convalescence was complicated by the development of a purulent pleurisy on the right side. On March 4th it required drainage. The patient was discharged on May 10th, 1923, with a small sinus leading into the pleural cavity. The hydatid complement fixation test was not carried out.

#### (8) HYDATID CYSTS OF THE LUNG WITH HYDRO-PNEUMO-THORAX.

(Under the care of Dr. Hone, Hon. Physician, and Dr. Cudmore, Hon. Surgeon. Notes by Dr. I. B. Jose, Registrar.)

R. L., a male, *æ*t. 22, a dairy farmer, born in Penola, South Australia, was admitted to the Adelaide Hospital under the care of Dr. Hone, on October 3rd, 1923. The onset of his illness had been 12 months previously when he had had a sudden fit of coughing, and had brought up a small quantity of watery fluid, but had not noticed any skins. He returned to work in a few weeks, his only disability being a slight cough and an occasional soreness in the chest and back. On July 23rd he had to discontinue work on account of increasing breathlessness. He also noticed that he coughed whenever he moved about, and that he had a sensation of fluid splashing about in his chest.

On examination the patient had no apparent distress. Examination of the chest showed a fulness of the whole of the right side, which moved less than the left on respiration, and the lower intercostal spaces on the right side bulged. The cardiac impulse was felt in the sixth space in the left anterior axillary line. His right chest showed the signs of a total pneumo-thorax. The left lung was normal.

X-ray examination of the chest (Plate I.) on October 9th showed a hydro-pneumo-thorax on the right side with a quantity of fluid present at the base, the lung being collapsed against the mediastinum, and a large circular mass in the lower part of the right thorax attached to the mediastinum and lying above the diaphragm. The hydatid complement fixation test was positive. No tubercle bacilli were found in the sputum. The Wassermann reaction was negative.

On October 6th Dr. Cudmore made an incision in the mid-axillary line, and resected sub-periosteally 6in. of the sixth, seventh, and eighth ribs. On incision of the pleura, air escaped under positive pressure. A large hydatid cyst was seen in the right lower lobe, and above this a small cavity in the collapsed lung, where apparently another cyst had lodged and had ruptured into the pleural cavity, causing the latter to contain a fair quantity of blood-stained fluid and small free hydatid daughter cysts. The large cyst was brought to the surface, incised, and the cyst wall removed. The pleural cavity was cleaned out, the wound and the chest wall partly opened and a drainage tube inserted. During convalescence he discharged several portions of hydatid membrane and daughter cysts.

On November 16th an X-ray of the chest showed that the pneumo-thorax was still present. The site of the ruptured cyst apparently was connected to a small bronchial tube, and by means of a valve action a pneumo-thorax under positive pressure had developed.



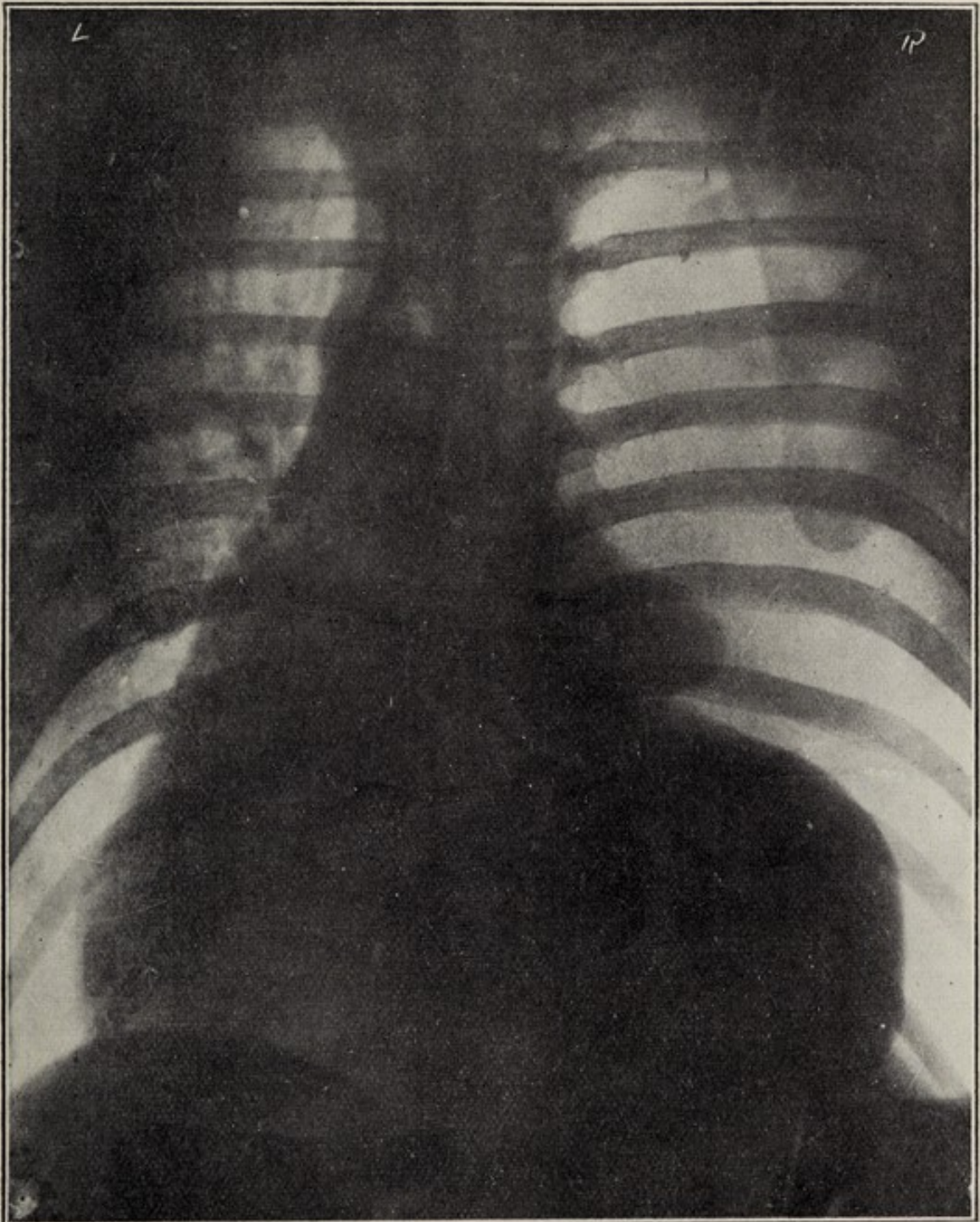



Plate I.

Case 8—Hydatid Cysts of the Lung, with Hydro-pneumo-thorax.:

*To face p. 8, Sup.]*





## (9) HYDATID CYSTS OF THE SPLEEN.

(Under the care of Dr. Johnson, Hon. Physician, and Dr. Simpson Newland, Hon. Surgeon. Notes by Dr. I. B. Jose, Registrar.)

A. McN., a female, *æt.* 39, was admitted to the Adelaide Hospital on August 14th, 1923. She complained of attacks of pain in the left epigastric region, gnawing in character, and coming on between a quarter to two hours after food. These pains had been severe and more frequent for the last six months, and were associated with vomiting at intervals. The attacks had begun 20 years ago, and had occurred at intervals of a few months. She also, on three occasions at long intervals, had had hæmatemeses. She had not lost weight.

On examination of the abdomen a rounded tumor was felt in the left hypo-chondrium, which moved on respiration, projected about 2in. below the left costal margin, and was smooth and rounded in outline below. The splenic dullness was not enlarged. The Wassermann reaction was negative. The blood count was normal, and the eosinophiles 1.6 per cent. The hydatid complement fixation test was negative. A barium meal and X-ray examination showed an apparent hour-glass condition of the stomach. The acidity of the gastric juice was within normal limits, as shown by a fractional test meal. A preoperative diagnosis was made of a gastric ulcer. From the character of the swelling an hydatid cyst, growing probably from the under surface of the left lobe of the liver, was suspected.

On August 31st, 1923, laparotomy, through a left paracostal incision, was performed and the spleen was found to contain several small hydatid cysts, and one larger cyst projecting from its anterior border, pressing into the centre of the greater curvature of the stomach and indenting it, with an adhesion across the body of the stomach to the under surface of the liver. Splenectomy was performed. Another obsolescent hydatid cyst was found in the gastro-splenic omentum and was removed.

Convalescence was normal. A further hydatid complement fixation test was negative.

## (10) HYDATID DISEASE OF THE PELVIS.

(Under the care of Dr. Cudmore, Hon. Surgeon. Notes by Dr. Webb, House Surgeon.)

J. B., a male, *æt.* 38, was admitted to the Adelaide Hospital on August 20th, 1923, suffering from difficulty of micturition. His history was as follows:—His illness had commenced four and a half weeks before with diarrhœa and vomiting. The diarrhœa had been marked—12 to 14 motions a day—at the beginning of his illness, but the intensity had gradually lessened till, on admission, it had cleared up. The vomiting, however, persisted throughout. The patient was pale and looked very ill, but till the onset of his present illness he had been in fairly good health. Examination revealed the presence of a median hypo-gastric tumor. The upper border of this was rounded and felt hard, and the shape was somewhat pyriform. It extended up from the symphysis pubis for 5in. On the assumption that this tumor was the greatly distended bladder, an attempt was made to catheterise the patient. This, however, ended in failure, persistent obstruction being encountered both with a rubber and a metal catheter at a point 7½in. from the external meatus. Treatment with hot packs and purgatives rendered the patient more comfortable, but did not lessen the size of the tumor in spite of the fact that the patient said he was passing his urine more easily. He also suffered from severe headaches, which were relieved by free epistaxis. The urine was alkaline on admission. Two days later blood appeared



for the first time, and on the 24th the patient passed 10ozs. of frankly blood-stained urine. The laboratory examination of the urine revealed the presence of many blood and pus cells, and also an abundant growth of bacteria. The blood-urea nitrogen was much above the normal, being 50 milligrams per 100 c.c. of blood.

On the 24th an operation was performed under ether anaesthesia. First a No. 12 metal catheter was passed quite easily. In spite of the withdrawal of a few ounces of turbid slightly blood-tinged urine, the swelling persisted in the hypogastrium. This was most easily felt just below and to the left of the umbilicus, was tense, and did not move with respiration. A median subumbilical incision was then made, the left rectus muscle was retracted and its posterior sheath incised. The peritoneum, which had been pushed up above the swelling, was opened and then closed again. Next the attenuated upper pole of the bladder was identified. After this, a small incision was made into the swelling and a few compressed daughter cysts were seen. The opening was then enlarged and many compressed cysts evacuated, followed by 10 or 12 cysts which were of the size of bantam's eggs. The cavity, which could be seen to be entirely extraperitoneal and retrovesical, was then flushed out and the mother cyst and remainder of the daughter cysts evacuated. The cavity thus resulting was drained and the wound closed in layers *seriatim*. The patient recovered from the immediate post-operative shock, but gradually became weaker and weaker till finally he died next day in a state of coma. After the operation he passed several ounces of blood *per urethram*, but this was not sufficient to account for his collapse. The death of the patient appeared to be due to uræmia analogous to the condition occurring after prostatectomy.

Permission was granted for a limited *post-mortem* examination of which the following account is extracted from the notes (Autopsy No. 130/23):—The bladder wall was very thin and the viscus was distended with blood-stained urine. Lying posterior to and on the left side of the bladder was a typical hydatid cyst wall. This was firmly adherent to the bladder and extended up to the level of the umbilicus. To the posterior surface of the cyst were adherent a loop of ileum on the right side, and on the left side some 3in. of pelvic colon. Corresponding to the portions of gut adherent there was an area of mucous membrane much inflamed. The ureters were greatly dilated, coiled and convoluted, and were similar in appearance to the ileum. The kidneys presented the picture of chronic hydronephrosis, the cortex being pale and narrowed, the pelves and calyces much dilated. On the diaphragmatic surface of the right lobe of the liver was a flattened hydatid cyst 3in. in diameter. There was no evidence of any stricture of the urethra; failure to pass the catheter before anaesthetisation was apparently due to spasm excited by tenderness of the urethral mucosa. The cause of the tenderness was an inflammatory condition excited by the pressure of the cyst upon the urethra.

#### (11) HYDATID CYSTS OF THE PELVIS, LIVER, AND ABDOMINAL CAVITY.

(Under the care of Dr. Newland, Hon. Surgeon. Notes by Dr. I. B. Jose, Registrar.)

J. McL., a male, *æt.* 30, was admitted to the Adelaide Hospital on October 15th, 1923, complaining of a lump in the abdomen, which had been present for two months to his knowledge. He had discovered it after a severe attack of vomiting and pain in the lower abdomen. He was habitually constipated, but had never passed any blood *per rectum*.



On examination there was felt a swelling in the hypogastrium, extending up from the pelvis. This showed fluctuation, was slightly movable, and did not disappear on emptying the bladder. In diameter it was 2in. Rectal examination did not reveal any large mass in the pelvis. Another larger, freely movable cystic swelling was also felt in the abdominal cavity. The hydatid complement fixation test was positive. A differential blood examination showed 4 per cent. of eosinophiles.

On October 2nd laparotomy was performed through a subumbilical incision, and immediately an hydatid cyst, arising from the omentum and connected by adhesions to the small intestine, presented. This was 4in. in diameter. Below this, between the rectal and the bladder walls, another cyst could be felt. The first cyst was removed. The second cyst was incised, evacuated of its membrane and several daughter cysts, and the cavity washed out with 1 per cent. formalin solution and closed with deep sutures. The abdominal cavity was explored further, and a small hydatid cyst could be felt in the Spigelian lobe of the liver, and several others on the posterior abdominal wall to the right of the vertebral column. These formed a chain extending from the liver to the pelvis, the largest cyst being about 1½in. in diameter. Convalescence from the operation was normal.

#### (12) OBSOLETE HYDATID CYST OF THE SUBCUTANEOUS TISSUES OF THE BACK.

*(Under the care of Dr. Corbin, Hon. Assistant Surgeon. Notes by Dr. I. B. Jose, Registrar.)*

D., a male, *æt.* 58, was admitted to the Adelaide Hospital on September 4th, 1923, suffering with hæmorrhoids. On examination of the back a small round cystic swelling about 1in. in diameter was found in the left lumbar region over the erector spinæ muscle, just below the level of the twelfth rib. This swelling was fixed to the muscle and not connected to the skin. It was excised and found to be a small obsolete hydatid cyst. The hydatid complement fixation test was negative.

#### Hydatid Cysts Found Accidentally during Autopsies.

*(Reported by Dr. J. B. Cleland, Hon. Pathologist.)*

#### (13) A DEGENERATED HYDATID CYST OF THE LIVER.

*Autopsy No. 17/23.*—M. G., a woman, *æt.* 73, who died from heart failure secondary to a comminuted fracture of the femur, was found to have in the right lobe of the liver, about 2in. from the right edge and just in front of the diaphragmatic attachment, a projecting boss which, on incision, was found to contain folded bile-stained hydatid membrane. The cyst was about 2in. in diameter. There was some inspissated bile on the posterior wall of the cavity. The wall showed a tendency to calcification. A loculus in front of the cyst showed a much thickened caseous bile-stained wall about a quarter of an inch thick. Attached to the diaphragm in front of the liver was a pea-sized calcified nodule, probably also an old hydatid cyst. The rest of the liver was yellowish and fatty, but fairly firm.

#### (14) DEGENERATED HYDATID CYST OF THE LIVER.

During an autopsy (No. 96/23) on a male, *æt.* 51, who died on July 2nd from failure of an hypertrophied heart, secondary to chronic interstitial nephritis, an old hydatid cyst 1½in. in diameter and containing degenerated hydatid membrane was found in the right lobe of the liver, 2in. from its junction with the left lobe and reaching the surface of the upper convex part.



## (15) OBSOLESCING HYDATID CYST OF THE LIVER.

The patient, a woman, *æt.* 58, died on October 28th as a result of malignant cyst-adenomata of the ovaries which had extended to the peritoneal cavity and given rise to ascites. At the autopsy (No. 170/23) it was found that the growth had involved the tissues between the stomach and transverse colon, and that there were malignant plaques on the peritoneal coat of the liver and malignant deposits in the hilum of the liver. Contrasting with the malignant growths was an obsolescing hydatid cyst of the right lobe on its under aspect with an adventitious capsule a quarter of an inch thick. The weight of the liver was 63½ ozs.

## REFERENCES TO RECORDS OF AUSTRALIAN CASES OF HYDATID CYSTS AFFECTING THE PELVIS AND URINARY ORGANS.

By J. BURTON CLELAND, M.D., Hon. Pathologist, and A. L. WEBB, M.B., B.S., House Surgeon.

## Abbreviations—

*A.M.G.*—*Australasian Medical Gazette.*

*A.M.J.*—*Australian Medical Journal.*

*I.M.C.*—*Proceedings of Intercolonial Medical Congresses.*

*I.M.J.*—*Intercolonial Medical Journal.*

*I.Q.J.*—*Intercolonial Quarterly Journal of Medicine and Surgery.*

*M.J. of A.*—*The Medical Journal of Australia.*

*N.S.W. Med. Gazette*—*New South Wales Medical Gazette.*

1862, 1863.—Mr. S. J. Cooper (*A.M.J.*, VII., p. 279; VIII., p. 122) reported to the Medical Society of Victoria having had two cases of large hydatid cysts affecting both kidneys. There seems some doubt, however, as to the correctness of the diagnoses, and the cysts were possibly simple ones. The *post-mortem* description of one of the cases states that "in both kidneys a large hydatid cyst was found," the patient also having albuminuria and dying from coma, probably uræmic.

1865.—Mr. MacGillivray (*A.M.J.*, X., p. 244) described a case of hydatid disease of the pelvis in a man, *æt.* 28. There was a fluctuating tumor above the pubes and bulging into the rectum. An exploratory examination by trocar led to the drawing off of 8ozs. to 10ozs. of clear fluid. The cyst refilled and was tapped again later with a hydrocele trocar. This was followed by a considerable return of the swelling, which finally disappeared and the patient was discharged cured.

Dr. Martin (*A.M.J.*, X., p. 289) reported a case in which hydatid cysts were present in the lung, liver, and kidneys—one being present in each kidney.

1868.—H. W. Maunsell (*A.M.J.*, XIII., p. 183) reported a case of a boy, *æt.* 12, who was admitted to the Melbourne Hospital with retention of urine, and who, after much difficulty, was catheterised. There was enormous distension of the bladder, and yet only a few ounces of urine were drawn off by catheter. The patient died, and the *post-mortem* examination disclosed an hydatid cyst of the lung which had ruptured into the pleura, a cyst of the liver, and in the pelvis a large hydatid cyst which had pushed up the bladder and had given rise to much dilatation of the ureters.

1869.—G. Hogarth Pringle, of Parramatta (*A.M.J.*, XIV., p. 136), described a large tumor affecting the left sacro-iliac synchondrosis (gluteal region) in a married woman of 26. It had been noticed for six years. It was dissected out, and weighed 14lbs. The capsule



was dense, being half an inch in thickness, and the cavity was full of hydatid cysts ranging from the size of a pin's head to that of a small orange.

1872.—J. J. Hill's case (*N.S.W. Med. Gazette*, Jan.) of hydatids of the uterus was probably an example of hydatidiform mole.

1879.—Dr. Allen before the Medical Society of Victoria (*A.M.J.*, I., pp. 397 and 478) detailed a case of an hydatid cyst 4in. in diameter in the pelvic cavity that had opened into the right Fallopian tube.

J. R. Thomson (*A.M.J.*, I., p. 425) described a case of an hydatid cyst rupturing into the bladder. A tumor was detected which was hard, rounded, nodulated, tense and apparently non-fluctuating, and fixed to the bladder. The patient had pain on walking. The urine was normal. The cyst ruptured during examination on using a fine trocar, the tumor disappearing. Hooklets were found in the urine. Three days later the patient had an itchy rash.

1880.—H. S. Wood (*A.M.J.*, II., p. 38) reported a case under Mr. Fitzgerald of renal hydatid in a married woman, *æt.* 64, who 17 months previously had had an hydatid cyst the size of a hen's egg removed from her left thigh. She complained of the presence of a tumor in the left side of her abdomen, gradually increasing in size, but giving rise to no pain or detriment to health. The diagnosis of cystic tumor of the kidney, probably hydatid, was made. This was aspirated, and 37ozs. of colorless hydatid fluid of specific gravity 1006, with no albumin but with clusters of scolices, were removed. The patient was discharged well.

Dr. Williams (*A.M.J.*, II., p. 447) exhibited before the Medical Society of Victoria specimens showing several hydatid cysts of the liver, the patient also having one large one in the kidney, and several cavities apparently of hydatid origin in the left lung.

W. E. L. Hearn, of Inglewood Hospital (*A.M.J.*, N.S., II., p. 59), described an hydatid cyst attached to the bladder. A farmer had been thrown from his horse and died two days later from peritonitis. A collapsed cyst the size of a turkey's egg was found attached to the bladder, but there were none elsewhere. The bladder itself was not ruptured.

1881.—F. J. Newman (*A.M.J.*, III., p. 8) reported a case of hydatid cyst of the bladder which was under the care of E. M. James. The patient, *æt.* 44, had been admitted to the Melbourne Hospital in August, 1879, complaining of a small lump on the left side in the lower part of the abdomen, which had gradually increased in size. On examination a smooth, firm semi-solid tumor was found on the left side of the hypogastrium, which appeared to arise in a curved direction from the pelvis. There was difficulty in passing a sound into the bladder. Later, during manipulation, the tumor disappeared and the patient passed a large quantity of pale odourless fluid *per urethram*. This was followed on the fourth day by an itchy roseolar rash. He was readmitted in December, 1880, stating that the swelling had reappeared and was now causing severe pain in the legs and increased frequency of micturition. There was a well-defined tumor in the lower part of the umbilical and left iliac regions. By means of an aspirator 20ozs. of clear transparent fluid were drawn off by a puncture some 2in. above the pubes. This was followed by an attack of pain and tenderness in the lower part of the abdomen, a febrile reaction, and the appearance of a similar rash. The fluid removed had a specific gravity of 1010 and had an abundance of chlorides, but no trace of hydatid membrane was found. The patient recovered and was discharged free from pain and uneasiness.

S. Zichy-Woinarski, of Clunes (*A.M.J.*, III., p. 494), describes a case of hydatid cyst of the bladder with peritonitis and death in a



patient *æt.* 23. The illness had commenced with pains of a dull aching and irregular character about the region of the bladder, with intermittent marked dysuria; there was no pain on defaecation. There were also, at the onset, shooting pains down the thighs and legs. The patient was treated with medicine till retention of urine called for catheterisation, which was unsuccessful. The patient became worse. There was great feverishness and almost constant vomiting, swelling of the legs, and intense pain about the bladder. On admission to the Clunes Hospital the bladder was found distended almost to the umbilicus, and the abdomen was very tender. Attempts to pass a catheter failed, and by the rectum a hard semi-fluctuant tumor could be felt extending directly from the prostate upwards and backwards. On aspirating the bladder 2½ pints of dark urine were drawn off, followed by 6 to 8 drachms of clear transparent fluid. The patient was easier for a while, but gradually the pain increased, the temperature rose, the pulse became very feeble and rapid, and death ensued. At the *post-mortem* examination there was evidence of peritonitis and apparently of old-standing inflammation of the pelvic cellular tissue. The ureters were dilated and the kidneys congested. At the under and posterior aspect of the bladder was found a ruptured cyst 3in. x 2in. in extent, adherent to the bladder, and extending directly backwards from the prostate, from which it was with difficulty separated. Examination showed the presence of lamination in the cyst wall and evidence of hooklets in the fluid.

Dr. Jamieson (*A.M.G.*, Dec., p. 45) detailed a case of hydatid disease of the pelvis in a single woman, *æt.* 31. For 13 years she had had a tumor in the left hypogastrium which had grown in an irregular way, each increase in size being accompanied by severe pain. When seen by Dr. Jamieson the pain was constant and she had had several attacks of retention of urine and frequent bouts of vomiting. A tumor was found filling the whole of the left side and reaching almost to the umbilicus. A vaginal examination revealed a thin-walled fluctuant swelling which had displaced the uterus upwards and forwards. This was tapped by a fine trocar through the vagina, and nearly a pint of fluid containing scolices was drawn off. After a month she had improved in health, and all that she complained of was pain at the end of micturition.

In the same issue Mr. Whitcombe, of Ballarat, described a pelvic hydatid cyst which somewhat simulated pregnancy, except for the history that it had arisen from the right side. Five pints of fluid were removed by trocar and canula, and the patient ultimately passed the cyst *per rectum*.

1882.—Dr. Allen (*A.M.J.*, IV., p. 160) described a large hydatid cyst of the pelvic cavity situated between the bladder and the uterus. The cyst lay on the anterior surface of the uterus, which was thoroughly retroverted. There was a slight filmy adhesion of lymph to the peritoneum. Scolices were seen in the cyst wall. The patient was admitted moribund from uræmia, the kidneys being small, red, and granular.

1884.—J. Davies Thomas' monograph, entitled "Hydatid Disease with Special Reference to its Prevalence in Australia," Adelaide, E. Spiller, Government Printer, appeared containing general references based chiefly on Australian experience to hydatids of the pelvis and urinary organs.

1889.—T. C. Fisher (*I.M.C.*, second session, Melbourne, p. 618) described an hydatid cyst of the right kidney. The patient had nausea, vomiting, and difficulty in micturition, with slight occasional rigors. An attempt at catheterisation failed. The next day there was nocturnal delirium, a sub-normal temperature, vomiting, occasional rigors, and the passage of scanty urine. The patient gradually



became comatose, and died on the fourth day after admission. At the autopsy there was evidence of peritonitis. The left kidney was large and congested. The right kidney appeared to be absent. The upper part of this ureter was converted into a narrow cord, which appeared to come from a mass of peri-renal fat. Embodied in the fat was a cyst the size of a walnut, apparently a degenerated cyst. A collapsed hydatid cyst was found in the bladder. Evidently the kidney had been destroyed by the cyst, as the shrunken condition of the upper part of the ureter pointed to its previous existence. The bladder was evidently affected by way of the ureter, then followed the urinary symptoms, culminating in uræmia, peritonitis, and death.

1890.—Dr. A. Shewen (*A.M.G.*, March, p. 134) described a case of an hydatid cyst of the pelvis in a girl, *æt.* 20. She had been attending hospital on account of fits, and was found to have a large tumor of the pelvis, enlargement of the liver, and a small tumor beneath the navel. She suffered from incontinence of urine. On incising the pelvic mass through the vagina, about 3 pints of horribly stinking fluid containing small cysts, old cyst walls, and pus was evacuated, and a large drainage tube inserted. Recovery was uneventful. Dr. Shewen also described an hydatid of the kidney, again in a girl *æt.* 20, who had had a tumor on the left side for a long while. Preliminary aspiration revealed scolices in the fluid obtained, and a few days later the cyst was drained by an incision in the loin.

1891.—Dr. (later Sir) James Graham, of Sydney, published "Hydatid Disease in its Clinical Aspects," Young J. Pentland, Edinburgh and London. Several pelvic and renal cases are dealt with. Plate XXI. shows very numerous minute hydatid cysts in the serous pouches behind and in front of the uterus, extensive peritoneal seeding having followed tapping of an hydatid cyst of the liver three months before. Plate XXIV., B, represents a cyst on the serous surface of the kidney from a case of multiple hydatids (p. 124). In Plate XXIV., C, is seen an hydatid cyst replacing the suprarenal capsule in the case of a patient, *æt.* 35, who had some symptoms suggestive of Addison's disease, and was found also to have a small cyst in the liver and numerous cysts in the peritoneum (p. 126). Plate XXXIV. shows two large cysts in the right broad ligament and two other cysts filled with purulent contents growing from the upper surface of the fundus of the uterus in a patient who died after an operation for the removal of a large hydatid cyst of the liver (p. 137).

1892.—Professor Watson (*A.M.G.*, September, p. 353), of Adelaide, exhibited the right kidney of a man who had died of nephritis four weeks after evacuation of pus and daughter cysts by lumbar incision for an hydatid cyst in his kidney. Professor Watson (*A.M.G.*, December, p. 437) also exhibited specimens of incipient hydatid disease involving the spleen and kidneys.

1893.—Dr. F. J. T. Sawkins, of Sydney (*A.M.G.*, November, p. 363), detailed two cases of pelvic hydatids causing retention of urine. The first patient, admitted suffering from retention of urine with passive overflow, yielded on catheterisation a large amount of urine, and rectal examination showed a large swelling that appeared to be a greatly enlarged prostate. The patient died, and at the autopsy a large hydatid cyst containing over a pint of fluid and daughter cysts was found attached in front to the base of the bladder and behind to the cavity of the sacrum and wall of the rectum.

The second patient was a male, *æt.* 39, who had had several attacks of retention of urine and had frequency of micturition. There was no history of gonorrhœa. Under an anæsthetic a large cystic swelling was disclosed by bimanual examination. After drawing off the urine an operation was performed, an hydatid cyst being opened, the



endocyst removed, and a drainage tube inserted. The patient made an uninterrupted recovery. In commenting on his cases, Dr. Sawkins states that as to the mode of origin Torgett says that these cysts originate in the plane between the muscular coat of the bladder and the sheath of the rectovesical fascia. This fascia, besides enclosing the prostate and the lower portion of the bladder, forms the sheath for the vesiculæ seminales. Hence, gradual enlargement of the cyst dissects off from the bladder the vesiculæ which are thereafter found in connection with the walls of the cyst, this being the exact condition found at the *post-mortem* examination on case No. 1.

Dr. Lendon (*A.M.G.*, Dec., p. 410) detailed the spontaneous cure of a peritoneal hydatid found in the pelvis of a woman who had died of a suppurating hydatid cyst of the liver.

1894.—In this year Dr. A. A. Lendon edited the second volume of J. Davies Thomas's "Hydatid Disease," the publishers being L. Bruch, of Sydney, and Bailliere, Tindall, & Cox, of London.

Dr. W. Gardner (*I.Q.J. of Med. and Surg.*, I., p. 137) wrote a valuable paper giving the symptoms of hydatid cysts of the kidneys, and also a list of cases, all of which had affected the left kidney. He also referred to three specimens of hydatid cysts of the kidney in the museum of the University of Melbourne, one of which was unruptured, in the second the cyst had been passed by ureter and urethra, and in the third case there was a large retrogressing hydatid cyst of the left kidney.

Dr. S. Connor, of Coleraine, V. (*I.Q.J. of Med. and Surg.*, I., No. 3, Nov., p. 264), gives an account of an hydatid cyst of the kidney with spontaneous evacuation by the urethra of membrane and a calculus.

1895.—W. Anstey Giles (*I.Q.J. of Med. and Surg.*, I., p. 355) mentions a case in which a marble-sized hydatid cyst of the right kidney was discovered at autopsy, its presence not being suspected during life.

1897.—Dr. R. Humphrey Marten, of Adelaide (*I.M.J.*, II., p. 544), described a case of pelvic hydatids removed through the peritoneum. The patient had been operated upon three times, viz., in 1893, 1895, and 1896, for hydatid disease of the liver and abdomen. On the latter occasion an hydatid cyst in the hypogastric region had been aspirated to render possible the passage of a catheter to relieve an urgently distended bladder. It was thought that aspiration had cured this condition, but over a year later he returned complaining of a painful swelling in the lower part of the abdomen and constant dribbling of urine. A discharging sinus was present over the site of the left hepatic hydatid and a rounded hypogastric swelling (about the size of a foetal head at term) rose up from the pelvis, and attached to this and situated at the junction of the left lumbar and hypogastric regions was a second cyst (about as large as a hen's egg) with several smaller cysts around (about as big as marbles). Rectal examination disclosed the presence of cystic swellings bulging into the rectum and apparently continuous with the abdominal cysts. Two days later the patient passed a collapsed cyst *per urethram*. Three days after this an operation was performed. An attempt to reach the cyst through the abdominal wall was abandoned on account of the bladder blocking the approach to the cyst by this route. Perineal section was then performed, and the cyst opened and drained of an enormous number of daughter cysts, and the mother cyst washed out. A glass drainage tube was inserted for 21 days. In a note by the author, he refers to a similar case under the care of Dr. B. Poulton, in which both anterior and posterior walls of the bladder were traversed before reaching the cyst. He preferred the perineal route, because of the better drainage afforded and also because in males pelvic hydatids appear to originate in the neighbourhood of the



prostate and are entirely extraperitoneal, and by this route not only is the peritoneum not opened, but also there is better possibility of freeing the prostate of cysts.

Dr. J. L. Beeston (*A.M.G.*, March, p. 121) detailed a case of hydatid disease of the pelvis with abdominal section. The patient, a woman, had complained of retention of urine at various intervals during the past 12 months. After catheterisation a tumor was palpated in the right iliac fossa slightly to the right of the mid-line. This was thought to be the uterus. Vaginal examination revealed an elastic swelling, free from tenderness, filling the whole of Douglas's pouch. The only symptom complained of was a sense of dragging in the pelvis after standing for some time. Her general health was good. Abdominal section was performed, and the uterus and appendages were found pushed forward. A large globular swelling about the size of a foetal head was discovered between the uterus and the rectum. On attempting to enucleate it, the cyst burst and revealed its nature. The patient recovered.

1898.—Dr. R. A. Stirling, of Melbourne (*I.M.J.*, III., pp. 17 and 18), referred to a case of an hydatid cyst attached to the bladder, which had freely discharged through that viscus. He mentions also another case of pelvic hydatid disease of uncertain origin.

Dr. Mollison (*I.M.J.*, III., p. 685) showed, before the Medical Society of Victoria, a large hydatid cyst of the kidney removed *post-mortem* by Dr. Ritchie, of Horsham. The cyst occupied almost the whole of the kidney substance, one very small piece of the cortex alone remaining at one end. It contained a mother cyst and several small daughter cysts that communicated with the renal pelvis by an aperture not quite as large as a sixpence. The patient had passed several small cysts in the urine shortly before death.

Dr. (now Sir) J. C. Verco (*A.M.G.*, December, p. 518) described a case of a pelvic hydatid removed by perineal incision. The patient was an enginedriver, *æt.* 41, who had suffered for about three weeks with pain inside the left iliac bone. It came on when he wanted to have his bowels moved and disappeared when they had acted. Finally the pain became continuous, and the stools loose and contained much mucus. The temperature was 101° F. A lump was present in the hypogastrium to the left of the middle line, rising not quite three fingers' breadth above the symphysis. *Per rectum* a spherical mass was palpable in the upper part of the pelvis, occupying its left front and projecting into the rectum and pointing at one part as if about to burst. The patient was sent into hospital, and a silver catheter was easily passed into the bladder, but with distinct deviation to the right. A large hypodermic needle was inserted into the projecting tumor in the bowel to ascertain its nature. A drachm or so of hydatid fluid was withdrawn. An incision was then made in the perinæum, as for left lateral lithotomy, and the cyst exposed and removed. There were no daughter cysts. The patient recovered.

1899.—W. Moore (*I.M.C.*, fifth session, Brisbane, p. 185) described a case of retro-peritoneal hydatids extending into the pelvis with a large cyst of the right lobe of the liver. The patient had noticed an abdominal swelling for four months, and the urine had become pale and more abundant. There was a rounded swelling on the right side of the abdomen extending from the rib margin into the right iliac fossa and moving on respiration, and a large irregularly rounded elastic mass in the lower part of the abdomen, especially on the left side, extending deeply into the pelvis in front and to the left of the rectum and pressing the bladder downwards. The pulse was weak and rapid, and she was suffering from nausea and vomiting. The specific gravity of the urine was low with occasional traces of albumin and hyaline casts. The cyst was drained through an



abdominal incision, but the patient gradually became uræmic and died 10 days after operation.

Professor Watson, of Adelaide (*A.M.G.*, August, p. 344), described the burrowing or dry form of utero-pelvic hydatid disease from a multipara, *æt.* 53. The cyst had pushed up the bladder, absorbed the cervix, and effaced the left broad ligament. Another fist-sized tumor stuffed with grape-skin vesicles was adherent to the abdominal wall, sigmoid flexure, ileum and omentum, with which latter it had formed a *caput medusæ*. The uterus and incorporated cyst were removed from the pelvis with the exception of a sacculated cup of leather-like capsule, the removal of which would have imperilled the left ureter and rectum.

1900.—Dr. Bennett, of Ballarat (*A.M.G.*, November, p. 481), showed a specimen of an hydatid cyst of the kidney.

1901.—Dr. Cameron, of Queensland (*A.M.G.*, June, p. 254), gave notes on a case of hydatid disease in the pelvic region. The patient was a stoutish girl, *æt.* 22, who complained of retention of urine. She had had difficulty in micturition for over two years, but had not had retention before. On attempting to pass a catheter it was found that the vaginal passage went straight up behind the pubes with consequent difficulty in passing the catheter. The pelvis was occupied by a large swelling which rose to within 2 in. of the umbilicus, was slightly more prominent on the left side, and felt almost solid. Douglas's pouch was distended by an obviously tense fluid part of the swelling which had bulged the vagina forwards. This could be plainly felt from the rectum as a fluctuating swelling. Another swelling occupied the splenic region. About six weeks after tapping the large swelling by the vagina, the abdomen was opened and the specimen exhibited was removed without any difficulty. It was apparently in the omentum. The shape was peculiar. The sac wall was very thin, and a few smaller cysts could be seen at the small end. A third smaller lump was also removed from its peritoneal investment. The author pointed out that, according to Davies Thomas, cysts of the peritoneum, omentum, and mesentery only provide about 1.4 per cent. out of 1,900 cases of hydatid disease.

Dr. Bennett (*A.M.G.*, November, p. 498), at a meeting of the Ballarat District Branch of the B.M.A., showed a multilocular hydatid cyst which had occupied the greater part of the pelvic cavity.

Dr. Llewellyn Lambert, of Melbourne (*I.M.J.*, VI., p. 547), reported a case under the care of Dr. R. A. Stirling, in which typhoid fever was complicated by an hydatid cyst of the pelvis, and acute appendicitis was simulated. The patient had been admitted to the Melbourne Hospital, and the history was one of illness commencing with headache and sleeplessness, followed in three days by severe abdominal pain, which two days later settled down in the right iliac fossa. Vomiting and epistaxis occurred about this time. On the ninth day of his illness, on an operation being performed for the supposed appendiceal disease, a smooth rounded tumor was found extending from the lower part of the iliac fossa into the pelvis behind the bladder, to which it appeared to be attached. This was incised and drained of a quantity of fluid and many daughter cysts; and the edges sutured to the margins of the parietal wound. The appendix was quite normal. After the operation a steady rise of temperature persisted, and ultimately the condition was diagnosed as typhoid fever, this being confirmed by Widal's reaction. Convalescence was uneventful.

1903.—Dr. Saw, of Perth (*A.M.G.*, June, p. 265), recorded the case of an hydatid cyst below and behind the urinary bladder, which was removed through the bladder, the patient making an uneventful recovery.



1904.—Dr. R. Dick (*A.M.G.*, August, p. 434) showed, at a meeting of the Sydney Pathological Club, an hydatid cyst passed *per urethram*.

1905.—Professor Watson (*A.M.G.*, December, p. 669) exhibited an hydatid cyst of the kidney.

1906.—Dr. Trethowan, of Perth (*A.M.G.*, September, p. 468), exhibited an hydatid cyst which was retro-peritoneal near the right kidney and showed a cauliflower-like growth.

1908.—Dr. F. J. T. Sawkins, of Sydney (*A.M.G.*, April, p. 179), described two cases of large pelvic hydatids, one in a female, and the other in a male. The first was a young woman who had aborted on two occasions, at the fifth and seventh months. Her tumor had been tapped twice and 10 pints of greenish fluid drawn off. When seen later the tumor rose as high as the umbilicus and pushed the uterus upwards and to the right. On exploring the abdomen a huge hydatid cyst was seen, which had displaced upwards all the pelvic viscera, except the rectum, and which was practically extra-peritoneal. The cyst was drained, and the patient made an uneventful recovery. The second case was in a male, *æt.* 63, who was suffering from retention with overflow of urine. His bladder reached almost to the umbilicus. After catheterisation a rectal examination revealed a large cystic tumor bulging into the rectum. The cyst was drained through the perinæum, and the patient ultimately recovered after passing quantities of daughter cysts *per anum*, as the anterior wall of the rectum had broken down 6 in. from the anus.

Dr. Burkitt (*A.M.G.*, p. 409) referred to having had a case of hydatid disease of the kidney.

1911.—Dr. A. J. Nyulasey (*B.M.J.*, II., July 15th, p. 112) described a case of suppurating hydatid cyst of the broad ligament in a female Western Australian aborigine, aged about 20 years, who was admitted suffering from severe abdominal pain. After a long and tedious dissection he was able to remove the cyst. The case is described fully, and the patient recovered.

1915.—W. J. Denehy (*M.J. of A.*, April 10th, p. 337) recorded an hydatid cyst of the kidney in a patient who died of diabetic coma. There were no signs or symptoms of its presence during life.

J. B. Cleland (Sixth Rep. Microbiol. Lab., Dept. of P. Health, N.S.W., p. 251) recorded finding laminated hydatid membrane in the urine from a patient who had had old-standing renal colic, followed by the passage of shreds in the urine. The left kidney was the size of a coconut.

1916.—Cleland (*loc. cit.*, Seventh Rept., p. 252) mentioned the passing of laminated hydatid membrane in the urine of a patient from Wellington, N.S.W.

1918.—W. Denehy (*M.J. of A.*, Jan. 5th, p. 19) exhibited an hydatid cyst of the kidney before the Victorian Branch of the B.M.A. The cyst was found *post-mortem* in a case of cerebro-spinal meningitis, no symptoms from its presence having been noted during life.

1923.—Dr. A. Aspinall (*M.J. of A.*, October 6th, p. 370) described a case of an hydatid cyst of the kidney in a girl of 14 who had always lived in Sydney. She gave a history of pain in the left loin, vomiting, and frequency of micturition for the previous 12 months. An apparently cystic mass could be felt in the left hypochondrium. Cystoscopy revealed two separate ureters on the left side, and by means of a pyelogram one was found passing to the upper, the other to the lower pole of the kidney. All the ureters were acting and the renal functions were normal. There was 3 per cent. of eosinophilia. The diagnosis lay between cystic kidney, a malignant growth, a horse-shoe kidney, and hydatid disease. Nephrectomy was performed by the lumbar route. A large hydatid cyst with daughter cysts was found occupying mainly the region of the pelvis of the kidney. The patient made an uninterrupted recovery.



## II.—FURTHER CASES RESEMBLING ENDEMIC TYPHUS FEVER (Brill's Disease).

(DR. F. S. HONE, Honorary Physician.)

Subjoined will be found detailed notes of the eight further cases resembling typhus fever which have been treated in the wards of the Adelaide Hospital during 1923. These notes were taken by the various House Physicians, and have been collected by the Registrar. It will be noticed that in their general features they bear out the clinical and serological picture presented by those previously reported in these archives and elsewhere. In the third case (H. W.) the rash was mistaken for measles when first seen in his own home; other cases were sent in as typhoid fever—as in previous years. Although the rash is said to have come out on the second day of H. W.'s illness, it will be noted that on this reckoning his temperature was normal by the 10th day. This fact, from previous experience, makes it certain that his onset needs to be put earlier. In this case one of the macules was excised, but microscopical examination revealed no *Rickettsia* bodies in the capillaries, or any other abnormality.

The case of G. C. (eighth in the series), which was watched from early in the disease, shows clearly the rash appearing on the 7th day, and defervescence on the 14th.

These cases were almost evenly divided between the two sexes, and there was one death in this series—*post-mortem* examination again revealing nothing but the usual changes found in infective conditions. It will be noted that they were almost evenly distributed through the year.


Interesting as these records are, they are still more interesting in association with other cases which were observed during the year outside the hospital. In one of these, the youth had been confined to bed for 10 days before the abrupt onset of symptoms with an injury to his knee received at football, bearing out the previous suggestion of an incubation period of about 14 days.

In the case, in this series, of D. C., a grocer, investigations by officers of the City Health Office showed nothing noteworthy in his home surroundings. For two or three weeks before his illness began he had been working in a small packing room of a large grocery establishment. A month after his illness another patient was seen in private practice, living in quite a different part of the city, who worked in the same grocery establishment as D. C. His usual employment was in the office, but for about three weeks before his illness he had been weighing out groceries in this same packing room. On account of this coincidence, an attempt was made to investigate conditions. That part of the building was just about to be knocked down when these investigations were made. There was a large number of rats in evidence; groceries were examined for evidence of infestation, but nothing beyond rats and ordinary insects were found. This group of two shows how easy it would be in isolated cases under different medical men to miss a common association. It brought up again the question of association with foodstuffs, and although in many of the cases no association can be found, it is noted that in the majority of shop assistants who have contracted the disease, the shops they worked in were related to food. V. W., for instance, in this series, living at Prospect, served in a confectionery shop, and although the branch in which she usually worked was new and clean, she stated that she had been relieving in another branch where she had noticed a number of rats in the shop.



Case 1.—(Under the care of Dr. Cowan.)—L. W. female, *æt.* 50, was admitted to the Adelaide Hospital on January 26th, 1923, complaining of pain in the back and headache. The onset of her illness had been 10 days before admission, and occurred suddenly with pain in the back while she was ironing. She had had continuous headache and occasional dry retching since.

On examination of the abdomen the spleen was palpable, and she had a profuse maculo-papular rash over her trunk which disappeared on pressure. Her arms and legs were not affected. This rash had faded considerably on January 27th. The temperature on admission was 100° F., and fell to normal on January 30th, and remained so. A white blood count on January 29th showed 15,000 leucocytes. The Widal reaction was negative, and the Weil-Felix reaction showed complete agglutination against *Bacillus proteus* x 19 in a dilution of 1 in 160, partial in 1 in 320. On February 6th it showed partial agglutination in a dilution of 1 in 640. Convalescence was normal, and she was discharged well on February 13th.



Case 2. (Under the care of Dr. Johnson.)—L. G., male, *æt.* 17, was admitted to the Adelaide Hospital on February 15th, 1923, complaining of headache. His illness had begun on February 8th with feelings of dizziness and tiredness. The following day he had gone to work, but a severe headache came on which obliged him to



go to bed. The headache persisted, and on February 12th he noticed numerous small pinkish spots scattered over his trunk and limbs. His headache had become worse since the rash appeared. On February 14th the rash began to fade; on this day he had bleeding from the nose for the first time. Since he left school he had worked as a type-setter. He had had influenza two years before his present illness.

On the day of admission to hospital, his tongue was furred; he had tenderness in the left hypochondriac region; the lower edge of his spleen could be felt, and a rash consisting of small, slightly-raised pink spots, varying in size from a pin's head to a small bead and disappearing on pressure was visible over the whole body, being most thickly distributed on the abdomen. Physical examination revealed no other abnormal signs.

His temperature on admission was  $98.4^{\circ}$ , but rose in the evening to  $102.5^{\circ}$ . The pulse rate was 96; respirations, 20. He was given a fluid diet. The day after admission the rash had almost completely faded. He still had headache, and was stuporose. On February 19th his mental condition had greatly improved, and his spleen was no longer palpable. On February 20th he no longer had headache, and on March 7th he went home.

On February 24th his blood gave a negative agglutination test against *B. typhosus* and *B. paratyphosus* A and B, but a complete agglutination against *B. proteus* x 19 in a dilution of 1 in 640, partial in a dilution of 1 in 1,280. On March 3rd his blood gave complete agglutination against *B. proteus* x 19 in a dilution of 1 in 320, and partial in dilutions of 1 in 640 and 1 in 1,280.

*Case 3. (Under the care of Dr. Guy Lendon.)*—H. W., male, *æt.*, 17, metal worker, living in Adelaide, was admitted to the Adelaide Hospital on April 13th, 1923. His illness had commenced on April 9th with what the patient thought was a bilious attack, consisting of vomiting, constipation, and headache. He slept very little at night, and had a marked feeling of lassitude. His appetite was poor, and he remained constipated. He had no epistaxis.

On admission his temperature was  $101^{\circ}$  F.; pulse, 120. His conjunctivæ were congested, his tongue was furred and moist, and no adventitiæ were heard in the lungs. There was a fullness in the left hypo-chondrium, though the spleen was not definitely palpable. He presented a diffuse roseolar rash, covering the whole of the trunk, both upper extremities including the palms, and both legs. The spots, which were bright pink in color, disappeared on pressure, were not raised, and in size varied from a pin's head to a  $\frac{1}{4}$  in. in diameter. This rash had apparently come out on the second day of the illness, and began fading on the fourth day.

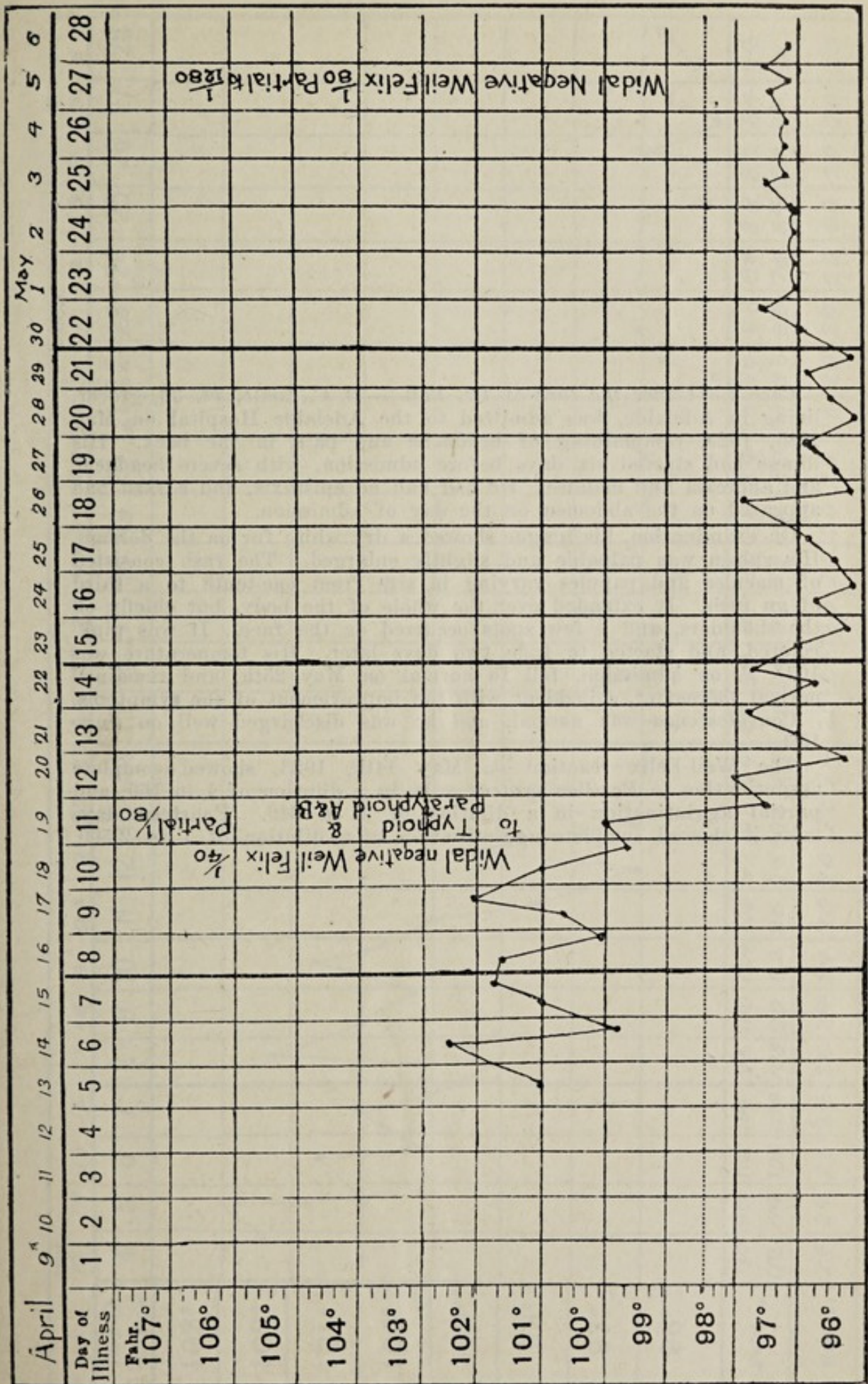
On April 18th the Widal reaction was negative. The Weil-Felix reaction to *Bacillus proteus* x 19 showed complete agglutination in dilutions of 1 in 20 and 1 in 40, and partial in 1 in 80.

On the tenth day of his illness, April 19th, the temperature had fallen to normal, and remained so afterwards. The rash had totally disappeared by the 13th day of the illness, and convalescence was progressive. A white blood count showed 5,000 leucocytes per c.mm. On May 5th the Widal reaction was again negative, and the Weil-Felix reaction was complete in dilutions up to 1 in 80, partial up to 1 in 1,280.

Convalescence was uncomplicated, and the patient was discharged well on May 6th.

A day or two after admission, while the rash was well marked, a macule was excised for examination for Rickettsia bodies, but microscopic examination revealed nothing abnormal.







*Case 4. (Under the care of Dr. Ray.)*—D. C., male, *æt.* 36, grocer, living in Adelaide, was admitted to the Adelaide Hospital on May 13th, 1923, complaining of headache and pain in the back. His illness had started six days before admission, with severe headache and anorexia and malaise. He had had no epistaxis, and a rash had appeared on the abdomen on the day of admission.

On examination, his tongue showed a dry white fur on the dorsum. His spleen was palpable and slightly enlarged. The rash consisted of macules and papules varying in size from one-tenth to a third of an inch. It extended over the whole of the body, but chiefly on the shoulders, and a few spots occurred on the face. It was pink-colored, and started to fade two days later. His temperature was 103° F. on admission, fell to normal on May 25th, and remained normal thereafter, coincident with the improvement of the symptoms.

Convalescence was normal, and he was discharged well on June 10th.

The Weil-Felix reaction on May 14th, 1923, showed complete agglutination to *Bacillus proteus* x 19 in a dilution of 1 in 160, and partial agglutination in a dilution of 1 in 640. Fourteen days later it showed complete agglutination in a dilution of 1 in 2,560.







*Case 5. (Under the care of Dr. de Crespigny.)*—J. G., male negro, *et.* 61, a builder's laborer, was admitted to the Adelaide Hospital on August 28th, 1923, complaining of pain in the back and headache, which came on suddenly. Four days before admission he had had an attack of epistaxis, and had had two attacks since. The illness had commenced with a rigor. He had had no vomiting or diarrhoea.

On examination, the tongue was covered with white fur. He had scattered crepitations at the base of the left lung posteriorly. The spleen was not palpable. His urine contained heavy albumen. His temperature on admission was 104° F. He was delirious at night. The signs of consolidation in the left lung increased. His temperature during his 10 days in hospital gradually diminished. He died on September 7th, apparently from broncho-pneumonia.

The white blood count on August 29th showed 6,500 leucocytes per c.mm. On August 31st the Widal reaction was negative. On September 7th the Weil-Felix reaction showed complete agglutination to *Bacillus proteus* x 19 on a dilution of 1 in 2,560.

This patient was a negro, born in the West Indies, hence the absence of any notes about a rash being visible. The absence of such rash caused the true condition to be overlooked, until revealed just prior to death by the positive Weil-Felix reaction.

*Autopsy, No. 141/1923 (J. B. Cleland).*—The body showed a few papery scars on the shins. There was no evidence of the presence of pubic or head lice. The teeth were loose from pyorrhœa, and there was much tartar. The trachea was congested, and the larynx somewhat congested. The bronchi were deeply congested, but no mucopus was present in them. The left lung showed considerable congestion posteriorly, and in the lower part; its left lobe was partly collapsed, almost airless, and dark red in color; its weight was 18½ozs. In the right lung the lower lobe was deeply congested and somewhat œdematous, but there was no definite consolidation; its weight was 27ozs. The right side of the heart was somewhat dilated; there was slight hypertrophy and dilatation of the left ventricle; the valves were normal save for slight thickening of the edges of the mitral; the heart muscle was somewhat pale in color, and a little softer than normal; the coronary vessels were healthy. The liver was large, weighing 80ozs., and seemed tougher than normal. Its cut surface was a little mottled with vascular dilatations, and pale, fatty areas; the bile was dark-colored, rather thick and viscid. The spleen, weighing 5½ozs., was of normal size and color, though slightly softer than usual. The suprarenal glands were firm, and very little pigmented. The left kidney weighed 9½ozs., the right 11½ozs.; fetal lobulation was somewhat marked; the capsules slipped off very easily, leaving a rather pale surface with some distended venules; on section, the cortex was found to be decidedly swollen, the ratio of cortex to medulla being more than 1 : 2; its color was yellowish, with interspersed distended vessels; the cortical striæ were still recognisable. The stomach showed some slaty pigmentation, and some ecchymoses. The intestines and pancreas appeared normal. The testes were normal. The brain weighed 37½ozs., and showed moderate congestion and a slight excess of cerebro-spinal fluid.

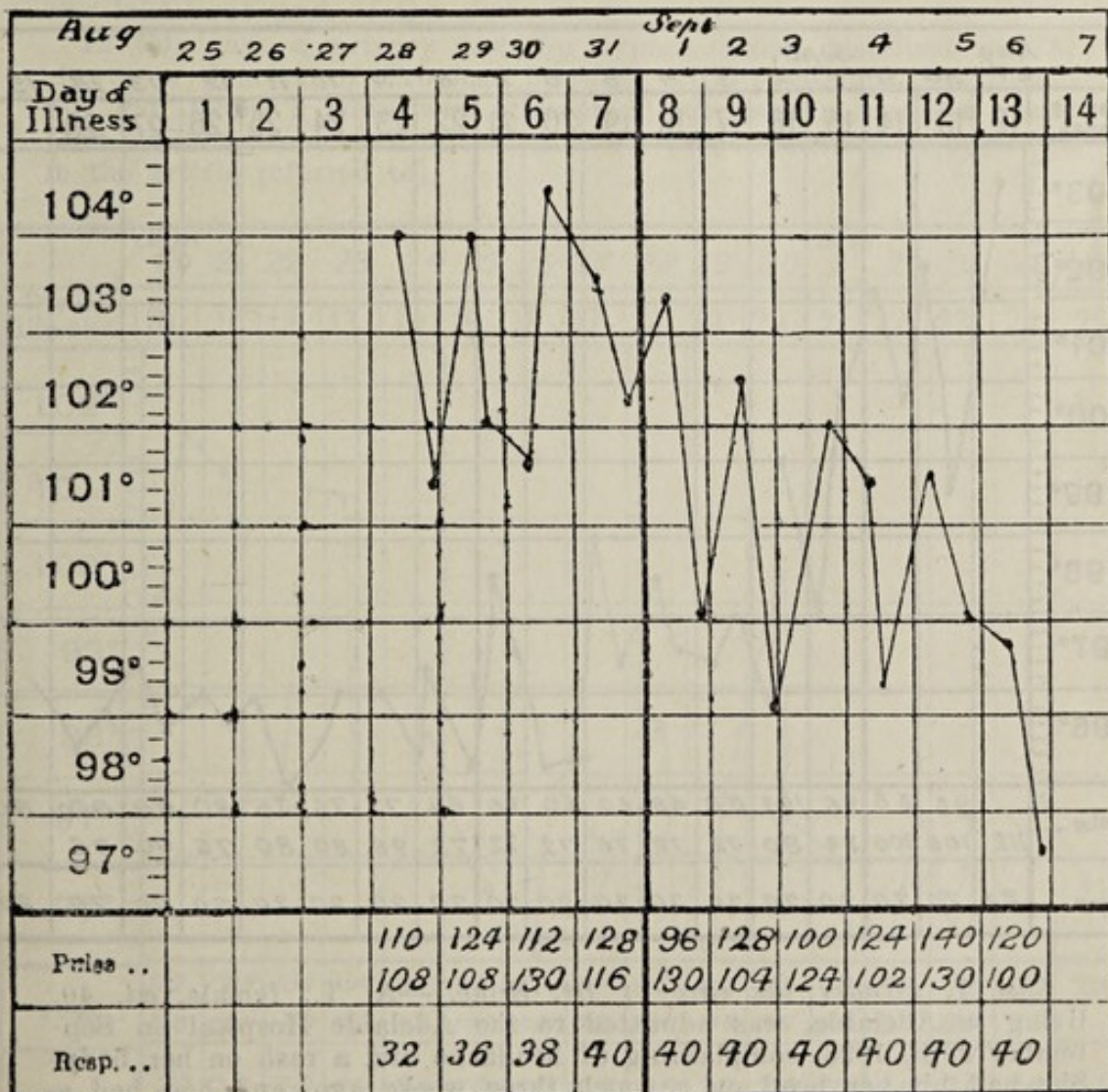
*Histological Examination.*—In the small intestine the peripheral portion of the epithelium had disappeared in places down to the submucosa; in the remaining stroma lymphocytes, plasma cells and larger rounded cells were present. In the kidney the cells of the convoluted tubules were swollen, and filled with spherical globules varying in size, and taking on the iron hæmotoxylin stain to some extent; some of these cells were also peppered with minute chromatic specks; there were also several areas of round and plasma cell



infiltration, one of these being beside a small arteriole. The liver showed considerable plasma and round-cell infiltration of Glisson's capsule; there was also congestion of the capillaries and vacuoles and some bile pigment crystals in some of the liver cells. The lungs showed a slight granular exudate in some of the alveoli; the lung tissue was partly compressed, and there was some increase of fibrous tissue. The spleen showed hæmorrhage and blood pigment; the Malpighian bodies were present. The heart showed congestion of its capillaries. The pancreas, thyroid, suprarenal glands, testes, and brain showed no abnormalities.

*Animal Inoculations.*—1 c.c. of an emulsion of the brain was inoculated intraperitoneally into guinea pig No. 361 on September 8th, and an emulsion of various organs (spleen, liver, and kidneys), similarly into guinea pig No. 362. Neither animal showed any departure from normal, and both were killed on September 18th. A microscopic examination of the organs, including the brain, heart, kidneys, and liver, did not reveal the presence of any pathological changes that could be recognised, with the exception of the spleen of guinea pig No. 362, which showed microscopic polymorphonuclear abscesses.

In this patient, giving a positive Weil-Felix reaction just before death and dying with pulmonary congestion and in a febrile state after 11 days' stay in hospital, histological examination of the tissues and guinea pig inoculations failed to give any conclusive support to the diagnosis of endemic typhus (Brill's Disease).



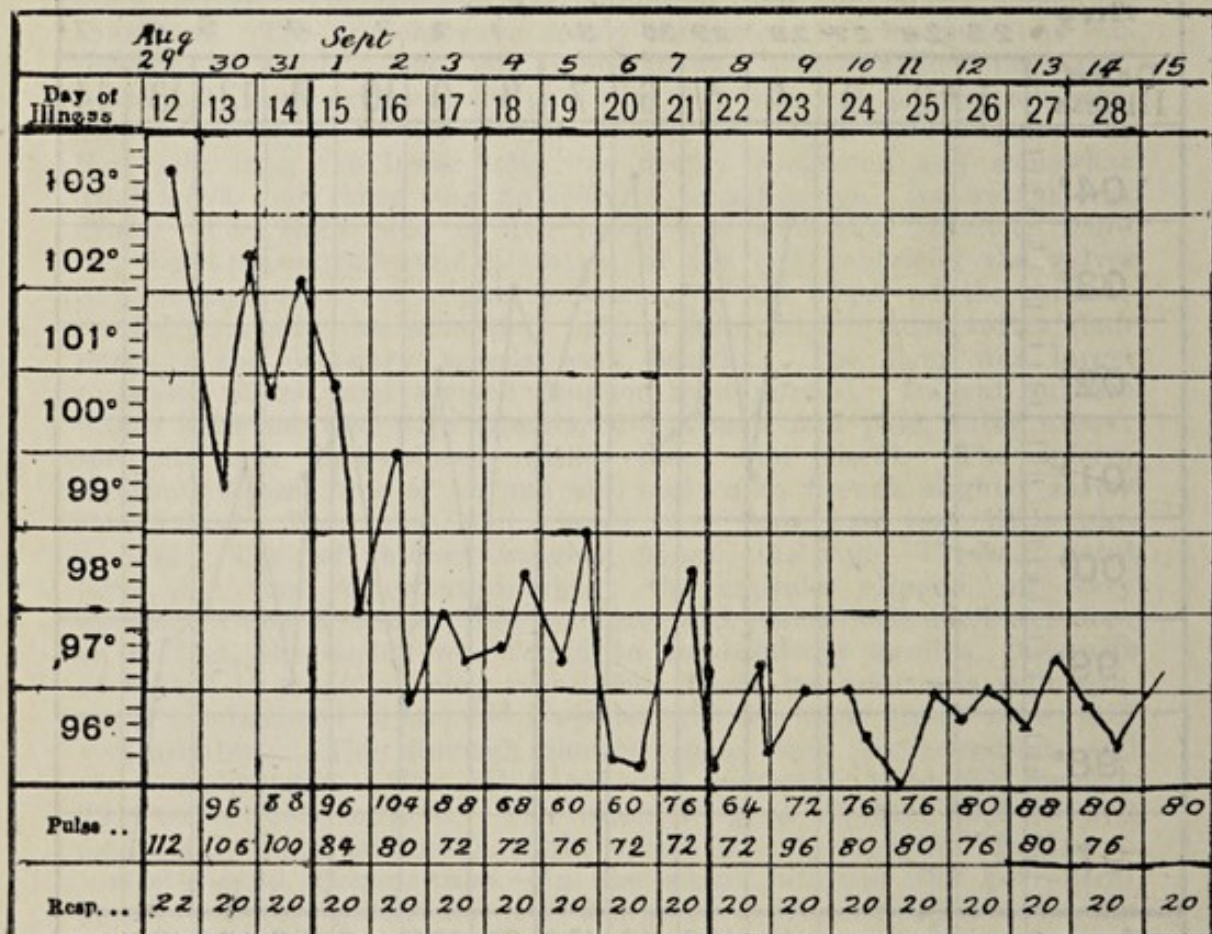


Case 6. (Under the care of Dr. Hone.)—V. W., female, *æt.* 22, shop assistant, living in Prospect, was admitted to the Adelaide Hospital on August 29th, 1923, complaining of intense headache and aching of the limbs. Her illness had begun 12 days before with malaise, headache, and anorexia. For six days she had been confined to her bed. She had had no coryza, and no vomiting, except once after medicine. A rash had appeared on her arms and trunk on August 27th. This was of a maculo-papular nature and of a pink color, but was fading when she was admitted. The spleen was not palpable, but there was a slight tenderness in the epigastrium on palpation.

On August 31st a Widal reaction was negative, and a Weil-Felix reaction showed complete agglutination up to a dilution of 1 in 80, partial up to 1 in 160 to *Bacillus proteus* x 19. The white blood count showed 7,300 leucocytes per c.mm.

On September 10th a Weil-Felix reaction was positive up to a dilution of 1 in 320, and a blood count showed 9,600 leucocytes per c.mm.

Her temperature on admission was 103° F., but returned to normal within a week, and remained practically so afterwards. The rash had completely faded by September 9th, and her symptoms disappeared as her temperature returned to normal. Convalescence was normal. The notes state that this patient worked at a branch sweets depot in Rundle Street. She boarded at Prospect in an old house with two other people, who were both well. No fowls were kept, and no wheat was on the premises.



Case 7. (Under the care of Dr. Hone.)—A. T., female, *æt.* 40, living in Adelaide, was admitted to the Adelaide Hospital on September 20th, 1923, complaining of headache and a rash on her body. She had hit her head on a couch three weeks ago, and had had a



headache as a result of this. On September 10th, 10 days before admission, she had had a severe headache accompanied by shivering attacks, which recurred frequently for seven days. The headache was of a throbbing nature, and vertical and frontal in site, and was relieved by phenacetin powders.

On September 15th a rash had appeared on her forearms, trunk, and thighs. It did not itch. Some spots, she said, were raised, others were not. They continued to come out for three days, and then began to fade. The illness had been diagnosed by one doctor as typhoid fever, and by another as measles.

On admission there were scattered macules and slightly raised papules on the skin on the arms, forearms, and trunk. The papules did not disappear completely on pressure. A subcuticular mottled appearance was observed, especially on the trunk.

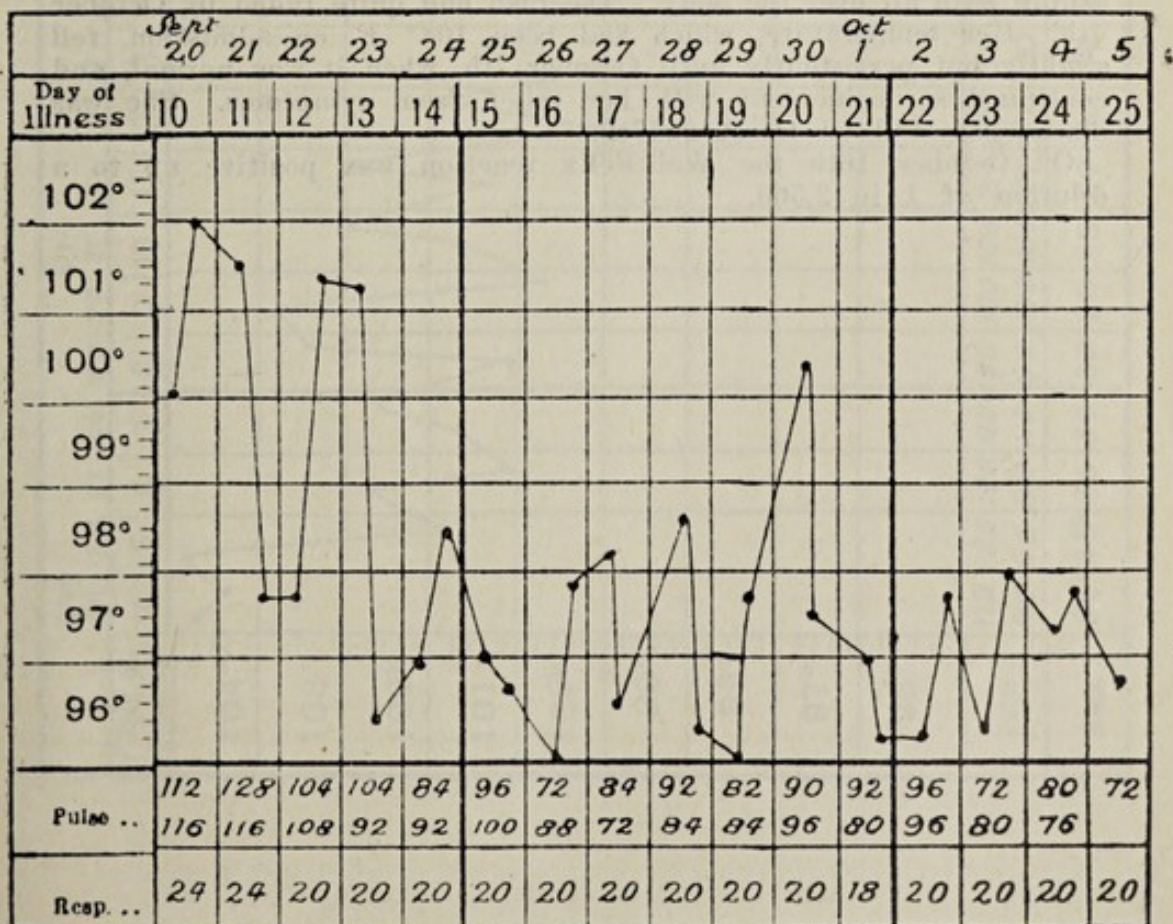
Her tongue, on admission, was thickly coated with fur on the dorsum, and was red at the tip and edges. The spleen was impalpable. The rash had completely disappeared by September 24th. There were no further symptoms.

The Weil-Felix reaction was positive up to a dilution of 1 in 2,560 on September 26th.

Her temperature was 103° F. on admission. It returned to normal on September 24th, and remained so for the rest of her convalescence, except for a slight rise on September 30th.

The notes state that there were numerous rats in her house, which was in a poor part of the city.

In this case a urinary test for typhus fever, described in *The American Journal of Tropical Diseases*, with potassium permanganate and Jenner's stain was attempted, but gave a negative result (but a control case also did not give the proper reaction as described in the article referred to).



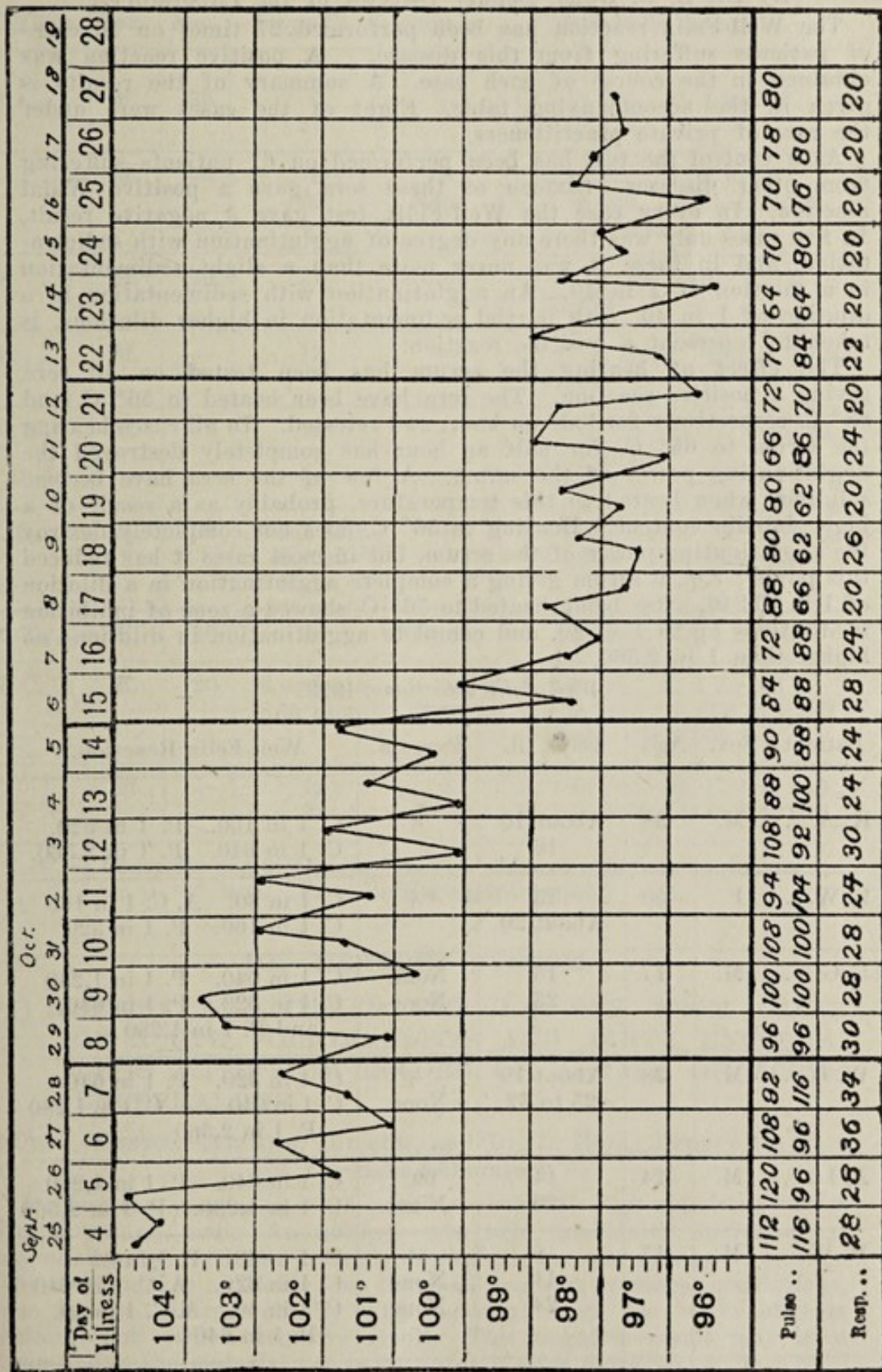


Case 8. (Under the care of Dr. de Crespigny.)—G. C., female, *æt.* 20, waitress, living at Hindmarsh, was admitted to the Adelaide Hospital on September 25th, 1923, complaining of severe headache, abdominal pain, and vomiting. Her illness had begun on September 22nd with a sudden pain in the lower part of the left chest, which had been increased by deep breathing, but had not been accompanied by cough. She had been drowsy since the onset of her illness, and had had diarrhœa during the first two days. She had had no epistaxis. Her spleen was slightly enlarged, and she was tender on palpation in the right hypochondrium. No rash was present. On September 26th agglutination reactions against the *B. typhosus* and *B. paratyphosus* A and B were negative.

On September 29 a rash consisting of pink-colored macules and papules appeared on her arms, hands, thighs, feet, and trunk. These disappeared on pressure, and varied in size from a pin's head to a third of an inch in diameter. She also complained of a severe aching pain all over the body. The rash had quite faded by October 4th. Her temperature, which had been 104° F. on admission, fell slightly but persistently until October 7th, when it was normal, and continued so, coincident with her relief from symptoms. She was discharged well on October 17th.

On October 16th the Weil-Felix reaction was positive up to a dilution of 1 in 2,560.







# EXAMINATIONS ON THE SERUM OF CASES RESEMBLING TYPHUS FEVER (BRILL'S DISEASE).

(By Dr. L. B. BULL, Deputy Director of the Laboratory.)

The Weil-Felix reaction has been performed 27 times on 16 cases of patients suffering from this disease. A positive reaction was obtained in the course of each case. A summary of the results is given in the accompanying table. Eight of the cases were under the care of private practitioners.

As a control the test has been performed on 61 patients suffering from other diseases. Sixteen of these sera gave a positive Widal reaction. In every case the Weil-Felix test gave a negative result. In five cases only was there any degree of agglutination with sedimentation, and in these it was never more than a slight sedimentation in a dilution of 1 in 40. An agglutination with sedimentation in a dilution of 1 in 40, with partial sedimentation in higher dilutions, is taken to represent a positive reaction.

The effect of heating the serum has been tested on 13 sera giving a positive reaction. The sera have been heated to 56° C. and 65° C. respectively for half an hour, and retested. In all cases heating the serum to 65° C. for half an hour has completely destroyed the agglutinating power of the serum. A few of the sera have become solidified when heated to this temperature, probably as a result of a high globulin content. Heating to 56° C. does not completely destroy the agglutinating power of the serum, but in most cases it has reduced this power; *e.g.*, a serum giving a complete agglutination in a dilution of 1 in 10,240, after being heated to 56° C. showed a zone of inhibition in dilutions up to 1 in 80, and complete agglutination in dilutions no higher than 1 in 2,560.

## Weil-Felix Reactions, 1923.

Patient.	Sex.	Age.	Days Ill.	Pyrexia.	Weil-Felix Reaction.
K. A. . .	M.	38	About 10 16	+	C. 1 in 160. P. 1 in 320. C. 1 in 640. P. 1 in 2,560.
L. W. . .	F	50	15 About 20	+	C. 1 in 80. A. C. 1 in 160 C. 1 in 160. P. 1 in 320
L. G. . . .	M.	17	15 23	None None	C. 1 in 640. P. 1 in 1,280 C. 1 in 320. P. 1 in 640, and P. 1 in 1,280
W. B. . .	M.	38	About 19 25 to 32	+	C. 1 in 320. P. 1 in 640 C. 1 in 640. A. C. 1 in 1,280 P. 1 in 2,560
A. L. . . .	M.	24	14 20	99° None	C. 1 in 640. P. 1 in 1,280 C. 1 in 1,280. P. 1 in 2,560
H. W. . .	M.	17	8 11 24	+	C. 1 in 40. P. 1 in 80 C. 1 in 320. A. C. 1 in 640 C. 1 in 40. A. C. 1 in 80. P. 1 in 640
W. J. . .	M.	—	—	—	C. 1 in 320

(C. = Complete agglutination. A.C. = Almost complete agglutination. P. = Partial agglutination.)



*Weil Felix Reactions, 1923—continued.*

Patient.	Sex.	Age.	Days Ill.	Pyrexia.	Weil-Felix Reaction.
D. C....	M.	36	7 21	+	C. 1 in 160. P. 1 in 640 C. 1 in 2,560
C. ....	M.	40	9 29	+ None	C. 1 in 160. P. 1 in 320 C. 1 in 160. A. C. 1 in 320. P. 1 in 640
D. ....	M.	70	21	None	C. 1 in 10, 240. P. 1 in 20,480
W. ...	M.	—	13	—	C. 1 in 2,560. Slight 1 in 5,120
V. W. .	F.	22	12 25	+ None	C. 1 in 40. A. C. 1 in 80. P. 1 in 160 P. 1 in 320
J. G. ...	M.	61	About 11th day of fever	+	C. 1 in 5,120. A. C. 1 in 10,240. P. 1 in 20,480
A. T....	F.	40	14	None	C. 1 in 160. P. 1 in 640
G. C. ...	F.	20	9 or more 18 or more	+ None	C. 1 in 40. P. 1 in 160 C. 1 in 640. A. C. 1 in 1,280. Slight 1 in 2,560
P. ....	M.	—	12 23	+ None	C. 1 in 160. A. C. 1 in 640 C. 1 in 320. A. C. 1 in 640

(C. = Complete agglutination. A. C. = Almost complete agglutination. P. = Partial agglutination.)

**III.—NERVOUS SYSTEM.**

(1) MONKEY AND OTHER INOCULATIONS FROM CASES OF ACUTE POLIOMYELITIS AND ACUTE ENCEPHALITIS WITH THE RECORD OF A CASE OF ACUTE ENCEPHALITIS.

(Dr. J. BURTON CLELAND, Director, and Dr. L. BULL, Deputy Director of the S.A. Laboratory.)

During the year a case of acute encephalitis was admitted under Dr. Ray, and died. An autopsy was held, and later microscopical examination showed the presence of typical, but not extensive, lesions. The only monkey available, one that had received previous inoculations, was injected intracerebrally with material from the brain of this patient, but with a negative result. This negative result may have been due to the material not being infective for monkeys, or may have been due to the monkey being immune as the result of a previous slight attack of acute poliomyelitis.

It has seemed advisable to place on record the result of certain inoculations of monkeys and other animals with material from a



case of the Australian X-disease (acute encephalitis) and with other materials from cases of ordinary infantile paralysis. The result of these inoculations were either negative or somewhat indefinite. A monkey and four sheep inoculated with fresh material from a typical case of X-disease under circumstances in which one might have expected a "take" gave absolutely negative results. Another monkey inoculated at the same time as the first monkey, but with preserved material from a case of the ascending type of infantile paralysis, developed slight symptoms (facial paresis) suggesting a mild "take". These two monkeys were inoculated a second time nearly a month after the first inoculation with fresh material from a case of the medullary type of infantile paralysis. As a result, the monkey inoculated originally from the case of X-disease developed slight paretic symptoms which suggested a possible "take"; the other monkey did not seem to be affected. It was this X-disease monkey which had developed slight paresis as a result of its second inoculation, and had been unaffected by the first inoculation, that 18 months later received a third intracerebral inoculation with material from the now reported case of acute encephalitis. It remained unaffected thereby.

The case of X-disease from which monkey A was inoculated was one of a small series of typical cases with high temperatures that occurred in the Renmark district in February, 1922. The case may be considered as typical of those met with previously at Broken Hill and in the western districts of New South Wales. The cases of infantile paralysis (acute poliomyelitis) occurred in the Adelaide district and were typical of the medullary or ascending type of this disease.

#### THE INOCULATIONS INTO MONKEYS.

*Monkey A* was inoculated on February 22nd, 1922, intracerebrally in the frontal region with an emulsion of brain and spinal cord tissue comprising parts of the pons, medulla, basal nuclei, floor of the lateral ventricles, two areas of the cortex, cervical enlargement, dorsal cord and lumbar enlargement. The patient from whom these materials had been obtained had died at Renmark on February 19th from the Australian form of encephalo-myelitis (X-disease). His death had occurred at 3 p.m. on a warm day. The autopsy was conducted from 8 to 10 p.m. that evening, that is, five to six hours after death. Small pieces of the brain and spinal cord were immediately cut out, placed in 50 per cent. glycerine, and kept surrounded by ice in a cloth till their arrival at Adelaide on the morning of February 22nd. The inoculation into the monkey occurred at 4 p.m. The animal took the anæsthetic well. As the result of this inoculation the animal showed no evidence of illness whatsoever.

It was used for a further inoculation on March 18th. At 11 a.m. on this date the animal received an intracerebral injection in the frontal region of an emulsion containing portions of the cervical enlargement, dorsal cord, and lumbar enlargement from a child who had died the afternoon before at the Adelaide Children's Hospital from infantile paralysis of the ascending type. The spinal cord material had been kept in the ice chest over night. The emulsion was made in normal saline solution, about 0.5 c.c. being injected. On March 20th the animal seemed well and was eating well. On March 21st the monkey was very shivery and looked rather miserable. As had previously been the case, it still got very angry when teased. Till March 29th it remained much the same, still looking miserable. On March 31st it seemed definitely ill—in addition to looking miserable its ears would shake, it had shivers from time to time, it occasionally yawned, and sometimes would suddenly seize the bars of the cage or



hang its head. There was no apparent paresis. By April 3rd the monkey appeared quite well again, but on April 5th it seemed worse than it had previously been. There were irregular tremors of the head, ears, and limbs, it seemed depressed, its face seemed rather shrunken, and the left wrist appeared weak. On April 6th it was much the same. Similar tremors were still present, but the shivering seen on the previous day was less marked, possibly because April 6th was warmer. There was distinct weakness of the left wrist and doubtful slight weakness of the right wrist. It could not catch hold of objects properly with the left hand, catching them between the first and second fingers instead of between the thumb and first finger. It seemed as if there was special weakness of the first finger and thumb with almost complete loss of power. On April 13th the monkey appeared quite well again, though rather thin.

On October 9th, 1923, this same monkey (now No. 369) received an intracerebral inoculation in the frontal region of about 0.25 c.c. of an emulsion of the brain and spinal cord from the case of acute encephalitis described in this report. The animal recovered from the operation and remained well and free from symptoms. *Rabbit No. 370* was inoculated at the same time with 0.2 c.c. of the same emulsion intracerebrally. It developed symptoms of cerebral irritation suggestive of meningitis, and died on October 11th. Sections showed some meningeal hæmorrhage, but no microscopic evidence of encephalitis.

*Monkey B* was inoculated intracerebrally in the frontal region at the same time as *Monkey A*, on February 22nd, 1922, but with material from the spinal cord and medulla of a child who had died in the Adelaide Children's Hospital in December from the ascending and medullary type of acute polio-myelitis. Thin slices from the medulla, pons, three areas of the spinal cord and the basal nuclei had been preserved in 50 per cent. glycerine till this date, when an emulsion was made in normal saline solution and used for the injection. On March 6th, that is, 12 days after the inoculation, the monkey seemed shivery, it looked sick, pale, and depressed, and had not eaten its food for two days, but there was no obvious paresis. The next day it seemed better and practically well again, and its cage was placed in the sun. The monkey was not closely inspected by us for several days preceding March 11th. On this date a marked left-sided facial paralysis was present, especially noticeable when the animal yawned, which it frequently did. Before, or immediately after, its inoculation we did not notice any such paralysis or paresis, but we did not specially examine the monkey to see whether any such defect were present. We think, however, that had such paralysis been present before the operation we would almost certainly have noticed it, even if the animal had not yawned. The monkey on this date also looked depressed. Its ears and body were generally trembling. The shoulders were shrugged and twitched when it yawned, the tongue could be put out normally, there was no obvious paresis. The paralysis did not involve the orbicularis palpebrarum. The monkey was still inquisitive. On March 13th it was apparently the same. By March 18th the facial paralysis was perhaps a little less prominent, but was still marked when the animal yawned, as it often did.

At 11 a.m. on March 18th this monkey was re-inoculated, as well as *Monkey A*, intracerebrally in the frontal region with material from the spinal cord from a recent case of ascending acute anterior polio-myelitis, as described in the case of *Monkey A*. On March 20th the animal appeared normal and eating well, and thereafterwards the animal showed no further departure from normal, the second inoculation being apparently without effect.



## INTRACEREBRAL INOCULATION IN SHEEP.

The material from which these five nearly full-grown lambs were inoculated was obtained from the typical case of encephalo-myelitis (X-disease) that died at Renmark on February 19th, and from whom Monkey A received its first injection. The patient had died at 3 p.m., the autopsy was held from 8 to 10 p.m., and small pieces of the brain and spinal cord were removed and kept fresh surrounded by ice until 10 a.m. next morning, when the material was emulsified and intracerebral injections of about 1 c.c. of a thick emulsion in normal saline were made in the frontal regions. No illness suggestive of encephalitis was shown by any of the sheep thus inoculated.

## A CASE OF ACUTE ENCEPHALITIS.

*(Under the care of Dr. Ray, Hon. Physician.)*

S. H., a female, *æt.* 16, was admitted to the Adelaide Hospital at 3 a.m. on October 4th, 1923, in a comatose condition. Her illness had begun on September 30th with a cold in the head, a frontal headache, and fever. Two days later her parents had noticed that her right eye had developed an internal squint. No further history of her condition before admission could be obtained.

She was a well-developed, well-nourished girl. When admitted her face was entirely expressionless, she could hardly be roused by shouting. The skin was acting freely. Her temperature was 100° F., the pulse 112, regular and of good volume, the breathing regular, rate 22 per minute. She kept her eyelids closed and resented having them opened. The pupils were equal and reacted to light. No strabismus was evident. Nystagmus was present, more marked in the left eye, on looking to the right. There was no evidence of facial paralysis. She protruded her tongue slightly on command in the midline, and it was covered with white fur. There were sordes on her lips. She had no coryza. Her chest showed a transient erythematous rash, and a marked tache cerebrale. Her lungs and heart were normal. Her abdominal muscles were held slightly rigid. There was some indefinite difference on the two sides of the body for sensation and muscular power. She resented a sharp pin prick on both sides of the face, and sensation was more impaired on the right arm and the right half of the abdomen than on the left, and also was impaired in both legs, where no difference was noted on the two sides. The right leg was slightly more flaccid than the left. There were definite katatonic manifestations in the arms. The left abdominal reflex was present, the right absent. No arm tendon-jerks were obtained. The knee-jerks were present on both sides, the right slightly more than the left. The left plantar reflex was flexor, the right extensor. Lumbar puncture was performed, and cerebrospinal fluid escaped under pressure and was clear.

On October 5th the patient answered a few questions rationally. The katatonia was more marked, the plantar reflexes were both flexor, and she was able to lift either hand voluntarily to her forehead to indicate the position of her headache. Her temperature continued to rise daily until she died on October 8th. Examination for optic disease showed no abnormality.

*Autopsy No. 160/23.*—The lungs showed considerable congestion. On opening the pericardial cavity some petechiæ were noticed on the posterior aspect. The heart muscle seemed a little pale, but was firm in texture. There were no valvular lesions. The liver appeared normal in color and texture. The spleen, weighing 7ozs., was firm and dark red. The kidneys, each weighing 4½ozs., showed some



congestion, and the cortex seemed a little pale. There were petechiae beneath the mucosa of the stomach. The pancreas was normal. The brain appeared normal to the naked eye.

*Histological Examination.*—No special changes were seen in the liver, spleen, or pancreas. In the kidneys there was definite cloudy swelling in many tubules, some being a little dilated. In the brain, sections from four parts of the cortex revealed no lesions. In the optic thalamus definite lymphocytic infiltration was present around some of the vessels, and there were some islands of these small cells. In the crus cerebri there were some lymphocytic sheaths with a few polymorphonuclear cells round some vessels. In the pons occasional vessels showed some definite lymphocytic infiltration with rarely some polymorphonuclear, plasma, and endothelial cells; there were some small areas showing diffuse infiltration; there were occasional early examples of neuronophagocytosis.

The autopsy was carried out on the morning of the day after death. Early in the same afternoon freshly emulsified material in normal saline of the cortex, basal ganglia, pons, medulla, and upper part of the cervical cord was inoculated intracerebrally into Monkey No. 369, with a negative result as already described.

#### IV.—MEDICAL CASES.

##### (1) ACUTE GASTRIC ULCERS WITH SUICIDE.

*(Under the care of Dr. Angus Johnson, Hon. Physician. Reported by Dr. J. B. Cleland, Hon. Pathologist).*

A patient, male, *æt.* 50, was admitted to the Adelaide Hospital with "mental trouble" of a melancholic type. He appeared quite quiet during his stay, but committed suicide on the second day by cutting his throat.

At the autopsy (No. 98/23) the right kidney was found reduced to a small fibrotic mass. The left kidney was hypertrophic and weighed 8ozs. In the stomach were found an acute ulcer of the lesser curvature, situated 2in. from the pylorus, and three other punched-out ulcers the size of threepences, two of these being just at the pylorus.

*Comment.*—It is of interest to note the presence of several acute ulcers in the stomach at the time that the patient's mental disturbance became so pronounced as to lead to his committing suicide. Were the ulcers in any way responsible for the mental condition, either by originating or by aggravating it?

##### (2) TYPHOID FEVER WITH PERFORATION OF AN ULCER AND INFARCTS IN THE SPLEEN.

*(Under the care of Dr. de Crespigny, Hon. Physician. Reported by Dr. J. B. Cleland, Hon. Pathologist.)*

J. B., *æt.* 19, a laborer, was admitted on June 2nd, 1923. He had been ill about seven days, but had not felt well for a few days before this. He had taken to his bed five days before admission, after he had suddenly become worse whilst at work, being seized with cold shivers, headache, and pain in the back. Since then he had been feverish, with great thirst, and a dry mouth. He had had headache and backache all the time. He had had a slight cough, but had expectorated practically no sputum, and he had had no appetite since his illness commenced. On the day of admission he had vague



pains in his abdomen. His bowels had been constipated since he had become ill. He had had no other illnesses. He had been travelling about for the last four or five weeks with an uncle who had been ill with fever, diarrhoea, and pain in the stomach about five weeks ago.

On examination he was well nourished, but with an apathetic expression. His temperature on admission was  $97.5^{\circ}$  F. Three hours later it had risen to  $102.5^{\circ}$ . The pulse was 100, regular and dicrotic; the respirations, 20. He had brown fur on his tongue and sordes round the teeth. There were no spots on the abdomen. There was slight tenderness all over the abdominal cavity, most marked in the right iliac fossa. The spleen was not palpable. The urine was normal. On June 4th at 9.30 a.m. he was seized with severe abdominal pain. His pulse rose from 112 to 120, but the temperature remained at  $99.2^{\circ}$  F. till two hours later, when it had risen to  $105.6^{\circ}$  F. There was moderate rigidity all over the abdomen. His white cell count was 9,500 per c.mm. At 2 p.m. the pain was still severe, there was moderate rigidity of the abdomen, the liver dullness had diminished, but there was no sign of fluid in the abdomen. Morphia and atropine were given. At 6 p.m. the pain was still severe; the abdomen was of board-like rigidity, and very tender to palpation all over, the pulse was 135, and there were signs of free fluid in the abdomen. The white cell count was 13,300, of which polymorphonuclear cells comprised 66 per cent., and lymphocytes 34 per cent. At 6.30 p.m. the abdominal cavity was opened under ether. General peritonitis was present. A perforation 0.75 cm. in diameter, was found in the ileum 12 in. from its termination. The perforation was in the centre of an ulcer about 2.25 cm. in diameter. The perforation was closed by purse-string and mattress sutures. A tube drain was placed in the abdomen. On June 5th his condition was fair, the pulse 130. He had had some vomiting in the early morning after the operation. On June 6th the tube was removed. There was a moderate purulent discharge from the wound. He was given 1 c.c. of pituitrin. The bowels were open half an hour later. He died at 11.20 a.m. on June 7th.

At the autopsy (No. 79/23) peritonitis was present. The small intestines showed typical typhoid ulceration involving the ileocaecal valve. The spleen weighed 12½ ozs. and was uniformly enlarged. Its surface showed a number of irregular paler areas which were slightly elevated. These infarcted areas occupied approximately half of the splenic surface. On section they appeared as red infarcts with a narrow, pale peripheral zone. Some of the infarcts were superficial, extending in only about one-third of an inch, but some involved the deeper parts as well. No thrombosis was found in the splenic vein, the superior mesenteric vein or the chambers of the heart. *B. typhosus* was cultivated from the gall bladder and the spleen.

*Comment.*—Infarcts of the spleen are not common in typhoid fever. Their occurrence in this case may be explained by the definite tendency to thrombosis that occurs in this disease.

### (3) AMOEBIC DYSENTERY WITH ABSCESS OF THE LIVER, SUBPHRENIC ABSCESS AND PURULENT PERICARDITIS.

(Under the care of Dr. Hone, Hon. Physician. Reported by Dr. J. B. Cleland, Hon. Pathologist.)

The patient, R. W., *et.* 53, was admitted on May 7th, and died on May 15th. He had been born at Nairne, South Australia, but no information is available as to whether he had ever lived outside Australia. He had been sent in with a diagnosis of perforated



gastric ulcer. He had had indigestion for five weeks. There had been a sudden onset of acute pain over the whole of the lower part of the chest with collapse. The pain had disappeared, but the collapse remained. At the autopsy (No. 68/23), at and just beyond the ileocaecal valve an extensive irregular ulcer was found 1½ in. in lateral extent, and 1 in. longitudinally. There was little reaction round the ulcer, which extended deeply but irregularly into the coats of the intestine. Its base showed granulation tissue and whitish necrotic sloughs. There was no involvement of the peritoneal surface. Near this ulcer were four early necrotic patches varying in size up to that of a threepence, appearing as white areas with hæmorrhagic gelatinous appearance, and with but slight reaction around them. Below the attachment of the pericardium to the diaphragm was a large abscess cavity between the left lobe of the liver and the diaphragm, which contained 4 ozs. of anchovy-sauce-colored pus. This communicated with an abscess cavity in the upper part of the left lobe of the liver, extending in about an inch, and surrounded by dense fibrosis. The pericardial sac was covered with long, shaggy, fibrinous tags. Though the patient had been dead 36 hours at least, a typical still motile *Entamæba histolytica* was found in scrapings from the wall of the liver abscess.

*Comment.*—The amœbic dysentery had given rise to an amœbic abscess in the liver. This had led to a subphrenic abscess, and from the latter organisms had pierced the diaphragm, and given rise to purulent pericarditis.

#### (4) ULCERS IN THE SMALL AND LARGE INTESTINES WITH A PURPURIC RASH AND STREPTOCOCCAL SEPTICÆMIA.

(Under the care of Dr. Ray, Hon. Physician. Reported by Dr. L. B. Bull, Deputy Director of the Laboratory.)

O.K., a boy, *æt.* 17, was admitted on May 10th, and died on May 25th. The history given was that he had been struck on the nose by a horse 23 days before death. From this he bled freely for eight hours. He was later admitted to the Angaston Hospital, where his temperature ranged from 102.8° to 104.4°. In the Adelaide Hospital he showed an extensive purpuric rash on the trunk, and upper arms, and thighs. This rash was most marked round the axillæ, and in the sacral region. His temperature varied after admission, reaching as high as 105.4°. The rash disappeared after five days. He complained of pains in the joints, and there was also slight swelling of the forearms. Dimness of vision was present for the last eight days, and the epistaxis recurred four days before death.

*Autopsy, No. 74/23 (Dr. Webb).*—The mucous membranes and lungs were very pale. There were a number of petechial spots in the epicardium. There was no evidence of endocarditis. The kidneys showed some petechiæ over the surface of the cortex; the medulla was pallid. The spleen was soft, and fairly dark red. The liver was rather pale and fatty. There was moderate congestion of the lower part of the small intestine. In the large intestine, just below the ileocaecal junction and extending down for about a foot were several large ulcerated masses, the edges of which were much raised over the level of the surrounding mucosa. The centres were crateriform, and seemed somewhat careous, whereas the edges were firm and somewhat tough. The edges were yellowish-white in color, and the centres more of a greenish hue. One ulcer was surrounded by a large inflamed area of mucosa. The ulcers varied in size from



an inch in diameter up to lin. x  $3\frac{1}{2}$  in. in the case of two ulcers which had become confluent. The direction of the ulcers was transverse. There was no constriction of the lumen, and no involvement of the serosa. In the colon below the area of the ulcers numerous whitish, raised spots, varying in size from that of a pin's head to that of a split pea were present. The proximal two-thirds of the appendix were normal, but towards the distal end was a large bulbous swelling, at first suggesting caseation, but on section appearing as a hypertrophic mass occluding the lumen and resembling the hypertrophic ulcerated masses in the colon. In the ileum several feet above the cæcum was a large, circular, solitary, hypertrophic ulcer of the same appearance as those in the colon, and about 3 ft. above this was another ulcer. The peritoneum showed no tubercles. There was no other abnormality. No evidence of tuberculosis was detected elsewhere.

Port-mortem cultures from the heart's blood yielded a pure growth of *Streptococcus pyogenes*. No growth was obtained in culture media inoculated with material from the spleen. Microscopically the ulcers of the intestines are seen to have their origin in the lymphatic follicles. There is an intensive invasion of all the tissues by mononuclear leucocytes, and some plasma cells and a very few polymorphonuclear cells are also present. The leucocytic invasion is most intense in the submucosa, but extends to the subserous tissues. There is destruction of the mucous membrane, and necrosis of the adjacent tissues. In the larger and older ulcers the necrosis is very massive, and extends into the muscular layers.

*Comment.*—The nature of this case and the sequence of events is obscure. The kick on the nose can hardly have been the initial process, unless the injury and loss of blood enabled the streptococci to establish themselves. It seems more likely that the patient was already infected, and that the continuance of the bleeding from the injured nose was due to changes in the vessel-walls or lessened coagulability of the blood. Later the patient became anæmic and purpuric. These conditions may be attributed to his streptococcal infection, and to absorption from the ulcers in the intestine. The ulcers in the intestine presented a very unusual appearance. They were large, were very heaped up, were extensively necrotic, and had evidently existed for some time. Their location in both large and small intestine was unusual. They do not conform in appearance or in location or in microscopic structure with any of the usual forms of ulceration of the intestinal tract. Presumably they formed the sites of entrance for the streptococci, though it is by no means certain that they owed their origin to these organisms.

#### (5) FIBROSING TUBERCULOSIS OF THE PLEURA SUGGESTING SCIRRHOUS CARCINOMATOUS DEPOSITS.

(Reported by Dr. J. B. Cleland, Hon. Pathologist, and Dr. C. Turner, Medical Superintendent.)

The following case is of interest as presenting an unusual form of chronic tuberculosis, found accidentally during the course of an autopsy on a woman of 35 who had been killed in a motor car accident. The appearance of the tuberculous lesions, owing to the contraction of their fibrous tissue, suggested pleuritic deposits of a scirrhus carcinoma. This appearance led to a complete but unsuccessful search of the whole body for a primary growth, and it was only when sections were cut that the tuberculous nature was recognised. On the pleural aspect there were some flattened projections, sometimes semi-pedunculated, rather suggestive of "the grapes", characteristic of a common form of bovine tuberculosis of the pleura.



*Autopsy, No. 190/23.*—C. S., a woman, *æt.* 35. Death was due to fractures of the ribs and extensive lacerations of the liver and spleen. Beyond these signs of trauma there were no other pathological lesions, except a large, hard, shotty gland in the lesser omentum and the lesions in the lung and adjacent parts. Scattered over the parietal and visceral pleuræ of both lungs and over the pulmonic surface of the pericardium were numbers of whitish, hard nodules with a fibro-cartilaginous appearance. The nodules were raised and appeared to have arisen in the subserous layer of the pleura. They varied in size from that of a rice grain to that of a cherry stone, and some of them tended to be pedunculated. On section they were hard and white, and cut like firm fleshy masses. On the lateral aspect of the middle lobe of the right lung was a whitish-grey mass the size of a florin. Its surface was slightly concave, and on section it extended over 1.5 cm. into the lung tissue. Its appearance suggested a secondary carcinomatous deposit. The following glands were enlarged, hard, and on section presented a fleshy, greyish-whitish appearance, viz., one gland in the lesser omentum, the œsophageal group, and the glands at the roots of the lungs. The latter glands also appeared mottled with carbon pigment. The lungs were congested. There was no sign of invasion of the lung substance by the superficial nodules, these all appearing to be associated with the pleura, pericardium, and lymph glands. The apices of both lungs were firmly adherent to the chest wall, and at the left apex was an old tuberculous nodule in which caseation had occurred.

Microscopic sections of the lesions show numerous and very large giant-cells embedded in cellular fibrous tissue in which are many elongated fibroblasts. Here and there the fibroblasts become fewer, and their nuclei tend to disappear until in the centre a small, granular, unstained, necrotic area results.

## V.—DISEASES OF THE SKIN.

### (1) A FATAL CASE OF IODIDE IDIOSYNCRASY WITH FACIAL GRANULOMATA.

(By Dr. C. Turner, Medical Superintendent.)

Mrs. Z., *æt.* 58, married, and residing at Barossa, was admitted to hospital on December 7th, 1923. She had suffered from "rheumatism" for many years, and examination showed her to be a typical case of rheumatoid arthritis. She had sent to America for some patent medicine which was advertised as a cure for rheumatism. Seven days prior to admission she had taken three of the pills supplied, and on the same evening a few blisters had appeared on her forehead. The following day she took three more pills, and her face became much swollen. The swelling had increased on the third day and blisters had appeared on her nose, eyelids, tongue, and lower lip. The blisters broke and a scab formed over the sites of the blisters. She had not been able to open her eyes for five days because of the swelling of the eyelids. On admission the swelling had begun to subside and she could just see.

On examination the temperature was 98.4° F., the pulse 110, and the respirations 24 per minute. The temperature rose slightly in the evening. The face showed the following lesions affecting the forehead, both upper eyelids, and the nose. (See Plate II.) There were areas covered with a thick dark-brown crust which, when removed, left a finely granular surface which tended to bleed. The patches



were raised and thickened, and exuded a small quantity of serous exudate. Surrounding the patches there was a zone of hyperæmia and outlying vesicles. The vesicles were filled with a turbid fluid and varied in size from 2 to 5 mm., and were umbilicated, the umbilication being marked by a small point of commencing crust formation. The tongue showed a superficial condition of gangrene at the tip, and the whole tongue was somewhat swollen and protruding between the lips. There was a group of early vesicles on the dorsum of the right hand. The urine contained a fair cloud of albumin. Excepting for the well marked condition of rheumatoid arthritis there was no other abnormality.

An examination of the pills taken showed them to contain iodine, starch, and cinnamon. The weight of each pill was about 5 grains.

Cleansing treatment and stopping the iodide brought about a rapid improvement in the lesions, cultures from which showed the presence of *Staphylococcus aureus*.

Twelve days after admission, when the lesions were almost healed, the patient became breathless with auricular fibrillation and developed broncho-pneumonia, and died the next day. The sketch, which was done by Miss Buxton, shows the condition the day following her admission.

At the autopsy (No. 199/23), fibrinous pericarditis with a bread-and-butter appearance and with 6ozs. of fibrinous serum was present, and the probable cause of death. The lungs were congested, and there was broncho-pneumonic consolidation in the lower lobe of the left lung. The liver was slightly fatty. The lower end of the stomach, the duodenum and upper part of the jejunum showed some diffuse blackish pigmented areas in the mucosa with surrounding congestion.

*Comment.*—This type of idiosyncrasy to iodides is rare, but well known. The diagnosis of the case gave rise to some difficulty, but the key to its solution was forthcoming in the voluntary statement that the patient had been taking pills for "rheumatism." The most likely constituent of such quack pills is iodide in some form, as this drug will probably give the patient some relief, and so the patient keeps on purchasing more in the hope that the joint trouble will eventually disappear. On first seeing the patient, the possible diagnoses that presented themselves for consideration included multiple primary vaccinia pustules from accidental contact with a recently vaccinated person, or multiple primary chickenpox sores. The appearances presented might quite well occur in either of these diseases, but there was no history of exposure to any likely source of infection. The condition did not resemble herpes or pemphigus, or any of the cutaneous manifestations of syphilis. Knowing the history of the taking of quack pills, the provisional diagnosis made was that of iodide rash. References to the published accounts of cases showed that the condition in others was almost identical with the affection in our patient, and a chemical analysis of the pills showed the presence of iodine. The patient's death is to be attributed only indirectly to the iodine idiosyncrasy. The organisms flourishing in the exudate of the rash and the injured tissues apparently finally invaded the blood-stream giving rise to broncho-pneumonia and purulent pericarditis, or owing to the patient's weakened state broncho-pneumonia and secondary pericarditis developed.



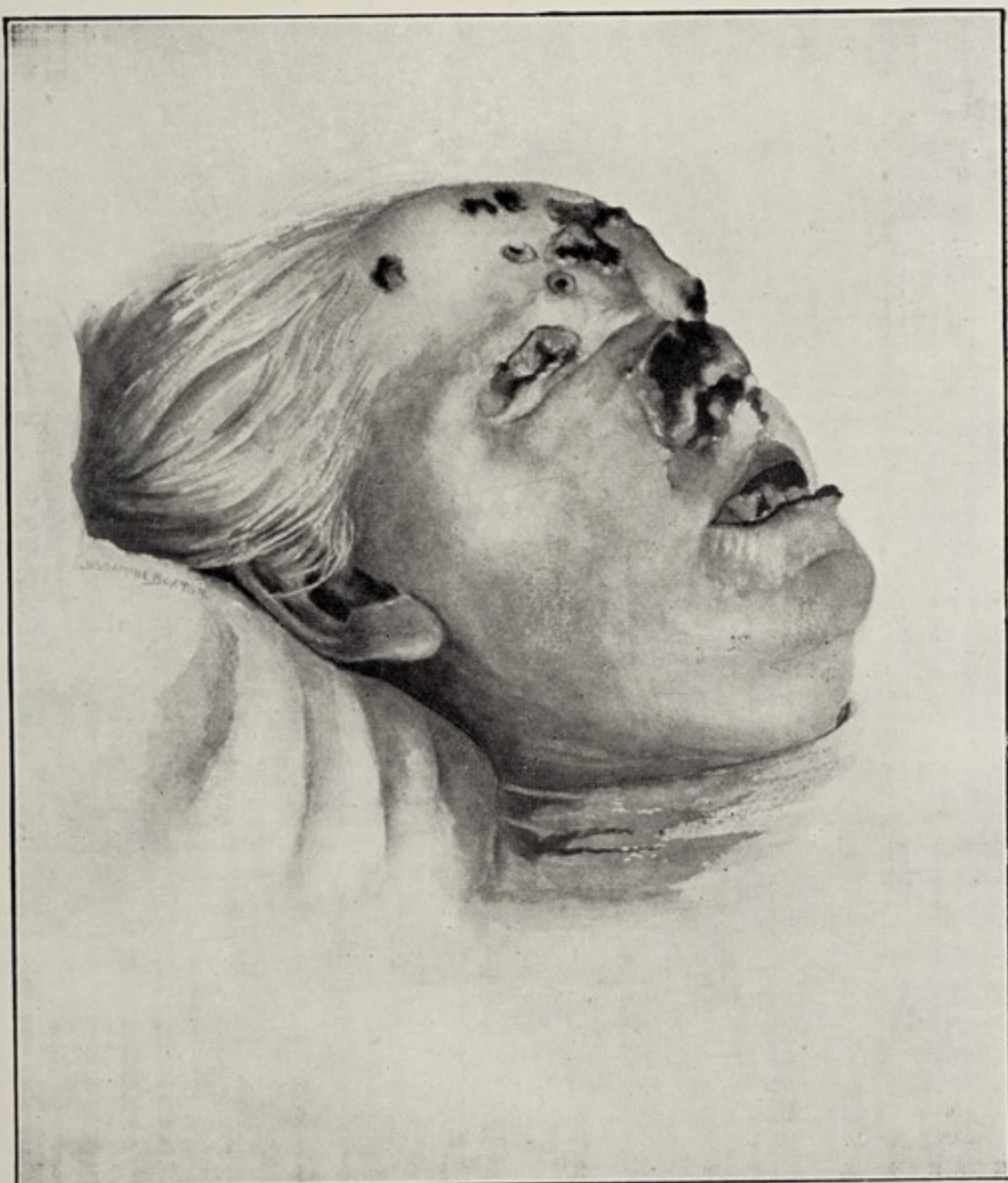



Plate II.  
Iodide Rash, with Facial Granulomata.







## VI.—SURGICAL CASES.

(1) DEATH FOLLOWING A SUPERFICIAL WOUND,  
POSSIBLY FROM DIPHThERITIC INTOXICATION.

(Under the care of Dr. Newland, Hon. Surgeon. Reported by  
Dr. J. B. Cleland, Hon. Pathologist.)

In the following case the correct diagnosis was not certainly established. It was only on reviewing the case after autopsy and before giving evidence in the Coroner's Court that the likelihood of diphtheritic toxæmia suggested itself as an explanation of the course of illness and fatal result, in spite of a statement that the patient had had diphtheria previously (we do not know how long before). It was too late for cultures to be taken, and all that could be done was to make sections of the ulcerated area and stain them by Gram's method. These sections revealed the presence of organisms morphologically like diphtheria bacilli, though possibly not so. It will be noticed that the patient received a comparatively superficial injury, that superficial sloughs formed over this ulcer, that the urine became albuminous and showed the presence of casts, pus, and blood cells, and that the autopsy revealed no outstanding lesion to which death might be attributed. On the other hand the lesions found were such as might be expected in diphtheritic toxæmia, including an ante-mortem clot in an auricular appendix.

A. W., a boy, *æt.* 15, had been knocked from a bicycle two weeks before admission to the hospital, on November 23rd, injuring the right groin. He had been unconscious or confused for about an hour after the injury. The abrasion was treated by fomentations, but did not improve. On admission, in the right groin, was found a somewhat oval necrotic patch extending from the right superior iliac spine across the groin to the inner side of the thigh. In its widest part it was about 2 in. across. The surface was blackish, dry, and dull. At the edge this gave place to fresher colored skin. There were some loose patches of necrotic epithelium at the periphery. The albuminous urine contained many epithelial, as well as hyaline and granular casts, and pus and blood cells. The wound was treated with eusol compresses, but still did not show signs of healing. On December 2nd, at 7 a.m., the patient's general condition became suddenly worse. He was cyanosed, and the pulse rate reached 180. He improved for a time after an injection of 1 c.c. of pituitrin, but later the pulse rose to 230. The skin acted freely. His condition continued to get worse, and he died at 4.30 p.m. on December 3rd, apparently collapsed from some severe form of toxæmia.

At the autopsy (No. 183/23) there was found a large superficial ulcer in the right groin, about 6 in. by 3 in. in extent, about half of the surface being covered with irregular brown sloughs, the rest being yellowish-red in color, but free from sloughs. The ulceration was comparatively superficial and did not extend into the deeper tissues. The lungs were œdematous and somewhat congested. There was a slight excess of pericardial fluid. The right auricle was distended with dark clot, and its auricular appendix was filled with a grayish-red clot which could only be removed from the wall with some difficulty. It was apparently an ante-mortem clot, but not one of long duration. The heart muscle was of good color and firm texture. There were no valvular lesions. The liver was congested, and the spleen normal in size and of firm texture. The kidneys, each weighing 3½ ozs., were congested, but showed no other obvious changes. Their pelvises were normal. The stomach, intestines, pancreas, suprarenal glands, bladder,



prostate, and brain appeared normal. There was no evidence of fracture of the skull and no thrombosis of the iliac vein. Microscopical examination of the wound showed infiltration of the tissues beneath the squamous epithelium near the edge with polymorphonuclear cells and lymphocytes. In other parts there was necrosis and extensive polymorphonuclear infiltration. Sections stained by Gram's method showed the presence of gram positive bacilli in groups, sometimes showing granules at each end, the bacilli being morphologically like diphtheria bacilli. They occurred in necrotic tissue near the surface of the wound and appeared to be the predominating organism. The liver and kidneys showed cloudy swelling. In the lung many catarrhal cells had been shed into the alveoli.

## (2) HORSESHOE KIDNEY AND PATENT DUCTUS ARTERIOSUS IN A DEAF AND DUMB PATIENT.

*(Under the care of Dr. Corbin, Hon. Assistant Surgeon. Reported by Dr. J. B. Cleland, Hon. Pathologist.)*

The patient, a deaf and dumb male, *æt.* 47, was admitted unconscious, having fallen down in the street.

At the autopsy (No. 99/23), the cause of death was found to be subdural hæmorrhage. The kidneys presented a typical horseshoe shape. There was also a patent ductus arteriosus with an opening 1 cm. in diameter.

*Comment.*—In this patient three congenital defects were present, apparently unconnected developmentally with each other. He was deaf and dumb, the ductus arteriosus had not completely closed, and the kidneys were united in horseshoe fashion.

## (3) PNEUMOCOCCAL ABSCESS FOLLOWING PNEUMONIA.

*(Under the care of Dr. Verco, Hon. Gynecologist. Notes by Dr. I. B. Jose, Registrar.)*

I. H., a female, married, *æt.* 36, was admitted to the Adelaide Hospital on August 25th, 1923, with a tumor about 4in. in diameter over the lower part of the left rectus muscle, which she had noticed for four weeks. The swelling was firm, merging into the surrounding tissues at its edge, was slightly painful on manipulation, but was neither red nor hot. Rectal and abdominal examination showed that it was confined to the abdominal wall. She had had pneumonia 12 weeks before. A diagnosis was made of pneumococcal abscess, and it was incised and found to be in the subcutaneous tissues just anterior to the rectus sheath. A pure culture of pneumococci was obtained from the pus. Her convalescence was normal.

## VII.—NEOPLASMS.

### (1) AN EXTENSIVE RODENT ULCER INVOLVING THE SKULL.

*(Under the care of Dr. Newland, Hon. Surgeon. Notes by Dr. I. B. Jose, Registrar.)*

H. C., male, *æt.* 46, married, a sailor, was admitted to the Adelaide Hospital on September 18th, 1923, complaining of extensive ulceration on the vertex of his head about 5in. in diameter. Fourteen years before he had been hit on the head with a pulley block. The wound had never properly healed, except for a short time four years ago,



after which it broke down again and was for a long time about 1½ in. in diameter. Recently it had increased rapidly to its present size.

Examination of the ulcer showed that an area of bone, including both tables of the skull, had ulcerated through, exposing the dura mater which was pulsating. This was surrounded by a zone of exposed necrotic bone, outside which was an area of ulceration of the scalp. Venereal disease was denied, and a Wassermann reaction was negative.

A section of the edge of the ulcer showed it to be a rodent ulcer.

## (2) LYMPHO-SARCOMA OF THE SMALL INTESTINE WITH INVOLVEMENT OF THE SUPRARENAL GLANDS.

*(Under the care of Dr. Cavanagh-Mainwaring, Hon. Surgeon. Reported by Dr. L. B. Bull, Deputy Director of the Laboratory.)*

In the following case, as the result of symptoms pointing to intestinal obstruction, a laparotomy was performed and a new growth found encircling a limited portion of the small intestine. This was excised and a lateral anastomosis performed. Microscopically the neoplasm presented the appearance of a lympho-sarcoma. The patient died the day after operation, and at the autopsy the remaining lesions found were confined to the suprarenal glands.

H. H., male, *æt.* 37, was admitted on January 19th. He gave a history of the onset of his illness a month previously. There had been colicky pain, wasting, and vomiting. On examination the temperature was 97° F., respirations 24, and the pulse 120, feeble and running. The right rectus muscle was on guard and a hard mass was felt near the umbilicus. Laparotomy was performed and a new growth removed by excising a small portion of the small intestine. The appearance presented by the tumor in the preserved specimen is as follows:—The bowel is sharply bent at an angle of 60°. On one side of the attachment of the mesentery is a whitish-grey-colored mass, the under surface of which shows adhesions of the omentum. The mass itself measures approximately 3½ in. by 2 in. On incision the mass is found to contain a flattened cavity connected with the lumen of the bowel, and through which the bowel contents must have passed. The internal surface of the tumor mass, or lining of the cavity, shows large irregular bosses. The wall is from 3/16 in. to ½ in. in thickness, and appears to be supported by a muscular coat under the peritoneal surface. There is constriction of the bowel at the inner angle, which is invaded here by the new growth. The tumor appears to have originated in the bowel wall where the tumor cells have replaced the normal tissue, but the outer muscular coat has grown ahead of the invading cells in an attempt to confine them. The result is a pouch-like tumor on the lateral aspect of the bowel. On microscopic examination the tumor cell is seen to be a round cell somewhat larger than a small lymphocyte, and the chromatin network of the nucleus is loose. The cell also possesses more cytoplasm than a small lymphocyte. Numerous cells show mitotic figures, and occasionally large, multinucleated cells are to be seen. The cells are supported by a fine connective tissue stroma. The tumor cells are invading the normal tissues and leading to their destruction. Scattered throughout the mass of tumor cells are irregular islands of lymphocytes, which appear to have resulted from hyperplasia of lymphocytes cut off by invasion of the tumor cells which have probably arisen in a Peyer's patch. The internal surface of the pouch-like tumor shows no mucous membrane, but is lined by a vascular granulation tissue which is necrotic in parts. The histological picture is



that of a lympho-sarcoma. After the operation the condition of the patient was grave, and he died the following day. An autopsy was made by Dr. D. L. Barlow.

At the autopsy (No. 9/23), the only lesions of note were in the neighborhood of the suprarenal glands. The right was enlarged, measuring 3in. x 1½in., and irregular in shape, and on section showed soft tumor-like masses, irregular in size and shape, resembling lympho-sarcoma or early caseation, and leaving little of the normal structure remaining. The left gland was also enlarged (2in. x 1½in.) and showed soft tumor-like masses throughout.

Microscopic examination shows the mass in each case to consist of hyperplastic areas of lymphoid tissue, large areas of necrotic tissue with small scattered areas of adrenal tissue, and a diffuse invasion by tumor cells resembling those in the tumor of the intestine.

*Commentary.*—The interesting points about this case are, first, the very low condition of the patient after the operation which could not be explained at the time, but which was apparently due to the almost complete loss of function of the suprarenal glands. Secondly, the occurrence of lympho-sarcoma of the small intestine, which is comparatively rare. Thirdly, the secondary involvement of both suprarenal glands. It is interesting to note that a similar involvement of the suprarenal glands was found in a case of carcinoma of the prostate in which there were secondary deposits in other situations as well (*vide* the next case, No. 3).

### (3) CARCINOMA OF THE PROSTATE WITH DEPOSITS IN BOTH SUPRARENAL GLANDS, RIBS, PERICRANIUM, AND DURA MATER.

(Under the care of Dr. Cudmore, Hon. Surgeon. Notes by Dr. J. B. Cleland, Hon. Pathologist.)

A. G., a male, *æt.* 72, had been operated on for carcinoma of the prostate a year ago, and had a persistent suprabic vesical fistula. He died after developing fits, suggestive of uræmia. At the autopsy (No. 73/23) the prostate was found enlarged, and showed on section firm yellowish masses which were not spongy; the growth did not appear to invade the surrounding tissues. The kidneys showed some thinning of the cortex, but there was no definite interstitial nephritis and no pyelitis. The ureters were not dilated. Both suprarenal glands were enlarged, the right especially so, its diameter being half an inch; in the centre of each gland was a firm whitish growth, chiefly situated in the medulla, but affecting the adjacent parts of the cortex. Over several of the ribs there was a somewhat diffuse thickening present, affecting both surfaces. The bone marrow in the femur was yellowish in the centre, but reddish at the periphery. The surface of the skull was covered with bosses of various size and shapes; on section these showed a whitish plaque-like thickening, gelatinous fluid of pus-like consistency exuded, and the surface of the skull beneath these areas was eroded in many places. On removing the skull cap the dura mater appeared thickened all over with, in addition, scattered irregular nodules, tending to cause erosion of the internal aspect of the skull. In the anterior fossa a number of these small nodular thickenings of the dura mater were present. A tumor mass was present in the left occipito-parietal region, attached to the dura mater and projecting into and invading the brain substance. The other organs showed no lesions of moment.

Microscopically the deposits present varying appearances, often in the same section. In the prostate itself, the growth is seen as nearly



solid areas of carcinomatous cells, opening out in places with a more reticular arrangement and invading the surrounding tissues. In the suprarenal glands the malignant cells are arranged in acini with large irregular lumina partly subdivided by papillary ingrowths, and often nearly filled by broken down cells; these acini are separated from each other by slender strands of cellular fibrous tissue; in the younger areas the acini are smaller and more solid, with one or several spaces which enlarge as the growth gets older; the cortex of the gland shows extensive invasion, but has not yet all disappeared. In one kidney a small adenoma, apparently continuous with the renal parenchyma, was present and was considered as an independent growth. The carcinomatous deposits in the lung vary from nearly solid masses to a reticular arrangement with lumen formation and papillary processes. In the neighborhood of the skull the growth occurs as groups of acini, united by delicate fibrous strands into lobules, and these into larger masses; most of the groups of acini are nearly solid, though with several small lumina or barely any lumen at all, and only occasionally do these open out to form large spherical spaces containing a little exudate.

#### (4) RETICULAR LYMPHATIC PERMEATION IN SECONDARY CARCINOMATOSIS OF THE LUNGS.

(*Dr. J. B. Cleland, Hon. Pathologist, and Dr. D. L. Barlow, Hon. Assistant Pathologist.*)

During the year a remarkably fine example of reticular lymphatic carcinomatous permeation of the lungs, secondary to a primary growth in the stomach, was met with at autopsy. A second case, when only a small area of lung was involved in this type of infiltration, occurred later. A few years ago Dr. de Crespigny conducted a *post-mortem* examination on a third case, the lung specimens from which have been preserved and closely resemble the pronounced example that occurred this year. It has seemed worth while bringing these several cases together as presenting a pathological picture of some interest.

*Case A.*—W. S., a male, *æt.* 49, was admitted to the Adelaide Hospital, under Dr. de Crespigny, on May 31st, 1923, complaining of general malaise for the last five months with a succession of severe colds. Six weeks before admission he had had pain in the lumbar region, and dyspnoea on exertion. The pain had lasted for four weeks. Two weeks ago he had noticed a swelling of the left side of the neck, extending down the arm, and of the left side of the chest, the swelling resembling bruising from blood extravasation under the skin (Dr. Wilton). This came on gradually, and since then he had felt weaker, and had had to remain in bed. He had had very little expectoration. He had sweated freely for one week, and had been slightly feverish. Five days before admission 10ozs. of blood-stained fluid, which contained many lymphocytes and polymorphonuclear cells, had been aspirated from his left chest. He had vomited occasionally, and had had a bilious attack six weeks ago. There was no other history of indigestion.

On examination there were crepitations over the whole of the right lung. The percussion note at both bases posteriorly, and at the left apex anteriorly, was impaired, and there was tubular breathing. Oedema of the left arm was present. The abdomen was distended and tympanitic, but there was no fluid present. There was no lumbar pad. There was a faint cloud of albumen in the urine. On June 3rd there was œdema of both arms, and the respirations



were rapid. There were râles posteriorly over the whole of the right lung and the base of the left lung. He gradually became weaker until he died on June 13th. His blood count was normal. There was a negative complement fixation test for hydatid disease. There were no tubercle bacilli in the sputum, and the Wassermann reaction was negative.

*Autopsy, No. 84/23.*—In the stomach was found a crateriform carcinomatous ulcer on the posterior wall near the greater curvature and 2 in. from the pylorus. There was an extensive involvement of the coronary, hepatic, pancreatic, and aortic glands. The gastrocolic omentum attached to the region of the ulcer was firm, fibrotic, and matted. The serous surface near the pylorus showed fine, small, somewhat flaky, markings very similar to the reticulations over the surface of the lungs. The glandular involvement extended to the posterior mediastinal glands and those of the hila of the lungs, and also to the supraclavicular glands on both sides. Both subclavian veins and the left internal jugular vein were occupied by clot, which extended for about 6 in. along the latter vein. There was a pint of blood-stained fluid in the left pleural cavity, and about 10 ozs. in the right. There was slight, old, fibro-caseous tuberculosis at both apices. The surface of both lungs showed a reddish, mottled appearance with vague, pale, reticular markings mapping out the lobules. On section the lungs were reddish, very finely granular in appearance, and larger than normal. There was a large red infarcted area at the base of the right lung. The left lung weighed 29 ozs. and the right 37 ozs. Microscopic examination of the lung showed that there was a diffuse carcinomatous infiltration, the carcinoma cells apparently travelling by the lymphatics, and being seen as narrow columns in the perivascular and peribronchial spaces. In places, there appeared to be a cancerous pneumonia, the alveoli and infundibula being filled with masses of much-swollen cancer cells. These cells looked degenerated and hydropic, the nuclei being sometimes pressed to the side by the swollen contents. Some polymorphonuclear cells were amongst the cancer cells, and in places red cells and a little fibrin filled groups of alveoli (pneumonia). The cancer cells infiltrated strands of fairly dense fibrous tissue in the neighborhood of some of the large vessels. The cervical lymph glands showed the presence of carcinomatous cells similar to those seen in the lung.

*Case B.*—O. O., a male, *æt.* 70, was admitted to the Adelaide Hospital on October 29th, 1919, under Dr. de Crespigny, when he complained of pain in the abdomen on the left side just beneath the ribs. This had been present almost constantly for seven weeks, but did not usually disturb his sleep. Frequently vomiting had occurred a few minutes after taking food, and usually it was preceded by coughing. A dry cough had been present for some weeks, and he had lost about 35 lbs. in weight in three months. He complained of a pain across the back in the lumbar region, but had noticed this to a lesser degree for several years. He had always been a healthy man, and had had no severe illness, but his right eye had been removed on account of a "growth" 14 years earlier. The patient had numerous carious teeth, and showed considerable pyorrhœa alveolaris. Examination of the lungs proved that he had a somewhat flat percussion note everywhere, and the breath sounds appeared somewhat weak, but no adventitiæ were present. No abdominal tumor could be felt, but he always kept the muscles rigid. Gastric analysis showed an absence of free hydrochloric acid, and the presence of lactic acid. He was transferred to a surgical ward, where a laparotomy was performed on November 25th. The liver was found to have numerous malignant nodules present in it, and



therefore nothing further was done. The patient became much thinner, and died on December 30th.

At the autopsy adhesions were found between the liver and the anterior wall of the stomach and the hepatic flexure of the colon. There were numerous much-enlarged malignant glands along both borders of the stomach, and in the hilum of the liver. The stomach was considerably dilated. There was a malignant ulcer 3in. in diameter on the lesser curvature near the pyloric end. The liver had a number of small, umbilicated deposits in it. The lungs were enormously enlarged. The right weighed 74ozs., the left 66ozs. The whole of the lower lobes and the greater portion of the upper lobes were densely infiltrated by carcinomatous growths. On the surface this appeared as a network of broad lines apparently following the path of the lymphatic channels. The lower lobes were almost entirely solid, whilst the upper lobes were solid in parts. The bronchial, posterior mediastinal and left cervical lymphatic glands were also considerably enlarged by carcinomatous growths. The deposits in the lung showed that the growth was adeno-carcinomatous with irregular tubule formation. It was in places extending into and filling the alveoli, giving rise to a cancerous pneumonia.

*Case C.*—J. N., a male, *æt.* 73, was admitted to the Adelaide Hospital on May 16th, 1923, complaining of pain in the right side of the chest and the right arm. It had begun five weeks before with pain in the left ear, which had lasted three days; he then had experienced pain in the right shoulder and in the arm along the inner side of the elbow, of a sharp, stabbing nature, leaving the part sore. He had had a cough for the past week, associated with pain in the right chest and a large amount of phlegm. There was no history of indigestion.

On examination he had tenderness along the course of the right ulnar nerve. There was no wasting or loss of power in the right arm. There were râles at the bases of both lungs and in the right axilla. The pain was severe, and had to be treated by morphia. On May 28th his appetite was very poor, and the pain prevented sleep, and was practically continuous. On June 12th he was vomiting after food. Thirty ounces of blood-stained fluid were drawn off from the left chest. On June 23rd aspiration yielded 20ozs. He was vomiting frequently, and became weaker until he died on July 2nd. His Wassermann reaction was negative. X-ray examination of the chest showed widening of the mediastinal shadow, and an effusion at the left base. The clinical diagnosis was mediastinal tumor, probably secondary to an unlocated primary growth (possibly in the stomach).

*Autopsy, No. 94/23.*—The lesser curvature of the stomach was involved by a scirrhus carcinoma in its submucous and muscular coats with a very slight ulceration of the mucosa over a portion, and small plaques of carcinomatous infiltration of the serosa. The coronary glands and celiac glands were enlarged and hard. The liver was studded throughout with nodules of secondary carcinoma, which were umbilicated on the surface. The mediastinal glands were extensively involved by carcinoma and matted together into a large mass, which formed a tumor 3in. in diameter just above and behind the aortic arch on the left side of the trachea. This mass had prolongations formed of hard matted glands and tissue extending into the hila of both lungs, and a prolongation upwards joining the infra- and supra-clavicular glands on the left side. The main mass was causing some pressure on the œsophagus, and was adherent to the top of the aortic arch, which it had ulcerated through over an area  $\frac{1}{2}$ in. in diameter, but there had been no extravasation of



blood. The mass was adherent through the pleura to the apex of the left lung. The left pleural cavity contained 22ozs. of blood-stained fluid. The left lung was adherent to the carcinomatous mediastinal glands, and was invaded by growth at its apex. At the apex of the left lower lobe was an area, 2in. in diameter, invaded in a different manner as if by a network of carcinomatous growth along the lymphatic channels, appearing on section as multiple hard whitish specks closely set in a firm, congested area of lung. The supra-clavicular glands on both sides were hard, enlarged, and matted with growth, and adherent to the cords of the brachial plexus on the right side.

### VIII.—TUBERCULOSIS.

#### NOTES ON CASES OF PLEURISY WITH EFFUSION AND ITS RELATION TO TUBERCULOUS INFECTION.

(By Dr. I. B. JOSE, Registrar.)

A series of cases has been collected of 25 patients diagnosed clinically as pleurisy with effusion, in whom portions of the fluid had been inoculated into guinea pigs.

Out of these 25 cases, which are generally regarded as having a tuberculous origin, only four gave positive evidence of the presence of tubercle bacilli in the pleuritic effusion, as shown by the guinea pig inoculation test. Twenty-one gave no such evidence.

The object of the inquiry was to review the original histories, to see if any other positive evidence of tuberculosis at the time of the pleurisy existed, and the subsequent histories and present condition of as many of the cases as possible, so as to confirm, or otherwise, the supposition that so-called primary pleurisy with effusion is a tuberculous affection in view of the fact that so large a proportion of the guinea pig inoculation tests were negative.

#### SUMMARY OF CASES.

##### 1. *Cases with a Negative Result on Guinea Pig Inoculation.*

Cases I., II., and IV. showed definite clinical evidence of tuberculosis of the lungs nine, three, and three years respectively after their attack of pleurisy.

Cases III. and XIV. showed definite clinical evidence of tuberculosis of the lung at the time of the attack of pleurisy.

Case V. was a case of polyorrhomenitis, which, it is generally agreed, is of tuberculous origin.

Cases VI., VII., VIII. showed suggestive evidence of tuberculosis of the lung.

Cases IX. to XXI., owing to lack of notes, unfortunately are of no value.

##### 2. *Cases with Positive Results on Guinea Pig Inoculation.*

Case XXIII. showed definite evidence of tuberculosis of the lung at the time of his pleurisy, and the disease has apparently since been overcome by the patient.

Case XXII. showed evidence of tuberculosis of the lung at the time of his pleurisy.

In Cases XXIV. and XXV., unfortunately, there is a lack of sufficient clinical notes, but the inference is that they had tuberculosis of the lung.

Case I.—E. C., a male, *æt.* 69. In 1914 he suffered from chronic bronchitis and loss of weight. No tubercle bacilli were found in the sputum. A large pleural effusion was withdrawn and inoculation of



portion into a guinea pig gave a negative result. From 1915-1917 he did over two years' active war service, and was gassed in France in 1917, with a subsequent return of chronic bronchitis and loss of weight. Tubercle bacilli were found in the sputum in 1918, and he had two attacks of hæmoptysis. An examination in August, 1923, showed signs of an advanced tuberculosis of both lungs with cavity formation.

Case II.—A. P., a male, *æt.* 35, a barman. In 1921 he suffered from chronic bronchitis, and in August, 1921, got a sudden attack of pleurisy with effusion. Sputum examination for tubercle bacilli was negative. Inoculation of a guinea pig with portion of the pleuritic effusion gave a negative result. He had had three years' war service, but had not been gassed. A sister had died recently of pulmonary tuberculosis. Examination in August, 1923, showed diffuse fibrosis of the lung, probably due to long-standing tuberculosis.

Case III.—L. B., a female, *æt.* 70, was admitted in May, 1923, with pleurisy with effusion. She had had chest trouble for two years, and during her stay in hospital showed signs of active tuberculosis at the right apex, though tubercle bacilli were not found in the sputum in two examinations. A guinea pig inoculated with portion of the pleural effusion gave a negative result.

Case IV.—N. F., a female, *æt.* 21, by occupation a nurse, showed definite clinical signs of tuberculosis at the right apex in 1920. During the year she had an attack of pleurisy with effusion, and a portion of the pleuritic fluid inoculated into a guinea pig gave a negative result. After a prolonged rest and general treatment she was well enough to continue her training as a nurse, but examination in June, 1923, showed still a small patch of consolidation at the right apex.

Case V.—N. V., a male, *æt.* 17, was suffering from polyorrhomenitis in 1917. A portion of pleuritic fluid inoculated into a guinea pig produced no lesion. No further history has been obtained.

Case VI., a male, *æt.* 33; case VII., a male, *æt.* 31; case VIII., a female, *æt.* 32; case IX., a male, *æt.* 13; case X., a female, *æt.* 16; and case XI., a female, *æt.* 20, were all cases of pleurisy with effusion of sudden onset. Inoculations of portions of the pleuritic fluids into guinea pigs gave negative results. In all one sputum examination was negative. In case VI., X-ray examination of the chest showed fibrosis of the right upper lobe, suggesting tuberculosis. In case VII., X-ray examination showed irregular mottling of the left apex, suggestive of tuberculous consolidation, and his mother had died of pulmonary tuberculosis. Case VIII. gave a positive von Pirquet reaction. In cases IX., X., XI. the notes were not sufficient to give any other definite proof of tuberculosis, either at the time of illness or subsequently.

Cases XI. to XXI. were all cases diagnosed as pleurisy with effusion, and were mostly private cases. No notes at all could be obtained for these. In all, however, the guinea pig inoculation tests gave negative results.

The following cases gave positive evidence of tuberculous lesions in the guinea pig after inoculation:—

Case XXII.—C. C., a male, *æt.* 19, had a sudden attack of pleurisy with effusion in August, 1922. The sputum showed no tubercle bacilli. X-ray examination of the chest showed opacities in both apical regions suggestive of chronic tuberculosis, and the clinical signs at the lung apices supported this view. The guinea pig inoculated with portion of the pleuritic fluid showed tuberculous nodules in the glands and spleen.

Case XXIII.—L. C., a male, *æt.* 10, had pleurisy with effusion in 1921. He also suffered from tuberculous glands in the neck, with a superadded pyogenic infection. X-ray examination showed



opacities at the left apex suggesting tuberculosis. The guinea pig inoculated with portion of the pleuritic fluid showed tuberculous nodules in the glands and spleen. Examination of the boy in August, 1923, revealed that since his discharge from hospital in October, 1921, he had lived in the country and progressed well, having put on weight, that he had no coughs, and that the glands in the neck had entirely subsided and were now impalpable. He has now no signs of active tuberculosis in the lungs.

Case XXIV.—J. M., a male, *æt.* 18, had pleurisy with effusion in 1915 with repeated re-collection of fluid after tapping. Inoculation of a guinea pig with portion of the pleuritic fluid produced tuberculous deposits in the glands and spleen in five weeks.

Case XXV.—J. L., a male, *æt.* 25, had pleurisy with effusion in 1919. Inoculation of a guinea pig with portion of the pleuritic fluid produced tuberculous deposits in the spleen in seven weeks.

Conclusion.—All the eight cases where sufficient notes were obtained showed at least fairly definite evidence of tuberculosis of the lungs, either at the time of their pleurisy or in their subsequent histories, and four of these showed definite clinical evidence, although no evidence of tubercle bacilli in the pleuritic effusion could be obtained.

This supports the view that cases of so-called primary pleurisy with effusion are due to tuberculosis, even though the guinea pig test may show no evidence of tubercle bacilli in the pleural effusion.

