

A manual of diseases of the eye / by Charles H. May and Claud Worth.

Contributors

May, Charles Henry, 1861-1943.
Worth, Claud Alley, 1869-1936.

Publication/Creation

London : Baillière, Tindall and Cox, 1930.

Persistent URL

<https://wellcomecollection.org/works/s3xvszsa>

License and attribution

This work has been identified as being free of known restrictions under copyright law, including all related and neighbouring rights and is being made available under the Creative Commons, Public Domain Mark.

You can copy, modify, distribute and perform the work, even for commercial purposes, without asking permission.



Wellcome Collection
183 Euston Road
London NW1 2BE UK
T +44 (0)20 7611 8722
E library@wellcomecollection.org
<https://wellcomecollection.org>

DISEASES
OF THE EYE


MAY & WORTH

SIXTH EDITION




22101423740





A MANUAL OF
DISEASES OF THE EYE



Digitized by the Internet Archive
in 2019 with funding from
Wellcome Library

<https://archive.org/details/b3136360x>

PLATE I.

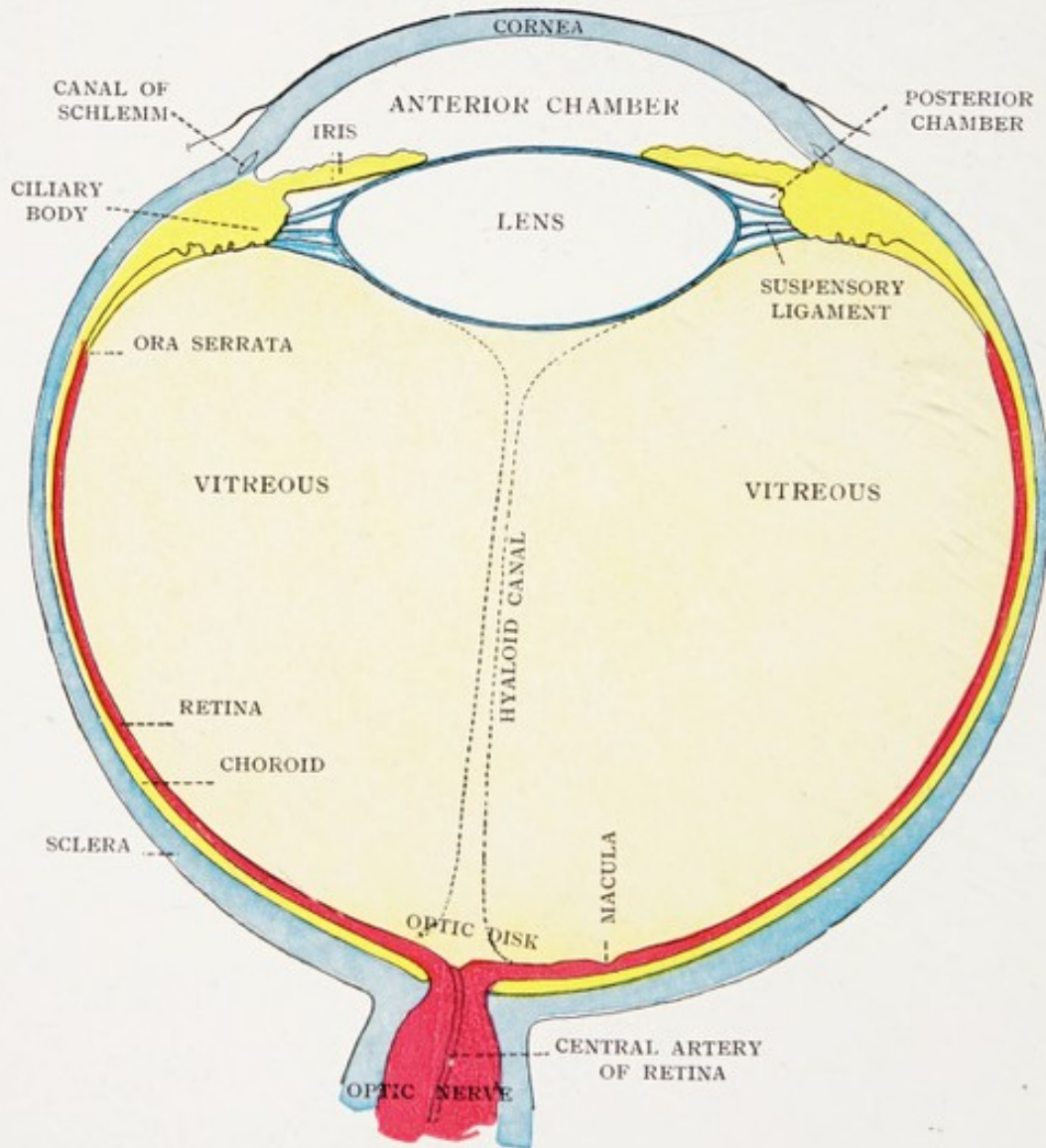


FIG. 1.—HORIZONTAL SECTION OF THE EYEBALL. MAGNIFIED ABOUT $3\frac{1}{2} \times$

Frontispiece.

A MANUAL
OF
DISEASES OF THE EYE

BY
CHARLES H. MAY, M.D.

CONSULTING OPHTHALMOLOGIST TO THE MT. SINAI HOSPITAL, TO THE
FRENCH HOSPITAL, TO THE ITALIAN HOSPITAL, NEW YORK,
AND TO THE MONMOUTH MEMORIAL HOSPITAL

AND
CLAUD WORTH, F.R.C.S. ENG.

CONSULTING SURGEON TO THE ROYAL LONDON OPHTHALMIC HOSPITAL, MOORFIELDS
CONSULTING SURGEON TO QUEEN MARY'S HOSPITAL FOR THE EAST END

SIXTH EDITION



LONDON
BAILLIÈRE, TINDALL AND COX
7 & 8, HENRIETTA STREET, COVENT GARDEN, W C. 2

1930

First English Edition, April, 1906
Second Edition, May, 1908
Reprinted, January, 1909
Third Edition, October, 1911
Reprinted, April, 1912
Fourth Edition, November, 1914
Reprinted, January, 1917, January, 1918,
February, 1919, March and September
1920, April, 1922
Fifth Edition, September, 1924
Reprinted, May, 1927

Sixth Edition, February, 1930 WELLCOME INSTITUTE LIBRARY	
Coll.	welMOmec
Call	
No.	WW100
	1930
	M46m

PRINTED IN GREAT BRITAIN

PREFACE TO THE SIXTH EDITION

THE book has again been carefully revised. While it would not be possible to discuss all recent work in ophthalmology and new methods of treatment, some of which may not survive the test of experience, every endeavour has been made to keep the book abreast of approved modern theory and practice.

The slit-lamp and corneal microscope have proved their value in clinical examination, and their use now forms part of the ordinary curriculum of students of ophthalmology.

Mr. T. Harrison Butler has kindly contributed a chapter on the subject which will add considerably to the value of the book.

CLAUD WORTH.

February, 1930.

PREFACE TO THE FIRST EDITION

IN the following pages the authors have endeavoured to present a concise, practical, and systematic Manual of the Diseases of the Eye, intended for the student and the general practitioner of medicine. An attempt has been made to give the fundamental facts of ophthalmology, and to cover all that is essential in this branch of medicine, always keeping in mind that the book has been written for students and general practitioners. Space, therefore, has been allotted as the necessities of such readers require, estimated by an extended experience in teaching. Thus, rare conditions have merely been mentioned; uncommon affections, of interest chiefly to the specialist, have been dismissed with a few lines; and common diseases, which the general practitioner is most frequently called upon to treat, have been described with comparative fulness.

The illustrations, excepting those showing instruments, are original, and have been inserted wherever it seemed that they would be of value in elucidating the text. Those in colours represent the most common changes in the fundus, a knowledge of which is desirable in the treatment of general diseases, as well as in ophthalmic practice. These plates form a fairly complete ophthalmoscopic atlas.

Since the year 1900 four editions of May's 'Manual of Diseases of the Eye' have been published. It is hoped that the present volume may prove equally popular.

March, 1906.

CHARLES H. MAY,
698, MADISON AVENUE,
NEW YORK.

CLAUD WORTH,
HARLEY STREET,
LONDON, W.

CONTENTS

CHAPTER	PAGE
I. EXAMINATION OF THE EYE - - - -	I
II. SUBJECTIVE OR FUNCTIONAL EXAMINATION OF THE EYE -	10
III. OBJECTIVE EXAMINATION OF THE EYE CONDUCTED IN THE DARK ROOM - - - - -	20
IV. THE SLIT-LAMP AND CORNEAL MICROSCOPE - -	38
V. AFFECTIONS OF THE EYELIDS - - - -	47
VI. DISEASES OF THE LACRYMAL APPARATUS - -	72
VII. DISEASES OF THE ORBIT - - - -	81
VIII. DISEASES OF THE CONJUNCTIVA - - - -	94
IX. DISEASES OF THE CORNEA - - - -	129
X. DISEASES OF THE SCLERA - - - -	152
XI. DISEASES OF THE IRIS - - - -	157
XII. DISEASES OF THE CILIARY BODY - - - -	170
XIII. DISEASES OF THE CHOROID - - - -	176
XIV. SYMPATHETIC OPHTHALMITIS—PANOPHTHALMITIS -	182
XV. INTRA-OCULAR TUMOURS - - - -	187
XVI. GLAUCOMA - - - -	190
XVII. DISEASES OF THE VITREOUS - - - -	212
XVIII. DISEASES OF THE LENS - - - -	220
XIX. DISEASES OF THE RETINA - - - -	247
XX. DISEASES OF THE OPTIC NERVE - - - -	266
XXI. AMBLYOPIA AND FUNCTIONAL DISEASES OF THE RETINA	276
XXII. COLOUR-BLINDNESS - - - -	287
XXIII. GENERAL OPTICAL PRINCIPLES - - - -	294
XXIV. OPTICAL CONSIDERATION OF THE EYE - - -	310
XXV. ERRORS OF REFRACTION - - - -	330
XXVI. ANOMALIES OF ACCOMMODATION - - - -	358

CHAPTER	PAGE
XXVII. PARALYSIS OF EXTERNAL OCULAR MUSCLES	363
XXVIII. COMITANT SQUINT -	379
XXIX. HETEROPHORIA -	391
XXX. OPERATIONS ON THE EXTERNAL OCULAR MUSCLES -	400
XXXI. THE OCULAR MANIFESTATIONS OF GENERAL DISEASES -	407
XXXII. VACCINES IN OPHTHALMOLOGY -	421
XXXIII. OCULAR THERAPEUTICS: GENERAL RULES FOR OPERA- TIONS UPON THE EYE -	431
XXXIV. VISUAL REQUIREMENTS FOR BRITISH AND INDIAN PUBLIC SERVICES -	450
INDEX	456

DISEASES OF THE EYE

CHAPTER I

EXAMINATION OF THE EYE

OPHTHALMOLOGY is a branch of general medicine and surgery from which, in practice, it cannot be entirely separated. For this reason all licensing authorities have wisely decided that he who would practise ophthalmology must first qualify for general practice. The ophthalmologist should keep up his general knowledge and be familiar with recent developments in medicine and surgery, at least in their broad outlines.

By examination of the eye is meant not the investigation of an isolated organ, but the examination of the patient with special reference to that organ and its functions.

Every case should be investigated thoroughly and according to a definite routine, otherwise there would be a danger of the attention being concentrated upon some obvious symptom, while something else, perhaps more important, might be overlooked. A beginner should write a list in their proper order of all the points to be investigated, and should, while examining a patient, consider each point in turn, rejecting those which obviously do not apply to the case in question, and investigating those which may be relevant. With increasing experience it will no longer be necessary for him *consciously* to go through the list. He will have acquired the habit of systematic enquiry.

Before beginning the examination of the eye, it is well to hear what the patient has to say about his symptoms and history. While one is making notes of any parts of his narrative which seem to be of importance, the patient himself should be studied.

The examination of the eye may be divided into Objective and Subjective or Functional.

The objective examination consists in—

Examination of the appendages and the anterior portions of the eyeball by means of inspection and palpation; this part of the examination may be conducted in daylight or artificial light.

Examination of the cornea and of the interior of the eyeball in the dark-room, with artificial light, by means of oblique illumination, transillumination, corneal microscope, ophthalmoscope, etc.

EXTERNAL EXAMINATION OF THE EYE

Inspection.

The patient should be seated facing a window or adequate source of artificial illumination. A general inspection will reveal any obvious symptoms which may be present, such as congestion, discharge, lacrymation, photophobia, undue prominence of the eyes, obvious squint, etc.

Proceeding from the superficial to the deeper parts, we commence with the *lids*, noticing their thickness, colour, and position; the condition of their margins, whether swollen, crusted, or ulcerated; the power of opening and closing; the size of the palpebral aperture, and the position and permeability of the lacrymal puncta. Then passing to the region of the *tear-sac*, we see whether this is swollen, and whether pressure with the tip of the index finger causes escape of secretion. We examine the condition and direction of the *cilia*, and notice whether any are misdirected.

Next we inspect the inner or *conjunctival surfaces of the lids*, observing any change in smoothness, thickness, and secretion of this membrane, and looking for foreign bodies.

Exposure of the conjunctiva of the lower lid is easy: Place the thumb near the margin of the lid, press downward, while the patient looks up (Fig. 2).

Eversion of the upper lid requires a little practice: Grasp the central lashes between the thumb and index finger of the right hand, and draw the lid strongly downward and away from the globe, directing the patient to look down

(Fig. 3); place the left thumb (or a probe held horizontally) at the upper margin of the tarsus, and press downward, at the same time quickly turning the lid. Having turned the lid, it can be kept everted by shifting the left thumb against

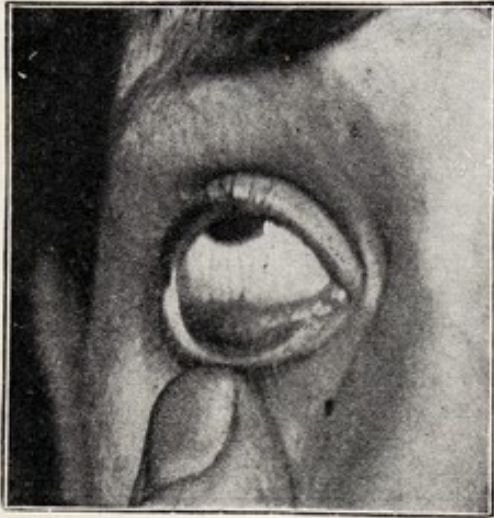


FIG. 2.—EVERSION OF THE LOWER LID.

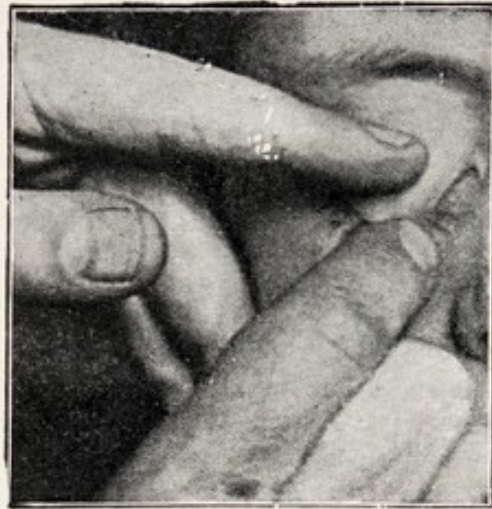

FIG. 3.—FIRST STEP IN EVERSION OF THE UPPER LID.

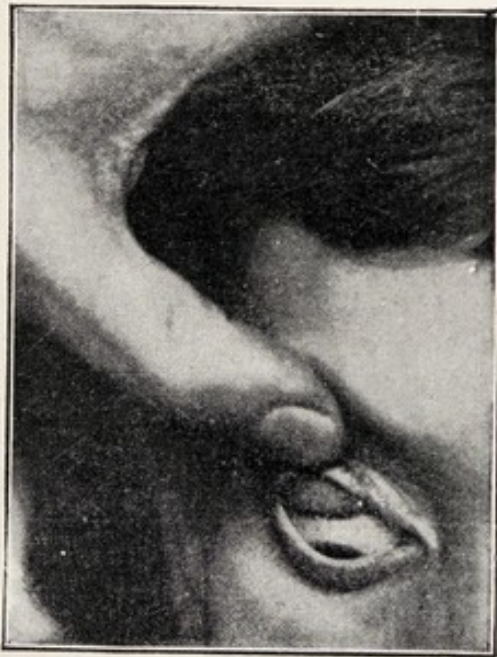

FIG. 4.—KEEPING THE UPPER LID EVERTED.

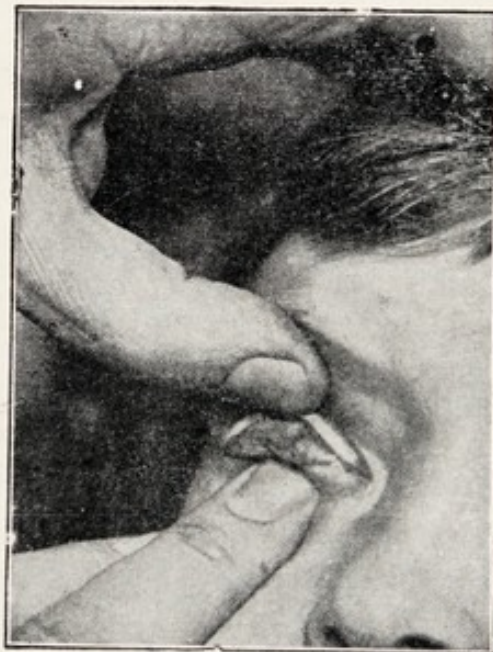

FIG. 5.—EXPOSURE OF THE RETROTARSAL FOLD OF THE CONJUNCTIVA OF THE UPPER LID.

the margin, the other fingers of the left hand being applied to the patient's forehead (Fig. 4).

This exposes the tarsal portion of the conjunctiva. If we wish to inspect the *retrotarsal fold* (and this is important

in the examination for trachoma), it is necessary to continue as follows: Press the edge of the everted upper lid firmly against the supra-orbital margin with the thumb of the left hand; then push the lower lid upward over the cornea with the right index finger, at the same time exerting gentle backward pressure upon the eyeball (Fig. 5).

There is a better method of everting the upper lid, which is easily learned. Put the tip of the index finger on the upper lid just above its margin. Put the thumb on the lower lid just below its margin. Tell the patient to look down. Push the upper lid up and back: this tilts its margin away



FIG. 6.—PLACIDO'S DISC.



FIG. 7.—CORNEAL REFLECTION OF PLACIDO'S DISC.

A, Normal; *B*, distortion caused by foreign body on the cornea.

from the globe. With the thumb slide the lower lid under the upper lid. The upper lid is now grasped between the finger and thumb, and is readily everted by a sort of semi-rotary movement of the thumb and finger. The whole act is continuous, and is done quickly, easily, and with a minimum of discomfort to the patient. Only one hand is required. There is no danger of pulling out lashes.

Next we proceed to the *eyeball*, and notice its position in the orbit, whether this is normal or whether the globe is pushed forward (exophthalmos, Fig. 93, p. 83) or sunken (enophthalmos).

We observe whether there is any œdema of the bulbar conjunctiva (chemosis), or congestion of the anterior part of the eyeball. If the latter is present, it should be examined carefully, for the nature of this injection points to the seat of inflammation (pp. 95 and 161).

The *cornea* is next inspected, and may show inflammation, ulceration, vascularization, opacities, or foreign bodies. The cornea, however, is best examined in the dark-room by the methods described in Chapter III.

Placido's disc is a simple and very useful instrument for detecting inequalities in the corneal curvature. It is a disc about 8 or 10 inches in diameter, with a handle, and a hole in the centre. Its face is painted in alternate white and black rings. It is convenient to have a lens about 2.5 D. set in the central hole. The patient sits with his back to a good diffused light, natural or artificial. The disc is held about 14 inches from his face with its plane at right angles to the line from its centre to the patient's eye. On looking through the hole the surgeon sees on the patient's cornea a miniature image of the disc. All the rings should be circular, even when the patient turns his eye moderately up or down or to one side. Irregularity of surface due to old corneal ulcer or injury would make the rings irregular at this point; high corneal astigmatism would make the rings uniformly oval; kerato-conus would make the rings pear-shaped when the patient is not looking directly at the centre of the instrument.

To bring an abrasion or ulcer of the cornea more clearly into view, we may instil a drop of a 2 per cent. solution of fluorescein, washing off the excess with water. Wherever the corneal epithelium is absent there will be a green stain. This examination is best made in the dark-room with oblique illumination and corneal magnifier.

We often find evidences of previous ulceration of the cornea in the form of opacities. When a corneal opacity is very faint and cloud-like, it is called a nebula; when denser, a macula; and when perfectly opaque and white, a leucoma (Figs. 135, 136, 137).

The *sensitiveness* of the cornea may be noted by touching it gently with a thread or piece of soft paper, taking care not to touch the lids or lashes.

When there is much irritation, spasm of the lids (blepharospasm) prevents a proper examination. In such cases, the

instillation of a solution of cocaine, 2 per cent. in liquid paraffin, will aid us in exposing the eyeball.

In *infants or very young children*, when blepharospasm, swelling, inflammation, or obstinacy prevents us from inspecting the cornea in the usual way, the child is laid upon its back across the nurse's lap, its hands are held, and its head is steadied between the knees of the examiner (Fig. 8). Under such circumstances the lids may usually be everted by pulling

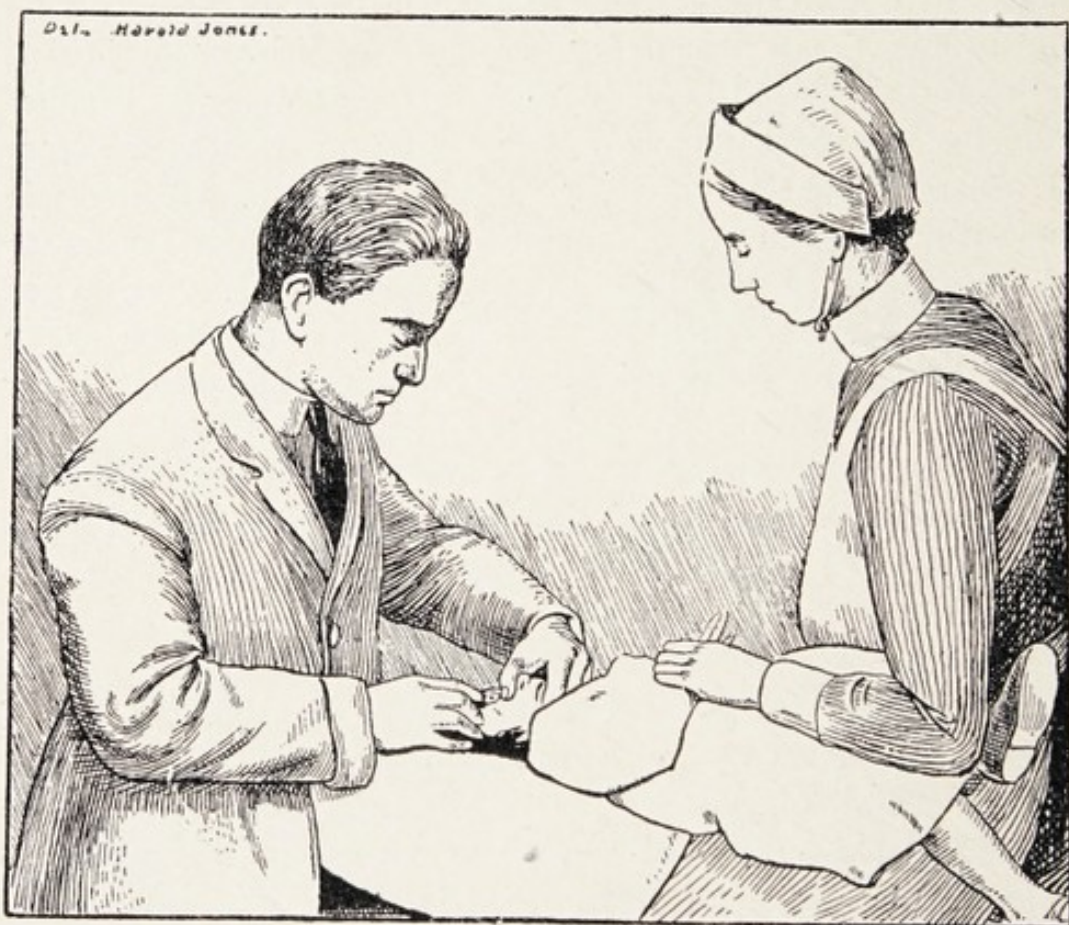

FIG. 8.—METHOD OF EXAMINING THE EYES OF INFANTS AND YOUNG CHILDREN.

upon them at a little distance from the margin. To inspect the eyeball, we part the lids by placing our thumbs at the edges, rolling in the latter somewhat, and then separating, keeping close to the surface of the eyeball (Fig. 9). Having exposed the eyeball, we may replace the thumb of the right hand by the index finger of the left, thus leaving the right hand free for other uses. The eye will usually be found turned upward, hence the cornea will be hidden from view; but after a minute

it will appear in the palpebral aperture. Care must be taken not to scrape the cornea and cause an abrasion, nor to exert any pressure upon the eyeball, on account of the danger of perforation in case the cornea has become weakened by ulceration.

It is sometimes necessary to use retractors (Fig. 10) in order to separate the lids under such circumstances, and with these the same caution is required against wounding the cornea or pressing upon the eyeball. If this procedure should prove unsatisfactory, a general anæsthetic must be employed.

When forcibly separating the lids we must remember that pent-up secretions are released suddenly, and may squirt into the eyes of the examiner.

Next we examine the *anterior chamber* and note its depth, whether normal, shallow, or increased, and whether the aqueous humour is clear; if the latter is altered, we observe whether the exudation consists of pus (hypopyon), blood (hyphæma), spongy exudation, or the like. This examination should be repeated with focal illumination in the dark-room.

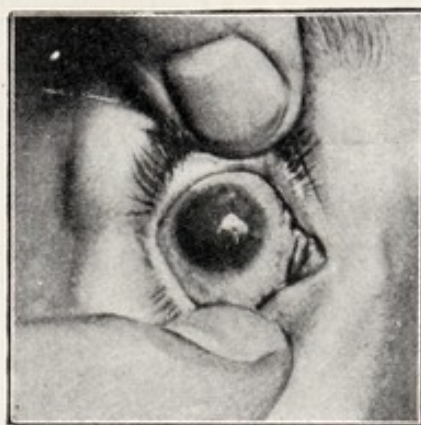


FIG. 9.—METHOD OF EXPOSING THE EYEBALL.



FIG. 10.—DESMARRE'S LID RETRACTOR.

The *iris* comes next. We note its colour, smoothness, and thickness, whether its markings are clearly defined or blurred, and whether it is steady or tremulous during movements of the eyeball. Adhesions to the cornea (anterior synechiæ) or to the capsule of the lens (posterior synechiæ) are looked for. These may require the instillation of a mydriatic for their detection,

Then we note the characteristics of the *pupil*: size, shape, and position; also its reaction to light, and in accommodation and convergence as explained on p. 168. Behind the pupil

we see the central part of the anterior surface of the *lens*, and observe its transparency or any abnormal condition which may be present, such as cataract and deposits. To explore the lens fully, dilatation of the pupil and artificial illumination are required.

Palpation.

Palpation gives us information regarding the presence or absence of sensitiveness in the ciliary region, the tension of the eye compared with that of a normal eye, and may possibly reveal the existence of a tumour or swelling in or about the orbit.

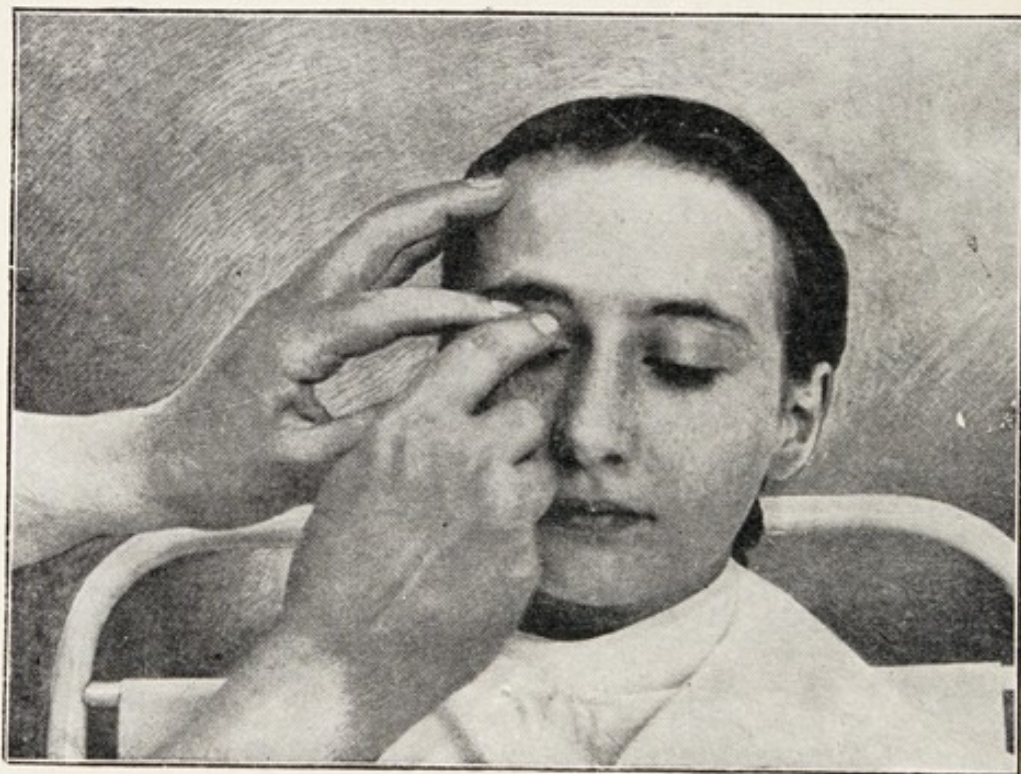

FIG. 11.—TESTING THE TENSION OF THE EYEBALL.

Ciliary Tenderness.—By exerting gentle pressure upon the sclera, just behind the cornea (Fig. 11), as described below, we may discover increased sensitiveness of the ciliary body; this is an important symptom of cyclitis.

Eyeball Tension.—To ascertain the tension, we direct the patient to look down, and then gently palpate the sclera above the cornea, by means of the two index fingers placed upon the upper lid (Fig. 11), just as in feeling for fluctuation

in an abscess. We estimate the degree of tension by comparison with the other eye, if normal, or with another healthy eye. An educated finger gives more reliable information than any instrument. 'Tonometers' have been devised for the purpose, the most generally used being that of Schötz. The patient's eyes are anæsthetized with 2 per cent. cocain in liquid paraffin, as a watery solution of the salt makes the corneal epithelium more susceptible to accidental abrasion; he looks vertically upwards. The lower end of the tonometer is applied to the centre of the cornea. Little weights are put upon the instrument. These and the deflection of a needle on a scale show the pressure required to dimple the cornea.

Increase of tension is a prominent symptom of glaucoma; perforating wounds and degenerated conditions of the eyeball cause diminished tension; alternations in tension are sometimes found in cyclitis.

Tension is expressed by the sign T. followed by n. when normal, by + or - when increased or diminished, with numerals indicating the degree of change, as follows:

T.n. = Tension normal.
T. + = Tension increased.
T. + 1 = Appreciable hardness.
T. + 2 = Decided hardness.
T. + 3 = Board-like hardness.

T. - = Tension diminished.
T. - 1 = Appreciable softness.
T. - 2 = Decided softness.
T. - 3 = Eyeball very soft.

CHAPTER II

SUBJECTIVE OR FUNCTIONAL EXAMINATION OF THE EYE

THE *subjective examination*, dependent upon the statements of the patient, comprises the testing of the function (sight) of each eye separately. The functions to be tested are the form sense in direct vision, the extent of the fields of vision, the colour sense, and the light sense.

The *form sense* is the faculty which the eye possesses of perceiving the shape or form of objects in direct vision, and is expressed as acuteness of vision. The *field of vision* of each eye is mapped out by a series of points showing the angular distances from the fixation point at which light can be perceived. The *colour sense* is the power which the eye has of distinguishing light of different wave lengths—*i.e.*, distinguishing colours. The *light sense* is the faculty of perceiving different degrees of intensity of illumination (brightness).

The Acuteness of Vision.

Central or Direct Vision.—When we wish to see an object clearly, we look directly at it so that the image falls upon the macula lutea, the portion of the retina which is adapted for the most acute vision. The acuteness should be tested both for distant and for near vision.

Distant Vision.—In testing for distance a range of 20 feet (6 metres) is selected, since rays of light from a point at this distance are nearly parallel. For this purpose we make use of *Snellen's test types*, which are constructed upon the following principle: Each letter is inscribed within a square (Fig. 12), which subtends a visual angle of 5' at the distance at which

the normal eye should distinguish the letter. The visual angle is included between two lines drawn from the extremities of the object through the nodal point of the eye (Fig. 13).




FIG. 12.—CONSTRUCTION OF SNEELEN'S TEST TYPES.

Each side of the square is subdivided into five equal parts; the smaller squares thus formed subtend a visual angle of $1'$, which is the minimum visual angle for the normal eye—that is, if two black objects on a white ground are separated by a space subtending a smaller angle, they will no longer be seen separate. In order to subtend the same visual angle, the size of the letters must increase the farther they are removed from the eye (Fig. 13).

Snellen's test types consist of square-shaped letters arranged upon a chart, the size of the letters diminishing from above downward. The height of each letter subtends a visual angle of $5'$, the component lines a visual angle of $1'$. The uppermost letter is of such a size that it can be read at 60 metres; then follow rows of letters which should be read at 36, 24, 18, 12, 9, 6, and 5 metres respectively (Fig. 14).

The *acuteness of vision* is expressed by a fraction, the numerator of which corresponds to the number of metres

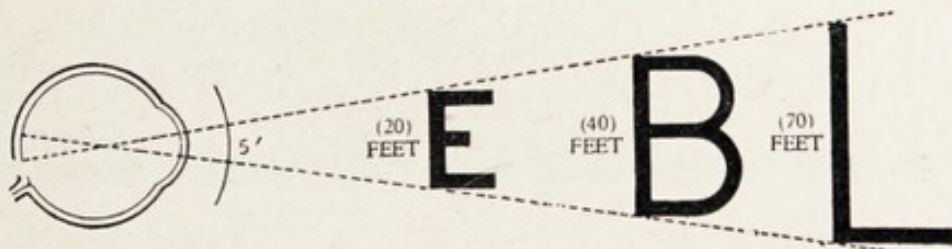


FIG. 13.—THE ESTIMATION OF THE SIZE OF SNEELEN'S TEST TYPES AT VARIOUS DISTANCES.

separating the patient from the chart (preferably 6 metres), and the denominator to the number indicating the distance at which the smallest letter read by the patient should be read by the normal eye. If the patient's sight is normal, his acuteness of vision will equal $\frac{6}{6}$; this is expressed $V. = \frac{6}{6}$. If he can see only the third line from the top, $V. = \frac{6}{24}$. If he cannot read more than the top letter, $V. = \frac{6}{60}$. If he reads some letters in the $\frac{6}{18}$ line, but not all of this size, $V. = \frac{6}{18}$ —or $\frac{6}{24} +$. Many

persons, especially during youth, can read the line which should be read at 5 metres from the chart; the fraction in this case would be $\frac{6}{5}$.

If the patient's vision is less than $\frac{6}{5}$, we reduce the distance from the chart. If he sees the largest letter at 2 metres, $V. = \frac{2}{5}$. If he cannot read the top letter at any distance, we record the distance in feet or inches at which he can correctly

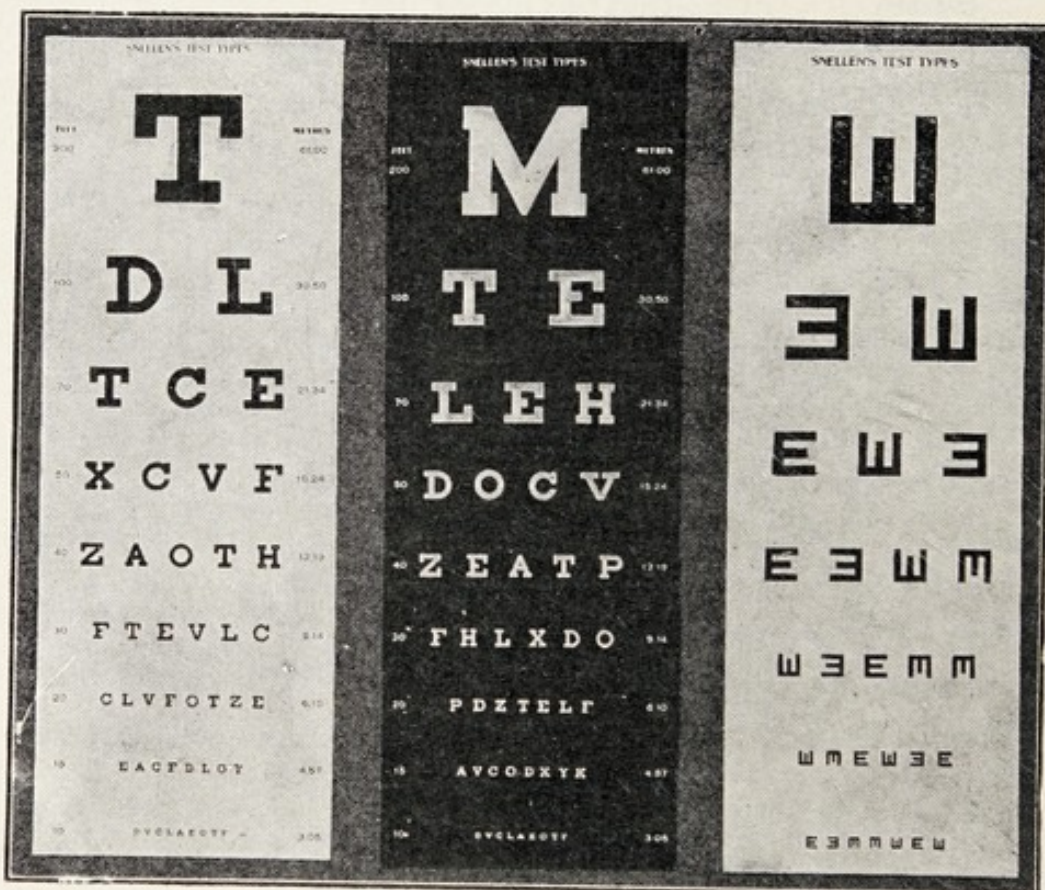

FIG. 14.—SNELLEN'S TEST TYPES.

FIG. 15.—SNELLEN'S TEST TYPES (WHITE ON BLACK GROUND).

FIG. 16.—TEST TYPES FOR ILLITERATES.

count the examiner's fingers held against a dark background; for example, $V. =$ Fingers at 1 foot or $V. =$ Fingers at 7 inches. If he has less sight than this, we move the hand before the eye, and if he is capable of appreciating such movements, we say he has 'perception of hand movements.' If his vision is still further reduced, we ascertain whether he has perception of light (P. L.) by alternately shading and exposing the eye. This is done by means of the hand, or by

throwing light upon the eye with the ophthalmoscopic mirror in the dark-room, and noting whether he indicates the presence or absence of illumination.

Each eye is tested separately, one eye being covered with a card, or with the opaque disc supported in the trial frame. Daylight may be used for illuminating the chart, but artificial light thrown directly upon the test letters is preferable, being more uniform. The test types are hung opposite a window, at about the level of the patient's eyes, and the patient is placed with his back to the source of illumination. When the person is illiterate, we may employ a series of letters E, with sizes corresponding to those of the Snellen types, in which the openings point downward, upward, and to the right and left (Fig. 16); the acuteness of vision is then fixed by the smallest row of which the patient can correctly tell the direction in which the figures are open.

Near Vision.—When in a state of rest, the eye is adapted for parallel rays coming from a distant object. In order that divergent rays from a near object shall be focussed on the retina, there must be an increase in the refractive power of the eye. This change is known as accommodation; it will be more fully described in Chapter XXIII.

The test types usually employed to determine near vision consist of different sizes of ordinary printer's types; the finest is numbered 1, successive numbers indicating coarser type. They are known as Jaeger's test types (Fig. 17).

The patient should be placed with his back to the light, so that the page is well illuminated, and each eye tested separately. His near vision is expressed by J., followed by the number corresponding to the finest print which he can read; thus, J. 3 means that the patient is able to read the third paragraph.

The Field of Vision.

Peripheral vision is exercised when the image falls upon some part of the retina outside the fovea centralis; such vision is indistinct, but of great importance.

The field of vision represents the limits of peripheral or

1.

As she spoke, Moses came slowly on foot, and sweating under the deal box, which he had strapped round his shoulders like a pedlar. "Welcome, welcome, Moses! well, my boy, what have you brought us from the fair?"—"I have brought you myself," cried Moses, with a sly look, and resting

2.

five shillings and twopence is no bad day's work. Come, let us have it then"—"I have brought back no money," cried Moses again. "I have laid it all out in a bargain, and here it is," pulling out a bundle from his breast: "here they are; a

4.

mother," cried the boy, "why won't you listen to reason? I had them a dead bargain, or I should not have brought them. The silver

6.

the rims, for they are not worth sixpence; for I perceive they are only copper varnished over."—"What!"

8.

with copper rims and shagreen cases? A murrain take such trumpery! The block-

10.

the idiot!" returned she, "to bring me such stuff: if I had them I would throw them in

12.

By this time the unfortunate

14.

asked the circumstances

15.

to a tent, under

indirect vision; it is the space within which an object can be seen while the eye remains fixed upon some one point. It usually refers to one eye, the other being covered, and, when not otherwise stated, applies to a white object. The field can be outlined roughly by the hand, more accurately by a piece of chalk upon a blackboard, or a lighted candle, most exactly by means of a perimeter.

The Hand Test.—The patient is turned with his back to the light, and the examiner faces him at a distance of 2 feet. After covering one eye, the patient is directed to fix that eye of the examiner which is opposite. The examiner closes his other eye. The hand with extended fingers is then moved from various parts of the periphery inward, midway between examiner and patient, and the latter indicates when he sees the fingers. In this way the examiner can compare the patient's field with his own; if both be normal, patient and examiner must see the fingers simultaneously. This is a very simple and rapid method, and will reveal any large defect in the field. Instead of the hand, a small white knob upon the end of a rod may be used to measure the field.

The Candle Test.—When the patient is no longer able to see the hand, we make use of a lighted candle, or light reflected from an ophthalmoscopic mirror, in the same manner, in the dark-room.

The Blackboard Test gives us an approximately correct graphic representation. The patient is placed 12 inches in front of a blackboard, upon which we mark a cross to serve as the point of fixation. A piece of chalk is now gradually brought from the periphery towards the centre, and the patient indicates when he sees it in the several directions. These points are marked, and by connecting them an outline of the field is obtained.

The Perimeter (Fig. 18) furnishes the most exact method. It consists of a metallic semicircle or quadrant, which can be revolved so as to take the direction of any meridian. This arc is marked in degrees, '0' corresponding to the middle point and '90' to either extremity. The patient's head is supported upon a chin-rest, one eye covered and the other fixed upon an

object placed at the centre of the arc. The test object, a piece of white paper 10 mm. square, is carried along the inner surface of the arc, and the points where it is first seen in the different principal meridians are marked upon diagrams of the normal field; the lines connecting these form the boundary of the field.

Extent of the Normal Field of Vision.—Toward the temporal side it is 90° (or over); in other directions it is less extensive, on account of the more anterior termination of the percipient layers of the retina on the nasal side. On the nasal side the field extends 60° ; above, 60° ; below, 70° (Fig. 19).

Pathological Alterations in the Field of Vision.—These consist of limitation and defects. Limitations may assume the form of contraction evenly in all directions (concentric) (Fig. 223), irregular contraction (Fig. 168), or loss of part of the field, on one side or the other (Fig. 228).

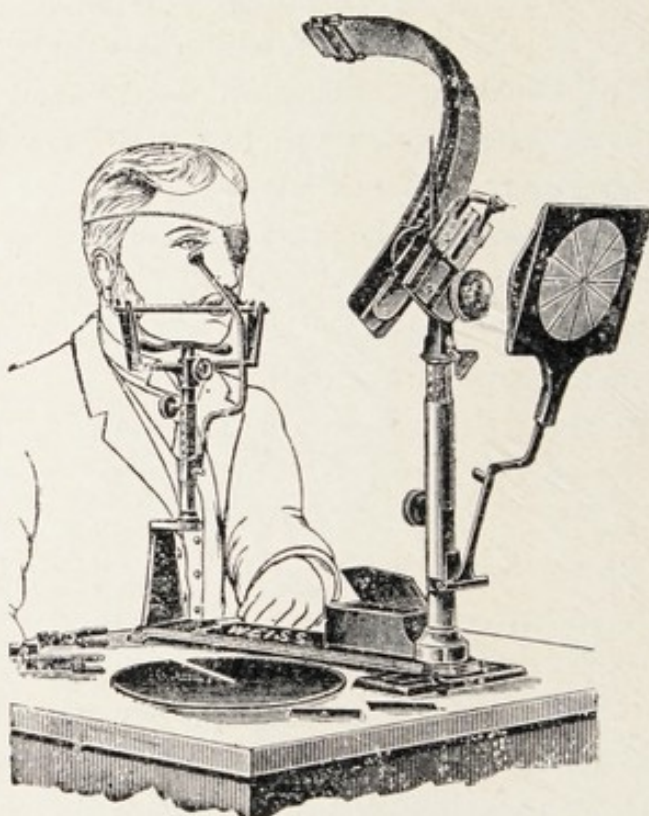

FIG. 18.—MCHARDY'S PERIMETER.

Concentric contraction affects all parts of the periphery alike; when considerable, nothing but central vision may remain (Fig. 223); such contraction with preservation of good central vision is met with especially in retinitis pigmentosa. The contraction may affect only one side of the periphery; in such cases we speak of temporal or nasal contraction, or upper or lower contraction. When one-half of the field is absent (Fig. 228), it constitutes *hemianopsia* (p. 270). Sector-shaped contractions sometimes exist; the

defect then has the shape of a triangle the base of which is peripheral. Certain affections produce characteristic contraction of the visual field; for instance, in atrophy of the optic nerve the contraction is concentric; in glaucoma it is usually greatest on the nasal side.

A *scotoma* is a defect within the visual field. A physiological scotoma is the blind spot, the situation of which is about 15° to the temporal side of the point of fixation, corresponding to the entrance of the optic nerve (the black spot



FIG. 19.—NORMAL FIELDS FOR WHITE AND FOR COLOURS (BLUE, RED, AND GREEN).

in Fig. 19). According to their situation, we divide scotomata into central and peripheral. A central scotoma corresponds to the point of fixation (Fig. 222); when marked, it interferes with or abolishes central vision altogether; the scotoma caused by hæmorrhage at the macula furnishes an example. Peripheral scotomata cause little disturbance of sight, and may exist without the patient's knowledge, especially when situated far from the point of fixation; disseminated choroiditis furnishes examples of scotomata of this sort (Fig. 157).

Scotomata may be *positive*, when the patient sees them as black spots in his field, or *negative*, when they exist as defects in the visual field, but are not perceived by the patient until the visual field is examined. Positive scotomata are due to changes in the media or in the retina. If the opacities exist in the vitreous, the scotomata are motile; *muscæ volitantes* represent one variety of defects of this sort. Negative scotomata may be *absolute*, when perception of light is entirely lost over the defective area, or *relative*, when there is only diminished perception of light, or loss of perception of certain colours over this area. Toxic amblyopia gives us an example of a scotoma which is central, relative, and often negative (Fig. 222).

For the detection of scotomata white or coloured test objects having a diameter of 2 mm., mounted on a black disc, are best for general use. If the visual acuity of the eye be low, larger test objects must be used.

Bjerrum's method is more sensitive than the perimeter, as it gives a larger projection of the defect. He uses a large black curtain with a fixation-point in the middle of it. The patient is 2 metres from it. A test object on the end of a long black rod is used to map out defects in the field of vision.

The Colour Sense.

The colour sense as a whole (*i.e.*, the faculty of distinguishing different colours) is investigated by the methods described in Chapter XX.

Central perception of colour is tested by the method described on p. 259. The peripheral extent of the colour fields is ascertained by small objects, such as squares of coloured paper or small coloured knobs 10 mm. in diameter, which are moved from the periphery towards the centre, on the perimeter or in the coarser methods of testing the field.

The field for colours is smaller than that for white, but has the same general shape. It varies also for different colours; that for blue is the largest, next comes red, while green has

the smallest field. The limits (given in Fig. 19) correspond to the points at which the colours are recognized, not to those points at which merely the presence of a moving object is perceived. The examination of the colour fields is of considerable importance, since we frequently find that contraction of the field for colours exists at an earlier period than that for white. It is a more delicate test, and detects diminution of visual power before it has become sufficiently pronounced to affect the field for white.

The Light Sense.

The power of perceiving gradations in intensity of illumination (brightness) is tested by means of instruments known as photometers. We determine either the smallest degree of light with which an object is still visible, or the smallest difference in illumination which can be appreciated. Diminution in the light sense is not always proportionate to changes in the acuteness of vision. Marked reduction of the light sense is seen in cases which are accompanied by night blindness—retinitis pigmentosa, for instance.

The examination of the motility of the eye is described in Chapters XXVI., XXVII., and XXVIII.

CHAPTER III

OBJECTIVE EXAMINATION OF THE EYE CONDUCTED IN THE DARK-ROOM

THE examination in the dark-room comprises the following steps:

I. *Oblique illumination*, for the physical examination of the anterior portions of the eyeball.

II. *Examination with the ophthalmoscope at a distance*, for exploring the media of the eyeball, and to determine whether the eyes fix binocularly.

III. *The indirect method of ophthalmoscopy*, for examining the fundus, giving an inverted picture of low magnification.

IV. *The direct method of ophthalmoscopy*, for examining the fundus, giving an erect picture of greater magnification.

V. *Transillumination*.

VI. *Examination with the corneal microscope and the slit-lamp*.

The examining-room should have rather dark walls, and all light should be excluded except that given by the surgeon's lamp. The source of illumination usually preferred is an electric light upon a 'universal bracket,' which permits the light to be placed on either side of the patient, and to be raised and lowered at will. The patient should be seated; the examiner may be either standing or seated.

Oblique Illumination.

Oblique, lateral, or focal illumination furnishes a very valuable means of minutely exploring the cornea, anterior chamber, iris, and lens. By means of a strong convex lens of 2 or 3 inch focus, light is concentrated upon the eye in such a manner that the apex of the cone of light corresponds to the part to be examined (Fig. 20). The source of illumination should be about 18 inches to the side of the patient,

several inches in advance, and on a level with the eye. The lens is grasped by its margin between the thumb and index finger, held so that its surfaces are at right angles to the direction from which the light proceeds, and steadied by means of the little finger placed against the side of the patient's



FIG. 20.—OBLIQUE ILLUMINATION.

face. After having examined one eye, without removing the supporting finger, we turn the patient's head slightly toward the light and illuminate the opposite eye. The flame may be placed on either side; if on the patient's right, we use the left hand for holding the lens; if on the left, we use the right hand. After having examined the cornea, the lens is brought nearer to the eye, so that the apex of the cone of light corresponds to the deeper structures which we wish to explore.



FIG. 21.—CORNEAL MAGNIFIER.

With a second strong convex lens held at its focal distance (1 or 2 inches) in front of the patient's eye, we can magnify the illuminated area, and thus obtain greater detail.

Opacities of the cornea, aqueous, or lens, seen by oblique illumination, appear as grayish or white spots upon the black ground of the pupil (Figs. 27, 29, 31, 33, Plate II.).

The Ophthalmoscope.

The ophthalmoscope was invented by Helmholtz in 1851. Previous to this period we had practically no knowledge of the interior of the eye during life.

The essential portion of this instrument is a perforated

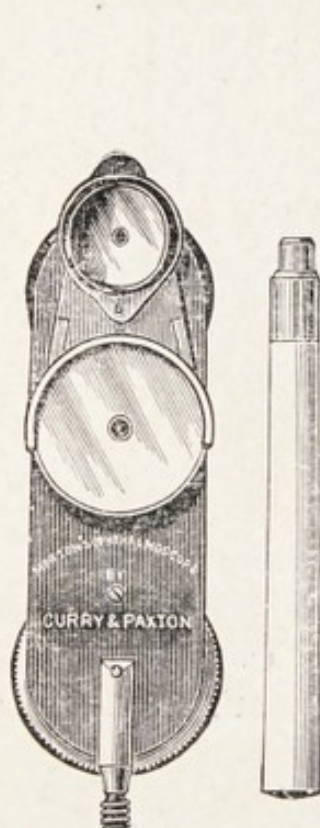


FIG. 22.—MORTON'S OPHTHALMOSCOPE.




FIG. 23.—OPHTHALMOSCOPE OF MORTON TYPE, SELF LUMINOUS.

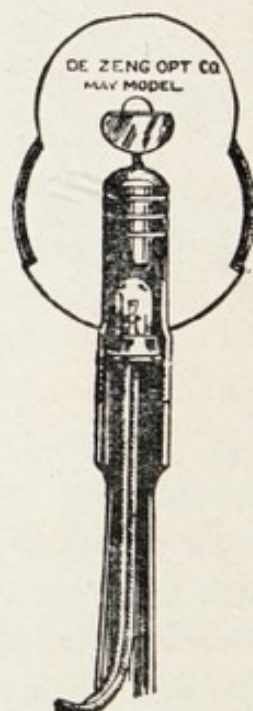


FIG. 24.—MAY'S ELECTRIC OPHTHALMOSCOPE.

mirror. This is mounted upon a convenient handle and supplemented behind by a disc containing convex and concave lenses.

The mirror serves to reflect light into the interior of the eye, while the aperture allows a portion of this light, after returning from the patient's eye, to pass into that of the observer. The mirror commonly employed is concave, of about 10 inches focus, either circular or of the form of a parallelogram, which allows it to be tilted to the right or left.

The lens disc is placed behind the mirror and provided

with a collection of lenses, which follow each other in regular order from the weaker to the stronger. By means of the finger applied to a milled edge the disc can be rotated so that any lens is placed behind the perforation in the mirror. Opposite each lens is a number indicating its strength in dioptries.

The electric ophthalmoscope (Fig. 24) is self-illuminating, the lighting current being usually supplied by a small portable storage battery. It is very convenient for bedside use, since the patient can readily be examined in any position, and no specially darkened room is necessary.

The Ophthalmoscope Examination.

Before examining the fundus one should explore the media. This preliminary step is important, since it will explain modifications in the picture obtained by subsequent methods, or failure to see the fundus in cases in which changes in the media exist. One mode of obtaining such information, oblique illumination, has already been described; it is particularly applicable to the anterior media. A second method is:

Examination with the Ophthalmoscope at a Distance.

This method explores all the media—cornea, aqueous, lens, and vitreous. The light is reflected from the mirror into the eye, and, returning from the background, traverses the media before reaching the eye of the examiner through the aperture in the mirror.

The source of illumination is placed on either side of the patient, on a level with the eye and several inches to the side and behind, so that the light strikes the patient's temple, leaving his face in darkness. The patient faces the examiner, the latter standing or sitting directly in front. The ophthalmoscope is held in front of either eye of the observer, so that he can look through the perforation, and is steadied against the side of the nose and supra-orbital margin. The distance between patient and examiner is about 15 inches.

From the mirror the light is reflected into the eye of the patient. Reaching the background, it is coloured orange-red by contact with the choroidal vessels and retinal and choroidal pigment. This tinted light returns through the patient's eye and enters the eye of the examiner by means of the aperture in the mirror. The tint varies with the colour of the background of the individual, depending upon the abundance of choroidal and retinal pigment; hence it is brighter in persons of light complexion, and darker in others. It is also influenced by the amount of illumination, and consequently the reflex is brighter when the pupil has been artificially dilated. The patient is told to move the eyes in various directions, and in this manner different parts of the media are explored.

In the normal eye a homogeneous orange-red reflex (fundus reflex) is obtained (Fig. 25, Plate II.). If any details of the vessels of the fundus are seen, the eye is ametropic (Fig. 26, Plate II.). If, when the observer moves his head from side to side, these vessels appear to move in the same direction, the eye is hypermetropic; if in the opposite direction, it is myopic.

If fairly large and dense opacities exist in any of the media, they will appear as dark or black spots upon the coloured background of the pupil. They are dark because they intercept a certain part of the light (Figs. 28, 30, 32, 34, Plate II.).

Opacities of the media may be either fixed, in which case they move only with the eye, or movable (floating), when they float about after the eye has been rapidly moved and then suddenly stopped; the latter occur only in the vitreous. The situation of opacities of the media can often be estimated by oblique illumination. Another method consists in noting the displacement of the opacity with regard to the pupil, when the observer's head is moved slowly from side to side. When there is no apparent motion of the opacity, it is in the plane of the iris; when it appears to move in the opposite direction, it is in front; and when in the same direction, it is behind this plane. A third method is based upon the relationship of the motion of the opacity to that of the eyeball. If, when the patient moves his eye, the opacity moves

PLATE II.

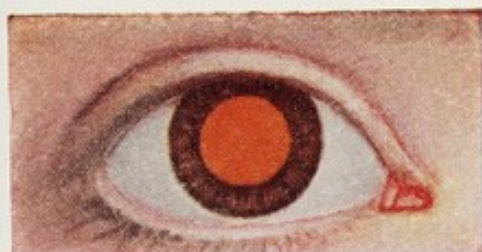


FIG. 25.—NORMAL FUNDUS REFLEX.
Ophthalmoscope at a distance.

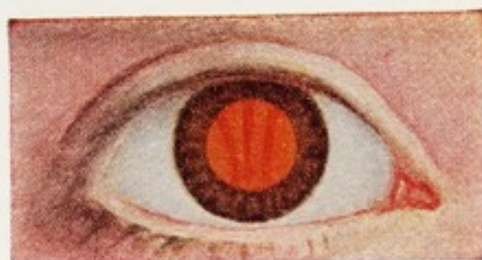

FIG. 26.—FUNDUS REFLEX IN AMETROPIA.
Ophthalmoscope at a distance.

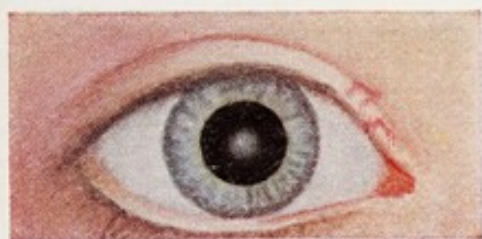

FIG. 27.—OPACITY OF THE CORNEA.
Oblique illumination.

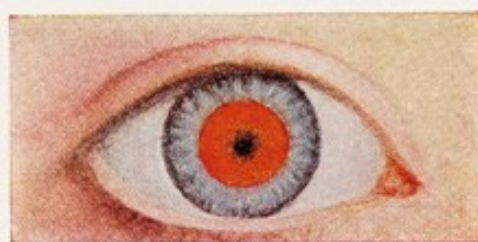

FIG. 28.—OPACITY OF THE CORNEA.
Ophthalmoscope at a distance.

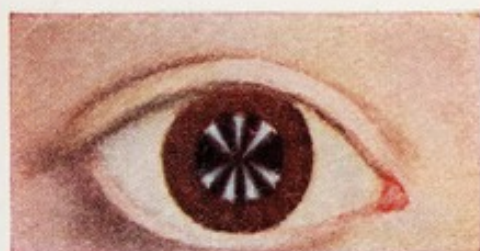

FIG. 29.—SENILE CATARACT (CORTICAL)
Oblique illumination.

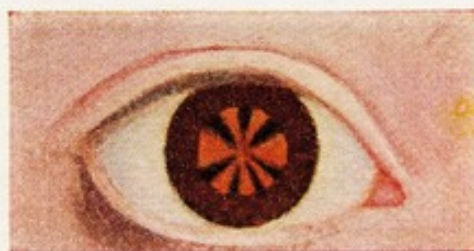


FIG. 30.—SENILE CATARACT (CORTICAL).
Ophthalmoscope at a distance.

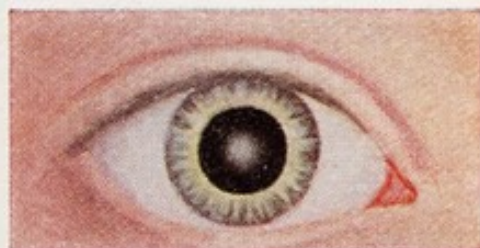

FIG. 31.—SENILE CATARACT (NUCLEAR).
Oblique illumination.

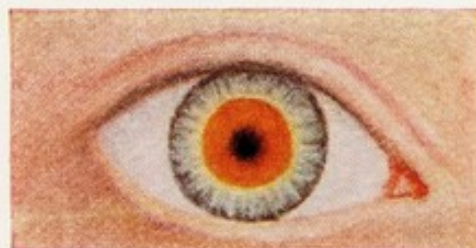

FIG. 32.—SENILE CATARACT (NUCLEAR).
Ophthalmoscope at a distance.

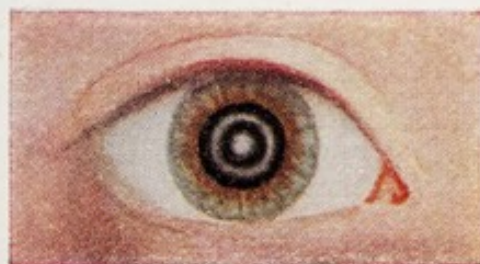


FIG. 33.—LAMELLAR CATARACT.
Oblique illumination.

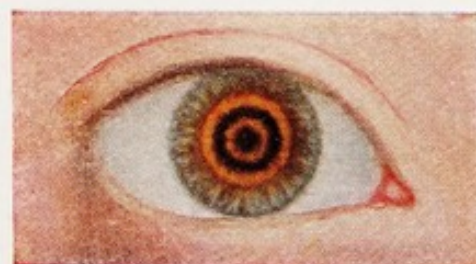

FIG. 34.—LAMELLAR CATARACT.
Ophthalmoscope at a distance.

FIGS. 25 TO 34.—EXAMINATION OF THE MEDIA WITH OBLIQUE ILLUMINATION, AND WITH THE OPHTHALMOSCOPE AT A DISTANCE, THE PUPIL BEING MODERATELY DILATED.



with (in the same direction as) the eye, it must be in front of the centre of rotation of the globe (which corresponds to the anterior portion of the vitreous, about 10 mm. in front of the retina); if it moves in the opposite direction, it must be behind this point; if it has no motion, it must be exactly at the centre. In both of these tests the greater the apparent motion the more removed is the opacity from the plane of the iris and the centre of rotation of the globe respectively.

The presence or absence of squint should be determined at this stage by the method described on p. 382.

Additional detail of changes in the media and iris may be obtained by placing strong convex lenses (from 5 to 20 D.) in the sight-hole of the ophthalmoscope, gradually approaching the eye as the strength of the lenses is increased.

The examination may usually be made through a pupil of natural size. It may be necessary to dilate the pupil, however. Moderate dilatation is secured by instilling one drop of a 4 per cent. solution of cocaine; after fifteen minutes the pupil will be of sufficient size, and the effects will pass off in half an hour, thus causing no discomfort to the patient. A 5 per cent. solution of euphthalmin acts more energetically, and the effects pass off in a few hours. Greater dilatation follows the instillation of one drop of a 2 per cent. solution of homatropine, or of a mixture of 2 per cent. homatropine and 1 per cent. cocaine; these cause mydriasis in from twenty to thirty minutes, and the effects last from twenty-four to forty-eight hours. Before using a mydriatic one should be quite certain that none of the symptoms of glaucoma are present. After examination of the eyes of an elderly person under a mydriatic, it is a wise precaution to instil a myotic.

The Indirect Method of Ophthalmoscopic Examination.

With the indirect method we obtain an inverted image of the fundus, magnified about four diameters. The source of illumination is in the same position as when we examine the media—behind, to the side, and on a level with the eye

--and the examiner and patient retain the same relative positions. In the aperture of the ophthalmoscope we place a 3 or 4 D. convex lens, which enables the examiner to obtain a clear image with his accommodation at rest. Placing the ophthalmoscope before either eye, at a distance of about 15 inches from the patient, we obtain the fundus reflex. A strong convex lens of about 2 to 3 inches focus (called the objective lens) is now held at about its focal distance in front of the eye to be examined. This lens is grasped at its edges by the thumb and index finger of the left hand, and steadied by placing one of the other fingers against the forehead of

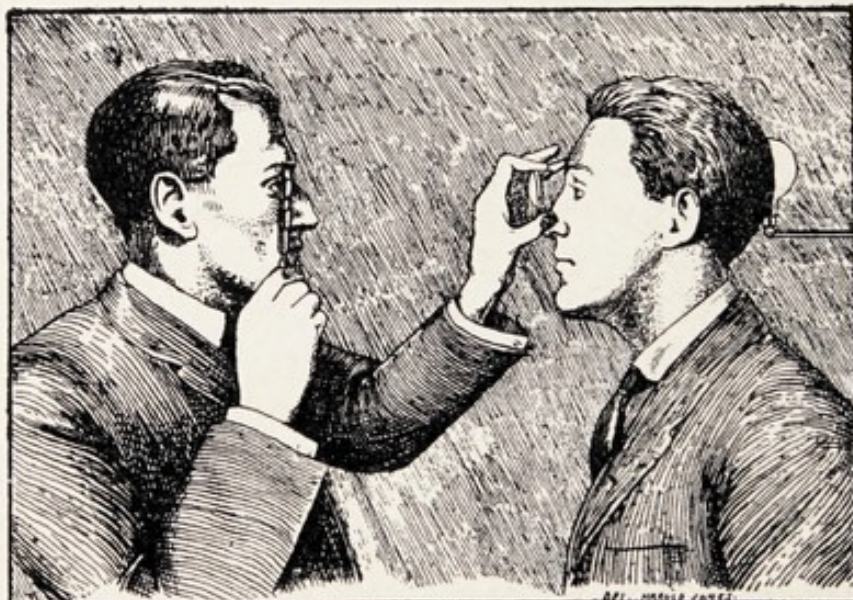

FIG. 35.—INDIRECT METHOD OF OPHTHALMOSCOPIC EXAMINATION.

the patient (Fig. 35). If a clear view of some part of the background is not obtained, we vary the distance from the patient by slowly moving the head backward or forward, until there appears a distinct aerial, inverted image of the fundus at a short distance in front of the lens, corresponding to its focus.

After having seen the right fundus, we proceed to the examination of the left, without making any changes in the position of the light, ophthalmoscope, patient, or examiner. We merely move the lens so as to cover the patient's left eye, now steadying it with the middle finger placed upon the forehead; the little and ring fingers are flexed into the palm of the hand, so that they will not obstruct the right or free

eye of the patient, and thus prevent him from gazing in any direction which we indicate. In the examination of the left eye we may, if we prefer, hold the ophthalmoscope in the left hand and the lens in the right.

We always begin the examination by looking for the entrance of the optic nerve (the disc or papilla), this being the most prominent feature of the background. The optic nerve entrance is a little to the inner or nasal side of the visual axis; hence, in order to bring it into view, it is necessary to direct the patient to move the eye in somewhat, which will rotate the posterior pole of the eyeball outward. When we are directly in front of the patient, this is accomplished by causing him to look over our right shoulder, on a level with the upper border of the ear, when we examine the right eye, and over our left shoulder on a corresponding level when we examine the left eye.

To see the parts surrounding the disc, we move the lens or the head slightly in various directions, always remembering that the image is inverted, and that it moves with the lens, but in the opposite direction to that taken by the head. More peripheral parts are brought into view when the patient moves his eye up, down, to the right, and to the left.

When the patient looks directly at the ophthalmoscope, it brings the macula into view; but since he must accommodate when fixing so near an object, the pupil will contract. On this account it is well to dilate the pupil when we wish to get a view of the macular region with the indirect method.

The beginner may encounter a number of difficulties in using the indirect method. He may have trouble in bringing the disc into view, because the patient persists in watching the ophthalmoscope instead of looking across the examiner's shoulder. Owing to defects in the manufacture of the instrument, there are often very confusing reflexes from the margins of the sight-hole and perforation of the mirror. There is frequently a very annoying reflection of the flame from the cornea or from the surfaces of the lens which we hold before the patient's eye. These reflexes may be obviated by a slight inclination of the lens, a change in the angle of the

mirror, or a little variation in the position of the examiner or source of illumination, which experience alone will teach us.

The Direct Method of Ophthalmoscopic Examination.

With the direct method we obtain an erect picture of the fundus magnified about fourteen diameters.

The examiner sits or stands to the side of and facing the patient (Fig. 36). The ophthalmoscope is supported as in



FIG. 36.—DIRECT METHOD OF OPHTHALMOSCOPIC EXAMINATION.

previous methods, and brought directly in front of the patient's eye as close as possible. There should not be a greater distance than an inch between the eye of the patient and that of the observer. The light occupies about the same position as in previous methods.

When we examine the right eye, the examiner and the light must be on the right side, and consequently the ophthalmoscope must be placed before the right eye of the observer. When the left eye is being examined, the light and examiner must be to the left, and the observer must use his left eye.

When the ophthalmoscope is provided with a tilting or rotating mirror, the surface of the latter must be turned toward the source of illumination.

When both examiner and patient are emmetropic, and both relax their accommodation, the observer looks through the sight-hole and obtains a clear view of the fundus without any lens. The patient is told to look at the opposite wall, directly forward, over the shoulder of the examiner. This brings the disc into view. The parts around the disc are next examined. The periphery of the fundus is brought into view when the patient looks in various directions. The macular region is found to the outer side of the disc, the distance corresponding to about twice the diameter of the papilla. When the pupil has been artificially dilated so that it cannot contract in accommodation, the macula can also be brought into view by directing the patient to look into the aperture of the mirror.

The size of any particular lesion is compared with that of the disc. Changes in the level of the fundus (elevations or depressions) are measured in dioptries; an elevation of 1 mm. corresponds to 3 D.

The beginner is often annoyed by reflexes from the surface of the cornea. These can be obviated by a slight change in the angle of the mirror, the position of the examiner or that of the light.

If the observer be ametropic, he must either wear his correcting distance glasses or have a special correcting lens fitted behind the aperture, or he may rotate his correcting lens before the aperture from one of those contained in the disc of the instrument. When the patient is ametropic, a suitable lens must be rotated into place behind the aperture; if he is myopic, this will be the weakest concave lens, and if hypermetropic, the strongest convex lens, which will give a distinct picture. This gives an indication of the manner in which the direct method is employed for the estimation of errors of refraction.

The emmetropic observer will be unable to obtain a distinct view of the fundus of a myopic eye by the direct method

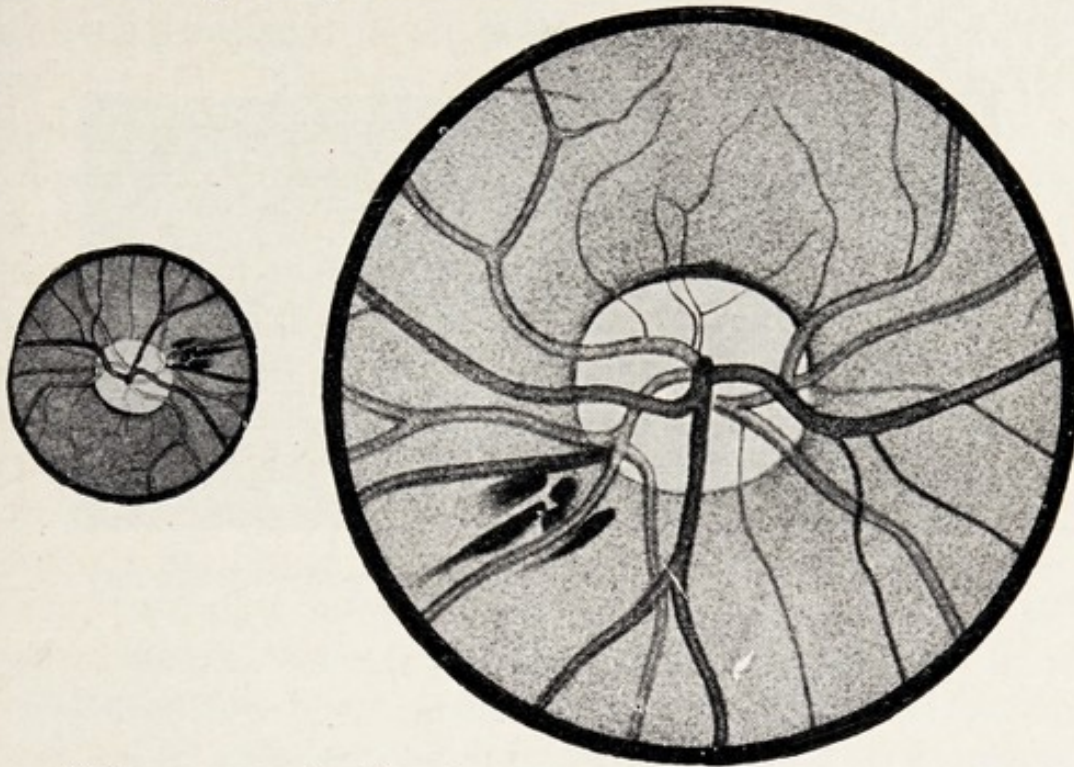
without putting behind the sight-hole in the ophthalmoscope mirror a concave lens of a strength at least sufficient to neutralize the myopia. He can examine a hypermetropic eye either by putting up a convex lens or by using his accommodation. But in the direct method the observer must learn to relax his accommodation. The beginner often finds this difficult, since he cannot forget that he is looking at a very near object, and he accommodates accordingly. He is very apt to place a concave lens in the sight-hole to neutralize the effects of such efforts, even though the patient has no myopia. Relaxation of accommodation is absolutely indispensable in using the direct method for the purpose of estimating errors of refraction. It is encouraged by keeping both eyes open and looking in the distance with the uncovered eye. The sensation of relaxing the accommodation is experienced when we hold a book at the usual reading distance and stare at the print until it becomes blurred and fades. Such an exercise may be used to cultivate the habit.

The Indirect and Direct Methods Contrasted.—The *indirect method* gives us a larger field, though a smaller magnification, and hence presents a general view of the background, which is inverted (Fig. 37). It can be used successfully independent of errors of refraction in the patient's eye. On account of greater illumination we are often able to get details of the fundus, even when slight opacities of the vitreous exist.

The *direct method*, on the other hand, gives us an erect picture, which is more highly magnified (Fig. 38), though a smaller portion of the field is seen at a time; hence it permits of more minute exploration of particular parts to which our attention has been directed by the indirect method. It is also the method of using the ophthalmoscope for the estimation of errors of refraction.

Theory of the Ophthalmoscope.—As ordinarily seen, the pupil appears black because the light which leaves it is necessarily reflected in the direction from which it came. If the eye of the observer be placed so as to intercept the returning rays, the interior of the observed eye will appear illuminated. With the ophthalmoscope light is reflected

into an eye under examination, and the observer's eye is placed in the path of the returning rays and receives some of these through the perforation in the mirror.



FIGS. 37 AND 38.—THE INDIRECT AND DIRECT METHODS OF OPHTHALMOSCOPY CONTRASTED.

Fig. 39 illustrates the illumination of the interior of the eye with the ophthalmoscope at a distance. E represents

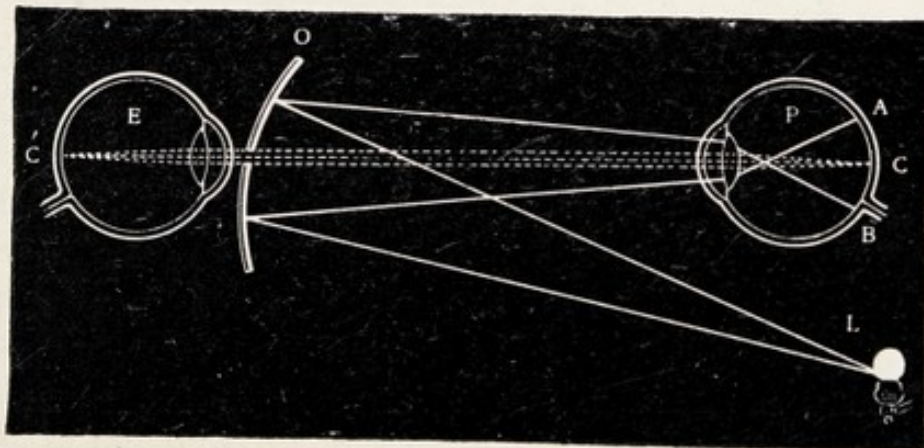


FIG. 39.—OPHTHALMOSCOPIC EXAMINATION AT A DISTANCE.

the eye of the examiner and P that of the patient. Divergent rays of light, proceeding from the lamp L, strike the ophthalmoscopic mirror O, are reflected and made con-

vergent, passing into the eye P, crossing in the vitreous, and illuminating the fundus between A and B. From any point of this illuminated area, C for instance, rays are reflected, pass out of the eye, being made parallel by its refracting

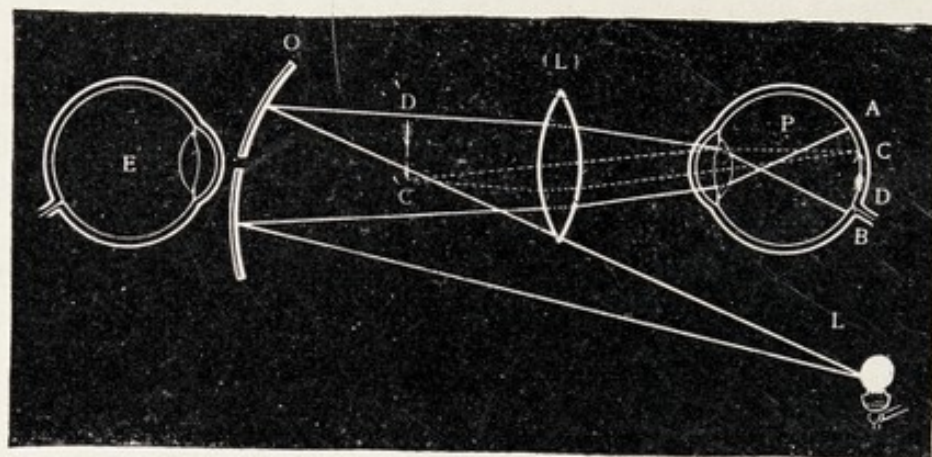


FIG. 40.—INDIRECT METHOD OF OPHTHALMOSCOPIC EXAMINATION.

apparatus, and proceeding, pass through the aperture of the mirror O into the eye of the examiner E. The dioptric apparatus of E brings these rays to a focus on the retina, and they form at C' an image of C.

Fig. 40 explains the indirect method. From L. divergent

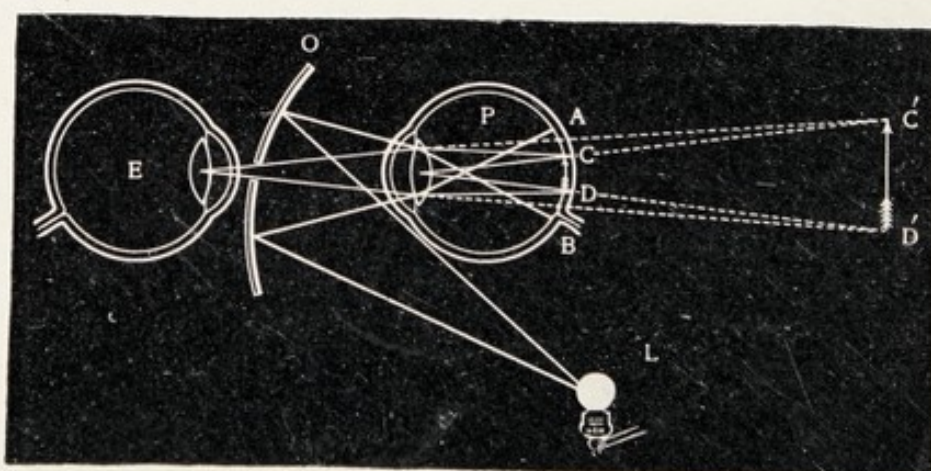


FIG. 41.—DIRECT METHOD OF OPHTHALMOSCOPIC EXAMINATION.

rays proceed to the mirror O, are reflected and made convergent, passing into the examined eye P, crossing in the vitreous. They illuminate the fundus between A and B. From any portion of this illuminated area, C D for instance,

rays are reflected, and passing out of the eye, are rendered parallel by its refracting apparatus. They fall upon the convex lens (L), and are brought to a focus at $C' D'$, forming an enlarged inverted image in the air at the focus of the lens (L), which image can be seen by the eye of the examiner E.

Fig. 41 illustrates the direct method. Divergent rays proceeding from L to the mirror O are reflected and made convergent, passing into the examined eye P, crossing in the vitreous. The fundus from A to B is lighted up. From any portion of this illuminated area, C D for instance, rays are reflected, pass out of the eye P, being made parallel by its dioptric apparatus, through the perforation of the mirror O, into the eye of the examiner E. Here they are brought to a focus on the retina. They are convergent, and being prolonged backward, form a magnified and erect image of C D, behind the eye of the patient P, at $C' D'$.

Ophthalmoscopy with Red-Free Light.—If the fundus be examined by light from which the red rays have been excluded by a suitable filter, the background will appear of a yellowish-green colour, the macula standing out as a lemon-yellow area, the disc white, the fundus reflexes very marked, and the vessels almost black with sharply-cut outlines; the nerve fibres become clearly visible, those going to the macula running in a straight line, those more peripheral forming elliptical arches; thus we are able to note any disappearance of such fibres, for instance, in optic nerve atrophy. Slight alterations in the vessels, minute retinal hæmorrhages, ill-defined exudates, and obscure changes at the macula become more easily detected than with ordinary light. A disc, having an aperture fitted with green glass, is attached to some ophthalmoscopes, to be slid over the sight-hole; this is very imperfect compared to large and special apparatus; the light must be more intense than when ordinary light is employed; the method is used only for the detection of minute changes in the background when doubt exists with the ordinary examination.

The Normal Fundus.

The normal fundus exhibits a great many variations in detail. It presents an orange-red surface, upon which we distinguish the disc, the bloodvessels, and the macula (see Plates III., IV., IV. A, and V.).

The *Disc* or *Papilla* represents the entrance of the optic nerve; it is usually circular, but sometimes oval. Its colour

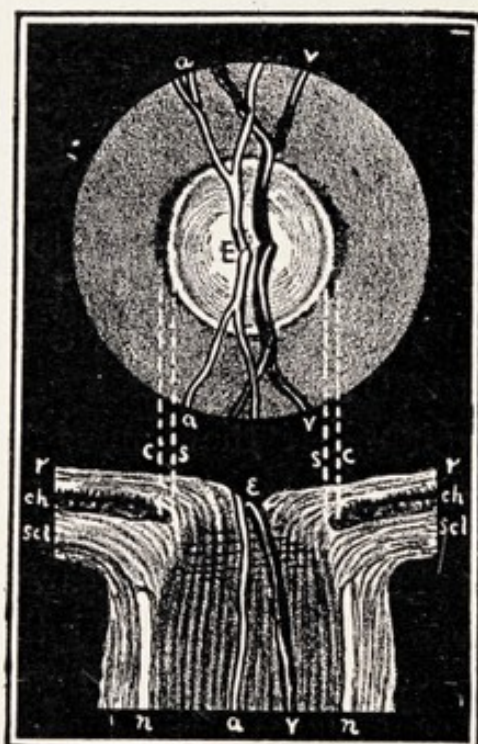


FIG. 42. — OPHTHALMOSCOPIC VIEW AND LONGITUDINAL SECTION OF THE DISC.

a, Central artery; *v*, central vein; *E*, physiological excavation; *s*, scleral ring; *c*, choroidal ring; *r*, retina; *ch*, choroid; *scl*, sclera.

is light pink, more pronounced over the inner half, the outer portion being paler. The disc is much lighter in colour than the rest of the fundus, and is separated from adjacent portions by a sharply-defined margin, especially at the outer side. This margin often presents two rings: an inner, the scleral (*s*, Fig. 42), of white colour, formed by exposure of the sclera when the opening in the choroid is larger than that in the sclera, and an external ring, the choroidal (*c*, Fig. 42), of dark colour, formed by an accumulation of pigment at the margin of the aperture through which the optic nerve passes. This pigmented ring may be complete or incomplete. In the latter case it is generally found

at the outer border. The margins of the normal disc are occasionally slightly indistinct, especially above and below. This appearance is sometimes seen in hypermetropic eyes of young subjects, and must not be mistaken for neuritis.

The centre of the papilla presents a funnel-shaped depression (*E*, Fig. 42), formed by the separation of the nerve fibres. This appears whiter than the rest of the disc. It is known as

the 'physiological depression' or 'cup.' It may be comparatively large and occupy one-half or more of the disc, but never the entire papilla, in which respect it differs from the pathological excavations of glaucoma and of optic nerve atrophy (Figs. 169, 170, 171). At the bottom of this physiological excavation, when marked, we frequently see grayish spots. These represent the openings in the lamina cribrosa, the connective-tissue layer through which the fibres of the optic nerve pass (Fig. 47, Plate V.).

The *Central Artery and Vein* of the optic nerve (*a* and *v*, Fig. 42) pass along the inner wall of the excavation, and upon reaching the surface of the disc usually divide into superior and inferior branches; each of these soon divides and subdivides, giving off nasal and temporal branches; from these smaller twigs are derived, which become terminal and do not anastomose. Small branches are often given off from the main trunks and pass across the disc. The macular region is devoid of larger vessels, though finer branches are seen to approach this area. The arteries are readily distinguished from the veins by their smaller calibre, bright red colour, and straighter course. They present a bright reflex running along the centre. The veins are of greater thickness, of a darker red colour, more tortuous, and the light streak is fainter. Arteries and veins usually follow the same course. The veins sometimes present a distinct pulsation, most marked where the central trunk appears on the disc, and increased by pressure upon the eyeball; this is physiological. Pulsation in the retinal arteries, on the other hand, is pathological, and occurs in glaucoma, cardiac disease, and in profound anæmia.

The *Retina* itself is transparent. The colour of the background is derived from the choroidal vessels, and modified by the pigment-epithelium layer of the retina and the pigment of the choroid. It is bright orange-red in persons of fair complexion, while in darker individuals it has a deeper, brick-red colour. The fundus presents a granular or stippled appearance, caused by the pigment cells. When the pigment-epithelium layer of the retina is well developed, the choroidal vessels cannot be seen. More often considerable detail of

the vessels of the choroid will be visible. This occurs under two conditions: In some cases there is no obscuration by the pigment layer of the retina, and the choroidal pigment is very abundant and collected into the intervascular spaces; then these stand out as dark islands separating bright-red lines and bands, which anastomose freely, the choroidal vessels (Fig. 45, Plate IV.). In other instances there is very little pigmentation in either retina or choroid, allowing the choroidal vessels to be seen plainly, now presenting the picture of bright-red anastomosing channels with brighter interspaces (Fig. 44, Plate III.). The choroidal vessels are most markedly visible in the periphery, and are readily distinguished from retinal vessels by being less sharply defined, flat, having no light-streak, by their free anastomosis, and by the fact that they obviously lie in a plane posterior to the latter.

The region of the *Macula Lutea* (Fig. 48, Plate V.), physiologically the most important part of the fundus, is situated rather less than two disc-diameters to the temporal side of the entrance of the optic nerve, in the line of direct vision. Very often this region presents scarcely any distinctive feature. It is always devoid of visible vessels, and is somewhat darker than the rest of the fundus. Frequently a bright spot is seen in its centre corresponding to the position of the fovea centralis, or there may be two or three of these bright spots. Sometimes the macular region is represented by a bright spot surrounded by an area of dark red colour, about the size of the disc, oval horizontally, and this again encircled by a bright halo; this reflex is best seen in the indirect method, and is most marked in children of dark complexion, especially if they be hypermetropic.

Physiological Variations.—In children of dark complexion the fundus not infrequently presents a bright lustre, which changes its position with movements of the mirror. It is most marked along the bloodvessels; it resembles the shimmer of watered silk. Another peculiar but physiological appearance is sometimes occasioned by opaque nerve fibres. In such cases the axis cylinders of some of the optic-nerve fibres

PLATE III.

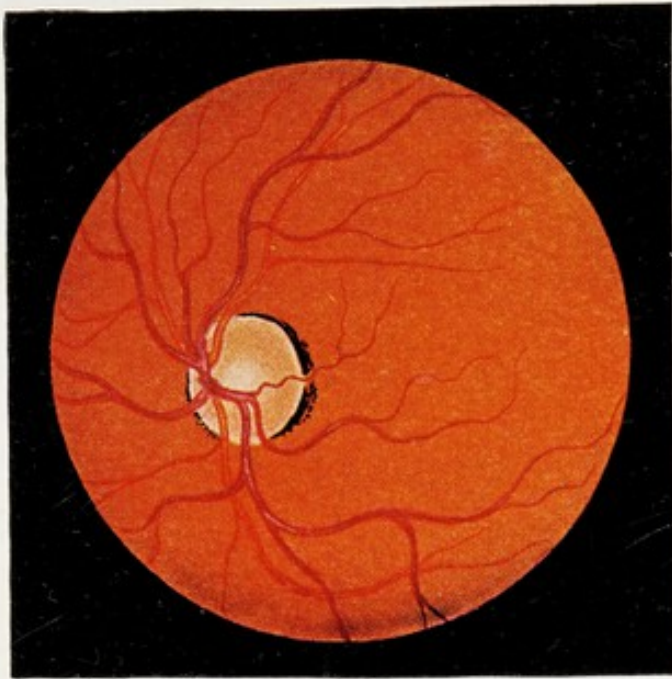

FIG. 43.—NORMAL FUNDUS OF AVERAGE TINT.

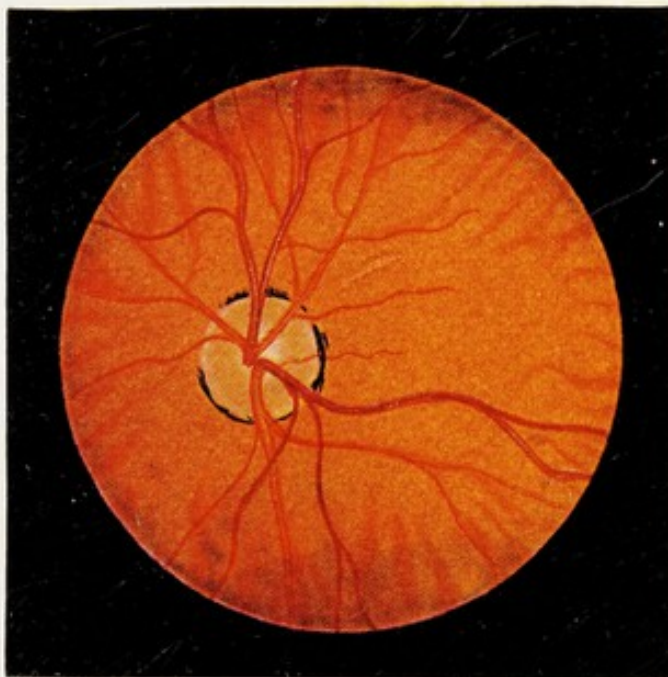

FIG. 44.—NORMAL FUNDUS IN A PERSON
OF LIGHT COMPLEXION.

To face page 36.



PLATE IV.

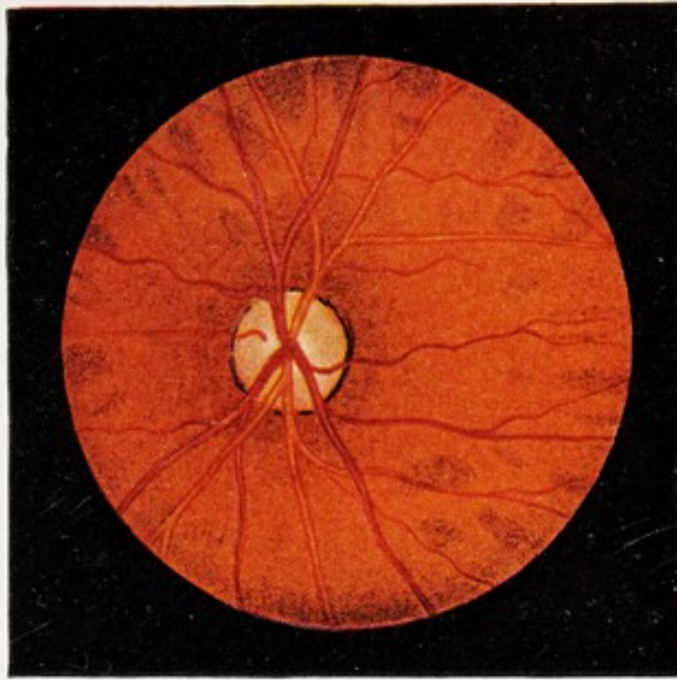

FIG. 45.—NORMAL FUNDUS IN A PERSON
OF DARK COMPLEXION.

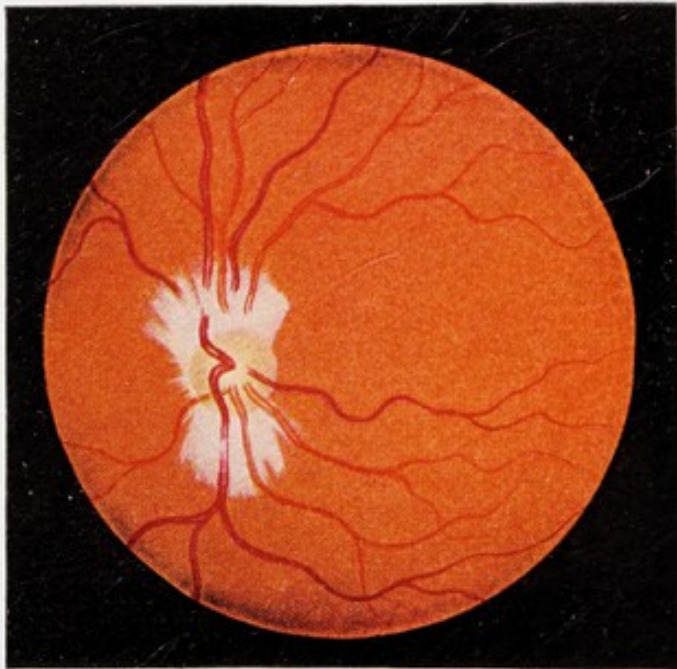

FIG. 46.—OPAQUE NERVE FIBRES.



PLATE IVA.

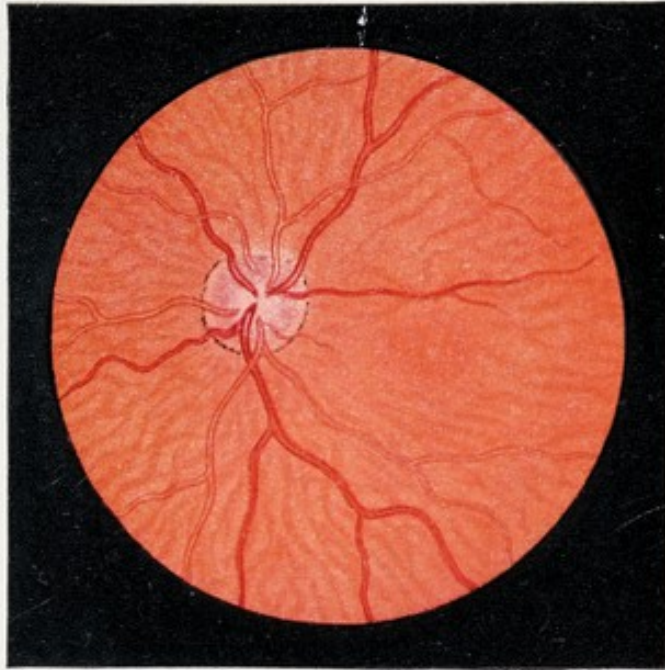


FIG. 46A.—NORMAL FUNDUS OCULI IN A PERSON OF
VERY FAIR COMPLEXION.

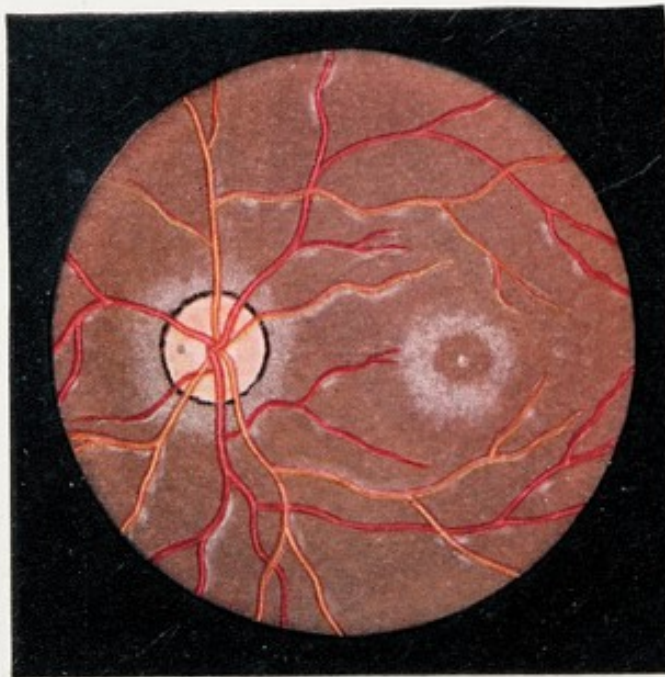


FIG. 46B.—NORMAL FUNDUS IN A NEGRO.

To face page 36.




PLATE V.

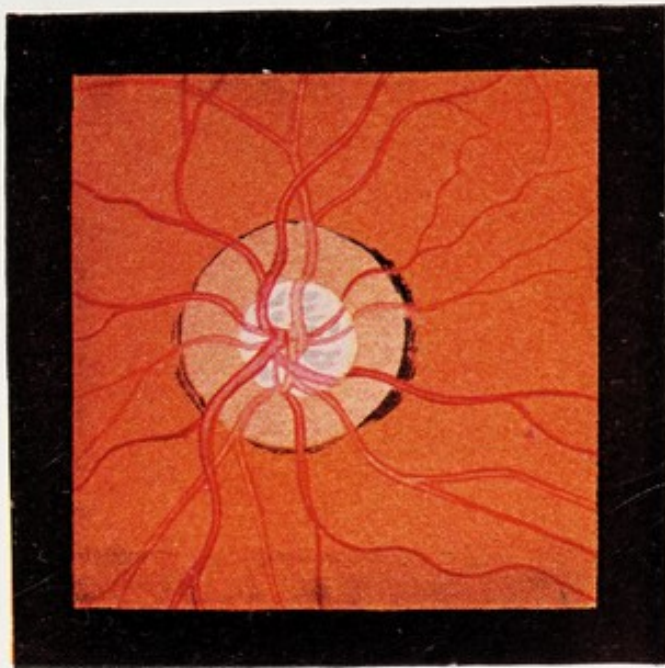


FIG. 47.—“PHYSIOLOGICAL CUPPING” OF THE OPTIC DISC.

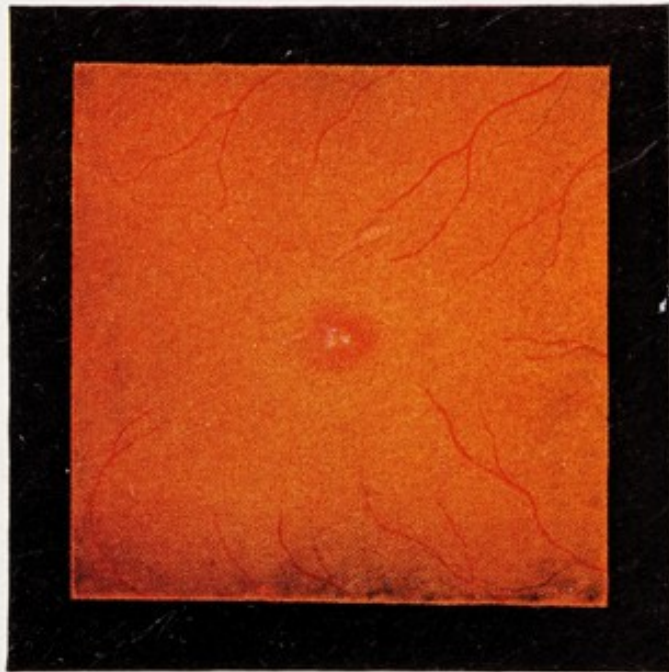



FIG. 48.—THE NORMAL MACULA LUTEA.



regain their medullary sheath at the disc, and continue in this condition for some distance beyond the papilla, presenting one or more whitish areas extending for a variable distance from the disc and terminating in brush-like extremities (Fig. 46, Plate IV.).

Transillumination.

An ocular transilluminator is an instrument shaped like a pencil and having a tiny electric lamp and system of lenses which project a beam of light through a little hole at the end. If a solid tumour is suspected to underlie an accessible part of the sclerotic, but cannot be seen ophthalmoscopically, the eye is lightly anæsthetized and the instrument is pressed against the eye in this situation, the light being, if possible, directed slightly forward. A solid tumour may cast a shadow noticeably darker than the red illumination of the pupil obtained by placing the instrument on another meridian in the same latitude.

The Corneal Microscope and Slit-Lamp (Gullstrand's) furnish a combination which, though elaborate and expensive, is coming into use for the study of minute changes in the anterior portion of the eye. The slit-lamp furnishes an extremely brilliant light which is condensed into a very sharp and narrow band which, traversing the parts to be examined, shows them in optical section, the remainder of the eye being in darkness. This illuminated section is then examined with the binocular microscope. With this intense, concentrated illumination and added magnification we are enabled to study microscopic changes in the conjunctiva, cornea, iris, lens, circumlental space, ciliary body, and even the anterior portion of the vitreous. The apparatus is expensive, and its use needs considerable practice. But, as this method of examination is of great importance and now forms part of the curriculum of students of ophthalmology, a separate chapter is devoted to it.

CHAPTER IV

THE SLIT-LAMP AND CORNEAL MICROSCOPE

By T. HARRISON BUTLER

OBLIQUE illumination of the eye by the light of a lamp or ordinary electric bulb of the 'Osram' type gives information about the cornea, the iris, and the anterior part of the lens, but its usefulness is limited because the diffuse light has little penetration and cannot be brought to a sharp focus, and by the low magnification of the loupe. The last difficulty can be overcome by the binocular corneal microscope, which has a useful magnification up to about 35 diameters, and gives stereoscopic vision. If instead of the usual frosted globe we use a 'half-watt' bulb of 60 candle-power we can focus the image of its circular filament as a bright line upon any object, or alternatively by throwing the condensing lens out of focus we obtain diffuse illumination superior to that given by the orthodox bulb. We can project a somewhat ill-defined beam into the depths of the eye, gaining the necessary penetration to view objects deep in the globe.

The slit-lamp, invented by Alvar Gullstrand of Upsala, is in effect a small searchlight which projects a sharply-defined beam into the eye, which can be focussed as desired. The latest model of the Zeiss slit-lamp is shown in Fig. 48A. The microscope seen in Fig. 48B slides upon an adjustable table, and the slit-lamp is fitted to it in such wise that the beam can be projected at any angle and can rapidly be transferred from one eye to the other. The light passes through an adjustable slit varying the width of the beam from 1 to $\frac{1}{40}$ mm. The adjustable chin and forehead rests are seen in the illustration.

Having at command a beam of bright light—the nitra-lamp used has 50 candle-power—which can be directed at any angle and focussed upon any spot, we possess selective methods of examination. We can focus directly upon an object—a foreign body in the cornea or the surface of the iris—*direct focal illumination*. Alternatively we can focus the beam on to a reflecting surface behind the object under examination, and observe it by transmitted light—*retro-illumination*. We can form a bright secondary source of light on the iris and examine the cornea




FIG. 48A.—THE CORNEAL MICROSCOPE AND GULLSTRAND'S SLIT-LAMP.

by transmitted light, or by focussing the beam upon the posterior capsule of the lens we can illuminate the iris from behind, showing up atrophied areas or fissures in its pigmented layer. If the cornea is vascularized the actual circulation of the blood in the tenuous vessels is clearly visible. A third method makes use of the *zone of specular reflection*. We can so adjust the angle of the beam and the line of gaze of the patient to the axis of the microscope that the light from a reflecting surface is received by the eye of the examiner. On

the edge of the bright area the endothelium cells lining the back of the cornea can be distinguished, and the *shagreen* surface of the anterior and posterior lens capsules can be studied. The use of this *mirror light* gives valuable information regarding changes in the cornea and lens.




FIG. 48B. — MICROSCOPE HEAD WITH DR. ULBRICH'S GRADUATED DRUM ATTACHED.

An examination with the slit-lamp can be made with either the broad or the narrow beam. The *broad beam* is chosen mainly to gain information about the reflecting surfaces of the eye. These are: the anterior surface of the cornea; Descemet's membrane; the posterior corneal surface; the anterior capsule of the lens; the surfaces of the various *nuclei* of the lens; the posterior capsule; and, finally, the surface of the retina. The optical conditions of the eye limit the range of the apparatus to the anterior third of the vitreous, but if the refraction of the

cornea is abolished by using a *contact glass*, the posterior parts of the vitreous and the retina are brought within the scope of the instrument. The *narrow beam* is used for examining the eye in *optical section*, and is of supreme value. The ordinary methods are limited to two dimensions; the slit-lamp gives the third dimension. We can estimate the depth of structures in the eye, mainly by inspection, taking advantage of the stereoscopic properties of the microscope, but also, if necessary, by actual measurement with the micrometer eye-piece, and by using the micrometer drum, which is fitted to the microscope and registers the travel of the tubes in tenths of a millimetre. We focus the

endothelial cells of the cornea and then the surface of the iris; the travel of the microscope read on the drum will give a fairly accurate measurement of the depth of the anterior chamber, which may be useful in glaucoma.

We can view the cornea in optical section, and estimate its thickness and the nature of its curvatures. The depth of an ulcer can be gauged by inspection, and its extent mapped out by moving the beam across its surface. In Fig. 48c a corneal ulcer is seen on the left illuminated by the broad beam, and on the right in optical section by the narrow beam. The dark colouration shows the depth of penetration of fluorescein. The changes in conical cornea become obvious to the eye, and the site of a foreign body or the location of an inflammatory focus is determined with accuracy.

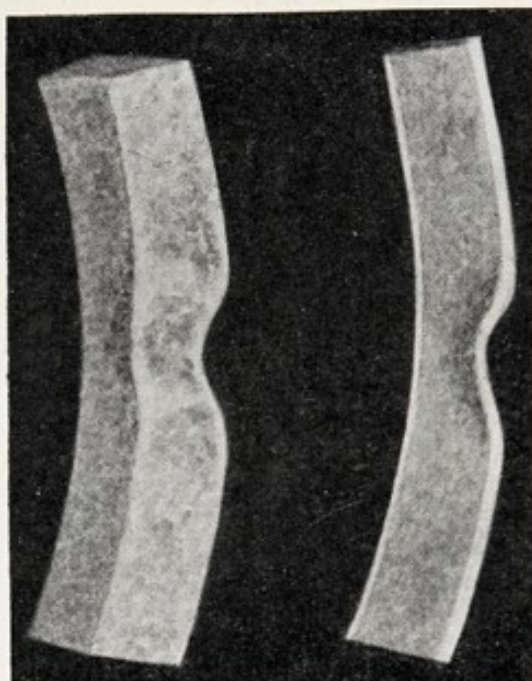


FIG. 48c.

The Architecture of the Lens.

Using the narrow beam the lens can be divided into a series of concentric *nuclei*. The *capsule* is seen as a thin bright line, and under it is a clear area limited by the *subcapsular line*. In glassblowers' cataract a thin film may be seen peeling off from the anterior surface of the capsule. This is the *zonular lamella*. The fibres of the suspensory ligament are inserted into this structure, and can be seen with the aid of the slit-lamp in such conditions as congenital coloboma of the iris and subluxation of the lens. They are arranged in bundles which lie in the valleys between the ciliary processes, one on each side, and run back to an insertion near the ora serrata. Their arrangement is seen in Fig. 48D.




FIG. 48D.—A CONGENITAL COLOBOMA OF THE IRIS, SHOWING THE FIBRES OF THE SUSPENSORY LIGAMENT ARRANGED IN BANDS.

The first lens nucleus is called the *cortex*, and within it is the *adult nucleus*. The next nucleus is the *infantile nucleus*,

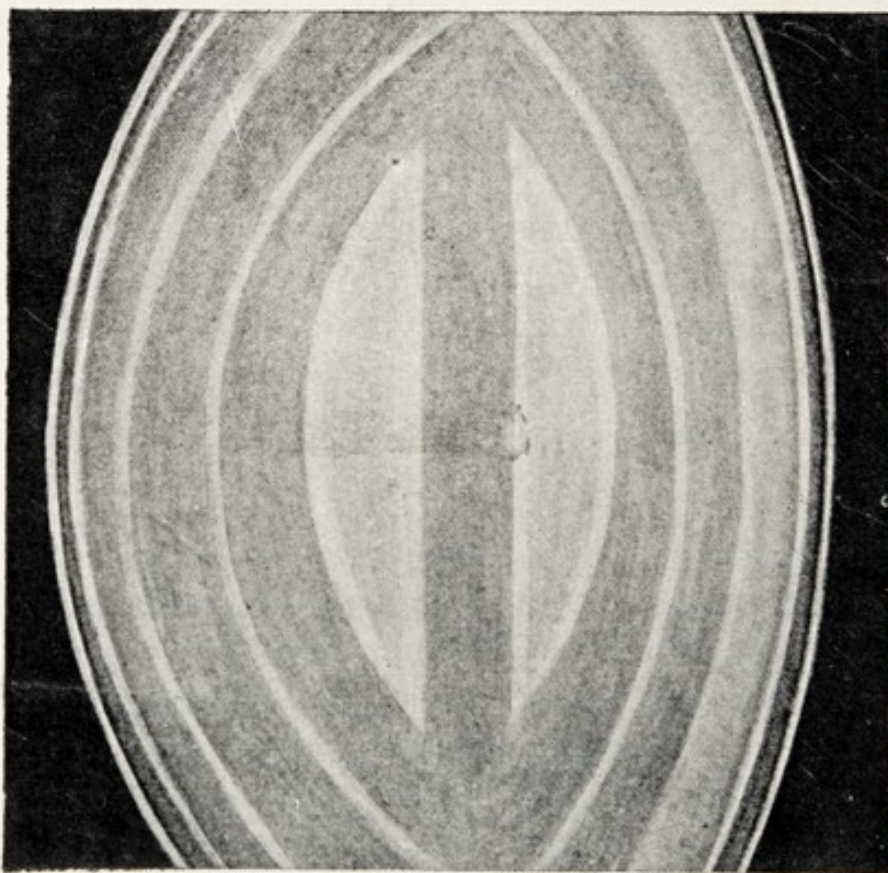


FIG. 48E.—AN OPTICAL SECTION OF A TYPICAL NORMAL LENS.

and then we have the *fœtal* nucleus, consisting of two plano-convex bodies placed plane surface to plane surface. Finally,

in the centre of the lens there is the *embryonic nucleus*, or central lucid interval. This is the oldest part of the lens. The appearance of a typical adult lens in optical section is shown in Fig. 48E.

With the broad beam we can examine the surfaces of some of these nuclei with their characteristic *sutures*. The student must refer to a manual on the slit-lamp for a full description of these sutures, which are intimately concerned with the growth

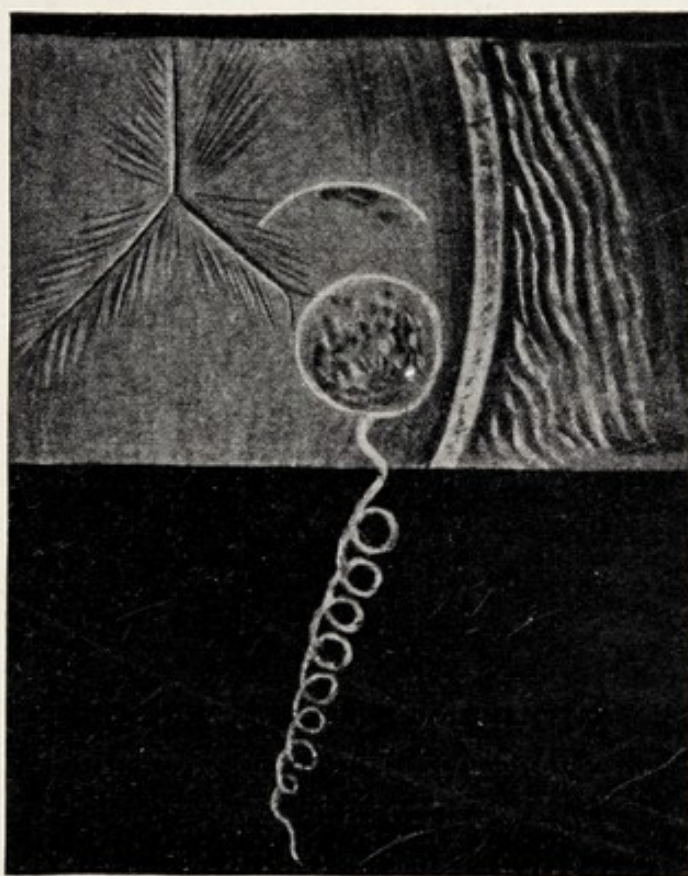


FIG. 48F.—THE POSTERIOR Y SUTURE AND THE ARC LINE WITH A SECOND ARC ABOVE.

The hyaloid artery is very distinct.

of the lens. The most interesting, and one well known before the advent of the slit-lamp, is the *Y suture* on the surface of the foetal nucleus. This suture can often be seen with an ordinary loupe in some examples of lamellar cataract. The anterior *Y* is erect, the posterior inverted. In all textbooks of anatomy and in most on the eye the reverse position is described. Simple inspection with the slit-lamp will show the correct

posture of the Ys. From the arms of the Y the lens fibres can be seen radiating out to the equator of the nucleus, where they bend over to join the opposite Y suture.

In most children and in some adults the anterior remnant of the hyaloid artery can be seen hanging down into the retrolental space like a piece of twisted string. It is attached to the posterior lens capsule somewhat nasally from the posterior pole. The posterior Y suture with the lens fibres and the hyaloid remnant are shown in Fig. 48F.

The Clinical Value of the Slit-Lamp.

It is obvious that the exact localization given by the apparatus is of great value. In industrial areas it is constantly used to decide whether a foreign body has perforated the cornea, and often this examination shows that there is a fragment of metal within the globe. The age of a perforating corneal scar can be estimated, information sometimes of critical value in a medico-legal case. The nature and position of opacities in the lens are determined with exactitude, and their progress can be watched. Many new kinds of cataract have been discovered with the slit-lamp, and the nature of well-known types is now better understood. In old persons the central part of the lens sclerosis and the surface of the adult nucleus may now reflect almost as much light as the capsule itself. If this sclerosis is accompanied by increase in the index of refraction, the central nucleus, having a stronger curvature than the outer surface of the lens, refracts light more than the peripheral part of the lens; thus originates the *lens with a double focus*. In old persons the pupil is generally small, so the change in refraction leads only to lental myopia; but if the pupil be wide there is much blurring of the retinal image, and without the slit-lamp it would be difficult to account for the defective acuity, because the lens is often quite transparent.

In inflammatory conditions of the eye the slit-lamp is indispensable. With its aid we are able to see particles, perhaps actual cells or clumps of cells, floating in the aqueous in the

anterior chamber and retrolental space, and in the vitreous. Whereas the cornea is colder than the iris, there are convection currents in the anterior chamber; therefore, these particles circulate, rising on the iris side, falling behind the cornea. If the inflammation becomes more intense, the aqueous becomes albuminous and the convection currents cease; the particles are at rest. The beam of light now becomes visible as it traverses the anterior chamber, the so-called *flare*. The detection of flare and the presence of particles in the aqueous are often the earliest signs of such serious inflammations as *sympathetic ophthalmitis*, and the use of the slit-lamp enables us to detect this formidable complication some days earlier than we could by the ordinary methods of examination. Immediate treatment with N.A.B. can be initiated, and in most cases of sympathetic ophthalmitis both eyes can be saved. Generally the presence of cells in the anterior chamber is an indication of choroiditis, and careful search with the ophthalmoscope will often detect a focus in the fundus oculi.

The nature of corneal precipitates elucidated with the slit-lamp is of diagnostic value. Pigmented deposits are not of serious import. Clumps of lens cortex after an extraction may adhere to the posterior surface of the cornea, and cause anxiety till the slit-lamp reveals their true nature. Pellucid keratic precipitates, on the other hand, indicate serious inflammation of the ciliary body and choroid. Gelatinous precipitates upon the surface of the iris and at the pupil margin have the same significance as pellucid keratic precipitates. They come and go, and may be mistaken for tubercles. We are often in doubt whether the globe contains a malignant growth or an inflammatory exudate. This is especially the case in children; the diagnosis rests between glioma or 'pseudo-glioma.' The detection with the slit-lamp of definite signs of inflammation suggests that the condition is inflammatory in nature.

It is obvious that not all can possess a slit-lamp, which costs about £80, but one who has mastered slit-lamp technique can apply his knowledge to the simple examination with the loupe and half-watt lamp, or he can project a parallel beam

from an electric ophthalmoscope into the eye. He can now apply the varied methods of illumination, and, knowing what he is looking for, he will gain far more from oblique illumination than one who uses the ordinary frosted bulb and has no knowledge of the slit-lamp.

Further knowledge of the slit-lamp can be gained from 'The Microscopy of the Living Eye,' by Koby (translated into English by Goulden and Harris); and 'An Illustrated Guide to the Slit-Lamp,' by T. Harrison Butler.

CHAPTER V

AFFECTIONS OF THE EYELIDS

Anatomy and Physiology.—The eyelids consist of movable folds formed, from before backward, of skin, loose connective tissue, muscular tissue, tarsus and fascia, and conjunctiva. In addition, they

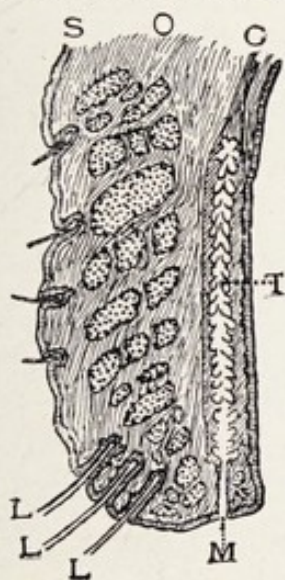


FIG. 49. — LONGITUDINAL SECTION OF THE UPPER LID.

S, Skin; O, orbicularis muscle; C, conjunctiva; T, tarsus; M, opening of Meibomian gland; L, lashes.

present eyelashes, numerous glands, bloodvessels, lymphatics, and nerves.

The integument is thin and delicate, and joined to the subjacent muscles by loose areolar tissue, free from fat. These characteristics explain the readiness with which extravasations of blood and œdematous swellings occur in this region.

The margin of each lid presents in front a rounded, anterior lip, from which the eyelashes (cilia) spring. These form two or three rows of short, thick, curved hairs, their roots deeply embedded in the connective tissue and muscle. They are provided with sebaceous follicles, known here as Zeiss's glands. Behind, the lid margin presents a sharp, posterior lip; directly in front of this are the openings of the Meibomian glands, and anterior to these the openings of modified sweat-glands, the glands of Moll. The surface between these two lips is known as the intermarginal space. The margins of the lids unite at an acute angle externally (external canthus). At the internal canthus the junction presents a rounded space, which is occupied by

a small, reddish elevation of modified skin, the caruncle.

In and behind the subcutaneous connective tissue we find the muscles of the eyelids. The levator palpebræ superioris arises from the apex of the orbit, and is attached to the upper border and anterior surface of the tarsus and to the skin of the middle of the upper lid. The orbicularis muscle lies between tarsus and integument, being

attached to the latter, but gliding loosely over the former. It forms a flattened ring surrounding the palpebral aperture. We also find a layer of unstriped muscular tissue inserted into the upper border of the tarsus, and known as Mueller's muscle.

The tarsus consists of a thin plate of dense fibrous tissue, giving to each lid its firmness; it is larger in the upper than in the lower lid. The tarsi are connected with the lateral walls of the orbit by means of the internal and external tarsal ligaments, and to the upper and lower margins by an aponeurotic layer of fibrous tissue known as the palpebral fascia or ligament. In the substance of the tarsus, occurring in parallel rows, are found the Meibomian glands, thirty to forty in the upper and twenty to thirty in the lower lid. These are elongated sebaceous glands, with blind extremities and numerous cæcal appendages, filled with fatty secretion and opening on the free margin of the lid.

The palpebral conjunctiva is thin, vascular, and closely adherent to the tarsus.

The arterial supply of the lids is derived principally from the ophthalmic artery. The veins empty into the ophthalmic, temporal, and facial. The lymphatics pass to the pre-auricular, submaxillary, and parotid lymphatic glands. The third nerve supplies the levator, the facial the orbicularis, and the sympathetic the unstriped muscular tissue (Mueller's muscle). The sensory nerve supply is derived from the fifth.

The lids protect the eyes from external injury, foreign bodies, undue exposure, and excessive light. They serve to distribute the tears and the secretions from the various glands, thus lubricating the eyeball, keeping the surface of the cornea moist and transparent, and washing away any dust which may have found its way into the eye.

The Common Affections of the Eyelids are blepharitis, hordeolum, chalazion, trichiasis, entropion, ectropion, ptosis, tumours, and injuries.

Blepharitis.

A very common chronic inflammatory condition of the margin of the lids, usually associated with the formation of scales and crusts (Fig. 52, Plate VI.). It occurs under two forms: (1) *non-ulcerative*; (2) *ulcerative*.

Symptoms.—In the superficial or *non-ulcerative form* the margins of the lids are swollen and reddened, and usually present numerous whitish scales at the bases of the lashes. The latter fall out readily, but are replaced, since there is no

PLATE VI.

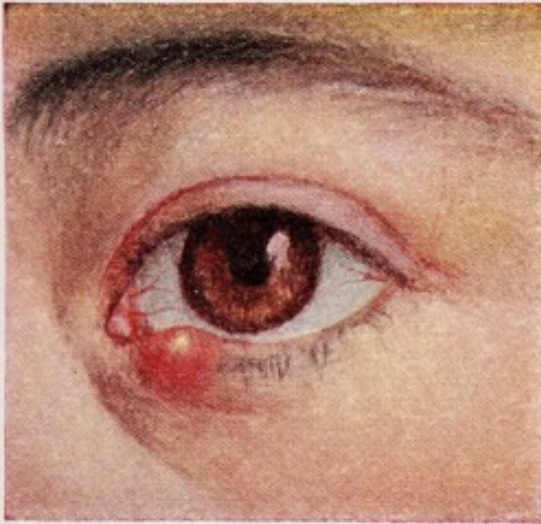

FIG. 50.—HORDEOLUM OR STYE.

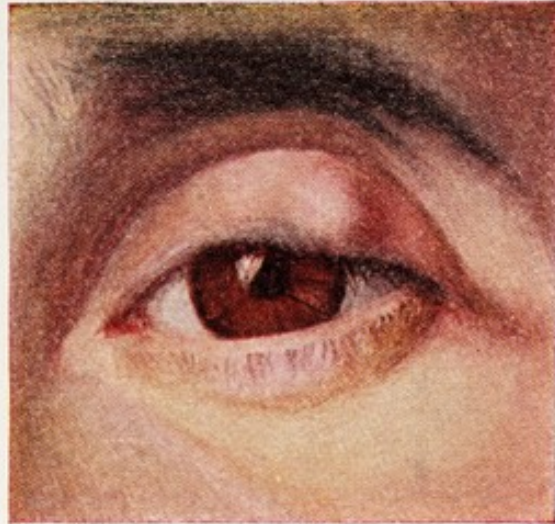

FIG. 51.—CHALAZION OR MEIBOMIAN CYST.

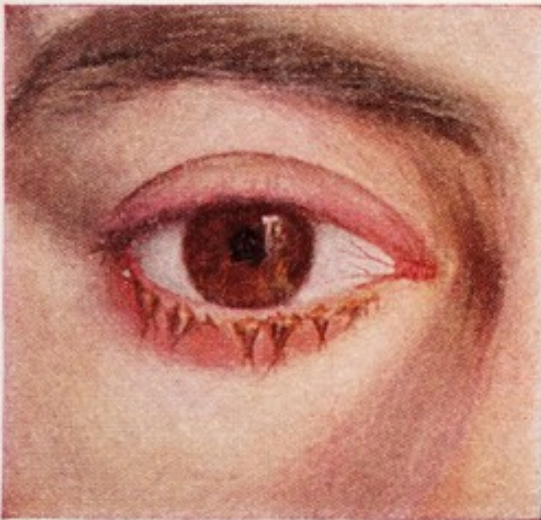

FIG. 52.—CILIARY BLEPHARITIS.

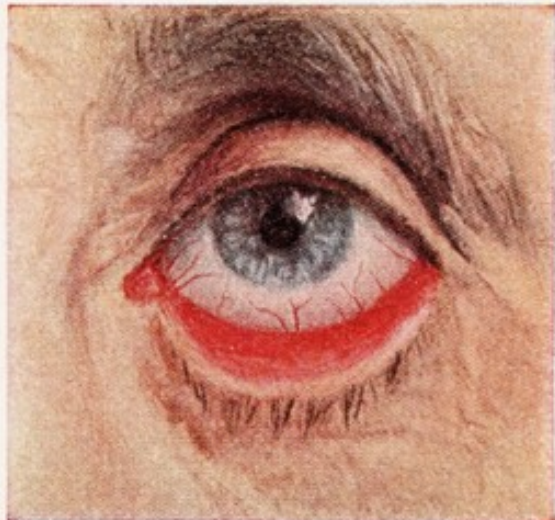



FIG. 53.—ECTROPION.

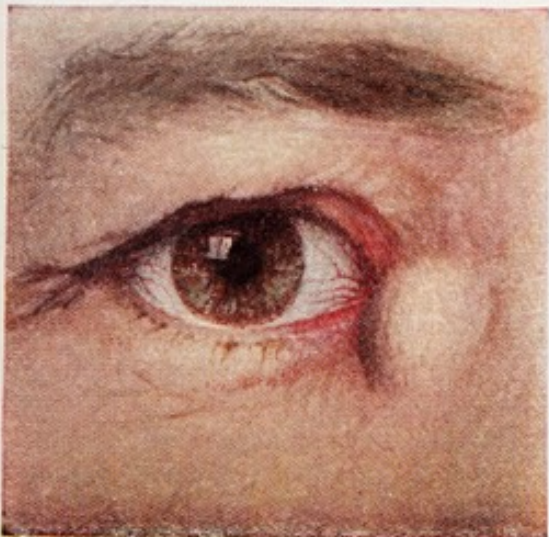

FIG. 54.—MUCOCELE.

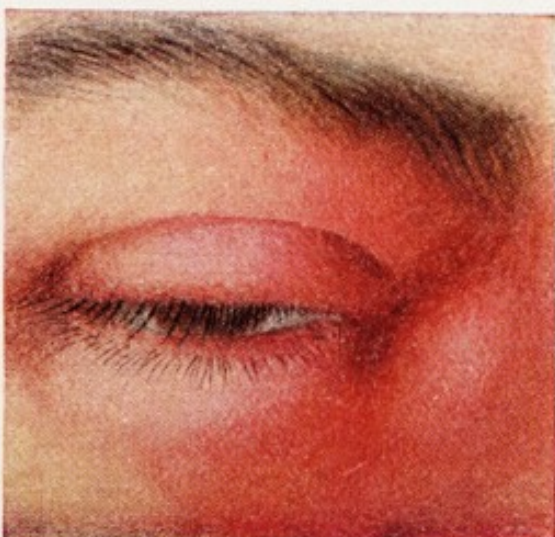

FIG. 55.—ACUTE DACRYOCYSTITIS.



destruction of the hair follicles. Persons with very fair complexions are especially liable to this affection.

In the deep or *ulcerative form* the edges of the lids are reddened and swollen, and present yellowish crusts, which glue the lashes together. On removing these crusts, small ulcers are seen about the attachments of the lashes; these ulcers bleed readily. The lashes become distorted, fall out, and grow scarce, since they are not replaced on account of destruction of the hair follicles. In both forms there will be itching, soreness, epiphora, and sensitiveness to light.

Sequelæ occur especially in the ulcerative form. There may be permanent loss of a greater or lesser number of lashes, hypertrophy of the lid margin, trichiasis, and ectropion.

Etiology.—Poor hygienic surroundings; debilitated conditions of the system; following the exanthemata, especially measles; exposure to irritating atmosphere—smoke, wind, dust; late hours; insufficient sleep; uncorrected errors of refraction, especially hypermetropia and astigmatism; chronic conjunctivitis; nasal affections; lacrymal disorders; pediculi; lack of cleanliness. The disease occurs at all ages, but is very common in children.

Treatment.—The disease is apt to be obstinate. Removal of the cause, if possible, is of the greatest importance. Cleanliness, change of faulty habits, and correction of errors of refraction are great aids to local treatment. The edges of the lids must be washed gently but thoroughly with soap and water, so as to dissolve away all scales and crusts, dried and then covered with the ointment of the yellow oxide of mercury, ammoniated mercury, or ichthyol. To remove the crusts, soap and water, or water to which a little borax or bicarbonate of soda has been added, should be used and applied upon cotton-wool. In the ulcerative form an occasional application of a 1 or 2 per cent. solution of silver nitrate to the raw spots will prove useful. In severe and long-standing cases it will be necessary to pull out all the lashes, and then to apply the treatment given above.

Œdema of the Lids is a very common symptom, being favoured by the structure of these parts. It may be (1) in-

inflammatory, accompanying affections of the lids and adjacent parts, such as styas, dacryocystitis, and affections of the nasal accessory sinuses, or existing as a symptom of violent inflammations of the interior of the eye, such as iridocyclitis, acute glaucoma, panophthalmitis, and orbital cellulitis; (2) *traumatic*, when due to injuries, including the sting of insects; (3) *systemic*, in renal and cardiac disease; and (4) *non-inflammatory*, of which a rather frequent type is *angioneurotic œdema*, a recurrent variety which comes on rapidly, is often marked enough to close the lids, is unaccompanied by any change in the eyes, causes much alarm to the patient, and disappears about as quickly as it came on. This form is most frequently seen in women, especially at the menstrual period; it is allied to urticaria, and is most promptly relieved by a brisk saline cathartic and large doses of sodium bicarbonate.

Syphilis of the Eyelids is occasionally seen as a primary sore, in the secondary stage or in the form of gumma. Chancre having the same characteristics as when found elsewhere occurs upon the lid margin, usually near the inner canthus, accompanied by enlargement of the pre-auricular and submaxillary lymph glands; it might be mistaken for styne, suppurating chalazion, dacryocystitis, vaccinia, or rodent ulcer.

Vaccinia of the Eyelids is now and then met with as the result of the careless inoculation with the secretion from vaccine pustule elsewhere. It presents an ulcer covered with greyish exudate or crust, situated at the margin of the lids—usually the lower, sometimes upon both; it is accompanied by marked swelling and redness of the lids, and by enlargement of the pre-auricular and submaxillary lymph glands.

Hordeolum or Styne.

A circumscribed acute inflammation of the tissues about the follicle of an eyelash, generally ending in suppuration.

Symptoms.—A red swelling (Fig. 50, Plate VI.) appears at the margin of the lid, accompanied by pain, tenderness, and often by considerable œdema. Very soon a yellowish point will be seen, indicating suppuration

Etiology.—Styes occur at all ages. They are very common in young adults. They often appear in crops. They are frequently associated with a deranged condition of the system, constipation, and uncorrected errors of refraction.

Treatment.—It is sometimes possible to abort a styne by the use of cold compresses. As a rule, however, this is unsuccessful. Hot compresses are then indicated to hasten suppuration. As soon as a yellow spot is seen, the pus should be evacuated either by pulling out one or more lashes or by a horizontal incision. To prevent the formation of others, the general health should be looked after, constipation relieved, and errors of refraction corrected. Calcium sulphide, gr. $\frac{1}{8}$ t.i.d., or syrup of the hypophosphites with iron, \mathfrak{z} i. t.i.d., may be of service.

Chalazion.

Chalazion (tarsal tumour, tarsal cyst, Meibomian cyst) is an enlargement of one of the Meibomian glands in consequence of stoppage of its duct, accompanied by a chronic inflammation in the surrounding tarsus. It occurs most frequently in adults. Uncorrected refractive error is believed to be a predisposing cause. Very often several are found at the same time.

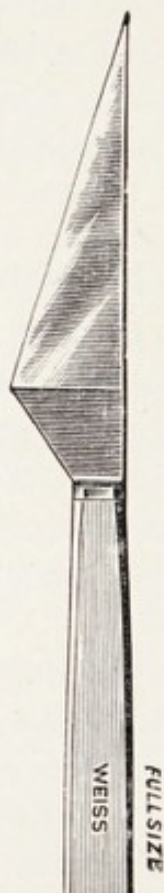
Symptoms.—The process develops slowly with insignificant or no symptoms until, after weeks or months, it has reached the size of a small or large pea. Then it presents a noticeable swelling (Fig. 51, Plate VI.), which feels hard, and is adherent to the tarsus, but not to the skin. On everting the lid, its situation is shown by discoloration of the conjunctiva, and sometimes by a small mass of granulation tissue. Sometimes chalazia disappear spontaneously; they sometimes remain for years without alteration in size and without inflammatory symptoms; occasionally they suppurate, this change being accompanied by inflammatory symptoms.

Pathology.—Microscopically, the contents of a Meibomian cyst consist of small round cells with some giant cells. The central portion undergoes mucoid degeneration. It is bounded by fibrous tissue, but there is no true cyst wall.

Treatment.—When small, they need not be interfered with. Occasionally we can cause their disappearance by the frequent application of ointments of the yellow oxide of mercury, ammoniated mercury, or boric acid, associated with massage and hot compresses. When larger, we remove them by operation, usually through the conjunctiva. The eye is cocainized; the lid is everted. A vertical incision is made through the conjunctiva and wall of the chalazion with a small scalpel (Fig. 56) or Beer's knife (Fig. 57); the contents



FULL SIZE

FIG. 56.—SMALL
SCALPEL.

FULL SIZE

FIG 57.—BEER'S
KNIFE.

FULL SIZE

FIG. 58.—CHALAZION
SCOOP.

(Meibomian secretion, granulation tissue, and mucilaginous fluid) are removed and the walls thoroughly scraped with the chalazion scoop (Fig. 58). When a suppurating chalazion points externally it may be necessary to evacuate it through the skin. In this case the incision should be horizontal, so that the scar may be hidden in the folds of the integument.

After the operation the cyst will be filled with a blood-clot ;

this causes a continuation of the disfigurement for several days. Absorption may be hastened by gentle massage for a few minutes several times a day. Daily massage also tends to prevent recurrence of chalazia.

Trichiasis.

Trichiasis is an inversion of a varying number of lashes, so that they rub against the cornea (Fig. 60).

Distichiasis is an infrequent condition, usually congenital, in which the lashes can be separated into two rows, the posterior of which is directed backward so as to rub against the eyeball (Fig. 61).

In both of these conditions the margins of the lids have a normal position, the displacement affecting the lashes only.

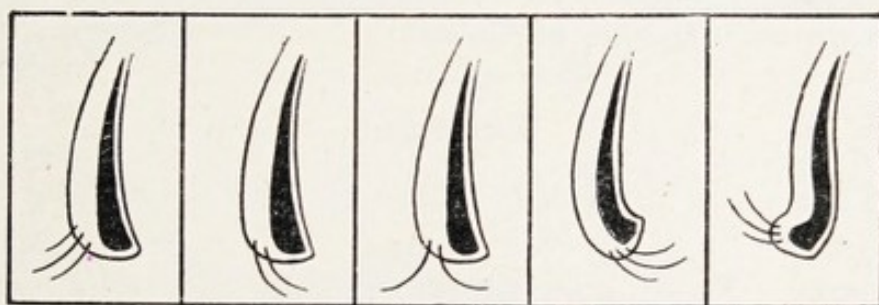


FIG. 59. FIG. 60. FIG. 61. FIG. 62. FIG. 63.

Figs. 59-63.—Section of the Upper Lid, showing Normal and Abnormal Position of Tarsus and Lashes. Fig. 59, Normal lid; Fig. 60, trichiasis; Fig. 61, distichiasis; Fig. 62, entropion; Fig. 63, ectropion.

Symptoms.—The misdirected lashes cause mechanical irritation and injury to the cornea, with irritation, pain, lacrymation, photophobia, opacities, and ulceration.

Etiology.—The most frequent cause is cicatricial contraction of the conjunctiva and tarsus in old cases of trachoma. Other causes are blepharitis, burns, injuries to the lids, and operations upon the lids.

Treatment.—I. *Epilation.*—When the misdirected lashes are few in number, we may epilate with the cilia forceps (Fig. 64), repeating this every few weeks, since the lashes grow again.

2. *Electrolysis.*—A sponge electrode corresponding to the positive pole is applied to the temple, and a fine platinum needle forming the negative pole is introduced into the hair

follicle, destroying the latter; a very weak galvanic current (2 milliampères) is employed. This method results in a permanent cure, but is quite painful; cocaine should be injected into the lid margin.

3. *Operation*.—When a great number or all of the lashes



FIG. 64.—CILIA FORCEPS.

are misdirected operations must be performed. These have for their object correction of the faulty position or transplantation of the lashes. Since trichiasis is frequently associated with entropion, these operations will be considered in connexion with the latter disease.

Entropion.

A rolling in of the margin of the lid (and with it the lashes) (Figs. 62 and 65).

Varieties.—There are two forms: (1) Cicatricial, due to cicatricial changes in the conjunctiva and tarsus, most commonly affecting the upper lid. (2) Spasmodic, due to spasm of the palpebral portion of the orbicularis muscle, almost always occurring in the lower lid. The second variety is generally found in old persons (senile entropion) who are predisposed through relaxation of the palpebral skin and the deep position of the eyeball resulting from the absence of fat.

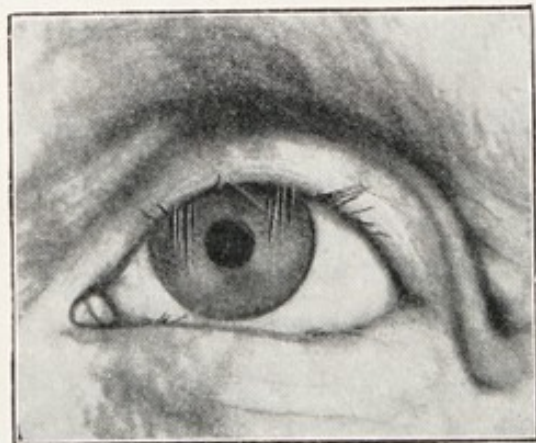


FIG. 65.—TRICHIASIS OF THE UPPER LID; ENTROPION OF THE LOWER LID.

Symptoms.—Those due to mechanical irritation and injury to the cornea: irritation, pain, lacrymation, photophobia, opacities, and ulceration of the cornea.

Etiology.—Cicatricial form : principal cause, the cicatricial changes in old cases of trachoma, also burns and other injuries to the lids, and operations upon the lids. Spasmodic form : atrophy or absence of eyeball, blepharospasm, inflammatory conditions of the lids and conjunctiva, and the prolonged wearing of a bandage.

Treatment.—Non-operative treatment may be of service in the spasmodic variety. If a bandage causes the entropion, we must either leave this off or apply a small roll of lint to the orbital margin beneath the bandage, exerting pressure in such a manner as to neutralize the inversion. In other cases



FIG. 66.—HORN PLATE.

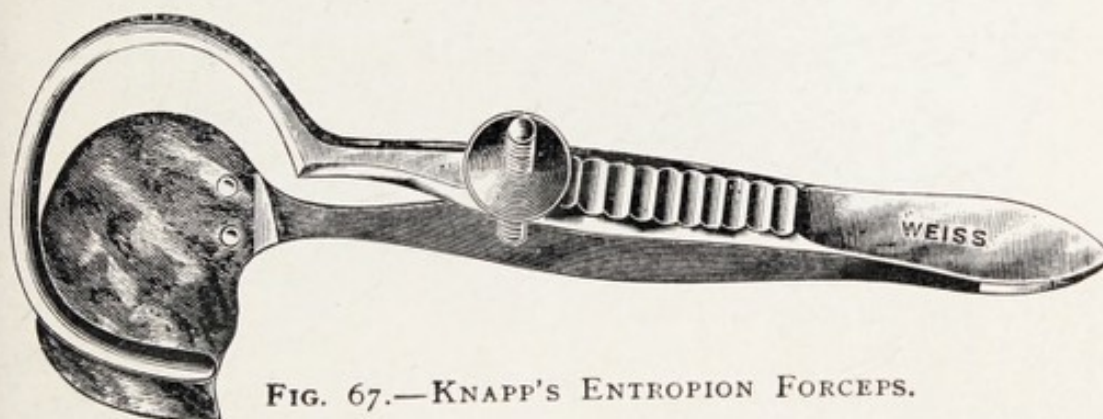


FIG. 67.—KNAPP'S ENTROPION FORCEPS.

we try to remove the cause. The lid may be kept everted for a few days by collodion painted on the external surface, or by adhesive plaster passing from the margin of the lid to the cheek. If these simple means do not answer, an operation is indicated. In the cicatricial form operation is always necessary.

Operations for Trichiasis (Distichiasis) and Entropion.—The choice of an operation (there are a great many) is influenced by the peculiarities existing in the individual case. The object of these operations is to remove the displaced lashes from contact with the eyeball either (1) by changing

the direction of the lashes from a faulty to a correct one ; (2) by transplanting the offending zone ; or (3) by straightening the curved tarsus.

In these operations we use either a horn plate (Fig. 66) or Knapp's entropion forceps (Fig. 67), to protect the eyeball, check hæmorrhage, and give proper support to the lid. The horn plate is passed beneath the lid and pressed forward. If the lid-clamp be used, its solid blade is passed beneath the lid, and the latter secured by tightening the screw of the instrument.

The *Jaesche-Arll Operation* attaches the zone of hair fol-

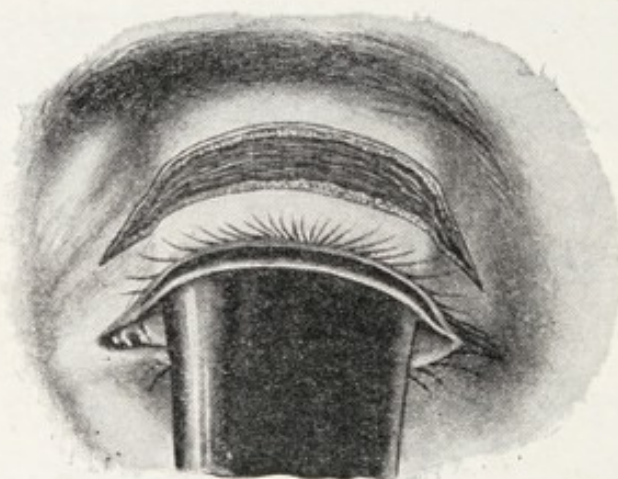


FIG. 68.—THE JAESCHE-ARLT OPERATION FOR ENTROPION INCISIONS.

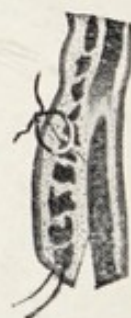

FIG. 69.—THE JAESCHE-ARLT OPERATION COMPLETED.

licles at a higher level by shortening the skin of the lid. The lid is split through its entire length in the intermarginal space (Fig. 68), so that the anterior lip contains the hair follicles. A second incision, dividing the skin down to the tarsus, is made 4 mm. from and parallel to the margin of the lid. A third incision extends upwards in a curve between the two ends of the second incision. The elliptical piece of skin bounded by the second and third incisions is dissected away without injury to the orbicularis, and the margins of the defect are united by fine silk sutures. In this manner the strip of integument containing the cilia is drawn upward and the lashes are tilted forward, away from

the cornea. The area from which the skin and lashes have been displaced may be allowed to cicatrize, or may be covered by the excised strip of integument properly trimmed, which will attach itself in a few days.

Hotz's Operation raises the zone of hair follicles by attaching the skin to the upper border of the tarsus. A curved incision is made through the skin of the lid following the upper border of the tarsus, from 2 mm. above one canthus to a corresponding distance above the other. While the edges of the wound are separated, a narrow strip of orbicularis along the upper border of the tarsus is excised. The sutures,

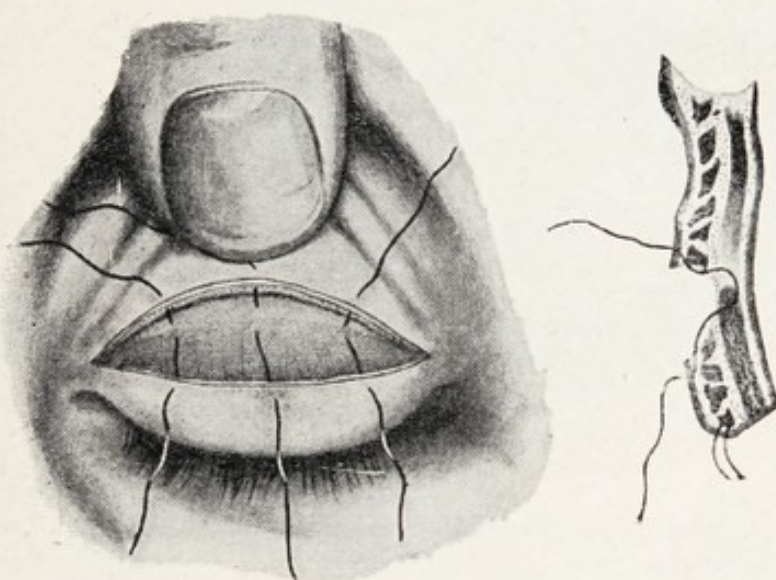


FIG. 70.—THE HOTZ OPERATION FOR ENTROPION.

three or more in number, are then passed through the lower wound margin, upper border of tarsus, returning through the orbito-tarsal fascia, and finally through the upper wound margin (Fig. 70). This operation may be modified by the addition of an intermarginal incision, by grooving the tarsus, and by excising a horizontal strip of integument.

The *Streetfeild-Snellen Operation* aims at straightening the inverted lid by the removal of a wedge-shaped piece from the tarsus. A transverse incision is made through the skin, 2 mm. above and parallel to the margin of the lid along its entire length. A strip of orbicularis is excised, thus

exposing the tarsus. A wedge-shaped piece, the apex of which is directed toward the conjunctiva, is removed from the tarsus along its entire length. The cut surfaces of the tarsus are brought into contact by three sutures, provided with needles at both ends, in the following manner: One needle is passed through the tarsus above the groove; both needles are then carried down in front of the wound in the tarsus, and then between tarsus and skin, and brought out just above the free margin of the lid (Fig. 71) about 4 mm. apart. More pronounced eversion is produced if the threads

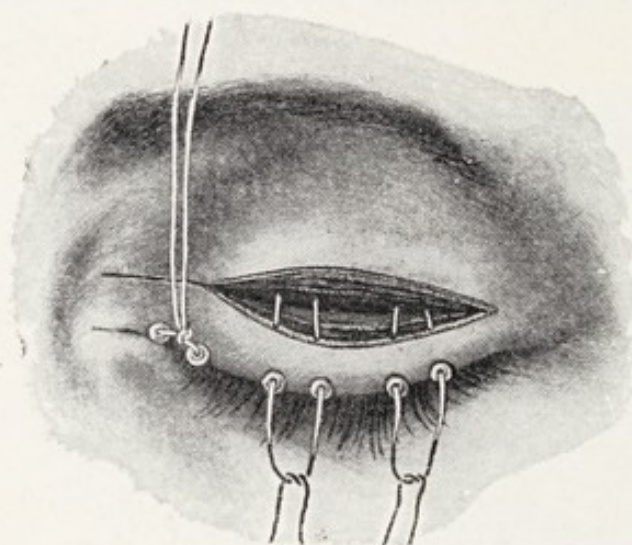


FIG. 71.—THE STREATFEILD-SNELLEN OPERATION FOR ENTROPION.

One suture has been tied.

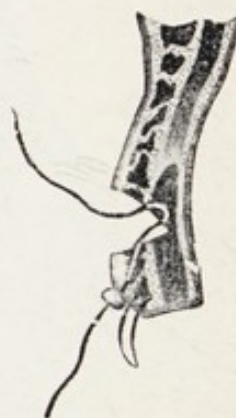

FIG. 72.—THE STREATFEILD-SNELLEN OPERATION FOR ENTROPION.

View in section.

are brought out behind the cilia, at the posterior lip of the lid margin (Herbert's modification). The two threads are tied upon a bead and then turned up over the forehead and secured by plaster. The cutaneous wound closes of itself.

Operations for Spastic (Senile) Entropion include (1) *excision of a horizontal strip of skin* with the underlying orbicularis, the width being gauged so that when pinched up it shall cause the disappearance of entropion without producing ectropion; the margins of the wound are then united by silk sutures; (2) Hotz's operation; and (3) canthoplasty.

Canthoplasty consists in an enlargement of the palpebral fissure by division of the external canthus. The lids being separated and stretched at the external canthus with the fingers, one blade of blunt-pointed, straight scissors is introduced behind the external commissure as far as possible, and the entire thickness divided, the wound in the skin being made a little longer than that in the conjunctiva. This leaves a rhomboidal wound. The conjunctiva at the apex of the wound is loosened from underlying tissue and stitched

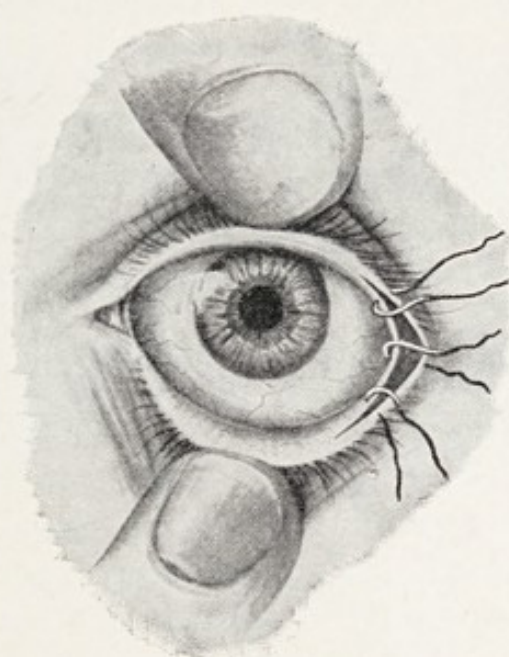


FIG. 73.—CANTHOPLASTY.

to the centre of the incision in the skin. A second suture is passed through the upper, and a third through the lower part of the wound, uniting conjunctiva to skin (Fig. 73).

The sutures are inserted so as to prevent reunion, thus making the effect permanent. If a temporary enlargement is desired, we omit the sutures; the operation is then known as canthotomy or temporary canthoplasty.

The indications are blepharospasm associated with spastic entropion, and certain cases of trachomatous pannus. Temporary canthoplasty is indicated in acute purulent conjunctivitis, when swelling of the lids exerts injurious pressure upon

the eyeball, in, blepharospasm, and in the removal of an enlarged eyeball or an orbital tumour.

Ectropion.

An eversion of the lid with exposure of more or less conjunctival surface (Fig. 63, and Fig. 53, Plate VI.). It may affect the upper or the lower lid, or both.

Symptoms.—Epiphora (from eversion of punctum) causing excoriations and eczema of the lower lid, which, in turn, through contraction, increase the deformity. The exposed conjunctiva becomes reddened and hypertrophied. In marked cases the cornea may suffer, as a result of imperfect closure of the lids.

Etiology.—(1) Cicatricial contraction from wounds, operations, burns, ulcers, and caries of the orbital margin or surrounding surfaces (cicatricial ectropion). (2) Chronic conjunctivitis and blepharitis associated with considerable hypertrophy. (3) Relaxation of the skin and orbicularis in old people (senile ectropion), affecting only the lower lid. (4) Affections of the facial nerve, causing paralysis of the orbicularis (paralytic) ectropion, affecting only the lower lid. (5) Spasmodic contraction of the marginal portion of the orbicularis (spasmodic ectropion), seen especially in children with acute conjunctivitis associated with considerable blepharospasm.

Treatment.—*Non-operative*: The spasmodic form is frequently relieved by a suitable retaining bandage applied after the lid has been properly placed. In the paralytic form we employ a bandage, at the same time attempting to cure the facial paralysis. In the senile form, the patient should be instructed, when wiping away the tears, to press upward and inward and not downward and outward. In slight cases of ectropion associated with much conjunctival hypertrophy, painting the exposed surface with a 2 per cent. solution of silver nitrate may be of service. Careful massage of a cicatrix may give some relief. When these simple procedures do not answer, and in cicatricial ectropion, we must resort to operative intervention.

Operations for Ectropion.—In some cases the lower lid margin appears to be everted by a chronic hypertrophy of the conjunctiva and subconjunctival tissue. Two horizontal incisions, removing a wedge-shaped piece of the whole width of the hypertrophied mass, will effect a cure. No sutures are needed. In senile and paralytic forms of ectropion the lid may be replaced (1) by reduction of the length of the lid-border; and (2) by tarsorrhaphy.

Shortening the Margin of the Lid (Adam's Operation) is

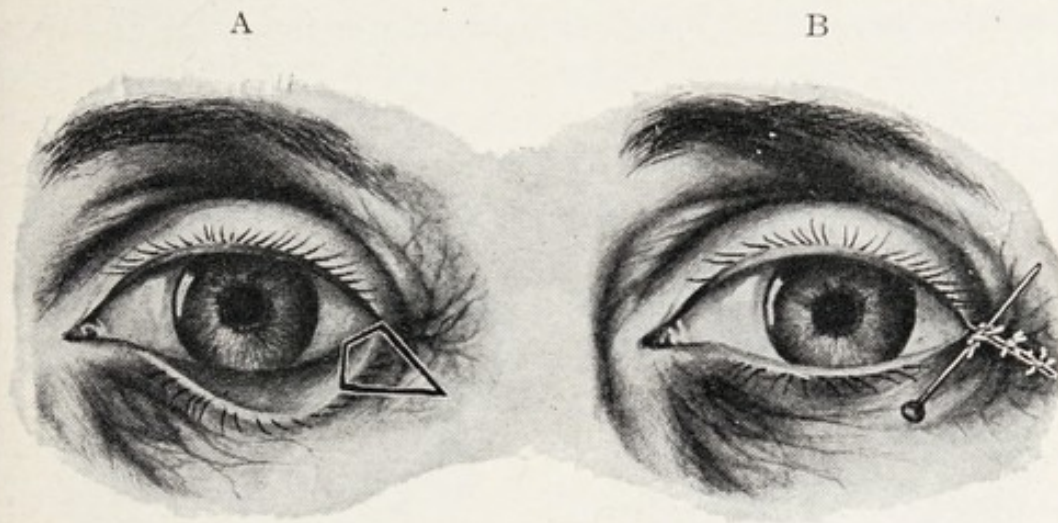


FIG. 74.—ADAM'S OPERATION FOR ECTROPION.

A, Incisions; B, completed.

applicable when there is considerable elongation. A wedge-shaped piece is excised from the whole thickness of the lid, the base corresponding to the margin of the lid, and varying from 5 to 10 mm. in width, according to the amount of shortening required (Fig. 74, A); the edges are brought together by a hare-lip pin and the cutaneous margins by silk sutures. The piece may be excised from the centre of the lid; but, to prevent notching, it is better to operate at the external canthus (Fig. 74, B).

For cicatricial ectropion a great many operative procedures have been advocated. An essential condition for success is the thorough division of all cicatricial adhesions, so that the lid assumes a natural position. the object of any operation

being to prevent recicatrization. If the ectropion is slight and but little skin has been lost, it may be sufficient to divide the cicatricial bands subcutaneously, or to cut out the scar portion and bring the margins of the wound together by sutures. A procedure very frequently used is—

The *V Y Operation* (Wharton Jones).—A V-shaped incision is made with the apex directed away from the palpebral margin, the incision including the cicatrix. The skin is freed from underlying parts, not only in the V-shaped area, but also to either side. The V-shaped area is then slid upwards

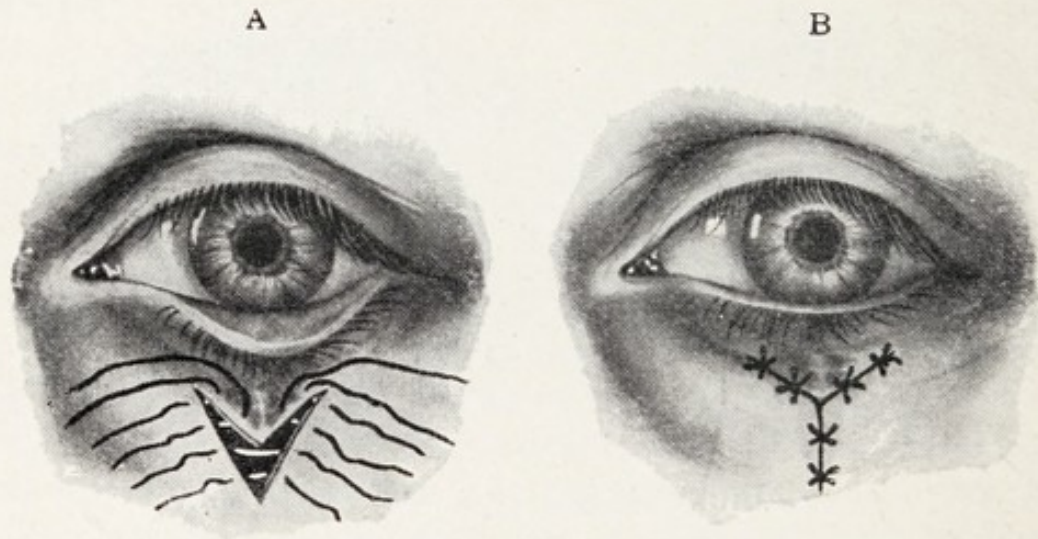


FIG. 75.—THE V Y OPERATION FOR ECTROPION.

A, Incisions : Sutures in place ; B, Completed.

until slight inversion of the lid-margin is produced. The margins of the incisions are then brought together by sutures in such a manner that the figure Y results (Fig. 75).

In more extensive cicatricial ectropion a plastic operation is usually required (blepharoplasty).

Blepharoplasty consists in covering the defect formed by the excision of a cicatrix, new growth, or extensive ulceration, with skin-flaps with a pedicle, taken from some adjacent part, or by means of skin-grafts. In such operations it is customary to close the lids temporarily by several sutures so as to prevent the contraction of the cicatricial tissue from undoing the result accomplished by the operation. Of the innumerable

blepharoplastic operations with pedunculate skin - flaps. Knapp's, Dieffenbach's, and Fricke's methods are the ones most commonly employed.

Knapp's Method (lower lid) consists in detaching a lateral flap on each side of the defect in the lid, freeing it from adjacent tissue, drawing the two flaps over the defect, and uniting them by a vertical row of sutures.

Dieffenbach's Method (lower lid) makes use of an adjacent quadrangular flap taken from the cheek and slid inward so as to cover the defect of the lid.

Fricke's Method (upper or lower lid) consists in taking a tongue-shaped flap somewhat larger than, and having the shape of, the defect in the lid from the temple or cheek; the base of the flap adjoins one end of the lid-wound, and is the part which becomes twisted when the flap is transplanted into the defect.

Skin-Grafting.—The defect is filled in by one large piece of skin or by a number of smaller ones after the lid has been fastened in its proper position by temporarily suturing the two lids together. The grafts are taken from some part of the body in which the skin is thin and delicate, such as the inner side of the arm or thigh. The area of the graft or grafts must be one-third larger than the defect to be covered, to allow for shrinkage. The graft may consist of the entire thickness of the skin (Wolfe's method), or comprise only the epidermis (Thiersch's). The area to be covered must be clean and free from blood. When in place, the graft is covered with a layer of rubber or silk protective, and then with an anti-septic dressing. The dressing is not disturbed for three days, and the original protective layer over the graft is often left in place still longer.

Skin-grafting is now used very extensively and with very good results. If a portion of the graft sloughs, the corresponding defect can be freshened and another graft applied. This method causes less disfigurement than when pedunculate flaps are used. Thiersch's grafts, being thinner and softer than Wolfe's, produce better results cosmetically, and the lid is not so heavy.

Tarsorrhaphy.—The object of this operation is to reduce the width of the palpebral fissure by uniting the edges of the lids at the outer commissure. The edges of the lids are approximated at the outer canthus to the required extent, so as to give the operator exact knowledge as to how much union is desired. A horn spatula is passed behind the outer commissure, and the desired length of the border of each lid is excised, including the hair follicles. The length of the flap varies according to the effect desired (about 3 to 6 mm.); its breadth is about 1 mm. To obtain firmer adhesion, the border of the lid, excluding the cilia, is denuded for 2 or 3 mm. beyond the point at which the first incision stops. The denuded edges are then brought together by silk sutures (Fig. 76). This operation is indicated in lagophthalmos, especially in Basedow's disease, in some cases of senile and paralytic ectropion, and in connexion with blepharoplasty.




FIG. 76.—TARSORRHAPHY.

Blepharospasm, a tonic or clonic spasm of the orbicularis, may be a symptom of ocular disease or of a neurosis. The tonic forms may be caused by foreign bodies, corneal ulcers, corneal inflammations, or any inflammatory condition of the eye, or by fissure at the outer canthus. The clonic form is often manifested in fibrillar twitchings of a portion of the muscle, and, although of no grave import, is often alarming to the patient. Digestive troubles and uncorrected errors of refraction are the most frequent causes.

Lagophthalmos is an incomplete closure of the palpebral fissure when the lids are shut, as a result of which there is exposure and consequent injury to the bulbar conjunctiva and the cornea. The condition may be due to congenital or acquired shortening of the lids, ectropion, paralysis of the orbicularis and protrusion or enlargement of the eyeball; it is seen also in unconscious and moribund individuals.

Ptosis.

A drooping of the upper lid due to paralysis or deficient development of the levator. All degrees of ptosis occur. When marked, it interferes with vision by covering the pupil. Patients attempt to raise the lid by forced action of the occipito-frontalis muscle, wrinkling the skin of the forehead (Fig. 77); they favour exposure of the pupil by throwing the head backward; this attitude is characteristic.

Etiology.—Ptosis may be *congenital* or *acquired*. When congenital it is usually bilateral, due to deficient development



FIG. 77.—EPICANTHUS AND BILATERAL PTOSIS.

of the levator, and often associated with other congenital defects. Acquired ptosis is usually unilateral; it is caused by paralysis of the branch of the third nerve which supplies the levator, and is usually associated with paralysis of other ocular muscles supplied by the oculomotorius. When not associated in this way it is not infrequently the result of cerebral disease.

Mechanical ptosis is a variety due to (1) increased weight of the lid (trachoma, tumours, etc.); (2) lack of support (atrophy of globe and after-enucleation); and (3) lack of connective-tissue connexion between skin and levator and upper border of orbit, in which the relaxed skin forms a fold which falls over the margin of the lid.

Treatment.—In the ordinary variety of the acquired form we seek the cause of the paralysis of the third nerve and treat this; syphilitic cases respond well to treatment. Electricity is used. If this treatment fails to remedy the deformity after a lengthy trial, in the congenital variety and in some mechanical cases, operation is indicated.

Operations for Ptosis.—Operations for ptosis usually produce some improvement, but a really satisfactory result is rarely obtained. Care should be taken that closure of the lids be not made difficult by the operation.

Excision of a Strip of Orbicularis (Graefe's Operation).—A horizontal incision of the skin is made across the entire lid, 5 mm. above its margin. The edges of the wound are separated and undermined, and a band of orbicularis is excised. If the skin be redundant, a strip may be excised. The wound is closed by deep sutures, which include muscle and skin.

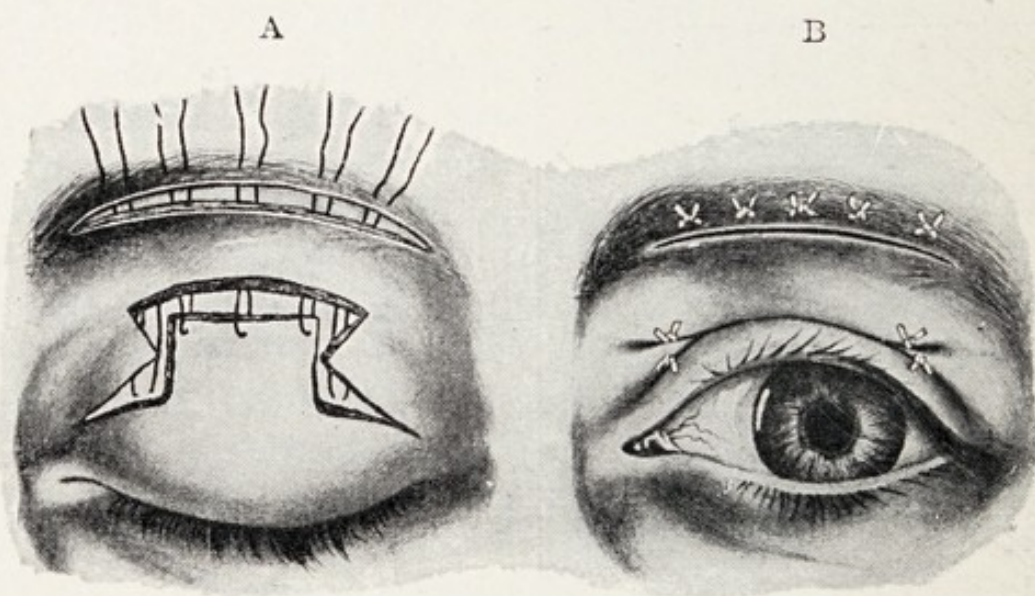
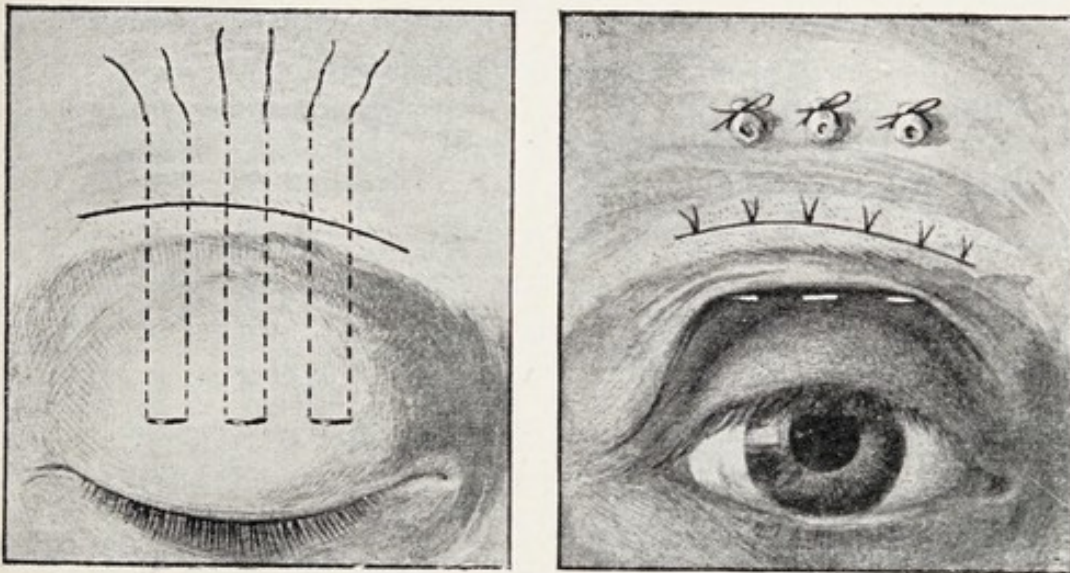


FIG. 78.—PANAS'S OPERATION.

A, Incisions, and sutures in place; B, completed.

Panas's Operation.—A horizontal incision (3 cm.) is made in the eyebrow down to the periosteum, and another (2 cm.), equally deep, at the margin of the orbit; this bridge of skin and muscle is undermined. A tongue-shaped flap (15 mm. wide) is marked out, its surface denuded of epithelium, and separated from the lid, including muscle. This flap is drawn up under the bridge, and stitched to the upper edge of the upper wound by three sutures. The sutures are removed after four days. The operation leaves an ugly scar. An inexperienced operator is apt to produce an excessive shortening of the lid, resulting in lagophthalmos.

Pagenstecher's Sutures attempt to bring the occipito-frontalis to act on the lid by means of cicatricial bands. A silk thread is provided with a needle at each end. One of these needles enters the skin just above the lid-margin, and, after moving horizontally a short distance, passes upward beneath the skin and emerges above the eyebrow. The other needle enters the first puncture, and, passing upward, emerges by the side of the first. The result is a subcutaneous loop of thread just above the lid-margin. The two ends of the thread are tied over a piece of rubber tubing. The threads are gradually tightened until they cut their way out, or allowed



FIGS. 79 AND 80.—HESS'S OPERATION FOR PTOSIS.

to remain and gradually drawn out above. Two or three such double sutures are used.

Hess's Operation is a modification of Pagenstecher's. A 3 cm. incision through the skin of the eyebrow permits undermining down to the lid-margin. Three double sutures are then introduced, so as to form loops about 7 mm. from the lid-border, and passed upward beneath the brow, emerging 1 cm. above the incision, where they are tied upon small rolls of gauze (Figs. 79 and 80). The skin wound is closed with sutures. The double threads are allowed to remain for two weeks. In this operation the skin of the lid is displaced upwards, adheres, and gives the occipito-frontalis greater purchase; the effects are therefore better than when simple sutures are used.

Epicanthus.

Epicanthus is a congenital condition, usually bilateral, in which a perpendicular fold of the skin extends from the root of the nose to the inner end of the brow, concealing the inner canthus and caruncle. In Mongolians it is a racial characteristic. In slight degree it is often seen in young children associated with a flattened bridge of the nose, and often disappears with the development of the face. When sufficiently marked to constitute a deformity, it can be relieved by excising an elliptical piece of skin from the root of the nose, long axis vertical, and sticking together the free margins.

Herpes Zoster Ophthalmicus.

Herpes zoster ophthalmicus is characterized by a unilateral herpetic eruption following the distribution of the ophthalmic division of the fifth nerve. The affection begins with severe

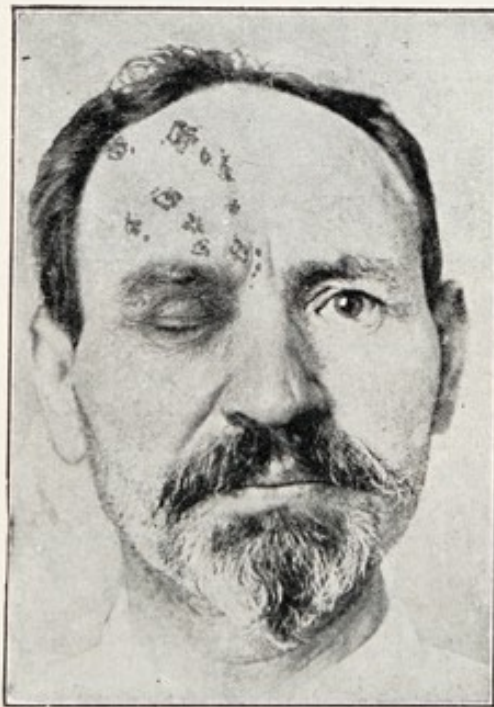


FIG. 81.—HERPES ZOSTER OPTHALMICUS.

neuralgic pain of one side of the head and face, and constitutional disturbance. The eruption presents vesicles situated upon inflamed bases. The vesicles are at first filled with clear fluid, but this soon becomes cloudy; subsequently discoloured crusts form and drop off, leaving permanent and disfiguring scars. In some cases the nasal branch is also attacked, and then the eyeball becomes implicated; the cornea presents one or more vesicles changing to ulcers, and the iris and ciliary body and even the entire globe (panophthalmitis) may be involved.

The affection is due to disease of the Gasserian ganglion. It is most frequently observed in elderly patients of feeble con-

stitution. Its duration is from several weeks to several months. The prognosis is usually good, but is serious when the cornea is involved.

Treatment.—Bland dusting-powders (bismuth subcarbonate, zinc oxide, or talcum) or 10 per cent. ichthyol ointment. Internally quinine and iron and the salicylates are most useful. The severe pain may need to be controlled by aspirin or morphine. The eyeball may become involved, necessitating treatment for corneal ulcer or possibly iridocyclitis.

Tumours of the Eyelids.

Benign Tumours include xanthelasma, molluscum, verruca (wart), fibroma, cyst, nævus, and milium.

Xanthelasma is a flat or slightly-raised yellowish discoloration beneath the skin, found most frequently near the inner canthus in elderly women. It is due to degeneration of the muscle fibres.

Molluscum is a small, white, rounded tumour about the size of a small pea, presenting a depression at its apex; several usually occur at the same time. They are considered contagious by some authorities. They represent a diseased condition of the sebaceous glands.

Milium is a small, yellowish-white elevation about the size of a pin's head, due to retention in a sebaceous gland.

The others resemble tumours of the same class occurring in other parts of the body. Benign tumours of the lids may be excised, providing too great a loss of skin is not occasioned by the operation.

Malignant Tumours.—*Sarcoma* is rare. *Carcinoma*, when it attacks the lids, usually assumes that form of epithelioma known as '*rodent ulcer*.' This occurs in elderly persons, especially at the inner end of the lower lid-margin. It begins as a small pimple or wart, covered by a crust, soon changes to an ulcer with indurated walls, and spreads, if unchecked, to neighbouring parts. Its growth is, however, slow, and many years may elapse before it assumes any considerable size.

Treatment of rodent ulcer consists in removal by excision,

or by the repeated application of carbon dioxide snow or of radium; this is always possible if done early. If advanced, we may excise the lesion and cover the defect by blepharoplasty. If all the diseased tissue cannot be excised, radium or the X rays may be used.

At Moorfields Hospital many rodent ulcers have been treated by carbon dioxide snow (see page 443)—forty to sixty seconds' application of the pencil every second day at first, and afterwards once a week. The ulcers healed with a minimum of scarring, and the cures are permanent.

In early stages radium has given perfect results. Once a week a tube containing 5 milligrammes of radium bromide is applied to the ulcer, and retained in contact with it for from ten to thirty minutes, the frequency and duration of the applications depending upon the amount of reaction. On the day after the application the ulcer should show only slight hyperæmia.

Injuries of the Eyelids.

These are quite common, and include contusions, wounds, burns, and insect bites. Ecchymosis and œdema are often marked symptoms, on account of the looseness of the subcutaneous connective tissue.

Ecchymosis ('black eye') is usually of no importance, merely causing disfigurement, which lasts one or two weeks. If seen immediately, cold compresses may be of service. After a day or two hot compresses and gentle massage are indicated to promote absorption of the extravasated blood. Occasionally in debilitated individuals, especially if associated with abrasion, abscess of the lid results, and may require horizontal incision. In fracture of the base of the skull, blood may travel along the floor of the orbit, and after a day or two appear in the lower lid and bulbar conjunctiva.

Insect bites give rise to a great deal of swelling, which is best controlled by cold compresses.

Incised wounds cause considerable gaping, if vertical, on account of division of the orbicularis, and then the scar is apt to be noticeable; if horizontal, the lips of the wound do

not tend to separate, and usually heal without deformity. Incised wounds should be cleansed and stitched at once, using fine silk and delicate needles. A vertical wound of the margin must be carefully sewed so that no indentation will remain.

Lacerated and contused wounds, if extensive and accompanied by much swelling, should not be closed at once. The wound should be thoroughly cleansed, and cold compresses applied to reduce the swelling, after which the edges may be brought together. Injured parts, however slenderly attached, should not be removed. Care must be taken not to produce deformity or shortening by too tight sutures. It may be advisable to use skin-grafts.

Burns should be irrigated with solution of boric acid, dried, and covered with a bland oil or ointment. When granulating, skin-grafts should be supplied if the defect is extensive.

Emphysema associated with injury to the lids denotes a solution of continuity of the walls of the orbit, permitting communication with the neighbouring air cavities. The lids will present a soft swelling of considerable size, often closing the palpebral aperture; bubbles of air, becoming displaced in palpation, give rise to the sensation of crepitation. A firm bandage will hasten the disappearance of the air. The patient must be instructed to avoid any straining efforts, such as blowing the nose, which will increase the emphysema.

CHAPTER VI

DISEASES OF THE LACRYMAL APPARATUS

Anatomy and Physiology.—The lacrymal apparatus consists of a secretory portion, the lacrymal gland, and an excretory portion, which collects the tears and conducts them into the inferior meatus of the nose.

The *lacrymal gland* is a small, oblong body, placed in the upper and outer part of the orbit, and divided into two portions. The upper part, the larger, about the size of a small almond, is situated in a depression in the orbital plate of the frontal bone, the lacrymal fossa, to which it is fixed by connective tissue; the lower division, the smaller, is known as the accessory lacrymal gland, and is placed just beneath the outer part of the conjunctiva of the fornix. In structure the lacrymal resembles the salivary glands, consisting of acini containing cuboidal cells. The excretory ducts of both portions of the gland, the lacrymal ducts, six to twelve in number, pass downward and empty into the external half of the superior fornix conjunctivæ by separate orifices.

The excretory portion of the lacrymal apparatus (Fig. 82) consists of the puncta, the canaliculi, the sac, and the duct. The *puncta* are two minute openings, one of which is seen upon an elevation on each lid about 6 mm. from the inner canthus; they are the orifices of the *canaliculi*. The latter extend vertically for a short distance, and then continuing at right angles, pass horizontally inward in a curved course, and empty separately or together into the lacrymal sac.

The *lacrymal sac*, situated at the inner side of the internal canthus, is the upper, dilated portion of the lacrymo-nasal duct, and is placed in a groove formed by the lacrymal bone and the nasal process of the superior maxillary bone. It measures 12 mm. in the vertical



FIG. 82.—DIAGRAM-MATIC SKETCH OF THE EXCRETORY PORTION OF THE LACRYMAL APPARATUS.

and 6 mm. in the horizontal and transverse diameters ; its walls are thin ; it is covered in front by the internal tarsal ligament and some fibres of the orbicularis muscle.

The *nasal duct* passes downward and slightly outward and backward in a canal formed by the superior maxillary, lacrymal, and inferior turbinated bones, and terminates below in the fore-part of the inferior meatus of the nose ; its length varies from 18 to 24 mm., and its diameter from 4 to 6 mm. ; it is somewhat contracted where it joins the sac and again at its lower extremity. Both sac and duct are formed of fibrous and elastic tissues, and mucous membrane lined with columnar epithelium which may be ciliated. The lower part of the duct is surrounded by a dense plexus of veins.

The *lacrymal secretion* is a slightly alkaline liquid containing a comparatively large amount of sodium chloride. Ordinarily the lacrymal gland secretes just enough to moisten the eyeball, and this is lost by evaporation. As the result of psychical stimulation or of irritation of the eye or the nose, there is increased secretion. The conveyance of tears from the conjunctiva to the lacrymal sac is effected by the act of winking, the lubrication of the margins of the lids by fatty material ordinarily preventing the tears from flowing over.

Epiphora.

Epiphora ('watery eye'), an overflow of tears upon the cheeks, is a very pronounced symptom in all affections of the tear-conducting apparatus. It may also be dependent upon increased secretion (foreign bodies, inflammations, exposure to bright light and smoke, affections of the nose, irritation affecting the terminal twigs of the trigeminus). The two forms may be combined.

Anomalies of Puncta and Canaliculi.

Normally, the lower punctum is directed backward and upward toward the eyeball. In *eversion of the punctum* (lower) it looks forward and away from the depression in which the tears accumulate, and the result is epiphora. The condition may be due to a relaxed state of the lids in old age, to conjunctivitis, blepharitis, and ectropion.

Contraction and Obliteration of the Puncta and Canaliculi may be congenital, or acquired as a result of wounds and chronic inflammations of this region. Foreign bodies (eyelash or concretion) may obstruct the canaliculi.

Diseases of the Lacrymal Apparatus may be divided into those of the gland and those of the conducting portion. The former (acute and chronic dacryoadenitis) are very rare ; the latter (acute and chronic dacryocystitis) are very common.

Chronic Dacryocystitis.

A chronic inflammation of the lacrymal sac frequently due to an obstruction in the nasal duct. It is also known as blennorrhœa or catarrh of the lacrymal sac, and as mucocele.

Symptoms.—The constant symptom is epiphora, increased by exposure to cold, wind, dust, smoke, etc. There is fulness in the region of the lacrymal sac. By pressing upon the distended sac a viscid fluid of whitish, yellowish, or greenish colour (depending upon the amount of pus) escapes from the puncta ; but sometimes the sac is emptied in the reverse direction, and the accumulation is pressed into the nose.

The course is chronic, and extends over years. A long period may elapse before the patient seeks relief. After the mucopurulent material has filled the sac for a long time there is atrophy of its mucous membrane and distension of its walls (Fig. 54, Plate VI.). A form of chronic conjunctivitis affecting chiefly the inner canthus (lacrymal conjunctivitis) and blepharitis are frequently present ; eczema occurs sometimes and there may be more or less ectropion. As a result of contamination by micro-organisms from the conjunctiva (especially streptococci, Fig. 55, Plate VI.), a purulent inflammation of the lining of the sac may be set up.

The infectious character of the accumulation in the lacrymal sac is shown, when any abrasion or ulcer of the cornea exists, by the readiness with which the wound or ulcer becomes infected. In operations upon the eye such a condition is a very frequent cause of infection.

Etiology.—In many cases there is stricture of the nasal duct, the result of previous probing or of an affection of the nasal cavity, usually rhinitis. The duct is predisposed to obstruction by the existence of a plexus of veins encircling its lower end. As a result of rhinitis, there is swelling or cicatricial contraction of the mucous membrane of the duct. More

rarely pressure from tumours (polyps and hypertrophies), ulcerations, caries, and periostitis are responsible.

Treatment.—In recent and slight cases we may relieve the epiphora by curing the nasal affection which produces the obstruction. Locally, stimulating and astringent remedies,



FIG. 83.—WEBER'S PROBE-POINTED CANALICULUS KNIFE.

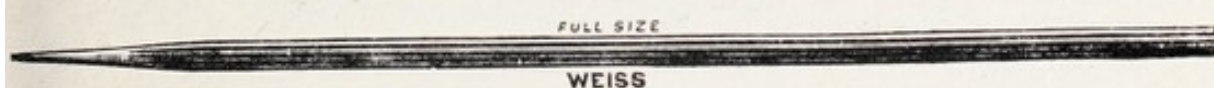


FIG. 83a.—NETTLESHIP'S DILATOR.

such as zinc sulphate and the ointment of the yellow oxide of mercury, may be applied to the inner part of the eyeball, followed by gentle massage over the sac so as to favour entrance of some of the remedy. The patient is instructed to empty the sac by pressure several times a day. The sac should be washed out with warm and weak solutions of salt, boric acid, or zinc sulphate, using a small syringe with




FIG. 84.—LACRYMAL SYRINGE.

delicate nozzle (Fig. 84). It is often necessary to dilate the lower punctum with the fine conical sound (Fig. 83a) before the nozzle can be introduced. If the nasal duct is pervious, the solutions will enter the nose and escape from the anterior nares when the patient inclines the head forward. In this case, continued syringing will cure the trouble. And even if the fluid cannot at first be got to flow through the nasal duct, one usually succeeds if one keeps up the treatment long enough. Daily washing out of the sac gradually brings it into a more healthy condition, and, as the congestion of the

mucous membrane of the nasal duct subsides, the duct again becomes pervious.

If the sac cannot be syringed out, and a lacrymal abscess forms, this should be opened through the skin. The direction

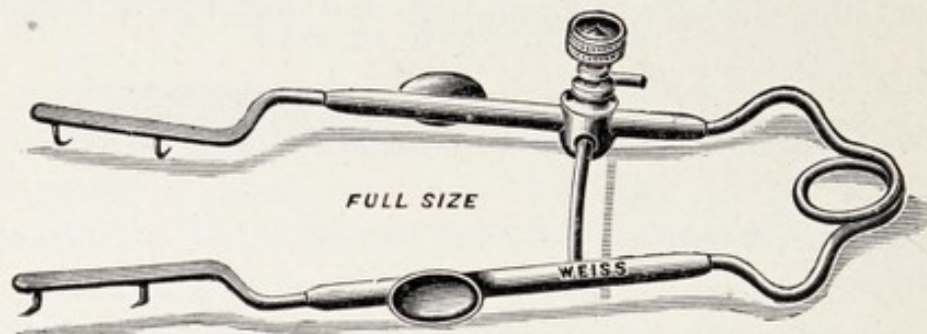


FIG. 85a.—RETRACTOR.



FIG. 85b.—BLUNT DISSECTOR AND SPOON.

of the incision should be down and out, so as to lie in the natural folds of the skin and leave no noticeable scar.

In the case of persistent purulent inflammation of the lacrymal sac with cicatricial obliteration of the nasal duct or disease of the nose, the best treatment is excision of the sac.

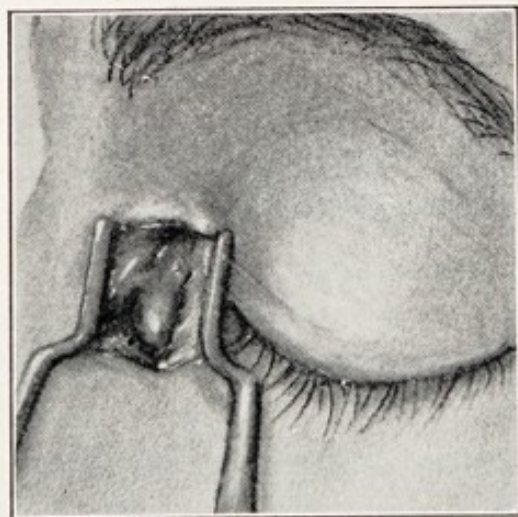


FIG. 86.—EXTIRPATION OF THE LACRYMAL SAC.

Excision of the Lacrymal Sac.—Instruments required are: Strong fixation forceps, dissection forceps, small scalpel, retractor (Fig. 85a), scissors, blunt dissector and spoon (Fig. 85b). A general anæsthetic may be used in the case of a very timid patient. Local anæsthesia (see Chapter XXXIII.) is

preferable, as there is almost complete absence of hæmorrhage: Novocain (1 per cent.) in adrenalin chloride (1 in 10,000). About 30 minims are injected at the

site of the operation with a hypodermic syringe. The skin of the eyelids is pulled outwards with the finger so as to make the internal palpebral ligament prominent. A curved incision is made from just above the upper border of the internal palpebral ligament downwards and slightly outwards for about $\frac{1}{2}$ inch along the margin of the orbit. The incision is only about $\frac{1}{8}$ inch internal to the inner canthus. A more median position would involve risk of wounding the angular vein, with troublesome hæmorrhage. The incision enters into the sac above, but is shallower below. The crest of the lacrymal bone, which can be felt by the finger, forms the guide to the sac. The retractor is inserted. The mucous membrane of the sac is grasped with forceps, and is separated from the bone on the inner side. Hæmorrhage is stopped by



FIG. 87.—COWPER'S PROBES.



FIG. 88.—ONE OF TEALE'S PROBES.

keeping the incision stretched by retractors, and by pressing into the wound for two or three minutes a plug of wool soaked in adrenalin. The sac is then freed all round, especially remembering the top of the sac. The sac is pulled up and the duct cut as low down as possible. The duct is then curetted with a small Volkmann's spoon. When all hæmorrhage is stopped, the wound is closed with sutures.

Treatment of Lacrymal Obstruction by Probing the Nasal Duct.—Never be the first to pass a probe into the nasal duct, especially an inflamed duct. Even with the greatest care cicatricial stricture is likely to follow injury of its delicate mucous lining. But in a case which has been probed before, continued probing will probably be required. Avoid, if possible, slitting up the canaliculus. The tears find their way along the canaliculus, not by gravity, but by capillary attrac-

tion, just as paraffin soaks up a lamp-wick. To slit the canaliculus destroys this capillary action.

To Slit Open the Canaliculus.—The surgeon stands behind and supports the patient's head against his body. Weber's

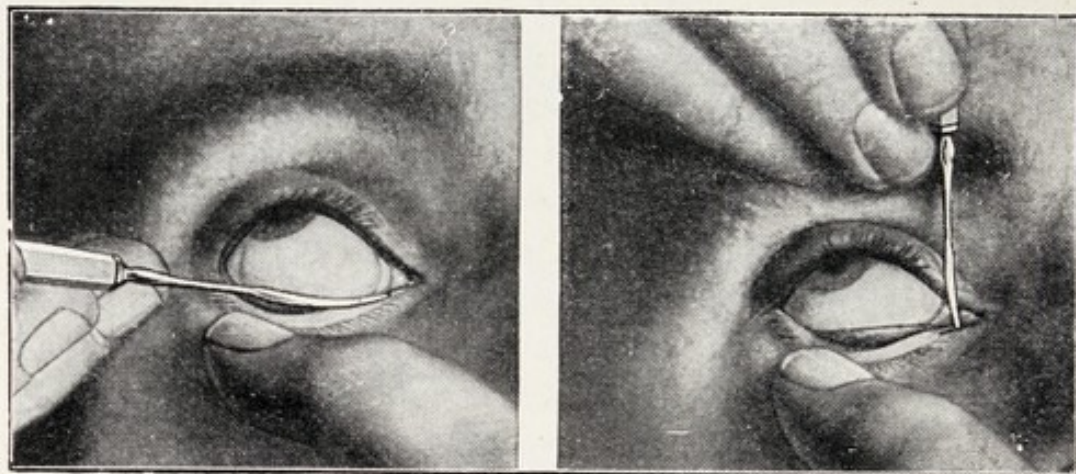


FIG. 89.—SLITTING OPEN THE LOWER CANALICULUS.

probe-pointed canaliculus knife (Fig. 83) is most frequently used. The lower lid is pulled outward by the thumb of one hand, and with the other the knife is introduced vertically

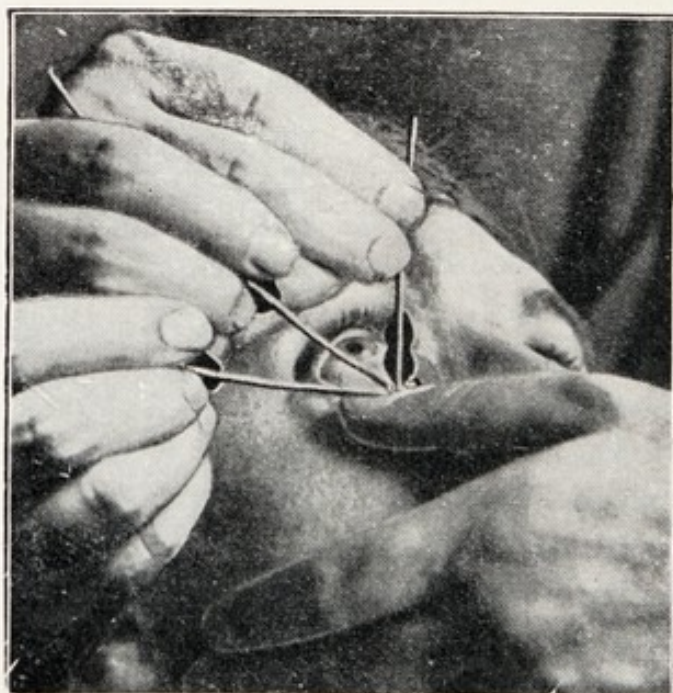

FIG. 90.—PASSING A PROBE INTO THE NASAL DUCT.

until it passes the punctum, and then horizontally. Its edge is upward, and looks toward the eyeball so as to cut into the conjunctiva and not into integument (Fig. 89). It is pushed

horizontally inward until its extremity meets with the firm resistance of the inner bony wall of the sac; then the knife is raised into a vertical position.

To Pass Probes into the Nasal Duct.—Commencing with a small size—say a No. 3—we pass this horizontally inward exactly as the knife is passed, the surgeon standing behind the patient. When the probe reaches the inner wall of the sac, which we can be certain of when in lifting the probe there is no wrinkling of the skin of the lower lid, it is raised so that its lower end points toward the furrow between nose and cheek. It is then pushed downward gently until it reaches the floor of the nasal fossa (Fig. 90). If the probe does not pass readily, we must not use force, but withdraw it slightly and try again, or try a smaller or larger size. The probe is left in from fifteen to thirty minutes, and the proceeding is repeated every other day, gradually using larger probes; then the intervals between probing are increased.



FIG. 91.—LACRYMAL STYLE.

Sometimes the stricture is cut, a strong narrow knife being passed in the same manner as a probe, and the obstruction divided in two or three directions; this is immediately followed by probing. The treatment is painful, and the benefit, if any, is only temporary. Such a case, therefore, is better treated by excision of the sac.

In some cases leaden or silver styles (Fig. 91) are passed and left in for days or weeks.

Acute Dacryocystitis.

An acute inflammation of the region of the lacrymal sac occurring in the course of a chronic dacryocystitis, as a result of an acute exacerbation. It is also known as abscess of the lacrymal sac (Fig. 55, Plate VI.).

Symptoms.—The skin over the lacrymal sac becomes red and swollen. This condition extends to the lids and conjunctiva, and is often sufficiently pronounced to lead to

a suspicion of erysipelas. There are great pain and tenderness, some fever and constitutional disturbance. After two or three days a yellow discoloration appears at one point. Here pus will be present, and should be evacuated. This will be followed by relief and a subsidence of symptoms.

The opening may heal completely, and the case again have the symptoms and slow course of chronic dacryocystitis. In other cases the opening persists, and the escaping fluid changes its character and becomes watery. This constitutes lacrymal fistula. As long as this remains open the patient is safe; as soon as it closes, he is liable to have a recurrence of abscess. Sometimes merely a minute passage is left, insufficient to admit a probe, from which a drop of fluid escapes from time to time.

Etiology.—Lacrymal abscess involves not only the sac, but the surrounding connective tissue as well. The decomposed contents of the sac find a small defect in the lining, through which micro-organisms (especially streptococci, Fig. 105, Plate VIII.) reach the neighbouring tissues and excite inflammation and suppuration.

Treatment.—If the case is seen early, we try to prevent the formation of abscess, by pressing out the accumulation and syringing with mild antiseptic solutions (boric acid 4 per cent., or bichloride 1 in 10,000). If this cannot be done, or is not effective, as is often the case, hot fomentations should be used.

As soon as fluctuation occurs, we make a free incision through the anterior wall of the sac, or the skin beneath which pus has formed. After evacuation the incision is packed with a strip of gauze, which is changed daily, until all inflammatory signs have disappeared, and the fluid is no longer purulent. We try to restore permeability of the duct, after which the fistula closes spontaneously. If this does not happen after the duct becomes pervious, we freshen and unite the edges of the opening, or cauterize them with the actual cautery, or scrape out the track with a sharp spoon. In some cases it may be advisable to extirpate the sac, but not until all acute symptoms have subsided.

CHAPTER VII

DISEASES OF THE ORBIT

Anatomy. — The orbit is formed of *bony walls* having the shape of a quadrilateral pyramid ; the apex corresponds to the optic foramen ; the base is directed forward, and is bounded by the strong, thick, projecting margin of the orbit. The nasal wall, the thinnest, is formed by the lacrymal bone and the os planum of the ethmoid ; it presents in front the groove for the lacrymal sac. The inner walls of the orbit are almost parallel, but the outer diverge considerably from each other from behind forward.

The apex or posterior portion of the orbit presents three openings leading to adjacent cavities : (1) the optic foramen, transmitting the optic nerve and the ophthalmic artery ; (2) the sphenoidal fissure, transmitting the ophthalmic vein, the nerves for the ocular muscles, and the first branch of the trigeminus ; (3) the spheno-maxillary fissure, transmitting branches of the second division of the trigeminus.

Besides communicating with the cavity of the skull by means of the openings at the apex, the orbit is surrounded by a number of other cavities (Fig. 92). These are the nasal fossæ and accessory cavities — the ethmoidal and sphenoidal sinuses, the frontal sinus, and the antrum of Highmore. These relations are important.

The *contents* of the orbit consist of the eyeball and optic nerve, the ocular muscles, the lacrymal gland, bloodvessels, and nerves ; the spaces between these are filled with fat and fasciæ.

The *eyeball* is composed of the segments of two spheres ; the anterior (cornea), about 12 mm. in diameter, is the smaller and more prominent ; the larger, posterior, corresponds to the sclera. The eyeball measures about an inch in diameter (24·5 mm. from side to side, 24 mm. from before backward, and 23·5 mm. from above downward).

The *orbital fascia* is extensive, and presents numerous subdivisions. It serves as periosteum to the walls of the orbit (peri-orbital). A portion closes in the opening of the orbit, forming an anterior wall, and extending from the margin of the orbit to both tarsi, and to the external and internal tarsal ligaments, thus constituting the septum orbitale. Prolongations of the orbital fasciæ surround the muscles, and connect them with one another, the lids, and the margins of the orbit.

In addition, a layer of fascia surrounds the globe from the cornea to the posterior part, separating the organ from the orbital fat, and forming an articular socket, which permits free movement of the eyeball in every direction. This investment is known as Tenon's capsule. The contiguous surfaces of the sclera and of Tenon's capsule are smooth and lined with endothelium. In this manner a lymph space is formed, known as Tenon's space, which is continuous posteriorly with the supravaginal space surrounding the external sheath of the optic nerve. Where the tendons of the ocular muscles pierce Tenon's capsule, the latter is reflected upon them, becoming continuous with their fasciæ.

The *arteries* of the orbit are derived from the ophthalmic. The

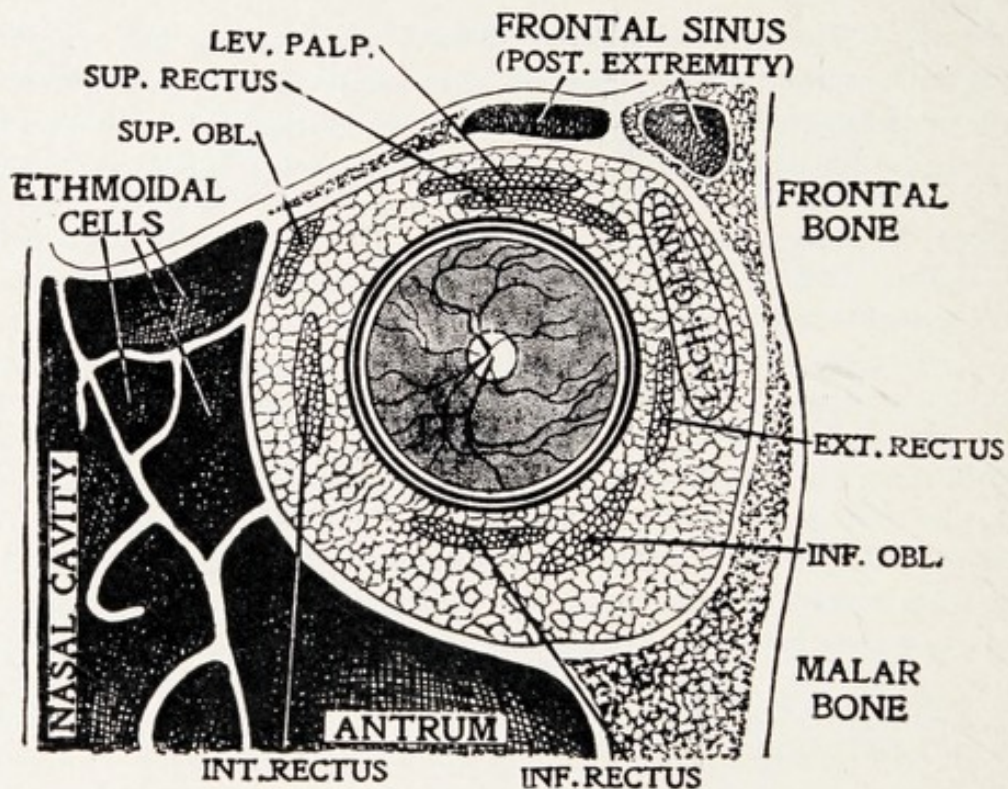


FIG. 92.—SECTION OF ORBIT AT PLANE OF EQUATOR OF EYEBALL.

veins empty into the ophthalmic veins, which pass through the sphenoidal fissure to the cavernous sinus. The *nerves* of the orbit are motor and sensory; the motor nerves, the third, fourth, and sixth, supply the ocular muscles; the sensory nerves are the first and second branches of the trigeminus. The ciliary ganglion lies to the outer side of the optic nerve. It receives motor fibres from the third, sensory fibres from the fifth, and sympathetic filaments from the carotid plexus. It gives off the short ciliary nerves which enter the eye at its posterior part. The orbit contains no lymph vessels or lymphatic glands.

Affections of the Orbit frequently present a characteristic symptom, exophthalmos.

Exophthalmos (proptosis) is a protrusion of the eyeball from the orbit (Fig. 93). It is caused by inflammations, tumours,

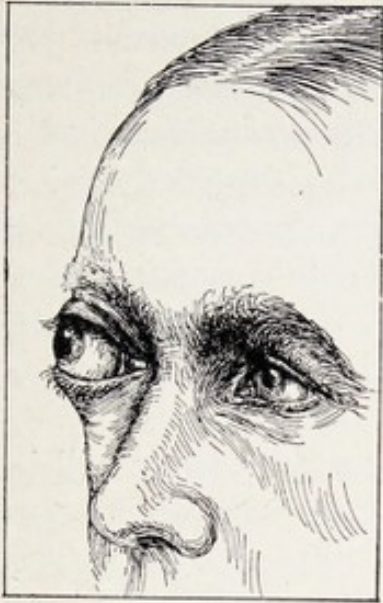

FIG. 93.—EXOPHTHALMOS.

and injuries of the orbit, dilatation of adjoining cavities, Basedow's disease, pulsating exophthalmos, thrombosis of the cavernous sinus, and in some cases by paralysis of the recti muscles and tenotomies of these muscles. When of high degree, it may cause interference with the mobility of the eye, imperfect closure of the lids (lagophthalmos), with resulting keratitis from exposure, ectropion of the lower lid, diplopia (if lateral displacement is added), and interference with vision from inflammation and atrophy of the optic nerve.

Enophthalmos is the recession of the eyeball into the orbit. With the exception of the cases seen in the aged and in extreme emaciation, due to the decrease of orbital fat, it is rare. Other causes are paralysis of the sympathetic, injuries to the orbit causing cicatricial contraction, and fracture of the orbital wall.

Orbital Periostitis.

An inflammation of the orbital periosteum, either acute or chronic in its course, and either limited to a portion of the margin of the orbit or spreading more deeply.

The products of inflammation often consist merely of a thickening of the membrane. Sometimes there is a deposit of bone or gumma (syphilis); there may be the formation of an abscess, with or without caries or necrosis of a part of the wall of the orbit.

Symptoms.—These depend upon whether the affection runs an acute or a chronic course, the part of the orbit involved, and the nature of the products of inflammation.

The most common variety is that attacking the margin of the orbit. In such a case there may be no other symptoms

than pain, tenderness on pressure at the orbital margin, hard, immovable swelling in this situation, and some swelling of the lids and conjunctiva. Such a case frequently results in complete absorption of the products of inflammation; less commonly, periosteal thickening or bony deposit remains. If, on the other hand, there is pus, a periosteal abscess is developed at the margin of the orbit, which perforates through the skin, leaving a fistula through which the probe detects either bare or necrosed bone. Such a fistula remains open for months until all the dead bone has been extruded, and after it heals there is a depressed scar and sometimes ectropion and lagophthalmos.

If the periostitis is situated more posteriorly, there will be more pain of a deep-seated character, tenderness upon pressure upon the globe, swelling and redness of the lids and conjunctivæ, perhaps exophthalmos, and marked constitutional disturbance. Such a case may result in absorption of the products of inflammation, or in periosteal thickening or bony deposit. But if such a deep-seated process goes on to the formation of an abscess, it becomes much more serious, and presents the symptoms of orbital cellulitis (*q.v.*), from which it frequently cannot be differentiated. The pus tends to find its way to the surface, but this may take some time. Meantime there may be danger to life through extension to the cranial cavity and the occurrence of meningitis or cerebral abscess.

Etiology.—Injuries, tuberculosis (in children); tertiary syphilis (in adults); rheumatic diathesis; extension from neighbouring cavities or bones. Rheumatic and syphilitic cases usually run a chronic course, and produce periosteal thickening without any tendency to suppuration.

Treatment.—That of syphilis, rheumatism, or tuberculous diathesis. Locally, moist, warm compresses. Incision as soon as there are any signs of suppuration. Early incision by means of a narrow knife is indicated as soon as we suspect the existence of pus, so as to prevent the extension of suppuration to the brain. The opening is drained by means of a strip of iodoform gauze, until pus no longer escapes. Caries and necrosis may require subsequent operative intervention.

Orbital Cellulitis.

Orbital cellulitis is an inflammation of the cellular tissue of the orbit, terminating in suppuration. It runs an acute course, accompanied by marked constitutional symptoms.

Symptoms.—Great swelling of the lids, chemosis, exophthalmos, impairment of mobility of eyeball, violent pain in the orbit and side of head, increased by pressure against eyeball. These local signs are accompanied by marked constitutional symptoms, with high fever; cerebral symptoms may be added. Vision may not be affected, or it may be reduced or abolished, owing to the occurrence of optic neuritis. After these symptoms have lasted about a week, pus appears at a certain part of the skin of the lids and perforates, or it may empty into the fornix. After early evacuation of pus in an uncomplicated case, the symptoms rapidly subside, and the opening heals.

Complications.—Optic neuritis; less frequently, thrombosis of the retinal vessels; occasionally panophthalmitis. Cases following influenza are especially apt to be complicated with corneal ulcer. Extension of the process to the brain may be fatal.

Etiology.—(1) Injuries and operations followed by infection; (2) extension of inflammation from neighbouring parts; (3) influenza; (4) facial erysipelas; (5) metastasis (pyæmia, puerperal septicæmia, etc.); (6) sometimes no cause can be discovered.

Treatment.—Hot fomentations. Early and deep incision in the spot where we suspect the abscess to be situated, either through the conjunctiva or through the skin. Even when we do not strike pus, we relieve tension, and prepare a route for the subsequent evacuation. The wound should be irrigated frequently with warm hydrogen peroxide lotion (3 volumes) and kept freely open until it heals from the bottom.

Thrombosis of the Cavernous Sinus (almost always infective) may be due to extension of a thrombus in the orbital veins occurring in orbital abscess, or may be caused by other neighbouring pus foci situated in the pharynx, tonsils, teeth, and the accessory nasal sinuses, or may follow erysipelas, caries of the petrous bone, and metastasis in pyæmia and the infective diseases. The signs and symptoms are similar to

those of orbital abscess; in addition, there are neuro-retinitis and marked distension of the retinal veins and severe cerebral symptoms. The disease is always fatal.

Tenonitis.

Tenonitis is a rare affection consisting of serous inflammation of Tenon's capsule, and resulting in cure in a few weeks. Its symptoms are moderate swelling of the upper lid, chemosis, slight exophthalmos, limitation of movements of the eye, and some pain on motion of eyeball. It may follow a tenotomy of one of the recti muscles, exposure to cold, be idiopathic, or due to rheumatism. Treatment consists of cold or warm fomentations and the treatment of the rheumatism if present.

Pulsating Exophthalmos.

Pulsating exophthalmos presents the following symptoms: exophthalmos, pulsation of the eyeball and surrounding parts, bruit heard over the eye and forehead, noises in the head, pain, marked distension of the bloodvessels of the retina, conjunctiva, and lids, and occasionally optic neuritis. Compression of the carotid of the same side causes a diminution or disappearance of the pulsation and bruit. It is most frequently produced by an arterio-venous aneurism due to rupture of the carotid into the cavernous sinus, generally caused by traumatism. Some cases are due to aneurism of the ophthalmic artery or one of its branches, or of the internal carotid, or to a vascular tumour. The condition may be fatal from hæmorrhage. Treatment consists in digital or instrumental compression of the common carotid. If this does not succeed, ligation of this vessel. Many cases are cured in this manner

Tumours of the Orbit.

These are of infrequent occurrence. They may arise from the walls or the contents of the orbit. The symptoms will depend upon the size, position, and nature of the tumour. Exophthalmos is usually present. The direction of the protrusion and the impairment of motion of the eyeball will be determined by the exact situation of the tumour. Pressure

upon the optic nerve may cause optic neuritis and atrophy. The tumour may perhaps be felt by the tip of the finger passed between the margin of the orbit and the eyeball. Benign tumours usually grow slowly, and frequently give few symptoms; malignant tumours increase in size very rapidly, and cause much pain. Benign tumours of the orbit include dermoid cyst, aneurism, angioma, pulsating exophthalmos, meningocele, osteoma, and distension of neighbouring cavities. Malignant tumours, sarcoma and carcinoma, usually necessitate complete exenteration of the orbit. In the case of a benign tumour requiring removal, an attempt should be made to preserve the eyeball, especially if the sight be good. Krönlein's operation (cutting through and turning back the temporal wall of the orbit, the parts being subsequently replaced) may be useful in the case of posteriorly situated benign growths.

The Ocular Manifestations of Disease of the Nasal Accessory Sinuses.

The accessory sinuses of the nose (frontal sinus, anterior and posterior ethmoidal cells, sphenoidal sinus, and maxillary antrum) surround the orbit, being separated by bony walls which are very thin in places. They are lined by an extension of the nasal mucous membrane, and, as a result of such relationship, often become infected. If the natural outlet of the sinus becomes blocked, there will be an accumulation of secretion and consequent distension of the walls of the sinus, often with encroachment upon the orbit and exophthalmos. If this retention is of a mucoid character, the condition is known as mucocoele; if of a purulent character, as empyema. Such a sinusitis may run an acute or a chronic course.

Frontal sinus disease may be accompanied by a bulging at the upper and inner angle of the orbit, with tenderness on pressure over this area, and sometimes redness of the overlying skin, severe frontal headache, and dizziness on stooping. There may be protrusion of the eyeball downward and outward, diplopia, œdema of the lids, conjunctival and episcleral congestion, and lacrymation. Orbital periostitis and cellulitis may result.

Ethmoidal disease may present a tumefaction at the upper and inner part of the orbit, with swelling of the integument of the adjacent lids, displacement of the globe downward and outward, diplopia, marked pain, conjunctival and episcleral congestion, and lacrymation. The process may involve the orbit, causing periostitis or cellulitis.

Disease of the sphenoidal sinus is usually associated with ethmoidal disease. The optic nerve is in close relationship to the walls of this cavity. A case of disease of this sinus may present no external evidence of inflammation, and yet may give rise to optic neuritis, neuro-retinitis, and retrobulbar neuritis, leading to optic nerve atrophy if the cause is not removed. There may be a central, paracentral, or annular colour scotoma, which later may become absolute, usually with but little contraction of the visual field. Another fairly constant symptom is enlargement of the blind spot. There may be deep-seated pain, and tenderness when the eyeball is pressed backwards.

Antrum disease is not often accompanied by ocular symptoms. There may be pain, swelling of the lids, conjunctival congestion, and lacrymation, but involvement of the orbit is rare.

Far more frequently than is generally supposed the outlet of an antrum becomes blocked so that the cavity becomes distended with a clear or slightly turbid mucoid fluid. The condition may remain unsuspected for years, while the sufferer, otherwise in perfect health, consults one ophthalmic surgeon after another for the relief of symptoms which he feels sure are caused by eye trouble. There is a constant dull ache behind the eyes and a sensation of pressure within the cranium. The symptoms are usually more pronounced on stooping. The pain may become so acute as to confine the patient to bed. Transillumination usually shows no marked opacity of the antrum. Evacuation of the fluid with trocar and canula, gives instant relief.

PLATE VIII.

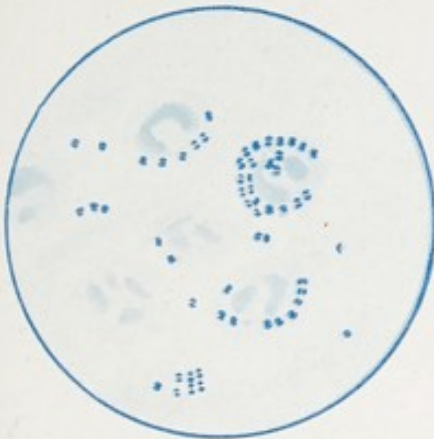


FIG. 101.—GONOCOCCUS.

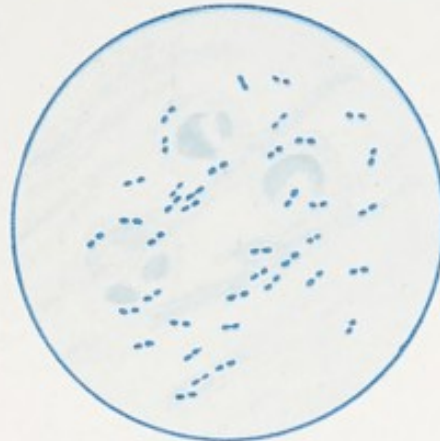

FIG. 102.—PNEUMOCOCCUS.

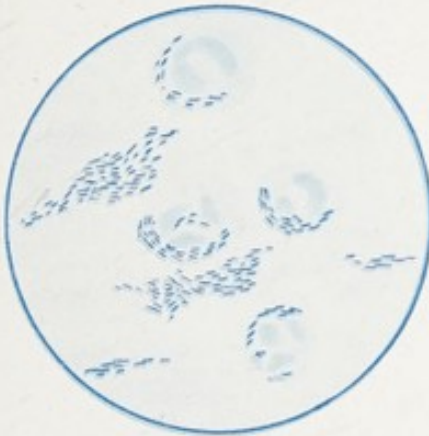

FIG. 103.—KOCH-WEEKS BACILLUS.

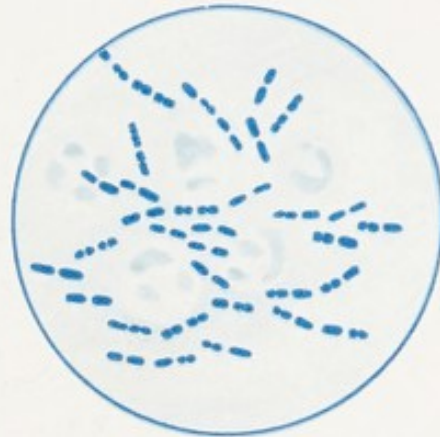


FIG. 104.—MORAX-AXENFELD
DIPLO-BACILLUS.

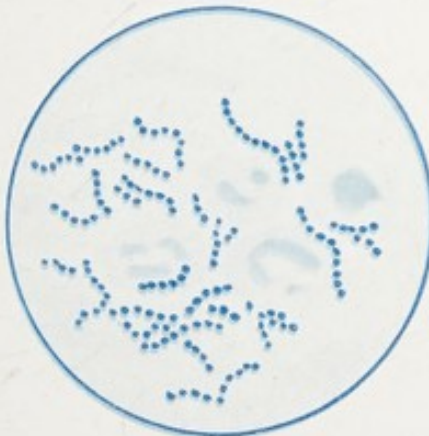

FIG. 105.—STREPTOCOCCUS.

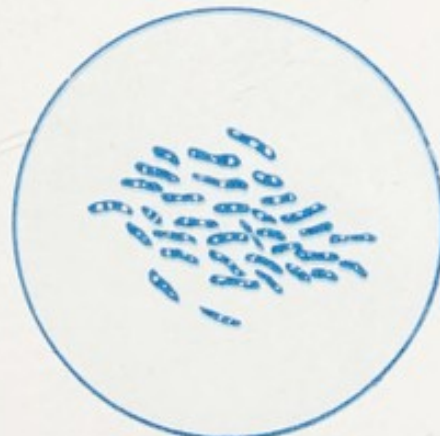



FIG. 106.—DIPHTHERIA BACILLUS.

FIGS. 101 TO 106.—MICRO-ORGANISMS FOUND IN VARIOUS FORMS OF
CONJUNCTIVAL, LACHRYMAL, AND CORNEAL DISEASES.



Injuries of the Orbit.

These include contusions, incised and penetrating wounds, foreign bodies, and fracture of the orbital wall. A prominent sign is hæmorrhage into the orbit, causing exophthalmos and perhaps ecchymosis of the lids and conjunctiva. A blow or stab with a blunt body may rupture the globe or dislocate it in front of the eyelids. *Penetrating wounds* may destroy the eyeball, injure the optic nerve, causing blindness, or sever some of the muscles, resulting in paralysis and diplopia; if infected, such wounds are followed by orbital abscess. *Foreign bodies* may be tolerated if aseptic; if infected, suppuration ensues. *Fracture* may involve the anterior wall, or the inner wall causing emphysema, or the apex involving the optic canal and injuring the optic nerve; the last may result from direct injury or indirectly (*contrecoup*) and produce blindness without ophthalmoscopic evidence, followed in a few weeks by atrophy of the optic nerve.

Treatment consists in cleansing and disinfecting wounds and endeavouring to extract foreign bodies (with the aid of an X-ray examination). If the situation is such that extensive manipulation would be necessary for its removal, and we have reason to believe that the substance is aseptic (such as shot), it is often better to allow the foreign body to remain. Free exit for secretions must be maintained. A bandage aids in the absorption of blood and air.

Congenital Anomalies of the Eyeball.

These are usually bilateral. Anophthalmos is a small solid or cystic mass occupying the place of the eyeball. Microphthalmos consists

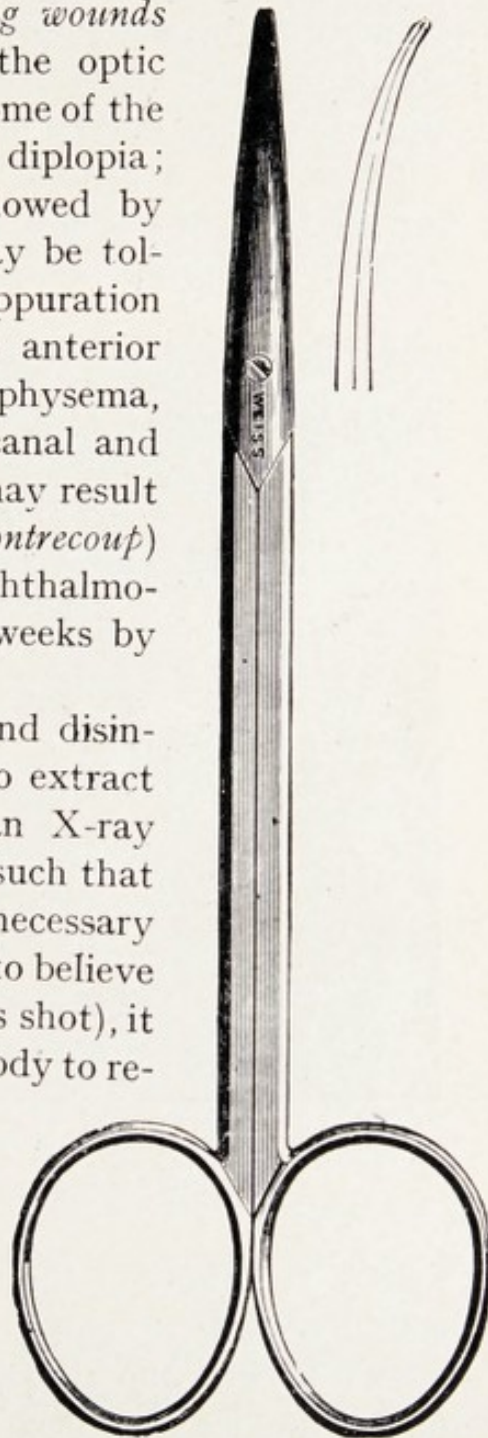


FIG. 94.—ENUCLEATION SCISSORS.

of an eyeball of diminished size in all diameters. Buphthalmos (congenital glaucoma) is an increase in size of the eyeball, with symptoms of glaucoma, usually resulting in blindness.

Operations upon the Eyeball.

Enucleation of the Eyeball.—The instruments required are. Eye speculum (Fig. 176), fixation forceps (Fig. 177), blunt-pointed strabismus scissors (Fig. 324), squint hook (Fig. 325), strong, curved enucleation scissors (Fig. 94), needle-holder (Fig. 326), fine, curved needle, and thin black silk.

Operation.—A general anæsthetic is usually given. After introduction of the speculum, the conjunctiva is divided all around the cornea, *as close to its border as possible*, and dis-

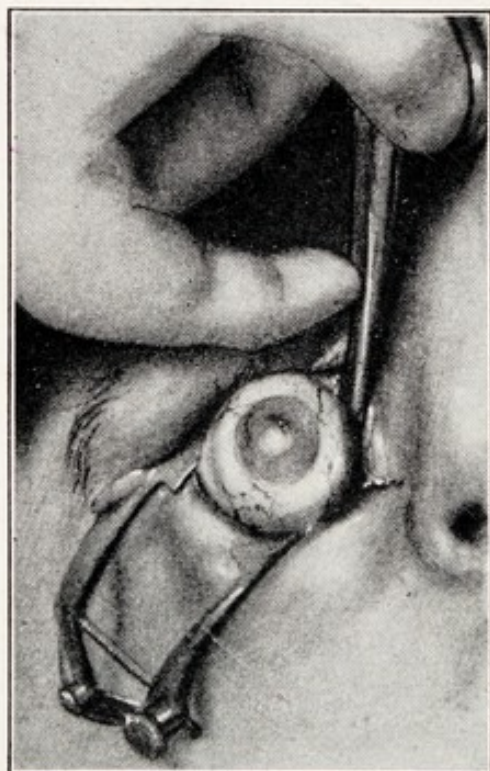


FIG. 95.—ENUCLEATION OF THE EYEBALL.

sected back as far as the insertions of the recti muscles. A squint hook is passed beneath the tendon of the internal rectus, and the latter is divided with the strabismus scissors close to its insertion; then the other straight muscles are cut in the same way, together with the subconjunctival connective tissue, for some distance beyond the equator. The points of the scissors must always be directed toward the eyeball, and the latter stripped as clean as possible to avoid any unnecessary removal of orbital tissue. Instead of commencing with a circumcorneal division of the conjunctiva, we may begin

with a tenotomy of the internal rectus, and then divide the conjunctiva as we pass from tendon to tendon. The hook is passed around the globe to make sure that the attachments of the muscles have been completely divided. The eyeball is then dislocated forward by pressing the speculum backward, and thus the optic nerve is put on the stretch. The enuclea-

tion scissors (Fig. 94), closed, are passed between sclera and conjunctiva, feeling for the optic nerve; they are withdrawn a little, slightly opened (Fig. 95), and the nerve is divided close to the sclera. The eyeball is held between the thumb and index finger of the left hand, and the oblique muscles and other unsevered attachments are divided. The socket is irrigated with a large quantity of perchloride of mercury lotion, 1 in 5,000. The orbit is plugged for a few minutes to control hæmorrhage, and the conjunctiva is usually closed either with a single suture, which is passed through its edge at intervals and tied like the string of a pouch, or by interrupted sutures. The eye is bandaged and the patient kept in bed for a day.

Care should be taken to avoid rupturing the globe. A collapsed globe makes the operation more difficult. Troublesome hæmorrhage may occur; it can be controlled by hot water or by a firm bandage. When an eyeball containing a malignant growth is enucleated, as much of the optic nerve as possible should be removed. In rare cases infection of the wound has led to abscess, thrombosis, and even fatal meningitis. The danger of meningitis is somewhat increased in enucleation of suppurating eyeballs; hence many oculists consider panophthalmitis a contra-indication to enucleation, and postpone operation until after the suppurative process has ceased.

The indications for enucleation are: (1) Injuries of the ciliary region, when the eye is completely blind, or the traumatism so extensive that the form of the eyeball cannot be preserved; (2) to prevent or cure sympathetic ophthalmia; (3) severe pain in a blind eye; (4) iridocyclitis, phthisis bulbi, and glaucoma, when accompanied by severe pain or inflammatory symptoms, and when the eye is blind or is certain to become so; (5) malignant tumours, either intra-ocular or epi-ocular (excepting small tumours of the iris, which can be entirely removed by iridectomy); (6) anterior staphyloma, if the eye is blind, troublesome, and disfiguring; (7) panophthalmitis; (8) foreign bodies in the eye when they cannot be removed and cause irritation, or the eye is blind.

Evisceration of the Eyeball.—In this operation the cornea and entire contents of the eyeball are removed, the sclera alone remaining.

The instruments required are: Eye speculum (Fig. 176), fixation forceps (Fig. 177), curved strabismus scissors, Graefe knife (Fig. 195) or Beer's knife (Fig. 57), sharp spoon, needle-holder (Fig. 326), small curved needles, catgut, and silk sutures.

Operation.—After insertion of the speculum, the eye is transfixed just behind the cornea with a Graefe or Beer's knife, which is made to cut its way out at the upper sclero-corneal junction; the other half of the cornea is removed with the scissors. The contents of the eyeball are then removed thoroughly with a sharp spoon, care being taken that nothing but sclera is left. The cavity is irrigated and allowed to fill with blood, or else dried. The scleral edges

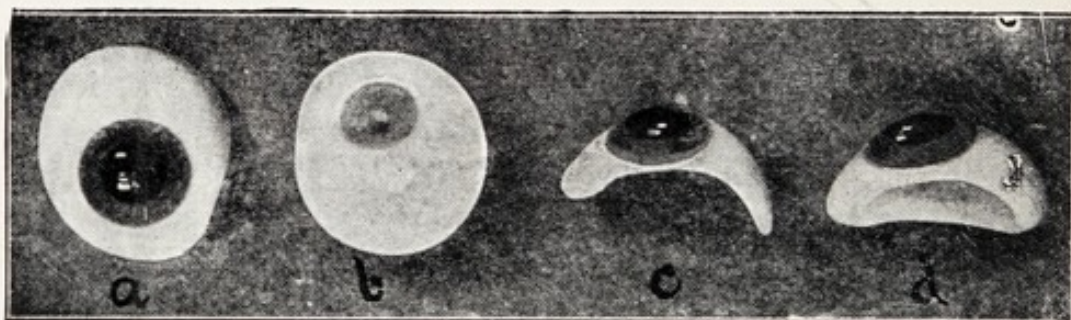


FIG. 96.—ARTIFICIAL EYES.

a, Front view; *b*, rear view; *c*, section of shell eye; *d*, section of Snellen 'reform' eye.

are brought together in a vertical line with catgut sutures, and the conjunctiva is united horizontally with silk sutures.

Recovery is less rapid than after enucleation, and the pain and reaction are greater; the support for an artificial eye is usually better. The operation may be substituted for enucleation in all cases excepting malignant tumours, foreign bodies, and sympathetic ophthalmitis.

Evisceration with Insertion of an Artificial Vitreous (Mule's Operation).—Following evisceration, after the scleral cavity has been cleansed and hæmorrhage checked, a hollow sphere of glass or silver (or some other substance) is introduced.

This ball must not be too large. Its introduction is facilitated by slitting the sclera and by the use of a special inserting instrument. The wound is then closed and dressed as after the ordinary evisceration. There is considerable reaction after this operation, and the patient is confined to his room for a week. The stump is undoubtedly superior to that furnished by any other method, but it frequently happens that the ball is extruded.

Artificial Eyes (Fig. 96) are worn after enucleation and evisceration, for cosmetic purposes, and to fill out the cavity left between the lids. They can be worn as soon as the socket is free from inflammation, usually after several weeks. The artificial eye should be washed frequently, and must be removed every night. After a year its surfaces and edges become roughened, and it must be replaced by a new one. When there is a stump of good size, a shell-shaped artificial eye may be indicated; but with a small stump or after enucleation, the more modern Snellen 'reform' artificial eye gives better cosmetic effect; the latter has a certain thickness, and is hollow (Fig. 96, *d*).

Kronlein's Operation is employed for the removal of innocent retro-ocular growths without sacrifice of the eye. It consists in incision down to the bone along the temporal margin of the orbit, separation of the periosteum from the temporal wall of the orbit, temporary resection and bending outwards of the bony wall, and replacement of the parts after removal of the tumour.

Exenteration of the Orbit is practised in early malignant diseases of the orbital contents. It consists in stripping the periosteum from the walls of the orbit and removing the whole contents up to the apex.

CHAPTER VIII

DISEASES OF THE CONJUNCTIVA

Anatomy.—The conjunctiva is a thin layer of mucous membrane which lines the eyelids, and is reflected on to the eyeball, forming a sac, the conjunctival sac. We distinguish three divisions: (1) The palpebral or tarsal conjunctiva, covering the under surface of the lids; (2) the ocular or bulbar conjunctiva, coating the anterior portion of the eyeball; and (3) the fornix, the transition portion, forming a fold between lid and globe. The conjunctiva differs somewhat in structure in each of these portions.

The *palpebral conjunctiva* is thicker than the other portions. In the greater part of its extent it is closely adherent to the subjacent tarsus, allowing the Meibomian glands to be seen through it. Its surface is smooth, but presents a number of minute projections, or papillæ. It is covered with cylindrical epithelium. Its stroma is of an adenoid character, containing a large number of lymph corpuscles, which may in some cases be collected into small rounded masses (lymphoid follicles). It is a disputed question, however, whether these are normal or are the result of pathological processes. Numerous mucous glands are also found.

The *conjunctiva of the fornix* is similar in structure to that of the lids. It constitutes a very loose fold, ensuring great freedom of movement to the eyeball. It is richly supplied with bloodvessels. This and its lax condition explain its liability to marked swelling in inflammations of the conjunctiva. It has opening into it the lacrymal ducts and numerous mucous glands.

The *bulbar portion of the conjunctiva*, thin and transparent, covers the anterior surface of the eyeball, being loosely attached to the sclera by connective tissue (episcleral tissue), with the exception of the margin representing the boundary between cornea and sclera (limbus), where it is firmly adherent. In structure it resembles the rest of the conjunctiva, but contains no glands. It is covered with laminated pavement epithelium, which is continued uninterruptedly over the cornea, and constitutes its outer layer. Near the inner canthus it forms a crescentic fold (*plica semilunaris*), the rudiment of the nictitating membrane or third eyelid of the lower animals.

PLATE VII.

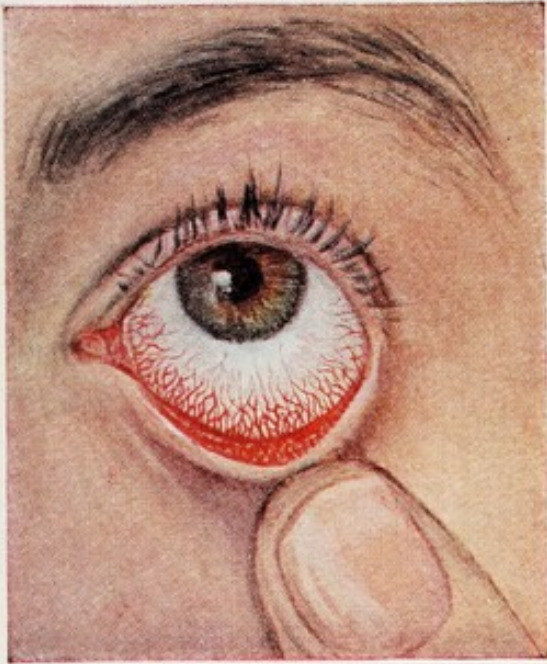


FIG. 97.—CONJUNCTIVAL INJECTION.

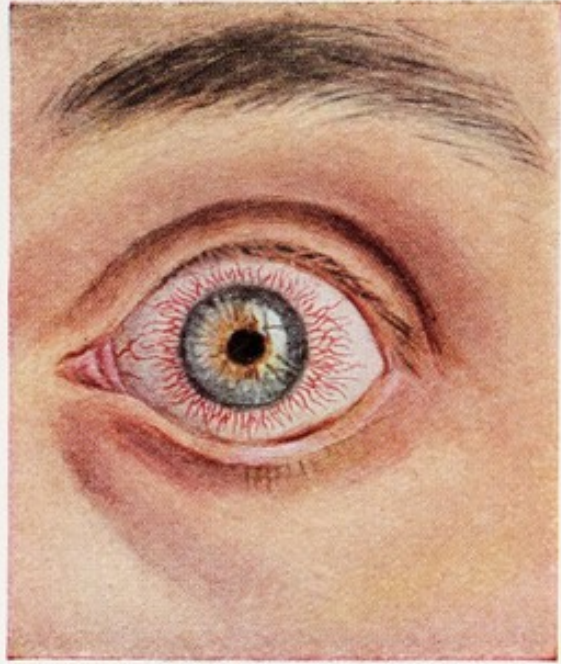

FIG. 98.—CILIARY INJECTION.

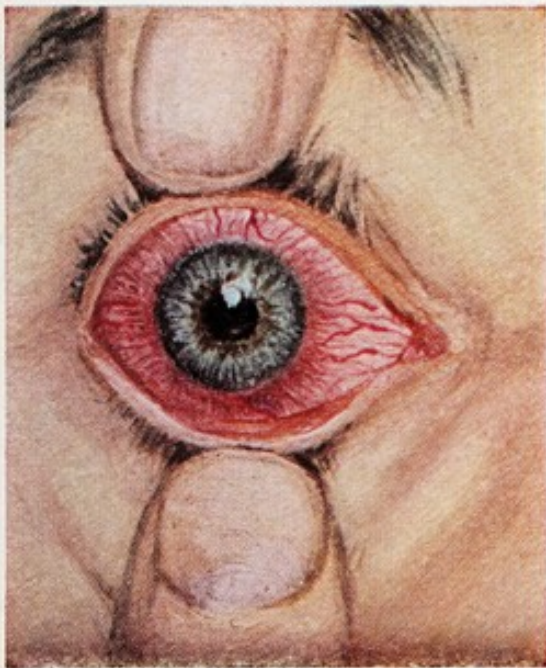


FIG. 99.—IRITIS WITH INTENSE CILIARY INJECTION.

The pupil has partially dilated under atropine.

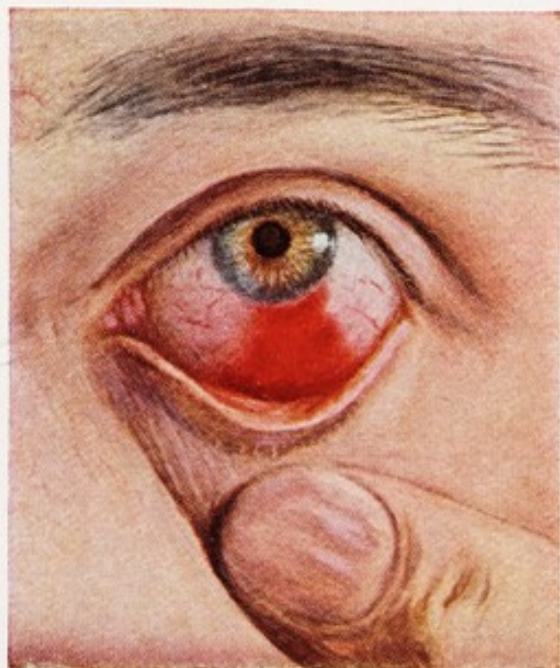

FIG. 100.—SUBCONJUNCTIVAL HÆMORRHAGE.

To face page 94.



The *vascular supply* of the conjunctiva is derived from the blood-vessels of the fornix—the posterior conjunctival (derived from the palpebral) and from the anterior ciliary. The latter pass forward along the recti muscles and pierce the sclera near the limbus to reach the interior of the eye, giving off one set of branches which form vascular loops surrounding the cornea, and supplying it with nourishment, and another set (anterior conjunctival) which pass backward in the conjunctiva and anastomose with the posterior conjunctival. This arrangement, together with the posterior ciliary arteries and the retinal system of vessels, constitutes the entire vascular system of the eye. Thus the bulbar conjunctiva presents two vascular systems—the posterior conjunctival and the anterior ciliary. The nature of the injection in any given case is of some value in locating the seat of the congestion.

The *nerves* of the conjunctiva, branches of the fifth, terminate in end-bulbs, and are especially abundant in the palpebral portion. *Lymphatic vessels* are found in considerable numbers in the conjunctiva, forming a superficial and a deep layer.

Conjunctival and Ciliary Injection.

The differences between conjunctival and ciliary or circumcorneal injection (Figs. 97 to 99, Plate VII.) are as follows :

Conjunctival Injection.

1. Derived from posterior conjunctival vessels.
2. Accompanies diseases of the conjunctiva.
3. More or less muco-purulent or purulent discharge.
4. Most marked in fornix conjunctivæ.
5. Fades as we approach the cornea.
6. Bright brick-red colour.
7. Composed of a network of coarse, tortuous vessels, anastomosing freely, and placed superficially, so that the meshes are easily recognized.
8. Can be moved with the conjunctiva by pressure on lower lid.

Ciliary Injection.

1. Derived from anterior ciliary vessels.
2. Accompanies diseases of the cornea, iris, and ciliary body.
3. Often lacrymation, but no conjunctival discharge.
4. Most marked immediately around the cornea ; hence called 'circumcorneal.'
5. Fades toward the fornix.
6. Pink or lilac colour.
7. Composed of small, straight vessels, placed deeply, so that the individual vessels cannot be recognized easily, but are seen indistinctly as fine, straight lines radiating from the cornea.
8. Cannot be displaced by movement of the conjunctiva.

In severe forms of diseases of the anterior part of the eye these two types of congestion are often found associated, as one would expect when one remembers that the two systems of vessels anastomose freely.

When very pronounced, particularly when there is much venous congestion, ciliary injection assumes a violet colour. A form of injection of this sort involves the episcleral tissue between the equator of the eyeball and the cornea, presenting a deeply-placed, violet-coloured patch seen in scleritis and glaucoma.

CONJUNCTIVITIS.

Inflammations of the conjunctiva are known as conjunctivitis, or ophthalmia. The varieties are :

1. Catarrhal : (a) acute, (b) chronic, (c) follicular.
2. Purulent : (a) ophthalmia neonatorum, (b) gonorrhœal.
3. Membranous : (a) non - diphtheritic or croupous, (b) diphtheritic.
4. Granular or trachoma.
5. Phlyctenular.

Acute Catarrhal Conjunctivitis.

An acute catarrhal inflammation of the conjunctiva, accompanied by mucoid or muco-purulent discharge. It is also known as acute muco-purulent and acute simple conjunctivitis.

Objective Symptoms.—The palpebral conjunctiva and that of the fornix are of a brilliant red colour and swollen. There is slight congestion of the bulbar conjunctiva ; but in severe cases this may become marked, and there may be added œdema of the bulbar conjunctiva (chemosis), small conjunctival hæmorrhages, and œdema of the lids. The secretion, increased in amount and altered in character, varies according to the severity. In mild cases, it is mucoid ; in severer forms, it is muco-purulent. In very marked examples the amount of pus may be so considerable that for a day or two we may be in doubt whether the disease is not the beginning of a

purulent inflammation. The secretion accumulates during the night, and dries upon the edges of the lids during sleep.

Subjective Symptoms.—Itching and smarting sensations referred to the lids, which feel hot, heavy, and as though sand or a foreign body were underneath. There is more or less photophobia. There may be some blurring of sight when the altered secretion lies upon the cornea. The symptoms are usually worse toward evening. They vary in severity with the degree of inflammation.

Course.—The patient may perhaps get well in two or three weeks, even without treatment. Sometimes the acute symptoms subside, and a chronic catarrhal conjunctivitis remains. Blepharitis may be present. In severe cases small, grayish infiltrations may form at the corneal margin. The coalescence of a number of these may cause a marginal ulcer, which is usually unimportant, superficial, and heals readily, but occasionally becomes deep and serious. Rarely iritis occurs as a complication.

Etiology.—The disease occurs at all ages and at all times during the year, but is most common in the spring and autumn. The causes may be divided into : (1) Mechanical—foreign bodies, exposure to wind, dust, smoke, etc. (2) Epidemic—in spring and autumn, and depending upon some atmospheric condition (the presence of certain micro-organisms). (3) Infection—through contact with fingers, towels, handkerchiefs, etc., of patients suffering from the disease. The discharge is contagious, especially when free and containing much pus ; hence the affection often presents a number of examples in the same household or school. (4) Exanthemata, accompanying or following measles, scarlatina, and small-pox. (5) Associated with coryza, hay fever, and influenza.

Clinical Varieties. — Certain forms of this disease are distinguished by qualifying adjectives, indicating the etiology.

Traumatic Conjunctivitis is the name often given to acute catarrhal conjunctivitis when excited by the presence of a

foreign body or by traumatism. Under this head are included the forms of conjunctivitis due to intense light ; for example, the electric arc light or that used in electric welding, and that produced by reflection from snow (snow blindness). In such cases there are symptoms of conjunctivitis, and, in addition, marked photophobia, lacrymation, intense smarting of the lids, contraction of the pupil, and sometimes œdema of the lids and superficial ulceration of the cornea.

Lacrymal Conjunctivitis (Fig. 55, Plate VI.) accompanies dacryocystitis. It is most frequently limited to the inner third of the palpebral and ocular conjunctiva. It is caused by the purulent secretion from the inflamed lacrymal sac, which contains streptococci (Fig. 105, Plate VIII.).

Exanthematous Conjunctivitis, when associated with the exanthemata ; most commonly seen in measles.

Acute Epidemic Conjunctivitis, popularly known as ' blight ' or ' pink eye,' is a very contagious form of acute catarrhal conjunctivitis occurring most frequently in the spring and autumn in which the symptoms are apt to be marked and the discharge is profuse. The contagious element is the Koch-Weeks bacillus (Fig. 103, Plate VIII.), or the pneumococcus (Fig. 102, Plate VIII.). This is the variety which not infrequently gives rise to such severe objective symptoms, including swelling and redness of the lids and copious discharge, that one may be in doubt whether the affection is an example of the catarrhal or of the purulent form of conjunctivitis. It is advisable, when first called to treat severe cases of this sort, to examine a smear of the conjunctival secretion under the microscope, and to decide definitely upon the nature of the infection only after the responsible organism has been identified.

The *Morax-Axenfeld Diplo-bacillus* (Fig. 104, Plate VIII.) causes a subacute conjunctivitis, which is more common in adults. It soon passes into the chronic form.

Other Clinical Varieties of acute catarrhal conjunctivitis have been classified according to the micro-organism which seems responsible for the inflammation. One form, which

clinically resembles acute epidemic conjunctivitis, presents an abundance of pneumococci (Fig. 102, Plate VIII.) in the discharge. In another variety, streptococci (Fig. 105, Plate VIII.) are found in considerable numbers. Staphylococci, xerosis bacilli, and diplococci, resembling in appearance the pneumococci, are usually present in the normal conjunctival sac, so that it is difficult to classify clinical varieties according to bacteriological findings.

Follicular Conjunctivitis is considered by some authorities as a variety of acute catarrhal conjunctivitis, by others as a form or stage of trachoma. It will be described separately.

Treatment.—Though the disease tends eventually to get well without interference, treatment reduces the duration and prevents the change into chronic conjunctivitis. The conjunctival sac should be irrigated several times a day with salt solution (3i. to Oi.) or saturated solution of boric acid, or with perchloride of mercury lotion (1 in 20,000, gradually increased to 1 in 10,000). When there is abundant tenacious discharge frequent irrigation with warm hydrogen peroxide lotion (1 to 2 volumes) may be used with advantage. A bland ointment (vaseline or boric-acid ointment) is applied to the edges of the lids at night, to prevent them from becoming glued together during sleep. A 10 per cent. solution of protargol or argyrol may be applied to the everted conjunctiva daily, as long as the discharge is abundant. The patient should be cautioned concerning the contagiousness of the discharge.

If the disease shows a tendency to become obstinate or chronic, weak astringent solutions are indicated (alum, zinc chloride or sulphate $\frac{1}{2}$ grain in 3i.) accompanied with an occasional application of a 1 per cent. silver nitrate solution or the alum-stick to the everted lids.

Chronic Catarrhal Conjunctivitis.

A chronic catarrhal inflammation of the conjunctiva, presenting similar symptoms to those found in the acute form, but associated with only slight changes in the quantity and

quality of the normal secretion. It is also known as chronic simple conjunctivitis.

Objective Symptoms.—The conjunctiva of the lids is reddened and smooth. In old cases it may be hypertrophied and velvety. The secretion is usually but slightly altered, and there is very little increase; there may be enough to make the eyelids stick together in the morning or to present some dried secretion at the inner canthus. There is apt to be some excoriation at the outer angle (angular catarrh). In some cases there appears to be less than the normal amount of secretion (dry catarrh).

Subjective Symptoms are the same in kind as in the acute form: Itching, burning, dryness, feeling of sand or foreign body, heavy feeling in lids, some sensitiveness to light, and the eyes tire easily. These symptoms are worse at night.

Course.—The disease is probably the most common of ocular affections. It usually occurs in adults and frequently in old persons. It is apt to be of lengthy duration.

Complications.—Blepharitis is frequently present. Eczema of the lower lid and eversion of the inferior punctum occur not infrequently, and sometimes ectropion and corneal ulceration.

Etiology.—It may be the sequel of an acute catarrh. It may be caused by improper hygienic surroundings, vitiated atmosphere (overcrowding), irritating atmosphere (smoke dust), insufficient sleep, late hours, alcoholic excesses, exposure of the conjunctiva in ectropion, eye-strain, overuse, local irritation, such as trichiasis, chronic dacryocystitis, etc. It is usually bilateral, but when due to local irritants it may be unilateral.

Treatment.—We must endeavour to remove the cause of the inflammation. Locally: Astringent solutions (zinc, borax, alum, tannic acid, silver nitrate $\frac{1}{10}$ grain, or $\frac{1}{3}$ to $\frac{1}{2}$ i.); ointments of the yellow oxide and ammoniated mercury; silver nitrate, 1 per cent., brushed on the everted lids once a week, or the occasional use of the alum or sulphate of copper stick; bland ointments to the edges of the lids at night to prevent

gluing together and excoriations. As in all chronic catarrhal affections, the remedies must be changed from time to time.

Angular Conjunctivitis is a subacute or chronic inflammation caused by the Morax-Axenfeld diplo-bacillus. It occurs usually in adults. There is redness and perhaps swelling of the palpebral conjunctiva and lid margins, especially at the angles (hence the name). The patient complains of smarting and itching and a feeling as though there were sand in the eye. On waking in the morning the lashes may be glued together with a scanty tenacious discharge. Collyria of zinc sulphate or chloride ($\frac{1}{2}$ grain in 1 ounce) usually acts almost as a specific. In obstinate chronic cases a useful prescription is hydrarg. oxycyanid. gr. i.ss., zinci sulph. gr. x., aq. distil. 3xx., to be used in an eye-bath three or four times a day.

Collyria.—For the proper methods of using collyria see p. 431. This is of great importance, as the want of success in treating conjunctival affections is often due to these remedies not being properly applied.

Follicular Conjunctivitis.

This disease, also known as follicular catarrh, may be regarded as an obstinate form of catarrhal conjunctivitis, with the occurrence of 'follicles' upon the lower lid (Fig. 111, Plate IX.).

Objective Symptoms.—In addition to the appearances found in catarrhal conjunctivitis, the conjunctiva of the lower lid presents a variable number of small, pale, round granules, about the size of the head of a pin. If many are present, they may be arranged in rows. They are most abundant in or near the fornix. Occasionally some are found on the upper lid. These follicles consist of small masses of adenoid tissue, in which respect the microscopic appearance resembles that of trachoma.

Subjective Symptoms are identical with those of catarrhal conjunctivitis. In many cases patients do not complain of

any symptoms, and the existence of the granulations is discovered accidentally.

Course.—The disease may be either acute or chronic. In either case the course is obstinate; in chronic cases the follicles may persist for months, and even years. It is sometimes difficult, especially in acute cases, to differentiate between follicular catarrh and granular conjunctivitis, and we may have to await the results of several weeks' treatment in order to decide definitely. The follicles, in this disease, disappear after a time, leaving the conjunctiva in a natural condition, and they affect principally the lower lid. In trachoma, on the other hand, there are permanent changes in the conjunctiva, and when the granulations are confined to one lid it is usually the upper which is involved.

Etiology.—It occurs most frequently in children and in young persons; it is often found in schools and asylums. The exact cause is not definitely known. Contagion seems responsible in some cases. Poor hygienic surroundings, especially indoor life, seem to predispose. The various causes of catarrhal conjunctivitis act as exciting factors.

Treatment.—The same as that given for acute and chronic catarrhal conjunctivitis. It is of especial importance to correct any interference with the general health, and to place such children under the best hygienic surroundings. Locally, the ointment of the yellow oxide of mercury, applied within the conjunctival sac, is a favourite remedy. The occasional use of a 1 per cent. solution of nitrate of silver may be of service. When the patient no longer complains of any symptoms and the follicles persist, they may be allowed to remain, and treatment discontinued.

Purulent Conjunctivitis.

An acute purulent inflammation, due to contagion from gonorrhœal virus. The contagious elements are the gonococci (Neisser). They occur in gonorrhœal secretion, are found in the pus-cells and conjunctival epithelium, and are arranged in pairs (diplococci) and generally in colonies

(Fig. 101, Plate VIII.). The disease is also known as acute blennorrhœa of the conjunctiva.

Clinical Varieties.—(1) Adult purulent conjunctivitis or gonorrhœal ophthalmia or conjunctivitis; (2) infantile purulent conjunctivitis or ophthalmia neonatorum (occurring in the new-born).

Gonorrhœal Ophthalmia or Adult Purulent Conjunctivitis.

Symptoms.—*First Stage, Infiltration.*—After a period of incubation varying from a few hours to two or three days (short in severe cases), there occur great swelling and redness of the lids, so that the latter cannot be opened voluntarily, and can be separated only with difficulty. The conjunctiva of the lids and fornix is intensely swollen and reddened, and is uneven. There is chemosis (œdema of the ocular conjunctiva, causing it to swell up around the cornea). The secretion is at first serous, somewhat coloured with blood, and containing a little pus. The eye is tender to touch. The patient complains of a hot, smarting pain in the eye, and a dull aching in the brow and temple. There are some constitutional disturbance, slight fever, and some swelling of the pre-auricular gland. This stage lasts about two days, and is followed by the

Second Stage, the Stage of Purulent Discharge.—The swelling of the lids and conjunctiva and the chemosis diminish, and the eye becomes less tender. A very profuse, purulent discharge appears, and escapes continually from between the lids. This condition continues for two or three weeks, all symptoms gradually diminishing.

Third Stage, Convalescence, or Papillary Swelling.—The eye may return to a normal condition in two or three weeks. More frequently, however, there is a stage of papillary swelling, a chronic inflammation of the lids, the palpebral and retro-tarsal conjunctiva remaining thickened and red, and presenting, especially over the tarsus, an uneven granular or velvety appearance, with hyperæmia of the ocular conjunctiva.

Course.—The disease occurs in various degrees of severity. Cases in which there is slight infection, or in which the disease

is acquired from a chronic gonorrhœa (gleet), are the mildest. The very intense cases have probably been acquired through contagion from the secretion of a very virulent gonorrhœa, and especially from contamination during the early stages.

Etiology.—The disease is always acquired through infection from gonorrhœal secretion, either directly, the fingers of the patient transferring the virus from the genitals, or indirectly by means of contaminated towels, etc.

Complications.—A very frequent and important complication is corneal ulceration. This begins with a circumscribed grayish infiltration, becoming yellow and breaking down, so that ulcers are formed. The ulcers vary in situation,

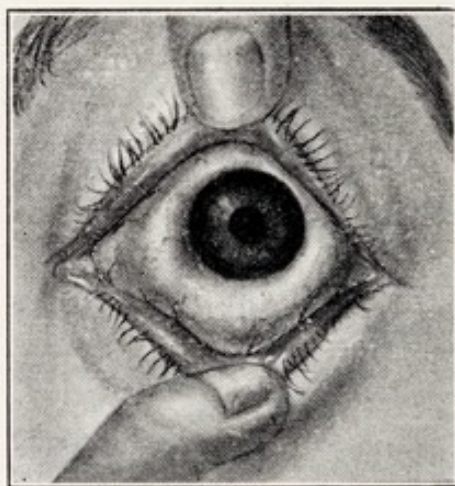


FIG. 107.—CHEMOSIS OF THE CONJUNCTIVA.

size, and course. They may be central or marginal; the latter may be confluent, so as to form an annular ulcer. The ulcers may perforate, and this be followed by cicatrization with or without incarceration of the iris, staphyloma, and other sequelæ of corneal ulceration. Panophthalmitis may result. Severe and early involvement of the cornea is most common in intense attacks. In such cases serious and permanent damage to the eye is very common.

Prognosis depends upon the severity of the case, and upon the behaviour of the cornea. It is always grave.

Treatment—Prophylactic.—Great precautions must be observed to prevent infection of the eyes of the physician, nurse, and attendants through spurting of the discharge

during examination or treatment. Protecting glasses should be worn whenever exposed to this risk. Contaminated fingers must be carefully disinfected. Materials which have been used for cleansing the eye must be burned.

The non-affected eye should be protected from infection by the application of Buller's shield (Fig. 108). This consists of a watch-glass, securely held in place by adhesive plaster applied to the side of the nose, the cheek, and forehead. The junction of skin and plaster is sealed by a layer of collodion. The centre of the glass is left uncovered by plaster, to permit inspection of the eye, and a small part of the outer margin of the watch-glass is usually left free in order to




FIG. 108.—BULLER'S SHIELD.

allow air to enter and contribute to the comfort of the shielded eye.

Treatment of the First Stage.—Iced compresses are used continuously day and night. The eye must be carefully cleansed, and the secretion removed as rapidly as it forms. When very abundant, this will be necessary every quarter or half an hour. For this purpose a saturated solution of boric acid is most frequently employed, being allowed to trickle in between the lids from a piece of absorbent cotton dripping with the solution. Then the secretion which has been washed out is gently wiped off the margins of the lids.

The iced compresses may be used continuously at first. But when the tense, reddened, and swollen condition of the

lids becomes less marked, the application of cold must be reduced to every other hour, or every third hour. Too much refrigeration interferes with the nutrition of the cornea. When the cornea is involved, we must carefully gauge the amount of cold so as not to use an excess. In the *later stages*, when there is little swelling, and corneal infiltration or ulceration exists, hot applications may be used, in order to improve nutrition by stimulating the flow of blood to the part.

Other cleansing and antiseptic solutions may be tried: mercury perchloride (1:20,000 to 1:10,000), hydrogen peroxide (1 volume), permanganate of potassium (1:500), etc. The instillation of a few drops of a 25 per cent. solution of argyrol or protargol every three hours is of value.

In the initial stage, if the disease be very severe, from three to six leeches, applied to the corresponding temple, may be of service. Occasionally there is so much tension that the eye cannot be cleansed, on account of the difficulty in separating the lids, and in addition harmful pressure is exerted upon the eyeball. In such cases it may become necessary to widen the palpebral fissure by a division of the external canthus (temporary canthotomy, p. 59).

Treatment of the Later Stages.—When the lids have lost their swollen and angry appearance, and the discharge begins to diminish, a 1 or 2 per cent. solution of nitrate of silver is brushed upon the everted conjunctiva once a day. This may be done even though the cornea be implicated. It is continued until the patient is well, or until the papillary swelling has persisted for some time. After each application the eye should be irrigated with warm water to remove any excess of caustic, lest the cornea be attacked. Then, if silver no longer exerts a favourable influence, we may apply glycerole of tannin (5 to 10 per cent.), the alum-stick, or sulphate of copper pencil once a day.

The treatment of corneal complications resembles that of infected corneal ulcers, and is described in the next chapter.

Ophthalmia Neonatorum or Infantile Purulent Conjunctivitis.

An acute purulent conjunctivitis occurring in the new-born, presenting similar symptoms, complications, and course, and requiring the same treatment, as in the gonorrhœal ophthalmia of adults.

Symptoms.—The period of incubation being the same as in adults, the first symptoms are usually noticed on the second or third day after birth. When the onset is later than the third or fourth day, infection has taken place subsequent to the birth of the child.

The symptoms are the same in kind as those of gonorrhœal ophthalmia, but are often less severe, and more apt to be limited to the palpebral and retrotarsal conjunctiva. Both eyes are usually involved. The cornea is implicated in a much smaller proportion of cases, especially if the affection is treated from the start. If the case is seen early, before the cornea is affected, and properly managed, this part very often escapes destruction or serious damage.

The prognosis, therefore, with early and proper treatment, is generally favourable.

Etiology.—Infection by gonorrhœal secretion from the genitals of the mother during parturition. In rare cases infection occurs before birth. Sometimes it occurs subsequent to the birth of the child, through infection from sponges, napkins, towels, or the fingers of the nurse, which have been in contact with the genitals of the mother.

It is a question whether every case of ophthalmia neonatorum is produced by infection from a gonorrhœal vaginitis. The great majority of cases are undoubtedly of gonorrhœal origin. It is probable, however, that a few cases result through infection from simple catarrhal (non-gonorrhœal) secretion. Such exceptional cases run a mild course, and are not usually complicated by corneal ulcers.

Treatment.—The conjunctival sac should be irrigated every hour with warm normal saline solution or with warm solution of potassium chlorate (gr. x. ad ʒi.). Vaseline should be applied to protect the corneal epithelium. Applications of 1 or 2 per cent. solution of nitrate of silver may be used after

the swelling and redness have diminished and the discharge begins to be less profuse, continued throughout the stage of papillary swelling. Once a day will be sufficient, followed immediately by warm-water irrigation. Other useful remedies are, in the acute stage irrigation every hour with warm H_2O_2 solution ($\frac{1}{2}$ volume), and in the later stage zinc chloride drops ($\frac{1}{4}$ grain ad \mathfrak{z} i.) twice a day.

If there is much swelling of the lids, iced compresses may be applied, but we must be careful not to use them too continuously, and they must be stopped as soon as the redness and swelling begin to diminish. In adults, the sensations of the patient guide us to a certain extent, and we use the pads less often when they no longer feel grateful, as happens when the redness and swelling subside. In infants we cannot receive this information; hence great care must be used not to injure the cornea by excessive cooling, especially if there be corneal infiltration. In such cases hot compresses are often substituted for the cold.

Every day the cornea should be examined. If any ulcer be observed, warm lotions should be used every hour and atropine ointment ($\frac{1}{4}$ per cent.) thrice daily.

The general health of the infant must be looked after, since enfeebled conditions render treatment unsatisfactory, and favour corneal complications.

Credé's Method of Prophylaxis.—Ophthalmia neonatorum is practically preventable. Through the adoption of Credé's method, its occurrence has been made infrequent in lying-in hospitals, and in private practice. The method consists in cleansing the eyes of the child with water immediately after birth, and instilling one drop of a 2 per cent. solution of nitrate of silver into each eye. This often causes a slight redness of the conjunctiva for a day or two. It acts by destroying any gonococci which may have entered the conjunctival sac. Antiseptic irrigation of the vagina of the mother before delivery is also useful as a prophylactic measure.

Catarrhal Conjunctivitis in the New-Born.—Sometimes we meet with a slight catarrhal conjunctivitis in the new-born, lasting a few days, and presenting merely hyperæmia, slight

swelling, and a little mucoid discharge. These are not examples of ophthalmia neonatorum. But at the start we may be in doubt whether they are not purulent cases, and it will be safer to treat them as such until the character of the inflammation becomes certain. In such cases bacteriological examination of the discharge may furnish valuable information.

Membranous Conjunctivitis.

This term comprises two clinical varieties : (1) Diphtheritic conjunctivitis, and (2) non - diphtheritic or croupous conjunctivitis. This subdivision is based upon the clinical pictures presented. The bacteriological peculiarities of the exudation may be, and often are, identical.

Diphtheritic Conjunctivitis.

An acute inflammation of the conjunctiva, associated with exudation and infiltration, purulent discharge, with tendency to necrosis of the involved tissues. The disease is rather rare and occurs in children. It spreads by infection. The secretion contains the Loeffler bacillus (Fig. 106 Plate VIII.) and is contagious.

Symptoms.—The lids are very much swollen, reddened, hot, and tender. The conjunctiva of the lids and fornix is intensely inflamed and is covered by a grayish-yellow exudation, which also infiltrates the underlying tissues. In this way the lids become hard and cannot be everted. The exudation causes compression, and, as a result, there is a tendency to sloughing of the infiltrated parts. Besides this fibrinous exudation, there is a discharge of a thin, cloudy fluid. With these local signs there are the prostration and other constitutional symptoms of diphtheria, and often local evidences of the disease in other parts of the body.

At the end of a week the exudation disappears, partly through absorption, partly through necrosis and sloughing, causing a loss of substance covered by granulations. The secretion now becomes more abundant and purulent.

The defects in the lining of the lid gradually cicatrize, this process causing various deformities : symblepharon, trichiasis, and entropion. There is frequently corneal ulceration. When the diphtheritic process is severe, the cornea is seriously involved and sight is always lost.

The *prognosis* in regard to sight is always serious; in regard to life, it depends upon the constitutional effects and general condition of the child.

Treatment.—*Prophylactic*: The precautions described under gonorrhœal ophthalmia must be employed in this disease to protect physician, nurse, and attendants. Besides being contagious, the disease is infectious; hence the patient should be isolated; other children must be removed. The second eye must be shielded.

Treatment of the Affected Eye.—Careful cleansing with weak antiseptic solutions (boric acid, corrosive sublimate). Cold compresses may be applied, but must be used cautiously on account of the enfeebled circulation. After a short period hot compresses are used. When the exudation has separated, we apply a 1 per cent. solution of nitrate of silver. We endeavour to prevent sequelæ due to cicatrization by frequent separation of the lids from the globe, and by keeping the two surfaces apart by a piece of fine linen smeared with some bland ointment. Corneal ulceration must be treated as described in the next chapter.

Constitutional.—We must remember that the eye affection is merely the local manifestation of a constitutional disease. Hence the general treatment of diphtheria must be carried out. Injections of antitoxin are of great value, producing a rapid improvement in the local as well as the general condition.

Croupous Conjunctivitis or Non-diphtheritic Membranous Conjunctivitis.

A form of inflammation in which there is the deposit of an exudation upon the surface of the conjunctiva, upon which it hardens into a membrane. There is no infiltration into the tissues; this constitutes the essential difference between croupous and diphtheritic conjunctivitis. Bacteriological examination may reveal the Loeffler bacillus and other micro-organisms, and these may be identical with those found in diphtheritic membrane. There are, however, no constitutional symptoms such as accompany diphtheria.

Symptoms.—Those of catarrhal conjunctivitis. A fibrinous membrane forms upon the palpebral conjunctiva; when this exudation is pulled off, a raw surface presenting a few bleeding points is seen; under such circumstances the membrane re-forms.

Etiology.—It may be caused by irritants (mechanical, chemical, or thermic), or by the action of various micro-organisms. Examples of the former are nitrate of silver, acids, lime, molten lead, burns, and injuries in general.

Treatment.—That of catarrhal conjunctivitis. As soon as the membrane shows no tendency to re-form, applications of a 1 per cent. solution of nitrate of silver are useful.

Granular Conjunctivitis, Trachoma, or Granular Lids.

An inflammation, generally of lengthy duration, accompanied by hypertrophy of the conjunctiva and the formation of 'granules,' with subsequent cicatricial changes. It occurs at all ages. It is not common in England except among immigrants from Eastern Europe. There is more or less secretion, which is contagious. It is a very important affection on account of its disastrous complications and sequelæ, which are responsible for many cases of partial or total blindness.

Subjective Symptoms.—More or less photophobia, lachrymation, itching, and burning sensations, feeling of foreign body, pain, and visual disturbance. In a good many cases there are no subjective symptoms.

Objective Symptoms.—Swelling of the lids, narrowing of the palpebral aperture, and drooping of the upper lid (from weight and swelling). There is a variable amount of mucopurulent discharge, marked in recent cases, scanty in chronic forms. The conjunctiva of the tarsus and fornix is reddened, thickened, and uneven, on account of hypertrophy and the occurrence of granules. The ocular conjunctiva is often somewhat injected.

Forms.—Basing the subdivisions upon variations in local appearances, we distinguish three forms: (1) Papillary, (2) granular, and (3) mixed.

1. *Papillary Form*.—A large number of small elevations (*papillæ*) are seen upon the greatly-thickened conjunctiva, giving the latter a velvety appearance, or, if the *papillæ* are larger, a granular aspect. This form affects only the tarsal conjunctiva, and usually only the upper lid. The *papillæ* are caused by the hypertrophied conjunctiva being thrown into folds, covered by an increase in epithelium, the connective-tissue interior being infiltrated with cells.

2. *The Granular Form* presents a preponderance of trachoma granules (Fig. 112, Plate IX.). These are grayish or yellowish, rounded, translucent bodies showing through the conjunctiva. They may be small and rounded, larger and warty, or flattened and succulent. They are present principally in the fornix, and when numerous are arranged in rows. In the tarsal conjunctiva they are less numerous, smaller, and less distinct, being hidden by the *papillæ*. Occasionally trachoma granules are formed upon the semilunar folds and the bulbar conjunctiva. The granules are rounded collections of lymph corpuscles in a connective-tissue reticulum, resembling what we see in Peyer's patches in the intestines; they may present an incomplete capsule in old cases.

3. *The Mixed Form* represents the common condition, the papillary and granular varieties being almost always found together, the former more prominent in the palpebral conjunctiva, the latter predominating in the fornix. Occasionally the two forms occur separately.

Course.—The process progresses up to a certain point, and is then followed by cicatricial changes in the conjunctiva (cicatricial stage). This cures the trachoma, and the *papillæ* and granules disappear; but the conjunctiva does not return to a normal condition, the cicatricial changes and contraction leading to certain sequelæ; the seriousness of the latter depends upon the severity of the process and the amount of hypertrophy and subsequent cicatrization. In the tarsal conjunctiva the cicatricial process causes narrow whitish bands and scars (Fig. 126, Plate X.), sometimes a network; in advanced and severe cases the entire surface may be replaced by a pale, smooth cicatricial membrane. In the fornix cicatrization changes the conjunctiva into a pale, bluish-

PLATE IX.

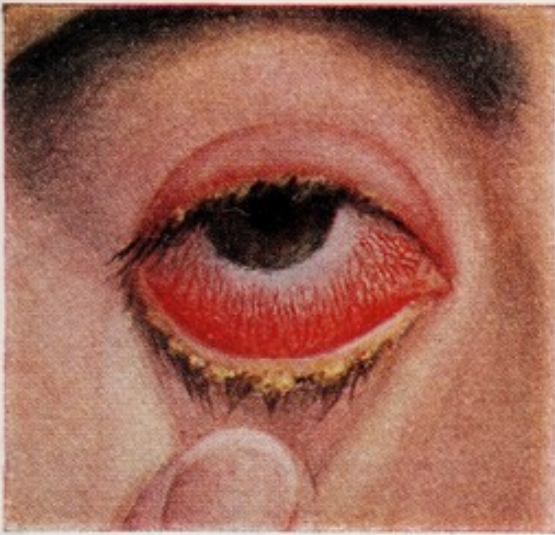

FIG. 109.—CATARRHAL CONJUNCTIVITIS.

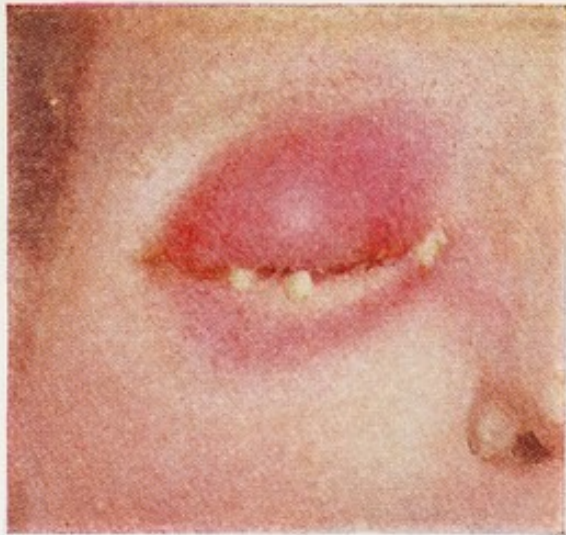

FIG. 110.—OPHTHALMIA NEONATORUM.

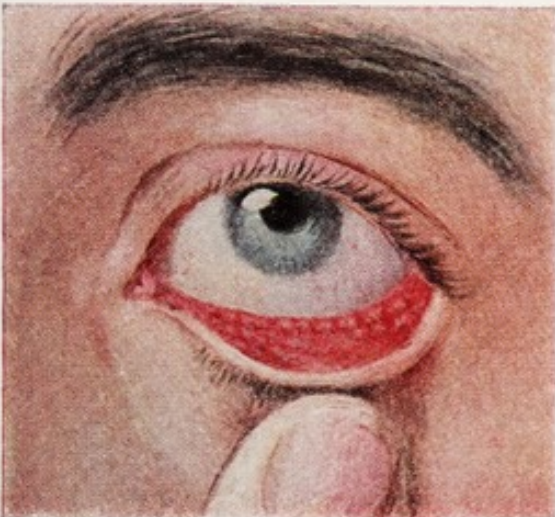

FIG. 111.—FOLLICULAR CONJUNCTIVITIS.

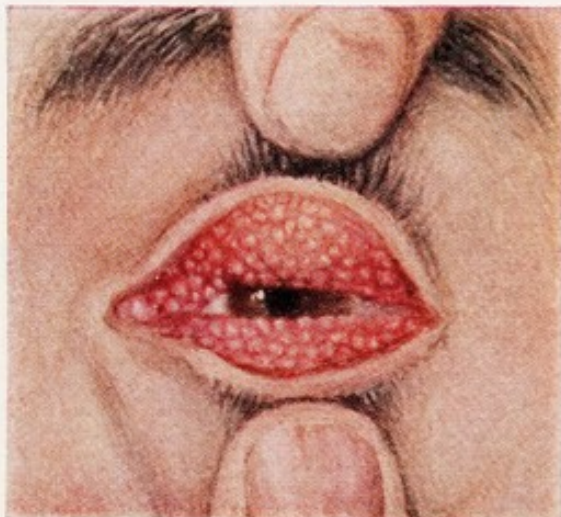


FIG. 112.—TRACHOMA.

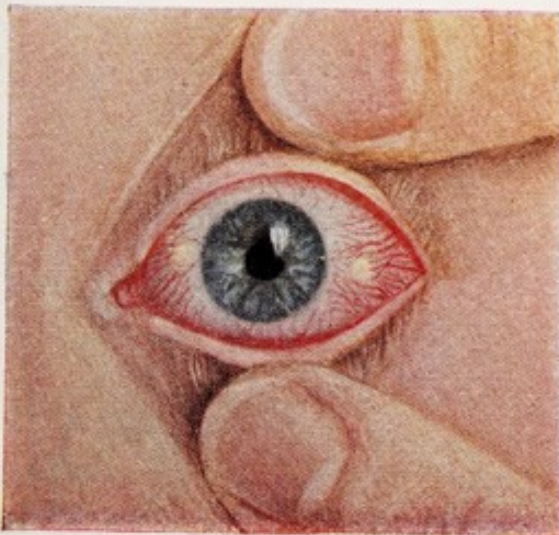

FIG. 113.—PHLYCTENULAR CONJUNCTIVITIS.

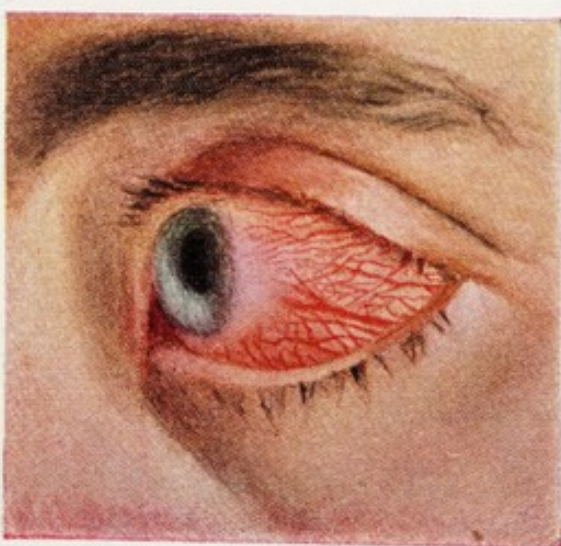

FIG. 114.—EPISCLERITIS.



white membrane, and as a result of contraction the transition fold is shortened or disappears.

Clinical Varieties.—Clinically, trachoma presents a number of varieties. Occasionally the invasion is acute and accompanied by marked inflammatory symptoms and profuse purulent discharge; such cases resemble purulent conjunctivitis. The finding of gonococci in the secretion and the presence of the trachoma granules serve to differentiate, but frequently the swelling hides the latter; we may have to wait several days, until the swelling subsides somewhat, before we can decide.

Frequently the disease begins insidiously; it may exist unknown for months, before the subjective symptoms become annoying. Most cases of trachoma are chronic in their course, and the duration is months or years.

Clinically, two forms of trachoma are met with: (1) inflammatory trachoma, with inflammatory symptoms, very contagious, leading to cicatrization of the conjunctiva and various sequelæ when unchecked; and (2) simple or non-inflammatory trachoma, in which, with moderate or marked deposition of granulations of the granular form in the palpebral and retrotarsal portions of the conjunctiva of both lids, there are but slight or no symptoms of irritation or discomfort.

Besides these differences in the intensity of the inflammatory symptoms there are great variations in the amount of change in conjunctiva and cornea. There are mild cases, in which there are but little hypertrophy and insignificant cicatricial changes in the conjunctiva, so that afterward we can scarcely be sure that trachoma has existed; such mild cases usually remain free from corneal complications.

In moderate and severe cases there always remain permanent cicatricial changes, which enable us to diagnose the previous existence of trachoma. When the cornea is implicated the case is always a serious one.

Trachoma does not always progress uninterruptedly; there are often intermissions and exacerbations. Relapses are quite frequent, especially when treatment has been discontinued too soon.

Complications.—The most frequent are pannus and corneal ulceration, both causing disturbance of sight.

Pannus consists of a newly-formed vascular tissue, which usually covers the upper part of the cornea (Fig. 126, Plate X.). The affected portion of the cornea presents a cloudy appearance, and is grayish and translucent; its surface is uneven and vascularized, the bloodvessels springing from the conjunctival vessels at the limbus. The process advances until it covers the upper half of the cornea. Finally, the entire cornea may be covered, in which case vision is reduced to perception of light. Unless subsequent changes occur, complete retrogression is possible, so that the cornea can become transparent again. In marked cases iritis is apt to develop. Pannus is not merely due to mechanical irritation, but to a change similar to that which occurs in the conjunctiva.

Ulcers of the cornea occur with or without pannus. They leave opacities, which interfere with vision according to their seat and density.

Sequelæ.—Complete cure is usually effected in the mildest cases alone, or in more severe forms only when they are subjected to early treatment. Sequelæ are very common, affect the conjunctiva, cornea, and lids, and produce permanent disability of the eye.

1. Trichiasis and entropion occur as a result of cicatricial contraction of the conjunctiva with curving of the tarsus; they are more pronounced in the upper lid. As a result of this distortion of the lid with consequent changes in the position of the cilia, there is mechanical interference with the cornea, causing ulceration.

2. Ectropion (usually of the lower lid) follows in some cases, as a result of hypertrophy of the conjunctiva and contraction of the orbicularis.

3. Symblepharon results from cicatricial contraction of the conjunctiva; when considerable, there is obliteration of the fornix. This condition restricts the movements of the eyeball.

4. Corneal opacities result from pannus and corneal ulcers. After lasting some time, pannus changes into a thin, permanent layer of connective tissue.

5. Staphyloma of the cornea follows in some cases.

6. Xerosis, a contracted, dry, and scaly condition of the conjunctiva, with changes in the cornea, may occur in very severe cases.

Etiology.—Trachoma is caused by contagion from another eye, being transferred through the secretion. The danger of contagion depends upon the amount of secretion in any given case. The transfer from one eye to another may take place by the finger, but usually by towels, handkerchiefs, and the like, which are used in common by many persons. Hence the disease spreads most extensively in schools, asylums, and barracks, and among people who live crowded closely together, and who are careless in regard to cleanliness. It is scarcely ever seen in private practice in England. Certain races seem predisposed—Jews from Russia, Germany, Austria, and the Balkan States. It occurs with especial frequency in certain countries—Arabia, Egypt; it is endemic in the latter country. During the Napoleonic wars the affection was carried to Europe by soldiers (hence often called Egyptian ophthalmia). In Europe it occurs much more extensively in the east than the west, and much more frequently in low lands (Belgium, Holland, Hungary) than in elevated countries (Switzerland). Negroes are said to be comparatively immune to the disease. The contagious principle in the secretion is thought to be a micro-organism. Noguchi isolated an organism from cases of trachoma with which he was able to produce trachoma in monkeys.

Treatment consists in an attempt to reduce the inflammatory symptoms and secretion, and to check and remove hypertrophy of the conjunctiva, thus shortening the duration and diminishing the liability to conjunctival cicatrization and to sequelæ. This is accomplished either by the use of certain irritating applications, or by mechanical (surgical) means.

Irritating Applications.—Sulphate of copper in the form of a crystal or pencil is the favourite local application. Nitrate of silver (1 or 2 per cent. solution), glycerole of tannin (5 to 25 per cent.), and the alum stick are also employed.

Surgical treatment includes expression, grattage, excision,

curettage, electrolysis, X rays, radium, and galvano-cautery. Expression is the most popular of these mechanical methods, and has the widest range of usefulness. The kind of treatment best suited for trachoma depends upon the nature of the affection, the presence or absence of inflammatory symptoms, and the stage of the disease. Mechanical treatment is indicated in the granular and mixed forms of trachoma, with well-marked translucent granulations, when there is an absence of severe inflammatory symptoms; it is particularly useful in the form which Knapp calls simple or non-inflammatory. Irritating applications are indicated as supplementary treatment to surgical procedures, and for cases of chronic trachoma, in which the granulations are of small size, or of the papillary variety, particularly when there is considerable thickening of the conjunctiva.

In acute forms and in acute exacerbations of chronic cases, when there is much discharge, solution of nitrate of silver, 1 or 2 per cent., is applied to the conjunctiva, the excess being washed away with water or salt solution. In many cases of this sort, however, it is often advisable to suspend temporarily all irritative treatment, and to prescribe cold compresses, instillations of a 25 per cent. solution of argyrol, and mild cleansing and antiseptic washes.

During the cicatricial stage copper is no longer indicated; the ointment of the yellow oxide of mercury is then of service.

If treatment is not continued until every trace of hypertrophy has disappeared, relapses are very common.

FIG. 115.—SULPHATE OF COPPER STICK.



Sulphate of Copper.—The pencil is applied to the everted lids once a day, or every other day; it is drawn lightly across the conjunctiva two or three times, but applied only to the hypertrophied portions. The application should include the palpebral portion of the transition fold of the upper lid; in passing the copper stick under the tarsus the cornea is protected by the lower lid

(Fig. 117). The stick of copper sulphate should have a flat, blunt end, as shown in Fig. 115, and not be pointed or conical. After each application, the excess of copper sulphate is washed off with water or solution of boric acid; subsequently iced compresses are applied for half an hour or longer. This treatment is continued for months until every trace of hypertrophy has disappeared. After a time the applications are made more lightly and less frequently.

Expression is best performed with Knapp's roller-forceps, by means of which the granulations are squeezed out between two fluted rollers at the end of the shafts (Fig. 116). The operation is painful, and a general anæsthetic is required. The upper lid is everted, and the trachoma follicles are squeezed out between the two extremities of the forceps. One extremity is passed back into the fornix and the other




FIG. 116.—KNAPP'S ROLLER-FORCEPS FOR TRACHOMA (FULL SIZE).

over the tarsus. Using moderate compression, the forceps is drawn forward, pressing out the contents of the granules (Fig. 118). This procedure is repeated until the lid is free from granulations and presents a dark-red surface with small red points. The lower lid is then operated upon in the same manner. After expression the conjunctiva is often brushed vigorously with a solution of mercuric bichloride, 1 : 500. Care must be taken not to cause abrasions of the cornea and not to tear the conjunctiva. If the granulations are hard and horny, it may be well to scarify them before using the roller-forceps. There are swelling and ecchymosis for a day or two after the operation, but no other evidences of reaction. Cold compresses and irrigations with solution of boric acid are indicated for several days; then any remaining roughness is treated with gentle applications of the sulphate of copper crystal every other day for a few weeks, or until the lids are normal.

The other mechanical or surgical means of treating trachoma are used much less frequently than expression. *Grattage* consists in scrubbing the granulations, with or without previous scarification, with a stiff tooth-brush until all the granules are removed, and then thoroughly rubbing in a solution of mercuric bichloride, 1 : 500. *Excision* consists in the removal of the fold of conjunctiva, about 10 mm. broad, containing the granules. Both of these methods cause

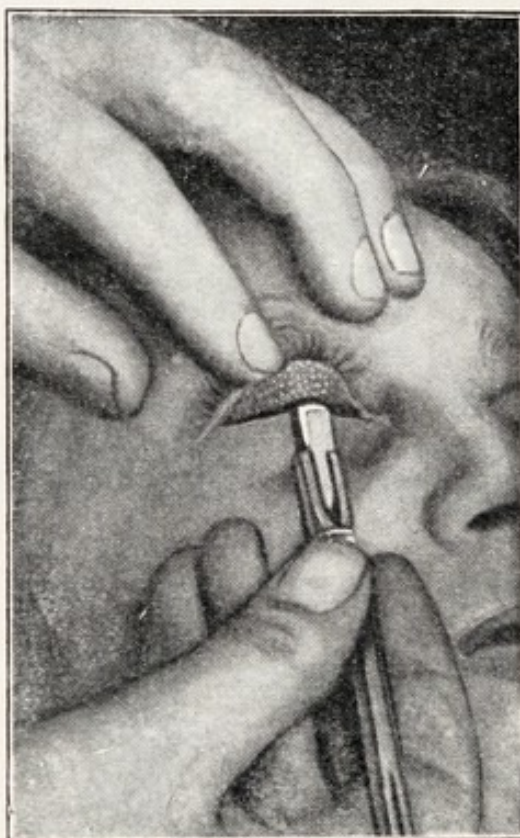


FIG. 117.—METHOD OF APPLYING THE SULPHATE OF COPPER STICK TO THE CONJUNCTIVA OF THE UPPER LID.

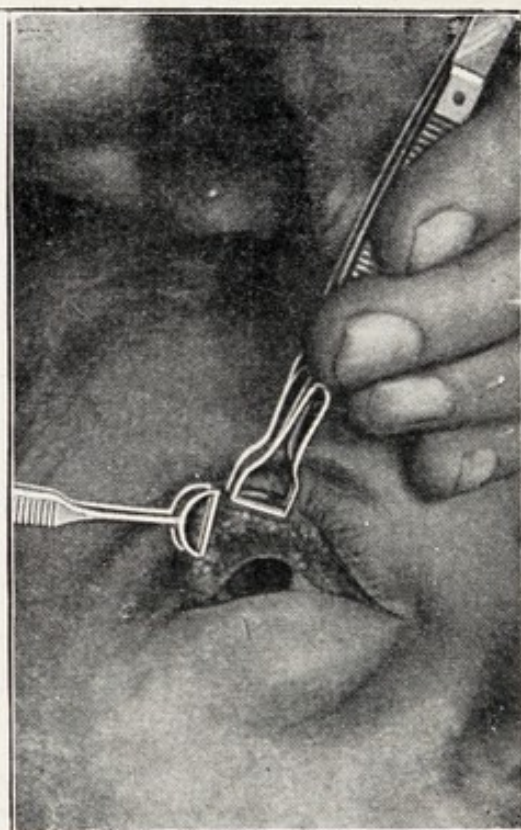


FIG. 118.—THE OPERATION OF EXPRESSION FOR TRACHOMA, AS APPLIED TO THE UPPER LID.

more injury to the conjunctiva than is the case with expression. Some surgeons recommend exposure of the everted conjunctiva to the influence of X rays or of radium. Either of these agents may cause much damage in unskilful hands.

Treatment of Complications.—Recent pannus is best relieved by the treatment of the conjunctiva. In addition, we may use atropine occasionally, so as to keep the pupil dilated and prevent posterior synechiæ, since iritis is frequently

present in these cases. If the pannus is very dense, we may apply the copper directly to the cornea. The operation of peritomy, the excision of a narrow strip of conjunctiva surrounding the cornea with a view of cutting off the vascular supply, is occasionally performed for the relief of severe cases of pannus. For active ulceration, nitrate of silver is often used, and atropine if iritis is suspected.

General treatment must not be neglected. The eye should be kept cleansed by the frequent use of solution of salt, boric acid, or bichloride of mercury (1:10,000). The hygienic surroundings of the patient should be made as perfect as possible, with proper ventilation, plenty of outdoor exercise, and good food.

Prophylaxis is very important. The patient and his family must be warned of the contagiousness of the secretion, and impressed with the necessity for keeping the patient's handkerchiefs, towels, wash-basin, etc., apart from those of other persons. In schools, asylums, institutions, and barracks, the prevention of epidemics of trachoma is a very serious matter, requiring constant vigilance, careful inspection of every new addition or inmate, and the isolation of trachoma cases so long as the latter are capable of conveying the disease.

Phlyctenular Conjunctivitis.

This disease, also known as pustular conjunctivitis and as scrofulous ophthalmia, is a circumscribed inflammation of the conjunctiva, accompanied by the formation of one or more small reddened projections called phlyctenulæ. The latter consists of accumulation of lymphoid cells, which soften at their apices, forming small ulcers. The phlyctenulæ may occur upon the ocular conjunctiva, and then the disease is called phlyctenular conjunctivitis. They may occur upon the cornea, when the affection constitutes phlyctenular keratitis; or they may occur, and most frequently do occur, at the limbus, and then we might speak of the disease either as a keratitis or as a conjunctivitis. Very frequently they occur in all three situations in the same individual. The

pathology, symptoms, and treatment being the same in all cases, it is convenient to describe the three varieties collectively under the title of phlyctenular ophthalmia.

Objective Symptoms.—The essential sign is the occurrence of one or more small, grayish elevations or nodules, about the size of a millet-seed, at some part of the conjunctiva or cornea, frequently at the limbus. The phlyctenule is surrounded by an area of conjunctival hyperæmia (Fig. 113, Plate IX.). The non-affected parts of the ocular conjunctiva are but slightly changed from the normal. The phlyctenule soon presents a small ulceration at its apex, which then occupies the level of the surrounding conjunctiva. It heals without leaving behind any changes in the conjunctiva. The entire process lasts from a few days to two weeks.

Generally a number of phlyctenulæ appear at the same time. In this manner the entire ocular conjunctiva may be reddened. In such cases the palpebral conjunctiva will be congested. The nodules may become absorbed without going through the stage of ulceration.

When the phlyctenule appears upon the cornea, the infiltrations and subsequent ulcers are usually superficial, and heal without the production of lasting changes in the cornea. But sometimes they spread into the corneal substance, and then leave a permanent opacity. In rare cases the ulcer perforates the cornea. Sometimes a number of them may, by confluence, spread along its surface.

Fascicular Keratitis.—The ulcer resulting from the phlyctenule may advance from the margin to the centre of the cornea, drawing after it a fascicle of bloodvessels. In this manner there is formed a narrow, red band of vessels, extending some distance over the cornea (Fig. 127, Plate X.). At the apex of this fascicle is seen a small, gray crescent, corresponding to the advancing margin of the ulcer, which has healed in the peripheral parts. This form of ulceration always remains superficial. When the process terminates, the bloodvessels gradually disappear and a superficial linear opacity remains.

The phlyctenule may, in severe cases, involve the deep

layers of the cornea, forming deep infiltration. This either becomes absorbed completely, or leaves an opacity of the cornea. It rarely becomes purulent, and a deep ulcer results.

There is usually considerable lacrymation. If there is any discharge, it is mucous or muco-purulent, and not abundant.

Subjective Symptoms.—Photophobia is marked when the cornea is involved; slight or absent in conjunctival cases. When prominent, there is considerable blepharospasm, and the eyes can be examined only with difficulty.

Course.—The phlyctenules usually occur in crops. Before one is completely cured another is apt to appear. In this way the course may become protracted, and may extend over weeks. Each phlyctenule lasts from a few days to a week or two. Relapses are very common. The affection occurs most frequently in children and in young persons, but is also seen in adults. In adults a single large phlyctenule often gives the local appearances of episcleritis.

As a result of constant lacrymation, there are frequently added blepharitis, excoriations, and eczema of the lids.

The prognosis is favourable. Serious results are rare. The phlyctenulæ usually leave no traces. In some cases corneal opacities of greater or lesser density remain, and if these are central, sight will be interfered with. Frequent recurrences may result in a number of cloud-like opacities of the cornea with superficial bloodvessels.

Etiology.—The disease is very common. It seems dependent upon some constitutional error. It occurs frequently in children who suffer from the tuberculous or so-called scrofulous diathesis. It is especially frequent among the lower classes, in whom dirt, poor food, and improper hygienic surroundings are contributory factors; also in children debilitated from disease. One frequently sees other manifestations of the predisposing diathesis, such as swelling of the cervical lymphatic glands, adenoid vegetations, eczema, coryza, blepharitis, chronic otorrhœa, etc. Sometimes, however, the affection occurs in children of the better classes, apparently in good health.

Treatment. — *Local.* — Finely powdered washed calomel dusted upon the eyeball once a day. This is believed to be

slowly changed to corrosive sublimate by the action of the tears, and in this way to keep the eye bathed in an antiseptic fluid. The calomel is apt to cause irritation if the patient is taking iodides internally, probably owing to local formation of mercuric iodide. A favourite remedy is the ointment of the yellow oxide of mercury (1 or 2 per cent.); a piece about the size of a hemp-seed is deposited in the conjunctival sac and rubbed about with the lids. When there is a great deal of irritation, it is wise to withhold the yellow oxide ointment until less inflammation exists. If the symptoms of irritation are very prominent, it is better to irrigate with solution of boric acid, and to apply cold pads if the phlyctenulæ involve the conjunctiva, and hot compresses if they form upon the cornea.

If there is infiltration or ulceration of the cornea, atropine, hot compresses, and mild antiseptic washes are indicated. If there is fascicular keratitis, the ointment of the yellow oxide of mercury is employed. In such cases we can often cut short the progress of the disease by cauterizing the advancing edge of the ulcer with a fine galvano-cautery point (Fig. 129), or with tincture of iodine (p. 138). Bandages should not be applied. It is only in extreme cases of very deep ulceration that a bandage is indicated.

In corneal cases the photophobia and blepharospasm are often very annoying symptoms. Instillation of solution of holocain will give temporary relief. Douching the eye with cold water several times a day may be effective. If a fissure of the outer canthus is present, touching this with a 2 per cent. solution of silver nitrate or the stick of copper sulphate is of value.

General treatment is of great importance. Suitable and nourishing diet, improved hygienic surroundings, and cold sponging and bathing are useful. The nose and nasopharynx should receive proper treatment. These patients should not be allowed to remain in the house and in the dark, as they are inclined to do on account of the photophobia. Smoked glasses are prescribed to relieve this symptom. Preparations of iron (syrup of the iodide), quinine, and arsenic are useful for internal administration, and cod-liver oil is of great benefit.

Spring Catarrh.

A rather uncommon disease of the conjunctiva, of chronic course, lasting for years, continuing during warm weather, and disappearing entirely or to a considerable extent with the beginning of winter. It is also known as vernal catarrh. The disease occurs chiefly in children, most frequently in boys. It may attack the tarsal or the bulbar conjunctiva, or both.

Objective Symptoms.—The tarsal conjunctiva presents flattened papillæ covered by a delicate, bluish-white film. The bulbar conjunctiva presents at the inner and outer portions of the limbus hard, gelatinous hypertrophies, which may extend into the cornea for a short distance, and which sometimes surround it. During the winter these changes become less marked, or disappear. They return with the advent of warm weather.

Subjective Symptoms include a feeling of heat, lacrymation, itching, and photophobia. These become worse in warm weather, and disappear in the winter.

Course.—The disease usually attacks both eyes, and lasts in this intermittent way for several years or longer, finally becoming extinct, and leaving no traces behind. Its etiology is unknown. It may be associated with hay fever.

Treatment.—There is no known cure. The subjective symptoms can be made less annoying by the remedies in use for catarrhal conjunctivitis. The agents most frequently used are boric acid, corrosive sublimate 1:5,000, and white precipitate ointment. Acetic acid (1 drop of the dilute acid to $\frac{1}{2}$ ounce of water) and salicylic acid ointment (1 per cent.) have also been advocated. The greatest relief follows the instillation of a 1 per cent. solution of holocain in 1:10,000 adrenalin, the use of cold compresses, and the wearing of smoked glasses. If the hypertrophies are of considerable size, they may be removed. When the granulations are large, bluestone or expression may be of service.

Parmaud's Conjunctivitis is a rare disease of unknown origin which has been attributed to infection from animals. The

symptoms are considerable swelling of the lids with mucopurulent discharge, polypoid granulations of reddish or yellowish colour on the conjunctiva, small ulcers between the granulations, enlargement of the pre-auricular lymphatic gland. The gland becomes very tender and may suppurate. The disease is usually limited to one eye, though the other may become affected.

The treatment consists of antiseptic collyria and snipping off the larger granulations with fine-pointed scissors. The prognosis is favourable, though the disease may last several weeks or months.

Lithiasis of the Conjunctiva consists of calcarious changes in the secretion in the acini of some of the Meibomian glands. They form gritty projections on the surface of the palpebral conjunctiva and cause much corneal irritation. The condition occurs almost exclusively in elderly people.

The surface should be cocainized and the nodules picked out with a discission needle.

Symblepharon.

A cicatricial attachment between the conjunctiva of the lid and eyeball (Fig. 119). It




FIG. 119.—SYMBLEPHARON.

may affect both lids, but usually the lower. Sometimes it includes part of the cornea. It is called anterior or partial, when extending bridge-like from lid to globe, leaving a free portion of conjunctiva corresponding to the fornix; posterior, when it involves only the fornix; and complete when it affects all the conjunctiva. It is caused by the junction of two opposing granulating surfaces. Hence it occurs after injuries, especially burns from lime, acids, and

molten metal; sometimes it follows trachoma, and occasionally diphtheritic conjunctivitis.

Symblepharon often interferes with the movements of the eyeball, and this may cause diplopia. Traction upon the adherent part excites irritation. In severe cases the cornea is included and sight interfered with; or, if there is inability to close the lids, lagophthalmos and its sequelæ may be present.

Treatment.—If anterior and not extensive, we divide the band and keep the two raw surfaces from uniting by separating them daily with a probe until they have cicatrized separately. The interposition of a small roll of absorbent cotton saturated with some bland oil or ointment may aid in this purpose. Or the band may be ligated and the ligature allowed to slough through.

In more severe forms, and in all cases of posterior and complete symblepharon, the separated raw surfaces must be covered with conjunctiva or with grafts of skin or mucous membrane to keep them from uniting. This may be done (1) by loosening the adjacent bulbar conjunctiva and sewing it over the defect, (2) by transplanting pieces of mucous membrane from the lip or from the rabbit's conjunctiva, (3) by skin-flaps, passed from adjacent surfaces, and (4) by Thiersch skin-grafts, taken from other parts of the body, and supported on an artificial eye or piece of sheet-lead until adhesion has taken place.

Pinguecula.

A small, slightly raised spot of yellowish colour, situated at the inner and outer sides of the cornea, especially marked in old people. It is not formed of fat, as its name implies, but of connective-tissue thickening of the conjunctiva. It never calls for interference.

Pterygium.

A triangular fold of membrane, extending from the inner or outer part of the ocular conjunctiva to the cornea (Fig. 120). The apex is immovably united to the cornea; the base spreads out and merges with the conjunctiva.

Symptoms.—When recent, pterygium is rich in blood-vessels, and hence of a red colour. Later it changes into a white, tendinous membrane. It grows slowly towards the centre of the cornea, giving rise to moderate symptoms of conjunctival irritation, and it may eventually cover a considerable part of the cornea; finally it becomes stationary. Besides more or less irritation, it causes disfigurement, and it spreads over the cornea, interfering with vision. It is generally situated to the inner side of the cornea, less frequently to the outer side, or in both situations. It may occur in one or both eyes.

Etiology.—Pterygium is thought by some to originate from pinguecula, the process extending to the cornea and drawing the conjunctiva after it. It occurs usually in elderly persons who are exposed to wind or dust (farmers, coachmen, masons, sailors).

Treatment consist in removal by one of a number of different operative methods. The pterygium may be dissected away with a sharp scalpel or Beer's knife (Fig. 57), and cut off, the conjunctival defect being closed by uniting the upper and lower borders, undermining the conjunctiva if necessary to bring the edges together. The apex of the pterygium must be thoroughly excised from the cornea, and its attachment in this situation scraped or cauterized with the actual cautery, to prevent recurrence. Instead of cutting off the pterygium, it may be dissected up and stitched underneath the detached conjunctiva, either above or below; or it may be divided into two halves, of which one is transplanted above and the other below, being held in the conjunctival pocket by a stitch. Some cases show a tendency to recur, even after repeated removal. Both radium and carbon dioxide snow (ten seconds' application on alternate days) have been employed, occasionally with success.

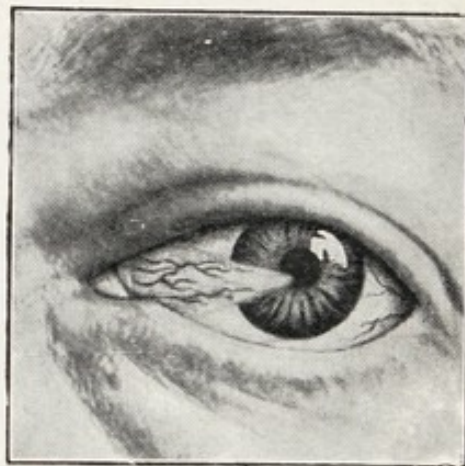

FIG. 120.—PTERYGIUM.

Subconjunctival Hæmorrhage.

Bright or dark red patches involving more or less of the bulbar conjunctiva (Fig. 100, Plate VII.), unaccompanied by inflammatory symptoms. Ecchymosis is seen after injuries, operations, and inflammations of the eyeball. It is frequently observed in old persons with brittle bloodvessels, being excited by various straining efforts, and in children after whooping-cough. It is of no importance, and becomes absorbed within a week.

Injuries of the Conjunctiva.

These are very common, and include:

1. *Foreign bodies* in the conjunctival sac, consisting of dust, iron, coal, or ashes. They usually adhere to the inner surface of the upper lid, causing severe pain and irritation, and are readily removed after eversion of the lid.

2. *Wounds*.—Extensive wounds of the conjunctiva should be closed with a stitch.

3. *Burns* are quite common, being due to boiling water, steam, lime, mortar, molten metals, and acids. Following the accident a grayish eschar forms. This separates and leaves a granulating surface, which heals by cicatrization. In this way symblepharon often results.

The treatment consists in the complete removal of the caustic substance as soon as possible. Solid particles are removed with absorbent cotton or forceps. Then the conjunctival sac is washed out with solutions which tend to neutralize the corrosive substance, or render it insoluble. In the case of lime, mortar, or caustic alkalies, we flush out with a solution of boric acid; or we may wash out the eye with oil. If the corrosive agent consisted of an acid, the eye is irrigated with a weak solution of sodium bicarbonate. But since it is of the utmost importance to remove the irritating and destructive agent without any delay it is unwise to wait for neutralizing solutions, but to irrigate with great quantities of water immediately, whether the foreign material is acid or alkaline. Solid particles are removed with absorbent cotton

of forceps. Subsequently we use cold compresses, atropine, keep the conjunctival sac filled with a bland ointment, such as 1 per cent. boric acid, and apply a loose gauze and cotton dressing. Unless the burn is very superficial, there will be eschars; when these loosen and come away, raw and granulating surfaces will be exposed; these have a great tendency to form adhesions; the latter must be separated frequently. Symblepharon is, however, very apt to occur notwithstanding the greatest care in separating these adhesions.

CHAPTER IX

DISEASES OF THE CORNEA

Anatomy.—The cornea is the clear, transparent, anterior portion of the external coat of the eyeball. It is nearly circular, but is

slightly wider in the transverse than in the vertical direction ; its radius of curvature is somewhat shorter than that of the sclerotic ; the junction of the two is known as the limbus, but their tissues are in complete continuity. The cornea is composed of five layers, from without inward : (1) Layer of epithelial cells ; (2) Bowman's membrane ; (3) the proper substance of the cornea ; (4) Descemet's membrane ; and (5) a layer of endothelium.

The *epithelium* covering the front of the cornea is of the stratified variety, formed of flattened, scaly epithelial cells superficially, of polygonal cells beneath these, and of columnar cells most deeply. Practically it is part of the bulbar conjunctiva.

Bowman's membrane is a thin, homogeneous membrane which separates the corneal epithelium from the proper substance of the cornea. Although usually described as a separate membrane, it is really a part of the corneal substance, and when highly magnified is seen to be composed of fine fibres which are intimately connected with the subjacent layer.

The *proper substance of the cornea*, the thickest layer, is formed of connective tissue arranged in lamellæ, the planes of which are parallel to the surface of the cornea ; these are

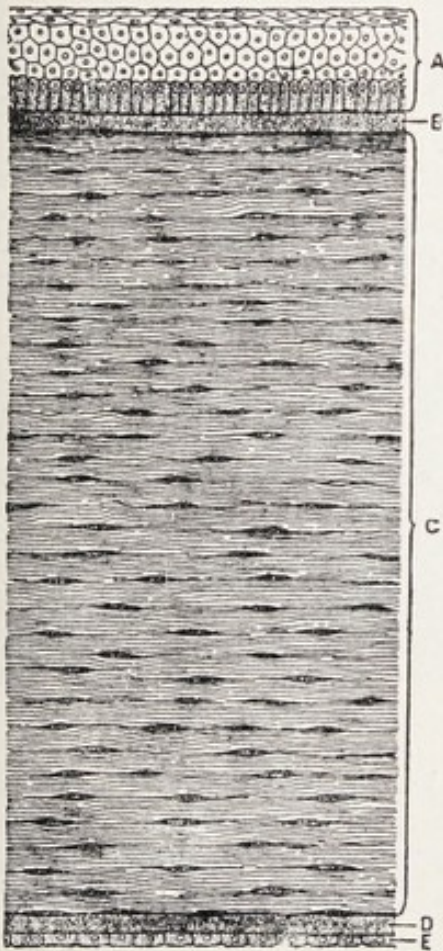


FIG. 121.—SECTION OF THE CORNEA, SHOWING MINUTE ANATOMY.

A, Layer of epithelial cells, etc.

connected with one another, and cross at right angles in alternating layers. The ultimate fibrils of which the lamellæ are composed, as well as the different bundles of fibrils forming the lamellæ, are held together by means of a transparent cement substance. The corneal substance is traversed by a system of spaces or lacunæ, situated in the cement substance separating the laminae, and sending off prolongations in every direction. These form small canals, by means of which the lacunæ of the same plane and those placed above and below communicate. The spaces are partly filled with branching cells (corneal corpuscles), the branches of the cells passing into the small canals, and communicating with adjoining cells. The cells do not completely fill the lacunæ, but leave room for the passage of lymph and lymph corpuscles. The proper substance of the cornea passes uninterruptedly into the sclera.

Descemet's membrane (the posterior elastic lamina) is a thin, firm, structureless, transparent, and highly elastic layer, placed posterior to the proper substance of the cornea. At the periphery of the cornea it passes over into radiating bundles of elastic fibres which form the *ligamentum pectinatum*.

Posteriorly, next to the anterior chamber is a single layer of flattened, hexagonal cells, the *endothelium*.

The cornea is not provided with bloodvessels. The capillary loops from the anterior ciliary vessels form a ring around the circumference of the cornea. Its nutrition is provided for by the system of lymph canals just described. It is richly supplied with *nerves* derived from the ciliary nerves.

The line between cornea and sclera is known as the *limbus*. Near the margin of the cornea, just within the sclero-corneal junction, we frequently find an opaque, whitish ring, or part of a ring. This is known as the *arcus senilis* (Fig. 122). It is due to a deposit of fatty granules, and most frequently occurs in advanced age, though occasionally it is found in younger persons.

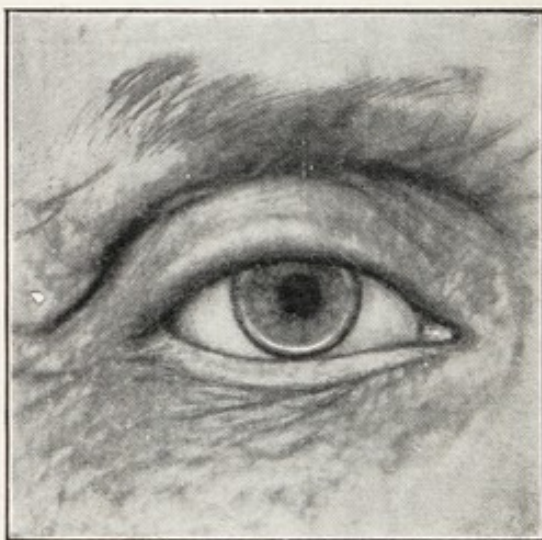

FIG. 122.—ARCUS SENILIS.

Inflammations of the Cornea.—Keratitis.

Keratitis in general presents the following symptoms :

Objective Symptoms.—(1) Infiltration, with dulness of surface and diminution of transparency. This may be followed

by (a) complete absorption of the infiltration ; (b) incomplete absorption, leaving opacities ; and (c) suppuration, with formation of an ulcer. (2) Limited or general vascularization, the bloodvessels being derived from the conjunctival loops at the limbus. (3) Circumcorneal injection. (4) There is often a complicating conjunctivitis. (5) Neighbouring deep parts are frequently involved (iris and ciliary body), as a result of which there may be pus in the anterior chamber (hypopyon).

Subjective Symptoms.—Pain, photophobia, blepharospasm, lacrymation, and interference with vision.

Varieties.—Keratitis may be divided into suppurative and non-suppurative.

Suppurative Keratitis.—The common forms are (1) phlyctenular keratitis, and (2) ulcers of the cornea. The uncommon forms are (3) keratitis from imperfect closure of the eyelids (lagophthalmos), (4) neuro-paralytic keratitis, and (5) xerotic keratitis.

Non-suppurative Keratitis.—The common forms are (1) interstitial keratitis, and (2) vasculo-nebulous keratitis (pannus). The uncommon forms are (3) vesicular keratitis, (4) keratitis profunda, (5) sclerosing keratitis, and (6) ribbon-shaped keratitis.

Phlyctenular Keratitis has been described under the title Phlyctenular Conjunctivitis (p. 108), and the special symptoms arising when the cornea is involved have been pointed out.

Ulcer of the Cornea.

An infiltration, followed by suppuration and loss of substance of the cornea. The affection is of very common occurrence.

Subjective Symptoms.—Pain, photophobia, lacrymation, and blepharospasm. Sometimes all these symptoms are slight, or even absent, and yet the ulcer may be a very extensive and serious one.

Objective Symptoms.—An ulcer begins with a dull, grayish, or grayish-yellow infiltration of a circumscribed portion of

the cornea. Suppuration takes place in this area, the superficial layers are cast off, and thus there is loss of substance. The process may progress in two directions: it may either travel over the cornea so as to involve a greater area, or it may become deeper; it may extend both in area and in depth. Very often the advance takes place in one direction across the cornea; sometimes there is at the same time a tendency to heal at the opposite side, so that the ulcer merely changes its situation (creeping or serpiginous ulcer). There is nearly always more or less grayish infiltration of the cornea immediately surrounding the loss of substance, and considerable ciliary injection.

If the ulcer is small and superficial it may cleanse itself in the course of a few days. The destroyed portion of the cornea will be cast off, the infiltrated border will become clear, and repair set in; this is accompanied by the appearance of bloodvessels which spring from the limbus; the process terminates in cicatrization. When the ulcer extends no deeper than the epithelium, the cornea may remain perfectly transparent. But when some of the proper substance of the cornea has been destroyed, new connective tissue takes its place, and such a scar is always more or less opaque. The seat of the ulcer may also be marked by a slight depression (corneal facet).

The detection of the extent of infiltration and ulceration is facilitated by the instillation of a few drops of a 2 per cent. solution of fluorescein, which stains green all such ulcerated or infiltrated parts.

When the ulcer is deeper both subjective and objective symptoms are more pronounced, and the complications and sequelæ are more serious. Neighbouring structures give evidences of inflammation—conjunctivitis, congestion of the iris, even iritis with its symptoms, including hypopyon. Hypopyon is a collection of pus in the anterior chamber. The pus is not derived from the ulcer, but is an exudation from the inflamed iris and ciliary body. It collects at the bottom of the anterior chamber (Fig. 124, Plate X.), or it may partially or completely fill this space. It may either remain

fluid, or when mixed with fibrin it may form a semi-solid, globular mass. Such an ulcer may heal with no other permanent injury except marked corneal opacity (Figs. 136, 137), or there may be bulging (anterior staphyloma) (Fig. 132). But deep and spreading ulcers frequently have their course modified by the occurrence of perforation of the cornea, which, in healing, affects the usefulness and safety of the eye in various ways.

The course of a simple ulcer is influenced greatly by the state of health and cleanliness of the patient. Even the smallest ulcer or abrasion in the cornea of a workman should not be regarded lightly.

Perforation of the Cornea is often preceded by a protrusion of Descemet's membrane through the floor of the ulcer, forming a small transparent vesicle. Perforation may be spontaneous, or it may be caused by increased pressure resulting from the blepharospasm, various straining efforts, such as crying, sneezing, or coughing, or occasionally by force exerted in examining the eye. The aqueous humour escapes, often carrying the iris into the wound; the eye feels soft; the anterior chamber is obliterated, and iris and lens are in apposition with the cornea. Perforation of the cornea has a favourable effect upon the course of the affection; the subjective symptoms are relieved, and the ulcer begins to heal as a result of diminished tension.

When the opening closes by cicatrization the iris may regain its normal position. But frequently it continues adherent to the walls of the perforation, or remains prolapsed, and becomes incorporated with the scar. Such a condition is called anterior synechia, and since the cicatrix forms a dense white opacity of the cornea it is known as adherent leucoma. Most frequently only a portion of the iris is drawn into the scar; the pupil is then more or less pear-shaped. Occasionally the entire pupillary margin may be adherent, causing both exclusion and occlusion of the pupil.

At the time of perforation the lens may become dislocated, and occasionally it escapes. When it is pushed forward and lies in apposition with the margins of the opening, and then recedes after the anterior chamber is re-established, it fre-

quently presents a proliferation of the subcapsular epithelium which has become irritated by the pressure of the lens upon the cornea, forming a white spot upon its anterior surface (Fig. 206), known as anterior capsular or anterior polar cataract.

Occasionally the perforation fails to close and a fistula of the cornea results ; this condition exposes the eye to subsequent serious inflammation and jeopardizes its safety. Iridocyclitis and even panophthalmitis may follow perforation, especially if the suppurative process be a virulent one.

Etiology.—Ulcers of the cornea are usually found in adult and aged individuals ; phlyctenular ulcers are the only ones which are common in children. Ulcers are much more frequent among the lower than among the better classes, and occur often in individuals in whom the general health is poor.

The process is essentially an infection by various microorganisms (pneumococci, streptococci, staphylococci, Plate VIII.), frequently introduced by the secretion of chronic conjunctivitis, and especially by that of dacryocystitis.

The exciting causes are : (1) Traumatism (foreign bodies, injuries)—this is one of the most frequent causes ; (2) conjunctival inflammations (gonorrhœal ophthalmia, ophthalmia neonatorum, trachoma, diphtheritic conjunctivitis) ; (3) phlyctenular keratitis ; (4) disturbances in the nutrition of the cornea (paralysis of trigeminus, keratomalacia, glaucoma) ; (5) infection during operations ; (6) variola ; (7) herpes.

Clinical Forms.—Certain variations in the course of corneal ulcers have already been considered. The nomenclature of ulcers of the cornea is quite extensive, and is founded upon peculiarities in the symptoms or course. The following warrant special mention :

Simple Ulcer is the name often given to a small and superficial ulcer, with symptoms of slight or severe irritation, no tendency to perforation, terminating in uncomplicated healing ; phlyctenulæ and slight injuries often cause such ulcers.

Deep Ulcer is one which shows a tendency to involve the deeper layers and to perforate rather than to spread over the cornea. The symptoms are apt to be marked, the iris is

usually involved, and hypopyon is often present; hence the results are often serious.

Serpent Ulcer (Ulcer serpens, Infected Ulcer, Hypopyon Keratitis) is a very virulent form, in which the process tends to spread over a considerable portion of the cornea, and at the same time extends into its depth. The subjective symptoms are usually severe, though occasionally they are slight. The process begins as a grayish-yellow infiltration near the centre of the cornea, rapidly changing to an ulcer with sloughing margins, especially at the advancing side, where there is frequently a yellowish crescent (Fig. 124, Plate X.). The rest of the cornea is often dull, gray, and infiltrated. The process advances very rapidly, much of the cornea becomes destroyed, and perforation takes place. There is early and intense iritis, and hypopyon is almost always present. Owing to the virulence of the ulcer and the accompanying iritis, much damage results to the eye. Adhesion and prolapse of the iris are frequent, the pupil is often occluded, and iridocyclitis and panophthalmitis are not uncommon. Considerable opacity of the cornea always ensues, and often staphyloma. There is, therefore, considerable impairment of vision, which not infrequently is reduced to perception of light. Pneumococci are found in the discharge.

Mooren's ulcer begins near the margin of the cornea, and gradually spreads over it. The advancing edge is undermined; meantime another part of the ulcer may be healing, though this usually breaks down again. The ulcer involves perhaps half the thickness of the cornea, and does not perforate. Both eyes may be affected. The disease is very rare. Microscopically the floor of the ulcer consists of a collection of small round cells like granulation tissue. The cause is unknown, though the clinical course leads one to think that it may be of neuropathic origin—analogueous to the perforating ulcer of tabes. Treatment seems almost hopeless. In three cases recently at Moorfields (one bilateral) we tried successively, during several months, cautery, caustics, radium, ionization, CO₂ snow pencil, hydrogen peroxide, cleaning the cornea, and sliding on to it a bridge of conjunctiva. Nothing succeeded in checking the ulceration, and one eye had to be excised on account of pain.

Marginal Ring Ulcer is rare, of slow and intermittent course, successively involving different parts of the margin, so that it tends to extend all around the cornea.

Transparent Ulcer is small, superficial, central, shows no tendency to spread or to perforate, occurs chiefly in children, and is followed by little or no opacity, but often by a small pit (facet).

Herpetic Ulcer results from a ruptured herpetic vesicle, and spreads superficially, involving more or less of the surface of the cornea.

Dendriform Ulcer (Dendriform Keratitis) is an infrequent and chronic form of superficial ulcer, which commences with a grayish line and spreads by sending out branches which present small knob-like extremities.

Catarrhal Ulcer is crescentic, marginal, and complicates catarrhal conjunctivitis.

Abscess of the Cornea is a purulent infiltration in the substance of the cornea, covered both superficially and posteriorly by sound tissue. The subjective symptoms are those of infected ulcer; it is usually accompanied by iritis and hypopyon. Occasionally, when deeply situated, the pus may become absorbed. Generally, however, the superficial layers burst, and an ulcer results.

Onyx is an obsolete term, which refers to the settling of pus between the layers of the cornea, the occurrence of which is now believed to be extremely doubtful.

Treatment may be divided into (1) constitutional, (2) treatment of pre-existing local conditions, (3) local treatment of the ulcerative process.

Constitutional.—Since ulcers usually occur in persons in whom the general condition is below par, it is necessary to improve the tone of the system by attention to diet, fresh air, hygienic surroundings, condition of the bowels, etc., and often to administer tonics.

Treatment of Pre-existing Local Conditions.—Foreign bodies are to be removed and other local irritating conditions remedied. The various forms of conjunctivitis and dacryocystitis must receive careful attention.

PLATE X.

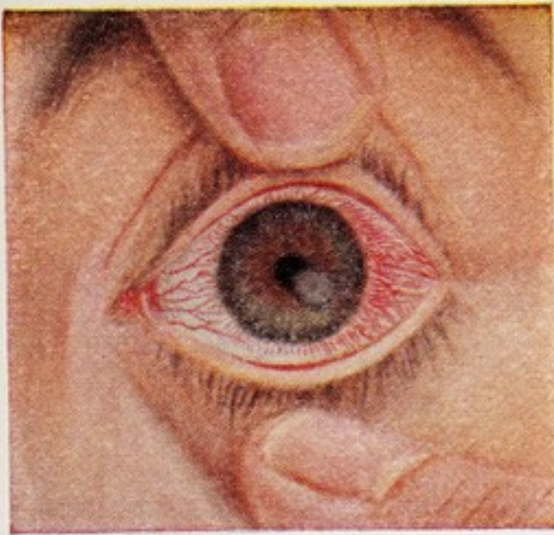


FIG. 123.—CORNEAL ULCER.

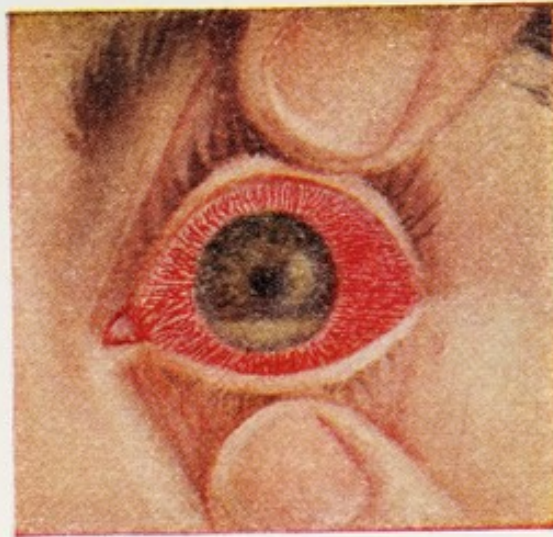

FIG. 124.—CORNEAL ULCER WITH
HYPOPYON.

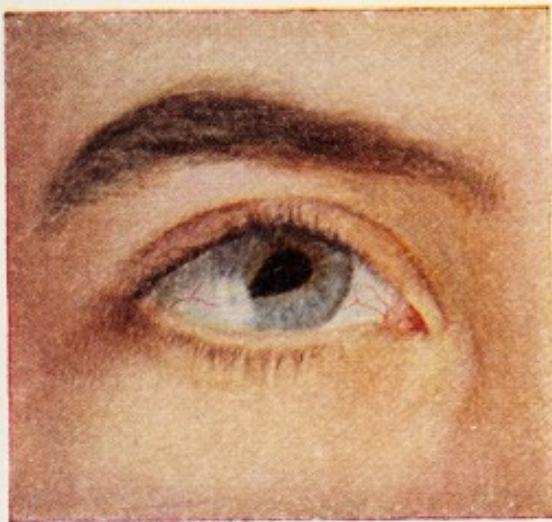


FIG. 125.—LEUCOMA ADHERENS.

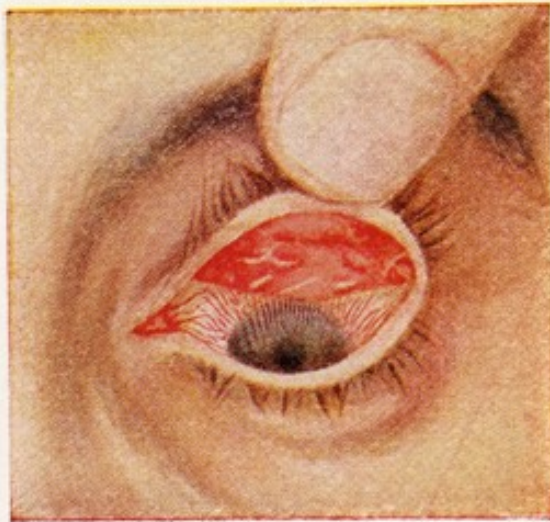


FIG. 126.—PANNUS, AND TRACHOMATOUS
SCARRING OF EYELID.

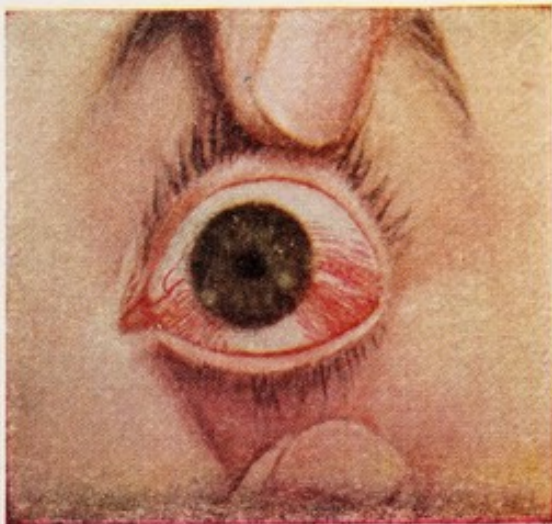


FIG. 127.—PHLYCTENULAR ULCERS OF
CORNEA. FASCICULAR KERATITIS.

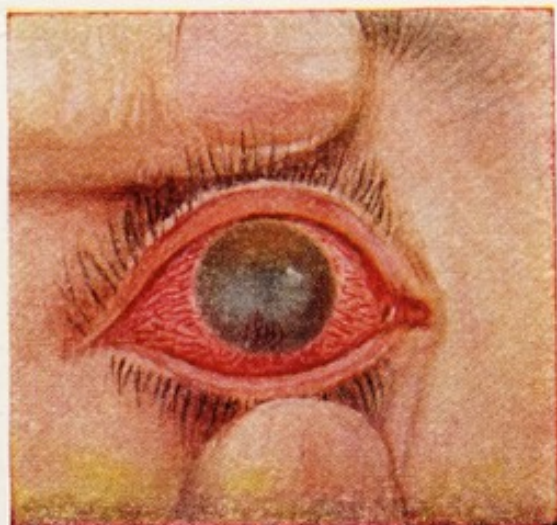

FIG. 128.—INTERSTITIAL KERATITIS..



Local Treatment includes atropine (sometimes eserine), bandage, hot compresses, antiseptic lotions, scraping, cauterization, and paracentesis of the cornea, and division of the ulcer by Saemisch's method.

Atropine anæsthetizes the sensory nerve-endings in the floor of the ulcer, and so allows the natural process of repair to proceed undisturbed by convulsive twitching of the lids. One drop of a 1 per cent. solution or a 1 per cent. ointment made with vaseline may be used three times a day or oftener. When the ulcer is peripheral, and so deep that a perforation is imminent, eserine (one-third of 1 per cent.) may be substituted for the atropine; thus the iris is drawn away from the seat of perforation, and there is less danger of adhesion or prolapse.

If there is intense pain, unrelieved by atropine, it may be necessary to use cocaine or holocaine for a day or two. These remedies, especially cocaine, should not be used for longer than is absolutely necessary, owing to their tendency to cause exfoliation of corneal epithelium.

Protection is afforded by smoked glass or by a bandage. When there is much discharge the bandage is contra-indicated in superficial ulcers. But in any case in which perforation of the cornea is liable to occur a firm (pressure) bandage is applied; this must be removed and replaced several times a day to permit cleansing of the eye and local applications.

Hot compresses should be applied for half an hour at a time, several times a day; they favour healing of the ulcer.

Antiseptic lotions, such as solutions of boric acid, sodium chloride, bichloride of mercury (1:6,000), act as cleansing agents, and are especially useful when there is much discharge.

Other measures are sometimes resorted to: Iodoform sprinkled upon the cornea or applied in the form of an ointment, subconjunctival injections of corrosive sublimate (1:5 100), protargol (10 per cent.), formalin (1:2,000).

To Limit Spreading.—If these remedies are insufficient and the ulcer spreads, we must destroy the infective focus either by scraping the floor and margins of the ulcer with a small sharp spoon or curette, or, better, by cauterizing this area.

Cauterization is effected by tincture of iodine, pure liquid car-

bolic acid, applied with a finely-pointed brush, the stick of nitrate of silver, and by the actual cautery or the galvano-cautery.

Tincture of iodine offers a very efficient mode of disinfecting and cauterizing corneal ulcers. A piece of absorbent cotton is wound firmly upon an applicator, dipped into tincture of iodine, and then exposed to the air for a few seconds so that there is no excess of liquid. It is now brushed upon the ulcer and its infiltrated margins. It is usually necessary to repeat the cauterization a number of times on successive days.

Galvano-Cautery.—After thoroughly anæsthetizing the eye and staining the ulcer with fluorescein, the electrode shown in Fig. 129 is placed cold upon the part to be cauterized,

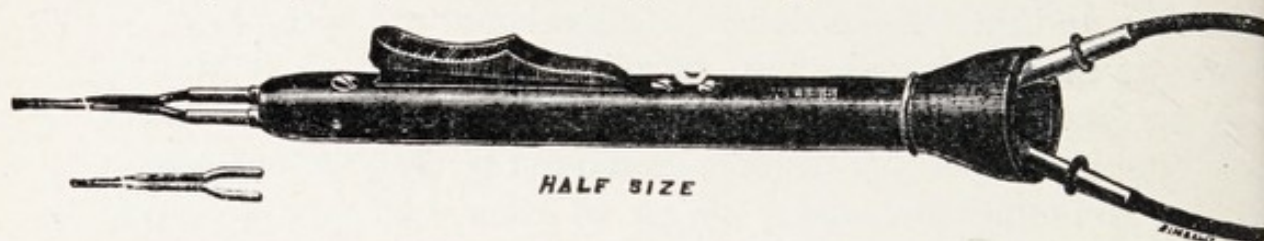

FIG. 129.—GALVANO-CAUTERY.

the connexion made so that the burner assumes a deep red colour, and then the connexion quickly broken. Or the electrode, already heated, may be rapidly applied to the points to be cauterized. Successive points (especially the margins of the ulcer) are cauterized in this manner, each for a very short period, so as to prevent perforation and the conduction of heat to deeper parts. An even better instrument in skilled hands is a little *platinum bulb* set in an ivory handle (Fig. 130).



FIG. 130.—PLATINUM CAUTERY.

The bulb is heated in a spirit-lamp. It is held ready until it just ceases to glow in daylight; it is then quickly applied to the surface of the ulcer. The shape of the bulb is more suitable for the purpose than that of the wire electrode; the small size of the instrument admits of more delicate handling.

Paracentesis of the cornea is another valuable measure. This puncture is frequently made with a paracentesis trocar,

which is provided with a thick shoulder to prevent the instrument from penetrating too far; it may be made with the lance-shaped knife (Fig. 178), or with the Graefe cataract knife (Fig. 195). After local anæsthesia and fixation of the eyeball with the fixation forceps (Fig. 177), the instrument is passed perpendicularly through the cornea, near its lower margin, unless the situation of the ulcer requires another site. As soon as its point reaches the anterior chamber, the handle of the instrument is depressed and the knife or trocar is pushed on horizontally, avoiding injury to the iris or lens, until the incision is about 3 mm. long. Then it is withdrawn slowly with pressure upon the posterior lips of the wound, so as to evacuate the contents of the aqueous chamber gradually. It may be necessary to repeat the paracentesis or to reopen the wound with a probe daily until the ulcer cleanses itself.

Threatened perforation should always be anticipated by paracentesis. Even when there is no danger of spontaneous perforation, the flushing out of lymphatic spaces due to the temporary lowering of pressure after paracentesis often starts the healing process in a previously intractable ulcer.

Saemisch's operation of splitting open the ulcer has been almost entirely abandoned in favour of paracentesis and the thermo-cautery, but it is useful in some severe forms of ser-piginous ulcers. A Graefe knife is thrust through clear corneal tissue 1 or 2 mm. to the outer side of the ulcer, made to traverse the anterior chamber, and brought out 1 to 2 mm. to the inner side of the ulcer. The edge of the knife is directed forward and the ulcer is split through its centre and the hypopyon removed.

After spontaneous perforation of an ulcer atropine is instilled, a pressure bandage applied, and perfect rest insisted upon. If there is a recent prolapse of the iris, the latter is freed from adhesion to the margins of the opening and then excised; this has the effect of an iridectomy. But if the prolapse has existed for some days it must be allowed to remain; subsequent operative interference may then be indicated.

After the healing process has become fairly initiated, certain

mildly stimulating remedies, such as the ointment of the yellow oxide of mercury, or, better still, dionin drops (1 per cent.) once a day, are used to hasten cicatrization, and to clear up the cornea as much as possible.

Keratitis from Defective Closure of the Lids.—This form of keratitis is due to exposure of the cornea when it remains uncovered by the lids (lagophthalmos). Under such circumstances the cornea becomes desiccated, the conjunctival secretion and atmospheric dust settle upon it, infiltration and ulceration take place, with the subsequent course of ulcer of the cornea. The causes are paralysis of the orbicularis (facial paralysis), marked exophthalmos, and various deformities of the lids. Treatment consists in relieving the lagophthalmos, if possible, frequent irrigation of the conjunctival sac with cleansing solutions, and closure of the lids by bandage or plaster. Unless the process has gone beyond certain limits, it can be controlled by this plan of treatment.

Neuro-paralytic Keratitis is a form of infiltration and ulceration of the cornea observed after paralysis of the trigeminus. The changes are considered by some to be trophic, by others to be due to exposure and lodgment of foreign substances upon the insensitive cornea. There is no pain or lacrymation, the course is chronic, and the result is considerable opacity of the cornea. Treatment consists in applying a bandage to the eye, or keeping the lids closed with plaster or suture. Atropine and hot compresses may be of service.

Xerotic Keratitis (keratomalacia) is the result of lack of nutrition of the cornea. It is an uncommon disease, which occurs in greatly debilitated children. The cornea corresponding to the palpebral aperture becomes cloudy, desiccated, covered with scales, and ulcerates and perforates. The great majority of such patients die from the disease which is responsible for the corneal condition. Treatment consists in measures to increase the general strength; locally, hot compresses, antiseptic lotions, bandaging, and atropine are indicated.

Interstitial or Parenchymatous Keratitis.

A cellular infiltration of the middle and posterior layers of the cornea, of frequent occurrence in childhood, chronic in its course, not leading to ulceration, but accompanied by more or less inflammation of the uveal tract.

Objective Symptoms.—The affection begins either in the centre or at the margin of the cornea. If it starts in the centre, this part will present a grayish infiltration, the superficial layers at first retaining their normal lustre. This central patch soon spreads, so that the whole cornea becomes implicated. If it commences at the periphery, one or more grayish crescents are seen, which soon spread toward the centre, and involve all the cornea. After the infiltration has become general, the cornea will become softened, of a dense grayish or sometimes yellowish-gray colour, so that the iris can no longer be seen, and vision is reduced to little more than perception of light. The surface of the cornea is now steamy, and resembles ground-glass. At this period, or even before, deep-seated bloodvessels (derived from the anterior ciliary) make their appearance, and pervade more or less of the cornea (Fig. 128, Plate X.). They cover either the periphery, circumscribed sectors, or the whole cornea. This vascularization gives rise to a dirty-red or yellowish-red discoloration, which is known as the salmon-coloured patch. The progress thus far is accompanied by irritative symptoms, and lasts one or two months.

The inflammation then begins to subside. The periphery of the cornea clears up, the bloodvessels become fewer, the irritative symptoms disappear, and vision improves. This process may take several months, or even a year, the centre of the cornea being the last portion to clear. In favourable cases, after a year or more, nothing but a very faint central opacity and evidences of a few minute peripheral vessels can be found.

Not all cases will, however, run such a benign course. The anterior portion of the uveal tract is regularly involved. In mild cases this will consist merely in congestion of the

iris. But in more pronounced types there will be iritis, choroiditis, cyclitis, and changes in the vitreous. In such cases, after the cornea has become less opaque, we may find evidences of these inflammations, in the form of adhesions of the iris to the lens (posterior synechiæ), changes in the iris and choroid, opacities of the vitreous, and even exclusion of the pupil and iridocyclitis. Staphyloma of the cornea may also follow. So that more or less serious impairment of sight may ensue as a result of these inflammatory processes. Furthermore, the clearing-up process in the cornea may come to a standstill, leaving a dense opacity, which also causes loss of useful vision.

Subjective Symptoms.—During the period of infiltration and vascularization there will be photophobia, lacrymation, pain, and interference with vision, the intensity usually depending upon the severity of the process. These symptoms gradually subside during the progress of absorption.

Both eyes are usually involved. Frequently the inflammation in the second eye commences after that in the first has existed for some weeks or months.

Etiology.—The disease usually occurs between the fifth and fifteenth years, less commonly after this period, and rarely after thirty. The great majority of cases are due to inherited syphilis. In few instances it depends upon acquired syphilis, tuberculosis, or occurs without known cause.

In many cases there will be other *Signs of Inherited Syphilis*, such as characteristic physiognomy, peculiar conformation of the skull (square forehead, prominent frontal eminences, depressed bridge of nose), radiating scars at angles of mouth (Fig. 131), scars in the mouth and pharynx, ozæna, enlarged cervical lymphatic glands, nodes on the bones, and more or less impairment of hearing. The permanent teeth are ill-developed, their angles rounded off, and there is often a crescentic notch in the free margin. These changes are especially marked in the upper central incisor teeth (Hutchinsonian teeth, Fig. 131).

Treatment—*Local.*—Atropine, protection from light by smoked coquilles, or by a shade, hot compresses. When the

cornea begins to clear, we employ mild, stimulating ointments, such as yellow oxide of mercury and calomel, often combined with gentle massage, or instil dionin in 1 per cent. solution. We must be careful not to apply stimulating treatment too early.

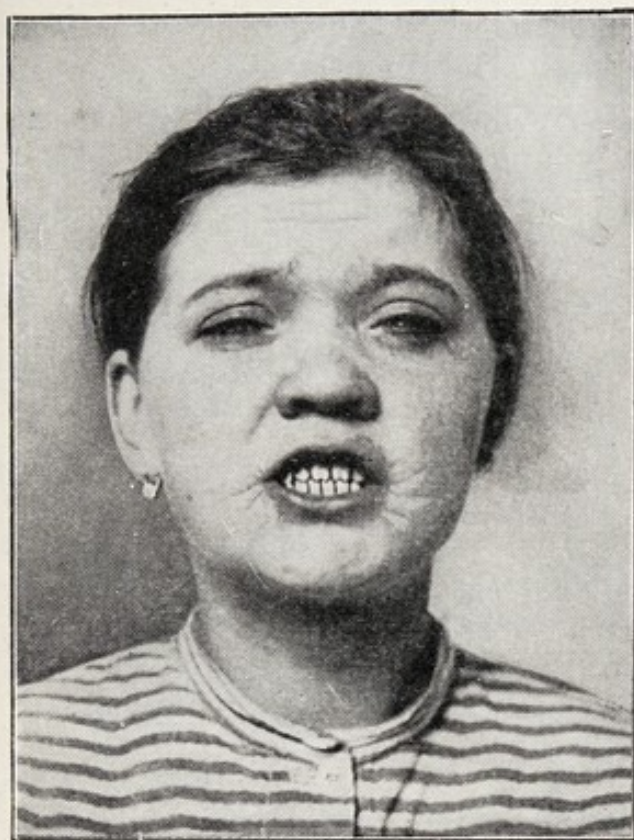

FIG. 131.—PHOTOGRAPH OF A PATIENT SHOWING THE SIGNS OF INHERITED SYPHILIS, INCLUDING HUTCHINSONIAN TEETH.

Constitutional.—Calomel, $\frac{1}{10}$ grain four times a day, gray powder, 1 grain twice a day, or potassic iodide, 5 grains, combined with corrosive sublimate, $\frac{1}{40}$ grain t.i.d. Syrup of the iodide of iron or other preparation of iodine, cod-liver oil, iron and quinine, and attention to the general health. In the uncommon cases occurring in adults we prescribe mercury by inunction or by hypodermic injection, also iodide of potassium.

Though salvarsan is usually less successful in the treatment of in-

herited syphilis than in the acquired disease, it has produced excellent results in some intractable cases, especially when combined with a course of treatment at Harrogate.

Pannus (vasculo-nebulous, or vascular keratitis) has been described in connexion with trachoma (p. 114).

Uncommon Forms of Non-suppurative Keratitis.

Vesicular Keratitis comprises a number of uncommon inflammations of the cornea, in which the distinguishing feature is the occurrence of groups of small, clear vesicles, or of a single large transparent blister, with marked irritative symptoms. Vesicles occur in herpetic keratitis (*herpes corneæ*) and in the keratitis accompanying zoster corresponding to the distribution of the fifth nerve, bullæ in keratitis bullosa.

Superficial Punctate Keratitis complicates acute affections of the respiratory tract, and begins with the symptoms of acute conjunctivitis. Numerous small gray spots appear in the superficial layers of the cornea, beneath Bowman's membrane. These are accompanied by gray radiating lines, and by some general clouding. The disease resembles herpes, but there are no vesicles, no ulceration, and deeper parts are not involved. It occurs in young persons, is usually bilateral, and lasts several months, after which there is complete absorption.

Treatment comprises attention to the conjunctivitis and the bronchial affection, the use of atropine, hot compresses, and smoked glasses, and later the ointment of the yellow oxide of mercury.

Keratitis Profunda is a form of deep-seated inflammation of the cornea occurring in adults, in which a gray, central opacity of the cornea develops, accompanied by irritative symptoms. It becomes entirely or almost perfectly absorbed in a few weeks, and requires treatment similar to that of interstitial keratitis.

Sclerosing Keratitis is the name given to the corneal complication of scleritis (p. 143). The portion of the cornea adjacent to the sclerotic nodule participates in the process, and a triangular opacity remains. The symptoms and treatment correspond to those of scleritis.

Ribbon-shaped Keratitis (Transverse Calcareous Film of the Cornea) is a whitish or grayish band, which extends across the cornea opposite the palpebral aperture, and often contains lime. It occurs usually in old persons and in eyes which have been seriously injured or lost by a previous intra-ocular affection. Treatment consists in gently scraping away the band and using solutions of sodium carbonate (gr. i. to ʒi.).

A number of other forms of keratitis are described, but are of rare occurrence.

Keratitis Punctata (*K. P. descemetitis*) is the name given to dot-like deposits upon the posterior surface of the cornea, which we now know to be part of the exudation in inflammations of the uveal tract (iritis, cyclitis, iridocyclitis). This

condition is never the result of an inflammation limited to the cornea. It usually shows upon the lower portion of Descemet's membrane, the area being triangular with the base at the margin, and the apex near the centre of the cornea (Fig. 149, Plate XI.). These deposits are usually absorbed.

Bulging of the Cornea.

This condition is either of inflammatory origin, when it is known as staphyloma, or of non-inflammatory origin, when it is called keratoconus.

Staphyloma of the Cornea.—A protrusion of a previously inflamed cornea (Fig. 132), formed of more or less corneal

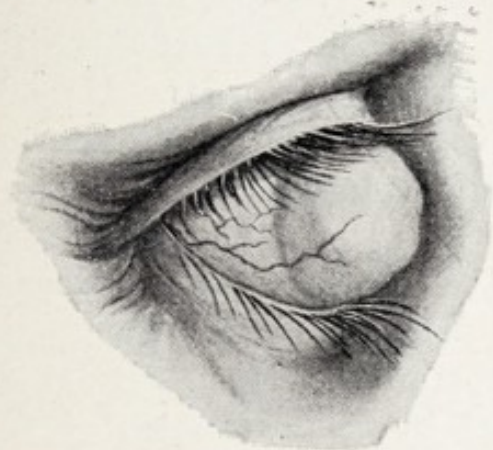


FIG. 132.—STAPHYLOMA OF THE CORNEA.

tissue, iris, and cicatrix. Very often the iris forms the chief part. It develops after corneal softening, ulceration, and perforation. It may be total, when it occupies the situation of the entire cornea, or partial, when it occupies only a portion of this area. It may be globular, conical, or lobulated. It is whitish with bluish areas representing spots where pigment shows through the thin cicatrix.

It may be all white or all bluish. Some bloodvessels are frequently seen on the surface. It varies in size, being small in some cases, and so large in others that the lids cannot close.

Symptoms.—Besides the objective signs just mentioned, there are changes in the eyeball, in the staphyloma, and in the lids. There is almost always increased tension, often due to obliteration of the pupil. This condition causes pain, produces changes in the interior of the eye (atrophy of the optic nerve, retina, and choroid), which lead to blindness, results in an increase in the size of the bulging, and is responsible for staphyloma of the sclera. The conjunctiva becomes the seat of inflammation from mechanical irritation. The

summit of the protrusion becomes dry and ulcerated, and there is frequently rupture, followed by closure of the opening. This process may be repeated a number of times, until the eye is lost and a shrunken globe remains.

Even before these secondary changes have taken place, there is considerable deformity, and sight is very much reduced. In total staphyloma there will be merely perception of light; in the partial form the amount of sight will depend upon the condition of the cornea which is preserved, the position of the pupil, and the extent to which the curvature of the cornea has become altered.

Treatment.—(1) In partial staphyloma an iridectomy should be performed (p. 201) for the purpose of reducing tension, flattening the protrusion and preventing its increase, and to serve for optical purposes. We select the part of the iris corresponding to the most clear portion of the cornea. If there is no anterior chamber, and the iris lies against the posterior surface of the cornea, this operation is impossible on account of the risk of injuring the lens. In such cases we may excise a portion of the staphyloma, and unite with sutures, followed by a pressure-bandage for a considerable period of time

(2) In total staphyloma we resort to incision, abscission, or enucleation. Incision is followed by the extraction of the lens if it still be present. Abscission is performed by cutting through one-half of the protrusion with the knife, and separating the other half from the ring of corneal tissue forming its base with forceps and scissors. The lens is removed. The edges of the corneal gap are then brought together with sutures drawn through the corneal tissue, or, better, through the conjunctiva, which has previously been freed around the limbus. Enucleation, or one of its substitutes, is practised in certain cases in which the staphyloma is very large, or in which, for various reasons, abscission is not advisable.

Keratoconus, or Conical Cornea.—A non-inflammatory conical protrusion of the centre of the cornea (Fig. 133), due to a gradual atrophic thinning, in consequence of which the cornea is unable to resist the normal intra-ocular pressure. The condition is not of frequent occurrence, and is usually

observed in young women. It is easily seen when well marked ; when less developed, it is recognized by the annular shadow produced when the eye is examined with the ophthalmoscope at a distance, by the alteration in shape of the image when Placido's disc is used, and by distortion of the picture of the

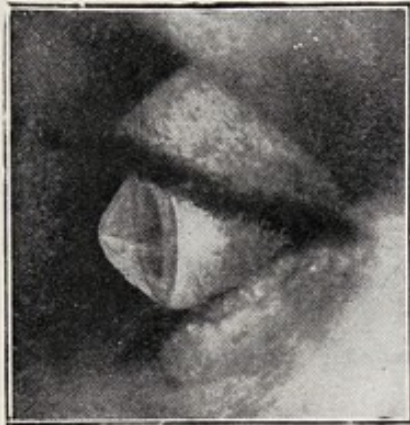


FIG. 133.—KERATOCONUS.

fundus as seen by the ophthalmoscope. The condition tends to progress for many years before it comes to a standstill. When pronounced, it often presents a slight opacity at its apex. It never ulcerates. Conical cornea causes myopia and astigmatism, and seriously interferes with sight, especially peripheral vision, even after the best possible correction with glasses. 10 D. to 20 D. of myopic astigmatism are not un-

common. Treatment consists in providing concave spherocylinders. Repeated paracentesis, followed by the long-continued application of a pressure-bandage, pilocarpine or eserine to diminish tension, and abscission or cauterization of the apex of the cone to cause flattening by subsequent cicatrization (followed by optical iridectomy to enable the patient to see past the central leucoma) have all been tried.

An operation has been devised by one of us and used at Moorfields and elsewhere with excellent results. It consists in making a graduated oval or crescentic excavation, with a thermo-cautery, midway between the apex and periphery of the cornea, the shape and position of the excavation being so regulated as to reduce the refraction in the meridian of greatest curvature only. Daily paracentesis of the anterior chamber and pressure-bandages for about ten days are an essential part of the after-treatment. No iridectomy is needed.

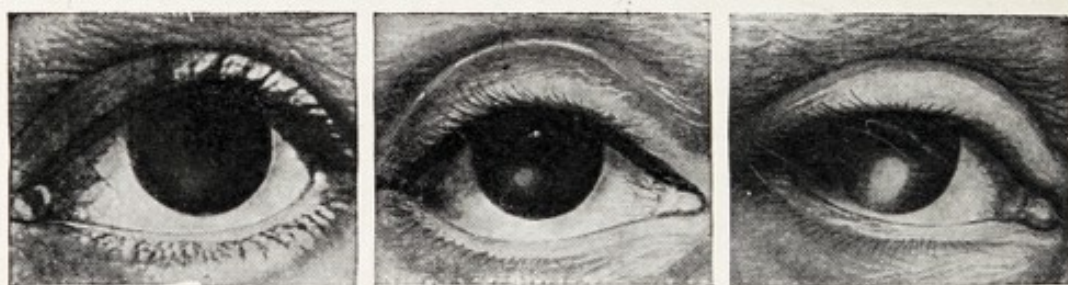

FIG. 134.—THERMO-CAUTERY FOR CONICAL CORNEA.

Opacities of the Cornea.

This term refers to a lack of transparency of the cornea resulting from inflammation, ulceration, or injury. According to density, the corneal opacity is called nebula when faint and cloud-like (Fig. 135), often overlooked until examined by oblique illumination; macula when more pronounced and appreciable as a gray spot in daylight (Fig. 136); leucoma when dense and white (Fig. 137). When the iris is attached to the scar tissue, the condition is spoken of as *adherent leucoma* (Fig. 125, Plate X.).

Opacities of the cornea interfere with perfect vision when they involve or encroach upon the pupillary area, the degree depending upon their density. Even slight opacities cause



OPACITIES OF THE CORNEA.

Fig. 135, Nebula.

Fig. 136, Macula.

Fig. 137, Leucoma.

considerable visual disturbance on account of the resulting diffusion of light. Denser opacities cause disfigurement.

Treatment.—Various measures are used to reduce the density of corneal opacities, or, if faint, to cause their disappearance. Such remedies are of value only when the opacity is recent. They act most successfully in children and when the change is superficial. Most commonly the ointment of the yellow oxide of mercury is placed in the conjunctival sac, after which the cornea is massaged for a few minutes, and then hot compresses are applied. Dionin has proved valuable.

When such measures are unsuccessful, and the leucoma entirely occludes the pupillary area, an iridectomy for artificial pupil may be performed, the coloboma being made opposite a clear part of the cornea.

One should not be in a hurry to make an artificial pupil

in the eye of a child, especially if the opacity is the result of interstitial keratitis. One occasionally sees a patient whose cornea has only the faintest opacity, but on whom an optical iridectomy was performed years ago when the opacity was presumably quite dense.

To remove the disfigurement in cases of leucoma, tattooing is often resorted to. The eye is anæsthetized, and the leucoma covered with a thick paste of India ink. The pigment is then

introduced obliquely into the corneal substance, either by means of an instrument consisting of a row



FIG. 138.—MULTIPLE TATTOOING-NEEDLES.



FIG. 139.—GROOVED TATTOOING-NEEDLE.

or bundle of round needles (Fig. 138) or with a grooved needle (Fig. 139). When an area is to be shaded, the superficial epithelium is scraped off and a neutral 4 per cent. solution of gold chloride is applied freely on cotton-wool and allowed to remain for four minutes before being washed away. A very dark brown stain remains. The colour fades in the course of a few years, and then the operation may be repeated. When the opacity covers only a part of the pupillary area, tattooing is useful in preventing the diffusion of light which is so annoying to the patient. The operation is contra-indicated when the eye is at all irritable, and at any time it is not without risk.

Injuries of the Cornea.

These comprise foreign bodies, burns, and wounds.

Foreign bodies, consisting of iron, coal, ashes, dust, etc., frequently adhere to or become embedded in the cornea, causing much pain, lacrymation, and photophobia. When the foreign body is small, it may be difficult to detect, unless we make use of oblique illumination. The mischief which a foreign body provokes depends upon the depth to which it penetrates, and whether or not it is infected. If present for a number of days, a surrounding area of infiltration appears, resulting in a small ulcer, and in this manner the foreign body

may become dislodged. If it consists of iron or steel, this ring will become stained by rust. Foreign bodies are frequently the cause of ulcers of the cornea.

To Remove a Foreign Body.—The eye is cocaineized. The patient is seated, facing a good light, with the surgeon standing behind and supporting the head. The lids are separated, and the eyeball is steadied by the fingers of the left hand. The index finger is applied to the margin of the upper lid, and the middle finger to the lower lid, and the two fingers are separated, at the same time gently pressing backward (Fig. 140).

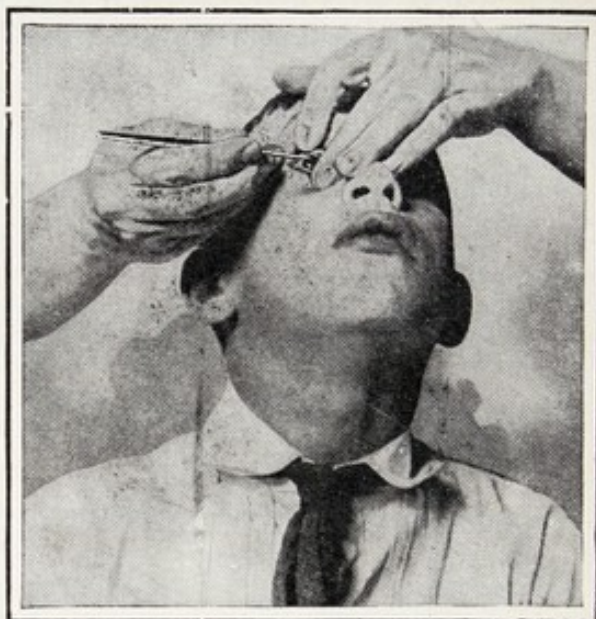


FIG. 140.—METHOD OF REMOVING A FOREIGN BODY FROM THE CORNEA, THE SURGEON STANDING BEHIND THE PATIENT.

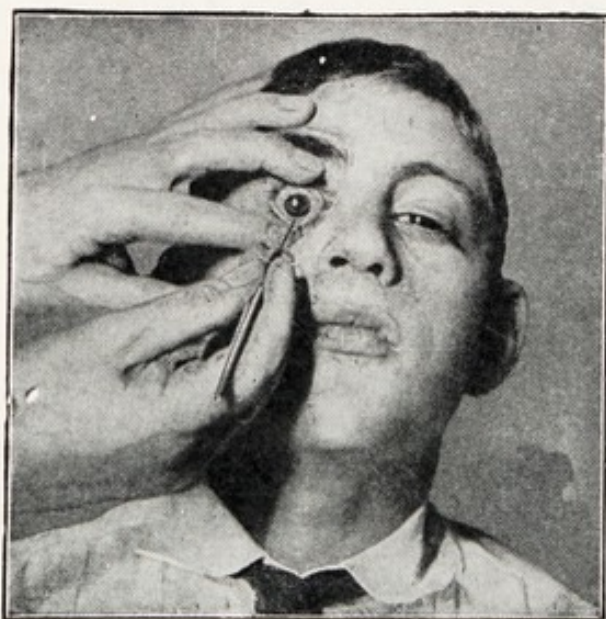

FIG. 141.—METHOD OF REMOVING A FOREIGN BODY FROM THE CORNEA, THE SURGEON STANDING IN FRONT AND TO THE LEFT OF THE PATIENT.

If the patient is seated in a chair provided with a suitable head-rest, the surgeon may stand in front and to the left. In separating the lids, the index finger is then applied to the lower lid and the middle finger to the upper (Fig. 141). The instruments used are either the blunt spud, the gouge, or the foreign-body needle, these should be sterilized before use. When the foreign body is superficial, the blunt spud will answer (Fig. 142). Very often it can be removed with a little absorbent cotton wound around the end of the

spud. When the foreign body has penetrated into the corneal substance, it must be picked or dug out with the gouge (Fig. 143) or the needle (Fig. 144). In such cases the instrument is passed behind the foreign body. The wound which results must be kept clean by frequent irrigation with solution of boric acid; frequently a protective bandage is indicated. If a ring of rust is present, this also should be removed. Care must be taken to inflict as little injury as possible, and, when the foreign body is deep, not to perforate the cornea. If it penetrates into the anterior chamber, a keratome (Fig. 178) should first be passed through the cornea and behind the



FIG. 142.—FOREIGN-BODY SPUD.



FIG. 143.—FOREIGN-BODY GOUGE.

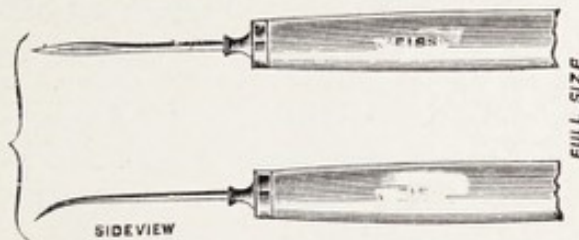


FIG. 144.—FOREIGN-BODY NEEDLE.

foreign body, so that the latter will not be pushed into this space during efforts at removal.

Burns of the cornea are treated like similar conditions of the conjunctiva.

Wounds may be non-penetrating or penetrating. Non-penetrating wounds are most commonly abrasions due to scratching with the

finger-nail, twig of a tree, or the like. Such injuries, though very painful, heal readily unless infected. They should be kept clean by frequent irrigation with solution of boric acid. A bandage may be indicated, and sometimes atropine.

Perforating wounds are more serious, owing to the danger of prolapse of the iris and injury to the deeper parts. They should be treated by thorough cleansing, atropine, or eserine, according as they are central or peripheral, and a pressure-bandage. If extensive and irregular, but probably not infected, it may be advisable to make two curved concentric incisions in the conjunctiva and slide a bridge of the membrane over the wound.

In penetrating wounds of the cornea the question of the entrance of a foreign body into the globe presents itself, and then an X-ray examination is indicated.

CHAPTER X

DISEASES OF THE SCLERA

Anatomy.—The sclerotic coat (sclera) is the tunic which with the cornea forms the external fibrous layer of the eyeball. It is strong, opaque, and inelastic, and serves to maintain the form of the globe. Its thickness is about 1 mm., but varies at different points. Its structure resembles that of the cornea, being composed of bundles of connective tissue with some elastic fibres, disposed in both longitudinal and transverse layers. These are connected by cement substance containing cell spaces, in which are lodged connective-tissue corpuscles. These parts are, however, much less regularly arranged than in the cornea. In the child, the sclera often has a bluish-white colour, owing to its being thinner, and allowing the dark pigment of the choroid to show through. The sclera is pierced about 2.5 mm. internal to the posterior pole of the eye by the optic nerve. Here it has blended with it the external fibrous sheath of the nerve. The part through which the nerve passes is known as the lamina cribrosa.

The outer surface of the sclera is white and smooth, covered by Tenon's capsule and the conjunctiva, to which it is joined by loose connective tissue (episcleral). In front it presents the insertions of the extrinsic muscles of the eyeball. Its inner surface is brown and rough, being covered by delicate, pigmented connective tissue, which is united to the choroid by filaments traversing the lymph space existing between the sclera and choroid. Where it is pierced by vessels and nerves, a communication between the capsule of Tenon and the suprachoroidea is established. Though traversed by many bloodvessels, the sclera itself has a very scant vascular supply; but the episcleral tissue contains numerous vessels.

Affections of the sclera include superficial inflammation (episcleritis), deep inflammation (scleritis), staphyloma, and injuries.

Inflammation of the sclera (scleritis) may be either superficial or deep. The superficial form, called episcleritis, is limited to the tissues superficial to the sclera, and is relatively

harmless. The deep form, known as scleritis, involves the sclera itself, and extends to subjacent and contiguous parts, causing serious consequences. There is often an absence of a very sharp line of division between the two forms.

Episcleritis.

An inflammation of the sub-conjunctival connective tissue.

Symptoms.—There are some discomfort, lacrymation, slight pain, and photophobia. A flat or somewhat raised inflammatory patch of a purple colour is seen, usually on the temporal side, adjacent to the cornea or a short distance from the limbus (Fig. 114, Plate IX.). There is no tendency to suppuration or ulceration. After a few weeks the purple spot will disappear; but others are apt to take its place. In this way the process may encircle the cornea. Owing to this tendency to relapses, the disease often lasts many months. Sometimes some discoloration of the sclera remains, but there is no interference with vision. Occasionally the adjacent portion of the cornea is implicated. The disease may resemble a marked case of phlyctenular conjunctivitis. It may merge gradually into scleritis.

Etiology.—It is usually observed in adults, especially in women. It is often found in rheumatic and gouty individuals. Syphilis, tuberculosis, and menstrual disorders have been suggested as possible causes.

Treatment should be of a sedative nature: warm fomentations; if photophobia be pronounced, smoked coquilles; if the cornea be implicated, atropine. Instillations of a 1 per cent. solution of holocain in 1:10,000 adrenalin will relieve the discomfort. Sub-conjunctival injections of bichloride of mercury (1:5,000) have been recommended, but injections of normal salt solution appear to be just as efficient and much less painful. The ointment of the yellow oxide of mercury, applied with gentle massage, is often of value, especially when the disease shows a tendency to become chronic. In chronic cases dionin may do good. When there is a rheumatic history, sodium salicylate or aspirin in large doses (10 to 15 grains every

two hours) should be given. Other constitutional disorders should be prescribed for. Iodide of potassium may be ordered, also hypodermic injections of pilocarpine. In the chronic cases eserine often does good.

Transient Periodic Episcleritis is a variety of episcleritis which appears in sudden attacks lasting several days, reappears at intervals of several weeks or months, and may recur for years. It is seen in gouty and rheumatic adults. The treatment is that recommended for scleritis.

Scleritis.

An inflammation of the sclera, in which the symptoms are acute, the course is prolonged, and the consequences are serious. In this disease the sclera itself is involved in the inflammatory process; it becomes softened, thinned, and bulging, and staphyloma results. Both eyes are frequently involved. Relapses are very common.

Symptoms.—Pain, usually severe, and frequently radiating to neighbouring regions, tenderness over ciliary region, lacrymation, and photophobia. The tension of the eyeball is frequently increased; secondary glaucoma often ensues.

There are well-marked dusky or violet patches adjacent to the cornea, often extending to the equator and frequently surrounding the limbus.

Complications.—The cornea is frequently implicated, and ulceration and opacity follow. Not uncommonly there are iritis, cyclitis, choroiditis, opacities of the vitreous, and secondary glaucoma; the combination of such complications is known as anterior uveitis. As a result of these changes, vision is often seriously interfered with, and sometimes lost. The thinning of the sclera results in staphyloma of the anterior portion of the globe, which presents a bluish appearance and causes myopia.

Etiology.—The disease is most common in adults, and especially in women. Rheumatism and gout, syphilis, tuberculosis, and disorders of menstruation, are predisposing factors. Exposure to cold is sometimes the exciting cause.

Treatment comprises the measures advocated in episcleritis, energetically applied. The eyes must obtain complete rest. Atropine is often indicated for the complications. After the acute symptoms have subsided, an iridectomy is sometimes advisable for diminishing glaucomatous tension or reducing the staphyloma.

Staphyloma of the Sclera.

A thinning and bulging of the sclerotic occurring either at the anterior portion, the equator, or the posterior portion of the eyeball.

Anterior and equatorial staphylomata are usually secondary to inflammations of the uveal tract and sclera which have caused softening of the sclera with or without increased tension. They present a bluish-gray bulging, which may be limited, or may extend all around the cornea (Fig. 145). This bulging shows a tendency to increase; occasionally it bursts. Iridectomy, if feasible, is the only treatment, and is done for the purpose of arresting the process. In some cases, when the enlarged eyeball causes much discomfort and is sightless, enucleation or evisceration is advisable.

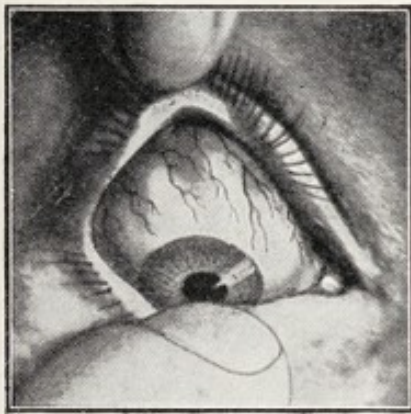


FIG. 145.—ANTERIOR STAPHYLOMATA OF THE SCLERA.

Posterior staphyloma is of common occurrence, and is generally associated with myopia and choroiditis (p. 179). It is seen with the ophthalmoscope, presenting a white, crescentic or irregular patch, which embraces the temporal side of the optic disc (Fig. 163, Plate XIV.).

Injuries of the Sclera.

The important injuries include rupture and perforating wounds. These are serious on account of the danger of escape of the contents of the eyeball and infection of the interior.

Small, clean, perforating wounds often heal without reaction, and require no other treatment than cleansing and the application of a bandage.

Large, gaping wounds and ruptures frequently allow escape of the vitreous. There will be blood in the vitreous, diminished tension, and some of the underlying tissues (choroid, ciliary body, or iris), varying with the position, will be found in the wound. Such wounds should be cleansed, the prolapsed parts returned when not too seriously injured, and the opening closed by sutures in the sclera, or preferably through the conjunctiva. The patient must remain absolutely quiet, and the eye should be bandaged.

Sometimes such wounds fail to excite much inflammatory reaction; then they heal quite readily, often with incarceration of the prolapsed parts in the scar. But frequently they give rise to panophthalmitis, with ultimate phthisis bulbi, or to plastic iridocyclitis, with loss of sight. When the wound involves the ciliary body, iridocyclitis is apt to be set up, and the injury becomes more dangerous on account of the liability of such wounds to excite sympathetic ophthalmitis.

Ruptures of the sclera are produced by blows and blunt instruments. They usually occur near the corneal margin, generally above. The conjunctiva may not be broken.

When injuries of the sclerotic are very extensive and cause considerable loss of contents of the eyeball, and when we believe that useful sight cannot be hoped for, the eyeball should be removed at once. This becomes still more urgent when the wound involves the dangerous zone, the ciliary region.

The presence of a foreign body in the eye is a serious complication. The attempt should be made to extract the foreign body, as described on p. 215.

In any case in which there is any doubt as to the presence of a foreign body within the globe, X-ray examination should be made.

CHAPTER XI

DISEASES OF THE IRIS

Anatomy and Physiology.—The second or vascular coat of the eye (uvea or uveal tract) lies immediately beneath the sclera. It provides for the nourishment of the eyeball, and it is formed of three parts, which from before backward are known as the iris, the ciliary body, and the choroid. These three portions are so intimately associated that when one part becomes diseased, the others frequently participate.

The *iris* is a coloured membrane, circular in form, hanging behind the cornea immediately in front of the lens, and perforated in its centre by an aperture of variable size, the pupil. It serves to regulate the amount of light admitted to the interior of the eye, and cuts off the marginal rays which would interfere with the sharpness of the retinal image. Its peripheral border springs from the head of the ciliary body and the ligamentum pectinatum. Its free inner edge, the boundary of the pupil, lies upon the anterior capsule of the lens when the pupil is contracted or moderately dilated; with maximum dilatation of the pupil it hangs free in the anterior chamber. The iris separates the anterior from the posterior chamber of the eyeball. Its anterior surface presents great variation in colour in different eyes, and is marked by radially directed, wavy lines, converging toward the circle of irregular elevations and small depressions (crypts) situated near the pupil; other finer lines are seen extending from this ring to the pupil. This appearance is produced by the subjacent blood-vessels.

In structure the iris consists of a delicate, spongy connective-tissue stroma, containing branched pigmented cells, muscular fibres, and an abundance of vessels and nerves. It is covered anteriorly by endothelium, and posteriorly by the posterior limiting membrane and the retinal pigment layers.

The colour of the iris depends partly on the pigment in the stroma cells, which is variable, and partly on that in the cells of the retinal layers, which is constant.

The muscular tissue, the *sphincter pupillæ*, is a narrow band, about

1 mm. wide, situated close to and encircling the pupil posteriorly, and supplied by the *third nerve*. The posterior limiting membrane consists of fibres which extend from the ciliary to the pupillary margin, which are regarded by some authorities as consisting of unstriated muscle fibres, and as contributing to the active dilatation of the pupil. The chief factor in active *dilatation* of the pupil is, however, the contraction of the thick muscular coats of the arteries, under the control of the *sympathetic*.

The posterior surface of the iris is covered by two strata of pigmented cells, the uveal layer, which extends to the free border, around which it turns a little, forming the black fringe of the pupillary margin.

The *vessels* of the iris come from the two branches of the ophthalmic known as the long posterior ciliary arteries. Each artery divides into an upper and a lower branch. These anastomose with the corresponding vessels of the opposite side and with the anterior ciliary, and form a vascular ring just behind the attached margin of the iris, the greater vascular circle of the iris. This gives off branches to the ciliary body and iris; the iris branches converge towards the pupil, and here form by anastomosis a smaller vascular circle, the lesser vascular circle of the iris. The veins of the iris follow the arrangement of arteries just described; in addition they communicate with the canal of Schlemm. They chiefly pass backward to the *venæ vorticosæ*.

The *nerves* are given off from the plexus in the ciliary body, and are derived from the third, the nasal branch of the ophthalmic, and the sympathetic.

Pupillary Membrane.—In the foetus the pupil is closed by a thin, transparent, delicate membrane—the pupillary membrane. The membrane and its vessels are gradually absorbed in the seventh or eighth month of foetal life. A few shreds may remain at birth; occasionally part or all of the membrane persists (persistent pupillary membrane).

Iritis.

An inflammation of the iris, which may be divided into the following

Varieties.—(1) According to its course, into acute, sub-acute, and chronic.

(2) According to the pathological products, into plastic, serous, purulent, and tuberculous.

(3) According to its etiology, into syphilitic, rheumatic, gouty, diabetic, gonorrhœal, tuberculous, scrofulous, traumatic, sympathetic, secondary, and idiopathic.

The classification according to the nature of the patho-

logical products is unsatisfactory, because one type merges into the other. It is better, therefore, to consider iritis in general, and then to mention the peculiarities of the different forms which have been named according to their etiology.

Objective Symptoms.—The iris looks altered (Fig. 147, Plate XI.). It appears swollen, dull, loses its lustre, its markings become indistinct, its colour changes and becomes greenish in blue or gray irides, and muddy in darker varieties. These changes are due to congestion of the iris and exudation of cells and fibrin into its substance; also to exudation into the anterior chamber.

The pupil is contracted, grayish, sluggish in action, and irregular (Fig. 146); the last peculiarity is due to adhesions

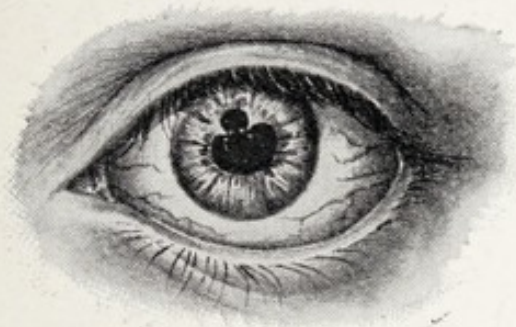

FIG. 146.—POSTERIOR SYNECHIÆ CAUSING IRREGULAR PUPIL IN IRITIS.

between the posterior surface of the iris and the anterior capsule of the lens (posterior synechiæ), best seen after the instillation of atropine.

The contents of the aqueous chamber show changes: there is frequently turbidity; there may be more or less dust-like deposit on Descemet's membrane (so-called

keratitis punctata), which often involves the lower part (Fig. 149, Plate XI.), or may give a cloudy appearance to the entire cornea. In this exudation there may be pus, which then gravitates to the bottom (hypopyon), or fibrin, which coagulates into a grayish mass (spongy iritis), or there may be blood (hyphæmia). The anterior chamber may be deeper than normal. The tension of the eyeball, though usually normal, may be increased.

The anterior capsule of the lens may present evidences of exudation, and also small spots of uveal pigment where posterior synechiæ have been torn away.

There is always marked circumcorneal injection, and with this pink zone there is more or less conjunctival congestion.

Subjective Symptoms consist of pain, photophobia, lacrymation, interference with vision, and sometimes general malaise.

The pain is often severe, neuralgic in character, radiating to the forehead and temple, and worse at night. It is sometimes accompanied by tenderness of the eyeball, a symptom pointing to involvement of the ciliary body.

The diminution in the acuteness of vision depends upon the cloudiness of the anterior chamber and the deposits in the pupil and upon Descemet's membrane. When very marked it indicates extension of the inflammation to the deeper parts.

Differential Diagnosis.—Iritis is most frequently mistaken for acute catarrhal conjunctivitis. Sometimes acute glaucoma is mistaken for iritis. The differential points between iritis and conjunctivitis are given in the table on p. 161.

Course.—Iritis may be acute and run its course in several weeks, or it may be chronic and last a number of months. A great many cases terminate favourably, especially when subjected to proper treatment early; the exudation becomes absorbed, and the iris returns to a normal condition, with no evidences or mere traces of former inflammation. Chronic cases present very mild inflammatory symptoms, or the latter may be entirely absent. Certain forms of iritis have a tendency to recur. Iritis may involve one or both eyes; when both eyes are attacked the second usually is affected a short time after the first.

Complications.—The neighbouring parts of the eye are sometimes involved in severe forms of iritis—conjunctiva, cornea, ciliary body, choroid, vitreous, optic nerve, and retina. The association of inflammation of the ciliary body (cyclitis) with iritis (iridocyclitis) is so common that some authors describe the two conditions together, and regard pure iritis as rare. The following symptoms, occurring in the course of an iritis, point to the existence of cyclitis: Violent inflammatory symptoms, marked diminution in vision, tenderness in the ciliary region, deposits upon the posterior surface of the cornea, and increase or decrease of normal tension.

PLATE XI.

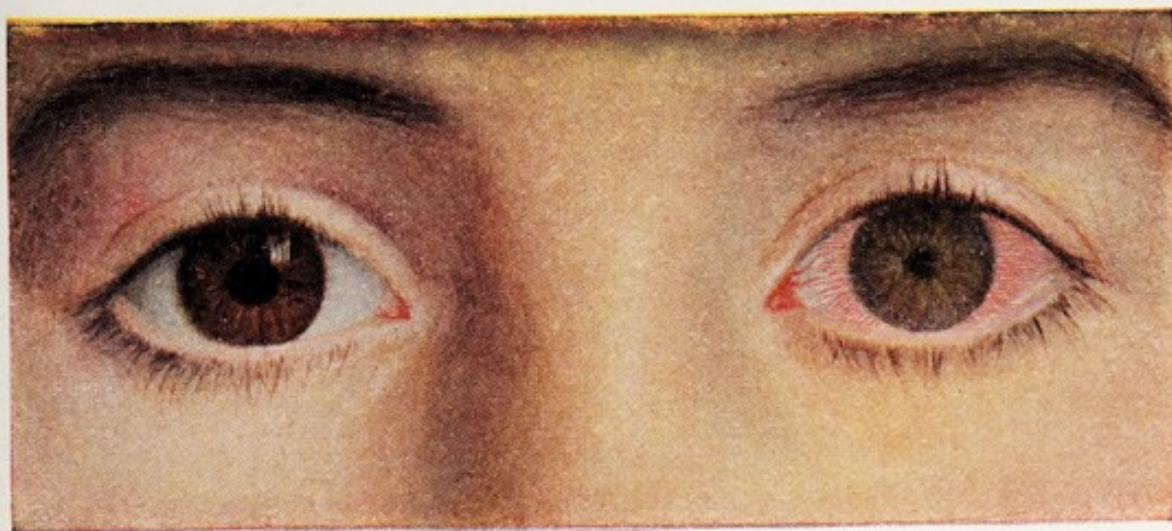

FIG. 147.—IRITIS IN LEFT EYE.

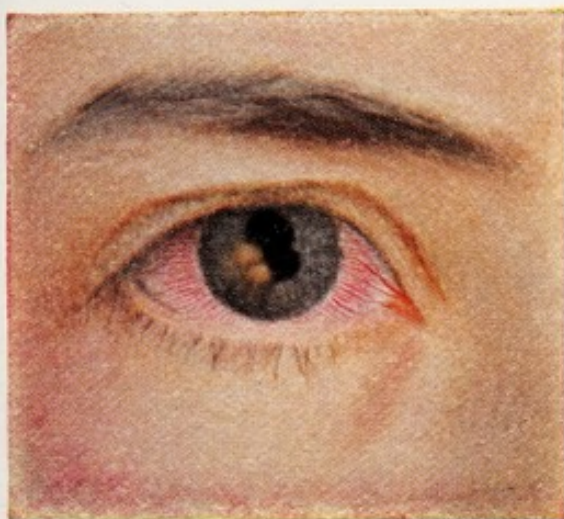

FIG. 148.—SYPHILITIC NODULES IN IRIS.

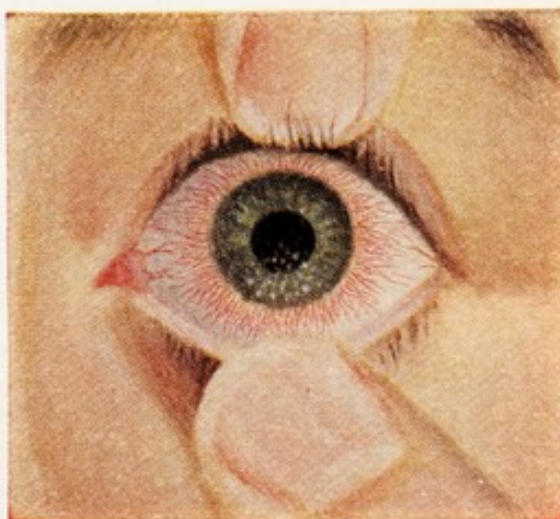


FIG. 149.—KERATITIS PUNCTATA.

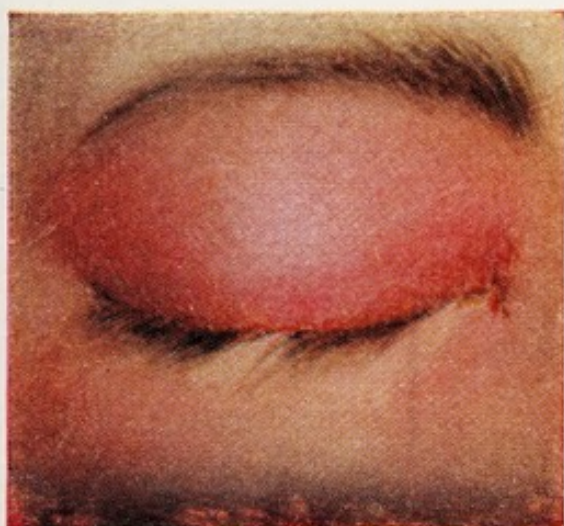

FIG. 150.—PANOPHTHALMITIS.

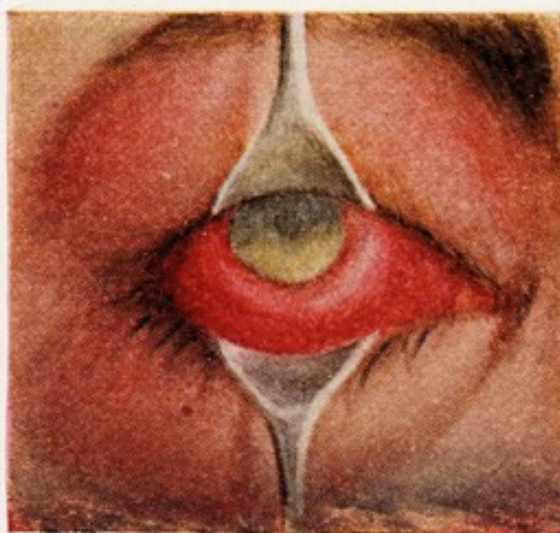

FIG. 151.—PANOPHTHALMITIS.



<i>Acute Iritis.</i>	<i>Acute Conjunctivitis.</i>	<i>Acute Glaucoma.</i>
<ol style="list-style-type: none"> 1. Iris swollen, dull, and discoloured. 2. Pupil small, gray, sluggish, irregular after use of atropine. 3. Anterior chamber of normal depth (deeper in serous form) and presents exudation. 4. Cornea transparent (may present deposits on posterior surface) and sensitive. 5. Ciliary (circumcorneal) injection; pink zone of fine vessels surrounding cornea and fading towards fornix. 6. Conjunctiva usually transparent. 7. Lacrymation, but no discharge. 8. Tension usually normal (occasionally increased). 9. Some ciliary tenderness. 10. Pain radiating to forehead and temple; worse at night. 11. Dimness of vision. 	<ol style="list-style-type: none"> 1. No change in iris. 2. Pupil is normal. 3. Anterior chamber normal. 4. Cornea transparent. 5. Conjunctival injection; coarse meshes, most pronounced in fornix, and fading towards the cornea. 6. Conjunctiva reddened and opaque. 7. Mucous or muco-purulent discharge. 8. Tension normal. 9. No ciliary tenderness. 10. Discomfort, hot, gritty feeling, but no real pain. 11. No interference with vision, except blurring caused by the discharge smeared over the surface of the cornea. 	<ol style="list-style-type: none"> 1. Iris congested, discoloured, dull, periphery pushed forward. 2. Pupil dilated, oval, immobile. 3. Anterior chamber shallow and aqueous; sometimes turbid. 4. Cornea steamy and insensitive. 5. Ciliary and episcleral injection (also conjunctival congestion). 6. Conjunctiva congested and chemotic. 7. Lacrymation, but no discharge. 8. Tension increased. 9. Ciliary tenderness. 10. Severe pain in and about eye, with headache. 11. Marked dimness of vision.

Sequelæ.—There are often posterior synechiæ and deposits upon the anterior lens capsule; less frequently there are exclusion of the pupil, occlusion of the pupil, atrophy of the iris, opacities of the vitreous, deposits upon the posterior capsule of the lens, and cataract. In exclusion of the pupil (annular posterior synechia), the iris is bound down throughout its entire pupillary margin, the pupil remaining clear (Fig. 153). This causes a loss of communication between the anterior and the posterior chamber; the aqueous secreted by the ciliary

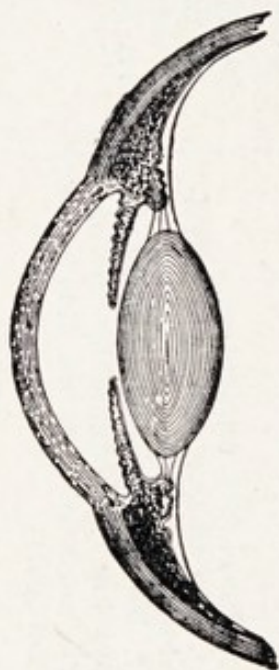


FIG. 152.—SECTION OF THE ANTERIOR PORTION OF THE EYEBALL, SHOWING THE IRIS IN ITS NORMAL RELATIONS.

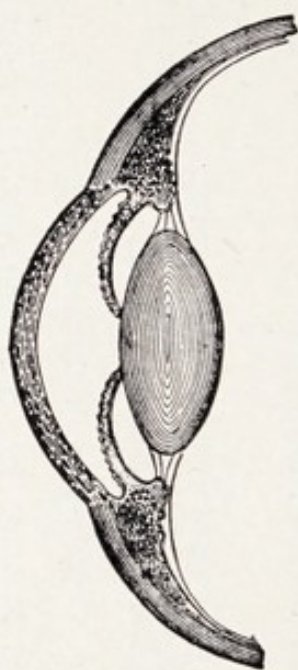

FIG. 153.—SECTION SHOWING ANNULAR POSTERIOR SYNECHIA (EXCLUSION OF THE PUPIL).

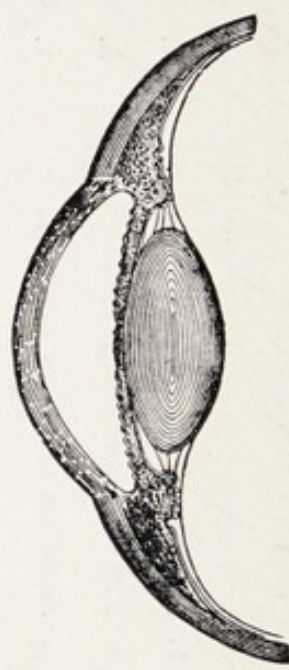

FIG. 154.—SECTION SHOWING TOTAL POSTERIOR SYNECHIA AND OCCLUSION OF THE PUPIL.

processes is hemmed in, the iris stretched (*iris bombé*) and atrophied, glaucoma results, and if unrelieved blindness follows. Occlusion of the pupil is a filling in with opaque exudate (Fig. 154).

Etiology.—Iritis is usually dependent upon some constitutional disease—syphilis, possibly rheumatism or gout, tuberculosis, gonorrhœa, acute infectious diseases, auto-intoxication from septic teeth or from the gastro-intestinal tract, and

diabetes. It may also be traumatic or sympathetic. In many cases no cause can be discovered.

Pathology.—Inflammation of the iris presents similar changes to those occurring in other connective tissue, modified by the great vascularity of this membrane and the looseness of its stroma. There are dilatation of the bloodvessels and exudation of lymph, lymphocytes, and fibrin into the stroma and anterior chamber. These products of inflammation may be completely absorbed, or may become organized into connective tissue, forming adhesions and causing degenerative changes in the iris.

Treatment.—(1) Atropine, (2) dionin, (3) leeches, (4) hot fomentations, (5) rest, (6) protection from light, (7) treatment of etiological factor.

Atropine diminishes the congestion of the iris, puts this part at rest, causes mydriasis, and thus prevents adhesions and tends to break up those which have already formed. It should be instilled every two hours at first, and after the pupil is dilated three or four times a day. When the inflammation is pronounced, the pupil will not dilate rapidly. The action of atropine is often increased by the addition of cocaine. In certain cases symptoms of atropine-poisoning occur, either local or constitutional, necessitating the substitution of some other mydriatic (duboisine, hyoscyamine, scopolamine—see Chapter XXXIII.); a solution of the aqueous extract of belladonna (1 : 8) often acts well in such cases. Exceptionally atropine causes an increase in inflammatory symptoms, and must be stopped; then a miotic may be of service. This action is apt to occur when there is increased tension, and sometimes when there is a complicating cyclitis.

Dionin relieves pain to a certain extent, and favours the absorption of exudates, by locally stimulating the circulation of blood and lymph.

Two or three *leeches* applied to the temple, or the abstraction of an ounce of blood from this region by means of the artificial leech, usually has a favourable effect.

Moist, warm *compresses* for several hours each day diminish

the pain and the inflammation in acute cases. In traumatic iritis iced compresses may be used in an attempt to check the inflammation in the early stage.

Absolute *rest* in bed in the early stage of acute iritis is an important aid in treatment.

Protection from light by means of smoked glasses or a shaded room is essential.

Other important indications are light diet, abstinence from alcohol, a brisk purge, and avoidance of all use of the eyes for near work.

Constitutional treatment must meet the indications in the different forms. In syphilitic iritis mercury is given, usually by inunction, up to the point of salivation; after the acute symptoms have subsided, mixed treatment (mercury and iodide of potassium) is substituted. Injections of salvarsan often produce rapid improvement. In certain cases in which no cause can be discovered small doses of mercury have a favourable effect. In rheumatic cases large doses of salicylate of sodium combined with small doses of aspirin improve the condition and relieve pain. This remedy also has a quieting effect upon the pain in other forms.

Paracentesis is occasionally resorted to for the purpose of relieving tension, and also in obstinate cases to produce a favourable effect upon the progress of the disease. Iridectomy was formerly performed for the same reasons. As a rule, however, operative procedures are useful only after the inflammatory symptoms have subsided, for the purpose of remedying sequelæ.

Vaccines (see Chapter XXXII.) are of value in tuberculous, gonorrhœal, and toxic cases.

Clinical Varieties.—*Syphilitic iritis* is a very common form. It occurs in the secondary stage of acquired syphilis; it is usually acute; the second eye becomes involved soon after the first; there is more or less plastic exudation; there are broad synechiæ; in some cases there are yellowish vascular nodules, usually situated at the pupillary border of the iris (Fig. 148, Plate XI.); pain is not pronounced; if properly treated relapses are not common. There are often other manifestations of

syphilis in the eye, choroido-retinitis, etc. Occasionally interstitial keratitis is complicated with iritis.

An acute form of iritis is often ascribed to *rheumatism*. Perhaps it would be more correct to say that rheumatism and iritis are often due to a common cause. It frequently attacks only one eye, but more often both; it occurs especially in adults; the effusion is serous with a few cells; pain is pronounced; relapses are common. Probably many of these cases are of gonorrhœal origin.

Gonorrhœal iritis is occasionally seen in persons suffering from gonorrhœa or gleet; it resembles rheumatic iritis.

Iritis from Septic Infection.—Decayed teeth, pyorrhœa, dental abscess, septic tonsils, infection of the nasal accessory sinuses, digestive trouble, colitis, chronic constipation, a septic wound, or any other source of auto-intoxication may cause iritis. The cause should be sought for, and if possible removed.

Diabetic iritis is plastic in character and chronic in course.

Tuberculous iritis is an uncommon form which occurs chiefly in children and young adults, and is not necessarily associated with tuberculosis in other parts. It occurs under two forms: (1) the miliary, in which small grayish nodules develop near the ciliary or pupillary border; (2) a single yellowish-gray mass in the ciliary part of the iris. The tuberculous deposits may, under favourable conditions, be completely absorbed. On the other hand, the process may lead to the destruction of the eyeball. The treatment is that of iritis in general, and of tuberculosis.

In a case in which the eye has been destroyed, but in which there is no evidence of tuberculosis in any other part, the eyeball should be removed.

Tumours of the Iris.

These may be (1) *inflammatory*—(a) syphilitic, (b) tuberculous, both of which have just been described; and (2) *new growths*: cysts, melanoma, and sarcoma, all of which are rare.

Injuries of the Iris.

These may be (1) non-perforating and (2) perforating.

1. *Non-perforating injuries* (concussion, blows upon the eyeball) may cause (a) mydriasis; (b) a tear in the pupillary margin, in both of these cases eserine being indicated; (c) iridodialysis, a separation of the ciliary border of the iris (Fig. 155), for which atropine is required.

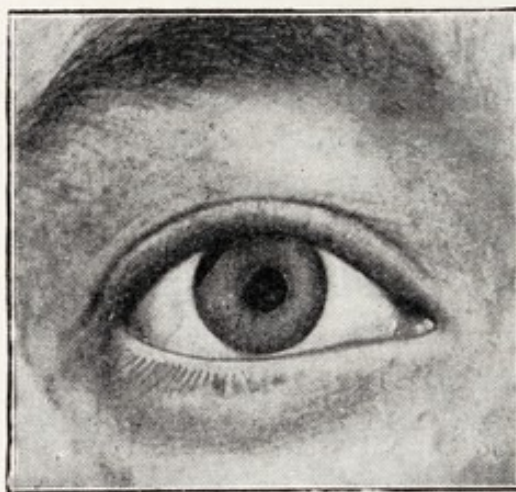


FIG. 155.—IRIDODIALYSIS.

2. *Perforating injuries* are usually complicated by wounds of the lens and other parts of the eye. A perforating wound of the eyeball may lacerate the iris or merely allow the latter to project through a wound of the cornea or of the ciliary region (*prolapse*). In cases of prolapse, the wound must be irrigated with a mild cleansing lotion, such as boric acid or weak bichloride; if seen early, within a few hours, and there is no injury to iris and lens, the iris may be returned into the anterior chamber, atropine or eserine used according to the seat of the perforation, and a bandage applied. If there is little hope of saving the prolapsed portion of the iris it should be excised, the cut edges carefully separated from the wound by a spatula, atropine or eserine used according to the seat of the injury, and the eye bandaged.

Operations upon the Iris.

Iridectomy is the only important operation upon the iris. It is described with glaucoma, which forms its most frequent indication.

Iridotomy and *Iridocystectomy* are operations the indications for which occur infrequently, when after loss of the lens following injury or cataract-operation the pupil has been closed by inflammation or been drawn towards the cicatrix. In iridotomy the iris fibres are cut transversely with a Graefe knife or with special forceps-scissors introduced through a small corneal incision. In iridocystectomy an incision is made through the cornea, and the capsule and the edge of the iris are drawn out by means of a blunt hook or forceps, and cut off. The object of both operations is the formation of an artificial pupil. However perfect the operative effect may be, the visual result is usually marred by vitreous opacities caused by the previous inflammation.

The Pupil.

The normal pupil is circular and regular in outline. It is larger in the young than in advanced life. Its size should equal that of its fellow; both should respond alike when one is subjected to a change in intensity of illumination. The movements of the pupil are contraction and dilatation.

The contracting fibres of the iris, the sphincter pupillæ (muscle), are supplied by the third nerve. The dilating fibres in the posterior limiting membrane are supposed to be supplied by the sympathetic. The bloodvessels of the iris, also supplied by the sympathetic, constitute the principal agents in active dilatation of the pupil; contraction of these vessels causes narrowing of the iris with dilatation of the pupil.

Contraction of the pupil is effected by stimulation of the oculomotor nerve and by paralysis of the sympathetic. Dilatation follows paralysis of the third nerve or stimulation of the sympathetic.

The oculomotor nerve fibres are conveyed through the ciliary ganglion and short ciliary nerves. The nucleus of origin of the

third nerve concerned in the movements of the iris is in the floor of the aqueduct of Sylvius, and can be divided into three portions: (1) that giving rise to the sphincter fibres of the iris; (2) accommodation (ciliary muscle); and (3) convergence (internal rectus). The sympathetic or dilating fibres are given off from the cilio-spinal centre of the lower cervical spinal cord.

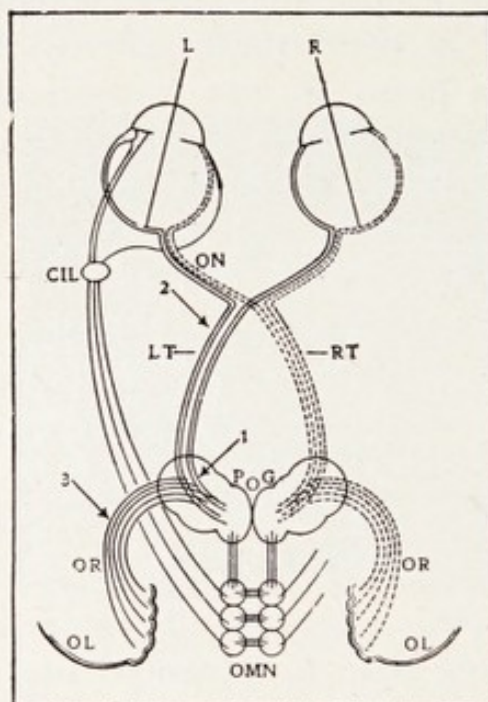


FIG. 156.—VISUAL AND PUPILLARY REFLEX PATHS.

L, Left eye; *R*, right eye; *ON*, optic nerve; *LT*, left optic tract; *RT*, right optic tract; *POG*, primary optic ganglia; *OMN*, oculomotor nuclei; *OR*, optic radiations; *OL*, occipital lobe; *CIL*, ciliary ganglion. Division of the fibres at 1 abolishes the reaction of the pupil to light upon illuminating the left half of either retina. At 2, the same result with right homonymous hemiopia. At 3, right homonymous hemiopia with preservation of the reaction of the pupil to light.

The pupil contracts upon exposure to light, with accommodation, and with convergence. The light contraction may be direct or consensual. The direct light reflex is obtained by exposing one eye to increased illumination and observing the contraction of the pupil of this eye. The consensual or indirect light reflex is obtained by throwing light into one eye, and observing the contraction of the pupil of the other eye. The accommodation and convergence reflex is obtained by directing the patient to look at an object held several inches

in front of the face in the middle line; the pupils will be seen to contract. These three actions are associated.

The dilatation reflexes of the pupil are seen upon shading the eye (both direct and consensual) and upon looking at a distant object. In addition there is a sensory reflex; when sensory nerves are stimulated, as by scratching or tickling the skin, both pupils dilate.

The consensual contraction is explained by the fact that the light stimulus in one eye is carried by the optic nerve and passes to both optic tracts, and in this way to the nucleus of the third nerve of each side (Fig. 156). Blindness in one eye abolishes the direct reflex in this eye, but its consensual reflex is preserved.

In certain pathological conditions there may be loss of light reflex, without interference with sight. The Argyll-Robertson pupil, so frequently a symptom of locomotor ataxia, contracts with accommodation and convergence, but does not respond to light. It is usually accompanied by miosis. It is explained by an interruption in the path from the optic nerve to the oculomotor nucleus, the connexions of the centres for accommodation and convergence remaining unaffected. The characteristics of the pupils—size, equality, and reflexes—are of great value in the diagnosis of various affections of the nervous system and in the localization of cerebral lesions. Hence it is important to be familiar with the afferent and efferent routes which control the movements of the pupil (Figs. 156 and 226, and Plate XXII.). The course of the afferent impulse is retina, optic nerve, both optic tracts, corpora quadrigemina, nuclei of origin of the third nerve in the floor of aqueduct of Sylvius (there being a communication between the two sides).

The efferent impulse travels on either side from these nuclei to the third nerve, the ciliary ganglion, short ciliary nerves, to the iris.

Mydriatics and miotics are described in the chapter on Ocular Therapeutics, and on p. 354. The hemianopic pupillary reflex is explained on p. 285.

CHAPTER XII

DISEASES OF THE CILIARY BODY

Anatomy.—The ciliary body is that part of the tunica vasculosa which extends backward from the base of the iris to the anterior part of the choroid. It consists of the ciliary processes and of the ciliary muscle. A longitudinal section is of triangular shape, with a narrow base directed forward, giving origin to the iris. The outer side of the triangle is formed by the ciliary muscle; the inner side can be divided into two parts: an anterior, which bears the ciliary processes, and a posterior portion, which is smooth.

The *ciliary muscle* (the muscle of accommodation) consists of non-striated muscular fibres arranged in bundles, anastomosing with one another frequently so as to form a sort of plexus, and running in three different directions—meridional, radiating, and annular. The proportion between circular and longitudinal fibres varies according to the refractive condition of the eye. The circular set is well developed in hypermetropia (Fig. 275, B), but atrophied in myopia (Fig. 276). When the ciliary muscle contracts, it draws the ciliary processes and choroid forward and inward, thus relaxing the suspensory ligament and allowing the lens to become more convex.

The *ciliary processes* consist of about seventy folds or thickenings, arranged meridionally, so as to form a circle. They have the same structure as the rest of the choroid, but are even more vascular. They serve to secrete the nutrient fluids in the interior of the eye which nourish neighbouring parts, especially the cornea, lens, and part of the vitreous. The inner surface of the ciliary body is covered by three layers: externally, a homogeneous membrane continuous with the posterior limiting membrane of the iris; next, pigment epithelium; internally, next to the vitreous, a layer of cylindrical non-pigmented cells.

The ciliary body is supplied by branches from the greater circle of the iris and by the anterior ciliary *arteries*. The *veins*, constituting the greater part of the ciliary processes, pass backward to the *venæ vorticosæ* of the choroid. A part of the veins from the ciliary muscle

pass backward, pierce the sclera, and run beneath the conjunctiva with the anterior ciliary arteries. These constitute the violet subconjunctival vessels seen running backward in ciliary injection and in deeper congestion (glaucoma). They anastomose with the conjunctival veins, and communicate with Schlemm's canal.

Cyclitis and Uveitis.

As already pointed out, iritis is frequently associated with cyclitis (iridocyclitis). While unmixed cases of cyclitis do occur, they are uncommon; usually, in inflammation of the ciliary body, adjacent portions of the uveal tract are involved.

Practically, the term iridocyclitis is reserved for those cases in which, with the symptoms of iritis, there are decided evidences of participation of the ciliary body.

Varieties.—Cyclitis (iridocyclitis) may be divided into (1) acute; (2) chronic, or uveitis—(a) mild type, and (b) severe type; (3) purulent; and (4) sympathetic.

1. Acute Iridocyclitis.

Acute iridocyclitis presents the picture of an attack of acute iritis with the addition of the following symptoms pointing to involvement of the ciliary body; marked circumcorneal injection, tenderness in the ciliary region, swelling of the upper lid, turbidity of the aqueous (occasionally hypopyon or hyphæmia), increased depth of anterior chamber, deposits upon Descemet's membrane, abnormal tension (increase or decrease), and greatly reduced vision (due to vitreous opacities and deposits in the pupillary space).

Prognosis varies with the severity of the symptoms and the general health of the patient, but is always serious. Although in many cases the disease may run a comparatively mild course and the eye recover with little injury, a severe attack may result in blindness with atrophy of the globe.

Treatment is that of iritis.

2. Chronic Iridocyclitis or Uveitis.

Chronic iridocyclitis or uveitis is an inflammation of the entire uveal tract (iris, ciliary body and choroid), occurs chiefly in young adults, is chronic in course, has a tendency to

relapse, may involve one eye, but often both. The severity of the inflammation varies, and in this sense the disease is divided into two types: (a) mild, and (b) severe.

Etiology.—Certain constitutional diseases: syphilis, gonorrhœa, tuberculosis, influenza, acute infective diseases, chronic rheumatism, gout, arthritis deformans, and diabetes; to auto-intoxication from the gastro-intestinal tract; not infrequently from the influence of toxins of bacterial origin (focal infections) derived from the gums and teeth (pyorrhœa, periapical abscess), tonsils, nose, nasal accessory sinuses, genito-urinary tract, and skin (furuncles); or the infective agent may arise from perforating wounds of the eyeball, including operations such as cataract extraction.

Symptoms.—(a) *The Mild Type* begins very insidiously with few, if any, symptoms of irritation. The patient complains chiefly of diminution of vision; there may be some ciliary congestion, slight pain, ocular fatigue, and limited photophobia. There occurs an exudate of serum and cells with slight admixture of fibrin, sometimes slightly pigmented, precipitated upon the posterior surface of the cornea as dots forming a triangular area over the lower part, apex above (Fig. 149, Plate XI). This sign has given rise to the terms 'keratitis punctata' and 'descemetitis' as synonyms, though objectionable ones, for this disease; these terms indicate merely this particular symptom. Sometimes a number of spots coalesce and form small masses, called 'mutton-fat' deposits, on account of their appearance. The anterior chamber is deeper than normal, and the aqueous may be slightly turbid. The pupil is somewhat dilated. Tension may be increased at first and lowered later, or there may be alternations of increase and decrease. Secondary glaucoma is an important complication. There are numerous minute opacities in the vitreous, and the latter may become fluid; there may be involvement of the choroid.

(b) *The Severe Type.*—The subjective symptoms resemble those of the mild form. But the objective signs are much more pronounced: the exudate is considerable, and consists largely of plastic material. On account of the nature of the

exudate, this type is known as plastic iridocyclitis, in contradistinction to the mild type, in which the exudate is chiefly serous, which is called serous iridocyclitis. The plastic exudate forms in the anterior chamber, pupillary space, behind the iris, and in the vitreous, forming dense membranes; its subsequent contraction causes detachment of the retina; the iris atrophies; the nutrition of the lens is interfered with, and secondary cataract results; choroid and retina atrophy. Finally, the blind and degenerated eyeball shrinks (atrophy of the eyeball). The eye may now remain quiet, or there may be attacks of pain and tenderness from time to time. The complications are secondary glaucoma, which is quite common, and scleritis.

Prognosis varies with the type of disease. The liability to secondary glaucoma always makes the prognosis uncertain. In many instances of the mild form the disease subsides after a lengthy course, with or without relapses, and the eye returns to an apparently normal condition, with little or no interference with vision; or there may be only small iritic adhesions or vitreous opacities. Such favourable outcome is possible because the exudate is largely serous with little or no plastic addition, and is capable of absorption.

In the severe form the prognosis is always grave. Although vigorous treatment in the early stages may save more or less useful vision, the sight is lost, owing to damage through the deposit, organization, and contraction of the plastic exudate.

Treatment is that of iritis, but the indications are for more vigorous interference. It is especially important to remove every source of infection as promptly as possible. Thus the removal of an infected tooth, a diseased tonsil, or the accumulation in accessory sinuses, the injection of salvarsan in a syphilitic, of tuberculin in a tuberculous subject, and colonic irrigations when there is intestinal auto-intoxication, will often prevent the mild from changing into the severe type.

Locally, atropine, hot moist compresses, hot bathing, or continuous dry heat applied in the form of a Japanese muff warmer or an electric light bulb in a pad of cotton-wool. Sub-

conjunctival injections of normal saline or other solutions are often used, but it is doubtful whether they do any good. Increase of tension in these cases is not a contra-indication for atropine; on the contrary, atropine may cause a reduction in tension. Increase of tension should be dealt with by paracentesis of the anterior chamber, and this may have to be repeated a number of times. Atropine ointment 1 per cent. with a soft paraffin basis is much less irritating than the P.B. preparation. In obstinate cases the addition of 2 per cent. of cocaine increases the effect of the atropine.

Diaphoresis is very useful. Mercury by inunction or by the mouth, even in the non-specific cases, is sometimes of value; also iodides and large doses of salicylates. The use of thyroid extract in these cases has been reported upon favourably.

Where a source of focal infection has been discovered, such as a tooth or the tonsil, a culture may be made from the infective material and then a vaccine. The use of vaccines in these cases is apt to be disappointing, but if other measures do not quickly cause improvement no possibly hopeful treatment should be neglected.

After the eye has become quite quiet, unless hopelessly lost, an iridectomy may be indicated for optical reasons, or to restore communication between the anterior and the posterior chambers, and thus prevent subsequent glaucoma.

3. Purulent Iridocyclitis (Purulent Uveitis).

Purulent iridocyclitis (purulent uveitis) is described under the heading of Purulent Choroiditis on p. 180, and of Panophthalmitis on p. 185.

4. Sympathetic Iridocyclitis (Sympathetic Uveitis).

Sympathetic iridocyclitis (sympathetic uveitis) is described under the heading Sympathetic Ophthalmitis on p. 182.

Injuries of the Ciliary Body.—The ciliary region, represented by a pericorneal ring about 6 mm. wide, is known as the 'dangerous zone,' because infected penetrating wounds in

this situation are apt to set up plastic uveitis, which may be followed by sympathetic ophthalmitis. After thorough cleansing, extensive ciliary wounds are closed by one or more sutures passed through the superficial layers of the sclera or through the conjunctiva; such wounds are often covered by a conjunctival flap. A prolapse of the iris should be excised, but a prolapsed ciliary body should not be removed. The presence of a foreign body in the globe must be excluded. A bandage is then applied. If the wound is very extensive and sight is lost, enucleation is indicated. Additional details of treatment are given in the paragraphs on Injuries of the Sclera (p. 155) and on Sympathetic Ophthalmitis.

CHAPTER XIII

DISEASES OF THE CHOROID

Anatomy and Physiology.—The choroid is a dark brown membrane placed between the sclera and the retina, extending from the ora serrata to the aperture for the optic nerve. It consists mainly of bloodvessels, united by delicate connective tissue containing numerous pigmented cells; these vessels are arranged according to their calibre into three superimposed layers.

This vascular structure is bounded on either side by a non-vascular membrane; accordingly, the choroid can be divided into five layers: (1) Externally, the suprachoroid, connected with the sclera by loose connective tissue. (2) The layer of large vessels. The spaces between these are filled with connective tissue and cells. The arteries are the short ciliary. The veins are arranged in curves (*vasa vorticosa*) converging to four or five principal trunks, which pierce the sclera near the equator of the eyeball. (3) The layer of medium-sized vessels. (4) The layer of capillaries (*chorio-capillaris*). (5) The lamina vitrea, a structureless, transparent membrane, which is placed next to the pigmentary layer of the retina.

The *function* of the choroid is chiefly to serve as a nutrient organ for the retina, vitreous, and lens. It forms the dark coating of the interior of the eyeball.

Inflammations of the Choroid (choroiditis) may be (1) exudative or non-purulent, and (2) purulent.

Exudative, Non-purulent, or Plastic Choroiditis.

This variety of choroidal inflammation (Plates XII. to XIV.) occurs under the following principal forms: (1) Diffuse; (2) disseminated; (3) central, including the myopic and senile varieties; and (4) syphilitic. In many instances the disease involves the retina as well as the choroid, and is then properly spoken of as choroido-retinitis, or retino-choroiditis.

PLATE XII.

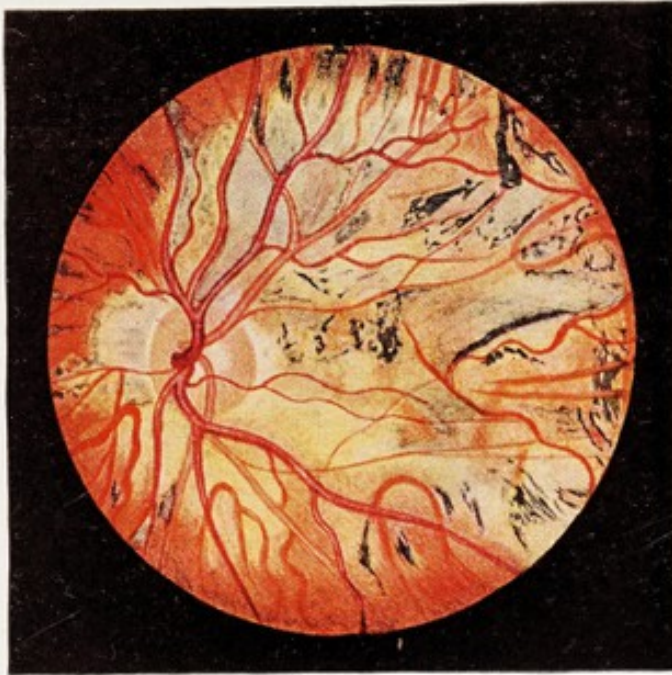


FIG. 158.—DIFFUSE CHOROIDITIS.

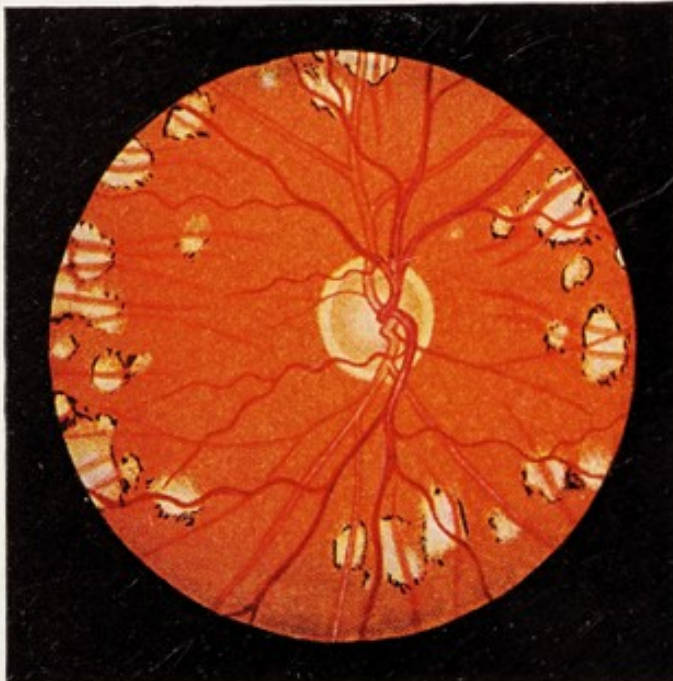

FIG. 159.—DISSEMINATED CHOROIDITIS.

To face page 176.



It will be of advantage to describe exudative choroiditis in general before giving the distinctive features of the several varieties.

Subjective Symptoms.—There are disturbances of vision, both diminution in acuteness, appearance of specks, and distortion of objects (metamorphosia). The latter symptom may be divided into micropsia, when objects appear too small, and macropsia, when they appear too large. There are often flashes of light, sparks or bright circles before the eyes. In the later stages there may be defects in the field of vision, both scotomata and peripheral contraction. There is no pain.

Objective Symptoms.—There are no external signs, but the ophthalmoscope reveals a well-marked picture. There are patches of exudation of plastic material, varying in size and position. At first these areas are yellowish or yellowish-white in colour, with ill-defined margins. The retinal bloodvessels are seen to be lifted and to pass over them. Later, after several weeks or months, the exudation becomes absorbed, leaving patches of choroidal atrophy. The latter appear as whitish areas (the sclera showing through) often marked with distinctly visible choroidal vessels. The atrophic spots are of various shapes, and more or less pigmented. Not infrequently the vitreous is involved, and then there are opacities of this medium. Very often the retina becomes atrophied opposite the patches just described. The optic disc may participate in the changes, and present a yellowish-white, dirty colour, a condition often spoken of as 'choroidal atrophy.'

Complications.—From this description it will be seen that neighbouring structures are frequently implicated: iris, retina, vitreous, and sclera. Choroiditis may also cause posterior polar cataract.



FIG. 157. — PERIPHERAL SCOTOMATA IN DISSEMINATED CHOROIDITIS.

Etiology.—Frequently some constitutional disease, especially acquired and hereditary syphilis, but also anæmia, scrofula, and tuberculosis; many examples are found in myopia. It may depend on septic infection from the teeth, oral and nasal cavities, or upon intestinal auto-intoxication; many cases of obscure origin are spoken of as idiopathic.

Prognosis depends upon the position of the patches of exudation, with subsequent atrophy. A single patch involving the macular region will seriously impair vision. On the other hand, the process may extend over a considerable part of the fundus, and yet vision remain good, if the macula escapes.

Treatment.—Removal of the etiological factor; iodides and mercury in syphilitic cases; inunctions of mercury are often used with success even in non-syphilitic cases; tuberculin in suitable patients; attention to the general health; diaphoresis is often valuable. Rest of the eyes, avoidance of bright light by the use of smoked glasses, sometimes a darkened room; subconjunctival injections of salt solution are often useful.

Diffuse Choroiditis (Fig. 158, Plate XII.).—In this variety the patches of exudation are of large size; later, the coalescence of the atrophic spots produces a large area of white or yellowish-white colour, more or less pigmented, and showing some choroidal vessels.

Disseminated Choroiditis (Fig. 159, Plate XII.) presents numerous round or irregular spots scattered over the fundus. The entire fundus may be studded, and yet the vision remains good if the macular region escapes. This form of choroiditis runs a very chronic course. After existing a long time, atrophy of the retina and optic nerve may be added.

Central Choroiditis (Fig. 160, Plate XIII.) is a form in which the changes are limited to the macula, and which occurs most frequently in myopia of high degree. The resulting central scotoma causes serious interference with vision. It also occurs as a result of senile changes (senile central choroiditis) and in syphilis.

Syphilitic Choroido-Retinitis is the name given to a diffuse inflammation of the choroid, associated with retinitis and

PLATE XIII.

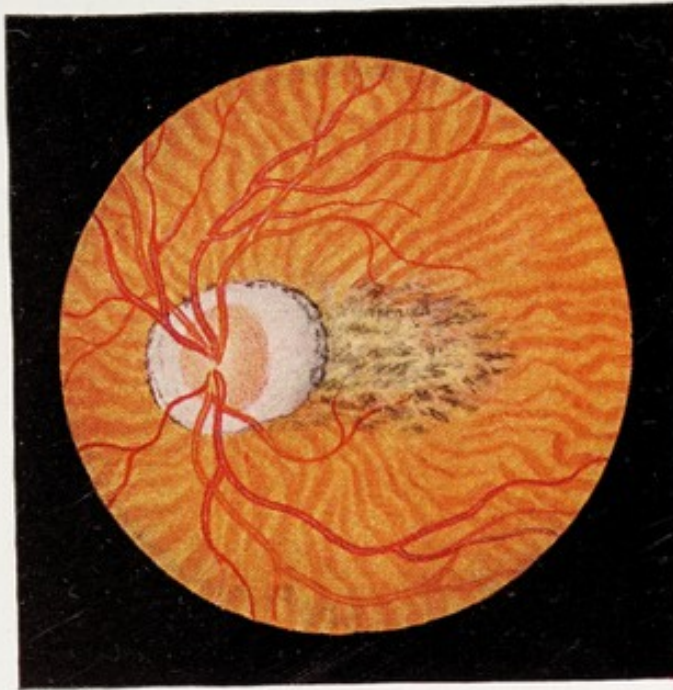


FIG. 160.—FUNDUS OF MYOPIC EYE.

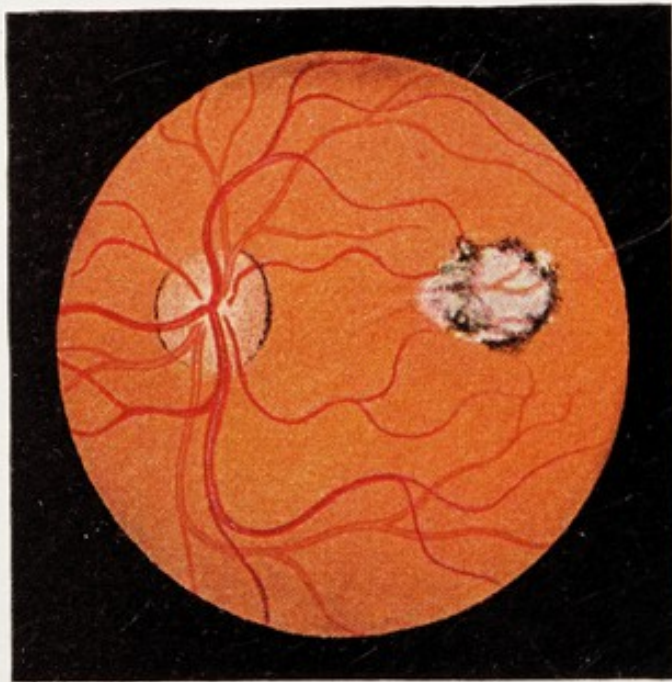


FIG. 161.—CENTRAL CHOROIDITIS.

To face page 178.



PLATE XIV.

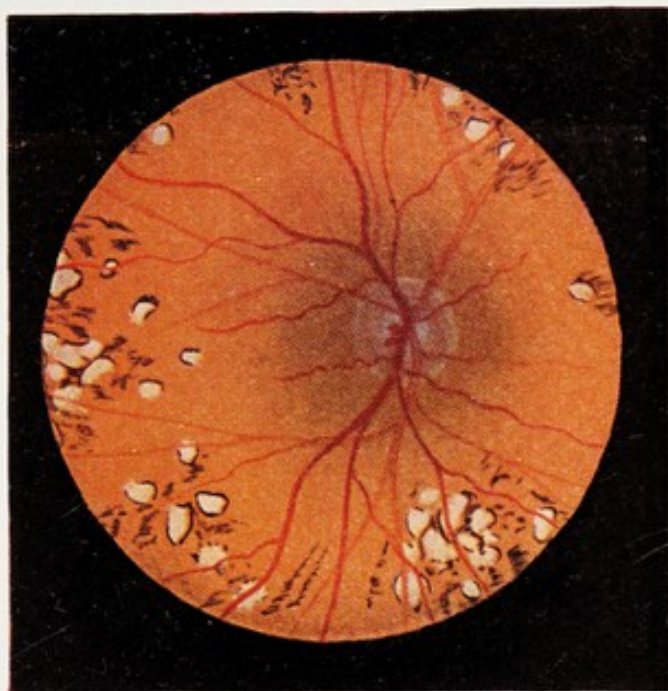


FIG. 162.—SYPHILITIC RETINO-CHOROIDITIS, WITH
DUST-LIKE OPACITY OF VITREOUS.

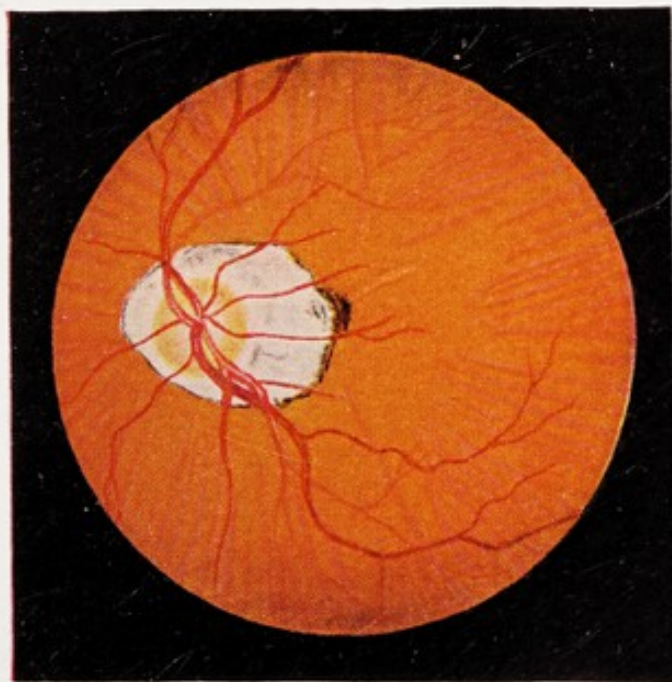



FIG. 163.—POSTERIOR STAPHYLOMA.

To face page 178.



changes in the vitreous, which occurs in the secondary stage of syphilis. At first there are diffuse cloudiness of the retina, numerous exudations in the choroid, especially in the region of the macula, and fine, dust-like opacities of the vitreous. Later, the cloudiness of the retina is replaced by atrophy, there are atrophic patches of the choroid, spots of pigment, and opacities of the vitreous (Fig. 162, Plate XIV.).

Choroiditis of Myopia; Posterior Staphyloma, or Sclero-Choroiditis Posterior. — The fundus of near-sighted eyes, especially if the myopia be of high degree, very often presents characteristic changes (Fig. 161, Plate XIII., and Fig. 163, Plate XIV.). Owing to the elongation of the eyeball, there is a bulging of the sclerotic at the posterior pole and atrophy of the choroid in this situation. This shows itself in a white crescent (myopic crescent) situated usually to the outer side of the disc, varying in size, and sometimes encircling the papilla. It is known as posterior staphyloma when very marked.

When this crescentic or annular patch is separated from healthy choroid by a sharply-defined margin, often pigmented, it is a sign that the process has come to a standstill. But when the border is ill-defined, it indicates that the changes are advancing (progressive myopia). Such knowledge is of great importance in emphasizing the necessity for attention to ocular and general hygiene. The size of the staphyloma is usually, but not always, proportionate to the degree of myopia. More or less superficial atrophy of the choroid is often observed in myopia of high degree, allowing the larger choroidal vessels to become plainly visible. Besides choroiditis in the macular region, there may be patches of choroidal atrophy in other parts of the fundus. These often coalesce with the posterior staphyloma, so that an extensive white area is seen, spotted or bordered with more or less pigment. The early changes in the macular region may be represented by fine lines or fissures. Hæmorrhages, especially in the macular region, and opacities of the vitreous also occur in myopia of high degree.

The treatment consists in avoidance of near work, rest for

the eyes, smoked glasses, outdoor life, and attention to the general health. During the progressive stage, the treatment recommended for choroiditis in general is indicated.

Purulent Choroiditis.

In this affection the choroid, ciliary body, and iris are involved in a purulent inflammation which leads to the destruction of the eyeball. In most cases all the structures of the eyeball are involved, and panophthalmitis results (p. 185). Rarely, the inflammation is limited to the choroid (suppurative choroiditis), the purulent exudate forming an abscess of the vitreous with no external evidences of inflammation, but with loss of vision.

The **Symptoms**, those of irido-cyclitis already given, are acute and severe. The pain is severe; the congestion of the conjunctiva is pronounced, with chemosis and swelling of the lids. The cornea becomes clouded, and pus appears in the aqueous and vitreous, so that no details of the fundus are visible. Sight is rapidly lost. There is usually much constitutional disturbance.

In those cases in which the process remains limited, after the acute symptoms subside, a sightless, degenerated, and atrophied eyeball remains. A yellowish or grayish-yellow reflex is then obtained from the interior of the eye, due to the purulent degenerated mass. This is known as pseudo-glioma, on account of its resemblance in colour to glioma of the retina.

Etiology.—Infection of the interior of the eye by pyogenic microbes, either from without or from within the body. Ectogenous infection occurs most frequently from penetrating wounds, including operations, perforating ulcers, thin corneal scars, and prolapse of iris. Endogenous infection results from septic embolism (metastatic ophthalmia), and is seen most frequently in puerperal pyæmia, also surgical pyæmia; extension from orbital cellulitis; also in meningitis and cerebro-spinal meningitis, especially in children, and sometimes infectious diseases.

Treatment.—It is impossible to save sight. Pain should be relieved by morphine and by the local applications of hot moist compresses. If the process has involved all the ocular structures, the treatment of panophthalmitis is indicated.

Coloboma of the Choroid is a congenital defect of the choroid and retina, showing itself in a large white patch, representing the exposed sclera. It is usually situated below the disc. The retinal vessels are seen passing across this patch. There is a scotoma corresponding to the defect. This condition is often associated with coloboma (a cleft) in the iris, and a notch at the equator of the lens opposite the coloboma.

Rupture of the Choroid sometimes results from contusions of the eyeball. The immediate effect of such an injury is an extravasation of blood into the vitreous. After this is absorbed, a long, yellowish-white streak with pigmented edges is seen, usually in the neighbourhood of the disc and to its outer side.

Tubercle of the Choroid occurs in acute miliary tuberculosis and in tuberculous meningitis. The tubercles appear as small, yellowish-white spots, surrounded by some retinal haze, vary in number, and are found near the disc, in the macular region, or scattered over the fundus. They resemble the spots seen in recent cases of disseminated choroiditis. Tuberculosis occasionally assumes the form of a solitary, irregular mass at the macula, which may be mistaken for glioma.

Sarcoma of the Choroid (see Intra-ocular Tumours, Chapter XV.).

CHAPTER XIV

SYMPATHETIC OPHTHALMITIS—PANOPHTHALMITIS

As its name implies, uveitis is an inflammation of the whole uveal tract—iris, ciliary body, and choroid. There are two forms: (1) serous and plastic, and (2) purulent. Both forms have been described in connexion with cyclitis, which, as already explained, is generally merely part of a uveitis. There are, however, two special varieties: (1) sympathetic uveitis, generally known as sympathetic ophthalmitis; and (2) the form of purulent uveitis known as panophthalmitis.

Sympathetic Ophthalmitis.

Sympathetic ophthalmitis (sympathetic ophthalmia) is a serous or plastic inflammation of the uveal tract in one eye, due to the effects of a similar inflammation in the other.

Etiology and Occurrence.—This inflammation is usually due to traumatic iridocyclitis of the first eye as a result of perforating injury, such as accidental or operative wound in the ciliary region, the danger being increased if iris or ciliary body be entangled in the wound. Foreign bodies in the interior of the eyeball are also apt to excite this disease. Sometimes it results from the iridocyclitis following perforating corneal ulcers. Rarely it occurs without any perforating lesion. Suppurative inflammations of an eyeball very rarely cause sympathetic ophthalmitis.

It is, fortunately, not of very frequent occurrence. Asepsis and antisepsis have lessened the danger of its occurrence after operations. It usually begins between five and eight weeks after injury in the exciting eye, rarely before three weeks. It may, however, occur many months after the injury.

The eye which has been originally affected is known as

the exciting eye ; the one secondarily involved as the sympathizing eye.

Symptoms.—In most cases, but not invariably, the disease presents a stage known as sympathetic irritation. It is very important to recognize this stage, since removal of the exciting eye at this period will almost certainly prevent the progression of the affection from irritation to actual inflammation.

The Symptoms of Sympathetic Irritation.—The sympathizing eye is 'irritable'; there are marked photophobia and lacrymation ; neuralgic pain in the eye and neighbouring parts ; dimness of vision occurs when the eyes are used for near work. There may be bright and coloured sensations.

The exciting eye usually presents an iridocyclitis or uveitis, which may be slight or severe. When the sympathizing eye becomes affected, there may be symptoms of irritation and marked tenderness over the ciliary region in the exciting eye.

These symptoms of irritation in the sympathizing eye may be intermittent. Each attack may last a number of days or weeks, then subside, and recur a number of times. They may finally disappear entirely. But, as a rule, if the exciting eye is not excised, sympathetic inflammation results. Examination with the slit-lamp may give valuable information in a very early stage.

The Symptoms of Sympathetic Inflammation.—These may follow directly upon those of irritation, or may occur after the sympathizing eye has been quiet for a time. They may begin acutely or insidiously. When once established, the inflammation is chronic, and its duration is months or even one or two years. In the majority of cases blindness results, though occasionally, if the inflammation be mild, useful vision may be preserved.

The symptoms are photophobia, lacrymation, dimness of vision, and tenderness in the ciliary region. There will be circumcorneal injection, punctate deposits upon Descemet's membrane, increased depth of the anterior chamber, contracted pupil, and increased tension.

In mild cases the symptoms may not pass beyond those of cyclitis or iridocyclitis ; but usually they develop into a plastic uveitis, including iris, ciliary body, and choroid, and giving

the following signs : The iris is thickened, its colour becomes changed, its markings are obliterated, and it presents new bloodvessels upon its surface ; it is firmly bound down by numerous and extensive posterior synechiæ. The plastic exudation fills up the pupil and more or less of the anterior chamber, which becomes shallow. Tension is diminished. The choroid and retina participate in the plastic inflammation, the vitreous presents numerous opacities, and the lens becomes opaque. Finally, there is detachment of the retina, the eyeball shrinks and passes into the condition of atrophy.

Theories of Transmission.—The mode of transmission is not definitely known. The theories which have been propounded are : (1) Infection spreading through the sheath of the optic nerve of one side to the chiasm and sheath of the nerves ; (3) conveyance by bloodvessels of the toxins of some unidentified bacteria which are supposed to be pathogenic for the eye only ; and (4) conveyance by lymph channels. The third seems perhaps the most probable.

Treatment.—Prophylactic treatment is of the greatest importance, and refers to the removal of the exciting eye under the following circumstances : We should enucleate the injured eye if it be sightless, or its condition such (especially when the ciliary region is involved) that we cannot hope to preserve useful vision. This is particularly imperative if it is irritable, has ciliary tenderness, presents the signs of iridocyclitis, or contains a foreign body which cannot be extracted.

When, however, there is useful vision in the injured eye, or a good chance of obtaining fair sight in this eye, the question of enucleation is often a difficult one to decide, since symptoms of sympathetic irritation may appear and then subside, and yet sympathetic inflammation never develop. In such cases we are often justified in waiting, if the injured eye remain quiet and free from inflammation, providing we can keep the patient under constant observation.

After sympathetic inflammation has made its appearance, enucleation of the injured eye has no effect upon the progress of the disease, and the exciting eye may ultimately possess

better vision than its sympathizing fellow. Hence, under such circumstances, the exciting eye should not be removed if it possesses vision ; if blind and exhibiting signs of inflammation, it should be enucleated, since its presence may aggravate the condition in the sympathizing eye.

The treatment of the sympathetic ophthalmia itself consists in the use of atropine (unless this seems to aggravate the symptoms), hot compresses, absolute rest, shaded room, and smoked coquilles. Leeches to the temples are sometimes of advantage. Mercurialization is frequently resorted to, either calomel internally or inunction of the oleate up to the point of salivation. Salvarsan has been tried in many cases, and is believed to have done good. Since the disease is of lengthy duration, the general health of the patient must be looked after.

Though the prognosis is unfavourable, and most cases end in blindness, the treatment must be carried out rigidly and patiently. In some cases at least, especially if the inflammation be of the serous type, fair vision may ultimately be obtained.

Panophthalmitis.

An intense purulent inflammation of the entire uveal tract, which fills the eyeball with pus, and ends in complete destruction of this organ. It is due to infection. It resembles purulent choroiditis (which term is often employed as a synonym), but the inflammatory process is more extensive.

Etiology.—It is almost always due to infected wounds of the eyeball, whether accidental or as a result of operation. It may also result from infective ulcers, metastasis in pyæmia and puerperal septicæmia, meningitis, and cerebro-spinal meningitis, especially in children.

Symptoms (already described in connexion with purulent choroiditis, p. 180) are apt to be acute and severe. The disease is usually ushered in by a rise of temperature, general febrile symptoms, headache, and sometimes vomiting. There are severe pain in the eyeball, rapid loss of sight, intense ciliary and conjunctival congestion, marked chemosis, and swelling and redness of the lids (Fig. 150, Plate XI.). The

iris soon becomes involved, the anterior chamber and vitreous become filled with pus, the cornea is clouded and yellow (Fig. 151, Plate XI.), and tension increased. There is infiltration of Tenon's capsule, followed by exophthalmos and limitation of the movements of the eyeball.

Pus usually breaks through the anterior portion of the sclera, after which the pain and other symptoms subside. In the course of several weeks the process has run its course, leaving a shrunken, sightless eyeball (phthisis bulbi, Fig. 164).

The **Prognosis** is always unfavourable. Sight is invariably lost. The condition does not cause sympathetic ophthalmia.

Treatment.—The indications are to alleviate pain by the use of hot, moist compresses, and to incise the sclera so as to allow the escape of pus. If the case

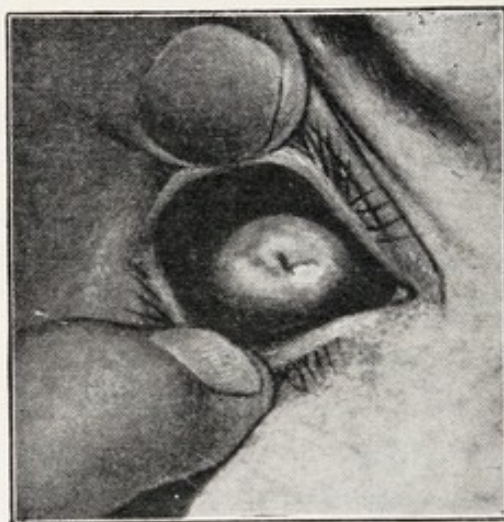


FIG. 164.—PHTHISIS BULBI.

is seen early, thorough and repeated cauterization of the focus of infection with the electro-cautery or the introduction of small rods of iodoform into the anterior chamber, or both measures combined, may be of value. It is not considered advisable to enucleate in the inflammatory stage, on account of the danger of setting up purulent meningitis (p. 91).

CHAPTER XV

INTRA-OCULAR TUMOURS

INTRA-OCULAR tumours are rare. Their recognition is, however, important, since early enucleation of the eyeball may save life. There are two varieties: (1) Sarcoma of the choroid, and (2) glioma of the retina.

Sarcoma of the Choroid.

This malignant growth usually occurs in adults between the ages of forty and sixty. It is always primary, single, and involves one eye only. It may be formed of spindle or of round cells, and is usually pigmented (melano-sarcoma). It forms a rounded mass which springs from the choroid, most commonly near the posterior pole, and advances toward the centre of the eyeball, pushing the retina before it (Fig. 165).

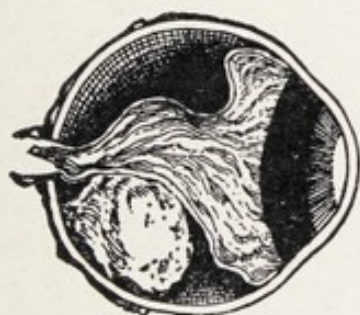

FIG. 165.—SARCOMA OF THE CHOROID, WITH DETACHMENT OF THE RETINA.

Symptoms.—There are four stages.

In the *first or quiescent stage* there will be a defect in the field and diminution in sight depending upon the exact seat of the tumour. With the ophthalmoscope a yellowish, brown, or black mass may be seen, over which

retinal vessels can be traced, and behind these other vessels belonging to the tumour itself.⁶ But very frequently the retina becomes detached, and thus obscures this picture. The anterior ciliary veins may be found dilated near the seat of the growth. This stage usually lasts from eighteen months to two years.

In the *second or irritative stage* the tumour enlarges in size, and gives rise to pain and other symptoms of inflammatory glaucoma.

In the *third or extra-ocular stage* the tumour bursts through the globe, and then increases very rapidly in size, and ulcerates. In most cases it perforates anteriorly, and a dark mass is seen. If it perforates posteriorly, exophthalmos results. It soon implicates neighbouring structures, including the brain.

The *fourth stage* is distinguished by the occurrence of metastases, most frequently in the liver.

Differential Diagnosis.—Sarcoma of the choroid may be mistaken for detachment of the retina, glaucoma, or possibly glioma of the retina. The last, however, occurs only during the early years of life. Ordinary detachment of the retina usually occurs suddenly in a myopic eye, or after a blow, and tension is diminished. There are no premonitory symptoms such as usually precede glaucoma, nor remissions in symptoms; one eye only is involved, and the characteristic field of glaucoma (nasal limitation) is not present, and usually sight is impaired before inflammatory symptoms appear. Transillumination with one of the instruments invented for the purpose will usually reveal any solid swelling in the anterior hemisphere.

Treatment.—Enucleation as soon as the diagnosis is established, cutting the optic nerve far back. It may be necessary to clear out the entire contents of the orbit. There is always danger of local recurrence and of metastases in internal organs. The affection is invariably fatal when not removed early, death taking place within five years.

Glioma of the Retina.

A malignant growth, consisting of small cells with some soft basement substance and bloodvessels. It occurs in children under five, usually in one eye, at times in both, and occasionally in successive children of the same family.

Symptoms.—We distinguish three stages.

In the *first or quiescent stage* there are no inflammatory

symptoms. The ophthalmoscope shows small whitish or yellowish masses with metallic lustre, growing into the vitreous. The surface presents newly-formed bloodvessels, and may also show hæmorrhages and white patches. The attention of the parents is attracted by the striking yellow reflex, easily seen through the pupil, which is usually dilated. In pre-ophthalmoscopic days this appearance gave rise to the term 'amaurotic cat's eye.'

In the *second or irritative stage* there are pain, increase of tension in about 50 per cent. of cases, and other symptoms of glaucoma. The tumour increases in size, and extends into the vitreous. Very soon the growth can no longer be seen on account of turbidity of the media.

In the *third or extra-ocular stage* there is bulging of the eyeball (both staphyloma and exophthalmos), and then perforation takes place. The growth passes backward along the optic nerve to the brain (in this way it becomes fatal), and forward through the cornea and sclera, increasing in size rapidly, and involving all tissues with which it comes in contact. Metastases are rather rare.

Differential Diagnosis.—We must distinguish glioma from pseudo-glioma (p. 180), the degenerated eyeball which is the outcome of purulent choroiditis following meningitis or cerebro-spinal meningitis in children. In the latter affection there will be the history of a previous acute febrile disease, with inflammation of the eyeball, and tension is diminished. Ophthalmoscopic examination is the chief guide. When in doubt, such eyes being always sightless, we should enucleate.

Treatment.—*Enucleation as soon as possible*, cutting the optic nerve far back. If the growth has perforated, the entire orbit must be cleaned out. Afterwards local treatment with radium or X rays may be advisable. Even then there is danger of recurrence. When excision is practised early there is a fair chance of cure. Unless this is done, death occurs within two or three years.

CHAPTER XVI

GLAUCOMA

Anatomy.—The aqueous chamber is bounded in front by the cornea, behind by the lens and its suspensory ligament, and laterally by the ligamentum pectinatum and anterior portion of the ciliary body (Fig. 166). Its depth varies; it is comparatively deep in the young, in myopic eyes, and when the eye is focussed for distant objects. The iris divides the aqueous cavity into an anterior and a posterior chamber. The former lies in front of the iris. The latter is the annular space between the iris and the lens. Since the iris is in contact with the lens only at its papillary margin, this space increases in depth from the pupil to the peripheral border of the iris, and is triangular in cross-section. The posterior communicates with the anterior chamber by means of the pupil.

The portion of the anterior chamber where the sclero-corneal margin, iris, and ligamentum pectinatum meet is known as the *angle or sinus of the anterior chamber* (often called the iris angle). This region is of great importance. Upon its integrity depends the proper circulation of the lymph which nourishes the anterior portion of the eyeball.

The *ligamentum pectinatum* is formed by the breaking up of Descemet's membrane at the margin of the cornea, into bundles which connect the sclera, with the root of the iris. These elastic laminae are covered by endothelium continued from Descemet's membrane. In this way spaces are formed which are continuous with the cavity of the aqueous, are lined with endothelium, and are known as the *spaces of Fontana*. To their outer side, at the sclero-corneal junction, is *Schlemm's canal*, a plexus of veins.

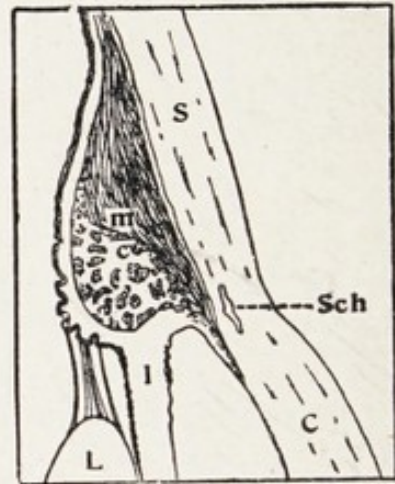


FIG. 166.—SECTION OF THE EYEBALL AT THE SCLERO-CORNEAL JUNCTION, SHOWING ANGLE OF ANTERIOR CHAMBER.

S, Sclera; C, cornea; I, iris; L, lens; cm, ciliary muscle; Sch, canal of Schlemm.

With the exception of the conjunctiva, no portion of the eyeball contains lymphatic vessels. In place of such vessels and serving the

same function, there are lymph channels and lymph spaces. These may be divided into those of the anterior and those of the posterior portion of the eyeball.

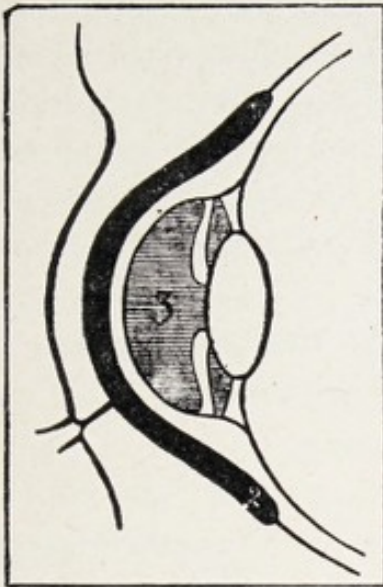


FIG. 167. — DIAGRAMMATIC SECTION OF THE ANTERIOR PORTION OF THE EYEBALL.

1, Upper conjunctival sac ; 2, lower conjunctival sac ; 3, anterior chamber ; 4, posterior chamber.

The *anterior lymph spaces* and cavities consist of the aqueous chamber and the parts immediately around the iris angle. The anterior and posterior chambers represent two large lymph spaces which collect the lymph of the anterior portion of the eye. This lymph is known as the aqueous humour, and consists of a clear, watery fluid, secreted by the epithelium covering the ciliary processes and the posterior surface of the iris. It first passes into the posterior chamber, then through the pupil into the anterior chamber, and leaves the eye through the spaces of the ligamentum pectinatum (Fontana's spaces) and Schlemm's canal, passing into the anterior ciliary veins ; a portion passes into the lymph spaces of the iris, and thence to the suprachoroidal lymph space.

The *posterior lymph passages* consist of the hyaloid canal of the vitreous, and of the suprachoroidal space (between choroid and sclera), communicating with Tenon's space along the *venæ vorticosæ*. Both have for an outlet the supravaginal and intravaginal spaces of the optic nerve.

Glaucoma is an important and common disease of the eye, which has for its characteristic sign an increase of intra-ocular tension.

Varieties.—It is (1) *primary*, when occurring without antecedent ocular disease ; and (2) *secondary*, when it follows as a result of some pre-existing disease of the eye.

Primary Glaucoma occurs under two forms : (1) *Inflammatory* or congestive, and (2) non-inflammatory or non-congestive, usually spoken of as *simple*.

The inflammatory variety is again divided into (1) acute, and (2) chronic.

These variations in clinical types of primary glaucoma

are explained by the rapidity with which the increase of intra-ocular pressure shows itself and the height to which it rises. When the increase of tension is rapid, the inflammatory type results; when gradual, the eyeball accommodates itself to a certain extent to the altered conditions, and symptoms of inflammation or congestion are absent or only very slightly marked. The disease is then known as simple glaucoma (non-inflammatory or non-congestive glaucoma). This type is always chronic in its course.

All forms of glaucoma present very characteristic remissions or intermissions in the course of the disease.

Acute Congestive Glaucoma.

Symptoms.—Glaucoma presents a clinical picture which varies with the type of disease, depending upon the suddenness of onset, duration, and the presence or absence of congestive signs; hence the classification into acute and chronic congestive or inflammatory cases. It is not always possible to draw a sharp line between the different clinical forms, and simple glaucoma may at any time change to acute or chronic congestive.

The affection can be divided into three stages: (1) the prodromal stage, (2) the stage of active glaucoma, and (3) the stage of absolute glaucoma. To these we may add a fourth stage, the stage of degeneration.

The Prodromal Stage.—This stage is present in most instances; it may, however, be absent. There will be some diminution in the acuteness of vision—the sight appears to be obscured by fog. A ring of rainbow tints will be seen around lights; the cornea, especially at its centre, will, upon careful inspection, be found slightly clouded. This condition (œdema) is the cause of the preceding symptoms. There will be a feeling of dulness or slight pain in the eye and head. The anterior chamber is rather shallow, the pupil somewhat dilated, often oval, and sluggish in reaction. The tension of the globe is increased. There is often slight circumcorneal injection.

These symptoms last for a number of hours, and then disappear entirely. The eye then returns to a normal condition,

except that there may be a diminution in the power of accommodation, so that the patient requires stronger glasses than are natural at his age. Hence a rapid increase of presbyopia should always excite suspicion of glaucoma. The attack may be precipitated by insomnia, worry, dissipation, insufficient food, some condition which causes venous congestion, and sometimes by a hearty meal, indigestion, or the local use of atropine. It is perhaps relieved by sleep. At first the attacks may be separated by intervals of weeks or months, but they soon become more frequent.

This stage may be absent or it may last for weeks or months, sometimes several years. Then the disease suddenly passes into the second stage.

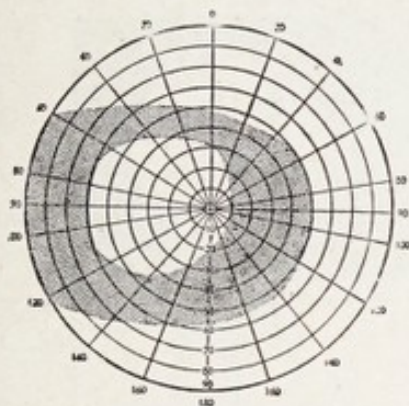


FIG. 168.—THE FIELD OF VISION IN GLAUCOMA; PERIPHERAL CONTRACTION, ESPECIALLY ON THE NASAL SIDE.

The Stage of Acute Glaucoma.—

The sudden onset which characterizes this stage may be due to one of the exciting causes which bring on the prodromal attacks. There are rapid failure of sight, contraction of the visual field, especially on the nasal side (Fig. 168), and severe pain in the eye, radiating along the branches of the fifth nerve and

causing violent headache. This pain is sometimes so severe that it occasions nausea, vomiting, general depression, and febrile disturbances, such attacks having been mistaken for bilious attacks.

Objective examination reveals marked increase in tension; the cornea is clouded or steamy (due to œdema), often presents punctate opacities, and is insensitive (from pressure upon nerve filaments). There is pronounced circumcorneal injection of a dark red colour; the episcleral veins are prominent (Fig. 172, Plate XV.) The pupil is dilated, oval, immobile, and often presents a greenish reflex. The iris is congested, discoloured, and dull. The anterior chamber is shallow, the aqueous sometimes turbid. The lens and the periphery of the iris are pushed forward. The lids are swollen and

œdematous. The ocular conjunctiva is markedly congested and chemotic. No details of the fundus can be seen with the ophthalmoscope, on account of the clouding of the media.

In many cases in the course of a few days or weeks a decided improvement takes place. The pain subsides, congestion and œdema of lids and conjunctiva disappear, the cornea clears up, and sight improves. But the eye does not return to a perfectly normal condition. It is left in a condition known as the *glaucomatous state*. Vision is not so acute as it was before the attack, and the visual field is some-

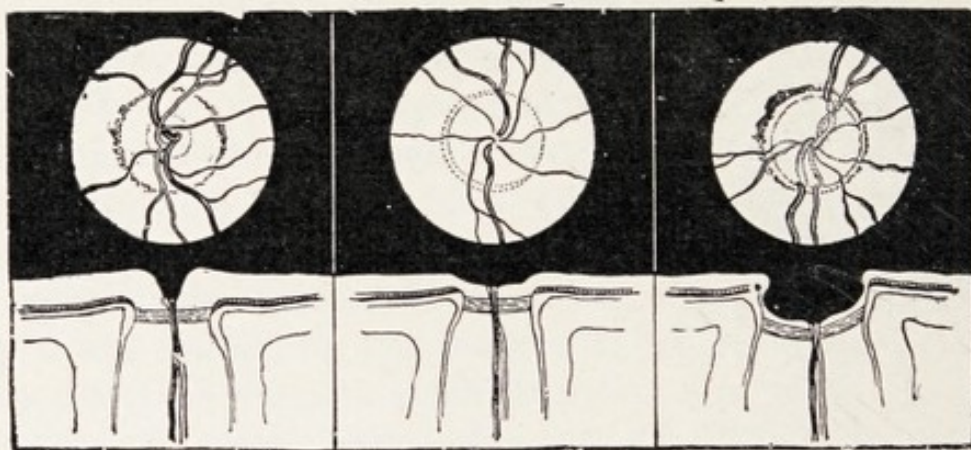


FIG. 169.

FIG. 170.

FIG. 171.

OPHTHALMOSCOPIC APPEARANCES AND LONGITUDINAL SECTION OF THE OPTIC-NERVE DISC.

Fig. 169, Normal disc; Fig. 170, disc in optic-nerve atrophy; Fig. 171, glaucomatous excavation.

what contracted, especially on the nasal side. The pupil remains dilated, oval, and sluggish, the iris discoloured, the anterior chamber shallow, tension increased, and there is more or less circumcorneal injection. The power of accommodation is diminished.

After a period of quiescence of variable length another attack occurs, similar to the first, and this is succeeded by others. Each attack causes greater reduction in sight.

After a while the increased tension causes excavation of the optic-nerve disc (Fig. 171), recognizable with the ophthalmoscope in the intervals between attacks, when the media are clear. The lamina cribrosa, the portion of the sclera

PLATE XV.

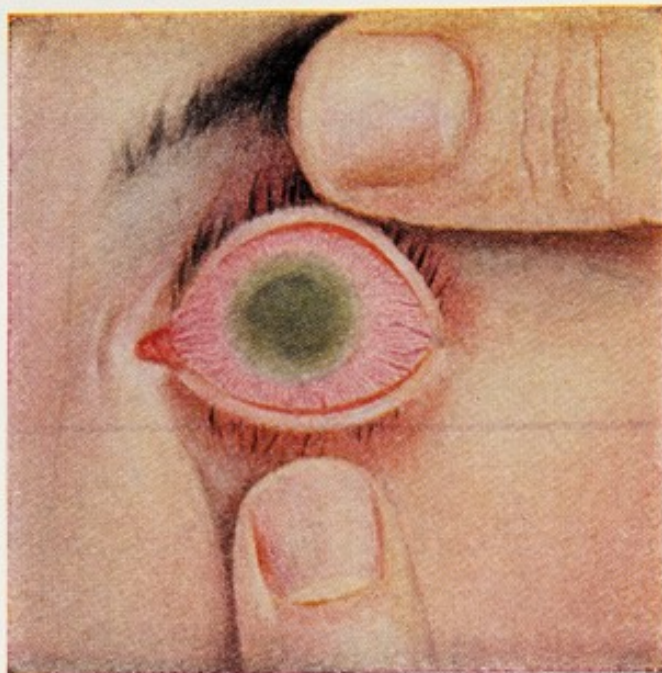


FIG. 172.—GLAUCOMA.

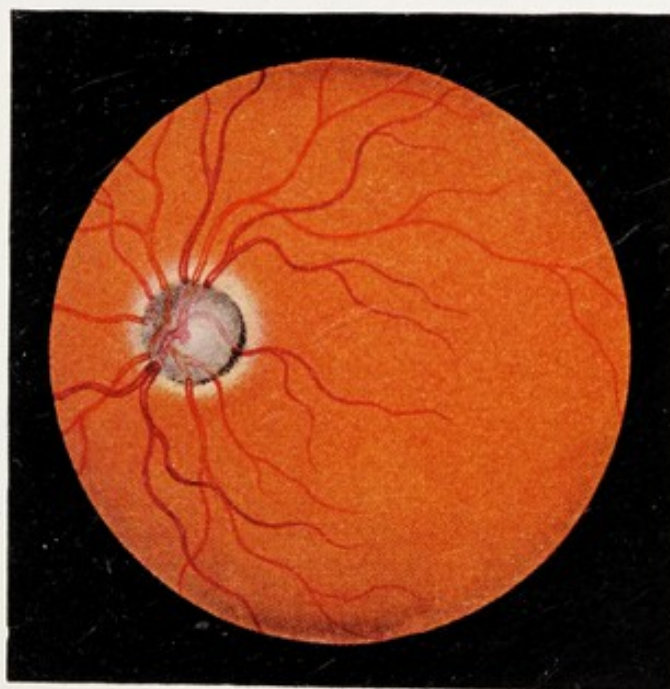


FIG. 173.—GLAUCOMA.

To face page 194.



which is perforated by the optic-nerve fibres, is most yielding, and hence bulges backward with the fibres of the nerve as a result of increased intra-ocular pressure. With the ophthalmoscope a deep depression with very steep or overhanging margins is seen. This is known as the glaucomatous cup or excavation (Fig. 173, Plate XV.). The bloodvessels bend sharply over the margins of this excavation, and often appear interrupted in this situation, being again seen, more or less faintly, at the bottom of the depression. They are pushed over toward the nasal side. The veins are distended and the arteries contracted. There is pulsation in the veins and in the arteries at the disc. Pulsation in the veins is often seen in health, but arterial pulsation is always pathological, and is an important symptom of glaucoma (it is also seen in certain forms of heart disease). If not spontaneous, it can be produced by slight pressure upon the eyeball. The optic nerve becomes atrophied, and the disc appears pale, or in late stages greenish or bluish. The disc is often surrounded by a whitish-yellow ring (glaucomatous halo or ring), due to atrophy of the choroid in this situation.

The Stage of Absolute Glaucoma.—With each succeeding attack the diminution in vision becomes greater, until finally blindness ensues. The condition is then known as absolute glaucoma. There are now no inflammatory or congestive symptoms, except a dark red zone of circumcorneal injection and dilated episcleral veins. The cornea remains clear or slightly clouded, and often more or less insensitive. The pupil is widely dilated, immobile, and often presents a greenish reflex. The iris is atrophied, narrow, gray, with a border of dark pigment. The anterior chamber is shallow. Tension is markedly increased. The fundus presents a deep excavation of the disc, the glaucomatous ring, and atrophy of the optic nerve. Pain may disappear entirely, but frequently continues, and the patient suffers from severe attacks at intervals.

The Stage of Degeneration.—After absolute glaucoma has lasted a variable length of time, the eyeball is apt to degenerate. The cornea becomes more or less opaque, and frequently covered by deposits or vesicles. The sclera bulges,

and bluish-black staphylomata appear between the cornea and the equator. Detachment of the retina often takes place. The lens is apt to become cataractous. The patient may experience subjective sensations of light. The final result is that the eyeball either softens, shrinks, and atrophies, or else there are ulceration and perforation of the cornea, followed by iridocyclitis, with subsequent atrophy of the eyeball, or panophthalmitis and phthisis bulbi.

Glaucoma Fulminans is the name given to a form, of rare occurrence, in which very violent symptoms of inflammation develop suddenly, and in which blindness may ensue in a few hours, unless proper treatment be instituted.

Chronic Congestive Glaucoma.

This form of glaucoma is much more common than the acute variety just described. Its symptoms resemble those of the acute variety, but are less intense and more gradual in their onset. Very often the prodromal stage passes uninterruptedly into the stage of active glaucoma, and there is no succession of attacks. The ocular conjunctiva is congested and dusky, the episcleral veins being very prominent. There is circumcorneal injection of a dark red colour; the cornea is steamy and more or less insensitive; the anterior chamber is shallow, and the lens and iris are pushed forward; the pupil is dilated, oval, and rigid, surrounded by the discoloured, narrow, and atrophic iris, and presents a greenish reflex. There is pain, but this is not so intense as in the acute form. There are gradual loss of sight and progressive limitation of the field, especially on the nasal side. After having lasted a sufficient length of time, the ophthalmoscope reveals the same changes in the fundus which are found in acute cases.

The chronic form has the same termination as the acute: absolute glaucoma and finally degeneration of the eyeball. In many cases no sharp line of differentiation can be drawn between the acute and the chronic forms of inflammatory glaucoma.

Simple Glaucoma.

In simple glaucoma (chronic non-inflammatory glaucoma) there is an absence of any marked external symptoms; there are no inflammatory attacks and no pain.

The diagnosis is made by noting the increase of tension, and by the picture presented when the ophthalmoscope is used.

This form develops very gradually, and may have lasted some time before the patient becomes aware of the existence of any abnormal condition. The eye may appear perfectly normal externally, or there may be slight circumcorneal injection and moderate dilatation of the episcleral veins. The pupil is slightly or moderately dilated and is sluggish. The tension is elevated, often moderately; sometimes the increase is not constant. After the disease has lasted a certain length of time, the ophthalmoscope shows glaucomatous excavation (Figs. 171 and 173, Plate XV.), atrophy of the optic nerve, and the circumpapillary ring of choroidal atrophy, the degree of change depending upon the duration of the process.

There may be periods when the patient complains of symptoms like those in the prodromal stage: Foggy vision, coloured halos around artificial lights, and diminished accommodation. There are gradual loss of sight, premature presbyopia, and progressive contraction of the visual field, especially on the nasal side. Paracentral scotomata are common, and there is usually enlargement of the 'blind spot.' Central vision is the last portion to be lost. On this account the patient may be able to read, and yet the field of vision be quite limited.

The course of simple glaucoma is very insidious, and its duration is years. If unchecked, it terminates in blindness if the patient lives long enough. Sometimes this form gradually changes into the chronic inflammatory type, and then goes through the stages of the latter disease.

Etiology.—Glaucoma is a disease of advanced life, occurring generally after forty years of age, infrequently before this period. The congestive or inflammatory form attacks women

more often than men; the simple type occurs equally in both sexes. It usually involves both eyes, the second eye generally becoming affected months or years after the first.

The cause of glaucoma is unknown. Jews appear to be more liable to the disease than others. There is not uncommonly a history of heredity. Arterio-sclerosis and cardiac disease, chronic constipation, and the gouty and rheumatic diatheses, are predisposing factors. A disposition toward glaucoma exists in hypermetropic eyes (myopic eyes are far less liable to the disease) as well as in small eyeballs, and in those in which the cornea is of small size. The exciting causes may be the following: Emotions, especially of a depressing character, insomnia, worry, injudicious use of

atropine, overuse of ametropic eyes, insufficient food, indigestion, dissipation, various fevers, especially influenza, and any condition which produces venous congestion.

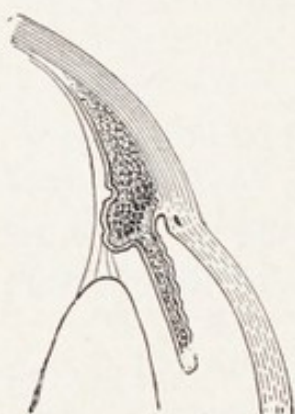


FIG. 174.—ANGLE OF THE ANTERIOR CHAMBER IN THE NORMAL EYE.

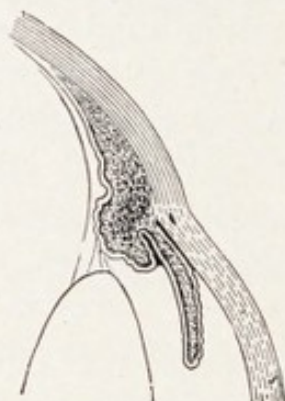


FIG. 175.—ANGLE OF THE ANTERIOR CHAMBER IN RECENT INFLAMMATION OF GLAUCOMA.

Pathology.—All the symptoms of glaucoma can be explained by the increase in intra-ocular pressure. But there is no general agreement

as to the exact cause of this increase. The intra-ocular fluids, after being secreted in the vitreous chamber of the eye, pass round the lens, through the pupil into the anterior chamber, to the iris angle, and are thence excreted into the canal of Schlemm. It is probable that the disease is due to some interference with excretion. The obstruction to the escape of the intra-ocular liquids is thought to be situated at the angle of the anterior chamber (iris angle). It is believed that this angle is obliterated by pressure of the peripheral portion of the iris against the sclero-corneal junction (ligamentum pectinatum) by the congested and swollen ciliary processes; later

there is an *adhesive inflammation* between these opposed surfaces through proliferation of the endothelium of Descemet's membrane and of the iris. As already explained, this iris angle forms the principal exit for intra-ocular fluids, and when it is blocked retention takes place. An additional causative factor is supposed to be the *narrowing of the circumlental space* (between the margin of the lens and the ciliary body) in eyes predisposed to glaucoma. This area serves for the passage of the lymph which is secreted by the choroid and part of that produced by the ciliary body; it is encroached upon by the increased size of the lens with advancing age and by the comparatively large size of the ciliary body and the smaller size of the eyeball in general in *hypermetropes*. This obstruction in the communication between vitreous and aqueous chambers would cause venous congestion, subsequent swelling of the ciliary body, overdistension of the vitreous, with the result of pushing the periphery of the iris against the sclero-corneal junction, thus blocking up the iris angle. But no explanation of the production of glaucoma satisfactorily fits all types of the disease; probably they are not all developed in the same manner.

Differential Diagnosis.—The inflammatory form of glaucoma has been mistaken for iritis and conjunctivitis. The use of atropine in such cases has caused great mischief. The dilated pupil, increase in tension, turbidity of cornea, as well as the subjective symptoms, ought to be sufficient to differentiate (see tables, p. 161). The peculiar greenish pupillary reflex has been diagnosed as cataract, and thus valuable time has been lost in awaiting the ripening of this supposed lens change. In acute cases, the violent headache and general constitutional symptoms have misled the medical practitioner, and been responsible for the diagnosis of some general febrile disease at a time when active ocular treatment was urgent.

Simple glaucoma is sometimes mistaken for primary optic-nerve atrophy. In the latter case there will be absence of increased tension, the excavation of the disc is shallow and gradual (Fig. 170, also Plates XV. and XX.), there is apt to be greater diminution in central vision, the form-fields present

more uniform contraction, and the colour-fields show greater peripheric loss. There are, however, instances in which the differential diagnosis between these two affections is not easy.

Prognosis is bad in every case if proper treatment is not carried out without delay. Vision becomes worse, more or less rapidly, but progressively, until complete blindness results. With correct treatment, the prognosis is more favourable. The disease in most cases can be arrested, so that the patient retains what sight he has.

Treatment.—(1) Operative, (2) medicinal, and (3) general. In general terms, it may be said that in recent cases iridectomy is the best treatment; but when the base of the iris has become permanently adherent in the iridic angle the formation of a leaking cicatrix is advisable.

Non-Operative Treatment consists chiefly in the local use of miotics. The miotics employed are eserine, salicylate or sulphate ($\frac{1}{4}$ to 1 per cent.), and pilocarpine nitrate (1 per cent.). The former has the stronger action, but produces more conjunctival irritation and ciliary congestion when used for a long time. These solutions are instilled two or three times a day or oftener. These act by drawing the iris away from the angle of the anterior chamber; hence they are of no value after the iris has become atrophic and is incapable of contracting, a condition observed in old cases of glaucoma. They usually prove only of temporary advantage. But in a mild chronic case in an old person their constant use may serve to keep the disease permanently in check. They should then as a rule be preferred to operation. They may be used in the prodromal stage to cut short the attack, or at other times if for any reason operation cannot be performed. They are sometimes useful in acute inflammatory attacks to alleviate pain, reduce tension, diminish cloudiness of the media, and increase the depth of the anterior chamber, thus rendering iridectomy easier of execution. During an acute attack, hot bathing of the closed lids, leeches to the temple, opium for the relief of pain, and eserine salicylate (1 per cent.) every hour may be prescribed.

General Treatment comprises rest, proper and sufficient food, salicylate of sodium, anti-rheumatic remedies, relief of constipation, correction of ametropia, avoidance of excess of eating, drinking, and late hours, and the relief of any of the other conditions which have been mentioned as predisposing to glaucoma.

Operative Treatment may consist of iridectomy, sclerotomy, or one of the operations designed to produce a cystoid filtering cicatrix.

Until recently, iridectomy was the operation of choice and the one resorted to almost exclusively. Since a few years, however, various procedures having for their object the production of a filtering cicatrix in the sclera, just beyond the limbus, have been used extensively. These operations have been resorted to frequently for all forms of glaucoma excepting the acute congestive type in which most operators still prefer iridectomy. But notwithstanding the conceded usefulness of these procedures, cataract and late infections of the eyeball have occurred in a sufficient proportion of cases to constitute a handicap which has to be considered; these late infections are made possible by the thinness of the barrier remaining between the interior and outside of the eyeball. In a case of unilateral glaucoma the patient should be warned that the second eye nearly always becomes affected sooner or later. He should be instructed in the early subjective symptoms of the disease and told of the importance and good prognosis of early treatment. In the absence of symptoms, the field of vision should, if possible, be mapped out three or four times a year.

Iridectomy.

The *instruments* required include an eye speculum (Fig. 176), a fixation forceps (Fig. 177), a bent, lance-shaped knife or a Graefe cataract knife (Fig. 177*a*), a curved iris forceps (Fig. 179), a curved iris scissors (Fig. 180), a metal spatula (Fig. 197), and a blunt iris hook (Fig. 181).

Cocaine may be employed in most cases. But in many

instances of the inflammatory forms of glaucoma, complete general anæsthesia is necessary, since the tense and congested tissues do not readily absorb local anæsthetics, and the cutting

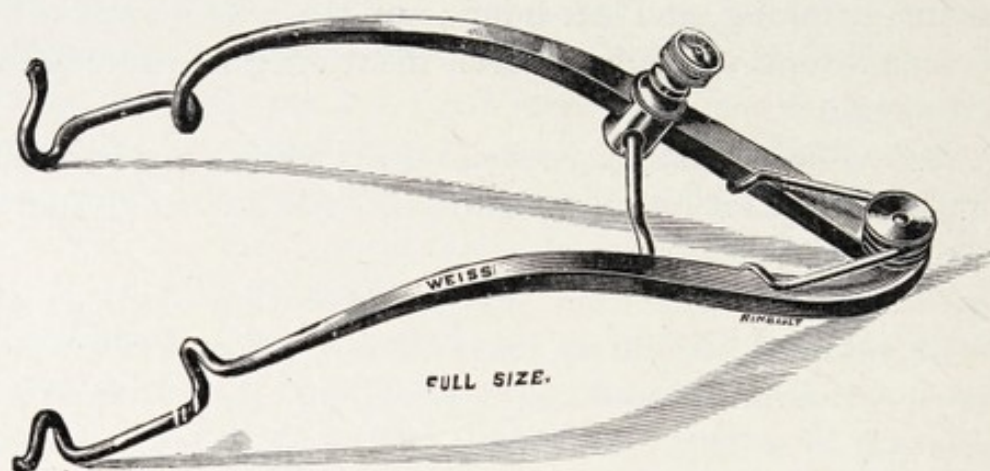


FIG. 176.—EYE SPECULUM.



FIG. 177.—FIXATION* FORCEPS.



FIG. 177a.—NARROW GRAEFE KNIFE



FIG. 178.—KERATOME.



FIG. 179.—CURVED IRIS FORCEPS.

of the iris is painful. Solution of adrenalin chloride (1:1,000) should be instilled two or three times before operation to reduce the congestion, whether one employs local or general anæsthesia.

Operation.—Iridectomy for glaucoma is usually done upwards, so that the defect is covered by the upper lid, thus limiting troublesome optical effects of the coloboma. The operator, standing behind the patient's head, introduces the speculum. A narrow Graefe knife is held between the thumb and two fingers of the hand corresponding to the eye to be operated upon, the fixation forceps being held in the other hand. The patient, if not under general anæsthesia, is told to look downwards a little. A firm hold is taken with the forceps of the conjunctiva just below the corneal margin. A gentle tension is kept on the forceps so as not to press on the globe and so increase the internal pressure. The knife is made to enter 1 mm. behind the limbus, at about the junction of the lower five-sixths with the upper sixth, passes across the anterior chamber (great care being exercised not to wound the iris or lens capsule), and emerges at a corresponding point 1 mm. behind the limbus on the opposite side, the incision being completed by to-and-fro movements. Towards the end of this section it is well to turn the edge of the knife a little backwards so as to get a little tongue of conjunctiva at the apex of the flap, as this helps the healing of the wound.




FIG. 180.—CURVED IRIS SCISSORS.

An assistant now takes the fixation forceps if a general

anæsthetic is being used. Otherwise the patient is asked to continue to look a little downwards and the fixation forceps is laid aside. The operator passes the closed iris forceps through the scleral incision to the pupillary margin, opens the instrument, seizes the pupillary border of the iris between its branches, and makes a radial cut in the iris at one end of the wound (Fig. 183). The iris is then torn away from its base as far as the other end of the wound, where it is cut off with the scissors. The piece of iris removed should comprise the entire width, including the ciliary attachment. It was formerly taught that at least one-fifth of the circle of the iris should be removed, but a moderate iridectomy appears to be just as efficient as a wide one.

In iridectomy performed on an aphakial eye (after cataract operations), it is difficult to grasp the iris with forceps. In such cases the iris is drawn out with the blunt hook (Fig. 181).



FIG. 181.—BLUNT IRIS HOOK.

The resulting coloboma must be cleanly cut, and the pupillary margin of the iris must return to its natural position, producing a keyhole-shaped pupil (Fig. 187). No iris tissue must be left in the wound, since this causes subsequent irritation and complications. Proper replacement of the iris is accomplished by stroking the wound with a spatula, or, if this is unsuccessful, by passing the spatula into the incision and freeing the angles.

Hæmorrhage into the anterior chamber is common. The blood is usually absorbed in a few days. It is not wise to make too great efforts to dislodge the blood, since undue pressure may cause the lens to become cataractous.

Until the operation wound is soundly healed, the pupil of the unoperated eye should be kept moderately contracted with eserine, lest the worry and the occlusion precipitate an acute attack in this eye at a time when operation would be inconvenient.

Both eyes are bandaged, and the patient is kept quiet in bed. After two days, the unoperated eye may be left uncovered. Recovery is uneventful in most cases. In some cases the anterior chamber is not re-formed for several days. Cystoid cicatrix sometimes results—a condition which, though it has dangers of its own, facilitates elimination of fluid, and is deliberately aimed at by some surgeons with that object.

Results of Iridectomy in Glaucoma.—The manner in which iridectomy relieves glaucoma is not definitely known. The earlier the operation is performed, the more sight is preserved. Hence it is advisable to do the operation as soon as possible.

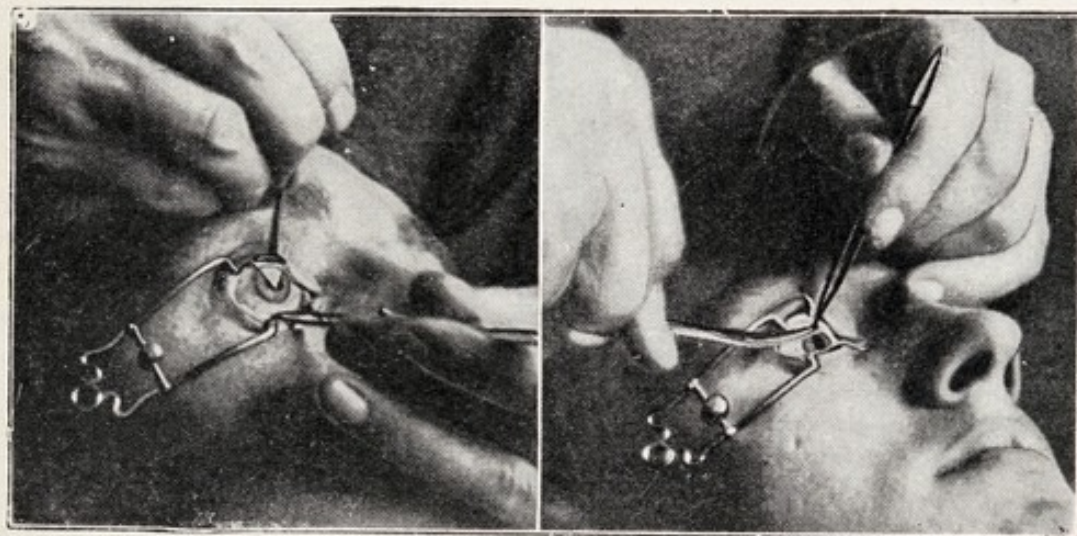


FIG. 182.—SECTION OF THE SCLERA
IN IRIDECTOMY.

FIG. 183.—DIVISION OF THE IRIS
IN IRIDECTOMY.

The best time is during the prodromal stage, in the interval between attacks. In inflammatory cases, during the stage of acute glaucoma, the operation is very difficult, on account of the severe congestion and the shallowness of the anterior chamber. Under such circumstances, it may be advisable to try hot bathing and eserine every half-hour for a few hours in order to reduce tension and increase the depth of the anterior chamber, and then to operate. But if these measures do not act promptly, the operation must be performed without further delay.

The most favourable results of iridectomy are seen in cases of acute inflammatory glaucoma. In such instances pain

and inflammatory symptoms subside rapidly, and sight returns up to the degree possessed before the onset of the attack. Furthermore, the results are generally lasting. If the acute attack has been preceded by a chronic glaucoma, the effects of iridectomy may be only temporary. Corneo-scleral trephining should then be done.

In chronic inflammatory glaucoma, the results of iridectomy are favourable, but not so brilliant as in acute cases. The operation relieves the pain and inflammatory symptoms, and the media again become clear; but since the disease has already caused permanent changes in the disc and optic

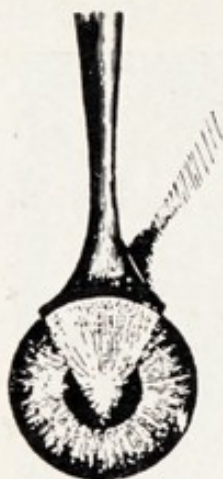

FIG. 184.—IRIDECTOMY: SCLERAL SECTION.

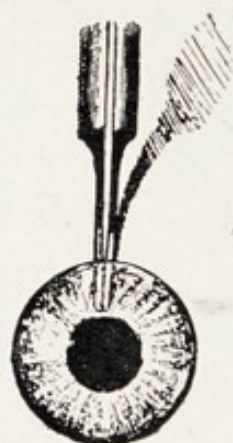

FIG. 185.—IRIDECTOMY: GRASPING THE IRIS.

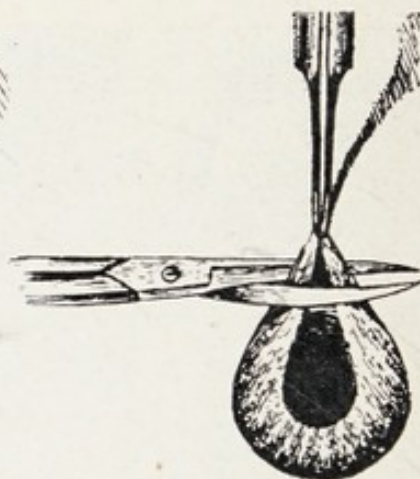


FIG. 186.—IRIDECTOMY: EXCISION OF THE PIECE OF IRIS.

nerve, the restoration of sight is limited. But the progress of the disease is generally checked, though sometimes a second operation must be performed. In a certain number of cases, however, there is progressive diminution in sight, notwithstanding the operative intervention.

In simple glaucoma, the results of iridectomy are apt to be less permanent than in the inflammatory variety. Corneo-scleral trephine is probably here the better operation. The most that we can expect from either operation is that the acuteness of vision existing at that time will be preserved, and that the progress of the disease will be arrested. This happens in the majority of cases. In some cases the disease

progresses after a shorter or longer interval of arrest, and blindness finally ensues. It occasionally happens that, though the tension of the eye remains normal or subnormal, optic nerve atrophy causes progressive loss of sight.

In absolute glaucoma enucleation may be necessary for the relief of severe pain.

Indications for Iridectomy.—Besides (1) glaucoma, the operation may be indicated in (2) some cases of chronic and recurrent iritis and iridocyclitis; (3) complete circular synechia; (4) partial corneal staphyloma; (5) tumours and foreign bodies in the iris; (6) recent prolapse of the iris; (7) as a part of the operation of extraction of cataract—here the coloboma should be smaller than in glaucoma (Fig. 187); (8) as a means of improving sight (artificial pupil, optical iridectomy) in central opacities of the cornea and lens, occlusion of the pupil, and keratoconus.



FIG. 187.—IRIDECTOMY.

In performing *optical iridectomy* a small incision (4 to 5 mm.) is made in the cornea, 1 mm. from the limbus, either with a keratome or with a 'broad needle' (Fig. 204a), the iris drawn out with curved iris forceps (Fig. 179) or the blunt hook (Fig. 181), and its pupillary portion excised, making as small a coloboma as is practicable. The best position for the artificial pupil is downward and inward; but when there is a corneal opacity, the site must correspond to the most transparent portion of the cornea. The effects of optical iridectomy are often disappointing; hence, before operating, it is well to dilate the pupil and, by applying a stenopeic slit held in different positions, to ascertain whether there is an improvement in sight under these circumstances.

Sclerotomy (incision through the sclera) is sometimes performed for the temporary relief of glaucoma. The incision in the sclera is made either in front of the iris (anterior sclerotomy) or behind the ciliary body (posterior sclerotomy).

In *Anterior Sclerotomy* an incision is made with a Graefe knife 1 mm. behind the limbus, similar to that made in iridectomy, but the middle third is left uncut, and forms a bridge connecting sclera and cornea.

In *Posterior Sclerotomy* an incision is made through the sclera into the vitreous with a Graefe knife or with a small trephine. The site usually selected is between the external and inferior recti muscles. The cut must not approach the cornea nearer than 7 mm., so as to avoid endangering the ciliary body. The opening becomes blocked with vitreous, so that the operation seldom produces even temporary relief of tension.

Formation of a Leaking Cicatrix.—When treatment of glaucoma has been delayed until the iridic angle has been permanently obliterated by inflammatory adhesion of the base of the iris, simple iridectomy seldom produces lasting benefit. But if prolapse of one of the pillars of the coloboma should prevent sound healing of the incision in the sclerotic, a leaking scar results through which the excess of intra-ocular fluid filters out under the conjunctiva. Operations have been devised to produce a similar result without inclusion of iris in the scar.

Corneo-scleral trephining is the operation which, in *chronic* glaucoma, is most commonly employed, and has given the best results. It may fail owing to the trephine hole becoming occluded with impermeable scar tissue. After successful trephining the interior of the eye is only protected by the thin conjunctival membrane, so that at any time abrasion or inflammation of the conjunctiva may possibly lead to loss of the eye, and this has happened in a considerable number of cases. But it is less uncertain, and no more dangerous than other permanent drainage operations.

Trephining for glaucoma was tried by Argyll Robertson fifty years ago, and by others since, but the operation as now performed was perfected by R. H. Elliot.

Instruments required are speculum, fixation forceps, iris forceps, squint scissors, iris scissors, trephine 1.5 mm. diameter (Fig. 190), Lang's knife (Fig. 188a), iris repositor, needle holder, small curved needle, and silk.

Everything having been prepared as described in Chapter XXXIII., and the eye having been cocainized and the conjunctiva blanched with adrenalin, the speculum is inserted.

The patient looks downwards. The conjunctiva is grasped with fixation forceps about one-third of an inch above the corneal margin. A large flap is cut, as shown in the diagram, and dissected to the corneal margin. The ends of the incision must not approach the corneal margin, or the percolation of aqueous under the conjunctiva might be interfered with.

The flap is turned over the cornea, and held with a little piece of lint wrapped round the fixation forceps. With Lang's knife the tissue is dissected from the sclerotic in the neighbourhood of the cornea, and the incision is carried horizontally into the cornea, splitting it for about 2 mm. The superficial laminae are turned back with the flap. The trephine is applied with its centre over the apparent corneo-scleral junction, and



FIG. 188a,—LANG'S KNIFE.

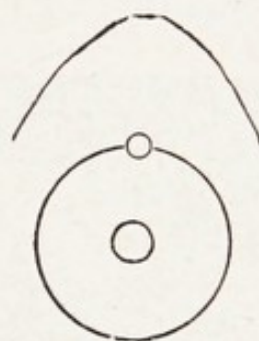


FIG. 188b.

the disc cut with a few semi-rotary movements with light pressure. One feels the trephine go through the coat of the eye, the patient usually experiences a sharp but not severe pain, aqueous escapes, and the pupil is displaced towards the wound. Usually the disc remains attached by a hinge on one side, and a knuckle of iris presents in the opening. Disc and iris knuckle are grasped together with iris forceps, and cut off with iris scissors. The iridectomy is a small peripheral hole. The flap is replaced over the wound, and its apex secured with one fine stitch. The upper lid is lifted by the lashes over the wound as the speculum is removed. Throughout the operation the greatest care must be taken to avoid button-holing the flap.

After the operation one drop of sterile liquor atropinae should be instilled, and this should be repeated every

day until all danger of iritis, a frequent complication, has passed.

Secondary Glaucoma is the name given to those cases in which increased tension and other symptoms of glaucoma are developed as a result of some other ocular disease or injury. The clinical picture varies with the disease which it complicates. The consequences, if the condition be not relieved, are the same as in primary glaucoma.

The ocular affections which are most frequently followed by secondary glaucoma are: Ulcers or wounds of the cornea with prolapse of iris, corneal cicatrices and staphylomata with incarceration of the iris, iridocyclitis, uveitis, choroiditis, and myopia of high degree, total posterior (ring) synechia, dislocation of the lens, traumatic cataract (swelling of the

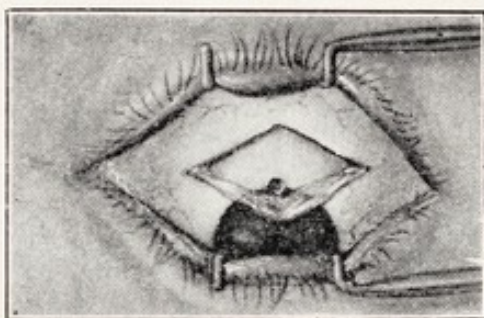


FIG. 189.—ELLIOT'S OPERATION FOR GLAUCOMA.



FIG. 190.—ELLIOT'S TREPHINE.

lens), the operations of extraction, needling of the lens and discission of secondary cataract, intra-ocular tumours, and foreign bodies in the eye. In old persons with arterio-sclerosis, a form of secondary glaucoma with retinal hæmorrhages is seen, and is known as hæmorrhagic glaucoma.

The treatment depends upon the primary disease. We endeavour, if possible, to remove the cause. Hæmorrhagic glaucoma does not respond favourably to treatment. Iridectomy is liable to be followed by an aggravation of symptoms. The other agents used in glaucoma may be tried, but are usually of no benefit.

Congenital Glaucoma (hydrophthalmos, buphthalmos) is a disease of early childhood, either congenital or developing in infancy, and usually involving both eyes. There is an

increase of intra-ocular tension which, on account of the yielding character of the sclera at this period of life, causes marked enlargement of the eyeball. The cornea is enlarged and bulging, and either remains clear or becomes clouded; the anterior chamber is very deep; the pupil is dilated, and the iris atrophied and tremulous; the sclera is thinned and bluish, owing to the uveal pigment showing through; the disc is deeply excavated. The disease progresses slowly. Though in some cases it comes to a spontaneous stop with the preservation of moderately good vision, it generally leads to blindness. The prognosis is therefore unfavourable. As a rule treatment is of no avail. Since, however, a few cases have been benefited by iridectomy, sclerotomy, and repeated paracentesis of the anterior chamber, one of these measures may be tried. Corneo-scleral trephining has been performed upon many of these cases at Moorfields, and in a few it appears to have arrested or retarded the progress of the disease.

CHAPTER XVII

DISEASES OF THE VITREOUS

Anatomy.—The vitreous is a transparent, colourless mass of soft, gelatinous consistence, which fills the posterior cavity of the eyeball behind the lens. Its outer surface presents a thin, structureless covering, the hyaloid membrane. The vitreous is traversed from the optic disc to the posterior capsule of the lens by a canal—the hyaloid canal—serving as a lymph channel in the developed eye, and containing the hyaloid artery during foetal life. In structure the vitreous consists of a transparent network, in the meshes of which are clear liquid and round and branching cells, probably emigrated white blood corpuscles. The vitreous has no bloodvessels, but receives its nourishment from the surrounding tissues, the choroid, ciliary body, and retina.

Persistent Hyaloid Artery.—The hyaloid artery usually disappears entirely during the later months of gestation. Occasionally a greater or lesser remnant persists during life. This can be seen with the ophthalmoscope, as a grayish cord or thread, which arises from the optic disc and stretches into the vitreous, with a free extremity or occasionally attached to the posterior pole of the lens. Rarely the hyaloid canal is abnormally dense, and is visible as a grayish, tubular cord extending from disc to lens.

Muscae Volitantes is the term employed for the appearance of spots before the eyes, without appreciable structural change in the vitreous or other media. They are caused by the shadows cast upon the retina by the cells normally found in the vitreous, and are present in all eyes under certain circumstances, such as exposure to a uniform bright surface, or in looking through a microscope. They are found more frequently in errors of refraction (especially myopia), and temporarily during digestive derangements. They occur as grayish shadows, which move with changes in the position of the eyes, having the shape of dots or globules, frequently collected into strings. They may have any shape. They

are annoying, and sometimes alarm the patient, but are of no importance, and do not affect the acuteness of vision. The treatment consists in correcting any error of refraction, or in relieving the disturbance of digestion. They often persist until the patient ceases to look for them, and thus forgets their existence.

Opacities of the Vitreous.—These are quite common. They may occur as a consequence of changes in the vitreous itself, but usually they are the result of disease or of hæmorrhages from the neighbouring structures—ciliary body, choroid, and retina. They vary in number, shape, and size:

1. A diffuse cloud or a dust-like haziness often accompanies cyclitis, choroiditis, irido-choroiditis, and retinitis. When dust-like it is suggestive of syphilitic choroido-retinitis and iridocyclitis.

2. The opacities may occur in the form of dots, flakes, threads, or membranous masses, the result of exudations or hæmorrhages.

3. Sometimes extensive membranes are met with, which are attached to the retina and provided with bloodvessels. These are supposed to result from chronic retinal disease, called *retinitis proliferans*.

Fluidity of the Vitreous (*Synchysis*) is a liquid alteration in consistency which, when limited in degree, may be merely a senile change; but when pronounced, it is due to degeneration of this structure dependent upon disease of neighbouring parts: choroid, ciliary body and retina, and found often in myopia of high degree. When opacities are present, these are observed to move freely in such fluid vitreous; there is often diminished tension of the eyeball, tremulousness of the iris, and sometimes a predisposition to detachment of the retina.

Occasionally small, glistening opacities are found in degenerated eyeballs and in some which are normal in other respects, especially in old persons. They fall in a silvery shower when the eyeball is moved. They are usually crystals of cholesterin in a fluid vitreous, and are known as *synchysis scintillans*.

Symptoms.—There is more or less disturbance of vision, depending upon the situation, size, and density of the opacities

The opacities are most frequently movable, indicating a fluid vitreous (synchysis), the result of disease of surrounding parts. On this account, the visual disturbance may vary according to the part of the vitreous occupied by the opacity, and the patient may be able to move the eyeball in a certain way so as to throw the opacity out of the line of sight. Fluid vitreous gives rise to diminished tension, often a tremulous condition of the iris, and may predispose to detachment of the retina ; but it is often discovered in an eye which in all other respects appears normal.

Diagnosis is made with the ophthalmoscope at a distance. The vitreous opacities appear as dark spots upon a red ground, when the eye is moved in various directions. When faint, the opacities are best seen with diminished illumination and with a plane mirror.

Prognosis varies with the size, density, and nature of the opacity. Syphilitic opacities and small hæmorrhages frequently clear up when treated early. Others become smaller and less dense after a time. A great many are permanent.

Treatment.—Anti-syphilitic treatment is indicated in specific cases. In others small doses of potassium iodide and mercury may be of service. Diaphoretics and cathartics are sometimes employed. Subconjunctival injections of physiological salt solution (0·6 per cent.) may be useful.

Hæmorrhages into the Vitreous.

These usually come from the choroidal vessels, and produce opacities of small or large size, causing the symptoms of opacities in the vitreous. When small, they have a red colour as seen with the ophthalmoscope ; when large, no red reflex can be obtained, and the pupil appears black. The smaller hæmorrhages are often absorbed ; the larger ones frequently leave dense membranous masses. They occur after injuries, after operations upon the globe, in choroiditis, myopia of high degree, and retinitis. They are not uncommon in old persons with atheromatous arteries. Sometimes they are found in the young without discoverable cause, and in such cases they may recur repeatedly. The exciting cause is often a strain of some sort, such as a cough.

Treatment consists in absolute rest, bandage to the eyes, treatment of any accompanying ocular affection or of the general condition.

Foreign Bodies in the Vitreous.

The entrance and lodgment of a foreign body (wood, glass, or metal) within the globe usually causes severe inflammation and destruction of the eyeball as a result of iridocyclitis or panophthalmitis, unless the substance be promptly extracted. The gravity of the accident depends upon the nature of the foreign body and the presence or absence of infection. Particles of iron which penetrate the eye during smiths' work, riveting, or stone breaking are usually so heated as to be sterile. Occasionally these substances remain quiescent and become encysted; but even in such cases there is danger of subsequent inflammation. The presence of a particle of iron for any length of time is apt to cause a rusty-brown or greenish discoloration of the iris and lens. A fragment of copper remaining within the globe almost invariably leads to destruction of the eye. Lead pellets, gold, silver, porcelain or glass, unless septic, may become encapsuled, and for a long time may cause little or no trouble, but eventually an eye containing a foreign body anywhere posterior to the lens usually becomes inflamed and disorganized. Stone in the vitreous leads to destruction of the eye, owing to the impossibility of removing it; moreover, stone is usually septic.

A foreign body in the iris is seldom left, being accessible, but if not septic, it may become encapsuled, and cause no trouble. A man presented himself at Moorfields with a yellowish swelling on the iris about as large as half a No. 6 shot. It caused no trouble, but he was going abroad again, and anxious to have




FIG. 191.—HAAB'S
GIANT MAGNET.

it removed. It contained a piece of stone which had entered the eye during blasting twelve years before.

Diagnosis.—If the patient comes under observation soon after the injury, before the media have become hazy, we may possibly be able to see the particle with the ophthalmoscope, or a careful examination of the field of vision, disclosing a scotoma, may locate the foreign body. The site of the wound of entrance and the probable direction which the foreign body took must be taken into account. In many instances an X-ray photograph will reveal its presence. By means of a special localizing apparatus, an expert in this branch of radiography may then be able to define its exact situation.

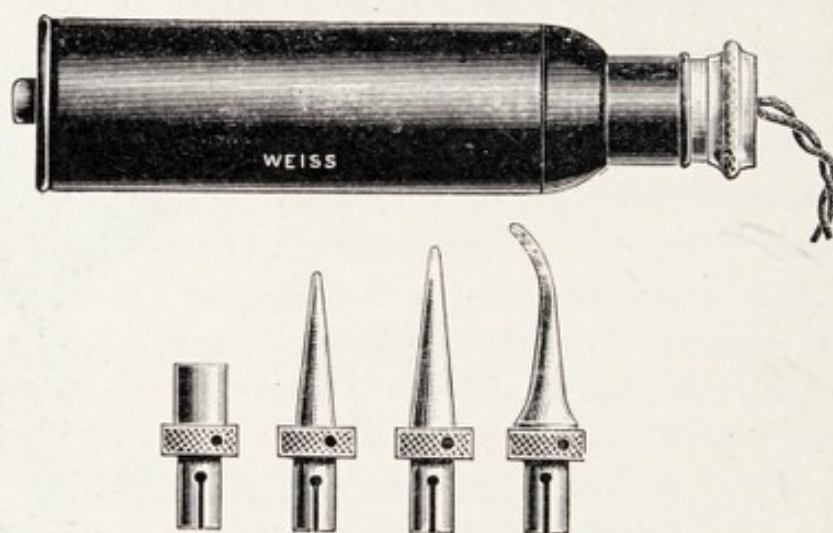


FIG. 192.—PORTABLE MAGNET.

But owing to the bones, and the minute size of the foreign body, and the fact that it may not be more opaque than the surrounding structures, a negative result is never conclusive. If it be of iron or steel, the giant magnet (Fig. 191) will frequently indicate the presence of the foreign body by the production of pain when the point is brought near the eyeball, or the bulging of the iris or forward movement of the lens when the particle is within these structures.

Treatment.—If the substance is a piece of iron or steel, an attempt to extract it with a magnet should be made at once. We should also try to remove other foreign bodies (glass, wood, copper, lead) as soon as possible after they have been located, by means of delicate forceps introduced through

the original wound, or through an opening into the vitreous cavity made at the point at which the foreign body has been located; but if this does not seem feasible, they should be left alone, especially if there be no symptoms of infection or irritation, and the patient can be kept under constant observation. In such cases, however, the question of enucleation must be considered.

Magnet Extraction.—A piece of iron or steel embedded in the iris is best removed by making an incision with a broad

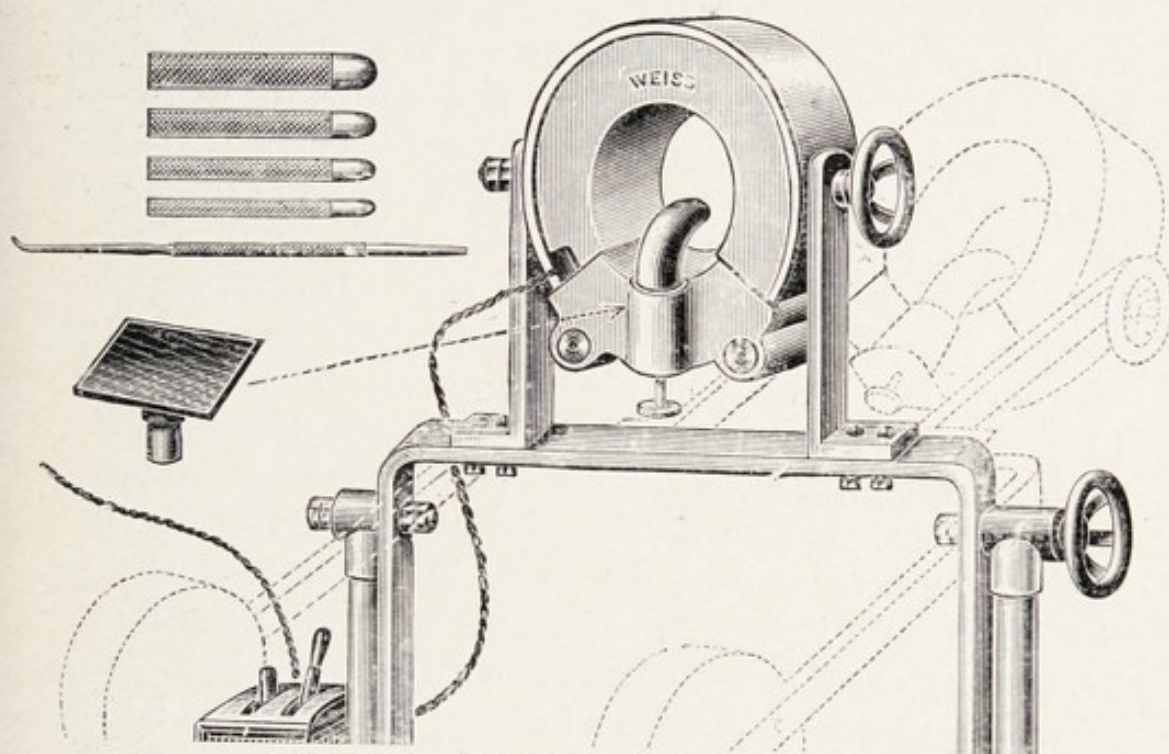


FIG. 193.—MELLINGER'S RING MAGNET.

needle or keratome 2 or 3 mm. from the limbus, and introducing the pole of a small portable magnet. If this fails a small iridectomy embracing the foreign body should be performed. If the piece of steel is free in the anterior chamber a similar incision should be made if possible without losing aqueous. The foreign body is drawn forward to the back of the cornea and drawn along towards the incision. As the pole of the magnet passes over the incision the posterior lip of the wound is depressed, and the foreign body may usually be drawn out through the wound. If a magnetizable foreign body is in the lens, an attempt should be made to draw it

forward into the anterior chamber by means of the giant magnet. If this proves successful, the patient is then put on the table and the foreign body removed as already described.

If the magnet extraction fails, or if the foreign body in the lens is non-magnetizable, in a young subject it is better to perform a curette evacuation of the lens at once. There is no need to needle the lens and wait. Such a course would increase the risk of sepsis, and the swollen lens pushing the inflamed iris against the cornea would certainly lead to extensive anterior synechiæ. In an older person in whom there would be a definite firm nucleus the lens may usually be extracted as in a case of senile cataract. Unless the character of the wound is such as to introduce complications, a non-cataractous lens may be extracted more easily and completely than a lens whose cortex is only partially cataractous. It is very seldom possible to remove a non-magnetizable foreign body from the vitreous. If it is of iron or steel, an attempt should be made to remove it by means of the giant magnet. Though it is a great advantage to know the exact position of a foreign body, the magnet should always be used at the earliest possible moment without waiting for X-ray localization, because a few hours later it may have become so firmly fixed by inflammatory exudate as to make removal impossible.

Haab's magnet is used as follows: The pupil is widely dilated, and cocaine instilled; the patient is seated before the magnet with his face supported and steadied by the surgeon's hands. The pole of the magnet is brought into contact with the cornea. The current is gradually turned on. The patient usually feels moderately severe pain. In a successful case the foreign body comes forward to the back of the lens as a rule, occasionally it passes through the lens, especially if this has been wounded. Perhaps it rests behind the iris, and is seen dragging the iris forward. By a little manipulation it may then be worked into the anterior chamber, whence it may be extracted as already described. If the magnet fails to draw the foreign body forward, the direction may be altered a little, and the current switched on and off again

several times. It sometimes happens that after several minutes of manipulation the foreign body suddenly frees itself.

If Haab's magnet fails, Mellinger's ring magnet should be used if it is available. This has the advantage that the patient lies on the table, and the solenoid is lowered over his head. Soft iron rods in the axis of the solenoid become powerful magnets when the current is turned on. If efforts at extraction have failed, the foreign body should, if possible, be accurately localized by X rays, and then an incision should be made and an attempt made to remove it with a small magnet.

CHAPTER XVIII

DISEASES OF THE LENS

Anatomy and Physiology. — The *crystalline lens* is a transparent, colourless body, bi-convex in shape, suspended in the anterior portion of the eyeball, between the aqueous and the vitreous chambers. It presents an anterior and a posterior surface (the latter being the more curved), an anterior pole, a posterior pole, and a rounded circumference (the equator). It is enclosed in a transparent capsule, and held in position by its suspensory ligament. The adult lens consists of a peripheral portion, the cortex, and a central part, the nucleus. The cortex is semi-solid, softer than the nucleus, and colourless; the nucleus is harder, and has a yellowish tint. There is, however, no sharp limitation, the transition being gradual. The nucleus increases in size with advancing years, and the cortex diminishes in proportion; in old age the entire lens is of the consistence of the nucleus, and is hard and unyielding. This change is known as sclerosis.

In structure the lens consists of concentric *laminæ* formed of long, hexagonal fibres, the edges of which are connected by a cement substance, leaving fine lymph channels. The fibres either start or end along Y-shaped or stellate figures, the lines of which radiate from the anterior and posterior pole to the equator, each fibre encircling the latter. The septa corresponding to the branches of the stellate figure divide the lens into sectors. These stellate and Y-shaped figures can often be recognized in the adult lens by oblique illumination.

The *capsule of the lens* is a thin, homogeneous, elastic membrane which covers the lens, being known as the anterior capsule in front and as the posterior capsule behind. The anterior capsule is the thicker, and its posterior surface is lined by a layer of cuboidal epithelium from which the lens fibres are formed.

The *suspensory ligament* of the lens is a delicate membrane, extending from the ciliary body to the lens capsule. It covers the inner surface of the ciliary body from the ora serrata to the apices of the ciliary processes, and then passes to the lens, dividing into three layers attached respectively to the anterior capsule, the equator, and the posterior capsule. Between these layers and the equator of the lens is a

space, triangular on section, known as the canal of Petit. It is in communication with the posterior chamber by means of slit-like apertures between the fibres of the anterior portion of the suspensory ligament.

The lens is devoid of bloodvessels except in foetal life, its nourishment being derived from the ciliary body.

The *function of the lens* is to focus rays so that they form a perfect image on the retina. To accomplish this, the refractive power of the lens must change with the distance of the object, according to whether the rays are parallel or divergent. This alteration in the refractive power of the lens is known as accommodation, and is produced by a change of shape mainly affecting its anterior curvature.

The lens presents variations in physical characteristics at different periods of life. In the foetus, it is nearly spherical, slightly reddish, and softer than at a later period. In the adult, its anterior surface is less convex than the posterior, and its substance is firmer. Sclerosis, which consists of a process of toughening, due chiefly to loss of water, begins in the centre of the lens in childhood, and advances slowly until adult life, after which its progress is more rapid, increasing the size of the nucleus at the expense of the cortex. In old age, the lens increases in size, is flattened, and assumes a yellow tinge, becoming tougher and less transparent. This process of sclerosis accounts for the gray reflex seen in the pupil of the aged, which may be mistaken for cataract (senile reflex). It also explains the inability on the part of the lens of advanced years to change its shape for the purposes of accommodation (presbyopia).

CATARACT.

A cataract is any opacity of the lens or of its capsule.

Varieties.—Cataracts may be divided into :

1. *Primary*, when independent of any other ocular disorder.
2. *Secondary, or Complicated*, when accompanying or following some other disease of the eye, such as glaucoma, uveitis, etc.

Cataracts are divided, according to the part of the lens involved, into :

1. *Lenticular*, when situated in the substance of the lens.
2. *Capsular*, when affecting the capsule.
3. *Capsulo-lenticular*, when involving both lens and capsule.

They are also known as :

1. *Stationary*, when they remain incomplete.
2. *Progressive*, when they spread and tend to affect the whole lens.

Stationary Cataracts may be divided into :

1. *Anterior polar.*
2. *Posterior polar.*
3. *Lamellar.*
4. *Various uncommon forms.*

Progressive Cataracts may be divided into :

1. *Senile* {
 - Cortical, when the opacities lie immediately under the capsule.
 - Nuclear, when the opacity is in the part of the cortex immediately surrounding the nucleus.
2. *Congenital and Juvenile.*
3. *Traumatic.*

In patients under about thirty-five all cataracts are of soft consistence throughout, and usually of a grayish-white colour. After this period the nucleus becomes hard and of a yellowish tint.

Etiology.—According to etiology, cataract may be classified as :

1. *Congenital*, due to faulty development or intra-uterine inflammation of the eye. To this class belong the anterior and posterior polar, lamellar, and occasionally complete cataract.

2. *Senile*.—This is the most common form. It usually appears after the age of fifty. The real cause is unknown. Heredity has some influence.

3. Due to *General Diseases* : diabetes, and less frequently nephritis, gout, and general arterial disease.

4. Due to *Ocular Diseases*, causing complicated or secondary cataract. The most common examples are severe forms of ulcerative keratitis, iridocyclitis, choroiditis, myopia of high degree, glaucoma, and detachment of the retina.

5. *Traumatic*, by the production of an opening in the capsule, thus allowing the lens to absorb aqueous humour; occasionally by mere concussion.

6. Caused by long-continued exposure to intense light or heat (as in the case of glass-blowers, iron-founders, etc.).

Symptoms.—There is (1) diminished acuteness of the vision, depending upon the situation and the kind of cataract. It is greatest when the opacity is central and diffuse, and least when the cataract is peripheral. When central, the patient

sees best in dim light—with dilatation of the pupil. The interference with vision increases with the progress of the cataract, until finally there is mere perception of light. (2) The patient complains of seeing spots which occupy a fixed position in the field. (3) Occasionally there is annoying diplopia or polyopia, due to irregular refraction of the lens. (4) Myopia often develops during the early stages, due to increased density and refractive power of the lens. For this reason the patient may be able to discard his reading-glasses for the time, but he may need concave glasses for distant vision.

Physical Signs.—There are no inflammatory symptoms. Examination by oblique illumination will show a grayish or whitish opacity on a black ground, and with the ophthalmoscope at a distance a black opacity upon a red field. (Plate II.). The pupil should be dilated, in order that the lens and the fundus may be examined. During the stage of swelling of complete cataract the anterior chamber is reduced in depth.

PROGRESSIVE CATARACTS.

Senile Cataract.

Senile cataract is the most common form. It is a disease of advanced life, though occasionally it is seen as early as forty years of age. As a rule, both eyes are involved, but generally one in advance of the other. The opacity may begin either in the superficial part of the cortex (cortical, Fig. 194), or in the part immediately surrounding the nucleus (nuclear, Fig. 195). Senile cataract involves the cortex, the nucleus remaining transparent throughout the process. The time required for full development varies greatly. It may ripen completely in a few months, or may require many years. It may become stationary at any stage of its progress.

The Stages of Cataract.—Four stages are usually described, though it must be remembered that each stage passes imperceptibly into the next.

1. *Incipient Stage.*—The opacity most frequently begins as streaks, which extend from the periphery of the cortex, where they are wider, to the centre of the lens, where they

narrow like the spokes of a wheel (Fig. 194). The periphery is affected first. These streaks appear grayish by oblique illumination, and black when seen with the ophthalmoscope. Between these sectors the lens is transparent. Less frequently, senile cataract begins with dot-like or cloud-like

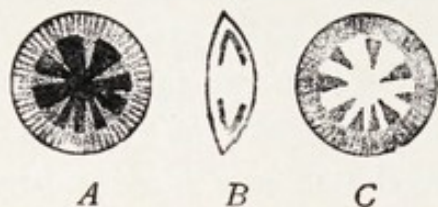


FIG. 194.—SENILE CORTICAL CATARACT.

A, Seen with oblique illumination; *B*, section of the lens; *C*, seen with the ophthalmoscope.

opacities situated in any portion of the lens. Sometimes the portion immediately surrounding the nucleus becomes opaque, constituting so-called nuclear cataract (Fig. 195). The last form causes relatively great visual disturbance. Cataracts sometimes remain stationary in the incipient stage, with little impairment of vision. Hence it is often wise

not to alarm the patient by acquainting him with his condition, though it may be advisable to communicate the knowledge to a relative, for one's own protection.

2. *The Stage of Swelling* (maturing stage).—The lens absorbs fluids, swells, and by pushing the iris forward reduces the depth of the anterior chamber. It appears bluish-white, shining, and presents distinctly the markings of the stellate figure. During this stage the iris casts a shadow upon the lens when the eye is illuminated from the side, since the superficial portion of the lens is still transparent, the opaque layer being some distance behind the iris.

3. *Mature Stage*.—The lens loses most of its fluid, shrinks somewhat, and becomes opaque and of a dull gray or amber colour, the stellate markings still being recognizable. The anterior chamber regains its normal depth, and there is no shadow thrown by the iris on the lens with focal illumination. Occasionally the entire lens is changed into a hard,

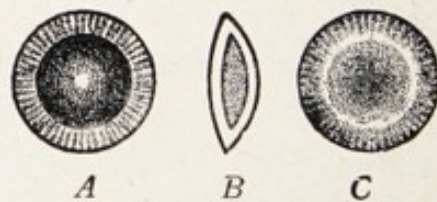

FIG. 195.—SENILE NUCLEAR CATARACT.

A, Seen with oblique illumination; *B*, section of the lens; *C*, seen with the ophthalmoscope.

dark-brown mass (black cataract). In this stage the cataract can easily be separated from the capsule of the lens. It is then said to be 'ripe' for operation, since it can be extracted whole, without leaving any portion of the cortex behind.

4. *Hypermature Stage*.—The cataract may continue in the mature stage for a long time. If changes continue, the surface of the lens loses its radial markings and becomes homogeneous, or presents irregular spots. The cataract may continue to lose water and thus a shrunken, dry, flattened mass results (shrunken cataract), with some deepening of the anterior chamber. Or, the cortex may become soft, liquid, and milky, and the nucleus sink to the bottom of this fluid (*Morgagnian cataract*), the cataract appearing white with a brownish colouring below. Very old hypermature cataracts often present the deposit of cholesterin or of lime-salts. The latter change (chalky cataract) is found chiefly in complicated cataracts. The anterior capsule may become thickened and opaque (capsulo-lenticular cataract). The lens (and iris) may become tremulous through stretching of the suspensory ligament. For these reasons operation upon over-ripe cataract is often less favourable and more difficult than during the mature period.

Pathology.—Senile cataract results from shrinkage of the nucleus together with the lens fibres, and presence of fluid in the spaces thus created. The lens fibres then swell, become cloudy, and disintegrate. The nucleus usually remains transparent, but becomes harder and denser.

Treatment.—*Extraction* of the lens by operation is the only means of relieving a patient of senile cataract. Discission is applicable only to cataracts of the young. No medicinal treatment, whether local or constitutional, has proved of curative value. The daily instillation of dionin drops (1 per cent.) has seemed to delay the progress of lens opacities, but, as these in many cases cease to progress without treatment, one cannot be sure. When an incipient cataract is detected, the eye should be carefully examined, and the result noted for future reference. The patient should be re-examined from

time to time. If glasses assist vision, they should be ordered. There is no objection to the patient's using a magnifying-lens or making any use he can of his failing sight. In cases in which the opacity is central, sight may be improved temporarily by the instillation of a weak solution of atropine ($\frac{1}{2}$ grain to $\bar{3}$ i.), to cause mydriasis and enable the patient to see through the peripheral transparent portion of the lens. But the effect of the mydriatic must be watched, and the possibility of a glaucomatous rise of tension must be borne in mind. Moreover, clinical experience seems to show that long-continued use of atropine predisposes to post-operative hæmorrhage into the anterior chamber.

The most favourable time for extraction of senile cataract is when the lens is completely opaque, and there is no shadow thrown by the iris—*i.e.*, when the cataract is ripe. If operated upon before this time, the lens is not always removed cleanly, and some transparent cortex is apt to adhere to the capsule and be left behind. This becomes opaque subsequently, and is absorbed slowly; besides, the remains of cortex after extraction tend to produce irritation, and interfere with smooth healing.

As a general rule we operate when the cataract of one eye is complete and the other has progressed far enough to cause considerable interference with vision. But there are exceptions to this rule. For instance, when the occupation and circumstances of the patient are such that, being unable to work, he cannot wait for the cataract of the first eye to become ripe; or when the cataract shows signs of hypermaturity before the second eye is very much affected. Removal of both cataracts should never be performed at one sitting. When both eyes are affected the patient may be incapacitated from following his occupation before either cataract is ripe. *Artificial ripening* is still sometimes resorted to. An incision is made through the periphery of the cornea, and the aqueous humour allowed to escape, so that the cornea falls against the lens. Then the cornea over the pupil is stroked with a smooth instrument, or the spatula or spoon may be introduced into the anterior chamber and applied

directly to the lens capsule. Such direct or indirect massage may be done with or without an accompanying iridectomy. After this operation, the lens may become opaque within a few weeks, and can then be extracted. Ripening operations are, however, not reliable nor free from danger. It is certainly safer and better to remove the immature cataract than to resort to such artificial ripening. The condition of immaturity in a cataract certainly adds somewhat to the risks of extraction, but with care the tenacious cortical remnants may usually be removed by manipulation or washed out by the injection of a warm, sterile salt solution (0.6 per cent.) into the anterior chamber. It is a good rule not to operate upon an immature cataract unless there is a definite reason for hastening the operation.

Extraction may be performed with (*combined extraction*) or without (*simple extraction*) an iridectomy. The question as to which is the better operation has been much discussed. The chief advantages of the simple operation (without iridectomy) are the avoidance of tags of capsule healing in the wound, less reaction, and less likelihood of iris becoming adherent to capsular membrane; its disadvantage is the danger of prolapse of the iris. The combined operation is undoubtedly the safer with a very large lens or in an eye which has suffered from iritis. A successful simple extraction leaves a beautiful round pupil, and the action of the iris is not impaired. But in the combined operation the coloboma is covered by the upper lid. The patients are usually quite old people, few of whom would choose to incur any extra risk to gain a slight improvement in appearance. Some operators perform a preliminary iridectomy, and an extraction several weeks later, as a means of lessening the dangers of extraction when complications are feared; but the disadvantages of an extra operation probably outweigh any advantage there may be.

Monocular cataract, with good vision in the other eye, should not as a rule be removed, since, owing to the difference in refraction, the eyes will not work together. Extraction may, however, be performed in such cases for cosmetic effect, to prevent hypermaturity, or to extend the field of vision on the affected side.

Aphakia.—After the extraction of cataract the patient is compelled to wear strong convex glasses, since, as a result of loss of the lens (aphakia), there is a high degree of hypermetropia and absence of the power of accommodation. This hypermetropia amounts to about 10 D. With it there is usually astigmatism (2 to 3 D.), generally 'against the rule,' a result of the incision. In an average case, therefore, a convex spherical lens of about 10 D., combined with a convex cylinder of 2 to 3 D., must be worn for distant vision. To this sphero-cylinder an additional convex sphere of 3 or 4 D. must be added for reading. Any previous error of refraction will, of course, modify this correcting lens. Glasses should not be prescribed until all signs of irritation have disappeared—generally at the end of a month. Changes in refraction, usually a lessening of the post-operative astigmatism, may continue for several months. The aphakial eye presents, besides hypermetropia and loss of accommodation, a deep anterior chamber and usually a tremulous iris. The images normally seen on the anterior and posterior surfaces of the lens are absent.

Prognosis.—A favourable result and useful vision should follow cataract extraction in nearly all uncomplicated cases. There is generally good, and often perfect, vision. The success of the operation is dependent not only upon skilful operation, but upon extreme gentleness on the part of the surgeon, and upon the establishment of a sympathetic understanding between surgeon and patient. There should be no eyes lost through patients 'behaving badly' during the operation. Before deciding to operate it is important to investigate the condition of the other ocular structures, and especially that of the retina. This is done by testing the field of vision with a light from an ophthalmoscope mirror for light perception and light projection. There should be a good field and good perception and projection of light. Lid margins, conjunctiva, and lacrymal sac must be examined by inspection and perhaps bacteriologically. If they are not clean and healthy they must be made so before operation is undertaken.

Projection is tested by throwing light from the mirror of the ophthalmoscope upon the upper, lower, inner, and outer

portions of the retina. There is good projection if, with the eye directed forward, the patient is able to state correctly the direction from which the light comes. This test may also be applied with the lighted candle made to approach the eye from various directions, at a distance of 1 metre, and also at a greater distance—3 to 4 metres. Although the cataract be fully matured, there should be good perception of light, even with faint illumination. Fingers can frequently be counted at several inches.

Cataract Extraction.

There are many possible variations in technique, the discussion of which would take up much space. It seems, therefore, best to describe the operation as one performs it oneself.

The combined operation is more commonly performed, especially when the cataract is immature. In many cases simple extraction is preferable. The combined operation is described first, as it is the operation recommended for a surgeon of small experience, and the points of difference in the simple extraction afterwards.

Instruments Required.—An eye speculum—Lang's (Fig. 195a) with solid blades has the advantage of keeping the lashes away from the knife. Fixation forceps (Fig. 177). A Graefe knife—a thin broad-bladed knife (Fig. 195b)—has the advantage that it enables the corneal section to be made in one thrust and withdrawal without losing much aqueous or wounding the iris, but it must be entered perfectly correctly and held in the same plane to the end of the incision, as the slightest alteration allows aqueous to escape; therefore an operator of small experience should use a narrow Graefe knife (Fig. 196). Cystotome and lens expresser combined (Fig. 198). Two silver spatulas (Fig. 197). A curette (Fig. 204). Curved iris forceps (Fig. 179). De Wecker's iris scissors (Fig. 199).

There should also be ready, although one hopes not to have to use them, a lens scoop (Fig. 200), or wire vectis (Fig. 201), and an irrigator for the anterior chamber. The irrigator consists of an undine to the nozzle of which is attached 18 inches of fine rubber tube with a fine flat canula (Fig. 203) at the other end. After the irrigator has been sterilized some

normal saline solution is run through it, it is filled with sterile normal saline solution, and the end with the canula is dropped into the large opening of the undine until required. The apparatus should stand in a bowl of warm water to keep it at about blood heat ready for use.

The patient lies on the table with his head well up to the end, and the chin slightly raised. See that he is in a comfortable, easy position, and that the height and the light are exactly right for the operator. Talk to the patient, explaining

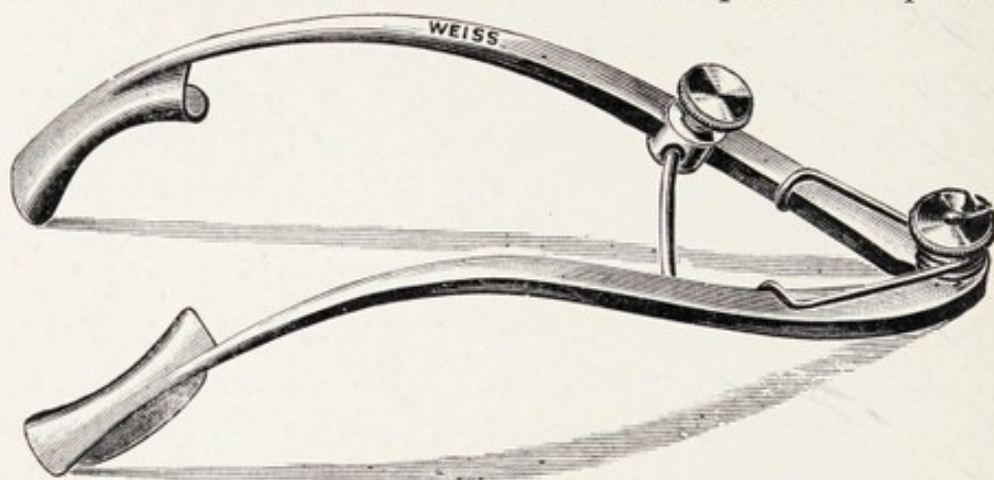


FIG. 195a.—LANG'S SPECULUM.



FIG. 195b.—THIN, BROAD CATARACT KNIFE.

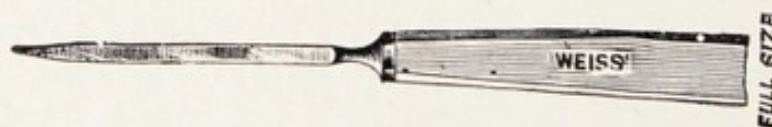

FIG. 196.—NARROW GRAEFE KNIFE.

that there will be no pain, and that the operation will not take long, and that it will help if he will look gently downwards during the operation. Explain to him that the lids will be held open by a prop to prevent blinking, but that he must be careful not to squeeze the lids together voluntarily lest it should injure the eye.

Insert the speculum and ask the patient to look a little downwards; if he has any difficulty about this, let a nurse hold up his hand in front of him and tell him to try to look

at it. Suppose, for example, the left eye is to be operated upon. The patient looking slightly downwards, the surgeon, standing behind the patient's head and holding the Graefe knife with the left hand, with the fixation forceps held in the right hand, takes a firm hold of the tissues near the lower margin of the cornea. The surgeon's left wrist is steadied against the patient's head. The Graefe knife is held between the thumb and two first fingers, the flat of the blade being parallel to the plane of the corneal margin with the edge directly upwards (anatomically). The point of the knife is entered just posterior to the plane of the transparent margin of the cornea about 2 mm. above the horizontal meridian. The knife

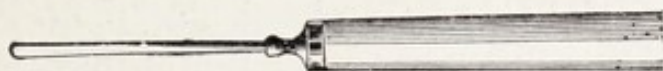

FIG. 197.—SILVER SPATULA.

is thrust across the anterior chamber and made to emerge at the corresponding point on the nasal side, so that the section comprises a little less than one-half the circumference of the cornea. If there is room without touching the side of the nose, the thrust is continued for the whole length of the knife blade, cutting upwards at the same time. Then the knife, still cutting upwards, is withdrawn until the point has nearly reached the nasal side of the section. Other to-and-fro movements are made if necessary, and the corneo-scleral section is completed. Conjunctiva lies in front of the knife near the apex of the incision. When the conjunctival flap is long enough, the edge of the knife is turned forwards and the apex of the flap cut through. During the incision a slight pull should be maintained on the forceps so as to keep up a little negative pressure in the eyeball. Before making the first thrust the




FIG. 198.—COMBINED CYSTOTOME AND LENS EXPRESSER.

operator should have considered carefully what he intends to do, so that no mistake will have been made as to the position of the knife, but if the point of engagement at the counter-puncture seems too deep or too shallow it should be corrected before the upward cutting movement begins. During the whole section great care must be taken to keep the knife exactly in the same plane without any twisting or turning, lest aqueous escape and the iris fall forward in front of the knife. The conjunctival flap should be about $\frac{1}{4}$ inch wide and about the same length.

On completing the section the conjunctival flap is turned back on to the cornea as the knife is removed. An assistant, who knows beforehand exactly what he has to do, passes his hand low down at the side of the patient's face and takes the weight of the speculum from the eye. The fixation forceps is laid aside, the patient continues to look slightly downwards, the surgeon takes the curved iris forceps in his left hand and the de Wecker scissors in the right, and with the forceps grasps a small piece of the iris near the upper margin of the pupil, draws it slightly out of the wound, and snips it off with the scissors, the blade of the scissors being held radially. The coloboma should be quite narrow.

The combined cystotome and lens expresser is now taken in the left hand, and the silver spatula, bent to a suitable angle, is taken in the right. The patient looking gently downwards, the cystotome with the tooth on the flat is insinuated within the lips of the wound. When the tooth has reached a position to the nasal side of the pupil and about half-way between the transverse diameter and the upper margin of the cornea, the instrument is rotated so that the tooth, turned

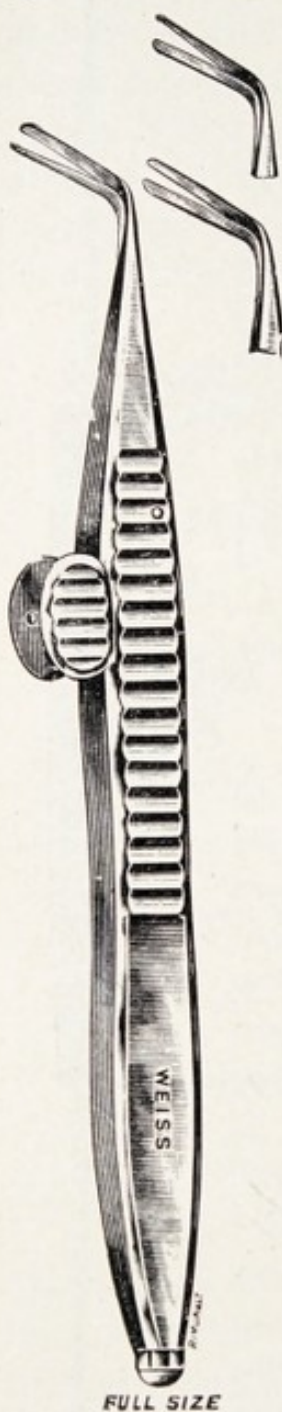


FIG. 199.—DE
WECKER'S IRIS
SCISSORS.

backwards, pierces the anterior capsule of the lens. It is then drawn outwards, making a transverse incision. The instrument is now turned round in the left hand and the expresser laid flat on the sclerotic encircling the lower margin of the cornea. It is gently rocked to and fro, and at the same time moved slightly upwards. By this means the lens is loosened and separated from its capsule. When the expresser has travelled well within the corneal margin it is gradually tilted so that its convexity presses downwards in order to tilt the lens. At the same time the posterior lip of the incision is pressed backwards with the silver spatula. The rocking movement of the expresser is continued as the lens travels forwards and upwards, presenting in the wound and coming out through the wound. Do not hurry with the



FIG. 200.—SPOON.




FIG. 201.—WIRE LENS VECTIS.

expresser, and take care that it does not travel in advance of the lens. If any part of the periphery of the lens appears to have been left behind the iris, it may perhaps be coaxed out by the expresser applied to the cornea. If there is soft lens matter remaining in the anterior chamber after the delivery of the lens, take the curette in place of the spatula, insert it just within the lip of the wound, and continue manipulation with the expresser. All, or nearly all, the soft lens matter will then run out along the groove of the curette. Gently wipe away with a piece of soft linen any blood or lens matter which may be on the wound. Take a clean spatula, insert it within the wound, and gently stroke the pillars of the iris into position. Then with the iris forceps search along the wound for any invisible tags of capsule which might become incarcerated in the wound. If a tag of capsule is grasped in the

forceps it should be snipped off. Replace the conjunctival flap carefully with the spatula, lift the upper lid by means of the lashes or the loose skin of the lid grasped between the finger and thumb. Remove the speculum and carry the lid away from the eye and downwards over the eye, and tell the patient to keep it gently closed. Lay a piece of soft linen over the closed lids of each eye with a bit of absorbent gauze over it. Secure the two pads with the Moorfields bandage (Figs. 336 and 337).

Accidents and Modifications.—In making the incision, if aqueous should escape and the iris fall across the knife, the

incision should be continued as if nothing had happened. The resulting coloboma will be large and ugly, but the eye will in all probability do quite well.

The object of the conjunctival flap is not to cover the wound, but to assist in the nutrition of the cornea. If a complete conjunctival flap is made as long as the incision itself, aqueous is pent up under

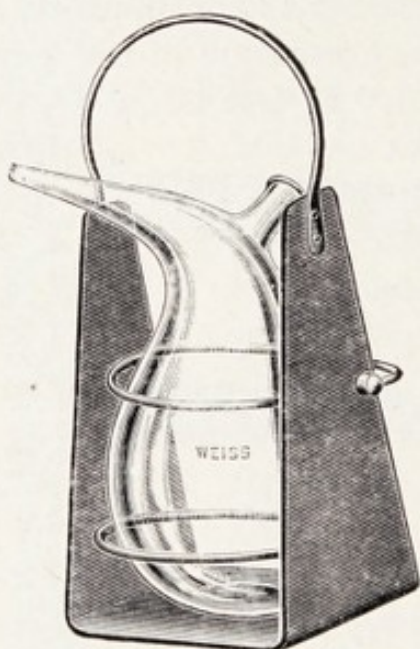


FIG. 202.—UNDINE IN STAND.



FIG. 203.—CANULA.

the flap, the wound gapes, and has to be filled with connective tissue, and there is much post-operative astigmatism.

In making capsulotomy a single straight incision is sufficient. Various incisions in the capsule have been planned, but it is seldom possible to carry them out, and they are unnecessary.

If the lens does not present in the wound, it may be due to the capsule not having been sufficiently opened, in which case the capsulotomy should be repeated. It may be due to too great haste with the expresser. Try again, taking plenty of time over it, and see that the expresser does not over-run the lens. It may be due to the incision being too small.

This is a bad mistake which should never be made if the surgeon thinks out the proposed procedure carefully beforehand. The only thing to do is to enlarge the incision with the Graefe knife.

Rarely, with a diseased eye and a weak suspensory ligament, the lens may become dislocated backwards. Attempts at expression should not be continued lest it disappear into the vitreous. The spoon or wire vectis should be pushed in well behind it, and it should be hooked upwards against the back of the cornea.

If the vitreous should present in the wound before the delivery of the lens, no attempt should be made to deliver it in the ordinary way, as this would certainly result in loss of vitreous. The scoop or vectis should be used at once. Vitreous may escape after the delivery of the lens and during manipulation for the removal of the cortical débris. Exceptionally this may be unavoidable, but it is usually due to want of gentleness in the manipulation or to violent squeezing on the part of the patient.

In operating upon an immature or hypermature cataract there may be tenacious lens matter which cannot easily be removed by manipulation from the anterior chamber. If this is quite small in quantity it may be left to absorb, otherwise an attempt should be made to remove it with the irrigator. The nozzle should be introduced just within the wound, slightly depressing the posterior lip. Only just sufficient head of fluid should be employed to enable it to enter the anterior chamber freely.

Simple Extraction differs from the combined operation essentially in the omission of iridectomy. Before the operation the pupil should be fully dilated with atropine. This facilitates the delivery of the lens, avoids straining the sphincter, and makes post-operative prolapse less likely.

Extraction with Peripheral Iridectomy.—Some surgeons proceed as in simple extraction, but omitting the preliminary atropinization, and then make a 'button-hole' in the iris as peripherally as possible. It is doubtful whether the 'button-hole' really lessens the danger of prolapse. One prefers to

use the simple extraction in all suitable cases, reserving the combined operation for cases complicated by diseases in the eye or mental degeneration in the patient.

After-Treatment.—The patient is directed to lie quietly upon his back. To each wrist a piece of bandage is tied, with the other end secured to the bed low down, so that the hands have some freedom, but are unable to reach the eye during sleep. An anodyne is often advisable. After twenty-four hours he may change to the side of the unoperated eye. His food should be fluid for the first day. The bowels need not be relieved artificially for three or four days. If the patient has a motion before this, he must be cautioned not to strain. The wound is inspected after twenty-four hours, extreme gentleness being especially essential at this first dressing. Atropine is instilled each day. On the fourth or fifth day the unoperated eye may be left free. After a week the patient may sit up in bed for an hour or two, and a day or two later may sit in an easy-chair the greater part of the day. After two weeks nothing but smoked glasses need be worn.

Post-Operative Complications.—If iridectomy has been performed one of the pillars may prolapse into the wound within a few hours. If it is not completely prolapsed it should be replaced with the spatula inserted into the wound. Any part of the iris which has remained for a few hours outside the eye should be excised and the stump replaced with the spatula. In simple extraction a considerable prolapse of the iris is usually announced by severe pain. It should be dealt with as soon as possible. It may be possible to do what is required under local anæsthesia, or a general anæsthetic may be needed. It is generally inadvisable to attempt to return any part of the iris which has been completely prolapsed, as it may not be sterile; moreover, the prolapse may probably recur. An incomplete prolapse may perhaps be smoothed out, with the spatula introduced into the wound at one side.

Hæmorrhage into the anterior chamber is from new capillary vessels which are bridging across the wound. It is more likely to occur if an exceptionally wide conjunctival flap has been made. The time after operation is almost exactly 120

hours. It is especially important, therefore, that the patient be kept very quiet for the first six days. The hæmorrhage may completely fill the anterior chamber. Nothing should be done beyond keeping the patient quiet. The blood may absorb completely, or the part in the area of the pupil may partly organize and add to the thickness of the capsular membrane.

Rarely there may be iritis due to the traumatism. Suppuration of the wound and panophthalmitis were frequent in pre-aseptic days, but are now very rare. Iridocyclitis with k.p. is a late complication due to auto-intoxication which we are not always able to guard against.

After-Cataract.—When the eye has healed after the extraction of cataract, examination with a lens and focal illumination shows a membrane in the pupillary area. This consists of posterior capsule, perhaps fragments of anterior capsule, and in some cases organized remains of blood-clot or lens matter enclosed between the posterior and fragments of the anterior capsule. There may be bands due to iritis. Sometimes the capsule is perfectly transparent and smooth, and does not interfere with vision. If it is wrinkled it may interfere with sight even though it be transparent. It may be so dense as to interfere very greatly with sight. Within a few weeks of the extraction this membrane is usually quite easily cut. The tendency is for it to become tougher and denser, so that a membrane which scarcely reduces vision at all at first may cause considerable diminution later. Usually discission with proper precautions is practically free from risk. It is therefore good practice to needle every case as soon as the eye is quiet, perhaps two or three weeks after operation. The eye having been cocainized and prepared and the pupil widely dilated with atropine, the speculum is inserted. The surgeon, standing behind the patient's head, grasps the eyeball with the fixation forceps a little below the corneal margin. A very sharp Zeigler's knife is introduced through the sclerotic just behind the periphery of the cornea, and below the original incision, and the point thrust through the membrane. The membrane should be cut with gentle sawing movements, carefully avoiding any dragging or tearing.

Curette Evacuation is performed for the removal of soft or

traumatic cataracts, or softened masses of lens matter produced by needling. Instruments required: speculum, fixation forceps, broad needle (Fig. 204a), curette (Fig. 204), and silver spatula (Fig. 197). Local anæsthesia is sufficient except in the case of very young children. The broad needle is entered through the cornea near its periphery on the temporal side, and it is thrust in, making a large rent in the anterior capsule of the lens. During the withdrawal of the instrument the incision is enlarged to a width of about 5 mm. The tip of the curette is then introduced just within the wound, slightly pressing back the posterior lip, the soft lens matter runs out along the groove of the curette. If no more lens matter comes away while a considerable amount is left, close the eye for two or three minutes to allow a little aqueous to form and try again. The curette should not be introduced far within the wound in an attempt to remove the lens matter mechanically. Any which will not come away may be left to absorb. If it is proposed to perform the curette evacuation in a young patient, there is no object in preliminary needling, as lens matter will come away quite well without.



FIG. 204.—CURETTE.



FIG. 204a.—BROAD NEEDLE.

Extraction of Cataract in its Capsule.—This operation is performed in enormous numbers of cases by some surgeons in India. The steps of this operation are somewhat similar to ordinary combined extraction, except that capsulotomy is omitted, the suspensory ligament of the lens being ruptured, and the lens expressed by pressure upon the cornea with a squint hook. The removal of the whole capsule with the lens is no doubt a great advantage in the case of Indian natives, who may not be able to return for subsequent needling, but the grave risk of loss of vitreous will prevent the operation ever being commonly employed in Europe.

Congenital Complete and Juvenile Complete Cataract.

These forms of cataract are infrequent. The lens is uniformly white or bluish-white, or it may have a pearly lustre. It is always soft. Sometimes it is fluid and milky. These forms of cataract may occur in eyes which are otherwise perfectly healthy, or they may be complicated cataracts, with changes in the retina, choroid, or optic nerve. One or both eyes may be affected. The congenital complete cataract is due to a disturbance of development, or to some intra-uterine ocular inflammation. The complete cataract of young people (juvenile) may be due to heredity, or arise without known cause. In some cases there is a history of convulsions.

Treatment consists in discission (needling). This should be done as early as possible, so that disuse of the function of sight may not cause amblyopia. The needle operation must usually be repeated a number of times. Sometimes there are remains of the lens which do not become absorbed, and must subsequently be removed by extraction. Semi-fluid cataracts are removed by linear extraction.

Discission of the Lens (Needling).

Indications.—(1) In zonular, congenital complete, and juvenile complete cataracts (soft cataracts), previous to the fifteenth year; (2) preliminary to extraction in cases of high degree of myopia.

Operation.—In young children a general anæsthetic is required; in others local anæsthesia is sufficient. The pupil must be dilated. The speculum is introduced, and the eyeball steadied with the fixation forceps. A knife-needle



FIG. 205.—KNAPP'S KNIFE-NEEDLE.

(Fig. 205) is thrust through the sclerotic near the margin of the cornea, and then through the capsule of the lens, making two cross-cuts, each about 4 mm. in length. The cuts must be superficial, especially if this is the first operation, so that

there will not be too rapid swelling of the lens. The lens substance may be broken up a little by rotating the needle. After some of the swollen lens matter has been absorbed (several weeks) the operation must be repeated. At the second operation the discission may be deeper and bolder. At the last of the several operations the incision must include the posterior capsule.

After-Treatment.—There is usually very little reaction. The pupil must be kept dilated with atropine. The lens substance swells, protrudes through the opening in the capsule, and pieces fall into the anterior chamber and become absorbed. Usually three operations are required. The entire duration of treatment is several months.

Complications.—Rapid and extensive swelling of the lens may cause a sudden rise of tension of the eye, requiring removal of the lens by linear extraction without delay. A bold discission is sometimes done with a view of extracting the lens a few days afterwards, as soon as there is marked swelling. This is the usual procedure when the lens is removed in high degrees of myopia. Iritis may occur after discission, occasionally iridocyclitis, and very rarely loss of the eye.

Traumatic Cataract.

This form of cataract is the result of a perforating wound of the lens capsule. Occasionally it ensues after contusions of the eyeball, without perforation (concussion cataract), though probably a rupture of the capsule occurs in such cases. Within a few hours after the injury the lens becomes cloudy at the seat of the wound from absorption of aqueous humour and swells. Opaque and swollen lens substance protrudes through the wound in the capsule, and often falls into the anterior chamber. The swelling and clouding continue until, after a few days, the entire lens has become opaque. Then the lens substance becomes absorbed. In favourable cases in young persons this process continues until there is spontaneous cure with a clear, black pupil. More frequently, however, part of the lens remains opaque in the capsule and requires subsequent operation. Occasionally the opacity of the lens remains limited to the injured

portion, due, probably, to closure of the small capsule opening. The course described may be less favourable. Inflammation of other parts of the eye may result—iritis or iridocyclitis, or when infection occurs, panophthalmitis. The swelling of the lens may cause iritis or glaucoma.

Treatment.—Immediately after the injury absolute rest, iced compresses, and atropine are to be employed. If the rapid swelling of the lens causes inflammation or much increase of tension, the cataract should be removed by extraction. But if such complications do not arise, it is wiser to allow absorption to proceed, and to defer operative intervention until there is no irritation or inflammation, and spontaneous improvement has come to a standstill.

Stationary Cataracts.

Anterior Polar or Pyramidal Cataract.—This lenticular opacity occurs in the form of a small, round, white opacity, often pyramidal in shape, situated at the anterior pole of the lens, beneath the capsule (Fig. 206. It may be congenital or acquired. The acquired form originates from an ulcer of the cornea in early childhood. Such an ulcer perforates, and allows contact and pressure between lens and cornea, setting up an irritation in the anterior capsule which results in a proliferation of the subcapsular epithelium. Afterwards the anterior chamber is restored. Sometimes there is an accompanying corneal opacity. As a rule this form of cataract does not interfere with vision sufficiently to require treatment.




FIG. 206.—ANTERIOR POLAR CATARACT.

A, Seen with oblique illumination; *B*, section of lens; *C*, seen with the ophthalmoscope.

Posterior Polar Cataract.—This form may be congenital (capsular) or acquired (cortical).

The *congenital form* is a capsular opacity consisting of a small, round, white deposit, situated at the posterior pole. With the ophthalmoscope it appears as a black dot upon the red fundus-reflex. It represents the remains of the hyaloid artery at the point of attachment to the posterior capsule of

the lens. It causes but trifling interference with vision, and requires no treatment.

The *acquired form* is a grayish, stellate opacity of larger size, situated in the cortical layer of the lens, at its posterior pole (Fig. 207). It is a form of secondary cataract, which develops in connexion with high myopia, choroiditis, disease of the vitreous, and retinitis pigmentosa. It remains stationary




FIG. 207.—ACQUIRED FORM OF POSTERIOR POLAR CATARACT.

A, Seen with oblique illumination; B, section of the lens; C, seen with the ophthalmoscope.

for many years, but is apt finally to become complete. In this affection there is considerable impairment of vision, caused not only by the cataract, but also by the accompanying disease of the deep structures. It does not admit of treatment.

Lamellar or Zonular Cataract.—

This variety of partial, stationary cataract is either congenital or forms in early childhood, and usually affects both eyes. It is the most common form of cataract seen in children. It is sometimes hereditary, and often associated with a history of convulsions and with the changes of rickets, especially in the teeth and bones. It consists of a gray, disc-like opacity of the layer surrounding the transparent nucleus, with clear cortex on the outside (Fig. 208). When the pupil is dilated, examination by oblique illumination shows a grayish disc surrounded by clear lens substance. From the margin of the opacity short striae are often seen projecting into the surrounding transparent cortex. The cataract is most dense at the margin of the disc.

This distinguishes it from nuclear cataract. By the use of the ophthalmoscope at a distance the cataract presents a dark disc surrounded by a zone of red fundus-reflex. The disc is somewhat lighter in the centre than at the periphery, and in the former situation allows some light to pass.

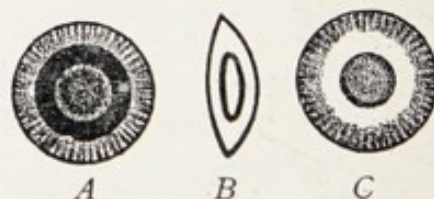


FIG. 208.—ZONULAR CATARACT.

A, Seen with oblique illumination; B, section of the lens; C, seen with the ophthalmoscope.

Lamellar cataract may remain stationary, or the opacity may increase. It causes interference with vision. The amount may be slight or decided, depending upon the extent and density of the opacity.

Treatment.—When sight is considerably interfered with we can improve vision by iridectomy, by discission in the young, or by extraction in older persons. Iridectomy (small coloboma downward and inward) is indicated when the vision is very materially improved after the use of a mydriatic. Its advantages are that the patient does not require strong convex lenses, and often retains binocular vision. Its disadvantages are the elongated pupil, and some dazzling due to this. Removal of the lens by discission or extraction is indicated in those cases in which there is little or no improvement in sight after dilatation of the pupil, and when there are indications of progress of the cataract.

Various Uncommon Varieties of Stationary, Partial Cataract are met with. These include (1) central cataract, a small, white opacity in the centre of the lens; (2) fusiform cataract, a spindle-shaped opacity running from the anterior to the posterior pole; and (3) punctate cataract, consisting of a number of very small white dots variously distributed through the lens. These opacities are usually congenital, cause little interference with vision, but are often associated with other ocular defects.

Complicated or Secondary Cataracts.

These accompany or follow other diseases of the eye. The most frequent ocular affections which lead to cataract are iridocyclitis, choroiditis, severe forms of corneal ulcer, glaucoma, retinitis pigmentosa, and detachment of the retina. Such cataracts frequently begin in the posterior part of the lens, often have distinctive features, and tend to degenerate. It is important to establish the fact that a cataract is complicated when the question of operation presents itself. The treatment of complicated cataract is usually very unsatisfactory, and the prognosis is always less favourable than in uncomplicated cases. This is because the

operation is rendered difficult and the effect on sight disappointing by the complicating ocular disease. Many cases cannot be operated upon.




FIG. 209.—ZIEGLER'S KNIFE.

Dislocation of the Lens.

Dislocation of the lens may be partial (subluxation) or complete (luxation).

Symptoms are disturbance of vision, interference with accommodation, a change in refraction, monocular diplopia, and tremulous iris. They differ according to whether the displacement is partial or complete. In addition there are complications and sequelæ which are often serious.

Partial Dislocation (Subluxation) may consist of a tilting of one edge of the lens, or of a lateral displacement—upward, downward, inward, or outward. In such cases the anterior chamber will be of unequal depth, being increased where the lens is absent. The convex edge of the lens can usually be seen (Fig. 210) in some part of the pupil, the portion of the latter which is free from lens being particularly black. With the indirect method of ophthalmoscopy the optic disc appears double, one image being seen through the lens and the other through the free pupil. Movements of the eyeball disclose a tremulous condition of the lens and iris (iridodonesis). There are considerable myopia in the area corresponding to the lens—the convexity of the lens being increased through relaxation of the suspensory ligament—and marked astigmatism. Monocular diplopia may be complained of, two images being formed on the retina. The subluxated lens may become opaque.

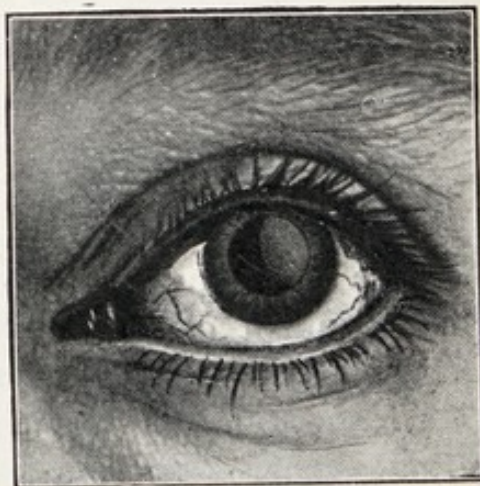


FIG. 210.—DISLOCATION OF THE LENS UPWARD AND OUTWARD.

Complete Dislocation (Luxation) of the lens may occur *anteriorly* into the aqueous, or *posteriorly* into the vitreous cavity. In traumatic cases in which there is rupture of the sclera the lens may lie *beneath the conjunctiva*.

When dislocated anteriorly, the lens is easily recognized. If it is transparent, it looks like a large drop of oil with a curved, golden margin when seen by oblique illumination. The anterior chamber is increased in depth.

When displaced into the vitreous, the lens sinks into the lowest part, and either becomes attached to the fundus by exudation or moves about. When opaque, it can be seen with the ophthalmoscope and sometimes with the unaided eye. The anterior chamber is deep, the iris tremulous, and the pupil very black. The eye is, as in aphakia, in a condition of extreme hypermetropia, and has lost its power of accommodation.

Complications and Sequelæ.—A partial dislocation often changes to a complete one. When subluxated, the lens may remain clear a long time, but completely dislocated lenses soon become opaque. Choroiditis and iridocyclitis, secondary glaucoma, and even sympathetic ophthalmia, sometimes follow. Displacement into the vitreous is tolerated better than anterior luxation.

Etiology.—Dislocation of the lens may be either congenital or acquired. In order that the lens can become dislocated there must be some defect in the suspensory ligament, such as rupture, stretching, or imperfect development.

The *congenital form* is partial, usually upward, often becomes complete in after-years, is generally bilateral, and often hereditary.

The *acquired forms* are either traumatic or spontaneous. Traumatic dislocation is generally the result of contusions. The predisposing cause of spontaneous dislocations is a change in the suspensory ligament seen in fluid vitreous, choroiditis, and myopia of high degree, detachment of the retina, and hypermature cataract. The exciting cause may be insignificant, such as various straining efforts.

Treatment.—In partial dislocation, if no symptoms of

irritation are produced, treatment consists in prescribing suitable glasses, usually strong convex lenses to correct the refraction of the aphakial portion. When the lens is dislocated into the anterior chamber it should be removed, by discission in young persons, by extraction in older cases. The lens should first be pierced by a needle to prevent its dislocation into the vitreous, and be removed by a spoon or wire scoop after corneal incision. If dislocated into the vitreous, an attempt to extract it is almost certain to fail. Strong convex glasses are prescribed for the aphakia. If inflammatory symptoms arise in a case in which the dislocated lens cannot be removed, an iridectomy may be tried; if in such cases the eye is sightless, enucleation is indicated.

CHAPTER XIX

DISEASES OF THE RETINA

Anatomy.—The retina is a thin, delicate membrane which consists, among other parts, of an expansion of the optic nerve. It is placed between the hyaloid membrane of the vitreous internally and the choroid externally. It extends forward to the ciliary body, where its termination is called the ora serrata ; devoid of nerve fibres, simpler and thinner, it is continued over the inner surface of the ciliary body and the posterior surface of the iris. In the living eye, it is transparent and of a purple-red colour. Under the influence of light it is quickly bleached ; after death it soon becomes opaque and white. The retina is connected with the subjacent choroid at the entrance of the optic nerve and at the ora serrata. Elsewhere it simply lies upon this tunic, but is not attached to it. When we detach the retina, the pigment cells which form its outermost layer adhere to the choroid, and on this account were formerly described as part of the latter.

The inner surface of the retina presents in the axis of the eyeball the *yellow spot or macula lutea*, about 1 to 2 mm. in diameter, and in its centre a small depression, the *fovea centralis*. This is the region of most distinct vision, and the part of the retina which is made to receive the image when we wish to get an exact impression of an object. About 3 mm. to the inner side of the posterior pole of the eye is a pale, round area, the *head of the optic nerve (papilla, or disc)*, corresponding to the point where the optic nerve pierces the retina (Fig. 42). The circumference of the disc is slightly elevated above the surface of the retina, but the centre presents a depression, the physiological cup or excavation. Here the bloodvessels of the retina enter the eye. The ophthalmoscopic appearances of the background of the eye and the distribution of the retinal vessels are given in Chapter III.

The *central artery* of the retina, accompanied by the corresponding *vein*, pierces the optic nerve about 2 cm. from the globe, and passes between the bundles of fibres to the inner surface of the retina at or near the middle of the disc. Excepting at the papilla, where minute communications are sometimes found between retinal and

ciliary vessels, the retinal arteries have no anastomoses. They are terminal branches; hence in obstruction of the central artery there is no compensatory collateral circulation, and blindness results. The retinal vessels lie in the inner layers. The external layers are destitute of bloodvessels, and are nourished by the adjacent chorio-capillaris. The fovea has no bloodvessels. In this situation, the chorio-capillaris is thickened. The bloodvessels are surrounded by lymphatic sheaths forming the lymphatics of the retina.

The *minute anatomy* of the retina is very complicated. We distinguish two kinds of tissue: (1) nervous elements, of which there are eight layers; and (2) supporting tissue (Mueller's fibres). The supporting tissue comprises the internal and external limiting membranes and numerous fibres serving to keep the delicate nerve-tissue in proper position.

Microscopic examination shows the following layers of the retina, from within outward (Fig. 211): (1) the internal limiting membrane; (2) the layer of nerve fibres, consisting of the expansion of the fibres of the optic nerve, destitute of medullary layer after piercing the eyeball; (3) the layer of ganglion cells, a stratum of large branching nerve cells; (4) the inner plexiform layer; (5) the inner nuclear layer; (6) the outer plexiform layer; (7) the outer nuclear layer; (8) the external limiting membrane; (9) the layer of rods and cones, the light-perceiving layer; (10) the layer of pigment cells, which bounds the retina externally, and consists of a single stratum of hexagonal pigmented cells.

The rods are much more numerous than the cones, excepting at the macula, where the cones preponderate. At the fovea there are no rods, and the cones, longer and narrower than elsewhere, are found exclusively. In this spot, also, all the layers of the retina are much thinner, there is no nerve-fibre layer, and Mueller's fibres are arranged obliquely. The disc consists of optic-nerve fibres exclusively. It has no other retinal nerve elements, and has no power of sight; hence it is called the blind spot.

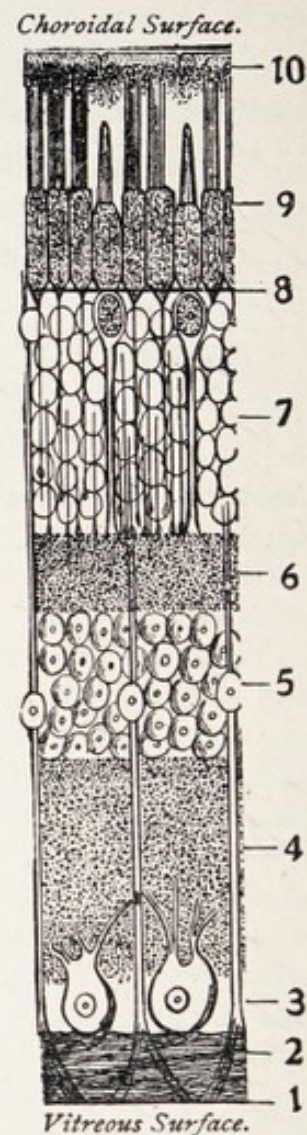


FIG. 211.—SECTION OF THE RETINA, SHOWING THE MINUTE ANATOMY. (Modified from Schultze.)

1, Internal limiting membrane; 2, layer of nerve fibres; 3, layer of ganglion cells; 4, inner plexiform layer; 5, inner nuclear layer; 6, outer plexiform layer; 7, outer nuclear layer; 8, external limiting layer; 9, layer of rods and cones; 10, layer of pigment cells.

Physiology.—The action of light changes the visual purple contained in the outer segments of the rods into a colourless substance. When the eye is in the dark, most of the pigment is stored in the body of the cell, and is withdrawn from between the rods. After exposure to light, the pigment granules push their way inward into the processes extending between the rods and cones, and the latter become contracted and shortened. The function of the pigment cells is the renewal of the visual purple of the outer segments of the rods after the bleaching produced by exposure to light.

The rods and cones, the terminal organs of the optic nerve, receive waves of light, which fall upon the retina and convert these vibrations into impulses, which are carried by the optic nerves and tracts to the brain. Here they produce the sensation of light. When the image of an object falls upon the macula, there is distinct vision; when it falls upon any other part of the retina, there is indistinct vision. Two points give rise to separate visual impressions when their images are at least 0.002 mm. apart, since this represents the diameter of the cones at the fovea. Images which are closer than this would only stimulate one cone, and consequently create but one visual impression. In other words, to be seen distinctly, two objects must subtend a visual angle of one minute or more (p. 10).

Images of an object give rise to a single visual impression when they fall upon corresponding retinal areas; otherwise there are double images. In binocular vision certain portions of the retina are associated; thus, the upper halves of the retina correspond, as do also the lower halves; but the nasal side of one retina corresponds to the temporal half of the other, and *vice versa*.

Rays of light impinging upon the retina come from the opposite side of the field; thus, the upper part of the retina is used for seeing objects in the lower part of the field, the temporal portion of the retina for the nasal part of the field, etc. The image on the retina is always inverted.

Affections of the Retina may be divided into :

1. *Inflammation*, the various forms of retinitis : (1) simple, (2) albuminuric, (3) diabetic, (4) leukæmic, (5) syphilitic, (6) hæmorrhagic, (7) purulent, (8) uncommon forms of retinal changes.

2. *Vascular Changes* : (1) Anæmia, (2) hyperæmia, (3) hæmorrhages, (4) arterio-sclerosis, (5) embolism, (6) thrombosis.

3. *Pigmentary Degeneration* (retinitis pigmentosa).

4. *Detachment*.

5. *Tumour* : glioma (see chapter on Intra-ocular Tumours).

Retinitis.

Inflammation of the retina presents varied clinical types. There are, however, certain signs and symptoms which are more or less common to all varieties. Retinitis may be (1) primary, or (2) secondary, when it is an extension of inflammation of neighbouring ocular structures. It usually extends to both the papilla and the choroid. When the involvement of the entrance of the optic nerve is marked, we speak of the affection as neuro-retinitis; when the choroid is prominently implicated, we call the condition choroido-retinitis. The disease may be confined to one eye; but since it is generally dependent upon a constitutional factor, it is almost always bilateral. It may be acute in course, but, as a rule, it lasts many weeks, or even several months.

Subjective Symptoms.—(1) Diminution in acuteness of vision, varying with the severity and extent of the retinitis, but generally considerable. It may be especially marked at night, constituting night-blindness. (2) Changes in the field of vision. There may be concentric or irregular contraction or scotomata. (3) Alterations in the shape of objects: micropsia, objects appearing smaller than they really are; macropsia, objects appearing larger than normal; metamorphosia, a distortion of the shape of objects, straight lines appearing wavy and bulging. (4) Diminution of the light sense. (5) Feeling of discomfort in the eyes. (6) Photophobia may be present, but pain is rare.

Objective Symptoms.—There are no external signs; the objective symptoms are all ophthalmoscopic: Diffuse clouding of retinal details, especially in the region of the papilla; congestion of the disc, with indistinctness of its edges; circumscribed exudations appearing as soft, white, or slightly yellow spots or patches, discrete or confluent, varying in size, and found principally along the retinal vessels and at the macula; tortuosity and distension of the vessels, which may be obscured in parts by swelling and exudation; hæmorrhages of various shapes and sizes, rounded when occurring in the deeper layers, and feathery or flame-shaped when superficial. There may be opacities in the vitreous.

Course.—The inflammation may subside completely, and

useful vision return ; or certain changes may occur in the retina as a result of atrophy, causing considerable impairment or absolute loss of vision. These changes are : Atrophy of the retina, allowing the choroidal vessels to become visible ; bright, white patches and bright dots replacing hæmorrhages or exudation, and frequently pigmented ; contraction of the vessels, which are bordered by white lines ; atrophy of the disc, which presents an indistinct outline and a pale, dirty colour (post-neuritic atrophy).

Prognosis depends upon the severity of the inflammation, the parts of the retina involved most, and the clinical form of the retinitis.

Pathology.—The changes consist in congestion, œdema, exudation of white blood corpuscles and of fibrin, fatty degeneration, and extravasation of blood. The white spots are due to exudation of leucocytes and of fibrin, swelling of nerve fibres and cells, and fatty degeneration of the retinal elements and of exudation. The walls of the bloodvessels become thickened, so that in extreme cases the lumen may be filled with connective tissue. When the retina becomes atrophied, the nerve elements disappear and the membrane is replaced by connective tissue more or less pigmented.

Etiology.—Retinitis occurs occasionally as a local lesion. But generally it is merely a manifestation of a constitutional disease, such as nephritis, diabetes, syphilis, affections of the vascular system, etc. It may be due to auto-intoxication, or to extension from the choroid or ciliary body.

Treatment.—The local treatment consists in absolute rest for the eyes, protection from light, either by smoked glasses or the darkened room, and the use of atropine. Internally we give small doses of mercury, also iodide of potassium, diaphoretics, and sometimes cathartics. In addition, it is of the greatest importance to treat the constitutional condition which is the cause of the retinal lesion.

Simple Retinitis.

This disease, also known as serous retinitis and œdema of the retina, is an inflammation of the superficial layers of the retina, slight in degree and simple or serous in type ; the

evidences of inflammation are limited to swelling, vascular distension, and occasionally hæmorrhages. Some authorities regard it, not as a distinct disease, but as the first stage of the more common forms of retinitis.

There is limited impairment of vision (often merely a blurred sensation), some distortion of images, and moderate peripheral contraction of the field. The ophthalmoscope reveals a hazy fundus especially around the disc, the margins of which are indistinct, veins somewhat dilated, tortuous, and hidden in places by the œdema, and at times hæmorrhages.

This form of retinitis may be due to excessive use of the eyes, especially with uncorrected errors of refraction and by poor illumination, the effect of intense light and heat, exposure to cold, or there may be no assignable cause. It may be merely the first stage of other forms of retinitis.

The prognosis is good when the affection remains of this type and does not change to the deep form. Treatment consists in the removal of the cause and the observance of the directions given above.

The Deep or Parenchymatous Type is a more intense inflammation involving the deeper layers of the retina; the pathological changes are more extensive, including, besides those occurring in the serous form, exudation, changes in the vessel walls, and hæmorrhages, and consequently capable of causing greater destruction with atrophy and permanent visual damage.

There are often marked ocular discomfort, much disturbance of vision and distortion of objects, peripheral contraction of the field, and scotomata. The ophthalmoscope discloses, in addition to the picture presented by the serous type, scattered yellowish patches of exudate, especially in the macular region, changes in the walls of the bloodvessels, and hæmorrhages.

This variety depends upon constitutional causes or represents an extension of or association with neighbouring ocular diseases. The prognosis is always serious; though some cases recover with fair or even good vision, many are left with marked impairment of this function. Treatment has been given under retinitis in general, and is discussed again in the clinical forms of retinitis in the following pages.

Albuminuric Retinitis.

Retinitis of Bright's Disease (Renal Retinitis) presents ophthalmoscopic signs which are often pathognomonic. It is usually bilateral, rarely unilateral.

Symptoms.—The subjective symptoms are those of retinitis in general (p. 250). The degree of disturbance of vision depends upon the severity of the inflammation and especially upon the position of the exudations and hæmorrhages. Minute changes in the macular region will cause considerable reduction in acuteness of vision, while extensive involvement of the rest of the fundus may affect the sight comparatively little.

Ophthalmoscopic Signs (Plate XVI.) are those of retinitis in general: swelling and haziness of the retina and of the papilla, distension and tortuosity of the retinal vessels, especially veins, and hæmorrhages either in the form of flame-shaped or round spots, or larger extravasations. To these are added the distinctive feature: white spots found chiefly at the macula and surrounding the disc, less frequently elsewhere. At the macula there may be at first merely a few dots, but later there are more pronounced spots, and these are usually arranged in radiating lines which form a star-shaped figure with the fovea for a centre; or when less complete, the lines resemble the sticks of an open fan; they have a certain brilliancy due to fatty degeneration of retinal elements and of exudation. Near the disc, and often more or less surrounding it, are larger white spots; these may coalesce and form a ring around the disc.

Though this is the most frequent picture of albuminuric retinitis, there are other and less characteristic signs in nephritis; there may be simply retinal hæmorrhages, simple retinitis, hæmorrhagic retinitis, neuritis, or even a picture of choked disc such as we are in the habit of associating with cerebral tumour. On the other hand a brain tumour may present ophthalmoscopic appearances identical with those of a typical case of albuminuric retinitis.

Albuminuric retinitis occurs under two forms: (I) the inflammatory, when swelling, congestion, and hæmorrhages

are the predominating features; and (2) the degenerative, when the white spots and hæmorrhages occur without swelling or congestion. The two forms are usually associated in varying proportions.

Etiology.—The affection is usually a complication of chronic interstitial nephritis; much less frequently of chronic parenchymatous nephritis; it may occur with any form of nephritis, including that of scarlatina and pregnancy. From one-quarter to one-half of all patients with nephritis present some form of retinal lesion.

Pathology.—The retina presents œdema, hypertrophy of its elements, deposits of fat and fibrin, and hæmorrhages. The retinal vessels are thickened and the seat of hyaline changes with proliferation of the lining epithelium; these changes are similar to those taking place in the vessels of the kidney. The spots in the macular region are caused by fatty degeneration of exudate and retinal elements; their arrangement in a star-shaped figure depends upon the disposition of Mueller's fibres in this situation.

Course and Prognosis.—Though the retinitis is often a late symptom of Bright's disease, the disturbance of vision may be the first symptom which calls attention to the nephritis. Occasionally ophthalmoscopic examination first reveals the presence of Bright's disease in a patient who was unaware of any defect of sight other than presbyopia. There is no fixed relationship between the course of the nephritis, the amount of albumin, and the degree of retinitis. There are cases in which the vision is but slightly affected even in the late stages, and others in which sight is seriously affected quite early. The condition is of great prognostic importance, and indicates, with but few exceptions, a fatal termination in from six months to two years. The exceptions usually are cases occurring during pregnancy and scarlatina.

Treatment should be directed to the nephritis. No local treatment is of any value.

Gravidie Retinitis is the name given to retinitis complicating the albuminuria of pregnancy. Its signs and symptoms are the same as in the other forms of albuminuric retinitis,

PLATE XVI.

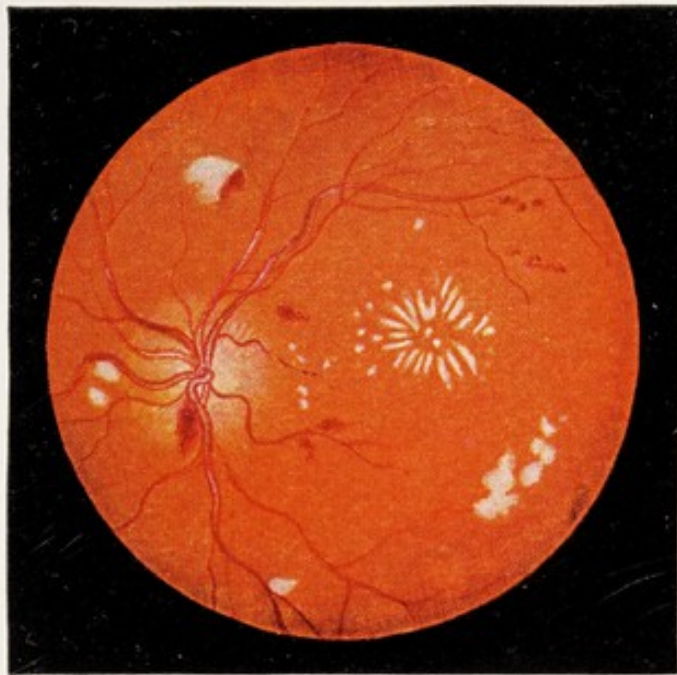

FIG. 211A.—ALBUMINURIC NEURO-RETINITIS.

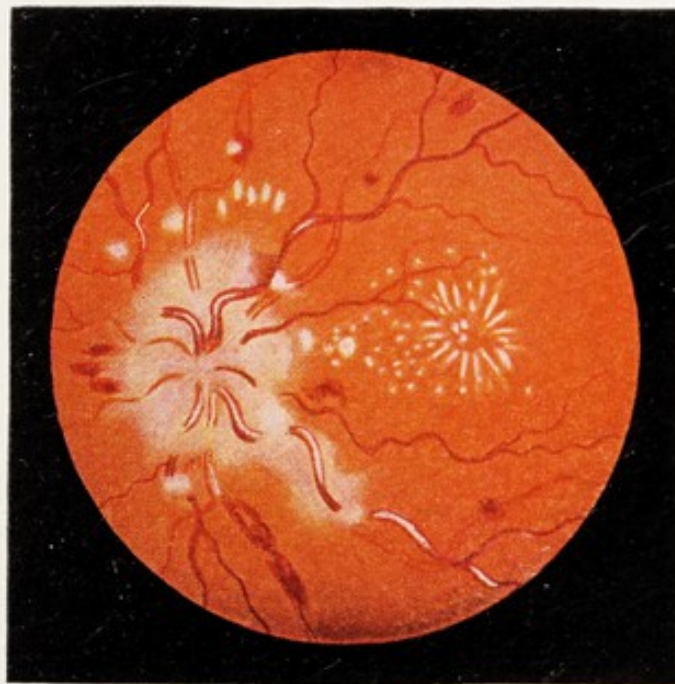

FIG. 212.—ALBUMINURIC NEURO-RETINITIS
(LATER STAGE).

To face page 254.



out they tend to clear up after delivery. It usually occurs during the final months of pregnancy, and the prognosis in regard to vision is often good, especially if labour be induced prematurely. When it occurs in the early months, the prognosis is less favourable, and the condition may warrant the induction of abortion in order to save sight.

Uræmic Amblyopia is the term used for loss of sight during an attack of uræmia, without any changes in the retina. It is cerebral, not retinal, being due to retention in the blood of waste products which should have been excreted by the kidneys. It occurs in pregnancy and during the late stages of scarlatina. Similar attacks may also occur in patients who have albuminuric retinitis. It appears suddenly, affects both eyes, and is associated with other symptoms of uræmia—headache, vomiting, convulsions, and coma. The pupils are dilated, but respond to light. After lasting a short time, or for a day or two, normal vision usually returns. Treatment is that of uræmia.

Diabetic Retinitis.

This form occurs as a late manifestation of glycosuria, but is not common. The ophthalmoscopic appearances (Fig. 213, Plate XVII.) resemble those of albuminuric retinitis in some cases, but in others they are characteristic: small, bright, white spots in and around the macular region, grouped irregularly and not in the form of a stellate figure; sometimes larger spots; numerous punctate or larger hæmorrhages. There is no swelling of the optic nerve and retina. The prognosis depends upon the systemic condition. The treatment is that of diabetes.

Leukæmic Retinitis.

This variety presents marked swelling of the retina and disc, and numerous hæmorrhages. The bloodvessels are greatly dilated and extremely tortuous, and the blood is very pale. The entire fundus is pale, and has a yellowish hue. There are white and yellow spots of exudation, and some of these present a pink border. They consist of white blood corpuscles surrounded by red blood cells.

Syphilitic Retinitis.

A common form of retinitis found in both hereditary and acquired syphilis (Fig. 162, Plate XIV.). In acquired syphilis it occurs in the secondary stage, during the first or second year, and usually involves both eyes. It is generally associated with choroiditis and often with iritis.

Ophthalmoscopic Signs.—In acquired syphilis there may be indistinctness of the fundus due to swelling of the retina and disc, and to fine, dust-like opacities of the posterior portion of the vitreous. These opacities cause the disc to appear red and hazy; scattered grayish or white spots often fringed with pigment, especially in the macular region, but also peripherally; circumscribed white exudations along the large bloodvessels, forming white lines. Later, deposits of pigment may be so pronounced as to resemble somewhat the picture of retinitis pigmentosa. There may be one or more large white exudates, leaving later an atrophic area with pigmented edges.

In hereditary syphilis general gray discoloration, spots of black pigment and atrophied areas are common, especially towards the periphery.

Subjective Symptoms consist of more or less diminution in the acuteness of vision, diminution in the light sense, night-blindness, annoying flashes of light, distortion, and changes in size of objects, central and ring scotomata, and, later, contraction of the field of vision.

Course and Prognosis.—The progress is slow, and relapses are common. The prognosis depends upon the stage during which treatment is begun. If begun early and carried out vigorously, the prognosis is good, though some impairment of vision usually remains. Neglected cases are often followed by disseminated choroiditis, pigmentary degeneration of the retina, and optic-nerve atrophy.

Treatment consists in the thorough use of mercury by inunctions, and afterwards iodide of potassium, rest of the eyes, protection from light, and atropine. Salvarsan may be tried.

PLATE XVII.

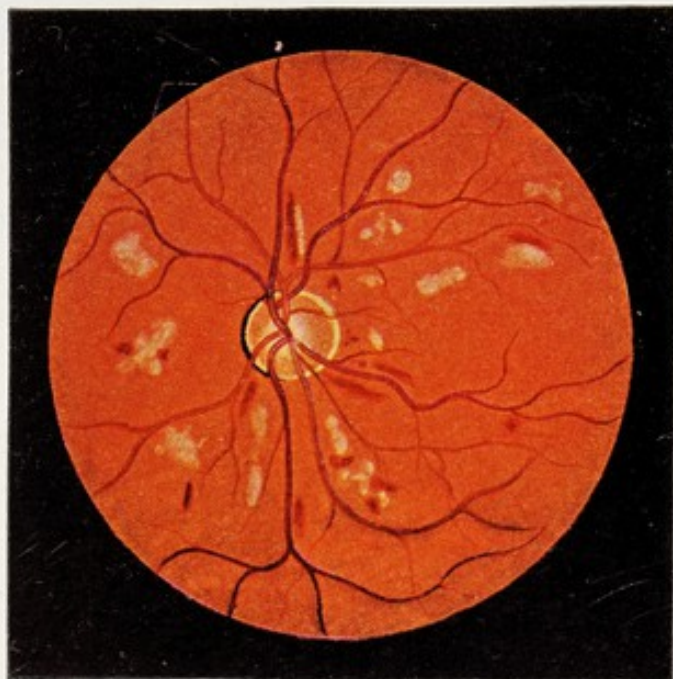


FIG. 213.--DIABETIC RETINITIS.

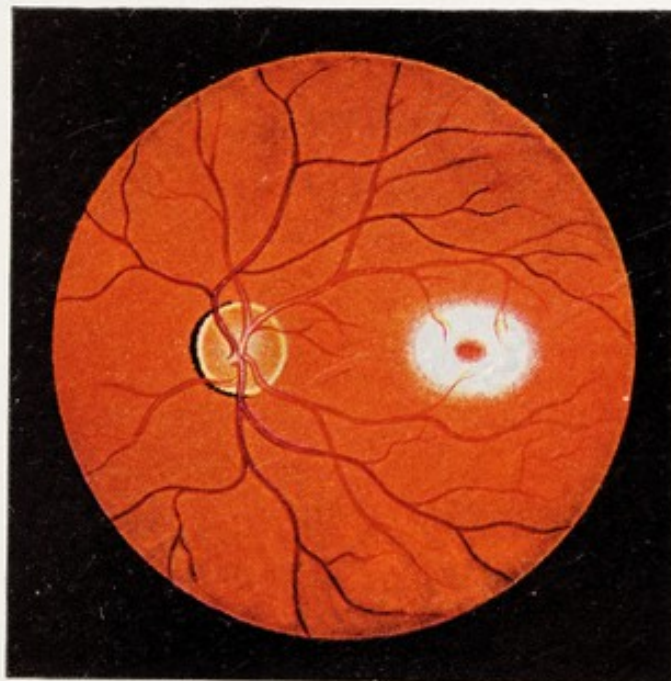


FIG. 214.—THE FUNDUS IN AMAUROTIC FAMILY
IDIOCY.

To face page 256.



Hæmorrhagic Retinitis.

In this form of inflammation, numerous and recurrent hæmorrhages are added to the other signs of retinitis. The extravasations of blood, both flame-shaped (superficial) and round and irregular (deep), are usually scattered all over the fundus. This affection usually occurs in elderly individuals as a result of diseases of the heart and bloodvessels. It may be monocular or bilateral. The prognosis is unfavourable. New hæmorrhages are apt to be added to the residua of the old ones. Sometimes the affection terminates in hæmorrhagic glaucoma. It is often a forerunner of cerebral hæmorrhage. Treatment consists in rest for the eyes, smoked glasses, sometimes local abstraction of blood, and ergot. Constitutional treatment is of the greatest importance in the endeavour to guard against hæmorrhage in other parts of the body.

Septic Retinitis.

This affection, also known as metastatic retinitis, results from the lodgment of septic emboli in the retinal arteries in the course of puerperal and other forms of septicæmia and pyæmia, and also from infected wounds and foreign bodies. In the first stage there are small white spots and hæmorrhages around the disc and in the macular region. Very soon, however, the uveal tract is invaded and the signs of purulent choroiditis (p. 180) appear. The inflammation ends in panophthalmitis or in degeneration of the eyeball without perforation (pseudo-glioma). Non-infected embolus gives rise to characteristic retinal changes (p. 260).

Uncommon Forms of Retinal Changes.

A number of pathological conditions are found in the retina, which, though uncommon, have received names describing the clinical picture in each case. Among these are retinitis circinata (presenting a crescentic or annular figure formed of white patches surrounding the macula);

angeoid streaks (pigmented striæ resembling a system of obliterated bloodvessels); striated retinitis (yellowish or grayish streaks radiating from the disc to the periphery); punctate retinitis (numerous small, white, or yellowish scattered spots); proliferating retinitis (dense vascularized masses of connective tissue which project from the retina into the vitreous).

Retinal Changes due to Excessive Light are seen after injurious exposure of the eye (1) to the sun, especially in watching an eclipse with insufficient protection; (2) to the electric light, as in electric welding; and (3) to sunlight reflected from snow (snow blindness). There are pigment changes at the macula, and, corresponding to this, a central, positive scotoma which may become less marked, but does not disappear entirely. The conjunctivitis which results from exposure to excessive light is described on p. 88.

Symmetrical Changes at the Macula in Infancy (amaurotic family idiocy).—This condition presents a clinical picture (Fig. 214, Plate XVII.) which somewhat resembles that of embolism of the central artery: a red spot at the macula surrounded by a grayish-white zone about twice the size of the disc. This is followed by optic-nerve atrophy. The disease occurs in infants who present general muscular and mental weakness. There is gradual loss of sight. Death results in a year or two. It attacks several children of the same parents. Nearly all recorded cases have been of Jewish parentage.

Contusion of the Retina (œdema of the retina) is a transitory clouding of the retina resulting from contusion of the eyeball. It causes some diminution in acuteness of vision, which disappears with the retinal change in a few days.

Circulatory Disturbances of the Retina.

Hyperæmia of the Retina, when slight, is recognized by increased redness of the disc and by slight striation of its margins. Such a condition is often found in persons suffering from the effects of errors of refraction (asthenopia), and in those whose vocations expose the eye to excessive light

or heat. Marked arterial hyperæmia is an accompaniment of inflammation of the retina and of surrounding ocular structures. Venous hyperæmia is seen as a result of pressure, in certain general diseases (especially heart disease), and in a most pronounced form in thrombosis of the central vein.

Anæmia of the Retina may be merely the ocular expression of a general condition, or it may be local. The latter form may be acute or chronic. Acute anæmia is known as ischæmia of the retina. It may result from occlusion (embolism of the central artery), compression, or spasm of the retinal arteries. There is extreme narrowing of the retinal arteries, pallor of the disc, and blindness. Such a condition is observed in cholera, and temporarily in migraine. Quinine poisoning furnishes an example of ischæmia in which some diminution in acuteness of vision and some contraction of the field of vision are permanent. The chronic form of anæmia is frequently seen after retinal disease causing atrophy. Here the bloodvessels become narrower or even changed into slender, empty threads.

Hæmorrhages in the Retina (retinal hæmorrhages, Fig. 215, Plate XVIII.) often occur without any signs of inflammation.

Objective Signs.—The hæmorrhages vary in size, shape, and position. They are found most frequently in the neighbourhood of the larger bloodvessels. When situated in the nerve-fibre layer, they have a striate or flame-shaped form; when deep, they are rounded or irregular in outline. Sometimes a large round extravasation is seen in the region of the macula, between the retina and vitreous. This is known as a subhyaloid hæmorrhage. Retinal hæmorrhages become absorbed slowly. The smaller ones may leave no traces. But more frequently white spots, sometimes pigmented, indicate their site.

Subjective Symptoms.—The interference with vision depends upon the size and particularly the situation of the hæmorrhage. If at the macula, vision is much diminished. A scotoma results if the retinal tissue has been injured. Subhyaloid hæmorrhage may cause no per-

manent change in vision after absorption, since the retina is not involved.

Etiology.—The *causes* of retinal hæmorrhages are : (1) Injuries. (2) Local disease of the vessels of the retina and choroid. (3) Diseased state of the bloodvessels, especially atheroma. This condition is commonly associated with heart and kidney disease, frequently found in old persons, and is often a warning of cerebral apoplexy. (4) Disturbances in the circulation, causing retinal embolism, thrombosis, hæmorrhages in the new-born, and after operations. (5) Valvular heart disease and cardiac hypertrophy. (6) Changes in the composition of the blood and in the walls of the bloodvessels, seen in anæmia, leukæmia, purpura, scurvy, pyæmia, and septicæmia, the malarial fevers, poisons, etc.

Treatment.—Management of the etiological factor is indicated. Locally, there is no treatment.

Changes in the Fundus in Arterio-Sclerosis are of importance in general prognosis, since the finding of such indicates similar lesions in other parts of the body, especially the brain. Ophthalmological evidence may be the first to reveal the existence of this serious vascular lesion. The fundus may present any or all of the following changes (Fig. 216, Plate XVIII.) : Increased tortuosity and beaded appearance of the bloodvessels ; greater opacity of the arteries and widening of the central light-streak ; apparent interruption of continuity in the veins where they are crossed by arteries, and dilatation just beyond these points ; white lines along the course of vessels (peri-vasculitis) ; retinal œdema near disc, along bloodvessels, or scattered in spots ; hæmorrhages.

Embolism of the Central Artery.—Plugging of the central artery of the retina by a non-infected embolus causes *sudden blindness*, which is sometimes unrecognized by the patient, because it is usually unilateral and there is no pain. The left eye is the one generally affected.

Symptoms.—There are no external signs, but the ophthalmoscopic picture is very characteristic. Within a few hours the *fundus* becomes *pale* and *œdematous*, *grayish*, or even *milky*. This is most pronounced near the disc and macula,

PLATE XVIII.

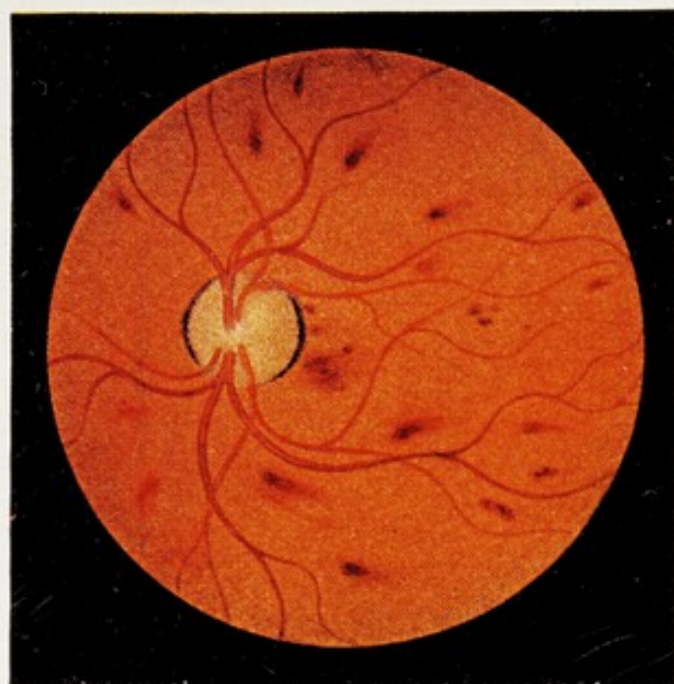

FIG. 215.—HÆMORRHAGES IN THE RETINA.

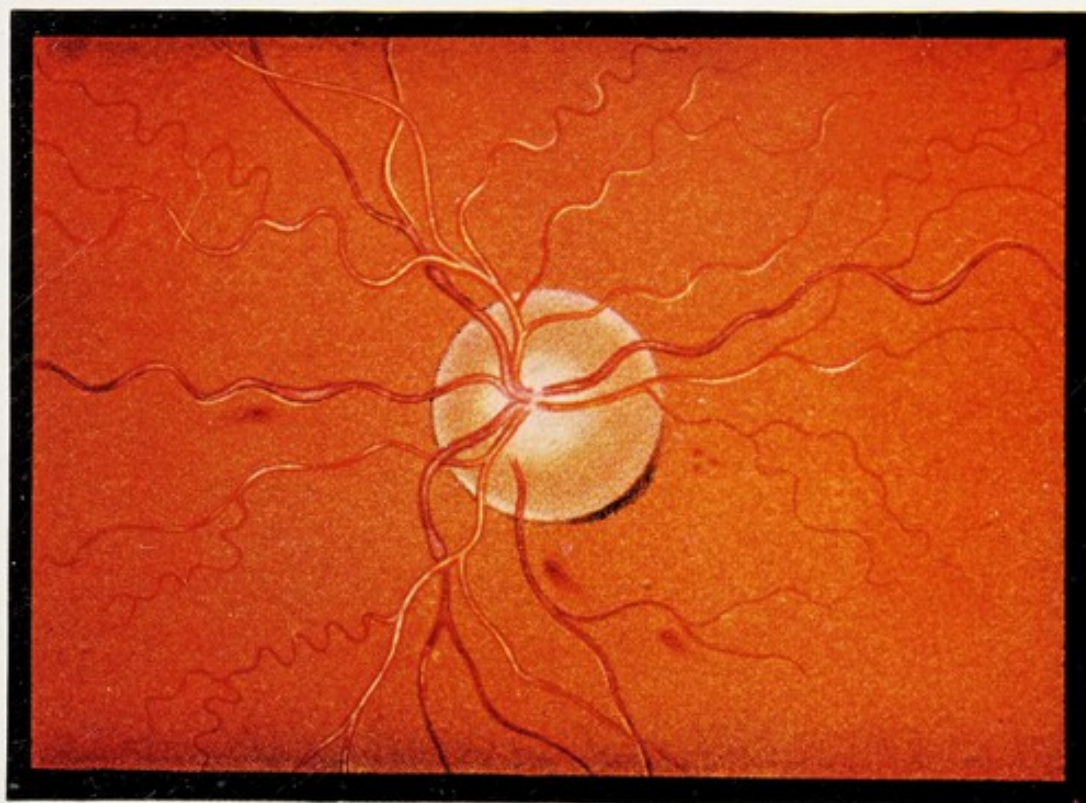


FIG. 216.—ARTERIO-SCLEROSIS.

To face page 260.

and fades out toward the periphery. In the situation of the fovea there is a bright *cherry-red spot*, which stands out in marked contrast to the neighbouring grayish-white retina. This is due to the red colour of the choroid seen through the very thin retina opposite this area. The *arteries are very thin*, and can be followed only a short distance from the disc. Beyond this point they may be lost entirely. The veins also contain less than the normal amount of blood. There may be small *hæmorrhages*. Pressure upon the eyeball does not produce arterial pulsation, but gives rise to the appearance of broken columns of blood with clear spaces between them.

There is sudden and complete blindness; even perception of light is lost. Occasionally good central vision is preserved. This is due to the existence of a small macular branch given off from the central artery below its bifurcation, where the embolus usually lodges; but even in such exceptional cases most of the field is lost.

After embolism of the trunk of the central artery has lasted a few days, degeneration of the retina occurs, and after a few weeks atrophy sets in. The œdema subsides, the disc atrophies, and the bloodvessels become shrunken or are represented by white lines.

The foregoing description applies to cases in which the main trunk of the central artery is occluded. The embolus may, however, lodge in one of the branches of the central artery. In such cases the interference with sight and the changes in the background will be limited to the area supplied by the occluded branch. Occasionally the embolus can be seen, but usually its presence is shown by a swelling in the artery, beyond which the vessel is thin or obliterated.

Etiology.—Plugging of the central artery is most frequently due to valvular heart disease, less often to atheroma, aneurism, Bright's disease, and pregnancy. A thrombus of the central artery may give rise to the same signs and symptoms as embolism, and a differential diagnosis is difficult or impossible.

Treatment is rarely effective. If the case is seen early, paracentesis of the cornea, massage of the eyeball, and inhalations of amyl nitrite have been employed for the pur-

pose of driving the plug along into one of the smaller branches, where it will give rise to less serious results. In a few cases such treatment has been beneficial.

Thrombosis of the Central Vein may occur in old persons with atheroma and cardiac disease; it also follows cellulitis of the orbit. It is one of the causes of hæmorrhagic retinitis. It may be complete or partial. There is diminution of vision, either corresponding to the entire field, or, if only a branch is affected, to the part of the retina supplied by it. The veins are greatly engorged and tortuous, the arteries very small; there are numerous large hæmorrhages, and indistinctness of the margins of the disc. The condition usually ends in atrophy of the retina and disc. There is no treatment.

Pigmentary Degeneration of the Retina, or Retinitis Pigmentosa.

A chronic form of retinitis, which has a constant tendency to become worse, and which consists of atrophy of the retina with migration of pigment from the pigment epithelium into the inner layers.

Symptoms.—*Night blindness* (hemeralopia), *concentric contraction of the field of vision*, *progressive diminution in sight*, terminating in advanced years in *complete blindness*.

In early life there is but slight reduction in the extent of the field with good illumination, and central vision is often perfect. But with feeble illumination the peripheral parts of the retina do not react, and on this account the patient cannot find his way about at night, because the field is small. With increasing years the field becomes contracted even with good illumination. Finally, in advanced life central vision becomes poor, and gradually complete blindness follows.

Ophthalmoscopic Examination (Fig. 217, Plate XIX.) shows *black spots in the periphery of the fundus*. These have the shape of *branching cells, like corpuscles with connecting bone processes*, and are found especially *along the bloodvessels*. In the course of years new spots form, and in this way the pigment circle gradually approaches the disc. Migration of

PLATE XIX.

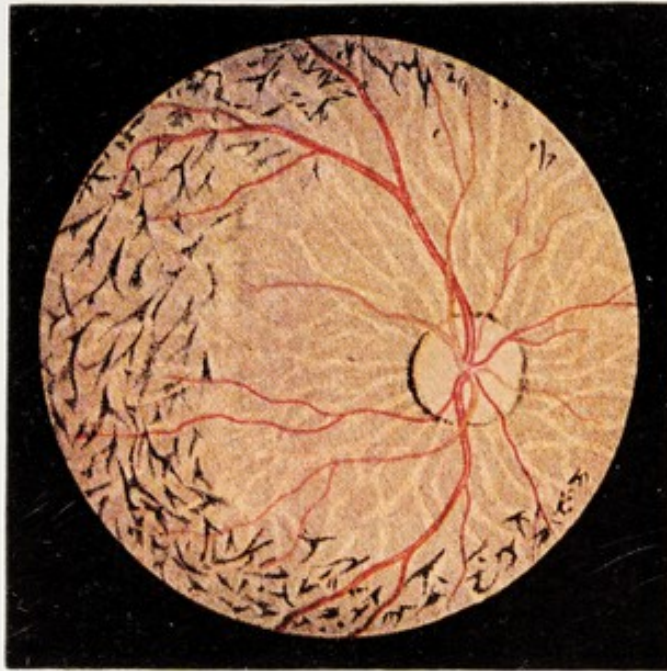



FIG. 217.—RETINITIS PIGMENTOSA.

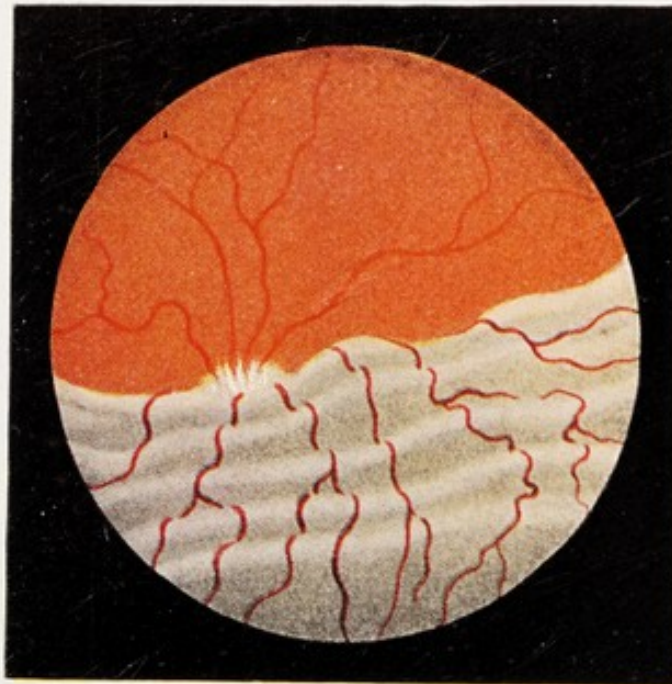

FIG. 218.—DETACHMENT OF RETINA.



colouring matter from the pigment layer of the retina allows the choroidal vessels to become plainly visible. The *disc and retina are atrophied*. The disc has a yellowish, waxy appearance. The retinal *arteries* are very *small*, and in the periphery are represented by mere threads.

There are cases of retinitis pigmentosa in which all the symptoms of this disease are present, and the ophthalmoscope shows all changes except the presence of pigment, and others in which the pigment is distributed in an atypical manner.

Syphilitic choroido-retinitis may give a picture similar to that of retinitis pigmentosa, but may be differentiated by the patches of choroidal atrophy.

Occurrence.—The disease affects both eyes. It is either congenital or develops in childhood. It is hereditary, and is often found in the offspring of consanguineous marriages. Not infrequently other congenital defects, such as deafness and defective intelligence, are present. It may be complicated with posterior polar cataract and other ocular anomalies.

Treatment is of no avail. Gland extracts may be tried.

Retinitis Punctata Albescens is a rare disease, having all the subjective symptoms of retinitis pigmentosa. There is no pigmentation, but small white spots are scattered all over the fundus. It is slowly progressive, and incurable.

Detachment of the Retina.

Retinal detachment is a separation of the retina from the choroid. The name usually refers to a separation by serum, but detachment may also occur as a result of subretinal hæmorrhage, exudation, or tumour.

Symptoms.—There is more or less complete loss of vision in that part of the field which is opposite to the detachment, and the appearance of a dark cloud before the eye. Early symptoms are metamorphopsia and flashes of light (photopsia). Central vision is preserved as long as the macula is not included.

Ophthalmoscopic Signs depend upon the degree and extent of detachment. When the detachment is flat, the retina

appears but slightly changed. It is somewhat cloudy, and its vessels are dark and tortuous. The variation in level of the affected portion can be recognized by the difference in the refraction of a bloodvessel on the separated part. When the detachment is steep, as is generally the case, it is usually found near the periphery. It is at first limited in extent. It may commence at any part of the retina, but as a result of sinking of the subretinal fluid it is usually found below. It tends to enlarge and become total, then involving the entire retina. It presents a collection of grayish, bluish-gray, or greenish folds (Fig. 218, Plate XIX.) with white tops projecting a variable distance into the vitreous and shaking with movements of the eye. The bloodvessels pass over and follow these folds, and are therefore very tortuous, and hidden at places. They appear prominent, and of a dark red, almost black, colour. Sometimes a rupture can be seen in the separated retina. In the later stages opacities of the vitreous and cataract are often added. The rest of the fundus presents a normal picture. Externally the eye appears normal, but tension is usually lowered and the anterior chamber deepened.

Etiology.—Serous detachment may be due to injury or disease. Traumatic detachment is usually the result of a blow. It may follow an accidental or operative wound, especially when there has been loss of vitreous. When due to disease, it is generally found in myopia of high degree, and after disease of the vitreous, iridocyclitis, and irido-choroiditis. In such cases the condition probably results from the shrinking of the vitreous, which thus pulls the retina from its attachment. Other forms of detachment are much less frequent, and are due to subretinal hæmorrhage, exudation, or tumour.

Diagnosis is readily made, but it is sometimes difficult to decide whether the detachment is serous or due to a tumour of the choroid (p. 187)

Prognosis is unfavourable. The detachment tends to enlarge, and to become total. Even after improvement relapses are the rule, and complete blindness is the usual end.

Treatment is sometimes followed by temporary improvement, but is rarely productive of lasting benefit. In recent cases the best treatment is absolute rest in bed, with a firm bandage applied to both eyes, kept up for six to ten weeks. Potassium iodide and daily subcutaneous injections of pilocarpine in sufficient dose to produce sweating and salivation ($\frac{1}{12}$ grain) are often tried.

Puncture of the sclera (posterior sclerotomy, p. 208) has been frequently tried, also subconjunctival injections of solution of sodium chloride, but it is doubtful whether either of these measures has ever caused any permanent improvement.

CHAPTER XX

DISEASES OF THE OPTIC NERVE

Anatomy.—The optic nerve may be divided into (1) an intra-ocular portion, the retina ; (2) an orbital portion extending from the eyeball to the optic foramen; and (3) an intracranial portion situated between the optic foramen and the chiasm.

The intracranial portion of the optic nerve is short and flattened. The optic foramen forms an unyielding ring, which serves to compress the nerve in inflammation and injury.

The nerve pierces the sclera and choroid a little to the inner side of the posterior pole of the eyeball. At this point the outer layers of the sclera become continuous with the sheaths of the nerve, while the inner layers, together with the modified choroid, stretch across the foramen, presenting numerous openings for the passage of the separate bundles of the optic nerve. This sieve-like arrangement is known as the lamina cribrosa. Here the nerve fibres lose their medullary layer and become transparent. Spreading apart before reaching the level of the retina, they leave a funnel-shaped depression at the middle of the disc (Fig. 42), the physiological excavation.

The lamina cribrosa represents the weakest portion of the layers of the eyeball, and in increased tension is the first to recede. It surrounds the bundles of the optic nerve with fibrous rings of connective tissue which serve as constricting bands when swelling occurs.

The orbital portion of the optic nerve presents a sigmoid curve, permitting free movement of the eyeball. The nerve consists of bundles of nerve fibres separated by connective-tissue septa ; between these there are lymph spaces. The optic nerve is surrounded by three sheaths originating from the three envelopes of the brain, and known as the pial, arachnoid, and dural sheaths. Between the pial and the dural sheaths is a space, the intervaginal space, divided into two parts by the arachnoid sheath. The two spaces thus formed are lymph spaces. They are lined by endothelium, and communicate with the corresponding cerebral spaces. Anteriorly, the intervaginal space ends in a blind extremity, and the sheaths unite with the sclera.

A short distance from the eyeball the central artery (a branch of the ophthalmic) enters, and the central vein emerges. The latter empties into the superior ophthalmic vein or directly into the cavernous sinus.

Affections of the Optic Nerve comprise (1) hyperæmia, (2) inflammation, (3) atrophy, and (4) tumours (very rare).

Hyperæmia, or Congestion of the Optic Disc.

The normal disc varies greatly in colour ; hence it is often difficult to decide whether the papilla is congested or not. When congestion exists it shows itself in increased redness, due to capillary injection, slight blurring and striation of the margins of the disc, often limited to a portion of the circumference, and some fulness of the veins.

Such a picture is frequently presented in eye-strain from hypermetropia and astigmatism, excessive use of the eyes, or after work with insufficient or excessive light. It is also found with inflammations of the deeper portions of the eyeball. It may be the incipient stage of optic neuritis.

Inflammation of the Optic Nerve, or optic neuritis, is divided into :

1. *Papillitis*, or intra-ocular optic neuritis, in which the head of the optic nerve is the part affected, and in which there are marked visible changes in the disc.

2. *Retrobulbar Neuritis* affecting the nerve fibres behind the eyeball, and in which the changes of the disc are slight or absent, and the existence of inflammation is often inferred from subjective symptoms.

Papillitis, Intra-ocular Optic Neuritis, or Choked Disc.

Symptoms.—There is more or less disturbance of vision. It is usually considerable, but it is not always proportionate to the severity of the inflammation as revealed by the ophthalmoscope. There may be complete blindness. The field of vision is usually contracted peripherally, especially for colours. There may be hemiopia or scotomata. There is no pain, and there are no external signs.

Ophthalmoscopic Signs.—The papilla appears swollen and

projecting (Fig. 219), enlarged, of whitish or grayish colour, striated, and often presenting white spots and hæmorrhages. Its situation is recognized only by the convergence of the retinal bloodvessels, its margins having become indistinguishable, and extending gradually into the surrounding retina. The retinal vessels are altered, and are interrupted in places. The arteries are either thin or of normal calibre; the veins are greatly distended and exceedingly tortuous. The sur-

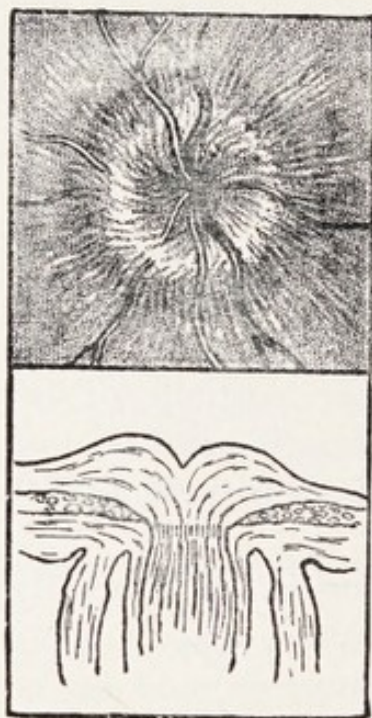


FIG. 219—PAPILLITIS
(CHOKED DISC).

The upper portion represents the ophthalmoscopic appearances; the lower half a longitudinal section.

rounding retina is usually œdematous, congested, and presents white patches and hæmorrhages. When a large portion of the surrounding retina is involved, the affection constitutes neuro-retinitis (Plate XX).

Clinical Forms.—Clinically we may distinguish between two types of papillitis: (1) Choked disc, in which there is marked swelling limited pretty sharply to the disc, with extreme dilatation and tortuosity of the veins. (Edema and engorgement are the predominating features. (2) Descending neuritis, in which there are less swelling and projection of the disc, less venous fulness and tortuosity, but more exudation and considerable extension of the latter into the surrounding retina. The picture in these cases points more to inflammation.

No sharp line can, however, be drawn between these two forms, either from the standpoint of pathology or of etiology, and transition forms occur frequently.

Course.—Though occasionally acute, the course is usually a chronic one, extending over many months. It is possible for the changes to subside and the disc to regain its normal appearance, with the preservation of good sight (especially in syphilitic cases). But, as a rule, papillitis is followed by

PLATE XX.

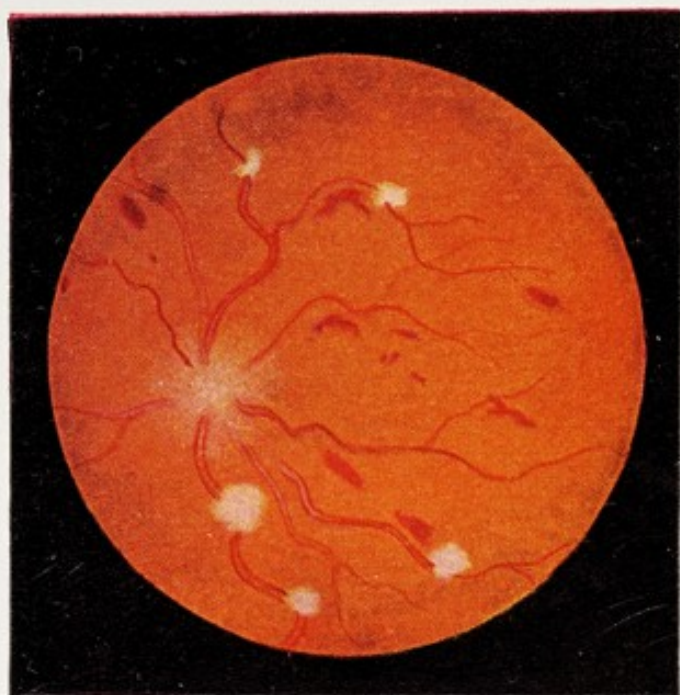


FIG. 220.—NEURO-RETINITIS.

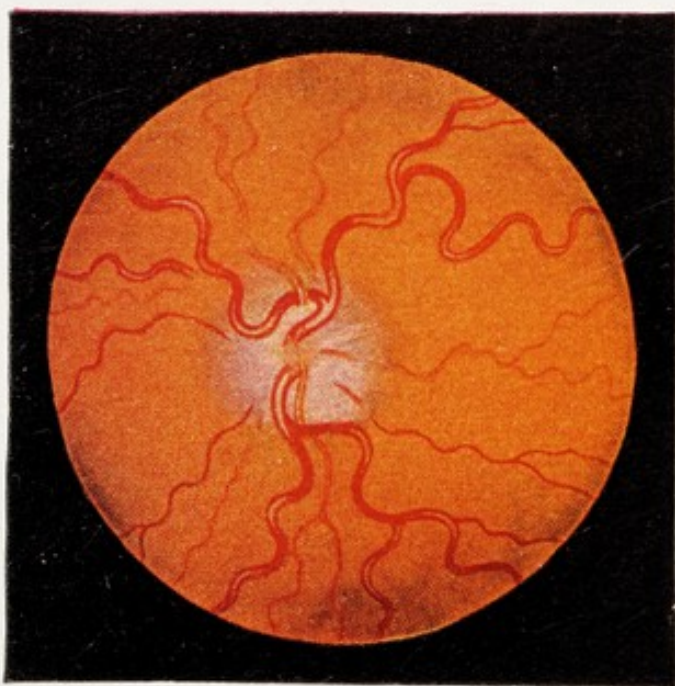



FIG. 221.—PAPILLITIS.

To face page 268.



post-neuritic atrophy. The disc becomes white or grayish-white, its margins are sharply defined but irregular, and surrounded by changes in the choroid, while the exudation becomes changed into connective tissue which covers the lamina cribrosa and fills up the physiological cup. The arteries are contracted and frequently bordered by white lines, but the veins remain dilated and tortuous (Fig. 224, Plate XXI.).

Prognosis is always serious. The degree of atrophy depends upon the intensity of the preceding neuritis, and determines whether vision finally becomes useful, much impaired, or totally lost.

Etiology.—Papillitis is almost always bilateral, but one eye may be affected before the other. The causes are: (1) Diseases of the brain and its envelopes; (2) syphilis (3) general diseases; (4) anæmia, either simple or the acute form, due to great loss of blood; (5) diseases of menstruation, pregnancy, and lactation; (6) lead-poisoning; (7) heredity; (8) idiopathic cases (when no cause can be found); and (9) orbital and peri-orbital affections.

Brain Tumour is the most frequent cause. Papillitis occurs in 90 per cent. of such cases, and then most commonly assumes the choked-disc type. Sometimes the neuritis is the first symptom of brain tumour. The occurrence or degree of papillitis does not depend upon the size or the situation of the tumour. It frequently exists with cerebellar tumours. The neuritis of brain tumour occasionally gives a picture resembling that of albuminuric retinitis with its star-shaped figure at the macula.

Next in frequency comes meningitis, especially basilar and tuberculous. In such cases the papillitis is apt to be of the descending neuritis type. Then come abscess and hydrocephalus.

Syphilis is a frequent cause, and acts either by direct implication or through the development of specific affection in the cranial or orbital cavities.

Acute Febrile Affections (measles, scarlatina, diphtheria, typhoid, grippe) are occasional causes.

General Affections, such as rheumatism, nephritis, and arterial disease, are sometimes responsible ; also exposure to cold.

Orbital and Peri-orbital Affections include inflammations of the orbit, tumours of the orbit and optic nerve, and diseases of the neighbouring cavities (sphenoid, ethmoid, frontal, and maxillary). These constitute the examples of unilateral cases.

Pathology.—The process consists of an inflammatory swelling, exudation of leucocytes, venous engorgement, hæmorrhages, and distension of the intervaginal space. The exact mechanism is still unsettled. Numerous hypotheses have been advanced. The most prominent are : (1) That it is due to increased intracranial pressure forcing cerebrospinal fluid into the intervaginal space of the optic nerve, causing stasis in the region of the lamina cribrosa, compression of the vessels resulting in venous engorgement and œdema (choked disc) ; (2) transmission of inflammation from the brain along the optic nerve to the papilla ; (3) inflammation excited by irritating substances which pass from the cranial cavity to the optic disc.

Treatment should be directed against the cause of the inflammation. In syphilis an injection of salvarsan followed by a vigorous course of mercury and iodide of potassium. Even in non-specific cases mercury and iodide of potassium are often prescribed. Locally, rest of the eyes, and shading from light. Orbital and periorbital affections may call for operative treatment.

Cerebral Decompression is frequently undertaken to relieve the intracranial pressure responsible for choked disc, thus enabling the optic nerves to resume their functions. In most cases this operation causes a subsidence of the papillary swelling and an improvement in vision, especially if it be resorted to before much degenerative change in the nerves has taken place ; incidentally other symptoms of tumour of the brain are relieved and life is prolonged. The operation is performed in the right temporal region for pretentorial

growths; but when the tumour is subtentorial, the opening is made in the suboccipital region.

Lumbar puncture also is occasionally resorted to to relieve intracranial pressure, but it is not free from risk.

Retrobulbar Neuritis.

This affection involves the orbital portion of the optic nerve. Hence, unless the case should progress to atrophy, there may be few or no changes in the disc. In most cases there is merely an implication of the papillo-macular fibres of the optic nerve, giving rise to a central scotoma, either absolute or relative. Retrobulbar neuritis may be acute or chronic.

Acute Retrobulbar Neuritis.

This rather uncommon affection is generally unilateral, occasionally bilateral.

Symptoms.—Neuralgia or headache on the same side, pain in and about the orbit, aggravated by movements of the eye, and tenderness on pressing the eye backward into the orbit. With these symptoms there is rapid impairment of sight, progressing in the course of a week to partial or complete blindness. Externally the eye appears normal.

Ophthalmoscopic Signs.—At first there are no changes. Later there may be slight haziness of the disc, with distension and sometimes diminished calibre of the retinal vessels.

Course.—The disease runs an acute course, and after a month or two the sight usually becomes normal; or recovery may be partial, and a central scotoma remain. Occasionally it terminates in permanent and total blindness.

Etiology.—Exposure to cold, rheumatism, syphilis, acute infectious diseases (influenza, etc.), alcohol, and other poisons, and extension of neighbouring inflammation.

Treatment.—Removal or treatment of the cause. Diaphoresis by the use of pilocarpine, sodium salicylate, potassium iodide, mercury, or strychnine.

Chronic Retrobulbar Neuritis, Toxic Amblyopia, Tobacco Amblyopia.

A chronic affection of the orbital portion of the optic nerve, of frequent occurrence, usually attacking both eyes, and due in the great majority of cases to excessive indulgence in tobacco, alcohol, or both combined.

Symptoms.—There is gradual diminution in acuteness of sight; foggy vision; the patient sees better in the evening, and the visual disturbance is more marked in bright light. The field of vision presents the normal peripheral boundary, but there is a central colour scotoma for red and green, corresponding to the distribution of the papillo-macular fibres of the optic nerve. This colour defect is usually small, but it may be more extensive, and correspond to the limits of the colour field.

The scotoma is detected by telling the patient to look steadily with one eye at the tip of the surgeon's nose at a distance of about 2 feet, the other eye being closed, and moving small pieces of red or green worsted or cardboard (from 2 to 5 mm. in diameter) from the periphery toward the point of fixation. When the test object arrives at the seat of the scotoma it will appear dull or colourless. This loss of colour is more marked on the temporal than on the nasal side of the fixation point—corresponding to the distribution of the papillo-macular bundle of the optic nerve—and is apt to be more pronounced for green than for red. Sometimes the scotoma becomes absolute (no perception of light over this area).

Ophthalmoscopic Signs.—Sometimes there are no changes in the papilla, or merely a slight haze with increased redness. At a later period there is very often a pallor of the temporal side of the disc.

Course.—The course of the disease is slow. If poisoning continues, vision becomes more impaired, and may be reduced




FIG. 222a.—THE FIELD OF VISION IN TOXIC AMBLYOPIA (CENTRAL COLOUR SARCOMA).

very much. If the cause be removed, there is usually gradual improvement, and sight is often restored to the normal. But in severe cases there may be some permanent reduction in the acuteness of vision, and the relative scotoma may continue indefinitely. Even though a man may have smoked heavily with impunity for many years, after one attack a small quantity of tobacco is liable to cause a relapse. A second attack is seldom completely recovered from.

Etiology.—The condition results most frequently from over-indulgence in tobacco, whether in smoking or chewing, occasionally after snuff-taking. The stronger tobaccos used in cigars and pipes are the forms which are most frequently responsible. Certain individuals are more susceptible than others. Impairment of the general health predisposes, as does also the practice of smoking when the stomach is empty. It occurs almost exclusively in middle-aged or elderly men. In most cases both alcohol and tobacco act together. Other poisons which in toxic doses cause a condition resembling tobacco amblyopia are iodoform, lead, arsenic, the poison of diabetes, wood-alcohol, bisulphide of carbon, and nitro-benzol.

Pathology.—The process consists of an interstitial neuritis of the papillo-macular (axial) fibres of the optic nerve, with subsequent degeneration of these fibres and the ganglion cells in the nuclear region.

Treatment consists in total and permanent abstinence from tobacco. If some stimulant is required, it must be restricted to a small amount with the principal meals. The general health should be improved. Strychnine may be given by mouth or hypodermically. Iodide of potassium in small doses (gr. ii. to gr. v.) is believed to assist in eliminating the poison.

Atrophy of the Optic Nerve.

This affection occurs either as a primary disease (simple, primary, non-inflammatory, or progressive atrophy) or secondary to some other affection of the nerve or retina (post-neuritic, secondary, or inflammatory atrophy).

Symptoms.—There are reduction in the acuteness of vision, concentric or irregular contraction of the field (Fig. 223), first for colours and then for form, diminution in the light sense, sometimes scotomata, and colour-blindness (first for green, then for red, then for blue). These symptoms tend to progress, and end in complete blindness.

Ophthalmoscopic Signs differ somewhat in the simple and post-neuritic forms:

In simple atrophy (Fig. 224, Plate XXI.) the disc is white, grayish, or bluish-white, its edges are sharply defined and regular, its size is somewhat diminished, and it presents a saucer-shaped excavation (Fig. 170); the lamina cribrosa is often seen very plainly. The minute vessels of the disc have disappeared. The retinal vessels may appear normal, but the arteries are usually diminished in calibre.

In post-neuritic atrophy (Fig. 225, Plate XXI.) the disc is covered by connective tissue resulting from the previous neuritis. It has a dense white or grayish colour, with more or less irregularity and obscuration of the margins, its minute vessels have disappeared, and the lamina cribrosa is hidden by the organized exudation. The retinal arteries are narrow, enclosed in white lines, and the veins are usually diminished in size and tortuous.

In the secondary atrophy following retinitis pigmentosa the disc has a dirty, grayish-red or yellow, waxy look (Fig. 217, Plate XIX.), the vessels are exceedingly narrow, and many disappear entirely.

After a time the differences in the appearances of simple and post-neuritic atrophy become much less marked.

It should be borne in mind that the disc varies in colour in health, and may appear atrophied as the result of congenital or senile peculiarities, although vision is normal and the field perfect. Hence in many cases the diagnosis cannot

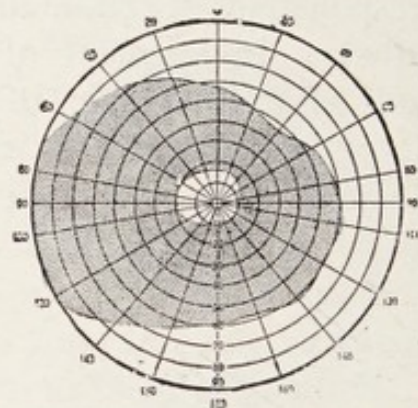


FIG. 223.—MARKED CONCENTRIC CONTRACTION OF THE FIELD OF VISION IN OPTIC-NERVE ATROPHY.

PLATE XXI.

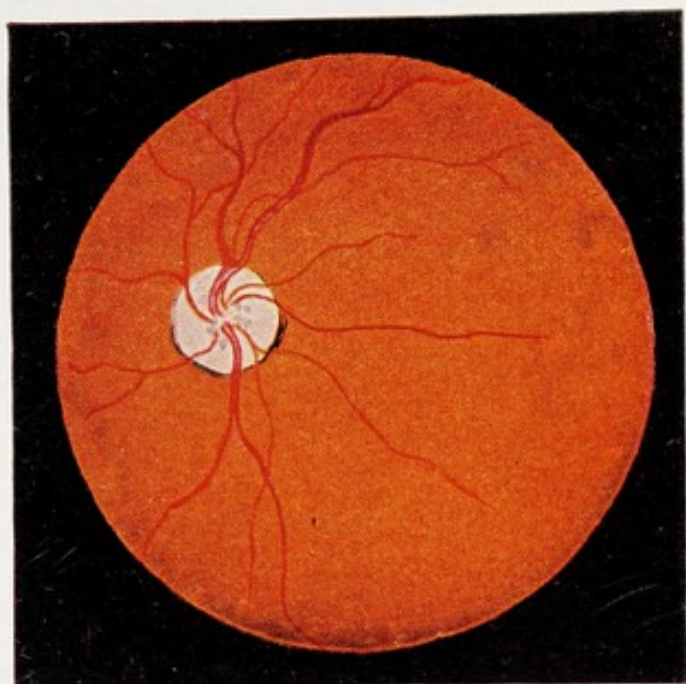


FIG. 224.—PRIMARY, OR SIMPLE, OPTIC.
NERVE ATROPHY.

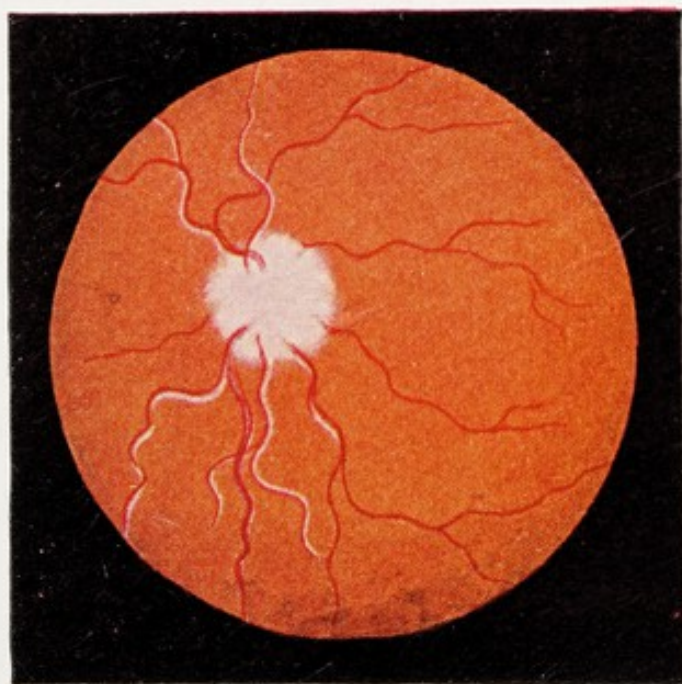


FIG. 225.—POST-NEURITIC ATROPHY

To face page 274.



be made from the ophthalmoscopic signs alone, especially when these signs are not pronounced.

Etiology.--Simple atrophy is frequently due to spinal diseases, especially locomotor ataxia. It develops in one-third of the cases of this affection, and is an early symptom. It is common also in affections of the brain: disseminated sclerosis, general paralysis of the insane, and tumours. It is also due to syphilis, malaria, diabetes, acromegaly, impaired nutrition, and certain poisons. Occasionally it is hereditary, and in some cases no cause can be found. It occurs chiefly in middle life.

Secondary atrophy follows papillitis, retrobulbar neuritis, retinitis, pigmentary degeneration of the retina, embolism of the central artery, and glaucoma. It may result from penetrating wounds of the optic nerve or injury to the nerve, due to fracture of the orbital canal, following a blow or other violence. In such cases the atrophy does not show itself for a number of weeks, though more or less reduction of vision and contraction of the field results immediately.

Pathology.—The process consists of increase in the interstitial connective tissue, with atrophy of the nerve fibres.

Prognosis is usually unfavourable. Simple atrophy generally progresses to absolute blindness. In secondary atrophy the prognosis is better, and depends upon how much sight has been destroyed by the antecedent inflammation.

Treatment consists in attempting to control the cause of the atrophy. For the atrophy itself very little can be done. Potassium iodide, strychnine, mercury, nitro-glycerine, and galvanism are the remedies most frequently employed.

CHAPTER XXI

AMBLYOPIA AND FUNCTIONAL DISEASES OF THE RETINA

AMBLYOPIA is a reduction in the acuteness of vision which cannot be relieved by glasses, and which is not dependent upon any visible changes in the eye. The term is sometimes used in a less restricted sense to designate poor sight, even when some changes are found in the eye, as, for instance, toxic amblyopia, in which temporal pallor of the disc exists.

Amaurosis is the name applied to absolute blindness when unaccompanied by discoverable ocular changes ; the use of this term has, however, been extended so as to include all cases of absolute blindness, including those which show ophthalmoscopic or external changes.

Congenital Amblyopia and Amblyopia ex Anopsia.

Congenitally defective vision ; nearly always affects one eye, only rarely both. It is nearly always associated with a high degree of astigmatism. There is frequently hypermetropia or myopia also. Probably in most of the so-called congenital cases the amblyopia is really acquired. The errors of refraction have prevented perfect images from being focussed on the retina, and this lack of training has caused amblyopia. The most careful correction of the error of refraction fails to produce normal vision ; in young patients, however, the sight can frequently be improved or brought up to the normal after suitable glasses have been worn for a time.

Any interference with vision dating from early life, which prevents perfect focussing upon the retina, causes amblyopia from non-use (amblyopia ex anopsia) ; hence the advisability

of operating upon congenital and infantile cataracts early. An obstacle to vision beginning after the age of seven or eight years does not usually interfere with the functional activity of the retina.

Unilateral amblyopia predisposes to squint by lessening the value of binocular vision. Very commonly amblyopia develops in an eye which has squinted from early life on account of its exclusion from the visual act, the retinal image in this eye being suppressed (p. 380).

Exercise of such an eye during youth, by forcing it to work while the sound eye is excluded, will frequently improve its visual power.

Bilateral congenital amblyopia of high degree is nearly always associated with nystagmus.

Congenital Word Blindness is a rather rare affection, said to be more common in males than in females. It is supposed to be due to a defect in the visual memory centre for words and groups of letters. There is a difficulty or inability to read words as a whole, though the words are recognized when spelt letter by letter. Special training often results in considerable improvement.

Hysterical Amblyopia.

This condition usually occurs in young girls and women, sometimes in young persons of the male sex. It is almost always unilateral.

Symptoms.—The most constant symptom is a diminution in the acuteness of vision, which frequently amounts to complete blindness. The field of vision is contracted concentrically, both for white and colours; since the retina becomes exhausted rapidly, this limitation may become more marked with each succeeding test during the same examination. The colour-fields have not the same relative areas as with the normal eye; they may be larger than that for white; their order is often reversed—*i.e.*, green the largest, red next, and blue the smallest. There may be scotoma or hemiopia. A great variety of other ocular symptoms may be present, such as photophobia, flashes of light, blepharospasm, corneal

anæsthesia, monocular diplopia, ptosis, and changes in the size and shape of images. The pupillary reflexes and ophthalmoscopic appearances are normal.

With these ocular manifestations there are usually other hysterical symptoms, especially hemianæsthesia of the affected side. It is sometimes difficult to distinguish between this affection and malingering. It sometimes follows injuries (traumatic hysteria) even when these do not involve the eye.

Prognosis is good, although the affection may last many months or even years.

Treatment is directed to the hysterical condition.

Simulated Amblyopia (Malingering).

Patients sometimes pretend to be blind in one eye in order to recover damages for alleged injury; occasionally bilateral blindness is simulated.

The detection of pretended monocular blindness is usually easy. One of the following tests may be employed:

Tests.—1. Place a lighted candle 15 or 20 feet in front of the patient, and put a prism of 6 degrees, base upward or downward, before the sound eye; if the patient admits seeing double, it is an indication that the vision is present in both eyes.

2. With the lighted candle in the same position, cover up the supposed blind eye. Then produce monocular diplopia by moving a 6-degree prism, base upward or downward, until the apex corresponds to the centre of the pupil. Next uncover the blind eye, and at the same time move the prism until it covers the entire pupil. If now there is still double vision (binocular diplopia) it is evident that both eyes see. This test is difficult to apply.

3. Place a strong convex lens (12 D.) before the good eye and a weak concave lens (0.25 D.) in front of the supposed blind eye, and direct the patient to read the distant test-types; if he succeeds, it is proof of malingering, since it is impossible for him to see with the sound eye when it is covered by the strong lens.

It is rare for a patient to simulate blindness in both eyes.

and more difficult to detect him in such cases. A diminution in acuteness of vision of both eyes is more frequently feigned than binocular blindness. In such cases malingering is suspected when there is an absence of agreement in the results of the functional and objective examination of the eyes, contradictory statements regarding the different steps in the functional examination, or contraction of the pupils to light. In rare instances, the pupils react on exposure to light in cases of absolute blindness, the lesion being situated in the visual centres or in the connexion between these centres and the corpora quadrigemina (3, Fig. 226). In feigned binocular blindness a close watch must be kept on the patient when he thinks he is free from observation, and the following test may be employed: Place a lighted candle in front of the patient; hold a 6-degree prism, base outward, before one eye; if both eyes see, the one covered by the prism will move inward in order to avoid diplopia; on removing the prism, it will move outward, the other eye remaining fixed.

Blindness of one eye may be due to neglected squint, or rarely to congenital amblyopia. Blindness of both eyes without ophthalmoscopic signs may occur immediately after a head injury. In case of doubt repeat the examination a month later. Presence or absence of pallor of the optic discs will then decide the question.

Since the passing of the Workmen's Compensation Act, most of the cases which present themselves are those in which some injury has been sustained. The question to be decided is to what extent, if at all, the workman is exaggerating his symptoms. When preparing a report upon the case, it should be remembered that the report may be the subject of cross-examination in a court of law, and any careless wording may subject one to much annoyance. Facts should first be stated definitely. Opinions and inferences should then be stated as such, and one should be prepared to give reasons for them. In a law court, such a statement as 'The patient suffers from headaches' would certainly be met by the question, 'Do you know this is a fact? If so, how do you know?'

Amblyopia and Amaurosis from Various Causes.

Besides the forms of amblyopia already described, there are others, of less frequent occurrence, due to uræmia, reflex irritation, malaria, and quinine. A considerable number of drugs are occasionally responsible for more or less complete amblyopia.

Uræmic Amblyopia has been described on p. 253.

Reflex Amblyopia, due to reflex irritation, is rare and of rather doubtful occurrence, except in the case of the teeth, irritation from which has been found responsible for amblyopia in occasional instances.

Malarial Amblyopia has been observed in malarial diseases. It affects one or both eyes, lasts some hours or days, and usually disappears completely as a result of the use of anti periodics.

Quinine Amblyopia, or amaurosis, occurs after large quantities of quinine have been taken, occasionally with moderate doses in susceptible individuals. Besides other symptoms of cinchonism, there are more or less complete blindness, often noticed suddenly, contracted fields, dilated pupils, and marked pallor of the disc, with extreme contraction of the retinal vessels. The condition is due to spasm of the retinal vessels causing anæmia of the fundus, degeneration of the ganglion cells and nerve fibres of the retina, and later atrophy of the optic nerve. After a time, central vision is restored completely or partially, and the field widens, but rarely regains its full extent. Treatment consists in discontinuing the drug, inhalations of nitrite of amyl, nitro-glycerine, the use of bromides, strychnine, and digitalis.

Night Blindness is a condition in which the sight is good by day or with good illumination, but more or less deficient at night, or with reduced illumination. It is a symptom of certain forms of retinitis, especially retinitis pigmentosa, but it also occurs without ophthalmoscopic changes. The latter form of diminished light-sense is caused by anæsthesia of the retina; it usually co-exists with xerosis of the conjunctiva.

and is dependent upon the same cause—diminished ocular nutrition, due to a debilitated state of the system, such as exists in starvation, profound anæmia, scurvy, and the like. The affection usually disappears with improvement of the general health by good and sufficient food tonics (cod-liver oil, iron), and the use of dark glasses.

Day Blindness is the name given to a condition in which the sight is better at dusk or in feeble illumination than in bright light. This symptom is found in tobacco amblyopia and with central scotoma in general. In cases in which there are central opacities of the lens or cornea the patient sees better in reduced illumination because the dilated pupil permits vision through the peripheral clear portion of the cornea and lens.

Hemianopsia.

Connexion between the Retinæ, the Fibres of the Optic Nerves and Tracts, and the Cerebral Cortex (Figs. 156 and 226, also Plate XXII.).—Familiarity with the course of the optic-nerve fibres from the eye to the cortex is of great practical value in the localization of various lesions causing defects in the field of vision.

The optic nerves terminate at the chiasm, which lies in the optic groove on the body of the sphenoid bone, where they semi-decussate; from the posterior border of the chiasm they are continued backward as the optic tracts. The optic tracts pass outward and backward, winding around the crura cerebri to the primary optic ganglia—the external geniculate bodies, the anterior corpora quadrigemina, and the pulvinar of the optic thalami (*POG*, Figs. 156 and 226). Here the fibres divide into two portions: (1) a smaller part passing to the nuclei of the oculomotorius and presiding over the reflex action of the pupils and the movement of the ocular muscles; and (2) a larger bundle, composed of visual fibres, which transfers its impulses (Fig. 156) to other fibres, which carry the visual impressions to the cortex; the latter fibres pass through the posterior portion of the internal capsule, then form the optic radiations or fibres of Gratiolet, and end in the cortical ganglion cells of the mesial surface of the cuneus and

the parts surrounding the calcarine fissure; this portion of the occipital lobe is known as the visual area of the cerebral cortex (*O*, Fig. 226).

In the ganglion cells of the visual area an excitation in the optic-nerve fibres is changed into a sensory perception (sight) or into permanent changes (memories, optical memory pictures). After destruction of this area, excitation of the

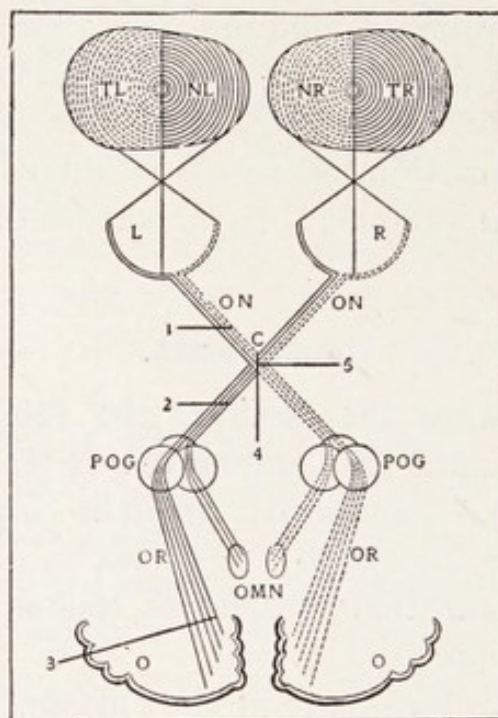


FIG. 226.—SCHEMATIC REPRESENTATION OF VISUAL PATHS.

L, left eye; *R*, right eye; *TL*, temporal field of left eye; *NL*, nasal field of left eye; *NR*, nasal field of right eye; *TR*, temporal field of right eye; *ON*, optic nerve; *C*, chiasm; *POG*, primary optic ganglia; *OMN*, oculomotor nuclei; *O*, occipital lobe; *OR*, optic radiations. Division of fibres at 1 causes complete blindness of the left eye and loss of direct pupillary reaction; at 2, right homonymous hemianopsia with loss of reaction of the pupil when the left halves of the retinae are illuminated; at 3, right homonymous hemianopsia with preservation of the reaction of the pupil when the left (and right) halves of the retinae are illuminated; at 4, bitemporal hemianopsia; at 5, left nasal hemianopsia.

optic-nerve fibres either fails to arouse visual sensation of any kind (blindness), or fails to summon forth any recollection of objects or circumstances acquired through previous education; in the latter case, objects are seen but not recognized (physical or cortical mind-blindness).

Each retina is supplied by optic-nerve fibres passing to both

PLATE XXII.

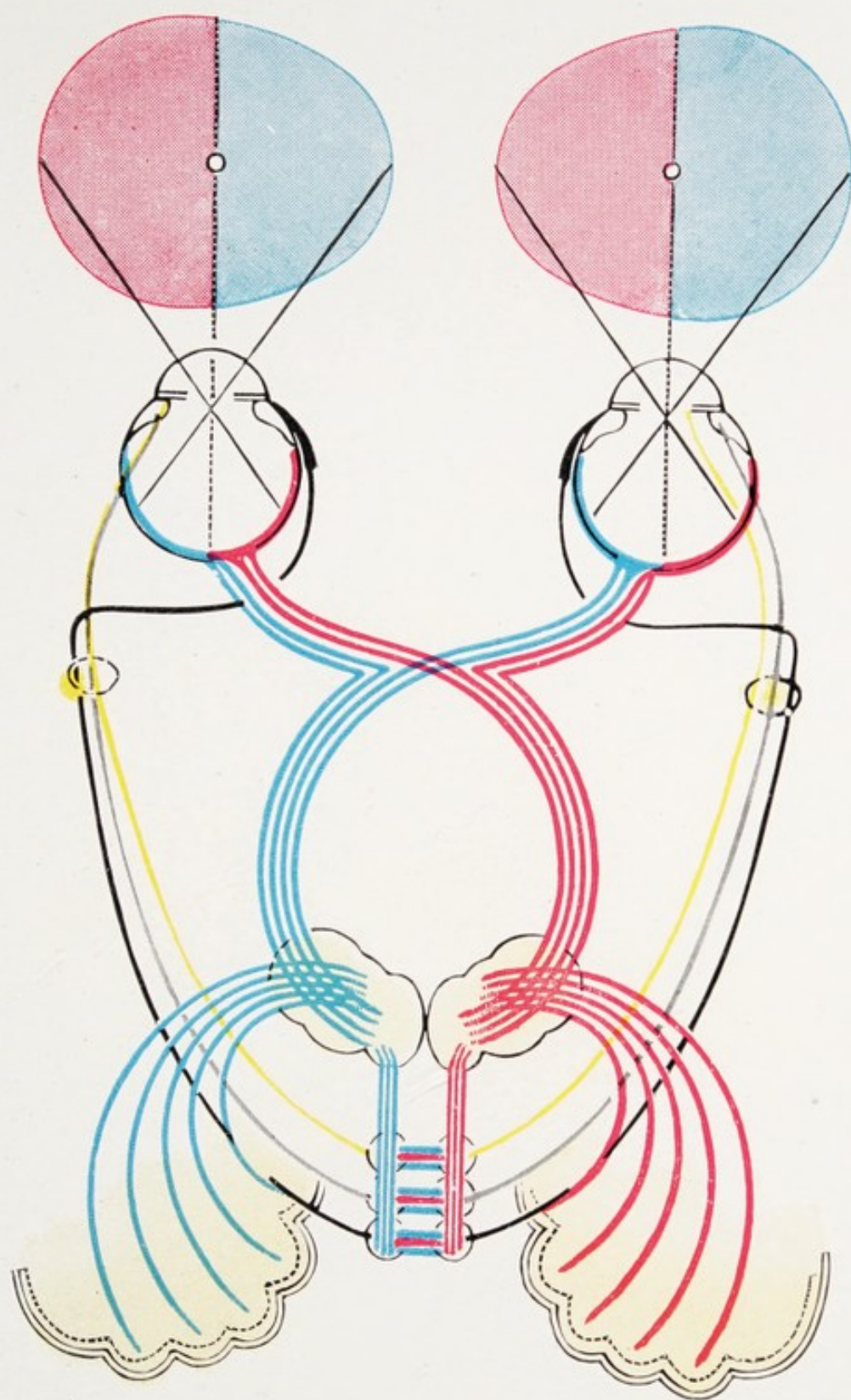


FIG. 227.—DIAGRAMMATIC REPRESENTATION OF THE
VISUAL AND PUPILLARY PATHS.

To face page 282.



sides of the brain. Each optic nerve is composed of an external set of fibres derived from the outer or temporal half of the retina, and an internal set derived from the inner or nasal half of the retina. In the axis of the optic nerve is found a special set of fibres which pass to the macula and the space between it and the disc. These macular fibres, when they reach the eyeball, are collected into a sector corresponding to the outer third of the disc, the apex directed toward the centre and the base toward the margin of the papilla. The external or temporal fibres are continued along the lateral part of the chiasm and tract, and pass to the primary optic centre of the same side. The inner fibres, derived from the nasal half of the retina, pass into the chiasm and decussate; they are continued in the tract of the opposite side, thus passing to the side of the brain opposite to the eye which they supply.

The chiasm presents laterally the direct or temporal fibres of both eyes, and in its centre the decussation of the inner or nasal fibres of both retinae. Consequently, the decussation in the chiasm is not complete, but partial—a semi-decussation.

Each optic tract contains fibres from both eyes. The right optic tract consists of non-decussating fibres from the right (temporal half) of the retina of the right eye, and decussation fibres from the right (nasal) half of the left eye. Hence the right halves of both retinae, and thus the left halves of both visual fields, are connected with the right tract (Plate XXII.). It follows, therefore, that the visual impulse, excited by objects placed to the left of the median line, passes to the cortex of the right hemisphere by means of the right optic tract; and that the perception of all objects placed to the right of the median line is conveyed by the left optic tract to the cortex of the left hemisphere.

Hemianopsia.—This arrangement of fibres in the chiasm explains the occurrence of a form of visual disturbance known as hemianopsia (hemianopia, hemiopia), by which we mean the loss of vision for corresponding halves or sectors of the visual fields. If a lesion interrupts the continuity of the right optic tract, the right cortical visual area, or any portion

of the visual path between these parts, there will be blindness of the right halves of both retinae; as a result the left halves of the fields of vision of both eyes will be lost, and only objects which are placed to the right of the median line will be perceived. This is known as homonymous or lateral hemianopsia, and in this particular case the condition is called left homonymous hemianopsia, because the left halves of the fields of vision are wanting. Homonymous hemianopsia (Fig. 228), therefore, always points to a lesion situated in the visual path or cortex on the central side of the chiasm, and upon the same side as the blind halves of the retinae. It is the commonest form of hemianopsia.

If a lesion extends antero-posteriorly through the chiasm it will destroy all the decussating fibres which supply the inner or nasal halves of both retinae, and there will be a loss of vision in the outer or temporal halves of the field of both eyes, a condition called bitemporal hemianopsia (4, Fig. 226). It is seen in acromegaly.

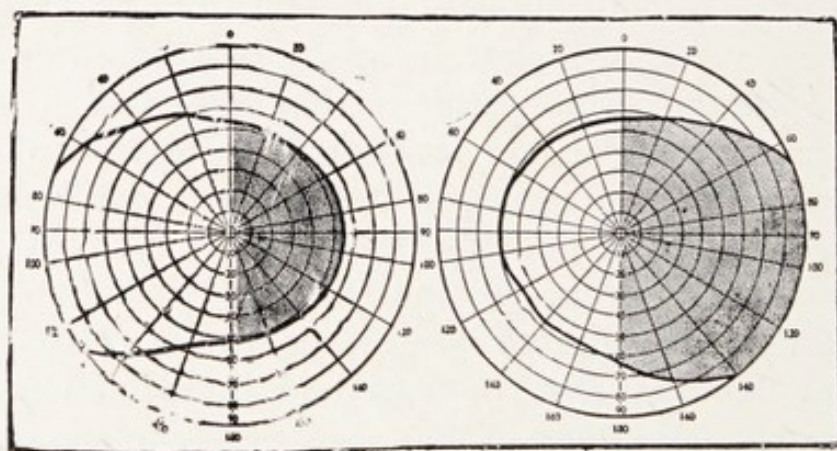


FIG. 228.—THE FIELDS OF VISION IN RIGHT HOMONYMOUS HEMIANOPSIA.

If a lesion attacks each side of the chiasm it will destroy the non-decussating fibres which come from the temporal halves of the retinae, and will, therefore, cause a loss of the nasal or inner half of the field of vision of each eye; this is known as binasal hemianopsia. Bitemporal and binasal hemianopsia are known as crossed hemianopsia. These forms are rare, as will be inferred when the situation of the lesion necessary to produce them is considered; it is doubtful

whether binasal hemianopsia ever occurs. Another rare form of hemianopsia is altitudinal (inferior or superior)—when the upper or the lower half of each field is wanting.

Hemianopsia is said to be complete when there is a symmetrical absence of the entire half of the field of vision. It is incomplete when there is an absence of a small portion or sector occupying a symmetrical position in the visual fields of the two eyes; the lesion then involves only a portion of the fibres of a visual tract or cortical visual area.

Even in cases of complete hemianopsia, the line between the absent and the preserved portion of the field seldom extends through the fixation point, the portion of the field corresponding to the macula being usually preserved. When both halves of the fields are lost successively (double homonymous hemianopsia), there will be blindness except at the situation of these macular fibres. This occurrence has been explained by supposing—(1) that the macula receives fibres from both hemispheres, and (2) that the cortical centre for the macula receives a special and abundant blood-supply.

Hemianopsia is known as absolute when there is loss of light, form, and colour sense, and relative when only the colour sense or both the colour sense and form sense are destroyed over the symmetrically defective areas, while the light sense remains relatively intact. This is known as hemiachromatopsia; it was formerly believed to indicate the existence of separate cortical centres for colour, form, and light perception, but is now explained by assuming the existence of a lesion of less intensity than that which causes absolute hemianopsia.

Complete blindness in one eye only is always due to a lesion situated in front of the chiasm. The same applies to scotomata, which are defects in the visual field of one eye (p. 16), or non-symmetrical defects in the fields of both eyes; when central, they indicate an involvement of the papillo-macular sector of the optic nerve.

The Hemianopic Pupillary Reaction (Wernicke) may be of value in determining whether a lesion causing homonymous hemianopsia is situated behind or in front of the primary optic

ganglia. If behind this point the pupillary light reflex will be preserved; if in front of these ganglia (in the optic tract) it may be diminished, when the blind half of the retina is illuminated (Fig. 156). This test is very difficult to apply in a conclusive manner.

Scintillating Scotoma (Transient Hemianopsia) is a form of temporary blindness of not infrequent occurrence, generally associated with migraine and probably due to a circulatory disturbance in the occipital lobe. The attack begins with a central dark spot before both eyes, which spreads by scintillating and coloured zigzag lines, until there is a considerable gap in the field, often hemianopic. Accompanying the attack there are headache, general malaise, vertigo, and sometimes nausea and vomiting. The attacks vary in frequency and last about fifteen minutes, after which the amblyopia disappears entirely. The affection occurs after excessive mental or physical exertion and following marked eye-strain. Unless associated with paralysis, aphasia, or other symptoms of cerebral trouble, it is not of serious import. Treatment consists in attention to the general health, correction of eye-strain, avoidance of fatigue of any kind, and the use of remedies suited to migraine.

CHAPTER XXII

COLOUR-BLINDNESS

BY THE LATE C. DEVEREUX MARSHALL

NOTHING is known with certainty as to the mechanism of colour vision. The various theories are merely conjectures by which it is sought to explain observed phenomena. The Young-Helmholtz theory assumes that there are three colour-perceiving elements in the retina—red, green, and violet—and by their combinations all other colours are produced. Hering's theory supposes the existence of three different visual substances in the retina, which when disintegrated produce the sensations white, red, and yellow, but when being regenerated they produce the sensations black, green, and blue. There is no direct evidence in support of either of these theories. Obviously, if yellow were a combination of red and green, as stated, if we were to remove the green, red would be left. We can carry out such an experiment thus: By flooding the retina with green light we can so exhaust the percipient elements that the eye no longer perceives it as green. A yellow light is then substituted for a green one, and it appears just as yellow as it does to the unexhausted retina.

Edridge-Green's theory is as follows: The rods of the retina secrete and hold the visual purple, and distribute it as required; the cones are the sensory nerve endings, which are stimulated when the visual purple is liberated. These terminal organs of the optic nerve cells and fibres cause impulses to travel to a centre in the brain, where they are

sorted and analyzed. If this centre is well developed, the difference between certain impulses is perceived, and thus we get the sensation of colours. If the centre be ill-developed, many of the impulses which would be differentiated by one better developed are not so recognized, and so they appear to be of the same colour.

Light consists of impulses of various wave-lengths. The longest wave which can be perceived by any human eye gives the sensation of red, and the smallest the sensation of violet. These impulses correspond respectively to wave-lengths of about 760·4 millionths of a millimetre for the red and 396·8 millionths of a millimetre for the violet. All wave-lengths situated between these measurements produce every colour sensation which we are able to recognize. Obviously, between these measurements (which differ somewhat in individuals) there are millions of light waves differing in wave-length, but no human being has ever been able to recognize more than seven distinct colours in the spectrum, which is the basis of all our ideas of colour, and very few people are able to see more than six. Thus, even the most perfectly developed colour sense is only able to distinguish between light waves when their lengths differ very considerably. The rays which we know exist beyond the limits given above are altogether invisible to the human eye. The more highly developed the visual centre, the better will be the power of the individual to perceive small differences; and, conversely, the more ill-developed it is, the less will be that power; so that what in a normal individual would be regarded as a distinct colour, may to another be considered to be identical with some other colour. The colours seen by the normal eye in the spectrum are red, orange, yellow, green, blue, and violet. About one person in several thousands is capable of seeing a seventh colour, and that is indigo, situated between the blue and violet.

In the primitive state, and in anyone whose colour vision centre scarcely exists, the whole of the spectrum appears to be of a more or less uniform dull grey colour. This condition may be termed 'monochromic vision.' As the centre

becomes developed, rays differing most from each other in refrangibility are seen to be different in appearance, and so at one end of the spectrum red becomes visible, and at the other end violet, but these two tinges of colour are joined by a large neutral band. This neutral band may become smaller and smaller until it disappears, and thus we have the dichromatic cases, with or without a neutral band.

As the centre becomes still more developed, the next colour to be differentiated will be seen at the point where the wavelengths differ most, and obviously that will be between the red and violet, and here green appears. This is the trichromatic condition, where red, green, and violet are seen.

The next colour to be perceived will again be at the point of greatest difference, between the red and green. Thus we get the tetrachromatic cases, which see red, yellow, green, and violet.

The next point of greatest difference will be between the green and violet, and here blue is interposed, and we have the pentachromatic, or five-unit, people. In the same way orange pushes itself between the red and yellow, and gives us the hexachromatic, or six-unit, people, who form the majority of mankind at the present time, and who are considered to represent the normal. Some few people have a still better developed centre, and they are able to perceive a seventh colour, indigo, situated between the violet and blue, and we thus have the heptachromatic, or seven-unit, people. They are able to see in the spectrum red, orange, yellow, green, blue, indigo, and violet. No one has ever yet been found with a centre so well developed that he could see eight colours, but if ever this does happen, the new colour will be situated between the red and the orange.

In the human race every one of these seven classes of people are represented. The monochromics, apart from disease, are very rare, but they are seen occasionally. The dichromics, with or without a neutral band, are met with frequently, and these form the majority of those who are recognized as colour-blind. The trichromics are very apt to be passed as normal by many of the matching tests, which are

therefore unsatisfactory; but they are dangerous when they have to recognize coloured signals, for although they will never mistake a red light for a green one, yet they will frequently be in difficulties with a yellow light, which will at one time be called red and at another time green.

From a practical point of view, these three classes are all dangerous, and such persons should be excluded from occupations in which recognition of coloured signals is essential. All above these, except the very worst of the tetrachromics, which are bordering on trichromism, are safe, for they will never mistake a signal light of the ordinary colours which are used.

If the defect be so slight that the candidate only fails to distinguish between blue and violet, or between yellow and orange, for practical purposes he may be considered normal, and should not be put in the same class as the dangerous colour-blind, who might confuse yellow and green, or even green and red.

There is, however, another class having a dangerous colour defect—an abnormal shortening of the red end of the spectrum. If a person be asked to look through a spectroscope and told to place a pointer at the exact spot at which no more red is visible, it will be found that all persons will not place the pointer at the same spot. Obviously, one person has a shorter red end than the other. These rays at the dark red end of the spectrum are those which in a fog penetrate the atmosphere farther than any other. A familiar example of this is the sun seen through a fog. It appears to be a dark red ball, because all the rays except the red ones have been absorbed by the atmosphere, and these are the only ones which can get through. As the fog gets thicker, the sun gets a darker and darker red until it is no longer visible to the eye at all. If, now, a person has a shortened red end to his spectrum, the sun will become invisible to him long before it is invisible to the normal-sighted. Similarly, a signal light which may be quite visible to a normal-sighted person may be entirely invisible to another who has abnormal shortening of this end of the spectrum.

The entire problem which the surgeon has to solve is this: He must be able to distinguish the dangerous cases—monochromic, dichromic, trichromic, and the worst of the tetrachromic cases—from the rest, which are all safe. He must also be able to find out those with a shortened red end of their spectrum. A test cannot be considered adequate which does not depend upon the naming of colours. A candidate must be able to say that a certain light is red, or green, or yellow. A test which depends upon a candidate matching fabrics, wools, etc., without naming the colours, is thoroughly bad. Colours have to be named, at least mentally, at sea, and action taken according to the coloured light which is shown. A man may be a good matcher of colours, and yet be so colour-blind as never to be able to recognize a colour with certainty unless he has another with which to compare it. Such a person is a source of great danger at sea or on the railway.

By far the best and most reliable test is a lantern, and that devised by Edridge-Green is the best. It consists of an electric or oil lamp, before which four discs, each carrying seven pieces of glass, are rotated. Three of the discs contain coloured glass, and one has seven modifying glasses, which consist of ground glass, ribbed glass, and five different thicknesses of neutral glass. The size of the light can also be increased or diminished by means of a diaphragm. The colours in the other discs are—(1) red; (2) red of a different density; (3) yellow; (4) green; (5) signal green; (6) blue; (7) purple. The candidate should be seated in a dimly lighted room at about 20 feet from the lantern, and should be asked to name the colour of the light produced by the coloured glass alone or in combination with one or other of the modifying glasses or of the other coloured glasses. A candidate should be rejected (1) if he call red green, or green red, in any circumstances. (2) If he call the white light red or green, or *vice versa*. (3) If he call red, green, or white lights black, or fail to see them. The size of the aperture should be varied, and particular care should be exercised to see if a red light with a dark neutral in front of it can be seen at a distance at which

it is visible to the normal-sighted examiner. The candidate's answers should all be noted carefully, but on no account should the examiner comment upon what the candidate says. No fixed plan of examination should ever be employed, but the lights shown should be used in any order, or candidates will soon know what light is to be expected. One wrong answer in naming a coloured signal light should be sufficient to cause the rejection of the candidate. It is sometimes useful to show a coloured light and ask the candidate to pick out a skein of wool or silk to match it.

The Bead Test.—This is a useful method, also introduced by Edridge-Green, and consists of a small tray, containing a large number of various coloured beads of different sizes which are all exposed to view. One portion of the box is divided into four compartments, with a cover to each, and in each cover is a hole. The first compartment is labelled red, the second yellow, the third green, and the fourth blue. The candidate is given a pair of forceps, and is told to pick out the beads and place them into the holes according to their colour. It has the great advantage that when once a bead has been dropped into one of the holes, it is lost to sight, so that the candidate never has a chance of seeing what he has done until after the test is over. The lids are then removed, and it is obvious what has been done.

The Holmgren test is not a good one, but it is the official test of certain public bodies. It consists of a number of skeins of coloured wool, and the three test skeins are green, pink, and purple. One of the test skeins is given to the candidate, and the colour is to be named neither by the examiner nor the examinee, but he is asked to pick out wools which are of the same colour as the test skein, though they may be darker or lighter. Inasmuch as this test rejects some normal-sighted persons, and can be readily passed by many colour-blind people after a little practice, no reliance can be placed on it. It also entirely fails to discover those with shortening of the red end of the spectrum.

The Edridge-Green classification test consists of four test skeins of wool and 180 confusion colours: 150 of them are

coloured skeins of wool, 10 of silk, 10 small squares of coloured cardboard, and 10 of coloured glass. The test skeins are—(1) orange; (2) violet; (3) red; and (4) blue-green. One of the test skeins should be selected, and the candidate asked to name its colour. Then he is to be asked to pick out other wools, silks, cards, and pieces of glass of the same colour. Thus, if the orange skein is selected and he names it correctly, he is to be asked to pick out all other things which are of an orange colour. If he picks out a wrong colour or a doubtful one, he may be asked to give it a name, and if he does this correctly he should be considered to have passed the test. Some colours are rather indefinite. Thus a man who is asked to pick out the greens may very likely pick out a bluish-green; but if he says that it is not a pure green, but a bluish-green, it should not be concluded that he has made a mistake. Slight differences will be noted in many people, and one who is never quite certain between yellow and orange, or between green and blue, should not be rejected, for although his colour sense is not of the best, yet such mistakes will never lead him to make an error in naming the ordinary signal lights. If, however, a candidate states yellow and green to be of the same colour, or mixes his drabs and browns with his greens, he is a dangerous case, and should be rejected. This classification test is greatly inferior to the lantern test.

The bead test or the classification test will suffice for all ordinary cases. In a doubtful case the lantern test should be used.

CHAPTER XXIII

GENERAL OPTICAL PRINCIPLES

FROM a luminous point, rays of light pass out in straight lines in every plane and in every direction; the lines of direction are called rays. These travel with a rapidity which diminishes with the density of the medium traversed.

The amount of divergence of the rays of light falling on a given area is inversely proportionate to the distance of the luminous source; the nearer this point, the more divergence. When proceeding from a point distant 20 feet or more, the divergence of rays is so slight that for practical purposes we may assume them to be parallel.

When a ray of light meets an opaque body, it is either absorbed or reflected. When it meets a transparent medium, some of it is absorbed and reflected, but the greater part traverses the medium (provided that the angle of incidence is not greater than the critical angle of the medium), being deflected in its course; this bending is called refraction.

Reflection occurs from any polished surface (mirror)—plane, concave, or convex. The ray striking the mirror is called the incident ray (I B, Fig. 229); that returning from the mirror, the reflected ray (B R, Fig. 229).

Laws of Reflection.—(1) The angle of reflection is equal to the angle of incidence; (2) the reflected and incident rays are both in a plane perpendicular to the reflecting surface. In Fig. 229, I B is the incident ray on the reflecting surface A C, B R the reflected ray, and P B the perpendicular. The angle of incidence, I B P, is equal to the angle of reflection, P B R. I B, P B, and B R lie in the same plane.

Reflection by a Plane Mirror.—The image is formed at a distance behind the mirror equal to the distance of the object in front of it; it is a virtual image, erect, and of the same size as the object. In Fig. 230, O is the object, I the image, and E the eye of the observer. The image of the candle, O, is formed behind the plane mirror, MM; the observer's eye, E, receives the rays from O as if they came from I.

Reflection from a Concave Mirror.—A concave surface may be considered as made up of a number of plane surfaces inclined toward one another. Parallel rays falling on a concave mirror are reflected as convergent rays which meet on the axis of the surface at a point called

the principal focus (Pf, Fig. 231); the latter is midway between the mirror and its optical centre, C. The distance of the principal focus from the mirror is called the focal length of the mirror.

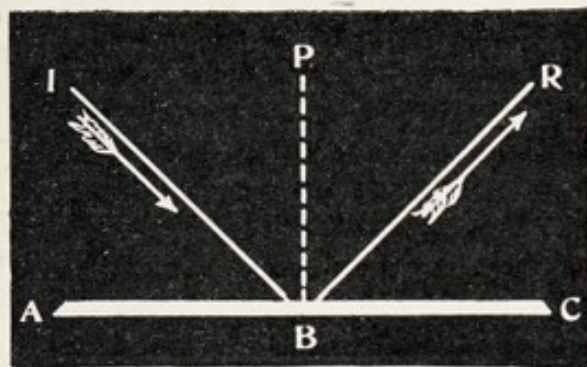


FIG. 22).—REFLECTION BY A PLANE SURFACE.

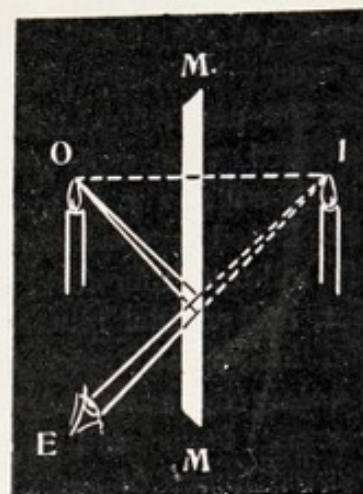


FIG. 230.—FORMATION OF IMAGE BY A PLANE MIRROR.

The position of an image formed by a concave mirror varies with the distance of the object from the mirror. If the object be placed at the principal focus, Pf, the reflected rays are parallel to each other and to the axis of the mirror. If the object be placed at the centre or

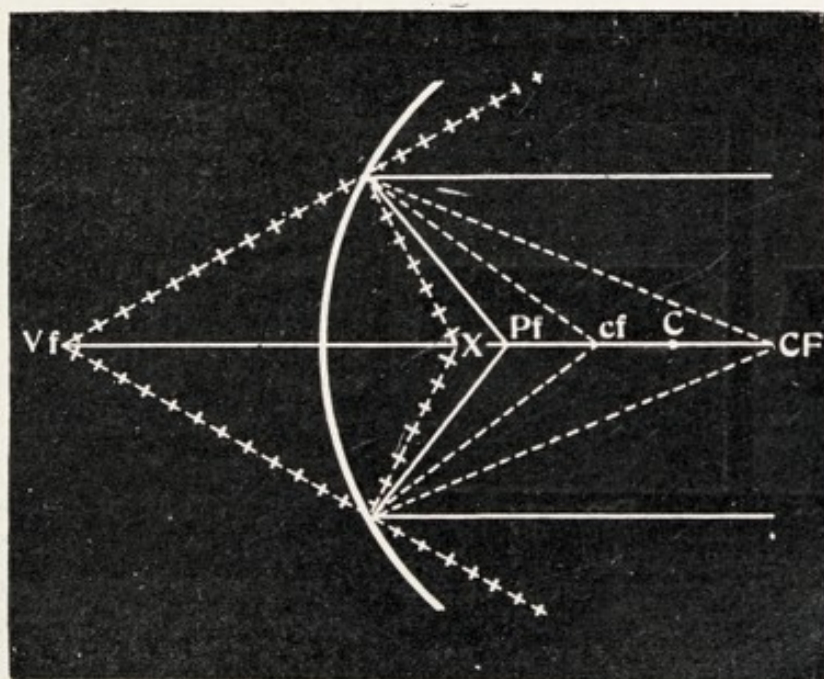


FIG. 231.—REFLECTION BY A CONCAVE MIRROR.

concavity, C, the reflected rays return along the same lines. If the object is beyond the centre, at CF, the reflected rays focus between the centre and the principal focus at cf; and conversely, if the object

be moved between the principal focus and the centre, at *cf*, its focus will be beyond the centre, at *CF*. These two points, *CF* and *cf*, bear a reciprocal relation to each other, and are known as conjugate foci. The nearer the object approaches the principal focus, the greater the distance at which reflected rays meet. If the object be placed nearer the mirror than the principal focus at *X*, reflected rays will be divergent and never meet; if, however, these divergent rays are continued backward, they will unite at a point, *Vf*, behind the mirror. This point is called the virtual focus, and an observer placed in the path of the reflected rays will receive them as though they came from this point.

It follows, therefore, that concave mirrors produce an enlarged, erect, and virtual image if the object is placed nearer than the principal focus; no image of an object placed at the principal focus; an enlarged, inverted, real image if the object is placed between the principal focus and the centre; an inverted image of the same size when placed at the centre; and a small, inverted, real image if the object is placed beyond the centre.

Reflection by a Convex Mirror.—

Parallel rays falling on a convex surface are reflected divergent, and hence never meet; but if prolonged backward a negative image is formed at a point called the principal focus (Fig. 232, *F*).

The image is always virtual, erect, and smaller than the object, independent of the position of the object before the mirror.

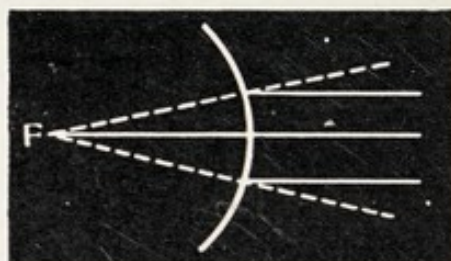


FIG. 232.—REFLECTION BY A CONVEX MIRROR.



FIG. 233

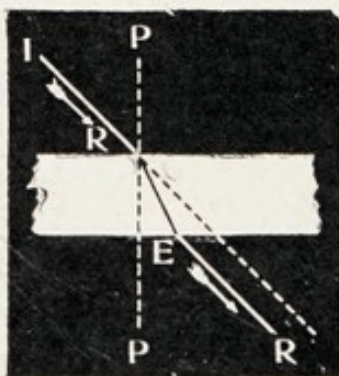


FIG. 234.

FIG. 233.—PASSAGE OF A PERPENDICULAR RAY THROUGH A TRANSPARENT MEDIUM.

FIG. 234.—REFRACTION BY A TRANSPARENT MEDIUM WITH PARALLEL SURFACES.

Refraction is the deviation in the course of rays of light in passing from one transparent (dioptric) medium into another of different density (refracting medium). The ray which falls perpendicular to the surface separating the two media is not refracted, but continues in a straight course (Fig. 233, *P P*).

In passing from a rarer to a denser medium, a ray is refracted toward the perpendicular to the refracting surface: in passing from a denser to a rarer medium, the ray is refracted away from the perpendicular. In Fig. 234 the incident ray, *I R*, in passing from a rarer medium (air) into a denser medium (glass), is refracted toward the perpendicular

P P; in passing from a denser to a rarer medium, the emergent ray, E R, is refracted from the perpendicular, P P. The ray continues in a line parallel to its original course, but has suffered lateral deviation. The angle formed by the incident ray with the perpendicular, I R P, is known as the angle of incidence; the angle formed by the emergent or refracted ray with the perpendicular, P E R, is known as the angle of refraction.

Index of Refraction.—The relative density, or the comparative length of time occupied by light in travelling a definite distance in different transparent media, is known as the index of refraction. Air being taken as 1.00, the index of refraction of water is 1.33, of the cornea 1.33, of the lens 1.40, of crown glass 1.5, of flint glass 1.6, and of diamond 2.50.

Prisms.

A prism is a piece of glass or other refracting substance bounded by plane surfaces inclined toward each other (Fig. 235). The angle formed by the two surfaces is called the refracting angle of the prism (B A C), the thin edge where the intersecting surfaces meet is known as the apex (A), and the opposite thick portion as the base (B C).

Refraction by a Prism.—Rays of light passing through a prism are bent toward the base. In Fig. 235 the incident

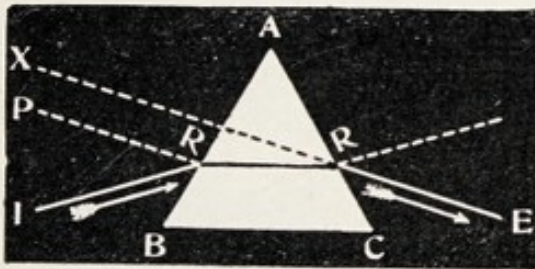


FIG. 235.—REFRACTION BY A PRISM.



FIG. 236.—PASSAGE OF PARALLEL RAYS THROUGH A PRISM.

ray I R is refracted toward the perpendicular P R, at R, and assumes the direction R R in the prism; on emerging, it is refracted away from the perpendicular and continues as R E toward the base of the prism. To the eye placed at E the ray R E seems to come from X; hence an object seen through a prism appears displaced toward the apex. A prism has neither converging nor diverging power, and therefore has no focus and cannot form an image; rays that are parallel before entering the prism are parallel on emerging (Fig. 236).

The Numbering of Prisms.—The strength of a prism is expressed (1) in degrees, (2) in centrads, and (3) in prism-diopters. In the first method (degrees), which in spite of certain faults is the one most generally used, the value of the prism corresponds to the refracting angle (geometrical angle), and is expressed: Prism 1° , 2° , 10° , etc. A centrad corresponds to a deviation, the arc of which is $\frac{1}{100}$ of the radius, and is expressed 1^∇ , 2^∇ , 10^∇ , etc. The prism diopter is a deviation, the tangent of which is $\frac{1}{100}$ of the radius, and is expressed: 1 P. D., or 1Δ ; 2 P. D., or 2Δ , etc. Within the limits of common use, the three scales can practically be considered alike. But the angle through which the prism bends a ray of light varies according to the kind of glass of which it is made. The degree of this angle is usually about half the number of the prism. (4) The most rational method is to number prisms according to the number of degrees through which they deflect a ray of light.

The Position of a Prism when placed in front of an eye is indicated by the direction of its base; 'base out' means that the thick part of the prism is toward the temple; the base may be up, down, in, or out.

The Use of Prisms.—(1) To counteract the effects of muscular paralysis or insufficiency; (2) for the exercise of weak muscles; (3) to test the extent to which the eyes can be diverted from parallelism; (4) as a test for muscular insufficiency; (5) for detecting simulated blindness.

Lenses.

A lens is a transparent refracting medium, usually made of glass, in which one or both surfaces are curved. There are two kinds: spherical and cylindrical lenses.

Spherical Lenses (abbreviated Sph. or S.) are so called because the curved surfaces are segments of spheres (Fig. 237); such lenses refract rays of light equally in all meridians or planes. There are two kinds of spherical lenses, convex and concave.

Convex Spherical Lenses may for the moment be considered as if they were formed of an infinite number of graduated

prisms with their bases at the centre of the lens and their apices radiating to the periphery (Fig. 238, A); the lenses are therefore thick at the centre and thin at the edge. They are known as converging, magnifying, positive, and plus lenses, and denoted by the sign $+$. They have the power of converging parallel rays and of bringing them to a focus (Fig. 241). There are three different forms: (1) Plano-convex, one surface plane, the other convex (1, Fig. 239); (2) bi-convex or double convex, both surfaces convex (2, Fig. 239). (3) concavo-convex (convex periscopic, convex or converging meniscus), one surface convex the other concave—the former having the shorter radius of curvature (3, Fig. 239). The periscopic lens (whether $+$ or $-$) diminishes spherical aberration and enlarges the field of vision.

Concave Spherical Lenses may similarly be considered as formed of prisms with their apices together and toward the centre (Fig. 238, B); they are therefore thin at the centre and




FIG. 237.—THE RELATION OF THE SURFACES OF LENSES TO SPHERES.

1, Plano-convex; 2, bi-convex; 3, convex meniscus; 4, plano-concave; 5, bi-concave; 6, concave meniscus.

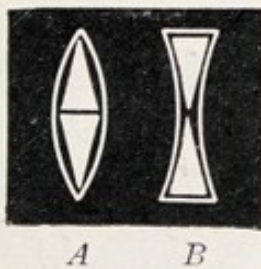


FIG. 238.—THE FORMATION OF LENSES BY PRISMS.




FIG. 239.—CONVEX LENSES.

1, Plano-convex; 2, biconvex; 3, convex meniscus.



FIG. 240.—CONCAVE LENSES.

1, Plano-concave; 2, biconcave; 3, concave meniscus.

thick at the edge. They are known as diverging, reducing, negative, or minus lenses, and denoted by the sign $-$. Rays of light after passing through a concave lens are rendered

divergent; if prolonged backward they form an image on the same side as the object (Fig. 242). There are three different forms: (1) Plano-concave, one surface plane, the other concave (1, Fig. 240); (2) biconcave or double concave, both surfaces concave (2, Fig. 240); (3) convexo-concave (concave periscopic, concave or diverging meniscus), one surface convex and the other concave, the latter having the shorter radius of curvature (3, Fig. 240).

The Action of Spherical Lenses.—Since spherical lenses are formed of prisms with their bases (convex) or apices




FIG. 241.—THE ACTION OF A CONVEX LENS ON PARALLEL RAYS.




FIG. 242.—THE ACTION OF A CONCAVE LENS ON PARALLEL RAYS.

(concave) in apposition, and since rays in passing through a prism are refracted toward its base, it follows that convex lenses cause convergence (Fig. 241), and concave lenses produce divergence, of rays (Fig. 242).

A line passing through the centre of the lens (optical centre or nodal point, *o*, Fig. 243) at right angles to the surfaces of the lens is called the principal axis (*A B*, Fig. 243). A ray passing through this axis (axial ray) is not refracted; all other rays suffer more or less refraction. Rays passing through the optical centre of a lens, but not through the principal axis (secondary rays), are slightly deviated, but emerge in the same direction as they entered (*C D* and *E F*, Fig. 243); the deviation in thin lenses is so slight that practically they may be considered as straight lines, and are called secondary axes.




FIG. 243.—PRINCIPAL AND SECONDARY AXES OF A CONVEX LENS.

Foci of a Convex Lens.—The point to which rays con-

verge after refraction by a convex lens is called its focus. The principal focus is the focus for parallel rays (F, Fig. 244); the distance of this point from the optical centre is called the focal distance of the lens (XF, Fig. 244). Since the course of a ray passing from one point to another is the same, independent of the direction, it follows that rays from a luminous point placed at the principal focus will emerge as parallel after passing through the lens.

In Fig. 244 the rays A B C strike the surface of the lens at L M N; the axial ray B strikes the lens at M perpendicular to its surface, and consequently continues in a straight line to F. The ray A strikes the lens obliquely at L, and is bent

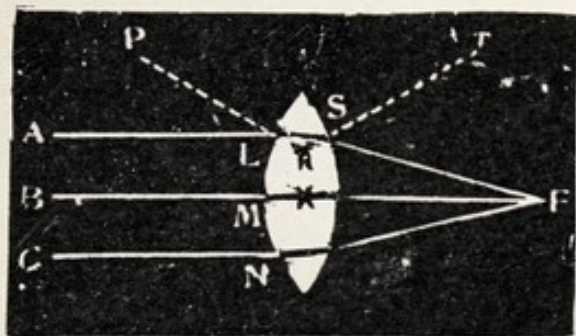


FIG. 244.—THE PRINCIPAL FOCUS OF A CONVEX LENS.

toward the perpendicular of the surface of the lens at that point, shown by the dotted line P R; on leaving the lens obliquely at S, it is deflected away from the perpendicular R T, being directed to F, where it meets the axial ray B F. The ray C is refracted in a similar manner; it is bent upon entering the lens at N, and rendered additionally convergent when emerging from the lens, and finally it meets the other rays at F. If, in this same illustration, the rays proceed from F, the principal focus, they emerge parallel (L A, M B, N C) after passing through the lens.

Conjugate Foci of a Convex Lens.—Conjugate foci are interchangeable foci in which the image can be replaced by the object and the object by the image. When divergent rays (*i.e.*, rays coming from a point nearer than 20 feet) proceed from a point beyond the principal focus, they will meet at a point beyond the principal focus on the other side of the lens. The more distant the luminous point, the nearer the principal focus on the other side of the lens will the rays be focussed. If the luminous point is situated at a distance equal to twice the focal length of the lens, the

rays will focus at the same distance on the opposite side. These are *conjugate foci*.

In Fig. 245 the rays diverging from O and passing through the lens converge at I; if they diverge from I they would

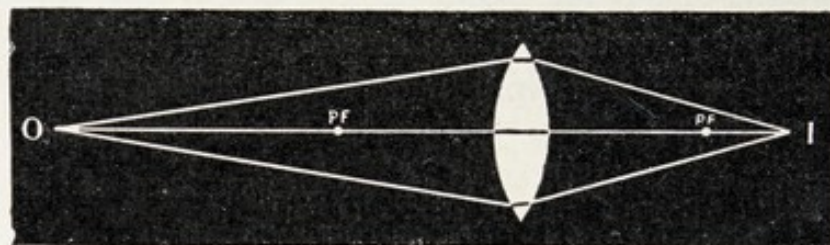


FIG. 245.—CONJUGATE FOCI OF A CONVEX LENS.

return in the same path and meet at O; the points O and I are conjugate foci. In the preceding example the conjugate focus is positive or real.

Virtual or Negative Focus of a Convex Lens.—When rays diverge from some point between the lens and its principal focus (O, Fig. 246), they will continue divergent after refraction, but less so than before entering the lens; if prolonged backward they will meet at a point (I, Fig. 246) on the same side of the lens from which they diverged; this point is a negative or virtual focus.

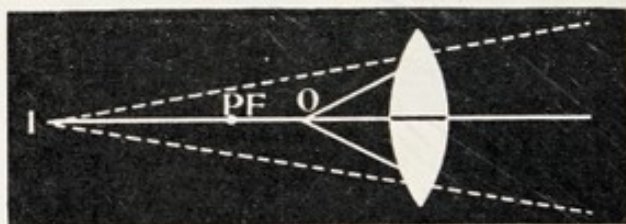


FIG. 246.—VIRTUAL FOCUS OF A CONVEX LENS.

Foci of a Concave Lens.—After passing through a concave lens, rays of light, whether originally parallel or divergent, are always divergent, and the focus is, therefore, always negative or virtual; it is found by continuing these divergent rays backward until they meet at a point (Fig. 242).

Formation of Images.—The image of an object formed by a lens is a collection of foci, each corresponding to a point in the object. Such images are either real or virtual. A real image is formed by the meeting of rays; it can be projected on a screen. A virtual image is formed by the prolongation backward of diverging rays until they meet at a point; it can only be seen by looking through the lens.

To find the position and size of an image formed by a lens, it is necessary to obtain the conjugate focus of each extremity of the object. Two lines are drawn from each of these points, one parallel to the axis of the lens and then

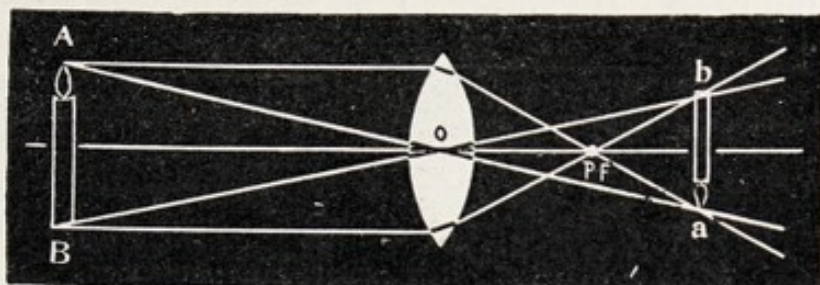


FIG. 247.—REAL, INVERTED, AND REDUCED IMAGE FORMED BY A CONVEX LENS.

through the principal focus, and the other through the optical centre; the image will be formed at the point where these rays intersect (Figs. 247, 248, 249).

In Fig. 247 A B is the object, o is the optical centre of the lens, and PF its principal focus. From A two rays are drawn, one parallel to the axis of the lens and then through the principal focus PF, and a secondary ray through o; the image of the point A is formed at a, where these two lines intersect. The conjugate focus of B is found in the same manner.

The relation in size between image and object depends upon their respective distances from the optical centre of the lens

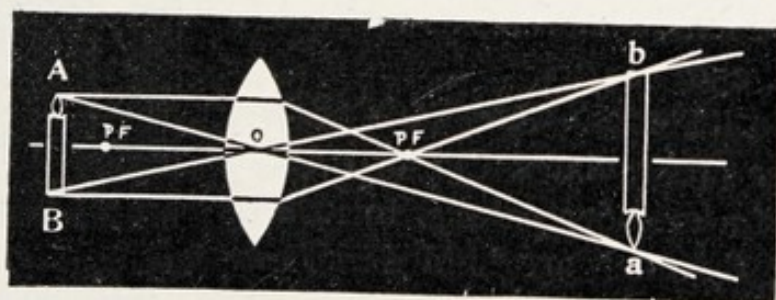


FIG. 248.—REAL, INVERTED, AND ENLARGED IMAGE FORMED BY A CONVEX LENS.

In Fig. 247 the object is placed at a greater distance than twice the principal focus, hence the image is real, inverted, and smaller. If the object is situated at exactly twice the distance of the principal focus, the image will be real, of the

same size, and inverted. If the object is situated just beyond the principal focus, the image will be real, enlarged, and inverted (Fig. 248). If the object be placed at the principal focus, the rays will be parallel after refraction, and no image will be obtained. If the object be nearer than the principal

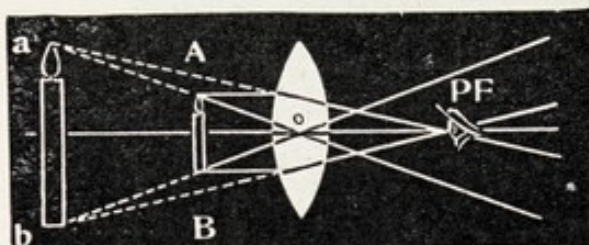


FIG. 249.—VIRTUAL IMAGE FORMED BY A CONVEX LENS.

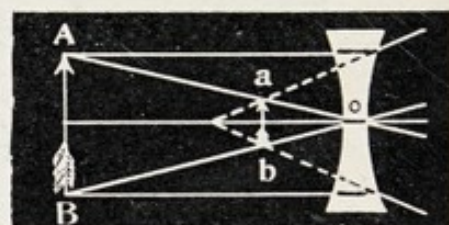


FIG. 250.—VIRTUAL IMAGE FORMED BY A CONCAVE LENS.

focus, the rays will be divergent after passing through the lens (Fig. 249), and no real image will be formed; but by projecting these rays backward they would meet, and an eye placed at PF, Fig. 249, will receive the rays from *a b* as if they came from *A B*; the image will be enlarged, erect, and virtual; it is on the same side of the lens as the object, and is seen only by looking through the lens, which acts as a magnifying-glass.

Images formed by concave lenses are always virtual, erect, and smaller than the object; they are seen only by looking through the lens, which acts as a reducing-glass (Fig. 250)

Cylindrical Lenses.—A cylindrical lens or cylinder (abbreviated Cyl. or C.) is a segment of a cylinder parallel to its axis (Fig. 251). Cylinders are divided into convex and concave. Light passing through a cylinder in the plane of its axis is not refracted, and behaves exactly as though passing through a plate of glass with parallel sides; in this direction the surface of the lens is straight. But when light passes through in a plane opposite or perpendicular to the axis of a cylinder, the




FIG. 251.—THE CONSTRUCTION OF A CONVEX AND A CONCAVE CYLINDRICAL LENS FROM A CYLINDER.

rays are rendered convergent or divergent, according as the cylinder is convex or concave; in this direction the surface of the lens is curved. Parallel rays of light after refraction by a cylinder are focussed in a straight line which corresponds to the axis of the cylinder (Figs. 252, 253). A spherical lens refracts equally in all planes; a cylindrical lens does not refract in the axial plane, but all other rays are refracted, those the most which pass at right angles to its axis. It is necessary to indicate the direction of the axis of a cylinder; in the lenses of the trial case, used for the estimation of the refraction of the eye, this is done by a short

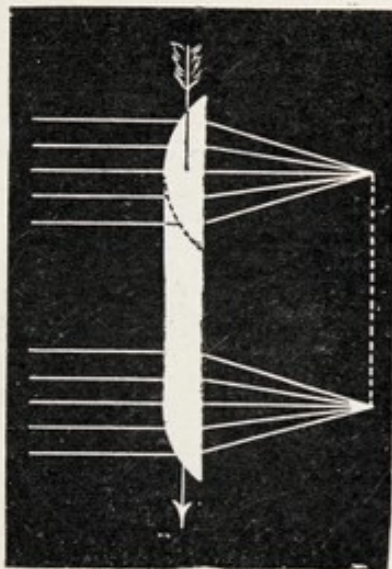


FIG. 252.—THE ACTION OF A CONVEX CYLINDRICAL LENS UPON PARALLEL RAYS.

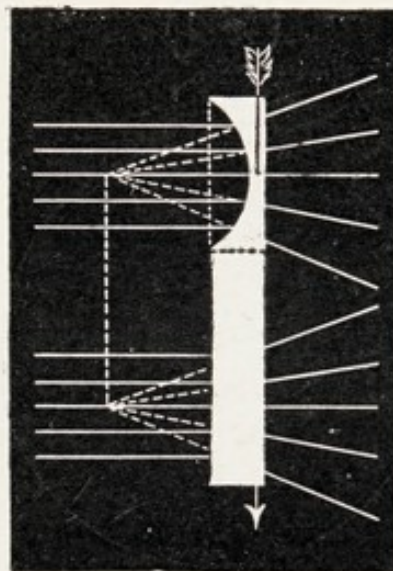


FIG. 253.—THE ACTION OF A CONCAVE CYLINDRICAL LENS UPON PARALLEL RAYS.

linear scratch on the lens at its margins, or by having a portion of the surface on each side ground parallel to its axis (Fig. 255).

The Numeration of Lenses.—The strength of a lens refers to its power of bringing parallel rays to a focus—*i.e.*, its refractive power; this is indicated by its principal focal distance, the interval between the optical centre of the lens and the principal focus. The shorter this distance the stronger the lens; the greater the principal focal distance the weaker the lens. The strength of a lens is the inverse of its focal distance.

The Metric or Dioptric System of numbering lenses accepts

as its unit a lens which has its principal focus at 1 metre distance ($39\frac{1}{3}$ English inches, in round numbers 40 inches); this lens is known as 1.00 diopter (abbreviated D.). Every lens is numbered by its strength in whole numbers and in decimal fractions (0.25, 0.50, 0.75). A lens which has twice the strength of the unit is known as 2 D.; its focal distance is $\frac{1}{2}$ metre. If the lens has a strength four times that of the unit, it is called 4 D., and its focal distance is $\frac{1}{4}$ metre. If ten times as strong as the unit, it is known as 10 D., and its focal distance is $\frac{1}{10}$ metre. If one-quarter, one-half, or three-quarters as strong as the unit, it is known as 0.25 D., 0.50 D.,



FIG. 254.—SPHERICAL LENS
FROM TRIAL CASE.




FIG. 255.—CYLINDRICAL LENS
FROM TRIAL CASE.

or 0.75 D. respectively. In this system the number of the lens does not express its focal distance; but the focal distance in centimetres is obtained by dividing 100 cm. by the number of the lens; for example, a 2 D. lens has a focal distance of $\frac{100}{2} = 50$ cm.; a 5 D. lens has a focal distance of $\frac{100}{5} = 20$ cm. The dioptric system is now universally adopted.

To convert the focal distance in inches into the focal distance in diopters, or *vice versa*, divide the number 40 by the number of inches or diopters expressed. For example, 8 D. = $\frac{40}{8} = 5$ inches = $\frac{1}{5}$; 0.50 D. = $\frac{40}{0.5} = 80$ inches = $\frac{1}{80}$; $\frac{1}{20}$ (20 inches) = $\frac{40}{20} = 2$ D.; $\frac{1}{10}$ (10 inches) = $\frac{40}{10} = 4$ D. The follow-

ing table gives the commonly employed (approximate) equivalents in the inch and the dioptric systems :

COMMONLY EMPLOYED (APPROXIMATE) EQUIVALENTS OF LENSES
NUMBERED IN THE DIOPTRIC AND INCH SYSTEMS.

Dioptrs.	Inches.	Dioptrs.	Inches.	Dioptrs.	Inches.	Dioptrs.	Inches.
0.25	160	2.25	18	5.50	7.0	13	3.0
0.50	80	2.50	16	6.00	6.5	14	2.8
0.75	50	2.75	14	7.00	5.25	15	2.6
1.00	40	3.00	13	8.00	5.0	16	2.4
1.25	32	3.50	11	9.00	4.5	—	—
1.50	26	4.00	10	10.00	4.0	18	2.2
1.75	22	4.50	9	11.00	3.5	—	—
2.00	20	5.00	8	12.00	3.3	20	2.0

The Trial Case (Fig. 256) is a box containing + and - spherical, and + and - cylindrical lenses, arranged in pairs. The spherical lenses (Fig. 254) usually correspond to those given in the preceding table (30 pairs), the weaker ones separated by intervals of 0.25 D., those of moderate strength




FIG. 256.—THE TRIAL CASE OF LENSES.

by 0.50 D., and the stronger ones by 1 D. The cylindrical lenses (Fig. 255) usually run from 0.25 D. to 6.00 D. The - lenses are mounted in nickelled rims, the + lenses in brass rims. Besides these lenses, the trial case usually contains a

set of prisms, various metal discs, one of which (obturator) is solid, and is used to exclude one eye in the examination, and a trial spectacle frame (Fig. 256).

Recognition of the Kind of Lens and Estimation of its Strength.—By moving a spherical lens before the eye and looking at an object, the latter will appear to move, rapidly if the lens is a strong one, slowly if a weak one. If the object seems to move in the opposite direction and appears enlarged, the lens is convex. If the object appears to move in the same direction and seems smaller, the lens is concave.

When a cylinder is moved before the eye in the direction of its axis an object looked at does not appear to change its position; when moved in the opposite direction objects appear to move as with spherical lenses—in the opposite direction when the cylinder is convex, in the same direction when concave.

Having recognized the character of the lens, the strength can be determined by neutralizing. Lenses of opposite kind and known strength are taken from the trial case and placed in front of that to be tested, and the two lenses moved in front of the eye. The neutralizing lens is the one which stops all apparent movement of an object looked at when the combined lenses are moved in front of the eye. The Geneva Lens Measure (Fig. 257) furnishes a very quick and fairly accurate method of determining the character and strength of any lens.

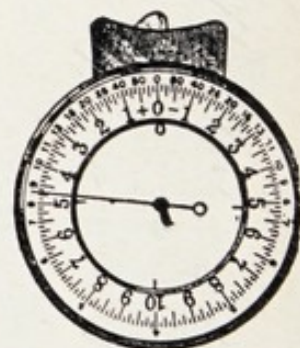


FIG. 257.—GENEVA LENS MEASURE.

Finding the Centre of the Lens.—The optical centre of a lens in the trial case should coincide with the geometric centre. To find the optical centre we look at two lines at right angles to each other through the lens held a few inches away. The portion of the vertical and of the horizontal line seen through the lens is made continuous with the portion seen beyond the lens; then the two lines should cross at the geometrical centre of the lens.

Varieties of Lenses Used to Correct Errors of Refraction.—

(1) Simple spherical lens, convex or concave. (2) Simple cylindrical lens, convex or concave. (3) Sphero-cylinder, a combination of a spherical with a cylindrical lens. (4) Cross-cylinder, a combination of two cylindrical lenses with their axes at right angles to each other (infrequently used). (5) Simple prism. (6) Prism combined with various lenses.

Abbreviations and Signs.—The following are in general use in ophthalmology :

Acc.	Accommodation,	O.D.	Optic disc.
Aq.	Aqueous humour.	O.P.	Optic papilla.
As.	Astigmatism.	P.	Pupil.
A.C.	Anterior chamber.	Pr.	Presbyopia.
Ax.	Axis.	P.L.	Perception of light.
C.	Cornea.	p.p.	Punctum proximum.
Ch.	Choroid.	p.r.	Punctum remotissimum.
cm.	Centimetre.	R.	Right eye (and L., left eye).
Cyl.	Cylindrical lens.	Ret.	Retina.
D.	Diopter or dioptric.	Scl.	Sclerotic.
E.	Emmetropia.	Sph.	Spherical lens.
F.	Field of vision.	T.	Tension of the eyeball.
H.	Hypermetropia.	T.n.	Tension normal.
H.l.	Latent hypermetropia.	T. + 1, T. + 2, T. + 3, } de-	
H.m.	Manifest hypermetropia.	T. - 1, T. - 2, T. - 3, }	degrees of increase and decrease of tension.
I.	Iris.	Vit.	Vitreous humour.
L.	Left eye (and R., right eye).	Y.S.	Yellow spot (and M.L., macula lutea).
m.	Metre.	V.	Visus, acuteness of sight, power of distinguishing form.
mm.	Millimetre.		
My.	Myopia.		
M.L.	Macula lutea (and Y.S., yellow spot).		
Oph.	Ophthalmoscope, ophthalmoscopic examination, ophthalmoscopic appearances.		

SYMBOLS.

+	Symbol for a convex lens.	'	Foot.
-	Symbol for a concave lens.	"	Inch.
		'''	Line.

CHAPTER XXIV

OPTICAL CONSIDERATION OF THE EYE

THE eye may be considered as an optical instrument, often compared to the photographic camera, in which by means of a refracting (dioptric) system a small and inverted image of external objects is formed on the retina. The impression received by the rods and cones is conveyed through the optic nerve to the visual cortical area where the visual act is completed and results in sight.

The eye is well adapted for its function of refraction. It is spherical in shape, about 24 mm. in diameter, and protected externally by the opaque sclera behind and the transparent cornea in front. The outermost portion of the retina consists of a layer of pigment cells which absorbs the excess of light and prevents dazzling.

Dioptric Apparatus of the Eye.—In passing through the eyeball rays of light traverse the cornea, aqueous humour, lens, and vitreous. The refracting surfaces of the eye are the cornea, the anterior surface, and the posterior surface of the lens; the refracting media are the aqueous humour, the substance of the lens, and the vitreous. These surfaces and media constitute the dioptric or refractive apparatus of the eye, a system which is represented by a convex lens of 23 mm. focus; hence in an emmetropic eye in a condition of rest parallel rays are brought to a focus on the retina. The greatest deflection of rays takes place at the anterior surface of the cornea; additional deflection occurs at the anterior and posterior surfaces of the lens. In each case the effect is one of convergence. By the term 'refraction of the eye' we

mean the changes which the transparent ocular media exert upon rays of light when the eye is in a state of rest.

Cardinal Points of the Eye.—It is necessary to be acquainted with the cardinal points of the eye (Fig. 258) in order to understand the course of rays of light through this organ; they are the two principal points, the two nodal points, and the two principal foci, all situated on the optical axis.

The Principal Points (P, Fig. 258) are two points so related that when an incident ray passes through the first principal point the corresponding emergent ray passes through the second principal point. These two points are placed so close together in the anterior chamber that they may be con-

sidered as one point, situated about 2 mm. behind the cornea.

The Nodal Points (N, Fig. 258) correspond practically to the optical centre of the dioptric system; they are so close together that they may be considered as one point situated near the posterior pole of the lens about 7 mm. behind the cornea. Rays passing through this point are not refracted, and form either the axial or secondary rays.

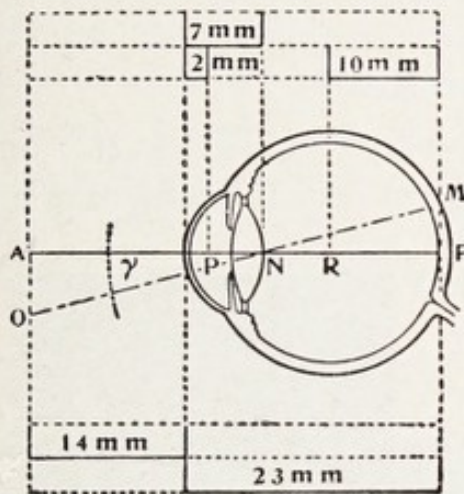


FIG. 258. — CARDINAL POINTS OF THE EYE.

The First Principal Focus (A, Fig. 258) is that point on the axis at which parallel rays in the vitreous meet; it is situated about 14 mm. in front of the cornea.

The Second Principal Focus (F, Fig. 258) is that point on the axis at which parallel rays meet after being refracted by the dioptric system of the eye; it is situated to the inner side of the macula, between it and the optic disc, about 23 mm. behind the cornea.

The Centre of Rotation of the eyeball (R, Fig. 258) is situated in the vitreous, about 10 mm. in front of the retina.

The Optical Axis (A F, Fig. 258) is the line connecting the centre of the cornea, the nodal point, and the posterior principal focus on the retina.

The Visual Line (O M, Fig. 258) is the line passing from the object looked at through the nodal point to the macula.

The Line of Fixation is the line joining the object looked at with the centre of rotation; practically it corresponds to the visual line.

The Angle Gamma (γ , Fig. 258) is the angle formed by the optical axis with the line of fixation (practically with the visual line); it varies with the refraction of the eye, being about 3 degrees usually in emmetropia, larger in hypermetropia, and smaller in myopia.

The Angle Alpha is the angle formed by the visual line with the major axis of the corneal ellipse.

Refraction of the Eye.

Emmetropia.—When parallel rays are focussed exactly on the retina with the eye in a condition of rest, the refraction of the eye is normal or emmetropic (Fig. 259, A), and the condition is known as emmetropia.

Ametropia.—When with the eye in a condition of rest parallel rays are not focussed on the retina, but behind or in front of it, the eye is ametropic, and the condition is known as ametropia. The forms of ametropia (errors of refraction) are hypermetropia, myopia, and astigmatism.

Hypermetropia (or far-sightedness) is that form of ametropia in which the axis of the eyeball is too short or the refractive power of the eye too weak, so that parallel rays are brought to a focus behind the retina (Fig. 259, B).

Myopia (near-sightedness) is that form of ametropia in which the axis of the eyeball is too long or the refractive power too

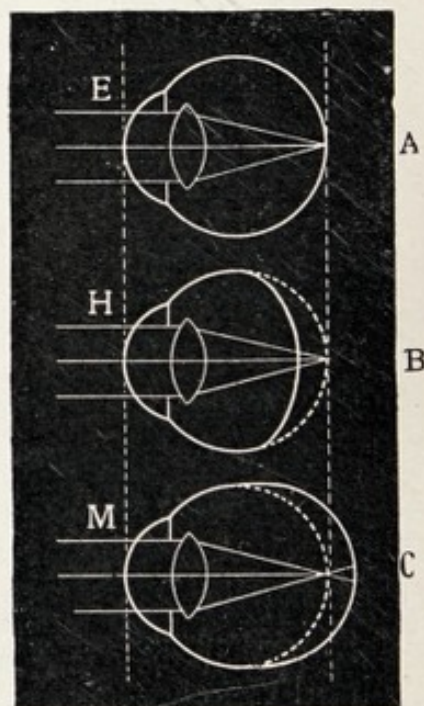


FIG. 259. — A, EMME-
TROPIA. B, HYPERME-
TROPIA. C, MYOPIA.

strong, so that parallel rays are focussed in front of the retina (Fig. 25), C).

Astigmatism is that form of ametropia in which the refraction in the several meridians of the eyeball is different (Figs. 281 to 285).

The Acuteness of Vision and the method of its determination for distance and near have been described with the functional examination of the eye in Chapter II.

Accommodation.

Accommodation is the act of altering the focus of the eye so that divergent rays (those coming from an object nearer than about 20 feet are appreciably divergent) are brought together on the retina. This is accomplished by means of an increase in the convexity of the lens and thus in its refractive power. The degree of accommodation must vary for every distance of object near.

In the emmetropic eye at rest parallel rays are brought to a focus on the retina (P F, Fig. 260), but rays coming from

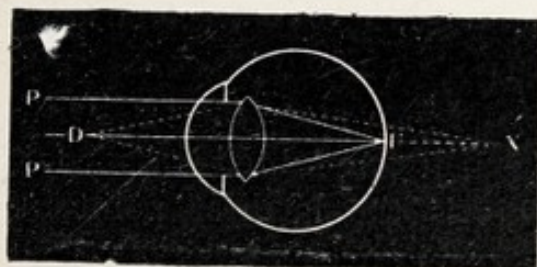


FIG. 260.—THE EMMETROPIC EYE IN A STATE OF REST.

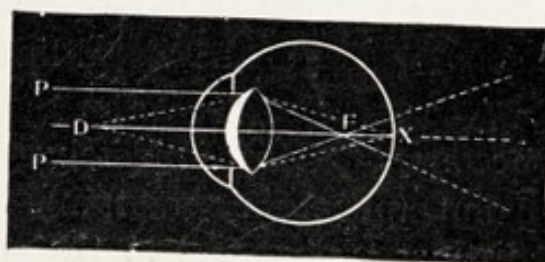


FIG. 261.—THE EMMETROPIC EYE DURING ACCOMMODATION.

a near object (divergent rays) are not brought to a focus at all, as they would tend to be focussed behind the retina (D X, Fig. 260); hence distant objects appear distinct and near objects blurred. If the refractive power of the eye is increased by accommodation, parallel rays will be brought to a focus in front of the retina (P F, Fig. 261), while divergent rays will be focussed on the retina (D X, Fig. 261); consequently near objects appear distinct and distant objects appear blurred during accommodation.

Mechanism of Accommodation.—The lens is an elastic structure, and when released from the flattening influence of its suspensory ligament tends to assume a spherical shape. During accommodation the ciliary muscle (especially

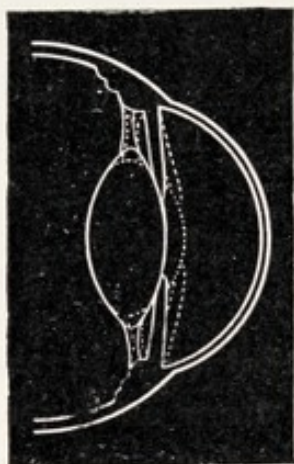


FIG. 262.—SECTION OF THE ANTERIOR PORTION OF THE EYEBALL.

The dotted lines illustrate the changes during accommodation.

the circular fibres) contracts, drawing forward the choroid and relaxing the suspensory ligament; this diminishes the tension of the lens capsule, and allows the inherent elasticity of the lens to increase its convexity. The change in curvature affects chiefly the anterior surface of the lens (Fig. 262). This is Helmholtz's theory and the one usually accepted. Tscherning has advanced a different theory. He maintains that the ciliary muscle increases the tension of the suspensory ligament during contraction, and that this causes peripheral flattening of the lens with bulging anteriorly at its centre.

The act of accommodation is accompanied by contraction of the pupil and, in an emmetrope, by convergence of the visual lines.

The Far Point.—When the eye is in a state of rest, with accommodation completely relaxed, it is adapted for its far point (*punctum remotum*). This is the farthest point of distinct vision, and in the emmetropic eye it is situated at infinity.

The Near Point (*punctum proximum*) is the nearest point at which the eye can see distinctly when employing its maximum amount of accommodation. It varies with the amount of accommodation possessed by the eye. The usual plan of determining the near point is to note the shortest distance at which the patient can read the smallest test-type (Jaeger, No. 1, Fig. 17) with each eye separately.

The Range of Accommodation is the distance between the far point and the near point.

The Amplitude of Accommodation is the difference between

the refractive power of the eye when at rest and when the accommodation is exerted to the utmost. It is expressed in diopters representing that convex lens which it would be necessary to place before the eye to take the place of accommodation for the near point.

The amplitude of accommodation in diopters is found by dividing 40 by the distance of the near point in inches, or 100 by the near point in centimetres; for example, if the near point of an emmetropic eye is 8 inches or 20 cm., $\frac{40}{8}$ or $\frac{100}{20} = 5$ D. = amplitude of accommodation; this rule applies to emmetropia.

In hypermetropia some of the accommodation is required for distant vision; hence we find the apparent amplitude of accommodation, and then add that lens which enables the patient to see distant objects without his accommodation; for example, if the near point of a hypermetropic eye is 8 inches or 20 cm., and the patient is compelled to use 2 D. of accommodation for distant objects, his amplitude of accommodation would be $\frac{40}{8}$ (or $\frac{100}{20}$) = 5 + 2 = 7 D. With the same amplitude of accommodation the near point is farther away than in emmetropia, since some of the power of accommodation is expended in adapting the eye for distant objects; and if the near point were the same, the amplitude of accommodation would be greater in hypermetropia than in emmetropia.

In myopia, since a concave lens is necessary to enable the patient to see distant objects clearly, we must deduct the strength of this glass from that the focal length of which equals the distance of the near point from the eye; for example, if the myopia equals 2 D. and the near point is 4 inches or 10 cm., the amplitude of accommodation will be $\frac{40}{4}$ or $\frac{100}{10} = 10$ D. - 2 D. = 8 D. With the same amplitude of accommodation, the near point is closer to the eye in myopia than in emmetropia; and if the near point were the same the amplitude of accommodation would be less in myopia than in emmetropia.

The power of accommodation gradually diminishes, and the near point recedes as age advances, owing chiefly to loss of

elasticity of the lens. In the emmetrope at ten years the p.p. is at 7 cm. ; at forty years it has receded to 22 cm. ; at sixty years to 100 cm. ; and at seventy-five years to infinity, the accommodation being suspended and the p.p. coinciding with the p.r. The following table gives the amplitude of accommodation and the near point at various periods of life. The near point applies only to emmetropic eyes, but the amplitude of accommodation applies to all eyes, whether emmetropic or ametropic. There is a tendency towards increased amplitude of accommodation in hypermetropic, and diminished amplitude in uncorrected myopia.

Year.	Amplitude of Accommodation in Diopters.	Near Point in Centimetres.	Near Point in Inches.	Year.	Amplitude of Accommodation in Diopters.	Near Point in Centimetres.	Near Point in Inches.
10	14.0	7.0	2.8	45	3.5	28.0	11
15	12.0	8.5	3.3	50	2.5	40.0	16
20	10.0	10.0	4.0	55	1.75	55.0	22
25	8.5	12.0	4.7	60	1.0	100	40
30	7.0	14.0	5.6	65	0.75	133	53
35	5.5	18.0	7.0	70	0.25	400	160
40	4.5	22.0	9.0	75	0.0	∞	∞

Presbyopia.—When the near point of the emmetropic eye has receded to a distance at which the finer kinds of work become difficult, the condition is known as presbyopia. This state is the result of a physiological process which affects every eye, and must not be considered a disease. It is usually said to be present when the near point recedes to a distance of more than 22 cm. (9 inches) from the eye, an event which generally happens between the fortieth and the forty-fifth years.

The Association between Accommodation and Convergence.

--The preceding considerations of the subject of accommodation referred to monocular vision or sight with one eye. With binocular vision it is necessary to consider convergence as well as accommodation, for these two actions (together with the contraction of the pupil) are normally associated.

Convergence is the power of directing the visual lines of the two eyes to a near point, and results from the action of

the internal recti muscles. When we look at a distant object accommodation is at rest and the visual lines are parallel. When we look at a near object we are compelled both to accommodate and to converge for that distance; with a certain amount of accommodation a corresponding effort of convergence of the visual lines is associated.

The angle which the visual line makes in turning from a distant object to a near one is called the angle of convergence. The unit of convergence is the metre angle (M.A.) which is the angle formed by the visual line with the median line at a distance of 1 metre (Fig. 263). If the eyes look

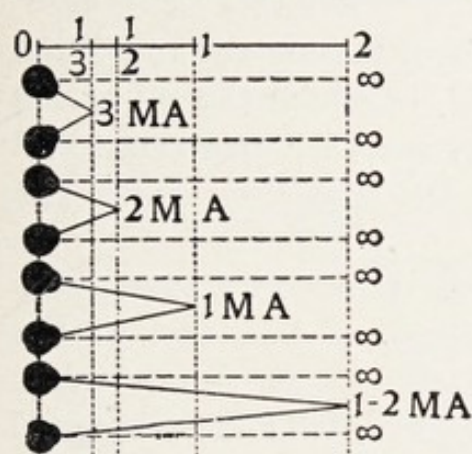


FIG. 263.—DIAGRAM ILLUSTRATING THE UNIT OF CONVERGENCE, THE METRE ANGLE.

at an object $\frac{1}{2}$ metre distant the convergence is twice that of the unit, and convergence (C.) = 2 M.A.; if directed toward a point $\frac{1}{3}$ metre distant, C. = 3 M.A.; if toward an object 2 metres distant, C. = $\frac{1}{2}$ M.A.

The emmetropic eye requires for each distance of binocular vision as many metre angles of convergence as it needs diopters of accommodation. To see an object at 1 metre distance, 1 metre angle of convergence is required,

and also 1 diopter of accommodation; at 10 cm., 10 metre angles of convergence and 10 D. of accommodation would be required.

This harmonious relationship between accommodation and convergence is not, however, unchangeable. Within certain limits either of these actions may take place independently of the other.

The Range or Amplitude of Convergence.—The far point of convergence is the point to which the visual lines are directed when convergence is at rest; the near point of convergence is the point to which the visual lines are directed with the maximum amount of convergence. The distance between the far point and the near point of convergence is

the amplitude of convergence ; it is expressed by the greatest number of metre angles of convergence of which the eyes are capable. In a state of rest the far point of convergence is at infinity and the visual lines are parallel. In cases of convergent squint the visual lines deviate inward even when convergence is relaxed as far as possible ; convergence is then said to be positive. In a case of divergent squint convergence is a negative quantity. Normally the eyes diverge, as a rule, during sleep.

Methods of Investigating the Refraction of the Eye.

There are three principal methods of testing the refraction of the eye : (1) the *subjective method*, in which the refraction is estimated by the acuteness of vision with test-types and trial lenses ; (2) *retinoscopy* ; and (3) the *ophthalmoscope*. The last two are objective methods.

Every examination should be undertaken in a systematic manner. We begin with the external examination of the eyes as described in Chapter I. Next the patient is taken into the dark-room, and the media and fundus are examined with the ophthalmoscope (Chapter III.). Then the refraction may be determined with the ophthalmoscope. The retinoscopic mirror is now employed to estimate the refraction with the shadow test. Finally, the patient is examined by the subjective method with test lenses and test types. By employing this order we will save time, since the ophthalmoscopic examination may show changes in the media or fundus which convince us of the impossibility of improving the patient's vision with glasses, or lead us to be satisfied with a limited result. The objective methods of determining the refraction of the eye give very close and accurate results ; the subjective method serves to verify these conclusions and sometimes perfects them.

The Determination of the Refraction by the Acuteness of Vision with Test-Types and Lenses. The Subjective Method.

After having determined the acuteness of vision for distance as described on p. 9, we endeavour to ascertain which lenses are necessary to correct any error of refraction, and to bring the vision up to the normal $\frac{6}{6}$. The patient is placed in front of the test-types, which must be well illuminated by daylight or artificial light, at a distance of 6 metres. The trial frame (Fig. 264) is worn by the patient, and the left eye excluded by means of a solid metal disc. After testing the right eye we proceed with the left.

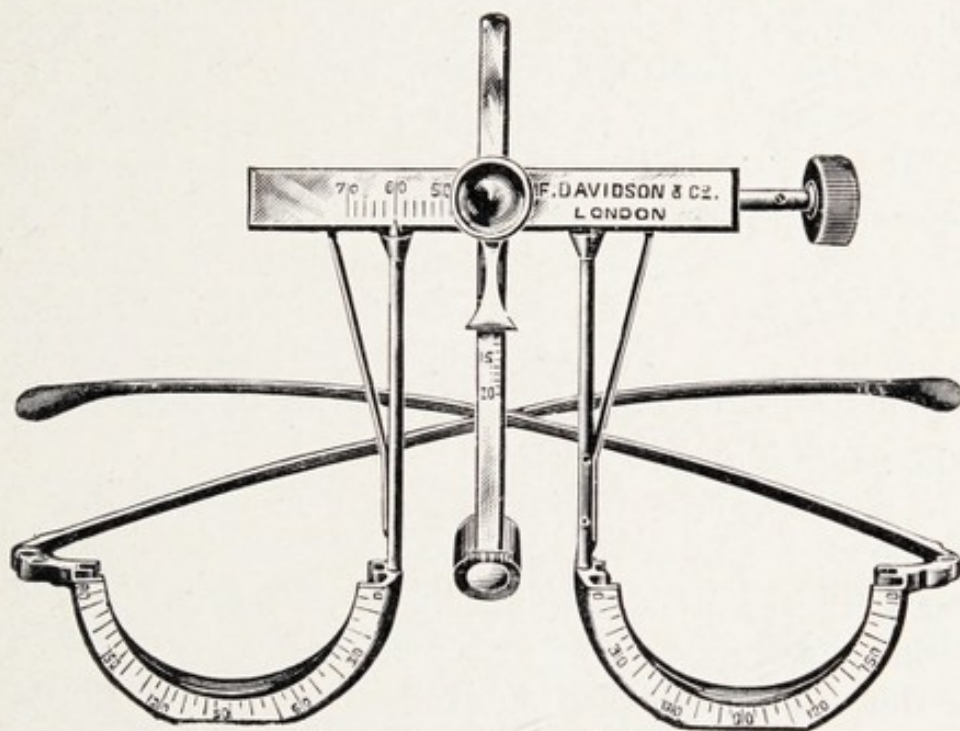


FIG. 264.—TRIAL FRAME.

If the patient reads $\frac{6}{6}$ without a glass he is probably either emmetropic or has hypermetropia. With bright illumination and contracted pupils an intelligent patient may be able to read $\frac{6}{8}$, even though he have myopia or astigmatism of 0.5 D. A weak convex spherical lens (+0.50 D. Sph.) is held in front of the eye; if he is easily able to read the $\frac{6}{8}$ line he has hypermetropia, and the strongest convex spherical lens with which he can read $\frac{6}{8}$ is the measure of his manifest hypermetropia. Even though he accepts a convex spherical lens, this is probably not the measure of his total hypermetropia, which can

be estimated in young persons only after the eye has been placed under the effects of a cycloplegic. The difference between the manifest and the total hypermetropia is known as the latent hypermetropia; it is this portion which is discovered after accommodation has been paralyzed.

If the patient reads $\frac{6}{8}$, and a weak convex spherical lens blurs his vision, he is either emmetropic or has hypermetropia which is latent.

If the patient's vision is below normal, and instead of reading $\frac{6}{8}$ he reads $\frac{6}{12}$ or $\frac{6}{18}$, he either has considerable manifest hypermetropia, or else he may be myopic or astigmatic; or he may have a combination of these errors. If hypermetropic, spherical lenses will improve his vision. If such improvement does not result upon placing convex spherical lenses before the eye we may try a weak concave spherical lens; if this aids his vision probably he is myopic, and the weakest concave spherical lens that brings his vision to $\frac{6}{8}$ is the measure of his myopia. If concave spherical lenses do not improve the vision, we assume the existence of astigmatism, and cylinders, alone or in combination with spherical lenses, are placed in front of the eye for the purpose of estimating the kind, the axis, and the amount of astigmatism.

This is briefly the method pursued in determining the refraction by means of the acuteness of vision (subjectively); greater details will be supplied in discussing the errors of refraction. But, as already pointed out, it is better and saves time to precede this subjective test by the objective methods, using the former to confirm the findings of the others; this is specially advisable if the error of refraction be a difficult or complicated one.

The vision for near is also tested. To the patient is given a page of Jaeger's test-types (Fig. 17), and we note the smallest type which he is able to read with each eye separately, the distance which he selects, and the nearest and farthest distances at which he is able to read. These data give us valuable information regarding the refraction. In myopia the patient may hold the print at a closer distance than normal. In presbyopia he will hold it at a greater distance than normal.

The Ophthalmoscope as a Means of Detecting and Estimating Refractive Error.

The Ophthalmoscope at a Distance (p. 21) gives us qualitative information regarding errors of refraction. When the patient is emmetropic, no details of the fundus will be seen when the light is thrown into the eye from an ophthalmoscope held at a distance of 15 inches. If some part of the disc or vessels is seen the patient is ametropic. If the examiner moves his head from side to side, and the vessels seem to move in the same direction, the case is one of hypermetropia (for in hypermetropia the rays emerge divergent and the image is a virtual erect one). If the vessels seem to move in the opposite direction the case is one of myopia (since in myopia the emerging rays are convergent, and form an inverted image). If the vessels of one meridian only are seen astigmatism is present; this is hypermetropic if the vessels move with the movements of the observer's head, myopic if they move in the opposite direction, and mixed if one set move with and the other against them.

The Indirect Method is not used for determining the amount of error of refraction, but we obtain information of the form of ametropia by noting the size and shape of the inverted image of the disc, and its behaviour upon withdrawing or approaching the lens before the patient's eye. If no change takes place in the shape and size of the image when we withdraw the lens, the eye is emmetropic. If the shape remains the same, but the image becomes smaller when the lens is withdrawn, it indicates hypermetropia. If the shape remains the same, but the image becomes larger on withdrawing the lens, the case is one of myopia. In astigmatism the disc usually appears oval, and the shape of its image changes on withdrawing the lens; one diameter decreases or increases while the other remains stationary in simple astigmatism; both increase or decrease unequally in compound astigmatism; and one increases and the other decreases in mixed astigmatism.

These two methods give no information as to the state of

the refraction which is not more readily obtained by retinoscopy, and are not generally used for the purpose. But, as they will be used in the general examination of the eye in any case, it is well that the student should train his power of observation by noting all there is to be seen.

The Direct Method is a very valuable means of determining the refraction, and, in case of error, the kind and the amount; reliable results are obtained, however, only after considerable practice. For accurate results it is necessary that the accommodation of both patient and observer be in abeyance. The beginner always has difficulty in relaxing his accommodation, and requires considerable training before he masters this necessary step (p. 30). The patient's accommodation is suspended by directing him to look at the wall or at a distant




FIG. 265.—THE ESTIMATION OF THE REFRACTION BY THE DIRECT METHOD OF OPHTHALMOSCOPY.

Both patient and observer are emmetropic.

object, or, better, by the use of a cycloplegic. The examiner, if ametropic, corrects his error by wearing suitable glasses, by having a special correcting lens applied to the sight-hole of the ophthalmoscope, or by subtracting the amount of his error from the result which he obtains in the examination. The examination is conducted in the manner described on p. 30; for accurate results it is essential that the shortest possible distance separate the eye of the patient from that of the observer.

Emmetropia.—The examiner selects a bloodvessel at the outer margin of the disc or between the disc and the macula. If the vessel appears distinct, and if upon rotating a $+0.50$ D. lens before the sight-hole it becomes blurred, the eye is emmetropic. Rays coming from an emmetropic eye at rest are parallel, and the observing eye will focus these rays on the retina (Fig. 265).

Hypermetropia.—If the image is blurred, we rotate the lens disc of the ophthalmoscope so as to place convex lenses in the sight-hole; if these render the image distinct the eye is hypermetropic. The strongest convex lens with which we get a distinct image is the measure of the hypermetropia. In Fig. 266 II is the hypermetropic eye under examination, and

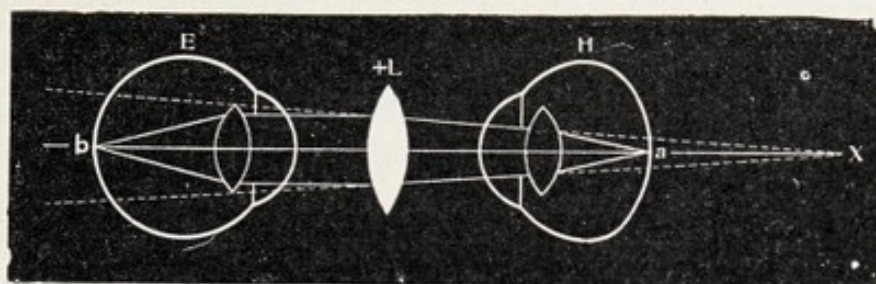


FIG. 266.—THE ESTIMATION OF HYPERMETROPIA BY THE DIRECT METHOD OF OPHTHALMOSCOPY.

E the emmetropic eye of the observer. Rays from *a* emerge divergent as though coming from X. The convex lens +L makes them parallel, so that they focus at *b*, on the retina of E, the emmetropic eye of the observer.

Myopia.—If when the image appears blurred a convex lens make it more indistinct, we rotate the disc of the ophthalmoscope so that concave lenses are brought opposite the sight-hole. If these render the image distinct the eye is myopic, provided that neither the patient nor the surgeon is accommodating.

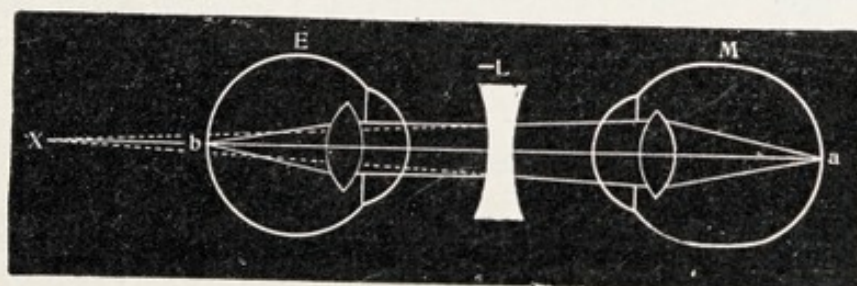


FIG. 267.—THE ESTIMATION OF MYOPIA BY THE DIRECT METHOD OF OPHTHALMOSCOPY.

The weakest concave lens is the measure of the myopia. We stop at the weakest concave lens which accomplishes this, since stronger lenses of this sort would only encourage the observer to accommodate. In Fig. 267 M is the myopic eye under examination, and E the emmetropic eye of the observer. Rays from *a* leave the myopic eye convergent, and would meet

at X. The concave lens—L renders them parallel so that they are focussed at *b* on the retina of the observer.

Astigmatism.—We find the lens with which a small vertical vessel is seen distinctly, and then the lens which enables a small vessel at right angles to be seen clearly, always remembering that the lens which clears up the image of a vessel in one direction is the measure of the refractive error of the meridian at right angles to it.

Suppose the horizontal vessels appear distinct without any lens, then the vertical meridian is emmetropic; and that the vertical vessels require a convex or a concave lens to render them distinct, then the horizontal meridian is hypermetropic or myopic; the case is one of simple hypermetropic or myopic astigmatism (Figs. 281 and 282).

If both vertical and horizontal vessels are rendered distinct by convex lenses, but a stronger one can be used for the horizontal, the case is one of compound hypermetropic astigmatism (Fig. 283), with the vertical meridian the more hypermetropic; if both vertical and horizontal vessels are best seen with concave lenses, but of different strength, the case is one of compound myopic astigmatism (Fig. 284).

If the vertical vessels can be seen clearly with a convex lens and the horizontal vessels require a concave lens, the case is one of mixed astigmatism (Fig. 285), the horizontal meridian being hypermetropic, the vertical meridian myopic.

Retinoscopy.

Retinoscopy, the Shadow Test, or Skiascopy, is a very accurate objective method of determining the state of the refraction by illuminating the eye with a plane or concave mirror, and observing the direction of the movement of the retinal illumination and its bordering shadows when the mirror is rotated. The shadow test has many advantages. It can be used in children, illiterates, and in markedly defective sight; it is entirely objective, and hence requires no co-operation on the part of the patient; it is quick and accurate; and it requires no expensive apparatus.

The principle of retinoscopy is the finding of the point of reversal or the myopic far point. In myopia an inverted image is formed in the air in front of the eye at the far point—the distance from which rays would be focussed on the retina; this point is known as the point of reversal. If the eye is hypermetropic or emmetropic, a convex lens is placed before it so as to give it an artificial far point.

When light is thrown into the eye by means of a plane or concave mirror at a distance of 1 metre, the fundus is illuminated. By looking through the sight-hole of the mirror an observer will see the illuminated portion (red fundus reflex) and also the shadow bounding this bright area. On rotating the mirror the illuminated area and the shadow will move across the pupil.

The examination is conducted in the dark-room, the darker the better. The source of illumination is placed above, or to one side of, the head of the patient and somewhat behind, so that his face is in darkness (Fig. 269, A). An unshaded electric focus-lamp may be used. Some surgeons prefer the light placed near the observer, about 6 inches to his left and in front, with a small (10 mm.) opening in the opaque chimney (Fig. 269, B).




FIG. 268.—RETINOSCOPIC MIRROR.

Either a plane or a concave mirror may be employed; the plane mirror has certain advantages and is more commonly used. The retinoscopy mirror (Fig. 268) usually has a diameter of $3\frac{1}{2}$ cm. with a 3 mm. opening, though sometimes a 2 cm. mirror upon a 4 cm. metal disc, with a 2 mm. opening, is preferred by those who place the light near the observer.

Unless the observer has had great experience in retinoscopy, the patient's pupils should be dilated, and his accommodation paralyzed. He is directed to look at the light. Each eye is tested separately, and one eye is usually covered.

The observer is seated at 1 metre distance (Fig. 269);

he should wear correcting lenses if ametropic; he need not relax his accommodation as in using the ophthalmoscope, since this does not influence the result. If the surgeon is presbyopic he will find it a comfort to have a small lens, $+0.75$ D. or $+1$ D. sph., cemented behind the sight hole of his mirror.

If now the mirror be rotated slowly from side to side on its vertical axis, so that the light moves across the pupil horizontally, the observer will see an illuminated area and a shadow coming from behind the pupil; if the mirror be




FIG. 269.—THE RETINOSCOPIC EXAMINATION.

rotated on its horizontal axis the light will move across the pupil vertically. The direction of movement of this light and shadow as compared to that of the mirror depends upon the state of the refraction of the eye. The shadow moves either in the same direction (with) or the opposite direction (against); if we turn the mirror toward the right and the shadow moves toward the right, we say it moves with the mirror; if upon turning the mirror toward the right the shadow moves towards the left, we say it moves against the mirror. The illuminated area and the shadow appear to move with the mirror when the observer is within the point

of reversal, and against the mirror when he is beyond this point. With the plane mirror the shadow moves with the mirror in hypermetropia, emmetropia, and in myopia of less than 1 D., and against the mirror in myopia of more than 1 D.

Besides the direction of the movement, we acquire information from the brightness, the form, and the rate of movement of the light and shadow. If the reflex is bright, its edge sharp, and the light and shadow move rapidly, the error of refraction is a low one; if the illumination is dull, its edge indistinct, and the movement of light and shadow slow, the error is a high one. If the shadow has a straight edge it is an indication of astigmatism (Fig. 270); in hypermetropia, myopia, or emmetropia, the shadow has a crescentic edge (Fig. 271).

We next find the correcting lens—*i.e.*, the lens which causes a reversal of the direction of movement of the shadow. This lens will be correct for the distance separating the observer from the patient, 1 metre. For infinity, we must add -1 D. to all results; this increases the myopia 1 D., and diminishes hypermetropia 1 D.

If with the plane retinoscope the shadow moves against the mirror, we place concave spherical lenses before the eye until we succeed in causing a reversal of the movement of the shadow—*i.e.*, cause it to move with the mirror; this lens, to which we add -1 D., is the measure of the patient's myopia. Suppose on placing -1 D. before the eye the shadow still moves against the mirror, the same with -2 D., but with -2.50 D. the movement of the shadow is reversed, then $-2.50 + -1 = -3.50$ D. is the correction.



FIG. 270.—RETINOSCOPIC ILLUMINATION AND SHADOW IN ASTIGMATISM.




FIG. 271.—RETINOSCOPIC ILLUMINATION AND SHADOW IN MYOPIA, HYPERMETROPIA, OR EMMETROPIA.

If with the plane retinoscope the shadow moves with the mirror, the eye may be hypermetropic, emmetropic, or myopic less than 1 D. In such a case we begin by adding a convex lens of +0.50 D. If this causes a reversal of the shadow the eye is myopic 0.50 D., since $\frac{+0.50}{-1.00} = +0.50$ D.

If the +0.50 D. lens does not alter the direction of the movement of the shadow, but the next lens (+1 D.) causes a reversal, the eye is emmetropic, since $\frac{+1.00}{-1.00} = 0 = E$.

If the +1.00 D. lens has no effect upon the direction of movement of the shadow, the eye is hypermetropic; we place stronger + spherical lenses before the eye until we find the one which causes a reversal of the movement of the shadow. Say this is +4 D.; then the hypermetropia amounts to $\frac{+4}{-1} = 3$ D.

In the previous examples the results were the same whether the mirror was rotated upon its vertical or its horizontal axis. In astigmatism, upon correcting each of the two principal meridians separately, one meridian will require a different lens from the other to cause a reversal of the shadow. The most common positions of the two meridians in astigmatism are vertical and horizontal. But frequently the edges of the shadows lie more or less obliquely. In such cases the mirror must be rotated so that the light moves obliquely and parallel with the movement of the shadow.

For example, suppose the shadow moves with the mirror in both meridians, but one shadow is more distinct and moves more quickly than the other, we diagnose astigmatism. Then we correct the vertical meridian, and find it requires +2 D. for the reversal of the shadow. Next we find that in the horizontal meridian +4 D. is required for reversal. We add -1 D. to each of these results, and have +1 D. vertical and +3 D. horizontal. The case is one of compound hypermetropic astigmatism, and requires for its correction +1 D. spherical lens combined with +2 D. cylinder, axis vertical.

Now, in order to find the exact axis of the cylinder, the

correcting cylinder and the reversing sphere are put in the trial frame and the axis of the cylindrical lens adjusted until the shadow is even in all meridians.

In practice, it is not necessary to work at exactly 1 metre. The observer may take whatever distance he pleases, provided that it is always the same. Having decided upon the most convenient distance, he must find out by experiment what deduction is to be made from the reversing lens.

CHAPTER XXV

ERRORS OF REFRACTION

IN emmetropia the eye in a state of rest, without accommodation, focusses the image of distant objects exactly upon the retina (Figs. 259, A, and 272, A); such an eye enjoys distinct vision for distant objects without effort or fatigue. Any variation from this standard constitutes ametropia, a condition in which the eye, in a state of rest, is unable to focus the image of distant objects (parallel rays) upon the retina. Ametropia includes hypermetropia, myopia, and astigmatism. The effects of ametropia are not only indistinctness of vision, but various pains and other symptoms comprised under the term asthenopia (weak sight, eye-strain).

Hypermetropia.

Hypermetropia is an error of refraction in which, with accommodation completely relaxed, parallel rays (rays from distant objects) tend to be brought to a focus behind the retina (Figs. 259, B, and 272, B); divergent rays (from near objects) tend to be focussed still farther back.

Etiology.—It is most commonly due to shortening of the antero-posterior diameter of the eyeball (axial H.), less frequently to diminished convexity of the refracting surfaces of the eye (H. of curvature), changes in the media, or absence of the lens (aphakia). It is by far the most frequent error of refraction, and is congenital. It is often hereditary. Children are usually hypermetropic at birth, and subsequently become less hypermetropic, emmetropic, or even myopic.

The Course of Rays.—The hypermetropic eye cannot, with

out accommodation, see either distant or near objects distinctly (Fig. 272, A). In a condition of rest it is adapted for convergent rays, and these are not found in nature. To focus parallel rays on the retina it must either accommodate—*i.e.*, increase the convexity of its lens, as shown in Fig. 272, B—or a convex lens of such a strength that the rays are made sufficiently convergent to be brought to a focus on the retina (Fig. 272, C) must be placed in front of the eye.

To focus divergent rays—*i.e.*, rays from near objects—the

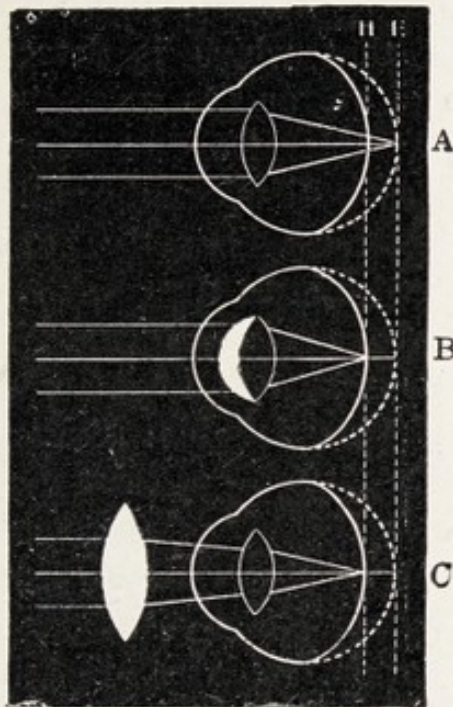


FIG. 272.—A, HYPERMETROPIC EYE IN A STATE OF REST. B, HYPERMETROPIC EYE DURING ACCOMMODATION. C, HYPERMETROPIC EYE CORRECTED BY A CONVEX LENS.

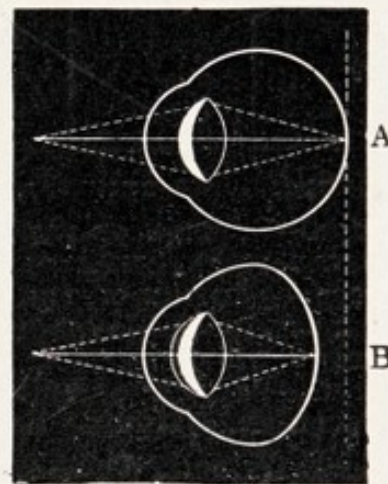


FIG. 273.—A, EMMETROPIC EYE ACCOMMODATING FOR NEAR VISION. B, HYPERMETROPIC EYE ACCOMMODATING FOR NEAR VISION.

hypermetrope must not only accommodate to the extent required of an emmetropic eye (Fig. 273, A), but to an additional extent to compensate for his error. In other words, he requires some accommodation constantly in order to see distant objects distinctly, and in addition the amount equal to that required by the emmetrope for near vision (Fig. 273, B). Such an eye (when the error is uncorrected) is never in a condition of rest as long as it enjoys distinct vision.

Changes in the Eye.—As a result of the constant strain and overaction of the ciliary muscle, the latter becomes hypertrophied, especially its circular fibres (Fig. 275); it remains in a greater or lesser condition of spasm. In high degrees of H. the eyeball may be diminished in size, the anterior chamber shallow, the sclera flat with a sharp curve at the equator, and there may be an apparent external squint owing to the high angle gamma (see pp. 299 and 368).

Hypermetropia is divided into (1) *manifest* and (2) *latent*, the sum of these being the (3) *total*.

The manifest hypermetropia is that which is detected without paralyzing the accommodation, and is represented

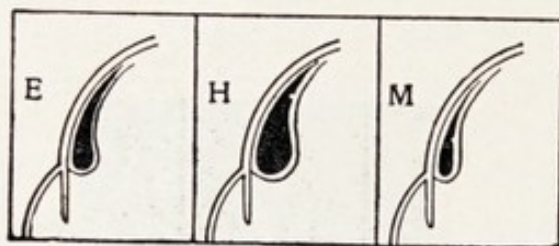

FIG. 274. FIG. 275. FIG. 276.

FIG. 274.—SECTION OF THE CILIARY MUSCLE IN AN EMMETROPIC EYE.

FIG. 275.—SECTION OF THE CILIARY MUSCLE IN A HYPERMETROPIC EYE.

FIG. 276.—SECTION OF THE CILIARY MUSCLE IN A MYOPIC EYE.

by the strongest convex glass with which the patient sees most distinctly; it corresponds to the amount of accommodation which he relaxes when a convex lens is placed before the eye. Manifest hypermetropia may be either facultative where it can be overcome by an effort of accommodation, or absolute when

it cannot be overcome in this manner.

The total hypermetropia is the entire amount of hypermetropia detected after the accommodation has been paralyzed or during complete relaxation of the ciliary muscle.

The latent hypermetropia is the difference between the Hm. and the Ht., and is the amount which is habitually concealed and is discovered only after the use of a cycloplegic.

The application of these terms can be illustrated by considering an example of H. of 2.5 D. in a young person. If in such a case $V = \frac{6}{12}$, and, without the use of a mydriatic, a + 1 D. spherical lens brings up the vision to $\frac{6}{8}$, and a stronger convex lens makes the vision again indistinct, we say Hm. = 1 D.; if now we paralyze the accommodation with a cycloplegic and find $V = \frac{6}{36}$, and that a + 2.50 D. spherical lens

increases this to $\frac{6}{8}$, the Ht. = 2.50 D. ; the difference between 2.50 D. and 1.00 D. = 1.50 D. = Hl.

The ratio between the manifest and the latent hypermetropia is not constant ; it depends more or less upon the age and vigour of the individual. In youth the amount of Hl. is apt to be considerable, and consequently a cycloplegic is essential in estimating the amount of hypermetropia. The older a person grows, the less accommodative effort he is able to make ; hence the Hl. becomes less, and the Hm. greater.

In old persons there is no Hl., the total hypermetropia becoming manifest.

Symptoms.—Unless the error be considerable or the patient be advanced in years, there is usually distinct vision for distance. A great many patients with hypermetropia present no symptoms whatever ; this is likely to be the case when the hypermetrope is young, in good health, and indulges in plenty of outdoor exercise. Under these circumstances he is apt to accommodate for his optical defect without any evidence of overaction of the ciliary muscle. In other cases the accommodative effort will be unequal to the task imposed in near work, and as a result the hypermetropia will give rise to accommodative asthenopia (weak sight, eye-strain).

The Symptoms of Asthenopia show themselves particularly after reading, writing, sewing, and other forms of near application, especially in the evening and with artificial illumination. They comprise pain referred to the eyes or above the eyes ; headaches, usually frontal, but also occurring in the occiput and other parts of the cranium ; various neuralgias ; congestion of the conjunctiva and margins of the lids ; lachrymation, blinking, and slight photophobia ; burning sensation in the lids ; and blurring of near vision. These symptoms are more pronounced whenever the general health is below par.

With advancing years there will be greater difficulty in reading without correcting glasses.

In children H. shows a physiological tendency to diminish with the growth of the child. In the adult it remains stationary.

In early childhood hypermetropia often causes convergent squint in a patient whose fusion-sense is deficient (see p. 381).

The smaller and flatter cornea and shallower anterior chamber often associated with hypermetropia form a predisposing cause of glaucoma. Conversely, glaucoma is uncommon in myopic eyes.

Hypermetropic eyes are predisposed to conjunctivitis and blepharitis, phlyctenular affections, and internal squint.

Tests.—These have been described in the preceding chapter. They are the following :

The Subjective Test with Test-Types and Test-Lenses.—We first record the acuteness of vision and then place convex lenses before the eye, commencing with + 0.50 D. The strongest lens with which the patient sees $\frac{6}{8}$ or better is the measure of the manifest hypermetropia. Then the accommodation is paralyzed and the test repeated ; the strongest lens 'accepted' (i.e., with which the patient's vision is improved) is the measure of his total hypermetropia.

The Ophthalmoscope at a Distance.—The retinal vessels appear to move in the same direction as the observer's head.

The Ophthalmoscope, Indirect Method.—On withdrawing the lens in front of the patient's eye the apparent size of the disc diminishes.

The Ophthalmoscope, Direct Method.—The disc and vessels can be seen distinctly with a convex lens in the sight-hole, the strongest being the measure of the H.

Retinoscopy.—With the plane mirror held at 1 metre, the shadow moves with the mirror ; the direction of movement is reversed by convex lenses placed in front of the patient's eye. The lens which causes a reversal, minus 1 D., is the measure of the H.

Treatment consists in prescribing such convex spherical lenses as will make vision distinct, and enable the patient to do near work without fatigue. The mere existence of hypermetropia is no indication for the use of correcting glasses unless these are worn in childhood for the cure of convergent squint. It is only when there is a diminution in the acuteness of vision or when symptoms arise indicating eye-strain that convex lenses should be used.

Though theoretically it would seem proper to prescribe the full correction (for Ht.), practically there are many objections and exceptions to this. In every case of hypermetropia occur-

ring in a young child the accommodation should be paralyzed with atropine before performing retinoscopy. An older child may require atropine. Each case should be considered on its merits. There may not be any object in finding out the Hl. if the patient sees perfectly and the correction of Hm. relieves all symptoms. A surgeon who is reasonably skilful in retinoscopy will very rarely need to use a mydriatic for an adult.

The symptoms of the individual give us reliable indications as to the proportion of the Ht. which ought to be corrected, and the constancy with which the glasses should be worn. In cases of squint, and when glasses are prescribed for the relief of conjunctivitis, blepharitis, and headaches, or the occurrence of which is independent of near use of the eyes, they must be worn constantly. In other cases glasses should be worn continuously or only for near, according to whether the symptoms are always present, or follow only after using the eyes for reading and the like. When distant vision is perfect and comfortable, and the patient does not suffer from any symptoms except when engaged in near work, glasses need be prescribed only for such use; this is often the case in young adults who enjoy good health. Under such circumstances the correction of the Hm. may be sufficient; or we may add to this the correction for part of the Hl., or we may correct the Ht. In cases in which the correction is only partial the glasses may require changing from time to time. In the case of a child, if glasses are required at all a good general rule is to order 0.5 D. less than the Ht. In hypermetropes after forty-five convex lenses may be worn to improve distant vision, and a stronger pair for near; the weaker set is for the H., the stronger pair to correct both the hypermetropia and the presbyopia. Under such circumstances bifocal lenses (Figs. 295 to 297) are very convenient, the upper segment corresponding to the weaker glass, the lower to the stronger.

Myopia.

Myopia (short-sightedness) is that refractive condition in which, with accommodation completely relaxed, parallel rays are brought to a focus in front of the retina. These rays cross in the vitreous; when they reach the retina they have become

divergent, forming a circle of diffusion and consequently a blurred image (Fig. 277, P P F). Certain divergent rays, coming from the myopic far point, are focussed on the retina (Fig. 277, D X) without accommodation.

The greatest distance at which the patient can read fine print is the far point. This is always at a definite distance corresponding to the amount of M.; the higher the M., the closer to the eye is the far point; the distance of the latter is the measure of the M. For example, if the far point is at 20 inches (0.5 metre) the $M = 2$ D. ($\frac{40}{20}$ or $\frac{100}{50} = 2$); if at 10 inches (0.25 metre) the $M = 4$ D. In these two instances concave

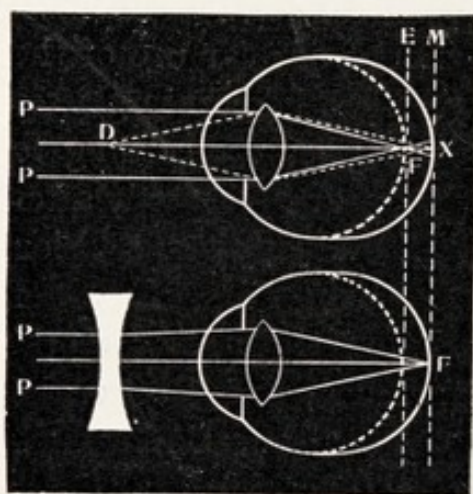


FIG. 277.—THE FOCUSSED OF PARALLEL AND DIVERGENT RAYS IN MYOPIA.

FIG. 278.—THE CORRECTION OF MYOPIA BY MEANS OF A CONCAVE LENS.

lenses of 2 and 4 D. respectively would render parallel rays as divergent as if they came from a distance of 20 and 10 inches (0.5 and 0.25 metre); and with these lenses the myope would be able to see distant objects distinctly (Fig. 278).

Etiology.—Myopia almost always depends upon a lengthening of the antero-posterior diameter of the eyeball (axial myopia); in M. of 3 D., for example, the eyeball measures 24 mm. in its antero-posterior diameter, and in M. of 10 D.,

27 mm. from before backward, instead of 23 mm., the normal diameter. Much less frequently M. is due to increased curvature of the cornea (anterior staphyloma and keratoconus), increase in the refraction of the lens from swelling in incipient cataract (often referred to by the laity as 'second sight,' because it sometimes enables an old person again to read print for a time without glasses), and spasm of accommodation. The determining causes are associated with the demands which civilization and education make upon near vision. It is rarely congenital, though there is often an hereditary tendency for its development. It is an acquired

change which commences at an early age when, during the developing period, the eyes are used excessively or improperly for near work. Its occurrence is in direct proportion to the standard of education, and also bears a certain relation to the general health and strength of the individual. It is much more common in cities than in the country.

Excessive study with insufficient outdoor exercise, fine or indistinct print, poor illumination, opacities of the cornea and other lesions causing imperfect vision, faulty construction of desks, sedentary habits, and poor health, are among the frequent exciting causes of myopia, especially in those who are predisposed.

The cause of the lengthening of the eyeball is attributed (1) to pressure of the extra-ocular muscles during excessive convergence causing the posterior pole, which is the least resistant part of the eyeball, to bulge; (2) to congestion, inflammation, and softening of the layers of the eyeball, together with increased tension, produced by fulness of the veins of the head as a result of stooping postures and other predisposing causes; and (3) to the shape of the orbit in broad faces causing excessive convergence, as seen in the German race, which is especially subject to this error of refraction.

Clinical Forms.—In most instances myopia is of low degree, develops during youth, and then comes to a standstill or increases very little; this is known as stationary or simple myopia.

In other cases the error reaches a considerable height in youth, and increases steadily up to the twenty-fifth year or even later, resulting in a high degree of myopia; this is known as progressive myopia. These are the cases which are accompanied by destructive changes in the choroid and other parts of the eye, leading to a considerable impairment of vision, and even blindness. In these cases myopia may properly be considered a disease. Extreme cases of progressive myopia are known as malignant myopia.

Symptoms depend on the degree of myopia.

In slight degrees and in many cases of moderate amount there are often no symptoms except indistinct vision for distance. Near work can be accomplished with comfort;

in fact, since the myope requires less accommodation than the emmetrope, he may have an advantage in close application. It is on this account that the circular fibres of the ciliary muscle are less developed than in the emmetropic eye (Fig. 276).

In other cases of moderate myopia and in high degrees, distant vision is very indistinct; there is often pain in the eyes after near use; the patient will be unable to continue at work for any length of time on account of excessive convergence; the eyes tire easily, are sensitive to light, and irritable; there are black spots before the eyes (*muscae volitantes*), and sometimes bright flashes of light. In some cases there may be absolute scotomata.

In high myopia there are often prominence of the eyes, a deep anterior chamber, and dilated pupils; the patient is apt to screw the eyelids together; there is sometimes an appearance of convergence. The strain of excessive convergence is so great and painful that the effort is sometimes given up and divergent squint results.

Ophthalmoscopic Signs.—In low (less than 3 D.) or moderate (3 to 6 D.) degrees there are frequently no changes except a crescent-shaped patch of atrophy of the choroid of whitish or grayish colour, embracing the outer side of the disc; this is called a myopic crescent.

In high myopia (more than 6 D.), a well-marked crescent is usually found, often posterior staphyloma (bulging of the sclera, Fig. 163, Plate XIV.), and there may be patches of choroidal atrophy with pigmented margins, exposing the sclera. In progressive cases there are frequently added to these lesions atrophic and pigmentary changes in the macular region, hæmorrhages, especially at the yellow spot, fluid vitreous floating bodies in the vitreous, and opacities of the lens; sometimes there is detachment of the retina. Owing to these changes the vision is often very markedly reduced, and is sometimes lost in severe forms of progressive myopia.

Tests.—*The Subjective Test with Test-Types and Test-Lenses.*—Distant vision is below the normal and the patient

requires a concave spherical lens to bring the sight up to $\frac{6}{8}$. The weakest lens which accomplishes this is the measure of the myopia. In young persons it is important to paralyze the ciliary muscle, so that spasm of accommodation will not cause the patient to select too strong a lens. The results are recorded as follows: R.E. $V = \frac{6}{80}$, $\tau - 4$ D. Sph. $= \frac{6}{8}$. The reduction in distant vision generally is proportionate to the degree of M.

The myope is able to read the smallest print, but at a shorter distance than that which the emmetrope selects. The farthest distance at which he is able to read the finest print is his far point, and this is also a measure of his M. (p. 322).

The Ophthalmoscope at a Distance shows an inverted image of the fundus which appears to move in the opposite direction to the examiner's head.

The Ophthalmoscope, Indirect Method.—The disc appears small, and seems to increase in size upon withdrawing the objective lens.

The Ophthalmoscope, Direct Method.—The fundus cannot be distinctly seen until a concave lens is placed behind the mirror; the weakest concave lens with which the details are seen clearly indicates the amount of myopia.

Retinoscopy.—With the plane mirror and the observer at 1 metre distance, the shadow moves in the opposite direction (except when M. is less than 1 D.), and is reversed by the addition of concave lenses. The lens which causes reversal plus -1 D. is the measure of the M. In high M. the shadow is very faint, but becomes plainer when concave lenses are added.

Prognosis.—In low and moderate degrees of stationary myopia the prognosis is good. Progressive myopia is always a serious condition, especially when the choroidal and vitreous changes are marked; it may necessitate absolute cessation of all near work. In malignant myopia the prognosis is grave.

Treatment consists in prescribing glasses where they are required and in avoiding anything which may lead to an increase in the myopia.

In general terms, it is proper to give a full correction for

low and moderate myopia in young persons as soon as discovered, and to direct these glasses to be worn for school and near work or perhaps constantly indoors in order to remove any temptation to hold objects too near the eyes. Excessive convergence to a very near point tends to cause an increase in the myopia. Out of doors the glasses may be worn as a matter of convenience, but their use need not be insisted upon (see p. 351). The glasses must be prescribed after the accommodation has been paralyzed, so that there will be no danger of over-correction on account of spasm of accommodation. Full correction corresponds to the weakest concave spherical lens which, with accommodation paralyzed, gives normal vision. In low degrees of M. an adult may be allowed to read without glasses if he finds this convenient.

In high myopia the full correction is prescribed for distance, and about two-thirds correction for near work; the reading-glasses should be such as to enable the patient to read at a comfortable distance, say 13 inches (33 cm.). Suppose -10 D. gives the best vision for distance; then -10 D. + 3 D. Sph. = -7 D. will enable him to read at this distance without accommodation.

After the age of forty-five the distance glasses cannot be worn for near work, since the convex lenses usually required for presbyopia must be added to the concave lenses, thus reducing the strength of the latter.

In prescribing glasses in M. every case must be considered on its merits. Many myopes wear strong lenses, representing the full correction, constantly and with absolute comfort; others require two sets of lenses, one for distance and a weaker pair for reading.

In order to check any tendency to increase of M., rigid hygienic rules, both local and general, should be carried out. These are of especial importance in the young.

The patient's habits should be regulated so that he will enjoy good health. He should have plenty of outdoor exercise and sufficient sleep. Constipation should be avoided.

In progressive myopia near work should be restricted, and the patient not be allowed to read too long at a time. The book should be held at not less than 13 inches (33 cm.). In

most cases the full correcting lenses should be worn for near work. The illumination should be good, neither too bright nor too dim, and should come from behind; the myope should avoid reading at dusk or with feeble illumination; the amount of work done with artificial light should be limited. The print should be large and clear, with ample spacing. Desks should be constructed so that the sitting posture is comfortable, and so that the child is not encouraged to stoop over his books; the myope must be taught not to bend over his work, but to lift the latter to the required distance from the eyes.

If, notwithstanding such precautions, myopia progresses rapidly, and especially if there are choroidal changes, it is necessary to forbid all near use of the eyes. It may be necessary to take the patient from school and send him to the country for a long period, during which he is instructed to be out of doors as much as possible, and to avoid all reading and near work. Young adults suffering from rapidly progressive myopia should give up sedentary occupations necessitating close application, and select those in which but little near use of the eyes is required. On the other hand, myopes usually prefer, and are best fitted for, sedentary occupations, so studies should not be entirely interrupted without real necessity.

Operative Treatment.—In children and young adults with high myopia, uncomplicated by excessive pathological changes in the fundus, the removal of the lens by discission and subsequent extraction has given good results. The lens is needled, and after several days the swollen lens substance is removed by extraction. The operation is limited to M. of at least 15 or 20 D. After the removal of the lens the eye may be almost emmetropic, since the optical effect in such highly myopic eyes is quite different from that which would follow if the lens were removed in an emmetropic eye; a weak convex glass may be required for distance, and a stronger one for near work, since the accommodation has been sacrificed. Suitable cases present themselves much less frequently in England than in Germany, where myopia is very common. Detachment of the retina appears to be more common in after-years in the cases operated upon than in those which have not. For this reason it is not advisable to operate upon both eyes.

Astigmatism.

Astigmatism is that refractive condition of the eye in which there is a difference in the degree of refraction in different meridians ; each of the principal meridians has, therefore, a different focus (Figs. 281 to 285).

In E., H., and M., rays coming from a luminous point are brought to a single focus at a certain distance behind the cornea. In astigmatism, since the refracting surfaces are not spherical, rays from a luminous point are brought to a focus at different points ; the shape of the image may be a line, an oval, or a circle, but never a point.

Varieties.—Astigmatism may be divided into (1) irregular, comparatively infrequent, and (2) regular, very common.

Irregular astigmatism consists in a difference of refraction in different parts of the same meridian. It is generally due to changes in the cornea, such as opacities and cicatrices following ulceration, injuries, or surgical operations, and keratoconus. It may also result from partial dislocation of the lens, or from a congenital or acquired change in the refractive power of different sectors of the lens. The acuteness of vision is considerably diminished, and cannot be improved materially by glasses. Details of the fundus when seen with the ophthalmoscope appear distorted. An insignificant amount of irregular astigmatism is present normally, and accounts for our seeing the stars as stellate points instead of round dots.

Regular Astigmatism.

Regular astigmatism is that form in which, though the refraction in a meridian is the same throughout, there is a difference in the degree of refraction of the two principal meridians. In other words, the curvature of the cornea is different in the two meridians ; these are called the principal meridians, and are always at right angles to each other ; one exhibits the maximum and the other the minimum refraction. When the term 'astigmatism' is used without qualification it refers to regular astigmatism.

Etiology.—Astigmatism is usually due to a change in the curvature of the cornea, with or without some shortening or lengthening of the antero-posterior diameter of the eyeball. It is also caused, in part at least, by defects in the curvature of the lens ; this lenticular astigmatism may partly neutralize that of the cornea. It is usually congenital, and there is often an hereditary tendency. It may, however, be acquired, and is then caused by corneal changes resulting from inflammation, injury, or operation. Pressure of the lids in ametropia is believed by some surgeons to be capable of producing permanent regular astigmatism.

Refraction of Rays in Regular Astigmatism.—Parallel rays refracted by a spherical surface form a circular cone, and come to a focus at a point. In astigmatism, those rays which pass through the meridian of greater curvature come to a focus sooner than those which pass through the meridian of lesser curvature, and the resulting cone will not be circular, but more or less oval ; hence the vision of astigmatic subjects is not simply indistinct, but the diffusion images are more or less elongated.

In looking at straight lines (which are made up of a succession of points), these may appear distinct or indistinct to astigmatic persons according to their direction. If an astigmatic eye, in which the vertical meridian is out of focus and the horizontal meridian normal, looks at a vertical line, this will be slightly elongated ; but the sides will appear distinct, since each point of light will be seen as a small vertical line, and these overlap each other. But if such an eye looks at a horizontal line each point of light will again be seen as a small vertical line, and consequently the line will appear blurred (Fig. 279). There is, therefore, one direction in which straight lines appear most distinct, and another, at right angles to it, in which they appear most indistinct ; this forms the basis for the construction of the astigmatic dial or fan (Fig. 286) commonly used as a test for this error. The lines parallel with the ametropic meridian are seen most clearly, and those parallel with the emmetropic meridian are seen most indistinctly (in simple As.).

Varieties of Regular Astigmatism.—According to the refraction of the principal meridians, astigmatism is divided into :

1. *Simple*, in which one meridian is emmetropic, and the other hypermetropic or myopic ; it comprises simple hypermetropic astigmatism (Fig. 281), and simple myopic astigmatism (Fig. 282).




FIG. 279.

FIG. 280.

FIG. 279.—VERTICAL AND HORIZONTAL LINES AS SEEN BY AN ASTIGMATIC EYE IN WHICH THE HORIZONTAL MERIDIAN IS EMMETROPIC.

FIG. 280.—VERTICAL AND HORIZONTAL LINES AS SEEN BY AN ASTIGMATIC EYE IN WHICH THE VERTICAL MERIDIAN IS EMMETROPIC.

2. *Compound*, in which both meridians are either hyperopic or myopic, but unequal in degree ; it comprises compound hypermetropic astigmatism (Fig. 283), and compound myopic astigmatism (Fig. 284).

3. *Mixed*, in which one meridian is hypermetropic and the other myopic (Fig. 285).

In most cases of astigmatism the cornea presents its maximum curvature in or near the vertical meridian, and the least curvature in or near the horizontal meridian, corresponding to the slight astigmatism of the normal eye ; when this is the case it is said to be astigmatism with the rule ;

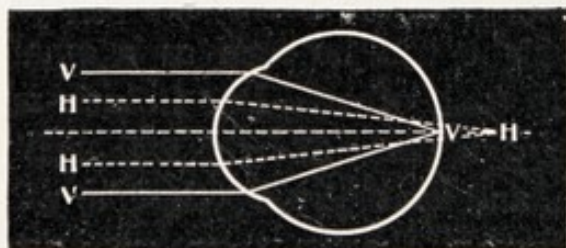


FIG. 281. — SIMPLE HYPERMETROPIC ASTIGMATISM.

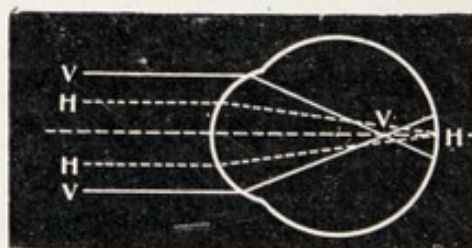


FIG. 282. — SIMPLE MYOPIC ASTIGMATISM.

when the relative curvatures are reversed it is astigmatism against the rule. In astigmatism with the rule the axis of the cylinder is vertical or nearly so in hypermetropic astigmatism, and horizontal or nearly so in myopic astigmatism. The chief meridians, though vertical and horizontal in the

majority of cases, may occupy an oblique position; in such cases they are most frequently symmetrical—*i.e.*, inclined an equal number of degrees from the vertical or horizontal on each side.

Symptoms.—There is always a diminution in the acuteness of vision, both distant and near. There is commonly considerable asthenopia, especially upon use of the eyes for near

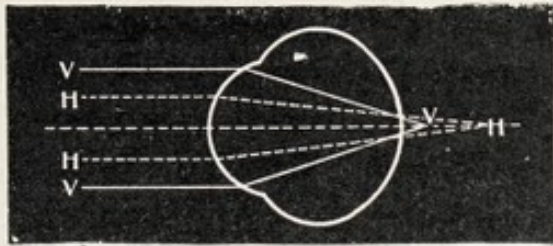


FIG. 283.—COMPOUND HYPERMETROPIC ASTIGMATISM.

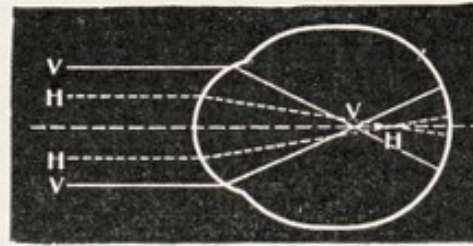


FIG. 284.—COMPOUND MYOPIC ASTIGMATISM.

work. These asthenopic symptoms are similar to those occurring in hypermetropia (p. 333), but are apt to be more pronounced and more continuous. They vary with the degree and variety of astigmatism, the amount of near work indulged in, and especially the state of the patient's health; a small amount (0.50 D. or even 0.25 D.) will, for instance, often give rise to severe asthenopic and nervous symptoms in a delicate, neurasthenic individual. The involuntary accommodative

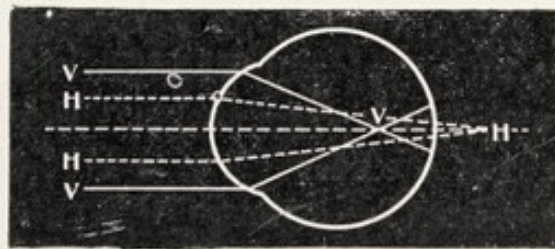


FIG. 285.—MIXED ASTIGMATISM.

efforts of the ciliary muscle, made to diminish the effects of the error, cause continuous eye-strain and explain the frequency of asthenopia.

The Correction of Astigmatism.—Astigmatism is corrected by cylinders, sphero-cylinders, or crossed cylinders. The curve of the correcting cylinder corresponds to the ametropic meridian; consequently its axis is at right angles to this meridian.

Tests.—We usually suspect astigmatism when the vision cannot be brought up to $\frac{6}{6}$ with spherical lenses, notwithstanding the fact that the fundus is normal and the media are clear. In testing for astigmatism in children, and sometimes even in young adults, it is necessary to have the eye under the influence of a cycloplegic. A skilful ophthalmic surgeon will scarcely ever need it for an older patient.

The Astigmatic Dial.—The diagnosis of astigmatism is made if the patient, when placed before the astigmatic dial or fan (formed of radiating lines numbered like the face of a clock, Fig. 286), is unable to see all the lines with equal distinctness. The line seen most distinctly and the line seen least distinctly indicate the axes of the two principal

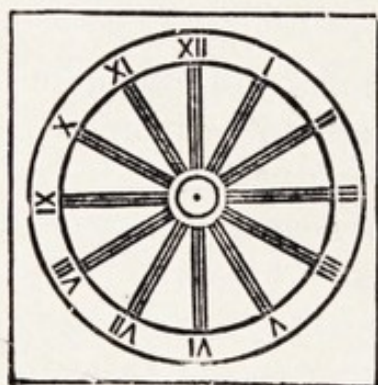


FIG. 286. — ASTIGMATIC DIAL.

meridians; the axis of the former corresponds to the ametropic meridian, that of the latter to the emmetropic meridian (in simple astigmatism).

Suppose in an example of simple astigmatism the patient sees lines XII and VI most distinctly, and those at right angles, IX and III, least clearly; then the ametropic meridian is vertical. If we place a weak convex lens in front of the eye, and find that this makes lines XII and VI indistinct, we know that the horizontal meridian is emmetropic. Next we find which spherical lens clears up lines IX and III; this glass is the measure of the refractive error of the vertical (ametropic) meridian.

The metal disc with stenopeic slit (about 1 mm. in diameter) may be used to discover the two principal meridians. It is placed in front of one eye, the other being excluded, and is rotated slowly so that the slit occupies each meridian successively. The patient is placed at 6 metres before the distant test-types, and the position of the slit in which the best vision is obtained is noted. Then convex or concave lenses are placed in front of the slit, and the strongest convex or the weakest concave lens which gives the most improvement

is the measure of the refraction in this meridian. The slit is then turned 90 degrees, and convex and concave lenses are again applied until one is found which improves vision most. In this way the refractive error of the two principal meridians is determined. If, for instance, when the slit is vertical the patient reads $\frac{6}{8}$, and convex lenses in front of the slit make the types indistinct, the vertical meridian is emmetropic; if, when the slit is horizontal, the patient reads $\frac{6}{18}$, but this increases to $\frac{6}{8}$ when +3 D. Sph. is placed in front, the horizontal meridian is hypermetropic 3 D. This case would be one of simple hypermetropic astigmatism corrected by a +3 D. cylinder, axis vertical.

The Subjective Test with Test-Types and Test-Lenses is best employed after the objective tests have furnished us with pretty definite conclusions regarding the correcting lenses. It then serves to confirm or improve upon the results obtained by objective methods. The lenses selected with the objective tests are placed in the trial frame and may require modification, either in the strength of the spheres or the strength and axis of the cylinder, so as to secure the most acute vision.

The Ophthalmoscope, Indirect Method.—The shape of the disc is oval instead of circular, and changes when the objective lens is withdrawn.

The Ophthalmoscope, Direct Method.—The disc appears oval, the elongation corresponding to the meridian of greatest refraction, and is at right angles to the long axis of the oval seen with the indirect method. To determine the kind and amount of error we estimate the refraction of a small vertical vessel, and then of a small horizontal vessel near the disc, by means of the strongest convex or the weakest concave lens with which these are distinctly seen. For instance, suppose a vertical vessel is seen clearly with +2 D. Sph. (indicating hypermetropia of horizontal meridian), and a horizontal vessel with +4 D. (indicating a greater amount of hypermetropia in the vertical meridian), the case is one of compound hypermetropic astigmatism. When the principal meridians are oblique, we find a vessel the direction of which

corresponds to one of the meridians, and then another at right angles to the first, and estimate the refraction of each.

Retinoscopy is the most rapid and reliable objective method of determining astigmatism. The principal meridians are clearly indicated by the edge of the shadow (Fig. 270). Each of the principal meridians is corrected separately by causing a reversal of the movement of the shadow by spherical lenses, and adding -1 D. (with plane mirror at 1 metre distance).

The Ophthalmometer (Fig. 287) is an instrument used for determining the principal meridians and the amount of



FIG. 287.—THE JAVAL-SCHIÖTZ OPHTHALMOMETER.

corneal astigmatism. It consists of a telescope containing a combination of convex lenses and a bi-refracting prism, supporting a graduated arc upon which are two sliding objects called 'mires.' The latter are of white enamel, one quadrilateral in shape, the other of similar size but cut out on one side into steps; both are divided in the middle by a horizontal black line. The patient's face is placed in a frame at the other end of the instrument, and steadied by chin and forehead rests. The mires are reflected upon the cornea, and the

observer, looking through the tube and focussing, sees four images in a line. The two peripheral images are ignored; the two central ones are approximated until their inner edges touch, and the black lines subdividing the mires form one continuous straight line; it may be necessary to revolve the barrel of the telescope more or less of 45 degrees to the right or left to accomplish this. This position, indicated on a dial, gives the meridian of least refraction. Next the arc is turned at right angles to this meridian. If the images of the mires are still in apposition, the curvature of the cornea is uniform, and there is no corneal astigmatism (Fig. 288). If in the




FIG. 288.




FIG. 289.



FIG. 290.



FIG. 291.



FIG. 292.

FIG. 288.—THE MIRES OF THE OPHTHALMOMETER INDICATING AN ABSENCE OF CORNEAL ASTIGMATISM.

FIG. 289.—THE OVERLAPPING OF THE MIRES OF THE OPHTHALMOMETER INDICATING 1 D. OF CORNEAL ASTIGMATISM.

FIG. 290.—CONVEX REFLECTION OF PLACIDO'S DISC IN EMMETROPIA.

FIG. 291.—THE SAME IN REGULAR ASTIGMATISM OF VERY HIGH DEGREE.

FIG. 292.—THE SAME IN IRREGULAR ASTIGMATISM.

second meridian the relative position of the images of the mires has changed, each step which is overlapped by the quadrilateral figure indicates 1 D. of astigmatism (Fig. 289). A man who has acquired reasonable skill in the practice of retinoscopy will find very little use for an ophthalmometer.

Placido's disc or keratoscope (Fig. 6) consists of a circular disc upon which are painted alternate rings of black and white. The patient is placed with his back to the light, and fixes the centre of the disc, while the examiner looks through an opening in the centre and sees an image of the concentric circles reflected upon the patient's cornea. If no astigmatism is present the rings are circular. If regular astigmatism exists the rings will appear elliptical with the long axis corresponding to the meridian of least curvature. If the cornea

is the seat of irregular astigmatism the rings will be distorted. This forms a very useful qualitative test.

Treatment consists in prescribing glasses which correct the error. In many cases of moderate or high degree it is impossible to obtain $V. \frac{6}{8}$ with the full correction; we may have

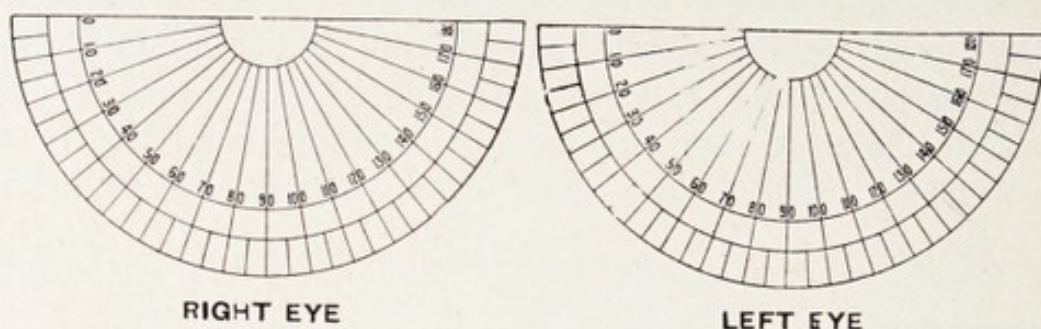


FIG. 293.—NOTATION OF THE AXIS OF CYLINDERS.

to be satisfied with $\frac{6}{9}$ or $\frac{6}{12}$. But the vision often improves after the lenses have been worn for a time. The glasses should be worn constantly. When the correction has been estimated with the eye under the effects of a cycloplegic, a slight reduction may perhaps be necessary in cases of moderate or high degrees of astigmatism, but as a rule the full correction

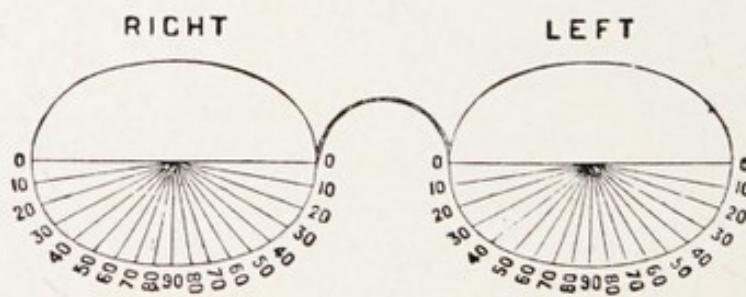


FIG. 294.—NOTATION OF THE AXIS OF CYLINDERS.

will be tolerated. The relief which cylinders give is usually very pronounced.

The direction of the axis of a cylinder is indicated according to two systems :

1. By the angle which the axis makes with the horizontal, the angles being numbered from 0 degree on our left side (as we stand before the patient and counting downwards) to 180 degrees on our right side (Fig. 293)—*i.e.*, commencing at

the temporal side of the right eye and the nasal side of the left eye of the patient.

2. The position of the axis is denoted by the angular deviation of the lower end of the cylinder from the horizontal meridian, either on the nasal or the temporal side.

Prescribing Glasses for Young Patients.

Having now discussed the correction of refractive error as it affects the eye, certain practical considerations demand attention.

The advantages one hopes to gain in prescribing glasses may be to prevent injury to the eye, to cure certain affections, such as squint or blepharitis, to relieve headaches or other subjective symptoms, or to improve sight. On the other hand, there are certain disadvantages; for example, the fact of a boy wearing glasses constantly at school handicaps him to some extent. In the case of a grown-up girl glasses may be a serious disfigurement. One should only prescribe glasses when the advantages to be gained decidedly outweigh the disadvantages.

Many boys and girls at school complain of headaches, and are very properly sent to an ophthalmic surgeon for an examination of the eyes. There may be a serious refractive error which needs correction. Very frequently one finds an insignificant degree of hypermetropia which could not be the cause of the headaches. But many surgeons are in the habit of prescribing glasses for these children, whereas the cause of the headaches should be sought for in another direction.

It is no great disadvantage to a girl to have to wear glasses while she is quite young, but every effort should be made to arrange matters if possible, so that she will not need to wear glasses constantly after leaving school. For example, a young myope nearly always needs glasses for near work in order to remove the temptation to hold the book too near. But a girl whose personal appearance in after years may be a consideration should never be allowed to wear glasses

constantly out of doors, or she will lose the faculty of interpreting blurred images, and may never be able to do without glasses.

If there is astigmatism the subjective symptoms should be the chief factor in deciding whether glasses are to be worn constantly or no.

Anisometropia.

This term is applied to cases of marked inequality in the refraction of the two eyes; slight differences are present in most cases of errors of refraction. Every possible combination may occur: (1) One eye may be emmetropic and the other ametropic; (2) both eyes may have the same variety of ametropia, but of unequal degree; (3) one eye may be myopic and the other hypermetropic, either simple or combined with astigmatism. Notwithstanding the unequal refraction, there is usually binocular vision; sometimes the eyes are used alternately, and in other cases one eye is habitually excluded from vision.

In prescribing glasses no arbitrary rules can be followed; each case must be considered by itself. When one eye is emmetropic and the other ametropic no glass will probably be required, unless it be to prevent the ametropic eye from suffering from disuse, or for the relief of asthenopic symptoms. When the difference in the refraction is not great (1 to 2 D.) and there is good binocular vision we may give each eye its correction. When the difference is greater the full correction sometimes causes discomfort, then we must be satisfied with a partial correction. When there is no binocular vision we generally give a correcting glass for the better eye. In such cases, if the poor eye still possesses vision, the patient should be advised to exercise it daily with the aid of a suitable lens, the good eye being excluded, so that the amblyopic eye may retain its vision and the defect be prevented from becoming worse.

Asthenopia.

Asthenopia, weak sight, or eye-strain, is a convenient term which embraces the group of symptoms dependent upon fatigue of the ciliary muscle or of the extra-ocular muscles.

Symptoms.—The condition is of very frequent occurrence, and causes a great variety of symptoms. The most common manifestations of asthenopia are: (1) *Pain* in or around the eyes or headache, usually aggravated by use of the eyes for close work, and in some cases present only after near use. (2) *Fatigue and discomfort* upon use of the eyes for near work; this shows itself by inability to indulge in such work for more than a short period at a time, without the occurrence of dimness of vision and confusion of the lines of print, pain in and about the eyes, headache, drowsiness, lacrymation, photophobia, and congestion, and an irritable condition of the lids accompanied by itching and burning sensations. These symptoms are regularly worse at night, when the patient is tired, or when artificial illumination is employed. (3) *Vertigo* and a tendency to diplopia. (4) *Nervous affections*, such as migraine, nausea, twitching of the facial muscles, chorea, etc.

The amount of asthenopia depends not only upon the degree of defect, but also upon the state of the patient's health, and is therefore pronounced in delicate, anæmic, and neurasthenic individuals.

Varieties.—(1) Accommodative; (2) muscular; (3) nervous or neurasthenic (reflex). Two of these varieties may be associated.

Accommodative Asthenopia is the most common variety. It is due to strain and fatigue of the ciliary muscle when used too constantly or excessively in ametropia. It is especially frequent in astigmatism and hypermetropia, but is common enough in myopia and in presbyopia. Treatment consists in the use of glasses correcting the error of refraction, as advised in preceding pages. In delicate and neurasthenic individuals attention to the general health is very important.

Muscular Asthenopia is due to a want of balance of the

motor apparatus of the eyes (heterophoria). It may be associated with ametropia, and its existence be dependent upon the latter error, or it may occur in emmetropia. It is often due to myopia, in which, on account of the far point being close to the eye, the patient is obliged to converge excessively. Heterophoria is fully discussed in Chapter XXIX.

Nervous, Neurasthenic, or Reflex Asthenopia is the variety which occurs in emmetropic patients or in ametropes in whom proper correcting lenses give no relief. It is a neurosis, and is dependent upon a general asthenic condition of the nervous system; consequently it is found most frequently in young women with hysterical tendency, who suffer from anæmia, neurasthenia, and often menstrual disorders; also in neurasthenic individuals in general, and in convalescents from debilitating diseases. The condition is often very troublesome and frequently obstinate. The more carefully one investigates the static and dynamic refraction and the motor balance of the eyes, the fewer cases one finds it necessary to class as neurasthenic. Treatment consists in removing the defect in the general condition, rest of the eyes, and particularly attention to hygiene, such as the regulation of habits, outdoor exercise, etc.

Mydriatics and Cycloplegics.

The actions of these agents and the method of obtaining the best results with them are described in Chapter XXXIII.

A cycloplegic is indicated in the estimation of the refraction in all cases of children and occasionally in young adults; very rarely it may be needed in an older patient. The frequency with which mydriatics become necessary in adults varies inversely with the skill of the surgeon. A surgeon who can perform retinoscopy through the undilated pupil can get better results without a mydriatic. Before using these agents in elderly persons any suspicion of *glaucoma* must be excluded.

Homatropine (2 or 3 per cent. solution), or homatropine 2 per cent., combined with cocaine 1 per cent., is the agent most frequently employed; one drop is instilled every five or ten minutes for three or four doses, and the examination begun at the end of half an hour after the last instillation. Sometimes homatropine fails to produce complete paralysis of accommodation, as shown by more or less contradiction in the results of the objective and subjective tests. In such cases we may resort to atropine (1 per cent. solution), one drop being instilled three times daily for two or three days (smoked glasses may be worn during this period), and a final drop directly before the examination.

In the case of children *atropine* drops or ointment (1 per cent.) should be used thrice daily for four or five days before the examination.

The Fitting of Eyeglasses and Spectacles.

Much of the comfort and relief which lenses bring will depend upon the skill with which the glasses are fitted to the face. Whether the surgeon orders eyeglasses or spectacles, the lenses must be supported in their frames in such a manner that the distance between their geometric centres corresponds to the interval between the centre of the pupils (interpupillary distance).

If the glasses are to be worn constantly, the geometrical centre of the lenses should be slightly below the centre of the pupils, and the lenses tilted so that their surfaces form an angle of about 15 degrees with the plane of the face. If worn for distance only the level of the lenses should be the same, and the tilting about 10 degrees. If worn for near work only the lenses should be lower, and inclined about 25 degrees.

In every case the glasses should be worn as near the eyes as possible, just avoiding the lashes.

Lenses are usually made of crown glass. The periscopic form of spherical lenses is preferred. In cylinders

one surface is generally plane and the other curved, but such lenses can also be ground with two curved surfaces, the convex surface in front. Sphero-cylinders usually have the spherical lens on one surface and the cylindrical lens on the other; but in toric lenses both the cylindrical and spherical curves

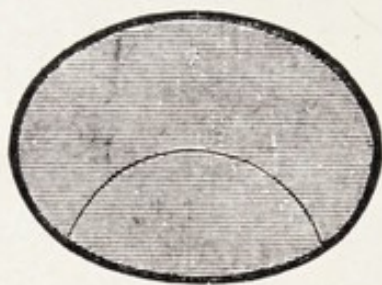


FIG. 295.—BIFOCAL LENS,
OVAL 'PASTER.'

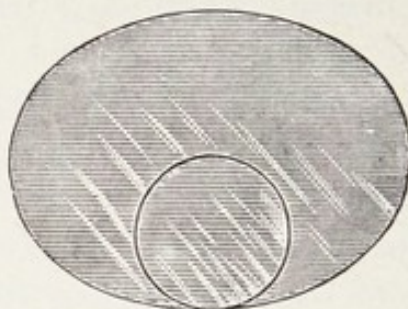


FIG. 296.—BIFOCAL LENS,
CIRCULAR 'PASTER.'

are ground on the outer surface; this gives an enlarged field, and reduces the weight and thickness of the lens. Lenses cut from crystal are known as pebbles; they have the advantage of being less easily scratched.

Bifocal lenses consist of an upper portion of one focus and

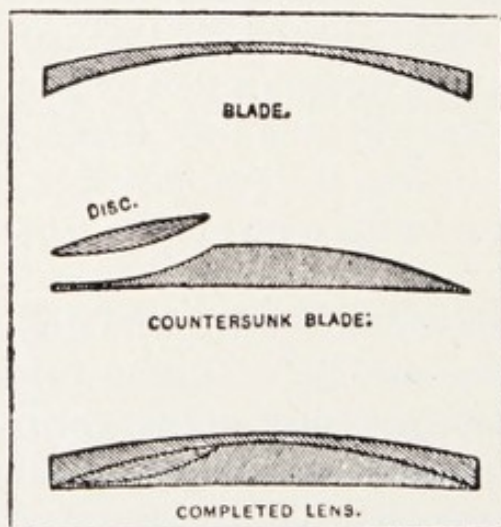


FIG. 297.—SECTION SHOWING THE CONSTRUCTION OF THE
INVISIBLE BIFOCAL LENS.

a lower part of another. They are used principally in cases of presbyopia associated with ametropia, the lower portion being used for reading and near work, and the upper for distance. The most commonly used bifocal lenses are those in which the addition consists of a small thin oval or circular

lens cemented to the lower portion of one surface of the distance glass (Figs. 295 and 296). This form is comparatively cheap, but the edge of the cemented lens is very obvious both to the wearer and to others. Moreover, changes of temperature sometimes cause cloudiness in the cement joining the two lenses.

The invisible bifocal lens is constructed of two blades of crown glass between which the presbyopic segment is inserted before they are cemented together (Fig. 297). The increased

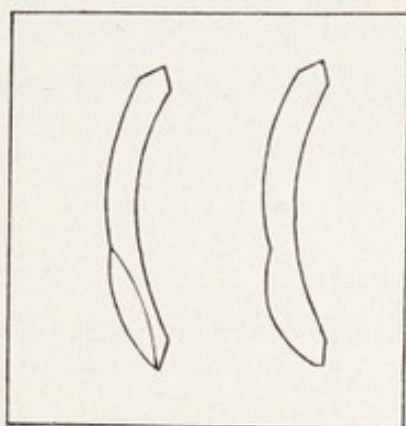


FIG. 297a. FIG. 297b.

FIG. 297a.—SECTION OF FUSED BIFOCAL LENS.

FIG. 297b.—SECTION OF ONE-PIECE BIFOCAL LENS.

strength of the smaller lens depends upon the higher refractive index of flint glass of which it is made. The lenses are now usually fused together instead of being cemented. In another form of bifocal lenses the distance and the reading segments are ground on a single piece of crown glass (Fig. 297b). Bifocal glasses need especial care in fitting.

In cases of astigmatism it is necessary that the axis of the cylinder be constant. On this account spectacles are often preferred to eyeglasses, because with the latter the axis of the cylinder may vary according to the way in which the glasses are worn or in which they preserve their original adjustment. But eyeglasses can be worn in such cases if the optician exercises sufficient skill in fitting. Lenses having a cylindrical element, for children, should not be quite round, lest they become slack in the frame and allow the axis to rotate into a wrong position.

CHAPTER XXVI

ANOMALIES OF ACCOMMODATION

Presbyopia.

PRESBYOPIA, or old sight, is a physiological change which affects every eye, becoming evident usually at about the forty-fifth year, as a result of which the near point recedes beyond the distance at which we are accustomed to read ordinary print. The change is due chiefly to loss of elasticity of the lens, whereby it is prevented from responding to the action of the ciliary muscle; consequently the power of accommodation is lessened. As explained on p. 315, this diminution in the power of accommodation begins early, about the tenth year. When it becomes sufficient to interfere with the comfortable exercise of near vision, presbyopia is said to be present.

At the age of forty there are 4.5 D. of accommodation, and the near point is at 22 cm., or 9 inches. To read at 9 inches such an individual would require all of his accommodation, and the effort would soon become fatiguing, since only one-half or two-thirds of this power can be used for any length of time without causing asthenopic symptoms. Generally, however, the adult holds print at about 13 inches (33 cm.), requiring 3 D. of accommodation, and leaving a reserve of 1.50 D.; this is usually sufficient to ensure comfort. At forty-five his accommodation has diminished to 3.5 D.; all or nearly all of this would be required to read comfortably at 13 inches,

leaving little or no reserve. If he keeps one-third of his accommodation in reserve he will have about 2.25 D. available for near work; with this his reading distance would be 45 cm., or 18 inches—too great for comfortable and continuous near work. Hence we must supply the defect in the power of accommodation by a convex lens of sufficient strength to bring the near point back to a convenient distance.

Symptoms.—The presbyope is compelled to hold reading, writing, sewing, and other forms of near work farther away than the usual distance, making such efforts uncomfortable. With this recession of the near point beyond the usual situation the print becomes pale and indistinct, and fine type can be read only with great difficulty. The patient is apt to use strong illumination; this produces contraction of the pupil, and thus improves the definition by diminishing the circles of diffusion. If the condition be uncorrected he suffers from asthenopic symptoms, especially pain, fatigue, lacrymation, dimness of vision, and irritation of the lids, all of these symptoms being more marked in the evening with artificial illumination. Presbyopia has no effect upon distant vision in an emmetrope.

Treatment consists in prescribing convex spherical lenses for near work, so as to compensate for the lack of power of accommodation, and to bring the near point back to a comfortable working distance.

One can generally make a rough guess as to the correcting glasses according to age. The following represents the average for a healthy emmetropic Englishman.

Age	45	Glass required	+ 1 D.
„	50	„	„ + 1.5 D. to + 1.75 D.
„	55	„	„ + 2.25 D.
„	60	„	„ + 2.75 D. to + 3 D.
„	65 and over	„	„ + 2.75 D. to + 3.5 D.

The numbers given are somewhat arbitrary. A tall, upright person will generally require a smaller presbyopia correction than a short person or one who stoops. The oft-quoted rule to allow +1 D. for every five years after forty has led many inexperienced surgeons astray. Apart from an

error of static refraction, when a patient complains that he cannot read comfortably with his recently purchased glasses, one generally finds that they are too strong. The age at which patients are obliged to wear glasses varies within a few years, and is influenced to a certain extent by the vigour of the individual; a delicate or neurasthenic person will require glasses for reading earlier than a robust individual.

The glasses must also be selected with reference to the occupation or the special use for which the patient wishes them. Thus in reading, writing, and sewing 13 inches (33 cm.) is a comfortable working distance for most persons; but a musician may prefer a distance of 20 to 25 inches, and consequently he will require a weaker glass.

The existence of ametropia will modify the strength of glasses required for presbyopia. Hence the patient's vision for distance, and his refraction, must be determined before estimating the glasses required for near work. In any case of ametropia the lenses required for distance must be added to those which would be selected for presbyopia in the emmetrope. This would have the effect of increasing the strength of the convex lens required for presbyopia in cases of hypermetropia, and of diminishing its power in myopia. For example, suppose a patient of fifty has hypermetropia of 1.75 D.; his glasses for reading would be H. 1.75 + Pr. 1.75 D. = + 3.50 D. A myope of 1.5 to 2 D. will require no glass at fifty, since his myopia and presbyopia neutralize each other. If the myopia amounts to 4 D., the patient will never require glasses for reading, since his far point will never be more than 10 inches. In astigmatism the cylinders must be added to the convex lenses required for the correction of presbyopia.

Since presbyopia increases with age, the glasses will require changing for stronger ones every few years. *When the glasses have to be changed for stronger lenses very frequently, we should suspect glaucoma, and examine the eye carefully for this disease.*

Paralysis of Accommodation.

Paralysis of accommodation (cycloplegia) is a partial or complete loss of power in the ciliary muscle due to paralysis or paresis of the third nerve, or of that branch of the motor oculi which supplies the ciliary muscle and iris. Though occasionally confined to the ciliary muscle, the paralysis usually includes the sphincter pupillæ. When limited to the ciliary muscle and iris it is known as ophthalmoplegia interna.

Etiology.—The most frequent cause is the use of mydriatics, such as atropine and homatropine. It may be part of a complete paralysis of the third nerve. It occurs not infrequently after diphtheria. Other causes are contusions of the eyeball, debilitated states of the system, influenza, syphilis, diabetes, and cerebral disease.

Symptoms.—These are loss of power of accommodation and dilatation of the pupil. If emmetropic, the patient will have good vision for distance, but be unable to do near work without convex glasses. If hypermetropic, both near and distant vision will be impaired. If myopic, the patient will be able to see distinctly only at his far point; he may therefore be able to do without his accommodation if the myopia is considerable.

Prognosis is usually good, especially when the affection is due to syphilis, diphtheria, or the use of a mydriatic. In traumatic cases the condition may be permanent.

Treatment.—One should attempt to remove the cause of the paralysis. In syphilis, specific treatment is indicated. In post-diphtheritic paralysis, and in that due to debilitated conditions, tonics should be given, especially strychnine. Locally, the myotics (eserine or pilocarpine) may be employed. In a normal visual apparatus these cause contraction of the pupil and of the ciliary muscle. The local application of electricity is sometimes useful. In traumatic cases, complete rest is indicated, in addition to the remedies just mentioned. If the paralysis does not soon disappear, convex glasses may be given for near work. The glasses may be reduced in strength, or abandoned if the ciliary muscle should ultimately recover its function.

Spasm of Accommodation.

Tonic spasm of the ciliary muscle is frequently met with in children and in young adults; it occurs generally in hypermetropia, but it may accompany emmetropia or any error of refraction.

Etiology.—It is usually due to long-continued application of the eyes for near work, especially when the young patient is in poor health, has uncorrected ametropia, and the work has been excessive and done with poor illumination.

Symptoms.—Both eyes are affected. There are asthenopic symptoms. In emmetropia, the spasm gives rise to the signs of myopia; in hypermetropia, it reduces the amount of manifest error and increases the proportion of latent hypermetropia, or it may even cause the patient to appear myopic; in myopia the error is increased. The diagnosis is made after instilling a cycloplegic; in most of these cases homatropine is insufficient, and atropine must be used.

Treatment consists in the abstinence from near work for a time, the correction of ametropia, attention to the general health, and the production of paralysis of accommodation for a few days by instillations of atropine.

CHAPTER XXVII

PARALYSES OF EXTERNAL OCULAR MUSCLES

Anatomy and Physiology.—The eyeball is moved by six muscles, *the extrinsic muscles*, consisting of the four straight and the two oblique. These arise from the wall of the orbit, and are inserted into the sclera.

The four recti (internal, external, superior, and inferior) arise from the circumference of the optic foramen at the apex of the orbit, run forward, surrounding the optic nerve and posterior portion of the eyeball, and are inserted into the sclera by means of flattened tendons about 10 mm. wide. The lines of insertion of these muscles are not equidistant from the cornea, but have somewhat the form of a spiral. That of the internal rectus is 5 mm., of the inferior rectus 6 mm., of the external rectus 7 mm., and of the superior rectus 8 mm., from the cornea.

The superior oblique arises from the border of the optic foramen, runs forward to the upper and inner angle of the orbit, at the anterior extremity of which it passes through a fibrous pulley; it then continues outward, passing beneath the superior rectus, and is inserted into the upper part of the sclera behind the equator. *The inferior oblique* arises from the superior maxillary bone at the inner portion of the lower border of the orbit, passes outward below the inferior rectus, and is inserted into the outer part of the sclera behind the equator.

The muscles are ensheathed by the fascia of the orbit—*Tenon's capsule*—which also covers the sclera and sends prolongations to the walls of the orbit. These prolongations are most prominent upon the internal and external recti muscles. They serve to restrain the excursions of the eyeball, and are known as 'check ligaments.'

Nerve-Supply.—The *third* nerve (oculo-motor) supplies all the muscles except the external rectus, which is innervated by the *sixth* (abducens), and the superior oblique, which is supplied by the *fourth* (trochlearis). The nuclei for these three nerves are found in the floor of the fourth ventricle.

Action of the Muscles.—The six extrinsic muscles serve to rotate the eyeball around a vertical, transverse, and antero-posterior axis, the centre of the rotation corresponding approximately to the centre of the eyeball, and the movements being free in all directions, like a ball-and-socket joint. The movements which take place about the vertical axis are adversion (toward the nose) and abversion (toward the temple) ; about the transverse axis, elevation and depression ; and about the antero-posterior axis, wheel rotation or torsion, by means of which the upper extremity of the vertical meridian is inclined inward or outward.

The external rectus moves the eyeball outward.

The internal rectus moves the eyeball inward.

The superior rectus moves the eyeball upward, inward, and turns the upper extremity of the vertical meridian inward.

The inferior rectus moves the eyeball downward, inward, and turns the upper end of the vertical meridian outward.

The superior oblique rotates the upper end of the vertical meridian inward, and moves the eyeball downward and outward.

The inferior oblique rotates the upper end of the vertical meridian outward, and moves the eyeball upward and outward.

Movements of the Eyeball.—In every movement of the eyeball several muscles act at the same time, as follows :

Adversion { Internal rectus.
Superior rectus.
Inferior rectus.

Abversion { External rectus.
Superior oblique.
Inferior oblique.

Elevation { Superior rectus.
Inferior oblique.

Depression { Inferior rectus.
Superior oblique.

Rotation inward of upper extremity of vertical meridian { Superior oblique.
Superior rectus.

Rotation outward of upper extremity of vertical meridian { Inferior oblique.
Inferior rectus.

The action of the superior and inferior recti and of the obliques varies according to the position of the eye. When the eye is abverted, the superior rectus is almost a pure elevator, and the inferior rectus a depressor; the more the eye is adverted, the more marked is the torsional action of these muscles. In the case of the superior and inferior obliques, the torsional action is greatest when the eye is abverted, and the vertical action greatest when the eye is strongly adverted. No muscle ever acts alone. Though one or two muscles may be the principal agent in a certain movement, all the other muscles are in action to steady the eye, and to eliminate undesired actions of these muscles.

Both eyes move always simultaneously (*associated movements of the eyes*). This association is regulated by centres of association which innervate certain muscles or groups of muscles of the two eyes simultaneously. The associated or conjugate movements occur either in the same direction, with the visual lines parallel, or with the lines inclined toward each other (convergence).

The Field of Fixation corresponds to the limits of movement of the eyeball in different directions, without moving the head. It is best estimated by the perimeter (Fig. 18). The patient's head is fixed so that the eye under examination is opposite the centre of the instrument. Small test-types are now moved along the arc of the perimeter, from the periphery to the centre, until the patient can name the letters. The movements must be made with the eye alone, without any change in the position of the head, and the other eye must be covered. The field of fixation in the normal eye is about 45 degrees upward, inward, and outward, and about 55 degrees downward.

Binocular Vision.—Under ordinary conditions, both eyes are concerned in the act of vision, and the relative directions of the visual axes are involuntarily adjusted, so that the image of an object is focussed on the macula of each eye. These two images are blended in the brain so that a single picture is perceived. The faculty of blending images is called the *fusion faculty*; the act of blending them is called *binocular vision*.

Diplopia.—When images fall on symmetrical points of the retinae of a normal pair of eyes, a single visual sensation is produced (*binocular single vision*). When the visual lines of the two eyes are not directed toward the same object—*i.e.*, when one eye deviates—*diplopia* (double images) results, if the fusion faculty be perfect. But if the fusion faculty be very deficient, or absent, the image of the deviating eye is disregarded or suppressed. In a case of paralysis of an external ocular muscle, the angular displacement of the false image is equal to the angle of deviation of the eye. The image which corresponds to the eye which ‘fixes’ the

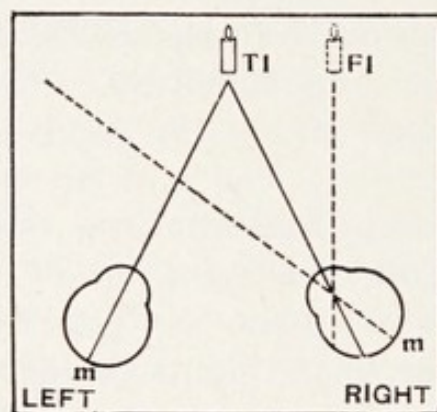


FIG. 298.—DEVIATION OF THE RIGHT EYE INWARD. HOMONYMOUS DIPLOPIA.

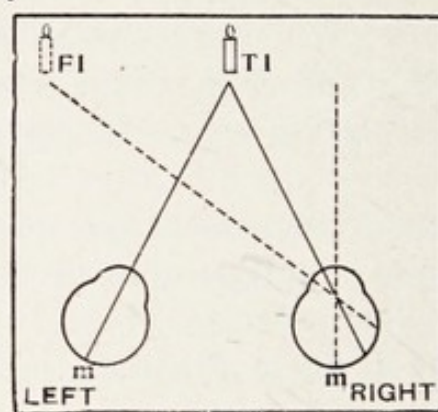


FIG. 299.—DEVIATION OF THE RIGHT EYE OUTWARD. CROSSED DIPLOPIA.

TI, True image; *FI*, false image; *TI*, True image; *FI*, false image; *m*, macula.

object is distinct, because it lies at the macula, and is known as the *true image*; the image of the deviating eye is less distinct, because it is perceived by a peripheral part of the retina, and is known as the *false image*.

Objects which are situated to the right of the point of fixation throw their images to the left of the macula; and those placed to the left of the point of fixation form images to the right of the macula. In the same manner, objects above or below the point of fixation cast their images below or above the macula respectively. By reversing this process, we judge of the situation of an object, and place it at the extremity of an imaginary line drawn from the retinal image

through the nodal point. This process is known as *projection*, and is learned by experience. It enables us to judge of the relative positions of objects. An object which forms its image to the right of the macula is situated to our left; one which throws its image below the macula is situated above, etc.

Diplopia is said to be *homonymous* when the false image is on the same side as the deviating eye, and *crossed* when it is on the opposite side.

In Fig. 298 the right eye is turned in, and consequently binocular diplopia results. The patient sees a true image with the left eye, the image of the candle forming at the macula and being referred to its proper place, TI. In the right eye, on account of the deviation inward, the image is thrown upon the retina to the left of the macula, and consequently is projected to the right, at FI. The image of the right eye being to the right of the image of the left eye, the case is one of homonymous double images.

In Fig. 299 the right eye turns out and double images result. The image of the candle lies on the macula in the left eye, and this eye refers the image to its right position; a true image is seen at TI. In the right eye, because of its outward deviation, the image falls to the right of the macula, and is consequently projected to the left, at FI. The images having crossed in their relative positions, that of the right eye being seen to the left of the image of the left eye, the case is one of crossed diplopia.

Double images may also be produced without any deviation, by placing a prism in front of the eyes. The prism will deflect the rays, so that instead of falling upon the macula, they reach the retina to one side of it.

Varieties of Ocular Deviations.—I. *Paralysis*, marked deviation due to loss of motion in one or more of the ocular muscles; when partial, it is known as *paresis*.

2. *Heterophoria* or *insufficiency*, a slight or moderate tendency to deviation, which is habitually overcome by muscular effort.

3. A deviation of the eyes from their normal *relative directions* is the most obvious symptom of *comitant squint*. But there is no defect of movement of either eye when tested separately.

Paralysis of the Ocular Muscles.

Symptoms.—1. *Limitation of Movement* of the eye on the side and in the direction of action of the paralyzed muscle; this is pronounced in complete paralysis and less marked in paresis. It can generally be recognized when the patient keeps his head fixed and tries to follow the examiner's finger moved in different directions. If the paralysis be slight, the defective movement may require more elaborate tests for its detection.

2. *Deviation.*—When the eyes are turned in the direction of the normal action of the paralyzed muscle, the sound eye will be directed properly, but the affected eye will refuse to move, and will deviate. The deviation is generally obvious, and is more marked the farther the eyes are moved in the direction of the paralyzed muscle. When the eyes are turned in the opposite direction, in which the paralyzed muscle need not participate, there is no deviation.

The deflection of the deviating eye is known as the *primary deviation*; it is always in the direction opposite to the normal action of the paralyzed muscle.

If the affected eye be made to fix an object and the sound eye be covered, the latter will deviate in a corresponding direction, and much more than the affected eye; this deflection of the sound eye is known as the *secondary deviation*. The excess of secondary deviation over the primary is due to the fact that the strong impulse of innervation required to enable the paralyzed eye to fix, being simultaneously transmitted to the associated muscle of the sound eye, produces an overaction of this muscle, and consequently a greater amount of rotation.

3. *Oblique Position of the Head.*—If the deviation be not of very high degree, the patient turns his head toward the side of the paralyzed muscle, and in the direction in which the paralyzed muscle would, if acting, move the eye. This is done so as to enable him to bring the visual axes into their normal *relative* directions. Hence there is a characteristic position of the head for every variety of paralysis.

4. *False Projection*.—The paralyzed eye does not see objects in their correct location. The false projection is due to markedly increased innervation, conveyed to the nerve supplying the paralyzed muscle in an effort to force it to act; this gives the patient an erroneous idea of the position of the eye. It can be demonstrated by closing the patient's sound eye and telling him to point quickly at an object in front of him. The finger will be directed to the side of the object corresponding to the paralyzed muscle.

5. *Diplopia* occurs when the patient looks at an object situated within the sphere of action of the paralyzed muscle, and becomes more marked the more the eyes are moved toward this side. The presence or absence of diplopia, the relative positions of the double images, and the increase or diminution of the distance between them in different parts of the field of fixation, form the most important means of determining the seat of the paralysis.

6. *Vertigo, nausea, and uncertain gait* are frequently symptoms dependent upon the diplopia and the false projection. They are relieved when the patient closes the paralyzed eye. On this account, patients frequently keep the affected eye closed or covered.

After paralysis has lasted a long time, there occurs contracture of the antagonist of the affected muscle, increasing the angle of the deviation, and so causing the false image to be formed on a more peripheral and less sensitive part of the retina. On this account the diplopia and false projection become far less obvious.

When one muscle only is paralyzed, the diagnosis is easy; but when several muscles are involved, it is often difficult to determine the exact combination.

Method of Investigating a Case of Oculo-motor Paralysis.—Apply the *mirror test* described on p. 382, throwing the light on to the eyes successively from the nine positions indicated by Fig. 300. It will immediately be seen which eye (if either) deviates, and in what direction. The direction in which the angle of the deviation tends to increase or diminish will also be noted.

The advantages of this test are its extreme rapidity and its reliability. It is a purely objective test, so that one is not liable to be deceived by a malingerer or by an hysterical or unintelligent patient.

The *diplopia test* is very commonly employed. It takes much time, and one is dependent upon the answers given by the patient. It is a very delicate test. In using this test care must be taken not to mistake a heterophoria for a paralysis.

For convenience of record and study a diagram is used, consisting of two horizontal and two vertical lines, forming nine spaces (Figs. 300 to 305). The patient must keep his head fixed and merely move his eyes. A red glass is placed before one eye, so as to distinguish its image. A candle is moved about in different positions in the field of fixation, and the nature of the diplopia noted in each of the nine spaces. The data required are : (1) in which position of the field there is single vision, and in which diplopia ; (2) whether the diplopia is homonymous or crossed ; (3) the relative distances between the double images ; (4) whether the two images are on the same or on different levels ; and (5) whether the images are erect or inclined.

The false image is situated in the direction of the normal action of the paralyzed muscle, and the distance between the double images increases in this direction and diminishes in the opposite direction. In fact, most of the symptoms—the limitation of movement, the false image, the turning of the face and oblique position of the head, the faulty projection, and the increase in the distance between the double images—are in the direction of the normal action of the paralyzed muscle. The deviation of the eye is the only symptom occurring in the opposite direction.

The anatomy of the extrinsic ocular muscles tells one all one need know about their actions. The student who has once thought out these actions for himself will have no difficulty in interpreting the data obtained by either of the tests just described. He has only to note in what direction movement is deficient, then consider what muscle or muscles should produce this rotation.

Varieties of Ocular Paralysis.—One muscle may be involved, or several muscles in various combinations may be affected. Paralysis of the external rectus is the most common; that of

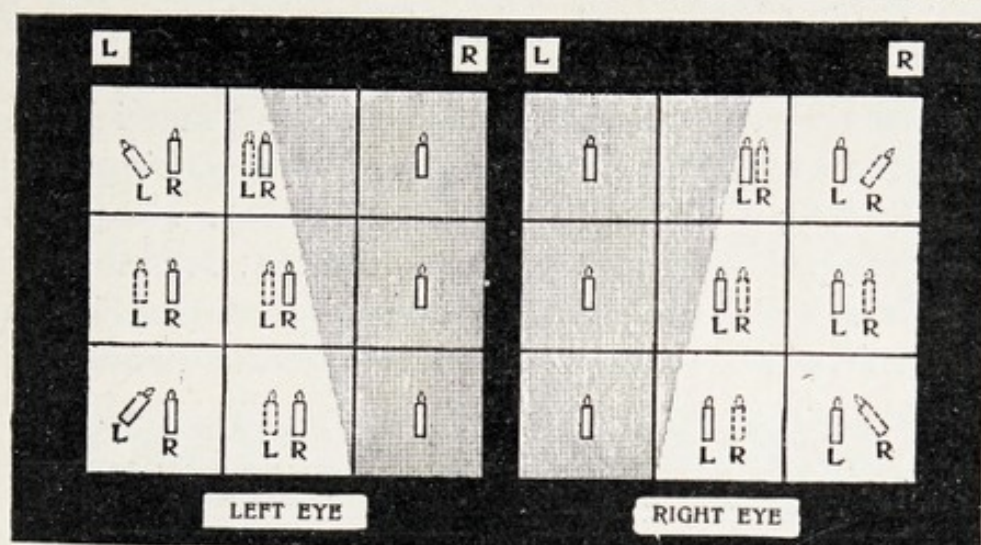


FIG. 300.—PARALYSIS OF THE EXTERNAL RECTUS.
The dotted outline refers to the false image.

the superior oblique is frequent; isolated paralysis of the remaining four muscles is much less common. Combined

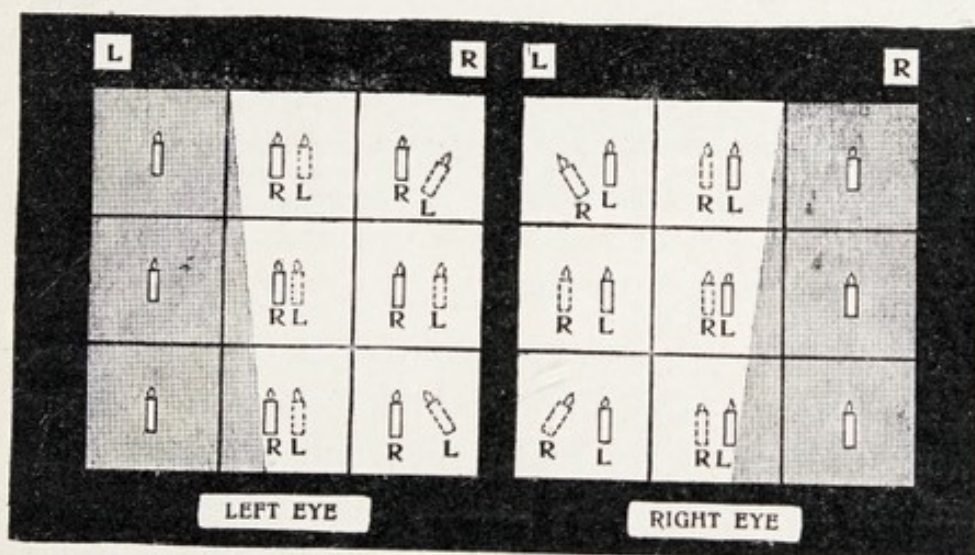


FIG. 301.—PARALYSIS OF THE INTERNAL RECTUS.
The dotted outline refers to the false image.

paralysis of some or all of the four muscles supplied by the third nerve is exceedingly common.

Paralysis of the External Rectus (Sixth Nerve).—There is limitation of movement outward, the eye is adverted, and the face is turned toward the paralyzed side. Homonymous

diplopia upon looking toward the paralyzed side; the images are on the same level and parallel (slightly tilted in the upper or lower portions of the field); the lateral separation increases with abversion of the paralyzed eye (Fig. 300).

Paralysis of the Internal Rectus.—There is limitation of movement inward, the eye is abverted, the face is turned toward the sound side. Crossed diplopia on looking toward the sound side; the images are on a level and parallel (slightly tilted in upper and lower portions of field); lateral separation increases with abversion of the paralyzed eye (Fig. 301).

Paralysis of the Superior Rectus.—There is limitation of movement upward and toward the sound side; deviation of

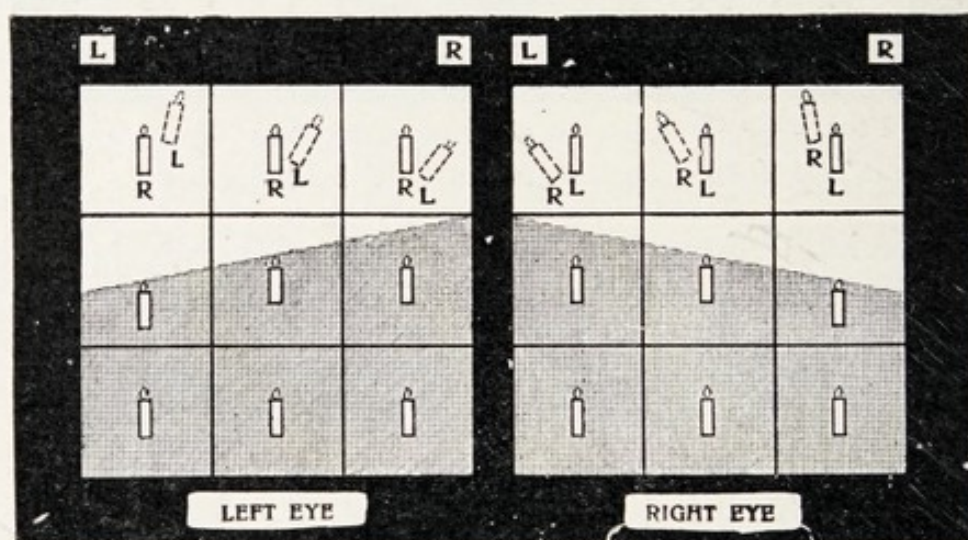


FIG. 302.—PARALYSIS OF THE SUPERIOR RECTUS.

The dotted outline refers to the false image.

the eye downward and a little outward, with the vertical meridian inclined toward the temple; the face is directed upward and toward the sound side, and the head inclined toward the shoulder of the healthy side. Crossed and vertical diplopia upon looking up; the false image is higher and its upper end inclined toward the nose; the vertical distance between the images increases and the inclination of the false image diminishes, upon looking upward and toward the paralyzed side (Fig. 302).

Paralysis of the Inferior Rectus.—There is limitation of movement downward and toward the sound side; deviation of the eye upward and slightly outward, with the vertical meridian

inclined toward the nose; the face is directed downward and toward the sound side, and inclined toward the shoulder of the paralyzed side. Crossed and vertical diplopia on looking down; the false image is lower, and its upper end inclined toward the temple; the vertical distance between the images increases and the inclination of the false image decreases, upon looking downward and toward the paralyzed side (Fig. 303).

Paralysis of the Superior Oblique (Fourth Nerve).—There is limitation of movement downward and toward the paralyzed side; the eye is deviated upward and slightly inward, with the vertical meridian inclined toward the temple; the face

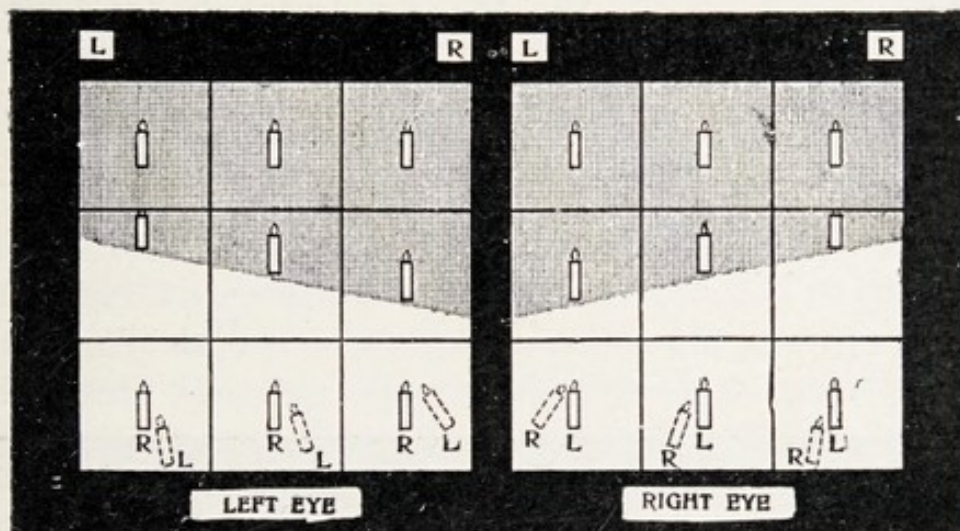


FIG. 303.—PARALYSIS OF THE INFERIOR RECTUS.

The dotted outline refers to the false image.

is directed downward and toward the sound side, and the head is inclined over the shoulder of the sound side. The patient has great difficulty in moving about, especially in going downstairs. Homonymous and vertical diplopia on looking down; the false image is lower, and its upper end inclined toward the sound side; the vertical distance between the images increases, and the inclination of the false image decreases upon looking downward and toward the sound side (Fig. 304).

Paralysis of the Inferior Oblique.—There is limitation of movement upward and toward the paralyzed side; the eye is deviated downward and slightly inward, with the vertical meridian inclined toward the nose; the face is directed upward and toward the paralyzed side, and the head is inclined

toward the affected side. Homonymous and vertical diplopia on looking up; the false image is higher and its upper end inclined toward the temple; the vertical distance between the images

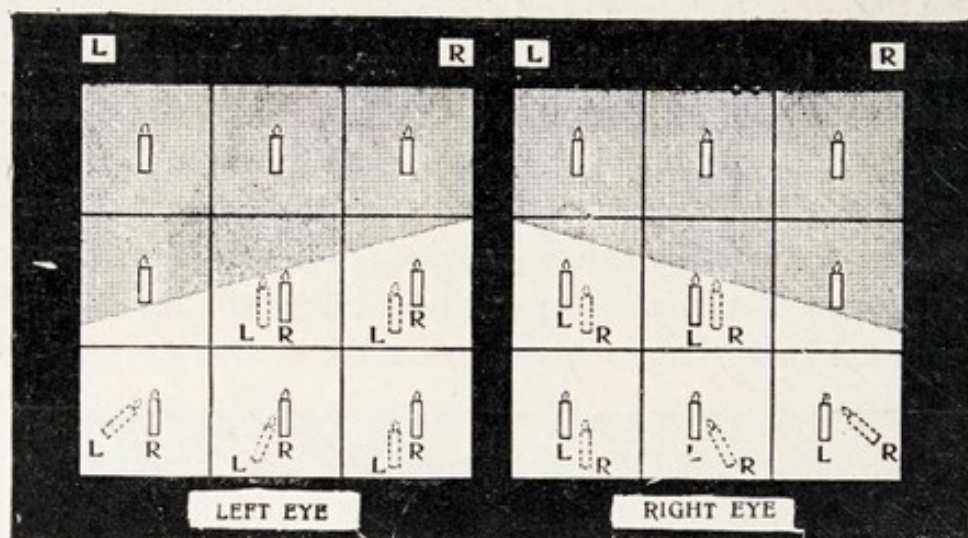


FIG. 304.—PARALYSIS OF THE SUPERIOR OBLIQUE.

The dotted outline refers to the false image.

increases, and the inclination of the false image decreases upon looking upward and toward the sound side (Fig. 305).

Paralysis of the Third Nerve.—With complete paralysis of

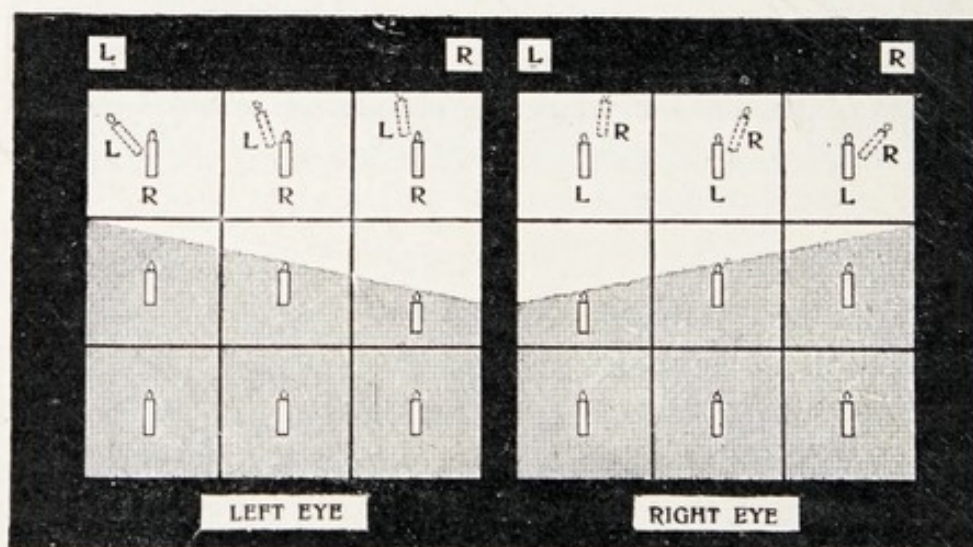


FIG. 305.—PARALYSIS OF THE INFERIOR OBLIQUE.

The dotted outline refers to the false image.

this nerve there is ptosis; the eyeball is almost immobile, the limitation of movement being upward, downward, and inward; the eye deviates outward and somewhat downward, with the upper end of the vertical meridian inclined inward,

especially upon looking downward; the face is directed upward and toward the sound side, and the head inclined to the shoulder of the paralyzed side. There is slight exophthalmos on account of the paralysis of the three recti which normally draw the eyeball backward; the pupil is dilated and immobile; accommodation is paralyzed; there is crossed diplopia—the false image is higher, and its upper end inclined toward the paralyzed side.

Paralysis of the third nerve is common; it is often incomplete, two or three of the muscles being affected. It may be associated with paralysis of other nerves.

When all the muscles of one eye are paralyzed, including the iris and ciliary body, the condition is known as *total ophthalmoplegia*.

When all the exterior muscles of the eyeball are paralyzed, but not the iris and ciliary body, the condition is known as *external ophthalmoplegia*. This form is more common than total ophthalmoplegia; the nuclei for the sphincter pupillæ and ciliary muscle being separate, they often escape involvement from destructive processes affecting the origin of the exterior ocular muscles. This form of paralysis is generally of central (nuclear) origin.

When only the sphincter pupillæ and the ciliary muscle are paralyzed, the condition is known as *internal ophthalmoplegia* (p. 347).

Associated or Conjugate Paralyses involve associated muscles such as the external rectus of one eye and the internal rectus of the other. They are due to lesions in the association centres.

Etiology.—The lesions causing paralysis may be situated anywhere in the course of the nerve tract, from the cerebral cortex to the muscle. According to its site, the lesion is distinguished as central and peripheral. Central lesions may be situated in the cortical centres (cortical paralysis), the association centres, the nuclei of origin (nuclear paralysis), or in the fibres which connect these centres. Peripheral lesions may affect the nerves in some part of their course, either between the point where they issue from the brain

and their entrance into the orbit (basilar paralysis), or in the nerve or its branches in the orbit (orbital paralysis).

The Differential Diagnosis between Central and Peripheral Paralysis is not always easy; it is based on the character of the paralysis and the accompanying symptoms. Complete paralysis, unaccompanied by any other symptoms, is generally peripheral. When central, the paralysis is generally less complete, more than one muscle is usually involved, there are apt to be cerebral symptoms, and there is commonly an absence of peripheral cause.

The Nature of the Lesion.—The lesion may be a neighbouring exudation, hæmorrhage, periostitis, tumour, injury, or vascular change, causing compression or inflammation of the nerves; less frequently it is a primary inflammation or degeneration.

The most common cause is *syphilis* (late symptom), which is responsible for one-half the cases. Rheumatism and exposure to severe cold sometimes cause oculo-motor palsies. Epidemic encephalitis is another cause. Muscle paralyses occur in various central nervous system diseases (tabes, general paralysis, disseminated sclerosis, etc.); after acute infectious diseases (diphtheria, influenza, etc.); in acute poisonings (alcohol, ptomaine, botulism, etc.); in diabetes; in rheumatism; in exophthalmic goitre.

Congenital paralyses are not uncommon, due to absence, abnormal insertion, or other structural defects of the muscles themselves. Congenital abnormalities most often affect the external rectus and the superior rectus.

Prognosis varies with the cause. Peripheral paralyses due to syphilis, rheumatism and cold, usually recover under appropriate treatment, but there may be relapses. In the paralysis accompanying serious spinal and cerebral disease the prognosis is often bad. Long neglected paralyses present an unfavourable prognosis, on account of the atrophy of the paralyzed muscle and the contracture of the antagonist. The course is always chronic, and even in favourable cases several weeks or months are required to effect a cure.

Treatment should, in the first place, be directed to the cause. In syphilis, mercurv. iodides, and salvarsan are indicated.

In rheumatism and gout, salicylate of sodium, iodide of potassium, and colchicum, singly or combined, are prescribed. In diphtheria, strychnine is indicated. In obscure cases, iodides with or without mercury should be resorted to. Hot baths and diaphoresis are sometimes employed.

Locally, we may use electricity, ocular-muscle exercises, prisms, and occlusion of one eye. In incurable cases, operative intervention may be resorted to.

Electricity may be tried; the constant current (3 milliamperes) is used, the negative pole being applied to the back of the neck, and the positive over the affected muscle.

The weakened muscle may be exercised by allowing the patient to look through a prism which almost corrects the diplopia, thus coaxing the paralyzed muscle into action. The same result can be achieved by directing the patient to move his head until the double images almost coalesce, and then to make a strong effort to fuse them without any further motion of the head. Such exercises are repeated ten times at each sitting, several times a day.

In chronic cases with moderate paresis, prisms may neutralize the diplopia, and thus add to the patient's comfort. In some cases use gradually strengthens the weak muscle so that prisms may be made weaker from time to time and ultimately dispensed with. Prisms stronger than 2 degrees or 3 degrees deflecting power (or 5 prism dioptries) for each eye cannot as a rule be worn with comfort, on account of their weight and chromatic aberration.

During the course of medicinal treatment the deviating eye may be occluded by a patch or a ground glass in an ordinary spectacle frame, so as to prevent the annoying diplopia.

If the condition persists for a long period in spite of all treatment, and the paralysis seems incurable, operative treatment is indicated. This consists in an advancement of the paralyzed muscle (p. 400), or musculo-capsular advancement, with or without tenotomy of the antagonist.

Nystagmus.

Nystagmus is not a paralysis, but it is convenient to discuss it in this chapter.

Nystagmus is a short, rapid, involuntary oscillation of the eyeball, usually affecting both eyes and associated with imperfect vision. The movements are most frequently from side to side (lateral nystagmus), or around the antero-posterior axis (rotatory nystagmus), sometimes up and down (vertical nystagmus). There may be a combination of the lateral or vertical with the rotatory movements (mixed nystagmus). The oscillations are similar in kind, duration, and frequency in the two eyes. They may be constant, or present or exaggerated only when the eyes are turned in certain directions. The patient is not, as a rule, inconvenienced by the existence of this condition; but when it commences in adult life there may be much annoyance from the apparent movement of objects.

Most cases exist from *infancy*. These may be caused by diminution in the acuteness of vision, as a result of opacities of the media, intra-ocular diseases, or congenital anomalies, such as albinism. But, as a rule, the motor inco-ordination is congenital, and causes amblyopia by rendering steady fixation impossible.

In *adults* it may develop with many cerebral affections, especially disseminated sclerosis, disease of the cerebellum, and Friedrich's disease. It is also found in coal-miners (miner's nystagmus). In these cases it is probably due to working in a recumbent position with the eyes turned upward and obliquely. Disease of the labyrinth is an occasional cause of nystagmus.

The infantile cases are not amenable to treatment, though the condition sometimes becomes less marked with advancing years; the correction of even high errors of refraction seldom improves the vision. Miner's nystagmus generally disappears with a change of occupation.

CHAPTER XXVIII*

COMITANT SQUINT

Convergent Squint.

THE most striking symptom in a case of comitant squint consists in (1) a deviation of the visual axes from their normal relative directions. There is always also (2) a defect of the fusion faculty (see pp. 365 and 381). Other symptoms are (3) the vision of the eye which is not being used for fixation is almost invariably suppressed, so that there is very rarely any diplopia; (4) there is, in rather rare instances, some congenital amblyopia; (5) there is very often, in the deviating eye, amblyopia, acquired as the result of disuse of this eye; (6) there is usually some refractive error, commonly hypermetropia and hypermetropic astigmatism.

When the visual axes deviate the patient makes a conjugate movement of both eyes until he has brought the better eye to bear upon any object which engaged his attention. This eye then becomes 'straight,' and the deviating eye manifests the convergence of both. If a patient fixes, say, with the right eye, and turns in the left, he is said to squint with the left eye. It must be remembered, however, that this does not accurately describe the condition, as, of course, comitant squint really concerns both eyes and certain cerebral functions also.

* Chapters XXVIII., XXIX., and XXX. are brief extracts from the sixth edition of 'Squint: its Causes, Pathology, and Treatment,' by Claud Worth, in which work will be found proofs of the statements contained in these chapters and a fuller description of the methods advocated.

In a case of comitant squint the separate movements of each eye are perfect. The conjugate movements also are perfect; when the fixing eye moves in any direction the deviating eye moves through the same angle. The association between accommodation and dynamic convergence is perfect; when the fixing eye fixes a near object the deviating eye rolls still farther inwards, a dynamic convergence being superadded to the abnormal static convergence.

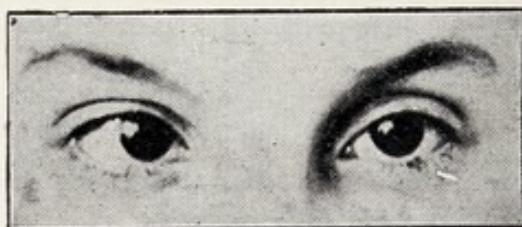

FIG. 306.—CONVERGENT SQUINT.

In fact, there is no motor defect of any kind in a typical case of convergent squint, but the primary position from which these movements start is a 'cross-eyed' position instead of parallelism of the visual axes.

The *clinical varieties* of convergent squint are : (1) *Occasional* squint, in which the deviation is not constantly present ; (2) *constant unilateral* squint, in which the deviation is constantly present, and is always manifested by the same eye ; (3) *alternating* squint, in which either eye indifferently is used to fix, while the other eye deviates.

Suppression of the Vision of the Deviating Eye.—When the fusion faculty is absent the patient is only able to receive visual impressions from one eye at a time. In a case of squint, therefore, almost invariably, the picture formed in the eye which is not being used for fixation is ignored or *suppressed*, so that there is *no diplopia*.

The Amblyopia of Squint.—When a patient first comes under observation after having suffered from constant unilateral squint for a considerable time, one very frequently finds that the deviating eye is more or less blind. This amblyopia is *rarely congenital*. Congenital amblyopia, moreover, never reaches a very high degree. The amblyopia has nearly always been *acquired* (*amblyopia ex anopsia*), as a result of a gradual loss of function in an eye which is never used. This acquired amblyopia sometimes reaches an extreme degree, so that fingers can barely be counted close to the face. When

the visual acuity, in a case of acquired amblyopia, falls below $\frac{6}{80}$ the patient loses the power of 'fixing' any object steadily with this eye, even though the other eye be covered, because the macular region has ceased to be more sensitive than the paracentral region of the retina (*lost fixation*).

Etiology of Convergent Squint.—The one *essential cause of squint is a defect of the fusion faculty*. So long as the fusion faculty is perfect the eyes cannot deviate from their normal relative directions without causing intolerable diplopia (*e.g.*, in a case of paralysis of an external ocular muscle); but if the fusion faculty be absent there is no tendency to fusion, and there is no diplopia when the eyes deviate. The eyes are then merely controlled by their motor co-ordinations, and anything which upsets the equilibrium of these co-ordinations will cause a permanent squint. This disturbing influence may be :

1. *Hypermetropia*. — Owing to the association between accommodation and convergence (see p. 316), when the eyes accommodate in looking at a near object the visual axes converge to a proportionate degree. Hypermetropic eyes must accommodate even in distant vision, and still more in near vision. There is a *tendency* for an abnormal convergence to be associated with the abnormal effort of accommodation. If the control of the fusion faculty be absent this tendency will give rise to an actual deviation.

2. *Anisometropia* and the rare congenital amblyopia predispose to squint by making binocular vision more difficult.

3. In the absence of the controlling influence of the fusion faculty a *motor imbalance* may give rise to squint.

4. *Specific Fevers*, especially whooping-cough, or any violent mental disturbance, may be the immediate exciting cause of the deviation in a case in which the fusion faculty is deficient.

Injury to the sixth nerve during birth in some cases causes a deviation which prevents the development of binocular vision.

The Method of Investigating a Case of Squint.—The presence or absence of a deviation may sometimes be determined by simple inspection, but often appearances are misleading.

The *mirror test* should be used. . . . The patient should be in the dark-room with the lamp behind him. The light is reflected from the mirror of an ophthalmoscope from a distance of about 2 feet into the patient's eyes. An infant will immediately look at the mirror ; an older patient should be told to do so. A tiny image of the mirror is formed on the patient's cornea. Owing to the angle gamma this reflection of the mirror is usually slightly to the nasal side of the centre of the pupil. By flashing the light rapidly from one eye to the other any want of symmetry in the position of the reflections in the two eyes may be detected. It can be seen, too, which is the deviating eye, and, with practice, a very good guess as to the extent of the deviation may be made.

Now cover the good eye, and note whether the previously deviating eye can fix the mirror so as to bring the corneal reflection of the mirror into a position similar to that which it formerly occupied on the good eye. If it can, the eye has *central fixation*, and its vision is probably not less than $\frac{6}{80}$. If not, *fixation is lost*, and the vision is less than $\frac{6}{80}$.

The *movements of each eye* may be tested with sufficient accuracy for practical purposes by keeping the child's head fixed and covering one eye, while he follows some object with the other. In abversion the edge of the cornea should touch the outer canthus. Adversion varies considerably, but the patient should be able to bring the corneal margin to within $\frac{1}{10}$ inch of the caruncle.

The *angle of the deviation* should be measured at each visit, and the result recorded. The *perimeter* method is troublesome, not very accurate, and it cannot be used in the case of small children. The patient is seated at the perimeter, which is adjusted so as to bring the deviating eye accurately into the centre of the arc. A candle is placed at the far end of the room in line with the zero of the perimeter and the patient's deviating eye. He is told to look steadily at the candle with his fixing eye. A second taper, with the eye of the surgeon looking exactly over the top of the flame, is carried round the arc of the perimeter till the reflection of the flame lies in the centre of the cornea of the deviating eye.

The position of the taper on the graduated arc of the perimeter shows the angle of the deviation in degrees.

For a description of more rapid and accurate methods requiring special apparatus the larger work must be consulted.

The state of the *refraction* should be ascertained by retinoscopy after the use, thrice daily for 3 or 4 days, of atropine ointment 1 per cent.

Treatment of Convergent Squint.

The objects to be kept constantly in view in the treatment of squint are : (a) To prevent deterioration of the vision of the deviating eye, and to restore, as far as possible, the sight of this eye in cases in which amblyopia from disuse has already been allowed to occur ; (b) to endeavour to remove the fundamental cause of the squint by training the fusion sense at the earliest possible age ; (c) to restore the visual axes to their normal relative directions.

There are five therapeutic measures at our disposal, any or all of which it may be necessary to use in our endeavour to attain these objects : (1) Optical correction of any refractive error which may be present ; (2) instillation of atropine into the *fixing eye only* ; (3) occlusion of the fixing eye ; (4) training the fusion sense ; (5) operation.

1. *Optical Correction.* — If retinoscopy under atropine reveals any important refractive error glasses should be ordered correcting all the astigmatism, and within 0.5 D. of the total hypermetropia. Myopia should be exactly corrected. The glasses should be very carefully fitted, and should be worn constantly. No infant is too young to wear spectacles should they be required.

2. *Instillation of Atropine into the Fixing Eye only.* — In a case of unilateral squint, as the deviating eye is never used, its vision gradually deteriorates. If the case has not been left too long the sight may be gradually restored by forcing the child to use the eye. Atropine has the property of temporarily paralyzing the ciliary muscle, and so suspending the power of accommodation of the eye. When, therefore, atropine is instilled into a normal emmetropic eye, or an eye

whose refractive error is corrected by glasses, this eye still sees distant objects clearly, but is unable to focus near objects. An unatropized eye, whose vision is only one-sixth or even one-tenth of the normal, is able to see objects at the reading distance more clearly than a normal eye whose accommodation is paralyzed by atropine. In the case of a young child whose deviating eye has not lost the power of central fixation, one should order atropine to be put into the *fixing eye only* every morning. The child soon learns to use the atropized fixing eye for distant vision, and the unatropized deviating eye for near vision. In this way the deviating eye is very thoroughly exercised with a minimum of trouble. The treatment may be kept up for many months—until the vision of the deviating eye becomes perfect, or until no further improvement can be got. The improvement in vision, as a rule, is inversely proportionate to the age of the child and the duration of the deviation. After seven or eight years of age usually not much improvement can be obtained, though there are many exceptions to this rule.

In a case of unilateral squint the surgeon should *on no account order atropine for both eyes*, except for as long as may be required for the retinoscopy. When the patient first begins to squint his choice of an eye is usually governed by the question of refractive error. Therefore, if the accommodation of both eyes is paralyzed by atropine it is certain that the deviating eye, which has the greater refractive error, will never be used.

3. *Occlusion of the Fixing Eye* is necessary in a case in which the deviating eye has lost central fixation. A gauze pad should be fixed over the eye with strapping plaster; the child will require constant supervision until the other eye begins to improve, or he will get the pad off. If continuous occlusion of the fixing eye restores central fixation in the deviating eye the case may be treated as described in paragraph 2. If this result is not attained in six or eight weeks, further attempts will be useless.

4. *Training the Fusion Faculty*.—Normally the fusion faculty begins to develop at a very early age, and reaches its

full development by the end of the sixth year. In a case of squint which is seen early enough, one should endeavour to remove the fundamental causes of the anomaly by training the fusion faculty. The most favourable age is between three and six years. After seven years of age the proportion of successes is very much smaller. There are two great difficulties in the way of fusion training in the case of young children. (1) Though the visual acuity of the child's deviating eye may be perfect, the vision of the eye is 'suppressed,' so that he is unable to receive impressions from it except when the fixing eye is closed. (2) The child is too young to understand the purpose of fusion training. He will therefore only permit the exercises so long as they amuse him. These difficulties have to a great extent been overcome by means of the amblyoscope.

The *amblyoscope* consists of two halves joined together by a hinge. Each half consists of a very short brass tube joined

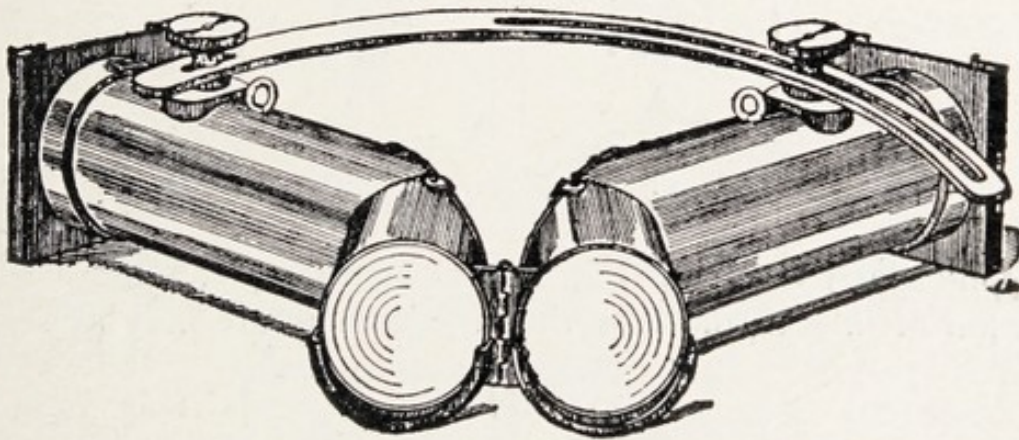
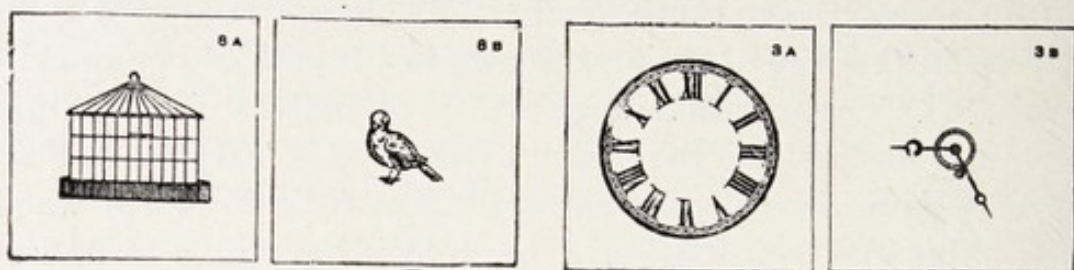


FIG. 307.—AMBLYOSCOPE.

to a longer tube at an angle of 120 degrees. At the angle of junction of the tubes is an oval mirror protected on the outside by an oval plate of brass. Each half of the instrument has at its distal end an object-slide carrier, and at its proximal end a convex lens having a focal length of 5 inches, the distance of the reflected image of the object-slide. In front of each lens is a slot into which a prism, axis vertical, may be inserted if required. The two parts of the instrument can be brought together to suit a convergence of the visual axes up to

60 degrees, or separated to suit a divergence of as much as 30 degrees.

The *object-slides* used with this instrument are of three classes: (1) Those which do not require any blending of images, but only simultaneous vision of dissimilar objects



FIGS. 308 AND 309.—DEVICES REQUIRING ONLY SIMULTANEOUS VISION.

with the two eyes. Fig. 308, showing a bird on one side and a cage on the other, is an example. (2) Devices of the




FIG. 310.—DEVICE REQUIRING FUSION OF IMAGES.

second class, of which Fig. 310 is an example, require true fusion of images, in order that the full picture may be seen

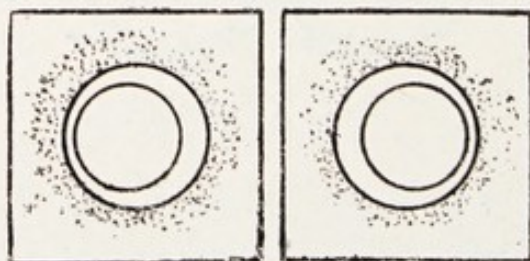


FIG. 311.—TEST FOR THE SENSE OF PERSPECTIVE.

(3) Devices such as Fig. 311 can only be appreciated by persons who have the sense of perspective.

Each object-slide is illuminated by a separate electric light, oil lamp, or candle. The intensity of illumination of each slide may be regulated by varying the distance of its light.

The first step in the treatment is to overcome the suppression of the vision of the deviating eye. The child is taken on the knee of the surgeon, and the amblyoscope approximately adapted to the angle of the squint. First a pair of slides requiring no fusion, only simultaneous vision, is shown (*e.g.*, Fig. 308). Suppose the cage is before the fixing eye and the bird before the deviating eye. The child on looking into the amblyoscope will see only the cage. He is told to look for the bird while the light before the deviating eye is brought nearer and nearer. At last a point is reached when the illumination of the picture before this eye becomes so intense that its image can no longer be suppressed. The relative distances of the lights are then readjusted until, after a few minutes of alternation of the vision of the two eyes, the child sees the bird and the cage simultaneously. The bird is then made to go in and out of the cage. Many other similar devices are shown until the suppression is entirely overcome while the child is looking into the instrument.

A pair of slides requiring fusion of images is now shown—Fig. 310, for instance. The child at first sees two men, each picture being imperfect. Soon a position is found in which he is able to blend them into a complete picture. After a time it is found that the angle of convergence of the instrument may be varied slightly without the fused picture coming to pieces. The child has now, under these special conditions of illumination and convergence, true fusion with some amplitude. This amplitude of fusion may now be increased by practice, while the intensities of the lights are gradually equalized. A patient who has good amplitude of fusion will usually be found to have acquired the sense of perspective also. Being shown the devices Fig. 311 in the amblyoscope, he sees a tub or bucket bottom up; when the slides are transposed he sees the inside of the tub.

If a good amplitude of fusion has been acquired there will be a strong tendency towards binocular single vision. This tendency will be sufficient to overcome a small deviation, or a deviation which has been approximately corrected by glasses or operation.

5. *Operation*.—In cases of convergent squint in which the deviation is not overcome by other means, operation becomes necessary. Two operative procedures, tenotomy of an internal rectus and advancement of an external rectus, are employed either singly or in combination.

Tenotomy of an internal rectus consists in a division of the tendon of this muscle at its insertion into the globe. This allows the eye to rotate outwards to an uncertain degree; it also causes some proptosis and weakness of adversion. In order to *advance* a muscle, the tendon is separated from the globe at its insertion. It is usually shortened. The cut end is then secured to the globe at a point nearer the cornea than the original insertion. For a description of these operations see Chapter XXX.

Many operations have been devised for shortening a muscle without advancing its insertion, either by exsection of part of the muscle, or by folding the tendon upon itself. Exsection is much easier to perform than advancement, and, provided that the muscle is normally inserted, will suffice for a quite small deviation.

Recession of a muscle is a tenotomy with suture by which it is sought to anchor the cut end of the tendon to the sclerotic further back. It presents no advantage to a surgeon who can perform advancement with certainty, and it would be a dangerous operation in unskilful hands.

Tenotomy alone is often unsatisfactory, and is always uncertain in its effects. Even if the result of a tenotomy appear to be satisfactory at the time, the eye is very liable to turn the other way in after years. In fact, no surgeon who had followed up his cases of tenotomy for ten years would be likely to continue to do this operation. By means of a properly performed advancement any degree of rotation of the globe may be safely and accurately produced. But if a very high degree of convergent squint is corrected by advancement of one external rectus, the globe is somewhat retracted. A good rule, therefore, is to correct deviations under about 15 degrees by unilateral advancement, and to correct higher deviations by advancement of both external recti. The one advantage of tenotomy is that anyone can do it; whereas accurate and

certain performance of advancement requires more skill and experience than any other operation in ophthalmic surgery.

Alternating convergent squint requires the same treatment as unilateral squint, except that there is no amblyopia to be prevented or cured.

DIVERGENT SQUINT.

Comitant divergent squint presents two distinct varieties differing widely in their pathology, appropriate treatment, and prognosis. They may be called respectively myopic and neuropathic.

Myopic Divergent Squint.

The divergence begins usually at about ten or twelve years of age. It may be either unilateral or alternating. Usually the patient is known to have been short-sighted for several years. At the time of the appearance of the divergence a myopia of 5 or 6 D. is common. Usually the fusion faculty is well developed. As a rule the deviation is not constant, the eye being sometimes 'straight,' sometimes widely divergent, but seldom divergent to a slight degree.

The mode of origin of a myopic divergent squint is as follows: During early school life the child gradually becomes more and more short-sighted, so that at, say, ten or twelve years of age his far point is very near his eyes. In reading he has to hold his book so near his eyes that it becomes difficult to converge to the required extent. He gives up the struggle, and allows one eye to wander outwards, while he reads without effort with the other. As a result of the convergence never being used the function becomes weakened, so that after a time the eyes diverge even in distant vision. The picture of distant objects formed in the fixing eye is already blurred owing to the myopia, so the faint eccentrically-placed image formed in the divergent eye causes no tendency to fusion.

The *treatment*, which in recent cases brings about a rapid cure, is spectacles, for constant wear, exactly correcting the myopia and myopic astigmatism. In some old-standing cases advancement of an internal rectus muscle is required also, never tenotomy of an externus.

Neuropathic Divergent Squint.

The divergence nearly always dates from infancy. It may be constant or occasional, unilateral or alternating. In the constant cases the fusion faculty is totally absent. In the occasional cases there is a feeble degree of fusion. In the unilateral cases the divergent eye may have acquired amblyopia. The refraction is as a rule quite normal. The degree of divergence is very variable. The power of dynamic convergence is deficient, and variable from day to day. The association between accommodation and convergence is very slight or even absent. In young subjects the power of inward rotation of each eye separately is perfect; in long-standing

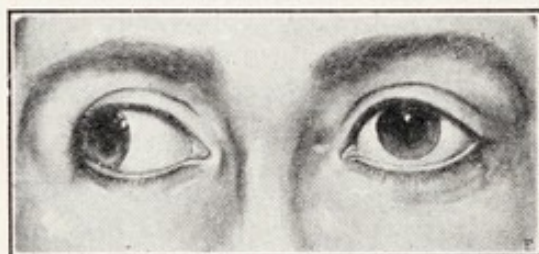

FIG. 312.—DIVERGENT SQUINT.

cases it is often deficient. In the occasional cases especially there is constant, or frequent aching and discomfort in the eyes.

The subjects of neuropathic divergence are usually bright and intelligent, but are almost always very 'nervous' and 'highly strung.' A family history of epilepsy or insanity is common.

Treatment.—An accurate advancement of both internal recti will remove the deformity and relieve the "asthenopic" symptoms. In unilateral cases amblyopia ex anopsia should be guarded against.

Non-comitant Divergent Squints other than Paralytic.

In *extreme myopia* the egg-shaped eyes tend to adapt their long axes to the divergent positions of the orbits. No treatment for the divergence should be attempted.

Blind eyes usually tend to diverge.

Tenotomy of an internal rectus in a certain proportion of cases produces an over-effect so that the eye diverges. The retracted internal rectus muscle should be sought for and advanced.

CHAPTER XXIX

HETEROPHORIA

IF a person with a perfectly normal pair of eyes looks steadily at any object both visual axes will continue to be accurately directed to that object even though one eye be shaded. In other words, his perfectly balanced motor co-ordinations are able to maintain the normal relative directions of the eyes even when the controlling influence of the fusion sense is temporarily withdrawn. This state of perfect oculo-motor equilibrium is called *orthophoria*.

Heterophoria is the name given to the condition of imperfect oculo-motor balance. There is here a *tendency* for the eyes to deviate from their normal relative directions. Ordinarily, however, this tendency is kept in check by the fusion sense, so that there is no squint. But if binocular vision be temporarily rendered impossible—*e.g.*, by covering one eye—this tendency gives rise to an actual deviation. Distinctive names are employed to indicate the direction of the tendency :

Esophoria is a tendency to abnormal static convergence of the visual axes.

Exophoria is a tendency to divergence of the visual axes.

Hyperphoria is a tendency of the two eyes to rotate vertically in opposite directions, so that one visual axis tends to lie in a higher plane than the other. The eye which tends to turn up relatively to the other is called the hyperphoric eye.

The *symptoms* of heterophoria are those of eye-strain in general—frontal headache coming on towards the end of the day, pain in the eyes after watching anything intently,

e.g., a play—migraine, dizziness (especially associated with hyperphoria), conjunctival hyperæmia, etc. In the higher degrees of heterophoria momentary deviation with diplopia is not uncommon.

Pseudo-heterophoria.—In a case of uncorrected ametropia there is frequently an apparent heterophoria, which disappears after correcting glasses have been worn for a time.

Heterotropia.—A person whose fusion sense has developed perfectly, but who has a high degree of heterophoria, will be able to keep his deviation tendency in check on ordinary occasions. But when he is very tired or in bad health the heterophoria may give rise to an actual deviation, with very annoying diplopia. This condition is neither a true squint nor a paralysis, but a further stage of heterophoria.

The Methods of Testing the Motor Balance of the Eyes.—In a case of heterophoria, under ordinary circumstances, the desire for binocular vision prevents the eyes from deviating from their normal relative directions. But if, by artificial means, the image formed in one eye be so altered in appearance or position as to make fusion with the other unaltered image impossible, the control of the fusion sense is suspended. The heterophoria then gives rise to a manifest deviation. The altered image in the deviating eye is not suppressed as in a case of squint. The diplopia, therefore, gives an easy means of ascertaining the direction and degree of the deviation. This is the principle on which all subjective tests for heterophoria are based.

The *instruments* required for the tests here described are the Maddox rod and double prism, two test-cards, and a set of prisms.

The *Maddox rod* (Fig. 313) is a piece of glass rod mounted before a narrow slit in a metal disc. It is in effect a very strong cylindrical lens, so that it disperses light in one

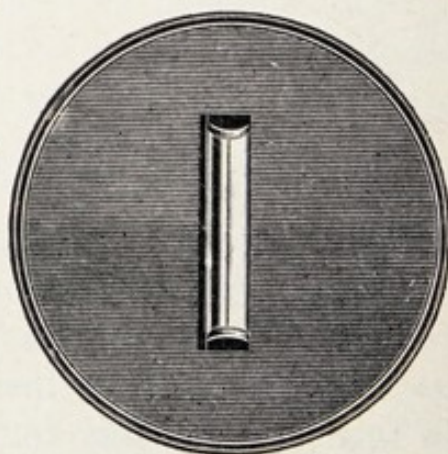


FIG. 313.—MADDOX ROD.

meridian only. In looking at a flame, with the rod before one eye and the other eye naked, the naked eye will of course see the flame and the surrounding objects; but to the rod-clad eye the flame will appear as a long streak of light, and less luminous objects will not be visible at all. It is not possible to blend two such dissimilar images as the flame and the streak, so the function of fusion is temporarily suspended, and the eyes are merely controlled by their motor co-ordinations. If there be no motor anomaly, the streak seen by the rod-clad eye will appear to pass through the flame seen by the naked eye. But if there be any heterophoria, it will now




FIG. 314.—DOUBLE PRISM.

be able to cause the eyes to deviate, the relative positions of the streak and light indicating the direction and degree of the deviation (Figs. 317 to 322).

The Maddox *double prism* (Fig. 314) consists of two prisms, each of 4 degrees actual deviating power, cemented base to base. When this double prism is placed with its apices vertical before one eye, so that the line of junction of

the bases crosses the pupil horizontally, two false images of any small object will be seen, one above and the other below its true position. If now the other (naked) eye be opened it will see the real image of the object midway between the two false images.

The *test-cards* consist of two pieces of white cardboard each about 20 inches square. No. 1 card has in its centre a horizontal black line 2 inches long. No. 2 card has in its centre some small letters with a large capital O in the middle.



FIG. 315.—
NO. 2 TEST-CARD.

In the *examination* the patient is in a darkened room 5 or 6 metres from a candle flame. He wears a trial frame with his correcting lenses if he is ametropic, and a Maddox rod, axis horizontal, before, say, the right eye. If the vertical

streak seen by the right eye appears to go through the light seen by the left eye (Fig. 317), the patient has no esophoria or exophoria in distant vision. Now rotate the rod so that its axis is vertical. If the horizontal streak now seen by the right eye appears to pass through the light seen by the left eye (Fig. 320), the patient has no hyperphoria in distant vision.

Now remove the rod, and replace it with the double prism, with line of junction of bases horizontal. Hand the patient No. 1 test-card. He will

see two false images of the horizontal line with the prism-clad eye, and between them he will see the true image with the naked eye. If the middle line appears equi-




FIG. 316.—LINE ON NO. 1 TEST-CARD WITH ITS TWO FALSE IMAGES. ORTHOPHORIA.

distant from each of the other lines, and has its ends level with their ends (Fig. 316), there is no hyperphoria, esophoria, or exophoria in near vision. If the middle line appears parallel to the other two lines, as in this figure, there is no cyclophoria. The patient's oculo-motor equilibrium, therefore, is perfect in every respect.

If, however, any anomaly be found during these proceedings, further examination will be required.




FIG. 317.

FIG. 318.

FIG. 319.

FIG. 317.—THE MADDOX ROD TEST IN ORTHOPHORIA.

FIG. 318.—THE MADDOX ROD TEST IN EXOPHORIA.

FIG. 319.—THE MADDOX ROD TEST IN ESOPHORIA.

In the *distant-vision test* with the Maddox rod, axis horizontal, before the right eye, if the vertical streak lies to the

right of the light (homonymous diplopia), there is esophoria (Fig. 319). If it lies to the left of the light (crossed diplopia), there is exophoria (Fig. 318).

In using the rod, axis vertical, before the right eye, if the horizontal streak is seen below the light, this indicates that the right eye tends to turn upwards relatively to the left eye (right hyperphoria ; Fig. 322). If the streak is seen above




FIG. 320.

FIG. 321.

FIG. 322.

FIG. 320.—THE MADDOX ROD IN ORTHOPHORIA.

FIG. 321.—THE MADDOX ROD IN LEFT HYPERPHORIA.

FIG. 322.—THE MADDOX ROD IN RIGHT HYPERPHORIA.

the light, the left eye tends to turn upwards relatively to the right eye (left hyperphoria ; Fig. 321). The degree of the defect may be measured by finding the prism which will cause the streak to pass through the light.

In the *near-vision test* with the double prism before the right eye and the No. 1 test-card, the middle line, seen by the left eye, should be equidistant between the two false images seen by the right eye (Fig. 316). If it lies nearer the upper false image, there is right hyperphoria. If it lies nearer the lower false image, there is left hyperphoria. The prism, base down, before the hyperphoric eye, which places the line half-way between the two false images, will serve to measure the degree of the anomaly.

A want of parallelism between the line on No. 1 test-card and its two false images indicates cyclophoria. Cyclophoria admits of no direct treatment.

If the three lines in Fig. 316 are not level with each other at their ends, hand the patient No. 2 test-card. The small letters are to ensure a normal effort of accommodation. If

presbyopic or ametropic, he is allowed glasses. He will see the true image of the object between its two false images. In orthophoria the three images will be in the same vertical line. If the middle image, seen by the left eye, is to the left of the two false images, the patient has esophoria in near vision. If it is to the right, he has exophoria in near vision. The prism, axis horizontal, which will bring the three O's in line is a measure of the defect. The study of esophoria and exophoria in near vision is intimately associated with that of convergence anomalies.

Prism duction should always be investigated in any case in which important heterophoria has been found. The patient, wearing a trial-frame and having both eyes open, is seated 5 or 6 metres from a candle flame. Prisms increasing in strength are successively put in the cell before the right eye. The highest prism, apex up, which the patient can bear without seeing the flame double gives the range of superduction of the right eye. The right subduction is tested with prisms apex down. The left superduction and subduction are similarly measured. Binocular abduction is measured with prisms apices out. Binocular

adduction is so intimately associated with accommodation that attempts to measure it with prisms (which cause the eyes to converge without accommodating) give misleading results. A rotary prism (Fig. 323) is very useful in making these measurements. The normal limits of prism duction, expressed in degrees of actual deflection, are as follows :

Superduction	.	.	.	$1\frac{1}{2}$ degrees to $2\frac{1}{2}$ degrees.
Subduction	-	.	.	$1\frac{1}{2}$ " $2\frac{1}{2}$ "
Abduction	-	.	.	4 " 5 "



FIG. 323.—ROTARY PRISM.

No amount of practice appears to increase the duction power in these three directions. Convergence, on the other hand,

can nearly always be much increased by practice. As the degree of prism duction does not vary from time to time, and is independent of voluntary effort on the part of the patient, the information obtained is reliable.

Esophoria.

Esophoria of moderate degree seldom causes trouble if the functions of abversion and binocular abduction are normal. In esophoria of high degree there may be occasional momentary deviation of the visual axes with diplopia (see p. 381). These cases should not be mistaken for occasional squint, the pathology of which is entirely different.

Treatment.—Moderate degrees of esophoria only cause trouble when the binocular abduction is deficient. The symptoms are relieved by the constant wearing of prisms, apices in, which represent the deficiency of abduction (*not* the degree of esophoria). Esophoria of high degree requiring treatment can only be dealt with by operation—advancement of an external rectus (see Chapter XXX.).

Exophoria.

Uncomplicated exophoria of moderate degree seldom causes any inconvenience. But if, as occasionally happens, there is a defect of dynamic convergence in addition, the patient is likely to suffer from frontal headache, not only after using the eyes in near vision, but often at other times also. In cases of exophoria of high degree the eyes may momentarily deviate, but this is less common than in esophoria.

Treatment.—Prisms are seldom of use in exophoria. If the case be complicated by convergence deficiency, treatment should be directed to this anomaly. In high degrees of exophoria, especially if adversion be deficient, the internal rectus muscle should be advanced.

Hyperphoria.

Clinically, hyperphoria is the most important of all forms of heterophoria, because of the severity of the symptoms to

which it is liable to give rise, and the certainty with which these symptoms may be relieved. The liability of a case to cause trouble depends not only upon the degree of the hyperphoria, but upon the extent of any deficiency of prism duction in the opposite direction. The commonest symptom is frontal headache, coming on towards the end of the day, not especially caused by near work. Some patients complain of giddiness on looking down. Momentary diplopia is not uncommon.

The *treatment* of a case of hyperphoria of moderate degree is by prisms to be worn constantly. The prism should be placed apex up before the hyperphoric eye. Or, if more than 1 degree is required, the effect may be divided between the two eyes, the prism before the other eye being placed, of course, apex down.

The strength of the prisms should be determined partly by the degree of the hyperphoria, and partly by the range of prism duction (see p. 396). One should attempt as nearly as possible to correct the hyperphoria, and to bring each eye into the middle of the vertical range of prism duction. For example, take a case of right hyperphoria of 2 degrees, in which the right superduction (and left subduction) is 3 degrees, and the right subduction, (and left superduction) is 1 degree. A prism of 2 degrees, apex up, before the right eye would correct the hyperphoria, but a prism of 1 degree would suffice to bring the eyes into the middle of the range of prism duction. In this case one would order a prism of $1\frac{1}{2}$ degrees as a compromise.

In a case of hyperphoria of very high degree, it may be necessary to advance the inferior rectus of the hyperphoric eye. Never tenotomize an inferior rectus.

Insufficiency of Dynamic Convergence.

This is not a heterophoria, but it is convenient to discuss it in this chapter.

Normally the visual axes are parallel in distant vision, but in looking at a near object they are convergent. The act of turning the eyes inwards to look at a near object is called

dynamic convergence. A person who has exophoria must make an effort of dynamic convergence even in distant vision in order to overcome his exophoria. Exophoria (insufficiency of *static* convergence) is discussed on p. 397.

The symptoms of insufficiency of dynamic convergence are pain in the brow after reading and a tendency to hold the book at a long distance from the eyes (apart from any refractive error).

The best *test* for insufficiency of dynamic convergence is to examine the horizontal motor balance of the eyes, first in distant vision, and then at 10 inches. If there is no more exophoria, or no less esophoria, in near vision than there is in distant vision, the patient has no insufficiency of convergence. If the patient has orthophoria in distant vision and exophoria in near vision, or if there is more exophoria or less esophoria in near than in distant vision, he has insufficiency of dynamic convergence of a degree equal to the difference.

In an uncomplicated case of insufficiency of convergence exercises should be tried. The following procedure is as good as any: Any error of static or dynamic refraction is corrected by glasses. The patient begins reading a book at the ordinary distance. Then, while still reading, he gradually brings the book nearer his eyes until the print begins to be blurred. He then slowly removes the book to the ordinary reading distance. This is repeated. At about every tenth line he looks into the distance for a moment in order to completely relax his convergence. Two or three pages should be read in this way three or four times a day for a month. This simple plan has given quite as good results as more elaborate methods.

If convergence training fails, prisms, bases in, may be combined with the reading glasses.

A presbyope who suffers from insufficiency of convergence should be ordered rather weaker convex glasses than he would otherwise require, in order that he may read at a greater distance and so require less convergence.

CHAPTER XXX

OPERATIONS ON THE EXTERNAL OCULAR MUSCLES

Advancement.

Worth's Operation.—In this operation a firm, unyielding hold is got for the sutures at each end, so that any desired degree of rotation of the eyeball may be produced. For moderate degrees of deviation it will be sufficient to operate upon one eye only. For squints of high degree both internal recti or both external recti should be advanced. In dealing with a true vertical deviation, the inferior rectus should be advanced. The anatomical relations of the advanced muscle are disturbed as little as possible. As the middle part of the muscle is not included in the sutures, its main blood-supply is not interfered with. The immediate effect produced is the final result.

The instruments required are speculum (Fig. 176), straight, blunt-pointed scissors (Fig. 324), two fixation forceps (Fig. 177), advancement forceps (Fig. 327), needle-holder (Fig. 326), small curved needles, straight lance-headed cutting needles for the sclera, with split eye (Fig. 324*a*), and silk thread. A general anæsthetic may be used for very young or timid patients. In other cases local anæsthesia will suffice.

The eye is anæsthetized with cocaine. Adrenalin is instilled before and from time to time during the operation. The patient lies on a table with his feet towards the window. His lids are held open by the speculum. The surgeon, standing behind the patient's head, grasps the conjunctiva with the toothed forceps, while with the scissors he makes a curved vertical incision through it rather more than $\frac{1}{2}$ inch long. The

convexity of the incision is close to the corneal margin. A similar incision is then made through the capsule of Tenon. The conjunctiva and capsule then retract, or, if necessary,

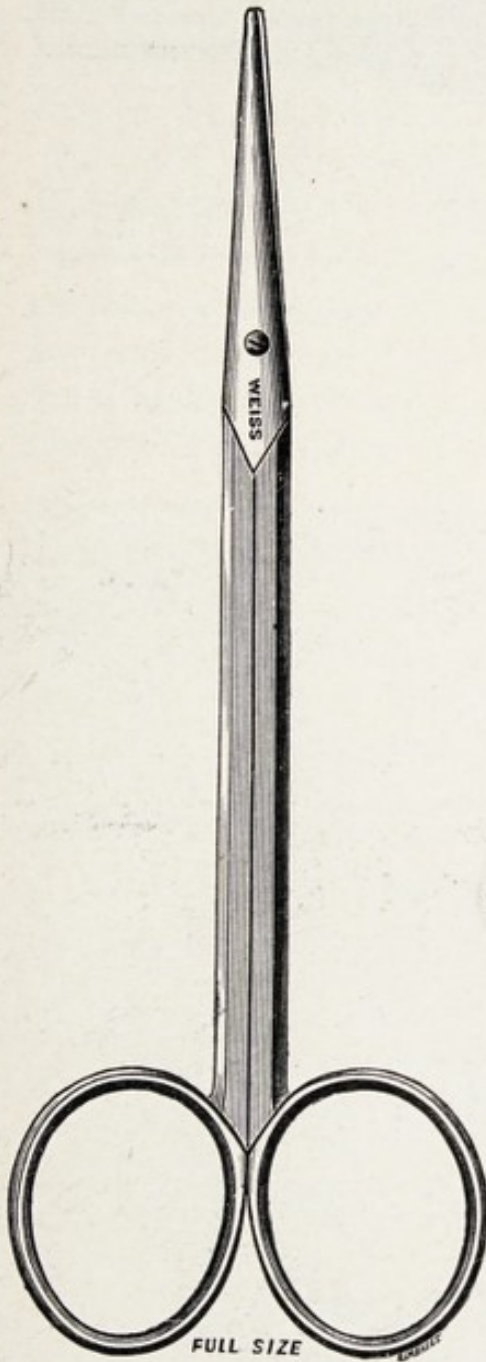


FIG. 324.—SQUINT SCISSORS.

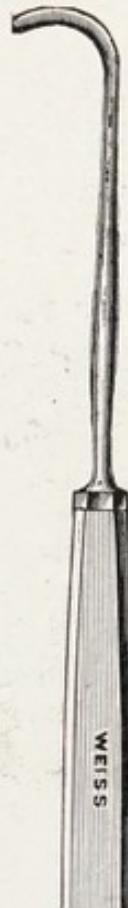

FIG. 325.—
HOOK.




FIG. 324a.—LANCE-HEADED CUT-
TING NEEDLE FOR SCLERA.

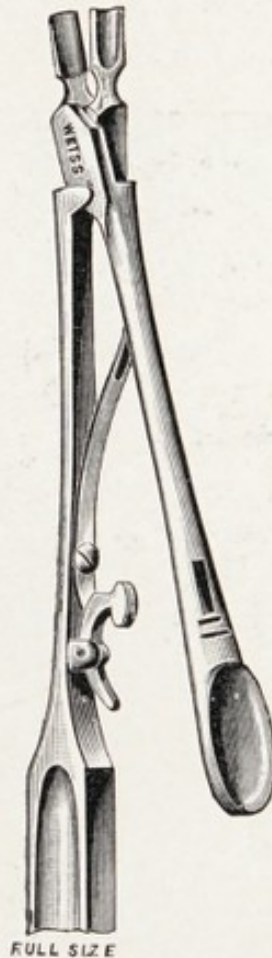


FIG. 326.—
NEEDLE HOLDER.

they are pushed back so as to expose the insertion of the tendon. One blade of the advancement forceps is now passed under the tendon after the manner of a tenotomy hook, the other blade being superficial to the conjunctiva. The forceps

is now closed, so that tendon, capsule of Tenon, and conjunctiva are all firmly clamped together, with their relations

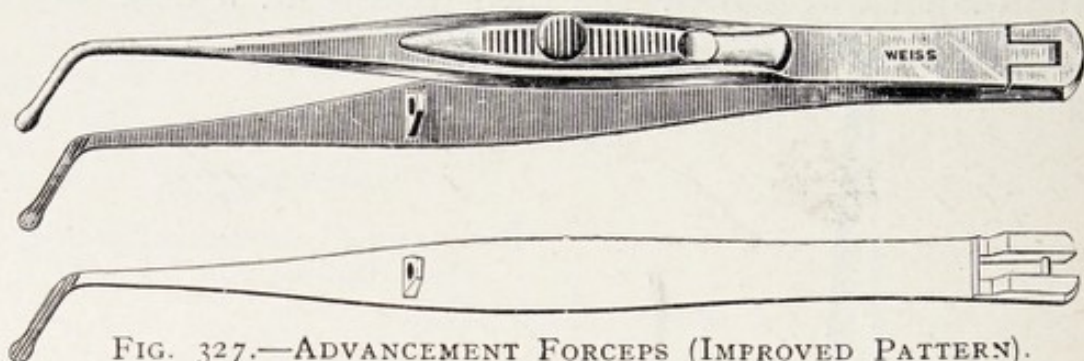


FIG. 327.—ADVANCEMENT FORCEPS (IMPROVED PATTERN).

undisturbed except for the retraction of the membranes. The tendon and a few little fibrous bands beneath the tendon

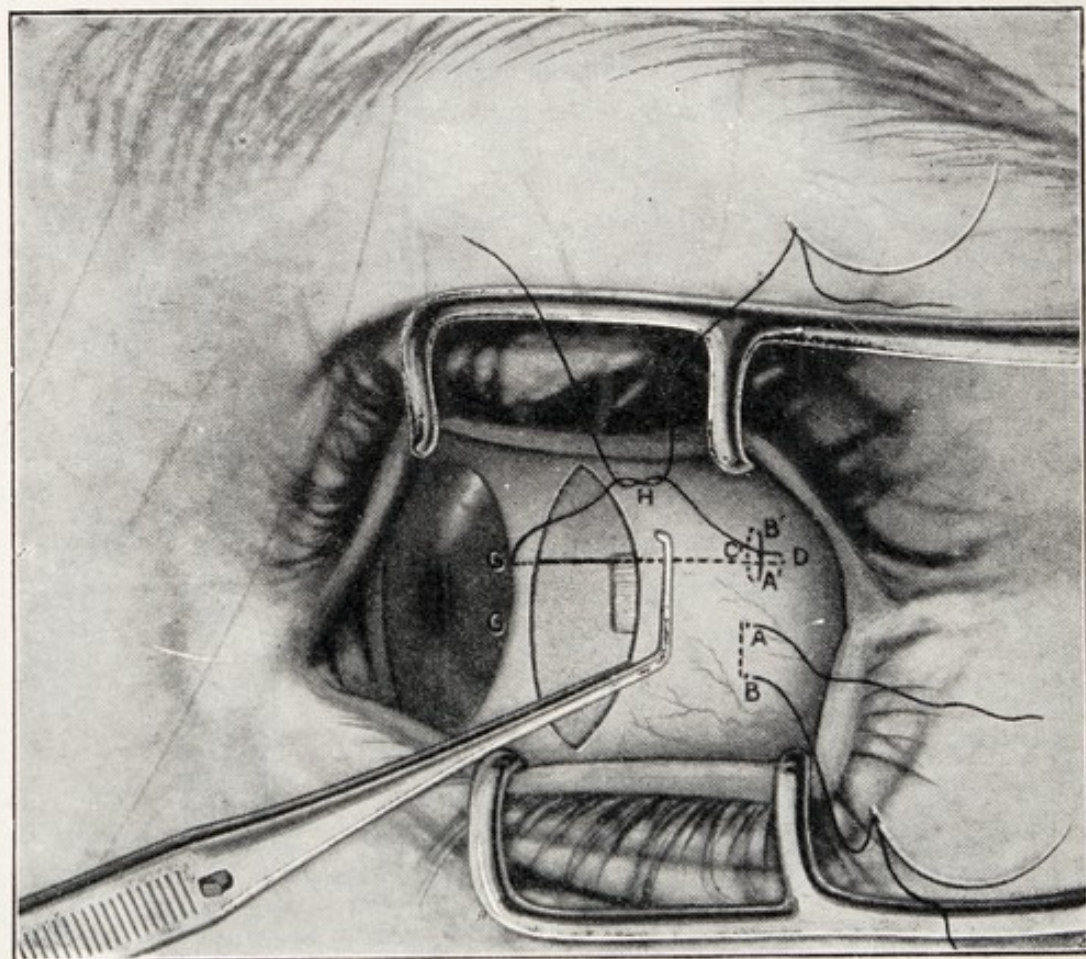


FIG. 328.—WORTH'S OPERATION OF ADVANCEMENT OF AN OCULAR MUSCLE.

are now divided with scissors at their insertion into the sclerotic. The advancement forceps, holding the tendon,

capsule, and conjunctiva, can now easily be lifted up so as to get a good view of the under side of the muscle.

One of the needles is then passed inwards at A, through conjunctiva, capsule, and muscle, and brought out at the under side of the muscle. It is then again passed through muscle, capsule, and conjunctiva, and brought out at B. The bight of the thread thus encloses about the lower fourth of the width of the muscle, together with its tendinous expansions and capsule and conjunctiva. The other needle is similarly entered at A', passed through conjunctiva, capsule, and muscle, and brought out at the under side of the muscle. It is then entered again at the under side of the muscle, and brought out through the conjunctiva at B', the bight of this suture thus enclosing the upper fourth of the width of the muscle, etc. The object of inserting both sutures before proceeding further with either is that they may be symmetrically placed. The ends of the thread from A' and B' are then crossed over at C. The end bearing the needle is then entered at D, and passed through conjunctiva, capsule, and muscle, and brought out beneath the lower blade of the advancement forceps. The first suture is then similarly dealt with. The anterior part of the muscle and capsule and conjunctiva are then removed by cutting them through with scissors behind where they are grasped by the advancement forceps.

The next stage in the operation, the insertion of the two sutures into the sclerotic at G and G, is one which requires great judgment and delicacy of touch. Take a lance-headed needle (Fig. 324a) in the holder. Remove the curved needle from a suture and insert the latter into the split eye. With the fixation forceps take a firm hold of the globe at the site of the old insertion. Lay the head of the needle flat on the sclerotic exactly in line with the position of the suture in the muscle, and about $\frac{1}{8}$ inch, or a trifle more, from the corneal margin. Press the point of the needle backwards so as to dimple the sclerotic a little. Then push it onwards so that it traverses at least half the thickness of the sclerotic, but taking the greatest care not to pierce the whole thickness.

The longitudinal extent of the insertion is about $\frac{1}{8}$ inch. The other suture is then similarly inserted. No verbal direction can be given for gauging the depth. One judges by sight and touch. The gap is now closed, and the eyeball rotated into its correct position by tying each suture at HH.

In operating under cocaine, before the knots are tied at HH, an assistant holds the globe in the primary position with forceps, while the patient is told to try to look away from the operated muscle. This relaxes the muscle while it is being drawn forward by the sutures. The sutures are then temporarily secured at HH by the first hitch of the 'surgeon's knot.' The assistant then releases the globe. The fine adjustment is done by tightening or loosening the hitches at HH, the result being checked by the mirror test or by the reflection of a candle flame on the cornea. The surgeon's knots at HH are then completed.

The longitudinal position on the muscle of the knotted loops ABC, A'B'C' varies approximately according to the degree of rotation required.

This is a brief outline of the technique which I have found to give the best results. But modifications are often employed to suit cases; for example, several additional sutures are sometimes used. Care should be taken to avoid injuring the fascial covering of the under surface of the muscle, lest the muscle form adhesions to its old insertion. If this should happen, the mobility of the eye in the opposite direction would be greatly impaired.

The patient should be kept in bed with both eyes bandaged for ten days after the operation.

Tenotomy.

There are several slightly different methods of performing this little operation. The following is as good as any other. The instruments required are speculum (Fig. 176), straight, blunt-pointed scissors (Fig. 324), fixation forceps (Fig. 177), and tenotomy hook (Fig. 325). The patient is prepared as for advancement. In operating upon the left internal rectus

it is more convenient to stand in front of the patient. In operating upon any of the other recti it is better to stand behind the patient's head. Insert the speculum. Tell the patient to look in a direction opposite to that of the tendon to be divided, so as to bring its insertion well forward. With the forceps pick up the conjunctiva over the insertion of the tendon, and with the scissors make an incision about $\frac{1}{8}$ inch long, in a direction at right angles to that of the tendon. Now divide the capsule of Tenon in the same way. This brings the insertion of the tendon into view. While the forceps still hold up the cut edge of the capsule, make a few short snips with the scissors near one border of the tendon until the point of the scissors is felt to slip freely back without encountering any resistance. Now lay down the scissors, and take up the hook in the right hand. Pass the point of the hook into this incision, and hook it round the insertion of the tendon until it appears at the other border. During this manœuvre the point of the hook should be kept in contact with the sclerotic. Now lay down the forceps and transfer the hook to the left hand. Take care to avoid any dragging with the hook, as this causes pain. With the scissors cut between the point of the hook and the globe until the tendon is divided at its insertion and the hook comes away. It is usual to reintroduce the hook to seek for any fibres of insertion which may have escaped division. Where the effect produced by the tenotomy appears very small there is a temptation to divide the indirect attachments above and below. This should on no account be done. It is not necessary or advisable to suture the conjunctiva unless the conjunctival incision is unusually large.

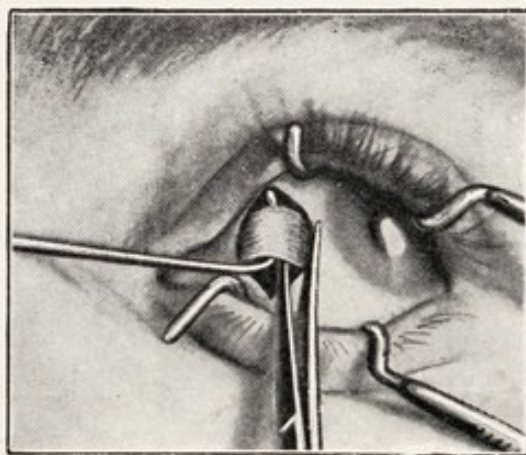


FIG. 329.—TENOTOMY.

After the operation there is a very considerable defect of

movement in the direction of action of the tenotomized muscle. This, to some extent, subsequently disappears. The *average* effect of a tenotomy of the internal rectus is 13 degrees, and of the other recti less than half this amount. But it varies within extremely wide limits, and in a very large proportion of cases of tenotomy of an internal rectus the eye gradually deviates outwards in after years.

A pad and bandage should be worn for the first forty-eight hours, after which it may be discarded. The eye should be bathed with boric lotion three or four times a day until the wound is healed.

CHAPTER XXXI

THE OCULAR MANIFESTATIONS OF GENERAL DISEASES

THE systemic diseases which most frequently give rise to ocular symptoms and diseases are: Syphilis, tuberculosis, rheumatism, nephritis, diabetes, arterio-sclerosis, cardiac affections, diseases of metabolism, chronic intoxications, infective diseases, and affections of the nervous system.

This chapter should be read in conjunction with the earlier chapters, in which the ocular symptoms have been fully discussed.

Diseases of the Blood.

Anæmia and Chlorosis give rise to pale pink conjunctivæ and pearly white scleræ. There may be pallor of the disc and the rest of the fundus, the retinal vessels being pale, tortuous, and the retinal veins broader than normal. Occasionally retinal hæmorrhages are found.

Pernicious Anæmia often causes retinal hæmorrhages, occasionally retinitis. The fundus exhibits great pallor.

Hæmophilia predisposes to profuse hæmorrhage after injury to the eye, and under such circumstances may cause hyphæmia, or hæmorrhage into the retina or into the orbit.

Leukæmia.—Retinal hæmorrhages are very common, and a peculiar form of retinitis, leukæmic retinitis, is often present.

Purpura is often accompanied by hæmorrhage beneath the conjunctiva, in the retina, skin of the lids, and occasionally into the orbit.

Severe Hæmorrhage may be accompanied by amblyopia. The latter may be temporary and accompanied by little or no

ophthalmoscopic change, or it may be permanent and followed by atrophy of the optic nerve. Such sudden and severe anæmia may cause retinal hæmorrhages.

Diseases of the Circulatory System.

Heart.—Valvular heart disease and fatty heart are often accompanied by hæmorrhages into the retina, less frequently into the vitreous. Aortic insufficiency causes pulsation of the retinal arteries. Endocarditis may cause embolism of the central artery of the retina. The oedema dependent upon cardiac disease may involve the eyelids, being noticed especially upon rising in the morning.

Aorta.—Aneurism of the aorta may give rise to mydriasis, enlarged palpebral aperture, and exophthalmos, as a result of irritation of the cervical sympathetic; or to miosis, slight ptosis, and enophthalmos, through paralysis of the same. This condition may also cause thrombosis and embolism of the central artery of the retina, or of one of its branches.

Arterio-sclerosis gives rise to characteristic changes in the fundus, which are described on p. 260, and illustrated on Plate XVIII. It is a predisposing cause of glaucoma.

Diseases of the Digestive System.

Teeth.—The occurrence of ocular symptoms and diseases more or less dependent upon toothache and dental disease is not rare, and in such cases the ocular condition may improve when the offending tooth is filled or extracted. Such symptoms include—Conjunctival congestion, photophobia, epiphora, asthenopia, and weakness of accommodation. Iritis, keratitis, and cyclitis may be dependent upon dental disease; oral sepsis is a common cause of 'quiet cyclitis.'

Stomach and Intestines.—In dyspepsia and chronic constipation absorption of septic matter from the gastro-intestinal tract may give rise to irido-cyclitis, choroiditis, and retinitis.

The straining associated with constipation may cause sub-conjunctival, retinal, or vitreous hæmorrhage. Hæmorrhage from stomach or intestines may cause anæmia (*q.v.*).

Diseases of the Ductless Glands.

Acromegaly exhibits many ocular manifestations. There is hypertrophy of the margins of the orbit and thickening of the skin of the lids. Disease of the hypophysis may cause characteristic bitemporal hemianopsia, though other abnormalities of the field of vision are met with, and there is often reduction in the acuteness of vision. There may be optic neuritis and optic nerve atrophy, and paralysis of one or more of the ocular muscles. Exophthalmos, hypertrophy of the lacrymal gland with epiphora, and sluggish reaction of the pupils, are also seen. Pain in the eyes and brow is sometimes complained of.

Myxœdema and Cretinism give rise to swelling of the eyelids, sometimes optic neuritis.

Exophthalmic Goitre (Graves' or Basedow's Disease).—Though this is a constitutional disease, and the ocular symptoms are not an essential part, the eye exhibits the most striking manifestations of the affection, some or all of the following ocular symptoms being present in almost every case: Exophthalmos is usually present. It varies in degree; it may be slight, or the proptosis may be so pronounced that the patient cannot cover the cornea with the lids. It is usually bilateral, but occasionally it affects only one eye. Von Graefe's sign consists in a failure of the upper lid to follow the eyeball normally when the patient looks downward; the upper lid lags behind. Stellwag's sign is the diminution in the normal involuntary power of nictitation, as a result of which winking is imperfect, less frequent, and more irregular than normal. Vision is not usually involved. The cornea may, however, suffer when the exophthalmos is extreme and causes much exposure; in such cases the lower part may become vascular, or dry, or ulcerated, and occasionally destruction of the eyeball is the outcome.

There is a brownish pigmentation of the skin of the lids in

some patients. There may be arterial pulsation visible in the fundus. Dilatation and inequality of the pupils may be present. The extrinsic ocular muscles, especially the abducens, may be the seat of paresis.

Diseases of the Ear.

Choked disc and congestion of the papilla are frequently observed in sinus thrombosis complicating mastoiditis. Nystagmus is common and of great diagnostic import in affections of the labyrinth.

Infective Diseases.

Cerebro-spinal Meningitis is often accompanied by ocular symptoms. Conjunctivitis occurs frequently. Œdema of the lids and conjunctiva may be seen. There may be paresis of the extrinsic ocular muscles, causing strabismus and ptosis. Nystagmus is encountered. There may be abnormalities of the pupils, keratitis, retinal hæmorrhages, optic neuritis, and optic nerve atrophy. Iridochoroiditis, and purulent choroiditis leading to pseudo-glioma, are not uncommon.

Diphtheria.—With the exception of diphtheritic conjunctivitis, which is now rather rare, the ocular manifestations of diphtheria occur after the acute stage of the disease has passed, and are therefore really post-diphtheritic symptoms. The latter include paralysis of one or more of the extrinsic muscles of the eye, usually the external rectus, and paralysis of accommodation. Occasionally optic neuritis occurs.

Erysipelas, when it spreads to the eye, causes great swelling and redness, so that the lids can be separated only with great difficulty. Following this there may be abscess of the eyelids, with sloughing of the skin. When the disease extends into the orbit, it causes orbital cellulitis, with exophthalmos and sometimes ulcer of the cornea. Thrombosis of the retinal veins, optic neuritis, and atrophy of the optic nerve, may follow under such circumstances. Glaucoma sometimes results, and occasionally inflammation of the lacrymal gland and sac.

Gonorrhœa is responsible for the local infection of the conjunctiva, resulting in purulent conjunctivitis in adults, and in ophthalmia neonatorum in the new-born. It also gives rise to chronic iritis. This affection is analogous to gonorrhœal arthritis, and is due to the presence of toxins. For some time after an attack of gonorrhœa is thought to have been cured, the vesiculæ seminales may contain gonococci, which may continue the intoxication.

Influenza is almost always accompanied by congestion of the conjunctiva. There is frequently severe pain in and behind the eyeballs. A great many ocular manifestations credited to influenza are probably dependent upon the marked depression which follows the disease; in this category may be placed weakness of accommodation and severe asthenopia. Infrequent ocular complications include corneal ulcer, pareses of extrinsic ocular muscles, retrobulbar neuritis, optic neuritis, optic nerve atrophy, and orbital cellulitis.

Leprosy attacks the eyelids similarly to the skin of the face. The conjunctiva and cornea may also be attacked.

Malaria infrequently gives rise to the following ocular manifestations: Herpes corneæ febrilis, optic neuritis, retrobulbar neuritis, hæmorrhages into the retina and vitreous amblyopia, and paresis of accommodation.

Measles is regularly accompanied by a catarrhal conjunctivitis, with subjective symptoms of greater or less severity. In addition there are very frequently blepharitis, phlyctenulæ, hordeola, superficial corneal ulceration, and asthenopia.

Mumps is complicated by dacryo-adenitis in a small number of instances; this rarely leads to suppuration. Œdema of the lids and chemosis may be present.

Pneumonia may be complicated by herpes of the cornea, sometimes followed by corneal ulceration.

Scarlatina.—Catarrhal conjunctivitis is an ocular complication of scarlatina, but it is less frequent and milder than in measles. Corneal ulcer is sometimes seen. Both of these complications are more apt to be found in the convalescent stage than early in the disease. When this disease is com-

plicated with nephritis, the characteristic fundus picture of albuminuric retinitis may be seen.

Septicæmia and Pyæmia give rise to retinal hæmorrhages, and sometimes to the lodgment of emboli in the choroid and retina. In the latter case the complications result either in purulent choroiditis, followed by pseudo-glioma, or in panophthalmitis.

Syphilis is frequently responsible for ocular disease. The primary sore may occur on the lids or conjunctivæ. Iritis is due to syphilis in perhaps 25 per cent. of cases. It is an early symptom of the secondary stage, at which time the anterior segment of the eyeball is the vulnerable part. The later stages of syphilis are more prone to attack the posterior segment, causing choroiditis, chorio-retinitis, optic neuritis, and diffuse opacity of the vitreous. In the tertiary stage, gummata may be deposited in the iris, ciliary body, and the periosteum of the orbital wall, and there may be optic neuritis and optic nerve atrophy, rarely interstitial keratitis. During this tertiary period, paralysis and pareses of the ocular muscles, both extra- and intra-ocular, are quite common. Inherited syphilis is responsible for at least the great majority of instances of interstitial keratitis, and also for some congenital ocular defects.

Tuberculosis, though rather rarely involving the eye, may affect the iris, choroid, and sclera, presenting characteristic deposits; still more infrequently the conjunctiva and lids present tubercular disease. In acute general miliary tuberculosis and in tubercular meningitis it is not uncommon to find small tubercle deposits scattered over the fundus. In pulmonary tuberculosis the pupils are often unequal in size.

In the 'strumous diathesis' there is a predisposition to blepharitis, chronic conjunctivitis, phlyctenular conjunctivitis and keratitis, and perhaps interstitial keratitis.

Vaccinia.—There have been a number of examples of accidental inoculation of the eyelids and conjunctiva with vaccine virus. In such cases the pustules excite marked swelling and induration, involvement of the pre-auricular

glands, and tendency to deformity of the lid from subsequent cicatrization.

Varicella may be complicated by conjunctivitis. The eruption may involve the conjunctiva and cornea, resulting in a superficial ulcer of little consequence.

Variola is responsible for destructive lesions of the eyelids and eyeball. The lids and conjunctivæ are often the site of pustules, and the subsequent cicatrices may cause deformity. Though pustules rarely appear upon the cornea, this part of the eye is not infrequently the seat of keratitis and of ulceration; the latter sometimes results in perforation, and may present as sequelæ opacities, adherent leucoma, or even destruction of the globe.

Whooping-Cough.—Subconjunctival hæmorrhage is often seen as a result of the severe paroxysms of coughing. Occasionally such an extravasation of blood takes place in the lid; rarely it involves the orbit, causing serious damage.

Yellow Fever, in its early stage, presents congestion of the conjunctiva. This redness is modified by the addition of yellowish discoloration at a later stage. Subconjunctival and retinal hæmorrhages are also found.

Diseases of the Kidneys.

Nephritis presents many ocular manifestations. Œdema is often present in the lids, and may also show itself in the conjunctivæ (chemosis). Albuminuric retinitis is common, occurring most frequently with the chronic parenchymatous variety, but also with other varieties, including the nephritis of scarlatina and pregnancy. During an attack of uræmia, amblyopia without ophthalmoscopic changes may be present; the pupils are dilated during this state.

Miscellaneous Diseases and Conditions.

Diabetes.—The common ocular complications of diabetes are cataract and hæmorrhages in the retina. Less frequently there occur retinitis, optic neuritis, retrobulbar neuritis, iritis, pareses of the external ocular muscles, and paralysis of accom-

modation. Diabetics occasionally present sudden and marked changes in the state of refraction of the eye, especially myopia, accompanying an increase in the amount of sugar in the urine, or due to pre-cataractous swelling of the lens.

Gout is sometimes responsible for episcleritis and scleritis, and rarely for marginal ulcer of the cornea, glaucoma, and hæmorrhagic retinitis. Gouty individuals often complain of dry catarrh, a condition in which the conjunctiva is congested, and the patient experiences a hot feeling in the lids and a sensation as though a foreign body were present. Such patients are sometimes subject to attacks of transient periodic episcleritis.

Headache, when persistent or frequently recurring, should always lead to a careful examination of the eyes. Errors of refraction are common causes of headache and neuralgia. Not infrequently we find anomalies of the extrinsic ocular muscles (heterophoria); less often, presbyopia and accommodation weakness. The error of refraction which most commonly gives rise to headaches is astigmatism; less often hypermetropia is responsible. The amount of astigmatism may be very small; even 0.25 or 0.50 D. may cause trouble to a sensitive person who uses the eyes much in near work. The site of the pain produced by uncorrected errors of refraction varies, but it is often supra-orbital and frontal. Depreciation of the general health is in many cases a predisposing factor (and a result); thus, we often find that the glasses required to relieve headaches in individuals who were debilitated are no longer necessary when the system has regained its normal tone.

The constant effort to keep the eyes straight in a case of "neuropathic divergence" usually causes a dull chronic headache. Similar symptoms may follow tenotomy of an internal rectus muscle.

Migraine.—This affection, thought to depend upon some disturbance in the circulation of the cerebral cortex, is characterized by periodic or irregular attacks, which begin with more or less blurring of vision. This visual defect occurs with or without scintillating scotoma, and is often more or less hemianopic in character. After a period varying from several

minutes to half an hour, vision again becomes normal; then a very severe headache develops, accompanied often by nausea and vomiting, and is followed by marked general depression. Though dependent, in part at least, upon depreciation in general health and excessive use of the eyes, the attacks are often aggravated by eyestrain. In such cases the seizures are prevented or made less severe by correction of errors of refraction or of heterophoria.

Rheumatism is the ætiological factor in some cases of scleritis, episcleritis, tenonitis, and palsies of the extrinsic ocular muscles. Or perhaps it would be more correct to say that rheumatism and these other diseases may be caused by the same toxin. Most cases of iritis supposed to be due to rheumatism are probably gonorrhœal or toxic.

Rickets.—The subjects of rachitis often present congenital cataract (zonular), interstitial keratitis, and phlyctenular kerato-conjunctivitis.

Scurvy is often accompanied by hæmorrhages beneath the conjunctiva, in the retina, skin of the lids, and occasionally into the orbit. It not infrequently presents a form of night blindness, which disappears when the general health improves.

Vertigo, with or without nausea, is often dependent upon ocular refractive errors, or to insufficiencies of the extrinsic ocular muscles, or perhaps pareses of these muscles.

Diseases of the Nervous System.

The eye furnishes information of great importance in the diagnosis of diseases of the nervous system, the intimate relationship between this part of the human anatomy and the visual organs being evident. Particulars regarding the condition of the optic nerves, the pupils, the eye muscles, the acuteness of vision, and the fields of vision, are of great value.

Apoplexy gives rise to a number of ocular manifestations, varying according to the part of the brain involved. Retinal hæmorrhages may precede the cerebral affection, and may serve as a warning of impending danger.

Encephalitis Lethargica frequently presents as an early symptom paralysis of the third cranial nerves, partial or complete, of one or both sides, giving rise to ptosis, squint, diplopia, and pupillary disturbances, especially eccentricity of the pupil. Sometimes the fourth or sixth nerve is involved. Nystagmus is common. Rarely there is optic neuritis.

Friedreich's Disease has no ocular disturbances, excepting a peculiar nystagmus, generally present, consisting of irregular twitchings seen when the eyes are fixed upon a moving object in the horizontal direction. Ocular palsies, optic neuritis, and Argyll-Robertson pupils occur rarely.

Meningitis often presents optic neuritis, abnormalities of the pupils, and palsies or spasms of the ocular muscles, causing deviations. These ocular manifestations are seen most frequently in tubercular meningitis, in which variety tubercles of the choroid are not infrequently found.

Myelitis is in rare instances accompanied or preceded by retrobulbar optic neuritis, with severe pain in the brow and orbit.

General Paralysis.—The subjects of this disease often present inequality and irregularity of the pupils, also miosis, and less frequently mydriasis. There is not uncommonly impairment or loss of the light reflex (Argyll-Robertson pupil); later there is added partial or complete loss of the reaction to accommodation. Sometimes atrophy of the optic nerve, with its attendant reduction in the acuteness of vision and restriction in the size of the field, is noted. Palsies of the third, fourth, and sixth nerves may occur, giving rise to diplopia, strabismus, and ptosis.

Disseminated Sclerosis presents many ocular manifestations; the latter are found in fully one-half of the cases. Nystagmus is a frequent symptom. The fields of vision often exhibit irregular peripheral contraction and central scotoma, either relative or absolute. An incomplete optic nerve atrophy, generally unilateral, is of common occurrence, resulting from retrobulbar neuritis. There are also partial paralyses of the extra-ocular muscles, giving rise to diplopia.

Tabes is accompanied by many ocular signs. The Argyll-Robertson pupil, in which the reaction to light is lost, while that to convergence and accommodation is preserved, is present in the great majority of cases, and usually exists on both sides. A deviation from the circular shape, inequality and marked contraction of the pupil (miosis), are very common; much less frequently mydriasis is present, but it is then frequently associated with blindness. Atrophy of the optic nerve occurs frequently, is an early symptom, is progressive, and generally leads to blindness. With this change in the optic nerve there is reduction in the acuteness of vision and concentric contraction of the field. Ocular palsies are very common; they often occur early in the disease, involve the third and sixth nerves, rarely the fourth, appear suddenly in many instances, are generally transient, and are accompanied by diplopia; if the third nerve is involved, also by ptosis. Epiphora is sometimes observed, also incoördinated movements of the eyeballs.

Tumour of the Brain (including Abscess) gives rise to choked disc in the majority of cases; this is generally bilateral, and probably is in most instances more marked on the side of the growth. There may be palsies of the ocular muscles and alterations in the field of vision. The characteristics of these changes may be of great aid in the localization of the seat of the tumour.

Functional Nervous Disorders.

Chorea.—Patients who suffer from choreic movements of the muscles of the lids and of the face and neck often suffer from errors of refraction, less frequently from lack of equilibrium of the eye muscles.

Coma.—Objective examination of the eyes may give important data in all forms of coma. If dependent upon organic brain disease, there may be choked disc, mydriasis, and deviation of the eyes. If due to cerebral hæmorrhage, there may be miosis, inequality of the pupils, and conjugate deviation. With increased intracranial pressure there may be dilated pupils. If accompanying uræmia, albuminuric

retinitis may be found. When alcoholic, there may be dilatation of the pupils, and pareses of external ocular muscles. If due to poisoning by opium or similar drugs, there may be extreme miosis.

Epilepsy.—The seizure frequently begins with a visual aura: transient flashes of light, coloured sensations, and hemianopia, or complete loss of vision. During the attack there may be narrowing of the retinal arteries; the pupils are generally dilated, and the light reflex is lost, and there is often spasm of the extrinsic ocular muscles, causing conjugate lateral deviation of the eyes. After the seizure there is distension of the retinal veins, often alterations in the size of the pupils, and not infrequently a temporary concentric contraction of the field of vision and a reduction in the acuteness of vision. Not very often, but certainly in some cases. epilepsy is made worse by eye-strain, and the number and severity of attacks are reduced by the wearing of proper glasses.

Hysteria is sometimes responsible for a great variety of ocular symptoms, the principal ones being diminution in the acuteness of vision (amblyopia, and even blindness), concentric contraction of the field of vision for form and colours becoming more marked with each repeated examination, and reversal in the relative size of the colour fields. Other ocular symptoms occurring in hysteria are scotoma, hemianopsia, photophobia, blepharospasm, and monocular diplopia. The pupillary reflexes and the ophthalmoscopic appearances are normal. The ocular manifestations are usually referred to one eye.

Diseases of the Nose, Naso-Pharynx, and Accessory Sinuses.

The communication between the nose and the conjunctiva sac by means of the lacrymal duct explains the frequent occurrence of ocular symptoms and affections as a result of nasal disease. In coryza and 'hay-fever' there is very often conjunctival congestion or acute catarrhal conjunctivitis, with marked lacrymation. In chronic rhinitis, whether catarrhal

or hypertrophic, chronic conjunctivitis, blepharitis, and phlyctenular affections, are very common. In addition, the nasal swelling may obstruct the lower end of the lacrymal duct, and as a result there may be lacrymal stenosis, dacryocystitis, and lacrymal abscess. The lacrymal duct may be the means of conveying infective material from the nose to the conjunctival sac, and thus explain the occurrence of corneal ulcer.

Adenoids not infrequently give rise to catarrhal conjunctivitis, follicular conjunctivitis, epiphora, and asthenopia.

Diseases of the accessory sinuses (maxillary, ethmoid, sphenoid, and frontal) are not infrequently responsible for ocular symptoms and diseases, the principal of which are—Exophthalmos, paresis or paralysis of the ocular muscles (both extrinsic and intrinsic), optic neuritis, and atrophy of the optic nerve.

Poisonings and Intoxications.

These conditions are not infrequently responsible for ocular symptoms and disease, especially retrobulbar neuritis (less frequently optic nerve atrophy), which results from poisoning by tobacco, wood-alcohol, iodoform, lead, arsenic (atoxyl), bisulphide of carbon, and nitro-benzol.

Pregnancy and Parturition.

Pregnancy may be complicated by gravidic retinitis, which may be so marked as to justify premature delivery, in order to save sight.

Parturition is accompanied by danger to the eyes of the child. Conjunctival infection may give rise to ophthalmia neonatorum. The use of the forceps during delivery has resulted in bruising of the lids, injury to the sixth nerve, injury to the cornea, orbital hæmorrhage, causing exophthalmos, and even rupture of the eyeball. During this period the eyes of the mother may present, on rare occasions, retinal hæmorrhages; and if there has been great loss of blood, amblyopia without ophthalmoscopic changes, or reduction of vision with

subsequent optic nerve atrophy, may ensue. Puerperal infection may result in metastatic choroiditis or in panophthalmitis, with loss of the eye. Parturition may also be followed by optic neuritis, atrophy of the optic nerve, retrobulbar neuritis, retinal hæmorrhages, and embolism of the central artery of the retina, though all of these complications are rare.

CHAPTER XXXII

VACCINES IN OPHTHALMOLOGY

By S. H. BROWNING

(*Bacteriologist, Royal London Ophthalmic Hospital*).

VACCINES have now taken their place in routine treatment, and active immunization affords a ready means of combating both acute and chronic eye infections.

The treatment must be carried out with care, for, although vaccines are quite harmless when injected into a healthy individual, when used to combat disease they are very powerful agents for good or ill. The particular organism responsible for the infection must be isolated and decided upon. Sometimes this may be an easy matter, as when one organism alone is present; but often the infecting organism has to be picked out from many contaminating ones, or there may be no organism obtainable, as in cases of gonorrhœal iritis or tuberculous episcleritis.

In eye work the clinical condition will often give one a clue to the infecting organism, as in the typical conjunctivitis of infection by the *Bacillus lacunatus*, or diplo-bacillus of Morax-Axenfeld. Then, again, smears made from pathological exudates, suitably stained, will often be of considerable assistance. As an instance of this may be cited the characteristic shape and appearance of Fränkel's pneumococcus when stained by Gram's method and the excess of eosinophiles in films stained by Leishman's stain in a case of spring catarrh. But there are often cases in which it is impossible to find any organism at the site of the lesion, and other measures must be used. Is a certain case of iritis gonococcal or not? The

examination of the material expressed from the prostate and vesicles and the effects on the iritis of specific vaccine treatment may help. Again, to differentiate between tuberculous or syphilitic choroiditis, one of the tuberculin tests or the Wassermann reaction may decide.

Smear Preparations.

To obtain material from the eye in making smears, a loop made of twisted platinum wire, in an aluminium holder, is the best instrument to use. The platinum loop is heated to redness in a flame, allowed to cool, and then drawn gently but firmly across the fornix of the everted lower lid, gathering up any beads of pus present. The material thus obtained is spread out on a glass slide or cover slip; the film is then allowed to dry in the air, or to hasten it the slide or cover slip is held between the fingers over the flame of a Bunsen or spirit flame. The film has then to be fixed to the slip, and this is done by passing the cover slip three or four times through the flame. If a slide is used, it must be held over the flame till the slide is just too hot to be placed on the back of the hand. The film is then ready for staining, and methylene blue or Gram's method counterstained with neutral red are the best ordinary stains for eye work.

At the same time as the smears are prepared, cultures should be made on suitable media, in order to show any organism which may have escaped observation in the direct smear, and to confirm the findings in the direct smear. Blood-agar made with human blood is the most useful medium for general diagnosis, as all the ordinary eye organisms grow well when planted on it, and no examination of an eye is complete unless cultures are made upon blood-agar. After the cultures have been incubated eighteen to twenty-four hours, the character of the growth should be carefully noticed, and then films made and stained, to further identify the organism present.

In the majority of cases the above methods will be found quite sufficient to enable one to arrive at a correct diagnosis of the offending microbe.

Cases, however, occur in which two or more organisms of a virulent nature are present, and it may be important to find out which of these organisms is chiefly responsible for the lesions produced. In these conditions the opsonic index may be of great use, or the patients blood-serum may be tested for specific agglutinins against the organisms found, or by the complement fixation method.

Opsonins are substances formed in the body in response to an infection by a pathogenic organism. They act by making the bacteria more capable of being ingested by the phagocytic polymorphonuclear leucocyte. A specific bacterium produces a specific opsonin. The amount of opsonin in the blood determines the rate and number of bacteria that the cell can take up.

The opsonic index is a figure representing the number of bacteria a leucocyte can ingest in the presence of the patient's serum divided by the average number of bacteria a leucocyte can ingest in the presence of normal person's serum.

Von Pirquet's cutaneous reaction is much used to help in the diagnosis of tuberculous conditions. A modification of the original method is advised, and the patient is tested both against human and bovine tuberculin in graduated dilutions. The skin over the outer surface of the arm or other convenient situation is first cleaned with warm water and lysol, and is then swabbed over with ether on a piece of lint. A drop of human tuberculin (T.) diluted to 50 per cent. is placed on the selected spot and under it about $\frac{3}{4}$ inch apart are placed drops of 25, 10, 5 and 1 per cent. Alongside and about an inch away are placed drops of 50, 25, 10, 5 and 1 per cent. bovine tuberculin (P.T.). Through these drops the skin is scarified as in vaccination against smallpox, though a much smaller surface is needed. The tuberculin is allowed to dry, and the whole is covered with a pad of sterile wool and fastened on with strapping. The reaction in tuberculous subjects consists of a hyperæmia round the test spots, and later (twenty-four to forty-eight hours) a papule develops on its site, and there is some induration of the surrounding tissues.

While the test is of great use in young children, it is of

less value in adults, as the positive reaction is present in those who have suffered from tuberculosis, as well as those who are suffering from tuberculosis. Of more value is the subcutaneous injection of old tuberculin; but this test should only be carried out by an expert, as much harm may be done by injudicious use. Calmette's ophthalmo-reaction is contra-indicated when there is any disease of either eye or lacrymal apparatus.

Of all the diagnostic methods now in use, not one approaches in importance the Wassermann reaction for the diagnosis of syphilis; and since the discovery of the Ehrlich-Hata '606,' its importance is still further increased. As, however, the Wassermann reaction is far too complicated to be carried out apart from a well-equipped laboratory, and as the reactions are only reliable when performed by an expert constantly doing the test and thoroughly versed in laboratory technique, it will be out of place to describe its performance here. A cutaneous test for syphilis, called the 'luetin reaction,' has been elaborated by Noguchi, which will probably prove of great value when its limitations have been discovered. It consists of the intradermal injection of killed emulsion of pure culture of the *Spirochæta pallida*; the positive reaction is determined by a local reaction, consisting of redness, swelling, induration of the tissues, and sometimes aseptic suppuration at the site of inoculation.

Having discovered the organism which is causing the disease, we are now in a position to choose a suitable vaccine, and the question arises, Is it necessary to have an autogenous vaccine made—that is to say, one made from the patient's own organism—or will a stock vaccine, as supplied by one of the wholesale chemists, do? An autogenous vaccine is best if it can be procured, but, as this is not always the case, it is well to know that staphylococcal cases often do very well with a polyvalent vaccine (dose, 50,000,000 to 1,000,000,000). Gonococcal cases also do well with a good polyvalent vaccine (5,000,000 to 500,000,000). If success does not follow, it may be because the polyvalent vaccine does not contain the same strain of organism as that infecting the patient, and

another brand of vaccine should be tried, or an effort made to obtain an autogenous vaccine.

It is almost always advisable to have an autogenous vaccine prepared for cases infected with *Bacillus coli communis*, pneumobacillus, pneumococcus, and streptococcus. A polyvalent Morax vaccine will nearly always suffice for cases of angular conjunctivitis. It is often advisable to use it in conjunctivitis with a mixed staphylococcal vaccine.

A vaccine is a suspension of killed bacteria in water, to which a little phenol or tricresol has been added. It is prepared as follows: Supposing it is desired to treat a case of marginal blepharitis with an autogenous vaccine. The margin of the lid is examined, the hair is pulled out of a suppurating follicle with sterile forceps, and placed on the surface of a sloped tube of medium, and then with a sterile platinum loop is rubbed over the surface of the medium.

The cotton-wool plug is then replaced, and the tube incubated for eighteen to twenty-four hours. It is then examined, and if any organism has grown up, a smear is made on a slide, stained, and examined. If the growth is a pure one—that is to say, only one type of organism is present; say in this case *Staphylococcus aureus*—it is now ready to be made into a vaccine. Into the tube in which the organism is growing 3 to 4 c.c. saline solution is poured, and then with a sterile platinum loop the colonies of *Staphylococcus aureus* are loosened from the medium and suspended in the saline. This emulsion of living bacteria is now poured into a clean sterile test-tube with some sterile glass beads, and closed with a rubber cap. The tube is then shaken to and fro for some time till the emulsion is quite uniform. We have now in the tube an emulsion of live *Staphylococcus aureus*, free from clumps, but we do not know how many organisms there are present—that is to say, whether we have 50,000,000 or 1,000,000,000 to the cubic centimetre. So the next process is to estimate the number of organisms present.

Into a capillary pipette with a rubber teat at one end, some 2 per cent. sodium citrate solution is drawn up, and then a given volume of blood is drawn up from the freshly pricked

finger. A bubble of air is allowed to enter the pipette, and then the same volume of the bacterial emulsion as of blood is drawn up into it. The citrate is to prevent the blood coagulating in the tube, and has no influence on the subsequent calculations. The mixture of blood, bacterial emulsion, and citrate is then blown out on to a glass slide, and thoroughly mixed by sucking it up and blowing it out again repeatedly. As much as possible is then sucked up again into the pipette, and half blown on to two clean glass slides. They are then spread as ordinary blood-films, and allowed to dry in the air. When dry they are stained with Leishman's stain, and are then ready to be examined. As soon as the test quantity of bacterial emulsion is drawn off, the test-tube must be immediately placed in a water bath at 60° C. and left there for one hour, to kill the *Staphylococcus aureus*, as it is this emulsion—suitably diluted—which is going to be used as a vaccine.

We now examine the slides under the microscope, using a $\frac{1}{12}$ -inch oil immersion lens, and we see the red blood-cells in the field with the staphylococci amongst them.

The average normal blood contains about 5,000,000 red cells per cubic millimetre; and if we counted the number of cells and bacteria in the field under the microscope, and found they were the same, we should be right in saying that there were 5,000,000 organisms per cubic millimetre of bacterial emulsion—that is to say, 5,000,000,000 cocci per cubic centimetre—and in this way we can make an accurate measure of the number of organisms present per cubic centimetre of bacterial emulsion.

Now, as *Staphylococcus aureus* is generally given in doses of about 50,000,000, 100,000,000, and 250,000,000, we must dilute the original emulsion till this number is contained in a suitable bulk of fluid—generally $\frac{1}{2}$ to 1 c.c.

These quantities are put into small glass bulbs, the ends of which are sealed off in a gas-flame; and in case during the manipulations any organisms may have crept in, they are sterilized at 60° C. for one hour.

The vaccine is now ready to administer. The neck of the glass bulb is broken off, and the contents drawn into a

sterile syringe and injected into the subcutaneous tissue of the patient. The skin is first scrubbed with a piece of lint soaked in alcohol. The most comfortable place for the injection is the lower portion of the anterior abdominal wall, but the loose skin of the upper arm may be used if more convenient. It is not necessary to apply any dressing after the injection.

Effect on Body produced by Active Immunization by Means of Vaccines.

When a vaccine is injected into the subcutaneous tissue, the immediate result is a combination of the opsonin present in the serum with the bacteria injected, and in consequence there is a temporary lowering of the patient's resistance, as proved by the patient not feeling so well, a rise of temperature, or by an exacerbation of symptoms and signs. This is called the 'negative phase.' In a time varying from twelve hours to several days, however, the patient feels much better; in purulent cases there is less discharge, there is less pain, and the clinical condition is improved. This is due to a rise in the opsonic index, and is described as the 'positive phase.' The positive phase lasts for a varying time, according to the patient's powers of resistance to disease and the size of the dose administered. It then drops a little, and stays at a period of equilibrium for some little while. Then comes a period of decline, during which the opsonic index falls to a point a little above that at which it started.

If a second injection be given before the end of the first negative phase, what is called a 'summation of negative phases' is produced, and the patient may become seriously ill, as his or her powers of reaction are tried so severely that they may not recover for a very long time, and in some cases permanent harm may be done. On the other hand, by giving injections at suitable intervals a 'summation of positive phases' may be obtained, and then the patient's recovery is hastened. Although this is theoretically the ideal to be aimed at, in practice it is generally better to wait till the end

of the period of decline before giving another injection. This generally occurs in a week to ten days.

In acute cases we must endeavour to cause only a slight negative phase, and this may be brought about by giving small doses to start with, and gradually increasing them as the patient's resistance is increased.

It is not necessary, when using vaccines, to estimate the opsonic index; the effect of treatment can be judged by watching the clinical signs. During the negative phase there is an exacerbation of the disease, which may be so slight as to be unnoticed by the patient or physician. If the symptoms are markedly increased, it means that too large a dose has been given.

For the treatment of tuberculous conditions it is impossible to obtain an autogenous vaccine, and so the stock tuberculin must be used. Treatment by tuberculin requires considerable skill and experience, and if given in too large doses or too frequent intervals harm may result. It is best to commence with a small dose, such as 0.00005 milligramme T.R., increased in seven to ten days to 0.0005 milligramme T.R., gradually increasing the dose each week as necessary. It must be remembered that as long as the patient is going well with a small dose, there is no need to go on to a larger one. There are many other kinds of tuberculin, each with its own merits, and it is often useful to combine them in treatment.

Perhaps, after tuberculin, the vaccine that gives the most satisfactory results in eye work is gonococcal vaccine. Cases of iritis clear up in a marvellous manner when treated with suitable doses, combined with the local treatment of any disease of the urethra, prostate or vesicles. It is not of much use in gonorrhœal ophthalmia neonatorum, but it is very successful in adult gonorrhœal ophthalmia.

Staphylococcal vaccines are of use in the treatment of all staphylococcal infections of the lids, conjunctiva, and orbit, and have also proved of considerable benefit in phlyctenular conditions of the bulbar conjunctiva. Corneal ulcers in association with acne also do well when the acne is treated with an autogenous vaccine.

Autogenous streptococcal vaccines are of great service in the treatment of acute dacryocystitis and in other streptococcal infections of the eye.

Pneumococcal vaccines should be used in all cases in which Fränkel's pneumococcus can be detected, and are especially useful in acute and chronic dacryocystitis, corneal ulcers, and post-operative infections.

Friedländer's pneumobacillus is occasionally the cause of a typical corneal ulcer, and these cases react in a very favourable manner to an autogenous vaccine. In chronic dacryocystitis associated with nasal catarrh, the pneumobacillus is often the causative organism, and these cases should be treated with a suitable vaccine. Chronic infections with Morax-Axenfeld diplobacilli, which are not cured by any of the usual remedies, often heal rapidly with a stock polyvalent vaccine.

Pyorrhœa alveolaris is a common cause of eye trouble. The eye condition often gets well when the teeth sockets are thoroughly cleaned by the dentist, and a vaccine made from the organism present in the pus is injected.

The use of vaccine does not imply that all other methods should be omitted, for they are an adjunct to, and not a substitute for, the usual treatment.

Bacteriological Examination of Eyes before Operation.

A certain number of eyes are lost as the result of bacterial infection, either at or following operation. The infection as a rule is secondary to an infection of the conjunctival or lacrymal sacs; it is therefore obvious that it is advisable to examine all conjunctival sacs bacteriologically before operation. This refers more especially to the operation for cataract extraction, though it is advisable before all operations if possible.

The method to be employed is as follows: The lower lid is everted, and a sterile swab of cotton-wool is rubbed gently but firmly over the conjunctiva of the lower fornix. The swab is then rubbed over the surface of tubes of blood-agar and the tubes incubated. The tubes are examined in twenty-four hours and again in forty-eight hours, and stained smears are

made from any growth present. If the *Pneumococcus*, *Streptococcus*, or *Bacillus pyocyaneus* are present, operation is contra-indicated, and it is dangerous to operate in the presence of large numbers of *Staphylococcus aureus*, and probably also the *Bacillus subtilis*. *Staphylococcus albus* and *Bacillus xerosis* are generally considered to be of little importance.

It has been proved by experiment that the practice of bandaging an eye before operation promotes the growth of bacteria, and definitely increases the risk of post-operative infection.

Salvarsan in Eye Disease.

Salvarsan and neosalvarsan are of great value in the treatment of syphilitic eye disease. All the acute acquired conditions respond rapidly to their use, and although at first the treatment of interstitial keratitis by the arsenical preparation was disappointing, the more intense method of treatment with N.A.B. or stabilarsan combined with mercury or bismuth has been rather more encouraging. The use of salvarsan is not accompanied by risk of injury to the optic nerve, and it is generally agreed that salvarsan ('606') is more efficient than neosalvarsan ('914'), though the ease of administration of the more recent preparations is an advantage. Salvarsan may be used with advantage in the treatment of sympathetic ophthalmitis, and also in certain cases of chronic infection after operation. All the ordinary precautions and the contra-indications suggested by Ehrlich should be observed before and during its use. The intravenous method of administration has proved the most successful, and is carried out as follows: The preparation it is desired to give is prepared strictly in accordance with the makers' instructions, and the suitable amount is drawn up into a syringe. A tourniquet is placed round the patient's arm, engorging the veins in the antecubital space, the skin is rendered sterile, and the needle is plunged into one of the prominent veins. The tourniquet is then removed. The solution is slowly passed into the vein. The needle is withdrawn, and a collodion dressing or a small piece of strapping applied.

CHAPTER XXXIII

OCULAR THERAPEUTICS: GENERAL RULES FOR OPERATIONS UPON THE EYE

THE eye, being a very delicate and sensitive organ, may easily be injured by injudicious use of local applications. It is essential, therefore, to observe especial care as to the manner and strength in which such remedies are employed.

Constitutional Remedies.—When any disease of the eye presents itself, one should consider whether it may be due either wholly or in part to some general constitutional disease. Syphilis, tuberculosis, Bright's disease, diabetes, tabes, chronic intoxications, anæmia, and other disordered states often give rise to well-marked eye symptoms. In such cases it is obvious that one cannot hope to cure the ocular disease unless one treats the constitutional disease of which it is a symptom.

Local Remedies.—Drugs intended for local use to the eye are usually dissolved in water or oil, or used in the form of ointment or powder.

Cleansing and Antiseptic Solutions.

These are employed for washing out the conjunctival sac and removing secretion. They should be used freely, and should be lukewarm when employed. They may be allowed to run between the lids from an undine (Figs. 330 and 331), or from a wad of sterilized cotton-wool.

The eye bath or cup is a popular means of applying a lotion to the eye, for it can be used by the patient without help. The eye-bath should be quite filled with the lotion, and throughout the application should be held upright, like a full wineglass.

The patient, sitting in a chair, leans forward until his face is horizontal and his eye dips into the lotion, while the rim of the eye-bath is pressed gently in place. Then he opens and shuts the eye and turns it in different directions so that the lotion reaches every part of the conjunctival sac. This should be continued for two minutes.

The cleansing and antiseptic solutions which are used most frequently are:

1. Sterilized water.
2. Boric acid in saturated solution (about $\frac{1}{2}$ ounce to the pint).



FIG. 330. — UNDINE FOR IRRIGATING THE EYE.

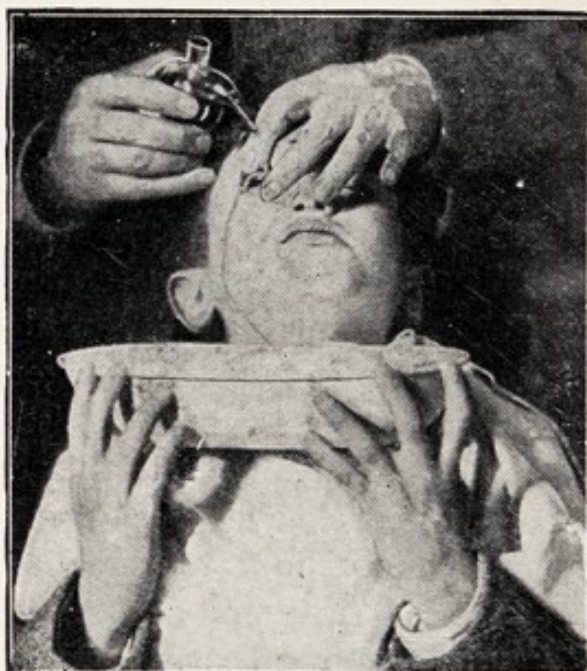

FIG. 331. — METHOD OF IRRIGATING THE EYE WITH A SOLUTION POURED FROM AN UNDINE.

3. Sodium chloride in physiological strength (0.6 per cent.; a teaspoonful to the pint).
4. Mercuric chloride, from 1:20,000 to 1:10,000.
5. Potassium permanganate, 1:2,000, about 4 grains to the pint.

Boric Acid is used more frequently than any other of these remedies. Though chemically an acid, it is neutral, bland, and soothing. It is often employed to irrigate the eye during operations. It is frequently prescribed with white vaseline (gr. x., ad 3j.), in the form of an ointment, to prevent adhesion of the lids overnight, when there is considerable discharge.

Stimulating and Astringent Remedies.

The remedies of this class used most frequently in diseases of the eye are: zinc sulphate, tannic acid, alum, borax, potassium chlorate, camphor, silver nitrate, copper sulphate, yellow oxide of mercury, ammoniated mercury, and calomel. They are intended to cure abnormal conditions of the conjunctiva, and are used principally in various forms of conjunctivitis. For this purpose they are prescribed in small quantity. Two or three drops of a watery solution are allowed to fall upon the everted lower lid from an eye-dropper; the latter must not be allowed to touch the lids, since this would lead to contamination of the liquid. Copper sulphate and alum are frequently employed in the form of a solid pencil.

Zinc Sulphate is used very largely in astringent collyria.

R	Zinci sulph.	-	-	-	-	gr. ij.
	Aquæ destill.	-	-	-	-	ʒi.

M. Sig.: Two drops in each eye three times a day.

R	Zinci sulph.	-	-	-	-	gr. ss.
	Acidi borici	-	-	-	-	gr. v.
	Aquæ destill.	-	-	-	-	ʒi.

M. Ft. collyr.

Tannic Acid is frequently used in combination with other astringents. Solutions of 5 to 25 per cent. are painted on everted lids in trachoma.

R	Acidi tannici	-	-	-	-	gr. ss.
	Zinci sulph.	-	-	-	-	gr. ss.
	Aquæ destill.	-	-	-	-	ʒi.

M.

Alum ($\frac{1}{4}$ to 1 grain to the ounce). Long-continued use is said to injure the cornea.

A crystal of alum, in the form of a flattened pencil, is applied to the everted lids in chronic conjunctivitis and in mild forms of trachoma.

Borax is used as a cleansing wash (ʒi. to Oi.), or in combination with other remedies.

R	Zinci sulph.	-	-	-	-	gr. ss.
	Sodii biborat.	-	-	-	-	gr. iiij.
	Aquæ destill.	-	-	-	-	ʒi.

A cleansing and soothing collyrium for use in an eye-bath for mild conjunctival irritations, after a dusty journey, etc.:

R	Sodii bibor.	-	-	-	-	-
	Sodii bicarb.	-	-	-	-	-
	Sodii chlor.	-	-	-	-	āā grs. xl.
	Liq. hamamelidis	-	-	-	-	ʒi.
	Aq. destill.	-	-	-	-	ad ʒx.

M. Ft. collyr. Sig.: Half fill the eye-bath with hot water, then fill it up with the lotion.

Potassium Chlorate is prescribed in solution, 10 grains to the ounce. A soothing lotion in conjunctival irritation.

Camphor.—Though feebly soluble in water, such solution (aqua camphoræ) is stimulating and astringent, and is often incorporated in collyria.

R	Acidi tannici	-	-	-	-	gr. $\frac{1}{4}$.
	Zinci sulph.	-	-	-	-	gr. ss.
	Aquæ camphoræ	-	-	-	-	ʒij.
	Aquæ destill.	-	-	-	-	ʒvi.

M.

Silver Nitrate, dissolved in distilled water, may be used in the strength of gr. $\frac{1}{16}$ to gr. $\frac{1}{8}$ to the ounce, dropped into the conjunctival sac. In stronger solution (1 to 5 grains to the ounce) it is brushed upon the everted lids in chronic conjunctivitis and in the papillary stage of purulent conjunctivitis. Solutions of nitrate of silver should be tightly stoppered and kept in the dark. The brush or cotton-applicator should not be dipped into the bottle, but some of the solution should be poured into a small vessel. The strong solutions should be applied only by the surgeon himself. Before the application the cornea should be protected by smearing with vaseline. Any excess of silver is neutralized by washing out the eye with normal saline solution. Silver solutions stain the conjunctiva (argyrosis); hence they should be used only for a limited period. Strong solutions act as caustics.

Copper Sulphate ('bluestone') may be employed in solution (gr. $\frac{1}{2}$ to ʒi.), but its chief use is in the solid form. A flattened pencil (Figs. 115 and 117) is rubbed across the everted lids (not omitting the retrotarsal fold) in trachoma, and the excess washed off with water or solution of boric acid. The pencil should be flattened and have a blunt, rounded extremity.

Yellow Oxide of Mercury is insoluble in water; it is employed in the form of an ointment made with white vaseline, cold cream, or lanoline. The ointment must be thoroughly mixed, and should be preserved in a covered jar which is impervious to light. Its strength is usually 1 or 2 per cent.

This ointment is very useful in blepharitis, chronic conjunctivitis, phlyctenular keratitis and conjunctivitis, interstitial keratitis, and opacities of the cornea. In blepharitis the ointment is smeared along the margin of the lid; in the other affections a small piece is transferred from the end of a glass rod or probe to the everted lower lid, and thus into the conjunctival sac.

Ammoniated Mercury is a white insoluble powder prescribed in the same strength and under the same circumstances as the yellow oxide of mercury.

R Hydrarg. ammoniat.	-	-	-	-	gr. i.
Adepsis	-	-	-	-	ʒij.

M. Ft. ungt.

Calomel, free from any trace of perchloride, in the form of an impalpable powder prepared by levigation, is dusted into the eye with a camel's-hair brush in cases of phlyctenular keratitis and corneal ulcers. This combination of mercury is thought to change slowly to corrosive sublimate as a result of contact with the tears. Calomel is apt to produce local irritation if the patient is taking an iodine salt internally, owing to the formation of iodides of mercury.

Ichthyol in 5 or 10 per cent. ointment, or mixed with zinc oxide, forms an excellent application in obstinate cases of ulcerative blepharitis.

R Ichthyol	-	-	-	-	-	gr. vi.
Vaseline	-	-	-	-	-	ʒij

M. Ft. ungt. Sig.: Apply to the edges of the lids after cleaning

R Ichthyol	-	-	-	-	-	gr. x.
Ungt. zinci ox.	-	-	-	-	-	ʒij.

M. Ft. ungt. Sig.: Apply to the edges of the lids after removal of crusts.

Lead Acetate *should not be applied to the eye.* It has the property of depositing an insoluble salt of lead upon any

corneal abrasion; this stain cannot be removed. Lead and opium wash, so frequently used in other parts of the body, is not, therefore, a desirable application for the eye.

Disinfectants.

True disinfectants (capable of destroying germs) cannot be instilled into the conjunctival sac under ordinary circumstances, since they would injure the cornea. They are, however, applied to circumscribed areas, the excess being washed off by some bland solution. Corneal ulcers, especially when indolent or infected, and purulent conjunctivitis furnish common indications for such use. Some of the remedies classified under this head, though not, strictly speaking, true disinfectants in the strengths in which they are employed, have an inhibitory action upon the growth and development of micro-organisms, and thus act as practical disinfectants. The disinfectants used most commonly in connexion with the eye are mercuric chloride, alcohol, chlorine water, carbolic acid, formalin, tincture of iodine, silver nitrate, protargol, iodoform, and the cautery.

Mercuric Chloride (corrosive sublimate) is prescribed very frequently in purulent conjunctivitis. It may safely be used up to a strength of 1 : 10,000. A stronger solution might damage the cornea, and must consequently be limited in its application to the everted lids, and the excess carefully washed off. A strong solution, 1 : 500, may be rubbed into the conjunctiva after this membrane has been freed from trachoma follicles by the operation of expression. Solutions of corrosive sublimate attack the metal of instruments and dull their cutting edges.

Absolute Alcohol, when combined with mechanical cleansing, is a fairly efficient disinfectant of the blades of eye instruments.

Chlorine Water diluted with 10 to 20 parts of water is sometimes employed in purulent conjunctivitis. It must be freshly prepared.

Carbolic Acid (3 per cent. solution) is used only for disinfecting instruments. Stronger solutions and pure carbolic acid are sometimes applied to infected ulcers of the cornea.

Formalin.—Solutions of 1 : 1,000 and 1 : 2,000 are used in purulent conjunctivitis; solutions of 1 : 500 are applied to infected ulcers.

Tincture of Iodine is an excellent remedy in the treatment of infected ulcers. It is applied upon a small piece of cotton rolled upon the end of a probe. Any excess is washed off with water.

Hydrogen Peroxide solution is sold in sealed bottles for dental use. It deteriorates after being opened. Diluted with 3 or 4 parts of water (or stronger), it is an admirable disinfectant and stimulant lotion for conjunctiva, lacrymal sac, and infected corneal ulcers.

Silver Nitrate is a very efficient and popular disinfectant. In 1 or 2 per cent. solution it is applied to the everted lids in purulent and in other forms of conjunctivitis, and the excess neutralized by a solution of sodium chloride. In 2 per cent. solution one drop is instilled into the eyes of the new-born as a prophylactic measure against ophthalmia neonatorum. In stronger solution and in the stick it is applied to infected and indolent ulcers, the excess being neutralized by salt solution. It is fused with potassium nitrate in various proportions, constituting the 'mitigated stick.' For the purpose of producing anæsthesia preliminary to silver applications, solutions of nitrate of cocaine should be used instead of the customary hydrochlorate, since the latter alkaloidal salt is incompatible and precipitates chloride of silver, which leaves a permanent stain upon the cornea.

Iodoform is a feeble disinfectant which is occasionally dusted upon corneal ulcers. It is not unfrequently dusted upon wounds after plastic operations. It should be very finely powdered.

Protargol is an organic salt of silver, soluble in water, forming a brown solution. It is used in 5 to 25 per cent. solutions. It is not precipitated by fluids containing sodium chloride and albumin, and is devoid of the irritating qualities of silver nitrate. Its action is feeble. When used for a long time it may stain the conjunctiva.

Argyrol has the same properties and uses as protargol.

The Cautery (p. 138) gives us the most certain means of

limiting the spread of corneal ulcers by destroying the infecting micro-organisms. It is also used in conical cornea (see p. 146).

Mydriatics and Cycloplegics.

Mydriatics are remedies which produce dilatation of the pupil. Cycloplegics are agents which cause paralysis of the ciliary muscle (paralysis of accommodation). Mydriatics

also produce more or less paralysis of the ciliary muscle.

The drugs which are commonly employed to induce mydriasis and cycloplegia are atropine and homatropine; very much less frequently duboisine, daturine, hyoscyamine, and scopolamine are used.

Cocaine and euphthalmin produce moderate dilatation of the pupil with only slight paresis of the ciliary muscle.

Indications.—Agents of this class are used (1) in iritis, for dilating the pupil, preventing adhesions, and exerting a sedative action; (2) in various

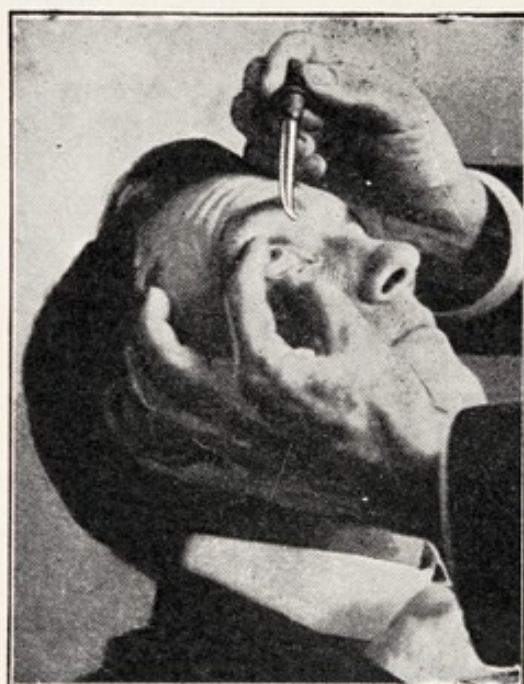


FIG. 332.—METHOD OF INSTILLING DROPS BY MEANS OF AN EYE-DROPPER.

diseases of the cornea and of the deeper structures of the eye; (3) in central ulcer of the cornea; (4) after certain operations; (5) to paralyze accommodation in order to investigate the refraction; (6) to dilate the pupil for ophthalmoscopic examination; and (7) to enlarge the pupil in lamellar and nuclear cataract.

Atropine, the alkaloid of belladonna, is the most commonly employed mydriatic; it is prescribed in the form of ointment of the alkaloid or solution of the sulphate. The strength of solution or ointment varies from $\frac{1}{2}$ to 2 per cent.; 1 per cent. is used most frequently. Atropine ointment made with soft

paraffin is less irritating than the P.B. preparation. In a case of iritis the addition of 1 per cent. cocaine helps the action of the atropine.

Atropine paralyzes the sphincter of the pupil and the ciliary muscle. Half an hour after the instillation of a drop of atropine mydriasis and nearly complete cycloplegia will be found; the effects last for a week or ten days. Atropine and other mydriatics have no effect on the tension of the normal eye, but may precipitate an attack of glaucoma in an eye which is predisposed to this disease. One should, therefore, carefully test the tension, and note the depth of the anterior chamber, in persons past middle life, before instilling atropine or any other mydriatic.

Atropine Poisoning.—In susceptible individuals atropine may cause general toxic symptoms: Dryness of the throat, flushing of the face, headache, vomiting, quick pulse, cutaneous eruption, excitability, and even delirium. These symptoms subside within a few hours of discontinuing the drug. In an extreme case it might be necessary to use the antidote morphine. In persons who show such an idiosyncrasy, or in others in whom we wish to push the remedy, it is well to instruct the patient to press the finger against the lacrymal sac during each instillation. When the susceptibility is very great one of the other mydriatics may be resorted to, or we may use a 10 per cent. solution of aqueous extract of belladonna in water; ophthalmic discs, which contain very small doses, may prove useful in these cases.

Atropine Irritation.—In some persons atropine may cause considerable local irritation, showing itself in œdema of the lids, eczematous condition about the lids, and conjunctival catarrh.

In using atropine or other solutions (myotics and anæsthetics) for the local effect upon the cornea or deeper portions of the eye, the drop is allowed to fall upon the cornea, the upper lid being raised, and the patient directed to throw the head back and to look down.

Duboisine sulphate (gr. $\frac{1}{2}$ to 3ij.), daturine sulphate (gr. $\frac{1}{4}$ to 3ij.), hyoscyamine hydrobromate (gr. $\frac{1}{2}$ to 3ij.), and scopolamine hydrobromate (gr. $\frac{1}{8}$ to 3ij.), are occasionally

used as substitutes for atropine. They have similar, though less certain, actions, are contra-indicated in increased tension, and may also produce systemic poisoning.

Homatropine Hydrobromide resembles atropine in its action, but is milder. It is very largely used to paralyze accommodation during the examination for errors of refraction. Though this effect is not so perfect as with atropine, it is sufficient for most purposes, except in children, and lasts only from one to three days, thus exposing the patient to very much less inconvenience. For refraction cases it is usually used in 2 per cent. solution, one drop being instilled every five or ten minutes for three or four doses; half an hour after the final dose the eye is ready for examination. It is frequently combined with cocaine for this purpose:

R	Cocain. hydrochlor.	-	-	-	gr. i.
	Homatropin. hydrobrom.	-	-	-	gr. ij.
	Aquæ destill.	-	-	-	ʒij.
				M.	

A solution of the alkaloids (not the salts) in liquid paraffin is even more effective, and the oil prevents drying of the cornea, which is a danger to be guarded against when using cocaine drops.

Euphthalmin is very useful for the purpose of dilating the pupil for ophthalmoscopic examination. The hydrochlorate is used in 5 or 10 per cent. solution; one or two drops cause mydriasis in thirty minutes, and the effects pass off in a few hours. It has but a feeble action upon accommodation.

Cocaine Hydrochloride is frequently used to produce moderate dilatation of the pupil for ophthalmoscopic examination. One or two drops of a 4 per cent. solution cause sufficient dilatation in twenty minutes, produce insignificant interference with accommodation, and the effects disappear within an hour or two as a rule. Cocaine acts by constricting the bloodvessels of the iris. It diminishes intra-ocular tension (in rare cases the opposite effect has been observed). It is sometimes combined with other mydriatics, and then increases the action of the associated remedy.

Myotics.

Myotics diminish the size of the pupil. They produce tonic contraction of the sphincter and of the ciliary muscle, and diminish intra-ocular tension. These agents are employed chiefly in glaucoma, sometimes in ulcers of the cornea, especially when peripheral. Eserine salicylate ($\frac{1}{8}$ to $\frac{1}{2}$ per cent.) and pilocarpine nitrate, or muriate ($\frac{1}{2}$ to 1 per cent.), are prescribed for these purposes. Eserine is stronger, and sometimes has a tendency to produce conjunctival irritation and iritis, and occasionally constitutional symptoms. Pilocarpine is milder and free from these drawbacks; it is sometimes given hypodermically to cause diaphoresis in certain diseases of the eye.

Local Anæsthetics.

Cocaine Hydrochloride is the most commonly employed remedy for producing local anæsthesia of the conjunctiva, cornea, and to a certain extent the iris during operations upon the eye. It may be used subcutaneously for operations upon the lid, bearing in mind its possible toxic effect. The strength of solution is usually 2 to 4 per cent. It is also of service as a temporary anodyne in corneal and iritic affections, and very useful as a mydriatic for ophthalmoscopic examinations. It assists the action both of mydriatics and myotics. It is frequently combined with atropine, homatropine, or with eserine. Cocaine has a tendency to cause desiccation of the cornea, and sometimes superficial ulceration; hence after the instillation of this remedy the patient should be directed to keep the lids closed. One drop of a 4 per cent. solution, and a second after a few minutes, is sufficient to anæsthetize the cornea for the removal of foreign bodies; for more penetrating effects the instillations are repeated three or four times at intervals of two or three minutes. Solutions of cocaine do not keep well, and should be freshly prepared previous to use in operations. Cocaine hydrochloride may be used in the form of powder.

Holocain Hydrochloride is a local anæsthetic which is preferred to cocaine by some surgeons. It is usually employed

in 1 per cent. solution. The advantages of this remedy as compared with cocaine are: it acts more quickly, is more penetrating, does not dilate the pupil, is not poisonous when applied locally, and its solution keeps well. It cannot be used hypodermically, since it causes toxic symptoms when employed in this way.

Novocain, 2 per cent., in adrenalin chloride solution (1 in 10,000), is an excellent local anæsthetic in lacrymal sac and eyelid operations, from 20 to 60 minims being injected hypodermically.

Other Therapeutic Measures.

Adrenalin is the active principle of the suprarenal gland. It is available in 1 : 1,000 watery solution of the chloride, a colourless liquid, which can be diluted with salt solution of physiological strength. This remedy is a valuable astringent and hæmostatic. After instillation of solutions varying from 1 : 10,000 to 1 : 1,000, marked blanching of the conjunctiva occurs as a result of contraction of the bloodvessels, beginning in less than a minute, and lasting half an hour or longer. It is very useful, therefore, in advancement of an external ocular muscle to insure a nearly bloodless field of operation. When the ocular structures are very much congested, cocaine or holocain produces unsatisfactory anæsthesia; if the instillation of these agents is preceded by that of adrenalin or suprarenalin solution, the anæsthetic effect is very much more pronounced. This remedy is used in some cases of conjunctivitis with marked congestion, in affections of the lacrymal passages to facilitate the expression of retained contents and the introduction of probes, in operations upon the lacrymal sac, glaucoma, and in congested conditions of the eye in general, to blanch the tissues, thus permitting a more or less bloodless operation, and making the action of local anæsthetics more satisfactory.

Dionin is a derivative of morphine. It is a local vasodilator and lymphagogue. It is used to promote absorption of exudates in iritis. It increases the mydriatic effect of atropine. Dionin indirectly relieves deep-seated pain in the same way as hot fomentations, by dilating the vessels. When a 5 or 10 per cent. aqueous solution is instilled into the con-

junctional sac, it causes very great chemosis in most cases, the swelling sometimes being so great that the eyelids cannot be opened. The swelling quickly subsides. After a few days the drug loses its effect, so that its characteristic reaction can no longer be produced. Dionin may be used also in the form of ointment, or the powder itself may be used.

Solid Carbon Dioxide.—Owing to its employment in the manufacture of aerated waters, liquid carbonic acid may easily be obtained in any large town. It is stored in steel cylinders under great pressure. If a jet of the liquid is allowed to play upon the surface of a towel, the very rapid evaporation of part of the liquid abstracts so much heat from the remainder as to cause it to be deposited in the form of snow. The snow is pushed into a small wooden tube, and by means of a wooden ram-rod and mallet is hammered into a pencil of solid ice. The pencil is then pushed out of the tube; one end is wrapped thickly in lint to protect the fingers; the other end may be cut with a knife into any desired shape. Evaporation from the surface of the pencil further cools it to a temperature at which the gas is very slowly given off, so that the pencil will last for an hour or two.

Prolonged application of the pencil to the skin will destroy the tissues like a hot cautery. Application for a few seconds causes blanching, followed by intense hyperæmia. In certain diseases, such as rodent ulcer, applications lasting from fifteen to sixty seconds, repeated once or twice a week, appear to destroy the less resistant diseased cells, while sparing the healthy cells.

Ionization.—When a weak electric current is passed through a solution of a metallic salt, the salt is slowly decomposed, the acid constituent seeking the positive electrode and the basic constituent the negative. By taking advantage of this fact, the ions of zinc or copper may be conveyed through the unbroken skin or conjunctiva. The electrodes are moistened with a solution of the salt, the positive being applied to the affected part and the negative elsewhere. A current of 1 or 2 milliamperes for the cornea or conjunctiva and 3 milliamperes for the skin is applied for one minute. The treatment has been strongly recommended in corneal ulcer, interstitial

keratitis, pterygium, trachoma, rodent ulcer, etc. Results obtained by the present writer have not been encouraging, and the treatment is very painful.

Electricity is used in the form of the electro-cautery. Electrolysis may be employed for the removal of distorted lashes. The galvanic and Faradic currents are occasionally resorted to in paralysis of ocular muscles.

Radium is used in the treatment of rodent ulcer, trachoma, and spring catarrh. A tube containing 6 milligrammes of radium bromide, applied directly to the surface of rodent ulcer for twenty minutes once a week, has in many cases cured the disease.

X Rays are also used for the same purposes, but should be employed very cautiously by an expert.

Heat.—Hot compresses are prescribed in affections of the cornea, iris, and ciliary body. They are applied by means of flannel or absorbent cotton wrung out of water which is as hot as can be borne (115°); they are placed upon the closed lids, and renewed every minute or two.

Cold.—Cold compresses are used in inflammatory affections of the conjunctiva. The best method of applying them is as follows: Strips of lint are folded so as to make pads of four thicknesses, about $1\frac{1}{2}$ inches square; a number of these are moistened and laid upon a block of ice; from the ice they are transferred to the closed eyelids, and changed as soon as they become warm. In the absence of ice the compresses may be wrung out of cold water. Ice should never be applied directly to the lids.

Local Blood-letting is of great benefit in affections of the deeper structures of the eye, especially in iritis. Leeches are very frequently prescribed; from two to four are applied to the temple, midway between the outer canthus and the tragus. The artificial leech of Heurteloupe is often used in this situation, and an ounce of blood abstracted.

Massage is sometimes prescribed in interstitial keratitis, glaucoma, corneal opacities, and quite recent embolism of the retinal artery. A small quantity of some form of ointment is placed in the conjunctival sac; then the finger is applied

to the closed upper lid, and the cornea massaged gently for a few minutes at a time.

Subconjunctival Injections are employed in episcleritis, scleritis, iridocyclitis, choroiditis, corneal ulcer, and in detachment of the retina. After local anæsthesia by means of holocain or cocaine, a fold of conjunctiva is seized with forceps about 8 mm. from the limbus, the needle of a hypodermic syringe introduced into this lifted tissue, and from 5 to 15 minims of fluid injected, or the needle may be introduced superficially under the conjunctiva without the aid of a forceps when the patient looks downward and the upper lid is raised. Various germicides (mercury bichloride 1 : 5,000 to 1 : 1,000, mercury cyanide 1 : 5,000 to 1 : 1,000, cinnamic acid 1 : 100) have been recommended, but a solution of sodium chloride of physiological strength is equally effective and much less painful.

General Rules for Ophthalmic Operations.

Preparation of the Patient.—When not operated upon in his own home, the patient should enter the hospital or nursing-home on the day previous to operation. He should take a bath and a mild cathartic on the night before, followed, perhaps, by an enema on the morning of the operation. He should be in good physical condition; old age, albuminuria, and diabetes are no contra-indications, but such patients require especial care.

It is imperative to examine the conjunctiva and the lacrymal sac before deciding to operate, especially if the eyeball is to be opened, as in iridectomy or cataract extraction. The presence of purulent or mucopurulent secretion from the conjunctiva or lacrymal sac renders an operation upon the eyeball extremely hazardous on account of the danger of infection. In such cases the conjunctival or lacrymal affection must be first cured by appropriate treatment. If there be the slightest doubt as to the condition of the conjunctival sac, a bacteriological examination should be made.

Preparation of the Hands of the Operator.—The hands should be scrubbed thoroughly with soap and warm water,

and then immersed for a minute in 1 : 1,000 corrosive sublimate solution.

Preparation of Instruments.—Blunt instruments should be cleaned and polished, boiled in 1 per cent. solution of soda, rinsed with sterile water, and then kept in a sterile solution of boric acid (4 per cent.), or dried and laid on sterilized gauze. Sharp instruments, especially cataract knives, should not be boiled for more than about one minute. Previous to sterilizing, the cutting qualities are tested upon thin kid stretched in the testing-drum (Fig. 333), and the edge and point examined with a magnifying lens.

Position of the Patient.—The patient should lie on a narrow operating-table. The light, whether daylight or artificial



FIG. 333.—DRUM USED TO TEST THE CUTTING-EDGES OF EYE INSTRUMENTS.

illumination, must be good, and the field of operation must be well illuminated; for the latter purpose a large condensing lens is often used to throw the light upon the eye during operations upon the lens or iris.

Preparation of the Region of Operation.—The eyelids, including the lashes and the surrounding skin, should be washed with soap and warm water, and then with corrosive sublimate solution (1 : 5,000). The everted lids are cleansed gently. The conjunctival sac should be flushed with a large quantity of unirritating sterile fluid.

Anæsthesia.—In the great majority of adult cases local anæsthesia is sufficient. Two drops of a 2 or 4 per cent. solution of hydrochloride of cocaine, or a little powdered cocaine, is instilled every few minutes for three or four doses,

the lids being kept closed in the intervals. Cocaine solutions must be freshly prepared, since they do not keep well.

In children and in nervous adults, also in enucleations, in glaucoma with very high tension, in blepharoplastic operations, and occasionally in other procedures, a general anæsthetic is necessary.

In operations upon the eyelids, or in excision of the lacrymal sac, subcutaneous injection of novocain and adrenalin (see p. 76) gives good results.

Cleansing Solutions.—In the course of operations upon the eyeball it is necessary to cleanse the seat of operation,

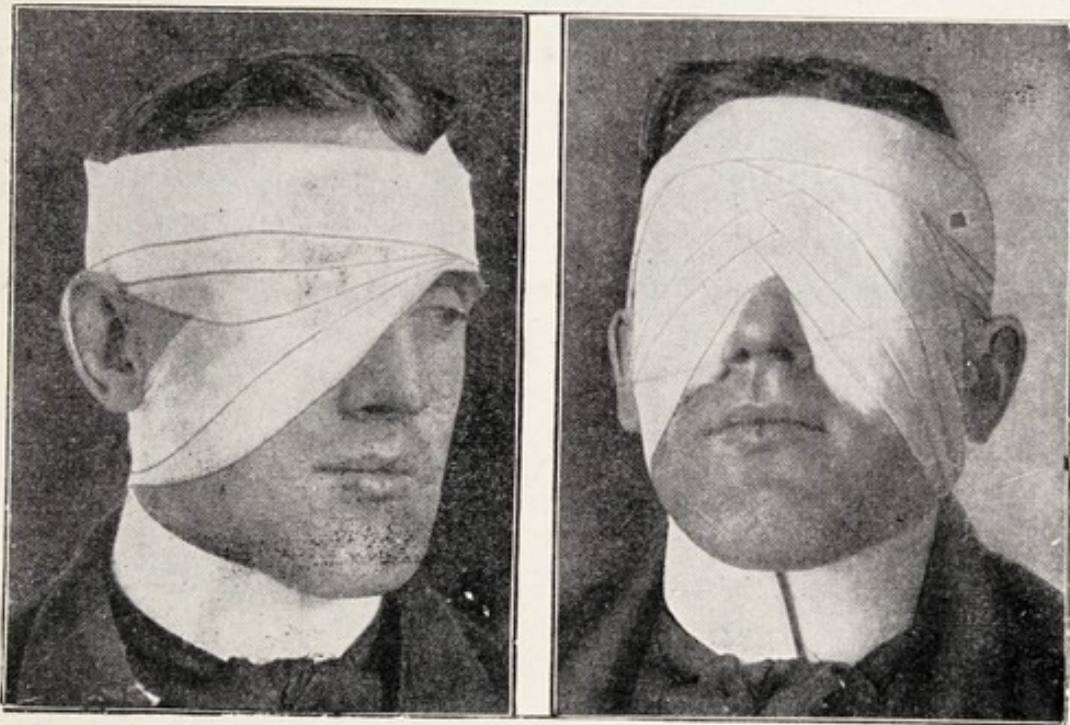


FIG. 334.—MONOCULAR BANDAGE. FIG. 335.—BINOCULAR BANDAGE.

and to irrigate the cornea frequently to prevent desiccation. The solutions used for this purpose are boric acid 4 per cent., salt 0.6 per cent., and mercuric chloride 1 : 10,000. These cleansing solutions are applied by means of small wads of absorbent cotton-wool.

Dressings vary with the nature of the operation. Sterilized gauze, used dry or soaked in sterilized salt solution, are generally applied next to the closed eyelids, covered by

additional layers of absorbent gauze, and retained by a bandage covering one or both eyes, sometimes by strips of isinglass plaster.

Eye bandages are $1\frac{1}{2}$ inches wide, 5 or 7 yards long, and

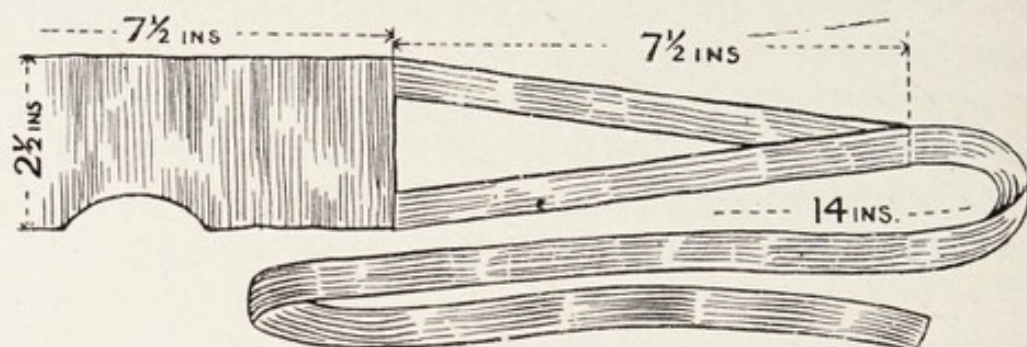


FIG. 336.—THE MOORFIELDS HOSPITAL BANDAGE.

made of gauze or muslin. If used for protection only they are applied lightly; if for pressure, they are put on tightly; in the latter case, care must be taken that the depression between the supra-orbital margin and the nose is properly filled out.

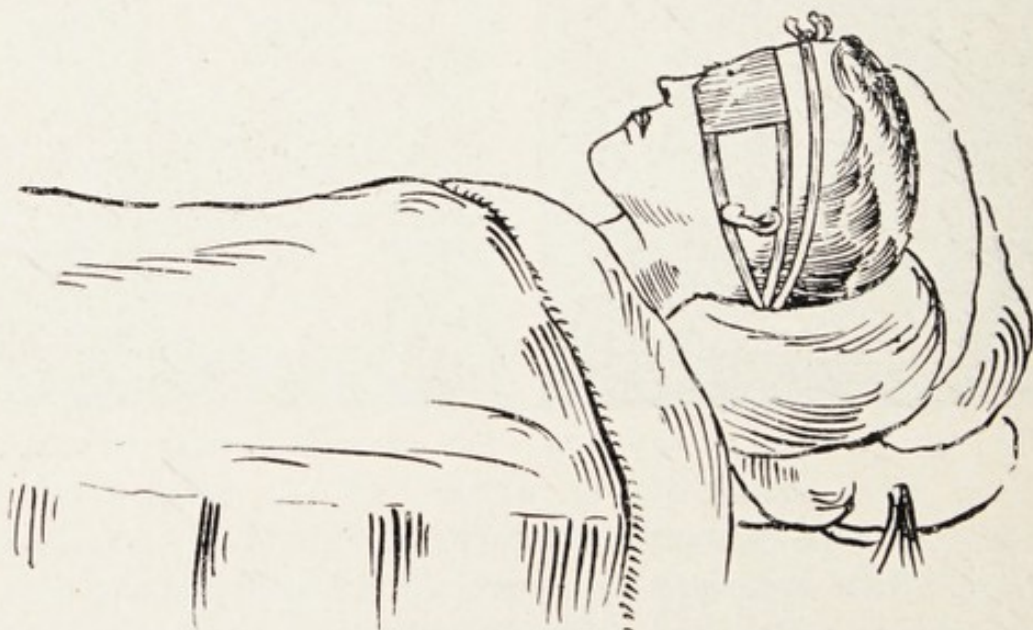


FIG. 337.—THE MOORFIELDS BANDAGE APPLIED.

The Monocular Bandage (Fig. 334) is applied as follows: Begin over the temple of the same side as the affected eye (the right, for example); make one turn around the forehead, then pass across the occiput, below the right ear, and obliquely across the right eye; then another turn about the forehead,

below the right ear, across the right eye; and alternate in this way three or four times.

The Binocular Bandage (Fig. 335).—Begin over the temple of one side (the right, for example); make a full turn around the forehead, and continue to the left temple; then obliquely across the occiput, below the right ear, across the right eye, around the upper occipital region, above the right ear, downward over the left eye, below left ear, across the occiput, below the right ear, across the right eye; and alternate in this manner for three or four turns.

The Moorfields' Bandage (Figs. 336 and 337) is far superior to any other for most eye operations. It is made of stout linen and tape. The figures show the exact dimensions and the manner of applying it. It enables one to change the dressing without lifting the patient's head from the pillow. After untying the knot, the bandage is lifted a little from the patient's face, and passed upwards on to his forehead. The dressing having been changed, the bandage is replaced and the tapes tightened and tied.

CHAPTER XXXIV

VISUAL REQUIREMENTS FOR BRITISH AND INDIAN PUBLIC SERVICES

Royal Navy.—Candidates for naval cadetship must possess full normal vision as determined by Snellen's tests, each eye being separately examined (*i.e.*, $\frac{6}{6}$ and Snellen's 0.6 or J 1). There must be no ocular disease and no squint. Colour vision must be normal.

(A high hypermetrope or a boy whose eyes are progressing towards myopia may pass the tests, but would be liable to be rejected as unfit in after years.)

Candidates for Other Branches of the Royal Navy.—Full normal vision is not required, but any defect of vision must be due to errors of refraction, which can be corrected to normal by glasses, and vision without glasses must in any case be not less than $\frac{6}{8}$ with each eye, and he must also be able to read Snellen's 0.6.

Imperfect colour-vision will disqualify a candidate, so also will any chronic disease of eyes or eyelids, lacrymal apparatus, squint, or any defect of the ocular muscles.

The following ratings are required to have full normal acuteness of vision without glasses: The seamen class, marines (except bandsmen), armourers, engine-room artificers, electricians, and boy artificers.

For candidates for other artisan ratings and for stokers the vision must be at least $\frac{6}{8}$. For all other ratings, including writers, ship-stewards' assistants, ship's cooks, sick-berth staff, officers' stewards and cooks, the vision must not be less than $\frac{6}{12}$.

Defects of vision must be due to errors of refraction only, and must be capable of correction by means of glasses. The candidate must be able to read Snellen's 0.6 without glasses. Marine bandsmen, sick-berth staff, writers, ship's stewards' ratings, ship's cooks' ratings, and officers' servants, are allowed to wear glasses. Ship's cooks' ratings and officers' servants are not disqualified by colour-blindness; all the others are.

The British Army—Commissioned Officers.—The examination for determining the acuteness of vision includes two tests: one for distant, the other for near vision. The army test types will be used for the test for distant vision without glasses at a distance of 20 feet, and for

the test for near vision without glasses at any distance selected by the candidate. The standards of the minimum acuteness of vision with which a candidate will be considered fit are as follows:

STANDARD I.

Right Eye.

Distant vision, $\frac{6}{8}$.
Near vision, Snellen's 0.6.

Left Eye.

Distant vision, $\frac{6}{8}$.
Near vision, Snellen's 0.6.

STANDARD II.

Better Eye.

Distant vision, $\frac{6}{8}$.
Near vision, Snellen's 0.6.

Worse Eye.

Vision without glasses not below $\frac{6}{8}$, and after correction with glasses, not below $\frac{6}{24}$.
Near vision, Snellen's 1.

STANDARD III.

Better Eye.

Distant vision without glasses not below $\frac{6}{24}$, and after correction with glasses $\frac{6}{8}$.
Near vision, Snellen's 0.8.

Worse Eye.

Vision without glasses not below $\frac{6}{24}$, and after correction with glasses not below $\frac{6}{12}$.
Near vision, Snellen's 1.

Each eye must have a full field of vision as tested by hand movements.

Squint or any morbid condition of the eyes or of the lids of either eye liable to the risk of aggravation or recurrence will cause the rejection of the candidate.

Each eye will be examined separately, and the lids must be kept wide open during the test.

Inability to distinguish the principal colours will not be regarded as a cause for rejection, but the fact will be recorded, and the candidate will be informed.

No relaxation of the standard of vision will be allowed under any circumstances.

Recruits—Vision.—In examining a recruit's vision he will be placed with his back to the light, and his visual acuteness will be tested by means of army test types placed under good illumination at a distance of 6 metres (20 English feet) from the recruit.

Each eye will be tested separately, and the lids must be kept wide open during the test.

A recruit for the regular army will be considered fit—

(a) If his vision *without* the aid of glasses is not less than $\frac{6}{18}$ with each eye.

(b) If his vision in the left eye *without* the aid of glasses is not less than $\frac{6}{36}$, provided that his vision in the right eye *without* the aid of glasses is not less than $\frac{6}{8}$.

(c) In the case of recruits enlisting into the Royal Artillery, Royal Engineers, Royal Corps of Signals (except operators, visual), Tank Corps, and R.A.S.C., with a view to appointment as tradesmen (except drivers), and in the case of recruits enlisting into the R.A.M.C., Army Dental Corps, R.A.O.C., R.A.V.C., and C.M.A.—

- (i.) If his vision in one eye (right or left) *without* the aid of glasses is not less than $\frac{6}{80}$, provided that his vision in the other eye *without* the aid of glasses is not less than $\frac{6}{12}$;
- (ii.) If his vision *without* the aid of glasses is not less than $\frac{6}{24}$ in each eye.

The vision of a recruit enlisting with a view to employment as a driver (Horse Transport or Mechanical Transport) in any corps *without* the aid of glasses must not be less than $\frac{6}{18}$ with each eye, provided that *with* the aid of glasses, if necessary, his vision is not less than $\frac{6}{8}$ in one eye (right or left) and $\frac{6}{12}$ in the other.

A candidate for the Army Educational Corps will be accepted if the medical examiner is satisfied that his vision, *with* or *without* glasses, is sufficiently good for the satisfactory performance of his duties.

Each eye must have a full field of vision as tested by hand movements.

Squint or any morbid condition of the eyes or of the lids of either eye liable to the risk of aggravation or recurrence will cause the rejection of the recruit.

The visual acuity of each eye will be entered on the medical history sheet of approved recruits.

Board of Trade Tests for the British Mercantile Marine.—"If he can read correctly nine out of the twelve letters in the sixth line ($\frac{6}{6.7}$) from the top, and eight of the fifteen letters in the seventh line ($\frac{6}{8}$) with one eye, and the whole of the eight letters in the fifth line ($\frac{6}{10}$) with the other eye, he may be considered to have passed the test. If he cannot do so, his case should be submitted to the Principal Examiner of Master and Mates.

"Every candidate who fails to pass the form test is to be examined with the pellet test as follows:

"The pellets should be placed on a white plate, and the first test pellet (which is of the same colour as the first wool-test skein) should then be placed at a little distance from the box on a white plate. The candidate should be required to pick out and lay by the side of the test pellet all pellets of the same colour. The same should be done with the other test pellets, and the examination should proceed in the same way as the wool test.

"**Colour-Vision Test.**—The colour vision of candidates is to be tested by means of Holmgren's wools. Five test-skeins are now used: (1) Light green, (2) pink, (3) red, (4) purple, (5) yellow.

"During the colour-vision test the examiner should avoid naming

the colours of any of the wools, and should explain to the candidate that he does not require them to be named to him.

"Colour-Ignorance Test."—1. The object of this test is simply to ascertain whether the candidate knows the names of the three colours—red, green, and white—and the test is to be confined to naming these colours.

"2. One or two of the purest red and green skeins should be selected from the set of wools, and the candidate should be required to name their colours. He should also be required to name the colour of any white object, such as a piece of white paper."

Home Civil Service.—There are no definite rules, but the candidate must have no defect of vision which is likely to interfere with his work.

Indian Civil Service (*i.e.*, Ecclesiastical, Education, Geological, Survey, Agriculture, Indian Finance, Customs, Civil Veterinary, and other departments not specially provided for).—1. The candidate will be admitted if ametropic in one or both eyes, provided that with glasses he sees not less than $\frac{5}{8}$ with one eye and $\frac{5}{8}$ with the other, there being no morbid change in the fundus of either.

2. If myopic, the ametropia in either eye is not to exceed 2.5 D., with no active morbid changes in choroid or retina, though he may have a posterior staphyloma.

3. If the defect of vision is due to a corneal nebula, he will be disqualified if his vision is less than $\frac{1}{2}$ in either eye, and in such case the acuteness of vision in the better eye must equal $\frac{5}{8}$ with or without glasses.

4. Squint, or any morbid condition subject to risk of aggravation or recurrence in either eye, may cause the rejection of a candidate. The existence of imperfection of colour-sense will be noted.

The Departments of Forest, Survey, Telegraph, Factories, and for Various Artificers in the Indian Civil Service.—1. If myopia in one or both eyes exists, the candidate may be passed if it does not exceed 2.5 D., and if, with correcting glasses not exceeding 2.5 D., he sees $\frac{5}{8}$ with one eye and $\frac{5}{8}$ with the other, there being normal range of accommodation with the glasses.

2. If myopic astigmatism exists, the combined spherical and cylindrical glass must not exceed -2.5 D., and with that one eye must see not less than $\frac{5}{8}$ and the other $\frac{5}{8}$.

3. A candidate having total hypermetropia not exceeding 4 D. is not disqualified provided the sight in one eye (when under atropine) equals $\frac{5}{8}$ and the other $\frac{5}{8}$, with +4 D. or any lower glass.

4. Hypermetropic astigmatism will be allowed if the combined lenses required to correct the error do not exceed 4 D., and that with or without the glasses the sight is equal to $\frac{5}{8}$ in one eye and $\frac{5}{8}$ in the other.

5. If the defect is due to a corneal nebula, the sight of one eye must

not be less than $\frac{1}{12}$. In such a case the better eye must be emmetropic. Defects of vision from pathological or other changes in the deeper structures of either eye which are not referred to in the above rules may exclude a candidate.

6. Squint, or any morbid condition subject to risk of aggravation or recurrence in either eye, may cause the rejection of a candidate. The existence of imperfection of colour-sense will be noted.

Artificers engaged in map and plan drawing may be considered separately, and this standard relaxed if it appears to be desirable.

Public Works Department and Superior Establishments, Railway Department of India.—1. If myopia exists, it must not exceed 3.5 D., but if with a 3.5 D. glass the candidate sees $\frac{5}{8}$ with one eye and not less than $\frac{5}{8}$ with the other, he will be passed. Range of accommodation must be normal.

2. If myopic astigmatism exists, the combined spherical and cylindrical glass must not exceed 3.5 D., and with this the vision must be equal to at least $\frac{5}{8}$ in one eye and $\frac{5}{8}$ in the other. Range of accommodation must be normal.

3. Hypermetropia must not exceed 4 D., and the sight of one eye (when under atropine) must equal $\frac{5}{8}$, and the other $\frac{5}{8}$ with a +4 D. glass, or one of any less power.

4. Hypermetropic astigmatism is allowed if the combined correcting glass does not exceed 4 D., and that the sight, with or without lens, equals $\frac{5}{8}$ in one eye and $\frac{5}{8}$ in the other.

5. If a corneal nebula exists, the vision must not be less than $\frac{1}{12}$ in that eye, but the other eye must be emmetropic. Defects of vision arising from pathological or other changes in the deeper structures of the eye, which are not referred to in these rules, may exclude a candidate.

6. Squint, or any morbid condition subject to risk of aggravation or recurrence in either eye, may cause the rejection of a candidate. Any imperfection of the colour-sense is a disqualification for appointment to the engineering branch of the Railway Department, or as assistant-superintendent in the Traffic Department. In all other cases a note as to any imperfection of the colour-sense will be made.

The Indian Medical Service and Indian Police.—The same as the British Army.

Indian Pilot Service, and Candidates for Appointments as Guards, Engine-Drivers, Signalmen, and Pointsman on Railways.—1. A candidate is disqualified unless both eyes are emmetropic, his acuteness of vision and range of accommodation being perfect.

2. A candidate is disqualified by any imperfection of his colour-sense.

3. Strabismus or any defective action of the exterior muscles of the eyeball disqualifies a candidate.

Indian Marine Service, including Engineers and Firemen.—1. A candidate is disqualified if he has an error of refraction in one or both

eyes, which is not neutralized by a concave or convex 1 D. lens or some lower power.

2. He is disqualified by any imperfection of his colour-sense.

3. He is disqualified by strabismus or any defective action of the exterior muscles of the eyeball.

COMMISSIONS IN THE ROYAL AIR FORCE

The regulations governing the examination of eyesight are as follows:

1. The examination for determining the acuity of vision will be conducted with well-illuminated standard test types at a distance of 20 feet. The candidate must be able to read the test types without hesitation. The minimal standard of acuteness of vision without correcting glasses is: Distant vision in each eye tested separately - V.: $\frac{6}{8}$. Hypermetropia as tested by a + lens of 2 D. or more in either eye shall disqualify. Where a candidate is otherwise specially fit, the eye specialist may recommend acceptance—

(a) For permanent commissions when the visual acuity is equal to $\frac{6}{8}$ in each eye;

(b) For short service commissions when the visual acuity is equal to $\frac{6}{12}$ in each eye;

provided that in each case such vision is correctable by glasses to $\frac{6}{8}$ in each eye and the conditions in paragraphs 2, 3, and 4 are fulfilled.

2. Both eyes must have good fields of vision as tested by hand movements.

3. Colour vision must be normal.

4. There must be good (i.) binocular fusion, (ii.) convergence, (iii.) balance of eye muscles.

INDEX

- ABBREVIATIONS, 309
 Abscess, brain, 417
 cornea, 136
 eyelids, 50
 lacrymal sac, 79
 orbital, 83
 Abscission, 146
 Absolute alcohol, 436
 Accessory nasal sinuses, 87
 Accommodation, 313
 amplitude of, 314
 and convergence, 316
 anomalies of, 358
 mechanism of, 314
 paralysis of, 361
 range of, 314
 spasm of, 362
 Acromegaly, 409
 Acuteness of vision, 10, 313
 Adam's operation (ectropion), 61
 Adrenalin, 400, 442
 Advancement operation, 400
 After-cataract, 237
 Albuminuric retinitis, 253, 413
 Alcohol, absolute, 436
 Alternating convergent squint, 380
 Alum, 433
 Amaurosis, 276
 quinine, 280
 'Amaurotic cat's eye,' 189
 family idiocy, 258
 Amblyopia, 276
 after hæmorrhage, 407
 congenital, 276
 ex anopsia, 276
 hysterical, 277
 malarial, 280
 of squint, 380
 quinine, 280
 reflex, 280
 simulated, 278
 tobacco, 272
 toxic, 272
 uræmic, 255, 280
 Amblyoscope, 385
 Ametropia, 312
 Ammoniated mercury, 433
 Amplitude of accommodation, 314
 of convergence, 317
 Anæmia, 407
 of the retina, 259
 pernicious, 407
 Anæsthesia, 446
 local, 441
 Anatomy of choroid, 176
 ciliary body, 170
 conjunctiva, 94
 cornea, 129
 eyelids, 47
 glaucoma, 190
 innervation of pupil, 167
 iris, 157
 lacrymal apparatus, 72
 lens, 220
 normal fundus, 34, 247
 optic nerve, 266
 orbit, 81
 retina, 247
 sclera, 152
 visual paths, 281
 vitreous, 212
 Aneurism, 87
 of aorta, 408
 Angioma, 87
 Angioneurotic œdema, 50
 Angle, alpha, 312
 gamma, 312
 iris, 198
 metre, 317
 minimum visual, 11
 of convergence, 317
 of the anterior chamber, 190
 Angular catarrh, 100
 Anisometropia, 352
 Annular posterior synechia, 162
 Anomalies of accommodation, 358
 of the eyeball, 89
 Anophthalmos, 89
 Anopsia, 276

- Anterior chamber, 7
 Antiseptic solutions, 431
 Antrum disease, 88
 Aorta, aneurism of, 408
 Aortic insufficiency, 408
 Aphakia, 228
 Aphakial eye, iridectomy in, 204
 Apoplexy, 415
 Aqueous chamber, 190
 humour, 191
 Arcus senilis, 130
 Argyll Robertson pupil, 169, 416
 Argyrol, 437
 Argyrosis, 434
 Army, visual requirements for, 450
 Arsenic poisoning, 273
 Arteria centralis retinae, 35, 247
 embolism of, 260
 Arterial pulsation (disc), 195
 Arterio-sclerosis, 260, 408
 Artery, hyaloid, persistent, 212
 Artificial eyes, 93
 leech, 444
 ripening of cataract, 226
 vitreous, 92
 Asthenopia, 333
 accommodative, 353
 muscular, 353
 nervous, 354
 reflex, 354
 Astigmatic dial, 346
 Astigmatism, 313, 324, 342
 correction of, 345
 ophthalmoscope in, 347
 Placido's disc in, 349
 regular, 342
 refraction in, 343
 varieties of, 344
 retinoscopy in, 348
 tests, 347
 treatment, 350
 varieties, 342
 Astringent remedies, 433
 Atrophy, choroidal, 177
 of optic nerve, 256, 273
 Atropine, 438
 irritation, 439
 long use of, 226
 poisoning, 439
 Autogenous vaccines, 424
 Axis, optical, 311

Bacillus coli communis, 425
 lacunatus, 421
 pyocyaneus, 430

Bacillus subtilis, 430
 xerosis, 430
 Bacteriological examination of eyes before operation, 429
 Bandage, binocular, 449
 monocular, 448
 Moorfields, 234, 449
 Basedow's disease, 409
 Bead test, Edridge-Green's, 292
 Beer's knife, 52
 Biconcave lens, 300
 Biconvex lens, 299
 Bifocal lens, invisible, 357
 Binasal hemianopsia, 284
 Binocular bandage, 447
 vision, 365
 Bisulphide of carbon poisoning, 273
 Bitemporal hemianopsia, 284
 Bjerrum's method, 18
 Blackboard test, 15
 Black cataract, 225
 'Black eye,' 70
 Blepharitis, 48
 Blepharoplasty, 62
 Dieffenbach's, 63
 Fricke's, 63
 Knapp's, 63
 Blepharospasm, 6, 64
 'Blight,' 98
 Blind spot, 248
 Blindness, colour, 287
 day, 281
 embolic, 260
 night, 280
 snow, 98, 258
 uræmic, 255
 word, 277
 Blood agar, 422
 diseases of the, 407
 letting, local, 444
 Bluestone, 434
 Board of Trade tests for Mercantile Marine, 452
 Borax, 433
 Boric acid, 432
 Bowman's membrane, 129
 Brain, abscess of, 417
 tumour, 269, 417
 Bright's disease, retinitis of, 253
 Broad needle, 207
 Buller's shield, 105
 Buphthalmos, 90, 210
 Burns of conjunctiva, 127
 cornea, 151
 eyelids, 71
 'Button-hole' in iris, 235

- Calmette's ophthalmo-reaction, 424
 Calomel, 433, 435
 Camphor, 433, 434
 Canal, hyaloid, 212
 of Petit, 221
 of Schlemm, 171, 190
 Canaliculi, 72
 anomalies of, 73
 Canaliculus knife, 75
 slitting, 78
 Candle test, 15
 Canthoplasty, 59
 Canthotomy, temporary, 59
 Canthus, 47
 Canula, 234
 Capsule, extraction of cataract in, 238
 of Tenon, 82
 of the lens, 220
 Capsulo-lenticular cataract, 221
 Capsulotomy, 234
 Carbolic acid, 436
 Carbon dioxide snow, 70, 443
 solid, 443
 Carcinoma of eyelids, 69
 Cardiac disease, 408
 Cardinal points of the eye, 311
 Caruncle, 47
 Case-taking, 1
 Cataract, 221
 accidents, 234
 after-, 237
 after-treatment, 236
 anterior capsular, 134
 polar, 134, 241
 artificial ripening of, 226
 black, 225
 canula, 234
 capsular lenticular, 225
 central, 243
 chalky, 225
 complicated, 243
 concussion, 240
 congenital, 239, 241
 curette evacuation, 237
 delivery of the, 233
 discission of, 239
 dressing after, 234
 etiology, 222, 225
 extraction of, 229
 complications of, 236
 fusiform, 243
 glass-blowers', 41
 in capsule, 238
 juvenile complete, 239
 lamellar, 242
 monocular, 227
 Morgagnian, 225
 needling of, 239
 nuclear, 222
 operation, modifications in, 234
 pathology, 225
 physical signs, 223
 post-operative complications, 236
 posterior polar, 177, 241
 prognosis, 228
 progressive, 222, 223
 punctate, 243
 pyramidal, 241
 ripe, 225
 secondary, 221, 243
 senile, 223
 shrunk, 225
 stages of, 223
 stationary, 222, 241
 symptoms, 222
 traumatic, 240
 treatment, 225
 varieties, 221
 uncommon, 243
 zonular, 242
 Catarrh, spring, 123
 Catarrhal conjunctivitis in new-born, 108
 ulcer (corneal), 136
 Cautery, the, 437
 galvano-, 138
 platinum, 138
 thermo-, 147
 Cavernous sinus, thrombosis of, 85
 Cellulitis, orbital, 85, 410
 Centrads (prisms), 298
 Cerebral decompression, 270
 Cerebro-spinal meningitis, 410
 Chalazion, 51
 scoop, 52
 Chalky cataract, 225
 Chemosis, 4, 96, 104
 Children, examination of, 6
 Chlorine water, 436
 Chlorosis, 407
 Choked disc, 253, 267, 417
 in ear disease, 410
 Chorea, 417
 Chorio-capillaris, 176
 Choroid, anatomy of, 176
 atrophy of, 177
 coloboma of, 181
 diseases of, 176
 rupture of, 181

- Choroid, sarcoma of, 181, 187
 tubercle of, 181
 Choroiditis, 176, 445
 central, 178
 diffuse, 178
 disseminated, 178, 256
 exudative, 176
 myopic, 179
 non-purulent, 176
 plastic, 176
 purulent, 180, 257
 senile central, 178
 syphilitic, 178
 Choroido-retinitis, 176
 syphilitic, 178
 Cicatrix, leaking, 208
 Cilia, 47
 forceps, 54
 misplaced, 53
 Ciliary body, anatomy of, 170
 diseases of, 170
 injuries of, 174
 injection, 95
 muscle, 170
 processes, 170
 tenderness, 8
 Cinnamic acid, 445
 Circulatory system, diseases of, 408
 Classification test, Edridge-Green's, 292
 Cleansing solutions, 431, 447
 Cocaine as dilator, 25
 hydrochloride, 440
 nitrate, 437
 Cold compresses, 444
 Collyria, 101, 431, 434
 Coloboma of choroid, 181
 of iris, 203
 Colour blindness, 287
 dangerous cases, 290
 ignorance, 453
 perception, theories of, 287
 sense, 10, 18
 vision, tests for, 291, 452
 Colour-perceiving elements in the retina, 287
 Colours, field for, 18
 in spectrum, 288
 Coma, 417
 Comitant squint, 357, 379
 Concave lens, foci of, 302
 meniscus lens, 300
 mirror, 294
 periscope lens, 300
 spherical lens, 299
 Concavo-convex lenses, 299
 Concussion cataract, 240
 Congenital anomalies of eyeball, 89
 cataract, 239
 dislocation of lens, 245
 glaucoma, 90, 210
 word-blindness, 277
 Conical cornea, 146
 operation for, 147
 Conjugate foci, 301
 Conjunctiva, 47
 anatomy of, 94
 burns of, 127
 diseases of, 94
 foreign bodies on, 127
 hæmorrhage under, 127
 injection of, 95
 injuries of, 127
 lithiasis of the, 124
 wounds of, 127
 xerosis of, 115, 280
 Conjunctivitis, 96
 acute catarrhal, 96
 epidemic, 98
 muco-purulent, 96
 simple, 96
 adult purulent, 103
 angular, 101
 catarrhal, in new-born, 107
 chronic catarrhal, 99
 simple, 100
 croupous, 110
 differential diagnosis, 161
 diphtheritic, 109, 410
 exanthematous, 98
 follicular, 99, 101
 gonorrhœal, 103
 granular, 111
 infantile purulent, 107
 lacrymal, 74, 98
 membranous, 109
 Parmaud's, 123
 phlyctenular, 119
 purulent, 102
 pustular, 119
 trachomatous, 111
 traumatic, 97
 Constipation, 409
 Contrecoup, injury by, 89
 Convergence, amplitude of, 317
 and accommodation, 316
 angle of, 318
 insufficiency of, 398
 range of, 317
 Convergent squint, 379
 etiology, 381
 operation in, 388

- Converging lens, 299
 meniscus lens, 299
 Convex lens, foci of, 300
 meniscus lens, 299
 mirror, 296
 periscopic lens, 299
 spherical lens, 298
 Convexo-concave lens, 300
 Copper sulphate, 115, 434
 Cornea, abscess of, 136
 anatomy of, 129
 bulging of, 145
 burns of, 151
 conical, 146
 diseases of, 129
 examination of, 5
 in infants, 6
 fistula of, 134
 foreign bodies in, 149
 inflammation of, 130
 injuries of, 149
 onyx, 136
 opacities of, 5, 148
 paracentesis of, 138
 perforation of, 133
 sensitiveness of, 5
 staphyloma of, 145
 tattooing, 149
 ulcer of, 131
 wounds of, 151
 Corneal facet, 132
 magnifier, 21
 microscope, 37, 38
 precipitates, 45
 ulcer, atropine in, 137
 clinical forms, 134
 fluorescein in, 132
 iodine in, 138
 serpent, 135
 vaccines in, 429
 Corneo-scleral trephining, 208
 Corrosive sublimate, 436
 Cortical visual area, 282
 Cowper's probes, 77
 Credé's prophylaxis, 108
 Cretinism, 409
 Croupous conjunctivitis, 110
 Crystalline lens, 220
 Cupping of disc, 35, 194
 Curette, 229, 237
 Cyclitis, 171
 and oral sepsis, 408
 mild, 172
 purulent, 174, 180
 'quiet,' 408
 severe, 172
 Cyclophoria, 394
 Cycloplegia, 361
 Cycloplegics, 354, 438
 Cylindrical lens, 304
 Cyst, Meibomian, 51
 tarsal, 51
 Cystoid cicatrix, 205
 Cystotome, straight, 229
 Dacryoadenitis, 74
 Dacryocystitis, acute, 79
 chronic and corneal infection,
 74
 vaccines in, 429
 'Dangerous zone,' 174
 Dark-room examination, 20
 Daturine, 439
 Day-blindness, 281
 Decompression, cerebral, 270
 Degrees (prisms), 298
 Dendriiform keratitis, 136
 ulcer (cornea), 136
 Dental disease, 408
 Dermoid cyst, 87
 Descemet's membrane, 130
 Descemetitis, 144, 172
 Desmarre's lid retractor, 7
 Detachment of retina, 263, 445
 De Wecker's iris scissors, 229, 232
 Diabetes, 413
 Diabetic retinitis, 255, 273
 Dial, astigmatic, 346
 Dichromics, 289
 Dieffenbach's blepharoplasty, 63
 Digestive system, diseases of, 408
 Dilatation of pupil, 25
 Dilator, Nettleship's, 75
 Dionin, 140, 149, 153, 163, 442
 Diopters (prisms), 298
 Dioptic apparatus of the eye, 310
 system, lenses, 305
 Diphtheria, 410
 Diphtheritic conjunctivitis, 109
 Diplo-bacillus of Morax-Axen-
 feld, 421
 Diplopia, 366, 369
 crossed, 367
 homonymous, 367
 monocular, 244
 test, 367, 370
 Direct method, ophthalmoscopic
 examination, 28, 322
 Disc, choked, 253, 268
 excavation of, 194
 optic, 27, 34, 247
 Placido's, 4, 349
 Discission for after-cataract, 237
 of lens, 239

Disease:

abscess of brain, 417
 apoplexy, 415
 Basedow's, 409
 blood, 407
 cardiac, 408
 cerebro-spinal meningitis, 410
 chorea, 417
 choroid, 176
 ciliary body, 170
 circulatory system, 408
 coma, 417
 conjunctiva, 74, 94
 cornea, 129
 dental, 408
 diabetes, 413
 digestive system, 408
 diphtheria, 410
 disseminated sclerosis, 416
 ductless glands, 409
 ear, 410
 encephalitis lethargica, 416
 epilepsy, 418
 erysipelas, 410
 Friedreich's, 416
 general, ocular manifesta-
 tions of, 407
 paralysis, 416
 gonorrhœa, 411
 gout, 414
 Graves', 409
 headache, 414
 heart, 408
 hysteria, 418
 infective, 410
 influenza, 411
 intestines, 408
 intoxications, 419
 iris, 158
 kidneys, 413
 lacrymal apparatus, 72
 lens, 220
 leprosy, 411
 malaria, 411
 measles, 411
 meningitis, 416
 migraine, 414
 mumps, 411
 myelitis, 416
 naso-pharynx, 418
 nephritis, 413
 nervous system, 415
 nose, 418
 optic nerve, 266
 orbit, 81
 poisonings, 419
 pneumonia, 411

Disease:

pyæmia, 412
 retina, 247
 rheumatism, 415
 rickets, 415
 scarlatina, 411
 sclera, 152
 scurvy, 415
 septicæmia, 412
 stomach, 408
 syphilis, 412
 tabes, 417
 teeth, 408
 tuberculosis, 412
 uveal tract, 171
 vaccinia, 412
 varicella, 413
 variola, 413
 vertigo, 415
 vitreous, 212
 whooping-cough, 413
 yellow fever, 413
 Disinfectants, 436
 Dislocation of lens, 244
 Dissector, blunt, 76
 Disseminated sclerosis, 416
 Distant vision, 10
 Distichiasis, operation for, 55
 Divergent squint, 389
 Diverging lens, 299
 meniscus lens, 300
 Dressings, 447
 Dry catarrh, 100
 Duboisine, 163, 439
 Ductless glands, disease of, 409
 Dynamic convergence, insuffi-
 ciency of, 398
 Ear, diseases of, 410
 Ecchymosis, eyelids, 70
 Ectropion, Adam's operation for,
 61
 cicatricial, 60
 operations for, 61
 paralytic, 60
 senile, 60
 spasmodic, 60
 Edridge-Green's bead test, 292
 classification test, 292
 lantern test, 291
 theory, 287
 Egyptian ophthalmia, 115
 Ehrlich-Hata, '606,' 424
 Electricity, 444
 Electric ophthalmoscope, 22
 welding, 258
 Electrolysis, 53, 444

- Elliott's operation, glaucoma, 208
 Embolism, central retinal artery, 259, 260, 408
 Emmetropia, 312, 322
 Emphysema, eyelids, 71
 Encephalitis lethargica, 416
 Endocarditis, 408
 Enophthalmos, 83
 Entropion, 54
 cicatricial, 54
 forceps, Knapp's, 55
 operations for, 55
 Hotz, 57
 Jaesche-Arlt, 56
 Streatfeild-Snellen, 57
 senile, 54
 spasmodic, 54
 spastic, 58
 Enucleation of the eyeball, 90
 in glaucoma, 207
 Epicanthus, 68
 Epilation, 53
 Epilepsy, 418
 Epiphora, 73
 Episcleral tissue, 94
 Episcleritis, 152, 153, 445
 transient periodic, 154
 Epithelioma, eyelids, 69
 Errors of refraction, 330
 Erysipelas, 410
 Eserine salicylate, 441
 Esophoria, 391, 397
 Ethmoidal sinus, 88
 Euphthalmin, 25, 440
 Eversion of eyelid, 2
 Evisceration of eyeball, 92
 Examination of the eye, 1
 colour sense, 18
 eyes of infants, 6
 field of vision, 13
 for heterophoria, 392
 for muscular paralysis, 361, 368
 for squint, 381
 iris, 7
 lens, 20, 23, 223
 objective, 1, 20
 of anterior chamber, 7
 ophthalmoscopic, direct, 26
 distant, 23
 indirect, 25
 refraction, 318
 subjective, 10
 Exanthematous conjunctivitis, 98
 Excision, eyeball, 90
 lacrimal sac, 76
 Exclusion of pupil, 162
 Exenteration of the orbit, 93
 Exophoria, 391, 397
 Exophthalmic goitre, 409
 Exophthalmos, 82, 408
 pulsating, 86
 External ocular muscles, action
 of, 364.
 operations on, 400
 paralysis of, 363
 Extraction by magnet, 216
 Eye, artificial, 93
 Snellen's, 93
 bath, 431
 cardinal points of, 311
 dioptric apparatus of, 310
 examination of, 1
 motor balance of, 392
 nodal points of, 311
 optical consideration of, 310
 principal points of, 311
 refraction of, 310, 312
 Eyeball, 81
 centre of rotation of, 311
 congenital anomalies of, 89
 enucleation of, 91
 evisceration of, 92
 movements of, 364
 tension of, 8
 Eyeglasses, fitting of, 355
 Eyelids, affections of the, 47
 anatomy of, 47
 burns of, 71
 carcinoma of, 69
 contused wounds of, 71
 ecchymosis of, 70
 emphysema of, 71
 incised wounds of, 70
 injuries of, 70
 insect bites, 70
 lacerated wounds of, 71
 physiology of the, 47
 rodent ulcer, 69
 sarcoma of, 69
 syphilis of, 50
 tumours of, 69
 vaccinia of, 50
 Eye-strain, 353
 Facet, corneal, 132
 Far point, 314
 Far-sightedness, 312
 Fascia, orbital, 81
 Fascicular keratitis, 120
 Fatty heart, 408
 Field for colours, 18
 of fixation, 365

- Field of vision, 10, 13
 perimeter in, 15
 tests for, 15
- Finger counting, 12
- Fistula of cornea, 134
- Fitting of eyeglasses, 355
 of spectacles, 355
- Fixation, field of, 365
 forceps, 202
- Flare, 45
- Fluorescein in corneal ulcer, 132, 138
 in examination, 5
- Focal illumination, 20
- Foci of concave lens, 302
 of convex lens, 300
- Focus, conjugate, 301
 first principal, 311
 negative of convex lens, 302
 principal, 301
 second principal, 311
 virtual, of convex lens, 302
- Follicular catarrh, 101
 conjunctivitis, 101
- Fontana, spaces of, 190
- Forceps, advancement, 402
 cilia, 54
 curved iris, 202
 entropion, Knapp's, 55
 fixation, 202
 roller, Knapp's, 117
- Foreign bodies, conjunctiva, 127
 cornea, 149
 instruments for, 150
 magnet extraction of, 217
 vitreous, 215
- Form sense, 10
- Formalin, 437
- Fornix conjunctivæ, 94
- Fovea centralis, 247
- Fränkel's pneumococcus, 421, 429
- Fricke's blepharoplasty, 63
- Friedländer's pneumobacillus, 429
- Friedreich's disease, 416
- Frontal sinus, 87
- Functional examination of the eye, 10
 nervous disorders, 417
- Fundus oculi, examination of, 25, 28
 normal, 34
 reflex, 24
- Fusion faculty, 365
 in squint, 381
 training of, 384
- Gait, uncertain, 369
- Galvano-cautery, 138
- General paralysis, 416
- Geneva lens measure, 308
- Germans, myopia in, 337
- Glands, lacrymal, 72
 Meibomian, 47
 of Moll, 47
 of Zeiss, 47
- Glassblowers' cataract, 41
- Glaucoma, absolute, 195
 acute congestive, 192
 stage, 193
 anatomy, 190
 chronic congestive, 196
 inflammatory, 196
 congenital, 90, 210
 cystoid cicatrix in, 205
 degeneration after, 195
 differential diagnosis, 199
 Elliott's operation, 208
 enucleation in, 207
 eserine in, 200
 etiology, 197
 fulminans, 196
 hæmorrhagic, 210
 iridectomy, 201
 iris angle, 198
 operation in, 201
 pathology of, 198
 presbyopia, 360
 prodromal stage, 192
 prognosis, 200
 sclerotomy in, 207
 secondary, 210
 simple, 197
 tension in, 198
 treatment, 200
 varieties, 191
- Glaucomatous cup, 195
 halo, 195
 ring, 195
 state, 194
- Glioma of the retina, 188
 Pseudo-, 45, 180, 257, 412
- Glycosuria, retinitis in, 255
- Goitre, exophthalmic, 409
- Gold chloride, 149
- Gonococcal vaccine, 428
- Gonorrhœa, 411
- Gonorrhœal iritis, 165
 ophthalmia, 103
 vaginitis, 107
- Gout, 414
- Graefe knife, 230
 narrow, 202
 operation for ptosis, 66

- Graefe sign, 409
 Grafts, skin, 63, 125
 Granular conjunctivitis, 111
 lids, 111
 Gratiolet, fibres of, 281
 Grattage in trachoma, 118
 Graves' disease, 409
 Gravidic retinitis, 254, 419
 Gullstrand's corneal microscope,
 37, 38
 Gummata, 412

 Haab's magnet, 215
 Hæmophilia, 407
 Hæmorrhage after cataract opera-
 tion, 236
 amblyopia after, 407
 into the vitreous, 214
 retinal, 407
 subconjunctival, 127
 subhyaloid, 259
 Hæmorrhagic glaucoma, 210
 retinitis, 257
 Hand test, 15
 Hands of operator, preparation
 of, 445
 Headache, 414
 Heart disease, 408
 Heat, 444
 Helmholtz theory, 314
 Hemeralopia, 262
 Hemiachromatopsia, 285
 Hemianopia, 283
 pupillary reaction in, 285
 Hemianopsia, 16, 281, 283
 altitudinal, 285
 binasal, 284
 bitemporal, 284
 crossed, 284
 homonymous, 284
 lateral, 284
 transient, 286
 Hemiopia, 283
 Heptachromics, 289
 Herbert's operation, 58
 Hering theory (colour), 287
 Herpes corneæ, 143
 zoster ophthalmicus, 68
 Herpetic ulcer, 136
 Hess's operation, 67
 Heterophoria, 354, 367, 391
 Heterotropia, 392
 Heurteloupe, leech of, 444
 Hexachromics, 289
 Holmgren's test, 292
 Holocain hydrochloride, 441
 Homatropine, 25, 355
 Homatropine, hydrobromide, 440
 Home Civil Service, visual re-
 quirements for, 453
 Homonymous diplopia, 367
 hemianopsia, 284
 Hook, iris, blunt, 204
 tenotomy, 401
 Hordeolum, 50
 Horn plate, 55
 Hot compresses, 444
 Hotz's operation, 57
 Hutchinsonian teeth, 143
 Hyaloid artery, persistent, 212
 canal, 212
 membrane, 212
 Hydrogen peroxide solution, 437
 Hydrophthalmos, 90, 210
 Hyoscyamine, 163, 439
 Hypermetropia, 312, 323, 339
 changes in the eye, 332
 symptoms, 333
 tests, 334
 treatment, 334
 Hyperphoria, 391, 397
 Hyphæmia, 7, 159
 Hypophysis, disease of, 409
 Hypopyon, 7, 132, 159
 keratitis, 135
 Hysteria, 418
 traumatic, 278
 Hysterical amblyopia, 277

 Ichthyol, 435
 Illumination, focal, 20
 lateral, 20
 oblique, 20
 source of, 325
 Image, false, 366
 real, 302
 true, 366
 virtual, 302
 Images, 294
 formation of, 302
 Immunization by vaccines, 427
 Inch system, lenses, 306
 Index of refraction, 297
 Indian Civil Service, visual re-
 quirements for, 453
 Factory Department, 453
 Forest Department, 453
 Marine Service, visual re-
 quirements for, 454
 Medical Service, 454
 Pilot Service, 454
 Police Service, 454
 Public Works Department,
 454

- Indian Railway Department, 454
 Survey Department, 453
 Telegraph Department, 453
 various artificers, 453
- Indigo, 288
- Indirect method, ophthalmoscope, 25, 321
- Infant, examination of, 6
- Infantile purulent conjunctivitis, 107
- Infections, post-operative, 429
- Infective diseases, 410
- Influenza, 411
- Injection, ciliary, 95
 conjunctival, 95
- Injections, subconjunctival, 445
- Injuries, ciliary body, 174
 conjunctiva, 127
 cornea, 149
 eyelids, 70
 iris, 166
 orbit, 89
 sclera, 155
- Insect bites, 70
- Inspection, 2
- Instruments, preparation of, 446
- Insufficiency, muscular. *See* Heterophoria
 of convergence, 398
- Internal rectus, paralysis of, 372
- Interstitial keratitis, 131, 141
- Intestines, disease of, 408
- Intoxications, 419
- Intra-ocular tumours, 187
 optic neuritis, 267
- Invisible bifocal lens, 357
- Iodine in corneal ulcer, 138
 tincture of, 437
- Iodoform, 437
 for cataract, 243
 poisoning, 273
- Ionization, 443
- Iridectomy, 167, 243
 in cataract extraction, 232
 indications for, 207
 in glaucoma, 205
 optical, 207
- Iridocyclitis acute, 171
 chronic, 171, 445
 purulent, 174
 serous, 173
 sympathetic, 182
 plastic, 173
- Iridocystectomy, 167
- Iridodialysis, 166
- Iridodonesis, 244
- Iridotomy, 167
- Iris, anatomy of, 157
 angle, 190, 198
 bombé, 162
 diseases of, 158
 examination of, 7
 forceps, curved, 202
 hook, blunt, 204
 injuries, 166
 operations upon, 167
 scissors, 232
 curved, 203
 tumours of, 165
- Iritis, 158
 clinical varieties, 164
 complications, 160
 diabetic, 165
 differential diagnosis, 160
 etiology, 162
 gonorrhœal, 165
 idiopathic, 163
 paracentesis in, 164
 pathology, 163
 rheumatic, 165
 scissors, curved, 203
 septic, 165
 sequelæ, 162
 spongy, 159
 symptoms, objective, 159
 subjective, 160
 syphilitic, 164
 treatment, 163
 tuberculous, 165
- Irrigating apparatus, 229
- Jaeger's test-types, 14, 320
- Jaesche-Arlt operation, 56
- Japanese muff warmer, 173
- Javal-Schiötz ophthalmometer, 348
- Keratitis, 130
 bullosa, 143
 dendriform, 136
 due to exposure, 140
 fascicular, 120
 herpetic, 143
 interstitial, 130, 141
 neuro-paralytic, 130, 140
 non-suppurative, 131
 parenchymatous, 141
 phlyctenular, 119, 131
 profunda, 131, 144
 punctata, 144, 159, 172
 (descemetitis), 144
 ribbon-shaped, 131, 144
 sclerosing, 131, 144

- Keratitis, superficial punctate, 144
 suppurative, 131
 vascular, 143
 vasculo-nebulous, 114, 131, 143
 vesicular, 131, 143
 xerotic, 140
 Keratoconus, 146
 Keratomalacia, 134, 140, 151
 Keratome, 202
 Keratoscope, Placido's, 5, 349
 Kidneys, 413
 Knapp's blepharoplasty, 63
 entropion forceps, 55
 knife-needle, 239
 roller forceps, 117
 Knife, Beer's, 52
 Graefe's, 230
 Lang's, 209
 Weber's, 75
 Ziegler's, 237, 244
 Knife-needle, Knapp's, 239
 Koch-Weeks bacillus, 98
 Krönlein's operation, 87
- Lacrymal apparatus, anatomy of,
 72
 diseases of, 74
 conjunctivitis, 74, 98
 gland, 72
 sac, 72
 abscess of, 79
 excision of, 76
 secretion, 73
 style, 79
 syringe, 75
 Lagophthalmos, 64, 83
 Lamellar cataract, 242
 Lamina cribrosa, 152, 266
 vitrea, 176
 Lance-headed needle, 401
 Lang's eye-speculum, 229
 knife, 209
 Lantern test, Edridge-Green's, 291
 Latent hypermetropia, 332
 Lateral illumination, 20
 Lawyer's questions, 279
 Lead acetate, 435
 poisoning, 273
 Leaking cicatrix, 208
 Leech, artificial, 444
 Leeches, 444
 Lens, anatomy of, 220
 architecture of, 41
 biconcave, 300
 biconvex, 299
 bifocal, 335, 356
 capsule of, 220
 Lens, centre of, finding, 308
 complete dislocation of, 245
 concave, foci of, 302
 meniscus, 300
 periscopic, 300
 concavo-convex, 299
 concavo-spherical, 299
 converging, 299
 convex, foci of, 300
 periscopic, 299
 spherical, 298
 convexo-concave, 300
 cylindrical, 304
 diseases of, 220
 dislocation of the, 244
 diverging, 299
 meniscus, 300
 expresser, 229
 Helmholtz theory, 304
 luxation of, 245
 magnifying, 299
 measure, Geneva, 308
 meniscus, 299
 minus, 299
 negative, 299
 neutralizing, 308
 nucleus, 42
 partial dislocation of, 242
 periscopic, 299
 physiology of, 220
 plano-concave, 299
 plano-convex, 299
 plus, 299
 positive, 299
 reducing, 299
 scoop, wire, 229
 spherical, 298
 structure of, 41
 subluxation of, 244
 sutures, 43
 Tscherning theory, 314
 Lenses, 298
 numeration of, 305
 trial case, 307
 varieties of, 309
 Leprosy, eye affections of, 411
 Leucoma, 5, 148
 adherent, 133, 148
 tattooing in, 149
 Leukæmia, 407
 retinitis in, 255
 Lid retractor, Desmarre's, 7
 Lids. *See* Eyelids, 47
 œdema of, 49
 Ligament, suspensory, 220
 Ligaments, palpebral, 48
 tarsal, 48

- Ligamentum pectinatum, 190
 Light, excessive, 258
 sense, 10, 19
 Limbus corneæ, 129
 Lime burns, 127
 Line of fixation, 312
 Linear extraction, 229
 Lithiasis of the conjunctiva, 124
 Local anæsthetics, 441
 blood-letting, 444
 Locomotor ataxy, 275
 Lost fixation, 381
 Luetin reaction, 424
 Lumbar puncture, 271
 Luxation of the lens, 245

 Macropsia, 177
 Macula, 5, 148
 lutea, 36, 247
 changes in infancy at, 258
 Maddox double prism, 393
 rod, 392
 Magnet extraction, 216
 Haab's, 215
 Mellinger's ring, 217
 Magnifying lens, 299
 Malaria, 411
 amblyopia in, 280
 Malingering, 278
 Manifest hypermetropia, 332
 Marginal ulcer, cornea, 136
 Massage, 444
 May's electric ophthalmoscope, 22
 McHardy's perimeter, 16
 Measles, 411
 Mechanism of accommodation, 314
 Meibomian cyst, 51
 glands, 47, 48
 Melano-sarcoma, 187
 Membrana nictitans, 94
 Membranous conjunctivitis, 109
 Meningitis, 185, 269, 416
 cerebro-spinal, 410
 Meningocele, 87
 Meniscus lenses, 299
 Mercantile Marine, Board of
 Trade tests for, 452
 Mercuric chloride, 436
 Mercury, ammoniated, 435
 bichloride, 445
 yellow oxide, 435
 Metamorphosis, 177, 250
 Metastatic ophthalmia, 180
 retinitis, 257
 Methods of investigating field of
 vision, 15

 Methods of investigating oculo-
 motor paralysis, 369
 refraction, 318
 test-types, 319
 Metric system, lenses, 305
 Microphthalmos, 89
 Micropsia, 177
 Microscope, corneal, 38
 Migraine, 414
 Miliun, 69
 Mind-blindness, 282
 Miner's nystagmus, 378
 Minus lens, 299
 'Mires,' 348
 Mirror, reflection by, 294
 test, 369, 382
 Mitigated stick, 437
 Moll, glands of, 47
 Molluscum, 69
 Monochromic vision, 288
 Monochromics, 289
 Monocular cataract, 227
 bandage, 448
 Mooren's ulcer, 135
 Moorfields bandage, 234, 449
 Morax-Axenfeld bacillus, 98, 421, 429
 Morgagnian cataract, 225
 Morton's ophthalmoscope, 22
 Motor balance of eyes, 392
 imbalance, 381
 Movements of the eyeball, 364
 Mucocoele, 74
 Mueller's fibres, 248
 muscle, 48
 Mules's operation, 92
 Mumps, 411
 Muscæ volitantes, 18, 212, 338
 Muscle, ciliary, 170
 levator palpebræ, 47
 Mueller's, 48
 orbicularis, 47
 Muscles, external ocular, 363
 operations on, 400
 paralysis of, 368
 'Mutton fat' deposits, 172
 Mydriatics, 25, 354, 438
 Myelitis, 416
 Myopia, 312, 323, 335
 choroiditis in, 179
 clinical forms, 337
 etiology, 336
 in Germans, 337
 malignant, 337
 operative treatment, 341
 ophthalmoscopic signs, 338
 prognosis, 339

- Myopia, progressive, 337
 simple, 337
 stationary, 337
 symptoms, 337
 tests, 338
 treatment, 339
 Myopic crescent, 179
 divergent squint, 389
 far point, 325
 Myotics, 25, 441
 Myxœdema, 409
- N.A.B., 430
 Nasal affections, 49
 duct, 73
 probing, 77
 sinuses, 87
 Naso-pharynx, diseases of, 418
 Nausea in diplopia, 369
 Naval cadets, vision of, 450
 Navy, visual requirements for, 450
 Near point, 314
 sightedness, 312
 vision, 13
 Nebula, 5, 148
 Needle holder, 401
 tattooing, 149
 Needling of cataract, 239
 Negative focus, 302
 lens, 299
 phase, 427
 Neo-salvarsan, 430
 Nephritis, 413
 retinitis of, 253
 Nerve paths, 167, 281
 Nerves of ocular muscles, paralysis of, 363
 Nervous disorders, functional, 417
 system, diseases of, 415
 Nettleship's dilator, 75
 Neuritis, descending, 269
 retrobulbar, 271
 Neuro-paralytic keratitis, 130, 140
 Neuropathic divergence, 414
 divergent squint, 390
 Neuro-retinitis, 268
 New-born, conjunctivitis in, 107
 Night-blindness, 262, 280
 Nitrate of cocaine, 437
 of silver, 434
 Nitro-benzol poisoning, 273
 Nodal points of the eye, 311
 Noguchi's test for syphilis, 424
 Non-comitant squint, 390
 Normal fundus, 34
 Nose, diseases of, 418
 Novocain, 442
- Nuclear cataract, 223
 Numeration of lenses, 305
 Nystagmus, 377
 in ear disease, 410
 lateral, 378
 miner's, 378
 rotatory, 378
 vertical, 378
- Objective examination of eye, 20
 Oblique illumination, 20
 inferior, paralysis of, 373
 superior, paralysis of, 373
 Obturator, 308
 Occlusion of pupil, 162
 Ocular deviations, varieties of, 367
 manifestations of general diseases, 407
 muscles, external, paralysis of, 363
 paralysis of, 368
 external rectus, 371
 fourth nerve, 373
 inferior oblique, 373
 rectus, 372
 internal rectus, 372
 operation in, 377
 prognosis, 376
 sixth nerve, 371
 superior oblique, 373
 rectus, 372
 third nerve, 374
 treatment, 376
 varieties of, 371
 therapeutics, 431
 Oculo-motor paralysis, investigation of, 369
 Oedema, angio-neurotic, 50
 of the lids, 49
 Old sight, 358
 Onyx, 136
 Opacities, cornea, 22, 148
 media, 24
 vitreous, 213
 Operations, Adam's (ectropion), 61
 advancement of an ocular muscle, 400
 blepharoplasty, 62
 canaliculus slitting, 78
 canthoplasty, 59
 canthotomy, 59
 cataract, 225
 cicatrix, leaking, 208
 conical cornea, 147
 corneo-scleral trephining, 208
 Dieffenbach's, 63

- Operations, dissection, 239
 distichiasis, 55
 ectropion, 61
 electrolysis, 53
 Elliott's (glaucoma), 208
 entropion, 55
 enucleation of eyeball, 90
 epicanthus, 68
 epilation, 53
 evisceration of eyeball, 92
 excision of lacrymal sac, 76
 exenteration of the orbit, 93
 expression, trachoma, 116
 external ocular muscles, 400
 eyeball, 90
 Fricke, 63
 general conditions, 445
 glaucoma, 201
 Graefe's (ptosis), 66
 Herbert's modification, of
 Streatfeild-Snellen, 58
 Hess's, 67
 Hotz's (entropion), 57
 iridectomy for glaucoma, 203
 iridocystectomy, 167
 iridotomy, 167
 iris, 167
 Jaesche-Arlt, 56
 keratoconus, 147
 Knapp's, 63
 Krönlein's, 87, 93
 Mule's, 92
 needling, 239
 Pagenstecher's sutures, 67
 Panas' (ptosis), 66
 paracentesis, cornea, 138
 in iritis, 164
 preparations for, 445
 probing nasal duct, 79
 ptosis, 66
 Saemisch's (ulcer), 139
 sclerotomy, 207
 skin-grafting, 63
 spastic entropion, 58
 Streatfeild-Snellen, 57
 tarsorrhaphy, 64
 tenotomy, 388, 404
 trichiasis, 55
 V Y (ectropion), 62
 Wharton Jones's, 62
 Worth's, 147
 squint, 400
 Operator's hands, preparation of, 445
 Ophthalmia, 96
 Egyptian, 115
 gonorrhœal, 103
 Ophthalmia neonatorum, 107
 prophylaxis, 108
 scrofulous, 119
 Ophthalmitis, sympathetic, 171, 182
 symptoms, 183
 theories of, 184
 treatment, 184
 Ophthalmometer, 348
 Ophthalmoplegia, 375
 interna, 361, 375
 Ophthalmoscope, 22
 at a distance, 321
 examination by, 23
 direct, 28, 322
 indirect, 25, 321
 May's, 22
 Morton's, 22
 refractive error by, 321
 source of illumination, 325
 theory of, 30
 Ophthalmoscopy with red-free light, 33
 Opsonic index, 423, 428
 Opsonins, 423
 Optic disc, 27, 34, 247
 congestion of, 267
 cupping of, 35
 scotoma, 17
 nerve, anatomy of, 266
 atrophy of, 273
 diseases of, 266
 inflammation of, 267
 neuritis, 267
 Optical axis, 311
 considerations of the eye, 310
 iridectomy, 207
 principles, general, 294
 Ora serrata, 247
 Oral sepsis, 408
 Orbit, anatomy of, 81
 diseases of, 82
 injuries of, 89
 tumours of, 86
 Orbital cellulitis, 85, 410
 fascia, 81
 periostitis, 83
 Organisms, estimation of, 425
 Orthophoria, 391
 Osteoma, 87
 Pagenstecher's sutures, 67
 Palpation, 8
 Panas' operation, ptosis, 66
 Pannus, 114, 131, 143
 Panophthalmitis, 182, 185
 Papilla, 27, 34, 243. *See* Optic disc

- Papillitis, 267
 Paracentesis in iritis, 164
 of cornea, 138
 Paralysis, accommodation, 361
 associated, 375
 basilar, 376
 central, 375
 congenital, 376
 conjugate, 375
 cortical, 375
 differential diagnosis, 376
 external ocular muscles, 363
 nuclear, 375
 ocular, 368
 oculo-motor, 369
 orbital, 376
 peripheral, 376
 Parenchymatous keratitis, 141
 Parraud's conjunctivitis, 123
 Parturition, 419
 'Paster' lenses, 356
 Patient, history of, 1
 position of, 446
 preparation of, 445
 Pediculi, 49
 Pentachromics, 289
 Perception of light, 12
 Perforation of the cornea, 133
 Perimeter, 15, 365
 in squint, 382
 Periostitis, orbital, 83
 Peripheral vision, 13
 Periscopic lens, 299
 Peritomy, 119
 Pernicious anæmia, 407
 Persistent hyaloid artery, 212
 Phlyctenular conjunctivitis, 119
 keratitis, 120, 131
 Photophobia, 121
 Photopsia, 263
 Phthisis bulbi, 186
 Physiological cuppings of disc,
 35
 Pilocarpin in glaucoma, 200
 muriate, 441
 nitrate, 441
 Pinguecula, 125
 'Pink eye,' 98
 Placido's disc, 4, 349
 keratoscope, 4, 349
 Plane mirror, 294
 Plano-concave lens, 300
 Plano-convex lens, 299
 Plastic cyclitis, 173
 Plica semilunaris, 94
 Plus lens, 299
 Pneumobacillus, 425
 Pneumococcal vaccines, 429
 Pneumococcus, 99, 430
 Pneumonia, 411
 Poisoning, atropine, 439
 Polyvalent vaccines, 424
 Positive lens, 299
 phase, 427
 Potassium chlorate, 434
 permanganate, 432
 Pregnancy, 419
 Preparation of hands, 4
 instruments, 446
 patient, 445
 region, 446
 Presbyopia, 316, 358
 glaucoma in, 360
 symptoms, 359
 treatment, 359
 Prescribing glasses for young
 patients, 351
 Principal points of the eye, 311
 Prism duetion, 396
 Maddox, 393
 position of, 298
 refraction by, 297
 rotary, 396
 Prisms, numbering of, 298
 use of, 298
 Probe, Cowper's, 77
 Teale's, 77
 Probing nasal duct, 77
 Projection, 228, 367
 false, 369
 Proptosis, 83
 Protargol, 437
 Pseudo-glioma, 180, 257, 412
 Pseudo-heterophoria, 392
 Pterygium, 125
 Ptosis, 65, 374
 operations for, 66
 Graefe's, 66
 Hess's, 67
 Pagenstecher's, 67
 Panas', 66
 Pulsating exophthalmos, 86
 Puncta lacrymalia, 72
 anomalies, 73
 Punctum proximum, 314
 remotum, 314
 Pupil, the, 7, 167
 Argyll Robertson, 169
 dilatation of, 25
 occlusion of, 162
 Pupillary membrane, 158
 reaction, hemianopic, 285
 reflex nerve paths, 167
 Purpura, 407

- Purulent conjunctivitis, 102
 infantile, 107
 cyclitis, 171
 retinitis, 257
 Pustular conjunctivitis, 119
 Pyæmia, 412
 Pyorrhœa alveolaris, 429
 Pyramidal cataract, 241

 Quinine amblyopia, 280
 ischæmia, 259

 Radium, 116, 189, 444
 bromide, 70, 444
 rodent ulcer and, 70, 444
 spring catarrh and, 444
 trachoma and, 444
 Range of accommodation, 314
 of convergence, 317
 Recti muscles, 363
 Rectus externus, paralysis of, 371
 inferior, paralysis of, 372
 internus, paralysis of, 372
 superior, paralysis of, 372
 Red-free light, ophthalmoscopic
 examination with, 33
 Reducing lens, 299
 Reflection, 294
 concave mirror, 294
 convex mirror, 296
 plane mirror, 294
 specular, 39
 Reflex paths, pupillary, 167
 senile, 221
 visual, 167
 Refraction, 294
 errors of, 330
 index of, 297
 methods of investigating, 318
 of the eye, 310, 312
 ophthalmoscope method, 321
 prism, 297
 subjective method, 319
 Remedies, astringent, 433
 constitutional, 431
 local, 431
 stimulating, 433
 Retina, 35
 anæmia of, 259
 anatomy of, 247
 central artery of, embolism,
 260
 thrombosis, 262
 circulatory disturbances of,
 258
 colour perceiving elements in,
 287
 Retina, contusion of, 258
 detachment of, 263
 diseases of, 247
 functional diseases of, 276
 glioma of, 188
 hæmorrhages, 259
 hyperæmia of, 258
 ischæmia of, 260
 œdema of, 251, 258
 physiology of, 249
 pigmentary degeneration of,
 262
 section of, 248
 Retinal changes due to excessive
 light, 258
 uncommon forms, 257
 hæmorrhages, 257, 407
 Retinitis, 250
 albuminuric, 253
 Bright's disease, 253
 circinata, 257
 deep, 252
 diabetic, 255
 gravidic, 254, 419
 hæmorrhagic, 257
 leukæmic, 255, 407
 metastatic, 257
 parenchymatous, 252
 pigmentosa, 262
 proliferans, 213, 258
 punctate, 263
 purulent, 257
 renal, 253
 septic, 257
 serous, 251
 simple, 251
 striated, 258
 syphilitic, 256
 Retino-choroiditis, 176
 Retinoscopy, 324
 Retractor, 76
 Desmarre's lid, 7
 Retrobulbar neuritis, 272
 Retro-illumination, 39
 Retrotarsal fold, 3
 Rheumatism, 415
 iritis in, 162, 164
 Ribbon-shaped keratitis, 144
 Rickets, 415
 Ripe cataract, 225
 Rod, Maddox, 392
 Rodent ulcer of eyelids, 69
 radium and, 444
 Rods and cones, 248
 Roller forceps, Knapp's, 117
 Rotary prism, 396
 Rotation, centre of, 311

- Royal Air Force, visual requirements for commissions in, 455
 Royal Navy, visual requirements for commissions in, 450
 Rupture of choroid, 181
- Sac, lacrymal, 72
 Saemisch's method, 139
 Salvarsan, 430
 Sarcoma, choroid, 187
 eyelids, 69
 Scalpel, 52
 Scarletina, 411
 Schlemm's canal, 171, 190
 Schötz, tonometer of, 9
 Scintillating scotoma, 286
 Scissors, enucleation, 89
 iris, curved, 203
 de Wecker's, 229, 232
 squint, 401
 Sclera, anatomy of, 152
 diseases of, 152
 injuries of, 155
 staphyloma of, 155
 Scleritis, 152, 154, 445
 Sclero-choroiditis, 179
 Sclerotomy, anterior, 207
 in glaucoma, 207
 posterior, 208, 265
 Scoop, chalazion, 52
 wire lens, 229
 Scopolamine, 163, 429
 Scotoma, 17, 250
 colour, 272
 scintillans, 286
 Scrofulous ophthalmia, 119
 Scurvy, 415
 'Second sight,' 336
 Secondary glaucoma, 210
 Senile cataract, 223
 entropion, 54
 reflex, 221
 Septic retinitis, 257
 Septicæmia, 412
 Serous retinitis, 251
 Serpent ulcer, cornea, 135
 Service requirements, visual, 450
 Army, 450
 Home Civil Service, 453
 Indian Civil Service, 453
 Factory Department, 453
 Forest Department, 453
 Marine Service, 454
 Medical Service, 454
 Pilot Service, 454
 Service requirements, Indian Police Service, 454
 Public Works Department, 454
 Railway Department, 454
 Survey Department, 453
 Telegraph Department, 453
 Various Artificers' Department, 453
 Navy, 450
 Shadow test, 324
 Short-sightedness, 335
 Shrunken cataract, 225
 Sight-testing, 319
 Sign, Stellwag's, 409
 von Graefe's, 409
 Signs used in ophthalmology, 309
 Silver nitrate, 434
 Sinus, ethmoidal, 88
 frontal, 87
 nasal, 87
 of the anterior chamber, 190
 sphenoidal, 88
 Sixth nerve, paralysis of, 371
 Skiascopy, 324
 Skin-grafting, 63
 Thiersch's, 63
 Wolfe's, 63
 Slit-lamp, Gullstrand's, 37, 38
 Smear preparations, 422
 Snellen's artificial eyes, 93
 test-types, 10
 Snow-blindness, 98
 Sodium chloride, 432
 Solid carbon dioxide, 443
 Solutions, antiseptic, 431
 cleansing, 431, 447
 Spasm of accommodation, 362
 Spatula, silver, 231
 Spectacles, fitting of, 355
 Spectrum, colours in, 288
 Specular reflection, 39
 Speculum, 202
 Sphenoidal sinus, 88
 Spherical lenses, 298
 action of, 300
 Sphincter pupillæ, 157, 167
Spirochæta pallida, 424
 Spoon, 76, 233
 Volkmann's, 77
 Spring catarrh, 123
 and radium, 444
 Squint, advancement for, 400
 alternating convergent, 389

- Squint, amblyopia of, 380
 amblyoscope in, 385
 angle of deviation, 382
 atropine in, 383
 comitant, 380
 convergent, etiology of, 381
 operation in, 388
 treatment of, 383
 varieties of, 380
 divergent, 389
 method of investigating, 381
 mirror test in, 382
 myopic, 389
 neuropathic, 390
 non-comitant divergent, 390
 occlusion of eye in, 384
 operations for, 400
 optical correction in, 383
 perimeter in, 382
 scissors, 401
 tenotomy in, 388
 training fusion faculty, 384
 treatment of, 383, 389
 Staphylococcal vaccines, 428
Staphylococcus albus, 430
 aureus, 425, 430
 Staphyloma, anterior, 155
 cornea, 145
 equatorial, 155
 posterior, 179
 sclera, 155
 Stationary cataracts, 241
 Stellwag's sign, 409
 Stenopeic slit, 346
 Stimulating remedies, 419
 Stomach, disease of, 408
 Strabismus. *See* Squint
 Streetfeild-Snellen operation, 57
Streptococcus, 430
 Strumous conjunctivitis. *See*
 Phlyctenular conjunctivitis.
 diathesis, 412
 keratitis. *See* Phlyctenular
 keratitis.
 Styte, 50
 Style, lacrymal, 79
 Subconjunctival hæmorrhage, 127
 injections, 445
 Subhyaloid hæmorrhage, 259
 Subjective examination of the
 eye, 10, 319
 Subluxation of lens, 244
 Superficial punctate keratitis, 144
 Suppurative keratitis, 131
 Suprachoroid, 176
 Suprarenalin, 442
 Suspensory ligament, lens, 220
 Sutures, Pagenstecher's, 67
 Symblepharon, 124
 in trachoma, 114
 Symbols used in ophthalmology,
 309
 Sympathetic ophthalmia, 182
 Synchysis scintillans, 213
 Synechia, anterior, 7, 133
 posterior, 7, 142
 Syphilis, 412
 and papillitis, 269
 of the eyelids, 50
 Syphilitic choroido-retinitis, 178,
 263
 iritis, 164
 retinitis, 256
 Syringe, lacrymal, 75
 Tabes, 417
 Tannic acid, 433
 Tarsal cyst, 51
 tumour, 51
 Tarsorrhaphy, 64
 Tarsus, 48
 Tattooing cornea, 149
 Teale's probe, 77
 Teeth, diseases of, 408
 Hutchinsonian, 143
 Tenon's capsule, 82, 363
 Tenonitis, 86
 Tenotomy in squint, 388, 390, 404
 Tension of eyeball, 8, 145, 197
 Test, astigmatism, 347
 blackboard, 15
 Calmette's, 424
 candle, 15
 colour vision, 291
 diplopia, 370
 dynamic convergence, 399
 hand, 15
 Holmgren, 292
 malingering, 278
 mirror, 369, 382
 in squint, 382
 motor balance of eyes, 392
 types for illiterates, 12
 Jaeger, 14, 320
 method, 319
 Snellen's, 10
 von Pirquet's, 423
 Wassermann, 422
 Testing-drum, 446
 Tetrachromics, 289
 Theory, colour perception:
 Edridge-Green's, 287
 Hering's, 287
 Young-Helmholtz, 287

- Theory, Helmholtz, lens, 314
 ophthalmoscope, 30
 Tscherning, lens, 314
 Therapeutics, ocular, 431
 Thiersch's skin-grafting, 63
 Third nerve, paralysis of, 374
 Thrombosis of artery, central, of
 retina, 261
 of cavernous sinus, 85
 Tincture of iodine, 437
 Tobacco amblyopia, 272
 Tonometer of Schötz, 9
 Toric lenses, 356
 Toxic amblyopia, 272
 Trachoma, 111
 clinical varieties, 113
 complications, 114
 course, 112
 etiology, 115
 expression in, 117
 granular form, 112
 grattage in, 118
 mixed form, 112
 papillary form, 112
 prophylaxis, 119
 radium and, 444
 sequelæ, 113
 treatment, 115
 Transient hemianopsia, 286
 Transillumination, 37
 Transparent ulcer, cornea, 136
 Traumatic cataract, 240
 conjunctivitis, 97
 hysteria, 278
 Trephine, Elliott's, 210
 Trephining, corneo-scleral, 208
 Trial case, lenses, 307
 frame, 319
 Trichiasis, 53
 operations for, 55
 Trichromatism, 289
 Trichromics, 289
 Tscherning theory, lens, 314
 Tubercles of the choroid, 181
 Tuberculin, 428
 old, 424
 Tuberculosis, 412
 Tumours, intra-ocular, 187
 of brain, 269, 417
 of eyelids, milium, 69
 molluscum, 69
 xanthelasma, 69
 of iris, 165
 orbit, 86
 Ulbrich's graduated drum, 40
 Ulcer of cornea, catarrhal, 136
 dendriform, 136
 herpetic, 136
 marginal ring, 136
 Mooren's, 135
 of cornea, 131
 serpens, cornea, 135
 spontaneous perforation of,
 139
 transparent, 136
 Uncertain gait, 369
 Undine, 229, 431
 Uræmic amblyopia, 255
 Uvea, 157
 Uveitis, 171
 anterior, 154
 purulent, 174
 sympathetic, 174
 Vaccines, autogenous, 424, 429
 effect on body, 427
 gonococcal, 428
 in ophthalmology, 421
 pneumococcal, 429
 preparation of, 424
 staphylococcal, 426
 streptococcal, 429
 treatment by, 174
 Vaccinia, 412
 of the eyelids, 50
 Valvular heart disease, 408
 Varicella, 413
 Variola, 413
 Vasa vorticosa, 176
 Vascular keratitis, 114, 143
 Vasculo-nebulous keratitis, 114,
 143
 Vectis, wire, 229
 Vein, central, of retina, 35, 247
 thrombosis of, 262
 Vernal catarrh, 123
 Verruca, 69
 Vertigo, 369, 415
 Vesicular keratitis, 143
 Virtual focus, convex lens, 302
 image, 302
 Vision, acuteness of, 10, 313
 binocular, 365
 central, 10
 colour, 287
 direct, 10
 distant, 10
 field of, 10, 13
 monochromatic, 288
 near, 13
 peripheral, 13
 suppressed, 380
 Visual angle, minimum, 11

- Visual area, 282
 line, 312
 paths, 289
 requirements for public services, 450
Vitreous, anatomy of, 212
 diseases of, 212
 foreign bodies in, 215
 hæmorrhages into, 214
 opacities, 213
Von Graefe's sign, 409
Von Pirquet's test, 423
V Y operation, ectropion, 62

Wassermann reaction, 422
Watery eye, 73
Weak sight, 353
Weber's knife, 75
Wernicke's hemianopic reaction, 285
Wharton-Jones's operation, 62
Whooping-cough, 413
Wire lens scoop, 229
Wolfe's skin-grafting, 63
Wood-alcohol poisoning, 273


Word-blindness, congenital, 277
Workmen's Compensation Act, 279
Worth's operation, 147, 400
Wounds of cornea, 151
 of eyelids, 71
 of sclera, 156

Xanthelasma, 69
Xerosis of conjunctiva, 115, 280
Xerotic keratitis, 131, 140
X rays, 116, 189, 216, 218, 444

Yellow fever, 413
 oxide mercury, 435
 spot, 247
Young-Helmholtz theory, 287
Young patients, 351
Y suture of lens, 43

Zeiss, glands of, 47
Ziegler's knife, 237, 244
Zinc sulphate, 433
Zonular cataract, 242
 lamella, 41





An Abridged List of Works

PUBLISHED BY

BAILLIÈRE, TINDALL & COX.

BALDWIN, PETROFF & GARDNER'S Tuberculosis, Bacteriology, Pathology and Laboratory Diagnosis (Trudeau Foundation Studies, Vol. II.) Royal 8vo. Pp. xvi+342. With 4 Coloured Plates and 81 Illustrations. Price 21s. net.

BASS & JOHNS' Practical Clinical Laboratory Diagnosis.
Third Edition. Size 6×9 ins. Pp. xviii+190, with 125 Illustrations and 20 Plates. Price 34s.

BAYLIS' Helminthology.
Size 9½×6½ ins. Pp. xii+304, with 200 Illustrations. Price 30s.

BESREDKA'S Immunity in Infectious Diseases
Size 8×5 ins. Pp. vi+320. Price 18s.

BIGGER'S Handbook of Bacteriology.
Second Edition. Size 8×5½ ins. Pp. xvi+454, with 5 Coloured Plates and 82 Figs. 12s. 6d. net.

BLAIR BELL'S Some Aspects of the Cancer Problem.
Size 11½×8 ins. Pp. xvi+544, with 90 Plates. Price 63s.

BOVERI'S The Origin of Malignant Tumours.
Size 8×5½ ins. Pp. viii+119. Price 11s. 6d.

BROWN & SAMPSON'S Intestinal Tuberculosis. (Being Vol. I., Trudeau Foundation Studies.) Royal 8vo. Pp. xii+304, with 112 Illustrations. Price 18s. net.

BUCHANAN'S Manual of Anatomy.
Fifth Edition. Demy 8vo. Pp. xvi+1702, with 810 Illustrations, mostly original and in several colours. Price 35s. net.

BUCHANAN & FULMER'S Physiology and Biochemistry of Bacteria. Size 9½×6¼ ins. Pp. xi+516, with 78 Figs. Price 34s.

BULLOCK'S Law Relating to Medical Practice.
Size 8¾×5½ ins. Pp. xvi+1317. Price 12s. 6d.

BURROWS' Pitfalls of Surgery.
Second Edition. Demy 8vo. Pp. x+524. Price 12s. 6d. net.

CABOT'S Physical Diagnosis.
Ninth Edition. Royal 8vo. Pp. xxii+536, with 6 Plates and 279 Illustrations. Price 25s. net.

CALKINS' The Biology of Protozoa.
Royal 8vo. Pp. x+624, with 238 Illustrations. Price 35s. net.

CHAPIN & ROYSTER'S Diseases of Infants and Children.
Sixth Edition. 9×6 ins. Pp. xvi+675, with 10 Coloured Plates and 184 other Illustrations. Price 30s. net.

CLARK'S Determination of Hydrogen Ions.
Third Edition. Size 9¼×6¼ ins. Pp. xvi+717. 107 Figs. Price 30s. net.

CLARKE'S Refraction of the Eye.

Fifth Edition. Crown 8vo. Pp. viii+243, Coloured Plate and 92 Figs.
Price 8s. 6d. net.

CLAYTON'S Physiotherapy in General Practice.

Second Edition. Size $8\frac{3}{4} \times 5\frac{1}{2}$ ins. Pp. x+251, with 9 Plates and 30 other Illustrations. Price 12s. 6d. net.

FRANK'S The Female Sex Hormone.

Size 6×9 ins. Pp. xiv+324, with 86 Figs. Price 25s.

FRENCH & NUTHALL'S Medical Laboratory Methods and Tests.

Fourth Edition. Crown 8vo. Pp. xii+244, with 3 Coloured Plates and 62 Illustrations. Price 7s. 6d. net.

FULTON'S Muscular Contraction.

Royal 8vo. Pp. xv+644, with 215 Illustrations. Price 45s. net.

GILLESPIE'S Sleep and the Treatment of its Disorders.

Size $7\frac{1}{2} \times 5$ ins. Pp. viii+267. Price 7s. 6d.

GILL'S The Genesis of Epidemics.

Size $9\frac{1}{4} \times 6\frac{1}{4}$ ins. Pp. xxvi+550, with 19 Charts and 10 Maps. Price 21s.

GRAHAM'S Diseases of Gall Bladder and Bile Ducts.

Size $9\frac{3}{4} \times 5\frac{3}{4}$ ins. Pp. xvi+480, with 8 Coloured Plates and 224 other Figs. Price 35s.

GREEN'S Pathology.

Fourteenth Edition. Demy 8vo. Pp. viii+650, with 9 Coloured Plates and 260 other Illustrations. Price 21s. net. (*University Series.*)

HENRICI'S Morphologic Variation and the Rate of Growth of Bacteria.

Size 9×6 ins. Pp. 208, with 36 Illustrations. Price 13s. 6d.

HULL'S Diseases Transmitted from Animals to Man.

Size $6 \times 8\frac{3}{4}$ ins. Pp. xxiv+352, with 29 Illustrations. Price 25s.

IRWIN'S Urinary Surgery.

Second Edition. Crown 8vo. Pp. viii+271. Price 10s. 6d. net.

JELLETT & MADILL'S Manual of Midwifery.

Fourth Edition. Size $9\frac{1}{2} \times 5\frac{1}{2}$ ins. Pp. xii+1281, with 570 Illustrations. Price 25s.

JUNG'S Two Essays on Analytical Psychology.

Authorised Translation by H. G. and C. F. BAYNES. Size $8\frac{3}{4} \times 5\frac{1}{2}$ ins. Pp. xvii+280. Price 10s. 6d. net.

KAHN'S The Kahn Test: A Practical Guide.

Size 9×6 ins. Pp. xii+204, with 7 Plates and 36 Tables. Price 18s.

KAHN'S Serum Diagnosis of Syphilis by Precipitation.

Size 9×6 ins. Pp. xii+237, with 56 Tables. Price 13s. 6d.

KENDALL'S Bacteriology—General, Pathological and Intestinal.

Third Edition, thoroughly revised. $9\frac{1}{4} \times 5\frac{1}{2}$ ins. Pp. 733, with 8 Plates and 103 Figs. Price 31s. 6d.

KOHLER'S Röntgenology: Rendered into English from the Fifth German Edition by Arthur Turnbull.

Size 10×7 ins. Pp. xii+554, with 754 Illustrations. Price 42s. net.

KOLMER'S Serum Diagnosis by Complement Fixation.

Size 9 × 6 ins. Pp. xx + 583, with 65 Illustrations. Price 31s. 6d.

KUNTZ'S Autonomic Nervous System.

Size 9½ × 6 ins. Pp. xii + 576, with 70 Illustrations. 31s. 6d.

LAKE & PETERS' Handbook of Diseases of the Ear.

Fifth Edition. Demy 8vo. Pp. x + 310, with 4 Coloured Plates and 80 other Illustrations. Price 12s. 6d. net.

LAMB'S Practical Guide to Diseases of the Throat, Nose and Ear.

Fifth Edition. Crown 8vo. Pp. xvi + 450, with 73 Illustrations, with X-ray Supplement of 31 Plates. Price 12s. 6d. net.

LEVINE'S Coronary Thrombosis.

Size 10½ × 6½ ins. Pp. viii + 178, with 1 Coloured Plate. Price 13s. 6d.

LOCKHART-MUMMERY'S After-Treatment of Operations.

Fifth Edition. Size 7½ × 5 ins. Pp. x + 282, with 37 Illustrations. Price 7s. 6d.

McCARRISON'S The Simple Goitres.

Crown 4to. Pp. x + 108, with 143 Illustrations. Price 10s. 6d. net.

MACKENNA'S Diseases of the Skin.

Second Edition. Royal 8vo. Pp. xii + 452, with 36 Coloured Plates and 143 other Illustrations. Price 25s. net.

McKITTRICK & ROOT'S Diabetic Surgery.

Size 9 × 6 ins. Pp. 269, with 79 Illustrations. 21s.

MACLAREN'S Medical Insurance Examination.

Second Edition. Demy 8vo. Pp. xvi + 650. Price 30s. net.

MATHEWS' Physiological Chemistry.

Fourth Ed. Royal 8vo. Pp. xv + 1124, with 109 Figs. Price 30s. net.

MAY & WORTH'S Diseases of the Eye.

Sixth Edition. Demy 8vo. Pp. viii + 475, with 337 Illustrations, including 23 Coloured Plates. Price 15s. net.

MONRO'S Manual of Medicine.Fifth Edition. Demy 8vo. Pp. xx + 1023, with 55 Illustrations, plain and coloured. Price 25s. net. (*University Series.*)**MUSKENS' Epilepsy : Comparative Pathogenesis, Symptoms, Treatment.**

Pp. xiv + 435, with 55 Illustrations. Price 27s. 6d.

NEWSHOLME'S Evolution of Preventive Medicine.

Crown 8vo. Pp. 240, with 7 Plates. Price 13s. 6d. net.

PARK & WILLIAMS' Pathogenic Micro-organisms.

Ninth Ed. Royal 8vo. Pp. x + 819, with 220 Illustrations. Price 30s. net.

PEMBERTON'S Arthritis and Rheumatoid Conditions.

Size 9½ × 6 ins. Pp. xii + 350, with 1 Coloured Plate and 42 other Illustrations. Price 25s.

POLITZER'S A Text-Book of the Diseases of the Ear.

Royal 8vo. Pp. xiii + 776, with 302 Illustrations. Price 31s. 6d. net.

RAMSAY'S The Eye in General Medicine.

Size 8¾ × 5½ ins. Pp. x + 225. Second Edition. Price 12s. 6d.

RIVERS' Filterable Viruses.

9 $\frac{1}{4}$ × 6 ins. Pp x+428, with 27 Illustrations and 6 plates. Price 34s. net.

ROBERTSON'S Principles of Biochemistry.

Second Ed. Royal 8vo. Pp. xii+708. With 57 Illustrations. Price 35s. net.

ROSE & CARLESS' Manual of Surgery.

Twelfth Edition. Demy 8vo. Pp. xii+1554, with 19 Coloured Plates, an X-Ray Supplement and 639 other Illustrations. Price 30s. net.

SNYDER'S Bloodgrouping in Relation to Legal Medicine.

Size 9 × 6 ins. Pp. xii+154, with 28 Figs. Price 22s. 6d.

SOLOMONS' Handbook of Gynæcology.

Second Edition. Demy 8vo. Pp. xii+300, with 2 Coloured Plates and 217 other Illustrations. Price 12s. net.

SPAAR'S Care of Children in the Tropics.

Size 7 $\frac{1}{2}$ × 5 ins. Pp. xiv+265. Price 7s. 6d.

STANDER'S Toxemias of Pregnancy.

Size 9 × 6 ins. Pp. vii+161. Price 13s. 6d.

STEDMAN'S Illustrated Medical Dictionary.

Eleventh Edition. Royal 8vo. Pp. xii+1146, with about 400 Illustrations and Coloured Plates. Price 35s. net.

THOMSON & ROBERTSON'S Protozoology.

Size 10 × 7 $\frac{1}{2}$ ins. Pp. xvi+376, with 4 Coloured Plates and 220 Illustrations. Price 30s.

THORNHILL'S Varicose Veins, Hæmorrhoids, Varicocele and Hydrocele.

Second Edition. Size 7 $\frac{1}{4}$ × 4 $\frac{3}{4}$ ins. Pp. xvi+112. Price 5s. (*Minor Monograph Series.*)

TINDAL'S Gleanings from General Practice.

Size 7 $\frac{1}{4}$ × 4 $\frac{3}{4}$ ins. Pp. xii+200, with 7 Illustrations. Price 6s.

TREDGOLD'S Mental Deficiency.

Fifth Edition. Size 9 × 6 ins. Pp. xvi+520, with 35 Plates and 78 Original Illustrations. Price 25s. net.

VEDDER'S Medicine: Its Contribution to Civilization.

Size 9 $\frac{1}{4}$ × 6 ins. Pp. vii+398. Price 22s. 6d.

WENYON'S Protozoology.

Large Royal 8vo. In 2 Volumes. Pp. xxvii+1563, with 20 Coloured Plates and 565 Illustrations. Price 84s. net.

WHEELER'S Handbook of Operative Surgery.

Fourth Edition. Demy 8vo. Pp. xvi+442, with 298 Figs. Price 15s. net.

WHEELER'S Injuries and Diseases of Bone.

Demy 8vo. Pp. xx+148, with 100 Illustrations. Price 10s. 6d. net.

WHITLA'S Dictionary of Treatment.

Seventh Edition. Demy 8vo. Pp. viii+1100. Price 25s. net.

WILLIAMS' Minor Maladies and their Treatment.

Fifth Edition. Crown 8vo. Pp. xiv+414. Price 7s. 6d. net.

WORTH'S Squint: its Causes, Pathology and Treatment.

Sixth Edition. Size 8 $\frac{1}{2}$ × 5 $\frac{1}{2}$ ins. Pp. x+242. With 42 Illustrations. Price 10s. 6d.

BAILLIÈRE, TINDALL & COX,

7 & 8, HENRIETTA STREET, COVENT GARDEN, LONDON, W.C. 2.





