

The treatment of infantile paralysis / by Oskar Vulpius ; translated by A. H. Todd.

Contributors

Vulpius, Oscar, 1867-1936.

Publication/Creation

London : Bailliere, Tindall & Cox, 1912.

Persistent URL

<https://wellcomecollection.org/works/a22mxmnx>

License and attribution

This work has been identified as being free of known restrictions under copyright law, including all related and neighbouring rights and is being made available under the Creative Commons, Public Domain Mark.

You can copy, modify, distribute and perform the work, even for commercial purposes, without asking permission.




Wellcome Collection
183 Euston Road
London NW1 2BE UK
T +44 (0)20 7611 8722
E library@wellcomecollection.org
<https://wellcomecollection.org>


THE TREATMENT
OF
INFANTILE PARALYSIS

OSKAR VULPIUS



22101674112





**THE TREATMENT OF INFANTILE
PARALYSIS**

THE TREATMENT OF INFANTILE PARALYSIS

BY

OSKAR VULPIUS, M.D.

PROFESSOR-EXTRAORDINARY AT THE UNIVERSITY OF HEIDELBERG

TRANSLATED BY

ALAN H. TODD, M.B., B.S., B.Sc. (LOND.)

HOUSE SURGEON, GUY'S HOSPITAL

LATE RESIDENT SURGICAL OFFICER, ROYAL NATIONAL ORTHOPÆDIC HOSPITAL

WITH INTRODUCTION BY

J. JACKSON CLARKE, M.B. (LOND.), F.R.C.S.



LONDON
BAILLIÈRE, TINDALL AND COX
8, HENRIETTA STREET, COVENT GARDEN

1912

[All rights reserved]

26463

-20229 899

E

WELLCOME INSTITUTE LIBRARY	
Coll.	welby Q mee
Coll.	
No.	We 555
	1910
	V99b3E

INTRODUCTION TO THE ENGLISH TRANSLATION

WHEN the publishers sent me a copy of Professor Vulpius's monograph, asking me to find someone to translate it into English, it was the first time that I had enjoyed the pleasure of turning over its pages. The feature that most impressed me on this first perusal was the wealth of clinical observation vividly recorded in the photographic illustrations. I felt that on this ground alone the book was one that claimed a wide circulation among medical readers in English-speaking countries. A closer study of the book made me feel that a good English translation was urgently called for. Of the ever-widening horizon of medicine, there is no part that has of late extended more strikingly than that occupied by infantile paralysis.

The broad and scholarly spirit in which the author has conceived and performed his task renders the work almost as interesting to the physician as it is to the surgeon. Indeed, the present translation cannot fail to confer a signal benefit on the profession by doing much to explain to physicians the aims of the surgeon in his efforts to diminish the tendency to deformity in the earlier, and to overcome or mitigate established deformity and disability in the later, period of this disease.

To the surgeon the full and critical consideration given to the various instrumental and operative measures as applied at the present day cannot fail to be of great service, both absolutely and as it compares with works relating to the same subject already published in the English language. The historical chapter and those which deal with the pathology and ætiology of the disease may make us pause and ask whether the harsh mercies of surgery may not some day be replaced by the gentler remedies of medicine; that, when the ætiology of the disease is thoroughly known,

whether preventive measures may not succeed ; or, failing these, whether anterior poliomyelitis, together with other infective fevers, may not some day be made to yield completely to some medicine as yet undiscovered, or not as yet applied to this end.

I may add that in finding a translator my task was an easy one. Mr. Alan H. Todd was at the time Resident Surgical Officer to the Royal National Orthopædic Hospital, and, to my great satisfaction, he undertook the task. The result will speak for itself, but I may be permitted to say that, not only is the original German conscientiously translated into good English, but also the translation has been made by one who has a full understanding of all the bearings of the subject dealt with.

J. JACKSON CLARKE.

LONDON,

July 4, 1912.

PREFACE TO THE GERMAN EDITION

JUST fifty years have elapsed since von Heine brought out his exhaustive monograph on infantile paralysis, and clearly defined the disease as a separate entity. Since that time, the treatment of the condition itself, and of the distressing sequelæ to which it may give rise, has made striking progress, especially as regards the surgery of the paralysis itself. It is remarkable that no orthopædist has as yet undertaken to review the really gratifying progress that has been made during that period.

I have long been thinking of trying to fill this gap in our surgical literature, but have been too busy to do so. I felt, moreover, that if I were to improve upon von Heine's work, it could only be by basing my statements upon a very extensive personal experience.

The number of paralytics who have passed through my hands during the past fifteen years is certainly greater than any collection of cases that has yet been recorded in an epidemic.

In the matter of treatment, too, orthopædic methods continue to advance, and new surgical modes are constantly being introduced. It seems well, therefore, to delay no longer, but to bring out this book at once, while current events are directing public as well as surgical interest to the question of infantile paralysis.

The work deals almost exclusively with the orthopædic treatment of the sequelæ of epidemic myelitis, but a few introductory chapters have been added, dealing with the symptomatology, ætiology, and pathological anatomy of the disease. They are by no means a complete account, but may serve as an introduction. The rest of the book is divided into two parts, of which the first deals with the therapeutic methods in use at the present time; the second comprising a description of the paralyzes of the various parts of the body, and of their treatment.

I have endeavoured to give a truthful representation of the views of

others, so as to present a well-balanced picture of the state of our knowledge at the present time. The deficiencies, however, are obvious enough, and no attempt has been made to conceal them, for they will serve as a stimulus to further progress. It is to be hoped that the good work already accomplished will do credit to the science of orthopædics, and that the crippled and deformed, all the world over, will derive fresh hope and help from the researches that have been made into the nature and treatment of their afflictions.

If my book does something to forward this end, it will be an ample reward for the labour that I have expended upon it.

OSKAR VULPIUS.

HEIDELBERG.

CONTENTS

CHAPTER	PAGE
PREFACE - - - - -	vii
INTRODUCTION - - - - -	1
SYMPTOMATOLOGY AND COURSE OF DISEASE - - - - -	3
ÆTIOLOGY - - - - -	11
PATHOLOGICAL ANATOMY - - - - -	20

PART I

GENERAL

I. GENERAL TREATMENT IN THE ACUTE STAGE AND STAGE OF REPAIR DURING THE FIRST YEAR OF ILLNESS - - - - -	27
II. ORTHOPÆDIC APPARATUS - - - - -	35
III. THE SURGERY OF PARALYSES - - - - -	48
A. TREATMENT OF PARALYTIC CONTRACTURES AND DEFORMITIES ("REDRESSEMENT," TENDON LENGTHENING, AND TENOTOMY) - - - - -	48
B. RESTORATION OF FUNCTION - - - - -	57
1. MUSCLE IMPLANTATION - - - - -	57
2. ARTHRODESIS - - - - -	61
3. TENDON SHORTENING - - - - -	67
4. TENDON TRANSPLANTATION - - - - -	71
5. NERVE TRANSPLANTATION - - - - -	93

PART II

SPECIAL

I. PARALYSIS OF THE MUSCLES OF THE NECK: PARALYTIC TORTICOLLIS - - - - -	127
II. PARALYSIS OF THE MUSCLES OF THE BACK AND ABDOMEN: PARALYTIC KYPHOSIS, LORDOSIS, AND SCOLIOSIS - - - - -	130
III. PARALYSIS OF THE SHOULDER - - - - -	149
IV. PARALYSIS OF THE ELBOW-JOINT - - - - -	195
V. PARALYSIS OF THE HAND AND FINGERS - - - - -	200
NOTE.—COMPLETE PARALYSIS OF THE ARM - - - - -	207

CHAPTER	PAGE
VI. PARALYSIS OF THE FOOT - - - - -	208
1. FLAIL ANKLE - - - - -	208
2. PES EQUINUS - - - - -	215
3. PES VARUS - - - - -	226
4. FLAT FOOT - - - - -	234
5. PES CALCANEUS - - - - -	239
VII. PARALYSIS OF THE KNEE - - - - -	248
VIII. PARALYSIS OF THE HIP - - - - -	271
NOTE.—PARALYSIS OF THE WHOLE LOWER EXTREMITY - - - - -	280
IX. TREATMENT OF SHORTENING - - - - -	282
X. PARALYSIS OF EXTREME SEVERITY - - - - -	289
INDEX OF SUBJECTS - - - - -	302
INDEX OF NAMES - - - - -	316

THE TREATMENT OF INFANTILE PARALYSIS

INTRODUCTION

WE owe to Jacob von Heine the first description of infantile paralysis; his monograph appeared in the year 1840. Unterwood, in 1784, had described a few cases of weakness of the lower extremities in children, and his account bears some resemblance to acute poliomyelitis. Some years later, Shaw (1822) mentioned a disease which came on suddenly with paralysis in children, and connected it with weaning. Jörg, Bartsch, Brück, and Hutier also wrote about similar cases, but their descriptions were so vague as to be of little service.

In 1835 Badham gave an admirable account of the disease in four case reports, concluding with the following words: "What is at the bottom of this paralysis? What is its nature? And what treatment should be employed? I wish that we could answer these questions, and I hope that physicians in every country will advance our knowledge of the disease by publishing their observations and their opinions."

The answer to these questions was not forthcoming till 1840, when J. von Heine made a very full communication on the subject. Basing his remarks on twenty-one cases which he had personally observed, he described in six chapters the symptomatology, ætiology, pathological anatomy, diagnosis, and treatment of "Paralytic Conditions of the Lower Extremities."

He refers the disease, with remarkable penetration, to the spinal cord, though, of course, he was unable to prove his theory for want of microscopical sections. Later experience confirmed his hypothesis, and when he brought out the second edition of his book, twenty years later, he entitled it, "A Monograph on Spinal Paralysis in Children." The successes which he described, in text and in illustration, aroused the greatest interest.

Rillier and Barthez were unable (1851) to demonstrate any changes in the spinal cord; they therefore named the disease "Essential Paralysis of

Children." Duchenne, on the other hand, shared with Heine the opinion that the condition was fundamentally a spinal one. In 1855 he described the fatty degeneration of the muscles, and later on published the first case of the disease in an adult. Since that time a number of other well-authenticated cases have taught us that there is, indeed, such a malady as acute poliomyelitis in the adult.

Cornil and Laborde were the first to describe pathological changes in the cord (1863-64), but they missed the essential feature, the affection of the anterior horns, which was recognized soon after by Prévost and Vulpian (1865). The full significance of these discoveries was not appreciated until the days of Charcot, Joffroy, and Parrot (1870). Charcot associated the atrophy of the ganglion cells in the anterior horn with the atrophy of the muscles, and put forward the ingenious theory that the nerve cells acted as trophic centres for the musculature.

His idea was that the disease consisted in a primary affection of the ganglion cells, leading to atrophy. This theory formed the basis of much discussion and research. The controversy turned on the question of whether or not the inflammation was interstitial—*e.g.*, an affection of the vessels—the atrophy of the nervous elements being a secondary result. We shall allude to this again in a later chapter.

Great advances were made in the pathological anatomy of infantile paralysis. Roger and Damaschino, Roth, Leyden, Schultze, Goldscheider and von Kahlden, must be specially mentioned. Progress was made in treatment also, and the apparatus devised by von Heine for his patients, crude as it was, attained no small measure of reputation and success. Modern walking apparatus represents a still greater advance, and is free from the disadvantages of the older appliances. The value of electricity, hydrotherapy, massage, and gymnastics has come to be more thoroughly appreciated.

The advent of antiseptics and asepsis marked a new era in the treatment of paralysis, and the great possibilities of orthopædic surgery became apparent. Arthrodesis has proved a measure of the greatest value in flail conditions of joints, and plastic operations, such as tendon lengthening and shortening, have in great measure replaced subcutaneous tenotomy. Tendon transplantation was introduced towards the end of the century, and the striking and interesting results that were obtained attracted great attention. The analogous operation on peripheral nerves has been introduced quite recently, and seems to be fraught with great possibilities.

The battle against infantile paralysis and its sequelæ still goes on, and every accession to our knowledge is of increasing value, for epidemics of the disease, at one time a thing unknown, are now increasing in frequency and in extent, and their danger is brought home to us by the occurrence of

larger and larger epidemics in our own country. The increasing frequency of the disease will tend to enlighten us concerning its ætiology, and orthopædist will vie with one another in investigating the diagnosis and the treatment of the malady.

One very important fact that has recently come to light, as the result of carefully studying an epidemic, is that recorded by Medin, and later by Wickmann, in Sweden. These observers maintain that the cerebral and spinal palsies of children are really one and the same disease, differing only in the anatomical structure which they chance to affect. It would be well, therefore, to adopt some comprehensive name for the disease, but it is difficult to find one that satisfactorily describes its ætiology. Wickmann speaks of it as "Heine-Medin's disease," and so pays a graceful tribute to the value of their researches. Krause prefers the name "acute epidemic infantile paralysis," describing the disease by its chief symptom. It may be that the condition with which we are concerned is only one of a group of epidemic paralyzes in children, but its symptoms and its after-effects are so clearly defined that there is no difficulty in treating it as a separate and distinct complaint, especially in a book such as this, which is almost entirely devoted to treatment. Cerebral paralysis differs from spinal, not only in the different treatment that is required, but also in the success that results.

SYMPTOMATOLOGY AND COURSE OF THE DISEASE.

Onset.—As a rule, the onset of the disease is very acute, but sometimes vague **prodromal symptoms** are present for several days, before the well-known clinical features of the illness manifest themselves.

The temperature rises sharply to 102° F. or so, remains at this level for a few days, and then gradually falls. Sometimes there is an initial rigor. Neither the pyrexia nor any of the other early symptoms have any prognostic value. Profuse **sweating** is not uncommon, and **drowsiness** or even coma is fairly frequently observed. **Headache** is almost always present; it is often occipital. Later on, pain in the nape of the neck and backache set in, and some stiffness of the spine, indicative of meningeal irritation. The pain may be so severe that the patients dread the slightest movement or disturbance. Hyperæsthesia of the extremities is not uncommon, and the patients complain of severe pain in the arms and legs when they are touched. The muscles and nerves are peculiarly susceptible to pain, and this **hyperæsthesia** has lately been emphasized as an early symptom. Sometimes it is so prominent a feature that a wrong diagnosis of polyneuritis may be made and the hyperæsthesia may persist for many weeks or even months. Excepting occasional decrease of cutaneous sensibility to electrical stimulation, these are the only sensory signs that are at all constant.

These signs of sensory disturbance are more frequent than was at one time recognized, but motor symptoms are quite the exception; convulsions are rare, and usually occur only in cases of encephalitis.

In many epidemics **gastro-intestinal symptoms** are a prominent feature at the beginning of the attack, occurring in perhaps 90 per cent. of the cases. **Vomiting** is very frequent, but is never protracted or severe. Severe **diarrhoea** occurs in two-thirds of the cases, with foul-smelling green stools, and may so dominate the clinical picture that a diagnosis of simple epidemic gastro-intestinal catarrh is made. Constipation sometimes follows, but this is infrequent. It has been noted of late in several epidemics that whilst whole families may suffer from diarrhoea, certain members only show signs of paralysis later on, so that one is disposed to regard the affection of the others as an abortive form of the disease. In other epidemics feverish sore throat and bronchitis usher in the attack. Now and again, but not often, bladder symptoms appear during the pyrexial stage, and the commonest is retention of urine, requiring the use of the catheter for its relief. The fluid obtained by lumbar puncture is under increased pressure, and contains an increased amount of albumin—up to double the normal quantity (Eichelberg), and a deficiency of lymphocytes.

Paralytic Stage.—The temperature now rises slightly, and the **stage of paralysis** sets in. In severe cases it is discovered after the alarming initial symptoms have subsided. In other cases, no less severe, the onset is quite mild, and may even pass unnoticed. The child is put to bed bright and, apparently, perfectly well, and next morning, to the consternation of the relatives, the paralysis is discovered. It has been observed in a certain number of carefully recorded cases that slight motor weakness and a tendency to fatigue are present during the earliest febrile stage of the disease, and these symptoms may either remain stationary, slowly fade away, or advance to the stage of complete paralysis. It is not improbable that this early stage is often missed, so that an acute onset is erroneously ascribed to the illness.

The disease almost invariably remains **confined to the motor system**, and in uncomplicated poliomyelitis is a flaccid paralysis. It usually advances with great rapidity, so that its full extent becomes obvious within a few hours, but in exceptional instances it continues to spread during the next day, or even for several weeks (Wickmann, Förster). This initial spread of the disease varies considerably in degree, but may be serious.

There may be complete loss of power in both legs, in the arms as well, or even in the muscles of the back, neck, and abdomen, and the child lies helpless and immobile. Passive movements cause obvious indications of pain. Incontinence of urine is sometimes seen. If the intercostal muscles and the diaphragm are partly or completely paralyzed, severe dyspnoea

occurs, and death from asphyxia may follow—a termination that is not so rare as was formerly supposed, for it represents 12 to 15 per cent. in some epidemics, and may even mount up to 40 per cent. of the total mortality.

In addition to pure spinal paralysis, with which alone this book is concerned, other forms have been described, and their nature investigated by means of post-mortem examination. Landry's paralysis, bulbar or pontine paralysis, and encephalitic, ataxic, polyneuritic, and meningitic forms of the disease have been described and classified as atypical forms, but forms, nevertheless, of the same disease. We cannot enter into the pros and cons of this classification or into that of the abortive forms already mentioned. It is to be hoped that the investigations of the near future will shed fresh light on this difficult question.

Stage of Recovery.—Fortunately the condition does not remain as hopeless as it appears at first. The earliest signs of recovery appear at the end of a week, and the true extent of the paralysis can be determined. Slight but definite movements are the first indication of the recovery of voluntary muscular control, and improvement continues to take place throughout several months, rapidly during the early stages, and then more slowly. The muscles remain flaccid at first, but show increasing power of contraction.

The stage of regeneration lasts for six months or more, but never extends beyond a year from the onset of the paralysis. Complete recovery is unfortunately very rare, though it does occur, as already mentioned. The final condition varies enormously as regards localization, severity, and extent. Frequently the paralysis is confined to one limb, a part of a limb, or even to certain muscles, and these may show varying degrees of injury in different bundles.

We shall allude again, in a later chapter, to the fact that **certain muscles very constantly escape** being affected, for this has an important bearing on our treatment. It is probable that the explanation of this immunity is to be found in the fact that these muscles have a nerve-supply that is derived from several segments of the cord, and it is unlikely that all of them would be affected. The extensors of the leg are more often affected than the flexors, and the extensor hallucis is the most frequently paralyzed. The quadriceps falls a prey to the disease much more often than the hamstrings, and the sartorius and tensor fasciæ usually escape. The glutei are often paralyzed, or at any rate severely paretic, but the ilio-psoas not infrequently escapes. The muscles of the abdomen and back will frequently be found affected, if only one remembers to examine them.

The deltoid and triceps are more often paralyzed than the biceps, and the extensor part of the forearm than the flexor.

In addition to the obvious paralysis, there may be small patches in one or more of the other limbs, of which the patient and his friends were not aware, and which are only discovered by the surgeon on careful examination of the whole muscular system.

Distribution of Paralysis.—Paralysis of one leg is certainly by far the commonest occurrence, then comes paralysis of both legs (usually to a very unequal extent), whilst paralysis of one arm or both arms is much less frequent, whether it occurs alone or in addition to an affection of the lower extremities.

Paralysis of arm and leg is usually crossed, and hemiplegia, though not common, as was at one time supposed, is of occasional occurrence.

One must be cautious, however, in drawing deductions on this point from the class of patients that consult an orthopædist. The reason is not far to seek. A little while ago paralysis of the upper extremity was not amenable to orthopædic or any other treatment. In consequence surgeons hardly ever saw these cases, whilst persons with palsy of the lower limbs have sought their aid for many years. For this reason I have not been through the tedious process of tabulating my cases. The statistics of Duchenne, Seeligmüller, and Tubby are quoted instead :

	Duchenne.	Seeligmüller.	Tubby.
One leg	32	42	140
Both legs	9	14	28
One arm	10	13	27
Both arms	2	1	10
All four extremities	5	2	9
One arm and one leg	3	3	29

It must be remembered, too, that we have to consider not only the situation of the paralysis, but also its degree. These two factors present so many different combinations that few diseases show such diversity as poliomyelitis, and any surgeon who has seen many cases of it knows that there is no such thing as a standard type.

Stage of Degeneration.—Very soon after the appearance of the paralysis the affected muscles begin to **atrophy**, so that in a few weeks they are not only flaccid, but considerably wasted. The degeneration may reach such a pitch that the limb comes to look as if it were made of nothing but skin and bone. Sometimes the atrophy is concealed by an excessive development of fat in the form of a **fatty infiltration** of the muscle and subcutaneous tissue.

R.D.—The **electrical reaction of degeneration** appears towards the end of the first, or the beginning of the second, week, and is of great prognostic importance. Faradic excitability is always lowered during the first few days, but if it has not disappeared at the end of the second week, it may be assumed that the muscle fibres which still react will recover. Complete loss of faradic excitability, however, does not indicate permanent paralysis of the muscle, for this may recover its power, and, indeed, it may happen that voluntary movement may return before normal electrical reaction.

Alteration in the galvanic excitability is of much more gloomy import. As a general rule the appearance of partial or complete reaction of degeneration, with the typical slow muscular contraction, means that the fibres concerned are injured beyond recovery.

At this stage the general health remains good; the patient eats and sleeps well, but constipation may persist. It results from lack of muscular exercise, and not infrequently becomes chronic, and in those cases where the abdominal muscles have been weakened or completely paralyzed by the disease, defæcation may be rendered exceedingly difficult, from impairment of the intra-abdominal pressure.

Sensory disturbances are rare, but occasionally one finds changes in pain and tactile sensibility—a phenomenon which is to be attributed in great part to disturbances of the cutaneous circulation. Loss of control of the sphincters is exceptional at any stage, and never persists after the first few days.

Paralysis of the bladder was a prominent symptom in one case of poliomyelitis that I recently observed.

The child became suddenly ill and very feverish, and on the second day the only symptom discoverable was retention of urine. The catheter was repeatedly used, and acute cystitis followed. This was regarded as the cause of the retention rather than as the result of the treatment. It was only when the child got up after the illness that paralysis of both legs was discovered and the real diagnosis made.

The cutaneous and tendon reflexes are decreased in the less severely affected areas, and are lost in the paralyzed muscles.

Vascular Phenomena.—The changes which occur in the **skin** of paralytic limbs are very striking; it is often mottled, or of a uniform cyanotic tint. Sometimes it is rather œdematous, and it always feels cold, especially if the external temperature is low, when the skin may feel like ice.

Von Heine made some accurate observations on the skin temperature of paralyzed limbs, and showed that the temperature of the periphery of the body was lowered (down to 64° F.), and that there was a loss of body heat when the paralysis had existed for some time. The following table, taken from von Heine's book, shows this point very clearly :

Age.	Axilla.	Back.	Loin.	Thigh.	Leg.	Dorsum of foot.	Sole of foot.
4½	93° F.	90	90	86	76	75	72
6	97° F.	93	90	84	77	74	70
8	—	95	93	80	65	—	64
12	97° F.	92	90	74	70	—	65

The coldness and cyanosis are, of course, due to the defective circulation. This, in turn, is partly due to the loss of movement in the limb, but chiefly to the **vasomotor system** being **involved in the paralysis**. Chilblains and chronic ulceration of the skin frequently result from the impairment of the blood-supply. It is not improbable that other structures besides the skin suffer from loss of nutrition, and that this is the explanation of the deficient growth of the bones.

Affection of Bones.—The alterations in the growth in length and thickness of the **long bones** have not yet been studied in sufficient detail, although the X rays have proved a great advance on the methods of palpation and measurement. It is certain, however, that the condition is not solely caused by defective circulation and insufficient use, but is an actual **disuse-atrophy**. Volkmann showed that there is often a relationship between the severity of the paralysis and that of the impairment of development. In paralysis of the lower leg the femur may show considerable shortening, so that marked disability may persist in patients who have recovered from a so-called "transitory" paralysis. Nonne reports the case of a girl of sixteen, who was ill for four years with infantile paralysis, which left her with a complete palsy of one arm. The skiagram showed translucency and rarefaction of the bones of the hand and forearm, especially of the epiphyses. The greater part of the diaphyses, especially of the humerus, was unaffected. It must be recognized, therefore, that trophic disturbances of nervous origin may occur in the skeleton, in addition to the muscles, and that these are particularly liable to take the form of Sudeck's atrophy. Careful and protracted observation and measurement of paralyzed limbs will be necessary in order to learn something of the origin and course of the disorder of growth.

Quite recently a remarkable phenomenon has been observed, in the shape of an **elongation** of paralytic limbs. Von Seligmüller and Neurath had already written on the subject, and later on von Kalischer added some further observations. It has been suggested that rickets, which was noted in the majority of the cases, may be the cause of the apparent lengthening. The effect of this disease is to inhibit growth, and it may chiefly affect the good leg, being the one upon which the weight of the body is chiefly borne. Consequently, this leg may have its growth more impaired than the paralyzed

one, so that it exhibits a relative shortening. Later on, however, the disturbing effect of the paralysis shows itself in the opposite limb, and investigations in cases which have been followed up for a considerable time have revealed the fact that the difference in length tends to disappear.

This explanation is clearly somewhat far-fetched. It fails, too, to account for two cases described by Tubby and Jones, in which both legs were paralyzed, but the less affected limb was the shorter. Here we have a splendid example of the fact that the extent of the paralysis bears no relation to the severity of the trophic disturbance. I myself have frequently seen cases of elongation of the affected leg. But it was only an apparent lengthening, due either to contracture of the abductors and tilting of the pelvis, or to paralytic forward dislocation of the hip-joint. In two patients the elongation appeared to amount to $1\frac{1}{2}$ or 2 centimetres.

Deformity and Contracture.—The most interesting stage to the orthopaedist is that of recovery after the first onset, for it is then that paralytic deformity and contracture begin to appear.

The **causation** of paralytic contracture is not easy to explain. Various theories have been advanced, and the resulting controversy has been keen. The fact is, that none of the explanations offered is sufficient to explain the whole difficulty, but there is an element of truth in all of them. In order to understand them properly, we must go back to the physiology of the muscles. But here we are at once confronted with the difficulty that physiologists themselves are not agreed on the point. There can be no doubt that the normal position of a joint in the living body is determined and maintained by the equilibrium subsisting between the various muscles surrounding the joint. But how is this brought about? Mainly by the elastic tension of the muscles and tendons—that is to say, by a mechanical force—but also by muscular tone, a factor whose existence has been frequently denied, but which appears, according to recent work, to come into play. We have proof of its existence every time that we perform tenotomy of a tendon. The muscle retracts as soon as it is divided, and the gap between the two ends of the tendon affords a measure of the previous degree of tension on the muscle. Retraction also occurs in the antagonist, because it cannot extend fully after a contraction, without the help of its opponent. The same thing happens in muscular paralysis, but the causation of the contracture varies according as the paralysis is partial or complete. Total paralysis is followed by relaxation of the joint capsule; flail-joint ensues, and the position of the peripheral part of the limb is solely controlled by its weight. If one posture is maintained uncorrected for any length of time, shortening occurs in those muscles whose points of attachment have been approximated. In time the bones also become adapted to the new position, and osseous deformity ensues. In the case of partial paralysis, the

mechanism is different. When the contractility of a group of muscles is impaired by paralysis, the opponents fail to relax properly in response to the voluntary nervous impulse, and a residual shortening is left, which gradually develops into the permanent contracture. In certain cases, however, the overstretching may be the result of gravity; for instance, the dorsi-flexors of the ankle may be elongated by the weight of the foot, in consequence of paralysis of the calf muscles. In any given case, the resulting deformity depends upon the condition of the extensors. If they exert less mechanical effect than the weight of the foot, pes equinus follows; but if they are more powerful, pes calcaneus is produced. When the paralysis is such that weight and muscular contraction act in the same direction, contracture and bony deformity are the more likely to appear. From this explanation it will be clear that there is something to be said for both the theories that have been put forward.

The more extensive the paralysis, the more severe are the contractures, and subluxation, or even complete dislocation, may take place. The saddest and most revolting cases of paralysis are those in which the unfortunate patients, deprived of all power of locomotion, and completely helpless, are wholly dependent upon the compassionate assistance of those about them.

It nearly always happens in partial paralysis that certain of the surviving muscles undergo **hypertrophy**. This must be regarded as a response to the extra work that is thrown upon them—*i.e.*, it is an example of functional adaptation. For instance, the extensor longus hallucis hypertrophies in paralysis of the tibialis anticus, and the sartorius in place of the quadriceps. Considerable hypertrophy of the sound limb sometimes occurs in unilateral paralysis, and must be regarded as another manifestation of this tendency to compensation; so also is the marked development of the arms in patients with severe paralysis of both legs—*i.e.*, in those patients who use their arms for purposes of locomotion. A very striking example of the extent to which this process may be carried is recorded by von Rubinstein, who describes the almost incredible uses to which the hypertrophied tongue was put by a girl with extensive paralysis of the extremities.

Lastly, we may add (though more for the sake of completeness than for any practical value that the fact possesses) that infantile paralysis is followed in a small proportion of cases by chronic amyotrophic muscular paralysis. Charcot and Vulpian described the association of the two complaints, and the labours of Dutil, Etienne, Filbry, and Bernheim have confirmed their observations. Bernheim asserted that there was a direct causal relationship between the two diseases, and that the later illness was due to the old inflammatory focus breaking out afresh.

ÆTIOLOGY.

The various phenomena described in the foregoing chapter are all attributable, fundamentally, to an **inflammatory process** which takes place in the **grey matter of the anterior horns**, and results, during healing, in degeneration of nervous elements and limited formation of scar tissue.

How is this affection of the spinal cord brought about ?

The disease occurs in every nation and race. It was thought at one time that its incidence was greater in malarial districts, but it appears that this statement is due to the confusion of infantile paralysis with true multiple neuritis. We shall allude to this question again later on.

Heredity is not a factor, though occasionally cases occur in several members of the same family. These are probably due to simultaneous infection.

Sex also is without effect on the question, for the disease occurs with equal frequency in boys and girls. Difficult dentition was formerly blamed as a cause of infantile paralysis, but this can hardly be correct, or else the disease would be even commoner than it now is. This explanation fails, too, in the cases of paralysis in adults.

Recently it has been thought that many cases have followed **chills**, and there is often a history of getting wet through, bathing whilst overheated, or something of the sort. I myself saw, for instance, a case of a nine-year-old girl in whom the disease appeared on the evening after bathing in the sea.

✓ The relations often give a history of a fall preceding the onset of the paralysis. Importance can only be attached to such a statement in those instances where the injury was a severe one, and took place only a short time before the onset of the disease—a few days at most. ✓ Other authors, too—*e.g.*, Kenedy, Beaver, Jordan, Auerbach, Schultze, Zappert, and Beyer—attach little value to a history of **trauma** in the ætiology or diagnosis of the condition. But one must admit some association in the instance recorded by Schultze, where a child fell lightly on the back of the head, and fever and paralysis appeared “after a few days.” Schultze, too, relates how a child fell out of bed, and six days later the arm became paralyzed. In these cases the injury was slight, and the interval between it and the onset of symptoms was brief. If severe concussion could give rise to poliomyelitis, it would be frequently seen in accident cases. But this is not the case. The reverse holds good. Examples of chronic anterior poliomyelitis have been placed on record, which have come on after an accident, but have presented none of the features of an acute attack. Such cases have been reported by Erb, Thiem, and Franke, and I had recently an opportunity of observing another. Typical anterior poliomyelitis came

on suddenly in a young man of eighteen, a private patient of mine, after a fall from a bicycle on to the buttocks. Only a few weeks had elapsed between the accident and the onset of the illness, so that a causal relationship between the two was not improbable. It is possible that the injury produced a *locus minoris resistentiæ* at which subsequent infection took place. Occasionally, however, the distinction from hæmatomyelia is not easy. Grünow relates how a farmer, who had spent the day picking cherries under a burning sun, was overtaken by paralysis, and, although he regarded the illness as accidental, he admits that a diagnosis of acute myelitis is not at all impossible.

The whole clinical course of poliomyelitis suggests that it results from an acute infection, as Strümpell and Marie maintained. There are a number of good reasons for this view, which we must consider in greater detail.

In a striking majority of cases, the disease occurs in children. It is uncommon in the earlier months of life, but has been seen in a child of fifteen days, and even at birth (Falk).

The incidence increases in the second half of the first year, and reaches its maximum between the second and the fourth year. It is not yet certain whether or not **intra-uterine poliomyelitis** occurs. Sometimes the relatives are very definite in their statement that the child was born with the paralysis. A case of this kind came under my notice recently ; there was no question as to the diagnosis of infantile paralysis, and the mother and the midwife both asserted that paralysis of the leg was noticed when the child was being given its first bath. Such a case as this throws some doubt on the contention that "antenatal" poliomyelitis is really due to infection some days after birth, or to intra-partum hæmorrhage into the spinal cord.

If intra-uterine paralysis were of more frequent occurrence, we should have more opportunities of studying its sequelæ, and the resulting contractures and deformities. Our knowledge of congenital deformities is as yet in its infancy, and observations on the changes in the spinal cord have not been made in sufficient numbers. In cases of congenital club foot, I have repeatedly investigated the condition of the muscles whilst performing tendon transplantation, and have found degeneration absolutely analogous to that seen in ordinary infantile paralysis. I will quote one particularly striking case, taken from the series which I have published elsewhere :

G. W., æt. 12. Congenital club foot, left side, treated for some time with apparatus, without success. Foot tough, with bony locking, adduction and supination to about 90°. The appearance of the right foot suggested to me that the condition of the left was due to paralysis. It was in the equino-cavus position, such as is commonly seen in paralytic cases. The deformity was not severe, and had not caused any trouble ; indeed, it had hardly been noticed. It was so obvious, however, that I made a diagnosis of congenital paralytic club foot on the left side, and therefore performed the open operation, after *redressement*. The condition found entirely confirmed my suspicions :

Extensor longus digitorum completely paralyzed and degenerated, only a thin bundle remaining. Tibialis anticus pink, also wasted. Extensor longus hallucis very strong, colour normal. Peronei, tibialis posticus, and flexor longus digitorum light yellow; gastrocnemius fairly good.

The details of the treatment, which consisted in *redressement* and tendon transplantation, do not concern us here.

In such an instance as this, anatomical investigation of the spinal cord would be of the greatest value in confirming the diagnosis. Courtillier and others have described degenerative changes in congenital club foot, but further research into the condition of the muscles, the nerves, and the cord in cases of congenital contracture and deformity is necessary before the question of intra-uterine poliomyelitis can be regarded as definitely settled.

Poliomyelitis an Acute Infection.—After this digression, let us return to the discussion of the view that acute poliomyelitis is an infectious disease. This is supported by the fact already mentioned, that children who possess but little natural power of resistance to disease are by far the most frequently attacked. Other points of resemblance are the severe onset, and the nervous and general disturbance that is produced. Not infrequently poliomyelitis directly follows one of the infectious diseases of childhood; measles, scarlet fever, and whooping-cough seem to be particularly frequent antecedents, and some cases have followed diphtheria, influenza, erysipelas, pneumonia, or vaccination. It is not known whether these diseases are the direct cause of the inflammation of the spinal cord, or whether they only prepare the soil on which the specific toxin of poliomyelitis becomes subsequently implanted, or whether they merely produce a state of lowered vitality as the result of their toxins passing into the circulation. We shall allude to this matter again later on.

Epidemics.—The incidence of the malady is greatest during the hot summer months. Forty-seven out of fifty-seven of Wharton-Sinklers' patients were attacked between May and September. Medin observed forty-three cases between July and October; Briegleb of Jena, five in June and July; and thirty-six out of fifty-six cases studied by von Baumann occurred in the summer months. Confirmatory evidence of the same sort is afforded by the epidemiology of the disease, which is a subject upon which much labour is being bestowed at the present time. Colmer was the first to report a striking local prevalence of poliomyelitis; this was in 1843. He found seventeen cases in children of less than two years of age within a radius of a few miles, and all these occurred within three or four months. He seems, however, to have personally observed only one of them. Bergenholtz reported to the Medical Council (in 1881) an epidemic occurring in Umea, in the North of Sweden, in which eighteen children were stricken between

July and November. Oxholm was the first to publish a statement in 1887; he described five cases occurring in the summer of 1886.

In 1888 Strümpell recorded three cases which had occurred in his practice in one village, and which seemed to lend support to his view of the ætiology of the complaint published in 1884.

In the same year Cordier related seeing thirty cases in children between one and thirty months of age in Sainte-Foy, in the South of Germany. In one instance he was able to determine an incubation period of thirty-six hours. Two children, who lived in a neighbouring village, went one day into the infectious area, and, returning home in the evening, were both taken ill the same night.

Larger epidemics were reported from America in 1894 by Putnam and Macphail Caverly. The latter described 140 cases which were seen in Otta-Creek Valley (Vermont), between June and September. Most of the patients were children, but a few were adults, and one was an old man of seventy. Even domestic animals sickened and died with similar symptoms—horses, dogs, and chickens.

In addition to a number of typical cases of poliomyelitis, a certain number of cases of multiple neuritis were included, and a few which proved fatal were regarded as cerebro-spinal meningitis. The author regarded the simultaneous appearance of these three acute inflammatory conditions, each definitely localized to its own part of the nervous system, as a proof of ætiological similarity. This suggestion has recently been revived, and there appears to be some reason for regarding it as at any rate partially correct.

In 1890 Medin made a communication to the Tenth International Medical Congress concerning an epidemic of forty-three cases which he had observed in 1887 in Stockholm and its environs. This does not represent, however, the full severity of the outbreak, for other cases occurred in the practice of other physicians. In the next few years, the largest epidemics occurred in Scandinavia; six took place in Norway, and one, in 1905, included over 700 cases which were reported to the Medical Council. Another, equally extensive, occurred in Sweden, and is the largest and best recorded that is known up to the present time. In 1905 Wickmann published a book on these huge and very interesting epidemics, which included altogether more than 1,000 cases; the work is one which should be better known and appreciated than it is. He made splendid use of the great amount of material at his disposal, and was enabled to make authoritative statements concerning the epidemiological facts of infantile paralysis.

A few of his most important conclusions must be quoted.

The epidemic reached its climax during the months of July to October, as the following table shows:—

January	1
February	5
March	4
April	4
May	7
June	20
July	137
August	367
September	243
October	140
November	69
December	28
Total	1,025

The extent and distribution of the epidemic is accurately depicted in a large number of maps. The towns suffered little, and the disease was practically confined to the plains. Its distribution about the larger areas was for the most part radial, whilst in the smaller ones one finds several members of the same household, or inhabitants of neighbouring houses, afflicted with the disease. Direct or indirect contact can be demonstrated between almost all those who were attacked. It follows that the epidemic spread along the lines of social intercourse, the main roads and the railways. Symptoms of paralysis were observed in dogs, guinea-pigs, and even in fowls.

Several small epidemics have been recorded in Italy, France, Austria, America, and Australia, and a larger one of about 1,000 cases took place in New York and other Eastern States. In Germany occasional notes of increased incidence were made, as, for instance, by Pleuss, of Kiel, in 1897, and by Auerbach at Frankfurt in 1898, but the authors were not able to establish any epidemiological facts of importance. It was not until 1909 that we experienced in Germany the horrors of an epidemic, and then one arose in Breslau, and another and a larger one in Rheinland and Westphalia, affecting in all more than 500 persons, and causing over sixty deaths. The average mortality was stated to be 15 per cent., and it was thought that the disease was increasing in virulence, and changing somewhat in its clinical features. In this epidemic scientific investigations were made in the affected areas, and legislative measures were introduced. Such accounts of the outbreak as have been published up to the present time have fully confirmed the observations of our Swedish confrères, and especially of Medin and Wickmann. As in the American epidemic, the death of fowls with paralytic symptoms was recorded.

At about the same time Styria was overrun by an epidemic which amounted to more than 1,000 cases, and a serious outbreak occurred in the Western States of America, extending to the Pacific coast.

There can be no doubt that the disease is an infectious one. It is probable that the **virus finds entrance** by way of the alimentary canal, though proof of this is not forthcoming at the present time. The first symptoms to appear are alimentary, and the later ones are due to generalization of the infection; paralysis results from infection reaching the central nervous system. Food appears not to act as a vehicle, for breast-fed children contract the disease. Eichelberg thought that earth was frequently a carrier of infection. He advanced the following arguments in support of his theory: (1) The appearance of the disease in the families of shoemakers who had soled boots for sick children from other villages; (2) the prevalence of cases amongst children who had gardens to play in; (3) the special frequency of the disease amongst the rural classes. The domestic animals are probably to be exculpated, though there are certain remarkable instances of simultaneous illness appearing in man and beast. In a few cases the diagnosis has been confirmed by an autopsy.

It is quite clear that **man himself is the chief carrier** of infection.

The **incubation period** seems to be usually one to four days, though it may be longer. The average in some epidemics has been a week, and in others about ten days.

Bacteriology.—Our knowledge of the immediate cause of the disease is even more scanty. Schultze examined the cerebro-spinal fluid on the thirteenth day of the attack, and found chains and tetrads of diplococci, which resembled the Weichselbaum-Jäger meningococcus. Cultivation was negative. In this case there were also slight signs of meningitis, and Schultze therefore concluded, on clinical as well as on pathological grounds, that there existed a disease intermediate in its characters between poliomyelitis, meningitis, and encephalitis. A little later he was able to confirm his first result by lumbar puncture during the acute stage, and again finding diplococci in the fluid. Looft and Dethloff also published confirmatory accounts of the microscopical and cultural features of two cases. Concetti found bacteria in the cerebro-spinal fluid in three cases during the first week of the attack; in two they were the Talamon-Fränkell diplococcus, and in the third the meningococcus of Weichselbaum. In earlier cases the fluid had been found sterile. Ellermann has recently described Rhizopods, but his work has not yet been confirmed by others.

Geirsvold investigated the cerebro-spinal fluid in fifteen cases, and demonstrated the same micrococcus three times by direct examination, and twelve times by cultural methods. In one case pneumococci were present in pure culture. The organism which he described was a bean-shaped diplo- or tetra-coccus. This work also lacks confirmation.

Wickmann, in his big epidemic, was unable to corroborate Geirsvold's results; his bacteriological work was entirely negative. A similar lack of

success has attended the labours of Krause and Meinicke in Westphalia, of Eichelberg in Göttingen, and of Leiner and Wiesner at Vienna. Römer, of Marburg, also found the fresh cerebro-spinal fluid sterile, whilst Beneke in the same place found staphylococci both in it and in the blood, though he regarded them as a mere insignificant contamination.

Beneke also mentions that on two occasions he found some small, rapidly moving bodies of uncertain nature in the blood, in hanging-drop preparations. He demonstrated Gram-positive bodies, resembling diplococci, in the pia and in sections of the cord removed at post-mortem examinations; it may be that these were only nosoparasites.

Finally, Potpeschnigg states that he found Gram-positive diplococci in the cerebro-spinal fluid in fourteen cases.

The results of inoculation experiments are slightly more satisfactory, though still far from conclusive. Geiersvold reports that he produced paralysis in mice, guinea-pigs, and pigeons by the intravenous injection of his pure cultures. Pasteur, Foulerton, and MacCormac injected cerebro-spinal fluid from a case of poliomyelitis into rabbits, and reproduced the disease in them. Landsteiner and Popper gave intraperitoneal injections of a sterile emulsion of the cord of a child who had died of a severe form of poliomyelitis, employing rabbits, guinea-pigs, mice and apes for their experiments.

Symptoms of paralysis appeared in the two latter animals, and the cord showed typical poliomyelitis. An attempt to reproduce the disease by inoculation of a second generation failed. Knoepfelmacher repeated the experiment with the cord of a case that had died with the symptoms of Landry's paralysis. A piece about 10 centimetres long was removed fourteen hours after death, placed for fifteen minutes in sublimate solution, 0.1%, washed with sterile salt solution, made into an emulsion with the same, and injected into the peritoneal cavity of a monkey. Fever appeared in eight days, and paralysis in eleven. The cord showed multiple areas of inflammation, which were particularly numerous in the anterior horns. In this case also subinoculation proved unsuccessful. Both authors were unable to find bacteria in the material used; they therefore suggest that the virus is, perhaps, a filtrable one, or of a protozoal nature.

Krause and Meinicke were less fortunate, for they were unable to demonstrate any pathogenic properties in the "virus" on inoculation of monkeys, mice, guinea-pigs, fowls, and doves. They succeeded, however, in killing rabbits by subdural, intravenous, and intraperitoneal injections; symptoms of disease of the central nervous system appeared, but no macroscopical changes were found at the autopsy. Eichelberg and Rosenthal's attempts to infect rabbits by intracranial inoculation with cerebro-spinal fluid from recent cases were entirely negative. Beneke placed emulsified cord, together

with a solid portion of it, in the peritoneal cavity of two rabbits. The animals sickened on the ninth or tenth day with sweating and general malaise, and died soon after, without any paralytic symptoms. A third rabbit received a small quantity of spinal-cord substance intradurally; twelve days later there appeared paresis of the fore-limbs, and of the head, together with a tendency to convulsive movements of the hind-legs; death took place on the next day. Neither macroscopical nor microscopical changes were found in the brain or cord of any of the animals, but there was much hæmosiderin in the spleen. All the other investigators of recent times deny the susceptibility of the rabbit, as well as of other mammals, from horses, cattle, and pigs on the one hand, to rats and mice on the other.

Monkeys, however, have proved valuable as experimental animals, for not only has successful inoculation been made with human virus, but also subinoculation has been carried out from one monkey to another, even to the seventh generation. These experiments have been performed by Flexner and Lewis in New York, by Leiner and Wiesner in Vienna, by Landsteiner and Levaditi in France, and by Römer in Germany.

Römer inoculated cerebro-spinal fluid without success, but on employing human spinal cord from cases of poliomyelitis, he obtained a successful result in three cases, and an unsuccessful in two. When using the cords from experimentally produced poliomyelitis in apes, he obtained five positive results, and only one negative one. He attributes the failures to the selection of pieces of cord that were not really affected by the disease, so that the total amount of virus introduced was a sublethal one.

He injects 5 per cent. emulsion of the central nervous system, giving 0.5 c.c. intracranially, and 4 to 5 c.c. intraperitoneally. This combination he regards as the most reliable for the production of experimental poliomyelitis.

Römer found that the clinical features of the disease developed, on the average, in nine days, which corresponds with the incubation period in man.

A number of isolated facts with regard to the nature of the virus and its distribution have already been ascertained by experiment, but only one will be quoted here. The virus remains active for two months in undiluted glycerine, resembling in this respect lyssa and chicken-plague. A temperature of 41° F. does not destroy it after forty days (Flexner and Lewis). It is improbable, therefore, that the very low incidence of the disease in winter is due to a direct destruction of the virus by the lowering of the temperature.

Desiccation may exert a destructive effect upon it (Leiner and Wiesner). Landsteiner and Levaditi, Flexner and Lewis, found that the virus was filtrable through Berkefeld filters, but Leiner and Wiesner state that it does not pass through Reichel filters.

Flexner and Leiner found that the disease could be inoculated by intra-

neural or perineural injection, as well as by intracerebral or subdural injection. Leiner and Wiesner also succeeded in producing infection by way of the peripheral lymphatic glands, introducing the virus by feeding with spinal-cord matter, or by giving it as an enema. Cerebro-spinal fluid, blood, and spleen appear to be useless for the purpose of transmitting the disease.

In successful inoculations, the presence of the virus can be demonstrated on the fifth day, whilst the earliest histological changes in the cord are to be seen on the third day, before any of the clinical symptoms of infection have developed.

The question of acquired immunity is of the greatest importance. The experiments of Flexner and Lewis, and of Römer, seem to suggest its existence. For the first few days after infection the animal's resistance to reinfection is somewhat diminished, but after a period varying between twenty-six and thirty-three days immunity may have developed (Römer). Römer claims to have discovered an innocuous method of **vaccination** against the disease.

My own view is, that it is unnecessary to assume a single ætiology or a single cause for the inflammatory process in the anterior cornual cells in all the epidemics that have occurred. Clinical experience seems to show that such an attitude would be incorrect, and a case recorded by Engel lends colour to my suggestion :

A child of five with otitis developed osteomyelitis of the clavicle, and this was followed by poliomyelitis. On the fifth day of the latter illness lumbar puncture was performed, and a culture of *Staphylococcus pyogenes albus* was obtained.

The results of experiments on animals show that a diversity of micro-organisms are capable of causing the typical inflammation. Roger injected rabbits intravenously with *Streptococcus erysipelatis*; Gilbert and Léon used *Bacillus coli*; Vincent, *B. typhosus*; Thoinet and Masselin, *B. coli* and *Staphylococci*; Ballet, *Staphylococci*; Crocq, *B. diphtheriæ*—all these are stated to have given rise to an illness resembling poliomyelitis.

Wickmann, who was the only investigator to obtain negative results with *Streptococci*, contended that these experiments were altogether unreliable.

Very important positive results were obtained by Enriquez and Hallion. They inoculated some dogs and a monkey subcutaneously with diphtheria toxin, and found numerous inflammatory foci in the anterior cornua, corresponding with those seen in infantile paralysis. Charrier and Claude were equally successful with subcutaneous injections of snake-venom.

In the present state of our knowledge, therefore, we may conclude that there are several sources of infection, which, either by their local action or by the remote effect of their toxins, are capable of causing poliomyelitis.

PATHOLOGICAL ANATOMY.

The disease is commonly regarded as an acute inflammatory process affecting the anterior horns of the spinal cord, but it must be recognized nowadays that this is only the place at which the condition reaches its maximum intensity. The pathological process affects the whole central nervous system, but particularly the spinal cord, and it can be regarded as consisting of three stages—namely, the stages of the acute illness, repair, and restoration of health.

First, or Acute, Stage.—The changes in the cord during the acute stage can easily be observed with the naked eye in bodies examined soon after death. The grey matter stands out red or brownish-red against the white matter, and fine red streaks or spots indicate capillary hæmorrhages or dilatation; the most severely affected parts are yellowish-red. Fatal cases, of course, show the pathological changes in a severe degree, and to this extent they are abnormal. The inflammation extends throughout the whole length of the anterior cornua, and also into the antero-lateral and posterior columns, so that the whole of the grey matter in the hemisection of the cord stands out prominently, though the changes are always most marked in the anterior horns. As a rule, an area about 1 to 3 centimetres long is affected, situated in the cervical and lumbar enlargements, and more often unilateral than bilateral. It is remarkable that unilateral paralysis may be associated with bilateral cord lesions. The white matter is very slightly affected, if at all. The whole cord is usually somewhat œdematous, the cut surface bulges, and the grey matter is prominent. There is often slight leptomeningitis, with small opaque areas. The medulla oblongata, pons, cerebrum, and meninges are often hyperæmic and œdematous, and there may be blood-stained fluid in the ventricles.

The viscera also show changes of the kind that is associated with infectious disorders. The intestinal mucosa is red and swollen, and especially the Peyer's patches and the solitary follicles. The tonsils are occasionally covered with false membrane. The spleen is often enlarged, and the liver hyperæmic. The kidneys show cloudy swelling, or even true nephritis. The internal organs have not as yet been subjected to microscopical investigation, but it is probable that inflammatory infiltration would be found similar to that which takes place in the cord.

As we have already seen, a very important question in the pathology of poliomyelitis is that of the situation of the initial inflammation. Is it in the parenchyma or in the connective tissue? Charcot supported the "parenchymatous" view, and adduced the regular anatomical distribution of the lesion amongst the ganglion cells as an argument in support of his teaching. His ingenious suggestion as to the trophic function of the

anterior horn cells was also based upon this observation. His opponents, however, of whom Roger and Damaschino were the first, explained this as due to the anatomical arrangement of the bloodvessels. Roth, Goldscheider, and Dauber supported the "interstitial" theory, Rissler and von Kahlden sided with Charcot, whilst others, including Leyden, Kawka, and Schmaus adopted the *via media*. It is impossible to enter into all the arguments in detail, especially as a final decision of the question has not yet been arrived at. Schwalbe, however, has put forward a very fascinating suggestion by which one is enabled to reconcile the opposing schools of thought. He points out that changes are constantly found in the parenchyma, the connective tissue, and the vessels, and that these are sometimes equally pronounced in all three, and in other cases the parenchymatous or the interstitial element may preponderate. From this he deduces that there is one common cause for all three changes, and that there is no such thing as primary or secondary affection of one or other element. Illuminating as this suggestion is, Wickmann, after investigating an unusually large amount of material with the greatest possible skill and care, came to a totally different conclusion. He regards the disease as a disseminated myelitis, whose tendency to localization is particularly marked in the brain and medulla, both of which he found affected in the cases which he investigated. In addition to infiltration, oedema occurs, and gives rise to patches of interstitial change which do not correspond in position to any particular ganglion cells or groups of ganglion cells. This is well seen in the medulla, where the changes are always better marked in the parts around the nerve nuclei than in the nuclei themselves. In the cord it is the rule to find changes beyond the limits of the anterior horns, extending to the rest of the grey matter, as well as to the white matter and to the pia. The pathological process reaches a maximum in the enlargements of the cord. In the lower dorsal and upper lumbar regions, however, it is not so advanced in the anterior horns as in the columns of Clarke. This modification is associated with a corresponding difference in the arrangement of the blood-supply. The pathological process follows the vessels closely, arteries and veins alike, and seems to affect equally the central and the peripheral veins. It seems to show no special predilection for the arteria centralis.

There is no evidence of an embolic origin of the disease, though Beneke recently advocated this view very strongly.

Interstitial and parenchymatous change as a rule run side by side. Degeneration of the ganglion cells is accompanied by lesions of the connective tissue, though occasionally, and particularly in the medulla, the ganglion cells will be found normal, whilst the vessels are affected. The inflammation of the interstitial tissues is the chief cause of the damage to the nervous elements.

Second, or Reparative, Stage.—The second stage in the pathological history of the malady is that known as the “reparative stage,” wherein “the organism strives to make good the damage done to its nervous system” (Rissler). The destruction of those elements which were attacked during the acute stage rapidly takes place. The products of their disintegration are carried away in the lymphatic system, partly free, and partly as cell inclusions. It is possible that a certain amount of proliferation of the glia takes place at the same time, but this is not of any material importance.

Third, or Residual, Stage.—In the third, or residual, stage (Schwalbe) one finds patches of scar tissue, 1 or 2 centimetres in length, with atrophy of the anterior cornua, or even in some cases of half the cord. The nervous material will be found almost completely absent in the affected areas (Figs. 1 and 2).

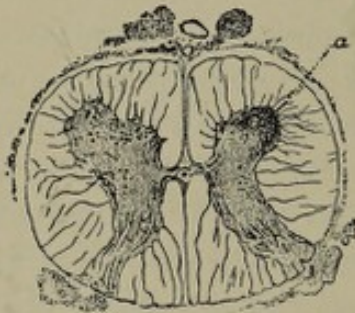


FIG. 1.—ACUTE ANTERIOR POLIOMYELITIS, LUMBAR, BILATERAL. FINAL CONDITION. (AFTER OPPENHEIM.)

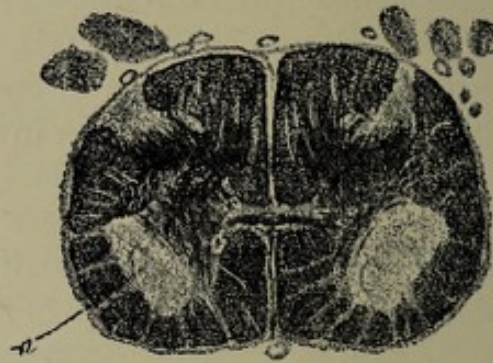


FIG. 2.—ACUTE ANTERIOR POLIOMYELITIS. ATROPHY OF RIGHT ANTERIOR CORNU. (AFTER OPPENHEIM.)

The anterior roots at the level of the cicatricial patch are also decreased in size, and exhibit degeneration and atrophy, together with relative, or even absolute, increase of connective tissue. A similar condition obtains in the motor nerves. Signs of inflammation have not been found in them.

The **muscles** of the affected parts of the limb show very marked changes. They decrease very rapidly in size, and exhibit degenerative atrophy of variable distribution and severity. The normal fibres are distinguished by their bright red colour, whilst the degenerate ones are of a yellowish-white hue, caused by the fatty degeneration of their substance. The separate fibres of which the bundle is composed can scarcely be distinguished, if at all.

Areas of streaky degeneration are sometimes seen in a muscular bundle, lying side by side with healthy fibres. These are the so-called “tabby-cat” muscles.

Not infrequently a considerable deposit of fat takes place in and around the degenerate muscle, and brings about the complete degeneration of whatever muscle substance may remain. Certain muscles, though subnormal in size, often show a more or less exaggerated red colour; these are fibres which

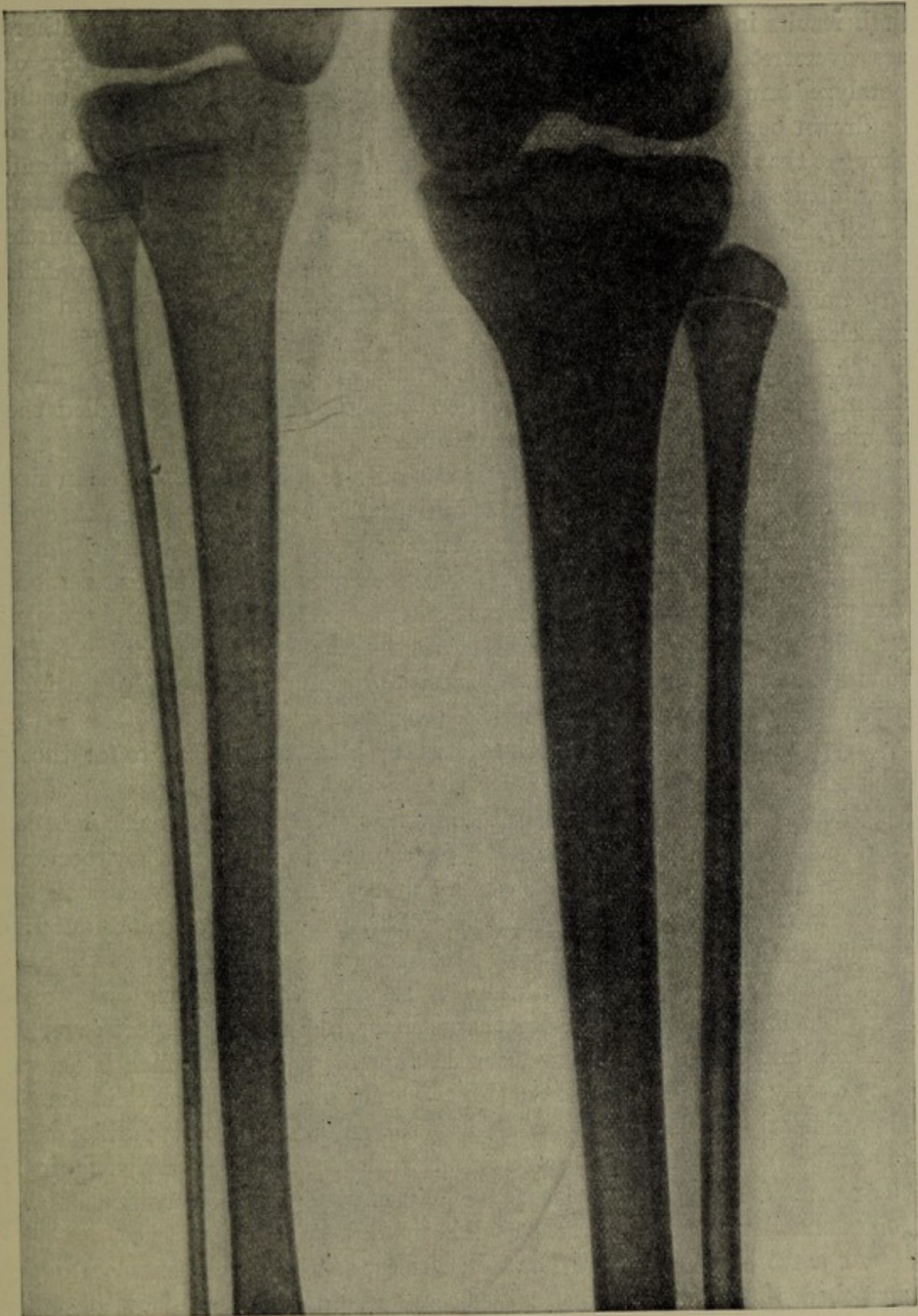


FIG. 3.—INFANTILE PARALYSIS IN GIRL OF 14. ONSET AT ONE YEAR.

have undergone disuse-atrophy or overstretching. A faulty position of a limb results in the shortening and wasting of some muscles, whilst others are overstretched. Jamin performed experiments upon the atrophy of paralyzed muscles, and arrived at the conclusion that no distinction could be drawn between degenerative atrophy and that due to disuse. He also thought that degenerative atrophy due to a nervous lesion was a myth, and that disuse-atrophy of the muscle itself was the common phenomenon. Finally, he maintained that direct toxic or traumatic injury of the muscle fibres was the only cause of true degenerative atrophy. Charcot was unable to demonstrate any specific trophic effect of the nerve centres upon the muscles.

These conclusions are based upon experiments made with dogs. They accord fairly well with the observations made by Koch, who studied the results of poliomyelitis in the human subject.

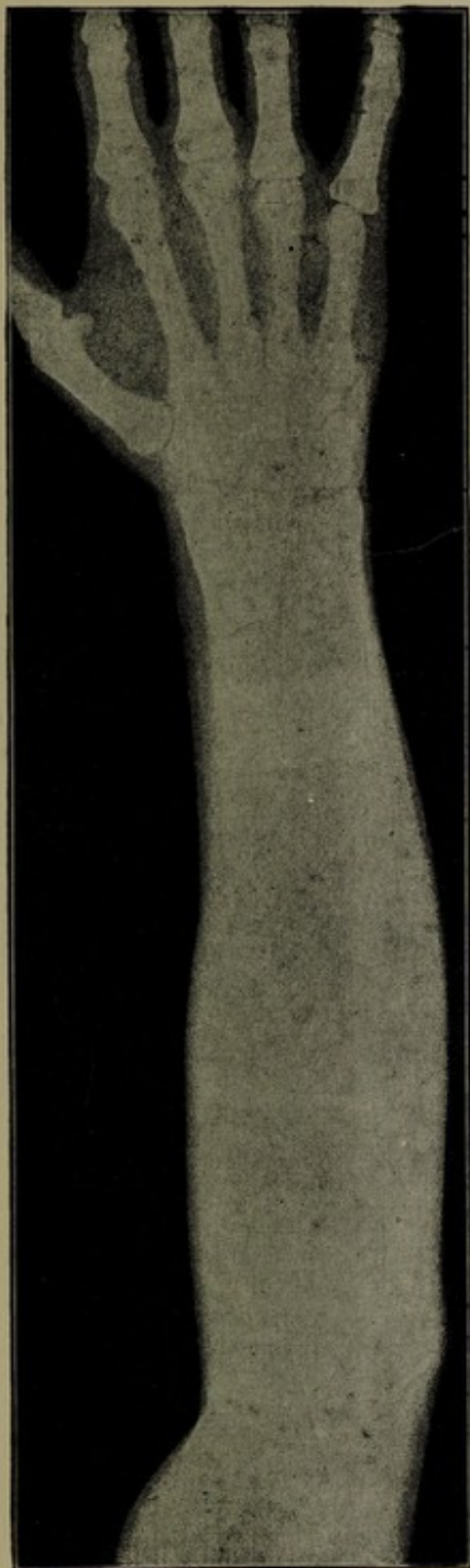
He found that when the paralysis was only partial, such decrease in size as occurred was not due to wasting of individual muscle fibres. The affected bundles, on the contrary, showed considerable development of new fibres, and this process went on irregularly for some time. Restoration of function, was prevented, however, by the loss of the physiological tone of the muscle, and this never recovered, however much the fibres might regenerate. He found that repair in the spinal cord and in the muscles reached its height seven to nine months after the onset of the attack.

Hypertrophy of certain muscles then took place to compensate for those which had been paralyzed.

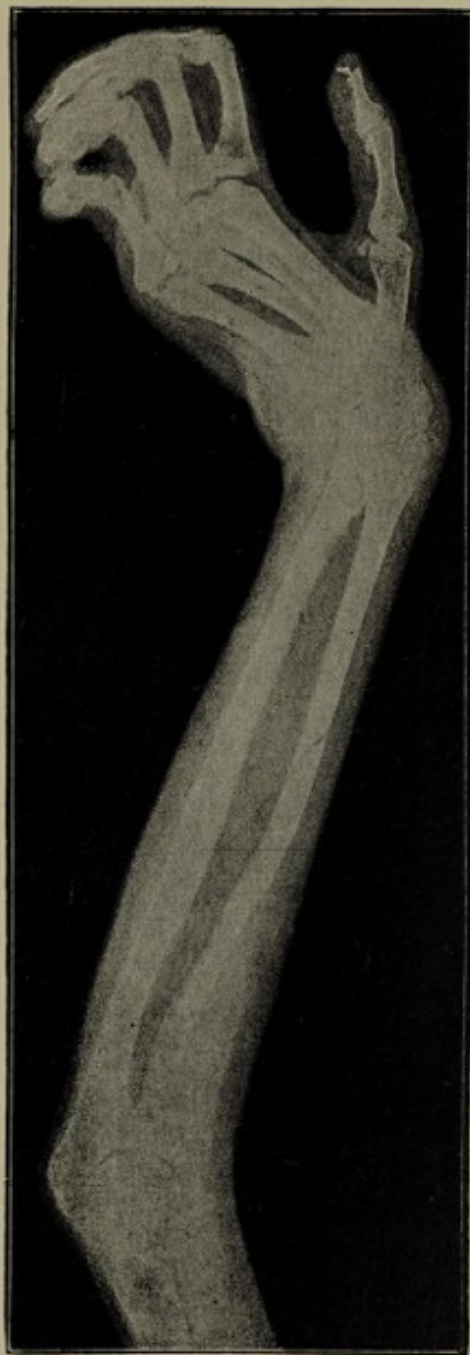
The **tendons** also participate in the process of atrophy, but this is to be attributed to disuse rather than to degenerative change. They become smaller, and therefore somewhat weaker, and where they are intersected by degenerated muscle, they are particularly likely to yield—*e.g.*, in the quadriceps tendon.

The changes in the **skeleton** are very remarkable. The long bones of a paralytic limb are more slender than usual; the outer, compact layer is rarefied, and the medulla is reduced in amount, a change which is shown very clearly by the Röntgen rays (Figs. 3 and 4). The difference in length is particularly marked, and may amount to several centimetres; differences of as much as 20 centimetres have been recorded. The bones may acquire a permanent deformity as the result of long-continued faulty position of the joints and the unequal stress that is laid upon them in consequence.

As a rule, the **joints** are relaxed; the capsule and ligaments are overstretched, the articulation becomes loose, and subluxation follows, or even complete dislocation, with the familiar changes in the articular surfaces. In other cases one finds more or less marked contracture due to partial paralysis of the muscles; with this is associated unilateral shortening of the capsule.



(a)





(b)

FIG. 4.—ACUTE CERVICAL POLIOMYELITIS DURING CHILDHOOD. (AFTER FÜRNBÖHR.)
PATIENT ÆT. 36.

(a) Good Arm.

(b) Paralyzed Arm.



PART I
GENERAL

CHAPTER I

GENERAL TREATMENT IN THE ACUTE STAGE AND STAGE OF
REPAIR DURING THE FIRST YEAR

UNTIL quite recently the physician very rarely had an opportunity of treating poliomyelitis during the acute stage, for, as a rule, the diagnosis was not made until the severe initial attack had passed off. Nowadays it is possible to make an early diagnosis when the disease occurs in epidemics, but it is extremely doubtful whether we can cut the disease short by early treatment, and produce what has been termed an "abortive attack."

Early Treatment.—In doubtful cases the most important step is the **isolation** of the patient, in hospital if possible. Children who have been in contact with the case are forbidden to attend school during the acute stage. Vomit, urine, and fæces must be disinfected, sputum and nasal discharge destroyed, and all bedclothes and personal attire disinfected. If possible, the whole house should be similarly treated. In spite of this measure, however, the disease has been known to appear in families which have inhabited the same rooms in succession.

Alimentary symptoms are nearly always prominent, so disinfection of the tract and a smart purge are indicated. This is best achieved by the administration of calomel. Hot, dry applications to the body seem to do good.

It is extremely doubtful whether the inunction of Crédé's silver ointment can affect the spread of infection.

Diaphoresis, by means of hot drinks, hot packs, or hot-air baths, is of undoubted value. Warm baths are not advisable, for they interfere with that absolute rest that is so important a feature in the treatment. The application of cold to the spine by means of icebags is bad, especially in children, because it entails lying on the side.

Local abstraction of blood by means of a cupping-glass or a leech is easily

carried out; these are usually applied at the probable seat of the inflammation, as well as at the cervical and lumbar enlargements.

Blistering and inunction of grey ointment have been suggested for the purpose of bringing blood to the skin.

Repeated lumbar puncture may be of value in severe cases.

It is hardly necessary to mention drugs, such as ergotin, atropin, strychnine, and silver nitrate, which have been recommended at various times.

Thownsend and, later, Lange advised the use of a plaster bandage in painful cases to keep the spine at rest. This, however, is a measure that is not free from inconvenience, and a simpler way is to use a plaster-bed, as recommended by Machol.

If cerebral symptoms become urgent, warm baths and cold applications to the head and neck may be employed (Kussmaul).

If the disease has entered upon the second stage, we have a double duty to perform; in the first place, we have to promote the resolution of the inflammatory process, and check, if possible, the destruction of nervous elements, and, in the second place, we have to maintain the muscles in a good state of nutrition until normal impulses begin to reach them once more—symptomatic treatment.

The **galvanic current** has long been regarded as a valuable means of treatment. It is said to act by means of its katalytic action, but it must be admitted that the subject is one that is not very well understood, and that there still remains some doubt as to the way in which this katalytic effect is produced. Erb directs that an electrode large enough to cover the whole of the diseased area should be placed upon the back, whilst another is applied to the front of the body. A moderately strong current is used, and the anode and kathode are alternately applied for one or two minutes at a time. In order not to frighten children, it is well to begin with quite weak currents, and not to exceed 2 to 4 milliampères. There is no unanimity of opinion as to the proper duration for this line of treatment. It has been proved experimentally that the spinal cord is susceptible to the galvanic current. But it is not possible to demonstrate precisely the curative effect of the treatment, or to dispose altogether of the pessimists' objection, that the improvement that is observed would take place just as well without the electricity. We have the high authority of Erb, however, for the statement that whilst he has not had any brilliant successes, he has seen many instances of improvement which were undoubtedly to be attributed to the use of the galvanic current. It is our duty, therefore, to apply it, with occasional intermissions, throughout the first year of the illness. It is **useless to prolong electrical treatment beyond a year**, for, as we have seen, the pathological process in the cord is completed by this time, and cicatrization has taken place. Indeed, it becomes not only a burden and an expense to the family,

but a positive danger as well, for children so treated become extremely nervous and excitable.

In addition to electrical treatment, the maintenance of good general health is of great importance; abundance of good food, open-air life, and careful preservation of the skin are all of importance, and the administration of preparations of iron and iodine is valuable. Thermal or sun baths, or iron baths in the case of anæmic children, are certainly of service.

We have already drawn attention to the necessity of treating the partially paralyzed muscles and the peripheral nerves, in addition to the cord itself. Here, again, electricity is of undoubted value. When the reaction of degeneration is present, and the muscles no longer react to the faradic current, galvanism should be employed. The technique is simple; the kathode is moved about over the nerves and muscles of the paralyzed area, whilst the anode is applied to the spine at the upper limit of the affected part. For very atrophic and inexcitable muscles, current reversal should be employed, both electrodes being placed upon the muscles. The strength of current should be such as to produce definite twitching and redness of the skin. Moist electrodes should be used in applying faradism. Hoffa has pointed out that the muscles must not be on the stretch whilst the treatment is carried out, and that the limb must be placed in a position of rest. It is hardly necessary to add that the physician should, whenever possible, apply the electricity himself, and not leave the apparatus to the use of the relatives.

One must not place too great faith in the results of the electrical treatment of the muscles. Erb himself writes: "Even after a year very little improvement will be noticeable." Nevertheless, the method should be employed during the first six or eight months, for it undoubtedly does a certain amount of good. It must not be regarded as a specific remedy, but rather as a method to be employed in conjunction with others, presently to be described. It should not be prolonged after a year for the reasons already given.

Massage acts in a similar manner to electricity, but its effect is more general. It improves the general circulation, and produces a transitory improvement in the deficiency of vascular tone that is so common in paralytic limbs. The coldness, cyanosis, and trophic lesions of the skin are much decreased by it. The blood-flow through the muscles is also increased, and therefore their nutrition improves. Effleurage is the most important movement, but pétrissage and tapotement are also employed to stimulate the muscles directly. There is no doubt as to the good that may be done by these mechanical movements when carried out by a skilful person. They are of the greatest value in improving the condition of partly or completely paralyzed muscles, or muscles that have wasted from disuse. They must be carried out once or, better still, twice a day, for some considerable time;

no possible harm can result. Massage effects a sort of artificial feeding of the muscles of the whole limb, until their ultimate fate has shown itself. It is unsuitable for cases of very long standing, and for muscles which have undergone complete paralysis, but is of great value in cases of paresis and wasting from disuse. Gymnastic exercises act in a similar manner to massage, and are equally serviceable in the treatment of infantile paralysis. Passive exercises, carried out either by hand or by means of apparatus, produce a rhythmical stretching of the muscles and tendons, and so replace the pull of the opposing muscles, to the importance of which we have already




FIG. 5.—SIMPLE EXERCISER. (AFTER HEINE.)

alluded. Contractures are thus prevented. In addition, the movements of the extremities improve the circulation of the blood, and particularly tend to promote a good venous return.

Active movements can, of course, only be carried out in limbs that are partially paralyzed or wasted from disuse, but in these cases they are of the greatest value. They prevent the development of secondary atrophy, resulting from paralysis of adjacent groups of muscles. The blood-supply and general nutrition are also improved, and the intact fibres are stimulated by use to physiological hypertrophy. Neither active exercise nor massage can restore life to a dead muscle fibre, but they can effect a great improve-

ment in the function of a paralyzed limb; for the intact fibres may be strengthened sufficiently for them to take on the functions of the paralyzed muscles, or at any rate afford material for later operative procedures—viz., transplantation. Thilo drew attention to the extraordinary improvement that may be brought about in paretic muscles and limbs by exercise. Finally, active exercise has an important beneficial effect on the central nervous system, though it remains to be shown how this is caused. We know that regeneration of nerve is possible, in the sense that new paths of conduction may be developed to replace any that have been destroyed. Gymnastic exercises, by inducing regular, concentrated, voluntary impulses, are of considerable value in opening up these new paths.

Simple active movements, or exercise against resistance, may be carried out according to the so-called German or Swedish methods.

Special gymnastic apparatus may also be employed with advantage. A number of different patterns are obtainable at the present time. In Krukenberg's appliance, a swinging pendulum is used. In the Zander and Herz-Bum apparatus, the physiological principle of graduated resistance to muscular effort is employed. Even with the simplest apparatus, however, much good may be accomplished. A sketch of Heine's primitive exercising chair is given above, as a matter of historical interest.

It is only right to add that objections have been made to gymnastics. Thus, Dally feared that only one-half of the body might be strengthened, so that the development of contractures would be favoured, an objection which it is difficult to refute completely.

We shall refer again to the use of conduction exercises as an important part of the after-treatment of operative procedures in cases of paralysis.

Walking is itself another form of exercise that may be employed, but with young patients, and occasionally with adults also, it is necessary first to teach them to walk. In some instances the art has been lost through long disuse.

The greatest patience and experience are needed in teaching severely paralyzed patients to walk, for they have so many things to think of at once—the management of their centre of gravity, the moving of their legs, and so on. Various kinds of walking-machines, bars, wheeled crutches, and the like have been devised to accustom patients gradually to the art of walking.

In addition to electricity, massage, and gymnastic exercises, the various methods of inducing **local hyperæmia** may be employed with advantage. Warm baths, hot limb baths, hot and cold douches, wet or dry hot packs (the latter being most easily arranged as thermo-compresses, or baths of hot air, sand, or earth), mud baths, Bier's hyperæmia, for an hour at a time, and friction of the skin with spirituous liniments—all these methods serve the

same purpose of improving the circulation of the limb, and may be employed with advantage separately, or in combination.

Due provision must be made, too, for the proper protection of the limb from cold.

Prevention of Deformity, etc.—Finally, there is the question of the *prevention of contractures, and of overstretching of muscles and joint capsules.*

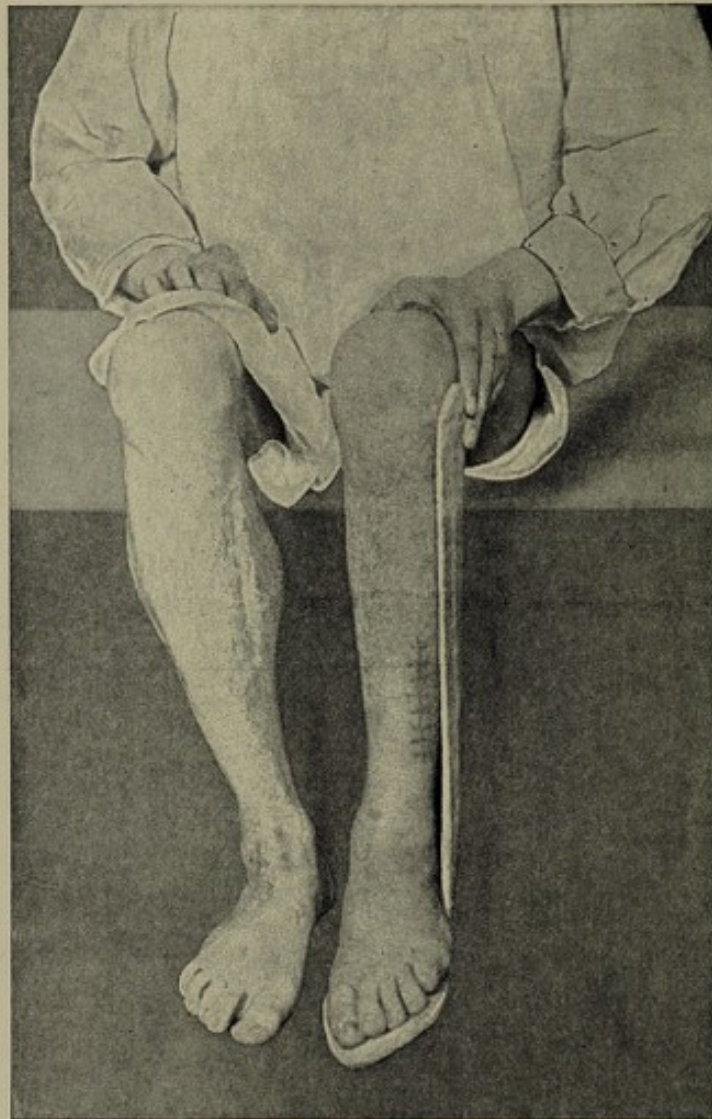

FIG. 6.—NIGHT SUPPORT FOR FOOT AND INSTEP.

This is a most important matter, and one that is only too frequently forgotten or neglected. I am particularly anxious to lay stress on this point, because I so frequently find that neither the family doctor nor the neurologist have recognized the necessity for orthopædic precautions, and yet, when the case comes into my hands, it is clear that the deformity is of long standing.

Attention has already been drawn to the value of passive movements in this connection. In addition, care must be exercised with regard to the

posture of the patient; joints must not be maintained in an abnormal attitude for any length of time, and injurious pressure must be avoided. The weight of the bedclothes is sufficient to produce talipes equinus, a bad position of the legs tends to cause genu recurvatum, and an unsuitable mattress may give rise to contracture of the hip.

A further method of protecting the patient from deformity consists in enclosing the paralyzed member during the night and part of the day in a simple retentive apparatus. Fig. 6 shows such an appliance, consisting of a tin sole plate and rectangular trough for the calf. This prevents the development of talipes equinus, which otherwise occurs very frequently, and comes on rapidly. By fixing the ankle in this way in the neutral position, or even in slight dorsal over-correction, we avoid contracture of the muscles of the calf, and also overstretching of the anterior muscles. Experience shows that prolonged stretching weakens the muscles exceedingly, so much so that they may even seem to be paralyzed, whilst, on the other hand, relief of the tension for a time may be followed by restoration of power. Overstretching of the posterior part of the capsule of the knee-joint, and disablement from resulting genu recurvatum, are simply and effectively prevented by prolonging the external bar to the upper third of the thigh, and encircling it with one or more padded bands.

There is, therefore, a great deal to be done by the practitioner during the second, or reparative, stage of the disease, and the *ultimate condition of the patient depends to a very large extent upon the care, patience, and intelligence with which he carries out his duties during the first year after the attack.*

Third Stage.—The patient at length arrives at the third and final stage of the complaint, when the paralysis shows a definite limitation of its severity and extent, and the condition shows no further improvement under treatment. The paralyzed muscles cease to show any recovery, but treatment is still of value, and should be continued. It is well not to go on with the electricity, for reasons already given, but massage, exercises, and hydrotherapy are still the best methods for preventing atrophy of the muscles, contractures, circulatory disturbance, trophic lesions of the skin, and impairment of growth.

Additional measures must now be adopted in the shape of special orthopædic therapy. Treatment has hitherto been in the hands of the physician, the neurologist, and, possibly, some institution specially fitted up for providing gymnastic exercises. Beyond the application of simple retentive apparatus, the orthopædic surgeon is not called in until about the end of the first year, when it becomes necessary for him to take the case into his own hands.

We must now consider, therefore, the modern modes of treatment that

are at his disposal. Apparatus constitutes the oldest method, and will be first described. We shall then discuss operative proceedings, which have proved a most successful line of advance, and a great improvement upon the older pure mechanical treatment. Schildbach wrote in 1877 that "orthopædics can do much for any cripple," and if this was true in his time, when there was very little in the way of treatment, it is still more true to-day, as the following pages will show.

CHAPTER II

ORTHOPÆDIC APPARATUS

Uses of Apparatus.—Orthopædic apparatus is applied for various purposes in the treatment of infantile paralysis ; it is used for the partial or complete fixation of flail-joints, for controlling the extent and direction of movement at the joints, for the correction of deformities, and as a substitute for the action of the paralyzed muscles.

Instrumental treatment of paralyzed limbs has been practised for a considerable time, without any great advances being made. Recently, however, great strides have been made, as is strikingly illustrated in the accompanying photographs. The first (Fig. 7) represents an apparatus constructed by Heine, and brought out in 1840 ; this, it must be remembered, was the work of an orthopædist who acquired a world-wide reputation on account of his success in the treatment of this class of case. A great contrast is presented by the modern appliance, as used in all good orthopædic institutions (Fig. 8).

The improvement consists in the introduction of moulded sheaths instead of the simple straps and bands hitherto employed. In order that the importance of this change may be fully appreciated, we shall enter at some length into the construction of orthopædic apparatus.

It is not the purpose of this work to enter into technical details, but we shall describe the various parts of an appliance and the principles upon which it is constructed at sufficient length to enable the reader not only to prescribe one, but also to criticize its construction.

Description of Apparatus.—There are two parts to every apparatus, the curative part and the fixative. Accurate therapeutic effects can only be obtained when the instrument takes a good bearing from the fixed points of the body. Firm attachment was formerly obtained by means of circular straps, which had to be drawn very tight in order to get a good grip. This resulted in an annular constriction of the limb, and marked grooves could often be observed in patients who had worn instruments for any length of time. The bands not only caused atrophy of the fatty subcutaneous tissue, but also of the muscles, a very serious disadvantage in a limb which is already more or less weak and paralyzed. Besides the direct pressure, the nutrition of the muscles suffered from partial arrest of its blood-supply. Lastly, the

grip obtained by the bands was often insufficient, because the surface of contact was too small.

The modern method of fixing an apparatus is by means of sheaths accurately moulded to a cast of the limb. In this way a far better grip is secured, because the fitting is exact, and a larger surface of the limb is grasped. No inconvenience is experienced, even when the appliance is firmly laced

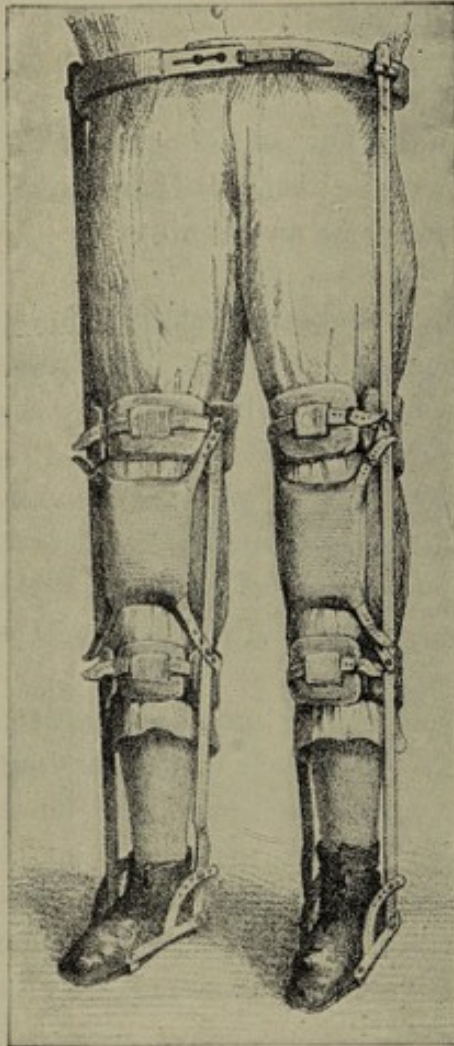


FIG. 7. — PRIMITIVE WALKING APPARATUS. (AFTER HEINE.)

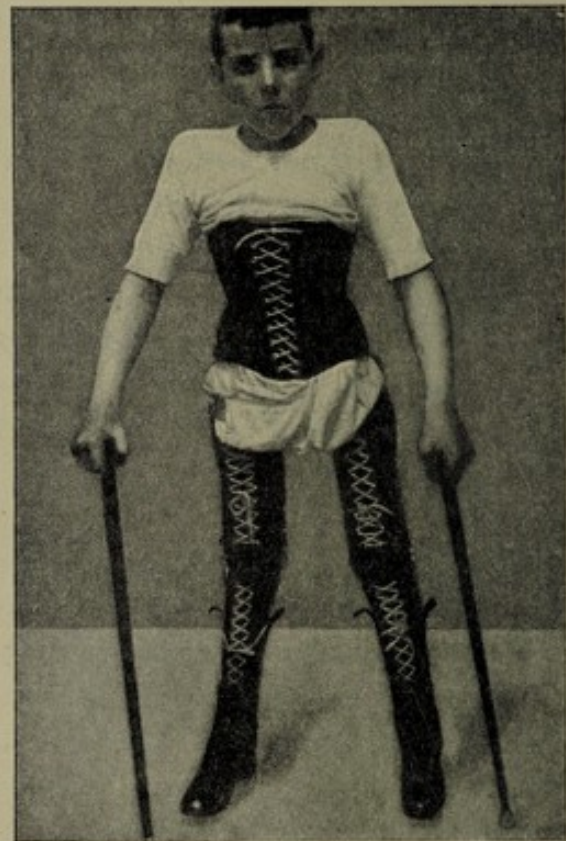

FIG. 8.—MOULDED WALKING APPARATUS.

up, because the pressure is evenly distributed. Impairment of the circulation and injury of the muscles are greatly reduced, though certainly not abolished. The atrophy which results from long wearing of an apparatus is much in evidence with the band type of fixation, but can also be demonstrated with the sheath type, for after some months the appliance becomes too large, and no longer fits the limb closely. The subcutaneous fat is the first to go, followed by the muscles, and finally by the bones, as the Röntgen rays have shown us.

It is important to appreciate fully the disadvantages that are inseparable from the use of instruments, so that appropriate measures for their correction may be instituted. Such include daily baths, rubbing, massage, and movements.

The smooth fitting of the sheath apparatus has the additional advantage that the appliance can be worn under the clothes and does not show. The foot-piece is concealed in the boot, and the leg-part is hidden by the stockings or leggings.

At one time the models on which the apparatus was fitted were always made of wood, and a skilled workman was therefore needed to construct them. This rendered the appliance more expensive, but the difficulty can be overcome by using a plaster model instead. Plaster bandages are applied directly to the skin, or over a very thin undergarment, and when they are dry, they are taken off, and a cast is made from them. The model thus obtained is smoothed, covered with stockinet, and furnished with light, strengthening bars and screw-plates for the attachment of the irons. A leather case, cut to a suitable shape and well soaked in water, is then applied, and pressed on. After being dried on for a long time, the sheaths are fitted to the patient, polished, and dried. Fastenings are then provided, and they are ready for the therapeutic part of the appliance—that is to say, the steel bars.

The discovery of this form of apparatus has effected a revolution in the field of mechanical treatment. The credit for the invention must be attributed to Hessing, of Göggingen, in Augsburg. This man is not a qualified practitioner, but a self-taught mechanic. He is a person, however, of the greatest technical ingenuity, and as such has always been a most valuable assistant to orthopædic surgeons in the carrying out of their ideas. For over fifteen years I have striven to attribute due praise to Hessing's work in this connection. I am totally opposed, however, to his practice of prescribing instruments for patients without their being under a qualified surgeon's care. I consider that such conduct is no less reprehensible than the promiscuous dosing of the public by a chemist, or the ordering of glasses by an optician. Patients should never be sent for treatment to an unqualified practitioner; medical students should learn for themselves the construction and use of orthopædic apparatus. It is unnecessary that they should be familiar with the technical side of the subject, but they should be trained in the anatomical and physiological considerations which arise in the adaptation of instruments to defective limbs, as well as in the pathological indications for their use; the surgeon would in this way be prepared to undertake the responsibility of designing and prescribing instruments, as well as to be capable of taking entire charge of an "instrument" case. Those who are unable to acquire experience of this kind should send their patients to a proper specialist, and not to a layman. Thus they avoid not only a breach

of etiquette, but also the application of an instrument to a case that might be treated more satisfactorily by other means.

Sheath appliances of the kind that I have described are expensive, but it may be possible in time to open State-subsidized polyclinics, at which the poor may procure the necessary instruments at reasonable prices.

Let us return now to the consideration of the details of the apparatus.

The metal bars which unite the sheaths form the therapeutic part of the instrument. They are made of wrought steel, and are hollow, in order to combine strength with lightness. They are affixed with screws in such a manner that the length and breadth of the instrument can be adjusted as required. Thus the apparatus can be very accurately fitted when first it is made, and later on it can be adapted to alteration in the shape of the limb, whether due to atrophy or to growth.

The steels are fastened together by means of joints, of which the pattern represented in Fig. 9 is the best for our purpose. The end of each iron

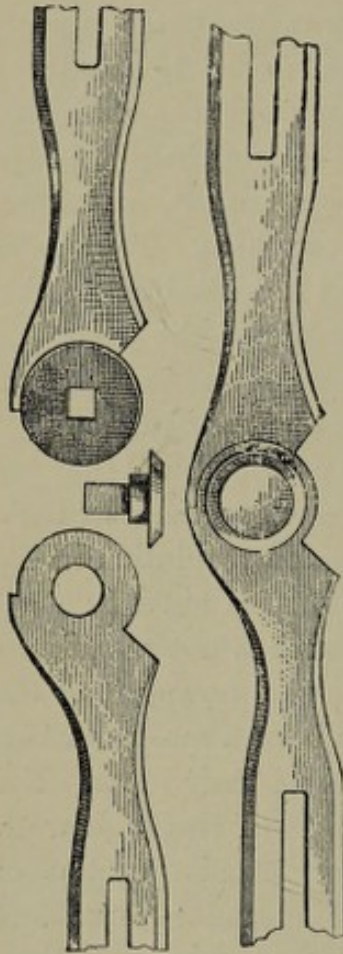


FIG. 9.—DOUBLE RULE JOINT. (AFTER HOFFA.)

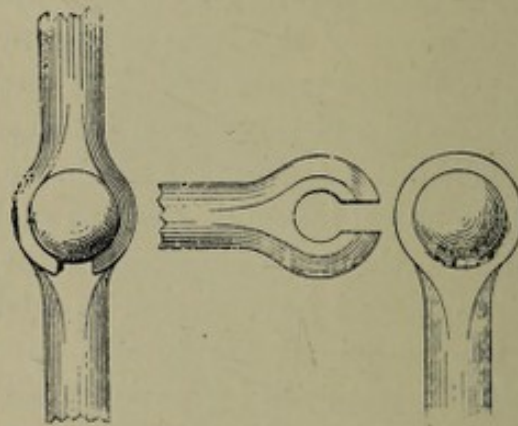


FIG. 10.—KEYHOLE CATCH JOINT. (AFTER HOFFA.)

is thinned out to half its ordinary thickness, and ends in a circular joint surface; the rivet passes through a circular hole in the outer one, and is fixed in a square hole in the inner.

When it is desired that the apparatus should take a part, the keyhole catch joint shown in Fig. 10 is employed. The irons are held at right angles, whilst they are fitted together, and when the joint is straightened out, they are prevented from coming apart by the peculiar form of the pin. Sometimes the steels are made to overlap, and the pin of the one fits into a mortice in the other, whilst a well-fitting ring slides down and holds the joint fast (Fig. 11).

The rule joint, of course, only allows of movement about one axis. To obtain movement about two axes, it is best to combine a rule joint,

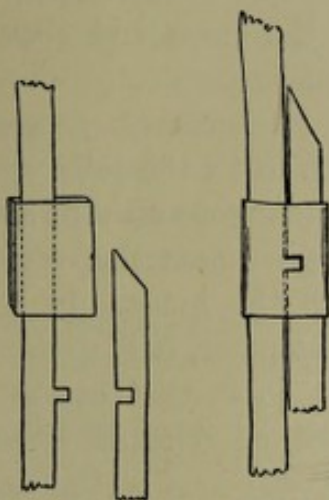


FIG. 11.—MORTICE JOINT.

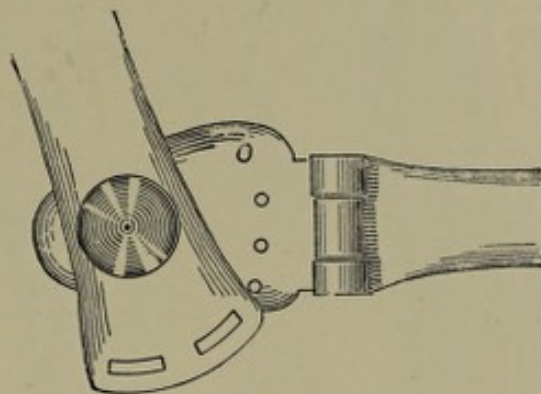


FIG. 12.—COMPOUND JOINT. (AFTER GOCHT.)

permitting extension and flexion, with a hinge joint, providing for abduction and adduction; these are placed one above the other (Fig. 12). In our own institute a gimbal joint is used, which permits of movements in both axes at once (Fig. 13).

Uses of Joints.—Let us now consider the use of these various joints. Given an absolutely flail-joint, which moves in every direction, we can limit its mobility to one axis—*e.g.*, that of flexion and extension—by the application of an apparatus with a uniaxial joint. Again, the normal direction of movement may be maintained and deformity prevented in cases of partial paralysis—*e.g.*, the supinating force of the tibialis anticus in paralysis of the extensor digitorum may be prevented from acting on the ankle-joint in a false direction, and so producing paralytic club foot.




FIG. 13.—GIMBAL JOINT.

Joints also serve to limit the range of mobility of the limbs. In the double rule joint, each iron carries a "front-" and "back-stop." The

nearer the edges of the stops are together, the more limited is the range of movement at the joint. In this manner it is possible to immobilize a limb completely at the commencement of treatment, and then gradually to file away the stops and allow of greater range of movement.

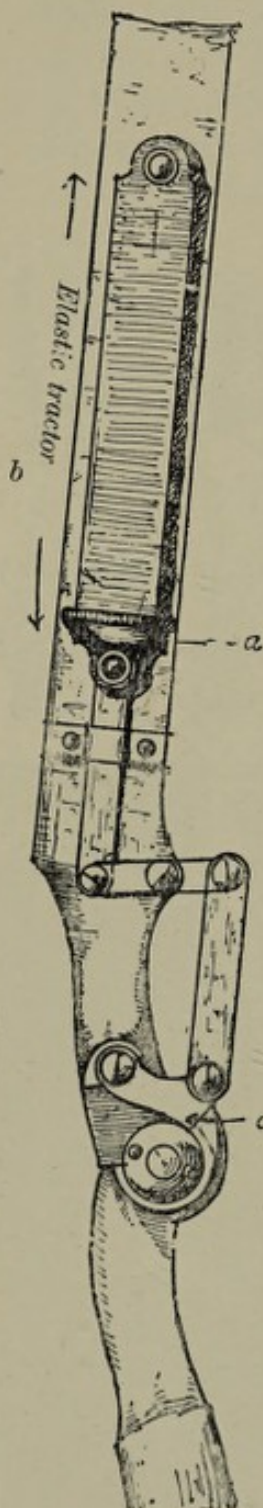


FIG. 14.

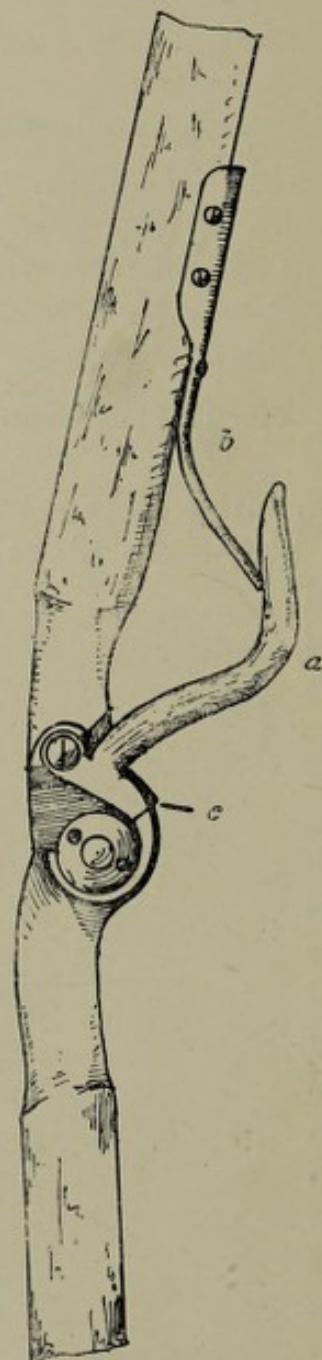


FIG. 15.

various other simple forms of catch which we have found useful. Fig. 14 shows a bolt which is attached at *a* to an india-rubber tractor *b*, and transmits its force by means of levers to the point *c*, where it locks the joint. When the bolt is pressed down, flexion can be carried out, but as

If it becomes necessary later on to fix the joint again, either new stops must be fitted, or a pin must be screwed through the hinge. In some cases, however, it is desired to have a joint that can either be fixed or released at will; in this case one of the many kinds of catch joint is employed. The simplest consists of a bolt which passes over the hinge, and can either be fastened or drawn back. We ourselves employ a simple pin, which engages in a slotted disc. The pin is controlled by a spring lever, which, when pressed, raises it out of the disc and sets the joint free. Pressure on the lever is exerted through the clothes. Whenever the joint is fully extended, the pin springs automatically into place, and locks the joint in this position. When it is necessary to be able to fix the limb at various angles, a corresponding number of slots must be provided, and these are fitted on a semi-circular expansion of one of the side irons. There are

soon as the joint is extended, it locks automatically. Fig. 15 illustrates an even more primitive device; the lever *a* is held by the spring *b*, but when it is lightly pressed, the catch *c* is released and the joint can be flexed.

Stillmann's sector joint allows of fixation at any desired angle. Its construction is clearly shown in the figure. Hoffa has invented a more complicated joint for the hip. He describes it as follows:

The connecting bar between the corset and the thigh-piece carries a rule joint opposite the articulation. The lower of the two irons entering into the joint carries at its upper end an expansion perforated by three or four holes. The upper end of the lower iron has one hole of similar size. A strong spring is screwed to the outer side of the upper iron, and just above the hinge it is sharply curved so as to look from before downwards and from above backwards, and present a sharp convexity outwards. A triangular lever fits accurately into this curve, and can be turned by means of a ferrule attached to it. When the pin is turned down towards the joint, it releases the spring of the hinge, its upper end engaging with the oblique part of the spring. A peg attached to the lower end of the spring is thus disengaged from the holes

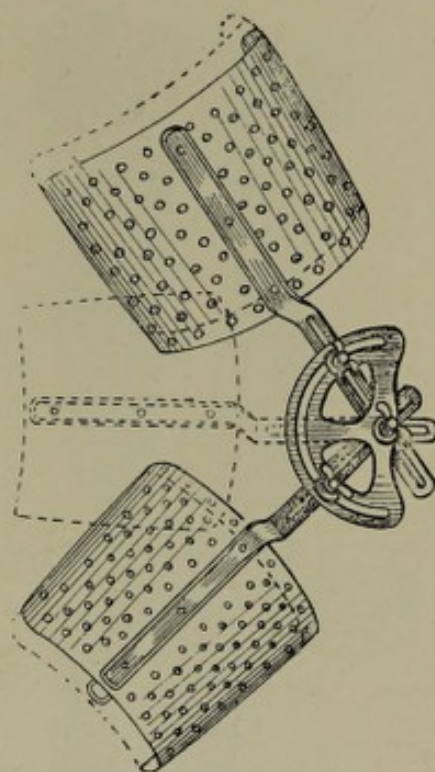


FIG. 16.—STILLMANN'S SECTOR JOINT.

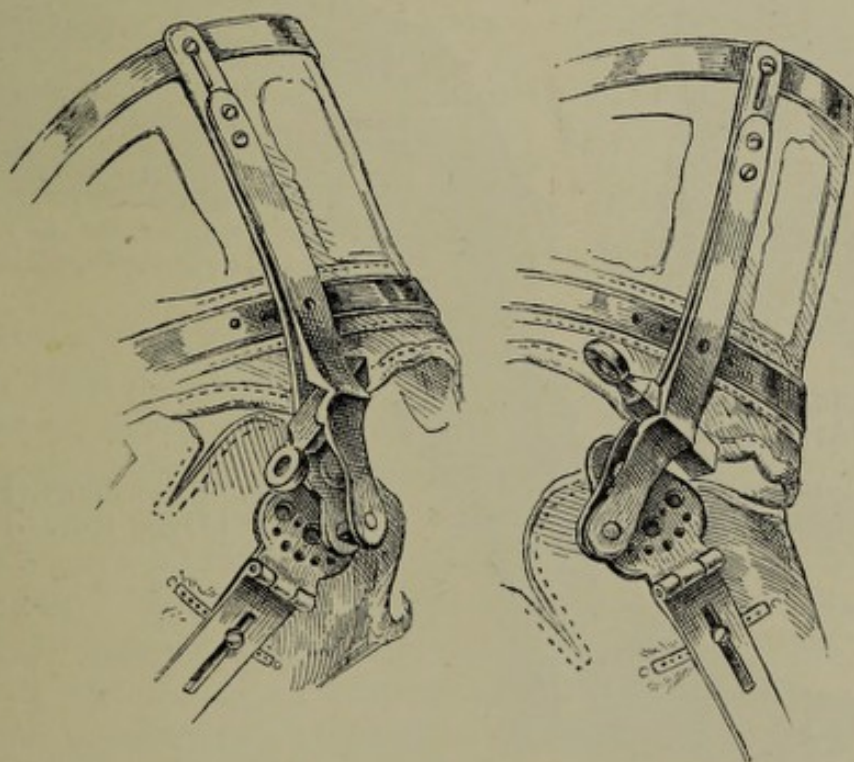


FIG. 17.—HIP-JOINT. (AFTER HOFFA.)

in the lower segment into which it previously fitted. Thus the hip-joint is set free. On drawing the triangular bolt up again, so that it lies in the bend of the spring, the peg at the lower end of the spring drops once more into the holes, and the joint is fixed. The patient moves the bolt up or down with his finger or with a string.

Hoffa also devised a joint for use at the knee. His description and illustration are copied into Gocht's book (Figs. 18 and 19).

A steel band encircles the back of the knee, and is jointed to the upper irons, inside and outside, just above the knee-joint. From the middle of this band there passes downwards a rubber tractor, which tightens up when the knee is extended, and causes the projection on the semicircular bar to engage in the notches of the knee-joint, locking it. A cord runs upwards and forwards, ending in a small lever, and when this is pulled the knee is released again.

Elastic Traction.—It was observed at the beginning of this chapter that the **second object** of orthopædic appliances was the **replacement of the functions of paralyzed muscles**. Delacroix attributes to Duchenne the idea of using elastic traction as an artificial substitute for the




FIG. 18.—KNEE-JOINT, EXTENDED. (AFTER HOFFA.)

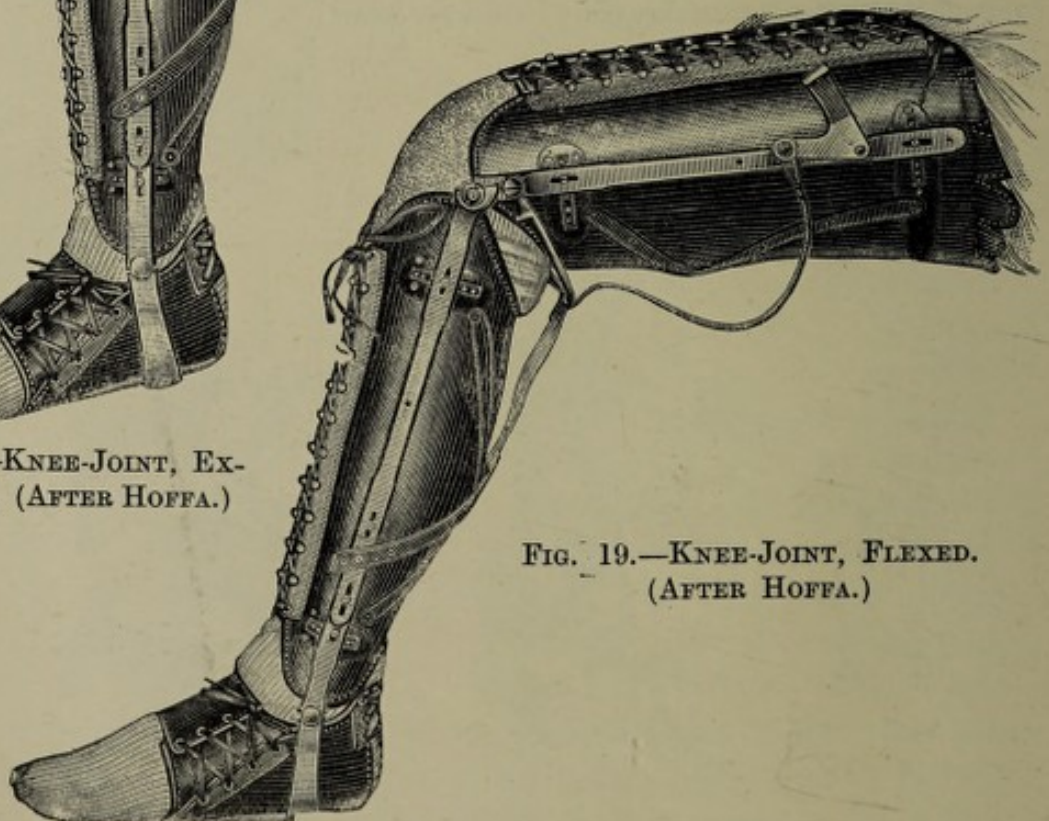


FIG. 19.—KNEE-JOINT, FLEXED. (AFTER HOFFA.)

injured muscles. Volkmann introduced the method, with several modifications, into Germany. He writes as follows on the subject :

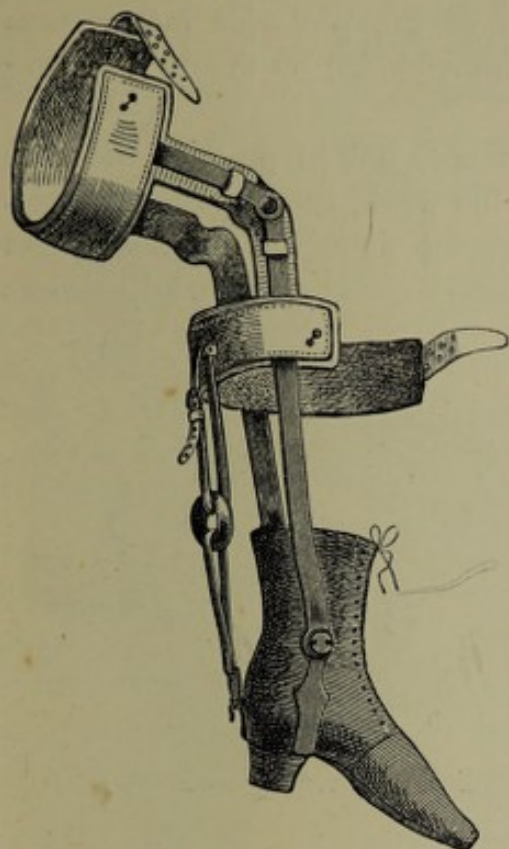


FIG. 20. — ARTIFICIAL GASTROCNEMIUS. (AFTER VOLKMANN.)

“ It is essential that the opposing muscles should be absolutely or relatively intact, and that the joints should be capable of slight passive movement. Nor must there be any contracture of the muscles. Given a patient with, say, a paralyzed extensor and a healthy flexor, the idea is that he will be able to perform both flexion and extension if he wears an elastic tractor, arranged so as to pull the affected limb into the extended position as soon as the flexor ceases to act.”

By alternately contracting and relaxing his flexors, the patient is enabled to perform all the necessary movements for walking.

Either steel springs or india-rubber may be used as the contractile force. Fig. 20 shows Volkmann's artificial gastrocnemius, made of rubber. Figs. 21 and 22 illustrate a quadriceps, made of two crossed elastic bands, which are pivoted on a metal bridge articulating on either side with the knee-joints, and are attached to the thigh- and leg-pieces.

Fig. 23 shows Duchenne's complicated apparatus, in which spiral steel springs are used as substitutes for the extensors of the fingers. Fig. 24

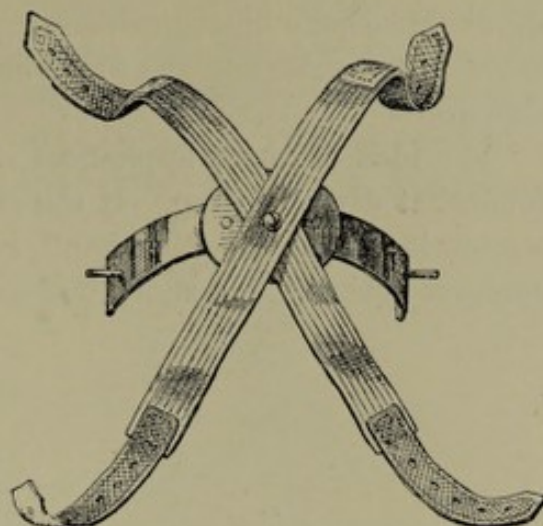


FIG. 21.—ARTIFICIAL QUADRICEPS.




FIG. 22.—ARTIFICIAL QUADRICEPS.

shows Heusner's instrument for paralysis of the posterior interosseous nerve. The wrist and the first phalanges are encircled by moulded leather sheaths.

The idea of these appliances is a good one, but in practice they are somewhat disappointing. If the elastic is too weak, the opposing muscles stretch it; if, on the other hand, it is drawn too tight, the muscles cannot contract against it; in short, it is difficult to attain that delicate adjustment

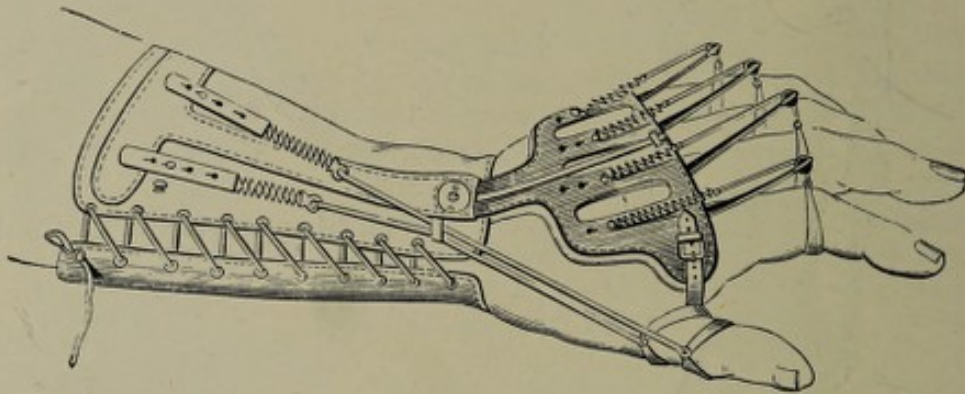


FIG. 23.—ARTIFICIAL EXTENSOR OF FINGERS. (AFTER DUCHENNE.)

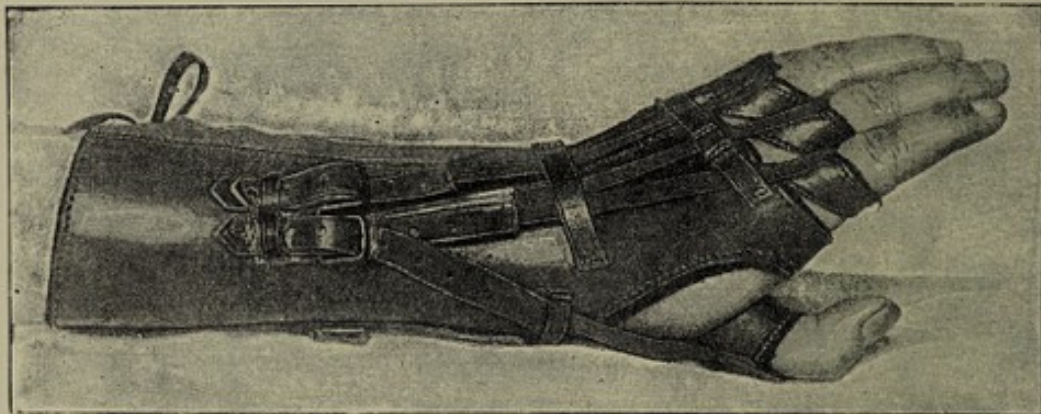


FIG. 24.—APPARATUS FOR POSTERIOR INTEROSSEOUS PARALYSIS. (AFTER HEUSNER.)

between the artificial and the natural forces which is essential to the proper working of the apparatus.

Opinion is much divided with regard to our **third use** for orthopædic apparatus—viz., the **treatment of contractures**. It appears quite reasonable to attempt to stretch a shortened muscle by continuous mechanical traction. For this purpose the exact fit of the leather sheaths is of the greatest importance, as otherwise the force will be expended in moving the apparatus instead of in improving the position of the joint. It is not impossible to fulfil this condition, but it must also be made clear to the patient or his friends that a cure of deformity by this means calls for a considerable expenditure of time and patience, not to mention money.

Screws or elastic traction may be employed as the correcting force. A few illustrations will be given rather than any lengthy descriptions. For the hip-joint, Hoffa employs an arrangement attached to the thigh-piece, with which abduction or adduction can be obtained at will. A long steel spring is fastened on to the side of the pelvic band at the hip and at the

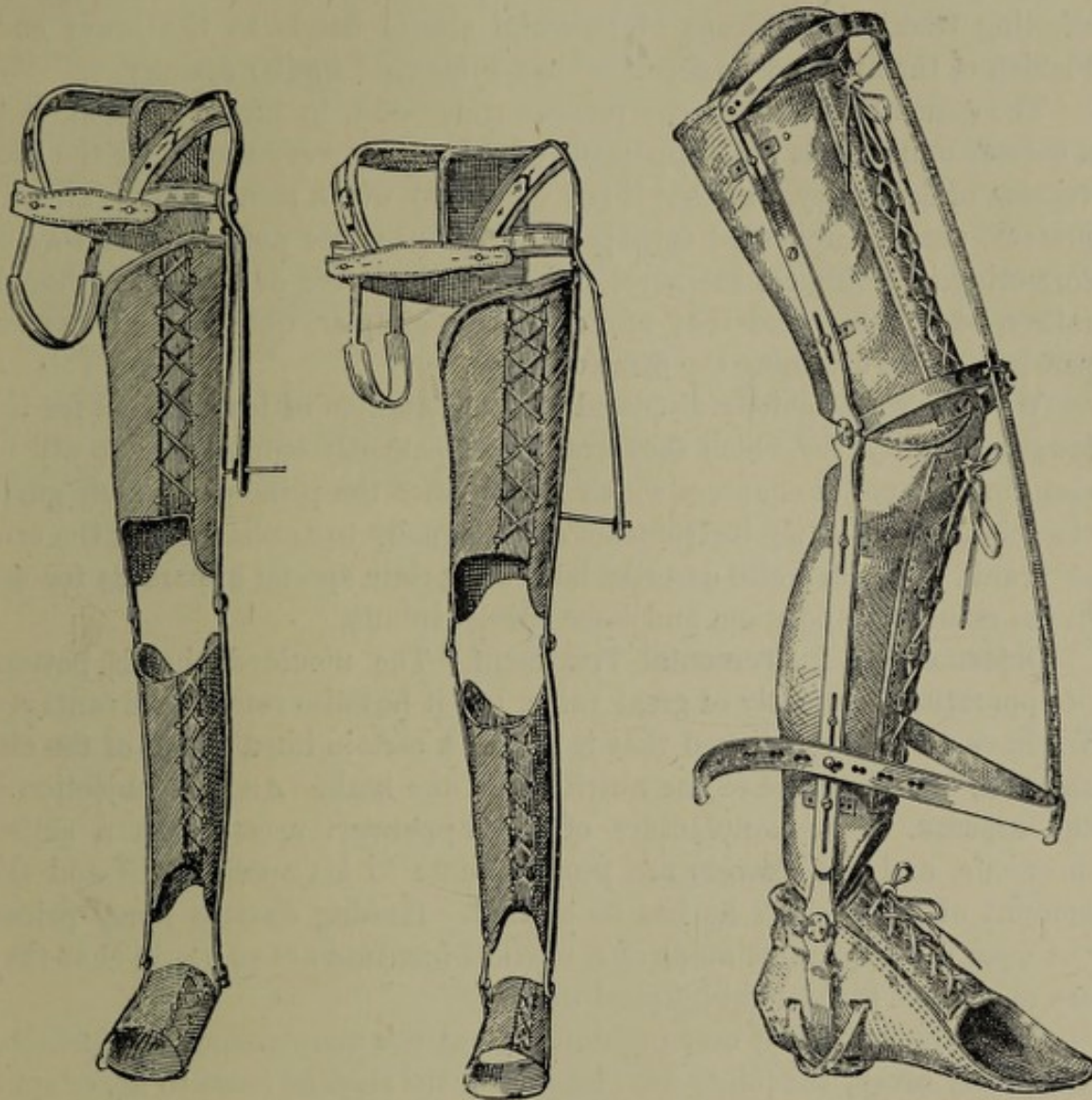


FIG. 25.—ABDUCTION
IN HIP - SPLINT.
(AFTER HOFFA.)

FIG. 26.—ADDUCTION
IN HIP - SPLINT.
(AFTER HOFFA.)

FIG. 27. — EXTENDING KNEE-
JOINT. (AFTER HOFFA.)

trochanter, and reaches to the lower third of the thigh-piece. At the lower end is a hole, in which fits a threaded steel bar projecting at right angles from the outer thigh-piece. The leg is abducted by bracing it up to the spring with a screw-nut (*vide* Fig. 25), and by reversing the mechanism it can be pushed towards the midline—*i.e.*, adducted (Fig. 26).

Elastic force is employed in an apparatus for overcoming contracture of

the knee. A steel spring is fastened at its upper end, by means of a bridge, to the leather thigh-piece; in the middle it is attached by another bridge to the sides of the knee-joint; and at its lower end it is joined by means of straps to the leg-piece. In this way extension of the knee is effected (Fig. 27).

An alternative way is to use a strong **steel bar** instead of the spring, exerting traction by means of powerful elastic bands at the lower end. Flexion of the hip may be corrected in a somewhat similar manner.

The general opinion at the present time—and, in my estimation, it is a correct opinion—is that apparatus of this sort is very useful for the prevention of deformity, but that if any deformity worth mentioning is already present, such complicated orthopædic appliances are not the best way of correcting it. Surgical measures, either manipulative or operative, should, rather, be adopted, and they afford a surer, simpler, quicker, and less expensive way of attaining the same object.

We have so far chiefly discussed the construction of instruments for the lower extremity, for which they are more frequently employed. It will be seen, in the special chapters which follow, that the principles which guide the manufacture of leg instruments apply equally to appliances for the arm or trunk. We shall also describe later on certain special apparatus for use in the recumbent position, and some special splints.

Objections to Instrumental Treatment.—The moulded sheath pattern of apparatus is certainly of great value, but it has also some disadvantages. We have already mentioned that it entails a certain **impairment of the circulation**, and therefore of the nutrition, of the limb. Another objection is the **expense**. The manufacture of the apparatus necessitates a skilful mechanic, and his charges are proportionate to his special skill and the amount of time which he has to expend. Hession charges fancy prices, but even the appliances made at a medical institute are so costly that they are unsuitable for general hospital work.

Not only is the first cost prohibitive, but the maintenance is expensive. The steels break, the joints wear loose, and the sheaths cease to fit, or split, especially in the foot-piece, where they are exposed to the sweat. The apparatus is thus quite a considerable source of expense during the year, but its advantages outweigh this fault in the case of well-to-do patients. The poor, however, cannot afford it, and find, too, that the apparatus wears out too soon. Hession, at his institute, has only the rich to consider, but the ordinary physician has to devise something for those less fortunately placed. Very often the old apparatus with bands is the only thing that can be used, and, indeed, it answers quite well when instruments are only required for a time. Therapeutic devices, such as back-stops, elastic tractors, and the like, can be adapted to it.

We have no space for a description of all the devices which have been brought out for providing cheap apparatus.

For rich and poor alike, orthopædic instruments are, and always must be, a lifelong burden and a nuisance, serving to remind their wearer continually of his infirmity. At any moment the apparatus may break and render him helpless, or, at any rate, place him in a very awkward predicament. A striking example of this came to my notice recently: An old patient came to me for a spare set of instruments to take with him on his honeymoon, in case of accident! For these various reasons the desire of the majority of patients to be free of their apparatus is a very natural one, and *the surgeon must try to limit the application of instruments to those cases in which there is no other treatment possible.* This is the fundamental difference between the surgeon and the mechanic. The former seeks to dispense with instruments, the latter to devise them with great cunning.

Fortunately we have now, in orthopædic surgery, a method which not only allows us to dispense with a great deal of apparatus, but also greatly increases its utility. We must turn now to the discussion of this branch of our subject.

CHAPTER III

THE SURGERY OF PARALYSES

A. TREATMENT OF PARALYTIC CONTRACTURES AND DEFORMITIES ("REDRESSEMENT," TENDON LENGTHENING, AND TENOTOMY).

WE have considered in the previous chapter the proper uses of instruments in the treatment of paralysis, and have seen the limitations of this method. We agreed that it was not proper to employ it when surgical methods could be adopted. **Orthopædic surgery has a twofold purpose**, just as instrumental treatment had. Its objects are the **restoration of the function** of the paralyzed muscles and the **correction of paralytic contracture and deformity**.

The first problem has only been successfully solved within the last decade or so, and within recent years it has become possible to reproduce the action of paralyzed muscles by means of plastic operations. It may be that in the near future even greater success will be attained by means of nerve-grafting methods.

We shall treat the subject in chronological order, and describe first the methods which are employed in the treatment of the secondary results of paralysis—viz., contracture and deformity.

Treatment of Deformity.—"Redressement" is the first method at our disposal. It may be effected slowly by means of weight-extension, and in many of the recent and less severe cases it succeeds admirably. **Forcible correction** is quicker and more certain. Deep anæsthesia is employed to relax the shortened muscles. Either manual force or a special apparatus may be employed, and the stretching must be slowly and carefully carried out, so as to overcome the shortening of all the soft parts, from the skin right down to the joint capsule. The process must be continued until the limb is straight, the joint at least at the mid-position, and the shortened structures have lost all their elastic resistance. It is only when this has been done that the corrected position can be maintained by means of bandages and splints, and recurrence prevented. A firm bandage insures success during the next few weeks.

Redressement may be employed not only for contractures, but also for bony deformity. The capsule of the joint must be so stretched that the

proper position of the skeleton can be restored. Under the influence of the altered forces acting upon them, the bones acquire their normal shape, and the force which formerly produced the deformity now serves to correct it.

Risks of "Redressement."—The method has the great advantage that it entails no risk to life beyond that of the anæsthetic. It is not so free from danger, however, as the description might suggest. The bones are brittle, and by incautious manipulation it is easy to produce a **fracture**, or a **separation of the epiphysis**, the consequences of which may be very displeasing in a limb whose powers of growth are already impaired by paralysis. If the contracture is considerable, it should not be fully corrected at one sitting, for this may result in **rupture of a bloodvessel** and gangrene of the limb. **Overstretching of the nerves** may produce paralysis, which is specially dangerous in muscles that have already suffered from poliomyelitis.

Fat embolism is another considerable danger, which it is impossible to foresee. It sometimes happens that one operates during life on the atrophic bones of the tarsus, and one sees the medulla run out, like the inside of a broken egg, as soon as the hard cortex is cut through; this suggests that fat embolism is always to be feared during *redressement*. There are not many cases recorded in the literature, but in practice it is not so rare an accident, for the correct diagnosis is not made in every case.

However successful the *redressement* may have been, it does not destroy the force which brought about the deformity, and recurrence may therefore occur when the limb is released from the splint.

Tenotomy.—*Redressement* has been rendered easier, and its results more lasting, by the introduction of the operation of **tenotomy**. The invention of this method has marked an important era in the history of orthopædics. It is not possible to give a full account of the history of this simple and excellent operation, but a short account will be of service in explaining the value of the proceeding.

The first tenotomies were performed by itinerant specialists, for wry-neck, in the early part of the seventeenth century. In 1668 Florian divided the sterno-mastoid with scissors, and at about the same time Roonhuysen performed the operation by means of an oblique cut, giving it the somewhat alarming name of "Halsgericht."

The tendo Achillis was first divided by Lorenz in 1784, and independently by Sartorius in 1806, and by Michaelis in 1809. The latter surgeon carried out a series of nine such operations. Delpech was the first to do subcutaneous section of the tendon. This was in 1816. Dupuytren, or more probably Dieffenbach, performed a similar operation on the sterno-mastoid.

The full technique of subcutaneous tenotomy was elaborated by

Stromeyer, of Hanover, who became, in consequence, the father of modern orthopædic surgery. The operation had hitherto only been performed in a few isolated instances, and many had regarded it, in view of the danger of suppuration, as unjustifiable. Now, however, it came quickly to the fore. Dieffenbach, in particular, became an enthusiastic tenotomist, after he had convinced himself of the value of the operation in the case of a patient, who became later on an illustrious orthopædist (Little). Dieffenbach did his first tenotomy in 1836, and in five years' time he had operated on 120 wry-necks, 350 club feet, and 700 squints.

His followers taught the operation far and wide, though the consequences were not entirely favourable. In some instances the operation came to be abused. Thus Guérin, in spite of the warning given by Bouvier, recommended tenotomy of the spinal muscles in scoliosis.

At the present time complicated tendon operations have somewhat replaced tenotomy, but simple subcutaneous or open division of tendons remains as valuable a proceeding as ever. Indeed, its value is so generally admitted as to be beyond discussion.

The **technique** of the operation has not changed since the days of Stromeyer and Dieffenbach. Their instrument, too, the pointed, sickle-shaped tenotome, is still in use.

[The skin is displaced laterally, and the knife is introduced with the blade parallel to the tendon, and passing from within outwards. As soon as the point is felt on the far side, the blade is turned through ninety degrees, and the tendon is stretched and severed with a sawing movement. At the moment when it gives way, one feels a jerk, caused by the retraction of the muscle. The inexperienced may accidentally divide the skin at the moment when the tendon snaps, and so convert a subcutaneous into an open operation. The tenotomy completed, the knife is withdrawn in the same position as it occupied during introduction, and a small aseptic dressing is applied. Bouvier and Guérin were accustomed to divide the tendon from without inwards, in a similar manner, using a tenotome shaped like a chopper. This method is practically given up at the present time.

The fact that the division is complete is indicated by the appearance of a dimple in the skin, due to the gap between the ends of the tendon. This interval is soon filled up by the effusion of blood into the tendon-sheath, and one may thus be led into imagining that an unusually rapid regeneration of the tendon has taken place.

This brings us to the question of the process of repair. This begins at the moment of completion of the operation, and goes on until the interval is filled up with connective tissue. The exact details of the process are still uncertain, in spite of much research work. Busse, Enderlen, Schraditz-Ricker, and others, give diametrically opposed accounts, some maintaining

that growth takes place from the walls of the sheath, and others that it only occurs at the divided ends of the tendon.

Seggel takes up an intermediate position. He says that the blood effused between the cut ends is first organized by elements derived from the synovial sheath. On and after the sixth day, however, tendon fibres proper begin to sprout out from the cut surfaces, first from the deeper ventral layers, whose nutrition is better, because the sheath has here been left intact, and afterwards from the dorsal fibres, where division has been complete. In this way the reparative material at first produced by the sheath is entirely replaced by permanent tendinous fibres.

Borst and Fritz give somewhat similar accounts. They say that the primary hæmatoma delays the process of repair and the outgrowth of tendon fibrils. Proliferation begins on the fourth day at the swollen stump of the tendon. Connective tissue is simultaneously thrown out from the sheath, and is moulded into a sort of tendinous band by its fibres taking up a longitudinal direction. A considerable time elapses, however, before it acquires the minute structure of the tendinous fibres that are produced by proliferation from the cut ends. When hæmorrhage is excessive, or the progress of the case is marred by the occurrence of infection or some other accident, the connective tissue outgrows the true tendinous tissue. But repair is always slow, even when the case pursues a favourable course.

Seggel found nothing definite after three months, Borst ascertained by experiments on animals that the characteristic pearly appearance of tendon was lacking after 240 days, and Adams found the same after three years. My own experience confirms their statements entirely. I have often had occasion to expose tenotomized tendons, years afterwards, for the purpose of operation, and have often found the site of the section indicated by a scar in the tendon, adhesion to the sheath, or slight thickening.

Not much is known about changes taking place in the muscle attached to the divided tendon. At any rate, it must lose its elastic tone for the time, and this must make some difference to the muscle, although clinical experience shows that it remains functional.

Although the details of the process of repair are not yet definitely known, it is certain that **in almost every case the tendon joins again satisfactorily.**

We have only spoken, so far, of subcutaneous tenotomy, which, in its day, was always employed in preference to the more dangerous open operation with a long skin incision. At the present time this risk has practically disappeared, and a return to the open method has lately been advocated. It is said that it allows of free division of all contracted structures, and prevents accidental or dangerous injury of surrounding structures. On the other hand, the sheath is much more severely damaged in this method, and the scar may give trouble later on. It appears to me that one or

other operation should be chosen, according to the circumstances of the case and the site of the lesion. I always divide the heel-tendon and the adductors of the hip subcutaneously, and the sterno-mastoid and tendons about the knee by open operation. In the former case my object is to avoid infection, and interfere as little as possible with the process of repair, and in the latter case I avoid injury of vessels and nerves.

In dividing the Achilles there is less likelihood of severing the artery if the incision be made upon the internal aspect of the tendon.

The tenotomy over, the after-treatment begins. Delpech advised that the deformity should not be corrected until some time later on, in order that the distance between the ends might not be too great, and danger of non-

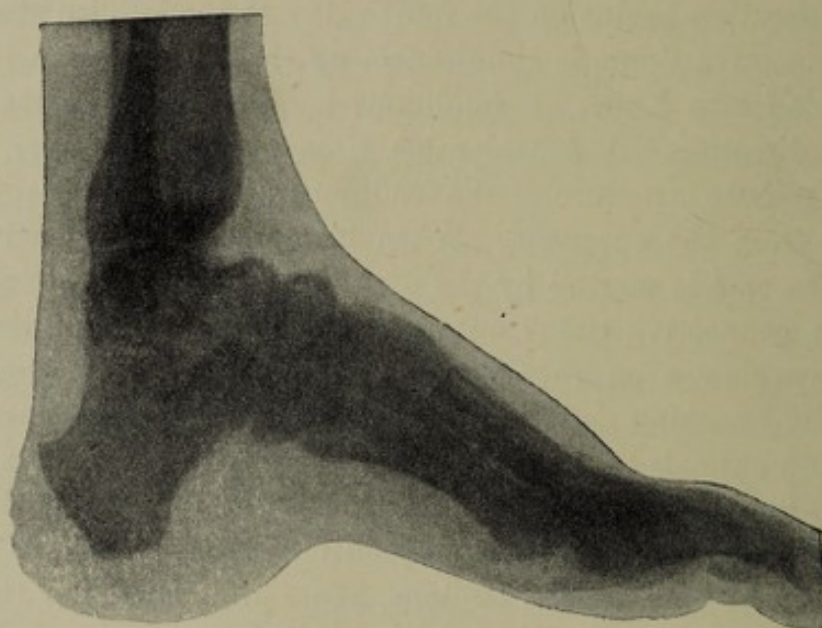


FIG. 28.—PES CALCANEUS, AFTER NON-UNION OF TENOTOMY OF THE TENDON OF ACHILLES.

union occur. This suggestion is very rarely adopted at the present time. It is customary to correct the deformity immediately after the tenotomy.

In some thousands of tenotomies that I have performed, I have experienced failure of repair in a few cases, and I have seen it repeatedly in patients operated on elsewhere. It is necessary, therefore, to be on the lookout for the possibility, and avoid it. Regeneration of the tendon may fail in adults, when the separation exceeds $1\frac{1}{2}$ or 2 centimetres, in spastic contracture, in inflammatory shortening of the muscle, and in cases where there has been unusual destruction of the sheath.

Disability no less serious will result if we allow the newly formed tendon to be stretched too soon. In this case the original talipes equinus may only be converted into a severe talipes calcaneus, with typical pointing of the os calcis—an accident which I have frequently observed (Fig. 28).

Elongation.—For this reason various methods of effecting **plastic elongation** of the tendon have been devised and carried out. The simplest way is to cut obliquely from left to right, or from before backwards, instead of straight across. It is difficult to obtain much lengthening by this method, because the two ends are then so narrow and tapering that approximation is bad.

Bayer's Z-shaped section is a rapid and elegant operation. The tendon is split into right and left halves by a sagittal incision, and division is completed by cutting inwards and outwards at either end of the first cut. The two portions may now be slid along on one another to the full extent of the

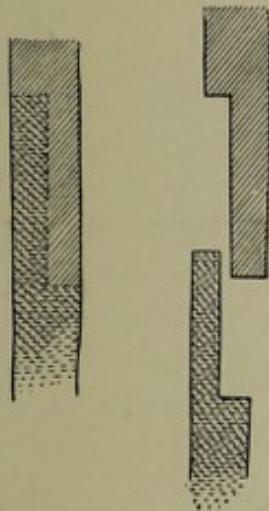


FIG. 29.—BAYER'S Z-SHAPED SECTION.

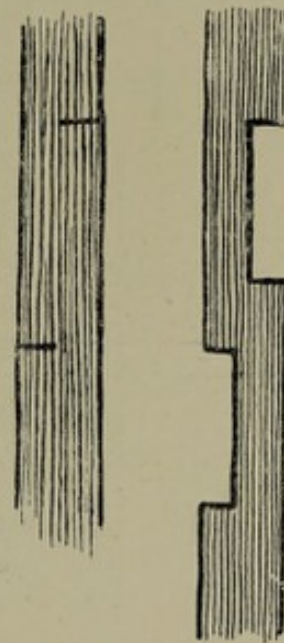


FIG. 30.—SUBCUTANEOUS ELONGATION.

longitudinal incision, so that the ends are brought into approximation (Fig. 29).

This effective and accurate method can also be carried out **subcutaneously**. In this case only the transverse cuts are made, and the lengthening of the tendon is brought about by vigorous manipulation, the two ends sliding on one another (Fig. 30). It is important that the longitudinal incision should be made as exactly as possible in the mid-line, otherwise the thinner half may tear away, and an unintentional transverse tenotomy result. The direction of pull of the peripheral part of the tendon can be determined to a certain extent by the direction in which we make the lateral cuts. Bayer's method has only one disadvantage, and that is, that as the width of the tendon is halved, it must be of fair breadth at the start. Prioleau and I have got over this difficulty by dividing the tendon into anterior and posterior portions, by a coronal incision, followed by forward

and backward cuts, on the same principle as before. Thus the full width of the tendon is preserved. Or one may adopt Hacker's incision. In this case, as the illustration shows, two-thirds of the full width of the tendon are preserved, and at the same time lateral lengthening and approximation are carried out (Fig. 31).

Sporon's method is still more complicated. The tendon is cleft by two longitudinal incisions, equidistant from one another, and from the free

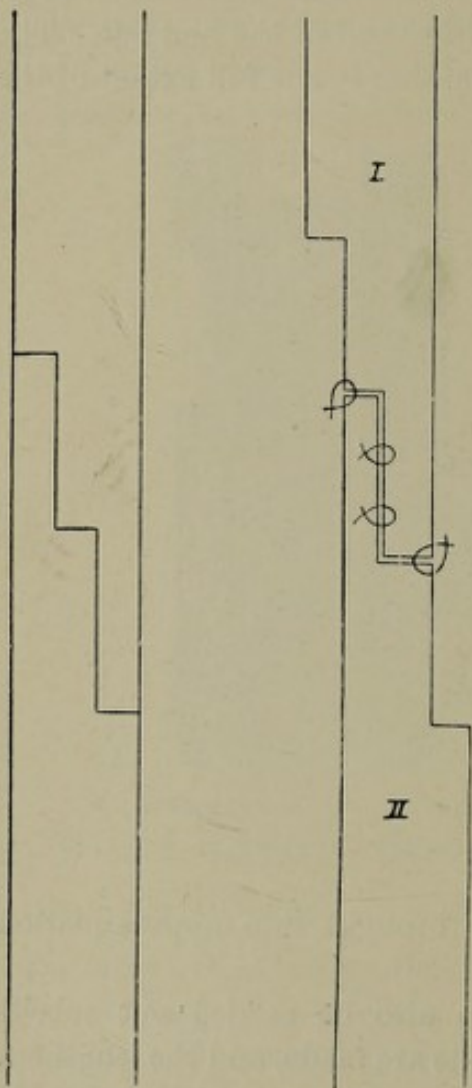


FIG. 31.—HACKER'S TRIPLE INCISION.

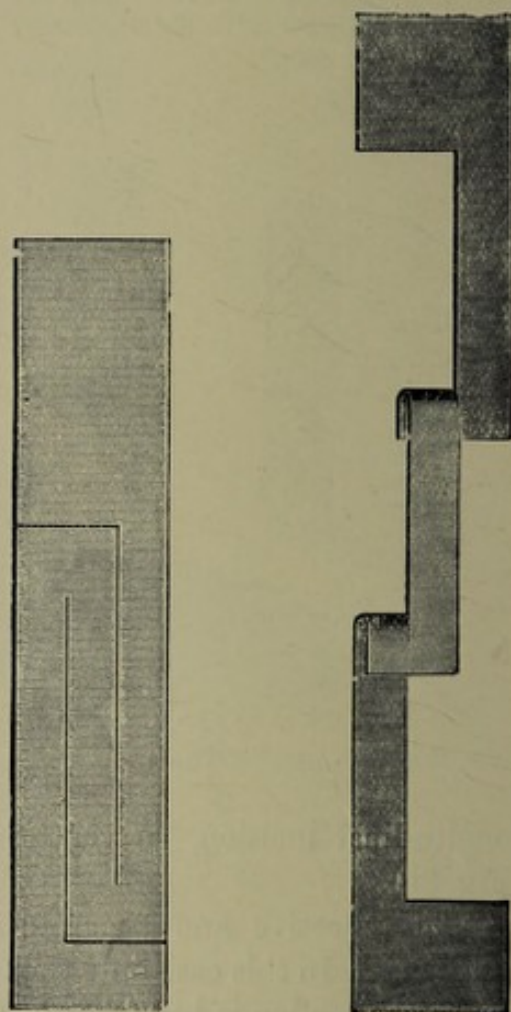


FIG. 32.—TENDON LENGTHENING.
(AFTER SPORON.)

border of the tendon. One cut is placed higher up than the other, and transverse cuts are made in opposite directions, from the upper end of the one and the lower end of the other (Fig. 32). The tendon can thus be lengthened, without being divided, by nearly as much as the united length of the two longitudinal incisions. The method has the advantage that continuity is maintained, but this is outweighed by the danger of rupture and the severity of the injury done to the tendon. The same objection

applies to Poncet's method, which consists in making transverse cuts, two-thirds of the way across the tendon, at alternate sides. The result is that the tendon opens out, something like a concertina, and undergoes a considerable elongation (Fig. 33).

Finally, I must mention a very simple method, which was introduced by Lange of New York and myself, but is only suitable for tendons which extend a long way up the belly of the muscle. The tendon is divided high up, and, after prolonged manipulation, is left in contact with the muscle at whatever level is necessary.

Of all the methods that we have described for tendon lengthening, Bayer's seems to be the simplest and best, and it has the additional advantage that it can be performed subcutaneously.

The process of repair after Z-shaped tenotomy is similar to that which obtains after ordinary tenotomy. The proliferation of the synovial sheath, the outgrowth of young tendinous fibrils from the cut ends, and their arrangement in interlacing longitudinal strands are easily seen in these cases. The surrounding connective tissue plays an important part. If everything runs its proper course, the connective tissue developed will be largely tendinous (Borst). It is advantageous that the tendon should be under some tension, for this stimulates the production of true tendon fibres.

Artificial Tendons. If the interval between the ends of the tendon is thought to be too wide, it may be bridged over with an artificial tendon. We shall allude, later on, to elongation by means of transplantation. We are only concerned here with the introduction of foreign bodies into the gap resulting from the tenotomy.

The possibility of this measure was mainly demonstrated and made known as the result of the untiring researches of Glück. He recommended the introduction of grafts of human or animal tendon. His experiments on animals were confirmed by Wölfler, Fargin, Assaky, and myself, and later on about half a dozen similar implantations were carried out in men (Helferich, Czerny, Bouglé, Peyrot, Monod, Hoffa).

Much more is known with regard to the introduction of inanimate matter, such as catgut or silk threads. Glück's suggestion and experiments showed the way, but he experienced great opposition at first. He showed a whole series of cases at the Surgical Congress of 1890, but found few supporters. Kümmell was one of those who took his part. Lange was the

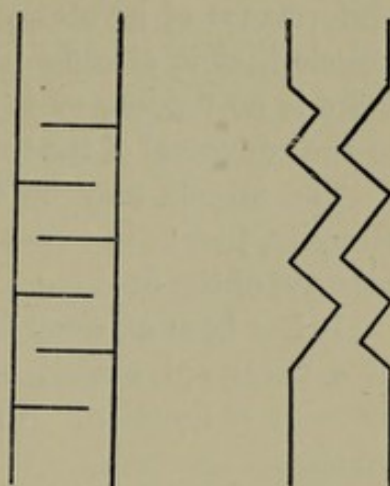


FIG. 33.—TENDON LENGTHENING. (AFTER PONCET.)

first to take up the method with any enthusiasm, and he introduced it into orthopædic surgery, especially in connection with tendon transplantation. There is now no doubt whatever that bridges of this kind heal up satisfactorily.

It will be seen from all that we have said that the various methods of elongation constitute a great advance on mere tenotomy, and if the results are not perfect as regards anatomy and histology, they are, at any rate, satisfactory as regards functional efficiency.

A shortened muscle may be lengthened by cutting through the muscular belly, instead of the tendon, but **myotomy** is undoubtedly a more serious and more bloody operation than tenotomy. Repair is effected at first by proliferation of the intramuscular connective tissue, by which means the continuity of the muscle is restored. Later on muscle fibres grow in from either end, and partially or completely replace the connective tissue. The performance of myotomy entails, however, the infliction of injury upon a muscle that is already partly paralyzed, and this is to be avoided, unless there is no tendon, or it is difficult to reach. Examples of this are seen in the adductors of the thigh, and the spinous muscles in flexure of the hip.

The muscle may be divided subcutaneously after displacing the skin laterally, just as in tenotomy. Any bleeding that occurs is arrested by the pressure of the dressing.

It has been affirmed by Joseph, and often reasserted, that the division of a paralyzed muscle or tendon may cause a striking and unexpected recovery of function. No confirmation of this has been reported up to the present.

Treatment of Bony Deformity.—We have seen that whilst slight and recent contractures may be successfully treated by manipulation, severe cases must undergo tenotomy or plastic elongation of the tendons. If, however, the contracture has existed so long that fixed bony deformity has occurred, it may sometimes be necessary first to attack the skeleton. In such cases deformity of the long bones may be corrected without difficulty through a short skin incision, by means of **linear "subcutaneous" osteotomy**, though in some instances it may be necessary to exercise a **wedge**.

Transverse osteotomy is intended solely for the cure of deformity, but **oblique and zigzag division** of bone, analogous to Bayer's tendon operation, have been devised for the purpose of elongating the shortened bones of paralytic patients. We shall allude to these modifications of osteotomy in the special part of this book.

Partial or complete **extirpation** of certain bones may also be necessary in exceptionally severe cases of paralysis of the foot.

B. RESTORATION OF FUNCTION.

When the contracture has been corrected by one or other of the methods described, it remains to prevent the recurrence of the deformity. Risk of this is always present, because the conditions which caused the contracture remain more or less unchanged.

Operative Methods.—Setting aside the use of walking apparatus, which we have already described, we come now to the description of operative measures. This is a most important part of the surgery of paralysis, and one that has undergone extraordinary development within recent years.

1. Muscle Implantation.

The line of treatment that is to be adopted depends entirely upon whether all the muscles that move a joint are paralyzed, or whether they are only partially affected, whilst their opponents remain intact.

If the paralysis is complete, there is no possibility of restoring functional activity, though such a feat is not quite beyond imagination. The ideal method of treatment would be to make use of a human or animal muscle entirely freed from its attachments, in place of the degenerated muscle. But a muscle that is severed from its original blood- and nerve-supply always degenerates, as far as we know, and experiments on these lines must therefore be regarded as unpromising and impermissible. Some experiments upon animals carried out by Glück afford a certain amount of hope, however.

He first excised two-thirds of a dog's gastrocnemius and the tendons attached. He then removed a similar but rather larger preparation from another dog, and grafted it into the first, where it acquired an attachment. Later on he showed that the transplanted muscle was capable of considerable activity.

A similar experiment was carried out by Salvia, in 1870, on a dog. A portion of the rectus femoris was removed, measuring, after retraction, 3 centimetres long by 1 centimetre thick, and a fresh piece of rectus, 2 centimetres thick, taken from a rabbit, was sutured with catgut into the space. Three months later no trace of the line of union could be found, either microscopically or macroscopically, and the rabbit's fibres had merged completely into those of the dog.

Salvia drew the following conclusions from this successful experiment :

1. Transplantation of muscle from one animal to another is possible, even though the animals be not of the same species.

2. The transplanted muscle may join up *per primam* with that of the host, without setting up any inflammation. To accomplish this it is necessary that the graft should completely fill the gap caused by the retraction of the

divided ends, and that the operation should be carried out with the strictest asepsis.

3. Union of the transplanted fibres and those of the host is effected by the development of new, transversely striated muscle, which joins the two in absolute continuity, so that no trace of the line of junction remains.

4. The transplanted fibres lose their anatomical characteristics little by little, and take on those of the animal into which they have been grafted, so that after a time it becomes impossible to demonstrate any difference between them, even on the most careful microscopical examination.

5. The function of the muscle recovers completely and comparatively rapidly after the transplantation.

Unfortunately, Capurro was unable to confirm these results after performing twenty-five aseptic implantations. Macroscopical and microscopical investigation of the fate of the part transferred brought him to the following conclusion: Free transplantation of striated muscle, whether into animals of the same or of another species, gives entirely negative results, however the operation be carried out. Destruction of the graft takes place in the majority of cases by a process of rapid ischæmic necrosis, showing itself sometimes as caseation, and sometimes as the so-called "fibrous metamorphosis."

I myself made several experiments with free implantation in rabbits. I excised large portions of muscle, turned them through 180° , and sutured them again into the wound. In other cases I cut pieces out of the right and left muscles, and transposed them. In the absence of sepsis, faultless union took place, without any fibrous degeneration, so that after some months the only indication of the site of implantation was that afforded by the sutures. I had no time to repeat these experiments, or to confirm them by microscopical research.

Deschin also experimented with isolated portions of dogs' muscle. He came to the conclusion that the results were very contradictory, but suggested, on the whole, that such grafts might survive.

The majority of experiments indicate that detached muscle is not of such low vitality as was formerly believed. Muscle implantation was once performed in man by Helferich, and Salvia states, with regard to this case, that "a biceps brachii, removed chiefly on account of fibro-sarcoma, was successfully replaced by the biceps cruris of a dog."

The pectoral has sometimes been successfully transferred to the position of the deltoid, but this is not quite the same thing as absolute isolation of the muscle, followed by transplantation, though it is of the same nature (*vide* Part II., Chapter III.).

Recent work in neuroplasty also tends to show that the vitality and regenerative powers of muscle have been underrated. No one would have

thought until recently that the muscles of the face, after sixteen years' paralysis, would show signs of returning motility six weeks after facio-hypoglossal anastomosis. Nevertheless, such cases have been recorded, though they still await explanation. There is no obvious reason why one should not graft a healthy muscle and maintain its contractility by simultaneously implanting an adjacent nerve, or by means of neuroplasty. At any rate, careful experiments must be made before we give up such an attractive prospect as unattainable.

Another possible method is to transfer portions of healthy muscle, leaving their base of attachment intact. Animal experiments have been conducted on these lines also. Rydygier excised the lower half of a dog's sterno-mastoid, and replaced it by turning the clavicular portion of the pectoralis major outwards. The result was successful. Four months later no degenerative changes could be found in the muscle, even under the microscope. In another case he cut a large flap from the rectus femoris, leaving it attached close to the patella, and turned it down into the extensor longus digitorum. Four months later the graft was still functional, but it showed unmistakable degeneration, the result, no doubt, of interference with its nutrition from its being bent so sharply upon itself. Rydygier laid down the following conditions as essential to success :

1. First and foremost, there must be perfect asepsis.
2. The skin incision must not lie over the muscle flap.
3. The muscle must be injured as little as possible, and therefore the lines of deep incision should correspond with the larger connective-tissue septa.
4. The pedicle should be on the side of the vessels and nerves.
5. The flap must not be turned through too sharp an angle.
6. The fascia should be preserved as far as possible.

Capurro's experiments are also of importance, though he took his grafts from the immediate vicinity, and not from a distance. His conclusions are as follows :

Transplantation of flaps serves the purpose of a plastic operation as far as the strengthening of the part and the maintenance of its function are concerned. The strength of the contractions obtained varies considerably, according to the method of implantation employed.

1. Other conditions being equal, more powerful contractions are obtained with partial than with total transplantation ; with moderate tension than with considerable ; also, when the grafts are put into muscles lying near to those from which the flap is cut, and running parallel with their fibres, rather than into muscles at a distance, or in a direction oblique to their long axis.

2. More power is obtained when the flap is only turned through a small angle.

3. It is greater when the graft is sewn to the aponeurosis and not to the muscle itself.

4. It is considerably reduced when the flap is slack, or stretched to the full extent, or implanted upon a tissue that yields.

5. The position of the pedicle is not a matter of any particular importance, nor is the question of whether the muscle into which the graft is made pulls in the same or in the opposite direction.

Hildebrandt carried out a series of very important experiments, first at Basle, and then at Berlin. Wanner had previously employed the rectus femoris muscle of the rabbit, isolating about 10 centimetres above and below the insertion of the nerve-supply, and implanting the piece into a gap in the vastus externus, or into the space created by the complete removal of the pectineus. Union occurred in five cases. Later investigation showed that after some weeks or months the muscle gave prompt and powerful contractions on electrical stimulation. Hildebrandt went still farther, and isolated the whole extensor of the toes in the rabbit, dividing it close to its proximal attachment to the tibia, and its junction with the tendon. Care was taken not to pull or pinch the muscle or the nerve at this stage. The muscle was then approximated to the aponeurosis at the upper end, and to the tendon at the lower. It was found that the muscle did not survive when the arteries and veins accompanying the nerves had been ligatured. In those animals in which the nerve was left as the only attachment, the muscle, after seventy days, looked like a firm, horny mass, which showed only a small number of muscle fibres under the microscope. These, however, possessed definite cross-striation, were of various widths, and contained numerous nuclei; they were, in fact, young muscle fibres. But even if capable of contracting, they were prevented from doing so effectively by the surrounding mass of horny tissue.

The rapid degeneration of the muscle was very plainly seen in examinations made eight to twelve days after the first operation. The fibres were pale and of a muddy yellow colour, transverse striation was still present, though the separate bundles were often broken up into irregular lumps; the nuclei were few in number and stained badly; now and again they were increased at the periphery. The bundles were infiltrated with numerous round cells, and separated from one another.

Hildebrandt's results were quite different, when he did not disturb the vessels accompanying the nerves. In animals killed after three months he found the grafted muscles hardly smaller than those of the other side, though rather pale and rough. They reacted promptly and vigorously to stimulation of the nerve or of the fibres themselves. Microscopically the fibres were of normal width, and showed good transverse striation, though their outline was rather wavy. Examination at an earlier stage revealed

the regenerative process very beautifully. It followed the embryonic type. The new muscle can be distinguished from the old for a long time by its excess of nuclei, the narrowness of the fibrils, and the character of its striation.

We learn, then, from this instructive research, that it is *possible to graft successfully a muscle that is almost completely severed from its attachments, provided that its connections with its blood-supply and its nerve centre are maintained intact*. Most of the fibres degenerate at first, but regeneration occurs.

Deschin also arrived at an encouraging conclusion as the result of his experiments. He states that the work which has been done on transplantation of isolated muscle leaves no doubt as to the future of the operation.

Several plastic operations of a similar kind have already been carried out on man. The pectoral has frequently been freed partly or completely at its origin, and transferred to the spine of the scapula. This is described in Part II. (v. Winiwarter, Morestin, Hildebrandt).

Czisch closed a defect in the abdominal wall by isolating and turning upwards a piece of the sartorius, 30 centimetres long. Tubby grafted a great part of the sternal portion of the pectoralis into the paralyzed serratus, with complete and permanent success.

Such results suggest that the principle might be extended, and that cases of partial or complete paralysis of various parts of the extremities might be treated by the ideal method of restoring active motility. This, however, has not yet been done, and we must now return from the field of speculation to the consideration of what can actually be accomplished at the present time.

2. Arthrodesis.

This is an operative proceeding which effects **very great functional improvement in a totally paralyzed limb**, even though it does not restore the musculature.

The destruction of all the muscles results not only in loss of voluntary movement, but also, as we have already seen, in relaxation of the joints. The latter, deprived of their support, become flail, in consequence of the overstretching of the capsule and its thickenings, and passive movements take place in pathological directions, and beyond the normal range. Fixation in the correct position can be secured by means of orthopædic apparatus, and also by means of operative stiffening of the joint, a proceeding known as "arthrodesis" or "arthrocleisis."

This ingenious operation is associated with the name of Albert, who first performed it on July 10, 1878, on a girl of fifteen with paralytic flail-knee. Various other experiments to the same end had been made, as, for

instance, with ignipuncture and injections. L. Bauer, of New York, had undertaken the resection of an unstable genu valgum after traumatic separation of the epiphysis, and Szymanowski and Braatz had performed stiffening of a joint. It was Albert, however, who placed the operation on a systematic basis, and applied it to the knee, ankle, elbow, and shoulder.

Von Lesser has also claimed priority, but not correctly, for the partial resection of the ankle which he describes was not carried out until February, 1879.

Albert's operation only received a definite name some years after the publication of his first paper, and a considerable time elapsed before it was recognized and repeated by other surgeons. The indications for the operation were beginning to be known, when tendon transplantation was introduced, and proved a rival to arthrodesis, which lost favour for the time, and ceased to attract so much attention. Latterly, however, it has been revived, and the limitations of each measure have been defined.

The special value of arthrodesis in the treatment of a flail-joint consists in the fact that it is the joint itself that is attacked. A limited resection is performed, and there is in actual practice no hard and fast line between arthrodesis and resection. The difference lies in the indication. In resection our chief object is to eliminate diseased bone, whereas in arthrodesis we aim at fixation of the joint by the production of bony union of the articular surfaces.

Resection is intended as a rule to result in a movable joint, whereas arthrodesis aims at an ankylosis.

Indications.—It must be clearly understood that the only possible result of the operation is to replace one pathological condition, that of flail-joint, by another, that of ankylosis. Arthrodesis is only permissible, therefore, when it offers the best possible termination of the case. It must not be performed until all hope of the return of sufficient movement of the joint, or the restoration of a useful joint by less destructive means, has entirely disappeared. In infantile paralysis the joint itself is unimpaired, and its deliberate destruction by *arthrodesis is only justified when all possibility of regeneration of the muscle is gone*. One must wait, therefore, until **at least nine months** have elapsed since the onset of the paralysis, and the joint has assumed a position that is not only useless in itself, but also dangerous to the ultimate utility of the limb.

The question of performing arthrodesis depends in any given case on the amount of disability that results from the flail-joint, on the one hand, and on the other upon the amount of improvement that can be expected if the joint is stiffened.

The **age of the patient** is also a point. A mutilating operation of this kind cannot be recommended during early life. If the child can be enabled

to walk by the stiffening of one or other joint, it is better to effect this stiffening by means of some simple orthopædic apparatus, and delay the decision as to operation until later on.

Jones says that arthrodesis should not be performed before the age of eight, because it fails to produce the desired end. My experience does not confirm this. Further delay seems to me to be inadvisable if the child cannot get about without an arthrodesis. Disuse of the limb results in impaired development and an unnecessarily large amount of shortening, or else contractures and deformities are produced, which render arthrodesis more difficult and complicated later on. It is inadvisable, therefore, to delay the operation until the age of ten, as has been suggested by Kirmisson, Bradford, and Soutter, or until the patient is grown up, as advised by Lange.

Technique.—The technique of arthrodesis is very like that of resection. It is well to exsanguinate the limb, after Esmarch's method, but this cannot be done in the case of the hip and shoulder. The joint cavity must be opened widely, so that the whole of the articular surfaces of the bones is exposed to view. Next the cartilage is divided with a knife, sharp spoon, and, if need be, with a saw. Special instruments for this purpose are unnecessary. Opinion is divided as to the proper depth for the cut. Some advise that only a thin layer of the cartilage should be removed, for fear of injury to the epiphysial line. I think that it is better to expose the bone, at any rate, in some places, for we wish to produce a result similar to that which obtains in subcutaneous osteotomy—*i.e.*, ankylosis of adjacent bony surfaces. After considerable practical experience I recommend this deep removal of the cartilage. It is hardly necessary to add that great care must be taken of the epiphysial line.

Another suggestion is that the bony surfaces should be made irregular. Several grooves may be cut obliquely across them with a sharp spoon. In this way a kind of serration is produced, and this is said not only to insure consolidation, but also to promote the vascularity of the joint. Such grooving is unnecessary in older patients, in whom the bone is freely laid bare, and in younger persons with a thick layer of articular cartilage, perforation down to the bone at various points, as previously advised, serves the same purpose.

I have lately been in the habit of producing a sort of natural serration or mortising by means of boring pieces out of the bone and cartilage with a sharp spoon or a small gouge, leaving a bridge, however, to maintain continuity with the rest of the articular surface. These pieces were then turned up, and when the bones were approximated, they interlocked with one another.

This modification is perhaps specially valuable in the obliteration of the ankle-joint, an operation in which it is particularly difficult to secure

good union between the bare surface of the astragalus and the wide mortice of the malleoli.

Others advise that the surfaces should be rendered as smooth as possible, to insure exact adaptation. Herz recommends the filling of cavities with paste after the manner of Mosetig. I do not think that it is necessary to remove the synovial membrane or the whole of the joint capsule in order to prevent the secretion of synovia into the wound. It is worth while, however, to go over them with a sharp spoon, having in view the fact that intra-articular fractures often heal badly in consequence of the secretion of synovia.

Some surgeons, after removing the slices of bone, search the wound carefully for small splinters of bone. Experiments, to which we shall refer again later, have shown that such fragments do no harm, but rather assist ankylosis by their proliferation. I never hesitate to fill up any cavities in the joint with these fragments, and thus to complete the apposition of the bony surfaces.

Numerous attempts have been made to carry out arthrodesis in the strict sense of the word, by **fixing the cut surfaces together**. Thus they have been united with catgut, silk, or silver wire. Nails and screws have been put through the joint; ivory or bone pegs have been employed (Lexer), and silver staples (Herz).

Solid union is difficult to obtain in cases where the bones are highly atrophic, because the foreign bodies introduced do not obtain a sufficiently firm hold. The fact that they are apt to cause rarefaction, which is only discovered when they are removed, is an objection to their use.

Artificial fixation was thought to be of use, not only in securing the bony surfaces, but also in stimulating them, so as to accelerate consolidation. For the same purpose the wound has been plugged, glass-wool put in, or the surfaces painted with tincture of iodine. Mencière's method of dabbing on pure carbolic acid, and then washing it off with absolute alcohol, is particularly effective. It is known as **phenarthrodesis**.

The production of suppuration seems to me to be neither necessary nor desirable. I prefer that the wound should run a normal course and heal by primary intention.

After approximating the skin-edges accurately with silk, I apply a **plaster bandage** at once. In this way fixation is rendered exact, and it can be prolonged for a considerable time. *The six weeks' fixation that is quoted by many is much too short to secure a good and lasting result.* I generally fix my cases in plaster for *three or four months*.

Early walking exercise has been advised in the case of arthrodesis of the knee and ankle. I agree that this is sound, considering the success that has attended the ambulant treatment of fractures.

The danger of arthrodesis is so slight when careful asepsis is maintained, that several joints may be operated upon at one sitting.

I myself have performed hundreds of arthrodeses, and have only had two cases of suppuration. Occasionally there has been an initial rise of temperature from absorption of blood serum or localized dry gangrene of the edges of the incision. In one of the cases mentioned, partial exfoliation of the astragalus took place, though without prejudicing the final result. It must be remembered, however, that in two of Moore's cases, in children over ten years of age, fat embolism occurred. It is impossible to say whether this must be attributed to the operation itself, or to the *redressement* which preceded it.

It is obvious that *redressement* must be carried out before any operation is performed. Anyone who has actually seen the thin-walled, fatty bones of a paralytic ankle, will be surprised that death from fat embolism is not more frequent than it is. It is usually unnecessary to employ great force in the correction of paralytic deformities, and, indeed, this is never justifiable, for the bone can always be freed later on by arthrodesis, and restored to its proper shape.

Results.—We come now to the results of arthrodesis. The object of the operation is the production of firm and, generally speaking, bony ankylosis. How far is this realized?

The literature of the subject does not afford a definite answer. We know that genuine bony ankylosis may occur, but that in many cases we have to be content with more or less solid fibrous ankylosis.

The study of the method of repair is of great interest, and a good deal remains still to be explained. Cochon made experiments on dogs with simple freshening of the surfaces, with freshening and plugging, and with freshening and pegging, but unfortunately he did not obtain any conclusive results. Bidone carried out a more useful research, operating on the knees of rabbits, cats, and dogs, and subsequently making microscopical investigations. He found that the wounded cartilages proliferated freely, and that cartilaginous ankylosis ensued. This was gradually replaced, later on, by fibrous union, at any rate, in the middle, and lastly, any pieces of cartilage that might have been left free in the joint grew, and blended completely with that which was left. Still less is known about the process of repair after exposure of the bone, which is remarkable, considering the great assistance that might be derived from the use of the Röntgen rays for investigation. I am able to give some information with regard to the late results. It is possible for the two bony surfaces to undergo absolutely ideal fusion, so that they form a single skeletal unit, and develop a new arrangement of their cancelli. The trabeculæ pass uninterruptedly from the one to the other. In other cases bridges of bone only are developed,

and these are surrounded by bands of dense fibrous tissue. I have further been able to confirm these X-ray findings by examination of the tissues themselves at later operations.

Some skiagrams, showing the mode of ossification which I have just described, are reproduced in various chapters in Part II.

Reference must also be made to Part II. for information concerning the frequency of bony or fibrous ankylosis, and the failure of the operation, for the percentage of these results varies considerably in the different joints.

A very important question is that of the **effect of arthrodesis on the rate of growth**. The operation itself produces very slight shortening. If the epiphysial line is not actually injured, impairment of the growth of the bone is out of the question.

It has been repeatedly stated—and my own experience confirms the statement—that the *shortening of the bone ceases*, or practically ceases, *when arthrodesis has been performed*, so that the *paralyzed limb grows almost as rapidly as the good one*. Rieger once noted that the limb increased 2 centimetres in length in five months, after arthrodesis of the knee and ankle. It is evident that the stimulus provided by using the hitherto useless limb has a beneficial effect upon the skeleton as well as upon the circulation. It is impossible to determine accurately the effect of the operation upon the growth of the bone, because one cannot eliminate or estimate the anomaly due to tropho-neurotic disturbances. Further light upon the question can only be obtained by means of much careful observation of cases after operation.

Failure of Ankylosis.—Whilst endeavouring to do this I have discovered something much less gratifying—viz., that arthrodesis may fail in various ways. First and foremost, ankylosis may fail to occur, and a flail-joint ensue. The fault in this case lies in the technique, and it is necessary to devise such modifications as will prevent this form of failure. Much has been accomplished in this direction, to which we shall allude later on.

In other cases ankylosis seems good at first, but gives way later on, and the functional value of the limb is decreased. The number of failures of all kinds will decrease in proportion as true bony ankylosis is obtained. The most important thing, however, is to **keep the limb fixed for a long time** in an apparatus, and when it is removed to stimulate the growth of bone and fibrous tissue by painting with iodine, and by systematic congestion. Further, the tightly stretched connective tissue should be protected from overstretching by means of a simple orthopædic apparatus with lock joints, or no joints at all. Such appliances are described in Part II.

The most displeasing result of all is **after-contracture** or -deformity, and unfortunately this is not an infrequent occurrence in certain joints.

The likelihood of this trouble can be reduced, though not completely abolished, by careful attention to the details of the operation and of the after-treatment. In some cases manipulation or re-operation becomes necessary years later.

Taking into consideration all that has been said about the permanent results of arthrodesis, we are justified in stating that when the cases are carefully chosen, the technique is good, and after-treatment conscientious, the advantages of the operation far outweigh its disadvantages. On the other hand, no one can destroy the glistening cartilage of a healthy joint surface with knife or spoon without a feeling of regret. A paralytic joint can be fixed with equal, or, at any rate, with sufficient, firmness by means of an orthopædic apparatus, and its excessive mobility limited to any desired extent. A flail-joint may be fixed or set free at will, according to the arrangement of the apparatus. For these reasons, each and every case must be carefully considered before one or other method is decided upon.

Operation v. Apparatus.—The use of apparatus also entails certain disadvantages, as we have seen, and it is therefore necessary to choose that line of treatment which constitutes the lesser evil for the particular patient in consideration. The decision depends partly upon personal inclination, and the views and experience of the orthopædist or surgeon, but chiefly upon external circumstances. The rich will probably prefer the wearing of apparatus to the lasting mutilation which has, not altogether unjustly, been described as *operatio pauperum*.

In forming an opinion, not only the paralytic joint itself has to be considered, but also the other joints, and the condition of the affected limb, and of the whole body. If paralysis of the central joint renders an apparatus necessary, it is inadvisable to perform arthrodesis of a peripheral joint. If, however, the stiffening of this one joint will enable the sufferer to dispense permanently with his apparatus, he will often, even when well-to-do, submit to the operation. The condition after numerous arthrodeses in both limbs is not a comfortable one for the patient, but in exceptional cases this is the right mode of treatment. Apparatus without arthrodesis is the other possibility, which we shall discuss in Part. II.

3. Tendon Shortening (Plastic Operations upon Tendons and Ligaments).

A perfectly natural hesitation to bring about artificial ankylosis of a joint has led surgeons to seek a milder method of fixing flail-joints. Tendon shortening is the outcome of their efforts.

In a paralytic flail-joint, the tendons are overstretched, in common with the other weak parts. This results from the continual dragging of the

peripheral part of the limb. This suggests that the position of the joint should be improved by shortening the weakened tendons.

The operation is a good one for quite a different reason. We know that a muscle is injured by prolonged stretching, and that atrophy follows, whilst, on the other hand, a certain degree of physiological tension is necessary to maintain it in functional condition. It is often noticed that a muscle which was previously paralyzed, or, at any rate, seriously paretic, rapidly recovers power when the normal tone is restored.

Tendon shortening, therefore, may either be performed upon hopelessly paralyzed muscles, for the purpose of *tendinous fixation* of the corresponding joint, or it may be designed to bring back the power to muscles that are suffering from the effects of insufficient tension.

The **technique** is almost the same in the two cases. One is to cut out the superfluous piece, and sew the ends together. This gives so small an area

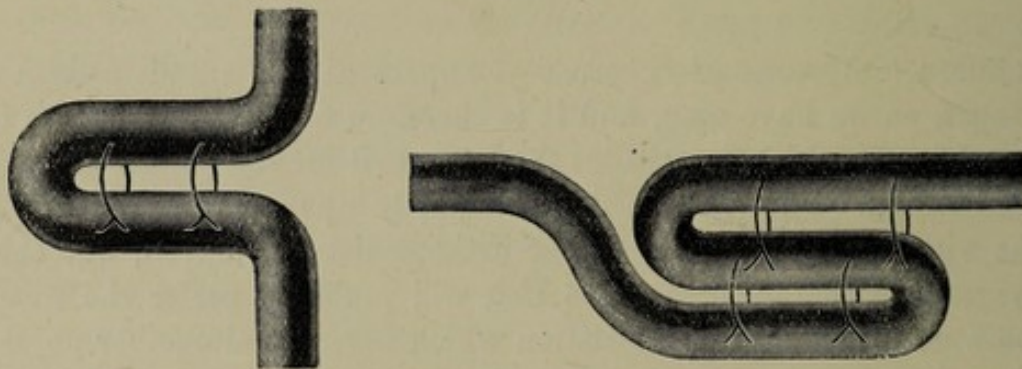


FIG. 34.—TENDON SHORTENING BY PLEATING.

of contact that union cannot be assured. A better method is to cut the tendon straight across, and insert the stump into its fellow as high up as may be necessary, thus doubling the thickness of the tendon. This method has the disadvantage that in case of failure to unite the continuity of the tendon has been destroyed, and it is therefore in a worse condition than it was before the operation.

Pleating, as advised by me, avoids this difficulty. The tendon is held with tissue forceps, and lifted up. The two sides of the fold thus produced are fastened together with several sutures, the angle is sewn down, and in this way a triple thickness of tendon is produced (Fig. 34).

In the case of broad tendons, the following method may be adopted :

A flap, including about half the tendon, is cut and fixed to a more peripheral part of the tendon, after its surface has been freshened. The freshening may be effected by cutting a small flap and sewing it to the upper part of the tendon. When both flaps are pulled upon, the tendon is folded and shortened.

Hoffa performed pleating *en masse*, and after sewing the base firmly together, excised the whole mass.

Lange's suture consists in a double thread of silk, passed in and out in the longitudinal axis of the tendon. When the ends of the silk are pulled, the tendon is pleated and shortened (Fig. 35).

After the operation the thickening in the tendon gradually disappears, and it presents a uniform spindle-shaped outline, which does not hinder movement in any way.

The process of repair is quite well known, thanks to experiments by Hoffa, Borst, Seggel, and Fritz. Lange's operation and pleating after my method, were performed upon animals, and these were killed in the second to the ninth week. Microscopical investigation showed that reaction is much greater in pleating operations than in mere implantation. The connective tissue and the fibrous material surrounding the tendon, even at a considerable distance away, take a great part in the process, and hæmorrhage and necrosis are abundant at the point of approximation. Proliferation of the tendon cells is not an important feature in early stages. Later on there is an unmistakable increase in the connective tissue around the pleat, whilst in the distal part there occur quite early an increase in the tendon cells, and a formation of numerous young tendon fibrils.

Furthermore, striking proliferation has sometimes been seen at a considerable distance from the junction. This must be due to the increase of tension caused by the operation.

A microscopical research was made in the case of a man who had undergone Lange's operation on his tibialis posticus tendon eight months previously. At the site of the operation was found a mass of fibrous tissue, still infiltrated with small round cells, and within this the pleat could be recognized, indicated by an irregular swelling in the outline of the tendon. Some of the stitches were encased in connective tissue, whilst others had healed up without any signs of reaction. It would appear that even after eight months the tissues had not settled down to their final condition.

The **clinical results** of tendon shortening may be very satisfactory if the muscle itself is still recoverable. Otherwise the temporary success of the operation will soon disappear, because the tendon stretches afresh, and the degenerate muscle yields to the strain that has been put upon it.

Tendinous fixation of a joint brought about by shortening the various surrounding tendons, becomes slowly but surely less, and the method is therefore unreliable as a substitute for arthrodesis. Since it is the muscle-

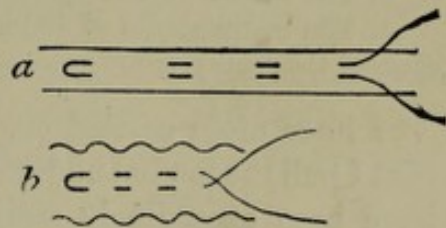


FIG. 35.—LANGE'S PLEATING SUTURE.

belly that is at fault, attempts have been made to exclude it altogether, and to utilize only the tendon for fixation purposes, this being much less affected by the paralytic process. Tilanus reported an operation of this kind in 1899. He freed the extensor hallucis, and fixed its peripheral stump into the periosteum of the tibia. The systematic use of tendons in this manner was first advocated by Codivilla in 1900 and by Sangiorgi in 1901. Codivilla got the idea from frequently seeing tendons embedded in callus, in cases of fracture of the leg. He made a periosteal flap on the proximal bone, at a suitable distance from the joint, and then cut a groove beneath it to receive the tendon. The latter was then sewn down under suitable tension, and the flap replaced. Codivilla and Sangiorgi stated that the following were the advantages of the method as a substitute for arthrodesis :

1. Movement at the joint is only restricted, instead of being completely abolished.
2. The mechanical condition produced is better, in that the artificial ligaments made by the surgeon are attached farther from the axis of the joint than are the intra-articular adhesions resulting from ankylosis.
3. The extra-articular operation is simpler.
4. The manufacture of artificial bands and ligaments is a more physiological proceeding than ankylosis.

I have often carried out Codivilla's operation with this modification—that I pull the tendon underneath a flap of bone and periosteum. The results have been exceedingly satisfactory. Recently, however, I have adopted a different technique in the case of the ankle-joint, which is easier to carry out, and gives just as good results. The tendons are stitched for 2 to 3 centimetres of their length to the deep fascia and to the periosteum. The operation is known as **fasciodesis**.

Reiner invented the same procedure independently of Codivilla, and published his method in 1903. He pleats the tendons after Lange's method, and then sews them down to the periosteum, or passes the silk ligatures through holes drilled in the bone—**tenodesis**. He either leaves the continuity of the tendons undisturbed, giving his silken ligaments whatever attachment he will, or else he cuts the tendon through on its proximal aspect. The clinical results and the pathological anatomy of the operation are not yet properly known. In particular, it is not known whether the newly formed tendinous ligaments grow or not, though it would appear that they must. If not, contracture would be inevitable in course of time.

Lange even went so far as to experiment with artificial intra-articular ligaments. At first he tried to shorten the joint capsule and the ligaments by pleating them—a proceeding which has also been described by Bardenheuer and Frank. This plan failed, however, owing to the abnormal delicacy and atrophy of the tissue.

[He also made **artificial ligaments** out of four to nine strands of No. 12 silk,

securing them in the place of the natural structures by means of deep stitches or drill-holes in the bone. A firm bandage was then applied with the joint in such a position that there was no tension on the silks. He found that primary union took place, and that the silks became surrounded with fibrous tissue; also that these bands grew thicker when the limb was used. The advantages of the method over arthrodesis are, he states, that a certain amount of passive movement remains, the operation is safe and easy, and but little destruction is done. I have performed the operation a few times, but cannot offer an opinion as to its value and the results of the method. Experiments on animals are needed to clear up these points. Reiner's work, already mentioned, did not further our knowledge. I think that Codivilla's method or mine is the best for performing tendinous fixation, as it does not necessitate the introduction of foreign bodies. I do not think that tenodesis or fasciodesis will completely replace arthrodesis, but I regard them as valuable adjuncts to resection of the joints, especially in the case of the ankle (*vide* Part II.).

4. Tendon Transplantation.

We have considered so far the methods that may be employed in a case of total paralysis to compensate for the loss of function. The methods are at best but a poor substitute for what has been lost, but they enable the joint to be used.

When the **paralysis is only partial**, much more can be done. The improvement consists in **tendon transplantation**.

This operation had been performed for traumatic conditions for some time, but it was not until 1880 that Nicoladoni introduced it into the treatment of infantile paralysis. Unfortunately, he tried the operation first on a case of talipes equinus, a paralytic condition which it is exceedingly difficult to cure by tendon transplantation. Very little success attended his experiment, and he failed to follow up the idea any further, or to induce others to follow his example.

Parrish (1892), Winkelmann (1894), and Milliken (1895), all invented the method independently of one another. In 1896 Drobnik published in German a series of sixteen cases. He drew a clear distinction between *total* transplantation and *functional* transplantation, by means of the grafting of part of a tendon—partition of function. About the same time Franke appreciated the possibilities of the operation. He spoke of it as "the greatest advance in orthopædic surgery since Stromeyer's introduction of tenotomy," and extolled the operation very highly, inasmuch as it rendered "radial paralysis quite a thing of the past." His first publication was the cause of my taking a special interest in the plastic treatment of tendons. Subsequent experience has convinced me of the great value of

the method, and I have felt it my duty to make it known far and wide in numerous publications. The literature of the subject has multiplied rapidly in every civilized country, and the indications for the operation have been increased, though it continues to be chiefly employed for the after-results of infantile paralysis.

Lange did much to develop the technique of the operation. Not only did he sew one tendon to another, but he also adopted Drobnik's method of stitching them to the periosteum, and practised the insertion of silk fibres. Hoffa in Germany, Codivilla in Italy, Robert Jones in England, and Tilanus in Holland, worked with enthusiasm and success.

The Congress of the German Society for Orthopædic Surgery presented in 1903 a comprehensive report on the position of tendon transplantation at that time, and in the following year the American Orthopædic Association held an inquiry into the subject. In 1907 the French Surgical Congress met to discuss the value of the operation and the permanence of the results. Many of our French colleagues at that time remained unconvinced, and even to-day Lorenz and his school regard the operation with a kind of unwilling toleration. Such widespread success, however, has attended the adoption of this method that the opposition of these few critics will not displace the operation from the position which it has won in the estimation of the surgical profession.

It is true that the operation was too frequently performed at first, and that too rosy accounts were given of the results. This, however, is the fate of every new method. The principle upon which it is based is so simple, so ingenious, and so sound, that its success in practice is beyond doubt.

Transplantation consists in replacing a paralyzed muscle by an adjacent one that has escaped. It is essential that the paralysis should be a limited one, and that sufficient healthy muscle should be available within the area of operation. This condition is admirably fulfilled in infantile paralysis, for the widespread initial paralysis soon resolves into certain definitely limited areas, in which certain muscles, groups, or even parts of muscles, are affected, whilst adjacent muscles are left comparatively or entirely unaffected.

With this distribution of the disease, and the antagonists remaining intact, tendon transplantation is indicated for two reasons :

1. The partial motor lesion results not only in loss of movement, but also in perversion of its direction. Tendon transplantation serves to restore the proper direction of pull.

2. Paralysis of one muscle and contracture of its antagonist lead to paralytic deformity. This may be avoided by means of tendon transplantation. When the paralysis is of limited extent, and occurs in a favourable part of the body, the operation is particularly appropriate. Success is

more difficult to attain when the paralysis is more widely distributed, so that there are border-line cases in which it is difficult to decide between arthrodesis and transplantation. In these instances, which are by no means uncommon, the choice is dictated not only by the experience and personal opinion of the individual operator, but also by the circumstances of the patient, for tendon operations generally require a much more careful after-treatment. The choice also depends upon the joint that is affected. If it is one that has to undergo severe strain later on, solid ankylosis is often to be preferred. We shall refer to all these points in Part II.

Tendon transplantation was at first confined to the leg, but later on it was successfully carried out in the thigh. It has recently been shown that the method is applicable to the hip-joint, and even to the upper extremity.

What is the proper time at which to perform the operation? It is obvious that it must not be undertaken until the paralysis has settled down to its final distribution. I think that it is well to **delay operation until a year after the onset** of the attack. There is no harm in waiting longer, provided that, in the meantime, overstretching of the paretic muscles is prevented by means of simple supports. During the interval some of the muscles may hypertrophy, and so become specially suitable for transplantation. The assertion of Kirmisson, a strenuous opponent of the method, that "it is a shame to operate inside six months," is crude, but correct, as far as infantile paralysis is concerned. In the same discussion, Pierre stated that he had proposed operation in one case after more than three years, but had been unable to obtain consent. The event justified the patient's refusal, for within the next six months the muscle recovered. It is evident that there was some error in the observations, and the case is no argument in favour of waiting for such a long time.

As regards the **best age** at which to operate, it has been suggested that one should wait until the patient is at least four years old, because the intellect is not sufficiently developed before then to enable the patient to assist in the after-treatment. I agree with this advice, although I have operated with success in younger children. In such cases, however, the tendons are so slight that it is difficult to sew them securely.

There is no upper age limit, and I have repeatedly operated with the greatest success upon patients in the fourth decade of life. It is possible that cerebral adaptability decreases as middle age approaches, but, at any rate, there is no doubt that tendon transplantation is best and most successfully performed during early life.

Technique.—We come now to the question of technique.

Before operation is undertaken, any paralytic deformity that is present must be corrected, as far as possible, by bloodless means. If *redressement*

is accomplished without difficulty, as is usually the case, the tendon operation can be performed at the same sitting. But if considerable exertion is required, and the manipulations occupy some time before the normal or slightly over-corrected position is obtained, the bruising, extravasation, and œdema may be so great as to endanger the uneventful recovery after the tendon operation. In these cases it is better to wait for a fortnight and then operate. Lorenz and his pupils have advised that one should wait for a month after *redressement*, putting the patient in plaster meanwhile. They state that, after a month's interval, operation is usually unnecessary, for the muscles and tendons recover from the overstretching, and adapt themselves to the corrected position of the skeleton. This, however, is not the usual opinion. We know, unfortunately, that even the healthy muscles of congenital club foot do not retract sufficiently after *redressement* and prolonged fixation in plaster to move the normally formed foot in the proper direction. We know, also, that muscular insufficiency of this kind is a frequent factor in causing relapse. It is clear that if healthy muscle cannot retract to the required extent, paretic atrophic muscle certainly will not.

Lorenz's optimism may be justified in slight pareses of recent date and in trivial deformities. *I have never seen a severe talipes equinus recover the power of active dorsiflexion after fixation at a right angle, or a bad paralytic flat foot cured by being put in plaster in the varus position.* I am unable, therefore, to recommend as a general principle the Lorenz method of performing transplantation some months after full correction of position. Treatment in several stages takes up much time, and is not always practicable with middle-class patients. Neither is the prolongation of fixation good for the paretic or any other muscles. There is no doubt about the harm that this does, whilst the spontaneous recovery of the paretic muscles is, to say the least of it, doubtful.

Plan of Operation.—Before beginning the operation, it is necessary to decide as accurately as possible which muscles are paralyzed, which have partly or entirely escaped, and how much strength they possess. Having arrived at an exact opinion on this point, it is possible to decide how best to employ the power that remains. The **examination of the active movements** that are possible is one of the best ways of ascertaining the localization of the paralysis. Older patients will give us some assistance in this direction, but with children we have to proceed slowly and patiently to study their movements whilst they play. Sometimes assistance may be derived from performing similar movements on the sound side, or from stimulating reflex movements—*e.g.*, by tickling the sole of the foot or pricking it with a needle, as recommended by Spitzzy.

|There are certain fallacies in the method of testing the muscles by

means of the voluntary movements of which they are capable. In cases where there is contracture, it may prevent certain active movements, although the corresponding muscles are unaffected. The presence or absence of tension in the tendon then gives the clue to the diagnosis. Again, some muscles may have undergone disuse-atrophy from overstretching or long-continued contracture, and we may fail to observe that they still possess a small amount of power, which may be redeveloped when the contracture has been remedied.

We are not altogether able to avoid these sources of error, for we have no sure method of distinguishing disuse-atrophy from true paralysis. Still less are we able to prophesy to what extent these atrophic muscles are capable of recovery.

The nature of the deformity gives no reliable indication as to the position of the paralysis, for it is caused not only by the unbalanced pull of the intact muscles, but also by purely mechanical factors, such as gravity and the habitual position of the limb.

The determination of the **electrical reactions** is of assistance in the diagnosis, though it cannot replace direct clinical observation. The method, however, is a valuable one, and should be carried out in every case, as Cone, Gocht, Konik, and Piéchaud have insisted. It must be borne in mind, however, that it is often misleading for various reasons. With small, nervous children, the continual struggling is a source of difficulty, whilst the electric current gives us no guide in the case of disuse-atrophy. Like Codivilla, I do not regard the method as one of great diagnostic value, and its employment has never led me to alter the plan of action that I had devised as the result of my clinical examination.

There are other difficulties, however, in deciding what is to be done. Thus it is difficult, if not impossible, to estimate the mechanical effect of transplanting the whole or part of a tendon, and it is still more difficult to gauge the extent to which the brain will be able to adapt itself to the altered condition of parts. This factor varies considerably in different individuals.

Practice leads to greater certainty in devising operations [for different patients, and, within limits, lack of balance is compensated for by cerebral adaptation.

In performing the operation, the strictest asepsis must be maintained. The idea that a slight inflammatory process serves to stimulate the growth of connective tissue is not only incorrect, but dangerous. Infection is undesirable, because it endangers the primary union of the tendon, and prevents the necessary immobilization in plaster. Animal experiments have shown that aseptic healing of tendons is much to be preferred.

They have also taught us the advantage of avoiding a hæmatoma. For

this reason we operate with an Esmarch's band, and only remove it after the plaster has been applied.

It is unnecessary to enter into detail concerning the methods of securing asepsis. They are those of everyday surgery.

Many authors (including Codivilla) have described special methods of

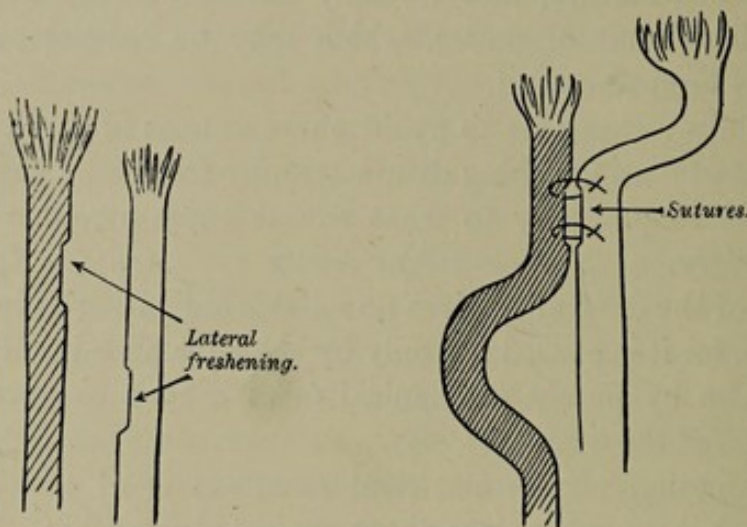


FIG. 36.

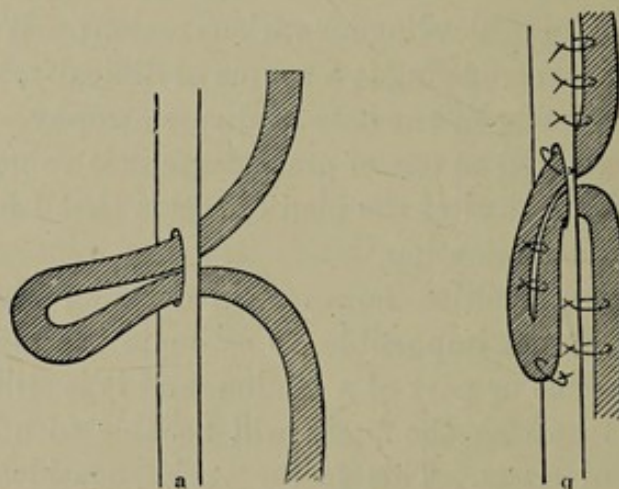


FIG. 37.

preparation. These seem to me to be quite unnecessary, as are also the various special instruments that have been advocated.

Our skin incisions are longitudinal or slightly oblique, and, generally speaking, we avoid flaps. When possible, the **incision is placed so as not to lie over the join in the tendon.** Thus infection and adhesion of the tendon to the skin are avoided. Sometimes several incisions are necessary, either because the surgeon needs to investigate the condition of the musculature very fully, or because the tendon is being transplanted from some distance. The cut should never be longer than is really necessary, though it is not true

that there is a special liability to non-union. It must be admitted, however, that the skin takes rather longer to unite in these paralytic patients than in normal persons. On the other hand, the incision must be long enough to expose the insertion of the muscle. Bradford and Soutter recommend that it should be smeared with vaseline to prevent drying. As soon as the fascia is divided we come down on the muscle, and its colour indicates its condition, as already described.

The sheath must be carefully treated, for we know that it is only capable of partial regeneration; that, if it is injured, the tendon suffers; and that (as Wollenberg's clever experiments showed) it gives rise to tendon fibrils which contribute to the repair. For these reasons the sheath must not be extensively split or pushed back.

Before proceeding to the actual tendon operation, the surgeon will reconsider his plan, after actually seeing the exact state of affairs. He then begins to prepare the selected tendons for transplantation. The union of two tendons can be carried out in several different ways.

Methods of Uniting Tendons.—The simplest way is to freshen their edges, or, better still, their surfaces, at two points which do not correspond, and then sew them together. The paralyzed tendon must be pulled in a centripetal direction, and the good one towards the periphery, so as to put the two on the stretch (Fig. 36).

This method of lateral anastomosis, which was introduced by Parrish, can only be carried out when the paralyzed and the healthy tendon lie immediately side by side. It has the advantage that the continuity of the tendons is not interrupted, and the disadvantage that the contact between the two tendons is not very intimate, and is therefore rather liable to yield. It is, therefore, not often employed. I have introduced a simple modification, which renders it much more useful, without affecting the principle of leaving the continuity intact.

The good muscle is drawn in a fold or loop through a slit in the paralyzed tendon, and is secured there by several sutures on each side. This method combines the advantages of total transplantation, of which we have already spoken, with the simplicity of peripheral implantation (Fig. 37, *a* and *b*).

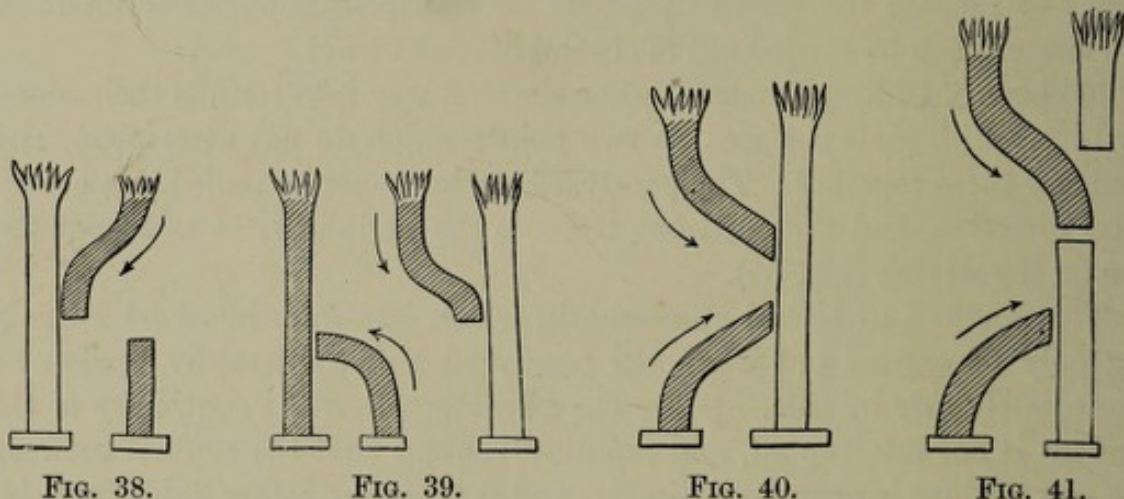
A second method is that of **total transplantation**, which may be regarded from the physiological standpoint (as Drobnik said) as a "transplantation of function." The healthy tendon is completely severed, and sewn to the powerless one (Fig. 38). It is an essential condition for this operation, that the transplanted tendon should be one of slight functional importance, or that its original action should be a harmful one, so that the loss of its natural function is of no matter. Experience shows, however, that the number of muscles that are functionally unimportant is small, and therefore permanent harm may be done if we under-estimate the value of a tendon

and divide it completely. In order to avoid this difficulty and yet perform total transplantation, one may attach the peripheral portion of the divided, healthy muscle, under suitable tension, to a neighbouring healthy muscle (Fig. 39). In this way its function is not completely lost, though its individuality of action is sacrificed.

The same effect is obtained by suturing the peripheral part of the good muscle to the paralyzed tendon below the point at which the union has been made (Fig. 40). The muscle and the tendon of the healthy structure are thus reunited, though only through the intervention of a piece of the paralyzed tendon.

This method bears a great resemblance to anastomosis with a loop, as shown in Fig. 37, *a* and *b*.

There are various methods of fastening the divided healthy tendon to the paralyzed one. The latter may be cut completely through, so that the



two tendons are placed in end-to-end apposition in cases where, for technical reasons, lateral approximation cannot be effected.

The central stump of the recipient tendon is left unattached, whilst the peripheral part of the active muscle is either sewn to the paralyzed one (Fig. 41), or to a neighbouring one (Fig. 42).

Complete transection of paralyzed tendons is, of course, only permissible when the paralysis is complete and irrecoverable. As it is rarely possible to be perfectly certain of this, it is better to suture it in continuity, as shown in Figs. 37-40.

Another way of preserving continuity is given in Fig. 43. The sound muscle is cut across and sewn to a strip of the paralyzed tendon, cut with its base below.

There is another class of case, in which the active muscle is not cut completely across, because it is impossible to dispense with its normal function, and it is inadvisable to treat the peripheral stump in one of the ways already described.

Two methods are at our disposal when total transplantation is out of the question. The one is **partial transplantation**, which was introduced by Drobnik as a means of partition of function. The healthy tendon is split up to the muscular belly, and is then joined to the paralyzed tendon in one of several ways. The latter may be partially (Fig. 45) or completely (Fig. 44) severed, or it may be sewn on in continuity (Fig. 46).

The other method is to leave the active muscle altogether untouched,

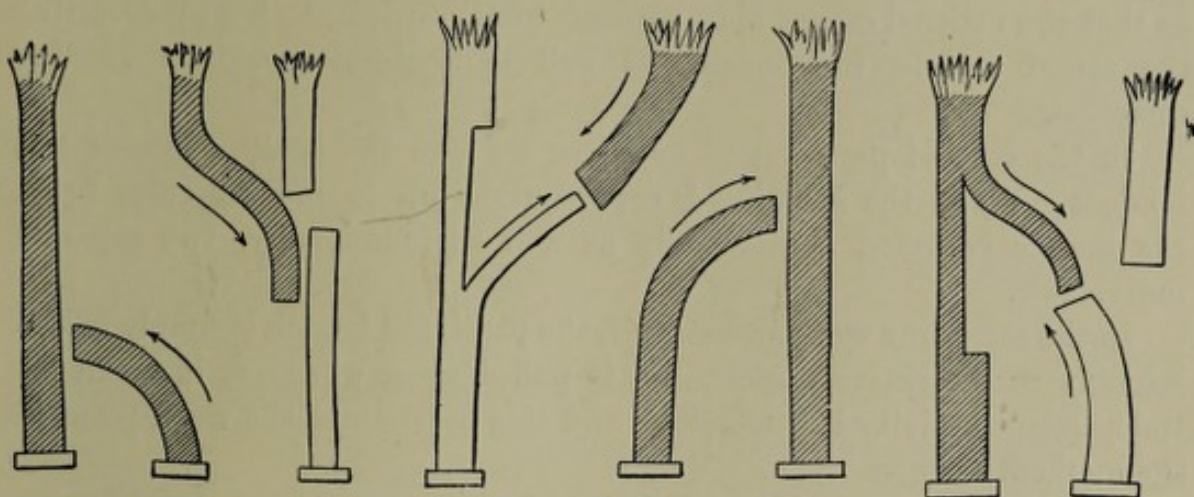


FIG. 42.

FIG. 43.

FIG. 44.

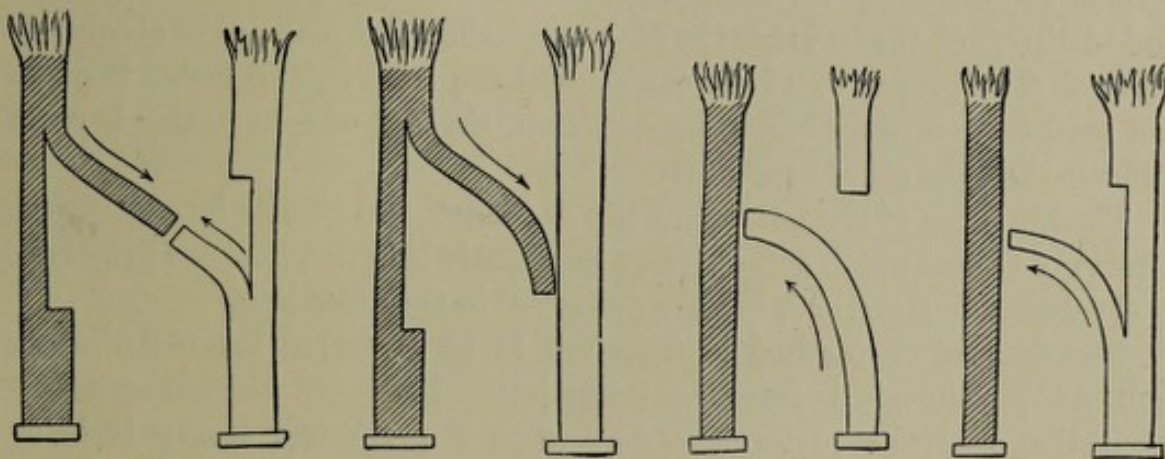


FIG. 45.

FIG. 46.

FIG. 47.

FIG. 48.

and graft on to it either a part (Fig. 48) or the whole (Fig. 47) of the recipient tendon.

Terminology.—For the purpose of comparison the various methods may be classified by means of arrows showing the direction in which the tendon is made to point; those in which they point to the periphery I have designated “**descending**,” and the centripetal ones “**ascending**”; those in which the arrows meet are known as “**bi-directional**.” This nomenclature has been almost universally adopted. Hoffa calls the descending cases “**active**”

transplantation, because it is the healthy tendon that is displaced, and, in the same way, he describes ascending transplantation as "passive." Friedrich has given the significant names of "intraparalytic" (descending) and "intrafunctional" (ascending) transplantation.

The choice of a method, however, is of greater importance in practice than that of the name. We have to consider the question from the technical and from the physiological point of view. To begin with the latter, our object is to divert the force exerted by a sound muscle into a paralyzed one, so that the rational course is to perform total transplantation by diverting the sound muscle, functionally as well as anatomically, into another direction.

In the case of partition of function, we give the healthy muscle two tendons. When the splitting is carried right up to the muscular belly, the muscle becomes, anatomically as well as functionally, two separate individuals.

In the ascending method, however, the paralyzed tendon is simply united laterally to the active muscle, and is pulled upon whenever it contracts. Independent activity is impossible, and this constitutes the weak point in the method.

We have next to consider questions of technique. The paralyzed tendon is not nearly so seriously affected as the muscle, though it is weakened to a certain extent. It is certainly not advisable to transplant it completely, and to disregard the fact that the muscle attached to it may not be absolutely useless. The proper way is to cut a small tag from it, and fasten it on to the good tendon in an ascending direction, though, of course, this is more difficult than the other procedure.

The nutrition of the tendon, or slip of tendon, has also to be considered. There are vessels which enter it from the muscle belly. These are preserved in the descending method, but are destroyed in the ascending.

The **descending method is therefore to be preferred** for technical as well as physiological reasons. Sometimes, however, ascending transplantation must be performed—*e.g.*, when a peripheral stump is being grafted.

In deciding between total and partial transplantation, questions, again, of physiology and of technique have to be borne in mind. In total transplantation greater injury is done to the structure and the nutrition of the muscle and tendon. Again, it is evident that transference of function is more easily effected than partition of function. Lange has declared himself in favour of total transplantation. His advice, if not novel, is at least valuable, in that it promotes the adoption of a simple method instead of one that is unnecessarily complicated.

Let us return now to the **details of the operation** itself; the next question

is the choice of the tendons which are to be transplanted. Preference is given, as far as possible, to those muscles that are functionally similar to those that are paralyzed. If, however, the anatomical conditions are such that this is impossible, we need have no hesitation in utilizing antagonists. In order to avoid this, indirect transplantation has been introduced; for instance, the tendo Achillis is implanted into the peroneus, and the latter into the extensor digitorum, instead of the heel tendon being put directly into the extensor. This, however, is a tedious and unnecessary elaboration, which we prefer to avoid.

Before a tendon is completely divided, its peripheral end is secured with forceps or a loop of silk. In many muscles in which the tendon extends a long way up the belly the tendon can be divided so high up that its peripheral part remains in continuity with the muscle (Fig. 49). In partial transplantation a strip of sufficient strength is cut with a sharp scalpel, and the separation is carried well up into the muscle by blunt dissection, so as to injure the vessels and nerves as little as possible. The tendon must be freed sufficiently to enable it to be displaced easily to its new insertion. Its direction should be as far as possible longitudinal, and its position subfascial. Sometimes it may be threaded through the muscle by means of a pair of dressing forceps, or, when an extensor is to be converted into a flexor, it may be passed through the interosseous membrane. Lange suggests that it is better to let it lie in the subcutaneous tissue, because adhesions are less likely to form there. I do not consider this altogether a sufficient reason for the change, and am of opinion that the subfascial position is more natural and more reliable.

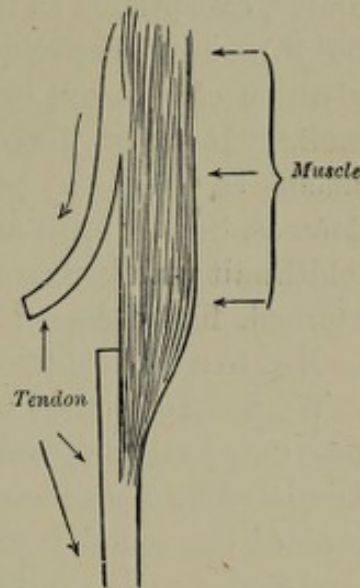


FIG. 49.

The next stage is the fastening of the tendon in place. This must be done securely, and a moderate degree of **tension** must be insured. The important experiments of Capurro have shown (Fig. 49), as already mentioned, that transplanted tendon flaps survive best when they are under normal tension. If the tension is excessive, the vitality is just as much endangered as if it were too slight, and there is a risk of tendinous fixation of the joint. The exact degree required can only be learned by practice and personal experience.

The best results are obtained when the surface of contact is broad. With flat tendons it will suffice to sew the surfaces together; with round ones it is better to thread them through a hole in the paralyzed tendon, and

secure them there with stitches on both aspects. During the suturing the tendons are drawn together with tissue forceps to keep them on the stretch. From four to six interrupted stitches are put in, and in between one or two mattress sutures, which surround small portions of tendon, and serve to prevent the union being torn apart. Continuous suture is not trustworthy in these cases. The remaining free end of the tendon is either cut off or looped up in the proximal direction (Codivilla). For suturing I use silk, as in most orthopædic operations. It is loosely wound on spools, and boiled in sublimate or oxycyanide shortly before the operation.

In spite of all precautions, the silk sometimes works out after several months, or even years, a temporary sinus resulting. This cannot be due, after so long a time, to defective sterilization; it must be the result of the introduction of a foreign body. Lange has tried recently to avoid this trouble, exceptional as it is, by the use of silk sterilized in paraffin (m.p. 155° F.). If the technique that we have described is followed, however, the extrusion of a suture is very unusual, and, even when it occurs, no harm results. It seems, therefore, to be unnecessary to employ a material so difficult to handle as paraffin-sterilized silk. Codivilla sews with crin de Florence, Schanz with aluminium-bronze wire, Witzel with silver wire, and Goldthwait with kangaroo tendon. After experimenting with thread I have returned, like Lange, to silk. Lange also recommends the use of round needles, to avoid splitting the tendon. Special needles are unnecessary.

We have discussed hitherto the attachment of tendon to tendon. We come now to a modification that was first carried out by Drobnik, and was elaborated by Lange—viz., **periosteal fixation**. This consists in the attachment of the sound tendon to that point of the skeleton upon which the paralyzed muscle exerted its maximum effect. Lange considers that the great advantage of the method consists in the fact that the use of the paralyzed and weakened tendon is altogether avoided. He fears that it cannot stand the strain of full functional activity later on, and that it often stretches and spoils the result. He thinks that suturing into the periosteum gives a much firmer hold than the attachment of tendon to tendon. In children the tendon may be fastened right through the cartilage, though the joint must never be entered. He has made experiments which show that tendons united in this way stand strain exceedingly well. I think that whilst this may be true of children, it does not hold good for adults, in whom there is no cartilage, and periosteal fixation alone is possible. My opinion is shared by other operators of experience.

I still think that for general use the union of tendon to tendon is the best method, and that one may expect the paralyzed and weakened muscle to regain something of its old strength under the stimulus provided. In exceptional cases periosteal fixation may be adopted—*e.g.*, in the case of the

tendon of the quadriceps, which is so intimately mingled with muscular fibres that it affords only a very infirm attachment when the muscle has degenerated. The old and the new methods are not in any way antagonistic, but each serves to supplement the other.

My objection to Lange's modification is based not so much upon the actual periosteal method of fixation, as upon certain practical results which ensue. Lange states that one advantage is that it allows him to adopt any insertion that seems advisable. Frequently, however, the tendons will not reach far enough, and he then has to introduce artificial fibres of silk to fasten the end of the tendon to its point of insertion. It is a most interesting thing to know that tendons of 20 centimetres and longer can be introduced in this way, and it is still more interesting in connection with the study of the process of repair. But the routine use of silk is an undesirable and unnecessary complication of the operation. This opinion is shared by various surgeons who can speak from experience concerning the method.

The **technique of making a silk ligament** is as follows: Several silk sutures are passed through the tendon to be transplanted; they are then fastened to the periosteum and cartilage by means of special needles. There are certain objections to the process. The chief is that the silk may work out, and the operation become a failure. This may be an exceptional occurrence, but it is one that cannot be avoided with absolute certainty. Decubitus may occur, too, whilst the silk is cutting its way through the skin. The commonest trouble, however, is adhesion of the silk to the tissues around, causing limitation of function. It was on account of these adhesions that Lange introduced the method of placing the natural and artificial tendons under the skin in the fatty tissue. They rarely occur in the method of "tendon to tendon."

My final opinion, therefore, is that, whilst the introduction of silk ligaments has led to an increase in our knowledge, its systematic employment, as in Lange's operation, is greatly to be deprecated. I have no objection to the adoption of periosteal fixation of natural tendon in cases where it is specially indicated. Lange himself admits that pure periosteal fixation is not absolutely reliable, for he introduces deep sutures into the cartilage when he can. Various surgeons have introduced other modifications for a similar purpose. Thus, Wolff placed the tendon in a groove in the bone, and Müller threaded it right through. Codivilla drew the tendon under a bridge of periosteum, and fastened the free end backwards in a loop to the descending part of the tendon. In other cases he fastened it to the bone by means of staples. Tubby, Jones, and Watkins are amongst the adherents of periosteal fixation.

The other variants of transplantation have hardly any practical interest—*e.g.*, the approximation of the muscle bellies, or the method in which the

central origin of the muscle is dissected up and united to the divided tendon of an adjacent healthy muscle.

The transplantation completed, the skin incision is closed, best by means of silkworm gut, which produces no irritation within a week. Lange recommends drainage for the first few days, thinking that this avoids suppuration and extrusion of the stitches. The general consensus of opinion is opposed to this, however.

The **after-treatment** is of great importance with regard to the result obtained. The limb is immobilized in a well-fitting plaster case, in a position which relaxes the stitches as far as possible. I think that it is well to keep the patient at rest in bed during the period of fixation, in order to avoid all dragging on the stitches. After six weeks the real after-treatment begins, consisting in the exercising of the muscle and the improvement of its innervation. Baths, massage, and electricity are used for the first purpose, whilst gymnastic exercises are good for the nerves as well as the muscles. The exercises must be carefully carried out, however, in order to avoid stretching the young tendon fibrils. Zander and pendulum exercises are particularly to be avoided. Active movement and exercise against resistance serve our purpose. Care must be taken, too, when the patient begins to walk, and it is well to limit and control the movements at the joints with a light orthopædic apparatus whilst the muscles are still insecurely united.

It will be appreciated, then, that the after-treatment requires someone who understands the work, and that it cannot be as effectively carried out by the relations as by the surgeon. The more thorough, careful, and prolonged the treatment, the more thorough will be the cure. Certain brilliant cases of recovery without any after-treatment—or, at any rate, without a sufficient amount—have been reported, but these do not affect the general rule.

Results.—We come now to the consideration of *results*, as far as they lend themselves to generalization. We shall then discuss the process of repair, as revealed by animal experiments.

Transplantations were performed upon animals by Hoffa, Borst, and Fritz, and also by Italia and myself. Borst describes the microscopical appearances as follows :

“Proliferation of the tendon sheath and surrounding tissue first takes place, and in this way the site of the operation is enclosed, and the blood that has been extravasated is organized. The connective tissue between the anastomosed tendons and the internal and external endothelium of the sheaths also proliferates. Multiplication of the tendon cells begins on the fourth day, and young fibrils grow out in fascicles into the newly formed tissue, in the neighbourhood of the stump. In addition they grow out of the distal part into the proximal, transplanted tendon, so that the old tendon is replaced by new. Round about the stump, too, there take place partially retrogressive changes, especially in those bundles which have been encircled by the silk ligatures. Apart from this, slight impairment of nutrition is often to be seen in the free end of the tendon ; tendinous tissue is very susceptible to this sort of thing.”

We have often had opportunities at later operations of investigating the result of the previous operation, as far as this could be determined without special preparation or prejudice to the patient. The fascia had invariably joined up, although the broken line in its fibres showed where the split had been made. The sheaths, on the other hand, had not developed as much as one would have expected. The tendons were movable, and quite distinct from the surrounding tissue, though they lacked the delicacy and polish which characterize the intact sheath. The transplanted tags often showed a definite opacity, rendered conspicuous by a whitish-grey discoloration. The silk stitches showed as little encapsuled knots in the transparent tissue. Such observations as have been made up to the present time show that, however well the wound may heal, there may be a great difference between the anatomical and the functional result, the latter being better than the former. The technique is still capable of considerable improvement, especially in the direction of avoiding injury to the tendon sheaths.

We return now to the question of the fate of artificial tendons. Glück, whose work on the implantation of artificial tendons to fill gaps in the natural ones has already been mentioned, says that there are three possibilities in the after-history of the silk and catgut strand :

1. It undergoes no change, but in the course of time it becomes enclosed in a sheath of connective tissue, within which is a fluid-like synovia.
2. It is completely replaced by fibrous tissue.
3. After some time, large portions of the strand may be extruded, the bridge of connective tissue that has been formed remaining intact.

Glück also demonstrated, in a tendon removed at a secondary operation, that a thick wall of connective tissue surrounded the silk sutures. He described the foreign-body tendon as the trellis along which the newly formed tissue grew.

A similar condition was described by Kümmell in 1896, and double staining showed clearly the growth of connective tissue along the silk strands. The preparation was obtained from a man who died a few months after the operation. I have obtained similar results in some of my experimental transplantations. Lange's clinical and microscopical observations of his silk tendons are very interesting. He is the most experienced worker at the present time in this branch of surgery. He was able to show that they became perceptibly thicker as the result of use. It was found that silken tendons as thick as a knitting-needle became as large as the little finger in two years. He also had an opportunity of examining three such tendons which had been functioning for two years and more.

In the first case the tendon was dense, rounded, and as thick as a lead pencil, bluish in colour, and surrounded by a layer of loose connective tissue, which hardly amounted to a true sheath. The strand itself consisted of a

tube of tissue, with a wall 2 to 3 millimetres thick enclosing the silk threads, which were unbroken and showed no sign of destruction. On histological examination it was found that the tissue immediately adjacent to the silk was identical in structure with ordinary tendon. The fibres ran in a longi-

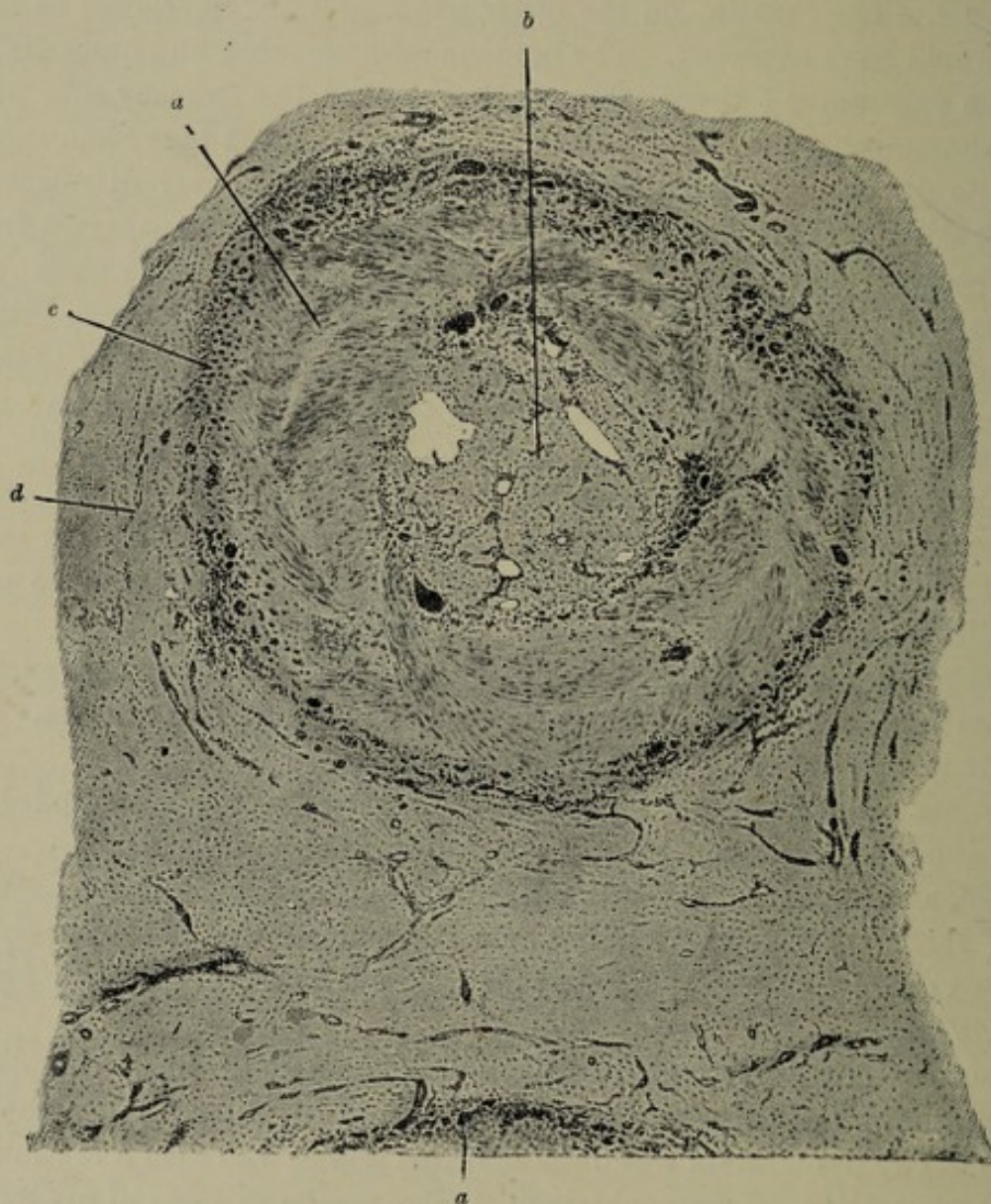


FIG. 50. (AFTER LANGE.)

a = Silk; *b* = connective tissue in middle of tendon; *c* = cellular and vascular layer surrounding the silk; *d* = tendon tissue, devoid of cells and vessels.

tudinal direction, and elastic fibres and vessels were almost entirely absent. The cells and fibres at the periphery were similar to those of normal tendon, but here and there were vessels and adipose tissue (Fig. 50).

The other two tendons came from patients aged five and eighteen years respectively, and had been in place for two years. On examination it was found that the new tendon did not merely grow round the silk strand,

but actually infiltrated it, and formed a central core of true tendon material.

These preparations show that the silk is first of all enclosed by young connective tissue, which in turn is replaced by proper tendon fibres. In the layer immediately surrounding the silk one finds young connective tissue with giant cells and numerous vessels, whilst towards the periphery the

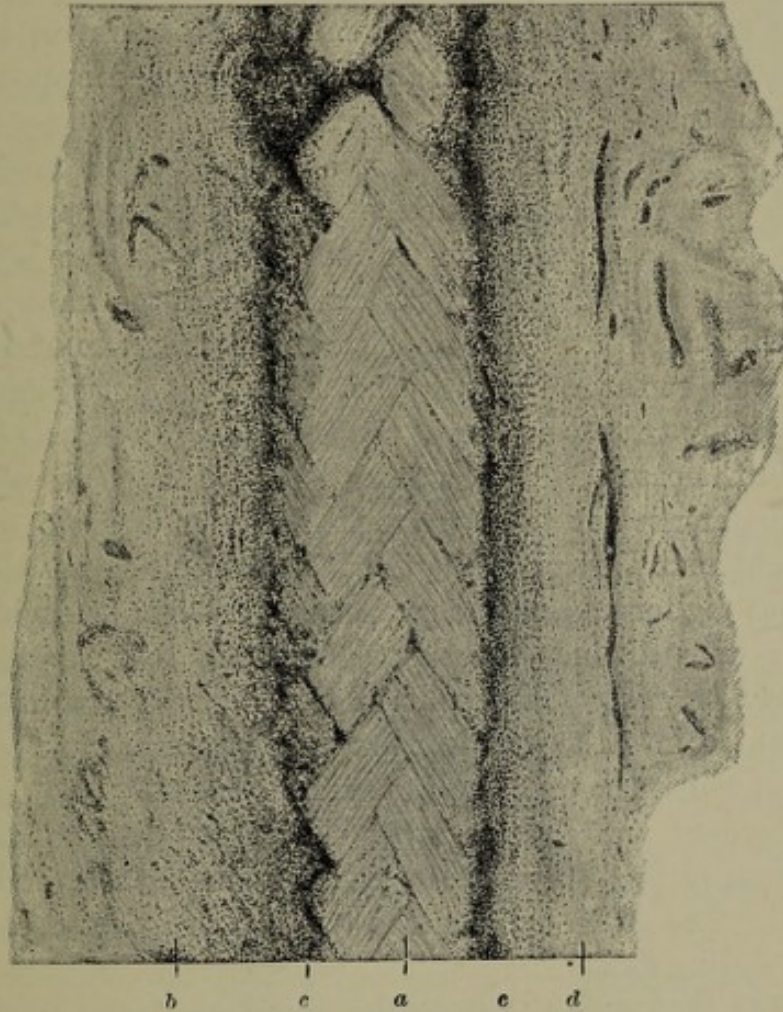

FIG. 51. (AFTER LANGE.)

a=Silk ; *b*=tendon tissue ; *c*=young connective tissue ; *d*=tendon sheath.

tissues are clearly more mature, and contain less and less cells and vessels, and bear more and more resemblance to ordinary tendon (Fig. 51).

The conditions essential to success are sound union of the anastomosed tendons and free mobility within a loose, sheath-like wall of connective tissue. It is more likely to be attained in cases of limited paralysis, and may be complete in cases where only one muscle has to be replaced. Where the palsy is more extensive, one has to be content with restoring the more important functions of the affected limb. The surgeon's task is then more difficult, for there is often little muscle to work with, and only a partial

success results, though it is precisely in these cases, rather than in those of paralysis of a single muscle, that a surgical and artistic success is to be desired. It is, as a rule, difficult, if not impossible, to give any prognosis as to the result. The amount that can be done, and the absolute and practical value of the result, vary with every case. The position of the available muscle is of importance, as well as its amount. The more nearly related are the functions of the anastomosed muscles, the more complete and the more rapid will be the improvement. If, however, an analogous one is not available, one of different function, or even an opponent, may be employed with success.

Adaptation.—Partition of function is another possible method. There is no doubt that a muscle can acquire the function of its antagonists. Thus, after a successful plastic operation on the quadriceps, the biceps, having been totally transplanted, will perform extension at the knee-joint. Codivilla showed that the dislocated peronei acted as extensors of the foot. As soon as they were replaced by operation, they were innervated as flexors. Even Lange admits that partition of the function of a muscle is possible—at any rate, in the case of the tibialis anticus—although he quite properly expresses a preference for total transplantation as being a more reliable method. Gocht and I emphasized the fact that other muscles—*e.g.*, the extensor longus digitorum and the gastrocnemius—can be divided into two distinct parts with distinct functions. Codivilla told me that even an antagonist may be successfully split in this way. Thus, half a gastrocnemius, implanted into the extensor longus digitorum, took on the action of an extensor, whilst the other half remained at rest.

I have observed and demonstrated the same phenomenon in a most convincing manner by transplanting part of the triceps tendon into the biceps brachii. The contraction of the transplanted part could be plainly felt and seen during flexion.

The **interval that elapses before the result** of the operation becomes manifest varies considerably. Some slight indication may be observed when the plaster is removed. Improvement continues to take place throughout the after-treatment, though never at a steady pace. Sometimes rapid and sometimes slow, it occasionally seems to occur, as the patients express it, “all in a night.” The **brain has to be educated** to control the new arrangement of the musculature.

It will, of course, be obvious that the improvement in motility is due not only to the restoration of the functions that were lost, but also to abolition of the action of the antagonists now transplanted. Those muscles, too, which had undergone disuse-atrophy are greatly improved by the resumption of regular, co-ordinated movement. The circulation, also, is greatly benefited by the increased use of the limb. The coldness, cyanosis,

and chilblains disappear, and, as Drobnik pointed out, the patients "feel new life" in the limb.

Lastly, restoration of function has a beneficial effect on the growth of the long bones.

Universal experience, therefore, which is worth a great deal more than all the arguments of sceptics and opponents, goes to show that tendon transplantation is no less successful in practice than it is brilliant in conception. It is equally certain, too, that the success that is obtained by operation may become a permanent success. This is not my experience alone, but that of every surgeon who has followed up a series of cases for ten years or so. I say "may become" advisedly. We pass on now to consider the **causes of failure**, for failures there are, as in everything else that is mortal. They do not discourage us, however, but show us how to avoid them in future, and so improve our results.

Contra-Indications.—In the first place the choice of the case may be fundamentally bad, and failure inevitable. We have seen that the prognosis is best when the paralysis is limited. When the patient has been left with nothing but a few wasted, paretic muscles, incapable of active contraction, these will be insufficient to make up for the widespread destruction that has occurred, and transplantation is valueless. In cases of extensive paralysis of long standing, where extraneous, unfavourable influences, such as overstretching, have been at work on the remaining muscles for some time, we must be cautious in selecting transplantation as the line of treatment. There are, as we have already said, border-line cases, which are amenable to one or other method, according to the individual surgeon's views. I myself incline to arthrodesis combined with plastic treatment of the tendons, rather than to transplantation, in those border-line cases in which the patient is poor, and only one joint is affected.

Given a suitable case, failure may yet occur from a faulty or insufficient plan of action. We may over- or under-estimate the power of the muscles with which we have to deal. In the first case no improvement—or, at any rate, no permanent improvement—will follow; in the second, over-correction will result, and one paralytic deformity will be converted into the opposite.

There is another way, however, in which we may under-estimate the value of a muscle, and that is when we perform total transplantation, and fail to appreciate the importance of the function which we are destroying. It not infrequently happens that the true value of a muscle is only made manifest when it has been put out of action. This difficulty has been overcome by not leaving the peripheral stump loose, but fastening it in an ascending direction to some adjacent muscle. This step increases the value of total transplantation, and renders it superior to partial operation. *The ideal technique undoubtedly consists in the employment, whenever it is*

possible, of total transplantation, using muscles that are analogous in function, and uniting them after the descending method.

A third group of failures are to be attributed to **faults in technique**. Incomplete reduction of paralytic deformities, imperfect asepsis, injury of vessels or tendon sheaths, displacement in a direction other than longitudinal, deficient area of contact between the united tendons, or insufficient tension—these are the chief pitfalls that we have to avoid. Even then, success will not be assured unless the after-treatment is properly carried out, when the plaster has been removed. The results of failure or neglect may often be rectified at a subsequent operation.

It will be seen that there are dangers in the method from first to last, and that they may render it worthless if they are not recognized or regarded. On the other hand, they may be lessened and overcome with care and increasing experience, so that in the majority of cases tendon transplantation may be relied upon to give a satisfactory result.

Physiology.—Finally, we come to the physiology of tendon transplantation, if one may so describe it. We shall allude to certain experiments of ours, which have been recorded elsewhere. Various authors have already mentioned that interesting physiological observations may be made, but, unfortunately, these still lack explanation.

Our knowledge of the actions of muscles, independent and combined, is increased by the study of the distribution of the paralysis before operation, in conjunction with the condition discovered at operation. The effect of surgical interference upon mobility is a more difficult but more profitable study. Let us consider the case of a total transplantation—*i.e.*, a case in which the action of a muscle has been completely transferred. If the union has been made between two muscles that are functionally related, the effective contraction of the muscle in its new position is only what one would expect. If we dorsiflex a normal foot, the tibialis anticus contracts simultaneously with the extensor longus hallucis, and it requires a certain effort to raise the foot, whilst keeping the great toe flexed. If, then, we replace a paralyzed tibialis anticus by the extensor of the great toe, the latter muscle will take on its new function without any difficulty. But where the muscles operated upon are of different function, the physiological process becomes difficult to understand, and when they are actually antagonistic it is almost impossible to explain it. Two theories have been offered. It is well known that the central nervous system is not a mature, preformed organ at birth, but that it undergoes development. External stimuli, acting by way of the muscles, are transmitted to the brain as muscle sensations, and these, after constant repetition, lead to the formation of centres presiding over certain definite co-ordinated movements. If, now, the peripheral stimuli are changed in character, the mechanism of the nerve centres will

be changed too, and a rearrangement or reconstruction take place. Tendon transplantation results in the **adaptation of the nerve centres** to the new grouping of the muscles (Drobnik).

The process requires a certain time for its accomplishment, and the movements, in the meantime, are not accurately co-ordinated. It is sometimes remarkable how hesitating and uncertain they are at first, to increase slowly later on in strength and exactitude. Thus, a grown-up man, for whom Müller had grafted the flexor carpi ulnaris into the extensor digitorum, writes that "at first he was confused, because his hand would not do as he willed, and, even when he began to perform movements of extension, he did not feel as if the hand were extended." Later on, however, he acquired normal movements and normal sensation. Another man, operated upon by Schanz for musculo-spiral paralysis, felt as if he were flexing his hand, when he was actually extending it. He performed the movement with hesitation. By degrees, however, he acquired the sensation of extension.

We shall revert, later on, to the consideration of the very remarkable extent to which the brain can adapt itself to changes in peripheral relations. The theory of gradual adaptation fails to explain those cases in which a flexor takes on with remarkable rapidity the function of an extensor. Thus, Franke found that extension was already possible a fortnight after suturing the flexor carpi ulnaris to the extensor digitorum.

How comes the transplanted flexor to be stimulated when extension is desired?

To answer this question we must consider briefly the physiology of normal movements. Here, however, we are faced with the difficulty that the question that chiefly interests us—namely, the function of the antagonists—is imperfectly understood. Galen thought that a certain movement of a muscle evoked the opposing movement in its antagonist. This theory obtained until the time of Duchenne, who thought that both muscles participated in every movement, and that a slight preponderance of one or other determined the direction of the resulting movement. Brück and von Kries shared this opinion. At the present time physiologists incline to Duchenne's view, as shown by Hering and Sherrington's work. It is stated that stimulation of a muscle to contract is associated with an inhibitory impulse to its antagonist. I think that the facts of tendon transplantation go to support Duchenne's theory. For example, if we ask a patient with paralyzed extensors but intact flexors to raise his toes, we get a movement of flexion. (This, however, does not take place if the paralysis has been of long standing.) Originally, when the patient wished to perform flexion, the flexors and extensors worked together; later on the flexors alone survived, and for a time they contracted unopposed. Finally, co-ordination was lost. If, then, the flexors be transplanted, before the paralysis is too old, into the

weakened muscle, extension will be regained, and after some practice the movement will become quite powerful. When the lesion is an old one, the co-ordinating centre has to be awakened from its lethargy, and to be adapted to the new state of affairs. I published this view some years ago, though I knew nothing at that time of the confused state of the physiology of the subject. I stated that the rôle of the antagonists in regulating movement was quite obvious, and I think so still. One can both see and feel that all the muscles of the leg are more or less active, according to the stage of the movement, during dorsiflexion of the foot. The possibility of *slow* dorsiflexion of the foot can only be explained by assuming the co-operation of the muscles of the calf, which may be compared to a brake, whilst the preservation of the mid-position of the foot during extension must be due to simultaneous action of the pronators and supinators. Codivilla has expressed his agreement with my view, and Thilo has recognized its accuracy with regard to the physiology of the normal.

From what has been said, the combination theory seems to me to be the most apposite. I think that the initial stimulus to the development of the new function is afforded by the constant activity of the antagonists; that further education depends upon practice and the adaptation of the cerebral centres; and that this is effected by the motor and sensory stimuli that travel along the sensorimotor paths.

Partition of function remains to be described and explained. It is easy to understand how there can be one contraction and two functions, when the muscle belly has been left intact, and only the tendon has been split and given two separate insertions. But it is a truly remarkable thing that a muscle can be divided into two distinct parts, with two distinct functions. Codivilla explained it by reference to the phylogenetic differentiation of the musculature, and regarded this particular instance as an ontogenetic extension of the process. Moritz, however, was of opinion that a large muscle, like the tibialis anticus, was innervated, not merely by a single nerve cell, but by a whole group of cells, which, as a general rule, all worked together. Supposing that certain only of these cells were thrown into activity, the muscle having a single insertion, the only possible result would be that the action of the muscle would be weakened, its direction remaining unchanged. But if half the muscle were given a new insertion, then only the corresponding group of cells would be stimulated, and the patient would acquire a new movement and a new sense of movement. After frequent repetition, the power of voluntarily effecting this movement alone might be acquired. Given the requisite peripheral conditions, the question of differentiation in the use of the muscles is purely one of educating the cerebral cortex, and can only be attained by practice. Electrical stimulation of the two parts of the divided muscle might be of value in providing those stimuli that are essential to the education of the cortical centres (Moritz).

5. Nerve Transplantation.

Historical.—Richard Volkmann, in 1870, wrote an article on “Infantile Paralysis and Paralytic Contractures” in the opening number of the *Sammlung klinischer Vorträge*, and added the following prophecy, after insisting upon the necessity of preventing the occurrence of secondary lesions in the extremities: “No one has yet succeeded in restoring the continuity of the path from the nerve centre to the motor apparatus, nor is it likely that this ever will be accomplished.” Nevertheless, the improbable is to-day within measurable distance of attainment, and nerve transplantation has passed beyond the stage of interesting experiment. The value of the method has been demonstrated, and there can be no doubt that the operation has a promising future before it.

During the earlier stages of the development of orthopædic surgery, operative measures were restricted to the muscles, joints, and tendons. No attempt was made for a long time to attack the peripheral nerves, although the old idea that tetanus was almost certain to result had long been exploded. Baudens, in 1835, was the first to report a successful nerve suture in man, and he was followed in 1854 by Langenbeck, and in 1863 by Nélaton. Numerous accounts of more extensive operations then began to appear, until to-day omission to perform primary nerve suture is regarded as a mark of incapability. Secondary suture, too, has given gratifying results. In many series of cases 90 per cent. of favourable results have been reported. In cases of injury to the nerve roots plastic operations were performed, based upon various methods of great physiological interest, which had been put to experimental test. The following may be mentioned: Autoplasty, by means of a flap taken from the stump of the injured nerve; transplantation of a piece of human or animal's nerve into the gap; the union of the divided ends by means of catgut or other animal material; the introduction of tubes of bone, gelatin, or india-rubber; and, lastly, nerve grafting—*i.e.*, the union of the paralyzed nerve to an adjacent healthy root.

The credit for the last idea is due to Létiévant, who, in 1872, suggested the freshening of a portion of healthy nerve, and sewing the peripheral stump of the injured nerve into it. This applied particularly to the case of the median and musculo-cutaneous. He did not carry out the operation himself, and it remained for Desprès, in 1876, to implant a cut median into the intact ulnar nerve. Gunn performed the converse operation in 1886, with partial success. Neugebauer attempted (1896) to graft the peroneal into the tibial nerve, but the result was a failure.

The first really brilliant success was reported by Sick and Säger. They sutured a flap from the median into the radial nerve; the patient recovered

complete use of his hand. Dumstrey also succeeded in grafting the peripheral part of the ulnar into the median. The operation of nerve grafting began to attract much more attention when it was found that good results could be obtained in facial paralysis. In 1895 Ballance had united the facial to the spinal accessory, with a certain amount of success, and his example was followed by Faure and Furet, Glück, Kennedy, and many others, so that the literature of the subject now includes more than half a hundred cases.

There was one impediment to the development and recognition of the method, and that was the neurone theory as originally propounded. This difficulty was removed, however, by the successful cases of nerve transplantation, few and partial though they were. The theory may be briefly summarized thus: The peripheral neurone consists of the anterior cornual cell, and the fibres which arise from it and run uninterruptedly and without branching right down to the motor end plates. The ganglion cell is the trophic centre of the neurone.

If the theory be accepted completely and unreservedly, nerve grafting must appear purposeless, and little or nothing can be expected of it. But this view underwent a change during the controversy over the neurone theory, and splitting and anastomosis of nerve trunks came to be recognized procedures. At the same time, the question of the regeneration of divided nerves was revised and investigated, as we shall shortly see, and the results that were obtained enabled nerve grafting to be placed upon a firm and scientific foundation.

The vague reports that were published of facio-accessory or facio-hypoglossal anastomoses led to the precise study of the physiological and practical issues by means of animal experiment. Similar researches had been carried out some time previously: Flourens, in 1828, divided the two nerves that go from the brachial plexus to the wing in a hen, and united them crosswise. The bird learned to use the wing again in a normal manner in the course of some months. Rawa, similarly, interchanged the peroneal and tibial nerves after completely dividing them, and observed regeneration and partial adaptation of function. Gunn, assisted by Davis and Sheldon, carried out complicated crossing of the three great nerve cords of the upper limb, and obtained positive results. These, however, can only be explained upon the assumption that peripheral anastomoses exist.

In animals it is particularly difficult to estimate the success that has attended an operation of this kind, on account of the so-called *motilité supplée*, whilst active contractions of the muscles that are not paralyzed, and a certain clumsiness in moving, may prevent the recognition of a successful operation as far as the paralysis is concerned.

Manassé performed some extremely careful experiments in 1900, consisting in the lateral anastomosis of the peripheral part of the facial with the spinal accessory, without previous freshening of the surfaces. Dogs were used for this purpose. The result, clinically, was only a partial success, but

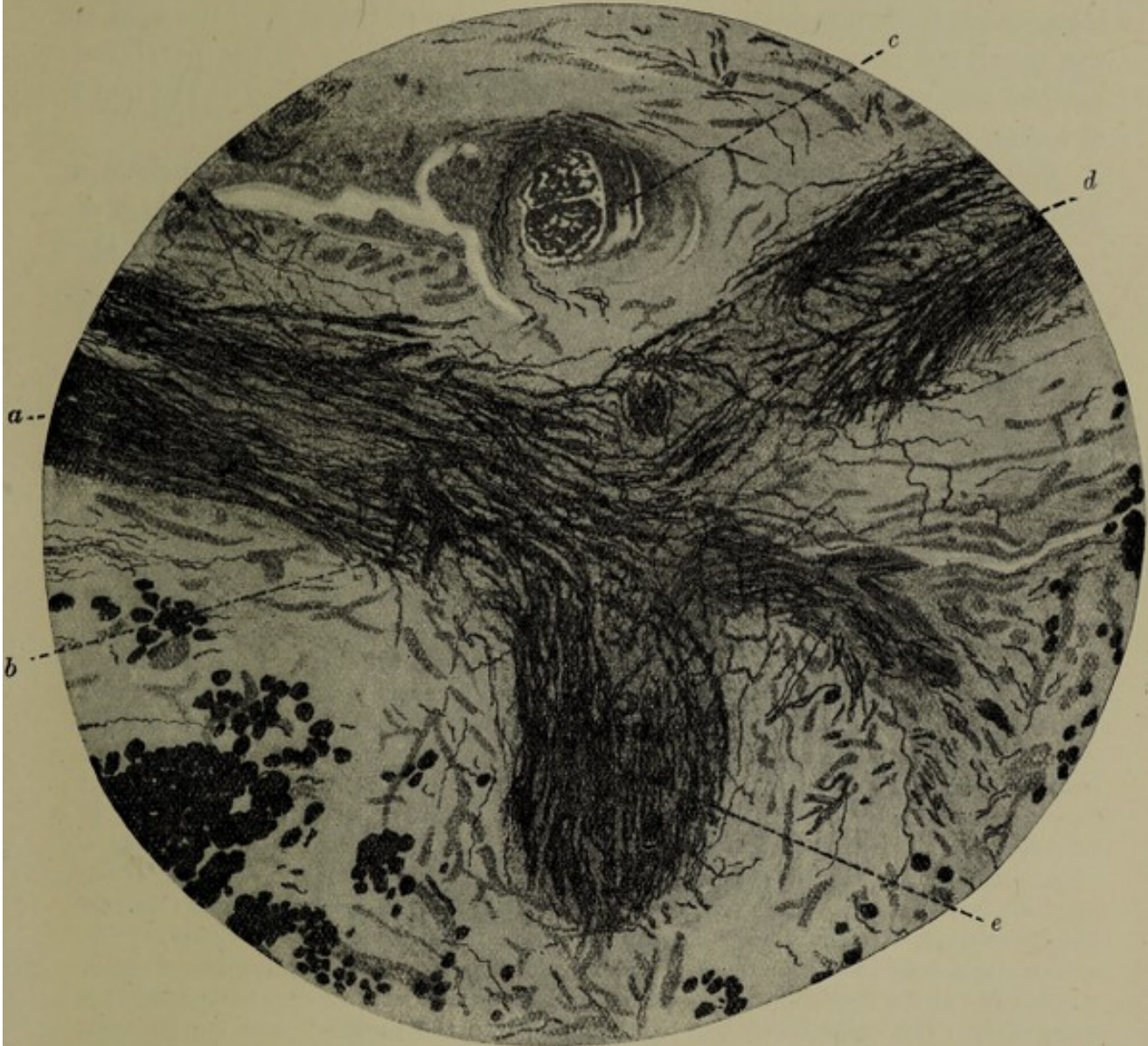


FIG. 52. (AFTER MANASSÉ.)

a = Facial nerve ; *b* = site of the neuroplasty ; *c* = silk-fibres ; *d* = spinal accessory nerve, peripheral end ; *e* = spinal accessory nerve, proximal end.

the microscopical findings were of the greatest importance, proving conclusively, as they did, that nerve fibres actually grew down to fill the deficiency. The anastomosis was exposed a year after the operation, and showed perfect union, whilst the facial area could be excited by electrical stimulation of the accessory. The microscopical preparation is reproduced

here, on account of the clear proof which it affords of the continuity of fibres between the accessory and the adjacent facial (Fig. 52).

Analogous experiments upon the extremities are, of course, of far greater value to the orthopædist. The most careful technique and criticism are required to dispose of Manassé's objections to this form of treatment. It is necessary to demonstrate the clinical restoration of function in the area of the paralyzed nerve, the return of electrical excitability in the paralyzed muscles and nerves, and anatomical and histological continuity at the point of union.

Spitzzy, whose untiring activity in the field of neuroplasty has done a great deal to maintain interest in the operation, has carried out a series of experiments upon these lines with the greatest care. We shall give a detailed account of the course of one of them, and of the conclusions that were drawn :

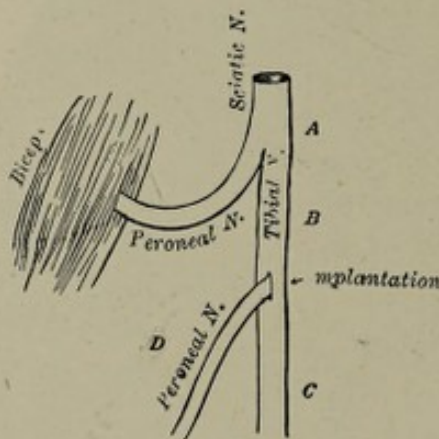


FIG. 53. (AFTER SPITZY.)

“On November 9, 1903, a dog æt. 2 years was operated upon under morphia and ether. The right sciatic trunk was exposed as far down as the separation into tibial and peroneal nerves. The peroneal was divided and fastened by means of a longitudinal suture into a slit in the tibial. The central end of the peroneal was doubled back, passed through the biceps muscle, and fastened to its mesial aspect; in this way spontaneous union of the two parts of the nerve was prevented (Béthé's method, Fig. 53). Primary union oc-

curred. The animal was unable to use the leg for three weeks, and then began to make cautious movements; the extensor muscles of the foot felt flabby, and could only be excited by means of very strong faradic currents. No movements of extension could be executed. Manifest improvement took place. On February 4—*i.e.*, after three months—a plastic operation was performed on the dog's left leg. He had learned by this time to get about on the other one; he could raise his paw like other dogs. On March 17—*i.e.*, after four and a half months—the tone of the extensor muscles had returned, and they felt as hard as those of the non-operated limbs.

The site of the operation was exposed, and the sciatic nerve found embedded in a mass of fat; the tibial nerve was seen running into the junction, and the peroneal issuing from it, surrounded by a knob-like swelling. About 4 centimetres higher up was the peroneal nerve, running through the biceps muscle. The genuineness of the anastomosis was thus established, and there was no question of reunion of the two parts of the peroneal.

The nerves were isolated, and stimulated in the following manner (*vide* Fig. 53):

1. Electro-galvanic and mechanical stimulation at *A*, on proximal side of cicatrix; contraction in distribution of tibial and peroneal.
2. Stimulation of tibial, at *B*, on proximal side of cicatrix; contraction in distribution of tibial and peroneal.
3. Stimulation of tibial at *C*, distal to cicatrix; contraction in tibial region (slight ditto in peroneal distribution).
4. Stimulation of peroneal at *D*, distal to cicatrix; contraction in peroneal distribution.

The tibial nerve was then cut through at *C*, about 1 centimetre peripheral to the cicatrix.

5. Stimulation of sciatic at *A*, or tibial at *B*, on central side of cicatrix ; contractions in peroneal distribution only ; tibial region unaffected.

6. Stimulation of peripheral part of tibial nerve at *C* ; contraction in tibial distribution, without any movement in peroneal area.

This technique avoids all possibility of innervation from lateral anastomoses, arising either from the central stump or from the intact nerve beyond the point of union.



FIG. 54. (AFTER SPITZY.)

Next, the nerves were cut through, a few centimetres away from the junction on either side, and were fixed in correct physiological position for the purpose of histological examination. They were hardened in Zenker's solution, embedded in paraffin, stained by the Pal method, and cut into fairly thick sections. Difficulty was experienced from the fact that the different parts lay in different planes, so that it was not easy, even in a large number of sections, to pick out ones in which the structures concerned could be traced for any distance. Microscopical investigation showed, however, that anatomical union and interchange of nerve fibres had taken place (Fig. 54). This is illustrated by the reproduction of a photo-micro-

graph, although, as a matter of fact, it is derived from another experiment in which the tibial nerve was implanted into the peroneal. Fibres are seen, running obliquely from the union into the stump of the tibial nerve.

Scientists have not yet agreed as to the exact manner in which **degeneration and regeneration** occur after a nerve has been divided. The first event is a rapid destruction of the nerve fibres, taking place within a few days, and affecting not only the whole peripheral part of the nerve where it is cut off from its ganglion cell, but also a certain part of the central end. The adherents of the neurone theory see in this a proof of the dependence of the nerve fibres upon the trophic influence of the corresponding nerve cells, but their opponents attribute the event partially or entirely to trauma.

The nuclei of the sheath of Schwann do not participate in the general destruction, and at the peripheral part of the nerve they undergo active proliferation. They are stated by their activity to produce new fibrils (autogenous regeneration), and these join with the fibres put out by the central end, whose capacity for regeneration is certainly greater than that of the peripheral part, and is more marked in young patients. In addition to proliferation there have been various accounts of budding and bifurcating of the central nerve fibres.

Innervation occupies altogether a year or so. But cases are recorded in which conductivity has returned within a week or two. Apart from errors of observation, the only explanation at present of such a condition is that it is due to the formation of lateral anastomoses.

Much remains to be done in the way of following up the cases, and in studying the details of the process, but there is no sort of doubt about the essential fact, that *two nerves can be united not only in an anatomical, but also in a histological, sense.* Nervous conductivity can be restored by lateral communication, and this justifies the introduction of the operation into orthopædic surgery.

Indications.—Amongst the numerous indications for nerve grafting, we shall deal only with infantile paralysis. The **requisite conditions** for the operation are that the paralysis should be limited to the distribution of one large nerve, and that a healthy nerve should lie at a convenient distance from the site of operation.

The more peripheral the union, the better, theoretically, is the case; for we then escape the zone of mixed fibres and enter that of purely motor fibres, and, in addition, the length of degenerated nerve that has to be innervated is so much the less. When there is no absolutely healthy nerve available for grafting, the indication for operation becomes less and less, in proportion as the surrounding nerves are affected. We shall have cause to refer repeatedly, later on, to the indications for nerve grafting in the

different extremities and parts of the extremities, and to the indications for the operation, in preference to muscle and tendon operations.

When is the proper time to perform the operation ?

The tendency of the leading authorities on the subject is to shorten the delay, although it has been found by experience that recovery may take place after ten years or more. Our object, however, is not the performance of an experiment, or the restoration to the injured muscle of a feeble power of contraction or electrical excitability, but the production of a really useful muscle, so that long delay is to be deprecated. Within the first six months after the onset of the attack of paralysis, we can tell which muscles are completely destroyed, and which are capable of further improvement: any time within the next six months, up to the next twenty, the condition of the muscles will remain so far constant that no further change in the plan of treatment need be contemplated. It may be remembered, too, in deciding upon the operation, that it causes hardly any disturbance, so that if it does not succeed, some other method, such as a tendon operation, can always be performed later on. The longer the operation is postponed, the more extensive becomes the degeneration of the nerve and its end organ, the more do the very atrophic muscle and the weakened joint capsule become overstretched, and the prospects of success become diminished. I think it is well, therefore, to **resort to neuroplasty about six months after the onset** of the illness, if the conditions are such as to suggest this as a suitable mode of treatment. The operation may be performed later on, however, even if it be not the time of election, in patients who only present themselves for treatment after some time. It has been stated that the first three years are the most favourable, and that afterwards the chances become less; our experience in this direction, however, is so scanty that such opinions must be based more upon conjecture than upon actual knowledge.

On the other hand, I think that it is not well to operate sooner than I have said. Spitzzy, in his earlier work, said that he thought the operation was indicated if, four to six weeks after the onset of symptoms, the reaction to electricity was growing weaker, thus indicating that the destruction of muscle and nerve was progressing. He adds—and with good reason—that there is an objection to this method, in that success might follow even if the operation had not been performed, and he compares the problem to that of surgical interference in appendicitis. This, however, is not quite on a par, for the question of saving life is there of paramount importance.

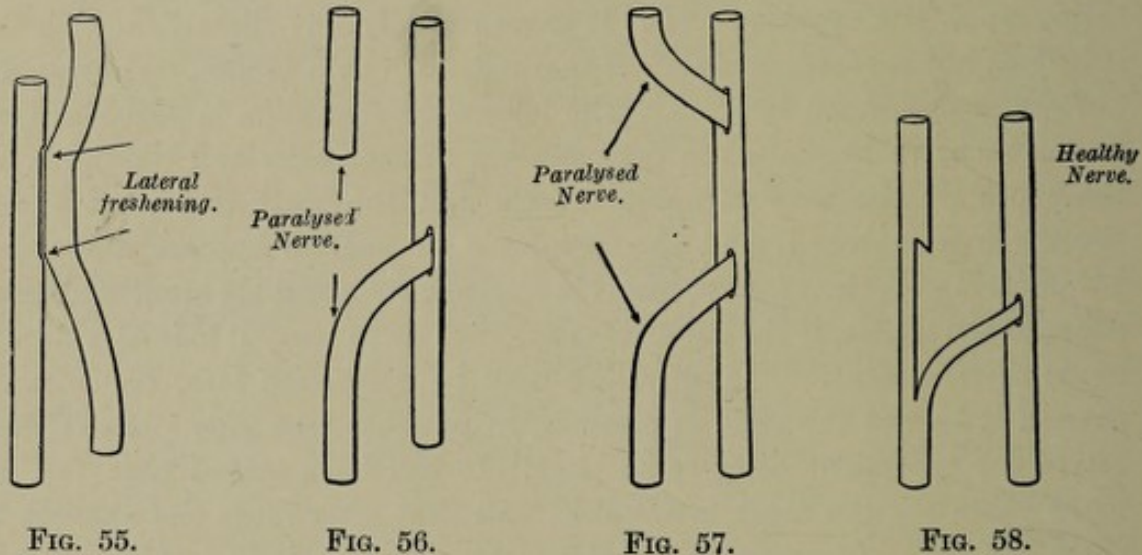
I am of opinion that we should only undertake cases within the three months' limit under very exceptional circumstances, when there is a special indication for surgical interference. Otherwise, it is difficult to estimate the value of the operation *per se*, as well as in comparison with other methods.

Accurate judgment of cases is a matter of experience.

Technique.—We turn now to the question of technique.

The skin incision is so arranged that the nerve anastomosis does not come to lie immediately under it. This insures the best possible healing of the union, and prevents any keloid formation that may occur from extending into the depth of the wound. The ends of the nerves are cleaned as gently as possible, especial care being taken to avoid injuring their sheaths more than is absolutely necessary. Every conceivable method of uniting the two ends has been practised, with varying degrees of success. No single technique can be described as the best, though perhaps the preference should be given to that form of operation in which two transverse sections are sewn together; on theoretical grounds, at any rate, this method is the most likely to give a good result.

We now proceed to discuss several points bearing upon the choice of a



method. The simplest and least destructive method consists in freshening the adjacent surfaces of the nerves for several centimetres at a point where they run close to one another, and then suturing the two together. This is known as Lateral Apposition (Fig. 55).

Another way is to cut through the paralyzed nerve and fix its peripheral portion into the healthy one—Total Ascending Transplantation (Fig. 56). The central stump may either be left alone, or it, too, may be implanted in the healthy nerve (Fig. 57).

A simpler way is to cut a stout flap, with its base attached to the peripheral part of the paralyzed nerve, and to graft this into the sound one—Partial Ascending Transplantation (Fig. 58).

Total and Partial Descending Transplantations are performed on similar lines (*vide* Figs. 59, 60, and 61).

A reciprocal transplantation, or Partial Decussation, may be estab-

lished by cutting flaps from both nerves and uniting them end to end, as shown in Fig. 62. Total Decussation is effected by cutting both nerves completely across and joining the proximal end of the one to the peripheral end of the other (Fig. 63). The nomenclature which I have employed in describing these operations is based upon that which I proposed in connection with tendon transplantation. It has already been adopted for this purpose, so that it would be convenient to retain the same system in describing the analogous operation of neuroplasty.

Spitzzy describes the descending method as "central," and the ascending as "peripheral," and there is no particular objection to the method, though I must confess that I, personally, find it difficult to remember which is which without the aid of a *memoria technica*.

Spitzzy has also devised a special pair of forceps for preventing injury

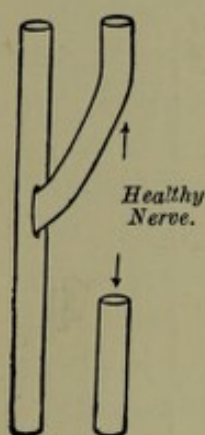


FIG. 59.

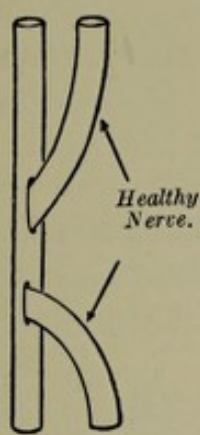


FIG. 60.

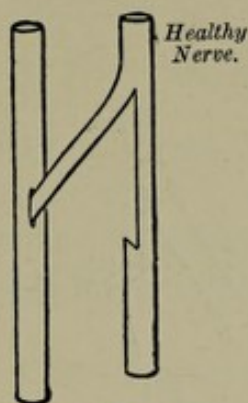


FIG. 61.

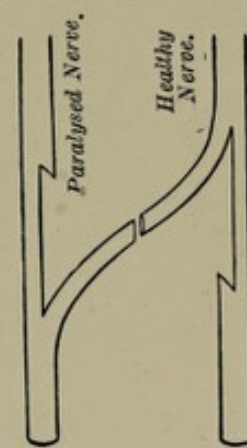


FIG. 62.

to the nerve during manipulation; each blade has a groove near the end, in which the nerve lies, free from pressure.

He has a special method, too, of cutting the flaps. The incision is made at an angle, instead of transversely, so that the divided ends of the fibres are left exposed upon a sort of shelf of the healthy nerve. This shelf is stitched down, and in this way the down-growth of fibres into the peripheral part of the good nerve, beyond the anastomosis, is facilitated (Fig. 64).

The size of the flap depends upon the functional importance of the nerve from which it arises. The question is more serious in the case of an "ascending" operation, in which the flap is taken from the healthy nerve. A larger portion can be sacrificed without anxiety in "descending" operations, but the flap should never include more than a third, or, at most, a half, of the root from which it arises.

There is another matter in connection with the fashioning of the flap which deserves far more attention than it has yet received. We shall discuss it in detail, but first we must complete the description of the various steps of the operation.

The suturing of the two nerves or flaps is quite easy when they lie close together; but if one of them has to be displaced any distance this must be effected without any bruising or other injury. Spitzzy's "tunneller" may be of use for this purpose; it consists of a thin metal tube, which is passed through the soft tissues in the required direction, and through which the nerve is drawn by means of a silk thread.

There are various methods of uniting the two nerves. We can cut one end obliquely, and sew it on to the side of the other nerve after refreshing it; or we can insert it in a longitudinal slit, so that it lies within the other nerve; or, lastly, we can perform end-to-end anastomosis. We have frequently drawn the transplanted part right through a slit in the recipient nerve, and then fixed it into the interior upon the opposite side, so as to prevent retraction. This last modification is, as we have already said, the best,

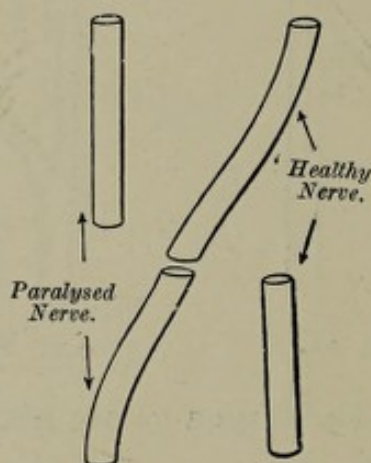


FIG. 63.

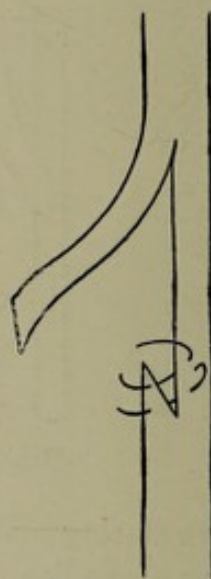


FIG. 64.

on theoretical grounds, because it seems to insure the most rapid down-growth of young nerve fibres. In actual practice, however, the method most frequently employed is that of introducing the graft into a simple longitudinal slit.

The same applies to the choice between ascending or descending methods of operating. The latter is the better method, on physiological grounds, but it frequently happens that it cannot be adopted—*e.g.*, because the nerve is too thin to allow of freshening or splitting. In such instances the ascending method must be chosen.

The duration and extent of the paralysis also affects the choice of the method. If the lesion is an old one, and the nerve is totally paralyzed, a total ascending transplantation is indicated, because separation from its trophic centre is of no importance. If, on the other hand, there is still

some possibility of improvement, and the nerve is not altogether incapable of conduction, partial ascending transplantation would be the method selected in order to avoid unsatisfactory sequelæ.

There are other factors, too, which we learn by experience to appreciate.

We pass on, now, to consider the details of suturing the two parts together. Fine silk or catgut is employed for the purpose. The nerves are united without any tension, so that the stitches may be few in number, and quite superficial, so as to crush as few fibres as possible. For the same reason Spitzzy passed his sutures in a longitudinal direction. It is exceedingly important that only a minimal amount of fibrous tissue should form at the site of the anastomosis, because it is apt to penetrate into the interior of the nerve and interrupt the down-growth of the fibres. Spitzzy, therefore, surrounded the union with a piece of a dog's artery, hardened after Foramitti's method;* with the same object a special line of fascial sutures has been recommended, in the case of superficial nerves. The skin incision is closed right up, and the limb immobilized for about a fortnight.

After-Treatment.—The after-treatment is then begun. It consists, at first, of systematic **electrical stimulation** of the muscles and nerves, and later on of prolonged **massage** and **exercises**. Meanwhile, the limb may with advantage be fixed in some simple **appliance**, to prevent overstretching of the paralyzed muscles.

Neuroplasty has frequently been combined with operations on the tendons. If any paralytic contracture is present this must, of course, be reduced by manipulation, and, if necessary, by tenotomy, before the nerve operation is performed. Such a line of treatment, however, is open to the objection that if the operation succeeds, it is impossible to know whether the credit is to be attributed to the nerve grafting or not. This argument applies particularly to those cases in which tendon shortening or transplantation has been performed at the same time, for we know that either of those operations, apart from nerve grafting, is very likely to give a brilliant result.

The adherents of neuroplasty insist that the muscles must be under a certain tension if they are to remain or to become contractile. They maintain that this tension must be replaced by operation if it has been destroyed by disease, and that it is only then that successful innervation of the muscle becomes possible. Their opponents, on the other hand, state that tendon shortening alone, in conjunction with the appropriate after-treatment and exercises, is sufficient to bring about restoration of function (Pürckhauer, Wittek). The only operations, therefore, from which reliable conclusions

* "Cargile Membrane" is frequently used in this country for the same purpose, and is efficient.—TRANSLATOR.

may be drawn, are those in which neuroplasty alone has been performed. Even then, sceptics object that the prolonged fixation of the limb in a position of relaxation has had something to do with the successful result. The only conclusive cases, therefore, are those brilliantly successful examples of nerve grafting in traumatic nerve lesions, where no other treatment has been employed. Before we discuss results, however, we must revert to the question of the manner of forming the flap.

It has hitherto been the practice to cut it without any reference to the arrangement of the nerve fibres within it. It has been assumed that the choice of the part to be grafted is as much a matter of indifference as it is in the case of the tendons. In the same way the site of implantation has been chosen in a perfectly haphazard manner, the surgeon trusting that the young fibres would hit upon the path desired, and find their way to the appropriate muscles. Medical literature, however, affords but little information upon the internal structure of the nerves, and anatomists have hardly begun to study it. Spitzzy remarks, in this connection, that "too little is known about the topographical arrangement of the various tracts in the large nerve trunks, and one cannot tell that in preparing the surface for grafting, one is not dividing important strands." Bruandet, writing upon this subject in 1905, though not in connection with nerve grafting, made an announcement that seems to dash all hopes of ascertaining accurately the distribution of the different paths. He found, as the result of physiological experiments, that the motor fibres in a peripheral nerve do not run in a compact bundle, but are diffused throughout it, mixed up with all the other fibres.

Internal Anatomy of Nerve Trunks.

Dr. Stoffel, the chief physician of my clinic, undertook to place the operation of nerve transplantation upon a secure and detailed anatomical basis, or, in other words, to work out the course of the fibres in the large nerve trunks by clinical and anatomical methods. This laborious research is as yet by no means complete or confirmed, but the facts already ascertained are of such importance in connection with technique and the proper understanding of the operation, that we shall enter into the results at some length.

The method of clinical investigation adopted consisted in picking up nerves that were exposed during operations, bundle by bundle, with fine-pointed forceps, and squeezing them lightly. The muscular contractions that resulted were accurately noted.

Post-mortem bodies were used for the anatomical studies. Unfortunately we had to be content, for the most part, with still-born foetuses. Portions were taken and stripped of fat and skin; they were then placed

for a week in a mixture of 5 parts of nitric acid and 95 parts of 70 to 80 per cent. alcohol. After a thorough washing, the preparations were ready for examination. The whole of the connective tissue of the nerves is rendered soft and œdematous by this process, whilst the nerve fibres are hardened. The nerve is then fastened, every 2 or 3 centimetres, to the underlying structures (muscles), by means of silk sutures, so that it cannot move

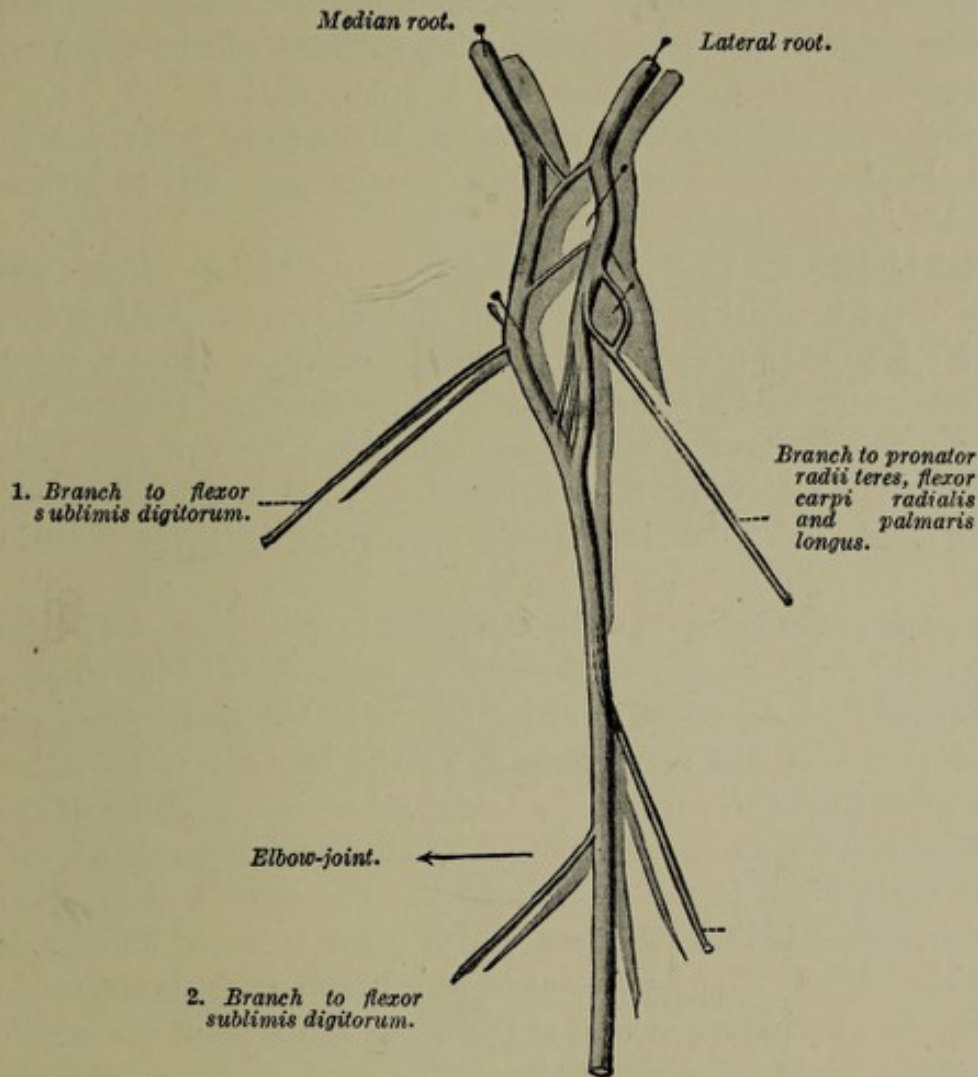


FIG. 65.—INTERNAL PLEXUS OF MEDIAN NERVE.

during the dissection. All perineural connective tissue is removed, and then each muscular branch is followed up to its attachment to the main trunk from the periphery. In this way, Stoffel succeeded in tracing many of the muscular branches for a long way—*e.g.*, from the upper limb up to the brachial plexus. The dissection was performed with the back of the knife, so that there was no question of artifact. When a motor path was isolated, it was represented schematically, so that when all the tracts were worked out a complete transverse section could be drawn. Examples of the results are given in Figs. 66 and 71.

A peripheral nerve, therefore, must be regarded simply as an aggregate of separate twigs, which are united together by numerous anastomoses. One may describe this arrangement as the "internal plexus" of the nerve (see Fig. 65).

A large number of anatomical investigations of this kind were made, and the results confirmed by investigation of the nerves during life, and in freshly amputated limbs, and considerable uniformity of results was obtained. A large amount of further painstaking research will be required, however, before the question can be regarded as finally settled.

Stoffel's results are still so new that it seems to me to be better not to describe them in the various chapters of the special part, but to give a collected account of them here.

Musculo-Spiral Nerve.—The musculo-spiral nerve arises from the posterior cord of the brachial plexus. It then divides into two distinct and easily separable groups of fibres. One group, consisting of about a third of the total bulk of the nerve, includes the fibres for the three heads of the triceps and for the anconeus. It lies beneath the origins of the teres major and subscapularis. We will describe these as the "ulnar" fibres, the arm being considered as resting upon a flat surface, with the forearm supinated.

The second and larger group includes the fibres to all the muscles of the forearm innervated by the musculo-spiral nerve; it lies close to the coracobrachialis, and may be described as the "humeral" division. On more detailed examination of the first group it will be found that the three muscular branches to the triceps can be traced from the periphery to the place where they unite into a single nerve, which then runs on to the plexus. This nerve is easily found in the living subject. The tendon of insertion of the latissimus dorsi is dissected free, and a nerve is found crossing it almost at a right angle. That part is taken which looks towards the origin of the muscle. In a transverse section of the nerve at this point the bundle in question would be found towards the ulnar side, in addition to a few fibres on the dorsal aspect. The root to the subscapularis and teres major has a similar relation to the latissimus dorsi. The inner head of the triceps is innervated, according to Stoffel, by two fairly large branches, which then unite and run up to the plexus, lying on the ulnar, and somewhat on the palmar, aspect of the main nerve. In the same region, there is a third root that can be isolated, which breaks up into several branches at the periphery; it supplies the outer head of the triceps and the anconeus, and also gives sensory fibres to the external cutaneous branch of the musculo-spiral. These fibres also run in the ulnar part of the main trunk in the axilla, but rather more towards the palmar aspect than the previous ones. We may summarize the arrangement by saying that all the fibres to the extensors

of the upper arm run, in the axilla, in the ulnar portion of the musculospiral nerve, either towards its palmar or its dorsal part.

We will next trace the lower arm fibres upwards from their distribution. On dissecting out the various branches given off in the groove between the brachio-radialis and the brachialis muscles, twigs will be found going to the brachio-radialis, the extensor carpi radialis longior and brevior, and the supinator brevis, as well as sensory fibres to the skin and the deep motor branches to the extensors of the fingers. All these branches can be followed

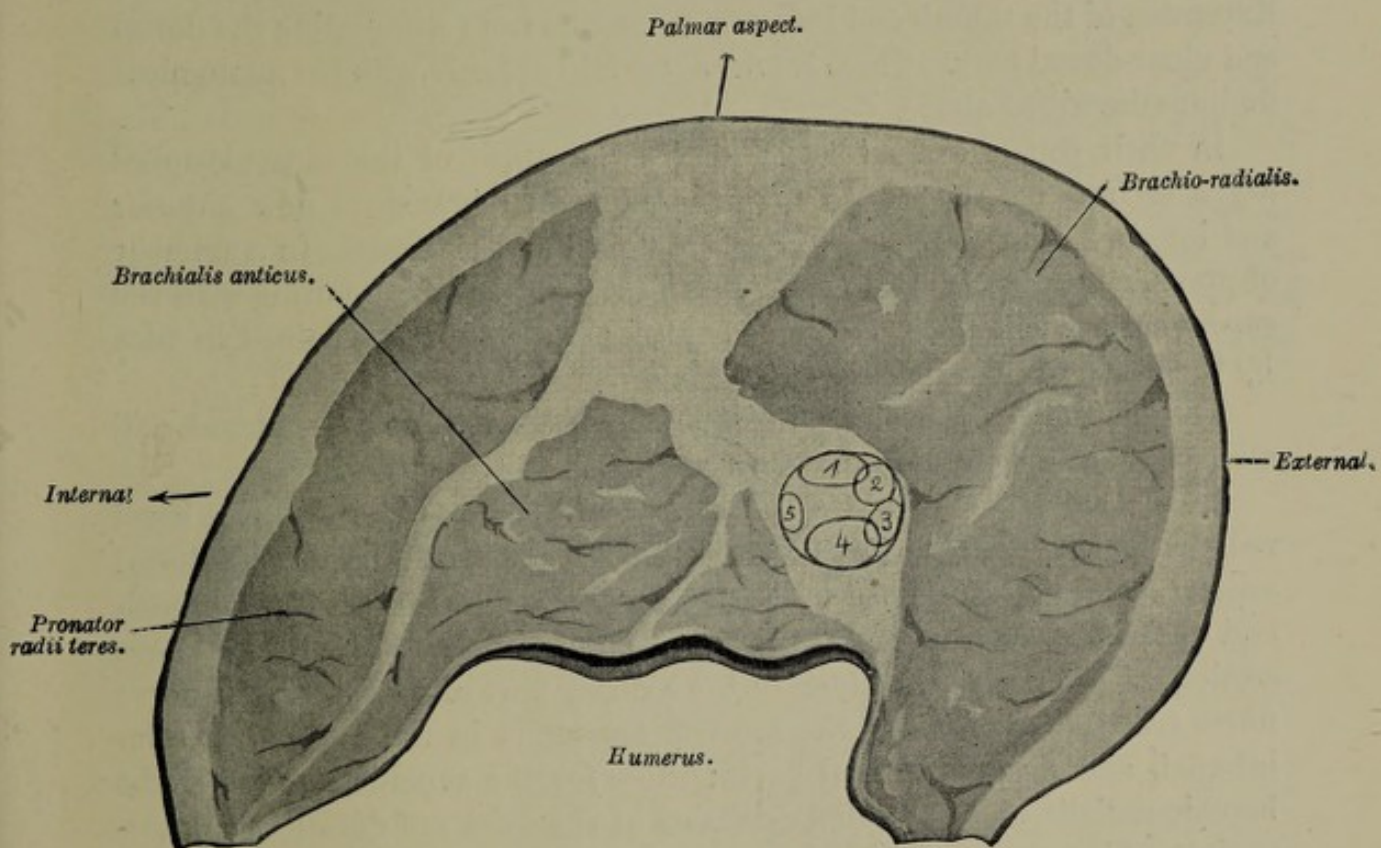


FIG. 66.—TRANSVERSE SECTION OF THE EXTENDED ELBOW AT THE LEVEL OF THE TWO EPICONDYLES. PROXIMAL HALF. (AFTER TOLDT.)

Musculo-spiral nerve drawn on larger scale for diagrammatic purposes. Section shows: 1 = fibres of superficial branch. 2 = fibres to brachio-radialis muscle; 3 = fibres to extensors of wrist. 4 = fibres to deep branch. 5 = fibres to supinator brevis.

up in the nerve trunk. Fig. 66 represents the arrangement which they occupy in a transverse section taken at the proximal third of the groove before mentioned.

Immediately anteriorly runs the superficial branch (1); slightly more towards the radial side runs the bundle for the brachio-radialis (2). Next come the fibres for the extensor carpi radiales muscles, whilst those for the supinator brevis lie on the ulnar side, but slightly towards the palmar

aspect (5). The remainder of the motor part of the nerve, including the deep branch for the finger extensors, is directly dorsal (4).

Stoffel found this arrangement almost constant in numerous preparations that he made.

The distribution of the fibres can also be demonstrated by clinical methods. If the surface of the palmar aspect of the nerve be lightly pinched, no muscular contractions ensue; if, however, a rather deeper grip be taken, the thumb is abducted. On pressing the radial side, definite extension of the hand occurs, whilst on the ulnar side vigorous supination is produced. Extension of the thumb and index-finger results from stimulating the dorsal and ulnar-dorsal part. These results agree fairly closely with the anatomical findings described above.

In their course around the humerus the fibres of the musculo-spiral nerve become rearranged, so that the superficial branch is now anterior and internal, whilst the deep fibres are dorsal and external. In a number of preparations the nerve to the brachio-radialis was found uniting with the superficial branch, and the common trunk thus formed was joined in turn by the nerve to the extensors of the hand.

The anatomy of the nerve, difficult enough at any time, is rendered still more complicated by the spiral turn round the humerus.

In the axilla the nerve to the brachio-radialis and the extensor carpi radialis longior and brevior, and the superficial branch, lie on the dorsal aspect, looking towards the humerus, whilst the fibres of the deep branch and those for the supinator brevis are antero-internal. In a transverse section of the nerve, therefore, in the axillary part of its course, the nerve fibres for the extensors of the forearm are found in the internal, antero-internal, and postero-internal parts; those for the superficial branch, the brachio-radialis, and the radial extensors of the wrist are dorsal and dorso-radial; whilst the fibres for the deep branch and the supinator brevis are anterior and antero-internal.

The value of this detailed knowledge of the anatomy of the musculo-spiral nerve may be illustrated by a case which was recently under treatment, in this clinic.

The case was one of complete paralysis of the musculo-spiral nerve, which it was proposed to remedy by means of a neuroplasty. The median, ulnar, and musculo-spiral in the forearm were not absolutely intact, and the mother would only consent to nerve grafting on condition that the hand and fingers should be left entirely unaffected, so that we were restricted as to choice to the nerves of the upper arm. The muscles innervated by the musculo-cutaneous nerve were paralyzed, but the long head of the triceps worked well. The internal and external heads also contracted fairly well, so that we had little hesitation in sacrificing the long head to restore the function of so important a muscle as the deltoid.

The nerve bundle which our anatomical investigations had shown to be associated with the long head (Fig. 67) was therefore dissected out of the musculo-spiral trunk,

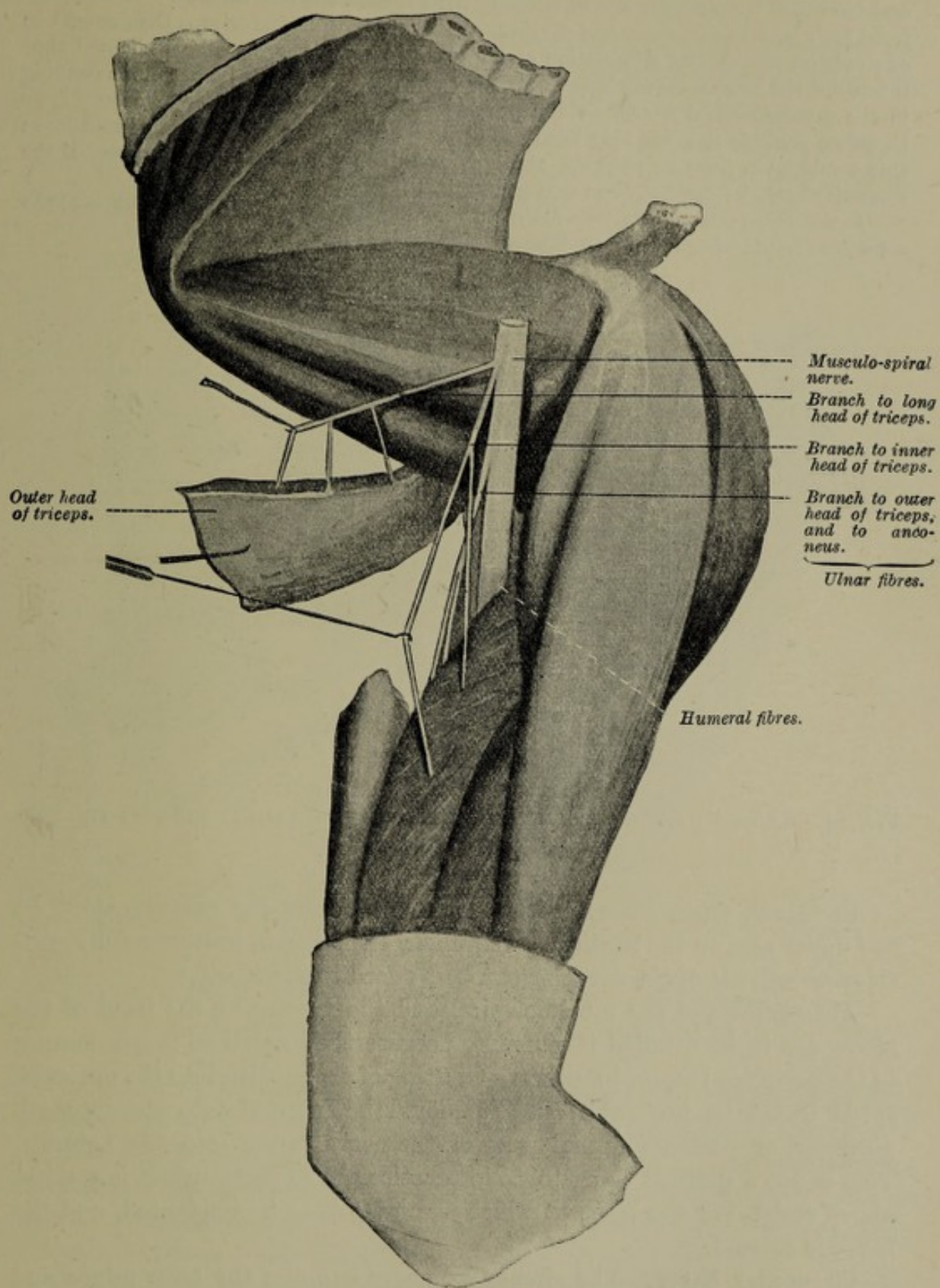


FIG. 67.—MUSCULO-SPIRAL NERVE IN THE UPPER ARM: TOPOGRAPHY OF THE FIBRES TO THE TRICEPS MUSCLE.

and identified by pinching it and noticing the contractions that ensued. It was then freed for 4 or 5 centimetres, and divided. The long head of the triceps then ceased to contract on mechanical stimulation of the musculo-spiral nerve. This indicated that it was not the branch for the long head that was separated, but its higher fibres running in the musculo-spiral nerve, on the proximal side of its point of emergence. It is therefore possible that the long head will again become innervated at some later date; this would have been improbable, and only possible by means of anastomoses, if the muscular branch itself had been transplanted.

On removing the splint after a fortnight the long head was still inexcitable, and the other two heads were as before. The deltoid was beginning to be innervated.

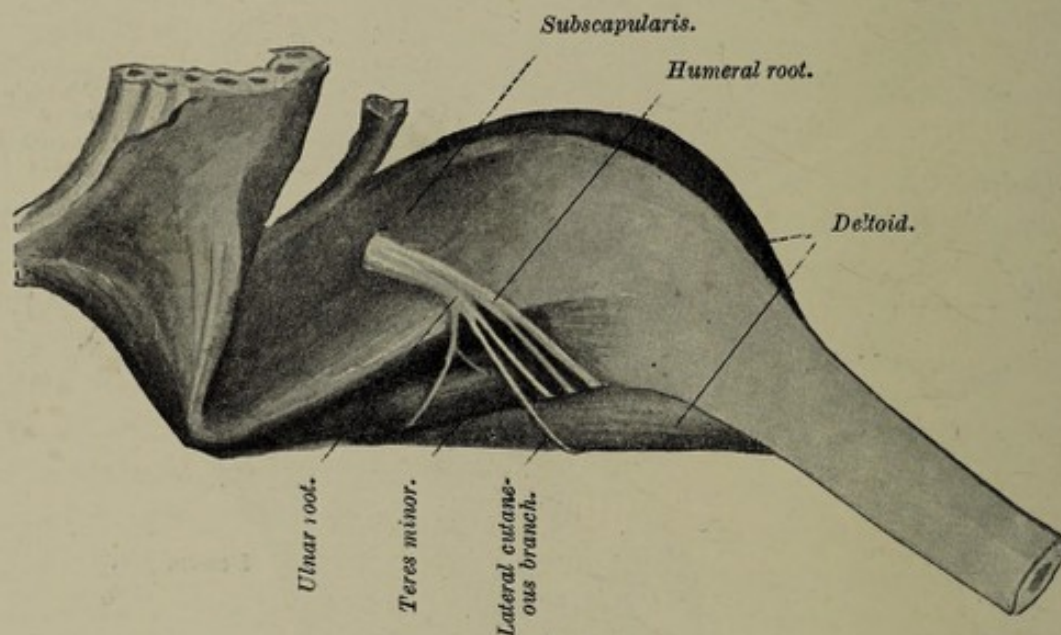


FIG. 68.—COURSE OF THE CIRCUMFLEX NERVE IN THE AXILLA, SHOWING ITS TWO DIVISIONS.

In future, then, whenever it is decided to unite the musculo-spiral in the upper arm to the median or the ulnar, the surgeon must carefully consider which part of the nerve he can best afford to sacrifice.

Anastomoses of the musculo-spiral and the median at the bend of the elbow are to be avoided if possible, because they entail so much damage to the peripheral motor branches. Grafting of the median into the musculo-spiral would be preferable, and it should be inserted into the internal, posterior, or postero-external part of the nerve, never into the anterior. This is not a difficult thing to do in practice. The perineurium is grasped above and below the place at which the graft is to be implanted, and the nerve is rotated.

Circumflex Nerve.—The circumflex nerve supplies the teres minor and the three parts of the deltoid—*i.e.*, the clavicular, acromial, and spinous portions. It arises from the fifth, sixth, and seventh cervical nerves, from the posterior cord of the infraclavicular part of the brachial plexus. At

the place where it turns under the lower border of the subscapularis, Stoffel was able to separate it into two main divisions (Fig. 68). The larger one lies nearer to the humerus, the other, described by Stoffel as the ulnar root, looks towards the origins of the subscapularis and teres minor.

The humeral root disappears under the edge of the deltoid, giving off a twig before doing so; the ulnar root breaks up into three—viz. : (1) the motor branch for the teres minor, which lies most internal; (2) a sensory

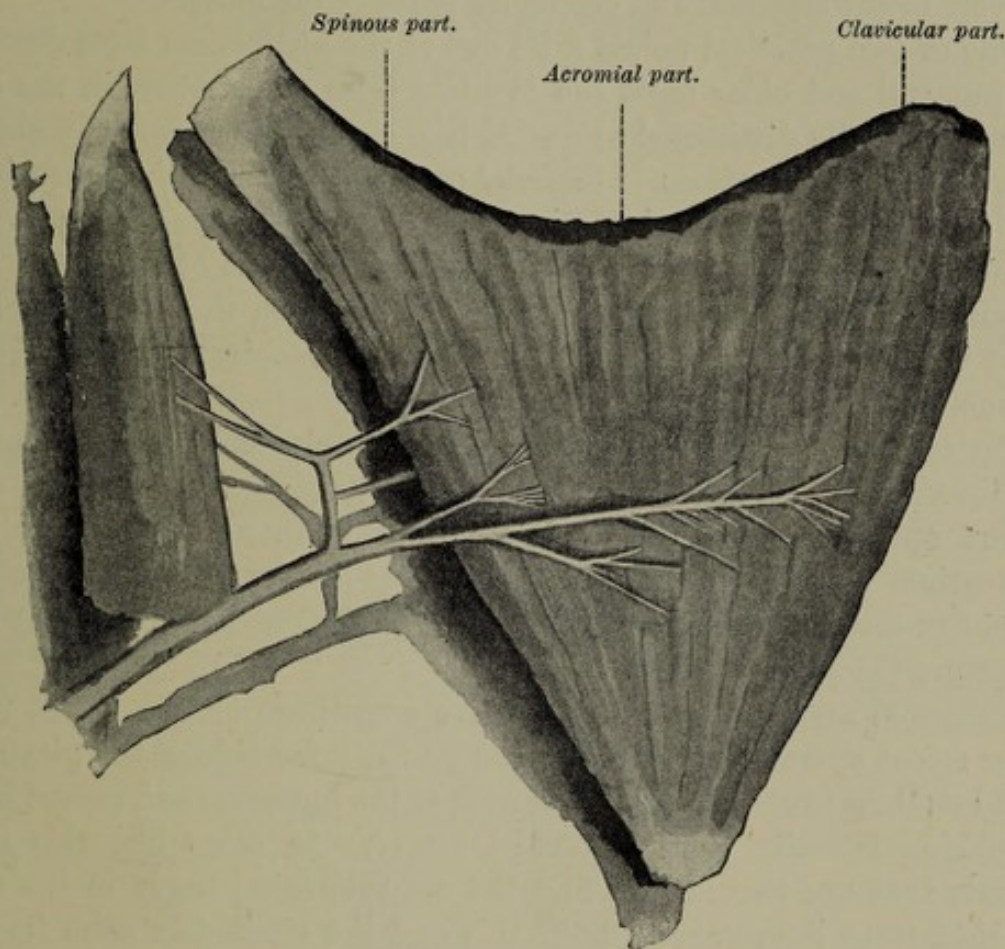


FIG. 69.—DISTRIBUTION OF THE CIRCUMFLEX NERVE.

Deltoid, teres minor, and nerve cut free and spread out flat.

twig, the N. cutaneus brachii lateralis, and (3) a third branch, which also passes out of sight under the border of the deltoid (Fig. 69).

The distribution of the whole circumflex nerve may be beautifully displayed by cutting the deltoid and teres minor away from their origins, together with their nerves, and spreading the whole preparation out with the under-surface of the deltoid uppermost.

The ulnar root gives only one small branch to the deltoid, which supplies the spinous portion. The humeral root gives off the nerves to the acromial and clavicular portions, and is therefore of paramount importance in the nerve-supply of the muscle. The branch already mentioned supplies the

greater part of the acromial portion, whilst the rest of the nerve (apart from a twig which runs down towards the insertion of the acromial part), breaks up in the clavicular portion. Fig. 69 shows these details clearly.

The essential facts to remember, with regard to the performance of neuroplasty, are: That the ulnar root of the circumflex takes but a minor part in the innervation of the deltoid muscle, giving off only one small branch which goes to the spinous portion. The humeral root goes exclusively to the acromial and clavicular parts of the muscle.

One or two practical points arise out of the anatomical facts described. The humeral and ulnar roots run separate from one another in the axilla, and can be easily distinguished during life—a fact which we have observed at two separate operations. Especial care will therefore be taken in performing descending transplantation not to unite the graft exclusively to the ulnar root, for the humeral is the more important of the two. If the implantation can be made above the point at which the ulnar root comes off, it is possible that the whole of the musculo-spiral nerve will recover its function.

Easier cases are those in which only the clavicular or the acromial part is affected.

The operations described are not difficult in actual practice. The perineurium must be treated with the utmost gentleness. If the posterior circumflex arteries are injured they must be tied, and in one case we had to ligature the subscapular artery.

Abnormal arrangements of the nerve sometimes occur. Thus, in one of our recent operations, it did not run on the inner side of the plexus, but turned straight towards the surgical neck of the humerus, and passed behind it, running laterally to the brachial artery. In cases like this Stoffel suggests that one should first find the musculo-spiral nerve in the axilla, and then trace it upwards. Both this and the circumflex arise from the posterior cord, so that one can be sure of finding the nerve in this way.

Median Nerve.—This nerve lends itself particularly well to investigation by Stoffel's method, because it runs a straight course and can easily be unravelled. The result is shown in Fig. 65.

The two roots of the nerve, forming the so-called "median loop," unite again, and can be traced for a considerable distance. On following out the fibres to the three most superficial muscles of the forearm, arising from the internal epicondyle (*i.e.*, the pronator radii teres, the flexor carpi radialis and the palmaris longus), one finds that they arise not only from the main trunk, as stated in the textbooks of anatomy, but also from a small root which can be traced up to the proximal third of the upper arm (Fig. 70). This nerve lies to the anterior aspect of the median trunk, somewhat to its outer side, and it lies, therefore, in contact with the biceps (Fig. 71). The

whole arrangement may be summarized as follows: In transverse sections of the median nerve in the middle and distal thirds of the arm, the fibres

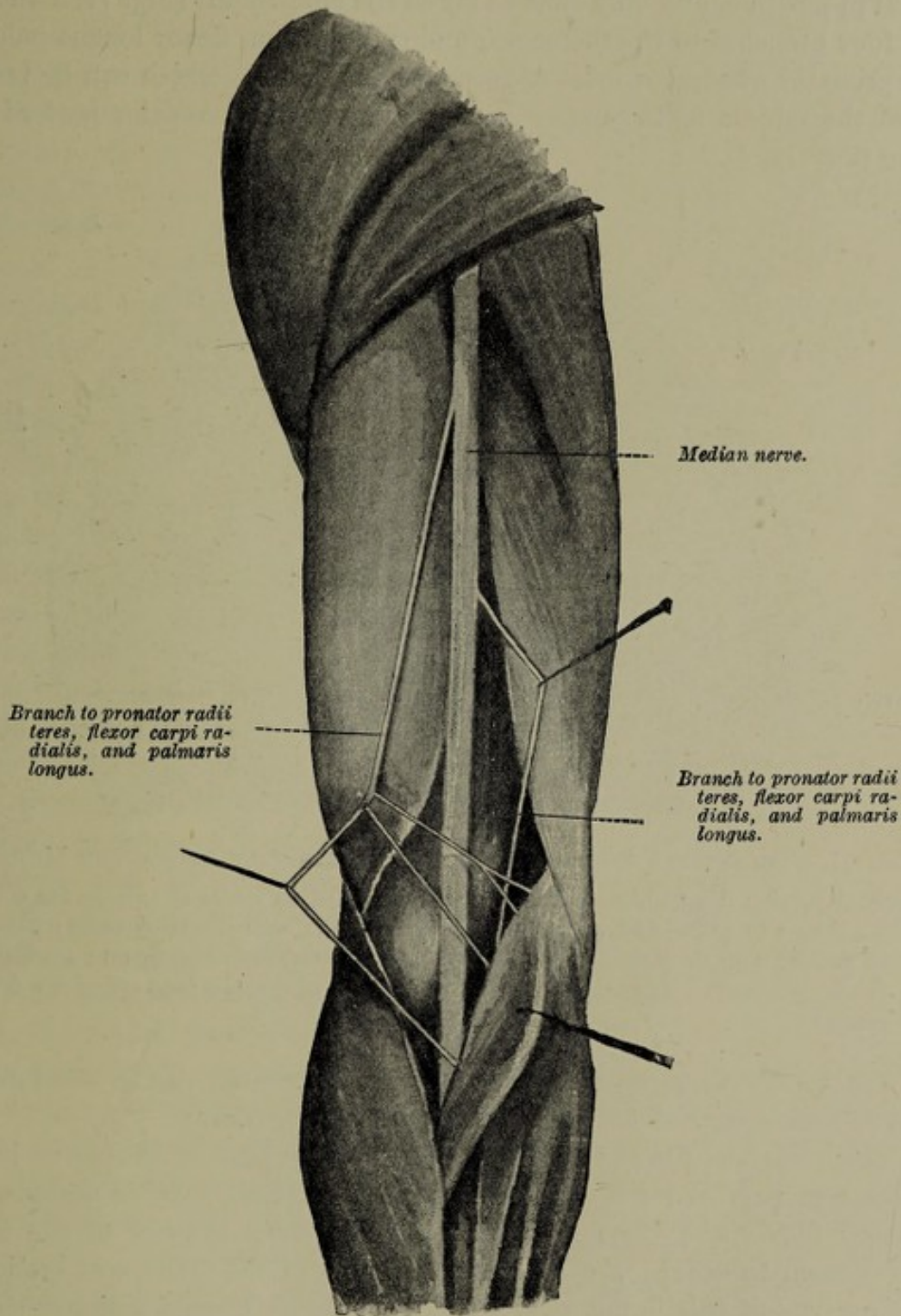


FIG. 70.—FLEXOR ASPECT OF RIGHT ARM, MEDIAN NERVE.

for the pronator teres, flexor carpi radialis, and palmaris longus lie close to the biceps, in the anterior part of the section, rather to its outer part (see 1, Fig. 71). Stoffel found that there were two bundles for the flexor

sublimis digitorum. One can be traced up to the middle of the upper arm, and runs in the internal part of the ulnar trunk; the other is rather more dorsal in position, and only runs as far as the elbow-joint (Fig. 71, 2 and 3). The four branches to the flexor profundus digitorum, flexor longus pollicis, and pronator quadratus meet to form a stout branch, which can be traced up to the middle of the upper arm, running in the posterior part of the nerve (Fig. 71, 4).

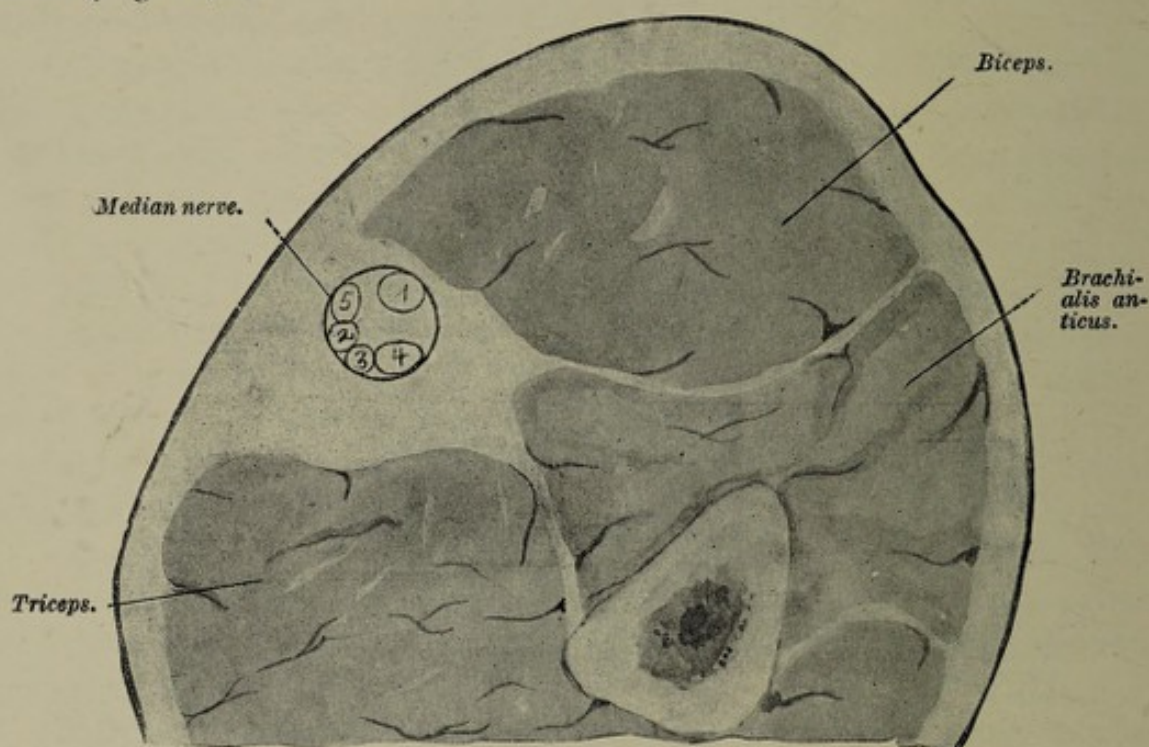


FIG. 71.—TRANSVERSE SECTION OF LEFT ARM, SLIGHTLY BELOW THE MIDDLE.

Proximal portion diagrammatically represented. Median nerve shown on large scale. 1= Fibres to palmaris longus, flexor carpi radialis, and pronator teres; 2= fibres to flexor sublimis digitorum; 3= fibres to flexor sublimis digitorum; 4= fibres to flexor profundus digitorum; 5= fibres to ball of thumb (according to clinical results).

All the nerves for flexion of the fingers, therefore, run in the internal and posterior parts of the median nerve in the upper arm.

These various fibres account for the greater part of the nerve in the upper-arm part of its course. The remainder of its bulk is occupied by sensory fibres, and the motor fibres for the short muscles of the hand. These seem to occupy a considerable amount of the transverse section of the nerve, but this is not really very remarkable when we remember the size of the median nerve in the forearm. The fibres for the ball of the thumb run in the outer part of the nerve in the forearm.

The more important points indicated by the anatomical examination were confirmed by the clinical method. On stimulating the ulnar part of the nerve, contractions occurred in the ball of the thumb (Fig. 71, 5). This

localization had not been demonstrated by the anatomical method. On pressing the nerve rather more anteriorly, the flexors of the fingers twitched.

It is obvious that Stoffel's results have an important bearing upon the performance of nerve grafting. If it is desired to innervate the flexors of the fingers, the graft must be introduced into the internal and postero-internal parts of the median nerve, whilst if it is the thenar eminence that is affected, the anterior part must be attacked.

Ulnar Nerve.—In the case of the ulnar nerve the isolation of the branches for the two forearm muscles is difficult, and can only be effected for a short distance. The bundle supplying the flexor profundus digitorum lies in the internal and posterior parts of the section, during the course of the nerve through the forearm, and around the epicondyle. If it is followed upward, it changes its position, so that in the middle of the upper arm it occupies the posterior and postero-external parts of the section. In the forearm the dorsal cutaneous branch to the hand lies to the inner side, whilst the posterior part, which corresponds to the large ramus profundus, includes the fibres to the hypothenar muscles, the interossei, third and fourth lumbricals, adductor pollicis, and the deep head of the flexor brevis pollicis.

The sensory fibres of the ramus superficialis run in the anterior part of the section. The deep branch, with which we are particularly concerned, can be traced as far as the elbow-joint, and then disappears on the reverse side of the nerve, where it appears to run for some distance farther.

A section taken at the middle of the upper arm, therefore, has the following structure: The fibres for the flexor carpi ulnaris, flexor profundus digitorum, and the small muscles of the hand are posterior and postero-external, whilst the sensory fibres are anterior and internal.

This anatomical localization may be confirmed to a certain extent by a clinical test, in the proximal third of the upper arm. Stimulation of the external and postero-external parts of the nerve causes contractions of the flexor carpi ulnaris, and brisk reaction in the interossei. Pinching the palmar aspect of the nerve causes flexion of the fourth and fifth fingers, and also, to a certain extent, of the second and third, as well as twitching of the hypothenar muscles. The latter does not agree with our schema. It is possible that the points of the forceps penetrated too deeply towards the centre of the nerve, or even towards its dorsal parts.

The determination of the topography of the fibres of the deep branch is of special importance. There has been hitherto no successful treatment for paralysis of the short muscles of the hand, and the serious sequelæ to which it gives rise. It would therefore be particularly gratifying if one could successfully innervate them by means of a graft implanted into the posterior part of the nerve, in the forearm or upper arm.

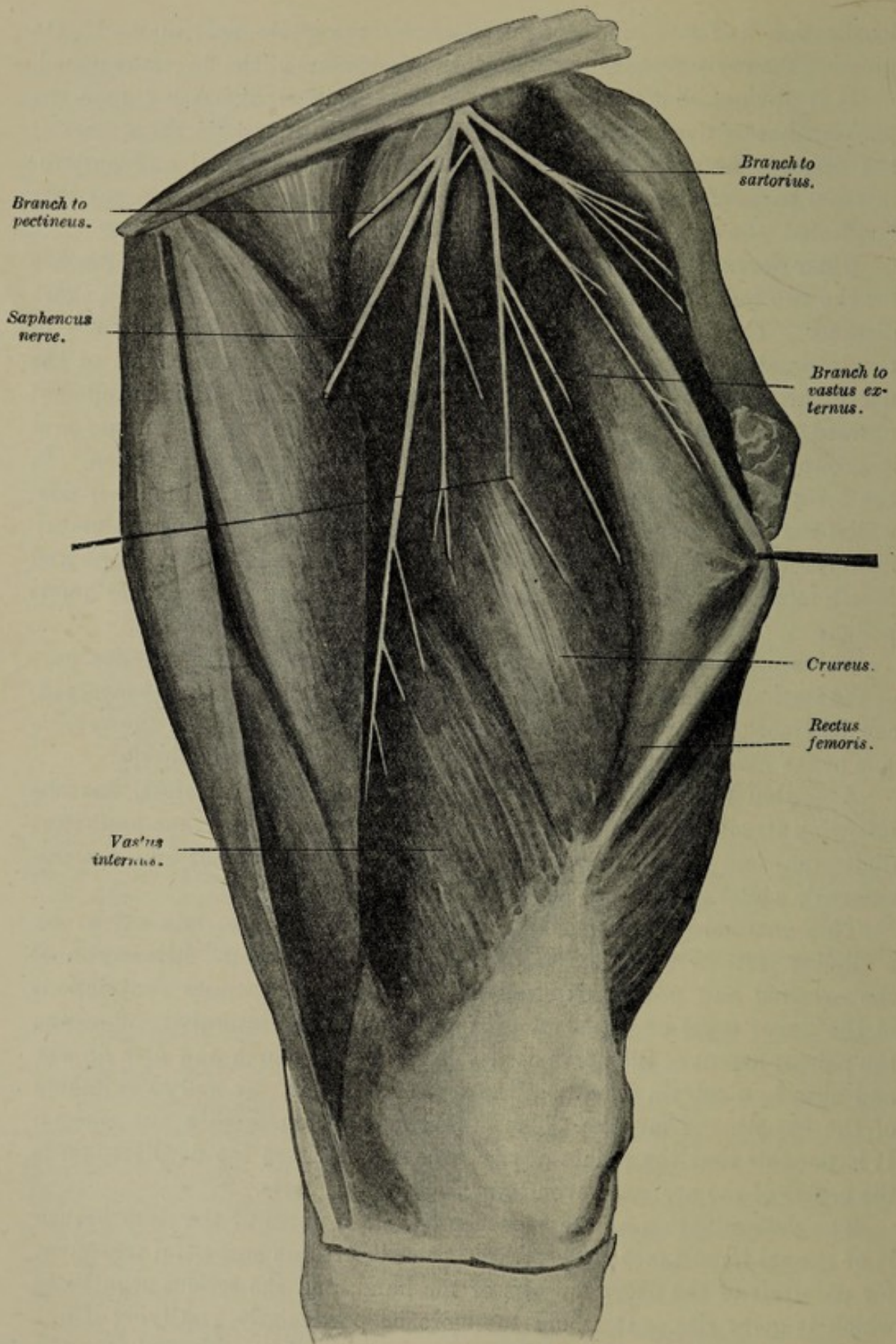


FIG. 72.—ANTERIOR VIEW OF LEFT THIGH: ANTERIOR CRURAL NERVE DISPLAYED.

Anterior Crural Nerve.—It is only the part that lies below Poupart's ligament that lends itself to surgical treatment, but it may be mentioned.

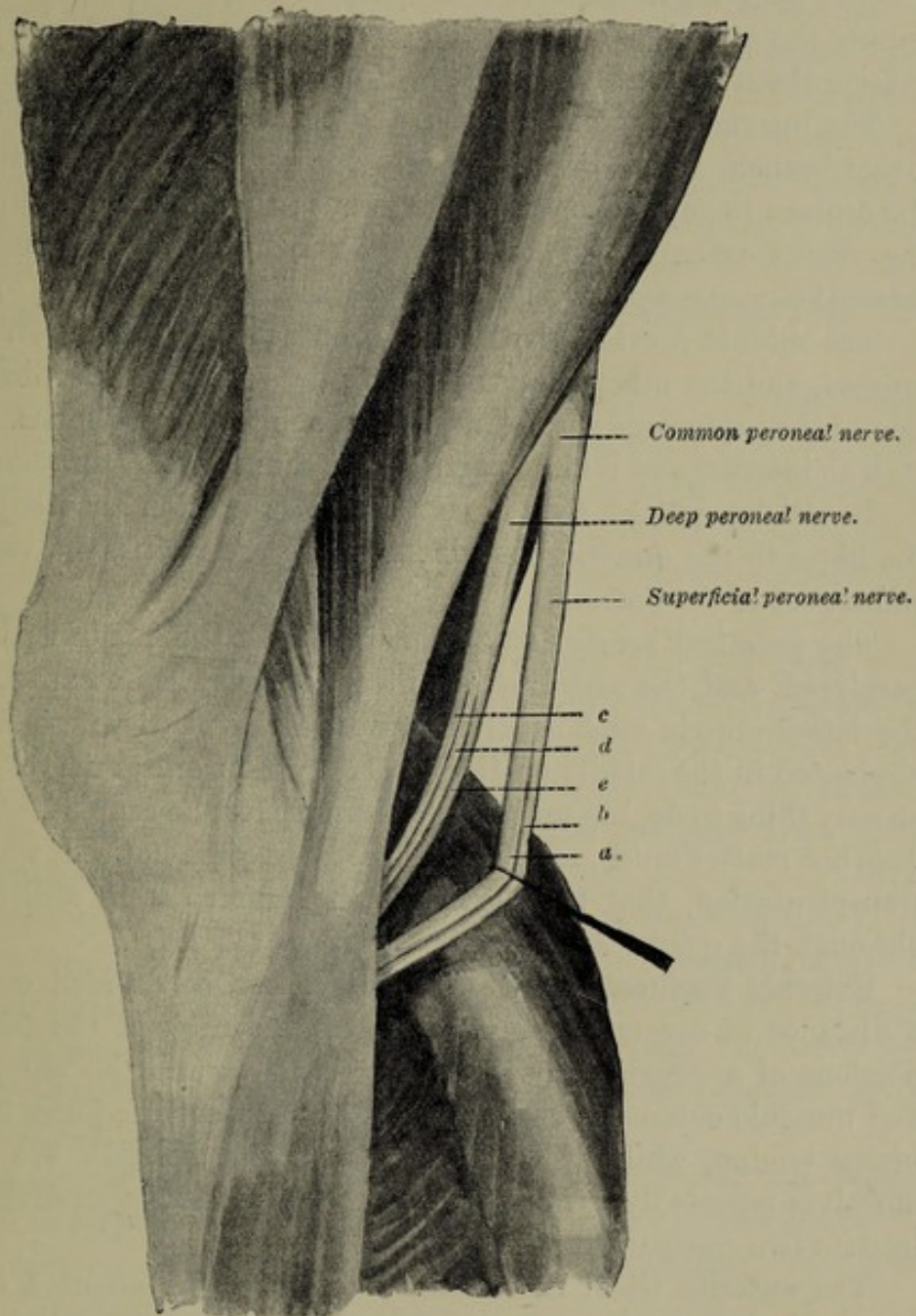


FIG. 73.—EXTERNAL POPLITEAL NERVE (= COMMON PERONEAL), DISSECTED OUT IN A FRESHLY AMPUTATED LEG.

a = Motor nerve to peronei; *b* = sensory fibres; *c* = fibres to tibialis anticus; *d* = fibres to tibialis anticus and external longus digitorum; *e* = fibres to external longus hallucis, extensor brevis digitorum, and dorsal digital nerves.

for the sake of completeness, that the proximal part also can be very easily split up into its constituent parts, and that these can be followed right up to the spinal cord.

Stoffel found that the nerve broke up into three chief portions, immediately below the fold of the groin (Fig. 72).

The lateral portion soon breaks up into four end-branches, which all supply the sartorius, entering the inner border and posterior surface of the muscle about $2\frac{1}{2}$ centimetres below Poupart's ligament.

The internal portion comprises the branch for the rectus femoris and a larger branch, which breaks up into three. The external division crosses the crureus to supply the vastus externus; the middle one supplies, chiefly, the vastus externus, but also gives some fibres to the crureus; and the internal one goes exclusively to the vastus internus.

The middle portion gives off two branches, of which one supplies the crureus, and the other the vastus internus. This portion lies on the inner side of the saphenous nerve, and the branch to the pectineus.

The internal and middle portions are connected by an anastomosis.

It will be noticed that it is the middle portion that supplies most of the fibres to the quadriceps—viz., those to the rectus, the vastus externus, and a part of the crureus.

The practical bearing of all this is, that if the quadriceps is completely paralyzed, and the sartorius, as often happens, has escaped, the nerve to the latter muscle may be divided above the place where it divides, and implanted in the middle portion of the anterior crural nerve. This is quite an easy thing to do, but no provision is made for the crureus. This, however, does not matter much, and, indeed, we have often noticed, when performing transplantation, that the nerves to the crureus were still quite healthy, although the quadriceps, as a whole, was paralyzed.

External Popliteal Nerve.—This nerve can be divided quite easily, for a distance of several centimetres above the neck of the fibula, into two portions of approximately equal size, corresponding to the anterior tibial and musculo-cutaneous nerves (Fig. 73). The former fibres lie close to the biceps tendon, whilst the others are near the tibialis. We have satisfied ourselves repeatedly at operations as to the possibility of dividing the nerve into its two constituent parts.

The anterior tibial nerve can be divided, for about 4 centimetres of its length, into three bundles. One division (Fig. 73, *c*) lies nearest to the biceps tendon, and includes the motor fibres for the greater part of the tibialis anticus; the middle one (Fig. 73, *d*) contains the fibres for the remainder of the tibialis anticus, and for the extensor longus digitorum; the third supplies the extensor longus hallucis, the extensor brevis digitorum and the dorsal digital (sensory) nerves (Fig. 73, *e*).

The musculo-cutaneous also consists of two divisions: the larger lies near the anterior tibial nerve, and the smaller looks towards the popliteal space (Fig. 73, *a* and *b*). The former includes the sensory fibres for the

ankle and foot, and the latter supplies motor fibres to the two peroneal muscles.

Internal Popliteal Nerve (= *Tibial N.*).—All the branches to the triceps suræ arise from one common root, which runs in that part of the internal popliteal nerve which looks towards the knee, and can be separated up to about the middle of the thigh. A little way above the knee-joint it divides into two main branches: an external one, which supplies the motor fibres to the outer head of the gastrocnemius and the soleus, and an inner one, which supplies the corresponding head of the gastrocnemius. The rest of the nerve is occupied by the fibres to the tibialis posticus, flexor longus digitorum, and the flexor longus hallucis. Stoffel did not succeed in isolating these fibres to his entire satisfaction.

The topography of the nerves of the popliteal space is of the greatest practical importance. If the peronei are paralyzed, nerve grafting should be performed into that part of the external popliteal nerve which looks towards the knee-joint. When the paralysis affects the distribution of the anterior tibial nerve, its division into three parts, as described above, must be remembered.

When the internal popliteal nerve is paralyzed, the best piece of the external to graft into it is the anterior tibial portion, because it contains the greatest number of motor fibres, and the destruction of one of the nerves to the tibialis anticus is not of any great importance, owing to its double supply. If it is the triceps suræ that is at fault, the graft is implanted into the popliteal aspect of the internal popliteal nerve. If, on the other hand, the triceps suræ is intact, the internal popliteal nerve may be utilized to furnish a graft, cutting it from the tract described, above the origin of the muscular branches. This is then implanted in the external popliteal or anterior tibial nerve. A more reliable way, however, is to sacrifice the middle muscular branch to the inner head of the gastrocnemius. The outer head and the soleus are then left intact.

After this digression, which shows very plainly how much our operation has yet to be improved, we return to the consideration of what is known at the present time with regard to the **results of neuroplasty** in infantile paralysis.

Spitzzy states that the operation is successful in about 70 per cent. of cases. This statement needs considerable modification, however. In the first place, his figures are based upon all the published cases of neuroplasty, whereas only a small proportion of these are instances of infantile paralysis. Again, as we have already pointed out, the valuable results obtained by neuroplasty have frequently been discounted by the simultaneous performance of some operation on the tendons. Lastly, Spitzzy describes as a "success" cases in which innervation has proceeded so far that the muscles

have regained their power of contracting. He attaches no importance to the comparative uselessness of these weak, wasted muscles.

I have taken the trouble to amplify the summary of the subject published by Sherren in 1906. The results are given here in tabular form, whilst the individual cases, and my own operations, are described in the appropriate chapters of Part II.

Whilst this book has been in the press, several other cases have been brought to my notice, and may be briefly described.

Taylor performed ascending transplantation of the eighth cervical and first dorsal nerves into the junction of the fifth and sixth cervical, in two cases of infantile paralysis of the forearm, of four and eight years' duration respectively. In one case some power of extension of the wrist and fingers returned in the course of a year, but in the other little improvement resulted.

Tubby treated six cases of paralysis of the upper and lower extremities by this method, and four showed distinct signs of improvement.

Maragliano, in one case, implanted the paralyzed external popliteal nerve into the internal, and observed marked improvement. In another case, in which the anterior crural, obturator, and sciatic nerves were affected, he transplanted a piece of the anterior crural from the sound side into the anterior crural of the paralyzed side. After five months the thigh had increased in size, and the knee could be slightly extended.

Eighteen out of the twenty-five cases recorded in the table consist of paralysis in the distribution of the external popliteal nerve. The result of the operation was positive in thirteen cases, and in four or five only did a really useful limb result; in the other eight the result could only be described as a partial success. Two transplantations into the paralyzed internal popliteal nerve met with special success, and an encouraging result followed a similar operation upon the circumflex nerve. The notes of the cases of grafting into the median and the anterior crural are instructive. Two plastic operations were performed upon the fifth nerve root. One failed, but the other was a brilliant success. Success, in Spitzzy's acceptance of the word, was therefore obtained in over 70 per cent. of cases, but if we adopt a more rigid standard, such as is required for practical purposes, the percentage sinks to less than half.

No.	Operator and Reference.	Paralysis.	Interval between Onset and Operation.	Operation Done.	Result.
1	PECKHAM (<i>Provincial Medical Journal</i> , January, 1900, p. 5; <i>American Journal of Orthopædic Surgery</i> , August, 1904, p. 32)	Peroneal group	10 years	Central anastomosis. Two of the four muscular branches to gastrocnemius divided and put into peroneal.	Extension of toes after 6 weeks. Definite power over peronei in 2 to 4 months. No perceptible weakness of gastrocnemius.
2	YOUNG (<i>Journal of Nervous and Mental Diseases</i> , June, 1903, p. 369; <i>American Journal of Orthopædic Surgery</i> , August, 1904, p. 27)	Tibialis anticus	3 years	December 4, 1902. Nerve to tibialis anticus divided and grafted into vertical slit in musculo-cutaneous.	June 1, 1904, all muscles of anterior group react well to faradism.
3	HACKENBRUCH (<i>Arch. für klin. Chir.</i> , 1903, p. 638; <i>Deutsche med. Woch.</i> , 1905, p. 25)	Peronei	15 months	February 24, 1903. A third of internal popliteal nerve grafted into external.	Failure.
4	HACKENBRUCH (<i>ibid.</i>) ..	Peronei	9 months	Ditto	Failure.
5	HACKENBRUCH (<i>ibid.</i>) ..	Peronei	10½ years	Ditto	After 4 months, abduction of femur possible; extensors functional after 8 months, co-ordinated movements after 18 months; no faradic excitability.
6	WARREN LOW (<i>British Medical Journal</i> , 1903, ii. 1035)	Deltoid, supraspinatus, and infra-spinatus	6 months	Upper part of fifth cervical nerve implanted in transverse slit in sixth.	Slight abduction of arm in 11 months. Rapid improvement. Child able to raise arm above head. Muscles began to react to faradism in 15 months.

No	Operator and Reference.	Paralysis.	Interval between Onset and Operation.	Operation Done.	Result.
7	FRAZIER (<i>Journal of the American Medical Association</i>)	Tibialis anticus	2 years	<i>Cf. No. 2</i>	"Mother is convinced that there is some improvement" (?).
8	SPITZY (<i>Zeitsch. f. Orth. Chir.</i> , xiv., 1905)	Peronei	14 months; patient 23 months old	January 21, 1905. Ascending partial implantation of external popliteal into healthy internal.	Some extension of fingers in 3½ months; peronei in 4½ months; some movement in tibialis in 8 months.
9	MURPHY (<i>Neur. Surg.</i> , 1907)	Distribution of external popliteal nerve	6 years	Ascending implantation of external popliteal nerve into internal; also numerous tendon operations.	Partial success in 1 year. Recovery of tibialis anticus and extensor digitorum.
10	VAN DER BERGH (<i>Zentralbl. f. Chir.</i> , 1907, p. 556)	Quadriceps and adductors	—	Anterior crural, ascending into sciatic.	Child able to stand on affected limb after some months. No longer supports thigh with hand when walking.
11	TUBBY (<i>British Medical Journal</i> , March 3, 1906)	Gastrocnemius and soleus	7 years	Muscular branches implanted in external popliteal nerve.	Definite power of extension in 3 months. No reaction to faradism.
12	TUBBY (<i>ibid.</i>)	Ditto	6½ years	Ditto	Power considerable, and increasing, after 4½ months.
13	TUBBY (<i>ibid.</i>)	Peronei	—	Whole external popliteal nerve grafted into internal by ascending method.	No improvement after 3 months.

No.	Operator and Reference.	Paralysis.	Interval between Onset and Operation.	Operation Done.	Result.
14	TUBBY (<i>British Medical Journal</i> , March 3, 1906)	Peronei	—	External popliteal nerve divided and both ends grafted into internal.	No improvement after 7 months.
15	TUNSTALL TAYLOR (<i>New York Medical Journal</i> , July 7, 1906)	Peronei	2½ years	External popliteal nerve divided, and peripheral end implanted in vertical slit in internal popliteal nerve.	Dorsiflexion of toes possible in 92 days. Considerable improvement in 236 days. Peronei react to faradic current.
16	TUNSTALL TAYLOR (<i>ibid.</i>) ..	Peronei	10 years	External popliteal nerve divided and united end to end to descending flap of internal popliteal nerve.	Foot can be adducted and dorsiflexed after 120 days. Toes also. Muscles react to faradism.
17	SHERREN (<i>Edinburgh Medical Journal</i> , October, 1906)	Anterior group	2 years	Anterior tibial nerve divided and peripheral end implanted in musculo-cutaneous.	Some movement of tibialis anticus in 8 months, and of extensor digitorum in 18 months. Foot still weak. Muscles react to strong faradic current.
18	SHERREN (<i>ibid.</i>)	Peronei	9 months	Ascending transplantation of external popliteal into transverse slit in internal popliteal nerve.	Unsuccessful after 4 months. No lesion in distribution of internal popliteal nerve.
19	SHERREN (<i>ibid.</i>)	Erb-Duchenne	1½ years	See No. 6.	No improvement for 13 months, then recovery of power and faradic excitability in biceps. Deltoid still paralyzed.

No.	Operator and Reference.	Paralysis.	Interval between Onset and Operation.	Operation Done.	Result.
20	SPITZY (<i>Wiener klin. Woch.</i> , 1907, 48)	Distribution of external popliteal nerve	7 months; patient aged 13 months	Total ascending transplantation of external popliteal nerve into central flap of internal.	2 months later normal power in tibialis anticus and extensor digitorum; peronei poor. Sluggish electric reaction in the latter.
21	GALEAZZI (Italian Orthopædic Congress, 1907)	Deltoid	—	Ascending transplantation of circumflex into median nerve.	Partial result after 8 months, but promising.
22	BARDENHEUER (<i>Deutsch. Zeitsch. f. Chir.</i> , 1907, 96)	Total paralysis of external popliteal nerve and slight weakness of internal	Since 3 years; age of patient, 4 years	Ascending transplantation of external popliteal nerve into slit in internal. Numerous tendon operations.	Some dorsiflexion after 6 weeks, considerable after 6 months. Recovery of power in 8 months.
23	BARDENHEUER (<i>ibid.</i>)	<i>Cf. No. 22</i>	Since 2 years; age of patient, 6 years	Ditto	Trace of dorsiflexion in 9 days.
24	OSTERHAUS (<i>New York Medical Record</i> , July 11, 1908)	Paralytic talipes	—	Central bundle of internal popliteal nerve implanted in peripheral of internal popliteal nerve.	Good result. Improved by massage and electricity.
25	MAYER (Deutsch. Orth. Kongr., 1909)	Median in forearm and hand	From early childhood; patient aged 10½ years	Lateral anastomosis of median and ulnar in upper arm.	Slight flexion of thumb in 4 weeks. Writing movements in 6 months; flexion of index-finger later on.

The time that elapses before innervation takes place varies considerably. When the nerve is completely divided, it takes at least six to eight weeks, but very often as many months, before the earliest voluntary movements are made. Further progress is also very slow, and may occupy two years after the operation. Occasionally a successful result appears in one to three weeks, but no explanation of this phenomenon has yet been given.

Another important question is that of the loss of function that necessarily results from dividing healthy nerve fibres in performing descending transplantation. It has been found that injuries of this kind undergo relatively rapid repair. Even in cases of infantile paralysis, where the impoverished muscle will not stand much damaging, we repeatedly find it stated that no lasting harm has resulted. Our own experience agrees with this statement.

This question can only be accurately studied when we possess full information concerning the distribution of the various bundles in the peripheral nerve roots, and can localize lesions with exactitude.

Very little is known about associated movements, and their representation in the peripheral nerves. Whilst they are common in plastic operations upon the facial nerve, and only disappear slowly, the power to convey isolated motor impulses seems to appear much more rapidly in the peripheral nerves. It is difficult to understand why, when a flap of the internal popliteal nerve has been transplanted by the descending method into the external popliteal nerve, the flexors alone do not contract when the patient wishes to raise the foot, and later on, the flexors and extensors simultaneously.

On surveying critically the present position and value of neuroplasty, and comparing it with tendon operations, we arrive at the following **conclusions**.

The idea of the nerve operation is quite different from that of the tendon operation. It attacks the disease at its actual site, and if it is successful, it is an ideal method of treatment, for it brings about functional recovery without anatomical disturbance of the musculature.

The operation, however, is not as satisfactory in practice as it is attractive in theory. The results that have been obtained after much laborious work are certainly promising, but do not compare in point of efficiency with those of tendon operations. For not only does the latter method insure the recovery of power in the muscles, but it is a very reliable proceeding, and one that justifies us in giving a fairly confident prognosis to the patient and his relatives. The rapidity of the result is another point in favour of tendon transplantation. Social reasons frequently necessitate our effecting a cure as quickly as possible. Where time and money are of little moment, neuroplasty may reasonably be employed, but it is unsuitable for the

bulk of ordinary hospital patients. Arthrodesis has been described as the *operatio pauperum*, because it is an inexpensive line of treatment as compared with the use of apparatus. In the same way neuroplasty may be termed the *operatio divitum*, because it entails a greater expenditure of time and money, with frequently a smaller chance of success. The expenditure, however, is not unavailing, for the method represents a new line of advance, and it is our privilege and our duty to render it a practical, safe, and successful method. The task is a difficult one, but the problem is encouraging, and the successes that have already been attained render our ultimate success certain.

PART II
SPECIAL

CHAPTER I

**PARALYSIS OF THE MUSCLES OF THE NECK : PARALYTIC
TORTICOLLIS**

THE muscles of the neck have frequently been found to be paralyzed during the acute stage of the attack, especially since our knowledge of the earlier signs and symptoms has been increased by the study of the larger epidemics. The head falls backwards in a limp manner that is quite different from the rigid hyperextension that characterizes cerebro-spinal meningitis. This fact has been put forward as a means of differential diagnosis.

It is very unusual, however, for this initial paralysis to persist, wholly or partially. I myself have only seen three children in whom a considerable part of the musculature was lacking or severely paretic after the lapse of a year.

The neck looks long, thin, and shapeless. The position of the head is determined by the few muscles that remain. It is very "wobbly," and falls over to one side, or, more often, backwards, if the slightest push be given to it (Fig. 74).

The treatment consists in the use of regular gymnastic exercises, and a supporting apparatus. A narrow leather hoop, fastened at the side, encircles the chin and occiput. Three or four round, thin steel supports are jointed to it, and extend down to the waist, being modelled accurately to the neck and thorax. Elastic tractors are fastened to their lower ends, and also to the axillary crutches of a spinal jacket. A waistband with slits in it keeps the supports in their proper position. The position of the head can be regulated at will by arranging the elastics (Fig. 75).

I myself employ a simpler device, which prevents the head from falling forwards, and also has the advantages of being inconspicuous, and easy to take off. The foundation of the apparatus consists of two moulded leather shoulder-pieces, reaching to the breasts. These are fastened together in

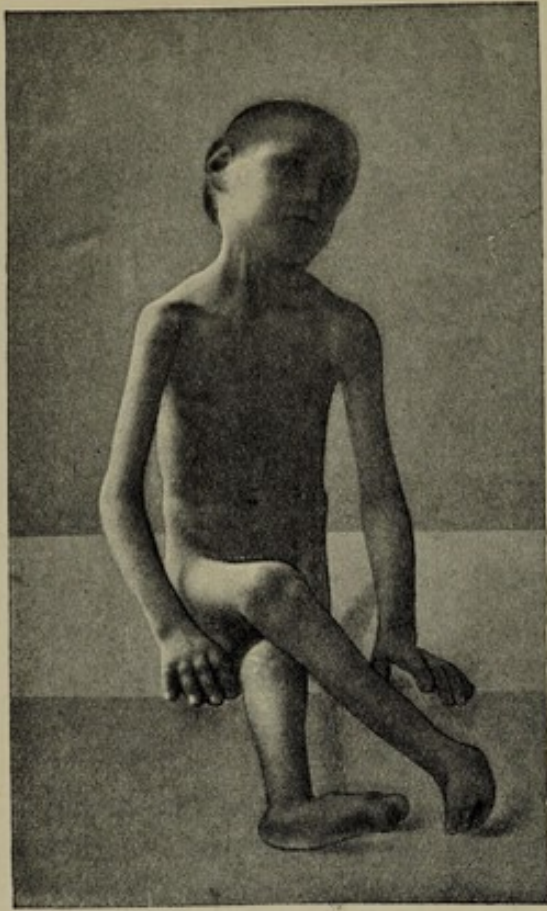

FIG. 74.

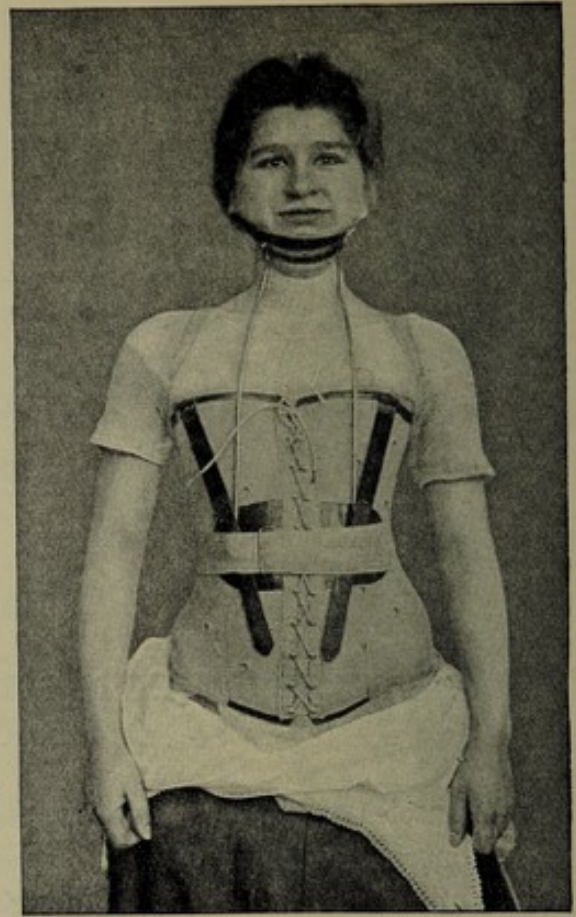


FIG. 75.

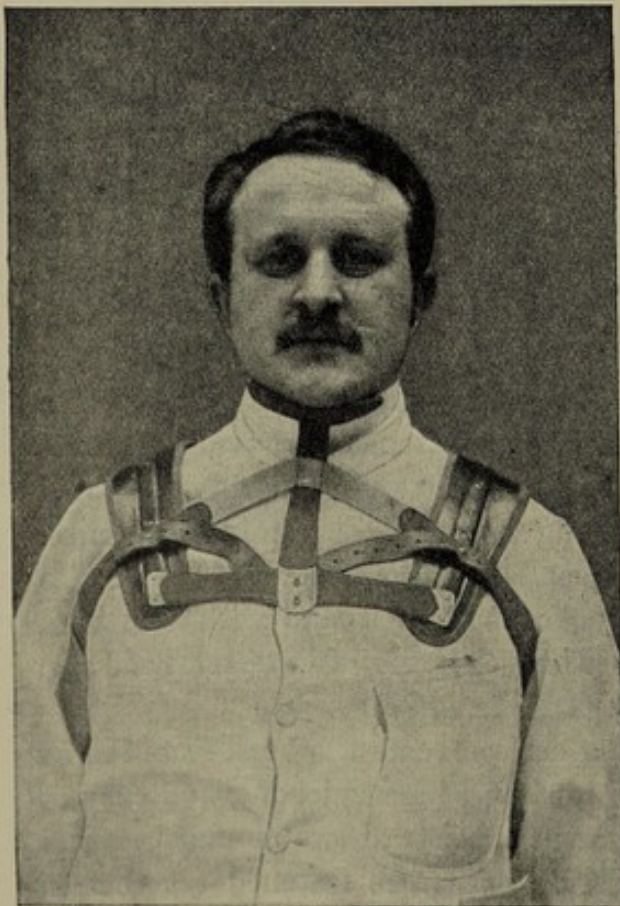

FIG. 76.

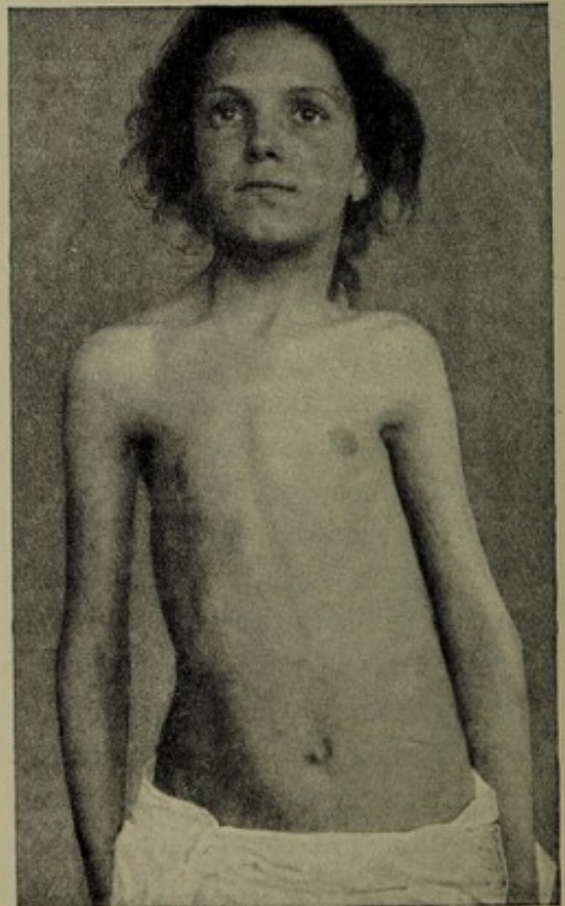


FIG. 77.

front by a transverse steel strip, and behind by two straps, which cross one another. A thin steel passes up from the front bar to the chin, moulded to the contour of the neck. It carries a moulded pad, upon which the chin is supported. The vertical support is fastened to the transverse bar by a sort of bayonet catch, so that it can be easily disjoined by a slight upward pull (Fig. 76).

Unilateral paralysis of the sterno-mastoid results in **paralytic torticollis**, a very rare condition, of which Hoffa has seen and described two cases. I myself have only had the opportunity of seeing and operating upon one of these cases (Fig. 77). The head inclines slightly towards the healthy side, and the chin in the opposite direction. Voluntary turning of the head towards the other side is difficult, but the movement can be performed by the surgeon without difficulty. On requesting the patient to move the chin downwards or to one side, against resistance, it will be noticed that the muscle does not become prominent on the affected side.

In long-standing cases, with shortening of the muscles, the treatment is the same as in any other torticollis—viz., tenotomy of the sound sterno-mastoid, followed by massage and exercises. Hoffa obtained satisfactory results in this way in the case of a girl aged six, and another of sixteen, who also had paralysis of the legs. My own case was associated with severe paralytic scoliosis.

CHAPTER II

PARALYSIS OF THE MUSCLES OF THE BACK AND ABDOMEN— PARALYTIC KYPHOSIS, LORDOSIS, AND SCOLIOSIS

PERMANENT paralysis of the muscles of the back and abdomen is rare, though not so rare as was at one time imagined. As a rule, it is associated with extensive paralysis and paresis of the limbs, though it sometimes happens that the severity of the latter part of the affection causes the fact that the back muscles are involved to be overlooked for some time.

The anatomy and physiology of the spinal muscles are so complicated that it is difficult to study their paralysis. It is possible, therefore, that cases of limited paralysis of the muscles of the back may escape observation more frequently than is the case with the abdominal muscles. When the lesion is severe, a very striking clinical picture results, and the diagnosis is easy.

Paralytic Kyphosis.

Instances of paralytic scoliosis are very uncommon.

Heine, in his famous book, mentions the disease, but what he describes by this name is a motor and sensory paraplegia associated with localized kyphosis of the vertebræ—*i.e.*, spondylitic paralysis and gibbus. He mentions this merely as a point of interest in the differential diagnosis. All kyphosis is the expression of the insufficiency of the spinal muscles. In addition to telescoping, the vertebral column sinks forwards as far as the compressibility of the intervertebral discs and the tension of the ligaments and joint capsules will allow. Such total kyphosis is particularly well marked in paralysis and extensive paresis of the erector spinæ muscle. We find it in patients who sit much—*i.e.*, in the first few years of life. The deformity reaches its maximum in those cases in which the pelvis sinks backwards, as the result of simultaneous paralysis of the muscles of the hip, and especially of the ilio-psoas. The patient can then only sit up if he restores his centre of gravity by throwing his spinal column forwards (see Fig. 78).

The most important part of the **treatment** consists in careful, patient massage and exercises, continued for many months or years.

If the paralysis is complete, the only thing that can be done is to apply

a spinal support. This may also be used with advantage in paresis. The best fixation is afforded by a corset made of leather, poroplastic, cellulose, celluloid, plaster of Paris, or some material of that kind (see Fig. 79). A

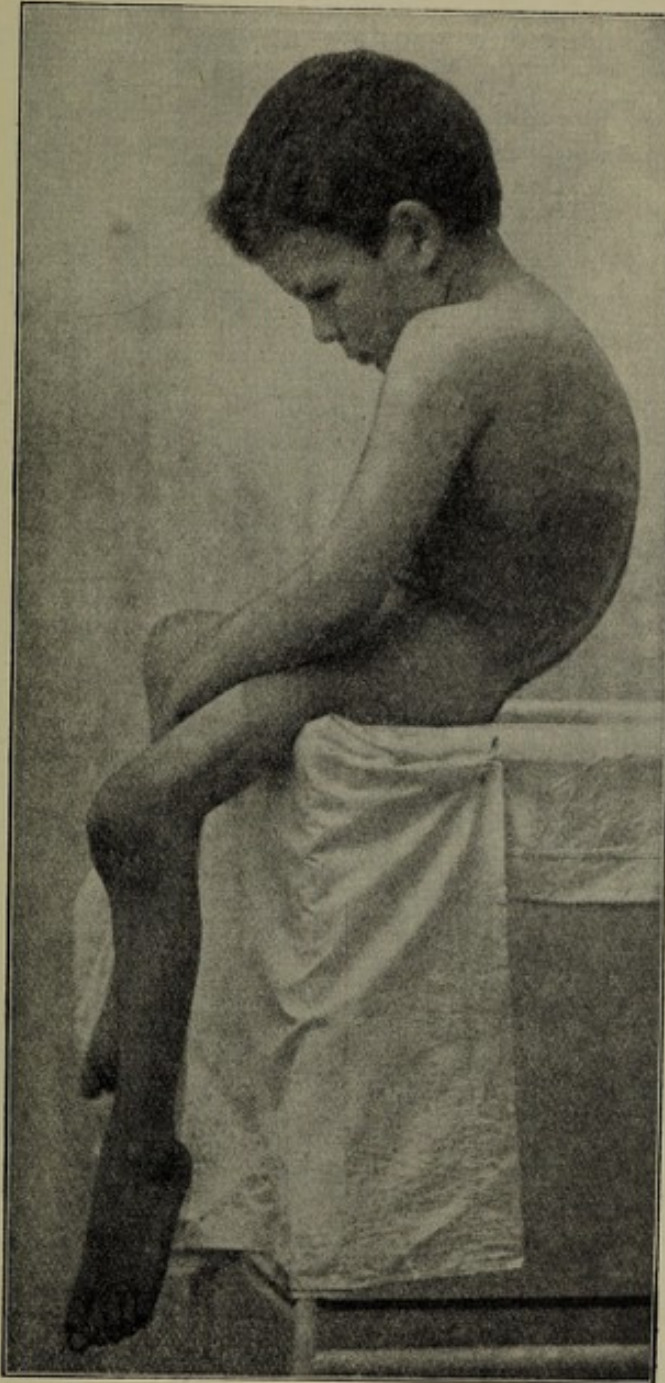


FIG. 78. (AFTER SCHULTESS.)

more comfortable appliance is a jacket made of stuff, and fitted with pelvic bands and steel supports (Fig. 80).

In some cases the application of a simple chest-brace of the well-known pattern is all that is necessary (Fig. 82).

In the more severe cases it is often necessary to combine a supporting apparatus for the legs with the spinal jacket. We shall describe these combined instruments, and the assistance which they afford in walking, in a later chapter.

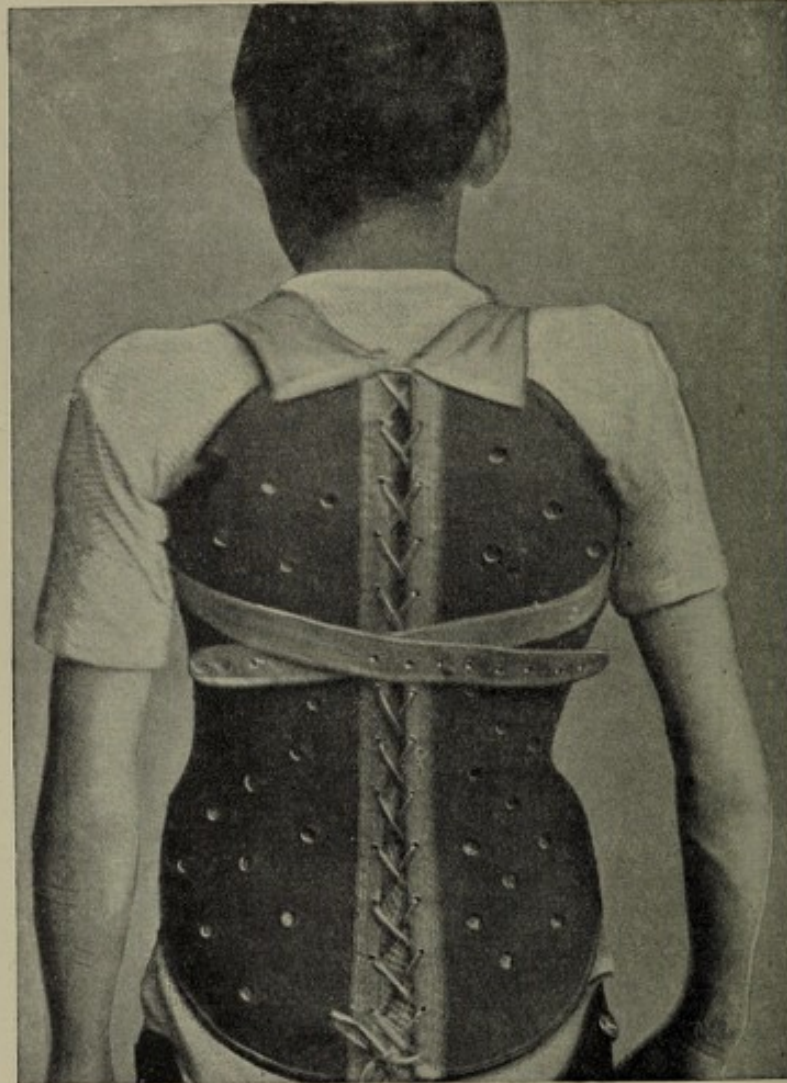

FIG. 79.

Paralytic Lordosis.

Lordosis may arise as a **compensatory** mechanism in double contracture of the hip, due to paralysis of its muscles. Locomotion and the restoration of the upright position are then rendered possible by means of exaggerated flexion of the lumbar spine.

True **paralytic lordosis**, however, is that which follows affection of the trunk muscles. We have already mentioned that this is commonly associated with paralysis of the lower extremities, and as severe paralysis often goes with contracture of the hip, it is quite possible that true paralytic lordosis is not very commonly observed.

Heine described and figured a deformity of this kind (Fig. 81).

The condition may result from paralysis of the abdominal muscles, as well as of the back. If the back muscles are paralyzed, the patient is liable to fall forward as the result of the unopposed action of the flexors of the spine—*i.e.*, the abdominal musculature. He avoids this by bending his spinal column into a position of



FIG. 80.

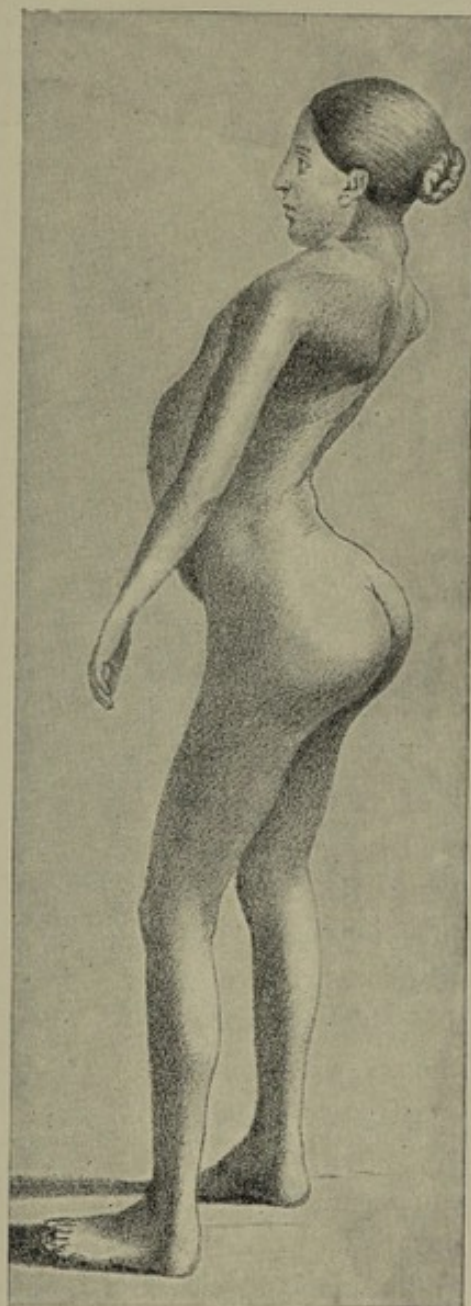


FIG. 81.

lordosis, until he establishes a kind of equilibrium between the weight of his trunk and the pull of his abdominal muscles. The lordosis is localized in the lumbar vertebræ, this being the most movable part of the spine (Fig. 83). The hip-joints are thus markedly extended, and the pelvis is tilted forwards. A plumb-line, dropped from the most prominent spinous process, falls behind the sacrum.

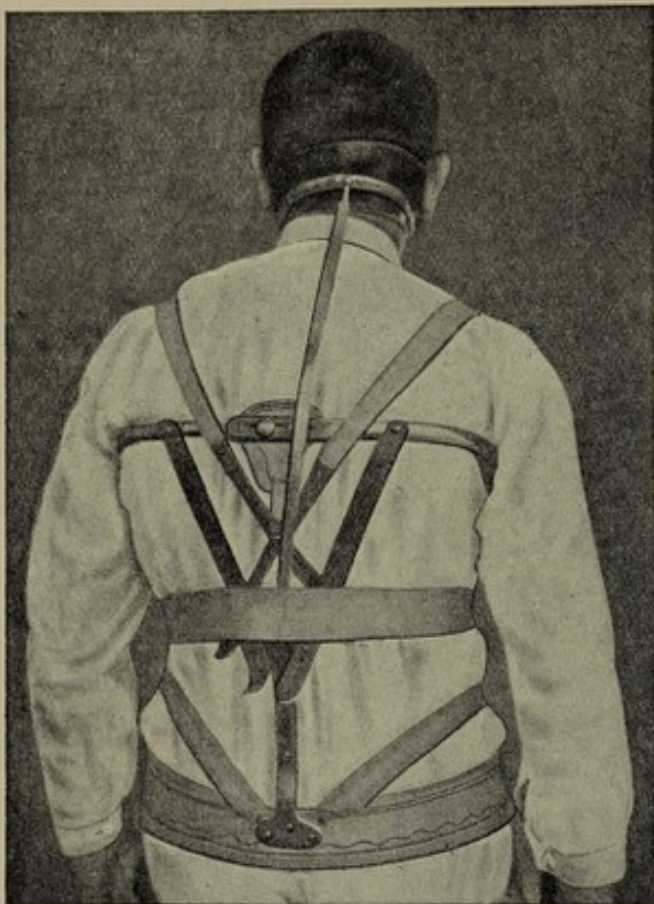

FIG. 82.

is afforded by **treatment** with a corset, but massage and exercises are of considerable importance, whilst the constipation that is always present, as the result of the paralysis of the abdominal muscles, must be treated by medical means.

Permanent paralysis of the abdominal muscles is not so uncommon as the literature of the subject would

If the abdominal muscles are paralyzed, the erector spinæ has no antagonist. The pelvis is tilted strongly forward, the lumbar vertebræ are drawn into marked lordosis by the contraction of the ilio-psoas, and the upper part of the trunk is thrown forward. The extensors of the back, therefore, perpetuate the lordosis, and prevent the vertebræ from sagging backwards. The plumb-line falls on to, or in front of, the sacrum (Fig. 84). The lordosis may reach such a severe degree that the sacrum is almost horizontal. It disappears altogether when the patient lies on his back, and only becomes permanent when the deformity has been present for a long time. Great relief

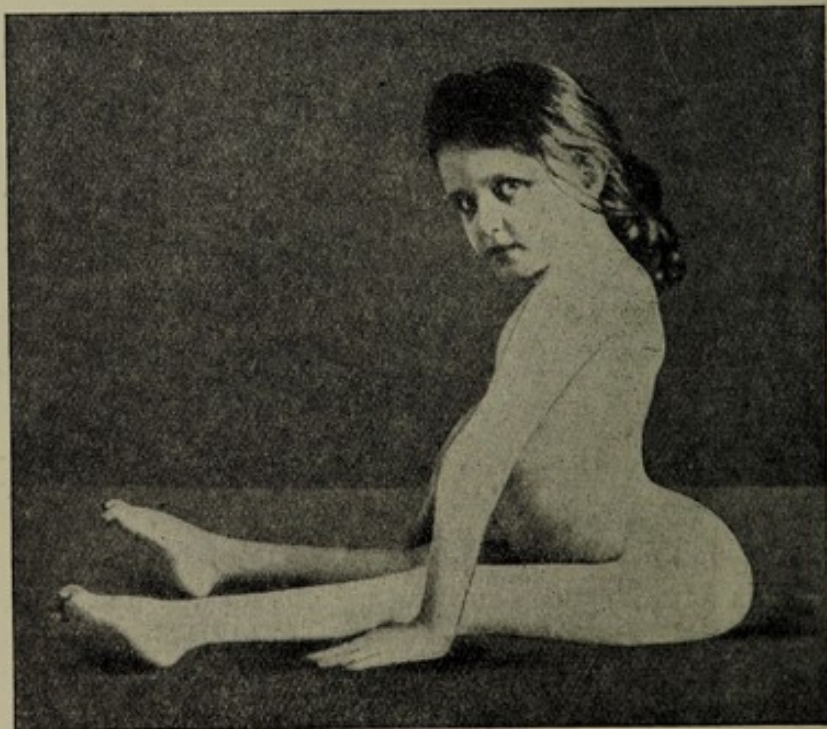

FIG. 83.

suggest. The oblique muscles are much more frequently affected than the recti. The abdominal walls are slack, and bulge out when the patient cries or strains. This condition is far more easily missed, if the surgeon does not specially look for it, than a localized paralysis in some part of the wall. The latter condition bears some resemblance to a hernia (Fig. 85).

It is uncertain whether it arises from a very limited initial focus, or whether it remains as the residuum of a more diffuse paralysis. There is no doubt, however, that some improvement may occur, although I have observed patients with irreparable damage to their abdominal walls.

We have already described the sequelæ, and the proper methods of dealing with them.

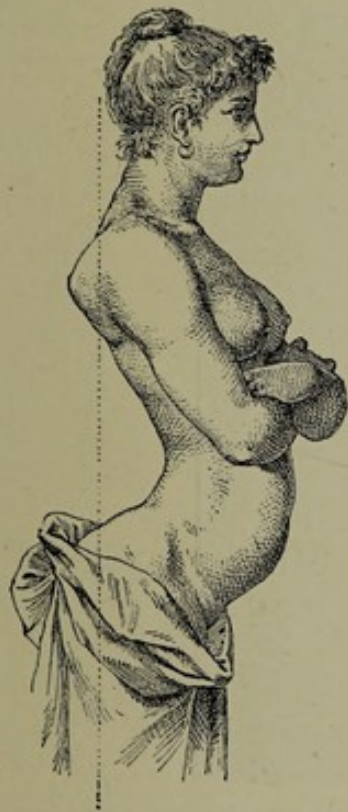

FIG. 84.

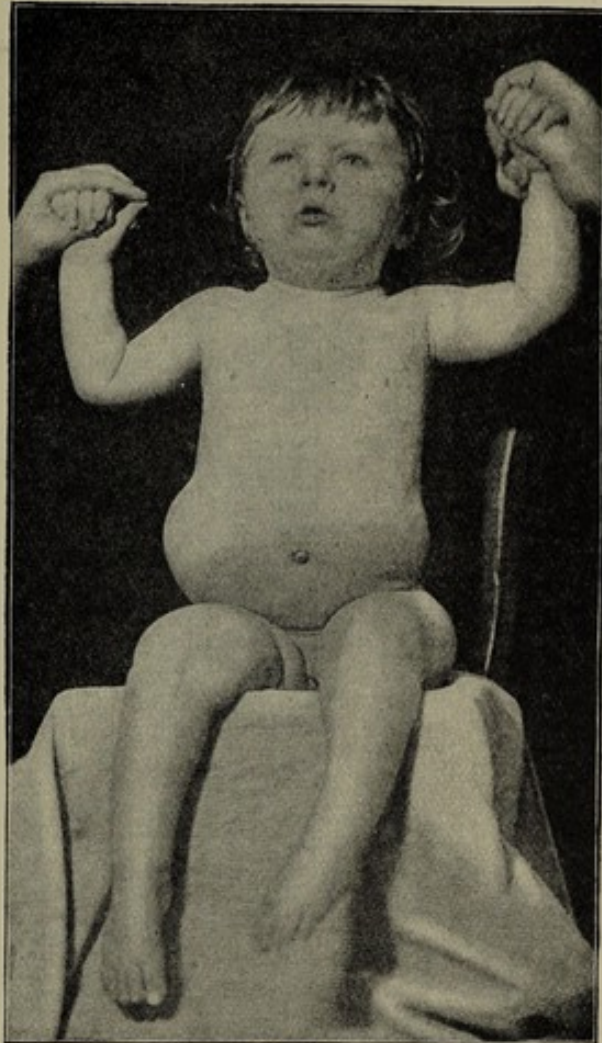


FIG. 85.

Paralytic Scoliosis.

[This is a much commoner result of infantile paralysis, and is due to the spinal muscles being unequally affected. Some authors (Morton, Sparre, Pintschovius) have stated that the so-called "habitual scoliosis" is ætiologically related to poliomyelitis in 75 per cent. of cases.

A distinction must be made between true and static paralytic scoliosis. We are not concerned here with that form of scoliosis that results from

paralysis and interrupted growth of a leg. In these static cases the lumbar convexity of the spine is directed towards the injured limb, and the pelvis is tilted in the same direction (Fig. 86).

Nor shall we discuss that form which follows paralysis of the shoulder muscles. We shall confine ourselves to that form of scoliosis which is caused by unilateral or unequal paralysis of the muscles of the back. If the patient goes about, the tendency to scoliosis is increased by certain other




FIG. 86.—STATIC PARALYTIC SCOLIOSIS.

factors—*e.g.*, the attitude that is adopted in the effort to maintain a proper centre of gravity. In order, therefore, to estimate accurately the effect of unilateral paralysis of the back in producing scoliosis, we must study patients who have not walked about. Observations on this subject are urgently needed, for we have no precise information about the nature and mechanism of paralytic scoliosis, although Heine described and illustrated cases (Fig. 87).

Insufficient attention has hitherto been paid to the static effect of external

influences, apart from the direct asymmetric action of the muscles in distorting the spine. This has always to be borne in mind in considering the descriptions that are given of paralytic scoliosis.

Most authors state that the most important item in the **diagnosis** is the fact that the *convexity is almost always directed towards the side of the healthy muscles*; only in the rarest cases are these found on the concavity—*e.g.*, five instances recorded by Firmin Charles. Landerer tried to explain this uniformity of the distortion by comparison of the spine to a mast supported by a number of ropes stretched on either side of it. If a rope is




FIG. 87.

loosened, the mast sinks towards the other side, and if the muscles are weak on one side, the spine falls over towards the good side. This comparison, however, is by no means apt. The spine has no fixed point, like a mast, and in addition to the powerful muscles which pass from the pelvis to the vertebræ, it has a number of other intrinsic muscles which modify its movements very considerably. Furthermore, the comparison fails, in that if a rope is loosened (*i.e.*, if a muscle is paralyzed), the spine becomes convex *towards* the paralyzed side. Schultess and Lorenz think that the scoliosis is caused by the patient's attempts to maintain his proper centre of gravity, and the perpetuation of osseous limitation of movement by the pull of the

healthy muscles. The usual result is scoliosis, with the convexity on the good side, but occasionally the healthy side will be concave. The healthy muscles, then, lie chiefly on the convex side, but sometimes on the concave side also, as was the case with lordosis.

This explanation is undoubtedly correct for long-standing paralytic scolioses, but it takes account solely of static forces, and leaves the effect of the muscles entirely out of count.

Other observers have regarded trophic disturbances of the growth of the bones as the cause of the deformity. The vertebræ are said to become softened on the paralyzed side, and to bend under the superincumbent weight. The ribs do the same (Redard, Leyden). Others, again, have thought that the bodies and ribs undergo unilateral arrest of growth similar to that which occurs in the long bones of the extremities. The result is scoliosis with the convexity towards the sound side (Messner, Hoffa, Mirallie).

Montsarrat and Schultess attribute the deformity to a combination of muscular action and trophic disturbance of growth.

Important information has been derived from investigation of the question in the living subject, and in post-mortem bodies, as well as from animal experiments.

Surgeons sometimes assume that, because the right arm and leg are paralyzed, the musculature of the back is also affected upon the same side—a conclusion which is not justifiable.

Neither can an accurate opinion be arrived at by palpation of the muscles of the two sides, for the outline and apparent bulk of the muscles are considerably altered by rotation of the vertebræ.

Estimation of differences in the contractility of the erector spinæ muscles is also liable to lead to mistakes, if the vertebræ are at all fixed. Electrical testing is equally unsatisfactory. Indeed, we know that even in habitual scoliosis differences in electrical excitability are the rule, and it has been thought, for this reason, that almost all scolioses are paralytic. It is impossible to estimate by electrical means the functional capacity of the lateral flexors of the spine and the rotator muscles, so deeply are they placed.

Cases of accidental rupture of the erector spinæ on one side have been recorded by Golebiewski and Leibold, and have presented features analogous to ordinary scoliosis. In both instances total scoliosis with the convexity to the injured side was the result. It is unreasonable, however, to draw general conclusions from these isolated cases.

The post-mortem room affords an opportunity of comparing the nature of the deformity with the condition of the muscles, bones, nerves, and spinal cord. Very few results, however, have been obtained. Klippel has found

unilateral atrophy of the spinal cord on the same side as the scoliosis and the degenerated muscles on three occasions. Monsarrat investigated Klippel's cases in greater detail, and found degeneration of the muscles of the left half of the thorax in a man of fifty-four, who was paralyzed in both extremities, and had a humpback on the left side.



FIG. 88.

The rhomboids and longitudinal muscles of the back were light yellow or pink in colour, rather like connective tissue, though some normal fibres were intermingled with them. On examining the cord, the cervical roots were found to be thinner and greyer on the left side than on the right, whilst the wasting of the anterior horns could be traced by the naked eye throughout about half the cervical part of the cord; microscopically, it showed atrophy of the ganglion cells. The second case was that of a

woman of forty-nine, with total left scoliosis. The autopsy revealed pallor of the muscles of the back on the left side and atrophy of the anterior cornual cells on the left side in the dorsal region.

In both cases, therefore, the convexity of the scoliosis was on the side of the paralysis. These, however, were elderly individuals, in whom static

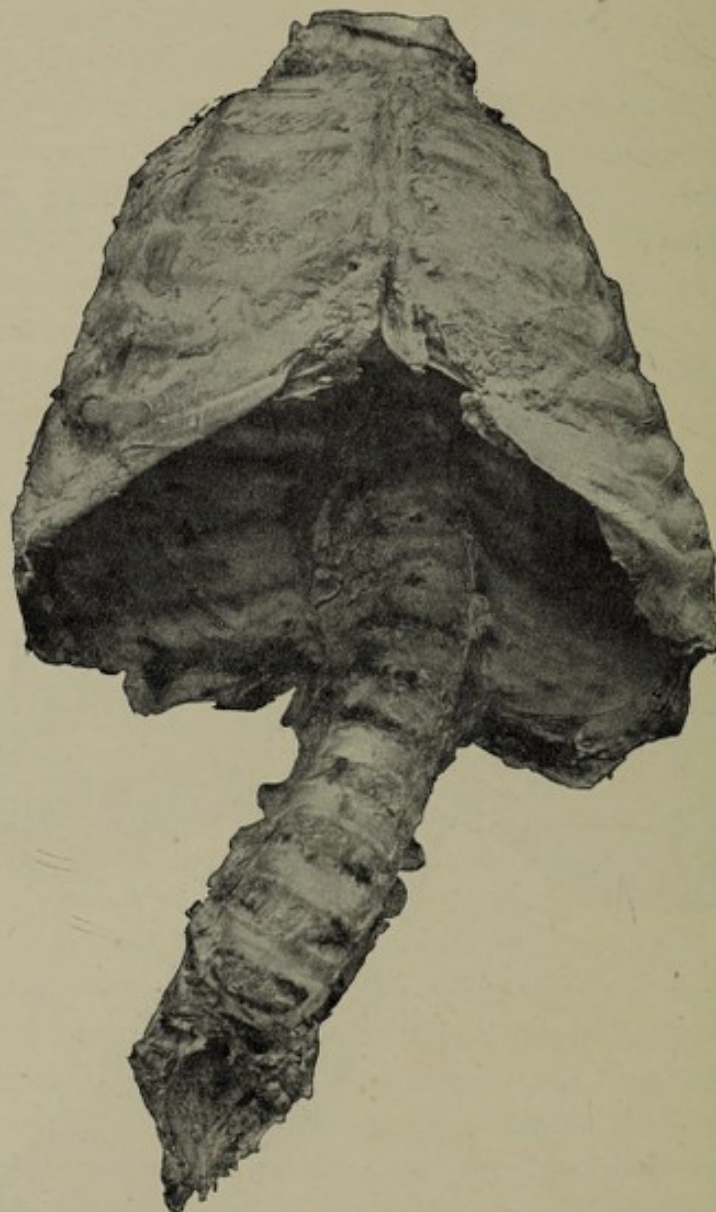

FIG. 89.

forces had been at work for some time, in addition to the pull of the muscles.

The conclusions arrived at by Ewald in a recent anatomical study of a pure paralytic scoliosis in my clinique are of far greater significance. We will quote his results at length :

The history is, unfortunately, very incomplete. The patient was an adopted child, *æ*t. two years. He was healthy at birth, but fell ill with a feverish attack during his first year of life. The right leg then became completely paralyzed, and he became

quite unable to stand or to get about. He also had difficulty in sitting, and had to support himself with both hands. He preferred to lie down by day as well as by night. He lay quite contentedly in his plaster bed, and hardly ever moved. He had complete paralysis of the right leg, which was in the position of rectangular abduction and slight flexion at the hip-joint; he had also total scoliosis, convex to the left, and left-sided humpback, with torsion in the lumbar region. At the age of two years and four months the child died of pneumonia.

The changes in the vertebral column and ribs are best shown in the photographs of the preparations made soon after the autopsy (Figs. 88 and 89). There is a total left scoliosis, beginning at the sacrum, and extending to the first dorsal vertebra. On drawing a line from the sixth cervical vertebra to the tip of the coccyx, and marking out the distances from it of the various spinous processes, a figure like Fig. 90 is obtained. This, however, gives but a very imperfect idea of the severity of the lateral deviation of the spine, on account of the rotation of the vertebrae. This is shown in Fig. 89. The figure shows, nevertheless, that the curve leaves the mid-line at the second dorsal vertebra, increases steadily until it reaches its maximum of 2½ centimetres at the eleventh dorsal vertebra, and then turns inward again, to reach the mid-line once more at the last sacral vertebra.

The rotation and torsion of the lower dorsal and upper lumbar vertebrae are so severe that the lateral processes of the ninth, tenth, eleventh, and twelfth dorsal vertebrae on the left side lie in the same frontal plane as the spinous processes of the vertebrae, whilst the transverse processes of the right side lie 1·2 centimetres in front (Fig. 91).




FIG. 90.

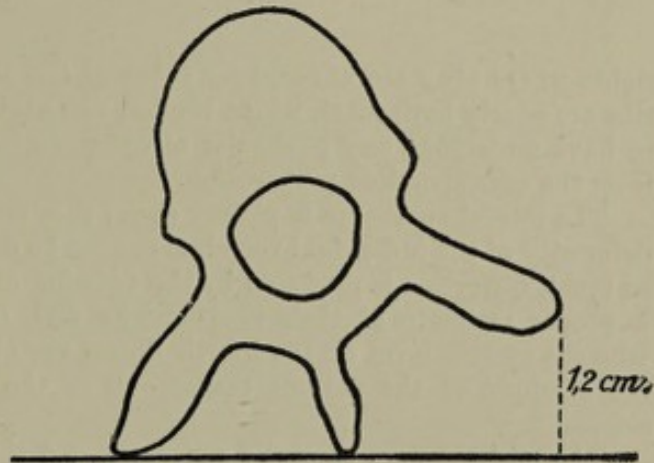


FIG. 91.

Fig. 92 shows diagrammatically a transverse section of the thorax at the level of the tenth dorsal vertebra, seen from below. It illustrates the asymmetry of the thorax, the diminution of the size of the left chest as compared with the right, the narrow costal angle on the left, and the flattening of the angle of the ribs on the right, with the corresponding deformity of the chest in front, similar to that which is seen in scoliosis, though smaller in degree. It is clear that the deformity has not yet reached its height,

otherwise the sternum would have been pushed still farther over to the right. The photographs show, at any rate, the relative breadth and depth of the right half of the thorax, compared with the flattening and diminution of capacity on the left.

The **X-Ray photograph** is very instructive as regards the lateral deviation, the rotation of the bodies, and the pathological position of the ribs (see Fig. 93). The twisting of the vertebræ is very plainly shown; hence the transverse processes of the right side are very plainly seen, whilst the shadows of the bodies coincide with those of the transverse and spinous processes on the left; the arches of the vertebræ are displaced towards the right, and the shadows of the spinous processes—which only show very indistinctly, because little ossification has taken place—are displaced to the

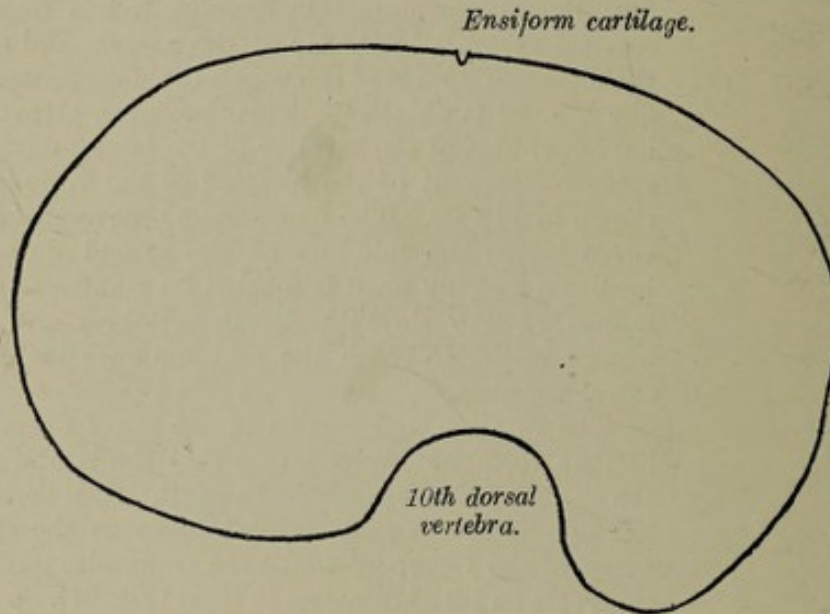


FIG. 92.

right, where they are covered by those of the articular processes. Lastly, the right ribs are nearly horizontal, whilst the left run abruptly downwards; they do not appear to have undergone any particular atrophy, as far as one can tell from the picture or from the corresponding preparation.

The lateral curvature is plainly seen; it is greatest at the eleventh vertebra. The deformity of the individual vertebræ cannot be demonstrated with the X-rays, because so much distortion is produced by the twisting of the bodies that it is difficult to form a proper estimate of their shape. The fifth lumbar vertebra looks fairly normal, whereas at the level of the fourth dorsal vertebra (the upper limit of the picture) the shadows of the various bodies and of the ribs differ considerably on the two sides.

The muscles were carefully prepared, and the functional value of each muscle or group of muscles was estimated from its colour and volume. It was found that the flexion and abduction of the right hip were explained by the paralysis of the adductors and the pull of the healthy ilio-psoas and gluteus medius. The condition of the trunk muscles is indicated in the following table, in which the muscles that are described as "paralyzed" are those that showed a pure yellow colour, quite distinct from the dark red tint of the unaffected fibres.

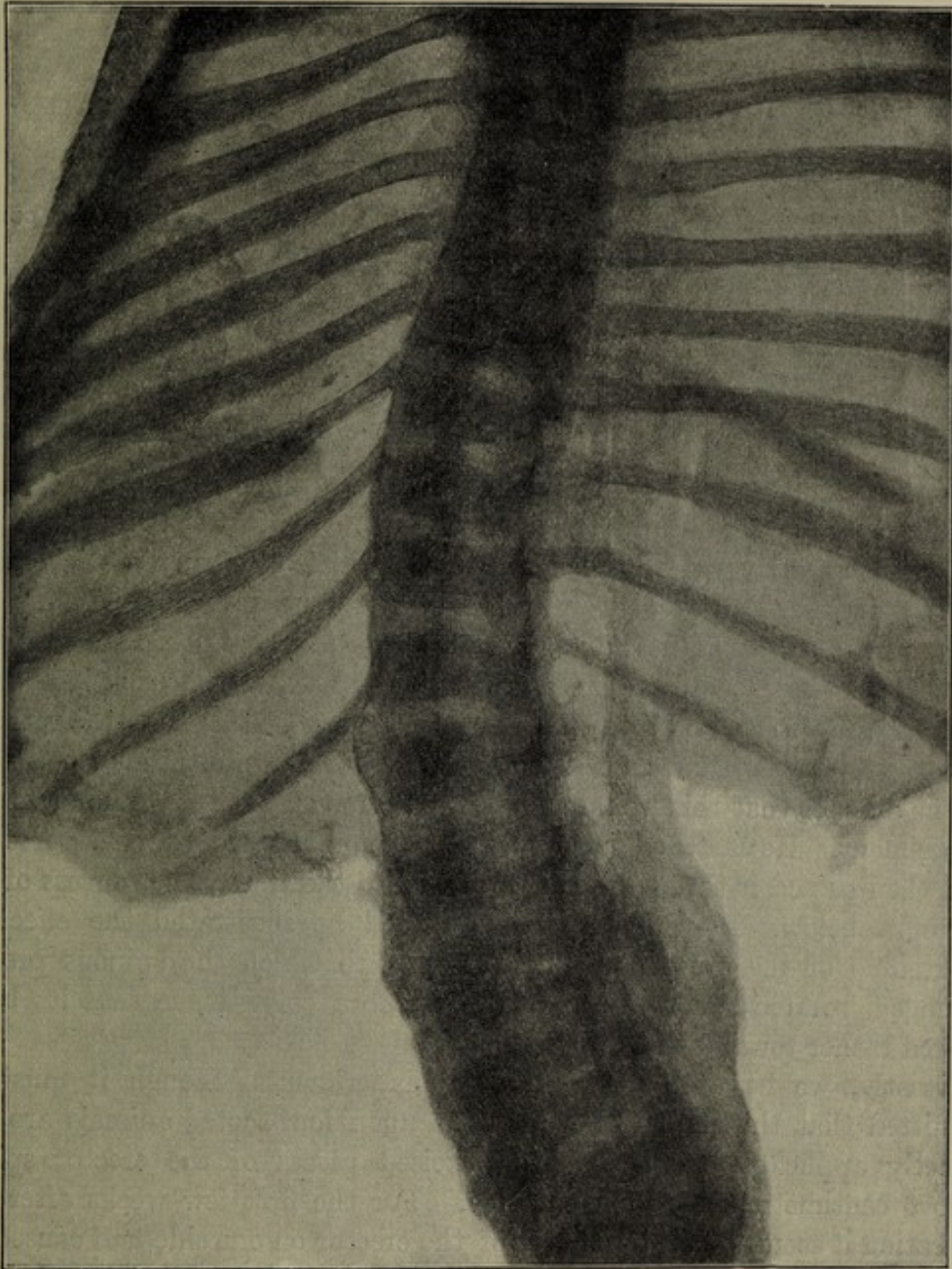


FIG. 93.

MUSCLES OF THE BACK.

Muscle.	Right.	Left.
Trapezius	Intact	Intact.
Latissimus dorsi	Intact	Intact.
Ilio-costalis	Intact	Intact.
Longissimus	Intact	Intact.
Semispinalis dorsi	Intact	Paralyzed.
Multifidus	Intact	Paralyzed, except cervical part.
Rotators, interspinales, inter- transverse	Intact	Paralyzed.
Quadratus lumborum	Intact	Intact.

Pathological changes, then, were present in the semispinalis, the multifidus, and the small and deeply placed muscles of the left side, especially in the dorsal and lumbar part.

The special value of this research consists in the fact that it was undertaken in an early case of scoliosis, uncomplicated by any static effects, so that it affords a picture of the results of pure muscular action. We learn, then, that *deviation takes place towards the paralyzed side*, and that this is due to paralysis of the small, deep muscles of the back, the semispinalis, multifidus, and rotators. The same cause accounts for the rotation of the vertebræ. Duchenne demonstrated that the multifidus functioned in the manner that this would suggest by means of a simple and irrefutable experiment. He fastened a ligature to the spinous process of a vertebra, and then passed it through a ring attached to the transverse process of the vertebra below. By pulling on the thread he illustrated the effect of shortening of the muscle. "The vertebra, to which the spinous process belonged, rotated somewhat upon the vertebra below it, so that its body looked rather towards the opposite side."

Lastly, we have to discuss animal experiments, though it must be admitted that the results of work done upon four-footed animals are not directly applicable to man. Arnd excised pieces of the erector spinæ, 5 to 6 centimetres thick, on one side. For the first few weeks after the operation it seemed as if the defect of the erector on one side had caused an overaction on the other. The convexity of the spine looked towards the operated side. "But the convexity was very soon replaced by a concavity, and there appeared a regular scoliosis of the second or third degree, with the maximum concavity at the site of the defect in the musculature."

Arnd was unable to give a satisfactory explanation of the development of the convexity upon the stronger side. The scoliosis was a most embarrassing condition for the animal, inasmuch as he could only go straight

forward by taking unequal steps with his right and left legs, so as to maintain the equilibrium of the spinal column. The healthy erector prevents compensation to a certain extent, but much less, when the animal has learnt to over-correct the concavity, and convert it into a convexity. It is difficult,

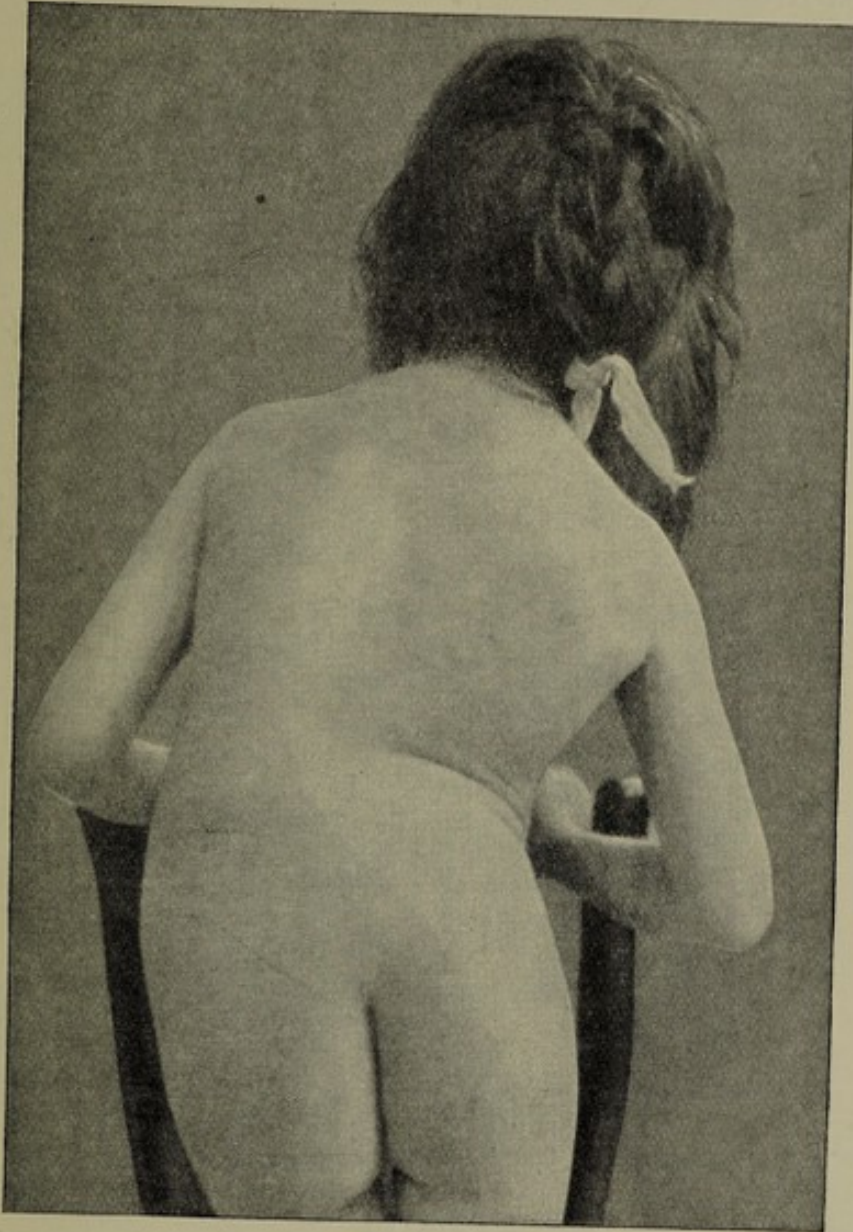

FIG. 94.

however, to see how this can be accomplished when the necessary muscles have been removed.

Schultess has explained away this difficulty. He thinks that the convexity is brought about as follows: "The removal of the muscle leaves the spinal column without any resistance on that side. Longitudinal strain is concentrated at that spot. The spine is therefore pulled over towards that side which is covered by muscles, and is therefore capable of being

strengthened by alteration of their shape. Thus it bends towards the side of the intact muscles."

In some experiments undertaken in the Vulpius clinic for another purpose pieces of the whole thickness of the erector spinæ, 5 to 6 centimetres long, were excised from rabbits, and the animals were killed after six months. The convexity was found upon the non-operated side, but one received the

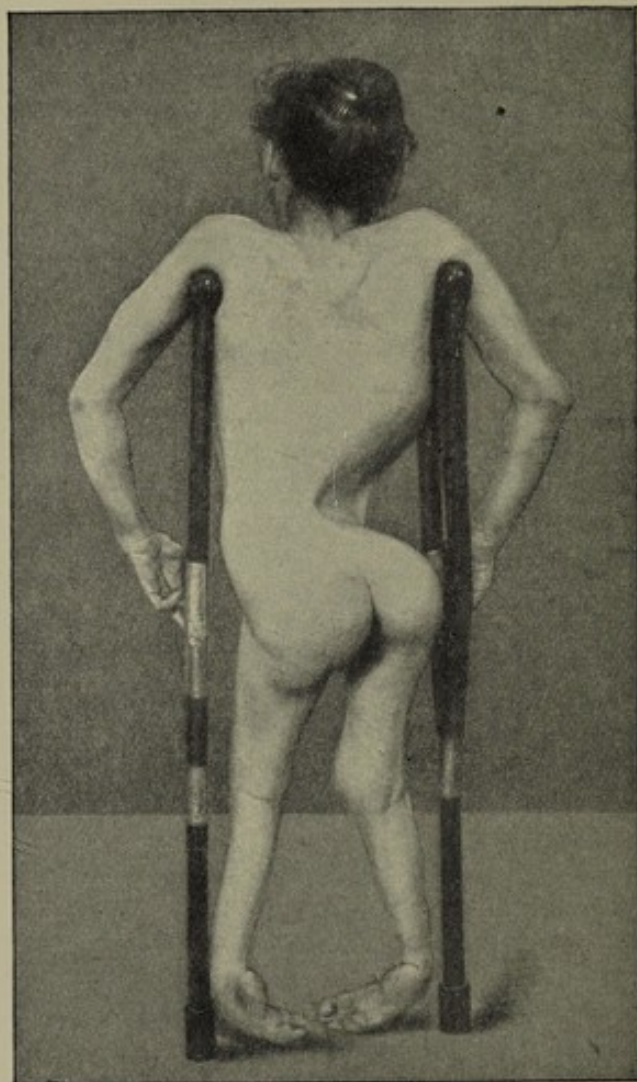

FIG. 95.

impression that the fibrous tissue developed at the site of the operation was strong enough to overpower any muscular pull, and accounted for the development and direction of the curve. The connective tissue contracts more and more as time goes on, and its influence becomes more obvious as the patient grows older. It may be the cause of the deformity, and the determining factor, in Arnd's experiments. Arnd specially mentions that he removed all muscle right down to the kidneys, and that he took particular precautions, by hæmostasis and tamponading, to avoid the formation of

a hæmatoma, but he does not tell us what took the place of the 5 or 6 centimetres of muscle that he removed. It is true that it is mentioned, in the only complete account of an autopsy that is given, that no connective-tissue formation could be demonstrated, and that the skin and fascia passed smoothly over the gap. But the muscle was not directly united to muscle at the operation area. It is much more probable that in the interval, as well as close to the bodies of the vertebræ, where it is impossible to get all the connective tissue away, the latter first proliferated and then gradually became converted into fibrous tissue. It is absolutely impossible to prevent this happening, however much tissue be taken away. Thus

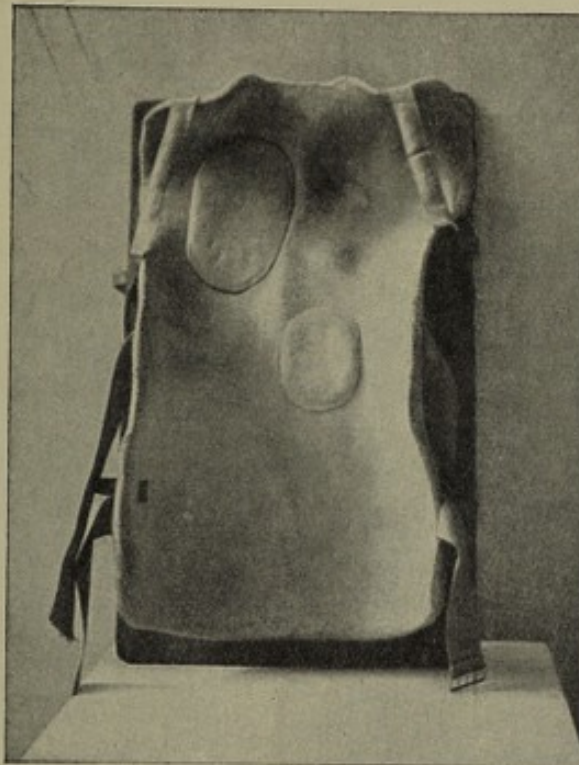


FIG. 96.

we find activity of the muscles upon the intact side for the first few weeks in Arnd's rabbits (=convexity towards the operated side), and then "very soon" activity of the muscles, or, rather, contraction of fibrous tissue, upon the operated side (=convexity towards the intact side).

We have still to complete the picture of the **clinical appearance** of the cases. The deformity consists of lateral deviation, which may affect the whole spinal column or only a part of it, and occasionally gives rise to compensatory curves in the adjacent segments, and also rotation, or torsion, leading to humpback. Although Heine had described severe deformity, with hump-formation, the idea has gained currency that paralytic-scoliotic spines remain freely movable, on account of the slight trophic energy of

the skeleton. Messner, in particular, laid stress upon the absence of fixation and deformity of the vertebræ. With increasing experience, we have learned that this is incorrect, and that paralytic scoliosis may appear very early, and reach a very high degree, as our preparation proves (Figs. 94 and 95).

The marked asymmetry of the thorax, too, has suggested that the whole paralyzed side had suffered arrest of growth. The appearance, however, is chiefly due to rotation of the vertebræ, and this, again, is shown in our specimen.

After all this, we can but agree with Kirmisson, that the **prognosis** is by no means a good one. We have therefore to think of prophylaxis, and to remember the possibility of scoliosis in all cases of early paralysis that we see. This must at once be **treated** with electricity, massage, exercises, and suitable recumbency. If scoliosis has already appeared, the use of a corrective plaster bed for the first few years is emphatically to be recommended. The patient lies in this, with his spine in the best possible position, during part of the day, and the whole of the night (Fig. 96). In older children the customary treatment of scoliosis must be carried out with great energy for a considerable time. I particularly recommend treatment in an institution, where they receive a combination of ordinary education and surgical treatment. Spinal jackets, however valuable they may be for other purposes, are not to be employed under any circumstances for paralytic scoliosis. It is hardly necessary to add that in those particularly severe cases, in which the paralysis of the back is accompanied by real or apparent shortening of one limb, this defect must be compensated by the use of appropriate apparatus.

CHAPTER III

PARALYSIS OF THE SHOULDER

PARALYSES of the upper limb are not common, even in orthopædic practice, but of all these paralysis of the shoulder is the commonest. It varies considerably in severity. It is often restricted to the deltoid, but it may extend to the rotators, the supraspinatus, and infraspinatus, the muscles of the shoulder girdle, or even to the various muscles of the upper arm.

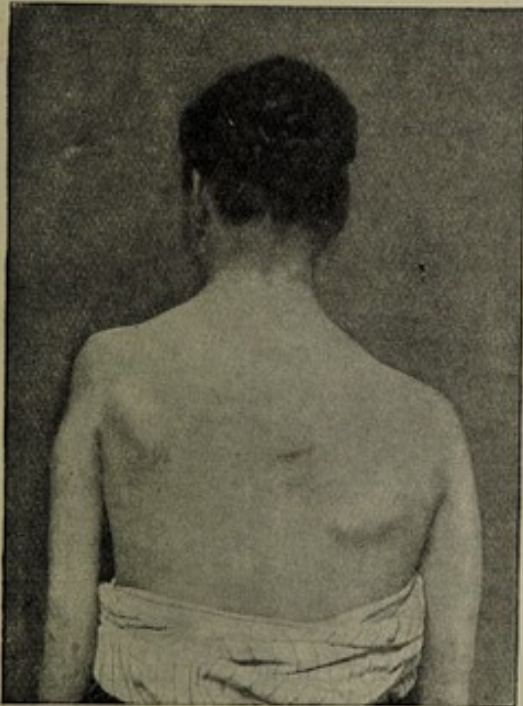


FIG. 97.

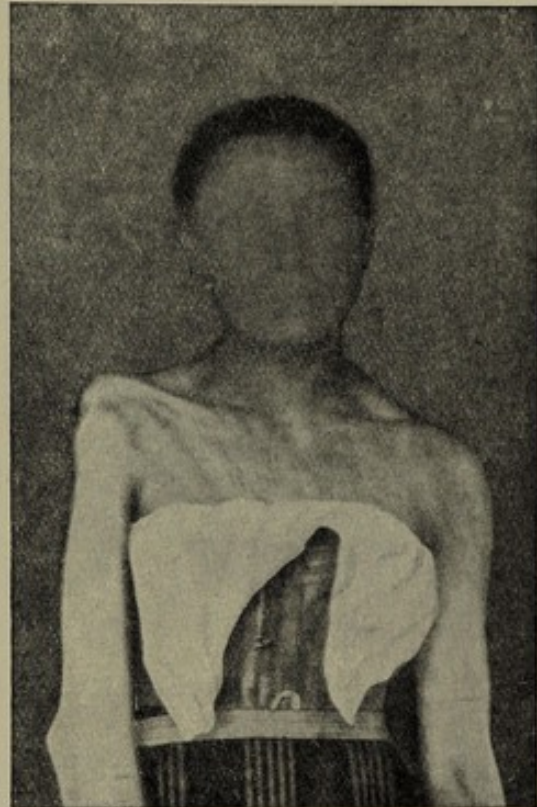


FIG. 98.

Appearance.—The type that interests us most is the **paralysis of the deltoid**. The shoulder lacks roundness, on account of the severe wasting of the muscle, whilst the muscles of the forearm, if they are unaffected, form a prominent lump when seen from behind (Fig. 97).

The acromion stands out strongly, especially when it is raised, together with the clavicle, by means of the powerful trapezius. The arm, no longer

supported by the deltoid, drops down as far as the weakened and overstretched joint capsule will allow, and comes to occupy the position of severe subluxation, or even complete dislocation. The head of the humerus, the tuberosities, the coracoid process, and the acromion process are easily seen through the skin and wasted layer of muscle. There is often a depression between the coracoid and the acromion, comfortably admitting two or more fingers. It is caused by the empty joint-capsule sinking in under atmospheric pressure (Fig. 98).

The humerus can easily be replaced in its proper position, but falls back

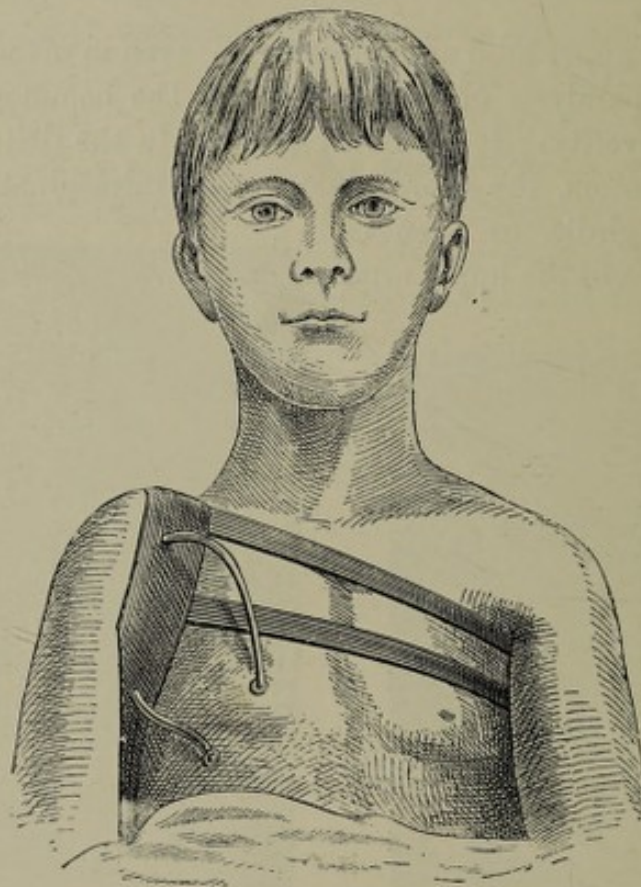


FIG. 99. (AFTER SCHÜSSLER.)

again as soon as the support is removed. The arm is usually somewhat inwardly rotated. Active movement at the joint is lost, and only swinging movements of the arm are retained. The limb thus comes to be more and more of a useless appendage, and in course of time the muscles of the upper arm become as incapable of function as those that are actually paralyzed, as the result of the constant stretching. The whole shoulder girdle can still be raised by the trapezius, but this movement is no longer transmitted to the joint in its flail condition.

It sometimes happens that the hand and fingers move well, but are prevented from being of much use by the paralysis of the upper arm. Under

these circumstances, as well as when the upper arm only is affected, an attempt should be made to remedy the condition. The muscle should be treated by electricity, massage, and exercises, in the hope of effecting its restoration.

It has been stated, as a point in favour of treatment by exercises, that not only is the deltoid strengthened, but also the other accessory muscles of similar function. The records of cases of this kind are not altogether satisfactory, however, for it has not been shown that the deltoid was completely paralyzed at the outset. Thus Cron succeeded in enabling a ten-year-old girl to raise her arms in front of her, and then carry them out sideways, and later on, to raise them directly from her sides. The poliomyelitis, however, had not affected one of the anterior bundles of the muscle. It has not been conclusively shown that accessory muscles are capable of replacing the deltoid, when this muscle is definitely and completely paralyzed, and such an event is extremely improbable if the supraspinatus is in any way impaired.

Medico-mechanical treatment is of no value unless at the same time the muscles are protected from the special liability to overstretching and consequent subluxation. This may be accomplished by means of a suitable bandage, a triangular arm-sling, or the continued wearing of an orthopædic apparatus. Schüssler's appliance for this purpose consists of a shoulder band, to whose inner surface three air cushions are attached, and whose inner border, spread out flat, forms an arc of a circle of about 45 centimetres radius. The air cushions are inflated as much as may be necessary, and then afford the necessary support to the shoulder-joint, without causing symptoms of pressure upon the vessels or nerves.

By the use of this instrument, together with massage, exercises and electricity, Schüssler succeeded in one case in enabling the patient to write, draw, work, and even play the piano tolerably well, after six and a half years' treatment. Billroth, Collin, and Hoffa have devised other appliances for the same purpose—viz., the support of the arm, and prevention of drooping (Figs. 100, 101).

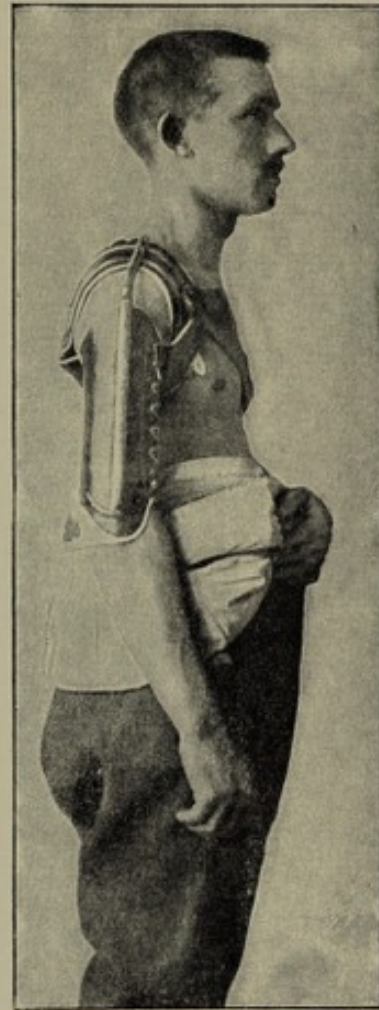

FIG. 100.
(AFTER HOFFA.)

Hoffa describes his instrument as follows: A moulded leather sheath encloses the upper arm, but is cut away at the elbow so as to allow of free flexion of the forearm. It may be carried down over the extensor aspect of the elbow, so that it supports the upper arm more effectively. The arm is then supported against the scapula by fastening the arm-piece to a shoulder-cap by means of steel supports. The shoulder-cap is fastened on with straps passing through the opposite axilla. Hinge joints between the

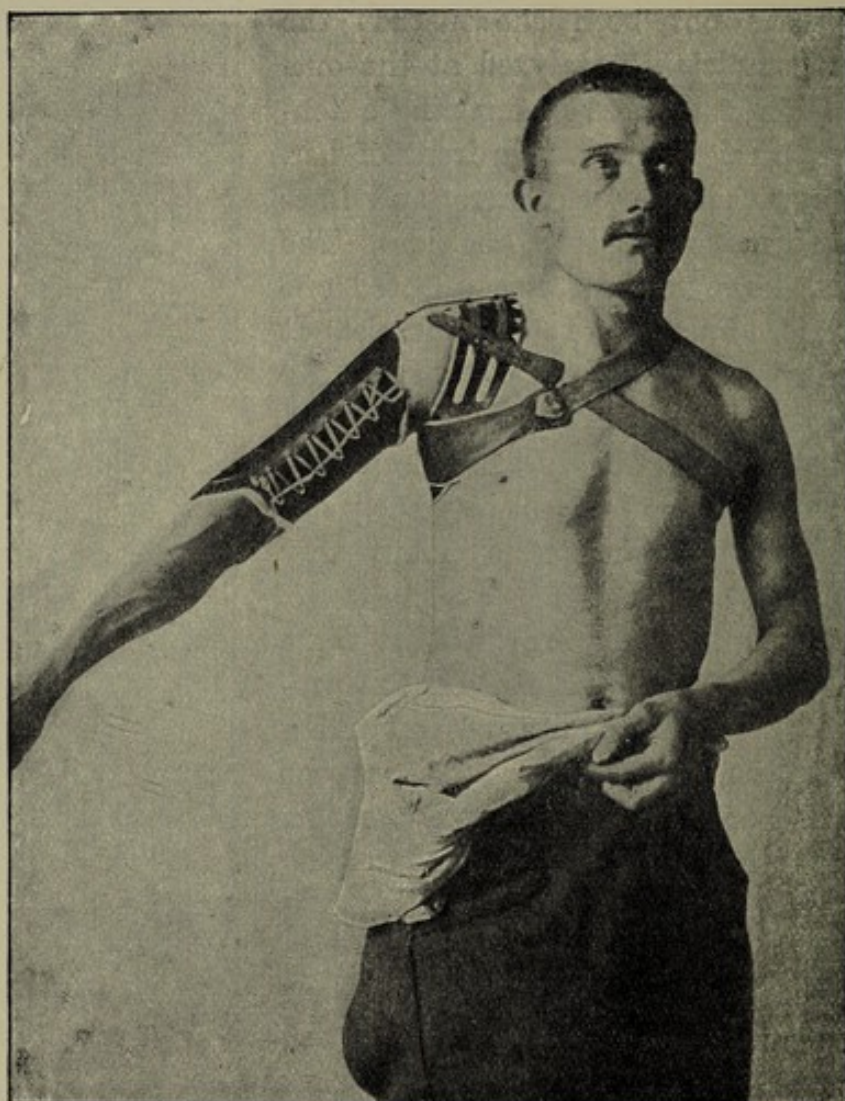


FIG. 101. (AFTER HOFFA.)

various parts allow of sufficient movement of the arm. India-rubber tractors may be used to replace the injured muscles.

In the apparatus which I employ, movement at the shoulder-joint is sacrificed altogether. The arm is fixed in a position of wide abduction by means of a single leather sheath, enclosing the thorax and upper arm, jointed to a forearm sheath (Fig. 102). Naturally, this instrument can only be worn indoors, for cosmetic reasons.

Silver recommends that the arm should be raised right up, and fixed in this position for six to eighteen months. Medico-mechanical treatment is employed in addition. He claims to have repeatedly obtained satisfactory results.

Nothing very brilliant can be expected from the methods of treatment described, and the time and discomfort that it entails are out of all proportion to the amount of good that results. Complete cure is out of the question, and the apparatus tends to abolish compensatory movements of the scapula rather than to promote them. I therefore recommend medico-

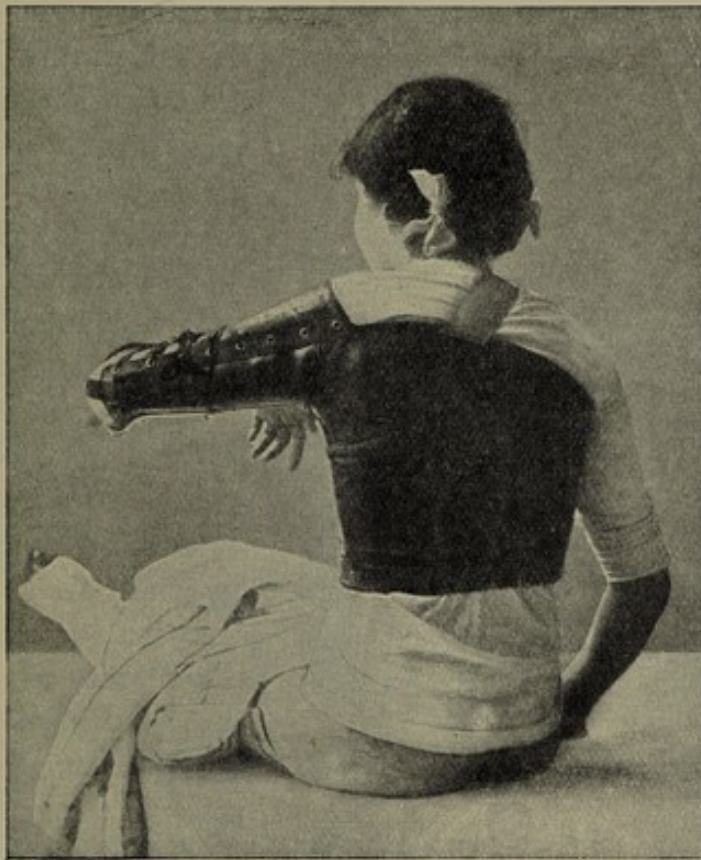

FIG. 102.

mechanical treatment only for recent, or comparatively recent cases, and in partial paralysis of the deltoid.

When there is complete paralysis of the deltoid, and the development of a flail-joint is inevitable, **arthrodesis** should be employed. This is a method whose value and wide range of applicability have been insufficiently known up to the present. Albert, who invented arthrodesis, first performed the operation upon the shoulder-joint in 1879, in the case of a girl of four, with infantile paralysis. Later on, he repeated the operation in another case. Then J. Wolff operated upon two patients. He thought that bony ankylosis was so improbable that he did not trouble to freshen the joint

surfaces, but merely fixed the head of the humerus to the glenoid cavity by means of a suture. This is known as **arthrorrhaphy**. Karewski also performed arthrodesis of the shoulder on one or two occasions, but was little pleased with the results. He writes that "monoplegia of the arm is not a suitable field for arthrodesis." Schüssler, too, was against operation, maintaining that equally good results could be obtained more simply by the use of his instrument. Hoffa also is pessimistic. "Arthrodesis," he says, "is only a last resort, and can only be recommended as such. True ankylosis certainly cannot be obtained." Bothézat published three cases in 1901, in which useful results had been obtained; they attracted

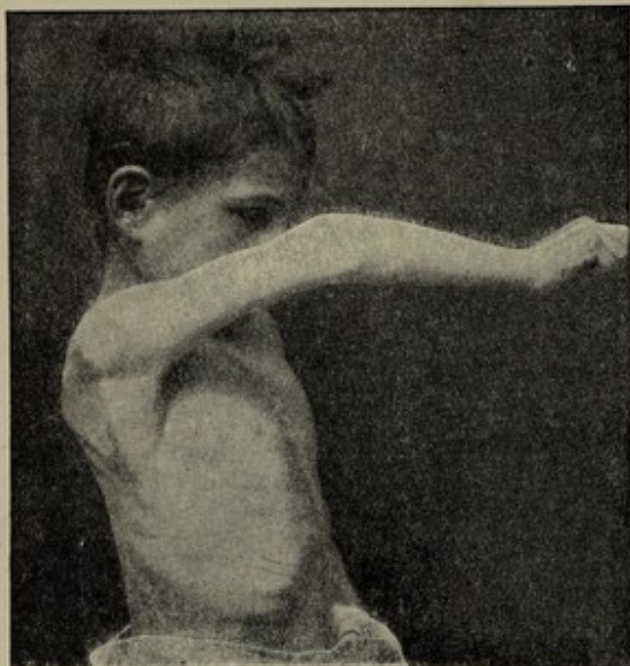


FIG. 103.

The fundamental idea of the operation is, that when the humerus and the scapula are united together, the muscles of the shoulder girdle, the trapezius, serratus, and others, will be able to raise the arm by abduction and rotation of the scapula. It is essential, therefore, that these muscles should be intact.

The functional improvement of the arm that results from fixation of the shoulder in a good position is occasionally illustrated by patients who have suffered from some pathological process resulting in ankylosis.

Several cases of this accidental stiffening of the shoulder-joint, followed by recovery of power in the arm, have recently come to our notice, and it will be useful to relate them briefly, as they lend support to our argument in favour of arthrodesis of the shoulder :

no attention, however. In 1904 Hevesi warmly recommended the operation, as the result of very favourable personal experience of it; but again little notice was taken of his paper.

The method, therefore, has attracted few adherents, though Tilanus (van Nees) and Tubby have taken it up, and no improvements have been made in the technique.

A discussion of the results, especially as regards their duration, is impossible from the literature, so that I must supply the deficiency by a short account of my own experience in the matter.

1. J. O., *æt.* 7 years. Very difficult labour, especially as to the arms. Right arm noticed at the time to be hanging powerless. Active movement observed for the first time nine months later. Right shoulder-joint found to be firmly fixed, only allowing slight movement. Head of humerus luxated downward and fixed in this position, partly by shortening of soft parts and partly by muscular action; 60 degrees abduction. Deltoid atrophic, but not completely paralyzed. Right scapula smaller than left, and 2 centimetres higher; spine measures 9 centimetres (*cf.* 9½ centimetres), and vertebral border, 10 centimetres (*cf.* 11 centimetres); arm, 3 centimetres short (48:51). Slight right dorsal scoliosis. Arm can be raised by passive movement: 160 degrees forwards, 110 degrees laterally, 30 degrees backward; active movement, 135, 90, 0 degrees (Fig. 103).

2. K. F., photographer, *æt.* 28 years. Paralysis of left arm noticed after birth; gradual improvement. Left arm found to be considerably shortened and wasted. Difference in length, about 11 centimetres (84:73) = 5 centimetres in upper arm and forearm, and 1 centimetre in hand. Atrophy = 7.5 centimetres in shoulder, 6 centimetres in upper arm, 4.5 centimetres in forearm, and 2.5 centimetres in hand. Paralysis of extensors of hand, supinators, interossei, and thenar muscles; deltoid severely affected, triceps and biceps slightly. Flexors of fingers, deltoid, and trapezius intact. Head of bone displaced upwards and backwards, rendering deltoid prominent. Shoulder-joint almost completely fixed, allowing only slight range of movement. Left scapula distinctly smaller than right, and higher. Difference = 3 centimetres in length. Slight total scoliosis, convex to left. Arm could be voluntarily carried forward to the horizontal position by means of the muscles of the shoulder girdle (Fig. 104).

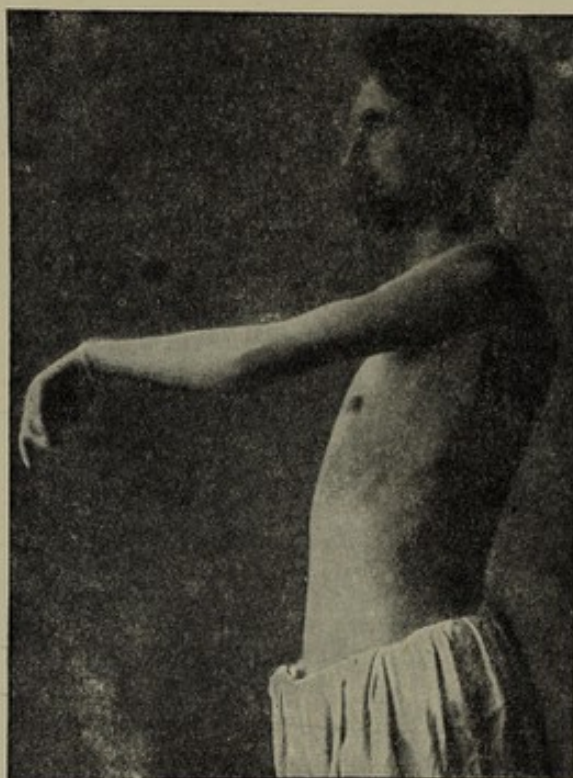

FIG. 104.

3. R. T., boy, *æt.* 15 years. Severe osteo-myelitis of humerus seven years previously, affecting, among other structures, the shoulder and elbow joints. Both firmly ankylosed. Bony union at oblique angle at the elbow; firm fibrous union at shoulder, allowing very limited range of movement. Humerus almost at right angle with outer border of scapula. Abduction must have been due to long separation of arm from side to allow of escape of pus. Ankylosis took place during this time in useful position. Arm can be raised voluntarily by means of shoulder girdle, and reaches horizontal position laterally as well as in front (Fig. 105). Extent of passive movement rather greater = 115 degrees in front and 110 degrees sideways.

In all three cases ankylosis of the shoulder took place in the abducted position, although they had quite different pathologies. This fact accounts for the striking amount of use which the patients were able to make of their stiff arms.

A recent case illustrates very forcibly the value of the abducted position in ankylosis of the shoulder-joint :

A lad was brought to my clinic on account of complete stiffness of the shoulder following chronic inflammation. The arm was markedly adducted, and useless. The intra-articular adhesions were stretched under an anæsthetic, and the limb abducted to a right angle, whilst the scapula was fixed. A plaster splint was applied for three months. The boy can now raise his arm without difficulty almost to the vertical position (Fig. 106). On examining him without restricting the movements of the scapula, it would hardly be noticed that complete ankylosis had really taken place.

We return now to my own personal experience of arthrodesis of the shoulder, and shall give the **histories** of a dozen cases, the majority of which have been repeatedly ex-



FIG. 105.

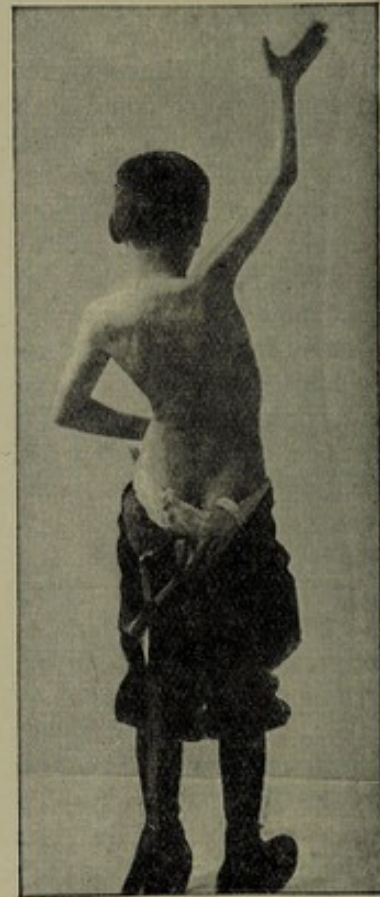

FIG. 106.

amined since. Ten of these operations were performed more than two years ago, six more than four years, and four more than six years, so that the results described can be regarded as permanent.

1. Z. A., boy, *æt.* 2 years. Paralysis of left arm noticed during first year of life. Arm hanging limply by side, slightly rotated inwards. No difference in length. Marked wasting of upper arm. Subluxation of head of humerus, which seems to lie just under skin. Deltoid cannot be demonstrated, either by palpation or by mechanical or electrical stimulation. Little or no contraction in muscles of upper arm. Operation, October, 1898; head of bone exposed through anterior incision, and freed from surrounding structures. Glenoid cavity and under-surface of acromion process carefully

freshened. Head replaced and fastened to acromion with silver wire. Part of capsule removed. Skin sewn up. Velpeau bandage applied. Uneventful recovery. Dressing changed on October 17, 1898. Ankylosis appeared to have taken place. Patient discharged with new bandage, the latter removed by parents; patient not brought up for after-treatment. When next seen, four years later, the mother stated that the use of the arm had slowly returned. Shoulder looks very atrophic, from wasting of deltoid, contrasting very strongly with the upper arm, which shows no wasting. Head of humerus occupying proper anatomical position. On fixing scapula, just a trace of movement at the joint seems to take place. Firm fibrous ankylosis at least has been obtained. X-ray examination impossible, on account of child not keeping still. On passive movement, the scapula moves with the arm. Arm can be raised voluntarily to the horizontal in front and to 50 degrees at the side. Disturbance of growth insig-

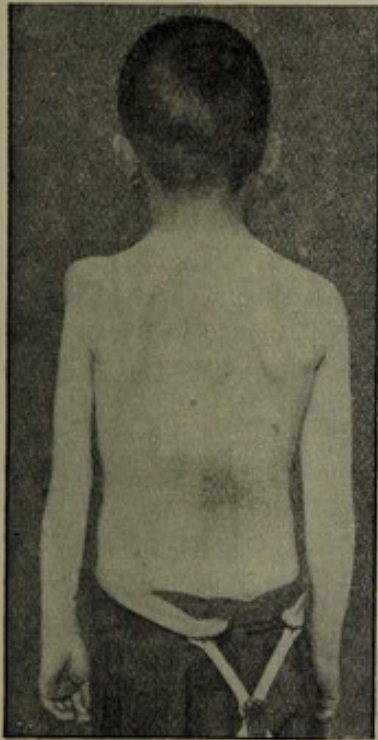


FIG. 107.

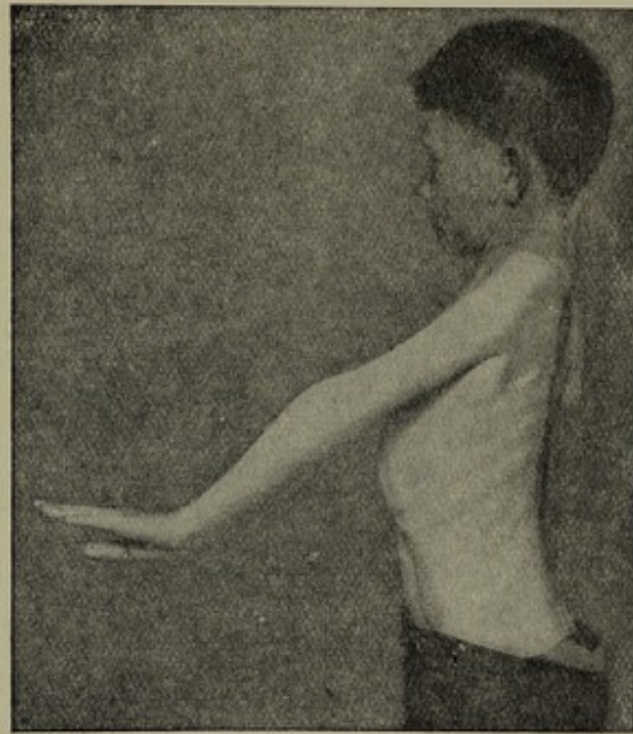


FIG. 108.

nificant; difference = 1 centimetre, partly due to dropping of shoulder. Muscles of upper arm somewhat recovered, especially the biceps. Eight and a half years after the operation, patient had never had any pain, and no sinuses had developed in the region of the shoulder. Patient used the arm constantly, and could move it about freely. Head somewhat uneven, but in proper position. Only minimal movements of rotation and lateral play possible at joint. X rays show that the epiphysis of the head is directed more towards the cartilaginous acromion than towards the glenoid cavity. No bony union. Fragments of silver wire sticking into the head and into the acromion. Humerus forms an angle of 60 degrees with the axillary border of the scapula. On passive movement, the arm can be raised 30 degrees above the horizontal, in the forward direction; laterally up to the horizontal; and backwards, up to 50 degrees from the vertical. For active movement the corresponding figures were: forwards, 60 degrees; laterally, 40 degrees; backwards, 40 degrees. Biceps and triceps contract well, though not powerfully. Slight left total scoliosis, much accentuated by lateral elevation of the arms. Scapulae equally high; spine measures $10\frac{1}{2}$ centi-

metres on the left and 12 centimetres on the right ; vertebral border measures 11 centimetres from angle to base of spine on both sides. Arms measure 56 centimetres on left, and 58½ centimetres on right. Figs. 107, 108, and 109 show the shape of the arms and back, as well as the range of movement possible. Nothing special to be mentioned about the X-ray pictures.

2. K. N., girl, æt. 14 years. Onset of paralysis at age of two. Arm hanging powerless by side. Deep hollow, admitting several fingers, between acromion and head of humerus, which stands out prominently beneath the skin. Deltoid, triceps, and biceps seem to be completely paralyzed ; trapezius, latissimus, and pectoralis present, but affected with disuse-atrophy. Hand and fingers can be moved, though not with any power. Arm 4 centimetres short. Operation, January 7, 1899. Anterior incision

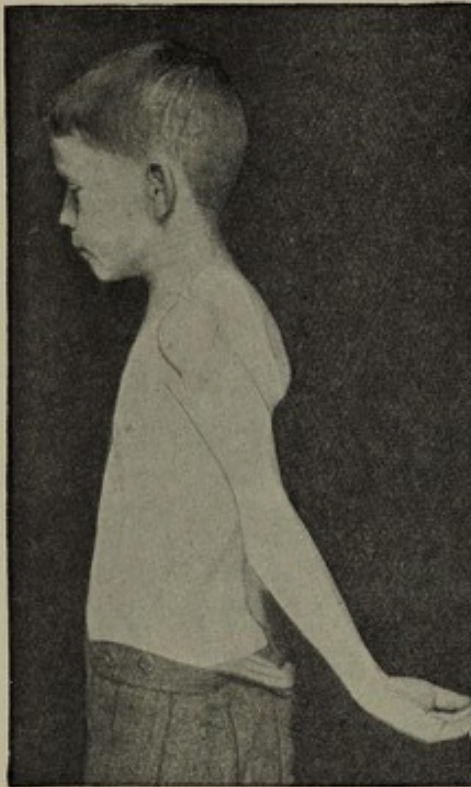


FIG. 109.

5 centimetres long ; deltoid found to be excessively thin, separated from capsule, and a portion of the anterior part of the latter excised. Head of humerus displaced and thoroughly freshened. Glenoid cavity very small ; cartilage apparently normal ; removed down to spongy layer of bone. Coracoid and under-surface of acromion similarly treated. Head fixed to acromion and coracoid with one silver suture. Uninterrupted recovery. Bandage changed after two months, when patient ceased to attend. One and a half years later she came back, and a piece of silver wire was removed from a sinus. Three and a half years after the operation the girl could use the arm well. The head of the humerus was absolutely fixed to the scapula, though it still seemed to lie just under the skin. X-rays showed bony ankylosis. A piece of wire lying in the head ; no sinus. Left scapula smaller than the right ; arm still about 4 centimetres short. Upper part of trapezius developed, but middle and lower portions still deficient. Biceps weak, but capable of contracting. Arm could be raised 55 degrees laterally and 65 degrees in forward direction with elbow flexed, and 45 degrees when extended. Strength of hand subnormal, but sufficient for ordinary purposes

(40 degrees on dynamometer). Eight and a quarter years after operation—*i.e.*, on March 12, 1907—patient, now twenty-two years old, reported that a sinus had been present for about a year after she was last seen ; but this had healed up after a piece of silver wire had been removed from it. No trouble since. She could use the arm for dressing and undressing herself, and also for all her domestic and outdoor duties. Head of humerus absolutely fixed in proper anatomical position, the slightest movement of the arm being communicated to the scapula. X-rays show complete synostosis between head and glenoid cavity ; no line of demarcation can be demonstrated between the two, and the bony lamellæ show absolute continuity (Fig. 110). The head is united to the acromion and coracoid by a firm bony bridge. The humerus forms an angle of about 80 degrees with the outer border of the scapula. No silver wire can be seen. The upper border of the left scapula is about 2 centimetres higher than the right. The inner border measures 11 centimetres on the left, and 13 centimetres on the right, whilst the spines measure 14½ and 16¼ centimetres respectively. Right humerus = 32½ centimetres, and the left = 29½ centimetres. Whole arm measures 63 centimetres

on left, and 66 centimetres on right. Shortening is therefore due to disturbance of growth of upper arm. Definite right dorsal scoliosis, with torsion, slight lumbar and cervico-dorsal compensatory curves. Passive movement of arm to 140 degrees forwards, 100 degrees laterally, 60 degrees backwards. With extended elbow, arm can be raised to 45 degrees forwards, 45 degrees sideways (see Fig. 111), 70 degrees with elbow flexed, and 30 degrees backwards. Trapezius hypertrophied; well seen in Fig. 111, and specially prominent in consequence of atrophy of deltoid. Biceps retains elbow in flexed position, but not powerfully; triceps gone. Grip good.

3. F. B., girl, *æt.* 14. Paralysis of right arm at one year. Severe flail condition of right shoulder; deltoid completely destroyed; biceps, triceps, supraspinatus, and

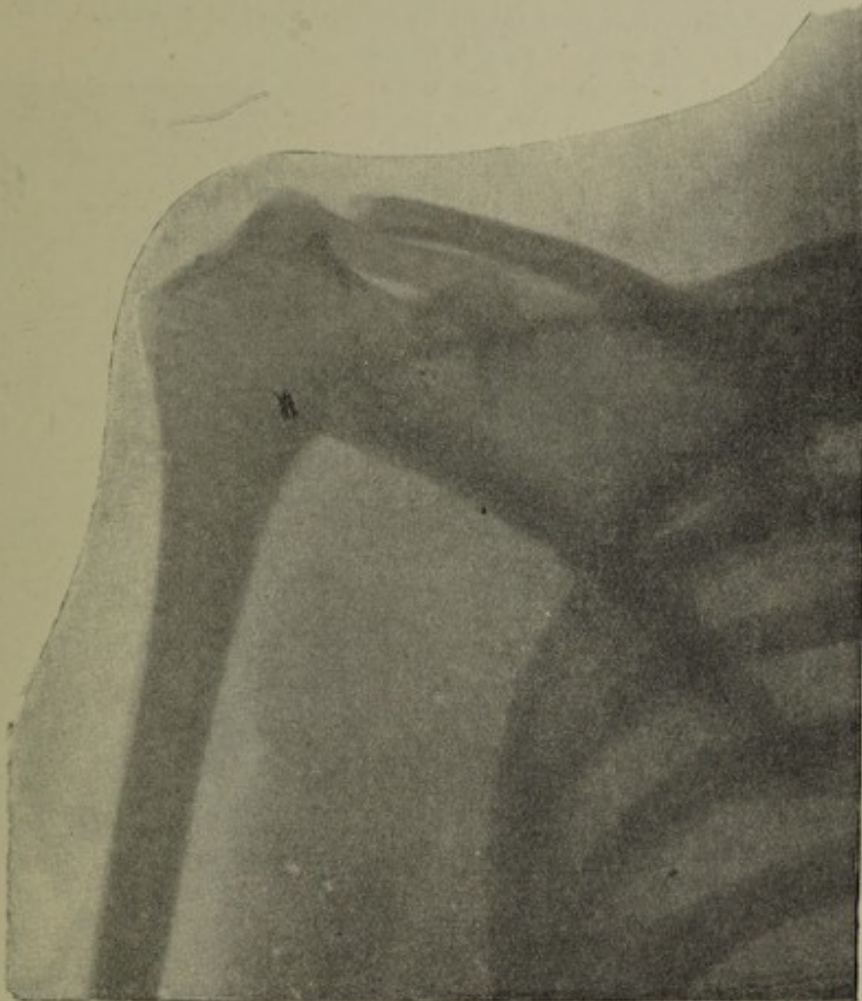


FIG. 110.

infraspinatus severely atrophied. Arm at least 4 centimetres short; hangs limp and motionless at the side. Operation, May, 1900. Capsule exposed through anterior incision; head of humerus displaced and freshened; acromion ditto; part of capsule removed; head fastened to acromion with silver wire in position of slight abduction, also to glenoid cavity by means of a nail. Uneventful recovery. Fixation for four months. Nail and part of wire removed on account of sinus. After-treatment by means of massage and exercises to improve the condition of the muscles of the shoulder girdle, and increase its range of mobility. Also a laced sheath, to insure maintenance of abducted position. Two and a quarter years after operation the girl stated that she had suffered no inconvenience, but had made steady progress in the use of the limb.

She could dress and undress herself, whereas she was formerly dependent upon the assistance of a friend, and she was also able to perform all her domestic and outdoor duties. The head of the humerus occupied its proper position in contact with the acromion, but seemed to lie directly under the skin. The muscles of the upper arm had improved considerably, rendering all the more prominent the wasting of the shoulder. The scapula moved whenever the slightest movement of the arm was carried out. The X-rays demonstrated that firm, bony union had taken place. The arm could be moved up to the horizontal plane in the forward direction by voluntary effort, to 70 degrees sideways, and to 30 degrees backwards. The biceps had recovered power, and the hand could be raised to the face. Grip good. Seven years after the operation—*i.e.*, March 9, 1907—patient was now twenty-one years old, and had married. She had no pain or other discomfort that might be referred to the operation. She could do a great deal with her right arm—*e.g.*, she could write, iron, dust, and perform all her other domestic duties. She could even put her hand to her occiput, though slowly. With her elbow half flexed, she could lift a 10-pound weight, and her power in lifting was hardly weaker

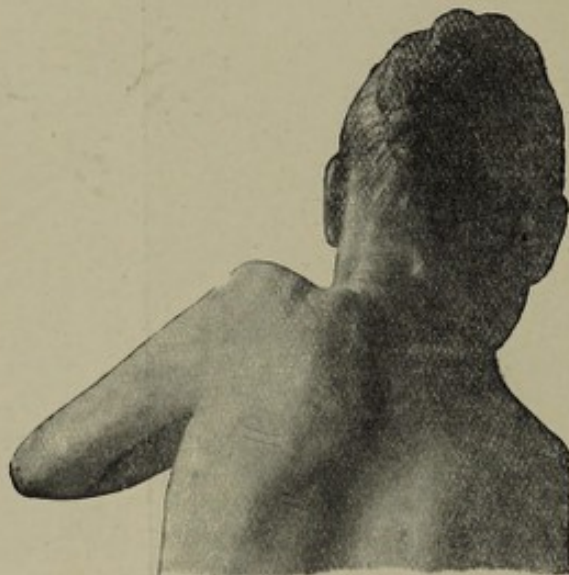

FIG. 111.



FIG. 112.

than on the good side. The extent of active movement was as great as the passive: the arm could be raised sideways to the horizontal position, forwards to the horizontal, and backwards to 30 degrees (see Figs. 112, 113, and 114). The X-rays show complete bony ankylosis between the humerus and the glenoid cavity (Fig. 115). The outlines of the latter are very difficult to detect, except below, where it projects beyond the head, which is rather high. The spongy bone of the humerus and the glenoid cavity are continuous. The acromion and the coracoid are also synostosed to the humerus. A piece of silver wire is embedded in the head and in the acromion, but is not producing any reaction there. The angle between the humerus and the outer border of the scapula measures about 60 degrees. There is no scoliosis, even upon raising the arm. Palpation of the scapulæ is difficult, on account of the presence of much subcutaneous fat; but the spine is about 1 centimetre short (*cf.* 14 to 15 centimetres). The left arm measures 75 centimetres, and the right 71½ centimetres.

4. W. S., girl, *æ*t. 14. Paralysis of right side during first year of life. Typical paralytic luxation of shoulder, together with extensive affection of the forearm and hand. Upper arm, in addition, much deformed by numerous fractures. Operation, July, 1907. Opening and freshening of joint surfaces in usual manner. Head wired to coracoid and acromion. Uneventful recovery. Removal of wires three months later, on account of sinus formation. Two and a quarter years later, head firmly fixed in socket, though perhaps rather too far forward. Somewhat small and irregularly formed. X-rays show bony ankylosis. Active movements=40 degrees forwards, 35 degrees laterally, and 20 degrees backwards. Hand, however, not of much use, because the tendon transplantation that had been carried out in the forearm had not been very successful. Six and three-quarter years after operation—*i.e.*, on March 15, 1907—patient, now twenty years old, stated that she had experienced no inconvenience



FIG. 113.

FIG. 114.

from the operation on her shoulder, but thought that it would have been of great value to her if the hand could only perform voluntary movements. She was able, however, to move her arm at will, whereas formerly it was a mere useless appendage, and she could use it to support the left limb. The head was immovably fixed to the scapula, and was somewhat more prominent in front than normal. X-rays show bony ankylosis between the head of the humerus, which is somewhat irregular in shape, and the glenoid cavity, whose outline is no longer distinguishable, since there is an unbroken layer of spongy tissue uniting the two bones. Acromion also certainly synostosed to head, coracoid process possibly so, by means of bridge of bone. Angle between humerus and outer border of scapula=about 50 degrees. Right shoulder distinctly higher than left; growth of scapula arrested in all directions; spine=11½ centimetres on right, 13½ centimetres on left; inner border=10½ centimetres, right, and 12 centimetres, left. High dorsal scoliosis, convex to right, with torsion, and slight general deviation to left. Right upper arm measures 27 centimetres; left=30½ centimetres; whole limb=61 to 61½ centimetres.

Arm can be moved passively 75 degrees forwards, 75 degrees laterally, and 40 degrees backwards. Active mobility amounts to 40 degrees forwards, 35 degrees laterally and 15 to 20 degrees backwards. No voluntary movement at elbow, hand, or finger joints.

5. G. O., girl, æt. 5½ years. Paralysis during second year. Typical flail paralytic left shoulder. Fair power in trapezius. Biceps and triceps very weak. Operation, June, 1902. Head of humerus wired to acromion and glenoid cavity. Uneventful recovery. Plaster bandage for twelve weeks, then leather sheath, securing arm in

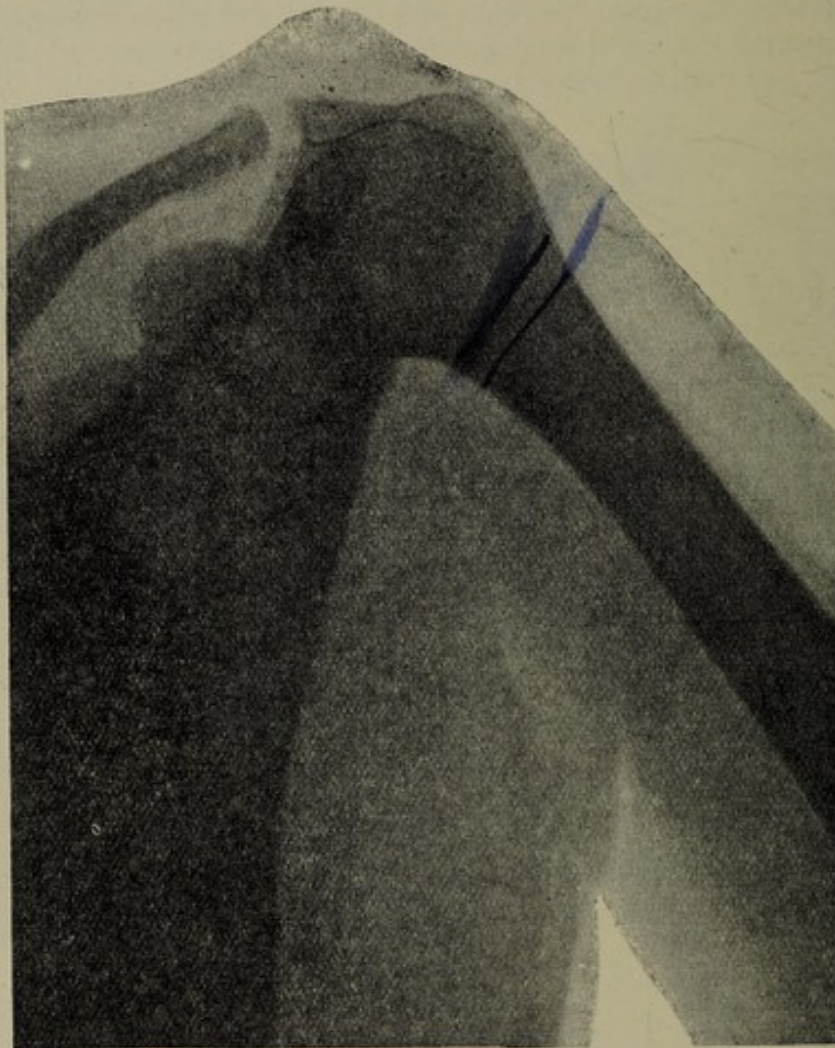

FIG. 115.

abduction. Fibrous ankylosis had already taken place, and allowed little movement. The functional result was therefore rapid, and surprisingly good. Treatment was given up six weeks later, and the hand could then be raised to the mouth or to the ear. On March 24, 1907—*i.e.*, four and three-quarter years after the operation—patient was seen again; she was able to use the arm for dressing and undressing, playing, writing, knitting, and so on. The humerus and scapula were absolutely firmly ankylosed together. The silver wire had come out. No shortening of the arm. Left shoulder rather higher than the right; inner border of scapula measures 12 centimetres on right, 11½ centimetres on left; spine=10 centimetres on each side. Slight scoliosis, convex to left, without deformity of ribs. Biceps and triceps improved. Arm can be

raised passively to 135 degrees forwards, 115 degrees laterally, and 45 degrees backwards; actively to 90, 40, and 0 degrees.

6. E. H., boy, *æ*t. 2 years. Paralysis noticed soon after birth. Continuous treatment up to present time useless. Left arm hanging limply down; head of humerus subluxated. Forearm muscles normal. Operation, November 13, 1902, on usual lines. Head wired to acromion in position of abduction; slight elevation and internal rotation; strong catgut put through coracoid. Uneventful recovery. Fixation for three months, then removable leather sheath, and after-treatment by massage, etc.

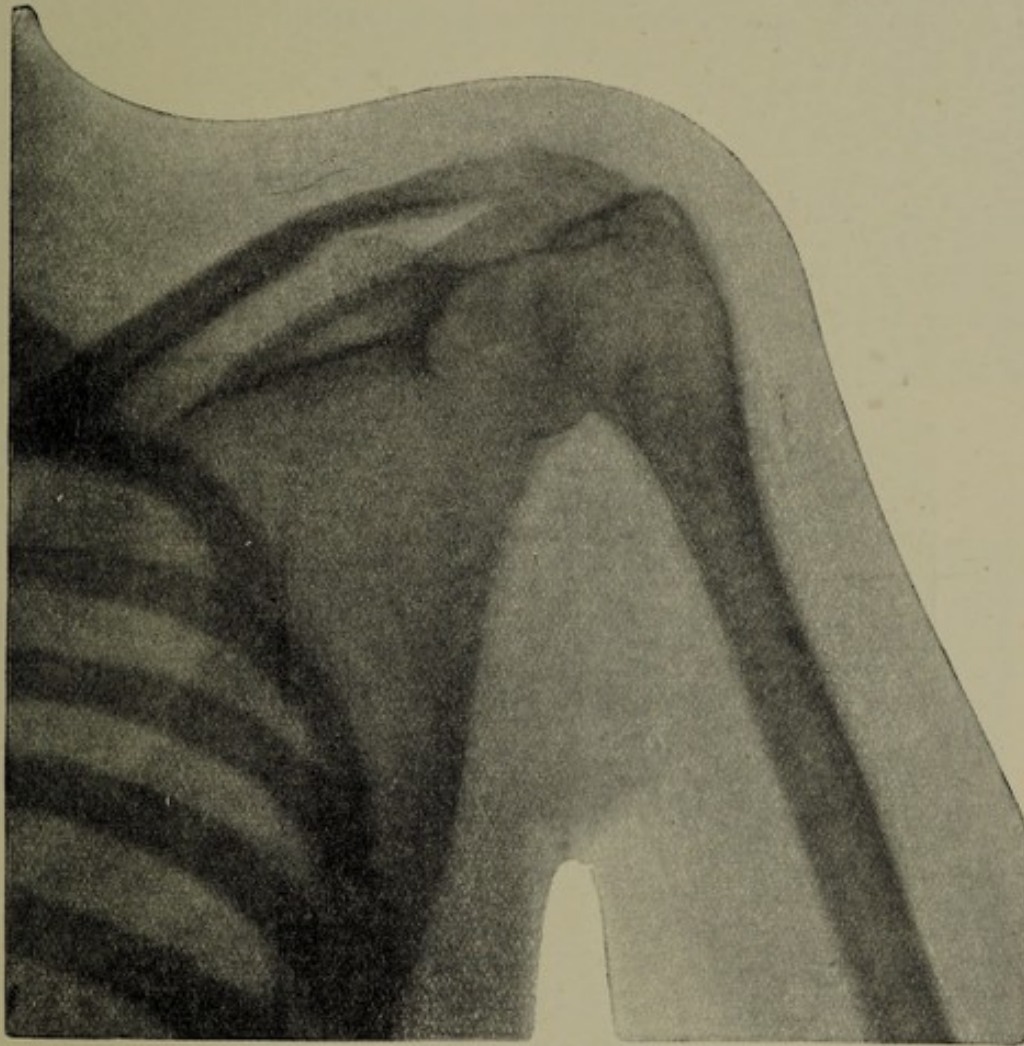


FIG. 116.

Four months after operation strong fibrous ankylosis was present. Arm could be raised laterally to the horizontal. Flexion and extension at elbow well performed. Four and a quarter years after the operation—*i.e.*, on March 11, 1907—patient now six and a quarter years old. Parents very pleased with result. Patient able to use arm for all purposes, without noticeable difference between them. No bony ankylosis; passive movement demonstrable at shoulder-joint. X-rays show that humerus forms an angle of 110 degrees with the outer border of the scapula (Fig. 117). Glenoid cavity deep; between it and the head is a distinct space, partly filled up, probably by cartilage. Head in intimate contact with the acromion. Wire broken in at least three places. Left scapula rather higher than the right, and smaller in all dimensions. Left spine = 9 centimetres, right = $10\frac{1}{2}$ centimetres; inner border, left = $8\frac{3}{4}$ centimetres,

right = $9\frac{1}{4}$ centimetres. Slight tendency to total left scoliosis. Left arm measures 48 centimetres, right = $49\frac{1}{2}$ centimetres; difference in length confined to humerus; *cf.* 22 and $23\frac{1}{2}$ centimetres. Biceps and triceps quite powerful. Arm can be raised passively to 135 degrees forwards, 100 degrees laterally, and 70 degrees backwards; actively, to 100, 90, and 30 degrees (Figs. 118, 119). Power almost as good as on the sound side.

7. H. E., girl, *æt.* 11 years. Onset of paralysis at eight and a half years. Typical flail left shoulder, with subluxation. Deltoid completely paralyzed; trapezius intact. No contractions in muscles of upper arm. Slight affection only of forearm. Arm hangs motionless by side. Sharp dorsal scoliosis, convex to right, since five years.

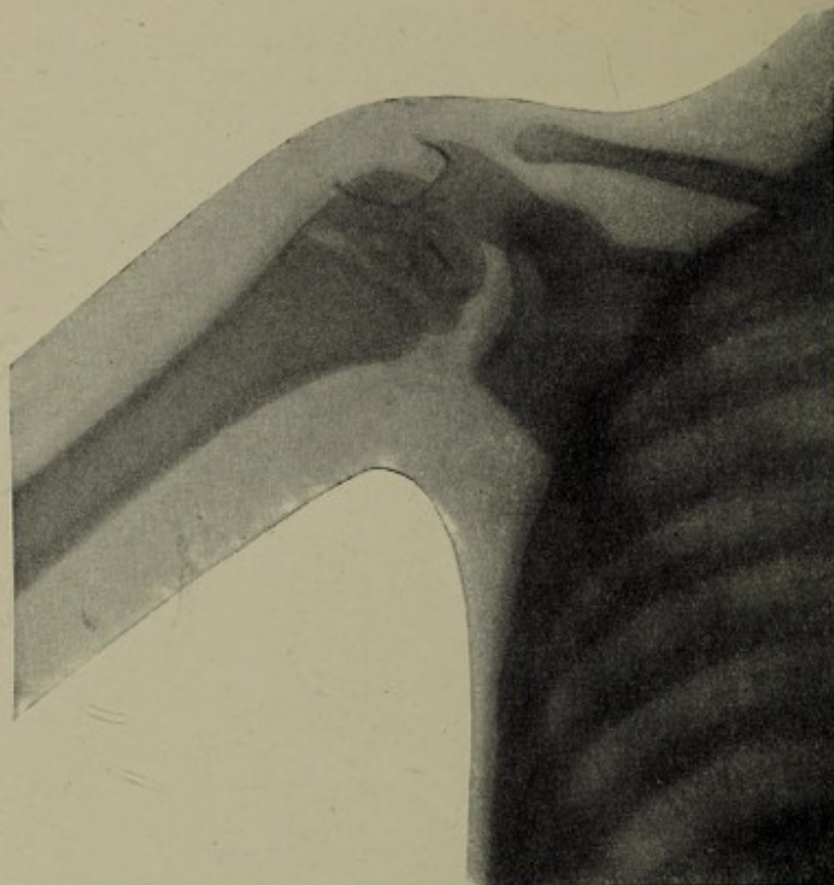


FIG. 117.

Operation, April 16, 1904. Typical arthrodesis; head freshened, and fastened with a single wire to the acromion and coracoid. Uneventful recovery. Plaster for three months, then leather sheath. Six months, and again a year, later, portions of wire were removed on account of sinuses. Three years after operation—*i.e.*, on March 4, 1907—patient was now fourteen years old; she was very pleased with the result of the arthrodesis and the tendon transplantation which had been performed at the same time in the forearm. The arm could now be used for all purposes—for washing, eating, writing, working, and opening the door. The fact that the shoulder-joint is stiff causes no inconvenience whatever. Absolute synostosis present (see Fig. 120). The outline of the head is very difficult to make out; the cortex of the humerus is almost completely gone, so that the spongy bone passes in a continuous layer from the scapula into the head of the humerus—an excellent example of architectural adaptation in the skeleton. The humero-scapular angle is 90 degrees. A piece of wire is sticking into the head, but is not causing any irritation there. The acromion and coracoid

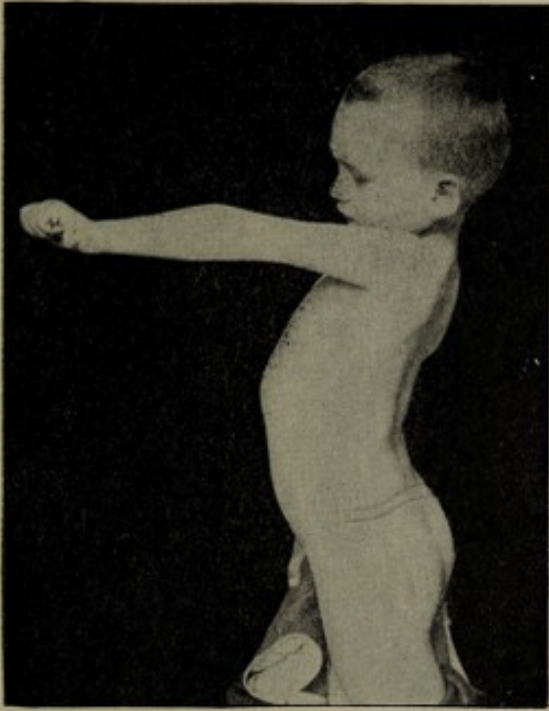


FIG. 118.

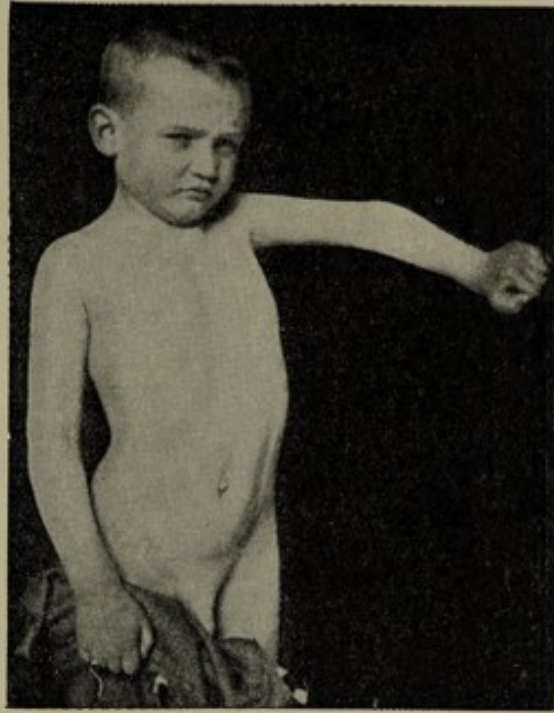


FIG. 119.

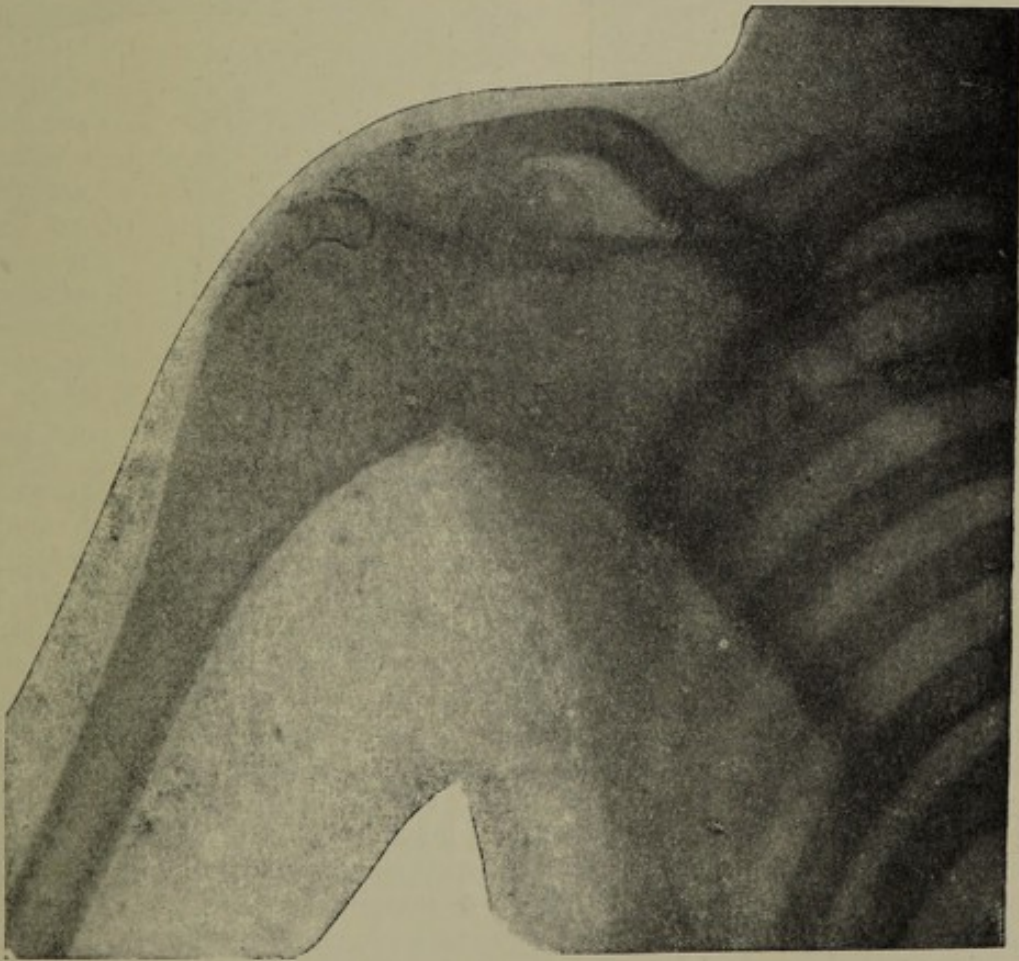


FIG. 120.

seem also to be firmly united to the head. The shoulders are about equally high; the whole back inclines to the right, and there is a very marked dorsal scoliosis, with the convexity to the right, and acute flexion of the ribs. The compensatory lumbar scoliosis is less marked. The left scapula is smaller than the right; the left spine measures 11 centimetres, the right 13 centimetres; the clavicles are of equal length.

The left arm is about 4 centimetres short (*cf.* 46 and 50 centimetres), the difference being equally distributed between the upper arm and the forearm. The elbow can be voluntarily flexed and extended. Active elevation of the arm amounts to 90 degrees forwards, 90 degrees laterally, and 30 degrees backwards (Figs. 121, 122). The girl can raise her hand to her eyes, and would be able to do her hair if she could supinate her forearm.

8. W. L., girl, *æt.* 14 years. Onset of paralysis at six months. Typical flail condition of left shoulder, with severe subluxation; deep recess between the acromion and the coracoid on the one side and the head of the humerus on the other. Deltoid, *teres major*, and *triceps* completely gone; *supraspinatus* and *infraspinatus* very weak;



FIG. 121.



FIG. 122.

biceps rather better; *trapezius* good. Left shoulder higher than right; growth of scapula impaired. Operation, April 15, 1904. Ordinary arthrodesis; head wired to acromion. Put up in plaster in abduction, 45 degrees; leather sheath in three months' time; no after-treatment. Three years later—*i.e.*, on March 8, 1907—patient was pleased with the success of the operation; she could use the arm, dress and undress herself, and wished to become a seamstress. The wound had broken down for a short time a year previously. The wire had not worked out. Head firmly fixed, close under acromion, and somewhat irregularly shaped. Firm fibrous ankylosis. A slight amount of movement of the arm possible in a forward and backward direction when the scapula was fixed. Left scapula perceptibly smaller than right; spine measures 10 centimetres on left, 13 centimetres on right; inner border = 11 centimetres on left, 13 centimetres on right. Spine rather inclined to left (hardly amounting to a scoliosis); lumbar torsion on right. Left arm about 5 centimetres short; *cf.* 66 and 71 centimetres. Arm can be raised passively to the horizontal, forwards and laterally. Active movement to 40 degrees forwards, but only 20 degrees laterally and backwards. *Biceps* functional, but not the *triceps*.

9. K. A., *æt.* 4 $\frac{3}{4}$ years. Onset of paralysis at one year. Very flail right shoulder. Deltoid completely absent; triceps ditto; trapezius fairly good; biceps weak; forearm muscles almost intact. Operation, July 15, 1904. Arthrodesis as usual; wire between head and acromion. Uneventful recovery. Plaster four months, then leather sheath. No further after-treatment. Head remained fairly firm, but was not absolutely fixed. Two and three-quarter years later scar sound; no discomfort at any time. Can use arm as well as anybody else; writes and plays with right hand; has not learned to use left. Head immovable. X-rays show head irregularly shaped, and united to glenoid cavity by firm bridge of bone (Fig. 124). Intimate contact with acromion. Humero-scapular angle = 110 degrees. Wire still in position. Right scapula smaller than left. Length = 10 : 11 centimetres; inner borders = 8 : 9 $\frac{1}{2}$ centimetres. Slight left dorsal scoliosis. Right arm = 46 $\frac{1}{2}$ centimetres; left = 49 $\frac{1}{2}$ centimetres. Arm can be raised passively to 120 degrees forwards, 100 degrees laterally, and 50 degrees backwards (Fig. 125). Corresponding figures for active movements are 90, 75, and 45 degrees. Patient can put hand up to forehead and to nape of neck. Very fair power. Biceps good, triceps poor.

10. P. E., *æt.* 9 $\frac{1}{2}$ years. Paralysis at four. Right shoulder flail; severe subluxation. Deltoid and biceps completely paralyzed; pectoralis and biceps fairly good; trapezius and muscles of forearm and hand good. Arm, 1 centimetre short. Operation, November 24, 1904. Arthrodesis as usual; head and acromion wired together. Part of triceps grafted into biceps. Uneventful recovery. Fixation for three and a half months. Two and a half years later patient reported that sinus had formed after six months, but no wire came out. Arm can be voluntarily raised to the horizontal, and is very serviceable—*e.g.*, patient can write and bowl a hoop. There is only moderate fibrous ankylosis, however. The biceps contracts well.

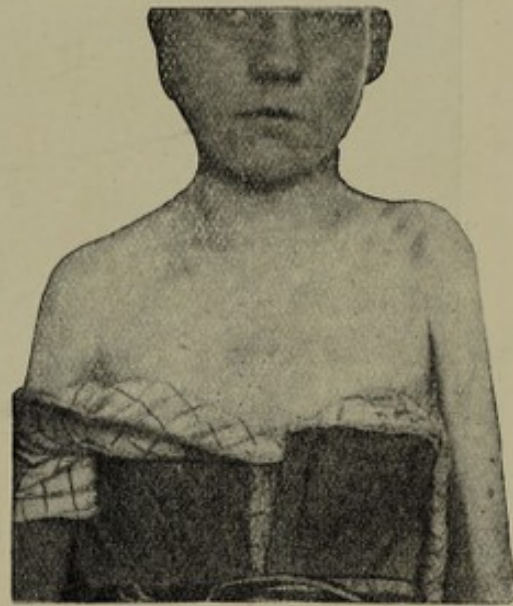

FIG. 123.

11. H. R., boy, *æt.* 6 $\frac{1}{2}$ years. Paralysis at eight months. Right shoulder quite flail; head of humerus can be subluxated forwards. No shortening of arm. Deltoid completely absent; biceps weak; muscles of shoulder-blade, forearm, and hand good. Right dorsal scoliosis, with slight lumbar compensatory curve. Operation, June 26, 1905. Arthrodesis as usual; head wired to acromion. Uneventful recovery. Leather sheath after three months. After-treatment for two months. On March 8, 1907, shoulder-joint was not stiff, and on fixing the scapula, arm could be moved 50 degrees forwards and 45 degrees laterally, whilst crepitation could be felt in the joint. With elbow flexed, patient could raise arm to 70 degrees forwards, though still keeping it pressed against the thorax. Abduction to 30 degrees. Right scapula smaller than left; spines measure 10 and 11 centimetres; inner borders, 8 and 10 centimetres. Right arm = 49 $\frac{1}{2}$ centimetres, left = 53 centimetres. Dorsal vertebræ show scoliosis to right, without torsion; lumbar compensatory curve. Patient has learnt to write with his left hand as the result of a mistake on the part of his teacher. Re-excision proposed, to remedy the unsatisfactory result of the first operation.

12. W. P., male, *æt.* 18 years. Paralysis during sixth year. Right arm hangs limply by side, all but useless. Flail joint; head can be dislocated backwards or forwards. Deltoid completely wasted; trapezius good in upper part. Biceps largely

disappeared; triceps quite gone. Arm $9\frac{1}{2}$ centimetres short, distributed thus: upper arm, 2 centimetres; forearm, 4 centimetres; hand, $3\frac{1}{2}$ centimetres. Severe left lumbar paralytic scoliosis. Operation, January 29, 1906. Shoulder arthrodesis as usual; one wire used to unite head, acromion, and glenoid cavity. Uneventful recovery; no sinus. Plaster for two months, then leather sheath. One and a quarter years later on, rigid ankylosis, due to bridge of bone passing from head to glenoid fossa, limiting abduction at 110 degrees (see Figs. 126 and 127). Patient can raise the arm to the horizontal in the forward direction, and to 70 degrees laterally. Biceps and triceps have become fairly powerful. Limb now moderately useful. Patient, a Russian, particularly pleased with the result, as he is now able to raise a cigarette to his lips.

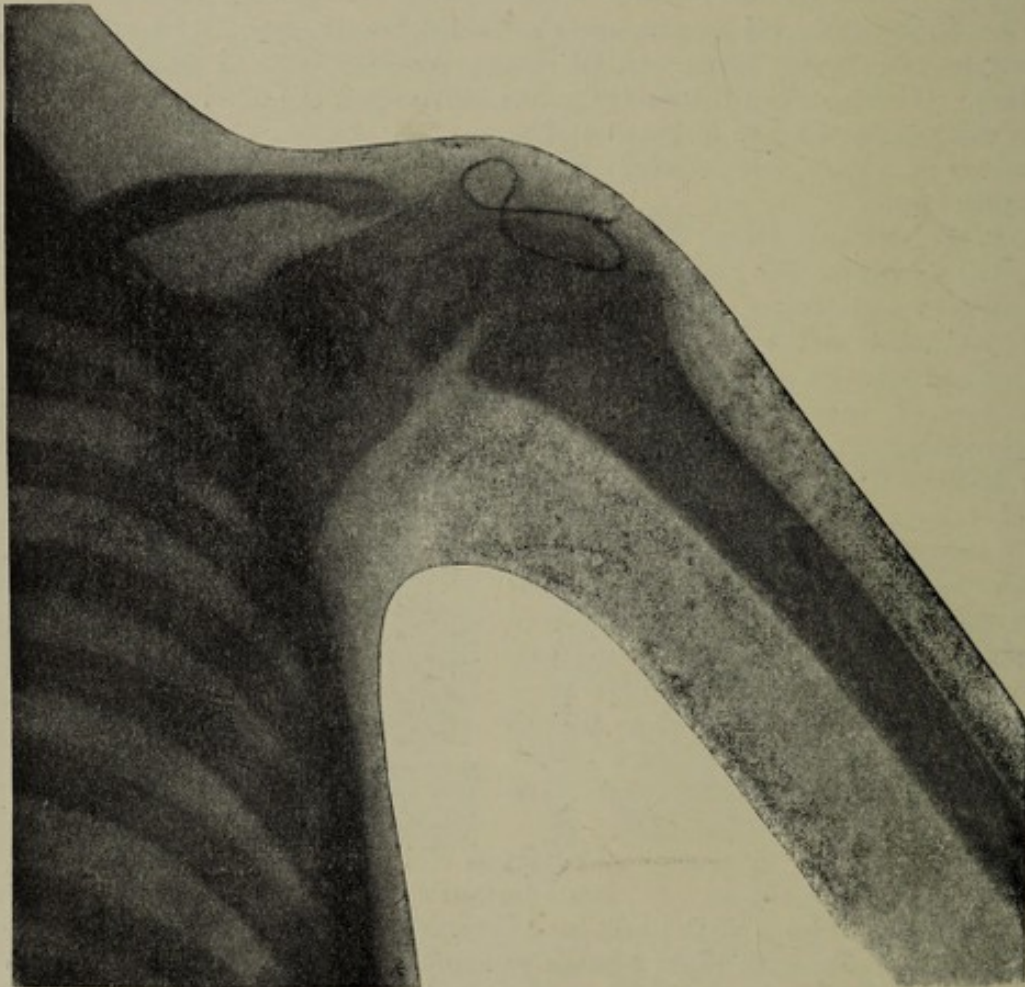


FIG. 124.

Results.—Let us now analyze these statistics, and see what they teach us as regards the technique and the pathological, anatomical, and functional results of arthrodesis.

My own experience comprises six operations upon the right shoulder and six upon the left. Operations performed within recent years are not included. The date of onset of the paralysis was as follows: First year, seven; second year, two; fourth, sixth, and eighth years, one each. Age of patient at time of operation: two at 2 years, one each at 4, 5, 6, 9, 11, and 18 years, four at 14 years. Duration of observation after operation: 1 to 2 years in

two cases ; 2 to 3 years in four cases ; 4 to 5 years in two cases ; 6 to 7 and 8 to 9 years in two cases.

These results are summarized in the following table :

No.	Onset of Paralysis.	Age at Operation.	Date of Operation.	Present Age.	Duration of Observation.
1	First year	2 years	Aug. 5, 1898	10 years	8½ years.
2	2 years	14 "	Jan. 7, 1899	22 "	8¼ "
3	First year	14 "	May 11, 1900	21 "	7 "
4	First year	14 "	July, 1900	20 "	6¾ "
5	Second year	5½ "	July 2, 1902	10¼ "	4¾ "
6	First month	2 "	Nov. 13, 1902	6¼ "	4¼ "
7	8½ years	11 "	April 16, 1904	14 "	3 "
8	6 months	14 "	April 15, 1904	17 "	3 "
9	1 year	4¾ "	July 15, 1904	8 "	2¾ "
10	4 years	9½ "	Sept. 24, 1904	12 "	2½ "
11	8 months	6½ "	June 26, 1905	8 "	1¾ "
12	Sixth year	18 "	Jan. 29, 1906	19½ "	1¼ "

A similar **technique** was employed in all these operations. An antero-external incision was made, about 5 centimetres long, dividing the skin, the thin layer of degenerated muscle, and the capsule of the joint. The long tendon of the biceps was held aside, and the head displaced, so that the interior of the joint could be inspected. The head of the humerus, the glenoid cavity, the under-surface of the acromion, and the coracoid process were all thoroughly freshened. Then the silver wire was passed, and fastened, the head being replaced. The skin was sutured and a plaster splint applied, enclosing the thorax, shoulder, upper arm and forearm (see Fig. 128). After about three months, the fixed apparatus was replaced by a laced leather sheath, and massage and exercises were begun, for the purpose of strengthening the remaining musculature of the shoulder girdle (see Fig. 129).



FIG. 125.

With regard to the wire sutures, one point of importance must be mentioned. It is not enough to fix the head to the acromion with a single wire ;




FIG. 126.

two must be used to insure a good result. In six of our cases we used a single wire, and the results were as follows : one bony ankylosis, five fibrous ankyloses, two of which were unsatisfactory. In the remaining six cases, two wires were employed, passing into the acromion and the coracoid in three instances, and through the acromion and the glenoid fossa in the other three. Synostosis resulted in all six cases. We are of opinion that this is not a coincidence, but a matter of great technical importance, and we recom-

mend the adoption of the method with *two wires in all cases*. The position of the arm whilst the suture is inserted, and afterwards in the plaster case, is also very important. The surgeon should aim at securing ankylosis in the position of marked abduction, elevation in a forward direction, and slight internal rotation. It is hardly possible to overdo the abduction ; through insufficient attention to this point we have on several occasions greatly impaired the result. Acting upon the experience gained in our earlier cases, we have recently increased the amount of abduction, with very favourable results, as shown in Figs. 130 and 131.

two must be used to insure a good result. In six of our cases we used a single wire, and the results were as follows : one bony ankylosis, five fibrous ankyloses, two of which were unsatisfactory. In the remaining six cases, two wires were employed, passing into the acromion and the coracoid in three instances, and through the acromion and the glenoid fossa in the other three. Synostosis resulted in all six cases. We are of opinion that this is not a coincidence, but a matter of great technical importance, and we recom-




FIG. 127.

The angle between the humerus and the outer border of the scapula, seen by the Röntgen rays, was found to measure 110 degrees in three of our cases, 60 degrees in two, and 50, 80, or 90 degrees in one. The effect of these angles upon the functional result is indicated in a table which follows. The advantage of fixing the arm in abduction is at once manifest. The more the arm approaches the position in which the muscles of the shoulder girdle normally begin to act upon it (*i.e.*, the more nearly it approaches the horizontal), the more effectively will the scapula control the humerus when ankylosis has been produced. A certain amount of anterior elevation and internal rotation render it easier for the patient to raise his hand to his head or to his face.

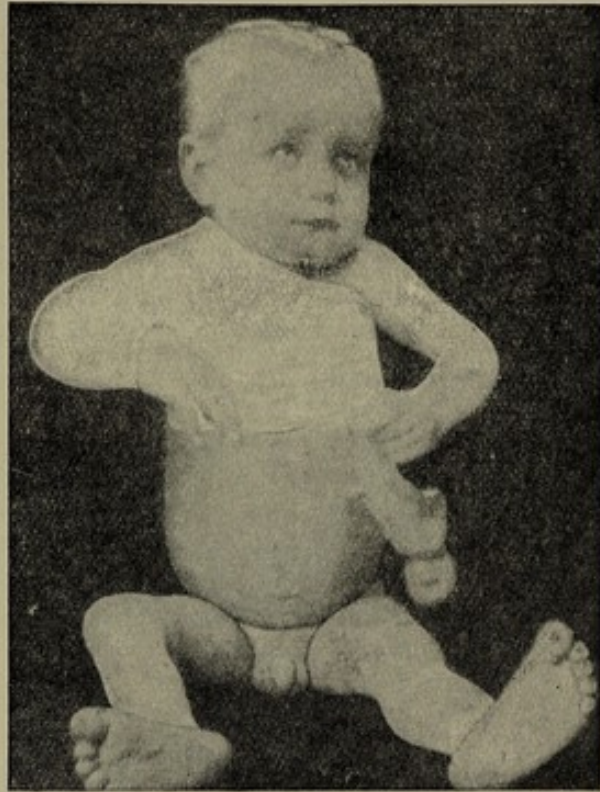

FIG. 128.

We pass on now to the ana-




FIG. 129.

tomical results. The most important question of all is the attainment of ankylosis. We succeeded in this respect on ten occasions. Seven of these were bony unions, and three were firm fibrous unions, sufficiently strong to be useful. Failure resulted in two cases, in both of which the technique was faulty, in that only one wire was inserted.

The age of the patients did not exert much effect upon the occurrence of bony ankylosis. Synostosis took place in patients of 4, 5½, 11, 14 (three times), and 18 years, fibrous ankylosis at 2 years (twice), and at 14; whilst the failures were in patients

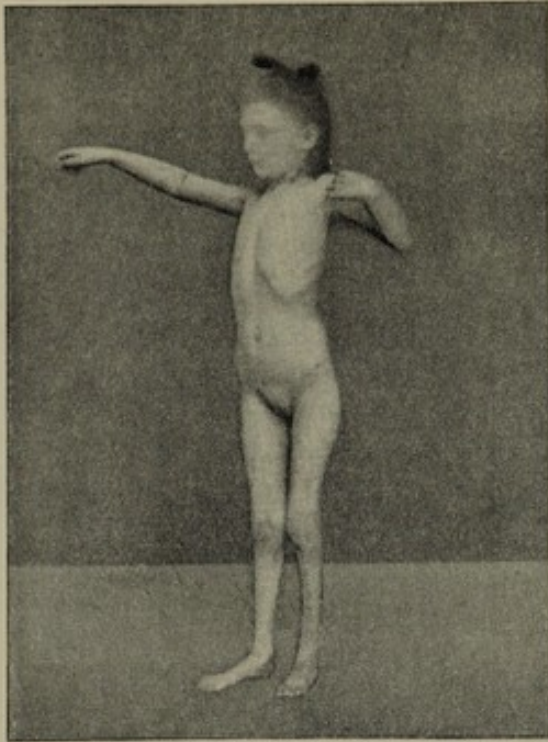

FIG. 130.

acromion than to the glenoid cavity, but contact with the acromion was so good, that the functional result was unimpaired, and the paralytic subluxation of the head was completely cured.

The head of the bone, examined after some years, sometimes showed irregularity and bossing.

An important matter is the effect of arthrodesis upon the growth of the scapula and arm. Unfortunately, we are unable to make a decisive statement upon this point, as our case reports are deficient in this respect. A certain limitation of growth has been determined, but this need

aged $6\frac{1}{2}$ and $9\frac{1}{2}$ years respectively. There is no doubt, therefore, that firm bony union between the humerus and the scapula can be obtained, and that this can be demonstrated by means of the X-rays. By this means, too, we have learnt the extraordinary adaptation which takes place, the cortex of the bones disappearing, and the spongy tissue passing in a homogeneous layer from the one bone into the other.

Ankylosis almost always takes place in the proper position as regards the glenoid cavity. In one case only did the head assume a position too far forward, overhanging the edge of the fossa. In another instance, the head was nearer to the

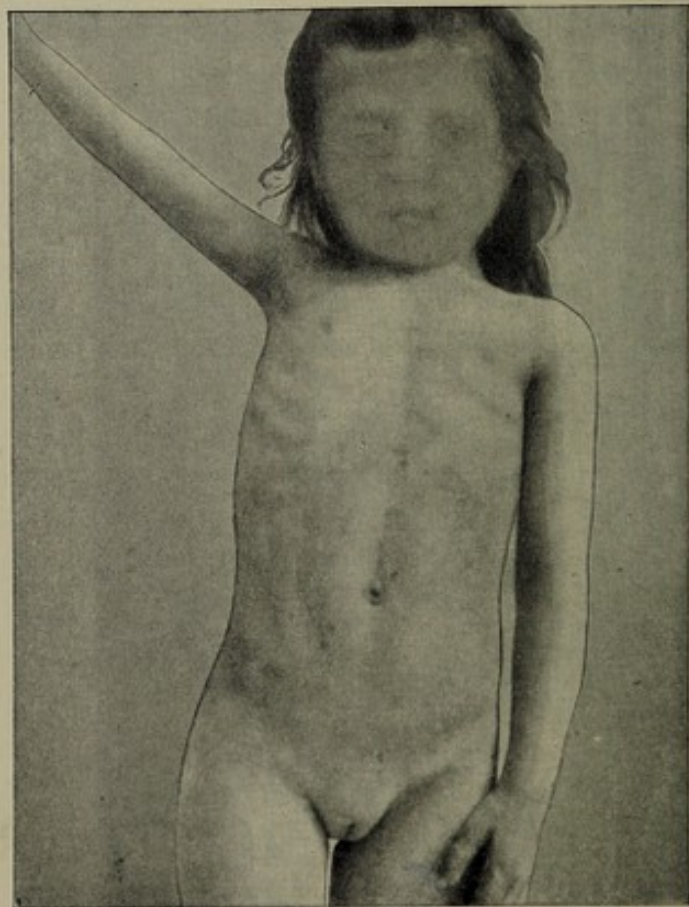


FIG. 131.

not be attributed to the deleterious effect of the operation, as Schüssler thought. It is more probable that it is due to the trophic changes associated with the original lesion. It is impossible, however, to dissociate from one another disuse-atrophy, interference with growth of spinal origin, and that due to operation.

The following observation points to the fact that the operation has a favourable effect upon the growth of the bones. It has been found that in growing individuals the difference in length on the two sides tends to diminish as time goes on, and that this diminution is not only absolute, but relative. In other words, the difference in length between the paralyzed and the healthy limb tends to disappear as the patient grows older.

The various measurements of the scapula are given in the following table :

Number.	Age at Time of Operation.	Duration of Observation.	Shortening of Arm.		Length of Spine.	Inner Border of Scapula.
			Before.	After.		
1	2 years	8½ years	—	2½	10 : 12	11 : 11
2	14 ..	8¼ ..	4	3	14½ : 16¼	11 : 13
3	14 ..	7 ..	4	3½	14 : 15	—
4	14 ..	6¾ ..	10	8½	11½ : 13½	10½ : 12
5	5½ ..	4¾ ..	—	—	10 : 10	11½ : 12
6	2 ..	4¼ ..	?	1½	9 : 10½	8¾ : 9¼
7	11 ..	3 ..	?	4	11 : 13	—
8	14 ..	3 ..	2	5	10 : 11	10 : 9¼
9	4 ..	2¾ ..	?	3	10 : 11	8 : 9¼
10	9½ ..	2½ ..	1	?	—	—
11	6½ ..	1¾ ..	0	3½	10 : 11	8 : 10
12	18 ..	1¼ ..	9½	9½	—	—

The scapula, therefore, was smaller in all cases but one. The difference in length between the spines and the inner borders of the two sides did not usually exceed 1 to 2 centimetres.

The table tells us rather more as regards the difference in length of the arms. In three patients who underwent operation at the age of fourteen, the shortening diminished within six to eight years by ½ to 1½ centimetres. On the other hand, it amounted to 2½ centimetres in a child who was operated upon at the age of two. This was after eight and a half years. This is probably as much as would have been present in a paralytic patient who had not undergone operation. In one instance no shortening was present, 4¾ years after operation upon a 5½ year old child.

The most interesting point of all is the functional result. We will first set forth the range of passive movement possible in the arm+scapula. This

Number.	Arthrodesis.		Present Age.	Kind of Ankylosis.	Duration of Observation.	Excursion.						Scapular Angle.
	Left.	Right.				Passive.			Active.			
						Forward.	Backward.	Lateral.	Forward.	Backward.	Lateral.	
1	1	—	10 years	Firm fibrous	8½ years	120	50	90	60	40	40	60
2	1	—	22 "	Bony	8¼ "	140	60	100	45	30	70	80
3	—	1	21 "	Bony	7 "	90	30	90	30	90	90	60
4	—	1	20 "	Bony	6¾ "	75	40	75	40	20	35	50
5	1	—	10½ "	Bony	4¾ "	135	45	110	90	0	45	—
6	1	—	6½ "	Firm fibrous	4¼ "	135	70	100	100	30	90	110
7	1	—	14 "	Bony	3 "	?	?	?	90	30	90	90
8	1	—	17 "	Firm fibrous	3 "	90	?	90	40	20	20	—
9	—	1	8 "	Bony	2¾ "	120	50	20	90	45	70	110
10	—	1	12 "	Bad fibrous	2½ "	?	?	?	90	?	?	—
11	—	1	8 "	Bad fibrous	1¾ "	Considerable failure of arthrodesis	?	?	70	0	30	—
12	—	1	19½ "	Bony	1¼ "	?	?	?	90	?	70	110

tells us how much active movement ought to take place if the muscles functioned to their fullest extent. The actual amount of active movement possible will then give us the degree to which the result approximates to the ideal condition.

The extent of *Passive Movement*, therefore, was as follows :

Elevation in a forward direction amounted to—

135-140 degrees	in 3 cases
120	„ „ 2 „
90	„ „ 2 „
75	„ „ 1 case.

The maximum excursion was 140 degrees, the minimum was 75 degrees, and the average was 115 degrees.

Abduction amounted to—

110 degrees	in 1 case
100	„ „ 3 cases
90	„ „ 3 „
75	„ „ 1 case.

The maximum excursion was 110 degrees, the minimum was 75 degrees, and the average was 95 degrees.

Elevation in a backward direction amounted to—

70 degrees	in 1 case
60	„ „ 1 „
50	„ „ 2 cases
45	„ „ 1 case
40	„ „ 1 „
30	„ „ 1 „

The maximum excursion was 70 degrees, the minimum was 30 degrees, and the average was 50 degrees.

The extent of *Active Movement* was as follows :

In a forward direction it amounted to—

100 degrees	in 1 case : fibrous ankylosis
90	„ „ 6 cases : 5 bony, 1 fibrous ankylosis
70	„ „ 1 case : fibrous ankylosis
60	„ „ 1 „ „ „
45	„ „ 1 „ : bony
40	„ „ 2 cases : 1 bony, 1 fibrous ankylosis.

The maximum excursion was 100 degrees, the minimum was 40 degrees, and the average was 75 degrees.

The maximum was attained in a case of fibrous ankylosis, the minimum occurred in one case of fibrous and one of bony ankylosis. The nature of the ankylosis, therefore, had no effect upon the usefulness of the result.

Active elevation to the side amounted to—

90 degrees	in 3 cases	: 2 bony and 1 fibrous ankylosis
70	„ „ 3 „	: 3 bony ankyloses
45	„ „ 1 case	: bony ankylosis
40	„ „ 1 „	: fibrous ankylosis
35	„ „ 1 „	: bony ankylosis
30	„ „ 1 „	: fibrous ankylosis
20	„ „ 1 „	: „ „

The maximum excursion was 90 degrees, the minimum was 20 degrees, and the average was 60 degrees.

The cases of osseous ankylosis seem, on the whole, to give more favourable results, but there is, of course, an inevitable element of chance.

Active elevation in a backward direction amounted to—

45 degrees	in 1 case	: bony ankylosis
40	„ „ 1 „	: fibrous ankylosis
30	„ „ 4 cases	: 3 bony, 1 fibrous
20	„ „ 2 „	: 1 bony, 1 fibrous
0	„ „ 1 case	: bad fibrous ankylosis.

In three cases the excursion in this direction was not measured.

The maximum was 45 degrees, the minimum was 20 degrees, and the average was 30 degrees.

Here, again, the greater success attending the cases of bony ankylosis might be attributed to accident.

The majority of the cases that show good movement in a forward direction also show it laterally. This, however, does not invariably hold good, as the following table shows :

Number.	Elevation.		
	Forwards.	Laterally.	Backwards.
1	100	90	30
2	90	90	30
3	90	45	?
4	90	90	30
5	90	70	45
6	90	?	?
7	90	70	?
8	70	30	0
9	60	40	40
10	45	70	30
11	40	35	20
12	40	20	20

Thus, in Case 10 there is slight movement forwards, but good lateral elevation, and in Case 3, in which anterior was very good, lateral movement was the worst in the whole series.

Good anterior mobility is not as a rule accompanied by good backward movement. On the contrary, the average figures are rather low.

Reckoning the figures for anterior and posterior movement together, so as to obtain a measure of the total range of antero-posterior movement, we find that the maximum is 135 degrees, the minimum is 60 degrees, and the average is 95 to 100 degrees.

The scapula, therefore, moves to such an extent as to allow of the arm swinging through rather more than a right angle in a fore-and-aft direction.

One would suppose that the more the arm could be raised in a forward direction, the less would be its range of movement backward, inasmuch as the total range is limited to about 95 or 100 degrees. As we have seen, however, this is not borne out by the tables. The explanation is, that persons who have limited elevation in a forward direction have also weak shoulder-girdle muscles, so that they cannot exert much power in backward elevation.

The amount of movement on the right and on the left side is contrasted in the following table :

LEFT SIDE.		
60 degrees.	40 degrees.	40 degrees.
45 "	70 "	30 "
90 "	45 "	0 "
100 "	90 "	30 "
90 "	90 "	30 "
40 "	20 "	20 "

Average.

70 degrees.	60 degrees.	25 degrees.
-------------	-------------	-------------

RIGHT SIDE.		
90 degrees.	90 degrees.	30 degrees.
40 "	35 "	20 "
90 "	70 "	35 "
70 "	30 "	0 "
90 "	70 "	?

Average.

75 degrees.	60 degrees.	25 degrees.
-------------	-------------	-------------

Movement is as good on the one side as on the other.

The relation of Active to Passive Movement is shown in this table :

				Active.	Passive.
Anterior elevation (average)		75 degrees	115 degrees
Lateral	„	„	60 „	95 „
Backward	„	„	30 „	50 „

The muscles, that is to say, exert, on the average, two-thirds of the full range of possible movement—a result with which we have every reason to be satisfied.

We mentioned, in describing the symptoms of paralysis of the shoulder, that the muscles of the upper arm might become absolutely functionless, although unaffected by the paralysis. This is due to the subluxation of the arm and the consequent permanent overstretching of the muscles.

One would expect the biceps and triceps to recover after the performance of arthrodesis, and the release of the muscles from the undue strain thrown upon them. We have found this to be the case.

Number.	Before Operation.		After Operation.	
	Bic. ps.	Triceps.	Biceps.	Triceps.
1	-	-	+	+
2	-	-	+	-
3	-	-	+	+
4	-	-	-	-
5	-	-	+	+
6	-	-	+	+
7	-	-	+	+
8	+	-	+	-
9	-	-	+	-
10	-	+	+	+
			(Transplantation)	
11	-	-	+	-
12	-	-	+	+

The minus sign indicates loss of function, and the plus recovery of function.

The table shows, in the first place, that the muscles of the upper arm are, almost without exception, severely affected in flail-joint. In one case only could the triceps and biceps be demonstrated. Ten out of eleven patients with impairment of the biceps recovered power in it, though in one case an accessory transplantation was performed.

In six out of the eleven cases the triceps recovered. Lastly, in six

cases the biceps and triceps both recovered their function. It follows that **atrophy of the muscles of the upper arm is not a contra-indication to the performance of arthrodesis**, although if the paralysis is extensive, it renders the success and value of the operation very problematic.

The results of arthrodesis of the shoulder are therefore very satisfactory from the point of view of functional utility as well as of pathological anatomy.

To complete our description, however, we must discuss the disadvantages of the method and the causes of failure.

There were two failures in our series. Of these, one (No. 4) was not due to lack of success in the operation itself, but to failure of the muscles of the forearm to redevelop. The arthrodesis of the shoulder succeeded, but the tendon transplantation in the forearm failed, and the hand remained useless. Probably, we made an error of judgment in performing the operation, although the patient is not dissatisfied with the result, as she can now use the arm better than formerly to assist the good one. The other case, No. 11, is a total failure, for no solid ankylosis at all was obtained. This is to be attributed, as later experience showed, to an error of technique, in that only one wire was used. Neither case, however, was really disastrous, and a certain proportion of failures is incidental to every new method; indeed, it is from the failures, rather than from the successes, that we chiefly learn.

We come now to the **temporary and permanent disadvantages** of the method. Amongst the former, the chief is the formation of a sinus, as the result of burying the silver wires. This took place in six of our patients, in some instances after a few months, in others after six months, a year, two years, or even after four years. It is therefore possible that in four other cases, which have not yet been under observation for four years, sinuses will eventually develop. The sinuses close after the wire has been removed. In two cases, however, they healed up, although portions of the wire were left in, and remained healed for between four and a half and six years, so that the small fragments that remained cannot have caused much irritation. It must be remembered, in this connection, that in three patients in whom no sinus formed, the X-rays revealed that the wire had broken into several pieces. In two cases it was found uninjured one and a quarter and two and three-quarter years after the operation, the patients being eighteen and four years old respectively at the time of the operation. The arm had been assiduously exercised in the meantime.

There are certain cosmetic disadvantages, more persistent than the fistulæ. These are the *displacement of the scapula* and the *curvature of the spine*. It might be expected that the abnormal and excessive pull of the trapezius would result in the elevation of the scapula, so that there would be a difference of height in favour of the paralyzed side, although

the bone had suffered from arrest of growth. We have found that this was actually the case in four patients, although the difference only reached a marked degree in two of them.

It is obvious that another anomaly in the position of the scapula must occur—viz., rotation about a sagittal axis. The more the arm is abducted, the more the scapula is rotated, until, finally, the arm hangs perpendicularly by the side. There is, of course, no objection to this rotation.

Lastly, we have to discuss whether or not the performance of arthrodesis tends to produce **scoliosis**. If we believe that the preponderance of right-sided dorsal scoliosis is due to the greater use of the right arm, a similar reasoning would apply to cases of unilateral paralysis. In our six cases of left-sided paralysis, we found four examples of left scoliosis; two of these were total left, two were slight left dorsal, one was right dorsal with marked deformity of the ribs, and one was a severe right dorsal paralytic scoliosis. Amongst six patients with right-sided paralysis there were one severe left lumbar paralytic scoliosis, one slight left and right dorsal, and one more marked right dorsal, with torsion. There is, therefore, no uniformity as to the direction of the curve. We cannot say that the greater activity of the right arm produces scoliosis on that side, nor can we show that the abnormal use of the scapula brings about a spinal curvature. We have often noticed, however, that patients increased their range of movement when striving to raise the operated arm as high as possible, by producing scoliosis on the same side. It is unlikely, however, that this leads to permanent scoliosis, for in unilateral paralysis the good arm remains the better arm, however successful the arthrodesis, and therefore the spine is more liable to curve towards the healthy side.

We see, then, that the disadvantages of arthrodesis are not many, whether objective or subjective. The patients were asked carefully about the latter, but nothing of interest was elicited.

The **advantages**, on the other hand, are enormous. There is no denying, however, that the operation of arthrodesis of the shoulder or any other joint brings about a pathological condition, which is only justifiable if the functional value of the joint is rendered greater than the disadvantages which the condition entails. The method will have to be given up as soon as some better operation has been introduced, enabling us to leave the joint intact.

As we saw in Part I. of this book, tendon transplantation has been put forward as a rival to arthrodesis. Let us consider, therefore, what is known as to its effectiveness in the case of the shoulder-joint.

Within the last ten years, experiments have been described, in which attempts have been made to replace the paralyzed deltoid by means of **muscle transplantation**. It appears, however, on searching the literature, that a plastic operation on these lines was performed some years earlier.

v. Winiwarter (before 1892, according to Roersch) performed the following operation upon a girl of eight who had paralysis of her shoulder muscles, the pectoralis major and supraspinatus being unaffected: he made an incision along the clavicle, and then along the arm. The sternal and inner part of the clavicular portions of the pectoral were dissected up, and the flaps were turned round and fastened to the spine of the scapula. Definite improvement was noted after the lapse of three months. The patient could raise the arm a little from her side, and put her hand to her head—a thing which she was quite incapable of doing before.

This pioneer operation attracted no attention, probably because it was not published in a very prominent manner.

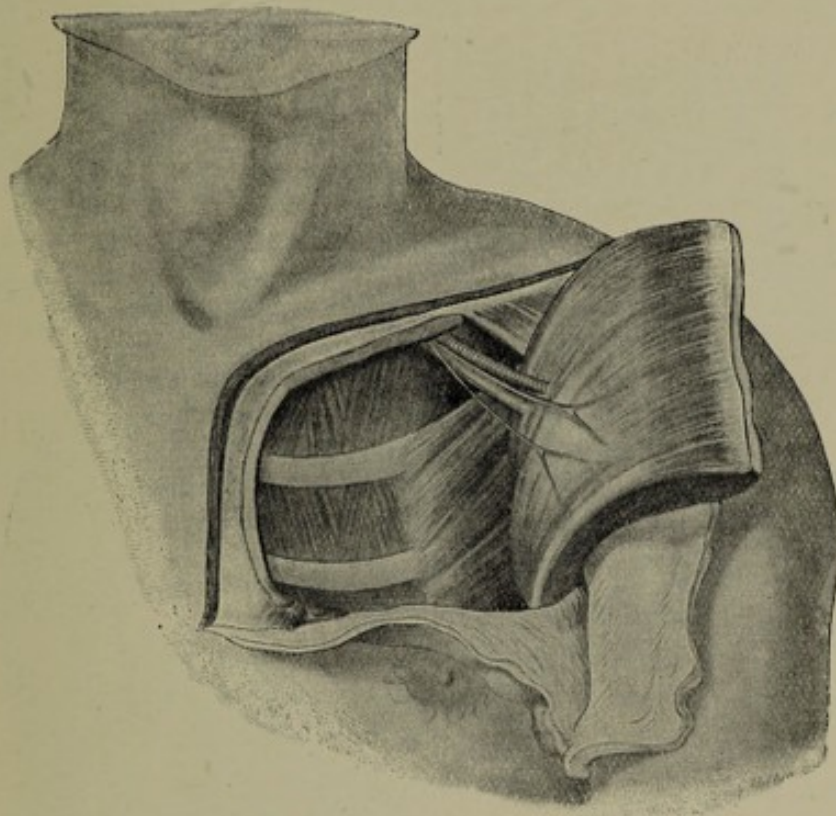


FIG. 132.

Hoffa independently undertook a similar operation in 1901, turning a flap from the healthy trapezius to replace the paralyzed deltoid. He succeeded not only in preventing the subluxation of the head of the humerus, but also in materially improving the function of the limb. Later attempts at grafting the trapezius and the pectoral seem to have yielded less satisfactory results.

Reichardt modified Hoffa's work by dividing the deltoid into three parts and stitching them in an ascending manner into the trapezius. Elevation of the arm was possible to about 20 degrees laterally and forwards, and one could feel the anterior part of the deltoid tightly stretched beneath the fingers. No further improvement taking place, however, he decided later on to perform arthrodesis. Schanz also performed a plastic operation upon the trapezius. Morestin used a part of the trapezius and the clavicular head of the pectoralis major; a year later slight power of abduction was present. Hildebrandt reported the first really striking success in 1905. The patient was a child who had had her shoulder severely affected by poliomyelitis one and a

quarter years previously. The trapezius, serratus, infraspinatus, deltoid and teres minor were paralyzed. There was marked flail-joint, and two fingers could be introduced with ease between the head of the humerus and the acromion. Only swinging movements were possible. He made an incision from the attachment of the fourth rib to the sternum to the sterno-clavicular joint, then along the clavicle to the acromion and down the arm, almost to the insertion of the deltoid. The pectoralis and deltoid were now exposed. The sternal and clavicular origins of the pectoral muscle were separated from the bone, and turned away from the thoracic wall. The anterior thoracic nerves and the vessels were carefully preserved. When the deeper fibres also had been freed from the thorax, the muscle could be rotated through 80 degrees; it was placed over the attachment of the deltoid, and sutured to the outer third of the clavicle and to the acromion process with stout catgut stitches (Figs. 132 and 133).

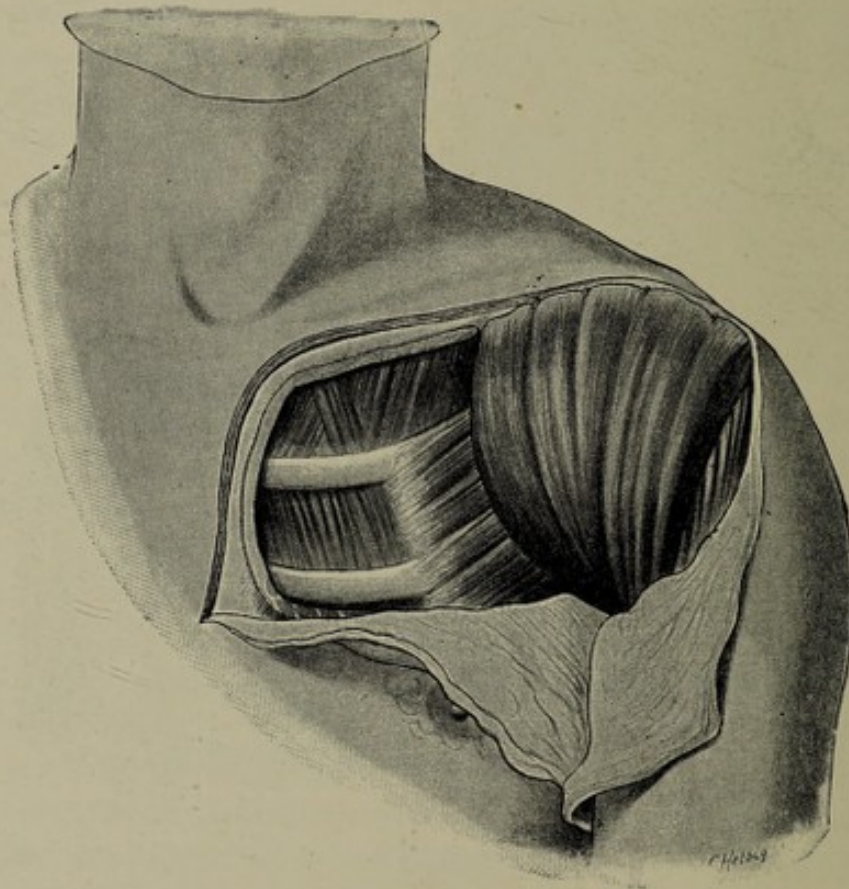


FIG. 133.

The result was fully equal to the surgeon's expectations. The flail-joint had completely disappeared six weeks after the operation, and the little patient was able to raise her arm almost to the horizontal, in the forward direction, and could also bring her hand up to her nose or to the back of her head. The electrical reactions showed that the muscle could be stimulated either directly or indirectly through its nerves.

A similar operation was performed by Sachs in 1906. He displaced the pectoralis without turning it, and sewed it to the spine of the scapula, the acromion process, and the clavicle, taking special care not to injure the nerves. The patient acquired full power of raising the arm from the side.

A still more brilliant success was recorded by Gersuny, who operated for a rheumatic (?) paralysis of the deltoid, of five months' duration. His explanation of the result is not free from objection, however. An incision was made over the middle

of the acromion, and the trapezius freed from its insertion into the spine of the scapula and the acromion; the deltoid was also dissected up over the same area. On raising the arm the deltoid could be pushed for a considerable distance under the trapezius, where it was then fastened. Movement returned in two months, and had reached the normal amount in another two months. The deltoid could not be stimulated, however, by means of the spinal accessory or the circumflex nerve. On voluntary contraction, the muscle stood out as a tense band, whilst those portions that had not been attached to the trapezius contracted in the normal manner (spontaneous healing, formation of anastomoses?).

Lengfölnner has recently described total transplantation of the pectoralis as "an anatomical and physiological error," because the nerves are so short that they will only stand very slight displacement. In one case, therefore, he employed only the clavicular portion of the pectoralis to replace the anterior part of the deltoid, whilst he fastened the middle and posterior part of the trapezius to the corresponding part of the deltoid. The anterior and posterior parts of the deltoid acted very well, but lateral elevation of the arm remained very weak.

Lengfölnner and Frohse made some important observations upon the technique, etc., of transplantation at the shoulder, by means of post-mortem investigations. We shall give a short account of them here.

Transplantation of the clavicular part of the pectoralis is justified on anatomical grounds. One frequently finds the inner portion of the deltoid blending with the clavicular part of the pectoralis major. Again, there is often a natural anatomical division between the clavicular and the remaining portions of the pectoral muscle.

The operation is a very easy one. A skin incision is made, about 10 centimetres long, from the tip of the coracoid to the sternum, just below and parallel with the clavicle. The muscle is then raised from its origin about 1 millimetre away from the periosteum, so as to limit the bleeding as much as possible. The muscle is freed for about 3 centimetres. During this process the nerves should not come into view at all. The muscle is then sutured to the anterior portion of the deltoid, the stitches taking in the periosteum also, if desired.

Transplantation of the clavicular part of the trapezius is also employed to replace the anterior part of the deltoid. This operation, too, is justified on anatomical grounds, for it will be remembered that in animals which have no clavicle, the trapezius has a broad attachment to the upper arm and forearm.

The technique of the operation is as follows: The skin incision extends from the middle third of the clavicle to the acromion process. The clavicular attachments of the trapezius and of the deltoid are dissected up from the bone. The muscles are then united with silk stitches.

Elevation of the shoulder is possible if the levator anguli scapulæ and clavicular insertion of the sterno-cleido-mastoid remain intact, but much more powerful leverage is exerted upon the outer part of the shoulder girdle if the sterno-mastoid is transferred from the middle third of the clavicle to a point as far outward as the particular structure of the part allows.

A horizontal incision is made across the spine of the scapula from the acromion for 3 centimetres inwards. The lateral, tendinous part of the trapezius is set free, and the muscle itself is divided for about 2 centimetres. One should not go farther than this towards the middle line, for fear of injuring the spinal accessory nerve. The fascia infraspinata is then dissected up, and a quadrangular flap is cut, 2 centimetres broad and 3 centimetres long, consisting of the fascia and a good portion of the atrophied muscle. The muscle and the flap are then sewn together with several silk sutures. An elevator is then introduced beneath the trapezius, and the whole muscle belly is divided down to the bone as far as the acromion. In the same way the deltoid is freed from its origin from the spine of the scapula. Lastly, a few bundles of the trapezius will require division, and the supraspinatus will come into view. The origin of the deltoid and the insertion of the trapezius can then be united without difficulty over the spine of the scapula, and the trapezius thus acquires an indirect insertion into the deltoid tuberosity. In dissecting up the fascia infraspinata, a short incision, about 2 centimetres long, is required.

The operation may be modified as follows :

Instead of completely freeing the attachments of the muscles from the spine of the scapula, one may perform a permanent resection of the free border of the spine, which can always be seen, or, at any rate, felt, under the skin. One of the two muscles must always be left attached to the bone—the deltoid when the trapezius is paralyzed, and *vice versa*. On anatomical grounds it is probably better to free the deltoid, which has an extensive tendinous origin, rather than the trapezius, which has little or no tendon at this place.

If the case is one of paralysis of the deltoid, we first set free the triangular lateral aponeurosis of the trapezius, and then divide it at its origin, about $1\frac{1}{2}$ centimetres below, and parallel with, the spine of the scapula. Next, we free the origin of the muscle. In doing this, some fibres of the infraspinatus muscle may also be divided. An elevator is then pushed beneath the tendon of the trapezius at the point where we are going to free the deltoid from the spine of the scapula, rather towards the posterior angle of the acromion. We then divide the spine of the scapula at this spot, and pass a Gigli saw along the elevator to the root of the spine, without injuring the soft parts. The spine is then sawn through, and the trapezius is left, still in contact with the broad subcutaneous surface of the spine and the origin of the deltoid. The rough edges of the bones are trimmed off with bone forceps, so as to prevent, as far as possible, the free portion from reuniting with the rest of the shoulder-blade. The part to which the muscles are attached thus forms a sort of sesamoid bone. Lastly, the adjacent edges of the supraspinatus and infraspinatus are sewn together across the raw edge of the spine.

Special care is taken during the performance of the operation not to injure that part of the scapular spine which adjoins the surgical neck, as it is from this part chiefly that the acromion is developed ; otherwise the shoulder-joint would be seriously impaired. Again, the preservation of this part enables the supraspinatus and infraspinatus to work at greater advantage, as far as they are capable of voluntary contraction at all. If necessary, a piece can be cut out of the back part of the acromion, to prevent union from taking place too easily between it and the divided spine.

When the acromial and spinal parts of the deltoid are paralyzed, the corresponding parts of the trapezius may be transplanted to replace them. The levator scapulæ is only utilized in cases of paralysis of the trapezius. The supraspinatus is never used ; it is too difficult to get at for surgical purposes. On the other hand, the upper part of the rhomboideus major may be employed for transplanting.

The teres major is particularly useful ; total transplantation of the origin and insertion has been performed. The operation is carried out as follows : A skin incision, 12 centimetres long, is made along the posterior border of the deltoid ; the fascia covering

the muscle is left ; then the long head of the triceps is separated by blunt dissection on its mesial aspect, and freed from the tendon of the latissimus dorsi. Lastly, the tendon is divided and sewn to the superficial aspect of the teres minor. Thus the teres major is given an attachment similar to that of the teres minor, instead of being its antagonist. The skin incision is then prolonged to the posterior border of the shoulder-blade, where it ends in the middle of the infraspinous fossa. The skin and fascia over the teres major are then undercut and pushed downwards. The origin of the muscle from the inferior angle of the scapula is divided, together with the strong infraspinous fascia. The muscle is completely isolated, except for its attachment to its nerves and large vessels. The skin is then pushed upwards, until the posterior border of the deltoid and its tendinous origin are exposed ; into this the central stump of the muscle is sutured. Then the incision is prolonged downwards for 2 centimetres over the deltoid tuberosity, the posterior border of the deltoid is freed, the deep tendon divided, and the distal stump of the muscle sutured into it (fascia infraspinata above, and latissimus and tendon below).

For completeness' sake, we shall mention some other recent work upon the substitution of other muscles of the shoulder girdle.

Samter, in 1897, fastened a part of the pectoralis to the scapula in a case of traumatic paralysis of the serratus. He states that the result was entirely successful. Tubby had previously carried out the same idea, dissecting up a part of the pectoralis, splitting it, and sewing it bit by bit to the paralyzed serratus. The result was satisfactory and permanent. Katzenstein also succeeded in grafting parts of the pectoralis and trapezius into the serratus. More recently this surgeon has published a successful but more complicated operation, which he performed for paralysis of the trapezius. A piece of the latissimus dorsi and the fibres of the trapezius of the good side, corresponding in direction with those that were paralyzed, were used for this purpose.

I myself have never been able to decide upon doing one of these operations at the shoulder-joint. I am so convinced of the marked and permanent success that follows arthrodesis, that I am not disposed to give the operation up in favour of a new and uncertain method. We have very little knowledge of the results as yet, but even when they are favourable, they are undeniably inferior to the majority of arthrodeses. In addition, the operation is a very extensive one, and the scar is large and unsightly—points which, in my opinion, turn the scale in favour of extirpation of the joint, as a matter of practical surgery. I think it is unlikely that the technique of the method will be so far improved as to render transplantation the better operation ; time alone can show.

Nerve Grafting.—Nerve grafting is a much more promising line of treatment. At any rate, this method has advantages which justify us in adopting it in those cases in which the patient's circumstances allow of a prolonged course of treatment, and of a second operation, if the first fails. Thus, the operation is simple, it is not destructive, and it does not render a further operation more difficult than usual. Very little is known at present with regard to operations of this nature upon the circumflex nerve. Warren Low, in 1903, reported a plastic operation upon the roots ; he grafted a part of the fifth cervical nerve into the sixth. There was slight power of abduction of the arm after eleven months. This increased rapidly, so that

the child could eventually raise his hand to his head. It is true that the paralysis of the deltoid, supraspinatus, and infraspinatus had only existed for six months, so that it may be objected that the muscles had undergone spontaneous recovery. On the other hand, the first voluntary muscular contraction was not noted until after the lapse of seventeen months—a period at which spontaneous recovery of paralyzed muscles would not occur. Sherren tried the same operation upon the deltoid in 1906, but without success. Tubby, in 1909, wrote a short account of two plastic root operations :

1. Boy, *æt.* 9 years. Paralysis two months previously. Deltoid, supraspinatus, infraspinatus, biceps, and supinator longus affected. Energetic treatment for six months ; no improvement. Operation : fifth cervical nerve root divided, both ends grafted into sixth. No improvement in first year. Then biceps and hinder part of deltoid became innervated. Slight progress during next year.

2. Boy, *æt.* 12 years. Paralysis two years previously. Localized paralysis of deltoid. Operation : ascending transplantation of upper and lower parts of fifth cervical root into sixth. Subsequent history : Contraction of deltoid perceptible after a year. Arm could be separated 6 inches from the side after eighteen months, and 8 inches after two years.

Galeazzi, in 1907, performed an ascending transplantation of the circumflex nerve into the median, for paralysis of the deltoid. The result was still far from perfect after eight months, but it “ gave promise of ultimate success.”

Before we describe our own cases, let us consider the functions of the deltoid and supraspinatus. The views which we shall adopt are those of Stoffel.

The deltoid must be regarded, from the physiological standpoint, not as one muscle, but as a group of three muscles.

Functions of Deltoid.—For each part, the clavicular, acromial, and spinous, has its own action. The *clavicular part* raises the upper arm in a forward and inward direction. If it is paralyzed, the patient is unable to hold his arm out straight in front of him, to grasp anything lying in his line of sight, or to put his hand up to his head. The *spinous part* raises the upper arm backwards or laterally to an angle of 45 degrees. If abduction is carried as far as 90 degrees, this part of the muscle exercises an antagonistic function. It brings the arm down again to 45 degrees. The deltoid, therefore, considered as a whole, may be regarded as the abductor and adductor of the arm. If this part is paralyzed, the patient cannot raise his arm backwards—*i.e.*, he cannot put his hand to his hip-pocket. The *acromial part* performs the movement of pure lateral elevation to the horizontal. If this portion alone is paralyzed, the patient is still able to abduct his arm, because he can contract the two remaining portions simultaneously, and thus compensate for the defect. The clavicular portion,

therefore, seems to be the most important. It has a valuable function to perform, and cannot be replaced by either of the other two parts. Injury of the middle third of the muscle, on the other hand, causes the least disturbance. The supraspinatus is synergic with the deltoid, but can only raise the humerus by imparting to it, at the same time, an outward movement and slight internal rotation (Duchenne). It also has another action: it fixes the humerus against the glenoid cavity during abduction, and holds the bone up in position during rest. **Paralysis of the supraspinatus** shows itself, therefore, in two different respects: the power of abduction is decreased (assuming that the deltoid is unimpaired), and a flail-joint is rendered more likely to occur. The deltoid muscle is the chief factor in raising the arm to 90 degrees, as its bulk would lead one to suppose. The supraspinatus, however, works under more favourable mechanical conditions. Its muscle belly and tendon run at right angles to the lever which is to be moved, whereas the fibres of the deltoid are parallel with the long axis of the humerus, whatever be the position of the arm. Nevertheless, the power of abducting the arm depends to a great extent upon the possession of a strong deltoid muscle.

Internal Structure of Circumflex Nerve.—I can only speak of the minute anatomy of the circumflex nerve, and the distribution of the various fibres within the bundle, in general terms. The reader will appreciate the great value of Stoffel's work in this connection. The circumflex nerve consists of a humeral and an ulnar root, which are distinguishable as high up as the axilla. The humeral root is the more important, and gives off the nerves to the deltoid. In performing descending grafts from a good nerve, it is therefore necessary to insert the flap exclusively into the ulnar root. But provision must also be made for the distribution of the latter nerve, or else the spinous part of the deltoid may remain paralyzed. It is best, therefore, to make a cut on the proximal aspect of the site of origin of the ulnar root, so as to divide both the humeral and the ulnar fibres. In this way the innervation of the whole of the circumflex distribution is assured. Cases of partial paralysis (*e.g.*, those in which only the clavicular or the acromial part is lacking, or in which both are intact), are easier to deal with. In the first case, we have only to deal with the humeral head, and in the second no operation is required, because function is so little impaired.

Our own case reports are as follows:

1. A. D., girl, *æt.* 2 years. Right arm and leg affected with flaccid paralysis six weeks previously. Arm hanging limply by side; head of humerus subluxated downwards; roundness of shoulder quite gone. Marked depression below acromion. Movement at shoulder-joint completely impossible. Deltoid and biceps quite paralyzed, and not excitable by electricity. Supraspinatus seems to be paralyzed. Levator anguli scapulæ and trapezius contract well; triceps slightly impaired. Forearm musculature quite intact. Arm placed in abduction splint, treated regularly with hot appli-

cations, massage, and electricity. Paralysis of leg improved, but arm not improved in the least. Operation, October 10, 1908. Circumflex nerve exposed and divided;

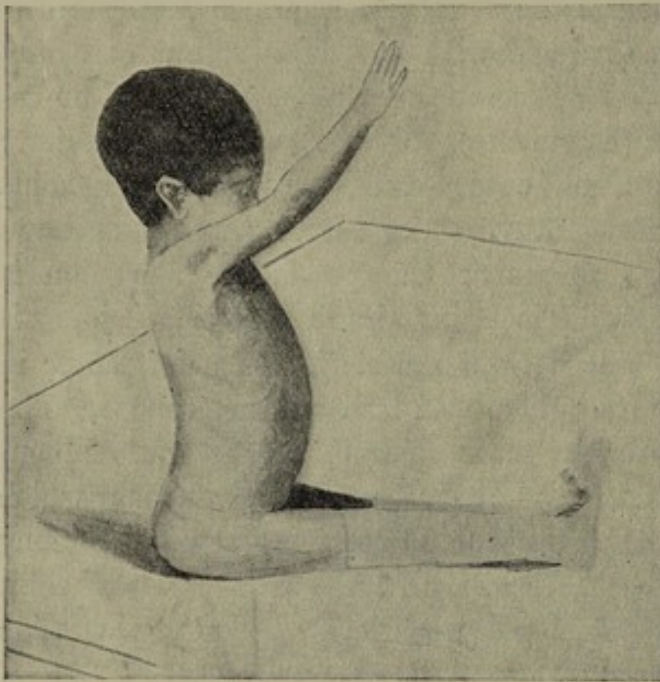


FIG. 134.

2. F. M., boy, *æt.* 3 years. Paralysis of right arm, left hand, and both legs for fourteen months. Right deltoid completely paralyzed, arm hanging down powerless, no active movement at shoulder at all, but elbow good. Muscles of shoulder girdle intact. Left interossei paralyzed. Operation, May 26, 1909. Brachial plexus exposed. Circumflex nerve dissected out; several veins cut and tied during the process. Separation of nerve into its two parts seen. Flap, about 6 centimetres long, cut from median nerve, including about half its width, inserted into slit in circumflex nerve on proximal aspect of point of division, and sutured there with several fine silk stitches. Plaster, 90 degrees abduction. Uneventful recovery.

August 2, 1909.—Discharged. Child can raise upper arm with difficulty to 30 degrees. Result disappointing.

peripheral stump inserted into slit in palmar aspect of ulnar nerve, and peripheral end of musculocutaneous into median. Bandage at right angles.

October 24, 1908.—Dressing changed. Arm placed in Heidelberg abduction splint.

November 19, 1908.—Slight reaction in biceps and anterior part of deltoid, which no longer hangs quite so limply.

December 5, 1908.—Patient discharged. Biceps sometimes shows slight contraction when patient makes a powerful effort of will. Anterior part of deltoid distinctly stronger; posterior part weak. Supraspinatus very atrophied. Less subluxation.

December 6, 1909.—Patient seen again. Arm has not been exercised at all at home; condition as before.

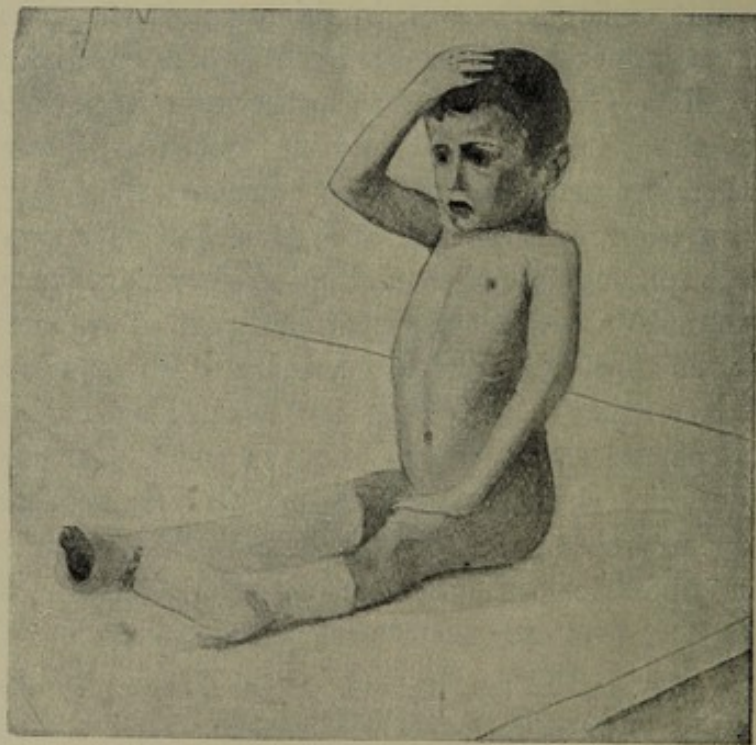

FIG. 135.

September 22, 1909.—Child not treated at all at home. Came back to Out-Patients. Deltoid much larger; no longer feels flabby. Patient can raise the arm in forward direction beyond the horizontal (see Fig. 134). Clavicular part of deltoid can be felt to be tightly stretched; lateral elevation to 50 to 55 degrees. Patient can raise hand to mouth and to head (Fig. 135).

3. Girl, *æt.* 6 years. Paralysis of back, right arm, and both legs at nine months.

January 20, 1909.—Right arm hanging by side; head of humerus can easily be displaced to lower border of glenoid cavity. Deltoid functionless and very atrophied; no reaction to electricity. Supraspinatus also paralyzed. Muscles of shoulder girdle somewhat impaired. Biceps, triceps, and muscles of forearm good.

January 26, 1909.—Plastic operation on circumflex nerve. Nerve found much undersized. Ulnar half of median split for 5 to 6 centimetres, passed from behind into slit in circumflex nerve, and embedded there.

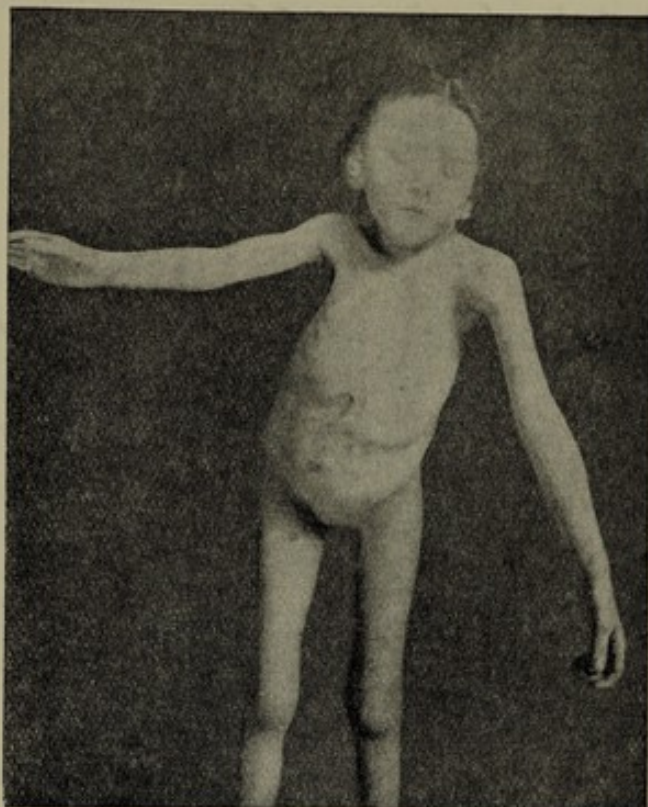

FIG. 136.

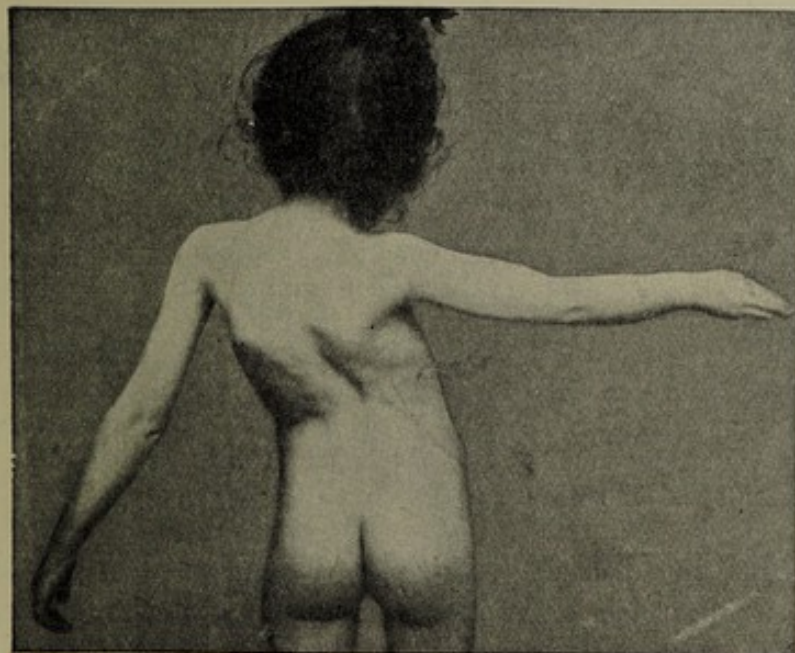


FIG. 137.

November 10, 1909. Muscles recovering function surprisingly quickly. Obvious contractions on stimulating the deltoid electrically, especially in the middle part.

November 12, 1909.—Girl can raise arm 45 degrees forwards and 40 degrees laterally.

April 5, 1909.—Arm can be raised to 90 degrees in forward direction, and also laterally; clavicular portion becomes prominent.

October, 1909.—Arm can be raised beyond the horizontal

(see Figs. 136, 137, and 138). Mother says that the arm varies considerably in usefulness on different days: sometimes it is almost as good as a sound limb, and at other times it is

very weak. On examination, we found that the muscles were very easily tired; this the mother had apparently regarded as a "bad" day. No treatment had been carried out at home.

4. A. S. T., girl, *et.* 12½ years. Paralysis of both legs and left arm three years previously.

September 13, 1909.—Deltoid very atrophied; no voluntary movement at shoulder. On anodal galvanism, very slight contraction occasionally perceptible in middle third of deltoid. Supraspinatus completely paralyzed; marked subluxation of head of humerus. Biceps weak; long head of triceps good; other muscles distinctly impaired. Small muscles of hand weak; forearm muscles fairly good.

September 28, 1909.—Plastic operation on circumflex nerve. Median and ulnar distribution almost completely paralyzed. Mother would only consent to operation on condition that no impairment of hand or fingers should be risked; the only muscle, therefore, that could be touched was the long head of the triceps. Fibres to this muscle were found in the musculospiral, and isolated for 5 to 6 centimetres. They were then divided and grafted into the circumflex rather above its point of division, as in Case 3. Circumflex was very difficult to find, as it ran behind and somewhat to the outer side of the brachial artery. Fixation in Heidelberg splint at 90 degrees abduction.

November 11, 1909.—Healed up. Long head of triceps quite paralyzed. After-treatment.

November 29, 1909.—Contractions of spinous portion first noticed on galvanic stimulation.

December 6, 1909.—Ditto in acromial portion.

December 24, 1909.—Arm can be abducted to 20 degrees from side. On raising arm from side and then dropping it, it falls slowly, and not in a lifeless manner. Contractions of acromial and spinous parts of deltoid can be seen and felt. On supporting patient's hand a little, she can raise it to the horizontal, and keep it in that position for several seconds. The muscle is not yet strong enough to carry the weight of the whole limb.

January, 1910.—Contractility of whole muscle recovered.

On critically surveying these cases, one cannot be pleased with the result of the first. The lack of success is to be attributed to several factors, including the small amount of available healthy nerve material, and the operative technique adopted. The circumflex nerve was too short to reach the ulnar nerve comfortably. The implantation was only accomplished after stretching the nerve. This is a bad thing to do, not only because the



FIG. 138.

sutures are very liable to come out, but because it renders proper innervation less likely to take place. Lastly, the slit was made in the palmar part of the ulnar nerve—a part which, as we now know, contains no motor fibres. All these various reasons considered, the failure of our first case is not to be wondered at. The last three, on the contrary, show striking success. In Cases 2 and 3 the shoulder came to function well, if not perfectly. Case 4 will probably give a good result, as far as one can judge from its present condition.

Certain features in the histories call for notice. In Cases 2 and 3 it was the clavicular part that recovered first and remained the strongest in the end. It would appear that the fibres of the graft grew mainly into the humeral root of the circumflex nerve.

In Case 4 it was the spinous portion that first showed active contractions. One assumes that the ulnar root was the first to be innervated. But the fact that the acromial part also distinctly showed contractions indicates that some growth took place into the humeral part. We knew very little at the time of this operation about the internal anatomy of the circumflex nerve. Stoffel's researches were only published later on. Our operative results show how important they were.

Restoration of function took place remarkably quickly in Case 3. It is difficult to explain why this occurred, but similar observations have been recorded by others—*e.g.*, by Bardenheuer. The phenomenon is perhaps to be attributed to anastomoses with the anterior thoracic nerves, which are often present in the anterior third of the deltoid. It is probable, too, that early or late restoration of function is to a large extent dependent upon peculiarities and accidents in the course of the healing of the wound. Rapid recovery takes place when the fibres grow straight down into the path that is to be innervated. If some obstruction is present, such as blood clot, fibrous tissue, or other material, the fibres have to take a more roundabout course, and a longer interval elapses before any improvement is seen. As regards the effects of grafting upon the healthy nerve, our first case is valueless, because the transplantation was an ascending one. In Case 4 paralysis of the long head of the triceps occurred, but this now seems to be improving. Cases 2 and 3 show some impairment of the finger movements, especially in flexion of the index-finger. This is innervated exclusively by median fibres. The paresis lasted for several weeks, and then improvement took place. We had no instances of severe paralysis, and in the future the amount of damage that is done should become less, as we get to know more about the distribution of the fibres in the various parts of the nerve trunk, and can arrange our incisions accordingly.

It has been said by some that the real reason for our success is the fact that we fix the arm in the abducted position, and therefore take the weight

off the overstretched muscles. Case 1 disproves this objection, for this line of treatment had been employed without success before resorting to operation. Again, in Case 2, the patient left hospital with a poor result, had no treatment at home, never wore a splint, and yet returned later on with recovery of the deltoid. It would be incorrect, however, to assume that after-treatment is therefore unnecessary. It must be assiduously carried out for as long as possible if the best result is to be obtained.

Small as our experience is, it is yet sufficient to show that nerve grafting is to-day a practical method of treatment for paralysis of the shoulder. Our results will improve with further experience.

Lengfellner and Frohse have made anatomical investigations upon the use of the subscapular nerve for grafting into the circumflex, and upon transplantation of the fifth into the seventh cervical nerve.

Transplantation of the Subscapular Nerve (Teres Major) into the Circumflex.

The incision is the same as that for ligature of the axillary artery. The motor nerve to the teres major is found in a triangle bounded by the axillary vein, the subscapular vein, and the thoraco-dorsal nerve—*i.e.*, that subscapular nerve which goes to the latissimus dorsi. This is divided, and grafted into the circumflex.

It would be possible also to graft the branch for the latissimus dorsi into the circumflex, or, at any rate, a part of it. But in view of the great importance of the latissimus dorsi, this is rather a risky proceeding.

Transplantation of the Fifth into the Sixth Cervical Nerve.

When the deltoid and supraspinatus are paralyzed, or the supraspinatus and the infraspinatus, it will be assumed that the suprascapular nerve is affected, and the question of grafting it into the healthy part of the brachial plexus arises. The nerve is quite easy to identify, because it is the first that leaves the plexus. It is advisable, for technical reasons, to graft it into the deep part of the plexus. The nerve itself consists chiefly of elements derived from the fifth cervical nerve, so that, as this is diseased, grafting into the seventh is the natural thing to do. The distance between the very long suprascapular nerve and the seventh cervical is quite small—*viz.*, about 1 centimetre. It is better not to choose a deeper cervical nerve, such as the eighth, or the first dorsal, because there is a danger of injuring the subclavian or transverse cervical veins, the lymphatic duct, or the dome of pleura.

We do not know as yet the possibilities of the method; it is therefore impossible to compare nerve grafting with the other methods that are in use. But the operation is, at any rate, justifiable under the circumstances

which we have already enumerated. If it fails, we can still resort to arthrodesis or muscle transplantation. I myself prefer arthrodesis. I have already given my reasons for the choice.

Paralytic Internal Rotation of the Arm.

Slight internal rotation is frequently associated with paralysis of the deltoid. Marked paralysis of the external rotators, the infraspinatus and teres minor, without impairment of the deltoid, is very uncommon. The symptoms are, of course, identical with those of the so-called "birth palsy" of the plexus (see Fig. 139).

The function of the arm is very greatly impaired. The result of the internal rotation is to twist the transverse axis of the elbow-joint, and this renders

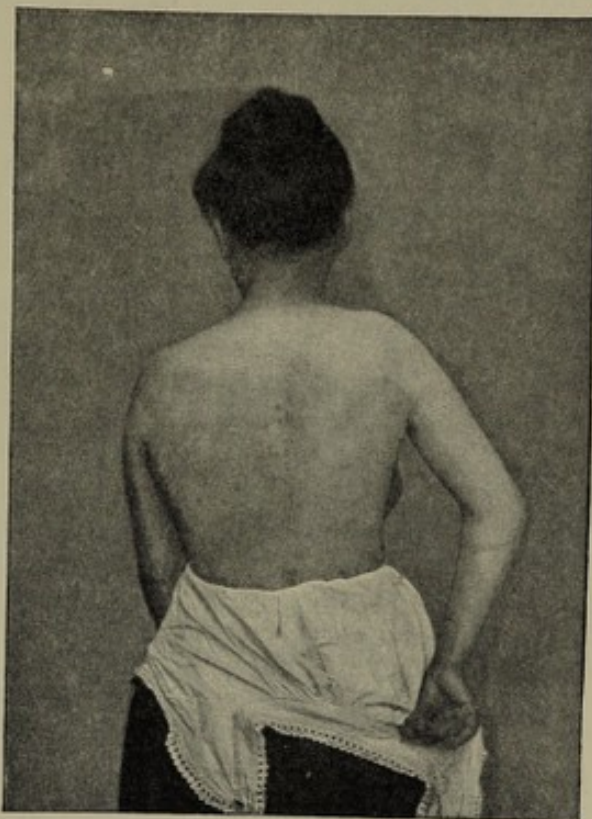


FIG. 139.

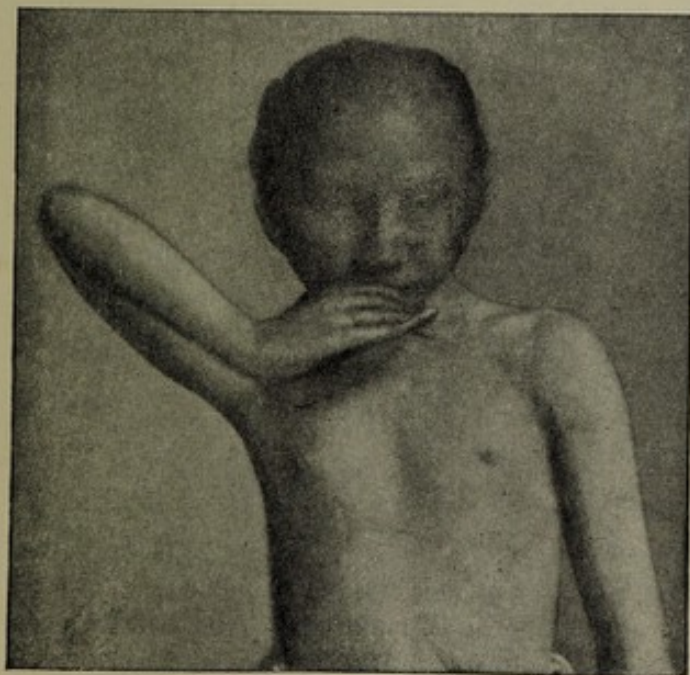

FIG. 140.

the use of the hand very difficult. The patient is unable to hold out his hand unless he raises his upper arm, and to bring his hand to his mouth requires an almost grotesque elevation of the arm (see Fig. 140).

Various methods have been adopted to correct this internal rotation. Tenotomy of the internal rotators, especially the pectorals, is not to be recommended, for the destruction of sound muscle is bad policy in such a disease as infantile paralysis. The

simplest procedure is undoubtedly osteotomy of the humerus with external rotation of the distal fragment. Mencière, in 1902, reported a

successful operation of this kind upon the lower end of the humerus. Hoffa, Spitzzy, and I have performed the operation at the upper third of the bone. I have repeatedly attained the most striking recovery of function, even in adults, by this very simple proceeding.

In the case of the patient shown in Fig. 140, I did something different. The posterior part of the capsule of the shoulder-joint was freely exposed, and the part adjacent to the insertion of the infraspinatus was pleated as tightly as possible. The arm was fixed for several weeks in abduction and




FIG. 141.

extreme outward rotation, and then a leather splint was applied for a considerable time, to maintain this position. The operation succeeded admirably, and the result was permanent, as I ascertained to my great surprise ten years later.

One or other of the operations described is preferable to the permanent use of an apparatus such as that devised by Heusner. In this appliance a spiral steel spring surrounds the arm about twenty or thirty times, and is attached at the upper end to the crutch of a corset, whilst at the lower end it is fastened to a leather sheath embracing the upper part of the hand.

CHAPTER IV

PARALYSIS OF THE ELBOW-JOINT

PARALYSIS of the muscles of the upper arm is **almost invariably associated with the paralysis of the shoulder** ; indeed, there is a causal relation between the two, for, as we saw in Chapter III., the overstretching of the muscles resulting from the dropping of the arm tends to produce a progressive atrophy. Sometimes, however, there occurs true infantile paralysis of the biceps, triceps, or both. In total paralysis of the elbow, slight flail-joint may develop, but **contracture is rare**. It is equally uncommon to see limitation of extension when the biceps is intact, or contracture, when it is paralyzed. The weight of the limb serves to maintain its proper position, and replaces the action of the paralyzed muscles. On the other hand, the continual inactivity of the arm has a bad effect upon the intact muscles of the forearm and hand. The hand and fingers begin to move better as soon as the shoulder and elbow have begun to recover power, as the result of treatment. We have seen in previous chapters that arthrodesis of the shoulder often has a marvellously good effect upon the recovery of the biceps and triceps, even when marked or complete atrophy from overstretching has been present. Active movement at the elbow may be accelerated and improved by means of electricity, massage, exercises, and the wearing of a sling.

When the muscles of the upper arm are definitely paralyzed, various **methods of treatment** may be employed. The choice depends upon the degree of the paralysis. If only the triceps is injured, the function of the limb is not much affected, whereas if the biceps is gone, the use of the hand is very seriously impaired.

It is, therefore, rather odd that all the attempts that have yet been made to replace the paralyzed muscles have been concerned with the weaker extensor muscles. Karewski advised the use of an elastic tractor to replace the biceps, thinking that it might act as the antagonist of the triceps. Simple as this idea is in theory, it is unsuccessful in practice, as we showed in Part I.

The earliest plastic operations on the upper arm were carried out on the

extensor aspect. Milliken⁷ transplanted a flap of the deltoid into the tendon and tendinous expansion of the triceps. The patient was a boy aged

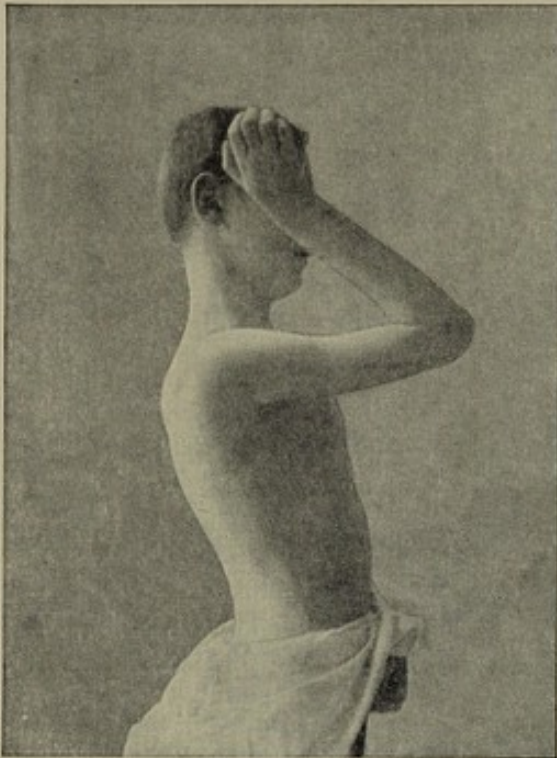


FIG. 142.

two and a half years, who had had paralysis of the triceps for a year. The deltoid took on its new function well, and the result was a decided success. Hoffa performed a different operation for a girl of seven, who had paralysis of the triceps, with an intact deltoid. The long and external heads were separated high up, and dissected up from the bone. The arm was raised to the horizontal, and the elbow extended. The triceps tendons were then sutured to the deltoid. Good power of extension resulted. It is not easy, however, to give a satisfactory explanation of how this took place.

to be seriously considered. The best nerve to employ for the purpose is the median; the ulnar is less suitable for several reasons. It contains relatively few motor fibres; the paresis of the small muscles of the hand that results from its employment is very inconvenient; and such motor fibres as it contains are placed upon the dorsal aspect, and are therefore difficult to reach for technical reasons. We have already explained, in Part I. of this book, the anatomical considerations that limit the choice of the flap. It must be made from the appropriate part of the median, and im-

If the surgeon decides to operate in a case of **paralysis of the triceps only**, nerve grafting is a measure

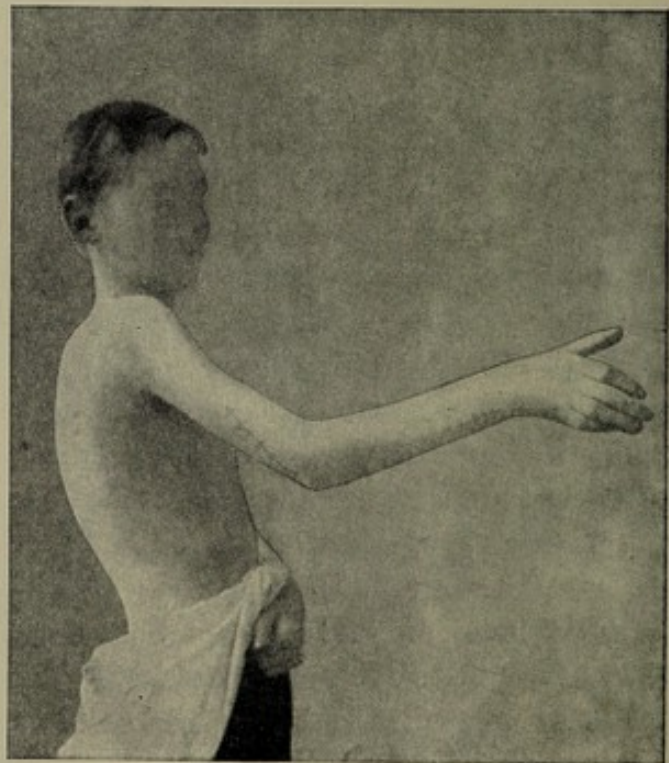


FIG. 143.

planted in the ulnar part of the musculo-spiral, since Stoffel has shown that it is in this portion that the fibres to the triceps run.

We come next to **paralysis of the biceps only**. Muscle transplantation is here particularly appropriate, and we have found it very successful in four or five operations. One is able to observe very clearly how the transplanted half of the triceps takes on the functions of the flexor, and acts quite independently of the remaining half. The **technique** of the operation is simple. The triceps and its tendon are exposed by a free lateral incision. The outer half of the tendon is split, and the corresponding part of the muscle is freed by blunt dissection for some distance upwards. The biceps and its tendon are exposed by a second palmar incision. A hole is made to allow of the triceps being brought forward, and the forearm is somewhat flexed. The triceps tendon is then sewn to the flexor tendon near its insertion. Figs. 142 and 143 show a patient who had had paralysis for four years. The triceps was transplanted, and began to exert its new function as soon as the splint was removed—*i.e.*, after five weeks.

After a further six weeks, flexion was fairly powerful, and almost as extensive as in a normal person. The contraction of the triceps could be both seen and felt. Voluntary extension was also powerful, though rather limited by the tension of the newly formed biceps. Tubby, also, has successfully transplanted the outer head of the triceps into the biceps on four occasions.

It is possible that in the future nerve grafting will prove an even more effective means of treatment of paralysis of the biceps than muscle transplantation is. No investigation has yet been made of the arrangement of the fibres within the musculo-cutaneous nerve. The performance of a descending graft is therefore, at the present time, purely a matter of chance. On one or two occasions we have grafted the divided musculo-cutaneous into the ulnar nerve, in an ascending direction, but no improvement followed. Nothing was known, however, at the time about the arrangement of the ulnar fibres.

It might be well to cut the graft not only from the musculo-spiral, but also from the ulnar, so as to produce only a partial paralysis of the triceps. The median can also be utilized, and is appropriate on account of the analogous nature of its functions. It would seem, however, from our successful cases of muscle transplantation, that the conversion of an extensor of the upper arm into a flexor takes place without much difficulty.

Arthrodesis.—In **complete paralysis of the elbow** various methods of treatment, operative and non-operative, may be employed. We shall first discuss arthrodesis, which was employed by Albert in 1879. He removed the articular cartilage, extirpated the capsule, and united the bones at an acute angle with silver wire. Inflammation set in, and bony ankylosis

failed to take place. Karewski also recommended the operation in cases of total paralysis, stating that it had an excellent effect upon the forearm muscles. He performed the operation upon a child, simultaneously with arthrodesis of the shoulder. A certain amount of spring and mobility remained, but the patient was able to use the arm for various purposes, whereas it had formerly been quite useless. Later on, he himself described the result as "tolerably satisfactory." In 1901, Bothézat described an arthrodesis of the elbow through two lateral incisions, with fixation of the joint at an acute angle. No stitches were used. Solid ankylosis took place, but the limb was not of much use, because the movements of the hand were considerable impaired. Tubby and Jones tried to attain fixation of the joint by a less mutilating method. They excised a lozenge-shaped portion of skin, and sewed up the wound transversely, so as to produce an artificial contracture at the elbow (Fig. 144).

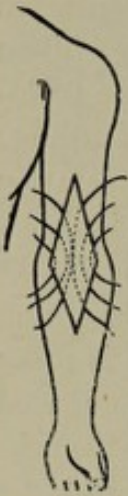

FIG. 144.

Five operations of this sort were carried out, but they were only able to follow up one for as long as two years. In this case the "contracture"



FIG. 145.

remained satisfactory. Incidentally it may be mentioned that a certain amount of power of voluntary flexion had returned.

I myself should not adopt either operation. There can be no doubt that if stiffening of the elbow is necessary at all, ankylosis at a right angle

gives the most favourable functional result. At the same time, permanent stiffening is a great disadvantage for some callings, and the power to flex or extend the joint, as required, may be very valuable to the patient. Again, permanent flexion is undesirable from the cosmetic point of view. For these reasons I prefer to use apparatus for paralysis of the elbow-joint.

A leather sheath is adapted to the upper and lower arm, with joints at the elbow. The amount of flexion is controlled by a leather strap (Fig. 145) ; or else the steels carry a sector, with perforations, into which a bolt fits, held in place by springs.

This arrangement, in my opinion, gives the most useful arm. The appliance does not increase the weakness of the forearm muscles, for the sheaths do not need to fit tightly.

CHAPTER V

PARALYSIS OF THE HAND AND FINGERS

Anatomy, etc.—Paralysis of the forearm is particularly prone to affect the distribution of the musculo-spiral nerve. The hand is flexed, and there is more or less radial or ulnar abduction, according to the exact distribution of the lesion. The flexors are intact, but the hand is useless, because the power of fixation of the wrist is gone ; the grip is therefore lost. In addition to paralysis of the posterior interosseous nerve, there is often diffuse paralysis of the median or ulnar. It is necessary to describe in detail all the varieties of paralysis which may be caused in this way. They differ from the familiar neurological type in this respect only, that contracture of the fingers is slow in appearing, and is never severe in degree. But occasionally one sees severe loss of function resulting from claw-finger, in cases in which the ulnar is chiefly affected.

Treatment.—A good deal can be done for these cases, and especially for posterior interosseous paralysis, by means of mechanical orthopædics. **Appliances** have been devised for the purpose of replacing the injured extensors. Amongst other inventors Delacroix, Duchenne, Carrière, Heusner and others must be mentioned. Several instruments of this kind were described and figured in Chapter II. They are incapable of restoring perfect functional utility to the hand, but they have their uses all the same. They prevent the continual overstretching of the extensors, and thus allow of their recovery, at any rate, to a certain extent. We have repeatedly laid emphasis upon this point in our earlier chapters. Improvement is accelerated if exercises are employed. Tubby and Jones have recorded cases in which excellent results followed the use of medico-mechanical treatment for a considerable time. The case was one of paralysis of the hand and fingers. Recovery of power in the limb may be attained more quickly by means of **operative interference**. The extensors may be shortened, and thus the supporting effect of the orthopædic apparatus is obtained in a much shorter time. Lange has strongly recommended this operation in the case of paralysis of the forearm. Pürckhauer, one of his pupils, has recently suggested that the results that are obtained by means

of **tendon shortening** are as good as those of **nerve grafting**. It is incorrect, however, to assume that the latter is a useless and unsuccessful operation; but before discussing the value of neuroplasty, we must review the results that have been obtained hitherto by means of tendon operations.

Only a few have been performed upon the flexor aspect of the limb; the great majority have been carried out upon the extensors, and a set plan of operation has now been evolved, in the case of posterior interosseous paralysis. The most important step is the correction of the drop-wrist, so that the patient may have a powerful grip. For this purpose the extensor carpi radialis is shortened. It is not sufficient, according to Frank, to reinforce it by means of the flexor carpi radialis. I think that it is well to shorten the extensor carpi ulnaris, in addition, so as to prevent radial abduction of the hand.

Thus the first symptom of posterior interosseous paralysis—viz., flexion at the wrist-joint, is corrected, though at the expense of voluntary palmar flexion. The flexor carpi ulnaris can be made to take on the function of the paralyzed extensors, if it is sewn, under fair tension, to the extensor tendons. The most difficult part of the operation, and the most important, as regards its success, is the determination of the exact amount of tension that is necessary.

The flexor carpi radialis can also be utilized to provide for extension of the thumb.

In cases of partial extensor paralysis it is, of course, easier to replace the injured muscles. If it is required to transfer a muscle from the flexor aspect, this may be done either by bringing it round the bone, or by passing it through a hole in the interosseous space.

An account will now be given of the cases that are recorded in the literature:

1. DROBNIK, 1894.—Girl, *æt.* 4½ years. Paralysis at three. Posterior interosseous distribution. All extensor muscles paralyzed, except extensor carpi radialis longior and brevior, also interossei. Operation: Extensor carpi radialis longior grafted into extensor digitorum, and half of extensor brevior into extensor longus pollicis. Fixed in extension. Result: Extension of fingers at proximal joint possible, simultaneously with radial extension of wrist. Patient learned to grasp objects with the hand. The thumb could be extended at will, and utilized for grasping. The power of extending the terminal joints was permanently lost, on account of the uncorrected paralysis of the interossei; but the general condition of the patient was markedly improved.

2. ROCHET, 1897.—Paralysis for nine years. Extensor carpi radialis, abductor, and extensor pollicis paralyzed. Flexor and extensor carpi ulnaris retracted, retaining the hand in a position of firm ulnar abduction. Operation: Flexor carpi ulnaris divided; extensor carpi ulnaris fastened to the two tendons of the thumb; put up in position of over-correction. Result: Hand quite straight after four months. The thumb, which formerly was pressed firmly against the index-finger, can now be voluntarily abducted. Electrical stimulation of the extensor carpi ulnaris gives the same result.

3. ROCHET, 1897.—Boy, *æt.* 13 years. Paralysis of extensor of thumb and abductor

longus pollicis. Operation: Extensor longus pollicis divided, and peripheral end sutured to tendon of extensor proprius indicis, without cutting the latter. Result: Extension became possible, though only in association with that of the index-finger. Patient much pleased with the result, as he could use the thumb for writing and movements of opposition; also, the last joint was no longer fixed in rigid flexion. The ascending transplantation enabled the boy to carry out voluntary movements of the thumb, but not by themselves. Perhaps power to do this will be acquired later on.

4. ROCHET, 1897.—Boy, *æt.* 14. Paralysis affecting right forearm and hand. Wrist-joint very flail. Voluntary flexion of fingers good, but extension quite impossible, except in the case of the ring-finger and thumb, and the fingers remain in the half-flexed position. The thumb is pressed against the second metacarpal, and can be neither abducted nor opposed. Marked atrophy of the thenar eminence. Operation: Longitudinal incision on extensor aspect of forearm. Tendons not divided, but united side to side, as follows:

- (1) Extensor brevis pollicis to abductor longus pollicis.
- (2) Extensor longus pollicis to extensor indicis.
- (3) Extensor tendons of middle and little fingers to tendon of ring-finger.

Result good three and a half months later. Index and little fingers can be voluntarily extended, but middle finger is not improved. Thumb somewhat abducted whilst being extended, in consequence of the tendon anastomosis.

5. FRANKE, 1898.—Girl, *æt.* 7 years. Onset of paralysis in second year. Hand hanging limply down; flexion good; no power of extension. Flexor carpi ulnaris stronger than flexor carpi radialis; therefore hand is drawn to ulnar side during flexion. Terminal joints of fingers can be extended, also thumb, fairly well. Child unable to grasp thin objects. Operation: Shortening of extensor carpi radialis. Hand strongly extended, then flexor carpi ulnaris sutured to extensor digitorum. After-treatment begun in fourteen days. Result: Hand in position of radial extension. Fingers can be flexed and extended to the full. No power of flexion at wrist. Child able to grasp small objects.

6. GOCHT (HOFFA), 1898.—Girl, *æt.* 7 years. Onset of paralysis at three years. Complete posterior interosseous paralysis. Flexors present, but weak; the best is the flexor carpi ulnaris. Operation: Flexor carpi ulnaris separated from pisiform, passed under extensor carpi ulnaris, and attached to extensor digitorum. Extensor carpi radialis divided and sutured together again under moderate tension. Put up in full hyperextension. Result: Good power of gripping things attained, so that hand, formerly useless, is now a useful member. Eight months later function had improved still further. No details given.

7. HOFFA.—Boy, *æt.* 14 years. Posterior interosseous paralysis since early childhood. Operation: Extensors shortened by pleating; flexor carpi ulnaris and flexor carpi radialis sutured to them. Result: Excellent; hand and fingers can be extended well.

8. LUDWIG (v. MIKULICZ), 1899.—Girl, *æt.* 11 years. Paralysis two years previously. Claw-hand; radial abduction possible, together with dorsiflexion. No palmar flexion at wrist. No extension of fingers, except slight movement of index. Paralysis of extensor carpi ulnaris, abductor longus pollicis, abductor and flexor quinti digiti, flexor carpi radialis, flexor carpi ulnaris, flexor brevis pollicis, extensor communis digitorum and thenar muscles. First operation: Extensor carpi radialis divided, and sutured to divided extensor digitorum. Peripheral part of extensor carpi radialis longior sutured to brevior. Result: Extension of all the fingers possible in fourteen days; index-finger the weakest. Improvement lost, however, in three weeks. Hence second operation: Supinator longus sutured to extensor digitorum. Result: Two months later, extension of all fingers possible, though weak; in four months, hand

in position of slight dorsiflexion. Voluntary extension possible at proximal and distal joints. Flexion of fingers almost unimpaired. Definite contraction of supinator longus in electrical stimulation. The mistake in the first operation lay in the double transplantation and in the insufficient period of fixation.

9. WHITE, 1900.—Paralysis of extensor of thumb. Operation: Extensor carpi radialis sutured to extensor of thumb. Unsuccessful.

10. VULPIUS, 1904.—Girl, *æt.* 9 years. Onset of paralysis three years previously. Index-finger of right hand can be flexed and extended; remaining fingers are flexed, and voluntary extension is quite impossible (see Fig. 146). Interossei and lumbricales poor. Operation: Extensor digitorum completely degenerated, extensor proprius indicis sound. Half of extensor carpi radialis passed through tendon of extensor digitorum, and sutured to it. Extensor proprius indicis united in descending manner to common extensor tendon, and peripheral end of index tendon and those of extensor proprius V. united in ascending direction to common extensor tendon. Result: Splint removed in four weeks; flexion and extension of all four fingers simultaneously pos-

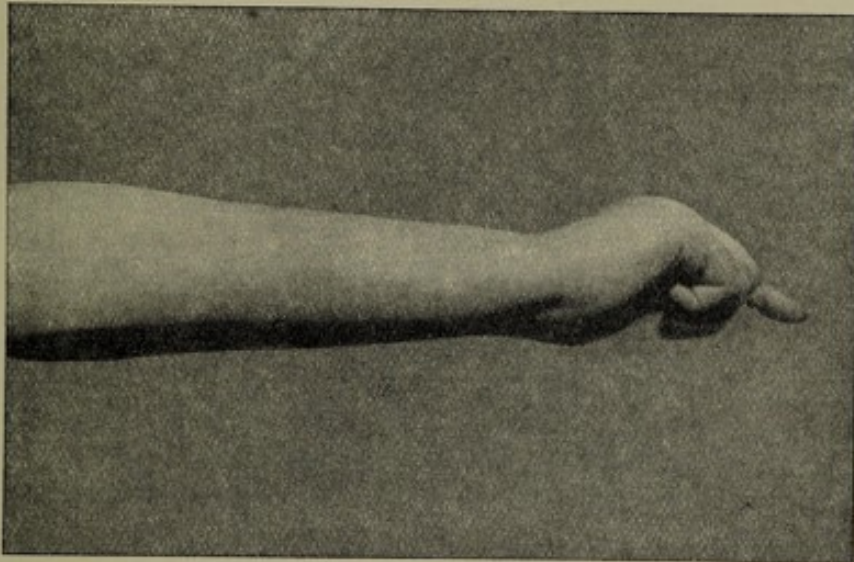


FIG. 146.

sible. Flexion and extension of wrist attained in another month. Fingers ditto, separately. Individual movement best in index-finger; less free in the others (see Figs. 147 and 148). Patient can make a fist. Five years later result was found to be excellent as regards wrist and fingers.

Tubby has five times lengthened the flexor carpi radialis and ulnaris with silk, and sutured them to the bases of the second and fourth metacarpals. He obtained dorsiflexion.

I have only been able to find three cases of tendon transplantation for paralysis in the distribution of the median and ulnar nerves.

11. VULPIUS, 1897.—I. A. K., *æt.* 6 years. Paralysis of left arm and right leg since five years. Shoulder and elbow move well. At the wrist the only functional muscles are the extensor and flexor carpi radialis, the latter of which is fairly strong, so that the hand is permanently deviated to the thumb side. The extensors are intact, with the exception of the extensor proprius indicis; but the flexors are all but absent, there being only a trace of movement in the fourth and fifth fingers. The fingers are kept almost completely extended, and stiff. The thenar and hypothenar eminences are

almost gone. Operation: Longitudinal incision, 6 centimetres long, on flexor aspect of forearm, exposing tendon of flexor carpi radialis; the latter split in upward direction. Flexor profundus digitorum found. Flexor carpi drawn through split in this, and sutured there with silk, fingers and wrist being flexed as far as possible. After-treatment begun in six weeks. In six weeks the result was surprisingly successful. The patient could flex the middle and terminal joints of the fingers to the full extent, though, of course, only in association with radial abduction. To effect extension, he instinctively allows his hand to adopt the position of ulnar deviation. The ultimate

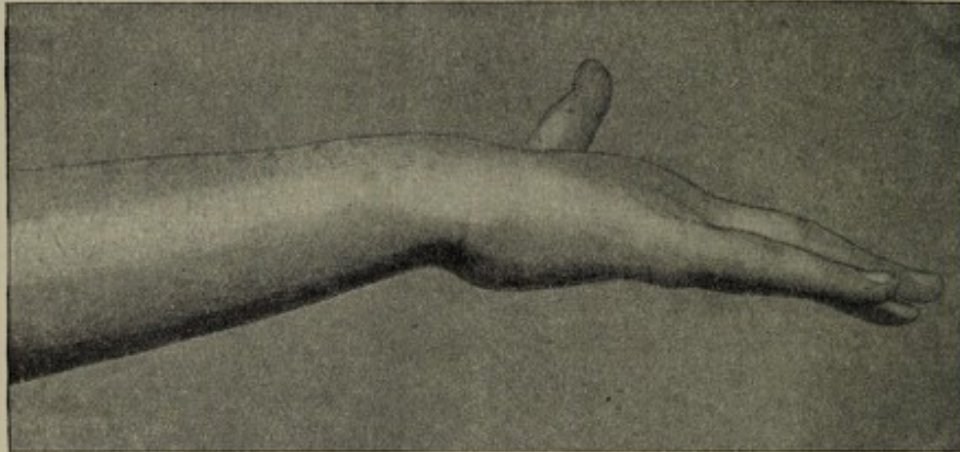


FIG. 147.

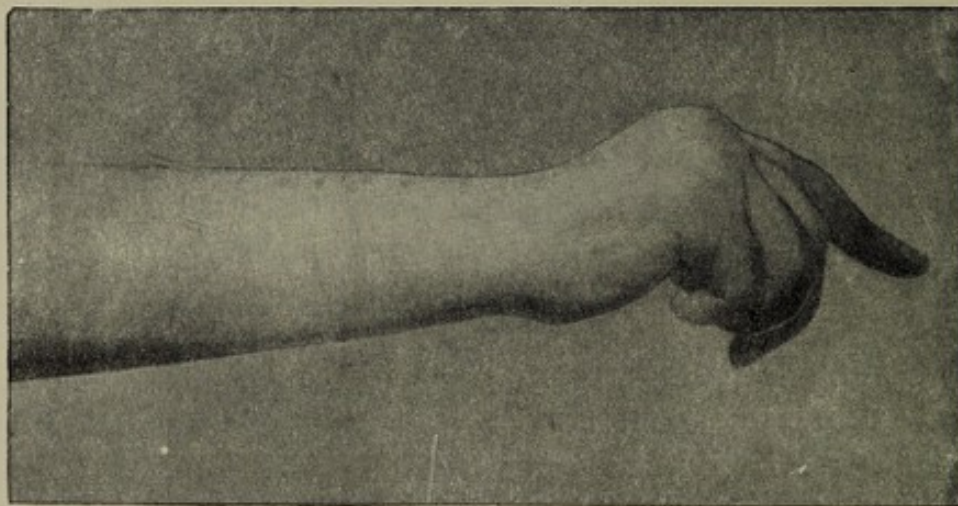


FIG. 148.

result, however, will not be satisfactory, for there is no power of flexion in the proximal joints, and therefore the patient is unable to make a fist. One and a quarter years later the condition was as follows: Wrist freely movable. Full flexion at first interphalangeal joints of fourth and fifth fingers, none at first and last joints. Good flexion at both joints in second and third fingers, which can be brought to within $1\frac{1}{2}$ centimetres of the palm. Flexion is sufficient to enable the patient to hold a small pencil. Radial abduction takes place simultaneously with flexion, and ulnar abduction with extension. Full extension, and even hyperextension, is possible at the proximal joint, the other joints remaining meanwhile in a position of slight flexion.

12. BÜLOW-HANSEN, 1902.—Paralysis of median and ulnar. Operation: Extensor carpi radialis brevis split into two parts, one sutured to flexor sublimis digitorum, the other to the flexor longus pollicis. Result: Good flexion and extension at wrist.

13. HEVESI, 1904.—Girl, æt. 5 years. Flexor carpi ulnaris only paralyzed. Operation: Flexor carpi ulnaris divided; peripheral part fastened in ascending direction to flexor profundus digitorum. Result: Ulnar palmar flexion possible without associated movements after a fortnight.

Tendon transplantation has also been employed in the case of the small muscles of the hand.

1. CODIVILLA (L., Case 17), 1889.—Patient æt. $7\frac{1}{2}$ years. In addition to other paralysis, atrophy of the thenar eminence, opponens pollicis paralyzed. Operation: Flexor sublimis quinti digiti divided, displaced, and fastened to insertion of opponens. Result unsuccessful, either on account of weakness of the transplanted muscle or as the result of cicatrization.

2. CODIVILLA (L., Case 18), 1899.—Girl, æt. 19 years. Atrophy of thenar, hypothenar and interosseous muscles, in addition to other paralyzes. Weakness of flexors of fingers. Operation as in first case. Result: Thumb moved towards ulnar side when hand hyperextended. This movement was formerly quite impossible, but does not amount to actual opposition even now.

I myself once attempted to strengthen the paralyzed lumbricales by grafting into them strips from the long flexors (1897). At the operation the tendons of the lumbricales could not be found, so that I had to abandon my plan. Perhaps it would have been possible to restore some of the movement of the joint by affixing slips of the flexor tendons to the periosteum at the base of the first phalanx.

The few statistics that are obtainable show that tendon transplantation in the forearm is a very effective measure. This is satisfactory, if only because the opponents of the operation admit that the arm is the site *par excellence* in which to perform it. On the other hand, it cannot be denied that the results that have been obtained, and the prospects of the operation as regards its future success, are not as brilliant as in the case of the lower extremity. The reason is not far to seek. The anatomical arrangement of the muscles is much more complicated, their functional differentiation is more complete than in the lower limb, their associated movements are correspondingly more complicated, and therefore they are more difficult to replace when impaired. In the case of the foot, all we have to do is to replace dorsal or palmar flexion. In the hand we have to restore the more delicate movements of the fingers. With increasing experience better results may be obtained, but too much must not be expected when there is extensive affection of the flexors of the forearm or of the small muscles of the hand. Lange, however, hoped that material could be obtained with which to provide for the movements of the fingers. His idea is to sacrifice the voluntary movement of the wrist-joint, and to fix it by means of arthrodesis or artificial ligaments. The tendons can then be utilized for restoring the movements of the fingers. He also suggested that the forearm muscles might be employed, by means of silk tendons, to do the

work of the interossei and lumbricales. These ideas, excellent in themselves, have not yet been tested in actual practice.

Nerve Grafting.—For these various reasons we turn with special interest to the question of nerve grafting, and it is in this field, if we are not much mistaken, that the operation is pre-eminently adapted to give the most brilliant results. In paralysis of the **posterior interosseous** nerve, descending transplantation of a slip of the median at the elbow or higher in the arm would be employed. A point in favour of selecting the lower situation is the fact that we know the internal topography of the nerve at this point. We should take the palmar and radial parts of the median, including the fibres to the pronator teres, the flexor carpi radialis, and the palmaris longus (*vide* Part I.), and graft them into the dorsal and dorso-radial parts of the musculo-spiral, but not into the palmar part. In this way we avoid innervating the sensory superficial part of the nerve. There is a technical disadvantage about grafting at the elbow. The slip from the median has to be transferred rather a long way to reach the musculo-spiral. It is perhaps a good method to take it beneath the tendon of the biceps. If we operate higher up, there is considerably more difficulty from the topographical point of view, for the spiral turn round the humerus introduces complications, as we pointed out in an earlier chapter. There are no cases on record in which operations have been carried out on these lines for infantile paralysis. Taylor tried to perform a neuroplasty in two cases of forearm-paralysis of four and eight years' duration respectively. The eighth cervical and first dorsal nerve roots were cut off close to the foramina, and sutured in an ascending direction to the junction of the fifth and sixth roots. In one case some slight power of extension of the wrist and fingers was present a year later, but very little.

When the **median** is paralyzed, the graft must be taken from the musculo-spiral high up. The ulnar nerve is unsuitable, for the reasons that we have already given. The fibres to one part of the triceps are taken, and introduced into the ulnar part of the median, or, if the distribution of the paralysis suggests it, into the more dorsal part.

In the only operation for paralysis of the median nerve that is recorded in the literature, quite a different method was employed :

LENGFELLNER, 1908.—Boy, *æt.* 10½ years. Onset of paralysis in very early childhood. Flexors and pronators of forearm paralyzed. Wasting of thenar and hypothenar eminences very marked. Flail wrist. Operation : Shortening of extensor carpi radialis and lateral union of median and ulnar nerves in upper arm, after freshening. Slight flexion of the thumb was present after four weeks. A little later on the hand could be bent to the radial side, and the fingers, except the index-finger, flexed at the metacarpo-phalangeal joint. Six months after the operation the patient began to write. Later on he acquired flexion of the index-finger also.

In paralysis of the **ulnar** nerve the chief disability is due to loss of the small muscles of the hand. We have, therefore, to endeavour to innervate

the fibres of the deep branch, which run, according to Stoffel, in the dorsal part of the ulnar nerve. For this purpose a flap may be taken from the median or from the musculo-spiral nerve.

We once performed neuroplasty between the median and the ulnar, below the midpoint of the upper arm, before the days of accurate knowledge of the internal anatomy of the great nerves. The result was a failure.

When all is said and done, there is very little actual fact upon which to base an opinion in recommending nerve-transplantation in the treatment of paralysis of the hand and fingers. But Stoffel has placed the subject upon a firm anatomical foundation, and there is every reason to hope that satisfactory operative measures will soon be devised for the treatment of this important variety of infantile paralysis.

Note on Complete Paralysis of the Arm.

If all the joints of the upper extremity are paralyzed, great and small—which, fortunately, is a very unusual occurrence—the limb is greatly shortened, and is nothing but a useless burden to its owner. Nevertheless, it is not so absolutely valueless as to justify amputation, as Durrieux and Dartiques have stated.

Quite apart from the cosmetic and psychical advantages of possessing the proper number of limbs, the paralyzed member has a certain use, or, to be more accurate, a certain use can be bestowed upon it. Anyone who has to work for his living will be glad of even the smallest assistance from his paralyzed limb. In a case of this kind I think that it is best to perform arthrodesis of the shoulder at right angles, and then to provide a variable range of movement at the elbow by means of the simple appliance described in Chapter IV. The forearm sheath can be provided with a variety of attachments, enabling the limb to be used with considerable effect for various purposes. In this way the formerly useless member is made to assist the good arm in its work.

CHAPTER VI

PARALYSIS OF THE FOOT

1. Flail Ankle.

When all the leg muscles are paralyzed, or reduced to very small bulk, the foot sinks down under the influence of gravity, and a loose equinus results. As a rule there is, in addition, a small element of varus deformity. This is attributed by Hüter to the fact that the axes of movement of the foot do not correspond with the lines of greatest weight. The axis of the mid-tarsal joint runs from below, behind, and outside, in a direction forwards, inwards, and upwards.

Further, increase of the normal concavity of the foot is not infrequently seen, when the short muscles of the foot are still functioning properly. The degenerated muscles yield more and more to the stretching process that is going on, especially the extensors of the leg, the joint capsules give way, and the foot becomes completely flail. Sometimes the weakness is limited to the ankle-joint itself, or is mainly there; in other cases it affects the astragalo-calcanean and the mediotarsal joint as well.

In course of time the picture changes. The points of attachment of the calf muscles being constantly approximated, the muscles themselves shrink, and permanent talipes equinus results, from contracture of the soft parts. Still later on, the form of the bones is altered, and particularly that of the astragalus. Thus the deformity becomes osseous, consisting of paralytic equinus combined with slight varus (Fig. 149).

The alteration in the shape of the bones takes place more quickly, and in greater degree, if the patient is able to get about. The flail ankle then turns over, and the varus element of the deformity predominates. If both joints are affected, the child will not learn to walk. I have also noticed that when one foot is flail, and there is also localized paralysis of other parts of the same or the opposite leg, the patient will be unable to walk properly, and will only hobble about.

Treatment.—The question of treatment turns upon the presence or absence of contracture, in addition to flail-joint. If it be present, the first thing to be done is to correct the deformity. As a rule, this may be accom-

plished by means of repeated manipulation, together with tenotomy of the tendo Achillis. It is advisable to go slowly and carefully to work, so as to stretch the contracted soft parts without damaging the bones. We have already referred, in Part I. of this book, to the danger of fat embolism.

In exceptional cases of severe and long-standing deformity, when the astragalus has undergone much change of shape, it may be impossible to replace it in the space between the malleoli. An open operation is then necessary.

The foot restored to its proper shape, the next question is how to keep it there. Many persons think that prolonged fixation in the corrected position is sufficient to retain it. This is true in the case of older patients. The astragalus is wedged firmly into the mortice of the ankle-joint, and this, added to the inflammatory reaction set up by the process of forcible manipulation, sometimes causes permanent stiffening. This is rendered the more probable, because the articular cartilages, which have been separated and functionless for a considerable time, disappear to a large extent, and ankylosis takes place between the bony surfaces that are thus brought into contact. We have frequently observed at operation the loss of the articular cartilages.

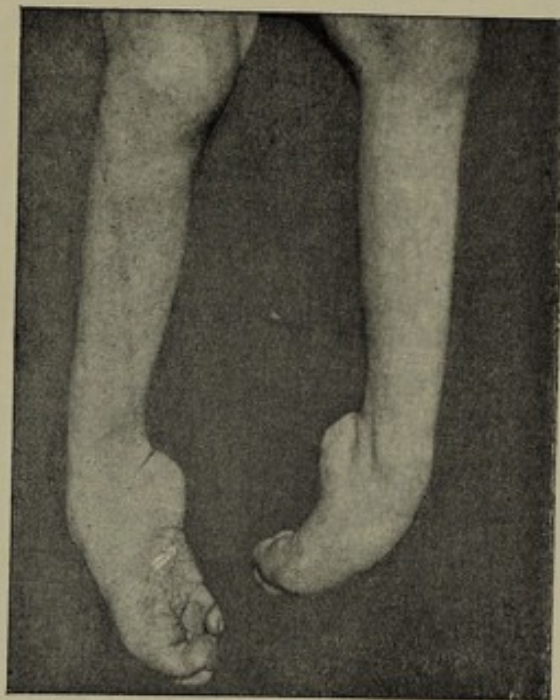


FIG. 149.

These, however, are exceptional cases. As a general rule, the weight of the foot begins to reproduce the deformity as soon as the splints are removed, and a permanent deformity begins to appear.

Two methods may be employed to prevent it—the use of **orthopædic apparatus**, and **arthrodesis**. The poor are unable to afford more than a calf-band and steel supports going into the boot. If the ankle is fixed at right angles, the gait is rendered halting, and the patient walks only on his heel. A certain amount of plantar flexion must therefore be allowed, and, later on, an elastic tractor can be applied.

A far better apparatus is the moulded leather appliance with steel supports. An elastic heel-tractor keeps the foot to the ground, and is controlled by the steel supports.

Indications for Arthrodesis.—Apart from social considerations, there

are, I think, two conditions in which arthrodesis is to be preferred : (1) If the condition of the rest of the limb does not require the use of an apparatus and an operation will enable the patient to dispense with its use altogether, arthrodesis should be performed, so as to render the patient quite independent for the rest of his life ; (2) if an operation is needed to remedy the position of the foot, this may as well be extended to the performance of a proper arthrodesis.

Technique.—We come next to the question of technique. The method usually recommended consists in opening the ankle-joint by an anterior incision, dividing the tendons and nerves, and subsequently uniting them. A better incision, because it inflicts less damage, is a curved one, passing round the external malleolus, and then continuing in an upward and inward direction as far as the extensor tendons. The foot can be turned inwards fairly easily as soon as the joint is opened, and all the surfaces can be examined. It is often possible to preserve the peroneal tendons, but if they must be divided, this should be done behind the external malleolus. The articular cartilage is removed with the curette, particular care being taken to get it all away from the adjacent surfaces of the tibia and astragalus, whilst it need only be removed in streaks from the lateral surfaces of the astragalus and the inner surfaces of the malleoli. The latter precaution is specially necessary when there is a risk of the astragalus being too loose for its socket, after the removal of the cartilage. Other details will be found in Part I. of this work.

Certain modifications may be mentioned. In order to bring the inner surfaces of the malleoli into good contact with the astragalus, Wittek resected the inferior tibio-fibular joint, thus allowing the bones to come more easily together. This step, however, complicates the operation. Goldthwait did an oblique osteotomy of the fibula, for the same purpose. Starz advised the longitudinal splitting of the astragalus so as to broaden it. It would then be necessary to put a piece of cartilage into the gap, to keep the two parts of the bone permanently apart.

Some surgeons have tried to insure ankylosis by uniting the bones with ivory or metal pegs. This step is not without risk, however, in those cases in which the astragalus is so atrophic that neither nails nor sutures will hold in it. For this reason I have never adopted this modification.

Osseoplasty is undoubtedly a safer method. This was performed once by Hoffa as an addition to arthrodesis. An osteoperiosteal flap was removed from the posterior surface of the tibia, turned downwards, and fastened to the os calcis. This would probably prove a very valuable method, judging by the striking successes that I have obtained by the treatment of pseudoarthroses with osteoperiosteal flaps. Cramer removed a large flap of this

kind from the anterior surface of the tibia, and placed it on the front of the ankle-joint, where it "took."

Lexer introduced *bolting* of the bones as a substitute for arthrodesis. The foot is placed in its proper anatomical position, and an incision, 3 centimetres long, is made through the sole at the anterior part of the os calcis, in front of the tuberosity and in the middle line. This goes right down to the bone. A hole is drilled through the os calcis, astragalus, and joint, up into the tibia. A bone bolt is placed in the hole, and driven in with a hammer. The projecting end is smoothed off. Lexer's earliest case had been operated on two years before the publication of his article, and showed absolute stiffness of the joint. There was no disturbance of growth from injury of the epiphysis of the tibia. The bolts were made either from post-mortem bones or from the fibula of a recently amputated leg, or from the patient's own fibula. When fresh bone was used, the patients were able to bear their weight on the joint soon after the operation, but where post-mortem preparations were employed, the pain lasted longer. The X-rays showed that there was some irregularity of the post-mortem bone, and some rarefaction at the ends. The freshly transplanted bones showed thickening of the cortex, which passed gradually into the structure of the ankylosed bones. The condition of the bolt in the joint was particularly interesting in the case of the patient who had been operated on two years previously. There was a general broadening, merging in the bony lamellæ around, but within the joint cavity the bolt was narrower, especially at the point where it pierced the cartilage. Even the joint cavity, however, can be seen to contain fine lines of ossification, spreading out from the bolt.

Lastly, we have to discuss **excision of the astragalus**, followed by freshening of the upper surface of the os calcis. This is a more extensive and more mutilating operation, and in my opinion it does not render ankylosis any more certain than the ordinary tibio-astragaloid method. If the astragalus is misshaped, the projecting parts should be removed, but the body of the bone should be retained.

There has been much discussion, especially between Karewski and Samter, as to whether it is enough to ankylose the ankle-joint only, or whether one should also operate upon the subastragaloid and astragalonavicular joints. I think that nothing will be gained by going into this discussion at length, and I shall therefore content myself with stating my own views upon the subject, which are derived from observation of the results of some hundreds of arthrodeses.

I have frequently stated it to be my opinion, that *fixation of the ankle can be compensated in a sufficient and perfectly satisfactory manner by the slight movements that take place at the other joints of the foot*. Experience confirms my state-

ment. Sometimes, however, the laxity of the subastragaloid joint becomes excessive, and sufficient displacement of the bones occurs to spoil the result, functionally as well as cosmetically. A varus deformity is produced, as a rule, but occasionally a valgus. Again, if the astragalo-navicular joint is much relaxed, the anterior part of the foot drops down into the equinus position. This, however, is not a very disabling complication.

It has been my practice to prevent these difficulties from arising by performing tenodesis or fasciodesis in addition to arthrodesis. Recently I have excised the calcaneo-cuboid joint in addition to the subastragaloid joint, and, I think, with advantage. A short external incision, in addition to the ordinary one used in arthrodesis of the ankle, affords access to the joints named; these are then bared of their cartilage by two strokes of the chisel. I have never employed any wire, or other apparatus for fixing the bones together. I hardly ever touch the astragalo-navicular joint, though others have performed arthrodesis through a special internal incision. Nor do I think it necessary to stiffen the joint between the cuboid and the fifth metatarsal, as recommended by Lexer.

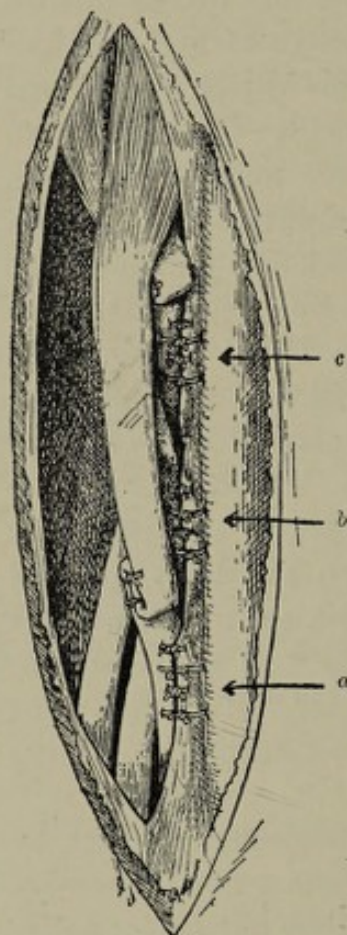


FIG. 150.—FASCIODESIS.

a = Tibialis anticus; *b* = extensor longus digitorum; *c* = extensor longus hallucis.

To return to the technique of arthrodesis of the ankle. The cartilage having been satisfactorily removed, the foot is replaced in its proper position. Any "shake" between the malleoli is easily remedied with a few pieces of cartilage. The skin is then sewn up, any redundant parts being first removed. I always close the wound completely, regarding drainage as quite unnecessary.

As already stated, it is my routine to follow up arthrodesis with an operation on the tendons. Originally one shortened the extensors, either singly or *en masse* (Hoffa); gradually, however, this was found to be unsatisfactory, because the degenerated muscles yielded and the tendons lengthened again. It is therefore more rational to employ the tendons only, converting them into ligaments by sewing them to the periosteum or subperiosteal tissue of the malleoli (Tilanus, Codivilla, Reiner). My operation of fasciodesis serves the same purpose, and is easier to perform, more rapid, and less severe (Fig. 150).

A longitudinal incision is made over the front of the ankle, so as to expose

the three extensor tendons, and leave a strip of fascia about $\frac{1}{2}$ to 1 centimetre broad attached to the crest of the tibia. The tendons are grasped with forceps and drawn sufficiently tight to bring the foot into good position. The tendons are then sutured to the fascia and periosteum of the crest of the tibia in such a way that they are as far as possible subfascial—*i.e.*, they lie in the recess between the outer surface of the shin-bone and the line of attachment of the fascia. The tibialis anticus is fixed in this manner for about 2 to $2\frac{1}{2}$ centimetres, as far down as possible. The tendons of the extensors of the toes are then drawn beneath the tibialis, and fastened higher up at *b* and *c*. The result of this is to render the upper part of the muscle too slack. We usually remedy this by pleating it. This also takes some of the tension off the fascio-tendinous sutures.

In addition to fixing the ankle, fasciodesis has another advantage—*viz.*, that it raises the paralyzed toes. Paralysis of the toes is a considerable disadvantage to the patient, as is well known, for it renders it very difficult to put on boots or stockings. Shortening of all the tendons fixes the toes firmly, and prevents the occurrence of secondary deformity, due to the clothes. I have frequently completed the operation of tendo-fixation by affixing the peronei to the periosteum of the fibula, in an ascending direction, after dividing them or tearing them through.

The use of the tendons as ligaments seems to me to be in every respect preferable to Lange's method of putting silk bands from the navicular to the tibia, and from the cuboid to the fibula, even though perfect asepsis be maintained, and connective tissue be thrown out satisfactorily around them. Herz opposes the use of silk threads on the ground of their unsuitability, whilst Lange has had some cases of over-correction. He thinks that success depends upon a proper degree of tension being provided, together with suitable after-treatment.

Niény combines arthrodesis and tendo-fixation in a somewhat different manner. He ankyloses the subastragaloid and the astragalo-navicular joints, and corrects the equinus at the ankle by a tendon operation only. He thinks that this method renders walking easier, and so avoids secondary varus or flat foot.

As regards the position in which the foot is fixed, we always retain an appropriate amount of equinus, when there is shortening, so as to correct it (see Chapter IX). Fixation in plaster must be very carefully carried out. It must also be prolonged—*i.e.*, it must be continued for at least three months, and preferably for a longer period in younger children.

It is perhaps well to allow the patients to walk after the first few weeks, for the body weight serves to consolidate the bony union. Care must, of course, be taken that the plaster is thick enough to prevent any movement of the parts. I think that it is extremely important to protect the joints

from injury for a further period, after the plaster has been removed. I am accustomed to order a night-shoe (*vide* Part I.), together with a rigid laced boot by day, and, in some cases, an outside support, or one of Marcinowski's concealed springs.

It is not necessary to order a laced leather sheath, for the retentive apparatus will only be required for a few months.

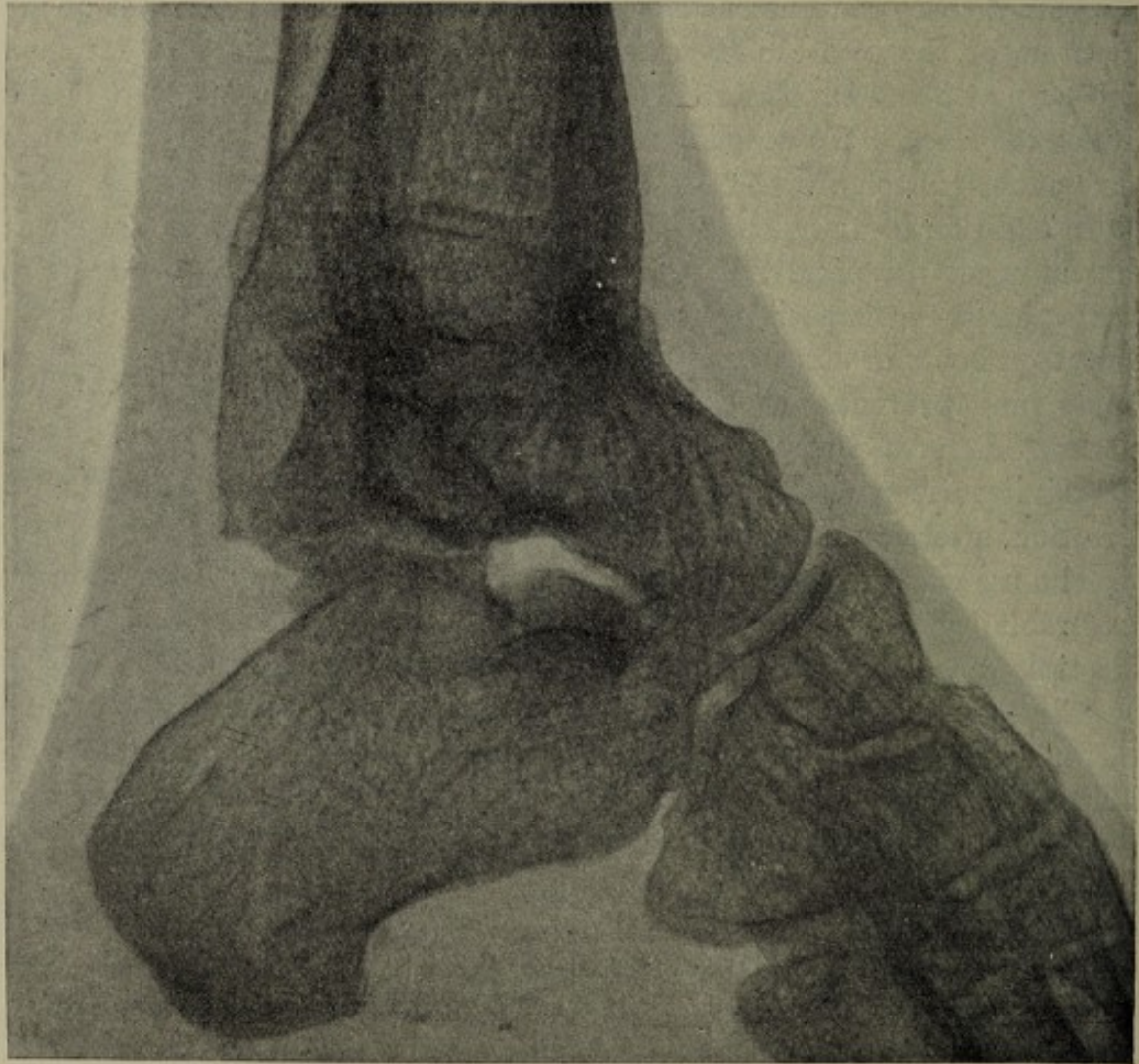


FIG. 151.

Results.—We must now discuss the results that are obtained.

As regards the **anatomy** of the parts, true bony union occurred in about 50 to 60 per cent. of my cases. Karasiewicz gives about the same figures. The older the patient, the more probable is it that bony ankylosis will occur. In some cases absolute fusion of the astragalus and the tibia seems to take place. The skiagram shows the continuity of the osseous structures, and the obliteration of the cavity of the joint. The arthrodesis had been performed four years previously, in this particular case. In a further 20 to

25 per cent., fibrous union takes place. This yields somewhat, but is, nevertheless, sufficiently firm to be serviceable. There is a certain fallacy to be borne in mind in estimating the firmness of such a joint, and that is, that movement at the subastragaloid joint may be wrongly referred to the ankle. In 15 to 20 per cent. the operation was a failure. In some cases insufficient fibrous union occurred; in others there was excessive mobility at the remaining joints, and deformity ensued—generally varus, occasionally valgus. It has been suggested that the deficiency of ankylosis was due to the absolute lack of irritation during the healing process, and packing and similar methods have been proposed as means of providing the necessary stimulation. I do not think that this explanation holds good. I regard the failures as due to faults in the technique of the original operation.

Nor do I think it necessary to postpone the performance of arthrodesis in all cases until the patient is at least eight or ten years old (Bradford, Souther, and others), in order to insure good bony surfaces. It is frequently inexpedient to allow the deforming process to go on for so many years, or inadvisable to fix the joint with apparatus, which may bring about atrophy of the bones.

The number of failures will be materially reduced by due attention to details—the manner in which the cartilage is removed, the firm fixation of the astragalus, the adoption of tendo-fixation, osseoplasty, or the use of bone pegs, arthrodesis of the smaller joints of the foot, and prolonged fixation in plaster, and adequate after-treatment.

Regarded from the **functional** point of view, the results are better than the anatomical, for firm fibrous union is as effective as true osseous ankylosis.

The value of operative stiffening of the ankle is increased by the fact that it carries with it no disadvantages of any importance. Patients have never complained to me that it is a nuisance. On the contrary, the improvement in their powers of standing and walking is so great that the operation must be regarded as a particularly brilliant one.

2. Pes Equinus.

In this and the following sections we have to deal with those deformities of the foot that arise as the **result of partial paralysis** of the leg. Under the heading of Pes Equinus we do not include that form that invariably follows total paralysis of the muscles of the lower leg. This form has already been dealt with in the last chapter. For although the appearance of the case is similar, the treatment and the results are totally different. Nor are we concerned with static pes equinus, which is the result of Nature's efforts at compensating shortening of the limb. After it has existed for some time it becomes, to a certain extent, fixed. This form is discussed in Chapter IX.

The variety with which we are about to deal is that produced by paralysis or paresis of the anterior muscles of the lower leg. The weight of the foot causes its anterior part to sink down, the dorsiflexors being so weak that they are unable to resist the effect of gravity. The ankle is restored to a right angle during standing and walking, but as a rule the triceps suræ contracts, and this takes place all the more rapidly and completely when the muscle is powerful.

When there is real arrest of growth of the leg, the calf muscles do not stretch, and the tension of the tendo Achillis soon becomes marked. Thus the extensors come to be permanently on the stretch, and lose what little contractility remained. The gastrocnemius is unopposed, and the heel rises farther and farther from the ground. It stands out prominently

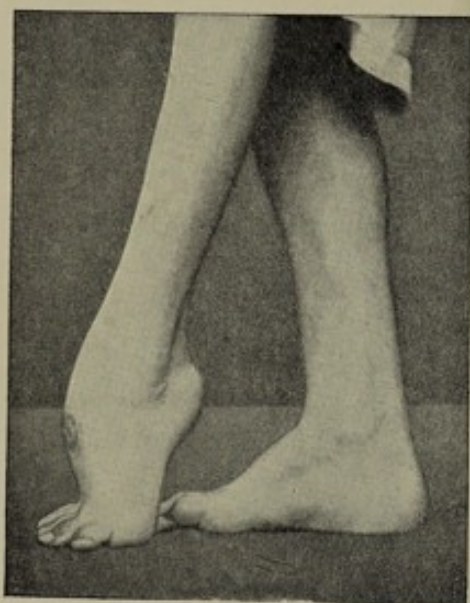

FIG. 152.

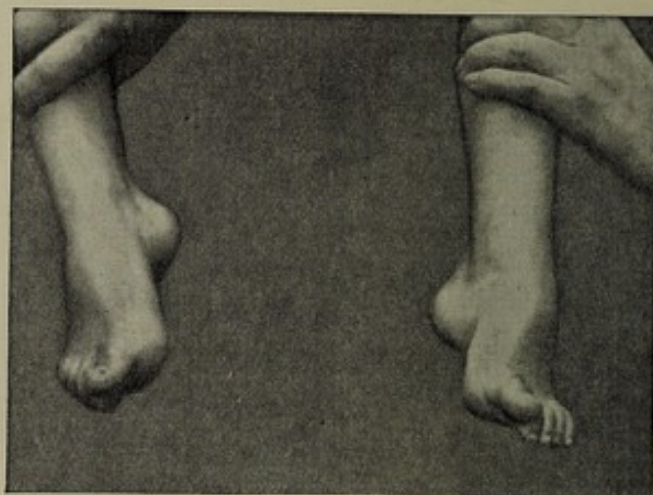


FIG. 153.

when any attempt at correction is made. The patient walks on the balls of the toes, and painful corns form under them. The weight of the body causes dorsiflexion of the toes (Fig. 152). If, however, they are bent downwards from the first, the foot is turned more and more backwards into the line of the leg, until finally the patient may come to walk upon the dorsum of the foot.

In addition to equinus, there is often increase of the arch of the foot (*pes excavatus*). This is due partly to the foot doubling up under the weight of the body, and partly to the contraction of the muscles of the sole (Fig. 153). Severe equinus produces, of course, functional lengthening of the limb, exceeding, as a rule, any shortening that may have been present. The patient has therefore to flex the hip and knee, in order to equalize the length of his two legs. There may even be a *static scoliosis* produced.

In a minority of cases, pure uncomplicated talipes equinus is seen. More frequently, the paralysis of the extensors is irregularly distributed, or unequal

in its intensity. This, added to the patient's mode of transmitting the body weight, brings about some lateral deviation, usually varus, from the supinating action of the gastrocnemius, but sometimes valgus.

Where the deformity is primarily tendinous, considerable strain is thrown upon the foot, and changes in the skeleton soon take place. The tarsal bones become broader on the dorsum, and narrower underneath, looking as if a wedge of bone, with the base upwards, had been driven into the tarsus. The cartilage disappears from that part of the astragalus that is no longer in contact with the malleoli. In very advanced cases the os calcis may even articulate with the back of the leg bones (Fig. 154).

The condition of the muscles, as revealed by clinical examination and exposure during operations, does not always correspond with the deformity that is present, and may seem incompatible with the forces that they would be expected to exert. Sometimes the three anterior muscles are found to be completely paralyzed, and in a state of fatty degeneration. In other cases the tibialis anticus and extensor digitorum will be degenerated, and the extensor hallucis not only normal in colour, but contractile and even hypertrophied. Indeed, this particular distribution is of rather frequent occurrence. Or one muscle only, but never the middle one, will be absolutely destroyed, whilst the extensor digitorum or the tibialis anticus will show

the pinkish coloration that characterizes a muscle that is overstretched, and undergoing disuse-atrophy. Sometimes this colour will be observed in all three muscles, but they may retain a certain functional capacity, even though the fibres be decidedly pale in hue.

The calf muscles do not by any means always escape. Sometimes they are relatively less affected, but occasionally they are the only ones to suffer.

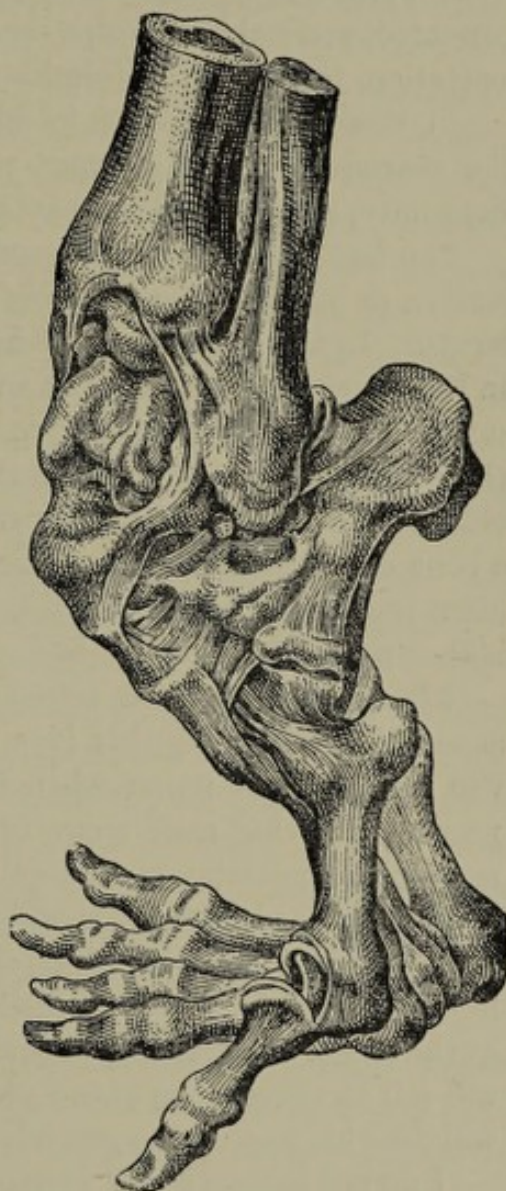


FIG. 154. (AFTER JOACHIMSTHAL.)

The treatment varies according to the particular case that is under consideration. If it is one of pure equinus, the only thing that is necessary is to provide the patient with a suitable boot, designed to take the weight off the heads of the metatarsals. The deformity serves to compensate for the shortening of the limb. This question is further discussed in Chapter IX.

If pronation or supination is present in addition, this must first be corrected, preferably by *redressement*, and later on, if necessary, by a tendon operation, to cure any deformity that remains.

In those rare instances in which the equinus is insufficient to remedy the shortening, our treatment will consist in deliberately increasing the deformity, as described in Chapter IX.

The last and commonest condition is that in which the equinus is excessive, or interferes considerably with the proper balance of a leg of normal length. In the former case we have only to remove the excess of equinus; in the latter we must do away with it altogether. Manipulative treatment suffices only in the early stages. The shortening of the tendo Achillis and the plantar fascia soon renders this method impossible. It is only in very old cases, however, that changes take place in the skeleton, rendering a bone operation necessary. The foot can usually be brought up sufficiently after transverse, or better still, plastic tenotomy of the heel-tendon. It is then put up in plaster.

The question has been raised whether this is sufficient. Many surgeons assert unconditionally that it is. They think, or hope, that the extensors will recover their power when they are released from the overstretching process, and that their recovery will be facilitated by the employment of massage, gymnastics, etc. I quite agree that when once the foot has been replaced in good position, it will remain there, provided that the conditions named in the first section of this chapter are fulfilled—viz., that the astragalus is firmly fixed between the malleoli, and no passive movement is possible at the ankle. Otherwise the equinus will gradually reappear, or the patient will fail to acquire the power of voluntary dorsiflexion of the foot, and he will drag his toes on the ground.

I do not believe in the existence of a "transient" equinus, as described by Saxl, nor do I believe that the extensor muscles are capable of recovery when once they have become severely paretic. Such recovery would necessitate the presence of a certain degree of tension (Lange), and this is absolutely abolished, as far as the anterior muscles are concerned, by the process of *redressement*. I think, therefore, that this operation should be reserved for those cases in which we have decided to treat the patient permanently by means of orthopædic apparatus. We have already discussed in the foregoing section the various considerations affecting our decision on this point, as well as the kind of apparatus that might be used. A tendon-

operation, on the other hand, is particularly indicated when there is some prospect of the paralyzed muscles recovering. Our object is to restore sufficient tension to the weakened muscles to stimulate their restoration. The operation consists in an appropriate amount of tendon shortening.

When *redressement* has been particularly difficult, we operate after an interval of a fortnight. We see no reason for waiting for several months, as does Lorenz. He states that after all this time the patients will not hear of a further operation. This is quite natural, but is not to be commended on surgical grounds. By following up manipulation with a timely operation, we may find that the muscles are so far impaired that recovery with tendon shortening alone is impossible; or, again, we may discover the particular pathological condition that has determined the appearance of varus or valgus. Under these circumstances tendon transplantation would be performed if possible, instead of mere shortening. This brings us to the question of **tendon transplantation** in the leg. A few general remarks will first be made, dealing with the principles that are involved in the treatment of the various kinds of talipes that are described in this and the following sections.

The anatomical conditions in the leg are very well adapted to the performance of the operation. The muscles are arranged in three groups, each consisting of several muscles, of more or less allied function. There is some connection, too, between the functions of the different groups of muscles. Thus, the tibials have a similar function, though one is contained in the anterior group, and the other in the posterior, whose general function is exactly the opposite of the anterior. The third external group of peronei is to a certain extent the supplement of the other two. Transplantation can therefore be undertaken not only between various members of the same group, but also between members of other groups, and numerous combinations may be made.

Technique.—The technique is very simple. For transplantation within one group, or sometimes for transplantation from one group to the next, a single longitudinal incision will suffice. When a tendon is to be transferred from the posterior to the anterior group, two incisions are required. In more complicated cases, anterior, posterior, and external incisions will be needed to explore the condition of the muscles concerned. A cutaneous nerve is pretty constantly exposed by the anterior and the external incisions. This can be held aside. The fascia is divided as sparingly as possible, whilst care is taken not to injure the annular ligaments or the retinacula of the peronei. The foot is then pushed up sufficiently to enable the surgeon to cut good long tendon slips. If the transplantation is being effected between the anterior and external groups of muscles, a forceps is thrust into the anterior compartment, the fascia is loosed from

its attachment to the fibula, and the peroneus is passed through the rent and affixed to its new point of attachment. A similar method may be employed to graft a lateral slip of the tendo Achillis into the outer muscle of the anterior group—viz., the extensor digitorum. If, however, it is necessary to transplant one of the median muscles of the posterior group into the anterior, or *vice versa*, it may be brought along the inner border of the tibia, and a groove cut in the bone to accommodate its tendon. It is better, however, to take it through the interosseous membrane, as recommended by Codivilla. The neuro-vascular bundle is carefully retracted, and the membrane is split, or, better still, widely incised, so as to avoid the likelihood of adhesions to the tendon. The window must be placed in such a position that the transplanted tendon lies in the same straight line with the tendon to which it is attached.

Before deciding upon the operation to be adopted, the function of the various muscles must be carefully considered. This is important in determining which forces require to be reconstituted. But, in addition, it is only by a thorough knowledge of the anatomy of the parts that we are enabled to select the appropriate muscles for our operation. In the following account we adhere to the classical description of Duchenne, which is of the greatest importance in this connection. On the other hand, our results amplify and confirm his statements.

Functions of Leg Muscles.—The foot is moved at the ankle by seven muscles: The triceps suræ, peroneus longus, tibialis anticus, extensor longus digitorum, extensor longus hallucis, tibialis posticus, and peroneus brevis.

The first two produce plantar flexion of the foot, the three next are dorsiflexors, and the last two effect lateral movement, apart from flexion or extension.

None of the muscles produces pure flexion or extension of the foot. There is always a certain amount of abduction or adduction, in addition, or else pronation or supination. The triceps suræ produces extension and adduction, the peroneus longus extension and abduction, and the two together bring about simple extension.

The tibialis anticus produces flexion and adduction, the extensor longus hallucis has a similar function, and the extensor digitorum is the flexor and abductor of the foot. Acting together, these muscles produce pure elevation of the foot.

The **actions of the various muscles**, described in detail, are as follows:

The *triceps suræ* extends the posterior part of the foot and the outer half of the anterior part of the foot with considerable power. It has no action upon the inner half.

The *peroneus longus* depresses the inner part of the anterior half of the

foot, and maintains the arch. If the foot is in the position of extension, it also exerts an abducting and pronating action.

The *tibialis anticus* produces dorsiflexion of the foot, marked supination, and slight adduction.

The *extensor longus digitorum*, as its name implies, extends the toes, but it has really a more powerful action in dorsiflexing and abducting the foot, together with considerable pronation.

The *peroneus brevis* abducts the foot, raises its outer border, and places it in a valgus position, midway between flexion and extension.

The *extensor longus hallucis* is regarded by Duchenne as an unimportant accessory of the *tibialis anticus*, as far as dorsiflexion of the foot is concerned.

The *tibialis posticus* produces direct adduction of the foot, together with slight supination. It also tends to place the foot midway between flexion and extension.

If the *tibialis anticus* is paralyzed, the *extensor longus hallucis* tries to take on its functions, though it is inadequate to replace it fully as far as elevation of the foot is concerned. The great toe, however, is drawn up into the position of dorsal luxation, and the muscle undergoes hypertrophy in consequence of the stress that is laid upon it. It also counteracts to a slight extent the abducting action of the *extensor communis digitorum*.

Duchenne attributes but little importance to the *flexors of the toes*. Codivilla's views upon the functions of the muscles differ considerably from this account. His results are summarized in a very interesting table. This shows not only the separate functions of the muscles, but also their relative importance in the execution of any given movement. It indicates that the *plantar flexors are almost double as powerful as the dorsiflexors, and the supinators as the pronators*.

Muscle.	Dorsi- flexion.	Plantar Flexion.	Adduc- tion.	Abduc- tion.	Prona- tion.	Supina- tion.
Tibialis anticus	1	—	—	—	—	2
Extensor proprius hallucis ..	3	—	—	—	—	6
Extensor communis digitorum ..	2	—	—	3	3	—
Peroneus brevis	—	6	—	2	2	—
Peroneus longus	—	3	—	1	1	—
Triceps suræ	—	1	1	—	—	1
Tibialis posticus	—	4	2	—	—	3
Flexor proprius hallucis	—	2	3	—	—	4
Flexor longus digitorum	—	5	4	—	—	5

In order to determine the relative importance of the various muscles of the leg, as well as their specific functions, Hübscher measured their volumes. The nine long muscles were dissected free, and their bulk deter-

mined by displacement of water. Expressed in percentages, the results were as follows :

Triceps suræ	50.38
Tibialis posticus.. .. .	7.03
Flexor longus hallucis	8.07
Flexor communis digitorum	3.25
Peroneus longus.. .. .	7.13
Peroneus brevis	4.42
Tibialis anticus	11.13
Extensor hallucis	2.72
Extensor communis digitorum	5.87

100.00

These figures are undoubtedly of great interest and practical importance, but unfortunately they argue neither in favour of tendon transplantation nor against it. The power of a muscle is determined not only by its bulk, but also by certain mechanical factors, such as the direction of its tendon, and the place of its insertion. Again, a muscle may undergo abnormal development as the result of special strain thrown upon it. Nevertheless, it will be well to bear in mind Hübscher's figures and Codivilla's table of functional capacity when making out our plan of operation.

Hübscher's figures are no less important when applied to pathology, especially as regards the size of the muscles in flat foot. This observer has noted a constant and considerable decrease in bulk of the flexor longus hallucis—a fact which he associates with W. Engel's remarks upon the statics of the foot. The latter authority regards the strong tendon of the flexor longus hallucis as exerting a considerable leverage upon the sustentaculum tali, in an upward direction, so that it prevents excessive axial rotation from taking place. This function of the muscle, which was unknown to Duchenne, would explain its large size. It is third, after the triceps suræ and the tibialis anticus. If we accept Engel's view, we must, as far as possible, leave the muscle intact, and not sacrifice it in the ready way that was customary with Lange.

Much keen controversy has taken place, too, over the tibialis anticus and its functions. Giani has investigated the matter by clinical and anatomical methods.

He thought that the muscle exerted an adducting action in some cases, depending upon its attachments to the cuneiform and metatarsal. Müller had made similar observations of a clinical nature at an earlier date.

It will be apparent from what we have said that much still remains to be done in the way of physiological research before the operation of transplantation can be considered to rest upon unassailable foundations. It is obvious, too, that the mechanics of the foot are not as simple as they

would appear from Lange's *Schema* (Figs. 155 and 156). In this diagram are indicated, with apparent simplicity and effect, the points in the skeleton of the foot to which muscles must be attached.

The first point is the insertion of the tendo Achillis, which is marked I. in Fig. 155. II. and III. indicate the insertions of the dorsiflexors; II. is the attachment of the tibialis anticus to the internal cuneiform, and III. is an attachment not present in a normal foot. The muscle to be attached there runs, like the extensor digitorum, down the anterior surface of the leg. Its action is to produce dorsiflexion and pronation, in which respect it is similar to the peroneus tertius. IV. is the insertion of the tibialis posticus, the chief supinator, and V. is that of the peroneus brevis, the principal pronator.

Lange's idea was that if there were enough muscles at the operator's disposal, a muscle might be attached to every one of these points. If there were not enough, the number of insertions would be reduced in accordance

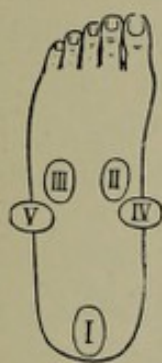


FIG. 155. (AFTER LANGE.)

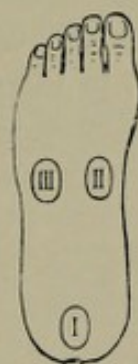

FIG. 156. (AFTER LANGE.)

with the simplified scheme shown in Fig. 156. After an operation of this kind, flexion is performed by the gastrocnemius, inserted at I. II. and III. subserve dorsiflexion, II. alone dorsiflexion and supination, I. and II. plantar flexion and supination. Pronation similarly results from III. alone, or I. and III. together. If only two muscles are available, pronation and supination must be sacrificed, though plantar flexion and dorsiflexion will still be possible if points II. and III. are provided with muscular attachments. If only the gastrocnemius remains, it may be split into an internal and an external portion, and attached to these two points.

The descriptions appended by Lange to his figures are very valuable, in that they reduce the mechanical conditions of the foot, and the operative interference that is needed in any given case, to very simple formulæ. They render easy to the beginner that which is already obvious to the expert. To this extent we approve of Lange's work, but we differ from him altogether on questions of actual practice.

I think that it is unwise to employ other than the natural attachments

of muscles, and all modern work upon the complicated synergies of the foot tends to support this view.

We have just alluded to the new views that have been put forward concerning the **importance of the flexor longus hallucis**. These illustrate the fact that the action of a muscle is dependent not only upon its points of attachment, but also upon the course and direction of its tendon. I am convinced that similar reasoning applies to other muscles, such as the extensor longus digitorum. Lange's schematic insertion at III. deprives it of the very function from which its name is derived, although, admittedly, this is not its most important function. Nevertheless, as we have already said, paralysis of the toes is a considerable nuisance to the patient. For this reason, if not for any other, we consider that the insertion of the muscle at Point III. is not good, though it is quite permissible to divert a slip, having an action similar to that of the peroneus tertius. We know that the normal extensor of the toes is quite a good pronator.

Lange's operation necessitates the use of numerous silk tendons. I have stated my objections to these at sufficient length in Part I.

I also adhere, in the case of the foot, to the "old" method of transplantation (one tendon to another), and in devising my plan of operation I calculate upon total transplantations, such as are preferred by Lange.

After this long digression upon the general aspects of the subject, we shall now return to the discussion of the treatment of talipes equinus by this method.

We have seen that there is not infrequently some localized paralysis or paresis of other muscles, in addition to the affection of the anterior group of muscles. It is not possible to discuss all the theoretical combinations, so that we shall restrict ourselves to paralysis of the extensors.

Details of Treatment—1. *Paralysis of the Tibialis Anticus only*.—Extensor hallucis, and possibly a part of the extensor digitorum grafted into the paralyzed tendon. Peripheral end of tendon of extensor hallucis attached in ascending direction to extensor digitorum.

2. *Paralysis of Extensor Longus Hallucis only*.—Tendon is fastened in ascending direction to that of extensor digitorum.

3. *Paralysis of Extensor Digitorum only*.—Extensor hallucis and perhaps also a part of the tibialis anticus are attached to the extensor digitorum. Peripheral stump of extensor hallucis fastened in ascending direction to tibialis anticus.

4. *Paralysis of Tibialis Anticus and Extensor Hallucis*.—Peroneus longus grafted into tibialis anticus, and peripheral stump in ascending direction into peroneus brevis. Extensor hallucis ascending into extensor digitorum.

5. *Paralysis of Tibialis Anticus and Extensor Digitorum*.—Extensor

hallucis grafted into tibialis anticus, and peroneus longus into extensor digitorum.

6. *Paralysis of Extensor Hallucis and Extensor Digitorum.*—Peroneus longus attached to extensor digitorum, and extensor hallucis in ascending direction to tibialis anticus.

7. *Paralysis of the Three Anterior Muscles.*—Flexor hallucis grafted into tibialis anticus, peripheral part of flexor hallucis given firm ascending attachment; peroneus longus put into extensor digitorum, and into extensor hallucis.

It is, of course, obvious that these schemes for treatment can, and frequently must, be modified, but I have thought it worth while to give them, although my efforts in this direction have previously been misunderstood and wrongly criticized.

Experience alone will show which is the best of the many ways that have now been described.

To conclude, a short collection of case reports may be given, illustrating the methods employed, and the kind of result that is obtained:

1. VULPIUS.—E. E., æt. 7 years. Foot-drop noticed for several years, and gait becoming progressively worse. Tenotomy of tendo Achillis performed; only result was to convert a marked varus into a mild valgus. Tibialis anticus found to be weak; extensor hallucis very good; extensor digitorum poor, and pink in colour; peronei, ditto. Operation: Half of tendon of tibialis anticus grafted in ascending direction into extensor hallucis, after passing it through a hole in the recipient tendon. Result: Slight power of dorsiflexion after a month. Three weeks later, foot could be raised almost as far beyond the right angle as on the sound side; moreover, it was raised in the proper direction—*i.e.*, without lateral deviation. The gait was proportionately improved. The position and mobility of the foot remained satisfactory after three years.

2. VULPIUS.—M. K., æt. 7 years. Onset of paralysis during first month of life. Severe equinus gradually developed. Tibialis anticus bad, extensor digitorum better, extensor hallucis very good. Operation: Tenotomy of Achilles and forcible *redressement* performed; then extensor hallucis attached to tibialis anticus, extensor digitorum shortened, and peripheral stump of extensor hallucis sutured to it. Uneventful recovery. Result: Position and mobility of foot good in every respect at end of two months. Very satisfactory dorsiflexion, plantar flexion, pronation, and supination after three and a half years. Big toe somewhat flexed, and sole rather hollow.

3. VULPIUS.—C. K., æt. 9 years. Paralysis of foot noticed at three; anterior part of foot hanging down, and inclined to varus position. Tibialis anticus completely lacking; extensor hallucis and extensor digitorum present. Peronei weak. Operation: Anterior longitudinal incision. Extensor hallucis and a third of extensor digitorum divided, both sutured to tibialis anticus. Peripheral stump of extensor hallucis grafted to tibialis. Uneventful recovery. Result: Foot comes up to right angle six weeks after operation. Further dorsiflexion and adduction possible. Discharged after short after-treatment. Foot satisfactory two and a half years later; active movement in all directions. Patient can walk well for a considerable distance; goes in much for gymnastics, and is not incapacitated in any way.

4. H. E., æt. 11 years. Onset of paralysis at eight years. Marked equinus, and flexion at hip and knee, in consequence of lengthening of limb (Fig. 157). Operation:

Plastic elongation of tendo Achillis. Tibialis anticus exposed by anterior longitudinal incision. Extensor hallucis and extensor digitorum found to be normal in colour. Extensor hallucis united in descending direction to tibialis anticus, and peripheral stump of extensor hallucis in ascending direction to extensor digitorum. Uneventful recovery. Some movement of tibialis observed when dressing removed. Full flexion, and extension of ankle four months later, also pronation and supination (Fig. 158). Result permanent three years later.

Similar equally satisfactory operations have been recorded by many other surgeons.

Talipes equinus is a particularly favourable field for tendon trans-

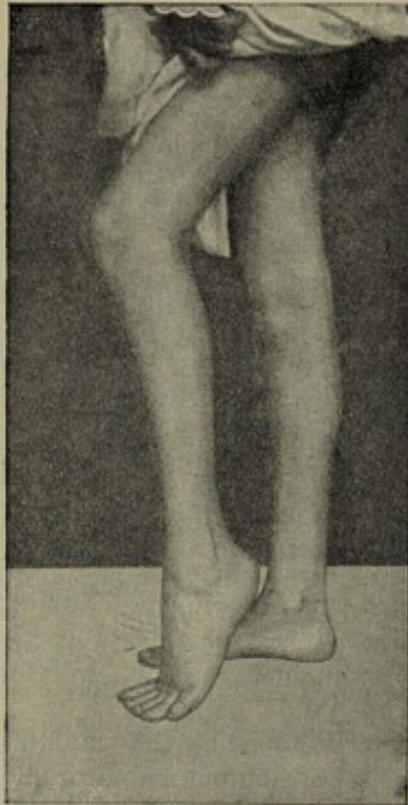


FIG. 157.

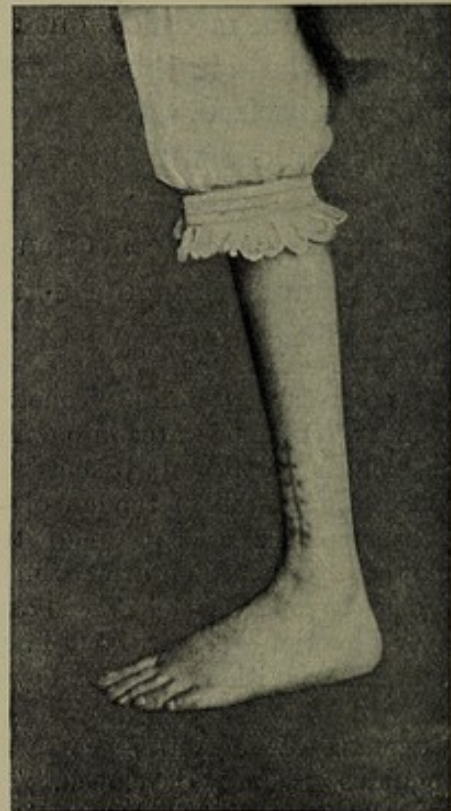

FIG. 158.

plantation, when only one muscle is degenerated. It is usually possible to restore the foot to its normal condition.

We had intended to deal with various other operations that are employed in more difficult cases of pes equinus—*e.g.*, correction of pes cavus, bone operations in severe deformity of the skeleton, and experiments and results in neuroplasty. It will be better, however, to discuss these in the next section so as to avoid repetition.

3. Pes Varus.

We saw in the first section of this chapter that total paralytic flail foot may gradually go on to fixed talipes varus. The same may occur in partial paralysis affecting the distribution of the peroneal nerve. The foot drops

down, and deviates inwards, in consequence of the obliquity of the axis of the astragalo-calcanean joint.

Thus pes equinus usually shows some varus as well. The deformity becomes more marked when the abductors and pronators of the foot have been paralyzed, and the antagonists, being left unopposed, undergo shortening. According as one or other component predominates, we describe the condition as one of pes equino-varus, or varo-equinus, or varus. As in the case of pes equinus, the flail condition of the foot is gradually succeeded by tendinous fixation, and then by bony deformity.

Distinction between Congenital and Paralytic Cases.—In this way there is gradually developed a considerable resemblance to congenital talipes, at any rate, at first glance. After some clinical experience, one soon learns to distinguish the two at sight. With **paralytic feet** there is more equinus and less supination, and, as a rule, less cavus. Adduction is sometimes considerable in both forms. In **congenital cases** of moderate degree we find that the inversion of the foot is fairly evenly distributed, whilst in paralytic cases it is unequal. There is apt to be some angular deformity, the foot doubling up upon itself at the mid-tarsal joint. These characteristics are explained by more accurate clinical investigation. The astragalus is found to be markedly deviated, and its trochlear surface may be luxated forwards. It is also supinated, so that its area of contact with the inner surfaces of the malleoli is diminished. The os calcis remains longitudinal, but its plantar surface undergoes some rotation, coming to look inward. The adduction and supination are due to subluxation taking place between the head of the astragalus and the navicular. The articular surface of the former stands out prominently, whilst the scaphoid is inwardly displaced, and rotated. In congenital talipes, therefore, it is the whole of the tarsus that produces the deformity, whilst in paralytic varus it is chiefly due to the subluxation of the joints.

The **position of the toes** is also very characteristic. In paralytic cases the toes are often irregularly arranged, and the great toe is often pushed underneath the adjacent ones; in congenital cases they are normally arranged. This distinction may, of course, be abolished in later years, for pathological changes may occur in "congenital" toes.

We need only allude to the diagnostic features of the rest of the leg: the **blueness**, the **coldness** of the skin, and the **shortening**.

Treatment.—Coming now to the question of treatment, our first aim must be the absolute correction of the deformity. As a rule it is enough to replace the foot by means of *redressement*, not too forcibly carried out. In cases of greater duration this is not sufficient to restore the proper position of the joint, and the head of the astragalus remains prominent. If the adduction and supination of the fore part of the foot can be corrected by

forcible manipulation, it is usually sufficient to straighten out the sole by stretching, and possibly rupturing, the plantar fascia and ligaments. If, however, a severe degree of cavus is present, this must first be corrected, and then, at a second operation, reposition can be completed by forcing the foot up into full dorsiflexion. The plantar fascia stands out as a tense band, which gives way at once before the tenotome. I am much averse to the employment of extensive division of the structures in the sole in paralytic cases, for these produce considerable disturbance of the circulation, which is very bad for the already impoverished foot. On the other hand, it is not well to leave a marked pes cavus unremedied, for sooner or later painful corns will form under the heads of the metatarsals. I think that the best way is to perform a careful tenotomy, confining oneself to the obvious tight bands, and then to stretch the sole out by degrees until it is quite

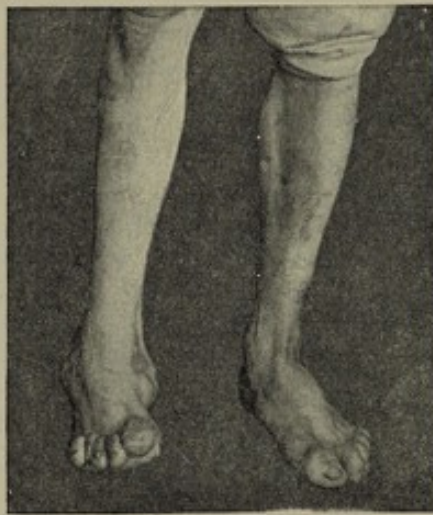


FIG. 159.

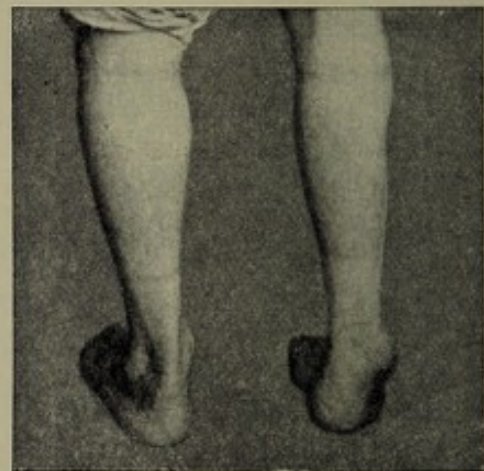

FIG. 160.

flat. This done, a plaster is applied for some weeks, and then the astragalus can be safely replaced, best by means of a plastic division of the tendo Achillis.

In children it is often possible to effect the whole process at one sitting, but in adults this may not succeed. We are then faced with the alternatives of leaving an unsightly subluxation at the mid-tarsal joint, so that the foot becomes practically plantigrade, or of extirpating the obstruction—viz., the astragalus. This operation is quite efficacious, for the os calcis as a rule undergoes no rotation, and fits quite well into the mortice between the malleoli. The result is not only a shapely foot, but, in some cases, a movable ankle-joint (Figs. 159, 160, 161).

Redressement completed, we are in much the same position as after the correction of a talipes equinus, and the arguments that we adduced in the last section with regard to orthopædic apparatus apply equally here. *The only case in which a tendon operation is not indicated is that in which*

there is stiffening of the ankle in an elderly patient. But even in older patients tenoplasty is worth trying after the impacted astragalus has been excised.

Transplantation provides for voluntary dorsiflexion, abduction and pronation. The only really powerful dorsiflexor is the extensor longus digitorum, and this is associated with pronation. It is therefore exceedingly important to provide a substitute for this muscle, if it is paralyzed.

The preservation of the peroneus tertius is valuable, as Lange pointed out. This can be done without interfering with the main insertion of the toe extensor. The muscle is subject to some anatomical variation, and if its tendon is absent, it may be replaced by a slip from the extensor, fastened periosteally or transosseally to Lange's Point III. There is no need to employ a silk tendon.

The next most important matter is to replace the peronei. Sometimes one muscle can be grafted into both tendons, for although they are not quite analogous in function, there is no harm in their simultaneous activity.

In addition to grafting into the peroneus tertius, one or both of the peroneal tendons proper may be displaced in front of the external malleolus (Schanz), so as to produce not only pronation, but also dorsiflexion and abduction. I have frequently adopted this measure with success. Kofmann and Topuse provide for pronation and dorsiflexion by severing the outer half of the tendo Achillis from the os calcis, taking it round the external malleolus, and sewing it to the extensor bundle on the dorsum of the foot.

The distribution and severity of the paralysis in paralytic talipes varus are so manifold that it is impossible to give more explicit directions for its treatment than are contained in Part I. We shall therefore content ourselves with quoting a few case reports, which will, perhaps, illustrate some of the important features in

different classes of case, and give some idea of the kind of result that is obtained. Neither is there anything much to be said with regard to **after-treatment**. If it is carried out for a sufficient length of time, flexion,

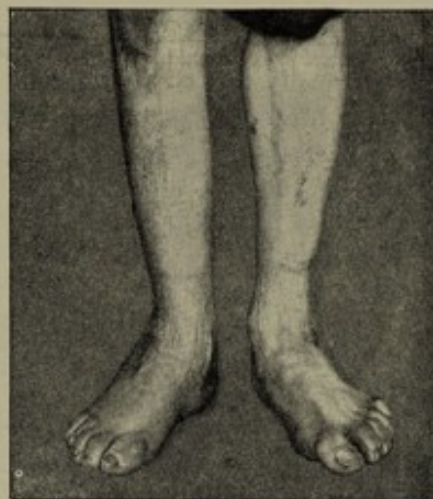

FIG. 161.

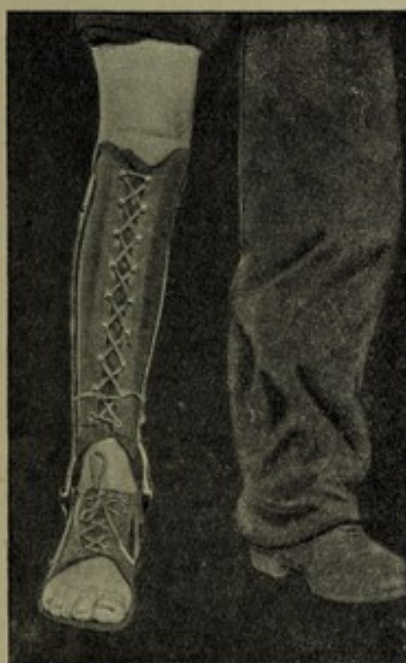

FIG. 162.

pronation, and supination should all be recovered to the full extent. A simple splint should be used at night, and a sheath apparatus, or a boot with steel supports and elastic traction at the ankle-joint will insure a good position during the first few months, and the ultimate development of the desired range of movement (Fig. 162).

1. VULPIUS.—K. K., æt. 4 years. Onset of paralysis one and a half years previously; moderate talipes equino-varus; fixation by marked early bony deformity. Tibialis anticus fairly good; extensor hallucis very powerful; extensor digitorum and peronei weak; posterior group good. Operation: Forcible manipulation, then suturing of extensor hallucis to extensor digitorum, tibialis posterior to peroneus brevis, part of Achilles to peroneus longus, shortening of tibialis anticus, and suturing of peripheral end of extensor hallucis to extensor digitorum, high up. Uneventful recovery.

It would have been better not to have divided the whole of the tibialis posticus, or, at any rate, to have provided some attachment for its peripheral stump. The tendo Achillis might quite well have been grafted into both peronei. However, the method adopted was fairly efficient, as the result shows.

Two months later the foot was in normal position, and all movements could be performed, though only over a limited range. After two and a half years the position and mobility of the foot and the patient's powers of walking were almost as good as anyone else's.

2. VULPIUS.—P. L., æt. 7 years. Onset of paralysis in first year. Very severe equino-cavo-varus. All muscles except peroneus longus and toe extensor paralyzed. Operation: *Redressement* very difficult, especially the correction of the equinus. Flexor hallucis and flexor digitorum transferred through interosseous membrane, and grafted into tibialis anticus; extensor hallucis shortened. Half of peroneus longus sutured to extensor longus digitorum, and a slip of the tendo Achillis to the shortened peronei.

Later on, the tibialis anticus and the extensor digitorum were again shortened. Uneventful recovery.

Position of foot completely corrected. No suggestion of movement. Result unchanged three and a half years later. Position of foot as before; tendinous fixation has not yielded at all. Patient walks well in the usual apparatus. No disability.

It would have been much better to have fastened the flexor hallucis to the tibialis anticus, and the flexor digitorum to the extensor digitorum. This would have resulted in the restoration of voluntary movements instead of the production of tendinous fixation. It is not clear, however, why the toe flexors remained immovable after the operation described.

3. VULPIUS.—M. M., æt. 9 years. Onset during first month. Talipes equino-cavo-varus gradually developed. Paralysis of extensor digitorum only. Operation: *Redressement*, then half of tibialis anticus grafted into extensor digitorum. Uneventful recovery.

Position and mobility of foot good when dressings first removed. After four and a half years general condition was almost normal, and foot moved freely in all directions. The leg, however, was a little short.

Patient made no use of his extensor hallucis, so that perhaps it would have been better if this muscle had been transplanted. The idea, however, was to weaken the tibialis anticus, which was rather too strong.

4. VULPIUS.—H. M., æt. 16 years. Onset of paralysis in second year. Extreme equinus gradually developed, with moderate varus, probably due to patient's occupation (tailor). Quadriceps also affected. Paralysis of tibialis anticus and extensor hallucis. Operation: Plastic elongation of tendo Achillis, 5 to 6 centimetres. Peroneus longus sutured to tibialis anticus. Uneventful recovery.

On removal of plaster, after six weeks, position of foot was good, and slight move-

ment was possible. No after-treatment was carried out. Patient came back after three and a half years. He had been "on the tramp," visiting Karlsruhe, München, Innsbruck, Halle, Fulda, and Frankfurt on the way. I could hardly believe my eyes when I saw him. His foot was perfect, coming up to the right angle, and freely movable in all directions, with good power. In this case there was no flat foot, such as is stated by Duchenne to result from loss of the peroneus longus.

5. VULPIUS.—K. U., æt. 18 years. Onset of paralysis during first year. Severe talipes equino-cavo-varus. All muscles paralyzed except gastrocnemius. Operation: *Redressement* in two stages; one slip of tendo Achillis inserted in tibialis anticus, another into peroneus longus, the rest elongated. Uneventful recovery.

Slight over-correction resulted. Foot cannot be flexed beyond right angle, voluntarily or by passive movement; some power of passive extension. On attempting to perform voluntary elevation of the foot, the tibialis anticus, peroneus longus, and tendo Achillis stood out prominently, but no movement took place. Two years later the result was the same; then the patient died of phthisis.

If the two extensors of the toes had been intact, one would naturally have grafted them into the tibialis anticus and the extensor digitorum, and thus have afforded a certain *point d'appui* for the gastrocnemius.

6. VULPIUS.—F. G., æt. 18 years. Onset at six years, resulting in severe talipes equino-cavo-varus. Tibialis anticus and extensor hallucis good; extensor digitorum degenerated. Peronei good; posterior muscles decidedly moderate. Operation: *Redressement*, then plastic elongation of tendo Achillis and shortening of peronei. Extensor hallucis and half of tibialis anticus put into extensor digitorum. Uneventful recovery.

At present time—*i.e.*, four months after operation—foot is straight; anterior part rather depressed in consequence of shortening of leg; movement possible in all directions, though limited in amount; pronation especially satisfactory. Patient's walk, formerly very laborious and uncertain, is now good, and he is not easily fatigued.

7. VULPIUS.—C. L., æt. 19 years. Onset in fourth month. Talipes equino-varus developed, rendering walking very difficult, on account of constant yielding of foot under the body weight. Tibialis anticus and extensor digitorum completely paralyzed; extensor hallucis very good; peroneus longus quite paralyzed; peroneus brevis almost as bad; gastrocnemius worse than one would have expected. Operation: *Forcible redressement*, then a third of tendo Achillis grafted into peroneal tendons; the rest elongated. Extensor hallucis sutured in descending direction into tibialis anticus and extensor digitorum (ascending) into tibialis anticus below point of implantation. Slight equinus left on account of shortening of leg. Uneventful recovery.

Result: Position of foot good, slight power of voluntary movement. Position unaltered after one and a half years; moderate mobility in all directions. Wearing high boot, patient walks well, and without difficulty. The turning over of the foot has entirely disappeared.

8. VULPIUS.—L. M., æt. 27 years. Onset in third year. Gradual development of severe talipes equino-cavo-varus. Painful corns on dorsum of foot. Walking only possible by the use of instruments. Tibialis anticus shows striped degeneration. Extensor hallucis very good; gastrocnemius ditto; extensor digitorum and peronei totally paralyzed. Operation: Preliminary, instrumental *redressement*, then a slip of the tendo Achillis grafted into the peronei, and the rest elongated (plastic operation). Extensor hallucis and part of tibialis anticus grafted into extensor digitorum. Tibialis anticus somewhat shortened. Uneventful recovery.

Four months later, foot straight, but somewhat over-corrected. Mobility slight. Two and three-quarter years later position as before, and movement possible in all directions, though only to a limited extent. Patient walks well in ordinary boot. Patient is on his feet all day.

9. VULPIUS.—E. H., æt. 29 years. Onset in fourth year. Extreme talipes equino-cavo-varus. Patient walking on outer border of fifth metatarsal, and then

only with the help of apparatus. Foot gives at every step. Tibialis anticus good; extensor hallucis very good; extensor digitorum slightly paralyzed; peronei completely. Gastrocnemius good. Operation: Plantar fascia divided, then *redressement*; then extensor hallucis grafted into extensor digitorum, and part of tendo Achillis put into peronei; the rest elongated. Uneventful recovery.

Position of foot satisfactory three months later; active movement still slight. After two and a quarter years position was very good, and foot could be moved in all directions. Patient able to stand for hours in an ordinary boot.

These few reports show the variety of operations that have been employed in patients of different ages. The most important question is, of course, the ultimate result. Paralytic equino-varus is the commonest of deformities, and it is in these cases, therefore, that the majority of transplantations have been performed. A large number of them have been recorded in the literature, but in many of them the subsequent period of observation has been all too short, and the result is unreliable.

Results.—I have now operated upon about 300 patients with talipes equino-varus, of all degrees of severity and extent. The results have varied considerably. The operation has seldom proved a complete failure, and when it has, it has been due to inappropriate measures being adopted, or to over-estimating the strength of the surviving muscle. **Even in unfavourable cases the foot is restored to a good position**, and fixed there by means of the tendons. In many cases great improvement has been effected not only in the position and mobility of the foot, but also in the patient's power of walking. Between these extremes lie the great number of cases of moderate severity, in which some of the muscles are paralyzed, but other quite good ones remain. It is then possible to attain a good position, and also to secure active flexion and extension at the ankle between about 70 and 110 degrees in the normal plane, together with considerable pronation and supination.

Neuroplasty.—In conclusion, we shall allude to neuroplasty in talipes equino-varus—*i.e.*, in paralysis of the peroneal nerve, or of one of its branches. Two more cases have recently been published by Tubby, in addition to those given in the table in Part I. It will be seen that most of the cases in which this operation has been performed have been examples of equino-varus. In seven out of the twenty peroneal cases, a descending flap was taken out of the tibial nerve and grafted into the trunk of the peroneal; in three instances it was fastened to an ascending slip of the latter nerve. The operation succeeded in five cases, and failed twice. The most brilliant success of all was one of Hackenbruch's, which will be quoted *in extenso*:

“It appeared from the history that the child was seized with infantile paralysis at the age of one and a quarter years, and that the left leg was rather suddenly affected. When seen in August, 1903, the whole of the left leg was atrophic, and strikingly smaller than the right; the skin was cold, especially below the knee; the left foot was obviously

smaller than the right, and hung down limply in the equinus position when the child was sitting down. When the patient walked, the left foot "flopped" in the air, and the anterior part of the foot was first planted on the ground, whilst the toes were widely spread out; next moment the foot went over into the varus position. Corresponding with this, a hard corn was found over the outer border of the foot.

"The electrical reactions, taken by Dr. Hezel, indicated total paralysis of the peronei, and the extensor communis digitorum, longus and brevis. Even under very powerful faradic stimulation, with an anæsthetic, these muscles showed no contraction. An operation was performed on August 19, 1903. The peroneal nerve was found to be greyish-white in colour, and atrophic. It was slit longitudinally, and about a third of the fibres of the tibial nerve grafted into it. A few weeks after the wound had healed the patient was allowed to go away, wearing a moulded leather and steel apparatus. After an interval of rather more than four months—*i.e.*, on December 28, 1903—slight voluntary abduction could be seen in the left foot; the paralyzed muscles, however, showed no direct excitability to the faradic or galvanic current, though they responded to stimulation of the tibial nerve above the popliteal space (Hezel). Five months later—on May 13, 1904—the left foot could be extended and abducted with remarkable power; the muscles still showed no direct excitability. Indirect excitability, however, now extended to the popliteal space. After a further four months—*i.e.*, on September 27, 1904—the muscles were still inexcitable, but indirect excitability extended below the head of the fibula. About five months later—on February 11, 1905—a year and a half after the operation, the paralyzed muscles reacted to the kathode, but not to faradic stimulation—at any rate, with currents of medium intensity.

"In April, 1905, the patient was seen again, and clinical examination showed good use of the left ankle and foot. The instrument is no longer necessary, as the patient can now walk quite well on the left foot without it. The improvement in walking has gradually increased, until, at the present time, the girl is able to stand for an hour on the left foot without becoming tired. She can stand on her toes, or on the left foot only, without falling over. The corn has altogether disappeared from the outer border of the foot. The left leg is now only 2 centimetres shorter than the right, whereas it was 3 centimetres before the operation. The foot, also, has grown, and is now very little smaller than the right. The whole left lower limb, however, is somewhat weaker than the other, the left thigh being 2 centimetres, and the leg about 4 centimetres, smaller in diameter than its fellow. The muscular balance being restored, one may reasonably hope that in course of time the left leg will become stronger and stronger and more efficient."

Ascending transplantation was performed three times in paralysis of the tibialis anticus only. The muscular branch was embedded in the superficial branch of the peroneal nerve.

The result was not entirely satisfactory.

In the remaining eleven cases the trunk of the peroneal nerve was inserted into a slit in the tibial. Seven cases were successful, but two of these must be eliminated from the list, because extensive tendon transplantations were simultaneously performed by Bardenheuer. Only a moderate degree of success was attained.

Stoffel's researches will be of assistance in future operations of this kind. We will not repeat all that has been said in Part I. on this subject, but merely add that the graft should not be cut indiscriminately, but should consist of the internal muscular branch to the internal head of

the gastrocnemius. If the whole of the distribution of the peroneal nerve is affected, the whole of the nerve should be innervated. If the peronei are paralyzed, the slip from the tibial nerve is put into that part of the peroneal nerve which lies nearest to the popliteal space. If the anterior group is affected, the graft is placed in the deep branch which lies close to the biceps tendon. Innervation of the peroneal nerve by means of one of the tibial branches to the gastrocnemius has been actually and successfully performed on one occasion at least.

4. Flat Foot.

It is a remarkable fact that paralytic flat foot is a comparatively rare occurrence, cases being far less common than those of equino-varus. In static flat foot the foot tends to take up the position of pronation and abduction, and one would expect it to assume a similar attitude when the muscles are weakened by paralysis, and the foot is subjected to a relatively excessive weight.

We have already explained the occurrence of a varus deformity in the majority of cases of total paralysis as well as of paralysis of the anterior group. In partial paralyzes the deformity is due not only to static and mechanical causes, but also to the unopposed action of the muscles. The latter force is a considerable one, inasmuch as it is able to overpower the static element. In other words, the pronators and abductors must be sufficiently powerful to oppose the weight of the foot, and the supinators and adductors, which are normally the more powerful muscles, must be extensively destroyed. The latter muscles receive their nerve-supply from two different sources, so that there is no great likelihood of paralysis affecting the tibial and the deep peroneal nerves simultaneously. It is probably this double innervation that accounts for the comparative immunity of the supinators.

The muscles of the anterior group which help to produce supination are : (1) The tibialis anticus, which Codivilla regards as of secondary importance only in this connection ; (2) the extensor longus hallucis, which has only a very slight supinating action ; (3) the triceps suræ, which is the most important supinator of all the leg muscles. The other muscles are the tibialis posticus and the flexor longus hallucis. Hübscher describes the action of the last-named as being not so much a supinating action as a retention of the foot in the mid-line—*i.e.*, a prevention of excessive pronation. The function of the muscle is therefore one of limitation.

If these muscles are completely paralyzed, or are so far weakened that their supinating effect is greatly impaired, paralytic flat foot may be produced by the action of the opposing muscles, quite apart from static effects. The deformity may therefore arise in a patient who is lying in bed. It

increases rapidly, and becomes fixed as soon as the strain of standing and walking is thrown upon the foot. In time a condition of bony flat foot is developed, but its paralytic origin can always be demonstrated.

Paralytic Flat Foot.—Its distinctive characters are: (1) The very marked valgus position of the os calcis, which is specially well seen when the foot is looked at from behind; (2) the displacement at the astragalo-calcanean joint; (3) the prominence of the tendon of the extensor digitorum, which is only seen in static cases when inflammatory complications have occurred (see Figs. 163, 164).

The arch of the foot yields considerably whenever the weight is borne upon it, and recovers when it is taken off. If the short muscles of the foot remain intact, they delay the fixation of the pes planus for some time. On asking the patient to dorsiflex his foot, it becomes markedly pronated, and the anterior part is abducted, turning sharply upwards and outwards. A similar but less severe displacement takes place in plantar flexion, and the peroneal tendons stand out very prominently.

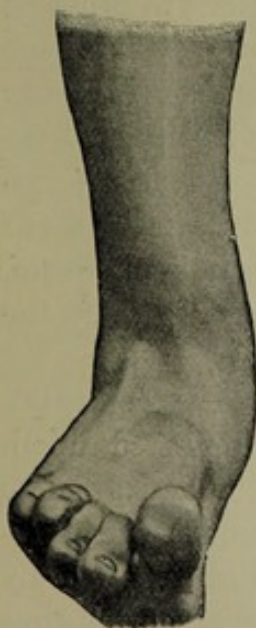

FIG. 164.

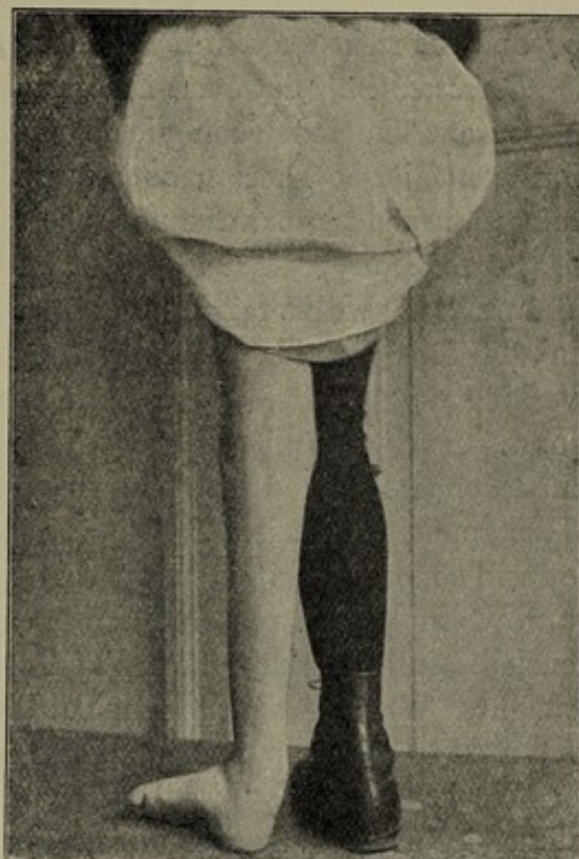


FIG. 163.

Treatment.—The treatment consists first of all in the reduction of the deformity, especially as regards the abduction and pronation of the foot. There remains more or less equinus, and the heel-tendon opposes complete correction. Subcutaneous tenotomy is not a good operation, because it weakens the supinating action of the triceps suræ, which is very important. Plastic elongation is greatly to be preferred, the outer part of the insertion into the os calcis being divided. The whole force of the muscle is then concentrated upon producing supination. Anzoletti has severed the whole insertion of the tendon and attached it to the inner side of the posterior process of the calcaneum, with the same object in view.

If the deformity is of some duration, considerable difficulty may be experienced in reduction on account of the change in form of the astragalus, and the astragalo-calcanean joint. It is then difficult to dorsiflex the foot beyond the right angle if it is held in the supinated position.

Redressement, however successful at the time, is not a permanent measure. The foot soon yields under the body weight, and the tibialis posticus fails to shorten as required. If further operative treatment is refused, a good apparatus must be applied, in order to prevent recurrence of the deformity. A simple boot and steel are useless, even if firmly built and provided with a raised inner sole. A flat-foot support must be employed in addition, gripping the inner and outer borders of the foot, and so preventing it slipping, and avoiding fresh deformity at the subastragaloid joint. During recent years we have been employing an excellent support made of two arched leather strips, with steel springs riveted in between. This appliance is fairly light, and, though firm, it can be bent and shaped at will; moreover, it is inexpensive. It is easy to make, too, so that we always employ this pattern in preference to all others. The foot is, of course, enclosed in a moulded leather and steel support, which carries some of the weight. Where financial difficulties exist, Marczinowski's inner shoe, fastened to a laced support, may be employed with advantage.

We have already discussed the choice between apparatus and arthrodesis. We have only to add some remarks upon the relative merit of arthrodesis and tendon transplantation. The latter is a more difficult operation in this case than in equinus or paralytic varus. In talipes equinus the tendons that are to be transplanted must be preserved at all costs to prevent overstretching by the weight of the foot. In talipes varus, when *redressement* has been effected, the weight of the body helps the muscles in bringing about pronation. With pes valgus, however, we have to provide sufficient muscle not only to supinate the foot, but also to bear the weight of the body. It follows that transplantation can only be of considerable and permanent value when some of the supinator muscles remain intact. If it is the two tibials that are gone, as very often happens, the damage may be easily made good. If, however, the flexor longus hallucis is impaired, or, still worse, the triceps suræ, arthrodesis is much to be preferred, especially when the remaining muscles are not absolutely perfect.

Arthrodesis presents no special technical difficulties. The astragalo-calcanean and astragalo-navicular joints must both be operated upon. It might be sufficient to fix the subastragaloid joint by arthrodesis, and to perform tenodesis only, after Niény's method, at the upper joint. The **after-treatment** consists in the prolonged use of a plaster splint, followed by a flat-foot support, or else in the wearing of a plaster for a shorter time (but not less than three months), followed by a leather and steel apparatus.

For the reasons already given, when describing the effect of gravity in these cases, it is well not to count upon the development of fibrous union within four months. I have repeatedly seen relapses occur through not observing this rule.

It is hardly necessary to add that the strength of the arthrodesis may be increased by performing fascio-tenodesis in addition.

If the condition of the muscles is such as to indicate **tendon transplantation**, the foot must be brought into the over-corrected position, and the tendons very firmly secured. If only the tibialis anticus is affected, the extensor hallucis and part of the extensor digitorum are grafted into it. If the extensor digitorum is itself somewhat impaired, and therefore unfit to be transferred, the peroneus longus may be utilized, its peripheral stump being attached in an ascending direction to the peroneus brevis. If the paralysis has affected the anterior and posterior tibials—a common distribution—the anterior muscle may be reinforced from one of the other extensor muscles, and the posterior by the peroneus longus. The flexor digitorum may also be employed, and the outer part of the tendo Achillis. The internal part must on no account be touched, nor must the flexor longus hallucis be utilized. If anything, these muscles should be shortened. If only the tibialis posticus is paralyzed, the peroneus longus is the best muscle to graft into it. The after-treatment consists in exercises intended to promote supination, and in the application of the instruments described. It is obvious from what we have said about the special difficulties of these cases that it must be carried out with great care and patience.

If all the required conditions are fulfilled, the permanent results will be excellent, as the following abstract of cases shows :

1. VULPIUS.—K. K., æt. 4 years. Onset of paralysis in second year. Severe equino-valgus. Tibialis anticus and posticus completely paralyzed; other muscles good; tendo Achillis and peronei shortened. Operation: *Redressement* and tenotomy of Achillis. Peroneus longus transplanted into tibialis posticus. Extensor hallucis and a large part of extensor digitorum put into tibialis anticus; extensor digitorum somewhat shortened. Peripheral stump of extensor hallucis fastened to tibialis anticus high up. Uneventful recovery. Two months later position of foot good; all movements possible. The latter much improved in course of one year. Adduction and supination quite powerful.

2. VULPIUS.—H. L., æt. 5 years. Onset of paralysis during first month. Severe pronation and pes equinus. All muscles very weak; tibiales completely paralyzed. Operation: Peroneus longus transplanted into tibialis posticus, extensor hallucis into tibialis anticus. Tenotomy of Achillis and *redressement*. Uneventful recovery. Three months later, position of foot good; all movements possible. A year later, foot could be voluntarily dorsiflexed to 60 degrees, and plantar-flexed rather beyond the right angle. Pronation and supination also, to a limited extent. The position of the foot is normal, and its shape good, even when the patient walks without support. The whole result is very satisfactory.

3. VULPIUS.—L. M., æt. 10 years. Onset in second year. Very severe pes pronatus developed, so that the internal malleolus touched the floor, and a painful corn resulted

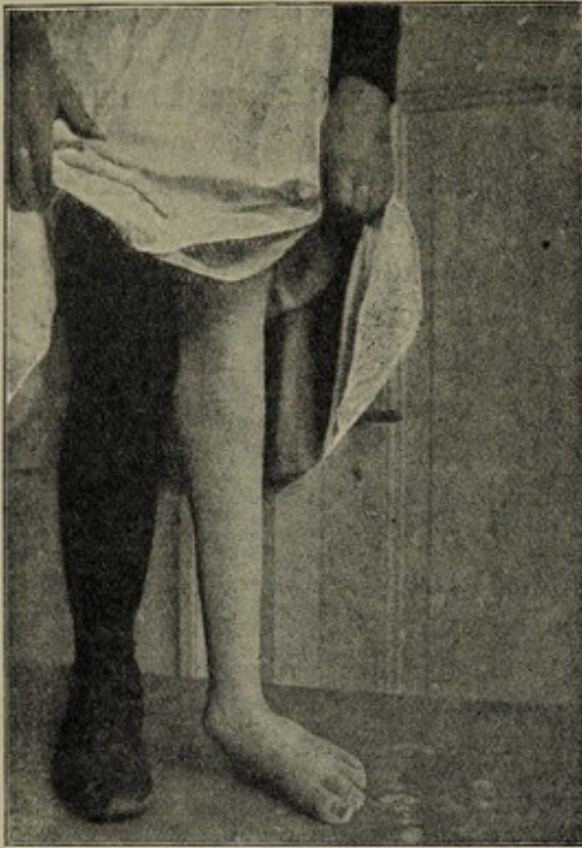

FIG. 165.

5. VULPIUS.—W. R., æt. 22 years. Onset in first year of life; excessively severe flat foot, with extreme abduction and pronation of fore-part of foot. Tibialis anticus and posticus completely paralyzed. Gastrocnemius weak. Peroneus longus also not quite normal; other muscles very good. Operation: Tenotomy of Achillis, grafting of peroneus brevis into tibialis posticus; extensor hallucis, and good part of extensor digitorum into tibialis anticus. The *redressement* mentioned was exceedingly difficult. Three months later, position good; movement possible in all directions, though limited. Three years later, shape and position of foot normal; active movement excellent. Plantar flexion to 65 degrees, dorsiflexion to 70 degrees; supination and adduction very good; abduction beyond the middle line not yet possible.

6. VULPIUS.—C. U., girl, æt. 6 years. Onset at one year. Tibialis anticus and posticus completely paralyzed; extensor digitorum some-

(Fig. 165). Tibialis anticus and posticus completely paralyzed; gastrocnemius weak; other muscles well developed. Operation: *Redressement*, very difficult. Peroneus longus put into tibialis posticus; extensor hallucis and at least half of extensor digitorum into tibialis anticus; and flexor digitorum into tendo Achillis. Uneventful recovery. Distinct supination after two months. Position of foot good. This was still maintained after four years (Fig. 166). Good movement in all directions. Gait weak, on account of paralysis of hip muscles.

4. VULPIUS.—H. L., æt. 11 years. Onset at nine years. Paralytic equinoplanus developed; foot gave considerably whenever weight put upon it. Tibialis anticus and posticus paralyzed; other muscles quite sound. Operation: *Redressement*, tenotomy of Achillis, grafting of peroneus longus into tibialis posticus, and extensor hallucis into tibialis anticus. Distinct supination after two months. Foot normal in every way four years after.



FIG. 166.

what weak; triceps ditto; toe-extensors, peronei, and extensor hallucis very good. Operation: Descending transplantation of extensor hallucis into tibialis anticus, peroneus brevis into tibialis posticus. Attachments provided for peripheral stump of extensor digitorum and peroneus longus. Position of foot very good; slight varus. Dorsiflexion, plantar flexion, pronation, and supination possible, but limited. No apparatus necessary. Gait very good.

Little work has been done on **nerve grafting** in paralytic flat foot: the anatomical relations are by no means favourable. If the case is one of paralysis of the tibialis anticus only, the superficial peroneal nerve may be employed for grafting. If the tibialis posticus only were affected, the muscular branch to the triceps suræ or the superficial peroneal nerve would be utilized. Ascending methods should be employed in all cases, for if the result is not successful, no harm has been done, and there is no difficulty about performing a secondary tendon operation. Young and Frazier have performed an ascending transplantation of the appropriate muscular branch into the superficial peroneal nerve in a case of paralysis of the tibialis anticus. The result was only very moderately successful. Kilvington seems to have performed the same operation, but he does not mention what the result was.

It is generally considered that tendon transplantation is a much more satisfactory operation.

5. Pes Calcaneus.

By pes calcaneus is meant that very rare deformity of the foot that results from the os calcis turning about its transverse axis until its posterior process looks downwards. This position of the bone corresponds with that which is observed when the foot is dorsiflexed. In all cases of this deformity the essential factor is paralysis of the triceps suræ. The intact, or relatively intact, muscles of the anterior group are therefore unopposed, and pull the foot upwards. Nicoladoni and Duchenne have distinguished two forms of paralytic flat foot, and subsequent observers have insisted very strongly upon the differences between the two. I cannot agree that these exist.

The two forms are described as follows: Pes calcaneus sursum flexus exhibits sharp dorsiflexion of the whole foot, the anterior part projecting prominently into the air, whilst the sole looks almost normal (Fig. 167). The fore-part of the foot may sink down more or less later on, and pes cavus result in addition.

In the other form of pes calcaneus, which occurs only in grown-up persons, the os calcis is very much more perpendicular in direction, and the front of the foot is bent down upon itself, so that there is marked cavus (Fig. 168).

In the first case the footprint consists in the impression of the dislocated os calcis only; in the latter, the foot rests upon the os calcis and the heads of the metatarsals, or, as in the majority, on that of the first metatarsal; occasionally, even upon the toes, which are plantar-flexed for the purpose.

I cannot see that there is any essential difference between the two. I think, on the contrary, that the two forms are ætiologically and fundamentally similar; and I explain the relationship of the two, and their dependence upon a common pathology, as follows:

The initial stage of talipes calcaneus is seen when paralysis of the tibial nerve occurs in early childhood. The shape of the heel is completely altered, for the tendo Achillis is no longer prominent between the malleoli, and there are no grooves between the tendon and the malleoli. The tendon can be felt, lying quite relaxed, on the posterior surface of the ankle-joint. The foot can be passively dorsiflexed to an extreme extent, without any

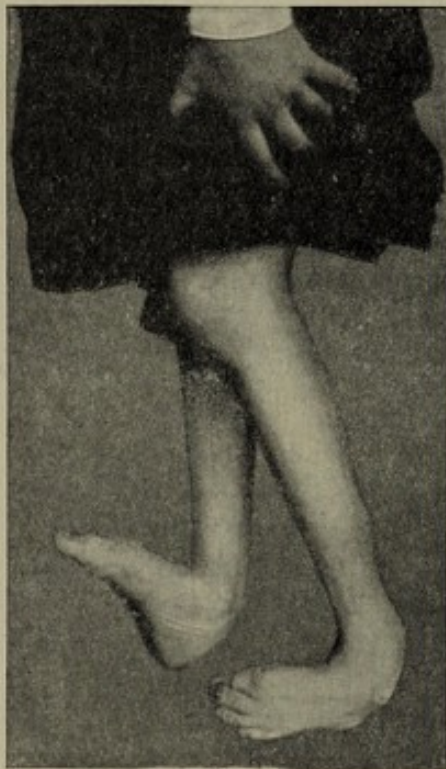

FIG. 167.

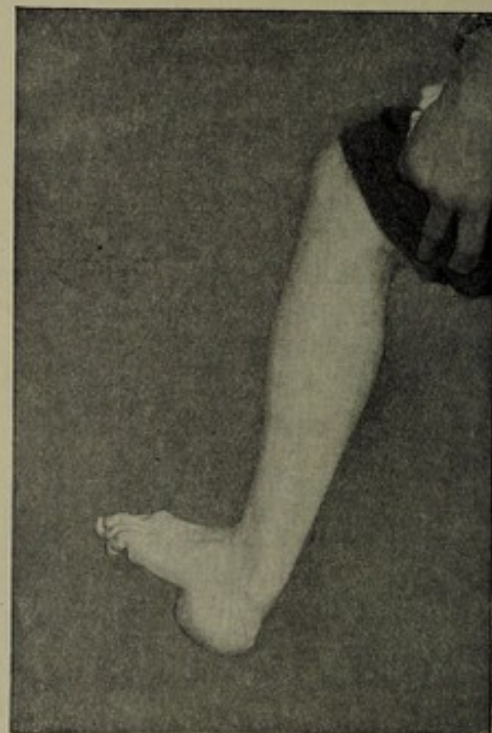

FIG. 168.

resistance being experienced. On active dorsiflexion, the extensors, and, as a rule, the peronei, stand out strongly. There is also some valgus. The latter is due to loss of the supinating action of the triceps. In addition, there is frequently paralysis of the tibialis posticus, so that the only supinator remaining to resist the healthy pronators and abductors is the feeble tibialis anticus. In those rarer instances in which the peronei are paralyzed, and, perchance, the extensor digitorum is not quite intact, a calcaneo-varus may be seen.

After the condition described has existed for some time, the effects of contracture begin to show themselves. Partial plantar flexion becomes possible, whereas formerly it was impossible, or could only be effected in the anterior part of the foot by means of the flexor longus digitorum. As

soon as the foot approaches the right angle, the dorsal tendons stand out strongly, especially the tibialis anticus. If one applies force, it is only the fore-part of the foot that can be pushed down. If the patient tries to walk, the os calcis assumes as vertical a position as the tension of the ligaments and joint-capsule will allow, the muscles of the calf no longer exerting any controlling action in this direction. Thus its posterior process, which normally looks backwards, comes to look downwards, and the gait becomes unsteady, especially if the deep flexors are impaired in addition. The patient realizes instinctively the necessity of a broader base to walk upon, and he depresses the anterior part of his foot until the heads of the meta-

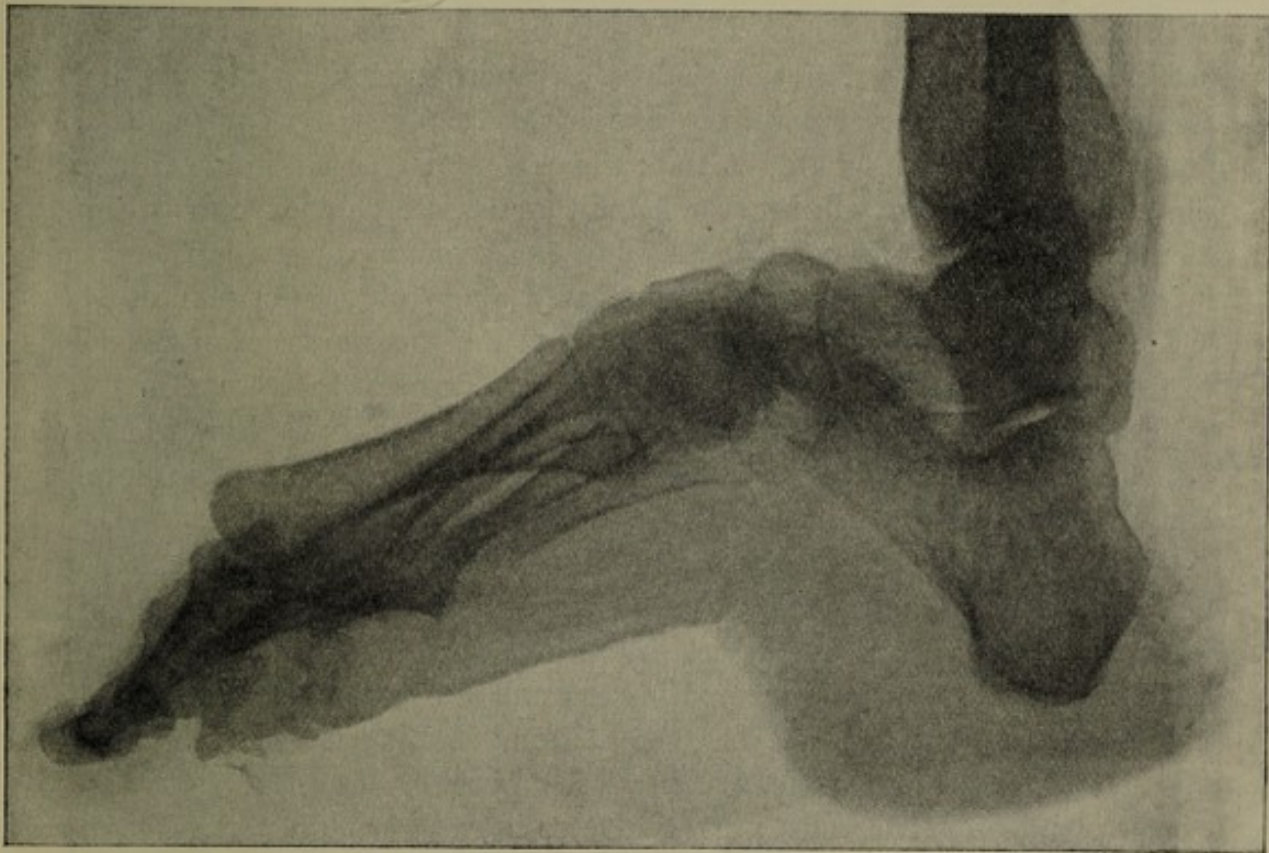


FIG. 169.

tarsals rest upon the ground. He is assisted in this by the weight of the foot, together with the progressive shortening of the muscles of the sole and the action of the long flexors of the toes. Not only is the fore-part of the foot affected by this retraction, but the os calcis is pulled upon also. In other words, a severe cavus is produced by the simultaneous dropping of the front half of the foot, and the increasing perpendicularity of the os calcis. Thus the complete picture of talipes calcaneus "sensu strictiori" is produced. The posterior process of the os calcis rotates through 90 degrees and becomes inferior; the heel is displaced downwards and forwards, and consists of a broad mass covered with corns and a bursa; the backward

projection of the heel disappears altogether. The sole of the foot is deeply hollowed, and forms almost a right angle with the anterior part of the heel. Dorsiflexion remains, but plantar movement at the ankle-joint is impossible, though some slight flexion is perceptible at the anterior part of the foot. It also shows some abduction and pronation. The foot is very inelastic, and the gait is awkward and pounding in consequence. The difficulty is increased by the presence of callosities and patches of inflamed skin. The X-rays show the skeletal changes very well (Fig. 169).

The extensive changes in the shape and internal structure of the os calcis are particularly striking, but it is unnecessary for us to discuss these at length.

In describing the changes which lead to the gradual development of pes calcaneus sensu strictiori from pes calcaneus sursum flexus, we have assumed the existence of paralysis of the triceps suræ at an early age. If the patient was already able to walk when the paralysis set in, he will not show the first stage at all, because he will immediately endeavour to bring as much of his foot as possible down to the ground. Cavus is therefore rapidly produced, without the preliminary stage of dorsiflexion of the whole foot. It is facilitated by the fact that the short muscles of the sole usually escape, and, not infrequently, the long flexors of the toes also.

Further anatomical, physiological, and clinical work will show whether or not my views are correct. At any rate, they seem to me to explain simply and satisfactorily the various stages in the evolution of the disease.

Treatment.—We come now to the question of treatment. The use of *instruments* is of the greatest importance with regard to prophylaxis. Lack of space prevents our describing all the appliances which have been introduced for the purpose of opposing the pull of the dorsiflexors, after the manner of the paralyzed triceps. The best and simplest is a moulded appliance enclosing the leg and foot, with steel supports so arranged as to allow of free plantar flexion, whilst preventing dorsiflexion much beyond the right angle. An elastic tractor placed at the back of the ankle acts as an artificial triceps, and keeps the front of the foot to the ground. An internal *splint* with an oblique foot-piece is worn at night, to prevent overstretching of the calf muscles. *Massage* and *exercises* should also be employed, in the hope of improving the triceps, though it is unusual for any improvement to take place.

Operative Measures.—In view of the unsatisfactory results of conservative treatment, it is unjustifiable to abandon a patient to the lifelong wearing of an apparatus or the infallible development of a deformity. Reiner proposed to perform tenotomy behind the heel, together with arthrodesis at the ankle-joint, or, in cases in which sufficient muscular power was available, to reinforce the movements of pronation, supination, and

(!) dorsiflexion. One should, at any rate, attempt to promote recovery of the gastrocnemius by operative shortening of the tendo Achillis (Walsham).

Sometimes the muscles are so poor that tendon-transplantation is out of the question. This condition presupposes the existence of fairly widespread paralysis. The extensors are so shortened as to be incapable of active contraction, and the peronei and tibialis posticus are wasted. In these cases I think that it is best to perform plastic elongation of the anterior group of muscles, correct the cavus as far as possible by tenotomy and *redressement*, get the foot straight, and then either tenotomize the Achilles, ankylose the joint, or do both.

If sufficient muscle is available, *tendon transplantation* is certainly worth considering. The prospects are not nearly as bad as Nicoladoni's early attempts would suggest. We have already pointed out in Part I. that, unfortunately, the earliest attempts at transplantation were carried out in cases of pes calcaneus—a condition in which considerable experience with the method and highly developed technique are essential to success. We know now, after a large number of successful operations have been reported, that transplantation does not justify us in promising recovery of the triceps suræ. On the other hand, we can promise, as has frequently been claimed, prevention of deformity and the restoration of sufficient muscular balance to give elasticity, security, and endurance to the gait.

A large number of muscles should be transplanted into the triceps, when possible, on account of the extreme importance of the tendon of Achilles. The peroneus longus should always be employed for this purpose. Its normal action is to produce plantar flexion, but its point of insertion is such that it also produces certain undesirable by-effects. It is better, therefore, to rearrange it so that its sole function is to plantar-flex the foot. The same applies to the flexor communis digitorum. The tibialis posticus may be sacrificed under two conditions: (1) The tibialis anticus must be intact, to provide for adduction and supination; (2) one peroneus must either be paralyzed, or have been transplanted, so that the abductors may not be stronger than the adductors. It is important also that the operation should be performed with the foot rigidly plantar-flexed, so that tendinous fixation of the foot in this position may be produced. The equinus must be attained when necessary before transplanting by plastic elongation of the extensor tendons. It must be maintained during after-treatment by means of some retentive apparatus, or a firm boot with a cork elevation under the heel. The equinus may be gradually diminished.

It is well to fasten the transplanted tendons to the inner side of the tendon of Achilles, or to the os calcis, so that they produce supination in addition to plantar flexion. This is another case in which periosteal attach-

ment may be employed with advantage. Müller went so far as to fasten the tendons into a tunnel bored through the bone.

Transplantation must be accompanied in all cases by vigorous shortening of the tendo Achillis, or excision of part of its length.

The patient must subsequently wear the aforementioned boot, with an internal elevation, and the leg part set obliquely, and strengthened. It is better at first to add a flat-foot support and internal steel, jointed in such a way as to prevent dorsiflexion, and consequent stretching of the sutures. This is Marczinowski's appliance, and it holds the foot more firmly if a laced foot-piece is used in addition.

The apparatus is light and inexpensive, and looks better and works better than the old-fashioned boot and iron. A regular sheath apparatus is usually unnecessary. A night-splint should also be used for a considerable time. It runs down the inner side of the leg, is curved to correspond with the internal malleolus, and ends in a steel foot-piece. It is curved to fit the position of the foot, and maintains it in slight varus position.

A few case reports will serve to illustrate what has been said.

1. VULPIUS.—L. E., girl, *æt.* 3 years. Onset a year previously. Calcaneus and valgus deformity. Gastrocnemius paralyzed; the other muscles present, though weak. Operation: Peroneus longus grafted to tendo Achillis, in position of marked equinus. Tibialis posticus shortened. Seven weeks later child was able to plantar-flex the foot when the leg was held vertically in the air. This shows that she could overcome the weight of the foot.

2. VULPIUS.—F. L., girl, *æt.* 2½ years. Onset in first year. Fairly rigid calcaneus; peronei tense. Gastrocnemius paralyzed; tibialis anticus weak; tibialis posticus and flexors of toes ditto. Operation: Peroneus longus and half of brevis grafted into tendo Achillis; half of extensor digitorum into tibialis anticus; tibialis posticus shortened. Two months later, foot could be dorsiflexed and plantar-flexed to 30 degrees; no pronation or supination. Gait good. Two and a half years later plantar flexion was very powerful. Child could stand on tiptoe. Some flat foot present.

3. VULPIUS.—D. U., girl, *æt.* 4 years. Onset in second year. Marked calcaneus and cavus. Tibialis anticus fairly good; extensor hallucis and extensor digitorum good; peroneus longus good; brevis paralyzed. Flexor digitorum and tibialis posticus very pale. Gastrocnemius paralyzed. Operation: Extensor hallucis divided at back of foot; peripheral stump fastened to extensor digitorum. Proximal end taken through interosseous membrane and sutured to tendo Achillis in full equinus. Peroneus longus also sutured there. Plastic elongation of tibialis anticus to allow of *redressement*. Position of foot good after four months; plantar flexion powerful, and almost normal in extent; dorsiflexion somewhat beyond the right angle. Some power of pronation and supination. Weight borne on whole foot in walking.

4. VULPIUS.—B. F., girl, *æt.* 6 years. Onset at two years. Marked calcaneus; active and passive plantar flexion only to a right angle. Paralysis of gastrocnemius only. Operation: Peroneus longus and half of flexor hallucis, flexor digitorum, and flexor brevis grafted into tendo Achillis in marked equinus position. Distinct plantar flexion possible when bandage removed, after six weeks. In three months gait excellent, and plantar flexion almost normal in power and extent. Result unchanged after one and a half years.

5. VULPIUS.—P. L., *æt.* 12 years. Onset in sixth year. Severe calcaneus, with

cavus. Big toe flexed to right angle. Patient walking on posterior process and ball of toe (Fig. 170). Operation: *Redressement* after plastic elongation of tibialis anticus and extensor digitorum and plantar fasciotomy. Great toe replaced by means of cuneiform resection of first metatarsal; extensor tendon shortened. Peroneus longus, flexor digitorum, flexor hallucis, and half of tibialis posticus grafted into tendo Achillis. Ten weeks later, position of foot

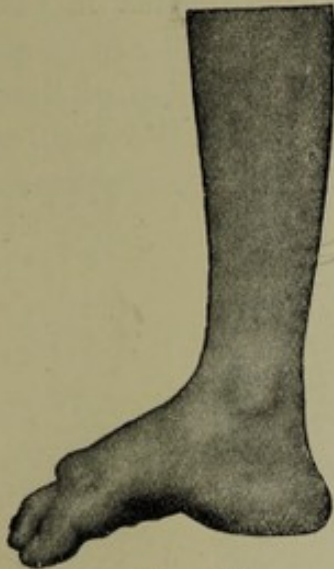

FIG. 170.

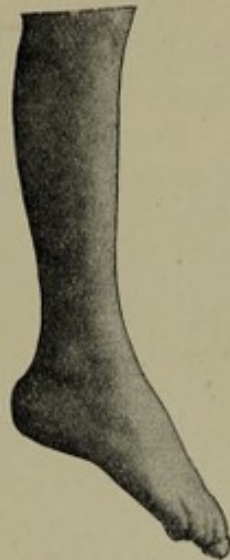

FIG. 171.

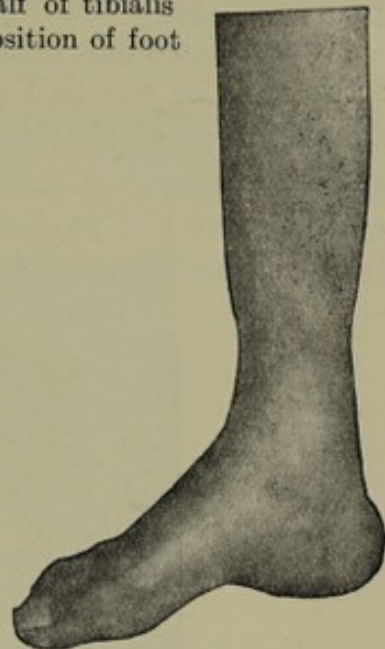

FIG. 172.

normal; plantar flexion quite powerful; patient able to stand on fore-part of foot. After three months, foot had grown so much stronger that he could even dance on the foot, which was quite normal in position. Position excellent after two years (Figs. 171 and 172). Movements good and powerful; no trace of the former severe paralysis. Patient able to go on long walking tours in the mountains. On several occasions he sent me picture-postcards, with notes of the "climbs" that he had made.



FIG. 173.

Lastly, we may draw attention to the amount of voluntary plantar flexion obtained by a boy of seven, in whom the peroneus longus and flexor digitorum were transplanted (Fig. 173).

When severe osseous deformity has already taken place, tendon transplantation is, of course, unable to undo the damage. Bone-operations are essential. Walsham divided the tuberosity of the os calcis in front of the insertion of the tendo Achillis, displaced it as far downwards as possible with the foot in extreme plantar flexion, and then fastened it in its new position with ivory pegs. Hoffa's method is certainly more rational. The tuberosity is chiselled through obliquely,

displaced upwards and backwards, and fastened there. The tendo Achillis is shortened to an appropriate extent (Figs. 174, 175). In a similar case I brought the posterior process back into an approximately normal position by means of a cuneiform resection.

Galeazzi combined osteotomy of the os calcis with tenoplasty, and arthrodesis of the flail mid-tarsal joint. Robert Jones operated in two stages for paralytic pes calcaneo-cavus: (1) Tenotomy of plantar fascia and *redressement* of foot. Internal incision, cuneiform resection of head of astragalus and navicular. Fore-part of foot brought into line with os calcis; cavus thus corrected. Apparent increase of calcaneus in consequence.



FIG. 174.

(2) A month later, incision at back of heel. Cuneiform resection of trochlea and both malleoli. Foot must be brought up to right angle with leg. Plaster till bony union occurs. In cases of partial paralysis, the first operation only is performed, and a month later the joint capsule and the tendo Achillis are shortened. Whitman recommended a remarkable combined operation. He removes the astragalus, and the cartilage of all the adjacent bones. Then he shortens the tendo Achillis and sutures the two peroneal tendons to it. Although he has performed this operation fourteen times with striking success, the method can hardly be regarded as rational. He first restores the calf musculature by transplantation, and then spoils the effect by a simultaneous arthrodesis.

We will conclude with a few words on the subject of **neuroplasty**, which has been employed successfully, though not frequently. In two cases of isolated paralysis of the gastrocnemius and soleus of six and seven years' duration respectively, Tubby grafted the corresponding nerves in an ascending direction into the peroneal nerve. The results were as follows :

The first patient showed remarkable power of extension after three months' interval. In two years it was really considerable, though still capable of improvement. In the second patient the first voluntary contractions were noted four and a half months after

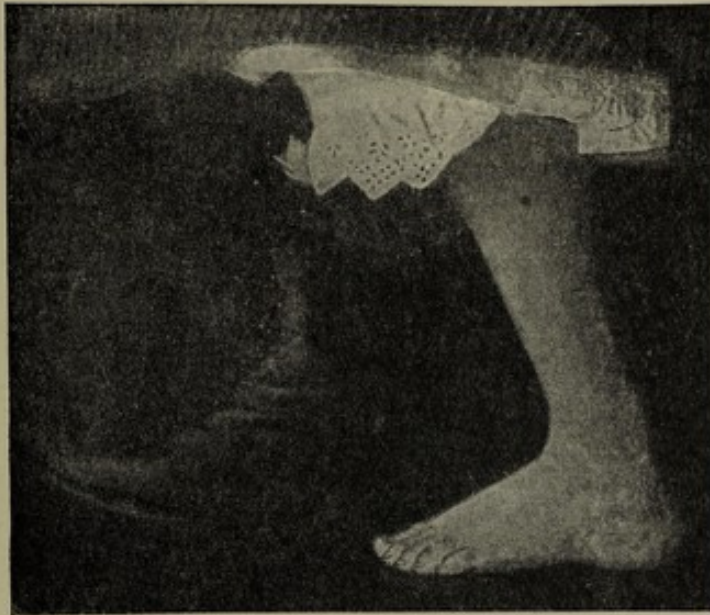

FIG. 175.

operation. After nine months the patient could raise the heel of the affected foot $\frac{1}{2}$ inch from the floor. No further progress was made.

Ashurst chose a case of severe paralysis, so that the failure of the operation is not to be wondered at. The patient was a boy of seven, and all the muscles of the lower leg were paralyzed except the peronei. He first transplanted the peroneus longus into the tendo Achillis, and then grafted the deep peroneal nerve in an ascending direction into the superficial peroneal. Later on, he found it necessary to perform arthrodesis, as one would have expected at the start.

Stoffel's researches indicate that in any further work of this sort, Tubby's method should be adopted, or else that a suitable branch should be taken from the peroneal nerve and implanted in a descending manner into that surface of the tibial nerve that looks towards the popliteal space.

CHAPTER VII

PARALYSIS OF THE KNEE

PARALYSIS in the region of the knee is of frequent occurrence. It is usually associated with an extensive paralysis of the leg, and not infrequently the hip is more or less severely affected in addition. Paralysis of the thigh only is a very unusual occurrence, but when it does take place, it is usually the quadriceps that is affected.

Although the knee-joint is not paralyzed in a great number of cases, yet the disability that it entails renders the subject one of grave interest and importance.

It must be remembered that not only the extent but also the severity of the paralysis of the various groups of muscles in the thigh has to be considered, and again, that both thighs may be affected, though to an unequal extent. It is clear, therefore, that the type of case and the treatment that is appropriate to each is subject to the greatest variation.

Taking the worst form first—viz., **total paralysis of the thigh**. This is an exceedingly rare occurrence. Usually one finds that one small muscle or part of a muscle has escaped the general destruction of the flexors and extensors. In other instances the adductors retain a fair amount of power. At operation one can often observe a few pink or reddish fibres, or bundles of fibres, amidst the vastus internus or externus. These, of course, have no functional value, and such cases must be included in the category of total paralysis. This does not mean, however, that the limb is useless, and one often sees patients getting along very well on a level surface, a slight limp being the only indication of the weakness of the leg.

The patient throws his centre of gravity in front of the transverse axis of the knee-joint—a mode of locking which Volkmann has aptly compared to that of an open pocket-knife. The body weight then presses the tibia and fibula together in front, whilst behind they are restrained by the tension of the ligaments and capsule of the knee-joint. In cases of this kind an apparatus may be used with great advantage, for there is a danger that the physiological limit of 10 per cent. may be exceeded, and the hyper-extension of the knee be increased until *genu recurvatum* results. It is

remarkable that this is not of more frequent occurrence. It may be that the flexors retain sufficient power to protect the posterior part of the capsule from overstretching. Again, there is no doubt that the gastrocnemius and the popliteus (the latter lying deep down in the popliteal space) serve to prevent recurvation. We shall allude to this question again later on. Finally, I think that not only the condition of the capsule, but also the patient's way of walking, may accelerate or retard the softening and displacement of the joint structures.

However that may be, the fact remains that many persons are able to walk very well in spite of extensive paralysis of their thigh muscles.

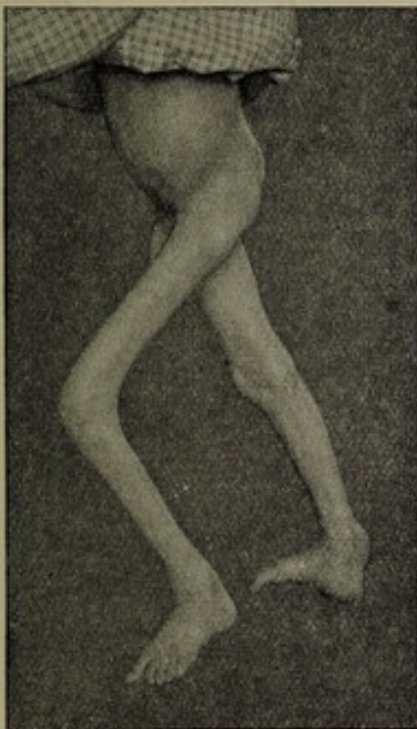

FIG. 176.

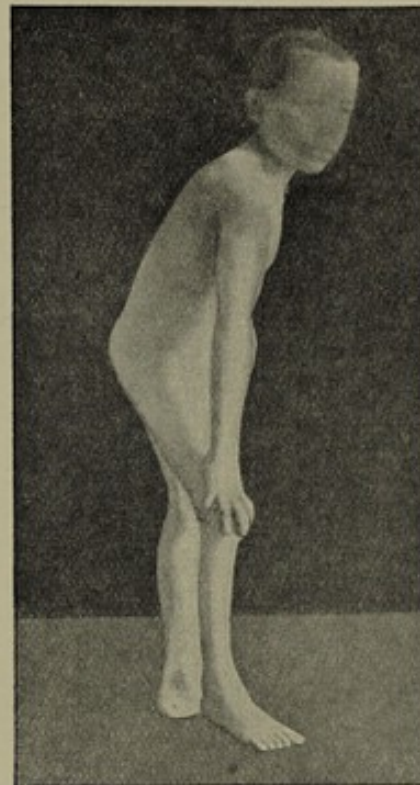


FIG. 177.

It is quite another matter, however, when deformity is present, in addition to paralysis. Thus there may be **contracture** of the knee. In cases of total paralysis this cannot be due to muscular action. Sometimes it dates back to early childhood, or to the time of onset of the paralysis. The affected limb is then permanently bent, and the child crawls about with his knees flexed. The soft parts become shortened, and the flexion is rendered permanent by interference with growth. This condition was frequently present amongst the patients depicted in Chapter X., even though no flexor muscles were demonstrable at all.

If these patients begin to walk later on, the effect of the body weight is not to stretch the structures of the popliteal space, but to promote and

accelerate deformity. If, on the contrary, paralysis sets in in children who have already walked, and is of a kind that does not prevent their walking, the leg is at once thrown into hyperextension, and contracture is prevented. Recalling the simile of the open pocket-knife mentioned above, one would imagine that it was impossible to walk with the knee flexed in this way, and that the leg must inevitably give way. We know from everyday experience, however, that this is not the case, for we constantly see men walking surprisingly well without any stick or crutch. Reiner and Saxl have studied the mechanics of the gait in paralysis of the thigh, and

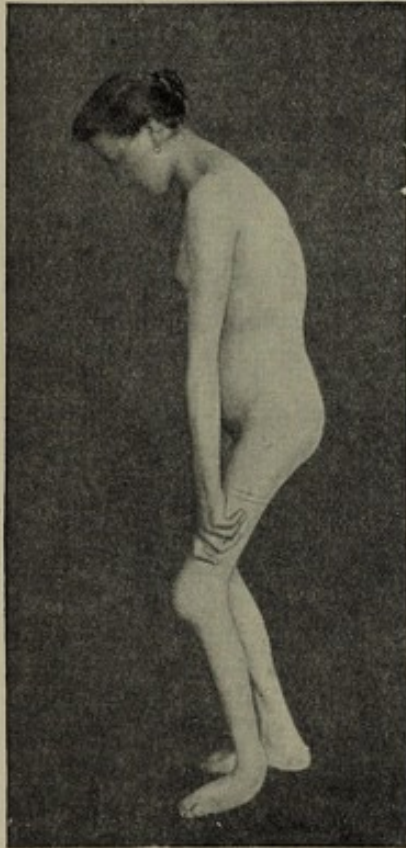

FIG. 178.




FIG. 179.

their results are as follows: To prevent the paralyzed limb giving way at the knee at the moment when he puts his weight on it, the patient has to throw his trunk well forward, thus bringing the line of force in front of the axis of the knee-joint. The effect of this is to extend the knee. It follows that at each step the patient makes a bend forwards. He then rapidly throws his centre of gravity still more forward, by "taking off" from the supporting leg, and thus quickly getting over the dangerous stage in his mode of progression.

Furthermore, the customary flexion of the knee of the supporting limb to about 15 degrees does not take place (du Bois-Reymond), and therefore the body has to move over a larger arc of a circle than when the knee is bent. The result is that the shoulder is raised at every step. Lastly, the patient finds that it is easier to walk with the affected leg outwardly rotated. This prevents the tendency of the knee to flex unexpectedly, by bringing the transverse axis of the joint into a more antero-posterior plane. There is produced, however, a liability to "give" in the lateral direction, so




FIG. 180.

that the patient eventually adopts an intermediate position—viz., about 45 degrees of external rotation.

In cases of **flexion and contracture**, special precautions are necessary (Fig. 176). The patient leans a good deal forward, and the walk is greatly impaired. The hand is placed upon the knee-joint or on the thigh (Figs. 177, 178), and firm pressure is exerted when the paralyzed leg is bearing the weight of the body. In order to do this, the back is considerably bent. In course of time a thick callosity forms upon the thigh. This method of progression is very wearisome, especially when the ankle-joint in addition is partially or entirely paralyzed. In the severest grades of contracture, the patient can only get about by means of crutches.

A moderate degree of flexion is not so disabling as its converse—**genu recurvatum**. If the posterior part of the capsule of the knee-joint begins to yield, the joint itself becomes flail, the leg gives at every step, and sometimes dislocation occurs. The amount of deformity may become extraordinary after some time (Figs. 179, 180, 181, 182).

We have said that it was quite possible to walk in spite of the existence of slight flexion at the knee. It must be added, however, that the gait is

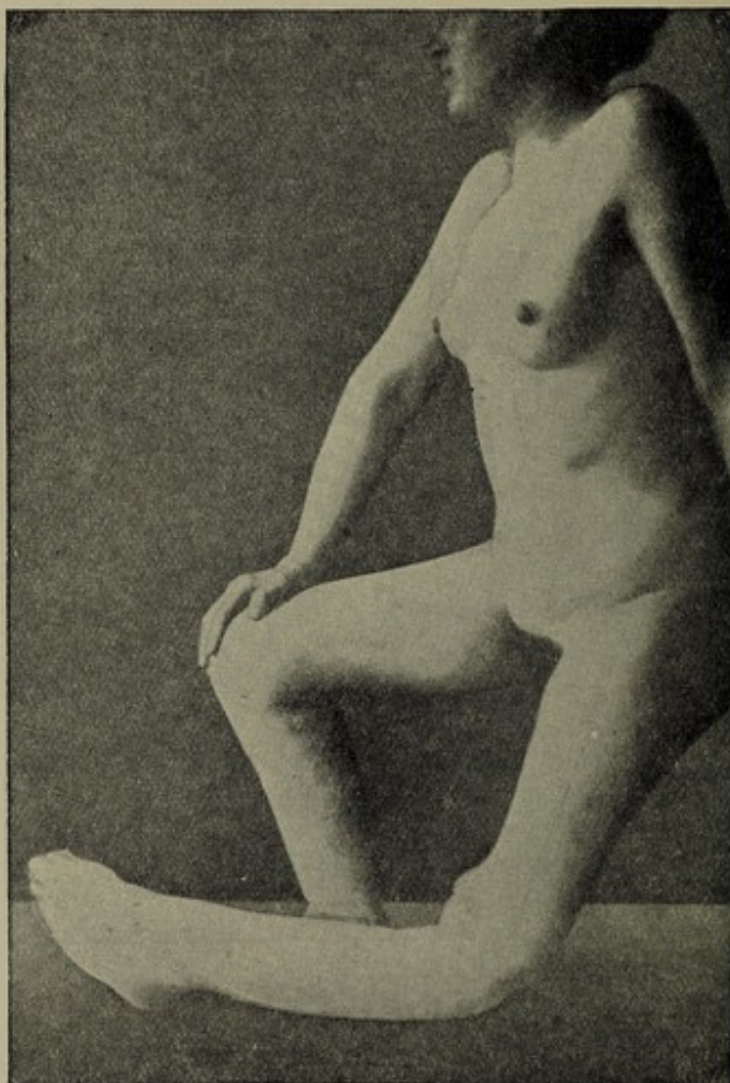


FIG. 181.

very unstable, and that a slight knock or catching of the toe is sufficient to upset the patient.

We come now to the question of **partial paralysis** of the thigh muscles. It was formerly taught that paralysis of the flexors resulted in genu recurvatum, and that loss of the quadriceps resulted in flexion and contracture. This theory does not work out in practice, however. It is unusual to meet with instances of pure paralysis of the flexors, but we frequently have an

opportunity of studying the condition when it is artificially produced by grafting the flexor muscles into a paralyzed extensor. The observations that have thus been made refute the old statement altogether, and also disprove the teaching that paralysis of the quadriceps and retention of a healthy flexor group result in a mild degree of genu recurvatum.

In conditions of this sort the mechanical and static effects of the body weight are particularly important, as we have already seen, and, possibly, trophic lesions of the joint capsule. The mechanism of standing and walking is pretty much the same as that described for total paralysis. It is clear, however, that the existence of powerful flexors disturbs the equilibrium, and renders the patient more liable to fall. On the other hand, the patient can hyperextend his knee with safety, because the flexor muscles, being intact, prevent excessive mobility. Lange writes as follows on the effect of paralysis of the quadriceps: The flexors, with the exception of the short head of the biceps, act on two joints, extending the hip and flexing the knee. The normal function of the quadriceps is to prevent the latter movement, and when the patient stands erect, it contracts in unison with the flexors. Paralysis of the muscle therefore renders it difficult to stand securely. He regards this as a sufficient reason for adopting operative treatment, as we shall see.

Lateral deformities of the knee-joint also occur in infantile paralysis, and particularly **genu valgum**. By this we do not, of course, mean that form of genu valgum which is developed on the good side as an effort at compensation for the shortening of the paralyzed leg. Abduction of the lower leg occurs on the affected side in partial as well as total paralysis, and sometimes reaches very severe degrees. It has been asserted that genu

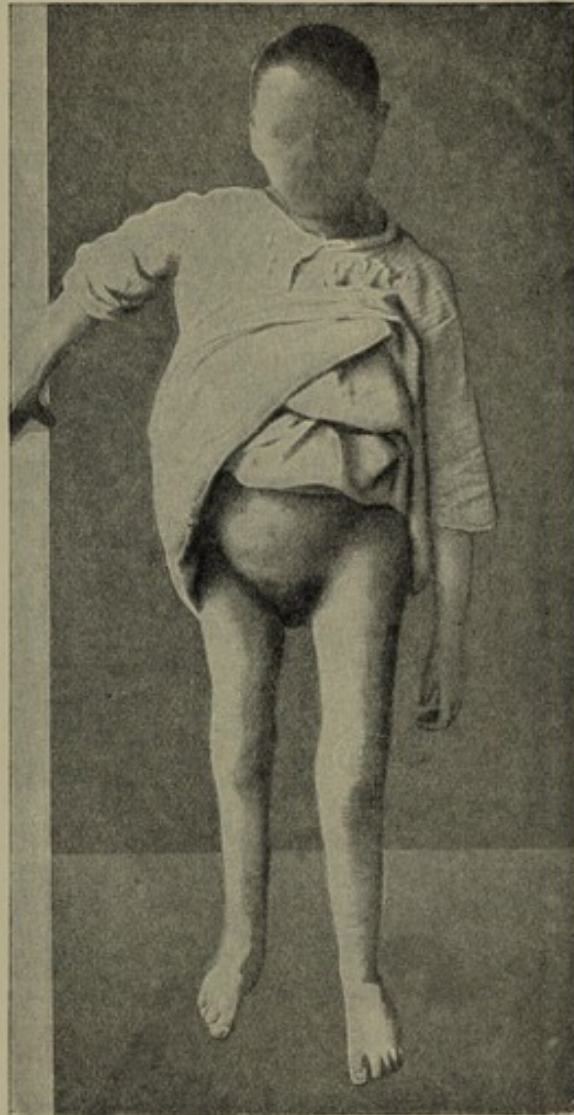


FIG. 182.—IMPROVEMENT EFFECTED BY ARTHRODESIS.

valgum results from paralysis of the internal flexors, in consequence of the pull of the biceps muscle, whilst genu varum is produced when the biceps is paralyzed (Fig. 183). This is found to be incorrect in practice, however. I have seen extreme valgus in association with paralysis of the biceps. Paralytic genu varum appears to arise, as a rule, from defective position of the leg (Fig. 184).

Treatment.—Treatment may be purely mechanical, when there is no contracture. When this is present, it must be corrected. This is often not a difficult task in recent cases. Weight-extension may be employed, or



FIG. 183.

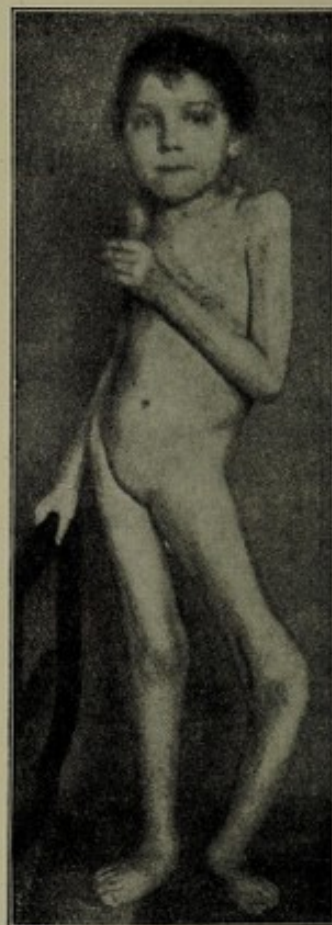

FIG. 184.

an apparatus with anterior steel bar traction (see Part I., Chapter II.). A more rapid method is to correct the deformity under an anæsthetic, tenotomizing the flexor muscles when necessary. I think that it is well to do this as a routine, in order to avoid injury to the peroneal nerve by overstretching. Lorenz advises supracondylar osteoclasis for the same purpose, and I myself have frequently performed osteotomy to avoid damaging the vessels and nerves of the popliteal space. Finally, Reiner has recommended shortening of the tendo Achillis, after reduction of the deformity, in order to restore the tension of the calf muscles, and so provide against recurva-

tion. When genu valgum is present in addition to contracture, osteotomy is the quickest and most effective method of restoring the limb to its proper shape. Genu recurvatum can be corrected without difficulty, provided that the deformity has not been present for such a length of time that the joint surfaces have been deformed.

Prolonged after-treatment is necessary in all cases, however, if recurrence is to be prevented. A sheath apparatus with movable knee-joint works very satisfactorily; the steel supports are bent sufficiently backward to prevent the joint giving way under the influence of the body weight (Fig. 185). To render walking and standing easier, a weak elastic quadriceps or a spring device at the knee may be employed. This does away with the possibility of recovery of the muscles, however. A simple leather splint for the whole leg is, of course, much cheaper, but the patient has to put it out straight in front of him when he sits down.

Where money is a difficulty, operative treatment of the genu recurvatum is advisable. Neither pleating of the capsule nor shortening of the degenerated flexor muscles is of any permanent use. Lange has, therefore, attempted to make artificial ligaments. He bends the knee to a right angle, and then fastens ten or twelve silk sutures to the periosteum of the tibia and fibula, above and below the joint capsule; later on, he gradually extends the knee. He thinks that these silk threads serve as a scaffolding upon which living connective tissue is built up, and that new ligaments of sufficient strength are thus formed. No record is given of the ultimate result, from the clinical or from the anatomical point of view. On one occasion I separated the flexor tendons from the muscles, and employed them as accessory ligaments with satisfactory results. In two other cases in which the flexors were not completely degenerated, I shortened them considerably, and thus prevented full extension of the joint taking place for a considerable time. In this way I corrected a deformity of the knee of two years' duration. Deutschländer has advocated supracondylar osteotomy, and such displacement of the fragments as will correct the recurvation. It remains to be proved that the

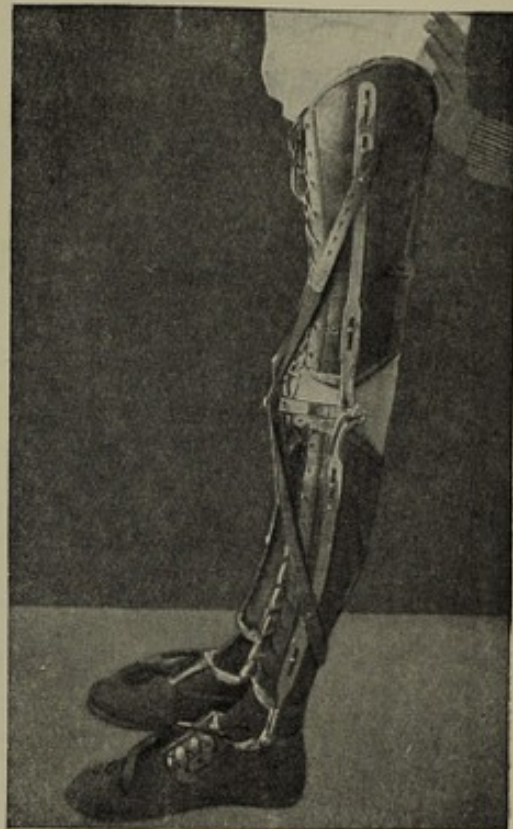

FIG. 185.

result is permanent. Lorenz bemoans the fact that the quadriceps is not suitable for transplantation; otherwise, he would have considered grafting of the muscle into the flexors as a much more valuable operation than a simple plastic operation on the extensor. In a case of genu recurvatum, with an intact crural nerve, one might quite well make the sartorius into a flexor. I think that this is a feasible suggestion, and that it might prove a useful one.

In cases of flail knee, in which the use of a walking appliance is undesirable, **arthrodesis** of the joint is undoubtedly preferable to any operation on the tendons or ligaments, for the result is more reliable. This operation, which was first carried out on the knee-joint, gives exceedingly good results, and has, therefore, come more rapidly into favour than tendon transplantation. The inventor of the latter had the misfortune, as we have already seen, to try his suggestion first of all on a very unsuitable subject—viz., a *talipes equinus*. In course of time, however, warning voices have been raised against arthrodesis, and Karewski, in particular, insisted upon the necessity of a very careful choice of cases.

There can be no doubt that the operation is indicated in cases of flail genu recurvatum, with displacement at the joint. It is absolutely essential when severe contracture of the knee has existed for any great length of time, and a bone operation is required for its correction. The question of the social position of the patient has been sufficiently discussed already. As regards age, we have mentioned in Part I. of this book that in a patient of less than eight years, the operation should only be performed when it is the only possible means of getting him on his legs. I think that to wait until adult life, as recommended by Lange, is an error in the opposite direction.

When the lesion is bilateral, one knee should be left movable, if possible. Nevertheless, I have ankylosed both knees in certain "desperate" cases, and have had the pleasure afterwards of seeing the patients walk without assistance.

The **technique** is that of ordinary excision of the knee. I formerly exposed the joint by an inferior semicircular incision, but I now employ a similar incision over the patella—a method which was suggested to me by Hübscher. The semilunar cartilages and crucial ligaments are removed. The cartilage is removed from the femur, tibia, and patella by means of a knife and sharp spoon, or in older patients with a saw. A large area of the condyles is exposed, to give a wide surface of contact. Finally, the anterior surface of the femur is bared at the point where the patella is to rest. In children the cartilage must not be removed right down to the bone. I usually bare it by cutting tracks or grooves through it. The synovial membrane also may be removed by means of the sharp spoon. The surfaces of bone are then swabbed with tincture of iodine or with carbolic acid. The

details of this method of *phenarthrodesis* are described in the section dealing with the analogous operation on the hip-joint. The bones are then replaced and fixed in position. Various devices have been introduced for this purpose. Karewski used ivory, Dollinger and many others have employed silver wire, whilst recently Herz has used silver staples. I myself have latterly been in the habit of dragging the patella and attached patellar ligament as far upwards as possible, and then screwing the bone to the femur (Fig. 186). Hübscher described this method of fixation. His object is not to secure absolute fixity, but only marked limitation of movement.

This he attains by merely roughening the posterior surface of the patella and the corresponding area of the femur, and then screwing the two together, as already described. Lexer also left the joint surfaces intact, merely passing bone pegs through from the tuberosity of the tibia. The result would appear, however, to have been unsatisfactory, for he remarks that arthrodesis is preferable in the case of the knee-joint. I agree that the ordinary set operation is the best if stiffening of the knee is required at all. Further, I consider that the removal of the patella, as practised by many surgeons, is a mistake, and I use it after Hübscher's method to strengthen the union between the tibia and

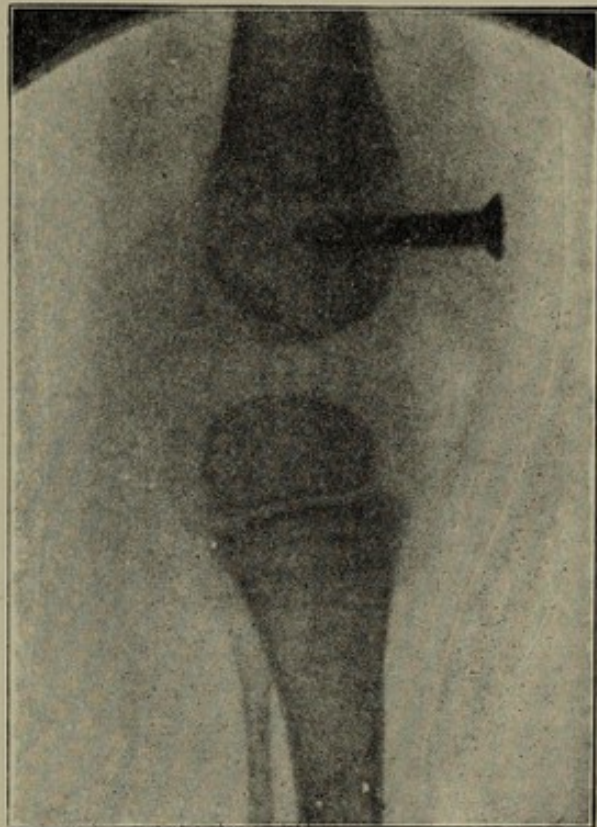


FIG. 186.

the femur. I think that **osteoplastic methods** have much to be said in their favour. Thus, a bridge of bone and periosteum may be cut from the anterior surface of the tibia, and turned upward, to be fastened to the femur or to the patella. By this means the success of the operation is secured. It is also very important to sew up the extensor muscles under sufficient tension. Omitting to do this is the explanation of many failures. Tenotomy of the flexors is also extremely important, whether they are partially or completely paralyzed or not. If the sartorius is intact, it may be displaced forwards and made into an extensor. It is possible to do this by leaving its insertion untouched, and merely displacing the muscle forwards (Kofmann).

After-Treatment.—The first plaster may be removed in a few weeks' time, to make sure that the position is satisfactory, but the **total period of fixation** must amount to at least three or four months. It is quite possible, however, for the patient to get about during this time, and it will accelerate

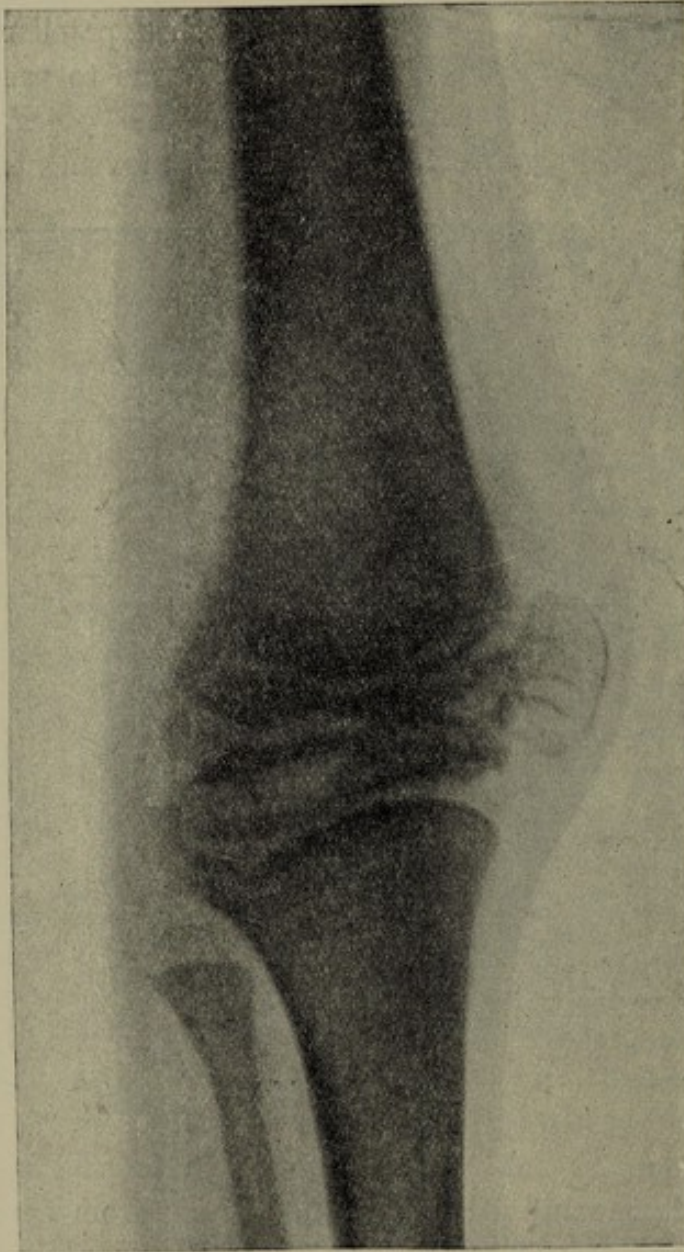


FIG. 187.

ossification if he does so. It is wise to apply a moulded apparatus for some time longer.

Results.—Arthrodesis of the knee is a very successful operation from the anatomical point of view. In fully 75 per cent. of cases bony or adequate fibrous ankylosis takes place. The blending of the two epiphyses can be very well seen in the two skiagrams (Figs. 187 and 188), which were taken three and four years respectively after the operation. The first one also shows the complete fusion of the bony lamellæ of the patella with those of the other two bones. In the remaining 25 per cent. some "play" remains, and the result can only be described as a partial success. With improvements in the technique, this percentage will be considerably decreased. The condition may sometimes be gradually remedied by means of repeated in-

jections of tincture of iodine, alcohol, zinc chloride, or some substance of this kind.

From the point of view of function, arthrodesis is all that could be required. It makes a useless flail limb into a useful member, and renders the patient independent of stick or crutch.

It must be admitted that sometimes an operation that is successful at

the time turns out ultimately to be a failure. This usually happens when fibrous ankylosis has been defective, or when after-treatment has been given up too soon. Flexion then takes place, and, as a rule, a secondary operation becomes necessary. The operation of excision of the knee has made us only too familiar with the marked tendency of this joint to undergo flexion. It must be prevented by tenectomy of the flexors, provision of adequate tension of the extensors, screwing down the patella, and the use of a moulded splint for at least a year, until the bone sutures are immovably fixed.

Arthrodesis of the knee is, and always will be, subject to certain disadvantages, and it is therefore fortunate that we possess in **plastic operations on the quadriceps** a much superior method for use in cases of partial paralysis of the thigh muscles. We have never considered it justifiable to excise the knee when the extensors have been paralyzed and the flexors have remained intact. At the same time, we have always lamented the ineffective

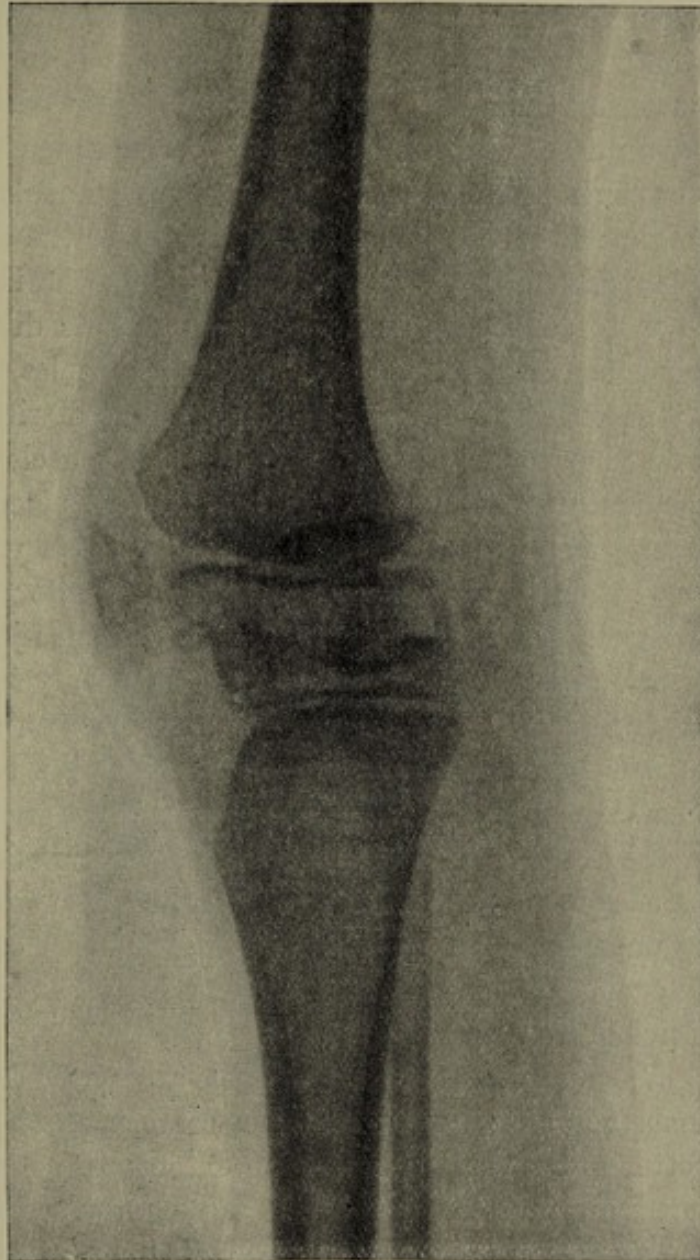


FIG. 188.

nature of the treatment that is commonly applied to these cases. At the present time we can only apply an instrument with an artificial quadriceps, the effect of which is to stiffen the joint rather than to facilitate walking. We do not consider that the mere existence of paralysis of the quadriceps is sufficient to justify tendon transplantation; we reserve the operation for cases in which considerable loss of function exists.

A very considerable amount of muscle is required to replace the quadriceps, and to perform its important functions. This has been repeatedly urged as a probable difficulty in the way of the success of the operation. Herz and Bum have investigated the average pull exerted by various groups of muscles by means of the dynamometer. They find that the force exerted when the knee is flexed amounts to between 82 and 115, taking 100 as standard with the joint extended—that is to say, that the flexors are more powerful than the extensors when they act at the greatest mechanical advantage. But when the knee is extended they exert less leverage, and the same holds good when they are transplanted on to the front of the thigh. They can never be equivalent to the extensors, even if they all act together (Reiner). On the other hand, the inherent tendency of the knee to undergo flexion has been explained as due to the greater bulk of the flexor as compared with the extensor muscles, quite apart from the atrophy of the extensors that is always associated with disease of the joint. Anyhow, the fact remains that there is no muscle anything like as powerful as the quadriceps that can be grafted into its place, even in the most favourable cases. Experience shows, however, that a weaker muscle is sufficient to prevent the various functional disablements that we have mentioned, and especially the sudden giving-way of the knee-joint. Transplantation of one or more flexors has a dual effect. Not only is the pull on the front of the thigh increased, but also the counter-force on the back is diminished. The patient is enabled to extend his knee whilst bearing his body weight upon it, and even if power of voluntary flexion is not acquired, the improvement in the usefulness of the limb is very marked. Further, the transplanted muscles respond to the increased amount of work that is thrown upon them by undergoing hypertrophy, so that in some cases the amount of voluntary extension that is present gradually increases until it finally becomes almost, if not quite, normal.

Various muscles are available for transplantation. The *tensor fasciæ femoris* is already a so-called accessory extensor of the knee, so that it is better not to graft it into the extensor tendon proper unless it is the only surviving muscle. In such a case, however, improvement will result from the operation (Schultess, Nägeli, Kofmann). Lengfellner and Frohse think that it is better to employ the posterior part of the ilio-tibial band for transplantation. The *sartorius* lends itself particularly well to this treatment in point of position and direction, and, in addition, it frequently escapes being affected by the paralysis (*cf.* the extensor longus hallucis). Goldthwait recommends a longitudinal incision, beginning at the inner border of the patella, and extending for several inches up the thigh. The *sartorius* is detached from its tibial insertion, and fastened to the fascia just above the patella. I usually make an extensive incision behind the inner condyle of

the femur, and thus expose not only the sartorius, but also the adductors, the semitendinosus, and the semimembranosus. A second longitudinal incision runs over the middle of the patella, giving access to the bone itself, the ligamentum patellæ, and the lower part of the quadriceps tendon. We now prefer a slightly curved incision, by which means we avoid the deep stitches lying immediately beneath the skin stitches, and prevent adhesion of the tendon to the skin. The bridge of tissue lying between the two incisions is easily undermined with the fingers, and the sartorius is displaced forwards, after being mobilized as much as possible.

The other muscles of the thigh are utilized in a similar manner. The *gracilis*, and, according to Lengfellner and Frohse, the *adductor magnus*, may be employed. They must be freed sufficiently high up to allow of their passing straight down to their new insertion on the extensor aspect of the limb. The tendons must be divided a long way down, so that they extend beyond the patella and down to the ligamentum patellæ. Krause suggests taking the semitendinosus and the semimembranosus forwards through a slit in the vastus internus, so as to avoid the femoral artery. I myself always make the space on the upper surface of the muscle.

The *biceps* may be exposed through a postero-lateral incision, and its tendon detached from the head of the fibula. If necessary, a little cartilage may be removed as well. The fascia over the muscle, and the vessels and nerves entering it, and especially the peroneal nerve, must be carefully preserved. Lengfellner and Frohse recommend that the tendon should be split into two parts, corresponding with the two heads of origin, and that the long head only should be employed for transplantation. The fascia lata is undermined through an anterior incision, and the muscle displaced forwards. Krause advises that it should be put through a hole in the vastus externus, but we have never found this necessary. Schanz pleats the quadriceps tendon just above the patella, and fastens the transplanted tendons to the pleat. It is better to transplant the external as well as the two internal flexors, if possible, not only in order to make the new muscle as strong as possible, but also to prevent a unilateral pull. In one case Heusner employed the biceps only, leaving the semitendinosus and semimembranosus intact. An O-leg resulted, which he attributed—rightly or wrongly—to the form of operation employed. I myself have not seen this happen, although I have performed transplantation of some only of the flexors. But in cases of paralysis of the semimembranosus and semitendinosus, in which the biceps has remained intact, I have met with severe genu valgum, necessitating operation for its relief. The same applies to paralysis of the biceps, the internal muscles being intact.

It is important to cut the tendons as long as possible. In severe paralysis the quadriceps tendon is often so friable and intermingled with fatty muscle

fibres that it is impossible to suture the flexors to it, as the stitches cut out. It is, therefore, necessary to suture the tendons to the periosteum or into the bone itself, so that the necessary tension may be permanently maintained. The external and internal tendons are fixed to the anterior surface of the patella, as near together as possible. A few stitches are also put in between the tendons and the quadriceps expansion. If possible, they are sutured to the ligamentum patellæ and tuberosity of the tibia as well. In cases of severe contracture, where the flexor tendons are too short, they may be elongated by Lange's method of using stout silk threads extending from the insertion to the tendon. By attaching the silks to the tuberosity, rather than to the patella or to the ligament, Lange has sought to illustrate one of the great advantages, in his opinion, of the periosteal method of transplantation—viz., that any desired artificial insertion may be employed. Longer tendons, however, are required than when the attachment is made to the upper border of the patella. Turner tried to avoid the use of silk by taking a fascio-periosteal flap from the region of the tuberosity, and turning it up to meet the tendon. I have sometimes employed Lange's technique in its most advanced form, and the results have been as good as those obtained by the ordinary methods, but not better, so that I unreservedly prefer the more usual technique. Provided that there is no very great contracture present, the flexor tendons can usually be mobilized sufficiently high up to reach to the middle of the patella. Even if silk extensions have to be used, I think that the employment of the natural insertion of the quadriceps tendon is just as good as that proposed by Lange, besides being simpler and more certain. Lange's work on the organization of the silken ligaments is very interesting, but as far as practical surgery is concerned there can be no doubt that the less foreign material that is introduced the better it is.

We have seen that a number of different muscles may be employed for transplantation. It remains to discuss the disadvantages that may accrue from abolishing the proper functions of these several muscles. This point has been greatly emphasized by the opponents of the operation, especially Lorenz and his pupils, Reiner and von Aberle. These observers consider that the loss of the flexors must inevitably lead to genu recurvatum—firstly, because the posterior part of the capsule, being unsupported, will yield before the force exerted by the extensors; and, secondly, because the new quadriceps will undergo contracture in accordance with the law of antagonists. Quite a large mass of muscle is available in the form of the sartorius or one or other of the adductors, but no mention is made of this; and Lorenz continues to treat the quadriceps in his own laborious and unreliable manner, when a better result could be more rapidly obtained by the employment of the sartorius.

I have frequently expressed my views upon the importance of the gastrocnemius, and possibly also of the popliteus, in preventing serious recurvation. I think that there is no real danger of this occurring when the triceps suræ is intact. However, in deference to Lorenz's views, I have often left one of the internal flexors in cases in which sufficient muscle was available to allow of this. Such a proceeding, nevertheless, has an inherent disadvantage—the muscular pull becomes unilateral, and genu varum appears. It would, therefore, be necessary to leave the biceps also on the

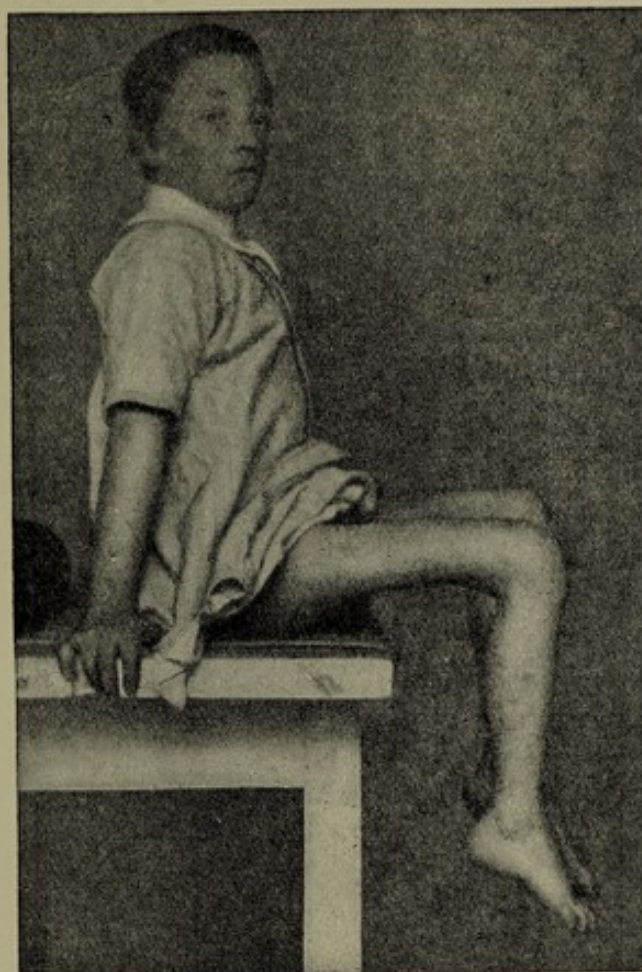


FIG. 189.

outer side; only one muscle (the semimembranosus or semitendinosus) can be spared from the back of the joint. It is clearly useless to attempt to perform a transplantation with such a small amount of material.

Fortunately, practical experience does not bear out these authors' fears. I have never had a serious genu recurvatum after transplanting all three flexors, nor have I seen lateral deviation after grafting one or more of the group. This is what one would expect, considering the fact that genu valgum is quite independent of the distribution of the paralysis, as we have already seen. In one case only have I seen a certain amount of disability

result from unilateral transplantation. The patella became subluxated inwards at the moment when a certain degree of flexion of the knee was attained. Selberg has recorded a similar case. He attributed it to the excessive power of the transplanted biceps, and corrected it by fastening the muscle more internally—*i.e.*, to the tuberosity of the tibia.

Let us return to the question of **which muscles are to be employed** for the operation. This is a matter which it is not easy to decide. We have



FIG. 190.

to consider not only which muscles are available, but which are most suitable for our purpose. On reviewing the literature we shall find that, since the earliest transplantations performed by Goldthwait between 1895 and 1897, every imaginable permutation and combination has been employed, and that success has attended the most diverse methods. Schultess recommends the use of the tensor fasciæ femoris. Kofmann employs this muscle and the sartorius. He merely displaces this muscle from its insertion without separating it completely. Schanz uses the biceps and sartorius.

I have tried to arrive at a definite conclusion by comparing the notes of sixty cases, although the value of the figures is greatly limited by the fact that the muscles concerned varied very much in functional capacity.

In cases in which the sartorius alone was transplanted, or the sartorius and the internal flexors, 60 per cent. acquired power of extension, and this was complete or nearly complete in 30 per cent. of the number. Eighty per cent. of partial successes resulted from the employment of the sartorius and biceps together, with full extension in 30 per cent. All the muscles together gave 90 per cent. of positive results, with full voluntary extension in 40 per cent. If I abandon the use of the semitendinosus and semi-membranosus, in deference to those who fear genu recurvatum, and compare my results with those of others—*e.g.*, Schanz—I arrive at the conclusion that the combination of the biceps and sartorius gives the best functional result.

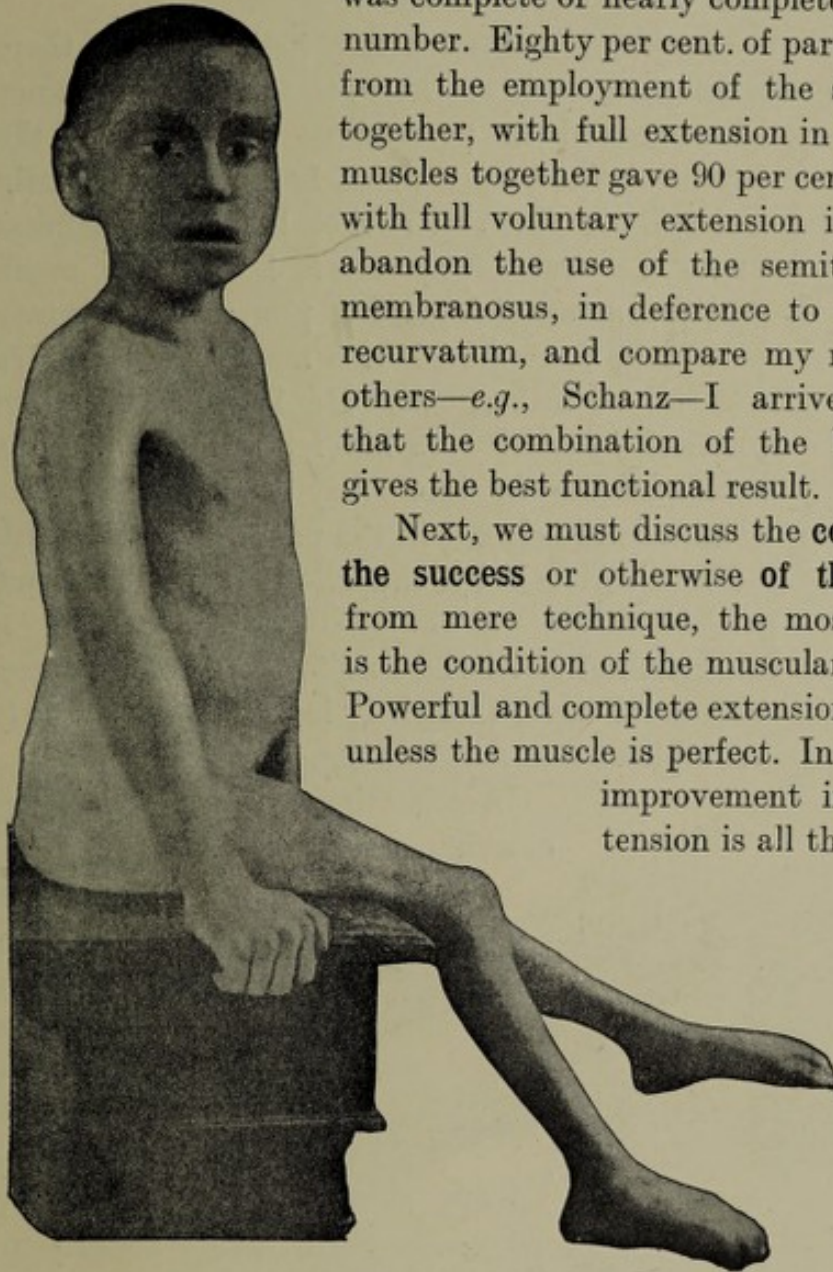


FIG. 191.

Next, we must discuss the **conditions determining the success** or otherwise of the operation. Apart from mere technique, the most important matter is the condition of the muscular tissue transplanted. Powerful and complete extension cannot be expected unless the muscle is perfect. In other cases a limited improvement in the power of extension is all that we can expect, but

even a partial result of this kind is of considerable value to the patient. The gait becomes much stronger, and the patient is able to walk for a much longer time. The relations have frequently mentioned

this to me. Lange gives a suggestive explanation. He says that the muscle undergoes functional adaptation. Thus, a transplanted flexor extends the hip-joint and the knee-joint simultaneously—a movement which is of the greatest importance in walking.

When the condition of the muscles is favourable, a still higher percentage of successes will be obtained. According to my series, we obtain

full power of extension in at least a third of the total number. It is unnecessary to enlarge upon the improvement in the gait which this produces. Selberg has performed a plastic operation on the quadriceps on both sides, and on two occasions I have done the same. As a general rule, however, it is better to fix the knee on the more severely affected side by means of arthrodesis or an instrument.

Besides the outward and visible success, there is another result of the operation, which cannot be expressed in percentages, and that is the psychical effect, upon which Lange has frequently insisted. If the patient has been quite helpless up to the time of operation, he will be much gratified at acquiring some power of voluntary extension, even though this may not amount to the full normal extent. He loses the sense of physical inferiority to his fellows, and takes a new pleasure in life. Any surgeon who has observed this change in the patient's outlook will be much struck by the all-round improvement that results.

I cannot resist the temptation to quote a few successful cases, though it is useless to multiply examples.

In estimating these persons' powers of walking there are certain fallacies to be avoided. Not infrequently they will be found to have adopted various dodges, in order to

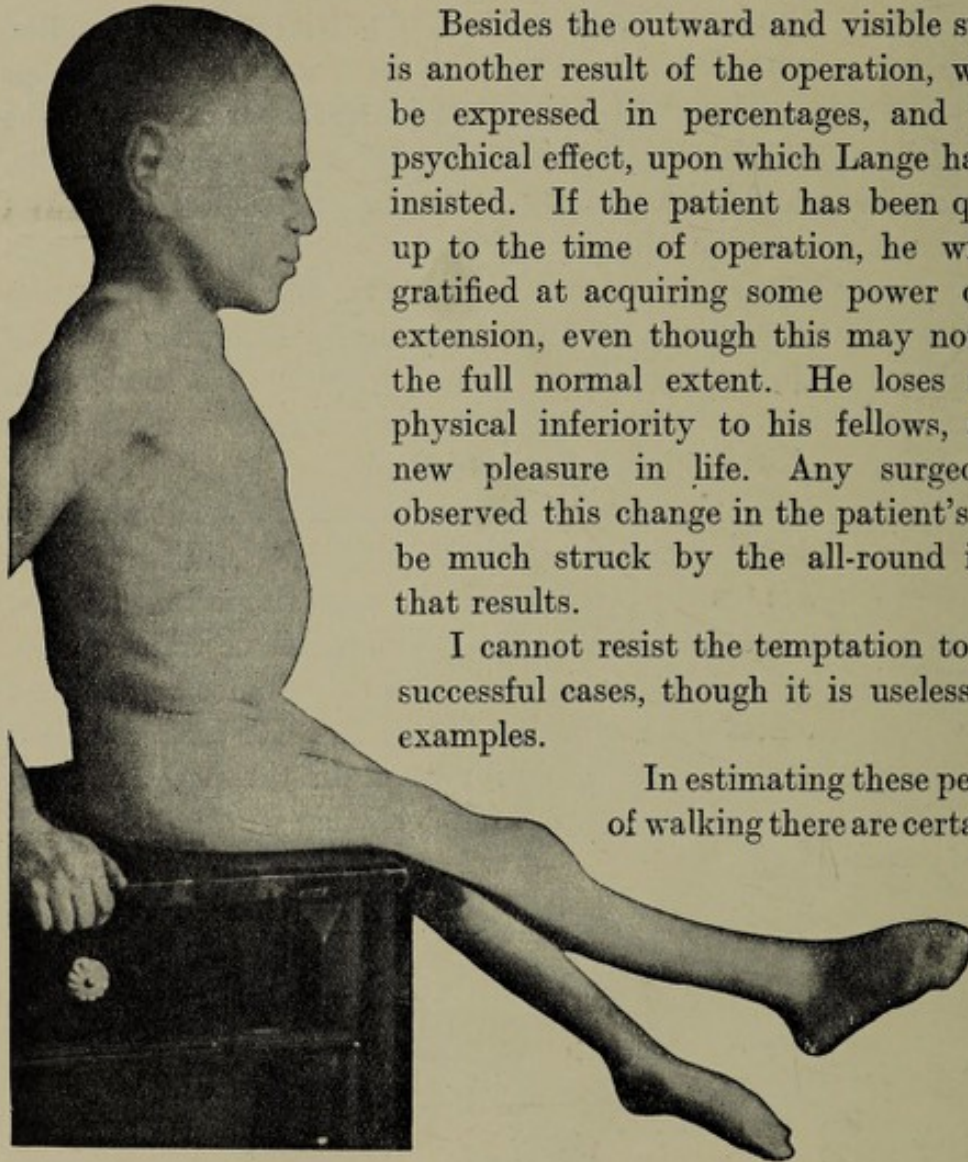


FIG. 192.

assist their mode of progression, though they are quite unconscious of the fact themselves. Thus, they may rotate the limb outwards. In this position the knee-joint is locked, and it is quite easy to carry the leg forward, quite apart from any question of tendinous fixity. Again, it has been shown that the power of extending the leg after the performance of transplantation varies considerably, according as the hip-joint is flexed or extended at the moment. The power of flexing and extending the knee is therefore shown with the patient sitting up as well

as lying down. We also have the usual gymnastic after-treatment carried out with the patient lying down, so that the hip is kept extended during the process. At first he lies on his side.

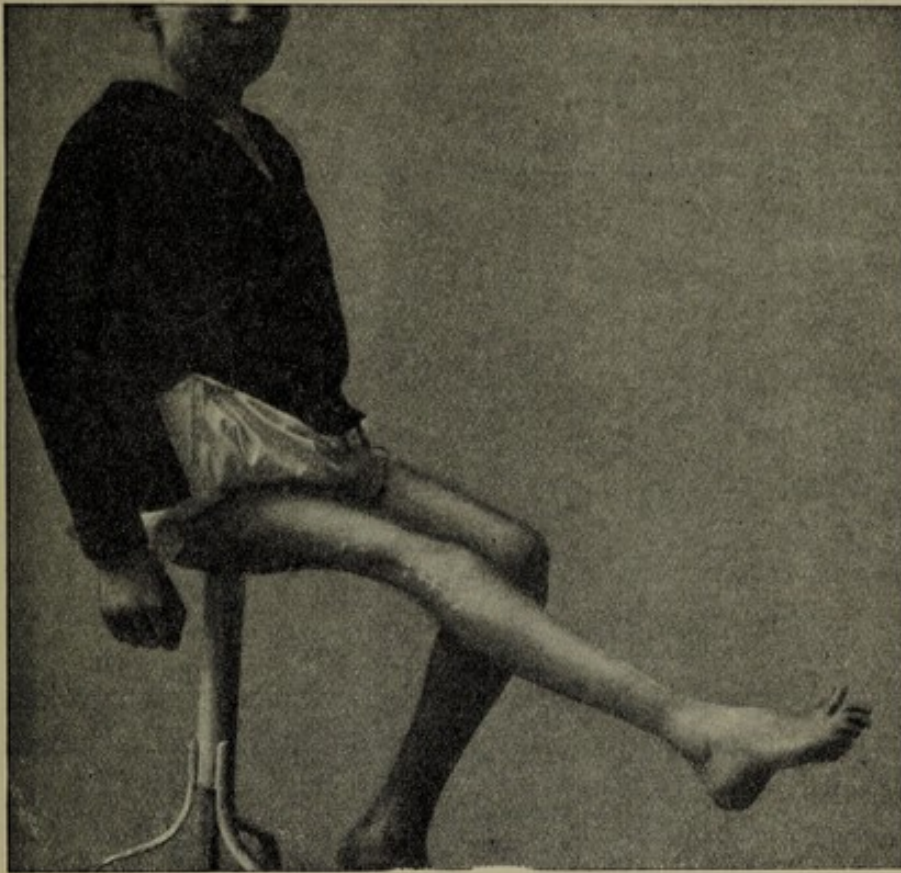


FIG. 193.

1. Transplantation of internal flexor one year after onset of paralysis (Figs. 189 and 190).

2. Internal flexor, biceps, and sartorius after one and a quarter years (Figs. 191 and 192).

3. *Cf.* 2, after four years. The contraction of the biceps is very clearly shown (Fig. 193).

4. Biceps and sartorius, after six months (Fig. 194).

5. Biceps and gracilis (Fig. 195), after two years. Contraction of biceps very plainly seen.

6. Sartorius and adductor, after four years (Figs. 196, 197, and 198).

Although the foot has to bear the weight of a special high boot, the



FIG. 194.

patient is able to extend the leg when sitting and when lying down, and can flex it to a right angle.

In conclusion, one may mention, as a curiosity, an operation performed by Hunkin. He dissected the rectus abdominis from its attachment to the

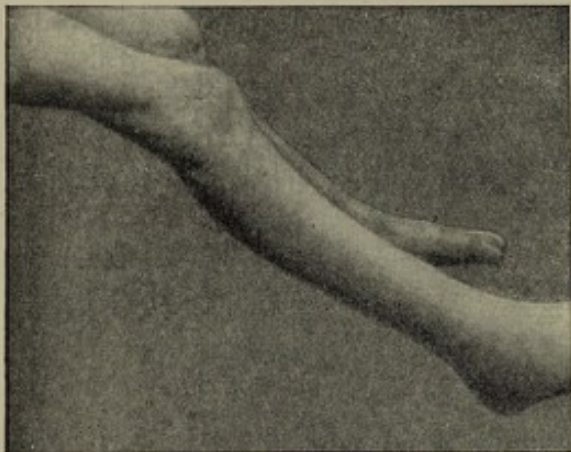

FIG. 195.

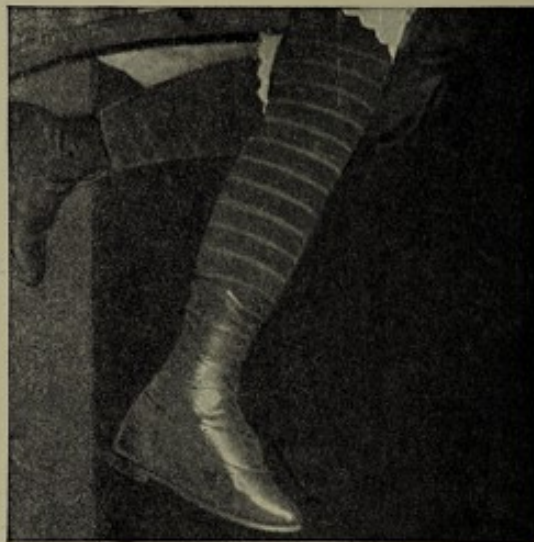

FIG. 196.

symphysis pubis, and attached it by means of silk tendons taken through the rectus sheath to the tuberosity of the tibia. The child learned to carry the leg forward.

Neuroplasty.—The difficulty that is present in the case of tendon trans-

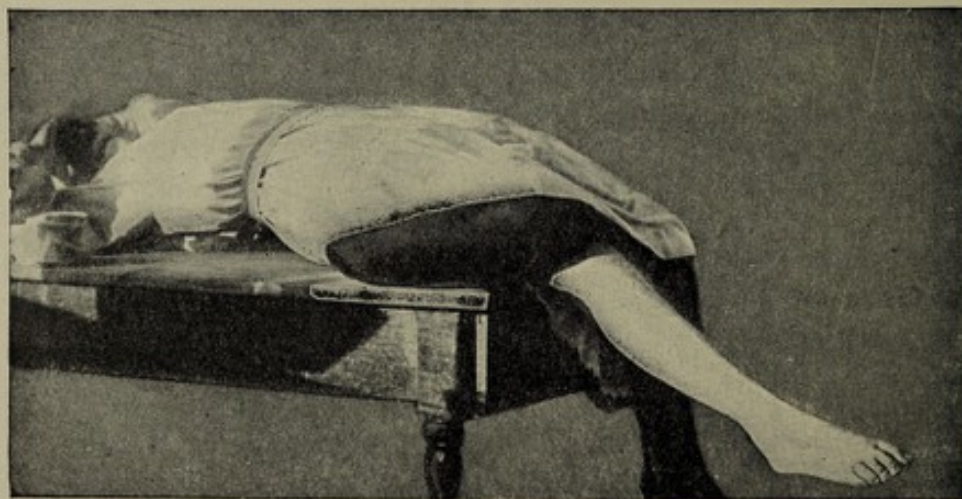


FIG. 197.

plantation is much more marked in the case of neuroplasty. The disparity between the tissue grafted and the recipient structure is much greater. It has been shown, however, that even a considerable inequality in size may be made up for by proliferation of the nervous tissue. Spitzzy has demonstrated the possibility of innervating the anterior crural nerve by means of

fibres from the obturator in animals. The operation was carried out with technical success on several occasions in dogs. The anterior crural nerve was divided, and the obturator grafted into it in a descending direction, and the functional conductivity of the anastomosis demonstrated by anatomical preparations. This was confirmed by clinical methods of examination. Spitzzy has not yet succeeded, however, in a human being.

Two incisions are used, one extending from Poupart's ligament, downwards and outwards, across the femoral artery, and exposing the anterior crural nerve. The other passes inwards from the pubic spine, internal to the tendon of the adductor longus. On dissecting between this muscle and the pectineus, one comes down upon the dis-

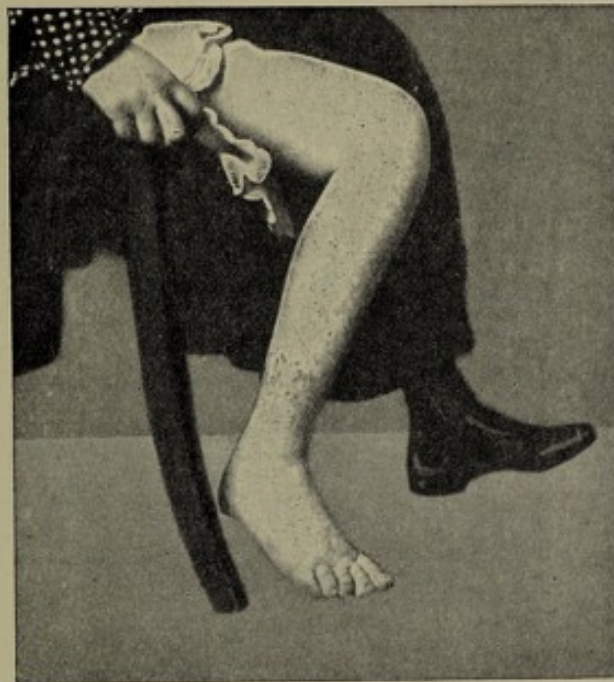

FIG. 198.

tribution of the obturator nerve. The various muscular branches are isolated, separated from the muscles at their point of entry, and fastened together into one bundle. By means of Spitzzy's "Tunnelleur," this is approximated to the crural nerve, into which it is implanted.

The sartorius frequently escapes paralysis, and if this has occurred, the muscular branch to it may also be employed for grafting. The upper nerve to the sartorius is dissected free and implanted in the middle part of the anterior crural nerve, which is the part chiefly concerned in the innervation of the quadriceps.

The anatomical relations of the crural nerve, both in its distribution and within the trunk itself, still require investigation, especially as Spitzzy and Stoffel are not agreed as to the position of the sartorius fibres. As long as this question remains undecided, the operation of neuroplasty is deprived of most of its value.

The third great nerve of the thigh has also been employed for transplantation. Van der Bergh divided the anterior crural nerve as high up as possible in a case of paralysis of the quadriceps, took it through to the flexor aspect by means of the tunneller, and implanted it in an ascending direction in the sciatic nerve. Some months afterwards the child, who had previously only been able to get about by supporting the knee with his hand, was running about quite well, and even standing on the affected leg only. Maragliano has recently reported a case of paralysis of the three nerves of the thigh of nine months' duration. He transplanted a portion of the corresponding nerve from the other side. In five months' time some power of extension of the knee had appeared.

CHAPTER VIII

PARALYSIS OF THE HIP

It is, fortunately, rare for all the muscles in relation to the hip-joint to be completely, or nearly completely, paralyzed. In severe cases some fibres of the sartorius and tensor fasciæ femoris usually escape, and the ilio-psoas, though impaired, is generally demonstrable. It enables the patient to adduct his thigh when lying down, and to swing his leg forwards with fair power when he is standing up. If the patients resume walking fairly soon after the onset of their paralysis, more or less severe flail hip commonly develops, together with coxa valga, even though they make use of a stick or a crutch.

If there is no contracture, and the flail condition is not bad, the patients often get about pretty well with the aid of a stick. They unconsciously shorten the time during which the whole weight of the body is thrown upon the leg, and during this brief period the joint is capable of bearing the stress that is cast upon it. In many instances the difficulty in walking is due to the associated condition of the knee and ankle joints, and not to the weakness of the hip. Severe paralysis of the hip is almost always accompanied by widespread destruction of the musculature of the rest of the limb.

Treatment.—Adequate support is often afforded by encasing the rest of the leg in a light plaster or an unarticulated apparatus. In other cases, however, the only thing that will suffice is arthrodesis of the hip-joint itself.

Fixation may be accomplished mechanically by the use of a sheath appliance for the whole leg suitably jointed to a spinal support or jacket (Fig. 199). A spring is provided, which can be easily felt through the clothes. When the patient wishes to sit down, he presses the spring; when he gets up, the lock closes automatically, and the hip-joint is fastened.

The lifelong use of an instrument of this kind is subject to many disadvantages, so that surgeon and patient alike frequently seek for some other method of treatment.

The most tiresome symptom of paralysis of the hip is inability to fix the pelvis upon the femur during that stage of walking in which the weight is being borne upon the affected limb. This is chiefly due, as is well known,

to destruction of the gluteus medius. We shall allude later on to the attempts that have been made to replace this muscle by a plastic operation upon the vastus externus. It is impossible as yet to criticize the operation, for not enough cases have been placed on record; and, again, the operation is only applicable to those uncommon cases in which the muscle has escaped paralysis.

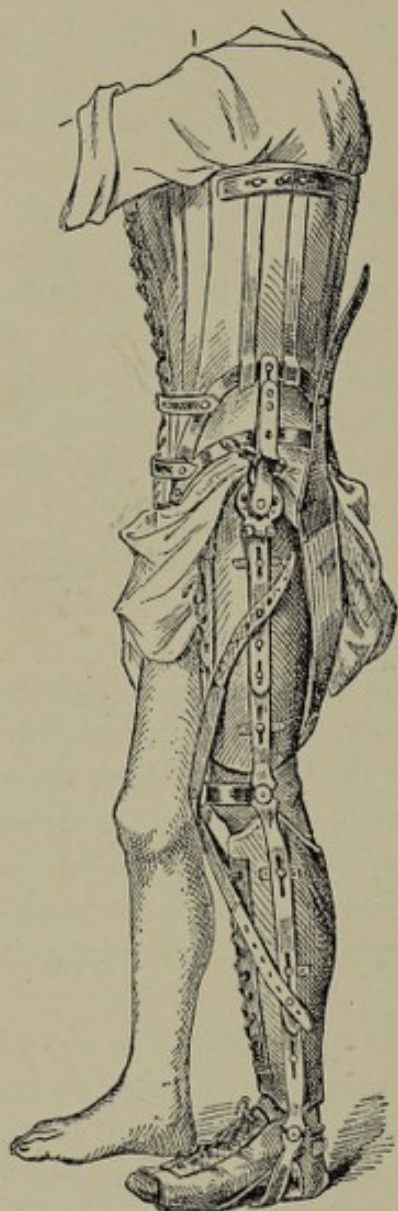


FIG. 199. (AFTER HOFFA.)

Arthrodesis.—Arthrodesis, therefore, remains our first line of treatment. It is particularly valuable in bilateral cases, though it is often distinctly indicated in unilateral cases.

In former days arthrodesis of the hip was regarded with considerable misgiving as being dangerous and unreliable; and, indeed, this opinion was justified under the conditions that obtained at that time. Dollinger was the first to stiffen the hip-joint. He repeated the operation on a later occasion with a strikingly good result. He opened the joint, displaced the head of the femur, removed the cartilage from the articular surfaces, and then drove a long screw through the trochanter, and the head and neck of the femur, into the bottom of the acetabulum. A nut was then placed upon the internal aspect of the screw by means of a second incision, giving access to the interior of the pelvis, and another nut was screwed on to the outer end.

It would appear that the severity of the operation deterred others from attempting it, as it did me, for no other surgeons have recorded cases.

Phenarthrodesis.—Mencière improved the technique of arthrodesis of the hip considerably. The head of the bone was exposed through an external incision, after separating the atrophied muscles. It was dissected quite free, and levered out of place. The articular cartilage was then thoroughly removed from it, and from the base of the acetabulum. At this stage Mencière swabs out the cavity with pure carbolic acid to induce aseptic inflammation and promote the formation of firm fibrous union. Care must be taken to protect the skin and soft parts from the acid. After thirty seconds the wound is washed out with an abundance of pure alcohol, dried, and carefully sutured up. Mencière advises the use of drainage, but I

have always omitted this step without any harm resulting. After this method of treatment the wound always looks appalling, so that after my first attempt I was very anxious as to the result. But there was no cause for alarm, as my subsequent series of eight phenarthrodeses of the hip has shown. I leave the **plaster** on for **ten to twelve weeks**. At the end of that time the joint is either completely stiff or only allows of a very limited range of movement. It is important to ankylose the joint in the position of slight abduction and some external rotation in anticipation of a possible contracture which will tend to produce adduction and internal rotation. For the same reason I order a **simple hip and thigh splint to be worn for some time longer**. Kofmann also reports a series of six phenarthrodeses, with equally satisfactory results. Moszkowicz performed an arthrodesis of the hip in 1907, but I have not been able to ascertain whether he employed Mencièrè's technique or not.

If the muscles of the back are sound, the patients walk extremely well with a stiff hip. They can keep on their feet for quite a considerable time. If they are afflicted with bilateral paralysis, an operation upon the worse side will not only enable them to walk—for this can be effected with apparatus—but will enable them to walk surprisingly well. There is but little difficulty in sitting down, for the spine undergoes a compensatory backward curvature. There are several examples in Chapter X. of very severely deformed children who were treated by arthrodesis of the hip.

Partial paralysis of the hip, unlike similar affections of the other joints, does not present an easier problem than total paralysis. Even the most favourable case—viz., isolated paralysis of the gluteus medius—presents a difficulty that has not been by any means satisfactorily overcome. The function of the muscle is to abduct the leg or to raise the pelvis on the sound side, and this requires a considerable output of energy, which has to be exerted under unfavourable mechanical conditions. Paralysis of the gluteus results in marked impairment of function, and renders walking very difficult. In bilateral cases it may be altogether impossible.

Lange has tried to treat these cases by tendon transplantation. At first he attempted to fasten silk threads from the trochanter to the crest of the ilium, in the hope that the newly formed connective tissue thrown out around the ligatures would suffice to balance the trunk on the thigh. In this, however, he was disappointed. Later on he employed the vastus externus, dissecting up its origin and elongating it at its free border by means of eight or ten stout paraffin-coated silk threads, which were then fastened to the crest of the ilium in a fan-like manner by the periosteal or transosseal method. A plaster splint is then applied with the limb fully abducted, and this is kept on for six to eight weeks. Gymnastic after-

treatment is then begun, and a simple retentive apparatus is applied to limit adduction at 150 degrees.

In one case the result was spoiled by the extrusion of the silks, but in the other three more or less success followed. One of the patients was able to support a weight of 2,800 grammes with his new abductor—only 900 grammes less than on the sound side. Lange has not yet committed himself to a final judgment on the method, but the results that he has obtained up to the present time justify the performance of the operation.

I have only had one opportunity of trying it myself. This was in the case of a girl of six. I operated in exact accordance with Lange's instructions, and after fourteen months she had acquired a fair range of voluntary abduction; and although the movement was not very powerful, it was yet sufficient to enable her to walk fairly well, and the hollowness of the thigh had disappeared.

Deutschländer recently took a graft from the gluteus maximus, and fastened it to the anterior superior spine after turning it through a right angle.

It is very doubtful whether neuroplasty would give any better results here.

Although isolated paralysis of the gluteal muscles does occur, the majority of partial affections of the hip-joint are much less satisfactory to deal with, for, as a rule, most of the hip-muscles are paralyzed. Various kinds of paralytic contractures are then developed, depending partly upon the localization of the surviving muscles, and partly upon the habitual position of the limb. The commonest result is that the leg takes up the position of flexion, abduction, and external rotation. The muscles concerned in its production are the ilio-psoas, the tensor fasciæ femoris, the sartorius, and the rectus femoris. In addition, a secondary contracture usually takes place at the knee. The leg is, of course, useless in this position, and there is great liability to the occurrence of some dislocation—*e.g.*, subluxation at the hip. The relaxation of the capsule and the alteration in shape of the neck of the femur (Kiewe) increase the risk of this occurring.

Paralytic luxation had been described as early as the year 1877 by Reclus, and attention was called again to the fact by Karewski's demonstration of the possibility of curing it by operative interference. More recently a number of writers, including Grisel, Saxl, Schultze, and Böcker, have described the nature, ætiology, and therapy of the deformity. At the present time there is no unanimity of opinion with regard to these questions.

There are two kinds of paralytic luxation. *Iliac luxation* results from paralysis of the abductors and external rotators—the deformity is then produced by the traction of the surviving antagonists (see Fig. 200); *infra-pubic luxation* results from the converse condition.

Dislocation of this kind is much more frequent than was formerly imagined. It is disguised by the associated contracture—adduction in the case of posterior luxation, and abduction with flexion in the case of infrapubic displacement.

Böcker has collected together the published cases of dislocation :

	Infrapubic.	Iliac.
Reclus	1	2
Karewski	7	1
Rehn	2	—
Albert	1	—
Appel	—	1
Martin	2	—
Mouchet	—	1
Garavini	1	—
Schultze	2	1
Böcker	1	3
	17	9

In addition, Grisel has recently reported a case of iliac subluxation, which, like Appel's case, ought rather to be included in the category of voluntary dislocations.

In spite of these statistics, Böcker states that the iliac is the commoner form of dislocation ; indeed, he goes so far as to say that he doubts the existence of a true anterior dislocation. His reason for this view is that no skiagram clearly illustrating the condition has yet been published. He regards the process as a gradual migration of the head towards the os pubis, though it never actually leaves the acetabulum. There is erosion of bone going on all the time, with the result that a "travelling acetabulum" is developed. On looking through my skiagrams I find, to my surprise, that they confirm Böcker's statement (Fig. 201).

The head is constantly found, however, in a position corresponding more or less with that of infrapubic luxation. Clinical examination is rendered very difficult by the marked atrophy of the muscles, and the alteration in shape and direction of the neck of the femur. Further, confirmation of the diagnosis by means of radiography is rendered uncertain by the presence of contracture. I have frequently found a pathological anterior displacement of the head, but I have only met with four instances of iliac luxation. In one of these the leg muscles were more severely paralyzed than those of the thigh, though the latter were distinctly affected. It was not easy to decide whether or not the girl had an associated congenital dislocation of the hip.

Another patient showed an iliac dislocation on one side, and an infrapubic on the other.

Reclus, Karewski, and Martin have pointed out that paralytic luxation occurs in bedridden children and others who have never walked. This shows that it may be caused by the contracture of the muscles. But mechanical factors also play a part, and Saxl has described them minutely.

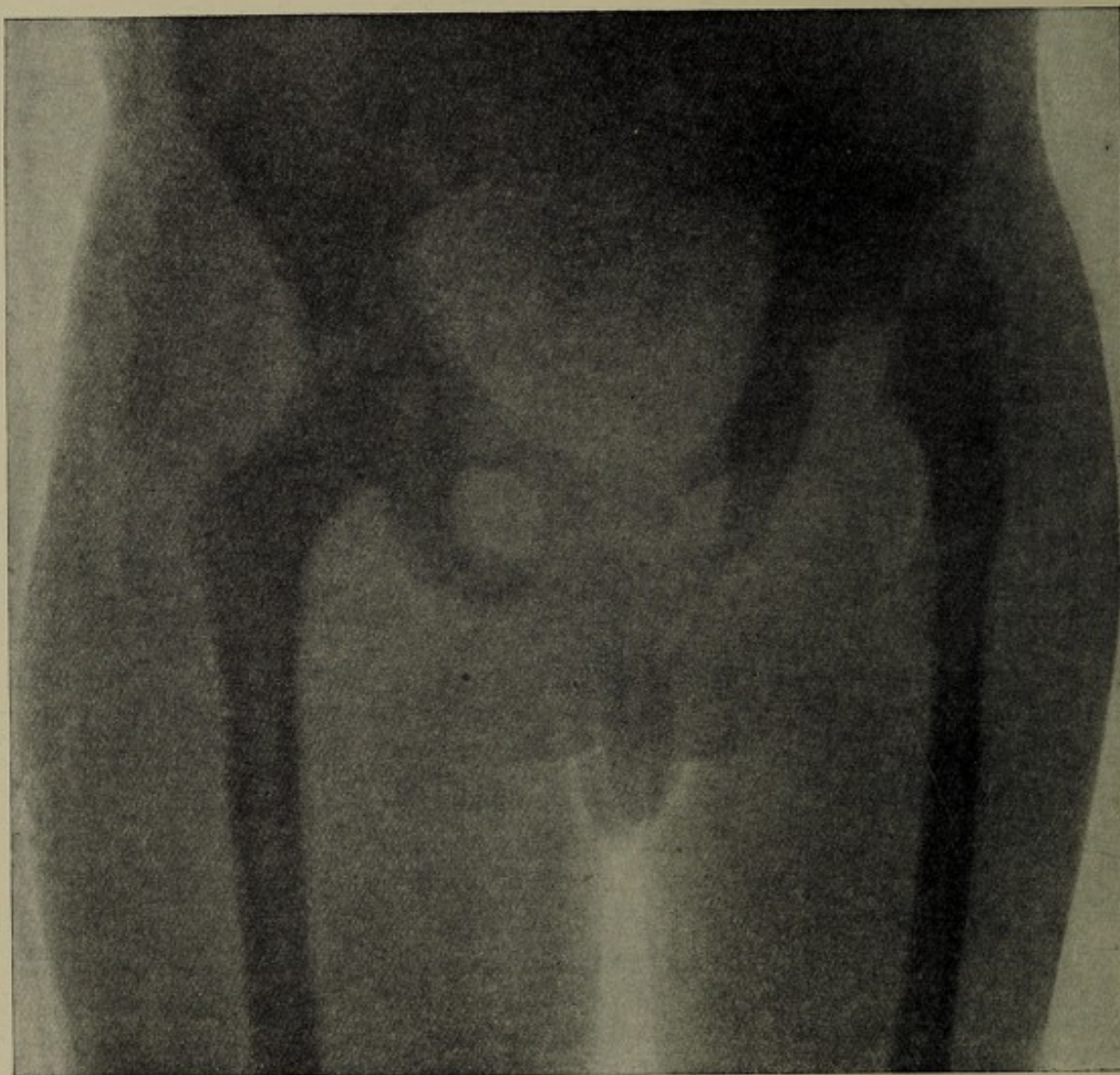


FIG. 200.

Prominent amongst the physical signs of these luxations are the contractures by which they are caused. Adduction of moderate degree renders walking difficult, but does not prevent it. Flexion and abduction, however, render the limb altogether useless, especially if there is paralysis or paresis of the quadriceps in addition—a not infrequent event.

The prevention of contracture is, therefore, one of the main objects of

treatment. The correction of contracture of the hip-joint by means of walking appliances, elastic traction, and the like, is not only tedious, uncertain, and clumsy, but expensive as well. It usually fails, for the reason that the trunk and hip are insufficiently fixed, and therefore *redressement* of the leg cannot be efficiently performed. The method is now being very properly abandoned.

In slight cases extension may suffice to correct the deformity. I have often noticed that after some weeks the weight of a plaster splint, put on, perhaps, after arthrodesis of the knee, has exerted a marked extending effect upon the hip.

If the spinous muscles, the fascia lata, and the anterior border of the

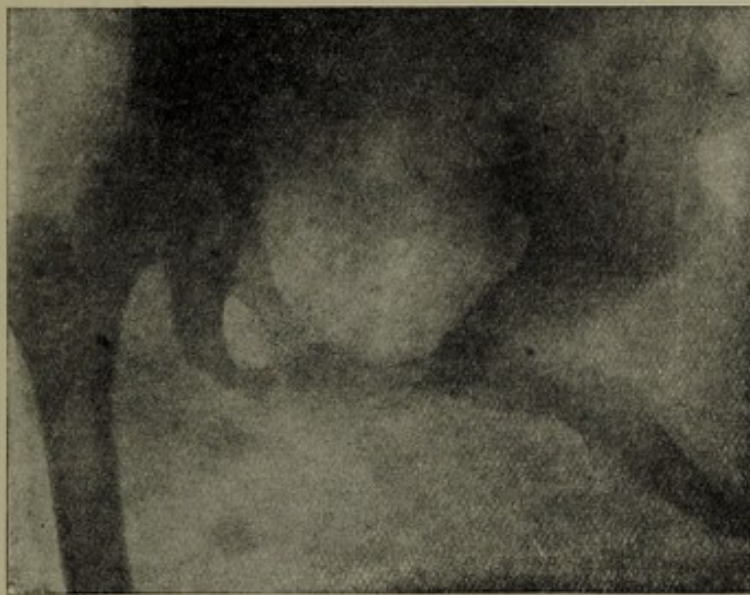

FIG. 201. (AFTER BÖCKER.)

glutei stand out prominently, subcutaneous or open tenotomy is indicated. On the other hand, the tendon of the ilio-psoas may cause considerable resistance in the case of contractures of long standing. Adduction will then be quite possible after tenotomy of the abductors if the hip is flexed, but not otherwise. Walzberg has tenotomized this tendon in the following manner: An oblique incision is made, 15 or 20 centimetres long, at the outer border of the sartorius, and with its highest point 8 to 10 centimetres below the anterior superior spine. The sheath of the sartorius is opened, and the muscle strongly retracted inwards. The dissection is then carried down deeply on the inner side of the rectus femoris. The deep vessels are divided between ligatures. The tendon of insertion of the ilio-psoas should now come into view.

I had performed the same operation myself previously, and found it by no means easy. Anzoletti's method is as follows: An oblique incision 6 to

8 centimetres long is made in the retrotrochanteric region corresponding with the position of the small trochanter and the gluteal neurovascular bundle. The muscle is divided. A finger is passed in between the adductor minimus and the quadriceps femoris, the apex of the trochanter is exposed by retracting the two muscles, and the tendon of the ilio-psoas then comes into view at its insertion. The trochanter is chiselled off and removed. This method is simple and not destructive, but the position of the incision is unfortunate from the point of view of asepsis.

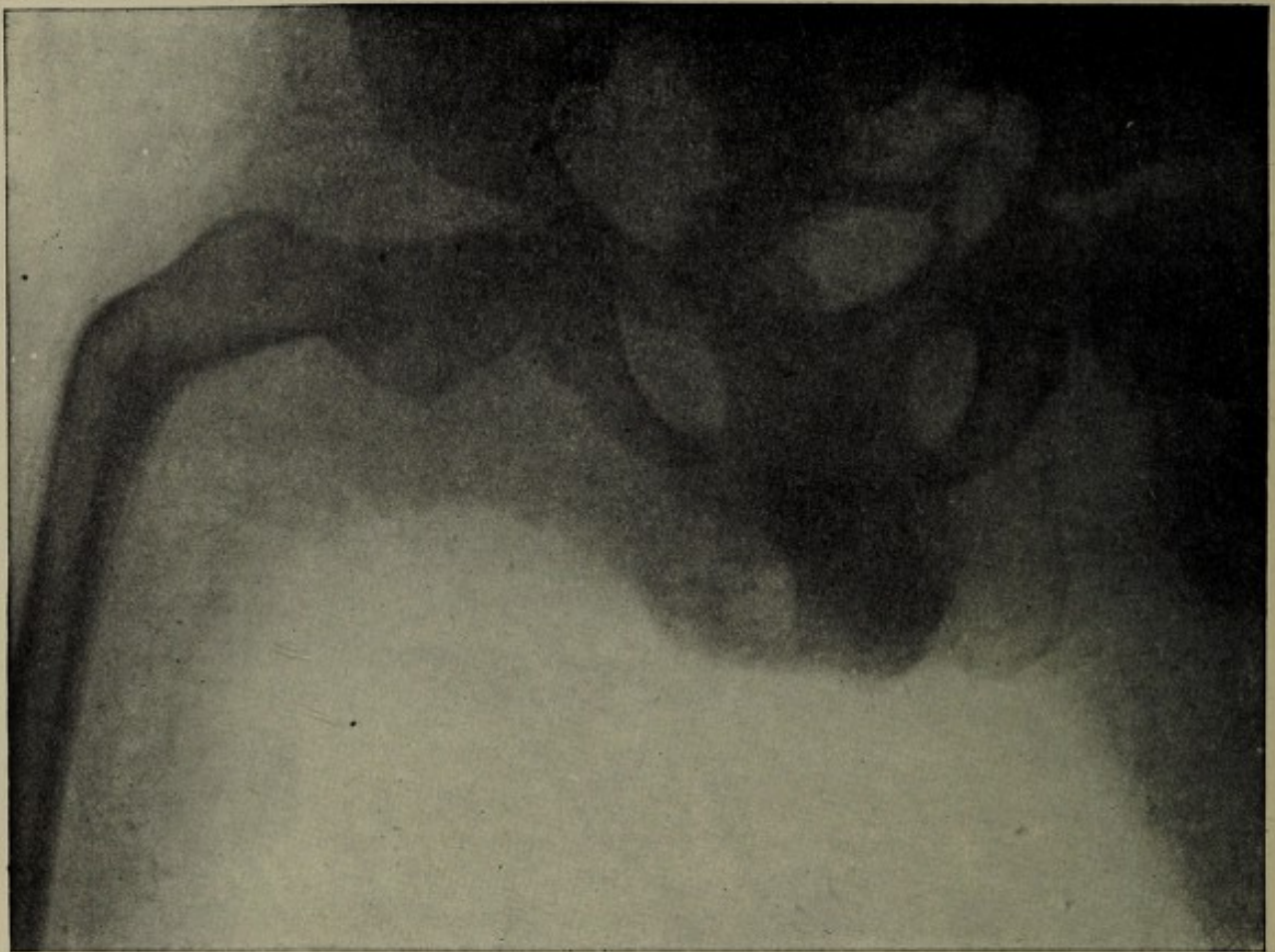


FIG. 202.

As a general rule, operative interference is unnecessary. Careful *redressement* eventually succeeds in overcoming all the resistance of the soft parts. Even infrapubic dislocations may be reduced in this way. The head of the bone gradually returns to its proper position, and sometimes a snapping sound can be heard as it goes back into place (Schultze, Riedinger).

If, however, this method fails, **operative replacement** can be carried out, and the results are satisfactory (Karewski).

The joint is exposed by Hüter's longitudinal incision. The contracted

muscles, the tensor fasciæ femoris, the rectus, and the vastus externus, and possibly also a part of the ilio-psoas, are divided, and the joint is opened. The shortened ilio-femoral ligament is then divided, the glutei, obturators, and pyriformis are dissected off the great trochanter, and then the head is replaced by a powerful movement of adduction. If the acetabulum is too small, it is enlarged with a gouge. As soon as the wound has healed, a plaster splint is applied with the limb in the position of adduction.

Karewski has performed this operation four times, and three of the patients were able to get about subsequently without apparatus. It is strange that he has not attempted to reduce congenital dislocations in the

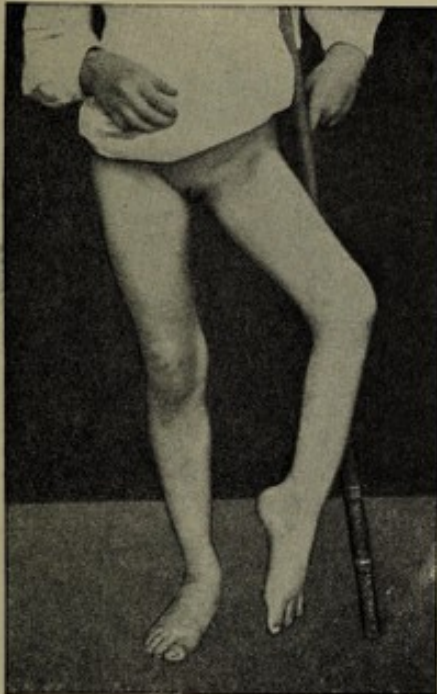

FIG. 203.

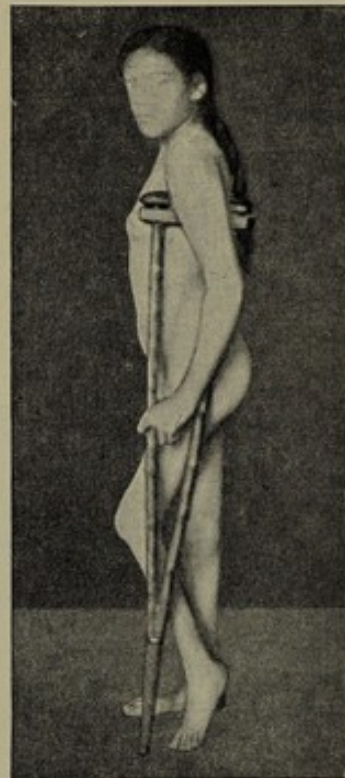

FIG. 204.

same way. The results that have more recently been obtained with this method in the case of congenital dislocation of the hip have not been of a kind to encourage us in submitting cases of old paralytic subluxation to the operation.

When repeated *redressement* fails to correct the deformity (which may occur in severe abduction-contracture), I divide the neck of the femur or perform a subtrochanteric or intertrochanteric osteotomy. The anatomical result is not elegant (*vide* Fig. 202). When abduction is marked, the osteotomy cannot be carried out as near to the neck of the femur as one would wish. The point of division is then rather lower down the femur. The abnormal shape of the bone does not impair the ultimate functional

result, as I have found in numerous cases of cripples who were previously only able to walk on their hands.

Finally, one must mention Böcker's suggestion of reinforcing the improved position by means of a transplantation. The tensor fasciæ femoris is detached at its origin, and sutured to the os pubis. It is thus converted into an adductor.

NOTE.

Paralysis of the Whole Lower Extremity.

It has been repeatedly pointed out in the foregoing chapters dealing with paralysis of the lower limbs that whilst all the muscles may be affected, the severity of the injury may vary very considerably, and not infrequently exhibits a progressive diminution from the periphery upwards. Thus, we find complete paralysis of the leg, marked paresis of the quadriceps and flexors, and slight insufficiency of the muscles about the hip.

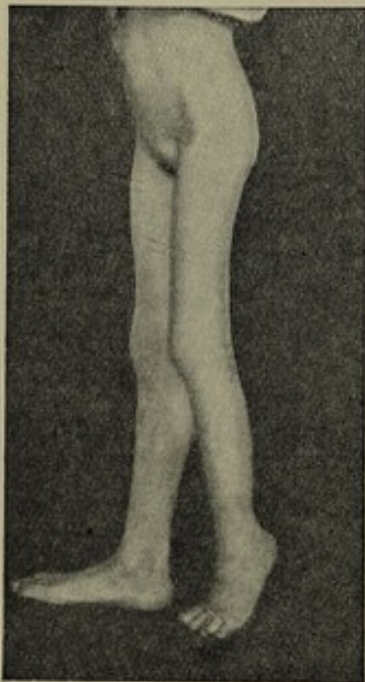

FIG. 205.

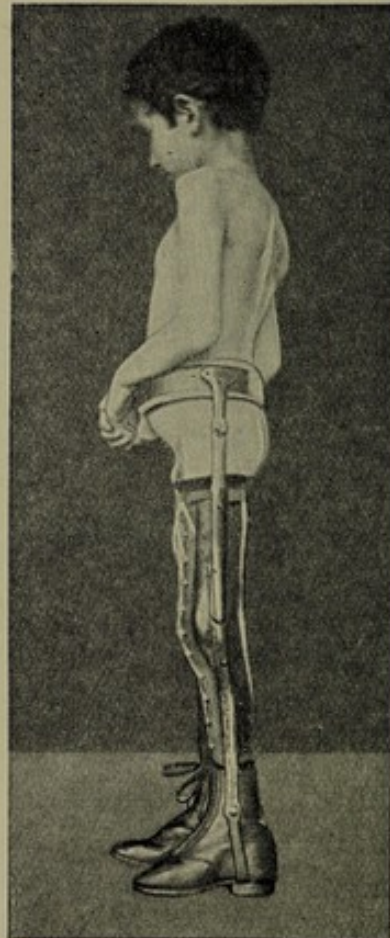

FIG. 206.

Sometimes, however, the paralysis extends with equal severity from the toes to the pelvis, or at any rate the amount of muscle that remains is so small that it may for all practical purposes be disregarded. The leg is flail and useless, its growth is arrested, and in course of time contractures appear

at all the three large joints. The patient has to take to a crutch, and becomes a lifelong cripple.

Even in cases of this kind much may be done. First of all, the contractures are corrected by means of *redressement* and tenotomies, the equinus only being interfered with if it is not beneficial in compensating for the shortening (Fig. 205). The limb is then enclosed in a light splint to determine whether the patient is able to walk when provided with a support. If he can, it has then to be decided whether he shall wear a walking apparatus—which will, of course, have to be made with a pelvic band—or whether arthrodesis at the knee and ankle is to be preferred.

CHAPTER IX

TREATMENT OF SHORTENING

TROPHIC disturbances of the skeleton arise, as we have already seen, partly as the result of inactivity of the limbs, and partly also in consequence of limitation of growth, which is frequently due to nervous influences.

Disuse-atrophy shows itself in rarefaction of the cortex of the bone, absorption of the medulla, deficient calcification, and fragility. The **effect of a nervous lesion**, however, is almost invariably to cause shortening. Its nature, course, and connection with paralysis are not completely understood. Shortening of the leg brings about tilting of the pelvis unless the patient instinctively corrects the shortening by walking on his toes. If he does not, static **scoliosis** of the lumbar and lower dorsal vertebræ gradually develops, the convexity being, of course, to the bad side. Later on, a secondary compensatory curve develops.

If the leg is so short that it is useless, or all but useless, for walking, a scoliosis is developed with its convexity to the good side to compensate for the line of the trunk.

The condition of the bones is greatly improved if their function is restored, wholly or in part, by means of exercise or operative interference.

Numerous attempts have been made to limit or to prevent disturbance of growth—*e.g.*, by painting the limb with iodine. Maas and Schmidt have tried to show, by the aid of experiments on rabbits, that some good results from this proceeding. Thus, if one leg was systematically painted with iodine from the time of birth, the bones on that side were found to be longer and stronger than those of the opposite limb. Venous hyperæmia has also been recommended. It is known from the results of its employment in the treatment of fractures that it exercises a beneficial effect upon the growth of bone. It is difficult to estimate the amount of good that results from so prolonged a treatment, but at any rate it can do no harm, and we always employ it in early cases.

The use of the limbs has a most important effect upon their growth. This is abundantly proved by the results of such operations as arthrodesis. Even in cases where the shortening has been increasing from year to year,

the affected leg begins to grow with as great rapidity as its fellow as soon as its use is restored, and in some instances the difference in length is diminished.

Ollier has adopted an heroic line of treatment. He repeatedly cauterizes the skin, scarifies the periosteum, and even drives nails into the diaphysis, close to the epiphyseal line, in the hope of stimulating the growth of the bone. In this way he has obtained an increase in length of the leg of $1\frac{1}{2}$ to 2 centimetres.

Treatment of Shortening.—Leaving the question of the prevention of impending shortening, let us turn to the consideration of the condition when it is already present.

The simplest method of compensation is the voluntary **lowering of the pelvis** upon the affected side. This, however, leads to static scoliosis, and is, therefore, not to be allowed, except in cases of slight shortening not exceeding 2 centimetres.

If the difference in length exceeds this amount, it must be corrected. The old method was to **build up the heel and sole** of the boot with cork. This rendered it heavy. A slight improvement consists in the use of hollow platforms made of aluminium. Such boots, however, look clumsy when used for cases of severe shortening, and render the gait ungainly. Light metal pattens have also been employed, but these look just as ugly. It is better in every way to **make use of the existing equinus** for correcting the shortening. A cork sole is put inside the boot, supporting the foot in this position. When the patient has been in the habit of depressing his pelvis for some years, he will not be able to bear the full correction at once. This can only be attained by degrees. It is necessary, therefore, to determine what amount of correction he can stand, and then to make a plaster cast of the foot in this position. A wedge-shaped inner sole is then fashioned to fit it, tapering away to nothing at the toes. The best material for this purpose is the so-called "industrial" cork, which can be obtained in commerce in strong, thick sheets, which can be sawn or cut. The sole is modelled in such a way as to afford an even support to the whole of the foot. *The space for the heel must be flat, or slightly hollowed out. This prevents the foot*




FIG. 207. (AFTER HOFFA.)

from sliding forwards, and undue pressure being exerted upon the toes. The toecap comes well up the boot to afford additional support to the ankle, and prevent its turning over. For the same reason the leg of the boot is strengthened. When the shortening and equinus are of considerable degree, the boot is particularly elegant, because there is no ugly prominence at the heel.

The use of a cork inlay of this kind is very simple, but it requires the services of a skilled and intelligent bootmaker. It is not applicable to cases in which the shortening exceeds 7 to 8 centimetres. At this stage the gait becomes unsteady, and it is necessary either to add a side-iron attached to

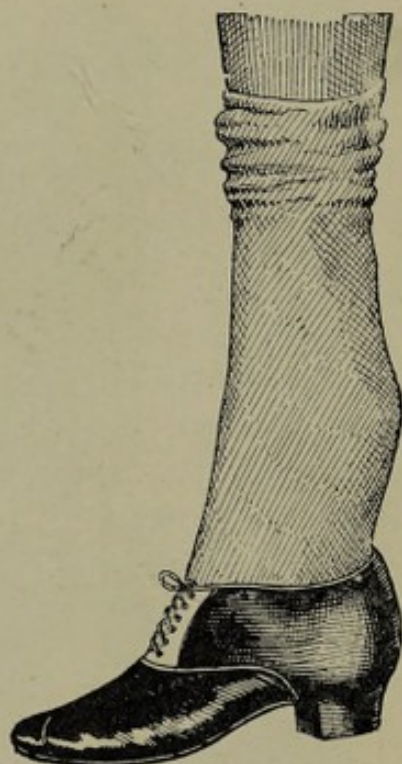


FIG. 208.

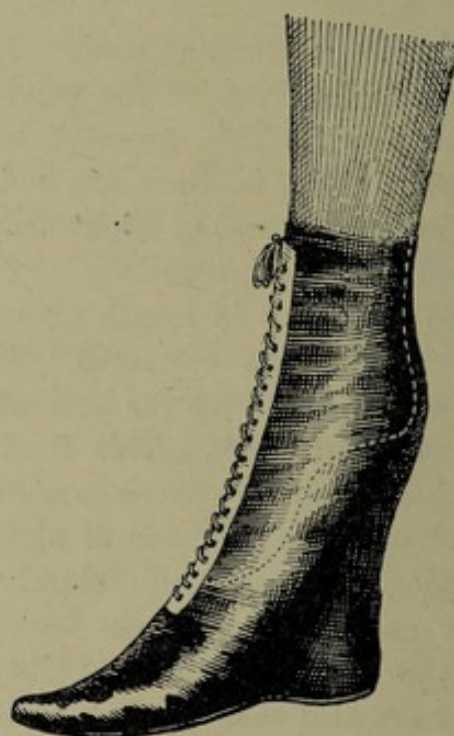


FIG. 209

the under-surface of the cork or to incorporate thin, broad steel supports in the leather of the boot. The latter is the more elegant arrangement.

Shortening of 10 to 20 centimetres is, of course, more difficult to deal with, but the problem has now been satisfactorily solved.

When appearance is of more moment than stability, an ordinary moulded appliance is constructed, enclosing the leg and foot, and jointed to a cork inlay of the kind already described (Fig. 207). Over this a laced boot is worn. If the shortening is very great, it may be necessary to prolong the cork beyond the toes, so as to make the foot of the same length as its fellow (see Fig. 208).

The O'Connor Extension.—In many cases a better cosmetic effect can be secured by the use of the so-called “extension” invented, and recently

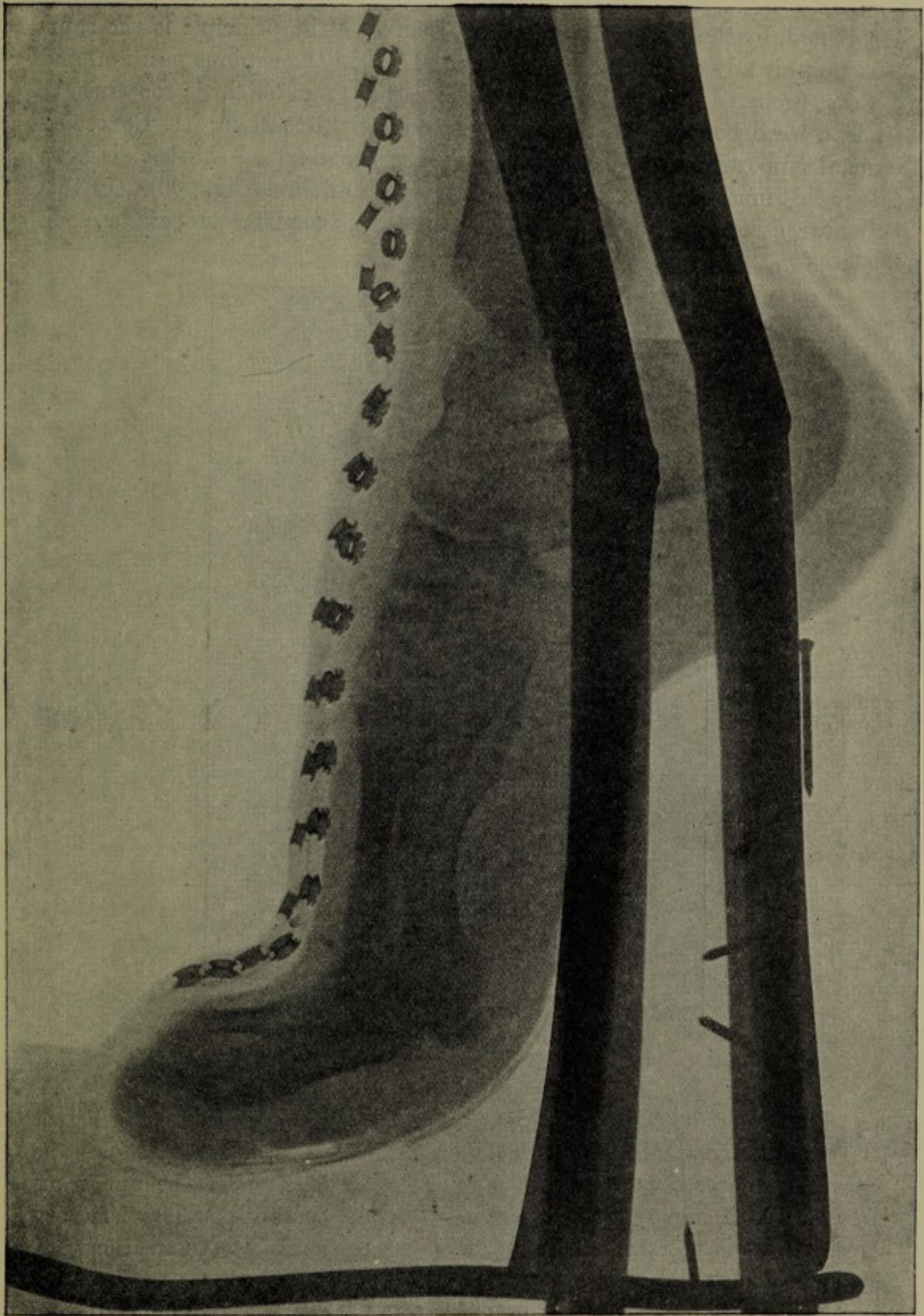


FIG. 210.

patented, by the English mechanic, O'Connor. The principle is the same as that already described. The foot is placed in the equinus position, and a cast prepared. A cork inlay of suitable shape and height is constructed, and a laced boot with a high leg and toecap is fitted over it. Concealed metal supports are added in cases of severe shortening. A thin sock is worn over this inner shoe, and then an ordinary outer shoe (Fig. 209). In this manner, cases of really severe shortening may be compensated, and as soon




FIG. 211.

as the patients have become accustomed to the equinus position of the foot they walk remarkably well in the appliance. The skiagram shows the position adopted, as well as the internal construction of the apparatus (Fig. 210). I employ it constantly in better-class practice, with satisfactory results. It is necessary, however, that the bootmaker to whom the work is entrusted should be a veritable artist.

When the foot cannot be brought into the necessary equinus position, the O'Connor extension needs to be modified in a certain manner. Fig. 211

illustrates the kind of appliance that is used. Even in cases of this kind a very good cosmetic and functional result is obtained.

Another method of correcting shortening is by means of **surgical interference**. There are two methods theoretically possible, and both have been carried out. One consists in shortening the good leg by resection of part of its length, or, more simply, by oblique osteotomy and deliberate overlapping of the fragments to an appropriate extent. Glässner and Deutsch-




FIG. 212.

länder have recently reported several operations of this kind, and it has received support from Heine, of Wurzburg, and from von Meyer and Nussbaum. In order to prevent the amount of shortening from changing, Deutschländer screwed the fragments together in a somewhat complicated manner. The method, therefore, is practicable, though to me it seems rather far-fetched. A far more reasonable proceeding is the lengthening of the affected leg by oblique or zigzag osteotomy, similar to the method employed in tendon elongation (von Eiselberg, Krukenberg). If the limb

is kept fully extended by means of weights during the process of repair, a lengthening of several centimetres may be effected.

Finally, the foot may be secured in the equinus position by arthrodesis of the ankle and subastragaloid joints. No special boot is then required to allow of the patient's walking about on his toes. It is only necessary to see that the heel is well supported, so as to prevent the whole of the body weight being borne upon the heads of the metatarsals.

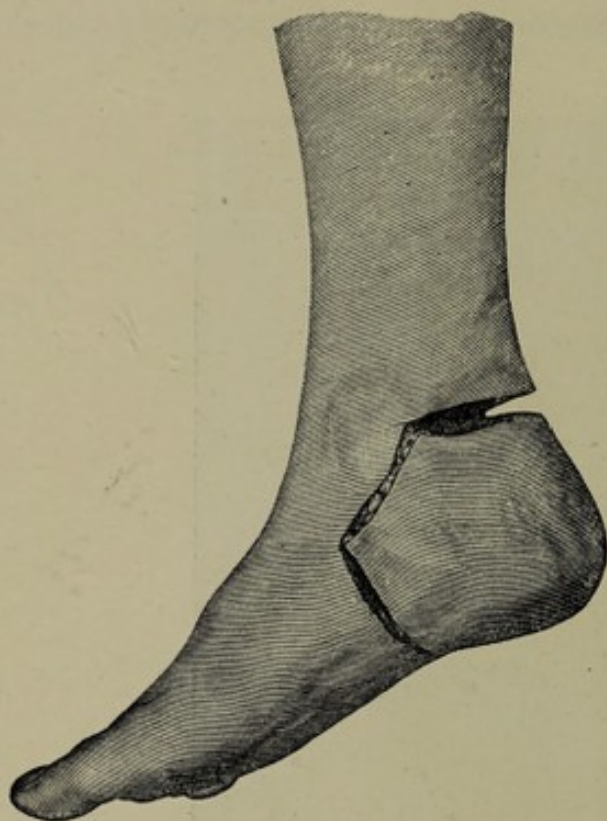


FIG. 213.
(AFTER ZUCKERKANDL.)

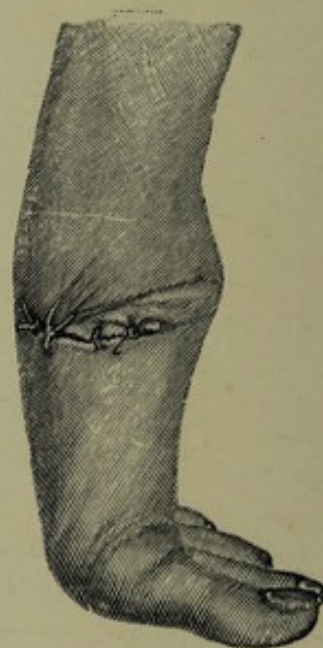

FIG. 214.

Wladimiroff and Mikulicz have devised an operation, by means of which the shortening is compensated, but the astragalus, os calcis, and part of the cuboid and navicular, as well as the skin of the heel, are sacrificed. I think that it is better to retain the heel and the proper length of the foot, and I therefore prefer arthrodesis. Figs. 213 and 214 show the technique and the result of this truly mutilating operation. Arthrodesis in the equinus position is decidedly the simplest means of correcting shortening within the limits that the foot allows, and only necessitates the simplest form of appliance. The operation is particularly appropriate in cases of flail foot, and in the poorer class of patients.

CHAPTER X

PARALYSIS OF EXTREME SEVERITY

WE are about to deal, in our concluding chapter, with those unfortunate cases in which there is paralysis of the majority, if not all, of the large joints of the limbs. These may not be affected with equal severity throughout, but we refer more particularly to paralysis of both hips. It not infrequently happens that the arms, in addition, show some residual paresis, due to the original paralytic attack.

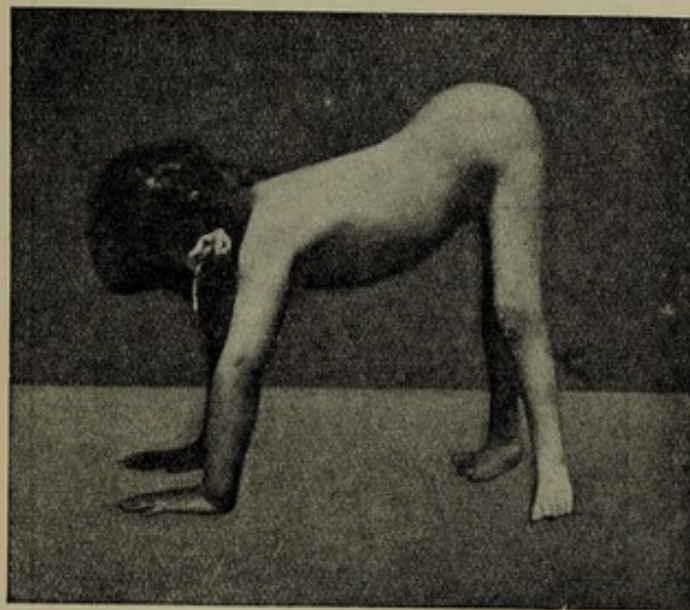


FIG. 215.

In cases of this kind it is quite impossible for the patients to stand or walk normally. They spend their lives in bed, or in invalid chairs; some learn to get about on crutches. This, however, only proclaims their misfortune, so that mental suffering is added to their physical disability. And again, there are certain difficulties, directly resulting from the use of crutches, which are accentuated when the arms are paralyzed.

Others adopt the animals' method of locomotion, and get about on all fours. These are the so-called "Hand-gänger." During my experience as

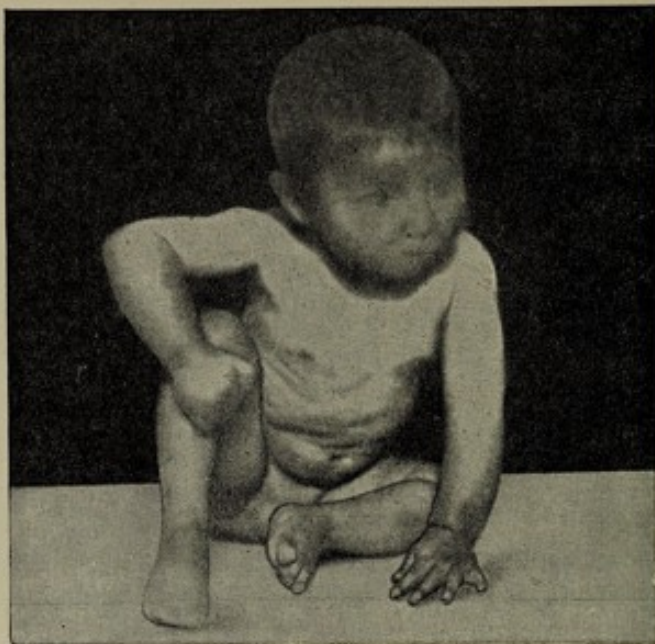

FIG. 216.

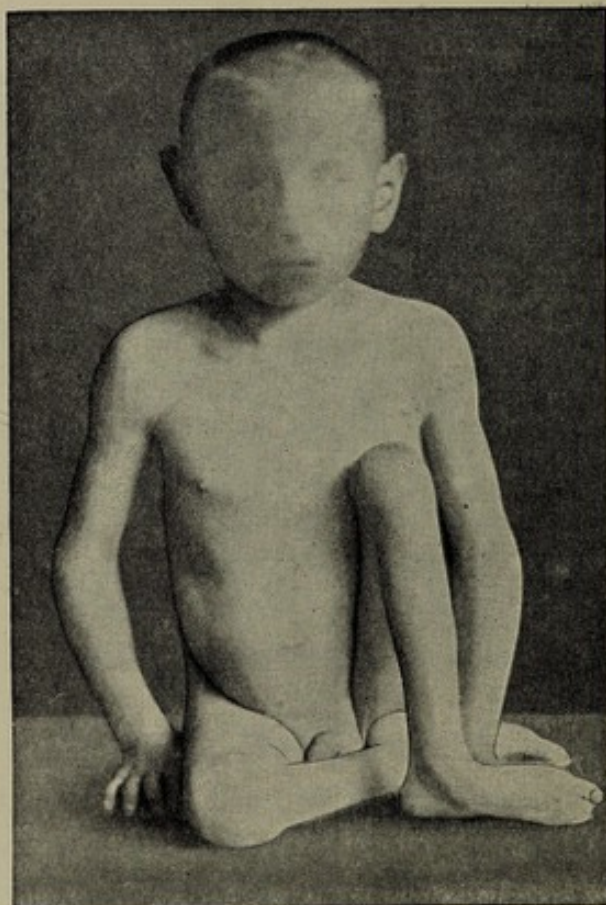


FIG. 217.

an orthopædic specialist, I have had opportunities of seeing and studying about fifty of these unfortunate patients, the majority of whom were children, though a few were adults.

Various types exist, which are illustrated in Figs. 215-219, 222-224 *et seq.* Some go along like an animal, with the body horizontal and the knees bent, though occasionally, on account of the distribution of the paralysis, they will be found extended. Sometimes the body is symmetrical, sometimes it is bent. The hip-joint is not only flexed, but also markedly abducted, so that the general appearance of the sufferer recalls that of a frog, half hopping and half creeping along.

Various contractures of the foot appear, depending upon the position of the hip and knee. Corns and bursæ indicate the pressure-points upon the palms and knees.

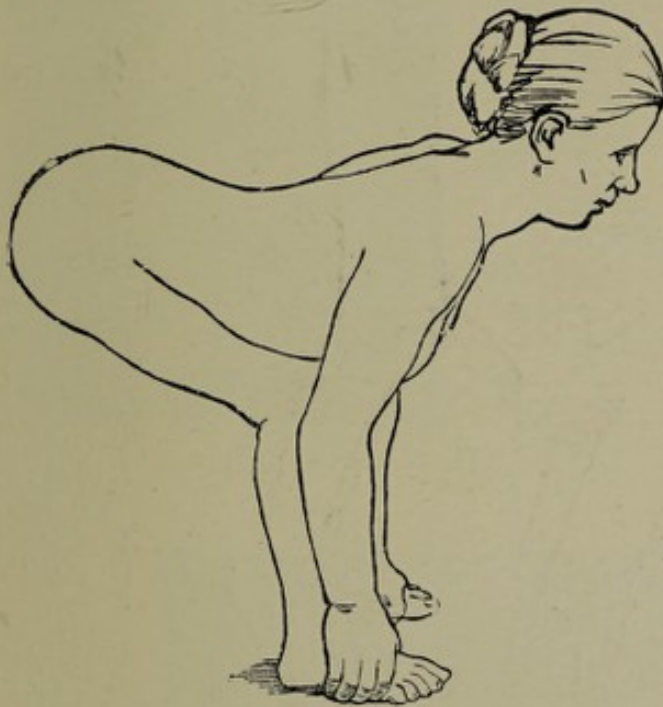

FIG. 218.
(AFTER HOEFTMANN.)

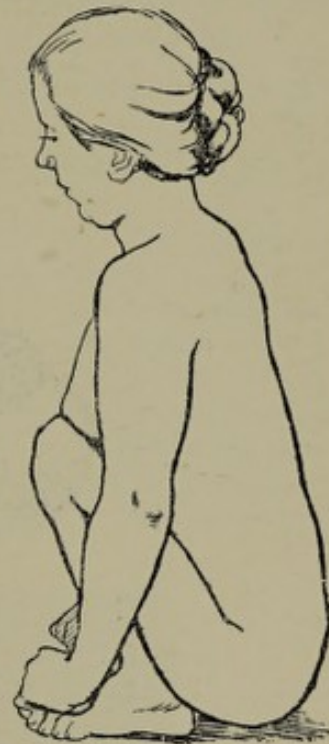

FIG. 219.
(AFTER HOEFTMANN.)

Others adopt a squatting attitude. The legs are crossed in various ways, and drawn up alongside the body. The body is swung forwards between the arms. The muscles of the arms become hypertrophied. Occasionally the knees are much flexed, and the hands grasp the feet and push them alternately forwards.

Lastly, there are rare instances of persons who get along entirely on their hands. Hoefmann (Fig. 220) and Joachimsthal have figured cases. One of these patients made use of his affliction to earn a living as a contortionist.

The natural result of the prolonged adoption of an attitude of this kind is the development of numerous severe contractures and deformities of the bones and joints, and disturbances of the growth of all the structures of

the body. It is useless to enumerate all these in detail. Heine, Waitz, Glück, Willard, and others, have described cases of this kind, and partially treated them.

Until quite recently, the majority of these sufferers have not visited the surgeons, but have shunned publicity, and sought retirement in almshouses and infirmaries. Nowadays, however, we are enabled to afford them more or less relief. It is, indeed, no easy task to correct so many deformities and such severe loss of function. The methods employed include *redresse-*

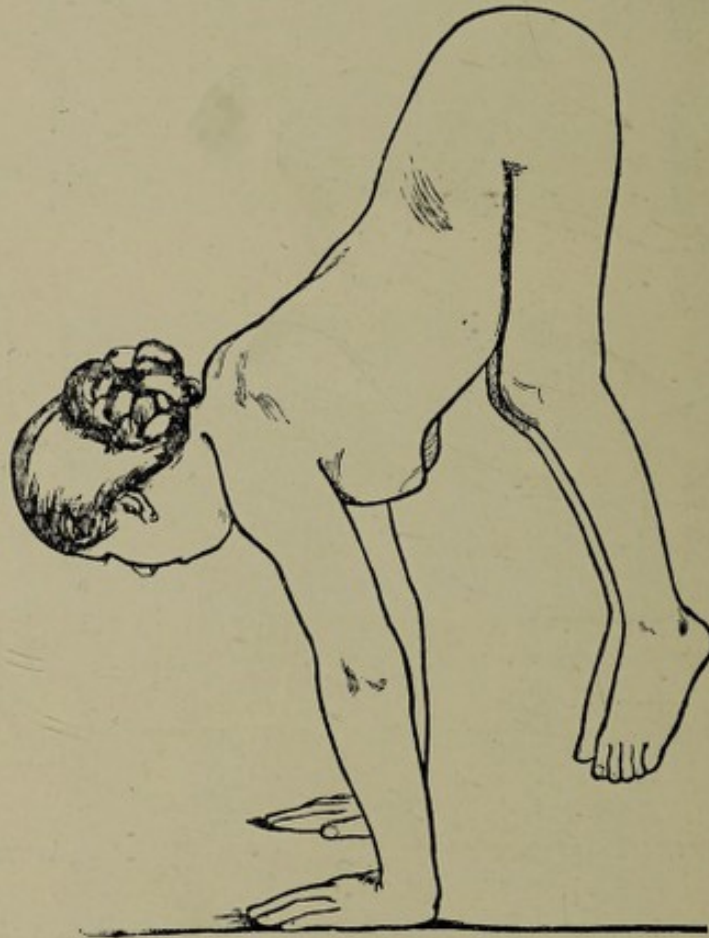


FIG. 220. (AFTER HOEFTMANN.)

ment, myotomy and tenotomy, osteotomy and arthrodesis, and tendon-operations of various kinds. These operations are carried out in various successions, and in several stages, until at length the upright position is restored, and the legs are once more normal. The patients must then be taught to walk by themselves, and for this purpose much patient after-treatment will be required. In some cases an orthopædic instrument will be required.

Yet how delightful is the result of all this expenditure of time and trouble! Few cases afford so much satisfaction to the surgeon as the sight

of a child whom he has raised to the upright position, after he has spent all his life as a four-footed animal.

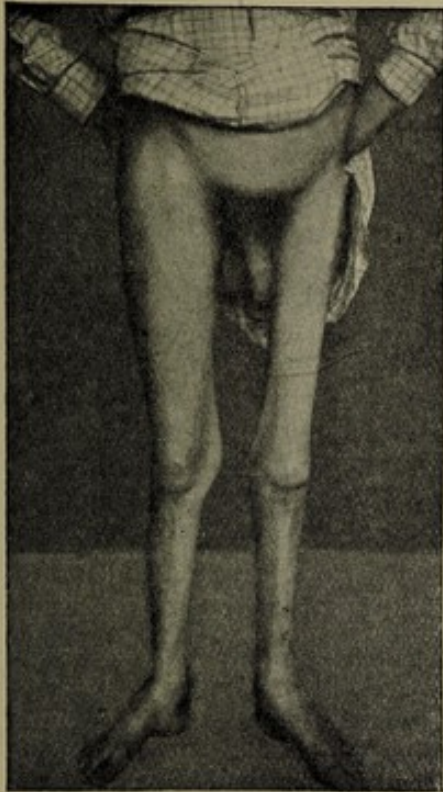


FIG. 221.

A certain number of sufferers remain, however, for whom we can do nothing, as far as surgery is concerned. It is our duty to render their condition as favourable as possible, and to afford them such education as will render their lives useful to themselves and to other people. But in the majority of cases of paralysis nowadays we can confidently look for improvement as the result of modern orthopædic methods.

A series of case-abstracts and photographs will best illustrate what can be done in the treatment of these very advanced cases.

1. W. J. Onset in first year. Not treated till fifth year—*i.e.*, 1893. Child wriggled along, with his legs drawn up alongside his body, one arm between his legs and behind the popliteal space, and the other stretched out on the floor in front of him. The left leg was completely paralyzed up to the gluteus, and the right was paretic; the right foot, however, was much deformed. Treatment: On the left side—Arthrodesis of knee and foot,

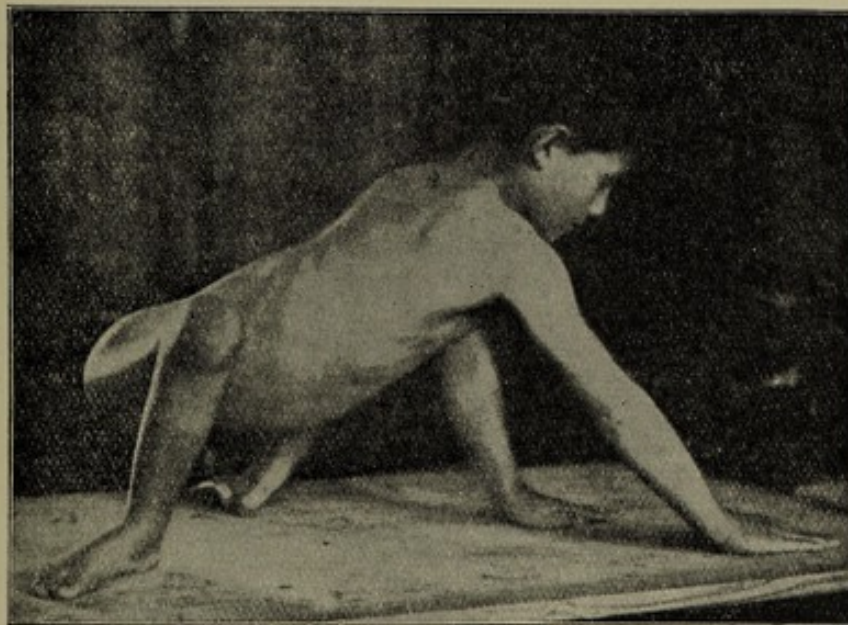


FIG. 222.

transplantation of flexors of knee into extensor tendon. On the right—*Redressement*, extirpation of astragalus, tenoplasty. Result: Fifteen years after operations,

patient (now *æt.* 20 years) can walk easily and without getting tired for two hours. He can also go upstairs (see Fig. 221). He earns his living as a town-clerk. There

is bony ankylosis; the left hip-joint is completely paralyzed; the right foot is in good position, and moves well.

2. F. J. Onset in second year. Treatment begun 1900. Severe contracture of hip and knee, with subluxation and flail equino-valgus foot. Mode of progression was a swinging of the body between the arms. Treatment: Section of the muscles attached to the anterior superior spine, arthrodesis of knee, plastic operation on quadriceps, arthrodesis of foot, tendon transplantation in leg. Result: Patient, now *æt.* 14 years, can walk at a good pace without any support. His father told me that he was the terror of the other village lads, on account of his pugnacity. Good bony union has taken place, the artificial quadriceps gives a full range of extension; but the transplantation in the leg is not altogether satisfactory, for the foot gives way somewhat.

3. W. F. Onset at one year; treatment begun at nine. Patient clambered about on his hands and feet, or occasionally on his knees (Fig. 222). Hips markedly flexed, abducted, and externally rotated. Knees flexed. Position of legs recalled that usually adopted after the reduction of bilateral congenital dis-

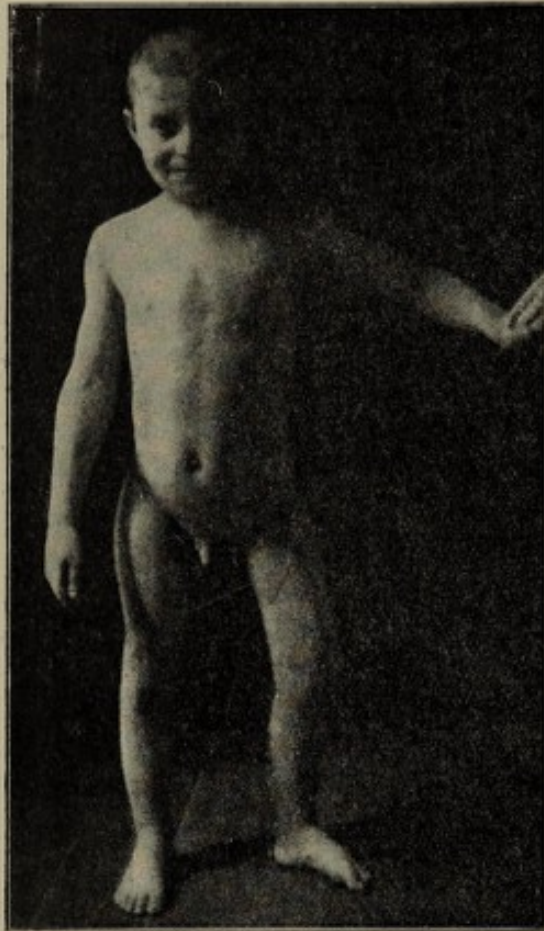


FIG. 223.

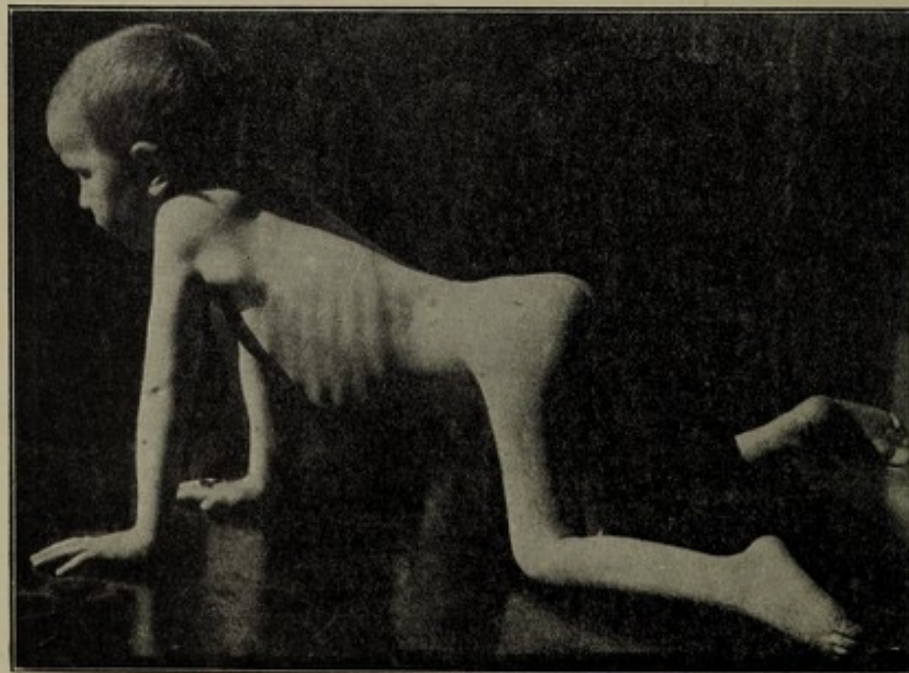


FIG. 224.

location of the hips. Operation: On the left—Division of spinous muscles, arthrodesis of foot and knee. On the right—Plastic operation on quadriceps, and subtrochanteric osteotomy of femur. When discharged, patient could walk if held by one hand. At the present time—six years after the operations—he is quite independent (Fig. 223).

4. A. L. Onset in first year. Treatment after four years, in 1904. Patient crawled on all fours. Left leg completely paralyzed; right only partially affected.

Operation: On left—Arthrodesis of knee and foot. On right—Transplantation in thigh and leg. Result: Patient, now eight years old, is on his legs all day long. I frequently see him about. The arthrodeses and tenoplasties are both satisfactory. Good voluntary movement of the foot.

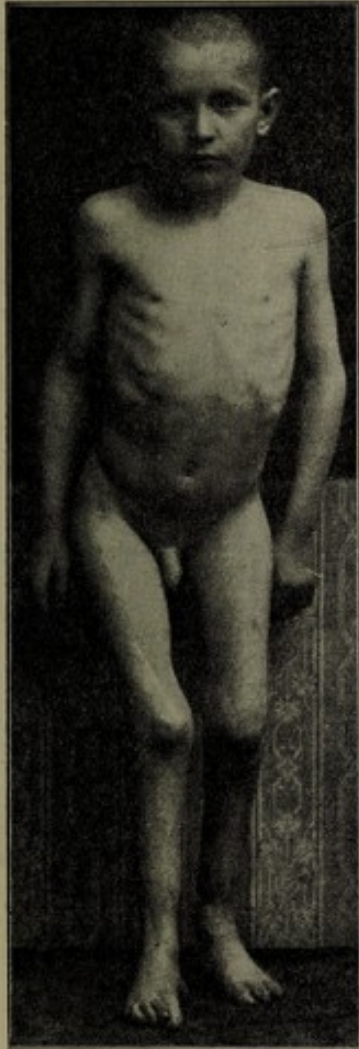

FIG. 225.

5. J. B. Onset at end of first year. Treatment at six and a half years, in 1904. Patient has various modes of locomotion. Sometimes he got about on his hands and knees (Fig. 224), at other times on his hands and buttocks, or else he sprawled his legs out sideways,

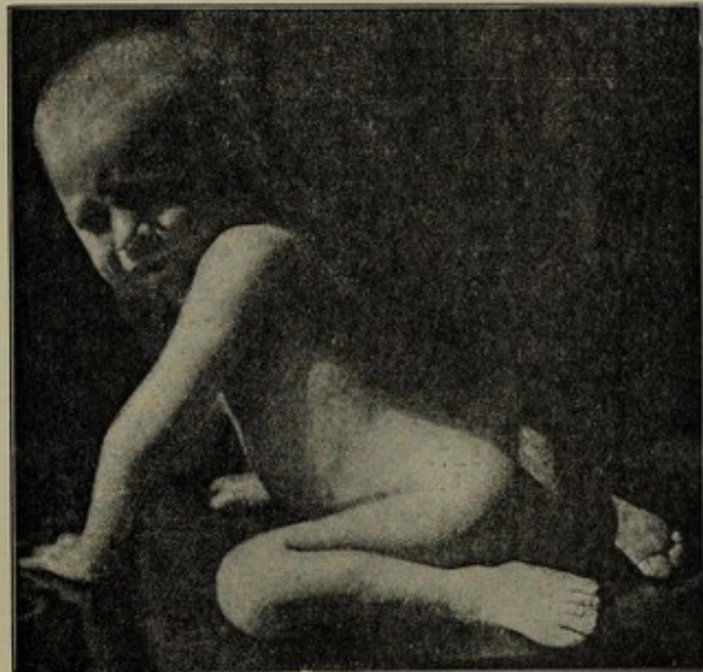

FIG. 226.

and walked on his hands and legs. Left leg completely paralyzed; right rather less severely affected. Hips much flexed, abducted, and contracted; knees flexed; feet equinus. Operation: On left—Arthrodesis of knee and foot, subtrochanteric osteotomy. On right—Plastic on quadriceps and arthrodesis of foot. Result: Patient, now ten years old, can walk without assistance for an hour, and is quite agile on his feet (Fig. 225). I went to see him recently, and found him playing with a top. The arthrodeses are quite firm, but the left knee is slightly flexed. The quadriceps contracts well.

6. S. L. Onset at six months, treatment at 3 years, 1904. Patient walked either on his hands and knees or squatting like a frog (Fig. 226). Contracture of knee and hip on left, together with tendinous equino-varus; pes equino-valgus on right. Operations: Transplantations and arthrodesis of foot on left; transplantation below knee on right. Result: Patient is now seven years old, and can walk very well (Fig. 227).

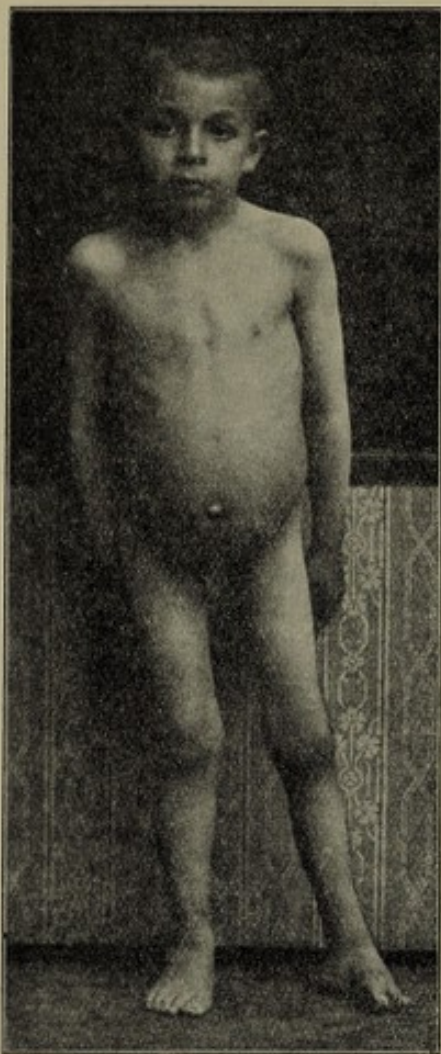


FIG. 227.

Ankle rigid, and movements of right foot quite normal, although plastic operation on quadriceps has failed.

7. B. J. Onset in first year. Treatment begun at three and a half years, 1906. Patient got about very cleverly on his hands and knees (Fig. 228). Left leg completely paralyzed, including the glutei; quadriceps and extensors of leg paralyzed on right. Operations: Arthrodesis of hip, knee, and ankle on left; transplantation above and below knee on right. Result: Patient can now walk very well (Fig. 229). Transplantations quite successful; firm ankylosis at hip and ankle, and adequate fibrous union at hip.

8. R. J. Extensive paralysis of both legs, with severe contracture, said to be congenital. Treatment begun at ten years. Patient walked by moving his feet forwards with his hands (Fig. 230). In addition to the contracture of the hips and knees, the lower ends of the femora were curved, and there was talipes equinus. Operations: Division of the spinous muscles on both sides, resection of both knee-joints, and partial astraglectomy. Result: Patient was able to walk with two sticks after four months (Fig. 231), and now, three years

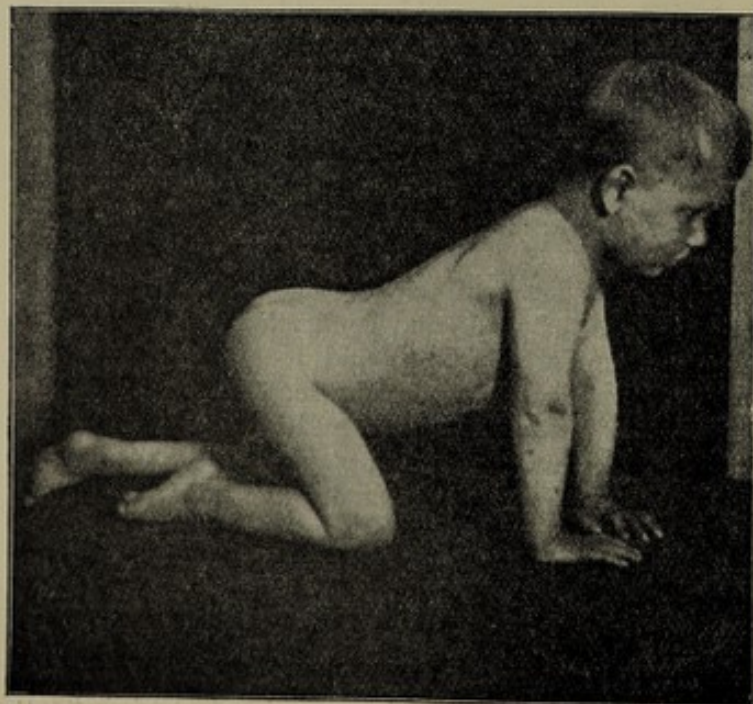

FIG. 228.

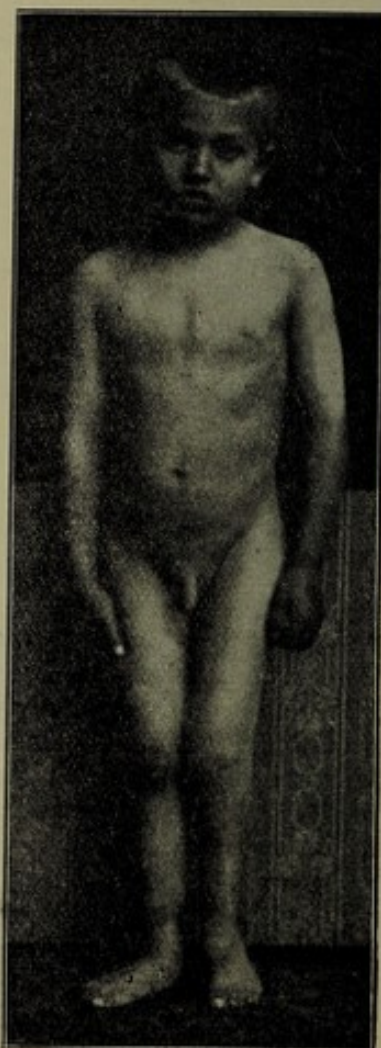


FIG. 229.

after the operations, he can stand up quite straight, and walk alone. He uses a stick when outdoors.

9. L. T. Onset at eight months. Treatment at three and a half years, 1906.

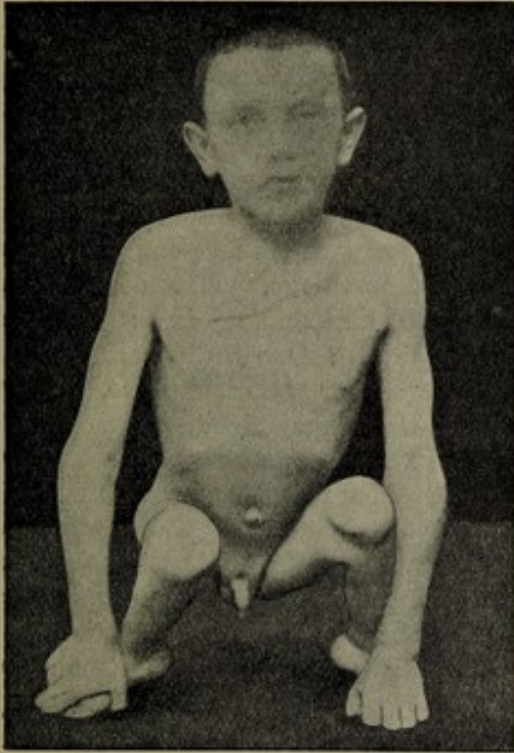

FIG. 230.

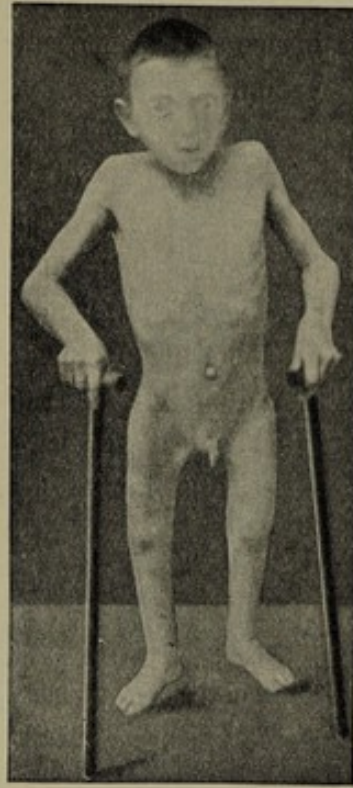

FIG. 231.

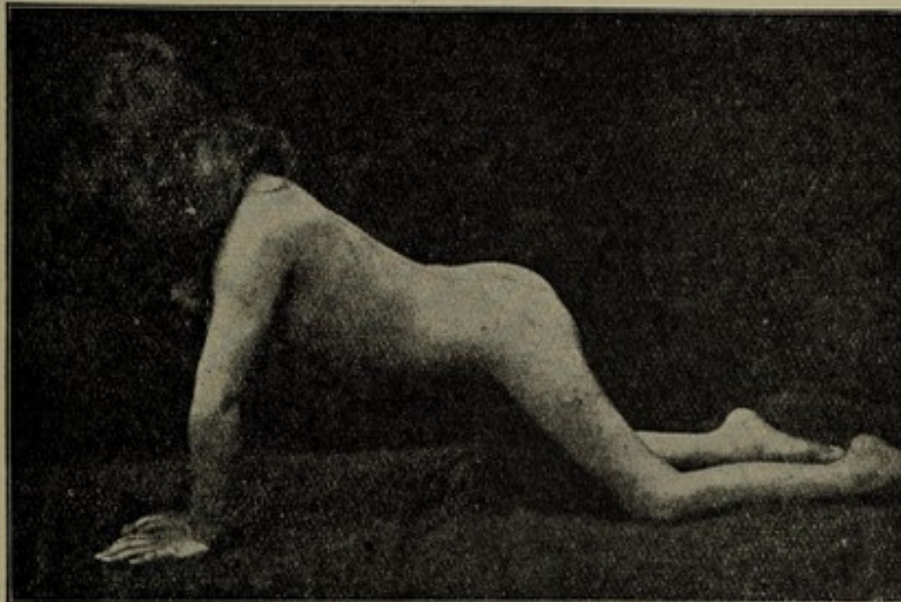


FIG. 232.

Patient crawled along in usual manner, on his hands and knees. Right leg completely paralyzed; on left, paresis of quadriceps and paralytic flat foot. Chief operations: Arthrodesis of foot and knee on right; tendon transplantations in left leg. Result:

Boy is now six years old, and can walk with perfect security and comfort for the whole day. The arthrodeses are quite firm, and the left foot moves well in all directions.

10. G. M. Onset at end of first year, treated after three and a half years, 1906. Crawled on hands and knees (Fig. 232). Left limb completely paralyzed; severe contracture of hip. Pes equino-valgus on right. Operations: Division of spinous muscles, and arthrodesis of foot on left. Transplantation of tendons, right leg. Result: Patient, now $\text{aet. } 5\frac{1}{2}$ years, can walk without difficulty or support. Arthrodesis firm, and transplantation satisfactory.




FIG. 233.

11. S. G. Onset in first year. Treatment at four years, 1907. Child crawled along on hands and knees. Left limb completely paralyzed, including glutei; right very parietic. Pes equino-valgus. Operations: Arthrodesis of left hip, knee, and ankle joints; transplantations in right leg. Result: One and a half years later, patient able to walk well, without assistance. Improvement effected at operations maintained.

12. P. H. Very extensive paralysis. Onset in second year, treated at four years. Left leg affected as high as hip; thigh intact on right side. Tendinous equinus on both sides. Operations: Arthrodesis of left knee; tendon transplantations in both legs. At present time—a year later—patient walks without assistance.

13. D. J. Onset in second year. Treatment begun at six years. Patient got a'long on his hands, dragging his legs behind him.

Legs were greatly flexed at hips and knees. On both sides, much adduction of hips, in addition to flexion; severe paresis of glutei; flail knee on right; contracture on

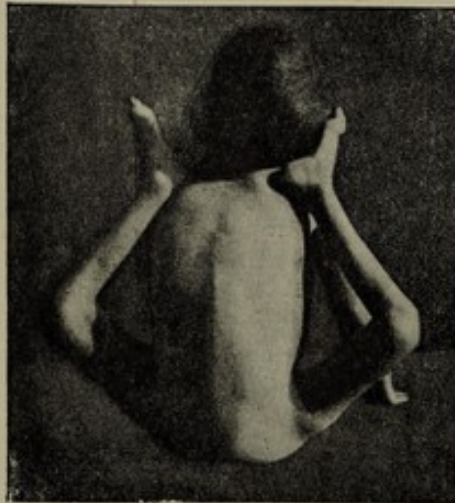

FIG. 234.



FIG. 235.

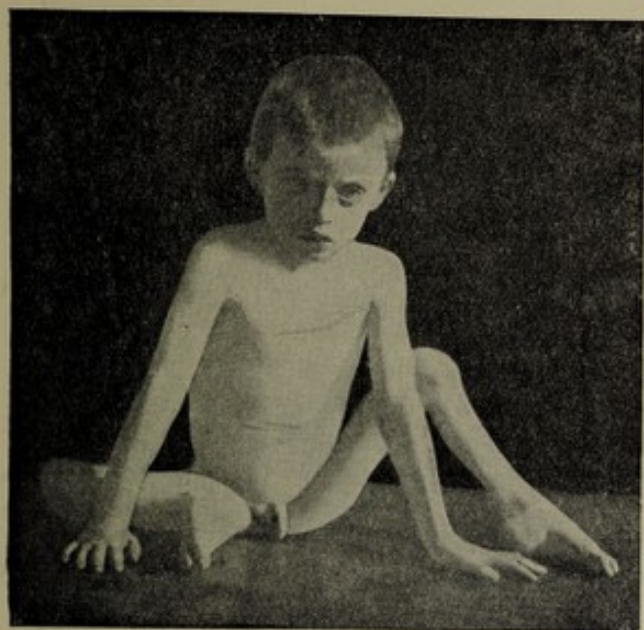

FIG. 236.

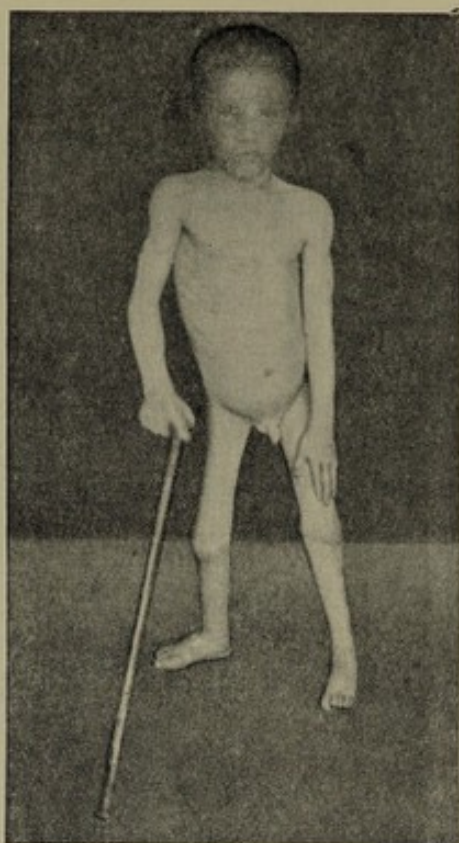

FIG. 237.

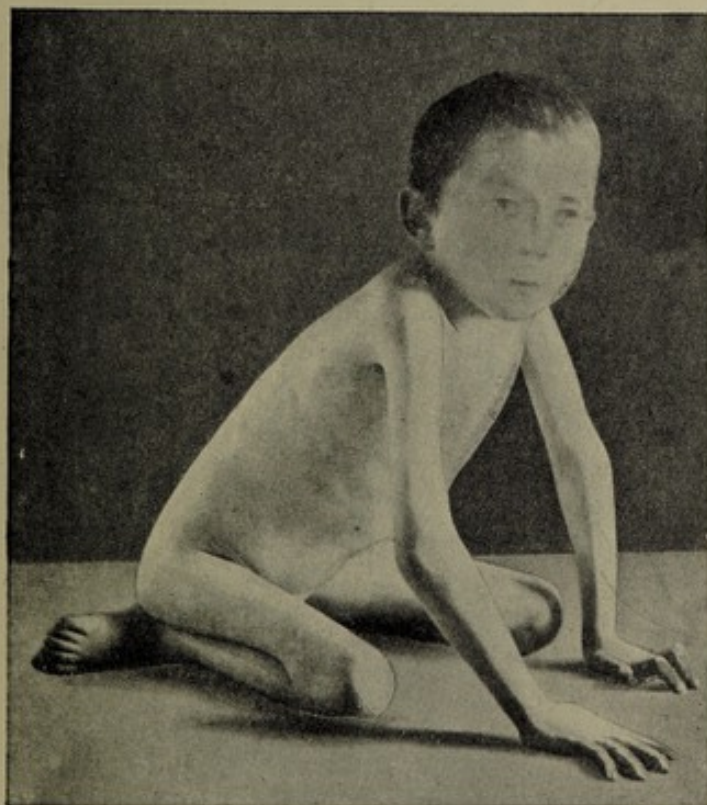

FIG. 238.



FIG. 239.

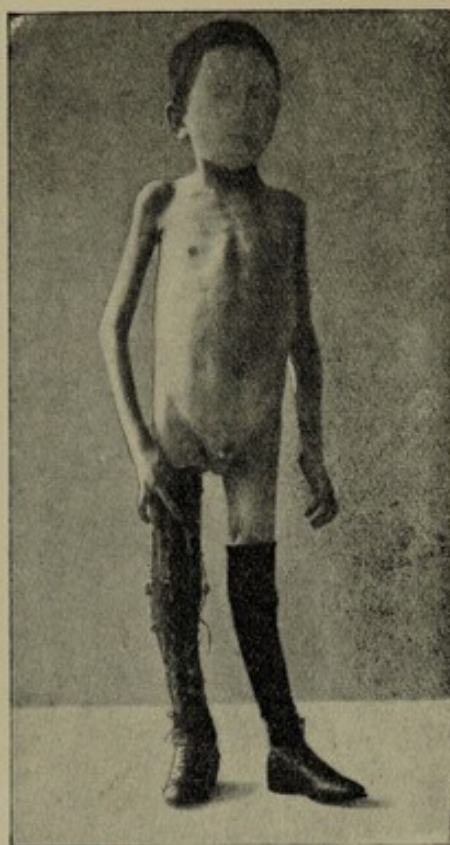


FIG. 240.

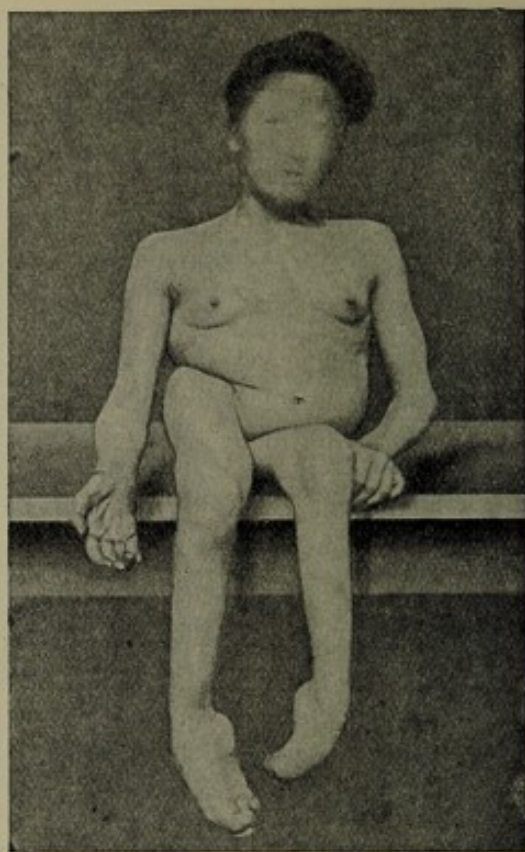

FIG. 241.

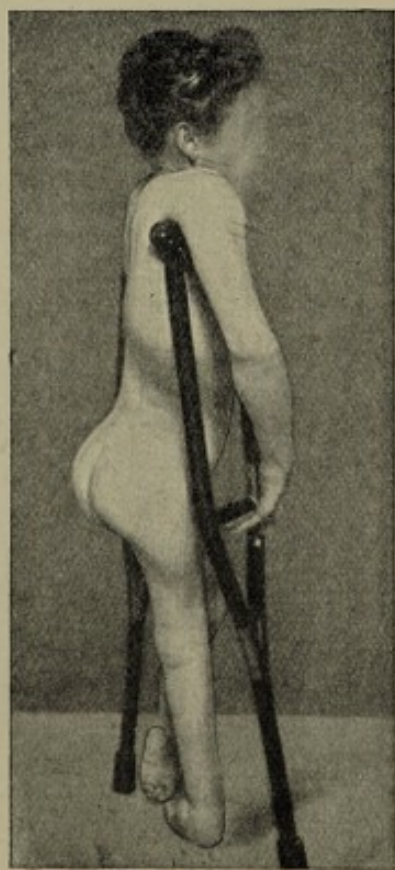


FIG. 242.

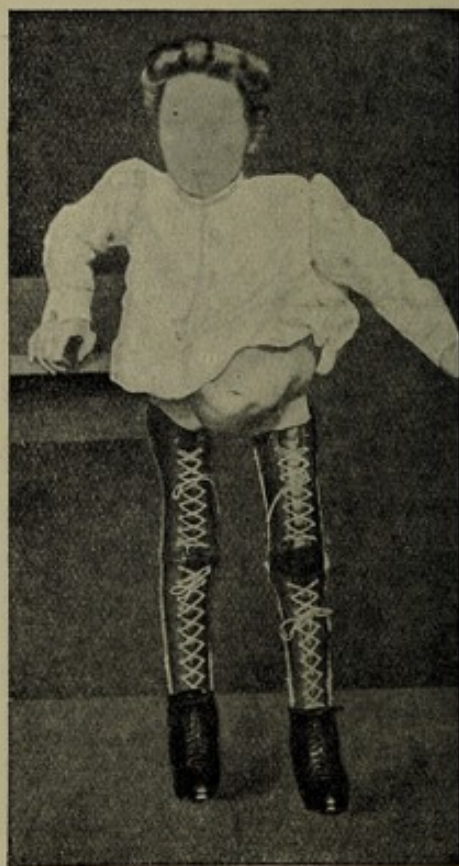

FIG. 243.

left; total paralysis of foot on right, with equinus; pes valgus on left. Both legs could be placed on the shoulders (Fig. 234). Operations: Spinous muscles divided on both sides; arthrodesis of knee and ankle on right. On left, transplantation of sartorius, gracilis, semimembranosus, and semitendinosus into the quadriceps. Result: Patient learned to walk with a stick.

14. P. G. Onset at three years; treated at five and a half years. Patient crawled along on hands, dragging his right leg behind him. The left was much flexed (Fig. 236). Psoas good; glutei very parietic; right-angled contracture of hip, with abduction; knees flexed; ankles flail. Operations: Open division of spinous muscles; arthrodesis of right knee; transplantation of sartorius, biceps, and adductor into left quadriceps; arthrodesis of both ankles. Result: Arthrodeses firm, quadriceps works well; boy learned to walk at first with one stick, and, later on, without any (Fig. 237).

15. J. A. Onset at one year; treatment begun at nine years. Patient crawled about rapidly on his hands and knees, squatting on his heels (Fig. 238). Contracture of hip and paresis of glutei, especially on right; rectangular contracture of knees on both sides, and flail ankle. Operations: Arthrodesis of right foot; tendon transplantation in left foot and both knees; contracture of hips and knees corrected by manipulation in several stages. Result: Patient able to walk with a stick or with a light support after five months; no support at all in another month's time (Figs. 239, 240).

16. L. M. Onset at two years; treated at twenty-seven years. Girl only able to get about by means of crutches; crutch-palsy in consequence. Severe tendinous equino-varus; almost complete paralysis of the hip, knee, and ankle on each side; iliac dislocation on the right side, with about 9 centimetres displacement; infrapubic dislocation on the left (Figs. 241, 242). Marked scoliosis. Operations: *Redressement* of feet; elongation and shortening of various tendons; subtrochanteric osteotomy on left. Result: Patient learned to walk in an apparatus, with the aid of two sticks (Fig. 243).

INDEX OF SUBJECTS

- ABDOMEN**, muscles of, general paralysis of, 130
 result of, 133, 134
 localized paralysis of, 134, 135
 Abduction of arm, in arthrodesis, 170, 171
 due to deltoid, 187
 Acetabulum, travelling, 275
 Active movement after arthrodesis (tables), 175, 176
 in treatment, 30
 Acute epidemic infantile paralysis, 3
 Adaptation, cerebral, after transplantation, 91
 functional (example), 10
 Adductor longus, transplantation of, 261
 Adult poliomyelitis, 2
 Ætiology, 3
 author's views, 19
 contagion, 15
 similarity in other diseases, 14
 sources of infection multiple, 19
 After-treatment of arthrodesis, 64, 66, 169, 170, 213, 236, 258, 272
 of nerve-grafting, 103, 185, 190, 191
 of tendon-transplantation, 84, 229, 237, 243, 274
 Age of patient in arthrodesis, 62, 171, 172, 215
 effects of, on results, 171, 172
 -incidence of paralysis, 12
 for tendon-transplantation, 73
 Amyotrophic muscular paralysis following infantile paralysis, 10
 Anatomy, pathological, 2, 20
 Animals, affected by paralysis, 14, 15, 17, 18
 nerve-transplantation in, 94
 not carriers of infection, 16
 results of experiments on, 19, 144
 tendon-transplantation in, 84
 Ankle, flail, 208
 apparatus in, 209, 214
 arthrodesis in, 209
 after-treatment of, 213
 failure of, 215
 results of, 214
 technique of, 210, 212
 with fasciodesis or tenodesis, 212
 Ankle, flail, astragalectomy in, 211, 296
 bone-bolting in, 210, 211
 Ankylosis of ankle, 209, 214
 after arthrodesis, 62, 65, 156, 171, 172, 176, 214, 258
 effect of age upon nature of, 171, 172
 failure of, after arthrodesis, 66, 215
 fibrous, after arthrodesis, 171, 215
 of shoulder, 154-168
 Antenatal poliomyelitis, 12
 Anterior crural nerve, grafting for paralysis of, 122
 internal anatomy of, 118, 120
 tibial nerve, grafting of, 123
 Apparatus after arthrodesis, 66, 236
 for flail ankle, 209, 214
 for genu recurvatum, 255
 gymnastic, 31
 Heine's original, 2, 31
 joints of, 38-42
 metal parts of, 38, 39
 modern, 35 *et seq.*
 band pattern, 35
 moulded pattern, 36
 moulded sheath type, 35
 advantages and disadvantages of, 36, 46, 47
 invention of, 37
 manufacture of, 37
 after nerve-grafting, 103
 for paralysis of arm, 207
 of deltoid, 151-153
 of elbow, 199
 of foot, 209
 of hand, 200
 of hip, 271, 272
 of knee, 249, 255, 259
 of neck, 127
 for paralytic flat foot, 236
 kyphosis, 131
 rotation of arm, 194
 torticollis, 33, 127
 in pes calcaneus, 242
 in pes varus, 228
 in pure pes equinus, 218
 Arm, paralysis of:
 complete, treatment of, 207
 initial, 4

- Arm, paralysis of, rotation of, 193
tendon-transplantation in, 72
- Arthrodesis, 61
advantages of, 180, 185
after-treatment of, 64, 65, 67, 169, 170, 258
age for performing, 62, 215, 256
alternatives for, 180, 211
of ankle. See "Flail ankle"
ankylosis after, 62, 65, 155, 156, 171, 176
curvature of spine in, 179
disadvantages of, 179
displacement of scapula in, 179, 180
effect upon growth, 66, 172, 173, 178
of the elbow, 197
in extreme deformity, 292
failure of, 66, 67, 179, 258
versus fasciodesis, 70
for flail ankle, 210
foot, 288
joint, 2, 61, 62
knee, 256
for flat foot (paralytic), 236
of hip, 271, 272
after-treatment, 272, 273
indications for, 271
results of, 272, 273
technique of, 272, 273
history of, 62, 153
indications for, 62, 63, 66, 67, 180, 209, 210, 236, 256
of knee, after-treatment of, 258
disadvantages of, 259
failure of, 257
results of, 258, 295-301
technique of, 256
versus muscle-transplantation, 185
osteoplastic methods of, 257
in paralysis of arm, 207
of deltoid, 153 *et seq.*
after-treatment, 169, 170
case reports of, 156-168
disadvantages of, 179
failure in, 179
movement after, 157
results of, 178
technique of, 169
of foot, 209
indications for, 209
technique of, 210
pegging in, 64, 210
repair after, 65
results of, 62, 65, 154-178, 197, 214, 258, 273, 295-301
scoliosis after, 180
in shortening, 287
of shoulder. See "In paralysis of arm," "In paralysis of deltoid"
statistics of, 168, 169
- Arthrodesis, technique of, 63, 154, 169, 210, 212, 256, 273
with tendon-fixation, 213
-transplantation, 89
wiring in, 170
of wrist, 206
- Arthrorrhaphy, 154
- Artificial ligaments, 70, 71, 213, 255, 273
technique of making, 83
tendons, 55, 83, 205, 262, 268
observations on, 85
- Asphyxia in intercostal or phrenic paralysis, 4, 5
- Astragalectomy, 211, 228
- Ataxic paralysis, 5
- Atrophy, disuse. See "Disuse-atrophy"
of ganglion cells, 2
of muscles, 22, 35
secondary prevention of, 29, 33
Sudeck's, 8
of tendons, 24
- Atypical paralyses, 5
- Autogenous regeneration of nerve, 98
- Bacillus coli*, *B. diphtheriae*, *B. typhosus*, causing paralysis, 19
- Backache, initial, 3
- Back, paralysis of, 130
results of, 133, 136
- Back-stop, 39, 40
- Bacteriology, 16
complex, 19
- Baths, 2, 31, 33
- Biceps, paralysis of, 197
treatment of, 197
- Bier's hyperæmia, 31
after arthrodesis, 66
- Bladder, paralysis of, 7
- Bone, changes in long, 24
deformity of, 9, 24, 208, 217, 291
disuse-atrophy of, 8, 228
extirpation of, 56, 57, 211, 282
- Bone-bolting: instead of arthrodesis, 210, technique of, 211
- Bone-filling paste, 64
in arthrodesis, 64
- Bones, impairment of growth. See "Growth"
rarefaction of, 8
- Bronchitis, initial, 4
- Bulbar paralysis, 5
- Carriers, 16
- Case reports, ankylosis of shoulder, 155
antenatal poliomyelitis, 12
arthrodesis of elbow, 198
of shoulder, 156 *et seq.*
attack following osteomyelitis, 12
degeneration of muscle in congenital talipes, 12
early, of poliomyelitis, 1

- Case reports, extreme deformity, 295-301
 intrauterine poliomyelitis, 12
 muscle-transplantation, 180-185, 229
 nerve-grafting, 121-124
 cervical nerves, 185, 186, 192
 circumflex, 186-187, 190
 musculo-spiral, 108-110
 peroneal, 233, 234
 subscapular, 192
 tibial, 232, 247
 onset after chills, 11
 after falls, 11
 tendon-transplantations, 201-205, 225, 226, 237-239, 244-245, 274
- Cerebro-spinal fluid, characters of, at onset, 4
 later on, 16, 17
 cultures from, 16
 inoculation of, 17, 18
 organisms in, 16, 17
- Cervical nerves, grafting of, 120, 185, 186, 192
 results, 121, 123
- Chest-brace, 131
- Chilblains in paralysis, 8
- Chills, 11
- Circulation, defective, causation of, 8
 improvement of, 29, 30, 31, 33
 results of, 8
- Circumflex nerve-grafting, 124, 186
 case reports of, 186, 187-190
 criticized, 190, 191
 technique of, 187
 internal anatomy of, 110, 111, 187
- Coma at onset, 3
- Congenital talipes, condition of muscles in, 12, 13
 differences from paralytic, 227
- Constipation, initial, 4
 in paralytic lordosis, 134
 persistent, 7
- Contagion, 15
- Contracture, after arthrodesis, 66
 appearance of, 9
 causation of, 9, 10, 33
 of hip causing lordosis, 130
 static, 33
 treatment of, 44, 276-280
 of knee, 44, 249, 255, 256, 274
 of paralyzed joints, 24, 249, 274, 291
 permanent, 10, 208, 291
 prevention of, 29-34, 276
 stage of, 9
 treatment by apparatus, 44, 277
 by operation, 56, 277
- Convulsions, 4
- Cord, spinal, affection of, first described, 1
 atrophy in scoliosis, 139
 changes in, in poliomyelitis, 220
 in scoliosis, 138, 139
 inflammation of, 11, 20
 lesions caused by diphtheria toxin, 19
 by emulsions of, 17
 by snake venom, 19
 by various organisms, 19
- Cork inlays, 283, 284
 soles, 283
- Corset in paralytic lordosis, 134
- Course of disease, 3
- Coxa valga with paralysis of hip, 271
- Cultivations, 16
 of cerebro-spinal fluid, 16
 inoculation of, 17
- Cyanosis of skin, 8
 treatment by massage, 29
- Death from respiratory paralysis, 5
- Degeneration, mode of, after section of
 nerve, 98
 of muscle, 22
 atrophy, 6, 7
 in congenital talipes, 13
 fatty, 2, 6, 22
 reaction of, 7
- Deltoid, function of, 185, 186
 paralysis of, apparatus in, 151
 arthrodesis in, 153
 after-treatment of, 169, 170
 case reports of, 156-168
 disadvantages of, 179
 failure in, 179
 movement after, 157
 results of, 154, 178
 technique of, 169
 muscle-transplantation in, 181-185. See also "Muscle, transplantation of"
 nerve-grafting in, 185-191, 192
 results of, 150
 treatment of, 151
- Dentition, difficult, 11
- Deviation in scoliosis, 144
- Diagnosis of poliomyelitis, differential, 3-5, 12, 127
 early, from disuse-atrophy, 75
 in epidemics, 27
 electrical reactions in, 75
 lumbar puncture in, 4
- Diaphoresis, 27
- Diaphragm, paralysis of, 4
- Diarrhœa, initial, 4
- Diphtheria, antecedent to poliomyelitis, 13
- Diplococci in cerebro-spinal fluid, 16, 17
- Disinfecting on, during epidemics, 26
- Dislocation of paralyzed joints, 10, 24, 274

- Distribution of paralysis, 6
 means of determining, 74
 universal, 11
- Disuse-atrophy, 282
 of bone, 8, 282
 diagnosis of, uncertain, 74, 75
 treatment by massage, 29
- Drowsiness at onset, 3
- Dyspnoea from paralysis of intercostals
 or diaphragm, 4
- Earth-borne infection, 16
- Elastic in correcting contractures, 45
 to replace paralyzed muscle, 42
- Elbow, paralysis of, 195
 apparatus in, 199
 arthrodesis in, 197
 muscle-transplantation in, 196
 nerve-grafting in, 197
- Electrical reactions at onset of attack, 7
 in talipes equino-varus, 232
 of degeneration, 7
 value of, 75
 in paralytic scoliosis, 138
- Electricity, use of, after tendon-trans-
 plantation, 84
 in early paralysis, 148
 in paralysis of deltoid, 151
 in treatment, 28, 33, 195
- Elongation. See "Tendon-lengthening"
- Embotic theory of disease, 21
- Encephalitis, convulsions in, 3
- Epidemics, 13-16
 early diagnosis in, 26
 isolation during, 26
- Equino-varus, paralytic, 232
 neuroplasty in, 232
 operation for, 232
- Equinus, "transient," 218
 used in correcting shortening, 283
- Erb-Duchenne paralysis, neuroplasty for
 (Case 19), 123
- Erector spinæ, paralysis and paresis, 130
 rupture of, 138
- Erysipelas before poliomyelitis, 13
- Exanthema before poliomyelitis, 13
- Exercises: after arthrodesis, 64
 after nerve-grafting, 103
 apparatus for, 31
 effect of, 31, 151
 German, 31
 gymnastic, 30
 in early paralysis, 29, 148
 in paralysis of deltoid, 151
 of elbow, 195
 of hand, 200
 in paralytic kyphosis, 130
 lordosis, 134
 torticollis, 129
 passive, 30
 in pes calcaneus, 242
- Exercises, Swedish, 31
 in third stage, 33
- Extensor hallucis specially affected, 5
 of leg, paralysis of, 224-226
 muscles, action of, 220, 221
- External popliteal nerve, grafting for
 paralysis of, 118, 120
- External popliteal nerve, grafting for
 paralysis of, results and
 table, 121, 124
 internal anatomy of, 118
- Fall preceding attack, 11
- Faradic excitability: initial decrease, 7
 significance of loss of, 7
- Fasciodesis, advantages of, 70, 212, 213
 in flail ankle, 212
 in flat foot, 237
 technique of, 212
- Fasciotomy, 228
- Fat embolism, 49, 65, 209
- Fatty infiltration of muscles, 2, 6
- Fingers, paralysis of, 200
- Fixation after arthrodesis, 64, 66
 tendinous, of joints, 68, 69, 70
- Flail, ankle. See "Ankle, flail"
 foot. See "Foot, flail"
 hip. See "Hip, complete paralysis of"
 joint after arthrodesis, 66
 fixation by apparatus, 33
 in total paralysis, 9
 arthrodesis for, 61, 209, 210,
 256, 288
 knee. See "Knee, arthrodesis of"
 treatment of, 271
 shoulder. See "Shoulder, flail"
- Flat foot (paralytic), apparatus in, 236,
 242
 arthrodesis in, 236
 after-treatment, 236
 indications for, 236
 causation of, 234
 characteristics of, 235
 fasciodesis in, 237
 nerve-grafting in, 239
redressement, 236
 tendon-transplantation in,
 236
 after-treatment, 237
 case reports, 237-239
 technique, 236
- Flexion of hip, 46, 274, 277
 of knee, 250, 251, 259
- Flexor longus hallucis, function of, 222
- Foot, flail, ankylosis for, 288
 causation of, 208
 paralysis of, treatment, 208, 209
- Front-stop, 39
- Function, adaptation of, 10
 of antagonist acquired by muscle, 88
 of deltoid, 186, 187

- Function, improved by exercises, 29
 loss of, after nerve-grafting, 125
 partition of, 71, 88, 92
 restoration of, 57
 after arthrodesis, 179
 delayed, 24
 effect on growth of bone, 89, 282
- Functional transplantation, 71, 77
- Galvanism, loss of reaction to, 7
 technique of, 28, 29
 in treatment, 28, 29
- Ganglion cells, atrophy of, 2
- Gastrocnemius, Volkmann's artificial, 43
 paralysis of. See "Pes calcaneus"
- Genu recurvatum, apparatus in, 33, 255
 causation of, 33, 262
 muscles preventing, 263
 operations for, 255, 256
 in paralysis of knee, 33
 valgum (paralytic), 253
 treatment by apparatus, 254, 255
 by operation, 255-257
 varum (paralytic), 253
- Gibbus, 130
- Glutei, paralysis of, 274
- Gram-positive bodies in cerebro-spinal fluid, 17
- Gravity causing muscular stretching, 10
 determines position of paralyzed limb, 9
 increasing scoliosis, 136, 137, 138
- Growth of bone, impairment of, 8
 causing scoliosis, 136, 138
 from rickets, 8
 improved after operation, 66, 89, 172
 not impaired by arthrodesis, 66
- Gymnastics after tendon-transplantation, 84
 apparatus, 31
 in paralysis of neck, 127
 in paralytic kyphosis, 130
 in pes equinus, 218
 value of, 2, 30
 See also "Exercises"
- Habitual scoliosis, 135
 electrical testing in, 138
- Hæmatomyelia, diagnosis from, 12
- Hand-gänger*, 290
- Hand, paralysis of, 200
 apparatus in, 200
 nerve-grafting in, 206
 tendon-shortening in, 200, 202
 tendon-transplantation, 201-205
- Head, position of, in cerebro-spinal meningitis, 127
 in paralytic torticollis, 127
- Headache at onset, 3
 "Heine-Médin's disease," 3
- Heine, von, apparatus, 2
 original description of disease, 1
 monograph, 1
 on skin temperature, 7
- Hemiplegia, occasional, 6
- Heredity, 11
- Hernia, simulation of, 135
- Hip, arthrodesis of, 271
 after-treatment, 272
 indications for, 271, 272
 results of, 273
 technique of, 272, 273
 complete paralysis of, apparatus in, 271
 arthrodesis in, 271
 after-treatment, 272
 results of, 273
 technique of, 272, 273
 phenarthrodesis in, 272
 contracture of, apparatus in, 44
 causing lordosis, 132
 prevention of, 276, 277
 static, 33
 paralytic luxation, 274
 causation, 276
 operations in, 277-280
 varieties tabulated, 275
 contracture in, 274, 277
 treatment of, 277-280
 nerve-grafting in, 274
 partial paralysis of, 273
 tendon-transplantation in, 73, 273
 after-treatment, 274
 results, 274
 technique, 273
- Histology of muscle-implantation, 58
 of tendon-transplantation, 84
 of viscera, in acute stage, 20
- Humpback in scoliosis, 147
- Hydrotherapy, 2, 31, 33
- Hyperæmia, methods of inducing, 31
 value in treatment, 31-32, 282
- Hyperæsthesia at onset, 3
- Hypertrophy, causation of, 10
 of arms, 10
 of sound limb, 10
 muscles, 24
 of transplanted muscles, 260
- Ilio-psoas, paralysis of, causing kyphosis, 130
 tenotomy of, 277
- Immunity, acquired, 19
- Implantation of muscle, 57
- Incidence, age-, 12
 geographical, 11
 seasonal, 13, 14, 15
- Incontinence of urine, 4, 7

- Incubation period, 14, 16
 in experimentally-produced disease, 18
- Indirect transplantation, 81
- Infantile paralysis. See "Paralysis" and "Poliomyelitis"
- Infection, earth-borne, 16
 man chief carrier of, 16
 mode of, 16
- Inflammation, interstitial and parenchymatous, 21
- Influenza before poliomyelitis, 13
- Injury before onset, 11
- Inoculation, cerebro-spinal fluid, 17, 18
 of cultures, 17
 -experiments, 17, 19
 of snake venom, 19
 of spinal cord, 17
 of toxins, 19
 of virus, 17
- Intercostal paralysis, 4, 5
- Internal anatomy of nerves, anterior
 crural, 117
 circumflex, 110-111, 187
 external popliteal, 118
 internal popliteal, 119
 median, 112
 musculo-spiral, 104-106
 ulnar, 115
 popliteal nerve, grafting in paralysis of, 119
 anatomy of, 118
- Intestines, condition of, in acute attack, 20
- Intra-uterine poliomyelitis, 12
- Iodine applications, after arthrodesis, 66
 in shortening, 282
- Isolation during epidemics, 27
- Joints of apparatus, 38-43
 uses of, 39
 arthrodesis of. See "Arthrodesis"
 changes in paralyzed, 24
 determination of normal position, 9
 dislocation of paralyzed, 24
 flail; see under various joints
 resection of, 62
 subluxation of paralyzed, 10, 24, 274
 tendinous fixation of, 68-70
- Kangaroo tendon, 82
- Kidneys, condition of, in acute stage, 20
- Knee, arthrodesis of, 256
 after-treatment of, 258
 disadvantages of, 259
 failure of, 257
 results of, 258
 technique of, 256
 contracture of, 249
 apparatus for, 44
- Knee, excision of, 256
 contra-indicated, 259
 flexion of, 260
 lateral deformities of, 253
 paralysis of. See "Paralysis"
- Kyphosis, paralytic, causation of, 130
 treatment of, 130
 by apparatus, 130
 by exercises, 130
- Landry's paralysis, 5
 inoculation of cord of, 17
- Lange, method of tendon-transplantation, 82, 223
 silk tendons, 85
- Lateral anastomosis of tendons, 77
 apposition of nerves, 100
- Legs, loss of power in, 4
- Lengthening of paralyzed limbs, 8
- Length of limbs, differences in (between sound and paralyzed), tends to disappear, 8, 173
- Ligaments, artificial, 70, 71, 213, 255, 273
 technique of making, 83
- Lordosis, paralytic, 130
 causation of, 133
 compensatory, 132
 constipation in, 134
 in paralysis of abdomen or back, 134
 treatment, 134
- Lower extremity, entire paralysis of, 280
 treatment of, 280, 281
- Lumbar puncture in diagnosis, 4
 in treatment, 28
- Luxation, paralytic, of hip, 274
- Manufacture of sheath apparatus, 37
- Massage, after nerve-grafting, 103
 after tendon-transplantation, 84
 in early paralysis, 148
 in paralysis of deltoid, 151
 of elbow, 195
 in paralytic kyphosis, 130
 lordosis, 134
 torticollis, 129
 in pes calcaneus, 242
 in pes equinus, 218
 in treatment, value of, 2, 29, 30, 33
- Measles before poliomyelitis, 13
- Median nerve, grafting into musculo-spiral, 110
 for paralysis of (Case 25), 114, 124, 206
 internal anatomy of, 112-114
- Medulla, pathological changes in, 2
- Meningitic paralysis, 5
- Meningitis, cerebro-spinal, diagnosis from paralysis of neck, 127
 in epidemics of infantile paralysis, 14

- Meningococcus, organisms resembling, in cerebro-spinal fluid, 16
- Micrococci in cerebro-spinal fluid, 16
- Monkeys susceptible to subinoculation, 18
- Mortality, 15
- Motilité supplée*, 94
- Motility, improvement in, causes of, 88
- Motor symptoms, weakness at onset, 4
- Mottling of skin, 7
- Moulded sheath apparatus. See "Apparatus"
- Movement, active, in paralysis, 29
 after arthrodesis, tables of, 173-178
 controlled by apparatus, 35
 passive, in prevention of contracture, 30, 31
 return of, 5, 7
- Multiple neuritis in epidemics of infantile paralysis, 14
- Muscle, development of new, 24
 ilio-psoas, not infrequently escapes, 5
 partition of function in, 88
 power of, factors in determining, 222
 tabby-cat, 22
 -testing, fallacies in, 74
 transplantation of, 59
versus arthrodesis, 180-185
 case reports of, 181-185
 conditions governing, 59, 61
 disadvantages of, 185
 in paralysis of the biceps, 197
 of the elbow, 195, 196
 of the peronei, 229-232
 of the shoulder, 180
 results of, 180, 183
 technique of, 183-185
 of the thigh, 252, 260-267
 technique of, 260-262
 results of, 265
 results of, 181-183, 185, 197, 230-232, 265
 technique: biceps, 197
 shoulder, 181-185
 thigh, 260-262
- Muscles of abdomen affected at onset, 5
 localized paralysis of, 134, 135
 acquire function of antagonists, 88
 adaptation of surviving, 10
 of ankle, 220
 actions of (Duchenne), 221
 of arms, recovery after arthrodesis, 178
 atrophy of, 6, 7, 22
 caused by apparatus, 35
 prevention of, 29, 33
 of back affected at onset, 5
 associated with paralysis of limbs, 130
 paralysis of, 130
 estimation of, 138
 certain, frequently escape, 5
- Muscles, changes in paralyzed, 22
 comparative strength of flexors and extensors, 260
 condition in congenital talipes, 12, 13
 degeneration of, in scoliosis, 139
 extensors more often affected than flexors, 5
 fatty degeneration of, 2
 of foot, functions of, 220
 paralysis of, 208
 schema of insertions, 223
 glutei often paralyzed, 5
 of hip, kyphosis in, 130
 hyperæsthesia of, at onset, 3
 hypertrophy of, 10, 24
 implantation, 57
 histology of, 58
 of leg, relative strength, etc., of, 221
 total paralysis of, 208
 of neck, transient paralysis of, in acute stage, 127
 overstretching, prevention of, 32, 33
 paralysis of tibialis anticus only, 239
 paralyzed, replaced by elastic, 42
 paretic, spontaneous recovery of, doubtful, 74
 in scoliosis and lordosis, 136
 shortening of, 9
 spinal, insufficiency of, leads to kyphosis, symptoms of, 130
 stretching, from gravity, 10
- Musculo-spiral nerve, grafting in paralysis of, 108
 internal anatomy of, 106-108
- Myotomy, 56
 in extreme paralysis, 292-301
 repair after, 56
- Nails, 64
- Neck, paralysis of: treatment, 127
- Nephritis in acute stage, 20
- Nerve, anterior crural, grafting for paralysis of, 118, 120
 internal anatomy of, 118
 autogenous regeneration of, 98
 circumflex, internal anatomy, 111
 plastic operations on, 112
 external popliteal, 118
 grafting for paralysis of, 118, 120
 results of (with table), 120-124
 -grafting, advantages of, 185
 after-treatment, 103, 187-191
 animal experiments on, 94
 of anterior tibial nerve, 122
 case reports, cervical nerves, 121-124, 185, 186
 circumflex, 186, 187-190
 musculo-spiral, 108-109
 peroneal, 233, 234

- Nerve-grafting, case reports, subscapular, 192
 tibial, 232, 247
 of cervical nerves, 120-121, 124, 185, 186, 192, 206
 circumflex, 186-191, 221
 in Erb-Duchenne paralysis, 124
 failure after, 190, 191
 flap-formation in, 104
 in flat foot (paralytic), 239
 indications for, 98
 median into musculo-spiral, 109, 110, 196, 197
 methods of uniting nerves in, 102
 neurone theory and, 94
 nomenclature of, 100
 in paralysis of anterior crural nerve, 118, 120, 122, 268
 technique of, 269
 of biceps, 197
 of circumflex nerve, 124
 of external popliteal nerve, 118, 120
 results of (with table), 120-124
 of hand, 206
 of internal popliteal nerve, 119
 results of, 119, 120, 124
 of knee, 268
 of median nerve, 115, 206
 case report, 206
 of posterior interosseous nerve, 206
 technique of, 206
 of thigh, 268
 of triceps, 196
 of ulnar, 109, 110, 206
 in paralytic flat foot, 239
 in partial paralysis of hip, 274
 in pes calcaneus, 247
 in pes equino-varus, 232 *et seq.*
 case report, 232, 233
 results, 232
 technique, 233, 234
 results of, 120-124, 185, 186, 187-191
 of subscapular nerve, 192
 sutures used in, 103
 technique of, 100-105 *et seq.*, 192, 206, 233
 time to perform, 99
versus tendon-grafting, 125, 126
 with tendon-grafting, 103
 internal popliteal, 119
 grafting in paralysis of, 119
 results of, 119
 median, grafting for paralysis of, 115
 206
- Nerve, median, internal anatomy, 112
 mode of degeneration uncertain, 98
 musculo-spiral, 106
 grafting for paralysis of, 108
 paralysis of posterior interosseous, 200
 apparatus in, 200
 case reports, 201-203
 tendon-shortening in, 201, 202, 203
 roots, plastic operations on, 93, 94
 spinal accessory, endangered in muscle-transplantation, 184
 suture of, early cases, 93
 ulnar, grafting in, paralysis of, 206, 210
 internal anatomy, 115
- Nerves, hyperæsthesia of, at onset, 3
 internal anatomy of. See "Internal anatomy"
 lateral apposition of, 100
 methods of uniting, 102
- Neurone theory, 94
- Neuroplasty. See "Nerve-grafting"
- Non-union after tenotomy, 52
- Nutrition, impairment of, in paralysis, causation and results, 7, 8
 of muscles impaired by apparatus, 35
- O'Connor Extension, 284
- Onset, mode of, 3
 of paralytic stage, 4
- Organisms. See "Bacteriology," "Cerebro-spinal fluid," "Diplococci," "Meningococcus," "Staphylococci," "Tetracocci"
- Osseous. See "Bone"
- Osteoclasis in contracture of knee, 254
- Osteoplasty in flail ankle, 210
- Osteotomy in contracture of hip, 279
 of knee, 254, 255
 extreme deformity, 292-301
 paralytic genu valgum, 255
 rotation of humerus, 193
 shortening, 287
- Pain, initial, 3
 in paralytic stage, 4
- Paralysis of abdominal muscles simulating hernia, 135
 age-incidence of, 12
 amyotrophic, with infantile, 10
 in animals, 14, 15
 of arm, 207
 ataxic, 5
 atypical, 5
 of biceps only, 197
 treatment of, 197
 of bladder, 7
 bulbar, 5
 of deltoid, apparatus in, 151
 arthrodesis in, 153
 after-treatment of, 169, 170

- Paralysis of deltoid, arthrodesis in, case reports of, 156-178
 disadvantages of, 179
 failure in, 179
 results of, 154-178
 technique of, 169
 muscle-transplantation in, 180-185
 nerve-grafting in, 185, 186, 187, 192
 symptoms of, 149
 treatment of, 150
- of diaphragm, 4
- differential diagnosis of, 3-5, 12, 127
- distribution of, 6
 fallacies in, 74
 methods of determining, 74
 statistics, 6
- versus* disuse-atrophy, 75
- earliest indications of, 4
- of elbow, apparatus in, 199
 arthrodesis in, 197
 muscle-transplantation in, 196
 nerve-grafting in, 197
- encephalitic, 5
- Erb-Duchenne, neuroplasty in, 123
- of erector spinæ, 130
- extent of, first determined, 4
 compared with trophic disturbances, 8
- extreme cases, 289
 treatment, 292-301
- of foot. See "Foot"
- of glutei, 274
- of hand. See "Hand, paralysis of"
- of hip. See "Hip"
- inoperable cases of, 293
- of joints, results of, 24
- of knee, 248 *et seq.*
 partial, 259
 apparatus in, 255
 bilateral, 266
 causation, 253
 effects of, 9
 genu valgum in, 253
 varum in, 254
 nerve-grafting in, 268
 osteoclasia in, 254
 osteotomy in, 254
redressement in, 254, 255
 tendon-transplantation in, 259 *et seq.*
 disadvantages of, 262
 genu recurvatum after, 262
 results of, 264
 technique of, 260
- of knee, 248 *et seq.*
 total, apparatus in, 248
 arthrodesis in, 256
 contracture in, 249
- Paralysis of knee, total, gait in, 250
 genu recurvatum in, 248, 252
- Landry's, 5
 inoculation of cord of, 17
- of leg, 8
 partial, 215, 217
 total, effects of, 9
 fat embolism, 209
 treatment of, 209
- of limbs, causing scoliosis, 136
 neuroplasty, 120
- meningitic, 5
- of muscles of abdomen, 130
 localized, 134
- of back, 130
 results of, 133, 135
- of shoulder, 149
 causing scoliosis, 135
- muscular hypertrophy in, 10
- of neck muscles, 127
 treatment of, 127
- of nerves. See "Nerve-grafting," etc.
 onset of, 4
- organisms causing, 16, 17, 19
- of peronei, muscle-transplantation in, 229
 nerve-grafting in, 119
- polyneuritic, 5
- pontine, 5
- recovery from, first signs of, 5
- of shoulder. See "Shoulder"
- statistics of distribution, 6
- of tibialis anticus only, and other muscles, 217, 218, 224
 treatment, 217, 218, 224, 237, 239
- of toes, fasciodesis in, 213
- transitory, 8
- of triceps only, 196
- of whole lower extremity, 280
- Paralytic contracture, 9
 deformity, appearance of, 8, 9
 flat foot. See "Flat foot, paralytic"
- genu valgum, 253
 apparatus in, 254
 operation in, 255-257
- hemiplegia, 6
- internal rotation of arm, 193
 symptoms of, 193, 194
 treatment, 193, 194
- kyphosis, causation, 130
 treatment, 130-132
- limbs, elongation of, 8
- lordosis, 130
 causation of, 133
 compensatory, 132
 constipation in, 134
 in paralysis of abdomen or back, 133
 treatment, 134

- Paralytic scoliosis. See "Scoliosis, paralytic," 135
 talipes, differences from congenital, 227
 torticollis. See "Torticollis"
- Paresis of erector spinæ, 130
- Partial ascending transplantation of nerves, 100
 decussation of nerves, 100
 transplantation of tendon, 78
- Passive movement after arthrodesis, extent of, tables, 173, 175
 in paralysis, 30, 32
- Paste, bone-filling, 64
- Pathological anatomy of affected muscles, 20, 22, 138-145
- Pathology, 2
- Pectoralis, total transplantation of, 183
- Pegs in arthrodesis, 64, 210, 257
- Pelvis, tilting of, 133, 136
- Periosteal fixation, of tendons, 82, 243, 262, 273
 modifications of, 83
- Peronei, action of, 220, 221
 paralysis of, 119, 229
 muscle-transplantation in, 229
 nerve-grafting in, 119
- Pes calcaneus, 239
 bone operations in, 245
 causation of, 10, 239
 development and symptoms, 240, 241, 242
 in non-union of tendo Achillis, 52
 treatment, 242, 243, 247
 after-treatment, 244
 varieties of, 239
- equinus, bony deformity in, 217
 causation of, 10, 33, 208, 215
 choice of operation, 218
 muscles affected in, 217
 results of, 216
 static, 33, 215
 prevention by apparatus, 216
 tendon-transplantation in, 219, 226
 technique of, 219
 shortening in, 219
 transient, 218
 treatment of: apparatus, 218
 massage, etc., 218
redressement, 209, 218, 219
 tendon-operations, 219, 224
et seq.
- equino-varus, or varo-equinus, 226, 227
 nerve-grafting in, 232 *et seq.*
 case report, 232
 results, 232
 technique, 233
- excavatus, causation of, 216
- varus, causation, 226, 227
- Pes varus, muscle-transplantation for, 227
et seq.
 after-treatment, 229
 case reports of, 230-232
 in total paralysis of leg, 208
 results of, 230-232
 symptoms of, 227
- Phenarthrodesis, 64, 257, 272
- Physiology of normal movements, 91, 92
 of partition of function, 92
 of tendon-transplantation, 90
- Plaster, after arthrodesis, 64, 169, 213, 258, 273
 after tendon-transplantation, 84
 -bed in acute stage, 28
 in scoliosis, 148
- Pleating joint-capsules and ligaments, 71, 194
 tendons, 68
- Pneumococci in cerebro-spinal fluid, 16
- Pneumonia before poliomyelitis, 13
- Poliomyelitis, adult, 2
 an infectious disease, 13, 16
 antecedents to, 13
 antenatal, 12
 cases resembling, 1
 distribution (geographical), 11
 early accounts of, 1, 2
 followed by amyotrophic paralysis, 10
 general symptoms of, 4, 5
 incidence, age-, 12
 seasonal, 13, 15
 spread of, 4
 vaccination against, 19
- Polyneuritic paralysis, 5
- Pontine paralysis, 5
- Posterior interosseous nerve, paralysis of, nerve-grafting in, 206
- Post-mortem examination in scoliosis, 138-141
- Posture causing deformity, 33
- Prodromal symptoms, 3, 4
- Prognosis in scoliosis, 148
 in tendon-transplantation, 87
- Prophylaxis of scoliosis, 148
- Purgation, 27
- Pyrexia at onset, 3
- Quadriceps, artificial, 43
 paresis of, 259
 transplantation in paralysis of, 259
- Radiography. See "X-rays"
- Rarefaction of bone, 8
- Reaction of degeneration, 6
 at onset of attack, 7
 in scoliosis, 138
 in talipes equino-varus, 233
 value of, 75
- Recovery, complete, rare, 4
 earliest signs of, 5

- Recovery, impossibility of, 24
 spontaneous, rare, in paresis, 74
 stage of, 5
- Recumbency in early paralysis, 148
- Redressement*, 48, 49, 65
 before tendon-transplantation, 73
 in extreme paralysis, 292-301
 in flat foot, not permanent, 236
 limitations of, 218, 219
 in paralysis of hip, 277, 278
 of knee, 254, 255
 in pes calcaneus, 246
 equinus, 209, 218
 varus, 227
 risk in, 49
- Reflexes in paralytic stage, 7
- Regeneration, after section of nerve, 97, 98
 autogenous, of nerve, 98
 stage of, 5
 duration of, 5
- Repair, after arthrodesis, 65
 myotomy, 56
 tendon-transplantation, 84
 tenotomy, 50-51, 54, 69
 stage of, 22
 treatment during, 28
- Resection of joints, 62
- Residual stage, 22
- Rest important in acute stage, 28
- Results of arthrodesis, 62, 65, 154, 178, 197, 214, 258, 272, 273, 293-301
 of muscle-transplantation, 180-183, 184, 185, 197, 265
 difficulties in estimating, 266
 of nerve-grafting, 120-124, 185, 186, 192, 232
 of tendo-fixation of joints, 69
 of tendon-shortening, 69, 200, 202
 transplantations, 84, 88, 201-205, 263, 264, 274
- Retention of urine, initial, 4, 7
- Rhizopods in cerebro-spinal fluid, 16
- Rickets, cause of elongation of limbs, 8
- Rigor at onset, 3
- Rotation of arm, paralytic, 193
 treatment of, 193, 194
 of vertebræ, 138, 141
- Sacrum, position of, in paralytic lordosis, 134
- Sartorius, transplantation of, 260
- Scapula, displacement and rotation after arthrodesis, 179
 injury to spine of, 184
 measurements of, in paralysis, 173
- Scarlet fever before poliomyelitis, 13
- Schema, Lange's, 223
- Scoliosis after arthrodesis, 179
 from rupture of erector spinæ, 138
- Scoliosis, habitual, 135
 paralytic, commoner than lordosis, 135
 distinction between static and true, 135
 static causation of, 136, 137, 217, 282
 direction of pelvis in, 136
 of spine in, 136
 true, causation of, 138
 clinical characters, 147, 148
 diagnosis of, 137, 138
 direction of convexity, 144
 nature of deformity, 146-148
 post-mortem appearances, 138-146
 prognosis, 148
 prophylaxis, 148
 treatment, 148
- Screws in arthrodesis, 64, 257, 272
- Sensibility, decrease of cutaneous, 3
 pain and tactile, altered, 7
- Sensory changes, initial, 3
 later, 7
- Sex, 11
- Shortening, 8
 after arthrodesis, 66
 arthrodesis in, 287, 288
 causes of, 282
 compensation for, 283
 effects of, 282
 of femur, 8
 iodine applications in, 282
 osteotomy in, 287
 prevention of, 282
 relative, 9
 residual, 10
 in scoliosis, 148
 treatment of, high boots, 283, 284
 inlays, 283, 284
 O'Connor Extension, 284, 286
 operative, 287, 288
- Shoulder, ankylosis of, 154, 155
 arthrodesis of, 153 *et seq.*
 after-treatment, 169, 170
 case reports of, 156-168
 movement after, 157
 results of, 154, 178, 207
 technique of, 169
 paralysis of the, 147
 cases tabulated, 169
 varieties of, 147
- Silk, as suture material, 82, 103
 ligaments, 70, 213, 255, 273
 technique of making, 83
 tendons, 55, 83, 206, 262, 268
 observations on, 85
- Skeleton, trophic disturbances in, 8, 24, 282
- Skiagraphy. See "X-rays"
- Skin, changes in, 7

- Skin, chronic ulceration of, 8
 treatment of, 31, 33
 spirit-friction of, 31
 temperature, 7
- Snake venom, inoculation of, 19
- Sore throat at onset, 4
- Spinal cord. See "Cord, spinal"
 supports for paralytic kyphosis, 131
 lordosis, 134
 bad in paralytic scoliosis, 148
- Spine, curvature of, in arthrodesis, 179
 stiffness of, at onset, 3
- Spleen, condition of, during acute stage, 20
- Spondylitic paralysis, 130
- Spontaneous recovery of paretic muscles doubtful, 74
- Stage, acute, 3, 127
 cord changes in, 20
 treatment during, 27
 of contracture and deformity, 9
 final, 33
 first (onset), 3
 paralytic, 4
 of recovery (regeneration), 22
 reparative, 22
 treatment in, 27
 residual, 23
 second, 22
 treatment in, 28
 third, 22, 33
 treatment in, 33
- Staphylococci, causing paralysis, 19
 in cerebro-spinal fluid, 16
- Staples in arthrodesis, 64
- Statistics, of arthrodesis, 168, 169
 of distribution of paralysis, 6
 of luxations of hip, 274, 275
 of monthly incidence, 15
 of mortality, 15
- Steels of instruments, 38
- Sternomastoid, unilateral paralysis, 129
- Stoffel's research. See "Internal anatomy of nerves"
- Stop-joints, 40
- Streptococci, causing paralysis, 19
- Subcutaneous osteotomy, 56
 tendon-lengthening, 53, 54, 55
- Subluxation of paralyzed joints, 10, 24, 274
- Sudeck's atrophy, 8
- Supraspinatus, functions of, 186, 187
- Sutures, extrusion of, 82
 in nerve-grafting, 103
 in tendon-transplantation, 82
- Sweating at onset, 3
- Swedish exercises, 31
- Symptomatology and course of disease, 3
- Symptoms, early: backache, bronchitis, coma, constipation, diarrhoea, drowsiness, gastro-intestinal, headache, hyperaesthesia, pain, pyrexia, retention of urine, rigors, sore throat, stiffness of spine, sweating, vomiting, 3-4
- Synostosis as result of arthrodesis, 171
- "Tabby-cat" muscles, 22
- Tables, cases of arthrodesis of shoulder, 169
 measurements of scapula, before and after arthrodesis, 173
 movements, active, 175, 176
 in arthrodesis, 174-178
 passive, 174, 175
 relative strength of leg muscles, 221
 size of leg muscles, 222
 results of neuroplasty, 120-124
- Talipes. See "Pes"
- Technique of arthrodesis, 63, 154, 169, 210, 212, 256, 272, 273
 ankle, 210, 212
 hip, 272
 knee, 256, 257
 shoulder, 169
 of bone-bolting in flail ankle, 211
 of electrical treatment, 28, 29
 of excision of knee, 256
 of fasciodesis in flail ankle, 212
 of making silk tendons, 83
 of muscle-transplantation, 181-185, 197, 260-262
 of nerve-grafting, 100-104 *et seq.*, 192, 206, 233, 234, 269
 circumflex, 187
 operative replacement in paralyzed hip-joint, 278, 279
 of phenarthrodesis, 272
 of tendon-lengthening, 53-55
 -shortening, 68
 -transplantation, 73, 82, 219, 223, 236, 237, 243, 260, 261, 274
 of tenodesis in flail ankle, 212
 of tenotomy, open, 51, 277
 subcutaneous, 49, 50, 53
- Temperature, initial rise of, 3, 4
 skin, in paralytics, 7
- Tendinous fixation of joints, 68, 69
 advantages of, over arthrodesis, 70
 with arthrodesis, 213
- Tendon, artificial, 55
 fate of, 84
 technique of making, 83
 atrophy of, 24
 -lengthening, 2, 49, 52-55
 open, 53, 54
 repair after, 55
 subcutaneous, 52, 53
 -pleating, 68
 -shortening, 2, 67, 200, 202, 203, 212, 219
 results of, 69

- Tendon-shortening, technique of, 68
 -transplantation, after-treatment, 84,
 229, 237, 244, 273, 274
 age for performing, 73
 arthrodesis with, 89
versus arthrodesis, 180
 case reports, 201-205, 225, 226,
 237, 239, 244, 245, 274
 cerebral adaptation after, 91
 conditions for successful, 87
 in contracture of hip, 279
 descending, 80
 in extreme deformity, 292
 failure in, 89, 90
 histology of, 84
 indications for, 72, 228-259
 indirect, 81
 in leg, 219
 case reports of, 226
 general remarks on, 219
 Lange's schema for, 223
 technique of, 219
 neuroplasty with, 103
 nomenclature of, 79
 in paralysis of hand, 201-205
 in paralytic flat foot. See "Flat
 foot"
 partial, 78
 in partial paralysis of hip, 273
 after-treatment, 274
 results, 274
 technique, 273
 of thigh, 259
 apparatus in, 259
 disadvantages of,
 262
 genu recurvatum,
 262
 results of, 264, 265
 technique of, 260
 periosteal fixation in, 82, 243
 physiology of, 90
 in *pes calcaneus*, 243
 equinus, 218, 219, 224
 technique, 219
 repair after, 84-88, 201-205, 265,
 274
 results of, 84-88, 201-205, 265, 274
 technique, 73-82, 219, 222, 223,
 237, 243
 faulty, 89
 total, 77
- Tendons, methods of uniting, 77-82
 periosteal fixation of, 82
- Tenodesis, 70
 in flail ankle, 212, 213
 in flat foot, 236
 technique of, 212, 213
- Tenotomy, 49 *et seq.*
 history of, 49
 in extreme paralysis, 292
- Tenotomy of ilio-psoas, 277
 non-union after, 52
 in paralytic torticollis, 129
 repair after, 50-51
 technique of, open, 52, 277
 subcutaneous, 49, 50, 53
- Tetracocci in cerebro-spinal fluid, 17
- Thigh muscles, partial paralysis of, 252,
 259
 relative strength of, 260
 paralysis of, apparatus in, 259
 excision of knee in (when contra-
 indicated), 259
 muscle-transplantation in, 253,
 260-267
- Tibialis anticus, action of, 220, 222
 paralysis of, nerve-grafting in, 239
 tendon-transplantation in,
 224
 posticus, action of, 221
- Tone, muscular, causing muscular equi-
 librium, 9
 important in neuroplasty, 103
 permanent loss of, 24
 proof of existence, 9
 recovered after tendon-shorten-
 ing, 68, 219
- Tonsils, condition of, in acute stage, 20
- Torticollis, paralytic, causation of, 129
 gymnastics in, 129
 initial, 127
 symptoms of, 127
 tenotomy for, 49
 treatment of, 127, 129
- Total ascending transplantation of nerves,
 100
 decussation of nerves, 100
 transplantation, 71
 conditions for, 77
 of tendons, 77
- Toxins, inoculation of, 19
- Transplantation, functional, 71, 77
 of muscle, 59, 180-185
 in animals, 84
 of tendon. See "Tendon-transplanta-
 tion"
- Trauma as aetiological factor, 11
- Travelling acetabulum, 275
- Treatment, in acute stage, 27
 electrical, 28, 29
 of extreme paralysis, 292
 of flail ankle, 208, 210, 211, 212-214
 general, 27
 foot, 208
 hip, 271
 knee, 256
 shoulder, 152
 of paralysis of deltoid, 150
 of elbow, 197
 of neck, 127
 of whole lower extremity, 280

- Treatment of paralytic genu valgum, 254-256
 kyphosis, 130
 scoliosis, 148
 torticollis, 129
of partial paralysis, 71
of pes calcaneus, 242, 243
 equinus, 218
 varus, 227, 229
of second stage, 28
of shortening, 282, 283, 287
of stage of repair, 27
in third stage, 33
Triceps, action of, 220
 paralysis of, 196
 treatment, 196
Trophoneurotic atrophy of muscle, 8, 22
 changes in skeleton, 8, 24
 causing scoliosis, 138
 skin lesions improved by massage, etc., 29, 33
Tunnelleur, Spitzzy's, 102, 270
Ulcers, chronic, of skin, 8
Ulnar nerve, nerve-grafting in paralysis, 110
 internal anatomy of, 115
Urine, incontinence of, 4, 7
 retention of, at onset, 4, 7
Vaccination against poliomyelitis, 19
 preceding poliomyelitis, 13
Vascularity improved by massage, 29, 30
Vertebrae, fixation and deformity in paralytic scoliosis, 148
 rotation of, in scoliosis, 144
Virus, properties of, 18
Viscera, appearance of, in acute stage, 20
Vomiting at onset, 4
Walking, as an exercise, 31
 -machines, 31
 teaching art of, to paralytics, 31
Wasting, 6
Weight determines position of paralyzed limb, 9
Whooping-cough before poliomyelitis, 13
Wiring in arthrodesis, 64, 169, 170, 257
 sinuses after, 179
 in tendon-transplantation, 82
X-rays, in study of bone-bolting, 211
 of growth and size of paralytic bones, 8, 24
 of luxations of hip, 275
 of paralytic scoliosis, 142
 of pes calcaneus, 241
 of results of arthrodesis, 65, 157, 158, 171

INDEX OF NAMES

- ABERLE, VON, 262
 Adams, 51
 Albert, 61, 62, 153, 197, 275
 Anzoletti, 235, 277
 Appel, 275
 Arnd, 144, 146, 147
 Ashurst, 247
 Assaky, 55
 Auerbach, 11, 15

 Badham, 1
 Ballance, 94
 Ballet, 19
 Banders, 93. See Bau-
 dens
 Bardenhauer, 70, 124, 191,
 233
 Barthez, 1
 Bartsch, 1
 Baudens, 93
 Bauer, 62
 Baumann, von, 13
 Bayer, 53, 55
 Beaver, 11
 Beneke, 17, 21
 Bergenholtz, 13
 Bergh, van der, 122, 270
 Bernheim, 10
 Beyer, 11
 Bidone, 65
 Billroth, 151
 Böcker, 274, 275, 280
 Bois-Reymond, du, 251
 Borst, 51, 55, 69, 84
 Bothézat, 154, 198
 Bouglé, 55
 Bouvier, 50
 Braatz, 62
 Bradford, 63, 77, 215
 Brieglieb, 13
 Bruandet, 104
 Brück, 1
 Brücke, 91
 Bum, 31, 260
 Busse, 50

 Capurro, 58, 59, 81
 Carrière, 200

 Charcot, 2, 10, 20, 21, 24
 Charles, Firmin, 137
 Charrier, 19
 Claude, 19
 Cochon, 65
 Codivilla, 70, 71, 72, 75, 76,
 82, 83, 88, 92, 212, 220,
 221, 222, 234
 Collin, 151
 Colmer, 13
 Concetti, 16
 Cone, 75
 Cordier, 14
 Cornil, 2
 Courtillier, 13
 Cramer, 210
 Crédé, 27
 Crocq, 19
 Cron, 151
 Czerny, 55
 Czisch, 61

 Dalby, 31
 Damaschino, 2, 21
 Dartiques, 207
 Dauber, 21
 Davis, 94
 Delacroix, 42, 200
 Delpech, 49, 52
 Deschin, 58, 61
 Desprès, 93
 Dethloff, 16
 Deutschländer, 255, 274,
 287
 Dieffenbach, 49, 50
 Dollinger, 257, 272
 Drobnik, 72, 77, 79, 82, 89,
 91
 Duchenne, 2, 6, 42, 43, 91,
 144, 187, 200, 220, 221,
 222, 231, 239
 Dumstrey, 94
 Dupuytren, 49
 Durrieux, 207
 Dutil, 10

 Eichelberg, 4, 16, 17
 Eiselberg, von, 287

 Ellerman, 16
 Enderlen, 50
 Engel, 19, 222
 Enriquez, 19
 Erb, 11, 28, 29
 Etienne, 10
 Ewald, 140

 Falk, 12
 Fargin, 55
 Faure, 94
 Filbry, 10
 Flexner, 18, 19
 Florian, 49
 Flourens, 94
 Foramitti, 103
 Förster, 4
 Foulerton, 17
 Frank, 70, 201
 Franke, 11, 71, 91
 Fränkel, 16
 Frazier, 122, 239
 Friedrich, 80
 Fritz, 51, 69, 84
 Frohse, 183, 192, 260, 261
 Furet, 94

 Galeazzi, 124, 186, 246
 Galen, 91
 Garavini, 275
 Geirsvold, 16, 17
 Gersuny, 182
 Giani, 221
 Gilbert, 19
 Glässner, 287
 Glück, 55, 57, 85, 94, 292
 Gocht, 42, 75, 88
 Goldscheider, 2
 Goldthwait, 82, 210, 260,
 264
 Golebiewski, 138
 Grisel, 274, 275
 Grünow, 12
 Guérin, 50
 Gunn, 93, 94

 Hackenbruch, 121, 232
 Hacker, 54

- Hallion, 19
 Heine, von, 1, 2, 7, 130,
 133, 136, 147, 287, 292
 Helferich, 55, 58
 Hering, 91
 Herz, 31, 64, 213, 257, 260
 Hessing, 37
 Heusner, 44, 194, 200, 261
 Hevesi, 154
 Hezel, 233
 Hildebrandt, 60, 61, 181
 Hoeftmann, 291
 Hoffa, 29, 41, 45, 55, 69, 79,
 84, 129, 138, 151, 154,
 181, 194, 196, 210, 212,
 245
 Hübscher, 221, 222, 234,
 256, 257
 Hunkin, 268
 Hüter, 208, 278
 Hutier, 1

 Italia, 84

 Jäger, 16
 Jamin, 24
 Joachimsthal, 291
 Joffroy, 2
 Jones, 9, 63, 72, 83, 198,
 200, 246
 Jordan, 11
 Jörg, 1
 Joseph, 56

 Kahlden, von, 2
 Kalischer, von, 8
 Karasiewicz, 214
 Karewski, 154, 195, 198,
 211, 256, 257, 274, 276,
 278, 279
 Katzenstein, 185
 Kawka, 21
 Kenedy, 11
 Kennedy, 94
 Kiewe, 274
 Kilvington, 239
 Kirmisson, 63, 73, 148
 Klippel, 138
 Knoepfelmacher, 17
 Koch, 24
 Kofmann, 229, 257, 260,
 264, 273
 Konik, 75
 Krause, 3, 17, 261
 Kries, von, 91
 Krukenberg, 31, 287
 Kümmell, 55, 85
 Kussmaul, 28

 Laborde, 2
 Landerer, 137

 Landsteiner, 17, 18
 Lange, 28, 55, 63, 69-70, 72,
 80, 82-84, 88, 200, 205,
 213, 218, 222, 223, 224,
 229, 253, 255, 256, 262,
 265, 273, 274
 Langenbeck, 93
 Leibold, 138
 Leiner, 17, 18, 19
 Lengfellner, 183, 192, 260,
 261
 Léon, 19
 Lesser, von, 62
 Létievant, 93
 Levaditi, 18
 Lewis, 18, 19,
 Lexer, 64, 211, 212, 257
 Leyden, 2, 21, 138
 Little, 50
 Looft, 16
 Lorenz, 49, 72, 74, 137, 219,
 254, 256, 262

 Maas, 282
 MacCormac, 17
 Machol, 28
 Macphail Caverly, 14
 Manassé, 94, 96
 Maragliano, 120, 270
 Marczinowski, 214, 236,
 244
 Marie, 12
 Martin, 275-276
 Masselin, 19
 Mayer, 124
 Medin, 3, 13, 14, 15
 Meinicke, 17
 Mencière, 64, 193, 272
 Messner, 138, 148
 Meyer, von, 287
 Michaelis, 49
 Mikulicz, 288
 Milliken, 71, 196
 Mirallie, 138
 Monod, 55
 Montsarrat, 138, 139
 Moore, 65
 Morestin, 61, 181
 Moritz, 92
 Morton, 135
 Mosetig, 64
 Moszkowicz, 273
 Mouchet, 275
 Müller, 83, 91, 222, 244
 Murphy, 122

 Nägeli, 260
 Nélaton, 93
 Neugebauer, 93
 Neurath, 8
 Nicoladoni, 71, 239, 243

 Niény, 213, 236
 Nonne, 8
 Nussbaum, 287

 O'Connor, 286
 Ollier, 283
 Osterhaus, 124
 Oxholm, 14


 Parrish, 71, 77
 Parrot, 2
 Pasteur, 17
 Peckham, 121
 Peyrot, 55
 Piéchaud, 75
 Pierre, 73
 Pintschovius, 135
 Pleuss, 15
 Poncet, 55
 Popper, 17
 Potpeschnigg, 17
 Prévost, 2
 Prioleau, 53
 Pürckhauer, 103, 200
 Putuam, 14


 Rawa, 94
 Reclus, 274, 275, 276
 Redard, 138
 Rehn, 275
 Reichardt, 181
 Reiner, 70, 212, 242, 250,
 254, 260, 262
 Riedinger, 278
 Rieger, 66
 Rillier, 1
 Rissler, 21, 22
 Roersch, 181
 Roger, 2, 19, 21
 Römer, 17, 18, 19
 Roonhuysen, 49
 Rosenthal, 17
 Roth, 2, 21
 Rubinstein, von, 10
 Rydigier, 59

 Sachs, 182
 Salvia, 57, 58
 Samter, 185, 211
 Sanger, 93
 Sangiorgi, 70
 Sartorius, 49
 Saxl, 218, 250, 274, 276
 Schanz, 82, 91, 181, 229,
 261, 264
 Schildbach, 34
 Schmaus, 21
 Schmidt, 282
 Schraditz-Ricker, 50
 Schultess, 137, 138, 145,
 260, 264

- Schultze, 2, 11, 16, 274, 275, 278
 Schüssler, 151, 154
 Schwalbe, 21, 22
 Seeligmüller, von, 6, 8
 Seggel, 51, 69
 Selberg, 264, 266
 Shaw, 1
 Sheldon, 94
 Sherren, 120, 123, 186
 Sherrington, 91
 Sick, 93
 Silver, 153
 Soutter, 63, 77, 215
 Sparre, 135
 Spitzzy, 74, 96, 99, 101, 102, 103, 104, 119, 120, 122, 124, 194, 268, 269
 Sporon, 54
 Starz, 210
 Stillmann, 41
 Stoffel, 104-108, 111, 112, 115, 119, 186, 187, 191, 197, 207, 233, 247, 269
 Stromeyer, 50, 71
 Strümpell, 12, 14
 Szymanowski, 62
 Talamon, 16
 Taylor, 120, 206
 Thiem, 11
 Thilo, 31, 92
 Thoinet, 19
 Thowson, 28
 Tilanus, 70, 72, 154, 212
 Topuse, 229
 Tubby, 6, 9, 61, 120, 122, 123, 154, 185, 186, 197, 198, 200, 203, 232, 247
 Tunstall, 123
 Turner, 262
 Unterwood, 1
 Vincent, 19
 Volkmann, 8, 42, 43, 93, 248
 Vulpian, 2, 10
 Waitz, 292
 Walsham, 243, 245
 Walzberg, 277
 Wanner, 60
 Warren Low, 121, 185
 Watkins, 83
 Weichselbaum, 16
 Wharton-Sinkler, 13
 Whitman, 246
 Wickmann, 3, 4, 14, 15, 16, 19, 21
 Wiesner, 17, 18, 19
 Willard, 292
 Winiwarter, von, 61, 181
 Winkelmann, 71
 Wittek, 103, 210
 Witzel, 82
 Wladimiroff, 288
 Wölfler, 55
 Wolff, 83, 153
 Wollenberg, 77
 Young, 121, 239
 Zander, 31
 Zappert, 11







✓

